Elements of anatomy / by Jones Quain.

Contributors

Quain, Jones, 1796-1865.
Quain, Richard, Sir, 1800-1887.
Sharpey, William, 1802-1880.
Todd, Robert Bentley, 1809-1860
Quain, Richard, Sir, 1800-1887
Sharpey, William, 1802-1880
King's College London

Publication/Creation

London : Taylor, Walton and Maberly, 1843.

Persistent URL

https://wellcomecollection.org/works/kmykwwre

Dr. Todd

From the Editors.

ELEMENTS OF ANATOMY.

BY

JONES QUAIN, M.D.

FIFTH EDITION.

EDITED BY

RICHARD QUAIN,

AND

WILLIAM SHARPEY, M.D.

PROFESSORS OF ANATOMY AND PHYSIOLOGY,
UNIVERSITY COLLEGE, LONDON.

ILLUSTRATED BY NUMEROUS ENGRAVINGS ON WOOD.

LONDON:
PRINTED FOR TAYLOR AND WALTON,
BOOKSELLERS AND PUBLISHERS TO UNIVERSITY COLLEGE,
UPPER GOWER STREET.

1843.

LONDON:
Printed by S. & J. Bentley, Wilson, and Fley,
Bangor House, Shoe Lane.

ADVERTISEMENT.

A New Edition of Dr. Quain's Elements of Anatomy having been called for, the Editors have sought to introduce such changes as the progress of the science has rendered necessary. The department of General Anatomy having made great advances within the last few years, it has been thought best to write anew the part of the work devoted to that subject. This has been undertaken by Dr. Sharpey, —and a portion is now published. The Descriptive Anatomy in the present Part has been prepared by Mr. Quain; the paragraphs headed "Dissection" and "Actions of Muscles" being printed from the fourth edition, with little alteration.

The concluding Part, which will be published as soon as possible, will contain a Preface by the Editors, explanatory of the changes they have made.

October, 1843.

ELEMENTS OF ANATOMY.

INTRODUCTION.

Division of natural bodies.

The material objects which exist in nature belong to two great divisions; those which are living or which have lived, and those which neither are nor have ever been endowed with life. The first division comprehends animals and plants, the other mineral substances.

In a living animal or plant changes take place and processes are carried on which are necessary for the maintenance of its living state, or for the fulfilment of the ends of its being; these are termed its functions, and certain of these functions being common to all living beings serve among other characters to distinguish them from inert or mineral substances. Such are the function of *nutrition*, by which living beings take extraneous matter into their bodies and convert it into their own substance, and, the function of generation or *reproduction*, by which they give rise to new individuals of the same kind, and thus provide for the continuance of their species after their own limited existence shall have ceased.

Organized bodies.

But in order that such processes may be carried on, the body of a living being is constructed with a view to their accomplishment, and its several parts are adapted to the performance of determinate offices. Such a constitution of body is termed organization, and those natural objects which possess it are named *organized bodies.* Animals and plants, being so constituted, are organized bodies, while minerals, not possessing such a structure, are *inorganic.*

Object of Anatomy.

The object of anatomy, in its most extended sense, is to ascertain and make known the structure of organized bodies. But the science is divided according to its subjects; the investigation of the structure of plants forms a distinct study under the name of Vegetable Anatomy, and the anatomy of the lower animals is distinguished from that of man or human anatomy under the name of Comparative Anatomy.

Organs and textures.

On examining the structure of an organized body, we find that it is made up of members or organs, through means of which its functions are executed, such as the root, stem, and leaves of a plant, and the heart, brain, stomach, or limbs of an animal; and further, that these organs are themselves made up of certain constituent materials named tissues or textures, as the cellular, woody, and vascular tissues of the vegetable, or the osseous, muscular, filamentous, vascular, and various others, which form the animal organs.

Most of the textures occur in more than one organ, and some of them indeed, as the cellular and vascular, in nearly all, so that a multitude of organs, and these greatly diversified, are constructed out of a small number of constituent tissues, just as many different words are formed by the varied combinations of a few letters; and parts of the body, differing widely in form, construction, and uses, may agree in the nature of their component materials. Again, as the same texture possesses the same essential characters in whatever organ or region it is found, it is obvious that the structure and properties of each tissue may be made the subject of investigation apart from the organs into whose formation it enters.

General and Descriptive Anatomy.

These considerations naturally point out to the Anatomist a twofold line of study, and have led to the subdivision of Anatomy into two branches, the one of which treats of the nature and general properties of the component textures of the body; the other treats of its several organs, members, and regions, describing the outward form and internal structure of the parts, their relative situation and mutual connexion, and the successive conditions which they present in the progress of their formation or development. The former is usually named "General" Anatomy, the latter "Special" or "Descriptive" Anatomy.*

---

* These names have been objected to, and the terms Histology (ἱστὸς, a web, and λόγος, a discourse,) and Morphology (μορφὴ, form, &c.) themselves not free from objection, have been proposed in their stead: there seems no sufficient reason for the substitution; the latter term, indeed, is often used in a different sense.

GENERAL ANATOMY.

GENERAL CONSIDERATIONS ON THE TEXTURES.

Enumeration of the textures.

The human body consists of solids and fluids. Only the solid parts can be reckoned as textures, properly so called; still there being some of the fluids, viz. the blood, chyle, and lymph, which contain in suspension solid organized corpuscles of determinate form and organic properties, and which are not mere products or secretions of a particular organ, or confined to a particular part, the corpuscles of these fluids, though not coherent textures, are nevertheless to be looked upon as organized constituents of the body, and as such may not improperly be considered along with the solid tissues. In conformity with this view the textures and other organized constituents of the frame may be enumerated as follows:—

The blood, chyle, and lymph.
Epidermic tissue, including epithelium, cuticle, nails, and hairs.
Pigment.
Adipose tissue.
Cellular tissue.
Fibrous tissue.
Elastic tissue.
Cartilage and its varieties.
Bone or osseous tissue.
Muscular tissue.
Nervous tissue.
Blood vessels.
Absorbent vessels and glands.
Serous and synovial membranes.
Mucous membranes.
Skin.
Secreting glands.

Organic systems.

Every texture taken as a whole was viewed by Bichat as constituting a peculiar system in the body, presenting throughout its whole extent characters either the same, or modified only so far as its local connexions and uses rendered necessary; he accordingly used the term "organic systems" to designate the textures taken in this point of view, and the term has been very generally employed by succeeding writers. Of the tissues or organic systems enumerated, some are found in nearly every organ; such is the case with the filamentous, which serves as a connecting material to unite together the other tissues which go to form an organ; the vessels, which convey fluids for the nutrition of the other textures, and the nerves, which establish a mutual dependence among different organs, imparting to them sensibility, and governing their movements. These were named by Bichat the "general systems." Others again, as the cartilaginous and osseous, being confined to a limited number, or to a particular class of organs, he named "particular systems." Lastly, there are some tissues of such limited occurrence that it has appeared more convenient to leave them out of the general enumeration altogether, and to defer the consideration of them until the particular organs in which they are found come to be treated of. Accordingly the tissues peculiar to the crystalline lens, the spleen, the suprarenal bodies, the enamel of the teeth, and some other parts, though equally independent textures with those above enumerated, are for the reason assigned not to be described in this part of the work.

General and particular or local systems.

It is further to be observed, that the tissues above enumerated are by no means to be regarded as simple structural elements; on the contrary, many of them are complex in constitution, being made up of several more simple tissues. The blood vessels, for instance, are composed of several coats of different structure, and some of these coats consist of more than one tissue. They are, strictly speaking, rather organs than textures; and indeed it may be remarked, that the distinction between textures and organs has not in general been strictly attended to by anatomists. The same remark applies to mucous membrane and the tissue of the glands, which structures, as commonly understood, are highly complex. Were we to separate every tissue into the simplest parts which possessed assignable form, we should resolve the whole into a very few constructive elements, and, having

Elements of structure.

regard to form merely, and not to difference of chemical constitution, we might reduce these elements to the following, viz. 1. *simple fibre*, 2. *homogeneous membrane*, either spread out or forming the walls of *cells*, and 3. *globules* or *granules*, varying in diameter from the $\frac{1}{12000}$ to the $\frac{1}{6000}$ of an inch. These, with a quantity of *amorphous matter*, homogeneous or molecular, might be said, by their varied combinations, to make up the different kinds of structure which we recognize in the tissues; and if we take into account that the chemical nature of these formative elements and of the amorphous matter may vary, it will be readily conceived that extremely diversified combinations may be produced.

PHYSICAL PROPERTIES.

Permeability of the tissues to fluids.

The physical properties of the tissues, such as consistency, density, colour, and the like, which they possess in common with other forms of matter, require no general explanation. An exception must be made however in regard to the property of imbibing fluids, and of permitting fluids to pass through their substance, which is essentially connected with some of the most important phenomena that occur in the living body, and seems indeed to be indispensable for the maintenance and manifestation of life.

All the soft tissues contain water, some of them more than four-fifths of their weight; this they lose by drying, and with it their softness and flexibility, shrinking up into smaller bulk and becoming hard, brittle, and transparent; but when the dried tissue is placed in contact with water, it greedily imbibes it again, and recovers its former size, weight, and mechanical properties. The imbibed water is no doubt partly contained mechanically in the interstices of the tissue, and retained there by capillary attraction, like water in moist sandstone or other inorganic porous substances; but it has been questioned whether the essential part of the process of imbibition by an animal tissue is to be ascribed to mere porosity, for the fluid is not merely lodged between the fibres or laminæ, or in the cavities of the texture; a part, probably the chief part, is incorporated with the matter which forms the tissue, and is in a state of union with it, which is supposed to be more intimate than could well be ascribed to the mere inclusion of a fluid in the pores of another substance. Be this as it may, it is clear that the tissues, even in their inmost substance, are permeable to fluids, and this property is indeed necessary, not only to maintain their due softness, pliancy, elasticity, and other mechanical qualities, but also to allow matters to be conveyed into and out of their substance in the process of nutrition.

Transmission of liquids through the tissues.

The tissues being permeable, we may next consider how fluids may be made to pass through them. This may be effected, 1. by the force of pressure, which again may be produced in various ways, easy to be understood. 2. It can be shown by experiment, that water imbibed by a tissue is given out from it again when the tissue is exposed to some substance with which the water has a tendency to mix or to combine, as for example, alcohol or salt, or a strong solution of salt; and if the experiment be so arranged that one surface of the tissue, say a piece of bladder, is kept in contact with water and the other with the alcohol or solution of salt, the water will be imbibed by the tissue at the one surface, and given off to the alcohol or saline solution at the other, and thus pass through in a continued current. In many cases of this kind both fluids pass through the membrane, and, of course, in opposite directions, the water to the salt and the saline solution to the water; and the interchange continues till the two fluids are thoroughly mixed, or until the solution acquires an uniform strength on both sides of the membrane. In such cases, however, it usually happens that one of the fluids is imbibed more readily by the tissue than the other, and is transmitted through it more rapidly, so that a greater quantity of fluid accumulates on one side of the membrane. In the case supposed, the water is imbibed, and transmitted more rapidly, than the saline solution; hence if the solution be contained in a tube closed at the bottom with bladder, and placed in a vessel of water, the level of the fluid within the tube will rise from the water entering more rapidly than the solution issues. Of course, if the relative position of the two fluids were reversed, the bulk of the fluid in the tube would diminish for the same reason as before, and its level sink. The same effect is shown very clearly by inclosing a solution of salt, sugar, or gum in a piece of gut or a small bladder, and immersing it in water; the bladder soon becomes distended, but when the water is put inside and the solution without, the bladder becomes flaccid; the water in both cases being more readily imbibed and transmitted by the animal tissue than the solution. The terms *endosmosis* and *exosmosis* have been employed to express these phenomena, the former denoting the greater, the latter the lesser, or weaker current, terms which, though in general use, are unquestionably ill chosen, seeing that their etymological import has led many to apply them to the entering and issuing current respectively, in experiments like the foregoing; a distinction which is quite unessential, for it is plain that the same kind of current may cause the entrance of fluid into a receptacle in one case, and its issue in another.

Water being imbibed by animal textures with more avidity than other fluids, it may be stated, as a general rule, that when water and a fluid of a different kind, with which it tends to combine or mix, are placed on opposite sides of an interposed animal membrane, the preponderating current will be from the water to the other fluid. This is the case, as has been already stated, with water and alcohol, or solutions of salt, or solutions of organic matters, such as gum, sugar, and albumen. Further, when a weaker and a stronger solution of the same substance are exposed to one another, the greater current will be from the weaker solution to the more concentrated. Dutrochet has however observed a remarkable and hitherto unexplained deviation from the above rule in the case of water and acids, especially the oxalic and some other vegetable acids. Lastly, the observer just named has found that solutions of different kinds of matter, though of the same density, differ in their power of producing endosmosis; thus, equally dense solutions of the following substances produced currents of water proportionate to the numbers given, viz., albumen 12, sugar 11, gum 5·17, gelatin 3.* Phenomena illustrative of the truths now stated present themselves in many of the processes which occur naturally in the animal economy.

Aeriform fluids.

The animal tissues are also permeable to aeriform fluids. It is well-known that the air in respiration produces changes in the blood, although the membranous coats of the blood-vessels are interposed between the two fluids; and if a bladder distended with carbonic acid be exposed to air, it will become flaccid from the escape of the contained gas. In such cases, however, the aeriform fluid does not pass through the moist membrane in its actual state of gas; it is first liquefied by the water in the soft tissue, and thus penetrates the tissue as a liquid; on reaching the opposite surface, it mixes with the blood in the one case, and in the other rapidly evaporates into the air, the tendency of the carbonic acid and air to diffuse into each other, a property they possess in common with other gases, greatly favouring the result. For further information on this interesting phenomenon, see Graham's Chemistry, p. 76.

CHEMICAL COMPOSITION.

Ultimate chemical constituents.

The human body is capable of being resolved by ultimate analysis into chemical elements, or simple constituents, not differing in nature from those which compose mineral substances. Of the chemical elements known to exist in nature the following have been discovered in the human body, though it must be remarked, that those at the bottom of the list occur only in exceedingly minute quantity; oxygen, hydrogen, carbon, nitrogen, phosphorus, sulphur, chlorine, fluorine, potassium, sodium, calcium, magnesium, iron, silicon, manganese, aluminum, copper.

Proximate constituents.

These ultimate elements do not directly form the textures or fluids of the body; they first combine to form certain compounds, and these appear as the more immediate constituents of the animal substance; at least the animal tissue or fluid yields these compounds, and they in their turn are decomposed into the ultimate elements. Of the immediate constitu-

---

* See Cyclopædia of Anat., and Phys., art. Endosmosis.

Proximate constituents.

ents some are found also in the mineral kingdom, as for example, water, chloride of sodium or common salt, and carbonate of lime; others, such as albumen, fibrin, and fat, are peculiar to organic bodies, and are accordingly named the proximate organic principles.

Their general characters.

The animal proximate principles have the following leading characters: They all contain carbon, oxygen, and hydrogen, and the greater number also nitrogen; they are all decomposed by a red heat; and, excepting the fatty and acid principles, they are, for the most part, extremely prone to putrefaction, or spontaneous decomposition, at least, when in a moist state; the chief products to which their putrefaction gives rise being water, carbonic acid, ammonia, and sulphuretted, phosphuretted, and carburetted hydrogen gases. The immediate compounds found in the solids and fluids of the human body are the following:

Enumeration.

I. *Azotized substances*, or such as contain nitrogen, viz., albumen, fibrin, casein, gelatin, chondrin, extractive soluble in alcohol, extractive soluble in water, salivin, kreatin, pepsin, globulin, mucus, horny matter or keratin, pigment, hæmatin, pyin, urea, uric acid, azotized biliary compounds.

II. *Substances destitute of nitrogen*, viz., fatty matters, (except cerebric acid,) sugar of milk, lactic acid, certain principles of the bile.

Some of the substances now enumerated require no further notice in a work devoted to anatomy. Of the rest, the greater number will be explained, as far as may be necessary for our purpose, in treating of the particular solids or fluids in which they principally occur; but there are a few of more general occurrence, which it will be advisable to give some account of here; these are, albumen, fibrin, casein, gelatin, chondrin, extractive, and fatty matters.

ALBUMINOID OR PROTEIN COMPOUNDS.

Protein compounds.

Albumen and fibrin, with casein, globulin, and perhaps some others, such as horny matter, belong to a group of compounds, which have been supposed to consist essentially of one and the same fundamental substance united with varying proportions of sulphur, phosphorus, salts, or other inorganic bodies. This common principle has been named Protein. In some of these instances, as albumen and casein, the protein comprehends the whole carbon, hydrogen, nitrogen, and oxygen of the compound; the proportions of these elements are therefore the same in each, and the substances are identical in essential composition, though they may differ in some of their properties. In other compounds, yielding protein, the proportion of the above-mentioned elements is not the same as in that substance; and in such cases it has been supposed, that some other organic substance is associated with protein, or the compound has been represented as consisting of protein with the addition of oxygen, the elements of water, or the elements of ammonia, or with some similar modification calculated to reconcile the supposed protein constitution with the actual analysis. The most general characteristic mark of these protein or albuminoid compounds is, that they are soluble in acids, and precipitated from their acid solutions by the ferro and ferricyanide of potassium (the yellow and the red prussiates of potash).

Albumen.

Albumen exists very extensively in the body, forming the chief ingredient of the serum of the blood, chyle, and lymph, and of the serous fluid which penetrates and moistens nearly all the tissues; it enters largely also into the composition of the brain and nerves. The white of eggs consists of liquid albumen.

In the albuminous liquids mentioned, which are all, more or less, alkaline from contained soda, the albumen is dissolved in water, but it may be obtained in a solid state by evaporation at a temperature of 120°, and successive washing of the dry residue with ether and alcohol, to remove foreign matters. Solid albumen thus obtained is soluble in water. In the liquid or dissolved state it is coagulated by a heat of 158°; but if its solution is much diluted, a boiling heat is required. Albumen is also coagulated, and its solutions rendered turbid by alcohol, creosote, most acids, the acetic, phosphoric, and pyrophosphoric, being notable exceptions, and by many metallic salts; also by the voltaic pile, which acts by decomposing salt in the albuminous solution. Ether coagulates the white of eggs, but not the serum of the blood.

Properties.

In its coagulated state albumen is insoluble in water; it is freely dissolved by caustic alkali. When exposed to an acid extremely diluted with water it is dissolved; by increasing the proportion of acid the albumen is precipitated, but this precipitate is again dissolved, if the acid be still more concentrated and heat applied. The solution in strong hydrochloric acid acquires a purple and then a blue colour. When dissolved in diluted acetic acid it is not precipitated by adding that acid in excess, and the tartaric, phosphoric, and pyrophosphoric acids, agree in this respect with the acetic. The acid solutions of albumen are precipitated by the ferroprussiates of potash.

Albumen unites with alkalies and metallic oxides, forming albuminates. The albuminates of the alkalies are soluble in water, those of the oxides in an excess of albumen. Metallic salts, as already stated, cause a precipitate in watery solutions of albumen, and none in a more marked manner than corrosive sublimate, which causes a milkiness in a solution containing no more than $\frac{1}{2000}$th part of albumen, and serves therefore as one of its most delicate tests. These precipitates appear not to be all of a similar constitution, some of them being compounds of albumen and the metallic salt; while in others the albumen is supposed to combine independently with the acid and with the base, and the precipitate accordingly to consist of albuminate of the acid and albuminate of the oxide. Whatever their constitution, the precipitates in question, not excepting that from corrosive sublimate, are soluble in an excess of albumen. Phosphate of lime is readily dissolved by liquid albumen, and a certain portion of that salt naturally exists in the albumen of the egg, and in the albuminous fluids of the human body; a fact of no small importance in a physiological point of view.

Composition of Albumen. *Protein.*

Albumen consists of *protein,* combined or associated with a small proportion of sulphur and phosphorus. To obtain the protein, albumen is dissolved in a solution of caustic potash, and heated to 120°; by this means the sulphur and phosphorus are converted into sulphuret of potassium and phosphate of potash; the alkaline solution is then to be saturated with acetic acid, and the protein separates as a gelatinous, greyish, semitransparent precipitate, which when washed and dried appears as a yellowish, hard, easily pulverised, and tasteless substance. According to the latest analysis, that of M. Dumas, the following is the composition of protein.

	From actual Analysis.	Calculated by Atoms.
Carbon	54·38	54·44 — C_{48}
Hydrogen	7·14	6·99 — H_{37}
Nitrogen	15·92	15·88 — N_6
Oxygen	22·56	22·69 — O_{15}
	100·—	100·—

Liebig's formula is C_{48}, H_{36}, N_6, O_{14}. These numbers will of course also represent the proportions of the respective elements contained in albumen; but the proportion of sulphur differs in the albumen of eggs and that of the serum of the blood. According to Mulder, the albumen of eggs consists of ten atoms of protein with one of sulphur, and half an equivalent of phosphorus, and is accordingly represented by the formula, $10\,Pr+SP\frac{1}{2}$. The albumen of serum contains twice the amount of sulphur, and its formula is therefore $10\,Pr + S_2\,P\,\frac{1}{2}$. Protein is insoluble in water and in alcohol; its solubility in acids follows the same law as that of albumen, and, like albumen, it is precipitated from its acid solutions by the ferroprussiates of potash. With concentrated acids it forms new compound acids.

Fibrin, liquid and concrete.

Fibrin exists in two states, liquid and coagulated. In the former condition it is found in the blood, and in its concrete state it may be obtained from muscle, of which it forms the basis.

Liquid fibrin.

The most characteristic property of liquid fibrin is its tendency to coagulate spontaneously, or at least independently of any apparent extrinsic cause; the coagulation of the blood itself, in fact, is owing to this property of the fibrin contained in it. Hence the difficulty of procuring fibrin in a liquid state, and indeed it has never been obtained pure in this condition. The fibrin and serum of the blood together constitute its colourless part or liquor sanguinis; this fluid, in certain states of the body, separates from the red particles before coagulation, and may be obtained by itself; or, if blood be diluted with serum the instant it is drawn, it may be filtered before coagulation, and the diluted liquor sanguinis, containing the liquid fibrin, is obtained free from the red particles, which remain on the filter. In both cases, however, the fibrin quickly solidifies and separates in a concrete form from the serum, and the same happens with fibrinous fluids, resembling the liquor sanguinis, occasionally found effused into cavities within the body.

Coagulated fibrin.

Coagulated fibrin may be procured by stirring fresh-drawn blood with a bundle of twigs, the solidifying fibrin is thus entangled and removed. When well washed, it then appears as a white, soft, stringy, somewhat elastic, substance, without taste or smell, which, by drying, loses about three-fourths of its weight, and becomes hard and brittle. The appearance of coagulated fibrin under the microscope will be afterwards noticed.

Properties.

Coagulated fibrin is insoluble in water, alcohol, and ether; but by long boiling in water, especially under pressure, it is dissolved, being however at the same time altered in nature. Like albumen, it is soluble in caustic alkalies, and combines with them, neutralizing their alkaline properties. It also combines with acids in different proportions, its neutral combinations being soluble in water, but precipitated by the addition of an excess of acid. Strong acetic acid is rapidly imbibed by it, and causes it to swell up into a transparent colourless jelly, which is soluble in hot water. This solution is precipitated by adding another acid, but not by acetic acid. The acid solutions of fibrin, like those of albumen, are precipitated by the prussiates of potash.

Many neutral salts, when added to the blood, prevent its coagulation by preventing the coagulation of its fibrin; and some of them, as nitre for example, may, with certain precautions, be made to dissolve freshly coagulated fibrin. Corrosive sublimate and the persalts of iron combine with moist fibrin, giving it increased firmness, and obviating its tendency to putrefy.

Moist coagulated fibrin decomposes binoxide of hydrogen, liberating oxygen, and reducing the binoxide to water, without itself undergoing any change. This property belongs to many organic substances which contain no fibrin, but it happens not to be possessed by coagulated albumen, which in most other respects so much resembles coagulated fibrin. The property just mentioned, and that of forming a jelly with acetic acid, are the most striking points of difference between the two substances.

Composition.

Fibrin was considered by Mulder as identical in composition with albumen of eggs, the formula he assigned for it being accordingly $10 \mathrm{Pr} + \mathrm{SP}\,\frac{1}{2}$; and in this view he has been followed by most other chemists. Dumas, however, after a very laborious experimental inquiry by M. Cahours and himself, has assigned to it a different composition; in the fibrin of human blood he found 52·78 of carbon, 6·96 of hydrogen, 16·78 of nitrogen, and 23·48 of oxygen; therefore, more nitrogen and less carbon than in protein or albumen. He states that, by long boiling in water, it yields a little ammonia and a peculiar soluble product, while the fibrin that remains undissolved is altered in nature, having become identical in composition with albumen; he therefore supposes that fibrin contains protein along with another substance. Fibrin yields on incineration about ⅔ per cent. of ashes, which consist principally of phosphate of lime, with a little phosphate of magnesia, and sometimes traces of silica.

Casein.

Casein is an albuminoid or protein compound, agreeing with albumen in constitution and in most of its properties. It is a well-known ingredient of milk; it exists also in smaller proportion in the pancreatic juice and some other secretions, and in the blood.

The most remarkable property of casein is that of being coagulated by rennet. Its solution is precipitated by acids, not excepting the acetic, and in this last circumstance it differs from albumen. The precipitates may be freed from acid, purified and redissolved in water, by which means pure casein may be obtained. In this condition it is soluble in water, and, to a small extent, in alcohol. Coagulated casein, on the other hand, is insoluble, or only very sparingly soluble. The acids combine with it, both in its liquid and coagulated state, its combinations closely resembling those of albumen, and it is precipitated from its acid solutions by ferroprussiate of potash. Like albumen, also, it forms soluble combinations with alkalies, and unites with alkaline earths; and the same earthy and metallic salts which precipitate liquid albumen likewise precipitate casein. Milk, or a concentrated solution of casein, is also precipitated by alcohol. When heated in an open vessel it becomes covered by an insoluble pellicle, which is ascribed to the formation of lactic acid by oxidation, and is said not to occur when milk is heated in carbonic acid.

Composition.

Casein yields on incineration 6 per cent. of phosphate of lime, and ½ per cent. of lime or its carbonate. It contains a little sulphur, but no phosphorus in chemical combination. Its basis is protein, and it may be represented as composed of 10 atoms of protein and one atom of sulphur.

GELATINOUS COMPOUNDS.

Gelatinous compounds.

Many of the solid parts of the body are, by long boiling in water, entirely or in great part reduced into a soluble substance, which has the remarkable property of forming a jelly with the water as it cools; and two distinct kinds of this substance have been recognized, which differ in a marked manner in many of their chemical characters, as well as in the sources from which they are derived. The one has been long known under the name of "gelatin," the other, being principally obtained from cartilages, has accordingly been named "chondrin." Neither kind of the gelatinizing substance is found in any of the animal fluids, nor, according to the view entertained by Berzelius, does it exist ready formed in the tissues which yield it; he conceives that these tissues are converted into gelatinous substance by the prolonged action of boiling water, somewhat in the same manner as starch may be changed into gum and sugar, and the analogy is strengthened by the fact, that in both cases the process is accelerated by the presence of a dilute acid.

Gelatin, its properties.

Gelatin, strictly so called, is obtained from the cellular and fibrous tissue, skin, serous membrane, and the animal basis of bone. The jelly derived from these tissues yields the dry gelatin in form of a hard transparent substance, which, when pure, is without colour, taste, or smell. It softens but does not dissolve in cold water; a gentle heat is, however, sufficient to effect its solution in water, and, as already stated, the solution, unless too much diluted, forms a jelly when cold. It is insoluble in ether, and very nearly insoluble in alcohol. With the aid of heat, it readily dissolves in acetic and diluted mineral acids.

A solution of gelatin in water is pecipitated by alcohol, creosote, and corrosive sublimate; but its most effectual precipitant is tannic acid, or a strong infusion of gall-nuts, which throws down gelatin, when dissolved even in 5000 times its weight of water; the precipitate, which has been named *tanno-gelatin*, is dissolved by adding a fresh quantity of gelatin. It is not precipitated by mineral acids, acetic acid, alum, sulphate of alumina, acetate and subacetate of lead, all which occasion a precipitate in a solution of chondrin; nor is gelatin thrown down from any of its solutions by the prussiates of potash, in which respect it differs from the albuminoid compounds. Gelatin combines with several salts; it readily dissolves freshly precipitated phosphate of lime, and it naturally contains about ½ per cent. of this salt, as appears by incineration.

Composition.

The composition of gelatin may be represented by the formula, C_{48}, H_{41}, $N_{7\frac{1}{2}}$, O_{18}, founded on an analysis of gelatin and of some of the tissues yielding it by Scherer. This formula gives the following proportions per cent.:—viz., carbon, 50·207, hydrogen, 7·001, nitrogen, 18·170, oxygen, 24·622. Hence it appears, that gelatin contains proportionally less carbon and more oxygen and nitrogen than are contained in albumen.

Chondrin, whence obtained; its properties.

Chondrin was first pointed out as a distinct substance by Müller. It is obtained from permanent cartilages, and the cartilage of bone before ossification, and from the cornea of the eye, by boiling these tissues for a long time in water. In its relations to water chondrin resembles gelatin, but the jelly it forms is not so firm. Like gelatin, also, it is thrown down from its solutions by tannic acid, alcohol, ether, creosote, and corrosive sublimate, and not by prussiate of potash. It differs from gelatin in being precipitated by the mineral and other acids, the acetic not excepted, also by alum, sulphate of alumina, persulphate of iron, and acetate of lead; the precipitates being soluble in an excess of the respective precipitants. According to Mulder, 100 parts of chondrin yield 49·96 of carbon, 6·63 of hydrogen, 14·44 of nitrogen, 28·59 of oxygen, and 0·38 of sulphur. Liebig gives the following formula from Scherer's analysis: C_{48}, H_{40}, N_{6}, O_{20}.

Composition.

EXTRACTIVE MATTERS.

Extractive matters, how obtained.

Serum of blood and several other animal fluids, on being freed from albuminous ingredients by heat or some other suitable means, and evaporated, yield a substance known under the name of animal extractive matter, usually mixed with fatty matters, from which it is to be separated by solution in water and subsequent evaporation. The same kind of substance may be extracted from many of the solid tissues, especially muscle, by macerating them in cold water, boiling the liquid to free it from albumen, and proceeding as before. The matter obtained from these different sources is associated with free lactic acid and several salts, especially the lactates of soda, lime, and magnesia, lactate of ammonia in minute quantity, the chlorides of sodium and potassium, phosphate of soda and phosphate of lime; moreover, the animal substance itself is separable into several different compounds, but even if the characters of these compounds were better defined than they are, it would here be out of place to enter into detail respecting them individually; it will be sufficient to point out the differences between the two principal classes of them.

Extractive, soluble in water.

1. *Extractive matters soluble in water only.*—While all are soluble in water, the substances included under the present head are insoluble in pure alcohol and rectified spirit; they are accordingly left undissolved after treating the mass with spirit of wine of specific gravity ·833, and along with them there remain the phosphates of soda and lime, with a portion of free lactic acid, rendered difficultly soluble in alcohol by its connexion with the animal matter. Of this group of extractive principles, one of the most important is a substance which has been named *zomidin*, from its being supposed to be the cause of the peculiar taste of boiled or roasted meat.

Zomidin.

Extractive, soluble in spirit.

2. *Extractive matters soluble in rectified spirit.*—By evaporating the spirit employed in the preceding operation there is obtained, along with the chlorides of sodium and potassium, and the greater part of the lactic acid and lactates, a yellowish brown matter, which was named *osmazome*, because the characteristic odour of soup seems to be owing to it. Berzelius has, however, shown that this matter may be further subdivided, by means of anhydrous alcohol, into an extractive substance, which is soluble in that menstruum, and another which is not; the lactic acid and lactates being shared between the two; for though the acid and salts in question are naturally soluble in pure alcohol, a certain portion pertinaciously abides by the insoluble organic substance. Finally, the two matters thus separated from each other by pure alcohol are themselves mixtures of two or more principles, which show different reactions with corrosive sublimate, subacetate of lead, tannin, &c.

Osmazome;

probably derived from transformation of the tissues.

The extractive compounds obtained from a tissue are supposed to be contained in the fluids which penetrate the solid substance, and Berzelius has suggested that these matters, as well as the lactic acid, lactates, and other salts, which seem invariably to accompany them, are the product of the continual change or waste of the tissues, especially of the muscular substance, which naturally takes place in the economy, and that they are destined to be separated from the tissue, and afterwards eliminated from the blood by the excretions; a view which, as he states, is strengthened by the fact, that principles of the same kind are found in the urine.

FATTY MATTERS.

Fatty matters; general characters of.

The substances of this class which are found in the human body possess the following general characters: They are lighter than water, fusible at a moderate heat, insoluble in water, and soluble in ether and in boiling alcohol. They are divided into the proper fats, or such as are capable of forming a soap with alkalies and oxides, and those which are not saponifiable.

SAPONIFIABLE FATS.

Saponifiable fats; their constitution.

The common fat of the human body may be represented as a mixture of a solid fatty substance, named "margarin," and a liquid oily substance, "olein;" the suet or fat of oxen and sheep, on the other hand, consists chiefly of a second solid principle, "stearin," associated with olein. These three substances, margarin, stearin, and olein, are themselves compounds of a base, named "glycerine," with three different fatty acids, the margaric, stearic, and oleic. In the saponification of fat these acids combine with the alkali or oxide employed, and the glycerine is set free.

Glycerine.

Glycerine.—The common base of the above-mentioned compounds, is obtained separately as a liquid of syrupy consistence, and remarkably sweet taste, from which circumstance it has received its name. It is supposed to be an oxide of a hypothetical radical "glyceryl," which again is composed of C_6, H_7, this, combined with 5 atoms of oxygen, forms an oxide, and the oxide of glyceryl, in separating from the acids with which it is naturally combined in fat, unites with one atom of water to form glycerine, so that glycerine is, strictly speaking, a hydrated oxide of glyceryl, and has the formula, $C_6, H_7, O_5 + HO$.

Margaric and stearic acids.

Margaryl.

Stearin.

Margarin.

Margaric and stearic acids.—These acids are both obtained as solid crystalline substances, soluble in ether and in boiling alcohol, and fusible, the margaric being more fusible than the stearic. They combine with bases, but, having weak acid properties, are separated from their combinations by most other acids. They are both compounds of a radical "margaryl," C_{34}, H_{33}, with different proportions of oxygen, and, in their uncombined state, are obtained as hydrates. One atom of margaryl, with three of oxygen, and one of water, form margaric or "margarylic" acid, $C_{34}, H_{33}, O_3 + HO$; and two atoms of margaryl, with five of oxygen, and two of water, $2(C_{34}, H_{33}), O_5 + 2HO$, form stearic acid, which is, therefore, "hypomargarylic" acid. The combined water quits them when they unite with bases. *Stearin*, or the acid stearate of glycerine, is soluble in alcohol and ether, and separates from its solutions in crystalline plates; but, on being fused and cooled, it appears as a white, waxy-like, pulverisable substance, which is not crystalline. *Margarin*, or margarate of glycerine, in most of its properties, resembles stearin, but it is more fusible and more soluble in ether and alcohol.

Oleic acid.

Olein.

Oleic acid is an oily liquid, possessing very distinctly acid properties. It solidifies into a crystalline mass a few degrees above the freezing point of water. Its formula is C_{44}, H_{39}, O_4. *Olein*, the oleate of glycerine is also a liquid substance at ordinary temperatures, insoluble in water, but easily soluble in ether and in alcohol. It is the chief constituent of the fat oils, and of most solid fats found in nature; with margarin it forms the human fat.

Cerebric Acid.

Cerebric acid.—From the researches of Fremy, it appears that the chief constituent of the fat found in the brain is a compound of soda, with a peculiar acid, the "cerebric," which also exists in a free state. The cerebric acid differs from other fatty principles as yet known in containing nitrogen; 100 parts of it consist of carbon 66·7, hydrogen 10·6, nitrogen 2·3, oxygen 19·5, and phosphorus 0·9.

Unsaponifiable Fats.

UNSAPONIFIABLE FATTY MATTERS.

Cholesterin.

Cholesterin is a solid, white, crystalline substance, which may be obtained in small quantity from the blood, the bile, and the substance of the brain and nerves. It is found much more abundantly in many morbid products, dissolved, swimming in fluid in form of crystalline scales, or forming solid concretions, as in biliary calculi, the most common species of which are formed of cholesterin, tinged with the colouring principles of the bile. Cholesterin fuses at 278°; it is soluble in ether, sparingly soluble in cold, but abundantly so in boiling alcohol. It possesses no acid properties, and is not acted on by alkalies; by nitric acid it is converted into cholestearic acid. The formula of cholesterin is C_{37}, H_{32}, O.

Serolin.

Serolin.—When blood is dried, deprived of matters soluble in boiling water, and repeatedly treated with boiling alcohol, a small quantity of a fatty substance thus named is obtained, which separates from the alcohol on cooling, as a shining flocculent mass. It possesses neither acid nor alkaline properties, fuses at 97°, is readily soluble in ether, sparingly so in boiling alcohol, and quite insoluble in cold alcohol.

SUMMARY OF THE LEADING CHARACTERS OF THE FOREGOING SUBSTANCES.

A. *Albuminoid principles*, albumen, fibrin, and casein. Coagulable, fibrin spontaneously, albumen by heat, casein by rennet. Precipitated by mineral acids, tannic acid, alcohol, corrosive sublimate, subacetate of lead, and several other metallic salts. *When coagulated*, not soluble in water, cold or hot, unless after being altered by long boiling; insoluble in alcohol; soluble in alkalies; soluble in very dilute and also in concentrated acids; the solutions precipitated by red and yellow prussiates of potash.

B. *Gelatinous principles*, gelatin and chondrin. Not dissolved by cold water; easily soluble in hot water, the solution gelatinizing when cold. Precipitated by tannic acid, alcohol, ether, and corrosive sublimate, and not by the prussiates of potash. *Chondrin*, precipitated by acids, alum, sulphate of alumina, and acetate of lead, which do not precipitate gelatin.

c. *Extractive matters*, associated with lactic acid and lactates. All soluble in water, both cold and hot; some in water only, some in water and rectified spirit; some in water, rectified spirit, and pure alcohol.

d. *Fatty matters.* Not soluble in water, cold or hot; soluble in ether and in hot alcohol.

VITAL PROPERTIES OF THE TEXTURES.

Vital properties and vital stimuli.

Of the phenomena exhibited by living bodies, there are many which, in the present state of knowledge, cannot be referred to the operation of any of the forces which manifest themselves in inorganic nature; they are therefore ascribed to certain powers, endowments, or properties, which, so far as known, are peculiar to living bodies, and are accordingly named "vital properties." These vital properties are called into play by various stimuli, external and internal, physical, chemical, and mental; and the assemblage of actions thence resulting has been designated by the term "life." The words "life" and "vitality" are often also employed to signify a single principle, force, or agent, which has been regarded as the common source of all vital properties, and the common cause of all vital actions.

Assimilative property.

1. Of the vital properties, there is one which is universal in its existence among organized beings, namely, the property, with which all such beings are endowed, of converting into their own substance, or "assimilating," alimentary matter. The operation of this power is seen in the continual renovation of the materials of the body by nutrition, and in the increase and extension of the organized substance, which necessarily take place in growth and reproduction; it manifests itself, moreover, in individual textures as well as in the entire organism. It has been called the "assimilative force or property," "organizing force," "plastic force," and is known also by various other names. But in reality the process of assimilation produces two different effects on the matter assimilated: first, the nutrient material, previously in a liquid or amorphous condition, acquires

determinate form; and secondly, it may, and commonly does, undergo more or less change in its chemical qualities. Such being the case, it seems reasonable, in the mean time, to refer these two changes to the exercise of two distinct properties, and, with Schwann, to reserve the name of "plastic" property for that which gives to matter a definite organic form; the other, which he proposes to call "metabolic," being already generally named "vital affinity." Respecting the last-named property, however, it has been long since remarked, that, although the products of chemical changes in living bodies for the most part differ from those appearing in the inorganic world, the difference is nevertheless to be ascribed, not to a peculiar or exclusively vital affinity different from ordinary chemical affinity, but to common chemical affinity operating in circumstances or conditions which present themselves in living bodies only; and undoubtedly the progress of chemistry is daily adding to the probability of this view.

Plastic and metabolic properties.

Vital contractility.

2. When a muscle, or a tissue containing muscular fibres, is exposed in an animal during life, or soon after death, and scratched with the point of a knife, it contracts or shortens itself; and the property of thus visibly contracting on the application of a stimulus is named "vital contractility," or "irritability," in the restricted sense of this latter term. The property in question may be called into play by various other stimuli besides that of mechanical irritation, especially by electricity, the sudden application of heat or cold, salt, and various other chemical agents of an acrid character, and, in a large class of muscles, by the exercise of the will, or by involuntary mental stimuli. The stimulus may be applied either directly to the muscle, or to the nerves entering it, which then communicate the effect to the muscular fibre, and it is in the latter mode that the voluntary or other mental stimuli are transmitted to muscles from the brain. Moreover, a muscle may be excited to contract by irritation of a nerve not directly connected with it. The stimulus, in this case, is first conducted by the nerve irritated to the brain or spinal cord; it is then, without participation of the will, and even without consciousness, transferred to another nerve, by which it is conveyed to the muscle, and thus at length excites muscular contraction. The property of nerves, by which they convey stimuli to muscles, whether directly, as

How excited.

in the case of muscular nerves, or circuitously, as in the case last instanced, is named the "vis nervosa."

Vis nervosa.

Supposed non-muscular contractility.

Besides the obviously muscular textures, there are others which possess a certain amount of vital contractility, although the existence of muscular fibres in them has not been satisfactorily demonstrated. In the present state of knowledge, therefore, we cannot with certainty affirm that vital contractility belongs exclusively to muscular structure. Some physiologists, indeed, have attempted to distinguish the contractility observed in textures not reputed muscular, from the contractility of muscle, and have named it "non-muscular" vital contractility; but, except as regards its seat, it cannot be said to have any distinctive character; for the contractility acknowledged to be muscular differs itself in different muscular textures in the rapidity and force with which it is exerted, as well as in the nature of the stimuli by which it is excited.

Tests of vital contractility.

The evidence that a tissue possesses vital contractility is derived, of course, from the fact of its contracting on the application of a stimulus. Mechanical irritation, as scratching with a sharp point, or slightly pinching with the forceps, electricity obtained from a piece of copper and a piece of zinc, or from a larger apparatus if necessary, and the sudden application of cold, are the stimuli most commonly employed. Heat, when of certain intensity, is apt to cause permanent shrinking of the tissue, or "crispation," as it has been called, which, though quite different in nature from vital contraction, might yet be mistaken for it; and the same may happen with acids and some other chemical agents, when employed in a concentrated state: in using such stimulants, therefore, care should be taken to avoid this source of deception.

Sensibility.

3. We become conscious of impressions made on various parts of the body, both external and internal, by the faculty of sensation; and the parts or textures, impressions on which are felt, are said to be sensible, or to possess the vital property of "sensibility."

a property of the nervous system.

This property manifests itself in very different degrees in different parts; from the hairs and nails, which indeed are absolutely insensible, to the skin of the points of the fingers, the exquisite sensibility of which is well known. But sensibility is a property which really depends on the brain and nerves, and the different tissues owe what sensibility they possess to the sentient nerves which are distributed to them. Hence it is lost in parts severed from the body, and it may be immediately extinguished in a part, by dividing or tying the nerves so as to cut off its connexion with the brain.

In estimating the degree of sensibility possessed by a tissue, whether in the human subject or by observations made on the lower animals, which for obvious reasons are much less satisfactory, several modifying circumstances must be taken into account, which will be duly adverted to in their proper place.

Relation of sensorial function and vis nervosa.

It thus appears that the nerves serve to conduct impressions to the brain, which give rise to sensation, and also to convey stimuli to the muscles, which excite motion ; and it is not improbable that, in both these cases, the conductive property exercised by the nervous cords may be the same, the difference of effect depending on this, that in the one case the impression is carried upwards to the sensorial part of the brain, and in the other downwards to an irritable tissue, which it causes to contract ; the stimulus in the latter case either having originated in the brain, as in the instance of voluntary motion, or having been first conducted upwards, by an afferent nerve, to the part of the cerebro-spinal centre devoted to excitation, and then transferred to an efferent or muscular nerve, along which it travels to the muscle. If this view be correct, the power by which the nerves conduct sensorial impressions and the before-mentioned "vis nervosa" are one and the same vital property ; the difference of the effects resulting from its exercise being due partly to the different nature of the stimuli applied, but especially to a difference in the susceptibility and mode of reaction of the organs to which the stimuli are conveyed.

DEVELOPMENT OF THE TEXTURES.

Original uniformity of structure.

The tissues of organized bodies, however diversified they may ultimately become, show a wonderful uniformity in their primordial condition. From researches which have been made with the microscope, especially during the last few years, it has been ascertained that the different organized structures found in plants, and, to a certain extent, also those of animals, originate by means of minute vesicles, or cells. These cells, remaining as separate corpuscles in the fluids, and grouped together in the solids, persisting in some cases with but little change, in others undergoing a partial or thorough transformation, produce the varieties of form and structure met with in the animal and vegetable textures. Nay, the germ from which an animal originally

Subsequent change.

springs, so far at least as it has been recognized under a distinct form, appears as a cell; and the embryo, in its earliest stages, is but a cluster of cells produced from that primordial one; no distinction of texture being seen till the process of transformation of the cells has begun.

No branch of knowledge can be said to be complete; but there is, perhaps, none which can, at the present moment, be more emphatically pronounced to be in a state of progress than that which relates to the origin and development of the textures, and much of the current opinion on the subject is uncertain, and must be received with caution. In these circumstances, in order both to facilitate the exposition, and to explain to the reader more fully the groundwork of the doctrines in question, we shall begin with a short account of the development of the tissues of vegetables; for it was in consequence of the discoveries made in the vegetable kingdom that the happy idea arose of applying the principle of cellular development to explain the formation of animal structures, and they still afford important aid in the study of that, as yet, more obscure process.

OUTLINE OF THE FORMATION OF VEGETABLE STRUCTURE.

Elementary structure of vegetables.

When a thin slice from the succulent part of a plant is viewed under the microscope, it is seen to consist chiefly or entirely of a multitude of minute vesicles adhering together, of a rounded or angular form, and containing various coloured or colourless matters in their interior; these are the elementary cells (fig. 1′; fig. 2′, [1, 2]). Besides such cells, phænogamous or flowering plants contain tubes, vessels, and other forms of tissue (fig. 2′, [4, 6]); but a great many plants of the class cryptogamia are composed entirely of cells, variously modified, it is true, to suit their several destinations, but funda-

Fig. 1′.*

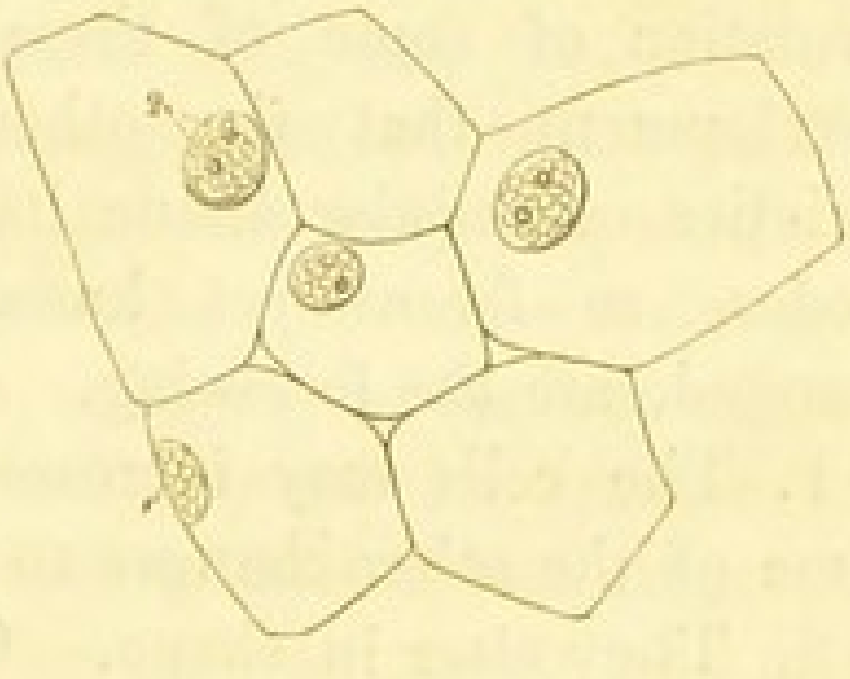

---

* Nucleated cells from a bulbous root; magnified 290 diameters. (Schwann.)

mentally the same throughout: nay, there are certain very simple modes of vegetable existence, in which a single cell may constitute an entire plant, as in the well-known green powdery crust which coats over the trunks of trees, damp walls, and other moist surfaces. In this last case, a simple detached cell exercises the functions of an entire independent organism, imbibing and elaborating extraneous matter, extending itself by the process of growth, and continuing its species by generating other cells of the same kind. Even in the aggregated state in which the cells exist in vegetables of a higher order, each cell still, to a certain extent, exercises its functions as a distinct individual; but it is now subject to conditions, arising from its connexion with the other parts of the plant to which it belongs, and is made to act in harmony with the other cells with which it is associated, in ministering to the necessities of the greater organism of which they are joint members. These elementary parts are therefore not simply congregated into a mass, but combined to produce a regularly organized structure; just as men in an army are not gathered promiscuously, as in a mere crowd, but are regularly combined for a joint object, and made to work in concert for the attainment of it; living and acting as individuals, but subject to mutual and general control.

Transformation of vegetable cells.

Now the varied forms of tissue found in the higher orders of plants do not exist in them from the beginning; they are derived from cells. The embryo plant, like the embryo animal, is in its early stages entirely formed of cells, and these of a very simple and uniform character; and it is by a transformation of some of these cells in the further progress of development that the other tissues, as well as the several varieties of cellular tissue itself, are produced. The principal modes, as far as yet known, in which vegetable cells are changed, are the following.

Enlargement.

1. The cells may increase in size; simply, or along with some of the other changes to be immediately described.

Change of figure.

2. They alter in shape. Cells have originally a spheroidal or rounded figure; and when in the progress of growth they increase equally, or nearly so, in every direction, and meet with no obstacle, they retain their rounded form. When they meet with other cells extending themselves in like manner, they acquire a polyhedral figure (fig. 2', [1, 2]) by mutual pressure of

their sides. When the growth takes place more in one direction than in another, they become flattened, or they elongate, and acquire a prismatic, fusiform, or tubular shape (fig. 2′, ³, ⁴, ⁵).

Fig. 2′.*

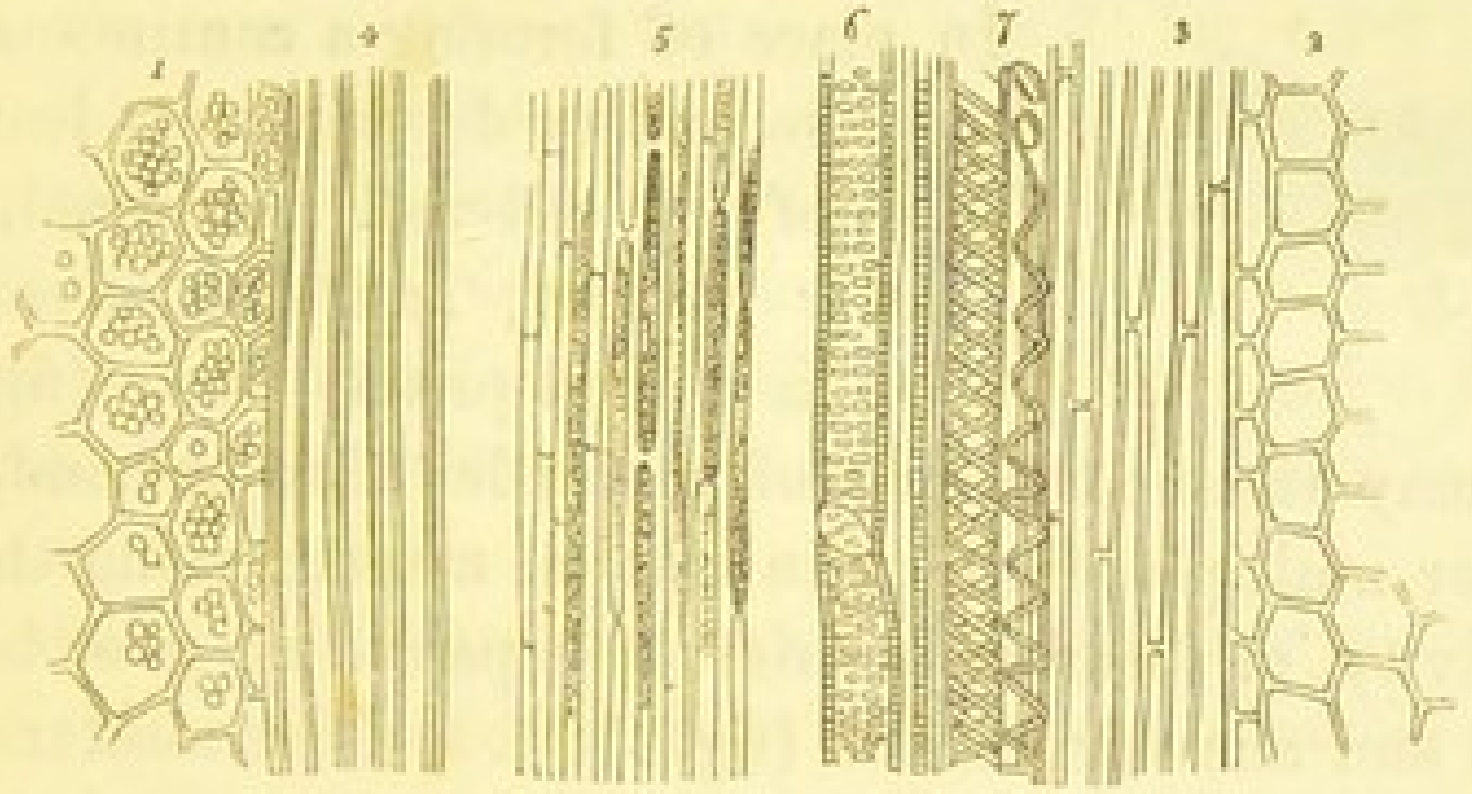

Sometimes, as in the common rush, they assume a star-like figure, sending out radiating branches, which meet the points of similar rays from adjacent cells (fig. 3′).

Fig. 3′.†

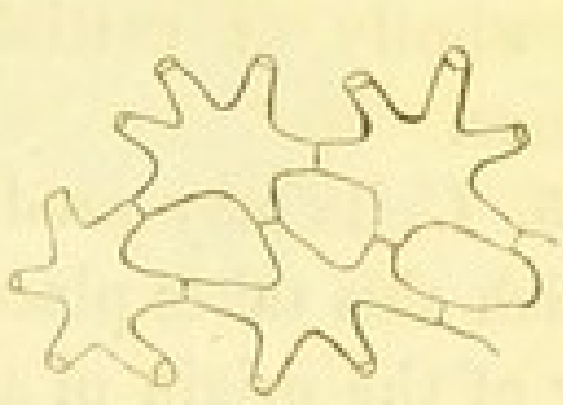

Coalescence with each other.

3. The cells coalesce with adjoining cells, and open into them. In this way a series of elongated cells placed end to end may open into one another by absorption of their cohering membranes, and give rise to a tubular vessel.

Alteration of substance.

4. Changes take place in the substance and in the contents of the cells. These changes may be chemical, as in the conversion of starch into gum, sugar, and jelly, and in the production of various coloured matters, essential oils, and the like. Or they may affect the form and arrangement of the contained substances: thus, the contents of the cell very frequently assume the form of granules, or spherules, of various sizes; at other times the contained matter, suffering at the same time a change in its chemical nature and in consistency, is deposited on the inner surface of the cell-wall, so as to thicken and strengthen it. Such "secondary deposits," as they are termed by botanists, usually occur in successive strata, and the deposition may

---

* Textures seen in a longitudinal section of the leaf-stalk of a flowering plant.

† Stellate vegetable cells.

go on till the cavity of the cell is nearly or completely filled up (fig. 4′). It is in this way that the woody fibre and other hard tissues of the plant are formed. It farther appears that the particles of each layer are disposed in lines, running spirally round the cell. In place of forming a continuous layer, these secondary deposits may leave little spots of the cell-wall uncovered, or less thickly covered, and thus give rise to what is named pitted tissue (fig. $2'$,^{6}); or they may assume the form of a slender fibre or band, single, double, or multiple, running in a spiral manner along the inside of the cavity, or forming a series of separate rings or hoops, as in spiral and annular vessels (fig. $2'$,^{7}). New matter may be absorbed or imbibed into the cells; or a portion of their altered and elaborated contents may escape as a secretion, either by transudation through the cell-wall, or by rupture or absorption of the membrane. Lastly, in certain circumstances, cells may be wholly or partially removed by absorption of their substance.

Fig. 4′.*



Production of new cells.

5. Cells may produce or generate new cells. The mode in which this takes place will be immediately considered, in speaking of the origin of animal cells.

FORMATION OF THE ANIMAL TEXTURES.

Resemblance of the process in animal and vegetables.

Passing now to the development of the animal tissues, it may first be remarked generally, that in some instances the process exhibits an obvious analogy with that which takes place in vegetables; certain of the animal tissues, in their earlier conditions, appearing in form of a congeries of cells almost entirely resembling the vegetable cells, and, in their subsequent transformations, passing through a series of changes in many respects parallel to some of those which occur in the progress of vegetable development. Cartilage affords a good example of this. Figures 5′ and 6′, A, are magnified representations of cartilage in its early condition; and whoever compares them with the appearance of vegetable cells, shown in figures 1′ and 2′, must at

---

* Cross section of ligneous cells containing stratified deposit.

once be struck with the resemblance. Fig. 6′, B and C, shows the subsequent changes on the primary cells of cartilage; the parietes are seen to have become thickened by deposit of fresh material, the spaces within the cells are consequently diminished, while the mass between the cavities is increased. Now this change seen to occur in the cartilage cells, though there may be a question as to the precise mode in which it is brought about, may very fairly be compared with the thickening of the sides of the vegetable cells, which takes place when they are converted into the woody and other hard tissues. Again, in most cartilages the cells increase in number as they diminish in size, new ones being formed within the old, as happens in many vegetable structures.

Fig. 5′.*

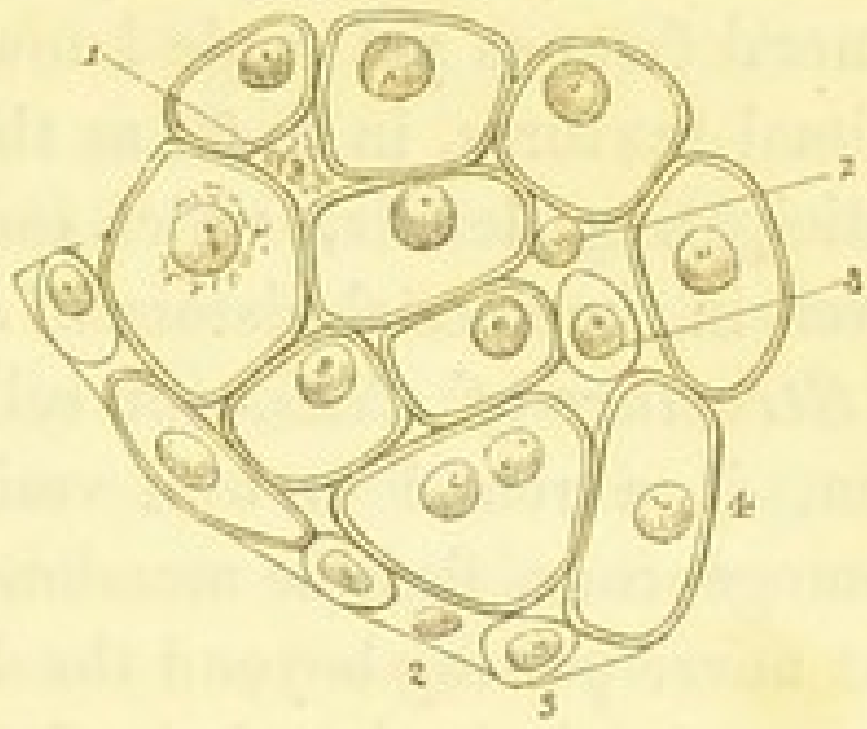

Fig. 6.′†

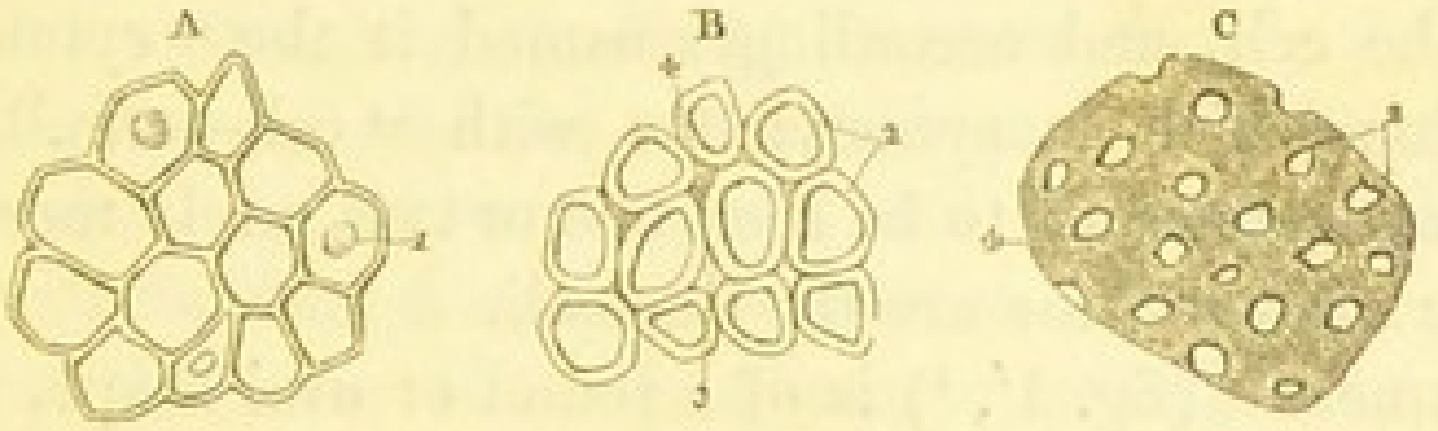

The instance now given, and others to the same effect which will be mentioned as we proceed, tend to show the fundamental resemblance of the process of textural development in the two kingdoms; but, when we come to inquire into the various modifications which that process exhibits in the formation of particular textures, we encounter serious difficulties. The phenomena are sometimes difficult to observe, and, when recognized, they are perhaps susceptible of more than one interpretation; hence have arisen conflicting statements of fact, and differences of opinion at present irreconcileable, which future inquiry alone

---

* Section of a branchial cartilage of a Tadpole, showing the early condition of the cells; magnified 450 diameters. (Schwann.)

† Cartilage of the branchial ray of a fish (*Cyprinus erythrophthalmus*) in different stages of advancement; magnified 450 diameters. (Schwann.)

can rectify, and which in the mean time offer serious obstacles to an attempt at generalization. In what follows, nothing more is intended than to bring together, under a few heads, the more general facts as yet made known respecting the formation of the animal textures, in so far as this may be done without too much anticipating details, which can only be suitably and intelligibly given in the special history of each texture.

Cells ;—their structure.

Structure of Cells.—A cell, before it has undergone alteration, is a round or oval vesicle, formed of thin, transparent, homogeneous, flexible membrane ; varying considerably in size, but never passing beyond the dimensions of a microscopic object. It contains in its interior a fluid or more consistent matter, pellucid or opaque, and in the latter case generally granular. In the greater number of cells there is also to be seen, at some period of their existence, a smaller body, called the "nucleus," which, as will afterwards appear, performs an important part in their economy. Schleiden attributed to it the function of producing the cell, and accordingly named it the "cytoblast," an appellation which is synonymous with "cell-germ." In the nucleus are commonly to be seen one or two, rarely more, minute eccentric spots ; these are the nucleoli.

Nucleus.

The nucleus (fig. 1′, ^{1}) is of a round or oval shape, and more constant in size than the cell itself: its average diameter in animal cells is from $\frac{1}{5000}$ to $\frac{1}{4000}$ of an inch ; its aspect is usually granular and dark, often with a yellowish hue, but sometimes quite homogeneous, transparent, and colourless. In some cases it is solid throughout, being then made up of fine molecular matter, or consisting of a cluster of large granules; in other instances, especially in animal cells, its mass appears to be hollow, or at least less consistent in the centre ; or it may present itself as a perfect vesicle, inclosing matters of very variable nature. It seems probable, also, that the large granules of which some nuclei appear to be made up, are in reality vesicles, containing peculiar matters in their interior ; examples, indeed, of composite vesicular nuclei of this description have been pointed out by Goodsir in various secreting structures.

Nucleolus.

As to the nature of the nucleolus (fig. 1′, ^{2}), little is known ; it has even been questioned whether the little spots termed nucleoli are actually corpuscles or vesicles inclosed in the nucleus, or merely minute cavities in its substance. Schleiden, however, states, that, in crushing the nucleus of vegetable cells, he has seen the nucleolus remain entire, and in such cases, of course, it must have been a distinct body. In many cells the nucleus presents no appearance of a nucleolus.

Situation of nucleus.

The nucleus may lie free in the cavity of the cell; more commonly it is attached to the inside of the cell-wall, and in some cases it is partially or wholly imbedded in the substance of the membrane. Henlé describes the nucleus of the pigment cells as situated quite on the outside, in a dimple of the cell-wall; but, I must confess, it has to me appeared otherwise: he also assigns an exterior position to the nucleus of the cells of the crystalline lens.

Effect of chemical agents.

It very generally happens, that, when cells are exposed to the action of certain chemical agents, their different parts are differently acted on. Thus, in many cases acetic acid speedily dissolves the granular or coloured contents of the cell, leaving the nucleus entire, and rendering it more sharply defined and more conspicuous; and the cell membrane itself may be sometimes dissolved by the same agent, and the nucleus liberated. But, notwithstanding this and other aids to investigation, it is not always possible to say whether a given corpuscle is to be reckoned as a cell, or as a vesicular nucleus.

Cells are often seen without nuclei; in vegetable cellular tissues, indeed, this is the general rule: but, doubtless, in most of these instances nuclei have at one time been present, and have subsequently disappeared. Cells occur, however, both in animal and vegetable structures, in which nuclei have never at any time been discovered.

Blastema.

Origin and Multiplication of Cells.—The soft or liquid organizable matter out of which cells are immediately produced, is named "blastema," or "cytoblastema." This substance may be contained in cells; it may be lodged in their interstices, or in the meshes of a tissue; or it may be deposited on the surface of parts. When the circulation of the blood is once established in the animal system, the clear part of that fluid, "the plasma," or "liquor sanguinis," as it is called, may be regarded as a generally diffused blastema, or at least as a general source whence the organizable material or blastema is derived. There is reason to believe that new cells may arise in any of those situations in which the blastema is found ; that is to say, they may be formed within previously existing or parent cells, or in the interstitial and free blastema. The included or "endogenous" mode of origin is the most general in the vegetable kingdom ; it occurs also in the animal body, as in the ovum, in cartilage, and in some other structures ; but Schwann maintains that in animals the free or interstitial mode of origin is the more common.

Now, as to the process by which cells are formed, it appears, from the statements of competent observers, that it may take place in more ways than one ; and it must be confessed that, for the present at least, these several modes of production of cells cannot with certainty be referred to one common principle.

Formation of a cell on a nucleus.

1. Formation of a cell on a nucleus.—A nucleus being produced in the first instance, by a process to be afterwards considered, the membrane of the cell is formed on the surface of the nucleus, at first closely surrounding it, but soon separating at one side, and gently rising up like a watch-glass on a watch (fig. 7′,^{4}). The cell-wall, continuing to extend, soon becomes much larger than the nucleus, which at last is left at some point of the circumference of the cell imbedded in the substance of the membrane, where it may either remain, or be removed by liquefaction or absorption (fig. 7′,$^{5, 6}$). This is the process, as it has been traced in vegetables by Schleiden, who was the first to discover the important part performed by the nucleus, or "cytoblast," as he accordingly named it. Schwann conceives that animal cells usually originate from nuclei or cytoblasts, in like manner. A layer of matter is deposited and condensed on the surface of the nucleus ; it then rises in form of a film or membrane, and separates to a greater or less extent from the nucleus, which remains adherent to its inner surface, or assumes a more central position. The cell membrane becomes firmer and usually thicker as it extends ; its expansion being accompanied by actual growth and increase of

Fig. 7′.*

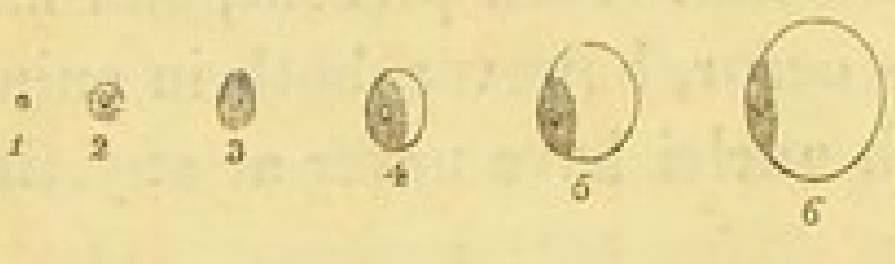

---

* Plan representing the formation of a nucleus, and of a cell on the nucleus, according to Schleiden's view.

substance, and not being simply the result of mechanical distension by the fluid which accumulates in its cavity.

Origin of nucleus.

Such being the manner in which a cell is formed round a nucleus, we have next to inquire how the nucleus itself originates; and here we meet with a difference of opinion. Schleiden and Schwann conceive that nucleoli first appear in the blastema; that then, round one or sometimes more of these nucleoli, fresh matter is aggregated, and the resulting little mass, becoming defined on the surface, constitutes the nucleus* (fig. 7′, $^{1, 2, 3}$). Schwann, indeed, regards the formation of a cell and the formation of a nucleus as a repetition of the same process; a deposit first taking place round the nucleolus to form the nucleus, and then a second layer being deposited on the nucleus to form the cell. He compares the process to that of crystallization, and ascribes the chief differences between the one and the other to the circumstance, that the permeable organic substance of the cell admits of increase, not only by external apposition of new particles, but by the intus-susception of new matter between the particles already deposited; whereas a crystal can grow only in the former way.† Henlé suggests a different view as to the formation of the nucleus, and brings forward arguments to show that it is formed independently of a nucleolus. He supposes that elementary granules of a discoid figure, and from $\frac{1}{12000}$ to $\frac{1}{6000}$ of an inch in diameter, first appear in the blastema; that two, three, or four of these group together to form the nucleus; that their union is at first imperfect, and may continue so even some time after the cell is somewhat advanced in formation; but that they ultimately become completely blended into a single mass. It is well known that in many cells, such as the corpuscles of lymph, mucus, and pus, the nucleus, when acted on by weak acetic acid, appears divided, either completely or partially, into

Elementary granules.

---

* Mr. Addison also describes the formation of cells and their nuclei (in lymph) in this manner. (Med. Gazette, 1841-42, p. 146.)

† Whatever opinion may be entertained as to the soundness of this and other speculative views of Schwann respecting the economy of cells, there can be no question that his discussion of them is highly instructive; it will be found in his admirable exposition of the whole subject of the cellular origin of the animal tissues. (Microscopische Untersuchungen, &c. Berlin, 1839.) To Schwann's celebrated work, as well as to the writings of Schleiden (translated in Taylor's Scientific Memoirs), Valentin, Henlé, and Barry, the reader is referred, as original sources of information on all that relates to the development of the textures.

two or three segments, and these Henlé conceives to be its constituent granules, as yet imperfectly united.

Nevertheless, he does not deny that a nucleus may be formed by the aggregation of matter round a single elementary granule, and it does not appear in what respect such a mode of formation differs from that proceeding from a nucleolus, as described by Schleiden. Indeed, it is not easy to see how, in any case, a distinction is to be made between the "elementary granules" of a nucleus, especially when they have not coalesced, and Schleiden's nucleoli. It is clear, also, that the nucleus contains, besides the granules, some other matter which surrounds them and binds them together, and which is softened or dissolved by acetic acid. Respecting these elementary granules, Henlé further states, that "they present themselves wherever new formations are about to take place." He supposes that they are, for the most part, minute vesicles filled with fat, but that in forming a nucleus their chemical nature is changed, the nucleus acquiring the characters of a protein compound. Lastly, he thinks it probable that these vesicular bodies are originally merely minute particles of oil which acquire a vesicular envelope of albuminoid matter, on the physical principle pointed out by Ascherson, viz. that globules of oil when brought into contact with liquid albumen, or some similar substance with which oil does not mix, become instantly surrounded with a coherent film or coating of that substance, and thus acquire a vesicular character.

Once the cell-wall is formed, the nucleus may remain without further change; or it may continue to grow larger, but always less rapidly than the envelope; or it may disappear altogether, as already stated: indeed this is the general rule with vegetable cells. Other changes which it undergoes will be afterwards mentioned.

Nucleus of a cell may produce new cells.

2. Resolution of the nucleus of a cell into new cells.—This mode of production has been inferred from the following succession of phenomena; which has not, indeed, been actually seen to occur in the same cell, but has been traced in a series of cells, apparently in different stages of progress. 1. A cell is seen with a nucleus. 2. The nucleus has vanished, and in its place a group of young nucleated cells have appeared, within the original cell. 3. The young progeny, increasing in size, escape by rupture or absorption of the parent cell.

In this case are we to suppose that the nucleus of the original cell becomes resolved into shapeless blastema, from which fresh nucleoli and nuclei arise and produce the new cells? or do the granules of the parent nucleus, or the segments into which it may divide, serve as nucleoli or perhaps as smaller nuclei round which cell membranes are formed, they themselves growing larger all the while ? or, lastly, are these granules really minute vesicular bodies which at once expand into perfect cells, subsequently acquiring nuclei, which in turn may go through the same process ? The undermentioned observations of Kölliker agree with the second, and several facts, stated by Barry and Goodsir, with the last of these suppositions. Dr. Barry, however, represents the nucleus as affording many series of cells in succession ; those last formed pushing outwards their older and larger predecessors in concentric ranks, towards the circumference of the parent cell (fig. 8′). He conceives, also, that the young cells themselves contain incipient cells of a still younger generation in their interior ; in short, that the same process which occurs in the primary cell takes place in each one of its progeny, and that it is impossible to say where the series of new generations terminates. Moreover, he states that only some of the young cells survive, namely, those into which the nucleus in the end divides ; the rest having only a temporary existence, and disappearing by liquefaction ; and he supposes that the transitory cells serve to elaborate material to be afterwards assimilated by the persistent ones.

Fig. 8′.*

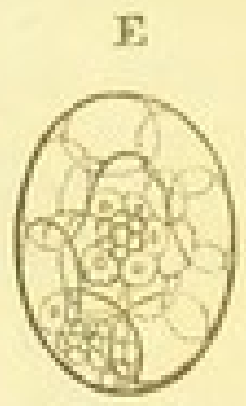

Reduplication of cells in the ovum.

To this head is to be referred the increase of cells by reduplication, which is seen to take place in the ovum after fecundation, and probably occurs also at after-periods in the growth of some of the textures. The following is an outline of that process, as observed by Kölliker,† in the ova of certain parasitic worms, in which it presents itself in its least complex form, and from the transparency of the objects can be traced with comparative ease.

Before impregnation there is seen, as usual, within the ovum in the midst of the yolk the vesicular body named the germinal vesicle ; this contains a smaller mass within it, the macula germinativa, and has therefore the aspect of a nucleated cell. After the ovum has been fecundated, the germinal vesicle vanishes, all trace of it being lost ; but in its place a nucleated cell soon presents itself, which appears to be a new formation (fig. 9′, A). This first "embryonic cell" is soon succeeded by two others (B), these by four (D), and these again by eight ; the number thus doubling, and the cells becoming individually smaller (F, G), till there results a large mass of cells (H),

---

* Scheme from Dr. Barry, showing young cells growing within a larger one in concentric series. One of the young cells is represented as filled with a still younger generation.

† Müller's Archiv., 1843, p. 68.

which assumes the form of the embryo. Now, in this case it is clearly ascertained that at every reduplication a pair of new cells are formed within each of those already existing, the old or parent cells then disappearing, and the new ones becoming free; and stages of the process are observed, in which the parent cells, not having yet disappeared, are seen with a couple of young ones still included within them (C and E).

Fig. 9′.[*]

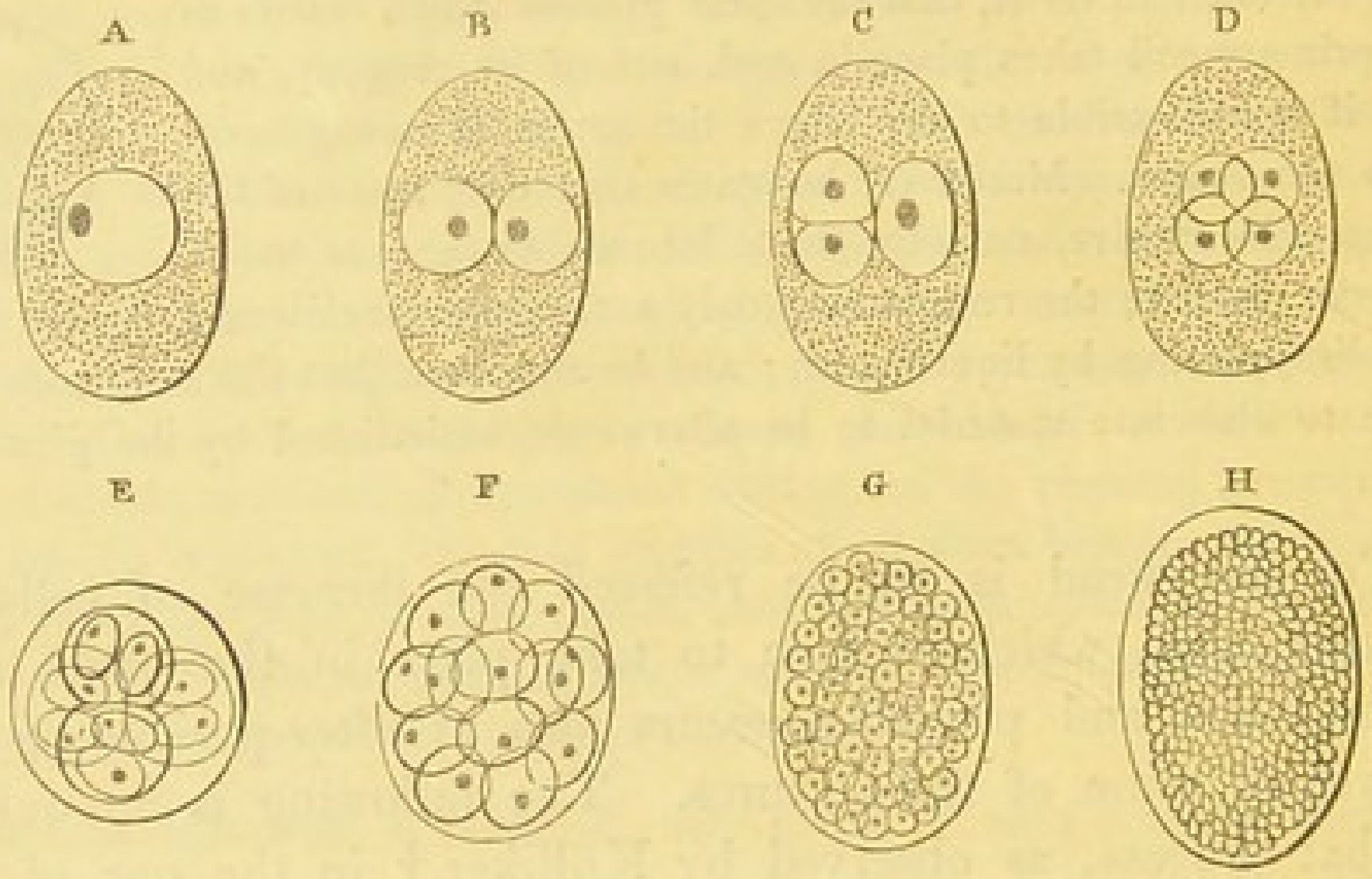

Division of nucleus.

It seems probable that, when the two young cells are about to be formed, the nucleus of the parent cell divides into two, and that each segment then gives rise to a new cell. In support of this view, Kölliker states that he has occasionally observed cells with the nucleus elongated; others in which it was constricted in the middle, as if about to divide; in others, again, there were two nuclei, of smaller size than the single nucleus of adjoining cells, as if they had just arisen from the division of a larger one[‡] (fig. 10′, $^{1, 2, 3, 4}$).

Fig. 10′.[†]

---

[*] A, B, C, D, successive stages of the ovum of Ascaris dentata, showing duplication of cells. E, F, G, H, ovum of Cucullanus elegans, showing the advance of the process. (From Kölliker's Memoir.)

[†] Cells from ovum of Cucullanus, showing supposed division of the nucleus. (Kölliker.)

[‡] The apparent division of a cell, by the formation of a partition across its cavity, which has been supposed to be a common mode of multiplication of cells in vegetables, is in most cases, very probably, as Schleiden explains,

3. Matter collects round a nucleated cell, and the whole becomes inclosed in an envelope, thus constituting a larger cell, to which the inclosed one serves as a nucleus. Cells of this kind have been called "complicated," or "complex" cells.* The ganglionic globules of the brain and nerves, to be afterwards described, have been looked on as complex cells, and are supposed to be formed in the manner described. The ovum itself is an instance of a complex cell: a small corpuscle, the "germinal spot," appears first; round this, as a nucleus, a cell, the "germinal vesicle," is formed; and then the matter of the yolk collects round the germinal vesicle, and gets inclosed in an exterior membrane; this becomes a second cell, and includes the germinal vesicle as its nucleus.

Complex cells.

The curious phenomenon of furrowing, or rather cleaving, of the yolk, now known to occur in the ova of many animals as one of the earliest effects of fecundation, is connected with the production of complex cells. This remarkable process appears to take place in the following manner.

When the ovum is fertilized, the germinal vesicle, as usual, disappears, and a new cell takes its place in the centre of the yolk. At the same time the mass of the yolk appears to shrink, as if its granules had become more densely congregated round the central cell. This first embryonic cell gives place to two others; then the yolk divides into two halves, and each half incloses one of the first pair of cells in its centre (fig. 11′, A). The first two cells are succeeded by twice as many new ones, and the two masses of yolk are subdivided into four, each new yolk-segment inclosing a cell in its centre, as before (fig. 11′, B). The central cells and the inclosing segments of the yolk are again doubled so as to form eight, and this duplication of the cells and concomitant cleaving of the yolk are continued till the masses are greatly increased in number and reduced in size (C, D, E); each of them being

Cells formed by cleaving of the yolk.

---

merely an instance of the endogenous production of twin cells, the contiguous sides of which form the septum, as in c (fig. 9′). But it is doubtful whether the multiplication by partition of a cell may not occur in the algæ, as Mohl has described; Valentin refers to corroborative observations by Shuttleworth, as yet unpublished.

[*] By Henlé: "secondary" cells might perhaps be a more fitting appellation, but that term has already been employed in another sense.

Fig. 11'.*

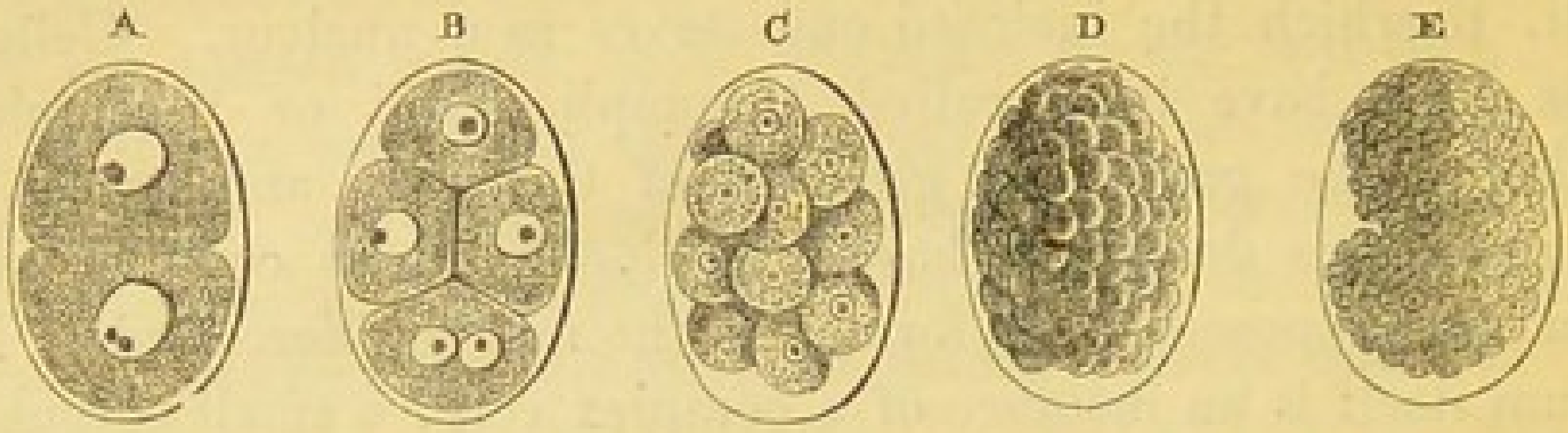

then a complex cell containing a smaller cell within, together with more or less of the matter of the yolk in different instances. Their further changes and ultimate destination it is unnecessary here to pursue.

While it is admitted that the segments of the yolk eventually become inclosed by membranes and form true cells, it has been questioned whether its earlier and larger subdivisions are really surrounded by an enveloping membrane. Acknowledging the difficulty of the question, I should nevertheless be disposed, from what I have seen in the ovum of the ascaris, to answer it in the affirmative, as regards that instance at least. As to the mode of multiplication of the included cells, we can hardly doubt that each pair of young cells are formed within the cell immediately preceding, by subdivision of its nucleus, in the manner previously described (see lower cell in A) ; the difference in this case being, that each of the young cells, on escaping from the maternal one, becomes wrapt up in the centre of a mass of yolk. The duplication of the cell must of course take place before the division of its including yolk-mass (see lowest segment of B), and is doubtless a necessary condition of it. As to the mechanism of the latter process, we may presume that the cells exercise a sort of attraction on the substance of the yolk, causing it to gather round them as so many separate centres. The shrinking of the granular mass, already noticed, apparently from the more close aggregation of its granules round the central cell, is in harmony with this supposition. I may remark that in the ova of the ascaris nigrovenosa, and asc. acuminata, the granules of the yolk exhibit very lively molecular movements. On one occasion, when one of the large segments, into which the yolk is first cleft, divided itself into two portions while actually under inspection, I first observed a very obvious heaving motion among the granules throughout the whole mass ; then ensued a constriction at the circumference, which, proceeding inwards, soon completed the di-

---

* Cleaving of the yolk after fecundation. — A, B, C, (from Kölliker,) ovum of Ascaris nigrovenosa ; D and E, that of Ascaris acuminata (from Bagge).

vision; but all this time the central cells were quite hidden by the enveloping granular matter.*

The process above described, in some animals, affects only a part of the yolk; while in others, again, it has not been discovered.

Origin independently of nuclei.

4. A cell may arise without the previous formation of a nucleus. Schwann describes such cells as occurring within larger ones in the "chorda dorsalis" (a transitory cartilaginous structure) of the tadpole and fish. He states that they commence as small spherules, which either from the beginning are, or subsequently become, hollow, and expand into cells. Vogt maintains that they afterwards acquire nuclei, but his description is ambiguous. Other examples are given of a cell commencing as a small granule or spherule, and subsequently acquiring a nucleus.†

Another mode in which a cell is said to be formed without a nucleus, is by the agglomeration of granular matter into a considerable mass, which becomes surrounded by a membrane; there results a cell filled with granular contents, but without a proper nucleus. The large granulated corpuscles which have been described as sometimes occurring in inflammatory exudations, and in various morbid growths, under the name of "compound inflammation globules," are said to be examples of this (Henle). The sporules of certain algæ are also described as being formed in the same way.

Multiplication by sprouting.

5. In some of the most simple vegetables multiplication takes place by a sort of sprouting of young cells from the old ones. In the yeast-plant, for example, (fig. 12′,) the young cells are seen in various stages of growth, springing from the circumference of older and larger cells ($^{1,\,2}$). The young cell

---

* Dr. Barry has called attention to the very interesting fact of the resemblance between the spontaneous division of infusorial animalcules, and the process here described. The phenomenon observed in infusoria of the division of a pellucid globule within the animal, which precedes the division of its entire body, is probably owing to the formation of two cells within a central one, and to their subsequent separation from each other, to become the central cells of the respective segments of the body, as happens in the divided yolk. It is worthy of inquiry whether certain phenomena observed in the vegetable kingdom may not be referable to a similar process; as, for instance, the subdivision of a granular mass into separate portions, which occurs in the formation of the sporules of mosses and hepaticæ.

† See, among others, Macleod, in Lond. and Edin. Journal of Medical Science, 1842, p. 829.

Fig. 12′.*

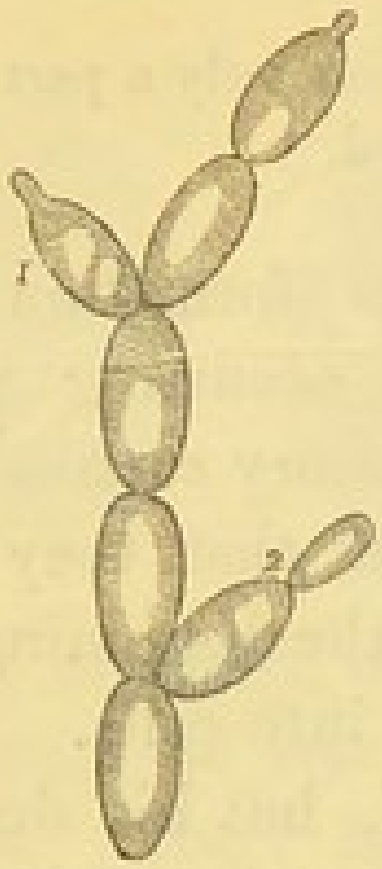

is usually described as being at first a mere saccular protrusion of the wall of the old cell (1), and becoming afterwards cut off from it (2) ; but I must confess that, in this instance, I have never been able to satisfy myself that the cavity of the young cell communicated with that of its parent cell, as represented in the figure, even in its earliest stages ; although the lateral protrusion of a cell doubtless occurs in various other algæ.

Nature of cell-germ.

Finally, as to the nature and origin of the cell-germ. From what has been stated in the preceding paragraphs, it will be apparent that a nucleus and a cell-germ, or cytoblast, are not always the same thing. In many cases the cell is formed round a nucleus, and the latter may be then properly called a cytoblast, though it may itself owe its origin to a nucleolus. In other instances the nucleus seems to be an after-formation in a cell originally without one, serving as a sort of reproductive or generative organ to furnish the germs or rudiments of young cells. It may be a cytoblast, therefore, in two senses,—by generating the cell which contains it, and by resolving itself into the germs of a new cell-family ; but it was in the former character that the term was applied to it by Schleiden, and in this sense there are other objects which equally deserve the appellation : we have seen, indeed, that a cell itself may stand in the relation of a cytoblast to a larger cell formed round it. When several cellules arise within a larger cell by resolution of its nucleus, their germs, or first rudiments, are described as minute spherules much resembling nucleoli ; and these, perhaps, becoming hollow, may at once expand into cells, or they may become surrounded by a cell-membrane, but without the intermediate step of forming the larger body usually termed a nucleus. The so-called nucleus in the cells of the ovum of the entozoa, already described (figs. 9′, 10′, and 11′), corresponds more with a nucleolus, if size be regarded as a character, and this body is supposed to divide into two cell-germs. Lastly, minute spheroidal cell-rudiments, which grow into cells, would seem to occur free in the blastema, from whatever source they have been originally derived.

Original source of germinative matter.

Seeing the successive generations of cells which proceed from a single one in the ovum, and the propagation of cells in a similar manner which in many circumstances occurs at after-periods, physiologists have been naturally led to look to the germinal vesicle of the ovum for the original source to which all succeeding cell-germs in the economy might be traced back ; and, that vesicle being itself derived from the parent organism, they

---

* Magnified figure of the yeast-plant, *Saccharomyces cerevisiæ*. (After Meyen.)

have conceived that a peculiar germinative matter, probably constituting the substance of the germinal spot, is handed down from parent to offspring, and, receiving an impulse by fecundation, begins in the ovum the series of assimilative and reproductive actions which is afterwards continued throughout life. Dr. Barry has given a formal theory of the origin and multiplication of cells, in which he represents the germinative matter as a peculiar pellucid substance, and proposes to call it "hyaline." He conceives that this substance is derived from the germinal spot of the ovum, and, after fecundation by the male, acquires remarkable properties, among others, that of increasing by the assimilation of new matter, and that of propagating itself by division; and he supposes that the globules into which it divides form so many germs of new cells: according to him, therefore, the cell-germ is a globule of hyaline. He is farther of opinion, that many cells which have but a transitory existence, are intended for no other purpose than to reproduce the hyaline; successive generations of them being sometimes employed in elaborating this substance.

Dr. Barry's theory.

It is in the very nature of this subject to excite speculation and engender hypotheses; and, as to those which have been already produced, we may be permitted to remark, that, however plausibly they may harmonize with some of the phenomena, we cannot receive any one of them with confidence until it shall have stood the test of a much more extended comparison, than has yet been made, with the results of observation.

Transformation of Cells and Blastema.—In the conversion of cells into the several textures, there is, in different instances, a great difference not only in the nature and extent of the change which the cells undergo, but also in the condition which these bodies have attained when the process of change commences. In some cases they have already acquired a distinct cell-wall and cavity; but in others they never attain the condition of cells, strictly so called, and the process of transformation begins whilst they may be said to be but in a nascent state. Indeed, in the development of certain textures, as will afterwards be explained, there is reason to believe that the preliminary process of cell-formation, if in the circumstances we may properly use such a term, goes no farther than the production of nuclei, and that the blastema surrounding or lying between the nuclei, which themselves undergo transformation, is at once converted into the elements of the tissue. The following are the principal modes in which cells or their elements are metamorphosed; it being understood that two or more of the processes, here to be mentioned, may occur in the same cell, and that the nucleus also undergoes changes which will subsequently be explained.

Transformation of animal cells.

Enlargement, alteration of shape.

1. Increase in size, and change of figure.—A cell may increase equally, or nearly so, in all its dimensions, in which case it preserves its globular shape; but more commonly the growth is greater in certain dimensions, and then the figure becomes depressed and discoid, or elongated and oval, fusiform or strap-shaped. When growing cells meet one another, they generally acquire an angular or polyhedral figure; and this may be combined with elongation into the prismatic, or flattening into the tabular form, as exemplified in the columnar and scaly varieties of epithelium. All these changes correspond with similar transformations already spoken of, which occur in vegetable cells. A more remarkable change of figure occurs in those instances where a cell shoots out into branches at various points of its circumference, as happens with certain varieties of pigment cells (fig. 13′); and this, too, may be aptly compared to the ramified or radiating cells found in the rush and some other plants (fig. 3′).

Fig. 13′.*

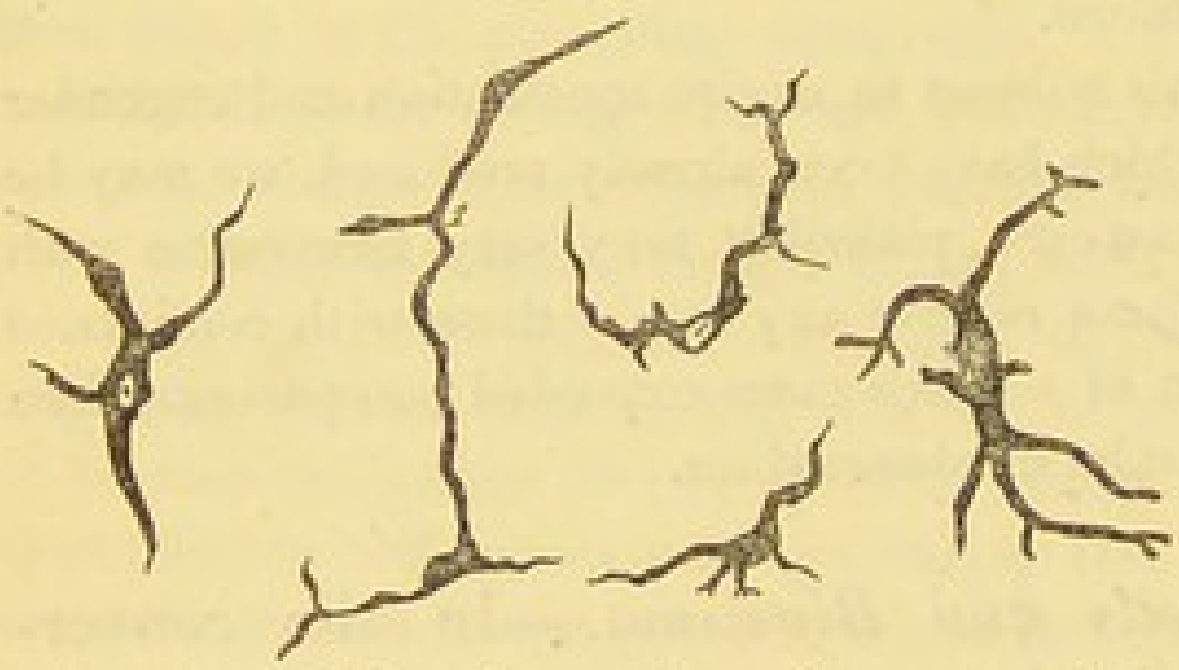

Alteration of substance and contents.

2. Alteration of substance and of contents.—While the above-described changes of figure are going on, the cell-wall usually acquires increased density and strength; and in a flattened cell, when much extended, the opposite sides cohere so as to obliterate its cavity. The substance of cells may also be changed in its chemical nature, as in the instance of the cuticle, where the cells, while deep-seated, and recently formed, are soluble in acetic acid, but, as they advance to the surface, lose this property and acquire a corneous character.

Consumption of contents.

Granular matter contained within cells may be dissolved and consumed whilst the cell extends itself, as happens with those of the yolk of the bird's egg when they join to form the early rudiments of the embryo.

New deposits.

On the other hand, new matters may appear, as fat and pigment within the adipose and pigmentous cells, and the peculiar constituents of certain

---

* Pigment cells from the tail of the Tadpole, magnified about two hundred and twenty-five diameters. (Schwann.)

secretions in the cells of secreting organs; in which last case the cells may eventually burst, and discharge their contents.

Thickening of cell-wall.

As in plants, too, the new substance may be so deposited as to augment the thickness and strength of the cell-wall, of which an example occurs in the thickening of the sides and narrowing of the cavity of cartilage-cells by layers of new matter on their internal surface. Or the process may assume still more of a plastic and organizing character, as in the endogenous production of young cells, already described, and the formation of the spontaneously moving bodies named spermatozoa, or spermatic animalcules, which, in plants as well as in animals, are produced in the cavity of a cell.

Cause of these changes.

These plastic changes are equally unexplained with the other alterations of form and structure which accompany the production and metamorphoses of cells. As regards the changes in the quantity and chemical nature of the contained matter, it may be remarked, that the introduction of new matter into a cell is so far a phenomenon of imbibition, and, as such, must be to a certain extent dependent on the endosmotic effect produced by the substance already within the cell, and on the comparative facility with which the matter to be introduced is imbibed and transmitted by the permeable cell-wall. Some substances, moreover, being more readily imbibed than others of a different nature, the quality as well as the quantity of the imbibed material will be so far determined by the same circumstances. But, while an alteration in the contents of a cell may be thus brought about by the imbibition of one kind of matter in preference to another, the contained substance may be also changed in its qualities by a process of conversion taking place within the cell, and there are two conceivable ways in which this conversive or "metabolic" process may possibly occur. 1. Chemical action may be mutually exerted between the matter originally contained in the cell, and that subsequently introduced into it. 2. It has been supposed that the process may be referred to the class of phenomena denominated by chemists "catalytic" actions, or actions by "contact," in which a chemical change is induced in a compound by the presence of a second body, which, as far as appears, does not itself necessarily suffer alteration, and it is conceived that the cell-membrane may exert this species of influence on the matters contiguous to it.

Movements within cells.

This seems also a fitting place to mention that the well-known tremulous movement which so frequently affects minute particles of matter, is not unfrequently observed in the molecular contents of cells. But in many vegetable cells a motion of a different character, and affecting larger-sized corpuscles, is seen. These corpuscles move in a steady and regular manner along the inside of the cell-wall, and in a constant direction. This motion is named "rotation" by vegetable physiologists; the Chara and Vallisneria afford beautiful and well-known examples of it.*

Division into fibres.

3. Division into fibrils.—In the formation of certain tissues, cells which have increased in size and altered in shape, generally by elongation and flattening, appear to be resolved into fine fibres. The cells, for example, which form the cortical layers of a growing feather, first become flattened and somewhat oblong, and then divide longitudinally into a number of slender fibres. These fibres at first cohere, but afterwards separate; the nucleus during this change gradually dwindles away, and at last disappears altogether (fig. 14′, 1, 2, 3). It is doubtful whether the fibrils are produced by the deposition of new matter in longitudinal lines within or on the flattened cell, in which case the substance of the cell which connects the fibrils together must be removed, or whether the substance of the cell is itself, as it were, cut up into fibres.

Fig. 14′.†

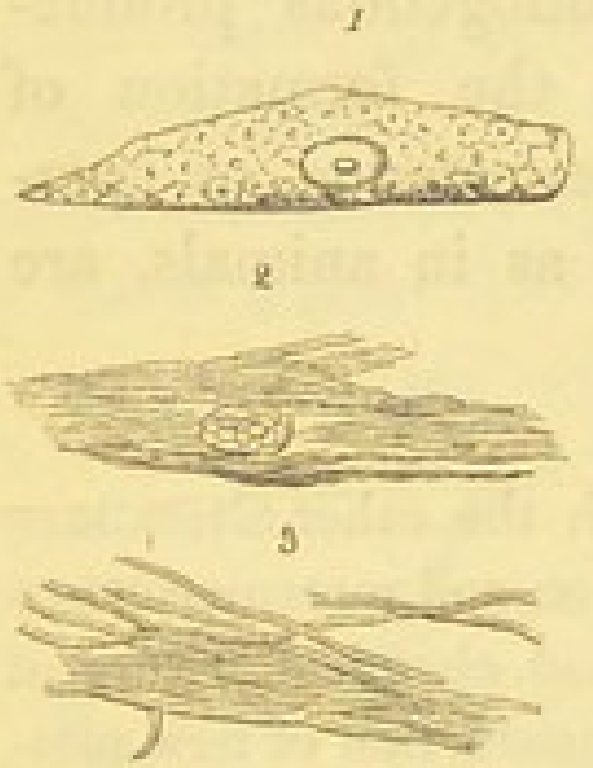

Fig. 15′.‡

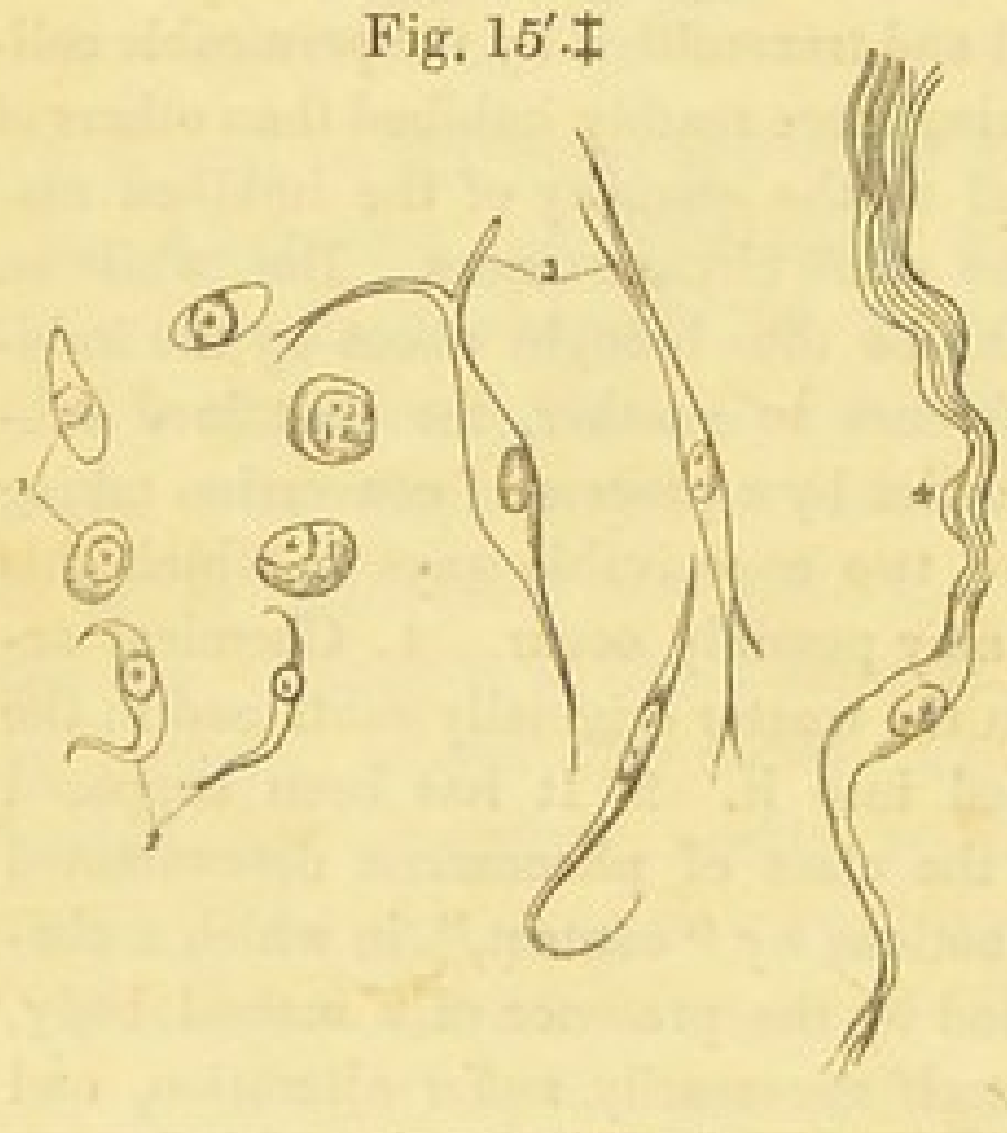

Schwann supposed that the bundles of fibrils which constitute the chief part of the cellular tissue, were formed by a similar process. He describes the cells as first extending themselves in two opposite directions, into an elongated and usually fusiform figure (fig. 15′, 1, 2), then dividing at the extremities into fibrils (fig. 15,′ 3); the division at length reach-

---

* I once noticed in a spherical epithelium-cell from a very young tadpole (of the toad) a motion of particles which seemed to me almost to go beyond the usual tremulous molecular movements. A little clump of dark granular matter or pigment revolved within the cell, and numerous separated granules coursed round and round it, making the complete circuit of the cavity.

† Cells from the cortex of a growing feather, showing their division into fibres.

‡ Cells becoming developed into cellular tissue, according to Schwann. Magnified four hundred and fifty diameters.

ing the middle part (fig. 15′, ^{4}), and extending through it, so as to convert the elongated cell into a bundle of parallel fibrils; the nucleus persisting for a time, but at last disappearing.

Henlé ascribes the formation of cellular tissue to quite a different process, as will be afterwards explained. He admits the occurrence of spindle-shaped cells, split or ramified at their ends, both in healthy tissues and in diseased growths, but he thinks they do not give origin to the fibres of cellular tissue. Though colourless, they seem allied to the system of ramified pigment cells.

4. Changes in the relation of cells to each other.

Insulated cells.

a. Cells may remain isolated, as in the instance of the corpuscles of blood, chyle, and lymph, and those formed in certain secretions. The first-mentioned corpuscles float freely in fluid, which may be looked on as a sort of liquid blastema.

Cohering cells.

b. They may be united into a continuous tissue, by means of a sufficiently consistent intercellular substance; their parietes remaining distinct. The epithelium and the cuticle, with its appendages, afford instances of this.

Blending of parietes.

c. The parietes of adjoining cells may be inseparably blended with each other, or with the intercellular substance; the sides of the cells being usually thickened, or their cavities almost filled up, by deposits in the interior. Cartilage is an example.

Union of cell cavities.

d. The parietes of adjacent cells coalesce at particular points, and, absorption taking place, their cavities become united. It is supposed that ramified cells may thus open into one another, and Schwann conceives that the networks of capillary vessels originate in that way. In other instances the coalescing cells are placed in a longitudinal series, and by their union form a continuous tube, as happens in the vasiform tissues of vegetables. The tubular ducts of some glands are supposed to grow in this manner. In certain cases, the tube formed by united cells becomes the receptacle of new and peculiar matter, which is deposited in it by an ulterior process of organization; thus, according to Schwann, in the formation of muscular and nervous tissue, a tube is first produced by the coalescence of a series of cells, and within this the muscular fibrillæ are formed in the one case, and the peculiar matter of the nervous fibre in the other.

e. We may here also include the process by which Henlé

Complex fasciculi.

conceives the hairs and some other structures to be formed. Cells placed in a row are supposed to coalesce into a sort of axis ; round this axis fibres are laid on, which are themselves derived from elongated or otherwise altered cells ; and outside of all is formed an inclosing sheath. Such a structure he names a " complex fibre," or " complex fasciculus," and he supposes that nervous fibres and the fibres (primitive fasciculi) of muscles are formed on the same principle ; the matter surrounding the axis being fluid in nerves, but in muscle arranged into fibrils : as to the mode in which the homogeneous inclosing tube is produced, he is uncertain. The axis of complex fasciculi may persist, or it may disappear.

Membranes and fibres formed without actual cells.

5. Formation of membranes and fibres from the blastema, without the intervention of actual cells.—As already mentioned, there are certain cases in which there is reason to suppose that the blastema, in place of forming distinct cells, which thereupon become blended, at once gives rise to continuous membranes or fibres. In such cases nuclei are present in the blastema, and subsequently disappear, or undergo metamorphosis ; but how far their presence determines the transformation of the surrounding substance, we have no means of deciding.

a. The blastema may in this manner form a simple homogeneous film, from which the nuclei for the most part disappear. The capsule of the lens, and the brittle layer on the posterior part of the cornea, are instances of such simple glass-like membranes, and probably arise in the way mentioned.

b. A membrane being produced, as in the last case, fine fibrillæ, uniting together in a reticular manner, may be formed on it, seemingly by the deposition and coalescence of minute granules. Then, frequently, the membrane is itself partially or wholly absorbed, leaving nothing but the network of fibrils. The fibrils withstand the action of acetic acid, and in this respect agree with the nuclear fibres, to be afterwards mentioned. An instance of this structure occurs in one of the coats of the arteries.

c. In the formation of the cellular, fibrous, and some other tissues, according to Henlé's view of that process, the blastema is first converted into long flattened bands, which lie between parallel rows of nuclei. Each of these bands, which are not more than $\frac{1}{4000}$ of an inch broad, is then subdivided into a bundle of fine, parallel fibrils, which soon acquire the waved aspect characteristic of the microscopic filamentous bundles of the cellular and fibrous tissues. While this goes on, the nuclei undergo remarkable changes, to be immediately noticed.

Changes of nuclei.

6. Changes in the nuclei of cells.—The nucleus may grow somewhat larger as the cell increases in magnitude, at least at first; thus it enlarges and flattens in epithelium cells. It may then remain without farther change, or it may disappear: it is persistent in most varieties of epithelium, but in the flattened cells of the cuticle and nails it disappears. In other cases, the substance of the nucleus may undergo a chemical change, of which the occasional production of fat globules in the nuclei of cartilage cells is an example.

Nucleus persistent or evanescent;

proliferous;

We have already spoken of proliferous nuclei, which are resolved into young cells.

metamorphic.

In many tissues composed of fibres, as the cellular, the fibrous, the substance of the cornea, and the muscular tissue, the nuclei become lengthened and attenuated, and often crescentic, crooked, or serpentine; in which state they may be seen lying between the fibres of the tissue, on applying acetic acid, in which they are insoluble. Having reached this condition, they may then disappear, being first broken up into rows of little dots. But many of them, instead of vanishing, extend themselves at both ends into a fibre, which meets and joins with similar prolongations from neighbouring nuclei; the little bodies themselves getting gradually thinned down, so that, in some cases, all trace of them in the thread is lost. In this manner a second set of fibres are produced, which have been appropriately named "nuclear fibres." The nuclear fibres lie between the other fibres, or bundles of fibrils, of the tissue in which they occur; sometimes parallel with these, like the rows of nuclei from which they were derived, sometimes winding round them, sometimes alternating with them in layers. They are remarkable for their dark, well-defined outline, and, like the nuclei themselves, are insoluble in acetic acid; so that, by means of that re-agent, they may be rendered conspicuous amidst the other elements of the tissue with which they are mixed. It will be afterwards seen that they strongly resemble the fibres of yellow elastic tissue; it is probable, indeed, that the two are identical.

Nuclear fibres.

Intercellular substance.

7. Ulterior Changes in the Blastema.—Intercellular Substance.—The blastema is usually in great part consumed in the progress of development, but a small portion remains between the cells or other elements of the tissues, generally increasing in consistency, and serving to cement them together; it then constitutes the intercellular or intermediate substance. This substance varies in its condition and aspect: it is represented as being granular in the cellular tissue; in cartilage it is at first pellucid and hyaline, but often undergoes a change, and becomes fibrous; in ossifying cartilage it is hardened and calcified by deposition of earthy salts. In cartilage, moreover, the substance interposed between the cell-cavities increases in quantity as development advances; but, as in this case there is also a thickening of the cell-walls, which are blended with the intervening substance, it is impossible to say how far the increase in question is due to true intercellular deposit.

NUTRITION AND REGENERATION OF THE TEXTURES.

Nutrition, what.

Nutrition.—The tissues and organs of the animal body, when once employed in the exercise of their functions, are subject to continual loss of material, which is restored by nutrition. This waste or consumption of matter, with which, so to speak, the use of a part is attended, takes place in different modes and degrees in different structures. In the cuticular textures the old substance simply wears away, or is thrown off at the surface, whilst fresh material is added from below. In muscular texture, on the other hand, the process is a chemical or chemico-vital one; the functional action of muscle is attended with an expenditure of moving force, and a portion of matter is consumed, whether directly or indirectly, in the production of that force; that is, it undergoes a chemical change, and, being by this alteration rendered unfit to serve again, is removed by absorption. The amount of matter changed in a given time, or, in other words, the rapidity of the nutritive process, is much greater in those instances where there is a production and expenditure of force, than where the tissue serves merely passive mechanical purposes. Hence, the bones, tendons, and ligaments are much less wasted in exhausting diseases than the muscles, or than the fat, which is consumed in respiration, and generates heat.

Up to a certain period, the addition of new matter exceeds the amount of waste, and the whole body, as well as its several parts, augments in size and weight: this is "growth." When maturity is attained, the supply of material merely balances the consumption; and, after this, no steady increase takes place, although the quantity of some matters in the body, especially the fat, is subject to considerable fluctuation at all periods of life.

Growth.

It would be foreign to our purpose to enter on the subject of nutrition in general; we may, however, briefly consider the mode in which the renovation of substance is conceived to be carried on in the tissues.

Nutritive material, whence derived.

The material of nutrition is immediately derived from the plasma of the blood, or liquor sanguinis, which is conveyed by the blood-vessels, and transudes through the coats of their capillary branches; and it is in all cases a necessary condition that this matter should be brought within reach of the spot where nutrition goes on, although, as will immediately be explained, it is not essential for this purpose that the vessels should actually pass into the tissue.

Differences in the mode of nutrition.

In cuticle and epithelium, the nutritive change is effected by a continuance of the process to which these textures owe their origin. The tissues in question being devoid of vessels, nutrient matter, or blastema, is furnished by the vessels of the true skin, or subjacent vascular membrane; cells arise in the blastema, enlarge, alter in figure, often also in chemical nature, and, after serving for a time as part of the tissue, are thrown off at its free surface.

But it cannot in all cases be so clearly shown that nutrition takes place by a continual formation and decay of the structural elements of the tissue; and it must not be forgotten, that there is another conceivable mode in which the renovation of matter might be brought about, namely, by a molecular change which renews the substance, particle by particle, without affecting the form or structure. Still, although conclusive evidence is wanting on the point, it seems probable that something more than a mere molecular change generally takes place, but of what precise nature, is, as yet, only matter of conjecture. Some have supposed that the nuclei seen among the fibres of many tissues may probably minister to their nutrition, and it has been imagined that these nuclei may serve as centres of assimilation and increase, inducing a deposition and organization of matter in their neighbourhood, and propagating themselves by spontaneous division.

Office of the vessels.

In the instance of cuticle and epithelium, no vessels enter the tissue, but the nutrient fluid which the vessels afford penetrates a certain way into the growing mass, and the cells continue to assimilate this fluid, and pass through their changes at a distance from, and independently of, the blood-vessels. Whether, in such cases, the whole of the residuary blastema remains as intercellular substance, or whether a part is again absorbed into the vessels, is not known. In other non-vascular tissues, such as articular cartilage, the nutrient fluid is doubtless, in like manner, conveyed by imbibition through their mass, where it is then attracted and assimilated. The mode of nutrition of these and other non-vascular masses of tissue may be compared, indeed, to that which takes place throughout the entire organism in cellular plants, as well as in polypes, and some other simple kinds of animals, in which no vessels have been detected. But even in the vascular tissues the case is not absolutely different; in these, it is true, the vessels traverse the tissue, but they do not penetrate into its structural elements. Thus the capillary vessels of muscle pass between and around its fibres, but they do not enter them; still less do they penetrate the fibrillæ within the fibre: these, indeed, are much smaller than the finest vessel. The nutrient fluid, on exuding from the vessels, has here, therefore, as well as in the non-vascular tissues, to permeate the adjoining mass by transudation, in order to reach these elements, and yield new substance at every point where renovation is going on. The vessels of a tissue have, indeed, been not unaptly compared to the artificial channels of irrigation which distribute water over a field; just as the water penetrates and pervades the soil which lies between the intersecting streamlets, and thus reaches the growing plants, so the nutritious fluid, escaping through the coats of the blood-vessels, must permeate the intermediate mass of tissue which lies in the meshes of even the finest vascular network. The quantity of fluid supplied, and the distance it has to penetrate beyond the vessels, will vary according to the proportion which the latter bear to the mass requiring to be nourished.

Removal of old matter.

We have seen that in the cuticle the decayed parts are thrown off at the free surface; in the vascular tissues, on the other hand, the old or effete matter must be first reduced to a liquid state, then find its way into the blood-vessels, or lymphatics, along with the residual part of the nutritive plasma, and be by them carried off. But, in certain cases, the mode of removal of the old matter is not clear; as, for example, in the crystalline lens, which is destitute of vessels, and grows by deposition of blastema and formation of cells at its surface: here we should infer that the oldest parts were nearest the centre, and, if we suppose them to be changed in nutrition, it is puzzling to account for their removal.

Non-vascular parts not necessarily unorganized.

From what has been said, it is clear that the vessels are not proved to perform any other part, in the series of changes above described, beyond that of conveying matter to and from the scene of nutrition; and that this, though a necessary condition, is not the essential part of the process. The several acts of assuming and assimilating new matter, of conferring on it organic structure and form, and of disorganizing again that which is to be removed, which are so many manifestations of the metabolic and plastic properties already spoken of, are performed beyond the blood-vessels. It is plain, also, that a tissue, though devoid of vessels, and the elements of a vascular tissue, though placed at an appreciable distance from the vessels, may still be organized and living structures, and within the dominion of the nutritive process. How far the sphere of nutrition may, in certain cases, be limited, is a question that still needs further investigation; in the cuticle, for example, and its appendages, the nails and hairs, which are placed on the surface of the body, we must suppose that the old and dry part, which is about to be thrown off or worn away, has passed out of the limits of nutritive influence; but to what distance beyond the vascular surface of the skin the province of nutrition extends, has not been determined.

Regeneration.

Regeneration.—When part of a texture has been lost or removed, the loss may be repaired by regeneration of a new portion of tissue of the same kind; but the extent to which this restoration is possible is very different in different textures.

Differences in different tissues.

Thus, in muscle, a breach of continuity may be repaired by a new growth of cellular tissue; but the lost muscular substance is not restored. Regeneration occurs in nerve, but only in a very limited degree: in bone it takes place much more readily and extensively, and still more so in fibrous and cellular tissue. The special circumstances of the regenerative process in each tissue will be considered hereafter; but we may here state generally, that, as far as is known, the reproduction of a texture is effected in the same manner as its original formation; lymph or fibrin derived from the liquor sanguinis is deposited as blastema, and in this the elements of the tissue appear in the way already described.

Differences in different animals.

In experimental inquiries respecting regeneration, we must bear in mind, that the extent to which reparation is possible, as well as the readiness with which it occurs, is much greater in many of the lower animals than in man. In newts, and some other cold-blooded vertebrata, indeed, (not to mention still more wonderful instances of regeneration in animals lower in the scale,) an entire organ, a limb, for example, is readily restored, complete in all its parts, and perfect in all its tissues.

Concluding remarks on the development of the textures.

Application of the study to pathological inquiries.

In concluding what it has been deemed advisable in the foregoing pages to state respecting the development of the textures, we may remark, that, besides what is due to its intrinsic importance, the study of this subject derives great additional interest from the aid it promises to afford in its application to pathological inquiries. Researches which have been made within the last few years, and which are still zealously carried on, tend to show that the structures which constitute morbid growths are formed by a process analogous to that by which the natural or sound tissues are developed: some of these morbid productions, indeed, are in no way to be distinguished from cellular, fibrous, cartilaginous, and other natural structures, and have, doubtless, a similar mode of origin; others, again, as far as yet appears, are peculiar in structure and composition, but still their production is with much probability to be referred to the same general process. The prosecution of this subject, however, does not fall within the scope of the present work.

THE BLOOD.

PHYSICAL AND ORGANIC CONSTITUTION.

Blood, its physical properties.

The most striking external character of the blood is its well-known colour, which is florid red in the arteries, but of a dark purple or modena tint in the veins. It is a somewhat clammy and consistent liquid, a little heavier than water, its specific gravity being 1052 to 1057; it has a saltish taste and a peculiar faint odour.

Consists of plasma and corpuscles.

To the naked eye the blood appears homogeneous; but when examined with the microscope, either while within the minute vessels, or when spread out into a thin layer upon a piece of glass, it is seen to consist of a transparent colourless fluid, named the "lymph of the blood," "liquor sanguinis," or "plasma," and minute solid particles or corpuscles immersed in it. These corpuscles are of two kinds, the red, and the colourless: the former are by far the most abundant, and have been long known as "the red particles," or "globules," of the blood; the "colourless," or "pale corpuscles," on the other hand, being fewer in number, and less conspicuous, have only within the last few years been generally recognized by microscopic observers. When blood is drawn from the vessels, the liquor sanguinis separates into two parts;—into fibrin, which becomes solid, and a pale yellowish liquid named *serum*. The fibrin in solidifying involves the corpuscles and forms a red consistent mass, named the clot or *crassamentum* of the blood, from which the serum gradually separates. The relation between the above-mentioned constituents of the blood in the liquid and the coagulated states may be represented by the subjoined scheme:

Change on being drawn.

Liquid blood { Corpuscles . . . . }
Liquid blood { Liquor sanguinis { Fibrin . . } Clot }
Liquor sanguinis { Serum . . . } Coagulated blood.

Red corpuscles, their figure and size in man.

Red corpuscles.—These are not spherical, as the name "globules," by which they have been so generally designated, would seem to imply, but flattened or disk-shaped. Those of the human blood (fig. 16′,^{1},^{2}) have a nearly circular outline, like a piece of coin, and most of them also present a shallow cup-like depression or dimple on both surfaces; their usual figure is, therefore, that of biconcave disks. Their magnitude differs somewhat even in the same drop of blood, and it has been variously assigned by authors; but the prevalent size may be stated at from $\frac{1}{3500}$th to $\frac{1}{3200}$th of an inch in diameter, and about one-fourth of that in thickness.

Fig. 16′.*

Figure and size in animals.

In mammiferous animals generally the red corpuscles are shaped as in man, except in the camel tribe, in which they have an elliptical outline. In birds, reptiles, and most fishes, they are oval disks with a central elevation on both surfaces, (fig. 17′, from the frog,) the height and extent of which, as well as the proportionate length and breadth of the oval, vary in different instances, so that in some osseous fishes the elliptical form is almost shortened into a circle. The blood-disks of the lamprey and other cyclostomatous fishes, are circular and biconcave; thus in figure exactly resembling those of man. The blood corpuscles of invertebrata, though they want the red colour, are also, for the most part, flattened or disk-shaped; being in some cases circular, in others oblong, as in the larvæ of aquatic insects. Sometimes they appear granulated on the surface like a raspberry, but this is probably due to some alteration occurring in them.

Fig. 17′.†

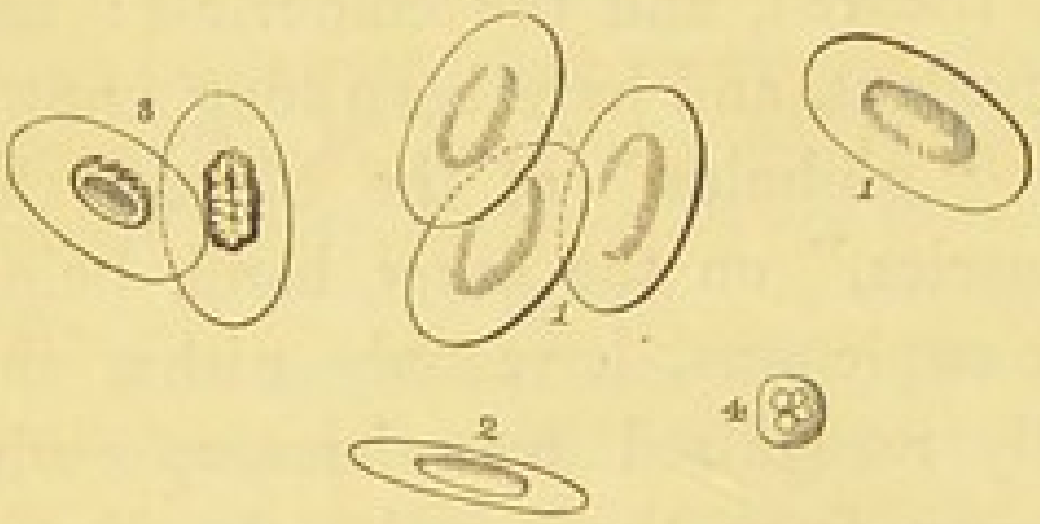

The size of the corpuscles differs greatly in different kinds of animals; it is greater in birds than in mammalia, and largest of

---

* Red corpuscles of human blood, magnified about five hundred diameters (Wagner). 1, shows depression on the surface. 2. A corpuscle seen edgeways. 3. Red corpuscles altered by exposure.

† Blood corpuscles of the frog, magnified about five hundred diameters. 1, shows their broad surface. 2. One seen edge-ways. 3, shows the effect of weak acetic acid; the nucleus has become distinct. 4. A colourless or lymph corpuscle (from Wagner.)

Varieties of size in animals.

all in the naked amphibia. They are for the most part smaller in quadrupeds than in man; in the elephant, however, they are larger, being $\frac{1}{2700}$th of an inch, which is the largest size yet observed in the blood corpuscles of any mammiferous animal: the goat was long supposed to have the smallest, viz. about $\frac{1}{6400}$th of an inch; but Mr. Gulliver has found that they are much smaller in the Napu musk-deer, being less than $\frac{1}{12000}$th of an inch in that animal. In birds they do not vary in size so much: from Mr. Gulliver's very elaborate tables of measurement it appears that they range in length from about $\frac{1}{1700}$th to $\frac{1}{2400}$th of an inch; he states that their breadth is usually a little more than half the length, and their thickness about a third of the breadth, or rather more. He found a remarkable exception in the corpuscles of the snowy owl, which measure $\frac{1}{1550}$th of an inch in length, and are only about a third of this in breadth. In scaly reptiles they are from $\frac{1}{1800}$th to $\frac{1}{1500}$th in length; in the naked amphibia they are much larger: thus, in the frog they are $\frac{1}{1000}$th of an inch long, and $\frac{1}{1700}$th broad; in the salamander they are larger still; but the largest yet known in any animal are those of the proteus, which are upwards of $\frac{1}{400}$th of an inch in length: the siren, which is so much allied to the proteus in other respects, agrees with it also in the very large size of its blood corpuscles; they measure $\frac{1}{435}$th of an inch in length, and $\frac{1}{800}$th in breadth. In the skate and shark tribe the corpuscles resemble those of the frog, in other fishes they are smaller.

From what has been stated, it will be seen that the size of the blood corpuscles in animals generally is not proportionate to the size of the body; at the same time Mr. Gulliver remarks, that, "if we compare the measurements made from a great number of different species *of the same order*, it will be found that there is a closer connexion between the size of the animal and that of its blood corpuscles than has been generally supposed;" and he has pointed out at least one example of a very natural group of quadrupeds, the ruminants, in which there is a gradation of the size of the corpuscles in relation to that of the body.

Structure of the red corpuscles in reptiles, birds, and fishes.

Structure.—The large corpuscles of the frog and salamander can be easily shown to consist of a thin, transparent, vesicular *envelope*, enclosing an apparently solid oval *nucleus* in the centre, with a quantity of softer *red-coloured matter* disposed round the nucleus and filling up the space between it and the envelope. When exposed to the action of weak acetic acid, (fig. 17′,[3]) the colouring matter is speedily extracted, and the nucleus becomes distinct, whilst the delicate envelope is rendered so faint as to be scarcely visible; but its presence may be still made obvious by adding solution of iodine, which gives it colour and opacity. If strong acid be used, the envelope will at length be dissolved entirely. Pure water extracts the colour and distends the vesicle by imbibition, altering its shape from oval to round, and making the nucleus more conspicuous. Both the one and the other of these re-agents sometimes cause the envelope to burst; the nucleus then escapes, and the structure of the corpuscle is demonstrated still more plainly. These effects are caused by the thinner exterior fluid passing through, by endosmosis, to the thicker matter within the vesicle; and precisely the opposite effect may be produced by immersing the corpuscles in a fluid of a sufficiently high degree of concentration, so as to cause the predominant current to pass from within outwards. Accordingly, on using a strong solution of salt or of sugar, the vesicles will shrink and become thinner; and, no doubt, the variations in plumpness which the corpuscles often naturally present are owing to differences in the degree of concentration of the surrounding liquid. The nucleus (fig. 17′,[3]) is rather more than a third of the length of the corpuscles; it appears, especially after being exposed to the action of vinegar, to be composed of tolerably large granules, and, when so treated at least, it is quite free from colour. The envelope appears as an exceedingly fine, homogeneous, and pellucid membrane. The coloured content of the corpuscle is a pale red matter, very faintly granular; it surrounds the nucleus, and occupies the space between it and the vesicular envelope. The envelope and red matter are obviously of a soft and yielding nature, for the corpuscles alter their shape on the slightest pressure, as is beautifully seen while they move within the vessels; they are also elastic, for they readily recover their original form again. It must be remarked, that the blood corpuscles when viewed singly appear very faintly coloured, and it is only when collected in considerable quantity that they produce a strong deep red.

Difference in man and mammalia.

A structure consisting of envelope, nucleus, and red matter, as shown in the large blood-disks of amphibia, may be demonstrated in many other instances, and by analogy has been inferred to exist in all, man not excepted. But the existence of a nucleus in the blood corpuscles of man and mammalia is, at best, extremely doubtful; and few inquirers have been able to satisfy themselves of it by actual observation. Hewson and Müller, it is true, believed that they had actually seen the nucleus in the human blood-disk, and that they could demonstrate its existence by the action of water (Hewson), or acetic acid (Müller); but, although the human corpuscle changes its figure and loses its colour when exposed to these agents, and although its pellucid vesicular envelope, and the pale, red, soft substance contained within, can be readily shown, yet some of the most careful observers who have recently inquired into the subject, and among them Mr. Gulliver, with whom my own observations would lead me to concur, profess not to have been able to discover a nucleus by any mode of examination they could devise; others deny its general existence in the human blood corpuscles, but believe it is present in a few of them.

Alteration by exposure.

The human blood corpuscles, as well as those of the lower animals, often present deviations from the natural shape, which are most probably due to causes acting after the blood has been drawn from the vessels. Thus, it is not unusual for many of them to appear indented or jagged at the margin, when exposed under the microscope (fig. 16′, ³), and the number of corpuscles so altered often appears to increase during the time of observation. This is, perhaps, the most common change; but they may become distorted in various other ways, and corrugated on the surface; not unfrequently one of their concave sides is bent out, and they acquire a cup-like figure. It is even a question with some observers, whether the biconcave figure which the corpuscles generally present may not be due to a distention of the circumferential part of an originally flat disk. Mr. Gulliver made the curious discovery, that the corpuscles of the Mexican deer and some allied species present very singular forms, probably in consequence of exposure; the figures they assume are various, but most of them become lengthened and pointed at the ends, and then often slightly bent, not unlike caraway seeds.

Aggregation into rolls.

The red disks, when drawn from the vessels, have a singular tendency to run together, and to cohere by their broad surfaces, so as to form by their aggregation cylindrical columns, like piles or rouleaus of money, and the rolls or piles themselves join together into an irregular network (fig. 18′). In a few moments after this has taken place, a heaving or slowly oscillating motion is observable in the mass, and the rolls may then become broken up, and the corpuscles more or less completely disjoined (Jones). Generally the corpuscles separate on a slight impulse, and they may then unite again. The nature of the attraction exerted between the corpuscles is doubtful; but it may be remarked, that the phenomenon will take place in blood that has stood for some hours after it has been drawn, and also when the globules are immersed in serum in place of liquor sanguinis.

Fig. 18′.*

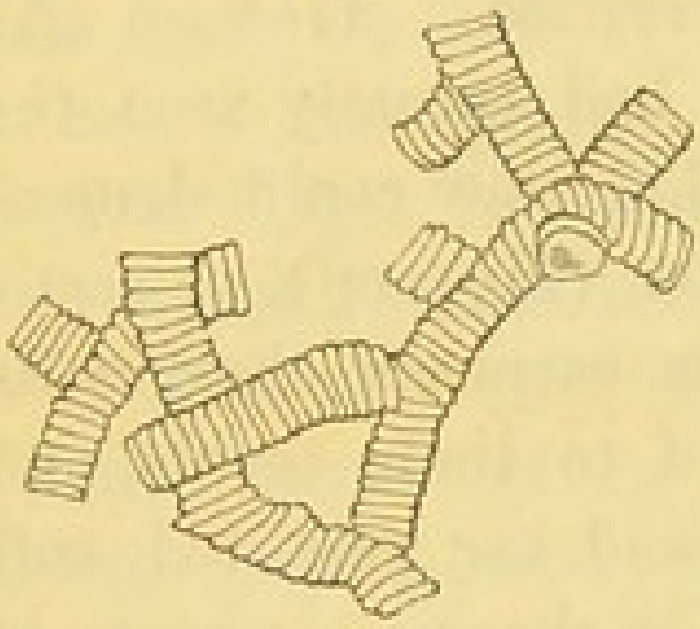

Pale corpuscles.

Pale or colourless Corpuscles (fig. 19′).—These are comparatively few in number, of a rounded and slightly flattened figure, rather larger in man and mammalia than the red disks, and varying much less than the latter in size and aspect in different animals. They are destitute of colour, finely granulated on the surface, and specifically lighter than the red corpuscles. Water has little effect on them; acetic acid brings speedily into view a nucleus, consisting sometimes of one, but more commonly of two or three, rarely four, large clear granules (fig. 19′,$^{2, 3}$); a delicate envelope at the same time comes into view, which becomes distended so as to augment the size of the globule, and is eventually dissolved, the nucleus remaining.

Fig. 19′.†

Plasma, its properties.

Liquor Sanguinis, or Plasma.—This is the pale clear fluid in which the corpuscles are naturally immersed. Its great character is its strong tendency to coagulate when the blood is withdrawn from the circulating current, and on this account it is difficult to procure it free from the corpuscles. Nevertheless, by filter-

---

* Red corpuscles collected into rolls (after Henlé).

† Pale corpuscles of human blood, magnified about five hundred diameters. 1. Natural aspect. 2 and 3. Acted on by weak acetic acid, which brings into view the single or composite nucleus.

ing the slowly coagulable blood of the frog, as was first practised by Müller, the large corpuscles are retained by the filter, while the liquor sanguinis comes through in perfectly clear and colourless drops, which, while yet clinging to the funnel, or after they have fallen into the recipient, separate into a pellucid glassy film of fibrin, and an equally transparent diffluent serum. When human blood is drawn in inflammatory diseases, as well as in some other conditions of the system, the red particles separate from the liquor sanguinis before coagulation, and leave the upper part of the liquid clear. In this case, however, the plasma is still mixed with the pale corpuscles, which, being light, accumulate at the top. On coagulation taking place in these circumstances, the upper part of the clot remains free from redness, and forms the well-known "buffy coat" so apt to appear in inflammatory blood. Now, in such cases, a portion of the clear liquor may be taken up with a spoon, and allowed to separate by coagulation into its fibrin and serum, so as to demonstrate its nature. Dr. A. Buchanan has pointed out another method of separating the liquor sanguinis from the red corpuscles, which I have repeatedly tried with success: it consists in mixing fresh-drawn blood with six or eight times its bulk of serum, and filtering through blotting paper; the admixture of serum delays coagulation, and a great part of the liquor sanguinis, of course diluted, passes through the filter, and subsequently coagulates.

How separated.

Coagulated plasma, whether obtained from buffy blood, or exuded on inflamed surfaces, presents, under the microscope, a multitude of fine filaments confusedly interwoven, as in a piece of felt; but these are more or less obscured by the intermixture of corpuscles and fine granules, the former having all the characters of the pale corpuscles of the blood. The filaments are no doubt formed by the fibrin, as it solidifies in the coagulation of the liquor sanguinis.

Microscopic characters.

Blood may be freed from fibrin by stirring it with a bundle of twigs, which entangle the fibrin as it concretes.

COAGULATION OF THE BLOOD.

Phenomena of coagulation.

In explaining the constitution of the plasma, we have been obliged so far to anticipate the account of the coagulation of the blood. The following are the phenomena which usher in and which accompany this remarkable change. Immediately after it is drawn, the blood emits a sort of exhalation, the "halitus," having a faint smell; in about three or four minutes a film appears on the surface, quickly spreading from the circumference to the middle; a minute or two later the part of the blood in contact with the inside of the vessel becomes solid, then speedily the whole mass; so that, in about eight or nine minutes after being drawn, the blood is completely gelatinized. At about fifteen or twenty minutes, or it may be much later, the jelly-like mass begins to shrink away from the sides of the vessel, and the serum to exude from it. The clot continues to contract, and the serum to escape, for several hours, the quickness and extent of the process varying exceedingly in different cases; and, if the serum be poured off, more will usually continue to drain slowly from the clot for two or three days.

Nature of change.

The nature of the change which takes place in the coagulation of the blood has been already spoken of; it is essentially owing to the coagulation of the liquor sanguinis, the fibrin of that liquid separating in form of a solid mass, which involves the corpuscles, but allows the serum to escape from it in greater or less quantity. But although the solidification of the fibrin, and formation of a red clot, would undoubtedly take place independently of any co-operation on the part of the corpuscles, still it must not be forgotten that, in point of fact, the red disks are not altogether passive while coagulation goes on; for they run together into rolls, as already described, and the circumstance of their doing so with greater or with less promptitude materially affects the result of the coagulating process. Thus,

Buffy coat.

there seems good reason to believe that, as H. Nasse has pointed out, one of the causes, and in inflammatory blood probably the chief cause, of the production of the buffy coat, is an exaltation of the natural tendency of the red disks to run together, whereby, being more promptly and more closely aggregated into compact masses, they more speedily subside through the liquid plasma, leaving the upper part of it colourless by the time coagulation sets in; and Mr. Jones has drawn attention to another influential circumstance derived from the same source, namely, the more rapid and close contraction of the network, or spongework, as he terms it, into which the little rolls of corpuscles unite, and the consequent expulsion of great part of the liquor sanguinis from its meshes before the fibrin solidifies, the mass of aggregated corpuscles naturally tending to the lower part of the vessel, whilst the expressed plasma, being lighter, accumulates at the top. Of course, it is not meant to deny that more tardy coagulation of the blood would produce the same result as more speedy aggregation of the corpuscles; it is well known, indeed, that blood may be made to show the buffy coat by delaying its coagulation, but buffed inflammatory blood is not always slow in coagulating.

Various causes accelerate, retard, or entirely prevent the coagulation of the blood; of these, it will here suffice to indicate the more important and best ascertained. Circumstances affecting coagulation.

1. Temperature.—Cold delays, and at or below 40 degrees Fahr. prevents, coagulation; but even frozen blood, when thawed and heated again, will coagulate. Moderate elevation of temperature above that of the body promotes coagulation. Temperature.

2. Coagulation is accelerated by free exposure of the blood, even *in vacuo*, but especially by exposure to air and various other gases; also, but in a less degree, by contact with foreign bodies generally. On the other hand, the maintenance of its fluidity is favoured by exclusion of air, and by contact with the natural tissues of the body, so long at least as these retain their usual vital and physical properties. Exposure.

3. Cessation of the blood's motion *within the body* favours coagulation, probably by arresting those perpetual changes of material, both destructive and renovative, to which it is naturally subject in its rapid course through the system. Agitation of *exposed* blood, even *in vacuo*, accelerates coagulation, most probably by increasing its exposure. Motion or rest.

4. Water, in a proportion not exceeding twice the bulk of the blood, hastens coagulation; a larger quantity retards it. Addition of water.

Blood also coagulates more speedily when the serum is of low specific gravity, indicative of much water in proportion to the saline ingredients.

Salts, and other substances.

5. Almost every substance that has been tried, except caustic potash and soda, when added to the blood *in minute proportion*, hastens its coagulation ; although many of the same substances, when mixed with it in somewhat larger quantity, have an opposite effect. The salts of the alkalies and earths, added in the proportion of two or three per cent. and upwards, retard, and, when above a certain quantity, suspend or prevent coagulation ; but, though the process be thus suspended, it speedily ensues on diluting the mixture with water. The caustic alkalies permanently destroy the coagulability of the blood. Acids delay or prevent coagulation. Opium, belladonna, and many other medicinal agents from the vegetable kingdom, are said to have a similar effect ; but the statements of experimenters by no means entirely agree respecting them.

Condition of the system.

6. Certain states of the system.—Faintness occasioned by loss of blood favours coagulation ; states of excitement are said to have, though not invariably, the opposite effect. Impeded aëration of the blood in disease, or in suffocative modes of death, makes it slow to coagulate. So also in cold-blooded animals, with slow circulation and low respiration, the blood coagulates less rapidly than in the warm-blooded ; and, among the latter, the tendency of the blood to coagulate is strongest in birds, which have the greatest amount of respiration and highest temperature.

Differs in arterial and venous. In the sexes.

7. Coagulation commences earlier, and is sooner completed, in arterial, than in venous blood. Dr. Nasse finds that woman's blood begins to coagulate nearly two minutes sooner than that of the male sex.

Proportion of clot and serum.

In general, when blood coagulates quickly, the clot is more bulky and less firm, and the serum is less effectually expressed from it ; and causes which affect the rapidity of coagulation will also occasion differences in the proportion of the moist clot to the exuded serum.

There is no sufficient evidence of evolution of heat or of disengagement of carbonic acid from blood during its coagulation, which some have supposed to occur.

CHEMICAL COMPOSITION OF THE BLOOD.

The blood is slightly alkaline; it has been found that a drachm of blood is capable of saturating rather more than a drop of vinegar. Carbonic acid, oxygen and nitrogen gases, may be extracted from it in proportions which differ in arterial and venous blood, and which will be subsequently given. On being evaporated, 1000 parts of blood yield, on an average, about 790 of water, and 210 of solid residue.

It has been ascertained by analysis that blood has the same ultimate composition as flesh; an observation which is obviously of great interest in reference to the office performed by the blood in nutrition. A comparative examination of dried ox-blood and dried flesh (beef), by Playfair and Bœckmann, gave the following mean result:

	Flesh.	*Blood.*
Carbon	51·86	51·96
Hydrogen	7·58	7·25
Nitrogen	15·03	15·07
Oxygen	21·30	21·30
Ashes	4·23	4·42

Deducting the ashes, or inorganic matter, the composition of the organic part is such as corresponds with the formula C_{48}, H_{39}, N_6, O_{15}.

Chemical constitution of red disks.

Red Corpuscles.—These consist, as already stated, of envelope, red contents, and, in many animals, a nucleus. The nucleus is, by some writers, considered to be of the nature of fibrin; but others have likened it to coagulated albumen, from the manner in which it withstands the action of acetic acid. The envelope approaches most to fibrin in its characters. The included red matter consists of two substances,—one named *globulin*, of itself colourless, and very nearly allied to albumen in its nature; the other, a colouring principle named *hæmatin*, or *hæmatosin*, which imparts redness to the first. These may be separated by the following process.

Blood deprived of fibrin by stirring is mixed with at least four times its bulk of saturated solution of sulphate of soda, and thrown on a filter ; a few of the corpuscles pass through with the liquid, but the greater part remain on the filter in form of a moist red mass, named the *cruor*. This is boiled with alcohol slightly acidulated with sulphuric acid ; the hæmatin is thereby dissolved, while the colourless globulin remains behind in combination with part of the sulphuric acid. Carbonate of ammonia is then added to the acid solution of hæmatin while it is yet hot, to remove the sulphuric acid, and, after being cleared by filtration from sulphate of ammonia, and a little globulin which is precipitated, the liquor is evaporated to a twelfth of its bulk ; it then deposits the hæmatin in form of a dark brown or almost black powder, from which a minute proportion of fat may be extracted by means of ether.

Hæmatin.

Hæmatin, as obtained by the above process, is insoluble in water, alcohol, and ether ; but it readily dissolves in any of these liquids after being mixed with potash, soda, or ammonia, forming deep red solutions. It dissolves also in alcohol, to which an acid has been added, but its acid combinations are insoluble in water. When burned, it yields nearly ten per cent. of peroxide of iron, representing near seven per cent. of iron. According to Mulder, it is composed of carbon 65·84, hydrogen 5·37, nitrogen 10·40, oxygen 11·75, and iron 6·64; or C_{44}, H_{22}, N_3, O_6, Fe.

Iron of the blood.

Chemists have differed in opinion as to the condition in which iron exists in the hæmatin : some have supposed that the metal enters into the formation of the organic compound, and holds the same rank in its constitution as the carbon, hydrogen, and other constituents; but others conceive that it is in the state of oxide or salt, and, as such, combined or mixed with the organic matter, in a similar manner, perhaps, as oxides and salts may be combined with albumen. An experiment of Scherer seems conclusive against the former view, and shows that the iron, though a constant ingredient in the red corpuscle, is not an essential constituent of the hæmatin. By treating cruor with sulphuric acid, the chemist named succeeded in entirely separating the iron from it, and after this it nevertheless imparted an intensely red colour to alcohol. This fact also proves that the red colour of the blood is not due to iron, as some have believed.

Globulin.

Globulin.—When the hæmatin has been extracted from the blood corpuscles by the foregoing method, the globulin remains in combination with sulphuric acid. It is a protein compound, agreeing with albumen in composition, and in all its properties, except the two following, viz. its insolubility in serum, that is, in a saline solution which holds albumen dissolved; and, secondly, its coagulation, by heat, in form of a granular mass, different in aspect from coagulated albumen. Henlé suggests that both peculiarities may be due to the circumstance, that the albuminous matter is enclosed, and, in some degree, protected, by the envelopes of the corpuscles, which remain after extraction of the hæmatin; and he thinks that globulin is probably nothing but albumen with the membranous envelopes (and nuclei, when present,) of the blood particles. Lecanu and Liebig consider it albumen.

Cruor.

The *cruor*, or matter of the red corpuscles, which consists of the globulin and hæmatin together, may be dissolved in water; and its solution, which contains the envelopes in suspension, coagulates by a heat of 181 degrees. Its effects with re-agents, both in its soluble and coagulated state, resemble those of albumen under like circumstances. Berzelius reckons the relative proportions of globulin and hæmatin as 94·5 of the former, and 5·5 of the latter. The corpuscles are supposed also to contain a solid phosphuretted fat in small quantity, but its proportion has not been determined. 100 parts of dry cruor yield by calcination about 1·3 of brown alkaline ashes, which consist of carbonate of soda with traces of phosphate 0·3, phosphate of lime 0·1, lime 0·2, subphosphate of iron 0·1, peroxide of iron 0·5, carbonic acid and loss 0·1.

Proportion of red corpuscles.

The red corpuscles form by far the largest part of the organic matter in the blood: their proportion may be ascertained by filtering beat blood mixed with solution of Glauber's salt, as already mentioned; or by weighing the dried clot, and making allowance for the fibrin it contains. From Lecanu's determinations we may reckon the amount of the corpuscles as about 120 or 130 parts in 1000 of blood. Simon gives a lower estimate; but, apart from differences due to the methods of determining it, the quantity is really subject to great fluctuation.

Differences in amount of crassamentum.

Denis and Lecanu state that, as a general rule, the proportion of red particles is greater in the blood of the male sex than in that of the female, whilst the proportion of albumen is about the same in both. Lecanu gives the following mean result, derived from numerous analyses, exhibiting the proportion of crassamentum and water in the blood of the two sexes. No deduction is made for the fibrin; but, considering its small relative quantity, any possible variation in it cannot materially affect the general conclusion.

	Male.	*Female.*
Crassamentum, from	115·8 to 148	68·3 to 129·9
Water	778 to 805	790 to 853.

He found the following differences according to temperament:

	Male.	*Female.*
Sanguine temperament	136·4	126·1
Lymphatic temperament	116·6	117·3

As regards age, Denis found the proportion of crassamentum greatest between the ages of 30 and 40. Sudden loss of blood rapidly diminishes the proportion of the crassamentum. In two women, who had suffered from uterine hæmorrhage, the crassamentum amounted to only 70 parts in 1000. The same effect may be observed to follow ordinary venesection. In a person bled three times in one day, Lecanu found in the first-drawn blood 139, and in the last only 76 parts of crassamentum in the 1000. This effect may be produced very suddenly after a bleeding. Prevost and Dumas bled a cat from the jugular vein, and found 116 parts of crassamentum in 1000, but, in blood drawn five minutes afterwards, it was reduced to 93. The sudden loss of blood probably causes a rapid absorption of serous and watery fluid into the vessels, and thus diminishes the relative amount of the red particles. It is found that the blood of warm-blooded animals is richer in crassamentum than that of the cold-blooded; and, among the former, the proportion is highest in the class of birds.

Fibrin;

Liquor Sanguinis.—The fluid part of the blood, as already described, separates spontaneously into fibrin and serum. The fibrin may be obtained by stirring the blood as soon as possible after it is drawn, or by washing the crassamentum with water, to free it from cruor. Procured in either of these ways, the fibrin contains pale corpuscles and a small portion of fat. From dried fibrin of healthy human blood, Nasse obtained near 5 per cent. of fat, and still more from the fibrin of buffy blood. The proportion of fibrin in the blood does not exceed 2½ parts in 1000; indeed, according to the greater number of observers, it is not more than 2⅓. As a general rule, the quantity is somewhat greater in arterial than in venous blood, and it is increased in certain states of the body, especially in inflammatory diseases and in pregnancy. Nasse thinks that the whole fibrin cannot be separated from the blood by the processes employed, for he believes that a portion remains suspended in the liquid in form of minute microscopic scales or films.

its proportion.

Denis pointed out, that fibrin obtained from the coagulum of venous blood, if quite recent, and not previously much exposed to the air, is capable of being slowly dissolved in a slightly-heated solution of nitre. Scherer and Nasse have confirmed this statement, and the latter finds that fibrin got by stirring may also be dissolved in the same way, provided it is quite fresh. On the other hand, nitre does not dissolve fibrin of arterial blood, nor fibrin that has been some time exposed to the air, from whatever source it may be derived; nor, according to Scherer, the fibrin of the buffy coat. The properties of pure fibrin have been already described (p. xxii).

Effect of nitre on fibrin.

Serum.—This is a thin and usually transparent liquid, of a pale yellowish hue ; its specific gravity ranges from 1025 to 1030, but is most commonly between 1027 and 1028 (Nasse). It is always more or less alkaline. When heated, it coagulates, in consequence of the large quantity of albumen it contains ; and, after separation of the albumen, a thin saline liquid remains, sometimes named " serosity." The following ingredients are found in the serum.

Serum.

Albumen.—The properties of this substance have been already stated ; its quantity may be determined by precipitating it in the solid form by means of heat or alcohol, washing with distilled water, drying, and weighing the mass. Its proportion is about 80 in 1000 of serum, or nearly 70 in 1000 of blood.

Albumen.

Casein.—A minute quantity of casein was detected in the serum of ox's blood by Gmelin ; it has also been found in human blood.

Casein.

Fatty compounds.—It has been already stated that the red corpuscles and the fibrin yield a minute quantity of fat ; but the greatest part of the fat of the blood remains in the serum, partly dissolved, and partly diffused in the liquid. It may be separated by gently agitating the serum with about a third of its bulk of ether, or by evaporating the serum and digesting the dry residue in ether, or in boiling alcohol. The turbid milky aspect which serum often exhibits, is in most cases due to a redundance of fat, and may accordingly be removed by agitation with ether.

Fat.

The fatty matters of the blood are of various kinds, viz. *cholesterin*, *serolin*, and the ordinary saponifiable fats of the body (*margarates* and *oleates*); also, according to Berzelius and Lecanu, a *phosphuretted fat*, similar to that found in the brain. Berzelius, indeed, is disposed to think that the blood contains

Different kinds of fatty matters.

every variety of fat that is found in other parts of the body. Lecanu could not obtain the phosphuretted fat from either the serum or the fibrin, and Berzelius therefore supposes that it is associated with the red corpuscles; he also states that the fat extracted from the fibrin is different from ordinary fat. The properties of most of these fatty principles have been already discussed (page xxxi). The usual quantity of fat of all kinds in 1000 parts of blood is stated by Lecanu to be 5·15, by Simon 2·3, and by Nasse 2·0.

Extractive matters.

Extractive matters.—When the serum has been freed from albumen by coagulation, and from fat by ether, and is evaporated to dryness, a yellowish or brown mass remains, consisting of organic matters mixed with salts; the former belonging principally to the ill-defined class of substances denominated "extractive matters."

Osmazome.

To examine them, Berzelius directs that the mass should be first treated with anhydrous alcohol; this takes up a substance which he thinks is probably derived (by decomposition or some other change) from the albuminous ingredients of the blood. Next, rectified spirit (of ·833 spec. grav.) is to be used, which dissolves from the residue chlorides of sodium and potassium, and lactate of soda, together with the heterogeneous mixture of extractive matters known under the name of *osmazome*, of which an account has been already given (page xxx). The residual mass, after this, contains alkaline carbonates, phosphates, and sulphates, and one or more animal substances, in small quantity. Among the latter may be noticed,—1. one that is precipitable by tannin, and which, like the one taken up by the pure alcohol, appears to be derived from the albuminous constituents of the blood: 2. a remnant of coagulated albumen, which has been kept in solution by free or carbonated alkali, but is thrown down when the alkali is saturated by acetic acid. Lecanu found, in 1000 parts of blood, 1·8 parts of extractive soluble in spirit, and 1·6 of extractive soluble in water only.

Yellow colouring matter.

Colouring principles.—A yellow or greenish-yellow colouring principle, which appears to be the same as that of the bile, has been found by various chemists in the blood of persons affected with jaundice, and, according to Lecanu and Denis, a certain amount of it may be detected even in healthy blood.

Alleged blue matter.

Sanson extracted a blue colouring matter from bullocks' blood; but his observation seems not to have been repeated by other chemists. He diluted the beat blood (red particles and serum) with water, precipitated it by acetate of lead, and boiled the dried precipitate in alcohol, which deposited the blue matter on cooling.

Three kinds of odoriferous matter.

Odoriferous matters.—Denis describes three. 1. One combined with fat, and of a garlick smell. 2. One supposed to depend on a volatile oil, with an odour said to be of peculiar character in each species of animal, and to be heightened by adding sulphuric acid to the blood. 3. One of a variable character, derived from the food.

Urea.

Urea.—This substance, which accumulates in the blood of animals after extirpation of the kidneys or ligature of the renal arteries, as well as in certain diseases, has been found in very minute quantity in the healthy blood of the ox and of the calf, by Marchand and Simon.

Salts.

Salts.—1. Having soda and potash as bases, combined with lactic, carbonic, phosphoric, sulphuric, and fatty acids. Also chlorides of sodium and potassium, the former in large proportion. 2. Lactate of ammonia. 3. Salts with earthy bases, viz. lime and magnesia with phosphoric, carbonic, and sulphuric acids.

The earthy salts are for the most part associated with the albumen, but partly with the crassamentum. As they are obtained by calcination, it has been suspected that the phosphoric and sulphuric acids may be in part formed by oxidation of the phosphorus and sulphur of the protein compounds. Nasse found in 1000 parts of blood 4 to 7 of alkaline, and 0·53 of earthy salts.

Gases.

Gaseous contents.— In a well-exhausted receiver of an air-pump, blood yields carbonic acid, and, according to Magnus, also oxygen and nitrogen gases. Carbonic acid may also be extracted from it by exposing it for some time to a stream of hydrogen. Chemists, however, are by no means all satisfied that the gas obtained by any of these methods exists in the blood in a free state.

Liebig brings arguments to prove that the carbonic acid extricated *in vacuo* is derived from bicarbonate of soda; a solution of which, it is well known, yields up a portion of its carbonic acid when atmospheric pressure is removed from it. It is also worthy of remark that hydrogen extracts more carbonic acid when the blood has stood for some time than when it is perfectly recent; from which it is suspected that the carbonic acid evolved in that process may have been liberated by some reaction of the ingredients of the blood on each other.

Magnus found that, when arterial and venous blood were submitted to the air-pump, the former afforded all the three gases in larger proportion than the latter, but that the ratio of the carbonic acid to the oxygen was greater in the venous than in the arterial. The actual amount was very variable, but the mean quantities (by volume) obtained from 100 parts of blood were as under, viz.

Gases.	*From arterial blood.*	*From venous blood.*
Carbonic acid . .	7·10 . .	5·35
Oxygen	2·65 . .	1·21
Nitrogen . . .	1·35 . .	1·13
	11·10	7·69

There is, however, some ambiguity as to the oxygen, since neither Dr. J. Davy nor Enschut could obtain that gas from either kind of blood. Both these experimenters obtained more carbonic acid from venous than from arterial blood.

Enumeration of contents of blood.

The following statement of the mean composition of human venous blood is from Lecanu. (Etudes chimiques sur le sang humain, Paris, 1837.)

Free oxygen, nitrogen, and carbonic acid Extractive matters Fatty matters, viz. Phosphuretted fat Cholesterin Serolin Oleic and margaric acids (free) Ditto combined with soda Volatile odoriferous oily acid (combined with a base). Salts, viz. Chloride of sodium „ potassium Hydrochlorate of ammonia Carbonate of soda „ lime „ magnesia Phosphate of soda „ lime „ magnesia Lactate of soda Yellow colouring matter		10·98	Serum . . . 869·15
Albumen		67·80	
Water		790·37	
Fibrin		2·95	Crassamentum 130·85
Hæmatin . . .	2·27	Corpuscles 127·90	
Albumen (globulin)	125·63		
			1000

Arterial and venous blood compared.

Differences between Arterial and Venous blood.—The different effects they are capable of producing in the living body are not considered here. Arterial blood is, according to most observers, near two degrees Fahr. warmer than venous. It is said to coagulate sooner (Nasse). Its specific gravity is a very little lower than that of venous blood, and it contains a very little more water (about 5 parts in 1000) in proportion to its solid ingredients (Nasse, Simon, and Hering). The amount of albumen, fat, extractive matter, and salts taken together scarcely differs in the two kinds of blood. The fibrin is somewhat more abundant in arterial blood, and differs from that of venous in being insoluble in nitre. The amount of red corpuscles is said, by Lecanu and Letellier, to be greater in arterial blood; but this is denied by Nasse and others. The red corpuscles of venous blood contain more hæmatin in proportion to their globulin than those of arterial blood (Simon). Marcet and Macaire found, by ultimate analysis, more oxygen and hydrogen, and less carbon, in the elementary composition of arterial than in that of venous blood; Michaelis maintained that there was a larger proportion of oxygen to the red corpuscles of arterial blood, but not in its other ingredients. Berzelius doubts the correctness of both statements. The alleged difference in the proportion of gases, and the discrepancies of the observations on that head, have been already mentioned. The most striking and well-known difference between the two bloods is in their colour. Venous blood is rendered bright red by exposure to atmospheric air, or to oxygen. This effect is greatly promoted by the saline matter of the serum, and may be accelerated by adding salts or sugar to the blood, especially by carbonate of soda and by nitre; but, according to Nasse, the presence of serum, or of saline matter, is not indispensable to its production, for although the clot, when washed free from serum, does not redden on exposure to oxygen, yet he found that the fresh clot, or red matter of the blood, when deprived of serum, and dissolved or diffused in water, still becomes perceptibly brighter and more transparent on exposure to oxygen, though the effect is slow in appearing, whilst the colour is deepened, and the solution acquires a turbid aspect, on being agitated with carbonic acid. Salts added to dark blood, without exposure to air or oxygen, cause it to assume a red colour, which, however, Nasse

Change of colour.

maintains, does not equal in brightness the arterial red. Exposure to carbonic acid darkens arterial blood. The immediate cause of the change of colour is uncertain; it has, with most probability, been ascribed to a change in the state of aggregation of the colouring matter, and in the figure of the corpuscles.

Blood of the portal vein.

Portal blood.—The blood of the portal vein is said to contain proportionally less fibrin than other blood, more fat, and, though perhaps not constantly, more hæmatin and more carbonated alkali.

xxx✓

OSTEOLOGY.

THE SKELETON.

The skeleton.

The osseous structure is peculiarly fitted, by its solidity and hardness, not only to give support to the soft parts, but also to furnish points of attachment to the muscles, by which the different movements are executed. This solid frame-work of the body is made up of a number of separate pieces, the aggregate of which has been termed "*the skeleton*," (sceletum, *σκελλω, to dry.*) The vertebral column may be considered as the central or fundamental part of the whole, both because it exists in all animals which possess an internal osseous skeleton, and also because the different parts of the osseous system are either immediately or mediately connected with it as a common centre. Thus, on its superior extremity, or apex, it supports the skull; laterally it gives attachment to the ribs, which arch forwards, to form, with the sternum, a bony case for the lodgment of the organs of respiration and circulation, at the same time that they furnish, externally, points of support for the superior extremities: inferiorly the column is immovably connected with the pelvic bones, which are articulated with those of the lower extremity.

The vertebral column is its essential constituent.

When proceeding with the description of the human body, it is usual to consider it as divisible into head, trunk, and extremities, which is sufficient for the purposes of a regional division; but the skeleton must be viewed in a different way, particularly if reference is made to its conformation in the various orders of animals—to its developement—and to the subordination of its component parts. The spine being its essential constituent, all the others (viz. the ribs and sternum, clavicle, scapula, and upper extremities, the pelvic bones and lower extremities,) rank as accessories. The sacrum and coccyx are obviously parts of the spine, so likewise are the cranial bones; for though in outward appearance they differ so much in man and the higher animals from the bones of the spine which are placed beneath them, and with which they are articulated, they still are but modifications of similar organic elements—repetitions, in fact, of like parts differently developed to suit the peculiar relations into which they enter, and the purposes which they are designed to serve.

Number of the bones.

The number of pieces which compose the osseous system varies in the different ages of life; for some, which in the first instance are divided into two or more portions, become soldered together as the process of ossification goes on. But authors are far from being unanimous as to the number of bones which they recognise even in the adult. Do the sesamoid bones form parts of the skeleton, or are they mere accessory structures developed in tendons? Are the teeth, os hyoides, and ossicula auditûs, to be enumerated as components or accessories? Monro and Sœmmering reckon 260 bones; and Meckel, who takes the number at 253, includes the teeth, patellæ, ossa sesamoidea, os hyoides as five pieces, sternum as three, coccyx as four, and the small bones of the ear. If, however, we omit those just named, as being either accessories or connected with special organs, the whole number of pieces found in the ordinary skeleton will be 197, as follow:—

The spinal column, properly so called, consists of 24 vertebræ, the sacrum and the coccyx	26
The skull is made up of eight cranial bones, viz. the occipital, two parietal, two temporal, the frontal, the ethmoid and sphenoid:—and of fourteen facial, viz. two nasal, two lachrymal, two superior maxillary, two malar, two palatal, two turbinated, one vomer, and the inferior maxillary bone	22
The ribs are 24 in number (twelve on each side), with the sternum	25
The two superior extremities consist each of a clavicle and scapula, humerus, radius, and ulna, eight carpal bones, five metacarpal, and fourteen in the digital rows . .	64
The two inferior extremities comprise, each, one pelvic bone (innominate), one femur, tibia, and fibula, seven tarsal bones, five metatarsal, and fourteen digital . .	60

In the skeleton we recognise two great cavities (which are again variously subdivided); one anterior and inferior, comprising the thorax and abdomen; the other posterior and superior, formed by the union of the vertebral canal with the cranial cavity.

VERTEBRAL COLUMN.

Its situation; The *vertebral column* (columna vertebralis, rachis, spina,) is situated along the median line, at the posterior part of the trunk, the length of which it determines. Anteriorly it presents the form of an irregular pyramid—posteriorly, a series of elongated processes (spinæ), disposed regularly one beneath the other, from which circumstance the term "spine" is derived. Viewed as a whole, it resembles at first sight the shape of a long bone, but it is very differently constructed. As it receives the weight of the head and trunk, and transmits it to the base on which it rests, it requires to be firm and resisting, its power of resistance increasing gradually from above downwards. Being the centre of all the movements of the body, it must be as pliant and flexible as a bow, but yet firm, in order to give adequate protection to the spinal cord which it encloses. All these conditions are attained by its being made up of several small pieces united by an elastic substance, the motion permitted between each pair being slight, while the aggregate of all is considerable.

shape; uses; construct-tion.

VERTEBRÆ.

Vertebræ; true and false.

The *vertebræ*, or separate pieces of which the column is made up, are so named from their mobility (vertere, to turn). They are divided into *true* and *false;* the former term being applied to those which remain separate in the adult, and retain their mobility; the latter to such as become united into one mass (viz. the sacrum), or degenerate as it were, and lose all the ordinary characters of vertebræ (viz. the coccyx). The size of the vertebræ increases from above downwards as far as the first pieces of the sacrum, from which it diminishes towards the end of the coccyx, where it terminates by a point; so that the column may be said to consist of two pyramids applied to one another at their bases. The superior, or movable vertebræ, however, do not taper regularly from above downwards; they become somewhat narrowed and constricted as it were at the third dorsal vertebra, after which they gradually enlarge towards the lower end.

A. THE TRUE VERTEBRÆ.

Classification.

The *true vertebræ* are divided into three sets, named from the regions which they occupy, *cervical*, *dorsal*, *lumbar*.

Their characters—general; peculiar to the regions; and special to individuals.

They present, 1. certain general characters by which they may at once be distinguished from bones of any other class; 2. those of each region (cervical, dorsal, lumbar,) exhibit peculiar characters by which they are severally distinguished; 3. certain vertebræ present special or individual characters.

1. GENERAL CHARACTERS OF A VERTEBRA.

The general characters.

Adaptation of the parts of a vert. to the uses of the column.

The objects presented by each vertebra are, a ring, a body, articulating processes, transverse and spinous processes, and notches. Of these, the ring, or foramen, merely to suit the purposes of methodical description, may be considered the central part. As the whole series of vertebræ is intended to form a pillar of support, each, with the exception of the first, presents in front a convex mass (the body), which is a section of a cylinder, and which, by being piled one over the other, form the pillar. As each bone must be securely joined with the one above it and that below it, there exist certain prominences (articulating processes) for articulation with them. The column being flexible, and partaking in the several movements of the body, it is required that there be levers (transverse and spinous processes) for the attachment of the muscles or moving powers. Finally, it is necessary that a free communication should be allowed for the nerves with the nervous centre contained in the canal, and this purpose is served by the notches.

The various parts of a vertebra here named require more detailed notice.

Foramen.

The *ring* (foramen vertebrale, rachidium,) is formed in front by the body, and posteriorly by what is named the *arch* of the vertebræ, from which latter the several processes project. As the vertebræ are piled one over the other, the rings are arranged so as to form, with the aid of the interposed ligamentous structures, a flexible canal for the lodgment and protection of the spinal cord.

Body

The *body* forms the anterior and most considerable part of the bone. Rounded before, and marked in the middle by a transverse groove, which gives it a constricted appearance, it is slightly hollowed posteriorly, where it contributes to the formation of the vertebral canal, and in most instances is flat on the superior and inferior surfaces, by which, through the medium of fibro-cartilage, it is connected with the contiguous bones. Its outer surface all round presents numerous foramina for the passage of blood-vessels, principally veins. One of the holes situated about the middle of the posterior surface exceeds the others very much in size; it lodges a large vein.

Arch.

From the body at its lateral margins two processes pass backwards, called "pedicles." The pedicles join with the laminæ, or plates, and these, by inclining inwards, meet at the median line posteriorly, so as to complete the "arch" of the vertebra. From the point of junction of the pedicles with the laminæ at each side, the articulating and transverse processes project; and from the union of the two laminæ the spinous process takes its origin.

Articulating processes.

Articulating or *oblique processes.*—For maintaining the connexion between the contiguous vertebræ, there are four processes,—two superior, and two inferior,—which project, one on each side, from the junction of the lamina with the pedicle. Two of these processes project upwards, and two downwards; the smooth surfaces of the upper pair look backwards, those of the lower, forwards; they are coated with cartilage, and articulate with corresponding processes of the next vertebræ. Their margins are rough for the attachment of ligaments.

Transverse processes.

The *transverse* and *spinous* processes form a series of levers for the attachment of muscles. The transverse processes, two in number (one on each side) and named from their direction, project laterally from the arch near the articulating processes, between which their bases are interposed. The *spinous* process is a single projection, situated posteriorly in the median line; this process, or rather the appearance presented by the aggregation of those of the several vertebræ, has given to the entire column one of its designations (spine).

Spinous process.

Laminæ.

Laminæ or *plates.*—The parts of the arch which intervene between the bases of the spinous and the transverse processes are thus named.

Pedicles.

Pedicles and *notches.*—Lastly, the processes which extend from the plates to the body of the bone, are called "pedicles," as above stated. In each pedicle are seen two excavations, or notches (incisuræ), one on the upper, the other on the lower border, the latter being deeper than the former. When the vertebræ are placed in their natural position, the notches in the contiguous margins of each pair of them form rounded apertures, which communicate with the vertebral canal, and give transmission to the spinal nerves and to the entering and emerging vessels. From their position and mode of formation, they are called the *inter-vertebral foramina.*

Notches.

Interverte-bral foramina.

2.—CHARACTERS PECULIAR TO THE VERTEBRÆ OF EACH REGION OR CLASS.

CERVICAL VERTEBRÆ.

Cervical vertebræ.

Size.

Foramen.

Body.

Fig. 1.*

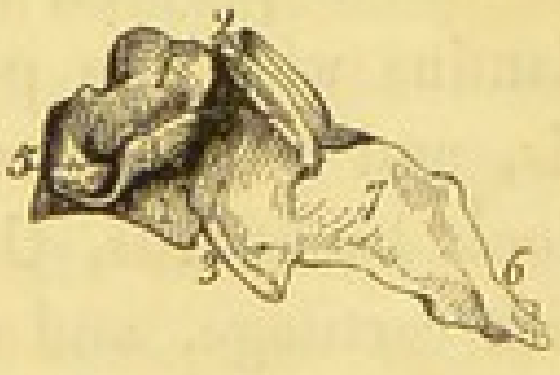

The cervical vertebræ, fig. 1, are seven in number; they are smaller than those in the other regions, which results from the size of the body and processes being less than that of the corresponding parts in the dorsal and lumbar classes. The vertebral foramen is of a triangular form, and larger proportionally than in the other classes. The body,[1] elongated transversely, is thicker anteriorly than posteriorly; for the under and fore part of each dips down a little. The upper surface is broader than the under one, and is rendered concave from side to side, by two little plates, which project upwards from its lateral margins. The lower surface is slightly convex, and rounded off

---

* This is a representation of a cervical vertebra, seen from the left side. 1. The body. 2. The superior articular process. 3. The inferior articular process. 4. The transverse process. 5. The groove of this process. 6. The spinous process. 7. The plate or lamina.

at the sides. The superior articular processes[2] are flat and oblique in their direction, so as to look backwards and upwards, whilst the inferior[3] incline downwards and forwards. It is only in the cervical vertebræ that these processes can be fitly named "oblique." The articular surfaces are supported on rounded and elongated little masses or pillars of bone. The transverse processes,[4] short, and bifid at their extremities, present a deep groove superiorly,[5] for the transmission of the nerves, and at their base a foramen, through which in most of them the vertebral artery passes. It will be observed, that these processes have two roots or points of connexion with the vertebra. The posterior one springs from the junction of the pedicle with the arch, and therein corresponds with the transverse processes in the back and loins. The anterior one is attached to the side of the body of the vertebra, and ranges with the ribs, of which it is a rudiment. The formation of the foramen can, from these facts, be readily indicated. The osseous points, which here represent the ribs, not being required for any special purpose, remain in their rudimentary condition, and merely incline backwards, so as to become anchylosed with the true transverse processes which lie behind them. They thus enclose a space, viz. the foramen, which, however, cannot be said to be intended to lodge the vertebral vessels, as it exists in the seventh cervical vertebra, through which they rarely pass, and in the sixth and fifth in those cases in which the artery enters the fourth. The spinous process[6] is short, projects horizontally backwards, and is bifid at its extremity. The plates, or laminæ,[7] are narrower and longer than in the other regions. The notches are deeper and larger in the upper than in the lower border of the pedicles, in all except the second. They lie behind the articular processes in the first, but before them in the rest.

Articular processes.

Transverse process;

its foramen.

Spinous process.

Plates and notches.

DORSAL VERTEBRÆ.

The dorsal vertebræ, fig. 2, twelve in number, are intermediate in size as well as in situation, between the cervical and the lumbar. The foramen is smaller than in the cervical or lumbar region, and is nearly circular in its form. The lateral notches, [1] [2] and consequently the inter-vertebral foramina which they

Size.

Foramen.

Notches.

Body;

its articular surfaces.

Articular processes.

Transverse processes;

their articular surfaces.

Spinous process.

Plates.

form, are larger than those in the neck ; and those at the lower margin of the pedicles are much larger and deeper than those on the upper. The breadth of the body[3] from side to side, exceeds the depth from before backwards much less than in the cervical or lumbar vertebræ. It is convex and prominent on the anterior surface, flat and plain at the upper and lower; at each side of the body may be observed a slight notch,[4] [4] in the superior as well as in the inferior border,—these are covered with cartilage and, when the vertebra is placed in apposition with the adjacent ones, form oval depressions for the reception of the heads of the corresponding ribs. The articulating processes[5] [6] are nearly vertical in their direction; the superior looking backwards, the inferior forwards. The transverse processes[7] are long, thick, and inclined backwards, and on the anterior surface of each of their tubercular terminations is situated a slight excavation,[8] which in the fresh state is tipped with cartilage, and articulates with the tubercle of the rib. The spinous processes,[9] elongated and triangular, are directed downwards, and terminate in a tubercle.[10] The plates are broad and thick, but shorter than those in the neck.

Fig. 2.*

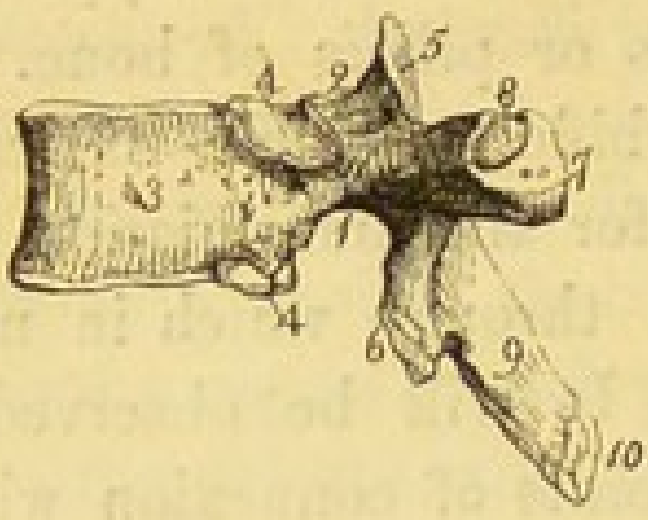

LUMBAR VERTEBRÆ.

Lumbar vert.
Size.
Foramen.
Notches.
Body.

The lumbar vertebræ, fig. 3, five in number, are larger than either of the other sets. The foramen of each vertebra in this region is large and triangular. The notches,[1] [1] for the formation of the inter-vertebral foramina are very deep, especially the inferior pair. The body,[2] much broader from side to side than from before backwards, is flat on its superior and inferior surfaces. It is not so convex anteriorly as that of the dorsal

---

* One of the middle dorsal vertebræ is here seen on the left side. 1. The lower notch. 2. The upper notch. 3. The body. 4, 4. The articular surfaces for the heads of ribs. 5. The superior articular process. 6. The inferior articular process. 7. Transverse process. 8. Articular surface for the tubercle of a rib. 9. Spinous process; and 10. its tuberculated end.

Articular processes.

vertebræ. The articulating processes are thick, strong, and disposed vertically; the superior pair,[3] concave, look backwards and inwards; the inferior,[4] convex, forwards and outwards; the former are farther apart than the latter, hence they receive and in a manner embrace the lower articulating processes of the vertebra above them. From each of the superior articulating processes a "tubercle" projects backwards. The transverse processes,[5] long, thin, and horizontal, do not project backwards like those of the dorsal vertebræ. The spinous process is broad, flat, and nearly of a square form, so that it terminates not by a pointed extremity, like those in the dorsal region, but presents rather a compressed and rough border.[8] The plates or laminæ,[7] though shorter, are deeper and thicker than those of the dorsal vertebræ.

Fig. 3.*

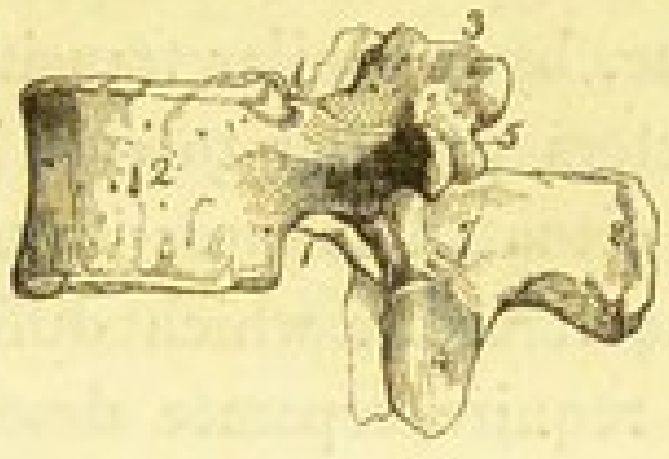

Transverse process.

Spinous process.

Plates.

Each part of the vertebra, characteristic of the class.

If, now, the three vertebræ (cervical, dorsal, and lumbar,) here described separately, are taken together and contrasted, it will be found that the several parts of one differ so much from the same parts in another, and are so characteristic of the region to which they belong, that any one of them would serve to distinguish the classes of the vertebræ. Thus, that the ring, the body, or any process would be sufficient to determine whether a vertebra is of the cervical, the dorsal, or the lumbar part of the column.

3. PECULIARITIES OF CERTAIN VERTEBRÆ.

Transition from the characters of one class to those of another, is gradual.

The general characters of vertebræ, and the differences which characterise those of different regions, being considered, it remains to point out certain peculiarities presented by some individual bones in each set. It may be here stated generally, that

---

* A lumbar vertebra viewed on the left side. 1, 1. The notches. 2. The body. 3. The upper articular process. 4. The lower articular process. 5. The transverse process. 7. is placed on the root of the spinous process near the lamina. 8. The spinous process.

the vertebræ situated at the extremities of each region assimilate in some degree to the characters of those in whose vicinity they are placed. Thus, for instance, the lower pieces of the cervical region begin to resemble the dorsal vertebræ, and the latter become, by a similar transition, assimilated to the lumbar,—the characters peculiar to each region being best displayed by the bones situated towards its middle point.

Vertebræ having peculiar characters.

The vertebræ which differ from others of their class so much as to require separate description are the following: the first two and the last cervical; the first and last three dorsal; and the last lumbar.

THE FIRST, SECOND, AND SEVENTH CERVICAL VERTEBRÆ.

Atlas,

has neither body nor spinous process.

The ring, divided into two unequal parts.

Fig. 4.*

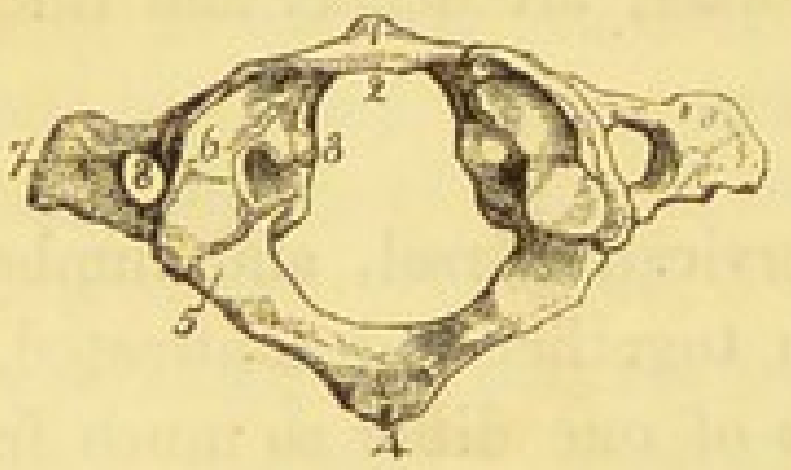

The first vertebra, or *atlas*, fig. 4, (so called from supporting the head,) is an irregular ring of bone, which presents nothing analogous either to the bodies or spines of the other vertebræ. The ring, in the fresh state, is divided into two parts by a transverse ligament,—the anterior one being occupied by the odontoid process of the axis, the posterior by the spinal cord;—it presents in front a small arch of bone, the anterior surface of which is marked by a tubercle,[1] the posterior by a smooth depression,[2] adapted to the odontoid process of the axis. The posterior segment of the ring is considerably larger than the anterior; at its middle point it presents a tubercle,[4] which is the analogue of the spinous processes; it is thick and round in the greater part of its extent; but at its junction with the rest of the vertebra there exists on the upper border at each side a smooth groove,[5] which lies behind the superior articular process, and marks the tortuous

Posterior arch grooved for vert. artery.

---

* A view of the upper surface of the atlas. 1. The anterior tubercle. 2. is opposite the articular surface for the odontoid process of the axis. 3. is placed near a rough surface for the attachment of ligament. 4. The posterior tubercle. 5. The groove on the posterior arch for the vertebral artery. 6. A superior articular process. 7. Transverse process. 8. Its foramen for the vertebral artery.

course pursued by the vertebral artery previously to entering the cranium. This groove is analogous to the notches in the other vertebræ, for it transmits the first spinal nerve as well as the vertebral artery; it is sometimes converted into a foramen by a spiculum of bone. The articulating surfaces are horizontal and large. The superior pair[6] receive the condyles of the occipital bone; they converge in some sort towards the forepart of the bone; and as their form is oval, and their surface concave from before backwards, they look towards one another; at the inner margin of each is a rough surface,[3] which gives attachment to the transverse ligament. The inferior pair, on the contrary, are flat, and nearly circular in their form. The parts of the vertebra (*lateral masses*) on which these processes are situated are of very considerable thickness, because the weight of the head, which in others is received by the bodies, rests here on the articular surfaces. The transverse processes[7] project considerably on each side, and terminate in a rounded point; at the root of each is situated the foramen,[8] which transmits the vertebral artery.

Articular surfaces.

Lateral masses.

Transverse processes;

their foramina.

Fig. 5.*

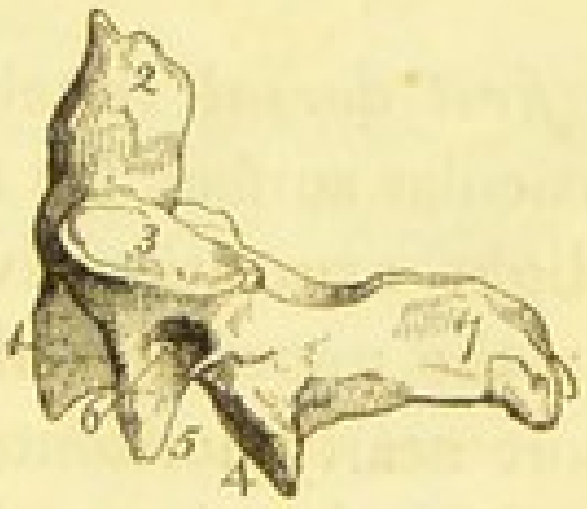

The second vertebra, vertebra dentata, or *axis*, (so called from forming the pivot on which the head rotates,) is somewhat triangular in its form. The body, fig. 5.[1] presents anteriorly a vertical ridge, bounded on each side by a depression for the attachment of the longus colli muscle; superiorly it is surmounted by a process,[2] (*odontoid, p. dentatus;* whence is derived the name *vertebra dentata,*) presenting two smooth surfaces, one for its articulation with the atlas, the other with the transverse ligament which retains it in its situation; being constricted inferiorly, and somewhat enlarged towards the summit, these parts of the process are called respectively its *neck* and *head*. The superior articulating processes[3] are of consider-

Axis.

Shape.

Body.

Odontoid process.

Articular,

---

* The axis—its left side. 1. The body. 2. Odontoid process. 3. The superior articular process. 4. The inferior articular process. 5. The transverse process. 6. Its foramen. 7. The spinous process.

able size, and nearly horizontal; they are close to the body, so as to communicate to it the weight of the head, transmitted to them by the articular processes of the atlas; the inferior pair[4] are oblique, and of the same size as in the vertebræ beneath them. The transverse processes[5] are neither grooved nor bifurcated, and the foramen at their root[6] is inclined obliquely outwards. The spinous process[7] is very large, and gives attachment to several muscles; it is deeply grooved on its inferior surface; the plates which support it are of proportionate size.

transverse,

and spinous processes.

The prominent vertebra.

The *seventh*, or prominent vertebra, approaches in its characters to those of the dorsal region; its spinous process terminates in a tubercle, and is so long as to be, in the natural condition, felt underneath the skin; whilst the other cervical spines lie more deeply, and are covered by muscles; hence the term "prominent," so commonly applied to this vertebra. The transverse process, though pierced by a foramen, presents but a slight appearance of a groove on its upper surface, and seldom more than a trace of a bifurcation at its extremity.

THE PECULIARITIES OF SOME DORSAL VERTEBRÆ.

First dorsal.

Its connexion with ribs.

The *first dorsal* vertebra is marked at each side by a complete articular surface for the first rib, and on its inferior border by a slight excavation, which receives half the head of the second: the upper articular processes are oblique, and the spinous more nearly horizontal than those below it.

Tenth dorsal.

The *tenth* dorsal vertebra is usually marked by an articular surface, which receives the entire of the head of the corresponding rib.

Eleventh.

The *eleventh* has but a single articular surface on the side of its body. Its transverse process is much reduced in size, and does not articulate with the tubercle of the rib. The form of its spinous process, of its laminæ and body, approaches that of the lumbar vertebræ.

Twelfth; its distinguishing character.

The *twelfth* dorsal vertebra, in most of its characters, resembles the eleventh, and is to be distinguished by its greater similarity to the lumbar vertebræ, especially by means of the lower articular processes, which are convex and look outwards, like the same processes in the lumbar region.

THE FIFTH LUMBAR VERTEBRA.

Fifth lumbar.

Amongst the *lumbar* vertebræ, the fifth only is distinguishable by any peculiarity deserving of notice, its body being thicker anteriorly than posteriorly, and its transverse process short, thick, and rounded.

B. THE FALSE VERTEBRÆ.

False vertebræ, whence the term.

Some of the vertebræ at the lower part of the column lose by their union into a single mass (the sacrum) that character of mobility from which the term vertebra is derived, and others, (the coccygeal,) dwindled to mere tubercles, have none of those important uses to which the true vertebræ serve. Hence the general designation, "false vertebræ," applied to them.

THE SACRUM.—OS SACRUM.

Fig. 6.*

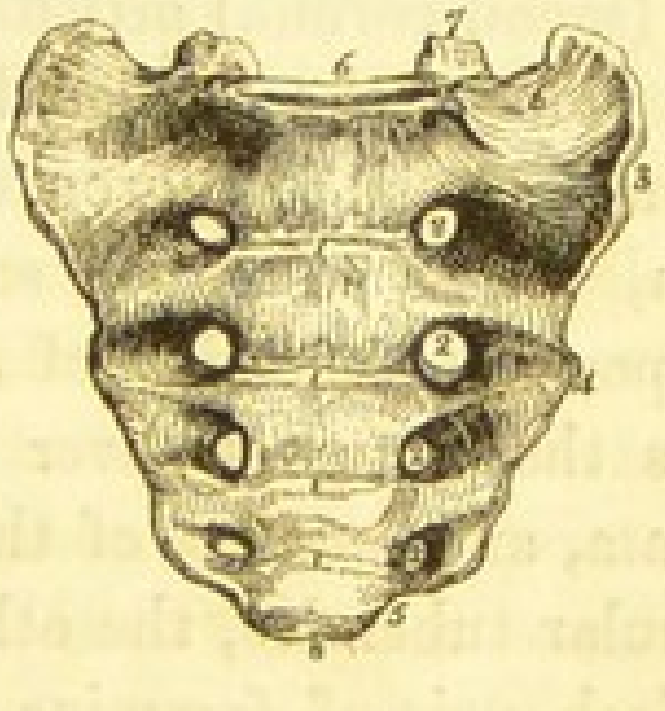

Sacrum.

Situation.

The sacrum, fig. 6, much the largest piece of the vertebral column, is placed, when the body is in the erect position, at the superior and posterior part of the pelvis, beneath the last lumbar vertebra, above the coccyx, and between the ossa innominata, between which it is inserted, in some measure like a key-stone into an arch.

Direction.

Sacro-vert. angle.

The sacrum is placed very obliquely. It projects backwards from the upper margin, receding to give capacity to the pelvis, and it therefore forms, with the body of the last lumbar vertebra, a projection named the sacro-vertebral angle, or promon-

---

* A front view of the sacrum:—1, 1. Ridges indicating the place of separation between the sacral vertebræ. 2. Anterior sacral foramina. 3, 4. Lateral surface. 5. A notch which contributes to form a foramen for the passage of the fifth sacral nerve. 6. Surface for connexion with the body of the last lumbar vertebra. 7. Articular process on each side. 8. Surface for connexion with the coccyx.

Form.

tory. Its figure is triangular in its general outline,—the base being upwards; concave anteriorly, convex posteriorly. We consider successively its surfaces, borders, and extremities.

Anter. surface; its ridges, foramina, and grooves.

The anterior or pelvic surface, which is here shown, is concave from above downwards, slightly so from side to side, and marked by four transverse lines,[1] indicating its original division into five pieces; laterally it presents four foramina,[2] (anterior sacral,) for the transmission of the anterior branches of the sacral nerves. These are directed outwards into grooves which lead from them, and diminish gradually in size from above downwards; external to the foramina the surface gives attachment to the pyramidalis muscle.

Poster. surface; its spines, grooves, tubercles (two sets), foramina.

The posterior or spinal surface is narrower than the anterior, for the bone is somewhat wedge-shaped from before backwards as well as from above down. This surface is convex, and presents along the median line four small eminences, usually connected so as to form a ridge; these are rudiments of the spinous processes; and beneath them is a triangular groove, or rather an opening, marking the termination of the sacral canal. The margins of the opening present two tubercles, which give attachment to the ligament that closes in the canal, and the inferior pair (sacral cornua) articulate with the horns of the coccyx. At each side of the median line are two sets of tubercles, and between these is the groove, pierced by the posterior sacral foramina, which are much smaller than the anterior, and transmit the posterior branches of the sacral nerves. The groove represents that situated over the plates of the vertebræ above the sacrum, and one row of the tubercles corresponds to the lumbar articular tubercles, the other ranges with transverse processes.

Cornua.

Intervert. foramina.

Each pair of foramina (anterior and posterior) lead from a single foramen situated within the bone, and this is analogous to the inter-vertebral foramen in other parts of the column.

Lateral surfaces.

The borders, or lateral surfaces of the sacrum, present two distinct parts,—one superior, the other inferior. The superior (iliac) is large and irregular,[3] and in front is, in the fresh state, covered with cartilage, and articulated with the ilium; whilst posteriorly it is concave and rough for the attachment of strong ligaments. The anterior cartilaginous part is often named "the *auricular surface*." The inferior part of the lateral surface[4] is thin and sinuous, and gives attachment to the sacro-sciatic ligaments. A small indentation[5] terminates this border, which, with the corresponding extremity of the coccyx, forms a notch for the transmission of the fifth sacral nerve.

Base. The *base*, or superior extremity, broad, and expanded, presents, towards the middle line, an oval surface,[6] cut off obliquely, which articulates with the likewise oblique body of the last lumbar vertebra; behind this a triangular aperture marking the orifice of the sacral canal; on each side a smooth convex surface, inclined forwards, and continuous with the iliac fossa; an articular process,[7] concave from side to side, which looks backwards and inwards, and receives the inferior articular process of the last lumbar vertebra. Before each articular process is a groove, forming part of the last lumbar inter-vertebral foramen, and behind them is a curved, sharp, and depressed border which bounds the sacral canal, and therefore corresponds with the laminæ of the vertebræ, and gives attachment to the last ligamentum subflavum.

Apex. The *apex*, or inferior extremity,[8] directed downwards and forwards, presents an oval convex surface, which articulates with the coccyx.

Sacral canal. The sacrum in its interior contains much loose spongy substance, and its exterior layer is but moderately compact. Its central part is also hollowed into a canal (sacral), which curves from above downwards as the bone does; it is of a triangular form, and gradually narrows as it descends. The canal ends on the posterior surface of the bone between the sacral cornua.

Muscular attachments. *Attachments of muscles.*—The sacrum gives attachment, by the lateral parts of its anterior surface, to the pyramidales muscles; by its posterior surface at each side to the gluteus maximus, sacro-lumbalis, longissimus dorsi, and multifidus spinæ; by the inferior part of each border to part of the coccygeus; and by the outer parts of its base to the iliacus muscle of each side.

Articulations.—The sacrum articulates with the last lumbar vertebra, the two iliac bones, and the coccyx.

PECULIARITIES OF THE SACRUM.

Peculiarities. The peculiarities of the sacrum are very numerous. 1. In some cases this bone consists of six instead of five pieces, and it has been found—but much more rarely—reduced to four.*

2. Occasionally the bodies of the first and second sacral vertebræ are not joined, although complete union has taken place in every other part.

3. The lower end of the sacral canal may be open for some extent, in consequence of the vertebral laminæ not having grown together.

The curve, its differences;

4. In no respect does the sacrum vary more in different skeletons than in the degree of its curve. It is difficult to submit the peculiarities in this respect to a precise and sufficiently comprehensive arrangement; still, after examining a considerable number of skeletons, the majority appeared to admit of being grouped into three sets, as follows:—

classification of them.

a. In one series the anterior surface was comparatively straight, and the slight bend which existed was situated near the lower end.

b. Another group contrasted strongly with the preceding,—the bone being much curved in its whole length, but especially about its middle.

c. A considerable number may be described as holding an intermediate place between the two foregoing classes. The degree of curve was moderate, and chiefly affected the lower third of the bone.

Difference in the male and female.

Difference in the sexes.—Besides possessing the ordinary distinctive character of all parts of the skeleton,—viz. more regularity and smoothness of surface,—the sacrum of the female body is, proportionally to the size of the pelvis or of the skeleton, broader than that of the male.

The curve not characteristic of sex.

The degree in which the bone is bent has been relied on by anatomical writers to distinguish between the sexes; but, on comparing their statements, it will be found that they are contradictory—some assigning the greater curve to the female, others, on the contrary, to the male. The measurement of a considerable number of those bones taken from both sexes has shown me that the curvature cannot be relied on as a distinctive character. I find that the general remarks made in the preceding paragraphs on the varieties presented by the sacrum, with

---

* Sœmmering "Lehre von den Knochen und Bändern, &c., herausgegeben von Rudolph Wagner."—1839.

reference to the point in question, are applicable either to the female or the male taken singly, with only this reservation, that those bones which were most curved, and which constitute the second series in the classification there ventured on, commonly belong to the male body.

It is said by many good observers, that the sacrum usually inclines backwards from the direction of the lumbar vertebræ to a greater extent in the skeleton of the female than of the male, —thus retiring more from the cavity of the pelvis, and forming a more prominent sacro-vertebral angle.*

THE COCCYX.—OSSA COCCYGIS.

Coccyx.

These bones, when united together, which is usually the case in advanced life, are supposed to resemble a cuckoo's bill, and are therefore called coccygeal (κοκκυξ, a cuckoo). Most commonly there are four of them, sometimes but three; in a few instances five have been found. They diminish gradually in size from above downwards, which gives them, when taken together, a pyramidal form. As they are placed in a continuous line with the inferior third of the sacrum, they form a slightly concave surface anteriorly, a convex one posteriorly.

Four pieces.

Fig. 7.†

Characters of each.

The first of these bones[1] resembles, in some measure, the last false vertebra of the sacrum. Its body is small and concave at its upper aspect,[b] which articulates with the extremity of the sacrum; posteriorly, two small processes, termed cornua,[a] project, which rest upon the sacral cornua. The second bone of the coccyx is somewhat square, the third oblong, and the fourth is a small rounded nodule.

The margins (shoulders, as this part has been named,) of the first piece, in some cases, project upwards, and, joining with the sacrum, construct a fifth sacral foramen — as exemplified in fig. 12. B.

---

* This observation is stated by Blumenbach ("Geschichte und Beschreibung der Knochen," S. 314,) to have been first made by Bonaccioli, a Professor at Ferrara, in the fifteenth century.

† The anterior surface of the coccyx.

Attachments of muscles.—The coccyx gives attachment to the gluteus maximus, and to the coccygeus of each side, and by its point to the sphincter ani.—Its base articulates with the sacrum, and in advanced age becomes united to it.

THE VERTEBRAL COLUMN.

The column; its length; does not determine the height of body.

The true and false vertebræ, when ranged in their natural position, form a column, the average length of which is equal to about two feet two or three inches. The length of the column does not vary in different persons as much as might be anticipated from a comparison of their stature; the relative height of individuals depending more on the length of their lower limbs than of the vertebral column.

Form, double pyramid.

Form.—Its form is pyramidal—rather it consists of two pyramids joined by their bases; the upper one being formed by the true vertebræ, the lower one, by the sacrum and coccyx. The upper pyramid, however, instead of tapering regularly from the top to the bottom, becomes narrow in the upper part of the dorsal region. It is most narrowed about the fourth dorsal vertebra, and the column above this point has been held to admit of subdivision into two pyramidal parts, meeting by their bases about the first dorsal vertebra, and the apex of one being the vertebra dentata, that of the other the fourth or fifth dorsal vertebra.

Curves, anterior and posterior;

The curves.—When viewed in profile, it presents four curves depending, except perhaps the last, on the different degrees of thickness of the anterior and posterior part of the bodies of the vertebræ in the different regions, but still more on that of the inter-vertebral substance. The curves are directed alternately backwards and forwards; in the neck and loins the convexity looks forwards, in the back and pelvis it is in the opposite direction.

lateral; its cause.

A slight degree of lateral curvature is also observable in most cases in the dorsal region, the convexity of which is directed towards the right side. The older anatomists imagined this to be produced by the action of the aorta beating against the left side of the column; but Bichat attributed it to the effect of muscular action, and explained it in the following way:—As most persons are disposed to use the right arm in preference to the left, the muscles of that side become stronger, and act with more power on the points to which they are attached; when making efforts, as in pulling, the body is curved to the left, which gives an additional advantage to the muscles; and the habitual use of this position gives rise to some degree of permanent curvature. In support of this explanation of the fact, Béclard has stated that he found in one or two individuals, who were known to have been left-handed, the convexity of the lateral curve directed to the left side. A further confirmation of the correctness of this view is afforded by an observation made by Professor Otto.* In a case in which the aorta arched to the right instead of the left side, he found that the curve of the vertebral column had the usual direction; so that the great vessel was connected to its convexity. It is stated, too, that the right arm was more muscular than the left.

Illustrative cases.

For a detailed examination of its parts, the column will be considered as presenting an anterior and a posterior surface, two lateral surfaces, a base, and a summit, each deserving a particular notice. The part formed by the sacrum and coccyx having been already sufficiently referred to, may be excluded from consideration in this place.

Anterior surface; its varying breadth and transverse grooves.

The *anterior surface* is broad in the cervical, narrow in the dorsal, and again expanded in the lumbar region; it is marked by a series of transverse grooves corresponding with the centre of the bodies of the vertebræ, and in the fresh state is covered by the anterior common ligament.

Posterior surface; its spines; grooves.

The *posterior surface* presents along the median line the spinous processes, varying in form and direction, as has been already stated, being horizontal in the cervical and lumbar regions, and nearly vertical in the dorsal. Those in the cervical and dorsal regions correspond pretty exactly with the middle line, but in the back the spines will be observed in many instances to incline, some to one side, some to the other. On each side of these are the vertebral grooves, extending from the base of the skull to the sacrum; their breadth corresponds with that of the laminæ; they are broad but shallow in the neck, and become deep and narrow lower down. Along the grooves are

---

* "Seltene Beobachtungen," Th. 2, S. 61. See also "The Anatomy of the Arteries with its applications to Pathology and Operative Surgery," by R. Quain, p. 19.

seen the spaces between the laminæ, which in the natural condition are filled up by the yellow ligaments. The breadth of these intervals is very trifling in the neck and in the greater part of the back; it increases in the lower third of the dorsal, and still more in the lumbar region. The interval between the occipital bone and the atlas is considerable, and so is that between the last lumbar vertebra and the sacrum.

Lateral surfaces.

The *lateral surfaces* present the transverse processes, varying in form and character in the different regions; before these are situated the inter-vertebral foramina, and more anteriorly still, in the dorsal region, the articular surfaces which receive the heads of the ribs.

Summit and base.

The *summit* of the column is surmounted by a sort of capital, (the atlas), which is articulated with the occipital bone, and supports the head. The *base* rests on the sacrum, and by this bone the weight of the trunk is communicated to the lower extremities through the medium of the innominate bones.

Vertebral canal.

Along the entire extent of the column runs the *vertebral canal*, which is broad and triangular in the cervical and lumbar regions, circular and contracted in the dorsal. The canal may be said to expand at its upper extremity into the cranial cavity; its lower end is prolonged into the narrowing canal of the sacrum.

Arrangement of the osseous structure.

The *arrangement of the osseous structure* is not the same in the different parts of a vertebra. The arch and the processes projecting from it have a thick covering of compact tissue. The body, on the contrary, is composed nearly altogether of spongy substance. This part of the bone, when sawed through, will be found to consist of cells bounded by thin plates of bone; and it contains large canals for the lodgement of veins. The canals differ somewhat in disposition in different cases, but they will be found to have the same general direction from behind forward, radiating with more or less regularity from the large foramen on the posterior aspect of the body.

Cells and canals in the body.

OSSIFICATION OF THE VERTEBRÆ.

Ossification; uncertainty as to the time of its commencement.

General observations on the time when ossification begins.— The process of ossification begins at different periods in the several parts of the skeleton, and it becomes an object to assign to each centre of bony deposit the time at which it appears. This is a subject of considerable difficulty, and a few general remarks with reference to it are necessary before describing the ossification of individual bones.

The accuracy with which the date of ossification may be determined must depend on the exactness with which the age of the embryo is ascertained. But much uncertainty exists with respect to this point, for the evidence as to the period of conception is not to be fully relied on; and, moreover, the embryo submitted to examination is most commonly in a morbid state, and may have ceased to live some time previous to its separation from the parent. To these sources of uncertainty another may be added : the difference, namely, which actually occurs in the growth of bone in different cases. It seems reasonable that the time of ossification should be influenced by the quality of nutrition ; the opinion, however, that there is some variety among the stages of ossification in different individuals, is not founded on such general grounds, but on a comparison one with another of cases which have fallen under my notice, and on the result afforded by contrasting observations accurately made by myself with some which bear the appearance of having been carefully made by others. It is, doubtless, in a measure at least, in consequence of circumstances such as those referred to, that so great a difference prevails between the statements of various observers on the point in question. These considerations lead us to the conclusion, that the period of the commencement of ossification in a given bone does not admit of being set forth with absolute certainty, especially as regards those bones in which the process begins at very early periods. As to this part of the subject, therefore, we must be content with an approximation to exactness.

Causes.

Conclusion as to the time.

But the relation which the time of the appearance of bony matter in one piece of the skeleton has to the time of its appearance in another, admits of being stated with more accuracy; and it will, in our progress, be referred to whenever it shall appear material. To exemplify what has been said, it may be added, that we may not be able to state with rigid accuracy when bone makes its appearance in the several divisions of the vertebral column, or in the clavicle ; but we can with confidence determine which of them precedes the other in its ossification.

Relation of the times of commencement in different bones.

Ossification of vertebræ.

Division of the subject.

The observations on the growth of bone in the vertebræ will be arranged under three heads, as follows :—*a*. The first will contain an account of the common characters of the ossification of a vertebra. *b*. Under the second head will be placed the peculiarities that occur in the growth of certain vertebræ or parts of the vertebral column. *c*. Lastly, the progress of ossification in the column generally will be reviewed.

a. OSSIFICATION OF A VERTEBRA.

COMMON CHARACTERS.

The process in a single vertebra.

Exclusive of certain exceptional cases, to be afterwards noticed, each vertebra is formed of three principal pieces, to which five small epiphyses are added at an advanced period, and as if for the completion of the bone.

Three principal pieces.

Of the principal pieces two are destined for the formation of the arch and the processes which project from it (fig. 8.^{1} ^{2}). The body of the vertebra is produced from the third (fig. 8.^{3}).

Fig. 8,[*]

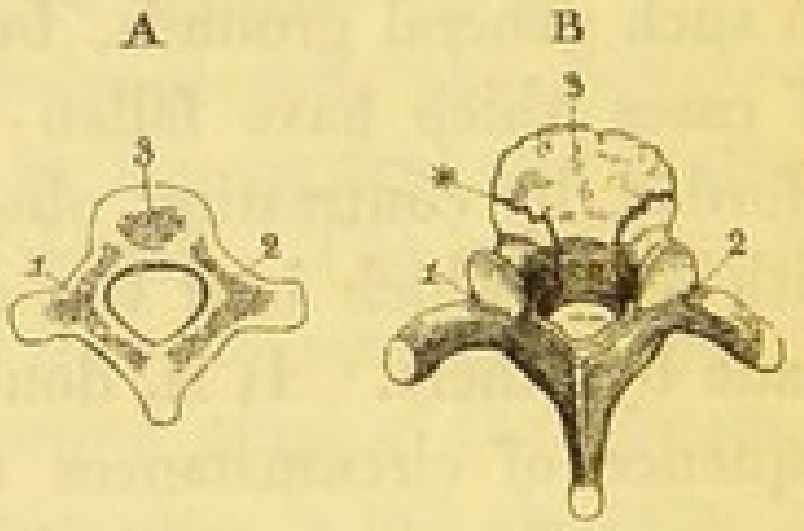

Time of commencement.

Osseous substance is first observable in the vertebræ about the seventh or eighth week from the time of conception, and it commences in the arch (but not invariably) a little before the body.

Lateral pieces for the arch.

The osseous granules for the arches make their appearance on each side at the situation from which the transverse processes project ; and from this place the formation of bone extends in different directions,—forwards to the body, inwards to the spine, and outwards to the transverse process, as well as into the articular processes ; and thus two irregularly-shaped angular pieces of bone are produced.

The body.

The single nodule from which the greater part of the body of the vertebra is formed appears in the middle of the cartilage.

---

[*] A. The three principal pieces of the vertebræ are seen to be distinct one from the other. B. The lateral pieces have joined behind. The spinous and transverse processes remain cartilaginous at their ends. The arch is still separable from the middle anterior piece, and the cartilage having been removed from the body, the surface of this is rounded, rough, and fissured.

1. 2. The lateral pieces. 3. The anterior part for the body. * Line of separation between the lateral pieces and the anterior.

Condition at birth. Union begins with the arch.

At the usual period of birth the three primary pieces are still separate. The process of union commences in the first year after birth. It commences with the lateral pieces, which, at the period mentioned, begin to join behind—in the situation of the spinous process; and by this junction the arch of the vertebra is constructed.

The three pieces joined. Body of vert. how formed.

In the course of the third year the central anterior part joins the arch on each side in a few of the vertebræ, and the junction is effected in such manner that the body is formed from the three original centres of ossification. Each end of the arch contributes a small angular portion (fig. 8. B).

Epiphyses.

Fig 9.*

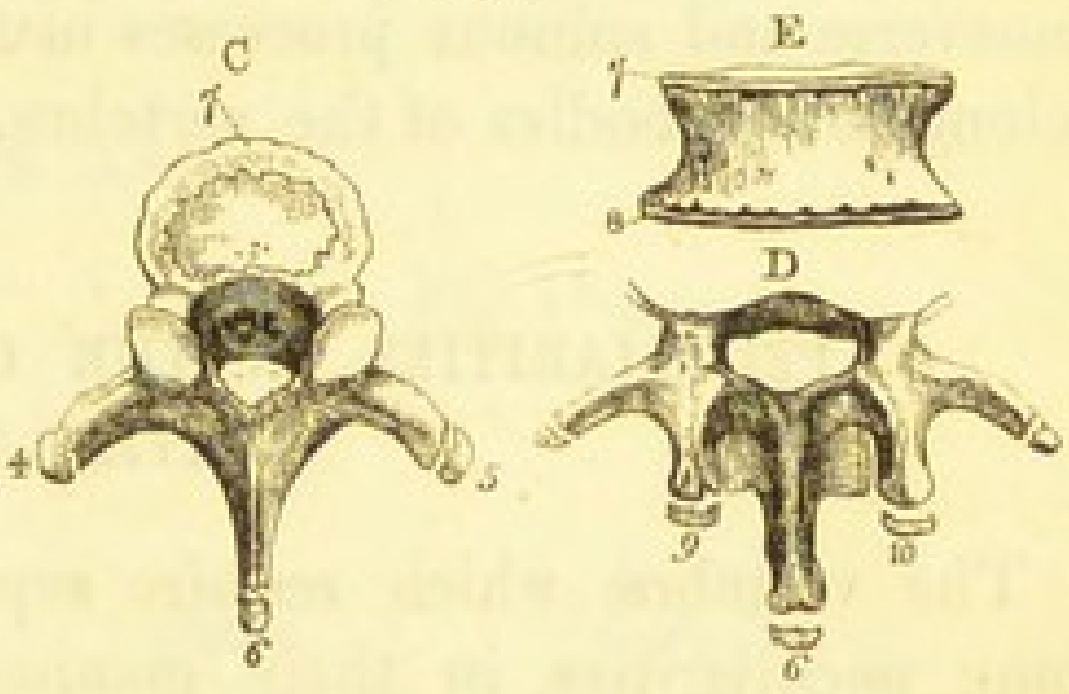

State of the bone before they are added;

Epiphyses. — The spinous process projects backwards from the point at which the lateral pieces have joined, and no further change occurs except the general increase of the different parts of the vertebra and the extension of ossification from the primary pieces, till about the age of puberty. If the bone is examined before that period it will be found, on stripping the cartilaginous ends from the transverse and spinous processes, that the cells of the osseous structure are exposed; and on separating the bodies of the vertebræ one from the other, the cartilages, which still belong to their upper and lower surfaces, remain adherent to the

---

* These figures are intended to show the epiphyses of a vertebra. That marked C represents a dorsal vertebra. The epiphyses of the processes are drawn slightly away from the rest of the bone. D. The arch and processes of a lumbar vertebra, with the epiphyses. These are somewhat elongated, corresponding to the processes which they cover, but the bone having been viewed from above, their ends only came under the artist's eye; and this circumstance will account for their small size in the drawing. E. A front view of the body of a vertebra to exhibit the thin epiphyses which belong to its upper and lower surfaces. 4, 5. The ends of the transverse processes. These processes are not numbered in figure D. 6. Spinous process. 7, 8. The two epiphyses of the body; the flat surface of one is seen in figure C; the edges of both are marked in figure E. 9, 10. Epiphyses of the articular tubercles of a lumbar vertebra.

intervertebral substance, and the osseous part is rough, fissured, and wanting at its circumference the angular shape and dense external covering which belongs to the perfect bone (fig. 8. B).

their position and the times of their appearance;

At the age of about sixteen years, separate osseous points begin to be observable in the cartilaginous ends of the transverse and spinous processes, and they ultimately cover and complete the processes (fig. 9. c. $^{4\ 5\ 6}$). At a later period, soon after twenty years, two thin circular plates begin to be formed, one on the upper, the other on the lower surface of the body, at its circumference (fig. 9. c. E. $^{7\ 8}$).

their junction and completion of the vertebra.

All the secondary or accessory pieces having joined, the bone is completed before the thirtieth year.—The epiphyses of the transverse and spinous processes usually join before those which belong to the bodies of the vertebra.

b. PECULIARITIES IN THE GROWTH OF CERTAIN VERTEBRÆ.

Peculiarities in certain vertebræ.

The vertebræ which require separate notice, by reason of some peculiarities in their manner of growth, are the first, second, and last cervical; those of the lumbar region; together with the sacrum and coccyx.

THE ATLAS.

Atlas.

Principal pieces.

Fig. 10.*

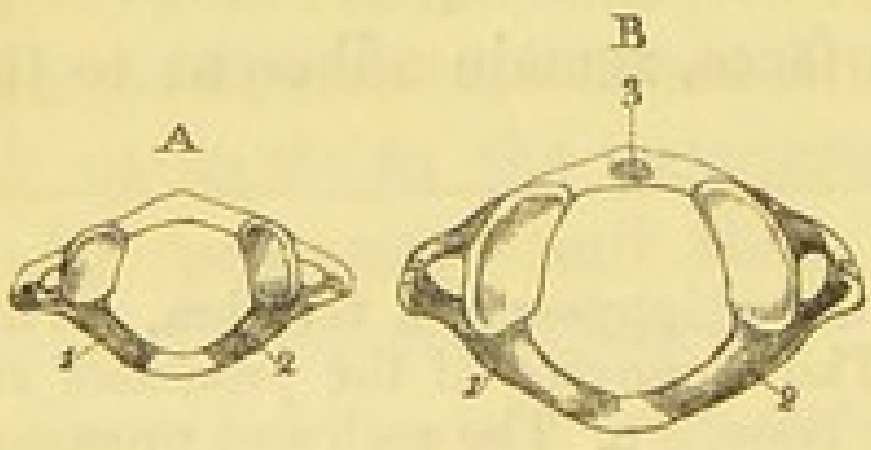

The *atlas* is usually formed from three principal osseous nuclei. The ossification of the lateral parts of the vertebra (fig. 10.$^{1\ 2}$) commences at a very early period.

State at birth.

At birth the interval between the articular processes of the vertebra (the anterior arch) is altogether cartilaginous,

---

* The atlas is seen from above in both figures. A. The lateral pieces are separated by a cartilaginous interval in front and behind. B. This figure is intended to show a nucleus in the anterior arch. It has been modified from one given by Kerckringius in his 37th plate.

and there is a smaller space posteriorly between the two lateral pieces (fig. 10. A).

Anterior arch.

The nucleus for the anterior arch (fig. 10.^{3}) appears soon after birth, very rarely, if ever, before that period. But the ossification in this part sometimes proceeds from more than one centre. According to Béclard, two occur in the proportion of one instance in four or five; and Albinus* and J. F. Meckel† observed each a case in which there were three granules in the anterior arch.

The union.

The posterior arch is formed by the junction of the lateral pieces, between the second and third years, and the arch joins the anterior part at the age of five or six years.

There is frequently a small epiphyses on the posterior tubercle.

THE AXIS.

Axis; its peculiarities in the body and odontoid process.

Fig. 11.‡

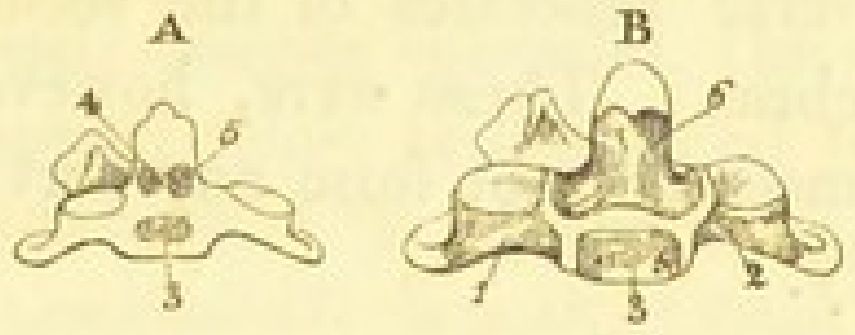

The formation of the arch of the axis corresponds with other vertebræ. The peculiarities occur in the anterior part, which is developed from three points or centres—one being destined for the lower part of the body, the two others for the odontoid process and the upper part of the body (fig. 11. $^{3\ 4\ 5}$). These nuclei appear about the sixth month of fœtal life, the lower single one preceding the others by a short space of time. The two superior lying on the same horizontal plane, enlarge and join before birth. At this period the axis consists of four pieces — the two lateral and two anterior (B. $^{1\ 2\ 3\ 6}$). The body and odontoid process form a single mass about the fourth year (second or third, Béclard).

State at birth.

---

* "Icones Ossium Fœtus," p. 68.

† "Archiv." &c. Band 1, S. 648, and Taf. vi. 1815.—Meckel's case had the additional peculiarity of a separate nucleus interposed between the lateral pieces posteriorly.

‡ The anterior surface of the axis is represented in both drawings. A. The three nuclei for the anterior part are here shown. In B, four pieces are seen connected by cartilage.—1, 2. The lateral pieces. 3. The nucleus for the lower part of the body. 4, 5. Those for the odontoid process and the upper part of the body. 6. The single piece resulting from the junction of 4 and 5.

THE SEVENTH CERVICAL VERTEBRA.

Last cervical; its transverse process.

The anterior part of the transverse process of this vertebra is frequently, if not constantly, formed from a separate osseous nucleus, which unites on the one hand to the body, and on the other to the posterior division of the transverse process. The time of the appearance of this point of ossification is stated by Béclard to be the second month of fœtal life, but my own observation would lead me to set it down for a later period—the sixth month. It is united to the rest of the bone about the fifth or sixth year.

Cervical rib.

Occasional instances occur of the continuance of this process as a separate bone, and in such cases,—being lengthened to an extent which varies in different instances,—it forms what has been termed a cervical rib.*

Meckel† also observed separate centres of ossification in the tranverse processes of the second, the fifth, and sixth cervical vertebræ. These were, however, of small size, and in some instances did not form any part of the foramen for the vertebral artery.

THE LUMBAR VERTEBRÆ.

Lumbar vertebræ have two additional epiphyses.

In addition to the centres of ossification which belong to the vertebræ generally, those of the lumbar region have each two small epiphyses for the tubercles that project from their superior articular processes (fig. 9. D. ^{9} ^{10}).

The so-named transverse process of the first lumbar vertebra is sometimes observed to be developed altogether from a separate centre. The persistence of a process so formed, as a separate piece, would account for the existence of a lumbar rib,—examples of which have occasionally been met with.

Lumbar rib; how formed.

---

* Two examples of the cervical rib are described in "The Anatomy of the Arteries, with its applications," &c. by R. Quain, pp. 149 and 187, and plate 25. J. F. Meckel ("Archiv." &c. B. 1, Taf. vi. 1815.) has figured a case resembling one of those in the circumstance of the end of the cervical rib being connected to a prominence on the first proper rib.

† Loc. citat.; and "Journal Complement. du Dict. des Sciences Med." vol. ii. p. 218.

THE SACRUM.

Sacrum; its vertebræ at first resemble others.

The *sacrum* results from the union of five vertebræ. In the manner of their ossification these do not at an early period differ from the vertebræ in other parts of the column.

Fig. 12.*

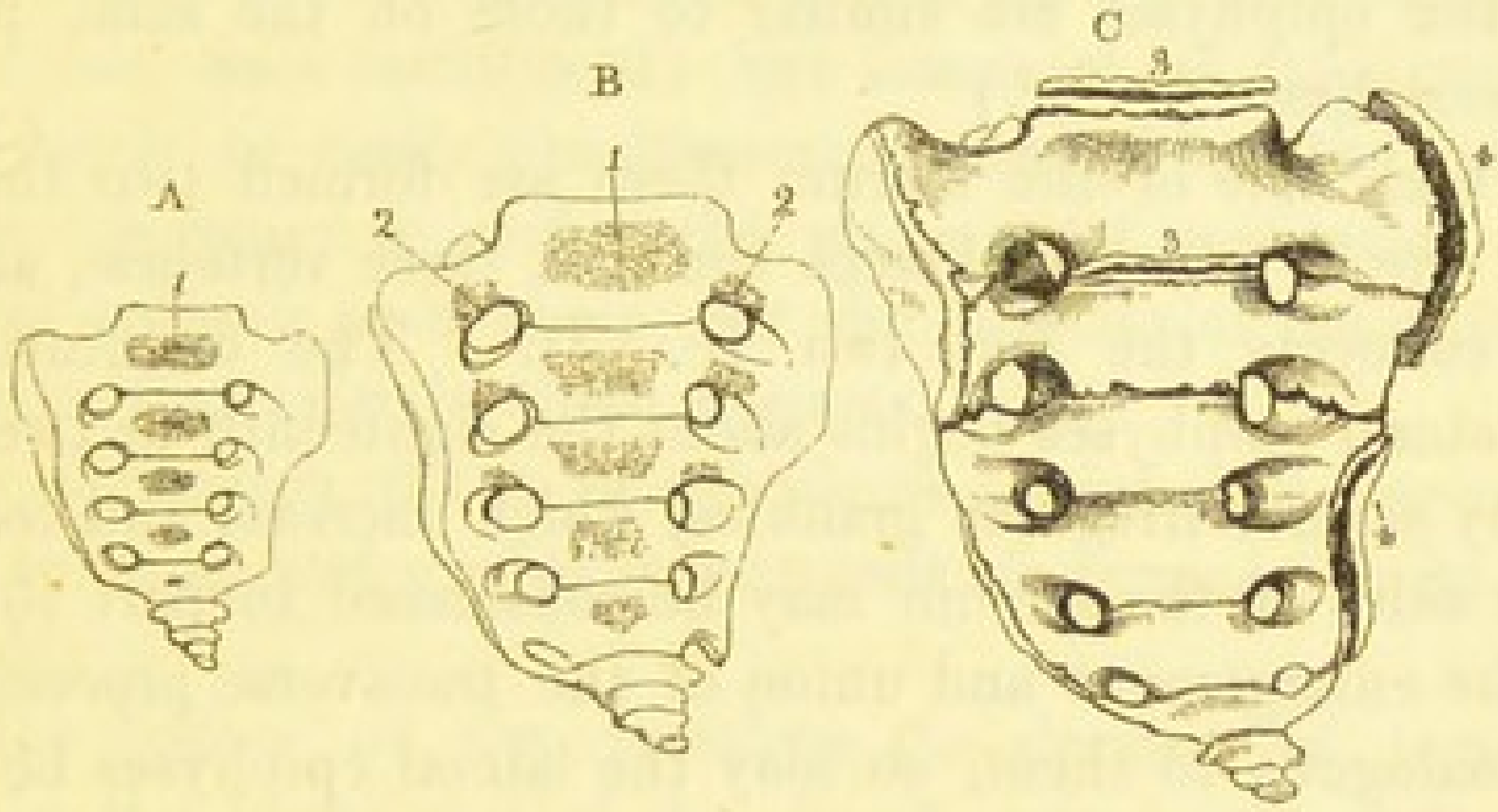

The peculiar centres of ossification.

About the sixth month characteristic osseous tubercles, three in number on each side, begin to appear, close to the sacral foramina—between them, except the first (B. ^{2} ^{2}). They belong to the first three vertebræ, and are successively deposited from the sixth to the eighth or ninth month — the highest appearing first and the lowest last. Each of the first three pieces of the sacrum has thus two centres of ossification added to those which belong to other vertebræ.

The order in which the parts of the vertebræ unite.

The lateral pieces join behind to constitute the arch, and subsequently become united to the body in the manner of other vertebræ; but the order in which this junction occurs in the different pieces is deserving of notice. The process of union commences in the lowest vertebra, and progressively extends upwards. The parts of the fifth are joined about the second

---

[*] These figures display different stages of the ossification of the sacrum. Fig. A. taken from a fœtus which had not reached the sixth month, contains in front only the nuclei for the bodies. In fig. B (from a child at the usual period of birth) three additional nuclei are deposited on each side, close to the sacral foramina. The coccyx has no ossific point. Fig. C. is from a body aged about twenty-five years. Epiphyses are visible on the sides of the bone, and are still apparent on the body of the first vertebra. The lower vertebræ have completely joined, while the first two are but partially united.—1. The body. 2. Nuclei peculiar to the sacrum. 3, 3. Epiphyses for the body of a sacral vertebra. 4, 4. Lateral epiphyses.

year, while the first does not appear as a single piece before the fifth or sixth year.

The sacral vertebræ remain separate one from the other, being united only by cartilage and the intervertebral substance, till about the sixteenth year. At this period they begin to unite one to another, and epiphyses begin to form.

Epiphyses: those of the bodies of the vertebræ.

Epiphyses.—On the middle part or body of each sacral vertebra the epiphyses are similar to those on the same part in other vertebræ. (c. ^{3} ^{3}.)

Lateral plates.

On each side of the sacrum there are formed two thin flat plates, one of which embraces the first three vertebræ, and the other connects the last two (c. ^{4} ^{4}). The ossification of these lateral epiphyses begins about the eighteenth or twentieth year, by several irregular granules, which increase and coalesce. As the sides of the sacrum may be considered in part to result from the enlargement and union of the transverse processes, or parts analogous to them, so may the lateral epiphyses be taken to represent the epiphyses of those processes,—altered, indeed, and, as it were, fused together.

The order in which the sacral vert. join.

The *consolidation of the sacrum.*—About the time last mentioned (the eighteenth year) the fourth and fifth vertebræ are joined one to the other, and the process of union gradually proceeding upwards (fig. 12. c), reaches the first two from the twenty-fifth to the thirtieth year; at which period the lateral epiphyses become part of the general mass, and the growth of the sacrum is complete.

OSSIFICATION OF THE COCCYX.

Coccyx; usually one centre for each vert.

Each of the coccygeal vertebræ is usually ossified from a single centre; occasionally one of the first three is found to contain two granules, placed side by side. A nucleus appears in the first piece about the time of birth, or in the course of a few months after (fig. 12. B. note). The periods assigned by Béclard for the ossification of the other coccygeal vertebræ are the following, viz. for the second, five to ten years; the third, ten to fifteen; and the fourth, fifteen to twenty. As age advances the bones unite in pairs, the first to the second, the third to the fourth; and at a later period of life, they are formed into a single piece by the union of the third and fourth. Lastly, the

Times of their appearance.

Union of the pieces.

coccyx becomes joined to the end of the sacrum in old age, and this is said to occur most frequently in the female.

c. THE PROGRESS OF OSSIFICATION IN THE VERTEBRAL COLUMN GENERALLY.

Same parts ossify at different periods in different regions of the vert. column.

In the observations on the growth of a single vertebra the date at which the osseous points appear for the first time in the column has been mentioned; but inasmuch as the same parts do not begin to ossify simultaneously throughout the spine, it becomes necessary to review the progress of ossification in the vertebral column as a whole, for the purpose of indicating the differences that exist in these respects.

The lateral pieces, and the bodies in various situations.

The ossification of the lateral pieces begins at the upper end of the column, and gradually proceeds downwards to its opposite end.

In the bodies of the vertebræ the deposit of bone first occurs in the lower part of the dorsal region (about the ninth dorsal vertebra), and from this the process is extended upwards and downwards, reaching last of all the atlas at one extremity, and the coccyx at the other; both of which, as has been previously stated, do not ossify till after birth. But it is to be borne in mind, that though the nuclei of the lower dorsal vertebræ appear first, they do not long continue the largest. As growth advances they are surpassed in size by those below them, and in the full-grown fœtus the nuclei are largest in the lower lumbar and the first sacral vertebræ. In fact, their relative size at this period corresponds with that of the vertebræ.

THE BONES OF THE SKULL.

The skull; divided into cranium and face.

The skull is of a spheroidal figure, compressed on the sides, broader behind than before, and supported by its base on the vertebral column. It is divided by anatomists into two parts, the cranium and the face; the former being composed of eight bones, viz. the *occipital*, two *parietal*, the *frontal*, two *temporal*, the *sphenoid*, and the *ethmoid;* the latter is made up of fourteen bones, viz. two *superior maxillary*, two *malar*, two *ossa nasi*, two *ossa palati*, two *ossa unguis*, two *inferior tur-*

The bones of each.

binated bones, the *vomer*, and *inferior maxilla;* the frontal bone is so situated as to be common to the cranium and face. The bones of the ear are not included in this enumeration, as they belong rather to a special organ than to the skeleton considered as the frame-work of the body.

THE OCCIPITAL BONE.

Occipital bone.

its position; form.

The outer surface.

External occipital protuberance.

Super. curved line.

Infer. curved line.

Ext. occip. crest.

The occipital bone, figs. 13 and 14 (os occipitis,) is situated at the posterior part of the base of the skull; broad behind, much narrowed before, of a trapezoid figure, presenting two surfaces, four borders, and four angles. To place the bone in its natural position, hold it so that the great foramen and the articulating processes beside it shall look directly downwards; the thick process in front of the foramen will then project forwards into the base of the skull, whilst the broad expanded part behind it, arches upwards and a little forwards, forming the posterior wall of the cavity. *External surface:* this is convex in its general outline, and presents a little above its centre a rough prominence,[1] the *external occipital protuberance*, the part between which and the superior angle is smooth. Extending obliquely outwards at each side from the protuberance is a rough line,[2] called the *superior curved line*, to distinguish it from another, which is lower down between it and the great foramen, called the *inferior curved line*;[3] both are prominent, and give attachment to muscles, as also do the rough depressions between them. These are crossed by a vertical raised line (*external occipital crest or spine*),[4] extending forwards from the protuberance to the foramen magnum.

Fig. 13.*

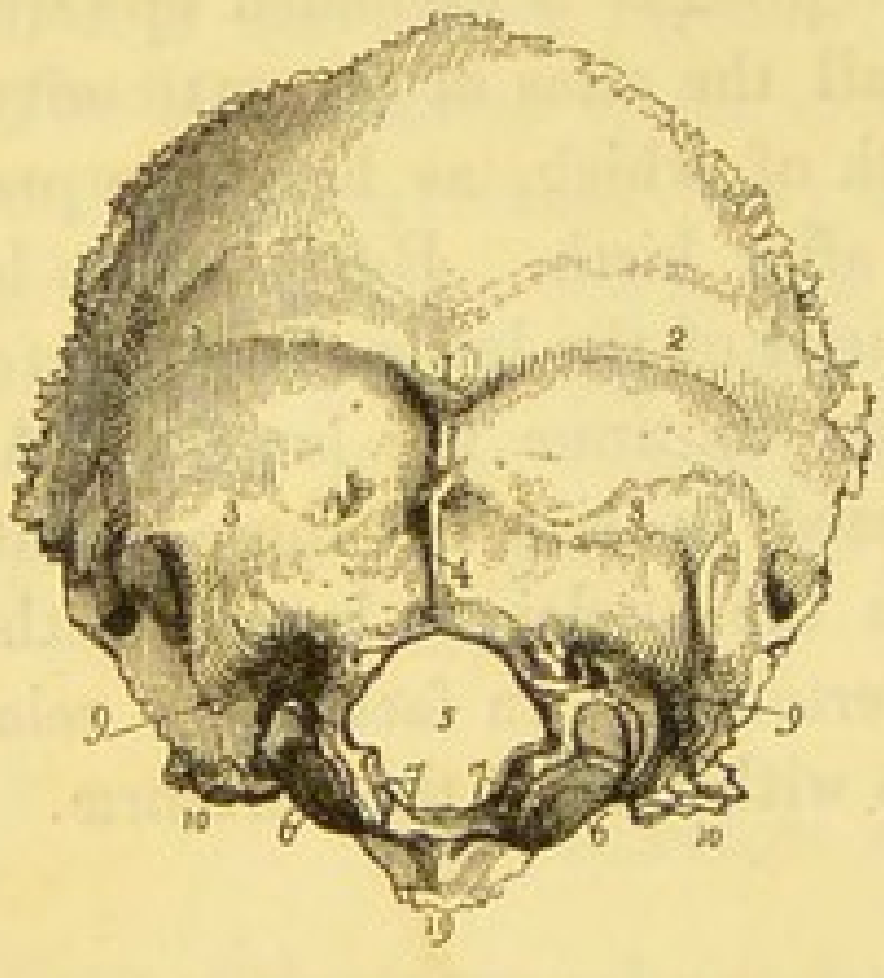

---

* External or cutaneous surface of the occipital bone. 1. External occipital protuberance. 2. Superior curved line. 3. Inferior curved line. 4. External occipital crest. 5. Foramen magnum. 6. Condyles. 7. Surface for the attachment of ligaments. 9. Posterior condyloid foramina. 10. Rough surface corresponding to the transverse process of a vertebra.

Foramen magnum.

The *occipital foramen*,[5] (foramen magnum,) which is of an oval figure (its long diameter extending from before backwards), gives transmission to the spinal cord, the vertebral arteries, and spinal accessory nerves.

Condyles.

At each side of the foramen, but nearer its anterior part, are situated the articulating processes,[6] [6] (*condyles*,) two oblong eminences, which articulate with the first vertebra. These converge from behind forwards; their inferior surface, which in the fresh state is smooth, covered with cartilage, and convex in its general outline, looks downwards and outwards, and is adapted for moving on the concave surface presented by the articulating processes of the atlas. The inner border of each condyle,[7] [7] is rough, and receives the insertion of the check ligaments, which extend up from the odontoid process of the axis; the outer border, depressed and not so well marked, gives attachment to the ligament connecting it with the atlas.

Condyloid foramina.

External to the fore-part of the condyles are two fossæ, in the bottom of which are two foramina, fig. 14.[8] [8] (*anterior condyloid*,) which look outwards and forwards, and transmit the hypoglossal nerves; behind them are also two larger pits, in which are generally, but not always, found foramina,[9] [9] (*posterior condyloid*,) which give passage to a vein and small artery: sometimes a foramen exists at one side, and not at the other. External to each condyle is a rough surface,[10] [10] which overhangs the transverse processes of the vertebræ, and of which it may be regarded as the "analogue;" it gives insertion to the rectus lateralis muscle.

Fig. 14.*

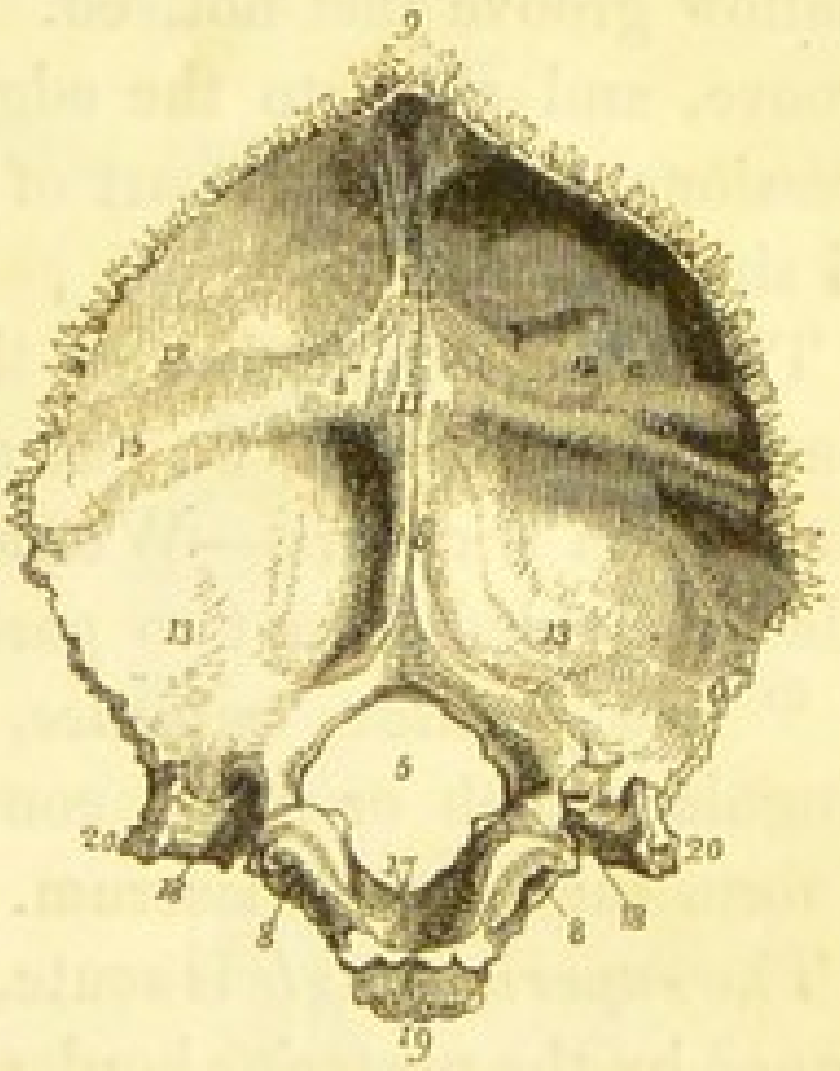

The inner surface.

Crucial ridges.

The *internal surface* of the bone (fig. 14.*) is marked by two crucial raised lines or ridges (lineæ cruciatæ eminentes,) — one vertical, extending from the upper angle of the bone to the

---

* The occipital bone: its internal or cerebral surface. 5. Foramen magnum. 8. Anterior condyloid foramina. 9. The superior angle. 11. Internal occipital protuberance. 12. Superior occipital fossæ. 13. Inferior occipital fossæ. 14. Upper division of the crucial ridges grooved for the

great foramen, and the other transverse from one lateral angle to the other. These intersect towards the central point,[11] (internal occipital protuberance,) and mark off four broad pits, of which the upper pair,[12] [12] (superior occipital fossæ,) receive the posterior lobes of the brain, and the lower[13] [13] (inferior occipital fossæ) lodge the lateral lobes of the cerebellum: the superior line[14] and the two transverse ones [15] [15] are generally grooved, and correspond with the course of the longitudinal and lateral sinuses. The inferior one,[16] which is commonly named the internal occipital spine or crest, gives attachment to the falx cerebelli. The anterior border[17] of the foramen magnum is slightly excavated, and becomes continuous with the *basilar groove*, a shallow excavation on the surface of the basilar process, which supports the medulla oblongata; close to the margin of the foramen are the anterior condyloid foramina, and a little external to it are two fossæ, [18] [18] marking the terminations of the lateral sinuses.

Intern. occip. protuberance.

Occip. fossæ.

Intern. occip. crest.

Basilar groove.

The thick triangular process[19] which projects forwards into the base of the skull from the foramen, is called the *basilar* process; its margins are rough, and contiguous to the pars petrosa of the temporal bone; its under surface presents slight depressions for the insertion of muscles, and the upper one the shallow groove just noticed. Along the lateral margins of this groove, and close to the edges of the bone, are two linear depressions, which form part of the grooves for the inferior petrosal sinuses.

Basilar process.

Petrosal grooves.

The *superior borders* of the occipital bone are dentated and converge to a point, 9, but are frequently interrupted by bony islets (ossa triquetra—Wormiana); the inferior border at each side is divided into two parts by a prominent piece of bone, [20] [20] the *jugular eminence*, which surmounts an excavation (jugular notch or fossa) contributing with the temporal bone to form the foramen lacerum.

The margins; superior, inferior.

Jugular eminences.

The *superior angle* is acute, and received into the retiring angle formed by the posterior border of the parietal bones; the anterior is represented by the extremity of the basilar process, which is

The angles.

---

longitudinal sinus. 15, 15. Transverse parts of same grooved for the lateral sinuses. 16. Internal occipital crest. 17. is opposite the basilar groove. 18. Groove for the end of the lateral sinus. 19. Basilar process. 20. Jugular eminence.

thick, and in the adult shows the internal structure of the bone, because of being sawed from the sphenoid; the lateral angles, not very prominent, correspond with the line at which the postero-inferior angle of the parietal bone joins with the mastoid part of the temporal.

The angles.

In some parts the occipital bone has considerable thickness, especially at the occipital protuberances and the anterior part of the basilar process. In the lower occipital fossa it is very thin.

Various thickness.

Articulations.—The occipital articulates with six bones, viz. with the two parietal by its superior borders—the two temporal by the inferior—with the sphenoid by its basilar process—and with the atlas by the condyles.

Articulates with six bones.

Attachments of muscles.—On each side—the posterior third of the superior curved line gives attachment to the trapezius; its anterior two-thirds to the occipito-frontalis above, and to the sterno-mastoid below: the inner part of the space between the curved lines to the complexus: the external part to the splenius capitis: the space between the lower ridge and the great foramen to the recti (major and minor), and more outwardly to the obliquus superior: the under surface of the jugular eminence to the rectus lateralis: the fossa at the inferior surface of the basilar process to the recti antici (major and minor), and still more anteriorly to the superior constrictor of the pharynx.

Attachments of muscles.

Ossification.

Ossification of the occipital bone.—During a considerable time before and after birth this bone consists of four pieces,—namely, the posterior, proper occipital or proral part: the anterior or basilar: and the two lateral or condy-

Four pieces.

Fig. 15.*,

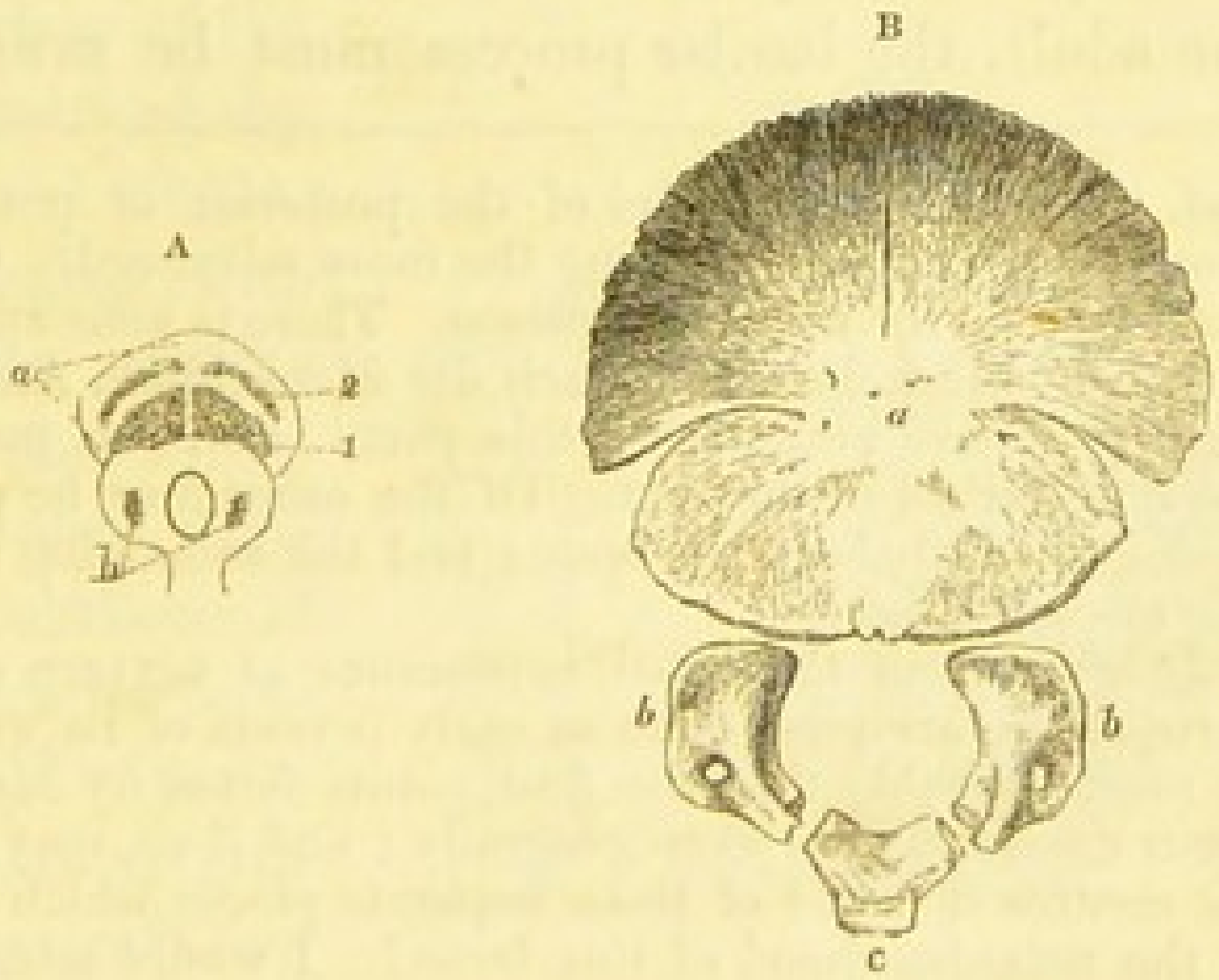

---

* The occipital bone at different periods of its growth,—namely, about the tenth week and at the ordinary period of birth. The figure marked A. has been copied from one published by Meckel in his "Archiv." (B. 1,

loid (fig. 15, B). These pieces meet around the foramen magnum. Each of them requires separate notice.

Period of commencement.

The poster. part has four nuclei.

The ossification of the occipital bone precedes that of the vertebræ in the time of its appearance. It begins with the proper occipital part. For this division there are four nuclei, which are placed in pairs above and below the occipital protuberance (fig. 15, A $^{1\,2}$). The two inferior nuclei appear first, and soon join into a single piece. The superior pair of granules unite one to the other also, and the two pieces thus resulting from the four primitive centres uniting speedily form a single mass.[*]

The condyloid and basilar pieces have each one nucleus.

Soon after the posterior part of the bone, the two condyloid pieces begin to ossify (A, ^{b}), and they are followed by the basilar portion. Each is formed from a single central point. It is to be observed, that the condyles of the occipital bone are not supported altogether on the pieces named condyloid;—a small portion of each is borne by the basilar part.

State of the bone at birth.

At birth the four pieces are distinct (fig. 15, B, *a*, *b*, *c*), and the posterior one is partially divided by deep fissures (two being horizontal and one vertical) extending from the circumference towards its middle.

The period at which the pieces join.

Union with the sphenoid.

About the fourth year of age the process of union begins by the junction of the posterior and the two condyloid pieces, and the bone is a single piece about one or two years later. Subsequently the occipital unites with the sphenoid bone, so that, in the adult, the basilar process must be sawed across in order to

---

Taf. vi.) The four nuclei of the posterior or proral part of the bone are shown,—the two lower being the more advanced. Germs of ossification are observable in the condyloid pieces. There is none apparent in the basilar part.

[*] J. F. Meckel ("Handbuch der Menschlich. Anat." B. 2, § 543,) assigns eight primitive granules to this part. Four he makes to correspond with those described in the text. Of the other four he places two close together at the upper angle of the bone; and the remaining two in its lateral angles, one at each side.

Judging from the usual appearance or texture of the upper and lateral parts of the occipital bone at early periods of its growth, it seems to me to be most probable that the four points found by Meckel in its angles do not occur constantly, or even generally; and if so, may they not be regarded as the centres of some of those separate pieces which are often to be met with in the neighbourhood of this bone? I would add, as facts bearing on the question, that an independent lateral nucleus existed only on one side of the preparation by which Meckel seems to have been influenced in forming his judgment on the number of the centres of ossification, (see the figure in his "Archiv. für die Physiolog." B. 1, Taf. vi.—1815); and that the upper part of the bone is occasionally altogether detached.

separate them. And it was in consequence of this circumstance that Sœmmerring described them as a single bone under the name spheno-occipital or basilar.

THE PARIETAL BONE.

Fig. 16.*

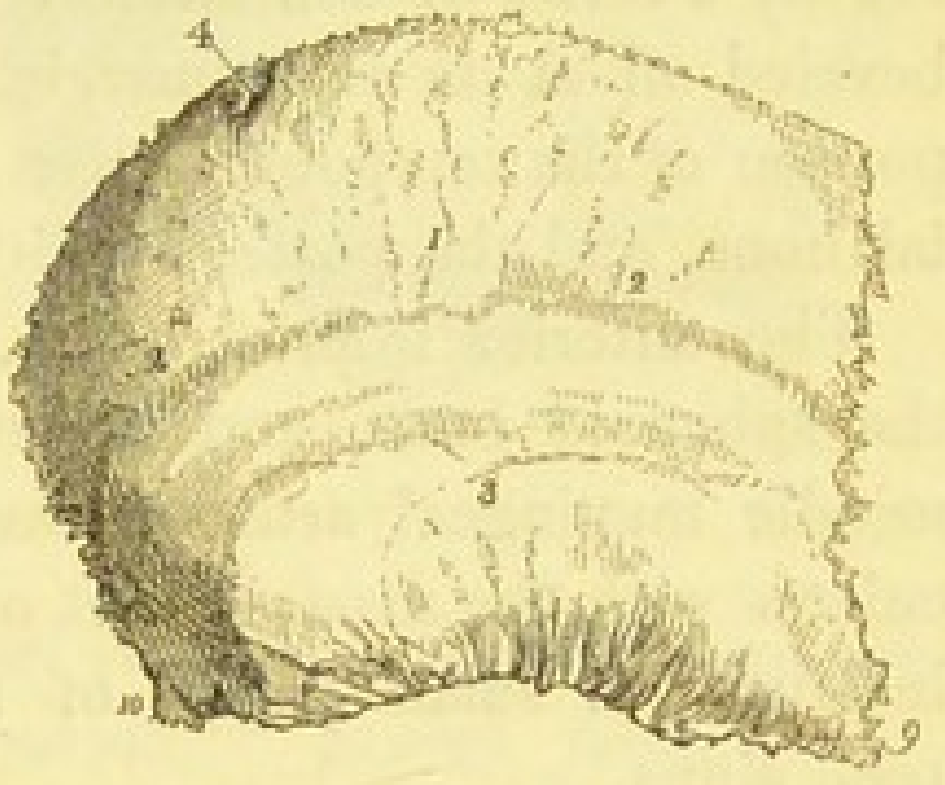

Parietal bones; their position and shape.

The parietal bones (ossa parietalia, verticis, bregmatis) form a principal part of the roof of the skull; they are of a square form, convex externally, concave internally, and present each two surfaces and four borders. The external surface, fig. 16, rises towards its middle, where it presents a slight elevation, called the *parietal eminence*,[1] below which is a curved line,[2] [2] forming part of the temporal ridge, and bounding a flat surface (planum semicirculare),[3] which forms a part of the temporal fossa. At the upper and back part of the bone, usually about two lines from the sagittal suture, is a small hole,[4] (foramen parietale,) which transmits a communicating vein; its position is exceedingly variable; even its existence is not constant.

External surface.

Parietal eminence,

and foramen.

Fig. 17.†

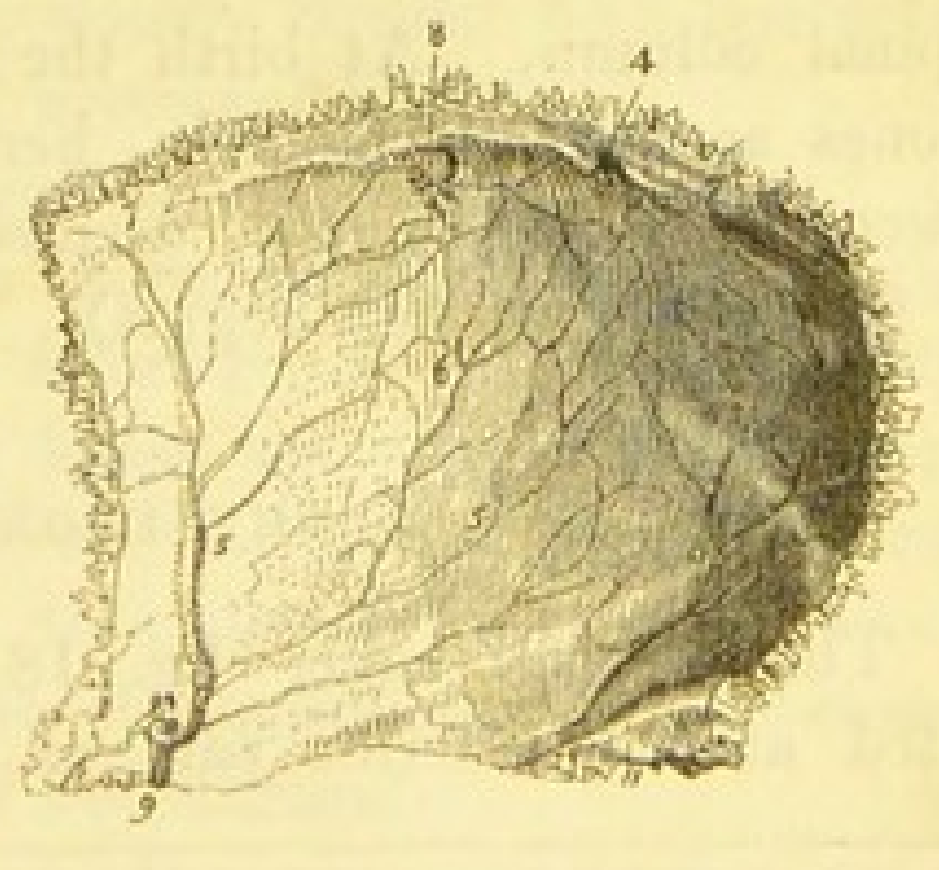

Internal surface.

Grooves, depressions,

and fossa.

The internal surface of the bone, fig. 17, is marked by branching lines (sulci meningei),[5] [5] [5] corresponding with the course of the middle meningeal artery, and by depressions (impressiones digitatæ) for the convolutions of the brain. Towards its middle is a depression,[6] "parietal fossa," corresponding with the eminence (parietal) on

---

* The parietal bone; its convex surface. 1. Parietal eminence. 2. Semicircular line. 3. Planum semicirculare. 4. Parietal foramen.

† The internal or cerebral surface of the parietal bone. 4. The parietal

the outside. Along the superior border is a slight depression,[7] [7] which with a similar one in the corresponding bone forms a groove adapted to the course of the longitudinal sinus; and in the same situation (in most skulls, particularly those of old persons) are some small pits (foveæ glandulares),[8] corresponding with the so-named glandulæ Pacchioni.

Margins. The superior border is straight, and articulated with its fellow by a series of dentations; the inferior border, concave and beveled off at its outer margin, is overlapped by the squamous portion of the temporal bone; the anterior unites with the frontal bone, and the posterior with the occipital.

Angles. The anterior inferior angle,[9] dips down to the great wing of the sphenoid bone, and presents a groove,[9] internally for the middle meningeal artery: the posterior inferior angle,[10] articulates with the mastoid part of the temporal bone, and presents internally a small part[11] of the groove which lodges the lateral sinus.

Attachment of a muscle. Each parietal bone gives attachment to the temporal muscle by that part of its surface which lies beneath the temporal ridge (planum semicirculare): the remainder of its outer surface is covered by the aponeurosis of the occipito-frontalis.

Connexion with other bones. *Articulations.*—It articulates with its fellow of the opposite side, and with the frontal, the sphenoid, the temporal, and the occipital bones.

Ossification. *Ossification.*—Its growth proceeds from one ossific centre which corresponds with the parietal eminence, and is first perceptible about the same time that ossification begins in the spinal column. At birth the antero-superior angles of these bones are not developed; hence there exists an interval between them and the still divided os frontis, which is called the "fontanelle" (fons, bregma).

THE FRONTAL BONE.

Frontal bone; The frontal bone, fig. 18, (os frontis, coronale,) situated at the anterior part of the skull, and upper part of

---

foramen. 5. Grooves for the middle meningeal artery. 6. The parietal fossa. 7. "Sulcus sinus longitudinalis." 8. "Foveæ glandulares." 9. The anterior inferior or sphenoidal angle. 10. The posterior inferior or mastoid angle. 11. "Sulcus sinus lateralis."

division of.

the face, is divisible into two parts (frontal and orbital), differing in size and position: of these, one extends upwards towards the vertex, forming three-fourths of the extent of the bone; the other, inferior and horizontal in its direction, forms the roof of the orbits. To place the bone in its natural position, hold it so that the orbital plates shall look downwards, and the smooth convex surface forwards.

Fig. 18.*

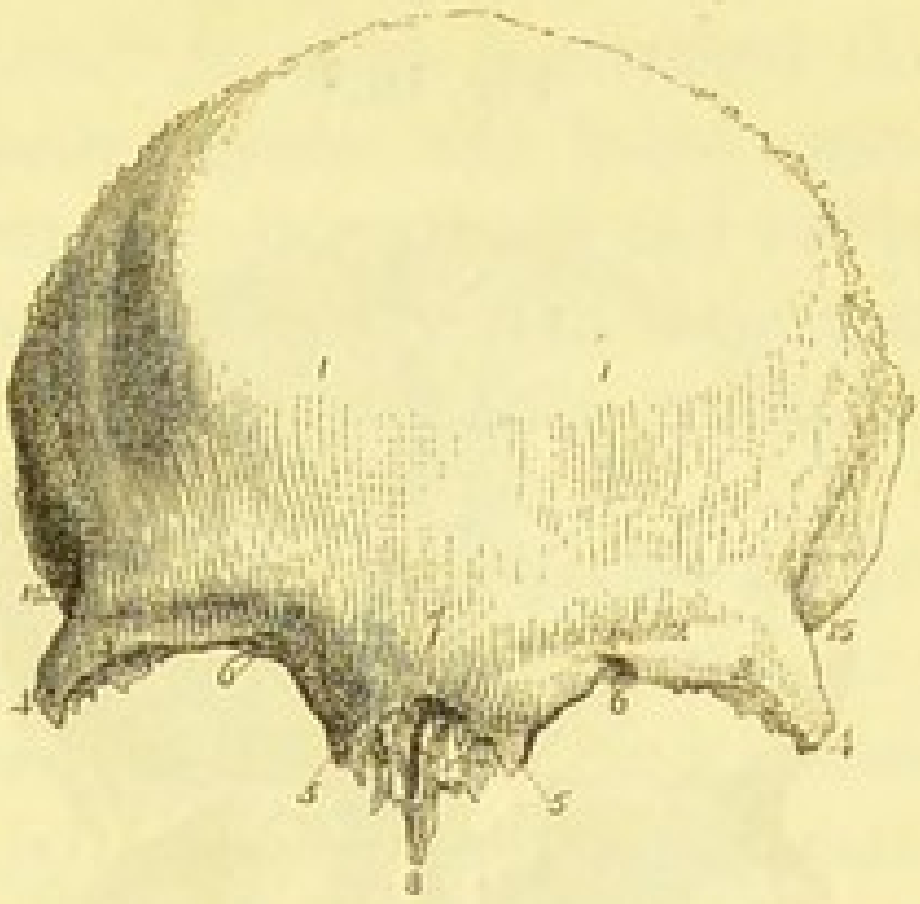

Frontal part; its convex surface.

Frontal eminence.

Supercil. ridge.

The frontal part.—Its *external surface* is smooth, and presents on each side a slight elevation,[1] [1] named *frontal eminence*, which corresponds with the most prominent part of the forehead: beneath this is an arched depression, bounded below by a prominent curved line,[2] [2] called the *superciliary ridge*, or arch, which is more or less prominent in different individuals. Immediately beneath this is the margin of the orbit (*orbital arch*),[3] [3] which is better defined towards its outer part, where it curves down to the malar bone, and forms the external angular process,[4] [4] than at its inner portion,[5] [5] where it gradually subsides towards the root of the nose. Towards the inner third of the orbital arch is a small foramen,[6] [6] (*supra-orbital*,) or sometimes a notch, crossed by a ligament, which transmits the supra-orbital nerve and artery.

Glabella.

Nasal spine.

Between the superciliary ridges is the *nasal eminence*,[7] or glabella, which is prominent in proportion to the size of the frontal sinuses: it is bounded inferiorly by a rough surface which articulates with the nasal bones and the ascending processes of the superior maxilla. From this surface projects downwards in the median line a flat thin process[8] called the *nasal spine;* it articulates in front with the nasal bones, and behind with the perpendicular lamella of the ethmoid.

---

* The frontal bone viewed from before. 1. Frontal eminence. 2. Superciliary ridge. 3. Orbital arch. 4. External angular process of the orbit. 5. Internal angular process of the orbit. 6. Supra-orbital notch. 7. Glabella. 8. Nasal spine. 15. Part of the temporal fossa.

Concave surface.

The *internal surface* of this part of the bone is concave, and presents along the median line a groove (sulcus frontalis), fig. 19, [9] corresponding with the longitudinal sinus. The margins of the groove gradually approach towards the forepart of the bone, and in some cases unite so as to form a ridge (crista frontalis); but in others the groove, narrowed almost to a line, continues apparent down to the foramen cæcum. In either case it gives attachment to the falx; this ridge terminates in a minute foramen,[10] called *foramen cæcum*, from its having been supposed to be merely a cul-de-sac, but it is in reality pervious, and lodges a small spur-like process of the dura mater, and transmits a vein which enters the sinus from the nasal fossæ.

Fig. 19.*

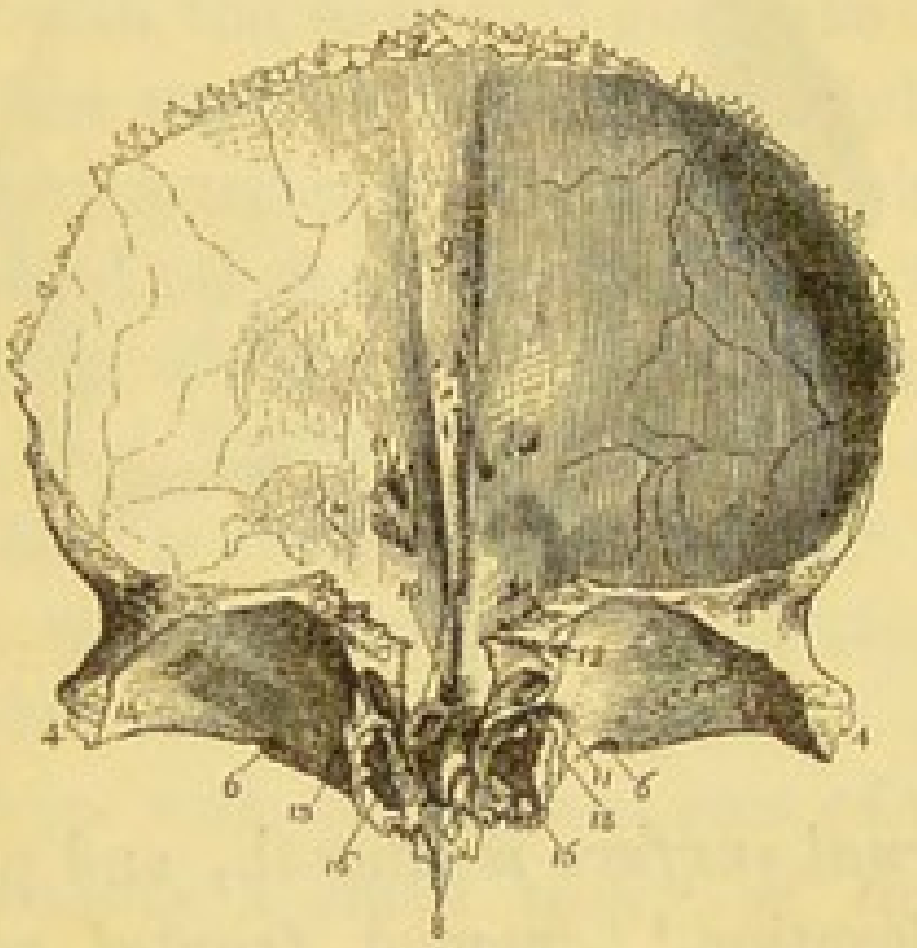

Orbital part.

The *orbital plates* or processes are smooth and concave at their inferior surface; the superior or cerebral is convex, and marked more or less in different instances by elevations and depressions corresponding with the sulci and convolutions of the anterior lobes of the brain which rest upon them. They are separated by a deep excavation (incisura ethmoidalis), which

Nasal part.

receives within it the cribriform plate of the ethmoid bone, and round its margins are several cells which complete the cavities lodged within the lateral parts of the last-named bone. In this margin may also be observed two foramina,[11] [12] (*anterior* and *posterior orbital*,) which are common to the frontal and ethmoid bones, as their contiguous margins contribute to their formation. The anterior one transmits the nasal twig of the ophthalmic nerve, and the anterior ethmoidal artery; the other the posterior ethmoidal artery and vein. Each orbital plate

---

* The frontal bone from behind—its concave or cerebral surface. 9. "Sulcus frontalis." 10. "Foramen cæcum." 11, 12. Anterior and posterior internal orbital grooves. 13. "Fovea trochlearis." 14. Lachrymal fossa. 16. Openings of the frontal sinuses.

is bounded externally by a thick well-marked prominence,[4] [4] called the *external angular process;* and internally by a depressed and smooth one (*internal angular process*). Near the inner one is a slight depression,[13] to which is attached the cartilaginous pulley of the trochlearis muscle, and hence sometimes named fovea trochlearis; near the outer process and within the orbit, is a depression[14] for the lodgment of the lachrymal gland; the external side of this process is slightly hollowed, fig. 18,[15] and forms part of the temporal fossa.

Various thickness.

The thickness of the frontal bone varies considerably in different parts of it. The orbital plates are thin and translucent; the nasal and external angular processes are thick and prominent. The upper or broad part is thinner at the frontal eminences than elsewhere, if these are well-marked so as to indicate a full developement of the corresponding cerebral parts. In childhood the two tables are separated only by the diploë, as in other bones; but, in adult age, an interval exists between them at the middle line over the nasal process, and extending outwards for some way under the superciliary ridges. This interval, the extent of which varies in different individuals, is divided by a ridge of bone into two parts or cavities,[16] [16] called the *frontal sinuses;* they are lined by mucous membrane, and communicate with the anterior ethmoidal cells.

Frontal sinuses; period of their formation.

Connexions with other bones.

Articulations.—The frontal articulates with twelve bones; superiorly with the two parietal; laterally and behind with the sphenoid; inferiorly with the ethmoid, with the nasal bones, with the ossa unguis, with the ascending processes of the superior maxillary bones, and with the malar bones. The mode of articulation differs in different parts of its circumference. Thus, the superior border is found to overlap and rest on the parietal bones, whilst towards the lateral and inferior parts the exterior table of the bone is beveled off, and is covered in by the parietal. The posterior border of the orbital plates, straight and squamous, is in a manner inserted between the margins of the two alæ of the sphenoid bone, with each of which it articulates.

Muscular attachments.

Attachments of muscles.—It gives attachment to the corrugator supercilii—to a small part of the temporal and of the orbicularis palpebrarum.

Ossification.

Ossification.—This bone begins to ossify before the vertebræ, Two points. from two osseous points, which appear at the orbital arches.

Fig. 20.*

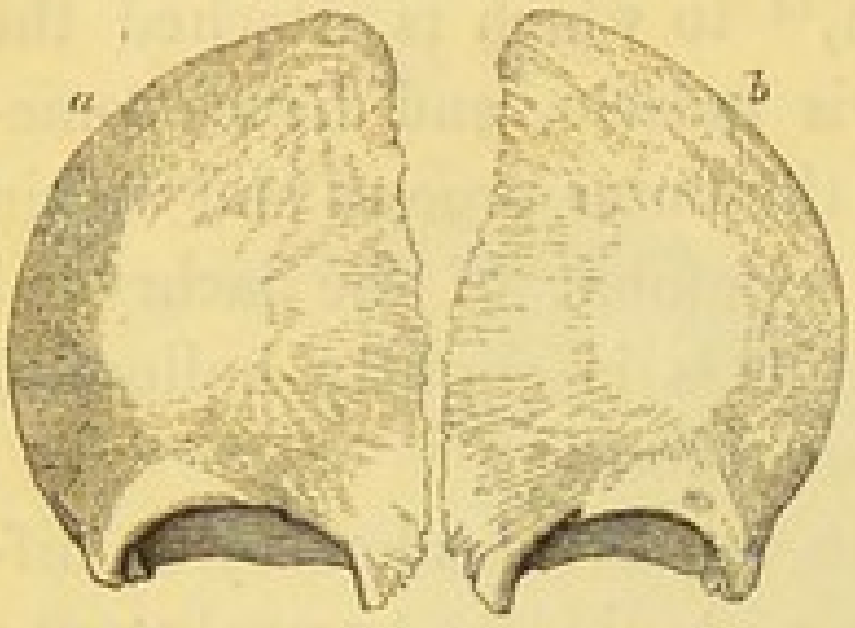

The lateral pieces formed by the spreading of the ossification are quite distinct at birth (fig. 20, $^{a\ b}$). They afterwards become united along the middle by a straight suture, which runs from the vertex, where it is continuous with the sagittal suture, down to the nose. The suture is obliterated within a few years after birth, but the period varies in different cases, and in some instances it is found to remain during life.

THE TEMPORAL BONE.

Temporal bone; The temporal bones, two in number, are so named because they occupy that part of the head on which the hair first becomes white, and thus indicates the ravages of time (*ossa temporis*).

Fig. 21.*

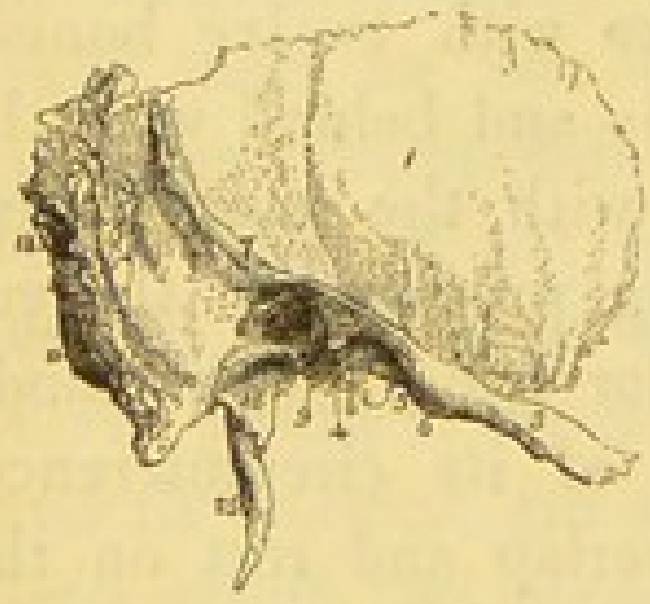

position. The *temporal* bone, figs. 21 and 22, (os temporis,) is placed at the side and base of the skull. When viewed in its natural position, it presents two portions, one at the side of the skull towards its middle and lower part, which is flat and vertical in its direction; whilst the other is horizontal and projects inwards so as to be wedged between

---

* From the frontal bone of a fœtus born a short time before the usual period of birth.

† Figures 21 and 22 show respectively the outer and the inner surface of a temporal bone of the right side. 1. Squamous part; its external surface. 2. The internal surface of same part. 3. Zygoma. 4, 5. Roots of the zygoma. 6. Tubercle for the external lateral ligament. 7, 8. Parts of one of the roots of the zygoma. 9. Fissure of Glaser. 10. Mastoid part. 11. Digastric fossa. 12. "Sulcus sinus lateralis." 13. Mastoid foramen. 14. Small occipital groove. 15. Petrous part. 18. Carotid canal. 19. Anterior surface of the petrous part. 20. Depression for the Gasserian ganglion. 21. Meatus auditorius internus. 22. Opening of the aqueduct of the vesti-

Division into three parts.

the occipital and sphenoid bones. But to facilitate its description, it may be divided into three parts, of which one is superior, flat, scale-like, and named the squamous portion (squama, a scale); another posterior, thick at its base, but tapering downward like a nipple, the mastoid part; the third, called petrous from its hardness, is internal and intermediate, projecting into the base of the skull.

Squamous part.

A. The *squamous* portion,[1] (pars squamosa,) by its external surface which is smooth, forms part of the temporal fossa, and is bounded above by an arched border, below by a horizontal process called "zygoma." The inner surface, fig. 22,[2] of the squamous part of the bone, slightly concave in its general outline, is marked by cerebral impressions like the other bones of the head, and by slight linear grooves for branches of the middle meningeal artery. Its upper edge is beveled off so as to form a thin scale which overlays the parietal bone.

Fig. 22.*

The zygoma;

The *zygoma*,[3] or zygomatic process (ζευγνυμι, to connect or yoke together), forms a yoke connecting the temporal with the malar bone, and under which the temporal muscle passes; it is broad posteriorly at its base, where it projects outward from the squamous part of the bone, but soon narrows, and turns forward; its outer surface is convex and subcutaneous, the inner surface is concave and bounds the temporal fossa; the superior margin, very thin, gives attachment to the temporal fascia; the inferior one is thicker and shorter, owing to the end of the process being beveled off so as to rest on the malar bone, with which it articulates. At its base the upper surface is concave and supports the posterior border of the temporal muscle. The

---

bule. 23. Rough surface on the inferior aspect for the attachment of muscles. 24. Jugular fossa. 25. Styloid process. 26. Its vaginal process. 27. Stylo-mastoid foramen. 28. Superior petrosal groove. 29. Eustachian tube. 30. Opening of the aqueduct of the cochlea.

* For explanation, see the last note.

its roots; tubercle for the ext. lat. ligament. Glenoid fossa. Fissure of Glaser.

under surface forms the border of the glenoid cavity; here it presents two roots, of which one[4] runs horizontally backwards, forming the outer margin of the glenoid cavity, whilst the other,[5] turns inwards and forms the anterior border of that cavity. At the point of division is a slight tubercle,[6] which gives attachment to the external lateral ligament of the lower jaw. Now the anterior root widens and subsides, becoming concave from without inwards and convex from before backwards, as it forms part of the articular surface upon which the lower jawbone moves; in its natural condition it is covered with cartilage. The other root, which is continued horizontally backwards, bifurcates;—one part[8] turns inwards to the fissura Glaseri, whilst the other[7] gradually subsides as it passes backwards over the auditory tube, yet marks the separation between the squamous and mastoid portions of the bone. The *glenoid fossa* (γλήνη, a shallow pit), marked off as here indicated, is elongated from without inwards, and divided into two parts by a fissure,[9] (*fissura Glaseri,*) which transmits the chorda tympani nerve and laxator tympani muscle, and gives attachment to the processus gracilis of the malleus. The part before the fissure is smooth, and articulates with the lower jaw; the remainder lodges a process of the parotid gland.

Mastoid part. Digastric fossæ and occipital groove. Groove for lateral sinus. Mastoid foramen.

B. The *mastoid* part[10] of the bone externally is rough, for the attachment of muscles, and prolonged downwards, forming the mastoid, or nipple-shaped process (μαστος, a nipple or teat,) from which this division of the bone is named. This process overhangs a groove, fig. 22,[11] (*digastric fossa,*) for the attachment of the digastricus muscle; close to this is a slight groove[14] (the occipital groove). When viewed at its inner surface, the mastoid part presents a broad and generally a deep groove (sulcus sinus lateralis),[12] which curves forwards and downwards; it here supports part of the lateral sinus. It is usually pierced by a foramen,[13] (f. mastoideum,) which opens into the sinus from the outer surface, commencing near the posterior border of the bone. The size and position of this hole vary in different instances; it sometimes exists in one temporal bone and not in the other.

Petrous part; its shape;

C. The *petrous* part,[15] pars petrosa, named from its hardness, (πετρος, a stone,) forms a triangular pyramid (pyramis trigona) which projects into the base of the skull forwards and inwards. It contains the organ of hearing, and presents for examination a base, an apex (truncated), three surfaces, and three borders. In the base is situated the orifice of the auditory canal, which is bounded above by the posterior root of the zygoma; inferiorly, and in the greatest part of its circumference, by a curved, uneven lamella (*auditory process*), to which the cartilage of the ear is attached: this process is in the fœtus a separate piece. The canal itself (*meatus auditorius externus*), narrower in the middle than at its extremities, is directed obliquely forwards and inwards, and leads into the tympanum. The *apex* or inner end of the pars petrosa, rough, irregular, and, as it were, truncated, forms part of the foramen lacerum medium, and is pierced by the termination of the carotid canal,[18] (canalis caroticus):—this canal commences in the inferior surface of the bone anterior and internal to the jugular fossa, ascends at first perpendicularly, but soon turns horizontally forwards and inwards to the apex, where it ends.

position.

Contains intern. ear.

Base.

Meatus auditor. extern.

Apex.

Carotid canal.

The *anterior* or *upper surface*[19] of the petrous portion forms part of the middle fossa in the base of the skull, where it looks obliquely upwards and forwards. Towards the apex it is slightly depressed,[20] where it corresponds with the ganglion of the fifth pair of nerves (Gasserian). A narrow groove is seen to run obliquely backwards and outwards to a foramen; it lodges a nerve ("the large superficial petrosal," a branch of the Vidian); the foramen is named the *hiatus Fallopii*, and leads to the aqueduct of Fallopius. More externally is a small aperture, which gives passage to a nerve named "the small superficial petrosal." Farther back is a rounded eminence indicating the situation of the superior semi-circular canal. The *aqueduct* of Fallopius just alluded to commences at the internal auditory meatus; it is a small osseous tube lodged in the interior of the bone, and passing at first in an arched direction, outwards and upwards, then backwards and downwards towards the base of the skull, where it ends in the stylo-mastoid foramen; it transmits the portio dura, and receives, through the hiatus Fallopii, the Vidian nerve.

Anterior surface;

depression for Casserian gangl.

Hiatus and aqueduct of Fallopius.

The *posterior surface* looks obliquely backwards, and forms part of the third or posterior fossa at the base of the skull. In it will be observed a large orifice,[21] leading to a short canal (*meatus auditorius internus*). The canal is oblique in its direction, having an inclination outwards and forwards. It conveys

Posterior surface.

Meatus auditor. inter.

the auditory and facial nerves. Its fundus is formed by a lamella of bone (*lamina cribrosa*), divided into two parts by a crest or ridge; the upper or smaller part is pierced by a foramen which transmits the facial nerve, whilst the lower presents several very small apertures through which the fibrils of the auditory nerve pass. About three lines further back than the orifice of the meatus is a narrow fissure,[22] oblique in its direction. It is the termination of the aquæductus vestibuli. Between the aperture of the aqueduct and that of the meatus is an irregular depression, into which a small process of the dura mater is fixed.

Aqueduct of the vestibule.

Inferior surface.

On the *inferior surface* of the pars petrosa, which is exceedingly irregular, we observe, proceeding from within outwards and backwards, a rough surface[23] giving attachment to the levator palati and tensor tympani muscles, the carotid foramen, the jugular fossa, the vaginal and styloid processes; lastly, the stylo-mastoid foramen. The carotid foramen leads into the curved canal (canalis caroticus) already noticed. The *jugular fossa*,[24] (fossa bulbi venæ jugularis internæ, "the thimble-like cavity,") with a larger depression in the margin of the occipital bone, forms the "foramen lacerum posterius." This large foramen is in some cases divided into two parts, but unequally, by a spiculum of bone; the anterior and inner portion gives passage to the glosso-pharyngeal, vagus, and spinal accessory nerves, whilst the posterior and larger one transmits the jugular vein. In the plate of bone which separates this fossa from the carotid canal is the opening of a small canal, through which the nerve of Jacobson passes to the tympanum. External to the margin of the jugular fossa is the styloid or pencil-like process,[25] long and tapering, with an inclination downwards and forwards. Its length varies from an inch to an inch and a half; it gives attachments to three muscles and two ligaments. Close before the base of the styloid process is a compressed bony plate,[26] the *vaginal* process (vagina processus styloidei), the free surface of which looks obliquely forwards. Between the root of the styloid process and the mastoid (and named from its position with regard to them) is the *stylo-mastoid foramen*,[27] (f. stylo-mastoideum.) It forms the outlet or termination of the aqueduct of Fallopius, and gives exit to the facial nerve. Near this foramen and at the back part of the jugular fossa is another, by which the auricular branch of the vagus nerve enters the bone.

Place for muscles.

Carotid foramen.

Jugular fossa.

Canal for Jacobson's nerve.

Styloid process.

Vaginal process.

Stylo-mastoid foramen.

Foramen for auricular nerve.

Borders. Petrosal groove. Eustachian tube. Processus cochleariformis.

The *superior border* of the pars petrosa is grooved for the petrosal sinus;[28] the *anterior*, which is very short, forms, with the squamous part, an angle at their point of junction, in which is situated the orifice of the Eustachian tube,[29] a canal which leads from the pharynx to the tympanum: above this, and separated from it by a thin horizontal lamella (*processus cochleariformis*), is another osseous tube, that gives passage to the tensor tympani muscle. The *posterior border* articulates with the basilar process of the occipital bone, and forms with it the foramen lacerum. About the middle of this edge or border is a minute foramen,[30] the opening of a small canal leading from the cochlea (*aquæductus cochleæ*).

Aqueduct of the cochlea.

Connexion with other bones.

Articulations.—The temporal bone articulates with the parietal, malar, inferior maxillary, sphenoid, and occipital bones.

Muscular attachments.

Attachments of muscles.—To the zygoma is attached the masseter; to the squamous portion, the temporal; to the mastoid process, the retrahens aurem, the sterno-mastoid, splenius capitis, and behind the process the trachelo-mastoideus; to the digastric fossa, the digastricus; to the styloid process, the stylo-glossus, stylo-hyoideus, and stylo-pharyngeus; to the apex of the petrous portion, the levator palati and tensor tympani.

Ossification; period of its commencement.

The *ossification* of the temporal bone begins at an early period,—about the time that osseous matter begins to form in the vertebræ.

Several centres.

It proceeds from several nuclei. These belong to—1. the zygoma; 2. the squamous part; 3. the tympanic bone; 4. the petrous and mastoid part; 5. the styloid process. The centres of ossification here mentioned are exclusive of those for the internal ear, and the small bones of the tympanum, which will not be referred to in this place.

Fig. 23.*

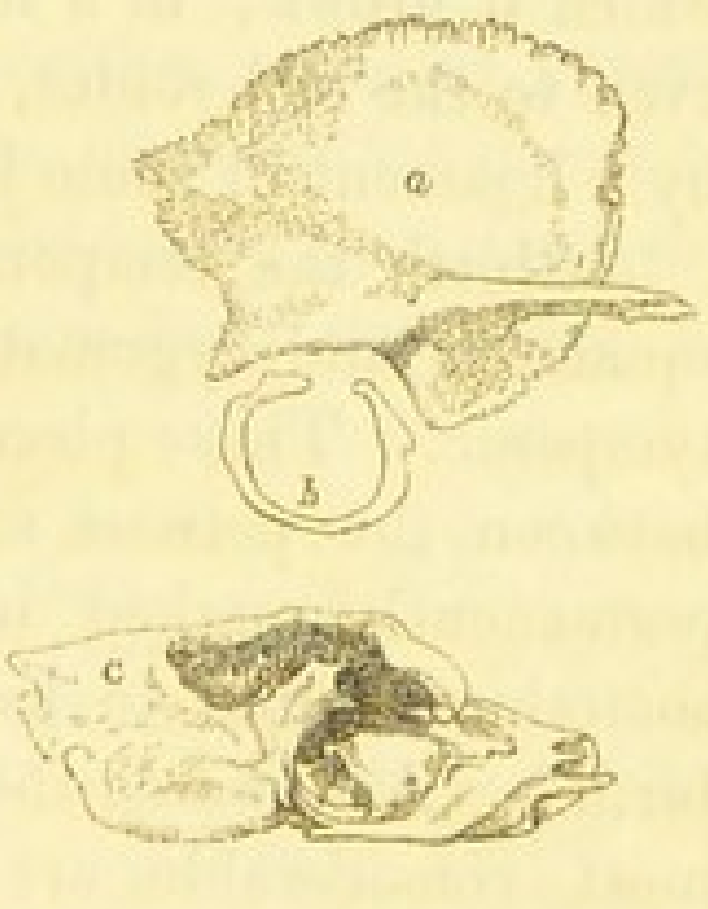

---

* A temporal bone of the right side, consisting of three separate pieces. *a.* The squamous part and zygoma. *b.* The tympanic bone. *c.* The petrous and mastoid part. The letter (*c*) is placed on the mastoid end. The remainder of this piece is, in the natural state, covered by the other divisions of the bone; part of it is the inner wall of the tympanum.

The zygoma and squamous part.

The formation of bone begins with the *zygoma* and the *squamous* part (fig. 23,^{a}); and it is not ascertained with certainty if they are formed from separate nuclei. Béclard speaks of them as seeming to be distinct; but, if they are so, they very speedily coalesce.

The tympanic bone.

The growth of the *tympanic* bone soon succeeds the preceding. This little bone forms about three-fourths of a circle; the deficiency being at the upper part (fig. 23,^{b}). The shape is rather elliptical than completely circular. It is grooved along the concave surface for the membrane of the tympanum (annulus membranæ tympani); and it remains distinct from the rest of the temporal bone till about the full period of intra-uterine existence, when it becomes joined by the two extremities beneath the roots of the zygoma.

The petrous and mastoid parts.

The *petrous* and *mastoid* parts (fig. 23,^{c}) are formed from the same centre, and the ossification of the latter is to be regarded as a continuation backwards from that of the former. The mastoid process is also in some instances found to have one or even more independent nuclei.*

The styloid process late in its growth and in its junction.

The part of the temporal bone which is latest in its ossification is the *styloid process*, which remains a separate piece for a considerable time;—in some cases it is never united to the rest of the bone. This process varies very much in the length to which it grows; in a few instances it has been found to reach even to the os hyoides, instead of being connected to that bone by a ligament of some length.

Condition of the bone at birth.

At birth the temporal bone consists of three pieces, viz. the squamous and zygomatic; the petrous and mastoid; and the tympanic. These pieces soon unite, and the place of junction between the petrous and squamous parts is, for some extent, permanently marked by a sort of suture. (Partial union is sometimes found to have taken place at the usual period of birth.)

Changes afterwards.

Afterwards the bone undergoes several changes. The most considerable are the following:—The tympanic piece extends outwards, so that it forms a canal, at the bottom of which the membrane of the tympanum is placed, instead of being on a level with the surface of the skull, as it is before that change has taken place in the bone; the glenoid fossa

---

* Kerckringius, "Ostogenia Fœtuum," Tab. 35, 36.

becomes much deeper; the surface of the petrous part, previously irregular, is filled up, so to say, and becomes more uniform; and the mastoid part enlarges, and is rendered prominent by the formation of cells in its interior.

THE SPHENOID BONE.

The sphenoid bone; its extensive connexions.

Fig. 24.*

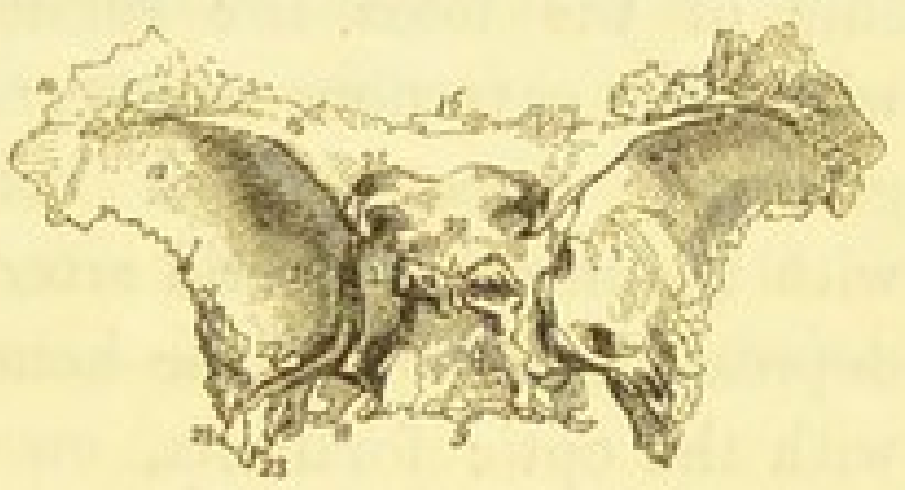

The sphenoid, a single bone, figs. 24, 25, placed transversely at the base of the skull, enters into the formation of the cavity of the skull, of both orbits, of the nasal fossæ, of the temporal and the zygomatic fossæ, and may be said to contribute in a small degree to the hard palate. It is articulated with all the bones of the cranium and several of those of the face, between which it is inserted somewhat like a wedge; whence its name (σφην, a wedge; ειδος, like). The form has been likened to that of a bat with its wings extended, and the comparison is not very far-fetched, particularly if the ethmoid bone remains attached, as often happens. Like other irregular bones, it may be divided into body and processes.

Form.

Division into parts.

To place this bone in its proper position so as to perceive clearly the relations of its different parts, observe that it has two thick processes somewhat like legs. Hold it so that these shall project downwards, as if from beneath the body and wings, and

---

* Explanation of figures 24 and 25:—In the former the sphenoid bone is viewed from above; in the latter it is seen in front. 1. Sella Turcica. 2. The outer part of the body. 3. Groove for the carotid artery. 4. is placed above the left posterior clinoid process. 5. The rostrum. 6. A groove which forms part of the pterygo-palatine canal. 7. points to the sphenoidal sinuses. 8. Sphenoidal spongy bones. 9. Basilar surface. 10. One of the great wings. 11. Its orbital surface. 12. Its upper surface. 13. Its external surface. 14. is intended to mark the ridge by which the external surface is divided into a temporal and a zygomatic part. 15. One of the small wings. 16. Ethmoid spine. 17. Anterior clinoid process. 18. Internal pterygoid process. 19. Its hamulus. 20. External pterygoid process. 21. Fissure between the pterygoid processes. 22. Olivary process. 23. The spine. 24. Sphenoidal fissure. 25. Optic foramen. 26. Foramen rotundum. 27. Foramen ovale. 28. Foramen spinosum. 29. Pterygoid foramen—the opening of the vidian canal.

let those edges of the processes which are channeled into vertical grooves look backwards.

The body; its upper surface.

Of the body, or central part of the bone.—To give precision to its description we say that it presents six aspects or surfaces, each of which looks in a different direction and has distinct relations:—The *superior surface*, which forms part of the basis of the skull, is of limited extent, yet is hollowed into a deep pit,[1] which lodges the pituitary gland: hence this excavation is called *pituitary fossa*, and sometimes "sella Turcica," from some resemblance to a Turkish saddle (ephippium). On each side of the fossa the surface is depressed,[2] and corresponds with the cavernous sinus; farther back are two superficial grooves,[3] directed from behind forwards, which correspond with the internal carotid arteries. Before the fossa, is a slightly depressed portion of the bone (processus olivaris),[22] on a level with the optic foramina, on which rests the commissure of the optic nerves;—behind it, is a prominent ascending lamella, of a square form, and sloping backwards, so as to be continuous with the basilar groove of the occipital bone: the corners of this lamella project over the fossa, and are called the *posterior clinoid processes*,[4] (κλινη, a bed.)

Sella Turcica.

Poster. clinoid processes.

Lower surface.

The *inferior surface* of the body is the narrow interval between the pterygoid processes; it is intersected by a prominent spine, fig. 25,[5] called the *rostrum* or azygos process, which dips downwards and forwards to join the vomer. At each side are two small and slightly everted lamellæ (projecting from the base of the pterygoid processes), which articulate with the margins of the vomer. Farther out is a small groove,[6] which contributes with the head of the palate bone to form the *pterygo-palatine canal.*

Rostrum.

Fig. 25.*

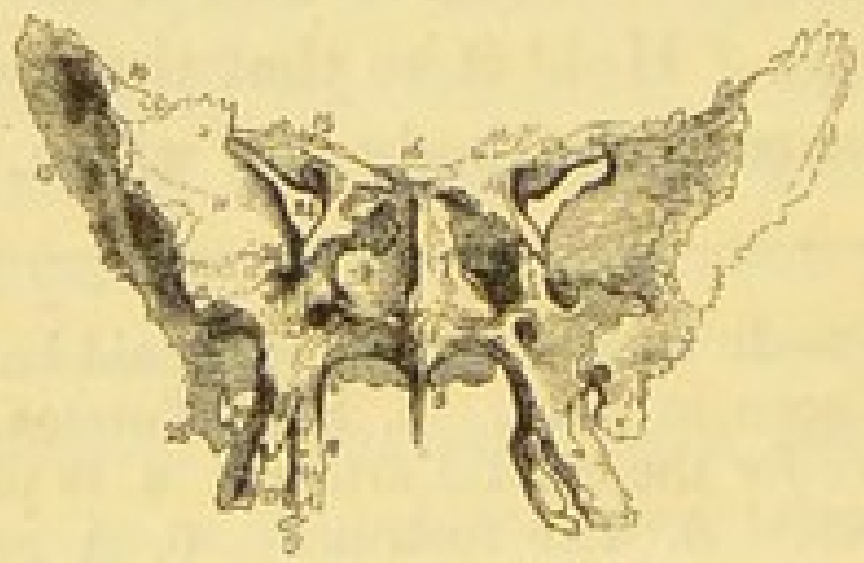

Anterior surface.

Sinuses;

The *anterior surface* is very irregular, and presents the openings of two deep sinuses,[7] into which the bone is hollowed: these *sinuses* (*sphenoidal*) do not exist in young chil-

---

* For explanation, see foot note, page 47.

dren ; in the adult, in whom they are of considerable size, they are separated by a thin partition (*septum sphenoidale*), which is continuous inferiorly with the rostrum, and in the front projecting as a crest (*crista s. spina sphenoidalis*) it articulates with the central lamella of the ethmoid bone. The sinuses are covered in anteriorly by two thin osseous plates,[8] the *sphenoidal spongy bones* (cornua sphenoidalia, cornets sphenoidaux) ; these do not, however, altogether seal up the sphenoidal sinuses, but leave a circular aperture, by which they communicate with the posterior ethmoidal cells. In early life they are distinct, and easily separable ; but in the adult they become united either with the margins of the sinuses or with the ethmoid or the palate bone.

their septum.

Spongy bones.

Posterior surface.

The *posterior surface*, fig. 24,[9] is flat, and united with the basilar process of the occipital bone,—in early life by cartilage, but in adult age by osseous matter.

The lateral surfaces are continuous with the great wings, which branch out from them on either side.

The processes.

Of the processes.—The principal processes are, the great wings, the small wings, and the pterygoid processes ; the minor ones are the ethmoid spine, processus olivaris, clinoid processes, the rostrum, the hamular and spinous processes.

The great wings.

The three surfaces of each, viz. orbital, cranial, and temporo-zygomatic.

The *great wings*,[10] (alæ majores,) project outwards, forwards and upwards, from the sides of the body of the bone, and are so formed as to present each three surfaces, looking in different directions. One, *anterior*, (*orbital*,)[11] is square, smooth, inclined obliquely forwards, and forms part of the outer wall of the orbit. The second,[12] (*superior* or *cerebral*,) of much greater extent, is elongated from behind forwards, and concave, so as to form part of the middle fossa of the base of the skull, which supports the middle lobe of the brain. The third,[13] (*external* or *temporo-zygomatic*,) looking outwards and forming part of the side of the cranium, is elongated from above downwards and slightly hollowed. But it will be observed, that this surface, taken as a whole from the top of the wing down to the root of the pterygoid process, presents two parts divided by a ridge or crest of varying size.[14] The upper and longer division forms part of the temporal fossa, and the inferior or smaller one enters into the zygomatic fossa.

The small wings :

The *small wings*,[15] (alæ minores,) called also wings of In-

in cavity of skull and orbits.

Anterior clinoid process.

Optic foramen.

grassias, are triangular in form, horizontal in direction, and extended forwards and outwards, on a level with the upper surface of the body—its fore-part. Their upper surface, plain and flat, supports part of the anterior cerebral lobes, the inferior one overhangs the back part of the orbit and its sphenoidal fissure. The anterior border, sharp, thin, and rough, articulates in the greater part of its extent with the orbital plate of the frontal bone, and internally, at the middle line, where the bases of the two processes are united, there is a slight angular process,[16] (*ethmoidal spine*,) which articulates with the cribriform lamella of the ethmoid bone. The posterior border, rounded and smooth, is free and unattached, and corresponds with the fissure (fissura Sylvii) which separates the anterior from the middle lobe of the brain. The external and anterior ends of these processes are sharp and pointed, whilst posteriorly they terminate in two blunt tapering productions (the anterior clinoid processes)[17] which incline obliquely backwards, towards the pituitary fossa, and overlay the cavernous sinuses and the carotid artery. They are perforated at the base by a round foramen (*optic*), which transmits the optic nerve and ophthalmic artery.

Pterygoid processes, external and internal; their differences.

Pterygoid fossa.

Fossa navicularis.

The *pterygoid processes* are seen at the inferior surface of the bone, from which they project down like legs rather than wings, though the name given to them would indicate the reverse (πτερύξ, a wing). Each of these consists of two narrow plates (*pterygoid lamellæ*), united at an angle in front, and diverging behind, so as to form an angular groove (*pterygoid fossa*). The internal plate,[18] longer and narrower than the external, is prolonged into a slight round process,[19] named, from its crooked form, the hook-like or *hamular process*, round which plays the tendon of the tensor palati muscle. The external lamella[20] looks outwards, and somewhat forwards, bounds the zygomatic fossa, and gives attachment to the external pterygoid muscle. At the root of the internal lamella is situated a slight depression (*fossa navicularis*), which gives attachment to the tensor palati muscle; in the groove or fossa, between the two plates, arises the internal pterygoid muscle. The groove is incomplete at its lower part when the sphenoid bone is examined by itself; for an angular insterstice[21] exists between the pterygoid lamellæ. This, however, is filled up by a part of the pyramidal process of the palate bone, which is inserted between the margins of the lamellæ.

Ethmoid spine.

The *ethmoid spine*, already noticed, is a very small angular plate[16] which projects forward on a level with the upper surface of the lesser wings in the middle line, and articulates with the cribriform lamella of the ethmoid bone.

Olivary process.

The *processus olivaris* is a minute elevation,[22] seen on that depressed piece of bone on a level with the optic foramina, and which supports the commissure of the optic nerves.

Clinoid processes.

The *clinoid processes* are two pair, one[17] before, the other[4] behind the pituitary fossa; therefore called anterior and posterior. A spiculum of bone often passes from the anterior to the posterior clinoid process at one or both sides. And occasionally one dips down from this to the body of the bone; it is called the *middle clinoid process*.

Rostrum.

The *rostrum* is the prominent angular ridge,[5] which projects downwards from the under or guttural surface of the bone, dividing it into two parts.

Hamulus.

The *hamular process*[19] projects from the termination of the internal pterygoid plate, is thin, constricted, and curved in the greater part of its extent, but ends in a small blunted tubercle.

The spine.

The *spinous processes*[23] are placed at the posterior and inner terminations of the great wings, from which they project downwards about two lines.

Sphenoidal fissure.

Fissures and foramina.—Each lateral half of the bone presents a fissure, four foramina, and a canal. The fissure,[24] (*fissura sphenoidalis*,) triangular and elongated, is placed between the lesser and greater wings, opens into the orbit, (hence sometimes named foramen lacerum orbitale,) and transmits the third, the fourth, and the sixth nerves, the ophthalmic branch of the fifth and the ophthalmic vein. This fissure is separated at its base from the foramen opticum by a narrow plate of bone which passes from the under surface of the anterior clinoid process (at its root) obliquely down to the body of the sphenoid bone; to this is attached a small tendon, common to the inferior, internal, and external recti muscles of the eye. Of the foramina, — the *optic foramen*[25] inclines outwards and forwards on a level with the fore-part of the body of the bone; it transmits the optic nerve and the ophthalmic artery. Farther back and on a lower plane, inasmuch as it is situated in the great wing, is a round aperture,[26] leading forwards; it is the

Foramina optic;

rotundum; *foramen rotundum*, which transmits the superior maxillary branch of the fifth pair of nerves. A little farther back and more external is a large foramen[27] of an oval form, hence called ovale; *foramen ovale;* it gives passage to the inferior maxillary branch. Near the posterior angle of the ala is the *foramen* spinosum; *spinosum*[28]; it is very small, and transmits the middle meningeal artery. The root, or base, of each internal pterygoid process is pierced by a circular foramen, fig. 25,[29] more properly a canal, (*pterygoid*, *Vidian*,) extending horizontally from before backwards, slightly expanded before, narrowed behind, and giving passage to the posterior branch (Vidian) from Meckel's ganglion.

pterygoid. Vidian canal.

Connexions with other bones.

Articulations.—The body of the sphenoid bone articulates posteriorly with the basilar process of the occipital; anteriorly with the ethmoid; with the orbital processes of the frontal by the lesser and greater alæ; with the anterior inferior angles of both parietal, and the squamous portion of the two temporal by the great alæ; and by the spinous processes with the angles between the petrous and squamous portions of that bone: with the vomer it articulates by the rostrum; with the malar bones by means of the external border of the orbital plates, and with the palate bones by the pterygoid processes;—in all, twelve bones.

Muscular attachments.

Attachments of muscles.—Round the optic foramen in each orbit are attached the four recti, the obliquus superior, and levator palpebræ muscles; to the external surface of the great ala at each side, the temporal muscle; to the external pterygoid process, the external pterygoid muscle; to the pterygoid fossa, the internal pterygoid; to the inferior half of the internal pterygoid plate, the superior constrictor of the pharynx; to the fossa navicularis, the circumflexus palati; and to the spinous process, the laxator tympani.

Ossification; time of its beginning.

The ossification of the sphenoid bone begins soon after it has commenced in the occipital. As this bone is developed from many centres, and some arrangement is necessary for the sake of clearness, it will be considered as divisible into a posterior and an anterior part, which, with Béclard, we may name spheno-temporal and spheno-orbital. Each will be noticed separately.

The bone divided into two parts.

Spheno-templ. part.

1.—The posterior or spheno-temporal division includes the great wings, the pterygoid processes of both sides, and the

Fig. 26.*

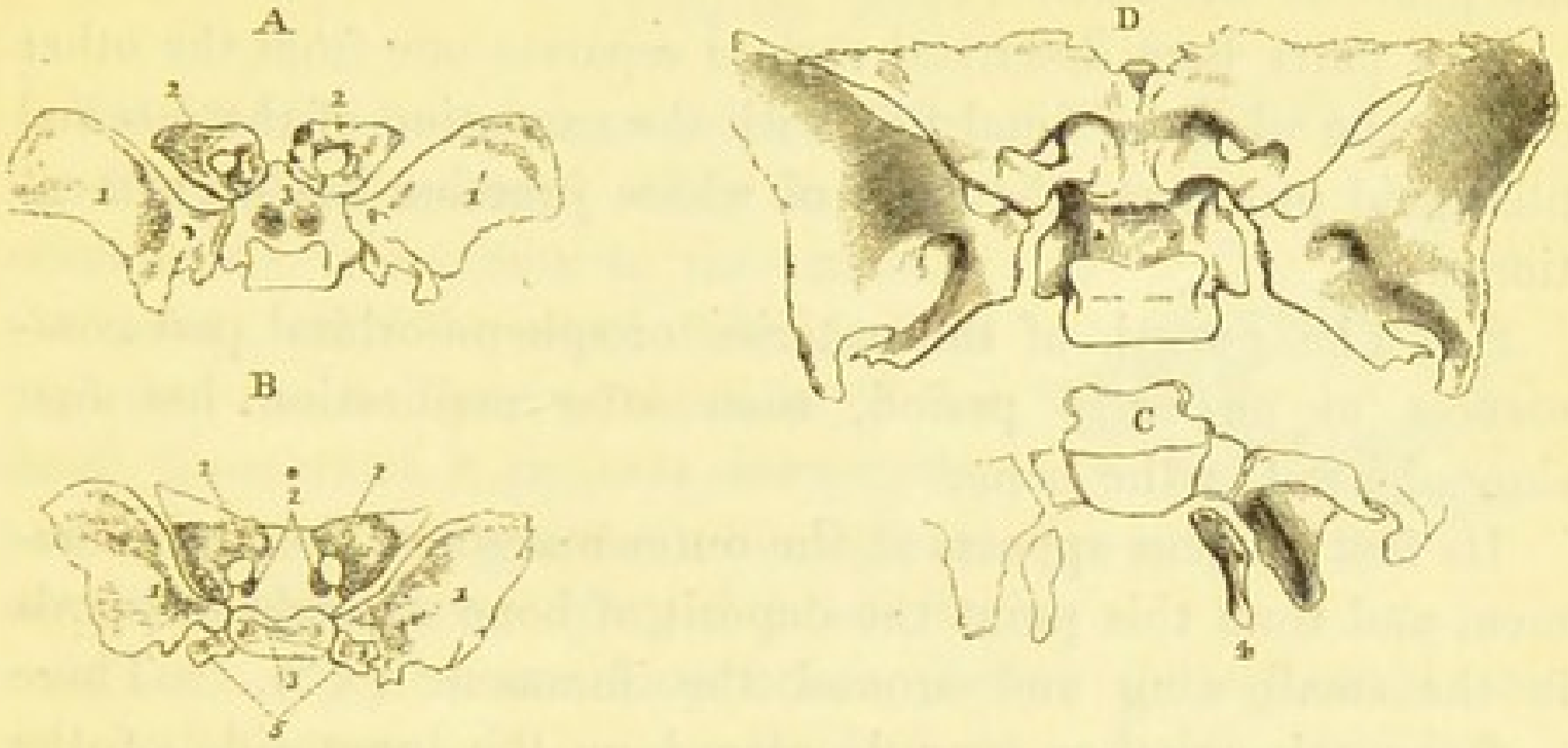

Lateral pieces.

interposed body. The first nuclei for this part (they are the first that appear in the bone) are deposited one on each side close to the foramen rotundum, and from this point the ossification spreads outwards into the great wing, and downwards into the external pterygoid process (fig. 26, A, B, C,$^{1\ 1'}$).

Internal pterygoid process.

The internal pterygoid processes are formed separately, each from a distinct centre (C^{4}), and they unite with the external plate soon after the middle of fœtal life.

Body.

For the formation of the body two rounded granules are placed side by side in the cartilage beneath the sella Turcica (A^{3}). These enlarging, unite about the fourth month into a single piece, which is elongated transversely and notched in the middle (B^{3}). This piece subsequently presents on each

---

[*] A. The sphenoid bone of a fœtus, aged about three months, is seen from above. The great wings are ossified ; the body has two round granules of bone beneath the sella Turcica, and the rest of it is cartilaginous. In the small wings which are formed from a single centre, the ossification has encircled the optic foramen, and a small suture is distinguishable at its posterior and inner side. The internal pterygoid processes are still separate (c^{4}) in the preparation from which the drawing was made. B. This figure is copied from Meckel ("Archiv." B. 1, Taf. vi. F. 23). It is stated to be from a fœtus at the middle of the sixth month. The two granules for the body are united, and a trace of their union is observable in the notch in front. The lateral projections of the body (^{5}) are separate pieces. C. is a sketch of the back part of the preparation drawn in A. The internal pterygoid process, which was united only by cartilage to the rest of the bone, has been drawn aside. D. This figure represents the sphenoid at the usual period of birth. The great wings are separate. The anterior sphenoid is joined to the body.

1. The great wings. 2. The small wings. 2*. Additional nuclei for the small wing. 3. The body. 4. The internal pterygoid process. 5. The lateral processes of the body.

side a projection, which Meckel describes and figures as an independent formation (B ^{5}).

The parts here described remain separate one from the other during the whole of fœtal life, with the exception of the internal pterygoid processes, the time of whose junction has been mentioned.

Spheno-orb. part;

2.—The growth of the anterior or spheno-orbital part commences at an early period, soon after ossification has first showed itself in the bone.

its lateral pieces;

Its first nucleus appears at the outer margin of the optic foramen, and from this point the deposit of bone extends outwards in the small wing and around the foramen (A ^{2}). There is frequently another granule placed on the inner side of the foramen (B ^{2*}).

its middle.

The middle of this division of the bone either results from the union of the lateral pieces just referred to, or is the product of an independent growth.

Sphenoidal crest.

The sphenoidal crest is perhaps generally produced by extension of the ossification of the middle of the spheno-orbital part, and therefore — according to the manner in which the middle is formed — proceeds either from the lateral pieces or from the central one. It is, however, not unfrequently altogether independent in its formation.

The condition at birth.

Some time before the end of fœtal life, the parts of the anterior sphenoid are joined together, and they unite with the body of the posterior division. So that at birth the sphenoid consists of three large pieces, viz: 1. the great wing and the pterygoid processes of one side; 2. the same parts of the opposite side; 3. both the spheno-orbital parts and the body united into a single piece (fig. 26 D).

The spongy bones.

To the three principal pieces present at the usual period of birth must be added, the rudiments of the sphenoidal spongy bones, whose ossification begins about two months before that time.

Completion of the bone.

In the course of the first year after birth the great wings and the body are no longer separable. About the age of puberty the spongy bones are joined to the sphenoid; they subsequently are connected to the ethmoid, and in consequence of this union they are often broken during the separation of the bones of the adult skull. Lastly, the sphenoid unites with the occipital bone.—See page 34.

ETHMOID BONE.

Fig. 27.*

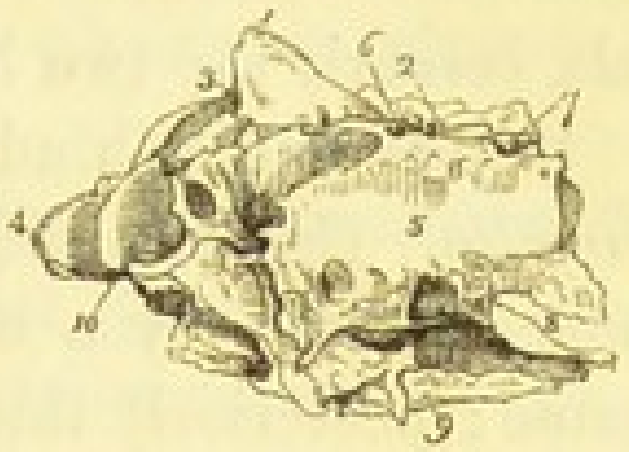

Ethmoid bone; its position;

its lightness.

The bony matter, thin and papyraceous.

The *ethmoid*, or sieve-shaped bone, fig. 27, (*ηθμος*, a sieve; *εἰδος*, form; os ethmoides,) is common to the cranium, the orbits, and the nasal fossæ; it is placed at the fore part of the base of the skull, from which it projects downwards, and is inserted between the orbital plates of the frontal bone, lying behind the nasal and superior maxillary bones, before the sphenoid and above the vomer. It is exceedingly light and thin, considering its size, and seems at first, but a collection of irregular cells, enclosed between plates of bone as thin as paper. It is of a cuboid figure, symmetrical, and composed of two lateral masses, between which is interposed a central vertical plate. This points out a mode of dividing the bone for the purpose of description, but it is more convenient to consider it as a whole, and examine separately each of its six surfaces.

The surfaces.

To place the bone in its proper position, observe that its upper surface is the one from which arises a smooth angular process like a cock's comb. The short border of this looks forward, and the long sloping one backwards.

The superior.

Crista galli.

The *superior* or *cerebral* surface of the bone is at once recognised by its presenting a triangular process, which projects upwards from it, in the middle line; this process,[1] from some resemblance to a cock's comb, is called *crista galli*. The surface of the crista is smooth and compact, its form triangular, the base being horizontal, and on a level with the cribriform plate, below which it is continuous with the perpendicular lamella forming the septum narium; the posterior border of this process is long, and slopes backwards, but the anterior is short, and nearly perpendicular; at its junction with the base two small bony masses sometimes project forwards, leaving between them a

---

* The ethmoid bone seen from the left side. 1. Crista galli. 2. Cribriform plate. 3. Fissure for the foramen cæcum. 4. Perpendicular or central plate. 5. Os planum. 6, 7. Grooves which form parts of the internal orbital foramina. 8. The posterior end of the superior spongy bone. 9. The second spongy bone. 10. Infundibulum.

Foramen cæcum.

fissure which forms part of the "foramen cæcum," placed in the middle line at the junction of this bone with the frontal. The crista galli is usually perpendicular, but occasionally inclines to one side; it is sometimes bulged a little at the sides, and is then found to enclose a small sinus; it gives attachment to the falx cerebri, the two layers of which in a manner embrace it.

The cribriform plate.

Beside and behind the crista is the sieve-like or *cribriform lamella*[2] (lamella cribrosa). It consists of a narrow plate of bone, pierced by a number of holes, from which it derives its name; posteriorly this plate of bone is, for a very little way, even and horizontal; it then becomes depressed into two grooves beside the crista, which lodge the ganglia of the olfactory nerves. This part of the surface is narrow, elongated from behind forwards, and pierced by numerous foramina, for the transmission of the filaments of the olfactory nerves. The *foramina* in it are of three sorts: those which lie along the middle of the groove are mere holes or perforations which permit the filaments of the nerves, with their membranous investments, to pass down to the roof of the nares; the external and internal rows are larger, and form the orifices of small canals, which are grooved in the bone, and subdivide as they descend into the septum and spongy bones. In the anterior border of the cribriform lamella, and close to the crista galli, is a fissure at each side of its base, which transmits the nasal filament of the ophthalmic nerve. Along the outer margin of the cribriform plate we observe several small cellules, which are open, and, as it were, incomplete when the bone is detached from its natural situation, but are closed in by the orbital plates of the frontal bone, and completed by a junction with the cells observed in their border. At the posterior margin of this surface, and in the middle line, is a slight notch, which receives the ethmoid spine of the sphenoid bone.

Its foramina for the olfactory nerves;

their varieties.

A fissure for the nasal nerve.

Cells.

The anter. surface.

The *anterior surface* of the bone presents in the middle the edge of the perpendicular or nasal lamella;[4] at the sides of this are narrow grooves which separate it from the lateral masses, and form the upper part of the nasal fossæ; still farther out are some open cellules, which when the bone is in its place are closed by the ascending process of the superior maxillary bone.

The poster. surface.

The *posterior surface* presents also in the middle the edge of the perpendicular lamella, then the grooved posterior margins of the ethmoidal turbinate bones, and still more externally large open cellules which are closed by the sphenoid bone and its turbinate bones, and lower down by the head of the palate bones.

The sides in the orbits. Os planum.

The *lateral* or *orbital surfaces* are smooth and plain;[5] each is formed of a thin plate of bone (lamella plana; os planum,) which lies in the inner wall of the orbits.

Inferior surface.

The *inferior* or *nasal* surface of the bone is of considerable extent, and presents in the middle line a flat plate of bone, and two lateral masses separated from it by a narrow interval: these lateral parts are formed of thin plates, enclosing cellules, which appear so complex as to be likened by some persons to a labyrinth.

Division into a central plate and lateral masses.

Thus far we can proceed with our description of the bone as if it were a single piece, which presented several aspects, each requiring to be noticed; but when we look at it from below, we find it expedient to consider it as divisible into a central or median plate, and two lateral parts or masses.

The central plate is part of the nasal septum;

The descending or *nasal* plate (lamella nasalis), called also the perpendicular or central plate, though it frequently inclines to one side, forms a considerable part of the septum nasi (fig. 39, [2]); it is continuous above with the base of the crista galli, as already stated; below, it articulates with the vomer and the triangular cartilage of the nose; its anterior margin joins by its upper part with the nasal process of the frontal bone, and lower down supports the ossa nasi; the posterior margin articulates with the septum sphenoidale. This plate presents a number of grooves and minute canals, leading from the foramina of the cribriform lamella, for the transmission of the olfactory nerves: in the natural condition it is covered by the pituitary membrane.

its grooves and canals.

The lateral masses.

Extern. surface (os planum).

Lateral masses.—The external surface of each of these consists of a thin, smooth, and nearly vertical plate of bone, fig. 27,[5] (*lamella plana, os planum,*) which closes in the ethmoidal cells and forms a considerable part of the inner wall of the orbit: it articulates above with the orbital plate of the frontal bone; below, with the superior maxilla and palate bone; in front, with the os unguis; and behind, with the sphenoid. At its anterior and posterior margins the ethmoidal cells are open when the bone is detached from its connexions; in the former situation they are closed by the os unguis; in the latter, by the sphenoid

Grooved to form foramina with frontal.

spongy bones. In its upper margin are two grooves,[6 7] which are formed into foramina by similar indentations in the frontal bones, and so form the internal orbital foramina (*foramen orbitarium internum, anterius et posterius*).

The internal surface.

The inner surface of each lateral mass (fig. 38) forms part of the external wall of the corresponding nasal fossa, and consists of a thin osseous plate, connected above with the cribriform lamella, from which it hangs down, and below ends in a free margin, which is convoluted a little, and represents the middle spongy bone. At its upper and fore part is a square, flat, but rough surface, which is pierced by a number of grooves, leading from the foramina of the cribriform lamella; posteriorly are placed two thin and also rough osseous plates, curved a little, so as to represent small bivalve shells, from which circumstance they are called *ethmoidal turbinate* bones; but from their texture, being cellular and porous on the surface, they are named *spongy* bones. Of these, the first or upper one (fig. 38,[5]), (concha superior,) which is also placed farther back, is very small; by the curve or coil which it makes it arches over, and forms a groove or channel (*meatus naris superior*): this is of small extent from before backwards, not being more than half that of the ethmoid bone; it communicates with the posterior ethmoidal cells, and the sphenoidal sinuses. Still lower down is another osseous lamella (fig. 38,[7]) thin, rough, and convoluted, which is the second ethmoidal spongy, or turbinate bone. Its lower margin is more rough and prominent than that of the upper one, and its extent from before backwards nearly double. Beneath this is a groove or channel which it overhangs so as to form the second *meatus naris*, which communicates with the anterior ethmoidal cells, the frontal sinuses, and the antrum of Highmore.

Two spongy bones.

Superior meatus naris.

Middle meatus naris.

Canals for the olfactory nerve.

The surface of these spongy bones is studded over with holes, which are the orifices of canals lodged in the substance of this slender structure. These (the canals) lead from the foramina in the cribriform plate, and they vary in length, some reaching only a very short way, while others extend to the lower margin of the bone. Their direction is nearly vertical, with, in most instances, a slight inclination backwards, and they conduct the branches of the olfactory nerve to the lining membrane of the nasal fossa at different points.

There are also generally, if not always,* to be found on the second spongy bone—on the posterior margin, and for a short space in front of it—one or two slight horizontal grooves marking the course of small nervous filaments, which enter through the spheno-palatine foramen.

Grooves for other nerves.

The osseous plate here described gives attachment by its outer surface to a number of osseous lamellæ, thin and delicate, which pass across the space between it and the lamella plana, dividing it into a number of *cells* (*ethmoidal*). These do not all communicate; they are separated into two sets by a sort of transverse partition, the posterior being small and few in number—from four to five,—whilst the anterior, larger and more numerous, communicate with the frontal sinus. The cellule (fig. 27, [10]), which directly communicates with the middle meatus, is prolonged, in a curved direction, upwards and forwards, opening by a small aperture into the anterior ethmoidal cells, and by another, farther on, into the frontal sinus; and, as it is broad below, and tapering above, it assumes somewhat the form of a funnel, and hence is named *infundibulum.*

The cells are posterior and anterior.

Infundibulum.

The superior border of each lateral mass presents some incomplete cells, before noticed when describing the cribriform plate; the inferior gives off some irregular lamellæ, which articulate with the side of the maxillary sinus and the inferior turbinate bone; the anterior also exhibits some incomplete cells, which are closed in by the os unguis and the nasal process of the superior maxillary bone.

Articulations.—The ethmoid articulates with thirteen bones—the frontal, the sphenoid, and vomer, two nasal, two ossa unguis, two superior maxillary, two palatal, and two inferior spongy bones.

Connexion with other bones.

Ossification.—In the ethmoid bone this process begins about the middle of fœtal life—from the fourth to the fifth month—a later period than belongs to its commencement in any other bone of the cranium. Bone is first visible in the outer sides—the ossa plana,—and soon after becomes apparent in the spongy bones, but the middle plate remains cartilaginous till after birth.

Ossification; time of its commencement; where first apparent.

At the usual period of birth the ethmoid consists of two parts—the lateral masses,—and these are small and narrow. Subsequently, (in the course of the first year,) the middle plate

Condition at birth.

Completion of the bone.

and the lamina cribrosa begin to ossify, and the bone becomes a single piece by the union of the latter to the lateral masses.

The peculiar character of the ethmoid is afterwards gradually developed by the unfolding, as it were, of its substance, and the increase in the size of its cells.

OSSA TRIQUETRA.

Ossa Wormiana.

Their most frequent position.

Accidental, or supernumerary bones, are not unfrequently found in skulls. From their form, which is very variable, they are sometimes called triquetra, at others, triangularia, or ossa Wormii, from Wormius, a learned Danish professor, who is said to have given the first detailed description of them. They are osseous plates, with serrated margins, inserted, as it were, between two cranial bones (ossa intercalaria, epactalia), and appearing like islets placed in the sutures. Their most ordinary position is in the lambdoid suture, next in the sagittal, seldom if ever in the coronal, never in the squamous. The superior angle of the occipital bone sometimes occurs as an accessory piece ; so does the anterior inferior angle of the parietal. They are not found before the sixth or eighth month after birth ; and whatever varieties of size and appearance they may present, the principle of their formation is the same in all cases. As the broad bones grow by successive deposits, extending from their central points towards the margins, whenever the natural process is retarded or interrupted, the mode of osseous deposition takes a new direction, a new centre is established in the layer of cartilage between the margins of the bones, and therefore in the situation of the suture, from which it extends outwards, until it comes into contact with the margins of the contiguous bones, with which it becomes united in the usual way by suture.

BONES OF THE FACE.

These, as above stated, page 29, are fourteen in number.

THE SUPERIOR MAXILLARY BONE.

Superior maxilla; its parts.

Fig. 28.*

This bone, fig. 28, (maxilla superior,) is very irregular. It presents an external convex surface, corresponding with the anterior and lateral parts of the face; another, internal, of considerable extent, corresponding with the nasal cavity; one, superior, smooth, and inclined inwards, forming the floor of the orbit, and surmounted internally by a triangular process, forming the side of the nose; lastly, a surface which projects horizontally inwards, to form the arch of the palate. The external surface is bounded inferiorly by a thick, dependent border (alveolar), for the lodgment of the teeth; to this as to a common point of union, all the other parts of the bone may be referred.

Alveolar border.

The *alveolar border*,[1] thick, semicircular, convex externally, concave internally, is pierced along its margin by a number of deep pits (*alveoli*), into which the teeth are inserted. The pits or sockets vary in form and depth, conforming in these particulars to the roots of the teeth which they receive. From this border the external side ascends to the margin of the orbit, presenting some depressions and elevations; but at its fore-part it is interrupted and excavated so as to present a deeply concave margin,[2] which, with a similar one in the corresponding bone, forms the anterior nares. This excavation is surmounted by a process[3] (*ascending* or *nasal*), prolonged as far as the frontal bone, with which it articulates.

Nasal process.

---

* The outer surface of the left superior maxilla:—1. The middle of the alveolar border. 2. The side of the anterior nares. 3. The nasal process. 4. Groove for the nasal duct. 5. The malar process. 6. Canine fossa. 7. Infra-orbital foramen. 8. Myrtiform fossa. 9. The tuberosity. 10. The orbital plate. 11. A ridge, terminating anteriorly at 12, the anterior nasal spine.

The external surface of the nasal process, slightly grooved, gives attachment to the orbicularis palpebrarum muscle and the levator labii superioris alæque nasi. The internal, or nasal surface, somewhat concave, presents a rough line, running from before backwards, which articulates with the inferior spongy bone; above this is a depression corresponding with the middle meatus of the nose, and, towards the summit, a rough surface, which closes in the anterior ethmoidal cells. The anterior border is rough, for its attachment to the nasal bone; the posterior presents a well-marked groove,[4] running from above downwards, and a little backwards with a slight curve, and which is completed into a canal by a similar one in the os unguis, for the lachrymal sac.

Lachrymal groove.

The part of the external surface a little above the molar teeth, is elevated into a rough projection,[5] (*malar process, eminence, tuberosity,*) for its articulation with the malar bone. Anterior and inferior to this is observed a fossa,[6] (*fossa canina,*) which gives attachment to the levator anguli oris. Between this fossa and the margin of the orbit is the *infra-orbital foramen,*[7] which transmits the superior maxillary nerve. A little above the sockets of the incisor teeth is a slight depression,[8] (*myrtiform*, or *superior incisor fossa,*) which gives attachment to the depressor muscle of the ala of the nose. Behind the malar tuberosity the surface is slightly excavated, and forms part of the zygomatic fossa; towards the posterior border it is plain, and forms one side of the spheno-maxillary fissure; and, at its junction with the orbital plate, it is rounded off and leads to the entrance of the infra-orbital canal. It terminates by a slight *tuberosity*, (tuber maxillare,)[9] which projects behind the last molar tooth, and is perforated by a number of foramina, which transmit the superior dental nerves and arteries. The inner surface of its posterior border is rough, for its attachment to the tuberosity of the palate bone, and presents also a slight groove, contributing to the formation of the *posterior palatine canal*, which transmits the descending palatine branches from Meckel's ganglion.

Malar eminence.

Canine fossa.

Infra-orbital foramen.

Myrtiform fossa.

The tuberosity.

Nerves.

From the upper border of the external surface, the *orbital plate*[10] projects inwards, forming the floor of the orbit; its surface is smooth, being merely interrupted by the groove which leads to the infra-orbital canal; and at its inner and fore part,

The orbital plate, and infra-orbital canal.

near the lachrymal groove, is a minute depression, which gives origin to the inferior oblique muscle of the eye. The *infra-orbital canal* commences behind on the surface of the orbital plate as a groove; becoming deeper in front and being changed into a complete canal, it opens on the anterior surface of the bone at the infra-orbital foramen, some distance below the margin of the orbit. It gives passage to a large nerve and an artery. In the interior of the bone a small canal leads downwards from the larger one, and conducts a nerve (anterior dental) to the front teeth.

Palate plate.

The spine.

Anterior palatine canal.

The horizontal or *palate* plate of the bone projects inwards, forming the roof of the mouth and the floor of the nares. Its nasal surface is concave from side to side, and smooth; externally it is continuous with the body of the bone, internally it presents a rough surface, which is articulated with the corresponding bone, and surmounted by a ridge,[11] which completes the septum narium by articulating with the vomer and nasal cartilage; in front it is prolonged a little, so as to form a small process[12] (*anterior nasal spine*); beside it is the *incisor foramen*, leading into the *anterior palatine canal.* The inferior surface of the palate plate which overhangs the mouth is arched and rough, and among the prominences of the surface it is slightly grooved for a large nerve which reaches the palate through posterior palatine canal.

Fig. 29.

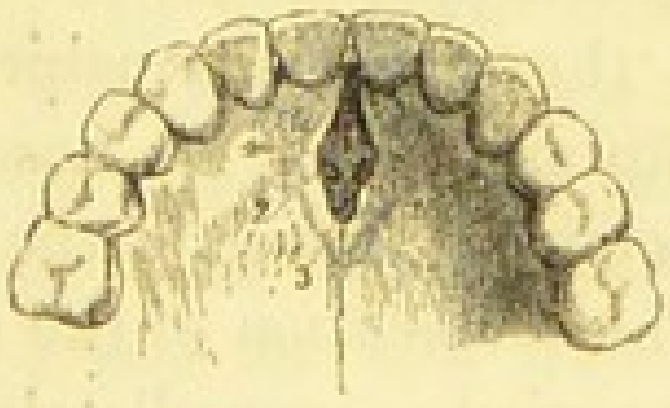

The openings into it.

On examining with attention the large canal or fossa, named the anterior palatine, fig. 29, (in the skull,) it will be found that it contains four openings—two placed laterally,[1] [2] and two in the middle, one[4] before the other[3]. The two former are described as the foramina of Steno * (of Stenonis more properly) in many of the older anatomical works. They are mentioned above as the "incisor" foramina. The others, which were

---

* The name is usually thus written in English books; but it should be mentioned, that the real name was "Stenson," and of this the ordinary Latin version was "Stenonis."—See, among others, Haller, "Elem. Physiol." t. i. p. 353.—Blumenbach, "Introduct. in Histor. Medicinæ Litt." p. 253.

first brought under notice by Scarpa, are placed in the intermaxillary suture, so that both maxillary bones contribute to form each of them. They are smaller than the preceding pair, from which they are separated by a very thin partition, and the lower orifice of the posterior one is larger than that of the anterior. It is through these median smaller canals (of Scarpa) that the naso-palatine nerves pass,—the nerve of the right side occupying the posterior one, and the nerve of the left side, the anterior.*

The antrum.

The body of the bone is hollowed into a large cavity, *antrum Highmori*, or *maxillare*, which in the fresh state is lined by mucous membrane and communicates with the middle meatus of the nose. Its orifice appears of great size in the dried bone when detached from its connexions, but it is considerably diminished when the contiguous bones are in their natural position, viz. the ethmoid, the inferior turbinate, and the palatal.

Connexion with other bones.

Articulations. — With the corresponding bone; with the frontal, by its nasal process; also with the ethmoid and os nasi; with the palate bone; with the malar, by the malar eminence; with the os unguis, the vomer, the inferior spongy bone, and the nasal cartilage.

Muscular attachments.

Attachments of muscles. — Proceeding from below upwards; —above the border of the alveolar arch, the buccinator, and the depressor labii superioris alæque nasi; to the canine fossa, the levator anguli oris and the compressor nasi; to the margin of the orbit, part of the levator labii superioris; to the nasal process, the orbicularis palpebrarum, and the common elevator of the lip and ala of the nose; and just within the orbit, the inferior oblique muscle of the eye.

Ossification.

The *ossification* of the upper maxillary bone begins at a very early period,—immediately after the lower maxilla and the clavicle, and before the vertebræ. The facts hitherto ascertained with respect to its earliest condition are not adequate to determine the number of nuclei from which this bone is formed, or the manner of its growth. If it is produced from several centres— and to this the balance of evidence inclines — the very early

Number of nuclei undetermined.

---

* The median canals have not unfrequently a different disposition. Thus, *a*. They may join one with the other, and open inferiorly by a single common orifice. *b*. Either may be wanting. *c*. One may be found to open into a lateral (incisor) canal. See Scarpa, "Annotat. Anatom." lib. ii. cap. 5.

period at which the osseous deposit begins, and the rapidity of its progress over the bone, will account for the difficulty of marking the phases of change.

Observation of Béclard.

Béclard, whose opportunities of observing the growth of this and most other bones were considerable, states that he had found it to consist of four pieces, viz. 1. A palatal part, including all the palate except the incisor portion. 2. An orbital and malar division, comprising the parts implied by these names. 3. The nasal and facial connected. 4. The incisor piece,—being a small part of the palate behind the incisor teeth, and including in front the posterior margin of the alveolar border. But this anatomist adds, that he had not had the means of determining where the several pieces unite one to the other, and he admits that further observations of the bone at very early periods are necessary to determine the manner of its ossification.

Fig. 30.*

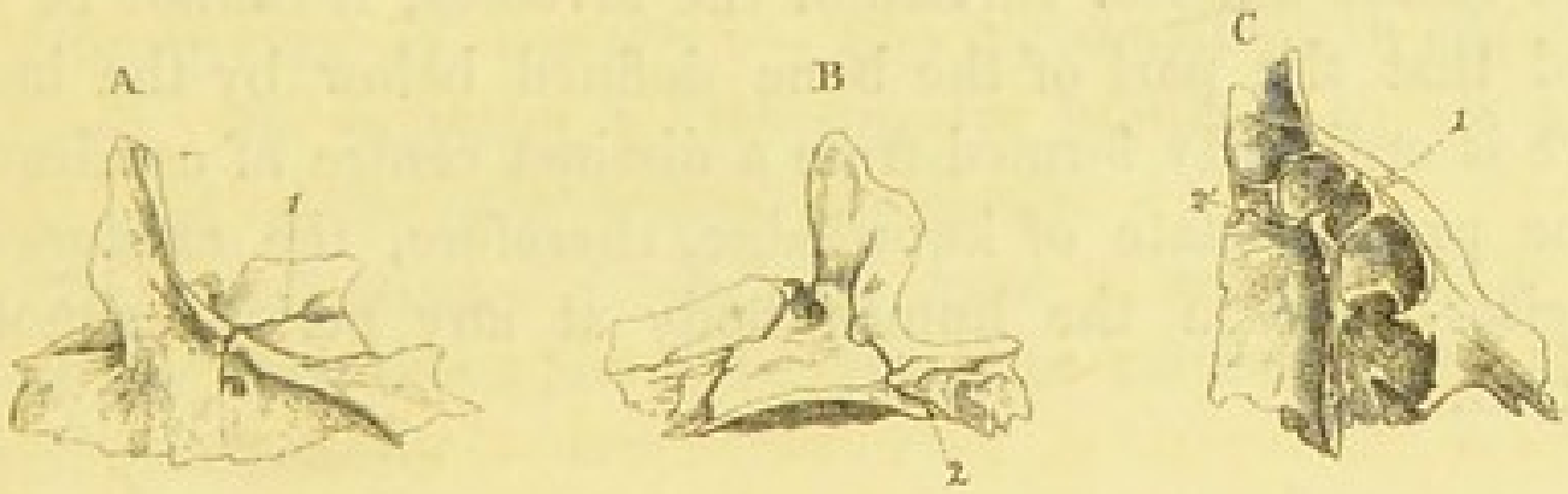

Fissures; orbital and incisor.

Taking this bone when a single piece, it presents two fissures, one along the floor of the orbit (fig. 30, A^1): the other (the incisor groove) marking off a small portion of the palate behind the incisor teeth (B, C^2). Now, the question arises, are these the limits of ossification proceeding from different centres? There does not appear to be evidence that the first is so, for its presence may be owing solely to the construction of the canal over which it is placed. But with regard to the second, there

---

* The superior maxillary bone at early periods:—On the outer side, A, a fissure extends through the orbit and ends at the infra-orbital foramen. B. is a view of the inner side of the bone. The incisor fissure reaches upwards through the horizontal plate and some way on the nasal process. C. The alveolar border and palate plate are displayed from below, and the incisor fissure is seen to cross those parts. At the outer side a small portion of the orbital fissure was noticeable in this view of the bone, and it has been represented. 1. The orbital fissure. 2. The incisor groove or fissure.

Is there a separate incisor piece? are circumstances which would incline us to expect that the portion of bone it circumscribes should prove to be a distinct growth. The circumstances alluded to are the following: 1.

Reasons for expecting to find one. The existence, in some cases of hare-lip, of a detached piece corresponding in its extent on the palate to the line of this fissure, and including the entire thickness of the alveolus with the incisor teeth. 2. The strictly defined extent of this piece: it never reaches beyond the line of the fissure—never includes a canine tooth. 3. No similar portion is ever found detached from another part of the upper or from the lower maxillary bone. 4. Lastly, may be added the existence of an intermaxillary bone in animals with which an incisor piece in man would be analogous.

Its existence not proved. The foregoing facts render it probable that the incisor part is formed separately from the rest of the bone. Still, seeing that, except in cases of malformation, a distinct piece has not hitherto been clearly observed by any anatomist, and that the trace of separation which exists on the palate has never been found to extend to the anterior surface of the alveolus, it cannot be concluded that the part of the bone defined below by the incisor groove is ordinarily formed from a distinct centre of ossification. In the present state of knowledge, therefore, the existence of an incisor bone in the human body at any period cannot be admitted.

THE MALAR BONES.

Malar bone. There are two bones named malar (os malæ, malare, jugale, zygomaticum). Each is common to the face and orbit, forming the most prominent point of the side of the former, and the greater part of the outer border of the latter. Its form is quadrangular.

Surfaces; anterior; its foramina. The facial or anterior surface, pierced by some *foramina* (*malar*) for small nerves and vessels, is convex, and gives attachment to the zygomatic muscles; — the posterior overlays the zygomatic fossa, and is rough at its fore part for its articulation with the superior maxillary bone. superior; The superior surface, smooth, narrow, and lunated, extending into the orbit, articulates with the frontal, sphenoid, and superior maxillary bones, and contributes by a small smooth margin to bound the spheno-maxillary fissure. its foramina. It is pierced by two or three foramina, and gives passage to a small nerve, which passes backwards through it.

Borders. Zygomatic arch.

The superior border forms the outer margin of the orbit; the inferior is on a line with the zygomatic arch, which it contributes to form, supporting the zygomatic process of the temporal bone; the anterior articulates with the maxillary bone; the posterior, curved, gives attachment to the temporal aponeurosis.

Angles; their differences.

The angles of the bone are readily distinguished one from the other. They are four in number. The anterior is slender and pointed, and rests on the superior maxillary bone. The posterior is thin, and supports the zygomatic process of the temporal; the suture between the two bones is often vertical at the lower end. The superior angle, which is very thick, supports the external angular process of the frontal bone; and the lower one is less prominent than the others.

Connexion with other bones.

Articulations.—It articulates with the frontal, superior maxillary, temporal, and sphenoid bones.

Muscular attachments.

Attachments of muscles.—The zygomatici, to its anterior surface; the masseter to its inferior border; to its anterior angle, part of the levator labii superioris.

Ossification.

The ossification.—It extends from a single ossific point, which appears about the time that the ossification of the vertebræ commences.

THE NASAL BONES.

Nasal bones.

The nasal bones (ossa nasi), situated beneath the frontal bone, and between the ascending processes of the superior maxillary, are small and irregularly quadrilateral, and form what is called the "bridge" of the nose. They are thick and narrow in their upper part, but gradually become wider and thinner lower down. The anterior surface of each, concave from above downwards, convex from side to side, presents a minute vascular foramen; the posterior, or nasal, is marked by the passage of a branch of the nasal nerve; the superior border articulates with the frontal bone; the inferior with the nasal cartilage; the external with the ascending process of the maxillary bone; and the internal with its fellow of the opposite side, supported by the nasal spine of the frontal bone, and the perpendicular plate of the ethmoid.

They give attachment to the pyramidales and compressores nasi.

Ossification.—They are developed each from a single osseous centre, which is discernible about the same time with those which first appear in the vertebral column.

OSSA UNGUIS—OSSA LACHRYMALIA.

Os unguis.

These small bones are named "ungual" from a resemblance, if not in form, at least in thinness and size, to a finger-nail (unguis); they are also called the "lachrymal" bones, from their presenting each a groove, which, with a similar excavation in the nasal process of the superior maxilla, forms the lachrymal canal. Placed at the inner and anterior part of the orbit, the os unguis presents two surfaces and four borders; its external or orbital surface, plain in the greater part of its extent, is hollowed anteriorly by a groove which runs from above downwards, and contributes, as above stated, to lodge the lachrymal sac. Part of the internal surface, which is rough, corresponds with the anterior ethmoidal cells, the rest with the middle meatus narium. The superior border is articulated with the orbital process of the frontal bone; the inferior with the superior maxillary bone; and where it dips down, to form a part of the lachrymal canal, it joins the inferior spongy bone; anteriorly, it rests on the nasal processes of the superior maxillary bone, and posteriorly on the os planum of the ethmoid.

Ossification.—Each os unguis is developed from one osseous centre, which is apparent shortly after the ossification of the vertebræ is begun.

THE PALATE BONES.

Fig. 31.*

Palate bone;

its position.

Division.

Each palate bone, figs. 31 and 32, (os palati,) wedged in between the superior maxillary and sphenoid bones, is common to the cavity of the mouth, nares, and orbit. In its form this bone somewhat resembles that of the letter L, one part being horizontal, the other vertical.

The horizontal plate.

The horizontal or *palate* plate[1] of the bone, which is nearly square, and forms the

---

* Fig. 31 is a view of the left palate bone, seen from behind and slightly on the inner side. In fig. 32 the outer side of the bone is represented. 1.

It separates the nasal fossa from the mouth.

Connexion of soft palate.

Posterior palatine canal.

back part of the roof of the mouth and of the floor of the nares, articulates anteriorly with the palate plate of the maxillary bone; internally it presents a rough thick border which rises up into a ridge,[2] which joins with its fellow of the opposite side, and with it forms a groove which receives the lower border of the vomer; externally it unites at right angles with the vertical portion of the bone; posteriorly it presents a thin free border, forming the limit of the hard palate, and giving attachment to the velum or soft palate which projects downwards from it; it is slightly concave, and has at the inner angle a pointed process, [3] (*the palate spine*). The superior surface of this plate or process is smooth, and forms the back part of the floor of the nasal cavity: the inferior, which forms part of the roof of the mouth, is unequal, and marked by a transverse ridge, into which the tendinous fibres of the circumflexus palati muscle are inserted; it presents also an oval foramen, being the inferior termination of the posterior palatine canal, which transmits the large descending palatine nerve and accompanying vessels; and farther back, another of smaller size, which transmits the middle palatine nerve.

The tuberosity.

At the junction of the horizontal and vertical portions is situated a thick rough tubercle[4] (*tuberosity*, *pyramidal process,*) projecting downwards and backwards. This is marked by three vertical grooves; the two lateral ones are rough, and receive the inferior borders of the pterygoid plates of the sphenoid bone; the middle one,[5] smooth, corresponds with and completes the fossa between the pterygoid plates.

Vertical part; its position.

Grooved.

The vertical portion of the bone is flat and thin; it presents two surfaces; the internal one (*nasal*) is divided into two parts by a transverse ridge (crista transversa),[6] which articulates with the inferior spongy bone; the space below the ridge forms part of the inferior meatus, that above it of the middle meatus. The external surface, rough and unequal, fig. 32, is divided by a vertical groove,[7] which is completed into a canal (*posterior palatine canal*) by the maxillary bone. The posterior part

---

The palate plate. 2. A ridge or crest. 3. The spine. 4. The tuberosity. 5. Its smooth part for the pterygoid fossa. 6. Crest for the inferior turbinate bone. 7. Groove for the posterior palatine canal. 8. Spheno-palatine foramen. 9. The sphenoidal process. 10. The orbital process; and 11, 12, 13, 14, its different surfaces.

of this surface articulates with the rough border and nasal surface of the maxillary bone; and the anterior, thin and scaly, with the side of the antrum.

Fig. 32.*

Divided into two parts,

The superior border of the vertical portion of the palate bone presents a notch,[8] forming the greater part of a foramen, which is completed by the sphenoid bone when the parts are in their natural position. This is called the *spheno-palatine* foramen; and outside it is placed the nervous ganglion of the same name (Meckel's ganglion). This notch divides the border of the bone into two processes or heads, the sphenoidal and the orbital.

between wh. is the spheno-pal. foram.

Processes,

sphenoidal;

The *sphenoidal* process,[9] smaller and not so prominent, presents three surfaces, of which one, internal, looks to the nasal fossa; another, external, forms a small part of the zygomatic fossa; and the third, superior, grooved on its upper surface, articulates with the under surface of the sphenoid bone, and with it forms part of the *pterygo-palatine* canal.

orbital.

The *orbital* process[10] inclines outwards and forwards, and has five surfaces, two of which are free, and three articulated; of the latter, the internal one rests against the ethmoid bone, and covers some of its cellules; the anterior[11] articulates with the superior maxillary bone; and the posterior[12] (which is hollow) with the sphenoid. Of the non-articular surfaces, one superior,[13] smooth and oblique, forms a small part of the floor of the orbit; the other, external,[14] looks into the zygomatic fossa.

Connexion with other bones.

Articulations.—With the corresponding palate bone; with the superior maxillary, ethmoid, sphenoid, vomer, and inferior spongy bone.

Muscular attachments.

Muscular attachments.—To its spine, the azygos uvulæ; to the centre groove on its tuberosity, a small part of the internal pterygoid; and to the transverse ridge on the palate plate, the aponeurosis of the circumflexus palati.

Ossification.—The palate bone is formed from a single centre, which is deposited at the angle formed between its parts. From this the ossification spreads in different directions —

---

* See note, p. 68.

upwards into the vertical plate, inwards to the horizontal one, and backwards to the pyramidal process. For a considerable time after it has been fully ossified this bone is remarkable for its shortness; the horizontal plate exceeds in length the vertical one in the fœtal skull.

THE VOMER.

Vomer; grooved in front.

The vomer (fig. 39,[3]), so called from its resemblance to a ploughshare, is flat, irregularly quadrilateral, and placed vertically between the nasal fossæ, presenting two surfaces and four borders. The lateral surfaces form part of the inner wall of the nasal fossæ; the superior border, thick and deeply grooved, receives the rostrum of the sphenoid bone; the margins of the groove expand and are articulated with two small lamellæ at the roots of the pterygoid processes of the sphenoid bone. The anterior border, also grooved, presents two portions, into one of which is implanted the descending plate of the ethmoid, and into the other the nasal cartilage. The posterior border, dividing the posterior nares, is thin and unattached: the inferior is received into the fissure formed by the palate plates of the superior maxillary and palate bones.

Ossification.

Ossification begins in the vomer about the same time as in the vertebræ. In the early periods it consists of two laminæ separated by a considerable interval, except at the lower border, where they are joined (fig. 33).

Fig. 33.*

THE INFERIOR TURBINATE BONES.

Each *inferior turbinate*, or *spongy bone*, (so called from its texture in the latter case, in the former from some resemblance to the lateral half of an elongated bivalve shell,) extends from before backwards, along the side of the nasal fossa:—it appears as if appended to the side of the superior maxillary and palate bones. It is slightly convoluted, and presents an external concave surface, which arches over the inferior meatus, and an in-

---

* The vomer from the skull of a fœtus. It consists of two plates (1, 2), united below.

ternal convex surface, projecting into the nasal fossa (fig. 38,[10]). This bone has not canals or foramina for the olfactory nerve, like the spongy bones of the ethmoid, but it is marked by two horizontal, branching grooves (in part canals) for other nerves. Its superior border articulates with the ascending process of the maxillary bone before, with the palate bone behind, and in the centre with the os unguis; it presents also a hooked process, which curves downwards and articulates with the side of the antrum; the inferior border is free, slightly twisted, and dependent.

The *ossification* commences about the middle of fœtal life, and from a single point.

THE INFERIOR MAXILLARY BONE.

Fig. 34.*

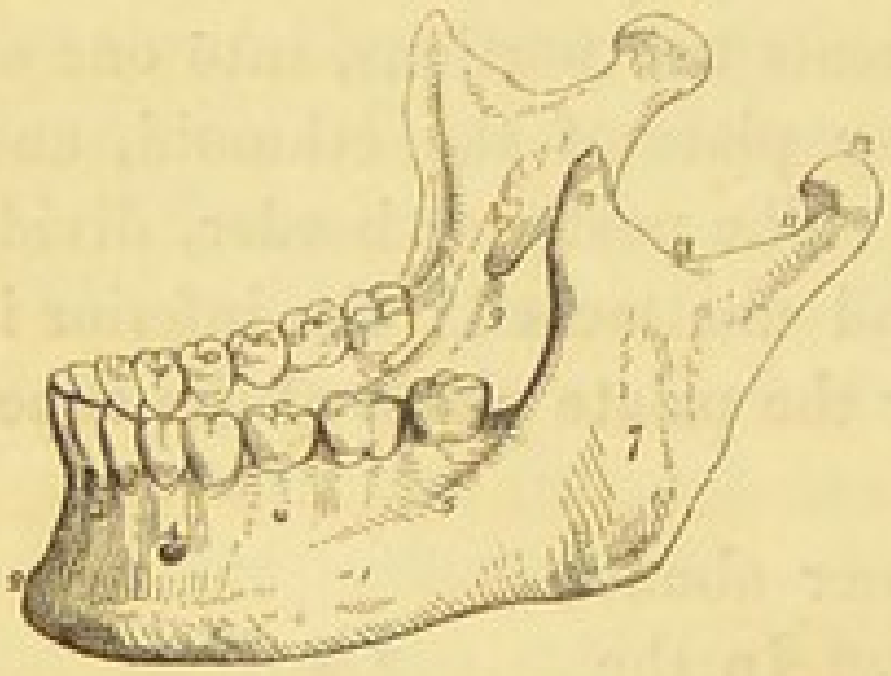

Inferior Maxilla.

Its shape.

Division into parts.

The inferior maxilla, fig. 34, (os maxillæ inferius: mandibula,) of considerable size, is the thickest and strongest bone of the face, of which it forms a large portion of the sides and fore part. It is convex in its general outline, and shaped somewhat like a horse-shoe. It is usually considered as divisible into a middle larger portion — its body, and two branches or rami.

The body.

Symphysis.

Foramen mentale.

The *body*[1] is placed horizontally; its external surface is convex, and marked at the middle by a vertical line[2] indicating the original division of the bone into two lateral parts, and thence named its *symphysis*. On each side of the symphysis, and just below the incisor teeth, is a superficial depression,[3] (the *incisor fossa*,) which gives origin to the levator menti muscle; and, more externally, a foramen,[4] (*foramen mentale*,) which transmits the terminal branches of the dental nerve and artery. A raised line may be observed to extend

---

* 1. The body. 2. The symphysis. 3. The incisor fossa. 4. Foramen mentale. 5. The external oblique line. 6. The mylo-hyoid ridge. 7. Ramus of the left side. 8. Inferior dental foramen. 9. Mylo-hyoid groove. 10. The coronoid process. 11. The neck. 12. Condyle. 13. Sigmoid notch.

obliquely upwards and outwards from near the symphysis to the anterior border of the ramus; it is named the *external oblique* line,[5] and is intended to give attachment to muscles. The *internal surface* of the body of the bone is concave in its general outline, and marked at its centre by a depression corresponding with the symphysis; at each side of which are two prominent tubercles (*spinæ mentales*), placed in pairs one above the other, and affording attachment,—the upper pair, to the genio-hyoglossi, and the lower to the genio-hyoidei muscles; beneath these are two slight depressions for the dygastric muscles. An oblique prominent line,[6] (the *mylo-hyoidean ridge*,) will be observed leading from the lower margin upwards and outwards to the ramus; above the line is a smooth depression for the sublingual gland, and beneath it, but situated more externally, is another for the submaxillary gland. The superior (*alveolar*) border of the body is horizontal, and marked by notches corresponding with the alveoli, or sockets of the teeth. The inferior border (*the base*), thicker at its anterior than at its posterior part, is slightly everted in front, so as to project somewhat forwards, constituting the *chin* (*mentum*, γένειον). The vertical direction of the bone below the incisor teeth, and the projection of the lower border forward in front, are peculiar to man. In other animals the maxillary bone at its anterior part retires or inclines backwards more or less below the alveolar border, leaving this the most prominent point.

Extern. oblique line.

Spinæ mentales.

Mylo-hyoid ridge.

Base.

The chin, a characteristic of man.

The *branches*,[7] (*rami*,) project upwards from the posterior extremity of the body of the bone, with which they form nearly a right angle in the adult, an obtuse one in infancy,—the "angle" of the jaw. They are thinner somewhat, and appear as if compressed. The external surface of each ramus is flat, and marked by slight inequalities; the internal surface presents at its middle a *foramen*,[8] (*inferior dental*,) leading into a *canal* (*dental*) contained within the bone, and lodging the dental nerve and vessels. Beneath the foramen a slight groove,[9] (occasionally and for a short space, a canal,) marks the passage of the mylo-hyoid nerve with an accompanying artery and vein; the rest of the surface being rough, for the insertion of the pterygoideus internus. The anterior border of each ramus is nearly vertical in its direction, and terminates in a pointed extremity, named the *coronoid process*;[10] it is grooved at its

Rami.

Dental foramen and canal.

Mylo-hyoid groove.

Coronoid process.

The neck.

Condyle; its direction.

Sigmoid notch.

commencement, for the attachment of the buccinator muscle. The posterior border is also almost vertical in adults; but in children and edentulous subjects it departs considerably from this direction, and approaches that of the base of the bone. This border is surmounted by a constricted part,[11] which appears as if compressed from before backwards, and is called the *neck* of the bone. It is slightly depressed at its fore part, and gives insertion to the external pterygoid muscle. Now the neck supports the articular head of the bone,[12] (the *condyle*,) which is convex and oblong, its greatest diameter being from without, inwards; the direction of its axis is oblique, so that, if prolonged, it would meet with that of its fellow of the opposite side at the anterior margin of the foramen magnum. The interval between the condyle and the coronoid process, deeply excavated, is called the *sigmoid notch* (incisura sigmoidea),[13] and if viewed when the bones are *in situ*, it will be found to form a complete circle with the arch of the zygoma.

Muscular attachments.

Attachments of muscles.—To the incisor fossa, the levator menti; to the external oblique line, the depressor labii inferioris, depressor anguli oris, and a small part of the platysma myoides. To the upper tubercles on the inner surface of the symphysis, the genio-hyo-glossi; to the inferior ones, the genio-hyoidei; to the depression beneath these, the digastricus; to the internal oblique line, the mylo-hyoideus, the buccinator, and posteriorly a small part of the superior constrictor of the pharynx. To the external surface of the ramus, the masseter; to the lower part of the inner surface, the pterygoideus internus; to the neck of the condyle, the pterygoideus externus; to the coronoid process, the temporal.

Fig. 35.*

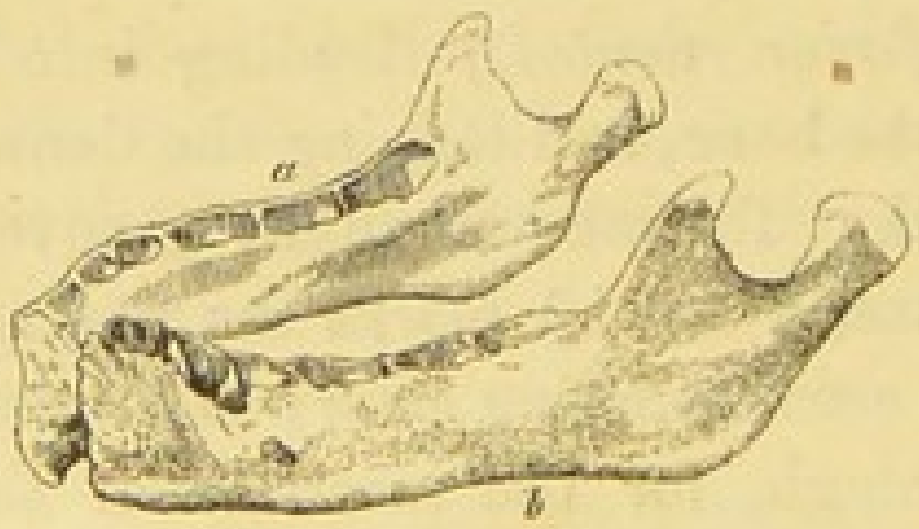

Ossification; its mode not determined.

Ossification. — The earliest conditions of this bone have not hitherto been determined in a satisfactory manner, as has been stated of the superior maxilla, and for the same reasons, namely, the earliness of the period

---

* The inferior maxilla of a fœtus at about the full period of intra-uterine life. The two sides are separate.

at which the ossification begins, and the rapidity of its progress.

The bone consists of two parts; their junction.

The inferior maxilla begins to ossify before any other bone, except the clavicle. It consists of two equal lateral parts, (fig. 35, ^{a} ^{b}) which are separate at the time of birth. They join in the first year after, but a trace of separation may be found at the upper part in the beginning of the second year.

Differences of observers concerning the number of nuclei.

Some observers admit no other than a single ossific centre for each side,—two for the entire bone;* while others describe more, without, however, agreeing as to the number. Thus,—besides one large piece for the body,—the coronoid process, the condyle, the angle, and the thin plate forming the inner side of the alveolus, and reaching from the dental foramen onwards, have been stated to possess each a distinct ossific point.† The question of the number of nuclei from which each side of the bone is produced we must consider to be still undetermined, especially since those anatomists who have described a plurality of them do not agree in their statements. It should, however, at the same time, be added, that the observations which have been referred to render it more than probable that there are commonly several nuclei; and the probability is increased by a considera-

---

* *e. g.* Nesbitt, Lect. ii. p. 96; and J. F. Meckel, Op. citat. B. ii. § 615.

† Kerckringius describes the coronoid process as a separate piece, (Cap. ix. p. 234,) and gives a representation of it connected by a suture to the rest of the bone (Tab. 33, fig. 6). Autenrieth (Wiedemann's "Archiv." &c. B. 1,) confirms the observations of Kerckringius, and mentions two other parts as growing separately: viz. the condyle and the angle. (Not having access to the original Essay, I have borrowed this statement from Spix and Meckel.) Spix ("Cephalogenesis," sect. i. p. 20, and tab. 3, fig. 5^{a}) states, that he had observed the pieces described by Autenrieth, and he adds another from his own observation,—namely, the inner margin of the alveolus; of this a representation is contained in the figure referred to. Béclard found the coronoid process distinct; and in the same preparation the condyle, the angle, and the inner margin of the alveolus were in such a state (the two first being joined by a very thin layer of bone, and the last separated largely by a fissure) that he inclined to regard them likewise as separate formations. M. Cruveilhier ("Anat. Descript." t. i.) admits the existence of but a single secondary piece,—the alveolar plate (of Spix). But Meckel says of this part, that it is only an extension backwards of the general ossification of the bone; and the appearance of separation he attributes to the depth of the groove of the mylo-hyoid nerve, which (according to this anatomist) is rather a fissure than a groove, in consequence of the comparatively large size of the nerve at an early period of life.

From this diversity, and even conflict of statement, it is manifest that the subject requires further investigation.

tion of the state of the same bone in some animals, as the crocodile, in which it is made up of several permanently separate pieces.

Changes in the bone connected with the teeth.

The body of the bone undergoes much change as its growth advances; but as the changes are connected with the evolution of the teeth, the detail of them will more fitly accompany the description of those parts. In this place it will be sufficient to say of the dried bone, that being at first little more than a groove or case lodging the dental sacs with the nerves and blood-vessels, it is afterwards divided by partitions; and that osseous matter having been largely added, we find it in the adult covered with a thick coating of compact substance, with cancellated structure in the interior; and in this the dental canal, from which small off-sets lead to the sockets of the teeth.

Condition in old age.

In old age the alveolar border disappears with the teeth; and the dental canal, with the mental foramen opening from it, is close to the upper margin of the bone. At the same time the prominence of the chin becomes more marked in consequence of the removal of the teeth and the upper part of the bone.

The differences in the relative direction of the rami and the body have already been noticed.

OS HYOIDES.—OS LINGUÆ.

Os hyoides;

Fig. 36.

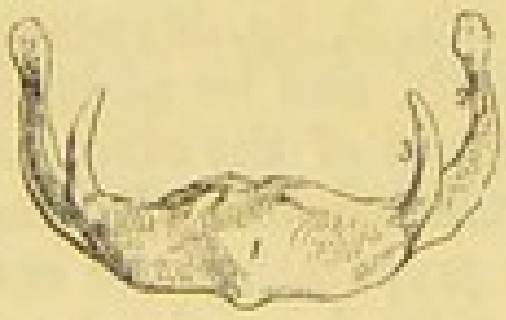

This is the U-shaped bone, fig. 36, so named from some resemblance to the Greek letter υ. It is occasionally called the lingual bone, from its important relations with the tongue; it is situated at the base of the tongue, and may be felt between the chin and the thyroid cartilage. It consists of a body, two cornua, and two cornicula.

its situation.

Division into parts.

Body.

The *body* or central piece[1] is small, quadrilateral in its form, and appearing as if compressed from before backwards; hence the direction of its plane is nearly vertical; but the great cornua seem as if compressed from above downwards, so that their plane appears horizontal. The anterior surface of the body is convex, and marked at the middle by a vertical line, on each side of which are depressions for the attachment of muscles; its posterior surface is concave, and corresponds with the epiglottis.

Cornua, larger and smaller.

The *cornua*[2] project backwards, and end in a rounded point. The cornicula,[3] short, irregularly conical in their form, and oblique in their direction, are placed at the junction of the body with the cornua, and give attachment to the stylo-hyoid ligament; they continue for a long time movable, as the cartilage which connects them remains unossified to an advanced period of life.

Attachments of muscles and ligaments.—The stylo-hyoid ligaments, to the cornicula; the thyro-hyoid, to the cornua. The anterior surface gives attachment to the stylo-hyoid, sterno-hyoid, and digastric muscles; the superior border, to the mylo-hyoid, genio-hyoid, genio-hyo-glossus, lingualis, hyo-glossus, and the middle constrictor of the pharynx; its lower border, to the omo-hyoid and thyro-hyoid muscles, and more internally to the thyro-hyoid membrane.

Five points of ossification.

Ossification.—There are five points of ossification for the os hyoides—one for each of its parts. Nuclei appear in the body and the great cornua towards the close of fœtal life. Those which belong to the small cornua make their appearance some time after birth.

THE CONNEXION OF THE BONES OF THE SKULL ONE WITH ANOTHER.

THE SUTURES.

The sutures of the skull; their number.

The bones of the skull, and those of the face, are joined together by seams or sutures. The cranial sutures are commonly said to be five in number, of which three are termed true, as the margins of the bones are, in a manner, dovetailed one into another; and two are called false or squamous, as they merely overlap one another, like the scales of fishes. The true sutures are, the coronal, the lambdoidal, and the sagittal. These names are obviously ill-chosen; they convey no notion of the position which the sutures occupy in the skull, or of the bones which they connect.

Coronal; why so named;

The *coronal* suture (sutura coronalis) has been so named from being situated where the ancients wore their garlands (coronæ).

its position; It connects the frontal with the two parietal bones, and hence it may with more propriety be called "fronto-parietal." It commences at each side about an inch behind the external orbital process of the frontal bone, where the anterior inferior angle of the parietal articulates with the great wing of the sphenoid bone. its character at different points. From this point it mounts rather obliquely up towards the vertex, having an inclination backwards. The dentations are better marked at the sides than at the summit of the head, for in the latter situation the suture approaches somewhat the squamous character, to allow the frontal bone to overlay the parietal. A similar change takes place at its lower part or commencement, with this difference, that there the parietal bones are made to overlay the frontal.

Lambdoidal; whence the name; The *lambdoid* suture (suture lambdoidalis) is situated between the occipital and the parietal bones, its form resembling somewhat that of the Greek letter Λ, whence its name has been taken. its position. It begins at each side on a line with the posterior inferior angle of the parietal bone, and thence inclines upwards and forwards to the point at which the two parietal bones are joined by the sagittal suture. It thus represents two sides of a triangle. It is often interrupted by accessory osseous deposits (ossa Wormiana). From its position and relation this suture may be named "occipito-parietal."

Sagittal; The *sagittal* suture (s. sagittalis—sagitta, an arrow) extends its position; directly backwards, from the middle of the coronal to that of the lambdoid suture, and connects the two parietal bones, from which circumstance it may be called the "inter-parietal" suture: varies in length. in children, and occasionally in adults, it is prolonged through the frontal bone, even to the root of the nose. Character of the serrations. The serrated appearance of the sutures is perceptible only on the external surface of the bones; the internal surface, or table of each, as it is called, being merely in apposition with the contiguous bone.

The line of union between the occipital and the temporal bone at each side used to be considered as a continuation of the lambdoid suture, or as an appendix to it, and was accordingly Additament. s. lambd.; named *additamentum suturæ lambdoidalis.* It may, however, be named *temporo-occipital*, as it connects the mastoid and petrous parts of the temporal bone with the occipital—principally its position and character. its basilar and condyloid portions. In this suture there are no regular dentations; in a great part of its extent the margins of the bones are merely in apposition.

Squamous;

The *squamous* sutures (suturæ squamosæ) are arched and mark the junction of the lower borders of the parietal bones with the squamous parts of the temporal, their edges being so beveled off as to allow the latter to overlay the former. At the point of junction between the squamous and mastoid parts of the temporal bone, the true squamous suture ceases; but from thence a short suture runs backwards to the lambdoid, connecting the mastoid part of the temporal with the postero-inferior angle of the parietal. This is termed *additamentum suturæ squamosæ*:—both together form the "temporo-parietal" suture.

position;

its additamentum.

The line of direction of the sutures (particularly the lambdoid and sagittal) is not unfrequently interrupted by additional bones, inserted between those hitherto enumerated. These, from being sometimes of a triangular form, are called *ossa triquetra*, and also *ossa Wormiana*.

Sutures connecting the cranium and face;

and those between the bones of the face.

The cranial bones are joined to those of the face by sutures, which are common to both sets of bones. The *transverse* suture, observable at the root of the nose, extends across the orbits, and connects the frontal with the nasal, superior maxillary, ossa unguis, ethmoid, sphenoid, and malar bones. The *zygomatic* sutures are very short; they are directed obliquely downwards and backwards, and join the zygomatic processes of the temporal with the malar bones. The *ethmoid* suture surrounds the bone of the same name; so does the *sphenoid;* they are necessarily complex in consequence of the many relations of these bones. The lines of connexion between the nasal and maxillary bones, though sufficiently marked, have not received particular names; but those observable between the horizontal lamellæ of the latter, and those of the palate bones, may be termed the palato-maxillary sutures.

THE GENERAL CONFORMATION OF THE SKULL.

The skull generally.

After having described, in detail, the separate bones of the head and face, it becomes necessary to review them collectively. The description of these bones forms the most difficult part of human, as well as of comparative osteology, as they are the most complex in the whole skeleton; but a correct knowledge of them is indispensable, in consequence of the many important parts which they serve to sustain and enclose; viz. the cerebral mass, with its nerves and vessels; the organs of sight, hearing, smell, and taste; and part of those of mastication, of deglutition, and of the voice. To facilitate the description of the numerous eminences, depressions, cavities, and foramina of the skull, anatomists examine successively its external and internal surfaces.

Its external and internal surfaces.

THE EXTERNAL SURFACE OF THE SKULL.

The external surface divided into five regions.

This surface may be considered as divisible into five regions, three being somewhat of an oval figure, and situated, one superiorly, another at the base, the third in front, including the face; the others comprise the lateral parts, and are somewhat flat and triangular.

Superior region; its bounds.

A. The *superior region* extends from the frontal eminences to the occipital protuberance, and, transversely, from one temporal ridge to the other; it thus includes the upper broad part of the frontal, almost all the parietal, and the superior third of the occipital bone, which together form the vaulted arch of the skull. It is divided into two symmetrical parts by the sagittal suture and its continuation when it exists; it presents no aperture or other inequality deserving of particular notice; it is covered by the common integument and occipito-frontalis muscle, on which ramify branches of the temporal, occipital, and auricular arteries, as well as filaments of nerves from the frontal branches of the fifth and portio dura, and also from the occipital nerve.

Inferior region, or base of the skull;

its bounds;

B. The *inferior region*, fig. 37, also oval in its outline, is the most complex of all, as it includes the entire base of the skull, extending from the incisor teeth to the occipital protuberance, and transversely, from the mastoid process and dental arch on one side, to the corresponding points on the other. It may be considered as divisible into three parts—anterior, middle, and posterior.

subdivided into three parts.

1. The *anterior part* of the base corresponds with the extent of the arch of the palate; it is divided into two parts by a line,[1] extending from before backwards, and marking the junc-

tion of the palate processes of the superior maxillary and palate bones; this is intersected by another,[2] running transversely between each palate bone and the corresponding maxillary bone. Anteriorly, and in the middle line, is a foramen,[3] (the *anterior palatine*,) which communicates with the nasal fossæ by four foramina or short canals (for a description of these see page 63). Posteriorly, on each side, and at the base of the alveolar border, is another foramen,[4] (*posterior palatine*,) for the posterior palatine nerves and artery.

Fig. 37.[*]

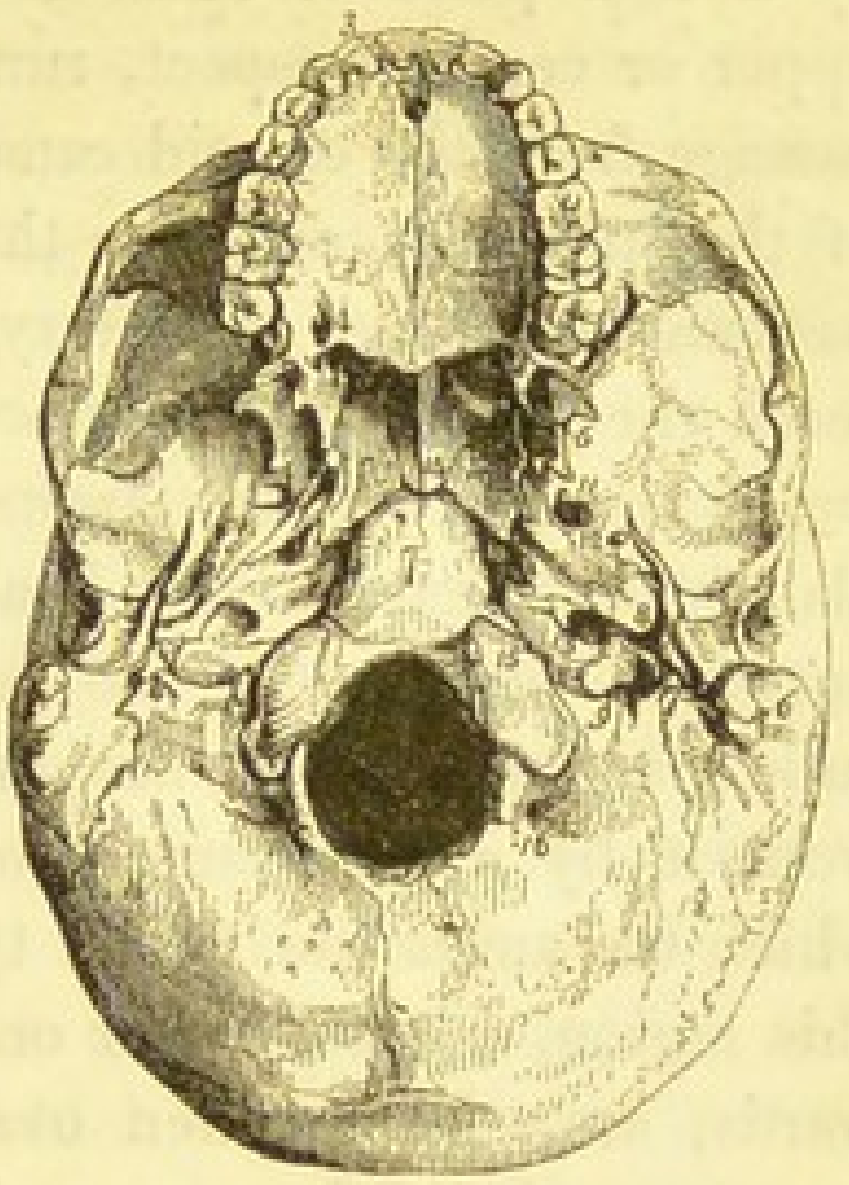

The anterior part or palate.

Middle or guttural part, its bounds,

2. The middle, or guttural part, is bounded at each side by a line extended from the pterygoid process,[5] as far as the mastoid process,[6] thus including the posterior aperture of the nares, and the central part of the base of the skull. In the centre is situated the basilar process[7] of the occipital bone, marked by slight inequalities, for the attachment of muscles, and towards its posterior extremity the anterior condyloid foramina, which transmit the ninth pair of nerves. On each side is the pars petrosa[8] of the temporal bone, in which may be observed the styloid and vaginal processes; more posteriorly is the jugular fossa, which is completed into a foramen[9] (*foramen lacerum posterius basis cranii*) by the border of the occipital bone. This is divided into two parts by a spiculum of bone, or a fibrous band, the internal and anterior one serving to transmit the glosso-pharyngeal, par vagum, and spinal accessory nerves; the other the jugular vein. Between the apex of the pars petrosa and the side of the

foramina, &c.

---

[*] 1. The longitudinal palatal suture. 2. The transverse palatal suture. 3. The anterior palatine foramen. 4. The lower opening of the posterior palatine canal. 5. The external pterygoid process. 6. The mastoid process. 7. The basilar process. 8. Petrous part of the temporal bone. 9. Foramen lacerum posticum. 10. Foramen lacerum medium: vel f. l. anterius basis cranii. 11. Foramen ovale. 12. Spinous foramen. 13. Carotid foramen. 14. Septum narium—the vomer. 15. The condyles of the occipital bone. 16. The condyloid fossa. 17. The stylo-mastoid foramen.

basilar process, and the body of the sphenoid bone, is the *foramen lacerum anterius basis cranii*,[10] which is closed inferiorly by a thin plate of cartilage : across its area, as viewed at its upper or cerebral aspect, runs the internal carotid artery in its passage from the carotid canal in the temporal bone to the side of the sphenoid, and also the Vidian nerve, after it has passed backwards through the pterygoid foramen, and is proceeding to reach the groove in the upper surface of the pars petrosa. Between the contiguous margins of the pars petrosa and the great ala of the sphenoid bone is a groove, which leads backwards and outwards, and lodges the cartilaginous part of the Eustachian tube; and above the osseous part of that tube, and separated from it by a thin lamella of bone, is the orifice of the canal which transmits the tensor tympani muscle. The foramina of this region, taken in their order from within outwards and backwards, are, the foramen ovale,[11] foramen spinosum,[12] foramen caroticum,[13] and foramen stylo-mastoideum.[17]

Posterior nares.

In front, this part of the base of the skull is continuous with the posterior aperture of the nares, which is divided into two parts by the vomer.[14] It is bounded above by the body of the sphenoid bone, below by the palate plates of the ossa palati, and on the sides by the pterygoid processes. Each opening measures about an inch in the vertical direction, and half that extent transversely. The pterygoid groove, in each of these processes, is completed inferiorly by the pyramidal process of the palate bone ; near its junction with the body of the bone is the scaphoid fossa, for the origin of the circumflexus palati ; and at its inferior termination is the hamular process, round which the tendon of that muscle is reflected. Between the base of this process and the posterior palatine foramen is situated a smaller foramen, leading down from the posterior palatine canal, and which transmits the middle palatine nerve.

The posterior part; bounds; foramina.

3. The *posterior part* of the inferior region includes all that is situated between the occipital protuberance and a line connecting the mastoid processes. It is divided into two lateral parts by a ridge, extending to the foramen magnum from the occipital protuberance, from which two rough curved lines branch outwards, giving attachment to muscles ; so does the space between the lines, and that between the inferior one and the foramen magnum. At the margin of the foramen, but nearer to

its anterior part, are the condyles[15] of the occipital bone, which articulate with the first vertebra; behind each is a depression,[16] (*condyloid fossa*,) and usually a foramen (*posterior condyloid foramen*), which transmits a small vein and artery. Before and a little to the outer side of each, in a spot also retiring and depressed, is the opening of the *anterior condyloid foramen*, which looks obliquely outwards and forwards, and transmits the hypoglossal nerve.

Anterior region; its extent;

c. The *anterior region* of the skull is of an oval form, and extends from the frontal eminences to the chin, and from the external border of the orbit and ramus of the jaw, on one side, to the corresponding points on the other, so as to include the whole of the face. The eminences, depressions, fossæ, and foramina observable in this region are as follow: viz. the frontal eminences, more or less prominent in different individuals, bounded inferiorly by two slight depressions, which separate them from the superciliary ridges; these curve outwards, from the nasal process of the frontal bone. Beneath the superciliary ridge, on each side, is the margin of the orbit, marked at its inner third by a groove, or a foramen, which transmits the frontal nerve and supra-orbital artery; and also by a slight depression which gives attachment to the cartilaginous pulley of the trochlearis muscle. At an interval corresponding with the breadth of the orbit is another ridge, forming its inferior margin; under which is situated the infra-orbital foramen, for the passage of the superior maxillary nerve; and still lower down, the fossa canina, which gives attachment to the levator anguli oris muscle; it is bounded below by the alveolar border of the upper jaw, and surmounted by the malar tuberosity. Towards the middle line, and corresponding with the interval between the orbits, is the nasal eminence of the frontal bone, which is prominent in proportion to the developement of the frontal sinuses over which it is situated. This is bounded by the transverse suture, marking the root of the nose. Beneath the nasal, and between the contiguous borders of the superior maxillary bones, is a triangular opening which leads into the nasal fossæ; it is broad below, and there its edge is surmounted by a prominent process, the nasal spine. Laterally it presents two sharp curved borders, which gradually incline inwards as they ascend to the nasal bones, so as to narrow it somewhat. Below the nasal aperture is a slight

objects included.

depression (myrtiform fossa), at each side of the middle line over the alveolus of the second incisor tooth. Farther down is the transverse rima of the mouth, between the alveolar borders of the jaws. In the inferior maxillary bone, besides some muscular impressions, is the mental foramen, which transmits the terminal branches of the dental nerve and artery.

Lateral regions; their extent.

D. and E. The two *lateral* regions of the skull are somewhat of a triangular figure, the apex of the triangle being at the angle of the lower jaw, the base at the temporal ridge, and the sides formed by two lines drawn, one upwards and forwards, over the external orbital process, the other upwards and backwards, over the mastoid process. In consequence of the great irregularity of the surface, it is necessary to subdivide each of these regions into three; the part above the zygoma being called the temporal region or fossa, that beneath it the zygomatic, the remainder being named the mastoid.

Each divided into three parts.

Temporal fossa; its extent and formation.

1. The *temporal* part, or fossa, being bounded by the temporal ridge above, and by the zygomatic arch below, is of a semicircular form, and extends from the external angular process of the frontal bone to the base of the mastoid process. It is filled up by the temporal muscle, lodges the deep temporal vessels and nerves, and is formed by the temporal, parietal, frontal, sphenoid, and malar bones.

Mastoid part; boundaries;

2. The *mastoid* part is bounded before by the transverse root of the zygoma, above by the horizontal one and the additamentum suturæ squamosæ, behind and inferiorly by the additamentum suturæ lambdoidalis. Proceeding from behind forwards, we observe the mastoid foramen, the process of the same name; anterior to which is the aperture of the meatus auditorius externus, which is circular in young subjects, and somewhat oval in adults, the longest diameter being from above downwards. The osseous tube, continuous, externally, with the fibro-cartilage of the ear, and bounded, internally, by the membrana tympani, is directed, obliquely, forwards and inwards, and is somewhat broader at its extremities than in the middle. Anterior to the meatus is the glenoid fossa, which is bounded before by the transverse root of the zygoma, behind by the meatus, and internally by the spinous process of the sphenoid bone. It is divided into two parts by a transverse fissure (*fissura Glaseri*), the anterior portion being smooth, for its articulation with the

foramina.

condyle of the lower jaw; the posterior, rough, lodges part of the parotid gland. This fissure gives entrance to the laxator tympani muscle and a small artery, and transmits outwards the chorda tympani nerve.

Zygomatic region; its bounds;

3. The *zygomatic* part of the lateral region, situated deeply behind and beneath the orbit, is bounded before by the convex part of the superior maxillary bone, and is enclosed between the zygoma and the pterygoid process. The posterior surface of the maxillary bone is pierced by some small foramina, opening into canals, for the transmission of the superior dental nerves. Between the superior border of this bone and the great ala of the sphenoid, is a fissure (*spheno-maxillary*), which is directed forwards and outwards, and communicates with the orbit; and between its posterior border and the pterygoid process is another (*pterygo-maxillary*), whose direction is vertical. The angle formed by the union of these fissures constitutes the *spheno-maxillary fossa*, which is situated before the base of the pterygoid process, behind the summit or posterior termination of the orbit, and immediately external to the nasal fossæ, from which it is separated by the perpendicular plate of the palate bone. Into this narrow spot five foramina open, viz. the foramen rotundum, which gives passage to the second branch of the fifth pair; the foramen pterygoideum, to the Vidian or pterygoid nerve and artery; the pterygo-palatine to a small artery of the same name (sometimes called also the superior pharyngeal); the posterior palatine foramen, leading to the canal of the same name; and the spheno-palatine, which transmits the spheno-palatine nerve and artery.

foramina.

Spheno-maxillary fossa; its bounds and foramina.

THE INTERNAL SURFACE OF THE SKULL.

Internal surface of the skull.

The internal surface of the skull may be divided into its arch and its base.

The arch; extent and division of.

The *arch* extends from the base of the perpendicular part of the frontal bone, as far as the transverse ridge on the inner surface of the occipital bone. Along the middle line, and corresponding with the direction of the sagittal suture, is a shallow groove, marking the course of the superior longitudinal sinus. Several slight, irregular depressions may also be observed, for the cerebral convolutions, and some tortuous lines for the branches of the meningeal artery; and in many cases irregular depressions over the points occupied by glandulæ Pacchioni. The surface is more or less depressed so as to form fossæ at the points corresponding with the frontal and parietal eminences, and also above the internal occipital ridge, where the posterior lobes of the brain are lodged.

Depressions for glandulæ Pacchioni.

The base; its three fossæ.

The *base* of the skull presents on the inner surface the several eminences, depressions, and foramina, which have been already enumerated in the description of the separate bones. Three fossæ may be observed at each side, differing in size and depth.

Anterior fossa; the bones which form it;

1. The *anterior fossa*, formed by the orbital plate of the frontal bone and the smaller wing of the sphenoid, and the cribriform plate of the ethmoid, serves to support the anterior lobe of the brain: it is marked by eminences and depressions corresponding with the cerebral convolutions and sulci; and, posteriorly, by a transverse line, indicating the junction of the bones just mentioned. The foramina in the anterior fossa are those in the ethmoid bone for the transmission of nerves and an artery to the nasal fossæ: viz. the olfactory nerve, the internal nasal branch of the fifth cerebral nerve, and the ethmoidal branch of the ophthalmic artery.

its foramina.

Middle fossa, formed by—

2. The *middle fossa*, formed by the great ala of the sphenoid, the squamous part of the temporal, and the anterior surface of the pars petrosa, lodges the middle lobe of the brain. It is marked by linear impressions for the meningeal artery, and by shallow pits for the cerebral convolutions; anteriorly, it opens into the orbit by the sphenoidal fissure, sometimes called foramen lacerum anterius to distinguish it from those placed farther back, and already noticed; it transmits the third, the fourth, and the sixth nerves, together with the ophthalmic branch of the fifth and the ophthalmic vein. Behind this is situated the foramen rotundum for the second branch of the fifth, the foramen ovale for the third, and, lastly, the foramen spinosum for the middle meningeal artery. Where the summit of the pars petrosa approaches the body of the sphenoid bone, there the internal orifice of the carotid canal opens. On the anterior surface of the pars petrosa, and directed obliquely backwards, there is a slight groove, leading to the hiatus Fallopii, and transmitting the Vidian nerve.

has foramina.

3. The *posterior fossa*, deeper and broader than the others, gives lodgment to the lateral lobes of the cerebellum. In the posterior surface of the pars petrosa, which forms the anterior limit of this fossa, may be observed the internal auditory foramen, and, within a few lines of it, a triangular fissure, which opens into the aquæductus vestibuli, and towards its inferior margin part of the groove for the lateral sinus, which leads down to the foramen lacerum posterius. Along the middle line, and taking the parts situated in the base of the skull from before backwards, we observe the crista galli of the ethmoid bone, and on each side the cribriform lamella of that bone; farther back, a slightly depressed surface, which supports the commissure of the optic nerves; and on each side the optic foramina. Behind this is the pituitary fossa, situated on the body of the sphenoid bone, bounded before and behind by the clinoid processes. Leading downwards and backwards from these is the basilar groove, which supports the pons Varolii and medulla oblongata, and terminates at the foramen magnum; at each side of this foramen are the condyloid foramina, and behind it a crista, leading upwards to the occipital ridge, and giving attachment to the falx cerebelli.

Posterior fossa; its position; objects it contains.

THE ORBITS.

The form of the orbits is that of a quadrilateral pyramid, whose base is directed forwards and outwards, and apex backwards and inwards, so that if their axes were prolonged backwards they would decussate on the body of the sphenoid bone.

The orbits. Their form. Direction. Axis.

The *roof* of each orbit forms part of the floor for the brain; it is concave, and composed of the orbital process of the frontal, and the smaller wing of the sphenoid bone: at its anterior and inner border may be observed a depression for the attachment of the pulley of the trochlearis muscle; externally, and immediately within the margin of the orbit, a shallow depression for the lachrymal gland; at the anterior border, a groove, sometimes a foramen, which transmits the supra-orbital or frontal nerve and artery; and posteriorly, at the apex of the cavity, the optic foramen, transmitting the optic nerve and ophthalmic artery. The *floor* forms the roof of the maxillary sinus: it consists of the orbital processes of the malar and maxillary bones, and of the small portion of the palate bone which rests on the latter; to-

Roof.

Floor.

wards the inner and anterior border, near the lachrymal canal, may be observed a slight roughness, for the attachment of the obliquus inferior muscle; posteriorly, a groove, terminating in the infra-orbital canal, which runs nearly horizontally forwards.

Sides; inner and outer.

The *inner side* or wall of the orbit runs directly backwards, being parallel with the corresponding side of the other orbit, and is composed of the ascending process of the maxillary bone, the os unguis, the os planum of the ethmoid, and part of the body of the sphenoid bone. Near the anterior border is situated the *lachrymal canal*, which is formed, for the most part, between the ascending process and body of the maxillary bone, the remainder being made up by the groove in the os unguis, and a small process of the inferior spongy bone; this canal, a little expanded at its extremities, is directed downwards, backwards, and a little outwards. The *outer* side of the orbit, composed of the orbital plates of the malar and sphenoid bones, presents some minute foramina, which transmit small nerves from the orbit to the temporal fossa.

Angles.

The *superior internal angle*, formed by the junction of the orbital process of the frontal bone with the os unguis and os planum, presents two foramina (*foramen orbitale internum, anterius et posterius*), which give transmission, the anterior to the nasal twig of the ophthalmic nerve, the posterior to the ethmoidal artery. The *internal inferior angle* is rounded off so as to be scarcely recognised; it is formed by the union of the os unguis and os planum with the orbital plates of the superior maxillary and palate bones. In the *external superior angle*, formed by the malar, frontal, and sphenoid bones, is observed the sphenoidal fissure, of a triangular form, situated obliquely, its base being internal and inferior, the apex external and superior. In the *inferior external angle*, formed by the malar, the great ala of the sphenoid, the maxillary, and palate bones, is situated the spheno-maxillary fissure, inclined at an angle with the former, and communicating with it, but of a different form, being broad at its extremities and narrow at the centre.

Base. Apex.

The *anterior extremity*, or *base* of the orbit, is directed outwards and forwards; and, as if to provide for a free range of lateral vision, the external wall retreats in some degree, and does not extend as far forward as the internal. The inner termination of the cavity, representing the summit of a pyramid, to which it has been likened, corresponds with the optic foramen. In each orbit, parts of seven bones are observed, viz. the frontal, ethmoid, sphenoid, os unguis, malar, maxillary, and palate bones; but as three of these, viz. the ethmoid, sphenoid, and frontal, are common to both, there are only eleven bones for the two orbits.

The bones which form the orbits enumerated.

THE NASAL FOSSÆ.

Nasal fossæ; their position; they communicate with the sinuses in several bones.

These fossæ, fig. 38, are two cavities, placed one at each side of the median line, separated by a flat vertical septum. They communicate, by foramina, with the various sinuses lodged in the frontal, the ethmoid, and superior maxillary bones, and open anteriorly, on the surface, by the nares, and posteriorly into the pharynx.

The depth of the fossa from the upper to the lower part is considerable (most so in its middle); so is the extent from before backwards or between the anterior and the posterior openings.

Boundaries.

But the breadth, or distance, from the outer to the inner wall is very limited, and it is less at the upper than towards the lower part of the fossa, and in the middle than at the anterior or posterior openings (the nares). The roof, the floor, the inner and the outer walls of these cavities require a separate consideration.

Fig. 38.*

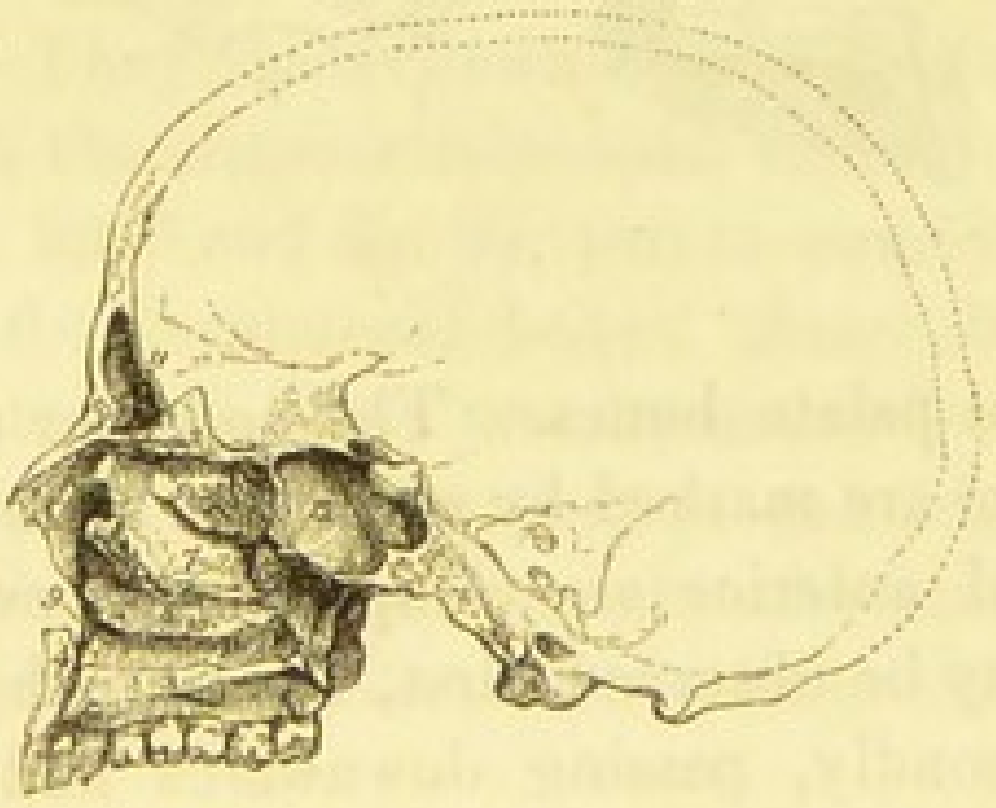

The anterior and posterior openings of the nasal fossæ have

---

* A vertical section of the skull, made from before backwards, a little to the right of the middle line. The outer boundary of the right nasal fossa is displayed:—1. is said to be on the nasal bone. 2. The crista galli—its base where it is joined to the cribriform plate of the ethmoid bone. 3. The hard palate. 4. is close to the anterior palatine canal. 5. The superior spongy bone (part of the ethmoid). 6. is said to point to the superior meatus; but it is below that groove. 7. The middle spongy bone (part of the ethmoid). 8. is a little below the middle meatus. 9. This points to the inferior meatus. 10. The inferior spongy bone. 11. Frontal sinus. 12. Sphenoidal sinus.

been described among the objects seen on the external surface of the skull (pp. 82, 83).

The roof; its direction and formation.

The *roof* is flat at its middle part, and sloped before and behind; it is formed in front by the inner surface of the nasal bones,[1] behind by the body of the sphenoid,[12] and in the middle by the horizontal or cribriform lamella of the ethmoid bone.[2]

The floor; its direction and formation.

The *floor*, smooth, concave from side to side, and formed by the palate plates of the maxillary and palate bones,[3] extends backwards, and a little downwards, from the nares to the pharynx. Towards the anterior opening may be observed the superior orifice of the anterior palatine canal.[4]

Internal wall or septum narium.

The *internal wall*, or septum narium, (fig. 39,) which extends from the roof to the floor of the cavity, is flat, nearly vertical (the deviation, if any, being usually to the left side), and composed of the perpendicular plate of the ethmoid bone,[2] the vomer,[3] and the nasal cartilage.

Fig. 39.*

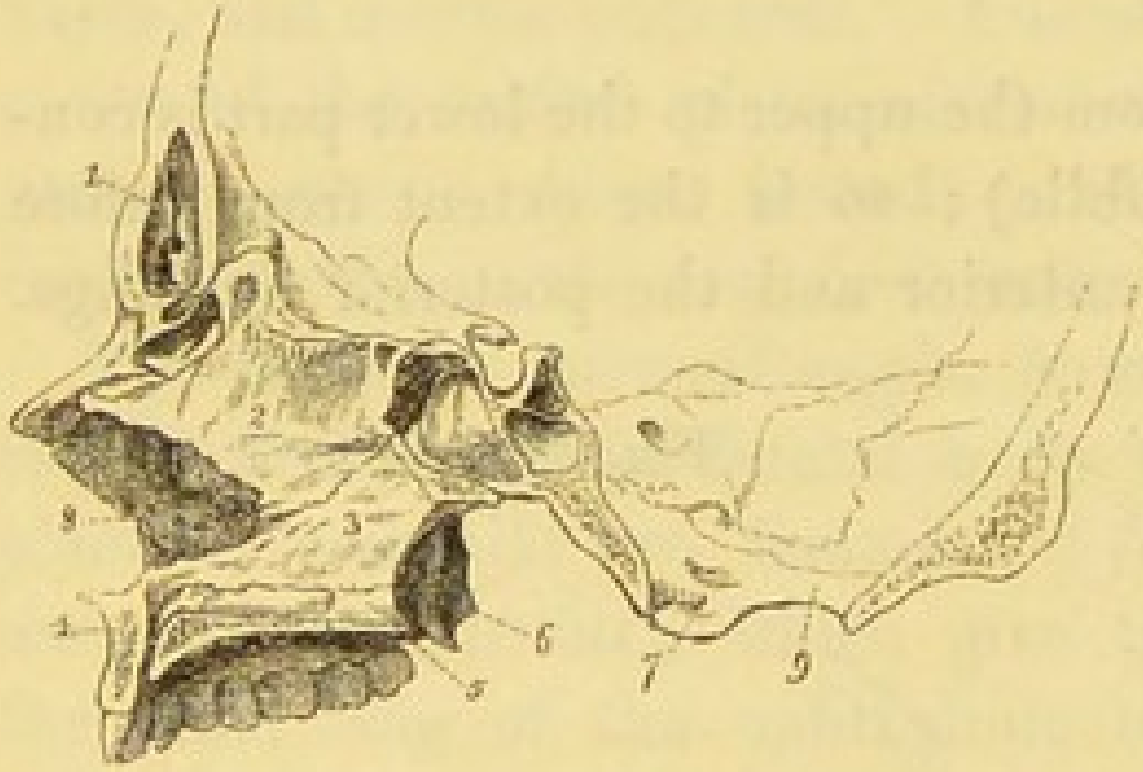

External wall.

The *external wall* (fig. 38) is formed by the ethmoid superior maxillary, os unguis, inferior spongy, and palate bones. The posterior and inferior parts of this surface are marked by a number of inequalities, whilst the superior and anterior are comparatively even. In the latter situation may be observed, first, the smooth surface just mentioned; and, secondly, passing downwards and backwards, three, and fre-

---

* The section of the skull in this case has been made a little to the left of the middle line. The left side of the septum narium (its bony part) is displayed; and beyond it a part of the external wall of the right nasal fossa is shown. The latter is dark, and the figure 8 indicates a portion of the spongy bones which belong to it. 1. A frontal sinus. 2, and 3, are the bones of the septum narium—2 being the middle plate of the ethmoid bone, 3 the vomer. 4, 5. Between these is the hard palate. One is in front of the superior maxillary bone: the other points to the palate bone. Towards the anterior part is seen the anterior palatine canal, or rather about half of it. 6. The pterygoid processes. 7. The right condyle of the occipital bone. 9. is opposite the right half of the foramen magnum.—N. B. Large sphenoidal sinuses are marked above and behind the base of the vomer.

quently four, arched and convoluted bones (spongy bones), beneath which are grooves (*meatus*) leading from before backwards. The superior spongy bone[5] is much shorter than the others; beneath it is the *superior meatus*,[6] into which will be found opening, anteriorly, a foramen from the posterior ethmoidal cells, and, posteriorly, the spheno-palatine foramen. The middle spongy bone[7] overhangs the *middle meatus*,[8] which communicates with the anterior ethmoidal cells; one of these curves forwards and upwards, and is continuous with the frontal sinus; more posteriorly is situated the opening of the maxillary sinus. The *inferior meatus*,[9] situated below the inferior spongy bone,[10] between it and the floor of the nasal cavity, is necessarily longer than the others; it presents anteriorly the orifice of the nasal canal.

The spongy bones. Three "meatus;" superior; middle; inferior. The openings into each.

THE FRONTAL, SPHENOIDAL, AND MAXILLARY SINUSES.

The *frontal sinuses*, fig. 38,[11] correspond with the superciliary eminences of the frontal bone. Of considerable size in the adult, but varying in different individuals, they are not at all developed in the fœtus. They are divided into two, sometimes three, compartments. They open downwards into the middle meatus narium through the anterior ethmoidal cells.

Sinuses; the frontal, their various size;

The *sphenoidal sinuses*, fig. 38,[12] and fig. 39, two in number, are placed within the body of the sphenoid bone; these also cannot be said to exist in infancy. They are separated by a partition. Above, behind, and on each side, they are bounded by the body of the sphenoid bone, and in front by two small spongy bones. They communicate with the posterior ethmoidal sinuses.

sphenoidal;

The *maxillary sinus* (antrum Highmori) is a large excavation in the body of the superior maxillary bone. It appears at an earlier period than any of the other sinuses, the developement commencing about the fourth month of fœtal life. Its form is irregularly pyramidal, the base being towards the nasal cavity, the apex corresponding with the malar tuberosity. Superiorly, it is enclosed by the orbital plate of the maxillary bone; and inferiorly by its palate plate: internally, it opens into the middle meatus of the nasal cavity by a foramen, which, though it appears very large in the dry bone when separated

the antrum of Highmore: its form: its opening is small and close to the upper wall:

from its connexions, is in the natural state small, being little more than sufficient for the admission of a probe; this diminution of size is caused by the lower edge of the ethmoid, the inferior spongy and the palate bones, and also by a fold of the mucous membrane. The narrow opening is placed close to the upper wall of the cavity. The bony plate by which the antrum is separated from the orbit is very slender, so likewise is the partition between it and the nasal fossæ; but in other parts the boundaries of the cavity have considerable thickness—especially the superior maxillary bone at its alveolar border. On the removal of a molar tooth it will, however, be found that its socket is separated from the antrum by a thin partition of bone.

various thickness of its boundaries.

ANALOGY BETWEEN CRANIAL BONES AND VERTEBRÆ.

The cranium analogous to vertebræ.

Anatomists have at all times perceived and recognised the analogy between the movable and motionless pieces of the spine —between those of the lumbar and dorsal regions, and those of the sacrum and coccyx: in the one, as well as in the other, similar organic elements are observed to exist, variously modified, in order to suit special purposes; but it is only of late years that any adequate attention has been directed to the points of similitude which exist between vertebræ, properly so called, and the cranial bones. Many persons who adopt, without hesitation, the terms false or pelvic vertebræ, as applied to the sacrum and coccyx, feel a repugnance to use the word false or cranial, as applied to the pieces of the skull; and deny, perhaps, without examination, the analogy upon which it is founded, as being unnatural or far-fetched. We have numerous instances of the harmony that subsists between containing and contained parts throughout the economy; in no case is it more striking than in the relation that obtains between the fundamental part of the osseous structure and the central mass of the nervous system. The spinal canal is accurately adapted in its different parts to the nervous cord which it encloses. In the pelvic region, the canal, at least in the human subject, becomes narrow, as it merely encloses nerves, whilst the body and processes take on a particular developement to meet a special purpose, that of forming a basis of support for the rest of the

Adaptation of the bones to the contained nervous centre.

column. This seems to result from the working of what may be termed a principle of compensation in the growth, as well as in the action of parts; for when one part of a given whole is developed to excess or to a maximum, others will remain at a minimum or atrophied: thus the spinal canal and the arches are at their minimum in the sacrum and coccyx, for the contained parts are there at a low point of developement; but at the opposite end of the column the reverse obtains; the contained parts, viz. the central parts of the nervous sytem, are evolved in the human subject to the greatest extent, and so must the containing parts also be. The portion of the osseous system which corresponds with the bodies of the vertebræ can, therefore, hardly be recognised; whilst that which is analogous to the arches is expanded so much as to retain but a slight similitude to them.

The occipital bone compared to a vertebra.

If we take the occipital bone, and examine it attentively, we shall readily perceive in it all the elements of a vertebra. The foramen magnum is the counterpart of the ring of a vertebra, and has a similar relation to the spinal cord; the basilar process represents the body; the condyles are true articulating processes; the rough surfaces external to them, and which give attachment to the recti laterales, correspond to the transverse processes; the vertical ridge extended backwards along the median line, from the foramen to the occipital protuberance, is, in the human subject, merely a rudiment of a spinal process; but in the dog, bear, and badger, it forms a sharp prominence well deserving the name of spine, and the likeness is still more striking in osseous fishes: finally, the broad plates on each side of the spine represent the arches. In this view of the matter, the occipital bone forms the first false vertebra of the cranial region.

The first cranial vertebra.

The second cranial vertebra.

In the second cranial piece or vertebra, it must be admitted that the analogies are not so striking; but when we recollect that the cavity of the skull, if examined in the different orders of animals, enlarges in proportion as the brain acquires an increase of developement, and that this enlargement attains its maximum in the human subject, we shall at once find sufficient reason to expect that the parts corresponding with the vertebral arches should, in this region, be greatly evolved, while the rest are in a manner atrophied. The parietal bones, with the squamous part of the temporal and the great wings of the sphenoid, taken together, represent the arches, whilst the posterior part of the sphenoid bone (such as it exists in the human fœtus before its ossification is complete, and such as it continues permanently in several lower animals) is the counterpart of the body, the mastoid processes of the temporal bones with the glenoid fossæ serve as transverse and articulating processes. These, together, form the middle cranial piece, which may be termed the spheno-temporo-parietal cranial false vertebra.

The third cranial vertebra.

The frontal bone, the ethmoid, and the anterior division of the sphenoid (which is that part of the body that sustains the smaller wings), form the third vertebra; the part of the sphenoid just named, together with the crista galli and the perpendicular plate of the ethmoid bone, form the body, which is here reduced to a rudimentary state, just as the coccygeal bones are at the opposite end of the column, of which it may be considered a repetition. The lateral and expanded parts of the frontal bone are the arches, and the external orbital processes may be likened to transverse processes.

The term "Zone" preferred to "vertebra" for the cranial pieces.

We have here used the term false vertebra as applied to the cranial pieces; perhaps it would be better to use the word zone, as sanctioned by the authority of Cuvier. The passage in which he recognises the principle of developement here indicated, as well as the application of it, (which appears to have been first inculcated by Dumeril, and traced in all its details by Geoffroy Saint-Hilaire,) is as follows:—"Le crâne se subdivise comme en trois ceintures, formées—l'antérieure par les deux frontaux et l'éthmoide, l'intermédiare par les pariétaux et le sphénoide, la postérieure par l'occipital."*

MAN ADAPTED TO THE ERECT POSTURE.

Contrast between man and lower animals.

Every part of the conformation of the human subject indicates its adaptation to the erect position. The feet are broader than those of any other animal proportionally to its size; the tarsal and metatarsal bones admit of very little motion; and the great toe is on the same plane with the others, and cannot be brought into opposition with them. The foot is thus fitted to sustain the weight of the body, but not to grasp or seize objects

---

* Règne Animal, tom. i. p. 63.

presented to it. The hands, on the contrary, though so well adapted for these purposes, are ill calculated for affording support; so that man is truly "bimanous" and "biped."* The tibia rests perpendicularly on the astragalus, and the os calcis projects backwards for the purpose of increasing the base, and also of lengthening the lever to which the strong muscles of the calf of the leg are attached. The whole extent of the tarsus, metatarsus, and phalanges, in man, rests on the ground, which does not obtain even in apes, the end of whose os calcis is somewhat raised, so as to form an acute angle with the bones of the leg. In dogs and digitated quadrupeds, the carpus and tarsus are considerably elevated from the ground, so that the body rests on the toes; and in the horse, and other solid-hooved animals, the third phalanges only rest on the ground, the os calcis being raised nearly to the perpendicular direction.

The limbs contrasted.

The femur, placed securely beneath the pelvis, affords a firm support during progression. The great breadth of the pelvis, serves to enlarge the base on which the trunk rests; and this is farther increased by the length of the cervix femoris. This peculiarity in the neck of the femur renders it necessary that the body of the bone should incline inwards, in order that its axis should approach the central line, and so support the centre of gravity. If its articular head be viewed in profile, it will be observed that the cartilaginous coating is distributed for the most part on its upper and inner aspect, showing its adaptation as a pillar of support in the erect position.

Pelvis.

The bones of the pelvis in the human subject are distinguished from those of other animals by some marked peculiarities. The sacrum is remarkably broad and expanded, so as to form a firm support for the spinal column which rests upon it; its lower part is curved and articulated with the coccyx, so that both incline forwards and enclose the pelvic cavity, constituting a support for the viscera when pressed down by muscular action. If a different arrangement of these bones obtained —if they were continued downwards in a straight line, they would project beyond the ischia, and render the sitting posture irksome or impossible.

Spinal column.

The spinal column, which is supported on the pelvis, is pecu-

---

* Règne Animal, tom. i. p. 82.

liarly adapted to the erect attitude. Its pyramidal form and enlarged base fit it to sustain the superincumbent weight; and by means of the different curvatures which it presents, a considerable range of motion is allowed to the trunk, the centre of gravity being still supported within the base. The form of the thorax is also peculiar. Shallow and compressed from before backwards, it is broad and expanded from side to side; by which means the preponderance of the trunk forwards is considerably lessened. The sternum, though broad, is very short, so that a considerable space intervenes between it and the pubes, which is occupied solely by muscular parts. But in quadrupeds, the thorax is compressed and flattened laterally, becoming gradually narrower towards the sternum, which is prominent and keel-shaped, so that the breadth from this latter bone to the spine is much greater than that from side to side. This conformation, together with the absence of clavicles in true quadrupeds, enables the anterior extremities to approach closely together, and fall perpendicularly downwards beneath the trunk, so as to give it a steady support. The sternum is elongated in these animals, and the ribs pass from the spine to that bone so directly, without making any angle, that they approach near to the cristæ of the ilia, and thereby increase the extent of firm support necessary to sustain the weight of the viscera. Even with these advantages, the muscles of the abdomen would be inadequate to the support of its contents, were they not assisted by a layer of elastic substance, which is placed over their entire extent, and which of itself marks their destination for the prone position.

Thorax.

Clavicles.

Sternum.

The upper limbs contrasted with the lower.

Though the upper and lower extremities present several points of similitude, they yet may be contrasted so as to show that they are adapted to totally different purposes. It is quite obvious that the scapula and os innominatum, the humerus and the femur, the bones of the fore-arm and those of the leg, the hand and the foot, are respectively constructed on the same plan; but the differences which they present indicate a difference of function.

Scapula and innominate bone.

The scapulæ, placed on the supero-posterior part of the trunk, are borne off by the clavicles; their glenoid cavities are directed forwards and outwards, so that the arms, which are, as it were, appended to them, are fitted to enjoy a considerable degree of motion in the anterior and lateral directions. But in true quadrupeds the glenoid cavities look downwards, and are approximated closely together, so that the thoracic limbs, which are articulated with them, descend beneath the fore part of the trunk; and, as they are thus calculated to support its weight, they possess little lateral motion. The glenoid cavity in man is quite shallow, so that the globular head of the humerus is merely applied to its surface; but the acetabulum is a deep cup-like cavity, indicating a quite different destination in the two joints. The breadth of the articular surfaces of the knee-joint, and the peculiar conformation of the ankle-joint, as contrasted with the elbow and wrist, are abundantly sufficient to show that fixity and strength have been designed in the one, mobility in the other. This difference is, if possible, more strongly marked in the conformation of the hand and foot: the latter, as has been already observed, being intended to support the body, is placed at right angles beneath the leg; the former is continuous with the line of direction of the fore-arm, otherwise it could not be guided with sufficient precision to the different objects which it is intended to seize. The tarsal bones are large, firm, and strong; those of the metatarsus are also thick and large, and placed all in a line. That which supports the great toe, being the stoutest of all and almost immovable, ranges with the others. But the metacarpal bones are quite differently disposed; that which supports the thumb admits of considerable motion in every direction, so as to perform a complete circumduction, and is placed so much out of line with the others that it can be opposed to them, as in grasping different objects. The hand and foot may be considered as divisible each into two parts, differing in their degrees of mobility, viz. the digital phalanges, and the row of bones which sustains them. The moveable phalanges of the hand are as long as the carpal and metacarpal bones taken together; but in the foot, they are not a third of the length of the tarsal and metatarsal bones.

The hand and foot.

No part of the osseous system of man affords more striking evidence of his adaptation for the erect posture than the cranium. Resting on the summit of the vertebral column, the line of its base forms a right angle with that of the column itself, which thus affords it a firm support. The condyles, or points of articulation, are situated very near the centre of its

Position of the head on the vertebral column.

base, being, however, a little nearer to the occipital protuberance than to the anterior surface of the jaws; by this arrangement very little active power is required to maintain it *in equilibrio.*[*] In other animals the condyles are placed much further back; so that, instead of resting on the column, the skull is, as it were, appended to its extremity, and is sustained by an elastic substance, (ligamentum nuchæ,) which is attached by one extremity to the spinous processes of the vertebræ, and by the other to the occipital protuberance. The head, as has been already observed, is composed of two parts, the cranium and face; the one being intended to contain the brain—the material instrument of the mind; the other to enclose the organs of sight, smell, and taste. The more the organs of smell and taste are developed the greater is the size of the face, and the greater its relative proportion to the cranium. On the contrary, the larger the brain, the greater must be the capacity of the skull, and the greater its proportion to the face. On this principle, a large cranium and a small face indicate a large brain with a restricted developement of the sense of smell and taste; but a small cranium and a large face mark an opposite conformation. The character and nature of animals is determined by the degree of energy with which their different functions are performed; they are guided and impelled by some leading propensity or disposition; and as the cranium and face bear to the brain and organs of sense the relation of containing and contained parts, the study of their relative proportions is one of great interest to the naturalist, inasmuch as they serve as indices of the faculties, instincts, and capabilities of different individuals as well as of classes.

Relative size of cranium and face.

Camper's facial lines.

Several methods have been suggested for determining the proportion of the cranium to the face; the simplest is that of Camper. If a line be drawn upwards from the side of the chin, over the most prominent part of the forehead, it will form an angle with a horizontal line drawn backwards over the external auditory foramen from the margin of the anterior nares; the size of the angle will indicate the degree of developement of the cranium and brain, as compared with that of the face and organs

---

[*] Lawrence on the Characters of the Human Head, passim.

of sense. In the crocodile these lines are so nearly coincident that there is scarcely any appreciable angle.

In the Horse it measures* . . .	23°
Ram	30
Dog	35
Ouran-outang†	56 to 60
European adult	85

Thus we find man at the top of the scale of animated beings, distinguished from all the rest, as well by his external conformation as by his internal organization. When the mind has passed in review the many links of the chain which connects the lowest with the highest—the mere animated dot, with man the lord of the creation, it cannot fail to be struck with astonishment at the immense chasm which separates them. Yet, when each link of the chain is compared with that which precedes and follows it, the transition from the one to the other is found to be so gradual as to be almost imperceptible. So easy are the steps of ascent from the organization of the higher orders of the quadrumana, up to the human species, that even Linnæus felt it difficult to assign the specific characters by which man is distinguishable from all others; but any doubt that may have existed on this subject has been long since removed. The physical and moral attributes of man are universally recognised as sufficient to elevate him much further from the higher mammalia than these are from the classes beneath them; and in the opinion of Cuvier,‡ he should be considered not merely as a distinct species, but even as forming a separate order by himself. Whether, then, with the zoologist, we consider the physical conformation of man as compared with that of other animals, or, with the moralist, reflect on his mental powers and high destination, we can scarcely refrain from saying, with the poet,

> Sanctius his animal mentisque capacius altæ
> Deerat adhuc, et quod dominari in cætera possit,
> Natus est homo.

---

* Cuvier, Leçons d'Anatomie Comparée, tom. ii. p. 8.
† Lawrence on Nat. Hist. of Man.
‡ Règne Animal, tom. i. p. 81.

THE THORAX.

The thorax; the bones which form it.

Into the composition of the thoracic portion of the skeleton, fig. 40, enter the sternum and ribs, which are proper and peculiar to it, and the vertebræ, which are common to it and other parts. The latter have been already described.

Fig. 40.*

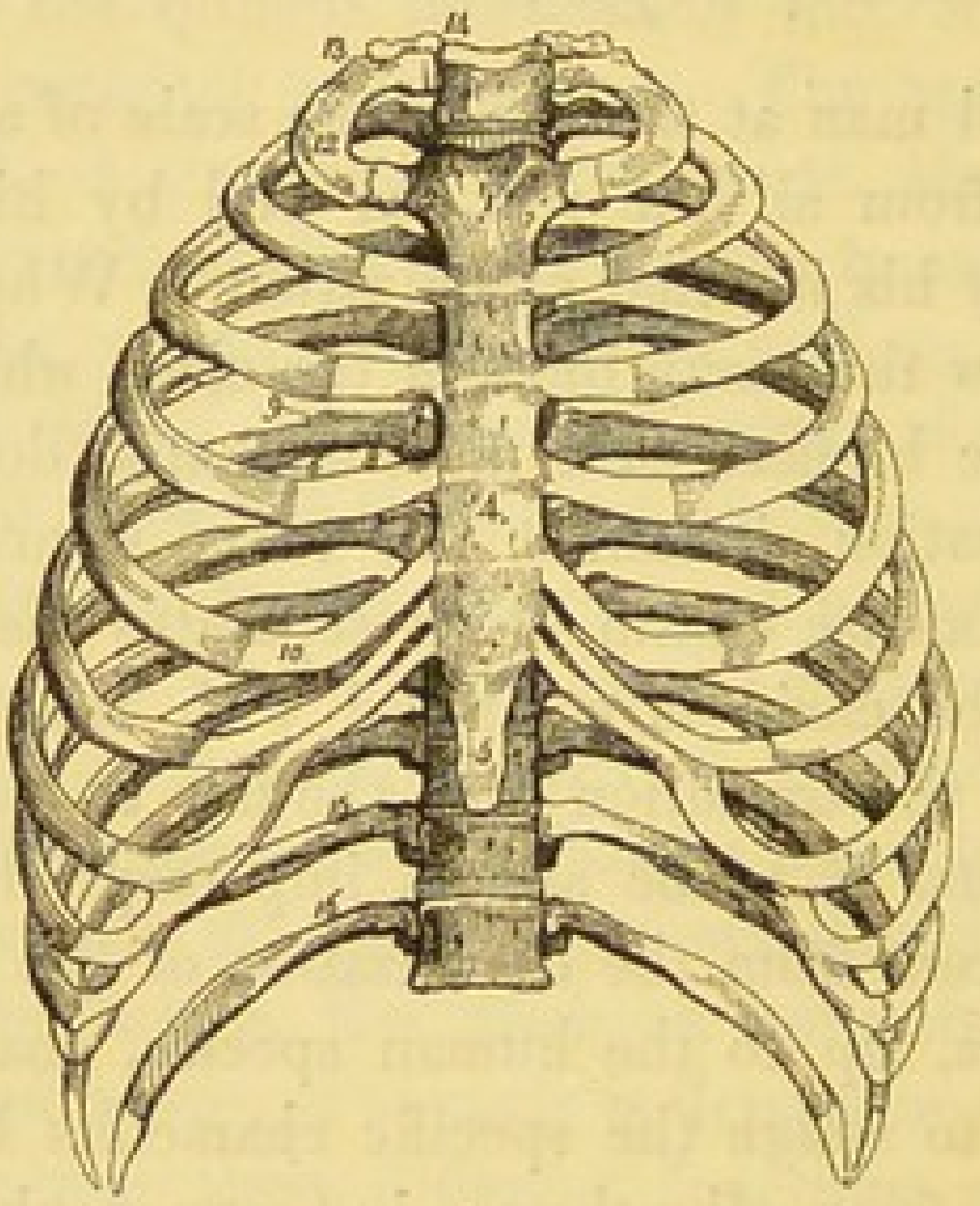

THE STERNUM AND ENSIFORM CARTILAGE.

The sternum; its position; shape;

The sternum (os pectoris: xiphoides) is situated in the median line, at the fore part of the thorax:[1 4] it is flat and narrow, but not of equal width in its entire extent, being broad at its upper part, then narrowed somewhat, after which it widens a little; finally it becomes compressed and narrow where it joins

---

* A front view of the bones of the thorax, viz. the dorsal vertebræ, the sternum, and the ribs, with their cartilages. 1. The first piece of the sternum. 2, is placed opposite the point at which a rib is joined to the sternum. 3, is close to one of the articular surfaces which the sternum has for the clavicle. 4, is on the middle of the second piece of the sternum. 5. The ensiform cartilage. 6. The groove which marks the lower margin of a rib. 7. The posterior end of a rib. 8. Its neck. 9. The tubercle. 10. The cartilage. 12. The first rib. 13. Its tuberosity. 14. The first dorsal vertebra. 15. The eleventh; and 16. the last rib.

the ensiform cartilage. Its direction is oblique from above downwards and forwards; and the inclination forwards, together with the curve backwards in the dorsal part of the vertebral column, causes a considerable increase in the antero-posterior diameter of the thorax. We have to consider successively its surfaces, extremities, and borders.

and direction.

Its surfaces; anterior, marked by lines;

The *anterior surface*, slightly convex, and subjacent to the skin, gives attachment to the aponeurosis of the pectoralis major and to the sterno-mastoid muscles, and is marked by four transverse lines, indicating its original division into five pieces. The union between the first and second of these pieces (corresponding with the insertion of the second costal cartilages) is frequently cartilaginous even in adult age.

posterior.

The *posterior surface*, somewhat concave, looks backwards, towards the cavity of the thorax, and gives attachment, superiorly, to the sterno-hyoideus and sterno-thyroideus muscles; inferiorly, to the triangularis sterni. Along the middle line it corresponds with the interval left by the divergence of the two pleuræ (anterior mediastinum).

Lateral margins.

The *borders* are thick, and marked on each side by seven angular depressions for the reception of the cartilages of the true ribs, which give them a notched or serrated appearance.

The upper end.

The *superior extremity*, broad and thick, is slightly excavated from side to side, and presents at each corner a depression for the reception of the sternal end of the clavicle.

The sternum, in early infancy, is divided into several pieces, but in adult age two only remain distinct. These two pieces, with the ensiform appendage, at one time received names derived from an imputed likeness of the whole to a sword; but the last-mentioned part now alone retains the designation grounded on this circumstance.*

The first piece.

The first division of the sternum[1] (manubrium or handle) is broader and thicker than the other; its form is nearly square;

---

* Vesalius, while stating that others regarded the sternum and ensiform cartilage as resembling a sword, prefers to compare the pieces of the sternum to the handle only of that weapon, adding, in support of his view, the curious reason, thus expressed, (Lib. i. p. 115,) "Secundum autem os, illi parti congruit, quam manus tota intus complectitur, in qua sinus costarum cartilaginibus parati, eum præstant usum, quem in gladiis ex manubrij asperitate quærimus, quoties intortis nodosisq' funiculis, aut scabra piscis cute, illud obduci curamus."

its lateral margins, thin and oblique, present each an oblong depression,[2] which receives the cartilage of the first rib; and at each inferior angle may be observed an articular half notch, which articulates with the second rib. The superior border is hollowed, and hence the names *incisura semilunaris* or *furcula*, which have been applied to it. At the angles which bound it are the fossæ,[3] which articulate with the clavicles, as has been already stated. The inferior border is straight, and united to the upper extremity of the second piece.

The second piece.

The second piece,[4] (the body,) much longer than the first, is marked on its anterior surface by some transverse lines, which indicate its original division into separate portions. Both surfaces are nearly flat. The upper border is narrow, corresponding in breadth with the termination of the first bone, with which it is connected by cartilage. The lateral margins present each five notches for the reception of the cartilages of the five lower true ribs, and a half notch superiorly, which, with a similar depression in the first piece, forms a cavity for the second costal cartilage. The five inferior notches approach one another more closely in proportion as they are situated lower down, and part of the last is occasionally made up by the ensiform cartilage.

Peculiarities.

If the sternum is examined in several adult skeletons, it will be found to differ in form,—*i. e.* in the length of its parts, as well as in its breadth at given points;—but these differences are very various, and are not so considerable as to require detailed notice. Other peculiarities, less frequently met with, and of more importance,—such as divisions running through the bone, and perforations of its substance,—will be treated of more conveniently in the account to be given of the ossification; for there the manner of their production can be explained by reference to the process of growth.

The ensiform cartilage;

The inferior extremity of the sternum, thin and elongated, gives attachment to a cartilaginous appendix,[5] called the *ensiform* or *xiphoid* (ξιφος, a sword; ειδος) cartilage, which in most cases remains in the cartilaginous state until an advanced period of life. Its form varies considerably in different individuals: and it is sometimes bent forwards, sometimes in the opposite direction, and sometimes pierced by a hole at its centre (fig. 41, A, B, D). It gives attachment to the aponeurosis of the abdominal muscles.

varies in shape.

Connexion with other parts.

Articulations.—The sternum articulates by its sides with the cartilages of the true ribs,—by its upper angles with the clavicles, and by the lower end it is connected to the ensiform cartilage.

Disposition of the osseous structure.

When sawed across, this bone presents a considerable quantity of loose spongy texture in its interior, with a very thin lamella of compact tissue on its outside;—hence it is very light.

Ossification. Situation of the nuclei.

Ossification.—As far as the middle of fœtal life, or a little later, the sternum is altogether cartilage (fig. 41, A). After that time the ossification begins with the formation of osseous granules in the middle of the intervals between the points at which the cartilages of the ribs are connected. There are five of these for the sternum exclusive of the ensiform appendage, and they form as many pieces. The process of ossification makes its appearance in the first piece between the fifth and sixth months, and soon following in the second and the third, it reaches the fourth at the end of fœtal life. The osseous centre of the last (fifth) varies considerably in the time of its appearance. It may be found soon after birth, and may not be visible for a considerable time (one or two years) after that period.

Time of their appearance.

Fig. 41.†

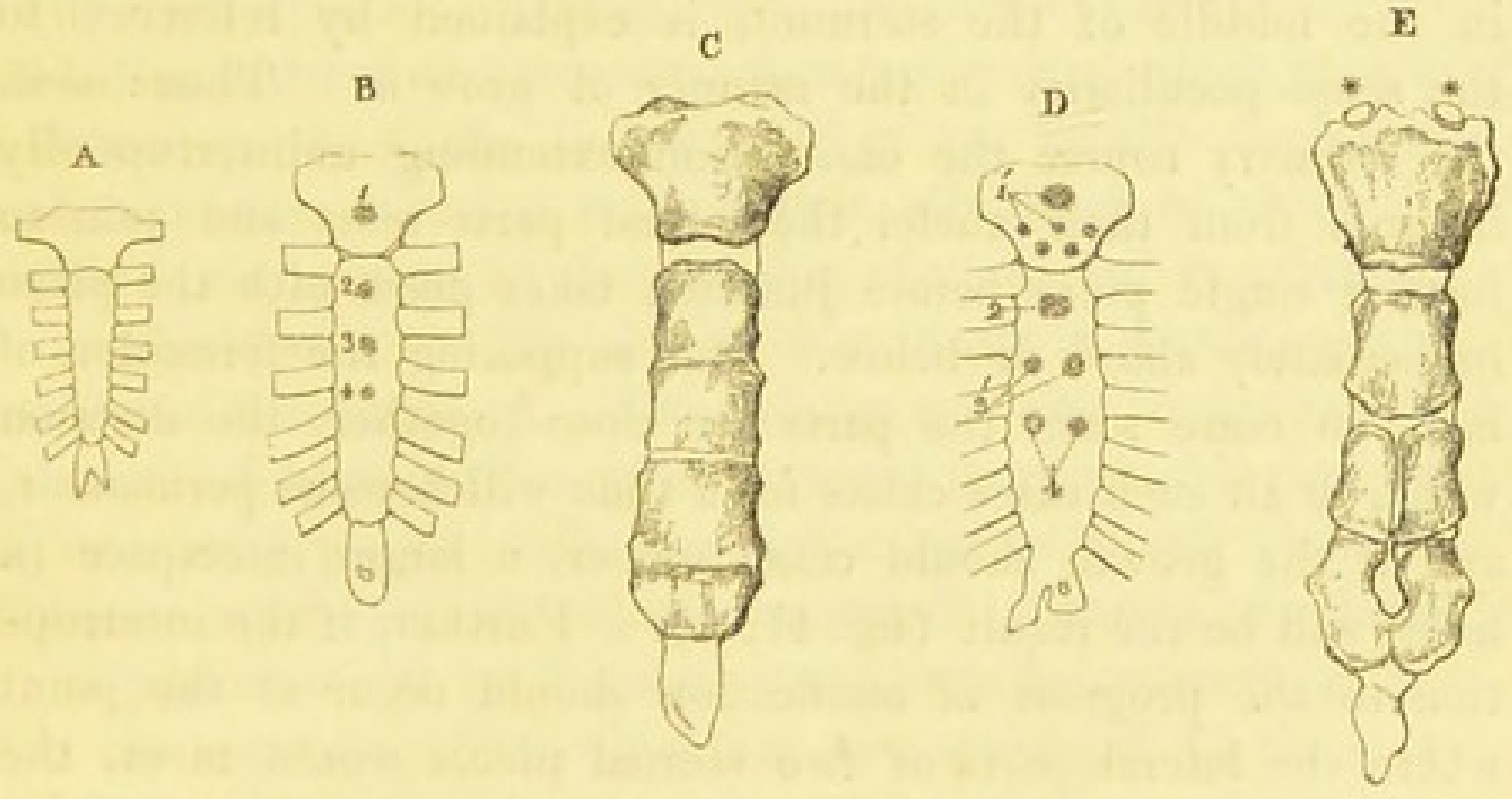

Variations

In many cases one or more of the divisions of the sternum

---

† Various conditions of the sternum are represented in these figures. They are described incidentally in the text. 1. The osseous nucleus of the first piece. 1′. Several granules for the same. 2. That of the second piece. 3, 4. Those of the third and fourth. 3′, 4′. Double nuclei for the same. * The epi-sternal granules.

of their number,

are formed from more nuclei than one, and there are peculiarities with respect to the number and position of these additional granules which require notice.

in the first piece;

in the others.

The first piece has often two points of ossification, placed usually one above the other; and it has been found to possess three. A number, which I believe to be very unusual (six), are contained in the preparation represented in figure D, $1'$. The second has not often more than a single granule (B, D^2), but the third, fourth, and fifth divisions are frequently formed from two nuclei, which are placed laterally with respect to one another,—not vertically, as occurs in the first piece (D,$^{3'}$ $^{4'}$).

Applied to explain the existence of division and holes in the sternum.

The presence of two points of ossification having the relative position mentioned, accounts for the vertical division sometimes found to run through one or more of the sternal pieces; and the occurrence of a hole, of various size, occasionally met with in the middle of the sternum, is explained by reference to the same peculiarity in the manner of growth. Thus:—in the ordinary course the ossification extending uninterruptedly inwards from their nuclei the lateral parts meet and join to form a single piece before junction takes place with the piece immediately above or below. But supposing the formation of bone to cease when the parts are close together, the division which in all such cases exists for a time will become permanent, and if the growth should cease sooner, a larger interspace (a hole) will be the result (fig. 41, E). Further, if the interruption to the progress of ossification should occur at the point where the lateral parts of two sternal pieces would meet, the hole is likely to have considerable size, for it may then result from an "arrest of the developement" proceeding from four centres,—each contributing a part.

Union begins at the lower end.

The five pieces of the sternum constructed in the manner above detailed begin to join at the lower end of the bone. The fifth piece is joined to the fourth soon after puberty, the fourth and the third are united between twenty and twenty-five years of age, and the body of the sternum is usually not completed by the junction of the third piece to the second before thirty-five or forty years. Lastly, the first division does not in general join with the rest of the sternum at any period; but should its union happen to take place, it is only to be met with in old age.

To the centres of ossification here described M. Brechet[†] has added two small epi-sternal granules, whose position is sufficiently shown in the indication of them given in figure E.* * They occur only at rather advanced periods of life; but they do not appear to be constant.

Epi-sternal nuclei.

The *ensiform* appendage begins to ossify some years after birth,—the time in different cases varying, according to the observation of Béclard, between two years and fifteen or eighteen. The ossification proceeds from a single centre situated at the upper part, and from this it gradually extends downwards; but in most instances a portion remains cartilaginous even in very advanced age.

Ensiform appendix.

THE RIBS AND THEIR CARTILAGES.

The *ribs* (costæ[‡]) extend from the dorsal portion of the vertebral column to the sternum, forming arches, which enclose the lateral parts of the thorax. They are usually twelve in number at each side, but cases occasionally occur in which the number is augmented by the addition of a cervical or a lumbar rib, to which reference has already been made in describing the vertebræ of those regions. The number may also be diminished to eleven. I have lately seen an instance in which this diminution was accompanied with the absence of a dorsal vertebra. The seven superior pairs, which are united by means of cartilaginous prolongations to the sternum, are called *sternal* or *true ribs;* the remaining five, which are not prolonged to the sternum, being denominated *asternal* or *false ribs.*

The ribs; their number; divided into true and false;

The ribs do not arch uniformly from the vertebral column towards the sternum: the greater number consist of parts of two circles or arches of different diameters, the anterior being much the larger. Thus the rib, directed at first backwards from its connexion with the bodies of the vertebræ, reaches and is supported by the transverse process (which in the dorsal region is

their direction.

[†] "Recherches sur différentes Pièces du Squelette des Animaux Vertébrés," &c. in "Annales des Sciences Naturelles," 2e Série, t. 10 (Zoologie), p. 91.

[‡] "As if they were *custodes* of those principal organs of the animal machine, the heart and lungs."—Monro, "The Anatomy of the Humane Bones," p. 234.—Edinb. 1726.

inclined backwards); after leaving the extremity of this process, it turns abruptly outwards, and finally is directed forward towards the sternum.

Differences of the ribs in length,

In their length, breadth, and direction, these bones present several varieties. From the first to the eighth their length successively increases, whilst from the ninth to the twelfth they gradually decrease, so that the last is very little longer than the first.

breadth,

Their breadth, considered in the whole series, diminishes gradually from the first to the twelfth; but in each rib it is greatest towards its external extremity.

direction.

As to their direction in reference to the vertebral column, the first forms almost a right angle with it, and the succeeding ones gradually incline downwards, so that their anterior extremity is lower than the posterior. The body of all the ribs, except the first, is, as it were, twisted on itself, so that their two extremities cannot be made to rest at the same time on a plane surface.

Their surfaces;

These bones present two surfaces, two borders, and two extremities.

The external surface is convex and smooth. The internal is concave, and corresponds with the pleura.

borders;

The superior border, smooth and rounded, gives attachment to the intercostal muscles; the inferior is marked on its inner aspect by a groove (sulcus costalis), fig. 40,[6] which is commonly said to be for the lodgment of the intercostal vessels, and also gives attachment to the intercostal muscles.

extremities.

The posterior extremity,[7] somewhat rounded and thicker than the other parts of the rib, and hence denominated its *head*, (capitulum costæ,) presents (except in the instances to be presently stated) two articular faces (separated by a slight ridge) which articulate with the corresponding small surfaces on the bodies of the dorsal vertebræ; the head is supported by a narrow round part,[8] or *neck*, terminated externally by a *tubercle*, (tuberosity, tuberculum costæ,)[9] which is smooth in one part for its articulation with the transverse process of the lower of the two vertebræ to which the head is connected, and rough in the other for the insertion of the posterior costo-transverse ligament.

Tubercle.

Anterior extremity.

The anterior extremity is broad, flat, and hollowed at its tip into an oval pit, into which is implanted the costal cartilage.

Between the tuberosity and the most convex part of the body of each rib is a rough line, marking what is termed its *angle*. The distance of the angle from the tuberosity increases gradually from the second to the eleventh inclusive. In the last it is not perceptible: in the first it is not distinguishable from the tuberosity. Angle.

The first two and the last two ribs present some peculiarities deserving of notice. Ribs having peculiar characters;

The *first* rib[12] is shorter and broader than either of the succeeding ones, its direction is nearly horizontal; its body not being twisted, as is the case in other ribs, it lies evenly when placed on a plane surface. One surface looks upwards, and is marked by two very slight depressions (over which slide the subclavian vessels), and an intervening roughness, sometimes well marked, which indicates the attachment of the scalenus anticus muscle. The other surface looks downwards, towards the cavity of the thorax. The external border, convex and rounded, is surmounted by the tuberosity;[13] the internal is thin, and forms the margin of the superior aperture of the thorax. The anterior extremity is broad and thick; the *head*, which articulates with the first dorsal vertebra,[14] is small, presents an undivided articular surface, and is supported by a slender neck. the first,

The *second* is longer than the first, and presents externally a prominent line for the attachment of the serratus magnus; its internal surface is somewhat grooved posteriorly. second,

The *eleventh*[15] has no groove on its inferior border, nor a tubercle, as it is not articulated with the transverse process; its angle is scarcely perceptible, and the head has but one articulating surface. The cartilage by which its anterior extremity ends is unconnected with those of the other ribs. eleventh,

The *twelfth*[16] differs little from the preceding one, except in being shorter; it has neither angle, tubercle, nor groove, and as its anterior extremity, which is pointed, seems loose and unattached, it is called a floating rib. The same designation has likewise been applied to the eleventh rib. twelfth.

Ossification begins in the ribs at a very early period—somewhat before it has made its appearance in the vertebræ, and the deposit of osseous matter extends rapidly over them. Each rib (with exceptions to be presently noticed) is formed from one principal piece (fig. 42,[1]) and two epiphyses. Ossification; time of commencement. Principal piece.

The epiphyses are small and thin, and one of them, which in most ribs is slightly angular in shape, belongs to the head, Epiphyses.

Fig. 42.*

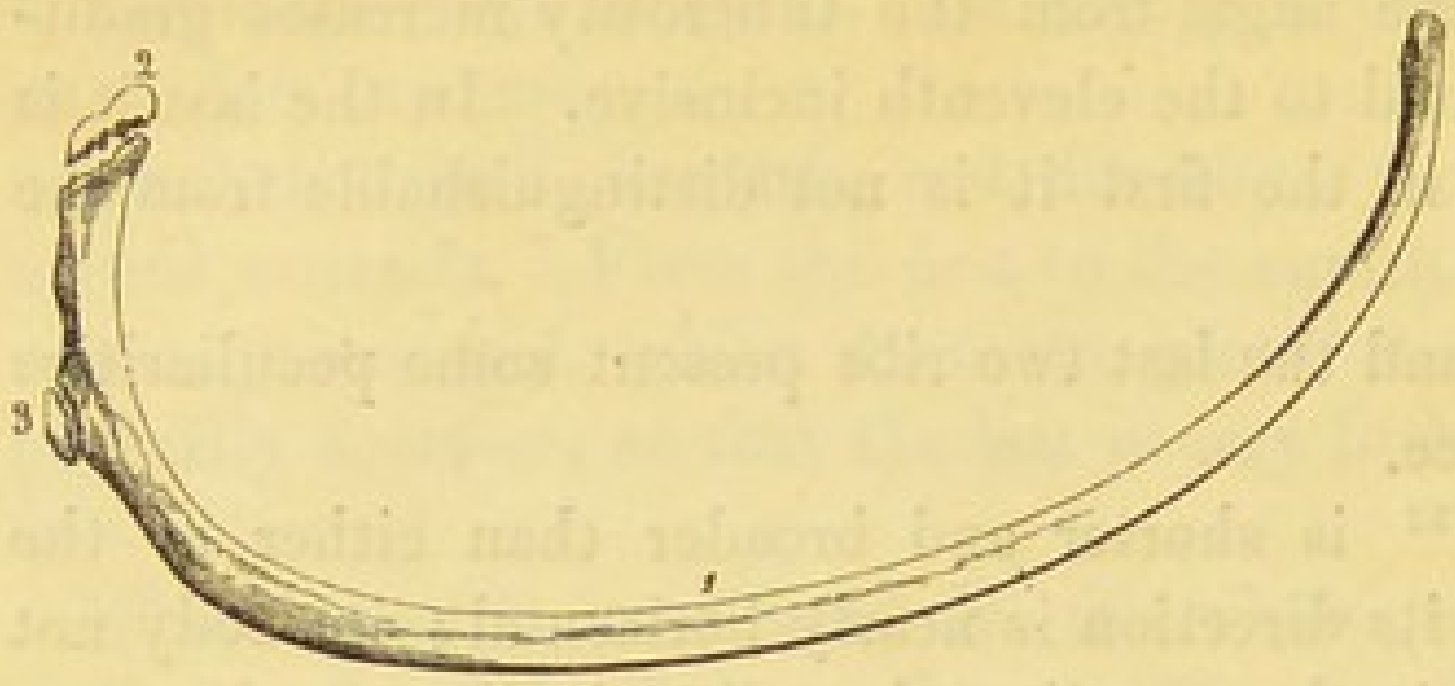

(fig. 42,^{2}); the other, to the tubercle, (fig. 42,^{3}). Their growth commences between the sixteenth and the twentieth year of age, and they are united to the rest of the bone a few years after,—about the twenty-fifth.

The last two or three ribs want the epiphysis of the tubercle.

COSTAL CARTILAGES.

The costal cartilages vary in length, breadth, direction.

These cartilages (fig. 40,^{10}—the numbers are omitted upon the others to avoid complexity in the drawing) are twelve in number, like the ribs, of which they form the elastic continuation; their breadth diminishes gradually from the first to the last, whilst the length increases as far as to the seventh, after which it becomes less in each succeeding one. Their line of direction also varies considerably. The first descends a little, the second is horizontal, and all the rest ascend more and more as they are situated lower down. The external or costal extremity, convex and unequal, is implanted into the end of the corresponding rib. The internal extremities of the cartilages of the true ribs, smaller than the external, and somewhat pointed, are articulated with corresponding angular surfaces on the sides of the sternum; each of the cartilages of the first three false ribs, becoming slender towards its extremity, is attached to and blended with the lower border of that which is next above it; in the last two it is pointed and unattached.

Their extremities.

Liability to ossification;

The first cartilage usually becomes more or less ossified in adult age, and at this period it is often connected to the sternum by bone. After the middle of life, osseous matter is likewise deposited to a greater or less extent in the other cartilages;

---

* One of the last true ribs. 1. The principal piece. 2. The epiphysis of the head. 3. The epiphysis for the tubercle. N. B. The epiphyses are represented of somewhat too large size.

and it is apparent at a later period in those of the false than of the true ribs.

in the male and female.

These observations apply to the male body; for in the female the process of ossification does not affect the cartilages until old age has arrived, and it always affects a comparatively small number, if it should happen to extend beyond the first, which commonly is not the case.

Muscular attachments.

Attachments of muscles to the ribs and their cartilages.— The two layers of intercostals to the contiguous borders of all the ribs; the scaleni to the first and second; the pectoralis major to the cartilages of the true ribs, except the first; pectoralis minor to the bodies of the third, fourth, and fifth; rectus abdominis to the cartilages of the last three true ribs and ensiform cartilage; obliquus externus to the last three true ribs, and all the false; the internal oblique and transversalis to the cartilages of the four or five false ribs; the diaphragm to the ensiform cartilage, and to those of the last six ribs.

The serratus magnus to the nine superior ribs; latissimus dorsi to the four inferior; serratus posticus superior to the third, fourth, and fifth true ribs; serratus posticus inferior to the last three; sacro-lumbalis to the angles of all the ribs; levatores costarum a little beyond their tuberosities.

BONES OF THE SUPERIOR EXTREMITY.

The upper limb; its division into parts.

The upper extremity consists of the shoulder, the arm, the fore arm, and the hand. The shoulder consists of the scapula and clavicle: the arm of the humerus; the fore-arm of the radius and ulna; and the hand of the carpus, metacarpus, and fingers.

SCAPULA.

The scapula; its position.

This bone, fig. 43, is placed upon the upper and back part of the thorax, occupies the space from the second to the seventh rib, and forms the posterior part of the shoulder.

Its form is irregularly triangular and flat. It presents for examination two surfaces, three borders, and three angles.

Subscapular fossa.

The anterior surface, (*fossa subscapularis*, *venter*,) looks towards the ribs, is triangular, slightly concave, intersected by prominent lines directed from within outwards and upwards, and therefore crossing the direction of the ribs.

Fig. 43.*

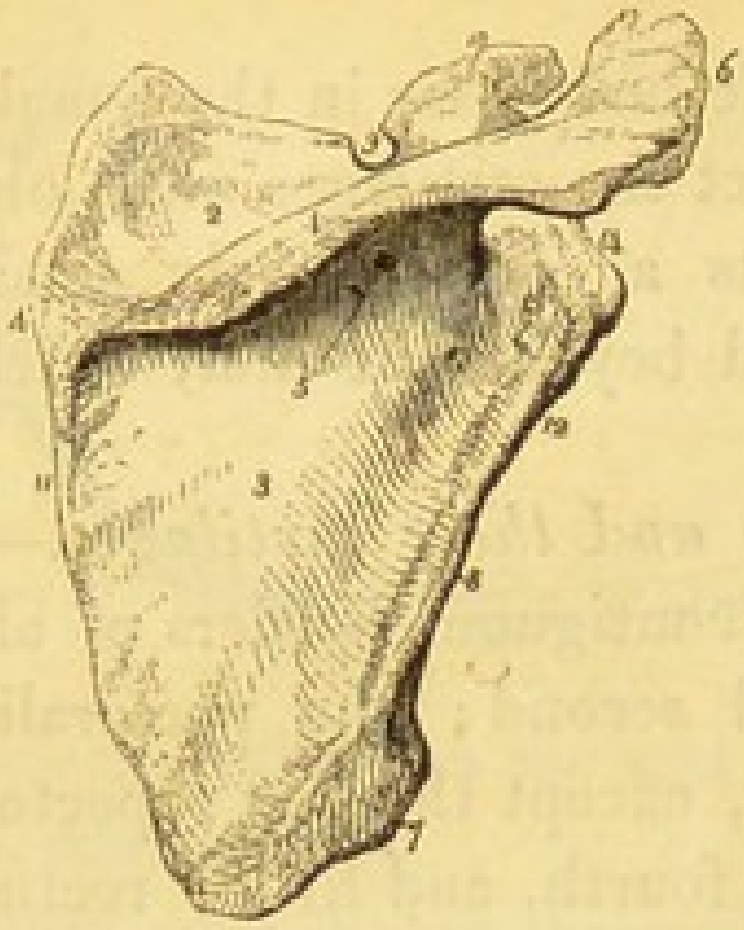

The "dorsum."

The posterior surface (*dorsum scapulæ*) is divided into two parts, but unequally, by a prominent ridge,[1] (the spine:) of these the superior one[2] is called fossa supra-spinata; the infeferior,[3] fossa infra-spinata.

The spine separates the supra-spinous and infra-spinous fossæ, and forms part of them;

Of the spine.—The spine of the scapula is a prominent ridge of bone, flattened from above downwards, commencing at the posterior border of the scapula, with a smooth flat triangular surface,[4] from which it becomes gradually more elevated as it proceeds forwards, until it terminates in an elongated process,[6] (acromion,) which surmounts the shoulder-joint. The form of the spine, considered by itself apart from the acromion, is triangular; hence we have to notice its two surfaces and three borders. Its superior surface is concave, and, conjointly with the superior part of the dorsum of the scapula, forms the fossa supra-spinata. The inferior surface is irregularly triangular, constitutes part of the infra-spinous fossa, and in its middle may be observed a small foramen,[5] for a nutritious vessel. On the projecting border of the spine, which is rough and broad, may be noticed two margins, of which the superior one gives attachment to the trapezius, the inferior to the deltoid muscle: the intervening edge is subcutaneous. The anterior or attached border, or base, is united with the dorsum of the bone. The external border, which is short, round, and somewhat concave, approaches the neck of the bone, and is continuous with the under surface of the acromion.

is partly subcutaneous.

The acromion;

Of the acromion process.—This considerable eminence[6] is flattened in the direction opposite to that of the spine, and, projecting outwards and forwards, forms the summit of the

---

* The scapula of the right side—its dorsal aspect. 1. The spine. 2. The supra-spinous fossa. 3. The infra-spinous fossa. 4. A triangular surface at the end of the spine. 5. The opening of a nutritious canal. 6. The acromion. 7. A square surface for the teres major muscle. 8. A ridge marking the point of attachment of the teres minor. 9. The supra-scapular notch. 10. The coracoid process. 11. The base. 12. A rough surface for the long head of the triceps muscle. 13. The neck. 14. The margin of the glenoid cavity.

shoulder-joint; hence its designation (*αϰρον*, a summit; *ωμος*, the shoulder). Its posterior and upper surface, convex and somewhat rough, is subcutaneous; the anterior and inferior one, concave and smooth, is in relation with the supra-spinatus muscle, and overlays the capsular ligament of the shoulder-joint; the superior border presents, anteriorly, a narrow oval surface for its articulation with the external extremity of the clavicle, and its summit affords attachment to the coraco-acromial ligament.

one surface is subcutaneous;

covers shoulder joint.

Supra-spinous and infra spinous fossæ.

The *fossa supra-spinata*,[2] wider towards its vertebral than the other extremity, is filled up by the supra-spinatus muscle. The *fossa infra-spinata*,[3] much larger than the preceding, is convex in the middle, somewhat concave, or rather grooved, inferiorly. Between the latter part and the axillary border is a slightly raised and elongated ridge,[8] which extends from the glenoid cavity obliquely downwards to within an inch of the posterior angle of the bone, where it subsides into a flat and nearly quadrilateral surface.[7] This latter part it is that gives origin to the teres major muscle, and over it slides the latissimus dorsi. Along the upper and rounded part arise the fibres of the teres minor; whilst the line of division between them marks the attachment of an aponeurosis, common to these muscles and to the infra-spinatus, which occupies the remainder of the fossa.

Three borders; the superior.

Coracoid process.

Posterior border or "base."

Of the three *borders* of the scapula, or costæ (as they are sometimes called), the *superior* is the shortest; at its outer part is situated a lunated notch,[9] (lunula; incisura semilunaris,) which is converted into a foramen by a ligament, and is traversed sometimes by the supra-scapular vessels and nerve, but usually by the nerve alone. In front of this opening it is surmounted by the *coracoid* process,[10] which being thick, elongated, and curved on itself, is named, from some fancied resemblance to a crow's beak (*ϰοραξ*, a crow; *ειδος*, form). This process, superiorly convex and unequal, gives attachment to the coraco-clavicular ligament; anteriorly, to the pectoralis minor muscle; posteriorly, to the coraco-acromial ligament; and by its extremity to the biceps and coraco-brachialis muscles. The *posterior*, or vertebral border,[11] named also the "base" of the scapula, is the longest of the three; superiorly it approaches to the vertebral column, inferiorly it is more removed from it.

Inferior costa.

The portion of this border which is above the spine will be observed to incline a little outwards. For the purpose of more easily assigning the attachments of the several muscles which are connected with it, we may regard it, though very thin, as divisible into two margins, with an inter-space; these are stated in the enumeration of the muscular attachments. The *axillary* border is inclined downwards and backwards from the lower margin of the glenoid cavity to the inferior angle of the bone; hence it is named the *inferior costa* of the scapula. It is of considerable thickness, being surmounted posteriorly by the ridge above noticed as giving origin to the teres minor. The edge itself presents a shallow groove running along the greater part of its extent. It corresponds with the lower border of the subscapular muscle. For about an inch beneath the glenoid fossa there is a well-marked linear impression,[12] which gives origin to the long head of the triceps muscle.

Angles.

The *postero-superior angle* is formed by the junction of the base with the superior costa of the scapula; it is somewhat inclined outwards. The *inferior angle* is placed at the union of the base with the axillary or inferior border of the bone; upon it may be observed an elongated flat surface[7] which gives origin to the teres major, and over which slides the latissimus dorsi muscle. At the convergence of the superior and inferior borders may be observed a narrow constricted part[13] denominated the neck.

Neck of the scapula.

Glenoid cavity; its shape, direction,

The *neck* (cervix scapulæ) separates the glenoid fossa and the coracoid process from the rest of the bone, and terminates above at the notch of the scapula. It is bounded below by a slightly raised rim[14] which gives attachment to the fibrous capsule of the shoulder-joint; and finally the rim surrounds the articular surface of the bone which is called the *glenoid cavity* (γληνη, a superficial cavity; εἶδος). This is a shallow, oval depression, broader below than above, covered with cartilage in the fresh state, and deepened somewhat by a fibro-cartilaginous border, which passes round it from the long tendon of the biceps muscle, whose origin is at its upper margin; its longest diameter is perpendicular, its direction outwards and forwards. In this last respect, however, it varies considerably; for during the more extended motions of the humerus, the scapula is made to turn, as it were, on a pivot driven through the centre of its dorsum, by which means the glenoid cavity is kept constantly in apposition with the head of the humerus, which is the chief security against its dislocation.

connexion with other bones.

The scapula *articulates* by its glenoid cavity with the humerus, and by the acromion process with the clavicle.

Muscular attachments.

It affords *attachment to the following muscles*:—The sub-scapular fossa (the anterior or costal surface of the bone) to the sub-scapularis muscle. Posterior or dorsal surface,—the spine (by its border and the acromion) superiorly to the trapezius, inferiorly to the deltoid: the fossa supra-spinata, by its posterior two-thirds, to the muscle of the same name: the fossa infra-spinata, in the greater part of its extent, to the infra-spinatus; by a slight oblique line situated near the inferior angle, to the aponeurosis common to the infra-spinatus, teres minor, and teres major; by a narrow rounded surface, near the axillary border, to the teres minor; by the flat surface, at its inferior angle, to the teres major.

The superior border, near the margin of its notch, to the omo-hyoideus; the coracoid process, anteriorly, to the pectoralis minor, by its summit to the biceps and coraco-brachialis. The posterior border or base, anteriorly, to the serratus magnus; posteriorly, to the supra-spinatus and infra-spinatus; in the inter-space to the rhomboidei and to the levator anguli scapulæ. The inferior, or axillary border, at its upper part by a rough ridge to the long portion of the triceps extensor; posteriorly, by an unequal surface, to some fibres of the teres minor; inferiorly, to the teres major.

The inferior angle to the teres major, and occasionally to some fibres of the latissimus dorsi; the anterior angle (glenoid cavity), by its upper margin, to the long head of the biceps muscle.

Ossification.

Primary nucleus; time of its appearance.

It forms the greater part of the bone.

The scapula has several centres of *ossification*, and the greater part of the bone, as in most other cases, is formed from one of them. This nucleus appears at the time that osseous matter is first deposited in the vertebræ, and from it the ossification spreads in different directions, to the spine, the glenoid cavity, and in short over all the bone, except the coracoid process, the acromion, the lower angle, and the base, each of which is a distinct formation.

At birth the parts last named are cartilaginous.

Fig. 44.*

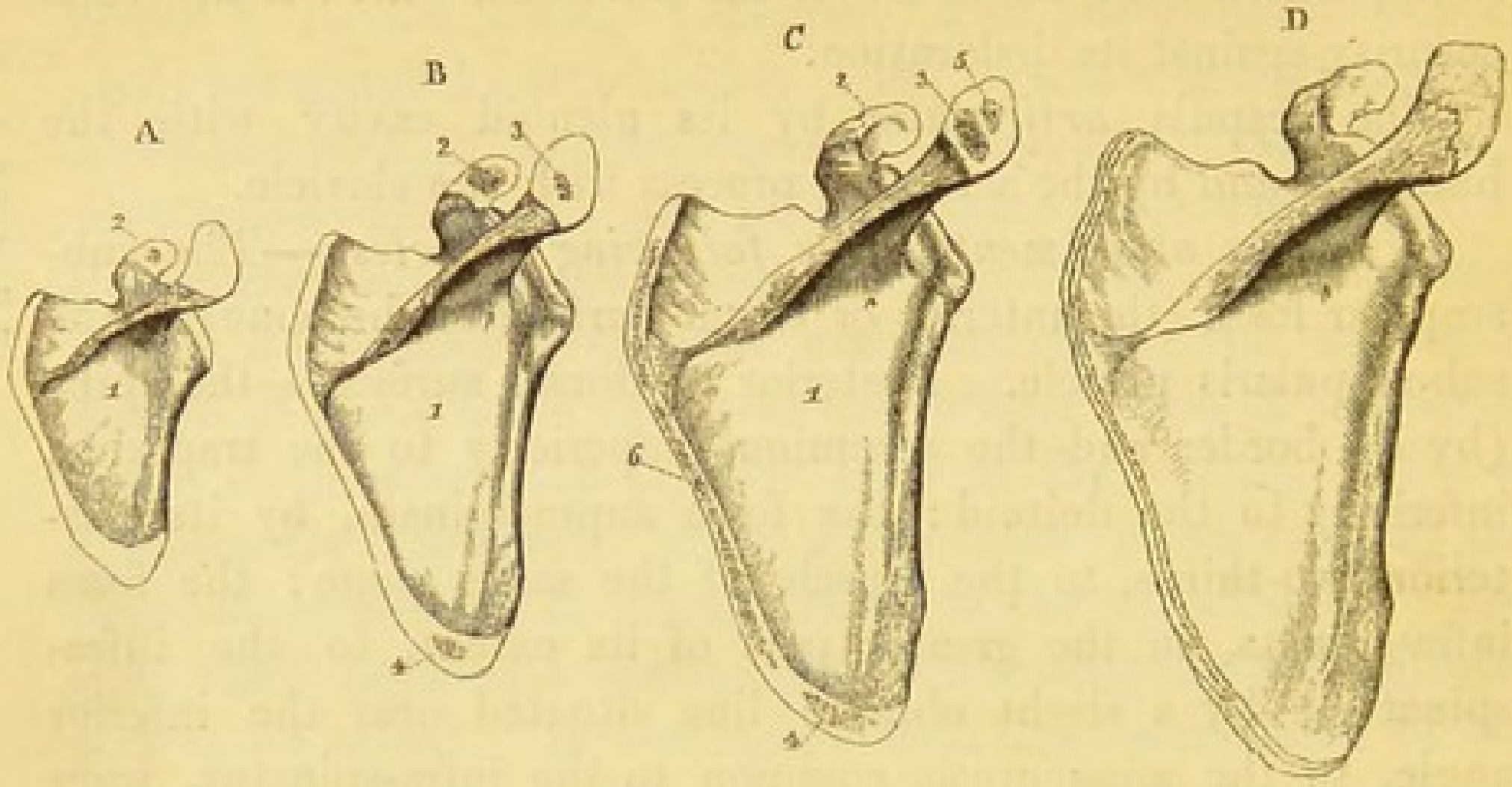

Coracoid process.

An osseous granule appears in the middle of the coracoid process (fig. 44, A^{2}), usually in the course of the first year after birth, and this part being largely ossified, is joined, or about to join, the rest of the scapula when the remaining pieces begin to form.

Situation and succession of other ossific points.

The additional centres of ossification succeed one to the other rapidly, between the fifteenth and seventeenth years, generally showing themselves in the following order:—1. in the acromion near the base;—and in the upper part of the coracoid process; 2. the lower angle; 3. again in the acromion; 4. the base. The several pieces constructed from these nuclei may be regarded as epiphyses. Each of them requires some remark.

The acromion.

The base of the acromion is an extension from the primary centre of ossification through the spine, and the extent to which

---

* The scapula is here represented at various periods of its growth. The figure marked A. shows the condition of the bone at about the end of the first or beginning of the second year of age; ossification is largely extended from the primary centre, and a nucleus has appeared in the coracoid process. B. From a boy aged about fifteen or sixteen years; the coracoid process is partly joined at its base, and nuclei have appeared in the acromion and in the lower angle. C. shows the condition of the bone at seventeen or eighteen years of age. A second point has formed in the acromion, and the ossification of the base is advanced. D. The scapula of a man about twenty-two years of age. The epiphyses of the acromion and the base are still separable. A thin epiphysis, which exists on the coracoid process of the preparation represented in the sketch has been accidentally omitted. N. B. One of those figures (C.) is to be regarded as altogether an illustrative plan. I do not possess a preparation showing this stage of the growth of the bone.

the ossification from this source reaches varies in different cases (fig. 44). The remainder of the process is produced from two or more irregular nuclei (C$^{3\ 5}$), which unite one to the other, and form a single piece to be subsequently joined to the spine, or rather to the projection from this (fig. 44, D).

Epiphysis of the coracoid process.

On the convex part of the coracoid process where it turns forward, a thin scale (an epiphysis) forms after the process has been joined on to the general mass of the scapula. I have observed this epiphysis to be in general broad at the upper part, and to taper downwards to the notch on the upper margin of the scapula.

The lower angle. The base.

The lower angle and the contiguous part of the base are always ossified separately (B, C, D,^{4}). The remainder of the base is also to be considered a distinct growth (C, D,^{4}); but from the appearance of completeness presented by its upper part in some scapulæ of young bodies, I think it not unlikely that a portion of it is occasionally formed by extension from the general ossification of the bone. The point, however, requires further investigation.

The epiphyses are joined to the bone between the ages of twenty-two and twenty-five years.

THE CLAVICLE.

The clavicle; its position, direction, shape, division into parts.

The clavicle (*clavis*,* a key), or, as it is popularly called, the collar-bone, is extended, transversely, between the acromion process of the scapula and the summit of the sternum, which it serves to connect; its direction, however, is not exactly horizontal, the acromial end being slightly elevated. This bone is curved somewhat like an italic *ſ*, the degree of the curvature being less in young and female subjects than in male adults; it

---

* Various reasons have been assigned for the name by which this bone is distinguished. It has been said to be taken from the likeness to a peculiar form of key. By most writers the name is considered to have been derived from uses attributed to the bone: such as that, key-like, it closes the chest; or that, as "a stay," it connects the scapula to the trunk. Thus, Riolanus —who is cited because of his character for extensive erudition—says (Comment. de Ossibus, cap. 21), "Clauis siue clauicula dicitur quod Thoracem claudat. . . . . Nam ex Aristotele Clauis, os claudens thoracem et instrumentum quo aliquid clauditur significat. . . . Vel quia clauis modo firmet et stabiliat cum sterno omoplatam. In architectura claues appellantur ligna aliis firmitudinem præstantia."

is rather thick and somewhat triangular towards its sternal end, but broad and flat towards the scapular extremity; it presents for our consideration a body and two extremities.

The body; its upper surface subcutaneous; lower surface uneven.

The superior surface of the *body* is principally subcutaneous. The inferior surface presents, near the sternal extremity, inequalities for the attachment of the costo-clavicular ligament; in the centre, a longitudinal depression, giving attachment to the subclavius muscle, the foramen for the entrance of the medullary vessels, and, more externally, a rough oblique line, to which the coraco-clavicular ligaments are attached; this surface corresponds internally to the first rib, externally to the coracoid process and the shoulder-joint, and in the middle to the axillary vessels and brachial plexus of nerves. The anterior border is broad and convex towards the sternal, thin and concave towards the scapular extremity; the posterior border presents, of course, the opposite arrangement of curvatures.

Ends of the bone; their differences.

The *internal* or *sternal* extremity is inclined downwards and forwards; it is considerably thicker than the other parts of the bone, and terminates in a triangular unequal surface, which is convex from above downwards, concave from behind forwards; this is tipped with cartilage, and articulates with the sternum, the articular surface of which it much exceeds in size; its entire circumference gives attachment to ligaments. The *external* or *scapular* extremity, compressed and flattened, inclines a little backwards and upwards, and articulates with the acromion by a narrow oblong surface which is covered with cartilage.

Muscular attachments.

Attachments of muscles.—The clavicle gives attachment, by the superior surface of its sternal extremity, to the sterno-cleido-mastoid; the longitudinal depression on its inferior surface, to the subclavius; the anterior border, by its sternal half, to the pectoralis major; by its acromial third, to the deltoid; the posterior border, by its acromial third, to the trapezius.

Articulations.

Articulations.—The clavicle articulates with the sternum and the acromion process of the scapula.

Various peculiarities of shape and thickness.

Peculiarities in the sexes and in individuals.—The clavicle of the female is more slender and less curved than that of the male. But occasional instances occur which do not conform to this general statement—which are even directly opposed to it. These exceptional cases are in a great measure, if not altogether, referrible to circumstances to be noticed in the following paragraph. It is also less bent in young persons than in adults.

The curves of the bone are greatest in persons employed in laborious occupations, and its ends become enlarged under the influence of the same circumstances. It has likewise been found that, from the same cause, a difference may exist between the clavicles of the same person—insomuch that M. Cruveilhier states, he was enabled to predicate correctly of a person that he was left-handed, founding his judgment solely on the relative size of the sternal ends of the clavicles.

Ossification.

Ossification.—The clavicle begins to ossify before any other bone. It is formed from one principal piece and a thin epiphysis, which belongs to the inner or sternal end of the bone. The epiphysis begins to form between the eighteenth and twentieth year, and it unites to the rest of the bone a few years after.

Fig. 45.[*]



THE HUMERUS.

The humerus;

division into parts.

The humerus or arm-bone, fig. 46, (os humeri,) the largest bone of the upper extremity, extends from the scapula to the bones of the fore-arm, with each of which it is articulated. Its direction is vertical, with an inclination inwards towards the lower end. Long and irregularly cylindrical in form, the humerus is divisible into a body and two extremities.

The shaft; divided by two lines.

The *body* or *shaft* of the bone,[1] thick and rounded superiorly, is somewhat expanded, and triangular inferiorly. It is divided into two nearly equal surfaces by two longitudinal lines, of which one is external and anterior,[2] the other internal and posterior.[3] These lines or ridges may be considered as rising, the former from the external, the latter from the internal condyle, near to which they are well marked, but gradually subside as they proceed upwards on the body of the bone: they afford

---

[*] *a.* The clavicle of a fœtus. *b.* This figure is taken from the clavicle of a man who had attained to about twenty-three years of age. N.B. The epiphysis is represented of somewhat greater size (thicker) than it is in nature.

Groove for a large nerve and an artery.

Surfaces.

The posterior

and anterior.

Bicipital groove.

Foramen for nutritious artery.

Rough surface for deltoid muscle.

attachment to the inter-muscular aponeuroses. The external one is interrupted about the middle,[4] by an oblique depression, or groove, which runs from above downwards, and marks the course of the musculo-spiral nerve and superior profunda artery; the surfaces separated by these lines are named posterior and anterior. The *posterior* surface is round superiorly, and inclined a little inwards; in the lower part it is broad, flat, and turned rather outwards; it is covered in the entire of its extent by the triceps extensor muscle, and towards its middle may be observed a small foramen for the medullary vessels. The *anterior* surface is divided superiorly into two unequal portions by a longitudinal groove,[5] directed obliquely downwards and inwards, for about one-fourth of the length of the bone; this lodges the long tendon of the biceps muscle, and is therefore named the *bicipital* groove; its anterior margin,[6] gives attachment to the pectoralis-major; the posterior,[7] to the latissimus dorsi and teres major. The portion of the anterior surface which is internal to this groove is smooth in the greater part of its extent, and presents, towards its middle, a linear elevation for the insertion of the coraco-brachialis, and lower down an oblique medullary foramen;[8] externally to the groove, and a little above the middle of the bone, may be observed a broad rough eminence,[9] for the insertion of the deltoid muscle, beneath which runs the oblique depression already noticed as corresponding to the course of the musculo-spiral nerve and the accompanying artery.

Fig. 46.*



The upper end.

The *superior extremity* of the bone presents a large hemispherical eminence,[10] covered with cartilage in the fresh state,

---

* The humerus of the right side seen from before. 1. The shaft. 2, 3. The external and internal condyloid ridges. 4. Opposite part of a shallow groove which corresponds to the course of the musculo-spiral nerve and the superior profunda artery. 5. The bicipital groove. 6. Its anterior margin. 7. Its posterior margin. 8. Foramen for nutritious artery. 9. Deltoid impression. 10. The head. 11. The neck. 12. The great tuberosity. 13. The small one. 14. The inner condyle. 15. The outer condyle. 16. Rounded articular surface (capitellum) for the radius. 17. Trochlea. 18. Fossa for the coronoid process.

and directed backwards and inwards to the glenoid cavity of the scapula, with which it articulates; this is called the *head* of the humerus. It is bounded by a slightly depressed groove, sufficiently marked on the upper, not on the under aspect, denominated the *neck* of the bone. The axis of this part does not coincide with that of the rest of the bone.—Supposing the humerus in its natural position with respect to the scapula, if the axis of its shaft be vertical, that of the head and neck of the bone is directed backwards and upwards. A little beneath, and to the outside of the head, are two eminences, which project from the ends of the shaft of the bone, and, from their relative size, are named the greater and lesser tuberosities (tubercula). The *greater tuberosity*,[12] is external and posterior in its situation, convex in its outline, and marked on its upper border by three flat surfaces for the insertion of the external rotator muscles. The *smaller tuberosity*,[13] rounded and more prominent than the other, gives attachment to the sub-scapularis muscle. They are separated by the bicipital groove.

The head.

Neck.

The axis of the shaft and that of the upper end of the bone do not coincide.

Tuberosities; their differences.

The lower extremity.—Towards its lower third the bone widens, and appears compressed and somewhat twisted frōm behind forward; its longest diameter is transverse; it presents internally a considerable projection,[14] the *inner condyle*, which is inclined backwards, and gives attachment to the internal lateral ligament of the elbow-joint, and to a tendon common to the greater number of the anterior muscles of the foramen. Externally is situated another smaller process,[15] (*external condyle*,) to which are attached the external lateral ligament and a tendon common to the muscles of the posterior and external surfaces of the fore-arm. Between the condyles is placed the inferior articular surface, which is inclined somewhat forwards. Proceeding in the enumeration of the parts which enter into its composition from the radial to the ulnar side, we observe a rounded eminence, (the *small head*, *capitellum*,)[16] placed rather on the anterior surface of the bone, and articulating with a cavity observable on the superior extremity of the radius, calculated to allow of all that freedom of motion which the radius enjoys, viz. flexion and extension on the humerus, and pronation and supination by rotation on its own axis;—a slight groove or depression corresponding with the circumference of this eminence, a semicircular ridge, which is lodged in the space inter-

The lower end is broad.

Inner condyle prominent.

External condyle.

Articular surface; its peculiarities.

Capitellum.

vening between the radius and ulna;—a wide and deep groove which receives the prominent part of the larger sigmoid cavity of the ulna; and, lastly, a prominent ridge, which is received into the internal part of the same cavity. This prominence descends much lower than the external portion of the articular surface, and determines an obliquity in the direction of the humerus, when its lower extremity is made to rest on a plain surface. The groove, with its margins, forms a well-marked pulley-like surface,[17] on which the sigmoid cavity of the ulna moves in flexion and extension; hence it is termed the *trochlea.*

Trochlea.

Fossæ for the coronoid process and olecranon.

At the fore part of the inferior extremity of the bone, and immediately above the trochlea, is a superficial depression,[18] which receives the coronoid process of the ulna during flexion, and posteriorly a more considerable fossa, which lodges the olecranon during the extension of the fore-arm.

Other names for the parts of the lower end of the bone.

A modification of the nomenclature applied to these different eminences has been proposed by Chaussier: retaining the term trochlea for the surface of articulation with the ulna, he calls that which articulates with the radius, the condyle, and for the two lateral eminences of insertion, now named condyles, he substitutes the terms *epi-trochlea* and *epi-condyle.*

Muscular attachments.

Attachments of muscles.—The posterior surface gives attachment to the triceps; the anterior (by the posterior margin of the bicipital groove) to the teres major and latissimus dorsi; in the middle, by a slightly-marked line, to the coraco-brachialis; inferiorly, to the brachialis anticus;—the external portion of the same surface, superiorly, by a rough eminence, to the deltoid; by the anterior margin of the bicipital groove, to the pectoralis major. The greater tuberosity gives attachment, by the three flat surfaces on its upper border, to the supra-spinatus, infra-spinatus, and teres minor muscles; the lesser tuberosity to the sub-scapularis. The inferior extremity, by its outer border, to the supinator radii longus and extensor carpi radialis longior; by its external condyle, to the extensor carpi radialis brevior, extensor communis digitorum, extensor carpi ulnaris, anconeus and supinator radii brevis; by the internal condyle, to a tendon common to the pronator radii teres, flexor carpi radialis, palmaris longus, flexor carpi ulnaris, and flexor digitorum sublimis.

Articulations.—The humerus articulates with the glenoid cavity of the scapula, and with the ulna and radius.

Ossification.

Ossification.—The humerus begins to ossify soon after the clavicle, and some time before the vertebræ. From a small cylindrical piece, appearing at the middle, the formation of bone extends towards the extremities, involving the entire shaft.

Fig. 47.*

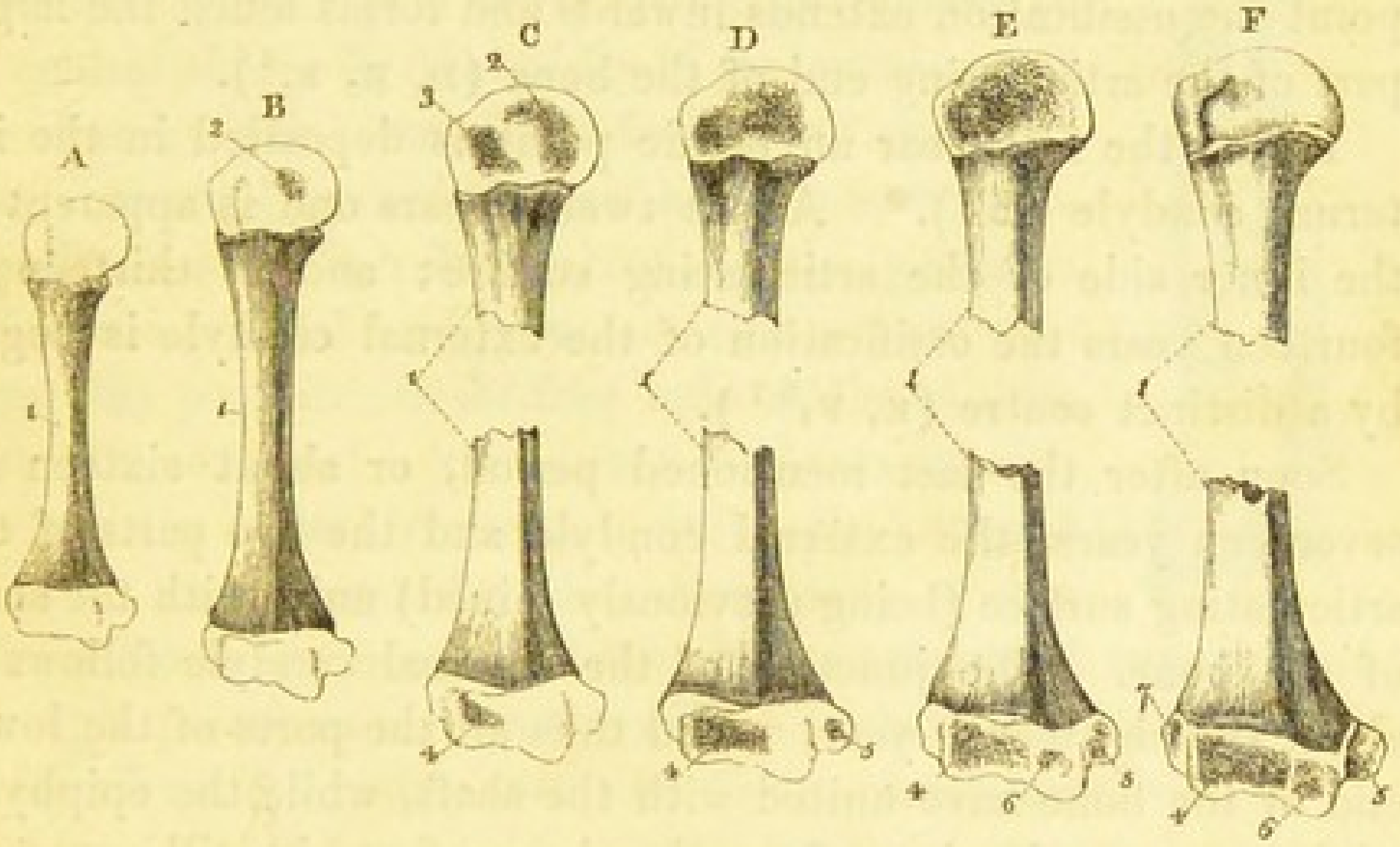

The shaft.

At the end of fœtal life the shaft of the humerus is ossified nearly in its whole length, and its ends are altogether cartilaginous. (fig. 47, A.)

Upper end.

There is a trace of bony deposit in the head of the bone towards the close of the first year after birth, and in the course of the second year a distinct nucleus has formed in this part (B^{2}). Between the second and third years a separate centre is deve-

---

* Several stages in the ossification of the humerus are shown in these figures. That marked A, is the representation of the bone of a full-grown fœtus. B. The condition of the bone at about two years of age. C. The bone in the third year. D. At the beginning of the fifth year. E. The state of the bone about the twelfth year. F. This bone is from a person about the age of puberty.—1. The primary piece. 2. Nucleus for the head. 3. That for the tuberosities. 4. For the outer side of the lower articulating surface. 5. For the inner condyle. 6. The inner part of the lower articulating surface. 7. The external condyle.

N. B. The separated centres of the upper extremity of the bone in figure C, have not been drawn from a preparation.

Some of the bones are represented in two parts, in order to make up in some degree for the absence of the proper proportion in their dimensions.

loped for the tuberosities (c^3). (Béclard mentions two—one for each tuberosity,—the second being very small and appearing after the fourth year.) The osseous nuclei of the head and tuberosities enlarge, join, and form a large epiphysis before the fifth year. (fig. 47, D.)

Lower end.

The growth of the lower end of the bone is more complicated. It begins, after the expiration of the second year, in the outer part of the articular surface—the small head (c^4), and from this point the ossification extends inwards and forms much the larger part of the articulating end of the bone (D, E, F,^{4}).

Before the fifth year an ossific point is deposited in the internal condyle (D^5).* About twelve years one is apparent in the inner side of the articulating surface; and at thirteen or fourteen years the ossification of the external condyle is begun by a distinct centre (E, F,$^{6\ 7}$).

Soon after the last mentioned period, or about sixteen or seventeen years, the external condyle and the two parts of the articulating surface (being previously joined) unite with the shaft of the bone. The junction of the internal condyle follows at about the eighteenth year. And thus all the parts of the lower end of the bone have united with the shaft, while the epiphysis of the upper end, whose formation began first, is still separate. Lastly, this too is no longer separable, and the bone is complete about the twentieth year.

THE RADIUS.

Radius; its length, position, form.

The radius, fig. 48,[1] shorter than the ulna by the length of the olecranon process, is placed at the external side of the fore-arm, extending from the humerus to the carpus. It is broader below than above, slightly curved in its form, and divided into a body and two extremities.

The shaft triangular.

As *the body*, or *shaft*, is somewhat triangular, we observe on

---

* As the date mentioned for the appearance of this centre of ossification is much earlier than that assigned by writers who treat of this department of anatomy, it may be well to state, that in one preparation in my collection, which was taken from a boy ascertained to have been a little over six years of age at the time of his death, the ossification of the inner condyle is well advanced;—and that in another—the arm of a female child which I amputated in consequence of an accident on the day after it had attained the fifth year—a small osseous granule is distinctly formed in the same part.

Fig. 48.*

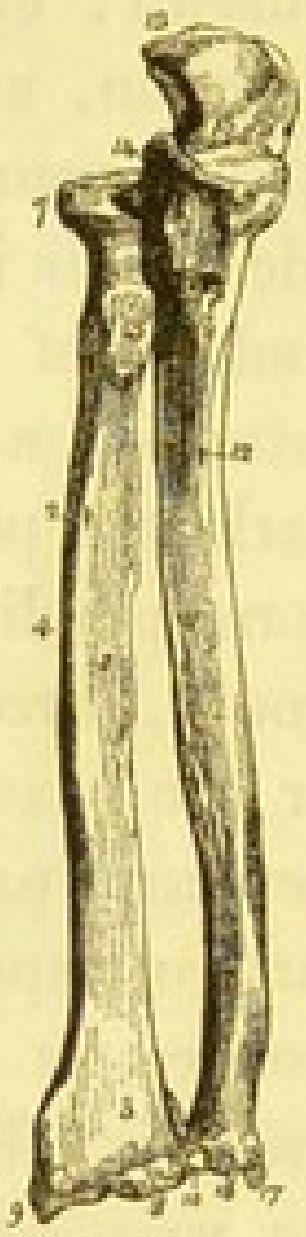

Anterior surface. Medullary foramen. Posterior surface. External surface. The margins.

it three surfaces, bounded by three margins, or ridges. The *anterior surface*,[1] expands towards the lower part, and is marked along its middle by a longitudinal groove for the flexor pollicis longus; superiorly is situated the foramen,[2] for the medullary vessels, its direction being from below upwards; and inferiorly a flat surface,[3] corresponding with the pronator quadratus. The *posterior surface*, convex in the greater part of its extent, is grooved at its central third, for the origin of the extensors of the thumb; the *external surface*, round and convex, is marked towards its middle by a rough impression,[4] which gives insertion to the pronator radii teres. Of the *margins* separating these surfaces, the posterior is distinct only at the middle part; the external is round, and becomes smooth towards the lower extremity; whilst the internal is acute and sharp, for the attachment of the inter-osseous ligament. The body is terminated superiorly by a rough prominence,[5] (tuber radii,) termed the *bicipital tuberosity*, from its giving insertion to the biceps muscle.

Bicipital tuberosity.

The upper extremity; neck, head, its concave articular surface.

Above the tuberosity the bone becomes narrowed and constricted into the form of a *neck*, which is again surmounted by the *head*,[7] intended by its extremity to articulate with the round convex part of the lower extremity of the humerus, its small head (condyle, Chauss.), while its margin rolls on the lesser sigmoid cavity of the ulna. The margin is smooth and convex; the upper surface, also smooth, is a shallow cup-like cavity; and both are covered with cartilage in the recent state.

The lower extremity.

The radius at its lower part becomes broad and thick; the anterior surface is flat and expanded, being covered by the pronator quadratus muscle; it is bounded below by a prominent

---

* The radius and the ulna of the right side viewed in front. 1, is on the middle of the radius—its anterior surface. 2, points to the medullary foramen. 3. A flat surface near the lower end. 4. A rough impression for the pronator teres muscle. 5. The bicipital tuberosity. 7. The head. 8. The lower margin. 9. The styloid process. 10. Articulating surface for the ulna. The remaining numbers are affixed to the ulna. 11. The anterior surface. 12. The medullary foramen. 13. The olecranon. 14. The coronoid process. 15. The large sigmoid notch. 16. The head. 17. The styloid process.

Grooves for tendons.

extensor

The styloid process.

Lateral articular surf.

Carpal articular surf.; its shape;

division into two parts.

line,[8] which gives attachment to the anterior ligament of the wrist-joint. The posterior surface is convex, and marked by longitudinal grooves, which transmit the tendons of the extensor muscles; of these, one, which is very narrow and oblique in its direction, and nearly in the middle line, lodges the tendon of the extensor pollicis (secundi internodii). At the inner or ulnar side of this is placed another, much broader, which transmits the tendons of the extensor communis and indicator; and at its outer side a third, divided into two parts by a linear impression, marks the passage of the ~~flexor~~ carpi radialis, longior and brevior. Corresponding with the external border of the bone is another groove, directed obliquely forwards, and divided into two parts, for the tendons of the extensores—primi internodii and ossis metacarpi pollicis. The outer side of the bone, particularly the part corresponding with the ridge which separates the two latter grooves, is prolonged downwards, and named the *styloid process*;[9] it affords attachment to the external lateral ligament of the wrist-joint. On the inner side of the bone is situated a small cavity,[10] (semi-lunar,) covered by cartilage, which articulates with the inferior extremity of the ulna. At its inferior extremity the radius presents its carpal articulating surface, scaphoid (navicular), which is included between the base of the styloid process and the oval cavity just mentioned, bounded before and behind by two rough margins for the attachment of the radio-carpal ligaments. It is divided from before backwards, by a line, into two unequal portions, of which the external is triangular, and articulates with the scaphoid bone; the internal is square, and articulates with the semi-lunar.

Muscular attachments.

Attachments of muscles.—The anterior surface of the body, by its grooved part, to the flexor longus pollicis; by the oblique line, leading from the tuberosity to the insertion of the pronator radii teres, to the supinator brevis and flexor sublimis; its inferior fifth to the pronator quadratus; the posterior surface, by a slight concavity in the middle, to the extensores pollicis; the external margin, by a rough surface, to the pronator teres; inferiorly, to the pronator quadratus and the supinator radii longus; whilst the posterior part of the bicipital tuberosity gives attachment to the biceps muscle.

Connexion with other bones.

Articulations.—The radius articulates with the humerus, the ulna, the scaphoid and semi-lunar bones.

Fig. 49.*

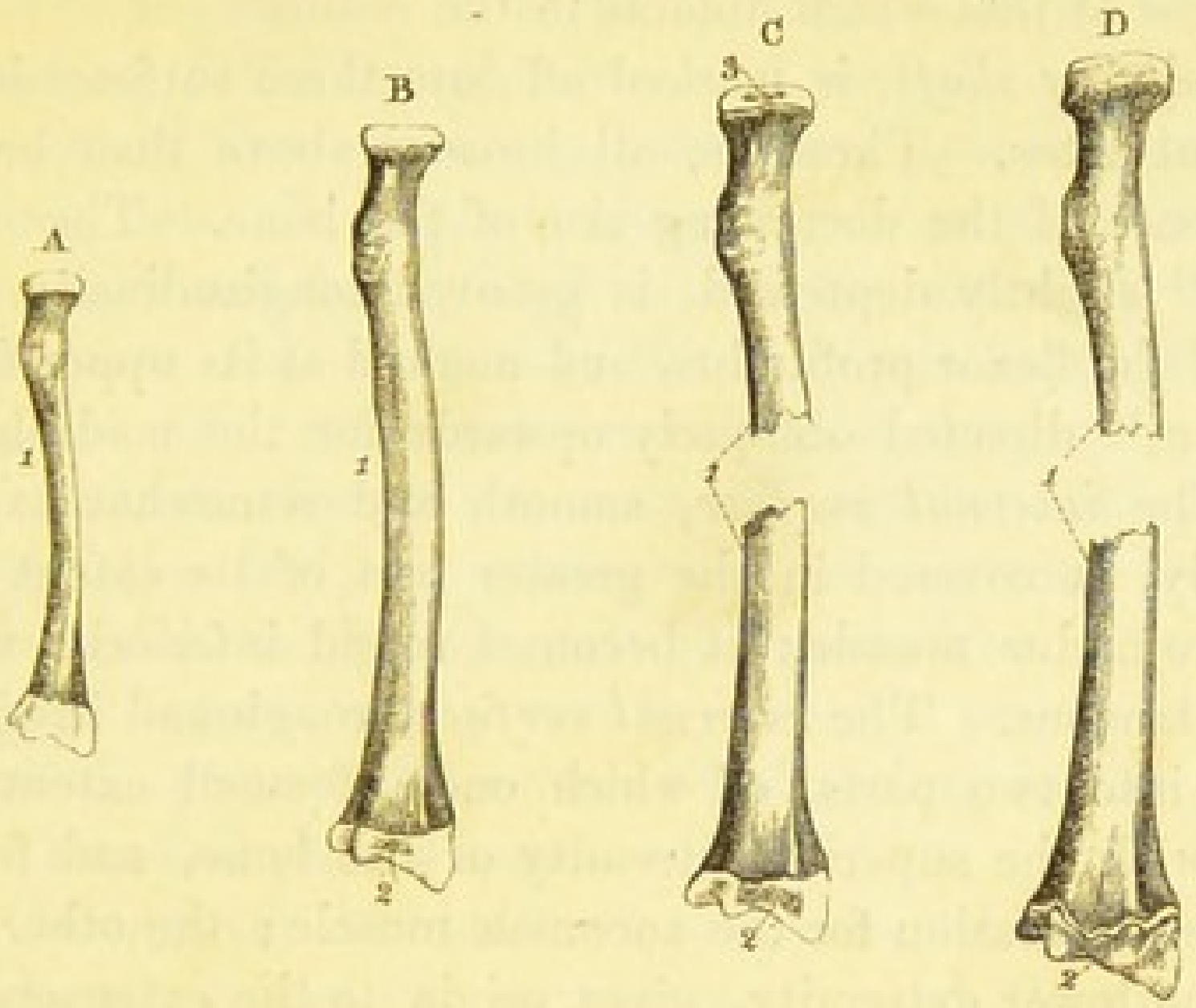

Ossification.—The radius is formed from three points of ossification. In the shaft osseous matter begins to form at its middle immediately after the process has commenced in the humerus, and before the vertebræ. The ossification from this centre extends nearer to the upper than to the lower end of the bone.

Ossification.

At the ordinary time of birth the radius is ossified except the ends, which are both cartilaginous.

A nucleus is deposited in the lower end in the course of the end of the second year, and in the upper one before the fifth year.† The epiphysis formed from the latter is flat and very thin. It joins the bone about the age of puberty. The lower epiphysis, of greater size, is united about the twentieth year.

THE ULNA.

The ulna; position, length.

The ulna, fig. 48, (ωλενη, cubitus,) is placed at the inner side of the fore-arm; it is a long and rather irregular bone,

---

* A. The radius of a full-grown fœtus. B. That bone at about two years of age. C. At five years. D. About eighteen years. 1. The primary piece. 2. The ossific point or epiphysis of the lower end. 3. That of the upper end.

† This statement differs widely from those of Meckel and Béclard. The former mentions seven years, and the latter eight or nine, as the time at which the upper epiphysis begins to ossify. The period stated in the text has been fixed on after repeated observation.

larger at the upper than at the lower extremity,—a conformation the reverse of that which obtains in the radius.

The shaft;
its anterior surface.
Medullary foramen.
Internal surface.
External surface.
The margins.

Its *body*, or *shaft*, is marked off into three surfaces by three prominent lines. These are all broader above than below, in consequence of the decreasing size of the bone. The *anterior surface*,[11] slightly depressed, is grooved longitudinally for the origin of the flexor profundus, and marked at its upper third by a foramen,[12] directed obliquely upwards for the medullary vessels. The *internal surface*, smooth and somewhat excavated superiorly, is covered in the greater part of its extent by the flexor profundus muscle; it becomes round inferiorly, where it is subcutaneous. The *external surface*, rough and irregular, is divided into two parts, of which one, of small extent, corresponds with the superior extremity of the bone, and forms an elongated depression for the anconeus muscle; the other, reaching to the lower extremity, gives origin to the extensors of the thumb and the supinator radii brevis. Of the three *margins*, the internal and posterior are round, and, for the most part, smooth; the external is sharp, and gives attachment to the inter-osseous ligament.

The upper extremity;
olecranon is partly subcutaneous;
coronoid process;

At the *superior extremity* of the bone are situated two eminences, so placed as to bound the cavity by which it articulates with the humerus. Of these, one called olecranon,[13] (ωλενη, ulna; κϱᾶνον,) is nearly on a line with the shaft of the bone; the other, the coronoid process,[14] (κοϱωνη, a crow's beak; ειδος,) projects from its anterior surface. The *olecranon* terminates in a rough tuberosity and an obtuse point; the former giving insertion to the triceps extensor; the latter being lodged, when the arm is extended, in the posterior cavity at the end of the humerus. Anteriorly, this process is smooth and hollowed out, to form part of the surface of articulation with the humerus; posteriorly, it presents a flat triangular surface, which is subcutaneous. The *coronoid process*, by a gentle ascent, rises upwards and forwards from the anterior surface of the bone, and terminates in a sharp ridge, which overhangs the articular surface, and is received during flexion into the anterior depression in the humerus; its anterior surface, rough and triangular, gives insertion to the brachialis anticus muscle; its upper aspect is smooth and excavated: its inner border gives attachment to the internal lateral ligament; the external is hollowed into a smooth two sigmoid cavities, greater and smaller.

depression, the *smaller sigmoid cavity*, which articulates with the head of the radius. The *great sigmoid cavity*,[15] formed by the junction of the smooth surfaces of these two processes, has been so named from some supposed resemblance to the form of the Greek letter Σ (*σιγμα, εἶδος*, form), as it was originally written. Covered by cartilage in its entire extent, it is divided into two parts (but unequally, the inner one being the larger,) by a smooth ridge running downwards from the peak or point of the olecranon to that of the coronoid process. This ridge and the concavities beside it correspond, the one with the groove, the others with the lateral parts of the trochlea. At the margins of the sigmoid cavity may be observed two notches which mark off the parts of the surface which belong to the olecranon and the coronoid process respectively.

The lower extremity; the head, styloid process and intervening depression.

At the *inferior extremity* of the bone, which is small and rounded, are situated two eminences, of which the external one, named the *head* of the ulna,[16] round and covered with cartilage, presents two aspects, of which one, nearly circular in its form, looks towards the wrist-joint, and corresponds with the triangular fibro-cartilage of that articulation; whilst the external one, narrow and convex, is received into the semi-lunar cavity in the contiguous border of the radius. The internal eminence,[17] named the *styloid process*, projects on a line with the posterior and inner surface of the bone; it is elongated in its form, and gives attachment to the internal lateral ligament of the joint. The head and the styloid process are separated posteriorly by a groove, which is traversed by the tendon of the extensor carpi ulnaris, and inferiorly by a depression at the base of the styloid process, into which the triangular fibro-cartilage is inserted.

Muscular attachments.

Attachments of muscles.—The anterior surface, superiorly, and in the middle, gives attachment to the flexor digitorum profundus; inferiorly, to the pronator quadratus; the posterior surface, to the anconeus, the extensor carpi ulnaris, supinator radii brevis, the extensores pollicis, and the extensor indicis; by the posterior longitudinal line, to an aponeurosis common to the flexor carpi ulnaris, flexor digitorum profundus, and extensor carpi ulnaris. The superior extremity, by the summit of the olecranon to the triceps brachialis; the coronoid process, by its anterior rough surface, to the brachialis anticus; and by its internal side, to the second origin of the pronator teres.

Connexion with other bones.

Articulations.—The ulna articulates with the humerus and the radius; it has no point of contact with the carpal bones, but it is brought into relation with the cuneiform bone by means of the inter-articular fibro-cartilage.

Fig. 50.*

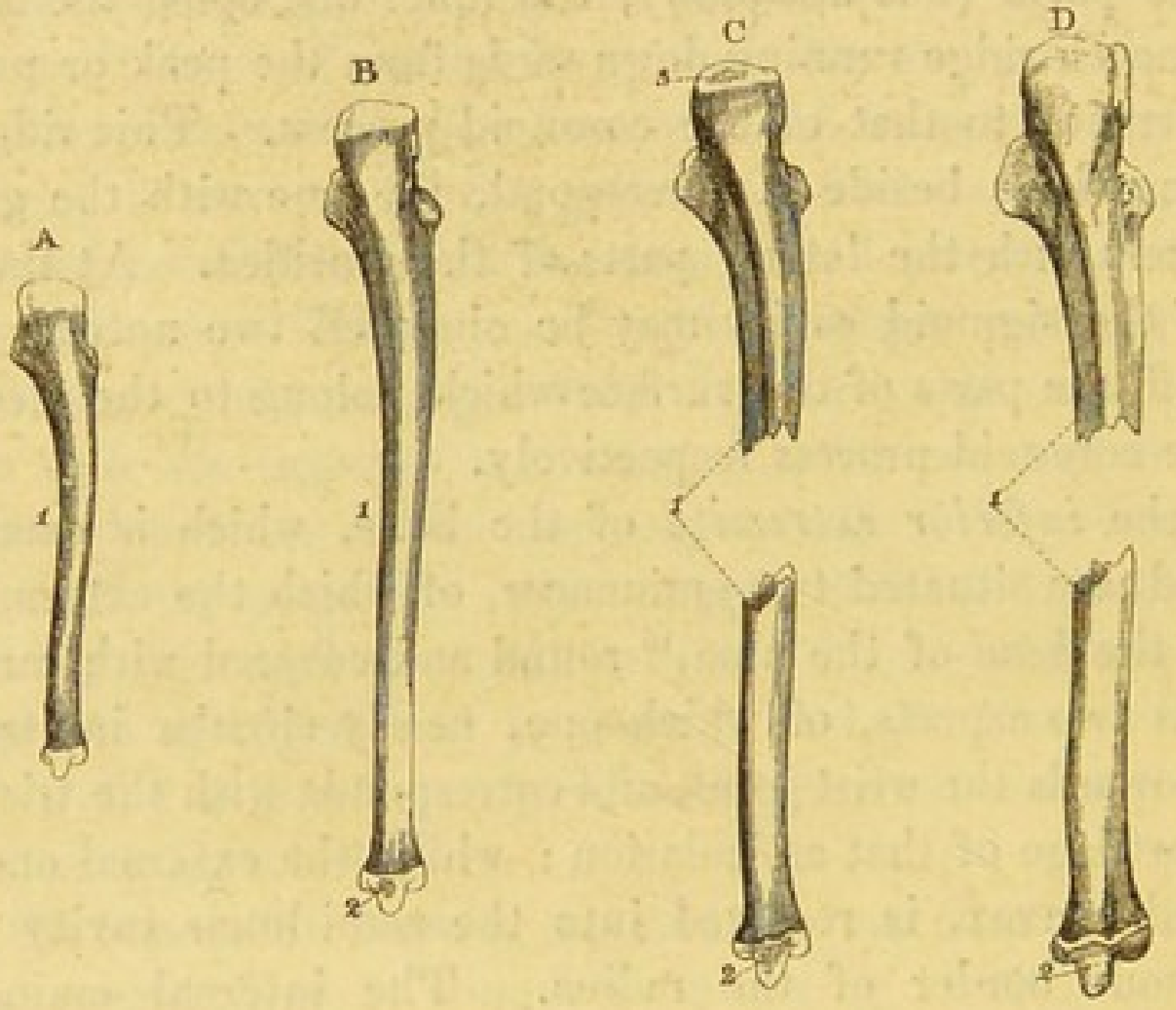

Ossification.

Ossification.—The ulna begins to ossify both in the shaft and the epiphyses a short time after the radius.

The ends are cartilaginous at birth. In the fourth year (sometimes later) a granule of bone forms in the lower end. It appears in the middle of the head, and afterwards extends to the styloid process.

The upper epiphysis is very small, the greater part of the olecranon being formed from the original centre of ossification. Ossific matter is perceptible in this part at the tenth year or soon after.

The epiphyses join:—the superior about the sixteenth year of age, and the inferior one about the twentieth year.

---

* A. The ulna of a fœtus born at the usual period. B. The bone of a child at the end of the fourth year. C. From a boy arrived at about twelve years. D. The bone of a male person at nineteen or twenty years of age.

1. The primary piece. 2. The nucleus for the lower end, or epiphysis. 3. The epiphysis of the upper end.

THE HAND.

Divisions of the hand.

The hand is composed of the carpus, metacarpus, and fingers.

CARPUS.

Carpus; situation, formed of two ranges of bones.

The first or superior part of the hand is named the carpus or wrist, fig. 52; it is placed between the fore-arm and the metacarpus, and composed of eight small bones, which are disposed in two ranges, each consisting of an equal number. Proceeding in the enumeration from the radial to the ulnar side, the bones which constitute the first or superior range are thus named from their shape—scaphoid[1], semi-lunar[2], cuneiform[3], and pisiform[4]; those of the second or inferior range are the trapezium[5], trapezoid[7], os magnum[8], and unciform[9].

The dorsal surface of the carpus is convex, the palmar concave and irregular, and marked by four bony prominences, across which is stretched the anterior annular ligament, so as to form a canal for the transmission of the flexor tendons.

BONES OF THE FIRST ROW OF THE CARPUS.

THE SCAPHOID BONE.

Scaphoid;

Fig. 51.*

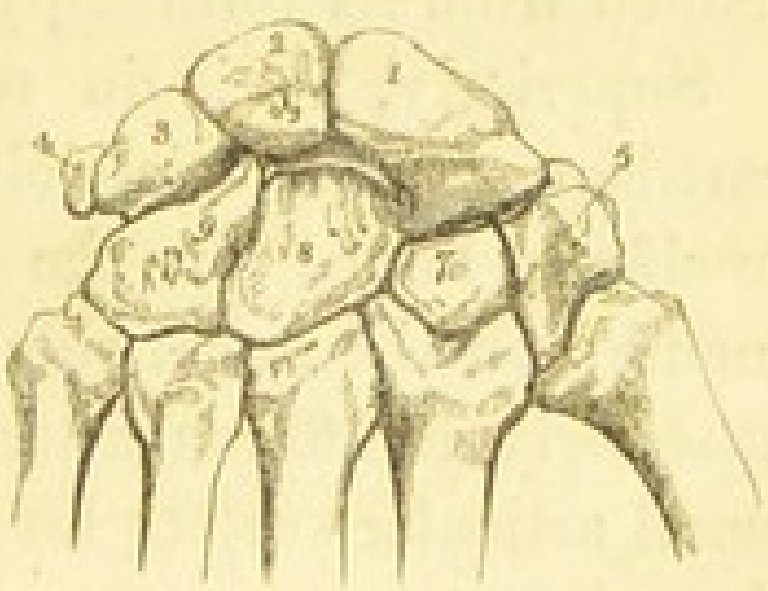

The scaphoid, fig. 51[1], (σκαφη, a boat,)—named also os naviculare: cotyloides—is the first of this row and the largest. Its position is oblique, so that its broad end is directed towards the trapezium and root of the thumb, whilst the narrow one inclines inwards and upwards to the middle of the articular surface of the radius.

position,

shape.

It is convex on one side, concave

---

* The bones of the carpus, with a portion of each of the metacarpal bones. 1. Scaphoid. 2. Semi-lunar. 3. Cuneiform. 4. Pisiform. 5. Trapezium. 6. A ridge on the trapezium (see fig. 52). 7. Trapezoid. 8. Os magnum. 9. Unciform.

on the other. The concave or hollowed (scaphoid) surface looks obliquely inwards and forwards, and is that which determines the form and gives name to the bone. Its upper articular surface, convex and triangular, is applied to the radius; the lower, also convex, articulates with the trapezium and the trapezoid bone. Its concavity receives part of the head of the os magnum; close to this is a narrow articular surface which is in contact with the semi-lunar bone; on its radial side is a rough surface, to which is attached the external lateral ligament of the wrist-joint; posteriorly is a narrow grooved surface for the attachment of ligaments; and anteriorly is a rough surface, the inner or ulnar half of which is narrow and slightly grooved, whilst the outer is prominent and tuberculated for the attachment of ligaments. It articulates with five bones.

Connexions of its surfaces.

THE SEMI-LUNAR BONE.

Semi-lunar.

The name of this bone[2] is taken from its being concave or crescentic on its inferior surface. Irregularly triangular in its form, convex superiorly, it articulates with the square part of the articular surface of the radius; inferiorly concave, with the os magnum and the unciform; on the ulnar side with the cuneiform; on the radial side with the scaphoid; anteriorly and posteriorly it gives attachment to ligaments. It articulates with five bones.

Connexion with other bones.

THE CUNEIFORM BONE.

Cuneiform.

This is the "wedge-shaped" bone[3]; sometimes also it is named from its form "pyramidal," as well as "os triquetrum."

Superiorly, it is in relation with the inter-articular fibro-cartilage of the wrist-joint; inferiorly, it articulates with the unciform bone; on the ulnar side, gives attachment to ligaments; on the radial side, articulates with the semi-lunar bone; anteriorly it affords attachment to ligaments, and presents a small articular surface for the pisiform bone. It articulates with three bones.

THE PISIFORM BONE.

Pisiform.

The "pea-shaped" bone[4] is placed on a plane anterior to the other bones of the carpus, and might more fitly be considered as an appendage to the tendon of a muscle—a sesamoid bone—than as a portion of the frame-work of the carpus.* The form is indicated by its name (pisum, a pea), and to it is due another designation—os subrotundum. It presents but one articular surface, which is situated on the posterior part, or base, and rests on the anterior surface of the cuneiform bone. It affords attachment to the annular ligament of the carpus, to the flexor carpi ulnaris muscle, and to the abductor of the little finger.

Adaptation of the first range to the second and to the fore-arm.

The first three carpal bones form, when in apposition, a rounded convex surface, which corresponds with the concavity presented by the radius and the inter-articular cartilage. The greater part of their lower surface constitutes a deep hollow, which receives the head of the os magnum and a small part of the unciform bone; and on the outer side a part of this range (the lower convex surface of the scaphoid) is received into a slight depression of the second row, formed by the trapezium and trapezoid. (See figure 51.)

BONES OF THE SECOND ROW.

THE TRAPEZIUM.

Name.

The name of this bone[5] is taken from its presenting four unequal edges at its posterior aspect, and it has also been known as the "os multangulum majus." It is placed at the radial border of the carpus, between the metacarpal bone of the thumb and the scaphoid bone. It is known by the angular appearance of its dorsal surface, and by the tubercle and groove at its palmar aspect.

How distinguished.

Superiorly concave, it articulates with the scaphoid bone; inferiorly, concave from behind forward, and convex transversely, with the first metacarpal bone; on the ulnar side, with the trapezoid bone, and, by a small surface situated more inferiorly, with the edge of the second metacarpal bone; on the radial and posterior sides it gives attachment to ligaments; anteriorly it presents a groove[6] traversed by the tendon of the flexor carpi

Groove and ridge.

---

* "Carpo extra ordinem appositum est, assidens patellæ in modum, aut sesamoidei."—" B. S. Albini de sceleto hum. liber," p. 410.

radialis, and a ridge to which the annular ligament of the carpus is attached. It articulates with four bones.

THE TRAPEZOID BONE.

Small size.

This is a small bone[7] compared with those between which it is placed, viz. the trapezium, scaphoid, and os magnum; in form and position it has some resemblance to a wedge, and but little to a trapezium, except that its posterior surface is bounded by four unequal edges. In contradistinction to the preceding bone, this received the name "os multangulum minus."

Name.

It articulates superiorly with the scaphoid bone; inferiorly, with the second metacarpal bone; on the ulnar side with the os magnum; on the radial side, with the trapezium: the anterior and posterior surfaces afford attachment to ligaments. It articulates with four bones.

OS MAGNUM.

Name.

"Head" and "Neck;"

connected with three metacarpal bones.

This[8] is the largest of the carpal bones; its form is oblong, round superiorly, cubic inferiorly; the superior surface, named its "head," (whence it is sometimes called "os capitatum,") is supported by a narrowed portion, named the "neck;" its greatest convexity is in the antero-posterior direction, where it is received into a cavity formed by the scaphoid and the semi-lunar bone; it articulates, inferiorly, by three distinct surfaces, of which the middle is the largest, with the second, third, and fourth metacarpal bones; on the ulnar side, with the unciform bone; on the radial side, with the trapezoid bone: the anterior and posterior aspects are rough (particularly the former) for the attachment of ligaments. It articulates with seven bones.

THE UNCIFORM BONE.

Unciform; its "hook."

The "hook-shaped" bone[9] (uncus, a hook,) is readily distinguished from the rest by the curved process[10] upon its palmar surface: it articulates, superiorly, with the semi-lunar bone; inferiorly, by two distinct surfaces, with the fourth and fifth metacarpal bones; on the ulnar side, with the cuneiform bone; on the radial side, with the os magnum: anteriorly its hooked process affords attachment to the anterior annular ligament of the carpus; posteriorly a rough surface also gives attachment to ligaments. It articulates with five bones.

THE METACARPUS.

Fig. 52.*

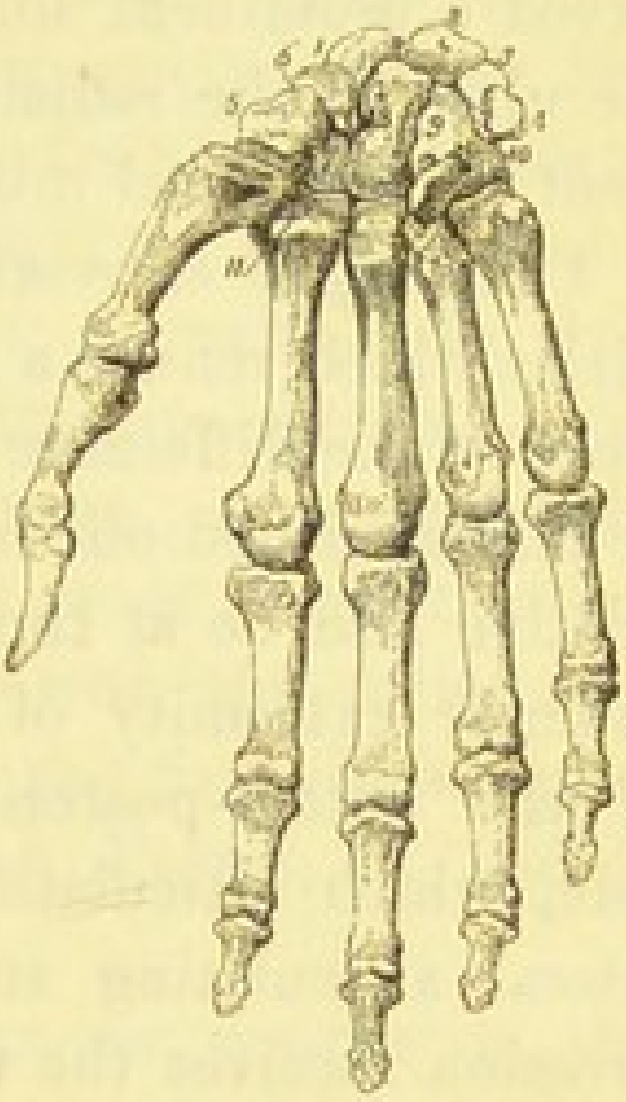

Metacarpal bones;

This forms the second or middle portion of the hand, being situated between the carpus and the phalanges; it is composed of five bones, which are named first, second, &c. in their numerical order, the enumeration being commenced at the radial side. These bones are placed parallel one with the other, and nearly on the same plane, with the exception of the first, which is more anterior than the rest, and alters in its relative position to them in its various movements.

their differences in size.

The metacarpal bones vary in size. The first is thicker and shorter than the others. The second and third do not differ strikingly one from the other in dimensions, and they are longer than the rest. The fourth exceeds the fifth in size. They are all slightly concave on the palmar surface, convex on the dorsal, larger at their extremities than in the body or middle part, terminated at the carpal extremity by an unequal eminence, and at the digital by a rounded head.

Bodies. Shape.

The *bodies* are triangular in shape; each presenting three surfaces, and as many borders. Of the surfaces, two are placed laterally, the third looks backwards; one of the angles is in front, and the others at each side of the dorsal surface. From this shape and position of the sides, it results that the bones become narrow towards the palmar aspect of the hand, and that the spaces between them (*interosseous*) increase from behind forward.

Interosseous spaces.

First, distinguished.

The body of the first metacarpal bone wants the triangular shape of the others; it is more compressed from before back-

---

* The bones of the hand—carpus, metacarpus, and fingers—seen on the palmar surface. For explanation of the numerals on the carpal bones, see note, page 129.

wards, and resembles one of the phalanges in shape. There are some slight peculiarities of the dorsal surface in the several metacarpal bones. It is convex and smooth in the first, and presents in the second, third, and fourth, a longitudinal line, which, bifurcating, forms the sides of a triangular surface, extending over two-thirds of their length; in the fifth, also, is observed a prominent longitudinal line, directed, obliquely, from the ulnar to the radial side. The lateral surfaces afford attachment to the dorsal interosseous muscles.

Bases are characteristic.

The *carpal extremity* (*base*) presents, in each, some peculiarities which render a separate description necessary.—By reference to the difference of their carpal extremities, the bones may be distinguished one from the other, and the more readily if their relative size be at the same time taken into account. On the superior extremity of the first is observed a surface, concave in the antero-posterior direction, and convex from side to side, which articulates with the trapezium; this bone has no lateral articulating surface.—In the second, an angular depression receives the trapezoid bone, and, on the radial side, a small surface articulates with the trapezium; at the ulnar side, the margin is extended obliquely backwards, so as to become wedged in between the trapezoid and the third metacarpal bone, and articulates by its tip with the os magnum.—On the third, a nearly plane surface articulates with the os magnum; on the radial and ulnar sides are surfaces for articulation with the contiguous metacarpal bones.—Two articular surfaces of the fourth join with the os magnum and unciform; the radial side has two surfaces, and the ulnar side one, for articulation with the corresponding surfaces of the bone on each side.—On the fifth, a concave surface, directed outwards, corresponds with the unciform bone; at the radial side is a surface for the fourth metacarpal bone, and on the opposite side there is a prominence without an articular surface.

Base of first; of second; of third; of fourth; of fifth.

Heads.

The *digital extremities* (*heads*) of all are convex, and articulated with the phalanges, the smooth surfaces extending farther on the palmar than on the dorsal aspect of the bones; and on the sides of these are inequalities for the attachment of ligaments.

BONES OF THE FINGERS.

These are fourteen in number; each, with the exception of the thumb, having three separate pieces (*phalanges, internodia*). Of these the first is longer than the second, and the second than the third. Like other long bones, each is divided into a body and two extremities, of which one represents the base and the other the head. Winslow and some other anatomists reckon three phalanges in the thumb, as they conceive that its posterior, or most moveable bone, resembles the first phalanges of the fingers, rather than the metacarpal bones. But if its conformation be examined with attention, more especially that of its anterior extremity, and also its mode of articulation with the bone in front of it, its analogy with the metacarpal range will appear more striking than with the first digital phalanges; and so it is considered by Meckel, Portal, H. and J. Cloquet.

Phalanges; their number.

Has the thumb three phalanges?

The *bodies of the first row* or phalanx are convex on the dorsal surface, and flat from side to side on the palmar, but arched from before backwards; the palmar surface is bounded by two margins which give insertion to the fibrous sheaths of the flexor tendons.

The first row;

The larger or *posterior extremities* present an oval concave surface, whose greatest diameter is from side to side, intended to receive the convex heads of the corresponding metacarpal bones. The *anterior extremities*, smaller than the other, end in two small lateral condyles, with a slight groove between them, both being adapted to the base of the contiguous bones, so as to form ginglymoid, or hinge joints. The articular surface is prolonged farther on the palmar than on the dorsal aspect, which allows a more free range to the motion of flexion. The margins of the articular surfaces are rough and prominent for the attachment of ligaments.

their terminal articular surfaces.

The *second* or *middle row* consists of four bones, the thumb having only two pieces corresponding with those of the first and last phalanx. Smaller than the preceding set, they still resemble them in their general outline. The broader, or posterior extremity, ends in an articular surface, divided by a slight ridge extending from before backwards, the lateral parts being con-

The second row;

posterior articular surface.

cave, for the reception of the two eminences on the contiguous bone; the anterior extremity is divided into two lateral convex surfaces, which are lodged in depressions in the base of the last phalanx.

The third row.

The *third row* (phalanges unguium,) consists of five pieces, that of the thumb being the largest. They are convex on the dorsal, flat on the palmar surface, rough at the summit, which corresponds with the points of the fingers, and at the base, for the attachment of ligaments and the flexor tendons. The articular surface, at the base, resembles that of the base of the second phalanx, in having two shallow concavities divided by a central convex line.

Muscular attachments to the carpus;

Attachments of muscles.—1. To the carpal bones. The *pisiform* bone gives origin to the abductor minimi digiti, and insertion to the flexor carpi ulnaris; the *trapezium* to the opponens and abductor pollicis; the *trapezoid* to part of the flexor brevis pollicis; the *os magnum* to part of the same; the *unciform* to the flexor brevis minimi digiti and to the adductor.

to the metacarpus;

2. To the metacarpal bones. The *first*, or that of the thumb, gives insertion to the extensor ossis metacarpi pollicis and to the opponens pollicis, and origin to part of the abductor indicis: the *second*, or that of the fore-finger, to the flexor carpi radialis at its palmar end, and to the extensor carpi radialis longior on the dorsal surface of its base, and by its lateral surfaces, to the first two dorsal inter-ossei muscles and one palmar: the *third*, to the extensor carpi radialis brevior, to the adductor pollicis, and also to two dorsal inter-ossei: the *fourth*, to two dorsal inter-ossei and one palmar: the *fifth*, to the extensor carpi ulnaris, and the adductor or opponens minimi digiti, to one dorsal and one palmar inter-osseous muscle.

to the phalanges.

3. To the bones of the fingers. Those of the *first* range of the four fingers give attachment by their lateral borders to the tendinous sheaths of the flexor tendons; their dorsal surface is covered by the expansion of the extensor tendons. The bones of the *second* row give insertion at their dorsal surface to the tendons of the extensor communis; the tendons of the flexor sublimis are inserted into their bases at the palmar surface. The *third* set gives insertion to the tendons of the flexor profundus; the fibres of the extensor communis are also continued on their dorsal aspect.

The *first* phalanx of the thumb gives insertion to the extensor primi internodii, to the flexor brevis, to the adductor and abductor pollicis: the *second* phalanx to the flexor longus, and to the extensor secundi internodii.

OSSIFICATION OF THE CARPAL BONES.

Condition at birth; one year after;

The carpus is altogether cartilaginous at the general period of birth (fig. 53, A). In the course of the first year after, ossification begins in the os magnum, which is followed speedily by the unciform bone (B. [1] [2]).

at three years;

The pyramidal or cuneiform is the next to receive an osseous deposit, and this occurs in the third year (C. [3]).

Fig. 53.*

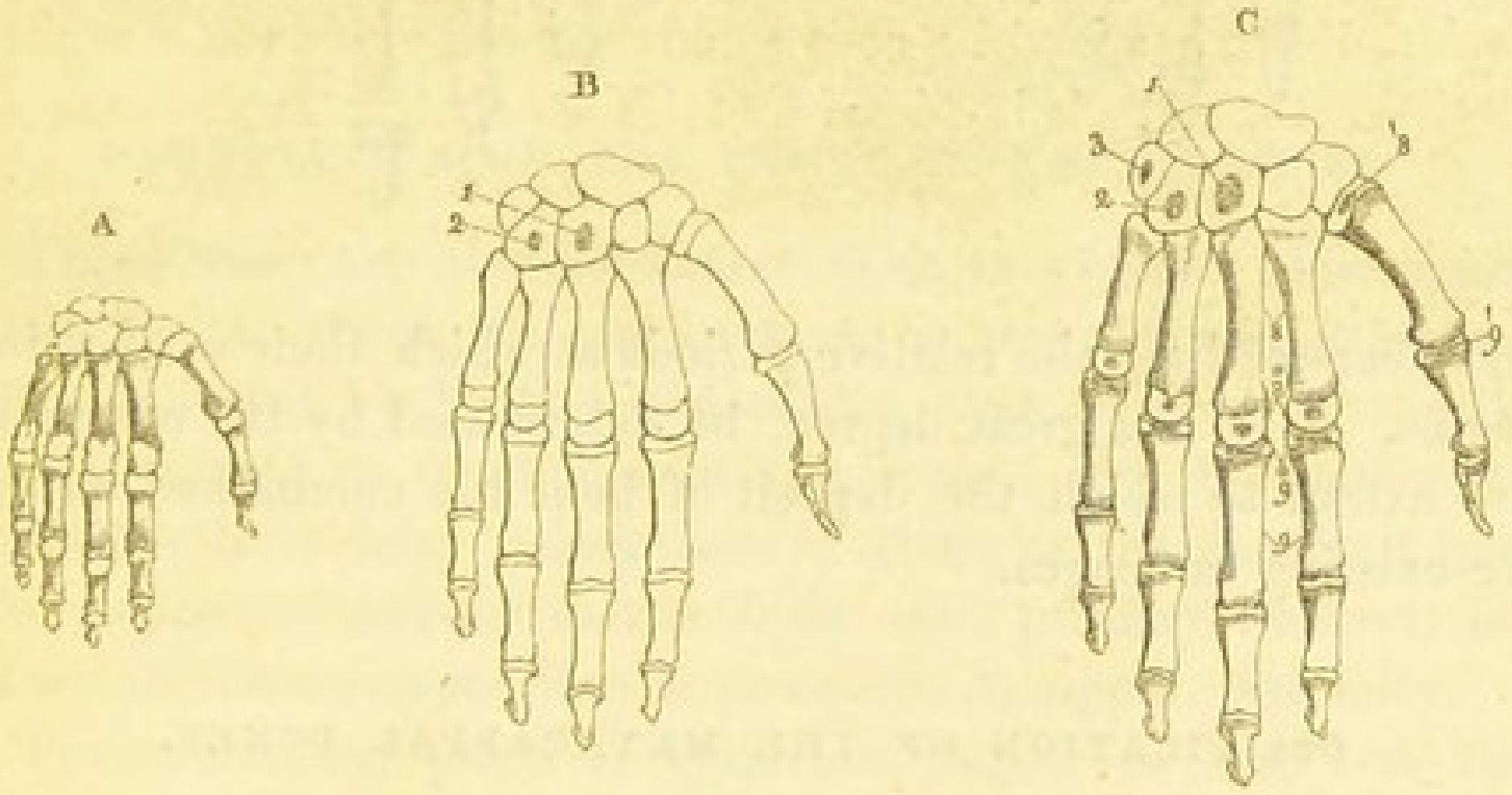

at five;

In the fifth year nuclei are formed in the trapezium and semi-lunar; and, as at the end of that year the nucleus in the former bone is the larger, it is to be inferred that it preceded the other in its growth (D. [4] [5]).

at eight;

At about eight years of age the scaphoid, and soon after the trapezoid, begin to ossify. The granule for the first makes its appearance near the lower end of the bone (E. [6] [7]).

at twelve.

Lastly, the pisiform contains an osseous granule about the twelfth year.

---

* A. The state of the various parts of the hand in a full-grown fœtus is shown in this figure. There is no osseous point in the carpus, but the metacarpal bones and the phalanges are ossified to a considerable extent. B. This figure represents the state of the bones about the end of the first year after birth; C. shows their condition about the third year; D. at the fifth year; and E. about the ninth.

1. Os

Only one centre for each bone.

The carpal bones are formed each from a single centre. It may be observed that, in examining their condition during the first years of life, the relative periods at which their ossification begins, may, in a great degree, be determined by the comparative extent to which the deposit of bone has encroached on the pre-existing cartilages.

Fig. 53 *(continued)*.

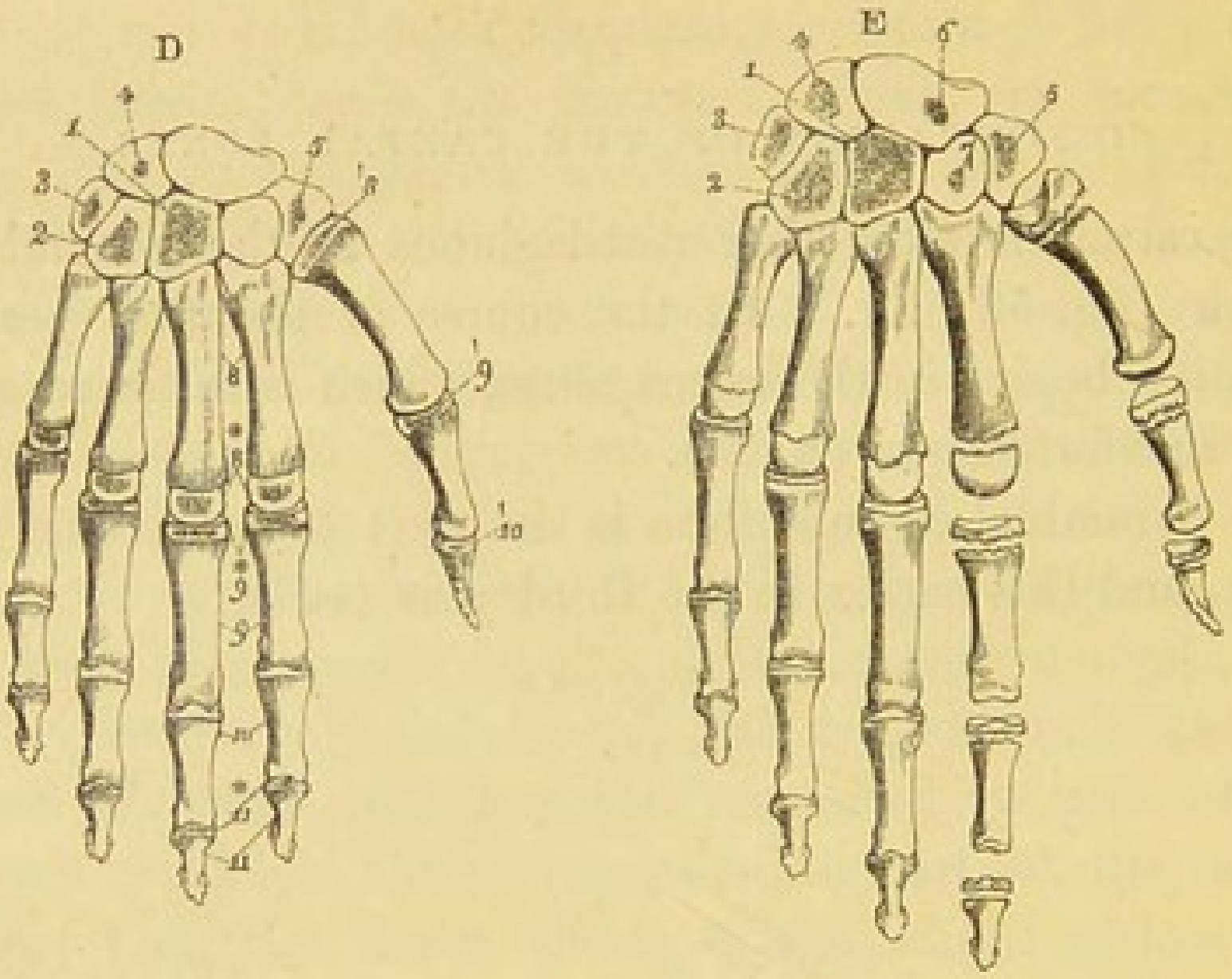

OSSIFICATION OF THE METACARPAL BONES.

Meta-carpus.

Two centres for each bone.

The other parts of the frame-work of the hand differ widely from the carpus in the time at which their ossification commences, inasmuch as the process is far advanced before the end of fœtal life. Each metacarpal bone is formed from two parts,

---

1. Os magnum. 2. The unciform bone. 3. The pyramidal or cuneiform. 4. Semi-lunar. 5. Trapezium. 6. Scaphoid. 7. Trapezoid. 8. Metacarpal bones—the principal piece. 8.* The epiphyses of the metacarpal bones of fingers. 8.¹ The epiphysis of the metacarpal bone of the thumb. 9. The first range of phalanges; 9.* their epiphyses. 9.¹ Epiphysis of the first bone of the thumb. 10. The second row of phalanges. 10.¹ The epiphysis of the second bone of the thumb. 11. The last row of the fingers; 11.* their epiphyses.

N.B. The carpal bones are numbered according to the order of their appearance, except the trapezium and semi-lunar, whose numbers have been accidentally transposed.—An appearance of ossification ought to have been shown in figure D. for the epiphyses of the second range of phalanges.

or of what may be considered a principal piece and an epiphysis. Its ossification begins shortly after the bones of the fore-arm in the middle of the body, and the process extends over the greater part of the bone, including its upper extremity (c. d. e.[8]*). About the third year of age an osseous granule appears in the lower end, and the epiphysis resulting from its increase joins the principal piece before mentioned towards the twentieth year. Such is the mode of construction of the metacarpal bones of the fingers. That of the thumb differs in the position of the epiphysis, which is formed on its upper or carpal extremity, instead of the lower extremity,—this being produced by an extension from the larger or principal piece of the bone (c. d. e.[8]). And thus, in the manner of its growth, as well as in its shape, the metacarpal bone of the thumb assimilates to the phalanges.

Early period of ossification in body.

Epiphysis; its position and time of appearance.

Peculiarity of the first metacarpal bone.

OSSIFICATION OF THE BONES OF THE FINGERS.

These bones are likewise formed from two parts. The ossification begins about the same time as in the metacarpal bones; but it is stated by Meckel and others, that the primary nuclei do not appear in the bones of the second row for some time after they have been perceptible in those of the first and last. The deposit of osseous matter from each primary nucleus, involves all the corresponding bone except its upper extremity.

Each has two centres.

The additional piece or epiphysis begins to ossify at the third or fourth year in the first row, and a year later in the others;* and the bones are completed by the junction of their parts before the twentieth year.

Epiphysis; its position, period of appearance, and union.

---

* The periods assigned by Béclard for the appearance of ossific granules in the epiphyses of the phalanges are as follows:—for those of the first range, three or four years; for the second or middle range, seven years; and for the last, or ungual, four or five years.

Some preparations in my collection demonstrate that the time here connected with the appearance of bone for the epiphyses of the second phalanges cannot be generally correct. One case bearing on the point may be specially referred to, because no doubt could exist concerning the age, or with respect to the previously healthy state of the limb. I amputated the arm of a delicate female child, who on the day before the operation had attained the age of five years. The removal of the limb was rendered necessary in consequence of an injury. In the hand of this child the epiphyses of the three sets of bones of the fingers are advanced in ossification, and proportionally to the size of the cartilage those of the ungual row appear smallest.

INNOMINATE BONE. (OS INNOMINATUM.—OS COXÆ.)

Position.

This bone, fig. 54, is of so complex and irregular a form, that it bears no perceptible resemblance to any other known object, and therefore remains "unnamed" and unnameable. The two bones thus distinguished by the negation of a name are situated at the inferior and lateral parts of the trunk, extending from the sacrum forwards to the median line, where they are connected together. Through the intervention of the sacrum, which is wedged in between them, they receive the weight of the body from the vertebral column, and transmit it to the lower extremities; thus placed, and being somewhat curved in their general outline, they circumscribe the greater part of the cavity of the pelvis, the sides and fore-part of which they form.

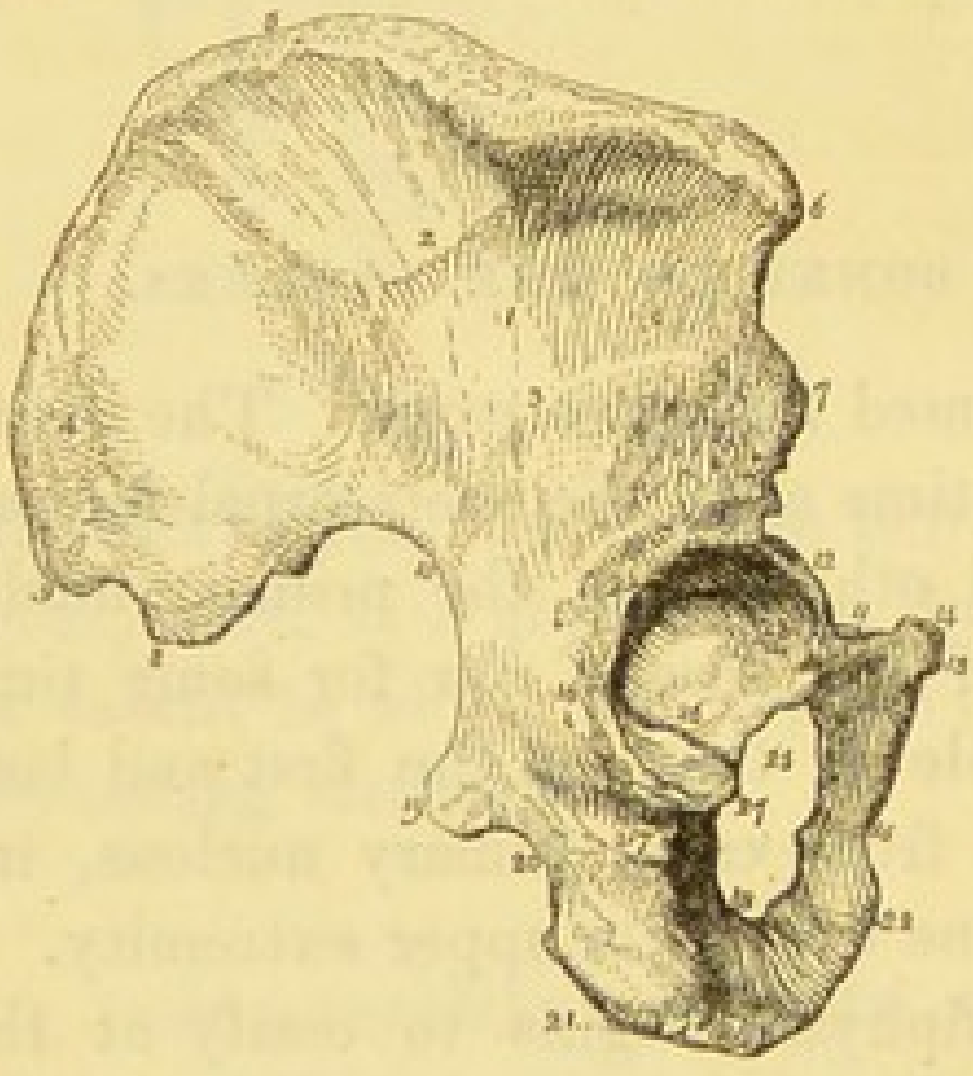
Fig. 54.*

Division into parts.

To facilitate the description of this very irregular bone, it is convenient to consider separately each of the parts into which it is found divided in early life, viz. the ilium, os pubis, and ischium.

---

* The innominate bone of the right side.—1. Dorsum ilii. 2. The superior curved line. 3. The inferior curved line. 4. Surface for the attachment of the gluteus maximus. 5. The crista of the ilium. 6. The anterior superior spinous process of the ilium. 7. The anterior inferior spinous process. 8. The posterior inferior spinous process. 9. The posterior superior spinous process. 10. A notch, which forms part of the sacro-sciatic notch. 11. The horizontal branch of the pubes. 12. The ilio-pectineal eminence. 13. The surface of the pubes, which goes to form the symphysis. 14. The angle of the pubes. 15. Its descending ramus. 16. The body of the ischium. 17. A groove for the obturator externus. 18. Line to which the quadratus femoris is connected. 19. The spine of the ischium. 20. A smooth cartilaginous surface on which the obturator internus turns. 21. The tuberosity of the ischium. 22. Ramus of the ischium. 23. The acetabulum. 24. The brim of the acetabulum. 25. The notch of the acetabulum. 26. The depressed non-cartilaginous part of the acetabulum. 27. The obturator foramen.

THE ILIUM. (OS ILIUM.)

The ilium, or iliac portion of the os innominatum, constitutes the upper part of the bone, where it is broad and expanded; it is situated at the superior and lateral part of the pelvis. Its surfaces, borders, and angles must be considered successively. Ilium;

The external surface (*dorsum*)[1], convex before, concave posteriorly, is marked by two curved lines running from before backwards. The superior one[2], commencing at the anterior superior spinous process, arches downwards to the margin of the sacro-sciatic notch. A space, narrowed before, and wider posteriorly, is included between the line just noticed, the margin of the crista ilii, and the border of the rough surface for the attachment of the gluteus maximus; from this space the gluteus medius arises. The inferior curved line[3] is shorter and less strongly marked than the superior; it commences at the anterior inferior spinous process, and inclines backward to the sacro-sciatic notch. The space between these lines gives origin to the gluteus minimus. On its posterior and superior part is observed a rough surface[4], which gives attachment to the gluteus maximus muscle. The internal surface of the ilium is divided into three parts. One anterior, smooth, concave, and of considerable extent, is called the *iliac fossa;* the posterior one is partly rough and uneven for the attachment of ligaments, and in part smooth for its articulation with the "auricular" surface of the sacrum; whilst the third is smooth, much smaller than the others, and is the only part that enters into the formation of the true pelvis. its dorsum. Curved lines, and spaces between them. Iliac fossa. Articular surface.

The superior border[5], (*crista ilii,*) extending from before backwards, is thick, convex, and arched; it forms an epiphysis in infancy, and is sometimes called the spine of the ilium, but more properly its crest or crista; its anterior extremity curves inwards, the posterior outwards. This border presents an external and internal lip (*labium*), and a rough interval, to each of which muscles are attached. The crista.

The anterior border, depressed and excavated, descends from the superior border or crista towards the os pubis, with which it is continuous; its junction with the crista is marked by a pro- The anterior border.

Anterior spinous processes, superior and inferior.
Ilio-pectin. eminence.

minent point, called the *anterior superior spinous process*[6]; and that with the pubes, by an obtuse elevation, common to the two bones, called the *ilio-pectineal* eminence[12]. This border presents two excavations, separated by a prominent point, called the *anterior inferior spinous process*[7]. The interval between the latter and the ilio-pectineal eminence gives transmission to the iliacus and psoas muscles, and that between the spinous processes transmits the external cutaneous nerve, and gives origin to some fibres of the sartorius muscle.

Posterior spinous processes, superior and inferior.

The posterior border also presents two notches, separated by a prominent point of bone, called the *posterior inferior spinous process*[8]; above which is another bony eminence, called the *posterior superior spinous process*[9]; of the notches, the inferior and larger one[10] contributes to form the sacro-sciatic notch.

Of the three angles of the bone, the two superior ones correspond with the spinous processes (anterior and posterior); the inferior is represented by the constricted part of the bone. Here we observe, besides the surfaces by which the ilium joins the os pubis and ischium, one external, smooth, concave part, forming a portion of the acetabulum, the deep cavity which receives the head of the femur.

Muscular attachments.

Attachments of muscles.—To the interval between the crista and the superior curved line on the dorsal surface, is attached the gluteus medius; to the space between the curved lines, the gluteus minimus; to the posterior rough surface, the gluteus maximus; to the internal surface, or iliac fossa, the iliacus muscle.

To the anterior half of the external lip of its crista is attached the obliquus externus abdominis; to the posterior third of the same lip, the latissimus dorsi; to the anterior two-thirds of the interval between the lips, the obliquus internus; and to the remainder, the erector spinæ; to the anterior three-fourths of the inner lip, the transversalis abdominis; to the posterior fourth of the same lip, the quadratus lumborum.

To the external surface of the anterior superior spinous process is attached the tensor vaginæ femoris; to the process and the notch beneath it, the sartorius; to the anterior inferior spine, the straight tendon of the rectus femoris; and to a depression above the brim of the acetabulum, the external tendon of that same muscle.

Articulations.—This bone articulates with the sacrum, and joins by bony union with the os pubis and the ischium.

OS PUBIS. (OS PECTINIS.)

Pubes.

The pubic bone forms the anterior and inner part of the os innominatum; and is divisible into two elongated portions, (branches, rami,) connected by a more expanded part, which may be considered the body of the bone.*

Horizontal branch;

Of the *rami*, the superior one (fig. 55, [11]) is thick and horizontal in its direction (*ramus horizontalis; crus superius*, Alb.), and presents three surfaces, separated by three prominent lines. The superior surface, slightly depressed, is covered by the pectineus muscle; the internal is smooth, and forms part of the pelvic cavity; the external or inferior, overhanging the obturator foramen, and looking downwards to the top of the thigh, is deeply grooved. The groove is directed obliquely forwards and inwards, and marks the course of the obturator vessels and nerve.

its oblique groove.

The external extremity of the bone is thick, and presents three faces; one, concave, forms part of the acetabulum; another, superior, connects it with the ilium (the junction being

---

* As the description here given of the pubic division of the innominate bone differs from that contained in other anatomical works, in so far as the part named "the body" is concerned, it is necessary to make reference briefly to some of those works, in order to prevent misapprehension.—Monro, Bichât, and Cloquet neither recognise the division into "rami," nor apply the name "body" to any part of the bone. Albinus usually mentions the rami under the name "crura," and refers to them as "cornua tanquam crura," but he does not use the term "body;" and Sœmmerring and Blumenbach pursue the same plan. Winslow, Sabatier, Boyer, and Cruveilhier treat of the pubes as divisible into the two branches, and likewise mention the horizontal branch as the body of the bone, using indifferently either term. Hildebrandt and Weber, and Meckel differ from the last-mentioned manner of naming the parts only by applying the word "body," not to the entire of the horizontal branch, but to its outer and thickest part, which joins with the ilium and ischium, and contributes to form the acetabulum.—Considering the difference thus shown to exist among anatomical authorities, and that the central expanded part, at which the rami meet, requires some designation (for more easy reference in the description of other structures), while it does not seem necessary so to distinguish the outer end of the bone, the plan pursued in the text is perhaps admissible.

marked by a rounded elevation[12], called the *ilio-pectineal eminence*); the third, inferior, is joined with the ischium.

The body.

Symphysis.

Crista, angle and tuberosity.

Pecten.

The internal extremity, *the body*[13], flat and compressed, is irregularly quadrilateral in shape. In front it gives attachment to muscles, and behind, forming part of the cavity of the pelvis, it looks towards the urinary bladder. The inner margin of the body is joined to the corresponding part of the opposite bone by an intervening cartilage, the junction being termed the *symphysis pubis* (*συμφυμι*, to grow together). Leading outwards from the symphysis, whose direction is vertical, may be observed another margin, nearly an inch in length, which is placed horizontally, and named the *crista*. The angle formed by the crista and symphysis, is termed the *angle* of the pubes[14]; the crista is terminated externally by a projecting nodule of bone—the *tuberosity* or spine, from which runs outwards a sharp line (*pecten*), a portion of the ilio-pectineal line, giving attachment to Gimbernat's ligament, and to the pectineus muscle, and marking the margin or upper boundary of the true pelvis.

Descending ramus joins ischium.

The *descending ramus*, or branch of the bone[15], inclines outwards and downwards from the body, forming an angle with it, becomes thin, and unites with the ascending ramus of the ischium. Its inner surface is smooth; the external is rough, for the attachment of muscles. One of its borders, thick and rough and somewhat everted, forms with the opposite bone an arch, called the arch of the pubes; the other border, sharp and thin, forms part of the margin of the obturator foramen.

Muscular attachments.

Attachment of muscles.—To the crista are attached the pyramidalis and rectus abdominis; to the tuberosity and anterior surface, the obliquus externus; to the pectineal line, the pectineus and Gimbernat's ligament; to the crista, and part of the same line, the obliquus internus and transversalis.

To the external surface, at the tuberosity, and a little below it, the adductor longus; to the body, the adductor brevis; to the line of the symphysis and the ramus, the gracilis; and to the margin of the foramen, at its inner side, the obturator externus. To the pelvic surface, part of the obturator internus and levator ani.

ISCHIUM. (OS COXENDICIS.)

Ischium. The *ischium* forms the posterior and lowest part of the os innominatum; it consists of two parts, a body and a ramus, united at an angle, so as to give the bone somewhat the figure of a hook.

The body. The *body*, fig. 54,[16], or larger part, short, thick, and somewhat triangular in form, presents three surfaces or aspects, which look in different directions; there are three borders, and two extremities. On its external surface may be observed a smooth concave part, which forms more than two-fifths of the acetabulum, and is surrounded by a curved prominent line, which forms the lower border of that cavity; beneath this is a groove[17], directed horizontally backwards, corresponding with the tendon of the obturator externus muscle; and still lower a rough line[18], which bounds the tuberosity of the ischium, and gives attachment to the quadratus femoris. The internal surface of this portion of the bone is smooth, and forms part of the cavity of the pelvis. This is broad at its upper part, as it comprises the interval between the spine or spinous process[19] and the margin of the obturator foramen. Below this process it becomes narrowed, constricted, and rounded off at its back, so as to form a pulley-like surface[20], in the interval between the spine and the tuberosity where the obturator internus muscle winds round its border. The posterior surface, broad at its upper part where it comprises the space between the spine and the margin of the acetabulum, then becomes narrowed and depressed, and finally ends in a rough and rather prominent surface bounded by well defined borders, which is the tuberosity of the ischium.

Spine.

Tuberosity. The *tuberosity*[21], (*tuber ischii,*) thick and rounded, forms the part on which the body is supported in the sitting position; to this circumstance the name of the bone has been supposed to refer (*ἴσχειν καθημένους* — quod sustineat sedentes).* This rough prominence presents three impressions upon it, corre-

---

* Riolanus "In librum Galeni de ossibus, ad tyrones commentarius" &c., cap. 26, in "Oper." p. 512.—The name in the German language—Sitzbein, or Sitzstück—has reference to the same circumstance.

sponding with the points of attachment of the three long flexor muscles of the leg.

The superior extremity of the bone (if it be examined in early life, when the bone can be detached from the ilium and os pubis, or after a section has been made of the os innominatum, so as to divide it into its three parts,) presents three surfaces, of which two are flat and triangular, and mark its junction with the ilium and os pubis; the other, concave and smooth, forms part of the acetabulum. The inferior extremity of the body of the bone is identified with the tuberosity.

Ramus.

The *ramus* of the ischium[22] is the flat, thin part, which ascends forwards and inwards from the tuberosity, towards the ramus of the os pubis with which it is united. One margin of the ramus, thick, rough, and somewhat everted, forms part of the inferior outlet of the pelvis; the other, thin and sharp, bounds the obturator foramen; its external surface looks outwards and downwards, is rough for the attachment of muscles; the inner surface forms part of the lower circumference of the pelvis.

Muscular attachments.

Attachments of muscles.—To the outer border of the tuberosity and the contiguous part of the ramus, the adductor magnus; to the inner margin of the tuberosity at its fore-part, the erector penis and the transversus perinæi; to the ramus, the compressor urethræ; the internal obturator muscle to the posterior surface of the bone behind the thyroid or obturator foramen; the external muscle of the same name to the inner margin of the obturator foramen in front of the bone.

To the posterior surface of the tuberosity, the three flexors of the leg, scil. the biceps, semi-tendinosus, and semi-membranosus; to the rough line on the outer surface which bounds the tuberosity, the quadratus femoris; to the external surface of the spine, the gemellus superior; to the adjacent border of the tuberosity, the gemellus inferior; to the spinous process, the levator ani and the coccygeus.

Acetabulum, formed by the three parts of the bone in unequal proportions;

Acetabulum.—At the junction of the three pieces of the os innominatum is situated the cavity which articulates with the head of the femur[23]. It is called *acetabulum*, also the *cotyloid* or cup-shaped cavity (κοτυλη, a cup; εἶδος). Of this the ischium forms somewhat more than two-fifths, the ilium somewhat less than two-fifths, the remainder being made up by the its notch and fossa;

os pubis. It is surrounded in the greater part of its extent by a margin or supercilium[24], which is most prominent towards the superior and external part; but at the opposite point, or towards the obturator foramen, it is deficient, leaving a notch[25], (*cotyloid notch*, sometimes also called *incisura acetabuli*). The greater part of the cavity is covered with cartilage in the natural condition; but towards the notch there is a part depressed beneath the rest[26], and which lodges the round ligament with some synovial fringes: this has no cartilaginous coating.

direction.

When we examine the pelvis as a whole, we observe that these articulating cavities, placed toward the lateral walls of the pelvis, look downwards and forwards, with an inclination outwards, and that they rest, when the body is erect, upon the globular heads of the thigh-bones, which they lodge. The margin of each cavity is rough and uneven; but in the recent state it is rendered smooth by a fibro-cartilaginous rim, which runs round it, and increases its depth. Where the osseous margin is deficient (at the cotyloid notch), its place is supplied by a fibrous band, so stretched across as not altogether to fill it up, but rather to bridge it over, leaving a space beneath it for the entrance of vessels into the interior of the joint.

Obturator foramen.

To the inner side of the acetabulum is found, in the dried bone, a large aperture[27]; which, however, in the natural condition, is almost completely closed by a fibrous membrane. It is called *obturator foramen*, (f. obturatorium, perhaps more properly obturatum,) from the circumstance of its being closed by a membrane or ligament. It is also called *foramen thyroideum* (shield-shaped, θυρεος, a shield), from its shape; and not unfrequently *foramen ovale*. It is somewhat of an oval form in the male, its longest diameter being extended obliquely downwards and outwards; in the female it is a three-sided figure, with rounded angles.

Ossification.

Primitive nuclei;

Ossification.—The innominate bone is formed from three principal pieces, one for each of the divisions of the bone, and four epiphyses, together with a thin stratum interposed between the principal divisions of the bone at their place of junction.

the first appears in ilium; date.

Osseous matter becomes apparent in the ilium at a very early period,—about the time it shows itself in the vertebral column, or soon after. It is first discernible at the lower part of this division of the bone, immediately above the sciatic notch.

Second, in ischium.

Pubes.

After a considerable interval of time, and about the third month from conception, a nucleus appears in the ischium, in the thick part below the acetabulum. And between the fourth and fifth months the last of the principal centres of ossification is distinguishable in the horizontal branch of the pubes.

Fig. 55.*

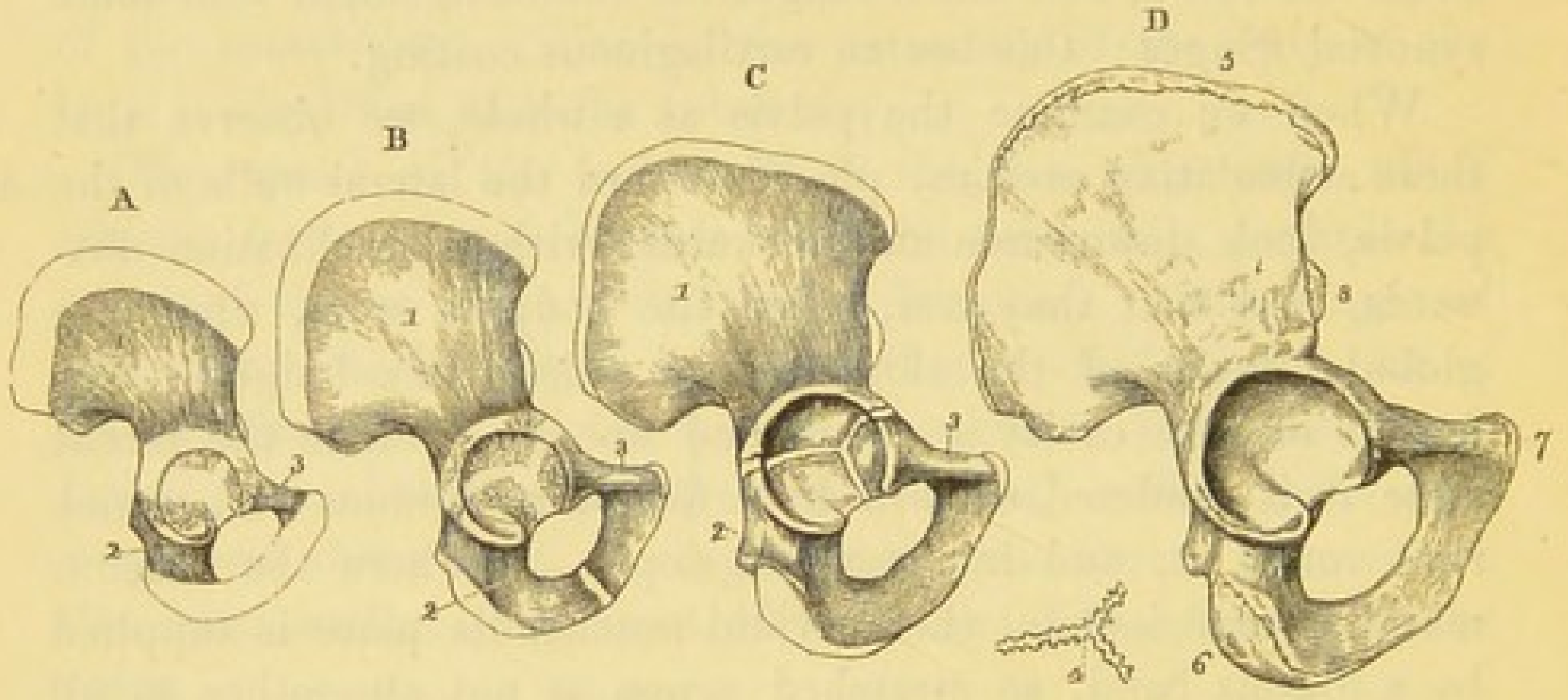

Condition at birth.

At the usual time of birth the deposit of bone has extended considerably from the primitive nuclei; but the crest of the ilium is still largely cartilaginous, and the internal parts of the ischium and pubes are in the same condition, bony matter having at this period only begun to incline to the inner side of the obturator foramen, fig. 55, A.

---

* Some stages of the growth of the innominate bone are here exemplified. Figure A. shows its condition in a full-grown fœtus. Ossification has extended from the primitive nuclei. But the crista ilii is largely cartilaginous; the pubes and ischium are in the same condition at the inner side of the obturator foramen, and a considerable cartilaginous interval separates the pieces in the acetabulum. B. This has been skĕtched from a preparation taken from a child under six years of age. Bony matter, spreading over the bone, has involved the inner side of the ischium and pubes, but the osseous parts of their rami are still at some distance apart. C. The rami of the ischium and pubes are joined; a cartilaginous Y-shaped interspace is apparent in the acetabulum. D. This figure is from the body of a person aged about twenty years. Union has taken place in the acetabulum, and the epiphyses are fully formed.

1. Ilium. 2. Ischium. 3. Pubes. 4. Y-shaped piece. (This is a plan. In the preparations of my collection this formation occurs in several fragments, which together would constitute a piece of this kind.) 5. Epiphysis of the crest of the ilium. 6. That for the tuber ischii. 7. For the pubes. 8. For the anterior-inferior spine of the ilium.

Rami of ischium and pubes join.

About the sixth year after birth the rami of the ischium and pubes are nearly altogether ossified, (fig. 55, B,) and they soon after join (C).

The three divisions of the bone approach one to the other in the acetabulum, by the extension of the ossific process from the primary nuclei (fig. 55, A. B. C.); and about the thirteenth or fourteenth year a distinct deposit of bony matter is observable in the cartilage which separates them in this situation. The added formation may occur in a single mass (I have hitherto found it to consist of several fragments); and, from the shape it necessarily assumes, it is named the Y-shaped piece. The union, therefore, of the ilium, ischium, and pubes occurs through the medium of the interposed piece or pieces now described, and it takes place after the usual time of puberty; the two first named joining in the first instance.

Y-shaped piece in acetabulum, and junction of the principal pieces here.

Epiphyses.

About the age of puberty epiphyses begin to make their appearance as follows:

a. On the crest of the ilium reaching over its whole length (D^5).

b. In the anterior-inferior spine of the same part (D^8). This epiphysis is not constant; it is said to occur more frequently in the male than the female.

c. The tuberosity of the ischium becomes covered by a broad, curved crust, which reaches upwards some way in a pointed form on the ramus (D^6).

d. Lastly, the inner margin of the pubes receives a small epiphysary plate (D^7), which is stated by Béclard to be present more frequently in the female than the male skeleton.

Completion of the bone.

The epiphyses are all joined to the bone about the twenty-fifth year.

THE PELVIS.

The pelvis.

The *pelvis*, or basin-shaped cavity, which is made up of the ossa innominata, the sacrum, and coccyx, deserves to be attentively examined, not merely as to the details of the parts which compose it, but as to its general conformation.

Its external surface.

The *external surface.*—Taking the objects which are deserving of notice on the external surface, from before backwards, and beginning at the median line, we observe the *symphysis pubis*, or the line of junction between the two bones of that name; its direction is vertical, its depth greater in the male than in the female; beneath it is an angular space, the *pubic* or *sub-pubic arch*, bounded by the rami of the ossa pubis and ischia at each side. On each side of the arch is the *thyroid* or *obturator foramen* above noticed, and still more laterally the *acetabulum*, above which rises the broad convex part of the ilium (dorsum ilii). Posteriorly, along the middle line, are situated the tubercles or spinous processes of the sacrum; external to these, the posterior sacral foramina, and next, a broad, unequal surface, to which the sciatic ligaments and gluteus maximus are attached; and lastly, the large, deep excavation (*sacro-sciatic notch*), bounded by the margins of the sacrum and os innominatum.

Internal surface.

The *internal surface* is divided into two parts by a prominent line (*ilio-pectineal*) leading from the tuberosities of the ossa pubis, outwards and backwards, to the prominent point of the sacrum (*the promontory*). This constitutes the margin or *brim* or *inlet of the true pelvis*, all the part above it being called the *false pelvis;* as in reality it belongs to the abdomen.

Divided into true and false pelvis.

Upper margin.

The *superior circumference* of the false pelvis is formed on each side by the crista ilii; posteriorly may be observed a deep notch, which is divided into two parts by the base of the sacrum, and anteriorly (in the interval between the anterior-superior spinous processes of the ilia) the margin of the bone subsides, so as to present a deep excavation, which in the natural condition is filled up by the soft parietes of the abdomen. Along this margin are placed the anterior-inferior spinous processes of the ilia, the ilio-pectineal eminences, the spines or tuberosities of the ossa pubis, with their cristæ and angles. The *inferior circumference* or *outlet of the pelvis* presents three bony eminences (the tuberosities of the ischia on the sides, and the sacrum and coccyx behind in the middle line), which are like so many promontories, separated by deep excavations. The anterior of these (*pubic arch*), triangular in its form, is bounded on each side by the rami of the ischia and ossa pubis, extending upwards and inwards from the tuberosities of the ischia to the symphysis pubis. The two other notches (*sacro-sciatic*) are placed behind and above the tuberosities, and correspond with the interval between the sacrum and os innominatum. When examined in the dried bones, their extent is considerable; but

Inferior margin or outlet.

in the natural condition they are divided into lesser spaces by the sacro-sciatic ligaments.

Direction of the pelvis is oblique.

Obliquity of the pelvis.—In the erect attitude of the body, the direction of the pelvis is so oblique (fig. 56,) that the anterior wall (pubes) looks towards the cavity upwards as well as backwards, and the posterior wall (sacrum and coccyx) is directed downwards and forwards. At the same time, the upper and lower apertures are inclined forwards. The base of the sacrum[2] is considerably higher than the upper margin of the symphysis of the pubes[1]; the extent varies in different cases, but in a large number of well-formed female bodies it has been found by M. Naegle to be three inches and nine or ten lines. The point of the coccyx is stated by the same observer to be—taking the average of a large number of cases—seven or eight lines higher than the inferior margin of the symphysis of the pubes.†—The obliquity of the pelvis is considerably greater in the fœtus and in young children than in the adult.

Fig. 56.*

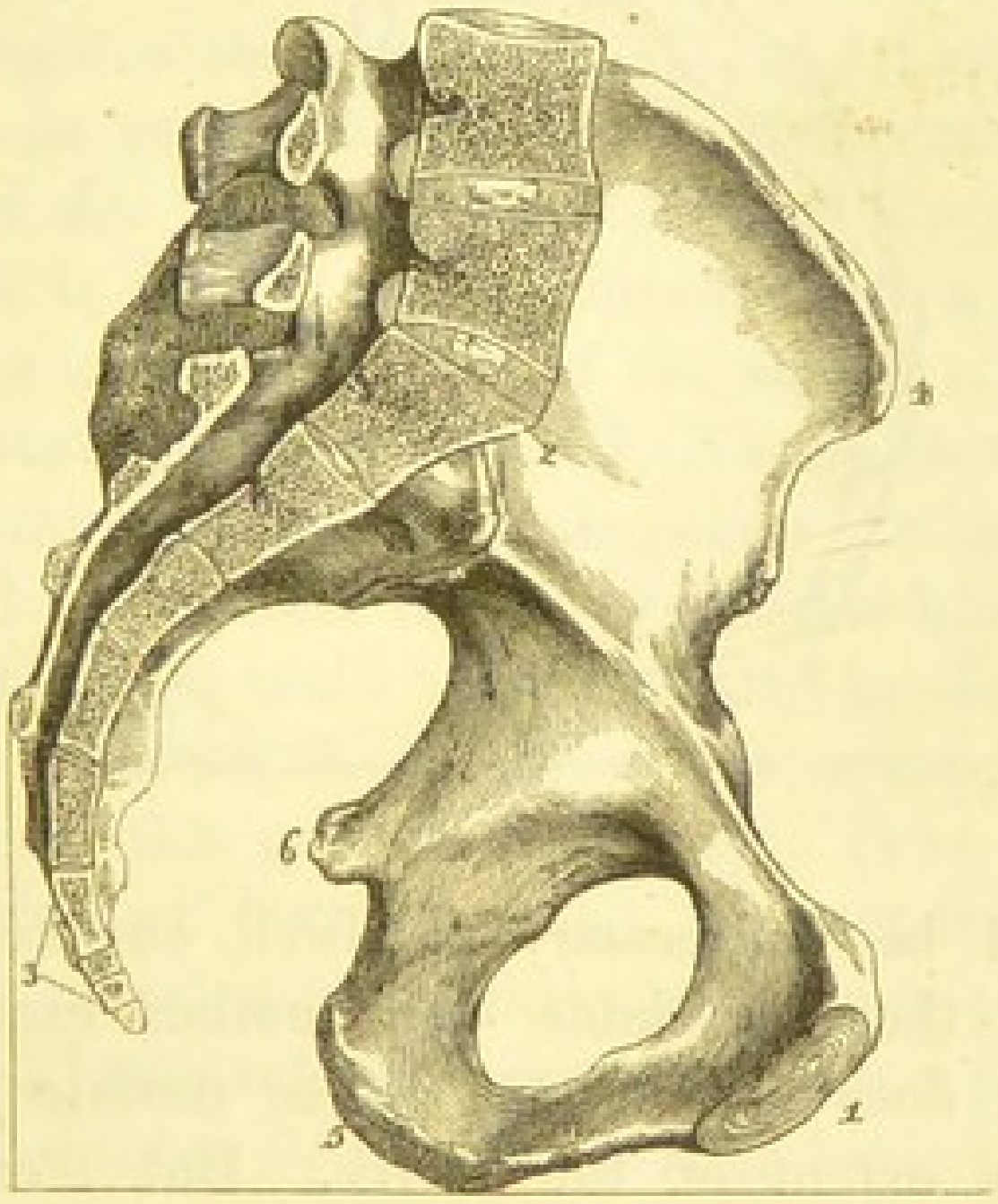

---

* A vertical section of a female pelvis made through the symphysis of the pubes and the middle of the sacrum, and showing the left lateral half; (reduced from Naegle's figure). 1. Symphysis of pubes. 2. Base of sacrum. 3. Coccyx. 4. Anterior-superior spine of ilium. 5. Tuberosity of ischium. 6. Spine of ischium.

† M. Naegle made observations on five hundred healthy females who

The axis;

Axis of the pelvis.—In determining the line which would be equally distant from the inner surface of the pelvis on all sides, it will be unnecessary to dwell on the lateral walls, inasmuch as these resemble one another exactly, and the middle point does not in any degree deviate to either side in the whole extent of the cavity. But there is so much difference between the anterior and posterior walls,—the one $1\frac{1}{2}$ to 2 inches in length, and oblique in direction, the other about 5 inches long, likewise oblique and much curved,—that the axis must be differently situated at different positions. It

does not deviate laterally;

curves in antero-poster. direction.

Fig. 57.*

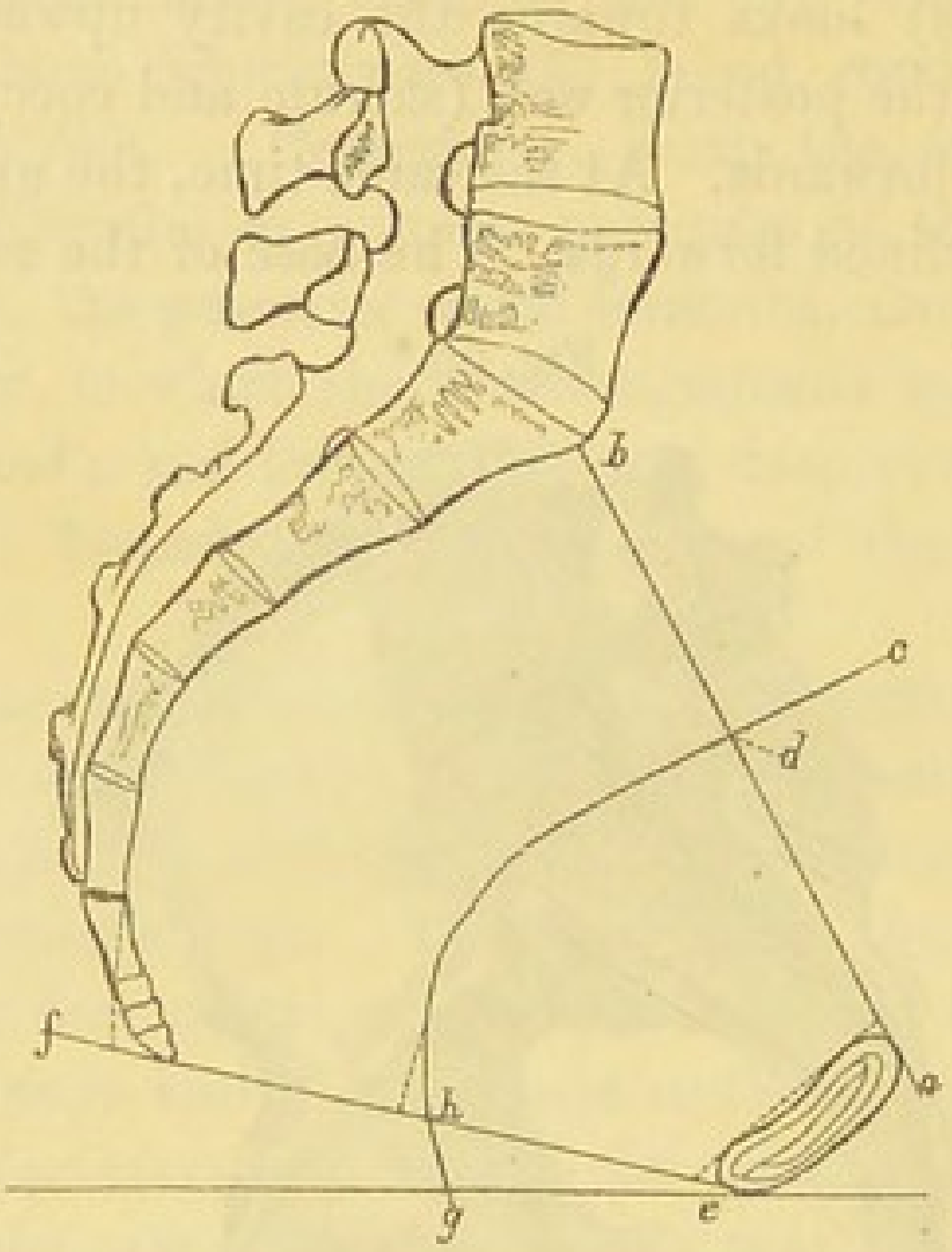

---

had borne children without the occurrence of unwonted difficulty: one hundred and forty-nine of the number were tall persons, fifty-seven of short stature, and the remainder were of middle height; and he found

That the point of the coccyx was higher than the inferior margin of the symphysis pubis (the upper angle of the pubic arch) in 454
That it was lower than the same point in . 26
And that it was on the same level in . . . 20

The maximum of elevation of the point of the coccyx above the apex of the arch of the pubes was twenty-two lines, and its maximum of depression below the same point nine lines. The average of all is stated in the text.—" Das weibliche Becken," &c. Carlsruhe, 1825.

* A vertical section in outline of the pelvis at its middle, with lines indicating the axis of the pelvis and a horizontal line below the figure.

is for this reason that several axes or axes for several parts are recognized; viz., one for the inlet to the true pelvis, another for the outlet, and another again for the intervening space, the cavity; and each of these requires some notice.—It must be premised that the direction of the axis at any point of the cavity will be marked by a line running at right angles with the middle of the plane of that part.

Axis of inlet, downw. and backw;

The axis of the inlet of the true pelvis.—The plane of the true pelvis will, in the section of the cavity, (fig. 56,) be represented by a line drawn between the base of the sacrum and the upper margin of the pubes, (fig. 57, *a*, *b*,) and a line at right angles with its middle, *c*, *d*, will give the direction of the axis. The axis of this part is therefore directed downwards and backwards, and it is usually said to coincide with a line drawn from the umbilicus to the lower part of the sacrum; and this is not far removed from correctness, for M. Naegle found that in the average of a large number of female pelves the lower end of such a line would fall against the coccyx (below the middle). As regards the *axis of the outlet*: it is indicated by the line *h*, *g*, at right angles with the middle of *e*, *f*, which represents, in the section, the plane of this part of the cavity. It is, therefore, directed downwards and forwards; and, if extended into the cavity, would cross an extension of the axis of the inlet. When the coccyx is moved backwards, this axis undergoes a corresponding alteration, as indicated by the dotted lines behind *h*.

of outlet, downw. and forwards;

of cavity, curved between two former.

The cavity of the pelvis being much curved, so likewise must its axis be; and for general purposes it will be sufficiently correct to say that, beginning with the axis of the inlet, and following the curve of the sacrum and coccyx in the middle of the cavity, it will terminate in that of the outlet—in the course of the curved line between *d* and *h*.*

It is to be borne in mind that the foregoing observations have reference to the pelvis in the skeleton, its osseous boundaries only being considered. To prevent any misapprehension, it may be well to add, even here, concerning the pelvis of the female (in respect to whom the direction of the cavity is

---

* The exact course of the line may be determined by finding the axes of different parts at very short intervals, from above downwards, through the cavity, on the principle already referred to, and drawing a line through them.

of especial practical importance), that in the natural state, the bones being clothed with soft parts, there is a difference which mainly affects the outlet. In that (the natural) condition, the anterior wall is not materially altered, but the posterior one is elongated at the lower end, the sacrum and coccyx being continued forward by the perinæum. And therefore the axis of the real outlet is situated much further forward than the position assigned to it in the osseous cavity alone.

Direction of outlet in natural state of parts.

Difference in the sexes.

The size and conformation of the pelvis differ very remarkably in the two sexes. In the female the bones are thinner, more smooth on the surface, the muscular impressions being less strongly marked, and, though its perpendicular depth is less, its breadth and capacity are greater. The alæ of the iliac bones are more expanded ; the upper aperture is more nearly circular, the projection of the sacrum less perceptible ; and the space between the tuberosities of the ischia greater. The depth of the symphysis pubis is less in the female than in the male, whilst the breadth of the pubic arch is greater.

Measurements in male and female.

The different dimensions of the male and female pelvis are stated as follows, by Meckel, Cloquet, and Burns :—

	MECKEL.				CLOQUET.		BURNS.	
	In the male pelvis.		In the female pelvis.		Female.		Female.	
	inch.	lines.	inch.	lines.	inch.	lines.	inch.	lines
Between the anterior-superior spinous processes of the ilia	7	8	8	6	10	0	10	0
Between the middle points of the cristæ of the ilia	8	3	9	4	11	1	11	1
The transverse diameter of the inlet	4	6	5	0	5	6	5	6
The oblique . . of the inlet	4	5	4	5	4	7	5	5
The antero-posterior . of the inlet	4	0	4	4	4	4	4	0
The transverse diameter of the cavity	4	0	4	8	—		—	
The oblique . . of the cavity	5	0	5	4	—		—	
The antero-posterior . of the cavity	5	0	4	8	—		—	
The transverse . . of the outlet	3	0	4	5	4	4	4	0
The antero-posterior . of the outlet	3	3	4	4	4	4	4	0

The last may be increased to five inches in consequence of the mobility of the coccyx.

Diminutive size and greater obliquity of pelvis in early life.

In the fœtus and young children the capacity of the pelvis is very small, and, at the same time, those viscera, which may be said to belong to the pelvis, lie chiefly in the abdomen. The obliquity of the cavity is greatest in early life.

BONES OF THE LOWER EXTREMITY.

The lower extremity is made up of three parts; the thigh, leg, and foot.

The osseous part of the first consists of one bone—the femur; that of the leg, of two—the tibia and fibula. The adjacent extremities of these, together with the patella (a sort of sesamoid bone), form the knee.

The foot is composed of three parts; the tarsus, metatarsus, and phalanges.

THE FEMUR.

Fig. 58.*



Femur, its size; oblique direction.

The femur or thigh-bone, fig. 58, (*os femoris,*) the longest and largest bone of the skeleton, is situated between the pelvis and the tibia. In the erect position of the body, its general direction is not vertical; it gradually inclines inwards towards the lower part, so that the bones of opposite sides, though separated at a considerable distance where they are connected with the pelvis, approach each other inferiorly, and come nearly in contact. The degree of this inclination varies in different persons, and is more marked in the female than the male. The femur presents a central part or body, and two extremities.

Shaft; its surfaces.

The *body*, 1, or *shaft*, as it is sometimes called, compressed, but nearly cylindrical towards the centre, and at the same time slightly convex or arched forwards, is expanded superiorly and inferiorly. Its anterior surface, convex and smooth, is broader towards the lower than the upper extremity. Both its lateral surfaces are compressed and somewhat flat; but it may be observed that the external is

---

* A front view of the femur of the right side. 1. The shaft. 2. The great trochanter. 3. The small trochanter. 4. The neck. 5. The head. 6 is above the trochanteric fossa. 7 is said to mark the external condyle. 8. The articular surface of the external condyle. 9. A pit for the tendon of the popliteus muscle. 10. The external tuberosity. 11. The internal condyle. 12. The internal tuberosity.

somewhat concave: it affords attachment to the vastus externus muscle. The surface, which superiorly looks inwards, is, in the lower third of the bone, inclined somewhat backwards, and gives attachment to the vastus internus. The anterior surface is separated, though not in a very marked degree, from the lateral surfaces by two lines, which may be traced upwards from the condyles, towards the superior extremity of the bone; but posteriorly, at the union of the two lateral surfaces, is a rough and prominent line (*linea aspera*), which gives attachment to several muscles.

Linea aspera;

its branches, upper and lower.

Medullary foramen.

The *linea aspera* is most prominent towards the centre of the bone, and, when examined with attention, presents two margins and a rough interstice, each giving attachment to muscles. Above and below the centre, it subsides as it were towards the extremities, and also becomes bifurcated. The two superior divisions or branches of the line terminate, the one (internal and somewhat shorter) at the lesser trochanter; the other, external, at the greater trochanter; in the course of the latter a rough and often strongly-marked ridge exists, which gives insertion to the gluteus maximus. The inferior divisions spread more asunder, and terminate at the condyles, enclosing between them and the margins of these prominences, a flat triangular portion of the bone, which corresponds with the popliteal vessels. Towards the superior part of the linea aspera may be observed a foramen directed from below upwards, which transmits the medullary vessels.

The upper end of bone; its direction.

At the *superior extremity* of the bone is placed its neck, which is directed upwards and inwards, so as to form an obtuse angle with the body or shaft; at its point of union with the latter are two eminences (trochanters), one the larger on the outer, the other on the inner side; it is from between these that the neck arises.

Great trochanter.

Trochanteric fossa.

The *trochanter major*[2] is prolonged from the external surface of the body of the bone, and nearly in a line with its axis. This apophysis, quadrilateral in its form, is convex and rough on its external surface, which is marked by a line directed obliquely downwards and forwards for the attachment of the gluteus medius; the internal surface, of less extent, presents at its base a pit[6], (*trochanteric* or *digital fossa,*) which receives the external rotator muscles; its superior, or terminal border, is flat and straight, and the posterior thick and rounded. At the posterior aspect of the great trochanter may be observed an oblique and prominent line, directed downwards and inwards, and terminating in the trochanter minor.

Small trochanter.

The *trochanter minor*[3], a conical rounded eminence, projects from the posterior and inner side of the bone, and gives attachment at its back part to the tendon of the psoas and iliacus muscles.

The neck.

The *neck* of the femur[4], which is so named from its constricted appearance and supporting the head, forms an obtuse angle with the body of the bone; it is compressed from before backwards, so that its diameter in this is much less considerable than in the vertical direction, in which greater power of resistance is required, for sustaining the weight of the body; its anterior surface is broad and smooth; the superior, inclined upwards, is short and somewhat concave; the inferior is the most extensive. The union of the neck with the rest of the bone is marked by the trochanters and two intervening oblique lines, (*inter-trochanteric*,) of which, the anterior one is rough, and but slightly prominent; the other, situated posteriorly, forms a smooth projecting ridge, which overhangs the trochanteric fossa.

Inter-trochanteric lines.

The head.

The neck is surmounted by the globular *head*[5], which forms a considerable segment of a sphere, is tipped with cartilage in the fresh state, and lodged in the acetabulum. A little beneath its most prominent point is a small cavity, which gives attachment to the round ligament.

The lower end of bone.

The *inferior extremity* of the bone, much thicker and broader than the superior, is terminated by two eminences, separated posteriorly by a deep fossa; these are named condyles, of which one is internal, the other external.

External condyle.

The *external condyle*[7], is larger, and projects forwards more than the internal; its articulating surface also is broader, and mounts higher up anteriorly; its external surface, rough and unequal, presents a deep pit[9], inferiorly, which gives attachment to the tendon of the popliteus muscle; and immediately above it, a projection[10], (*external tuberosity*,) which gives attachment to the external lateral ligament of the knee-joint.

Pit for popliteus.

External tuberosity.

Internal condyle.

The *internal condyle*[11] appears longer, and also to descend lower down than the other; but this is rather apparent than real, for, by means of the obliquity of the shaft of the bone, both condyles are brought to the same plane. The internal condyle presents at its inner side *a tuberosity*[12], which gives attachment to the internal lateral ligament of the knee-joint and the tendon of the adductor magnus.

Internal tuberosity.

Articular surfaces.

The *articular surfaces* of both condyles, covered with cartilage in the fresh state, are united anteriorly where they form a pulley-like surface[8], concave from side to side, on which the patella glides. Inferiorly, these surfaces diverge as they pass backwards, and, when they terminate at the posterior surface of the bone, are separated by a considerable interval (*the inter-condyloid fossa*).

Inter-condyloid fossa.

Articulations. — The femur articulates superiorly with the acetabulum; by its condyles with, inferiorly, the tibia, and, anteriorly, the patella.

Attachments of muscles.—To the anterior surface, the crureus and the sub-crureus; to the two lateral surfaces and to both lips of the linea aspera, the vastus internus and externus; to the centre of that line, the adductors and the short head of the biceps flexor; to the outer surface of the trochanter major, the gluteus medius; to the anterior part of its upper border, the gluteus minimus; to the fossa, at its posterior surface the other external rotators; to the posterior part of the same border, the pyriformis; to the posterior part of the lesser trochanter, and to a small portion of the line below it, the tendon of the psoas and iliacus; to the line descending from the great trochanter, posteriorly, the quadratus femoris; to the line below the lesser trochanter, the pectineus; to the rough impression beneath the great trochanter, the gluteus maximus; just above the inner and the outer condyle, the corresponding heads of the gastrocnemius; above the external condyle, the plantaris; to the fossa beneath the external tuberosity, the popliteus.

Ossification of shaft; time of commencement.

Ossification.—The femur begins to ossify before the vertebræ, and the process is first apparent at the middle of the shaft. From the osseous ring formed in this position, the ossification extends towards both ends, ultimately involving the shaft and neck of the bone (fig. 59). As it advances on the last-named part (the neck), osseous matter will be found first on its lower surface (B. C.).

Epiphysis of lower extremity;

Epiphyses.—The first of these additional centres of ossification appears in the lower end of the bone (B.[2]), in the last month of fœtal life, and from it the entire of the lower extremity of the femur (including both the condyles and tuberosities) is constructed (C. D. E.²).

Fig. 59.*

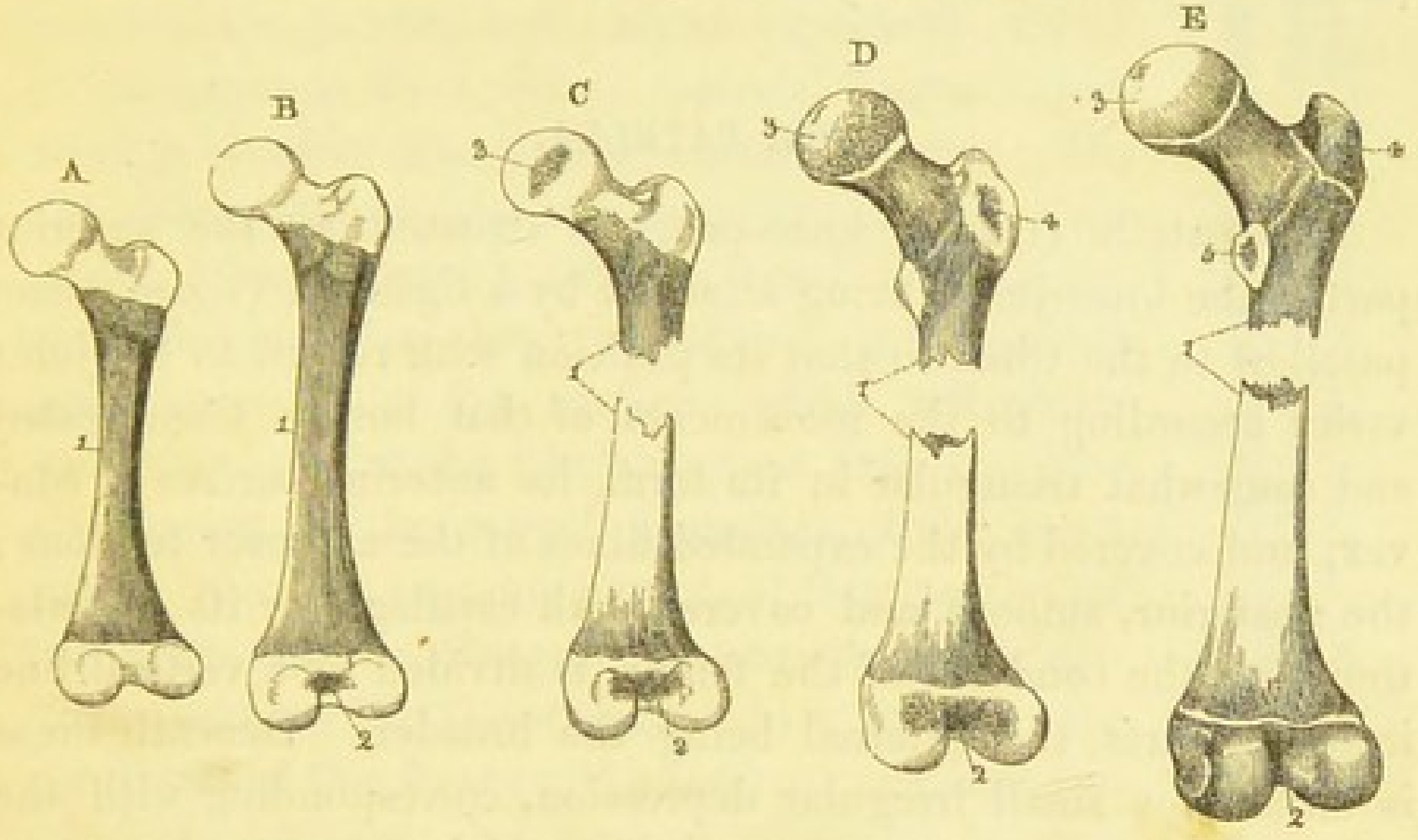

of head;

In the end of the first year after birth a nucleus is discernible in the head (C.³), and the ossification radiates from it over the globular end of the bone (C. D. E.³).

of trochanter major and minor.

The trochanters are distinct formations. Ossification begins in the larger (D.⁴) in the course of the fourth year,† and it does not show itself in the smaller till a considerably later period—the thirteenth or fourteenth year (E.⁵).

Epiphyses join in the inverse order of their appearance.

Consolidation.—The order in which the epiphyses are joined to the rest of the bone is the reverse of that in which they

---

* Successive stages of the growth of the femur are shown in these figures, up to the time when the union only of the parts is wanting to the completion of the bone.

A. Ossification has extended from the primitive centre over the shaft of the femur. The preparation was taken from the body of a fœtus of eight months. B. A nucleus is apparent in the interval between the condyles. This illustrates the condition of the bone in a full-grown fœtus. C. A granule is added in the head. D. One is present in the great trochanter, and E. in the smaller trochanter.

1. The shaft. 2. The lower extremity. 3. The head. 4. The great trochanter. 5. The small trochanter.

† In the thigh-bones taken from the body of a child, stated with correctness (as well as could be judged) to have been three years and a half old, I found at the base of each great trochanter a granule of bone equal in size to half a common pea.

appear: the small trochanter joins first, the great trochanter follows next, then succeeds the head, and lastly the lower epiphysis, whose ossification was the first to begin, ceases to be a separate piece. The bone is complete by the union of its parts after the twentieth year.

Growth completed.

THE PATELLA.

The patella (rotula, knee-pan,) is situated at the anterior part of the knee-joint, being attached by a ligament (ligamentum patellæ) to the tibia, so that its position with regard to the joint varies according to the movements of that bone. Compressed and somewhat triangular in its form, its anterior surface is convex, and covered by the expanded fibres of the extensor tendons; the posterior, smooth and covered with cartilage for its articulation with the condyles of the femur, is divided by a vertical line into two parts, the external being the broader. Beneath these is situated a small irregular depression, corresponding with the apex, or narrowest part of the bone, which gives attachment to the ligamentum patellæ. The superior extremity, broad and rounded off at its margin, gives attachment to the extensor muscles; the inferior, narrow and pointed, to the ligament already named; the lateral borders are convex, the external being thinner than the internal.

Two parts of artic. surf.; extern. the larger.

Lower end pointed.

Ossification. The patella is ossified from a single centre, which, according to Béclard, is apparent in the middle of the third year.

THE TIBIA.

Tibia, its size; direction.

The tibia, next to the femur, is the longest bone in the skeleton; situated at the anterior and inner side of the leg, it alone receives from the femur (under which it is placed vertically) the weight of the trunk, and communicates it to the foot. Like the other long bones, it is divided into a body and two extremities.

Its superior extremity.

The *superior extremity*, fig. 60,[1] much thicker and more expanded than any other part of the bone, (being proportioned in size to the lower extremity of the femur,) is broader from side to side than from before backwards; its circumference is somewhat rounded and convex in front and at the sides, but

Fig. 60.

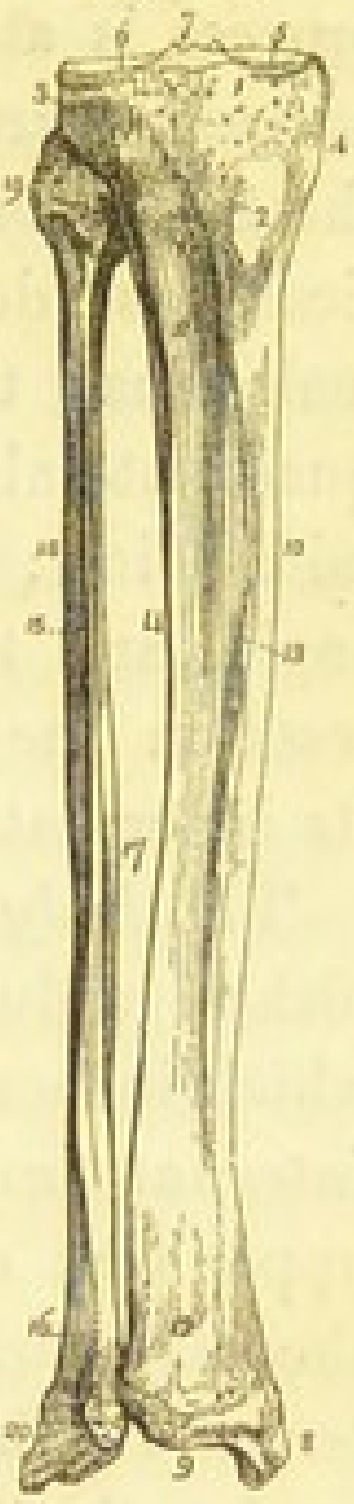

Anterior and lateral tuberosities.

Condyles.

slightly hollowed posteriorly; at the fore-part, a little below the head, is situated an eminence[2], sometimes called the anterior tuberosity, more properly the *tubercle*, which is somewhat rough at its lower part, for the attachment of the ligament of the patella, and smooth superiorly, where it corresponds to a small synovial bursa, intervening between that ligament and the bone. On the sides, and above this, are two rounded eminences (*tuberosities*), the external one[3] being somewhat smaller than the other[4], and marked posteriorly by a flat surface, which articulates with the head of the fibula; these processes give attachment to the lateral ligaments of the knee-joint. On the superior aspect of this portion of the bone may be observed two concave cartilaginous surfaces[5 6], (*condyles*,) which sustain the condyles of the femur; the internal one is somewhat the deeper; its greatest diameter is from before backwards; the external one is nearly circular. In the interval between the articular surfaces is situated a pyramidal eminence[7], the summit of which is usually divided into two tubercles; it is named the spine or spinous process of the tibia; before and behind this are two irregular depressed surfaces, which give attachment to the crucial ligaments and to the semilunar cartilages.

Lower extremity; is quadrilateral.

Malleolus; is subcutaneous.

Groove behind for tendons.

The *lower* or *tarsal extremity* of the bone is much smaller than the upper, and nearly quadrilateral in its form; the anterior surface, convex and smooth, is bounded below by a slightly rough margin which gives attachment to the anterior tibio-tarsal ligament; the posterior is flat, and slightly marked by a groove for the flexor longus pollicis; the external, slightly concave, is rough superiorly, for the attachment of the transverse ligament, and smooth below, to receive the extremity of the fibula. From the inner border of this end of the bone projects downwards a triangular apophysis[8], the *internal malleolus;* the inner surface of which is convex, and covered merely by the skin, the external is smooth, and articulates with the side of the astragalus; the anterior forms a rounded border, whilst the posterior is marked by two grooves for the tendons of the tibialis posticus, and flexor longus digitorum; to the most dependent part of the process is attached the internal lateral ligament. The lower articular surface of the tibia[9], or that part which enters into the formation of the ankle-joint, consists of two parts, one vertical, just described as being situated at the outer side of the malleolus; the other horizontal in its direction, concave and quadrilateral in its form, divided into two parts by a slightly raised line; of these two surfaces, which are united at a right angle, and tipped with cartilage in the fresh state, the latter rests on the dorsum of the astragalus, the former is applied to its inner flat border.

Artic. surface has two parts.

Shaft.

The *body* or *shaft* of the tibia, triangular in its form, diminishes gradually in size for about two-thirds of its length, after which it increases somewhat towards its lower extremity. The *internal surface*[10] is convex and subcutaneous, except at the upper part of its extent, where it is covered by the tendons of the sartorius, semi-tendinosus, and gracilis muscles. The *external surface,* slightly hollowed above[11], where it gives origin to the tibialis anticus, is convex, and somewhat inclined forwards below[12], where it is covered by the extensor tendons. The *posterior surface* is very deeply seated; not so uniform in its outline as the others, it is marked at its upper third by a line extending upwards and outwards to the external tuberosity; the part above this is triangular, and gives attachment to the popliteus muscle; that below it to the tibialis posticus and flexor digitorum; and from the line itself arises the soleus. Near this line may be observed a *medullary foramen* of large size, whose direction is from above downwards.

Its surfaces; internal is subcutaneous;

posterior, line for popliteus.

Medullary foramen.

The surfaces here indicated are separated by an equal number of borders. The *anterior border*[13], more or less sinuous in direction, sometimes considerably curved, is for the most part subcutaneous; sharp and prominent, especially towards the middle, and hence named the *crista* or *spine* of the tibia; it subsides towards the lower end of the bone, as if to allow a smooth surface for the passage forwards of the vessels and muscles, which superiorly are placed on the outer side. The *inner border*, thick and rounded, gives attachment to the soleus and flexor longus digitorum; whilst *the external*[14], somewhat sharp, divides inferiorly into two lines, which diverge towards the surface of articulation with the fibula. The inter-osseous ligament

Borders;

the spine; is subcutaneous.

is inserted into this external border. The body of the tibia is slightly twisted, so that the internal tuberosity inclines a little backwards, and the internal malleolus forwards, which conformation deserves attention in the diagnosis and adjustment of fractures.

Articulations.—The tibia articulates with the femur, the fibula, and the astragalus.

Muscular attachments.

Attachments of muscles.—To the external surface and external tuberosity, the tibialis anticus; to the latter also, the head of the extensor longus digitorum; to the inner surface, the sartorius, gracilis, semi-tendinosus, and semi-membranosus; the popliteus to the triangular space on the posterior surface; the soleus, tibialis posticus, and flexor longus digitorum to the rest of its extent, and, through the medium of the patella and its ligament, it may be said to give insertion to the extensors of the leg.

Ossification.

Ossification.—The tibia is formed from one principal centre of ossification and two for epiphyses. The process begins at the middle of the bone, about the same time as in the femur,—M. Cruveilhier mentions a case in which it preceded that bone,—and from this point extends over the shaft (fig. 61,[1]).

Fig. 61.*

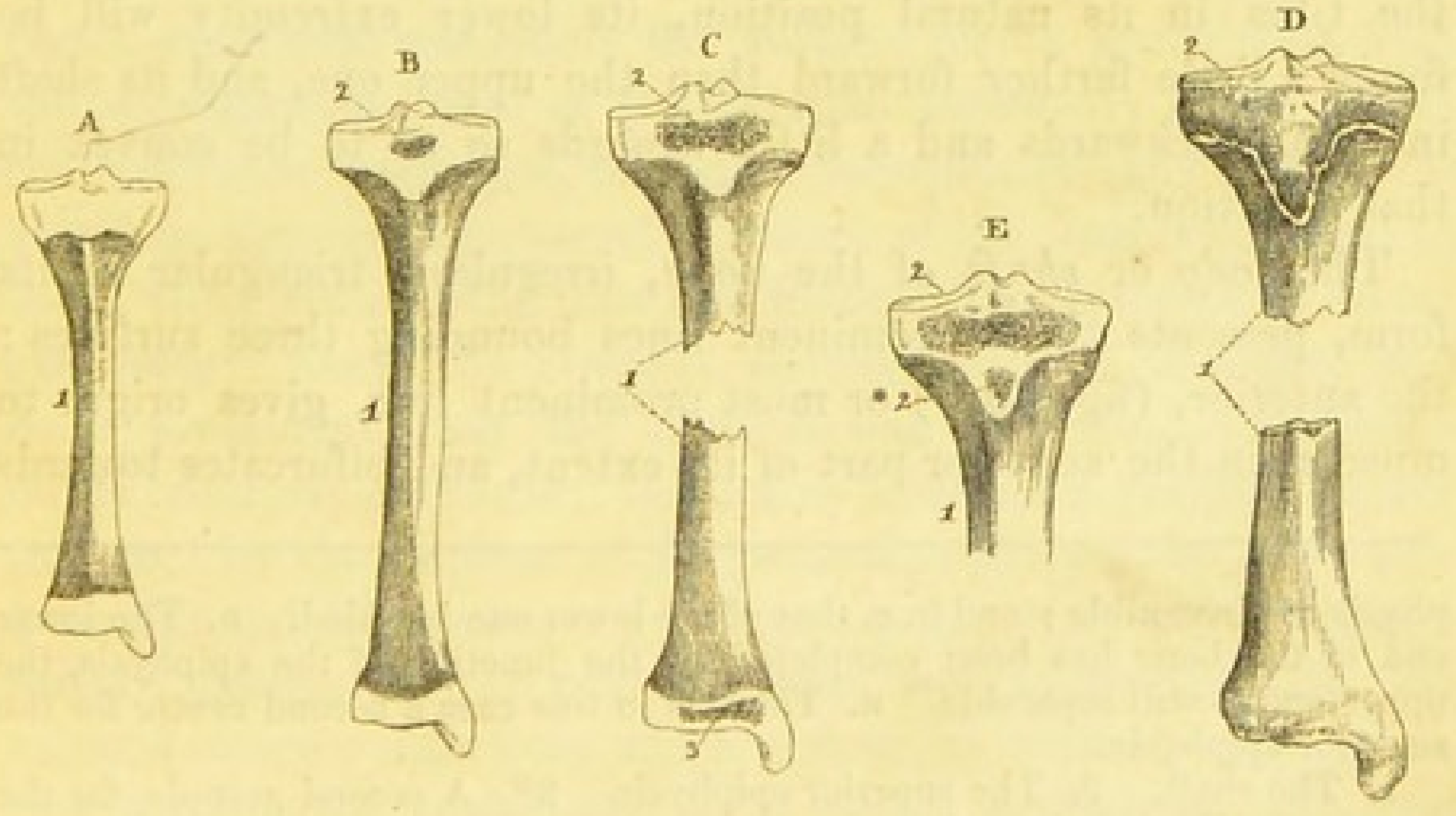

---

* A. This figure represents the state of the tibia some time before the usual period of birth. The shaft is ossified, the ends of the bone are cartilaginous. In B. (taken from a full-grown fœtus) the osseous centre of the upper epi-

Epiphyses, superior; (state of bone at birth;)

Epiphyses.—A small osseous nucleus is apparent in the upper extremity of the tibia in the full-grown fœtus (or, according to most authorities, in the first year after birth †) (B. C.²); and the epiphysis when fully formed is flat, with a thin pointed elongation in front for the anterior tuberosity of the bone (D.²).

inferior.

In the second year osseous matter is manifest in the cartilage of the lower extremity at its middle, and it extends from this as a centre over the entire of that part of the bone, including the malleolus.

Their junction with the shaft.

The epiphyses join the shaft between the eighteenth and the twenty-fifth year; the inferior preceding the other by a considerable time (D).

Peculiarities are occasionally met with in the manner of the ossification of the epiphyses. I have observed a separate nucleus in the tongue-shaped process of the superior one (E.²*); and Béclard has recorded an example of the malleolus being formed from an independent centre.

THE FIBULA.

Fibula; its size;

This bone (fibula, peroné, ϖεϱονη, a clasp,) is situated at the external side of the leg; it is nearly equal to the tibia in length, but is much more slender.

direction.

When the fibula is placed beside the tibia in its natural position, its lower extremity will be found a little farther forward than the upper one, and its shaft inclined backwards and a little inwards so as to be convex in that direction.

Shaft;

The *body* or *shaft* of the bone, irregularly triangular in its form, presents three prominent lines bounding three surfaces;

its borders;

the anterior, (fig. 60,¹⁵) or most prominent line, gives origin to muscles in the superior part of its extent, and bifurcates towards

---

physis is discernible; and in C. that of the lower one is added. D. The lower end of the bone has been completed by the junction of the epiphysis, the upper one is still separable. E. There is in this case a second centre for the superior epiphysis.

1. The shaft. 2. The superior epiphysis. 2*. A second granule for the same. 3. The inferior epiphysis.

† Albinus, Béclard, Cruveilhier, and others, date the commencement of ossification in this epiphysis in the first year after birth. But Nesbitt and Meckel state that bony matter is present at the usual time of birth, and I have found it so in two cases, while engaged in preparing these sheets for the printer. This difference respecting a fact so easily ascertained suggests the probability that the period actually varies.

its lower extremity, so as to enclose a slightly concave triangular surface[16], which is subcutaneous; the internal one also gives attachment to muscles, and inferiorly, where it inclines forwards, to the inter-osseous ligament. The *internal* surface[17], looks backwards for about a third of its extent, and somewhat forwards in the rest, and is divided, but unequally, into two parts, by a slightly marked longitudinal line, to which the inter-osseous ligament is attached for about two-thirds of its length; the part of the surface behind this is grooved,—it gives attachment to the tibialis posticus muscle; the anterior portion, the smaller, to muscles placed in front of the leg. The *external* surface[18], concave in the greatest part of its extent, gives origin to muscles,—towards its lower extremity, this surface is inclined backwards, conforming with the peronei muscles, which are connected with the superior part of the bone, and incline in that direction to pass behind the external malleolus. The *posterior* surface, convex and smooth, affords attachment to muscles, and presents towards its middle a small foramen, directed obliquely downwards for the transmission of the medullary vessels; in the lower part it inclines inwards, and is terminated by a rough surface connected with the tibia.

internal surface;

ridge for inter-osseous ligament;

external surface;

posterior surface.

Medullary foramen.

The *superior extremity* of the bone[19], called also *the head*, is smaller than the inferior one; it presents on the supero-internal part a small oval and nearly flat surface, for its articulation with the corresponding part of the external tuberosity of the tibia; the remainder is unequal, and gives insertion to the biceps flexor cruris, to the external lateral ligament of the knee-joint, and to those which connect the tibia and fibula. The *inferior* or *tarsal extremity*[20] forms the *external malleolus*, which is longer and more prominent than the internal one: in front it projects rather abruptly forwards; behind is situated a shallow groove traversed by the tendons of the peronei muscles; the outer side is convex and subcutaneous; the inner presents a small triangular surface, convex in the perpendicular, and nearly plain in the antero-posterior direction, which articulates with the astragalus, and is bounded posteriorly by a rough depression, affording attachment to the transverse ligament of the ankle-joint, whilst the apex gives origin to the external lateral ligament.

The head.

External malleolus;

is subcutaneous.

Articulations. — The fibula articulates at both extremities with the tibia, and at the inferior one with the outer border of the astragalus.

Muscular attachments.

Attachments of muscles.— The internal surface, by its anterior portion, to the extensor communis digitorum, extensor proprius pollicis, and peroneus tertius ; by the depression on its posterior part, to the tibialis posticus : the external surface, to the peronei ; the posterior surface, to the soleus and flexor longus pollicis ; its head, to the biceps flexor cruris.

Ossification, its commencement. State of bone at birth.

The ossification of the shaft of this bone occurs a little later than that of the tibia. Both ends are cartilaginous at the ordinary time of birth (fig. 62. A.)

Fig. 62.*

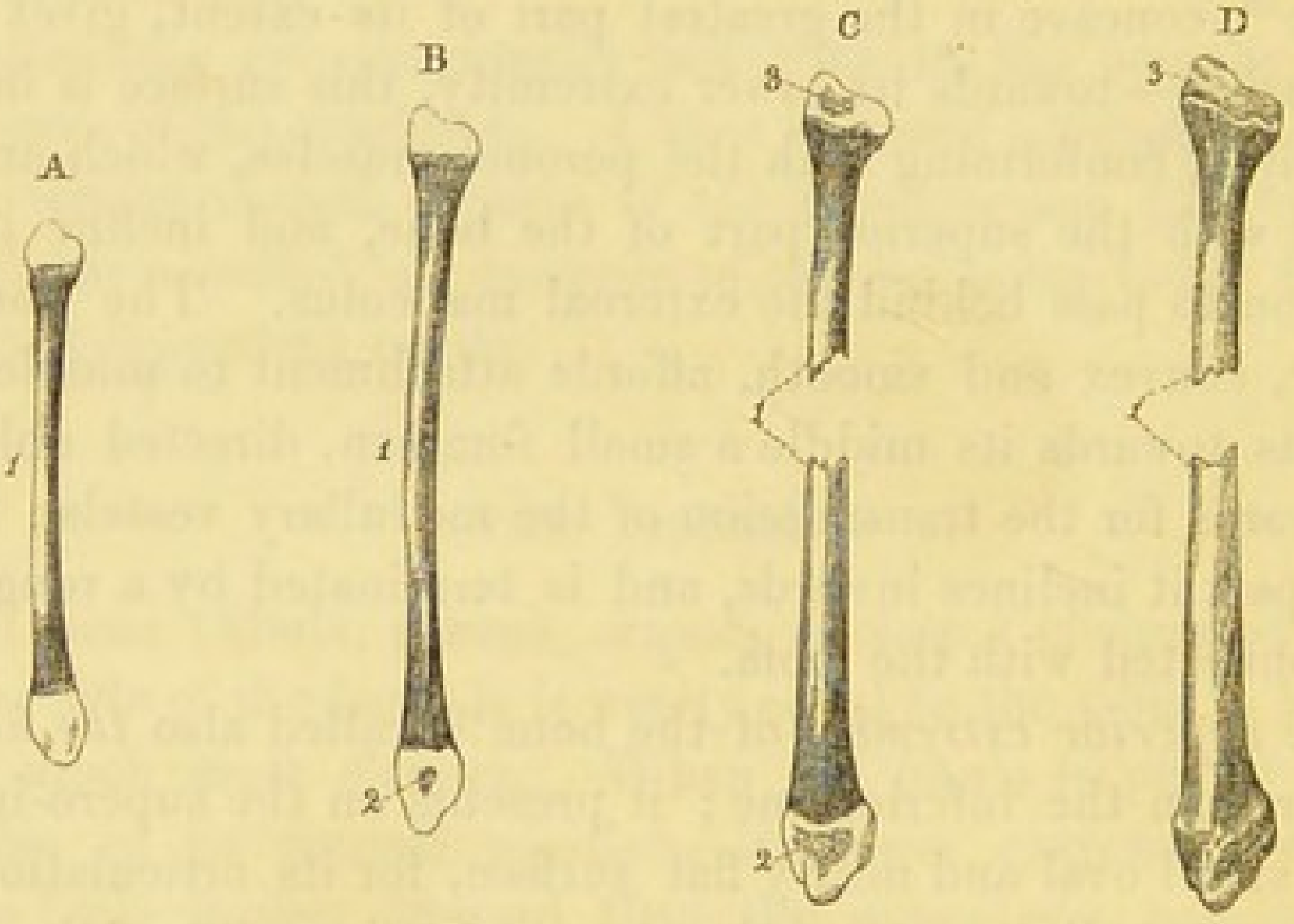

Epiphyses; lower and upper.

The epiphyses are likewise formed after those of the tibia. Their ossification begins with the lower one, in which an osseous granule appears in the second year (B.^{2}) ; and a commencement of the process is discernible in the upper epiphysis, between the third and the fourth year (C.^{3}).

Order of their junction is peculiar.

Consolidation.—Contrary to the order which prevails in the union of the parts of the femur and the tibia, that epiphysis of the fibula which is the first to take on the osseous state, namely,

---

* A. The preparation from which this figure has been drawn was taken from the body of a fœtus arrived at the usual period of birth. The shaft is ossified, and the ends of the bone remain cartilaginous. B. A nucleus has appeared for the lower epiphysis. C. That of the upper one is added. (When the upper epiphysis is ossified to this extent, the lower one is more advanced than is here represented.) D. The lower end of the bone is complete, the superior epiphysis being still separable.

1. The shaft. 2. The lower epiphysis. 3. The upper one.

the lower and larger one, is at the same time the first to join the shaft of the bone (D). The parts appear to unite somewhat later than in the tibia; the consolidation is complete between the twentieth and twenty-fifth year.

BONES OF THE FOOT.

The foot; its divisions.

The foot is composed, like the hand, of three parts, viz. the tarsus, metatarsus, and toes; their upper and under aspects are shown in fig. 63 and 63*. These parts will in the first place be described separately, and they will then be reviewed in their connection one with the other, constituting the frame-work of the foot.

TARSUS.

Tarsus; its composition.

The tarsus is composed of seven bones, viz. the os calcis, astragalus, cuboid, scaphoid, and three cuneiform.

THE CALCANEUM.

Os calcis forms the heel.

This bone, fig. 63, (os calcis—calcaneum,) is situated at the posterior and inferior part of the tarsus, and forms the heel by its projection backwards; elongated in that direction, and compressed laterally, it is the largest of the bones of the foot.

Fig. 63.

Articular surfaces for astragalus and groove between.

Superiorly it presents (taking the objects successively from behind forwards) a concave portion[1], intervening between the insertion of the tendo Achillis into its posterior border, and the surface which articulates with the astragalus; then the last-named surface, which is bounded by a rough depression for the insertion of a ligament (interosseous), and lastly a narrow concave surface, which also articulates with the astragalus. On the *inferior surface*, which is narrower than the preceding, and broader behind than before, are observed posteriorly two tubercles[2] [3], (the internal being the

Inferior tubercles.

Fig. 63.*

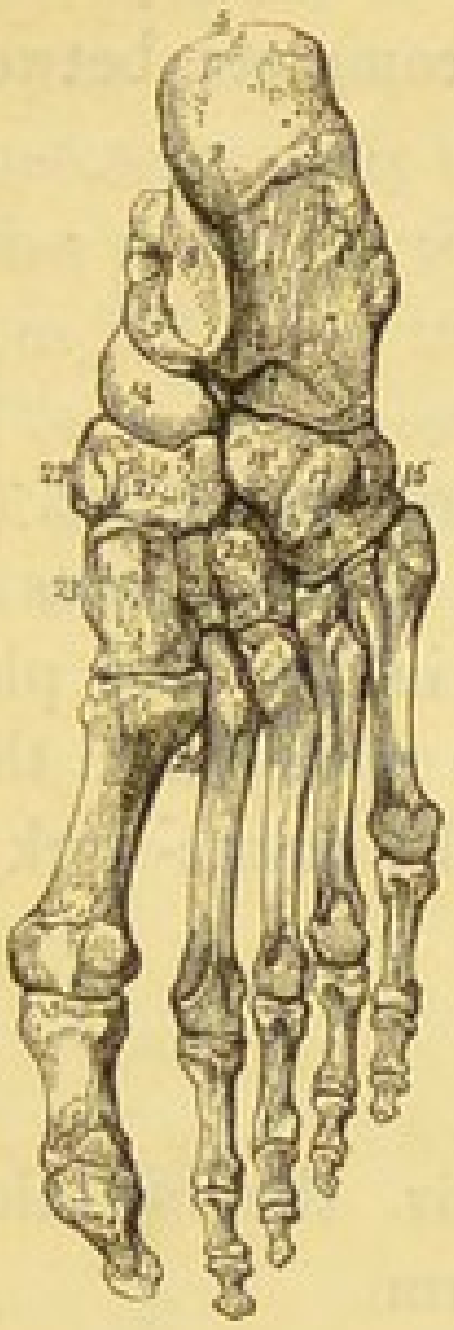

larger,) serving for the attachment of the plantar fascia and the superficial plantar muscles; between them a depression for the origin of the long plantar ligament, and in front another eminence[4], giving attachment to the inferior ligament (calcaneo-scaphoid) connecting this bone with the scaphoid. The *anterior surface*, the smallest, is slightly concave, and articulates with the cuboid bone. The *posterior surface*, convex, forms a rough projection inferiorly, (tuber calcis,)[5] which receives the attachment of the tendo Achillis, and is continued into the tubercles on the lower surface of the bone[2] [3], more especially the inner one. The upper part of the posterior surface[6], less prominent and smooth, is, in part, separated from the tendo Achillis by a synovial bursa. The *external surface*, nearly flat, broader behind than before, presents in the latter direction superficial grooves[7], for the tendons of the peronei muscles, and is subcutaneous in the rest of its extent. The *inner surface*[8], deeply concave, is traversed by the plantar vessels and nerves, and the tendons of the flexor muscles. At the anterior and upper part of this surface is a prominent process, which deepens the concavity; it is grooved beneath[9] for the tendon of the flexor longus pollicis, and above contributes to form the concave articular surface which supports the forepart of the astragalus, and hence the name "sustentaculum tali" applied to it.†

Tuber calcis; attachment of tendo Achillis.

External surface, partly subcutaneous.

Internal surface, deeply concave.

Sustentaculum tali.

Articulations.

The calcaneum articulates with the astragalus and the cuboid bone.

THE ASTRAGALUS. (TALUS.)

Astragalus.

The astragalus (αστραγαλος, a die,) is situated at the superior part of the tarsus; its form is irregular; it appears as if twisted on itself.

The *upper surface* presents, in front, a rough and slightly

---

† Or "sustentaculum cervicis tali,"—"Albini de sceleto liber," p. 302-4.

excavated part[10], serving for the attachment of ligaments; and behind it a large convex cartilaginous surface[11], which is longer and more prominent on the outer than on the inner side, broader before than behind, and articulated with the lower extremity of the tibia. On the *outer* and *inner sides* are situated two smooth surfaces[12 13], (the former the larger,) which are continuous with the preceding, and articulated with the inferior extremities of the tibia and fibula (the *malleoli*). On the *inferior surface* are observed, in front and somewhat internally, a narrow convex surface, and behind, a broad concave one, both articulating with the os calcis; these are separated by a groove, which receives the ligament that proceeds upwards from the last-named bone. The *anterior surface*[14], convex, is received into the hollow in the scaphoid bone; it is called the *head*, and the constricted part by which it is supported, the *neck* of the astragalus. The *posterior surface*, or rather border, is grooved and traversed by the tendon of the flexor longus pollicis.

Artic. surf. for tibia; its peculiar form; those for malleoli, their difference. Those for os calcis separated by groove. Head. Neck. Groove for tendon.

The astragalus articulates with the tibia and fibula above, with the os calcis below, and with the scaphoid in front.

Articulations.

THE CUBOID BONE.

This bone (*os cuboides, cuboideum,*) is situated at the external side of the tarsus; its form is indicated by its name.

Cuboid; its position.

The *superior surface*[15], rather rough, inclined obliquely outwards and upwards, gives attachment to ligaments. The *inferior surface* presents in front a depression[16], traversed by the tendon of the peroneus longus muscle, in the middle a transverse ridge, (tuberosity,)[17] and behind it an irregular surface[18], both of which give attachment to the calcaneo-cuboid ligament; the former also to some fibres of the ligamentum longum plantæ. At the *anterior aspect* of the bone is a smooth surface, directed from without inwards and forwards, and divided into two parts, the internal one being square, the external triangular, and articulated, the former with the fourth, the latter with the fifth metatarsal bone; at the posterior is a surface by which it articulates with the os calcis. The *external border*, which is short and rounded, presents a groove[19], continuous with that on the inferior surface, and serving for the transmission of the tendon of the peroneus longus muscle. On the *internal surface* may be

Ridge on lower surface. Short external border.

Lateral art. surface.

observed, towards its middle, an elongated smooth, and nearly flat portion[20], which articulates with the third cuneiform bone, the part before and behind it being rough for the attachment of ligaments. This surface likewise often articulates with the scaphoid.

Articulations.

The cuboid articulates with the fourth and fifth metatarsal bones before, with the os calcis behind, with the external cuneiform, and sometimes with the scaphoid.

THE SCAPHOID BONE.

Scaphoid; its position.

The scaphoid or navicular bone[21], so named from its excavated form (*σκαφη, navis*), is placed at the inner border of the foot, between the astragalus and the cuneiform bones.

Tubercle at inner side.

Concave artic. surf.

Facets for three cuneif. bones.

It presents a concave surface which looks backwards, and a convex one which is turned forwards. Its inner margin projects in the form of a tubercle[22] toward the sole of the foot. Upon its upper and inner surface are inequalities for the attachment of ligaments,—behind, a concavity for the head of the astragalus,—in front, three distinct surfaces for articulation with the three cuneiform bones; at its lower and inner border is the prominence or tubercle, above noticed, which gives attachment to the tibialis posticus muscle; on the outer side, in some instances, is a small articular surface, by which it is united to the cuboid bone.

Articulations.

It articulates with the three cuneiform bones, with the astragalus, and sometimes with the cuboid.

THE CUNEIFORM BONES.

Three cuneiform; their differences.

These bones[23 24 25] (ossa cuneiformia, wedge-shaped,) constitute the anterior and inner part of the tarsus; the name expresses their form. In number three, they are distinguished by their numerical order from within outwards.

The first is the largest, and has its base or broad border turned down into the sole of the foot,—the second, or middle, the smallest. The base, or broad border, of the second and third is at the upper or dorsal surface of the foot, and contributes to give it its arched form. They articulate behind with the navicular, and in front with the first, second, and third metatarsal bones. In consequence of their excess in length over the second, the first and third, in addition to articulating laterally with the corresponding sides of that bone, are in apposition with the base of the second metatarsal bone, which is inserted between them. The inner side of the first is subcutaneous, and the outer side of the third articulates, by a smooth flat surface with the cuboid, and by a small linear facet with the fourth metatarsal bone.

Muscular attachments.

Attachments of muscles to the tarsal bones.—The os calcis, by its dorsal surface, to the extensor brevis digitorum pedis; the inferior half of the posterior surface to the common tendon of the gastrocnemius and soleus (*tendo Achillis*), and to that of the plantaris; the inferior surface on the inner side, to the flexor accessorius, and part of the abductor pollicis: on the outer side, to the abductor digiti minimi; and between the two abductors, to the flexor brevis digitorum.

The cuboid bone, by the inferior surface, to a portion of the adductor pollicis and flexor brevis pollicis.

The scaphoid bone, by its tuberosity, to a portion of the tendon of the tibialis posticus.

The cuneiform bones. The first, by its base, to portions of the tendons of the tibialis anticus and posticus, and the second and third to part of the flexor brevis pollicis.

METATARSAL BONES.

Metatarsal bones; number; inter-oss. spaces.

The metatarsus, the second division of the foot, is placed between the tarsus and the toes, and consists of five bones, one for each toe. They are separated, except at their posterior extremities, where they are in contact, by four interspaces (*inter-osseous spaces*), which decrease in size from the inner to the outer side of the foot. These bones are named according to their numerical order from within outwards—that of the great toe being the first, and that of the little toe, the fifth or last; and the inter-osseous spaces are named in the same manner.

Common characters of the metatarsal bones.—They are long bones in miniature, and, like them, each may conveniently be considered to consist of a body and two extremities.

Bodies, triangular.

The *bodies* are in the longitudinal direction, somewhat concave on the plantar and convex on the dorsal aspect; and they have each, with more or less regularity, three sides and as many borders. One side corresponds with the dorsum of the foot, and the others bound the inter-osseous spaces.

Bases, wedge-shaped.

The *posterior* or *tarsal ends* (*bases*) of these bones are broad and squared on the dorsal surface, and becoming narrower in the opposite direction they contribute in consequence of their cuneiform or wedge shape to the general transverse arching of the foot. They terminate behind with plane articular surfaces for connexion with the tarsal bones; and, with exceptions to be noticed presently, they have likewise small articular faces on their sides, where they are in contact one with another.

Heads,

The *anterior* or *digital ends* (*heads*).—In front, the metatarsal bones are apart one from the other, and are marked on their sides by depressions and small tubercular projections. These are much smaller than the tarsal extremities, and they support the bones of the first phalanx of the toes by convex articular surfaces, which extend beneath the bones to their plantar aspect—the direction in which the toes are flexed.

their artic. surfaces.

Each has distinctive characters.

While the metatarsal bones thus resemble one another in some respects, or have certain characters in common, each presents peculiarities which serve to distinguish it from its fellows.

First; its size; no artic. surf. on sides.

Special or individual characters.—The great size is the most prominent distinctive mark of the *first*. It is much thicker, more massive, though shorter than any of the other bones. The tarsal end, or base, rough at its circumference, especially towards the plantar aspect, has no lateral articular facet, and wants the square shape which belongs to the others. The surface, which rests against the first cuneiform bone, is oval and slightly concave, and the joint formed between them is directed obliquely forwards and outwards. The digital end (*head*) forms the ball of the great toe. It is in contact, on the plantar surface, with two sesamoid bones; the part of the articular surface appropriated to these little bones is divided into two parts by a ridge, and is often grooved on one or both sides.

Second is the longest; artic. with three tarsal bones.

The *second* is the longest of the metatarsal bones. The posterior end has articular surfaces for the three cuneiform bones—it rests against the second, and is supported laterally by the first and third. On the outer side it is likewise articulated with the third metatarsal.

The distinction between the *third* and *fourth* is by no means so readily made as between others of the series. They have nearly the same length, but the third is slightly the longer. Moreover, the lateral articular surface on the inner side of the fourth is not so close to the end of the bone as it is on the neighbouring side of the third; from this it results, that, when the two bones are adapted one to the other in their proper relative position, the fourth projects behind the third; and this is necessary, in order that the bone should reach the cuboid, whose articular surface is in a corresponding degree behind that of the third cuneiform bone. It will likewise usually be found that the fourth has on its inner side, for connexion with the tarsal bone last mentioned (third cuneiform), a small additional facet, which would serve to characterize the bone.

Third and fourth distinguished.

The *fifth* is readily recognised by several striking characters, viz. the length, (which is less than that of any of the other metatarsal bones except the first,) the large size of its base, and some further peculiarities of this extremity: namely, the presence of a single lateral articular surface, (for the fourth metatarsal bone,) and a large rough tuberosity on the opposite side, which projects beyond the other bones at the outer side of the foot. This projection, which of itself at once distinguishes the fifth metatarsal bone, is readily felt through the integuments, and it marks, on the outer side, the position of the tarso-metatarsal articulation. The corresponding surfaces of this metatarsal bone and the cuboid are so oblique in direction, that, if a line drawn between them were extended across the foot, it would, on the inner side, reach the digital end of the first metatarsal bone.

Fifth, its length;

tuberosity.

PHALANGES OF THE TOES.

The number, form, and general conformation of the phalanges of the toes correspond with those of the fingers, in so much that, besides referring to the description of the latter, (*ante*, p. 135,) as being likewise generally applicable to the bones before us, it will only be necessary to add a statement of some points of difference.

Phalanges resemble those of hand.

The principal difference consists in the much smaller size of the phalanges of the foot. An exception is however afforded by the great toe, the bones of which are larger than those of the thumb.

Points of difference.

Peculiarities of phalanges of toes.

In addition to the small comparative size of the first phalanx of the four outer toes, they have this further peculiarity, viz. that the bodies are compressed laterally; and the bodies of the second row are so short that little of these bones remains beyond what is necessary to support their articular surfaces. The last two phalangal bones of the little toe are not unfrequently found connected by bony union in the skeletons of adults.

Attachments of muscles to the metatarsal bones and the phalanges of the toes.—The *first* gives attachment to the prolonged tendon of the peroneus longus, and the first dorsal inter-osseous muscle; the *second*, to the transversalis pedis, to the first and second dorsal inter-ossei; the *third*, to part of the adductor pollicis, to three inter-ossei, and part of the transversalis pedis; the *fourth*, to three inter-ossei also, and the transversalis pedis; the *fifth*, to the peroneus brevis and tertius, the transversalis pedis, part of the flexor brevis minimi digiti, to the fourth dorsal and third plantar inter-osseous muscle.

The *first* phalanx of the great toe gives insertion to the extensor brevis digitorum and to the abductor, flexor brevis, and adductor pollicis, with the transversalis pedis; the *second* phalanx, to the extensor proprius pollicis and flexor pollicis longus. The *second* phalanges of the other toes receive the insertion of the tendons of the flexor sublimis and of the extensors; and the *third*, those of the flexor profundus and of the extensors.

SESAMOID BONES.

They belong to tendons of muscles.

These do not properly form part of the skeleton; they may be considered as accessories to the tendons of muscles, and are found only in the limbs, never in the trunk. In the superior extremity, two are always found in the articulation of the metacarpal bone of the thumb with its first phalanx. In the lower extremity, two are frequently found behind the femoral condyles, and constantly beneath the first joint of the great toe, as well as in the tendons of the tibialis posticus and peroneus longus. They are situated in the direction of flexion (the only exception being the patella, which belongs to this class of bones), and serve the purpose of increasing the power of muscles, by removing them farther from the axis of the bone on which they are intended to act.

BONES OF THE FOOT AS A WHOLE.

The foot.

The osseous framework of the foot, constructed from the parts above separately described—tarsus, metatarsus, and phalanges of the toes—is placed horizontally beneath the leg, which rests on its upper surface.

Heel.

The posterior end (the heel), projecting behind the leg, is narrow and thick; the anterior part is broad, thinner, and expanded towards the toes. The upper surface ("dorsum" of the foot) is convex in two directions—longitudinally and from side to side. But in the latter direction the arch of the foot is much higher at the inner than at the outer side; and it is towards the inner and more arched, which is at the same time the longer and more massive side, that the weight of the body is received from the leg. The lower or plantar surface (sole of the foot) presents corresponding concavities. From this shape it results, that, when resting on a plane surface, the heel, the digital ends of the metatarsal bones, the toes, and the outer part of the sole of the foot, are in contact with the surface, but the middle, especially towards the inner side, is elevated from it.

Dorsum, convex in two directions.

Plantar surf. concave.

Foot contrasted with hand.

The constituent elements of the hand and foot are strictly analogous one to the other; but, by differences in the size and relative proportion of the parts, they are adapted to the very different uses of the limbs to which they respectively belong.

Thus: the prehensile organ is in the same line with the rest of the limb; the fingers are elongated, and comparatively free from the palmar part; and the thumb (including its metacarpal bone) has independent motion, and may be opposed to the other fingers. At the same time the carpus is small, serving only to connect the metacarpus to the bones of the forearm, and to contribute to the free motion of the wrist. On the contrary, the foot, an organ of support, is set on at right angles with the leg, and has no provision for the variety and facility of motion which belong to the upper limb. The toes, small in size, are cushioned at their roots by the soft parts of the sole of the foot, in which they are impacted; the great toe moves only with its fellows; and the tarsus is large in correspondence with the solidity required to bear the weight of the trunk. (For observations on the construction of the different parts of both limbs see *ante*, page 96.)

OSSIFICATION OF THE TARSUS, METATARSUS, AND PHALANGES OF THE TOES.

Only os calcis has more than one centre.

Ossific. of os calcis; astragalus.

The tarsus.—Each of the pieces of the tarsus is ossified from a single centre, except the os calcis. The process of ossification begins at a much earlier period than in the corresponding part of the hand. It becomes apparent in the os calcis in the sixth month of fœtal life (fig. 64, A.[1]), and about a month later in the astragalus (B.[2]).

Fig. 64.*

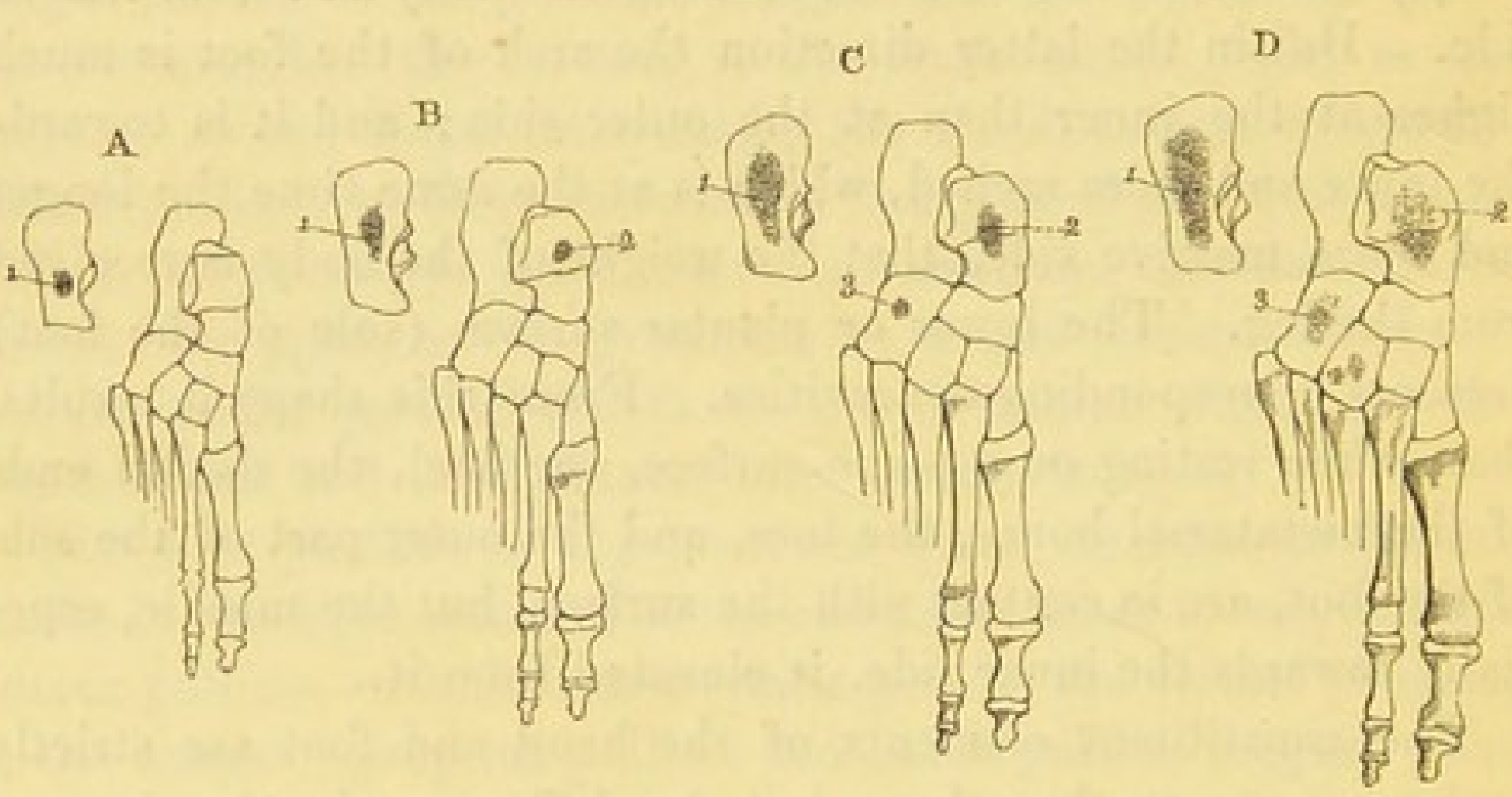

Cuboid; (state at birth).

In the full-grown fœtus a nucleus is apparent in the cuboid (C.[3]); but many good observers state that this bone does not begin to ossify till after birth.†

---

* The progressive advance of ossification over the tarsus is here illustrated. The metatarsal bones and phalanges are largely ossified long before the period to which the earliest of these cases belongs. A. This has been taken from a fœtus about the sixth month; a nucleus is distinct towards the anterior part of the os calcis. B. The age being from the seventh to the eighth month, the astragalus has received an osseous deposit. C. From a full-grown fœtus;—the cuboid has begun to ossify. D. The period being the end of the first or beginning of the second year, a commencement of ossification is apparent in the external cuneiform.

1. Nucleus of the os calcis. 1.* Fig. 65. Epiphysis of the os calcis. 2. Of the astragalus. 3. Of the cuboid. 4. Of the external cuneiform.

† Among others, Nesbitt, Albinus, and Béclard represent it to be cartilaginous at birth. Meckel specifically denies the correctness of the statement of Albinus, and describes the ossification to be far advanced at that time. The period of ossification mentioned by Wagner (in "Sœmmerring v. Baue d. menschlich. Körpers") agrees with that last mentioned: but this writer makes no reference to the grounds of his statement; neither does he refer to authorities, or to the differences among them.—In two cases,

Extern. cuneif. The external cuneiform succeeds to the cuboid, beginning to ossify in the course of the first year after birth (D.^{4}).*

Intern. cuneif. The ossification of the first or internal cuneiform follows—in the third year (E.^{5}).

Fig. 65.†

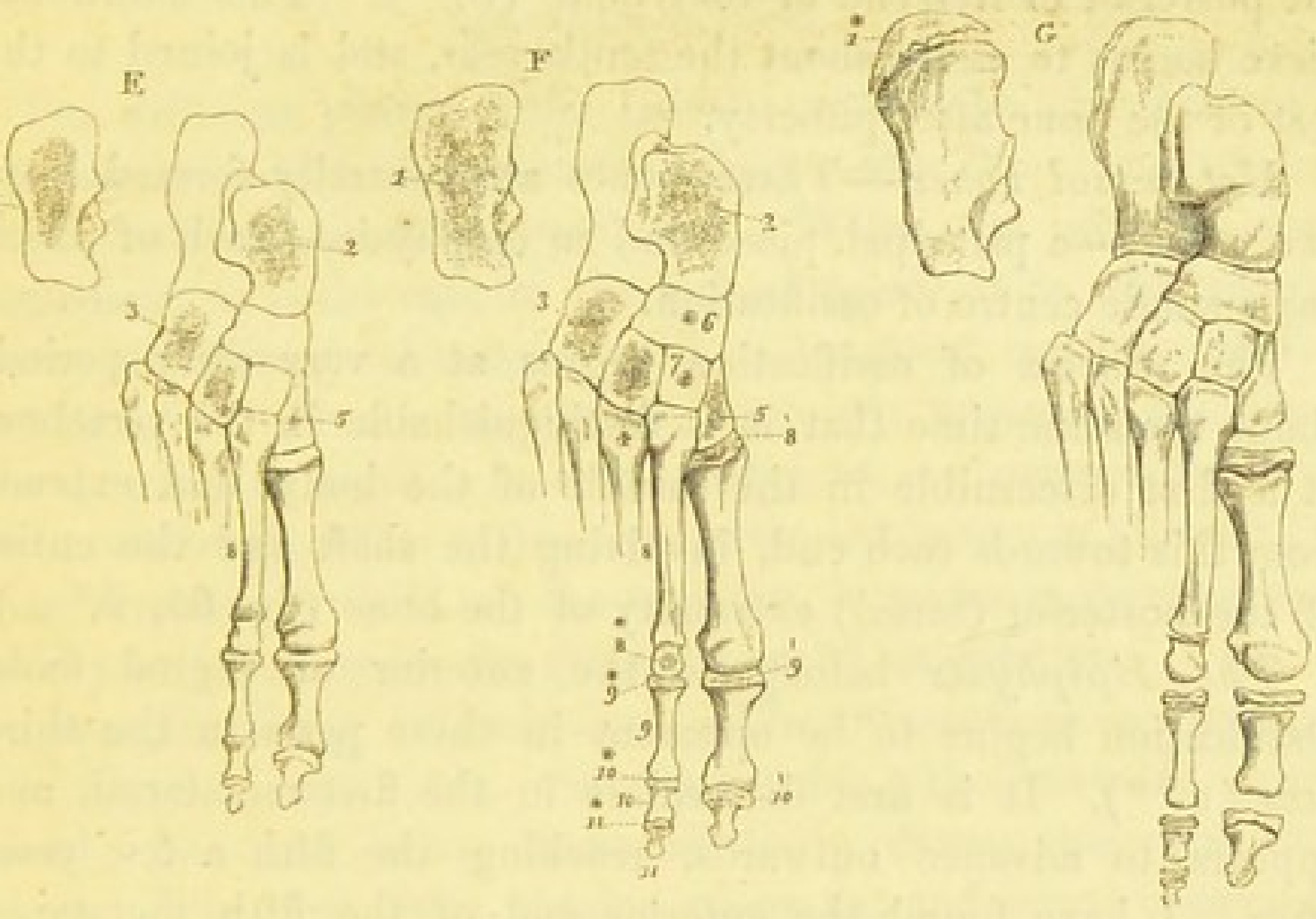

---

which I have lately examined, (full-grown fœtuses,) a very distinct osseous nucleus was present in each of the cuboid bones.

* It is remarkable, that some anatomical writers, who treat of the growth of bones, (including Béclard,) attribute to the first (internal) cuneiform the earliest ossification after the cuboid. I possess preparations which clearly show that the external one (third) precedes the first cuneiform by a considerable period, and Meckel's observations led him to the same conclusion.

† The progress of ossification in the foot is continued from fig. 64.— E. The state of the tarsus in the third year. Ossification has reached the internal cuneiform. Between the time to which this condition belongs and that to which the next figure is to be assigned, the epiphyses of the phalanges and metatarsal bones begin to form. F. The preparation here sketched was taken from the body of a child, stated to be between three and four years old. The middle cuneiform and scaphoid contain osseous nuclei; the former appears the more advanced. The epiphyses of the metatarsal bones and phalanges are partly ossified; the latter apparently more fully in proportion than the former. G. From the foot of a person about the age of puberty. The epiphysis of the os calcis is shown as if separated from the rest of the bone. The epiphyses of the metatarsal and phalangal bones are separable, and have been represented apart from the shafts of the bones.

5. Nucleus for the first or internal cuneiform. 6. The scaphoid. 7. The middle cuneiform.—The numbers before those here explained correspond with those of figure 64, and those which follow them are noticed in the text.

Mid. cuneif. and scaphoid.

The middle cuneiform and the scaphoid are the last to be developed. The deposit of osseous matter in them is apparent in the fourth year; and it is first discernible in the cuneiform bone (F.$^{6\,7}$).

Epiphysis of os calcis.

Epiphysis.—Only one of the bones of the tarsus, the os calcis, has an epiphysis. It is formed as a concave incrustation on the posterior or free end of that bone (G.^{1*}). This additional piece begins to ossify about the tenth year, and is joined to the rest of the bone after puberty.

Metatars.; each bone has two centres.

Metatarsal bones.—These bones are severally formed from two parts,—a principal piece and an epiphysis,—each of which has a single centre of ossification.

Early growth of shaft.

The process of ossification begins at a very early period, about the same time that it is distinguishable in the vertebræ. It is first discernible in the middle of the body, and extends from this towards each end, involving the shaft and the entire of the posterior (tarsal) extremity of the bone (fig. 65, F.^{8} G.).

Epiph. forms head of bone;

The Epiphyses belong to the anterior or digital ends. Ossification begins to be apparent in these parts in the third year (F.^{8*}). It is first discernible in the first metatarsal, and appears to advance outwards, reaching the fifth a few years after. I have found the anterior end of the fifth metatarsal bone wholly cartilaginous in a child seven years old. The epiphyses join the bone at between the eighteenth and the twentieth year.

except that of great toe.

The development of the metatarsal bone of the great toe has this peculiarity, namely, that the ossific process from the primary centre extends to the digital end (F.^{8} G.); and the epiphysis is formed on the opposite (tarsal) extremity (F.$^{8\prime}$ G.). In this respect, as well as in its shape, this bone has analogy with the digital phalanges.

Phalanges; two centres for each bone.

Epiph. forms base.

Phalanges of the toes.—Like the metatarsal bones, the phalanges are each formed from two parts, a principal one and an epiphysis; but the latter belongs to the posterior extremity of the bone (F. ^{9*} ^{10*} ^{11*} and G.).

The centres from which the bodies and the anterior ends of the phalanges of each toe are ossified become apparent some time after that of the corresponding metatarsal bone; and their epiphyses begin to ossify about the same time with the epiphysis of that bone. The ossification appears at an earlier period in the bones of the great toe than in the others, and latest in those of the little toe.*

THE CONNEXIONS OF THE PIECES OF THE SKELETON ONE WITH ANOTHER.

ARTICULATIONS.

The different pieces of the osseous system being connected together so as to form a skeleton, their modes of union must be as various as their forms and uses. When the union is not immediate, as is the case in the cranial bones, it is effected by means of different substances, such as ligament, cartilage, fibro-cartilage, and fibrous membrane, variously arranged and disposed, so as to permit, in some instances, no perceptible motion; whilst in others a free and extended range is allowed in every direction. Still, all the varieties, however numerous, are usually included under the general term " articulation."

Articulations; three classes.

Classification of articulations.—The articulations are divided into three classes; viz. the immovable, the movable, and mixed; the last being intermediate in degree between the others. The first form obtains where flat and broad bones are united to enclose cavities for the lodgment of important organs, as in the cranium and pelvis. In some instances the surfaces are indented and reciprocally impacted one into the other, so that complete solidity is ensured by the structure of the part; and, as this mode of union occurs only amongst flat bones, their deficiency in extent of contact is compensated by the indentations in their margins. There is another set of immovable articulations, in which the surfaces are merely in apposition with one another, yet total immobility is secured by what may be termed a mechanical contrivance. Thus, though the squamous part of the temporal bone merely rests against the inferior border of the parietal, no motion can exist between them, in consequence of the manner in which the petrous portion of the former bone projects into the base of the skull.

---

* In the foot of a child aged seven years and a month, the ossification of the epiphyses had begun in the metatarsal bones and the phalanges of all the toes, except the fifth. The great toe was much more advanced than either of the rest.

A.—IMMOVABLE ARTICULATIONS.—SYNARTHROSIS.

Synarthrosis, various forms of.

All the bones of the head and face, except the lower jaw, are joined by immovable articulation, or synarthrosis (συν, together; αρθρον, articulation), of which there are several forms.

Suture,

1. The first is called *suture* (sutura, a seam). In the true suture the union is effected by indentations in the contiguous margins of bones which are mutually received into one another, as may be seen between the two parietal, the occipital, and frontal bones; any varieties that occur being referrible to the form of the prominences. Thus, when they are tooth-shaped, the suture is termed *sutura dentata;* if like the teeth of a saw, *sutura serrata;* if the adjacent borders be bevelled off, as where the temporal and parietal bones are applied to one another, it is called a squamous suture (*sutura squamosa*). In some parts it may be observed that the mode of union and adaptation are alternated, in order to increase their power of resistance. Thus, at the superior part of the arch of the skull, the frontal overlies the parietal bones, and rests on them; but inferiorly and laterally the reverse takes place, where the parietal rests against the frontal.

dentated, serrated, and squamous.

Harmonia.

When the surfaces are merely placed in apposition with one another, as in the superior maxillary bones, the union is called *harmonia* (ἁρω, to adapt).

Schindylesis.

When a ridge in one bone is received into a groove in another, the articulation is called *schindylesis* (σχινδυλησις, a slit or fissure). The rostrum of the sphenoid, and the descending plate of the ethmoid bone, are joined in this way with the vomer. When a conical surface is impacted into a cavity, the term *gomphosis* (γομφος, a nail,) is adopted, which may be exemplified by the manner in which the teeth are lodged in the alveoli.

Gomphosis.

B.—MIXED ARTICULATIONS.—AMPHI-ARTHROSIS.

Mixed joints; a connecting substance intervenes

In the mixed form of articulation, or *amphi-arthrosis* (αμφι in the sense of αμφω, ambo, and αρθρον), the bones are connected by an intermediate substance, which allows some degree of motion. The articulations between the bodies of the vertebræ, the union at the pubic symphysis, and that between the first two bones of the sternum, are all constructed on this principle. As the surfaces in these cases are flat and plane, they possess, in themselves, no mechanical advantage; so that their union is maintained partly by the cartilages interposed between them, and partly by ligamentous and fibrous structures disposed round the articulations.

between the bones.

C.—MOVABLE ARTICULATIONS.—DIARTHROSIS.

Diarthrosis.

External connecting structures.

Influence of the muscles—

In the movable articulations, or diarthrosis (δια, through; αρθρον, articulation), as the surfaces are merely in contact with one another, the connexion between the parts is maintained by means of ligaments and fibrous membranes; for though cartilages are interposed between their adjacent extremities, they do not form a bond of union between them; on the contrary, they are calculated to facilitate motion, rather than to restrain it. But the muscles which surround the different movable articulations contribute materially to retain the articular surfaces in their natural situations, and to prevent displacement. This is particularly evident in the shoulder-joint, in which the head of the humerus is kept in contact with the glenoid cavity of the scapula, not so much by the fibrous capsule, which is weak and loose, as by the surrounding muscles; for, if these be weakened by paralysis, luxation may be readily produced.

Where movable joints exist.

The joints in the extremities are all referrible to the movable class: so is that of the lower jaw with the skull, and of the latter with the vertebral column.

Shape of the articular ends of bones,

and the names applied in consequence.

In the greater number of instances one of the articular surfaces is convex, the other concave; but each of these forms exhibits some varieties of conformation, which are marked by particular names. Thus, an articulating surface, which is rounded and globular, so as to represent a segment of a sphere, is called a *head;* but if it be elongated, the term *condyle* is used. These are in some cases supported by a contracted or thin portion (*neck*), which connects them with the body of the bone. If two condyles be placed in apposition, so as to leave a fossa between them, and constitute a pulley-like surface, it is termed *trochlea.* When plain even surfaces articulate, it is not necessary to mark them by any particular name; in describing them they are referred to generally as articulating surfaces. Some of the articulating depressions have also received names taken from certain peculiarities in their conformation. Thus, the superior extremity of the ulna, which receives the trochlea of the humerus, is called the sigmoid cavity, from some resemblance to the Greek letter Σ (*σιγμα*, *εἰδος*, form); others are denominated from their greater or less degree of depth or shallowness. The deep cup-shaped cavity which receives the head of the femur is called cotyloid (from *κοτυλη*, a cup, and *εἰδος*, form); and the shallow oval depression to which the head of the humerus is applied, receives the name of *glenoid* cavity (from *γληνη*, a shallow cavity, and *εἰδος*, form).

Enarthrosis.

The varieties of diarthrosis are:—1. *Enarthrosis* (*εν*, in; *αρθρον*, a joint), which in common language is called the "ball-and socket" joint; such as we see in the hip and shoulder. In these great freedom of motion is provided for.

Arthrodia.

2. *Arthrodia* (*αρθρον*, a joint; *ἄρω*, to adapt); which comprises joints with a limited motion, as in the case of the carpal and tarsal bones, which merely slide for a little way upon each other. The articulations between the tubercles of the ribs and the transverse processes of the vertebræ, and those between the articular processes of the last-named bones, also come under this head.

THE KINDS OF MOVEMENT ADMITTED IN JOINTS.

Kinds of movement.

As the extent and form of the articulating surfaces of joints, as well as their ligamentous connexions, vary in different instances, so must their degrees of solidity and mobility: and on a review of the whole of the articulations, it may be laid down as a general principle, that the greater their mobility, the less their solidity; or, in other words, that the one is inversely as the other. All the motions, however, which are admissible in joints may be arranged under four heads, viz. motions of gliding, angular movement or opposition, circumduction, and rotation.

Gliding.

1st. The contiguous surfaces of every movable articulation admit a certain degree of *gliding* motion upon one another, so that it may be regarded as common to all; but in some cases it is the only one which takes place, for instance, between the different bones of the carpus and tarsus. We thus observe that some joints admit of all the motions here indicated; some are deprived of rotation, retaining the rest; whilst in others nothing more than a mere gliding can take place between the surfaces; so that a regular gradation is established in their degrees of mobility between the most movable and those which are least so. The shoulder-joint admits of the greatest extent and variety of movement; those between the carpal and tarsal bones are exceedingly limited in these particulars; and, finally, between the latter and those which are altogether immovable, an intermediate grade may be traced, of which the pubic symphysis presents an example.

Angular movement.

2nd. The *angular* movement, or opposition, can only take place between long bones. If these be made to move in opposite directions, as from extension to flexion, or from abduction to adduction, they form with one another angles varying in degree according to the extent of the motion. This, in some cases, as in the elbow and knee, is confined to flexion and extension, which makes them strictly ginglymoid or hinge-joints (*γιγγλυμος*, a hinge); in others the motion is general, and extends to four opposite directions, including each of the points intermediate between them, as may be observed in the shoulder, in the hip, and the metacarpal joint of the thumb, all which joints admit of a circumduction in the part to which they belong.

Ginglymus.

Circumduction.

3rd. The motion of *circumduction* is performed when the shaft of a bone is made to describe a cone, its summit corresponding with the superior articulation, the base being at the inferior extremity of the bone. While this motion is being executed, the limb passes successively through the states of elevation, abduction, depression, adduction, and of course through all the intermediate points; and if a pencil be held between the fingers, and its point applied to any plain surface, such as a wall, it will trace a circle corresponding with the base of a cone, whose summit is at the shoulder-joint, whilst its side coincides with the line described by the out-stretched limb as it traverses the different points just enumerated.

Rotation.

4th. *Rotation* differs altogether from circumduction. In the latter the bone suffers a change of place as it moves from one point to another; in the former, it merely turns on its own axis, and therefore retains the same relative situation with respect to the adjacent parts. This movement, however, admits of two varieties; in one, it is performed on a pivot, as in the motion of the axis on the vertebra dentata; in the other there is a sort of compound motion, for instance, where the radius rolls on its own axis at one end, whilst at the other it moves upon the extremity of the ulna, by which its lower part describes a segment of a circle, and therefore changes place to a certain extent. The femur and humerus also admit of a rotatory motion; in the latter, as the head is closely applied upon the shaft, the axis of motion nearly coincides with that of the bone; but in the former, in consequence of the length of the neck, and of the angle which it forms with the bone, the rotation is performed round an imaginary axis, which may be conceived to pass from the globular head to the condyles.

Various movements of the hip and shoulder.

There are but two articulations in which all the motions of opposition, circumduction, and rotation can be performed, namely, the hip and the shoulder joint. In these a convex surface is applied to one which is concave, the former being hemispherical, which is essentially necessary to such a freedom of motion. As joints constructed on this principle are more liable to displacement than any others, their security is in a great measure provided for by their being placed at the superior extremity of the limb, by which they are withdrawn from the influence of external forces. This arrangement is made subservient not to the security of the joint solely, but also to a very important purpose in the functions of the limb. For as these free and extended motions are performed in the superior articulation, their effect is communicated to the whole limb, so as to compensate for the more restricted movements in the lower joints.

These joints contrasted.

Though all the motions above mentioned take place in the hip and shoulder joints, each of them, considered singly, is not performed with equal facility in both. Thus, circumduction is executed with greater ease in the shoulder than in the hip. Rotation, on the contrary, is more free and perfect in the latter than in the former. Circumduction can be executed with ease only when the axis of motion coincides (or very nearly so) with that of the lever to be moved, as is the case in the humerus; but in the femur, the length of the neck of the bone removes the axis of motion considerably from that of the shaft, and thereby impedes circumduction in proportion as it facilitates the rotation of the limb. These differences of structure in the superior joints of the two extremities bear a distinct relation to the conformation of their other articulations, and to the purposes for which they are adapted. For, as the inferior extremity is intended to sustain the weight of the body and for progression, the bones of the leg must be securely fixed, which could be effected only by diminishing their mobility; on this account no rotation or supination is allowed between the tibia and fibula; but, to compensate for this deficiency, rotation is permitted in the hip. But as the superior extremity, on the contrary, is fitted for the prehension of objects, and for quick and varied movements, free motion is allowed between the bones of the fore-arm, and between the latter and the carpus, in order that the hand and fingers may be more readily directed and applied to such objects as are required to be seized for different purposes; and the power of pronation and supination, thus conferred, more than compensates for any deficiency in the rotatory motion of the humerus.

Circumstances influencing the degrees of motion in different joints.

It has been already observed, that rotatory motion in a bone presupposes the existence of a globular head, placed so that its axis shall form an angle with the shaft. Wherever this requisite is wanted, motion is confined to opposition and circumduction, as occurs in the articulation of the thumb with the carpus, in the phalanges with the metacarpal bones, and in the clavicle with the sternum. In these joints, the articulating surfaces are placed at the ends of the more movable bones; and as their axes coincide with that of motion, rotation is prevented, but circumduction and opposition are freely performed. When these are limited in extent, as in the sterno-clavicular articulation, it arises rather from the accessory ligaments of the part than from any impediment in the surfaces of the bones; and if motion in one direction be more free than in another, as in the digital phalanges with the metacarpus, where flexion and extension are more free than abduction and adduction, it proceeds partly from the existence of the lateral ligaments, and partly from the great power possessed by the flexor and extensor muscles compared with those which perform the other movements. Though in the knee and elbow the axis of motion coincides with that of the bones, yet their movement is confined to two directions, viz. to flexion and extension. In these joints, all other motions besides those just mentioned are prevented by the breadth of the articulating surfaces, and by their mode of adaptation: however, when they are flexed, some degree of lateral motion, and also of circumduction, can be performed; as any individual may ascertain by resting his elbow on a table, when he will find that the fore-arm may be made to describe a cone with its summit at the olecranon and base towards the fingers.

ARTICULATIONS OF THE VERTEBRAL COLUMN.

Means by which vertebræ connected.

The different pieces of the spine are connected together by ligaments, by fibro-cartilage, and in some parts by synovial membranes; the former serving to retain them in their situation, the latter to facilitate motion between the different bones. The bodies are joined by two ligamentous bands, extending the whole length of the chain, and also by the inter-vertebral substances.

Anter. com. lig.

Fig. 66.*

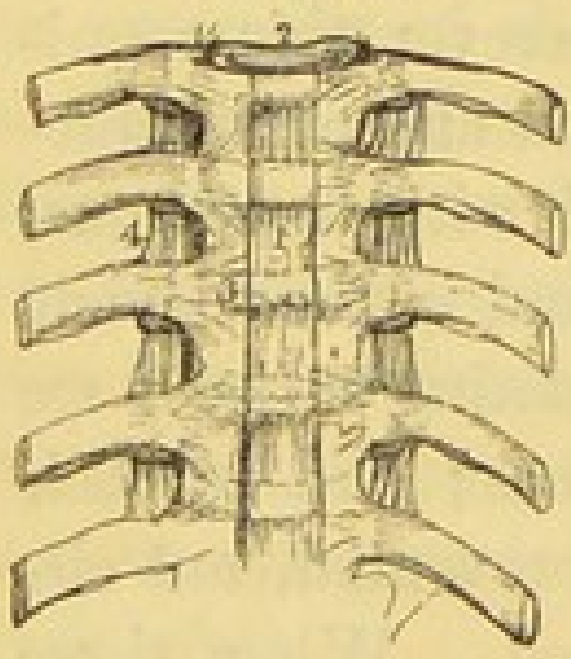

its position;

1. The *anterior common ligament*, (fig. 66, [1]) (ligamentum corporibus vertebrarum commune anterius, seu fascia longitudinalis anterior,—Weitbrecht,) is a strong band of fibres which is placed on the front of the bodies of the vertebræ, and reaches from the axis to the first bone of the sacrum, becoming broader as it descends. It consists of longitudinal fibres which are dense, firm, and well-ma^{r}ked. The superficial fibres extend from a given vertebra to the fourth or fifth below it; the set subjacent to these passes from the body of one to about the third beneath it; whilst the deeper ones pass only from one vertebra to that next it. The fibres are thicker towards the middle of the bodies of

length of fibres.

---

* A few dorsal vertebræ and parts of some ribs seen from before. 1. The anterior common ligament. 2. The inter-vertebral substance seen to a small extent. 3. The anterior costo-vertebral or stellate ligament. 4. The anterior or inferior costo-vertebral ligament.

the vertebræ than at their margins, or over the inter-vertebral cartilages; by which means their transverse depressions are filled up, and the surface of the column rendered even. It may also be observed that they adhere more closely to the margins of the bones than to the middle of their bodies, and still more closely to the inter-vertebral cartilages. Upon the sides of the vertebræ there are some fibres which are thin and scattered, and reach from one bone to the other.

Fig. 67.*

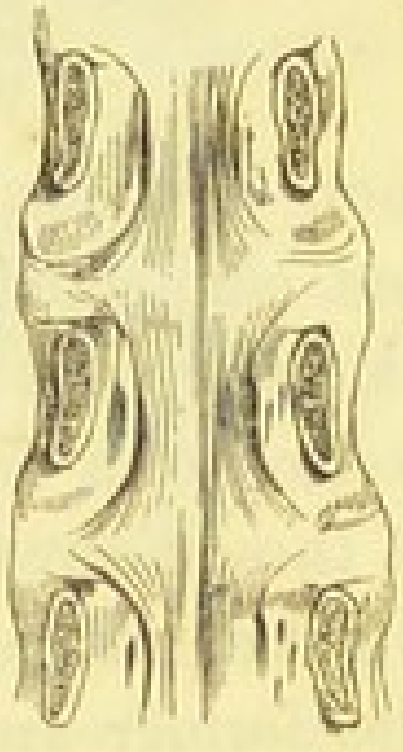

Poster.com. lig.

2. The *posterior common ligament*, (fig. 67,) (ligamentum commune posterius, seu fascia longitudinalis postica,—Weitbrecht,) is situated within the spinal canal, and attached to the posterior surface of the bodies of the vertebræ, extending from the occiput to the sacrum. It is smooth, shining, and broader opposite the inter-vertebral cartilages than opposite the bodies of the bones, so that its margins present a series of points or dentations with intervening concave spaces. And the ligament is altogether broader at the upper than the lower part of the spine. It adheres firmly to the fibro-cartilages and to the contiguous margins of the bodies of the vertebræ, but it is separated from the middle of the vertebræ by the transverse parts of the large venous plexus which is in contact with the bones. Between the ligament and the prolongation of the dura mater, which lines the canal, some loose cellular membrane is interposed.

its position;

its shape;

where most adherent.

Intervert. substance.

3. The *inter-vertebral substance* (ligamenta inter-vertebralia —Weitbr.) is a plate or disc of fibro-cartilage, (fig. 66, ²,) placed between the bodies of each pair of vertebræ, from the axis to the base of the sacrum; corresponding in shape to the parts of the vertebræ between which they are interposed. They are covered anteriorly and posteriorly by the common ligaments which are intimately adherent to them; in the dorsal region they are connected laterally, by short ligaments, to the heads of all the ribs, each of which articulates with two vertebræ.

shape and thickness;

---

* The arches have been removed from three vertebræ by sawing through their pedicles. The bodies remaining are seen on their posterior surface, with the posterior common ligament covering them to some extent.

Concentric plates.

Fig. 68.*

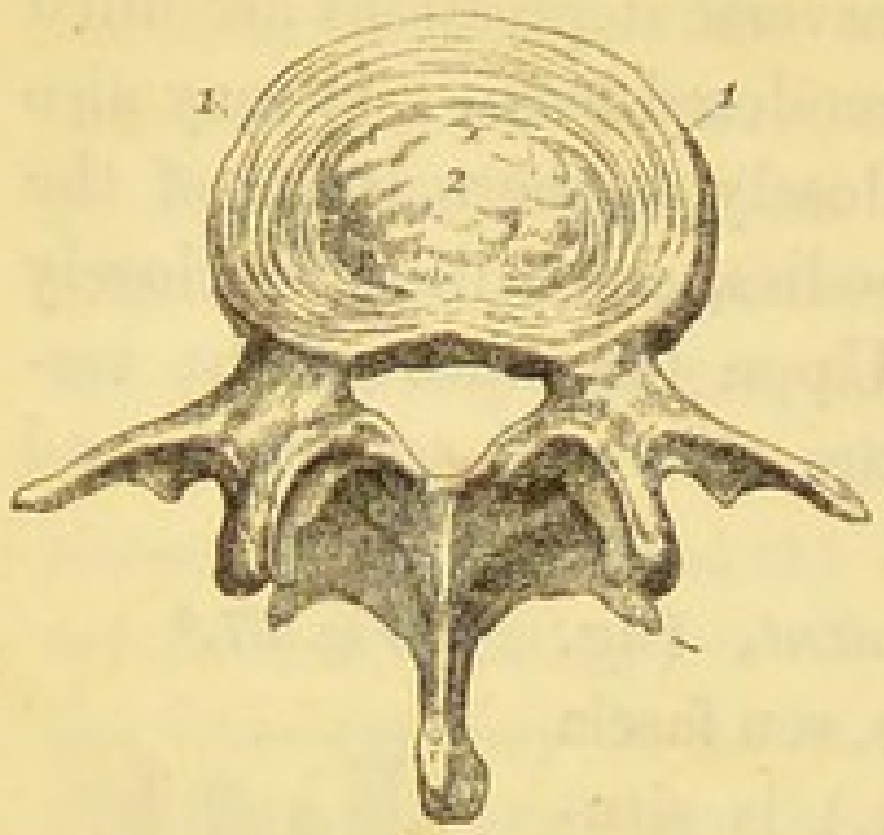

The inter-vertebral substance is composed, towards its circumference, of thin plates of fibro-cartilage, resting on their edges, and placed one within the other, as it were, concentrically (fig. 68, [1].) Thus the outer plate like a rim runs round the disc, its lower edge resting on the vertebræ beneath it; its anterior or convex surface being subjacent to the anterior common ligament, whilst its concave surface is in apposition with and connected by some fibres to the plate next within it. The plates are not vertical in their direction. On making a vertical section of a disc, (fig. 69,) it will be seen that a certain number of those nearest the circumference [1][1] curve outwards, while others situated more deeply are inclined in the opposite direction [2][2]; the former are more closely compacted together. When the spine is bent in any direction, the curves formed by the different layers are augmented on the side towards which the column is inclined. The interstices between the plates are

Outer and inner bend in different directions.

Fig. 69.†

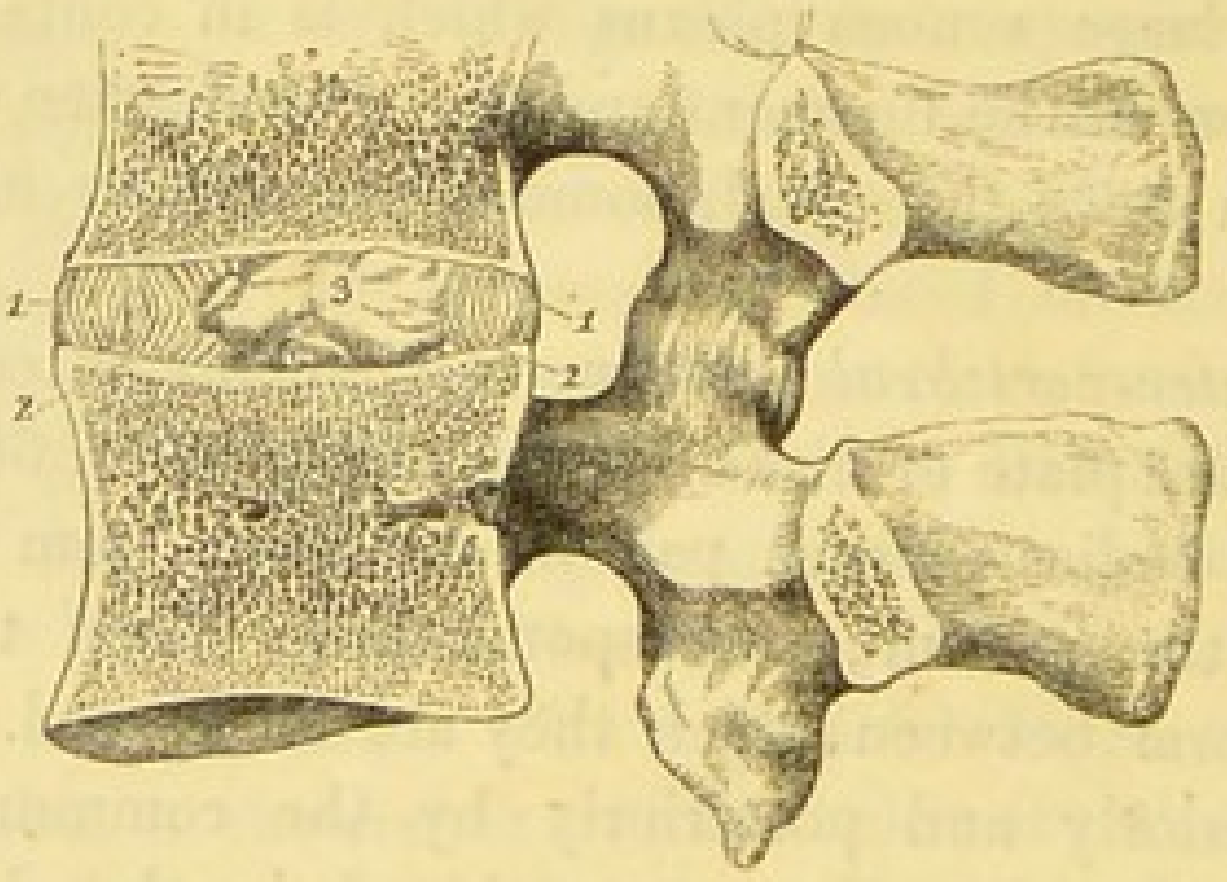

---

* A lumbar vertebra, with a horizontal section of inter-vertebral substance above it. At the circumference the concentric arrangement of the layers of the latter is shown, and in the middle the pulpy substance is indicated.

† A vertical section of two vertebræ, and the substance interposed between their bodies. The direction of the layers of the inter-vertebral substance is displayed. 1. Layers curved outwards. 2. Those curved inwards. 3. Pulpy substance in the middle.

Pulpy subs.

filled by a pulpy and apparently elastic substance ; and as the number of plates gradually decreases towards the centre, (fig. 68,^{2}, and 69,^{3}), whilst the pulpy matter increases, the quantity of the latter is such, that, when the pressure which confines it is taken off by cutting through the inter-vertebral substance, it will rise up so as to assume a conical form.

Fig. 70.*

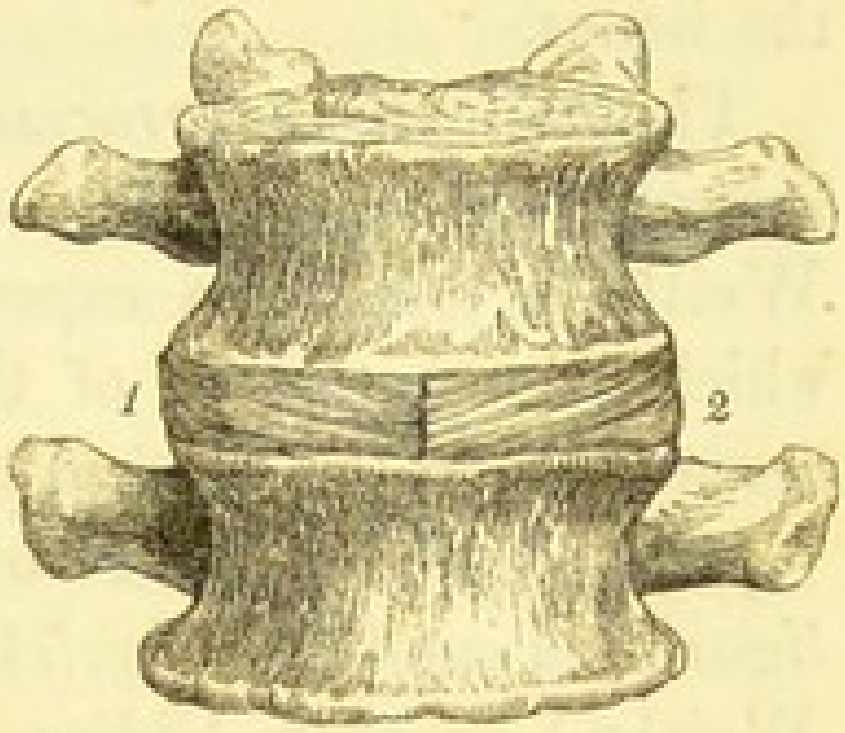

Fibres of one plate cross those of another.

The plates of the inter-vertebral tissue being examined singly, it will be found that each consists for the most part of fibres extending obliquely between the vertebræ, into both of which they are firmly fixed; and the direction of the fibres varies from layer to layer,—in one being from right to left, and in the next the reverse (fig. 70, $^{1\ 2}$). Some fibres will be found to be nearly horizontal.

Proportion of intervert. subst. in spine.

The inter-vertebral substance in the column generally.—Excluding from consideration the first two vertebræ, between which it does not exist, the inter-vertebral tissue forms in length about a fourth of the movable part of the column. But it is not equally distributed among the different parts. It varies in thickness from point to point, and the dorsal division of the spine has, comparatively with the length, a much smaller proportion, and has accordingly less provision for pliancy than the cervical or lumbar portions of the column.†

Interv. sub. causes curves in cerv. and lumb. and not in dorsal part of spine.

Moreover, the discs are not uniform in their thickness. In the cervical and lumbar regions, which are convex forwards, they are thickest in front; and by comparing the heights of the fore

---

* Two lumbar vertebræ with the inter-vertebral substance are seen from before. By removing a portion of one layer of the latter, another layer is partly exposed, and the difference in the direction of their fibres is made manifest.

† In an elaborate work on the joints and their various movements, the brothers W. and E. Weber have given various measurements of the individual vertebræ, and the interposed tissues, and have grounded on them calculations of the degree of flexibility of the column in different parts. In order to render their measurements more exact by preventing all separation of the parts, they placed a body in plaster of Paris, (after having removed some of the soft parts, but without interfering with the ligaments,) and when it was immovably fixed by this means, a vertical section was made through the middle of the trunk, dividing it into two equal lateral parts.—See " Mechanik der menschl. Gehwerkzeuge," S. 90, et seq. Göttingen, 1836.

and back parts of the bodies of the vertebræ, and comparing in like manner the heights of the anterior with the posterior margins of the inter-vertebral discs, it has been determined that the convexity of the cervical and lumbar portions of the column is chiefly due to the latter structure,—to it much more than to the bodies of the vertebræ; while the arching of the dorsal region was, on the contrary, found to be owing rather to the shape of the bones.

Artic. processes, how connected.

The *articulating processes* of the vertebræ are connected by irregular fibrous bands (ligamenta processuum obliquorum, Weitbr.), forming a capsule outside the synovial membrane which belongs to each of the joints. The latter are longer and more loose in the cervical than in the dorsal or lumbar regions.

Lig. subflava, their position; how brought into view; their extent;

The arches, or plates of the vertebræ, are connected by the *ligamenta subflava*, (fig. 71,) (ligamenta vertebrarum subflava,—Weitbr.) as their bodies are by the inter-vertebral fibro-cartilages. They are most distinctly seen when the pedicles and arches are detached from the bodies of the vertebræ, so that they may be viewed from within the spinal canal, as in this drawing (fig. 71); at the posterior aspect of the spine they appear short, and, as it were, overlaid by the arches (fig. 80, ^{3}.) They extend from the root of the transverse processes at each side backwards to the point where the two arches converge at the origin of the spinous processes. In this situation the ligaments are thickest, and the margins of the lateral halves may be observed to be merely in contact.

Fig. 71.*

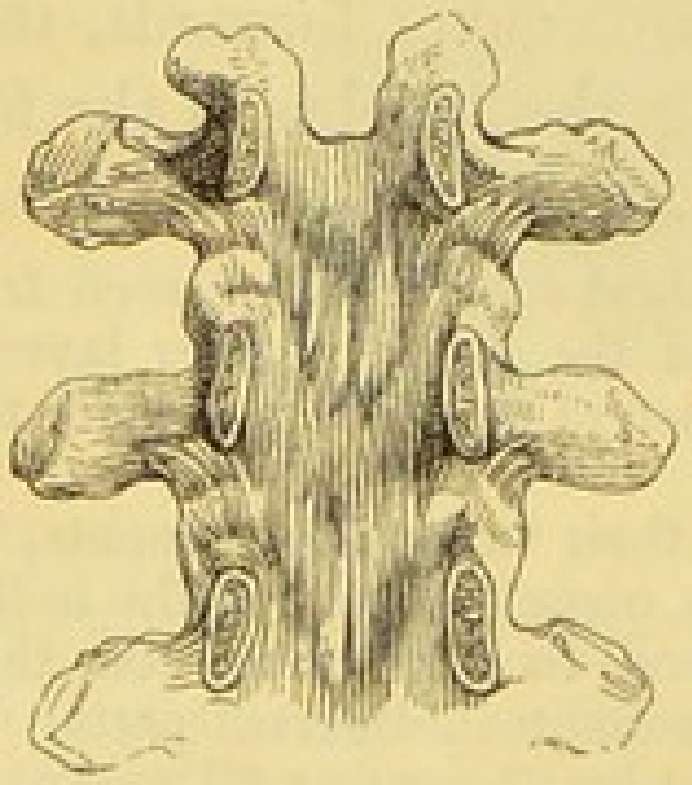

colour; arrangement of fibres;

These ligaments consist of yellow elastic fibres, almost perpendicular in their direction, as they pass from the inferior border of one arch to the adjacent border of that immediately below it. The superior border of the ligament is attached, not to the margin exactly of the arch, but rather higher up on its anterior surface; whilst the inferior border

---

* To show the "ligamenta subflava," the pedicles of the vertebræ were sawed through, and the bodies removed. The arches and the processes being left, the ligaments are seen from before, *i. e.*, on the surface which looks towards the vertebral canal.

is prolonged a little on the posterior surface, as well as the margin of its corresponding arch.

The ligamenta subflava do not exist between the occiput and the atlas, or between the latter and the axis; common fibrous membrane supplies their place in these two spaces. where not present.

The connexion of the spinous processes is effected by means of the supra-spinous and inter-spinous ligaments.

Inter-spinous and supra-spinous ligaments.

1. The *supra-spinous ligament* (ligamenta, queis apices committuntur,—Weitbr.) consists of small, compressed bundles of longitudinal fibres, which connect the summits of the spinous processes, and form a continuous chain from the seventh cervical vertebra to the spine of the sacrum. (See fig. 80, [1].) The posterior fibres pass down from a given vertebra to the third or fourth below it; those more deeply seated reach only from one to the next, or the second beneath it.

2. The *inter-spinous ligaments* (membrana inter-spinalis—Weitbr.), thin and rather membranous, extend from the root to near the summit of each spinous process, connecting the inferior border of one with the superior border of that next below it. They exist in the dorsal and lumbar regions only, and are intimately connected with the extensor muscles of the spine.

Inter-transverse.

The *inter-transverse ligaments* (lig. process. transv.—Weitbr.) are found only between the transverse processes of the inferior dorsal vertebræ, and even there very indistinctly, for they are united so intimately with the sacro-lumbalis muscle, that their fibres are quite confused; indeed, they appear to be rather appendages to the muscles than ligaments to connect the bones; and they are so considered by Weitbrecht, Meckel, and Sœmmerring. By the last-named author they are recognised as present in the lumbar as well as the dorsal region.

ARTICULATIONS OF THE TWO UPPER VERTEBRÆ ONE WITH THE OTHER.

Atlas with axis; no inter-vertebral substance.

The articulation of the axis with the atlas is effected by means of their articulating processes, also (in the place of inter-vertebral substance, which would be altogether incompatible with the requisite movements) by the odontoid process of the former, which is connected in a particular manner with the arch

Kind of movement.

of the latter, and constitutes the pivot on which the head turns in its rotatory motions. There are three ligaments and four synovial membranes in this articulation.

Transverse ligament;

Fig. 72.*

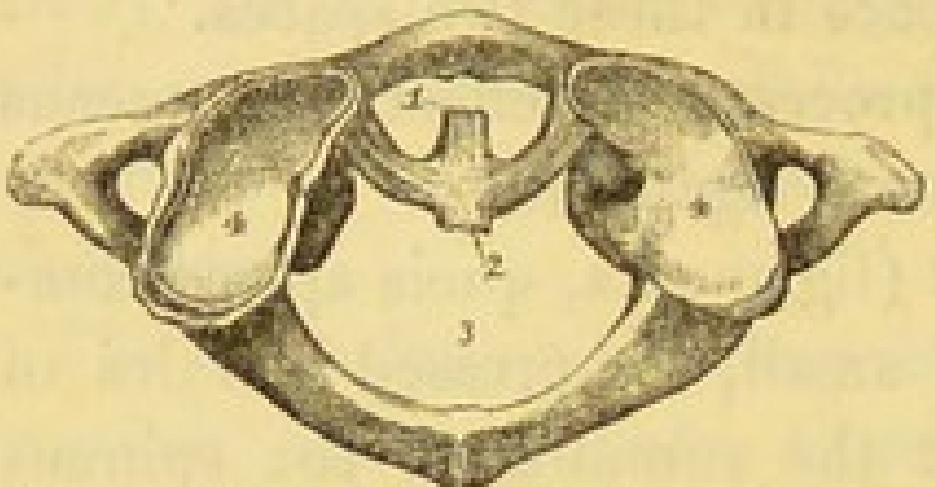

divides ring of atlas into two parts;

The *transverse ligament*, (fig. 72, ^{2}, and 73, ^{2},) (ligamentum transversale: pars principalis, — Weitbr.), is placed transversely behind the odontoid process of the axis, and forms with the anterior arch of the atlas a ring ^{1}, in which that process is lodged; dividing thus the great foramen of the first vertebra into two parts of unequal size, of which the larger ^{3} is appropriated to the spinal chord, and the smaller ^{1} is occupied in the manner already stated.

crosses odontoid process.

The ligament is a strong, thick fasciculus of fibres, compressed from before backwards, arched in its direction, as it crosses the odontoid process, and attached on each side to the inner border of the superior articulating processes of the atlas. The ligament is broader and thicker at the middle than at its extremities; and from the middle of its posterior surface a short thin bundle of fibres passes down to be attached to the root of the odontoid process, whilst another passes up to the basilar process. *These appendages* (lig. transv. appendices,—Weitbr.) form a cross with the transverse ligament, and serve to bind the occiput to the first two vertebræ; from this is derived the term *cruciform*, which is sometimes applied to the transverse ligament and its appendages together. (Fig. 73.)

With its appendages, is cruciform.

Fig. 73.†

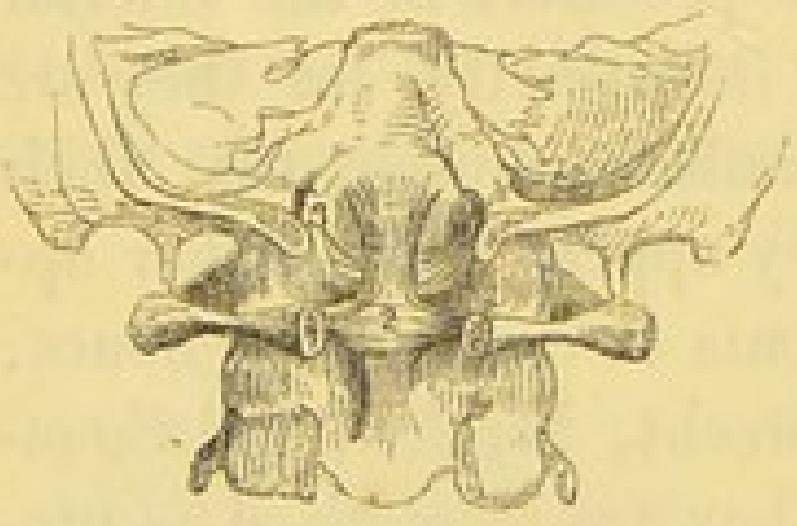

---

* A view of the atlas from above, showing the transverse ligament, with fragments of its appendages. 1. The space for the odontoid process. 2. The transverse ligament. 3. Space for the spinal cord. 4. Articular processes;—on one of these a remnant of the capsular membrane is seen.

† A small portion of the skull and the first two vertebræ are shown in this figure. They are viewed from behind. The back part of the occipital bone, and of each of the vertebræ, was removed together with the nervous centre and its membranes, as well as a ligament extending from the occiput to the axis (fig. 76,^{1}). 2, is placed on the middle of the trans-

Fig. 74.*

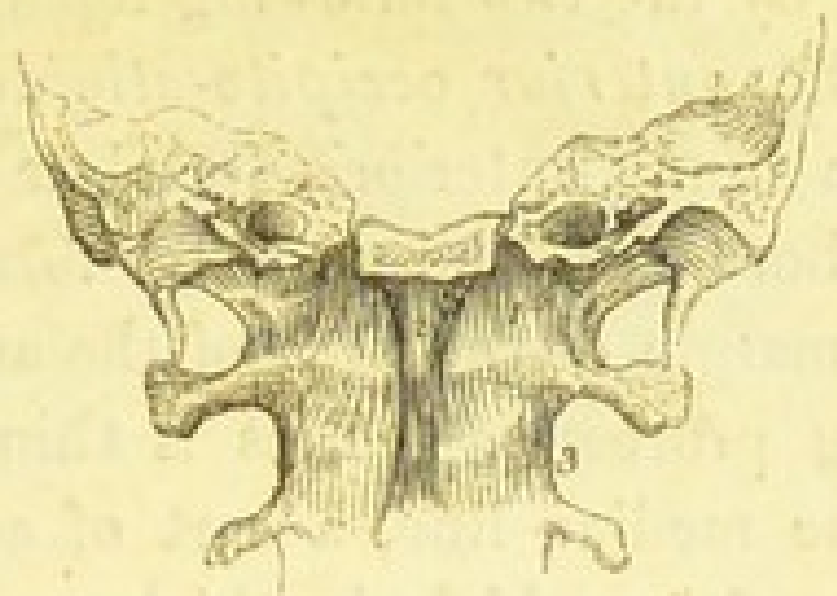

The *anterior atlo-axoid ligament* passes from the border of the anterior arch of the atlas, and its tubercle, to the body of the axis and the root of its odontoid process. It is thin and membranous, except at the middle, where it is more thickened, (fig. 74,^{3}).

Anter. lig. thin and loose.

The *posterior atlo-axoid ligament,* which is also thin and membranous, connects the posterior arch of the atlas with the plates of the axis (fig. 75, ^{2}). Thus the interstices between the plates or arches, which in all the other vertebræ are filled by the ligamenta subflava, are occupied by a loose membrane between the second and first, as well as between the latter and the occiput[1].

Posterior is membranous, instead of lig. subflav.

The edges of the articulating processes are connected by irregular fibres passing from one to the other.

Two *synovial membranes* are placed between the articulating processes of the atlas and axis. One between the odontoid process and the transverse ligament, another between it and the arch of the atlas.

Four synovial sacs.

ARTICULATIONS OF THE CRANIUM WITH THE FIRST TWO VERTEBRÆ.

The cranium is articulated with the atlas, and is connected by ligaments with the axis.

The *articulation of the cranium with the atlas* takes place between the condyles of the occipital bone and the superior articulating processes of that vertebra, which are connected by li-

Occiput w. atlas;

---

verse ligament; its appendages extend up and down—the whole constituting a crucial ligament. 3. The upper end of the odontoid ligament of the left side; the same part of the ligament of the opposite side is also visible.

* A part of the skull and two vertebræ are represented in this figure. The skull was sawed upwards, and the anterior parts taken away. The vertebræ are seen in front. 1. The anterior occipito-atloid ligament. 2. The middle (accessory) occipito-atloid ligament. 3. The anterior atlo-axoid ligament.

two articulations.

gaments and synovial membranes; it is also connected with the same by the two following ligaments.

Anter. lig. is thin;

thick fibres at middle.

The *anterior occipito-atloidean ligament* (fig. 74, [1]) (membrana annuli anterioris vertebræ primæ) extends from the anterior border of the occipital foramen, between the condyles, to the margin of the arch of the atlas between its superior articulating processes. This is thin, broad, and membranous; but in the median line, a sort of accessory ligament[2] is placed in front of it, which is thick, round, and composed of vertical fibres, attached above to the surface of the basilar process, and below to the small tubercle on the front of the atlas. The anterior surface of these ligaments is covered by the recti antici muscles, the posterior covers the upper end of the odontoid process and its ligaments.

Poster. lig. thin.

Position of vertebral artery.

The *posterior occipito-atloidean ligament*, (membrana annuli posterioris atlantis,) (fig. 75, [1],) also broad and membranous, is attached superiorly to all that part of the margin of the occipital foramen which is behind the condyles, and inferiorly to the adjacent border of the posterior arch of the atlas. It is partly blended with the dura mater. The posterior surface of the ligament is in apposition with the posterior recti and superior oblique muscles, the anterior looks towards the vertebral canal; at each side near the articular process the ligament forms part of the foramen through which the vertebral artery and suboccipital nerve pass.

Fig. 75.*

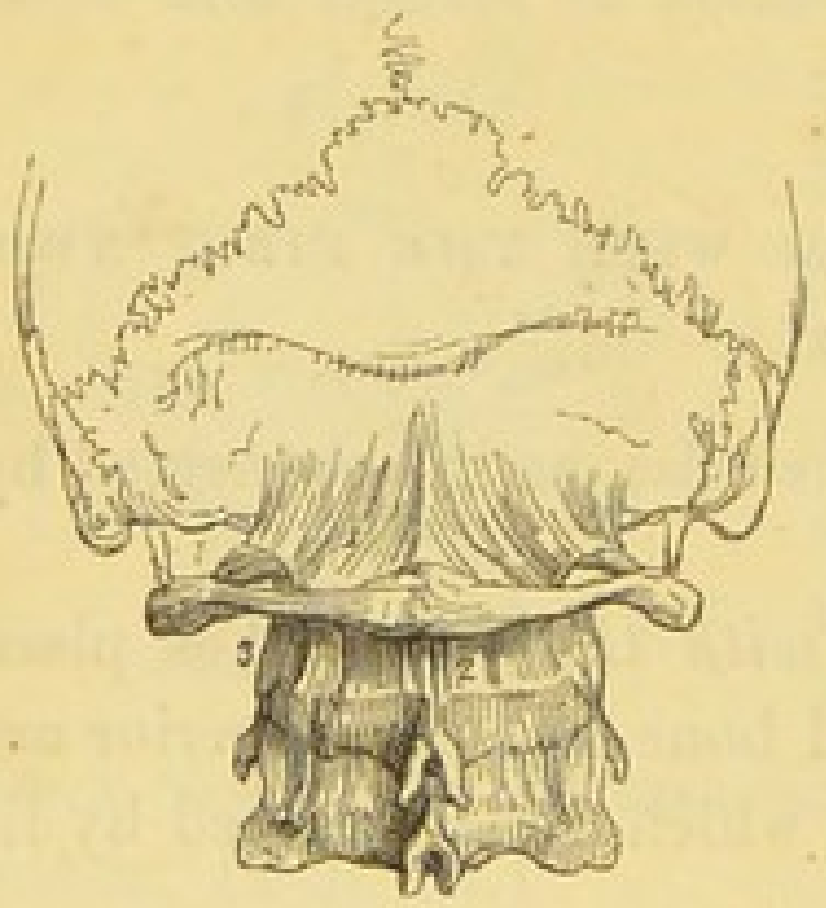

Occiput w. axis; no art. surfaces; ligaments in vert. canal.

The *articulation of the occipital bone with the axis* is effected through the medium of ligaments, as no part of their surfaces comes into contact, and the ligaments are placed within the vertebral canal, which must be laid open to exhibit them.

---

* The posterior surfaces of the occipital bone, and of three vertebræ, are represented in this figure. 1. The posterior occipito-atloid ligaments. 2. The posterior atlo-axoid.

Fig. 76.*

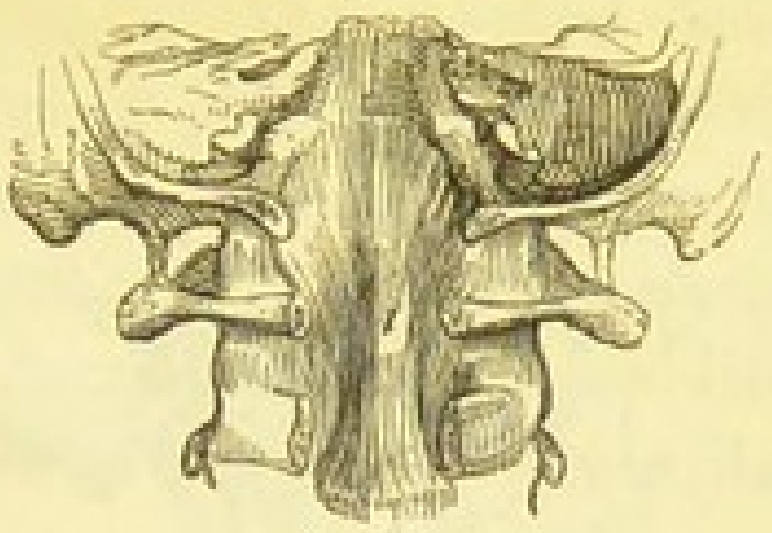

Apparatus ligam.

Covers odont. and cruciform ligs.

The *occipito-axoidean ligament* (apparatus ligamentosus) (fig. 76) seems to be a prolongation of the posterior common ligament ; it is attached above to the inner surface of the basilar groove, from which it descends perpendicularly, becoming narrow, and opposite the axis is blended with the posterior common ligament. It covers the odontoid process and its check ligaments, and is intimately connected with the transverse ligament.

Odont. ligs.

are oblique.

Lig. dentis medium.

Odont. are check ligts.

The *odontoid ligaments* (fig. 73, [3]) (ligamenta alaria) are two thick bundles of fibres attached below to each side of the summit of the odontoid process, and passing up diverging to be implanted into the rough depressions at the inner side of the condyles of the occiput, and also to a small part of the margin of the occipital foramen. Their direction, therefore, is obliquely upwards and outwards ; the triangular interval which they thus leave is filled by some fibres (ligamentum rectum medium, seu dentis suspensorium) passing almost perpendicularly from the margin of the foramen to the summit of the process. These are strictly check ligaments : the middle set, last described, assist in preventing what may be termed a retroversion of the head, whilst the lateral pair check its rotatory motions.

ARTICULATION OF THE LOWER JAW WITH THE CRANIUM. —TEMPORO-MAXILLARY.

Articular surfaces ; outline of joints.

The lower jaw articulates at each side by one of its condyles with two parts of the temporal bone ; viz. the glenoid fossa in front of the Glaserian fissure, and the articular root of the zygoma. Between the bones is placed an inter-articular cartilage, with a synovial membrane above, and another below it, and around the joint are disposed the ligaments.

---

* In order to show the ligament represented on this figure, the posterior part of the occiput, some of the posterior arch of the atlas and the spinous process, with a portion of the plates of the axis, were sawed off, and the spinal cord with its membranes was removed. The basilar process of the occipital bone (its cerebral surface) is exposed, with a ligament (1) stretching from it to the body of the axis (its posterior surface).

Fig. 77.*

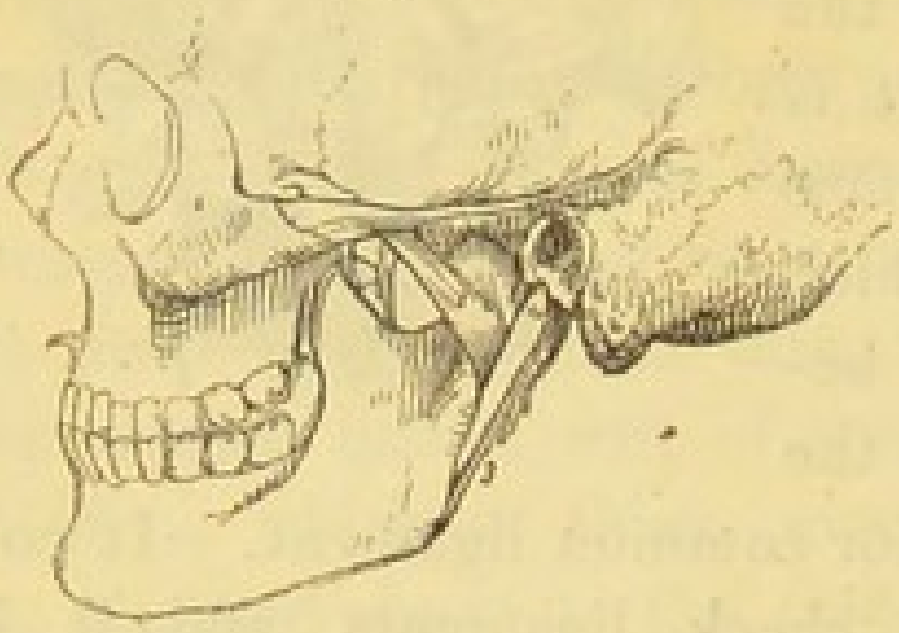

Ext. lat. lig. short, oblique.

The *external lateral ligament* (fig. 77, [1]) is a short fasciculus of fibres, attached above to the external surface of the zygoma, and to the tubercle at the bifurcation of its root; below, to the external surface and posterior border of the neck of the condyle, its fibres being directed downwards and backwards. Externally it is covered by the parotid gland, internally it is in relation with the inter-articular cartilage and synovial membranes.

Fig. 78.†

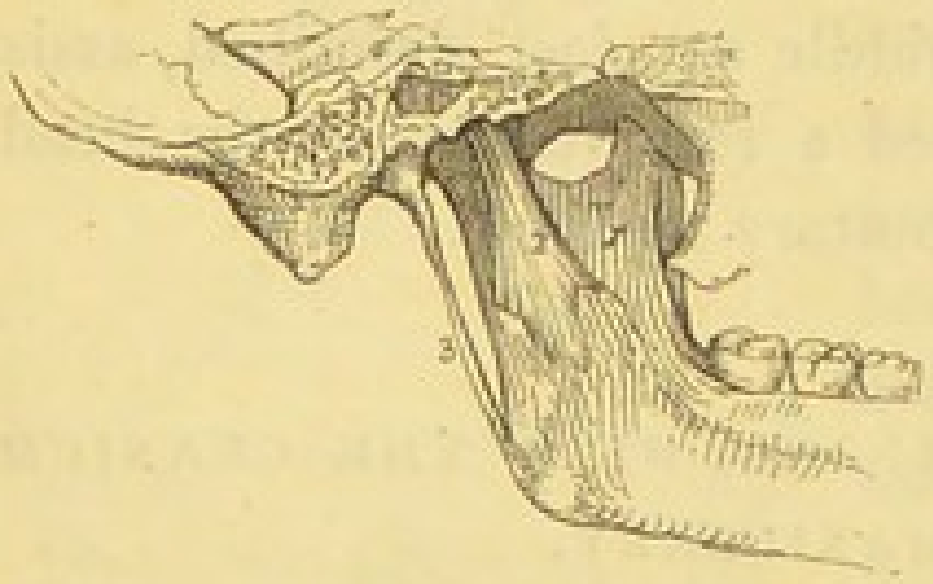

Int. lat. lig. thin, loose; not close to joint.

The *internal lateral ligament*, (fig. 78,[2]) thin, loose, and elongated, lies at some distance from the joint. It extends from the spinous process of the sphenoid bone downwards, and a little forwards, to be attached to the inferior maxillary bone at the lower border of the dental foramen, where it is somewhat expanded. Its external surface is in relation superiorly with the external pterygoid muscle, and in the rest of its extent with the ramus of the jaw, from which it is separated by the internal maxillary artery and dental nerve. Its inner surface is concealed by the internal pterygoid muscle. — The structure described here as a ligament has more connexion with vessels and muscles than with the joint. It is not recognised as a ligament by several anatomists.

Connexion with artery and nerve.

Stylo-maxillary does not belong to joint.

The *stylo-maxillary ligament* (figs. 77, 78, 79,[3]) thin and

---

* A small part of the skull and the external ligament of the temporo-maxillary articulation are here represented. 1. The external lateral ligament. 3. The stylo-maxillary ligament.

† The skull and the lower maxilla having been sawed through in the vertical direction and longitudinally, the inner side of the bones and of the temporo-maxillary articulation is brought to view. 2. The internal lateral ligament. 3. The stylo-maxillary. Both are seen on their inner aspect.

aponeurotic, being, in fact, a portion of the cervical fascia, passes from near the point of the styloid process to the inferior border of the angle of the jaw, where it is inserted between the masseter and internal pterygoid muscles. This membrane separates the parotid gland from the sub-maxillary. It has little claim to be considered an appendage to the temporo-maxillary articulation.

Fig. 79.*

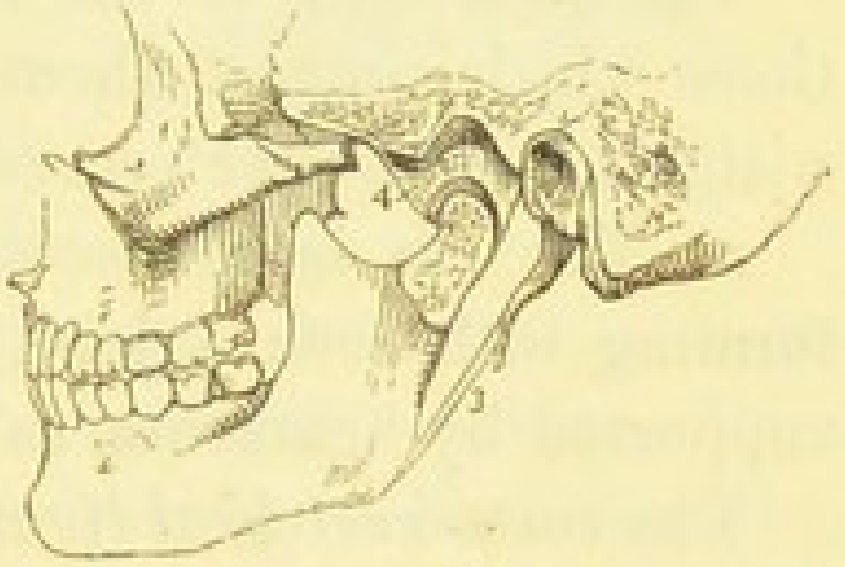

Fibro-cart. ;

is not fixed to bones;

its shape.

The *inter-articular fibro-cartilage*, (operculum cartilagineum mobile,—Weitbr.) (fig. 79,[4]) is a thin plate, placed horizontally between the articular surfaces of the bones; but is not, like most other similar structures, directly fixed to either. It is of an oval form, and thicker at its margins than at its centre, where it is sometimes perforated. The inferior surface, which is in contact with the condyle, is concave; the superior is alternately concave and convex when taken from before backwards, conforming in some way with the outline of the articular cavity. Its circumference is connected at the outside with the external lateral ligament, and anteriorly with the external pterygoid muscle.

Two synovial sacs.

Synovial membranes.—The larger and looser of the two which belong to this joint, after lining the superior surface of the inter-articular cartilage, is reflected upwards on the external lateral ligament, and over the smooth part of the glenoid cavity. The other synovial membrane is interposed between the inferior surface of the cartilage and the condyle; and thus there is constituted a double joint. When the fibro-cartilage is incomplete (perforated), the synovial membranes are continuous one with the other.

---

* The skull and the lower maxillary bone are seen on their outer surface, but the external ligament of the temporo-maxillary articulation, and a portion or layer of the bones (the temporal and inferior maxilla), have been removed, and in this manner the interior of the joint is exposed to view. 3. The stylo-maxillary ligament. 4. The fibro-cartilage intervening between the condyle of the lower maxillary bone and the articular part or parts of the temporal.

Membrana artic.

Thin and short additional ligamentous fibres surround a considerable part of the joint (membrana articularis,—Weitbr.), and serve to cover over the synovial membranes, as well as to maintain the connexion between the bones and the interposed fibro-cartilage.

ARTICULATIONS OF THE RIBS.

The ligaments of the ribs may be divided into three sets: those which connect them—with the bodies of the vertebræ; with their transverse processes; and with the sternum.

A. The rib is connected with the bodies of two vertebræ, forming with each a joint lined with synovial membrane, and supported by ligaments, as follows:—

The *costo-vertebral ligaments* (lig. capitulorum costarum) consist,—1, of an anterior ligament which connects the head of each rib with the sides of the bodies of the vertebræ (figs. 66, 81,[3]); its fibres, flat and radiated, are divided into three bundles, of which the middle one passes horizontally forwards upon the corresponding inter-vertebral cartilage, whilst the superior ascends to the body of the vertebra above it, and the inferior descends to that below. From the divergence of its fibres, this is usually called the *stellate ligament*. 2ndly. Of an *inter-articular ligament*, a thin and short band of fibres, which passes transversely from the ridge separating the two articular surfaces on the head of the rib to the inter-vertebral substance, and divides the articulation into two parts, each lined by a separate synovial membrane. The ligament does not exist in the articulation of the first, eleventh, or twelfth ribs, and in consequence there is in them but one synovial capsule.

Inter-artic. ligament; two synovial sacs.

Rib connected to transverse processes of two vert.

B. The rib is connected with the transverse processes of two vertebræ: with one it forms a joint lined by synovial membrane; to the other (being separated from it by a considerable interval) it is connected by ligamentous structure of some length.

Costo-transverse ligaments;

The *costo-transverse ligaments* connect the tubercle and neck of the rib with the transverse processes of the vertebræ; from their position they are named posterior, middle, and anterior.

posterior;

1. The *posterior costo-transverse ligament* (fig. 80,[5]) (lig.

transversarium externum costarum,—Weitbr.) consists of a very short thick fasciculus of fibres which passes from the posterior surface of the summit of the transverse process, to the rough unarticulated part of the tubercle of the rib. Those of the superior ribs ascend, those of the inferior descend somewhat.

Fig. 80.*

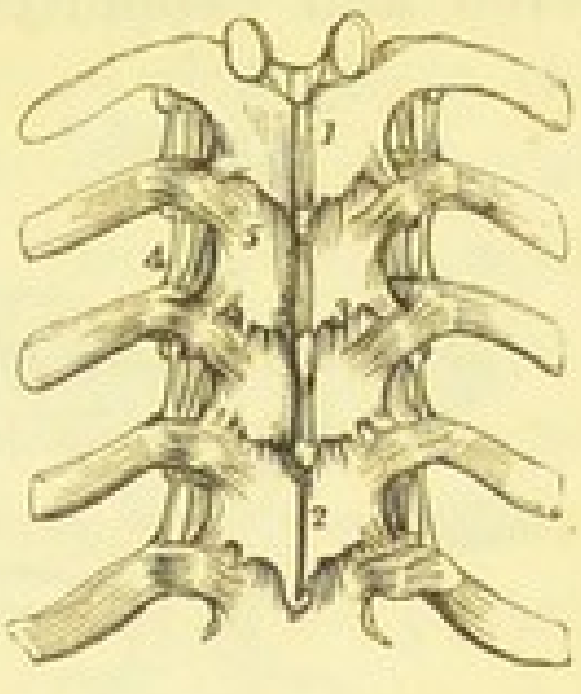

inter-oss.;

2. The *middle* or *inter-osseous costo-transverse ligament* (fig. 81,[6]) consists of a series of very short parallel fibres, which unite the neck of the rib to the anterior surface of the contiguous transverse process. These fibres are seen by removing horizontally a portion of the rib and transverse process, and forcibly drawing one from the other.

and anterior.

3. The *anterior* or *long costo-transverse ligament* (figs. 66, 80,[4]) (lig. transversarium internum, seu cervicis costæ internum,—Weitbr.) is usually divided into two fasciculi of fibres, both nearly in apposition, and on the same plane. They pass from the neck of the rib obliquely upwards and outwards to the lower margin of the transverse process next above it. These do not exist in the articulations of the first and last ribs.

Fig. 81.†

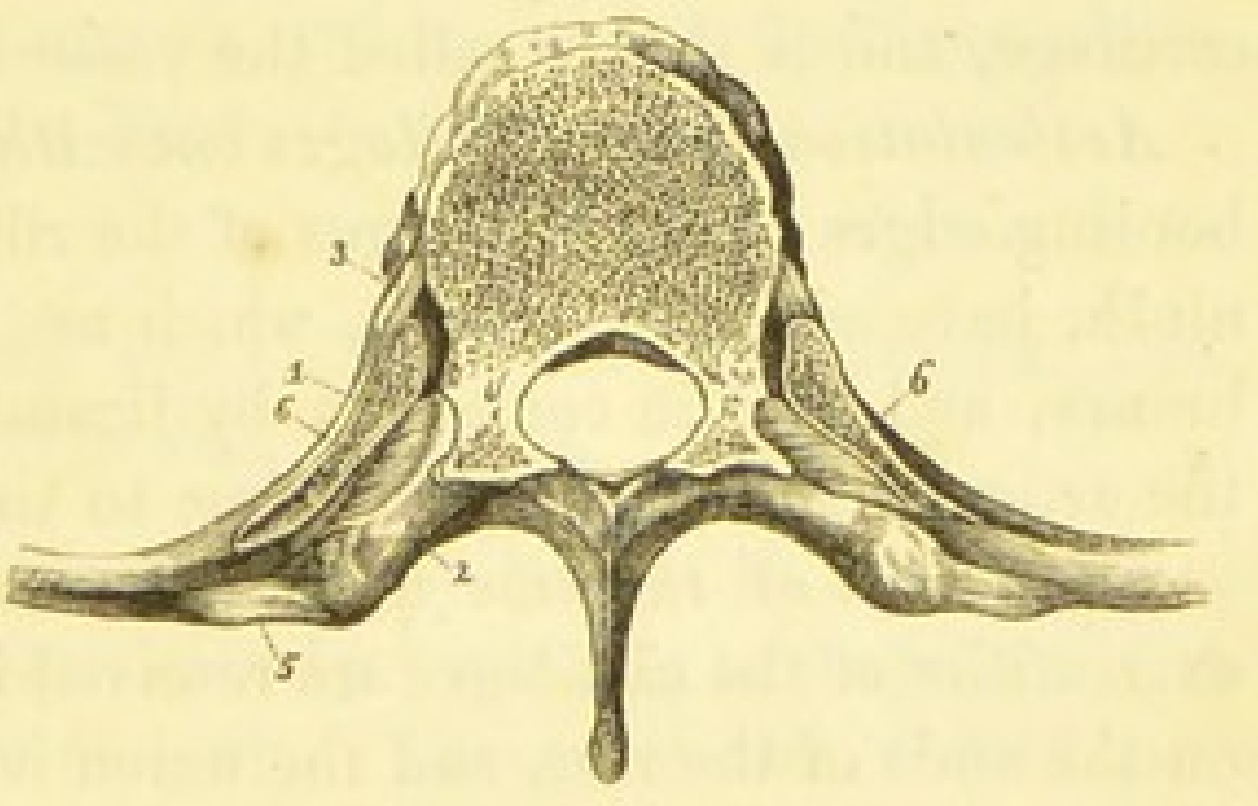

Synovial sac.

The articulation between the tubercle of the rib and the transverse process is provided with a synovial capsule.

---

* A few dorsal vertebræ, and ribs connected with them, are seen from behind. 1, 2, are on the laminæ of vertebræ, close to the inter-spinous ligaments. 3, is one of several ligamenta subflava, represented in the figure. They are but slightly seen, being for the most part covered by the plates of the vertebræ: see figure 71. 4. The anterior costo-transverse ligament. 5. The posterior costo-transverse ligament.

† A horizontal section of a vertebra and portions of two ribs, to show the inter-osseous ligament connecting the neck of the rib to the transverse pro-

Cart. of rib w. sternum.

anter. lig.; radiated;

posterior lig.;

super. and infer. fibres.

Synovial sac.

c. The *costo-sternal articulations*, situated between the anterior angular extremities of the cartilages of the ribs and the corresponding fossæ in the margins of the sternum, are covered and supported by, *a*, an anterior set of ligamentous fibres, (fig. 82,[6]) thin, scattered, and radiated, (ligamenta radiatim disiecta, — Weitbr.) passing from the extremity of the cartilage to the anterior surface of the sternum, where they interlace with those of the opposite side, and are blended with the aponeurosis of the pectoralis major muscle; *b*, a posterior set of fibres similarly disposed, but not so thick or numerous, connecting the thoracic surfaces of the same parts; *c*, some ligamentous fibres placed above and others below the joint; *d*, a synovial membrane, interposed between the ends of each true rib and the sternum. These can be demonstrated by slicing off a little of the anterior surface of the sternum and cartilages.

Fig. 82.*

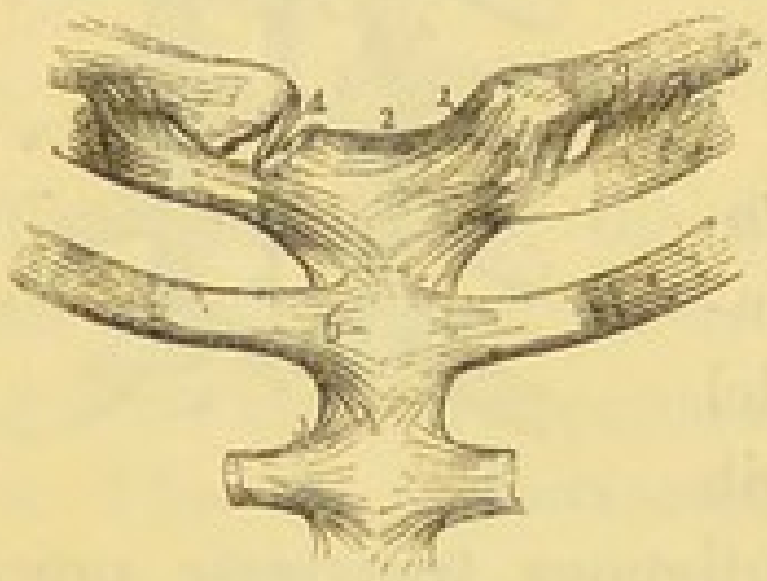

Costo-xiphoid.

A thin fasciculus of fibres connects the cartilage of the seventh rib (and, it may be likewise, the sixth) with the xiphoid cartilage, and is thence called the *costo-xiphoid ligament*.

Articulation of the cartilages one with the other.—The neighbouring edges of the cartilages of the ribs, from the sixth to the ninth, have articular surfaces, which are lined by synovial membranes, and held in connexion by ligamentous fibres. Some of the articular surfaces are from time to time found to be wanting.

Rib w. its cartilage.

Connexion of the ribs with their cartilages.—The external extremities of the cartilages are received into rounded depressions on the ends of the ribs, and the union is maintained only by the periosteum.

---

cess of the vertebra on each side. 1. The rib. 2. Transverse process. 3. Lig. capit. costæ. 5. Posterior costo-transverse. 6. Inter-osseous or middle costo-transverse.

* A portion of the sternum with the inner ends of the clavicles, and of some of the ribs, is here represented.

1. The anterior sterno-clavicular ligament. 2. Inter-clavicular. 3. Costo-clavicular or rhomboid. 4. Inter-articular fibro-cartilage. 6. Costo-sternal.

Ligaments of the sternum. (Membrana sterni,—Weitbr.)—The pieces of the sternum are connected by a layer of fibro-cartilage, placed between their contiguous borders; and, on the anterior and posterior surfaces, ligamentous fibres may be observed running longitudinally, which serve to strengthen their connexion. They are sometimes called the anterior and posterior sternal ligaments. The longitudinal fibres are mixed with those radiating from the costal cartilages, especially in front of the sternum, where likewise they blend with the aponeuroses of the pectoral muscles. The anterior portion has thus most of the accessory fibres, and is rough and irregular; the posterior one is smooth and pearly in its aspect. Membrana sterni.

ARTICULATIONS OF THE SUPERIOR EXTREMITIES.

The superior extremity has but one point of bony attachment to the trunk, namely, that at the sterno-clavicular articulation, the scapula being connected with the trunk by muscles only.

The articulations of the upper extremity may be arranged under the following heads, taking them in their anatomical order, from above downwards: 1, the articulations of the clavicle at one end with the sternum, and at the other end with the scapula; 2, that of the scapula and humerus; 3, of the elbow; 4, of the wrist; 5, of the hand; 6, of the fingers.

ARTICULATION OF THE CLAVICLE WITH THE TRUNK AND WITH THE SCAPULA.

The clavicle by its inner end articulates with the first bone of the sternum, and is connected by ligaments to its fellow of the opposite side and to the first rib. The outer end of the bone is joined in the same way with the scapula.

Sterno-clavicular articulation.—The inner end of the clavicle is considerably thicker than the articular part of the sternum, and the surface of each of the bones is somewhat concave and convex. The other structures of which the joint consists are, an anterior and posterior ligament, an inter-articular cartilage, and two synovial membranes. Clavicle w. sternum.

The *anterior sterno-clavicular ligament* (fig. 82,[1]) passes from Sterno-clavicular lig.; anterior;

the inner extremity of the clavicle, downwards and inwards, upon the surface of the sternum. It is broad, and consists of parallel fibres, and corresponds, internally, with the synovial membranes of the articulation, and with the inter-articular cartilage to which it is adherent; externally, with the sternal origin of the sterno-mastoid muscle.

posterior.

The *posterior sterno-clavicular ligament*, of similar conformation with the last, but not so broad or strongly marked, is placed between the same bones lying at the thoracic aspect of the joint. Its posterior surface is in relation with the sterno-hyoideus and sterno-thyroideus muscles.

Inter-artic. fibro-cartilage,

The *inter-articular fibro-cartilage*[1], nearly circular in its form, and thicker at the border than at its centre, is interposed between the articulating surfaces of the sternum and clavicle.

fixed to bones.

Towards its superior and posterior part it is attached to the margin of the clavicle, and at the opposite point to the cartilage of the first rib. In the latter situation it is thin and somewhat prolonged, so that the inferior border of the clavicle rests upon it.

Two synovial sacs.

Synovial membranes.—In this articulation, as in that of the lower jaw, there are two synovial membranes, of which one is reflected over the sternal end of the clavicle and adjacent surface of the fibro-cartilage, the other is disposed similarly between the cartilage and the articulating surface of the sternum.

Inter-clav. ligament.

The *inter-clavicular ligament*[2] is a dense fasciculus of fibres, placed transversely between the contiguous extremities of the clavicles. Its fibres do not pass directly across from one to the other; they dip down, and are attached to the upper margin of the sternum, by which the ligament is rendered concave from side to side.

Clav. w. first rib; rhomboid ligament.

The *costo-clavicular ligament*[3] (ligamentum rhomboides,—Weitbr.) does not properly form part of the articulation; yet it contributes materially to retain the clavicle in its situation. It is attached inferiorly to the cartilage of the first rib near its sternal end, and passes obliquely backwards and upwards, to be fixed to a roughness at the under surface of the clavicle.

Clav. w. scapula.

Connexion of the clavicle with the scapula.—At its outer end the clavicle articulates directly with the acromion, and is connected by ligamentous fibres with the coracoid process.

Acrom. clav. ligts.

superior;

inferior.

Fig. 83.*

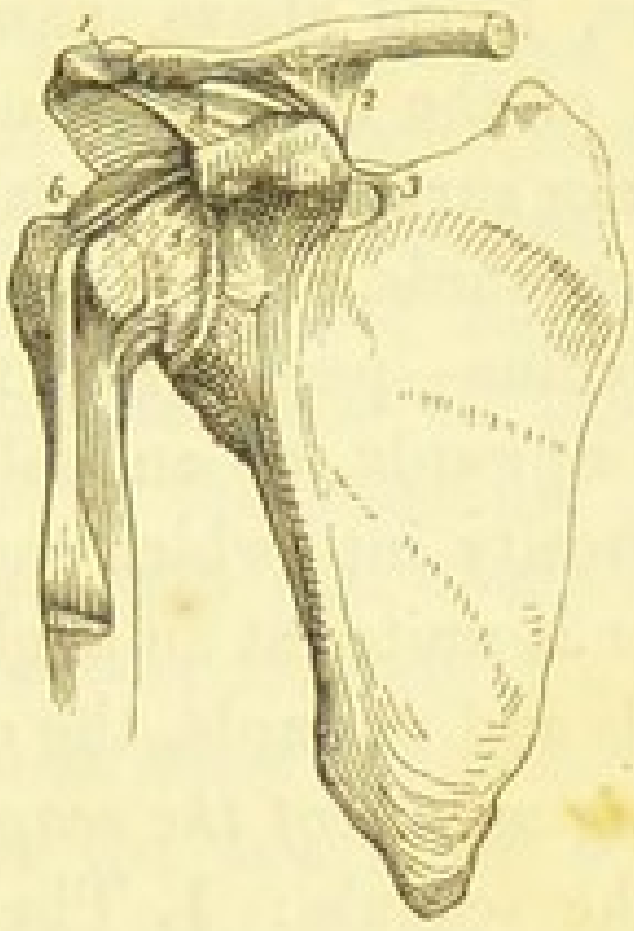

The *acromio-clavicular articulation* is effected between the acromion process of the scapula and the external end of the clavicle, each of which presents a small oval articular surface. These points are connected, 1st, by a *superior ligament*, (fig. 83,[1]) which is a thick, broad band of fibres, passing from the superior surface of the acromion to the adjacent extremity of the clavicle; 2ndly, by an *inferior ligament* similar to the preceding, but less thick, and placed at the under surfaces of the same bones; 3rdly, by a synovial membrane lining the two articular surfaces of the bones.

Synovial sac.

Fibro-cart. usually wanting; may be imperfect;

rarely complete.

An *inter-articular fibro-cartilage* is sometimes present, but it is more frequently wanting.† It has, in some instances, been found to extend through part of the joint, so as only partially to separate the bones.‡ I have seen the fibro-cartilage as distinct in this joint as it is in the temporo-maxillary articulation. Such cases, however, are of rare occurrence.

One synovial sac usually.

A *synovial membrane* lines the ligaments, and covers the articular surfaces of the bones in the usual manner. When there is an inter-articular cartilage which separates the bones completely, there are two narrow synovial sacs, disposed in the same way as those in the sterno-clavicular articulation.

Coraco-clav. ligament.

The *coraco-clavicular ligament* (fig. 83,[2]), which connects the clavicle with the coracoid process of the scapula, presents two parts, each marked by a particular name. There is, how-

---

* The scapula of the right side (its inner or concave surface) is here shown in connexion with a considerable part of the clavicle and the upper end of the humerus. The tendon of the biceps muscle hangs over this; but the capsule must have been cut through, to expose it so far up.

1. Acromio-clavicular ligament. 2. Coraco-clavicular (conoid and trapezoid). 3. Lig. proprium posterius (scapulæ). 4. Lig. propr. anter. 5. Capsular ligament. 6. Coraco-humeral.

† "Mihi vix vna alteraue vice inuenire contigit, etiamsi saepius studiose quaesiuerim."—Weitbrecht, "Syndesmologia," p. 17.

‡ Monro, "The Anatomy of the Human Bones," &c. fourth ed. p. 173; and Weitbrecht, Op. cit. p. 17, and tab. i. fig. 4

ever, no division between them, nor other distinction than that they look different ways.

Conoid part;

The *conoid ligament*, which is the posterior or internal fasciculus, broad above, narrow below, is attached, inferiorly, to the root of the coracoid process; superiorly to a rough space at the inferior surface of the clavicle, its fibres being directed backwards and upwards. The *trapezoid ligament*—the anterior or external fasciculus—passes from the superior surface of the coracoid process upwards, to an oblique line extending outwards from the tuberosity into which the conoid ligament is inserted; with the latter it unites at an angle, one of its aspects being directed forwards and upwards, the other downwards and backwards.

trapezoid part.

Proper ligts. of scapula; posterior is small;

Ligaments of the scapula.—There are two ligaments proper to the scapula: 1. The *coracoid ligament* [3] (ligamentum proprium posterius) is a thin flat band of fibres, attached by its extremities to the opposite margins of the notch at the root of the coracoid process, which it thus converts into a foramen for the transmission of the supra-scapular nerve, the artery most commonly passing external to it. 2. The *coraco-acromion ligament* [4] (ligamentum proprium anterius) is a broad, firm, triangular fasciculus, attached by its broader extremity to the coracoid process, and by the narrower to the acromion, between which it is stretched almost horizontally. Its inferior surface looks downwards upon the shoulder-joint, the superior is covered by the deltoid muscle.

converts notch into foram.

anterior (coraco-acrom.) is triangular.

SHOULDER-JOINT.

Bones.

The globular head of the humerus and the glenoid cavity of the scapula are the osseous parts which compose this articulation (*scapulo-humeral*). As the head of the humerus is large and prominent, whilst the cavity is merely a superficial depression, it must be evident that they are retained in their situation not by any mechanical contrivance, but by the capsular ligament, and the muscles which are attached to the two tuberosities of the humerus.

Capsular ligament;

The *capsular ligament* (fig. 83, [5]) is attached superiorly round the margin of the glenoid cavity, and inferiorly round the neck of the humerus, or rather a little beyond this, and more so on the lower than the upper part of the bone. It is much broader in the latter than in the former situation; and its laxity is such, that, if the muscular connexions of the humerus be detached, this bone drops away from the glenoid cavity. The superior and inner part of this membrane is covered and strengthened by a bundle of fibres[6] passing outwards and forwards from the coracoid process to the great tuberosity of the humerus (*coraco-humeral ligament*). Besides this, it receives additions from the thick tendons of the supra and infra spinatus, and the teres minor muscles, which are intimately connected with it, as they proceed to be attached to the tuberosities of the humerus. By means of these accessory structures the superior part of the capsule is thick and firm, while the inferior is comparatively thin and weak. At the inner side the ligamentous fibres of the capsule are wanting for a small space; and here the upper part of the tendon of the subscapularis muscle, passing through the opening (foramen ovale) comes into contact with the synovial membrane. The fibrous capsule is lined by the synovial membrane; the external surface, besides the muscles already mentioned, is covered by the deltoid; inferiorly, it is in relation with the long head of the triceps and the circumflex vessels. The insertion of its inferior border is interrupted to give passage to the long tendon of the biceps muscle.

its laxity.

Connexion of muscles.

Foramen for subscap. muscle;

foram. for tend. of biceps.

The *coraco-humeral*, or accessory ligament [6], above noticed, extends obliquely over the upper and outer part of the articulation; it is attached to the coracoid process, and thence descends, intimately connected with the capsule, to the greater tuberosity of the humerus.

Coraco-humeral lig.

The *glenoid ligament* appears to be continuous with the tendon of the long head of the biceps muscle: this, at its point of attachment to the superior margin of the glenoid cavity, separates into two sets of fibres, which, after encircling it, meet and unite inferiorly. These fibres, by elevating the border of the cavity, render it a little deeper.

Glenoid lig. continuous with tend. of biceps.

The *synovial membrane* lines the glenoid cavity, and is reflected over its lower margin until it reaches the inner surface of the fibrous capsule, on which it is prolonged as far as the neck of the humerus, where it separates from the capsule, and is applied upon the articular surface of the head of that bone, giving it a smooth investment. Viewed in this way, it appears a simple shut sac; and such it would be but for the peculiar

Synovial memb.;

relation of the long tendon of the biceps muscle to the shoulder-joint. The tendon is in fact enclosed in a tubular sheath, formed by an offset or process of the synovial membrane, which is reflected upon it where it is about to pass through the fibrous capsule, and is thence continued up to the summit of the glenoid cavity, where it is continuous with that part of the membrane which invests it. By this provision the integrity of the articulation and of the membrane is preserved.

tube for tendon of biceps.

Synovial bursa above joint.

On the superior and external surface of the capsule a considerable bursa mucosa is situated, by means of which the contiguous surfaces of the coracoid and acromion processes, and of the coraco-acromion ligament, are rendered smooth and lubricated, to facilitate the movements of the subjacent capsule, and the head of the humerus.

THE ELBOW-JOINT.

Articular surfaces;

kind of movement.

The lower extremity of the humerus is connected with the ulna and radius at the elbow, so as to form a hinge-joint. The sigmoid cavity of the ulna articulates with the trochlea of the humerus, so as to admit of flexion and extension only, while the cup-shaped depression on the head of the radius can turn freely on the rounded tuberosity to which it is applied. The bones are connected by four ligaments and a synovial membrane.

Internal lat. lig.;

is triangular; its attachments.

The *internal lateral ligament*, (fig. 84, [1]) composed of diverging and radiated fibres, presents two parts, each with a different aspect, one looking obliquely forwards, the other backwards. The anterior part is attached above, where it is narrow and pointed, to the front of the internal condyle of the humerus; its fibres, as they descend, become broad and expanded, and are inserted into the coronoid process, along the inner margin of the sigmoid cavity. The posterior part, of the same form (triangular), passes from the under and back part of the same process of bone downwards to the inner border of the olecranon; the superior fibres of this portion extend transversely between the points just named, the rest become successively more and more oblique.

Extern. lat. attached to orbic. lig.

The *external lateral ligament*, (fig. 85,[2]) shorter and much narrower than the internal, is attached superiorly to the external condyle of the humerus, and inferiorly becomes blended with the annular ligament of the radius; none of its fibres are prolonged to the surface of that bone—if they were, they would check its rotatory motion. It is intimately connected with the

Fig. 84.*

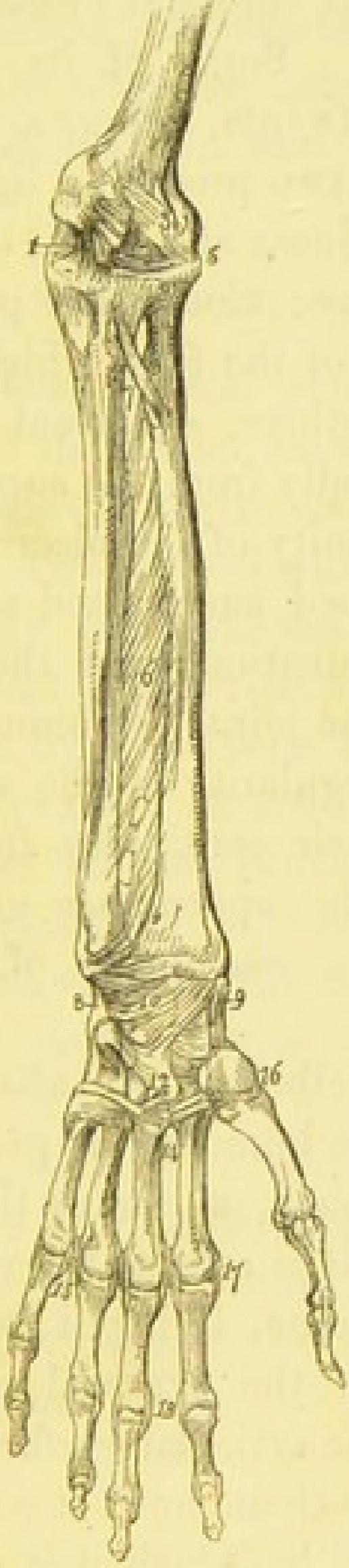

Fig. 85.*

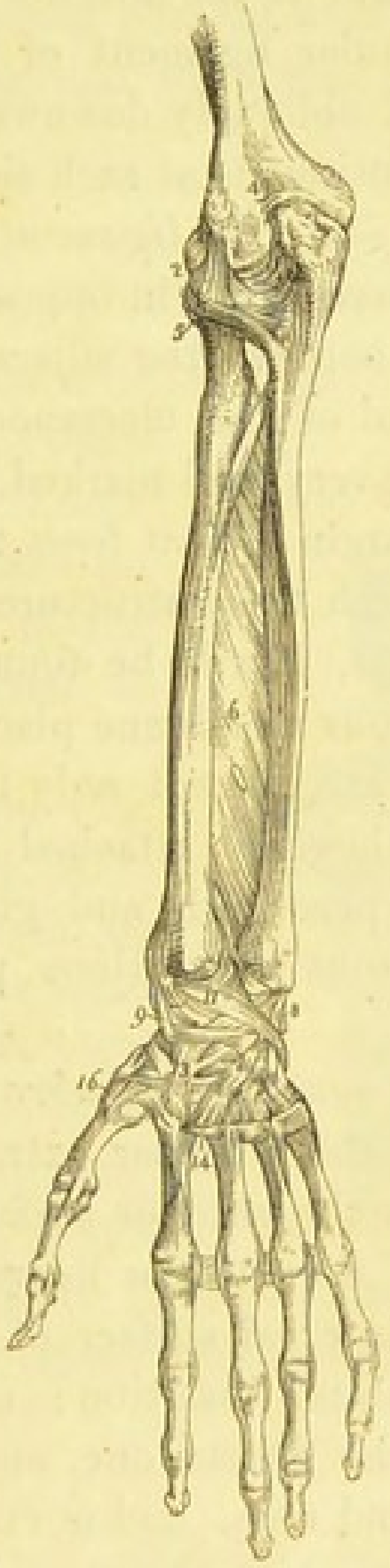

---

* Figures 84 and 85 are front and back views of the bones and ligaments of the left fore-arm and hand. 1. The internal lateral ligament. 2. The external lateral. 3. The anterior. 4. points to the posterior. 5. Orbicular ligament of the radius. 6. Inter-osseous membrane. 7. Round ligament. 8. Internal ligament of the wrist. 9. External of the same. 10. Anterior. 11. Posterior. 12. Palmar, and 13, dorsal carpo-metacarpal ligaments. 14. Ligaments connecting metacarpal bones. 15. Transverse metacarpal ligament. 16. Carpo-metacarpal ligament of thumb (capsular). 17. Lateral ligaments connecting the phalangal to the metacarpal bones. 18. Lateral ligaments of phalanges.

tendinous attachment of the extensor muscles; on which account, when dissected, it presents a jagged irregular appearance.

Anter. lig.

The *anterior ligament* (fig. 84,[3]) is a broad thin membrane, placed in front of the joint, extending from the rough margin of the fossa, which receives the coronoid process during flexion, downwards to the anterior border of the coronoid process, and to the annular ligament of the radius. Some of its fibres are directed obliquely downwards and outwards, others are vertical. It is continuous at each side with the two preceding ligaments.

Poster. lig. indistinct and loose.

The *posterior ligament*, (fig. 85,[4]) loose and weak, consists of fibres proceeding in opposite directions; thus some pass transversely between the adjacent margins of the fossa which receives the head of the olecranon; whilst others, subjacent to these, but not very well marked, pass vertically from the superior concave margin of that fossa to the extremity of the olecranon.

The ligaments are all continuous one with another.

Though these structures are described and named as separate ligaments, it will be found, on examination, that they form a continuous membrane placed round the joint, as fibrous capsules usually are, except only that the irregularity of the surfaces to which they are attached prevents their continuity from being readily perceived, and gives them the appearance of distinct ligamentous connexions passing from one point of bone to another.

Synovial membrane.

The *synovial membrane* of the elbow-joint, after having covered the articular extremity of the humerus, is prolonged a little on the anterior surface of that bone, as far as the attachment of the anterior ligament, where it is reflected, and applied to the internal surface of that membrane, lining it as far as its radio-cubital insertion; at that point the synovial membrane leaves the fibrous one, and invests the articular surfaces of the radius and ulna, and is extended over them until it comes into apposition with the posterior ligament, by which it is guided to the extremity of the humerus; in the same way, it lines the lateral ligaments. Besides these reflections, the membrane forms two pouches, one by being prolonged into the joint formed between the small sigmoid cavity of the ulna, and the head of the radius; the other where it passes between the annular ligament and the contiguous surface of the head of the radius.

extends between radius and ulna and beneath orbic. lig.

When the joint is laid open, and the bones extended, it will be observed that the head of the radius is not in contact with the rounded articulating process of the humerus. On which account, in the extended state of the limb, the rotatory motions of this bone are performed with much less ease than in that of flexion, from its wanting support at its upper end. The part of the humerus here referred to is moreover covered with cartilage only on its anterior aspect, indicating that the radius moves on it only when in the flexed position.

THE UPPER RADIO-ULNAR ARTICULATION.

Articular surfaces.

The head of the radius articulates with the small sigmoid cavity of the ulna, on which it rolls when it is made to turn on its axis. These surfaces are covered with cartilage, and invested by the synovial membrane of the elbow-joint. The radius is connected to the ulna by an annular ligament.

Synovial from elbow-joint.

Fig. 86.*

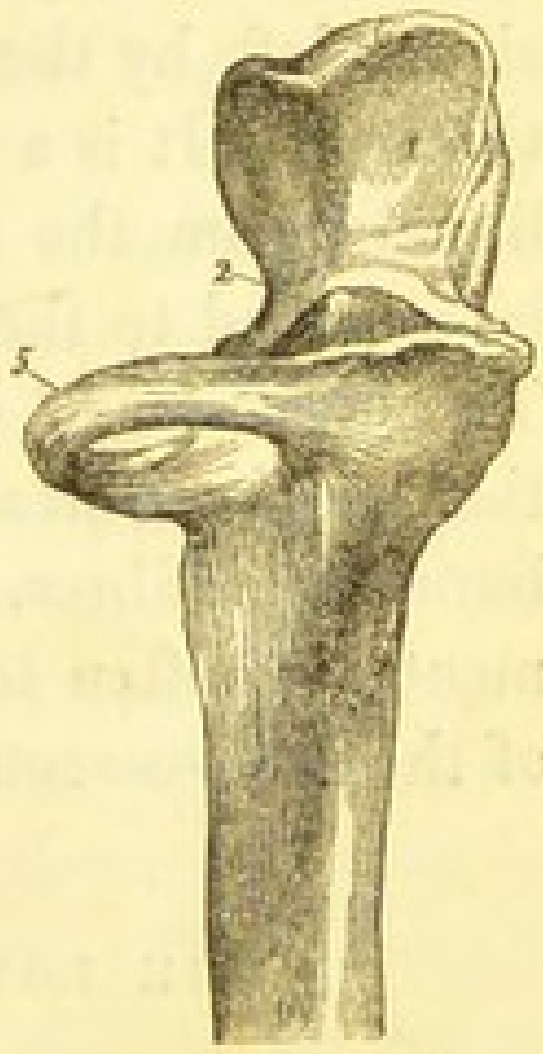

Orbicular ligament;

The *annular* or *orbicular ligament* (lig. orbiculare radii,—Weitbr.) (figs. 84, 85,[5]) is a strong band of circular fibres, which, by being attached to the borders of the small sigmoid cavity, forms a ring (fig. 86,[5]) encircling the head of the radius, and binding it firmly in its situation. Its external surface is connected with the external lateral ligament of the elbow, whose fibres are inserted into it; the internal is smooth, and lined by the synovial membrane of the elbow-joint.

connected w. ext. lat. lig.

THE MIDDLE RADIO-ULNAR ARTICULATION.

The interval between the radius and ulna in the fore-arm is occupied by an inter-osseous ligament and a round ligament, which serve to connect them together, and form what is called the middle radio-ulnar articulation.

The *inter-osseous membrane* (figs. 84, 85,[6]) (membrana

---

* The upper end of the ulna, with the orbicular ligament for the head of the radius. 1. Olecranon. 2. Coronoid process. 5. Orbicular ligament.

Inter-oss. membrane; direction of fibres; does not reach upper end of bones.

inter-ossea) is a thin, flat, fibrous membrane, the direction of its fibres being obliquely downwards and inwards, from the inner sharp border of the radius to the contiguous one of the ulna. It does not reach the whole length of the bones, as it commences about an inch below the tubercle of the radius. The surfaces of this membrane are intimately connected with the deep-seated muscles of the fore-arm, serving to increase their points of origin as well as to connect the bones. Above the lower margin it leaves an opening for the transmission of the anterior inter-osseous vessels to the back of the fore-arm; and the posterior inter-osseous vessels pass backwards in the space above the membrane (hiatus inter-osseus).

Foramen for artery.

Hiatus inter-oss.

Round lig.

The *round ligament* (ligamentum teres, v. chorda transversalis,—Weitbr.) (fig. 84,[7]) in some measure supplies the deficiency left by the inter-osseous ligament at the superior part of the arm. It is a thin narrow fasciculus of fibres, extending obliquely from the coronoid process, downwards and outwards, to be attached to the radius, about half an inch below its tubercle. The direction of its fibres is therefore altogether different from that of the fibres of the inter-osseous ligament.—Some small bundles of fibres, having the same direction as the round ligament, are often to be found at intervals on the posterior surface of the inter-osseous membrane.*

higher than inter-oss. membrane;

direction different.

THE LOWER RADIO-ULNAR ARTICULATION.

At the lower or carpal end of the radius and ulna, the former rotates on the latter as its point of support, the articulating surface of the radius being concave, that of the ulna convex. The bones are connected anteriorly and posteriorly by some fibres passing between their extremities, so thin and scattered as scarcely to admit or require description, but internally they are joined by a fibro-cartilage and a synovial membrane.

Thin fibres cover joint.

The *fibro-cartilage*, (cartilago intermedia triangularis,—Weitbr.) *triangular* in form and thick, is placed transversely between the bones (fig. 87,[6]). It is attached by its base to a rough line separating the carpal from the ulnar articulating sur-

Triangular fibro-cartilage fixed to bones at base and apex;

---

* Weitbrecht, Op. citat., p. 34, and fig. 11.

Fig. 87.†

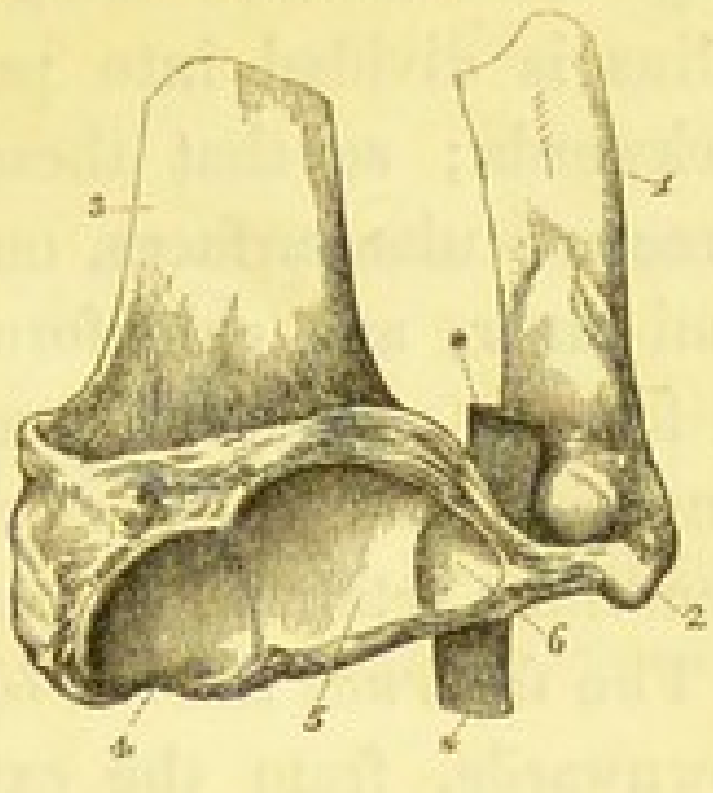

face of the radius, and by its summit to a depression at the root of the styloid process of the ulna, and to the side of that process. The superior surface of the fibro-cartilage looks towards the head of the ulna, the inferior to the cuneiform bone: both are smooth, and lined by synovial membrane; the inferior one by the large membrane of the wrist-joint, the superior by a small one peculiar to the radio-ulnar articulation. Its two borders are connected with the carpal ligaments. There is occasionally a perforation at the middle of the fibro-cartilage. As the radius rolls on the ulna, this cartilage is carried with it, and forms its chief bond of union with the latter bone.

is between two synovial sacs.

Membrana sacciformis;

The *synovial membrane* is frequently called *membrana sacciformis,* though there is nothing in its conformation, except, perhaps, its looseness, which distinguishes it from other synovial sacs. It may be considered as presenting two parts, one projecting perpendicularly upwards into the articulation of the radius and ulna, lining the contiguous surfaces of each; the other placed horizontally between the head of the ulna and the corresponding surface of the fibro-cartilage, lining them also; both, however, are formed by a continuous membrane. This "sacciform" synovial membrane is continuous with that of the wrist-joint, when the triangular fibro-cartilage, being perforated, is insufficient to form a complete barrier between the two membranes.

betw. radius and ulna, and betw. latter and fibro-cart.

THE WRIST-JOINT.

Articular surfaces.

This articulation (*radio-carpal*) is formed above by the radius and triangular fibro-cartilage, and the first three bones of the carpus below. The articular aspect of the former, when viewed in the fresh state, presents an oval and slightly concave surface,

---

† The lower ends of the radius and ulna, with the triangular fibro-cartilage connecting them. 1. Ulna; 2, its styloid process. 3. Radius; 4, its articular process for the scaphoid bone, and 5, that for the semilunar. 6. The triangular fibro-cartilage; its lower surface. A piece of whalebone (*) has been passed between the upper surface and the head of the ulna.

its greatest breadth being from side to side. The surface of the radius is divided into parts, by a line extending from before backwards; so that these, together with the cartilage, present three articular surfaces, one for each carpal bone. The scaphoid, semi-lunar, and cuneiform bones are articulated together, so as to form a rounded convex surface, which is received into the concavity above described. Four ligaments and a synovial membrane retain these parts in their situation, as follow:—

Internal lat. lig.

The *internal lateral ligament* (figs. 84, 85,[8]) passes directly downwards, from the extremity of the styloid process of the ulna, to be attached to the cuneiform bone; it also sends some fibres to the anterior annular ligament and the pisiform bone. Its form is that of a rounded cord; its inner surface is in contact with the synovial membrane of the radio-carpal articulation.

External lat. lig.

The *external lateral ligament*[9] extends from the styloid process of the radius to a rough surface on the outer side of the scaphoid bone, some of its fibres being prolonged to the trapezium, and also to the annular ligament of the wrist.

Anter. lig.

The *anterior ligament*[10], (*radio-carpal,*) broad and membranous, is attached to the rough border of the carpal extremity of the radius, and to the base of its styloid process; from which, and to a small extent from the ulna, its fibres pass down to be inserted into the anterior surface of the scaphoid, semi-lunar, and cuneiform bones. It is pierced by several foramina for the transmission of vessels: one of its surfaces is lined by the synovial membrane of the joint, the other is in contact with the tendons of the flexor muscles.

Poster. lig.;

The *posterior ligament*[11] extends obliquely downwards and inwards, from the extremity of the radius, and from a small portion of the ulna, to the posterior surface of the semi-lunar and cuneiform bones; its fibres appear to be prolonged for some way on the carpal bones. One surface is in contact with the synovial membrane, the other with the extensor tendons. Both the anterior and posterior ligaments are connected to the sides of the triangular fibro-cartilage which binds the radius to the ulna. The whole of the preceding ligaments are continued one into the other around the wrist-joint without interruption.

all are continuous one with the other.

Synovial.

The *synovial membrane*, after having lined the articular surface of the radius, and the triangular fibro-cartilage, is reflected on the anterior and posterior ligaments, and thence over the surface of the carpal bones.

ARTICULATIONS OF THE CARPAL BONES ONE WITH ANOTHER.

The bones of the carpus consist of two sets, each united by its proper connexions, so as to form a row; and the two rows are connected by fibrous bands and a synovial membrane, so as to form between them a joint.

Bones of first row connected by inter-oss. ligts.;

The connexions proper to the first row are inter-osseous fibro-cartilages, and ligaments placed on their dorsal and palmar surfaces.

The *inter-osseous fibro-cartilages* are two lamellæ, one placed at each side of the semi-lunar bone, connecting it with the scaphoid and cuneiform bones. The carpal extremity of these is smooth, and lined by the synovial membrane of the wrist-joint.

palmar;

and dorsal.

The *palmar ligaments* are two, one extending from the scaphoid bone to the semi-lunar, the other from the semi-lunar to the cuneiform, their direction being transverse; and, as their fibres are partly united, they may be considered as a continuous band connecting these bones. The *dorsal ligaments* are also two, disposed similarly, and connecting the same bones on their posterior surfaces.

Artic. of pisiform bone.

The pisiform bone stands out of the range, and rests on the palmar surface of the cuneiform, with which it is articulated by an irregular fibrous capsule and a synovial membrane. There are likewise two strong ligaments, by one of which the bone is connected to the unciform, and by the other to the fifth metacarpal bone.

Bones of second row; means of connexion nearly same.

The carpal bones of the second range are also connected by similar means. Three *dorsal* and *palmar ligaments* pass transversely from one bone to the other. There are, however, but two *inter-osseous fibro-cartilages*, placed one at each side of the os magnum, connecting it with the trapezoid externally, and the unciform internally. Such are the means of connexion peculiar to each row.

First row to second row, by lateral ligts.

The ligaments which connect the upper to the lower row of bones are placed at their palmar, dorsal, and lateral aspects.

The *lateral ligaments* are placed one at the radial, the other at the ulnar border of the carpus; the former connects the scaphoid bone with the trapezium, the latter the cuneiform with the unciform.

palmar and dorsal.

The *palmar* or anterior ligament consists of fibres, which pass obliquely from the bones of the first to those of the second range. The *dorsal*, or posterior, is similar in structure and arrangement.

Synovial membrane.

lines carpal joints;

Synovial membrane.—It may be observed, that the first range of carpal bones forms a concavity; the second, particularly the os magnum and unciform, a convexity, which is received within it: by these means a ball-and-socket joint is formed, which is completed by a synovial membrane reflected over the articular surfaces of the different osseous pieces which compose it. The membrane, likewise, sends two processes between the three bones of the first row, and three between those of the second, so as to facilitate their respective motions. It moreover continues downwards to the joints formed between the carpal and the four inner metacarpal bones; and in some cases there is a like continuity with the synovial membrane belonging to the wrist-joint.

is continued to carpo-metacarpal artic.; sometimes to wrist.

CARPO-METACARPAL ARTICULATIONS.

Bones.

The last four metacarpal bones are connected with those of the carpus by means of two sets of fibrous bands, situated one on the palmar (fig. 84, ^{12}), the other on the dorsal surface (fig. 85, ^{13}), the latter being better marked.

Dorsal ligts.

Palm.

Dorsal ligaments.—All but the fifth metacarpal bone receive two bands. Thus, to the second, or that of the fore-finger, a thin fasciculus of fibres passes from the trapezium, another from the trapezoid bone; the third receives one from the latter, and also from the os magnum; the fourth from the os magnum and also from the unciform; but the fifth is connected to the latter only. On the *palmar* surface a similar mode of connexion exists, but the fibres are not so well defined.

Inter-oss.

Inter-osseous ligament.—There are likewise short thick inter-osseous fibres in one part of the carpo-metacarpal articulation, —connecting the lower and contiguous corners of the os magnum and unciform to the neighbouring angles of the third and fourth metacarpal bones. This ligament is displayed by removing the dorsal ligaments, and with them a portion or layer of the osseous structure. The *synovial membrane* for the four inner carpo-metacarpal articulations is continued from that which lines the articulations of the carpal bones one with another.

The thumb; its free movement. The *metacarpal bone of the thumb* is articulated on quite a different principle from the others; for, as it admits of all the motions except rotation, it is connected to the trapezium by a capsular ligament (membranula capsularis,—Weitbr.) [16], which passes from the rough border bounding its articular surface to the trapezium. These parts are lined by a separate synovial membrane. Capsular membrane, and separ. synovial.

CONNEXION OF THE METACARPAL BONES ONE WITH THE OTHER.

Bones. The *carpal extremities*, or *bases*, of the last four metacarpal bones are bound together by three transverse fibrous bands [14], (which are slight, and often ill-defined,) on the palmar, and the same on the dorsal surface, passing from one to the other. These bones are likewise bound together by numerous *interosseous* ligamentous fibres which occupy part of their lateral surfaces. Another portion of each of these surfaces is covered with cartilage, and lined with synovial membrane continued down between the metacarpal bones from the carpo-metacarpal articulation. Dorsal, plantar, and inter-oss. ligts. Synovial is continued from above.

Heads of metacarp. bones; The *digital extremities* (*heads*) of the metacarpal bones are connected at their palmar aspect by thin ligamentous fibres passing across them from one to the other, and blended with the ligaments connecting the metacarpal bones to the phalanges. The whole is called the *transverse ligament* (membrana ligamentosa,—Weitbr.) Its place is indicated, fig. 84, [15]; but it is better shown, though not numbered, in fig. 85, at the metacarpo-phalangal joints. Transv. lig.

ARTICULATION OF THE METACARPAL BONES WITH THE PHALANGES, AND OF THE LATTER ONE WITH THE OTHER.

Articular surfaces. The rounded head of each of the last four metacarpal bones being received into the slight concavity situated in the extremity of the first phalanx, is maintained in its position by two lateral ligaments, an anterior ligament, and a synovial membrane.

Lateral ligts.

The *lateral ligaments* consist of dense and thick fasciculi of fibres (fig. 84, [17]), placed one at each side of the joint, and attached each by one extremity to the side of the metacarpal, by the other to the contiguous extremity of the phalangal bone, the direction of the fibres being downwards and forwards.

Palmar is joined to phal. and to lat. ligts.

The *anterior* or *palmar* ligament occupies the interval between the foregoing on the palmar aspect of each joint; it is very thick and dense, and is firmly united to the first phalangal bone, and but loosely adherent to the metacarpal. The anterior ligament is continuous at each side with the lateral, so that the three form one undivided structure which covers the joint, except on its dorsal aspect. Its palmar surface is grooved for the flexor tendons, whose sheath is connected to it at each side; the other surface, looking to the interior of the joint, is lined by the synovial membrane, and supports the head of the metacarpal bone.* In the ligaments of the thumb there are two sesamoid bones, placed one at each side.

Synovial.

The synovial membrane invests the surfaces of the heads of the bones, and is reflected on the ligaments which connect them.

Artic. of phalanges same as preceding.

The *phalanges are articulated with one another* [18], on the same principle as that which obtains in the articulation between their bases and the metacarpal bones; it is therefore unnecessary to repeat what has been just stated on that subject.

Some other ligamentous structures.

There are some other fibrous and ligamentous structures which deserve to be noticed in this place, but not as being connected immediately with the joints; they are rather accessories to the tendons of the muscles. Thus: along the margins of the phalanges, on their palmar aspect, are attached the *vaginal*

---

* M. Cruveilhier (Op. cit. t. i. p. 440) considers the name "glenoid ligament" to be most appropriate to these ligaments, on the ground that they serve to continue and complete the shallow (glenoid) articular cavity of the first phalanx; the size of which he regards as otherwise disproportionately small in comparison with the head of the metacarpal bone.

ligaments, which form sheaths for the flexor tendons, and bind them securely in their situation; these are thick and firm along the body of the phalanges, but over the flexures of the joints they are thin, so as not to impede their movements; their inner surface is lined by a fine membrane resembling the synovial class, which is reflected over the tendons, giving to each a smooth and shining appearance.

The *posterior annular ligament* of the wrist is continuous with the fascia of the fore-arm, of which it may be considered a part. It extends from the extremity of the radius, at its outer border, to the inner border of the ulna and the pisiform bone, and serves to bind down the extensor tendons.

The *anterior annular ligament* is a dense fasciculus of fibres, extended across the carpus from the pisiform and unciform bones to the trapezium and scaphoides, so as to form a canal which transmits the flexor tendons, retains them in their situation, and modifies their direction and power of action on the hand.

ARTICULATIONS OF THE PELVIS.

The os sacrum, considered as the common point of support of the vertebral column above, the os coccygis below, and ossa innominata on each side, is connected with each of these in the following manner:— Bones.

Sacro-vertebral articulation.—The base of the sacrum is articulated with the last lumbar vertebra by means similar to those which connect the different pairs of vertebræ throughout the column; 1, by an inter-vertebral substance placed between their oval surfaces; 2, by the continuation of the anterior and posterior common ligaments; 3, a ligamentum subflavum connecting the arches of the last vertebra with the posterior border of the sacral canal; 4, an inter-spinous ligament; 5, two synovial membranes and fibrous structure for the articulating processes; and lastly, a sacro-vertebral ligament. All these, except the last, being similar to the connecting media throughout the column, require no farther description in this place. Sacrum to vertebra; same ligts. as for one vert. to another;

The *sacro-vertebral ligament* (fig. 90, ¹) extends obliquely from the transverse process of the last lumbar vertebra down- except sacro-vert. ligament.

wards to the depressed lateral surface at the base of the sacrum; its form is triangular, as its fibres diverge and expand towards the sacro-iliac symphysis.

Lumb. vert. to ilium.

The *ilio-lumbar ligament*[2] is extended horizontally between the summit of the transverse process of the last lumbar vertebra and the posterior extremity of the crista of the ilium, where its fibres expand somewhat, so as to give it a triangular form. This is the only bond of union between the true vertebræ and the os ilium.

Sacr. to coccyx.

The *sacro-coccygean articulation* is effected by, 1, an *anterior ligament* (fig. 89, [3]), consisting of irregular fibres, placed in front of these bones, subjacent to the rectum; 2, by a *posterior ligament* more strongly marked, composed of fibres which descend upon the bones of the coccyx, from the margin of the inferior orifice of the sacral canal, which it serves to close in and complete; 3, by a thin layer of *fibro-cartilage*, which is of soft consistence, interposed between the contiguous extremities of the sacrum and coccyx.

Coccygeal bones one to another.

The several *pieces of the coccyx are connected one to the other* by a continuation of the anterior and posterior ligaments which unite the sacrum and coccyx, and by very thin interposed fibro-cartilages. M. Velpeau* states that he had found the fibro-cartilage to be annular in shape, and that the bones were covered with cartilage towards the middle of the joint. There is, in some instances, much softness and pliancy; and a synovial membrane has been mentioned† as present in those cases in which the coccyx is freely moveable.

Bony union in adult male.

In the adult male, the union between the sacrum and coccyx, and that between the pieces of the latter, is usually ossific. In the female this change most commonly does not occur till a more advanced period of life; the pieces of the coccyx unite one to the other in the first place, and the joint between the sacrum and coccyx is not ossified till old age comes on. The mobility increases during pregnancy.

The *sacro-iliac articulation*, often named the sacro-iliac symphysis, or synchondrosis, is formed between the rough lateral surfaces of the sacrum and ilium closely applied to one

---

* "Traité compl. de l'art des Accouchemens," tom. i. p. 9. Paris, 1835.

† M. Cruveilhier, "Anatomie descriptive," tom. i. p. 356. Paris, 1834.

another, and connected by an irregular lamella of a cartilaginous structure.

Posterior sacro-iliac ligaments very thick and short;

The *posterior sacro-iliac ligaments* consist of three or four sets of short irregular fibres, extended between the posterior rough portion of the surface on the side of the sacrum and the corresponding part of the ilium, behind the articular surfaces of the bones. Some of the fibres pass horizontally between the bones, others obliquely; of the latter, one band, (fig. 88,[6]) extending downwards from the posterior superior spine of the ilium to the tubercles on the third or fourth piece of the sacrum, is described separately, under the name of (from its direction) the *oblique*, or (from being situated superficially to the others) the *posterior sacro-iliac ligament.* They are all placed deeply in the groove formed by the ilium and sacrum, and covered by the origin of the lumbar muscles. The *anterior sacro-iliac ligament* consists of some thin irregular fibres, (figs. 89, 90,[7]) placed at the anterior aspect of the sacro-iliac symphysis, and attached to the pelvic surfaces of the sacrum and ilium.

oblique band.

Anter. lig. thin.

Fig. 88.*

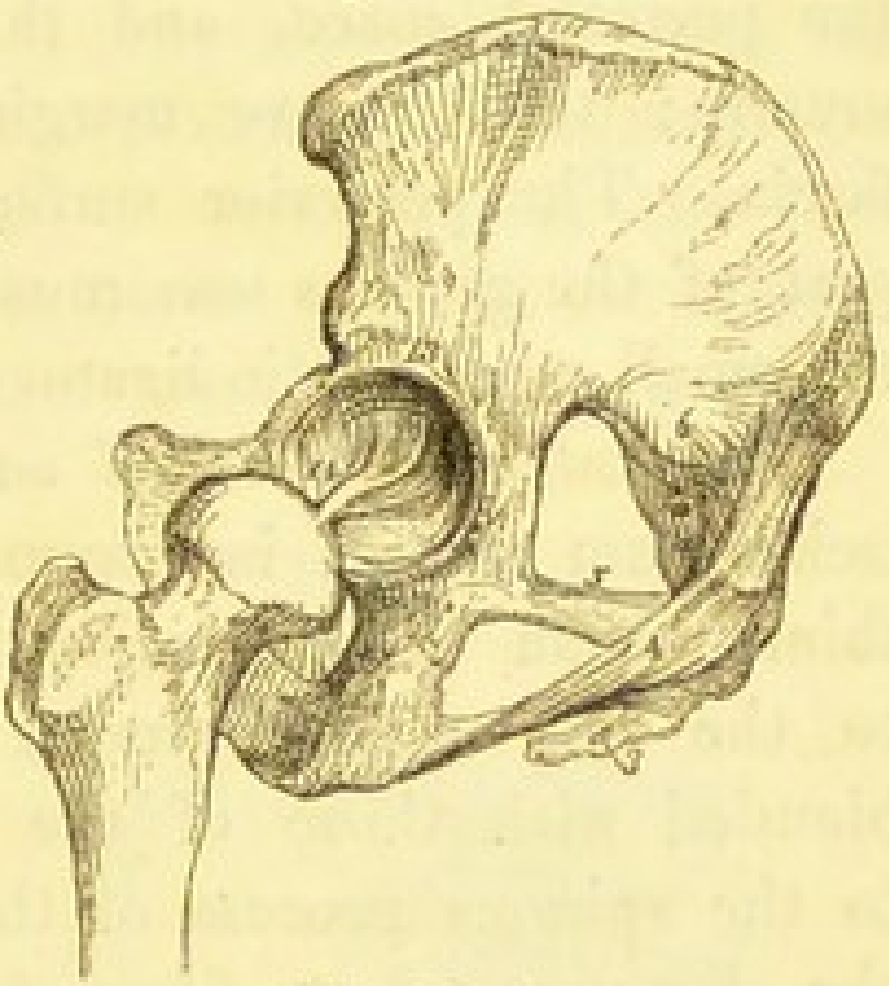

Fig. 89.†

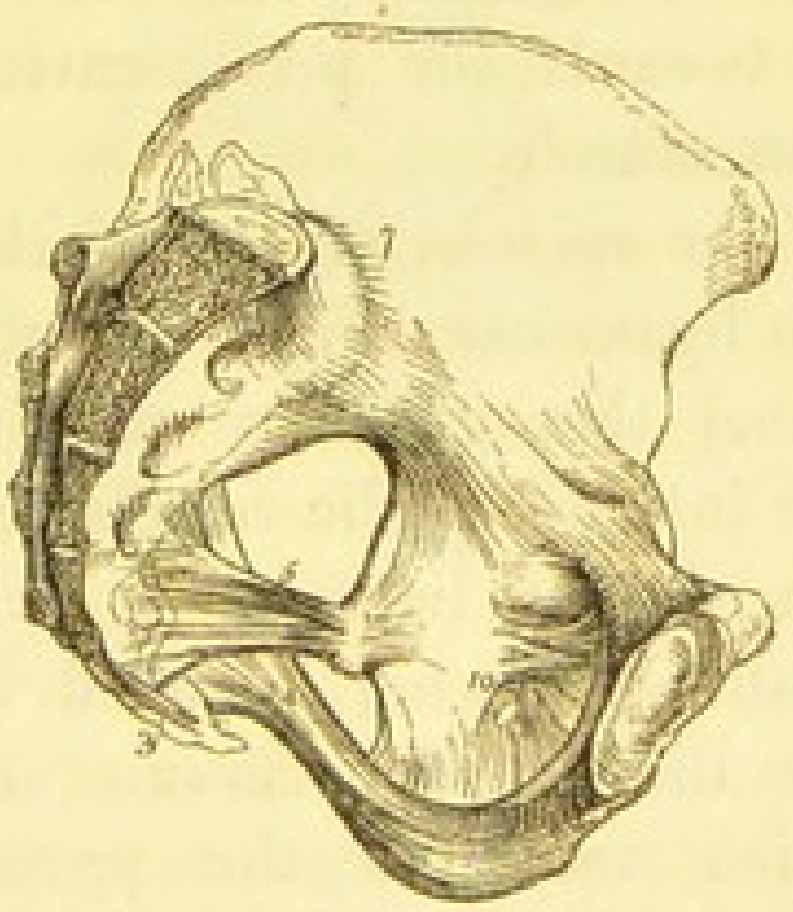

The sacrum and coccyx are likewise connected with the ischium by the following ligaments:—

Great sacro-sciatic lig.;

The *posterior* or *great sacro-sciatic ligament*, (figs. 88,[4], 89)

---

* The left side of the pelvis, and a part of the femur with ligaments. 3. Coccygeal ligaments. 4. The great, and 5, the small sacro-sciatic ligaments. 13. Cotyloid. 14. Ligamentum teres of hip-joint.—This sketch is inaccurate; e. g. the "small" sacro-sciatic ligament and foramen are too large; the round ligament of the hip-joint is fixed too high in the acetabulum.

† A section of the pelvis having been made, the left lateral half is seen on

(ligam. sacro-ischiaticum majus,—Weitbr.) elongated, broad, and triangular, is placed at the inferior and posterior part of the pelvis, whose lower aperture it assists materially in closing. Its base or broader part is attached to the postero-inferior spine of the ilium and to the side of the sacrum and coccyx; whilst its other extremity is fixed along the inner margin of the tuber ischii, where it expands somewhat, and sends upwards and forwards along the margin of the ramus of that bone a falciform process, which presents one surface looking towards the perinæal space, and the other to the internal obturator muscle; the concave margin is connected with the obturator fascia. The posterior surface of this ligament gives origin to part of the gluteus maximus; the anterior is covered partly by the small sacro-sciatic ligament.

falciform elongation.

Small sacro-sciat. lig.

The *anterior* or *small sacro-sciatic ligament* [5], (lig. sacro-ischiaticum minus, internum, —Weitbr.,) much shorter and thinner than the preceding ligament, is attached by its base to the side of the sacrum and coccyx, where its fibres are blended with those of the great ligament, and by its apex to the spinous process of the ischium; its form is triangular, the direction of its fibres forwards and outwards. This, the smaller ligament, has behind it the larger one, and in front, or towards the pelvic cavity, it is in contact with the coccygeus muscle.

Sacro-sciat. foramina,—small and large, and their contents.

The spinous process of the ischium, its tuberosity, and these two ligaments bound an oval interval, (small sacro-sciatic foramen,) through which pass the obturator internus muscle, and the internal pudic vessels and nerve; and above the border of the shorter ligament is a large oval opening, (larger sacro-sciatic foramen,) bounded before and above by the margin of the ilium and ischium, and behind by the great ligament, which transmits the pyramidalis muscle, the great sciatic nerve, the gluteal and ischiadic vessels and nerves. The ligaments, therefore, convert the sacro-sciatic notches of the bones into foramina.

Symphysis pubis;

The *pubic articulation* (symphysis pubis) is formed by the

---

the inner side with ligaments: viz. 3. Sacro-coccygean. 4. Great sacro-sciatic. 5. Small sacro-sciatic. 7. Anterior sacro-iliac. 10. Obturator.

junction of the ossa pubis in the median line anteriorly. This is effected by an elongated piece of fibro-cartilage, interposed between their surfaces, and connected to each, and ligaments surrounding the joints.

fibro-cartilage;

The *fibro-cartilage* consists of concentric lamellæ, as indicated in fig. 89, is thicker anteriorly than posteriorly, and frequently projects beyond the level of the bones in the latter direction. A provision is made in this part for a slight degree of movement, which, however, is more perceptible in the female than in the male. Each pubic bone, properly speaking, has its own plate of fibro-cartilage. These plates are connected by fibres passing transversely from one to the other at the fore part as well as at the upper and lower border; but at the middle and back part they are smooth, and often lined by a slight synovial membrane.

Fig. 90.*

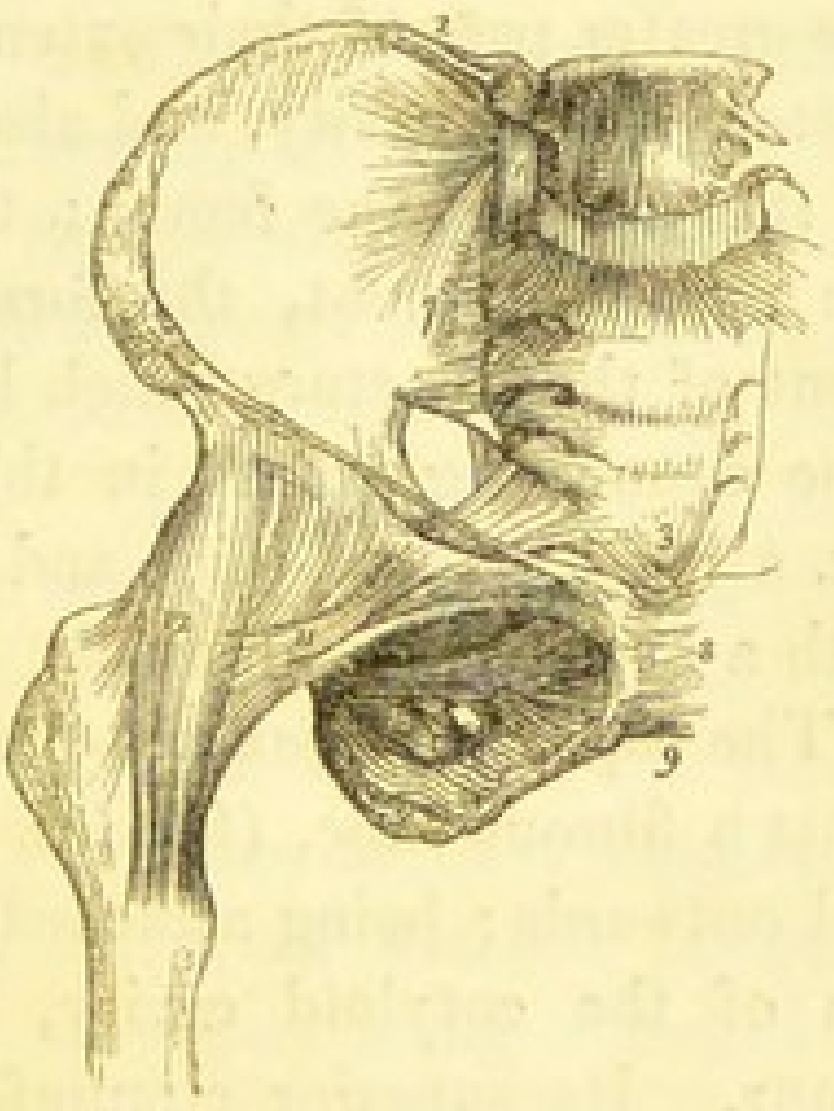

ligaments: anterior,

The union between the bones is strengthened, 1st, by an *anterior pubic ligament*, (fig. 90, [8]) which consists of irregular fibres, passing obliquely across from one bone to the other, and decussating on the anterior surface of the fibro-cartilage; the fibres are intermixed with those of the aponeuroses of the external oblique muscles of the abdomen; 2ndly, the *sub-pubic ligament*, (fig. 90, [9],) (ligamentum triangulare, arcuatum,) thick and triangular, which is placed beneath the symphysis, its sides being attached to the rami of the pubis, its base free and slightly concave, directed downwards and backwards to the perinæal space; 3rdly, by some indistinct fibres which are situated on the posterior surface of the articulation, and others placed on its upper border; these may be named from their position.

sub-pubic;

poster. and super. pubic fibres.

---

* The right side of the pelvis, and a portion of the femur with ligaments. 1. Sacro-vertebral ligament. 2. Ilio-lumbar. 7. Anterior sacro-iliac. 8. Anterior pubic. 9. Sub-pubic. 10. Obturator. 11. Capsule of the hip-joint. 12. Ilio-femoral.

Obturator ligament;

The *obturator ligament* (figs. 89, 90, [10]) (membrana obturans foraminis thyroidis,—Weitbr.) is properly a fibrous membrane, inserted into the border of the obturator foramen, which it closes in its entire extent, except at the upper and outer part of its circumference, where a small oval aperture is left for the exit of the obturator vessels. The membrane is fixed accurately to the margin of the bone at the upper and outer side of the foramen, and to its posterior surface on the inner side.* The obturator muscles are attached to its surfaces.

opening for vessels and nerve.

ARTICULATIONS OF THE LOWER EXTREMITY.

HIP-JOINT.

This is a true ball-and-socket joint, in which the globular head of the femur is received into the acetabulum or cotyloid cavity. The articulating surfaces are covered by cartilage in the greater part of their extent. It is deficient, however, at the bottom of the cavity, and also a little beneath the central point of the head of the femur; the latter marking the insertion of the round ligament, the former a shallow fossa for the lodgement of the structure which has been called the synovial gland. The connecting means in this articulation are three ligaments, viz. a capsular, cotyloid, and inter-articular ligament, together with a synovial membrane.

Artic. surfaces; where cartilage is wanting.

The *capsular ligament*, dense and firm in its texture, represents a fibrous tube, (fig. 90, [11],) whose direction is downwards and outwards; being attached by one extremity round the margin of the cotyloid cavity, by the other to the neck of the femur. Its superior circumference, in the greater part of its extent, is attached to the bone, within two or three lines of the cotyloid ligament; but opposite the notch, where the margin of the cavity is deficient, it is attached to the transverse ligament. Its inferior circumference is inserted in front into the oblique line leading from one trochanter to the other; but, superiorly and behind, its fibres are implanted into the neck of the bone, within

Capsular ligament,

points of attachment;

---

* A detailed description of the exact manner of connexion with the bone is given by Winslow in "An Anatomical Exposition," &c. Sect. ii. § 115.

a quarter of an inch of the trochanteric fossa, and about the same distance from the posterior inter-trochanteric line. The ligament is most dense and firm towards the superior and anterior part of the articulation; inferiorly, its fibres are comparatively thin. A firm fasciculus[12] of fibres extends obliquely downwards in front of the joint intimately connected with the capsule, being calculated to strengthen it, hence it is called its "accessory" ligament; but as one extremity of it is attached to the anterior inferior spinous process of the ilium, and the other to the anterior trochanteric line, it may be called the *ilio-femoral* ligament.

unequal thickness.

Ilio-femoral band.

The capsular ligament is rough on the outer surface, which is covered by many muscles; a synovial bursa separates it in front from the conjoined psoas and iliacus. The inner surface is lined with the synovial membrane of the joint. The bursa has been found to be continuous with the synovial membrane through an opening of the fibrous capsule.

Synovial bursa.

The *cotyloid ligament* is a fibro-cartilaginous ring, (fig. 88, [13],) placed round the cavity, and serving the purpose of increasing its depth, and completing its border, where it is deficient. It is inclined inwards from the point of its connexion with the bone, so as to narrow the acetabulum, and as it were to embrace the head of the femur. The broader part or base of this structure is attached to the bone, its thin edge is free, and both its surfaces are covered by the synovial membrane, the external being in contact with the capsular ligament, the internal with the head of the femur. Its fibres are not continued all round; they rather pass obliquely from without inwards, over the margin of the cavity, one extremity being attached to the outer, the other to its inner surface. At the cotyloid notch these fibres are continued from side to side, crossing one another, so as to render the circumference complete. Some additional fibres are superadded in this part; from which circumstance, as well as its being stretched across from one margin of the notch to the other, it is usually named the *transverse ligament*. Subjacent to the transverse portion an interval is left for the admission of the articular vessels.

Cotyloid lig. deepens and narrows acetabulum;

shape.

Transv. lig. over cotyloid notch.

Vessels to joint beneath lig.

The *inter-articular ligament* (fig. 88,[14]) is not unfrequently called the "round" ligament (tapering?) (ligamentum teres

Lig. teres,

points of attachment.

capitis femoris,—Weitbr.) It is a thick dense fasciculus of fibres, implanted by one extremity, which is round, into the fossa in the head of the femur; by the other, where it is broad, flat, and bifid, into the margins of the cotyloid notch, where its fibres become blended with those of the transverse ligament. The outer surface of this ligament is covered with a tubular process of the synovial membrane of the joint. It presents many varieties as to thickness and strength in different cases.

Synovial membrane;

tube for round lig.

The *synovial membrane* lines the contiguous surfaces of all the parts which enter into the composition of the articulation, giving them a smooth and shining appearance. From the margin of the articular surface of the femur, it may be traced along the neck of that bone as far as the insertion of the capsular ligament, the inner surface of which it lines as far as its superior attachment. There it turns inwards over the cotyloid ligament, and dips into the cavity, lining its entire extent, and, finally guided as it were by the inter-articular ligament (which it invests by a funnel-shaped process), it reaches the head of the femur, and invests it as far as the border of its cartilage, whence we proceeded in tracing its reflections.

THE KNEE-JOINT. (FEMORO-TIBIAL.)

Articular surfaces.

This is a ginglymus, or hinge-joint, formed by the condyles of the femur above, the head of the tibia below, (with two interposed fibro-cartilages,) and the patella in front, the contiguous surfaces of each of the bones being tipped with cartilage, and invested by a common synovial membrane. The joint is supported by the following ligaments, viz. the external and internal lateral, a posterior, two crucial, some fibrous membrane, which may be considered a partial capsular ligament; besides these, the ligamentum patellæ may be enumerated, and one or two other structures of minor importance will be mentioned in describing the details.

Internal lateral lig. broad and long.

The *internal lateral ligament*, (figs. 91, 92,[2]) broad and flat, connects the tuberosity of the internal condyle of the femur with the inner surface of the tibia. Inferiorly it is covered by the tendons of the sartorius, gracilis, and semitendinosus muscles, with a synovial bursa interposed; internally it rests on the synovial membrane, and is attached to the internal semi-lunar cartilage.

Fig. 91.*

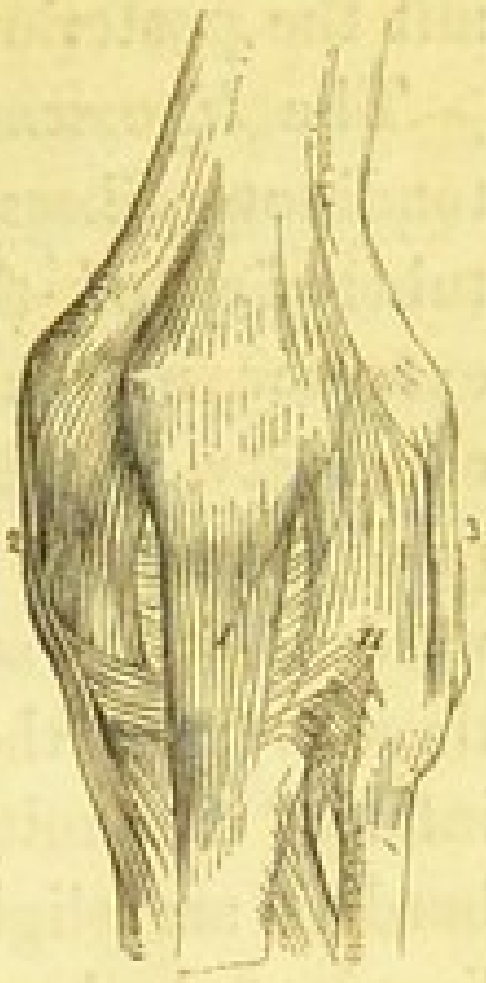

Extern. lat. ligament, thick, round, and short;

The *external lateral ligament*[3] is a rounded cord-like fasciculus of fibres, shorter than the preceding ligament, which passes from the tuberosity of the external condyle of the femur, to the head of the fibula; its direction is almost vertical; its internal surface corresponds with the tendon of the popliteus muscle and the external articular artery, the external being covered by the tendon of the biceps flexor cruris, and the expanded fascia of the extensor muscles. Posterior to this, but parallel with it, another ligament (fig. 92,[4]) is placed, connecting the femur and fibula; it is called the *short external lateral ligament*. The arrangement of this second or accessory part varies; it will occasionally be found to terminate in the capsular ligament.

a second portion.

Fig. 92.*

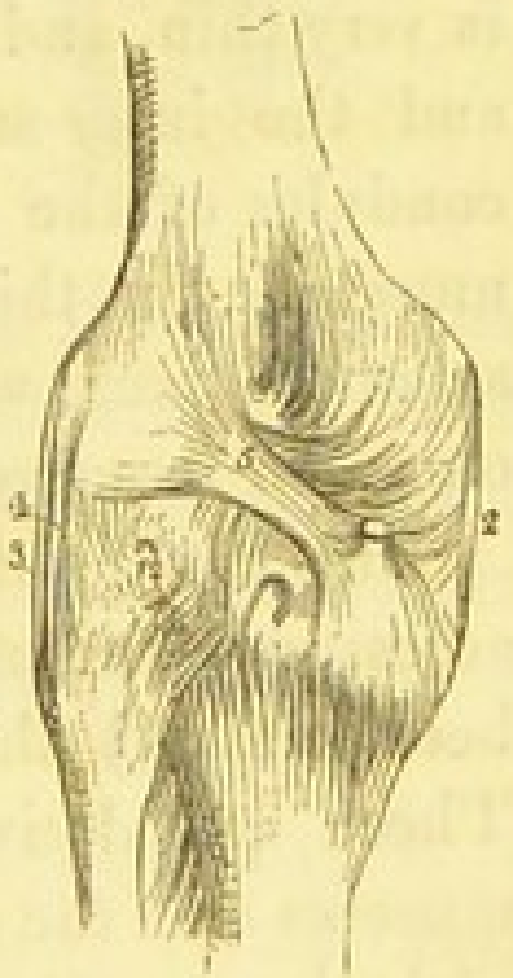

Lig. postic. of Winslow;

fr. semi-membranosus muscle.

The *posterior ligament*, (fig. 92,[5]) (ligamentum posticum Winslowii,—Weitbr.) broad and expanded, is a flat plane of fibres, stretched obliquely behind the articulation from the internal tuberosity of the tibia to the external condyle of the femur. The direction of the greater part of its fibres is from below upwards and outwards, running diagonally across the joint, being evidently continuous with the tendon of the semi-membranosus muscle, of which they may be regarded as a prolongation. This ligament, however, cannot be considered as formed solely by a reflection of the tendon of the semi-membranosus, or merely as the third insertion of that muscle; for several transverse and perpendicular fibres are observed in it, distinct from those of the reflected tendon.

---

* Figure 91 is a front view of the ligament of the left knee-joint; parts of the femur, the tibia, and fibula, with the patella, are discernible. Figure 92 is a back view of the same. 1. Ligament of the patella. 2. Internal lateral of knee-joint. 3, 4. External lateral of same. 5. Posterior ligament, in connexion with the tendon of the semi-membranosus muscle.

Some apertures may be observed between its fibres, which transmit the posterior articular vessels.

Ligament. patellæ;

The *ligamentum patellæ* (fig. 91,[1]) is a flat strong band of tendinous fibres, which connects the patella with the anterior tuberosity of the tibia, and through the medium of it the extensor muscles are inserted to this bone.* Its superior extremity is attached to the apex of the patella, and to a depression on its posterior surface; its superficial fibres pass upwards on the anterior aspect of the bone, and become continuous with those of the tendon of the rectus femoris; the inferior extremity is a little expanded; towards the middle its borders are slightly tucked in. The posterior surface of this ligament looks to the synovial membrane of the knee-joint, from which it is separated by some adipose substance, as it is inferiorly from the tibia by a synovial bursa.

covers synovial bursa at lower end.

Caps.memb.

Capsular membrane (membrana capsularis, — Weitbr.) — Under this name are described portions of fibrous membrane, which cover the synovial membrane in the intervals of the proper ligaments of the joint above described. This structure is very thin, and is connected to the patella, to the femur, tibia, and the inter-articular cartilages. Posteriorly it covers the condyles of the femur beneath the heads of the gastrocnemius muscle. In this situation the web is peculiarly slight, and a sesamoid bone will often be found in connexion with it over one, and less frequently over both condyles.

is thin; connected with bones.

Accessory structures;

But the joint is much more efficiently supported by other accessory structures ("corroborationes accessoriæ," as they have been named,) than by the slender membrane now pointed out. These are derived from the fibrous expansion of the vasti muscles and the fascia lata, which blend anteriorly and laterally with the capsular membrane, and are sometimes considered to form part of it: and under the same denomination may be included the heads of the gastrocnemius and the tendon of the

fr. muscles and fascia.

---

* From this circumstance, together with the fact that it does not connect pieces of the skeleton one to the other, (the patella can be regarded only as a large sesamoid bone and an appendage to muscles,) the so-named ligament is not unfrequently or unfitly regarded as the tendon of a muscle. It seems well, however, that it should, according to usage, be noticed among the ligaments, in consequence of its close connexion with the joint; and, in the words of Weitbrecht, it may be added, "Si quis vero illud cum Walthero pro vero ligamento habere malit, parum refragabor."

popliteus muscle, because of the support they afford to the joint.

Crucial ligts.

Anter. crucial.

Poster. crucial.

The *crucial* or *oblique ligaments* (ligamenta cruciata in poplite,—Weitbr.) are placed at the posterior part of the joint, external to the synovial membrane, but partially invested by it. As the name imports, their direction is oblique, so that they cross or decussate somewhat like the lines of the letter X; the posterior one, however, approaches more nearly a perpendicular direction. One is named anterior, the other posterior. The *anterior ligament* (fig. 93,[6]) is fixed by its lower extremity to a pit, situated before the spine of the tibia, where it is connected with the anterior cornu of the internal semi-lunar cartilage; its upper extremity is inserted into the inner side of the external condyle of the femur; hence its direction is upwards, backwards, and outwards. The *posterior ligament*[7] is attached inferiorly to the pit behind the spine of the tibia (where it is intimately connected with the posterior cornu of the external semi-lunar cartilage), and superiorly to the side of the inner condyle; its fibres being directed upwards and a little forwards. Its anterior surface is in contact with the last-mentioned ligament, and the posterior with the ligamentum posticum. Both are thus implanted into the fossa between the condyles.

Fig. 93.*

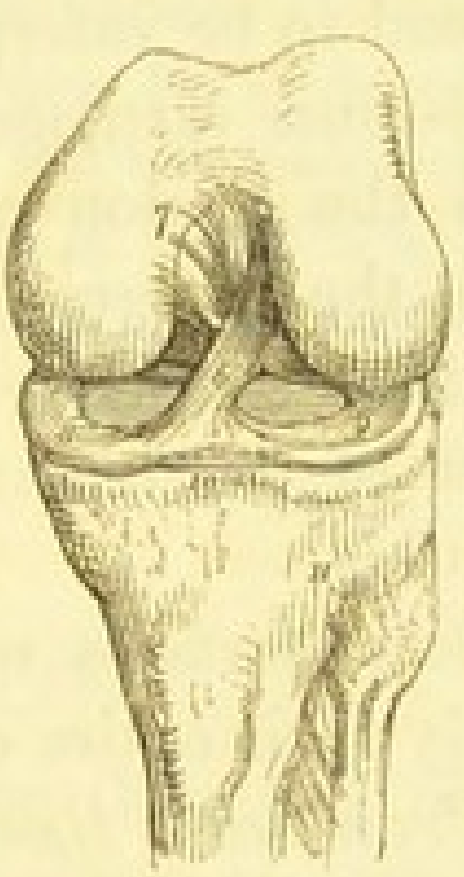

Semi-lunar cartilages; both fixed to tibia;

The *semi-lunar cartilages* are two crescent-shaped lamellæ of fibro-cartilage, placed on the articulating surfaces of the head of the tibia, (to which they are firmly fixed,) and interposed between them and the condyles of the femur. The outer border of each is thick and convex, the inner thin and concave, leaving the central part of the superior surface of the tibia uncovered.

---

* A view of the condyles of the femur and a portion of the bones of the leg of the left side. The lower surface of the condyles was brought into view by forcibly bending the knee-joint. 6. Anterior crucial ligament. 7. Upper end of the posterior crucial. 8, 9. Internal and external semi-lunar cartilages. 10. Transverse ligament. 11. Anterior tibio-fibular ligament.

internal, its shape;

The *internal semi-lunar cartilage*, (fig. 93,[8]) elongated from before backwards, is nearly of a semi-circular form; its anterior cornu is connected with the anterior crucial ligament, and is inserted into the pit before the spine of the tibia; the posterior is attached behind the spine, and is in relation with the posterior crucial ligament; its thick border is connected with the internal lateral ligament, the thin one is free and unattached.

external, its shape.

The *external semi-lunar cartilage*[9] forms nearly a complete circle; its two cornua, fixed one before, the other behind the spine of the tibia, are so close at their insertion that they may be said to be interposed between the insertions of the internal semi-lunar cartilage. Its external border is connected behind with the tendon of the popliteus muscle, and in the middle with the external lateral ligament. The superior surface of the fibro-cartilages is concave, and in apposition with the condyles of the femur; the inferior plane rests on the head of the tibia.

Both connected by transverse ligament, and covered by synovial membrane.

Both surfaces of each semi-lunar cartilage are invested in nearly their entire extent by the synovial membrane.

Transverse ligament.—Towards the front of the joint the convex borders of the inter-articular cartilages are connected by a slight transverse band[10], which receives this name. Its thickness varies much in different bodies.

Synovial membrane;

folds of.

Ligam. mucosum.

The *synovial membrane*, like all similar structures, forms a shut sac, whose surface is continuous throughout its entire extent, and, as it lines the contiguous surfaces of all the parts entering into the composition of the knee-joint, it must necessarily present rather a complex arrangement. This complexity is increased by the existence of a small funnel-shaped fold (improperly named *ligamentum mucosum*), which is stretched across the joint, reaching from the anterior part of the joint at some distance below the patella backwards to the margin of the fossa, between the condyles of the femur. In order to exhibit the arrangement of the membrane, the joint should be laid open by a vertical incision carried along the inner margin of the patella and its ligament, leaving the ligamentum mucosum untouched. A lateral view of the joint being thus obtained, all the parts remaining in their natural position, it will be observed that the synovial sac is intersected and in a manner divided into two parts by a transverse funnel-shaped process (*ligamentum mucosum*); the superior one, elongated and pyramidal, projects by its summit more than an inch above the patella, its base corresponding with the breadth of the process just named. The inferior division of the membrane is quadrilateral, one side being made up of the lower border of the same process, and the smooth surface of the femur with which it is continuous; another, by the articulating surface of the tibia; posteriorly it corresponds with the posterior crucial ligament, and anteriorly with the part of the membrane reflected on the ligamentum patellæ.

The course traced.

If we commence at the superior border of the patella to trace the reflections of the membrane, we find that it descends, lining its articulating surface; below its inferior border it corresponds with the ligamentum patellæ, from which it is separated by a considerable quantity of adipose matter; on reaching the margin of the tibia, it is reflected over its articulating surfaces, and also on both aspects of the semi-lunar cartilages, giving them a smooth investment; round the crucial ligaments also it forms partial investments, enclosing them as far as their attachments to the femur. The membrane will thus be found to be guided to the articulating surface of that bone at several points, viz. by the two crucial ligaments, by the funnel-shaped process, and by the external margin of the semi-lunar cartilages; from these points it expands over the condyles, and, after ascending for some way in front of the femur (forming a cul-de-sac between it and the tendon of the extensor muscles), it passes downwards to the margin of the patella, from which we proceeded to trace its reflections. At the sides of the patella the membrane forms two slight folds which are named "*alar*" ligaments (ligamenta alaria). Lig. alaria.

PERONEO-TIBIAL ARTICULATION.

Ends and shafts of bones connected.

The superior and inferior extremities of the tibia and fibula are connected by ligaments and synovial membranes, and the shafts of these bones are moreover maintained in relation by an inter-osseous membrane.

Super. articul.

The contiguous extremities of the bones present superiorly two flat oval surfaces covered with cartilage, which are closely applied to one another, and retained *in situ*, 1, by an *anterior ligament*, (ligamentum superius anticum,) (figs. 93,[11]; 94,[1],) which is a broad flat band of fibres, passing obliquely upwards and inwards, from the head of the fibula to the internal tuberosity of the tibia; it is covered and strengthened by the tendon of the biceps flexor cruris; 2, by a *posterior ligament*, (ligamentum superius posticum,) (fig. 92, [12],) similarly disposed behind the articulation, but stronger and thicker; 3, by a *synovial membrane*, which lines the articulating surfaces of the bones and ligaments. It not unfrequently happens that the synovial membrane is continuous with that of the knee-joint, of which, in such cases, it might be considered a prolongation.

Anter. lig.; Poster. lig.; Synovial often from knee-joint.

Inter-oss. membrane;

The *inter-osseous membrane*, (septum longitudinale inter-osseum,) (fig. 94,[2],) which connects the bodies of the tibia

Fig. 94.*

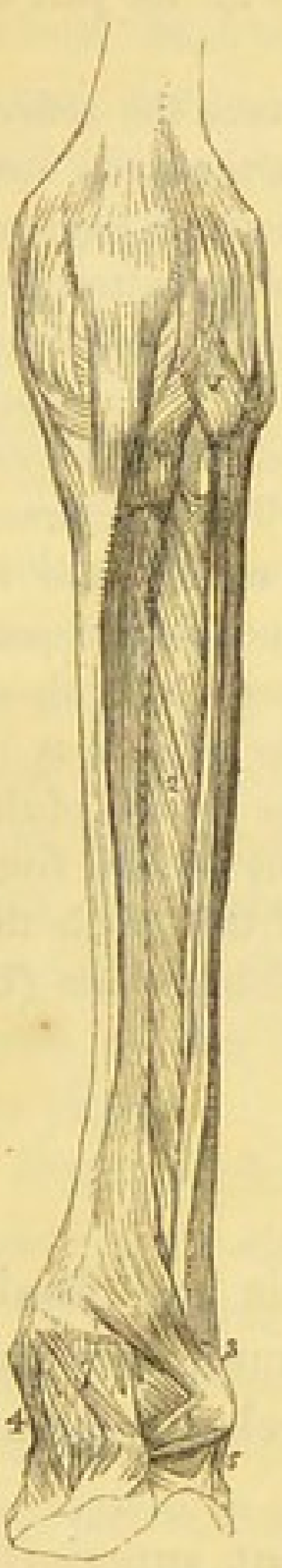

direction of fibres.

and fibula, flat and membranous, is composed of a series of parallel fibres, extending obliquely between the external ridge of the tibia, and the ridge on the inner surface of the fibula. Most of the fibres run outwards and downwards, others cross them; and the membrane they compose is broader above than below, and presents in the

Openings for vessels.

former situation an elongated opening for the transmission of the anterior tibial vessels, and inferiorly a small aperture for the passage of the anterior branch of the fibular artery.

Infer. artic.

The inferior extremities of the tibia and fibula present two articulating surfaces, of which that of the former is concave, and receives the latter, which is convex, both being for a little way covered with cartilage; these are connected by four ligaments and a synovial membrane.

Ant. inf. lig.

1. The *anterior ligament* (tibio-fibular) (fig. 94,[3]) is a flat band of fibres, extended obliquely between the heads of the bones, the direction of its fibres being downwards from the tibia to the fibula.

Poster. lig.;

2. The *posterior ligament*, (fig. 95,[1],) somewhat triangular, is similarly disposed behind the articulation; its external surface is covered by the peronei muscles.

two parts of,

one named transv.;

3. The *transverse ligament*, (fig. 95,[2],) longer but narrower than the former, with which its fibres are closely connected, being placed immediately below it, extends from the external malleolus to the tibia at a short distance from its malleolar process; it forms the posterior boundary of the ankle-joint.

Infer. inter-oss.

4. The *inferior inter-osseous ligament* consists of some short dense fibres, which connect the lower ends of the bones, as the great inter-osseous ligament does their bodies; it cannot be

---

* A part of the femur, the patella, the bones of the leg, and a range of those of the foot of the left side are viewed in front. Some ligaments of the knee-joint are distinguishable. 1. Superior anterior tibio-fibular ligament. 2. Inter-osseous membrane. 3, points to the anterior inferior ligament. 4. Deltoid of ankle-joint. 5. Middle division of external lateral; and 6. anterior division of same. 7. Anterior ligament of ankle-joint.

seen until the anterior and posterior ligaments are removed, and the bones in some degree separated.

The *synovial membrane* which covers the articular surfaces of the bones is derived from that of the ankle-joint.

Infer. synovial fr. ankle-joint.

THE ANKLE-JOINT.

Artic. surfaces.

This articulation consists of the inferior extremities of the tibia and fibula, united so as to form an arch, into which the superior convex surface of the astragalus is received. Their contiguous surfaces are covered with cartilage, lined by a synovial membrane, and retained in contact by the following ligaments. The *internal lateral ligament* (figs. 94,[4], and 95,[3]) (ligamentum deltoides) is a flat fasciculus of fibres much broader at the lower than the upper extremity. One extremity is attached to the inferior border of the internal malleolus, the other to the inner side of the astragalus, the os calcis, and the scaphoid bone. The ligament is covered by the tendons of the tibialis posticus and flexor longus digitorum pedis muscle.

Deltoid lig.

Fig. 95.*

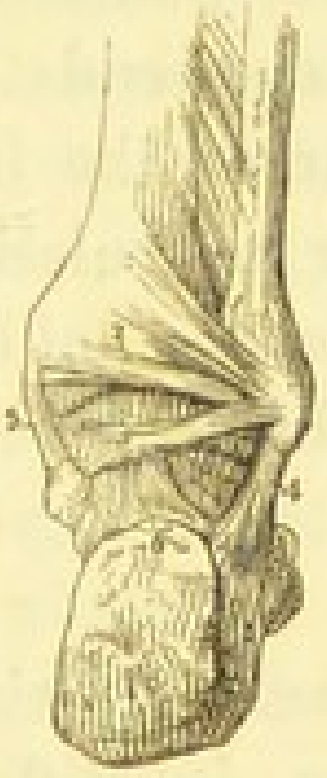

The *external lateral ligament* consists of three distinct fasciculi of fibres, separated by intervals, and disposed in different directions. 1. The central one (figs. 94, [5]; 95, [4]) (*ligamentum fibulæ medium*) descends from the extremity of the fibula, and is inserted into the middle of the external surface of the os calcis. It is crossed by the tendons of the peroneus longus and brevis muscles. 2. The anterior fasciculus (fig. 94,[6]) (*ligamentum fibulæ anterius*) passes obliquely forwards from the inferior extremity of the fibula, to the anterior border of the articular surface of the astragalus; it is the shortest of the three. 3. The posterior, (fig. 95,[5],) (*ligamentum fibulæ posterius*,) the strongest of the three ligaments, passes obliquely backwards from the extremity

Extern. lat.; three separ. ligaments;

middle to os calc.;

anter. and poster. to astrag.

---

* The lower end of the tibia and fibula of the right side, with the bones of the foot, seen from behind. 1. Posterior inferior tibio-fibular ligament. 2. Transverse ligament;—being the lower division of the inferior and posterior tibio-fibular ligament. 3. Posterior part of the deltoid ligament (ankle-joint). 4. Middle division of the external lateral ligament of same joint. 6. Posterior division of same.

of the fibula towards the posterior surface of the astragalus, where it is inserted into the border of the groove for the tendon of the flexor longus pollicis.

Anter. lig.

Anterior or *tibio-tarsal ligament.*—At the anterior aspect of the joint is a broad thin membranous band, (fig. 94,7,) composed of irregular fibres, extended obliquely from the border of the articulating surface of the tibia to the margin of the pulley-like surface of the astragalus. This ligament is covered by the tendons of the extensor muscles.

Synovial memb.; extends between tibia and fibula.

The *synovial membrane*, after having invested the articulating surface of the astragalus, is reflected upwards at each side upon the lateral ligaments, and, at the anterior and posterior part of the joint, upon the corresponding fibrous structures, so as to reach the articulating surfaces of the tibia and fibula by several points at once. These it lines in their entire extent, and also sends upwards between them a process which reaches as far as the inferior inter-osseous ligament; so that the inferior articulation between these bones may be said to form part of the ankle-joint, as both are lined by the same synovial membrane.

ARTICULATIONS OF THE FOOT.

The foot being divided into the tarsus, metatarsus, and phalanges, its different parts are respectively bound together by ligaments, and all are united so as to form a whole.

Bones.

The seven bones of which the tarsus consists may be divided into two sets; the os calcis and astragalus forming the first; the scaphoid, cuboid, and three cuneiform bones, the second. And their complicated articulations will be arranged in three divisions.—*a.* In the first will be placed the articulations of the bones of the first row or set one with the other.—*b.* The second division will contain the connexion of the first set with the bones of the second.—*c.* And the last will comprise the connexions of those (the second set of bones) one with another.

Their artic. arranged in three divis.

A. ARTICULATION OF THE FIRST RANGE OF TARSAL BONES ONE WITH THE OTHER.

Astrag. w. os calc.

The astragalus with the calcaneum.—The astragalus is connected to the calcaneum by three ligaments, the chief of which is situated between the bones, and unites them somewhat after the manner that bivalve shells are connected by their muscle. This is termed the *inter-osseous ligament;* its breadth from side to side is more than an inch; the fibres of which it is composed pass perpendicularly between the bones, one extremity being fixed to the groove between the articulating surfaces of the calcaneum, the other to a corresponding depression in the astragalus. The *posterior ligament* (fig. 95,[6]) connects the posterior border of the astragalus with the upper surface of the calcaneum; its fibres are oblique, its length and breadth not more than three or four lines. The *external ligament* is a slight fasciculus which descends perpendicularly from the under surface of the astragalus to the external side of the calcaneum; its direction is parallel with the middle division of the external lateral ligament of the ankle-joint. It may be farther observed, that as the astragalus is wedged in between the malleoli, and as the lateral ligaments pass downwards from these to the os calcis, they must contribute somewhat to retain the astragalus in its proper position with regard to the latter bone.

Three ligaments;

inter-oss. the principal one.

Poster. lig. small.

Extern. lig. small.

Synovial membrane.—There are two sets of articular surfaces by which the astragalus and calcaneum are in contact. The posterior one has a separate synovial sac; while the membrane which lines the anterior articulation is continued forwards between the astragalus and the scaphoid bone.

Two synovial memb.; one special, the other common to another joint.

B. ARTICULATION OF THE FIRST SET OF TARSAL BONES WITH THE SECOND.

This heading includes—1. The articulation of the os calcis with the cuboid. 2. The os calcis with the scaphoid. 3. The astragalus with the scaphoid.

The calcaneum with the cuboid bone.—The connexion between these bones is maintained by three ligaments and a synovial membrane. The *superior calcaneo-cuboid ligament* is a broad flat band of fibres, which connects the anterior and superior surface of the calcaneum with the adjacent part of the cuboid bone. The *inferior ligament* consists of two distinct fasciculi of fibres, differing in form and attachments; of which one is superficial, the other deep-seated. The superficial one, called the *long plantar ligament* (fig. 96, [2]) (ligamentum

Os calcis w. cuboid.

Super. calc. cuboid lig.

Infer. lig. has two parts, viz.

lig. long. plantæ, and deep calc. cub.

longum plantæ) is the longest of the tarsal ligaments. Its fibres, attached posteriorly to the inferior surface of the calcaneum, pass horizontally forwards, and become intimately connected with the rough tuberosity on the under surface of the cuboid bone; the greater number of them are continued forwards, and terminate at the base of the third and fourth metatarsal bones, after covering the tendon of the peroneus longus muscle. The *deep-seated plantar calcaneo-cuboid ligament*[3] lies close to the bones, being separated from the former by some cellular tissue; its breadth is considerable, its length scarcely an inch, one extremity being attached to the calcaneum before the long ligament, the other (somewhat expanded) to the under surface of the cuboid bone.

Inter-oss. calc. cub. lig.

Internal or *inter-osseous calcaneo-cuboid ligament.*—Besides the preceding ligaments there is another series of fibres placed deeply between the bones in the sinus or pit between the astragalus and os calcis (its anterior part). These extend from the os calcis to the inner side of the cuboid; and with these are others which are directed from the same part of the os calcis inwards to the scaphoid bone. Both may be considered as inter-osseous ligaments.—A *synovial membrane* lines the contiguous surfaces of the two bones, and is necessarily reflected upon the articular aspects of the ligaments.

Synovial memb.

Fig. 96.*

Os calcis w. scaph.

The calcaneum with the scaphoid bone.—This is effected by means of two ligaments, their surfaces not being in contact. Of these ligaments, the inferior, or plantar one, (fig. 96,[1]) (*ligamentum calcaneo-scaphoideum inferius*,—Meckel,) much the larger, passes forwards and inwards from the extremity of the calcaneum to the inferior surface of the scaphoid bone; its fibres are flat and horizontal, and in contact inferiorly with the tendon of the tibialis posticus

Infer. lig. supports astrag.

---

* The ligaments of the foot (plantar surface). 1. Inferior calcaneo-scaphoid. 2. Ligamentum longum plantæ. 3. Deep plantar calcaneo-cuboid. 4. Tarso-metatarsal. 5. Transverse ligament. 6. Lateral ligaments of the phalangal joints.

muscle; superiorly they form part of the fossa which receives the head of the astragalus, and are lined by the synovial membrane, which is continued forward from the anterior articulation of the astragalus and os calcis. The *external*, *dorsal*, or *inter-osseous ligament* (lig. calcaneo-scaphoideum externum) forms the external boundary of the cavity just mentioned; its fibres, very short, are directed from behind forwards between the contiguous extremities of the bones. As it lies deeply at the anterior part of the fossa between the astragalus and os calcis (sinus pedis), and is actually between the bones, the ligament may be regarded as inter-osseous. In connexion with it is another bundle of fibres already described as reaching from the os calcis to the inner part of the cuboid.

Extern. is inter-oss.

The astragalus with the scaphoid bone.—The astragalus forms with the scaphoid bone a ball-and-socket joint. The anterior articulating surface of the calcaneum, and the inferior calcaneo-scaphoid ligament, also may be said to enter into this articulation, as all the parts here mentioned are lined by a common synovial membrane. On the dorsum of the foot the astragalus is retained in its situation by the *ligamentum astragalo-scaphoideum*, a broad band of fibres extending obliquely forwards from the anterior extremity of the astragalus to the superior surface of the scaphoid bone. It is covered by the extensor tendons. The place of an inferior ligament to connect these bones is occupied by the calcaneo-scaphoid ligament, on which the astragalus rests; and this bone wants the security against displacement which would be afforded by the connexion of its inferior surface with the scaphoid bone. But on this arrangement of the bones and ligaments depends in a great measure the elasticity of the arch of the foot, as well as the freedom of motion which belongs to this part of the tarsus.—The *synovial membrane* lines the concave surface of the scaphoid bone, the calcaneo-scaphoid ligament, and the elongated articulating surface of the calcaneum; from these it is reflected to the under surface of the astragalus and its scaphoid ligament, and so to the bone of that name from which we began to trace it. In other words, the synovial membrane of this joint is continued from the anterior of the two joints formed between the os calcis and astragalus.

Artic. surf.; shape.

One lig.,—it is dorsal.

Calc. scaph. lig. in place of an infer. one.

Synovial is continued from behind.

C. ARTICULATIONS OF THE SECOND SET OR RANGE OF TARSAL BONES ONE WITH ANOTHER.

The second range of the tarsal bones, viz. the scaphoid, cuboid, and three cuneiform, are connected together in the following manner.

Scaph. w. cuboid. Small artic.

1. The *scaphoid* and *cuboid* bones, when in contact, which is not always the case, present two small articulating surfaces, at their edges covered with cartilage, and lined by a synovial membrane. They are connected by a *dorsal ligament*, composed of short thin fibres, extended obliquely between the two bones; a *plantar*, situated in the sole of the foot, and composed of transverse fibres; and an *inter-osseous* ligament, which intervenes between the bones, and is attached to their contiguous surfaces.

Dorsal, plantar, and inter-oss. ligts.

Cub. w. ext. cuneif. Dorsal, plantar, and inter-oss. ligts.; articulation.

2. The *cuboid* and the *external cuneiform bones* are connected by a *dorsal* ligament, which is a thin fasciculus of fibres extended between them; a *plantar ligament*, whose fibres are transverse, and rather indistinct; and a series of *inter-osseous* fibres connected to their neighbouring sides. Between these two bones a distinct articulation is formed by cartilaginous surfaces, lined by a process of the same synovial membrane which belongs to the scaphoid and cuneiform bones.

Scaph. w. three cuneif.

3. The *scaphoid* and the *cuneiform bones* are held together by dorsal and plantar ligaments. It will be recollected that the scaphoid bone articulates with the three cuneiform, by the smooth faces on its anterior surface. The *dorsal* ligaments, three in number, pass from the superior surface of the scaphoid to the first, second, and third cuneiform bones, into which they are inserted. The *plantar ligaments*, which are similarly disposed on the under surface of the bones, but not so strongly marked, are continuous with, or off-sets from, the tendon of the tibialis posticus.

Dorsal; and plantar ligts.

Three cuneif. together; Dorsal and inter-oss. ligts.

4. The three *cuneiform* bones are connected by transverse *dorsal ligaments* and strong *inter-osseous* fibres, which (latter) are their most efficient means of union. Plantar ligaments can scarcely be said to exist for the connexion of these bones; the internal one is broader and stronger than the other. The contiguous smooth surfaces of the bones are lined by syno-

vial membrane continued forward from the articulations last described.

ARTICULATION OF THE TARSUS WITH THE METATARSUS.

The four anterior bones of the tarsus, viz. the three cuneiform and the cuboid, articulate with the metatarsus. The first and third cuneiform bones project beyond the others, so that the anterior extremity of the tarsus is very irregular. The first metatarsal bone articulates with the internal cuneiform; the second is wedged in between the first and third cuneiform, and rests against the middle one; the third metatarsal bone articulates with the extremity of the corresponding cuneiform, and the two last with the cuboid bone. The articular surfaces of the bones are lined by synovial membranes, and they are held in contact by dorsal and plantar and inter-osseous ligaments.

Bones, and their artic.

The *dorsal* ligaments are flat, thin bands of parallel fibres, which pass from behind forwards, connecting the contiguous extremities of the bones just mentioned. Thus the first metatarsal bone receives a broad thin band from the corresponding cuneiform bone; the second receives three, which converge to its upper surface, one passing from each cuneiform bone; the third has one from the third bone of that name; and, finally, the two last are bound by broad fasciculi to the cuboid bone. The *plantar* set is disposed with less regularity; the first and second are more strongly marked than the corresponding ligaments on the dorsal surface; and the fourth and fifth metatarsal bones, which are connected by but a few scanty fibres to the cuboid, receive support from the sheath of the peroneus longus muscle. Ligamentous bands stretch in an oblique or transverse direction from the internal cuneiform to the second and third metatarsal bones, and from the external cuneiform to the fifth metatarsal.

Dorsal ligts.

Plantar less regular.

Oblique fibres.

The *inter-osseous* ligaments have especial interest, because of the difficulty they would occasion in separating the metatarsus from the tarsus (should this operation be considered a desirable one) in consequence of their deep position between the bones.*

Inter-oss. ligts.

---

* Attention was first particularly directed to these ligaments by M. Lisfranc, in connexion with the amputation of the foot through the tarso-metatarsal articulation. See "Manuel des Opérations Chirurgicales, &c. Par J. Coster." 3e. edit. Paris, 1829.

Intern. inter-oss.

a. The *internal* and largest of these lies to the outer side of the first cuneiform bone, and extends from this bone to the neighbouring side of the second metatarsal, as well as to the first metatarsal.

Extern.

b. The *external* inter-osseous ligament separates the articulation of the fourth and fifth metatarsal bones from the rest. It connects the outer side of the external cuneiform bone to the same side of the third metatarsal. *c.* Some fibres, of less strength and importance than the preceding, are observable in another situation, namely, on the outer side of the second metatarsal bone, connecting it to the middle cuneiform. These fibres, from their position, constitute a *middle* inter-osseous ligament.—The connexions of the inter-osseous ligaments may be found to vary somewhat from those here stated. They may be connected at the same time to the contiguous angles of two tarsal and two metatarsal bones.

Middle is slight.

Three synovial sacs; two special, one borrowed.

Synovial membranes.—There are three synovial membranes in this irregular series of articulations. *a.* One belongs to the internal cuneiform and the first metatarsal bone. The joint formed between these two bones is altogether distinct and out of the range of the rest. *b.* Another synovial membrane is reflected from the cuboid to the fourth and fifth metatarsal bones; and this is isolated on the inner side by the external inter-osseous ligament. *c.* The third or middle one is an elongation of the synovial membrane lining the articulations of the scaphoid and cuneiform bones, which is continued to the articulations formed between the two external of the last-named bones, and the second and third metatarsal.

CONNEXION OF THE METATARSAL BONES WITH ONE ANOTHER.

The metatarsal bones are bound together at their tarsal and digital ends; very firmly in the former, and, on the other hand, loosely in the latter situation.

Bases of four are articulated.

The tarsal ends or bases of the four outer bones articulate one with another, having lateral articular surfaces which are covered by synovial membrane, and they are connected by dorsal, plantar, and inter-osseous ligaments. The *dorsal* and *plantar* (fig. 96,[4]) ligaments are short transverse bands stretching from one bone to another, and placed in the manner which

Dorsal, plantar,

their names sufficiently indicate. The *inter-osseous* fibres, lying deeply between the bones, occupy the non-articular parts of their lateral surfaces. They are very resistent. The articular surfaces are covered by *synovial membrane*, which in each is continued forward between these bones from that lining the joints formed by their terminal surface and the tarsal bones. The first metatarsal does not articulate with the second.

and inter-oss. ligts.

Synovial fr. behind.

Transverse metatarsal ligament.—The digital extremities or heads of the metatarsal bones are loosely connected by a transverse band (fig. 96,[5]) which is identical in its arrangement with the corresponding structure in the hand; but with this exception, namely, that it extends to the great toe, whereas the other does not reach the thumb.

Heads of all connected by transv. lig.

ARTICULATIONS OF THE METATARSAL BONES WITH THE DIGITAL PHALANGES, AND OF THE LATTER ONE WITH ANOTHER.

The heads of the metatarsal bones are connected with the small concave articular surfaces of the first phalanges by two lateral ligaments, an inferior ligament, and a synovial membrane, similar in every respect to those which belong to the corresponding parts of the hand (*ante*, page 215).

The articulations of the phalanges with one another are also constructed on the same principle as those of the superior extremity (page 216). In each, the bones are held in contact by two lateral ligaments (fig. 96, [6],) and an anterior ligament, the surfaces being lined by a synovial membrane.

MUSCLES.

The muscles are divisible into a number of groups, which occupy different regions of the body, and combine in various ways for the performance of its actions. We shall in the first place name the individual muscles included in each group, then indicate the method of dissecting or exposing them to view; the detailed description of each shall follow, and the rationale of their actions conclude the section.

EPICRANIAL REGION.

On the roof of the skull we find but one muscle, viz. the occipito-frontalis.

Care necessary in raising the integument.

Reason of this.

Dissection.—Care must be taken in making the first incisions to expose this muscle, particularly along the vertex; for the tegument is very thick, and at the same time firmly adherent to the thin aponeurosis of the muscle, which is by almost every beginner detached with the tegument: this is the more likely to happen, as the aponeurosis is lifted up from the bone in the effort made to render the tegument tense. The better plan, therefore, is to commence the dissection in such a way as to expose the fleshy fibres of the muscle; and then, taking these as a guide, to elevate the tegument from

---

Note.—When proceeding with the dissection of a body, the examination of its upper and lower half is, for obvious reasons carried on at the same time by different persons. Begin the dissection of the upper half with the epicranial region, then take the auricular; observe the temporal fascia and muscle; then, without delay, open the skull, as the brain speedily decomposes, and proceed with the examination of its membranes, vessels, and internal structure (*see* Brain, dissection of.) When this is concluded, let the dissection of the different groups of muscles in the face, orbit, and neck, be continued in the order here set down. Do not pass over, or neglect, the brief directions given for the examination of each region.

Those to whom the lower half of the body is allotted should commence with the abdominal muscles. These are confessedly of great importance; but still no time should be lost in inspecting them, as it is necessary, as soon as it can be effected, to proceed to the abdominal viscera. The perinæal muscles should in the next place engage attention, as they too become, in before and from behind upwards to the vertex from off the aponeurosis. Place a high block under the back of the neck so as to raise the head nearly into the vertical position,—or, if the subject be turned prone, place the block under the chin. Make an incision across the forehead, about an inch above the upper margin of the orbit, and extending from the middle line outwards to the temple. Then a second incision may be carried from the inner termination of the one just indicated, upwards, over the middle of the forehead to the vertex ; raise the skin at the angle formed by the junction of these incisions, and cautiously dissect it upwards and outwards, which will expose the fleshy fibres of the frontal part of the muscle. Having proceeded so far at the fore part, make a transverse incision from the occipital protuberance to the root of the mastoid process, a little above, but parallel with the superior curved line of the occipital bone. Another incision may be drawn at right angles with this from the occipital protuberance upwards to the vertex ; and from the angle of union of these incisions begin and continue the dissection, raising the skin from the occipital part of the muscle, and so proceeding from the fleshy fibres upwards to the crown of the head. In conducting this dissection, the superficial filaments of the supra-orbital nerves will be seen in front, the temporal branches of the portio dura at the sides, and the ascending branches of the posterior divisions of the cervical nerves behind ; also the branches of the temporal and occipital arteries. When it is not deemed necessary to retain the large flap of tegument thus dissected off, and reflected down over the ear and side of the neck, it can be readily detached by an incision carried from the outer angle of the orbit backwards to the mastoid process.

Nerves and blood-vessels between integument and the muscle.

Occipito-frontalis; Douglas—(epicranius; Albinus.)—This is a flat, thin, digastric muscle (fig. 97,¹,¹) extended from the occiput to the forehead (from which circumstance its name is derived), and placed immediately beneath the cranial integument, to which it closely adheres, at the same time that it

---

a short time, pale and flaccid. Then take the muscles of the lower extremity in the order in which they are here placed.

If a student in his first essay at dissection has proceeded in this way, I (the author) would suggest to him to begin the second (its upper half) with the muscles of the back, which are usually left untouched till they are unfit for any purpose. As to the lower half, let that commence, for the like reason, with the gluteal and posterior femoral regions.

The remarks on the actions of muscles had better be passed over by junior students, until they become accurately acquainted with their points of attachment,—their form, and their lines of direction with regard to the axes of the bones. A perusal of them will then serve the purpose of a repetition, and suggest a strong motive to make another and a more careful dissection than could be expected in a first attempt. In doing this it will not suffice merely to trace the outline of each muscle ; its points of attachment should be exactly defined by carefully removing the cellular tissue and every extraneous substance which obscures them. (See the Table of Muscles, in the order of Dissection, at the end of this chapter.)

Two muscular parts, and an aponeurosis.

rests upon the arch of the skull, over which it slides. It consists of two broad but short fleshy bellies, united by an intervening aponeurosis.

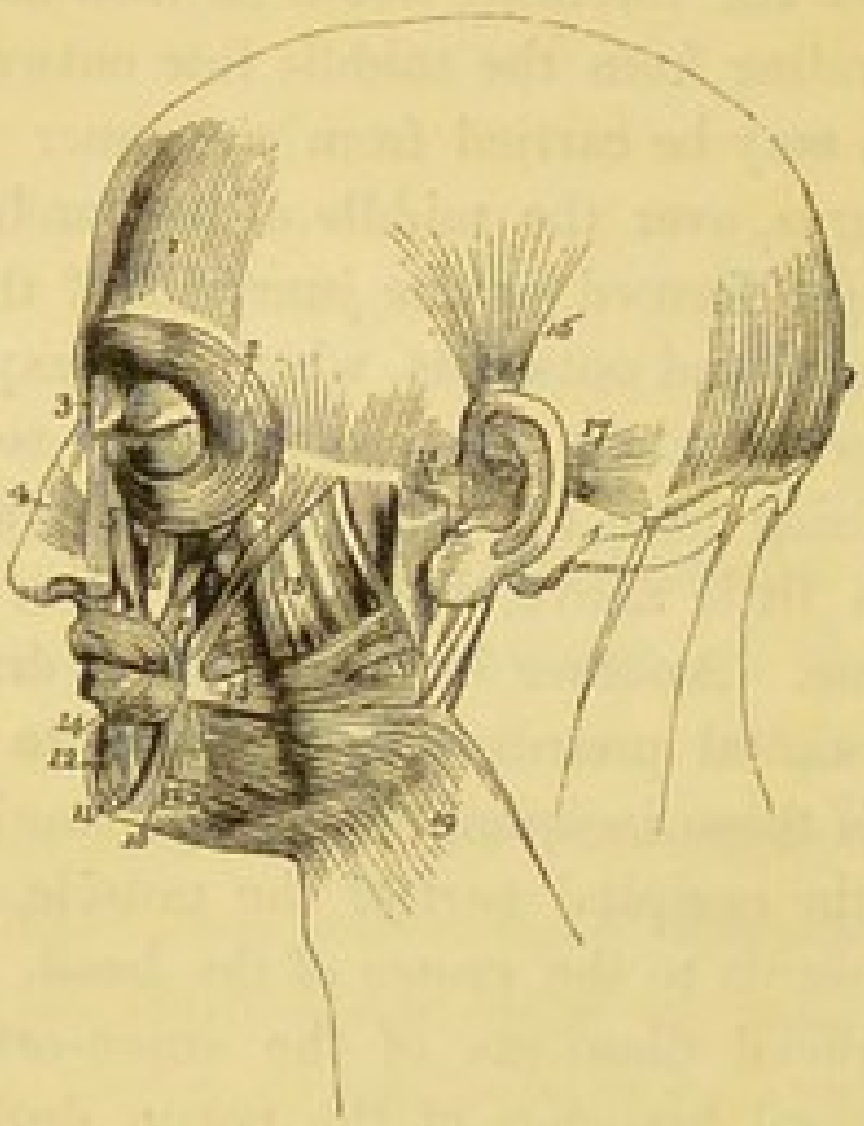

Fig. 97.*

Occipital part; connexion with bone;

The occipital part.—The posterior fleshy portion is attached, by short tendinous fibres, to the external two thirds, sometimes much less, of the superior curved line of the occipital bone, and to the mastoid portion of the temporal bone, immediately above the sterno-mastoid muscle. The fleshy fibres, which are from an inch to an inch and a half in length, proceed upwards and inwards, and terminate in distinct white tendinous fibres, which soon become continuous with the aponeurosis.

interval betw. both occip. parts.

Between the occipital muscles of opposite sides of the head there is a considerable, but in different cases a varying, interspace, which is occupied by the epicranial aponeurosis.

Frontal part;

larger than occip.

Frontal part.—The fleshy fibres, of which this portion of the muscle is composed, extend downwards and forwards on the frontal bone; they are longer and broader than those of the occipital part, but the fibres are paler and less distinctly muscular; their upper margin, being their junction with the aponeurosis, presents a curved line, which is a little below the coronal suture; the inner fibres, corresponding with the median line, descend vertically, and become continuous with the pyramidalis nasi[3]: the middle fibres, longer than the others, terminate by becoming blended with the orbicularis[2], and corrugator supercilii; and the external fibres curve inwards somewhat, and become blended with those of the orbicularis palpebrarum over

---

* 1. Occipito-frontalis. 2. Orbicularis palpebrarum. 3. Pyramidalis nasi. 4. Transversalis nasi. 5. Levator labii superioris et alæ nasi. 6. Levator labii superioris. 7. Levator anguli oris. 8. Zygomaticus minor. 9. Zygomaticus major. 10. Depressor anguli oris. 11. Depressor labii inferioris. 12. Levator menti. 13, points to buccinator. 14. Orbicularis oris. 15. Masseter. 16, 17, 18. Superior, posterior, and anterior auricular. 19. Platysma myoides.

the external angular process. The inner margins of the right and left frontal muscles are blended together for some space above the root of the nose.

Both frontl. parts join.

The *aponeurosis* of the occipito-frontalis (membrana epicrania; galea aponeurotica capitis) extends over the upper surface of the cranium uniformly from side to side, without any separation into lateral parts. It must therefore be regarded as a single structure, having connected with it the occipital and frontal muscular strata above described, and at the same time uniting the muscles of one side with the other, and combining their action.

Aponeurosis, connecting muscles;

Posteriorly, in the interval between the occipital parts of the muscles, the aponeurosis is fixed to the occipital protuberance and curved line above the trapezius; in front it presents in the middle an angular elongation, which intervenes for a short distance between the margins of the frontal muscles before they join; laterally, it has connected with it the superior and anterior auricular muscles. In the situation of the temporal ridge it loses the aponeurotic character, and is continued over the temporal fascia to the zygoma by a layer of laminated cellular membrane. The fibres are chiefly longitudinal, following the direction of the muscles; and they will be found distinctly tendinous where they receive the fibres of the occipital portions of the muscle.

attached to occip. bone.

The aponeurosis is firmly connected with the skin and subcutaneous granular fat (in which several blood-vessels and nerves ramify) by numerous short fibro-cellular bands; and it adheres loosely to the subjacent pericranium, through the medium of thin cellular membrane devoid of fat. Hence the muscles, when thrown into action, move the integuments with the aponeurosis (the hairy scalp) on the immediate investment of the skull. Hence, too, while they together admit of being easily and speedily stripped from the calvarium, the skin cannot be separated from the aponeurosis and muscle with facility. The integument is likewise closely connected with the frontal portion of the muscle, and the skin of the forehead is, in consequence, folded or wrinkled when this contracts.

Connected closely w. integ.; loosely w. pericranium.

Some anatomists consider the whole to be a four-headed muscle, having two fleshy portions behind, and two in front, all connected by a single layer of aponeurosis, which rests on the cranium. Others view it in a different way, the fleshy parts being taken as separate muscles, and named from their position, the anterior one being the "frontal" muscle, the posterior the "occipital."

Action on the eye-brows and skin of the forehead.

Actions.—All the muscular parts having one broad common aponeurosis, they act together: their first effect is to draw up the eye-brows, the next to throw the skin of the forehead into transverse folds or wrinkles; and to move the hairy scalp backwards and forwards, by bringing the occipital and frontal parts of the muscle alternately into action.

MUSCLES OF THE FACE AND SIDE OF THE HEAD.

Division into regions.

The muscles of the face are easily and conveniently arranged in groups, each occupying what may be called a region. The circumference of the orbit with the eye-brow and eye-lids forms the palpebral region; the side of the nose—the nasal; the cheek or side-face—the superior maxillary; the circumference of the mouth, and the space between the jaws—the inter-maxillary; that corresponding with the lower jaw—inferior maxillary. The interior of the orbit forms a separate region—the orbital; so does the space round the ear—the auricular; that of the temple and side of the jaw, the temporo-maxillary; finally, the region of the pterygo-maxillary fossa. In consequence of their position and their connexion with the aponeurosis of the occipito-frontalis, the muscles of the auricle will now be examined.

AURICULAR REGION.

Auric. muscles rudimentary.

In the space round the external ear are placed three small muscles, which in the human subject may be considered rudimentary, as they are not required to perform any action. They are attached by small tendons to the fibro-cartilage of the ear, and are quite superficial.

Dissection.—These muscles are generally removed together with the skin, when their dissection is attempted in the usual way by the beginner, who seeks to expose the fleshy part first: better at once reverse the process—seek for the tendons, and take them as guides. For this purpose, draw the pinna or broad part of the ear downwards; a very small tense cord will be felt under the skin, where it is reflected from the head to the ear, running from above downwards to the upper bulging part of the concha. This is the tendon of the attollens. Cautiously divide the skin by an incision drawn over the tendon from below upwards: reflect it to each side, and continue the process thus upwards from the tendon to its muscular fibres, which spread upon the temporal fascia. Proceed in the same way to expose the two other muscles—draw the pinna forwards, and the tendon of the retrahens will be readily perceived where it is inserted into the bulging part of the concha behind. Let a hook be inserted into the extremity of the helix at the point corresponding with the line of the zygoma. When the helix is drawn backwards, the tendon of the attrahens muscle is rendered tense, and can be exposed and dissected as in the previous instances.

Super. aur.

The *superior auricular* (fig. 97,[16]) (attollens auriculam; Alb.—temporo-auricularis,) is the largest. It arises from the aponeurosis of the occipito-frontalis, where it expands on the side of the head; its fibres, though delicate, being broad and radiated. The muscle ends in a compressed tendon, which is inserted into the upper and anterior part of the cartilage of the ear, on the outer side of the fossa between the division of the antihelix.

Poster. aur.

Posterior auricular[17] (retrahentes auriculam (tres); Alb.—mastoido-auricularis).—This muscle consists of two or three thin fasciculi, ranged one over the other; they arise from the mastoid process by short aponeurotic fibres, and are inserted into the back part of the concha. The fibres are much more distinctly marked than in either of the other auricular muscles.

Anter. aur.

The *anterior auricular*[18] (zygomato-auricularis) is pale and indistinct, and varies much in size. It is attached to the thin lateral elongation of the aponeurosis of the occipito-frontalis above the zygoma, and passes backwards, to be inserted into the fore-part of the helix.

Dissection.

To expose the muscles of the front and side of the face, begin by making an incision from the vertex along the middle line of the forehead and nose, taking care that it barely divides the skin. From this, two lines may be drawn outwards, one over the eye-brow to the side of the head, the other over the zygoma to the ear. The interval intercepted between these two parallel lines may be intersected, midway between the ear and orbit, by a perpendicular line drawn from one to the other. A square (*palpebral region*) is thus marked out over the orbicularis muscle, the skin of which should be carefully reflected from its borders and angles. The dissection is continued from its outer and upper border or circumference, the point of the scalpel being made to trace the course of the curved fibres of the muscle as far as the margin of the eye-lids. The external flap may then be reflected back over the ear, so as to expose the temporal fascia, artery, &c. The skin, in the next place, is to be carefully raised and dissected off the frontal muscle, from below upwards over the forehead as far as the vertex.

The fibres of the orbicularis, after being carefully examined, particularly at the inner border of the orbit, may now be divided along the eye-brow, so as to expose the corrugator supercilii; and if the lower border of the orbicularis be raised, it will expose the origin of the elevator of the lip, which will afford a guide to the dissection of that muscle, as well as of the common elevator of the lip and nose, down to their termination (*nasal region*). The transversalis nasi is partly concealed by the latter, but it emerges from under its inner border as it advances upon the side of the nose.

In order to expose the muscles and vessels of the lower part of the face, an incision may be made from the most prominent point of the cheek downwards to the margin of the jaw, from which the skin may be reflected backwards off the masseter muscle and parotid gland, taking care not to injure the duct of the latter, or the nerves and artery which accompany it; but the other flap of skin is to be carried obliquely inwards to the lip, in the direction of the zygomaticus. By this measure, the last-named muscle, and the levator anguli oris, and also the facial artery, will be exposed; and, by removing some adipose substance, the buccinator will be brought into view (*inter-maxillary region*). By turning aside the elevator of the lip, the second branch of the fifth nerve and the infra-orbital artery will be seen emerging from the foramen of that name.

PALPEBRAL REGION.

We have here four muscles, which act on the eye-lids, two being placed outside the orbit; viz. orbicularis palpebrarum and corrugator supercilii; and two within it, viz. levator palpebræ and tensor tarsi.

Orb. palpeb. *Orbicularis palpebrarum* (fig. 97,[2]) (naso-palpebralis).—This muscle is situated at the base of the orbit, forming a thin, flat plane of elliptic fibres, which is placed immediately under the skin of the eye-lids, resting on the eye-brow above, and spreading outwards somewhat on the temple, and downwards on the cheek. shape; The fibres form an ellipsis, whose great axis extends horizontally across the orbit from its inner angle to the temple, and corresponds with the fissure between the eye-lids; all the fibres describing concentric curves, the concavities being directed towards the fissure of the lids. where connected to bone. The only points of fixed attachment (to bone) which its fleshy fibres possess are at the inner margin of the orbit; they are free in the rest of their extent, except along the eye-brow, where they are blended with the occipito-frontalis and corrugator supercilii.

Tendon of the muscle. The *tendon* of the muscle (tendo palpebrarum).—At the inner commissure of the eye-lids is a small tendon, which is often obscured by the fibres of the muscle, but is rendered apparent by drawing the lids outwards: this tendon is about two lines in length, and one in breadth; it is attached to the anterior margin of the lachrymal groove, from which it runs horizontally outwards to the inner commissure of the eye-lids, where it divides into two thin fibrous lamellæ, which diverge as they pass outwards in the substance of the eye-lids, and terminate in the tarsal cartilages. One surface of the tendon is subcutaneous, the other crosses the lachrymal sac a little above its centre, and from it a thin but firm fascia is given off, which spreads over the lachrymal sac, and adheres to the margins of the groove which lodges it.

Attachm. of fibres;

The *muscular fibres are attached*, 1st, to the upper margin and anterior surface of the tendon just described; 2nd, to the surface of the nasal process of the superior maxilla, near the anterior margin of the lachrymal groove; 3rd, to the nasal process of the frontal bone. The fibres of the orbicularis muscle thus arising arch upwards and outwards in the direction of the eye-brow and upper lid, and thence descend over the external angle of the orbit, returning to the points above stated. The anterior surface of the muscle is subcutaneous in its entire extent, and closely adheres to the skin; the posterior rests upon the lower border of the frontal muscle and the corrugator, with both of which it is intimately connected; farther down it rests upon the upper eye-lid and the tarsal cartilage. The lower segment of the muscle rests on the origin of the elevator of the upper lip, and on the zygomatic muscles; and internally, on part of the common elevator of the lip and nose, and the lachrymal sac; also externally for a little way on the temporal fascia.

their direction.

Parts in contact.

Difference in character of fibres, and division of muscle in consequence.

The fibres of the orbicularis are thin and pale where they correspond with the eye-lids; they are also less curved; but those which rest on the cheek and margin of the orbit are well developed. These parts have been described as two muscles; the former being named "ciliaris," the latter "orbicularis latus."*

Corrug. supercil., its position.

The *corrugator supercilii* (fronto-superciliaris) is a small pyramidal muscle, placed in the eye-brow, whose direction it takes, being altogether concealed by the orbicularis palpebrarum and occipito-frontalis. It arises from the inner extremity of the superciliary ridge of the frontal bone, from which its fibres proceed outwards and a little upwards, and end at the middle of the orbital arch, by becoming blended with those of the orbicularis and occipito-frontalis lying between them and the bone. Its

---

* This division is mentioned by Riolanus as usual among the anatomical writers of his time.—"Anthropologia," lib. 5, cap. 10.

Attach. to bone.

anterior surface is covered by the muscles just named; the posterior rests upon the frontal bone and crosses the frontal branch of the ophthalmic nerve and the accompanying artery as they emerge from the orbit; its inner extremity is somewhat thicker than the external one, which gradually narrows to a point.

Lev. palpeb.; in orbit and lid; insert. to super. tars. cartilage.

Levator palpebræ (fig. 101,[1]) (orbito-palpebralis).—This slender muscle is concealed, in the greater part of its extent, within the orbit; it arises above and before the margin of the optic foramen, from which it passes forwards and outwards, mounting over the globe of the eye, and separated from the roof of the orbit only by the fourth and frontal nerves. It is very narrow and tendinous at its origin; it soon becomes fleshy and widens; finally it ends in a broad fibrous expansion, which curves downwards in the substance of the upper eye-lid, to be inserted into the margin of the tarsal cartilage. This muscle lies above the rectus superior and the ball of the eye; and, in the lid, is placed between the orbicularis muscle and the tarsal ligament, which (latter) separates it from the mucous membrane (conjunctiva).

Tens. tarsi.

The *tensor tarsi*—Horner, (musculus sacci lachrymalis,)—is a very thin, small muscle, placed at the inner side of the orbit, resting against the fibrous covering of the lachrymal sac and behind the tendon of the orbicularis. Its fibres arise from the posterior part of the lachrymal bone, and as they pass forwards they divide into two narrow processes; these diverge, cover the lachrymal canals, and become attached to the tarsal cartilages near the puncta lachrymalia.

This little muscle has been described as an offset of the ciliaris of both lids, with which the fibres appear to be continuous (Theile, Op. citat.)—It is often indistinct.

Action of corrug. supercil.; of orb. palpebr. Lev. palp. Tens. tarsi.

Actions.—The corrugator muscle being fixed by its inner extremity, draws the eye-brow and eye-lid inwards, and throws the skin into perpendicular lines or folds, as in frowning. The occipito-frontalis will, on the contrary, elevate the brow, and wrinkle the skin transversely; which actions are so frequently repeated by most persons, and so constantly by some of a particular temperament, that the skin is marked permanently by lines in the situations just referred to. The orbicular muscle is the sphincter of the eye-lids. It closes them firmly, and at the same time draws them to the inner angle of the orbit, which is its fixed point of attachment. The levator palpebræ is the direct antagonist of the orbicular muscle; for it raises the upper eye-lid, and uncovers the globe of the eye. The tensor tarsi draws the eye-lids towards the nose, and presses the orifices of the lachrymal ducts closely to the surface of the globe of the eye. It may thus facilitate the entrance of the tears into the ducts, and promote their passage towards the nose.

NASAL REGION.

We here find several muscles as follows:—

Pyramidalis nasi (fig. 97,[3] and 98,[1]) (naso-frontalis) rests on the nasal bone, and appears like a prolongation of the occipito-frontalis, with whose fibres it is intimately connected, as well as with those of the corresponding muscle. It extends from the root of the nose, where its fibres are continuous with the occipito-frontalis, to about half-way down, where it becomes tendinous and unites with the compressor nasi. The two pyramidal muscles diverge as they descend, leaving an angular interval between them, and each terminates in a thin fibrous lamella, which covers the side of the nose. At its outer border the fleshy fibres are connected with those of the orbicularis palpebrarum. It is covered by the common tegument, and rests upon the nasal part of the frontal bone and the os nasi.

Pyr. nasi;

continues fr. frontalis.

Its chief effect seems to be that of giving a fixed point of attachment to the frontal muscle; it also wrinkles the skin at the root of the nose.

The *levator labii superioris alæque nasi* (figs. 97,[5] and 98,[2]) (common elevator of the lip and nose) lies along the side and wing of the nose, extending from the inner margin of the orbit to the upper lip. It *arises* by a pointed process from the upper extremity of the nasal process of the superior maxillary bone, and as it descends separates into two fasciculi; one of these, much smaller than the other, becomes attached to the wing of the nose, whilst the other is prolonged to the upper lip, where it is blended with the orbicular and elevator muscles. It is subcutaneous, except at its origin, where the orbicularis palpebrarum overlaps it a little.

Lev. communis.

Compressor naris (figs. 97,[4] and 98,[3]) (transversalis v. triangularis nasi).—This is a thin, small triangular muscle, which lies close upon the superior maxilla and the side of the nose, the direction of its fibres being transverse from without inwards and upwards; it is concealed at its origin by the proper elevator of the lip, and is crossed by the common elevator. It *arises* narrow and fleshy from the canine fossa in the superior maxillary bone, from which its fibres proceed inwards and upwards, gradually expanding into a thin aponeurosis, which is partly blended

Compress. naris;

triangular;

transverse.

with that of the corresponding muscle of the opposite side and that of the pyramidalis nasi of the same side, and partly attached to the fibro-cartilage of the nose.

Musculus anomalus.

Beneath the common elevator of the lip and ala of the nose, and connected by the lower end with the origin of the compressor naris, will be found a longitudinal muscular slip, more than an inch in length, attached exclusively to the superior maxillary bone. It was named "rhomboideus" by Santorini, and (in consequence of being attached only to a bone, and having therefore no action,) "anomalus" by Albinus.

Depress. alæ nasi.

The *depressor alæ nasi* is a small flat muscle, lying between the mucous membrane and the muscular structure of the lip, with which its fibres are closely connected. From a depression (myrtiform) near the alveolar border of the superior maxilla the fibres ascend to terminate in the septum and the ala of the nose—the posterior part of each—(fig. 98,[6]). The external fibres curve forwards and downwards to the ala.

Besides the muscles above described there are other muscular fibres which cover the small cartilages of the nose. They are usually very indistinct, partly in consequence of the close connexion of the skin and cartilages of the nose, between which they lie, and the necessary removal of a portion of the short fibres when the skin to which they are attached is cut away. The muscular fibres admit of being divided into two distinct parts, as follows:—

Fig. 98.*

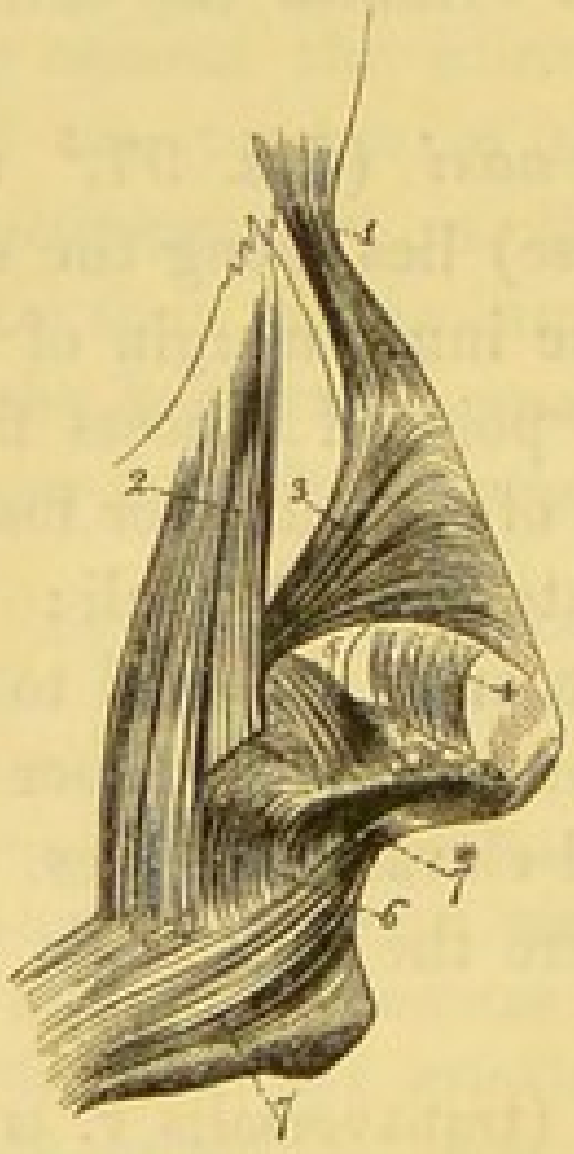

Lev. alæ nasi propr. poster.;

Levator proprius alæ nasi posterior (dilatator naris poster.) (fig. 98,[5]).—After the careful removal of the common elevator of the nose and lip, this muscle will be apparent often to the naked eye, but always with the aid of a lens. (Theile.)—Its fibres are

---

* Represents the muscles of the nasal region, with some of those of the lip. 1. Pyramidalis nasi. 2. Levator labii superioris alæque nasi. 3. Compressor naris. 4. Levator proprius alæ nasi anterior. 5. Levator proprius alæ nasi posterior. 6. Depressor alæ nasi. 7. Orbicularis. 7*. Naso-labialis.

attached to the margin of the mounting process of the superior maxillary bone and the smaller (sesamoid) cartilages of the ala nasi on the one hand, and to the skin on the other.—The anterior set of fibres (*lev. propr. alæ nasi anterior* v. dilatator naris anterior) (fig. 98,[4]) are interposed between the cartilage of the ala and the skin, to both of which they are attached.*

and anterior.

SUPERIOR MAXILLARY REGION.

Here are four muscles, viz. the elevator of the upper lip, the elevator of the angle of the mouth, and the two zygomatici.

Lev. labii super.;

The *levator labii superioris* (fig. 97,[6]) (the proper elevator of the upper lip) extends from the lower border of the orbit to the upper lip, lying close to the outer border of the common elevator, with which and the smaller zygomatic muscle it is blended inferiorly. It *arises* immediately above the infra-orbital foramen, where its fibres are attached, partly to the superior maxillary bone, partly to the malar. Its direction is downwards and a little inwards, ceasing at the upper lip, where it unites with the rest of the muscular apparatus of that part. At its origin, this muscle is overlapped by the orbicularis palpebrarum, but its lower part is subcutaneous; it partly conceals the levator anguli oris, and the compressor nasi.

origin covers infra-orb. foram.

Lev. ang. oris separ. from lev. labii by infra-orb. nerves and vessels.

Levator anguli oris (fig. 97,[7]) (musculus caninus).—The elevator of the angle of the mouth lies beneath the preceding, and partly concealed by it. It *arises* immediately below the infra-orbital foramen, from the canine fossa, whence the name *caninus*, and is inserted into the angle of the mouth. It is broader above than below, and inclines outwards somewhat as it descends; it lies at the middle of the face, deeply behind the outer border of the elevator of the upper lip, escaping from under it at the lower end, in consequence of the different direction of the two muscles. Its anterior surface supports the

---

* The muscular structure here described, or a great part of it, has been described and delineated under the name "pinnæ dilatator" by Santorini.—(Obs. Anat. cap. 1, § 14, and tab. 1.) But in recent observations two separate muscles (noticed in the text) have been recognised by Professor Theile, in the new ed. of "Sömmerring v. Baue d. menschlich. Körpers." M. Arnold (Tab. Anat. fascic. 2, tab. 8, figs. 6 and 7) apparently connects the posterior muscle with the depressor alæ nasi, describing both as one large "dilatator."

infra-orbital nerve and artery, which separate it from the preceding muscle; the posterior lies on the superior maxilla and on the orbicularis and buccinator muscles, with which and the depressor anguli oris its fibres become united.

The *zygomatici* are two narrow fasciculi of muscular fibres, extended obliquely from the most prominent point of the cheek to the angle of the mouth, one being larger and longer than the other.—*Zygomaticus minor* (fig. 97, [8]). This irregular little muscle *arises* from the anterior and inferior part of the malar bone, and inclines downwards and forwards to terminate by joining with the outer margin of the levator labii superioris; the junction sometimes occurring close to the origin of the zygomaticus minor. It lies internally to the succeeding muscle, but distinct from it in the whole length, and is sometimes joined by some fibres of the orbicularis palpebrarum; or its place may be taken by a muscular slip from this muscle. It may be altogether wanting. —The *zygomaticus major*[9] arises from the malar bone near the zygomatic suture, from which it descends, lying inferior and external to the smaller muscle of the same name, to the angle of the mouth, where it is continued into the orbicularis and depressor anguli oris. These muscles, at their origin, are concealed a little by the orbicularis palpebrarum, but become subcutaneous in the rest of their extent. The larger one crosses, just below its origin, a part of the masseter and buccinator muscles.

Zygom. minor joins lev. labii;

connexion w. orb. palp.

Zygom. maj.

INFERIOR MAXILLARY REGION.

This space contains three muscles, viz. the depressor of the angle of the mouth, the depressor of the lower lip, and the elevator of the lower lip.

Depressor anguli oris (fig. 97,[10]) (triangularis oris; maxillo-labialis).—This muscle lies at the side and lower part of the face, being extended to the angle of the mouth from the lower jaw. It arises from the external surface of the inferior maxillary bone, particularly from the oblique line which is marked upon it. It is triangular in form; the base of the triangle corresponding with its origin, and its apex with its insertion into the angle of the mouth. Its fibres pass upwards, gradually contracting so as to form a narrow process, which is inserted into the angle of the mouth, by becoming blended with the orbicular and great zygo-

Depress. ang. oris;

triangular.

matic muscles, and also with the termination of the levator anguli oris. It is covered by the skin, and, at its insertion, by the zygomaticus major, under which its fibres pass; it conceals part of the buccinator and of the depressor of the lower lip.

Depress. lab. infer. square.

Depressor labii inferioris (fig. 97, [11]) (quadratus menti; mento-labialis).—A small square muscle, lying nearer to the symphysis of the chin than the preceding muscle, by which it is partly concealed; it *arises* from the fore part of the inferior maxillary bone, and thence ascends to be inserted into the lower lip, its fibres becoming blended with those of the orbicularis oris, and also having previously united with those of its fellow of the opposite side. It has mixed up with it some of the fibres of the platysma, and it presents rather a peculiar appearance when dissected, owing to a quantity of yellow adipose matter being deposited in the interstices of its fibres.

Lev. menti.

Levator menti (elevator labii inferioris proprius — Cowper) (fig. 97, [12]) arises from a slight pit a little below the alveolar border of the lower jaw, near the symphysis. This pair of muscles occupies the interval between the two depressors of the lower lip. They are small, short, and somewhat tapering, being narrow at their point of origin, from which they increase in breadth towards their insertion. They incline downwards and a little forwards to reach the tegument of the chin, into which they are inserted.

Actions.—The names of most of the muscles included in the three foregoing groups sufficiently indicate their actions upon the lips, the nose, and the mouth. It will be found in conducting their dissection that they are intimately connected with the skin which covers them. Hence they are enabled to give to the face all those changes of state which are necessary for the expression of passion and feeling.

INTER-MAXILLARY REGION.

At each side of the face, in the part called the "cheek," is a muscle—the buccinator, and round the margin of the mouth, one—the orbicularis oris.

Buccinator;

The *buccinator* (fig. 97, [13]) (alveolo-labialis) is a thin flat plane of muscular fibres, quadrilateral in figure, occupying the interval between the jaws. It is attached, by its upper and attach. to maxil. bones and pteryg. maxil. ligt.

lower margins, to the alveolar margins of the maxillary bones, from the first molar tooth in each, as far back as the last; and posteriorly between these bones it is fixed to a narrow fasciculus of tendinous fibres, extended from the internal pterygoid plate to the posterior extremity of the mylo-hyoid ridge of the lower jaw, close to the last dens molaris. From these points the fibres are directed forwards, approaching each other, so that the muscle is narrowed and proportionally thickened near the angle of the mouth. Here it lies beneath the other muscles, and blends with them. The fibres near the middle of the muscle cross each other, those from above entering into the lower lip, and those from below into the upper one; but the higher and lower fibres are directed immediately into the nearest lip.

Fibres cross at angle of mouth.

Parts in contact.

Covered by fascia.

The internal surface of the buccinator is lined throughout by the mucous membrane of the mouth; the external is covered and supported by a thin fascia, which is closely adherent to the muscular fibres, and is overlapped by the triangularis oris, the terminal fibres of the platysma myoides, and by the labial artery and vein; also by the masseter and zygomatici, from which it is separated by a quantity of soft adipose tissue of a peculiar character. Opposite the second dens molaris of the upper jaw its fibres give passage to the duct of the parotid gland.

Duct of parot. gland.

Pter. maxil. lig.;

connected w. buccinr. and pharynx.

The *pterygo-maxillary ligament* (fig. 105,^{2}).—The tendinous band connected with the posterior margin of the muscle has, from its attachments, been thus called; one of its surfaces looks towards the mouth, and is lined by the mucous membrane; the other is separated from the ramus of the jaw by a quantity of adipose substance; the anterior border gives attachment, as has been here stated, to the buccinator muscle, and the posterior, to the superior constrictor of the pharynx. It is this connexion between the muscles just named which establishes a complete continuity of surface between the cavity of the mouth and that of the pharynx.

Risorius;

distinct fr. platysma.

Risorius (Santorini) —By this name is known a small bundle of muscular fibres of varying size and shape, but usually broadest at the outer end, which commences over the masseter, and extends transversely inwards in the fat of the cheek, to join the other muscles of the mouth—usually the depressor anguli oris below the angle of the mouth. It is placed over (superficial to) the platysma where this reaches the face, and crosses its fibres, and for these reasons was described as a separate muscle by Santorini.

Orbicularis oris (fig. 97,[14]; fig. 98,[7]) (labialis).—It belongs to the class of sphincter muscles, and like them is elliptic in its form, and composed of concentric fibres so placed as to surround the aperture of the mouth, but with this peculiarity, that the fibres are not continued from one lip into the other: if any fibres should be traceable from one lip to the other, they are few and slender. The muscle is flat and thin; its inner surface being in contact with the coronary artery of the lips, labial glands and the mucous membrane; the external with the skin and the fibres of the different muscles which converge towards the margin of the mouth. The longer axis of the ellipse is transverse, so as to correspond with the fissure between the lips; the curves described by the fibres of the upper segment look downwards, and those of the lower one upwards. One border of each segment is free, and corresponds with the red part of the lip; the other is blended with the several muscles which converge to the mouth from different parts of the face. The fibres are continued from these muscles, insomuch that they might be said to be borrowed from them. Orb. oris.

The fibres nearest to its margin continue uninterruptedly from side to side of the mouth; but to the outer part of the muscle (that most remote from the edges of the lips) some special fibres are added. There are two sets of these, connected with the maxillary bones; one set or pair for the upper, the other for the lower lip (four altogether). They are slender and arched, and they resemble one another in a great degree in their arrangement. Thus: the two bands of fibres for the upper lip (*accessorii orbicularis superioris**) arise close together above the alveolar border of the superior maxilla opposite the incisor teeth, and arch outwards, one on each side, to the angles of the mouth, to join with the other muscles.

Those for the lower lip (*accessorii orbicularis inferioris*†) are separated one from the other by a much larger interval than the preceding pair, and rather are accessory to the lower segment of the orbicularis than form a part of it. They are fixed to the lower maxilla, externally to the levatores menti, and arch outwards to the angles of the mouth to join the buccinator and the other muscles.

---

* Secundus fibrarum ordo (Santorini); sur-demi-orbiculaires (Winslow).

† Productores labri inferioris (Santorini); accessores buccinatoris (Courcelles); les accessoires du demi-orbiculaire inferieur (Winslow).

Naso-labialis.

To the superior segment of the orbicularis two small fleshy slips (*naso-labiales*—Alb.) descend, one on each side, from the septum narium (fig. 98,[7]*). As they diverge to the lip, these little muscles leave an interval between them, and at the same place a narrow interspace likewise exists between the accessory or external portion of the orbicularis above described. This small inter-muscular interval corresponds with the groove on the skin beneath the septum narium.

Actions.—The aperture of the mouth is susceptible of considerable dilatation and contraction; the former being effected by the different muscles which converge to it, and which may be compared to retractors drawing with different degrees of obliquity the lips, or their angles, in the direction of their respective points of attachment. The elevators are necessarily placed at the upper part of the face, the depressors in the opposite situation, and the proper retractors on each side; and these are the zygomatici and the buccinators. The buccinators also contract and compress the cheeks ; this power is brought into play when any substance becomes lodged in the interval between them and the jaws. The fibres of the muscles are then elongated and pressed outwards; but, when they begin to act, they form a flat plane, which is pressed inwards, and so forces the substance back into the cavity of the mouth. It is obvious that the orbicular muscle must be the direct antagonist of all those that converge to it. When describing the muscles, we may commence at the lips as a common point of departure, and trace their fibres from thence as they diverge, radiating to their respective attachments.

TEMPORO-MAXILLARY REGION.

This space, extending from the side of the head to the angle of the jaw, contains the temporal and masseter muscles.

Dissection.—To expose the masseter muscle, and with it the duct and the surface of the parotid gland, it will suffice to reflect back the skin from the lines of incision indicated in the previous dissections. In doing this, a large branch of the facial nerve will be found accompanying the parotid duct. This will serve as a clue to the trunk of that nerve, by following it back through the substance of the parotid gland ; and, when the trunk is found, there can be no difficulty in pursuing all its branches, as they diverge from that point in three different directions over the face and side of the head. The superficial temporal vessels are at the same time brought into view. Cut the duct across, raise it and the accompanying piece of the parotid gland together, and draw it out towards the ear. This will expose the anterior margin of the gland and its relations to the ramus of the jaw. A little more dissection is required to get a view of its posterior border, and of its relations to the parts deeply seated between the jaw and the ear.

The next thing to be done is to get at the insertion of the temporal muscle, and at the same time bring into view the pterygo-maxillary region: proceed as follows:—

The masseter muscle and parotid gland having been examined, the parts concealed inside the ramus of the jaw may be brought into view in the following way:—With a sharp chisel and mallet the zygoma may be divided at both extremities, and the attachment of the temporal fascia to its upper border severed. The bony arch, with the masseter still connected with it, may be drawn down to the angle of the jaw, the fibres of the latter being at the same time detached from the ramus. In the next place, with Hey's saw, the ramus of the jaw may be divided by a perpendicular cut, carried from just before its condyle to a level with the alveolar border, and there met by another line carried forwards to the latter, so as to insulate and detach all that part of it which belongs to the coronoid process. This being done, the piece of bone, with the temporal muscle attached, may be drawn upwards, so as fully to expose the two pterygoid muscles (*pterygo-maxillary region*), the internal maxillary artery, the gustatory and dental nerves, and the pterygo-maxillary ligament, which gives attachment to the buccinator and superior constrictor muscles.

Masseter. Position and direction.

The *masseter* (fig. 97,[15]) (zygomato-maxillaris) is extended from the malar bone and the zygomatic process of the temporal to the angle of the lower jaw. Its form is that of an oblong square; its direction downwards and a little backwards. It is a thick, compressed mass of fleshy and tendinous fibres, arranged so as to form two bundles, differing in size and direction.

Two parts; external, its tendon;

The *external*, or larger portion of the muscle, arises chiefly by thick tendinous structures (which afford a large surface for the origin of muscular fibres) from the lower border of the malar bone, and somewhat from the malar tuberosity of the superior maxilla, from which its fibres proceed downwards, and a little backwards, to be inserted into the lower half of the ramus of the jaw, extending as far as its angle. The *internal*, or smaller part, is, for the most part, vertical in direction (some fibres inclining a little forwards), and, therefore, crosses the larger portion. Consisting chiefly of fleshy fibres, it arises from the lower border of the zygomatic process of the temporal bone (reaching as far back as its tubercle), and is inserted into the upper half of the ramus of the jaw. This part of the muscle is concealed, in the greater part of its extent, by the larger portion, with which its fibres become united at their insertion; part, however, projects behind it, and is covered by the parotid gland.

internal crosses former.

Structures in contact.

The external surface of the masseter muscle is covered, for the most part, only by the skin and fascia; it is, however, overlapped above by the zygomaticus, below by the platysma, and behind by the parotid gland, whose duct also crosses it; the branches of the facial nerve and the transversalis faciei artery also rest upon it. Its inner surface overlays the buccinator, from which it is separated by some soft adipose tissue; also the tendinous insertion of the temporal muscle into the coronoid process; it is in intimate contact with the ramus of the jaw, and receives a nerve and artery which come from within over the sigmoid notch of the bone.

Temporal.

Position, size and shape.

The *temporal* muscle (temporalis; temporo-maxillaris; crotaphite — Winslow) is placed at the side of the head, occupying the whole extent of the temporal fossa; it is of considerable size, being broad, thin, and expanded above, where it is attached to the side of the skull, but it becomes thick, compressed, and narrowed to a point below, at its insertion. The fibres of the muscle present a radiating appearance; they are concealed from view by the temporal fascia, which must be removed before they can be seen.

Origin; from temp. fossa and fascia.

It *arises* from the whole of the temporal fossa, its fibres being implanted into all that depressed surface which extends from the external angular process of the frontal bone backwards to the root of the mastoid process, and from the curved line marked upon the parietal and frontal bones downwards to the ridge on the sphenoid bone which separates the temporal fossa from the zygomatic; it likewise takes origin from the inner surface of the temporal fascia. The fibres from this extensive origin converge as they descend, some being directed from before backwards, a considerable number obliquely forwards, whilst those in the middle descend almost vertically; but all terminate in a tendon whose fibres, at first radiating like those of the muscle itself, gradually become aggregated, so as to form a thick flat fasciculus, which is implanted into the inner surface as well as the anterior border of the coronoid process of the lower jaw-bone.

Insertion.

Tendon.

The upper part of this tendon is in a great degree concealed by the muscular fibres, many of which descend to be implanted into its external surface, whilst the deep-seated fibres come forward from the lower part of the fossa to be attached to its inner surface; the lower part, or insertion of the tendon, is altogether concealed by the zygoma and the masseter.

Between the muscle and the temporal fossa are the deep temporal arteries and the temporal nerves which penetrate its substance.

Temporal fascia;

The *temporal fascia* by which the muscle is covered and bound down is a remarkably dense firm membrane. It is attached inferiorly to the upper margin of the zygoma, where it is separated from the muscle by some loose adipose and cellular tissue; but higher up, the fascia expands, and becomes closely connected with the muscular fibres, and is attached along the curved line bounding the temporal fossa, where it gives origin to many of the superficial fibres of the muscle. The external surface of the fascia is overlaid by the aponeurosis of the occipito-frontalis muscle, by the orbicularis palpebrarum; moreover, two muscles of the ear—the superior and anterior—rest upon it, and the temporal artery and vein, with the ascending branches of the facial nerve, cross it as they pass up towards the arch of the skull.

its connexion w. bone and the muscle;

with other parts.

PTERYGO-MAXILLARY REGION.

Fig. 99.*

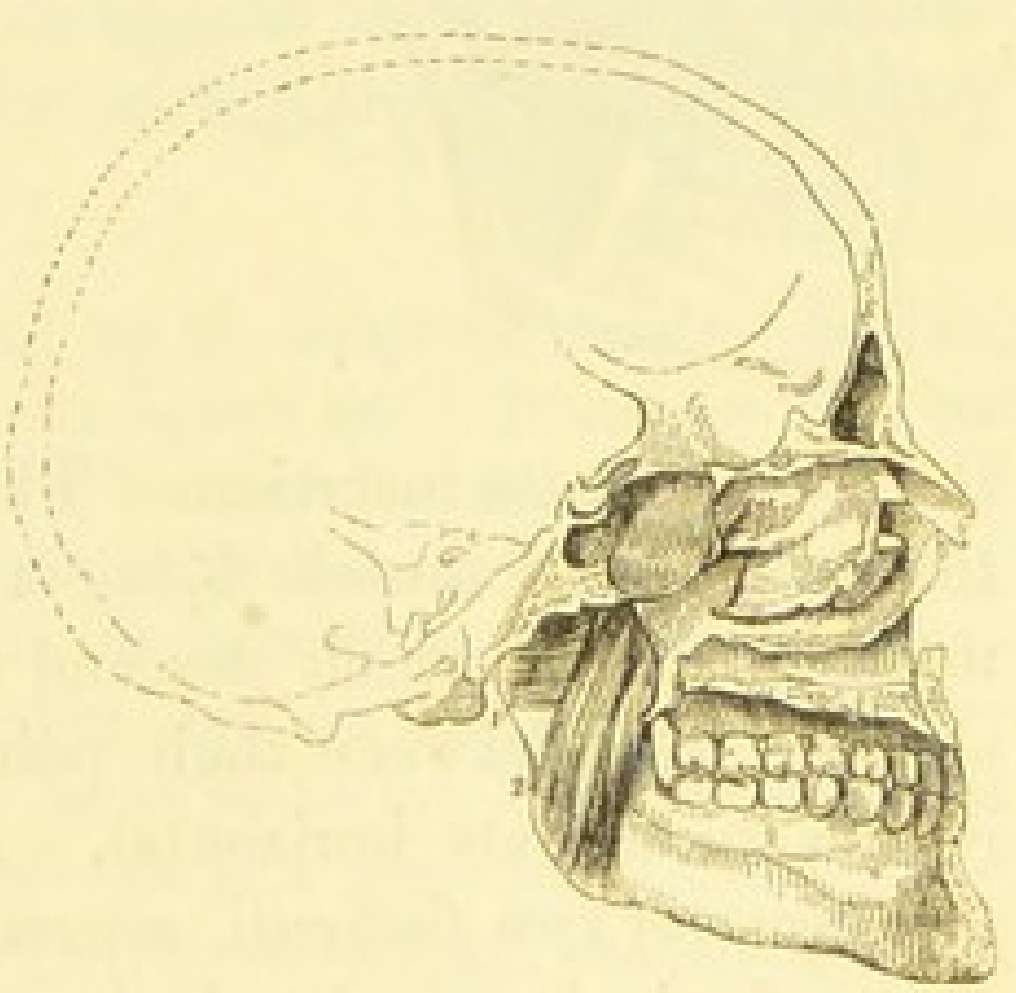

Intern. pteryg.;

intern. to ramus of maxilla.

The *internal pterygoid* muscle (fig. 99,[2] and 100,[2]) (pterygoideus internus; pterygo-maxillaris major) is directed to the inner surface of the ramus of the jaw, somewhat as the masseter is to its outside; but it differs widely from that muscle in the extent of connexion with the bone. It is flat and elongated; its form, like that of the masseter, being an oblong square. It *arises* from the pterygoid groove, or fossa, its fibres, tendinous and fleshy, being attached to the inner surface of the external pterygoid plate of the sphenoid

Origin.

---

* A vertical section having been made through the skull and face, a little to the left of the middle line, the two pterygoid muscles are seen on the inner surface. 1. The posterior extremity of the external pterygoid muscle. 2. Internal pterygoid, which is exposed in nearly its whole length.

Direction and insertion.

bone, and to the grooved surface in the tuberosity of the palate bone which is inserted between the pterygoid plates. From these points of attachment the muscle inclines downwards with an inclination backwards, and outwards, to be inserted into the inner surface of the ramus of the jaw, for about an inch above its angle.

Adjoining structures.

The external surface of the muscle above the place of its insertion is separated from the ramus of the maxilla by the internal lateral ligament, and by the internal maxillary artery, dental artery and nerve; and at its upper part is crossed by the external pterygoid muscle. Its inner surface, whilst placed in the pterygoid groove, is in contact with the tensor palati muscle, and lower down with the superior constrictor of the pharynx.

Fig. 100.*

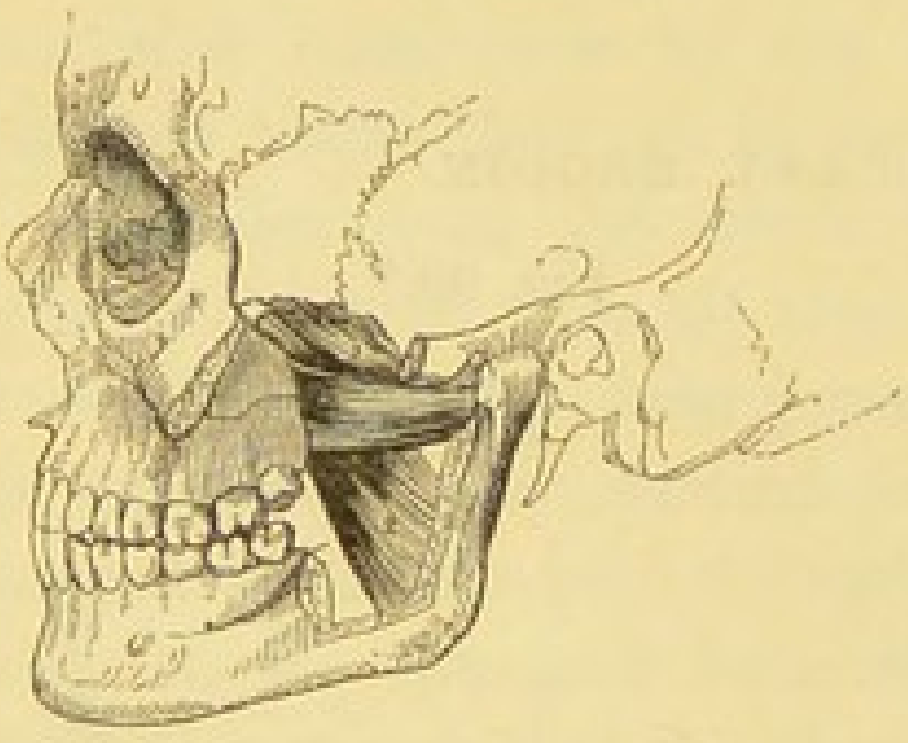

External pterygoid;

deep situation;

is horizontal,

and triangular.

Origin; (two parts.)

The *external pterygoid* muscle (figs. 99^1; 100^1) (pterygoideus externus; pterygo-maxillaris minor) is placed deeply in the zygomatic fossa, extending horizontally backwards and outwards from the process of that name to the condyle of the lower jaw. Its form is somewhat triangular, its base corresponding with its origin, and the apex with its insertion. The two extremities are tendinous, the rest of the muscle being a short, thick, fleshy mass, the upper fibres of which descend a little, and the lower ascend as they pass between their points of attachment, whilst those in the middle are horizontal. At its base the muscle appears to consist of two fasciculi, separated by a cellular interval; the upper fasciculus is attached to that part of the external surface of the great wing of the sphenoid bone which is near the root of the pterygoid process, including the ridge separating the temporal and the zygomatic fossæ; the other (the

---

* The outer side of the bones of the face, and a part of the skull, with the two pterygoid muscles. These parts have been brought into view by the removal of the zygoma, and a large portion of the ramus of the lower maxilla, together with the masseter and temporal muscles, and some other structures. 1. External; and 2. Internal pterygoid.

larger part) is attached to the outer surface of the external pterygoid plate, and to a small part of the tuberosity of the palate bone. It is inserted into the fore part of the neck of the condyle of the lower jaw, and also into its inter-articular fibro-cartilage.

Parts which cover the muscle.

This muscle, from its position in the zygomatic fossa, is concealed by the coronoid process of the jaw, and the insertion of the temporal muscle; but when the masseter is removed, part of it can be seen between that process and the condyle. Its external surface is crossed by the internal maxillary artery and the tendon of the temporal muscle as it passes to the coronoid process, and is further covered by the masseter; the inner surface rests against the upper part of the internal pterygoid muscle, whose direction it crosses, also the internal lateral ligament of the lower jaw, and the inferior maxillary nerve and middle meningeal artery; the upper border is in contact with the great wing of the sphenoid bone, where it forms part of the zygomatic fossa, and is crossed by the temporal and masseteric nerves. As the pterygoid muscles diverge to their destinations, they leave between them an angular interval, which transmits the gustatory and dental nerves, and the internal maxillary artery.

Those in contact with it.

Actions.—The lower jaw is elevated by the temporal, masseter, and internal pterygoid muscles, which conspire to this end. If the two first act together, the elevation is direct; but if the two last act, the obliquity of their direction enables them to carry the angle of the jaw a little forwards. The triturating movement is performed exclusively by the external pterygoid muscles. If both act together, they draw the condyles, and therefore the whole jaw, directly forwards, so as to make the lower teeth project beyond the upper; but when only one acts at a given time, it draws the corresponding condyle forwards, the other remaining fixed, and so makes the symphysis of the jaw deviate to the opposite side. A similar movement can be given by the corresponding muscle, and the alternation of these horizontal motions constitutes trituration.

ORBITAL REGION.

In the orbit, in connexion with the eye, and its appendages, eight muscles are enclosed, viz. the levator palpebræ, and tensor tarsi, together with six muscles of the eye-ball, namely, four recti and two oblique.

Dissection.—It is here taken for granted that the arch of the skull has been previously removed in order to dissect the brain. Now, to gain a clear view of the contents of the orbit, it is necessary to remove the greater part of its roof, and the whole of its outer wall. With this intent the malar bone may be sawed through on a level with the floor of the orbit, and as far back as the spheno-maxillary fissure. The orbital plate of the frontal should in the next place be cut through with a chisel along its inner third, and back to the anterior clinoid process; this incision should be continued along the floor of the middle fossa of the skull, close to the outside of the foramen rotundum and ovale, and thence back to the pars petrosa, so as to cut through the great wing of the sphenoid bone and the squamous part of the temporal bone. When this has been done, the whole may be pressed down and detached, by cutting along the base of the skull, from within outwards, the knife being inserted into the fissure thus made. These measures should first be considered, and marked out on the dried skull. A complete lateral view is thus obtained of the divisions of the fifth nerve, of all those in the cavernous sinus, as well as of the parts in the orbit.

Puncture the optic nerve with a coarse needle near the globe of the eye, and push it on into the latter, so as to make a free passage into it, through which you may convey a curved blow-pipe, and with a little air distend the globe; ligature the extremity of the nerve to prevent the air from escaping. Draw the eye-lids forward, fill them with a little cotton, and apply a few points of suture along their margins. The eye-lids and the globe can now be drawn gently forward, which will put all the muscles on the stretch; and their dissection merely consists in taking out cautiously the fat which fills the orbit.

Recti; their position. Each also named from its action.

Fig. 101.*

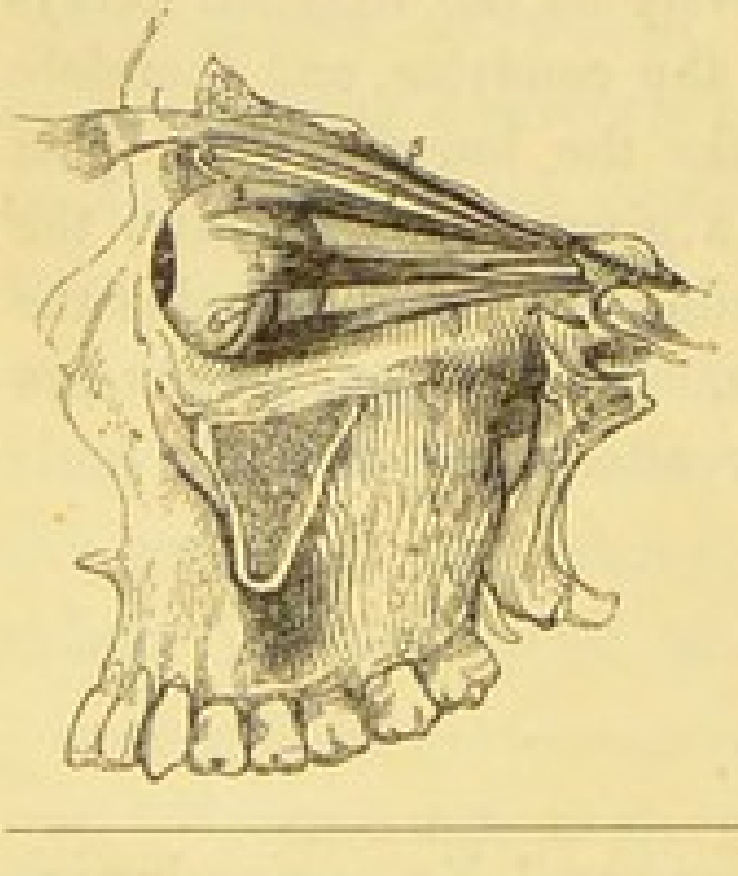

The four recti muscles of the eye at their origin surround the optic nerve, and at their insertion correspond with the opposite points of the globe of the eye; each of them has a double name, one being founded on its situation, the other on its action, as follows: viz. rectus superior vel attollens; rectus inferior v. depressor; rectus internus v. adductor; and rectus externus v. abductor.

Super. rectus.

The *superior rectus* (fig. 101,[2]) arises close by the foramen opticum,

---

[*] The superior maxillary bone, with the orbit opened on the outer side to show the eye with its muscles. 1. Levator palpebræ. 2, 3, 4. Superior, inferior, and external recti. 5. Superior oblique represented by a white line. 6. Inferior oblique.

and beneath the levator palpebræ[1]; it curves over the globe, and is inserted tendinous into the anterior part of the sclerotica.

The *inferior rectus*[3], *internal rectus*, and *external rectus*[4], all arise by a common tendon, which is attached to the bony lamella that separates the foramen opticum from the sphenoidal fissure; but the external rectus has another attachment besides that of the common tendon. Its second head arises from the margin of the sphenoidal fissure, near the superior rectus. Between these heads is a narrow interval, which gives transmission to the third and sixth nerves and the nasal branch of the fifth. The four recti, thus attached posteriorly, pass forwards diverging, and, after curving over the middle of the globe of the eye (to which they present a flattened surface) in the position implied by their names respectively, are inserted by short tendinous fibres into the fore part of its sclerotic coat at an average distance of four lines from the margin of the cornea.

Three other recti arise by common tendon.

Two heads of the external; nerves between.

Insertion of recti.

In length and breadth there are some differences among these muscles. The external rectus exceeds the internal one in length. On the other hand, the latter (internal rectus) has some advantage in width, being broader than any, and the superior one appears slightly the narrowest of all.

Differences in length and breadth.

The *superior oblique* (obliquus superior v. major; trochlearis —Cowper) is placed at the upper and inner part of the orbit, internally to the levator palpebræ. It arises about a line from the optic foramen at its upper and inner part. From thence, this long slender muscle proceeds towards the internal angular process, and terminates in a round tendon, which passes through a fibro-cartilaginous ring, or pulley (trochlea) attached to a depression on the frontal bone at the inner margin of the orbit. To facilitate movement, a delicate synovial sheath lines the contiguous surfaces of the pulley and the tendon, and they are covered over by a loose cellular or cellulo-fibrous membrane. At this point the tendon is reflected outwards and backwards, passing between the globe and the superior rectus, to be inserted into the sclerotica, midway between the superior and external recti muscles, and nearly equi-distant from the cornea and the entrance of the optic nerve.—This muscle is covered by the roof of the orbit, the fourth nerve entering

Super. obliq.

The trochlea.

Change of direction.

Insertion.

its upper surface, and beneath it lie the nasal nerve and the internal rectus muscle.

Infer. obliq. at front of orbit;

The *inferior oblique* (obliquus inferior) is the only muscle of the eye which does not take origin at the bottom of the orbit. It arises from a minute depression in the orbital plate of the superior maxillary bone just within the inferior margin of the orbit and close by the external border of the lachrymal groove. The muscle inclines outwards and backwards between the inferior rectus and the floor of the orbit, and ends in a tendinous expansion, which passes between the external rectus and the globe to be inserted into the sclerotica, at its external and posterior aspect.

oblique direction and insertion.

Other muscles in orbit.

Besides the six muscles here described as the special motors of the globe of the eye, two others are found within the orbit, and have been already described with the muscles of the eyelids, to which they belong, viz. the levator palpebræ and tensor tarsi (page 248).

Action of recti.

Actions.—The four straight muscles are attached in such a way at opposite points of the circumference of the globe of the eye, that, when the parts are viewed together in their natural position, the muscles with the globe represent a pyramid, whose summit is at the optic foramen, and base at the points of insertion. Now, as these points are anterior to the transverse diameter of the globe, and as each muscle, to reach its insertion, curves over the convexity of the eye, it will be obvious that, when in action, their effect must be to turn or rotate the globe, so that the cornea will be directed by them either upwards or downwards, outwards or inwards, as their names severally express. This will be better seen if a needle be inserted into the middle of the cornea, and each muscle be pulled by holding it with a pair of forceps near its origin. If any two recti act together, the cornea will be turned to a point intermediate between those to which they direct it separately. Thus the superior and external recti acting together turn the cornea upwards and outwards, the inferior and internal recti downwards and inwards. By this succession, combination, and alternation of action, the recti are enabled to direct the eye with the minutest precision to every point in the field of view. Sir E. Home attributes to them also the power of compressing the globe so as to lengthen its antero-posterior diameter, thereby becoming the principal means of its adjustment to seeing at different distances.

Of obliqui.

What is the action of the obliqui ? They were at one time supposed to serve as antagonists to the recti, and to draw forward the globe of the eye, after it had been retracted into the orbit by the latter muscles. This cannot be the case ; for they exist in animals in which the globe cannot be retracted, and they receive no increase of developement in those which possess

Involuntary movements of eye-ball.

a large retractor muscle in addition to the recti. The obliqui were considered by Sir Charles Bell to perform all the involuntary and revolving movements; the recti all those which are governed by the will. When volition is suspended in sleep, or during coma, the cornea is observed to be turned upwards under the upper eye-lid; and when the lid descends, as in winking, the globes revolve upwards at the same time, and for a special purpose. When the eye-lid descends like a curtain over the globe, it brings down any extraneous matters which may have lodged upon it. These would necessarily be collected into a line across the centre of the cornea and obstruct vision; but, by the revolving motion, the cornea is carried upwards as the lid descends, and all extraneous matters are brushed away.

Objection to that view.

The opinion above noticed that the oblique muscles preside over the involuntary movements of the eye seems to have been suggested by a theory concerning the influence of the fourth nerve, which is distributed to the superior one. And it is liable to the objection (among others) that, supposing the view respecting that nerve to be correct, there is no more reason for attributing involuntary movements to the inferior oblique than to the recti, which receive nerves from the same source. On the whole, it appears most probable that these muscles produce the revolving movements which have been described, and little more, and that they may with Dr. Jacob be regarded as "rotatory muscles," their office being, when acting together, to revolve the eye "round a longitudinal axis, directed from the open [the anterior part] of the orbit to its bottom."* But, supposing them to act singly, the axis would, in all probability, be slightly altered during the rotation. So that under the influence of the superior muscle alone, while the eye-ball was rotated, the pupil would at the same time be directed to the outer and lower side of the orbit; and, during the action of the inferior oblique, the rotatory movement of the eye would be attended with an inclination of the pupil upwards and inwards.

Are rotators of the eye;

and slightly alter its axis.

MUSCLES OF THE NECK.

The muscles of the neck are numerous, and at first sight appear to be rather complex in their distribution. They may be grouped into sets as follows:—

1. The muscles placed along the side of the neck being, at least comparatively, superficial, viz. the platysma myoides, and sterno-mastoideus	Superficial region.
2. Those placed obliquely at the upper part of the neck, viz. digastricus, stylo-hyoideus, stylo-glossus, stylo-pharyngeus	Sub-maxillary region.

---

* "On Paralytic, Neuralgic, and other Nervous Diseases of the Eye. By Arthur Jacob, M.D." In Dublin Med. Press. 1841.

3. Muscles placed towards the fore part, and above the os hyoides, viz. mylo-hyoideus, genio-hyoideus, hyo-glossus, genio-hyo-glossus, and lingualis . .	Genio-hyoid region.
4. The muscles placed in front, lying beneath the os hyoides, viz. sterno-hyoideus, sterno-thyroideus, thyro-hyoideus, crico-thyroideus, and omo-hyoideus .	Sterno-hyoid region.
5. Those placed deeply at the side and front of the vertebral column, viz. scaleni, rectus lateralis, rectus anticus, major and minor, and longus colli . .	Anterior vertebral region.

All these are in pairs at each side.

Side of neck quadrilateral;

its limits.

Two larger triangular spaces, and their boundaries.

Platysma.

Dissection and general view of the Muscles of the Neck.—The head being allowed to hang over a block placed behind the neck, and the side of the latter being turned forward, we may proceed to examine it as a separate region. In this view it presents itself to our notice as a quadrilateral space, bounded below by the clavicle, above by the margin of the jaw, and a line continued back from it to the mastoid process ; before, by the median line, extended from the chin to the sternum, and behind, by another from the mastoid process to near the external end of the clavicle. Now, the whole space is divided into two triangles by the sterno-mastoid muscle, which runs diagonally through its area. Each of these requires a particular examination ; for in the upper triangle, whose base corresponds with the margin of the jaw, and whose apex lies at the sternum, is lodged the carotid artery ; and in the external and inferior space, the base of which corresponds with the clavicle, the subclavian artery is placed in the situation in which it may be compressed or tied. When *proceeding with the dissection*, two incisions may be made through the skin ; one directed transversely along the base of the lower maxilla to the mastoid process of the temporal bone ; the other in the course of the sterno-mastoid, from the mastoid process to the sternum, so that the angular flap thus marked out may be raised and reflected forwards. By means of an incision made along the clavicle, another flap of skin may be turned backwards, and then the platysma will be exposed in its entire extent ; the direction of its fibres should be carefully considered in reference to the operation of opening the jugular vein. If the point of the lancet be directed upwards and forwards in the course of its fibres, it will merely make a fissure between them, and when withdrawn they will contract and close over the wound in the vein ; so that the operation is rendered ineffectual, and probably an ecchymosis will be produced. But if it be directed upwards and outwards, the fibres will be cut across and retract, so as to expose the vein and the aperture made in it.

Cervical fascia.

Cervical nerves.

The larger anterior triangle;

The platysma being now reflected, the cervical fascia will be fully exposed, particularly if the trapezius be turned back. (See the description with other structures of the same kind.) When the platysma is dissected off the sterno-mastoid, we see lying on it the ascending nerves of the cervical plexus, and passing downwards the descending set. In the area of the internal and superior triangular space, will be found the os hyoides and larynx and the muscles connected with them, together with the submaxillary gland and the large blood-vessels (carotid artery and jugular vein) enclosed with the vagus nerve in a sheath which has over it the nerves coursing to the infra-hyoid muscles. A smaller triangle is recognized within the larger space now described. It is circumscribed by the digastric muscle above, the omo-hyoid below, and the sterno-mastoid externally.

parts in its area.

Smaller triangle.

The external inferior triangular space, which is commonly said to be bounded by the sterno-mastoid, the trapezius, and the clavicle, will be found divided into two parts by the omo-hyoideus passing across it. The upper division contains the cervical nerves and several muscles. The lower and most important (supra-clavicular) part is very small, and is, in general, distinctly triangular. It is bounded by the sterno-mastoid and omo-hyoid as its sides, and the clavicle as its base; and contains the subclavian artery and the brachial nerves, with a part of the anterior scalenus muscle.

External large triangle divided into two parts by omo-hyoid.

SUPERFICIAL CERVICAL REGION.

Two muscles are extended beneath the skin, along the side of the neck : —

The *platysma myoides* (fig. 97,[19]) (latissimus colli,—Alb.; cutaneus; peaucier) is a flat, thin plane of muscular fibres, forming a fleshy membrane, placed immediately beneath the skin of the neck. Its fibres, which are pale and thin in their entire extent, commence in the cellular tissue, covering the upper part of the deltoid and pectoral muscles, and thence proceed upward and inwards over the clavicle, and upon the side of the neck, gradually narrowing and approaching the muscle of the opposite side. They pass over the margin of the inferior maxillary bone; some of them adhere to its external oblique line, becoming blended with the depressores labii inferioris and anguli oris; some incline inwards and mingle with those of the opposite platysma in front of the symphysis of the jaw, and even cross from one side to the other, those of the right side overlapping those of the left; whilst others farther back are prolonged upon the side of the cheek as far as the angle of the mouth, where they become blended with the muscles in that situation. In some subjects, a few fibres may be traced higher up on the face to the zygomatic muscles, or even to the margin of the orbicularis palpebrarum.

Platysma;

attached to infer. maxilla;

blends with muscles;

varies in extent on face.

The platysma is covered by the skin, to which it is connected by cellular tissue, usually called the superficial fascia of

Parts over and under it.

the neck. It covers slightly the pectoralis major, its upper or clavicular portion, as well as the clavicular part of the deltoid, and the clavicle; higher up it lies upon the sterno-mastoid muscle, external jugular vein, the sheath of the great cervical vessels, the submaxillary gland, the labial artery, the body of the jaw-bone and the side of the cheek.

Sterno-mastoid. Direction.

The *sterno-cleido-mastoid* muscle (fig. 102,[1]) is extended, as it were, diagonally across the side of the neck, from the top of the sternum to the mastoid process behind the ear: it is thick and rounded at the middle, so as to be at all times prominent, particularly when in action, but becomes broader and thinner at its extremities. It *arises* from the anterior surface of the sternum and the anterior and upper part of the clavicle, at its inner third, the attachment to the former being by a thick rounded fasciculus composed of tendinous fibres at its cutaneous aspect, the rest being fleshy. The clavicular portion, separated at first from the preceding by a cellular interval, is flat, and in form somewhat triangular; it is composed of fleshy and aponeurotic fibres, which pass perpendicularly upwards, whilst the sternal part inclines backwards as it ascends, so that both become inseparably blended, below the middle of the neck, into a thick rounded muscle,

Origin, in two parts;

interval between.

Fig. 102.*

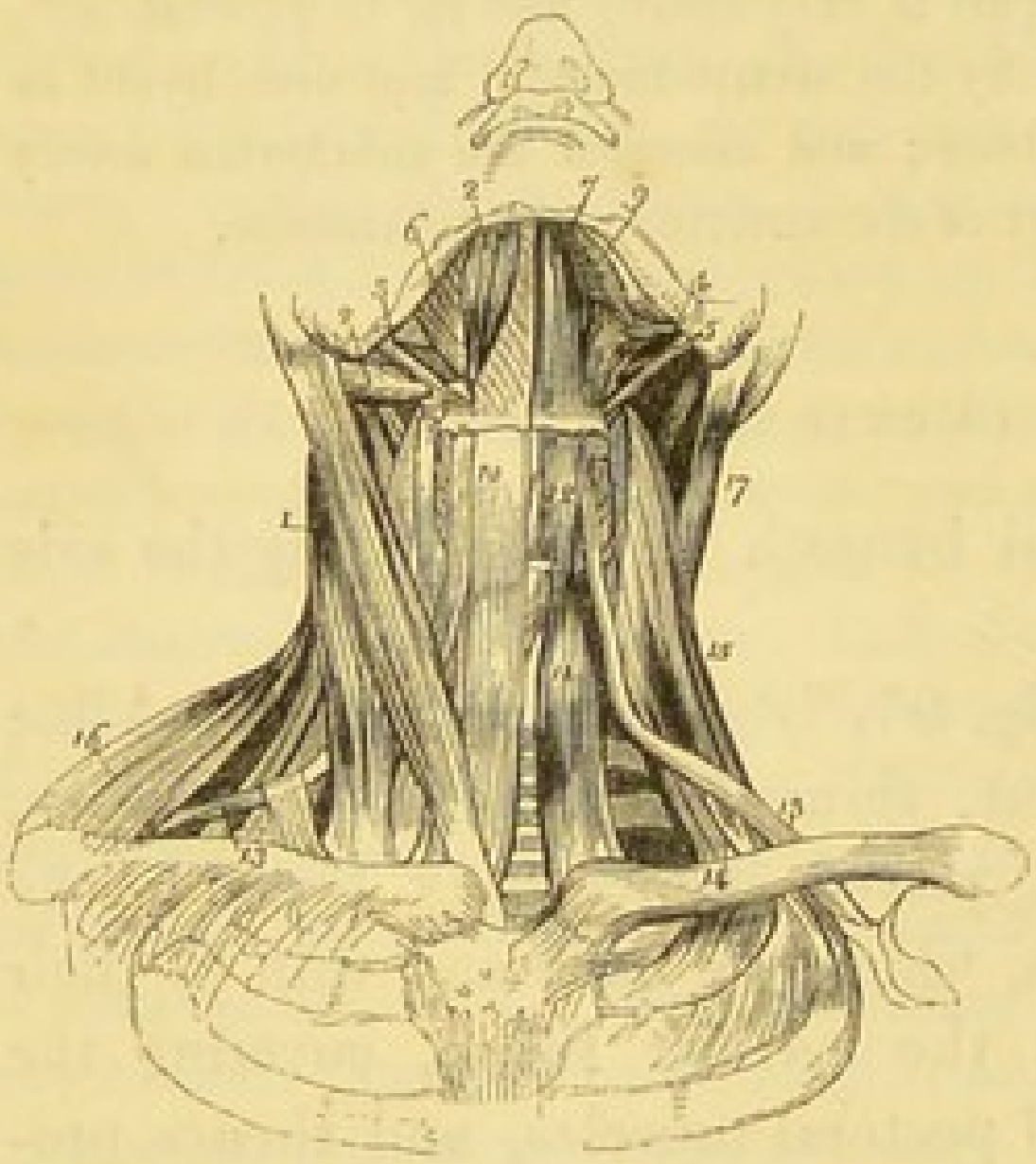

---

* A front view of the muscles of the neck, from the base of the lower maxilla to the sternum and clavicles.—Together with the integuments, fascia, and platysma, (which have been removed from both sides,) the sterno-mastoid, sterno-hyoid, digastric, and mylo-hyoid have been detached on the left side. 1. Sterno-mastoid. 2. Digastric. 3. Stylo-hyoid. 4. Stylo-glossus. 5. Stylo-pharyngeus. 6. Mylo-hyoid. 7. Genio-hyoid. 8. Hyo-glossus. 9. Lingualis. 10. Sterno-hyoid. 11. Sterno-thyroid. 12. Thyro-hyoid. 13. Omo-hyoid. 14. Scalenus anticus. 15. Scalenus posticus. 16. Trapezius. 17. Levator anguli scapulæ.

which is finally inserted into the anterior border and external surface of the mastoid process, and for some way into the rough ridge behind it, by a thin layer of aponeurotic fibres. Insertion.

Parts adjacent. The external surface of the muscle is covered by the platysma in the middle three-fifths of its extent, its upper and lower portions being left uncovered, so that its sternal origin and its insertion are covered only by the fascia and skin; part of the parotid gland overlaps it superiorly. In the middle it is crossed by the external jugular vein, and by the ascending superficial branches of the cervical plexus. It rests on part of the sterno-hyoid and sterno-thyroid muscles, crosses the omo-hyoid muscle, covers the cervical plexus of nerves and great cervical vessels in the lower part of the neck, and in the upper part the digastricus and stylo-hyoideus muscles, and spinal accessory nerve, which pierces it.—Both muscles diverge. The two sterno-cleido-mastoidei are placed closely together at their sternal attachment, whilst their insertions are separated by the whole breadth of the basis of the skull.

Described as two muscles. The sterno-cleido-mastoid has been, and indeed still occasionally is, described in anatomical works as two muscles, under the names sterno-mastoideus and cleido-mastoideus.—It varies in breadth. The muscle varies much in breadth at the lower end, the variation being due altogether to the clavicular part, which in one case may be as narrow as the sternal tendon, while in another it reaches to the extent of three inches along the clavicle. The same part of the muscle may likewise, when broader than usual, be divided into several slips separated by intervals near the clavicle. Connexion with trapez. A band of muscular fibres has, in a few instances, been found reaching from the trapezius to this muscle over the subclavian artery; their corresponding margins (which are usually separated by a considerable but varying interval) have been observed in contact.*—Rectus sternalis. A slender rounded and elongated muscle, of about the length of the sternum, is from time to time to be seen lying parallel with the outer margin of that bone, and over the inner part of the pectoral muscle. It is fleshy in the middle and tendinous at both ends, and one of these (the superior) is attached to the first bone of the sternum, in connexion with the tendon of the sterno-mastoid; the other is usually connected with the aponeurosis covering the rectus abdominis muscle. It is very rarely present on both sides of the same body. The names *rectus sternalis* and sternalis brutorum have been assigned to this "occasional" muscle.

Action of platysma; *Actions.*—The lower part of the *platysma* can exert no action of much

---

* "The Anatomy and Operative Surgery of Arteries," by R. Quain, p. 186, and plate 25.

importance in the human subject. The upper part of the muscle may assist in depressing the angle of the mouth; and when its action is general the skin of the neck becomes slightly creased or wrinkled. When the two *sterno-mastoid* muscles act together, they bow the head forwards; but if one acts by itself, it is enabled by the obliquity of its direction to turn the head, and therefore the chin, to the opposite side. It has been said that this muscle can draw the head down to its own side, approximating the ear to the shoulder. But, to effect this, its action must be combined with that of some other muscle, as the splenius; for then, as the latter arises from the spinous processes, whilst the former comes from the sternum, both converging to the mastoid process, the head may, by their combined effort, be drawn down to the point intermediate between their attachments, namely, to the shoulder.

of sterno-mastoid.

SUB-MAXILLARY REGION.

Digastric.

The *digastric* muscle (fig. 102,[2 2]) (digastricus; biventer maxillæ inferioris,—Alb.; mastoido-mentalis) is placed in a curved direction across the upper part of the neck, a little below the margin of the lower maxillary bone. As its name implies, it consists of two fleshy bellies, united by a rounded middle tendon, each of which parts has a separate attachment. The posterior belly, which is longer than the anterior, arises from the digastric groove in the temporal bone and the fore part of the mastoid process: the anterior is inserted into a rough depression at the inside of the lower border of the jaw-bone, close to its symphysis, whilst the tendon is connected with the side of the os hyoides by a dense fascia, and by the fleshy fibres of the stylo-hyoideus muscle[3], through which it (the tendon) passes. The posterior, or sub-mastoid portion, descends inwards and forwards, gradually tapering until it ends in the tendon; the anterior, or sub-mental portion, arising from the tendon, passes upwards and forwards, gradually widening towards its insertion, where it is in contact with the digastricus of the opposite side. Now, as the side of the os hyoides is beneath both points of attachment, and nearly in the middle between them, the fleshy bellies, where they end in the tendon, must form an angle with one another.

Two bellies; their origin, insertion, and middle tendon.

Parts adjacent.

The anterior belly, lying immediately under the fascia, rests on the mylo-hyoideus muscle, and is connected by dense fascia with its fellow of the opposite side; the posterior is covered by the mastoid process and the muscles arising from it, and crosses both carotid arteries and the jugular vein. Its upper margin bounds the sub-maxillary gland. The lower one forms one of the sides of the smaller anterior triangle of the neck.

Stylo-hyoid, its position. The *stylo-hyoid* muscle (stylo-hyoideus) (figs. 102,[3]; 103,[1]) lies close to the posterior belly of the preceding muscle, being a little behind and beneath it. Origin; insertion. It *arises* from the middle of the external surface of the styloid process of the temporal bone, from which it inclines downwards and forwards, to be inserted into the os hyoides at the union of its great cornu with the body. Division for digastr. Its fibres are usually divided into two fasciculi near its insertion, for the transmission of the tendon of the digastricus.

Parts in contact. Its upper part lies deeply, being covered by the sterno-mastoid and digastric muscles, and by part of the parotid gland: the middle crosses the carotid arteries; the insertion is comparatively superficial.

This muscle is sometimes wanting; occasionally a second is present (stylo-hyoideus alter,—Alb.) The position too may be altered—it has been found beneath the external carotid artery instead of over that vessel.*

Stylo-gloss. The *stylo-glossus* (figs. 102,[4]; 103,[2]) lies higher up, and is also shorter than any of the three muscles which arise from the styloid process. Its direction is forwards and a little downwards, so that it becomes nearly horizontal. Origin. It *arises* from the styloid process near its point, and from the stylo-maxillary ligament, to which, in some cases, the greater number of its fibres are attached by a thin aponeurosis, and Insertion. is inserted along the side of the tongue, its fibres expanding somewhat as they become blended with its substance; they overlay those of the hyoglossus muscle, (the fibres of the two slightly decussating,) and a few are continued forwards into the lingualis.

Parts in contact. This muscle lies very deeply beneath the parotid gland, and between the external and internal carotid arteries.—It occasionally is seen to arise from the inner side of the angle of the lower maxilla, and cases have been observed in which it was altogether absent.

Stylo-phar. *Stylo-pharyngeus* (figs. 102,[5]; 103,[3]).—This is larger and longer than the other styloid muscles, and also more deeply

---

* The work on Arteries, above referred to, plate 12, fig. 5.

seated; it extends from the styloid process downwards, along the side of the pharynx, slender and round at the upper part. Origin. It *arises* from the inner surface of the styloid process, near its root, from which it proceeds, downwards and inwards to the Passes under constrictor. side of the pharynx, where it passes under cover of the middle constrictor muscle, and, gradually expanding, it detaches some fibres to the constrictors of the pharynx, and, having joined with Insertion. the palato-pharyngeus, ends in the superior and posterior borders of the thyroid cartilage.

Parts in contact. The external surface of the muscle is, in the upper part of its extent, in contact with the styloid process and stylo-hyoideus muscle and external carotid artery; in the lower, with the middle constrictor of the pharynx. Internally it rests on the internal carotid artery and jugular vein; but more inferiorly it is in contact with the mucous membrane of the pharynx. The glosso-pharyngeal nerve is close to the muscle, and crosses over it in turning forward to the tongue.

Actions.—The *stylo-hyoidei* and *stylo-pharyngei* conspire in elevating the base of the tongue and the bag of the pharynx at the moment when deglutition is taking place, the latter pair of muscles tending at the same time to widen the pharynx. The peculiar mechanism of the *digastric* muscles enables them to contribute to the elevation of the os hyoides also; for when the two fleshy parts contract together, they come nearly into a straight line, and thereby draw up the bone just named, by means of the connexion of the middle tendon of the muscle with its cornu. As a preparatory measure, the mouth must be closed, and the lower jaw fixed, which is one of the first steps in the process of deglutition. If the os hyoides be kept down by the sterno-hyoideus, the anterior belly of the digastricus will serve to depress the lower jaw. The *stylo-glossi* muscles retract the tongue; they also act on its margins, and elevate them; if the genio-hyo-glossi (fig. 103,[7]) come into action at the same time, and draw down its raphé, or middle line, its upper surface will be converted into a groove.

GENIO-HYOID REGION.

Mylo-hyoid, its position. The *mylo-hyoid* muscle (mylo-hyoideus) (fig. 102,[6]) is a flat triangular muscle, placed immediately beneath the anterior belly of the digastric, and extended from the inside of the inferior maxilla to the os hyoides; its base, or broader part, being above, Origin. the apex being below. It *arises* from the mylo-hyoid ridge, along the inner surface of the lower jaw. The posterior fibres incline obliquely forwards as they descend to be inserted into the body of the os hyoides; the rest proceed, with different degrees of obliquity, to join at an angle with those of the corresponding muscle, forming, with them, a sort of raphé along the middle line, from the symphysis of the jaw to the os hyoides. The two join.

Parts in contact. The external surface of the mylo-hyoid muscle (which in the erect position of the head is inferior) is covered by the digastricus and sub-maxillary gland and sub-mental artery; the internal, which looks upwards and inwards to the mouth, conceals the genio-hyoideus and part of the hyo-glossus and stylo-glossus muscles, the ninth and gustatory nerves, and the sub-lingual gland with the duct of the sub-maxillary; its posterior border alone is free and unattached, and behind it the duct of the sub-maxillary gland turns in its passage to the mouth.

Both form floor of mouth. The two muscles of this name, by their junction in front, and by the inclination of the plane which they form, support the mucous membrane of the mouth and the tongue, constituting a muscular floor for that cavity.

Genio-hyoid; position. The *genio-hyoid* muscle (genio-hyoideus) (fig. 102,[7]; fig. 103, [5]) is a narrow muscle, concealed by the preceding, and lying close to the median line. It *arises* from the inside of the symphysis of the chin (its inferior sub-mental tubercle), and thence descends in contact with the corresponding muscle, and increasing a little in breadth, to be *inserted* into the body of the os hyoides. This pair of muscles lies between the mylo-hyoideus and the lower or free border of the genio-hyo-glossus.

Hyo-glossus. The *hyo-glossus* (fig. 102,[8]) is a flat, thin four-sided band of muscular fibres, extended upwards upon the side of the tongue from the lateral portion of the os hyoides. Origin. It *arises* from the whole length of the great cornu of the os hyoides, and from part of the body of that bone, and sometimes derives fibres from the small cornu. From this the muscular fibres incline upwards and outwards, (those from the body of the bone overlapping the others a little,) to be *inserted* into the side of the tongue, Insertion. where they expand, becoming blended with its substance: the direction of this muscle is almost vertically upwards, and that of the stylo-glossus horizontally forwards, so that they decussate upon the side of the tongue.

Parts adjoining. The hyo-glossus muscle is covered by the digastric and mylo-hyoid, and by other structures just mentioned as lying beneath the latter muscle. It covers the genio-hyo-glossus and the origin of the middle constrictor of the pharynx, together with the lingual artery and glosso-pharyngeal nerve.

Was described as three muscles.

Until a comparatively late period, the hyo-glossus was described by anatomists as three muscles; and they were named by Albinus, from the part of the hyoid bone with which they are each connected, basio-glossus, cerato-glossus, and chondro-glossus. The name by which the whole, considered as one muscle, is now usually known, was suggested by Winslow.

Genio-hyo-glossus,

Fig. 103.*

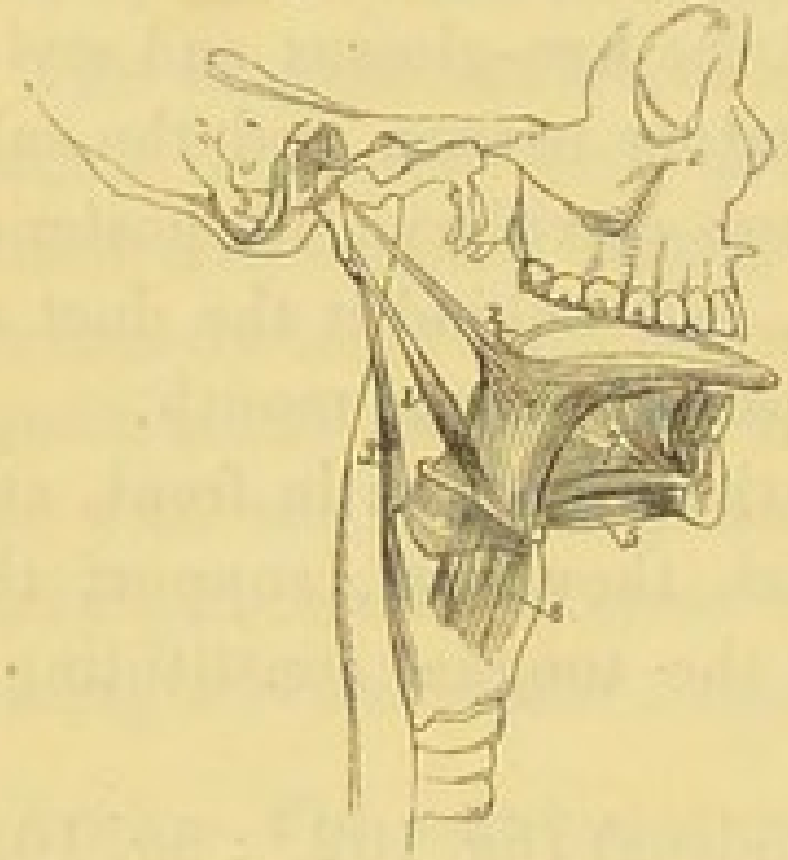

The *genio-hyo-glossus* (fig. 103, 7) is so called from its triple connexion with the chin, os hyoides, and tongue. The muscle forms a flat, triangular plane of fleshy fibres, placed vertically in the median line, the apex of the triangle being represented by its origin from the inside of the symphysis of the lower jaw, the base by its insertion along the whole length of the tongue from its point to its root, for the fibres spread out radiating like the ribs of a fan; one of the sides (the lower one) corresponds with the border which extends from the symphysis to the os hyoides, the other (upper and anterior) with the frænum linguæ. The inner surface is in contact with the corresponding muscle, the external being covered by those last described. It *arises*, by a short tendon, from the superior sub-mental tubercle on the inner side of the symphysis of the chin. To this the fleshy fibres succeed and diverge from one another, the inferior ones passing down to the os hyoides, above which a few are continued into the side of the pharynx; the anterior fibres are directed upwards to the tip of the tongue, and the rest proceed in different directions to the under surface of the tongue, with which they are blended in its entire length from base to apex.

is fan-shaped.

Origin.

---

* A small part of the skull, (including the styloid process of the temporal bone,) the left half of the inferior maxilla, the os hyoides, larynx, and a few rings of the trachea, together with the tongue, and several muscles, as follows: viz. 1. Stylo-hyoid. 2. Stylo-glossus. 3. Stylo-pharyngeus. 5. Genio-hyoid. 7. Genio-hyo-glossus. 8. Thyro-hyoid. The hyo-glossus is clearly seen, but it is not numbered.—This sketch is inaccurate, as regards the points at which the muscles are connected with the styloid process.

The internal surface of the muscle is in contact with that of its fellow, from which it is at first separated towards the posterior part of the tongue by the fibro-cellular structure which runs for some way through the middle of that organ, but both become closely adherent towards their termination. The external surface is in contact with the lingualis, hyo-glossus, and stylo-glossus, the sub-lingual gland, the ranine artery, and the gustatory and motor nerves of the tongue.

—The proper or "intrinsic" lingual muscles will be described with the other structures of the tongue.

Action of supra-hyoid muscles.

Actions.—The muscles that pass from the jaw-bone to the os hyoides are ordinarily employed in elevating the latter, and with it the base of the tongue, more particularly in deglutition. The genio-hyo-glossi, by means of their posterior and inferior fibres, can draw up the os hyoides, at the same time bringing it and the base of the tongue forwards, so as to make its apex protrude beyond the mouth. The anterior fibres will, subsequently, act in retracting the tongue within the mouth. The mylo-hyoidei may be compared to a movable floor or bed, which closes in the inferior and anterior part of the mouth, at the same time serving to sustain the body of the tongue.

STERNO-HYOID REGION.

Sterno-hyoid.

The *sterno-hyoid* (sterno-hyoideus) (fig. 102,[10]) lies at the fore part of the neck, near to the middle line, and in part immediately beneath the skin and fascia, extending from the thoracic surface of the sternum or the clavicle to the os hyoides. The *origin* varies between the sternum, the inner end of the clavicle, and the ligament connecting these bones (the posterior surface of each). Thus: it will be found to arise from the sternum and the posterior sterno-clavicular ligaments; from the clavicle and the ligament; or from the last-named bone only. It has likewise occasionally connexion to a small extent with the cartilage of the first rib. It forms a flat, narrow band of muscular fibres, and is *inserted* into the lower border of the body of the os hyoides.

Origin varies.

Insertion.

Parts in contact.

The muscle is concealed below by the sternum and sterno-mastoid, higher up only by the skin and fascia; and it lies on the sterno-thyroid and thyro-hyoid muscles, which it partly conceals, as well as the crico-thyroid membrane. The inner border is in contact with that of the corresponding muscle towards the middle of its extent, but is separated from it by an interval superiorly, and usually by a larger one near the sternum; the outer margin is in contact with the omo-hyoideus near the os hyoides.—The muscular fibres are, in many cases, interrupted by a transverse tendinous intersection.

Sterno-thyroid.

The *sterno-thyroid*, (sterno-thyroideus; sterno-thyreöideus,—Alb.) (fig. 102,[11]) broader and shorter than the preceding, behind which it lies,

Origin.

arises lower down than that muscle, from the thoracic surface of the first bone of the sternum, from which it ascends, diverging a little from the corresponding muscle, to be

Insertion.

inserted into the oblique line on the side of the ala of the thyroid cartilage.

Adjoining structures.

The greater part of its anterior surface is concealed by the sternum and the sterno-hyoid, as well as by the sterno-mastoid; the posterior rests on the vena innominata, the lower part of the common carotid artery, the trachea, and the thyroid gland. The inner margin is in close contact with the muscle of the other side in the lower part of the neck and behind the sternum.

Tendinous intersections.

This muscle is often partially crossed by transverse or oblique tendinous lines.—At the upper extremity a few fibres are often found to blend with the other muscles connected with the same part of the thyroid cartilage (the thyro-hyoid and inferior constrictor of the pharynx), and it sometimes happens that a few extend to the os hyoides.

Thyro-hyoid.

Thyro-hyoid muscle (thyro-hyoideus; hyo-thyreöideus,—Alb.) (figs. 102,[12], and 105,[8]).—This appears like a continuation

Origin and insertion.

of the preceding muscle, as it *arises* from the oblique line on the side of the thyroid cartilage, and thence passes up to be *inserted* into the lower border of the great cornu and the body of the os hyoides (a portion of each). Some fibres may be found to continue upwards from the sterno-thyroid.—It is concealed by

Adjoining parts.

the sterno-hyoid and omo-hyoid muscles, and rests on the ala of the thyroid cartilage, and on the thyro-hyoid membrane; between the latter structure and the muscle are placed the superior laryngeal nerve and artery before they enter to the larynx.

Cric.-thyr. belongs to larynx.

The *crico-thyroid* comes into view with the muscles now under observation. But, as it belongs exclusively to the larynx, the account of it will be more fitly placed among the muscles of that organ, with which it is associated in function.—See the description of the larynx.

Omo-hyoid;

The *omo-hyoid* (omo-hyoideus; coraco-hyoideus — Alb.;

scapulo-hyoideus) (fig. 102,[13]) is in structure a digastric muscle, as it consists of two bellies, united by a tendon. One of these (the upper and inner one) lies close to the external border of the sterno-hyoideus muscle, and is covered only by the platysma and fascia; the other is deeply seated, being concealed, in the greater part of its extent, by the clavicle and sterno-mastoid. It *arises* from the upper border of the scapula, near the supra-scapular notch, and from occasionally, likewise, the ligament which crosses it. From thence the muscle, forming a narrow, flat fasciculus, inclines forwards across the root of the neck, where it suddenly changes its direction, and ascends almost vertically, to be *inserted* into the lower border of the os hyoides, at the union of its body and cornu. The two parts of the muscle here described form an angle, where they lie behind the sterno-mastoid, and are connected to each other by a tendon, which varies much in length and form in different subjects. The tendon is enclosed within two lamellæ of the deep cervical fascia, which, after forming a sort of sheath for it, are prolonged down, and become attached to the cartilage of the first rib. It is by this mode of connexion that the angular position of the muscle is maintained.

is digastric.

Origin.

Insertion.

Middle tendon.

The omo-hyoid crosses over the scaleni muscles, the cervical nerves, the sheath of the common carotid artery and jugular vein with the nerves lying on it, and the sterno-thyroid and thyro-hyoid muscles. It subdivides the two large triangles into which the side of the neck is formed by the sterno-mastoid in the manner stated at page 266.

Parts adjoining.

Deviations from the ordinary arrangement and size are not uncommon in the omo-hyoid. One of the most frequent is the decrease of the extent of tendinous intersection which may be found to intercept only a few of the muscular fibres; and it may be altogether wanting. The muscle occasionally reaches only from the clavicle to the os hyoides, arising from the former bone about its middle, so that the posterior belly is absent.* In one case, on the other hand, the posterior part alone was present, and it was connected to the hyoid bone by a band of fascia.†

Peculiarities of the muscle.

Actions.—All the individuals of this group of muscles take their fixed point below, and therefore conspire in being depressors of the larynx and os

Actions of infra-hyoid muscles.

---

* See "Anatomy and Oper. Surg. of Arteries," by R. Quain, p. 186. plate xxv.

† Ibid., plate iv. fig. 2.

hyoides, for they draw down these parts as deglutition is being performed. As a preparatory measure to swallowing, the pharynx is drawn up, so also is the os hyoides; and, moreover, as a means of security, the larynx at the same moment is made to ascend, so as to be brought under cover of the epiglottis. After the ascent has been effected, the parts do not return to their original position by the mere relaxation of the elevators; they are drawn down by the action of the five muscles just described. The thyro-hyoideus is the only one of them that can act as an elevator; for when the os hyoides ascends, this muscle can draw upwards the thyroid cartilage with it.

VERTEBRAL REGION (LATERAL).

Fig. 104.†

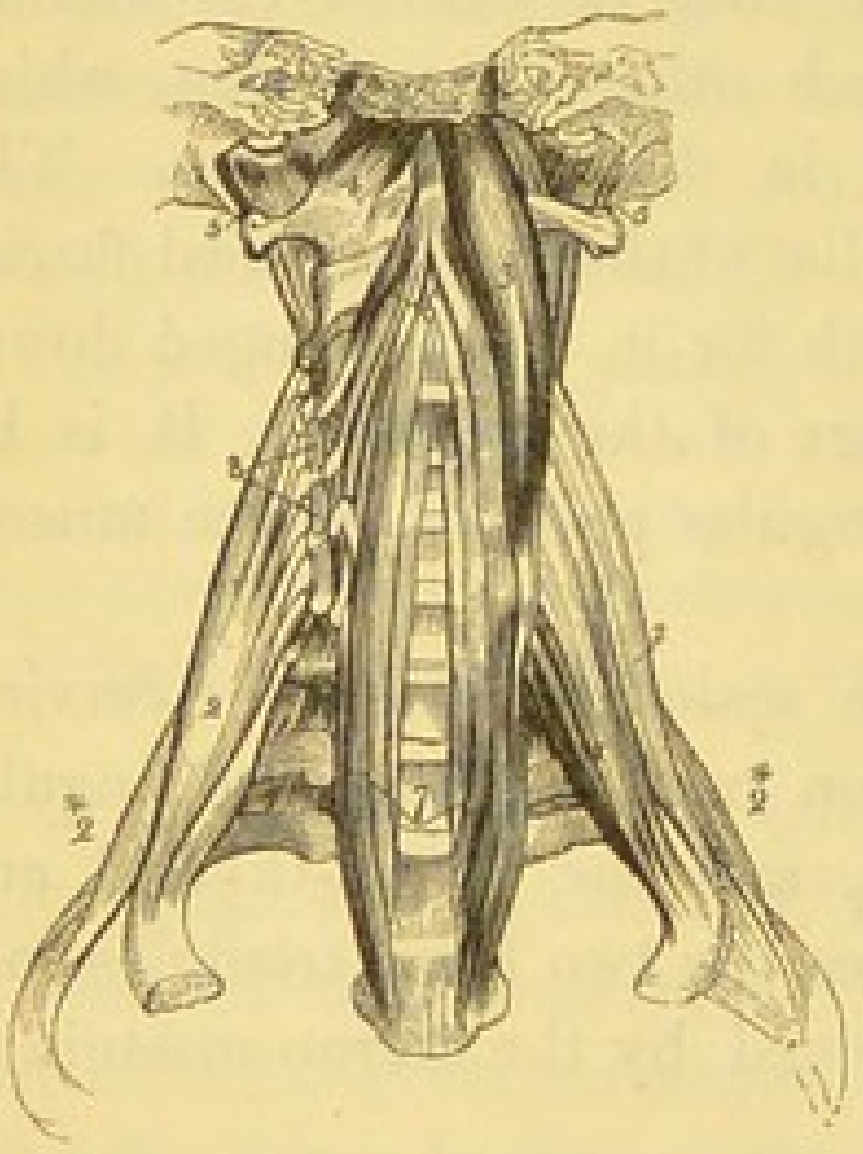

Anter. scalen.

Origin.

Insertion.

The *anterior scalenus* (scalenus anticus; scal. prior,—Alb.) (fig.102,[14]; fig.104,[1]) lies deeply at the side of the neck, behind and beneath the sterno-mastoid muscle. It *arises* by a flat, narrow tendon, from a rough surface (more or less prominent in different cases) on the inner border and upper surface of the first rib, from which its fleshy fibres ascend vertically, to be *inserted* into the anterior tubercles of four cervical vertebræ, from the third to the sixth inclusive.

Parts adjacent.

The muscle is partly covered by the sterno-mastoid (a small part only projecting behind its outer border), and the clavicle, and is crossed by the omo-hyoid. The lower part separates the subclavian artery and vein; the latter being in front of the muscle, and the former with the brachial nerves behind it. To its inner side lie the jugular vein and the branches of the subclavian artery.

---

† A small part of the skull: the cervical and a few dorsal vertebræ, and parts of two ribs with the deep-seated muscles, are seen from before. After the separation of the air-tube and gullet, the skull was sawed upwards nearly on a line with the fore part of the spine to expose the structures here represented; further, the scalenus anticus and rectus anticus major were removed from the right side. 1. Scalenus anticus. 2. Scalenus medius. 2*. Scalenus posticus. 3. Rect. capitis antic. major. 4. Rectus antic. minor. 5. Rectus lateralis. 6 and 7. Longus colli. 8. Inter-transversales.

The *middle scalenus* (scalenus medius) (fig. 102,[15]; fig. 104,[2]) is larger and longer than the preceding muscle, from which it is separated below by the subclavian artery, and above by the cervical nerves, as they issue from the inter-vertebral foramina. It *arises* from the first rib, a little behind the anterior muscle of the same name, the interval on the rib being slightly grooved for the large artery just named. The fleshy fibres ascend along the side of the vertebral column, and are inserted, by tendinous processes, into the posterior tubercles of the last six, or, it may be, to all the cervical vertebræ. Middle scalenus. Origin.

The middle scalenus is covered partly by the sterno-mastoid, and is crossed by the clavicle, the omo-hyoid muscle, and arterial branches. To the inner side, and intervening between this muscle on the one hand and the anterior scalenus and rectus major on the other, are the cervical nerves as they issue from the foramina; to the outer side lies the levator anguli scapulæ with the posterior scalenus muscle. Parts adjacent.

The *posterior scalenus* (scalenus posticus).—This is the smallest of the three scaleni muscles, and is deeply placed behind that last described, in some cases blending with it. It *arises* by a thin tendon from the second rib between the tubercle and angle, and, after enlarging as it ascends, divides into three or two small tendons, which are fixed into the transverse processes of as many of the lowest cervical vertebræ on their posterior tubercles. Poster. scalen. Position. Origin. Insertion.

Two accessory or supernumerary bundles of muscular fibres are occasionally observed in contact or connexion with the preceding muscles, of which they in general appear to be detached parts. The anterior of these (*scalenus minimus* of Albinus), lying between the anterior and the middle scalenus, is placed behind the subclavian artery interposed between the vessel and the large nerves. It is but partially separated from the anterior scalenus, and apparently results from the splitting of this muscle at the lower end by the passage of the subclavian artery through it.* The second accessory muscle (*scalenus lateralis*,—Alb.) is situated between the middle and posterior scaleni. After arising from the second rib or the first, it ends in tendons varying in number in different cases, and is connected to the vertebræ with the two muscles between which it lies, or close to them. Occasional muscles. Scalen. minim. Scalen. lateral.

There is much difference among anatomical writers of authority as to the number of these muscles.† The difference appears to depend chiefly on Authors differ as to the number.

---

* See the work on arteries before referred to, p. 151, and plate xxi.

† The scaleni were originally looked on as a single muscle perforated by

the fact that one or more (the number varying in different instances) of the short clefts of the upper part of the muscles happen occasionally to be continued to the lower end, as occurs so frequently in the muscle next behind the scaleni, viz., the levator anguli scapulæ. Something too depends on the degree in which the cellular membrane intervening between the muscular bundles happens to be removed.

Actions of lateral muscles on vert. and ribs.

Actions.—These muscles draw down the transverse processes of the cervical vertebræ, and thereby bend that part of the spinal column to one side. The inter-transversales [8], and rectus lateralis [5], of each side act in the same way, all conspiring to incline the head as well as the vertebræ laterally. This movement may be alternated by bringing the opposite muscles into action. If both act together, the head and spine will be maintained erect. When the scaleni take their fixed points above, they draw on the first ribs, rendering them fixed, as a preparatory step to making a forcible inspiration.

VERTEBRAL REGION (ANTERIOR).

This includes the muscles placed in front of the spine upon the cervical and upper dorsal vertebræ; viz. the rectus capitis anticus major and minor, with the longus colli.

Rect. ant. major.

Origin.

Insertion.

The *rectus capitis anticus major* (fig. 104,[3]) appears like a continuation of the anterior scalenus, being prolonged upwards from the points at which that muscle ceases. *Arising* from the anterior tubercles of the transverse processes of four cervical vertebræ (from the third to the sixth inclusive) by so many tendinous processes, it ascends, converging somewhat to the corresponding muscle, and is *inserted* into the basilar process of the occipital bone, in front of the foramen magnum. It is tendinous and fleshy in its structure.

Parts adjacent.

The anterior surface supports the pharynx, the sympathetic nerve, and the great cervical vessels, (the carotid artery, the

---

the subclavian artery and nerves (Vesalius, l. 2. c. 38); and the name "triangular" or "scalene" was applied to the mass (Spigelius, l. 4. c. 7). Cheselden speaks of one muscle dividing into two parts. Cowper (Myot. reform. p. 52) describes three; Winslow (sect. 3. § 574) two—but the anterior scalenus of this author consists of two branches separated by the subclavian artery and the brachial nerves; Albinus (and he is followed by Sœmmerring) five — those mentioned in the text, with the accessories. Haller (El. Physiol. l. 8. sect. 1. § 20), remarked the "auctorum dissidia," and, from his own observation, named seven. The modern French anatomists, joining the middle and posterior muscles, admit the presence of but two. While the plan pursued in this work, which has been modified from Albinus, accords with that of Meckel, Hildebrandt and Weber, and more recent German anatomical writers, as well as, in great part at least, Sabatier and Fyfe.

jugular vein,) with the vagus nerve, or rather the sheath which encloses these. The posterior surface overlays part of the longus colli, and the rectus anticus minor, also the articulation of the second with the first vertebra and of the latter with the occipital bone. The muscles of opposite sides are considerably nearer one to the other at their upper than their lower extremities.

Rect. ant. minor.

Position, origin, and insertion.

The *rectus capitis anticus minor* (fig. 104,[4]) is a short, narrow muscle, lying behind the superior part of the preceding, between it and the ligament connecting the first vertebra to the occiput. It *arises* from the fore part of the lateral mass of the atlas and a little from the root of its transverse process, and is *inserted* into the basilar process, between the margin of the foramen magnum and the preceding muscle, but a little farther out than the latter.

Rect. later.

Origin and insertion.

Vessels in contact.

The *rectus lateralis* (fig. 104,[5]) is a short flat muscle placed between the transverse process of the atlas and the occipital bone. It *arises* from the upper surface of the transverse process of the atlas, and is *inserted* into the jugular process of the occipital bone.—The anterior surface supports the internal jugular vein at its exit from the skull, and the posterior is in relation with the vertebral artery. This little muscle and the rectus anticus minor may be considered as completing the series of inter-transversales.[8]

Long. colli.

Position.

Three sets of fibres.

Super. obliq.

Infer. obliq.

Vert. series.

Longus colli.—This muscle rests on the fore part of the spinal column, from the atlas to the third dorsal vertebra. It is narrowed and pointed at the extremities, but becomes wider along the middle part; it is compressed throughout, and appears to consist of three sets of fibres, differing in length and in direction—two being oblique, the third vertical. *a.* The superior oblique portion (fig. 104,[6]) arises, by a narrow, tendinous process, from the anterior tubercle of the atlas, from which its fibres descend obliquely outwards, to be inserted into the fore part of the transverse processes of the third, fourth, and fifth cervical vertebræ. *b.* The inferior oblique, the smallest part of the muscle, extends obliquely inwards from the transverse processes of the fifth and sixth cervical vertebræ to the bodies of the first three dorsal. *c.* The vertical part is placed altogether on the bodies of the vertebræ, and is connected with the two preceding divisions, which are joined one to its superior and the other to its inferior extremity. It is fixed above to the bodies of the second, third, and fourth cervical vertebræ; and the tendinous and fleshy fibres[7], derived from these attachments, pass vertically downwards, to be inserted into the bodies of the three lower cervical vertebræ and the three upper dorsal. The two muscles of this name are separated by an interval inferiorly, but are joined one to the other at their superior extremities. They consist of tendinous and fleshy fibres; the former occupy the anterior surface, particularly at the extremities, some being also deep-seated; and the fleshy fibres, which are in general short, are placed obliquely between them. These muscles support the pharynx, the œsophagus, the sympathetic nerves, the carotid arteries, and the eighth pair of nerves.

Parts in front of muscles.

Actions.—The anterior recti muscles are the natural antagonists of those placed at the back of the neck. They restore the head to its natural position when it has been drawn backwards by the posterior muscles, and, continuing their effort, bow it slightly forwards. Beneath the base of the skull, and at opposite points, we find short and straight muscles, two in front (recti antici), two behind (rectus posticus, major and minor), one on each side (rectus lateralis), which are the direct agents in the restricted motions that take place between the head and the first vertebra. The horizontal movement of the head is effected by the obliqui, particularly by the inferior one. It is obvious that, if the inferior oblique acted by itself, the first vertebra only would be rotated on the second, the head remaining unmoved; but the recti minores and the superior oblique muscle conspire to fix the skull on the first vertebra, and thereby communicate to it any movement impressed on the latter by the inferior oblique muscle.

PHARYNGEAL REGION.

We have here the following muscles forming a hollow bag, open in front, the pharynx; viz. constrictor superior, constrictor medius, constrictor inferior, together with the stylo-pharyngeus and palato-pharyngeus.

Dissection.—After having examined the sides and fore part of the neck, when you are about to dissect the pharynx, larynx, and soft palate, proceed as follows:—Cut across the trachea and œsophagus a little above the sternum, and draw both together forwards. There then can be no difficulty in detaching the pharynx from the muscles in front of the vertebral column, as they are merely connected by loose cellular tissue. When this is done, a piece of cloth should be carried deeply to the base of the skull, and drawn across the pharynx, to serve as a retractor whilst the saw is being used. The edge of the saw should, in the next place, be applied behind the styloid processes, so as to cut through the base of the skull, from below upwards, thereby detaching the face, with the pharynx and larynx all pendent from beneath it. The pharynx should be stuffed, to render its muscles tense. When its exterior is sufficiently examined, a longitudinal slit made along the middle line posteriorly will expose its cavity, and that of the mouth and larynx.

Pharynx.

The pharynx is extended from the centre of the base of the skull to the œsophagus, with which it is continuous, and placed in front of the vertebral column, between the great vessels of the neck; it is immediately behind the nasal fossæ, the mouth, and larynx. The posterior and lateral parts of the pharynx are loosely connected to the adjacent structures by cellular tissue, and anteriorly it presents the several apertures that lead into the nose, mouth, and larynx. Its structure is made up, externally, of muscular fibres, (disposed in a very peculiar way, being formed into three lamellæ on each side, partially overlapping one another, the lowest being the most superficial,) and, internally, of mucous membrane, prolonged from the mouth and nares. These layers of muscle are called the constrictors of the pharynx; they have likewise received other names, taken from their points of attachment, which will be noticed in the detailed description of each muscle. The constrictors form the lateral and posterior boundary of the cavity, and as this is continuous or communicates with the nasal fossæ, the mouth, and the larynx, the anterior margins of the muscles are connected on each side successively with the outer part of the posterior nares, the boundary of the mouth, the lower maxilla, the tongue, the hyoid bone, and the large cartilages of the larynx. The lowest muscle, being the most superficial, will most conveniently be examined first.

Arrangement of muscular structure.

Connexion of constrictors w. parts in front.

Fig. 105.*

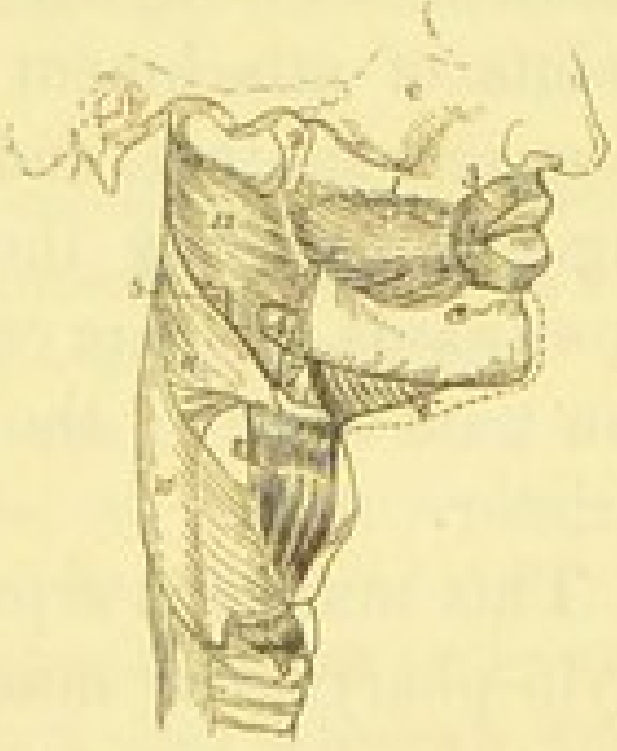

Infer. constrictor.

Origin.

The *inferior constrictor* of the pharynx (pharyngis constrictor inferior,—Alb.; laryngo-pharyngeus,—Fyfe) (fig. 105,^{10}) arises from the

---

* Intended to show the pharynx supported by a portion of the base of the skull, the inferior maxilla, (the ramus being removed,) the os hyoides, and the larynx. 1. is above the buccinator muscle. 2. placed on the pterygoid process, points to the pterygo-maxillary ligament. 3. Orbicularis oris. 5. Stylo-pharyngeus, cut short. 6. Mylo-hyoid. 8. Thyro-hyoid. 9. Crico-thyroid. 10. Inferior; 11. middle; and 12. superior constrictor.

external surface of the cricoid cartilage, and from the oblique ridge on the side of the great ala of the thyroid. From these attachments the fibres curve backwards and inwards, converging to those of the corresponding muscle of the opposite side, with which they unite along the middle line. The direction of the inferior fibres is horizontal, concealing and overlapping the commencement of the œsophagus; the rest ascend with increasing degrees of obliquity, and cover the lower part of the middle constrictor.

Joins fellow.

Direction of fibres.

Parts in contact.

The outer surface of the muscle is in contact at the side of the larynx with the thyroid body, the carotid artery, and the sterno-thyroid muscle, from which last some fibres are continued into the constrictor, where both muscles meet on the thyroid cartilage. The two laryngeal nerves pass inwards to the larynx, close respectively to the upper and lower margins of this constrictor—one being interposed between it and the middle constrictor, the other between it and the œsophagus.

Was considered two muscles.

The inferior constrictor was described by the older anatomists as two muscles which received various names, the most appropriate of these being thyro- or thyreo-pharyngeus and crico-pharyngeus.

Middle constrictor.

Origin.

The *middle constrictor*, (constrictor medius,—Alb.; hyo-pharyngeus,) (fig. 105,[11]) smaller than the preceding, is triangular or fan-shaped. It *arises* from the side of the great cornu of the os hyoides, also from its smaller cornu. From these points of attachment the fibres proceed backwards, diverging from one another, and are blended with those of the corresponding muscle along the middle line. The lower fibres incline downwards, and are concealed by the inferior muscle; the middle run transversely; the rest ascend and overlap the superior constrictor.

Blends with fellow.

Direction of fibres.

Parts in contact.

This muscle is separated from the superior constrictor by the stylo-pharyngeus muscle and the glosso-pharyngeal nerve, and from the inferior constrictor by the superior laryngeal nerve. Near its origin it is covered by the hyo-glossus muscle, the lingual artery being interposed; and it covers the superior constrictor, the stylo-pharyngeus, the palato-pharyngeus, and the mucous membrane.

Was known as several muscles.

The portions of this muscle derived from different places of origin were at one time described as distinct muscles, under names taken from those parts, *e. g.* cerato-pharyngeus, chondro-pharyngeus, &c.

Peculiarities.

Fibres of the middle constrictor have likewise been observed to arise from one of the following parts, viz. the body of the os hyoides, the thyro-hyoid ligament (syndesmo-pharyngeus of Douglas), and the stylo-hyoid ligament; and a few are occasionally continued into it from the genio-hyo-glossus muscle. The upper extremity of the two middle constrictors, where they join, has been found (Albinus) connected to the base of the skull by a fibrous band.

Super. constrictor. Origin. Joins with opposite. Upper margin.

The *superior constrictor* (constrictor superior,—Alb.; cephalo-pharyngeus,—Fyfe,) (fig. 105,[12]) is attached slightly to the side of the tongue (in connexion with the genio-hyo-glossus), and to the extremity of the mylo-hyoid ridge, also to the pterygo-maxillary ligament[2], and the lower third of the internal pterygoid lamella. From these different points the fibres of the muscle curve backwards, becoming blended with those of the corresponding muscle along the middle line, and are also prolonged, by means of the posterior aponeurosis, to the basilar process of the occipital bone. The upper margin curves beneath the levator palati mollis and the Eustachian tube, and the space intervening between this concave margin of the constrictor and the base of the skull is closed by fibrous membrane.

Parts in contact;

In contact with the outer surface of this muscle are the internal carotid artery, and the large nerves, as well as the middle constrictor, which overlaps a considerable portion, and the stylo-pharyngeus, which enters to the pharynx between the two constrictors. It conceals the palato-pharyngeus and the tonsil, and is lined by mucous membrane.

Was described as several muscles.

This, like the other constrictors, has been described as several muscles, each separate origin being considered a distinct muscle, named usually by prefixing the name of the place of its origin to the word pharyngeus.

Salpingo-pharyng. Often wanting.

Salpingo-pharyngeus (Santorini). Under this name is described a small muscle, which arising from the Eustachian tube, as the name implies, (σάλπιγξ, a trumpet,) descends in the interior of the pharynx towards its back part, and, after joining with the palato-pharyngeus, is lost in the muscular structure of the cavity. This little muscle is often indistinct, and is frequently absent.

Constrict. form lateral and poster. part of phar.

By the peculiar mode of attachment of the constrictor muscles, the bag of the pharynx is completed on the sides and posteriorly, and left open in front; and by the connexion of the upper constrictor with the pterygoid processes, and with the buccinator, (through the pterygo-maxillary ligament,) a continuous smooth surface is established from the nasal fossæ and from the commissure of the lips along the side of the mouth and fauces.— Besides the constrictors, we find at each side, in the pharynx, two other muscular fasciculi. One of these derived from the stylo-pharyngeus[5], which is insinuated between the adjacent borders of the superior and middle constrictor, has been already described (page 271). The other, the palato-pharyngeus, lies more internally, and shall be described with the muscles of the palate (page 289).

Other musc.

Actions of preceding in deglutition.

Actions.—The pharynx is drawn up when deglutition is about to be performed, and at the same time dilated in opposite directions. It is widened from side to side by the stylo-pharyngei, which are farther removed from one another at their origin than at their insertion, and can thereby draw outwards the sides of the cavity; and as the os hyoides and larynx are carried forwards in their ascent, the breadth of the pharynx from before backwards is also increased, inasmuch as its fore part is drawn in the same direction, by reason of its connexion with the larynx. When the morsel of food is propelled into the pharynx, the elevator muscles relax, the bag descends, and then the fibres of its own muscular wall begin to contract, and force the mass down into the œsophagus.

When we contrast the structure of the pharynx with that of the œsophagus, comparing the complex arrangement observable in the one with the simplicity of the other, we see abundant evidence of its being intended for something more than a mere recipient and propellent of such matters as are to be conveyed to the stomach. It exerts an important influence in the modulation of the voice, in the production of the higher tones of which it is brought into action.

General view of pharynx.

The description of the muscular structure of the pharynx may be given briefly as follows: it may be considered as a single muscle, consisting of two symmetrical halves, united by a raphé posteriorly along the middle line, the union extending from the basilar process to the œsophagus. The superior fibres curve downwards and outwards, to be fixed to the lower third of the internal pterygoid plate, to the pterygo-maxillary ligament, and to the mylo-hyoid ridge and side of the tongue; the middle set of fibres, broad, and expanded posteriorly at the line of junction, converge as they proceed forwards to be attached to the cornu of the os hyoides and the stylo-hyoid ligament, and are so disposed, that part is concealed by the succeeding set, whilst others overlap the preceding muscle. The lower fibres proceed forwards in the same way, to be attached to the side of the cricoid and thyroid cartilages. The tube is thus shown to be complete posteriorly and at the sides, being open in front, where it communicates with the nose, mouth, and larynx.

Parts seen in the cavity.

When the pharynx is slit open, we expose the cavities just mentioned, and the apertures which lead into them, as well as the orifices of the Eustachian tubes. (Fig. 106.)

PALATAL REGION.

The soft or pendulous palate (*velum pendulum palati*) forms a partial and movable curtain between the mouth and the pharynx. Its upper border is straight, and attached to the posterior margin of the palate bones; the lower presents, when viewed from before, a curved or arched border at each side, and in the middle a conical depending process, called the *uvula*. From this, as from a common point of departure, two curved prominent lines will be observed to extend, one at each side, and proceed downwards and forwards, to the side of the tongue. These correspond with the lower or free border of the palate, and mark the limits of the cavities of the mouth and pharynx, for they represent a narrowed or constricted line between them, which is termed the *isthmus* of the fauces. Farther back two other curved lines project, one at each side, which also commence at the uvula, and extend downwards and backwards along the sides of the pharynx. They diverge from the preceding curved lines so as to leave between them an angular interval, in which is lodged the *tonsil* or *amygdala*. The curved lines here described are usually called the *arches* of the palate, one pair being anterior to the other, and also more prominent.

Soft palate; its position; shape; uvula.

Isthmus of fauces.

Tonsil.

Arches of palate.

The soft palate consists of five pairs of muscles, enclosed by mucous membrane.

Dissection.—When the pharynx has been dissected and examined, it may be opened by an incision along the middle line or raphé; this will expose the soft palate: let the uvula be drawn down so as to render it tense; then the small muscles of the palate are at once exhibited by detaching the mucous membrane. The levatores palati are brought into view by merely removing the mucous membrane from the posterior surface of the soft palate; the circumflexi will be found along the internal pterygoid plates: their aponeuroses, which form the principal support of the soft palate, will be seen in front by dissecting off a thick layer of glandular substance, which is continued downwards upon it beneath the mucous membrane.

Levator palati mollis (fig. 106,[1]).—This is a long, thin, flat muscle, which, after passing to the interior of the pharynx above the concave upper margin of the superior constrictor, occupies the posterior surface of the soft palate. It *arises* from

Lev. pal. enters pharynx.

Origin.

Fig. 106.*

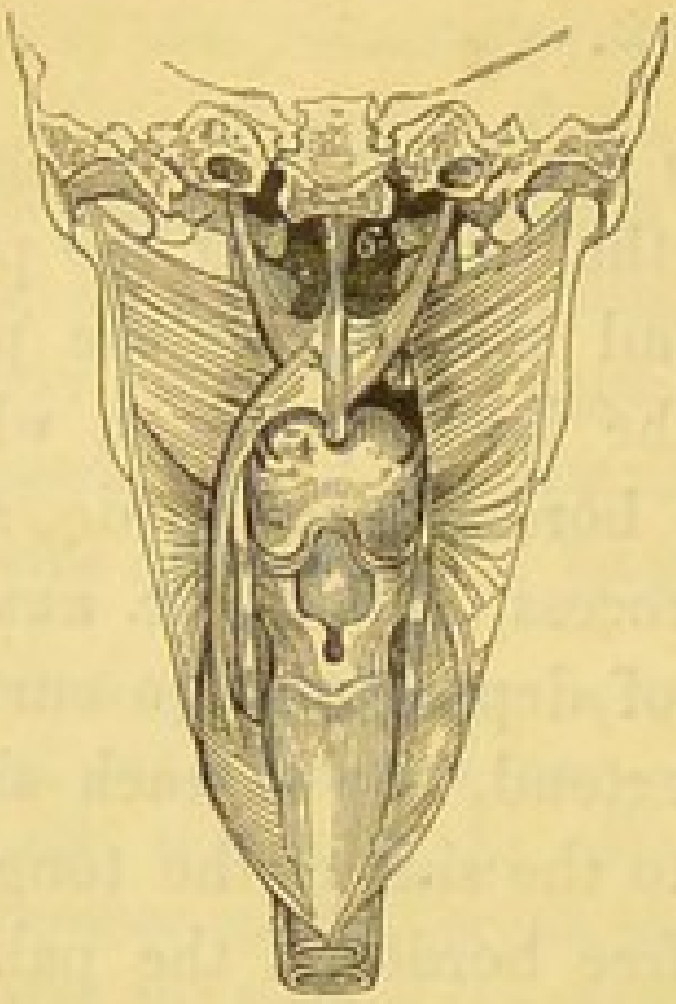

Position in palate.

the extremity of the petrous portion of the temporal bone, before the orifice of the carotid canal, and from the cartilaginous part of the Eustachian tube. The two muscles, converging as they descend, join one with the other at the middle of the palate, and blend with the other structures; at the same time that they are placed behind them with the exception of the azygos uvulæ and some fibres of the palato-pharyngeus.

Other names.

This muscle has been described by anatomists under the names (among others) salpingo-staphylinus and petro-salpingo-staphylin, which express its points of attachment more or less completely.

Tensor palati.

Origin.

Changes of direction.

Aponeurosis.

Insertion.

Circumflexus, or *tensor palati*, (pterygo-staphylinus; spheno-salpingo-staphylin) (fig. 106,^{2}) presents two portions which differ in their direction and relations. The muscle *arises* broad and thin from the small fossa (navicularis) at the root of the internal pterygoid plate of the sphenoid bone, from the anterior surface of the cartilage of the Eustachian tube, and from the bone in immediate connexion with it. From these points it descends perpendicularly between the internal pterygoid muscle and the osseous lamella of the same name, and ends in a tendon, which winds round the hamular process; there it inclines inwards, and expands at the same time into a broad aponeurosis, the fibres of which are inserted into the transverse ridge on the under surface of the palate process of the palate bone, and on reaching the middle line they unite with the aponeurosis of the corresponding muscle of the opposite side.

Azygos uv.

Azygos uvulæ (Morgagni) (fig. 106,^{3}) (palato-staphylinus—

---

* The pharynx having been laid open from behind, the constrictors were turned outwards, and the mucous membrane was removed from them and from the soft palate. The posterior nares, the tongue, and the opening into the larynx are seen, together with the following muscles, viz.—1. Levator palati mollis. 2. Circumflexus palati. 3. Azygos uvulæ. 4. This number rests on the tongue; it points to the palato-glossus. 5. Palato-pharyngeus. 6. Posterior naris of one side.

Douglas) was so called from its having been supposed to be a single muscle; but there are really two thin fasciculi, separated by a slight cellular interval above, which usually unite towards the lower part. Each arises from the tendinous structure of the soft palate, and, it may be, from the pointed process (spine) of the palate plate, and, descending vertically, becomes blended with the other structures in the uvula.—The muscle of the uvula lies behind the other muscles of the soft palate.

Pal.-gloss. in front of tonsil.

Palato-glossus, or *constrictor isthmi faucium* (fig. 106,[4]).—This small muscle inclines from the uvula forwards and outwards in front of the tonsil to the side of the tongue, where it may be considered as inserted. In the soft palate some of the fibres of this little muscle are continued into that of the opposite side, so that the two palato-glossi form to a certain extent but one muscle. It is merely covered by the mucous membrane, which it renders prominent, so as to form the anterior arch of the palate.

Contin. w. opp. muscle.

Anter. arch of palate.

Palato-pharyn.

The *palato-pharyngeus* (fig. 106,[5]) arches downwards and backwards, so as to leave an angular interval between it and the preceding. It commences in the soft palate, where the fibres are separated into two unequal parts by the levator palati mollis, and are partly connected with the fibrous structure of the palate, partly continuous with the muscle of the opposite side. Descending behind the tonsil into the pharynx, the palato-pharyngeus distributes some fibres in the pharynx, and after joining with the stylo-pharyngeus is attached with it to the thyroid cartilage. This muscle forms the posterior and larger arch or pillar of the velum palati.

is behind tonsil.

Poster. arch of palate.

Action of the muscles in deglutition.—The mass of food having, by the pressure of the tongue against the hard palate, been carried back to the fauces, the palato-glossi (the constrictors of the fauces) contract behind it; the soft palate is raised to some extent, and made tense; and the palato-pharyngei approaching one another nearly touch (the uvula lying in the small interval between them), and prevent the passage of the food towards the upper part of the pharynx, or the posterior nares, at the same time that they form an inclined surface for its guidance into the lower part of the pharynx, which is raised to receive the mass by elevator muscles already described (page 286). The concurrent elevation of the larynx, and closing down of the epiglottis over the entrance to the air-tube, have likewise been previously noticed (page 278).

MUSCLES OF THE BACK.

Muscles of the back;

The muscles placed along the posterior part of the trunk are found to be arranged in layers, or strata, placed one over the other, and differing materially in extent, attachments, and use. The superficial muscles are so broad as to cover all the others; and, as their extent is considerable, their number is proportionably diminished, being only two, viz. the trapezius and latissimus dorsi. We shall here place them in the order in which we find them in our dissections, proceeding from the tegument to the spine and ribs. Those in each group or layer diminish in size as they increase in number.

arranged in layers.

In the first layer are the trapezius and latissimus dorsi.

In the second, the rhomboidei and levator scapulæ.

In the third, the splenii and serrati postici.

In the fourth, the erector spinæ, sacro-lumbales, longissimus dorsi, cervicalis ascendens, transversalis colli, trachelo-mastoideus, and complexus.

In the fifth, the semi-spinales dorsi and colli, recti and obliqui.

In the sixth, the inter-spinales, inter-transversales, multifidus spinæ, levatores costarum.

Dissection.—The subject being turned prone, the chest and abdomen should be supported by blocks, and the arms allowed to hang over the sides of the table. An incision may be made through the integument, along the spinal column, from the occipital protuberance to the sacrum. This should be bounded at its superior extremity by a transverse incision, carried outwards to the mastoid process, and below by another extended along the spine of the ilium. The intervening space may, in the next place, be intersected by two lines; one drawn from the first dorsal vertebra, over the spine of the scapula, the other commencing at the last dorsal vertebra, and carried horizontally outwards.

As the space here marked out is so very extensive, it may be advisable to make an incision obliquely upwards from the last dorsal vertebra to the spine of the scapula, which will correspond with the lower border of the trapezius muscle; and the dissection may be commenced by raising the angular flap of skin thus included, proceeding in the direction of the fibres of that muscle, that is to say, from below upwards and outwards. The other portions of integument should be successively raised, taking care to expose accurately the tendinous fibres where they arise from the spinous processes, as they afford a guide to the fleshy part of the muscle.

When the latissimus and trapezius have been exposed and examined in their entire extent, which will take some time, in consequence of the quantity of surface that is to be gone over, they are to be removed, in order to bring into view the muscles that lie beneath them.

FIRST LAYER OF DORSAL MUSCLES.

Trapezius. Position, shape, and name.

Fig. 107.†

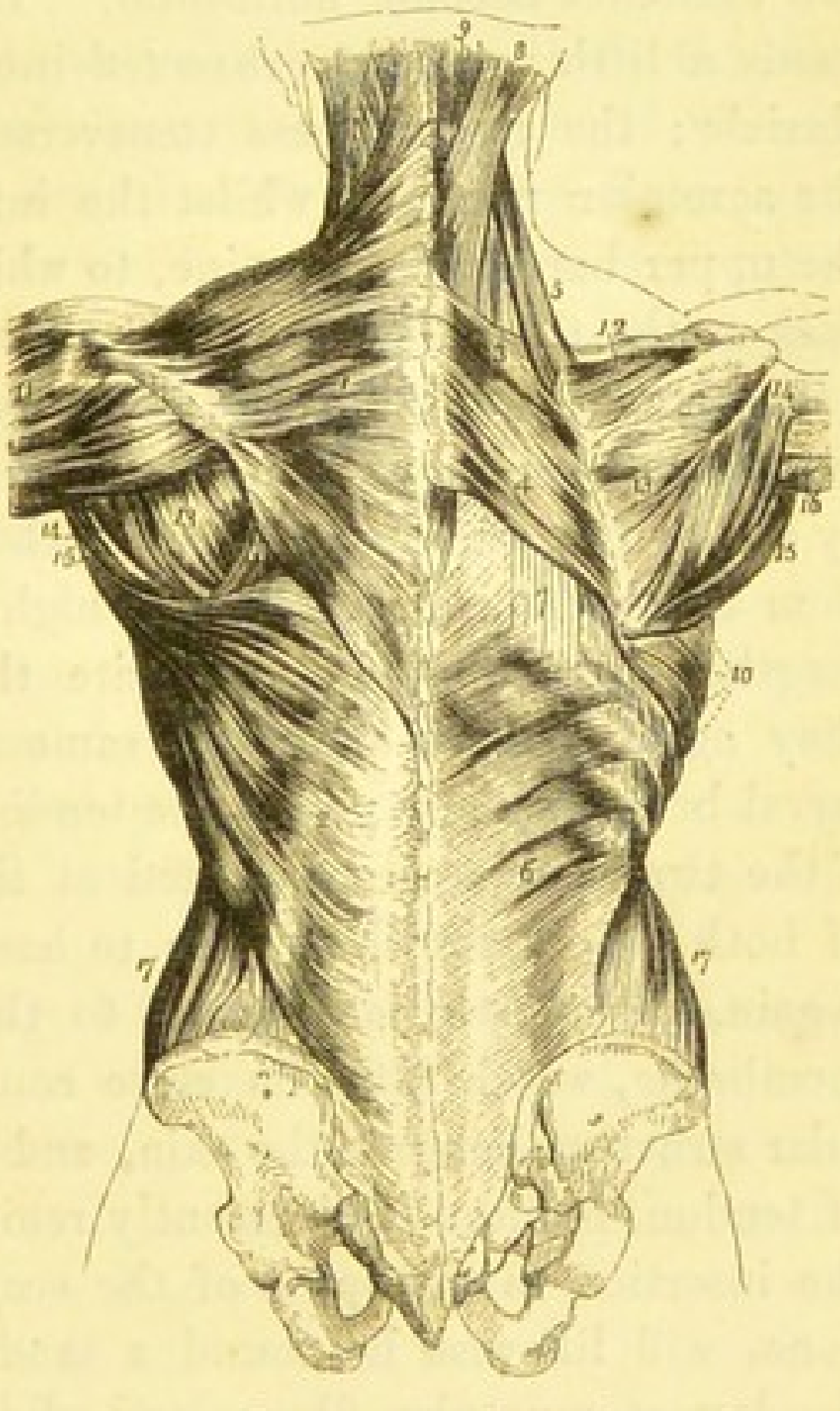

The *trapezius* (fig. 107,[1]) (cucullaris;* occipito-dorsi-acromialis) is a flat thin triangular muscle of considerable extent, which is placed immediately under the skin along the posterior part of the neck, as well as of the back and shoulder. If the two muscles of this name be taken together, they represent a four-sided figure (hence the name), two angles of which correspond with the points of the shoulders, one with the occipital protuberance, and the fourth with the spinous process of the last dorsal vertebra.

Origin.

The trapezius *arises*, 1, from the occipital protuberance, and from about a third of the curved line, extending forwards from it; 2, in the cervical region, from a

---

* " Cucullaris dicitur, quod cum conjuge suo cucullos monachorum non inepte exprimat." Spigelius, " De Hum. Corp. Fabr." l. 4, § 13.

† The muscles of the back are here displayed. On the left side the integuments only were removed; from the right, the trapezius and latissimus dorsi were taken away. 1. Trapezius. 2. Latissimus dorsi. 3. and 4. Rhomboideus minor and major. 5. Levator anguli scapulæ. 6. Serratus posticus inferior. 7. The sacro-lumbalis covered by the vertebral aponeurosis. 8. Splenius. 9. Complexus. 10. Serratus magnus. 11. Deltoid. 12. Supra-spinatus. 13. Infra-spinatus. 14. Teres minor. 15. Teres major. 16. Long head of triceps. 17. External oblique of abdomen.

tendinous band, called ligamentum nuchæ; 3, from the spinous process of the last cervical, and all those of the dorsal vertebræ, as well as from the supra-spinous ligament.

Direction of fibres.

From these different points of origin the fibres proceed towards their insertion into the clavicle, the acromion process, and the spine of the scapula, following very different directions; those from the occiput inclining downwards and outwards, and those from the lower part of the back upwards and outwards, the obliquity of each set diminishing, so that those intermediate between the two extremes become horizontal.

Insertion.

The superior fibres turn forwards a little, and *are inserted* into the external third of the clavicle; the middle pass transversely to the upper border of the acromion process; whilst the inferior ones ascend to reach the upper border of the spine, to which they are attached as far back as the triangular surface at which it commences.

Tendinous structure.

Structure:—the trapezius is fleshy in the greater part of its extent, and tendinous at its attachments. The tendinous fibres by which the muscle arises are rather short along the interval from the last dorsal vertebra as high as the fourth; there they lengthen gradually, but opposite the fourth cervical vertebra they again acquire about the same extent, so that in the interval between these points the tendinous part is extensive, and, if the two muscles are dissected at the same time, the tendons of both together will be seen to have an oval or elliptic form. Again, the muscle is attached to the occiput by fibro-cellular membrane, which from its close connexion with the dense cellular structure beneath the skin, and from its wanting the lustre of tendon, is often inadvertently removed by the dissector. At the insertion to the spine of the scapula, near the base of that bone, will likewise be found a tendinous piece which receives the lowest muscular fibres, and glides over the smooth triangular surface on that part of the bone by means of a synovial bursa.

Parts adjacent.

This large muscle is covered by dense cellular membrane, which alone separates it from the skin, so that in the living body its outline is readily discerned when in action. It conceals in part or altogether the following muscles, viz. the complexus[9], the splenii[8], levator anguli scapulæ[5], the supra-spinatus[12], infra-spinatus[13], the rhomboidei[3], [4], and the latissimus dorsi (a small part)[2]. The anterior border, which may be said to turn forward near the clavicle, forms one of the limits of the posterior triangular space at the side of the neck.

Peculiarities.

The trapezius is not unfrequently shorter than usual, and the number of dorsal vertebræ with which it is connected may be found diminished even to six or seven. In a very muscular body Tiedemann* found the trapezius and some other muscles (the pectoralis major and gluteus maximus) to a certain degree doubled (an additional muscular layer of some extent being under the ordinary one).—And here it may be mentioned, that, where the muscular development is large, added slips or portions will often be found in connexion with several of the muscles.

Ligamentum nuchæ.

Ligamentum nuchæ (ligamentum cervicis).—From the line of union of the two trapezii along the neck, a band of condensed cellular membrane, mixed with tendinous fibres, projects forwards, so as to reach the spinous processes of the vertebræ, forming a septum between the sets of muscles on each side of the middle line. It is attached by its upper extremity to the occipital protuberance, by the lower to the spinous process of the seventh cervical vertebra; its posterior border is blended with the fibres of the trapezii, whilst the anterior is fixed to the spinous processes of the last six cervical vertebræ. This structure is usually named as above. In the human subject it can only be considered as a rudiment of that peculiar elastic band which serves to sustain the weight of the head in the lower animals.

Latiss. dorsi.

Position and form.

The *latissimus dorsi*, (fig. 107,^{2}) (dorsi-lumbo-sacro-humeralis,) as its name implies, is of considerable extent, for it occupies the whole of the posterior part of the lumbar region, and the lower half of the dorsal. It is flat, broad, and thin in the greater part of its extent, but it gradually becomes contracted into a narrow fasciculus towards its insertion into the humerus.

Origin.

It *arises* by tendinous fibres, 1, from the spinous processes of five or six lower dorsal vertebræ, from all those of the lumbar region and of the sacrum, and from the supra-spinous ligament: over the sacrum the aponeurosis is blended with the tendon of the erector spinæ. The muscle takes origin likewise, 2, from the external border of the crista ilii (its posterior third); 3, and by fleshy digitations from the last three or four ribs, where they are interposed between similar processes of the obliquus ex-

---

* "Deutsches Archiv." 1818.

Aponeurosis.

ternus. The tendinous fibres from the two first lines of origin form by their intertexture, or union, a broad aponeurosis, from which the fleshy fibres proceed, converging towards the axilla. The fibres at the upper part are the shortest, and pass almost horizontally outwards over the lower angle of the scapula, from which it frequently receives a fasciculus of fleshy fibres; those lower down become longer and incline from below upwards, gradually increasing in the degree of their obliquity; finally, those which are attached to the ribs ascend almost vertically.

Fibres converge and are folded.

By this convergence, the fibres form a narrow and thick fasciculus. This rests on the teres major[15], which it accompanies towards the axilla, but gradually folding on itself (the fibres from below passing under or in front of those from above, and eventually above them) it likewise turns on that muscle, so as

Insertion.

to get to its anterior aspect, and is *inserted* into the bicipital groove in the humerus by means of a tendon about two or three inches long. The flat tendon by which the latissimus dorsi is inserted becomes united, particularly by its lower border, with that of the teres major: it ascends higher than this muscle, and also lies nearer to the brachial vessels.

Structure.

Structure:—tendinous along its point of origin from the spine and the ilium, aponeurotic in the lumbar region, tendinous at its insertion, fleshy in the rest of its extent,—where it lies over the ribs, the angle of the scapula, and the fold of the axilla.

Adjacent parts.

The latissimus dorsi is covered by the trapezius at its dorsal origin, and is subcutaneous in the rest of its extent, except where it ascends into the axilla. The anterior surface rests on part of the rhomboideus major[4], infra-spinatus[13], teres major[15], the serratus posticus inferior[6], and the deep lumbar muscles; and, between the crest of the ilium and the last rib, its tendon is united with the fascia lumborum, and binds down the erector spinæ muscle. The internal border is blended with the fibres of the corresponding muscle, along the middle line. The superior border is free, and describes a slight curve, whose concavity looks upwards—between it and the margins of the trapezius and the rhomboid may in some positions of the arm be observed a small angular space in which the intercostal muscles are not covered by other muscles; the anterior one, also free in the greater part of its extent, slightly overlaps the obliquus externus[17], below, and higher up the serratus magnus[10]; on the humerus the tendon is in contact with the axillary vessels and nerves.

Peculiarities.

The latissimus dorsi, like most other muscles of the back, varies in the extent of connexion with the bones: thus; the number of dorsal vertebræ to which it is attached varies from four to seven or eight, and the number of the ribs is not constant, as has been already mentioned. A muscular band is often seen to stretch from this muscle across the axilla to its anterior part, where it terminates variously—in the tendon of the greater pectoral, or the coraco-brachialis muscle, or in the fascia.

Action of trapezius on head; on scapula.

Actions.—The trapezius and latissimus dorsi direct or influence the motion of several parts, as must be evident from the extent of their attachments. If the shoulders be fixed, the *trapezii muscles*, acting together, draw the head directly backwards; but, if only one of them acts, it inclines the head to the corresponding side. If the head be fixed, the superior part of the trapezius elevates the point of the shoulder, and sustains it in that position, as when a burden is supported upon it; but if the effort required be considerable, or if it must be continued for any length of time, the cooperation of the serratus magnus becomes indispensable. It would appear at first sight, from a mere inspection of the fibres of this muscle, that those in the middle part of it could draw the scapula directly backwards, and the lower ones draw it downwards. This, however, is far from being the fact. As the muscle is attached to the spine of the scapula and the acromion, it will rather, in consequence of the obliquity of the direction of these processes, communicate a certain degree of rotatory motion to the whole bone, by means of which, when the acromion ascends, the posterior angle descends, and the inferior one comes forward; and, should the acromion be made to resume its previous position, the inferior angle will move backwards, the superior one upwards. The scapula, then, by the action of the trapezius alone, cannot be made to ascend or descend, to go backwards or forwards, in such a way that the direction of its different parts may remain exactly parallel, in their new situations, to those which they had previously occupied:—this bone will, on the contrary, be found to rotate, as it were, on a pivot driven through the centre of its dorsum. To draw the scapula directly backwards requires the combined effort of the trapezius and rhomboid muscles; for, as their fibres decussate, the direction of the one being obliquely downwards, that of the other upwards, the bone, by their combined action, is made to move in the direction of the diagonal of their forces, that is to say, towards the spinal column.

The scapula rotated; moved towards the spine.

Action of latiss. dorsi on humerus; on trunk.

The *latissimus dorsi*, when it acts on the shaft of the humerus, necessarily draws it downwards, and gives it at the same time a rotatory motion on its own axis, particularly if it had been previously everted, or turned outwards. When the shoulder and arm are rendered fixed, the muscle acts in various ways on the trunk. Thus it assists in forcible inspiration, by drawing on the lower ribs and elevating them. By conspiring with the abdominal and great pectoral muscles, it elevates and sustains the body in the effort of climbing; and, when an individual is constrained to resort to the assistance of crutches, the latissimus and pectoralis major are the chief agents in progression.

Both muscles acting on spine.

The trapezius and latissimus dorsi, more particularly the latter, can act under certain circumstances on the spine, preparatory to which the shoulder and arm must become (at least relatively) the fixed points of their attachment. When a man walks close to the margin of a raised foot-path, or of a curb-stone, and happens to incline a little beyond it, the body becomes curved to that side, and by its own weight would carry him over it, if a particular effort were not made to prevent such an occurrence. For this purpose the arm of the opposite side is, as it were, instinctively thrown out somewhat from the body, so as to render the insertion of the latissimus dorsi into that bone its fixed point of attachment. Thus sustained, the fibres of the muscle are enabled to act on the spine, and, by pulling on those parts of it which are curved, they draw them into a right line with the rest, and so restore the equilibrium of the body.

SECOND LAYER.

Dissection.—To expose the rhomboid muscles and the levator scapulæ, the trapezius must be removed. For this purpose, the fibres of the trapezius may be detached from their connexion with the clavicle and spine of the scapula, and reflected back to the spine. This will be found easier than the usual plan of detaching it from the latter, both because it is there very thin, and also because its fibres are connected with those of the rhomboid muscle. Its dorsal portion conceals the rhomboidei, and part of the latissimus dorsi; and the cervical, the levator scapulæ, the splenius, and complexus. These may be dissected in the course of their fibres, as the trapezius is being reflected back towards the middle line, where it may be separated from its fellow of the opposite side along the cervical region, so as to expose the ligamentum nuchæ. In doing this, insert the edge of the knife under the muscle at the occiput, and draw it from above downwards, in the line of the spinous processes.

Rhomboid.

The *rhomboideus muscle* (rhomboides; dorso-scapularis) is usually divided into two muscles, though they lie on the same plane, are similar in structure and use, and are separated only by a slight cellular interval. It is extended obliquely from the spinous processes of the lower cervical and upper dorsal vertebræ, to the base of the scapula.

Minor. Origin.

The *rhomboideus minor* (fig. 107,[3]) *arises* from the spinous process of the seventh cervical vertebra, and from the ligamentum nuchæ, its fibres being also closely united with those of the trapezius. It inclines downwards and outwards, to be

Insertion.

inserted into that part of the base of the scapula which corresponds with the triangular surface from which the spine commences.

Major.

Origin.

Insertion into bone and a tendon.

Rhomboideus major[4].—This is three or four times broader than the other, placed in close contact, and immediately below it. It *arises* from the spinous processes of the four or five upper dorsal vertebræ, and their inter-spinous ligaments, and is *inserted* into that part of the base of the scapula included between its spine and inferior angle; some of the fibres, instead of being fixed to the bone, end on a tendon which is connected to the scapula above the lower angle, and, in consequence of this arrangement, the muscle may, in part, be separated from the bone without division of its muscular or tendinous fibres.

Parts over and under muscle.

The rhomboideus major is covered by the trapezius in the greater part of its extent, and towards the lower part by the latissimus dorsi; but, when the arm is drawn away from the side, a small portion is left uncovered by these muscles, where they diverge at the base of the scapula. The rhomboidei rest against the serratus posticus superior and the posterior scapular artery with the ribs and deep muscles.

Lev. ang. scapulæ.

Origin.

Insertion.

The *levator anguli scapulæ*[5] (trachelo-scapularis)[*] is placed along the side and posterior part of the neck, forming a long and rather thick fasciculus of fleshy fibres. It *arises* from the posterior tubercles of the first three or four cervical vertebræ, by so many tendinous points. From these the fleshy fibres proceed, being at first slightly separated, but soon united to form a flat muscle, which is directed along the side of the neck downwards and a little backwards, and is *inserted* into that part of the base of the scapula included between its spine and superior angle.

Parts adjacent.

The muscle is covered by the sterno-mastoid muscle above, and by the trapezius below; it rests on the splenius colli, transversalis cervicis, and the posterior scapular artery.

---

[*] This muscle was known as the "musculus patientiæ," having been so named by Spigelius for the reason which he thus expresses:—"Secundus, scapulam attollens et leuator dictus, à me vero per jocum *patientiæ musculus*, quod ægrè ferentes, quæ nobis aduersa accidere, scapulam huius ope, cum humero, patientiæ amarum ingeminantes nomen, eleuemus."—Spigelius, "De h. corp. fabr." l. 4, § 13.

Peculiarities.

The levator anguli scapulæ may be found connected with but two vertebræ, or the number may be increased to five. A slip has been observed to extend to it from the mastoid process of the temporal bone (Theile), and from the second rib (Meckel). It often appears as several muscles, the parts connected with the vertebræ remaining separate, even to the place of insertion.

THIRD LAYER.

Dissection.—After having examined the muscles of the second layer, they must be removed in order to gain a view of those underneath them. For this purpose, the rhomboidei may be detached from the base of the scapula, and reflected backwards, which is the easier mode of attaining the end desired, and avoids any risk of raising with them the serratus superior, which is intimately connected with their origin. The aponeurosis of the latissimus dorsi may be divided by an incision carried from above downwards, along its middle; and, as the external half is reflected outwards, its intimate connexion may be observed with the obliquus abdominis, along the border of the deep lumbar muscles. The other portion of the aponeurosis may be drawn back towards the spine, by which means the serratus posticus is left untouched. The serrati and their connecting membrane may then be inspected.

Serr. post. super. Origin. Insertion.

Serratus posticus superior (cervici-dorso-costalis) is placed under cover of the rhomboideus; it is flat, and very thin. It *arises* from the ligamentum nuchæ, the spinous process of the last cervical, and from those of two or three upper dorsal vertebræ, by a thin aponeurosis, which inclines downwards and outwards, and, becoming muscular, is *inserted* by four fleshy digitations into the bodies of the second, third, fourth, and sometimes fifth ribs, a little beyond their angles. Its direction is obliquely downwards and outwards, resting on the deep muscles and the angles of the ribs. The aponeurosis forms a large part of this little muscle.—It is covered by the rhomboid and levator anguli scapulæ, and lies against the deeper muscles of the back. The vertebral aponeurosis is occasionally found to be connected with it.

Parts over and under.

Serr. post. infer. Greater part aponeurotic;

Serratus posticus inferior (fig. 107,^{6}) (dorsi-lumbo-costalis).—This is broader than the preceding muscle, from which it is separated by a considerable interval, as one of them corresponds with the upper, the other with the lower ribs. It *arises* from the spinous processes and inter-spinous ligaments of the last two dorsal, and two or three upper lumbar vertebræ, by a thin aponeurosis, which forms the greater part of the muscle. It ends in a fleshy lamella, which is *inserted* by four broad digitations into the bodies of the last four ribs. Its direction is oblique upwards and outwards.—The posterior surface is covered by the latissimus dorsi, with whose tendon the aponeurotic part is firmly united for some extent; the anterior rests on the deep lumbar muscles. The upper margin is connected with the vertebral aponeurosis.

is connected with latiss. dorsi and verteb. aponeurosis.

Vertebral aponeurosis.—On the same plane with the serrati is a thin, semi-transparent lamella thus named, which forms a septum between the third and fourth layer of muscles, separating those which belong to the shoulder and the arm from those which support the spine and head. Its fibres are for the most part transverse; some, however, take a contrary direction. It is connected below with the inferior serratus, and above passes usually beneath the superior serratus; and as the two muscles, with their connecting aponeurosis, are stretched from the spinous process to the angles of the ribs, they form with the vertebral grooves a sort of angular canal, in which are lodged the long extensor muscles.

Vert. aponeur. with serrati is a sept. betw. muscles.

Covers extensor muscles.

The *splenius muscle* (fig. 107,^{3}) is placed obliquely along the posterior part of the neck, diverging from the muscle of the opposite side, near the occiput, so that the two leave between them an interspace, in which the muscles beneath (complexi) come into view. The splenius is extended from the spinous processes of the upper dorsal and lower cervical vertebræ, to the side of the base of the skull, and the transverse processes of the superior cervical vertebræ. This separation at the superior attachment has given occasion for the division of this muscle into two parts; the lower being named splenius colli, the upper splenius capitis.

Splenius diverges from opp. muscle nr. occiput.

Division into two parts.

The *splenius colli* (dorso-trachelius) *arises* from the spinous processes of four dorsal vertebræ, from the third to the sixth inclusive: the fibres ascend, forming a flat, muscular plane, which is *inserted* by separate points into the transverse processes of the first three cervical vertebræ, close to the origin of the levator anguli scapulæ.

Spl. colli.

The *splenius capitis* (cervico-mastoideus) is placed above the preceding, and is also broader and thicker than it. It *arises* from the spinous processes of the first two dorsal vertebræ, and of the seventh cervical; also from the ligamentum nuchæ oppo-

Spl. capitis.

site the sixth, fifth, and fourth. From these points its fibres proceed upwards and outwards, to be *inserted* into the lower end of the mastoid process (which it embraces), to the posterior part of the same process, and the line curving upwards and backwards from it. Structure :—tendinous at its attachments, fleshy in the rest of its extent.

Parts over and under.

The splenius (the cranial and cervical parts being taken together) is covered by the trapezius, the rhomboid, and the serratus posticus superior; by the sterno-mastoid on the cranium. It conceals, in part, the complexus and trachelo-mastoid.

Peculiarities.

The splenius differs, in different cases, as to the number of the vertebræ with which it is connected ; and the two parts into which it is considered divisible vary in the extent to which they are really distinct one from the other.

Action of lev. ang. scap. and rhomb.

Actions.—The *levator anguli scapulæ* conspires with the *rhomboideus* in one of its more obvious actions. When the acromion process is elevated, the posterior angle of the scapula is depressed, and the inferior one carried forwards; but, as soon as the more powerful muscles cease to act, the levator draws upwards the posterior angle of the bone, whilst the rhomboid carries backwards and upwards the inferior angle, thus giving a slight rotatory motion to the whole bone, and at the same time depressing the acromion and point of the shoulder.—If the shoulder be fixed, the levator may incline the neck down to the same side, just as the trapezius draws the head under the like circumstances. If the rhomboid muscle conspires with the middle and lower part of the trapezius, the base of the scapula will, by their joint effort, be carried directly towards the spine.

Serrati post. act on ribs and on vert. aponeur.

The *serrati postici*, in their action on the thorax (which, from their size, is necessarily insignificant), are antagonists. The inferior one is enabled, by the direction of its fibres, to depress the ribs, and to assist in expiration ; but the other elevates the ribs, into which it is inserted.—Moreover, the serratus inferior, in consequence of its connexion with the vertebral aponeurosis, probably exerts some influence on the deeper muscles, by making that membrane tense ; and the serratus superior will produce a like effect when it happens to be connected with the membrane.

Splenius.

If the *splenii muscles* of both sides act together, they draw the head directly backwards, in which they conspire with the complexus and trapezius. When those of one side act separately, they incline the head laterally, giving it at the same time a slight rotatory motion.

Complexus.

The *complexus*, too, by reason of the oblique direction of its fibres, can give a certain degree of horizontal motion to the head, but in a direction contrary to that of the splenii, as must be evident from the fact, that the fibres of the one incline outwards as they ascend, and those of the other inwards.

FOURTH LAYER.

Dissection.—When you have sufficiently examined the muscles of the third layer, divide the serrati and their aponeurosis in the middle, and reflect the pieces, one inwards, the other outwards. When this is done, the sacro-lumbalis and longissimus dorsi may be traced from below upwards, by merely passing the handle of the scalpel along the cellular interval which separates them. The next step is to detach the splenii at their origin, by an incision carried from above downwards, close to the spinous processes. These muscles diverge at their upper part, and leave between them an interval, in which the complexi are seen. When the splenius has been detached from the vertebræ and reflected outwards, the transversalis cervicis and trachelo-mastoideus can be followed along the neck, taking them as continuations of the long dorsal muscles.

General view of muscles of spine.

Their position.

Are not distinct one fr. another.

Reason of this.

Fig. 108.*

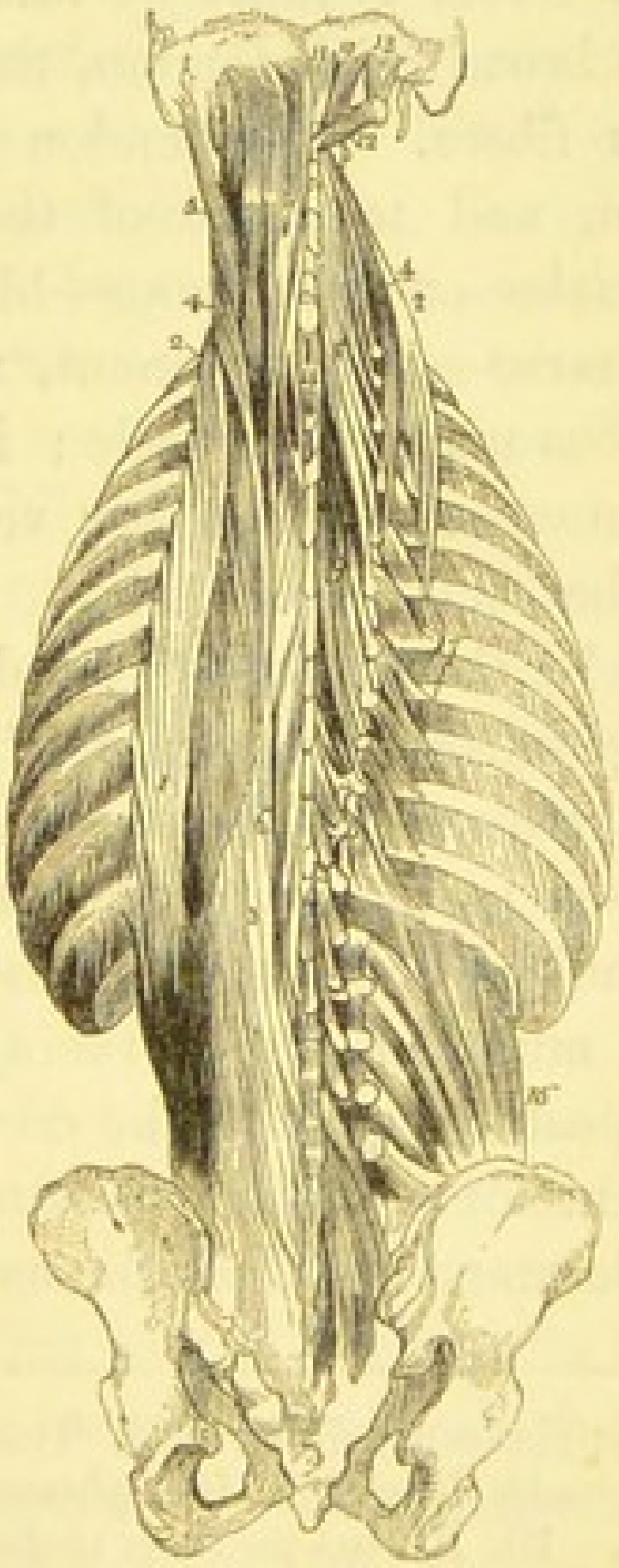

Erector spinæ (extensor dorsi communis; sacro-spinalis; lumbo-costalis) (fig. 108).—Beneath the vertebral aponeurosis and the serrati muscles in the dorsal region, beneath the tendon of the latissimus dorsi in the lumbar, and a layer of cervical fascia continued under the trapezius in the cervical, lie the large muscles which support the trunk and the head in the erect position of the body. These muscles generally have little of the distinct and independent arrangement presented where the joints are few, and the extent of movement in each well defined, as in the limbs. On the contrary, as the number of joints in the spine is very considerable, as the movement in each is indistinct, and as many associate for every change in the position or direction of the trunk, the points of attachment for the muscles are

---

* The proper muscles of the back, seen by removal of those displayed in fig. 107, are here represented. 1. Sacro-lumbalis. 2. Cervicalis descendens.

very numerous, and their fibres are short and incompletely separated; in so much that they are more or less conjoined one with another from end to end of the vertebral column.

Size in different situations.

The erector spinæ is small and pointed over the sacrum, where little more exists than the tendon of origin, and becomes suddenly enlarged in the lumbar region;—and this part may be considered the source from which fibres spread upwards to the bones. In the dorsal region it gradually lessens, being expended on the vertebræ and the ribs, till, in the neck, no more than a vestige of the lumbar mass remains. Finally, in this situation there are added, as it were to support the neck and the head in the erect position, special muscles of considerable size (splenius and complexus), between which the slender prolongations of the erector spinæ will be found.

Origin;

Origin of the erector spinæ.—At the lower end, where it is not divided on the surface, and where, the connexions being more fixed, it must be said to take origin, the mass is covered by a broad thick tendon, the most extensive source of its muscular fibres. The tendon is attached to the spines of the sacrum, and to some of the highest of the external row of tubercles on that bone—blending, in the latter situation, with the sacro-sciatic ligament, and connected with the origin of the gluteus maximus muscle; it is likewise attached to the spines of most of the lumbar vertebræ, and to the posterior part of the crest of the ilium. Thus fixed, the tendon gives origin, by the entire of its deeper surface, to a large part of the great muscular mass; and its cutaneous surface is, at the upper part, covered by the aponeurosis of the latissimus dorsi, but at a lower point—over the sacrum—the two tendinous structures are united one with the other, so as to be no longer separable. The muscular fibres, taking origin from the tendon and from the posterior part of the crest of the ilium (directly, and through the medium of fibrous structure in their substance), form a single mass, to which the name erector spinæ might be confined.

from large tendon,

and from bones.

---

3. Longissimus dorsi. 4. Transversalis cervicis. 5. Trachelo-mastoid. 6. Spinalis dorsi. 7. Complexus. 8. Semi-spinalis colli. 9. Semi-spinalis dorsi. 10. Rectus posticus major. 11. Rectus minor. 12. Obliquus inferior. 13. Obliquus superior. 14. Inter-spinales. 15. Multifidus spinæ is said to be indicated by this number. 16. Quadratus lumborum. 17. Levatores costarum.

It is limited in front (towards the abdomen) by the transverse processes of the lumbar vertebræ and the layer of the lumbar fascia connected with these processes; and divides, near the last rib, into two parts of unequal size—one external, the other internal and larger—which will now be separately considered.

Division into two parts.

Sacro-lumbalis (extensor dorsi externus) (fig. 108,[1]).—The external and smaller portion of the erector spinæ having no direct connexion with the sacrum or the lumbar vertebræ—none, except through the general tendon of origin—the name by which it is generally known conveys an incorrect notion of its position and connexions. Separating from the outer side of the general mass near the last rib, this muscle ends in a series of tendons which lie on its posterior surface, and are fixed to the ribs at their angles. The tendons derived from the lumbar mass may be said to be exhausted at the middle of the dorsal region (at the sixth or seventh rib); but the muscle is reinforced by bundles of muscular fibres, which take origin from the upper margins of all the ribs by thin flat tendons; and, by means of these additions, the sacro-lumbalis is continued to the higher ribs, as well as to the transverse processes of some of the cervical vertebræ. There is no separation between these accessory bundles, but they are usually considered to form two muscles, which are named "accessorius" and "cervicalis descendens."

Sacro-lumb.

(name ill-chosen).

Insertion into six ribs.

Continued by access. fibres.

Accessorius ad sacro-lumbalem.—The bundles of muscular fibres, derived from the lower six or eight ribs, are known under this name. They commence by flat tendons connected with the upper margins of the ribs, and, again ending in tendons, constitute that part of the sacro-lumbalis which is inserted into the higher ribs. To expose the accessorius, the lower part of the sacro-lumbalis (beneath which it lies) must be separated from the longissimus dorsi, and turned outwards.

Accessorius arises from lower ribs and inserted into upper.

Cervicalis descendens v. ascendens[2].—Thus are named the accessory slips, taking origin from four or five of the higher ribs, and continued upwards to terminate on the transverse processes of three or four cervical vertebræ. This part of the muscle lies to the inner side of the tendons of the sacro-lumbalis, which terminates on the highest ribs, and is recognised by this position and its muscular appearance. In the neck it is overlapped by the levator anguli scapulæ, lying between it and the complexus. It blends with the transversalis cervicis—an elongation from the

Cerv. descendens is super. part of access. fibres.

muscle to be next described, and, if long enough, with the cervical insertion of the splenius.

Other names of muscles.

Some anatomists, considering the name sacro-lumbalis not an appropriate one for the muscle, have suggested substitutes, *e. g.* sacro-costalis: ilio-costalis (Theile). But neither of these is unobjectionable; and indeed the points of attachment of the muscle are so numerous that any name derived from them must either be imperfect or very long.

Under the name "Cervicalis descendens," Diemerbroeck* described the fibres connected with the cervical vertebræ and with all the ribs; but he regarded them as descending from the vertebræ to the ribs, and having the opposite direction to the sacro-lumbalis. The contrary direction of its two sets of fibres this anatomist held to account for the opposite effects ascribed to the sacro-lumbalis muscle, namely, the alternately raising and depressing the ribs in inspiration and expiration. (Stenonis,† it should be observed, had previously given an account of the fibres on the ribs, now known as the accessorius.) The name thus applied to all the accessory part of the sacro-lumbalis was subsequently appropriated to the upper portion of it, which is commonly described as extending from below upwards, and on this account it was that Meckel suggested the alteration to cervicalis "ascendens."

Longiss. dorsi.

Longissimus dorsi[3].—The internal larger and longer portion of the erector spinæ is attached to parts situated internally to those which receive the sacro-lumbalis, viz. the lumbar vertebræ, the dorsal vertebræ, and the ribs within their angles. While the muscular mass of the lumbar region is yet undivided, its inner part (which may be assigned to the longissimus dorsi) is inserted into the whole length of the transverse processes of the lumbar vertebræ on their posterior aspect, including the tubercles (processus accessorii) projecting from the processes near their bases and the small depressions internal to them. Fibres will likewise be found inserted beyond the transverse processes to the layer of the lumbar fascia connected with their points; and this part, with the preceding, forms one broad insertion.

Insertion into lumb. vert.;

In the dorsal region, the longissimus dorsi is attached to the extremities of the transverse processes of all the dorsal vertebræ, and to a less number (varying from seven to eleven) of the ribs within their angles. This muscle is continued upwards to the neck and to the cranium by a slender accessory portion, which

dorsal vert. and ribs.

Is continued to neck and cranium.

---

* "Anat. corp. hum." l. 5, c. 6.

† "De musculis observationum specimen" in Mangetus, "Bibliotheca Anatom." t. 2, p. 528.

is described as two muscles—transversalis cervicis, and trachelo-mastoid.

Trans. cerv. *Transversalis cervicis*[4].—This slender part is placed at the inner side of the longissimus dorsi, and arises from the ends of the transverse processes of the highest dorsal vertebræ, and occasionally the last cervical, (about five altogether, but the number and their position are very variable,) and is inserted into the transverse processes of about four cervical vertebræ above the last. It blends with the cervicalis descendens, and still more with the trachelo-mastoid, with which latter the fibres are in great part continuous.

is conjoined w. trach. mastoid.

Trach. mastoid continues longiss. dorsi. The *trachelo-mastoid* muscle[5] (part of the complexus; complexus minor), the continuation of the longissimus dorsi to the head, extends, as the name implies, from the neck to the mastoid process of the temporal bone. Placed to the inner side of the transversalis cervicis, and inseparable from it, except with the aid of a knife, it arises from the last three or four cervical vertebræ—the tendons being attached to or immediately near the oblique processes. The narrow flat muscle, constructed from the several small points of origin, and frequently crossed by a tendinous intersection, is inserted into the posterior margin of the mastoid process under the splenius and sterno-mastoid muscles. It conceals partly the complexus and the obliqui capitis; and, on the cranium, the occipital artery crosses immediately beneath it, or, as not unfrequently happens, over it.

Origin.

Insertion.

Is crossed by occip. artery.

The spinous processes of the superior lumbar and the dorsal vertebræ, hitherto left unoccupied by the large muscles, (erector spinæ and its divisions,) have connected with them a series of tendinous fibres, which are in reality a part of the longissimus, but are described as a distinct muscle as follows:—

Spin. dorsi attached only to spines of vert.; *Spinalis dorsi*[6].—Placed at the inner side of the longissimus dorsi, and connected exclusively with the spinous processes, (whence the name,) this little muscle arises by tendons (three or four in number,) from the first two lumbar and the lowest dorsal vertebræ; and the slender bundle of muscular fibres, which springs from the tendons, ends by being connected with the higher dorsal vertebræ, the number of attachments varying from four to eight. The spinalis is separable from the longissimus dorsi only by artificial means; and it is connected with the muscle beneath it—the semi-spinalis.

joined to longiss. dorsi.

Spinalis cerv. very inconstant in form;

Spinalis cervicis (inter-spinales super-numerarii,—Albinus). In this place must be mentioned, because of the analogy with the spinalis dorsi, a small muscle, like it exclusively connected with the spines of the vertebræ. The fibres have seldom the same arrangement in two bodies, and they often differ on both sides of the same body. But it may be said that the muscle arises by tendinous or fleshy fibres, forming from two to four heads, from the spinous processes of the fifth and sixth cervical vertebræ, or likewise from others in the immediate neighbourhood of these, including one or two dorsal, and is again fixed by tendons into the spine of the axis, and, in some instances, to the two vertebræ next below it. The spinalis cervicis is connected with the semi-spinalis and the ligamentum nuchæ.

sometimes absent.

This muscle is sometimes placed over the spinous processes, and hence has been named super-spinalis (Cowper). It may be reduced to a single slip; and not unfrequently is altogether wanting. Its absence was found to occur in five cases out of twenty-four.*

Complexus.

Complexus[7] (trachelo-occipitalis) is a thick and rather broad muscle, situated upon the posterior part of the cervical region. It is directed obliquely inwards from the transverse processes towards the spines and the middle line, so that the two muscles of this name approach one another, whereas the fibres of the splenius, which covers it, have the opposite direction, and the complexi, therefore, are partly seen in the interval left between the splenii of both sides as they diverge to their connexion with the sides of the cranium. The complexus *arises* by about seven tendinous points from the posterior and upper part of the transverse processes of the first three dorsal and seventh cervical vertebræ, and from the oblique or articular processes of three more cervical (covering the joints and adhering to the ligamentous fibres which support them). The muscular fibres are soon aggregated into a mass, which is directed upwards and inwards to be *inserted* between the two curved lines of the occipital bone. Above its middle the muscle is partially intersected by a transverse tendinous intersection.

Approaches oppos. muscle.

Origin.

Insertion.

Intersection.

---

* A detailed account of a series of observations made with respect to this muscle, by MM. Henlé and Heilenbeck, will be found in Müller's "Archiv. f. Anat. Physiol.," &c. 1837.

The muscle is covered by the trapezius, splenius, and the slender muscles attached to the transverse processes of the cervical vertebræ; and is crossed by the occipital artery. It conceals the semi-spinalis colli, the posterior recti and obliqui capitis, together with the deep artery of the neck and several nerves, some of which (last) perforate it.

Parts over and under.

Biventer cervicis.—Close by the inner border of the complexus, and in most cases forming a part of it, is a long fasciculus, consisting of two fleshy bellies united by a tendon, and hence named as above. The lower end presents from two to four tendinous and fleshy points attached to as many transverse processes of the dorsal vertebræ from the fourth to the sixth or seventh, and the upper one is inserted into the occipital bone near the complexus. The tendon which divides this muscle is of considerable length, and is usually placed opposite the last cervical or first dorsal vertebra. And from the spines of one of the vertebræ now named, an accessory slip is often furnished to the biventer at its inner side.

Biventer cervicis is joined w. complex.

Origin and insertion.

Accessory fibres.

The name complexus being little applicable to the muscle now so called, it should be mentioned that the term originally included three muscles, viz. the complexus (of modern writers), the biventer, and the trachelo-mastoid.

Complex. included three musc.

The complexus and the biventer together constitute the second of the two principal muscles destined to maintain the head poised on the vertebral column in the erect position of the trunk; the splenius, which in a great measure covers it, being the first. Both these muscles may be considered as succeeding to the sacro-lumbalis and longissimus dorsi, and performing at the upper extremity of the spine the functions which the muscles just named fulfil at its lower part. It will be observed, too, that the slender elongations of the divisions of the erector spinæ are placed between the two large cervical muscles.

FIFTH LAYER.

To continue the examination of the muscles of the back, those which have hitherto been under observation are to be removed:—the complexus must be divided and turned aside (in doing this, the artery and nerves beneath it should be noticed); the spinalis and the longissimus dorsi are to be separated in the dorsal region; and its large tendon being divided longitudinally near the spinous processes of the lumbar vertebræ and the sacrum, the erector spinæ is to be raised from the inner side and thrown outwards. Then there will lie exposed the muscles which fill the grooves of the spine from the middle of the sacrum upwards, excepting from the axis to the occiput, where a different arrangement prevails, to be afterwards noticed.

To expose muscles in vertebral grooves.

The fibres will be found stretching obliquely from the transverse or the articular processes to the spines of the vertebræ. In the dorsal and cervical regions a layer of muscular and tendinous structure (semi-spinalis) is distinguished from the more general one, which lies beneath it, and extends from the sacrum to the axis (multifidus spinæ).

The *semi-spinalis* reaches from the lower part of the dorsal vertebræ to the second cervical; and, though there is no separation, it is described as two muscles, distinguished by their position.

Semi-spin. dorsi.

Semi-spinalis dorsi[9] (transversaire épineux du dos,—Winslow).—This thin and narrow stratum consists of a small portion of muscular structure, interposed between tendons of considerable length. The lower tendons are connected to the transverse processes of the inferior dorsal vertebræ (from the tenth to the fifth, inclusive), and the upper tendons to the spines of the higher dorsal and neighbouring cervical vertebræ (four of the former, and two of the latter).—It is covered by the spinalis and the longissimus dorsi, and in some degree by the semi-spinalis colli, and lies on the multifidus spinæ.

Connexions.

Semi-spin. colli thicker than former.

Semi-spinalis colli[8] (transversaire épineux du col).—Considerably thicker than the preceding, this part of the semi-spinalis takes origin from the transverse processes of usually the first five or six dorsal vertebræ, by as many tendinous and fleshy points, and terminates in about four parts on the spines of the cervical vertebræ, from the second to the fifth inclusive. The part connected with the axis is the largest, and is chiefly muscular. This portion of the semi-spinalis is covered by the complexus and biventer cervicis; it rests against the multifidus spinæ, and is firmly united with it towards the upper end.

Connexions.

Both the parts of the preceding muscle vary in their length, and consequently in the number of vertebræ with which they are connected. Their average extent is mentioned above.

The greater thickness of the cervical portion is dependent on the freedom of motion in that part of the column.

Multif. spin.

Multifidus spinæ[15].—This long and narrow mass of muscular, with an admixture of tendinous fibres, occupies the vertebral groove at the side of the spinous processes. It is fixed to the sacrum, and to all the vertebræ, except the atlas, covering them to a considerable thickness; some of its fibres (the deepest) reaching from one vertebra to the next, while others, placed

extends from sacr. to axis.

over those, extend to a greater distance. In conformity with the plan usually followed in the description of muscles, the origin and insertion of the fibres of this muscle may be stated as follows.

Origin of fibres.

At the lower end (where the muscle reaches to the interval between the second and third sacral foramina, and is adherent to the aponeurosis described in connexion with the erector spinæ,) the fibres may be said to arise from the higher external tubercles of the sacrum, from the ilium, and the ligament connecting both these bones; in the lumbar and cervical regions they take origin from the oblique or articular processes; and in the dorsal region from the transverse processes. From these several points the muscular bundles ascend obliquely, to be inserted into the laminæ of the vertebræ and the spines, from their bases nearly to their extremities. The fibres vary in length, for those from each point of origin are fixed to several vertebræ; some to the next above, while others extend further—from the second even to the fifth beyond. And thus they are placed fibre over fibre, and each vertebra receives some from different points of origin, and of different lengths, the longest being necessarily most superficial.

Their insertion.

Various length.

Rotat. spin.

Number.

Exist only on dorsal vertebræ.

Rotatores spinæ.—Under this name have been described* a series of eleven small, flat, nearly square muscles, placed at intervals on the dorsal part of the spine, under the multifidus spinæ, from which they are separated by a little cellular membrane. Each arises from the upper and back part of the transverse process, and is inserted into the vertebra next above, at the inferior margin of the lamina, and on part of its surface, as far as the root of the spinous process. The first occurs between the first and second dorsal vertebræ, the last between the eleventh and twelfth. But it not unfrequently happens that the number is diminished, by the absence of one or more from the upper or lower end. The bundles of muscular fibres thus described as distinct muscles, do not appear to be distinguishable from the deeper part of the multifidus spinæ, except by the interposition of a little cellular membrane.

Diminution of number.

Inter-spin.

The *inter-spinales*[14] are short fasciculi of fleshy fibres, placed

---

* Prof. Theile in Müller's "Archiv. f. Anat." &c. 1839.

in pairs between the spinous processes of the contiguous vertebræ—as their name implies.

Cervical inter-spin. muscles.

They are best marked in the neck, where they are connected one to each of the two parts into which the spinous process is divided. Six pairs may be counted, the first being between the second and third vertebræ, the last between the seventh and the first dorsal.

Dorsal few and inconstant.

In the dorsal division of the column only a few of the interspinous muscles are met with, and these are not constant. They will not unfrequently be found between the first and second vertebræ of this region, and occasionally between the eleventh and twelfth. A vestige of them likewise sometimes occurs in the second dorsal " interspinous" space.

Lumbar.

Four pairs of very thin layers occur in the intervals of the five lumbar vertebræ. One will likewise be, in some instances, found connecting the last of these vertebræ with the sacrum, and another connecting the first with the dorsal vertebra above it.

Extensor coccygis occasionally present.

Slender muscular fibres have been mentioned as occasionally found to extend over the lower part of the sacrum and coccyx, and apart from other muscles; and the name *sacro-coccygeus posticus*, or *extensor coccygis*, has been assigned them.* They arise by tendinous fibres from the first piece of the coccyx, or the last bone of the sacrum, or even at a higher point, and, reaching downwards, are fixed to the lower part of the coccyx. These have been considered a rudiment of the extensor of the caudal vertebræ of some animals.

Occasional fibres.

Arrangement of deep musc. nr. occiput.

Coinciding with the peculiar conformation of the joint formed between the first two vertebræ, and the kind of movement which belongs to it, the deep-seated muscular structure between the axis and the occiput is found to differ widely in arrangement from that which has been met with over the rest of the vertebral column, being aggregated into small muscles, which are independent one of the other, viz. the obliqui and recti, the "circumagentes" of some of the older anatomists.

Rect. post. major;

Rectus capitis posticus major[10] (axoido-occipitalis).—This muscle extends from the spinous process of the axis to the under surface of the base of the skull. It *arises* by a tendinous

---

* Günther and Milde, "Chirurgische Muskellehre," quoted in "Sömmerring von Baue," &c.

origin from the process just mentioned, and, enlarging considerably as it ascends, passes over the atlas, and is *inserted* into the inferior curved line of the occipital bone and beneath it. It diverges from the corresponding muscle of the opposite side, so as to be much more oblique than straight, as the name would imply.

passes over atlas;

is oblique.

The *rectus capitis posticus minor*[11] (atlo-occipitalis) extends from the atlas to the base of the skull, being smaller every way than the preceding. It *arises* from the posterior border of the atlas, and, expanding towards the other extremity, is *inserted* into the rough surface between the inferior curved line on the occipital bone and the foramen magnum. It lies nearer to the middle line than the preceding muscle at the occiput, and can therefore be seen without disturbing it.

Rect. post. minor;

not concealed by former.

The recti muscles take the place of the inter-spinales. The smaller pair may be considered strictly analogous; but the larger undergo a change in attachment and direction, referrible to the movements which they are required to effect. The latter do not remain on the atlas, for the movement of extension belonging to other parts of the spine does not exist between the first two vertebræ; and, moreover, their course upwards to the occiput, to which they are fixed, being oblique, they are calculated (besides the influence they exert in drawing the occiput backwards) to assist in the rotatory movements of which the axis is the pivot.

The *obliquus capitis inferior* v. major[12] (axo-atloideus), the largest of these muscles, is placed obliquely between the first two cervical vertebræ. It *arises* from the spinous process of the axis in its whole length, between the origin of the rectus posticus major and the insertion of the semi-spinalis colli, and is *inserted* into the extremity of the transverse process of the atlas.

Obliq. infer. large comparative size.

The *obliquus capitis superior*[13] (atlo-post-mastoideus) extends from the atlas, where the preceding muscle terminates, to the lateral and inferior part of the base of the skull. It *arises* from the extremity of the transverse process of the first cervical vertebra, inclines from thence obliquely upwards and inwards, expanding somewhat as it ascends, and is *inserted*, close behind the mastoid process, into the interval between the curved lines of the occipital bone.—The two oblique muscles, with the rectus major, form the sides of a small triangular space, in the area of which branches of the sub-occipital nerve will be found.

Intermusc. triangle.

Inter-transversales (Cowper), (inter-transversarii,—Albinus).

Inter-transversales.

—These little muscles occupy the spaces between the transverse processes of the vertebræ, and are most developed in the neck, and least so between the dorsal vertebræ.

Cervical series.

In the cervical part of the spine there are, in each space, two rounded bundles of muscular fibres, with tendinous filaments intermixed, attached, one to the anterior, the other to the posterior tubercle of the transverse processes—the cervical nerve, which lies in the groove between the tubercles, separating one muscle from the other. There are seven pairs in the neck, the first between the atlas and axis, the last connecting the seventh cervical to the first dorsal vertebra.

The rectus lateralis (page 281), which extends from the transverse process of the atlas to the base of the skull (jugular process of the occipital bone), may well be regarded as an inter-transversalis, and the rectus anticus minor (page 281) might be considered its fellow—but displaced, as it were, forwards, to the anterior part of the vertebra.

Lumbar.

In the loins, the inter-transversales are four in number, one between each pair of vertebræ. Those connected with the lowest vertebræ are attached to nearly the whole of the transverse process, while those at the upper part of this division of the spine do not exceed half the breadth of the process. The muscles now described are in single layers; but the small round fasciculi which are stretched between the accessory processes of the lumbar vertebræ, and hence named *musculi inter-accessorii*, or *inter-obliqui*, may be looked on as rudiments of posterior inter-transversales.

Inter-accessorii.

Dorsal set, round cords; few muscular.

In the dorsal region narrow rounded cords are found between the transverse processes. They are tendinous in structure, except in the lowest three interspaces and between the last dorsal and first lumbar vertebræ, in which they are muscular. These fasciculi range with the inter-accessorii above described, at the same time that they correspond with them in shape and size.

When proceeding with the dissection of the muscles here noticed, a series of fleshy and tendinous bundles, extended downwards and forwards from the transverse processes of the vertebræ to the margins of the ribs — the "elevators of the ribs"—will be exposed; for these, see page 365.

Muscles maintain

Combined actions.—The *sacro-lumbalis, longissimus dorsi,* and *multifidus spinæ* conspire in fixing the spinal column, and thereby maintaining the trunk erect. If they continue their effort, the body will be drawn somewhat backwards, as may be observed when a considerable weight is suspended from the neck, or in persons who have become excessively fat. In both these cases, the extensor muscles are required to make increased efforts to counterpoise the influence of the weight appended to the fore part of the body. trunk in erect position.

They alternate in action.

As these muscles have to sustain the trunk in the sitting as well as in the standing posture, it might be supposed that they scarcely admitted of any relaxation, and therefore are kept almost constantly in action. But it does not appear necessary, except in making great efforts, that all of them should be in action at the same moment, and even the different parts of the same muscle must, in most cases, act successively. Thus the lower fibres of the multifidus spinæ pass from the sacrum to the lumbar spines, and materially assist the quadratus lumborum and other muscles in fixing the lumbar vertebræ. These, or rather their transverse processes, become the fixed points from which the succeeding parts of the multifidus act on the spines throughout the entire length of the column, so that a succession of efforts is propagated from below upwards by a sort of vermicular motion. When, by such an arrangement, the action of one set of fibres succeeds that of another, each will have its alternations of contraction and relaxation, as well as the fibres of those muscles in which the change is more perceptible. The sacro-lumbalis can draw down the lower ribs ; and if the effort be continued, this influence must speedily be propagated to the spinal column, which is thus bent towards the side by means of the intimate connexion between the heads of the ribs and the vertebræ. The longissimus dorsi conspires to produce the same effect.

The spine admits, to a certain extent, of a rotatory movement. Thus the head may be carried round by a horizontal motion, until the chin comes nearly on a line with the point of the shoulder, after which the spine may be made to turn on its own axis, until the face shall have completed almost a semi-circle from the point at which its first movement began. The latter movement is effected by that peculiar action of the multifidus spinæ above alluded to ; but it is the muscle of the opposite side from that towards which the movement takes place that produces the rotation, assisted by the obliquus externus abdominis.

Action on ribs.

The influence of the sacro-lumbalis, in depressing the lower ribs, must be evident from its mode of attachment to them. But its accessory muscle (cervicalis descendens), by taking its fixed point at the cervical vertebræ, is enabled to draw up, and therefore elevate, the ribs into which it is inserted.

MUSCLES OF THE UPPER EXTREMITY.

The muscles of the upper extremity, taken in the order of their situation, may be divided into four groups, viz. those placed on the shoulder, on the arm, on the fore-arm, and on the hand. We must, however, commence the description of the moving powers of the limb with that of the two pectoral muscles and the serratus magnus.

Dissection of the upper arm.—The subject being laid on its back, and the arm drawn away from the side, an incision may be made through the skin, commencing at the middle of the clavicle, and extending down to the centre of the axilla. From this another line may be drawn, downwards and inwards, along the lower border of the pectoralis major. The angular flap thus included should then be raised from off the muscle just named, its dissection being conducted from without inwards to the fore part of the sternum, so as to expose the muscle. It may be necessary to make another incision through the skin, along the clavicle, to the sternum, from the point above indicated. The external flap of the skin may then be dissected off the remainder of the pectoral muscle, and part of the deltoid. When the external surface of the pectoralis major has been examined, it may be detached easily by drawing forwards its lower border, and inserting the scalpel between it and the costal cartilages, and cutting through its attachments to them, as well as to the sternum and clavicle, successively. The muscle may then be drawn outwards, and the fold in its tendon examined. The pectoralis minor is thus exposed, and the axillary vessels partly. The costal attachment of this muscle may be separated in the same way as the other. The axillary vessels are by these measures brought fully into view, little else remaining to be done than to remove the cellular tissue in which they are imbedded. For the Axillary Artery,—the Vein, and the Plexus of Nerves, see the account of those structures.

When commencing the dissection of the arm, an incision may be made from the middle of the interval between the folds of the axilla, and thence drawn down to the middle of the space between the condyles of the humerus. This indicates the course of the brachial artery. It should barely divide the skin, care being taken not to injure the fascia beneath it. It will be found convenient to bound it below by a transverse incision ; after which, the skin may be cautiously raised from the fascia all round the arm. In order to expose the deltoid, it will be necessary to make an incision through the integument, commencing at the external third of the clavicle, and extended along the acromion and spine of the scapula ; after which, it may be dissected off the muscle, proceeding from above downwards and outwards, until the whole flap of skin is removed. When the muscle has been examined, it may be easily detached from its origin, and reflected down on the arm, by inserting the scalpel under its posterior border, and cutting from within outwards, close along the margin of the spine of the scapula, and so successively along the acromion and clavicle. This will expose the circumflex vessels and the external rotator muscles.

The fascia of the arm may in the next place be divided, and reflected in the same way as the integument. In doing so, care should be taken not to injure the internal cutaneous nerve. As the fascia is being reflected, the biceps muscle and the brachial artery and the nerves, except the circumflex and spiral, are brought into view. Their relative position, particularly at the bend of the arm, should be attentively considered. If the arm be rotated outward, the direction of the spiral nerve and profunda artery can easily be traced, for some way, between the heads of the triceps muscle. At the outer side of the arm, the nerve will be found in the deep sulcus between the brachialis anticus and supinator longus, after it has made its turn behind the humerus. The external cutaneous nerve also has to reach the external side of the arm, but it runs in front of the humerus, piercing the coraco-brachialis muscle, and then lying between the biceps and brachialis anticus. The examination of the triceps had better be conducted from below upwards, and, when its three heads have been carefully traced out, a longitudinal incision may be made through the substance of the muscle; after which, when the two parts are drawn back, the manner in which the fleshy fibres proceed to the bone, from its tendon or aponeurosis, will be distinctly seen.

THORACIC REGION (ANTERIOR).

Pect. maj. narrows towards arm.

The *pectoralis major* (fig. 109,[1]) (pectoralis; sterno-costo-clavi-humeralis) is placed on the anterior and upper part of the thorax, and in front of the axilla. It is broad and expanded at the former situation, narrowing gradually towards the latter, and *arises* from the sternal half, or a little more, of the clavicle, from the anterior surface of the sternum, extending as far down as the insertion of the cartilage of the sixth rib, from the cartilages of the true ribs, except the first and last, and from the aponeurosis of the external oblique muscle. From this extensive origin the fleshy fibres proceed, converging towards the tendon of insertion; those from the clavicle, which are usually separated from the rest by a cellular interval, pass downwards and outwards; those from the lower cartilages obliquely outwards; the middle set horizontally. The muscular fibres become continuous with those of the tendon, and still retain their original direction as they proceed to their respective points of insertion into the humerus; and as the superior fibres descend, whilst the inferior ones ascend, the latter passing behind the former, the muscle is folded, the middle of the fold being along its axillary border. The muscular fibres end in a tendon which is folded on itself, like the muscle, and is fixed into the anterior margin of the bicipital groove of the humerus; an extension from it, at the same time, continuing across the

Origin.

Muscle and tendon folded.

Insertion.

groove, and in contact with the bone, to blend with the tendon of the latissimus dorsi. The tendon is likewise connected at its insertion with that of the deltoid muscle, and an expansion from it joins the fascia of the arm.

Fig. 109.*

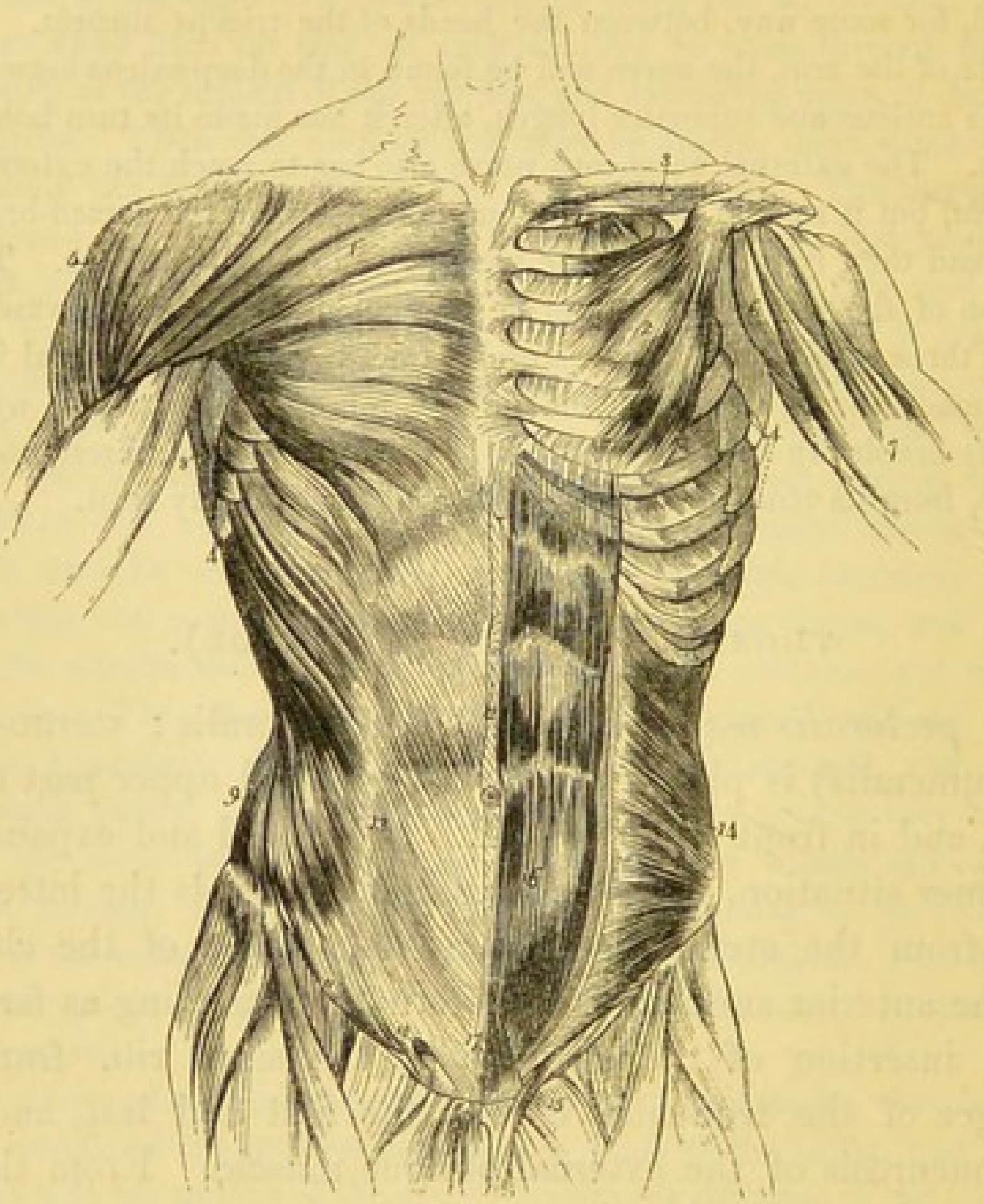

Structure:—The muscle is aponeurotic at its internal and external attachments, and fleshy in the rest of its extent.

Parts adjoining

The aponeurotic fibres of this muscle decussate with those of

---

* From the right side the integuments only were removed; from the left, the greater pectoral muscle and the external oblique, with the anterior part of the sheath of the rectus abdominis, were taken away. 1. Greater pectoral muscle. 2. The smaller pectoral. 3. Subclavius. 4. Serratus magnus. 5. Deltoid. 6. Coraco-brachialis. 7. A part of the biceps. 8. Latissimus dorsi. 9. External oblique of abdomen. 10. The external abdominal ring. 11. Poupart's ligament. 12. Linea alba. 13. Aponeurosis of the external oblique. 14. Internal oblique. 15. Cremasteric fibres on the spermatic cord. 16. Rectus abdominis. 17. Pyramidalis.

the corresponding muscle in front of the sternum; the inferior border overlaps the serratus magnus, and the superior runs parallel with that of the deltoid muscle, from which it is only separated by the cephalic vein and a small artery. The anterior surface is subcutaneous in the greater part of its extent, being only covered by some of the fibres of the platysma myoides, and by the mamma. The posterior surface, besides the sternum, clavicle, and ribs, covers the pectoralis minor, subclavius, and serratus magnus muscles, as well as the axillary vessels and nerves. The lower border of this muscle is at first separated from that of the latissimus dorsi by a considerable interval, in which may be observed the fibres of the serratus magnus; but they gradually converge towards the axilla, forming its folds or borders.

Separ. from deltoid by vein.

Covers axill. vessels.

Folds of axilla.

The interval on the sternum between the muscular parts of the right and left pectoral muscles varies in different cases; in some bodies which afford examples of large muscular development, they are separated only by a narrow groove. One or two muscular slips, taking rise from the aponeurosis of the external oblique muscle, are occasionally added to the lower margin of the pectoral muscle; and, on the contrary, a deficiency may be met with in the same situation. This was, in one case, found to be so extensive as to amount to the absence of all except the clavicular part of the muscle.*

Peculiarities.

Pectoralis minor (fig. 109,^{2},) (serratus anticus,—Alb.; costo-coracoideus).—The smaller pectoral muscle lies at the superior part of the thorax, covered by the preceding muscle, and extended obliquely across the axilla. It *arises* from the upper margin or the upper margin and external surface of three ribs, usually the third, fourth, and fifth, near their cartilages; the origin being notched or serrated, so that by some of the older anatomists the muscle was named from that circumstance. The fleshy fibres, as they proceed obliquely upwards and outwards, converge to a narrow tendon, which is *inserted* into the inner and upper border of the coracoid process near its extremity, and is joined to the coraco-brachialis and the biceps muscle, which are likewise attached to the same process.—The anterior surface is covered by the pectoralis major, the posterior crosses the axillary vessels and nerves.

Pectoralis minor.

Origin.

Is serrated.

Insertion.

Covers axil. vessels.

The *subclavius muscle* (fig. 109,^{3}) (costo-clavicularis) is,

Subclavius.

---

* See the work on Arteries before cited, page 233.

Origin.

Insertion.

Is over subclavian vessels.

as the name implies, placed under the clavicle, in the interval between it and the first rib. It *arises* by a short thick tendon from the cartilage of the first rib, close to the rhomboid ligament, from which it is directed outwards beneath the clavicle, forming a rounded fleshy fasciculus, which is *inserted* into the grooved and rough surface, along the costal aspect of the clavicle, for nearly half its length.—The upper surface is covered by the clavicle, a small part beneath it being overlapped by the pectoralis major, but which is at first not perceptible, until a dense fascia that covers it is dissected off; the costal surface lies in front of the subclavian vessels as they pass down from the neck.

THORACIC REGION (LATERAL).

Serrat. mag.

Nine digitations on eight ribs.

The *serratus magnus* (figs. 107,^{10} 109,^{4}) (costo-basi-scapularis) is placed upon the upper and lateral parts of the thorax, between the ribs and the scapula, being deeply seated in the greater part of its extent. It is broad, thin, and irregularly four-sided (trapezoid) in form. The anterior border presents nine fleshy points or digitations, giving it a serrated appearance, whence its name is taken. By these digitations at its points of attachment the muscle arises from the surface of the first eight ribs (two of the processes being connected with the second rib); and opposite the first as well as a few other intercostal spaces, fibres are derived from slender tendinous structures over the external intercostal muscles. From this extensive origin, the fibres of the muscle, forming a thin stratum and curving as they proceed backwards over the convexity of the ribs, are inserted into the base of the scapula on its inner or costal aspect, being interposed between the subscapularis on the one side and the rhomboidei and levator anguli scapulæ on the other.

Arranged in three parts on scap.

To receive insertions on an extent of surface so much less than that from which they arise, the fibres converge; but as their convergence is not uniform, and the fibres are differently arranged at the upper, middle, and lower ends, three parts of the muscle are recognized as follows. *a.* The fibres from the first and second digitations form a narrow and thick band which terminates on the inner surface of the scapula immediately below the upper angle. *b.* Those of the third and fourth digitations spread out into a thin layer (the thinnest part of the muscle), which occupies the scapula from the preceding part nearly to the lower angle of the bone.—Much the larger portion of this, the middle division of the muscle, is formed by the third digitation, which expands into a triangular form. *c.* From the five remaining digitations (which are received into notches in the external oblique muscle of the abdomen), the muscular structure converges to a thick and partly tendinous mass, and is inserted close to the lower angle of the scapula on its inner surface.

The fibres of the first part of the muscle coalesce from their origin, but the rest remain more distinct, being separated by linear depressions until they approach the scapula; and they have, therefore, a more fasciculated appearance.

Parts adjacent.

One surface of the serratus magnus rests on the superior ribs, the intercostal muscles, and part of the serratus posticus superior; the other is subcutaneous in the angular interval between the pectoralis and latissimus dorsi; higher up it is covered by both the pectoral muscles; in the rest of its extent it is in relation with the subscapular muscle and the axillary vessels.

Not unfrequently the number of digitations, and the number of the ribs with which the muscle is connected, are augmented by one or two; and occasionally the attachment to the first rib is wanting. Examples are recorded of the absence of the thin middle part of the muscle, and some other peculiarities of minor importance, e. g. the presence of additional muscular bands have been noticed.

Action of pectoralis major;

Combined actions.—The most obvious actions of these muscles are exerted upon the shoulder and arm, as being their more movable points of attachment. The *pectoralis major*, conjointly with the latissimus dorsi and teres major, depresses the humerus, if it has been previously elevated; it then conspires with them in pressing the arm closely to the side, and, continuing the same effort, will by itself trail it along the side and front of the chest.

pectoralis minor;

The *pectoralis minor* draws the point of the shoulder downwards and inwards to the thorax. If the arms be fixed, these muscles act on the ribs and assist in dilating the chest. This is frequently observed during the forcible efforts at inspiration made by asthmatic persons; the arms are rendered fixed, by seizing hold of some object, and then every muscular effort is called into play which can elevate the ribs.

and serratus magnus.

When the scapula is rendered fixed by the trapezius and rhomboid muscles, the *serratus* acts on the chest in the same way as the pectoral muscles do; but its most ordinary action is to draw the base and inferior angle of the scapula forwards, so as to elevate the point of the shoulder by means of the rotatory motion it can impress upon it conjointly with the trapezius, as has been observed when treating of the latter muscle. The continuation of the same effort retains the shoulder elevated, as when a burden is sustained upon it; but, as a preparatory measure, the thorax must be fixed. Whilst any important muscular exertion is being performed, the thorax must be fixed, and retained so by preventing the escape of the included air. This may be inferred from observation on what takes place under such circumstances, but was reduced to the test of experiment by M. Bourdon.* He opened the trachea, or larynx, of a dog that had been in the habit of jumping and tumbling when bidden; after which, the animal was no longer able to make any similar efforts, though evidently willing to do so. But when the aperture was closed, by drawing the margins of the wound together, the lost power was instantly restored.

ACROMIAL REGION.

Deltoid; curves over shoulder.

The *deltoid muscle* (fig. 109,^{5}) (deltoides; sub-acromio-humeralis) is situated at the superior and external part of the arm, covering the shoulder-joint over which it is curved,—being placed at the same time in front and behind it as well as on its outer side. Its form is triangular, the base above, and the apex below, and is thus the shape of the Greek letter Δ reversed, from which circumstance the muscle has been named.

Origin. Insertion.

It *arises* from the external third of the clavicle, from the lower border of the acromion, and from the spine of the scapula as far back as the small triangular surface in which it terminates; and is *inserted* into the rough prominence on the middle of the outer side of the humerus. At its origin the deltoid is tendinous and fleshy, except at the back part of the spine of the scapula, where it is tendinous only. Moreover, the surface of origin is much increased by means of processes of fibrous structure, which extend from the acromion downwards through the muscle and give rise to fleshy fibres. The lower end is muscular on the cutaneous surface, and its deeper part is formed by a thick tendon. The whole appearance of the muscle is coarse, the muscular bundles being separated by broad cellular interspaces.

Tendinous bands for origin of musc. fibres.

As the fibres converge, they necessarily have different directions. All are directed downwards,—those in the middle

---

* Mémoire sur les Efforts.

vertically, those from before and behind obliquely, the former being inclined backwards, the latter forwards.

Parts adjacent.

The deltoid is separated from the integuments by a thin layer of fascia, with a portion of the platysma and a few nerves. It covers the tendon of the pectoralis major, the circumflex vessels and nerve, the outer side of the humerus, the fibrous capsule of the shoulder-joint (a synovial bursa or laminated cellular membrane being interposed,) the coracoid process, the pectoralis minor, coraco-brachialis, biceps, subscapularis, coraco-acromial ligament, the external rotator muscles, and the triceps. The anterior border is in contact with the pectoralis major (from which it is partly separated by the cephalic vein,) and more inferiorly with the biceps; the posterior border is bound down by fascia.

Subdivisions of the muscle.

From the manner in which the tendinous structure is mixed with the fleshy fibres of this muscle at its middle, several subdivisions are to be recognized. Albinus* points out seven portions arranged into two orders. The first order consists of four parts, which are each characterized by being broad at the upper end, and narrowing downwards. Two of these, which are large, constitute the anterior and posterior parts of the muscle, and occupy, one the clavicle, the other the spine of the scapula; the two smaller are connected with the acromion. The second order consists of three slender parts. They are interposed between the former, and are distinguished from them by being narrow at the upper part of the muscle, where they begin as tendinous bands.

The arrangement here pointed out appears to resolve itself into the facts before indicated, namely, that most of the muscular fibres are derived from the bones directly, or from a short tendinous structure; and that tendinous bands descending from the acromion at intervals divide these fibres into parts (the first order of Albinus), and give origin to other fibres at some distance downwards (the second order of the same author). It should be added, that the arrangement of the fibres does not in all cases conform with the description of Albinus, though the general character is the same.—The extent to which the muscle reaches on the humerus varies in different persons.

SCAPULAR REGION (POSTERIOR).

Supra-spinatus.

Supra-spinatus (fig. 107,[12]).—This muscle is placed at the superior part of the shoulder, in the supra-spinous fossa of the

---

* The mode of considering the structure of the muscle, or the facts on

Origin. scapula. Its form is elongated and triangular. It *arises* from the posterior two-thirds of the fossa above mentioned, and from the fascia which covers the muscle; the muscular fibres converge to a tendon in their middle, which adheres to the capsule of the Insertion. shoulder-joint, and is *inserted* into the superior surface of the greater tuberosity of the humerus.

Parts over and under. The supra-spinatus is covered by the trapezius, coraco-acromion ligament, and deltoid. It lies against the scapula and the ligamentum proprium posticum, together with the supra-scapular nerve and vessels, the omo-hyoideus muscle, and the fibrous capsule of the shoulder-joint, with which it is intimately united.

Infra-spinatus. Origin. The *infra-spinatus* (fig. 107,[13]) occupies the chief part of the infra-spinous fossa, and is triangular in shape. It *arises* from the lower surface of the spine of the scapula, and from the posterior two-thirds of the convex part of its dorsum. The fibres converge to a tendon, at first concealed in a great degree within the substance of the muscle, but which afterwards proceeds forwards over the capsular ligament of the joint, to be Insertion. *inserted* into the middle facet of the great tuberosity of the humerus. The superior fibres are nearly horizontal, the inferior ones ascend obliquely to meet them.

Structures adjacent. The posterior surface is covered, partly by the deltoid, the latissimus dorsi, and trapezius, a small part also being separated from the integument only by the fascia. The anterior one rests on the bone, (vessels and nerves being interposed,) and the capsular ligament, to which it is intimately adherent. The lower border is in contact with the teres minor, and is united posteriorly with it and the teres major.

Teres minor. The *teres minor* (fig. 107,[14]) lies along the inferior border of the scapula; its form is elongated, narrow and round. It Origin. *arises* by a series of oblique fibres from the dorsal surface of that ridge which surmounts the axillary border of the scapula, and from two aponeurotic septa, placed between it and the infra-Insertion. spinatus and teres major muscles. Its *insertion*, which lies immediately below that of the infra-spinatus, into the greater

---

which it was founded, appear to have been suggested by Douglas in personal communication with Albinus.—See the " Histor. muscul. hom." p. 423.

tuberosity of the humerus, is effected by means of a thick tendon.

Parts adjacent.

The teres minor is covered by the integuments and the deltoid muscles. It is supported by the scapula, (the dorsal branch of the sub-scapular artery ramifying between them) the long head of the triceps muscle, and the fibrous capsule of the shoulder-joint, to which it adheres like the preceding muscles. The upper border lies in contact with the infra-spinatus; the lower with the teres major, from which it is separated anteriorly by the long head of the triceps; the posterior extremity is, as it were, inserted between the teres major and infra-spinatus, being connected with both, as has been above stated.

—The three flat surfaces marked on the upper part of the great tuberosity of the humerus give insertion to the three muscles last described, taken in their regular order, from above downwards.

Teres maj.

The *teres major* (fig. 110,[1]) extends from the inferior angle of the scapula to the humerus, contributing to form the posterior border of the axilla. It is rather broad and compressed than round or tapering, as its name would imply.

Origin.

It *arises* from the flat expanded surface placed at the inferior angle of the scapula, and from the septa interposed between it and the teres minor and infra-spinatus.

Insertion.

The *insertion* takes place by a broad flat tendon into the posterior border of the bicipital groove in the humerus, and is in close contact with the tendon of the latissimus dorsi. The direction of the muscle must necessarily vary according to the different positions of the scapula and humerus. Towards their insertion the fibres of the teres major appear to descend somewhat, whilst those of the latissimus ascend, so that the margin of the former is placed lower down than that of the latter muscle.

Adjacent structures.

This muscle is covered by the latissimus dorsi and integument, and is crossed by the long head of the triceps, which separates it from the teres minor; the anterior surface, in part of its extent, is in contact with the latissimus (in consequence of the change of direction of the latter), and slightly with the coraco-brachialis and the brachial vessels.

SCAPULAR REGION (ANTERIOR).

Sub-scapularis.

Origin.

Insertion.

Sub-scapularis (fig. 110,^{2}).—The sub-scapular muscle, triangular in form, fills up the hollow of the scapula, lying between that bone and the thorax, from which, however, it is separated by the serratus magnus muscle. It *arises* from the posterior two-thirds of the sub-scapular fossa, with the exception of a narrow line along the base, and two wider spaces near the upper and lower angles of the bone, which are occupied by the serratus magnus; a portion of the muscle is likewise derived from slender tendinous laminæ intersecting it and connected with the ridges on the bone. From this extensive origin the fibres are directed outwards, converging and augmenting the thickness of the muscle, and end in the tendon of insertion, (which is at first concealed among them,) as well as in several elongations of it, which penetrate deeply into the substance of the muscular structure. The tendon is attached to the small tuberosity of the humerus.

Fig. 110.*

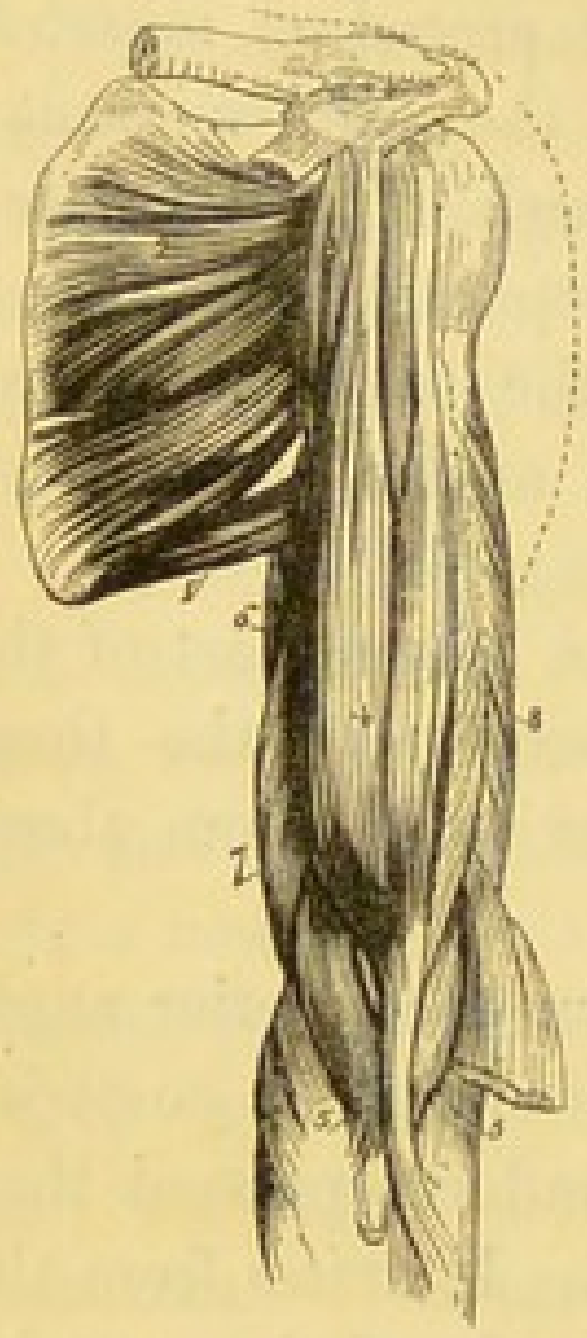

Parts adjacent.

The sub-scapular muscle is very deeply placed. It is in contact by the outer surface with the scapula and the capsule of the shoulder-joint (partly with the synovial membrane through an aperture in the fibrous structure); and, by the inner or anterior surface, with the serratus magnus, (loose cellular substance being interposed,) and the coraco-brachialis and biceps, with the axillary vessels and nerves. The upper margin is close to the coracoid process of the scapula, and a synovial membrane has been found between them.

A band of muscular fibres, from two to three inches in length, is sometimes found extending from the scapula to the neck of the humerus immediately below the sub-scapularis.

---

* Muscles of the left shoulder and arm. 1. Teres major. 2. Sub-scapularis. 3. Coraco-brachialis. 4. Biceps brachialis. 5. Brachialis anticus. 6, 7, 8. Triceps.

Elevators of the humerus.

Actions.—The *deltoid* can raise the arm directly from the side, so as to bring it at right angles with the body; after which, by means of its anterior and posterior fibres, it can carry the limb alternately backwards and forwards, being assisted in the former movement by the teres major and latissimus dorsi, in the latter by the pectoralis major. The mass of its muscular fibres is so considerable, that it is enabled, by pressing down the head of the humerus, to make it glide upon the surface of the glenoid cavity of the scapula, and then, by continuing the effort, to raise the limb directly upwards, so as to bring it to the vertical position. Its only assistant in elevating the arm is the supra-spinatus (whose power in this respect must be trivial, as it is inserted so near the centre of motion).

Rotators.

The *supra-spinatus*, *infra-spinatus*, and *teres minor* are the external rotators of the arm, whilst the sub-scapularis rotates it inwards; for, as they are opposed in situation, so they are antagonists in action. The power of these muscles is increased in no small degree by passing over the globular head of the humerus, and also by being inserted into the prominent processes of bone which remove the line of their direction to a distance from the axis of the humerus.

Depressors.

The *teres major* conspires with the latissimus dorsi in its actions; it depresses the arm, if raised, and rotates it on its axis. If the arm be fixed, as when, in the reclining posture, the elbow is removed from the side, these muscles, particularly the teres major, assisted by the long head of the triceps, can approximate the lower border of the scapula to the shaft of the humerus, thus conspiring with other muscles, viz. the pectoralis and latissimus dorsi, to trail the body after the out-stretched limb.

HUMERAL REGION (ANTERIOR).

Coraco-brachialis.

Coraco-brachialis (perforatus,—Casserius*) (fig. 110,^{3}).—This, the smallest muscle of the upper arm, is placed along the superior and inner part of the humerus for about half its length. It *arises* from the coracoid process of the scapula, between the pectoralis minor and the short head of the biceps; also from the tendon of the latter, with which it is intimately united for some way. The fleshy fasciculus thus formed passes downwards and a little outwards, to be inserted into the inner side of the humerus about its middle, where it is interposed between the brachialis anticus and the triceps. Structure:—aponeurotic at its attachments, fleshy in the middle.

The anterior surface of this muscle is covered above by the

---

* "Tabulæ Anatom." edited by Daniel Bucretius (Rindfleisch), tab. 19 and 20. The name has reference to the perforation by the musculo-cutaneous nerve.

deltoid and pectoralis major, and at its insertion is crossed by the brachial artery. The posterior surface runs over the tendon of the sub-scapularis, and those of the latissimus dorsi and teres major ; one border is in apposition with the biceps, the other with the brachial artery. The muscle is usually pierced by the musculo-cutaneous nerve.

Biceps.

The *biceps* muscle (fig. 110,[4]) (biceps flexor cubiti ; coraco-scapulo-radialis) lies along the anterior part of the arm for its entire length, extending from the scapula to the fore-arm. Superiorly it is divided into two heads, whence its name is derived. Of these, the internal or short head arises conjointly with the coraco-brachialis from the coracoid process of the scapula by a thick tendon, which spreads out and gives origin to the muscular fibres. The external or long head commences by an elongated and rounded tendon, which springs from the upper margin of the glenoid cavity of the scapula, and is continuous with the glenoid ligament. The tendon passing immediately over the head of the humerus, covered by a special tube of the synovial membrane of the joint, pierces the fibrous capsule at its humeral attachment, and, after descending some way in the groove of the bone appropriated to it, spreads into a round expansion from which the muscular fibres take their rise. The fleshy fibres of the two heads join and form what is named the belly of the muscle, which is broad and somewhat flattened, and ends above the bend of the elbow in the tendon of insertion. This sinks between the muscles of the fore-arm, to be inserted into the posterior part of the " bicipital " tuberosity of the radius ; from the anterior part of which process it is separated by a synovial bursa. The tendon is at first broad and thin, but it gradually narrows, and when approaching the radius is twisted on itself, so as to be applied by a flat surface to the bone on which it ends. At its commencement a fibrous expansion, presenting an arched border, is sent off from the tendon, and this process passes obliquely downwards and inwards, and becomes blended with the fascia of the fore-arm somewhat below the inner condyle.—The expansion is stretched across the brachial artery, median nerve, and part of the pronator teres muscle.

Short head. Long head. Tendon of insertion. Expansion from tendon covers artery.

Parts adjacent.

The anterior surface of the muscle is overlapped superiorly for some way by the deltoid and pectoral muscles ; but in all the rest of its extent it is covered only by the integument and fascia, with the exception, however, of the lower tendon, which sinks deeply between the muscles, and at its termination corresponds with a notch in the margin of the supinator brevis. The posterior surface, for about half its length, rests on the humerus and shoulder-joint, and in the rest on the brachialis anticus, being separated from the latter by the musculo-cutaneous nerve. The inner border is in contact with the coraco-brachialis for half its length, and with the brachial artery for the rest. The connexion of the long tendon of origin with the shoulder-joint has been sufficiently noticed.

Brachial artery along inner side.

A third head, taking origin from the humerus, is occasionally added to this muscle. The fibres are usually more or less blended at their origin with the brachialis anticus (I have seen them arise between it and the lower end of the coraco-brachialis); and they were, therefore, considered by Albinus to be an offset from that muscle to the biceps. The added part, which is sometimes equal to half the size of the coraco-brachialis, joins the biceps at its posterior and inner side near the tendon, and lies outside the brachial artery; but in at least two instances I found such an accessory piece crossing over the artery. A muscular band has been observed to extend in the opposite direction to the foregoing, viz. from the biceps to the inter-muscular septum above the inner condyle of the humerus. This had the appearance of a second coraco-brachialis; it lay over the brachial artery.*

An additional "head" to muscle.

Unusual insertion to humerus.

Brachialis anticus (brachialis internus,—Douglas and Albinus; humero-cubitalis) (fig. 110,^{5}).—This muscle lies under cover of the biceps, along the lower half of the arm. In form it is somewhat compressed, and is broader in the middle than at the extremities. It *arises* from the fore part of the humerus, commencing at the insertion of the deltoid, (which it embraces by two angular fleshy processes,) and extending nearly to the border of the trochlea; some fibres also arise from the inter-muscular septa at each side. After passing in front of the elbow-joint, the muscular portion ends in a thick fasciculus of tendinous fibres, which is *inserted* into the rough surface on the fore part of the coronoid process of the ulna, where it is received into a notch on the upper extremity of the flexor digitorum profundus. The middle fibres are vertical, those on each side converge a little to them.—The posterior surface rests on the bone and capsular ligament; the anterior, partly con-

Brachialis anticus.

Origin.

Notched for deltoid.

Insertion in notch of flex. profundus.

---

* See a Treatise on Arteries, before cited, page 270 and plate 57.

cealed by the biceps, projects somewhat at each side of it, and supports the brachial artery and median nerve.

Some fibres from the middle of the brachialis anticus have been found to pass in an unusual direction inwards over the brachial artery to be connected with the internal inter-muscular septum. See the work referred to for peculiarities of the biceps, p. 271.

Action of biceps and brach. ant.

Combined Actions.—The most obvious action of the *biceps* is that of flexing the fore-arm, in which it conspires with the *brachialis anticus;* it also serves to render tense the fascia of the arm by means of the process which connects its tendon with that membrane. If the arm be placed in the prone position, the biceps can turn it supine, being in this particular the direct antagonist of the pronator radii teres. When the fore-arm is rendered fixed by holding some firm object, the biceps and brachialis muscles can draw on the humerus, and bend it forwards on the arm, which is exemplified in the effort of climbing. They also can move the humerus on the scapula; but their influence in this respect must be very limited, as they run parallel with the axis of the bone. When the humerus is fixed, these muscles, by drawing on the coracoid process, move the scapula, and therefore the glenoid cavity on the head of the bone, so that the latter may receive support from the former, rather than that it should be pressed up against the capsular ligament solely.

HUMERAL REGION (POSTERIOR).

Triceps.

The *triceps cubiti*,—Douglas; triceps brachii,—Alb. (fig. 111), the only muscle that lies behind the bone and inter-muscular septa, rests against the posterior surface of the humerus in its entire length, and extends from the lower border of the scapula to the upper extremity of the ulna. Superiorly it is divided into three processes or heads, whence its name is derived, whilst its lower half, or more, is single and undivided. The *long head*[1] arises from the lower part of the glenoid cavity and an adjoining rough portion of the inferior costa of the scapula, by a tendon which spreads over the sides of the muscular structure to whose fibres it gives origin. The muscular fibres from this source, passing downwards between those of the other two parts or heads, end by joining with them in the common tendon of insertion. The *external head*[2] takes origin by tendinous and fleshy fibres from the humerus immediately below the great tuberosity, where it gives insertion to the teres minor, and from the surface of the bone below that point: from likewise the ridge above the external condyle, together with the external inter-muscular septum. The fibres proceeding from this extended ori-

Long head.

Extl. head.

Fig. 111.*

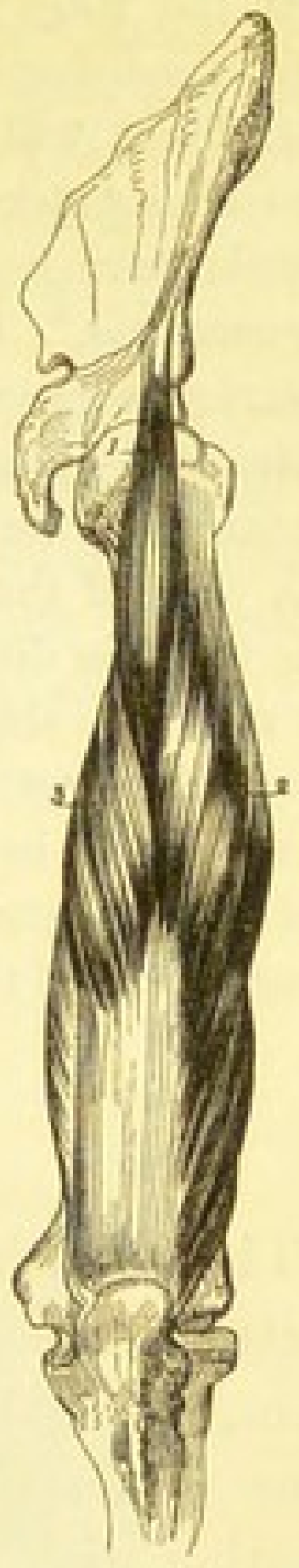

gin follow different directions to terminate in the general mass on the common tendon. The *short head*[3], placed to the inner side, and derived likewise from the humerus, commences by muscular fibres having a narrow and pointed form, near to the insertion of the teres major, taking their rise from this part, from the inter-muscular septum above the inner condyle and the posterior surface of the humerus; the fibres are directed, some immediately to the olecranon, the rest to the general tendon of insertion.

Short head.

The tendinous structure on which the large mass of muscular fibres is received inferiorly, consists of two strata. One of these, which is subcutaneous, covers the muscle to a considerable extent, and is the cause of the flatness above the elbow which is especially apparent when the muscle is put into action. The second layer is placed deeply, and both, after giving insertion to the muscular fibres, and joining together above the olecranon, are fixed to the posterior and upper part of that process.

Tendon of insertion.

The long head of the triceps lies between the two "teres" muscles, and is in contact with the capsule of the shoulder-joint. The muscle is separated from the bone by the musculo-spiral nerve and the superior profunda artery, which correspond with a groove before noticed and are covered by slender fibrous structure. It is separated at each side of the bone from the muscles in front of the arm by the inter-muscular septa connected with the ridges above the condyles of the humerus. The lower part covers the elbow-joint; and between the tendon and the top of the olecranon is interposed a synovial bursa which in some instances is multilocular.

Parts adjacent.

Synovial bursa.

M. Theile† limits the origin of the second head of the triceps muscle to the part of the humerus above the spiral groove for the musculo-spiral nerve; and this anatomist assigns to the short head all the fibres given

---

* The triceps muscle seen from behind. The scapula has been raised from its ordinary position.

† Müller's "Archiv." &c. 1839. S. 420, and "Sœmmerring v. Baue," &c.

from the posterior surface of the bone below that groove, as well as those from the ridge above the external condyle of the humerus.

Sub-anconeus.

On removing the triceps from the lower part of the humerus, some muscular fibres will be found connected with the capsule of the elbow-joint. Two slips extending from the bone above the fossa for the olecranon to the capsule have been described as distinct from the triceps, under the name *sub-anconæus.*[*] These fibres are analogous to the subcrureus, which occupies a corresponding place in the lower limb.

Actions.—When the fore-arm is flexed, the triceps, by drawing on the extremity of the ulna, is enabled to extend it on the humerus, and so bring both parts of the limb into a right line. In situation, as well as in action, it is thus the direct antagonist of the biceps and brachialis anticus. When the arm is in the extended position, the long head of the triceps may assist, in some degree, the teres major and latissimus in carrying it backwards. If the elbow be fixed, the scapula becomes relatively the more movable point of attachment of the muscle; and then its long head, by acting on the lower border of that bone, can approximate it to the shaft of the humerus.

MUSCLES OF THE FORE-ARM.

The muscles of the fore-arm are very numerous, and their relations complex. In order to facilitate the examination of them, we shall divide them into groups, according to the positions which they occupy. The tendon of the biceps muscle, together with the brachial vessels, as they dip down at the bend of the elbow-joint, are placed between two masses of muscles, one of which lies to the inner or ulnar side, the other to the outer or radial; the former being attached to the internal condyle of the humerus, the latter to the external. Another set of muscles, which likewise admits of subdivision, occupies the posterior aspect of the limb.

BRACHIAL REGION (INNER AND ANTERIOR).

The muscles here placed are disposed in two sets, one being superficial, the other deep-seated.

The *dissection* of the fore-arm may be commenced by making an incision through the skin, from the middle of the interval between the condyles of the humerus to the root of the thumb; this marks out the course of the radial artery, and may be bounded by a transverse incision at each extremity. If the integument be drawn tightly forwards, and reflected inwards, the cutaneous nerves may be seen running in the cellular tissue between it and the fascia; and, when once found, there can be little difficulty in tracing them

---

[*] Theile in "Sœmmerring v. Baue," &c.

in their entire extent, as they can be made to rest on the fascia, which gives them a firm support, whilst the scalpel is carried from above downwards along their cutaneous surface. After the superficial nerves and veins have been examined, the fascia may be dissected off the muscles. The examination of the muscles should be conducted in the order in which they are described, commencing with those attached to the inner condyle.

Superficial muscles ;

their common tendon.

The *superficial muscles* of the anterior and inner part of the fore-arm are, the pronator radii teres, flexor carpi radialis, palmaris longus, flexor carpi ulnaris, and flexor digitorum sublimis. These are all intimately united at their origin from the inner condyle, to which they are attached by a *common tendon* that gives a fasciculus of fibres to each, and also sends septa between them.

Pron. teres.

Origin in two parts, which are separated by median nerve.

Pronator teres,—Douglas and Albinus ; pronator radii teres,—Cowper (fig. 112,[1]).—This muscle is extended obliquely across the front of the arm at its upper third. It *arises* by two distinct heads ; one, large and superficial, is derived from the upper part of the inner condyle of the humerus, also from the common tendon above mentioned, from the fascia of the fore-arm, and the septum between this muscle and those nearest to it. The second head, a thin fasciculus deeply placed, comes from the inner margin of the coronoid process, and joins the other at an acute angle, being previously separated from it by the median nerve. The fleshy belly thus formed proceeds outwards and downwards, and ends in a flat tendon which turns over the radius, and is inserted into a rough surface on the outer side of that bone.

Fig. 112.*

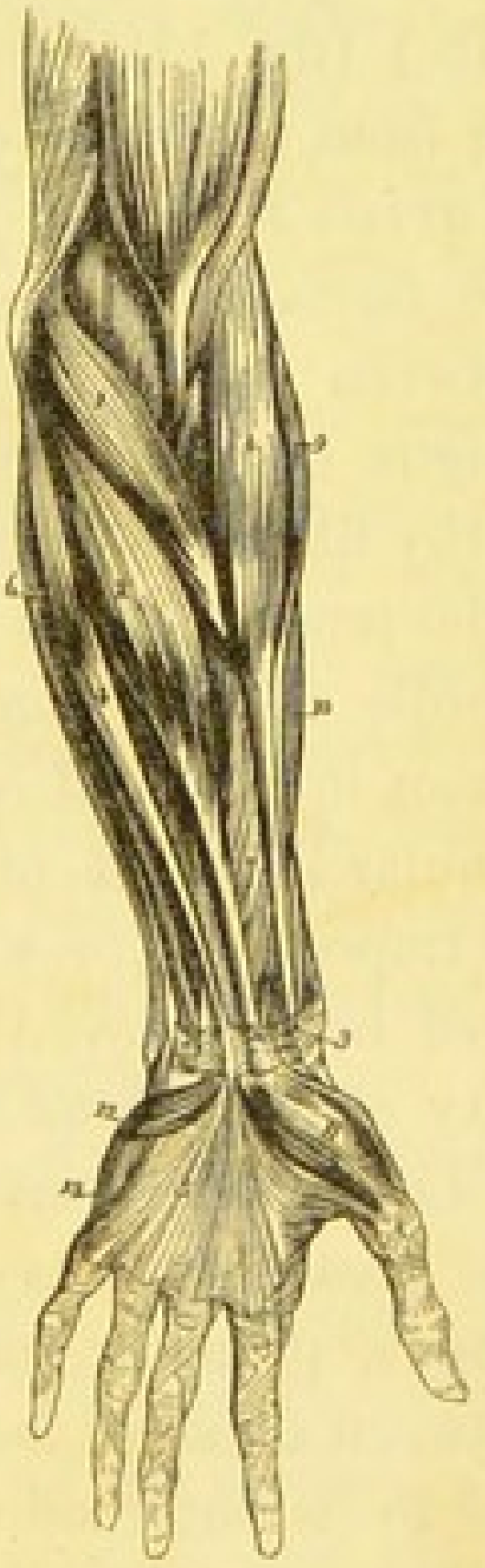

Parts adjacent.

The anterior surface of the pronator teres is superficial in the greater part of

---

* The superficial muscles of the left fore-arm. 1. Pronator teres. 2. Flexor carpi radialis. 3. Anterior annular ligament. 4. Palmaris longus. 5. Palmar fascia. 6. Flexor carpi ulnaris. 7. Flexor digitorum sublimis. 8. Supinator longus. 9, 10. Extensor carpi radialis longior and brevior. 11. Short muscles of the thumb. 12. Palmaris brevis. 13. Muscles of little finger.

its extent; but towards its insertion it is crossed by the radial artery and nerve, and the supinator longus muscle. The ulnar border is in contact with the flexor carpi radialis and palmaris longus: the radial border bounds, with the supinator longus, an angular space, in which are placed the brachial artery, the median nerve, and the tendon of the biceps muscle. The pronator teres covers the flexor sublimis digitorum and ulnar artery; and the fibres which arise from the ulna pass between the last-named artery and the median nerve.

[illegible] √

Increase in extent of origin.

The origin of the pronator teres sometimes increases in extent, the additional fibres being derived from the inter-muscular partition above the inner condyle of the humerus. The added portion is usually continuous with the upper margin of the muscle; but in some instances it will be found separated at first from it by an interval. This peculiarity of the muscle I have repeatedly found associated with a change in the direction of the brachial artery.*

Flex. carpi radialis.

The *flexor carpi radialis*, —Cowper, (radialis internus,—Alb.) (fig. 112,^{2},) is situated in front of the fore-arm, extending from the inner condyle to the outer side of the metacarpus. It *arises* from the inner condyle by the common tendon, from the fascia of the arm, and from the inter-muscular septa placed between it and the pronator teres on one side, the palmaris longus on the other, and the flexor sublimis posteriorly. The fleshy fibres soon end in a fibrous expansion, which narrows into a flat tendon, and is free from the muscular part a little below the middle of the fore-arm. Arrived at the carpus, the tendon passes in a special compartment at the outer side of the anterior annular ligament of the wrist, and runs through a groove in the os trapezium (to which it is bound by a thin fibrous sheath, lined by a synovial membrane), to be *inserted* into the extremity of the second metacarpal bone.

Parts adjoining.

The anterior surface is covered by the fascia and integument; the posterior rests on the flexor sublimis, the flexor pollicis longus, pronator quadratus, and wrist-joint. Its tendon lies between those of the supinator radii longus and palmaris longus, and to its outer side lies the radial artery.

Palm. long.

The *palmaris longus* (fig. 112,^{4}), the smallest of this mass of muscles, lies along the middle of the fore-arm, on the ulnar side of the preceding muscle. It *arises* from the inner condyle and the inter-muscular septa; the small fleshy belly of the

---

* "The Arteries," &c. page 260 and 264, and plates 36 and 37.

upper part soon ends in a long slender tendon which is *inserted* into the annular ligament of the wrist, continuing into the palmar fascia[5].—This muscle is placed between the flexores carpi radialis and ulnaris, resting on the flexor sublimis.

The muscle may be absent; or double.

The palmaris longus is frequently altogether wanting. When present, it is subject to many variations of form, e. g. the muscular fibres may occupy the middle of the muscle, which then commences and ends by an elongated tendon; or the muscular structure may occur towards the lower end, the upper part being tendinous. Occasionally there are two long palmar muscles, one having the ordinary shape, while the other has one of the forms above referred to. The most remarkable peculiarity is that in which a small muscle (a second palmaris longus, placed nearer to the inner border of the fore-arm than the usual muscle) covers the ulnar artery for some space above the carpus, and terminates, partly in the annular ligament of the carpus or the fascia, and partly in the short muscles of the little finger. I have elsewhere given an account of some examples of this peculiar muscle.*

Flex. carpi ulnaris.

The *flexor carpi ulnaris*,— Cowper, (ulnaris internus,— Alb.,) (fig. 112,[6],) lies superficial along the ulnar border of the fore-arm, being extended from the inner condyle to the inner margin of the wrist. It *arises* by two short processes, the interval between which is occupied by fibrous structure arching over the ulnar nerve. One of these is attached to the inner condyle, the other to the border of the olecranon. The muscle is also connected with inter-muscular septa, and for some distance with the inner side of the ulna by a dense fascia. The muscular fibres from these different points of attachment terminate in a tendon, which is *inserted* into the pisiform bone, and into the base of the fifth metacarpal bone. The tendon is at first concealed within the muscle, but it afterwards appears on the outer side, and receives muscular fibres on the opposite side nearly to its termination, and is, therefore, semi-penniform.

Origin—two parts, separated by ulnar nerve.

The anterior surface is covered by the skin and fascia, the posterior rests on the flexor profundus, and overlaps the ulnar nerve and artery;—towards the lower part of the fore-arm the artery is opposite the outer margin of the muscle, and this is taken by surgeons as a guide to the position of the vessel.

Is guide to uln. artery.

The *flexor digitorum sublimis vel perforatus* (perforatus,— Cowper; sublimis,— Alb).— The superficial flexor of the

---

* "The Arteries," &c. page 334, and plate 45.

Flex. digit. sublimis is between superficial and deep musc.

fingers (fig. 112,⁷) is placed at the anterior part of the fore-arm, between the preceding muscles which conceal it, and the flexor profundus and flexor longus pollicis which are beneath it. It is flat and broad in the upper part, and inferiorly divides into four tendons. It *arises* from the inner condyle, by the common tendon and the fibrous septa common to it and the other muscles, also from the internal lateral ligament, from the anterior surface of the coronoid process at its inner side, and from the oblique line extended downwards from the tubercle of the radius. The fleshy belly enlarges towards the middle of the arm, but diminishes somewhat before its division. The four tendons pass under the annular ligament of the wrist in pairs, one of which is placed in front of the other; the anterior pair consists of the tendons for the middle and the ring fingers, the posterior of those for the index and the little fingers.

Origin.

Four tendons

Fig. 113.†

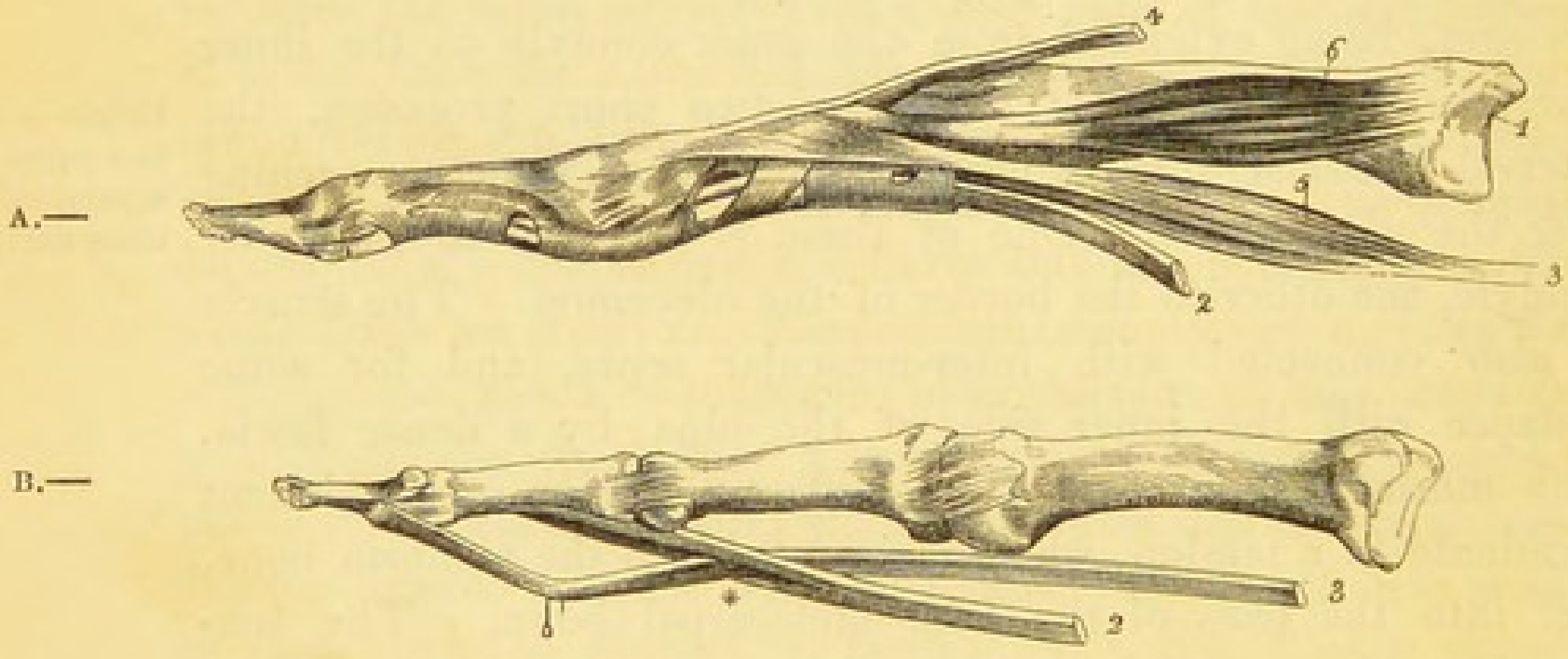

accompany tendons of flex. profundus.

As they proceed to their destinations the tendons diverge, (the largest being that for the middle finger, the smallest for the little finger,) and each, accompanied by a tendon from the flexor profundus, enters beneath fibrous bands (ligamenta vaginalia), (fig. 113, A,) which are firmly fixed to the margins of the phalanges, and bind both tendons together down to the palmar sur-

---

† The metacarpal and phalangal bones of two fingers, with the tendons. In the first figure the tendons of the flexor muscles are bound to the finger by the fibrous bands; in the second they are freed from that structure, as well as from the synovial membrane and the vincula accessoria. 1. Metacarpal bone. 2. Tendon of flexor sublimis. 3. Tendon of flexor profundus. * The perforation of the former by the latter. 4. Tendon of extensor digitorum communis. 5. A lumbricalis muscle. 6. An inter-osseous muscle.

face of the bones;—and thus a fibro-osseous canal is constructed for the tendons. Opposite the first phalanx the tendon of the flexor sublimis presents a fissured interval, (fig. 113, B,) which transmits that of the deep flexor, (whence the name perforatus,) and finally, after expanding somewhat and forming on its palmar surface a groove, which is adapted to the accompanying tendon, it is *inserted* into the fore part of the second phalanx. The same arrangement obtains in each instance within the canals on the fingers. A few slender and loose filaments are extended from the phalangal bones to both the tendons. They have been named "vincula accessoria tendinum," or "vincula vasculosa."

Both in canals on fingers.

Tendon perforated.

Insertion.

Vincula accessoria.

Superiorly, the flexor sublimis is concealed by the other muscles of this set, and is crossed near the radius by the radial artery; it rests on the flexor pollicis longus and flexor profundus, separated from the latter by the median nerve and the ulnar artery. In the palm of the hand, its tendons are covered by the palmar fascia, the superficial palmar arch of arteries, and the branches of the median nerve, and they lie in front of the accompanying tendons of the flexor profundus, except after they have been perforated by these. Where the tendons slide beneath the annular ligament, they are invested by a synovial membrane, and a similar provision for easy movement exists on the phalanges of each of the fingers.

Parts over and under.

Synovial sac under ann. ligt. and on each finger.

This muscle is subject to several slight variations from the arrangement above described. One or two may be referred to. A muscular slip is frequently given from it to the flexor profundus, or to the flexor longus pollicis. The tendon for the little finger is sometimes wanting, and I have seen this coincide with a similar deficiency in the foot.

The *deep-seated* muscles, on the anterior surface of the forearm, are the flexor profundus, flexor pollicis longus, and pronator quadratus.

Deep muscles.

Dissection.—When the superficial muscles have been examined, consisting of the pronator teres, flexor radialis, palmaris longus, flexor ulnaris, and flexor sublimis, their common origin may be divided, and the whole mass drawn down towards the hand, which will expose the flexor profundus and flexor pollicis longus, as well as the median nerve and ulnar artery. The inter-osseous nerve and artery will at once be found between the two muscles last mentioned.

Flexor digitorum profundus vel perforans (perforans,—Cowper; profundus,—Alb.)—The deep flexor of the fingers (fig.

Flex. profundus.

Origin.

Four tendons.

They perforate those of flex. sublimis.

114,[1]) lies towards the ulnar side of the fore-arm, covered by the preceding muscles. It is thin and compressed above, presents in the middle a fleshy belly of considerable size, and inferiorly is divided into four tendons. The muscle *arises* from the hollow at the inner side of the olecranon,—from the inner border and anterior surface of the ulna, to within a few lines of the edge of the pronator quadratus, and from the ulnar half of the inter-osseous ligament. The tendons are free from the muscular substance above the wrist, and that destined for the index-finger is distinct from the others, which are connected together as far as the palm. Under the annular ligament, they lie behind the tendons of the flexor sublimis, and they maintain the same relation to these latter as they pass along the metacarpal bones and digital phalanges. Opposite the first phalanx, the tendon of each finger passes through the fissure formed for its transmission in the tendon of the flexor sublimis (fig. 113, B), and proceeds to be *inserted* into the base of the last phalanx. The tendons are bound to the phalanges by fibrous bands, and loosely connected with those bones by the slender vincula accessoria, in the manner mentioned in describing the last muscle.

Fig. 114.*

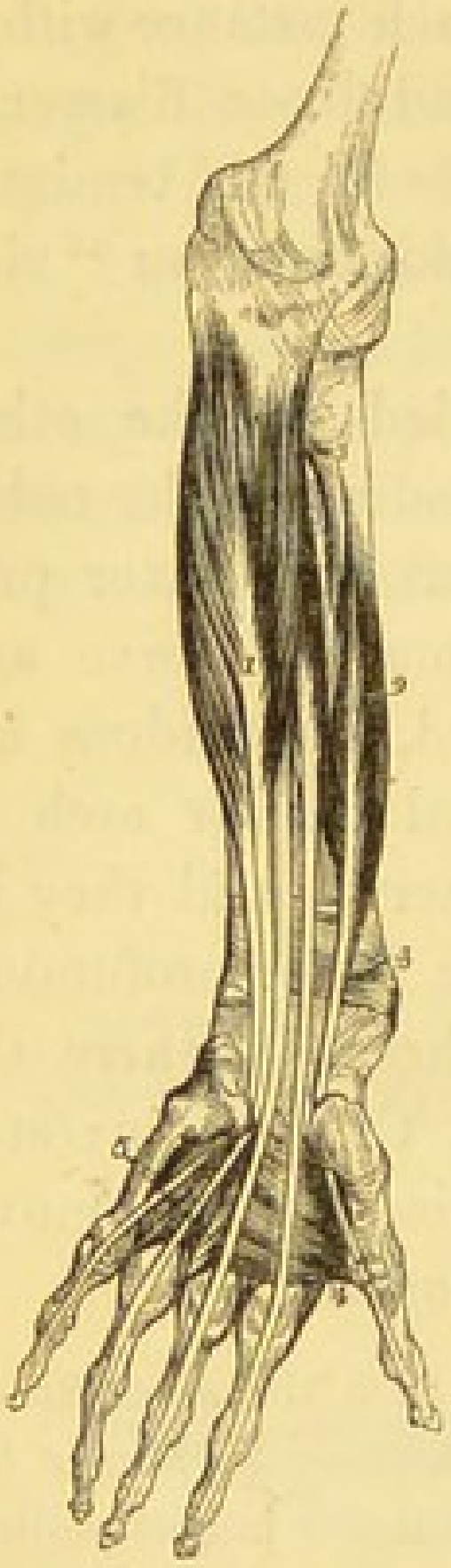

Parts adjacent.

Embraces brach. ant.

Supports ulnar artery.

The upper extremity of the muscle in a manner embraces the insertion of the brachialis anticus. The posterior surface rests on the ulna, the inter-osseous ligament, and pronator quadratus; the anterior one is covered by the ulnar artery and nerve, the median nerve, and the other flexor muscles. The external border is parallel with the flexor pollicis longus, from which it is separated, on the inter-osseous membrane, by the anterior

---

* The deep muscles of the anterior surface of the fore-arm. 1. Flexor profundus digitorum. 2. Flexor longus pollicis. 3. Pronator quadratus. 4. Adductor pollicis. 5. Inter-osseous muscles.

inter-osseous artery and nerve. The tendons are covered by the synovial sacs which have been mentioned in connexion with the flexor sublimis.

Synovial sacs.

The *lumbricales* (fig. 117,^{10}) are four tapering, fleshy fasciculi, extended from the tendons of the flexor profundus to the first digital phalanges, and are therefore to be considered accessories or appendages to that muscle. They arise by fleshy fibres from the outer or radial border of the deep flexor tendons, and proceed forwards to the corresponding sides of the fingers, where they are inserted into the tendinous expansion covering the dorsal aspect of the fingers. They are covered by the palmar fascia, and partially by the tendons of the flexor sublimis.

Lumbric. four;

fr. tendons of flex. profund. to extens. comm.

These little muscles are subject to many deviations from the ordinary arrangement. The number is not unfrequently diminished to three, or it may be increased (much more rarely, however,) to five or six. The destination of one or two of them is often changed, and one finger (most frequently the third or fourth) is found to be provided with two. Lastly, one may be divided between two fingers.

They vary.

Flexor longus pollicis manus (fig. 114,^{2}). The long flexor of the thumb lies on the same plane as the flexor profundus, resting on the radius. It *arises* from the grooved surface on the fore part of the radius,—commencing just below the oblique line which extends downwards from its tubercle, and reaching nearly to the edge of the pronator quadratus,—also from the adjacent part of the inter-osseous ligament. The fleshy fibres come forward to a tendon, which, after passing beneath the annular ligament of the wrist, turns outwards, lying between the two heads of the flexor brevis and the sesamoid bones, and then enters a canal, similar to those for the other flexor tendons. Finally the tendon is *inserted* into the base of the second phalanx of the thumb.

Flex. long. poll.

Origin.

Insertion.

This muscle is covered by the flexor carpi radialis, flexor sublimis, and somewhat by the pronator teres, also by the radial vessels. The inner border is in contact with the flexor profundus, the anterior inter-osseous artery and nerve being interposed. Towards the lower part of the arm, its fibres can be readily perceived between the tendon of the supinator longus and flexor carpi radialis.—In some cases the flexor pollicis receives a bundle of fibres from the flexor sublimis.

Parts adjacent.

Radial art. in front; inter-oss. art. inside.

Pron.quadr. deep position;

Pronator quadratus (fig. 114,[3]; fig. 118,[1]). This small square muscle is placed behind the other muscles, and is extended across the radius and ulna, immediately above their carpal extremities; it is flat and thick (especially so at the middle), and about two inches in breadth. Its origin, or fixed attachment, is from the anterior surface and the inner border of the ulna (curving over the bone), in the situation and extent just mentioned, and from a tendinous layer on its surface. The fibres pass directly across, to be inserted into the fore part and anterior surface of the radius.

curves over part of ulna.

Parts adjacent. (Inter-oss. artery and radial.)

One surface of the muscle rests on the bones and inter-osseous membrane, and covers the anterior inter-osseous artery and nerve; the other is covered by the tendons of the flexor muscles and the radial artery.

Combined Actions.—These muscles act on the fore-arm, the hand, and the digital phalanges.—The radius is made to turn on the ulna, and the hand thereby pronated by the *pronator teres* and *quadratus*, which take their fixed points, the one on the humerus, the other on the ulna, and draw the radius inwards across the latter bone. Should the pronator teres, after having effected so much, continue its action, it becomes virtually a flexor, and will assist the other muscles in bending the fore-arm on the arm.—So also the *flexors of the fingers*, after having bent the phalanges towards the palm, begin to act on the wrist, and then contribute to the flexion of the fore-arm by means of the mechanical advantage they derive by passing under the annular ligament of the wrist.—The *flexores carpi*, too, after having bent the wrist, become subsequently flexors of the fore-arm. The flexion of the phalanges is obviously effected by the superficial and deep common flexors, and by the flexor pollicis.

RADIAL REGION

The muscles placed along the outer side of the fore-arm are the supinator radii longus and brevis, the extensor carpi radialis longior and brevior.

Dissection.—These muscles are readily exposed by reflecting the skin and the fascia outwards, from a few inches above the external condyle down to the wrist; the preceding dissections obviously mark out the way of conducting this.

Supin.long.;

Supinator longus,—Douglas and Alb. (supinator radii longus,—Cowper; brachio-radialis,—Sœmmerring) (fig. 112,[8]; fig. 115,[1]).—This is the first and most prominent muscle of the its length.

external set, and lies upon the radial border of the arm, extended from nearly the middle of the humerus to the end of the radius. It *arises* from the external condyloid ridge of the humerus, nearly as high up as the insertion of the deltoid, where it is interposed between the brachialis anticus and the external inter-muscular septum, to which also its fibres are attached. The thin fleshy mass proceeding from this elongated source descends upon the anterior and outer border of the arm, and, about its middle, ends in a flat tendon, which, continuing the same course, is *inserted* into the external border of the radius, close to the base of its styloid process.

Origin.

Insertion.

Fig. 115.*

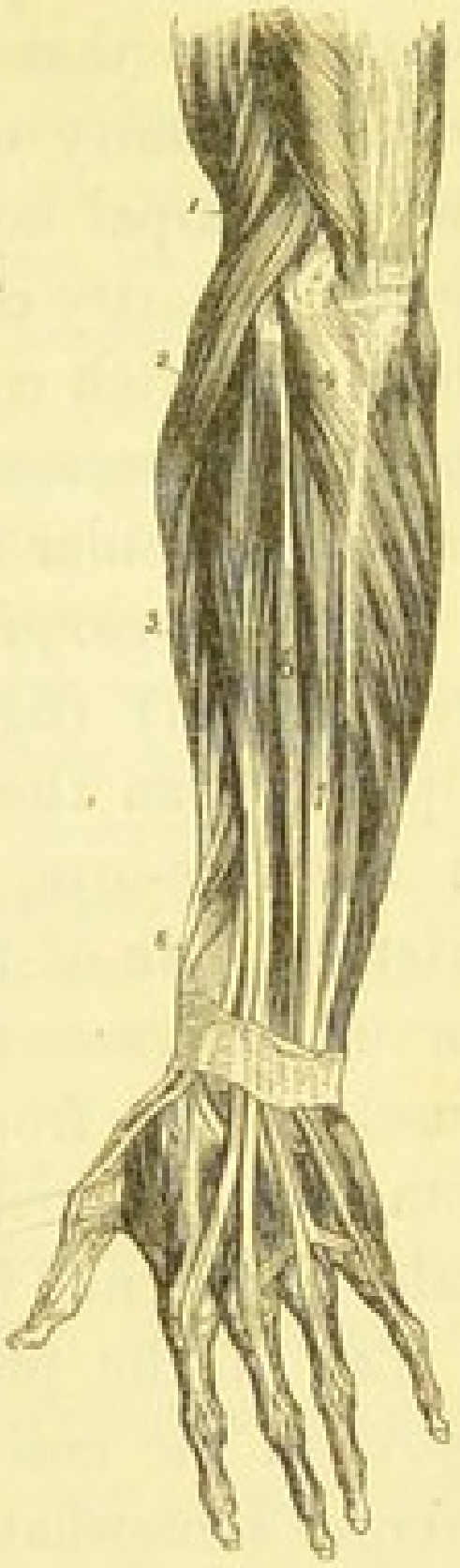

Parts adjacent.
Is subcutaneous.

This muscle is covered only by the skin and fascia, except the insertion, which is covered by the extensor muscles of the thumb. It rests on the humerus, extensor carpi radialis (longior and brevior), the insertion of the pronator teres, and the supinator radii brevis. The inner border is in contact, above the bend of the elbow, with the brachialis anticus, and with the musculo-spiral nerve and the accompanying artery; along the fore-arm it is in contact with the radial artery and nerve, and serves as a guide to the position of the vessel.

Guides to radial art.

Extens. carpi rad. long.

The *extensor carpi radialis longior* (radialis externus longior,—Alb.) (fig. 112,[9]; fig. 115,[2]) is partly covered by the preceding muscle, but its external border projects beyond it. It *arises* lower down than the supinator longus, from the external condyloid ridge as well as from the inter-muscular septum, and a tendon common to it and other muscles connected with the outer condyle. After passing along the

Origin.

---

* The superficial muscles of the posterior surface of the fore-arm. 1. Supinator longus. 2, 3. Extensor carpi radialis, longior and brevior. 4. Anconeus. 5. Extensor communis digitorum. 6. Extensor proprius digiti minimi. 7. Extensor carpi ulnaris. 8. The extensor muscles of the thumb.

outside of the articulation, it ends, at the upper third of the arm, in rather a broad, flat tendon, which descends along the outer and back part of the radius. The tendon passes, conjointly with that of the following muscle, in a groove in the lower extremity of the bone, and is inserted into the base of the metacarpal bone of the fore-finger. The fleshy part of the muscle is partly covered by the supinator longus, and the upper fibres are often continuous with the lower part of that muscle. Its tendon passes beneath the extensors of the thumb, and the posterior annular ligament of the wrist.

Tendon in groove of radius.

Extensor carp. rad. brev.

Extensor carpi radialis brevior,—Douglas (radialis externus brev.—Alb.) (fig. 112,[10]; fig. 115,[3]).—Shorter, as the name implies, than the preceding, to which it immediately succeeds on the fore-arm, this muscle *arises* from the extremity of the outer condyle of the humerus, by the common tendon and the fibrous processes which intervene between it and other extensor muscles, also from a tendinous expansion on its surface, and from the external lateral ligament of the elbow-joint. The fleshy belly ends in a flat tendon, which remains closely applied to that of the preceding muscle, and with it proceeds in the groove in the radius, and under the annular ligament, where it diverges somewhat, in order to be *inserted* into the base of the metacarpal bone of the middle finger.

Origin.

Tend. with that of former in groove of radius.

Insertion.

Action of the supinators, and radial extensors.

Combined Actions.—These are the direct antagonists of the pronators of the hand and flexors of the wrist. If the hand be previously pronated, the supinators, by rolling the radius on the ulna, turn the palm supine : but the extent and power of action of each differ considerably. The *supinator longus*, notwithstanding its length and size, can act but feebly in supinating the hand, inasmuch as its direction is parallel with that of the radius : its direction and attachments indicate it to be a flexor of the fore-arm. The *supinator brevis* (page 345), both by its direction and mode of attachment, is by far the more efficient agent in moving the radius on the ulna. The action of the *radial extensors* is fully indicated by their name ; if their effort be continued, they assist in extending the fore-arm on the arm.

BRACHIAL REGION (POSTERIOR AND SUPERFICIAL).

Poster. mus.

The muscles situated on the posterior aspect of the fore-arm are the anconeus, the extensor communis digitorum, extensor carpi ulnaris, and extensor minimi digiti, which are superficial ;

whilst the rest are deep-seated, viz. the three extensors of the thumb, the extensor indicis, and the supinator radii brevis.

Dissection.—The muscles on the posterior side of the fore-arm are numerous and closely connected together, so that their dissection and arrangement are sometimes deemed difficult. An incision may, in the first place, be made from the olecranon to the middle of the back of the hand, which should be bounded at each extremity by a transverse incision. The skin, having been thus divided, may be reflected off the fascia in its entire extent; and, when the fascia has been examined, it may be divided in the same way as the skin, and dissected off the muscles, which will be facilitated by proceeding from below upwards, taking the different tendons as guides to their respective muscles, until all of them are exposed, and their borders defined. When this has been effected, little difficulty will be experienced in distinguishing them from one another, if the first line of the description given of them be attended to, as it indicates the situation and direction of each; and, when the name of a muscle is known, everything relative to its anatomical characters will be found in the section which treats of it.

Anconeus. Triangular;

The *anconeus* (fig. 115,[4]; ἀγκὼν, the elbow) is placed immediately behind and beneath the elbow-joint, being a small triangular muscle. It *arises*, by a tendon, from the extremity of the outer condyle of the humerus, at its posterior aspect. From this the fibres proceed, diverging from one another, the upper ones being horizontal, the rest passing downwards with increasing degrees of obliquity; and all are *inserted* into the radial aspect of the olecranon and the adjacent surface of the ulna itself.

connected with triceps;

covers joint.

The anconeus is superficial in its entire extent, and lies below the outer part of the triceps extensor, with which it is continuous by its upper margin. It covers part of the ligament of the elbow-joint and of the supinator brevis, together with the recurrent branch of the inter-osseous artery.

Extensor communis.

Beneath ann. lig.

Tendons joined by lumb. and inter-oss.

The *extensor communis digitorum* (fig. 115,[5]) lies along the posterior part of the fore-arm. It *arises* by a tendon common to it and the other superficial extensor muscles, also from the fascia of the arm, and the septa between it and the adjoining muscles. Somewhat below the middle of the fore-arm the muscular part ends in four tendons, which, after passing beneath the posterior annular ligament of the wrist, diverge as they proceed along the carpus and metacarpus to reach the fingers. Each tendon expands, and, being increased by tendinous fibres derived from the lumbricales and inter-osseous muscles, forms a fibrous expansion (see fig. 113), which encases the back of the first and second digital phalanges, and terminates upon the third. It is attached to the second and third phalanges in the following manner. Opposite the second joint, the tendon appears to divide into two fasciculi, which leave, apparently, an elliptic interval between them. The tendon, however, is not deficient at this part; it is much thinner than at the sides, and this thin middle portion is inserted into the base of the second phalanx. The two lateral parts, continuing onwards, are joined together towards the middle or lower part of the second phalanx; and, having passed beyond this, are inserted into the last phalanx. On the index finger and the little finger the tendons are joined, before their division, by those from the special extensors of those fingers. Moreover, the tendon furnished from the common extensor to the fore-finger is separate from the rest; while the others are connected by transverse bands over the metacarpus.

Tends. expansion divides into three;

mid. part to second phal.; two lateral parts to last phal.

Tendons joined by special extensors.

At its origin, this muscle lies between the extensor carpi radialis brevior and the extensor digiti minimi, and maintains the same relation as it descends towards the wrist. It covers the supinator radii brevis, the extensors of the thumb at their origin, and the indicator. A synovial membrane encases the tendons as they pass under the annular ligament.

Parts adjacent.

Synovial sac.

Extensor minimi digiti (extensor proprius auricularis,—Alb.) (fig. 115,^{6}).—The extensor of the little finger is usually united with the common extensor. It is placed between that muscle and the extensor carpi ulnaris. It *arises*, in common with the extensor communis, by a thin tendinous part, giving origin to a slender bundle of fleshy fibres. The tendon in which it ends passes through a ring in the annular ligament appropriated to itself, and joins with the fourth digital tendon of the common extensor, conjointly with which it expands upon the posterior surface of the phalanges of the little finger.

Extensor digiti min. is joined to exten. digit. com.

Has separ. ring of ann. ligt.

Tend. joins that of extensor com.

Extensor carpi ulnaris (ulnaris externus,—Alb.) (fig. 115,^{7}) lies towards the ulnar border of the fore-arm, being extended from the external condyle to the root of the little finger. It *arises* from the external condyle of the humerus, by the common tendon and an elongation from it: from the ulna, for some space below the anconeus: and from the fascia of the arm. The muscular fibres derived from this source

Extensor carpi uln.;

incline somewhat inwards, and end in a tendon, which runs through a special groove in the carpal end of the ulna, and, after passing between the carpus and annular ligament, is inserted into the posterior extremity of the metacarpal bone, sustaining the little finger.—Like the foregoing muscles, it is covered only by the skin and fascia, and it conceals the supinator brevis in part, as well as the extensor of the index finger.

passes in groove of ulna.

Parts over and under.

BRACHIAL REGION (DEEP POSTERIOR).

The deep-seated muscles on the back of the arm are all less in size and length than the superficial set, from which they are readily distinguishable by the obliquity of their direction.

Dissection.—When the long extensors which arise from the external condyle have been examined, they may be detached from their origin, and drawn outwards, so as to expose those which lie deeply between, or on the bones. The supinator brevis and anconeus, both short muscles, and oblique in the direction of their fibres, will be seen close below the elbow-joint, whilst the extensors of the thumb, and the indicator, lie obliquely over the middle and lower part of the radius.

Extensor ossis metacarpi pollicis (fig. 116,²) (abductor longus pollicis manus,—Alb.)—This muscle, the extensor of the metacarpal bone of the thumb, which is the largest of the deep extensor muscles, descends obliquely over the bones of the fore-arm, from the posterior to the outer side, lying immediately below the border of the supinator brevis. It *arises* from the external surface of the ulna, and from the inter-osseous ligament and the radius, as it crosses each; its fleshy belly ends in a tendon, which passes through a groove in the outer border of the radius, common to it and the extensor of the first phalanx of the thumb, and is *inserted* into the base of the metacarpal bone of the thumb.

Extens. metacarp. poll. is largest of deep series.

Tendon w. that of next, in groove of radius.

The origin and upper part of the muscle are concealed by the common extensor, but it becomes superficial where it lies on the external border of the radius; and, whilst passing over the carpus, its tendon crosses those of the radial extensors.

Is oblique and partly superficial.

Extensor primi internodii pollicis (extensor minor pollicis manus,—Alb.)—The extensor of the first phalanx (fig. 116,³) is much smaller than the preceding, and lies close to its lower border. The muscle *arises* from the inter-osseous ligament

Extensor primi intern. poll. is small.

Accompanies preceding mus.

and radius, and slightly, if at all, from the ulna; it takes the same direction as the abductor, which it accompanies through the groove in the radius, and over the corresponding border of the carpus. The tendon proceeds onwards to the thumb, and is *inserted* into the upper end of its first phalanx.

Fig. 116.*

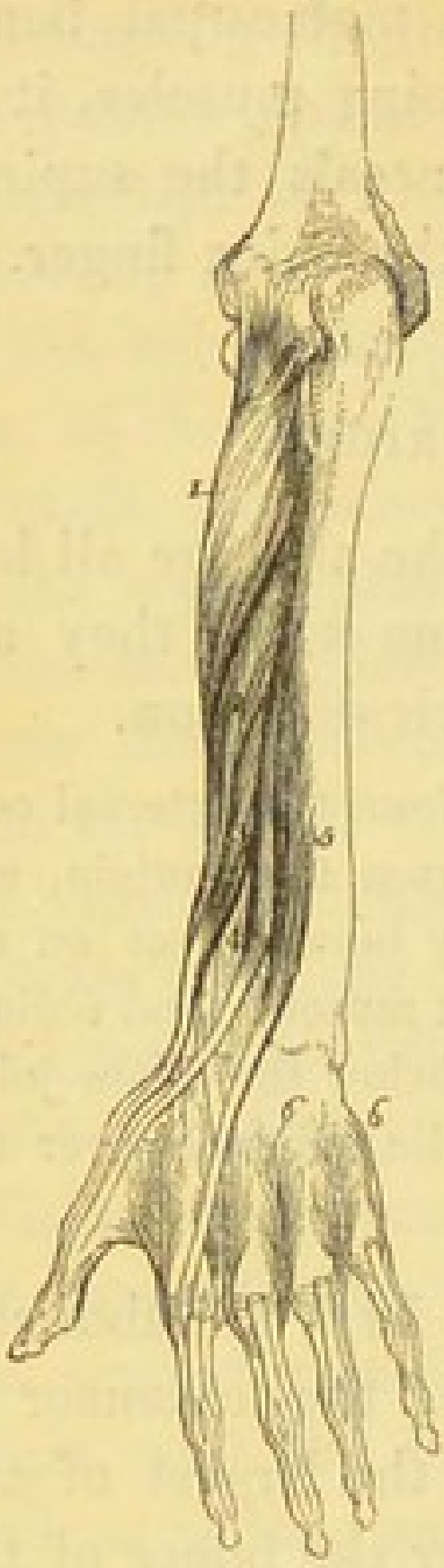

Extens. sec. internodii pollicis.

Extensor secundi internodii pollicis (extensor major pollicis manus,—Alb.)—The extensor of the second phalanx (fig. 116,[4]) is much larger than the preceding muscle, which it partly covers; its direction is obliquely downwards and forwards from the ulna to the thumb. It *arises* from the back part of the ulna, immediately below the great abductor, and from the adjacent part of the inter-osseous ligament. The fleshy belly derived from these attachments soon ends in a tendon, which is bound down in a separate compartment by the annular ligament, and runs through the narrow oblique groove (specially appropriated to it) at the middle of the carpal end of the radius, to be *inserted* into the base of the second phalanx of the thumb.

Has separ. groove on radius.

A part of the tendon of the extensor ossis metacarpi is often found to terminate in the upper end of the abductor pollicis.—The extensor primi internodii is not unfrequently united with the extensor of the metacarpal bone, and only a slender tendinous filament reaches the first phalanx.—A portion of the third muscle (extensor secundi internodii) has been found attached to the first phalanx.

Whilst passing along the groove, the tendon of this muscle is separated from those of the other extensors of the thumb, by the groove which lodges the radial extensors; and near the base of the first metacarpal bone, the radial artery is lodged in the interval which separates them.

---

* The deep-seated muscles of the back of the fore-arm, with the dorsal inter-osseous of the hand. 1. Supinator brevis. 2. Extensor ossis metacarpi, 3. Extensor primi internodii, and 4. Extensor secundi internodii pollicis. 5. Extensor indicis. 6, 9. Dorsal inter-osseous muscles.

Extensor indicis (fig. 116,[5]) (indicator).—The extensor of the index finger is nearly of the same size as the preceding muscle, whose lower border it accompanies. It *arises* from the posterior surface of the ulna, about its middle, also from the inter-osseous ligament. The tendon, which is continued from the muscular part, passes, together with the common extensor, beneath the annular ligament, comes in contact with the digital tendon of the latter, which is destined for the index finger, and unites with it to form the tendinous expansion; and through it both are *inserted* into the posterior surface of the second and third phalanges, in the manner mentioned in the description of the common extensor muscle.

Extens. ind.

with comm. extensor in ann. ligt.

On finger joins comm. extensor.

The *supinator brevis* (supinator radii brevis,—Cowper) (fig. 116,[1]) is a short triangular muscle, lying in close contact with the bones, and extended obliquely from the outer condyle of the humerus to the upper third of the radius, over which it is curved. It *arises* from the external condyle, and from the external lateral ligament, as far as its insertion into the annular ligament of the radius, also from a rough ridge and a depressed surface below the sigmoid cavity of the ulna. The fibres of the muscle, derived from these points of attachment, as well as from a tendinous expansion over the muscle, pass obliquely round the upper part of the radius, covering it, and connected with it, except at its inner side.

Supin. brev. curves over upper end of radius.

Origin.

Insertion.

The supinator brevis is covered by several muscles. It lies on the ligaments at the outer side of the elbow-joint; and the posterior branch of the musculo-spiral nerve passes through its fibres. By means of a notch in the anterior margin, it is adapted to the bicipital tuberosity of the radius.

Covers elbow-joint.

Is notched for biceps.

Combined Actions.—These muscles act on the fingers and hand in the first instance, and then, by a continuance of their effort, on the fore-arm, which they assist in extending. The common extensor, as well as those of the thumb, the fore-finger, and little finger, are, from their situation and attachments, the direct antagonists of the flexors; the latter, however, being, from their size and number, the more powerful agents. If the bones of the thumb be drawn inwards to the palm, as when an object is firmly grasped, their extensor muscles may, by reason of the obliquity of their direction, assist in supinating the hand. Their names indicate their more ordinary action. The anconeus assists the triceps in extending the fore-arm. The supinator brevis turns the radius on its axis, so as to bring the hand into the supine position.

MUSCLES OF THE HAND.

Muscles of palm. Three sets.

The muscles of the palmar surface of the hand admit of being divided into three sets or groups, viz. those of the thumb, those of the little finger, and thirdly, those placed in the middle of the palm. The extensors, which have been described in the foregoing pages, and the dorsal inter-ossei, are the only muscles on the back of the hand.

Dissection.—The first step in the dissection of the hand consists in exposing the palmar fascia in its entire extent. (See its description among the structures of the same class.) For this purpose a transverse incision may be made at the wrist, down to the annular ligament; for, as the fascia arises from it, it affords an easy guide to that membrane. The integument may then be raised, and reflected forwards to the fingers, or to either side. When the fascia has been examined, it may be detached from its connexion with the annular ligament, and removed altogether; by which means the flexor tendons, the superficial arch of arteries, and the branches of the ulnar and median nerves, are brought into view. The digital prolongations of these different structures can, in the next place, be traced along the fingers by merely removing the integument. The short muscles of the thumb, and those of the little finger, may next engage attention. But it will not be necessary to add anything to what is stated in the description of the muscles, as they are placed in their anatomical order, care being also taken to indicate their situation and general characters, so that no mistake can occur. Deep in the palm of the hand are situated one set of inter-ossei muscles; these cannot be seen until the flexor tendons are all removed. The extensor tendons must be displaced, in order to expose fully the dorsal inter-ossei. Particular attention should be paid to the position of the superficial palmar arch of arteries, as well as to its digital branches.

EXTERNAL PALMAR REGION:—THENAR.*

(MUSCLES OF THE THUMB.)

The fleshy mass which forms the ball of the thumb consists of four muscles, which are inserted into its metacarpal bone and the first phalanx—one to the former, and three to the latter.

---

* "Græci prominentiores partes palmarum appellant *θέναρα*, deducto vocabulo *ἀπὸ του θείνειν* (*θένειν*), à percutiendo. Alii non omnes prominentiores palmæ partes sic appellatas existimant, sed eas tantùm quæ pollici subiiciuntur," &c. Riolanus, "Anthropol." l. 5, c. 20.

Riolanus himself, however, used the word to designate one of the muscles, and applied the name "antithenar" to another. Winslow adopted and extended that plan of naming the muscles.

Abduct. pol. is small, and superficial.

The *abductor pollicis* (abductor brevis pollicis manus,—Alb.) (fig. 117,[4]) is a flat, narrow muscle, placed immediately beneath the skin. It *arises* from the annular ligament of the wrist[3], and from the os trapezium, and proceeds outwards and forwards, to be *inserted*, by a short thin tendon, into the base of the first phalanx of the thumb, at its radial border.—The muscle is superficial in its entire extent, and rests on the opponens pollicis.

Opp. poll.

Fig. 117.*

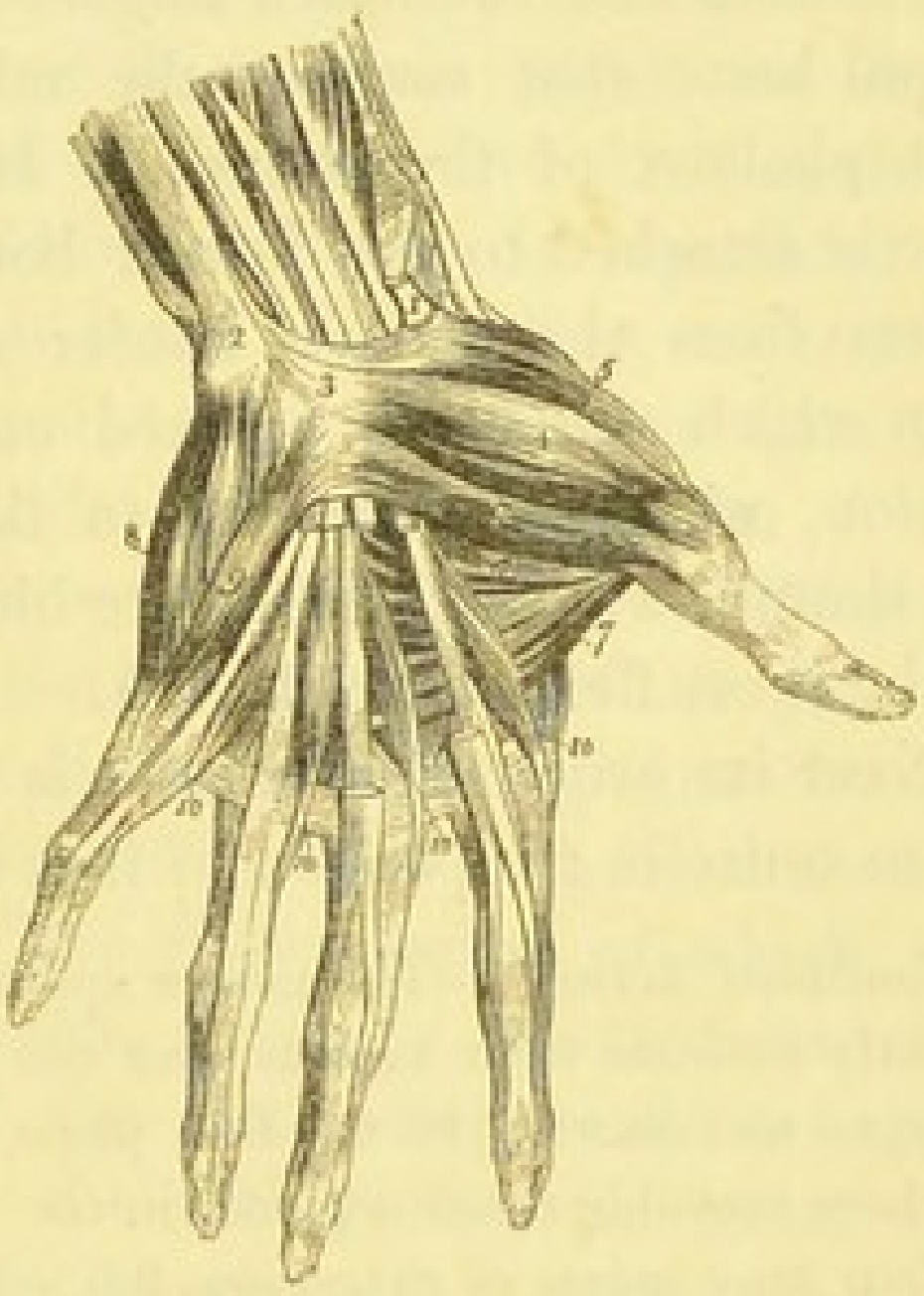

Opponens pollicis manus (fig. 117,[5]; fig. 118,[2]).—The part of the muscular substance thus named is triangular in shape and is placed beneath the preceding, but its borders project laterally, so as to be perceptible at each side of it. The fibres *arise* from the annular ligament and from the os trapezium, and thence proceed outwards and forwards, to be *inserted* into the whole length of the metacarpal bone of the thumb at its radial border. One surface is covered by the abductor and integument, the other rests on bones and ligaments.

Origin.

Insert. into metacarpal bone in whole length.

Flex. brev. poll. Two parts, separ. by tend. of long flex.

Flexor brevis pollicis manus.—This is larger than either of the preceding muscles, beneath which it is placed. Its carpal extremity is divided into two processes or heads[6],[6], the interval between which transmits the tendon of the long flexor. One of these, which is anterior, and therefore superficial, relatively to the other, *arises* from the inner surface of the annular ligament, and from the os trapezium; the other is attached to the os tra-

---

* The muscles and tendons of the palm—a portion of the tendons of the superficial flexor has been cut away to show the deep flexor and the lumbricales. 1. Tendon of flexor carpi radialis. 2. That of flexor carpi ulnaris ending at the pisiform bone. 3. Anterior annular ligament of the carpus. 4. Abductor pollicis. 5. Opponens. 6, 6. Flexor brevis; and 7. Adductor pollicis. 8. Abductor, and 9. Flexor brevis minimi digiti. 10. Lumbricales.

pezoides and os magnum. The fleshy fibres from these points of origin soon unite to form a single mass, but this again resolves itself into two short processes, which are *inserted* into the opposite borders of the base of the first phalanx of the thumb. In each of these tendons of insertion a sesamoid bone is placed, where it passes over the first joint of the thumb; and one of them is connected with the abductor, and the other with the adductor.

Insertion by two tends.

Sesam. bone in each.

Adductor poll. extends from midst of hand to first phal.

Adductor pollicis manus (fig. 117,[7]; fig. 118,[4]).—The adductor of the thumb is partly placed in the fold of skin between the thumb and the index finger, being extended from the metacarpal bone that sustains the middle finger, to the base of the first phalanx of the thumb. Its form is triangular, and the base is attached to the former bone, the apex to the latter. It *arises* from the palmar border of the third metacarpal bone, from which the fibres proceed outwards, converging to a short tendon, which is *inserted* into the base of the first phalanx of the thumb, where its fibres are blended with the inner insertion of the short flexor (fig. 118,[3]).

Near its origin this muscle is covered by the tendons of the flexor muscles; a portion of it is subcutaneous.

Action of muscles of thumb.

Combined Actions.—The names applied to the muscles of the thumb sufficiently indicate their actions and use; they are eight in all, and may be arranged as follows. In the first place, it should be recollected that there are three movable osseous pieces in the thumb, so articulated as to admit of the four movements of extension, flexion, abduction, and adduction. There are three extensors, one for each bone, viz., the extensor of the metacarpal bone, and those of the first and second phalanges; these are long muscles, placed on the dorsal aspect of the fore-arm and hand. Opposed in situation and action to these are the three flexors, lying on the palmar aspect of the thumb, viz. the opponens (which may be considered a flexor of the metacarpal bone), the flexor brevis, or flexor of the first phalanx, and flexor longus, which is the flexor of the second phalanx. There remain the abductor and adductor, which likewise are opposed to one another in situation and action; one being superficial and external, and therefore well calculated to draw the thumb away from the fingers, whilst the other is internal and deep-seated, and thereby enabled to approximate it to them. If these moving powers be made to act successively, circumduction is performed; or, in other words, the thumb moves so as to describe a cone, whose summit is at its carpal articulation, and base at the line traversed by its extremity.

INTERNAL PALMAR REGION:—HYPOTHENAR.

(MUSCLES OF THE LITTLE FINGER.)

The thick fleshy mass at the inner border of the hand also consists of four muscles. One of them is cutaneous, the others are the proper muscles of the little finger.

Palm. brev.

Palmaris brevis (fig. 112,[12]).—This is a very small "cutaneous" muscle. It forms a thin and square plane of pale fibres placed immediately beneath the skin. It *arises* from the annular ligament and palmar fascia, from which its fibres proceed transversely inwards, and are *inserted* into the skin along the inner border of the palm of the hand.—It is superficial to the muscles of the little finger and the ulnar artery and nerve; but these parts are covered immediately, and separated from the palmaris brevis by a thin elongation of the palmar fascia.

Origin from palm. fascia; insert. to skin.

Adduct. digit. min.

Abductor digiti minimi manus (fig. 117,[8]).—The abductor of the little finger runs along the ulnar border of the palm of the hand, *arising* by tendinous fibres from the pisiform bone[2], and annular ligament, where they are blended with the insertion of the flexor carpi ulnaris. The fleshy belly, of which the muscle consists, ends in a tendon, which is *inserted* into the base of the first phalanx of the little finger at its ulnar border.—The muscle rests on the fifth metacarpal bone, and on the "opponens" of the little finger, and is covered by the palmaris brevis and palmar fascia.

From pisif. bone to first phal.

Flex. brev.

The *flexor brevis digiti minimi* (fig. 117,[9]) is placed on the same plane with the abductor, lying to its outer side and joined with it at the insertion, so that in this situation both constitute but one muscle. But at their origin, where an interspace exists between them, they are separated by the deep palmar branch of the ulnar nerve, and the communicating branch of the artery. It *arises* from the anterior surface of the annular ligament, and from the unciform bone, and is *inserted* into the base of the first phalanx of the little finger in connexion with the preceding muscle.—In some instances the flexor does not exist, in which cases the abductor is found larger than usual. From this circumstance, as well as from its position and direction, it may be

From uncif. bone to first phal. with former.

Fig. 118.*

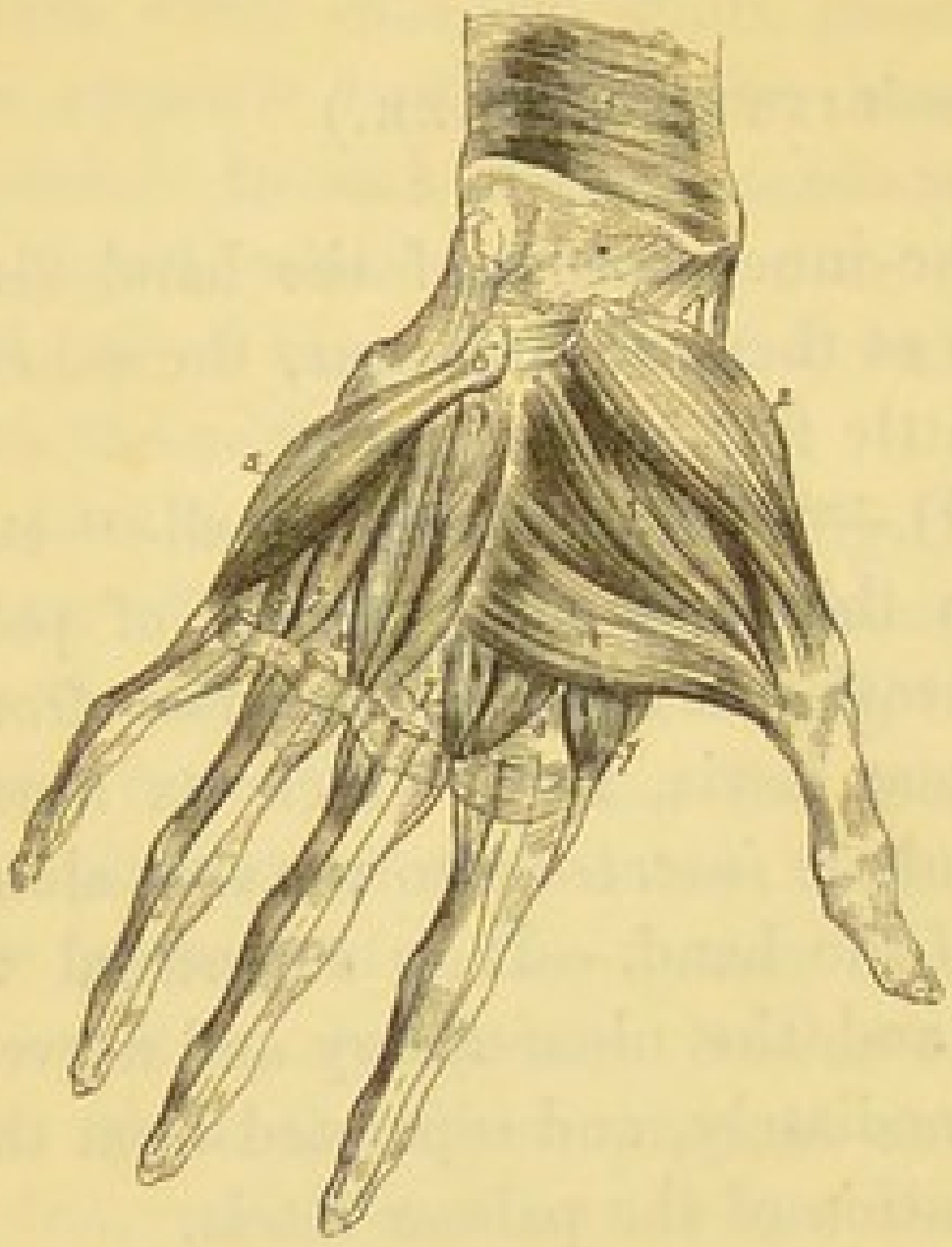

inferred that, in addition to its ordinary action of abduction, the last-named muscle can become also a flexor.

Oppon. digit. min.

Opponens digiti minimi (adductor ossis metacarpi digiti minimi,—Alb.) (fig. 118,^{5}).—This muscle is somewhat triangular in its form, and placed under cover of the others. It arises from the annular ligament, and from the hooked process of the unciform bone^{6}; from these points the fibres incline forwards and inwards, to be *inserted* into a large part of the fifth metacarpal bone.

From uncif. to metacarp. bone.

MIDDLE PALMAR REGION.

The muscles placed in the space intervening between the two borders of the hand, are the lumbricales and inter-ossei. The former have been already described with the flexor digitorum profundus.

Inter-oss.

The *inter-osseous* muscles (inter-ossei) occupy the intervals between the bones (metacarpal), and are named from that circumstance. They extend from the sides of those bones to the first row of phalanges (métacarpo-phalangiens latéraux,—Chaussier) ; and are divided into two sets, viz., those which are visible at the dorsal aspect of the metacarpus, and those seen only in the palm.

Two series.

Dorsal set four.

The *dorsal inter-osseous* muscles (inter-ossei externi v. bicipites) (fig. 116,$^{6\ 6\ 9}$) are four in number, and occupy each one of the spaces between the metacarpal bones. They are named, like the spaces, numerically, from without inwards (fig. 119,$^{1\ 2\ 3\ 4}$). One of them is known as the abductor indicis, and placed

---

* Chiefly the deep-seated muscles of the hand. 1. Pronator quadratus. 2. Opponens ; 3. Flexor brevis ; and 4. Adductor pollicis. 5. Opponens digiti minimi. 6. Unciform bone. 7, 8. Inter-osseous muscles.

amongst some of the other groups of muscles, though in position, mode of attachment, and structure, it is strictly an inter-osseous muscle. The general characters of these muscles are as follows:—They lie between the metacarpal bones, and appear on their dorsal aspect, yet project into the palm, where they are shown in fig. 118,[7] [7]. They arise from the contiguous sides of the bones between which they are placed, but more extensively from the metacarpal bone supporting the finger into which the muscle is inserted, and the fibres from these sources converge to a common tendon placed in the middle. The two parts or heads of this double origin are separated, at the upper extremity, by a narrow angular interval, in which a perforating arterial branch passes from one surface of the hand to the other. Lastly, the tendon of insertion of each terminates partly in the first phalanx at the side of its base, and partly also by joining with the tendon of the common extensor muscle on the dorsum of the finger (fig. 113).

Common characters.

Arise in two parts.

Separ. by artery.

Insert. into first phal. and extens. tend.

Fig 119.*

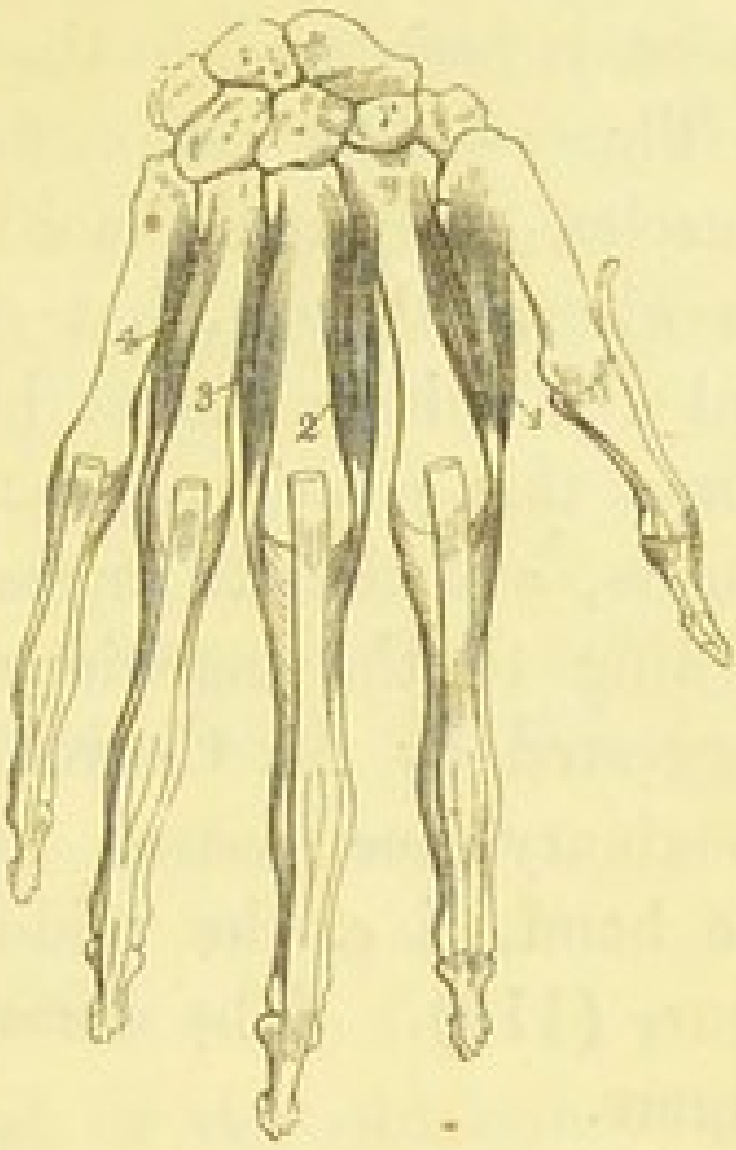

The *first* dorsal inter-osseous muscle (fig. 116,[9]) (abductor indicis) is larger than the others, and lies in the interval between the thumb and the index finger. It arises by two heads, of which one, external and larger, is attached to the ulnar border of the first metacarpal bone at its upper part, the other to the contiguous margin of the second in nearly its whole length, the angular interval between them serving to transmit the radial artery into the palm of the hand. Both soon unite, and become inserted, by a thin tendon, on the outer side of the index finger, in the manner stated above. The *second* dorsal inter-osseous muscle lies in the second metacarpal space. It arises from both bones, and terminates on the middle finger at its outer side.

First dorsal inter-oss.;

heads separ. by radl. art.

ends on outer side index.

Second ends on outer side, and

---

* The dorsal inter-osseous muscles of the right hand, and their connexion with the tendons of the long extensor muscles of the fingers, are here represented.

third on inner side of middle finger. Fourth, on inner side of ring finger.

The *third*, similarly placed in the third metacarpal space, is inserted likewise into the middle finger, but on the opposite side to the preceding. And the *fourth*, lying in the corresponding space, is inserted into the ulnar side of the ring finger.

Their actions.

Thus:—the index finger is furnished with one of these muscles, and it is placed on the outer side; the ring finger, likewise, with one, but situated on the opposite (inner) side; and the middle finger has two muscles, one on each side. From this position the muscles are calculated to separate the fingers, and thus to increase the breadth of the hand. Or, according to the ingenious method of explaining their action, suggested by M. Cruveilhier, they move the fingers from an imaginary line passed longitudinally through the middle of the hand, *i. e.* the middle of the middle finger. See the figure (119). The dorsal muscles, then, are abductors of the fingers.

Palmar inter-oss.

The *palmar inter-osseous* muscles (inter-ossei interni) lie rather on the palmar surface of the bones than in their intervals; and, as they are here mixed up with the preceding set (fig. 118), these should be removed, in order to facilitate the examination of the palmar series. They are three in number, and are named on the same principle as the dorsal muscles (fig. 120,[1] [2] [3]). Each *arises* from one metacarpal bone—that supporting the finger for which it is destined,—and terminates like the dorsal muscles in a small tendon, which is *inserted* into the base of the first phalanx at its side, and likewise joins with the common extensor tendon.

Three; arise from one bone.

Inserted as dorsal set.

Fig. 120.*

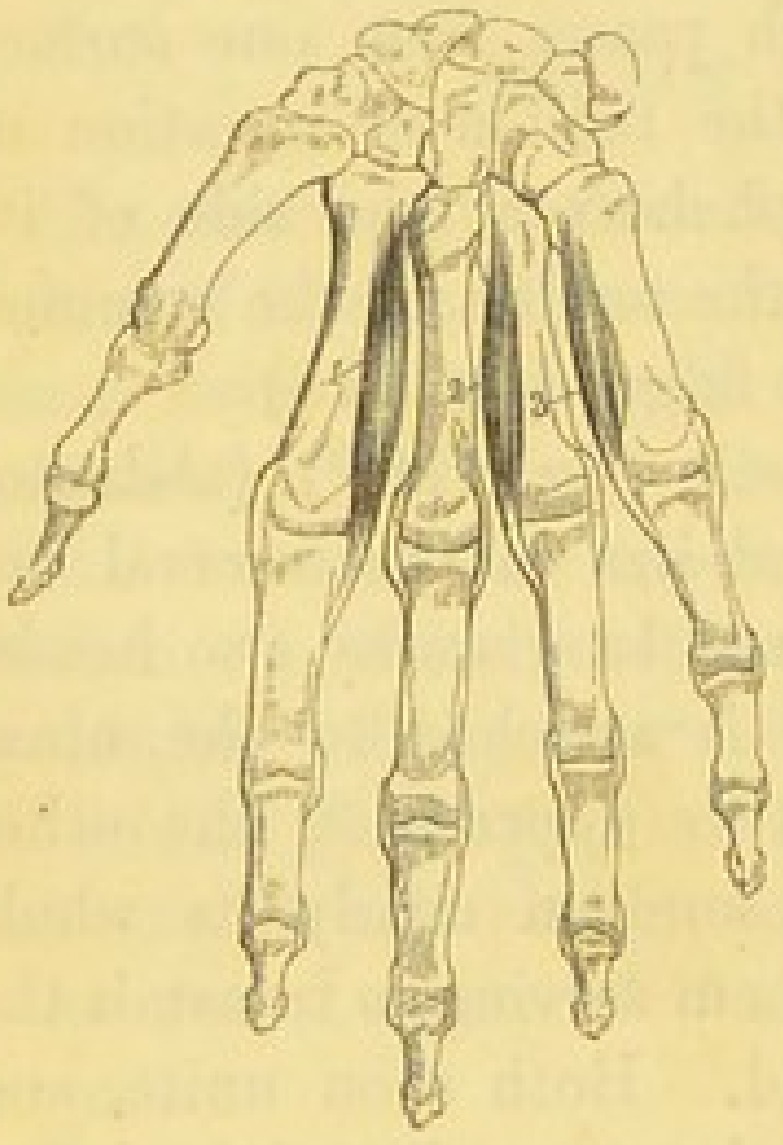

The *first* palmar inter-osseous[1] muscle arises from the second metacarpal bone on its ulnar side, and is inserted at the same side of the index finger. The *second*[2] arises from the radial

---

* The palmar inter-osseous muscles are shown in connexion with the bones of the right hand.

side of the fourth metacarpal bone, and is inserted on the same side of the ring-finger. The *third*[3] arises from the radial side of the fifth metacarpal bone, and is inserted into the little finger.

The palmar inter-osseous are opponents of the dorsal muscles. Each moves the finger towards its fellows, or towards the middle of the hand; they are, therefore, adductors of the fingers.

Palmar inter-oss. are adductors.

Actions.—Besides the influence they exert in separating the fingers and bringing them together, which has been already noticed, the inter-osseous muscles may, to a certain extent, assist the extensor communis in extending or drawing back the fingers; and again, if the fingers be but slightly bent, as the direction of the inter-ossei in that position forms an angle with that of the phalanges, they may assist in drawing them to the palm of the hand, that is, in flexing them.

ABDOMINAL REGION.

The abdomen is surrounded, except in the situation of the spine, by muscular and fibrous structures, which are called its "walls" or "parietes." The fibrous structure is usually considered an offset from the lateral muscles—these (the muscles) being said to end in the membranes or aponeuroses.

Structure of abdominal wall.

At each side, the abdominal wall is formed of muscular substance only, and consists of three muscular strata, the fibres of which are disposed in different directions. Viewing them as extending from behind towards the anterior part of the body, the fibres of the first stratum or muscle are directed obliquely downwards; those of the second, obliquely upwards; of the third, transversely. And they are named accordingly,—"descending oblique," "ascending oblique," and "transverse." The first two are also distinguished as "external" and "internal," on account of the position they hold one with respect to the other.

At sides, muscles only.

In front, the abdomen is bounded by aponeurotic as well as muscular structure. The former, being continued from the lateral muscles, is in layers, between which is placed a single muscle, close to the middle line on each side. The fleshy fibres of the muscle found in this situation have a vertical or straight course, and from this circumstance it is named "rectus."

In front, membrane and muscle.

The posterior is much the thickest part of the abdominal parietes, for here the vertebræ and the large muscles of the

Posterior, thickest part.

back enter into its composition. Exclusive of these, and anteriorly to them, layers of thin fibrous membrane extend from the "transverse" muscle to the vertebræ, encasing a single muscle, as in front. This muscle reaches between the ilium and the last rib, and is square; it is named "quadratus lumborum." And the membrane is called the "lumbar fascia."

Different extent of abdominal walls in front and at sides.

The structures above briefly noticed as constituting the walls of the abdomen, extend on each side from the middle line in front to the vertebral column, and occupy the interval between the ribs and sternum on the one hand, and the pelvis on the other. As their extent depends in a great measure on the interval to be filled up, a glance at the skeleton will show the length the muscles and membranes must have in different positions, and will make it evident that on the fore-part of the abdomen they must have considerably greater length than on the posterior or lateral aspect. To the above general statement concerning the length of these structures the external oblique muscle affords an exception, inasmuch as it reaches for some space above the margin of the ribs, and in so far forms a portion of the walls of the thorax.

The parts just reviewed in their combination will now be examined singly.

Dissection. To expose the external oblique muscle:—When commencing the dissection of the abdominal muscles, an incision may be made through the skin from the ensiform cartilage to the umbilicus, and another from thence to the most depending part of the margin of the thorax. The angular flap of skin, bounded by these lines, may be easily reflected by commencing at its point, and taking the tendinous fibres of the external oblique muscle as a guide, each stroke of the scalpel being directed obliquely upwards and outwards. The flap should be reflected until its base, or attached border, is brought on a line with the ensiform cartilage, or somewhat higher, which is necessary in order to expose the digitated processes of the muscle and their intermixture with those of the serratus magnus. An incision may, in the next place, be carried horizontally inwards from the anterior superior spinous process of the ilium to the linea alba, and there met by another drawn down from the umbilicus. The enclosed flap of skin should be reflected back to the posterior part of the lumbar region. If it be required to exhibit the muscle in its entire extent, the portion of integument still remaining on the lower part of the abdomen may be divided by an incision drawn from the pubes upwards, and the flap reflected down over Poupart's ligament. For the present, however, we shall leave untouched the integument, muscle, &c. in the iliac region, as they will require to be examined attentively when treating of the dissection of the parts connected with hernia.

Extern. oblique; largest of lat. musc.

The *external oblique* muscle of the abdomen, (fig. 109,[9]) (obliquus externus abdominis; obliquus descendens; costo-abdominalis; ilio-pubi-costo-abdominalis,) the largest of the three lateral muscles, is situated on the lateral and anterior parts of the abdomen, and consists of two parts: one, muscular, occupies the side of the abdomen; the other, aponeurotic, extends over the fore-part of that cavity.

Origin.

Inter-digit. with serrat and latiss. dorsi.

End of fleshy fibres.

Broad, thin, and irregularly quadrilateral in form, this muscle *arises* from the anterior surfaces of the eight or nine inferior ribs, by fibres arranged in so many angular processes, named digitations. These are placed between similarly formed parts (digitations) of the serratus magnus and latissimus dorsi (five in connexion with the former, and three or four with the latter), in the manner the fingers of one hand may be interposed between those of the other; and it is from this circumstance that the processes are named. The lower and the upper digitations of the muscle are connected with the ribs near their cartilages; but those in the middle are attached at some distance from them; the lowest embraces the point of the twelfth rib. The fleshy fibres from the last ribs pass down in nearly a vertical direction to be *inserted* into the external margin of the crista ilii, the anterior half of its length; all the rest incline downwards and forwards, and terminate in tendinous fibres, which form a broad aponeurosis[13].

Aponeurosis; its large size; covers abdomen in front.

Poupart's ligt.

This structure (the *aponeurosis* of the external oblique), which is wider at the lower than at the upper part, and is larger than that of either of the other abdominal muscles, covers the fore part of the abdomen, and terminates by uniting with that of the opposite muscle along the median line[12], from the ensiform cartilage to the symphysis pubis. The upper part of the aponeurosis is connected with the larger pectoral muscle. Its lower fibres are closely aggregated together, and extended across from the anterior superior spinous process of the ilium to the os pubis, in the form of a broad band[11], which is called Fallopius', or, more commonly, *Poupart's ligament.* This band is curved at the middle and outer part, the convexity of the curve being directed towards the thigh; and it is connected with the fascia lata of the thigh.

Ext. abdom. ring is triangular.

Near the pubes the fibres of the aponeurosis diverge from one another, leaving between them a triangular opening, called the *external abdominal ring*[10], for the passage of the spermatic cord in the male, and the round ligament in the female. The direction of this opening is upwards and outwards, its base being formed by the crista of the os pubis, and the sides by the two sets of diverging fibres, called its *pillars*. One of these is attached to the anterior surface of the symphysis pubis, interlacing with the corresponding fibres of the opposite muscle; the other pillar, which is the part before mentioned as Poupart's ligament, is external and inferior to the preceding, and is fixed to the spinous process of the pubes; whilst a third portion, reflected backwards and outwards from the latter, with which it is continuous, is inserted along the pectineal line. This last small part is triangular in form, and nearly horizontal in direction, and is considered to be a third insertion of the muscle into the pubes. It is in reality but a portion of the internal extremity of Poupart's ligament, which being expanded has here a broad connexion with the bone. Upon the aponeurosis at its lower part are laid a series of transverse fibres, most of which commencing from a narrow bundle over the outer part of Poupart's ligament, are directed inwards, and cross the fibres of the structure on which they are laid, binding them together. And a delicate web stretched between the "pillars" of the abdominal ring, and hence named *inter-columnar fascia*, gives a very thin prolongation downwards to the cord occupying that aperture.

Its pillars.

Insert. into symph.; into tuberosity; and into pect. of pubes; last two continuous.

Transverse fibres.

Parts adjacent to muscle.

The external oblique muscle is covered by the superficial fascia, which in some cases is loaded with a large quantity of fat. It conceals the internal oblique muscle and the intercostal muscles. The posterior margin is overlapped by the latissimus dorsi, or the two muscles are separated by a small interval.

To expose the internal oblique muscle:—When the external oblique muscle has been examined, it may be detached and reflected so as to bring into view the one subjacent to it, by cutting through its muscular fibres midway between its digitations and the margin of the ribs. Its posterior, or free border, will be found extending from the last rib to the crista of the ilium, and can be readily distinguished from the internal oblique muscle by the different course of its fibres. When this is effected, the fleshy fibres can be dissected from the crista ilii, as far as its spine, and the whole plane of muscle turned over to the opposite side. The internal oblique is thus exposed for two-thirds of its extent.

Internal oblique.

The *internal oblique* muscle, (fig. 109,[14]) (obliquus internus; obliquus ascendens; ilio-abdominalis; ilio-lumbo-costi-abdominalis,) placed under cover of the preceding, is of an irregularly quadrilateral form. The fleshy fibres *arise* inferiorly from the external half, not unfrequently from two-thirds of the inner surface of Poupart's ligament, from the crista ilii for two-thirds of its length, also from the lumbar fascia (page 362). From these attachments the fibres of the muscle pass in different directions, to be inserted as follows: those from Poupart's ligament, which are usually paler than the rest, arch downwards and inwards, over the spermatic cord, or the round ligament of the uterus, to be fixed into the crista of the pubes, and also for some way into the pectineal line, conjointly with those of the transversalis muscle, and behind the tendon of the external oblique where it is inserted into that line. A small interval is left between the lower margin of the muscle and the inner end of Poupart's ligament. The fibres, from the anterior part of the crista ilii, pass horizontally inwards, whilst the rest ascend obliquely, and terminate, some in an aponeurosis expanded in front of the abdomen, the rest at the lower margin of the cartilages of the last four ribs, on a plane corresponding with the internal inter-costal muscles.

Origin of fibres.

Their different directions.

Interval above Poup. ligt.

The *aponeurosis* continues the muscle to the middle line in front, where it joins with that from the opposite side of the body, and extends from the margin of the thorax to the pubes. It is wider at the upper than the lower end. At the outer border of the rectus muscle this structure divides into two layers, one passing before, the other behind that muscle; and they reunite at its inner border, so as to enclose it in a sheath. The anterior layer becomes identified with the aponeurosis of the external oblique muscle, and the posterior one with that of the transversalis. The upper border of the posterior lamina is attached to the margin of the first false rib, and the last true one, as well as to the ensiform cartilage. Towards the lower part of the abdomen, (between the umbilicus and the pubes,) the aponeurosis is undivided and is altogether in front of the rectus.

Aponeurosis divides into layers to sheathe the rectus.

The internal oblique muscle is covered by the external oblique, and behind, to a small extent, by the latissimus dorsi, with whose tendon it is connected, and through its medium may be said to be continued to the spines of the vertebræ. It lies on the transversalis. At the anterior ends of the last two inter-costal spaces the fibres are continuous with those of the last two layers of internal inter-costal muscles.

Parts adjacent.

Continuous w. internal inter-costal.

To expose the transversalis muscle:—When the examination of the internal oblique muscle has been completed, it is said to be difficult to detach it without injuring the muscle beneath it; yet, if just above the spine of the ilium the fibres be rendered tense by pressing the thumb and fore-finger of the left hand on them, and so straining the interval, they can be divided, with perfect precision, without interfering with the subjacent muscle; for the fibres are retracted when divided, and, after about three parts are cut through, the cellular interval between the muscles begins to be perceived, which, with the difference in the direction of their fibres, affords an unerring guide to their line of separation. Moreover, near the spine and crista of the ilium, these muscles are separated by the circumflex (ilii) vessels; and this is the part usually selected for cutting through the internal oblique, in order to expose the transversalis. When the line of separation is found, the muscular fibres should be detached from the crista ilii far back towards the lumbar region; after which they may be dissected from the cartilages of the ribs by insinuating the scalpel between the two planes of fibres, and then turning it so as to cut outwards. In this way the internal oblique muscle may be detached from its connexions, and reflected to the opposite side, so as to expose the transversalis.

Fig. 121.*

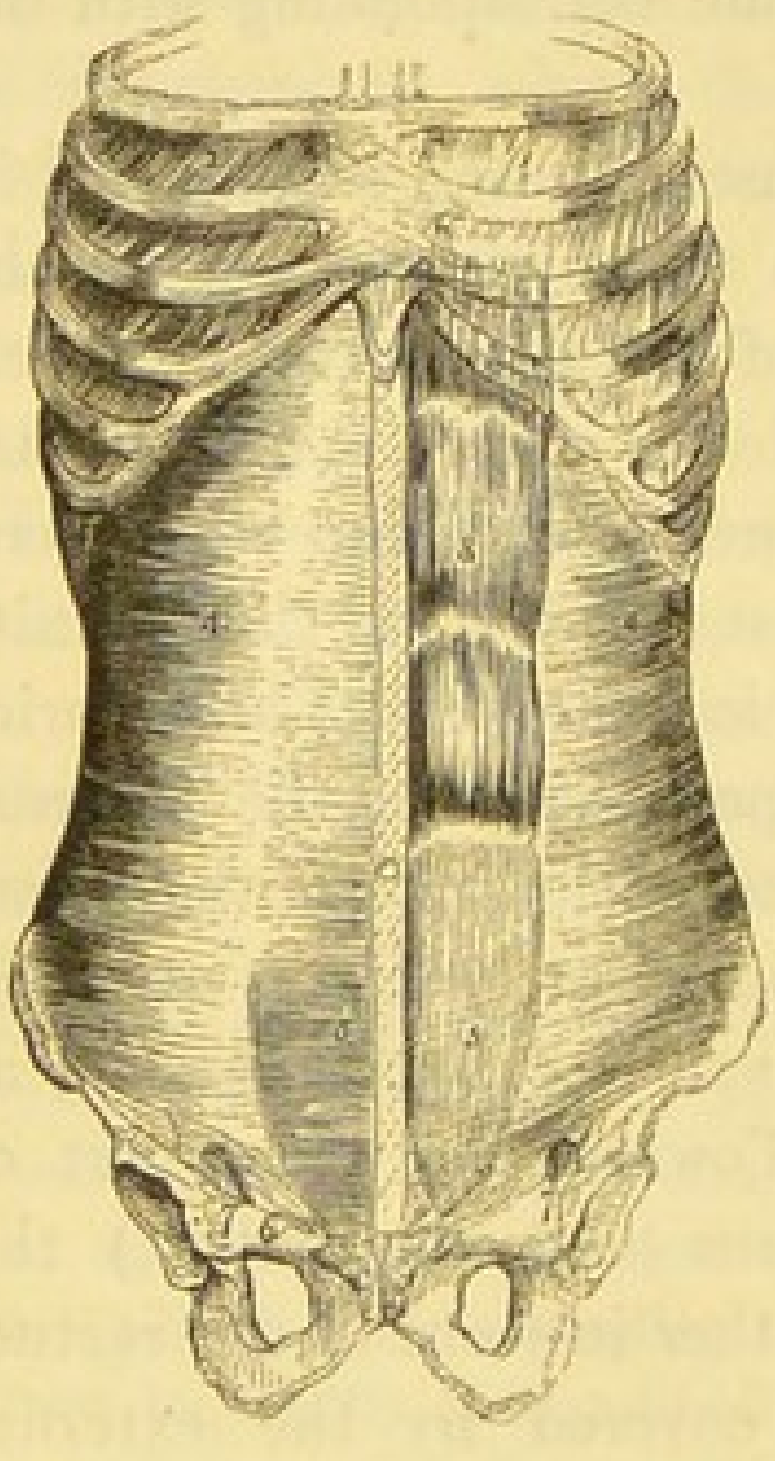

Transvers.

Origin.

The *transversalis* muscle (fig. 121,[4]) (transversalis v. transversus abdominis; lumbo-abdominalis) is subjacent to the internal oblique, and of the same form. It *arises* from the iliac half of Poupart's ligament: from the inner margin of the crista ilii for three-fourths of its length: from the cartilages of the last six or seven ribs on their inner surface: and, in the space intermediate between the crista ilii and the ribs, from an aponeurosis which is attached to the transverse processes of the lumbar vertebræ (see fascia lumborum). From these different points of origin the fibres pass horizontally forwards, and near the border of the rectus muscle they

---

* 1, 2. External and internal inter-costal muscles. 3. Rectus. 4. Transversalis; and 5, its aponeurosis. 6. The conjoined tendon of internal oblique and transversalis. 7. The internal abdominal ring.—The deficiency of the posterior lamina of the sheath of the rectus, which occurs towards the lower end, is not indicated in this figure.

end in an aponeurosis[5], which unites with the posterior layer of the internal oblique, and, together with it, joins with that of the opposite side at the linea alba. The inferior fibres curve downwards, and are inserted into the crista of the os pubis, and into the pectineal line. This insertion is so intimately connected with that of the internal oblique, that both together have received the name of the *conjoined tendon*[6] of these muscles. At its attachment to the under surface of the cartilages of the ribs, the transversalis digitates with the diaphragm, and is continuous with that muscle in the last two inter-costal spaces. This muscle is lined by the fascia transversalis, which separates it from the peritonæum.

Aponeurosis joins that of int. oblique.

Conjoined tendon of int. oblique and transv.

Inter-digit. w. diaphr.

The lower parts of the three foregoing muscles, and the manner of their connexion with the spermatic cord, or the round ligament of the uterus, together with the cremaster muscle and other coverings given to the cord in this situation, will be considered in the account of the "inguinal region."

To expose the rectus muscle:—The sheath of the rectus muscle should in the next place be examined. When this is being done, the connexions of the sheath with transverse tendinous bands, which intersect the muscle, must be cut through. Its anterior layer must be divided in its whole length, by an incision drawn down from the margin of the thorax to the pubes, and reflected off the rectus. By inserting the handle of the scalpel beneath the outer border of the muscle, it may be raised, and the posterior layer of the sheath brought into view. Lastly, if the muscle be cut across midway between the umbilicus and pubes, and the two parts drawn aside, the point at which the sheath is imperfect, posteriorly, can be determined by pushing the handle of the scalpel against it, so as to separate it from the subjacent membrane.

Rectus abdominis (fig. 109,[16]; fig. 121,[3]) (sterno-pubius).—This long, narrow, and flat muscle is situated at the fore part of the abdomen, separated from the muscle of the other side by a narrow interval, which however is wider at the upper than towards the lower end, and is occupied by tendinous structure (linea alba). It *arises* from the pubes by two tendons, of which the internal is much the smaller, and is connected to the ligaments covering the pubic symphysis, while the external one is fixed to the crista of the bone. Expanding and becoming thinner at the upper end, the muscle is *inserted* into the cartilages of three ribs, (fifth, sixth, and seventh,) and usually by three distinct parts of unequal size. In some cases a

Rectus.

Two parts of origin.

Insert. into ribs.

Lineæ transversæ; their number and its variations.

few fibres will be found attached to the ensiform cartilage. The fibres are interrupted by three irregular tendinous intersections (*lineæ transversæ*), one of which corresponds with the umbilicus, another with the ensiform cartilage, and the third is intermediate between them. Their number is in some cases augmented to four or even five, and the additional intersections are then placed below the umbilicus. These bands do not usually penetrate the whole substance of the muscle, and some of them extend only halfway across it.—The epigastric artery is placed behind the rectus muscle.

Sheath of rectus.

Aponeurosis of int. oblique splits; its parts joined by aponeur. of other muscle.

Sheath incomplete at lower part of abdomen.

Its connexion w. lineæ trans.

The rectus is enclosed in a sheath (*sheath of the rectus*), formed by the aponeuroses of the abdominal muscles, in the following manner:—The aponeurosis of the internal oblique, on arriving at the external border of the rectus, divides into two layers, of which the anterior one passes in front of this muscle, together with the aponeurosis of the external oblique, whilst the other is placed behind it, conjointly with that of the transversalis, and both are again united at the inner margin of the muscle along the linea alba. This arrangement obtains from the margin of the thorax, as far as to midway between the umbilicus and the pubes, but at this point all the aponeuroses pass in front of the rectus; so that the posterior part of its sheath is deficient in the lower third, the muscle being separated from the peritonæum by the fascia transversalis only. The deficiency in the sheath here indicated is usually marked by a well-defined lunated edge, whose concavity looks downwards towards the pubes. The sheath is firmly connected in front with the tendinous bands by which the muscle is intersected.

Pyramidalis.

Connexion with linea alba.

The *pyramidalis* muscle, (fig. 109,^{17}) triangular in its form, (the base being below, and the apex upwards,) and situated close to the linea alba, arises from the crista of the os pubis, and the ligaments of the symphysis, and, becoming narrow as it ascends, and extending over about a third of the interval between the umbilicus and pubes, is inserted into the linea alba, of which it may be considered as a tensor muscle. It is covered in front by the aponeuroses of the other muscles, and posteriorly rests on the rectus, to which it is in some degree accessory, for the size of the lower part of that muscle is augmented when the pyramidalis is wanting.

This little muscle is often absent on one or both sides, and, in some instances, has been found to be double. It occasionally exceeds the ordinary length above stated.

—Some tendinous structures, which have already been incidentally referred to, require a special notice in this place, viz. the linea alba, linea semi-lunaris, and lineæ transversæ.

Linea alba.

The *linea alba* may be considered as a tendinous cord (fig. 109,[12]), extended perpendicularly downwards from the ensiform cartilage to the pubes, and formed by the juncture of the aponeuroses of the two oblique and the transverse muscles, the tendinous fibres being continued from the muscles of one side to those of the other. Some longitudinal fibres are distinguishable towards its lower end. This structure is covered in front by the common integument; posteriorly it rests on the fascia transversalis, which separates it from the peritonæum, and on each side it is limited by the recti muscles; it is therefore broader above than below, as these muscles diverge from one another in the former situation. In the linea alba below its middle is situated the *umbilicus*, which in the fœtal state is a foramen for the transmission of the umbilical vein and arteries, but afterwards becomes obliterated.

Umbilicus.

Lineæ semi-lunares.

The *lineæ semi-lunares* are two curved tendinous lines extending, one on each side, from the cartilage of the eighth rib to the tuberosity of the os pubis. They thus correspond with the external borders of the recti muscles (the enclosed space being broad above and narrow below), and are formed by the aponeurosis of the internal oblique on each side, as it divides to enclose the rectus muscle.

The *lineæ transversæ* have been already noticed with the rectus muscle, as the tendinous bands which cross the substance of that muscle.

Quadratus lumborum.

The *quadratus lumborum*, (fig. 108,[16]) (ilio-costalis,) situated deeply in the lumbar region close to the vertebral column, is in form irregularly quadrilateral, being somewhat broader below than above. One part *arises* by tendinous fibres from the crista of the ilium behind the middle, and from the ilio-lumbar ligament; and it is *inserted* into the inferior border of the last rib for about half its length, and by four tendinous points into the transverse processes of the four superior lumbar vertebræ.

Two sets of fibres.

First series.

Second set of fibres.

Another series of fibres, *arising* by two or three tendinous points from as many of the inferior transverse processes at their upper margins, passes in front of those inserted into the same processes, and joins with the part of the muscle attached to the rib. This muscle is enclosed in a sheath resembling that of the rectus, but not so dense or firm in its structure (see the fascia lumborum).

The sheath.

Variations in size and extent of attachments.

The number of the points of insertion of this muscle to the vertebræ, and the extent of its connexion with the last rib, vary in different cases. It is in some instances attached to the last dorsal vertebra—the body or transverse process.

Dissection to show the fascia lumborum.—If the internal oblique be traced back, its muscular fibres will be found to end in an aponeurosis, which becomes intimately connected externally with the latissimus dorsi, close to the border of the deep lumbar muscles, and internally with the membranous elongation from the transversalis. Now, if the aponeurosis of the latissimus be divided in the middle of its breadth, by an incision drawn from the ilium to the last rib, and the two parts reflected, the thick mass of lumbar muscles will be exposed; and if the handle of the scalpel be inserted beneath their outer border, they will be found to lie on a membrane, which is connected with the lumbar vertebræ on the one hand, and with the abdominal muscles on the other, being, in fact, a prolongation of one of the latter (the transversalis). The mass of lumbar muscles may now be cut across by two incisions, one opposite the last rib, the other at the crista ilii, and then removed altogether. When this is effected, if attention be directed to the internal oblique muscle, it will be found that after contracting adhesion with the fascia derived from the transversalis, as above stated, it becomes likewise connected with the aponeurosis of the latissimus dorsi. In this stage of the dissection, an aponeurotic layer will be found stretched back from the transversalis to the transverse processes of the lumbar vertebræ. If this be divided by a perpendicular incision from the last rib to the ilium, the quadratus lumborum will be exposed; and, if the external border of this muscle be raised, another thin layer will be found resting on its abdominal surface, and connected with the roots of the transverse processes.

Fascia lum.

Fascia lumborum.—The two membranous layers now exposed to view have received this name. They extend backwards from the transversalis muscle to the lumbar vertebræ, encasing the quadratus lumborum. That which is in front of this muscle is very thin, and is attached to the anterior part of the transverse processes of the vertebræ at their roots, and superiorly, where it is connected with the last rib, it forms the ligamentum arcuatum externum of the diaphragm. The posterior layer, which is much thicker than the preceding, and

Two layers from transv. before and behind quadratus.

may be considered aponeurotic, is attached to the points and the margins of the same (transverse) processes. It separates the quadratus lumborum from the large muscular mass behind it.

The internal oblique muscle springs from the membranous elongation just noticed (the posterior one); and the tendon of the latissimus dorsi is connected with it further back, viz. at the outer margin of the erector spinæ. And thus, while the quadratus is sheathed by the layers of the lumbar fascia, the erector spinæ is encased with one of the layers of that fascia and the tendon of the latissimus dorsi which are joined at its outer margin.

Actions of the abdominal muscles.—The muscles here described not only enclose and support the abdominal viscera, but by their contractile power are capable of acting successively on them, on the thorax, and on the pelvis. When the pelvis and thorax are fixed, the abdominal muscles can constrict the cavity and compress its viscera, particularly if the diaphragm be made to descend at the same time, as occurs in vomiting, or in the expulsion of the fœtus, of fæces, or urine. If the vertebral column be fixed, these muscles compress the lower border of the thorax, and so contribute to expiration. When it is intended to continue the effort, so as to produce a forced expiration, the quadratus lumborum draws down the last rib, and makes it relatively the fixed point to which all the rest are drawn by their inter-costal muscles; but if the vertebral column be not fixed, the thorax may be bent directly forwards, when the muscles of both sides act; or it may be rotated to either side, should they act alternately. Thus, if the external oblique of the right side be made to act on the thorax, the first effect appears to be that of drawing its margin down towards the pelvis; but, if the effort be continued, the trunk will be rotated towards the opposite side. The left internal oblique will co-operate in this action, for the direction of its fibres coincides with that of the right external oblique. The pyramidales also contribute to the same effect, by rendering the linea alba tense. If the thorax be fixed, the abdominal muscles may be made to act on the pelvis; thus, in the action of climbing, the trunk and arms being elevated and fixed, the pelvis is drawn upwards, either directly, or to one side, as a preparatory step to the elevation of the lower limbs. A similar effect may be produced when the trunk is in the horizontal position, for the pelvis may be drawn forward and flexed upon the vertebral column by the recti and pyramidales.

COSTAL REGION.

Between the ribs we find two planes of muscular fibres filling up the intervening spaces, hence named " inter-costal,"—upon the ribs posteriorly the levatores costarum, and at their inner surface, and in front, the triangulares sterni.

It is not necessary to prescribe any particular mode of examining these, as they are necessarily exposed when the pectoral, the serratus, and external oblique muscles are removed.

Inter-cost. The inter-costal muscles are disposed in the form of two thin planes, one over the other, and named, from their relative position, " external," and " internal."

External. The *external inter-costal* muscles (inter-costales externi) are placed between the contiguous borders of each pair of ribs. Number. There are, therefore, eleven such muscular layers on each side, the direction of the fibres of all being obliquely downwards and Extent. forwards (fig. 121,[1]). Their extent in each instance is from the tubercles of the ribs nearly to the external extremity of their cartilages. From this point a thin fascia is continued forwards to the sternum, overlaying the inner inter-costals. There are many tendinous fibres mixed up with the muscular structure.

The external inter-costal muscles are covered by several large muscles, which are attached to the ribs. They conceal the corresponding internal muscle, the inter-costal nerves and vessels being interposed.

Internal inter-cost. The *internal inter-costal* muscles, (inter-costales interni) (fig. 121,[2]) placed under the preceding, are attached to the inner margins of the ribs and their cartilages. Commencing at the sternum in the spaces between the true ribs, and at the anterior Extent. extremities of the cartilages of the false ribs, they extend as far back as their angles. The fibres incline downwards and backwards, and decussate with or cross the former; but they are somewhat shorter and less oblique in their direction.

The internal are separated from the external inter-costal muscles by the inter-costal vessels and nerves; they are lined internally by the pleura.

Infra-cost. *Infra-costales* (Verheyen).—In connexion with the inner surface of the ribs several small bundles of fleshy and tendinous Cross ribs at inner surface. fibres, which are thus named, will be found extending over two, and in some instances over three, inter-costal spaces. They have the same direction with the internal inter-costals, and are often described as parts of those muscles. The fasciculi vary in Irregular in number. size and number, and may be found covering all the intercostal spaces, except perhaps the first, but they are most constant on the lower ribs.

Levat. cost.

The *levatores costarum* (levatores breviores costarum,—Alb.) (fig. 108,[17]) are narrow, tendinous, and fleshy fasciculi, which extend obliquely downwards and forwards (in this particular resembling the external inter-costals), from the extremities of the transverse processes of the dorsal vertebræ, to be inserted into the margins of the ribs between their angles and tubercles. Their fibres spread out and become flat at their insertion. Each rib receives one from the vertebra next above; there are therefore twelve muscles on each side, and that for the first rib is derived from the last cervical vertebra.

One to each rib.

Lower are attached to two ribs.

The inferior muscles of this series divide into two parts, one of which is distributed as above stated, but the other consisting of longer fibres passes over one rib and terminates on the second below; and thus each of these ribs receives muscular fibres from the transverse processes of two vertebræ. The longer bundles have been described as separate muscles under the name *levatores longiores costarum* (Albinus).

Triang. sterni is in thorax.

The *triangularis sterni* (sterno-costales,—Verheyen) is a thin flat plane of muscular and tendinous fibres, placed within the thorax, immediately behind the costal cartilages. This muscle *arises* from the inner surface of the ensiform cartilage, and of the lower part of the sternum and the cartilages of the lower true ribs, from which its fibres pass outwards and upwards, diverging, the lowest horizontally, the rest obliquely, and approaching more and more the vertical direction towards the upper part of the muscle. It is inserted by digitations (which give to the outer margin a serrated appearance) into the cartilages of the true ribs from the fifth to the second inclusive—on the lower border and inner surface of each.

One surface of the triangularis sterni is in apposition with the parts just mentioned, together with the internal mammary artery and the internal inter-costal muscle; the other surface is in contact partly with the pleura, which is reflected upon it, and partly with the pericardium and the interval called anterior mediastinum. At the lower margin the fibres are continuous with those of the transversalis muscle.

The triangularis sterni varies constantly in its extent and points of attachment in different bodies, and even on the opposite sides of the same body.

Actions.—The two planes of inter-costals act simultaneously; and, as they decussate with one another, the ribs on which they act are made to move in the direction of the diagonal of the moving powers, that is to say, directly upwards when the first rib is relatively the more fixed point, and downwards when the last happens to be so. In drawing up the ribs, they slightly rotate the bodies, and evert the lower borders of those bones; at the same time the middle and lower inter-costal spaces are widened, for the ribs are spread asunder somewhat like those of a fan. This arises from the peculiar mode of attachment of the last rib, which is prevented from ascending with the rest by the manner in which the quadratus lumborum binds it to the ilium, so that it serves to spread or separate them from one another.

Diaphragm; outline of its arrangement.

Fig. 122.*

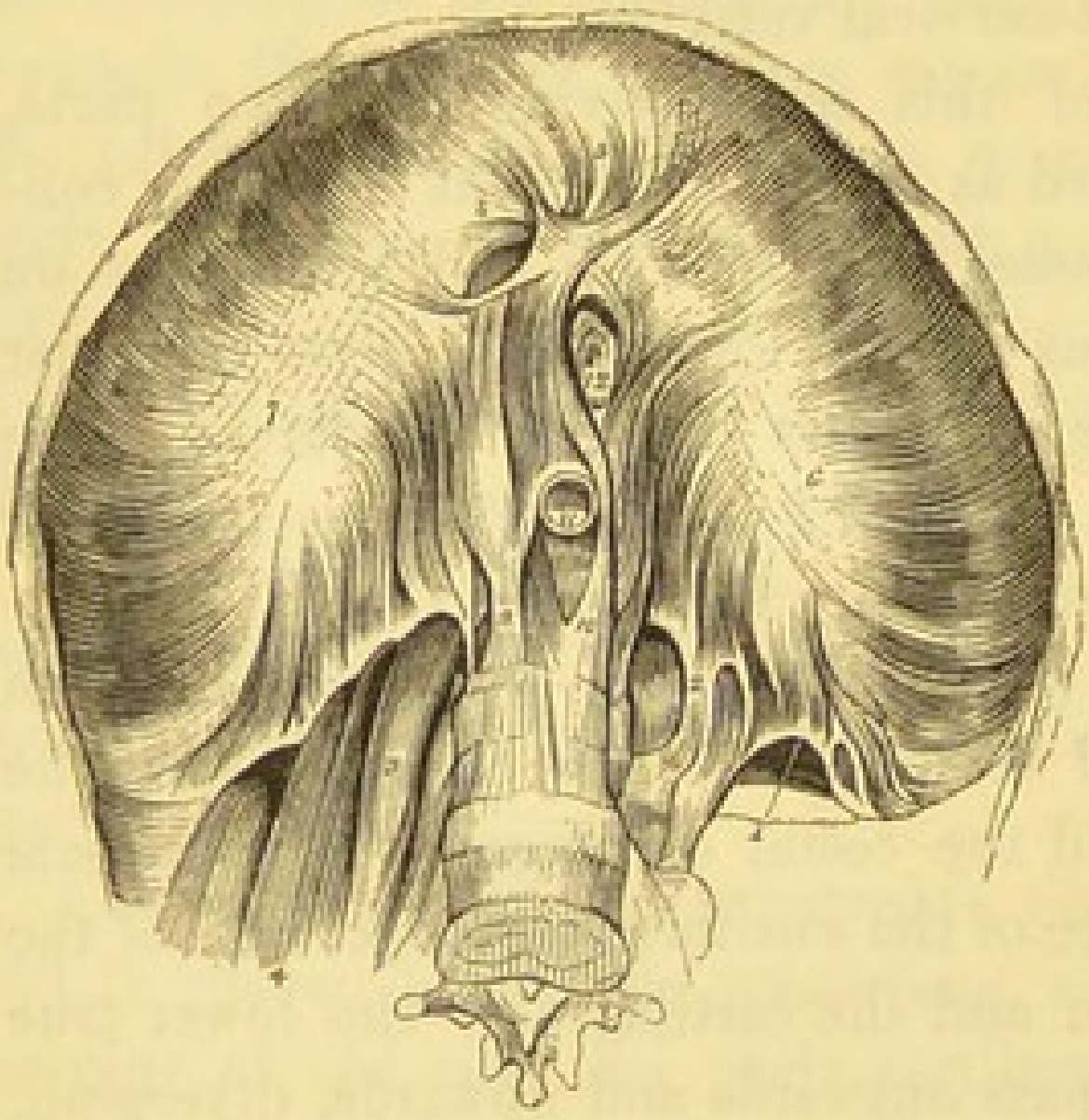

The *diaphragm* (fig. 122) (*διαφϱαγμα*†: φϱένες: septum transversum: midriff) is a thin muscular and fibrous partition between the thorax and abdomen, and is perforated for the passage of certain organs from one of these cavities to the other. From the lower margin of the thorax, to which it is attached at its circumference, the septum arches deeply upwards, and from this shape it results that some of the viscera situated at the upper part of the abdomen are, to a considerable extent, under the protection of the ribs; and as the height to which the septum arches is liable to variation, and is actually varied constantly during life, the capacity of the thorax and the abdomen is alternately enlarged and diminished, the enlargement of the one coinciding with the diminution of the other. It is connected directly with the thorax at its anterior and lateral part; but as the aorta is placed immediately against the spine, and the psoas muscles are attached to the sides of that column, at the same time that the last rib on each side is occupied by the

---

* A view of the lower surface of the diaphragm. 1, 2. Ligamenta arcuata — externum and internum. 3, 4. The muscles beneath the preceding. 5, 6, 7. The parts of the central tendon. 8. The foramen for the vena cava. 9, 10. The crura. 11. Hiatus aorticus. 12. The foramen for the œsophagus.

† *Διαφράσσω*, to separate two parts.

quadratus lumborum, the diaphragm is separated from the bones by these structures, and tendinous arches extending over them give origin to the fibres of the diaphragm.

Crura.

Right lower than left.

Muscular fibres; their decussation.

Origin of the fibres.—a. The crura—(fig. 122,[9],[10]). On the bodies of the lumbar vertebræ, and on each side of the aorta, is a thick tendinous band which consists of several sets of fibres. These tendinous fibres are usually aggregated into two bundles, and are attached over a considerable but varying extent of surface. On the right side they are connected with the first, second, and third lumbar vertebræ, and the interposed fibro-cartilages, or to the second, third, and fourth ; on the left side, the attachment is higher by the breadth of one vertebra. The tendons of both sides unite by their inner margins on the bones to which they are attached, and they are continued one into the other over the aorta by a small fibrous arch. Proceeding upwards they give origin to muscular fibres, and these with the tendons are named the *crura*, or sometimes the *pillars* of the diaphragm. The external muscular fibres emanating from this source are directed upwards and outwards to the aponeurotic centre ; but the fibres near the middle cross from each side to the opposite (those of the right usually being anterior to those from the left), and then curving upwards they construct an opening for the transmission of the œsophagus before ending in the common centre of the muscular fibres. The decussation of the fibres was found by Haller to be generally fourfold ; it measures about an inch in length.

Ligament. arcuata.

Internal over psoas.

External over quad. lumborum.

b. Ligamenta arcuata.—Externally to the bodies of the vertebræ are two fibrous arches on each side.* The first[2] extends from the body of the first lumbar vertebra to the transverse process of the same vertebra, or likewise to the second, and crosses over the psoas muscle. It is named the ligamentum arcuatum internum (arcus interior,—Haller). The second and broader fibrous arch[1] (ligamentum arcuatum externum) reaches from the outer extremity of the preceding (both being attached to the same part, the transverse process), over the quadratus lumborum, to the last rib. This band is continuous with the anterior lamina of the sheath of the muscle just mentioned, and is but the upper margin of that structure somewhat in-

---

* They appear to have been first clearly described by Senac, " Mém. sur le Diaphragme," in " Histoire de l'Acad. Royale des Sciences," 1729, p. 118.

Musc. fibres from.

creased in thickness. From both these tendinous bands muscular fibres take rise, and are directed to the posterior part of the common centre. Those above the last rib are usually thin, and separated one from the other by inter-spaces.

Origin from ribs;

from ensif. cartil.--this is separate.

c. Origin from ribs and the ensiform cartilage. — The remaining muscular part of the diaphragm is derived from the inner surface of the cartilages, and a little of the osseous part of all the ribs which form the margin of the thorax; viz. the five false ribs and the last true one (with in some instances one other,—the sixth). A narrow muscular slip likewise takes rise from the ensiform cartilage, and at each side of it there occurs an interval in which no more than cellular membrane is interposed between the abdomen and thorax, or rather between the proper lining membranes of those cavities. The extensive part of the muscle derived from the ribs commences by a serrated margin, and its angular processes are adapted to the transversalis muscle, whose edge is disposed in a corresponding manner.

Various lengths of fibres.

The muscular fibres proceeding from the several sources now reviewed have various lengths: those situated at the posterior and lateral part of the thorax are the longest, those in front are much the shortest. They all curve upwards and inwards to join the central tendon.

Central tendon.

Three parts (alæ) partially separ.

Fibres crossed.

The *central tendon* (cordiform tendon; phrenic centre; tendo diaphragmatis; centrum nerveum) is a thin tendinous lamina or aponeurosis, and is the highest part of the diaphragm. Elongated from side to side, and curved on itself at its circumference, the concavity of the curve being directed back towards the vertebral column, it consists of three parts [5],[6],[7], partially separated one from the other by indentations. The middle part is described as the largest; and the left division, which is elongated and narrow, is considered the smallest of the three. From being partially tripartite, the whole has been likened to a trefoil leaf, and each part has been named an "ala." The tendon is insulated by the muscular portion of the diaphragm, with which it is intimately connected—the fibres of the one being directly continued into those of the other. The tendinous fibres cross one another, and are interwoven at various points and in various directions, and thus the strength of this structure is assured.

Foramina.

Foramina of the diaphragm.—There are three large perforations for the passage respectively of the aorta, the œsophagus, and the vena cava, besides some holes or fissures, which are small and less regular than those.—*a*. The foramen for the aorta (hiatus aorticus) is almost altogether behind the diaphragm, for no more than a few of the tendinous fibres of the crura are posterior to the vessel. It is lower than any of the other openings, and is placed in the middle line immediately in front of the bodies of the vertebræ. The circumference is tendinous, being formed by the tendinous appendices of the crura and the curved band which connects them in front. Besides the aorta, this opening transmits the thoracic duct, and frequently likewise the vena azygos.—*b*. The foramen for the œsophagus[12], higher, and at the same time anterior, as well as a little to the left of the preceding, is separated from that opening by the decussating fibres of the crura. It is oval in form, and muscular in structure; but in some cases a small part, the anterior margin, will be found to be tendinous, being formed by the margin of the central tendon.—*c*. The opening for the vena cava[8] (foramen quadratum) is placed in the highest part of the diaphragm, in the tendinous centre at the commencement of its right ala, or between this and the middle one. Its form is quadrangular, or nearly so, and it is bounded by four bundles of tendinous fibres running parallel with its sides.

Foram. for aorta; the lowest; is tendinous. That for œsoph. is muscular. For vena cava, the highest, is square and tendinous.

Besides the foregoing large foramina, there are small perforations through the crura for the sympathetic and splanchnic nerves on both sides, and for the vena azygos minor on the left side. Moreover, the larger azygos vein often takes its course through the right crus.

Other small foram.

The upper or thoracic surface of the diaphragm, which is very convex at its middle, and rises higher on the right side than the left, is covered by the pleuræ and the pericardium; the fibrous layer of the latter structure blends with the tendinous centre. And, in as much as the lateral and posterior parts of the muscle ascend very obliquely from their connexion with the lower margin of the thorax, a considerable extent of the upper surface (in the situations now mentioned) is close to the ribs, and is separated from them only by a thin portion of lung.—The lower surface, deeply concave, is lined by the peritoneum, and has in apposition with it the liver, (which is bound to the diaphragm by folds of the peritoneum,) and the stomach, the spleen, and kidneys.

Upper surf. convex; parts adjacent. Lower surf. concave;

The diaphragm has received much of the attention of anatomists at all times, and their descriptions often contain expressions of their admiration of its structure and general disposition. These may be represented by the words of Spigelius, "Musculus unus omnium fama celeberrimus;" or by those of Haller, whose account of the muscle begins thus, "Nobilissimi, post cor, musculi historiam ultimo loco recensemus, ut eam pro dignitate aliquanto fusius exponere liceat."—The diaphragm has been described as a digastric muscle; one end of the fibres being represented to be on the vertebræ, the other end on the ribs, and the tendon interrupting them in the middle.*—It was likewise considered to be a double muscle,† and one part was named superior, the other inferior; the central tendon being the demarcation between the two. The inferior part, that which is connected with the lumbar vertebræ, was known as the "musculus inferior v. minor;" and in some modern books it is mentioned as the lumbar part—"pars lumbalis."

Different modes of considering the diaphr.

Peculiarities.

The part of the muscle situated above the last rib, which has been mentioned as often consisting of thin and scattered fibres, will, in some cases, be found to be to some extent fibrous rather than muscular in structure. The small band from the ensiform cartilage is in some cases altogether wanting.

Actions.—When the fibres of the diaphragm contract, the muscle descends, and becomes an inclined plane, whose direction is downwards and forwards. By these means the abdominal viscera are pressed against the lower and fore part of the parietes of the cavity, so that the capacity of the abdomen is diminished in proportion as the thorax is enlarged. Should the abdominal muscles and the diaphragm be both brought into action together, the viscera will be compressed between them, and forced towards the lower part of the cavity, as occurs in the expulsive efforts of accouchement, &c. After a complete expiration, the upper surface of the diaphragm is on a level with the lower border of the fourth rib.

PERINÆAL REGION.

The history of the muscles of this part will most conveniently accompany the description of the other structures of the perinæum, with which they are connected.

MUSCLES OF THE INFERIOR EXTREMITY.

ILIAC REGION.

In the iliac fossa, and along the upper border of the pelvis, we find placed the iliacus and psoas muscles. We need not

---

* N. Stenonis, "de musc. et gland. observ. specimen," p. 8.

† Casp. Bartholini, "Diaphragmatis structura nova," p. 19.

give any particular directions for their dissection, as it is never undertaken until the abdominal muscles have been examined and the viscera removed, and then they are at once brought into view, being merely concealed by the fascia iliaca.

The *psoas magnus* (figs. 122,^{3}; 125,^{1}) (lumbalis prælumbo-trochantineus;—ψόα, the loins) is situated along the sides of the lumbar vertebræ, the margin of the pelvis, and deeply at the superior part of the thigh, extending from the last dorsal vertebra to the small trochanter of the femur. It is thick and round at the centre, and gradually diminishes in size towards the extremities. The muscle *arises* from the sidess of the bodies of the last dorsal and of the lumbar vertebræ, with the interposed fibro-cartilages, also from the anterior surface and lower margins of the transverse processes of the last-named vertebræ near their base. With the bodies of the bones the connexion is effected by means of five distinct parts, which are each attached to the upper and lower margins of the vertebræ and the interposed fibro-cartilage;—the highest to the neighbouring margins of the last dorsal vertebræ and the first lumbar, and the lowest to the edges of the fourth and fifth lumbar vertebræ with the inter-vertebral substance. These at tachments are connected by thin tendinous arches, which extend over the middle of the bones and cover the lumbar vessels and some nerves. From these several attachments the muscle passes across the brim of the pelvis, beneath Poupart's ligament, and ends in a tendon, which is *inserted* into the posterior half of the small trochanter of the femur. The tendon is lodged at first in the substance of the muscle, and begins to receive the muscular fibres near its upper part. At a lower point it lies along the outer side of the psoas, between it and the iliacus, and receives the fibres of both muscles.

Psoas magn. reaches fr. last dorsal vert. to femur.

Is fusiform.

Origin from lumbar vert. —bodies and trans. processes.

Attachment to bodies of vert.;

separ. with intervening arches.

Insertion.

The tendon comm. to iliacus.

The muscles of opposite sides diverge one from the other in proceeding downwards, and at the lower end each is directed backwards to reach its destination.

The posterior surface of the psoas muscle corresponds above with the transverse processes of the lumbar vertebræ, the lumbar plexus of nerves, and the quadratus lumborum muscle, from which last it is separated by the anterior lamina of the fascia lumborum; towards the lower end it rests against the ilium and the capsular ligament of the hip-joint, a synovial mem-

Parts behind psoas.

Separ. fr. hip-joint by synovial bursa.

Narrows inlet to pelvis. brane being interposed; in the middle this surface overlays a portion of the pelvic cavity, and the muscles of both sides therefore limit the extent of the inlet to the cavity in the transverse direction. Parts in front. The anterior surface, placed behind the peritonæum, is in relation successively with the diaphragm, its ligamentum arcuatum internum, and the renal vessels, the ureter and the spermatic vessels. Is covered with iliac fascia. This surface is covered by the iliac fascia, and, while on the margin of the pelvis, it supports the femoral artery. The inner border is in contact superiorly with the bodies of the vertebræ, and with the sympathetic ganglia resting on these. Inner border w. sympath. nerv.; From the middle of these bones it is separated by the lumbar arteries, and branches of communication between the spinal and sympathetic nerves, as already stated. iliac and lumbar arteries. In the pelvic region the same border is in contact with the iliac artery; and on the thigh, with the pectineus muscle, from which it is separated by the internal circumflex artery. Ant. crural nerve betw. psoas and iliacus. Finally, the outer border of the psoas looks towards the iliacus muscle, from which it is at first separated by a slight cellular interval, and then by the anterior crural nerve.

Peculiarities. The upper extremity of the muscle is occasionally connected with the head of the last rib, or with the upper margin of the first lumbar vertebra only. The connexion with the transverse process of that vertebra is sometimes wanting. A portion of the fibres derived from the transverse processes may be found to be distinct from the rest of the muscle in its whole course.—(Albinus and Meckel.)

Iliacus. *Iliacus* (fig. 125,^{3}) (iliacus internus,—Spigel. and Alb.; ilio-trochantineus).—This muscle is situated in the iliac fossa, which it fills up, and at the upper and fore part of the thigh. Expanded in the former, and narrowing in the latter situation, it is somewhat triangular in shape. Origin. It *arises* from the fossa of the ilium, together with the inner margin of the crista of that bone, as well as its anterior border (the vertical part), including the two spinous processes. Fibres are likewise derived from the capsule of the hip-joint and the ilio-lumbar ligament, in some instances likewise from the base of the sacrum. Fibres join tendon of psoas; From these different sources the fibres pass down, and the greater number inclining obliquely inwards terminate in the side of the tendon common to this muscle and the psoas magnus; some reach femur. some of them are prolonged into the oblique line which leads downwards from the small trochanter of the femur—the process to which the tendon is attached.

Covers hip-joint—synovl. bursa between.

The iliacus rests on the ilium and the capsular ligament of the hip-joint, a synovial membrane separating it to some extent from this last, and the margin of the bone. It is subjacent to the iliac fascia and fascia lata of the thigh ; and to its inner side is the psoas muscle, the anterior crural nerve being interposed. In the abdomen the viscera of the iliac region are before the muscle, and some small nerves pass across it. —The psoas and iliacus, with the fascia which covers them, fill up completely the interval between Poupart's ligament and the margin of the ilium, from the ilio-pectineal eminence outwards.

Psoas and iliacus fill up space under crural arch.

Peculiarities.

This muscle is often still named iliacus internus, though there is now no correlative term in use, no muscle being called iliacus externus. Several of the older anatomists called the pyriformis by that name.—Some of the external fibres of the iliacus, those derived from the anterior inferior spine of the ilium close to the rectus femoris, are from time to time found separated from the rest, even from their origin to the termination on the femur below the small trochanter.—The psoas and iliacus are so completely united by their common tendon that they might be regarded as a single muscle. They have been so considered by several anatomists.

Psoas parv.

Origin.

Lies on larger psoas.

Is connected w. iliac fascia.

Psoas parvus (fig. 125,[2]) (præ-lumbo-pubius).—This long and slender muscle is situated along the anterior side of the psoas magnus. It *arises* from the bodies of the last dorsal and first lumbar vertebræ, with the fibro-cartilage between them, and soon ends in a flat tendon, which passes along the anterior and inner side of the psoas magnus, to be *inserted* into the ilio-pectineal eminence.—The muscle is covered at its origin by the diaphragm, and rests in its whole length on the psoas magnus. Its tendon is united with the fascia iliaca, and may exercise some influence on the tension of that membrane.

Usually absent.

Variations of origin.

The psoas parvus is most frequently absent. It was present in no more than one out of twenty bodies which M. Theile* examined with special reference to the muscle. When present, it is liable to many changes in the place of origin; thus, it may be connected only with the first lumbar vertebra, or with the second and the fibro-cartilage above it, and it has been observed to commence by two parts or heads separated by an interval.

Combined actions. The psoas and iliacus, when they take their fixed

---

* In Sœmmerring, op. ante citat.

point above, can bend the thigh on the pelvis, and rotate the limb somewhat outwards,—the latter power being derived from the direction of their common tendon and the mechanical advantage given them by the projection of the trochanter minor. These muscles assist materially in maintaining the erect position of the body, in which case they take their fixed point at their insertion into the femur, and then act upon the pelvis and spinal column, drawing them forwards so as to keep them erect upon the thighs. If this action be continued, the trunk may be bent forwards as in bowing. It is scarcely necessary to add, that this bending of the body will be directly forwards if the muscles of opposite sides act together, and obliquely to one side if they act separately.

GLUTEAL REGION.

In this space, which comprehends the posterior and external surface of the pelvis, we find the glutei, and the "external rotator" muscles of the thigh.

Dissection.—The subject being placed in the prone position, and the abdomen supported on a high block, the foot should be rotated inwards, and the limb abducted, in order to put the gluteus on the stretch. An incision may be made through the skin, from the coccyx obliquely upwards over the side of the sacrum and posterior spine of the ilium, and as high as its crista; from which point draw another obliquely downwards over the great trochanter. The flap thus included should be dissected cleanly off the muscle in the course of its fibres; that is to say, downwards and outwards. The remainder of the skin which covers the pelvis may be reflected upwards and outwards, the fascia serving as a guide. This will expose the tensor vaginæ femoris and part of the gluteus medius. The rest of the latter can be seen only when the gluteus maximus is detached. To effect this, let its lower border be drawn a little forwards, and the scalpel be inserted beneath it, so as to raise it from the sciatic ligament, and so successively from the side of the coccyx, sacrum, and ilium, proceeding from below upwards. When the muscle is detached, and turned down on the femur, the external rotators and gluteus medius come into view, and require little further dissection. As the gluteus medius covers the third muscle of that name, the easiest mode of reflecting it is by cutting through its tendinous insertion, and drawing it upwards. The external rotators should be attentively examined, more particularly the two obturator muscles. The internal one cannot be fully seen until the pelvis is divided; but the direction of its two parts, and the peculiar appearance presented by its tendon, where it slides over the ischium, can be observed by cutting it across near its insertion, and reflecting it outwards.

Glut.max. *Gluteus maximus* (fig. 123,[1]) (gluteus magnus,—Alb.; ilio-sacro-femoralis).—This is a very large muscular mass; and

Fig. 123.†

Size characteristic of man.

Origin.

Insert. into femur.

Larger part ends in fascia lata.

Fibres parallel in bundles.

its great size is characteristic of man, being connected with the power he has to maintain the trunk in a line with the lower limbs. It is placed at the back part of the pelvis, extending from it to the outer and upper part of the thigh, and it forms the prominence of the nates.* The great gluteal muscle *arises* from the posterior fifth of the crista of the ilium, and the irregular rough surface subjacent to that part: from the lateral tubercles on the posterior surface of the sacrum: from the posterior sacro-iliac ligament and the side of the coccyx. From this extensive origin the fibres of which the muscle consists pass downwards and outwards, and terminate as follows: — the lower fibres are inserted into the femur (between the vastus externus and adductor magnus) on the rough line or irregular ridge (as it to some extent is in cases of large muscular development) which lies between the base of the great trochanter and the linea aspera. The upper and larger part of the muscle ends in a thick tendinous structure, which covers the great trochanter, and joins with the fascia lata of the thigh.—The fleshy fibres generally are parallel one with the other, and they are aggregated into large bundles separated by cellular membrane and fat; and thus the muscle is characterized by a more than usually coarse appearance.

Lower border is towards perineum.

The muscle is covered by a thin elongation of the fascia lata. The upper border is firmly connected with the gluteus medius by that membrane; the lower one (the longest), which is free, forms the fold of the nates, and looks towards the perineum.

---

* Hence the name "gluteus" applied to the muscles in this situation,—Γλουτὸς, the nates.—Riolanus writes the name of the muscles "gloutius."

† The superficial muscles of the left thigh on its posterior aspect. 1. Gluteus maximus. 2. Part of gluteus medius. 3. Vastus externus. 4. Gracilis. 5. Biceps femoris, the long head; and 6, the short head. 7. Semi-tendinosus. 8. Semi-membranosus.

Parts beneath.

When the muscle is separated from its superior connexions and reflected downwards, it will be found that its inner surface covers (besides the parts with which it is connected) the gluteus medius, the gluteal, sciatic, and pudic vessels and nerves, the external rotator muscles, the great sciatic nerve, the trochanter major, and the tuberosity of the ischium, with the muscles arising from it.

Synovial bursæ.

—Between the tendon and the great trochanter of the femur are placed two or three synovial bursæ, or a single multilocular sac of large size. A bursa is also beneath it on the tendon of the vastus externus, and another on the tuber ischii.

Fig. 124.*

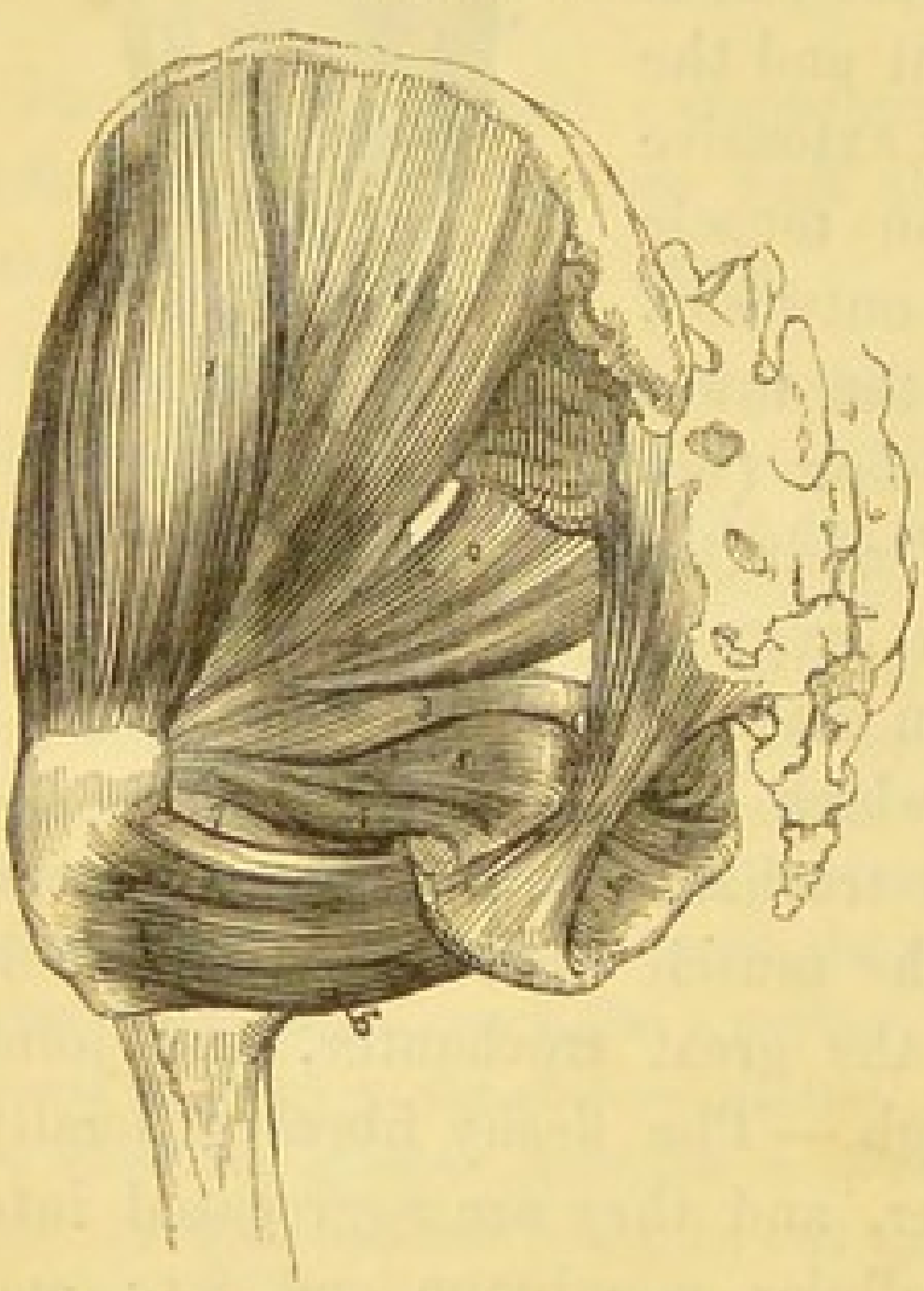

Glut. med.;

The *gluteus medius* (fig. 123,[2]; fig. 124,[1]) (ilio-trochantereus major) is situated on the external surface of the pelvis, partly covered by the preceding muscle, partly by the integument and fascia.

is fan-shaped.

Broad, and, as it were, radiating at its upper part, it becomes narrow and thick at the lower extremity.

Origin,

It *arises* by short aponeurotic fibres from an elongated surface of the ilium, which is broader behind than in front, and is bounded by the outer margin of the crista (its anterior four-fifths),

fr. dorsum ilii,

the superior curved line on the dorsum, and the line which marks the extent of the gluteus maximus on the bone.

and fascia.

Numerous fibres likewise take origin from the dense fascia which covers the muscle in front of the gluteus maximus.

Fibres converge.

The fleshy fibres descending from the different parts of this broad surface of origin proceed in different directions, (obliquely backwards, obliquely forwards, and verti-

---

* The gluteus maximus having been removed, the deep muscles on the posterior surface of the pelvis have been brought into view ; and, by the removal of the perineum and the pelvic viscera, the anterior part of the pelvis is seen from behind covered by the obturator internus.

1. Gluteus medius. 2. Pyriformis. 3. Gemellus superior. 4. Gemellus inferior. 5. Obturator internus. 6. Quadratus femoris. 7. Tendon of obturator externus.

cally,) and converge on a fibrous expansion, which becomes narrowed into a thick tendon. This (the tendon) is *inserted* into the outer surface of the great trochanter on a prominent line which crosses that process obliquely forwards and downwards. It is separated by a synovial bursa from the upper part of the trochanter.

The tendon, its insertion.

Synovial bursa.

The gluteus medius covers the third gluteal muscle, with the branches of the gluteal vessels and nerve. Its anterior border is blended with the gluteus minimus, and is connected with the special tensors of the fascia lata; and the posterior border is close to the pyriformis, the gluteal artery being interposed.

Parts adjacent.

The *gluteus minimus* (ilio-trochantereus minor), the third and smallest of the gluteal muscles, is placed under the gluteus medius, which must be removed to bring it into view; and, like that muscle, it is triangular or fan-shaped, the fibres converging from a broad surface of origin on the pelvis to a narrow place of insertion on the femur. It *arises* from all that space on the dorsum ilii between the superior curved line and the inferior one, which runs at a short distance above the brim of the acetabulum. A small part is likewise derived from the margin of the sciatic notch for a short space further back than the gluteus medius. The fibres approach one another; they descend and terminate on an aponeurotic expansion, which covers the muscle towards its lower end, and that structure narrows into a tendon, which is *inserted* into a portion of the upper margin and the anterior part of the great trochanter.

Glut. min.; is fan-shaped.

Origin below preceding.

Fibres converge.

Tendon, its insertion.

Between this muscle and the preceding one are placed a large part of the gluteal vessels and nerve, and a small portion is covered by the pyriformis, where it extends farther back than the gluteus medius. The anterior margin blends with the last-named muscle, and the posterior part of the tendon is often joined with that of the pyriformis.—A synovial bursa is interposed between the tendon (its anterior part) and the trochanter.

Parts over and under.

Blends with glut. med.

Synovial bursa.

Actions.—The glutei act alternately on the femur and pelvis, according as the one or the other becomes relatively their fixed point of attachment. All three act as abductors; the anterior fibres of the gluteus medius and minimus draw the trochanter forwards, the posterior backwards, giving it a slight rotatory motion. The gluteus maximus is a powerful abductor, and by the direction of its fibres is calculated to draw the femur backwards, at

Actions of gluteal muscles.

the same time that it rotates the whole limb outwards if it be kept extended. When the thighs become the fixed points, these muscles act on the pelvis. The great glutei draw it backwards, and maintain it and the body in the erect position; in this they are assisted by the semi-tendinosus, semi-membranosus, and biceps of each side, which act on the tuberosities of the ischia, and draw them downwards, so as to elevate the fore part of the pelvis. The gluteus medius and minimus are chiefly called into action in progression, and in standing on one leg; they draw the pelvis towards the femur, which is fixed, and by this action counterbalance the weight of the trunk, and maintain it erect on the limb. This alternation of action of the muscles of opposite sides during progression, gives to the pelvis that rotatory motion so perceptible in those who walk irregularly, and which is strikingly evident in females, in consequence of the great breadth of the pelvis.

External rotators.

The "external rotator" muscles form a group by themselves, being placed deeply at the back of the pelvis. They are the pyriformis, two gemelli, two obturators, and quadratus femoris.

Dissection.—Most of these are exposed by the removal of the gluteus maximus. The origin of the obturator internus and pyriformis cannot be seen until the pelvis is opened.

Pyriformis, in pelvis and on hip-joint.

The *pyriformis* (fig. 124,[2]) (pyramidalis; iliacus externus; sacro-trochantereus) is situated at first within the pelvis at its posterior part, and afterwards behind the hip-joint, extending from the anterior surface of the sacrum through the great sacro-sciatic notch to the great trochanter of the femur; and, as in this course it gradually decreases from a considerable size to a small tendon, the muscle has the shape its name implies. It *arises*, by three fleshy and tendinous digitations, from the second, third, and fourth divisions of the sacrum, interposed as it were between the anterior sacral foramina; a few fibres are also derived from the inner surface of the ilium, near its lower curved border (the sacro-sciatic notch), and from the sacro-sciatic ligament. From these attachments the muscle passes out of the pelvis by the great sacro-sciatic notch, becoming gradually narrow, and following nearly a horizontal course, and is *inserted* into the posterior border of the great trochanter by a rounded tendon, whose fibres are blended with those of the gemelli and often with the gluteus minimus.

Origin.

Tendon blends at insertion with others.

Parts adjacent in pelvis and out of that cavity.

Within the pelvis the pyriform muscle is placed behind the sciatic plexus of nerves, the internal iliac vessels, and the rectum (the last more especially at the left side). Outside the pelvis one surface rests on the ischium and the fibrous capsule of the hip-joint, the other is covered by the gluteus maximus. Its upper border is parallel with the gluteus medius, from which it is separated by the gluteal vessels as they emerge from the pelvis; and the lower border is a little above the gemellus superior, the interval being occupied by the great sciatic nerve, the sciatic and pudic arteries, and nerves.—A small synovial bursa is interposed between the tendon at its termination, and that of the gluteus medius.—The separation always existing at its points of origin sometimes continues to be apparent even after the muscle has passed out by the pelvis: when this is the case, the interval gives passage to one of the divisions of the great sciatic nerve.

Synovial bursa.

Muscle in some cases divided.

Sciat. nerve betw. parts.

The *obturator internus* (fig. 124,^{5}), (sub-pubio-trochantereus,) like the preceding muscle, is partly lodged within the pelvis, (and this is much its largest portion,) partly also over the posterior aspect of the hip-joint. From the anterior surface of the pelvis, which it covers to a large extent, it is directed outwards, and, having escaped from the cavity, turns forwards to the femur, with which it is connected through the medium of a narrow tendon. The two portions of the muscle have therefore different directions; and the angle between them, or turning part, is supported by the small sciatic notch of the ischium.

Obtur.inter. is placed in pelvis and behind hip-joint.

Different direction of parts.

The internal obturator muscle *arises* from the obturator membrane, together with the fibrous arch which protects the obturator vessels and nerve in passing by the muscle: from likewise the broad flat surface of the ischium external to the membrane, as far as the sciatic notch, and upwards to the brim of the pelvis. The fleshy fibres from this extensive surface are received within the pelvis on four or five tendinous bands, and by this arrangement the muscle becomes narrowed before emerging from the cavity. The tendinous bands turn over the small notch of the ischium, which is grooved, and covered with cartilage, lubricated with a synovial bursa. In proceeding forward, the fibrous processes soon unite into a single tendon; and this, passing horizontally onward, is inserted into the fossa beneath the upper margin of the great trochanter, and in connexion with the gemelli.

Origin.

Tendinous bands rest agst. notch of ischium.

Synovial bursa.

In the pelvis this muscle is covered by the pelvic and obturator fascia, and is crossed by the internal pudic artery

Fascia and pudic artery in pelv.

and nerve; and the same surface forms the outer boundary of the ischio-rectal fossa. The tendon, having united to it on each side the gemelli, is covered by the gluteus maximus, and is crossed by the great sciatic nerve. It is in contact with the capsule of the hip-joint. — There are usually two synovial bursæ connected with the tendinous part of the muscle. One has been already referred to, as occurring between it and the surface of bone over which it turns. The other, of much smaller size, is elongated and narrow, and is in contact with the tendon where it rests against the fibrous capsule of the hip-joint. In some instances the two are continuous one with the other, and form but a single sac.

Is crossed by sciat. nerve; is on capsule of hip-joint. Synovial bursæ.

Gemelli.

The *gemelli* (gemini; ischio-trochanterei) are two small narrow fasciculi, consisting chiefly of fleshy fibres extended horizontally at each side of the tendon of the obturator internus; and they are named from their relative position. The superior one (*gemellus superior*, fig. 124,[3]), which is the smaller, *arises* from the spine of the ischium; the inferior (*gemellus inferior* [4]) takes origin from the upper and back part of the tuberosity of the same bone. Passing outwards, they join with a tendon of the internal obturator muscle placed between them, in some instances covering and concealing it from view, and are *inserted* with that tendon into the fossa under the upper margin of the great trochanter of the femur. A part of the fibres end on the tendon of the obturator, and this is especially the case as regards those of the superior muscle.

Superior; inferior. They join tend. of obtur. intern.

Parts adjacent.

One of the gemelli is immediately below the pyriformis; the other is parallel with, and close to, the quadratus femoris, and at its termination is in contact with the tendon of the obturator externus muscle. With other parts they have the same immediate connexions as the part of the obturator internus which they enclose. They partly cover the synovial bursæ connected with that muscle.

Names.

The obturator muscles were so named, because of closing or covering the thyroid foramen.* The internal muscle was likewise named "Marsupialis," or "Bursalis," from having connected with it a synovial bursa, which is perhaps more than usually distinct.

---

* "Propterea quod foramen ossium pubis principiis suis obturent." Spigelius, "De h. corp. fabr." lib. iv. cap. 22.

The gemelli might well be considered with the older anatomists* as appendages to the obturator, with which they are blended. From their connexion with its synovial bursa they were regarded by some authors as the muscular "marsupium" of that muscle.†—The gemellus superior is often very small, and in some cases is altogether absent.

Gemelli are appendages to obt. inter.

The *quadratus femoris* (tuber-ischio-trochantereus) (fig. 124, 6) succeeds immediately to the muscles last described, intervening between them and the adductor magnus, and extending from the ischium to the great trochanter of the femur. It is short, flat, and square in shape; and from this last circumstance its name is taken.

Quadr. femor. immediately below preceding.

The fibres *arise* from the external curved border of the tuber ischii, and, proceeding horizontally outwards, are *inserted* into the lower part of the posterior, and outer part of the great trochanter, on a slight ridge which terminates on that leading to the linea aspera. The line of insertion of this muscle may properly be called *linea quadrati*, to distinguish it from the inter-trochanteric line; the latter being oblique in its direction, the former vertical.

Origin.

Insertion.

This muscular plane has an admixture of tendinous fibres at its attachments. It is covered by the same parts as the muscles immediately above it, and likewise, to a small extent, by the origin of the semi-membranosus muscle. On removing it, the outer part of the obturator externus is brought into view.

Parts over and under.

The *obturator externus* (sub-pubio-trochantereus externus) (fig. 124, 7) is triangular in shape, and is placed very deeply, extending horizontally from the anterior surface of the pelvis to the trochanteric fossa of the femur, which it reaches by passing behind the hip-joint. To expose its origin requires the removal of the muscles placed in front and to the inner side of the thyroid foramen, viz. the psoas, iliacus, pectineus, adductor longus, and brevis; and the tendon is shown by the removal of the gluteus maximus and quadratus femoris.

Obtur. extern.

Deep position.

The muscle *arises* from the rami of the os pubis and ischium, as far as the margin of the thyroid foramen, and from about half the surface of the obturator membrane. From this extensive origin the fibres pass outwards, converging to a tendon,

Origin.

---

* *e. g.* Vesalius, "Oper." p. 414.

† Among others, Spigelius, loc. cit.; Cowper, "Myot. Reform." § 155.

Insertion.

which is directed behind the neck of the femur, to be *inserted* into the trochanteric fossa, beneath the inferior gemellus.—The immediate connexions of the obturator externus with other muscles are sufficiently stated above. The obturator nerve lies on its upper part.

Action of extern. rotators, powerful.

Actions.—The transverse direction of these muscles, and their mode of insertion into the trochanter, together with the great mechanical advantage afforded them by the length of the cervix femoris, enables them to act powerfully in rotating the thigh, and therefore the whole limb, outwards. In position, direction, and action, they are analogous to the muscles which pass from the dorsum of the scapula to the great tuberosity of the humerus; the latter, however, are nearly equalled in strength by their antagonist, the sub-scapularis. But the external rotators of the thigh are very feebly opposed by the tensor vaginæ femoris, and the anterior fibres of the gluteus medius, which alone act directly in rotating the limb inwards, if we except the semi-tendinosus, which may, under some circumstances, co-operate in this action. If the femur be bent on the pelvis, the line of direction of these muscles nearly coincides with the axis of the bone; their power of rotation then ceases, but they may in a slight degree become abductors; at least this may be said of the pyriformis, both from its direction and point of insertion.

Intern. rotators, feeble.

Action of former changed by flexion of limb.

ANTERIOR FEMORAL REGION.

At the fore part of the thigh, we find immediately beneath the skin and fascia these muscles, viz. the tensor vaginæ femoris, sartorius, rectus, vastus externus and internus, crureus.

Dissection.—To expose the fascia lata:—In the first place, let the knee be slightly bent,—the limb rotated outwards and supported on a block. And, as in this position the course of the femoral artery is indicated by a line extended from midway between the anterior superior spine of the ilium and the pubic symphysis to the lower border of the patella, the first incision through the skin should be made to the same extent, and in the same direction. In order to reflect the integuments with facility, a second incision may be made transversely at the junction of the upper with the middle third of the thigh; and, finally, another in the same direction at the junction of the middle with the lower third: this marks the termination of the femoral artery. The flaps of skin thus formed are to be dissected back, so as to expose the fascia lata. This membranous investment should be attentively examined in its entire extent, particularly at the upper part; the differences of texture and thickness which it presents in different parts should also be carefully noted.

To expose the muscles:—In prosecuting the dissection, in order to expose the muscles on the fore part of the thigh (and it is with these the dissection usually commences), nothing more is necessary, after the skin has been removed, than to pinch up the fascia with the blades of the forceps, divide it with your scalpel, and reflect it from above downwards, in the direction of the fibres of each muscle. After the sartorius and rectus have been dissected in their entire length, and their attachments and relations attentively examined, the former may be cut across in the middle, and the parts drawn aside; the latter too may be divided near its origin, and turned down on the leg. The triceps extensor is thus brought fully into view, so that its three parts (the two vasti and the crureus) may be inspected successively, at the same time that it is considered as a whole. The muscle, in fact, may be compared to a hollow splint, encasing the anterior and lateral surfaces of the shaft of the femur, leaving unoccupied only the linea aspera and its bifurcations (superior and inferior).

To detach the vasti :—A perpendicular incision may, in the next place, be made through the muscle, extending from one extremity to the other over the middle of the femur. If the margins of the incision be drawn aside, a clear view will be obtained of the manner in which the fibres pass to be implanted, by so many separate points, into the surface of the bone. Holding the border of the incision tense, and with the blade of the scalpel placed in the horizontal position, the muscle may be detached from the bone inwards as far as the insertion of the adductors, and outwards to the attachment of the gluteus maximus, and the short head of the biceps, so as to denude the front and sides of the thigh-bone. Having proceeded so far, cut from within outwards through the vasti, so as to detach them altogether. When this is done, the two parts thus separated may be turned down on the leg, still left connected with the patella.

By these measures we shall bring into view the inferior attachments of the next set of muscles (adductors), which would otherwise lie in a great degree concealed.

Before the extensors are detached and reflected, the form and boundaries of the opening for the femoral vessels should be attentively examined, as the vastus internus constitutes a part of it; nor should the fascia be omitted which passes from the latter muscle to the adductors, covering the vessels.

Tensor vaginæ femor.

The *tensor vaginæ femoris*,—Alb. (musculus fasciæ latæ; membranosus; ilio-aponeurosi-femoralis) (fig. 125,[5]) is situated at the upper and outer part of the thigh, extending obliquely downwards, outwards and backwards, from the anterior superior spinous process of the ilium for some space below the great trochanter. The muscle is elongated and flat, and it is broader at the lower than at the upper extremity. It *arises* by aponeurotic fibres from the external surface of the anterior superior spinous process of the ilium, between the gluteus medius [4], and the sartorius [6], and terminates below the great trochanter of the femur, its fleshy fibres being received between two laminæ of

Parts adjoining.

the fascia lata, into which they are thus inserted.—The external surface of the muscle is covered by a layer of the fascia lata; the internal one is separated by another process of the same membrane from the rectus femoris and the vastus externus. Its anterior border is at first close to the sartorius; but lower down it diverges, and leaves an angular interval occupied by the rectus femoris. The posterior border is for some way applied to the gluteus medius, and is connected with it at its origin; but lower down these muscles are separated by an interval.

Actions.—As its name imports, the direct action of this muscle is to render the fascia tense, and thereby assist the other muscles. If this effort be farther continued, the obliquity of its direction will enable it to rotate the whole limb inwards, provided the other muscles remain quiescent. In the erect position, by taking its fixed point below, it will act on the pelvis.

Sartorius.

Fibres longer than those of any other muscle.

Changes of direction.

Tendon covers those of semi-tend. and gracilis.

Sartorius (fig. 125,[6]) (ilio-præ-tibialis.) This flat, narrow muscle extends from the outer side of the pelvis to the inner and fore part of the tibia, and its fibres are longer than those of any other muscle in the body. It *arises*, by tendinous fibres, from the curved margin of the ilium, between its anterior superior and inferior spinous processes, and from the former point of bone; and is *inserted*, by an expanded aponeurosis, into the upper and inner side of the tibia, just below its tuberosity. In this long course the muscle is directed over the anterior part of the thigh, obliquely inwards in the upper third, then vertically at the inner aspect of the limb as far as the knee, and below this it turns obliquely forwards to its place of attachment. The tendon of insertion, broad and expanded, covers those of the gracilis and semi-tendinosus (a synovial bursa being interposed), and sends off an ex-

Fig. 125.*

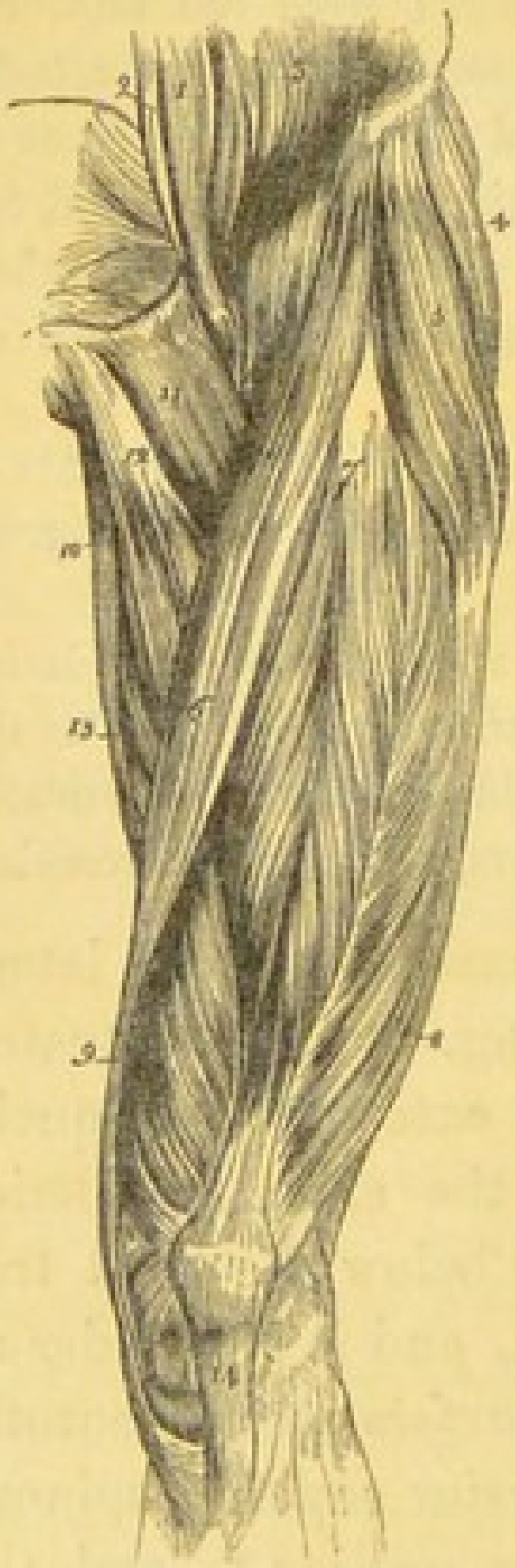

---

* The muscles of the fore part of the thigh, as seen after removal of the integuments and the fascia lata. 1. Psoas magnus (its lower part). 2. Ten-

pansion which strengthens the fascia of the leg, by becoming identified with it.

Parts adjacent.

The sartorius is covered only by the fascia lata and integument. It covers the iliacus, psoas, and rectus femoris muscles, the femoral vessels, the adductor longus, adductor magnus, vastus internus, gracilis, and semi-tendinosus muscles. Its internal border and the adductor longus form the sides, and Poupart's ligament the base, of a triangular space on the upper third of the thigh, through the centre and apex of which the femoral artery passes.

Name of muscle.

The name of this muscle has been taken from the influence ascribed to it on the position of the limb peculiar to tailors. It appears to have been first introduced by Spigelius.*

Direction varies.

As the direction the sartorius takes inwards varies in different cases, the position at which it covers the femoral artery (the most important practical point in the anatomy of the muscle) is by no means constant. In some cases it crosses inwards so speedily as to be placed over the vessel at a comparatively short distance from Poupart's ligament.†

Quadriceps.

Quadriceps extensor cruris (Sœmmerring).—The mass of the extensor muscles of the leg, which is distinguished by this general name, is of very large size, and covers the whole of the anterior and lateral surfaces of the thigh-bone. It is connected with the tibia by tendinous structure, which is undivided and common to the whole mass; but the upper extremity is separated into parts or heads, which are more or less distinct one from the other. One of the heads has no direct connexion with the femur. It reaches from the ilium to join with the other divisions of the muscle near the patella, having a straight course between these points over the fore part of the thigh; and hence is named "rectus femoris." The other divisions of the quadriceps are in immediate connexion with the femur, covering it from the trochanters to the condyles, except on the linea aspera and the intervals between the lines which extend from it towards

Is undivided at lower end, but upper part is divided.

One part not connected with femur.

Others cover great portion of that bone.

---

don of psoas parvus. 3. Part of iliacus. 4. Gluteus medius. 5. Tensor fasciæ latæ. 6. Sartorius. 7. Rectus femoris. 8. Vastus externus. 9. Vastus internus. 10. Gracilis. 11. Pectineus. 12. Adductor longus. 13. A small portion of adductor magnus.

* "Quem ego *Sartorium musculum* vocare soleo, quòd sartores eo maximè utantur, dum crus cruri inter consuendum imponunt."—Spigelius, "De h. Corp. fabr." l. 4, c. 23.—Riolanus named the muscle "*longus* sive *sutorius*."

† This point is illustrated in the work on Arteries before quoted, plate 74, figure 4.

Parts;—position and name of each.

the upper and lower ends of the bone. The portion laid on the outer side of the bone is named "vastus externus;" that on the inner side, "vastus internus;" these names being derived from the large number of the muscular fibres and the position they occupy. Another part placed on the anterior surface of the femur is named "crureus." This (last), it will however be found, is really not separable from the vastus internus.

Rect. femor.

a.—The *rectus femoris* (ilio-rotuleus,—Cowper) (fig. 125,[7]) is situated in front of the thigh, and is extended in a straight line from the pelvis to the patella—whence the name. It *arises* by two tendons, one of which embraces the anterior inferior spinous process of the ilium; the other, the "reflected" part or tendon, turns outwards, and is attached above the brim of the acetabulum. The tendons unite at an angle, and then spread out into an aponeurosis from which fibres arise. The muscle gradually increases in breadth and thickness towards its middle, from which it again diminishes towards its lower part; the fleshy fibres ending in another tendinous expansion, which gradually narrows, and is *inserted* into the patella in conjunction with the triceps extensor. The muscle tapers from the middle to both ends; and the fibres are disposed in two sets, united at acute angles along the middle line, from which they pass off obliquely, diverging to the borders. From this arrangement, which resembles that of the lateral fibrillæ of a quill or feather, the muscle is said to be penniform. The fibres of the superior tendon run down a considerable way on the fore part of the muscle; those of the inferior tendon are prolonged upon its posterior aspect.

Origin (two tendons).

Joins other parts of quadriceps.

Structures over and under muscle.

The anterior surface of the rectus is covered in all its extent by the fascia lata, except a small portion superiorly, where it is overlaid by the tensor vaginæ femoris, iliacus, and sartorius muscles (the reflected tendon is covered by the gluteus minimus). By the posterior surface the muscle is in contact with the fibrous capsule of the hip-joint and the vastus externus and crureus.

Vastus externus.

b.—*Vastus externus* (venter externus,—Sœmmerring).—This is the largest part of the muscle. It *arises* by an extensive aponeurosis, which is attached to the base of the great trochanter at its anterior aspect, and on a well-marked horizontal ridge on the outer side; likewise to the line or ridge extended between the trochanter and the linea aspera, as well as to the linea aspera itself (its outer margin). The aponeurosis thus connected spreads over the muscle, and gives origin to a very large number of muscular fibres. To these are added others, which spring from the inter-muscular fibrous layer attached to the line of the femur, reaching between the linea aspera and the external condyle; and the whole end in a large tendinous expansion, which is laid on the deeper surface of the muscle towards its lower end. This tendinous structure becoming narrowed is fixed to the patella, and joins with the other parts of the general extensor muscle. The fibres vary in direction,—the highest are perpendicular, the lowest nearly horizontal, and the rest gradually pass from one of those courses to the other.

Structures over and under muscle.

The vastus externus is covered to a small extent by the rectus, and the special tensor of the fascia lata; and the rest lies immediately beneath that membrane—the thickest (external) part of it. The muscle conceals, in part, the crureus; and some large branches of the external circumflex artery are likewise beneath it.

Vastus internus and crureus are not separable.

c. d.—*Vastus internus* and *crureus* (venter internus and venter posterior,—Sœmmerring).—There is no real separation between the parts which are distinguished by these names. Their position on the bone and the disposition of the tendon at the lower end alone serve to make the distinction.—The *vastus internus*, which occupies the inner aspect of the femur, increases considerably in thickness towards its lower end. It *arises* by a small aponeurosis from the line running downwards to the linea aspera of the femur, on the inner side, close to the small trochanter; from the linea aspera on its inner margin; and from the fibrous partition attached to the line extended between the linea aspera and the inner condyle in connexion with the tendon of the adductor magnus. From this extensive line of origin, and likewise from the inner surface of the bone, the fibres proceed downwards and outwards in directions necessarily varying, and are received on the tendon of insertion, which is for the most part on the anterior surface of the muscle. The tendon terminates by joining with the like structures from the other divisions of the extensor muscle in the neighbourhood of the patella. —The *crureus* (seu femoreus,—Cowper).—To this head is assigned the muscular structure arising on the anterior surface

Vast. intern.

Origin.

Tendon of insertion.

Position of lower tendon different from that of vast. intern.

of the femur, from the line between the trochanters to within a couple of inches of the patella. The tendon in which the fibres terminate inferiorly is laid on their anterior surface, and has, therefore, a different position with respect to the muscular substance from the tendon in which the vastus internus ends.

Parts adjacent.

The vastus internus is covered by the fascia lata and the sartorius, and is in contact at its inner side with the femoral vessels. The inner border is connected with the tendons of the adductor muscles. The crureus is covered by the rectus muscle, and partly by the vastus externus. Its lower end lies on the synovial membrane of the knee-joint.

Subcrureus.

Connected with synov. membrane of knee.

Subcrureus.—Under this name is described a small band of muscular fibres, which extends from the anterior surface of the femur to the upper part of the synovial membrane of the knee-joint, on which it ends in scattered fibres. This little muscle is placed beneath the crureus, (hence the name applied to it,) and in some cases it is united with that muscle. It is not unfrequently double, or consists of two separate bundles.

Tendons of quadriceps.

Patella in tendon.

Ligament. patellæ.

The *tendons of insertion* of the different parts of the great extensor muscle above described are joined together at the lower end of the thigh, (constituting the whole a single muscle,) and are attached to the patella, or more properly continue downwards to be fixed to the anterior tuberosity of the tibia. The patella is contained in the tendon; and the part of the tendinous structure below that bone, consisting of thick longitudinal fibres, is named the ligament of the patella (ante, p. 226). Moreover, an aponeurotic lamina is extended at each side of the patella from the vasti to the upper extremities of the tibia and fibula. The fibrous structure on the outer side is strengthened by, and for the most part is derived from, the fascia lata, which is very resistent in that situation. The tendinous structure covers the knee-joint.

By most French anatomists the vasti and crureus are described apart from the rectus as a three-headed muscle, and the name "triceps crural" is applied to the mass (see Sabatier, Gavard, Boyer, &c.); though that name had been assigned to the adductors by several anatomical writers, and even by one eminent authority in France (Winslow).

Actions of the extensor muscles of the leg.

Actions.—The most ordinary action of the foregoing muscles is to extend the leg upon the thigh, which they are enabled to do by their connexion with the patella and its ligament, the latter being inserted into the tibia. The immediate action of the sartorius is to bend the leg upon the thigh.

If the leg be fixed, as in the standing posture, the extensor muscles, taking their fixed point below, will act upon the femur and keep it perpendicularly on the condyles of the tibia, so as to counteract the influence of the weight of the body, which tends to flex the knee as well as the other articulations. The rectus and sartorius assist materially in maintaining the erect position of the body, for instance, when we stand on both legs, for they act on the pelvis and draw it forwards, so as to keep it fixed and upright on the femur; in this they become assistants to the psoas and iliacus. It may be observed that the oblique direction of the sartorius enables it to give a slight rotatory motion to the pelvis when we stand on one leg, by drawing the spinous process downwards and inwards.

INTERNAL FEMORAL REGION.

Along the inside of the thigh we find the following muscles, viz. the gracilis, pectineus, adductor longus, adductor brevis and magnus. The pectineus at its origin is rather at the fore part of the limb, but at its insertion it lies to the inner side.

Dissection.—To expose the muscles of this group, nothing more is required, after examining the extensor muscles, than to remove the fascia from the inner and fore part of the thigh. The direction and attachments of the adductor longus, running obliquely from the angle of the os pubis to the middle of the thigh, are at once obvious. The gracilis, too, will be observed running along its inner border. If the thigh be abducted, the fibres of these muscles will be rendered tense, and their dissection facilitated.

When proceeding with the dissection, the adductor longus may be severed from its superior attachment, and drawn downwards on the femur. In doing this, its posterior surface will be observed to be connected to the adductor magnus for a little way before their fibres reach the bone. The pectineus, lying to the outer side of the adductor, may in the next place be examined, and reflected after the same manner, which will bring into view the adductor brevis and the obturator externus.

Whilst these measures are being executed, both surfaces of each muscle should be dissected, or, in other words, all the cellular tissue connected with them should be removed by successive strokes of the knife, the edge being carried in the course of the fibres; and when their attachments, external conformation, and structure have been thus fully made out, each of them may be again restored to its place, that their mutual relations and bearings may be reconsidered. It is usual to direct that muscles, more especially the long ones, should be divided in the centre, and the two portions reflected. But if this precept be followed, it will be observed that students seldom examine, with any degree of accuracy, the points of attachment of muscles, without a precise knowledge of which it is quite impossible to reason correctly on their actions and uses. When a student is performing the dissection of the limb for the first time, it may be well if he confine his attention to the muscles, observing merely the general outline of the vessels and their branches; after which they may all be dissected away, in order to obtain an uninterrupted view of the muscles in their whole extent.

Gracilis.

The *gracilis* (fig. 125,[10]; fig. 123,[4]) (pubio-præ-tibialis) is situated along the inner side of the thigh, extending from the os pubis and its ramus to the inner and upper part of the tibia. The muscle is flat and thin; broad at its upper extremity, narrow and tapering at the lower. It *arises* by a thin aponeurosis from the body of the os pubis, close to its symphysis (the lower half of its depth), also from the border of its ramus; and is *inserted* by a tendon (which is at first round, but afterwards becomes flat) into the inner side of the tibia, close below its tuberosity, on the same plane with the semi-tendinosus, and under the expanded tendon of the sartorius. The direction of the muscle is vertical, but at the lower extremity it inclines forwards to the point of attachment.

Origin.

Inserted under sartorius.

Is close to fascia, except tendon.

The inner surface of this slender muscle is covered by the fascia lata, except a small part inferiorly, where it is overlapped by the sartorius; the external rests against the adductor longus, adductor magnus, and semi-membranosus, the knee-joint, and its internal lateral ligament.

Pectineus.

The *pectineus* (fig. 125,[11]) (pectinalis,—Douglas; pubio-femoralis) is situated at the superior and fore part of the thigh, and is extended from the horizontal branch of the os pubis (its upper surface) to the posterior and inner aspect of the femur. Flat and nearly quadrangular in form, it *arises* from the ilio-pectineal line, with the surface in front of it, between the eminence of the same name and the spine of the os pubis, and is *inserted* into the line, which connects the smaller trochanter to the linea aspera of the femur, immediately below the united attachment of the psoas and iliacus muscles. In its course downwards, the muscle inclines outwards, and backwards, and opposite the smaller trochanter turns on itself, so that the anterior surface looks somewhat outwards. It consists of fleshy fibres, except at the attachments, the lower of which is aponeurotic, and the upper one slightly so.

Origin.

Insertion.

Parts adjacent.

The pectineus is in contact, by the anterior surface, with the fascia lata and femoral vessels; by the posterior surface, with the obturator vessels and nerves, and the external obturator and adductor brevis muscles; by the outer border with the psoas magnus, by the inner border with the adductor longus.

Adductor longus.

The *adductor longus* (fig. 125,[12]) (adductor primus ; pubio-femoralis), situated on the same plane with the preceding muscle, is flat, irregularly triangular, and extends obliquely from the anterior and upper part of the os pubis to the middle of the linea aspera of the femur. It *arises* by a tendon from the fore part of the tuberosity of the pubes, and a small portion of the body of the same bone, and is *inserted* into the middle third of the linea aspera, between the vastus internus and the adductor magnus. Between these points it is directed downwards, with an inclination outwards, and backwards. And the fleshy fibres commencing by a tendon end in an aponeurosis inferiorly. From the aponeurosis several fibres are detached, which unite with those of the adductor magnus.

Origin.

Insertion.

Structures adjoining.

The muscle is covered by the fascia lata, the sartorius, and femoral vessels ; the posterior surface rests on the two other adductor muscles. The external border is parallel with the pectineus (a small portion of the adductor brevis being observable behind and between them) ; the inner border, which is much the longer, is in apposition with the gracilis.

Adductor brev. behind preceding.

The *adductor brevis* (adductor secundus ; sub-pubio-femoralis) lies behind the two preceding muscles. Its form is nearly triangular, being thick and narrow at its upper part, but gradually becoming broader and thinner towards its insertion. It *arises* by a narrow origin from the external surface of the os pubis, and is directed obliquely backwards and outwards, to be *inserted* (by a tendon) into the oblique line leading from the lesser trochanter of the femur to the linea aspera, immediately behind the insertion of the pectineus.

Origin.

Insertion.

Adjacent parts.

The short adductor is in contact, by the anterior surface, with the pectineus and adductor longus ; by the posterior, with the adductor magnus ; by the external border, with the obturator externus, and the tendon of the psoas and iliacus ; by the inner border, with the gracilis in part of its extent, the rest being concealed between the two other adductors. It is pierced by some of the perforating branches of the profunda artery.

Adductor magnus.

Deep position.

Adductor magnus (ischio-femoralis).—This very large muscle is situated deeply at the posterior and inner part of the thigh,—hence but a few of its fibres[13] can be seen in this view ; and it extends from the tuberosity and ramus of the ischium to the whole length of the linea aspera of the femur, and to the inner

Origin. condyle. It *arises* from the ramus of the os pubis and that of the ischium, also from the border of the tuberosity of the latter bone. Fibres diverge. The muscular fibres diverge from their origin, somewhat like the ribs of a fan from their central pivot; those from the os pubis, shorter than the rest, pass transversely outwards, and are inserted into the rough line prolonged from the linea aspera directly upwards; Their var. lengths and direction. others pass with varying degrees of obliquity downwards and outwards, to be inserted into the whole length of the linea aspera, and a small part of its internal bifurcation, where they end in a pointed process; finally, some of the fibres descend almost vertically, Extensive insertion. forming the inner border of the muscle, and terminate in a rounded tendon, which is inserted into the tuberosity on the inner condyle of the femur. The muscle thus presents two parts; one, a flat broad plane, inserted into the linea aspera, and forming a septum between the anterior and posterior muscles of the thigh: the other being the elongated part which goes to the condyle; and between them an angular interval is left for the transmission of the femoral vessels backwards into the popliteal space. This muscle forms the greater part of the muscular structure at the inner side of the thigh. The fleshy substance is arranged in large and easily separable bundles; it is connected by tendinous fibres with the pelvis, and ends on the femur in a broad aponeurosis and the tendon already noticed.

Parts adjoining. The superior, or shortest border, of the adductor magnus is parallel with and close to the quadratus femoris; the internal, or longest border, is covered by the fascia lata, the gracilis, and sartorius; the external border (its femoral attachment) is interposed between the two other adductors and the vastus internus, which lie in front of it, and the gluteus maximus, and short head of the biceps, which separate it from the vastus externus. The posterior surface is covered by the great sciatic nerve and hamstring muscles; the anterior by the sartorius, the adductor brevis and longus, and the femoral vessels. The anterior surface of the muscle is intimately blended with the adductor longus before it reaches its insertion; it also sends off an aponeurosis, which passes in front of the femoral vessels, and becomes blended with the vastus internus; finally, its prolonged portion is intimately connected with the last-named muscle. Space for femoral vessels. The interval left between the two parts of this muscle for the passage of the femoral vessels is triangular in its form, and fleshy and tendinous in its structure, when viewed from behind; but at its anterior aspect it is altogether tendinous in its entire extent, and oval in its form.

Actions of adductor muscles.

Actions.—These are the direct adductors of the femur, and their force must be considerable, both from their strength and number. As the linea aspera projects from the shaft of the bone, the adductors are removed proportionally from its axis, and so are enabled to rotate it outwards, thus conspiring with a distinct class of muscles, the external rotators. If the whole limb be in the extended position, they will draw it inwards, the gracilis assisting. The femur is bent on the pelvis by the action of the pectineus (and slightly by the adductor longus and brevis), thus conspiring with the psoas and iliacus. When the lower extremities are firmly fixed on the ground, these muscles contribute to maintain the body in the erect position, by taking their fixed point below, and thence acting on the pelvis. If this effort be continued, the pectineus and adductor longus may be made to flex the pelvis on the femur, by drawing the os pubis downwards.

POSTERIOR FEMORAL REGION.

At the back of the thigh are placed the three long flexor muscles of the leg, viz. the biceps, semi-tendinosus, and semi-membranosus. They are immediately subjacent to the skin and fascia, except at their superior attachment.

The *dissection* of this group should follow that of the muscles in the gluteal region. From the middle of the incision made along the fold of the nates, or, what will answer just as well, from opposite the middle point between the tuber ischii and the great trochanter, carry an incision through the skin straight down along the back of the thigh and popliteal space, so as to mark out the median line of both. Let this extend to about three inches below the flexure of the knee-joint, and be there bounded by a transverse incision five or six inches in length. Make a similar transverse incision at the union of the middle with the lower third of the thigh. Now with your forceps pinch up the angles of these flaps of skin, and carefully dissect them off the subjacent fascia, which you will recognise as a smooth shining membrane. Examine this carefully in its whole extent. At the lower part of the thigh you will see it stretched tightly across from side to side, covering an angular space (popliteal space, or the ham in popular language), enclosed by the flexor or ham-string muscles, viz., those which you are now about to examine. Make an incision through the fascia from above downwards, along the middle of this space; bound it above and below by two transverse cuts. Pinch up the flaps of fascia tightly, and dissect them off the muscles, and so proceed downwards to their insertion into the tibia and fibula: continue the same process upwards, until you expose the muscles in their entire extent.

The attachments of the semi-membranosus require attention. To gain a clear view of them, the muscle may be cut across in the ham and drawn down, when, by holding it tense, one set of fibres will be observed to pass along the inner tuberosity of the tibia, another obliquely behind the joint, whilst the third goes perpendicularly downwards, which, after being fixed to the posterior surface of the tuberosity of the tibia, sends a dense fascia over the popliteus muscle, which is ultimately continuous with the deep fascia of the leg.

Biceps femoris.

Biceps femoris (biceps flexor cruris; ischio-femoro-peronealis).—This muscle is situated at the posterior part of the thigh, and consists superiorly of two parts. These extend, one from the ischium (the long head), the other from the femur (short head), and unite to terminate on the fibula. The long head (fig. 123,[5]) *arises*, by a tendon common to it and the semi-tendinosus, from the upper and back part of the tuberosity of the ischium,—the femoral portion[6], (or short head,) from the linea aspera of the femur, between the adductor magnus and vastus externus muscle, nearly as high up as the insertion of the gluteus maximus. The fibres of the former end on an aponeurosis which covers the lower part of the muscle. This aponeurosis likewise receives the muscular substance of the short head, and is then narrowed into a tendon which is *inserted* into the head of the fibula. Moreover, the tendon, whilst being attached, separates into two portions, which embrace the external lateral ligament of the knee-joint; and one of these passing forwards is inserted into the tibia. An expansion is likewise given off, which strengthens the fascia of the leg.

Long head.

Short head.

Insert. to fibula and tibia.

Parts adjacent.

This muscle is covered by the gluteus maximus and fascia lata. In front it lies against the semi-membranosus, the sciatic nerve, and adductor magnus, and inferiorly, the gastrocnemius, with the external articular arteries. The peroneal nerve is to the inner side.

Semi-tend.

The *semi-tendinosus*, (fig. 123,[7]) (ischio-præ-tibialis) is situated at the posterior and inner part of the thigh. It *arises* from the posterior part of the tuber ischii, close to the inner side of the biceps, and continues to arise from the tendon of that muscle for three inches lower down, somewhat in the same way as the coraco-brachialis does from the biceps of the arm. A little below the middle of the thigh it ends in a long round tendon, from the length of which the muscle is named. The tendon, after passing on the semi-membranosus along the inner side of the popliteal space, is reflected forwards, to be *inserted* into the inside of the upper part of the tibia, below its tuberosity, where the tendon is on the same plane, and below that of the gracilis—both being under cover of the sartorius.

Joined with biceps at origin.

Tendon is long.

Insertion.

Adjacent parts.

The semi-tendinosus, except where it is slightly overlapped by the biceps, is covered by the fascia lata; the anterior surface rests on the semi-membranosus in the greater part of its extent; towards its termination, it runs beside the knee-joint.

Semi-membranosus. Orig. under preceding. Insertion in three parts.

Semi-membranosus (fig. 123,[3]) (ischio-poplito-tibialis).—This muscle *arises* from the posterior part of the tuberosity of the ischium, in front of the biceps and semi-tendinosus and behind the quadratus femoris, and is *inserted* by three portions, of which the middle one is fixed to the tibia, behind its inner tuberosity, and sends an expansion which covers the popliteus muscle; the internal portion passes forwards under the internal lateral ligament, and is inserted along the side of the inner tuberosity of the tibia; the third, broad and expanded, is reflected backwards and upwards behind the joint, and is inserted into the external condyle of the femur, becoming identified with the ligamentum posticum (fig. 128,[1]). The muscle begins by a strong flat tendon which spreads out to give origin to short and very numerous fleshy fibres, and these are directed obliquely downwards to another aponeurosis which is narrowed into the tendon of insertion.

Parts adjoining.

It is in contact by the posterior surface with the biceps, semi-tendinosus, and fascia lata; by the anterior surface with the quadratus femoris, adductor magnus, the popliteal artery, inner head of the gastrocnemius and knee-joint; by the inner border with the gracilis and fascia lata; by the outer border with the sciatic nerve. This muscle forms the larger part of the inner boundary of the popliteal space.—At the upper end it is separated from the conjoined origin of the two preceding muscles by a synovial bursa.

Synovial bursa.

Combined actions.—These are usually called the ham-string muscles, as they enclose the ham, or space at the posterior aspect of the knee-joint; the biceps being placed at its external side, the other two at the internal. Their direct action is that of flexing the leg on the thigh, and this they do directly backwards, when they conspire in their action; but if they be made to act alternately, the leg will be rotated slightly inwards or outwards; the latter motion, however, can only take place in the semi-flexed position of the limb. In the standing posture, these muscles, by taking their fixed point below, will act on the pelvis so as to prevent its flexion forwards; and, if the effort be continued, they will draw it directly backwards, and commence that series of muscular actions observable in tumbling and other feats of activity, in which the body is thrown backwards so as to form an arch.

MUSCLES OF THE LEG.

ANTERIOR TIBIO-FIBULAR REGION.

In the interval between the tibia and fibula we find three long muscles, viz. tibialis anticus, extensor proprius pollicis, and extensor communis digitorum.

Dissection. To expose the fascia.—The subject being placed on its back, bend the knee and place under it a high block, so that the leg should form an inclined plane ; turn the foot inwards, and fix it in that position. Now, make an incision through the skin, beginning above at the middle point, between the head of the fibula and the spine of the tibia, and continue it straight down over the middle of the ankle-joint and dorsum of the foot. As this is a very long incision, intersect it by a transverse one at each end, and another in the middle ; raise the flaps of skin tightly, you will see the dense fascia of the leg beneath it ; dissect back the flaps, and expose this membrane in its entire extent.

To expose the muscles.—Divide the fascia along the leg as you did the skin, but opposite the flexure of the ankle-joint leave undivided a band of it about an inch wide, where it stretches across obliquely from one ankle to the other, forming the anterior annular ligament. Beginning a little above the ankle, raise the fascia from the tendons, and, taking them as your guide, dissect it from below upwards from the muscles.

The muscles of the leg, taken altogether, may, to facilitate their classification, be divided into sets, each consisting of three. Thus, on the fore part of the leg, and lying between the tibia and fibula, we find the tibialis anticus, the extensor communis, and extensor pollicis, being the group which we are now examining. On the external side of the leg, and in close contact with the fibula, are placed the peroneus longus and brevis. The third muscle of this name is, in reality, a part of the extensor communis, and is separated from the other two by the breadth of the fibula. It still, however, is described as a separate muscle, probably to keep up the ternary division. Posteriorly there are two sets, one being superficial, consisting of the gastrocnemius, soleus, and plantaris ; and the other deep-seated, viz. tibialis posticus, flexor longus digitorum, and flexor longus pollicis.

Tibialis anticus.

The *tibialis anticus*,—Cowper, (tibio-super-tarseus,) (fig. 126,[1]) is situated at the front of the leg, being extended along the outer side of the tibia and reaching to the inner part of the tarsus. It *arises* from the external tuberosity of the tibia, and about two thirds of the flat surface beneath it : from a small portion of the inter-osseous ligament : from the fascia of the leg : and an aponeurotic septum placed between the muscle and the extensor digitorum communis muscle. The fleshy fibres end in a tendon which is at first con-

Origin from several sources.

Fig. 126.

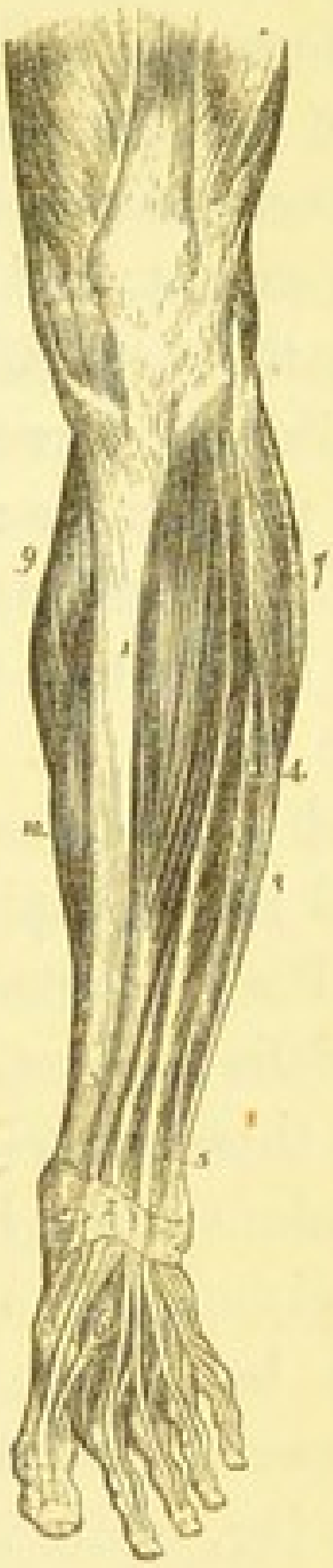

The tendon.

Insertion.

cealed in their substance, and becomes apparent at the anterior surface of the muscle towards the lower third of the leg. The tendon, freed from the muscular substance, passes through a separate compartment of the anterior annular ligament, and is *inserted* into the internal and lower part of the first cuneiform bone, and the contiguous extremity of the first metatarsal bone. This muscle has considerable breadth at its commencement, but it gradually lessens in size towards the lower part of the leg, as the fleshy fibres end on the tendon.

Contiguous structures.

The tibialis anticus is covered by the fascia, which adheres to the muscular structure superiorly, and gives origin to a considerable number of its fibres. It rests against the inter-osseous membrane in the greater part of the leg, but inferiorly the tendon is supported by the fore part of the tibia. And it has on one side the bone just named; on the other side, the extensor digitorum communis and extensor pollicis pedis. The anterior tibial artery and nerve lie along the outer side of the muscle, between it and the two muscles last mentioned.

Ant. tibial artery and nerve outside muscle.

Musculus catenæ.

The tibialis anticus was named "Musculus catenæ" by Spigelius, for a reason which, even if it were correct as to the fact, seems a singular one to found a nomenclature on, namely, that the tendon being divided or removed, the sufferer is compelled to raise the foot in walking with the aid of a sling.†

Extensor proprius pollicis, — Alb. (fig. 126, ³). — The special extensor of the great toe is placed at the fore part

---

* A front view of the leg and foot after the removal of the integument and fascia. 1, is on the tibia, and points to the tibialis anticus. 2. Annular ligament. 3. Extensor proprius pollicis. 4. Extensor longus digitorum pedis. 5. Peroneus tertius. 6. Extensor brevis digitorum. 7. Peroneus longus. 8. Peroneus brevis. 9, 10. Gastrocnemius and soleus.

† "Ab aliis tibiæus anticus, à me *catenæ musculus* vocatus, quòd dissecto per transversum huius tendine, aut amputato, catenam ægri, cuius beneficio ambulantes pedem flectant eleuentque, portare cogantur."—"De h. corp. fabr." l. iv. c. 24.

Extensor pollicis. Its position. of the leg and on the dorsum of the foot along its inner border, between the muscle last described and the extensor digitorum communis. This muscle is elongated, flat, and compressed in the middle, pointed at the extremities. Origin. It *arises* from the internal surface of the fibula for more than the middle third of its extent, and from the contiguous surface of the inter-osseous ligament, nearly as far as the ankle. The fleshy fibres run obliquely forwards into a tendon placed at the anterior border of the muscle; and the tendon, after passing beneath the annular ligament in a distinct compartment, and along the dorsum Insertion. of the foot, is *inserted* into the base of the second phalanx of the great toe. A delicate expansion given from the tendon on each side spreads over the joint between the metacarpal bone and the first phalanx.

Adjoining structures. Placed between the extensor digitorum communis, and the tibialis anticus, the extensor pollicis is overlapped for some way by these muscles, and on the foot it is covered, like the other tendons, only by the integument and fascia. It rests successively on the anterior surface of the tibia, the ankle-joint, and the bones of the foot. Changes position with respect to artery. This muscle changes position with respect to the anterior tibial artery, being outside that vessel on the leg, while it lies to the inner side on the foot, after having crossed over it.

Ext. long. digitor. *Extensor longus digitorum pedis* (fig. 126, ^{4}).—The long extensor of the toes is situated at the fore part of the leg and on the dorsum of the foot, extending from the head of the tibia to the toes. It is thin, or flattened from side to side, and at the lower end divides into four tendons. Origin from several parts. This muscle *arises* from the external tuberosity of the tibia: from the anterior surface of the fibula for about two-thirds of its length: and from the inter-osseous ligament: also from the aponeurotic septa intervening between it and the muscles, on each side, and from the fascia of the leg. The fleshy fibres from this extensive The tendons. origin pass obliquely into three flat tendons placed on the fore part of the muscle. These descend beneath the annular ligament, in the same sheath with the peroneus tertius; and on the dorsum of the foot the inner one divides into two parts, so as to increase the number of tendons to four, corresponding in number with the four smaller toes. Joined by extensor brev., lumb., Each of these tendons is joined on the first phalanx by the tendon of the extensor brevis digitorum on the outer side, as well as by tendinous processes from the lumbricales and inter-osseous muscles; and thus a fibrous expansion is produced, which covers that (the first) phalangal bone of the toe. The tendinous expansion divides, in the manner of those of the corresponding muscle of the hand, into three parts. The small middle division is inserted into the base of the second phalanx; and the two lateral parts, after joining together, terminate on the last phalanx. But the fourth tendon (that of the little toe) is not joined by an offset from the short extensor of the toes. From these tendons, slender bands spread over the joints of the metatarsal bones with the phalanges on each side. The same arrangement occurs in the hand.

and inter-osseous.

Insertion to last two phals.

The long extensor of the toes is covered only by the integument and fascia. It is placed between the tibialis anticus with the extensor of the great toe, which lie on one side, and the peronei muscles on the opposite side; and it rests successively against the bones of the leg, with their connecting (inter-osseous) membrane, the ankle-joint, and the short extensor of the toes.

Five tendons are ascribed to this muscle by Cowper;* the fifth, with the fleshy fibres it receives, being the muscle, or, more properly, the part of the long extensor commonly known as the "peroneus tertius."

The *peroneus tertius* is placed along the fore part of the fibula at its lower third, and lies just below the extensor longus, with which its muscular fibres[5] are united, and of which it is really but a part. It *arises* from the lower third of the fibula, being attached to the anterior border and inner surface of the bone; also from the inter-osseous ligament, and an aponeurosis which connects it on the outer side with the peroneus brevis. The muscular fibres end in a tendon, which, after passing through the annular ligament with the long extensor of the toes, is *inserted* into the upper surface of the fifth metatarsal bone, and likewise in some instances into the fourth.

Peron. tert. is part of preceding.

The peroneus tertius is liable to some deviations from the ordinary disposition. The part of the muscular structure which would be assigned to it may be equal in size to that which belongs to the extensor tendons of the toes. The tendon only may have much more than the ordinary size. It has been observed to terminate on the fourth metatarsal bone and the fascia covering the foot. And the muscle may be altogether wanting.

Extensor brevis digitorum pedis.[6]—The short extensor of

---

* Myot. Reform., c. 36, p. 111.

Extensor brev. digit.

Its position.

the toes is a broad and thin plane of muscular fibres situated on the dorsum of the foot, and dividing at its anterior extremity into four small parts. It *arises* from the dorsal surface of the calcaneum, and from the ligament connecting that bone with the astragalus, as well as from the annular ligament of the tarsus, and terminates in four tendons, the first or most internal of which is inserted into the tarsal end of the first phalanx of the great toe; the other three become severally united to the outer borders of the extensor tendons, proceeding to the three next toes.—This muscle is covered by the tendons of the long extensor and peroneus tertius, and it rests on the tarsus, metatarsus, and the dorsal inter-osseous muscles. The part destined for the great toe crosses over the dorsal artery of the foot.

Insertion on four inner toes.

Actions.—A very slight effort of the extensor communis and extensor proprius pollicis extends the digital phalanges, and, if their action be continued, they will be made to bend the foot upon the leg. This they are enabled to do by the manner in which their line of direction is altered by the annular ligament of the ankle-joint, as it gives them all the mechanical advantage of a pulley. The tibialis anticus and the peroneus tertius are the direct flexors of the foot on the leg, and, if either act separately, it will give a slight inclination towards the corresponding side. In the erect position, these muscles take their fixed point below, and, by drawing on the bones of the leg, keep them perpendicular on the foot. The extensor brevis is obviously but an accessory to the long extensor; but, from the obliquity of its direction, it is fitted not only to extend the toes, but also to draw them somewhat outwards.

Peroneus longus.

Origin.

Peroneus longus (peroneo-sub-tarseus) (fig. 126,[7]) is situated at the outer side of the leg, and under the foot. It *arises* from the two upper thirds of the external surface of the fibula—from a small part of the external tuberosity of the tibia, and from the fascia of the leg; also from aponeuroses interposed between it and the contiguous muscles, viz. the extensor communis digitorum on one side, and the soleus and flexor longus pollicis on the other. Proceeding from these attachments, it descends and becomes tendinous. The tendon, freed from the muscular structure at some distance from the foot, passes, with that of the peroneus brevis, in a groove on the posterior surface of the external malleolus, where they are covered by a fibrous band extended from the end of the fibula to the calcaneum, and invested by a common synovial membrane. The tendons then separate; that of the peroneus longus proceeds obliquely for-

Passes behind malleolus.

wards in another groove on the external surface of the calcaneum, to which it is connected by a separate fibrous band, lubricated with a synovial bursa. It then turns over the outer margin of the foot, and enters a groove on the lower surface of the cuboid bone, resting against the ridge behind that groove, and covered by a synovial membrane. From this point the tendon inclines forwards and inwards across the foot immediately beneath the bones, to be inserted into the tarsal end of the first metatarsal bone. The muscle therefore changes its direction at two points, namely, behind the lower end of the fibula and on the cuboid bone; and the bones on which it turns are to be considered as pulleys, changing the direction of the muscular power. At the two points of reflexion the tendon is thickened and indurated; at the lower one a sesamoid bone is often deposited in it.

In groove and against ridge of cuboid bone.

Two changes of direction.

Tendon thickened.

The peroneus longus is placed immediately beneath the fascia of the leg, and lies between the extensor longus digitorum, with the peroneus tertius which is before it, and the soleus and flexor longus pollicis placed in the opposite direction. In the foot, being near the bones, it is above all the plantar muscles.

Parts adjacent.

Peroneus brevis (semi-fibulæus,—Spigelius) (fig. 126,^{8}).—This muscle lies beneath the preceding, and is considerably shorter than it, neither reaching so high on the leg, nor extending so far on the foot.

Peron. brev.

It *arises* from the external surface of the fibula for about the lower half of its extent, and from the inter-muscular septa which dip in between it and the contiguous muscles. From these sources the fibres are directed to a tendon lying on their outer surface, a portion of them reaching as low as the malleolus. The tendon passes behind the external malleolus in the same groove and sheath; is invested by the same synovial membrane with the preceding muscle; and, after inclining forwards beneath the fibula, is *inserted* into the base of the last metatarsal bone, after having traversed a separate groove in the calcaneum, situated above that for the tendon of the peroneus longus.

Origin.

Actions.—The peroneus longus and brevis, by the change of their direction, after turning behind the external ankle, are enabled to draw the foot back, and so extend it on the leg. The peroneus tertius is, on the contrary, a flexor of the foot; it lies before the fibula, and combines with the extensor communis. The peroneus longus is enabled to evert the sole of the foot, by means of the mechanical advantage which it derives from turning round its external margin. This, however, is not readily perceptible in the natural condition of the limb; but, if the fibula be fractured, and the check afforded by the external ankle be in consequence diminished, it will take place to a considerable extent. When the peronei take their fixed point below, they act on the bones of the leg, and assist in maintaining them erect on the foot. This power is chiefly called into action when we stand on one leg. The weight of the body must then tend to incline the leg inwards; but the peroneus longus, acting from its fixed point in the sole of the foot, with the additional power given it by the pulley round which it turns, draws on the external side of the bones of the leg, and prevents them from obeying the influence which otherwise would incline them inwards.

POSTERIOR TIBIO-FIBULAR REGION (SUPERFICIAL).

On the posterior part of the leg there are two sets of muscles; one superficial, the other deep-seated. The latter consists of muscles, which are the antagonists of those in front, viz. the tibialis posticus, flexor digitorum longus, and flexor longus pollicis; together with the popliteus, which is placed above these muscles, and close to the knee-joint.

The superficial muscular structure (extensor tarsi suralis vel extensor magnus,—Douglas; musculus suræ, Sœmmerring) is a large mass, and constitutes the calf of the leg. The great size is characteristic of man. It is connected with his peculiar mode of progression, and is calculated to elevate the heel in opposition to the weight of the entire body.

At the lower end the mass is narrowed into a single tendon (tendo Achillis), which is attached to the heel; but the muscular substance is divided into two thick strata, which are connected one with the femur, the other with the bones of the leg.

Dissection.—The gastrocnemius may be exposed without any difficulty, by dissecting off the fascia, commencing where it is continuous with that covering the popliteal space; after which, the internal head of the gastrocnemius may be raised, and its border reflected outwards. By this expedient the thin tendon of the plantaris will come into view, and afford a guide to its muscular belly, which may otherwise be raised with the external head of the gastrocnemius, with which it is closely in contact. The soleus may in the next place be detached, taking the inner surface of the tendo Achillis as a guide; previously to which, attention should be directed to the structure of that part of its upper border, between its tibial and fibular origins, which is arranged for the transmission of the posterior tibial vessels.

Gastro-cnemius.

Fig. 127.*

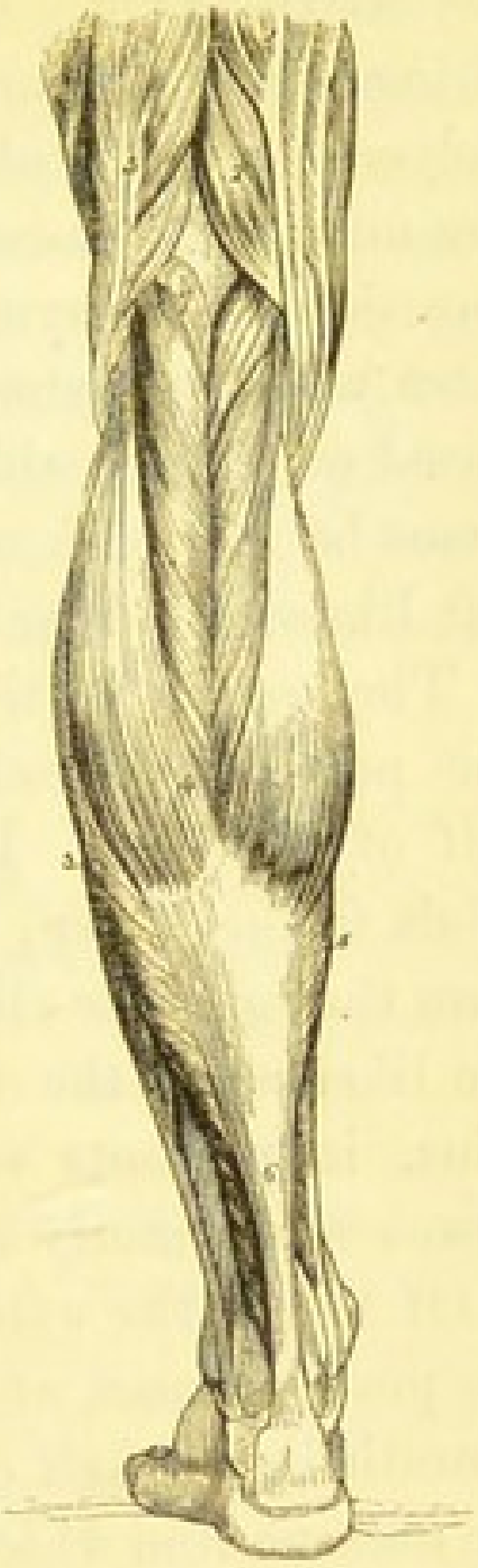

The *gastrocnemius* (fig. 127,^{4}) (gemellus,—Cowp.; bi-femoro-calcaneus) is situated at the posterior aspect of the leg, forming the greater part of what is named the calf (*γαστηρ*, a belly ; *κνημη*, the leg).

Two heads.

Origin.

It consists of two parts (hence the second of the names above applied to the muscle†), the internal of which is the larger. At the upper extremity the two parts diverge, and form the lower boundaries of the popliteal space. They are named “ heads,” and are distinguished as “ external” and “ internal.” Each head *arises* by a thick tendon which is fixed to an irregular and depressed surface above the corresponding condyle of the femur, as well as by a few tendinous and fleshy fibres attached higher up, especially on the left side, on which they are connected for a short space with the ridge running to the linea aspera. The tendon spreads out behind the muscle, and gives origin on its anterior surface to a large mass of muscular fibres. Some of the innermost muscular fibres from both sides meet at an angle on a fibrous structure which is common to them, but the two parts are not confounded one with the other ; and a groove indicates the place of separation. The great mass of the fleshy fibres are directed downwards and forwards, from the aponeurosis of origin behind, to one of insertion in front of the muscle; and the latter, gradually contracting, joins with another from the soleus. The tendo Achillis results from their union.

Arrangement of tendon and fleshy fibres.

Parts adjoining.

The gastrocnemius is covered by the fascia of the leg, and the short saphenous vein lies on it opposite the interval between its two parts. It conceals the plantaris, the soleus, and the

---

* The superficial muscles on the posterior part of the leg are here shown. 1. Semi-tendinosus. 2. Semi-membranosus. 3. Biceps. 4. Gastrocnemius. 5. Soleus. 6. Tendo Achillis. 7. Plantaris.

† “ Sunt *gemelli*, quia mole, robore, et actione pares.”—Riolanus, l. 5, c. 43.

popliteus, with the popliteal vessels and the internal division of the sciatic nerve. The "heads" are placed between the hamstring muscles; and between the external one and the biceps is lodged the peroneal nerve. Over the condyles, these parts of the muscle are in contact with the thin fibrous membrane of the knee-joint. Synovial bursa. A synovial bursa (which in some cases communicates with the synovial membrane of the knee-joint) is interposed on the left side. Fibro-cart. And a sesamoid fibro-cartilage will sometimes be met with over the outer condyle, occasionally over the left likewise. The last-mentioned substance is rarely osseous.

Soleus. The *soleus*[5] (tibio-peroneo-calcaneus) is situated beneath the preceding muscle, in conjunction with which it forms the calf of the leg. It is shorter than that muscle, but it extends farther down, before ending in the common tendon. Extends lower than preceding. In form the soleus is elliptic, and the name is said to be taken from the likeness to the shape of a sole-fish. Like the gastrocnemius, it presents superiorly two attachments, though by no means so distinctly separated.

Origin from bones of leg and a fibrous arch. Of these, the external one, the longer and larger, *arises* from the posterior part of the head of the fibula, and from the surface beneath it, for half of its extent; the inner portion *arises* from the oblique line which gives insertion to the popliteus, and from the inner edge of the tibia, two inches below that line; and, in the space intermediate between the bones, the muscular fibres are attached to a tendinous band extended from one to the other, over the posterior tibial vessels, which it secures from pressure or injury. Tendon of origin. The attachments to the bones are effected by tendinous structure, which expands on the anterior surface of this muscle and enters to some extent into its interior. The muscular fibres, taking origin from the tendinous expansion referred to, are directed backwards to a thin aponeurosis which spreads over the posterior surface; and this aponeurosis, diminishing in breadth and increasing in thickness, joins with that from the gastrocnemius to form the tendo Achillis.—Division of musc. subst. The fibrous structure likewise forms a longitudinal partition, which divides the muscle into two parts towards the lower end.

Parts over and under. The soleus is covered by the gastrocnemius, and between the two muscles is placed the slender tendon of the plantaris. It covers the deep-seated muscles, and the posterior tibial vessels and nerve.

The *tendo Achillis*[*] (chorda magna) is much the thickest and strongest tendon in the body. Formed by the junction of the terminal aponeuroses of the two preceding muscles, it measures about two inches in length, and is inserted into the tuberosity of the os calcis. It is expanded at its extremities, and most so at the upper one. The tendon is covered by the fascia and integument; and it is separated from the fascia, which lies over the deep-seated muscle and vessels, by a considerable interval, which is occupied with fat and cellular substance. And between the upper part of the os calcis and the tendon a synovial bursa is interposed.

Tendo Achillis.

Interval betw. tendon and deep structures.

Synovial bursa.

The gastrocnemius is, in some cases, joined by a bundle, which arises separately from the femur, above one of the condyles. This accessory slip ends variously, either joining the middle of the muscle on its deeper surface, or by blending with one of its heads. I have elsewhere[†] given illustrations of different forms of this peculiarity. In one of the cases referred to, the unusual muscular fibres passed between the popliteal artery and vein.—To the soleus an accessory portion is occasionally added at the lower part of its inner margin. The thick bundle of muscular fibres, added to this muscle, presents some variations in its extent and manner of termination. It usually ends on the inner side of the tendo Achillis. I have found it form a tendon which was attached separately to the os calcis.[‡]

The *plantaris*[7] is situated immediately behind the knee-joint and leg, between the gastrocnemius and soleus; it consists of a very long thin tendon, and a small pyriform muscular part, about two inches in length. It *arises* from the femur just above the external condyle, and from the posterior ligament of the knee-joint, where it is covered by the corresponding head of the gastrocnemius, and soon ends in a delicate tendon, which inclines inwards between the two large muscles of the calf of the leg, and running along the inner border of the tendo Achillis is inserted conjointly with it into the posterior part of the calcaneum.

Plantaris.

Origin.

The designation by which this little muscle is known has no reference to its position or connexion; but that name was assigned to it when the tendon was thought to terminate in the plantar fascia, as the palmaris longus does in the fascia of the hand. It was so described by Galen; and,

Name inapplicable.

---

[*] So named because Achilles was vulnerable only at the heel.
[†] Op. citat. plate 80, figures 4 and 5.
[‡] Ibid.

though the real manner of termination was correctly pointed out by Vesalius, (Oper. l. 2, p. 419,) the error was continued through many valuable works. It exists even in Cowper's "Myotomia Reformata" (p. 105).

The plantaris varies in its mode of termination. I have seen it encased in the lower part of the tendo Achillis; and, in one case, the tendon ended in the internal annular ligament, which binds down the tendons and vessels behind the inner malleolus.

Action of foregoing muscles in walking, standing, &c.

Actions.—The power of these muscles, as they are exerted successively in standing, walking, running, &c. is very considerable.

In walking, the gastrocnemius and soleus take their fixed point above, and by drawing on the os calcis lift it from the ground, so that the foot is made to represent an inclined plane. By this action an impulse is communicated to the body, and a direct tendency is given to progression. When the body is thus supported on the elevated foot, the opposite limb can be carried forward to its destination unimpeded by the inequalities of the surface over which it has to pass.

In standing, the soleus takes its fixed point at the os calcis, and, by drawing on the bones of the leg, retains them perpendicularly on the foot, thus preventing them from obeying the influence of the weight of the body, which constantly tends to bend them forwards. If this effort be carried as far as it will admit of, the gastrocnemius and popliteus will bend the femur on the tibia, and if at the same time the semi-tendinosus, semi-membranosus, and biceps be made to act on the ischium, so as to draw it downwards and backwards, the commencement of that series of muscular actions is made by which the body is retroverted, and carried towards the ground, as we see when a tumbler or mountebank arches his body backwards, the head and heels being brought to the same plane.

POSTERIOR TIBIO-FIBULAR REGION (DEEP-SEATED).

The muscles here placed are in close contact with the bones; they are the popliteus, flexor longus digitorum, flexor longus pollicis, and tibialis posticus.

Dissection. To expose the deep fascia.—Detach the two heads of the gastrocnemius from the condyles, also the plantaris: then separate the soleus from the tibia and fibula, proceeding from below upwards. When this is done, turn these muscles down towards the foot, and you will find behind and just beneath the knee-joint the popliteus muscle; and you will observe, that this as well as the long muscles, which lie lower down, and the posterior tibial vessels, are bound down by a thin fascia (the deep-seated fascia of the leg). This membrane extends down from the tendon of the semi-membranosus muscle, becoming connected on each side with the borders of the bones, and towards the ankles with the sheaths of the tendons; and, if traced along the interval between the inner ankle and the heel, it will be found to cover the vessels, and to terminate at the internal annular ligament.

To expose the deep-seated muscles.—Pinch up the fascia with your forceps, and detach it from the tendons of the muscles behind the ankles:—taking these as a guide, proceed upwards to the popliteus. In this way the deep-seated set of muscles become exposed, (viz. the flexor communis, placed along the tibia, the flexor pollicis on the fibula, and the tibialis posticus between both, and partly concealed by them,) and also the vessels which rest upon them.

Fig. 128.*

Popliteus.

The *popliteus* (fig. 128,[4]) is situated immediately behind and beneath the knee-joint, extending from the outer surface of the external condyle of the femur downwards and inwards to the tibia. It is flat and somewhat triangular in its form, for it gradually widens as it descends, The popliteus *arises* by a flat, thick tendon. about an inch in length, from a depression on the outer side of the external condyle, beneath the attachment of the corresponding lateral ligament of the knee-joint, and is inserted into all that triangular surface of the tibia which is above the posterior oblique line.

Origin from pit on extern. cond.

Insert. on tibia.

Parts adjacent.

Tendon lined with synovial of knee.

Covered by ext. lat. ligt.

A tendinous expansion from the semi-membranosus is adherent to the posterior surface of the muscle. It is covered by the gastrocnemius and plantaris, with the popliteal vessels, and the internal popliteal nerve; and it rests against the knee-joint and the tibia.—The tendon by which it is connected to the femur adheres to the external semilunar cartilage, (which sometimes is grooved for it,) and is invested by the synovial membrane of the knee-joint; and it is covered by the external lateral ligament of the knee-joint and by the biceps muscle.

Actions.—The popliteus assists in flexing the leg on the thigh, and vice versâ; but, when the leg is flexed, it draws the inner border of the tibia backwards, turning it in such a way that the toe is inclined towards the foot of the opposite side.

---

* The deep-seated muscles of the back of the leg are exposed. 1. Semi-membranosus. 2. Peroneus longus. 3. Peroneus brevis. 4. Popliteus. 5. Flexor digitorum longus. 6. Flexor longus pollicis. 7. Tibialis posticus.

Flex. long. digitor.

Flexor longus digitorum pedis (fig. 128,[5]) (flexor perforans). The long flexor of the toes is one of the muscles deeply seated behind the bones of the leg, from which it is prolonged horizontally into the sole of the foot. It extends from the upper part of the tibia to the phalanges of the toes. The muscle at its commencement is thin and pointed, but gradually increases in size, and then diminishes again as its fibres end in a tendon. Finally, the tendon becomes divided into four slips previously to its insertion. It *arises* from the posterior surface of the tibia, below the oblique line which gives attachment to the popliteus and soleus, and continues its attachment to within three inches of the inner ankle; some fibres also arise from an aponeurosis which covers the tibialis posticus. The fleshy fibres pass obliquely backwards into a tendon situated at the posterior aspect of the muscle. The tendon passes behind the internal malleolus, along a groove common to it and the tibialis posticus (the latter being next to the bone); thence it is directed beneath the arch of the os calcis, obliquely forwards and outwards, into the sole of the foot, where it crosses beneath the tendon of the flexor longus pollicis, with which it is connected by a transverse tendinous slip. The tendon (fig. 130,[2]) then divides into four processes, corresponding with the four smaller toes, and, as they run along their under surface, they, together with the tendons of the short flexor, are bound down to the phalanges by fibrous sheaths. Opposite the second phalanx, each tendon passes through a fissure in the tendon of the flexor brevis[5], (whence the term perforans is applied to the one, perforatus to the other,) and is inserted into the last phalanx of the toe at its base.—To the phalangal bones the tendons of the flexor muscles of the toes are bound by vaginal fibrous bands, and they are provided with synovial sacs and vincula accessoria in the same manner as the tendons of the corresponding muscles of the hand. The arrangement of the tendons of the two muscles, one with respect to the other, and their attachment to the bone, are likewise similar.

Origin.

Tendon connect. w. tend. of flex. pollicis; its division.

Each part perforates a tendon of flex. brev.

Connexion with phal. same as in hand.

Accessory musc. struct.

Flex. accessorius and lumbric.

Previously to its division, the tendon of the flexor longus gives insertion to an accessory muscular structure (flexor accessorius), which connects it with the calcaneum, and materially modifies the direction of its action on the toes. At the point of separation the tendons give origin to four small muscles (lumbricales), which may also be considered as accessories to the flexor longus.—These accessory parts are described with the other muscles of the foot (page 414).

Connexion w. tibial. post. behind malleolus.

Though in the dried bone only one impression is marked for the tendons of the tibialis posticus and flexor longus, behind the malleolus, the fibrous sheath which retains them in their situation is divided into two parts by a septum, or partition, so that each runs in a separate groove lined by a distinct synovial membrane. The direction of the muscle is vertical in the leg, horizontal in the foot.—In the former situation it is bound down by the deep fascia, and covered by the posterior tibial vessels, which separate it from the soleus; and the anterior surface rests against the tibia, and overlaps the tibialis posticus muscle. In the foot its tendon lies between those of the flexor longus pollicis, which is above it, and the flexor brevis digitorum, which lies beneath it.

Flex. long. pollicis.

Flexor longus pollicis pedis,—Alb. (fig. 128,^{6}).—The long flexor of the great toe is situated on the fibula, along the external side of the leg, and at the under and inner part of the foot. It *arises* from the posterior surface of the fibula (its inferior two-thirds): from the lower part of the inter-osseous membrane (to a very small extent): from the intermuscular septum interposed between it and the peronei: and from the aponeurosis covering the tibialis posticus. The fleshy fibres, continuing to arise nearly as far as the external ankle, pass obliquely backwards into a tendon placed on their posterior surface. The tendon traverses a groove on the tibia, external to that which transmits the tibialis posticus and flexor digitorum, and passes through another in the posterior border of the astragalus, in which it is retained by a fibrous band and a synovial membrane. It then runs in a groove beneath the tubercle of the os calcis (the sustentaculum tali), and so reaches the sole of the foot, where, after being connected to the common flexor by a tendinous slip, it turns forwards beneath the metatarsal bone of the great toe (fig. 130,^{1}). Lastly, the tendon is continued onward between the two heads of the flexor brevis pollicis, and after running through a fibrous sheath, which binds it to the first phalanx of the great toe, is *inserted* into the base of the second.

Origin.

In groove of os calcis.

Connect. w. flex. digitor.

Betw. heads of flex. brev.

Insertion.

Parts adjacent.

In the leg this muscle is bound down by the deep fascia which separates it from the soleus; its anterior surface rests on the fibula, and overlaps the tibialis posticus muscle and the peroneal artery. Its connexions in the sole of the foot have already been sufficiently indicated.

Tibial.post.; division at upper end. Artery between parts. Origin. Tendon in groove behind malleolus. Insertion.

The *tibialis posticus* (fig. 128,^{7}) (tibio-sub-tarseus) lies between the two preceding muscles, but commences considerably higher up than either. Its superior extremity is divided into two processes, or heads, by an angular interval, and the anterior tibial vessels pass forward between them. It *arises* from the posterior surface of the tibia, beginning along the oblique line of insertion of the popliteus: from the whole of the inter-osseous membrane, except two inches at the lower end: from the sides of the tibia and fibula for the same extent: and from the aponeurosis which covers the muscle behind. The muscular fibres end in a flat strong tendon, which turns beneath the internal malleolus in a groove of the bone, and in a sheath appropriated to itself. The tendon now changes direction, turning forward along the internal lateral ligament, and beneath the os calcis, to which it is bound by a short transverse fibrous band (which is connected with the tendon and the bone), and likewise beneath the calcaneo-scaphoid ligament, and is *inserted* into the tuberosity of the scaphoid and the base of the first metatarsal bone. Fibres of the tendon are likewise prolonged to the external cuneiform. The tendon is covered by a synovial membrane behind the malleolus, and likewise beneath the tarsus.

Parts adjacent.

In the leg the tibialis posticus is overlapped and concealed in the greater part of its extent by the two flexor muscles, but superiorly the part which is left uncovered by them supports the posterior tibial vessels. The anterior surface rests against the inter-osseous ligament and the tibia and fibula, from which it arises. Its tendon runs close to the inner ankle and tarsal bones, and where it slides under the latter near its termination is thickened by a cartilaginous or bony deposit within its fibres, analogous in form and use to the sesamoid bones in other situations.

Spigelius named this muscle "*nauticus*," because "sailors bring it chiefly into action in climbing the mast of a ship."—Op. citat. l. iv. c. 24.—The tibialis posticus is said by Albinus to have in some cases additional points of insertion into one or more of the following bones; viz. the second metatarsal, the third metatarsal, the cuboid, and second cuneiform.

Action of flexor musc. of toes.

Actions.—Like their antagonists on the fore part of the leg, the two flexor muscles act, in the first instance, on the phalanges of the toes, which they curve or bend, and then, by continuing their effort, they act on the foot. The latter effect they are enabled to produce by means of the mechanical advantage afforded to them by the pulley-like surface on which they slide as they pass from the leg into the sole of the foot. By this provision the flexor muscles conspire with the soleus and gemellus in extending the foot on the leg, for instance, in the effort to stand on tip-toe.

Of tibialis posticus.

The direct agent in extending the foot upon the leg is the tibialis posticus; but from its position it is also enabled to incline the foot inwards, thus antagonizing the peroneus tertius, which tends to turn it outwards. It may also, by elevating the inner border of the foot, turn the sole inwards; which action is directly opposed to that of the peroneus longus, which tends to incline it outwards.

Influence of flex. access.

It may be observed, that the toes would, in all cases, be drawn inwards whilst they are being flexed by the flexor communis, in consequence of the oblique direction of its tendon, but for the influence exerted upon it by the accessory muscle, which is connected with it in the sole of the foot. The direction of the latter being from behind forwards, it is well fitted by its contraction to modify the action of the long flexor on the toes, and to draw them towards the heel, where its fixed point of attachment is situated.

Action of foregoing on leg.

The action of these muscles may be reversed; for they may take their fixed points below at the foot, and from thence draw on the bones of the leg, so as to keep them in the erect position and prevent their inclining forwards.

MUSCLES OF THE FOOT.

Muscle of sole of foot.

The only muscle on the dorsum of the foot is the extensor brevis digitorum, which has been already described (page 399), together with the extensor longus, as they conspire in their actions; the present section therefore includes only the muscles in the sole of the foot. These may be considered as divisible into three regions, corresponding with the two borders and the intermediate space; the internal set consisting of the muscles of the great toe, the external, those of the little toe, those in the middle being common to all. But, in order to facilitate the examination of the parts contained in the sole of the foot, it is found more convenient to divide them into layers, lying one beneath the other; more particularly as, like the muscles on the back part of the leg, they are found to be separated into a superficial and deep set by a layer of fascia interposed between them and binding down the latter.

Three bundles.

Division in layers.

Plantar fascia.

Dissection. To expose the plantar fascia.—The subject, or the limb, if it be detached, being placed in the prone position, lay the dorsum of the foot on a high block, so as to bring the sole fully into view; secure it in that position. Make an incision from behind forwards in the middle of the sole, beginning over the heel. Cut down through the thick skin and the cushion of granular fat at the heel, until you see the white fibres of the fascia: then

Granular fat over fascia.

taking these as a guide, and everting the margins of the incision, incline your knife and dissect the skin off the fascia from behind forwards. You will observe its middle part to spread out beneath the metatarsus, and to give off five processes, which run along to the extremities of the metatarsal bones: the external portion, which binds down the muscles of the little toe, is thick and firm: but the internal one, which corresponds with the muscles of the great toe, is a thin membrane which appears to be prolonged from the fascia on the dorsum of the foot, and not to be properly an offset of the true plantar fascia (see its description, among other structures of the same kind).

Divisions of the fascia.

First layer of muscles.

To expose the first layer of muscles (fig. 129.)—These are three, viz. the abductor pollicis at the inner side, the abductor of the little toe at the outer, and the short flexor of the toes in the middle. The abductor pollicis is readily brought into view by raising the thin fascia which covers it, and dissecting it off, beginning over its tendon and thence proceeding backwards. The abductor of the little toe is exposed by raising the outer division of the plantar fascia from its attachment to the fifth metatarsal bone and reflecting it backwards. Now observe that the broad part of the fascia appears as if tucked in at its sides by processes or septa, which separate the middle from the lateral groups of muscles. Insert the knife under the fascia, raise it from the muscles a little, and then cautiously detach it from them, proceeding from before backwards. When severed from the calcaneum, you may carry it forwards, still leaving it attached by its digital processes. By these means you bring into view the short flexor muscle.

Fig. 129.*

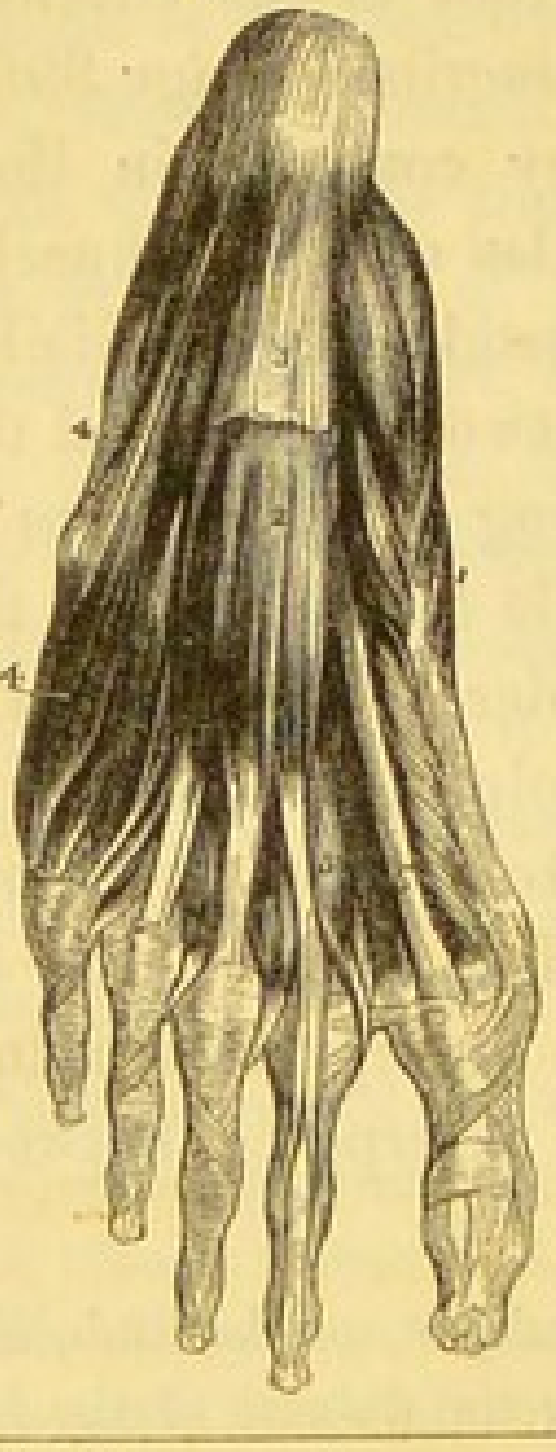

Abductor pollicis.

Origin.

Abductor pollicis pedis (fig. 129,^{1}).—The abductor of the great toe is placed horizontally along the inner side of the sole of the foot. It *arises* from the inner border of the protuberance of the calcaneum, from the internal annular ligament, from the septum between it and the flexor brevis digitorum, and from the superior surface of the plantar fascia. The fleshy fibres end in a tendon, which, after uniting with the external head of the flexor brevis pollicis, is inserted into the inner border of the base of the first phalanx of the great toe.

Joins with flex. brev.

Parts adjacent.

The plantar surface of this muscle is covered by the skin and fascia; the superior surface is in contact with the ten-

---

* The muscles seen after removing the integument and fascia only. 1. Abductor pollicis. 2. Flexor brevis digitorum. 3. A part of plantar fascia. 4. Abductor digiti minimi.

dinous insertion of the tibialis posticus, with the flexor brevis pollicis with which it is identified, and with the internal plantar vessels.

Flexorbrev. digitor.

Flexor brevis digitorum[2] (flexor perforatus).—The short flexor of the toes is placed in the middle of the sole of the foot, in contact with the plantar fascia. It *arises* from the internal or greater tuberosity of the calcaneum : from the plantar fascia[3] : and the intermuscular septa on each side. The muscle soon terminates in four thin tendons corresponding with the four smaller toes ; and opposite the extremity of the first phalanx each tendon divides into two fasciculi, so as to leave a fissure for the transmission of the tendon of the flexor longus, after which the fibres unite again into a broad lamella, which is inserted into the under surface of the second phalanx. The manner of its division for the passage of the other flexor tendon, and the mode of connexion with the bones, are strictly analogous to those in the hand.—The lower surface of this muscle is in intimate contact with the plantar fascia ; the upper with the flexor accessorius, with the tendons of the flexor longus digitorum, the lumbricales, and the plantar vessels.

Tendons, perforated by flexor longus. Arrangement same as in hand. Parts in contact.

Abductor digiti min.

Abductor digiti minimi[4].—This, the third muscle of the superficial stratum, is placed along the external border of the foot. It *arises* from the external border of the calcaneum, from the under surface of that bone in front of both tubercles, and from the upper surface of the process of the plantar fascia, which extends from the external tubercle to the base of the fifth metatarsal bone. The fleshy fibres end in a tendon, which, after sliding along a smooth impression on the inferior surface of the head of the fifth metatarsal bone, is *inserted* into the external surface of the base of the first phalanx of the little toe.

Origin. Insertion.

Parts in contact.

This muscle is covered by the plantar fascia. Its upper surface is in contact with the external head of the flexor accessorius, the ligamentum longum plantæ, and the flexor brevis digiti minimi.

Removal of first layer of muscles.

Dissection.—To expose the second layer of plantar muscles (fig. 130). Separate the two abductors and the short flexor from the calcaneum by inserting the knife under the border of each successively, and cutting obliquely backwards close to the bone. Then draw them forwards, leaving them still attached by their insertions, in order that you may restore them to their original positions, and inspect their attachments and relations again.

When these muscles are removed, a thin lamella (*deep plantar fascia*) of

Tendons of long flexor muscles brought into view, with accessories of flexor digitorum.

membrane will be observed, extending across from one side of the foot to the other, separating the first from the second layer of muscles, consisting of the tendons of the flexor longus pollicis, those of the flexor communis, and its accessories, viz. the flexor accessorius and lumbricales. The long tendons will be observed to cross one another at an acute angle, that of the flexor pollicis inclining inwards, and placed on a plane superior to the tendon of the flexor communis, whose direction is obliquely outwards, as if towards the base of the fifth metatarsal bone.

Flexor accessorius.

The *flexor accessorius* is divided posteriorly into two heads (fig. 130, [3], [3]), of which the internal, or larger one, *arises* from the inner or concave surface of the calcaneum ; the external, flat and tendinous, arises from the plantar surface of that bone, a little before its external tubercle. These origins unite at an acute angle, and form a flat fleshy mass, which becomes united to the external border, as well as to the upper surface, and slightly also to the lower surface of the tendon of the flexor longus, at its point of division. It may be observed, that the fibres of the accessory muscle, where they enclose the tendon of the long flexor, are tendinous, and so arranged as to form a groove, within which it is lodged.

The flexor accessorius is the "moles carnea" of Sylvius.†

Fig. 130.*

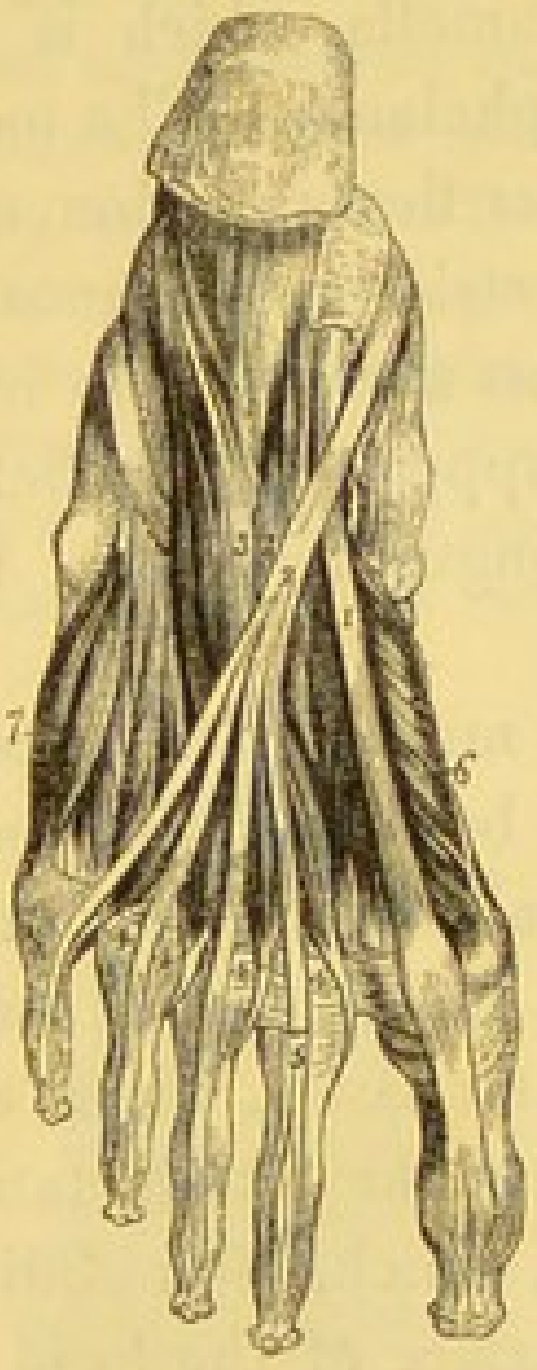

Lumbricales.

The *lumbricales* (fig. 130, [4], [4]) are four small tapering muscles, in form like worms, whence their name is derived ; they *arise* from the tendons of the flexor communis digitorum, at their point of division ; from which they pass forwards to the inner side of each of the lesser toes, where each becomes a thin tendon, which is

---

* The muscles of the plantar surface of the foot, after removal of the superficial series. 1. Tendon of the long flexor of the great toe. 2. Tendon of the long flexor of the toes. 3. Flexor accessorius. 4. Lumbricales. 5. Tendon of the short flexor of the toes. 6. Short flexor of the great toe. 7. Short flexor of the little toe.

† "In Hippocratis et Galeni Physiologiæ partem Anatomicam Isagoge a Jacobo Sylvio."—Cap. vii. Venet. 1556.

inserted into the base of the first phalanx at its inner border, and also becomes united to the tendinous expansions of the extensor muscles on the dorsal surface of the phalanges.

These little muscles are less distinct than those of the hand. They are liable to the same variations of arrangement.

Dissection.—Cut the flexor tendons across, detach the flexor accessorius from its origin, and draw them forwards or over the sides of the foot. When these muscles are removed, the third layer is exposed, filling up the deep irregular part of the sole of the foot.

Flexor brev. pollicis.

Origin.

Flexor brevis pollicis pedis (fig. 131, [1]).—The short flexor of the great toe is single and pointed behind, but divided into two parts or heads in front. It *arises* by a flat tendinous process, which extends along the greater part of its upper surface, from the inner border of the cuboid bone, slightly from the contiguous margin of the external cuneiform bone, and from the tendinous band sent to that bone from the tendon of the tibialis posticus. These origins can be best perceived when the muscle is cut across and detached carefully from before backwards. The fleshy mass divides into two parts, which are inserted, one into the inner, the other into the external border of the base of the first phalanx of the great toe; each head is also intimately connected with one of the sesamoid bones beneath the articulation. Moreover, before reaching its points of insertion, an intimate union is established between this muscle and the abductor pollicis on the one side, and adductor on the other. The tendon of the flexor longus runs along the interval between the heads of the short flexor.

Insertion in two parts, one on each side of first phal.

Sesamoid bones in tendons.

Connect. w. abductor and adduct.

Flexor long. between.

Fig. 131.*

Adductor pollicis.

Adductor pollicis pedis (fig. 131, [2]).—The adductor of the great toe is situated obliquely in the sole

---

* A view of deeper muscles than those shown in the preceding figure. 1. Short flexor of the great toe. 2. Adductor of the great toe. 3. Transversus pedis. 4. Short flexor of the little toe. 5, 6. Inter-osseous muscles. 7. Tendon of peroneus longus. 8. Ligamentum longum plantæ.

Origin. Insert. with flexor brev.

of the foot, forming a short, thick, fleshy mass. It *arises* from the cuboid bone, from the tarsal extremity of the third and fourth metatarsal bones, also from the sheath of the peroneus longus muscle [7], and is directed obliquely inwards to be *inserted*, conjointly with the external head of the flexor brevis pollicis, into the base of the first phalanx of the great toe.

Sesamoid bones.

The adductor of the great toe and its short flexor are thus found to be intimately united at their insertion, and if they be cut across about an inch behind the first joint, and reflected forwards, two small sesamoid bones will be found connected with their tendons, just as the patella is with the extensor tendon of the knee-joint. Like the patella, one of their surfaces is smooth, and enters into the composition of the articulation, being lined by the synovial membrane; and, like it, they are developed in the substance of the tendons, to increase their power of action.

Transvers. pedis; beneath joints of phalang. w. metatars.

The *transversus pedis* (fig. 131, [3]) is a narrow flat fasciculus of fleshy fibres, stretched beneath the digital extremities of the metatarsal bones, being interposed between them and the flexor tendons. Its external extremity is attached usually to the lateral ligament, connecting the fifth metatarsal bone with the first phalanx of the little toe; sometimes it commences at the fourth: it passes from without inwards, its fibres being connected with the heads of the fourth, third, and second metatarsal bones, or rather with the ligaments passing from them to the phalanges. It thus reaches the ball of the great toe, where it becomes blended with the fibres of the adductor pollicis.

Flex. digiti min. Origin. Insertion.

Flexor brevis digiti minimi pedis (fig. 131, [4]; 130, [7]).—The short flexor of the little toe is placed at the external side of the sole of the foot; it *arises* tendinous from the base of the fifth metatarsal bone, and from the sheath of the peroneus longus; the fleshy fibres terminate in a tendon, which is *inserted* into the base and external border of the first phalanx of the little toe. The upper surface of this muscle is in contact with the fifth metatarsal bone; the inferior is covered partly by the abductor digiti minimi, partly by the plantar fascia.

The *inter-osseous* muscles (inter-ossei), as their name im-

Inter-osseous; two sets;

named numerically.

plies, are placed between the metatarsal bones, filling up the intervening spaces. There are seven in all, and they are divided into two sets, which differ from one another in their position and arrangement. On the *dorsal* aspect of the metatarsus four of the muscles are perceptible, and they are named from this circumstance. The other set exist only on the *plantar* surface, and they are named accordingly. The seven interosseous muscles are distinguished numerically from within outwards, like the spaces which they occupy.

Dorsal inter-oss.;

each arises from both. bones.

Artery in notch at poster. end.

a.—The *dorsal inter-osseous* muscles (fig. 132) closely resemble one another in appearance, structure, and attachment. Their fibres arise from the contiguous surfaces of the bones between which they are placed, and pass obliquely forwards to a slight tendon that runs along the centre of each, so that they form a penniform muscle. Their posterior extremities are bifid, leaving angular intervals occupied by the perforating branches, which pass from the plantar to the dorsal arteries. These muscles dip down into the sole of the foot, where the plantar series are altogether placed; hence it is that, in this latter situation, their appearance and arrangement are somewhat complicated (fig. 131).

Fig. 132.*

First and second.

Third.

The first *two* dorsal inter-osseous muscles belong to the second toe, being inserted, the one (fig. 132,[1]) into the internal, the other[2] into the external side of its first phalanx, and into the margins of the extensor tendon as it expands upon its dorsal surface. The dorsal artery of the foot passes in the angular interval at the posterior end of the first, in its course downwards to join the plantar artery.—The *third* dorsal muscle[3] is inserted into the external side of the first phalanx of the third toe.—And the *fourth*[4] terminates in like manner on the first phalanx of the fourth toe.

---

* The bones of the foot, with the dorsal inter-osseous muscles, seen from above.

Plantar set.

b.—The *plantar inter-osseous* muscles are not, strictly speaking, situated between the metatarsal bones; they are placed rather beneath the third, fourth, and fifth metatarsal bones, inclining somewhat towards their inner border. These are single muscles, and are connected each with but one metatarsal bone.

Fig. 133.[*]

First plantar;

The *first* plantar inter-osseous muscle (fig. 133,[1]) arises along the inner border of the third metatarsal bone. The fleshy fibres end in a tendon, which is inserted into the base of the first phalanx of the same (third) toe, becoming blended with the tendinous expansion of the extensor communis.

second;

The *second* plantar inter-osseous muscle[2] arises from the inner side of the fourth metatarsal bone, and is inserted into the inner border of the first phalanx of the corresponding toe and the extensor tendon.

third.

The *third* plantar inter-osseous muscle[3] arises from the inner side of the fifth metatarsal bone, and is inserted into the base of the first phalanx of the little toe and the extensor tendon.

Actions of inter-osseous muscles;

—From the foregoing description it results, that the inter-osseous muscles now examined correspond with those of the hand, with the exception that, while the latter are so disposed as to abduct the fingers from, or adduct them towards, a line running through the *middle of the middle finger*, the dorsal muscles of the foot are calculated to move the toes from the *middle of the second toe*, and the plantar series incline them towards that point.—The dorsal muscles, therefore, increase the breadth of the foot, and the plantar muscles lessen it or restore the toes to the position from which they are removed by the former.

referred to middle of second toe.

---

[*] The bones and ligaments of the foot seen on the plantar aspect, with the plantar inter-osseous muscles.

TABLE OF THE MUSCLES

IN THE ORDER OF DISSECTION.

The student to whom the head and neck are allotted, will find sixty-six muscles at each side, disposed in sets or groups in particular parts, technically termed regions. He will find it convenient to dissect them in the following order. When a muscle forms part of two regions, it is enumerated in each, but is included within brackets ( ).

MUSCLES OF THE HEAD AND NECK.

Epicranial Region.

Occipito-frontalis.

Auricular Region.

Attollens aurem.
Retrahens aurem.
Attrahens aurem.

MUSCLES OF THE EYE-LIDS AND ORBIT.

Palpebral Region.

Orbicularis palpebrarum.
Corrugator supercilii.
(Levator palpebræ.)
(Tensor tarsi.)

Orbital Region.

Rectus superior.
——— inferior.
——— internus.
——— externus.
Obliquus superior.
——— inferior.
Levator palpebræ.
Tensor tarsi.

MUSCLES OF THE FACE.

Nasal Region.

Pyramidalis nasi.
Compressor narium.
Levator labii superioris alæque nasi.
Depressor alæ nasi.
Levator prop. alæ nasi posterior.
——————— anterior.

Superior Maxillary Region.

Levator labii superioris.
——— anguli oris.
Zygomaticus major.
——— minor.

Inferior Maxillary Region.

Triangularis oris.
Depressor labii inferioris.
Levator labii inferioris.

Inter-maxillary Region.

Buccinator.
Risorius.
Orbicularis.
Naso-labialis.

Temporo-maxillary Region.

Masseter.
Temporalis.

Pterygo-maxillary Region.

Pterygoideus internus.
——— externus.

MUSCLES OF THE NECK.

Superficial Region.

Platysma myoides.
Sterno-cleido-mastoideus.
(Rectus sternalis.)

Sterno-hyoid Region.

Sterno-hyoideus.
Sterno-thyroideus.
Thyro-hyoideus.
Crico-thyroideus.
Omo-hyoideus.

Sub-maxillary Region.

Digastricus.
Stylo-hyoideus.
——————— alter.
Stylo-glossus.
Stylo-pharyngeus.

Genio-hyoid Region.

Mylo-hyoideus.
Genio-hyoideus.
Hyo-glossus.
Genio-hyo-glossus.
Lingualis, and other muscles of the tongue.

Muscles of the Pharynx.

Constrictor inferior.
——— medius.
——— superior.
(Salpingo-pharyngeus.)
(Stylo-pharyngeus.)
(Palato-pharyngeus.)

Muscles of the Soft Palate.

Levator palati.
Circumflexus palati.
Azygos uvulæ.
Palato-glossus.
(Palato-pharyngeus.)

Muscles of the Larynx.

(Crico-thyroideus.)
Crico-arytænoideus posticus.
Crico-arytænoideus lateralis.
Thyro-arytænoideus.

Arytænoideus.
Arytæno-epiglottideus.
Thyro-epiglottideus.

Vertebral Region, lateral.

Scalenus anticus.
——— medius.
——— posticus.
Scalenus minimus.
——— lateralis.

Vertebral Region, anterior.

Rectus capitis anticus major.
——————— minor.
Rectus lateralis.
Longus colli.

MUSCLES OF THE UPPER EXTREMITY.

There are fifty-three muscles in each limb (including the pectorales, subclavius, and serratus), which may be examined one after another, in the order here set down.

Anterior Thoracic Region.

Pectoralis major.
——— minor.
Subclavius.
(Rectus sternalis.)

Lateral Thoracic Region.

Serratus magnus.

MUSCLES OF THE SHOULDER.

Acromial Region.

Deltoideus.

Scapular Region, posterior.

Supra-spinatus.
Infra-spinatus.
Teres minor.
——— major.

Scapular Region, anterior.

Sub-scapularis.

MUSCLES OF THE ARM.

Humeral Region.

Coraco-brachialis.
Biceps flexor cubiti.
Brachialis anticus.
Triceps extensor cubiti.
Sub-anconeus.

MUSCLES OF THE FORE-ARM.

Brachial Region, inner and anterior.

Pronator radii teres.
Flexor carpi radialis.
Palmaris longus.
Flexor carpi ulnaris.
——— digitorum sublimis.
——————— profundus.
(Lumbricales.)
Flexor pollicis longus.
Pronator quadratus.

Radial Region.

Supinator radii longus.
Extensor carpi radialis longior.
——————— brevior.
Supinator radii brevis.

Brachial Region, posterior.

Anconeus.
Extensor digitorum communis.
——— minimi digiti.
——— carpi ulnaris.
——— ossis metacarpi pollicis.
——— primi internodii pollicis.
——— secundi internodii pollicis.
——— indicis.

MUSCLES OF THE HAND.

Palmar Region.

Abductor pollicis.
Opponens pollicis.
Flexor brevis pollicis.
Adductor pollicis.
Palmaris brevis.
Abductor digiti minimi.
Flexor brevis digiti minimi.
Adductor digiti minimi.
Lumbricales.
Inter-ossei.

MUSCLES OF THE TRUNK.

Omitting the pectorales, subclavius, and serratus magnus, which are usually taken with the upper extremity, we find in the trunk of the body ninety muscles at each side, together with the diaphragm and levator ani, which are single.

MUSCLES OF THE ABDOMEN.

Abdominal Region.

Obliquus externus abdominis.
——— internus.
Cremaster.
Transversalis.
Rectus abdominis.
Pyramidalis.
Quadratus lumborum.

MUSCLES OF THE THORAX.

Anterior Thoracic Region.

(Pectoralis major.)
(Pectoralis minor.)
(Subclavius.)

Lateral Thoracic Region.

(Serratus magnus.)

Costal Region.

Inter-costales [externi, interni].
Infra-costales.
Levatores costarum.
Triangularis sterni.
Diaphragma.

MUSCLES OF THE PELVIS AND PERINÆUM.

Iliac Region.

Psoas magnus.
——— parvus.
Iliacus.

Perinæal Region.

Sphincter ani.
Transversus perinæi.
Accelerator urinæ.
Erector penis.
Levator ani.
Coccygeus.
Compressor urethræ.
(Erector clitoridis.
Constrictor vaginæ.)

MUSCLES OF THE BACK.

These are arranged in layers.

Dorsal Region.

1. Trapezius.
Latissimus dorsi.

2. Levator anguli scapulæ.
Rhomboideus minor.
——— major.

3. Serratus posticus superior.
——— inferior.
Splenius colli.
——— capitis.

4. Erector spinæ.
Sacro-lumbalis.
Cervicalis descendens.
Accessorius ad sacro-lumbalem.
Longissimus dorsi.
Transversalis cervicis.
Trachelo-mastoideus.
Spinalis dorsi.
——— cervicis.
Complexus.
Biventer cervicis.

5. Semi-spinalis dorsi.
Semi-spinalis colli.
Inter-spinales.
Inter-transversales.
Inter-accessorii.
Multifidus spinæ.
Rotatores spinæ.
Extensores coccygis.
(Levatores costarum.)
Rectus capitis posticus major.
——— minor.
Obliquus capitis superior.
——— inferior.

MUSCLES OF THE LOWER EXTREMITY.

In each limb there are fifty-six muscles, which may be dissected in the following order.

MUSCLES OF THE THIGH.

Femoral Region, anterior.

Tensor vaginæ femoris.
Sartorius.
Rectus.
Crureus.
Sub-crureus.
Vastus externus.
——— internus.

Femoral Region, internal.

Gracilis.
Pectineus.
Adductor longus.
——— brevis.
——— magnus.

Gluteal Region, superficial.

Gluteus maximus.
——— medius.
——— minimus.

Gluteal Region, deep-seated.

Pyriformis.
Gemellus superior.
Obturator internus.
Gemellus inferior.
Quadratus femoris.
Obturator externus.

Femoral Region, posterior.

Biceps femoris.
Semi-tendinosus.
Semi-membranosus.

MUSCLES OF THE LEG.

Tibio-fibular Region, anterior.

Tibialis anticus.
Extensor pollicis.
——— digitorum longus.
Peroneus tertius.
(Extensor digitorum brevis.)
Peroneus longus.
——— brevis.

Tibio-fibular Region, posterior superficial.

Gastrocnemius.
Plantaris.
Soleus.

Deep-seated.

Popliteus.
Flexor longus digitorum pedis.
——— ——— pollicis pedis.
Tibialis posticus.

MUSCLES OF THE FOOT.

Dorsal Region.

Extensor digitorum brevis.

Plantar Region.

Abductor pollicis.
Flexor brevis digitorum.
Abductor digiti minimi.

Flexor accessorius.
Lumbricales.

Flexor brevis pollicis.
Adductor pollicis.
Flexor brevis digiti minimi.

Transversus pedis.
Inter-ossei.

TABLE OF THE MUSCLES,

ARRANGED AFTER THE MANNER OF DR. BARCLAY, ACCORDING TO THEIR ACTIONS.

THE HEAD IS MOVED

Forwards by

Platysma myoides
Sterno-mastoideus
Rectus anticus major
——— ——— minor,

Assisted (when the lower jaw is fixed) by

Mylo-hyoideus
Genio-hyoideus
Genio-hyo-glossus
Digastrici.

Backwards by

Part of trapezius
Splenius capitis
Complexus
Trachelo-mastoideus
Rectus posticus major
——— ——— minor
Obliquus capitis superior.

To either side by

Platysma myoides
Sterno-mastoideus
Part of trapezius
Splenius capitis
——— colli
Trachelo-mastoideus
Complexus.

THE NECK IS MOVED

Forwards by

Platysma myoides
Sterno-mastoideus
Digastricus
Mylo-hyoideus
Genio-hyoideus
Genio-hyo-glossus
Omo-hyoidei
Sterno-hyoidei
Thyro-hyoidei
Rectus anticus minor
Longus colli.

Backwards by

Part of trapezius
Rhomboideus minor
Serratus posticus superior
Splenius capitis
——— colli
Complexus
Trachelo mastoideus
Transversalis colli
Inter-spinales colli
Semi-spinales colli
Rectus posticus major
——— ——— minor
Obliquus capitis superior
——— ——— inferior
Scaleni postici
Levator scapulæ.

Laterally by

Various combinations of those muscles which separately move it forwards and backwards, assisted by the scaleni, inter-transversales, and recti laterales.

THE TRUNK IS MOVED

Forwards by

Rectus abdominis
Pyramidalis
Obliquus externus abdominis
——— internus
Psoas magnus
——— parvus,

Assisted (when the arms are carried forwards) by

Pectoralis major
——— minor
Serratus magnus.

Backwards by

Trapezius
Rhomboideus major
Latissimus dorsi
Serratus posticus superior
——— ——— inferior
Sacro-lumbalis
Longissimus dorsi
Spinales dorsi
Semi-spinales dorsi
Multifidus spinæ
Inter-transversales dorsi et lumborum.

Laterally by

Obliquus externus
——— internus
Quadratus lumborum
Longissimus dorsi
Sacro-lumbalis
Serrati postici
Latissimus dorsi.

THE SCAPULA IS MOVED

Upwards by	*Downwards by*	*Forwards by*	*Backwards by*
Trapezius Levator scapulæ Rhomboidei.	Lower part of trapezius Latissimus dorsi Pectoralis minor.	Pectoralis minor Serratus magnus.	Part of trapezius Rhomboidei Latissimus dorsi.

THE HUMERUS IS MOVED

Forwards by	*Backwards by*	*Inwards by*	*Rotated inwards by*
Part of deltoid Part of pectoralis major, *Assisted in some circumstances by* Biceps Coraco-brachialis.	Part of deltoid Teres major —— minor Long head of triceps Latissimus dorsi.	Part of pectoralis major Latissimus dorsi.	Subscapularis, *Assisted occasionally by* Pectoralis major Latissimus and teres major. *Outwards by* Supra-spinatus Infra-spinatus Teres minor.

THE FORE-ARM IS MOVED

Forwards by	*Backwards by*	*Rotated inwards by*
Biceps Brachialis anticus Pronator teres, *Assisted by* Flexor carpi radialis —— sublimis —— ulnaris Supinator longus.	Triceps Anconeus.	Pronator teres Flexor carpi radialis Palmaris longus Flexor sublimis Pronator quadratus. *Outwards by* Biceps Supinator brevis Extensor secundi internodii.

THE CARPUS IS MOVED

Forwards by	*Backwards by*	*Outwards by*	*Inwards by*
Flexor carpi radialis Palmaris longus Flexor sublimis —— carpi ulnaris —— profundus —— longus pollicis.	Extensor carpi radialis longior —— —— brevior Extensor secundi internodii Indicator Extensor communis digitorum —— proprius pollicis.	Flexor carpi radialis Extensor carpi radialis longior —— —— brevior Extensor ossis metacarpi —— primi internodii.	Flexor sublimis —— carpi ulnaris —— profundus Extensor communis digitorum —— minimi digiti —— carpi ulnaris.

THE THUMB IS MOVED

Inwards and forwards, across the palm, by	*Outwards & backwards by*	*Upwards & forwards, away from the other fingers, by*	*Backwards and inwards, to the other fingers, by*
Opponens pollicis Flexor brevis —— longus.	Extensor ossis metacarpi pollicis —— primi internodii —— secundi internodii.	Abductor, *Assisted by part of the* Flexor brevis.	Adductor Extensor primi internodii —— secundi internodii.

THE FINGERS ARE MOVED

Forwards, or flexed, by	*Backwards, or extended, by*	*Outwards, to radial border, by*	*Inwards by*
Flexor sublimis —— profundus Lumbricales Inter-ossei Flexor brevis digiti minimi Abductor digiti minimi.	Extensor communis —— minimi digiti Indicator.	Abductor indicis Abductor digiti minimi Inter-ossei.	Abductor digiti minimi Inter-ossei.

THE THIGH IS MOVED

Forwards by	*Backwards by*	*Inwards by*	*Outwards by*
Psoas magnus	Gluteus maximus	Psoas magnus	Tensor vaginæ femoris
Iliacus	Part of gluteus medius	Iliacus	Gluteus maximus
Tensor vaginæ femoris	Pyriformis	Pectineus	——— medius
Pectineus	Obturator internus	Gracilis	——— minimus
Adductor longus	Part of adductor magnus	Adductor longus	Pyriformis.
——— brevis.	Long head of biceps	——— brevis	
	Semi-tendinosus	——— magnus	
	Semi-membranosus.	Obturator externus	
		Quadratus femoris.	

THE THIGH IS ROTATED

Inwards by	*Outwards by*
Tensor vaginæ femoris	Gluteus maximus
Part of gluteus medius,	Part of gluteus medius
	Pyriformis
And, when the leg is extended, by	Gemellus superior
	Obturator internus
Sartorius	Gemellus inferior
Semi-tendinosus.	Quadratus femoris
	Obturator externus
	Psoas magnus
	Iliacus
	Adductor longus
	——— brevis
	——— magnus
	Biceps cruris, slightly.

THE LEG IS MOVED

Backwards, or flexed, by	*Extended by*
Semi-tendinosus	Rectus
Biceps	Crureus
Semi-membranosus	Vastus externus
Gracilis	——— internus.
Sartorius	
Popliteus.	

THE FOOT IS MOVED

Forwards, or flexed, by	*Backwards, or extended, by*	*Inclined inwards by*	*Outwards by*
Tibialis anticus	Gastrocnemius	Extensor proprius pollicis	Peroneus longus
Extensor proprius pollicis	Plantaris	Flexor longus digitorum	——— brevis
——— longus digitorum	Soleus	——— pollicis	Extensor longus digitorum
Peroneus tertius.	Flexor longus digitorum	Tibialis posticus.	Peroneus tertius.
	——— pollicis		
	Tibialis posticus		
	Peroneus longus		
	——— brevis.		

THE TOES ARE MOVED

Backwards, or flexed, by	*Forwards, or extended, by*	*Inclined inwards by*	*Outwards by*
Abductor pollicis	Extensor longus digitorum	Abductor pollicis	Adductor pollicis
Flexor brevis digitorum	——— proprius pollicis	Inter-ossei.	——— digiti minimi
Abductor minimi digiti	——— brevis digitorum.		Inter-ossei.
Flexor longus pollicis			
——— digitorum			
Flexor accessorius			
Lumbricales			
Flexor brevis pollicis			
Adductor pollicis			
Flexor brevis minimi digiti			
Inter-ossei.			

UPPER GOWER STREET,
OCTOBER 2, 1843.

WORKS
PRINTED FOR TAYLOR AND WALTON,

BOOKSELLERS AND PUBLISHERS TO UNIVERSITY COLLEGE.

NEW EDITION, BY DR. SHARPEY AND MR. QUAIN.

One Volume Octavo, illustrated by very numerous Engravings on Wood, many for the first time contained in this Edition,

DR. QUAIN'S ELEMENTS OF ANATOMY

Fifth Edition.

EDITED BY RICHARD QUAIN, PROFESSOR OF ANATOMY,

AND

WILLIAM SHARPEY, M.D., PROFESSOR OF ANATOMY AND PHYSIOLOGY IN UNIVERSITY COLLEGE, LONDON.

⁂ The First Half of the Volume, cloth lettered, will be Published the beginning of October.

NEW DISSECTOR.

In One Volume, crown 8vo, 750 pages, 12s.

DEMONSTRATIONS OF ANATOMY;

A GUIDE TO THE DISSECTION OF THE HUMAN BODY.

By GEORGE VINER ELLIS, One of the Demonstrators of Anatomy in University College.

"We think Mr. Ellis's 'Demonstrations' are in every way fitted for the purposes for which they are intended, and we therefore strongly recommend the work to the notice of every member of the profession. We are convinced that it will quickly become the general Text Book of every working student in anatomy."—*British and Foreign Medical Review*, January 1841.

◆

COMPLETION OF MULLER'S PHYSIOLOGY.

In Two Volumes 8vo, each Volume 20s.

ELEMENTS OF PHYSIOLOGY.

By J. MULLER, M.D.

Translated from the German, with Notes, by WILLIAM BALY, M.D. With Steel Plates and very numerous Wood Engravings. Second Edition.

"We *do*, however, recommend it very strongly, and we have no hesitation in saying that it will supersede all other works as a Text Book for Lectures, and one of reference for students. It steers a middle course between the superficial brevity of many of our modern works, and the pleonastic and metaphysical jargon of Burdach."—*Med. Chir. Review*, April 1838.

⁂ *Subscribers are requested immediately to complete their sets.*

DISEASES OF THE LUNGS.

Fcp 8vo., 6s. 6d. cloth,

PHYSICAL DIAGNOSIS OF DISEASES OF THE LUNGS.

By W. H. WALSHE, M.D., Professor of Pathological Anatomy in University College, Physician to the Hospital for Consumption and Diseases of the Chest.

"The treatise is one of extraordinary merit. Indeed, we do not hesitate to say that there exists in no language any work on the physical diagnosis of diseases of the lungs, suited for students, so clear and precise, and at the same time so comprehensive and practical, as this."—*British and Foreign Medical Review.*

◆

ANATOMY AND OPERATIVE SURGERY OF THE ARTERIES.

Parts 1 to 16, each containing 5 Plates, Imperial Folio, and Letterpress, Octavo,—12s. per Part.

THE ANATOMY OF THE ARTERIES,

WITH ITS APPLICATIONS TO PATHOLOGY AND OPERATIVE SURGERY.

In Lithographic Drawings, the size of and drawn from Nature, with Practical Commentaries.

By RICHARD QUAIN, Professor of Anatomy in University College, and Surgeon to University College Hospital.

Parts I. to VII., forming Volume I. (if the Work be bound in 2 volumes,) may be had, half bound morocco, with the Plates folded into half their full size, price 5*l.* 5*s.*

⁂ *Part 17 will complete the Work, and will be shortly published.*

THE SURGICAL ANATOMY

OF THE

PRINCIPAL REGIONS OF THE HUMAN BODY.

By THOMAS MORTON, Assistant-Surgeon at University College Hospital, one of the Demonstrators of Anatomy in the same College. Royal 8vo. With Lithographic Plates and Wood Engravings.

I. THE PERINÆUM.

6*s.* plain, 7*s.* 6*d.* coloured.

II. THE GROIN, THE FEMORAL AND POPLITEAL REGIONS.

13*s.* coloured; 9*s.* plain.

III. INGUINAL HERNIÆ, THE TESTIS, AND ITS COVERINGS.

12*s.* coloured; 9*s.* plain.

IV. THE HEAD AND NECK, THE AXILLA, AND BEND OF THE ELBOW.

(*Preparing.*)

"We most cordially recommend Mr. Morton's treatise, as a satisfactory guide in the dissection of the perinæum and pelvis."—*British and Foreign Medical Review.*

"The production (volume on the Groin) is altogether one which we can conscientiously recommend to the working student. * * * The work will constitute a complete and elaborate treatise, that cannot fail to be highly useful to surgeons in general."—*British and Foreign Medical Review.*

"The present work is a worthy successor to those (on the groin and perinæum), and will prove, we do not doubt as great a favourite with students."—*Med. Chir. Review,* April 1841.

◆

A SERIES OF ANATOMICAL PLATES, IN LITHOGRAPHY,

With References and Physiological Comments. Illustrating the Structure of the different Parts of the Human Body.

Edited by JONES QUAIN, M.D., and ERASMUS WILSON, Lecturer on Anatomy and Physiology at the Middlesex Hospital.

Complete in 2 vols. royal folio, half bound morocco, gilt tops, 12l. plain,—20l. coloured.

The Work consists of the following Divisions:

THE MUSCLES. 51 Plates. 2*l.* 16*s.* plain; 5*l.* 5*s.* full coloured.

THE VESSELS. 50 Plates. 2*l.* 14*s.* plain; 3*l.* 18*s.* with the vessels coloured.

THE NERVES. 38 Plates. 2*l.* 4*s.* plain; 4*l.* 2*s.* full coloured.

THE VISCERA. Including the Organs of Digestion, Respiration, Secretion, and Excretion. 32 Plates. Price 1*l.* 18*s.* plain; 3*l.* 10*s.* coloured.

THE BONES AND LIGAMENTS. 30 Plates. 2*l.* plain; 2*l.* 15*s.* coloured.

⁂ *Any Volume may be purchased separately.*

The entire Work consists of 106 Numbers, containing 201 Plates, besides Indexes, &c. Subscribers are requested immediately to complete their sets.

ILLUSTRATED AND CHEAP EDITION OF DR. DAVIS'S MIDWIFERY.

Now ready, in One Volume, 8vo, with a 4to Volume of Plates, together 1l. 7s. 6d. cloth, or 1l. 5s. in Parts,

ELEMENTS OF OBSTETRIC MEDICINE,

WITH THE

DESCRIPTION AND TREATMENT OF SOME OF THE PRINCIPAL DISEASES OF CHILDREN.

By DAVID D. DAVIS, M.D., late Professor of Obstetric Medicine in University College.

Second Edition. Accompanied by all the Plates belonging to the original 4to Edition.

"Having, during a long series of years, accumulated a mass of important facts, Dr. Davis is entitled to the thanks of established practitioners, and to the gratitude of all the junior members of the Profession, for thus presenting to them, in an agreeable form, the results of an experience which it can be the lot of few, even eminent physicians, to enjoy."—*Notice of the First Edition.—Lancet,* Sept. 22, 1832.

◆

LINDLEY'S ILLUSTRATED BOTANY.

In One Volume 8vo, with many Hundred Figures on Wood, 10s. 6d. cloth, lettered,

ELEMENTS OF BOTANY,

STRUCTURAL, PHYSIOLOGICAL, SYSTEMATICAL, AND MEDICAL.

Being a Fourth Edition of the First Principles of Botany.

By JOHN LINDLEY, Ph. D., F.R.S., Professor of Botany in University College, London.

◆

DRESSING AND BANDAGING.

Fcap 8vo, with 100 Engravings on Wood, cloth 6s. 6d.

THE SURGEON'S PRACTICAL GUIDE IN DRESSING,

AND IN THE METHODIC APPLICATION OF BANDAGES.

By THOMAS CUTLER, M.D., late Staff-Surgeon in the Belgian Army. *Second Edition.*

ALLEN, (DR. M., of HIGH BEECH,) ON THE CLASSIFICATION OF THE INSANE. 8vo, 6*s.*

DAVIS, (DR. DAVID D.,) ACUTE HYDROCEPHALUS, OR WATER IN THE HEAD, an Inflammatory Disease, and Curable by the same means with other Diseases of Inflammation. 8vo, 9*s.* 6*d.*

HIND (G. W.), FRACTURES OF THE EXTREMITIES, exhibited in 20 Plates and 40 Woodcuts. Folio, 1*l.* 4*s.* cloth.

A PORTRAIT OF R. LISTON, ESQ., Surgeon to University College Hospital. Drawn on Stone by GAUCI, from the original by Eddis. Price 2*s.* 6*d.*

CHRISTISON'S (PROFESSOR) MEMOIR OF THE LATE DR. TURNER, Professor of Chemistry in University College. 8vo, 1*s.*

APPLIED CHEMISTRY;

IN

MANUFACTURES, ARTS, AND DOMESTIC ECONOMY.

EDITED BY

E. A. PARNELL,

AUTHOR OF "ELEMENTS OF CHEMICAL ANALYSIS;" LATE ASSISTANT CHEMICAL LECTURER IN THE MEDICAL SCHOOL OF ST. THOMAS'S HOSPITAL.

WITH NUMEROUS WOOD ENGRAVINGS, AND OTHER ILLUSTRATIONS.

To appear in Monthly Parts, 8vo., each 2s. 6d.

Among the subjects which will be introduced in the earlier numbers are—

- GAS ILLUMINATION.
- GENERAL PRINCIPLES OF THE ARTS OF DYEING AND CALICO-PRINTING.
- MANUFACTURE OF SULPHURIC ACID.
- INDIGO.
- COFFEE, TEA, AND CHOCOLATE.
- CAOUTCHOUC.
- BORAX.
- PRESERVATION OF WOOD.
- ZINC.
- BICHROMATE OF POTASH.

The articles on Dyeing and Calico-printing, and Dyeing Materials, will be illustrated with specimens of dyed and printed cottons, and those on Pigments, when practicable and necessary, with examples of the tints of such as are not commonly known.

PART I. (GAS ILLUMINATION), JUST PUBLISHED.

⁂ *A Prospectus may be had of the Publishers, or through any Bookseller.*

NEW WORK BY PROFESSOR LIEBIG.

In One Volume, fcap 8vo,

FAMILIAR LETTERS ON CHEMISTRY;

AND ITS RELATIONS TO COMMERCE, PHYSIOLOGY, AND AGRICULTURE.

By JUSTUS LIEBIG, M.D., Professor of Chemistry in the University of Giessen.

Edited by JOHN GARDNER, M.D., Member of the Chemical Society.

◆

NEW EDITION OF LIEBIG'S AGRICULTURAL CHEMISTRY.

Third Edition, with large additions and very numerous alterations, One Volume 8vo,

CHEMISTRY,

IN ITS APPLICATIONS TO

AGRICULTURE AND PHYSIOLOGY.

By JUSTUS LIEBIG, M.D., Ph. D., F.R.S., Professor of Chemistry in the University of Giessen.

Edited from the Manuscript of the Author, by LYON PLAYFAIR, Ph. D.

"It is not too much to say, that the Publication of Professor Liebig's Organic Chemistry of Agriculture constitutes an era of great importance in the history of Agricultural Science. *Its acceptance as a standard is unavoidable, for following closely in the straight path of inductive Philosophy, the conclusions which are drawn from its data are incontrovertible.*"—"We can truly say, that we have never risen from the perusal of a book with a more thorough conviction of the profound knowledge, extensive reading, and practical research of its author, and of the invincible power and importance of its reasonings and conclusions, than we have gained from the present volume."—*Silliman's Journal.*

NEW WORK ON ALKALIMETRY, &c.

In One Volume, 12mo,

NEW AND SIMPLE METHODS

OF ASCERTAINING

THE COMMERCIAL VALUE OF ALKALIES, ACIDS, AND THE OXIDES OF MANGANESE.

By Drs. FRESENIUS and WILL, Chemical Assistants in the Laboratory of the University of Giessen.

Edited by J. LLOYD BULLOCK, Member of the Chemical Society, and late of the Giessen and Paris Laboratories.

This little Work will prove of the highest importance to Calico Printers, Bleachers, Dyers, Manufacturers of Soap, Paper, and Prussiate of Potash; also to Chemists and to Dealers in Alkalies, Acids, &c.

◆

NEW EDITION OF LIEBIG'S ANIMAL CHEMISTRY.

In One Volume, 8vo, price 9s. 6d., the Second Edition, with additions, of

ANIMAL CHEMISTRY;

Or, ORGANIC CHEMISTRY IN ITS APPLICATIONS TO PHYSIOLOGY AND PATHOLOGY.

By JUSTUS LIEBIG, M.D., Ph. D., Professor of Chemistry in the University of Giessen.

Edited, from the Author's Manuscript, by WILLIAM GREGORY, M.D., Professor of Chemistry, King's College, Aberdeen.

"While we have given but a very imperfect sketch of this original and profound work, we have endeavoured to convey to the reader some notion of the rich store of interesting matter which it contains. The chemist, the physiologist, the medical man, and the agriculturist, will all find in this volume many new ideas and many useful practical remarks. It is the first specimen of what modern Organic Chemistry is capable of doing for Physiology; and we have no doubt that from its appearance physiology will date a new era in her advance."—*Quarterly Review*, No. 139.

TURNER'S CHEMISTRY, BY PROFESSORS LIEBIG AND GREGORY.

Seventh Edition, in One Volume 8vo, containing the whole of Organic Chemistry, 1l. 8s.,

TURNER'S ELEMENTS OF CHEMISTRY.

Edited by JUSTUS LIEBIG, M.D., Ph.D., Professor of Chemistry in the University of Giessen; and WILLIAM GREGORY, M.D., Professor of Chemistry in King's College, Aberdeen.

⁂ *Part III., No. 4, completing the Sixth Edition, and the Second Supplement, completing the Seventh Edition, are Published.*

"There is no English work on Chemistry, which has been in so many hands, and has met with such universal approbation, as 'Turner's Elements;' and there is scarcely any work which has received so many additions and improvements in passing through its numerous editions. The present one appears to fulfil all that can be desired of a work of this kind. In the former editions, which were conducted by the late lamented Dr. Turner, the inorganic division of the subject was treated with that clearness, perspicuity, and beauty of arrangement so peculiarly his own; but the organic part of the work, although giving a very good general outline of this part of chemistry, was not so full as could be wished, when the almost miraculous advances of this interesting branch of science were taken into consideration. The edition now before us, by W. Gregory and J. Liebig, leaves nothing to be desired in this respect; they have rendered it exceedingly complete, carrying out at the same time the original idea of Turner. As a compendium of the present state of chemistry, and a text-book for all beginners, we consider it as unequalled by any in the English language; and we even doubt whether there are any of the foreign manuals of an equal size, which can venture to compete with it."—*Chemical Gazette*, Dec. 1, 1842.

◆

CHEMICAL ANALYSIS.

In One Volume, 8vo, with Diagrams on Wood, price 10s. 6d. cloth,

ELEMENTS OF CHEMICAL ANALYSIS,

INORGANIC AND ORGANIC.

By EDWARD ANDREW PARNELL, late Assistant Lecturer on Chemistry in the Medical School of St. Thomas's Hospital.

"As an adjunct to the exertions of the teacher, but by no means superseding the necessity of oral and practical instruction, the work of Mr. Parnell appears likely to be in the highest degree useful; it will serve to convey to the attentive student a correct notion of the general routine of operations proper to each of the different classes of analytical research, and the principles upon which such modes of proceeding have been devised, besides affording him a fund of practical detail, an easy reference to which will certainly lighten his labours and accelerate his progress."—*Chemical Gazette*, Nov. 1842.

◆

PORTRAIT OF

PROFESSOR LIEBIG,

OF GIESSEN.

COPPER-PLATE. *Just ready.*

DR. BENCE JONES'S APPLICATION OF LIEBIG'S PHYSIOLOGY.

In One Volume, 8vo, price 6s.

AN APPLICATION

OF

PROFESSOR LIEBIG'S PHYSIOLOGY

TO THE PREVENTION AND CURE OF GRAVEL, CALCULUS, AND GOUT.

By H. BENCE JONES, M.A., Cantab.; Licentiate of the Royal College of Physicians, London; and Member of the Chemical Society.

"In thus expressing our opinion of the practical value of this publication, it is satisfactory to find ourselves supported by Professor Liebig himself, under whose immediate superintendence and sanction a translation into German is now preparing."—*Pharmaceut. Journal.*

◆

DR. GREGORY ON SCHOOLS OF CHEMISTRY.

In 8vo, price 1s. sewed,

SCHOOLS OF CHEMISTRY.

A Letter to the Earl of Aberdeen on the State of the Schools of Chemistry in the United Kingdom.

By WILLIAM GREGORY, M.D., F.R.S.E., Professor of Medicine and Chemistry in the University and King's College, Aberdeen.

◆

GIESSEN LABORATORY.

Lately imported, price 12s.

EIGHT FOLIO PLATES,

REPRESENTING THE

CHEMICAL LABORATORY

OF THE

UNIVERSITY OF GIESSEN.

Accompanied by a Pamphlet (in German) descriptive of the same.

By DR. JUSTUS LIEBIG.

◆

NEW CHEMICAL TABLES.

In Folio, PART I., price 4s.

TABLES OF THE ELEMENTARY AND COMPOUND BODIES.

Systematically arranged and adapted as Tables of Equivalents, or as Chemical Labels.

By CHARLES BUTTON & WARREN DE-LA-RUE.

◆

CHEMICAL APPARATUS.

For the Use of Analytical Chemists, Lecturers, Students, and Amateurs.

TAYLOR & WALTON have on Sale a Collection of

IMPROVED

CHEMICAL APPARATUS,

Selected from the Stock of GRIFFIN & Co., Glasgow.

Descriptive Catalogues of Messrs. Griffin & Co.'s entire Stock may be had, price 1s. 6d.

BRADBURY AND EVANS, PRINTERS, WHITEFRIARS.