Elements of anatomy / by Jones Quain.

Contributors

Quain, Jones, 1796-1865.
Cowley, Leonard H., active 1858
King's College London

Publication/Creation

London : Taylor and Walton, 1837.

Persistent URL

https://wellcomecollection.org/works/kzwe62fs

License and attribution

This material has been provided by This material has been provided by King's College London. The original may be consulted at King's College London. where the originals may be consulted.
This work has been identified as being free of known restrictions under copyright law, including all related and neighbouring rights and is being made available under the Creative Commons, Public Domain Mark.

You can copy, modify, distribute and perform the work, even for commercial purposes, without asking permission.

Wellcome Collection
183 Euston Road
London NW1 2BE UK
T +44 (0)20 7611 8722
E library@wellcomecollection.org
https://wellcomecollection.org

KING'S College LONDON

Quain Library
The elements of anatomy.
1837
KCSMD QM23.QUA

200772741 1
KING'S COLLEGE LONDON

LONDON
H. BAILLIERE,
Foreign Bookseller
& PUBLISHER,

BOUND BY
REMNANT

KING'S *College* LONDON

Library

The conservation of this volume was made possible by a gift from Dr. Donald Whiting.

Digitized by the Internet Archive
in 2015

https://archive.org/details/b21301591

Leavitt Courtney

Temple 1858

ELEMENTS OF ANATOMY.

KING'S COLLEGE LIBRARY MEDICAL SCHOOL

BY

JONES QUAIN, M.D.

" Pour connaître homme malade, il faut connaître homme sain."—CABANIS.

FOURTH EDITION,

REVISED AND ENLARGED.

ILLUSTRATED WITH STEEL PLATES AND NUMEROUS ENGRAVINGS ON WOOD.

LONDON:

PRINTED FOR TAYLOR AND WALTON,

BOOKSELLERS AND PUBLISHERS TO THE UNIVERSITY OF LONDON,

28, UPPER GOWER STREET.

1837.

582236 KCSMD QM23.QUA

5759
22.5.58.

KING'S COLLEGE HOSPITAL
LIBRARY
Medical School

LONDON:
PRINTED BY SAMUEL BENTLEY,
Bangor House, Shoe Lane.

PREFACE

TO

THE FOURTH EDITION.

The details of Anatomy are so numerous, and the relations which different textures and organs bear to one another are so various, that it can scarcely be expected of students to retain them all in memory, or to form correct ideas of them from merely reading their description. The objects themselves must be referred to, in order that their structure and properties should be rightly understood. As this, however, cannot at all times be done, much assistance is derived from a reference to correct sketches or drawings. To facilitate the progress of the student, I have introduced into the present edition of this work a number of drawings, which it is hoped will suffice, not only for the purpose of illustration, but will also be of use in the dissecting-room, by supplying views of the leading objects, such as muscles, vessels, nerves, &c. which are there examined from day to day, their names and relations being fully stated. The methods of bringing into view the objects delineated, will at the same time be found sufficiently detailed in the remarks on dissection in the different portions of the work.

For the illustrations I am indebted to Mr. W. J. E. Wilson. The preparations from which the drawings in the first two plates are taken were altogether made by him; he likewise directed their execution, as well as the various sketches for the wood-cuts throughout the book. While I make my acknowledgment for much assistance and kindness received from my friend, the works will, I believe, sufficiently speak for themselves.

The drawings are due to the pencil of Mr. William Bagg. They are taken in most instances from preparations and dissections made expressly for the work; the engraving has been conducted with great care by Mr. Bagg, sen.

TO THE READER.

It has been remarked by one* who thought deeply, and observed accurately, "that the best order in which truth can be set forth is that in which it might naturally have been discovered; and that the most attractive method of instructing others is to lead them along the path which we ourselves have followed in our own instruction; for in this way we seem not so much to place before them our own knowledge as to set themselves in the search of truth." Continuing the train of the thought suggested by the observation here cited, we may add, that if it be expedient to keep these objects in view in the conduct of courses of oral lectures addressed to youth, it is at least equally so in the composition of works written for their instruction.

This elementary work, the fourth edition of which is now presented to the public, is intended to serve as a guide and a key to the study of Anatomy. It sets forth the various facts usually included within the limits of the subject of which it treats,—points out the more important principles which follow from them, — indicates the most compendious methods of arriving at a knowledge of the one, and traces some of the practical applications which should be made of the other.

* Condillac.

A correct knowledge of the structure of the human body is confessedly necessary to a right understanding of the principles of Medicine as well as of Surgery. It should, however, be observed, that the method of study and investigation varies, according as it is undertaken in reference to the one or the other; for, although the principle of analysis guides us in each, the mode of conducting it is different. Thus, when we examine the structure of an organ previously to undertaking the investigation of its functions and diseases, we resolve it into the elementary textures of which it is composed, in order to study the characters and composition — the physical and vital properties of each texture, separately, as a preliminary measure to the examination of them in their combined state in the organs which they make up. This mode of considering the parts of organised bodies is not an unnatural abstraction, or a speculative refinement; it arises from the nature of their composition, and is founded on the most approved principles of philosophical investigation. It forms the basis of that department which has been, since Bichât's time, called General Anatomy; it may, perhaps, with more propriety be named "Structural, or Analytical Anatomy." An outline of the leading facts and principles included within its limits will be found in the first chapter of this work; its practical application may be exemplified by a reference to the use which has been made of it in the study of the diseases of the different viscera — for instance, the lungs. We find these organs invested externally by a serous, and lined internally by a mucous membrane, which pervades the bronchial tubes, even to their ultimate termination in the air-

cells. If we could just imagine the one to be drawn out from the interior, and the other peeled off from the outside, we should leave insulated what the older anatomists termed the parenchyma of the organ. Now, observation has shown that either of these three component parts may be inflamed separately, the others remaining unaffected; and pathologists have marked the inflamed condition of these textures by distinct names, the one being called pleuritis, the other bronchitis, the third pneumonia. The serous membrane when inflamed will present a certain set of characters, will go through a series of changes, and exhibit a train of phenomena in its anatomical characters and in the symptoms which supervene, as widely different from those presented by the mucous membrane under similar circumstances, as if these textures did not belong to the same organ. But, if we examine the progress of inflammation in the peritonæum, in the arachnoid membrane, or in the serous lamella of the pericardium, and compare its characters and symptoms with those presented by the pleura, we shall find the most striking similitude, though these membranes are placed in different cavities, and enter into the composition of organs which perform distinct functions. As, in consequence of their striking similarity in structure, properties, and anatomical characters, these membranes are ranged under one head, and form one class, so their diseases should also form one group; on the obvious principle, that the closer the similitude between parts in their structure, functions, and characters during health, the more nearly will they resemble one another in the changes induced by disease.

of exhibiting them by dissection, so as to bring them clearly into view. The detailed description of each follows; and, lastly, comes the account of their actions and uses.

The plan of proceeding here indicated is adhered to throughout the work: for instance, the muscles of the orbit are named; the mode of sawing through the bones in order to expose them is stated; in the next place the description of the muscles is given, and this is followed by the rationale of their actions. In a subsequent section, when treating of the globe or ball of the eye, its components are stated, and the methods of exhibiting them by different sections pointed out, —how it should be fixed whilst making the incisions, and how the membranes should be separated in order to obtain a clear view of each.

The description of the different orders of vessels— of the nerves, and the viscera, follows in regular order, each being treated in nearly the same way.

The student is not to suppose, that whilst examining the muscles of the body he is engaged in learning mere anatomical details, or that he is doing no more than collecting such facts as are necessary to enable him to understand the phenomena of muscular action. It is confessedly interesting to know the mechanism of the movements which the different sets of muscles can execute, and trace the nice adaptation of the various parts which are engaged in their performance. Almost every inquiring person feels a desire to know wherein consists the faculty we possess of accurately fixing the hand and fingers on the minutest objects — of turning the axis of the eye to every point within our field of vision — and of giv-

ing to the vocal cords the different degrees of tension and relaxation necessary to produce all the varieties of tone of which the voice is susceptible, and of combining at the same time the efforts of a great number of muscles, so as to impress upon it all that precision of modulation which is attainable both in singing and speaking. But our inquiries are not confined to these points; their value becomes considerably enhanced when we learn the practical applications to which they lead, and perceive that, whilst apparently engaged in learning the structure and actions of muscles, we are really studying two most important chapters in practical surgery, namely, those on dislocations and fractures. The muscles being the moving powers in all the efforts which our limbs perform, they become the controlling agents in the new circumstances in which bones are placed when dislocated. A knowledge of their several actions in their natural state will readily enable us to determine how to overcome the resistance of some, and avail ourselves of the co-operation of others, during our efforts to replace the bone. And in cases of fracture, we can regulate the position of the limb in such a way as to relax the muscles, and prevent their displacing the broken pieces after they have been adjusted.

The viscera, or, as they are usually named, the internal organs of the body, as being so many instruments for the performance of special purposes, are arranged according to their functions. These are divisible into two classes, of which one is intended for the support and well-being of the individual, and the other for the continuance of the species.

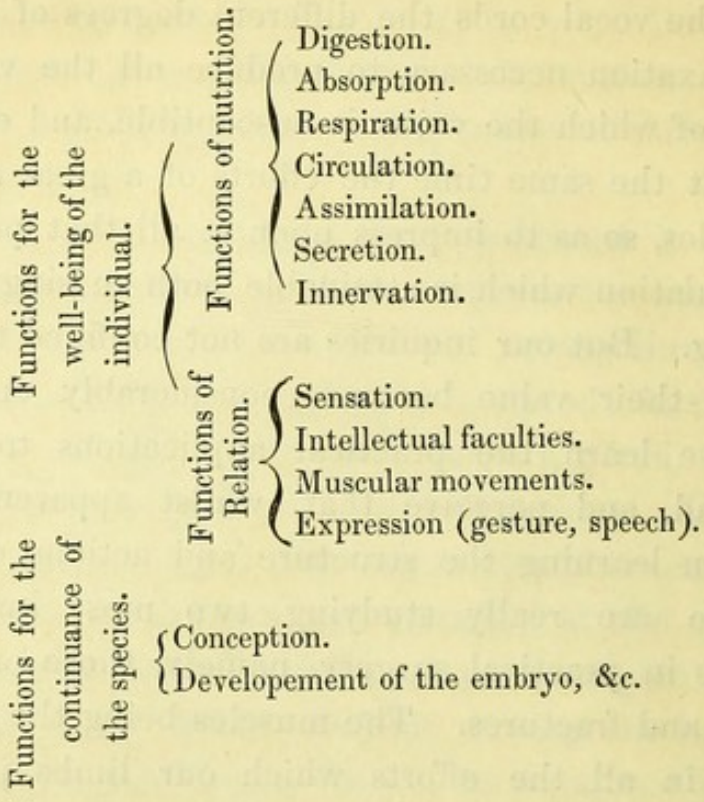

These different topics necessarily involve a great variety of facts and of inferences; so much so, that if the study of them be not conducted with method, the mind would become oppressed by a load of detail, and would be repelled from the pursuit by its complexity, instead of feeling an interest awakened by the nature of the inquiries which it every moment suggests.

What, then, is the proper method of study? The objects of study, from their very nature, must present themselves in different points of view, and require different methods of investigation. Thus you may consider the situation, form, and size of a given organ, and then its relations to contiguous parts. When you have stated all the facts relative to these points, you have given a description of the part, inasmuch as you have followed the *descriptive method;*

and this is all that is usually done in works on Descriptive Anatomy; they give merely the topography of parts. It must be obvious that it is not sufficient for our purposes thus to confine attention to the surface of things; our inquiries are not to be limited to external forms, or mere relations of place. We desire to become acquainted with the composition and structure of the human frame, or, in other words, with the elements of which it is made up. With this view, we resolve it into its constituents, and then examine the character and properties of each of these separately, as a necessary preliminary to a just appreciation of their powers when combined. This is the *analytical method.* Its application and use have been already pointed out in the remarks on General Anatomy.

As the phenomena included in a particular function, or in the derangement of it, do not present themselves to us at once, but occur in succession, it becomes necessary not merely to enumerate them, but to set them down in the exact order of their occurrence. When treating of the digestive function, for instance, we have to consider the mechanism employed in the prehension and mastication of food, its impregnation with saliva, its deglutition and conveyance to the stomach, the changes which the mass undergoes in that viscus, and afterwards successively, as it passes, step by step, through the different parts of the alimentary canal. When these particulars are fully stated, the narrative is complete, and we have conformed to what is termed the *historical method.*

We cannot, however, confine ourselves to a mere

statement of facts, or an enumeration of events. The very constitution of our minds compels us to draw inferences from the facts we have observed: we cannot help thinking, and to think is to theorise. This we at once recognise as the starting-place of all the speculative views and visionary opinions which the history of medicine records; and, unhappily, they are but too numerous: some of them evidently flow from the disposition so constantly manifested to deduce general principles from inadequate data; others are referable to that proneness which persons evince, when entering on speculations concerning the phenomena of life and the functions of living beings, to carry with them, and even rigorously apply, notions and principles taken from such pursuits as had previously, and perhaps exclusively, engaged their attention. Hence it is that the Philosophers of old introduced into medicine their peculiar hypotheses, and the Heathen priests tinctured it with their superstitious rites; whilst, in more modern times, the Mechanists sought to explain the functions of the body in health, and its derangements in disease, by principles deduced from hydraulics, and the Chemist referred them to the affinities which govern the processes they were wont to observe in their laboratories.

"From whence," said Bacon, when discoursing of the speculative systems which obtained in another department of science,—"from whence can arise such vagueness and sterility in all the physical systems which have hitherto existed in the world? It is not certainly from any thing in nature itself, for the steadiness and regularity of the laws by which it is governed clearly mark them out as objects of certain

and precise knowledge; neither can it arise from any want of ability in those who have pursued such inquiries, many of them having been men of the highest talent and genius of the ages in which they lived: it can arise from nothing else than the perverseness and insufficiency of the methods that have been pursued. Men have sought to make a world from their own conceptions, and to draw from their own minds all the materials they employed; but if, instead of doing so, they had consulted experience and observation, they would have had facts, not opinions, to reason upon, and might have ultimately arrived at a knowledge of the laws which govern the material world. As things are conducted at present, a sudden transition is made from sensible objects and particular facts to general propositions, which are accounted principles, round which, as round so many fixed poles, disputation and argument continually revolve. From propositions thus hastily assumed, all things are derived by a process compendious and precipitate, ill suited to discovery, but wonderfully accommodated to debate. The way that promises success is the reverse of this. IT REQUIRES THAT WE SHOULD GENERALISE SLOWLY, GOING FROM PARTICULAR THINGS TO THOSE WHICH ARE BUT ONE STEP MORE GENERAL, AND FROM THESE TO OTHERS OF STILL GREATER EXTENT, AND SO ON TO SUCH AS ARE UNIVERSAL. By such means we may hope to arrive at principles not vague and obscure, but luminous and well defined, such as Nature herself will not refuse to acknowledge."*

This is the *inductive method*, as taught by Bacon.

* Novum Organum.

To observe patiently, experiment cautiously, and generalise slowly, are the precepts it enjoins for the guidance of our own researches, and the tests which it suggests for estimating the value of the opinions and researches of others. The bias of prepossession and the influence of authority have for too long a time led away the mind from a conformity with its precepts: but happily these disturbing causes have now nearly passed away; for in our schools no general theory is taught — no uncompromising dogma is inculcated—no individual, however eminent he may be, can draw after him a crowd of followers ready to take his dictum as law, and resolved, when they set forward in life, to make their practice square with his injunctions; in a word, there no longer exists a monarchy in medicine; and, were we to look back to the history of those times in which the men of that profession were little else than the obsequious followers of a few distinguished individuals, we should find little reason to regret that their influence is at an end. And let not this excite surprise or regret—it should rather be a ground of satisfaction and gratulation, inasmuch as it has arisen, not from any causes tending to depress the few, but from the wide spread of knowledge, which has tended to elevate the many. There never was a period in the history of medicine in which there was less to discourage inquiry than the present—there never was a time in which so many circumstances conspired to invite a scrutiny into all its departments. The mind is no longer prostrated by the domination of authority, nor is reason warped by the influence of system. The errors of preceding inquirers are so many beacons to

warn those who succeed from straying into the devious tracks into which they wandered, and the failure of their methods of investigation points to the necessity of pursuing a different line of research from that which they adopted. Speculation and hypothesis have reigned too long; it has been too much the practice of system-makers to construct their edifices, if I may so say, "from their own conceptions, and to draw from their own minds all the materials they employed." Whilst notoriety, perhaps even distinction, could be attained by such compendious methods, we cannot feel surprise at the number of hypotheses which the history of medicine records, or at the fleeting credit they maintained. One heresy gave way to another, and a third succeeded, as short-lived as either of its predecessors. But, even at the present day, it is not a little difficult to repress speculation altogether, and confine inquiry within its legitimate bounds.

We constantly speak of the functions and powers of organs,—of the properties and qualities of different substances,—of the causes of diseases,—of the effects of remedies; yet how few are there amongst us who attentively consider the exact meaning of the words cause and effect, power and function, property and quality! Yet no class of men ought to be more precise and rigorous in the employment of them than the members of the medical profession. At the very outset of his pursuits, every student should know in what consists the relation of "cause and effect," and should be able clearly to perceive what it is that gives to one event or phenomenon the implied prerogative of "cause," and places the other in what is usually considered the subserviency of "effect."

"A cause," to use the words of Dr. Brown,* "may be said to be that which immediately precedes any change, and which, existing at any time in similar circumstances, has been always, and will be always, immediately followed by a similar change. Priority in the sequence observed, and in variableness of antecedence in the past and future sequences supposed, are the elements, and the only elements, combined in the notion of a cause. By a conversion of terms, we obtain a definition of the correlative *effect;* and *power*, as I have before said, is only another word for expressing briefly the antecedence itself, and the invariableness of the relation. * * * *

"It is this mere relation of uniform antecedence, so important and so universally believed, which appears to me to constitute all that can be philosophically meant in the words *power* or *causation*, to whatever objects, material or spiritual, the words may be applied. If events had succeeded each other in perfect irregularity, such terms never would have been invented; but, when the successions are believed to be in regular order, the importance of this regularity to all our wishes, and plans, and actions, has, of course, led to the employment of terms significant of the most valuable distinctions which we are physically able to make. We give the name of *cause* to the object which we believe to be the invariable antecedent of a particular change; we give the name of *effect* reciprocally to that invariable consequent; and the relation itself, when considered abstractedly, we denominate *power* in the object that is the invariable

* Inquiry into the Relation of Cause and Effect.

antecedent — *susceptibility* in the object that exhibits, in its change, the invariable consequent. We say of fire, that it has the *power* of melting metals; and of metals, that they are *susceptible* of fusion by fire,— that fire is the *cause* of the fusion, and the fusion the *effect* of the application of fire; but, in all this variety of words, we mean nothing more than our belief, that when a solid metal is subjected for a certain time to the application of a strong heat, it will begin afterwards to exist in that different state which is termed liquidity; that, in all past time, in the same circumstances, it would have exhibited the same change; and that it will continue to do so, in the same circumstances, in all future time. We speak of two appearances which metals present; one before the application of fire, and the other after it: and a simple but universal relation of heat and the metallic substances, with respect to these two appearances, is all that is expressed. * * * *

"The words *property* and *quality* admit of exactly the same definition; expressing only a certain relation of invariable antecedence and consequence, in changes that take place on the presence of the substance to which they are ascribed. They are strictly synonymous with *power*; or, at least the only difference is, that *property* and *quality*, as commonly used, comprehend both the *powers* and *susceptibilities* of substances,—the powers of producing changes, and the susceptibilities of being changed. We say equally that it is a property or quality of water to melt salt, and that it is one of its qualities or properties to freeze or become solid on the subtraction of a certain quantity of heat; but we do not commonly use the

word *power* in the latter of these cases, and say that water has the power of being frozen. . . . *Power*, *property*, and *quality*, are, in the physical use of these terms, exactly synonymous. Water has the *power* of melting salt; it is a *property* of water to melt salt; it is a *quality* of water to melt salt. All these varieties of expression signify precisely the same thing, that, when water is poured upon salt, the solid will take the form of a liquid, and its particles be diffused in continued combination through the mass. Two parts of a sequence of physical events are before our mind; the addition of water to salt, and the consequent liquefaction of what was before a crystalline solid. When we speak of all the powers of a body, we consider it as existing in a variety of circumstances, and consider, at the same time, all the changes that are or may be, in these circumstances, its immediate effects. When we speak of all the qualities of a body, or all its properties, we mean nothing more, and we mean nothing less. Certain substances are conceived by us, and certain changes that take place in them, which we believe will be uniformly the same, as often as the substances of which we speak exist in circumstances that are exactly the same.

"The powers, properties, or qualities of a substance are not to be regarded, then, as anything superadded to the substance, or distinct from it. They are only the substance itself, considered in relation to various changes that take place when it exists in peculiar circumstances."

The doctrine of cause and effect as here given, in the words of the most recent and generally approved writer on the subject, points to the necessity of being

careful to place facts and phenomena in the exact order of their occurrence, with a view to determine the invariable antecedent to any event the cause of which we seek to ascertain. So far it suffices for the purpose for which it has been introduced in this place. But, though invariably antecedence is a necessary ingredient in causation, there is no sufficient reason for contending that it constitutes its sole essence. We cannot divest ourselves of the impression that there is some connexion between the consequent and antecedent, more effective than that which is implied in mere sequence. When I remove the inkstand before me from one part of the table to another, or push the table on which I write from one side of the room to the opposite, I am conscious of an effort, and of the possession of a power to produce the removal in both cases. Hence, when I observe any marked change or particular result, I infer the existence of some power or influence which has been exerted to produce it. When vomiting follows the administration of a few grains of emetic tartar—when an intermittent fever ceases after a dose of quinine, we cannot but ascribe to these substances some quality or property from the influence of which the results follow.

It will be asked, Is there anything so recondite in medicine as to require an attention to the principles of the inductive philosophy? Or, is it to be supposed that, when hearing the report of a case, and resolving upon a plan for its treatment, we are to make an application to the doctrine of cause and effect? Is not medicine a science of observation? Cannot we use our eyes and ears, observe what is presented to

us, and then follow the dictates of common sense? Certainly. But, be it remembered (to use the words of Cullen in his oral lectures, as quoted by Mr. Macculloch,) that " to observe accurately requires a freedom from prejudice and an acuteness that belong to few. Many circumstances tend to vitiate statements dignified with the name of experience. The simplest narrative of a case almost always involves some theories. It has been supposed that a statement is most likely to consist of unsophisticated facts when reported by a person of no education: but it will be found an invariable rule, that the lower you descend in the medical profession, the more hypothetical are the prevailing notions. Again, how seldom is it possible for any case, however minutely related, to include all the circumstances with which the event was connected. Hence, in what is commonly called experience, we have only a rule transferred from a case imperfectly known to one of which we are equally ignorant. Hence that most fertile source of error, the applying inferences deduced from one case to another case, the circumstances of which are not precisely similar. WITHOUT PRINCIPLES DEDUCED FROM ANALYTICAL REASONING, EXPERIENCE IS A USELESS AND BLIND GUIDE."

In page 13 the reader will find a list of the most approved systematic treatises on general and descriptive anatomy. Besides these, the following monograph works and detached essays will be found cited or referred to, either in the text or in foot-notes of this volume, and may be consulted by those who wish for fuller information on the subjects of which they

treat, than can be conveniently brought within the limits of an elementary treatise.

Arnold—Icones Nervorum Capitis. *Heidelberg,* 1834.

Bichât — Recherches Physiologiques sur la Vie et la Mort. 8vo. *Paris,* 1800.

Bostock—An Elementary System of Physiology. *London,* 1827.

Bourdon—Mémoire sur les Efforts.

Breschet—Essai sur les Veines du Rachis. 4to. *Paris,* 1829.

Camper — Demonstrationes Anatomico-pathologicæ. Lib. II. fol. *Amsterdam,* 1760-62.

Clark—The Practical Anatomy and Elementary Physiology of the Nervous System. *London,* 1836.

Colles—A Treatise on Surgical Anatomy. Part I. 8vo. *Dublin,* 1811.

Cooper, Sir Astley — The Anatomy and Surgical Treatment of Inguinal and Congenital Hernia. fol. *London,* 1804. Observations on the Structure and Diseases of the Testis. 4to. *London,* 1830. The Anatomy of the Thymus Gland. 4to. *London,* 1832. Lectures on the Principles and Practice of Surgery, with additional Notes and Cases, edited by F. Tyrrel. 3 vols. 8vo. *London,* 1824-7.

Cruikshank — Anatomy of the Absorbing Vessels of the Human Body. 4to. *London,* 1786.

Cruveilhier—Cours d'Etudes Anatomiques. *Paris,* 1830.

———— Anatomie Descriptive. *Paris,* 1834.

Cuvier—Leçons d'Anatomie Comparée. 5 tom. 8vo. *Paris,* 1800-6.

——— Règne Animal. 4 tom. 8vo. new edit. *Paris,* 1829.

Dumas—Principes de Physiologie. 4 tom. 8vo. deuxième edit. 1806.

Dutrochet—Nouvelles Recherches sur l'Endosmose et l'Exosmose. 8vo. *Paris,* 1828.

Dupuytren — Thèse sur la Lithotomie, présentée et soutenue au Concours. 4to. *Paris,* 1812.

Edwards — De l'Influence des Agens Physiques sur la Vie, 8vo. *Paris,* 1824.

The English edition of this work by Dr. Hodgkin, contains an appendix and several notes.

Fodera — Recherches Expérimentales sur l'Absorption et l'Exhalation, 8vo. *Paris,* 1824.

Gall and Spurzheim—Anatomie et Physiologie du Système Nerveux en générale, et du Cerveau en particulier. 4 tom. fol. *Paris,* 1810-19.

GEOFFROY ST. HILAIRE — Philosophie Anatomique. 8vo. *Paris,* 1818–22.

GERDY—Mémoire sur l'Organisation du Cœur.

GLISSON—De Anatomiâ Hepatis. 12mo. *London,* 1654.

HALLER—Icones Anatomici. fol. *Gottingen,* 1781-2.

HARGRAVE—A System of Operative Surgery. 12mo. *Dublin,* 1831.

HARRISON—The Surgical Anatomy of the Arteries of the Human Body. 2 vols. 12mo. *Dublin,* 1824-5.

HARVEY—De Motu Cordis et Sanguinis in Animalibus. 4to. *Lugd. Bat.* 1639.

HOME, Sir EVERARD—Practical Observations on the Treatment of the Diseases of the Prostate Gland. 8vo. *London,* 1811. Various Papers read before the Royal Society. 2 vols. 4to.

LAWRENCE—A Treatise on Ruptures. 8vo. *London,* 1824.

——— Lectures on Physiology, Zoology, and the Natural History of Man. 8vo. *London,* 1819.

LOBSTEIN—De Nervi Sympathetici Humani Fabricâ, Usu, et Morbis. 4to. *Paris,* 1823.

MAGENDIE—Précis Elémentaire de Physiologie. 2de edit. 2 tom. 8vo. 1825.

——— Journal de Physiologie.

MURRAY—A Description of the Arteries of the Human Body, translated by A. Scott. 8vo. *Edinburgh,* 1801.

OLLIVIER—Traité de la Moëlle Epinière, et de ses Maladies. 2de edit. 2 tom. 8vo. *Paris,* 1827.

OTTO—A Compendium of Human and Comparative Pathological Anatomy, by South. 8vo. *London,* 1831.

PARRY—An Experimental Inquiry into the Nature, Cause, and Varieties of the Arterial Pulse. 8vo. *London,* 1816.

PHILIP—An Experimental Inquiry into the Laws of the Vital Functions. 3d edit. 8vo. 1826.

PREVOST and DUMAS—Mémoires in the Journal de Physiologie.

REISSEISSEN—De Structurâ Pulmonum.

SCARPA—Tabulæ Neurologicæ. fol. *Ticin.* 1794.

SERRES—Anatomie Comparée du Cerveau dans les quatre Classes des Animaux Vertèbres. 8vo. *Paris,* 1824-26.

SOEMMERING—Icones Oculi Humani.

——— Organi Auditûs.

SOLLY—The Human Brain—its Configuration, Structure, &c. *London,* 1836.

SWAN—A Demonstration of the Nerves of the Human Body. fol. *London,* 1830.

Swan—Demonstration of the Nerves. 4to. *London*, 1834.

Thomson, Allen—On the Developement of the Vascular System.

Tiedemann—Tabulæ Arteriarum Corporis Humani. fol. *Carlsrh.* 1822.

Tod—The Anatomy and Physiology of the Human Ear. 8vo. *London*, 1832.

Walter—Tabulæ Nervorum Thoracis et Abdominis. fol. *Berol.* 1783.

Weitbrecht—Syndesmologia. 4to. *Petrop.* 1742.

Whately—An improved Method of treating Strictures in the Urethra. 8vo. *London*, 1804.

Willis—Cerebri Anatome. 8vo. *Amst.* 1666. Pathologia Cerebri, et Nervosi Generis Specimen. 12mo. *Amst.* 1670.

DESCRIPTION OF THE PLATES.

FIGURE 1. A piece of cellular tissue, prepared so as to show its structure:—*a*, the cellules and the lamellæ which enclose them; *b*, *b*, some of the cellules laid open.

FIG. 2. A piece of adipose substance:—*c*, the exterior or enclosing cellules — their membranous parietes; *d*, a nutrient vessel ramifying amongst these; *e*, a single adipose vesicle as represented by M. Raspail.

FIG. 3. A portion of bone and its investing membrane:—*f*, the bone; *g*, the periosteum.

FIG. 4. A piece of corium, showing the appearance which its external surface presents when examined with a microscope:—*h*, the ridges or raised lines in which the papillæ are disposed in rows; *i*, the furrows between the lines, and called "interlinear," to distinguish them from those which intersect them, *k*, and which are named "interpapillar," as they are interposed between the papillæ.

FIG. 5. A single row of papillæ viewed in profile as they project from the corium.

FIG. 6. A diagram representing the position and relations of the three layers of which the common external tegument is composed,—the corium is shown connected to the subjacent parts by cellular and adipose substance; the papillæ which project from its outer surface are covered by the rete mucosum and epidermis, which, from their plastic nature, are as it were moulded upon them.

FIG. 7. A piece of corium, with the rete mucosum and cuticle raised so as to show the sweat-ducts:—*l*, the interpapillar lines, which, when viewed at the inner surface of the raised rete and cuticle, represent ridges; *m*, the interlinear ridges; *n*, slight hollows or pits, into which the papillæ project; *o*, the corium with its papillæ and lines; *p*, the sweat-ducts emerging from the corium and piercing the rete and cuticle.

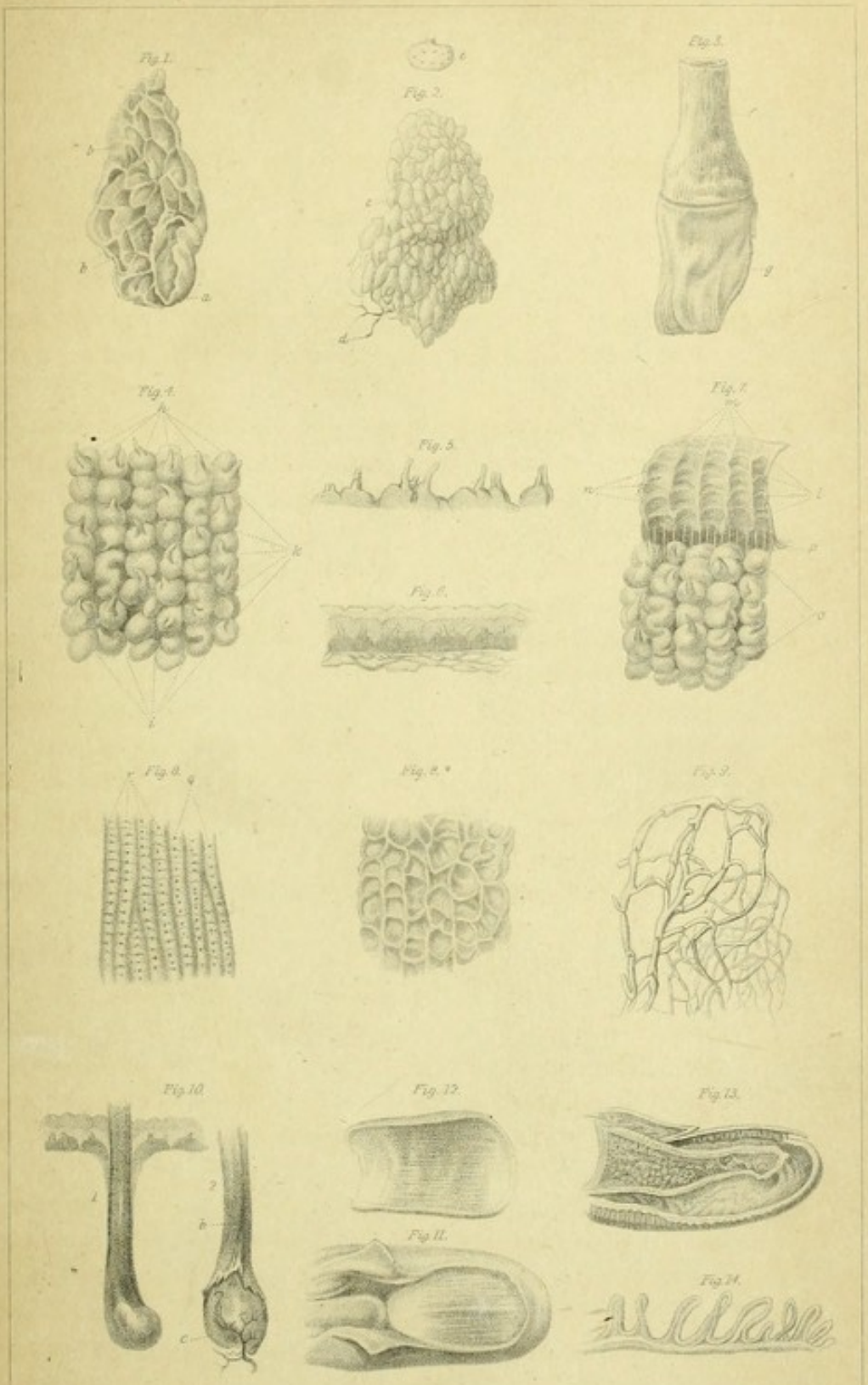

W. Bagg. ad nat. del. W. J. E. Wilson. direx. H. Adlard. sculp.

London. Taylor & Walton, Upper Gower Street, 1838.

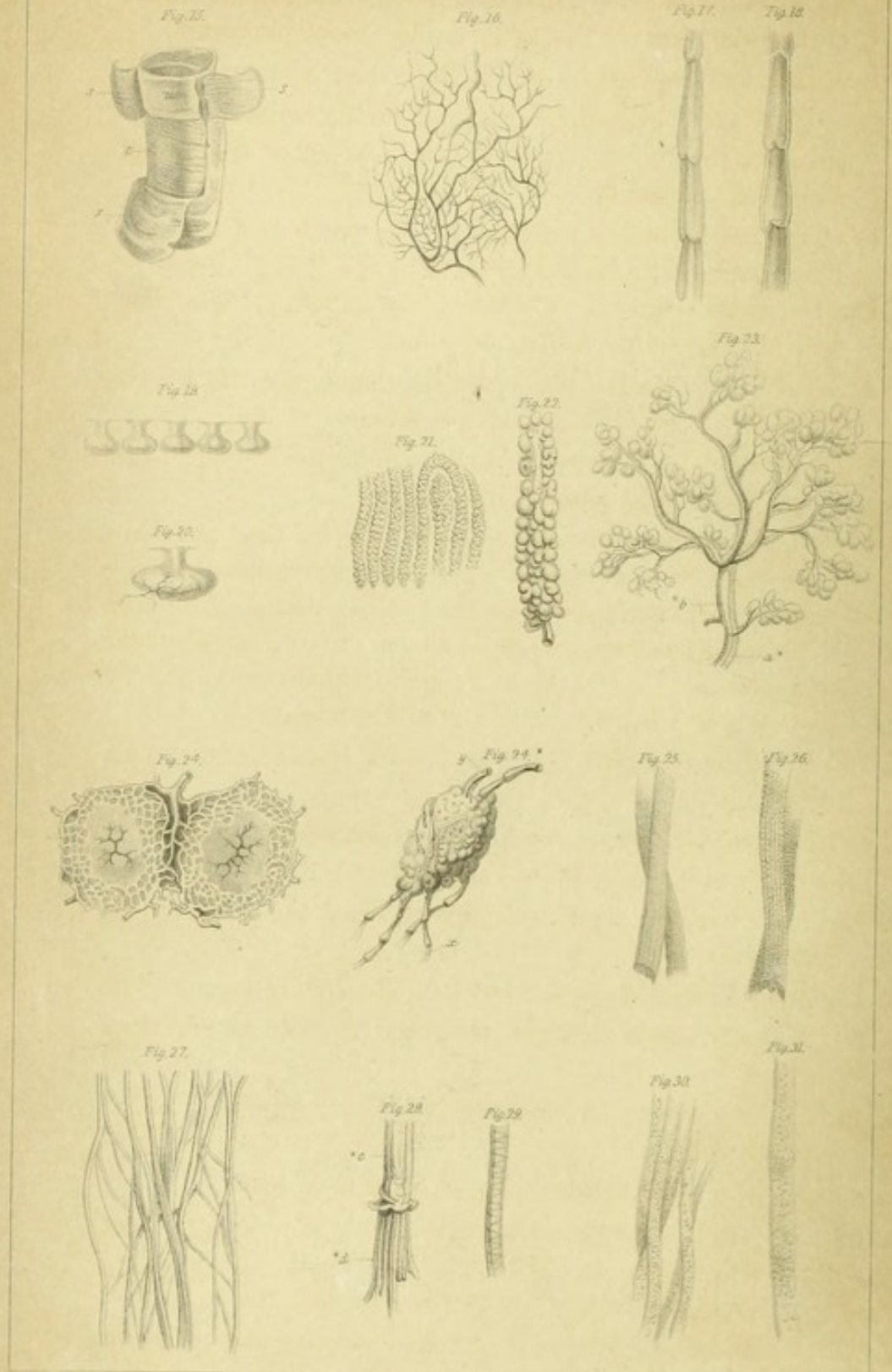

W. Bagg ad nat. del. W.J.E. Wilson, direx. H. Adlard, sculp.

London: Taylor & Walton, Upper Gower Street, 1838

Fig. 8. A piece of cuticle, showing the raised lines and furrows on its external surface :—*q*, the raised lines ; *r*, the pores or orifices of the sweat-ducts. Fig. 8*. A piece of rete mucosum.

Fig. 9. A plexus of lymphatic vessels in the corium injected.

Fig. 10.—1. A sketch indicating the connexion of a hair with its papilla, and the three layers of the tegument.—2. *b*, the bulb of a hair ; *c*, the papilla.

Fig. 11. The corium under a nail ; its papillæ are seen disposed in lines running from behind forwards.

Fig. 12. The under surface of a nail marked by furrows corresponding with the lines in the subjacent corium.

Fig. 13. A section of the last phalanx of the thumb, showing the relation of the nail to the corium and cuticle.

Fig. 14. The vessels in the rows of papillæ in the corium under the nail, showing their looped form.

Fig. 15. A piece of artery dissected so as to show the three membranous structures of which it consists :—*s*, *s*, *s*, the outer coat reflected in separate pieces,—on the two upper flaps some fibres of the middle coat are seen at their inner surface ; *t*, the middle or fibrous coat ; *u*, the inner or lining membrane exposed by dissecting and reflecting the outer and middle coats.

Fig. 16. A plexus of capillary arteries, taken from a piece of skin finely injected.

Fig. 17. An absorbent vessel, showing the constricted appearance it presents in the situation of the valves.

Fig. 18. An absorbent vessel laid open to show the valves in its interior.

Fig. 19. Mucous follicles, the simplest form of secreting apparatus.

Fig. 20. A single follicle enlarged, with the vascular ramifications upon it.

Fig. 21. The Meibomian follicles under the lining membrane of the upper eye-lid.

Fig. 22. A row of these follicles enlarged, with their duct.

Fig. 23. A lobule of a conglomerate gland unravelled :—A*, the duct branching out into ramifications as far as the ultimate follicles ; *b**, the artery following the duct and its branches.

Fig. 24. A plan of two lobules of the liver, showing the plexiform arrangement of the duct within them. Fig. 24*. A lymphatic

ganglion, with the vessels which enter it and emerge from it :— *x*, the inferent vessels ; *y*, the efferent vessels.

Fig. 25. Muscular fibres magnified, and showing the transverse lines upon them.

Fig. 26. Muscular fibre, composed of myolema and globules.

Fig. 27. A nerve dissected to show the filaments of which it consists and their plexiform arrangement.

Fig. 28. A piece of nerve, showing its outer investment or sheath, *c**, and its filaments, *d**, with their proper investment—the neurilema.

Fig. 29. A nervous filament, showing the waving lines on its surface.

Figs. 30 and 31. Filaments of nerve, showing their components, viz. neurilema and globules.

REFERENCES TO THE PLATES OF THE BRAIN.

Fig. 151. The base of the brain.

a. Section of the spinal cord, showing its interior structure. *b*. The corpus pyramidale of the medulla oblongata. *c*. The decussation of the corpora pyramidalia. *d*. The corpus olivare. *e*. The corpus restiforme. *f*. The anterior lobe of the cerebrum. *g*. The posterior lobe. *h*. The middle lobe. *i*. The fissure of Sylvius. *k*. The longitudinal fissure separating the two anterior lobes. *l*. The commencement of the transverse fissure of the brain. *m*. The substantia perforata antica. *n*. The commissure of the optic nerves. *o*. The tuber cinereum. *p*. The corpus albicantium of one side. *q*. The locus perforatus. *r*. The crus cerebri. *s, s*. The lobes of the cerebellum. *t*. The inferior vermiform process of the cerebellum. *u*. The crus cerebelli. *v*. The pons Varolii.

1. The olfactory nerve. 2. The optic nerve. 3. The motor oculi nerve. 4. The patheticus nerve (n. trochlearis). 5. The trifacial nerve (n. trigeminus). 6, 6. The abducentes nerves. 7. The seventh pair ;—*x*, the facial nerve (portio dura) ; *y*, the auditory nerve (portio mollis). 8 The eighth pair ;—*α*, the glosso-pharyngeal nerve ; *β*, the pneumo-gastric nerve (n. vagus, par vagum) ; *γ*, the spinal accessory nerve (n. accessorius). 9. The lingual nerve (n. hypo-glossus).

Fig. 152. A longitudinal section of the brain between the hemispheres. *a*. The inner surface of the right hemisphere. *b*.

Fig. 151

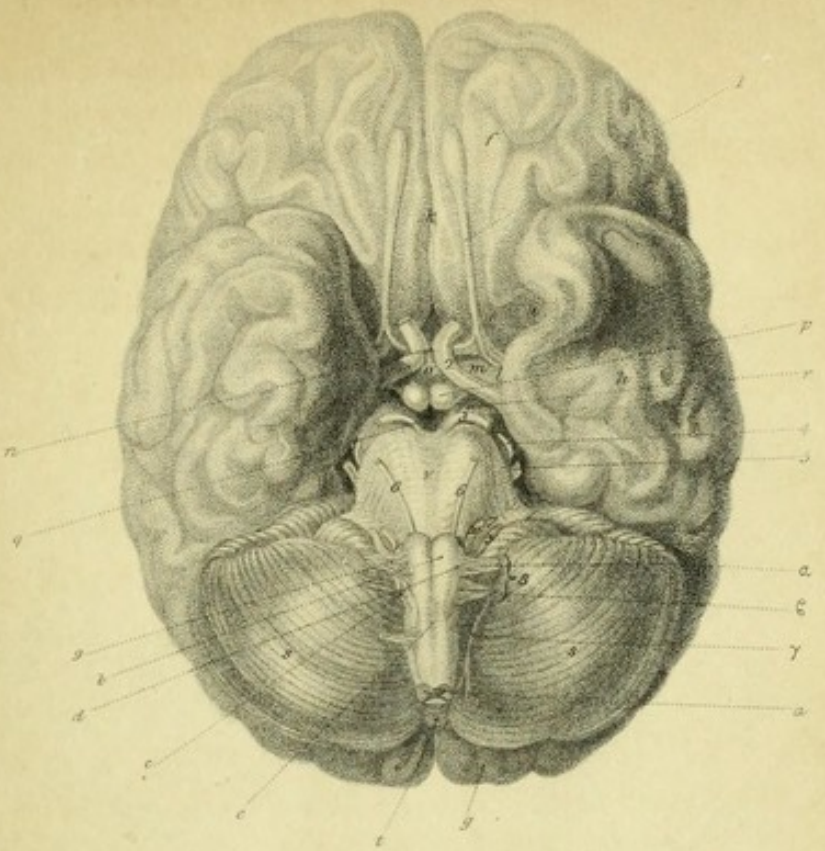

Fig. 152

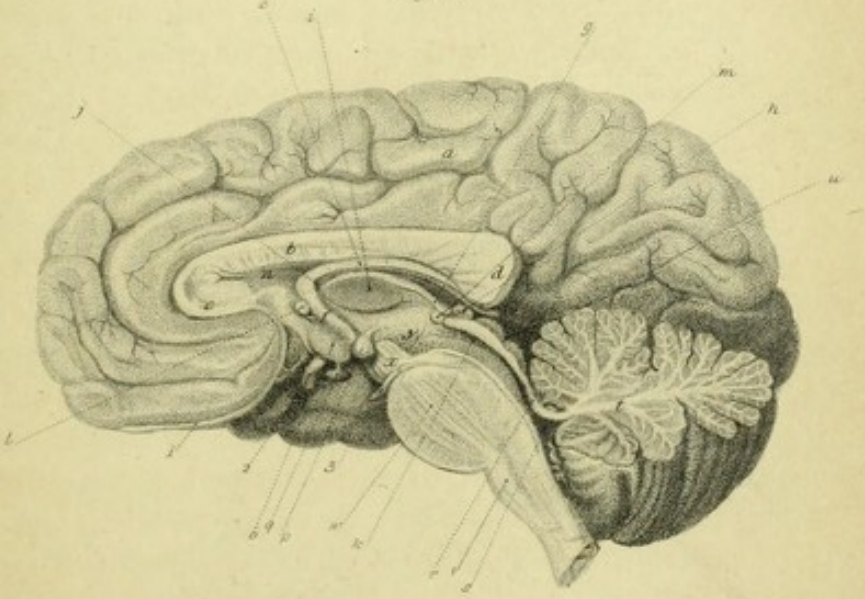

W. Hagg. ad nat. del. W. J. E. Wilson. direx. R. Adlard. sculp.

London: Taylor & Walton, Upper Gower Street, 1838.

Fig. 153.

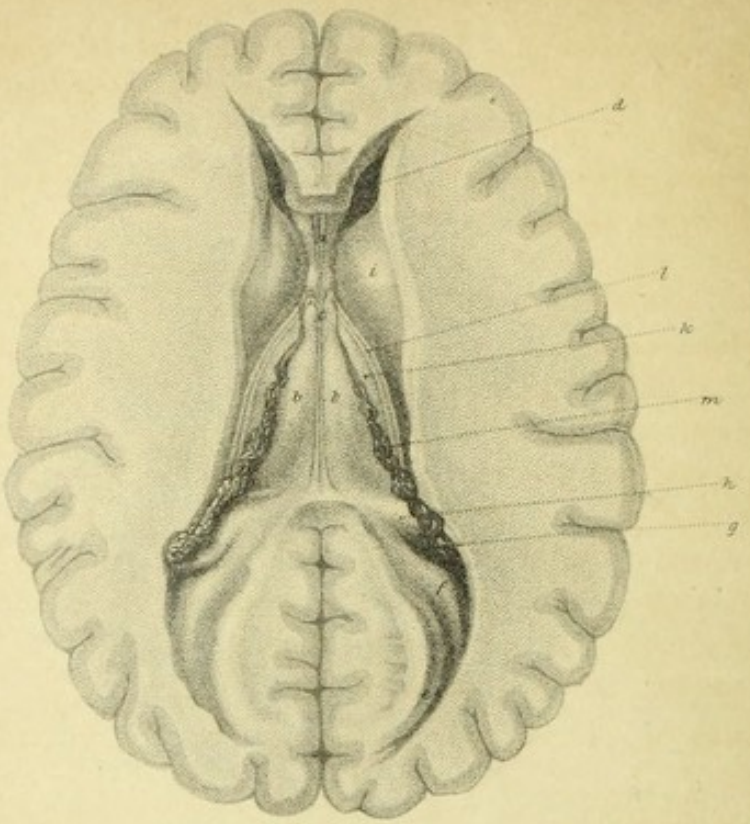

Fig. 154.

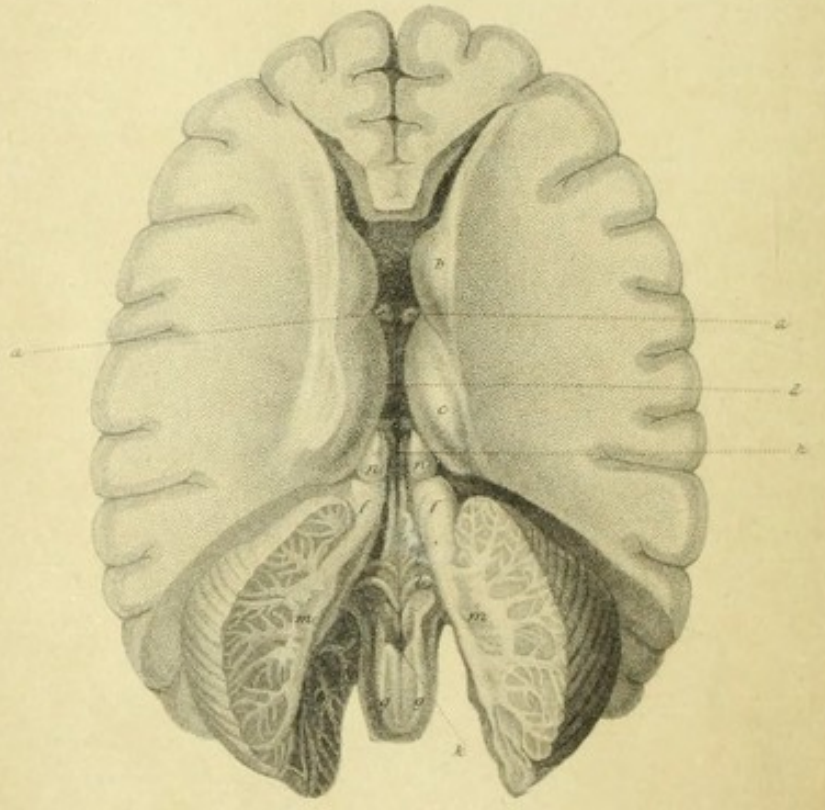

W. Bagg, ad nat. del. W. J. E. Wilson, direx. H. Adlard, sculp.

London: Taylor & Walton, Upper Gower Street, 1838.

The corpus callosum. *c.* Its anterior fold. *d.* Its posterior fold. *e.* The fornix. *f.* The right crus of the fornix. *g.* The right peduncle of the pineal gland. *h.* The pineal gland. *i.* Section of the middle commissure of the third ventricle (commissura mollis). *k.* The iter à tertio ad quartum ventriculum. *l.* Section of the anterior commissure. *m.* Section of the posterior commissure. *n.* The septum lucidum. *o.* The tuber cinereum. *p.* The right corpus albicantium, showing the white fasciculus which it receives from the thalamus opticus. *q.* The pituitary gland. *r.* The divided edge of the valve of Vieussens. *s.* The fourth ventricle. *t.* The arbor vitæ. *v.* The fasciculus of the corpus pyramidale seen passing into the pons Varolii. *w.* The separation of the fibres of the corpus pyramidale, with the admixture of the grey substance: this is the motor tract (tractus motorius). *x.* The crus cerebri. *y.* The locus perforatus.

1. The olfactory nerve. 2. The optic nerve. 3. The motor oculi nerve.

FIG. 153. The lateral ventricles of the brain.

a. The septum lucidum, with its cavity,—the fifth ventricle. *b, b.* The fornix. *c.* The crura of the fornix. *d.* The anterior cornu of the lateral ventricle. *e.* The posterior cornu or digital cavity. *f.* The hippocampus minor. *g.* The entrance to the descending or middle cornu. *h.* The commencement of the hippocampus major. *i.* The corpus striatum. *k.* The thalamus opticus. *l.* The tenia semicircularis. *m.* The choroid plexus.

FIG. 154. The third and fourth ventricles.

a, a. The divided ends of the crura of the fornix. *b.* The corpus striatum. *c.* The thalamus opticus. *d.* The third ventricle. *e.* The posterior commissure. *f, f.* The processus è cerebello ad testes. *g, g.* The corpora restiformia. *h.* The iter à tertio ad quartum ventriculum. *i.* The cavity of the fourth ventricle. *k.* The point of the calamus scriptorius, or ventricle of Arantius. *l, l.* The lineæ transversæ of the calamus scriptorius,—the fibres of origin of the auditory nerve. *m.* The corpus rhomboideum, or ganglion of increase to the cerebellum.

KING'S COLLEGE LIBRARY MEDICAL SCHOOL

CONTENTS.

CHAPTER I.

PAGE

The human body — divided into head, trunk, and extremities . 15
——— into two symmetrical halves . . . *ib.*
Organised bodies—contrasted with unorganised . . . 17
——— their composition . 18
——— their growth according to the law of eccentric developement . . . 19
The fluids of the body—their threefold division . . 20
——— their ultimate elements 21
——— their animal compounds — gelatine, albumen, fibrine, mucus . . *ib.*
The solid constituents of the body —their division and arrangement according to the views of the general anatomists . 23
Cellular tissue . *ib.*
Adipose tissue . . 28
Fibrous tissue . . 32
Fibrous membranes—aponeurosis—periosteum . 34
Perichondrium—tendon . 35
Fibrous sheaths—ligaments 36
Fibro-cartilage—cartilage 37
Elastic fibrous tissue . 38
Osseous system—general description . . . 39
Situation and number of bones . . 40
Division of bones into classes *ib.*
Elevations on the surfaces of bones . . . 42
Cavities and depressions — their uses . . 44
Structure of bone . . 45
Its chemical composition . 47
Process of ossification . 48
Serous membrane—character and description . . 51
Synovial membranes . . 54
Tegumentary membranes — corium . . . 57
Rete mucosum . . 61

PAGE

Cuticle . . . 63
Hairs 64
Nails 67
Mucous membrane . . 68
Plicæ—valvulæ conniventes 70
Villi 71
Mucous follicles . 72
Structure of mucous membrane . . . 73
Vascular system—division of vessels . . . *ib.*
Circulation—its division 74
Arteries—modes of communication . . 76
Veins—their conformation 77
Artery—origin of the term 78
its anatomy—external coat 79
—internal coat . 80
—middle coat . *ib.*
properties of arteries . 81
The pulse—various opinions on . . . 84
Developement of the vascular system . . . 85
Circulation in the fœtus . 91
Veins—their structure—coats 93
Absorbents . . 94
Glands . . . 97
Erectile tissue . . 100
Muscular system . . 101
Muscular fibre . . 102
Varieties of muscles—nomenclature . . . 107
Nervous tissue . . 108
Nervous system—symmetrical . . . 109
Structure of nerves . 111
Ganglia . . . 113
Tabular arrangement 116
The terms "Organ," "Apparatus," "Function"—their meaning 118
Descriptive Anatomy—its division into compartments . 119

CHAPTER II.

Osteology—the skeleton—its parts 120
Enumeration of the bones . 121

	PAGE
Vertebral column—division	122
General characters of a vertebra	123
Cervical vertebræ	125
Dorsal vertebræ	126
Lumbar vertebræ	127
Peculiarities of vertebræ	*ib.*
The skull—its bones	132
Occipital bone	*ib.*
Parietal bone	135
Frontal bone	137
Temporal bone	140
Sphenoid bone	145
Ethmoid bone	150
Ossa triquetra	154
The face—its bones	155
Superior maxillary bone	*ib.*
Malar bone	158
Nasal bones	*ib.*
Os unguis	159
Palate bone	*ib.*
Vomer	161
Inferior turbinate bone	162
Inferior Maxillary bone	*ib.*
Os hyoides	164
The skull—sutures of	165
Ossa Wormiana	167
General remarks on the conformation of the skull	*ib.*
Regions of the skull	168
Foramina in the base of the skull	169
The orbits	174
Nasal fossæ	175
Frontal sinuses	176
Sphenoidal and maxillary sinuses	*ib.*
Cranial bones—analogy to vertebræ	177
Peculiarities of the human skeleton—its adaptation to the erect position	179
Facial angle	182
The teeth—their number and classification	184
The thorax	186
Sternum	187
Ribs	188
Costal cartilages	191
Bones of the superior extremity :	
1. The shoulder :	
Scapula	192
Clavicle	196
2. The arm :	
Humerus	197
3. The fore-arm :	
Radius	200
Ulna	202
4. The hand :	
Carpus	205
os scaphoides	*ib.*
— semi-lunare	206
— cuneiform	*ib.*
— pisiform	*ib.*
— trapezium	207
os trapezoides	207
— magnum	*ib.*
— unciform	208
Metacarpus—its bones	*ib.*
Bones of the fingers	209
The pelvis	211
Sacrum	212
Coccyx	214
Innominatum	*ib.*
Ilium	215
os pubis	217
ischium	218
General conformation of the pelvis	221
Its axis and measurement in the male and female	222
Bones of the lower extremity :	
1. The thigh :	
Femur	223
2. The leg :	
Patella	227
Tibia	*ib.*
Fibula	230
3. The foot :	
Tarsus	
os calcis	232
Astragalus	233
os cuboides	234
— scaphoides	*ib.*
ossa cuneiformia	235
Metatarsus	236
Phalanges	237
Ossa sesamoidea	238

CHAPTER III.

The articulations—general view of	239
1. *Immovable articulations :* (Synarthrosis)	*ib.*
Sutura	240
Harmonia	*ib.*
Schindylesis	*ib.*
Gomphosis	*ib.*
2. *Mixed articulations :* (Amphi-arthrosis)	*ib.*
3. *Movable articulations :* (Diarthrosis)	*ib.*
Motions of gliding, opposition, circumduction, and rotation in joints, considered	242
Peculiarities of the hip and shoulder joints	244
Articulations of the trunk	245
Ligaments of the spine :	
Anterior common ligament	246
Posterior common ligament	*ib.*
Inter-vertebral substance	247
Spinous ligaments	*ib.*
Ligamenta sub-flava	248
Inter-transverse ligament	249
Ligaments between the atlas and axis	*ib.*

PAGE
Ligaments between the cranium and atlas . . . 250
——— between the cranium and axis . . 251
——— of the lower jaw . 252
——— of the ribs . 253
Articulations of the superior extremities . . . 255
Sterno-clavicular articulation *ib.*
Its ligaments . . 256
Scapulo-clavicular articulation *ib.*
Shoulder-joint—its ligaments . 258
Elbow joint . . 259
Ligaments between the ulna and radius . . . 261
Wrist-joint . 264
Carpus—its ligaments . . 265
Metacarpus—its ligaments . 266
Phalanges—their ligaments 267
Articulations of the pelvis . 268
Hip-joint . . . 272
Knee-joint . . 273
Ankle-joint . . 279
Articulations of the foot . 281

CHAPTER IV.

Of the muscles . . 286
Epicranial region — dissection . . . *ib.*
Occipito-frontalis . 288
Actions . . 289
Muscles of the face—dissection *ib.*
Palpebral region . . 290
Orbicularis palpebrarum 291
Corrugator supercilii . 292
Levator palpebræ . *ib.*
Tensor tarsi . . *ib.*
Actions . . 293
Nasal region . . 293
Pyramidalis nasi . *ib.*
Compressor nasi . . 294
Levator labii superioris alæque nasi . *ib.*
Depressor labii superioris alæque nasi . *ib.*
Superior maxillary region *ib.*
Levator labii superioris *ib.*
Levator anguli oris . 295
Zygomatici . . *ib.*
Inferior maxillary region 296
Triangularis oris . *ib.*
Depressor labii inferioris *ib.*
Levator labii inferioris . *ib.*
Intermaxillary region . 227
Buccinator . . *ib.*
Orbicularis oris . *ib.*
Actions . · 298
Temporo-maxillary region—dissection . . *ib.*
Masseter . . 299
Temporalis . 300
Pterygo-maxillary region 301
PAGE
Pterygoideus internus . 301
Pterygoideus externus 302
Actions . . 303
Auricular region . *ib.*
Attollens aurem . . 304
Retrahens aurem . *ib.*
Attrahens aurem . . *ib.*
Orbital region—dissection *ib.*
Rectus superior . . 305
Rectus inferior . *ib.*
Rectus internus . . *ib.*
Rectus externus . *ib.*
Obliquus superior . *ib.*
Obliquus inferior . 306
Actions . . *ib.*
Of the neck—dissection . . 307
Superficial cervical region 309
Platysma myoides . . *ib.*
Sterno-cleido-mastoideus 310
Actions . . 311
Submaxillary region . . *ib.*
Digastricus . . *ib.*
Stylo-hyoideus . . 312
Stylo-glossus . . *ib.*
Stylo-pharyngeus . . 313
Actions . . *ib.*
Genio-hyoid region . . 314
Mylo-hyoideus . . *ib.*
Genio-hyoideus . . *ib.*
Hyo-glossus . . *ib.*
Genio-hyo-glossus . . 315
Lingualis . . *ib.*
Actions . . . *ib.*
Sterno-hyoid region . 316
Sterno-hyoideus , . *ib.*
Sterno-thyroideus . *ib.*
Thyro-hyoideus . . *ib.*
Crico-thyroideus . . 317
Omo-hyoideus . . *ib.*
Actions . . . *ib.*
Vertebral region (lateral) 318
Scalenus anticus . *ib.*
Scalenus posticus . . *ib.*
Actions . . 319
Vertebral region (anterior) *ib.*
Rectus capitis anticus major *ib.*
Rectus capitis anticus minor *ib.*
Rectus lateralis . . *ib.*
Longus colli . . 320
Actions . . . *ib.*
Pharyngeal region—dissection 321
Constrictor inferior . 322
Constrictor medius . . *ib.*
Constrictor superior . *ib.*
Actions . . . 323
Palatal region—dissection 324
Levator palati . . 325
Circumflexus palati . *ib.*
Azygos uvulæ . . *ib.*
Palato-glossus . 326
Palato-pharyngeus . . *ib.*
Actions . . *ib.*
Laryngeal region—dissection *ib.*

PAGE
Crico-arytænoidei postici . 327
Crico-arytænoidei laterales ib.
Thyro-arytænoidei . ib.
Arytænoideus . . ib.
Actions . . 328
Of the back . . . ib.
Dissection . . 329
First layer :
Trapezius . . . ib.
Latissimus dorsi . 331
Actions . . . 332
Second layer :
Rhomboideus minor . 334
Rhomboideus major . ib.
Levator anguli scapulæ . 335
Third layer :
Serratus posticus superior ib.
Serratus posticus inferior . 336
Splenius colli . . ib.
Splenius capitis . . 337
Actions . . ib.
Fourth layer . . . 338
Sacro-lumbalis . . 339
Cervicalis ascendens . ib.
Longissimus dorsi . 340
Transversalis colli . . ib.
Trachelo-mastoideus . 341
Spinalis dorsi . . ib.
Complexus . . ib.
Fifth layer :
Semi-spinalis colli . . 342
Semi-spinalis dorsi . ib.
Rectus capitis posticus major . . . 343
Rectus capitis posticus minor . . . ib.
Obliquus capitis inferior . ib.
Obliquus capitis superior ib.
Inter-spinales . . ib.
Supra-spinales . . 344
Inter-transversales . . ib.
Multifidus spinæ . ib.
Combined actions . 345
Of the upper extremity—dissection . . . 346
Thoracic region (anterior) . 348
Pectoralis major . ib.
Pectoralis minor . . 349
Subclavius . . 350
Thoracic region (lateral) . ib.
Serratus magnus. . ib.
Combined actions . 351
Acromial region . . ib.
Deltoid . . . ib.
Scapular region (posterior) 352
Supra-spinatus . . ib.
Infra-spinatus . . ib.
Teres minor . . 353
Teres major . . ib.
Scapular region (anterior) ib.
Subscapularis . . 354
Actions . . . ib.
Humeral region (anterior) 355
PAGE
Coraco-brachialis . 355
Biceps flexor cubiti . 356
Brachialis anticus . ib.
Combined actions . 357
Humeral region (posterior)
Triceps extensor cubiti . ib.
Actions . . 358
Of the fore-arm :
Brachial region (inner and anterior) . . . 359
Superficial—dissection . ib.
Pronator radii teres . 360
Flexor carpi radialis . ib.
Palmaris longus . . 361
Flexor carpi ulnaris . ib.
Flexor digitorum sublimis ib.
Deep-seated—dissection . 362
Flexor digitorum profundus . . ib.
Flexor pollicis longus 363
Pronator quadratus . 364
Combined actions . ib.
Radial region—dissection . ib.
Supinator radii longus . 365
Extensor carpi radialis longior . . . ib.
Extensor carpi radialis brevior . . . 366
Combined actions . ib.
Brachial region (posterior and superficial) . . ib.
Dissection . . ib.
Anconeas . . 367
Extensor communis digitorum . . . ib.
Extensor digiti minimi . 368
Extensor carpi ulnaris ib.
Brachial region (deep, posterior) . . . ib.
Dissection . . ib.
Extensor ossis metacarpi pollicis . . . 369
Extensor primi internodii ib.
Extensor secundi internodii ib.
Extensor indicis . . 370
Supinator radii brevis . ib.
Combined actions . ib.
Of the hand—dissection . 371
External palmar region . 372
Adductor pollicis . ib.
Opponens pollicis . . ib.
Flexor brevis pollicis . ib.
Adductor pollicis . . 373
Combined actions . ib.
Internal palmar region . ib.
Palmaris brevis . 374
Abductor digiti minimi ib.
Flexor brevis digiti minimi ib.
Adductor digiti minimi . ib.
Middle palmar region . . 375
Lumbricales . . ib.
Inter-ossei (dorsal) . . ib.
Abductor indicis . ib.

PAGE
Inter-ossei (palmar) . 376
Actions . . . ib.
Abdominal region . ib.
Dissection . . 377
Obliquus externus abdominis 378
Obliquus internus . . 379
Cremaster . . 380
Transversalis abdominis . 381
Dissection . . ib.
Rectus abdominis . . 383
Pyramidalis . . 384
Quadratus lumborum . ib.
Actions . . 385
Costal region . . 386
Intercostales externi . ib.
Intercostales interni . 387
Levatores costarum . ib.
Triangularis sterni . ib.
Actions . . ib.
Diaphragma . . 388
Actions . . 390
Perinæal region . . 391
Dissection . . ib.
Erector penis . . 393
Accelerator urinæ . ib.
Transversus perinæi . 394
Compressor urethræ . 395
Compressor venæ dorsalis penis ib.
Erector clitoridis . 396
Constrictor vaginæ . . ib.
Sphincter ani externus . 397
Sphincter ani internus . ib.
Levator ani . . ib.
Coccygeus . . 398
Actions . ib.
Of the inferior extremity :
Iliac region . . . 399
Psoas magnus . . ib.
Psoas parvus . . 400
Iliacus . . . ib.
Combined actions . 401
Glutæal region . . ib.
Dissection . . ib.
Glutæus maximus . 402
Glutæus medius . . 403
Glutæus minimus . 404
Actions . . . 405
Pyriformis . . ib.
Gemelli . . . 406
Obturator internus . ib.
Quadratus femoris . . 407
Obturator externus . 408
Actions . . ib.
Anterior femoral region . 409
Dissection . . ib.
Tensor vaginæ femoris . 410
Actions . . 411
Sartorius . . . ib.
Rectus femoris . . 412
Triceps extensor cruris . ib.
Vastus externus . 413
Vastus internus . . ib.
Cruræus . . . ib.

PAGE
Actions . . 414
Internal femoral region . ib.
Dissection . . ib.
Gracilis . . 415
Pectineus . . 416
Adductor longus . ib.
Adductor brevis . . 417
Adductor magnus . ib.
Actions . . . 418
Posterior femoral region . 419
Dissection . . ib.
Biceps femoris . 420
Semi-tendinosus . . ib.
Semi-membranosus . 421
Combined actions . ib.
Of the leg . . . 422
Anterior tibio-fibular region . ib.
Dissection . . ib.
Tibialis anticus . . 423
Extensor proprius pollicis ib.
Extensor digitorum longus . 424
Peroneus tertius . 425
Extensor brevis digitorum ib.
Actions . . . ib.
Peroneus longus . 426
Peroneus brevis . . 427
Actions . . ib.
Posterior tibio-fibular region 428
Dissection . . ib.
Gastrocnemius . . ib.
Soleus . . . 429
Plantaris . . . 430
Popliteus . . 431
Actions . . . 432
Flexor longus digitorum pedis ib.
Flexor longus pollicis pedis 433
Tibialis posticus . . 434
Actions . . 435
Of the foot . . . ib.
Abductor pollicis . 437
Flexor brevis digitorum . ib.
Abductor digiti minimi . 438
Flexor accessorius . . ib.
Lumbricales . . 439
Flexor brevis pollicis . ib.
Adductor pollicis pedis . 440
Transversus pedis . . ib.
Flexor brevis digiti minimi 441
Inter-ossei . . . ib.
Actions . . 442
Direction to the student . . 443
Table of muscles in the order of dissection . . . ib.
Table of muscles in the order of their actions . . 446

CHAPTER V.

Fasciæ—cervical fascia . 449
Fascia of the arm . . 451
Fascia of the fore-arm . ib.
Fascia lata . . . 452

PAGE
Foramen saphenum . 455
Fascia of the leg . . 456
Fasciæ of the foot . . 457
Fasciæ of the abdomen . . 460
Surgical anatomy of inguinal hernia . . . . . *ib.*
Inguinal canal . . 464
Surgical anatomy of crural hernia 467
Fascia transversalis . . 469
Fascia iliaca . . 471
Its reflections . *ib.*
Femoral arch—its anatomy 472
Femoral ring . . . 473
Hernia — its different species — their diagnosis . . 474
——— inguinal—taxis . . 475
——————— operation . 476
——————— seat of stricture . 477
——— direct—coverings—operation 478
——— femoral—descent explained *ib.*
——————— taxis . 479
——————— operation . *ib.*
——————— seat of stricture . 480
Surgical anatomy of the perinæum 482
Deep perinæal fascia . . *ib.*
—— its connexion with the urethra . . . 483
Catheter — its introduction considered . . . 484
Lithotomy—as performed by Celsus 485
——————— Johannes Romanus 486
——————— Frère Jacques . *ib.*
——————— Cheselden . . 487
——————— as performed with a scalpel . . . 488
——————— Dupuytren . . 489
Admeasurement of the perinæum 491

CHAPTER VI.

Of the arteries . . 492
Aorta . . . *ib.*
Dissection . . 493
Coronaria dextra . 496
Coronaria sinistra . . *ib.*
Brachio-cephalica . 497
Varieties . . 498
Carotis communis . 502
Carotis externa . . 504
Thyroidea superior . 505
Lingualis . . . 506
Facialis . . *ib.*
Pharyngea ascendens . 508
Occipitalis . . 509
Auricularis posterior . 510
Temporalis . . 511
Maxillaris interna . 512
Varieties . . 515
Operations . . 516
Carotis interna . . 517
PAGE
Ophthalmica . . 518
Communicans posterior . 520
Cerebri anterior . *ib.*
Cerebri media . . *ib.*
Circle of Willis . . 521
Of the upper extremity . . *ib.*
Subclavia . . 522
Vertebralis . . . 524
Thyroidea inferior . 526
Supra-scapularis . . 527
Scapularis posterior . 528
Profunda cervicis . . *ib.*
Mammaria interna . 529
Intercostalis superior . 530
Varieties . . *ib.*
Operation . . *ib.*
Axillaris . . 531
Thoracica suprema . . 533
Thoracica acromialis . *ib.*
Thoracica alaris . . *ib.*
Thoracica longa . 534
Subscapularis . . *ib.*
Circumflexa posterior . 535
Circumflexa anterior . *ib.*
Brachialis . . *ib.*
Profunda superior . . 536
Profunda inferior . 537
Anastomotica . . *ib.*
Varieties . . 538
Operations . . 539
Ulnaris . . . 540
Recurrens anterior . . 541
Recurrens posterior . *ib.*
Inter-ossea . . . 542
Carpales . . 543
Communicans . . *ib.*
Digitales . . *ib.*
Radialis . . . 544
Recurrens . . 545
Superficialis volæ . . *ib.*
Dorsalis carpi radialis . *ib.*
Dorsales pollicis . . 546
Dorsalis indicis . *ib.*
Princeps pollicis . . *ib.*
Aorta thoracica . . 548
Pericardiacæ . . *ib.*
Bronchiales . . *ib.*
Œsophageales . . 549
Intercostales . . *ib.*
Aorta abdominalis . . 550
Cœliaca . . *ib.*
Coronaria ventriculi 551
Hepatica . . 552
Splenica . . 553
Mesenterica superior . 554
Ilio-colica . . 555
Colica dextra . . *ib.*
Colica media . *ib.*
Mesenterica inferior . 556
Colica sinistra . *ib.*
Hæmorrhoidalis superior . *ib.*
Sacra media . . 557
Phrenicæ . . . *ib.*

PAGE
Capsulares . . 558
Renales . . . *ib.*
Spermaticæ . . 559
Lumbales . . . *ib.*
Varieties . . 560
Iliacæ communes . . 562
Dissection . *ib.*
Iliaca interna . . 563
Ilio-lumbalis . 565
Obturatoria . . *ib.*
Glutæa . . 566
Sacra lateralis . . 567
Ischiadica . . 568
Pudica interna . . *ib.*
Hæmorrhoidalis media 571
Vesicales . . *ib.*
Uterinæ . . 572
Vaginalis . . *ib.*
Iliaca externa . . *ib.*
Dissection . . *ib.*
Epigastrica . . 574
Circumflexa ilii . . 575
Operations . 576
Femoralis . . . 578
Dissection . *ib.*
Pudendæ externæ . 582
Epigastrica superficialis 583
Circumflexa ilii superficialis . . . *ib.*
Profunda femoris . *ib.*
Circumflexa externa . 584
Circumflexa interna . 585
Anastomotica . . 586
Varieties . *ib.*
Operations . . 587
Poplitea . . . 588
Dissection . . *ib.*
Musculares . . 589
Articulares . . 590
Tibialis postica . . 591
Dissection . . *ib.*
Peronea . . 592
Operations . . 593
Plantaris interna . 595
Plantaris externa . . 596
Perforantes . . *ib.*
Digitales . . *ib.*
Tibialis antica . 597
Dissection . . *ib.*
Malleolares . . 599
Dorsalis pedis . . 600
Dorsalis pollicis . 601
Anastomoses . . . 602
Ilio-femoral . . *ib.*
Femoro-tibial . . *ib.*
Tibio-tarsal . . 603
Collateral circulation . . *ib.*
Sir A. Cooper's case, "Dissection of an aneurismal limb" 604

CHAPTER VII.

PAGE
Of the veins . . . 605
Division into compartments 606
Vena facialis . . *ib.*
temporalis . . 608
maxillaris interna 609
jugularis externa . *ib.*
jugularis interna . 610
——— of the upper extremity 612
Vena radialis cutanea . *ib.*
ulnaris cutanea . 613
basilica . . *ib.*
mediana . . *ib.*
ulnares profundæ . 614
inter-osseæ . *ib.*
comites radialis . 615
comites brachialis *ib.*
axillaris . . 616
——— of the trunk . *ib.*
Vena subclavia . . *ib.*
vertebralis . 617
intercostalis superior . 618
brachio-cephalica . *ib.*
thyroidea inferior . 619
mammaria interna *ib.*
cava superior . *ib.*
azygos major . . 620
azygos minor . *ib.*
bronchialis . . 621
——— of the spine and cranium *ib.*
Dissection . 622
Venæ dorsi spinales . *ib.*
medulli-spinales . 623
Preparation . . *ib.*
Venæ basis vertebræ . *ib.*
meningo-rachidiennes 624
Cerebral veins . . 625
Vena corporis striati . 626
Venæ Galeni . . *ib.*
cerebelli . *ib.*
Sinus longitudinalis . 627
longitudinalis inferior *ib.*
rectus . . 628
lateralis . *ib.*
occipitalis posterior . *ib.*
circularis . *ib.*
cavernosus . . *ib.*
petrosus superior 629
petrosus inferior . *ib.*
occipitalis anterior *ib.*
Vena ophthalmica . . 630
Venæ ossium cranii . *ib.*
——— of the lower extremity . *ib.*
Vena saphena major . 631
saphena minor . *ib.*
poplitea . . 632
femoralis . . *ib.*
iliaca externa . *ib.*
iliaca interna . 633
iliaca communis . *ib.*
cava inferior . . 634
sacra media . *ib.*
lumbales . . *ib.*

PAGE

Venæ spermaticæ . 635
renales . . ib.
capsulares . ib.
phrenicæ . . ib.
Veins of the liver . . ib.
Vena splenica . . 636
Mesenterica inferior . ib.
Coronaria ventriculi . 637
Mesenterica superior . ib.
Vena portæ . . . ib.
Venæ hepaticæ . . 638
——— of the heart . . ib.
Vena cordis maxima . ib.
media . . ib.
Venæ cordis parvæ . ib.
minimæ . . 639
Of the absorbents . . ib.
Vasa lactea . . . ib.
Thoracic duct . . 640
Vasa lymphatica . . 642
Lymphatics of the abdomen and pelvis . . . 644
——— of the pelvic viscera ib.
——— of the penis . 645
——— of the testis . . ib.
——— of the kidney . ib.
——— of the stomach . 646
——— of the spleen and pancreas . . . ib.
——— of the liver . . ib.
Mesenteric glands . . 647
Lymphatic glands of the abdomen 648
Lymphatics of the lungs . 649
——— of the thymus . ib.
——— of the heart . . 650
——— of the thorax . ib.
——— of the upper extremity 651
Axillary glands . . . 652
Lymphatic vessels and glands of the head and neck . ib.
Right lymphatic duct . . 654

CHAPTER VIII.

Of the viscera . . 655
Organs of digestion . ib.
The mouth . . 656
tongue . . ib.
soft palate . . 658
Salivary glands . ib.
Parotid . . . 659
Submaxillary . 660
Sublingual . . ib.
Pharynx . . ib.
Œsophagus . . 661
The abdomen . . 663
Regions . . . ib.
Contents of the different regions 665
Peritonæum — its general conformation . . 666
Preparation . . ib.
Folds or duplicatures . 667

PAGE

Great omentum . . 667
Small omentum . . 668
Mesentery . . . ib.
Meso-cola . . ib.
Appendices epiploicæ . ib.
Course of the vessels of the different viscera . . 670
Stomach . . . 671
Structure . . 673
Vessels and nerves . 674
Intestinal canal . ib.
Duodenum . . 675
Jejunum and ilium . ib.
Structure . . 676
Vessels and nerves . ib.
Large intestine . . ib.
Cæcum . . 677
Colon . . . ib.
Structure . . 678
Vessels and nerves . 679
Rectum . . ib.
Structure . . 680
Vessels and nerves . 681
Liver . . . ib.
Structure . . 684
Vessels and nerves . 685
Capsule of Glisson . ib.
Gall-bladder . . 688
Spleen . . . 689
Structure . . ib.
Pancreas . . 690
Structure . . 691
The thorax . . ib.
Organs of circulation . . 692
Pericardium . ib.
Heart . . . 693
Structure . . 699
Vessels and nerves . 701
Lungs . . 702
Pleuræ . . . 703
Structure . . 704
Bronchus . . ib.
Structure . . 705
Pulmonary artery and veins 706
Bronchial arteries . 707
Nerves of the lung . ib.
Lymphatics . . ib.
Thymus gland . ib.
Vessels and nerves . 710

Nervous system . . 711
Membranes of the brain and spinal cord . . ib.
Dura mater . . ib.
Falx cerebri . . 712
Tentorium cerebelli . 713
Pia mater . . ib.
Plexus choroides . ib.
Arachnoid membrane . 714
Reflections . . 715
Membrana dentata . 717

Spinal cord . . . ib.
——— dissection of . 718

	PAGE
Medulla oblongata	720
Tractus respiratorius	721
Corpora pyramidalia	*ib.*
Corpora olivaria	*ib.*
Corpora restiformia	722
Brain	723
dissection of	*ib.*
Its lobes and general form	725
Origins of nerves	*ib.*
Base	727
Commissure of the optic nerves	*ib.*
Pituitary gland	728
Corpora albicantia	729
Crura cerebri	*ib.*
Corpus callosum	*ib.*
Lateral ventricles	*ib.*
their cornua	731
Corpora striata	733
Optic thalami	*ib.*
Third ventricle	734
its commissures, &c.	735
CEREBELLUM	*ib.*
Processus vermiformes	736
Processus è cerebello ad testes	*ib.*
Fourth ventricle	737
Corpus dentatum	*ib.*
Cerebral protuberance	*ib.*
Tubercula quadrigemina	738
Fissure of Bichât	*ib.*
Ventricles of the brain	*ib.*
Foramen of Monro	*ib.*
Structure of the brain	739
Formative fibres	*ib.*
Cerebral nerves	742
Olfactory	*ib.*
Optic	744
the commissure	*ib.*
Auditory—portio mollis	746
Motores oculorum	747
Pathetici	748
Abducentes	749
Lingual	*ib.*
Descendens noni	750
Fascial—portio dura	*ib.*
Pes anserinus	752
Glosso-pharyngeal	753
Pneumo-gastric—par vagum	754
its branches	*ib.*
Recurrent nerve	757
Pulmonary plexus	758
Œsophagean plexus	*ib.*
Nervus accessorius	759
Phrenic nerve	*ib.*
DOUBLE-ROOTED NERVES	760
Trigeminus	*ib.*
Casserian ganglion	*ib.*
Ophthalmic nerve	761
Lachrymal	*ib.*
Frontal	762
Nasal	*ib.*
Superior maxillary	763
Inferior maxillary	764
Gustatory	765
Auricular	*ib.*
Dental	766
Cervical nerves	767
Plexus and branches	768
Brachial plexus	770
Nerves of the superior extremity	772
Cutaneous	773
Ulnar	775
Median	777
Radial	779
Intercostal nerves	781
Nerves of the lower extremity	783
Lumbar plexus—branches	*ib.*
Crural	787
Obturator	790
Sacral plexus—branches	792
Pudic nerve	793
Great sciatic	795
Popliteal	797
Plantar nerves	798
Peroneal	799
Anterior tibial	801
SYMPATHETIC NERVES	*ib.*
Cervical ganglia	806
Ophthalmic ganglion	810
Spheno-palatine	*ib.*
Naso-palatine	811
Vidian nerve	812
Otic ganglion	813
Cardiac	814
Cardiac nerves	815
Thoracic ganglia	816
Splanchnic nerves	*ib.*
Abdominal plexus	817
Semi-lunar ganglia	*ib.*
Lumbar ganglia	819
Sacral	820
APPENDAGES OF THE EYE	821
Eye-brows	*ib.*
Eye-lids	*ib.*
Tarsal cartilages	822
Eye-lashes	823
Meibomian glands	*ib.*
Caruncula lachrymalis	824
Lachrymal gland	*ib.*
Lachrymal sac	825
Nasal duct	826
Globe of the eye	*ib.*
Dissection	827
Conjunctiva	828
Sclerotic coat	829
Cornea	830
Ciliary ligament	*ib.*
Choroid membrane	831
Ciliary processes	833
Retina	*ib.*
Iris	834

PAGE

Humours of the eye . 836
Aqueous humour . . *ib.*
Crystalline lens . *ib.*
Vitreous humour . . 838

THE EAR . . . 839
Auricula . . . *ib.*
Muscles of the auricula . 841
Auditory tube . . 842
Membrana tympani . . 843
Tympanum . . *ib.*
Eustachian tube . . 845
Bones of the ear . . *ib.*
Malleus . . . 846
Incus . . . *ib.*
Orbiculare . . . 847
Stapes . . *ib.*
Muscles of the ear . . *ib.*
Internus mallei . *ib.*
Externus mallei . . *ib.*
Laxator tympani minor . *ib.*
Stapedius . . . *ib.*
Labyrinth . . 848
Vestibule . . . *ib.*
Semicircular canals . *ib.*
Cochlea . . . 849
Internal auditory foramen 850
Auditory nerve . . *ib.*
Aqueduct of Fallopius . 851
Vessels of the internal ear . 852

The nose . . . *ib.*
The tongue . . 853
The larynx . . . *ib.*
Thyroid cartilage . 854
Cricoid . . . 855
Artyænoid . . *ib.*
Epiglottis . . . 856
Ligaments of the larynx . 857
Epiglottic gland . . 858
Artyænoid gland . *ib.*
Mucous membrane . . *ib.*
Sexual developement . 859
Thyroid gland . . *ib.*
The urinary organs . . 861
Kidneys . . . 863
Structure . . *ib.*

CHAPTER IX.

PAGE

Vessels and nerves . 863
Supra-renal capsules . . 864
Ureters . . . 865
Bladder . . . *ib.*
Structure . . 868
Ligaments . . 869
Urachus . . 870
Urethra . . . *ib.*
Male organs of generation . 871
Prostate gland . . *ib.*
Penis . . . 872
Corpora cavernosa . . 873
Structure . . 874
Glans . . . 875
Urethra . . *ib.*
Cowper's glands . . 877
Testicles . . . *ib.*
their descent . . *ib.*
Scrotum . . 879
Dartos . . *ib.*
Vessels and nerves . 880
Tunica vaginalis . . 881
Tunica albuginea . 882
Tubuli seminiferi . . 883
Epididymis . . 884
Vas deferens . . *ib.*
Vesiculæ seminales . 885
Ejaculatory ducts . . *ib.*
Vessels and nerves . 886
Female organs of generation . 887
Vulva . . . *ib.*
Mons Veneris . . *ib.*
Hymen . . . *ib.*
Clitoris . . . 888
Vagina . . 889
Uterus . . . *ib.*
Ligaments . . 891
Vessels and nerves . . 892
Developement . . *ib.*
Ovaria . . . 893
Fallopian tubes . *ib.*
Mammæ . . . 894
Tubuli lactiferi . 895
Analogy between the male and female organs . . *ib.*

ELEMENTS OF ANATOMY.

INTRODUCTION.

1. Anatomy, (*ανατομη, dissection; ανατεμνω, to cut up,*) in its original and literal signification, meant dissection, or an artificial separation of parts. It required no more than a scalpel for its execution, and sufficed for all the purposes sought to be attained in the earlier periods of the history of medicine. But as the objects of pursuit became multiplied, the methods of examination were necessarily varied; and several other processes have been from time to time introduced, such as an injection, maceration, desiccation, chemical re-agents, &c. with a view to arrive at a more intimate knowledge of the composition and structure of the different parts of the body. Notwithstanding these changes, the same term is retained, and is allowed by general consent to include within its comprehension not only the means employed, but also the end which is sought to be attained. Hence it is that Anatomy is now considered synonymous with "Science of Organisation;" for it embraces all the varieties of organised bodies, and has for its object the study of their structure and properties, physical as well as vital. A science of such vast extent must necessarily comprise too great a variety of details to be adequately investigated by any single individual. Its progress and improvement up to the present time have been owing to the exertions of different persons devoting themselves each to a particular department of the pursuit; and if we may judge of the future by the past, it is not too much to say, that its further advancement must depend on a similar co-operation, conducted on the principle of the division of labour. Thus, some have applied themselves to the examination of the structure of plants, others to that of animals, whilst those engaged in the study of medicine have confined their attention to that of the human species; which

has given occasion to the formation of three distinct departments, viz. *vegetable*, *animal*, and *human*, anatomy.

2. The anatomy of plants, or Phytotomy, (φυτον, *a plant*, τομη, *cutting*,) has for its object to explain the composition of the vegetable tribes. Animal anatomy, or Zootomy, (ζωον, *an animal*, τομη,) is directed to investigate the structure of the lower animals. It is usually called Comparative Anatomy ; for, whilst treating of the conformation and developement of the different organs and systems in each class and order of animals throughout the series, reference is constantly made to the corresponding parts in the human subject, which is taken as a general standard of comparison. Human anatomy is studied, not merely because it serves to explain the structure of the body, nor because it leads to a knowledge of the uses of its different parts, but because of the light which it sheds on the seat, nature, and causes of disease, — a light without which medicine would be little else than a blind empiricism. Anatomy is included amongst the natural sciences ; so is zoology ; but they differ altogether both in their plan and object : the latter dwells on the external form and characters of animals, and is cultivated for the most part with a view to ascertain, by an examination of the different classes and orders, the characters common to all, as well as those peculiar to each, and thereby to establish a methodical arrangement of them founded on their natural affinities ; the former, on the contrary, seeks to explore their interior, and resolves them into their component parts, in order to arrive at a knowledge of their intimate structure.

An opinion seems to be entertained by some persons, that the study of zoology and comparative anatomy should be considered rather as an amusement than as a philosophical pursuit—as something calculated to employ light minds, or occupy hours of leisure and amusement. A slight examination of the subject, however, would suffice to show that the facts it unfolds are not only interesting in themselves ; but that they are instructive in the highest degree, as they tend to throw considerable light on several obscure points connected with the anatomy of the human body, by affording the means of comparing the composition, arrangement, and properties of its different organs, with the corresponding parts in the lower animals. " The varieties of organisation supply, in the investigation of each organ and its functions

the most important aids of analogy, comparison, contrast, and various combination; the nature of the process receives, at each step, fresh elucidation; and the basis of our physiological principles is rendered broader and deeper, in proportion as our survey of living beings becomes more extensive." Moreover, the study of comparative anatomy forms a useful exercise and discipline to the mind, by requiring a close attention to facts and principles, and the adoption of a clear and methodical arrangement. "This advantage of distributing and classing a vast number of ideas, which belongs in a remarkable degree to natural history, has not yet been so much insisted on as it deserves: it exercises us in that important intellectual operation which may be called method, or orderly distribution, as the exact sciences train the mind to habits of close attention and reasoning. Natural history requires the most precise method or arrangement, as geometry demands the most rigorous reasoning. When this art (if it may be so called) is thoroughly acquired, it may be applied with great advantage to other objects. All discussions that require a classification of facts, all researches that are founded on an orderly distribution of the subject, are conducted on the same principle; and young men who have turned to this science as a matter of amusement, will be surprised to find how much a familiarity with its processes will facilitate the unravelling all complicated subjects." *

3. A single instance will suffice to show the application which may be made of the researches of the comparative anatomists, in elucidating the structure and functions of one of the most complex organs of the human body, viz. that of hearing. It is obvious that the general conformation of organs must have a reference to the more or less perfect developement of the animals to which they belong, being more simple in those of the lower grades, and becoming more complex in proportion as they occupy a higher rank in the scale of animated beings; their structure, too, must bear some relation to the medium in which the animals live, and be influenced by the circumstance of their being inhabitants of the air or of water. When treating of a particular organ, for instance the ear, it may at first sight appear calculated to embarrass the subject with useless details, were we

* Lawrence, "On the Modern History of Comparative Anatomy," p. 29, Cuvier, "Règne Animal," preface, p. 18.

to review its conformation in the different classes of animals; it may be said, that it would be far better to confine our attention to the human ear, about which alone we can feel any interest. But it should be recollected, that if a subject carry within itself any degree of complexity, there is no course more likely to lessen it than that "of proceeding from things more simple to those more compounded;" and if this principle be applied to the subject just alluded to, we shall find, that so far from rendering it more difficult, it will remove from it even the appearance of difficulty. When we examine an organ in its simplest form, we at once ascertain its essential or fundamental constituent; and if we trace it through the different orders of animals, from the lowest to the highest in the series, we can recognise each of the accessory parts which are successively superadded, and assign to them respectively the rank which they fill and the duties they perform.

4. The simplest form of auditory apparatus is a small sac containing a fluid, and enclosing the sentient extremity of the auditory nerve; its exterior envelope is membranous, and presents an aperture which gives entrance to the nerve. In the lobster the sac is surrounded by the shell at every side, save one, where it is closed only by a membrane. Now as the sac is analogous to the vestibule in the higher animals, the openings here indicated may be said to correspond, the one with the meatus auditorius internus, the other with the fenestra ovalis. Within this first investment is placed a vascular membrane, which lines it throughout, and encloses and supports the nerve: this, however, is not expanded to the same extent as the nervous membrane of the eye; still, like the retina, it is in contact with a fluid which bears some analogy to the vitreous humour, for each is enclosed in a membrane which enables it to retain its form, and prevents it from being diffused in the cavity in which it is lodged; and both serve as media of transmission for the appropriate agents of impression. This simple apparatus is covered over by the cranial integuments; and as these exclude all contact with the medium in which the animal lives, the impressions of external objects must be conveyed to the sacculus through the surface of the head generally. The first modification which we observe in the structure of the organ is intended for the improvement of the acoustic or sentient apparatus, and consists in the addition, as it

were, to the sacculus of three semicircular canals, which are prolonged from it like so many diverticula. In some cartilaginous fishes, the organ still consists merely of the fundamental part (the sacculus or vestibule). In the scate and shark, the semicircular canals are added. In the batrachia the developement improves still farther; for in the frog there exists outside the vestibule, a cavity or chamber closed by a membrane, which circumstances assimilate it to the tympanum. In the Saurian reptiles, the first two parts of the labyrinth attain a more complete form, and a rudiment of the third is added, viz. the cochlea, which consists of the same structures as the others, and like them serves to contain a prolongation of the auditory nerve. In birds the vestibule and semicircular canals present nearly the same conformation as in the higher reptiles; the cochlea is still rudimentary; but the tympanum is large, and traversed by an ossiculum called columella; the membrana tympani may be observed at the bottom of a short auditory canal, round which the feathers and external tegument are sometimes folded, so as to represent a rudiment of a concha. In the mammalia, the auditory apparatus attains its complete developement; and as it comprises all those parts found in various degrees of perfection in the lower orders, it may be considered as divisible into four distinct compartments, each intended for a separate office.*

The essential or fundamental part (vestibule).

The accessory apparatus (semicircular canals and cochlea).

The middle chamber and its ossicula, for the transmission of sounds (tympanum).

The external apparatus for collecting and concentrating sound (external ear).

After reviewing in this way the different parts of the organ successively, and after inspecting it as a whole, we may not unaptly compare it to an edifice consisting of several apartments, each fashioned after a particular manner, and intended for a distinct purpose. The external part may be likened to the portals of the edifice, at which the visitors are collected previously to their entry, and after they have been there assembled and arranged, they are led across the ante-chamber by certain conductors stationed there for that purpose; by these the visitors are ushered into the presence-chamber, enclosed within the

* De Blainville, "Principes d'Anatomie Comparée," p. 450.

winding recesses of the labyrinth, and as they are successively introduced, they register on the tablet of the memory, their degrees, their titles, and their properties.

5. The study of human anatomy has been especially pursued by the professors of the healing art, who, on just grounds, consider it as the most secure basis on which they can rest their investigations of the functions of the body in health, and of its derangements in diseases. Were anatomists to confine their attention altogether to the human body, they would doubtless acquire a sufficiently accurate knowledge of the situation, form, connexions, and even composition of its different parts; but though an acquaintance with such details forms a necessary part of the pursuit, it is far from constituting the final object to be aimed at. The natural or healthy actions of the body must be studied as a preliminary step to the knowledge of their morbid conditions; the laws which preside over the formation and developement of living beings must be fully investigated before their functions can be rightly understood; and were we to restrict our views to the examination of any single species (even though it be the most perfect of all), our knowledge would be as inadequate, and our ideas of the laws of the economy as confined, as those of a geographer would be of the extent and resources of a kingdom, were he to limit his inquiries to a single province or department.

6. Human anatomy may be studied in two different conditions of the structures of the body, and so may be directed to two distinct objects. By the one, a knowledge of the healthy condition of parts is sought to be attained; by the other, of their morbid characters; and on this distinction is founded the division of the subject into two sections or departments, viz. *healthy* or *descriptive anatomy*, and *morbid* or *pathological*. The changes of structure induced by disease can only be ascertained by an examination of the body after death; but though a knowledge of these changes is confessedly a matter of importance, it can only be brought into practical application when they are connected with the alteration of functions, or the symptoms which had accompanied them during life. When by repeated and accurate examinations, the different lesions of each organ are fully investigated, and their appropriate symptoms so clearly ascertained that they are made to bear to one another the rela-

tion of sign and thing signified, the diagnosis of diseases may be considered as established on a basis sufficiently extended to warrant us in resting upon it our curative indications.

7. It is a mistake to suppose that the practice of medicine or surgery requires only a trifling knowledge of anatomy, or that a loose and general idea of it will suffice for the proper discharge of our professional duties. The history of surgery at once disproves such a notion, by showing that the fatality attendant on operations has diminished in proportion as anatomy has been more diligently cultivated — (the best proof of an improvement in its practice that can be adduced) ; and the rapid advances that have of late years been made in establishing the pathology and diagnosis of diseases, more especially of those of the cerebro-spinal system, as well as of the lungs and heart, are altogether attributable to the degree of attention which has been paid to that most important department of study, pathological anatomy. The latter position is fully borne out by the great success that has attended the researches of Laënnec, Abercrombie, Lallemand, and many others ; the former may readily be verified by a reference to the history of any of the more important surgical operations. The performance of lithotomy, for instance, once so formidable and so fatal, is now no longer so : it is executed with a degree of facility and success which could scarcely have been expected, if the many difficulties and dangers that beset it be taken into account. The tying of arteries for the cure of aneurisms has also been materially improved ; and the improvements have gone on step by step, in proportion as a more accurate knowledge has been attained of the structure and properties of vessels, and of the anatomy of those parts of the body which are the immediate seat of surgical operations. In the mechanical or dissecting part of these processes we can also recognise a corresponding improvement, as is evident from the greater ease and celerity with which they can be now performed. Operations which at no very distant period occupied an hour, or more, are now executed in a few minutes, and with complete success.

8. It may be asked, Is it a matter of much consequence whether an operation is performed quickly or slowly ? Will a difference of half an hour, or of a quarter, in its duration, influence its ultimate result ? Abundant evidence may be ad-

duced to show that it may, nay, that it has done so in several instances. When a patient has made up his mind to submit to an operation, he does so with a certain degree of consciousness of the risk which he encounters, and of the sufferings he is about to endure. If the operation be executed with great precision and celerity, the degree of suffering during its performance is far less than he had been prepared to expect; and when it is over, it may readily be perceived that confidence and self-congratulation at once take the place of doubt and despondency, and that a sense of security springs up in his mind, which exerts a most beneficial influence on the subsequent progress of the case. Another individual may happen to be placed under different hands, is harassed by a slow and protracted operation, begins to doubt the skill of his surgeon even whilst it is being performed, and to despair of obtaining the relief which he had so anxiously anticipated: even when the operation is completed, and he is replaced in his bed, confidence still forsakes him, for he cannot bring himself to believe that any human being could recover after sufferings so protracted, and after sustaining such a degree of derangement and injury. Those who have been long acquainted with the minutiæ of hospital practice—more especially those who have watched the cases from day to day, and noted their progress, need not be informed of the different results that attend the two classes of cases which are thus contrasted. The one they have seen cheerful and contented, making a gradual and steady progress towards improvement, whilst the others but too often sink irrecoverably, victims to constitutional irritation—to moral depression. They who have had opportunities of making such a comparison need not be told, that on the speedy and judicious performance of an operation depends alike the credit of the surgeon and the safety of the patient; and what motives more powerful can be adduced—what incentives more cogent can be urged, to impel a man of reflecting mind to apply sedulously to that pursuit on which so much depends?

9. Whilst conducting the examination of an organ, or when giving what may be termed its anatomical history, the anatomist (says Béclard)* should consider his subject as divisible into the following heads, and should treat each of them *seriatim et*

* Anatomie Générale, p. 132.

singulatim. 1st, its form and outline—its disposition, as being symmetrical or irregular; 2nd, its situation in reference to contiguous parts; 3rd, the direction of its great diameter, which may be parallel, oblique, or perpendicular, to the axis of the body; 4th, its size; 5th, its physical properties, viz. its degree of density, cohesion, elasticity, colour, &c.; 6th, its anatomical composition and texture, or the arrangement of its integral parts; 7th, its chemical composition; 8th, the fluids or humours which it contains or secretes; 9th, the properties it manifests during life; 10th, its vital action, and the connexion of that action with others; 11th, the varieties dependent on age and sex, or individual peculiarities; 12th, the morbid changes.

10. Some of these topics may appear to belong to the departments of chemistry, physiology, or pathology, rather than to anatomy; still, "none of them should be omitted, as all are necessary to guide the researches of the anatomist." * A correct and intimate knowledge of the structure and composition of each organ is indispensably necessary to the understanding of its functions; an acquaintance with the structure and functions leads, by an easy and natural transition, to the investigation of the lesions of structure and function induced by disease—the only data on which we can establish a correct diagnosis and a rational plan of treatment.

11. The skeleton may be considered as the fundamental part of the living fabric, inasmuch as it gives form and solidity to the whole, and constitutes the substratum, to which the other parts are, as it were, applied. The skeleton is made up of several distinct bones which differ from one another in form and size; we usually commence with the examination of these;—and as they are united together by certain means of connexion, so constructed as to admit of various degrees of motion between the parts, the consideration of the joints or articulations, and of the textures which enter into their formation, in the next place engages attention. The bones, with their ligamentous connexions, constitute together the passive instruments of locomotion; the active agents in progression, as well as in the different efforts required to be performed, being the muscles, which, as the name implies, are the moving powers of the body. Each of these exerts a peculiar action, which in most instances is

Bones.

Ligaments.

Muscles.

* Béclard, p. 132.

perceptible on the slightest inspection; but if any doubt arises, it can at once be removed by a consideration of the direction of its fibres, and of the bearing of the points between which they are stretched. Muscles, however, seldom act singly; two or more usually combine in the performance of each effort, by which some advantages are gained, at the same time that the symmetry of the different parts of the body is preserved. These considerations have suggested to anatomists the idea of dividing the muscles into groups, the division being established by a reference to the manner in which they are associated in their combined actions. Winslow, when reviewing the actions of the muscles of the upper extremity, arranges them under the following heads:

Their combined actions.

1. The actions of the muscles which move the bones of the shoulder on the trunk.
2. The actions of the muscles which move the os humeri on the scapula.
3. The actions of those which move the bones of the fore-arm on the humerus.
4. The actions of the muscles which move the radius on the ulna.
5. The actions of the muscles which move the carpus on the fore-arm.
6. The actions of those which move the fingers.

Bichât coincides with Winslow as to the propriety of studying the combined actions of muscles, but he has adopted a different division and arrangement, which the author has deemed it advisable to follow, as being more simple and easy of comprehension. To the practice of surgery, an accurate knowledge of the actions of muscles is indispensably necessary. It forms the basis of all our remedial means in the reduction of dislocations; in the treatment of fractures, it determines the proper position of parts under various circumstances of accident or injury; and though, within the wide range of the anatomist's study, many subjects present themselves well calculated to awake attention—to excite an interest, there are none more likely to do so than the varied phenomena of muscular action.

12. The muscles, the bones, and all the other constituents

of the body, require support; they must be supplied from some source with the materials of nutrition and growth as well as of reparation, should they become the subjects of accidental injury. These various purposes are fulfilled by the arteries, which convey the necessary supplies; these in the next place claim attention, and require a particular examination, in order to determine with precision their course, direction, and mode of distribution. As the blood conveyed by these tubes is not altogether expended in the functions they are intended to perform, the residue, altered considerably in its properties, passes into a new set of vessels,—the veins, by which it is conveyed back to the heart preparatory to its circulation in the lungs, in which it is aërated. Now, the remote or peripheral extremities of the veins are continuous with the ultimate or capillary terminations of the arteries, the trunk being implanted into the heart; and, as they serve to complete the circle, their distribution is examined after that of the arteries, taking it, however, in the opposite direction, viz. from the branches to the trunks.

Arteries.

Veins.

13. However intimate the connexion between these different structures may be, they are linked together even still more closely by another, which may be considered as superinduced upon them, for the purpose of associating into one harmonised mass all the parts of the body, and of establishing between them a reciprocal dependence and relation. These duties are in a manner delegated to the nervous system, whose ultimate fibrillæ are ramified through all the other textures, whilst their central terminations are blended with the cerebro-spinal mass. The examination of the nerves follows naturally that of the parts to which they communicate the powers of sensation and motion, and of whose nutritive functions they may be said to be the regulators; and this would complete the consideration of the deep-seated parts, if the materials of which the body is composed were allowed to remain fixed and unchanged in the situations in which they are at first deposited. But this is not the case. The component particles of all living structures undergo a slow but constant change; after a temporary sojourn, some parts are taken up and carried back again into the circulating mass, to make way for others which are deposited in their place. A peculiar set of vessels, the absorbents, effect these purposes, and

Nerves.

Absorbents.

are thus made subsidiary to the process of nutrition and growth. Finally, the integuments which enclose these different parts demand a greater or less degree of attention under different circumstances.

When the anatomical description of a particular part of the body is thus completed, when the structures which enter into its composition are successively examined in detail, observing at the same time a strict regard to their mutual relations and bearings, —when, in a word, the student has seen the part built up, as it were, before him, by a process resembling, as nearly as may be, a synthesis, he is naturally prompted to inquire what are the steps by which it may again be resolved into its elements, in order that he may study it for himself; or, in other words, how should he conduct its analysis or dissection? No part of the process should be treated as a matter of indifference. Every one may be turned to account if it be conducted with method. Even the first incision made through the skin may be so directed as to impress on the mind some useful practical facts. In order to illustrate the position last laid down, let us for a moment take as an instance the lower extremity, which has been kept in view whilst making the preceding remarks, and bearing in mind the leading facts which its examination has disclosed, we recollect the course taken by its main artery, the femoral. Now if the knee be somewhat bent, and the limb turned outwards, the direction of that vessel is at once marked out by a line extended to the lower margin of the patella, from a point midway between the anterior superior spinous process of the ilium and the symphysis of the pubes. This position, however, applies only so far as the vessel retains the name femoral, which is for two-thirds of the length of the thigh; for at the junction of the middle with the lower third the vessel changes its name, at the same time that it alters its relation to the bone, and is denominated popliteal. In the upper third of this course the vessel is uncovered by muscle, and is therefore the part most eligible for its compression, or the application of a ligature, whilst in the middle third it is deeply seated, and less favourably circumstanced. Now all these facts, with which every surgeon should be accurately acquainted, may be expressed, if such a phrase be allowable, by the incisions which the dissector is instructed to make, with this additional advantage, that they are the most conve-

Dissection.

nient that can be adopted for prosecuting the different steps of his examination, at the same time that they serve to leave a lasting impression on the mind; for, to use the words of Locke, "constantly repeated ideas cannot be lost."

14. In concluding these introductory remarks, it may not be amiss to point out the best systematic treatises from which information may be obtained on the subject of Anatomy, general as well as descriptive: further on, in different parts of the work, references shall also be given to such detached essays and monographs as it may be advisable for the student to consult.

Béclard, *Elémens d'Anatomie Générale.* Paris, 1823; or, the English edition of this work, translated by Dr. Knox. Edinburgh.

Bichat, *Anatomie Générale, avec des Additions* par Béclard. Paris, 1821.

Craigie, *Elements of General and Pathological Anatomy.* Edinburgh.

De Blainville, *Cours de Physiologie Générale et Comparée.* Paris.

Grainger, (R.D.) *Elements of General Anatomy.* London, 1829.

The treatises of descriptive anatomy are:

Bell (John and Charles), *Anatomy and Physiology of the Human Body,* 3 vols. London, 1826.

Bichât, *Traité d'Anatomie Descriptive,* 5 tom. Paris, 1802.

Boyer, *Traité Complet d'Anatomie,* 4 tom. Paris, 1815.

Cloquet (Hippolite), *Traité d'Anatomie Descriptive,* 2 tom. Paris, 1812; or, the Translation by Dr. Knox.

Cloquet (Jules), *Anatomie de l'Homme,* fol. avec figures lithographiées. Paris, 1824.

Cruveilhier, *Cours d'études Anatomiques.* Paris, 1830.

Fyfe, *Compendium of Anatomy.* Edinburgh, 1826.

Haller, *Opera Omnia.*

Monro, *System of Anatomy,* 3 vols. Edinburgh, 1792.

Portal, *Cours d'Anatomie Médicale,* 5 tom. Paris, 1823.

Soemmering, *De Corporis Humani Fabricâ,* 5 vols.

Winslow, *Anatomical Exposition of the Structure of the Human Body,* 2 vols. 8vo. translated by G. Douglas, M.D. Edinburgh, 1763.

ELEMENTS OF ANATOMY.

CHAPTER I.

15. The human body, considered as the subject of anatomical investigation, may be viewed as a whole made up of several parts, each ministering to distinct purposes, and all more or less necessary to the life and well-being of the individual. As effects cannot follow without causes, or actions be performed without instruments, so, in a fabric at once so complex and delicate as that of Man, many agents or organs must be employed to execute the various functions which are required for the support of the individual and the continuance of the species. These the anatomist studies, either singly or arranged in groups, according to their functions; or he resolves them into their elements, to ascertain their composition and structure. Even on a superficial inspection, an obvious division of the body at once presents itself, viz. into head, trunk, and extremities. The trunk, composed of two compartments, or cavities, encloses several of the more important organs; the inferior and larger cavity, the abdomen, contains the organs of digestion, those engaged in the secretion and excretion of urine, and part of the generative system; whilst in the thorax, or superior one, are placed those of respiration and circulation. The head gives lodgement to the organs of the senses, at the same time that its cavity, by means of its communication with the vertebral canal, encloses the central organs of innervation, viz. the brain and the spinal cord.

16. The trunk and head, in their composition, are symmetrical, being made up of two lateral halves, united along the middle line by a suture, or raphé, the traces of which are more or less perceptible in different parts; and this symmetry is closely maintained in the extremities, or agents of locomotion, which are connected, the one with the upper, the other with the lower part of the body. The external line of junction corre-

sponds with others observable in the interior, and which are the necessary results of the mode in which the body and its different organs are in the first place developed. Thus, the falx cerebri descends from the middle of the arch of the skull, taking the direction of an osseous ridge running along the frontal and occipital bones. Beneath this is the corpus callosum, forming a connecting medium between the cerebral hemispheres, and from which projects the septum lucidum, which bears to the internal cavities of the brain the same relation that the falx does to that of the cranium. The division of the nasal cavity is marked out by the septum narium; that of the mouth by the frœna of the tongue and lips, as well as by the uvula. The division in the thorax is indicated by the mediastinum, and in the heart, by the septum interposed between its cavities. In the abdomen, the only traces of its original division that exist in the adult are the falciform processes, extending from the umbilicus, the one upwards, with the remains of the umbilical vein, the other downwards, with that of the urachus; but in the penis and clitoris, the line is distinctly marked by the septum of the corpora cavernosa, and in the scrotum and perinæum by the raphé.

17. It has been hitherto supposed, that in the original developement and growth of organised bodies, the increase proceeded from the centre towards the circumference. Crystals of different salts, and other masses of unorganised matter, commence with a central nucleus, and increase by depositions upon its outer surface, their form being necessarily determined by the mode in which the deposit takes place. But in organised bodies, the outward form is sketched concurrently with the production of the inner parts, and is completed before many of them have made much progress in their developement. Their form, therefore, is not influenced by the operation of attraction, nor is the aggregation of their particles determined by its laws; for their growth proceeds from the circumference to the centre, which is exactly the reverse of what obtains in bodies acted on exclusively by mere physical agencies. Hence, in outward form, as well as in internal structure, they present the most striking contrasts with those masses of matter which belong to the mineral kingdom. This will be rendered manifest by even a cursory examination.

A mineral production, for instance a crystal, consists of particles of the same kind of matter, united by cohesive attraction. Its composition and specific gravity are fixed; and its size can be increased only by deposits laid on its external surface. Its form depends altogether on the arrangement of its components; hence it is occasionally found to be altered by the influence of various circumstances. A crystal presents several sides, bounded by right lines, meeting so as to form angles of various sizes; and by a little care it may be mechanically divided into layers, parallel with one another, and with some of the lines which bound its surface. Now as the formation of crystals is altogether owing to the deposition of particles of matter arranged according to the laws which regulate their aggregation, it must be obvious that when a crystallised body is once formed, it is quite impossible that any additional particles of the same sort can insinuate themselves between those of the mass previously existing. In order that they should do so, they must be acted on by a force greater than that connecting the particles of the crystal, which cannot be the case, as the power that acts on all is one and the same, viz. attraction. But, if a substance possessing a stronger attraction for one of the constituents of the crystal than they have for one another be made to act upon them, they are separated and dissolved, and the crystalline form is lost. We may, then, consider them as homogeneous bodies in the strictest sense of the word, the composition and specific gravity of their constituent parts being constant and determinate.

When we pass to the examination of organised bodies, we find, even in their external forms, essential differences between them and minerals. The surfaces of vegetables or animals are not bounded by straight lines; we never find in them the polyhedral form. Vegetables present externally a simple curve; animals, at least the higher ones, generally a double curve. Organised bodies cannot be separated into layers, in the same way that minerals can; for, though they present a lamellated arrangement, still the lamellæ cannot be detached or separated without being torn, or probably without causing the death of the body to which they belong. Yet water and some other fluids may be introduced into the meshes of their reticulated texture, without producing any alteration in their form, or inducing any other change except an increase in weight and size. From this it ap-

pears that the parts of organised structures are held together by a force not only superior to that of attraction, but altogether different from it.

The composition of organised bodies is not homogeneous throughout their entire extent, like that of minerals: on the contrary, it differs very considerably in different parts. Thus, phosphate of lime, the chief constituent of bone, could never be mistaken for fibrine, which is the basis of the muscular structure; and even when the integrant particles are identical, their arrangement and mode of distribution may vary considerably. Thus the long and hard bones differ very much in texture from those that are soft and spongy: the muscles of animal life can be easily distinguished from those of organic life. If these obvious facts be considered attentively, we must at once see that such marked differences could not exist if the integrant particles of animal structures were governed merely by the laws of attraction.

Unorganised bodies, such as crystals, commence with a central nucleus, and are enlarged by the deposition of layers on its surfaces. Hence, as the increase proceeds from the centre to the circumference, it may be termed concentric. Organised bodies, I should say those of the animal kingdom, grow and increase by a process the reverse of this. The developement of each part taken singly, and of the whole body taken in its aggregate, begins at the circumference, and thence proceeds towards the centre, so that the outline of each part and of the whole is first sketched, and then their completion is effected by successive depositions, taking place from circumference to centre; hence the process of growth is really eccentric, or the very reverse of what would happen were their components aggregated by attraction. This result is the fruit of modern research;* it has been deduced from an extended and cautious inquiry, and appears to be established by an adequate induction. Thus in the early periods of fœtal existence, as soon as the different textures are distinguishable, each organ and part of the body is in the first instance double, its parts being placed laterally with regard to one another; but as the process of nutrition goes on, they gradually approach and unite, so as to form organs usually termed single, from the circumstance of their having been examined only after

* Serret, "Anatomie Comparée du Cerveau."

their growth has been completed. The process of ossification, for instance, proceeds from the circumference towards the centre. Thus, in the cranial bones, the lateral parts are formed first, and their extension proceeds from the sides, beginning at the prominent points of the parietal and frontal bones, and thence extending to the central line. Each vertebra of the spinal column, and therefore the whole pillar itself, even including the sacrum, is open along its entire length, and appears as if composed of two parts, which finally become soldered together along the median line. The principle of eccentric developement obtains in the muscular system also, the lateral parts commencing earlier than those at the middle line of the body. On the head, the temporal, the masseter, and pterygoid muscles are the first that can be recognised; the zygomatici, the buccinator, and orbiculares come next in order; and lastly, those of the nose. On the thorax, the serrati and intercostals precede the muscles situated in the costo-spinal fossæ, as well as those attached to the sternum; and in the abdominal region, the oblique are formed in the first instance,—the recti and pyramidales, situated along the middle line, subsequently.

The nervous system, in its developement, obeys the same law: the nerves on the sides of the head, trunk, and pelvis are formed independently of the brain and spinal marrow, and their cords and filaments may be distinctly traced, so that the nerves may be said to begin where they have been hitherto thought to terminate, and *vica versâ*. The spinal cord, when just distinguishable, consists of two lamellæ, or bands, separated by a slight interval; these soon unite, at first in front, so as to form a groove, and subsequently at the opposite point, so as to constitute a cylindrical tube which is gradually filled up by a series of lamellæ deposited one within the other, until it is converted into a solid mass of a cylindrical form. The lateral masses of the brain when first deposited are quite distinct from one another; but as the process of growth extends towards the median line, the corpus callosum and the other commissures are produced, which establish a connection between them; and when the union is completed, its line of direction is indicated by the seam (raphé), perceptible along the upper surface of the corpus callosum, and which is found to extend quite through its substance.

18. The human body is made up of fluids and solids, each resolvable into a number of proximate constituents, and these again into ultimate elements. The solids disposed in areolæ and meshes, or formed into tubes, are permeated throughout their entire extent by the fluids, and so they bear to one another the relation of containing and contained parts. The fluids, or humours, may be divided into three sorts :

1. The blood, or central mass, which constantly flows, as it were, in a circle, alternately received into the heart, and propelled from it into all parts of the body.

2. The secreted fluids, which are separated from the blood by the different secerning organs, and are intended either for special purposes in the economy, or to be eliminated from it, viz. saliva, mucus, bile, urine, &c.

3. The fluids brought into the central mass from without ;—these are the product of digestion and absorption ; they are called chyle, and lymph, and are intended to supply the losses sustained by the processes of nutrition and secretion.

So long as life lasts, these fluids are subjected to a constant internal motion, in which we can trace evidences of an uninterrupted separation of old particles, and a correspondent admission of new ones. The form of the body remains the same, though its component parts are subject to perpetual mutation ; and over this ceaseless cycle of change presides that power which altogether suspends the ordinary play of affinities in the first moments of fœtal existence,—modifies and controls them during the succeeding stages of life, and allows them to come into action only when it is withdrawn at death.

19. As these changes necessarily imply that the fluid parts are constantly being converted into solid structures, to maintain their growth and nutrition ; and again, as the particles which had for some time formed part of the solids are taken up by the absorbent vessels, and carried back into the current of the circulation, to make way for the new matter about to be deposited in their stead ; it follows, that the ultimate constituents of the solids and fluids are identical, else this ceaseless conversion of the one into the other could not take place ; the only difference between them being in their mode of composition or aggregation. Thus, the following simple substances are found to exist (not se-

parately, but variously combined,) in animal compounds, viz. carbon, azote, hydrogen, and oxygen, which are the chief ingredients. To these are added some others, but in small proportions, such as phosphorus, sulphur, and iron. Various saline substances, with earthy and alkaline bases, also exist in different proportions: some, for instance, phosphate of lime, being found in considerable quantity; whilst others, such as the muriates of soda and potass, are sparingly diffused through some of the animal fluids. The soft parts are made up of azote, carbon, hydrogen, and oxygen; the hard parts of lime and phosphorus. The proximate animal compounds formed from these are not very numerous: the following enumeration includes all that are sufficiently well characterised and are of general occurrence: gelatine, albumen, fibrine, mucus, picromel, urea, osmazome, resin, sugar, oils, acids. The identity of the ultimate constituents of these substances will at once appear from the following tabular view, which it is unnecessary to extend beyond the first three.

	Carbon.	Hydrogen.	Oxygen.	Azote.
Gelatine consists of .	47·881	7·914	27·207	16·998
Albumen	52·883	7·540	23·872	15·705
Fibrine	53·36	7·021	19·685	19·934

Gelatine, or animal jelly, is an abundant ingredient in several of the solid parts of the body, as is evident from the fact that, by boiling, it can be extracted from skin, membrane, ligament, cartilage, and bone. The solution, on cooling, forms a tremulous mass; and if the aqueous part be dissipated by heat, the remainder becomes brittle, and breaks with a vitreous fracture: this is named animal glue. Gelatine is soluble in pure liquid alkalies, and is not precipitated from them by acids: this latter property distinguishes it from albumen, fibrine, and other animal products, and points out the method of separating it from them: its most active precipitant is tannin, with which it forms an insoluble compound.

Albumen, next to gelatine, is the most abundant constituent of animal substances. It is found in a fluid state in the blood, and in several secreted fluids, such as synovia, &c.; it forms a principal basis of some solids, of cellular membrane, skin, and glands. Its appearance is that of a viscid transparent fluid, without taste or smell, which may be coagulated by the action

of heat and of alcohol. The purest form in which we find it is in the white of eggs.

Fibrine forms the basis of the muscular structure, and by ablution with water may be obtained free from all the more soluble parts, except some albumen, which adheres to it. It is insoluble in water or in acids, but is dissolved by the caustic fixed alkalies. Fibrine, when pure, is destitute of taste or smell, of a pale colour, elastic, and divisible into filaments. It is obtained in considerable quantity from the crassamentum of blood, and may be recognised also in chyle.

Mucus is the viscid fluid which lubricates the mouth, nares, œsophagus, alimentary canal, and all the tubes and ducts which convey excrementitious fluids, or which open into the primæ viæ. It exists rather as an adjunct than an ingredient in some healthy secretions, such as saliva, bile, and urine, and is found in some accidental fluids, particularly in that effused in dropsies. Mucus does not exhibit either an acid or alkaline reaction. When exposed to the air, it dries, and presents the appearance of a thin pellicle. Heat does not coagulate it, by which circumstance it is distinguishable from albumen; it is not precipitated by tannin, but is thrown down by acetate of lead. It consists of water, holding in solution soda, muriate of soda and of potash, and an animal matter, which by some is called *mucine*, and considered a distinct principle.

For the description and distinguishing characters of the remaining animal compounds, such as urea, osmazome, picromel, acids, and adipose matter, the reader is referred to some of the elementary works on chemistry or physiology, as they more properly belong to these departments.

The quantity of the fluids exceeds considerably that of the solid parts of the body; but it is difficult to ascertain exactly their relative proportion, as it varies according to age, sex, and constitution. Chaussier obtained what may be considered as a fair approximation, by subjecting a body previously weighed, to destructive distillation,—the result of which was, that the fluids were found to be to the solids as 9 to 1.

20. The proximate constituents of the solid parts of the body, as obtained by what may be termed anatomical analysis, have been variously arranged by different anatomists. Haller contended for the existence of three elementary tissues, each com-

posed of fibres, distinguishable from those of the others by certain essential and characteristic properties, viz. cellular tissue, muscular fibre, and nervous substance. The two latter cannot be considered as elements in the strict acceptation of the term; for when examined with adequate attention, they are found to consist of two constituents—an animal matter composed of cellular tissue, the areolæ of which are filled with fibrine constituting muscle, or neurine forming nervous substance. Cellular tissue, according to its mode of aggregation, forms fibres or lamellæ, which are so disposed as to constitute cells or areolæ. This element, modified in various ways, may be said to form of itself, and directly, the greater number of the structures of the body; and when within its texture are deposited fibrine or neurine, muscular fibre or nervous fibre are the results; but the circumstances which determine the production of the one or the other cannot as yet be assigned.*

Adopting this division of the anatomical elements, we may, with Béclard† and De Blainville,‡ arrange the different textures of the body in the following order:

1. Cellular Tissue, the great pervading element forming the common basis of all the rest, and as such named by De Blainville "tissu générateur." This, variously modified, constitutes *adipose* and *medullary substance, fibrous membrane, tendon* and *ligament, serous* and *synovial membranes*, as well as the *tegumentary membranes*. It forms the animal basis of *bone*, the *coats* of ducts and vessels, and, according to some, even the middle coat of arteries.

2. Muscular Tissue.

3. Nervous Tissue.

CELLULAR TISSUE.

21. In plate 1, fig. 1, that structure is represented to which the name cellular tissue or texture is given. A piece of some size having been selected, it was inflated and partially dried; after which a small portion, free from adipose matter, was detached and placed before the draftsman. Numerous very thin plates

* Edwards, "Mémoire sur la Structure Elémentaire des Principaux Tissus Organiques de l'Homme." Paris, 1823.

† Anatomie Générale, p. 99. ‡ Principes d'Anatomie Comparée, p. 8.

(*a*) will be observed intersecting or impinging on one another, so as to enclose cells of various forms and sizes. Some of these have been laid open (*b*), others still remain closed and distended with air. A single plate, however minute it may be, can, when detached, be torn into fine filaments; hence, according to the way in which we view this as an anatomical constituent, we may say that it is laminated, thready, or filamentous: but if we look to the fact that these are so disposed as to enclose spaces, we may call it areolar or cellular. Hence arises the variety of synonyms applied to it; viz. cellular substance;—cellular membrane, or structure;—cellular system;—mucous web;—areolar, laminated, reticulated, or filamentous tissue. But, however it may be named by writers, it is confessedly the first of the solids which is developed, and that which is most generally diffused. It is made up of pale, elastic, and extremely fine plates or filaments intersecting one another in different ways, so as to form areolæ, or spaces of variable size and figure, and calculated to contain such fluids as may be deposited within them.

The quantity of cellular tissue found in different parts of the body varies considerably. In some regions we trace it in the form of a thin layer lying beneath the skin, and dipping into the interstices between the muscles. It is accumulated in considerable quantity in the flexures of joints, filling up the popliteal space, the axillæ, and surrounding the vessels at the groin. In the cavity of the abdomen a large deposit is found, usually about the kidneys; and in the pelvis a loose spongy web fills up the spaces between the reflections of the serous membrane and the different viscera. It may with propriety be said, that the cellular tissue of each region is continuous with that deposited in the neighbouring parts, and therefore forms a continuous whole throughout the system. The layer which lies beneath the skin in the neck gives off processes which pass inwards between the different muscles; it is prolonged upwards on the face, and downwards on the outside of the chest: moreover, by dipping deeply at the median line behind the sternum, it becomes continuous with that which is placed in the mediastinum, from which it is prolonged beneath the serous membranes. On each side, at the root of the neck, the cellular tissue dips under the clavicles into the axillæ, and so downwards beneath the skin of

the upper extremities. From the lower part of the abdomen (where it forms a dense layer) this structure reaches down upon the thighs on each side, and upon the genital organs and perinæum along the middle line; whilst that contained in the pelvis passes outwards through the interstices which transmit the vessels and muscles, and becomes blended with the deep-seated cellular deposits upon the outside of the cavity and along the lower limbs. The whole body has thus a general investment formed of the texture now under consideration; and moreover, every organ may be said to have a special coating derived from it: so that it may not unaptly be likened to a mould which represents the form of the whole as well as of each of its parts.

When we proceed to examine individual parts or textures, we find that each muscle is enclosed in a lamella, more or less dense, of cellular tissue; so also is each fibre of which the muscle is composed; each artery, vein, and nerve has a tubular coating formed of it; the serous membranes which line the cavities are connected to their walls by it; and where they are reflected over the viscera, the medium of attachment and connexion is still the same. Such is the case also with regard to the tegumentary membranes. The density and firmness of this structure varies considerably in different parts: in some it is thin, smooth, and semi-transparent; in others, loose and spongy, viz. round the kidneys and in the pelvis; whilst in the soles of the feet it is thickened like a cushion, and so elastic as to lessen the jarring impulse of progression. From this general view of the distribution of the cellular tissue, we can readily see why different parts of it have received different names; some taken from their situation,—such as "sub-cutaneous," where it lies under the skin, forming the connexion between it and subjacent parts,—"sub-serous," where it is in relation with a serous membrane, such as the pleura or peritonæum,—and "sub-mucous," where it supports a membrane of that class. In certain situations it forms layers which support or enclose parts, viz. the different fasciæ, superficial and deep-seated, in the neck, limbs, perinæum, &c. to each of which particular attention is paid in conducting dissections, and in examining the structure of different anatomical regions: in short, it may be said that the process of dissection consists in carefully removing the cellular or laminated matter, which is laid upon some parts, as the muscles, like a veil, so as to

obscure or conceal them, and forms a nidus or bedding for others, such as blood-vessels and their branches.

There are three technical phrases occasionally used to express certain circumstances connected with cellular tissue. Where it encases an organ or part, such as a muscle or a gland, it is spoken of as the "investing" cellular tissue (textus cellularis strictus); where it dips into the interior and envelopes the fibres of a muscle, or the lobules of a gland, it is termed "penetrating" (textus cellularis stipatus). Proceeding more deeply into the intimate texture of parts, we find it forming the basis which supports their proximate elements or constituents: here it is called organic or parenchymal (textus cellularis organicus vel parenchymalis). Thus we find that (disposed in minute elongated cellules like tubes) it supports and encloses the calcareous matter of bone, plate 1, fig. 3, f; the fibrine, which forms the proximate element of muscle, fig. 26; the neurine, of nerve, fig. 30; and in the interior of the secreting and other organs it supports the ultimate ramification of their ducts, vessels, and nerves, filling up the interstices between them, and binding all together: a reference to the lobules of the liver will exemplify this, fig. 24; the biliary duct at its ultimate ramification is here shown; if the arterial, venous, and nervous branches be conceived to be laid upon these, they must necessarily leave interstices between their surfaces, as all are cylindrical in form: a fine cellular tissue fills up these, and at the same time binds all the constituents together.

Not a little difference of opinion has prevailed amongst writers as to the intimate anatomical composition of this substance. It was supposed by Mascagni to consist of white vessels, which so far accorded with the views of Boerhaave, who contended that all the textures of the body were made up of packets of tubes, diminishing in size as they increased in number by successive divisions. Ruysch, too, from the minuteness of his injections, inferred it to be vascular. Bordeu, who wrote an essay expressly upon it, maintained it to be a homogeneous, viscid, and tenacious substance *(tissu muqueux)*, without assignable form, and scarcely deserving the name of a solid. Meckel adopts this opinion;—and it may be fairly tenable with regard to several of the lower animals, and to the fœtus at an early period; for in these cases, neither its fibres, laminæ, nor cells are easily per-

ceptible, but they may be rendered apparent by gently drawing apart any two structures between which cellular tissue is deposited. Meckel, however, seeks to explain this away by attributing the effect to the admission of air into its interior, which channels its naturally viscous and homogeneous substance into cells, or stretches it into filaments. Most persons now agree in considering it to be made up of cylindrical filaments, crossing in various ways, so as to form a net-work. The filaments, in most parts, by being aggregated together, constitute lamellæ, enclosing spaces or cells, which present an infinite variety of forms and of size, but which still freely communicate, as is proved by the gravitation of effused fluid in anasarca, and by the diffusion of air all over the body in some cases of emphysema.

The use of the microscope does not furnish us with any additional facts besides those just stated. Some imagine that they recognise in its filaments minute globules disposed in linear series. This, however, appears to be an optical illusion.

As to its physical properties, cellular tissue is very flexible, and therefore does not in any way restrain the movements of parts. It admits of considerable extension ; and when the distending cause is removed, whether it be a tumour or an effused fluid, it will gradually return to its original condition. This is obviously a result of elasticity. Its degree of cohesion varies considerably in different parts.

When considering its vital properties, we ask, Is it sensitive ? Is it contractile ? Formerly, not a few were disposed to answer both questions in the affirmative. It was sensitive according to the views of those who classed all membranous and tendinous structures amongst the most sensitive parts of the system. But any sensibility manifested during experiments on living animals is obviously owing to injuries done to the nerves which it lodges or transmits to contiguous parts. It does, however, become highly sensitive when inflamed. Contractility it does not possess, at least in that sense in which muscles are contractile : any power of retraction which it manifests appears to be an effect of elasticity.

The quantity of fluid contained in the vacuities of cellular tissue varies considerably from time to time : it is therefore the seat of exhalation and absorption. Are there, it will be asked, two sets of vessels, the one to pour out, the other to take up this

fluid? The existence of exhalant and absorbent vessels on the surface of membranes appears to be altogether an assumption, readily taken for granted, and assented to, merely because persons could not conceive by what other means fluids could be effused and then absorbed from the interior of cavities. The existence of such vessels (exhalants terminating upon, and absorbents commencing from free surfaces,) has never been demonstrated: it is therefore unphilosophic to assume it. Moreover, the phenomena can now be easily accounted for by the known properties of membranes. The property of imbibition, as demonstrated by Majendie and Fodera, or that of endosmosis and exosmosis, to use the terms devised by Dutrochet, supplies us with an adequate rationale of the phenomena in question. This shall be stated in the section on serous membranes.

When we inquire concerning the chemical composition of this substance, we find that Fourcroy considered it to be made up of gelatine. It is well known that gelatine can be extracted, by boiling, from membrane, tendon, ligament, and all those structures whose base is cellular tissue; also that it exists in greater abundance in young than in old animals. Mr. Hatchet's experiments lead to the conclusion that albumen forms the basis of this substance, with a variable proportion of gelatine: to these may also be added animal mucus. The ultimate constituents, according to Chevreul, are as follow: oxygen 23·872, hydrogen 7·540, carbon 52·883; azote 18·750. Probably, its power of resisting putrefaction is owing to the small proportion of azote which it contains.

ADIPOSE TISSUE.

The synonyms of adipose tissue are tela adiposa, tissu adipeux, tissu graisseux. Many persons consider adeps as a mere modification of cellular tissue; the only difference being in the nature of the deposit contained in the cells, which in one case is serous or watery, in the other oily. Not a few contend for the existence of vesicles which line the cells of the ordinary cellular tissue wherever fat is deposited, and act as secreting agents in producing it. Distinct adipose vesicles are not very easily demonstrated; their existence is inferred in order to account for certain phenomena. For instance, it is a matter of common observation, that fat, though fluid in some animals, as in the

spermaceti whale, and semifluid in many others, yet does not gravitate; and if a few particles of it be taken from an animal and placed in water, it does not diffuse itself so as to be seen on the surface of the fluid in the form of globules until heat is applied, which bursts the vesicles. Neither do fatty accumulations pit on pressure as dropsical effusions do. All this, it is said, leads to the inference that the deposit is enclosed in proper vesicles, between which no communication exists. Now, in the early stages of fœtal life, adipose matter appears in the form of granules beneath the skin, and in a few internal parts, as about the rectum. In youth its chief seat is beneath the skin; in old age, the limbs become thin, and the adeps accumulates in the omenta, about the abdominal viscera, and even round the heart. Are we then to conclude, that vesicles are produced preparatory to its reception, and that they appear and disappear in particular portions of the ordinary cellular tissue according as the secerning vessels discontinue or assume that action which is necessary to the deposit of fat? De Blainville* examines the matter in this way: He takes a fragment of mutton suet, or of marrow; at a low temperature it is granular, or even crystalline; a few of the granules are carefully detached, and placed on the port-object of a microscope previously warmed:—He observed them to melt without leaving a trace of any special envelope or vesicle. In fig. 2, a small piece of adipose substance is shown: the separate masses, *c*, appear like membranous cells, in every respect similar to those of cellular tissue; the question then arises, are there any distinct vesicles within these? Raspail† states that he can satisfactorily demonstrate the existence of such vesicles enclosing the granules of adeps, and connected with the cellular tissue which surrounds them by a hilus analogous to that which exists in more complex structures.

If a small piece of mutton suet be slowly torn into fragments over a gauze filter placed upon a glass vessel, and water be allowed to trickle upon it, granules of various sizes will be carried down. All extraneous matters will be arrested on the filter, the adipose grains alone passing through: these may be readily collected from the surface of the water in the glass vessel, and subjected to examination under the microscope. Their outline often presents defined facetts so as to give them a polyhedral or

* Cours de Physiologie, Leçon 11. † Chimie Organique, p. 190.

crystalline form; but a more attentive examination, with at the same time due attention to the regulation of the light, will show them to be rounded or slightly oblong. Their size varies in different animals, being greater in the hog than in the sheep or ox. "It may be objected," says Raspail, "that as these particles are as fluid, or nearly so, as oil, they are not really cellules, but drops of oily matter aggregated together. By puncturing one or more of them, it will be found that each is enclosed in its proper vesicle." Though De Blainville denies the existence of any envelope to the adipose granules distinct from the common cellular tissue, he still admits that each consists of a more concrete outer coating with something more fluid in the interior; but he seeks to explain this away by supposing that the two elements of adeps may even in the living state be distinct, the stearine forming the outer, and the oleine the inner part of the adipose granules. This opinion is not likely to be adopted by many.

Adipose tissue may be said to consist (on examining a small mass such as is represented, fig. 2,) 1. of cellular tissue which forms the nidus, or common substratum, the cellules of which, with their membranous walls, are distinctly seen, *c*; 2. of nutrient vessels, *d*, which ramify with extreme minuteness amongst these: 3. in the interior of each cell others are enclosed of still smaller size; and so, perhaps, in the third remove, we get to what may be considered the ultimate vesicle. These included vesicles appear to be attached at one point to the cell which contains them: this Raspail likens to the hilus in more complex structures, fig. 2, *e*. The vessels at their capillary terminations secrete or exhale the adipose matter into the vesicles, and this takes place in considerable quantity in certain states of the system, or under the influence of rest and nutritious diet. In opposite circumstances,—for instance, under privations, or in ill health, or febrile action,—a rapid absorption is observed to be set up. It appears, then, to be deposited as if by an exhalant action beyond the current of the circulation, but still so as to be readily brought back when the wants of the system require it.

The mode of distribution, as well as the appearance, colour, and consistence of adipose matter, vary considerably in different situations. It extends in the form of a layer of variable thickness under the external tegument. It forms masses which fill

the interstices between the parts in the orbits; also in the cheeks, in the flexures of joints, and round the kidneys. In the omentum it is deposited in branching lines or bands following the course of the blood-vessels. We find adipose deposits in the joints under the synovial membranes, particularly where they form folds, or are reflected over interstices between the inequalities of articulating surfaces. We find none immediately under the mucous membranes, nor in certain parts of the external tegument, such as the ear, nose, and eyelids, the prepuce or nymphæ. Neither does any exist in the cerebral cavity; though in the spinal canal a thin layer of soft adipose matter is found between the dura mater and the vertebral canal.

When digested in alcohol, adeps is resolved into two proximate constituents, called by Chevreul stearine (στεαρ fat) and oleine (ελαιον oil); names which express the leading characters of these principles, the former being comparatively solid, the latter fluid. Upon the relative proportions of these depend the different degrees of fluidity or of firmness in the fat of different animals, or of different parts of the same animal. Both are devoid of taste and smell; neither do they manifest acid or alkaline properties. Adeps contains no azote; carbon greatly predominates over its other constituents. In round numbers we may say that it consists of oxygen 9 per cent. hydrogen 11, and carbon 78.

Medulla, or marrow of bone.—The cavities and cells of bones are filled with a substance called marrow, which is most distinct in the canals of long bones, as in the femur and humerus. Its constituents are the same as those of common adeps, their relative proportions varying a little. It consists, according to Berzelius, of pure adipose matter, 96; extract, albumen, jelly, &c. 3; membrane, 1. It is more fluid and of a yellower tinge than fat. The medulla is enclosed within the meshes of a membrane, which forms a tubular lining for the canal within the bone, at the same time that, by means of lamellæ and processes projecting inwards, it forms a number of small cells containing the marrow. It was usual, at one time, to say that this deposit served the purpose of diminishing the fragility of bones, and rendering them more flexible, by permeating their structure. There is, however, no reason to suppose that it comes into direct contact with the earthy matter of the osseous tissue. Its

KING'S COLLEGE HOSPITAL LIBRARY Medical School

obvious purpose seems to be to fill up the cavities and areolæ of bones; and as it is demonstrable that these cavities lighten the bone without diminishing its strength, oily matter, by reason of its moderate specific gravity, is the best fluid that could be selected to fill them. Surgeons have often discussed the question, Is the marrow sensible? Animals, made the subject of experiment, will manifest sensibility or not, according to the point at which the marrow is exposed. If a long bone be sawed across beyond the foramen which transmits the vessels and nerves into the canal, sensibility will be exhibited if the marrow be irritated, for it is still in direct connexion with the central organ of the nervous system; but if the section be made at the proximal side of the foramen, this connexion is cut off, and the medulla will be no longer sensitive.

The existence of the medullary membrane in the interior of long bones may be demonstrated by sawing the shaft across, and exposing it to heat, which will crisp the membrane, and cause its separation in the form of a thin delicate lamella. Towards the extremities of the bones the medullary membrane appears to be continuous, with a similar lining of the different cells; but their extreme tenuity renders it difficult to demonstrate the fact.

FIBROUS TISSUE.

Some of the ancient anatomists included all the white structures under one denomination—nerve (νευρον). Hence, even to this day, a swelling upon a nerve and a tendon is called by the same name, viz. ganglion; though the one is a natural condition, and the other a diseased state. But the nerves, properly so called, were clearly distinguished from the ligamentous and tendinous structures by Praxagoras; and the distinction was followed out by Galen, and maintained by all anatomists since his time.

The fibrous tissue is indiscriminately termed ligamentous,—aponeurotic,—albugineous,—tendinous. It is also sometimes called the white fibrous texture, to distinguish it from the red or muscular. From the number of synonyms here indicated, it must be evident, not only that the structures collected under this head are variously named by different writers, but also that several apparently distinct structures are included within it. However different the objects may be in external form, appearance,

or use, they still agree in being made up of white and shining fibres, either disposed in planes, collected into bundles, or formed into tubes. Their colour is not uniform, being in some parts not unlike that of mother-of-pearl, in others white, with a slight yellow tinge. Being a modification of cellular tissue, which is proved by long-continued maceration in water, or by the action of dilute acids, its ultimate constituents are necessarily the same. Firmness and power of resistance are the best-marked properties of the fibrous tissue; hence the term "tissu scléreux," (σκληρος, hard, firm). It does not contract when irritated, and retracts but very little when divided. In its natural state it manifests no animal sensibility, but becomes highly sensitive when inflamed or greatly stretched, as happens in dislocations. It strongly resists any sudden distending force, (intense pain speedily following from the pressure it suffers,) but gives way to a slow, gradual distension, and again returns to its original condition when the cause is removed. This is observed in cases of effusions into joints or beneath investing membranes. The vessels of supply are very few; the pericardium and the dura mater receive a greater number than any other white fibrous structures; nerves and lymphatics have been found to terminate in scarcely any of them.

Bichât, when examining the fibrous tissues, adopted from some of the ancient anatomists the notion that they were not only connected together, but had a common centre from which they are all derived, just as the different parts of the vascular and nervous systems are said to be derived from the heart and the brain. This centre he located in the periosteum, which must be allowed to be a sufficiently extended one. There are no adequate reasons for attempting thus to centralise the different fibrous structures; for little, if any, sympathy or functional connexion exists between them: they do not even form a continuous whole, some of them being totally detached and insulated from the rest.

The arrangement of the fibres presents numerous varieties, for the organs they make up are calculated to serve many purposes, and therefore present several modifications. In reference to their form, however, all may be classed under two heads, viz. first, those which are broad, thin, and expanded into membranes; second, those whose length much exceeds their breadth,

in consequence of the fibres being aggregated into bundles or fasciculi.

Fibrous membranes. — These consist of a number of fibres running parallel in their whole length, and at the same time intersected and crossed by others in such a way as to form a close firm web. In some instances they expand so as to embrace a whole limb, like a band or sheath, and therefore receive the name *fascia:* hence have arisen the terms fascia lata of the thigh, fascia of the leg, fascia of the arm and fore-arm, cervical fascia, &c. Fibrous membranes also form special investments for many important organs, viz. the dura mater which surrounds the brain and spinal cord, the sclerotic coat of the eye, the external layer of the pericardium, the tunica albuginea of the testis. To these should also be added the capsular ligaments of joints, and those broad membranes which bind down or support parts, viz. the temporal fascia, the perinæal and obturator fasciæ.

Aponeuroses, in their general conformation, as well as in structure, resemble fibrous membranes; they are merely somewhat thicker, and their fibres more strongly marked. The term aponeurosis is now applied to an expanded fibrous lamella, which forms a continuation of a broad flat muscle, and serves as the means of attachment for its fibres; for instance, the aponeuroses of the oblique and transverse muscles of the abdomen, and of the latissimus dorsi. The crossing and interweaving of the fibres are obvious in all these examples, even on the most cursory inspection.

Periosteum (*περι* about, *οστεον* bone), as its name implies, is the immediate investment of bone, with which it maintains important relations. Plate 1, fig. 3, a small piece of the membrane *g*, which invests the bone *f*, is here represented as detached from it and thrown down; it is drawn from a preparation of the parts as they are seen suspended in a bottle. Having the same general shape as the bone with which it is in contact, it is intimately connected with the osseous structure by means of the nutrient vessels which pass through it, conveying materials of supply, and also by delicate filaments which accompany them. Its outer surface is rough and flocculent, by reason of the numerous connexions which it maintains, and the many points of attachment it affords to tendons, muscular fibres, &c. It is made up of dense, firm, pale, fibres; its thickness varies in different parts and at differ-

ent periods of life, being at first very thin and with little appearance of vascularity; but as ossification proceeds it becomes thick and vascular. The periosteum invests the bones throughout their entire extent, except at their articulating extremities; but though its continuity is interrupted at the movable articulations, the membrane passes over the immovable ones, and assists in maintaining the connexion between their parts. Its uses are various, as it not only forms an investment for the osseous structure, but also serves to transmit and support their nutrient vessels; it gives attachment to tendons, ligaments, and muscles, and so forms their bond or medium of attachment to the bones; and in infancy, before ossification is complete, maintains the epiphyses in connexion with the bodies of bones. The structure and general conformation of periosteum are readily exhibited after a bone has been for some time steeped in water, when the membrane can be detached, and with it the tendons, showing that it is the medium by which they are connected with the bone.

Perichondrium.—The investing membrane of cartilage is called perichondrium (περι about, χονδρος cartilage); its structure, uses, and general properties are similar to those of periosteum, the only difference being, that it is thinner and less vascular.

Compound fibrous membrane.—Fibrous membrane is often united with lamellæ of a different tissue, so as to form a compound structure. The fibrous periosteum of the palate and gums, of the nasal fossæ, and of the different sinuses which communicate with them, is connected with the mucous membrane which lines all these cavities, and is therefore usually described as a *fibro-mucous* structure. Again, the pericardium, the dura-mater, and the fibrous capsule (albuginea) of the testis, are termed *fibro-serous*, inasmuch as each of them is united with a serous membrane.

Tendon (τεινω to extend) is the most ordinary sort of fibrous adjunct to muscle, serving as the means by which it is prolonged and fixed to its points of attachment. Tendons present many varieties of form, some being narrow and cord-like, as we see in those which stretch along the wrist and ankle to reach the fingers and toes, where, by sliding over pulley-like surfaces, they take a new direction, and so modify the lines of action of their

respective muscles. In other parts we find them compressed and strap-shaped in the middle, and expanded at one or both extremities. The tendo Achillis is convex on its cutaneous surface, and flat at the other, its fibres spreading out considerably where they run into those of the muscle; the tendon of the plantaris is very narrow and thin, but may be easily spread out to ten times its natural breadth; its borders will then resemble a piece of chamois leather after being stretched, and scarcely a trace of fibre will remain in its structure, so smooth and even does it become.

Fibrous sheaths (thecæ) are tubes or canals which confine tendons to their proper positions. They are well marked at the palmar aspect of the fingers and toes, where they guide the flexor tendons to their destinations; their margins are attached along the borders of the bones, and their inner side lined by synovial membranes, as a protection against the effects of friction. A similar provision occurs where the tendons curve behind the ankles to reach the foot.

Ligaments (ligamenta, λειγω to bind) form the chief means by which the numerous pieces of the osseous system are bound together, so as to constitute one whole—the skeleton. Their form and size must vary considerably in different parts, some being flat bands, some rounded cords, and others short but wide tubes, attached at both ends to bones which admit of free movement upon one another, as we see in the capsular ligaments of the hip and the shoulder. Viewing ligaments in this way, we may divide them into two groups, the funicular or cord-like, and the capsular; they are also called, from a mere consideration of their position in relation to their respective joints, anterior and posterior, internal and external, lateral. Most ligaments enter into the formation of joints, and are therefore articular; some, however, merely fill up spaces, as the inter-osseous ligaments in the fore-arm and leg; or connect parts between which no motion exists, at the same time that they diminish vacuities, of which the sacro-sciatic, and the two proper ligaments of the scapula, furnish examples. The term "false ligament," is frequently applied to certain folds of serous and synovial membranes, from their being supposed to confine the parts to which they are attached. The broad processes of peritonæum extended from the bladder and uterus to the sides of the pelvis, also the

so-called ligamentum mucosum in the knee-joint, may be cited as instances: the expression is obviously ill-chosen, and should be discontinued.

Fibro-cartilage, as the name implies, is a structure intermediate between fibrous tissue and cartilage, and partakes of the qualities of both, viz. firmness and elasticity. Being calculated to serve different purposes in the economy, it presents not a few varieties both of appearance and structure. Thus, we find it in the form of broad thin plates in the pieces of the larynx and epiglottis, in the pinna of the ear, in the lateral and median cartilages of the nose, and in the tarsal cartilages of the eye-lids; for in these parts it forms their basis of support, and determines their form; whilst in the trachea it consists of narrow plates curved round the tube, forming a series of rings. In the immovable articulations, fibro-cartilage is interposed between the contiguous surfaces of bones, in layers of various forms and thickness, constituting in some instances the principal means of connecting them together, as we see at the junction of the ossa pubis, and also of the bodies of the vertebræ, in which instances the elastic property is of considerable utility. In some of the movable articulations, pieces of this structure are also placed, their form and size necessarily varying in each instance. In the knee-joint,—in the articulation of the lower jaw-bone, and in that of the clavicle with the sternum, they diminish the effects of jarring motions by their elasticity; and by a certain degree of mobility, which allows them to give way as the bones move upon them, they keep up a perfect adaptation between the parts, notwithstanding the many inequalities of their surfaces. In the hip and shoulder-joints they are so disposed as to deepen the articulating cavities, and lessen the liability to dislocation.

Cartilage (cartilago, tissu cartilagineux, χονδρος) is much more dense and solid than any of the preceding textures; it is highly elastic, and by its resiliency resumes its original position when any compressing force to which it may be exposed, is removed. Its colour is in general a silvery white, and not unfrequently presents that of mother-of-pearl; its density is such, that all trace of its cellular nature, or of its being a modification of cellular tissue, is lost. Mr. Hatchett considers its chemical composition to be albumen, and a small quantity of phosphate of lime. It contains a considerable quantity of water, conse-

quently soon dries on exposure to the air, becomes yellow, semi-transparent, and loses its elasticity; it resists maceration, and the action of cold water, for a long time, but is soon acted on by acids, or by boiling water, and converted into a gelatinous pulp.

Cartilage serves as an adjunct to bone, or a substitute for it. In early infancy the different pieces of the skeleton are cartilaginous; but in the progress of growth, bone becomes deposited in their place, and gradually supplants them altogether; such cartilages are termed *temporary*. The articulating extremities of bones are covered with layers of cartilage, not merely to smoothen them, but also, by their elasticity, to lessen the effects of concussion. The thickness of these layers varies from half a line, or even less, to two lines; it will generally be found greatest along the margins of concave surfaces, and towards the centre of those which are convex. The free surface of each articular cartilage is covered by the synovial membrane of the joint, from which it is impossible to separate it; the attached surface is in equally intimate union with the bone on which it rests.

The *costal* cartilages form so many elastic prolongations of the ribs, serving not merely to complete the arch from the spine to the sternum, but also, by means of their elasticity, to restore the ribs to their original position, after having been elevated by the effort of inspiration.

Elastic fibrous tissue (tissu jaune élastique—tissu fibreux jaune,—ligamenta flava—subflava) consists of pale yellow fibres placed parallel, whether their general direction is perpendicular or oblique, no decussation or crossing being observed between them; they are easily separable from one another, as but little cellular tissue connects them. As its name implies, elasticity is the chief property of this structure wherever it occurs, being developed to such a degree as to render it well calculated to form suspensory ligaments, or to invest parts which are subject to considerable alternations of distension and contraction. Thus, in quadrupeds a strong band of elastic tissue (ligamentum nuchæ) extends from the spinous processes of the neck, and from some of those of the back to the skull, the weight of which it supports without producing that sense of fatigue which would necessarily arise were muscle the sustaining power. The corresponding structure in man is reduced to a rudimentary state, the balanced position of the head on the spinal column rendering

any further provision unnecessary. The same material enters into the composition of the ligaments which connect the arches of the vertebræ (ligamenta subflava), and also, according to some, into that of the corpora cavernosa. The fibrous investment of the spleen, the ducts of salivary glands, and even the middle coat of arteries, are thought by many to be composed of elastic tissue. The consideration of the latter point must be reserved for the section on arteries.

OSSEOUS SYSTEM.

22. *General description.*—The osseous system (système osseux, ossa, *οστεα*) is peculiarly fitted, by its solidity and hardness, not only to give support to the soft parts, but also to furnish points of attachment to the muscles, by which the different movements are executed. This solid frame-work of the body is made up of a number of separate pieces, the aggregate of which has been termed "*the skeleton.*" It is a favourite opinion with some persons, that bones determine the form of parts, as well as the direction of the body. But we find, that in their developement they just keep pace with that of the soft parts, particularly of the central nervous masses. If these proceed regularly to their completion, so will the arches of the vertebræ, and the bones of the head; but if their growth be retarded or deranged, the bones will not arch inwards, and so the spinal and cranial cavities will remain open. Again, if we descend through the series of animals, the skeleton becomes gradually more simple and rudimentary, until it is reduced to its fundamental part—the spine; and even this may be composed of cartilage, with scarcely a trace of calcareous matter. A few grades lower down in the scale, we find multitudes of animals altogether destitute of a skeleton, either internal or external, so that the muscular structure alone remains as the means of locomotion. Bone is, then, the passive instrument—muscle the active agent: muscle is moreover prior in its appearance and importance in the animal series, bone being secondary in both respects. It may be asked, are we still to persist in drawing such a broad line of distinction as has been hitherto done, between the hard calcareous parts of crustacea and insects, and the osseous system of higher animals, as that the latter alone should be considered to merit the name of skeleton,

whilst the former is treated as a mere shell, or outward tegument? To put the question in a different way, is it more conformable with what we know of the economy of nature—is it more philosophic, to admit, at once and without examination, that these so-called shells or crusts are altogether new organs given to the animals they invest, (and as such, destitute of any analogy with the structures observed in higher grades of beings, and with which we are in general more familiar,) or to scrutinise these different parts attentively, and carefully note the points of similitude, if any, which may exist between them, with a view to determine whether they are not really modifications, or repetitions, of what occurs in other tribes, and so trace out (what analogy goes a great way to establish) a unity of plan throughout the animal series? The researches of Geoffroy Saint-Hilaire and others have thrown much light on this important question. The mere position of parts, whether internal or external, is a matter of little moment; a consideration of their structure, and adaptation to purpose and use, can alone determine whether any correspondence exists between them. The internal skeleton of a vertebrate animal, and the external one of the articulata, appear to be really analogous parts in the economy of these classes of animals, notwithstanding the vast distance which separates them in the scale of being; and the difference, though confessedly a considerable one, which exists between the rachis of a crustaceous animal and that of a fish, reptile, bird, or quadruped, seems to arise from the circumstance that a spinal marrow exists in the one but not in the other, a special conformation of the osseous system being required in each case.

Situation.—The osseous structure is situated deeply, being covered by the soft parts and common integuments; at least, this is the case in the vertebrated animals.

23. The *number* of bones is differently stated by writers, the difference arising from the period of life at which the enumeration is made: in early age the number is greatest, and subsequently diminishes, when, by the process of ossification, two or more previously distinct pieces become united into one. Their *form* and *size* present a considerable degree of variety. They are usually divided into long, short, flat, and mixed.

The *long* or *cylindrical* bones belong in general to the

parts intended for locomotion, and represent so many levers, to be moved by the muscles in various directions. When examined from the superior part to the inferior, viz. from the humerus or femur, to the phalanges of the fingers or toes, they are found to increase successively in number as they diminish in size—a disposition which gives to the superior division of each limb the great extent of motion it enjoys, whilst it allows to the inferior and terminal ones a variety of rapid movements within restricted limits.

Each long bone presents a body, or middle part, and two extremities. The shaft or body is round and cylindrical in some, prismatic in others, but somewhat bent or twisted on its axis, so that the direction of its superior extremity does not exactly correspond with that of the inferior. Whatever difference of outward form may obtain, there is little or none in that of the internal canal; it is circular in the tibia as well as in the femur. This canal is not intended merely to lodge and protect the medulla; it contributes very much to increase the strength of the bone, as has been satisfactorily shown by direct experiment. If two cylinders contain the same quantity of matter, one being solid, the other hollow, the power of resistance of the latter is greater than that of the former, owing to its greater diameter. By this conformation also, bones, without being increased in weight, acquire an adequate degree of lightness, together with sufficient superficial extent to afford a more expanded surface for the attachment of muscles, which are important requisites in what may be considered as the passive organs of locomotion.

The *short* bones are usually situated in parts in which solidity and firmness are required to be combined with freedom of motion; for instance, in the carpus, tarsus, and vertebral column. Their external conformation is necessarily influenced and determined by that of the parts into whose composition they enter, and as they are intended to co-operate in certain common functions, they present a number of articulating surfaces, prominences, and depressions, suited to their mode of adaptation and mutual connexion.

The *flat* or *broad* bones for the most part serve to form the walls of cavities, or to enclose spaces. They present two surfaces, one convex, and the other concave; which conformation,

by giving them an arched form, increases their power of resistance, and affords additional security to the organs they enclose. The bones of the skull and pelvis come under this denomination.

Some are so irregular in their form as not to be referrible to either of these heads. These are situated along the median line, as the occipital, the sphenoid, and ethmoid bones, and the vertebræ.

In addition to these divisions into classes, adopted by all writers, those who treat expressly of descriptive anatomy are obliged to have recourse to others. Thus, in order to facilitate the description of irregular bones, such as the ethmoid, or the sphenoid, they are considered as being divisible into a central part or body, and processes; the anatomical situation of the parts forming the ground of division. In other instances it is supplied by the mode of developement, as of the os innominatum into ilium, ischium, and os pubis. Finally, in some, the division is founded on the situation and relations of their parts, as when the frontal bone is resolved into a frontal, nasal, and orbital portions.

24. The *surfaces* of bones are marked by eminences and depressions adapted to various purposes. The eminences may be ranged under four heads. 1st, those of articulation; 2d, insertion; 3d, impression; 4th, reflection. Those for articulation vary according as they are movable or immovable, and shall be described in the next chapter. Those for insertion are variously adapted for the attachment of muscles, or for tendons and ligaments. They present numerous differences in their degree of projection, according to the sex, age, and muscular developement of each individual. Their form is equally various; some consisting of diffused asperities, others extending along the surface like rough lines, whilst others project more or less from the bone intended not only to give insertion to muscles, but also to serve the purpose of increasing their power of action, by removing their line of direction farther from the axis of the bone.

The eminences of impression are certain prominent lines interposed between depressions on the surfaces of bones. Thus, the shallow pits on the cranial bones corresponding with the convolutions of the brain, and the depressions on the external surface marking the insertion of muscles, are separated by pro-

minent lines, termed eminences of impression. The expression appears not to have been well chosen: it was originally founded on the supposition that the action of contiguous organs, by depressing certain parts of the surface of the bone, served to elevate others; but it is far more comformable to what occurs in other structures, to refer to the laws of nutrition and growth, (by which different parts are mutually adapted to one another,) the inequalities here alluded to, as well as those more prominent points to which muscles are attached. The latter are usually attributed to the action of the muscles drawing them out, and as it were moulding them; but, as Bichât observes, such an opinion, founded on what occurs in soft and inorganic substances, ill accords with the known phenomena of vitality. We observe eminences for the insertion of ligaments, which project more than those which give attachment to muscles; for instance, the spinous process of the ischium: there is, moreover, no proportion between the elongation of different apophyses, and the power of the muscles attached to them, viz. between the styloid process of the temporal bone and its muscles.

The term or phrase "eminence of reflection," is not often used. It expresses a fact which we occasionally observe, viz. that tendons slide upon elevations at the ends of bones, by which their direction is changed. As an instance, we may cite the case of the peronei muscles, and the flexors, which run behind the malleolar projections of the tibia and fibula, by which these tendons take a new direction, and modify the line of traction of their respective muscles.

The prominences on the surface of bones are variously named, according to their form, degree of elevation, and the uses which they serve. When of considerable size they are called *apophyses* (processus, apophysis, *απο* from, *φυμι* to grow). These, in most instances, are appendices to the body or shaft of long bones, in infancy and in early life, when they are called *epiphyses;* but as the process of ossification proceeds to its completion, they become, as it were, soldered to the rest of the bones. The term *tuberosity* (tuber) denotes an eminence, rather broad and rough, but not much projecting; *tubercle* (tuberculum) expresses something still smaller. A process, which is thin and tapering, is called *styloid*, from its resemblance to the Roman writing instrument (stylus). A sharp thin projection is called

spine (spina). But one which runs along like a ridge, is called a *crest* (crista). An apophysis, when rounded, is usually called a *head* (caput), and the constricted part supporting it represents its *neck* (cervix, collum). *Condyle* is a compressed apophysis, which forms part of an articulation.

25. The depressions and cavities on the external surface of bones are divisible into the articular and non-articular. The former shall be treated of in the next chapter; the latter, being very numerous, may be ranged under the following heads. 1st, those for insertion; 2d, for reception; 3d, gliding; 4th, transmission; 5th, nutrition. Those for "insertion" are well adapted for the attachment of muscle, ligament, &c. by increasing the extent of space allotted for that purpose, inasmuch as a concave surface presents a greater extent than a plane one bounded by the same line. Some of these, as the digastric and pterygoid fossæ, by the greater depth at which they allow the muscles to be inserted, increase their power, by permitting an elongation of their fibres.

The bones of the skull and face present several instances of "cavities of reception." Some correspond with the whole extent of a bone, as in the case of the parietal bone. Some occur in a particular part only, as the fossa in the nasal process of the superior maxillary bone, and os unguis for the lachrymal sac.

The depressions for "gliding" are situated about the heads of long bones, being grooves, in which tendons slide, as they pass to their destinations. The formation of these has been attributed to the influence of the mechanical pressure and friction of tendons. But such a rationale is inadmissible; for they are found in subjects paralytic from infancy, and are by no means proportioned in depth to the force of the muscular exertion which bears upon them. The different configuration of bones should rather be considered as the result of the laws of ossification which preside over the growth and developement of the osseous system, and by which its different parts are adapted to their appropriate purposes.

The cavities for "transmission" give passage to vessels and nerves; their form is various, some being mere fissures, others tubular, &c.; to this head are referrible most of the apertures at the base of the skull.

The foramina of "nutrition" transmit the vessels intended for

the support of the substance of the bones and of the medulla; they are divisible into three orders. The first usually receive the name of foramina of nutrition, though in strictness it does not belong to them more than to the others, the only difference between them being, that they transmit vessels to supply the medullary membrane, whilst the others give passage to those which are distributed to the substance of the bone. The first set, considerably the largest, are situated towards the middle of the long bones, and penetrate their substance in an oblique direction. The second order of foramina are much smaller, but very numerous; they are most perceptible towards the extremities of long bones, and generally all over the surface of the short and thick ones. But the third are so minute as to be perceptible only by the aid of a glass, by which we can discern them all over the surface.

The depressions and cavities in bones differ so much in form, size, and use, that it has been deemed necessary to devise certain terms to mark these differences. A deep pit which receives the globular head of a bone, is called a *cotyloid*, or cup-shaped cavity (κοτυλη a cup), or an *acetabulum* (an ancient cup or measure), *ex. gr.* the socket which receives the head of the thigh-bone. If shallow and superficial, it is said to be *glenoid* (γληνη a shallow pit); the articular surface of the scapula upon which the head of the humerus plays, is an instance. A large hollow or cavity in the interior of a bone, is termed a *cave* (antrum), such as that seen in the upper maxillary bone; when of a size smaller it is known as a *hollow* (sinus), as in the body of the sphenoid bone; and if still smaller, as a *cell* (cellula), as in the orbital process of the palate bone. A small depression is a fovea or fossa. The meaning of the terms canal (canalis), fissure (fissura), notch (incisura), and groove (sulcus), is sufficiently obvious.

Structure.—The proper structure of bone is fibrous in its character; the fibres, in some parts, by being closely aggregated together, constitute a firm and compact substance; but in others they lie so far apart as to enclose spaces or cells, on which depends the porous and spongy appearance of some bones.

The compact substance is so close in its texture, that the naked eye can discover no interstices in it; yet by the aid of a microscope a great number of minute vascular canals become

perceptible. In the long bones, these canals are all longitudinal, and maintain a communication laterally with the great medullary canal, and externally with the vessels on the surface of the bone.

The spongy or cellular part presents a multitude of spaces, of various forms and size, all of which communicate with one another, as may be proved by the following experiment; if the end of a long bone, or the surface of a flat one, be perforated, and some mercury poured in, it will be found not only to descend through the cells, but also to flow out through the vascular foramina on the surface. The interior of flat and short bones, then, does not differ so decidedly from that of cylindrical ones, as would at first sight appear. Each presents a cavity, which, at least in the one towards its centre, is a hollow tube, but in the other is divided, by a number of intersecting laminæ, into minute spaces communicating freely with one another.

Some peculiarities are observable in the arrangement of the compact and cellular structure in the different classes of bones. The body of long bones consists chiefly of compact substance, but the inner side of the tube is rendered rough by projecting filaments and lamellæ; towards their extremities, the compact substance is gradually reduced to a thin lamella, or layer, encasing the bone, the interior of which consists altogether of cells communicating freely with the central cavity.

The two surfaces of the broad and flat bones are compact in their texture, the interval between them being made up of areolar or spongy substance. This is usually called *diploé*. In its original acceptation the term diploe (διπλοος double) was applied to the two plates or tables of the cranial bones, together with the intervening cellular structure; subsequently it was restricted to the latter part alone; but it is now commonly extended to the loose tissue of all broad and flat bones. The internal table of the cranial bones is more dense than the external, and, from being also more thin and brittle, it is called *vitreous* (tabula vitrea). The short bones are made up for the most part of spongy substance, encased by a thin lamella of compact tissue. These differences arise altogether from the mode of aggregation and arrangement of the osseous particles; for, on examination, the composition of both is found to be the same, being made up of the same elements, viz. a cellular base, in the areolæ of which is deposited a peculiar earthy salt.

These constituents may be separated, so that each may be examined by itself. If a bone be macerated for some days in a dilute acid, the saline, or inorganic part is removed, whilst the organic remains; the bone is thus rendered soft and flexible, but retains its form, its weight being diminished in proportion to the quantity of saline matter taken up by the acid: when reduced to this state, it presents no appearance of any particular arrangement of fibres, but by a continued maceration in water it may be resolved into layers, each of which will be found to consist of a series of fibres aggregated together. If the process be still continued, the fibres become swollen and softened, and present an areolar texture, analogous to that of cellular tissue in other parts of the body. This then may be considered as forming the nidus for the deposition of that inorganic substance on which the solidity and firmness of bone depend. If a cylindrical bone be examined in this way, its central portion is found to consist of several laminæ, super-imposed one on the other: the external one is continuous throughout its whole extent, forming its general envelope; but those subjacent to it, as they pass from the centre, become gradually thinner, and turn inwards towards the axis of the bone, becoming continuous with the lamellæ which divide it into areolæ or cells (cancelli, lattice-work). In the flat and irregular bones, the compact structure which encloses them externally sends off filaments and plates to divide their interior into cells.

26. By long continued boiling, as is well known, a large part of the animal matter of bone is extracted, and a solution obtained, which concretes on cooling into a gelatinous mass. Again, if a bone be exposed to heat so as to expel all the animal matter, it is rendered brittle and light, but still retains its form; but if the heat be raised until the bone becomes red, it undergoes a semi-fusion, as occurs in other earthy substances under the same circumstances. The analysis of bone affords the following results:—

According to Fourcroy and Vauquelin.

Animal matter	51
Phosphate of lime	37.7
Carbonate of lime	10
Phosphate of magnesia	1.3
	100

According to Berzelius.

Cartilage	32.17
Blood-vessels	1.13
Fluate of lime	2
Phosphate of lime	51.04
Carbonate of lime	11.30
Phosphate of magnesia	1.16
Soda, muriate of soda, and water	1.20
	100

The general results of these analyses serve to show that the fibrillæ into which bone may be divided by maceration, consist of a cellular tissue, containing in its areolæ a quantity of earthy salts.

Respecting its ultimate fibre, several fanciful notions have been entertained by different persons. Thus, it was considered by some to consist of absorbent vessels, filled with phosphate of lime. Others thought it to be made up of lamellæ and fibres, between which was interposed an osseous juice, &c. Such gratuitous assumptions serve no other end than to lead inquiry out of the true path, and to retard instead of promoting the progress of useful knowledge.

Process of Ossification.—Of all the systems of organs, the osseous is that which arrives latest at its full period of developement, the progress of ossification not being fully completed in the different parts of the skeleton until about the sixteenth or eighteenth year; sometimes even still later. From its first commencement to its final completion, the ossific process runs through three distinct states or conditions, viz. the mucous, cartilaginous, and, finally, that of solid bone. But though these succeed one another regularly, it would be a mistake to suppose that the mucus becomes hardened into cartilage, or the latter solidified into bone, by any process similar to transformation; the facts observed by no means warrant such an inference. The change coincides with an alteration in the mode of nutrition in the part, in consequence of which bone is deposited in place of cartilage.

The embryo at the earliest periods in which it has been ex-

amined, presents no distinction of parts, all being equally soft and homogeneous. So, at least, it has appeared to the greater number of those who have investigated the subject. Sir E. Home, however, states that certain parts are distinguishable, even so early as the eighth day after conception. Towards the fourth week, the consistence of the parts corresponding to the future skeleton is sufficiently increased to admit of their being distinguishable from all others, and their outline defined. The vessels, at this period, convey and deposit gelatine, the basis of the cartilaginous state, which appears to be completed about the eighth week; for it is about this period that the deposition of bone begins in some places. The cartilages being temporary substitutes for bone, differ from it in many respects. They present no appearance of fibres or vessels, have no internal cavity or medullary tissue; they are solid and homogeneous in their whole extent, but possess the outward form of bone, and are invested by a fibrous envelope analogous to that of bone (perichondrium). There is another peculiarity which deserves notice: all those parts of the cartilage which are intended to be replaced by flat bones, viz. of the skull, face, and pelvis, represent a continuous layer, without any perceptible boundary or distinction, and the fibrous envelope passes uninterruptedly over the entire surface; but the femur, tibia, clavicle, and humerus are quite distinct and accurately defined: the latter, it will be recollected, are ultimately to be connected by ligaments, and contribute to form the movable articulations; the former still continue to be united by cartilage. About the eighth week, the cartilage, which, for a certain time, more or less in different instances, occupies the place and performs the functions of bone, becomes hollowed into irregular cavities, and shortly afterwards into canals lined by vascular membranes, and filled by a mucilaginous or viscid fluid; at this period a red dot appears at some particular point, and ossification immediately commences. The spot first ossified (*punctum ossificationis*) is always situated within the substance of the cartilage, never at its surface. Bichât was of opinion that the vessels were not developed at this period; that they existed before, but circulated only white fluids, and then for the first time began to admit red globules; but, be that as it may, the change is marked by the admission of blood into the interior of the cartilage, and the deposition of

calcareous matter, both appearing to be coincident. The cartilage appears red and injected, where it is in close contact with the ossified points; more externally it is somewhat opaque, and marked by grooves or canals; in the next remove it retains its original character, presenting, however, in a few points, some vascular canals directed towards the centre of ossification. As the process proceeds, the osseous point increases, as well by additions externally, as by interstitial depositions; whilst the cartilage, as it becomes excavated by canals and cavities lined by vascular lamellæ, diminishes gradually as the bone increases, and finally disappears, being as it were supplanted.

This is to be considered as the general outline of the process of ossification. The time of its commencement and completion varies considerably in different parts of the skeleton. The bones first formed are those which enclose the central organs of circulation, and of the nervous system, the vertebræ and ribs being developed very early. The long bones, viz. clavicle, femur, and tibia,* present along the centre of their shaft a broad ring of bone at the earliest moment at which their outline can be traced, constituting an exception to the general principle, that bone is deposited in the first instance in a bed of cartilage. The jaw-bones and clavicle are also ossified at a very early period; the sternum, pelvis, and extremities, being later, which corresponds with the order of their appearance and the date of their growth in the animal series. From the class of fishes, upwards, maxillæ are developed so rapidly as to be completed very early; so are the clavicles when they exist; whilst the sternum, pelvis, and limbs, grow tardily, and in many instances remain in a comparatively rudimentary state through life.

In reasoning on the phenomena of ossification, too much has been attributed to the periosteum: its importance and utility cannot be questioned, when we consider how frequently partial exfoliations, or even total necrosis of bones, follow as a consequence of injuries of their fibrous investment. Some persons have, however, gone farther than this, and have even contended that it is the periosteum which produces bone, as if the fibrous membrane acted as its secreting organ; but it may be said that it is its vessels which secrete, and not the membrane. The vessels, however, belong to the bone, not to the periosteum;

* Howship, Med. Chir. Transactions.

and moreover, in many parts, the first ossific deposits take place in the centre of cartilage, and therefore at a distance from that membrane.

SEROUS MEMBRANES.

27. Serous tissue, or membrane, has several synonyms, viz. tissu séreux, membrana serosa, pellucida.—The structures included under this head are so named, because their surface is constantly moistened by a thin albuminous fluid resembling the serum of blood; their form is that of a shut sac, without inlet or other interruption to its continuity. (Sacculi occlusi, "sacs sans ouverture.")—Each is a delicate membrane, smooth and homogeneous in its structure, and so thin as to be transparent, were it separated from the organs or parts with which it is in contact.

A membrane which, if detached and distended, would resemble a bladder or a balloon, (and such is the fact with regard to the serous membranes,) necessarily presents two surfaces. Of these the inner one is perfectly smooth in its natural condition, and lubricated by a fine halitus exhaled upon it, which is occasionally accumulated and condensed into the fluid form. The external surface is rendered rough and flocculent by a number of cellular filaments, which pass off from it to the contiguous viscera, and form the means of its connexion with them. In this class we find grouped together several structures which agree in possessing the conformation and character here indicated, and in exhibiting, when diseased, nearly the same forms of organic change, though no direct communication subsists between them, and each of them is perfectly insulated from the others. The arachnoid membrane, which invests the brain, lines its cavities, and is, moreover, prolonged over the spinal cord, belongs to the class of serous membranes; so do the two pleuræ, which invest the lungs, and the proper pericardium, which encloses the heart; likewise the peritonæum, which is reflected over the different viscera of the abdomen, and the two processes which extend from it upon the testes (tunicæ vaginales). The membrane which lines the anterior chamber of the eye and secretes the aqueous humour, is of the same structure; so is that which encloses the vitreous humour, viz. the hyaloid membrane, and also the capsule of the crystalline lens. The inner or lining coat of arteries and veins presents several points of similitude to those here enumerated.

KING'S COLLEGE HOSPITAL LIBRARY Medical School

28. As serous membranes are thus placed within the great cavities of the body, and as they line the inner surface of their walls, and surround, at the same time, to a greater or less extent, the contained parts, anatomists recognise in each of them two portions,—one *investing* the viscera, the other *reflected* upon the walls of the cavity. Thus, in the pericardium, one part of the serous membrane encloses the body of the heart, extends for some way on the great vessels, and then passes off to line the fibrous bag which retains that organ in its situation; so that it forms a single sac, one part of which is doubled within the other. This is strictly true with regard to the pericardium; it is not less so in the case of the peritonæum and arachnoid membrane, though from their extent, and the great complexity of their arrangement, it is not at first sight easily perceived.* It is the investing part of serous membranes which gives to different organs their shining appearance; and as it is very thin, their colour, form, and even the minute inequalities of their surface, are distinctly seen through it, as we observe when examining the heart, brain, lungs, &c. Though these structures appear destitute of fibres, or of any assignable internal organisation, (being what Haller considered them, merely condensed cellular tissue,) still, if any part of them be inflamed, vessels will be traced into their tissue. It requires some care to determine this point with precision; for the vessels which ramify in the subserous cellular web will often appear to run in the membrane itself, when in reality they are external to it.

29. Serous membranes allow a considerable degree of distension during life, as we see in cases of dropsy, and in the state of pregnancy, also in herniæ; and they retract slowly when the distending cause is removed. They exhibit no animal sensibility in their natural condition, but acute pain arises when inflammation is excited. They confine to fixed positions some organs, for instance, the large intestine, the liver, and stomach; in others, as the small intestines, they facilitate movement by means of the smoothness of their surface and the fluid which they secrete. By being reflected from one viscus to another, they necessarily, in the intervening spaces form folds, in which the vessels are conveniently lodged, and by which they are in a

* For the description of these membranes, and of their various folds, see the sections on Abdomen, Thorax, Brain.

manner guided to the organs which they supply. It must be evident that these membranes cannot completely invest at every part any of the organs with which they are in contact; each of them will be left uncovered at the points of reflection, and there the vessels can enter them without piercing the membrane, or interrupting its continuity. The folds or duplicatures of peritonæum, termed omenta, mesentery, meso-cola, afford illustrations of what has been here stated. There is but one exception to the general principle above indicated, viz. that serous membranes form shut sacs, without interruption to their continuity or external communication. It occurs at the free, or, as it is technically called, "fimbriated," border of the Fallopian tubes in the female; for there, the serous investing layer is continuous with the mucous lining, and is necessarily open, to give passage to the ovum.

30. Are serous membranes furnished with exhalant vessels to pour out the fluid which moistens them, and with absorbents to take up the surplus or residue of it? The existence of such vessels cannot be demonstrated; it has been assumed, in order to account for the effusion and absorption of fluids, which, until lately, were conceived to be inexplicable on any other hypothesis. It is now, however, clearly demonstrable, that fluids and gases can pass through organised membranes without being conducted across them by exhalant vessels. If a piece of membrane, or, what will answer better, if the cæcum of a common fowl, containing a few drachms of milk, of a solution of gum-arabic, or of common salt, be suspended in a glass filled with water, it will be found that in a few hours the water has entered the intestine, and ascended within its cavity until it overflows at the top. But if the mode of experimenting be altered,—if, whilst the intestine is filled with pure water, the fluid in which it is suspended be rendered specifically heavier by the addition of any saline substance, the direction of the current will be reversed; it will flow outwards from the interior of the membrane. Thus, in the former case, there is a passing into the interior of an organised structure, which M. Dutrochet calls *endosmosis* (ενδος, inward; ωσμος, effort); in the latter, the tendency is in the opposite direction, therefore called *exosmosis* (εξω, outward; ωσμος). But though the stream seems thus to run altogether from the rarer to the denser fluid, yet we find

that a minor current exists in the opposite direction. If a solution of prussiate of potash be enclosed within the intestine, endosmosis takes place rapidly, and at the same time exosmosis goes on, but in a slight degree, which may be proved by adding a few drops of muriate of iron to the external fluid, when it will be found to have received some of the salt of potash. Gases also percolate membranes, and in a determinate direction.* If a bottle, with a wide mouth, be filled with carbonic acid, and closed at top with a layer of Indian rubber, exosmosis will occur; for the membrane will become depressed into the glass, showing that the carbonic acid escapes out of it, though it has to go contrary to its gravity. If the experiment be reversed, by placing, under a receiver filled with carbonic acid, a bottle containing atmospheric air, closed in by a membrane, endosmosis will occur; for the cover becomes distended and elevated, showing that the carbonic acid has a tendency to pass in that direction in which the atmospheric air is placed. Mere gravity or density does not determine the direction of the current. The chemical composition of the substances employed appears to exert an influence on the result; so also does the galvanic agent.

SYNOVIAL MEMBRANES.

31. *Synovial membrane* (membrana synovialis, tissu synovial). —Under this head are included the lining membranes of all the articulations in the body, together with a great number of secreting sacs, (*bursæ mucosæ*,) which occur in various parts, more particularly in those which are subject to motion and pressure. The secretion poured out by both is quite the same, though the names given to them would imply a difference; and the purposes which they serve in the economy are also the same, viz. that of facilitating motion, and preventing the injurious effects of friction, by means of the fluid which they secrete. Synovial membranes, like those of the serous class, are shut sacs, without perforation or interruption of their continuity. They may be divided into two groups,—first, those which are enclosed within joints, and as such are called *articular*; second, those which are applied round tendons, where they slide over projecting bony surfaces, or within sheaths; from which circumstance they

* Faust and Mitchell. American Journal of Medical Sciences, No. 13.

are often named *vaginal*, or *thecal* (θηκη, a receptacle or sheath).

Articular synovial membranes.

32. Each *articular* synovial membrane lines the fibrous structures which connect the component parts of the joint, and is reflected over the smooth extremities of the bones. If a tendon passes across a joint, as that of the biceps muscle does in the shoulder, or if a ligament lies within it, as we see in the hip-joint, it is enclosed within a tubular sheath derived from the synovial membrane. Membranous processes and prolongations are found in some joints, attached by one extremity, the other being loose and floating. They consist of duplicatures of the synovial membrane enclosing some adipose tissue, together with delicate vessels. These were at one time called glands of Havers, after an anatomist of that name, who supposed them to be of a glandular structure, and to secrete synovia; but this fluid is now known to be produced from the whole surface, and not by any particular glands or follicles. As to the properties of the tissue under consideration, we find it to be, wherever it is situated, soft, thin, pale, and semi-transparent, admitting of distension by the effusion of fluid, as in hydrops articuli, and capable of a slow contraction when absorption takes place. It possesses little or no sensibility in its natural condition, but produces severe suffering when attacked by acute inflammation.

Vaginal synovial membranes.

33. The *vaginal* synovial membranes are so placed with regard to tendons, where they slide upon one another, or over projecting points of bones, that they are named the synovial membranes of tendons. They were formerly considered more analogous to the mucous than to the serous class of membranes, and hence they were called "membranæ mucosæ tendinum." They were also not unfrequently called capsules, sheaths, synovial bursæ. They are enclosed within the sheaths of tendons, and necessarily assume the tubular form, or, rather, each of them represents two tubes placed one within the other, and continuous at their extremities; of these, that which is internal surrounds the tendon, whilst the outer one lines the fibrous sheath which retains it in its situation.

Vaginal synovial membranes, however closely they may agree

in structure and use, present many varieties in extent and form. From the large tubes which encompass the great tendons at the malleoli to the small sheath which invests the tendon of the superior oblique muscle of the eye, we trace numerous gradations in their size and general conformation. Their number is considerable ; about a hundred pairs may be counted.

Bursæ Mucosæ.

34. Those simple secreting structures, ordinarily known as "Bursæ mucosæ," "mucilaginous bursæ," "subcutaneous bursæ," may with more propriety be called *vesicular synovial* sacs, a phrase which sufficiently expresses their real character and form. They are very numerous ; Monro described 140, and Rosenmüller has since considerably increased the list. We find a structure of this sort (which may be considered as a provision to lessen the effects of friction), where a bone moves over a ligament, as the acromion does upon the capsule of the shoulder-joint ; where a tendon slides upon a ligament, as that of the psoas and iliacus does over the capsule of the hip ; where a bone freely moves beneath the skin, as is the case with the patella ; or a prominent process, such as the great trochanter, under a muscle. The form and structure of bursæ may be distinctly traced when distended with fluid, or by inflating them with air. It may then be shown that the cavity of the sac, whatever its size may be, which is exceedingly variable in different instances, is rounded, and that its area is crossed by several partitions dividing it into cellules, none of which however are complete, as they all communicate freely. The wall of the cavity is thin ; but of sufficient strength to prevent the diffusion of its contents into the surrounding cellular tissue.

Various gradations may be traced in bursæ, from the more enlarged and complete forms of them here indicated, to that in which they scarcely differ from slightly enlarged or elongated cellules of cellular tissue. In several parts where much freedom of motion exists between the skin and under-lying prominences, whether of bone, tendon, fibro-cartilage, and occasionally of movable tumours accidentally developed, we find the subcutaneous cellular tissue loose and extensible, with its cellules more or less elongated, and their walls more distinct and membraniform ; it is so in the neck, where the prominence of the thyroid

cartilage slides freely up and down under the skin; and in the extremities, where the prominences of the digital articulations move so constant and freely beneath the tegument. Hence we see how readily bursæ may be produced, as in those cases of unreduced dislocations where the tendons slide over bones; instances of this have been frequently seen in such accidents at the shoulder-joint.

TEGUMENTARY MEMBRANE (EXTERNAL).

35. The tegumentary membranes, as their name implies (*tegere*, to cover), encase the whole surface of the body, and are also prolonged into its interior, so as to line all those cavities and passages which are in contact with external agencies. This gives rise to a very natural division of them into external and internal, or, in other words, into skin and mucous membrane.

The *skin* (cutis, pellis, common integument, tissu dermoïd,) presents the same form and extent as the body which it covers, and follows all its inequalities, whether they be elevations or depressions. It is a compound structure made up of three layers, viz. corium, rete mucosum, and cuticle.

The Corium.

36. The *corium* (cutis vera, δέρμα) forms the basis or principal part of the skin; it is much thicker than the others, and gives them support, as it is subjacent to them. By maceration, its tissue becomes softened, and in a manner unravelled; it will then appear to be made up of dense filaments, crossing in various directions so as to enclose spaces or areolæ. These are of considerable size at the inner or attached surface of the membrane, where granules of adeps project into them, but gradually diminish towards the outer surface, where the texture becomes so close and dense as to be considered by some anatomists as a separate layer, which they have named "textus papillaris." But though there are no adequate grounds for such a subdivision, the term employed expresses a fact which deserves attention, viz. that the surface is not quite smooth or homogeneous, but is studded with a number of minute projections called papillæ.

The corium when examined by itself is pale or dull white, whatever be the tinge which the tegument presents in different races of men or in individuals during life. Any changes of tint

which are observed to occur in it, are evidently owing to different degrees of vascularity or of injection, as we see in the state of blushing, and in the rosy hue of health as contrasted with the pallor of disease. Its thickness varies considerably, being in some parts not more than a quarter of a line, in others a line and a half or more. Thus it is very thin in the eyelids, on the mammæ and axillæ ; it is thicker at the back part of the trunk than in front, and at the outer than at the inner side of the limbs ; and acquires its greatest thickness on the palms of the hands and soles of the feet. As the fluids which it contains evaporate after death, it becomes hard, yellow, and elastic. It is extensible, as we see, when tumours become developed under it, or in pregnancy and hydropic affections ; when the distending cause is removed, it slowly retracts. It contains a great quantity of gelatine ; on this its capability of being tanned depends ; and on its great tenacity its usefulness in the arts when brought to the state of leather.

37. When proceeding to examine the structure of the corium, a small piece may be detached from some part where it is thick and highly developed ; for instance, from the bulb of the thumb, or, still better, from the under surface of the heel. By maceration in water for some while, the cuticle and rete mucosum admit of being easily removed ; after which, by immersion in hot water for a few minutes, the papillary projections upon the outer surface are rendered more distinct. The inner surface may, in the next place, be sliced away so as to leave merely the outer stratum rendered so thin as to be translucent. If in this state it be placed under the microscope, its papillary surface will present the appearance indicated in fig. 4 ; first, a number of minute conical elevations are seen, most of them slightly inclined towards their summits : next, it will be observed, that these are not scattered irregularly ; on the contrary, they are disposed in rows or lines, *h* : as here drawn, the lines appear to be straight, but in their natural position they represent curves in some parts, as on the bulbs of the fingers ; they are more or less oblique in others, as in the palm of the hand ; or they are transverse, as on the wrist. " These conical papillæ (observes Prochasca) are disposed in curved lines, so that on each line there is a double row of papillæ, between which minute holes are observed, corresponding with the pores visible in the epidermis through

which, when the hand perspires, we can see the drops of sweat to issue." When looking at a piece of corium so prepared, and placed as here indicated, the summits of the papillæ present an appearance not very unlike that given by the summits of bicuspid or molar teeth, as they are passing through the gums in the infantile state.

The papillæ are thus set in raised lines of the corium, fig. 4, *h*, separated from one another by linear depressions or furrows, *i*. Each raised line, however, is not a continuous ridge ; it is intersected from point to point by transverse lines, *k*. Now the latter may be called interpapillary, from their being interposed between the papillæ ; and the former, interlinear. Each interpapillar furrow will be observed to be slightly depressed at its middle, and at this point there is a minute pore or aperture which gives passage to a sudoriferous duct, as seen in fig. 7, *p*.

38. When about to examine the structure of the papillæ, a small slip as thin as it can be taken, may be detached from the edge of a piece of skin, selected as already intimated. A cataract knife will be found useful for such purposes. This slice may be laid on a small piece of glass, and viewed with a single lens, say of the tenth of an inch focus. It will present the appearance indicated in fig. 5, where the papillæ are seen in a row, corresponding with the ridge or linear elevation in the corium, already noticed ; when examined in this way they do not all appear of the same size. This may be owing to the displacement of the structure from its natural connexions, or to the want of its usual degree of vascular turgescence ; investigations of this kind cannot be conducted without such displacement. Now, in each papilla we can recognise as constituents, 1. the corium raised into a minute summit corresponding with the papilla. 2. Capillary vessels which ramify freely in the corium and around the nerve, but reach no farther than its papillary surface ; for if a part, say a finger, be minutely injected, the capillaries will be found to curve, form arches, and return into the veins. 3. The nerves of the skin, when traced in the subcutaneous adipose tissue, present the same characters as elsewhere ; but as they enter the corium they gradually become softer and present a waving appearance, and this seems to increase as each filament passes into its papilla. It is difficult to say how it terminates, whether it becomes soft and stripped of its

neurilema, or whether it curves and forms a loop; be this as it may, the nerve reaches the summit of the papilla, still without piercing it.

39. *Sudoriferous ducts.*—When noticing the appearance of the papillæ and their arrangement, mention was made of the fact, that in each interpapillar furrow a minute pore existed which transmits a sudoriferous duct. These ducts are easily shown by carefully raising and folding back the epidermis of a piece of skin for some time macerated; as it is slowly drawn back, small filaments will be observed along the line of reflection passing from the corium through the rete and epidermis, as represented fig. 7, *p*. These filaments are the ducts; they are tortuous, they admit of being stretched; when torn, they retract instantly, being highly elastic. They pierce the epidermis obliquely, and terminate by open pores upon its surface, as shown, fig. 8, *r*. As the sudoriferous ducts eliminate from the system an excrementitious fluid,—the perspiration—it will be asked, how do they commence, or whence do they receive this fluid? Is it from the capillary net-work of the corium? If so, the perspiration must exist already formed in the blood. Analogy with other fluids, such as the bile and urine, would lead us to infer, *à priori*, that the perspiration is elaborated by a distinct apparatus, not of course accumulated into a mass, like the secreting organs of the fluids just mentioned, but diffused in the form of separate particles or granules, and lodged in, or just under, the tegument. The duct, after piercing the corium, is traced to a small oblong vascular gland-like mass, which lies embedded in the subcutaneous adipose matter, and which appears to be the immediate secerning organ of the perspired fluid.

40. *Lymphatics.*—Besides the blood-vessels, nerves, and sudoriferous ducts, lymphatic vessels exist abundantly on the skin. Whilst injecting the lymphatics of the lower limb with mercury, the fluid, after filling the glands of the groin, will often pass inwards towards the penis and scrotum, creeping for a while under the skin; they then enter its texture, and ramify so freely as to represent a close and intricate net-work. In this way they are injected, contrary to the natural course of the fluids which circulate in them, and consequently in opposition to the valves if there be any. The valves appear to be complete, and to offer resistance to this process in the primary and secondary

vessels of this order, but at their peripheral and capillary ramifications the valvular apparatus becomes less and less perfect. This is indicated in fig. 9, where no appearance of valves is traceable in the minute branches, though it is sufficiently distinct in the larger efferent vessels passing from the part. All these, however, were injected by Mr. Wilson contrary to the course of the circulation, so that the valves gave no resistance. But it does not follow that they are equally inefficient in the living state when the vessels possess their natural contractile power.

If these vessels be regarded as inhalant or exhalant, how do they commence? Some have said, that they begin with pores, opening on the surface, perhaps from confounding them with the sweat-ducts, or from supposing, according to theoretic views, that there must be openings to admit of the entrance or exit of fluids. The uniform results, however, of injections seem to me to prove that these vessels, like blood-vessels, at their peripheral expansion, which may be regarded as their commencement, form an extensive net-work, and that, whatever passage of fluids takes place into or out of them must be by percolation or imbibition, and not by any capillary movement through pores.

The rete mucosum.

41. The *rete mucosum* appears at first as a glairy exudation between the corium and cuticle, adhering to both, particularly to the former. Malpighi (after whom it has been called rete Malpighi; corpus mucosum—rete glutinosum Malpighianum,) stated it to consist of soft fibres, so arranged as to form a net-work. It is more and more distinct, in proportion as the skin is of a darker hue, so that it is very easily demonstrated in the dark races. When a blister has been applied to the skin of a negro, if it be not very stimulating, the cuticle alone will be raised in about twelve hours. After this is detached, the exposed surface appears covered with a dark coating. But if the blister has been very active, another layer, of a dark colour, comes away with it. This is the rete mucosum, which gives to the different races of mankind their various shades of colour; for the other two layers of the tegument are pale and colourless, as we see when their separation is effected by maceration after death, or by vesicating the living surface.

The nature of the stratum which is thus found interposed between corium and cuticle has given rise to much discussion. Nerves cannot be traced into it, nor has any process of injection

shown blood-vessels within it in the healthy state. It appears to be a semi-fluid deposit or secretion, rather than an organised substance : some persons, however, consider it to be a partially organised cellular tissue, containing in its areolæ a dark substance resembling the pigmentum nigrum of the eye ; others, as Gautier and Dutrochet, go so far as to resolve it into four layers placed one over the other. In the white races the rete not only loses all colour, but becomes so thin, that it is difficult to demonstrate it ; indeed, some eminent anatomists, Bichât, Chaussier, and Dr. Gordon, from these circumstances, denied its existence altogether. But we generally find, on attentive examination, a viscid, semi-fluid stratum occupying the situation of the rete, which, however, is soft and glairy, and, most probably, a secretion produced by the vascular surface of the cutis, or by a special apparatus.

42. M. Breschet is disposed from various considerations to take the rete and the cuticle together, and to regard them as strata of corneous structure deposited upon the corium. " Nous considerons ici comme épiderme toute l'épaisseur de la couche cornée qui est située au dessus du derme, et qui est traversée par plusieurs organs. Le feuillet le plus externe de cette substance cornée constitue la cuticule ou l'épiderme proprement dit de beaucoup d'auteurs." [Recherches sur la structure de la peau, p. 38 note.] We still however shall continue to consider these two lamellæ as sufficiently distinct to retain them as separate structures and to treat of each separately. Though the rete possesses neither nerves nor blood-vessels, (we have already stated that both these reach no farther than the papillar surface of the corium,) still vessels of another kind are recognised by M. Breschet himself as existing in it, and which he considers to be analogous to lymphatics, and to constitute an inhalant apparatus. Now, as nothing of this kind exists in the epidermis, we may consider this circumstance, together with its scale-like texture and difference of colour, sufficient to distinguish it from the rete.

When a piece of skin has been sufficiently macerated to allow the cuticle and rete to be detached (having selected a part where the cuticle is thickened,) we can readily see the rete as a distinct layer, particularly if the piece so prepared be placed in spirit, so as to corrugate it a little. The rete, soft and thin, appears as if it had been moulded upon the corium ; it takes an exact impres-

sion of its lines and ridges and papillæ, as represented in fig. 8. Now when in raising the rete and epidermis, in order to see the sweat-ducts, as shown in fig. 7, we can with the aid of a glass recognise other tubes which are distinguished from the ducts by their smaller size, by anastomosing with one another, so as to form a net-work (which the ducts never do). Moreover, they are not tortuous, nor do they pierce the epidermis. Some offsets or efferent vessels issue from this net-work, and pierce the corium close to the pore which transmits the sweat-duct, and appear to terminate in the venous capillaries of the corium. Within the meshes thus formed is deposited that soft, glairy, mucus-like deposit which gives to the tegument its different shades of colour. Is this product exuded by the vessels here noticed, or by the capillary vessels of the corium; or is it secreted by a distinct apparatus? M. Breschet describes and delineates two distinct secerning organs, one for the mucus which he terms blennogenous (*βλέννα* mucus, *γενναω* I produce), and the other, for the colour, chromatogenous (*χρωμα* colour, *γενναω*). Those which produce the mucus he describes as minute red glands (petites glandes rougeâtres) placed just under the corium, embedded amongst adipose vesicles. From the summit of each a duct issues which pierces the corium and opens upon its surface. The colour-producing apparatus Breschet places towards the outer surface of the corium beneath and between the papillary ridges, and in the depth of the interlinear furrows. The secreted product is poured into the grooves by minute ducts.

The cuticle.

43. The *cuticle* (cuticula, epidermis, scarf-skin) is the outer layer of the tegument. Though very thin in most parts, it becomes thick and indurated in the soles of the feet, or wherever it is habitually subjected to pressure. Its inner surface is connected with the rete mucosum and corium by delicate filaments and by the sweat-ducts, but can be readily separated from them by decoction or maceration: the external surface presents a number of narrow lines or ridges, which make it appear, when examined with a glass, rugged and uneven. This observation seems to have led to an opinion entertained by some anatomists, namely, that the cuticle consists of scales, or lamellæ, disposed like those of fishes or imbricated. The raised lines here noticed,

fig. 8, *q*, correspond with those of the corium; their direction varies, being more or less curved, oblique, or transverse, as may at once be seen by viewing them with a lens upon the ends of the fingers, the palm of the hand, and then at the wrist. These lines are separated by furrows, which are depressed into those of the corium, the rete interposing. These interlinear furrows are intersected by transverse ones, in the middle of each of which we can readily see with the aid of a glass, and often with the unassisted eye, a minute porous depression or infundibulum (fig. 8, *r*), where the sweat-duct terminates. As the epidermis is very thin, its inner surface presents, when raised from its connexions, the reverse of these elevations and depressions: fig. 7, *m*, *n*. This view of it shows that it is so deposited upon the papillary surface of the corium, as to form a mould representing all its elevations and depressions. This is seen more distinctly if the epidermis be slightly corrugated by immersion in spirit or solution of alum. When first exuded, it resembles a thin pellicle of mucus laid upon the surface; it gradually dries and loses its semi-fluid appearance, whilst its lines and ridges become apparent. We can easily trace the steps of these changes, if we note what takes place when it is reproduced upon a part that has been blistered. When the cuticle is detached and laid in water, for some while its inner surface appears smooth and uniform. This is owing to its being stretched by the process to which it is subjected. Moreover, even the pores through which the sweat-ducts pass are invisible; hence many anatomists have denied their existence. Béclard says that he charged a shred of epidermis with a column of mercury, about the weight of one atmosphere, and yet could not perceive any proof of its being porous. This is explicable by reference to a fact above stated with regard to the sweat-ducts. viz. that they are so elastic, that when stretched they retract forcibly, and contract their calibre so as effectually to close the porosities. As the epidermis is insensible, and without vessels or nerves, we may liken it to a dry varnish, which protects the sentient surface of the corium from irritation; moreover, it lessens evaporation, and impedes if it does not altogether resist the absorption of injurious substances.

The hairs.

44. To the skin are attached, as appendages, the hairs and nails.

Hairs (crines, pili) are slender, conical, horny filaments, which in many animals cover nearly the whole body; but in man are principally developed upon the scalp, pubes, and chin. Each hair consists of a stem and a root. The former is free and unattached, of a different colour in different individuals, and tapering towards its summit, which is usually split, or subdivided into filaments; the root is destitute of colour, and widens a little, so as to become hollow and trumpet-shaped, at the same time that it loses its firm, horny texture, becoming softened and gelatinous at its margin. If a hair be plucked out, the part which had been lodged in the skin, fig. 10, is found covered by a thin white tubular sheath which still adheres to it, particularly at its widened edge, to which point it can readily be reflected or drawn down. If examined with a glass whilst still in its place, the stem of the hair being at the same time drawn tightly, as if in the act of plucking it out, the sheath here noticed appears at its outer edge to be continuous with the corium at the point where the hair pierces it. By dividing this tube, and drawing it aside with the point of a fine needle, another membrane, softer and thinner, appears within it, and which seems connected with the rete mucosum. In treating of this subject, we constantly employ the terms "bulb, follicle, papilla." Sometimes the word bulb is used as if it were meant to express the widened and colourless part of the hair, together with its membranous sheath, as they are seen when extracted; this obviously includes two things which are sufficiently distinct. Béclard (*Anat. Gén.* v. 336) takes bulb and follicle as synonymous terms; he says, "The bulb or follicle of the hairs, which Malpighi compared to the vessels in which gardeners plant flowers, is situated in the substance of the dermis, or beneath it." It seems to me better to restrict the word bulb to the root or point of origin of the hair, where it is colourless, soft, and a little enlarged; follicle will then properly express the tubular canal in which it is lodged whilst within the corium, and both will be sufficiently distinguished from the papilla or secreting organ. At the bottom of the tubular follicle is situated a minute conical elevation called the papilla, which is embedded in the subcutaneous cellular tissue, and connected with it by filaments. It is supplied with some minute capillary vessels, and also nervous filaments. Béclard, following out his general views as to the continuity of

tissues, views the matter in this way. The outer layer of the sheath is traced down from the corium, the other from the rete; both rise a little at the bottom of the tube to form the papilla: as to the cuticle, it is obviously reflected outwards upon the stem of the hair, and becomes united with its outer surface. The bulbs of the hairs, therefore, observes Béclard, "seem to consist of a small part of the skin, sunk, depressed, or folded upon itself, surmounted by a papilla, which is supplied with vessels and nerves." The analogy between hairs and nails, and a consideration of the mode of implantation and growth of the latter, support this view of the subject.* M. Breschet (*Recherches sur les appareils tégumentaires*, p. 84) observes, that he has not as yet determined (the subject being still under examination) whether the hairs arise, as they are commonly said to do, in a duplicature of the skin, or whether they are secreted by glandular organs placed at the inner surface of the corium (*à la base du derm*). He inclines to the latter opinion. If it be established, then, we shall have to modify our view of the matter slightly, and the facts will stand thus:—The bulb of the hair (fig. 2, *b*) is implanted on the papilla, *c*, which secretes it in the first instance, and supplies materials for its growth, which are added continually to its base, so as to elongate it and cause its protrusion. The papilla at its base is connected with the surrounding cellular tissue by filaments, and by nerves and vessels; whilst by its summit and sides it gives attachment to the bulb of the hair. The investing sheath, already noticed, continuous with the corium and rete at the point of emergence of the hair, dips down, enclosing it as far as its edge, where it is slightly connected with the papilla. But these are not the only means by which it is fixed in its situation: the cuticle dips into the orifice of the follicle for a little way, and so comes into contact with the surface of the hair, on which it is reflected and prolonged, so as to become in a manner identified with its structure.

The difference of colour in hair seems to depend, according to Vauquelin, on the presence or absence of a coloured oil. He found in black hair a substance resembling mucus, and which appears to be a modified albumen, with two oily matters, one colourless, the other a greenish black tinge, and rather thick. He obtained also in his analysis phosphate and carbonate of

* A plan or this arrangement, supposing it correct, is given, fig. 10. 1.

lime, oxide of manganese and iron, sulphur and some silex. In red hair the iron and manganese exist in less quantity, and the coloured oil is of a reddish tinge. In fair hair the coloured oil is less; in that which is perfectly white it is altogether colourless. The saline substance appears to be that which imparts the colour to the animal matter or oil: we know that hair admits readily of being dyed whilst still growing, or after it is cut off.

The nails.

45. The *nails* (ungues) are horny lamellæ, or scales, placed at the extremities of the fingers and toes, on their dorsal surface. The root of the nail, which is about one-fifth of its length, is thin and white, dentated at its margin, and received into a groove, or sulcus, in the corium; its external surface is convex, and marked by some slight longitudinal lines running from behind forwards. At the posterior, or attached extremity, a small portion will be observed, differing in colour from the rest, and usually called "lunula," from its form: the free extremity of a nail is its thickest part, and projects for some way beyond the end of the finger. The mode of connexion established between the nail and the tegument is as follows:—The subjacent part of the corium, fig. 11, 1, thick and red, is surmounted by a number of papillæ, placed in linear series on every part of it, except that beneath the lunula. The under surface of the nail is at the same time soft, and marked by narrow grooves, fig. 12, intended to lodge the papillæ just noticed, and to become intimately connected with them: again, its posterior extremity is received into a sulcus in the corium, fig. 13, which at this point is stripped of its epidermis; but the latter, at the root of the nail, dips into the sulcus and becomes reflected on its upper surface, forming a smooth, superficial lamella upon it. At the free extremity of the nail the epidermis, after covering the end of the finger, is reflected on its under surface, becoming identified with it. Finally, the disposition of the epidermis along the sides resembles, for a short way, that which takes place at the root; but further forwards it is reflected in the way that obtains at the free border of the nail.

In fig. 13, by a vertical section of the last phalanx of the thumb, the relation of the cuticle and corium to the nail, and of the latter to the papillæ, is shown. At fig. 14, an enlarged

view of the papillæ is given, and of the loops formed by the vessels within them.

Hairs and nails, with the analogous textures, feathers, wool, claws, and hoofs, in different animals, form a section by themselves under the head Corneous, or Horny tissue. They grow and increase by deposits at their base of a glairy fluid or semi-fluid matter, resembling mucus or modified albumen, which gradually concretes and becomes harder as it is pushed forward and protruded.

TEGUMENTARY MEMBRANE (INTERNAL).

46. The internal tegument, or mucous membrane, is differently named by writers, tissu muqueux, Bichât; membrana mucosa, villosa, mucipara —The tegumentary membrane, as has been above stated, is not confined to the external parts of the body; it is prolonged into their interior, where it serves a corresponding purpose; but in this situation it presents some important modifications in its character; and, from the nature of the fluid which covers and moistens it, receives the name of "mucous membrane." From the lips and nares, it extends along the whole length of the alimentary canal, as well as into the different follicles and excretory ducts which open into it. The larynx, trachea, bronchi, and air-cells of the lungs are lined in the same way by a mucous membrane; and, as the whole forms a continuous surface, it has been named by Bichât, the "*gastro-pulmonary mucous membrane.*" A similar mucous surface may be traced from the orifice of the meatus urinarius, along the urethra, bladder, and ureters, to their termination in the tubuli of the kidney; also into the vasa deferentia, from which it is probably continued into the tubular structure of the testes in males. In the female, it is prolonged from the vagina into the uterus, and thence into the Fallopian tubes to their termination. This continuous tube forms the "*genito-urinary mucous membrane.*"

Between the two great divisions of the internal tegument here pointed out, no organic connexion or communication exists. The general form of each may be said to be that of a canal, or tube, of considerable extent, but presenting numerous contractions and dilatations, corresponding with those of the hollow organs which they line. Their external surface is rough and

flocculent; for it is attached by cellular tissue (sub-mucous) to the contiguous textures. The strength and closeness of its adherence varies in different parts of its extent. In the stomach it is easily separated; from the pylorus to the ilio-cæcal valve it gradually becomes more firmly attached, at the valve itself it is less so; but in the large intestine it is again very closely adherent, and so continues to the rectum, near the extremity of which it is comparatively loose. The thickness of the membrane also varies; it is greatest in the stomach and duodenum, and thence diminishes gradually towards the lower part of the small intestine; at the ilio-cæcal valve it increases somewhat; it becomes thinner again along the large intestine (being about half as thick as in the stomach); but it increases perceptibly towards the extremity of the rectum. Its firmness and power of resistance are greatest in the stomach and duodenum, which seems to depend on its greater thickness in these parts.

The colour of the mucous membrane varies in different parts of its extent; to which circumstance, in a great degree, is owing the discrepancy we find amongst writers upon this point. Béclard says it is white, with a reddish tinge; Boyer, that it is yellowish grey, becoming red in the stomach, and reddish in the intestine; Gavard states it to be greyish, with an inclination to red. These statements are too general; for we find that the colour of the membrane is influenced by the age of the individual, by the circumstances which preceded his death, the condition of the thoracic viscera, by the time which has elapsed between death and the performance of the examination, and by the position in which the body has been laid. Hence arises the necessity of distinguishing that which is inherent in the membrane, from what is extraneous to it. For this purpose, a small piece must be carefully dissected off, and held up to the light; it will be found homogeneous, translucent, and of a pale white colour, or greyish, with a delicate rosy tinge. This is the healthy colour and condition of the membrane, when examined by itself after death; and if we inspect the intestine in a subject that has died without disease or disturbance of the abdominal viscera, we perceive, from the outside, some branching vessels creeping beneath the peritonæum, in a direction from the attached to the free border of the tube: a similar appearance will present itself from within, owing to the vessels lying in the

sub-mucous cellular tissue. During life, the vessels being necessarily more or less distended with blood, impart a tinge to the surrounding textures; and so the mucous membrane is rendered of a delicate rosy red, varying in degree according to the quantity of fluids circulating in a given part at any particular time. Hence it deepens in the stomach during the digestive process, and this deeper tinge creeps along the intestine as the alimentary mass passes from stage to stage during its progress; for the afflux of blood thus determined now to one point, now to another, carries with it the colour by a sort of derivation.

Plicæ, or *rugæ*. — The inner surface of the mucous membrane presents several inequalities (elevations and depressions) which deserve notice. In the stomach and in the bladder, when cut open, we observe numerous small ridges running in various directions, giving it an areolar aspect: these are termed rugæ; but they are not permanent; they arise from a contraction of the muscular fibres, and consequently disappear when the viscus is distended. In the œsophagus similar folds exist, but all running longitudinally.

47. *Valvulæ conniventes*.—In the small intestine we find folds which are permanent in their existence and fixed in their direction, showing that they depend, not on the contraction of the muscular coat, but on the special conformation of the mucous membrane itself. These are termed *valvulæ conniventes*, and are formed of duplicatures, or narrow plaits of the membrane placed transversely with regard to the axis of the canal, and projecting into its interior. None of these extend round the whole circle—few reach farther than one third of its circumference. Some depart a little from the transverse direction, becoming rather oblique; and a few, of minute size, may be observed to run longitudinally, intersecting the spaces enclosed by those which are larger. When the membrane is detached, and stretched a little, the valves are unfolded and disappear, as the sub-mucous cellular tissue which connects them is torn asunder. The point at which the valvulæ commence is at about an inch below the pylorus, where they are rather small and but slightly projecting; but they gradually increase in size and breadth from thence down to the middle of the jejunum, where they project inwards about two lines; but they gradually diminish along the

ilium, and cease at its lower end, a few oblique or longitudinal lines alone remaining. The term "plica" would better express the character and mode of formation of these projections than "valvula;" for they are merely folds of the membrane, which enlarge the extent of surface by which it comes into contact with the alimentary mass, and increase its absorbing power. The true valves are the ilio-cæcal and the pylorus; for they are contractile (muscular fibre entering into their composition), and exercise an influence on the course of the aliments. The term "valve" is also applied to three or four projecting and permanent ridges which exist in the interior of the rectum.* We shall recur to these when treating of the pelvic viscera.

Villi. — All the elevations hitherto noticed are readily perceived, even on a cursory inspection; they are easily shown in a piece of intestine inflated, dried, and then laid open, or without any preparation, by merely laying it open; there are others which require a little more attention in order to be distinctly seen. If the mucous surface be held up to the light, or allowed to float in water, it will be found covered with a vast number of minute downy processes, giving it a flocculent appearance. Some persons have likened this to the pile, or soft surface, of velvet; and hence arose the term "villi," by which the projections are known. Their intimate structure has been made the subject of much minute examination, and of not a little controversy; perhaps arising from the opinion, so very generally entertained, that absorption of chyle was effected by the capillary attraction of lacteal vessels, and that the open mouths of these must be placed in the villi. Lieberkuhn concluded (*Dissert. Anat. pathol. de fabricâ et actione villorum intestinorum tenuium hominis,*) from his microscopical researches, that each villus consists of a capillary lacteal vessel, and a nerve with a delicate vascular plexus spread upon the lacteal, which becomes expanded into an ampulla immediately after its origin, in the form of a minute pore. Sheldon, Cruickshank, and Hewson, admit generally the existence of a lacteal with vessels and nerves in each villus; but deny the existence of any expansion or ampulla in its interior. We cannot feel surprised at any difference of opinion which may exist concerning the intimate structure of

* Observations on the Mucous Membrane of the Rectum, by Dr. Houston, Dublin Hospital Reports, vol. v.

such minute objects, when we find that their outward form is said by some to be round, by others to be conical; whilst a third likens it to a mushroom with a stalk and pileus. All agreed in admitting an absorbing orifice at the extremity of each villus, whatever discrepancy may have existed upon other points. Béclard (*Anat. Générale*), however, after repeating the observations previously made by others, found that these projections are neither conical, tubular, nor expanded at the summit; but that they appear as so many plates, folia, or leaflets, set closely together, and forming a tufted pile. This is the true account of the matter: most of the antecedent observations bear evidence of being undertaken and conducted under the influence of a preconceived opinion as to the mechanism of absorption. There no longer remains any necessity for admitting the existence of pores, ampullæ, or capillary attraction, in order to account for the phenomena. Membranes we know to be permeable by fluids, and in a determinate direction; it matters little, then, whether, with Majendie and Fodera, we adopt the term imbibition to express the fact; or, with Dutrochet, name it endosmosis.

48. *Mucous Follicles.*—Along the alimentary canal we find, in various parts, minute orifices leading into small follicles, or shut sacs, which appear to be merely depressions into, or inversions of, the mucous membrane (fig. 19, 20). They are embedded in the sub-mucous cellular tissue, and can therefore be readily seen upon the external or attached surface of the mucous lining, if it be carefully dissected away. Their capacity is generally small; in some parts they are simple in their structure, detached, and scattered, as we see in the stomach and duodenum, where they are named glandulæ Brunneri. Towards the lower part of the ilium, and even higher up along the jejunum, they are clustered together into spots (glandulæ aggregatæ, glandulæ Peyeri). In some situations, several follicles open into a common dilated orifice, as into the lacunæ of the urethra and rectum, or into the foramen cæcum at the back of the tongue: finally, several follicles, by being united into bundles of various forms, constitute a compound secreting organ, with ramified ducts or lacunæ, as we see exemplified in the tonsils, the prostate and Cowper's glands. All these structures come under the general head "mucous follicles," for they have been supposed to secrete

the fluid which moistens the surfaces upon which they open. But it is more probable that mucus, like synovia and the serous halitus, is produced by every part of the membrane, and that the follicles elaborate each a distinct product. The secretion of the prostate gland appears to differ as much from that of the tonsils, as the cerumen of the ear does from the sebaceous matter exuded upon the glans penis, or clitoris.

The *structure* of the internal tegumentary membrane resembles that of the external or true skin, so far as that it consists of a corium or dermis, and an epidermis, which is here called epithelium (επι, upon ; θηλη, a nipple or papilla) ; for when traced inwards from the margin of the lips, it is found to cover the papillæ on the surface of the tongue. A rete mucosum cannot be demonstrated in any part of it. The corium is soft, cellular, and spongy, varying in thickness and density in different parts, as we have already stated. The epidermis is prolonged upon its surface for some way, and may be traced as far as the union of the œsophagus with the stomach. The vagina also is similarly coated as far as the neck of the uterus ; but the deeper-seated parts appear to be protected, not by an insensible epidermis, but by the mucous secretion poured out on the surface.

THE VASCULAR SYSTEM.

49. The vascular system (systema vasorum) is made up of a multitude of membranous tubes (*vessels*) ; some of which convey to the different organs and structures of the body the fluids destined for the maintenance of their functions and growth, whilst others receive from these different parts the effete fluid, and carry it back to the point from which it had set out. As the fluids, in a great number of animals, are thus made to flow, as it were, in a circle, the vessels which direct their course are called *circulating*, and the whole process, *circulation*.

The vessels are divided into three sorts ; two of which, the arteries and veins, contain blood (though of a different quality in each) ; the third, the lymphatics, are filled partly with chyle, the product of digestion, and partly with lymph, the residue of nutrition. As the lymphatics terminate in the veins, and pour their contents into them, they may be considered as tributaries to the venous system. The blood, brought back by the veins to the heart, is conveyed onwards from it, by the

pulmonary artery, to the lungs, from which it is returned to the heart again, to be propelled through the aorta into the system at large. Two streams may thus be said to begin and to terminate at the heart: one flowing from it to the lungs by the pulmonary artery, and returning by the pulmonary veins; the other extending through the whole body, and returning by the venæ cavæ. The former has been termed, from its shorter course, the *lesser* circle, and from its destination, the *pulmonary* circle; the latter is, with equal propriety, called the *greater* or *aortic* circle, and not unfrequently the *systemic*, from its connexion with the system at large.

Though some of the older anatomists had conceived sufficiently correct notions of the course of the blood in some parts of the system, yet none of them were able to combine these together, so as to form a connected whole; that was reserved for Harvey, who, about the year 1619, first described the true course of the blood in the different orders of vessels, and demonstrated the correctness of his opinions by a complete series of proofs and experiments.

50. The division of the circulation into the greater and the lesser, or the pulmonary and systemic, as established by Harvey, continued to be universally received, until Bichât (not by any means with a view to question its correctness or truth) adopted another, on physiological grounds. The blood in the branches and trunks of the venæ cavæ, in the right side of the heart and pulmonary artery, being of a reddish-brown colour (*venous*), whilst that in the pulmonary veins, in the left side of the heart, and likewise in the aorta and its ramifications, is red (*arterial*), suggested to the mind of this great physiologist a corresponding division of the circulation into that of the *red* and that of the *dark* blood. According to Harvey, the heart, placed at the commencement of each circle, receives the blood, and propels it forwards, to describe the greater and the lesser course. According to Bichât, the heart must be conceived to be situated at a point intermediate between the origin and termination of each system; of which one (the dark-blooded) begins in the general capillary vessels of the body, and terminates in the capillaries of the lungs; whilst the red-blooded commences in the latter vessels, and ends in the capillaries diffused throughout the body. In this view of the subject, the actions of the lungs, and those

going on in the body generally, may be considered as maintaining a constant antagonism, the one purifying and restoring the blood which becomes vitiated in the other.

Taking the heart as a determinate point in each circle,—that from which each current starts, and to which it returns, we see the tubes which contain the blood commencing by two trunks, the aorta and the pulmonary artery: the former gives off branches, which divide and subdivide, until they become reduced to the minutest capillary tubes in the intimate texture of organs; the latter ramifies in the same way in the lungs. Thus there are two arterial trees, whose trunks arise from the heart; the branches of the one being intended to diffuse the materials of growth and nutrition through the body at large, whilst those of the other convey the exhausted and effete blood to the lungs, to be there renovated.

51. The modes in which arterial trunks branch off, and divide from stage to stage, are various: in the limbs, the branches generally form acute angles with the main artery; within the body, we observe the aorta bifurcate into the common iliacs, and each of these into the two vessels of the same name (internal and external); the renal and lumbar arteries form right angles with the parent vessel; but the superior intercostals issue at obtuse angles. No assignable or fixed proportion seems to exist between the size of the vessel and its branches; from the aorta itself arise the spermatic arteries, which are exceedingly small, and the renal and carotid, which are very large; and between these extremes we see offsets of every variety of calibre. Where, however, a bifurcation occurs, the capacities of the two branches are always greater than that of the vessel from which they proceed; so that the stream of blood, in proportion as it is subdivided, becomes also more diffused, as it flows from a narrower into a wider channel. This was made a subject of particular consideration by those physiologists who, soon after Harvey's time, sought to follow up his views of the mechanism of the circulation. Adopting the opinion which he had taught, that the heart was the sole agent in propelling the blood, it became interesting to ascertain the impediments and resistance which it has to overcome. With this view they examined—the angles formed by the branches at their points of origin,—the number of divisions and subdivisions which took place down to their

termination in the veins,—the proportions subsisting between the calibre of the minor currents, as compared with those from which they proceed, — and, finally, the friction of the blood against the sides of the vessels having been taken into account, the calculations, to determine the question proposed, were carried on with all the precision which mathematical formulæ could give them. From such data, Borelli inferred the heart's force to be equal to 135,000 pounds, whilst Keill reduced it to five ounces.*

The modes of communication between vessels are various; sometimes two of them, from points more or less distant, converge, and meet, forming an arch by their junction, from which issue small ramusculi to the surrounding parts: we observe this along the intestinal canal, and about some of the joints. Very commonly arterial branches are connected only at their ultimate terminations; and under ordinary circumstances neither can be said to receive blood from the other, both being merely a means of supply to the parts to which they run; but if the direct flow in one be cut off, then it will become filled from the other, the current being in the opposite direction to what it was originally, viz. from the branches into the trunk. Another mode of junction is by a short canal extended between two parallel arteries, as in the case of the anterior cerebral arteries; or two of equal size join at an acute angle, and give rise to a third, as do the vertebrals to form the basilar artery.

52. The different communications here noticed are called anastomoses (*αναστομοω*, to make an opening, or communicate; *ανα*, *στωμα*, a mouth) or inosculations, which, literally, mean the same thing; yet in their technical application a difference is maintained between them; the latter being used where the union is free and open, the vessels themselves joining so that it becomes difficult to say at what point their opposing currents meet, as is exemplified in the colic, epiploic, and coronary arteries; the former is generally employed when speaking of cases in which the minute branches communicate. When organs receive the materials of their growth and nutrition from two or more sources, the supply is less liable to disturbance or interruption than it otherwise would be; and should an obstruction happen to occur, or be placed designedly upon the current from one

* Essay on several parts of the Animal Economy, pp. 80—87.

quarter, the deficiency will be made up by the others. It is by these means that the circulation is adequately carried on in a limb after the main artery has been tied:—the blood is directed into a new or devious route, finding its way through the anastomoses existing between smaller vessels, and so what is termed "a collateral circulation" is established.

53. The veins, like arteries, present a ramified appearance; but as the blood flows in them from their extreme branches (which are continuous with those of the arteries) towards the main trunk (vena cava), which opens into the heart, and as the diameter of that vessel is considerably less than the sum of the diameters of the veins which pour their contents into it, the motion of the current within them increases from stage to stage of its progress, because it is made to run from a wider into a narrower channel. The venous system, then, considered as a whole, seems to have been constructed on a hydraulic principle, which materially influences the passage of the blood it contains. It presents, on a general view, a series of cylindrical tubes, commencing in the interior of the different organs of the body, as well as in their remote or peripheral extremities. These, in the first instance, are so minute as to elude vision; but they gradually increase in size and diminish in number, forming successively vessels larger and larger, until finally all terminate in a large trunk. Though the calibre of any given vessel in the series is larger than that of either of the branches which open into it, yet its diameter is less than the sum of their diameters taken together; whence it follows, that the diameter of the common trunk is less than the sum of the diameters of the smaller vessels whose contents it receives. Now, when a current flows from a wider into a narrower bed (its level remaining unaltered), it necessarily becomes more rapid as it advances; and, by an extension of the same principle, when a number of tributary streams open into a channel whose width is less than that of these currents taken together, a certain impetus is given by the mere fact of such an arrangement, which materially aids any other collateral means that may have been devised for expediting its progress.

When describing the veins, it is not by any means necessary to enter into such details as are required when treating of arteries. They, for the most part, take the course of the arteries, and therefore maintain the same relation to contiguous parts;

but some lie beneath the tegument, particularly in the limbs and neck, being quite superficial. They are more capacious than arteries, and also more numerous, at least in the extremities, where two veins generally accompany each artery; but in the kidney, digestive canal, and testes, the number is equal; and in the umbilical cord there are two arteries and one vein. Abundant provision is established throughout for a free communication between the venous branches,—between the superficial and deep-seated sets at different points, and between the trunks, constituting so many various forms of anastomosis.

There is a part of the venous system so peculiarly disposed, as to form a sort of diverticulum out of the general current, viz. the vena portarum in the liver. It receives the residual blood from the digestive organs, by veins which unite and become continuous with the vessel just named; which, as it enters the liver, spreads out and ramifies within it, somewhat as arteries do. Here are two venous trees (to use a common illustration), with their trunks united to form the vena portarum; the branches of the lower one being diffused amongst the intestines and stomach; whilst those of the upper are lodged within the liver.

Having reviewed the circulating apparatus thus generally, it becomes necessary to notice the peculiarities of each of the three sets of vessels which compose it: as they exhibit not a few striking points of difference, more especially in structure and properties.

ARTERIES.

54. Artery, arterial tissue, arteria.—The term "artery," in its original acceptation, meant a tube containing air, (αηρ, air; τηρεω, to contain,) or some subtle agent, whether called archæus or vital spirits. It was at one time supposed that veins alone carried blood, as they were observed at all times to contain it, in the dead as well as the living: but as arteries were always found empty after death, they were imagined to be the conductors during life of something more refined and ethereal. Though this hypothesis has been long forgotten, the term to which it gave rise is retained even now, notwithstanding that centuries have elapsed since a very different doctrine has been completely established.

Arteries are usually deep-seated, their form tubular, and each, if viewed from its commencement to its termination, will be found not to taper gradually, but from stage to stage to present a series of cylinders, increasing in number as they decrease in size; for a portion included between any two branches, whether it be one inch or three in length, retains its diameter throughout.

The outer surface of each arterial tube is connected with the surrounding structures by cellular tissue and by vessels and nerves: these are derived from some of the contiguous small branches, and are termed *vasa vasorum*, because they circulate in the coats of the vessels, at least in the two exterior, not being traced into the inner one. Nerves also ramify upon and within their structure to the same extent; being derived, whilst in the cavities, from the sympathetic system, and in the limbs from the cerebro-spinal system. In many parts, as in the neck and extremities, the cellular structure becomes condensed, and forms a cylindrical investment (called "a sheath") for it: which, however, is not a part of its proper structure, as the connexion between them is very slight; moreover, the sheath encloses the vein as well as the artery, and in the neck we see the nerve included also.

55. An artery is a cylindrical and highly elastic tube, composed of three coats or tunics, placed one within the other. In fig. 15. a piece of artery is represented with its coats dissected. The outer coat is reflected in three slips, *s*, *s*, *s*; the lower one is thrown down so as to expose a part of the middle coat, *t*; a little higher up, where the outer coat is reflected to each side, the middle coat is dissected away so as to bring into view the inner coat, *u*.

i. The *external* coat is formed of cellular tissue, into which it may be reduced by maceration; its texture is closer where it is in contact with the middle coat, than externally where it is somewhat loose and flocculent: it admits of considerable extension, as we see when a jet of water is forced by a syringe into a piece of artery detached and tied at one end; it retracts again when the distending cause is removed; in this it follows the middle coat: its fibres, when separated by tearing them slowly, seem to be for the most part oblique and to cross diagonally; on this its firmness mainly depends, for we know it to be so tough, as not

to be divided by a hard ligature placed on the vessel, and so firm, as alone to resist the impulse of the current when the other coats are divided or torn.

ii. The *internal* coat not only lines the arteries, but is continued into the ventricles of the heart; hence it is sometimes called the common membrane; and as it is smooth, and moistened by a fine halitus, which appears to be poured out upon its surface, it is by some considered analogous to serous membranes, and named accordingly. It is thin, homogeneous, and transparent, and so fragile as to be easily torn. Its inner surface is at all times in contact with the blood, the outer being in close union with the middle coat. At each ventricular opening it forms three folds, whose base, or line of attachment, which is convex, is situated at the point of junction between the artery (aorta and pulmonary) and the corresponding ventricle; whilst their free and slightly concave border projects upward into the artery, one surface looking towards its axis, the other resting against its side in the relaxed condition; but when distended with blood, they bulge or project downwards, so as to become convex when viewed from the ventricle, and concave from the artery. Each valvular fold thus disposed encloses a minute stratum of cellular tissue as its bond of union, and is bound down to the middle coat at the margin of one of the convex processes which it presents at its commencement: in the free margin of each is a small granule, called "corpus aurantii" or "sesamoideum." Such are the *sigmoid* or *semilunar* valves, which prevent the reflux of the blood from the arteries back into the ventricles.

iii. The *middle* coat (called also muscular, fibrous, elastic) is that on which the most striking peculiarities of arteries depend. At its commencement it presents, in both vessels (aorta and pulmonary artery), not a straight border, but rather one which is scolloped by three notches into three processes, which pass down to the margin of the ventricle, but are not identified even by their tips with the fleshy fibres. It consists of pale, straw-coloured fibres, coiled obliquely round the circumference of the vessels, but none of them forming a complete circle. If an artery be stretched transversely, it will recoil and resume its original diameter; if elongated, it will retract. These are direct proofs of elasticity. When an artery no longer carries blood,

as, for instance, when a ligature has been applied upon it, the part beyond the ligature will contract, its tube will become obliterated, and finally, by an alteration in its mode of nutrition, will degenerate into a mere fibrous cord. This indicates a contractile power, different from that resiliency which characterises structures simply elastic, and has been termed contractility of tissue, to denote that it is in some sort a vital property. The coats of arteries resist the effects of maceration for a considerable time, and yield on decoction but little gelatine, and no fibrine: hence the structure of their middle coat has been assimilated to that peculiar substance called "tissu jaune"—"élastique," which forms the ligamenta subflava of the vertebræ, and the cervical ligaments in the lower animals. These physical and chemical properties constitute a marked line of distinction between the middle coat of arteries and muscles; but in some particulars, more especially in its vital properties, it manifests several points of resemblance to the muscular structure, so that it seems to constitute an intermediate link between it and the fibrous or fibro-cellular tissues.

56. That property of arteries which is here indicated, and which enables them to contract towards their centre, without having been previously distended, has been the subject of many controversies amongst physiologists. It has been variously denominated, by different persons,—tonicity, vital force, contractility, &c. The whole controversy may be reduced to this —Are all the phenomena of extension and contraction that are presented by arteries attributable solely to their elasticity? Haller, Bichât, and Majendie, have taken the affirmative side of the question; Hunter, Sœmmering, Thomson, and Home, the opposite. A decided difference of opinion between such high authorities affords abundant evidence of the difficulty of the subject, particularly when we consider the great attention which they have severally paid to it, and the many experiments which they performed with a view to arrive at some satisfactory conclusion. Bichât's arguments against the irritability of arteries are as follow:—1. Mechanical or chemical irritants applied to their external or internal surface, determine no contraction in them; nor, when divided longitudinally, do the edges of the incision become everted, as occurs in the intestines, or other irritable tubes. 2. When separated from the body, they mani-

fest no signs of contractility: if the finger be introduced into a vessel, it is not compressed. Galvanism produces no contraction; and if any is caused by the application of an acid, it is attributable rather to its chemical action on their coats than to any vital power in them. "The arteries," says Majendie,* "nowhere present any indication of irritability; they remain immoveable under the action of sharp instruments, of caustics, and of the galvanic current."

These results are not by any means conformable with those obtained by other physiologists. Dr. Thomson† "succeeded in producing complete contraction, by irritating, for some time, though gently, with the point of a needle, the small arteries in the web of a frog's foot." The same effect was also produced by weak volatile alkali; but when a saturated solution of common salt was applied with the point of a hair pencil, "the arteries, instead of being contracted, as they had so uniformly been by the application of ammonia, were actually and sensibly dilated."‡ Again: "when the capillaries are stimulated by the direct rays of the sun, by the application of gentle friction, or of spirits of wine, the velocity of the blood in them is immediately increased."§ The application of electricity has determined marked contractions in arteries, as has been observed by two Italian physiologists, Giulio and Rossi; and Sir E. Home succeeded in producing the same effect by irritating a neighbouring nerve. These direct proofs of the irritability of arteries derive additional support from several pathological facts. "The increased pulsation of the larger vessels supplying an inflamed part, sufficiently evinces their increased action."‖ Thus, if paronychia occur in one of the fingers, the corresponding radial artery will pulsate more strongly than that of the opposite hand. In cases of hemiplegia the strength of the pulse is diminished at the affected side, though it remains quite natural at the other; a proof that the arteries possess a power independent of the heart, and which is attributable to their irritability. The degree in which these two properties of arteries, elasticity and irritability, are manifested, differs according to the size of the vessels; the larger are more elastic, the smaller more irritable;

* Physiology, p. 415. † Lectures on Inflammation, p. 85. ‡ Eod. loco.
§ Wilson Philip on the Vital Functions, p. 285. ‖ Thomson, loc. cit.

and this latter property is more or less subjected to nervous influence.

The experiments of Dr. Thomson, above cited, cannot be considered as conclusive evidence that arteries are really irritable, at least in that sense in which muscles are known to be so. Even were it established that the capillaries are contractile on the application of stimuli, it would not follow that the arterial tubes which extend from the heart to these, are irritable or muscular. Pain is necessarily produced by irritating substances; pain and fear soon influence the circulation: the former will at first quicken it; the latter, from its depressing effect, will soon diminish its rapidity. Besides, it may be objected to all chemical agents, that they must act on the delicate tissues in which the vessels are enclosed, and upon their coats, if not upon their contents.

Whatever differences of opinion may exist on this much-litigated subject, few will deny that arteries assist, in some degree, in carrying on the circulation; for we know that they appear before the heart in the human embryo; and in several of the lower animals, in which there is no heart, the vessels alone propel the fluids. In fishes there is no systemic ventricle; in reptiles the arteries contract and propel the blood after the heart has been removed; and even in warm-blooded animals the blood has been observed moving freely in the capillaries, after all connexion with the heart had been cut off by a ligature on the aorta.* The circulation goes on in those acephalous monsters in which a heart has not been developed. Inferences drawn from a consideration of the structure and functions of the lower animals cannot always be extended to those of more complex and perfect organisation, as the analogy between them may not be sufficiently close to warrant the application; but from a general view of what has been stated with regard to the circulating system, we may conclude, that when the heart exists, it exerts a decided influence on the circulation; that by its action the stream of blood in the arteries moves on, not continuously, but in jets; and that it flows uninterruptedly, though the leading arterial trunks have become ossified. The vessels also have a part to perform, as is evident from the fact that they can pro-

* Inquiry into the Laws of the Vital Functions, p. 219, by Wilson Philip.

pel the blood after the heart has ceased to act; and so the heart and arteries may be considered as associated in the performance of a special function, each being to a certain extent endued with an independent power: one acting by direct propulsion, the others assisting by their vital force and elasticity.

57. *The pulse.*—The flow of blood in the arteries determines a peculiar phenomenon, called *pulse*. The number of arterial pulsations in a given time varies according to the age, sex, and constitution of each individual; but, setting aside these, and all other variations dependent on different circumstances, in health as well as in disease, when we come to inquire what is the change sustained by arteries during their pulsation, and what is the cause of the change, we find that even on these preliminary questions a considerable difference of opinion exists amongst physiologists. According to Mr. Hunter,* "arteries, during their diastole, increase much more in length than width. It is, however, the increased diameter that is perceived by the touch. This increase is so manifest as to be felt or seen, and produces what is called the *pulse*." According to Dr. Hales,† "at each systole of the heart the blood in the arteries is propelled forward with an increased impetus, thereby dilating the canal." Dr. Thomson's opinion is nearly to the same effect:—"The pulsation of arteries is derived entirely from the dilatation and elongation which they experience from the blood impelled into them by the systole of the heart."‡ Haller, in one part of his Elements, attributes the pulse to a dilatation of the arteries, but subsequently admits that the dilatation cannot be perceived, and that it is only inferred from the sensation communicated to the finger. Bichât, during the progress of his researches, frequently examined the condition of denuded arteries; and, as he could not observe any adequate dilatation in them, he came ultimately to the conclusion that the pulse was attributable to a locomotion in the whole artery, ("un mouvement de totalité,"§) which causes it to spring against the finger during the systole of the heart. Yet he still inclines to admit a dilatation in some degree:—"Quant à la dilatation, elle est *presque* nulle dans l'état ordinaire." It is scarcely necessary to allude to the hypothesis

* On the Blood and Inflammation, p. 23. † Hæmastatics.
‡ Lecture on Inflammation, p. 63. § Anatomie Générale, tom. ii. p. 335.

of Dumas,* that arteries are endued with a power of active dilatation, which enables them to expand, to receive the blood which is about to be propelled into them. The late Dr. Parry,† of Bath, assisted by Mr. Norman, made a great number of experiments to determine the condition of arteries during their pulsation. Whilst prosecuting his researches he laid bare fifty-five of the larger arteries in horses, sheep, and dogs, "yet could not by any mode of scrutiny detect, in a single instance, the smallest dilatation or contraction corresponding with the systole or diastole of the left ventricle of the heart." It is more than probable, as Dr. Wilson Philip has remarked, that the mode of measurement adopted in these experiments was not sufficiently delicate to ascertain the point with precision; for Dr. Hastings found that a ligature placed round an artery was tightened at each contraction of the heart. It appears, then, that the weight of testimony and authority inclines to that opinion which attributes the pulse to a dilatation and elongation of the artery, consequent upon the systole of the ventricles. It cannot be said to be altogether dependent on that cause; for if it were, no difference could exist in the state of the pulse in the corresponding arteries in different limbs, neither could it be raised above par, as we frequently find it, in a vessel leading to an inflamed part, nor depressed below it in a paralytic limb. It has hitherto been admitted, that the pulsation of arteries, no matter how near or distant they may be from the centre of the circulation, occurs at the same moment, being synchronous throughout the body; but some recent observations made by Dr. Corrigan and others, render it probable that a retardation takes place; the pulse in the posterior tibial artery, for instance, being later, by a minute interval, than that in the femoral or iliac.

58. *Developement.*—The formation of the vascular system has been examined of late years with the greatest attention by several physiologists, particularly by Meckel, Serres, Home, and A. Thomson, whose researches have thrown considerable light on this rather complex subject. Meckel has directed his inquiries for the most part to the following points:—to ascertain the parts of the system which are first developed; the ar-

* Physiologie, tom. iii. p. 314. † Essay on the Pulse.

rangement of these parts in the earlier stages of fœtal life; the relation which exists at different periods between the greater and lesser circulation, the dark and red-blooded system; and, finally, the proportion subsisting between the number, size, and capacity of the different orders of vessels at different periods of life.

It is difficult to determine with precision which part of the vascular system is first developed. But if the analogy between birds and the higher animals be sufficiently close to allow of an inference, deduced from observations on the developement of the one to be applied to the other, it may be stated that the veins of the vesicula umbilicalis are the first which become manifest; for the vesicula umbilicalis in the human embryo corresponds with the membrane of the yolk, or the yolk-bag, in birds; and it is demonstrable, that the veins which issue from the latter are the first that are developed. The vesicula umbilicalis is a minute membranous sac, placed between the chorion and amnios, and greater in size, relatively to the fœtus, the earlier it is examined. It appears to be formed before the new being, which in a manner rests upon it, the vesicula being closely in contact with its anterior surface. The cavity of the vesicle most probably communicates with that of the intestinal canal; but there is evidently a connexion by vessels between it and those of the mesentery up to the second month: these, consisting of an artery and a vein, extend in the first instance from the vesicula to the mesenteric vessels. At the period just referred to, they reach no farther than the parietes of the abdomen, and, finally, they disappear altogether. From their mode of connexion, these vessels are called *vasa omphalo-mesenterica.*

59. At the earliest period at which either structure or vessels become perceptible in the incubated egg, some small rounded vesicles, or rather spaces, are seen in the germinal membrane, which soon become filled with a clear and viscid fluid. Separated from one another at first, they represent so many islets, or rather a chain of vesicles, gradually increasing in number, until they form a net-work, which soon becomes filled with blood in place of the fluid previously contained. The minute radicles thus formed gradually unite to form branches, which coalesce and form a trunk—the omphalo-mesenteric vein. These are properly but rudimentary vessels; they

have no proper coats, they are merely canals hollowed, as it were, in the texture of the membrane, like the canals observed by Sir E. Home in a clot of blood, marking out the course of the vessels about to be developed within it. The substance of the membrane becomes thickened along the course of these canals, and forms the first rudiment of their walls; and then the process of developement goes on progressively, though slowly. When the omphalo-mesenteric vein is thus formed, it turns from below upwards, situated anteriorly with regard to the body of the embryo, and terminates in a vein which ascends perpendicularly, and presents a dilatation at the point where the heart is ultimately produced. From this the aorta issues, and distributes branches to the different organs of the body; the accompanying veins being formed nearly at the same time, and also the omphalo-mesenteric artery. It is more than probable that the umbilical vein and artery are developed in the same order as the omphalo-mesenteric vessels, viz. the vein first, the artery afterwards; for they in a manner supplant them. Though arguments founded on analogy so often lead to error, that it is hazardous to employ them in researches of this sort, we yet may use them for the illustration of our views, if not for their confirmation. During the germination of seeds, the new plant, in the first instance, is observed to derive its support from the farina of the seed, and from the leaflets developed within the cotyledons. When the radicula has shot down, and begins to derive nutriment from the soil, these leaflets perish, and the plant is supplied by its own roots. So the vesicula and its vessels appear to support the embryo until the umbilical veins are formed; after which it withers, and finally disappears, when the latter have established their connexion with the uterus, through the medium of the placenta.

The vein (*omphalo-mesenteric*) derived from the vesicula, opens into the mesentric vein of the fœtus, which is a primary branch of the vena portæ, so that the latter may be regarded as derived from the omphalo-mesenteric vein. The vena portæ, at this stage of fœtal existence, forms the principal trunk of the venous system, and ascends towards the point afterwards occupied by the heart, where it presents a slight ampulla, corresponding with the auricle; immediately beyond this another slight dilatation appears, and then a third, which represent the

auricle, the ventricle, and the primary arterial trunk—the bulbus arteriosus. These vesicular dilatations are separated by slight constrictions. The position of the auricle soon changes with regard to the ventricle; it ascends so as to get to its base or upper part. Each of these cavities, at first single, becomes divided into distinct chambers; but previously to indicating the steps of these changes, we may here observe that, whilst they are going on, progress is at the same time being made in the developement of other parts of the vascular system. The vena portæ, which originally lies behind the liver, and unconnected with it, becomes connected with the umbilical vein, and, conjointly with it ramifies in that organ, which then encloses the vein, and, for the first time, becomes a sort of diverticulum, in which the blood circulates before it passes to the heart. Cases have occasionally occurred in which the liver and vena portæ continued to retain the relative position above indicated; that is to say, the vein passed behind the liver without possessing any connexion with it, and opened directly into the vena cava. In these instances a fluid, resembling bile, was found in the gall-bladder, and the inference was at once deduced, that the bile is in all cases secreted from the blood of the hepatic artery, and not from that in the vena portæ. From what has been just stated, these are merely cases of deranged or imperfect developement, and cannot, as such, furnish legitimate data from which any inference can be drawn. But even were it otherwise, the conclusion would be invalid, on the obvious principle, "haud valet argumentum à particulari ad universalem."

60. As the developement of the heart proceeds, the auricle becomes divided into two cavities (but incompletely) by a septum, which projects inwards from its circumference. The division of the ventricles takes place somewhat in a different manner. The right ventricle at first appears like a small tubercle, extending downwards gradually towards the apex of the heart; the septum projects inwards along the line of constriction, which indicates the separation of the ventricular sac into two chambers; it developes also from below upwards—from the apex towards the base. In the next place, along the great arterial trunk a constricted line is observed extending gradually from below upwards, indicating its developement into two vessels—the

aorta and pulmonary artery. They remain, however, connected, and they still communicate during the whole period of fœtal life at their upper part,—the communication being reduced to that short branch or offset which leads from the distal end of the pulmonary artery into the aorta, and which is named the "ductus arteriosus." By means of this communication, the streams which issue from the two ventricles become blended, at least in part; and so the duct has the same effect on the action of the ventricles that the foramen ovale has on the auricles; it makes them, as it were, a single cavity, in so far as the currents which issue from the two chambers become blended after their exit.

61. In reviewing this succession of changes during the progress of developement, we recognise each of them as a temporary or transition stage, which, whilst it lasts, bears a certain degree of analogy to a fixed condition of the circulating apparatus in some of the lower orders of animals. Thus, when in the embryo of a vertebrate animal, a single vessel without any cardiac dilatation runs along the back, it at once suggests the idea of the dorsal vessel in insects. When, at the anterior part of this vessel, an enlargement occurs where the "punctum saliens" is seen, and which assumes the character of a ventricle, it is the analogue of what is found in the higher crustacea. In the next stage, where two cavities exist one just before the other, representing an auricle and ventricle, it corresponds with the condition of the central organ in the mollusca. When the auricle ascends and the ventricle comes forward, the bulbus arteriosus reaching upwards from its base, it is like the heart of fishes, in which it is called branchial or respiratory from its sending the blood into the gills or respiratory organ solely, and therefore discharges the function of the right or pulmonic heart in higher animals. When the auricular cavity becomes separated into two chambers by the growth of the septum, the ventricle still remaining single, it passes into the condition of the organ in the batrachial reptile. In the next place, as the developement of the ventricular septum proceeds from the apex upwards to the base, before it is completed a communication will still remain at this point; the heart in this stage consisting of two auricles and a partially divided ventricle, represents the condition of the organ in the ophidian reptile, and, were its growth arrested at this point (of

which many instances have occurred), that form of congenital malformation will remain through life in which the two sorts of blood are blended, owing to the imperfection of the septum. Lastly, even when all communication between the ventricular cavities is cut off by the completion of the septum, the streams issuing from them are still to a certain extent blended, by means of the current which passes from the pulmonary artery through the ductus arteriosus into the aorta. Hence, until this diverticulum is closed, an analogy will still remain between the conformation of the organs in the fœtus of the human subject and the higher animals with that of the reptile. It is finally cut off at the moment of birth, when the condition of the circulating apparatus in the new being passes from that of the cold-blooded to that of the warm-blooded animal.

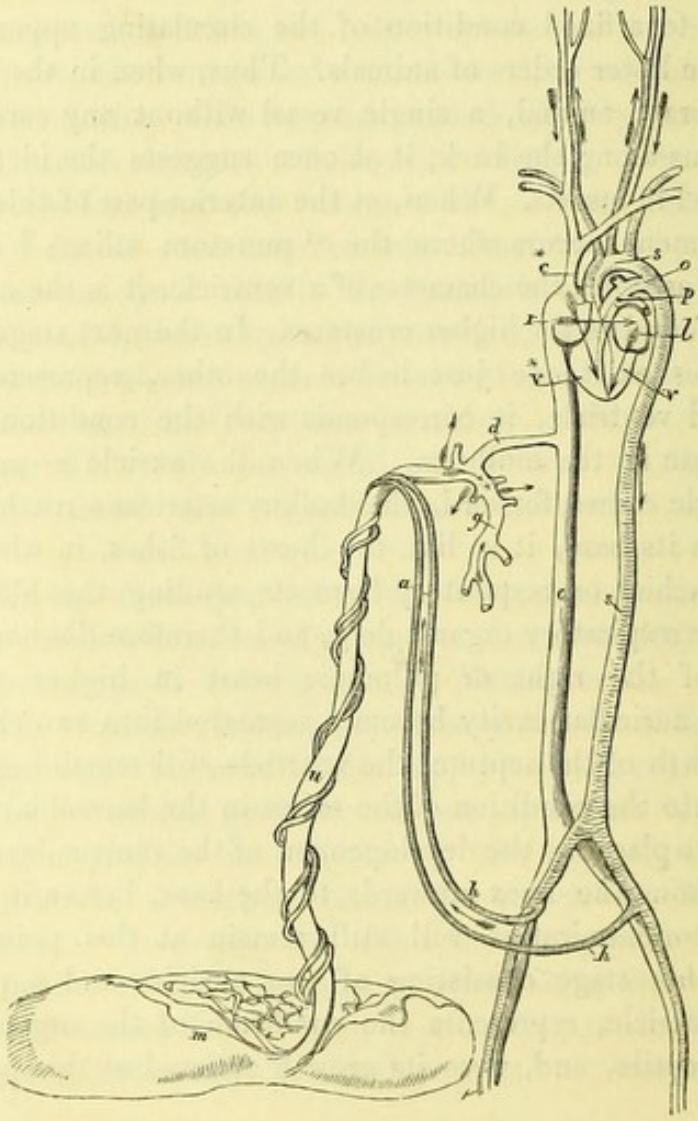

62. *Fœtal circulation.*—(Fig. 31 is a diagram of the circulation in the fœtus.)—When the placenta, *m*, is formed, and the fœtus, through its medium, begins to derive support from the parent, the course of the nutritive fluid is as follows:—A vein, *u*, (umbilical,) commencing by branches in the placenta, passes along from it; in its course two arteries (umbilical), *a a*, coil round it, which are continuations of the hypogastric arteries of the fœtus, *h h*; these arteries carry back to the placenta the residue of the blood which had previously circulated in the body of the new being. The umbilical vein, having reached the abdomen, passes towards the longitudinal fissure of the liver, in which it runs from before backwards, sending branches chiefly to the left lobe. At the transverse fissure it forms a direct inosculation with the vena portæ, *g*, so that the currents of the two veins are mingled at this point*, after which they circulate in the left lobe of the liver. The remainder of the blood brought by the umbilical vein is carried onwards to the vena cava by the ductus venosus, *d*, (which is lodged in the posterior part of the longitudinal fissure,) and so through the vena cava, *c*, to the heart.

Were it then required to indicate the course of a given quantity of blood derived from the placenta, and circulated through the fœtus, it would be found as follows:—When brought to the liver by the umbilical vein, part is given to this organ (its left lobe) without mixture, and part after being mixed with that of the vena portæ, whilst the rest, by means of the ductus venosus, is conveyed to the vena cava, and so to the right auricle, *r*, mingled with the blood of the vein.

When arrived at the heart, the current passes directly through the foramen ovale into the left auricle, *l*, and thence into the left ventricle, *v*. From the last-named cavity it is propelled through the aorta, *s*, and its ascending branches, into the head and upper extremities, a small part only being conveyed downwards into the descending part of the aorta, *s**.

Now, the blood which is brought back from the superior parts of the body and the head, by the jugular and subclavian veins, to the right auricle, is said to pass, (and experiments made by injecting from the umbilical vein upwards, and by the jugular in the opposite direction, with differently coloured injections, seem to prove the fact,) during the earlier periods, without any intermixture with the blood of the inferior cava, into the right

auricle, *r*, and thence into the corresponding ventricle, *v**, which, by means of the pulmonary artery, *p*, propels it partly into the lungs, but chiefly through the ductus arteriosus, *o*, into the descending aorta, and so into the inferior parts of the body. This descending current consists of a less pure fluid than that circulated by the superior aortic branches, as most of it had already circulated through the superior parts of the system of the fœtus, the rest being merely the portion which is conveyed downwards from the arch of the aorta, after having sent the chief part of its blood upwards into the subclavian and carotid arteries. The iliac vessels, into which the aorta divides inferiorly, convey the blood into the lower extremities; but the greater part of it is sent, by the umbilical arteries, to be circulated in the placenta. And as, in after-life, the capillaries of the lungs and those of the general system are opposed to one another, so, during fœtal life, a similar antagonism is maintained between the capillary system of the embryo and that of the placenta. The blood at this early period describes two circles, which intersect one another, and communicate at the heart, so as to describe (to use Bichât's expression) the figure 8.

At first, as has been stated, the blood of the superior and that of the inferior cava do not intermingle in the right auricle; but as the valve of the foramen ovale increases, and narrows the passage into the left auricle, some part of the blood of the inferior cava being prevented from flowing in that course, mixes with that of the descending vein, and with it is conveyed into the right ventricle, so that a gradual approximation is thus being made towards the condition and arrangement of the circulating system which obtain in after-life. The peculiarities which mark each of the organic systems of the fœtus, as well as that now under consideration, lessen as it approaches the period in which it is destined to pass from a dependent, and, as it were, parasitic existence, to a separate and independent one. The derivative passages (ductus venosus and arteriosus, the umbilical vein and arteries), which connect all the parts of the circulating system, gradually diminish, and the placento-fœtal arrangement approximates so nearly to the aorto-pulmonary, that the creature is prepared to pass from one mode of existence into the other, without disturbance or injury to its yet tender and delicate organisation.

VEINS.

63. *Veins, structure of.*—Veins, like arteries, are composed of three coats, which, however, are comparatively thin and flaccid. They are easily distended, admitting of considerable enlargement in the transverse direction ; but though susceptible of elongation, they are not so to the same extent as arteries. The *external* coat of veins consists of condensed cellular tissue, but is much thinner and less firm than that of arteries ; it is very closely united with the next membrane, which it encloses, viz. the *middle* coat. The latter, thinner and much more pliant than that of arteries, at first appears smooth and even in texture, as if altogether destitute of fibres : they do exist, however ; the greater number being longitudinal, some few only assuming a transverse direction. The venæ cavæ, near the heart, are surrounded by well-marked circular fibres ; but they are obviously muscular, and continuous with those of the auricle, of which they seem to be a prolongation. The middle coat is more strongly marked in superficial veins than those deeply seated. The *internal* coat is a thin shining membrane, continuous with that which lines the auricles of the heart. In its passage along the veins (those of the extremities) it is thrown into folds at different intervals, which constitute valves, which are so arranged as to allow the blood to flow freely towards the heart, whilst they effectually prevent its regurgitation backwards into the parts from which it had been conveyed. The valves are of a semi-lunar form, the convex border being continuous with the membrane lining the interior of the vessel, the straight or free one projecting towards its centre, where it comes into contact with a similar fold extending from the opposite side ; so that both form a complete septum across the interior of the vessel. The valves may be likened to so many minute flood-gates, all inclined in the direction towards which the stream flows, marking thereby its natural course, and constructed so as to prevent its return, at the same time that, by supporting the column of blood which intervenes between them and the heart, and preventing it from gravitating on that which follows, they remove a considerable impediment to its progress along the veins. They are very numerous in the extremities, particularly in the more depending parts, and in superficial vessels. They are said not

to occur in the veins within the great cavities; but they do exist at the termination of some of them, viz. the coronary vein of the heart and the azygos. The lining membrane alone sustains the blood in the bones, the other coats being deficient; this is also the case in the cerebral sinuses, in which the dura mater serves as a substitute for the two external venous tunics, which cease at the base of the skull, where the jugular veins become continuous with the sinuses.

ABSORBENTS.

64. The absorbent vessels are called also lymphatics, vasa lymphatica, absorbent system, système absorbant.—The term "absorbent" means, literally, sucking up; and is used to denote the property (ascribed to certain vessels found very generally diffused throughout the system) of imbibing substances placed in contact with them, and carrying them into the current of the circulation. Under this head are included two sets of vessels, together with a number of nodular bodies appended to them, called glands. The vessels are transparent, their coats being very thin, and appear white when filled with their fluid contents during life; they are very small when compared with the veins whose course they for the most part follow. Like veins, they present a branched or ramified distribution; their radicles commence in the different textures and organs of the body, and gradually converge, forming branches, and finally two trunks, which pour their contents into the veins. When injected, the vessels of this order look like jointed tubes, presenting numerous constrictions which indicate the position of valves in their interior, and enlargements just beyond them. This is shown in a large vessel, fig. 17, and in branches, fig. 9, which marks the contrast between lymphatics and arterial capillaries, as seen in fig. 16: taking the trunk and branches together, they present an arborescent form, like arteries and veins; their ramifications resemble a diffused net-work, and when artificially injected, look like jointed cords.

65. *Lymphatics and lacteals.*—From a difference in the nature of the fluid which the absorbent vessels contain, they are divided into two orders, viz. lymphatics and lacteals. The latter are confined to the cavity of the abdomen, and only absorb chyle, the product of digestion; the former are diffused through the

body at large, and are engaged in that process of absorption which is constantly going on in the various structures of which it is composed.

66. *Glands.*—In different parts of the course of the absorbing vessels, rounded or oval bodies are situated, called *glands* (*lymphatic* or *conglobate*), which in the extremities are found usually at the flexures of joints, but in the cavities are variously disposed. A sketch of one of these glands is given, fig. 24, with vessels entering it and issuing from it. They are found in considerable number within the abdomen, in the mesentery, and along the great vessels,—in the thorax at the root of the lungs, and in the mediastina,—in the neck along the course of the cervical vessels. Their size varies from that of a hemp-seed to that of an almond, but they are not so much elongated as the latter. Their surface is smooth, their consistence considerable, which is due to their capsule consisting of fibro-cellular membrane. The vessels, as is evident from the results of injection, on arriving at the glands, become intimately connected with them, and in a manner ramify through their interior; for if some quicksilver be introduced into the vessel, it will soon permeate the whole substance of the gland.

67. *Inferent and efferent vessels.*—The entering vessels are on this account called "vasa inferentia" (fig. 24, *x*). The vessels which issue from the glands appear to arise from their interior by a number of minute radicles, which unite to form tubes, of about the same size as those which had entered at the opposite side. These pass on in the course of the circulation; and as they convey away whatever fluids had passed through the glands, they are called "vasa efferentia" (fig. 24, *y*).

Anatomists are by no means agreed as to the precise distribution of the minute tubuli which are convoluted in the interior of the glands. The inferent vessels on reaching the gland creep for a little way on its surface, and then sink into its interior, gradually subdividing into smaller branches. The efferent vessels issue in the same manner; hence it is frequently asked, are the radicles of both directly continuous within the gland, and is this organ but a closely aggregated plexus? Malpighi showed the existence of cellules in the interior of these glands by injecting them. It is quite certain that, if they be filled with mercury and allowed to dry, the interior cells will be apparent

when they are cut open. Mr. Abernethy availed himself of an opportunity which presented itself to him of injecting these glands in the whale. The injection was first passed into the arteries, and then by the lymphatics both were found effused into cellules.—May they not have been extravasated?

68. *Thoracic duct.*—All the chyliferous vessels, as well as all the lymphatics, which arise from the lower extremities, from the left side of the thorax, the left upper extremity, and the lateral half of the head and neck of the same side, pour their contents into a common trunk—the "left, or great thoracic duct" (ductus thoracicus sinister vel major, Sœmm.). This is a tube similar in structure, but larger than those which open into it, which runs along the spinal column, from the second lumbar vertebra to the lower part of the neck, where it opens into the angle formed by the union of the left subclavian and jugular veins. The rest of the absorbents, consisting of those which return the lymph from the right upper extremity, from the right half of the thorax, and the corresponding side of the head and neck, terminate in a short trunk, the "right," or "small lymphatic duct," which opens into the junction of the right subclavian and jugular veins. These, it should be observed, are not the only points at which absorbents open into veins. Lippi has shown some of them terminating in the inferior cava, also in the iliac and renal veins.

Lymphatics for the most part follow the course of veins, and like them are divisible into two sets, one superficial, the other deep-seated. They are said to consist of only two coats, perhaps because the external or cellular one is too thin to be satisfactorily demonstrated. The internal coat, or lining membrane, like that of veins, is smooth, thin, delicate, and formed into folds which constitute valves, fig. 18, that allow the contained fluid to pass freely towards the common trunk, but prevent its return. The knotted appearance presented by lymphatics when injected, is owing to the column of the mercury, or other substance employed, being interrupted by the valves. The proper coat, corresponding with that of veins, is dense, firm, and most probably fibrous, though it is not easy to demonstrate the fact, except in the thoracic duct of a horse, or of some large animal. It is slightly elastic, and appears to be irritable; for we observe the acteals to contract, and force on their contents, when the

mesentery is exposed in an animal while the process of digestion is going on.

GLANDS.

69. We find a number of products elaborated from the circulating fluids, which are termed secretions. The organs in which these are produced are called glands (glandula, Ἀδήν), from the likeness which some of them present to an acorn. This, however, can with propriety be said to apply to the conglobate class, viz. the lymphatic glands. Various structures have been at different times included under this head. Some of the ancient anatomists, after the example of Hippocrates, included even the brain; and down to the present time the pituitary body and the conarium are spoken of as glands (pituitary and pineal).

70. Glands may be said to be secreting organs which elaborate from the blood special products. This necessarily excludes those two just named, as well as the thyroid body (gland) and the spleen, as we do not know what function they perform; the same may be said of the lymphatic glands, which present the characters rather of ganglia placed in the course of the absorbent vessels.

71. When examining the skin, we found it to be an extended, sentient, and secreting surface; such also is the internal tegument,—the mucous membrane. Now glands are not only dependencies upon these, but also, in the literal sense, productions of them, particularly of the mucous system. Thus some of them are minute cæca, little sacs closed at one end, and at the other opening by an orifice upon the tegument: a plan of this form of secreting organ is given in figs. 19, 20. When constructed in this way, they are termed follicles (ceruminous, mucous, or sebaceous, according to the characters of their secretions). They exist abundantly at the flexures of joints, at the orifices of cavities or passages; they are seen enlarged in their diseased state in acné and sycosis menti. Along the mucous membrane they are found either detached, and therefore termed solitary (glandulæ solitariæ), or collected into groups (g. agminatæ). Suppose for a moment the head of a pin to be pressed against the mucous membrane until a minute piece of it is made to bulge out, it will present to the mind a sufficiently exact notion of a follicle. In some places, for instance in the urethra,

they are lengthened into the tubular form so as to admit a bristle or fine wire for two or three lines; these are called lacunæ.

Follicles are not all single and simple, like those here noticed: we find them in some places aggregated into groups, as in the tonsils, which may be called conglomerate follicles; in others they are placed in rows, their orifices converging inwards from point to point, the secretions from all being evacuated by a single orifice. The Meibomian follicles under the lining membrane of the eye-lids are arranged in several rows running upwards from the free edge of the lids. They present, if laid with the conjunctiva upon a piece of glass, the appearance represented in fig. 21. Some of the rows curve at their distal end, so as to form a communication; at the lower or tarsal end, each row opens by a minute orifice. When viewed through a lens, the lateral follicles of a single row (fig. 22) are seen converging inwards; two or more open into one pedicle or duct, and all these communicate with the surface by means of the single duct seen at the lower end of this elongated cluster.

Proceeding from these simpler forms of glands to those considered complex, we find that they still consist essentially of a prolongation of mucous membrane drawn out, as it were, and lengthened into a tube, out of which offsets issue from point to point, until it assumes a branched or arborescent form as represented in fig. 23, which is taken from a preparation of a part of the parotid gland. From the duct of a lobe, a^*, branches diverge, and from these, as they spread out, others still smaller issue, until finally each ends in a minute closed sac. Here, then, the branching tube of mucous membrane is as much the essential constituent of a compound or conglomerate gland, as it is in the simplest mucous follicle. All the other constituents may be considered as accessories to this fundamental one: the artery b^* runs upon it and ramifies by its capillary offsets, even to the ultimate follicles; the nerve creeps upon the artery to the same points; and from them the veins and lymphatics issue. All these are as much accessories as the fibrous coat which supports the duct and its ramifications. The sub-maxillary gland and the pancreas are constructed in the same way; so is the liver, which is apparently the most complex of all. It is essentially a ramified duct prolonged from the intestinal mucous

membrane. But there appears to be this additional complication in the liver, that the duct, when arrived at the lobules, instead of ending in a simple closed sac, forms in each of them a plexus or net-work, as indicated in fig. 24. This plexus occupies the circumference and area of the lobule; the vein is seen commencing by radicles towards the centre.

However complex the structure of the liver may appear in the higher animals, we find that it becomes gradually resolved into lobes, and these into lobules, and finally into cæcal appendages, as we trace it step by step down from the vertebrate animals through the mollusca, crustacea, myriapoda, arachnida, to the annelida, or red-blooded worms. In the last it is represented by several simple cæca which open into the intestine. Even in some of the lowest division of the animal series, viz. the radiata, cæcal appendages are found which, from their position and relations, are inferred to be the analogues of the biliary organs. It is in this same simple form, viz. a cæcal appendage gradually evolving into an elongated branching tube or duct, that its developement commences in the higher animals.

The pancreas becomes unravelled and simplified in the same way in lower animals. It is still lobed and conglomerate in the shark, and higher cartilaginous fishes: in the osseous, as the cod and haddock, it is represented by numerous cæca, forming a fringe round the commencement of the intestine, and opening separately into it. In cephalopods and gasteropods one or two cæca exist in the same situation, marking the rudimentary condition of the organ.

72. Those who have treated of the structure of glands, adopt, for the most part, the views of Malpighi or of Ruysch. The former considered that the granules or lobules, (acini,) of which a composite or conglomerate gland is made up, are so many follicles, each opening into a common duct. They are so in the salivary glands, but not in the liver; neither are their extremities enlarged so as to present a greater diameter than the branches of the duct which terminates in them. Any enlargement which may appear to exist at these points is in part attributable to the accessory tissues which surround them, such as the cellular substance which supports the capillary vessels and nerves, and partly to the distension caused by injection. Malpighi's opinion, then, as to the intimate structure of glands, is

nearer to the truth than that of Ruysch, who concluded, from his examinations, that the lobules are coils or interlacings of capillary vessels, the arteries being prolonged so as to become continuous with the excretory ducts. Neither of these inferences is tenable with regard to the follicles or the conglomerate glands; both appear to have been deduced from the examination of the kidney, and by some are made still to apply to it; but though the cortical or vascular structure of this organ may be described as formed of capillaries coiled or interlaced, its tubular structure is essentially composed of branching offsets or cæca derived from the ureter, which is a prolongation from the genito-urinary mucous membrane.

ERECTILE TISSUE.

73. There are some parts whose ultimate vessels are so constructed as to admit of a considerable accumulation of blood, causing great distension, and what is termed erection; hence the origin of the term "erectile tissue," (vasa erigentia, tissu erectile,) which is applied to the capillary vessels of the corpus spongiosum, cavernosum, and to those around the vagina and nipple in females. It was formerly supposed that the blood was effused, during the venereal orgasm, into minute cells; for some erectile parts, particularly the corpora cavernosa, when inflated and dried, appear to consist altogether of cellules, formed by septa dividing the interior of the tube into a multitude of minute compartments. This mode of preparing the part for examination is obviously defective; for the vessels contained within the cells are necessarily compressed, and cease to be distinguishable from the fibres which form the septa. But if an injection be passed in by the arteries, or by the dorsal vein, which is the better mode, after having previously, by means of a probe, broken down the valves, it will be found not effused into cells, but contained in a plexus of delicate vessels consisting of minute capillaries communicating with venous radicles, the latter in many places presenting dilatations and free communications. Parts thus organised are known to be peculiarly sensitive; we find that they receive a considerable number of nervous filaments. A structure analogous to that here described is occasionally produced in different parts of the body by a dis-

turbance of the natural formative process, and is commonly known as aneurism by anastomosis.

THE MUSCULAR SYSTEM.

74. The active organs of locomotion are called "muscles" (musculus, à moveo). Taken in their aggregate they form the muscular tissue or substance of the body (tissu musculaire, musculus, μυς, μυες, flesh). In ordinary language they are known by the name flesh, and necessarily differ widely in colour and consistence in different orders of animals. A muscle is a compound structure made up of cellular tissue for its basis, which encloses in its areolæ fibrine as the essential constituent. Tendinous fibres are superadded in most muscles, particularly at their extremities, forming the means of attachment to the periosteum and bones. Arteries and veins circulate in them the materials of growth and nutrition; nerves give sensation and motion; and lymphatics take up the residue of nutrition. Muscle, then, and muscular tissue or fibre, do not mean the same thing; we must remove all the accessory parts just named in order to get at the fibre, or we must make abstraction of those, and contemplate this alone, when we reflect or reason on its properties.

75. When we look at a muscle dissected, it evidently appears made up of fibres arranged in a defined direction; several of these are observed to be aggregated into bundles (fasciculi), each of which is separated from the rest by a thin lamella of delicate cellular tissue. Each fasciculus admits again of being resolved into fibres, and these into fibrillæ; and the separation may be continued until we at length arrive at some so minute as to be incapable of farther division; these may be regarded, therefore, as ultimate fibres, at least in reference to our methods of analysis. The cellular investment of a muscle may be called its "sheath;" the thin lamellæ which dip between the fasciculi are so many processes derived from it. When we come to the fibrillæ, and find each composed of a tube of cellular tissue enclosing the essential constituent of muscle, we apply to it the term "myolema," figs. 25, 26.

By macerating muscle in water, it parts with the red colour which it possesses in higher animals, and becomes ash-grey,

KING'S COLLEGE HOSPITAL Medical School LIBRARY

with a slight straw-coloured tint; the water takes up from it the colouring matter, albumen, gelatine, extractive matter, and some salts; after which there remains fibrine with cellular tissue, the latter seeming to serve as the nidus in which the former is deposited.

76. *Muscular fibre — its intimate structure.* — Those who have examined muscular fibre with the microscope differ considerably in the statements which they make of the result of their observations. At one time it was supposed to consist of a series of vesicles, which were oblong or elliptical in the flaccid state, their long axes being in the direction of the fibre; but that when in action, their form changed to spherical, or, if it still continued elliptical, the major axis became transverse: in this way they accounted for the shortening of muscular fibre, the alterations in the form of the vesicles being produced by an afflux of animal spirits conveyed by the nerves. Many men of the present day, who reject this speculation, contend for the existence of globules placed in regular lines along the fibre, as if they were deposited in the areolæ of cellular tissue. Some represent the fibre as a hollow tube containing fibrine. Is it that the object seen appears to be of that form which prepossession in favour of some particular hypothesis concerning muscular action had rendered probable that it should be, or is the difference owing to defect in the instruments used? When examined with a microscope of ordinary power, globules appear to exist; but with other instruments, the fibre resembles a gelatinous thread, soft and homogeneous. Dr. Hodgkin and Mr. Lister, however, with the aid of an instrument, the power and accuracy of which are generally admitted, observed numerous cross lines placed parallel, and in a manner intersecting the fibre at minute distances. Hence some have inferred that the bead-like or globular structure attributed so generally to muscular fibre, is but an optical illusion, owing to the shadows produced by the transverse lines just noticed.

When in action, the fibres, instead of being straight and parallel, are thrown into waving lines, not unlike those seen on a watered riband. In this state the extremities of the muscle approach, it becomes shortened and contracted; its thickness, at least towards the middle part, being increased. Formerly it was contended that muscles acquired a positive increase of bulk

during their contraction, and the opinion was supported by experiment. Now, on repeating the experiments with proper attention to accuracy, no such increase can be detected; and it is altogether unlikely that new matter could be imparted or withdrawn at each alternation of action and rest in muscles.

77. Muscles being obviously subjected to nervous influence, we naturally inquire what anatomical relations subsist between the ultimate fibres of nerves and the fibrillæ of muscles. MM. Prevost and Dumas arrived at the following results, after an extended investigation of this subject. When a piece of muscle (the rectus abdominis of a frog, from its evenness and thinness, is the most convenient that can be selected,) was examined with a microscope, after some previous preparation, the nervous branches, on entering its fasciculi from the sides, appeared to give off threads which run between the fibres, and each pair of these is connected by minute parallel filaments running across the intervening muscular fibre. The latter, viz. the transverse filaments, after running a short way in the direction indicated, begin to curve and return to the branch from which they set out, or join, in the form of an arch, with some others. Thus the nervous filaments, after intersecting the muscular filaments, terminate by forming delicate loops or arches, both ends of which are in communication with the brain or spinal cord. Now a muscle is observed to form zig-zag lines when thrown into action; and the angles of inflection, which occur at very minute intervals, correspond with the points at which the nervous filaments impinge upon and cross them. In this way the muscle is shortened, and traction is made upon the point to which its ends are attached.

78. Raspail (Chimie Organique, p. 212) criticises this statement, and expresses a decided opinion that it is altogether untenable. He says it is difficult to conceive how elastic fibres can present such precise angular inflexions as those represented in the drawings of MM. Prevost and Dumas. And in the next place, when nervous fibrillæ approach in size that of the ultimate muscular fibres, the one cannot be distinguished from the other. Moreover, when a flat slip of muscle is laid on a plate of glass, it necessarily is in contact with many points of it; hence, if it be drawn at one end, or excited by a voltaic current, inflexions or zig-zags will appear in the fibres, owing to the resistance given

at the points where they are in contact with the glass. Raspail here assumes the fibres to be elastic, and reasons upon them as such; and also that they are placed upon a dry glass. In such experiments a pellicle of water is usually laid upon it, and confined to the middle of the glass by a simple contrivance. However, as I have not repeated the experiment, I have nothing to offer either upon the original statement or the comment. Raspail observes, that having had many opportunities of examining the movements in the muscular foot of gasteropods, he never saw anything in them like what Prevost and Dumas describe and represent. He constantly saw that the fibres, whilst they shorten, become at the same time enlarged in breadth, so as to present small swellings along their course.

79. Several methods have been adopted to determine these points relative to muscular fibre. Thus the Wenzels made their microscopic observations on pieces of muscle which had been previously steeped in spirit or weak acid. This is evidently objectionable, as the myolema is corrugated and rendered opaque; still they found the fibres to be composed of minute globules placed in lines. Such a mode of experimenting cannot be considered conclusive, as the globules may have been produced by the previous preparation which coagulated any albuminous matter that may have adhered to the fibre, or that which exists in the myolema. The muscular substance used should be fresh,—that of pork answers perhaps better than any. If a small fragment be detached and laid on a piece of glass, it can, by the aid of a fine needle, be resolved in filaments so minute as to be incapable, without breaking them, of being farther divided. A few of the finest and most perfect of these may be separated from the rest without disturbing them from the glass, and placed under the lens. Some of them give the idea of a homogeneous gelatinous thread of a slightly pink tinge; but others seen towards the centre of the field of view, and in better light, exhibit minute extremely close transverse bars, such as are indicated in fig. 25. These appear to be in the myolema, and to be owing to its being thrown into plicæ, as they disappear if the fibre is stretched. Continuing the observation, it will be found that the fibre is not homogeneous or gelatinous; but that it consists of a tube, the myolema, filled with minute globules, as represented in fig. 26. I repeated these observations with Mr. Wil-

son, the same results were obtained two or three times; and Mr. Bagg made these sketches from what he saw when the microscope was placed before him without knowing what the object was.

80. There are some opposing statements as to the relative size of muscular fibre and the globules of the blood, which may be here noticed. Prochasca concluded the former to be to the latter as 1 to 7. Sprengel, however, states the relative size of the fibre and the blood globule to be precisely the reverse, viz. the fibre is to the globule as 7 to 1.

81. Having proceeded in this discussion thus far, I am unwilling to prolong it, or offer any speculation as to the mechanism of muscular contraction. Still, as I have generally found persons better pleased to have a resting-place for the mind, even though it be but a provisional one adopted until a better can be devised, rather than be left in a maze of incertitude, I may offer one founded perhaps, it will be said, on a slight or remote analogy, yet one sufficiently recognised by physiologists. From what has been already stated, we know sufficient of muscular fibre to reason upon it; we know it to consist of a cylindrical tube—a myolema, (fig. 25,) enclosing minute globules in its interior (fig. 26). We know that all the movements and actions produced by muscles, are owing to that property which their fibres possess of shortening when excited or stimulated. We also know, from numberless facts, that this shortening or contraction of the fibres is determined in the first instance, kept up and regulated by an influence conveyed by the nervous filaments which reach them from the various nervous centres. Now, on what does this influence act, and in what way, assuming for a moment that there is an analogy between it and voltaic agency? We can hardly suppose it to be on the myolema, which is but a delicate or slightly modified cellular tissue; there remains then but one other constituent, namely, the globules, on which it can act. Now, if it be permitted us to suppose that the nervous agency influences the globules of the fibre, as the voltaic is conceived to do the molecules of a piece of metal on which it acts, —that it changes their state so as to render them attractive of one another, or repulsive, or simply quiescent, just as the voltaic can impress a given polarity upon the molecules of a mass, reverse it, or destroy it altogether,—we may conceive that the

fibre shortens when its globules are rendered mutually attractive, and also increased in width. When the nervous influence ceased to be directed to a particular set of fibres, they become quiescent, their particles returning to their neutral or unexcited state; it may then be determined to others whether assistants or antagonists, and so the succession and series of movements is kept up.

82. When seeking to express briefly the distinction between muscular tissue and others, it will not suffice to say that it is fibrous,—for several other structures possess that character which have little else in common with it;—nor that it is of a red colour, like blood, for it is white in most fishes, and in many of the lower tribes of animals. Its true distinguishing character is, the property it possesses of shortening or contracting in obedience to the will, or on the application of a stimulus. This is its essential attribute, and constitutes a broad line of distinction between it and other organised structures. This property has been variously denominated at different times, "vis insita," "irritability," "contractility," and has been at all times a fertile subject of controversy among physiologists; some contending that it is an endowment residing in the muscles themselves; others, that it is imparted by the nerves; whilst a third party takes up an intermediate position, admits the existence of a peculiar property in muscles, but contends that nervous influence is necessary to bring it into action. When a muscle is cut across, both ends retract slowly, and remain permanently shortened.

83. *Muscles, voluntary, involuntary.*—The muscular system is divisible into two parts, which are distinguishable not only by the situations they occupy, but also by their general conformation and functions. One is subjacent to the skin, and composed of a number of separate pieces, of various forms and sizes, all under the control of the will; the other, disposed in the form of a thin tubular layer around the alimentary canal, consisting of pale fibres, which are not influenced by the will. Hence the origin of the division of muscles into voluntary and involuntary, or, according to Bichât, into those of animal and organic life; the actions of the former, being performed with consciousness, serve to keep up our relations with the external world; whilst those of the latter, which are not attended by consciousness, are

confined to the functions of nutrition, or of vegetative life. There is, however, a third group, whose action continues even though consciousness be suspended, during sleep, or in comatose diseases; but which, under other circumstances, are, to a certain extent, influenced by the will, viz. the respiratory muscles, which in these particulars are intermediate between the other two, and are called mixed muscles.

84. *Muscles: their varieties and nomenclature.*—Muscles present numerous varieties in their form, size, and distribution of their fibres; some being broad and flat, like the muscles of the abdomen and the superficial layer of the back; some long and tapering, like the muscles of the fore-arm; some short and compressed, like the masseter and pterygoid. Their extremities or points of attachment are named *origin* and *insertion;* the former being the more fixed point, and that to which it ordinarily draws, the latter being less fixed: the intervening fleshy part is called the *body* or belly. Muscles are arranged in groups, according as they are associated for the performance of special actions; some being flexors, others extensors; some adductors, others abductors. The individuals of each group are called assistants; those which combine to oppose them antagonists. The nomenclature of muscles is not even yet constructed upon scientific principles; some being named from their position, such as the temporal and occipito-frontalis: some from their form, as the trapezius, serratus, rhomboideus; some from their position, as the pectoralis, brachialis, anconeus; some from the disposition of even their accessory parts, as biceps, triceps; many from their uses, as elevators, depressors, abductors, adductors; and not a few from their points of attachment, as sterno-hyoid, sterno-thyroid. This necessarily gives an unscientific and immethodical character to our myology, and increases not a little the difficulties which beginners find at the commencement of their studies. Throughout this work the nomenclature of Sœmmering is generally adhered to, as being that which is adopted by the most experienced teachers. Chaussier's terms are added to facilitate the perusal of French anatomical and surgical works; and those of Dumas, because they briefly mark the points to which each muscle is attached, but I have in most places Latinised their terminations to make them more in accordance with the other terms employed.

THE NERVOUS SYSTEM.

85. The nervous system, (*système nerveux*,) nervous tissue, (tissu nerveux,) nervus, νευρον, may, with great propriety, be said to preside over all the leading functions of the economy; for it would be restricting its influence to a very narrow limit, were we to say that it merely receives impressions from without, and transmits volitions from within: its dominion extends much further. When we see a limb deprived of sensation and motion by an apoplectic seizure, we at once admit that these powers are dependent on nervous action; and we cannot but infer that nutrition and animal heat are equally so, when, at a subsequent period, we find it wasted and reduced in temperature. All persons are aware how the secretions may become deranged and vitiated by injuries of the spinal cord: that of the kidneys, for instance, becomes small in quantity, turbid, and ammoniacal; digestion is suspended by the section of the vagus nerves; and the researches of Le Gallois and Wilson Philip have shown how the circulation is affected by and through the nervous influence. Finally, intellect and reason are instantaneously extinguished if a small fragment of bone be depressed upon the surface of the brain.

86. *Nervous system—general idea of.*—Many persons evince a disposition to compare and contrast objects, rather than formally describe them, perhaps with the view of conveying some general notion of their composition and characters. The nervous system has been dealt with in this way, having been likened to a tree; the brain serving as the root, the spinal cord the trunk, and the nerves as branches: but latterly it has been viewed in a different way; the nerves being considered the roots, as they are known to be formed first, and may, as in acephalous cases, exist, although the central masses are never formed: and lastly, it has been compared to a vast net-work of nerves, interlacing by their ultimate filaments at their peripheral terminations throughout the system, and also becoming united by decussation, or by commissures in the central masses. However vague, and in some respects questionable, such loose generalities as these may be, they serve the purpose of conveying to the mind the idea that the nervous system, though complex and subdivided, forms one whole, all its parts being intimately connected and associated, at the same time that some are placed in subordination to others.

87. *Nervous system, symmetrical.*—When viewed as a whole, the nervous system is symmetrical in the strictest sense. It consists of two lateral halves, which, being disposed similarly on each side of the central line, resemble one another in every particular. Thus, the brain is divided into two hemispheres, each presenting on its inferior surface three lobes; the cerebellum also is divided into two lobes; and the medulla oblongata into two lateral halves, (each consisting of three fasciculi, or bundles of fibres,) the division being established by two grooves or sulci, one on its anterior, the other on its posterior aspect, situated exactly in the median line. These sulci, by being continued along the whole length of the medulla spinalis, divide it also into two symmetrical portions. This symmetrical arrangement extends to the nerves so long as they retain the form of distinct cords; but when, at their peripheral termination, they become expanded into, and blended with, the minute texture of the different organs which they supply, their mode of distribution eludes our research. We can, however, infer that their filaments interlace one with another, so as to form a net-work, by which a complete and free communication is established between them.

Commissures.—Again, when we examine the central masses, we find that each lateral half is connected with the other by certain transverse bands, disposed along the middle line, and which are termed commissures. On this union and connexion between the different parts of the nervous system, by which they become intimately blended at their periphery, as well as towards the centre, the individuality of the animal essentially depends.

The central parts of the nervous system are deeply seated, being inclosed within the spinal canal and the cavity of the cranium. The nervous cords, too, are in a great degree withdrawn from the influence of external agencies by the situations in which they are placed during their course. Their final terminations only approach the surface, where, by being expanded on the internal and external teguments, they communicate to these parts their sentient and tactile properties.

88. *Composition.*—The nervous system is made up of two substances, readily distinguishable by their colour, texture, and consistence. One is greyish, or rather a pale ash-colour, and hence named *cineritious* (substantia cinerea); and as in the

brain it forms an investment for the white substance, it is usually termed *cortical* (s. corticalis). The other substance is of a pure white colour, and from the relation just indicated is called *medullary* (substantia medullaris). It cannot, however, be said with propriety that the one is external, or the other internal, as their position is reversed in different parts of the system. The grey substance invests the cerebral hemispheres, and forms at the same time several masses disposed in their interior; but in the medulla spinalis it is altogether deeply seated. The white substance, on the contrary, is enclosed by the grey in the brain, but becomes the cortex in the medulla. The cineritious substance is more soft and vascular than the other. The difference in these particulars is rendered more striking when the brain is minutely injected. Though the white substance in the natural state, more particularly in the fœtal state and in early infancy, is not much firmer than jelly, it acquires a great degree of firmness by maceration in spirit, and presents at all times a distinctly fibrous appearance. When these two sorts of nervous matter are attentively examined, they will be found to consist of a peculiar substance called *neurine*, deposited in the areolæ, of a delicate cellular tissue. This anatomical element, in its natural condition, is soft and as it were plastic to the touch, and wherever it predominates much, the part will be pulpy, whilst other portions of the structure are comparatively firm, by reason of the greater quantity of cellular tissue which they contain. The colour of neurine presents some varieties, being white, grey, or yellowish, and in some places of a dusky hue.

89. When a thin layer of nervous substance is examined with a microscope, it presents the appearance of small granules, placed in lines more or less regularly; but their form and size are liable to vary. These have been taken by some observers for globules, and have formed the basis of many speculations concerning the nature of nervous action: by some they are said to resemble much more nearly the delicate flakes observed in coagulated albumen. According to the analysis of Vauquelin, neurine consists of

Water	80·00 parts.
Albumen . . .	7·00
White fatty matter . .	4·53
Red fatty matter . .	0·70

Osmazome . . .	1·12
Phosphorus . . .	1·50
Sulphur . . .	5·15

M. Couerbe has detailed the results of his analysis of the brain (*Annales de Chimie*, June 1834), which bears out that of Vauquelin so far as it goes, and adds some other constituents to which he appears to attach consequence in a physiological point of view. He establishes the existence of sulphur, phosphorus, and osmazome, also the two fatty matters; but he gives them scientific names, calling the white matter "cerebrote," the other from its being pulverulent, "stearconote." He adds to the list an elastic fat (cephalote), and a reddish yellow oil (eleencephol); also cholesterine, and some inorganic salts. In his microscopic examinations of the cerebral mass he found it to be composed of globules, those of the white substance being smaller than the grey, in which particular he differs from other observers.

90. *Nerves, their structure.*—The nerves or nervous cords which issue from the central mass consist of a cylinder of neurine, of a perfectly white colour, enclosed in a thin firm sheath of condensed cellular tissue, called neurilema (*νευρον*, a nerve; *λεμμα*, a husk or rind). But the cords thus formed are not simple in their structure, for each may be divided into a number of smaller filaments, possessed of the same component parts as the nerve itself. According to the researches of Prevost and Dumas, one of these minor subdivisions is itself an aggregate of four delicate fibres, placed pair and pair—two external and two internal, the former being more easily recognised than the latter; and, in all, they observe a number of globules placed in regular lines, thus identifying their composition with that of the brain: but this does not accord with the researches of other physiologists. De Blainville denies the existence of regular globules in the nerves, nor does he admit them to contain even the corpuscles or granules which are seen in the central masses.

91. If we take a piece of a nerve two or three inches in length, for instance the median nerve in the arm, we find it white, firm, and cord-like; by rolling it between the fingers it is felt to be made up of several smaller cords; by squeezing it at the cut ends, soft white nervous matter can be forced from each filament. If its ends be pinned to a piece of board, the membrane which encloses all these filaments and gives them the

appearance of a single cord, can readily be dissected off. This is properly the sheath of the nerve. In fig. 28, the sheath is indicated at the upper part, c^*, but lower down it is detached and drawn up so as to expose the separate filaments. Now each of these, d^*, has its investment, and to this the term "neurilema" should be restricted, as it is in immediate contact with the neurine and constitutes its proper tunic. By dissecting the filaments of a piece of nerve, placed as above indicated, it will be found that they do not lie merely in apposition within their sheath; offsets pass from one to the other, as shown in fig. 27, constituting a plexiform arrangement. But this is not an anastomosis.

When a filament of nerve is examined with the microscope, its surface presents numerous delicate waving lives, as indicated fig. 29. These appear to be in the neurilema, the interior of which will be observed to contain rounded globules (fig. 30), which, however, do not present exactly the same size or form. In a memoir recently published, Ehrenberg establishes a distinction between the filaments which compose the anterior and posterior roots of the spinal nerves. He observed that the posterior or sensitive filaments present slight enlargements from point to point in their course. These he illustrates by numerous drawings.

92. *Cerebral substance—its structure.* The fibrous character of the white substance was distinctly recognised by Malpighi, —the grey he considered to be in its nature glandular. Gall, and all the inquirers of modern date, agree in recognising the fibres of the white substance, and in tracing them in the different directions in which they are disposed: as to the grey matter, Gall viewed it as being the terminus and the origin of the white fibres, its different masses strengthening it and reinforcing it, so as to deserve the name "ganglions de renforcement." Almost all those who have examined the cerebral substance with the microscope, agree in stating it to be composed of globules; but as to their size, form, and composition, many discrepancies exist, which are attributable partly to the intricacy of the subject, partly to the optical errors incidental to such modes of examination. Sir E. Home and Mr. Bauer (*Phil. Trans.* 1821), found the brain to consist of semi-transparent globules, but not of equal size, some being about equal to the nucleus of

blood-globules, others smaller. They recognised, moreover, "a transparent gelatinous substance and a fluid analogous to serum. Upon the relative proportions of these constituents depend the varieties of consistence observed in different portions of nervous matter. Thus, as in the grey substance the gelatinous and serous parts are more abundant and the globules smaller, its consistence is less. In the nerves, though the globules are arranged in lines constituting fibrillæ, they vary much in size." As to the composition of the globules, the Wenzells concluded from their observations (*De penitiori cerebri structurâ*), that they are vesicles filled either with grey or white matter, according to the part examined.

Some other observers state that the globules are largest in the brain, smaller in the spinal marrow, and still less in the nerves (De la Torre); whilst Milne Edwards contends that they are of the same size in all parts of the system.

93. *Ganglia.*—In different parts of the nervous system we find masses or bodies termed ganglia, which vary very much in size and form. Gall, and after him De Blainville, extend the application of the term; for they bring within its meaning the different masses of grey matter in the brain and spinal marrow. If this view be adopted, we shall have to consider as ganglia, 1. The grey masses just alluded to as existing in the spinal marrow, medulla oblongata, optic thalami, corpora striata, corpora rhomboidea, — the conarium, pituitary body, tuber cinereum. The structure of these may be said to be that of the grey cerebral substance, as above noticed. 2. The enlargements which exist upon the posterior roots of the spinal nerves from the fifth cerebral to the last lumbar. 3. Those which are found in the course of the cerebro-spinal nerves, or at the junction of some of their filaments, such as the ganglia of the vagus and glosso-pharyngeal, the submaxillary, spheno-palatine, ophthalmic, otic, petrosal, &c. 4. Those of the trisplanchnic nerves (sympathetic).

94. As to the structure of ganglia, not a few discrepancies exist amongst writers. We cannot be surprised at this when we see that they are very far from being identical objects; and therefore no one statement will rigorously apply to all. The ganglion (Casserian) of the fifth nerve, and all those on the posterior roots of the spinal nerves, seem to have been present to

the mind of those who have described them as closely woven plexuses in which the nervous filaments are divided and suitably arranged before proceeding to their respective points of distribution (Meckel ; Zinn). But the ganglia of the trisplanchnic nerves are very different in colour, texture, and composition. They are of a reddish grey colour, well supplied with blood-vessels, possess a smooth investment or capsule, and in their interior we find (if one of them be carefully sliced on a plane with the filaments which enter and emerge) white fibrillæ continuous with the nerves, and supported by grey matter which seems to be analogous to that of the brain. Structures such as these cannot be considered as mere plexuses; the opinion of Winslow, Johnstone, and Bichât, who regarded them as so many distinct nervous centres, appears more tenable. In radiated animals we see the nervous system reduced to a few ganglia, connected by filaments and giving some offsets which are sufficient for their simple economy ; and in the highest vertebrate animals, before the great nervous centres are developed, and in those acephalous cases in which their growth is altogether interrupted, the vegetative functions have no other nervi-motors than the ganglia and their filaments. It will be asked whether chemical analysis has shown the existence of neurine or cerebrine in the ganglia? There are few, if any, analyses recorded, save that by M. Lassaigne, founded on his examination of the ganglia in the horse. His results were albumen, fatty matter, fibrine, and phosphate of lime. There is no neurine, therefore, notwithstanding the existence of the white filaments continuous with those of the nerve. It is several years since this analysis was made ; if it were now repeated, it is very probable that a different result would be obtained.

95. The modes of dividing and arranging the parts of this complex structure, suggested by different writers, appear to have been adopted in the first instance in conformity with the opinions which they entertained of its functions and properties. According to Galen, the brain should be considered as the central or fundamental part ; Bartholin assigned that rank to the spinal cord. Most anatomists, in times past, divided the system into two parts, viz. the brain and spinal cord, or the central mass (axis cerebro-spinalis), and the nerves as prolongations from it. Bichât, guided by his peculiar views of the vital phe-

nomena, contended for the existence of two sorts of nervous influence; one being derived from the apparatus appropriated to animal life, viz, the spinal cord, brain, and cerebellum, and the nerves which are connected with them; the other, from the two knotted cords which lie along the spine, which he called the nerves of organic or vegetative life, but which are generally known as the sympathetic or trisplanchnic nerves. Dr. Gall extends the principle of subdivision much farther than his predecessors had done; his previous inquiry into the nature and manifestations of the mental faculties having led him to observe their different modifications in various tribes of animals, as well as in individuals of the same species, and conceiving them to be so many distinct powers, which necessarily require distinct material instruments,—he concluded that each, when in action, works by a distinct portion of cerebral substance, which may be considered as its seat and its organ. In this view of the subject, the nervous system appears to be divisible into as many parts as there are functions to be performed and faculties to be exercised, each part constituting a special apparatus or organ, as follows:—1. The spinal cord and the double-rooted nerves connected with it, forming the apparatus of sensation and motion; 2. The medulla oblongata and its nerves, being the apparatus of the special senses; 3. The cerebral masses, (cerebrum and cerebellum,) divided into the several organs of instincts, sentiments, moral and intellectual faculties.

96. Willis arranged the nerves under three heads: those arising from the brain, ten in number on each side; those of the spinal cord, thirty-one pairs; and thirdly, the sympathetic nerves. According to this arrangement, nerves differing materially in structure and in function are grouped together, and some which are totally distinct in every particular are set down as parts of one whole. The seventh pair of nerves, for instance, consists of a hard and a soft part (portio dura, portio mollis); and the eighth consists of three parts, the nervus vagus, glosso-pharyngeal, and spinal accessory. Sœmmering has in some measure lessened the confusion arising from this mode of arrangement, by separating the facial nerve from the auditory, and detaching the glosso-pharyngeal and the accessory from the vagus; but the classification still includes a consideration of their position only, without making any reference to structure or function.

An arrangement of the nervous system, perfectly free from objection, cannot be expected in the present state of our knowledge; for that pre-supposes a perfect acquaintance with its structure and conformation in all classes of animals, from the highest to the lowest,—of its developement, as tending to show the subordination and dependence of its parts,—and of the functions which each of them performs. The division of the nerves into cerebral and spinal cannot be adhered to any longer; for the fifth,* so called, cerebral nerve is strikingly contrasted in its structure and function with those around it, and with which it has hitherto been classed, whilst it is in every respect similar to those attached to the spinal cord. Neither ought we to continue, as heretofore, to enumerate the nerves in the order of their position from before backwards along the basis of the brain; for the first cerebral nerve (olfactory) has no similarity in character or in function with the third (motor), nor is the second (optic) more closely allied to the sixth (abductor), or the seventh (auditory) to the ninth (lingual). The nerves of the special senses form a distinct group. The following arrangement of the different parts of the nervous system will suffice for our present purposes, and will be found to conform to the views of the best-informed physiologists:—

Nervous system of animal life, or life of external relation (Bichát).

- Cerebro-spinal axis, composed of
  1. The spinal cord, with its cranial prolongation (medulla oblongata), which probably should not be restricted to the lower margin of the pons, but be considered as extending up to where the crura cerebri become identified with the hemispheres, thus including the tractus motorius.
  2. The cerebral masses (cerebrum and cerebellum).
- Nerves, or chordæ internunciæ grouped into sets, according to their structure and functions.
  1. The spinal nerves, symmetrical, with double roots, a ganglion on the posterior one, thirty-two pairs, including the fifth cerebral nerve.
  2. The "respiratory" or "superadded" nerves, attached to the side of the cord (its upper part), and distributed to the respiratory organs, according to the views of Sir Charles Bell.

* Sir C. Bell on the Nervous System.

Nervous system of animal life, or life of external relation (Bichât).

Nerves, or chordæ internunciæ grouped into sets, according to their structure and functions.

3. The simple motor nerves, attached by single roots to the cranial prolongation of the anterior fasciculi of the spinal cord (tractus motorius), 9th, 6th, 3rd.
4. The nerves of special senses, viz. smell, sight, hearing: taste and touch appear to be but modifications of the common tactile property.

Nervous system of organic, or vegetative life; the life of nutrition (Bichât).

The tri-splanchnic nervous system, whose ramifications extend through all the viscera (σπλαγχνα) called by some gangliac (though ganglia are not peculiar to it), also sympathetic. We may, with De Blainville,* consider it as divisible into two parts: one placed in front of the spine (præ-vertebral), composed of plexus and ganglia (semilunar and cardiac), whose branches are distributed to the primary organs of digestion and circulation; the other consisting of two knotted cords, extended along the whole length of the spine, communicating with the præ-vertebral plexuses on the one hand, and with the cerebro-spinal nerves on the other.

97. It will be observed that the nerves which are connected with the base of the brain, and are thence called cerebral, are here divided into three groups,—those of the special senses, the simple motor nerves, and the respiratory, as they are called, for want of a better name.

The two last M. Arnold (*Icones nervorum capitis*) arranges in a different way. The bones of the head have been long considered the analogues of vertebræ, the foramina at its base are similar to the intervertebral foramina,—if so, they transmit like parts; now, as the nerves which pass out of the intervertebral holes are compound, each having two roots, ministering, one to sensation the other to motion, the several nerves issuing from the base of the skull may be considered as separate fasciculi, some of motor roots, others of sensitive roots. But how many compound nerves are thus formed? That will depend on the number of cranial pieces admitted; and upon this a difference of opinion exists. Meckel, Carus, and Cuvier recognise three, as will be shown in the concluding remarks on the bones of the head. Bojanus admits four, and Geoffroy St. Hilaire raises the number to seven. M. Arnold adopts the former number, and therefore there can be but two intervertebral holes and two com-

* Cours d'Anatomie et de Physiologie Comparée.

pound nerves. In following out such an analogy as this, not a little latitude must be assumed.

- First compound cerebral nerve.
  - Anterior, or motor root, consists of — The third, fourth, sixth nerves, the smaller or motor division of the fifth, and the seventh (portio dura).
  - Posterior, or sensitive root. — The fifth nerve,—its ophthalmic, and superior and inferior maxillary divisions.
- Second compound cerebral nerve.
  - Anterior, or motor root. — The spinal accessory nerve, and the motor linguæ.
  - The sensitive, or posterior root. — The glosso-pharyngeal nerve, and the nervus vagus.

I should feel disposed to admit three pairs of compound nerves, and therefore four vertebræ. The first consisting of the third, fourth, and sixth nerves as its motor root, and of the ophthalmic division of the fifth as the sensitive portion: these pass out through the sphenoidal fissure. The second may be said to have for its motor part the anterior or small root of the fifth nerve, and the facial nerve; its sensitive root being composed of the two larger divisions of the fifth nerve. The third compound nerve will then have the spinal accessory and lingual for one root, and the glosso-pharyngeal and vagus for the other.

98. The anatomical constituent or elements, described in the foregoing pages, are found to enter (variously modified) into the composition of certain parts, each of which is marked by a particular conformation, and intended for a special purpose: these are termed organs. The word *organ* (organon, instrumentum) is used by anatomists to express the material instrument by which an action is executed, or a function performed; for instance, the organ of voice, the organ of respiration. An assemblage of two or more organs, associated in the performance of a common function, is termed *apparatus*, viz. the lachrymal apparatus, the digestive, &c.; and the result which follows a certain action, or is produced by an organ or apparatus, is termed *function*.

99. Descriptive anatomy includes several compartments, which are variously denominated, according to the subjects of which they treat: they are usually arranged in the following order:

Osteology (*οστεον, a bone; λογος, discourse* or *description*) comprises the description of the structure, form, and uses of the osseous system, and its different parts.

Syndesmology (*συνδεσμος, a ligament; λογος, a description*), or the description of the ligaments and other structures which serve as the means of connexion between bones, and constitute their articulations, or joints.

Myology (*μυων, a muscle; λογος, a description*), the description of the muscles, the active agents in the different motions and actions of the body.

Angeiology (*αγγειον, a vessel; λογος*), the description of the vessels which convey the circulating fluids.

Adenology (*αδην, a gland; λογοι*), the description of the glands and absorbent vessels.

Splanchnology (*σπλαγχνον, a viscus; λογος*), the description of the viscera situated in the large cavities, and which minister to the more important functions.

Neurology (*νευρον, a nerve; λογος*), includes the description of the nerves, brain, and organs of sense.

CHAPTER II.

OSTEOLOGY.

100. The osseous structure is peculiarly fitted, by its solidity and hardness, not only to give support to the soft parts, but also to furnish points of attachment to the muscles, by which the different movements are executed. This solid frame-work of the body is made up of a number of separate pieces, the aggregate of which has been termed "*the skeleton*," (sceletum, *σκελλω, to dry*). The vertebral column may be considered as the central or fundamental part of the whole, both because it exists in all animals which possess an internal osseous skeleton, and also because the different parts of the osseous system are either immediately or mediately connected with it as a common centre. Thus, on its superior extremity or apex it supports the skull; laterally it gives attachment to the ribs, which arch forwards, to form, with the sternum, a bony case for the lodgment of the organs of respiration and circulation, at the same time that they furnish externally points of support for the superior extremities: inferiorly the column is immovably connected with the pelvic bones, which are articulated with those of the lower extremity.

101. When proceeding with the description of the human body, it is usual to consider it as divisible into head, trunk, and extremities, which is sufficient for the purposes of a regional division; but the skeleton must be viewed in a different way, particularly if reference is made to its conformation in the various orders of animals—to its developement—and to the subordination of its component parts. The spine being its essential constituent, all the others (viz. the ribs and sternum, clavicle, scapula, and upper extremities, the pelvic bones and lower extremities,) rank as accessories. The sacrum and coccyx are obviously parts of the spine, so likewise are the cranial bones; for though, in outward appearance, they differ so much in man and the higher animals from the bones of the spine which are placed beneath them, and with which they are articulated, they still are

but modifications of similar organic elements—repetitions, in fact, of like parts differently developed to suit the peculiar relations into which they enter, and the purposes which they are designed to serve.

102. The number of pieces which compose the osseous system varies in the different ages of life; for some, which in the first instance are divided into two or more portions, become soldered together as the process of ossification goes on. But authors are far from being unanimous as to the number of bones which they recognise even in the adult. Do the sesamoid bones form parts of the skeleton, or are they mere accessory structures developed in tendons? Are the teeth, os hyoides, and ossicula auditûs, to be enumerated as components or accessories? Monro and Sœmmering reckon 260 bones; and Meckel, who takes the number at 253, includes the teeth, patellæ, ossa sesamoidea, os hyoides as five pieces, sternum as three, coccyx as four, and the small bones of the ear. If, however, we omit those just named, as being either accessories or connected with special organs, the whole number of pieces found in the ordinary skeleton will be 197, as follow:—

The spinal column, properly so called, consists of 24 vertebræ, the sacrum and the coccyx (26).

The skull is made up of eight cranial bones, viz. the occipital, two parietal, two temporal, the frontal, the ethmoid and sphenoid:—and of fourteen facial, viz. two nasal, two lachrymal, two superior maxillary, two malar, two palatal, two turbinated, one vomer, and the inferior maxillary bone (22).

The ribs are 24 in number (twelve on each side), with the sternum (25).

The two superior extremities consist each of a clavicle and scapula, humerus, radius, and ulna, eight carpal bones, five metacarpal, and fourteen in the digital rows (64).

The two inferior extremities comprise, each, one pelvic bone (innominatum), one femur, tibia, and fibula, seven tarsal bones, five metatarsal, and fourteen digital (60).

In the skeleton we recognise two great cavities (which are again variously subdivided); one anterior and inferior, comprising the thorax and abdomen; the other posterior and superior, formed by the union of the vertebral canal with the cranial cavity.

VERTEBRAL COLUMN.

103. The *vertebral column* (columna vertebralis, rachis, spina,) is situated along the median line, at the posterior part of the trunk, the length of which it determines. Anteriorly it presents the form of an irregular pyramid—posteriorly, a series of elongated processes (spinæ), disposed regularly one beneath the other, from which circumstance the term "spine" is derived. Viewed as a whole, it resembles at first sight the shape of a long bone, but it is very differently constructed. As it receives the weight of the head and trunk, and transmits it to the base on which it rests, it requires to be firm and resisting, its power of resistance increasing gradually from above downwards. Being the centre of all the movements of the body, it must be as pliant and flexible as a bow, but yet firm, in order to give adequate protection to the spinal cord which it encloses. All these conditions are attained by its being made up of several small pieces united by an elastic substance, the motion permitted between each pair being slight, while the aggregate of all is considerable.

The *vertebræ*, or separate pieces of which the column is made up, are so named from their mobility (vertere, to turn). They are divided into *true* and *false;* the former term being applied to those which remain separate in the adult, and retain their mobility—the latter to such as become united into one mass, (viz. the sacrum,) or degenerate as it were, and lose all the ordinary characters of vertebræ (viz. the coccyx). The size of the vertebræ increases from above downwards as far as the first pieces of the sacrum, from which it diminishes towards the end of the coccyx, where it terminates by a point; so that the column may be said to consist of two pyramids applied to one another at their bases. The superior, or movable one, however, does not taper regularly from above downwards in its entire length; it becomes somewhat narrowed and constricted as it were at the third dorsal vertebra, after which it gradually enlarges towards its base.

Vertebræ, division of.—The true vertebræ are divided into three sets, named from the regions which they occupy, *cervical*, *dorsal*, *lumbar*. The sacrum and coccyx, which form the remaining part of the column, shall be described with the bones

of the pelvis, as they enter into the composition of that cavity, and maintain important relations with the organs which it contains.

The true vertebræ present, 1. certain general characters by which they may at once be distinguished from bones of any other class; 2. those of each region (cervical, dorsal, lumbar,) exhibit peculiar characters by which they are severally distinguished.

104. *General characters of a vertebra.*—It is usual to say that a vertebra consists of body and processes—the body being the primary or fundamental part. The objects presented by each of these bones are, a body, a ring, articulating processes, transverse and spinous processes, and notches: of these, the ring, or foramen, merely to suit the purposes of methodical description, may be considered the central part. As the whole series of vertebræ is intended to form a pillar of support, each, with the exception of the first, presents in front a convex mass (the body), which is a section of a cylinder, and which, by being piled one over the other, form the pillar. As each bone must be securely joined with the one above it and that below it, there exist certain prominences for articulation with them. The column being flexible, and partaking in the several movements of the body, it is required that there be levers for the attachment of the muscles or moving powers. Finally, it is necessary that a free communication should be allowed for the nerves with the nervous centre contained in the canal.

The *ring* (foramen vertebrale, rachidium,) is formed in front by the body, and posteriorly by what is named the *arch* of the vertebræ, from which latter the several processes project. As the vertebræ are piled one over the other, the rings are arranged so as to form, with the aid of the interposed ligamentous structures, a flexible canal for the lodgment and protection of the spinal cord.

The *body* forms the anterior and most considerable part of the bone. Rounded before, and marked in the middle by a transverse groove, which gives it a constricted appearance, it is slightly hollowed posteriorly, where it contributes to the formation of the vertebral canal, and in most instances is flat on the superior and inferior surfaces, by which, through the medium of a layer of fibro-cartilage, it is connected with the contiguous

bones. Its outer surface all round presents numerous foramina for the passage of nutritious vessels. From the body at its lateral margins, two processes pass backwards called "pedicles." The pedicles join with the lamellæ, or plates, and these, by inclining inwards, meet at the median line posteriorly, so as to complete the "arch" of the vertebra. From the point of junction of the pedicles with the lamellæ at each side, the articulating and transverse processes project; and from the union of the two lamellæ the spinous processes take their origin.

Articulating processes.—For maintaining the connexion between the contiguous vertebræ, there are four processes,—two superior, and two inferior,—which project, one on each side, from the junction of the lamella with the pedicle. Two of these processes project upwards, and two downwards; the smooth surfaces of the upper pair look backwards, those of the lower, forwards; they are coated with cartilage, and articulate with corresponding processes of the next vertebræ. Their margins are rough for the attachment of ligaments.

The *transverse* and *spinous* processes form a series of levers for the attachment of muscles. The transverse processes, two in number (one on each side), and named from their direction, project laterally from the arch near the articulating processes, between which their bases are interposed. The *spinous* process is a single projection, situated posteriorly in the median line; this process, or rather the appearance presented by the aggregation of those of the several vertebræ, has given to the entire column one of its designations (spine). The parts of the arch which intervene between the bases of the spinous and the transverse processes are named *laminæ* or *plates*. Lastly, the processes which extend from the lamellæ to the body of the bone, are called "pedicles," as above stated. In each pedicle are seen two excavations, or *notches*, (incisuræ,) one on the upper, the other on the lower border, the latter being deeper than the former. When the vertebræ are placed in their natural position, the notches in the contiguous margins of each pair of them form rounded apertures, which communicate with the vertebral canal, and give transmission to the spinal nerves and to the entering and emerging vessels. From their position and mode of formation, they are called the *inter-vertebral foramina* (trous de conjugaison).

These remarks apply generally to all the vertebræ; but as each class presents peculiar characters which distinguish those included within it from others, and as there are peculiarities which mark certain individuals of each class, it becomes necessary to examine them more in detail.

105. The *cervical* vertebræ, fig. 32, are seven in number; they are smaller than those in the other regions, which results from the size of the body and processes being less than that of the corresponding parts in the dorsal and lumbar class. The vertebral foramen is of a triangular form, and larger proportionally than in the other classes. The body, fig. 32, 1, elongated transversely, is thicker anteriorly than posteriorly; for the under and fore part of each dips down a little. The upper surface is broader than the under one, and is rendered concave from side to side, by two little plates, which project upwards from its margins. The lower surface is slightly convex, and rounded off at the sides. The superior articular processes, 2, are flat and oblique in their direction, so as to look backwards and upwards, whilst the inferior, 3, incline downwards and forwards. The transverse processes, 4, short, and bifid at their extremities, present a groove, 5, superiorly for the transmission of the nerves, and at their base a foramen, through which in most of them the vertebral artery passes. It will be observed, that these processes have two roots or points of connexion with the vertebra. The posterior one springs from the junction of the pedicle with the arch, and therein corresponds with the transverse processes in the back and loins. The anterior one is attached to the side of the body of the vertebra, and ranges with the ribs, of which it is a rudiment. The formation of the foramen can, from these facts, be readily indicated. The osseous points, which here represent the ribs, not being required for any special purpose, remain in their rudimentary condition, and merely incline backwards, so as to become anchylosed with the true transverse processes which lie behind them. They thus enclose a space, viz. the foramen, which, however, cannot be

Fig. 32.

said to be intended to lodge the vertebral vessels, as it exists in the seventh cervical vertebra, through which they do not pass, and in the sixth and fifth in those cases in which the artery enters at the fourth. The spinous process, 6, is short, projects horizontally backwards, and is bifid at its extremity. The plates, 7, are narrower and longer than in the other regions. The notches are deeper and larger in the upper than in the lower border of the pedicles, in all except the second. They lie behind the articular processes in the first, but before them in the rest.

106. The *dorsal* vertebræ, fig. 33, twelve in number, are intermediate in size as well as in situation, between the cervical and the lumbar. The foramen is smaller than in the cervical or lumbar region, and is nearly circular in its form. The lateral notches, 1, 2, and consequently the inter-vertebral foramina which they form, are larger than those in the neck; and those at the lower margin of the pedicles are much larger and deeper than those on the upper. The depth of the body, 3, taken from before backwards, is greater than its breadth from side to side; it is convex and prominent on the anterior surface, flat and plain at the upper and lower; at each side of the body may be observed a slight notch, 4, 4, in the superior as well as in the inferior border,—these, when the vertebra is placed in apposition with the adjacent ones, form oval depressions for the reception of the heads of the corresponding ribs. The articulating processes, 5, 6, are nearly vertical in their direction; the superior looking backwards, the inferior forwards. The transverse processes, 7, are long and inclined backwards, and on the anterior surface of each of their tubercular terminations is situated a slight excavation, 8, which in the fresh state is tipped with cartilage, and articulates with the tubercle of the rib. The spinous processes, 9, elongated and triangular, are directed downwards, and terminate in a tubercle, 10. The plates are broad and thick, but shorter than those in the neck.

Fig. 33.

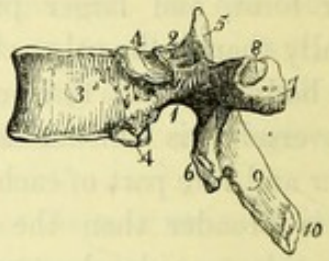

107. The *lumbar* vertebræ, fig. 34, five in number, are larger than either of the other sets. The foramen of each vertebra in this region is large and triangular. The notches, 1, 1, for the formation of the inter-vertebral foramina are very deep, especially the inferior pair. The body, 2, broader from side to side than from before backwards, is flat on its superior and inferior surfaces. It is not so convex anteriorly as that of the dorsal vertebræ. The articulating processes are thick, strong, and disposed vertically; the superior pair, 3, concave, look inwards and backwards; the inferior, 4, convex, outwards and forwards; the former are farther apart than the latter, hence they receive and in a manner embrace the lower articulating processes of the vertebra above them. The transverse processes, 5, long, thin, and horizontal, do not project backwards like those of the dorsal vertebræ. The spinous process is broad, flat, and nearly of a square form, so that it terminates not by a pointed extremity, like those in the dorsal region, but presents rather a compressed and rough border, 8. The plates, 7, though shorter, are deeper and thicker than those of the dorsal vertebræ.

Fig. 34.

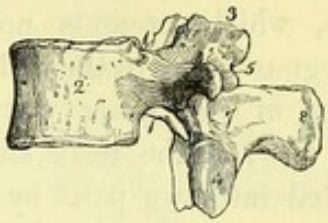

108. The general characters of vertebræ, and the differences which characterise those of different regions, being considered, it remains to point out certain peculiarities presented by some individual bones in each set. It may be here stated generally, that the vertebræ situated at the extremities of each region assimilate in some degree to the characters of those in whose vicinity they are placed. Thus, for instance, the lower pieces of the cervical region begin to resemble the dorsal vertebræ, and the latter become, by a similar transition, assimilated to the lumbar, — the characters peculiar to each region being best displayed by the bones situated towards its middle point.

Peculiarities of certain vertebræ. — The first, second, and seventh cervical vertebræ present some characters which distinguish them from the others.

Fig. 35.

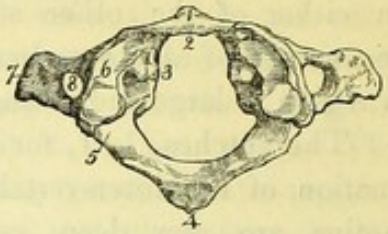

The first, or *atlas*, fig. 35, (so called from supporting the head,) is an irregular ring of bone, which presents nothing analogous either to the bodies or spines of the other vertebræ. The ring, in the fresh state, is divided into two parts by a transverse ligament,—the anterior one being occupied by the odontoid process of the axis, the posterior by the spinal cord,—it presents in front a small arch of bone, the anterior surface of which is marked by a tubercle, 1, the posterior by a smooth depression, 2, adapted to the odontoid process of the axis. The posterior segment of the ring is considerably larger than the anterior; at its middle point it presents a tubercle, 4, which is the analogue of the spinous processes; it is thick and round in the greater part of its extent; but at its junction with the rest of the vertebræ there exists on the upper border at each side a smooth groove, 5, which lies behind the superior articular process, and marks the tortuous course pursued by the vertebral artery previously to entering the cranium. This groove is analogous to the notches in the other vertebræ, for it transmits the first spinal nerve as well as the vertebral artery; it is sometimes converted into a foramen by a spicula of bone. The articulating surfaces are horizontal and large; the superior pair, 6, receive the condyles of the occipital bone; they converge in some sort towards the forepart of the bone; and as their form is oval, and their surface concave from before backwards, they look towards one another; at the inner margin of each is a rough surface, 3, which gives attachment to the transverse ligament. The inferior pair, on the contrary, are flat, and nearly circular in their form. The parts of the vertebra (*lateral masses*) on which these processes are situated are of very considerable thickness, because the weight of the head, which in others is received by the bodies, rests here on the articular surfaces. The transverse processes, 7, project considerably on each side, and terminate in a rounded point; at the root of each is situated the foramen, 8, which transmits the vertebral artery.

Fig 36.

The second vertebra, fig. 36, or *axis*, (so called from forming the pivot on which the head rotates,) is somewhat triangular in its form. The body, 1, presents anteriorly a vertical ridge, bounded on each side by a depression for the attachment of the longus colli muscle; superiorly it is surmounted by a process, 2, (*odontoid, p. dentatus;* whence is derived the name *vertebra dentata,*) presenting two smooth surfaces, one for its articulation with the atlas, the other with the transverse ligament which retains it in its situation; being constricted inferiorly, and somewhat enlarged towards the summit, these parts of the process are called respectively its *neck* and *head.* The superior articulating processes, 3, are of considerable size, and nearly horizontal; they are close to the body, so as to communicate to it the weight of the head, transmitted to them by the articular processes of the atlas; the inferior pair, 4, are oblique, and of the same size as in the vertebræ beneath them. The transverse processes, 5, are neither grooved nor bifurcated, and the foramen at their root, 6, is inclined obliquely outwards. The spinous process, 7, is very large, and gives attachment to several muscles; it is deeply grooved on its inferior surface; the plates which support it are of proportionate size.

The *seventh*, or prominent vertebra, approaches in its characters to those of the dorsal region; its spinous process terminates in a tubercle, and is so long as to be, in the natural condition, felt underneath the skin; whilst the other cervical spines lie more deeply, and are covered by muscles; hence the term "prominent," so commonly applied to this vertebra. The transverse process, though pierced by a foramen, presents but a slight appearance of a groove on its upper surface, and seldom more than a trace of a bifurcation at its extremity.

The *first dorsal* vertebra is marked at each side by a complete articular surface for the first rib, and on its inferior border by a slight excavation, which receives half the head of the second: the upper articular processes are oblique, and the spinous more nearly horizontal than those below it.

The *tenth* dorsal vertebra is usually marked by an articular surface, which receives the entire of the head of the corresponding rib.

The *eleventh* is distinguished by its transverse processes not presenting an articulating surface for the tubercle of the rib, whilst the form of its spinous process, of its lamellæ and body, approaches that of the lumbar vertebræ.

The *twelfth* dorsal vertebra resembles the eleventh in most of its characters; but its transverse processes are shorter, and the lower articular pair convex and directed outwards, so that its conformation resembles that of the lumbar vertebræ in these particulars.

Amongst the *lumbar* vertebræ, the fifth only is distinguishable by any peculiarity deserving of notice, its body being thicker anteriorly than posteriorly, and its transverse process short, thick, and rounded.

109. The bones just described, when ranged in their natural position, form a pyramid, the length of which is equal to about two feet two or three inches; taken as a whole it presents an anterior and posterior surface, two lateral surfaces, a base, and a summit, each deserving a particular notice.

110. The anterior surface is broad in the cervical, narrow in the dorsal, and again expanded in the lumbar region; it is marked by a series of transverse grooves corresponding with the centre of the bodies of the vertebræ, and in the fresh state is covered by the anterior common ligament. When viewed in profile, it presents three curves depending on the different degrees of thickness of the anterior and posterior part of the bodies of the vertebræ in the different regions, but still more on that of the inter-vertebral substance. In the neck and loins the convexity of the curve is forwards, in the back it is in the opposite direction. A slight degree of lateral curvature is also observable in most cases in the dorsal region, the convexity of which is directed towards the right side. The older anatomists imagined this to be produced by the action of the aorta beating against the left side of the column; but Bichât attributed it to the effect of muscular action, and explained it in the following way:—As most persons are disposed to use the right arm in preference to the left, the muscles of that side become stronger, and act with more power on the points to which they are at-

tached; when making efforts, as in pulling, the body is curved to the left, which gives an additional advantage to the muscles; and the habitual use of this position gives rise to some degree of permanent curvature. In support of this explanation of the fact, Béclard has stated that he found in one or two individuals, who were known to have been left-handed, the convexity of the lateral curve directed to the left side.

111. The posterior surface presents along the median line the spinous processes, varying in form and direction, as has been already stated, being horizontal in the cervical and lumbar regions, and nearly vertical in the dorsal. Those in the cervical and dorsal regions correspond pretty exactly with the middle line, but in the back the spines will be observed in many instances to incline, some to one side, some to the other. On each side of these are the vertebral grooves, extending from the base of the skull to the sacrum; their breadth corresponds with that of the laminæ; they are broad but shallow in the neck, and become deep and narrow lower down. Along the grooves are seen the spaces between the laminæ, which in the natural condition are filled up by the yellow ligaments. The breadth of these intervals is very trifling in the neck and in the greater part of the back; it increases in the lower third of the dorsal, and still more in the lumbar region. The interval between the occipital bone and the atlas is considerable, and so is that between the last lumbar vertebra and the sacrum.

The lateral surfaces of the column present the transverse processes, varying in form and character in the different regions; before these are situated the inter-vertebral foramina, and more anteriorly still, in the dorsal region, the articulating surfaces which receive the heads of the ribs.

The summit is articulated with the occipital bone, and supports the head, whilst the base, or broader extremity, rests on the sacrum. Along the entire extent of the column runs the vertebral canal, which is broad and triangular in the cervical and lumbar regions, circular and contracted in the dorsal. The canal may be said to expand at its upper extremity into the cranial cavity, and at its lower end to be prolonged into that of the sacrum.

112. *Developement.*—In the description here given of the vertebræ, each of them is considered as a single bone; and so it

is when fully formed. But in the fœtal state and in early infancy each consists of at least three pieces, representing so many centres of ossification, one corresponding with the body and one for each lateral mass. The spinous process has even been observed to commence by a separate point, and analogy would lead to the inference, that the anterior and posterior segments of the body are produced from distinct centres. Are we to go farther still, and admit that the body in the first instance consists of two lateral halves? If so, instead of three, we should have eight incipient osseous points in each of these bones. The atlas has three osseous nodules from which its ring is completed, one at each side for the lateral masses, and one in front for the anterior arch. Bichât found in some cases two additional points in the posterior arch. The second vertebra commences by five points at least, two of them being in its odontoid process.

OF THE SKULL.

113. The skull is of a spheroidal figure, compressed on the sides, broader behind than before, and supported by its base on the vertebral column. It is divided by anatomists into two parts, the cranium and the face; the former being composed of eight bones, viz. the *occipital*, *two parietal*, the *frontal*, two *temporal*, the *sphenoid*, and the *ethmoid*; the latter is made up of fourteen bones, viz. two *superior maxillary*, two *malar*, two *ossa nasi*, two *ossa palati*, two *ossa unguis*, two *inferior turbinated* bones, the *vomer*, and *inferior maxilla*; the frontal bone is so situated as to be common to the cranium and face. The bones of the ear are not included in this enumeration, as they belong rather to a special organ than to the skeleton considered as the frame-work of the body.

THE OCCIPITAL BONE.

114. The occipital bone, fig. 37, (os occipitis,) is situated at the posterior part of the base of the skull; broad behind, narrowed to a point before, of a trapezoid figure, presenting two surfaces, four borders, and four angles. To place the bone in its natural position, hold it so that the great foramen and the articulating processes beside it shall look directly downwards; the thick process in front of the foramen will then project forwards into the base of the skull, whilst the broad expanded

Fig. 37.

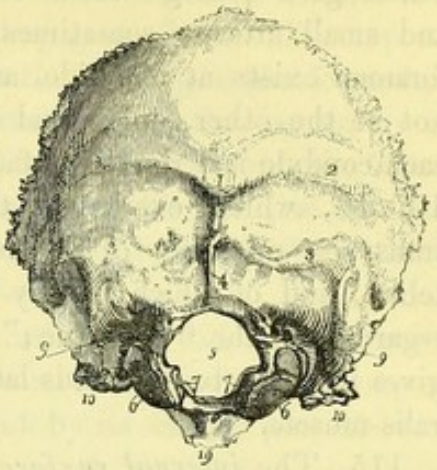

part behind it, arches upwards and a little forwards, forming the posterior wall of the cavity. *External surface:* this is convex in its general outline, and presents a little above its centre a rough prominence, 1, the *occipital protuberance*, the part between which and the superior angle is smooth. Extending obliquely outwards at each side from the protuberance is a rough line, 2, called the *superior curved line*, to distinguish it from another which is lower down between it and the great foramen, called the *inferior curved line*, 3; both are prominent, and give attachment to muscles, as also do the rough depressions between them. These are crossed by a vertical line, 4, extending forwards from the protuberance to the foramen.

The *occipital foramen*, 5, (foramen magnum,) which is of an oval figure (its long diameter extending from before backwards), gives transmission to the spinal cord, the vertebral arteries, and spinal accessory nerves.

At each side of the foramen, but nearer its anterior part, are situated the articulating processes, 6, 6, (*condyles*,) two oblong eminences, which articulate with the first vertebra. These converge from behind forwards; their inferior surface, which in the fresh state is smooth, covered with cartilage, and convex in its general outline, looks downwards and outwards, and is adapted for moving on the concave surface presented by the articulating processes of the atlas. The inner border of each condyle, 7, 7, is rough, and receives the insertion of the check ligaments, which extend up from the odontoid process of the axis; the outer border, depressed and not so well marked, gives attachment to the ligament connecting it with the atlas.

External to the forepart of the condyles are two fossæ, in the bottom of which are two foramina, fig. 38, 8, 8, (*anterior condyloid*,) which look outwards and forwards, and transmit the hypoglossal nerves; behind them are also two larger pits, in which are generally, but not always, found foramina,

Fig. 37.*

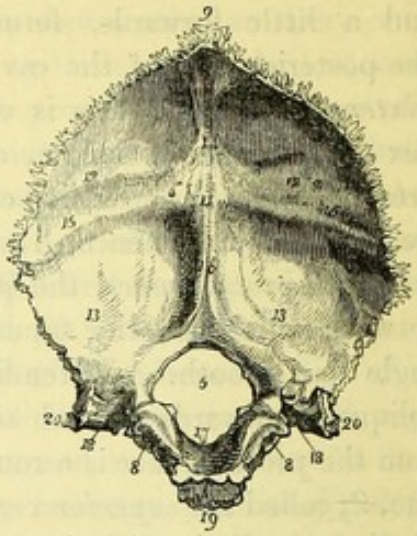

9, 9, (*posterior condyloid,*) which give passage to a vein and small artery: sometimes a foramen exists at one side, and not at the other. External to each condyle is a rough surface, 10, 10, which overhangs the transverse processes of the vertebræ, and of which it may be regarded as the "analogue;" it gives insertion to the rectus lateralis muscle.

115. The *internal surface* of the bone (fig. 37*), is marked by two lines—one vertical, extending from the upper angle of the bone to the great foramen, and the other transverse from one lateral angle to the other. These intersect towards the central point, 11, (internal occipital protuberance,) and mark off four pits, of which the upper pair, 12, 12, (superior occipital fossæ,) receive the posterior lobes of the brain, and the lower, 13, 13, (inferior occipital fossæ,) lodge the lateral lobes of the cerebellum: the superior line, 14, and the two transverse ones, 15, 15, are generally grooved, and correspond with the course of the longitudinal and lateral sinuses. The inferior one, 16, gives attachment to the falx cerebelli. The anterior border, 17, of the foramen magnum is slightly excavated, and becomes continuous with the *basilar groove*, a shallow excavation on the surface of the basilar process, which supports the medulla oblongata; close to the margin of the foramen are the anterior condyloid foramina, and a little external to it are two fossæ, 18, 18, marking the terminations of the lateral sinuses.

The thick triangular process, 19, which projects forwards into the base of the skull from the foramen, is called the *basilar* process; its margins are rough, and contiguous to the pars petrosa of the temporal bone; its under surface presents slight depressions for the insertion of muscles, and the upper one the shallow groove just noticed.

The *superior borders* of the occipital bone are dentated and converge to a point, 9, but are frequently interrupted by bony islets (ossa triquetra—Wormiana); the inferior border at each side

is divided into two parts by a prominent piece of bone, 20, 20, the *jugal eminence*, which surmounts an excavation contributing with the temporal bone to form the jugular fossa. The superior angle is acute, and received into the retiring angle formed by the posterior border of the parietal bones; the anterior is represented by the extremity of the basilar process; the lateral angles, not very prominent, correspond with the line at which the postero-inferior angle of the parietal bone joins with the mastoid part of the temporal.

Articulations.—The occipital articulates with six bones, viz. with the two parietal by its superior borders—the two temporal by the inferior—with the sphenoid by its basilar process—and with the atlas by the condyles.

Attachments of muscles.—The posterior third of the superior curved line gives attachment to the trapezius; its anterior two-thirds to the occipito-frontalis above, and to the sterno-mastoid below: the inner part of the space between the curved lines to the complexus: the external part to the splenius capitis: the space between the lower ridge and the great foramen to the recti majores and minores, and more outwardly to the obliquus superior: the under surface of the jugal eminences to the recti laterales: the fossæ at the inferior surface of the basilar process to the recti antici (majores and minores), and still more anteriorly to the superior constrictor of the pharynx.

Developement.—In the fœtus at birth this bone consists of four distinct pieces, of which one represents the basilar process, two the lateral or condyloid portions, and one the posterior or expanded part. Hence it is usually said to commence by four points of ossification. Meckel, however, is of opinion that it has no fewer than eleven separate centres, eight of them being in the broad (squamous) part. This doubtless has existed in some specimens which he examined; but ordinarily in the early stages of the developement there are found two ossific points in the lateral parts as above stated, one in the anterior or basilar, and four in the posterior broad part.

THE PARIETAL BONE.

116. The parietal bones (ossa parietalia) form a principal part of the roof of the skull; they are of a square form, convex externally, concave internally, and present each two sur-

Fig. 38.

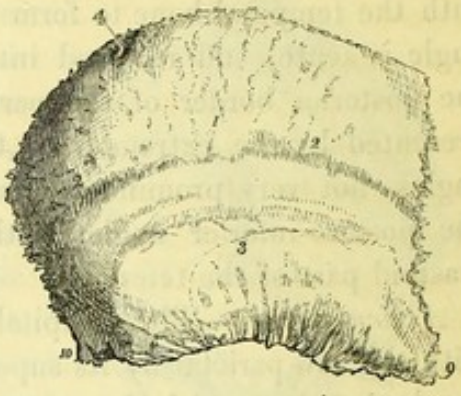

faces and four borders. The external surface, fig. 39, rises towards its middle, where it presents a slight elevation, called the *parietal eminence*, 1, below which is a curved line, 2, 2, forming part of the temporal ridge, and bounding a flat surface, 3, which forms a part of the temporal fossa. At the upper and back part of the bone, usually about two lines from the sagittal suture, is a small hole, 4, (foramen parietale,) which transmits a communicating vein; its position is exceedingly variable; even its existence is not constant.

Fig. 38*

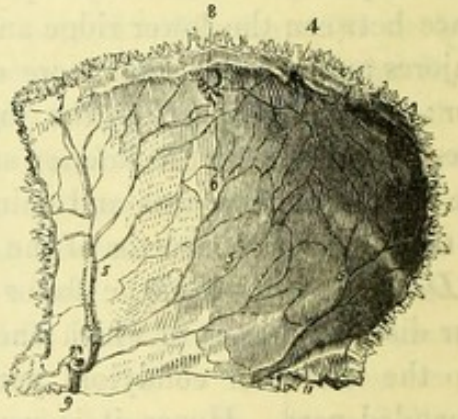

The internal surface of the bone, fig. 38*, is marked by branching lines, 5, 5, 5, corresponding with the course of the middle meningeal artery, and by depressions for the convolutions of the brain. Towards its middle is a depression, 6, "parietal fossa," corresponding with the eminence (parietal) on the outside. Along the superior border is a slight depression, 7, 7, which with a similar one in the corresponding bone forms a groove adapted to the course of the longitudinal sinus; and in the same situation (in most skulls, particularly those of old persons) are some small pits, 8, corresponding with the so-named glandulæ Pacchioni.

The superior border is straight, and articulated with its fellow by a series of dentations; the inferior border, concave and bevelled off at its outer margin, is overlapped by the squamous portion of the temporal bone; the anterior unites with the frontal bone, and the posterior with the occipital.

The anterior inferior angle, 9, dips down to the great wing of the sphenoid bone, and presents a groove, 9, internally for the

middle meningeal artery: the posterior inferior angle, 10, articulates with the mastoid part of the temporal bone, and presents internally a small part, 11, of the groove which lodges the lateral sinus.

Each parietal bone gives attachment to the temporal muscle by that part of its surface which lies beneath the temporal ridge: the remainder of its outer surface is covered by the aponeurosis of the occipito-frontalis.

Articulations.—It articulates with its fellow of the opposite side, and with the frontal, the sphenoid, the temporal, and the occipital bones.

Developement.—Its growth proceeds from one ossific centre which corresponds with the parietal eminence. At birth the antero-superior angles of these bones are not developed; hence there exists an interstice between them and the still divided os frontis, which is called the "fontanelle" (fons, bregma).

THE FRONTAL BONE.

Fig. 39.

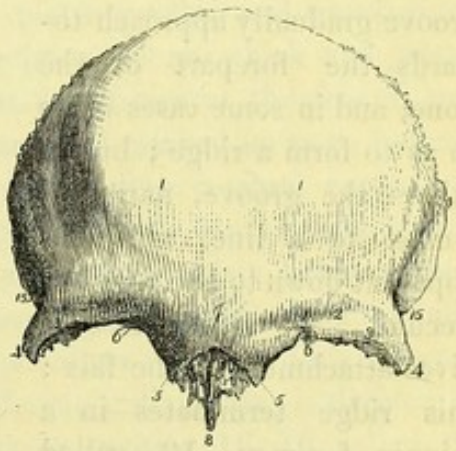

117. The frontal bone, fig. 39, (os frontis, coronale,) situated at the anterior part of the skull, and upper part of the face, is divisible into two parts (frontal and orbital), differing in size and position: of these, one extends upwards towards the vertex, forming three-fourths of the extent of the bone; the other, inferior and horizontal in its direction, forms the roof of the orbits. To place the bone in its natural position, hold it so that the orbital plates shall look downwards, and the smooth convex surface forwards.

The external surface of the frontal part is smooth, and presents on each side a slight elevation, 1, 1, named *frontal eminence*, which corresponds with the most prominent part of the forehead: beneath this is an arched depression, bounded below by a prominent curved line, 2, 2, called the *superciliary ridge*, or arch, which is more or less prominent in different in-

dividuals. Immediately beneath this is the margin of the orbit (*orbital arch*), 3, 3, which is better defined towards its outer part, where it curves down to the malar bone, and forms the external angular process, 4, 4, than at its inner portion 5, 5, where it gradually subsides towards the root of the nose. Towards the inner third of the orbital arch is a small foramen, 6, 6, (*supra-orbital,*) or sometimes a notch, crossed by a ligament, which transmits the supra-orbital nerve and artery.

Between the superciliary ridges is the *nasal eminence*, 7, or glabella, which is prominent in proportion to the size of the frontal sinuses; it is bounded inferiorly by a rough surface which articulates with the nasal bones and the ascending processes of the superior maxilla. From this surface projects downwards in the median line a flat thin process, 8, called the *nasal spine;* it articulates in front with the nasal bones, and behind with the perpendicular lamella of the ethmoid.

The internal surface of this part of the bone is concave, and presents along the median line a groove, fig. 39*, 9, corresponding with the longitudinal sinus. The margins of the groove gradually approach towards the forepart of the bone, and in some cases unite so as to form a ridge; but in others the groove, narrowed almost to a line, continues apparent down to the foramen cæcum. In either case it gives attachment to the falx; this ridge terminates in a minute foramen, 10, called *foramen cæcum*, from its having been supposed to be merely a cul-de-sac, but it is in reality pervious, and lodges a small spur-like process of the dura mater, and transmits a vein which enters the sinus from the nasal fossæ.

Fig. 39*.

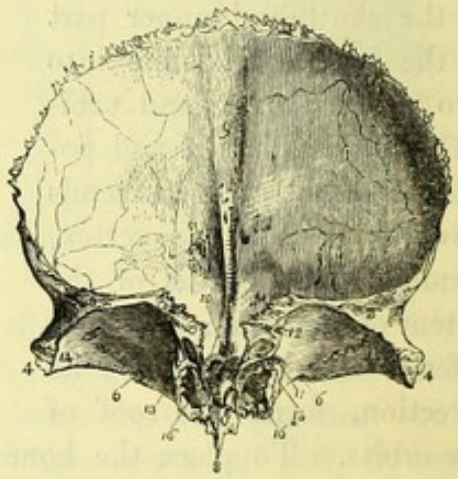

118. The orbital plates or processes are smooth and concave at their inferior surface; the superior or cerebral is convex, and marked more or less in different instances by elevations and depressions corresponding with the sulci and convolutions of the

anterior lobes of the brain which rest upon them. They are separated by a deep excavation (incisura ethmoidalis), which receives within it the cribriform plate of the ethmoid bone, and round its margins are several cells which complete the cavities lodged within the lateral parts of the last-named bone. In this margin may also be observed two foramina, 11, 12, (*anterior* and *posterior orbital*,) which are common to the frontal and ethmoid bones, as their contiguous margins contribute to their formation. The anterior one transmits the nasal twig of the ophthalmic nerve, and the anterior ethmoidal artery; the other the posterior ethmoidal artery and vein. Each orbital plate is bounded externally by a thick well-marked prominence, 4, 4, called the *external angular process*; and internally by a depressed and smooth one (*internal angular process*). Near the inner one is a slight depression, 13, to which is attached the cartilaginous pulley of the trochlearis muscle; near the outer and within the orbit, is a depression, 14, for the lodgment of the lachrymal gland; the external side of this process is slightly hollowed, fig. 39, 15, and forms part of the temporal fossa.

The thickness of the frontal bone varies considerably in different parts of it. The orbital plates are thin and translucent; the nasal and external angular processes are thick and prominent. The upper or broad part is thinner at the frontal eminences than elsewhere, if these are well-marked so as to indicate a full developement of the corresponding cerebral parts. In childhood the two tables are separated only by the diploë, as in other bones; but, in adult age, an interval exists between them at the middle line over the nasal process, and extending outwards for some way under the superciliary ridges. This interval, the extent of which varies in different individuals, is divided by a ridge of bone into two parts or cavities, 16, 16, called the *frontal sinuses*; they are lined by mucous membrane, and communicate with the anterior ethmoidal cells.

Articulations.—The frontal articulates with twelve bones; superiorly with the two parietal, laterally and behind with the sphenoid, inferiorly with the ethmoid; with the nasal bones by the nasal spine; with the ossa unguis; with the ascending process of the superior maxillary bones; and with the malar bones. The mode of articulation differs in different parts of its circumference. Thus, the superior border is found to over-

lap and rest on the parietal bones, whilst towards the lateral and inferior parts the exterior table of the bone is bevelled off, and is covered in by the parietal. The posterior border of the orbital plates, straight and squamous, is in a manner inserted between the margins of the two alæ of the sphenoid bone, with each of which it articulates.

Attachment of muscles.—It gives attachment to the corrugator supercilii—to a small part of the temporal and of the orbicularis palpebrarum.

Developement. — This bone begins by two osseous points corresponding with the frontal eminences. The lateral pieces formed by the spreading of the ossification ultimately become united along the middle by a straight suture, which runs from the vertex, where it is continuous with the sagittal suture down to the nose. It is generally obliterated at an early period.

THE TEMPORAL BONE.

119. The temporal bones, two in number, are so named because they occupy that part of the head on which the hair first becomes white, and thus indicates the ravages of time (*ossa temporis*).

Fig. 40.

The *temporal* bone, fig. 40, (os temporis,) is placed at the side and basis of the skull. When viewed in its natural position, it presents two portions, one at the side of the skull towards its middle and lower part, which is flat and vertical in its direction ; whilst the other is horizontal and projects inwards so as to be wedged between the occipital and sphenoid bones. But to facilitate its description, it may be divided into three parts, adopting the division which obtains in infancy before the ossification is complete. One is superior, flat, scale-like, and named the squamous portion (squama, a scale) ; another posterior, thick at its base, but tapering downward like a nipple, the mastoid part ; the third, called petrous from its hardness, is internal and intermediate, projecting into the basis of the skull.

The *squamous* portion, 1, (pars squamosa,) by its external surface which is smooth, forms part of the temporal fossa, and

is bounded above by an arched border, below by a horizontal process called "zygoma." The inner surface, fig. 41, 2, of the squamous part of the bone, slightly concave in its general outline, is marked by cerebral impressions like the other bones of the head, and by slight linear grooves for the branches of the middle meningeal artery. Its upper edge is bevelled off so as to form a thin scale which overlays the parietal bone.

Fig. 41.

The *zygoma*, 3, or zygomatic process (ζευγνυμι, to connect or yoke together), forms a yoke connecting the temporal with the malar bone, and under which the temporal muscle passes; it is broad posteriorly at its base, where it projects outward from the squamous part of the bone, but soon narrows, and turns forward; its outer surface is convex and subcutaneous, the inner surface is concave and bounds the temporal fossa; the superior margin, very thin, gives attachment to the temporal fascia; the inferior one is thicker and shorter, owing to the end of the process being bevelled off so as to rest on the malar bone, with which it articulates. At its base the upper surface is concave and supports the posterior border of the temporal muscle. The under surface forms the border of the glenoid cavity; here it presents two roots, of which one, 4, runs horizontally backwards, forming the outer margin of the glenoid cavity, whilst the other, 5, turns inwards and forms the anterior border of that cavity. At the point of division is a slight tubercle, 6, which gives attachment to the external lateral ligament of the lower jaw. Now the anterior root widens and subsides, becoming concave from without inwards and convex from before backwards, as it forms part of the articular surface upon which the lower jawbone moves; in its natural condition it is covered with cartilage. The other root, which is continued horizontally backwards, bifurcates one part, 8, turning inwards to the fissura Glasseri, whilst the other, 7, gradually subsides as it passes backwards over the auditory tube, yet marks the separation between the squamous and mastoid portions of the bone. The *glenoid fossa*

(γλήνη, a shallow pit), marked off as here indicated, is elongated from without inwards, and divided into two parts by a fissure, 9, *(fissura Glasseri,)* which transmits the chorda tympani nerve, laxator tympani muscle, and gives attachment to the processus gracilis of the malleus. The part before the fissure is smooth, and articulates with the lower jaw; the remainder lodges a process of the parotid gland.

The *mastoid* part, 10, of the bone externally is rough, for the attachment of muscles, and prolonged downwards, forming the mastoid, or nipple-shaped process (μαστος, a nipple; εἰδος) from which this division of the bone is named. This process overhangs a groove, fig. 41, 11, *(digastric fossa,)* for the attachment of the digastricus muscle; close to this is a slight groove, 14, the occipital groove. When viewed at its inner surface, the mastoid part presents a broad and generally a deep groove, 12, which curves forwards and downwards; it here supports part of the lateral sinus. It is usually pierced by a foramen, 13, (mastoideum,) which opens into the sinus from the outer surface, commencing near the posterior border of the bone. The size and position of this hole vary in different instances; it sometimes exists at one side and not at the other.

120. The *petrous* part, 15, pars petrosa, (πετρος, a stone,) forms a triangular pyramid (pyramis trigona) which projects into the base of the skull forwards and inwards; it presents a base, an apex (truncated), three surfaces, and three borders. In the base is situated the orifice of the auditory canal, which is bounded above by the posterior root of the zygoma; inferiorly, and in the greatest part of its circumference, by a curved uneven lamella *(auditory process)*, to which the cartilage of the ear is attached: this process is in the fœtus a separate piece. The canal itself *(meatus auditorius externus)*, narrower in the middle than at its extremities, is directed obliquely forwards and inwards, and leads into the tympanum. The apex or inner end of the pars petrosa, rough, irregular, and, as it were, truncated, forms part of the foramen lacerum medium, and is pierced by the termination of the carotid canal, 18, (canalis caroticus):—this canal commences in the inferior surface of the bone anterior and internal to the jugular fossa, ascends at first perpendicularly, but soon turns horizontally forwards and inwards to the apex, where it ends.

121. The anterior surface, 19, of the petrous portion forms part of the middle fossa in the base of the skull, where it looks obliquely upwards and forwards. Towards the apex it is slightly grooved, 20, where it corresponds with the ganglion of the fifth pair of nerves (Casserian). A narrow groove is seen to run obliquely backwards and outwards; it lodges a small nerve (the Vidian); it is named the *hiatus Fallopii*, and leads to the aqueduct of Fallopius. Farther back is a rounded eminence indicating the situation of the superior semi-circular canal. The *aqueduct* of Fallopius just alluded to commences at the internal auditory meatus; it is a small osseous tube lodged in the interior of the bone, and passing at first in an arched direction, outwards and upwards, then backwards and downwards towards the basis of the skull, where it ends in the stylo-mastoid foramen; it transmits the portio dura, and receives, through the hiatus Fallopii, the Vidian nerve. The posterior surface looks obliquely backwards, and forms part of the third or posterior fossa at the base of the skull. In it will be observed a large orifice, 21, leading to a short canal *(meatus auditorius internus)*. The canal is oblique in its direction, having an inclination outwards and forwards. It conveys the auditory and facial nerves. Its fundus is formed by a lamella of bone *(lamina cribrosa)*, divided into two parts by a crest or ridge; the upper or smaller part is pierced by a foramen which transmits the facial nerve, whilst the lower presents several very small apertures through which the fibrilla of the auditory nerve pass. About three lines further back than the orifice of the meatus is a narrow fissure, 22, oblique in its direction. It is the termination of the aqueductus vestibuli. Between the aperture of the aqueduct and that of the meatus is an irregular depression, into which a small process of the dura mater is fixed.

On the inferior surface of the pars petrosa, which is exceedingly irregular, we observe, proceeding from within outwards and backwards, a rough surface, 23, giving attachment to the levator palati and tensor tympani muscles, the carotid foramen, the jugular fossa, the vaginal and styloid processes; lastly, the stylo-mastoid foramen. The carotid foramen leads into the curved canal (canalis caroticus) already noticed. The *jugular fossa*, 24, (fossa bulbi venæ jugularis internæ,) is named by some the "thimble-like" cavity, also the "foramen lacerum

posterius." It is of large size, and formed in the contiguous margins of the temporal and occipital bones. It is in some cases divided into two parts, but unequally, by a spicula of bone; the anterior and inner portion gives passage to the glosso-pharyngeal, vagus, and spinal accessory nerves, whilst the posterior and larger one transmits the jugular vein. External to the margin of the fossa is the styloid or pencil-like process, 25, long and tapering, with an inclination downwards and forwards. Its length varies from an inch to an inch and a half; it gives attachments to three muscles and two ligaments. Close before the base of the styloid process is a compressed bony plate, 26, the free surface of which looks obliquely forwards and forms the back part of the glenoïd or articular cavity. This is named the *vaginal* process (vagina processus styloidei). Between the root of the styloid process and the mastoid is the *stylo-mastoid foramen*, 27, (f. stylo-mastoideum,) so called from its position with regard to the processes just named. It forms the outlet or termination of the aqueduct of Fallopius, and gives exit to the facial nerve.

The superior border of the pars petrosa is grooved for the petrosal sinus, 28; the anterior, which is very short, forms, with the squamous part, an angle at their point of junction, in which is situated the orifice of the Eustachian tube, 29, a canal which leads from the pharynx to the tympanum: above this, and separated from it by a thin horizontal lamella *(processus cochleariformis)*, is another osseous tube, that gives passage to the tensor tympani muscle. The posterior border articulates with the basilar process of the occipital bone and forms with it the jugular fossa. About the middle of this edge or border is a minute foramen, 30, the opening of a small canal leading from the cochlea *(aquæductus cochleæ)*.

Articulations. — The temporal bone articulates with the parietal, malar, inferior maxillary, sphenoid, and occipital bones.

Attachments of muscles. — To the zygoma is attached the masseter; to the squamous portion, the temporal; to the mastoid process, the retrahens aurem, the sterno-mastoid, splenius capitis and trachelo-mastoideus; to the digastric fossa, the digastricus; to the styloid process, the stylo-glossus, stylo-hyoideus, and stylo-pharyngeus; to the apex of the petrous portion, the levator palati and tensor tympani.

Developement.—The squamous, mastoid, and petrous parts of the bone have each a separate ossific centre. So have the processes, viz. the zygomatic, styloid, and auditory.

THE SPHENOID BONE.

122. The sphenoid is a single bone, figs. 42, 43, placed transversely at the base of the skull, and articulated with all the bones of the cranium and several of those of the face, between which it is inserted somewhat like a wedge; whence its name (σφην, a wedge; εἰδος, like); its form has been likened to that of a bat with its wings extended; and the comparison is not very far-fetched, particularly if the ethmoid bone remains attached, as often happens. Like other irregular bones, it may be divided into body and processes.

Fig. 42.

To place this bone in its proper position so as to perceive clearly the relations of its different parts, observe that it has two thick processes somewhat like legs. Hold it so that these shall project downwards, as if from beneath the body and wings, and let those edges of the processes which are channelled into vertical grooves look backwards.

123. *Of the body*, or central part of the bone.—To give precision to its description we say that it presents six aspects or surfaces, each of which looks in a different direction and has distinct relations:—The superior surface, which forms part of the basis of the skull, is of limited extent, yet is hollowed into a deep pit, 1, which lodges the pituitary gland: hence this excavation is called *pituitary fossa*, and sometimes "sella Turcica," from some resemblance to a Turkish saddle (ephippium). On either side of the fossa the surface is depressed, 2, and corresponds with the cavernous sinus; farther back are two superficial grooves, 3, directed from behind forwards, which correspond with the internal carotid arteries. Before the fossa, is a slightly depressed portion of the bone, on a level with the optic foramina, on which rests the commissure of the optic nerves;—behind it, is a prominent ascending lamella, of a square form, and sloping backwards, so as to be continuous with the basilar

groove of the occipital bone: the corners of this lamella project over the fossa, and are called the *posterior clinoid processes*, 4, (κλινη, a bed).

The inferior surface is the narrow interval between the pterygoid processes; it is intersected by a prominent spine, fig. 43, 5, called the *rostrum* or azygos process, which dips downwards and forwards to join the vomer. At each side are two small and slightly everted lamellæ (projecting from the base of the pterygoid processes), which articulate with the margins of the vomer. Farther out is a small groove, 6, which contributes with the head of the palate bone to form the *pterygo-palatine canal.*

Fig. 43.

The anterior surface is very irregular, and presents the openings of two deep sinuses, 7, into which the bone is hollowed: these sinuses (*sphenoidal*) do not exist in young children; in the adult, in whom they are of considerable size, they are separated by a thin partition (septum sphenoidale), which is continuous inferiorly with the rostrum, and in the front articulates with the central lamella of the ethmoid bone. The sinuses are covered in anteriorly by two thin osseous plates, 8, the *sphenoidal spongy bones* (cornua sphenoidalia, cornets sphenoidaux); these do not, however, altogether seal up the sphenoidal sinuses, but leave a circular aperture, by which they communicate with the posterior ethmoidal cells. In early life they are distinct, and easily separable; but in the adult they become united either with the margins of the sinuses or with the ethmoid or the palate bone.

The posterior surface, fig. 42, 9, is flat, and united with the basilar process of the occipital bone,—in early life by cartilage, but in adult age by osseous matter.

The lateral surfaces are continuous with the great wings, which branch out from them on either side.

124. *Of the processes.*—The principal processes are, the great wings, the small wings, and the pterygoid processes; the

minor ones are the ethmoid spine, processus olivaris, clinoid processes, the rostrum, the hamular and spinous processes.

The *great wings*, 10, (alæ majores,) project outwards, forwards and upwards, from the sides of the body of the bone, and are so formed as to present each three surfaces, looking in different directions; one, anterior, 11, (*orbital*,) is square, smooth, inclined obliquely forwards, and forms part of the outer wall of the orbit; the second, 12, (superior or *cerebral*,) of much greater extent, is elongated from behind forwards, and concave, so as to form part of the middle fossa of the basis of the skull, which supports the middle lobe of the brain; the third, 13, (external or *temporal*,) looks outwards into the temporal fossa, where it forms part of the side of the cranium. It is elongated from above downwards and slightly hollowed. But it will be observed that this surface, taken as a whole from the top of the wing down to the root of the pterygoid process, presents two parts divided by a slight ridge, 14; of these the upper and longer one just noticed forms part of the temporal fossa, and the inferior or smaller division, of the zygomatic fossa.

The *small wings*, 15, (alæ minores,) called also wings of Ingrassias, are triangular in form, horizontal in direction, and extended forwards and outwards, on a level with the upper surface of the body—its fore-part. Their upper surface, plain and flat, supports part of the anterior cerebral lobes, the inferior one overhangs the back part of the orbit and the sphenoidal fissure. The anterior border, sharp, thin, and rough, articulates in the greater part of its extent with the orbital plate of the frontal bone, and internally, at the middle line, where the bases of the two processes are united, there is a slight angular process, 16, (*ethmoidal spine*,) which articulates with the cribriform lamella of the ethmoid bone. The posterior border, rounded and smooth, is free and unattached, and corresponds with the fissure (fissura Sylvii) which separates the anterior from the middle lobe of the brain. The external and anterior ends of these processes are sharp and pointed, whilst posteriorly they terminate in two blunt tapering productions, 17, which incline obliquely backwards, towards the pituitary fossa, and overlay the cavernous sinuses. These are called *anterior clinoid processes*.

125. The *pterygoid* processes are seen at the inferior surface

of the bone, from which they project down like legs rather than wings, though the name given to them would indicate the reverse (πτερυξ, a wing). Each of these consists of two narrow plates (*pterygoid lamellæ*), united at an angle in front, and diverging behind, so as to form an angular groove (*pterygoid fossa*). The internal plate, 18, longer and narrower than the external, is prolonged into a slight round process, 19, named, from its crooked form, the hook-like or *hamular process*, round which plays the tendon of the tensor palati muscle. The external lamella, 20, looks outwards, and somewhat forwards, bounds the zygomatic fossa, and gives attachment to the external pterygoid muscle. At the root of the internal lamella is situated a slight depression (*fossa navicularis*), which gives attachment to the tensor palati muscle ; in the groove or fossa, between the two plates, arises the internal pterygoid muscle. The groove is incomplete at its lower part when the sphenoid bone is examined by itself; for an angular interstice, 21, exists between the pterygoid lamellæ. This, however, is filled up by a part of the pyramidal process of the palate bone, which is inserted between the margins of the lamellæ.

126. The *ethmoid spine*, already noticed, is a very small angular plate, 16, which projects forward on a level with the upper surface of the lesser wings in the middle line, and articulates with the cribriform lamella of the ethmoid bone.

The *processus olivaris* is a minute elevation, 22, seen on that depressed piece of bone on a level with the optic foramina, and which supports the commissure of the optic nerves.

The *clinoid* processes are two pair, 17, 4, one before, the other behind the pituitary fossa ; therefore called anterior and posterior. A spicula of bone often passes from the anterior to the posterior clinoid process at one or both sides ; and occasionally one dips down from this to the body of the bone.

The *rostrum* is the prominent angular ridge, 5, which projects downwards from the under or guttural surface of the bone, dividing it into two parts.

The *hamular* process, 19, projects from the termination of the internal pterygoid plate, is thin, constricted, and curved in the greater part of its extent, but ends in a small blunted tubercle.

The *spinous* processes, 23, are placed at the posterior and inner terminations of the great wings, from which they project downwards about two lines.

127. Each lateral half of the bone presents a fissure, four foramina, and a canal. The fissure, 24, (*fissura sphenoidalis*,) triangular and elongated, is placed between the lesser and greater wings, opens into the orbit, (hence sometimes named foramen lacerum orbitale,) and transmits the third, the fourth, and the sixth nerves, the ophthalmic branch of the fifth and the ophthalmic vein. This fissure is separated at its base from the foramen opticum by a narrow plate of bone which passes from the under surface of the anterior clinoid process (at its root) obliquely down to the body of the sphenoid bone; to this is attached a small tendon, common to the inferior, internal, and external recti muscles of the eye. Of the foramina,—the optic foramen, 25, inclines outwards and forwards on a level with the fore-part of the body of the bone; it transmits the optic nerve and the ophthalmic artery. Farther back and on a lower plane, inasmuch as it is situated in the great wing, is a round aperture, 26, leading forwards; it is the *foramen rotundum*, which transmits the superior maxillary branch of the fifth pair of nerves: a little farther back and more external is a large foramen, 27, of an oval form, hence called *foramen ovale;* it gives passage to the inferior maxillary branch: near the posterior angle of the ala is the *foramen spinosum*, 28; it is very small, and transmits the middle meningeal artery. The root, or base, of each internal pterygoid process is pierced by a circular foramen, fig. 43, 29, (*pterygoideum*,) more properly a canal, extending horizontally from before backwards, slightly expanded before, narrowed behind, and giving passage to the posterior branch from Meckel's ganglion (*Vidian*, *pterygoid*).

128. *Articulations.*—The body of the sphenoid bone articulates posteriorly with the basilar process of the occipital, anteriorly with the ethmoid; with the orbital processes of the frontal by the lesser and greater alæ; with the anterior inferior angles of both parietal, and the squamous portion of the two temporal by the great alæ, and by the spinous processes with the angles between the petrous and squamous portions of that bone: with the vomer it articulates by the rostrum; with the malar bones

by means of the external border of the orbital plates, and with the palate bones by the pterygoid processes ;—in all, twelve bones.

Attachments of muscles.—Round the optic foramen in each orbit are attached the four recti, the obliquus superior, and levator palpebræ muscles ; to the external surface of the great ala at each side, the temporal muscle ; to the external pterygoid process, the external pterygoid muscle ; to the pterygoid fossa, the internal pterygoid ; to the inferior half of the internal pterygoid plate, the superior constrictor of the pharynx ; and to the fossa navicularis, the circumflexus palati ; and to the spinous process, the laxator tympani.

129. *Developement.*—There are two osseous centres in the great wings, two in the pterygoid processes, and two in the small wings. The anterior and posterior segments of the body of the bone commence by distinct points ; and as these in some instances unite, one with the great wings and the other with the small ones, before they become joined to one another, this condition of the bone presents an analogy with its permanent state in fishes, reptiles, and most mammalia, in which we find an anterior and posterior sphenoid bone. There appear also two osseous points at the inner borders of the optic foramina.

ETHMOID BONE.

130. The *ethmoid*, or sieve-shaped bone, fig. 44, (ηθμος, a sieve ; ειδος, like ; os ethmoides,) is common to the cranium, the orbits, and the nasal fossæ ; it is placed at the fore-part of the base of the skull, from which it projects downwards, and is inserted between the orbital plates of the frontal bone, lying behind the nasal and superior maxillary bones, before the sphenoid and above the vomer. It is exceedingly light and thin, considering its size, and seems, at first, but a collection of irregular cells, enclosed between plates of bone as thin as paper. It is of a cuboid figure, symmetrical, and composed of two lateral masses, between which is interposed a central vertical plate. This points out a mode of dividing the bone for the purpose of de-

Fig. 44.

scription, but it is more convenient to consider it as a whole, and examine separately each of its six surfaces.

To place the bone in its proper position, observe that its upper surface is the one from which arises a smooth angular process like a cock's comb. The short border of this looks forward, and the long sloping one backwards.

131. The superior, or *cerebral* surface of the bone, is at once recognised by its presenting a triangular process, which projects upwards from it, in the middle line; this process, 1, from some resemblance to a cock's comb, is called *crista galli*. The surface of the crista is smooth and compact, its form triangular, the base being horizontal, and on a level with the cribriform plate, below which it is continuous with the perpendicular lamella forming the septum narium; the posterior border of this process is long, and slopes backwards, but the anterior is short, and nearly perpendicular; at its junction with the base two small bony masses sometimes project forwards, leaving between them a fissure which forms part of the "foramen cæcum," placed in the middle line at the junction of this bone with the frontal. The crista galli is usually perpendicular, but occasionally inclines to one side; it is sometimes bulged a little at the sides, and is then found to enclose a small sinus; it gives attachment to the falx cerebri, the two layers of which in a manner embrace it.

Beside and behind the crista is the sieve-like or *cribriform lamella*, 2 (lamella cribrosa). It consists of a narrow plate of bone, pierced by a number of holes, from which it derives its name; posteriorly this plate of bone is, for a very little way, even and horizontal; it then becomes depressed into two grooves beside the crista, which lodge the ganglia of the olfactory nerves. This part of the surface is narrow, elongated from behind forwards, and pierced by numerous foramina, for the transmission of the filaments of the olfactory nerves. The foramina in it are of three sorts: those which lie along the middle of the groove are mere holes or perforations which permit the filaments of the nerves, with their membranous investments, to pass down to the roof of the nares; the external and internal rows are larger, and form the orifices of small canals, which are grooved in the bone, and subdivide as they descend into the septum and spongy bones. In the anterior border of the cribri-

form lamella, and close to the crista galli, is a fissure at each side of its base, which transmits the nasal filament of the ophthalmic nerve. Along the outer margin of the cribriform plate we observe several small cellules, which are open, and, as it were, incomplete when the bone is detached from its natural situation, but are closed in by the orbital plates of the frontal bone, and completed by a junction with the cells observed in their border. At the posterior margin of this surface, and in the middle line, is a slight notch, which receives the ethmoid spine of the sphenoid bone.

The anterior surface of the bone presents in the middle the edge of the perpendicular or nasal lamella, 4; at the sides of this are narrow grooves which separate it from the lateral masses, and form the upper part of the nasal fossæ; still farther out are some open cellules, which when the bone is in its place are closed by the ascending process of the superior maxillary bone.

The posterior surface presents also in the middle the edge of the perpendicular lamella, then the grooved posterior margins of the ethmoidal turbinate bones, and still more externally large open cellules which are closed by the sphenoid bone and its turbinate bones, and lower down by the head of the palate bones.

The lateral or orbital surfaces are smooth and plain, 5; each is formed of a thin plate of bone, (lamella plana; os planum,) which lies in the inner wall of the orbits.

132. Thus far we can proceed with our description of the bone as if it were a single piece, which presented several aspects each requiring to be noticed; but when we look at it from below we find it expedient to consider it as divisible into a central or median plate, and two lateral parts or masses.

The inferior or *nasal* surface of the bone is of considerable extent, and presents in the middle line a flat plate of bone, and two lateral masses separated from it by a narrow interval: these lateral parts are formed of thin plates, enclosing cellules, which appear so complex as to be likened by some persons to a labyrinth. The descending or *nasal* plate (lamella nasalis), called also the perpendicular plate, though it frequently inclines to one side, forms a considerable part of the septum nasi; it is continuous above with the base of the crista galli, as already

stated; below, it articulates with the vomer and the triangular cartilage of the nose; its anterior margin joins by its upper part with the nasal process of the frontal bone, and lower down supports the ossa nasi; the posterior margin articulates with the septum sphenoidale. This plate presents a number of grooves and minute canals, leading from the foramina of the cribriform lamella, for the transmission of the olfactory nerves: in the natural condition it is covered by the pituitary membrane.

133. *Lateral masses.*—The external surface of each of these consists of a thin, smooth, and nearly vertical plate of bone, 5, (*lamella plana, os planum,*) which closes in the ethmoidal cells and forms a considerable part of the inner wall of the orbit: it articulates above with the orbital plate of the frontal bone; below, with the superior maxilla and palate bone; in front, with the os unguis; and behind, with the sphenoid. At its anterior and posterior margins the ethmoidal cells are open when the bone is detached from its connexions; in the former situation they are closed by the os unguis; in the latter, by the sphenoid spongy bones. In its upper margin are two grooves, 6, 7, which are formed into foramina by similar indentations in the frontal bones, and so form the internal orbital foramina (*foramen orbitarium internum, anterius et posterius*).

134. The inner surface of each lateral mass forms part of the external wall of the corresponding nasal fossa, and consists of a thin osseous plate, connected above with the cribriform lamella, from which it hangs hown, and below ends in a free margin, which is convoluted a little, and represents the middle spongy bone. At its upper and fore part, is a square, flat, but rough surface, which is pierced by a number of grooves, leading from the foramina of the cribriform lamella; posteriorly are placed two thin and also rough osseous plates, curved a little, so as to represent small bivalve shells, from which circumstance they are called ethmoidal *turbinate* bones; but from their texture, being cellular and porous on the surface, they are named spongy bones. Of these, the first or upper one, 8, (concha superior,) which is also placed farther back, is very small; by the curve or coil which it makes it arches over, and forms a groove or channel (*meatus naris superior*): this is of small extent from before backwards, not being more than half that of the ethmoid bone; it communicates with the posterior ethmoidal cells, and the

spenoidal sinuses. Still lower down is another osseous lamella, 9, thin, rough, and convoluted, which is the second ethmoidal spongy or turbinate bone. Its lower margin is more rough and prominent than that of the upper one, and its extent from before backwards nearly double. Beneath this is a groove or channel which it overhangs so as to form the second *meatus naris*, which communicates with the anterior ethmoidal cells and the frontal sinuses.

135. The osseous rough plate here described gives attachment by its outer surface to a number of osseous lamellæ, thin and delicate, which pass across the space between it and the lamella plana, dividing it into a number of cells (*ethmoidal*). These do not all communicate: they are separated into two sets by a sort of transverse partition, the posterior being small and few in number—from four to five,—whilst the anterior, larger and more numerous, communicate with the frontal sinus. The cellule, 10, which directly communicates with the middle meatus, is prolonged, in a curved direction, upwards and forwards, opening by a small aperture into the anterior ethmoidal cells, and by another, farther on, into the frontal sinus; and, as it is broad below and tapering above, it assumes somewhat the form of a funnel, and hence is named *infundibulum*.

The superior border of each lateral mass presents some incomplete cells, before noticed when describing the cribriform plate; the inferior gives off some irregular lamellæ, which articulate with the side of the maxillary sinus and the inferior turbinate bone; the anterior also exhibits some incomplete cells, which are closed in by the os unguis and the nasal process of the superior maxillary bone.

136. *Articulations.*—The ethmoid articulates with thirteen bones—the frontal, the sphenoid, and vomer, two nasal, two ossa unguis, two superior maxillary, two palatal, and two inferior spongy bones.

Developement.—There is an ossific centre in each lateral mass, and one in the perpendicular lamella.

OSSA TRIQUETRA.

137. Accidental, or supernumerary bones, are not unfrequently found in skulls. From their form, which is very variable, they are sometimes called triquetra, at others, triangularia,

or ossa Wormii, from Wormius the anatomist, who is said to have given the first detailed description of them. They are osseous plates, with serrated margins, inserted, as it were, between two cranial bones, and appearing like islets placed in the sutures. Their most ordinary position is in the lambdoid suture, next in the sagittal, seldom if ever in the coronal, never in the squamous. The superior angle of the occipital bone sometimes occurs as an accessory piece; so does the anterior inferior angle of the parietal. They are not found before the sixth or eighth month after birth; and whatever varieties of size and appearance they may present, the principle of their formation is the same in all cases. As the broad bones grow by successive deposits, extending from their central points towards the margins, whenever the natural process is retarded or interrupted, the mode of osseous deposition takes a new direction, a new centre is established in the layer of cartilage between the margins of the bones, and therefore in the situation of the suture, from which it extends outwards, until it comes into contact with the margins of the contiguous bones, with which it becomes united in the usual way by suture.

BONES OF THE FACE.

These, as above stated (Sect. 113), are fourteen in number.

THE SUPERIOR MAXILLARY BONE.

138. This bone, fig. 45, (maxilla superior,) is very irregular; it presents an external convex surface, corresponding with the anterior and lateral parts of the face; another, internal, of considerable extent, corresponding with the nasal cavity; one, superior, smooth, and inclined inwards, forming the floor of the orbit, and surmounted internally by a triangular process, forming the side of the nose; lastly, a surface which projects horizontally inwards, to form the arch of the palate. The external surface is bounded inferiorly by a thick, dependent border (alveolar), for the lodgment of the teeth; to this, as to a common point of union, all the other parts of the bone may be referred.

Fig. 45.

139. The alveolar border, 1, thick, semicircular, convex externally, concave internally, is pierced along its margin by a number of deep pits (*alveoli*), into which the teeth are inserted. The pits or sockets vary in form and depth, conforming in these particulars to the roots of the teeth which they receive. From this border the external side ascends upwards to the margin of the orbit, presenting some depressions and elevations; but at its fore-part it is interrupted and excavated so as to present a deeply concave margin, 2, which, with a similar one in the corresponding bone, forms the anterior nares. This excavation is surmounted by a process, 3, (*ascending* or *nasal*) prolonged as far as the frontal bone, with which it articulates. The external surface of this process, slightly grooved, gives attachment to the orbicularis palpebrarum muscle and the levator labii superioris alæque nasi. The internal, or nasal surface, somewhat concave, presents a rough line, running from before backwards, which articulates with the inferior spongy bone; above this is a depression corresponding with the middle meatus of the nose, and, towards the summit, a rough surface, which closes in the anterior ethmoidal cells. The anterior border is rough, for its attachment to the nasal bone; the posterior presents a well-marked groove, 4, running from above downwards, and a little backwards with a slight curve, and which is completed into a canal by a similar one in the os unguis, for the lachrymal sac.

140. The part of the external surface a little above the molar teeth, is elevated into a rough projection, 5, (*malar eminence*,) for its articulation with the malar bone. Anterior and inferior to this is observed a fossa, 6, (*fossa canina*,) which gives attachment to the levator anguli oris. Between this fossa and the margin of the orbit is the infra-orbital foramen, 7, which transmits the superior maxillary nerve. A little above the sockets of the incisor teeth is a slight depression, 8, (myrtiform fossa) which gives attachment to the depressor muscle of the ala of the nose. Behind the malar tuberosity the surface is slightly excavated, and forms part of the zygomatic fossa; towards the posterior border it is plain, and forms one side of the spheno-maxillary fissure; and, at its junction with the orbital plate, it is rounded off and leads to the entrance of the infra-orbital canal. This surface is pierced by a number of foramina, which transmit the superior dental nerves; it terminates by a slight tuberosity, 9, which

projects behind the last molar tooth. The inner surface of its posterior border is rough, for its attachment to the tuberosity of the palate bone, and presents also a slight groove, contributing to the formation of the *posterior palatine canal*, which transmits the descending palatine branches from Meckel's ganglion.

From the upper border of the external surface, the *orbital plate*, 10, projects inwards, forming the floor of the orbit; its surface is smooth, being merely interrupted by the groove which leads to the infra-orbital canal; and at its inner and fore part near the lachrymal groove is a minute depression, which gives origin to the inferior oblique muscle of the eye.

141. The horizontal or *palate* plate of the bone projects inwards, forming the roof of the mouth, and the floor of the nares. Its nasal surface is concave from side to side, and smooth; externally it is continuous with the body of the bone, internally it presents a rough surface, which is articulated with the corresponding bone, and surmounted by a ridge, 11, which completes the septum narium by articulating with the vomer and nasal cartilage; in front it is prolonged a little, so as to form a small process, 12 (anterior nasal spine); beside it is the foramen, leading into the anterior palatine canal, which lodges the naso-palatine ganglion. The inferior surface of the palate plate is rough, arched, and overhangs the mouth.

The body of the bone is hollowed into a large cavity, *antrum Highmori*, or *maxillare*, which in the fresh state is lined by mucous membrane and communicates with the middle meatus of the nose. Its orifice appears of great size in the dried bone when detached from its connexions, but it is considerably diminished when the contiguous bones are in their natural position, viz. the ethmoid, the inferior turbinate, and the palatal.

142. *Articulations.*—With the corresponding bone; with the frontal, by its nasal process; also with the ethmoid and os nasi; with the palate bone; with the malar, by the malar eminence; with the os unguis, the vomer, the inferior spongy bone, and the nasal cartilage.

Attachments of muscles.—Proceeding from below upwards; —above the border of the alveolar arch, the buccinator, and the depressor labii superioris alæque nasi; to the canine fossa, the levator anguli oris, and the compressor nasi; to the margin of the orbit, part of the levator labii superioris; to the nasal pro-

cess, the orbicularis palpebrarum, and the common elevator of the lip and ala of the nose; and just within the orbit, the inferior oblique muscle of the eye.

Developement.—In this case there are several ossific centres,—one in the nasal process, one in the orbital, one in the body, and one or two in the palate process. If the growth be interrupted, the fore part of the alveolar border with a portion of the palatal arch may remain separate from the rest of the bone, and represent an inter-maxillary bone.

THE MALAR BONE.

143. The malar bone (os malæ), common to the face and orbit, forms the most prominent point of the side of the former, and the greater part of the outer border of the latter. Its form is quadrangular. The facial or anterior surface, pierced by some foramina for small vessels, is convex, and gives attachment to the zygomatic muscles;—the posterior overlays the zygomatic fossa, and is rough at its fore part for its articulation with the superior maxillary bone. The superior surface, smooth, narrow, and lunated, extends into the orbit, and articulates with the frontal, sphenoid, and superior maxillary bones.

The superior border forms the outer margin of the orbit; the inferior is on a line with the zygomatic arch, which it contributes to form; the anterior articulates with the maxillary bone; the posterior, curved, gives attachment to the temporal aponeurosis.

Articulations.—It articulates with the frontal, superior maxillary, temporal, and sphenoid bones.

Attachments of muscles.—The zygomatici, to its anterior surface; the masseter, to its inferior border; to its anterior angle, part of the levator labii superioris.

Developement—It grows from a single ossific point.

THE NASAL BONES.

144. The nasal bones (ossa nasi), situated beneath the frontal bone, and between the ascending processes of the superior maxillary, are small, and irregularly quadrilateral, and form what is called the "bridge" of the nose. They are thick and narrow in their upper part, but gradually become wider and thinner lower down. The anterior surface of each, concave from above downwards, convex from side to side, presents a minute vascular foramen; the posterior, or nasal, is marked by the

passage of a branch of the nasal nerve; the superior border articulates with the frontal bone; the inferior with the nasal cartilage; the external with the ascending process of the maxillary bone; the internal with its fellow of the opposite side, and is supported by the nasal spine of the frontal bone, and the perpendicular plate of the ethmoid.

They give attachment to the pyramidales and compressores nasi; and are developed each from a single osseous centre.

OS UNGUIS—OS LACHRYMALE.

145. This small bone is named "ungual" from a resemblance, if not in form, at least in thinness and size, to a finger-nail (unguis); it is also called the "lachrymal" bone, from its presenting a groove which, with a similar excavation in the nasal process of the superior maxilla, forms the lachrymal groove. Placed at the inner and anterior part of the orbit, it presents two surfaces and four borders; its external or orbital surface, plain in the greater part of its extent, is hollowed anteriorly by a groove which runs from above downwards, and contributes, as above stated, to lodge the lachrymal sac. Part of the internal surface, which is rough, corresponds with the anterior ethmoidal cells, the rest with the middle meatus narium. The superior border is articulated with the orbital process of the frontal bone; the inferior with the superior maxillary bone; and where it dips down, to form a part of the lachrymal canal, it joins the inferior spongy bone; anteriorly, it rests on the nasal processes of the superior maxillary bone, and posteriorly on the os planum of the ethmoid.

It is developed from one osseous centre.

THE PALATE BONE.

146. The palate bone, fig. 46, (os palati), wedged in between the superior maxillary and sphenoid bones, is common to the cavity of the mouth, nares, and orbit. In its form this bone somewhat resembles that of the letter L, one part being horizontal, the other vertical.

Fig. 46.

147. The horizontal or *palate* plate, 1, of the bone, which is nearly square, and forms the back part of the roof of the mouth and of the

floor of the nares, articulates anteriorly with the palate plate of the maxillary bone; internally it presents a rough thick border which rises up into a ridge, 2, which joins with its fellow of the opposite side, and with it forms a groove which receives the lower border of the vomer; externally it unites at right angles with the vertical portion of the bone; posteriorly it presents a thin free border, forming the limit of the hard palate, and giving attachment to the velum or soft palate which projects downwards from it; it is slightly concave, and has at the inner angle a pointed process, 3 (*the palate spine*). The superior surface of this plate or process is smooth, and forms the back part of the floor of the nasal cavity: the inferior, which forms part of the roof of the mouth, is unequal, and marked by a transverse ridge, into which the tendinous fibres of the circumflexus palati muscle are inserted; it presents also an oval foramen, being the inferior termination of the posterior palatine canal, which transmits the large descending palatine nerve and accompanying vessels; and farther back, another of smaller size, which transmits the middle palatine nerve.

At the junction of the horizontal and vertical portions, is situated a thick, rough tubercle, 4, (*tuberosity, pyramidal process,*) projecting downwards and backwards. This is marked by three vertical grooves; the two lateral ones are rough, and receive the inferior borders of the pterygoid plates of the sphenoid bone; the middle one, 5, smooth, corresponds with and completes the fossa between the pterygoid plates.

148. The vertical portion of the bone is flat and thin; it presents two surfaces; the internal one (*nasal*) is divided into two parts by a transverse ridge, 6, which articulates with the inferior spongy bone; the space below the ridge forms part of the inferior meatus, that above it of the middle meatus. The external surface, rough and unequal, fig. 47, is divided by a vertical groove, 7, which is completed into a canal (*posterior palatine canal*) by the maxillary bone. The posterior part of this surface articulates with the rough border and nasal surface of the maxillary bone; and the anterior, thin and scaly, with the side of the antrum.

Fig. 47.

The superior border of the vertical portion of the palate bone, presents a notch, 8, forming the

greater part of a foramen, which is completed by the sphenoid bone when the parts are in their natural position. This is called the *spheno-palatine* foramen; and outside it is placed the nervous ganglion of the same name (Meckel's ganglion). This notch divides the border of the bone into two processes or heads, the sphenoidal and the orbital.

149. The *sphenoidal* process, 9, smaller and not so prominent, presents three surfaces, of which one, internal, looks to the nasal fossa; another, external, forms a small part of the zygomatic fossa; and the third, superior, grooved on its upper surface, articulates with the under surface of the sphenoid bone, and with it forms part of the *pterygo-palatine* canal.

150. The *orbital* process, 10, inclines outwards and forwards, and has five surfaces, two of which are free, and three articulated; of the latter, the internal one rests against the ethmoid bone, and covers some of its cellules; the anterior, 11, articulates with the superior maxillary bone; and the posterior, 12, (which is hollow) with the sphenoid. Of the non-articular surfaces, one superior, 13, smooth and oblique, forms a small part of the floor of the orbit; the other, external, 14, looks into the zygomatic fossa.

Articulations.—With the corresponding palate bone; with the maxillary, ethmoid, sphenoid, vomer, and inferior spongy bone.

Muscular attachments.—To its spine, the azygos uvulæ; to the centre groove on its tuberosity, a small part of the internal pterygoid; and to the transverse ridge on the palate plate, the aponeurosis of the circumflexus palati.

Developement.—From the position and complex relations of this bone, its mode of growth is difficult to be determined. It appears at first like a single osseous plate slightly curved, and produced from one centre of ossification.

THE VOMER.

151. The vomer, so called from its resemblance to a ploughshare, is flat, irregularly quadrilateral, and placed vertically between the nasal fossæ, presenting two surfaces and four borders. The lateral surfaces form part of the inner wall of the nasal fossæ; the superior border, thick and deeply grooved, receives the rostrum of the sphenoid bone; the margins of the groove

expand and are articulated with two small lamellæ at the roots of the pterygoid processes of the sphenoid bone. The anterior border, also grooved, presents two portions, into one of which is implanted the descending plate of the ethmoid, and into the other the nasal cartilage. The posterior border, dividing the posterior nares, is thin and unattached: the inferior is received into the fissure formed by the palate plates of the superior maxillary and palate bones. It is developed from a single osseous centre.

THE INFERIOR TURBINATE BONE.

152. The *inferior turbinate*, or *spongy bone*, (so called from its texture in the latter case, in the former from some resemblance to the lateral half of an elongated bivalve shell,) extends from before backwards, along the side of the nasal fossa:—it appears as if appended to the side of the superior maxillary and palate bones. It is slightly convoluted, and presents an internal convex surface, projecting into the nasal fossa; and an external concave one, which arches over the inferior meatus. Its superior border articulates with the ascending process of the maxillary bone before, with the palate bone behind, and in the centre with the os unguis; it presents also a hooked process, which curves downwards and articulates with the side of the antrum; the inferior border is free, slightly twisted, and dependent. It has one point of ossification.

THE INFERIOR MAXILLARY BONE.

153. The inferior maxilla, fig. 48, (os maxillæ inferior,) is of considerable size, and forms a large portion of the sides and fore part of the face. It is convex in its general outline, and shaped somewhat like a horse-shoe. It is usually considered as divisible into a middle larger portion — its body, and two branches or rami. The *body*, 1, is placed horizontally; its external surface is convex, and marked at the middle by a verti-

Fig. 48.

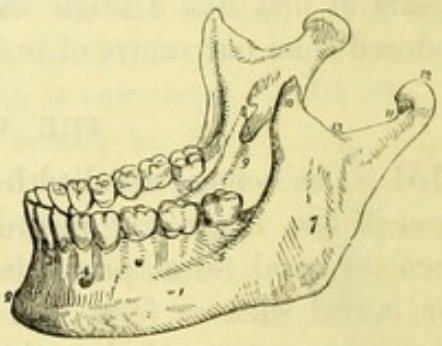

cal line, 2, indicating the original division of the bone into two lateral parts, and thence named its *symphysis*. On each side of the symphysis, and just below the incisor teeth, is a superficial depression, 3, (the *incisor fossa*,) which gives origin to the levator menti muscle; and, more externally, a foramen, 4, (*foramen mentale*,) which transmits the terminal branches of the dental nerve and artery. A raised line may be observed to extend obliquely upwards and outwards from near the symphysis to the anterior border of the ramus; it is named the *external oblique* line, 5, and is intended to give attachment to muscles. The internal surface of the body of the bone is concave in its general outline, and marked at its centre by a depression corresponding with the symphysis; at each side of which are two prominent tubercles placed in pairs, one above the other, and affording attachment,—the upper pair, to the genio-hyo-glossi, and the lower to the genio-hyoidei muscles; beneath these are two slight depressions for the dygastric muscles. An oblique prominent line, 6, (the *mylo-hyoidean ridge*,) will be observed leading from the lower margin upwards and outwards to the ramus; above the line is a smooth depression for the sublingual gland, and beneath it, but situated more externally, is another for the submaxillary gland. The superior border of the body is horizontal, and marked by notches, corresponding with the alveoli, or sockets of the teeth. The inferior border, thicker at its anterior than at its posterior part, is slightly everted, so as to project somewhat forwards.

154. The branches, 7, (*rami*,) project upwards from the posterior extremity of the body of the bone, with which they form nearly a right angle in the adult, an obtuse one in infancy,—the "angle" of the jaw. They are thinner somewhat, and appear as if compressed. The external surface of each ramus is flat, and marked by slight inequalities; the internal surface presents at its middle a foramen, 8, (*inferior dental*,) leading into a canal (dental) contained within the bone, and lodging the dental nerve and vessels. Beneath the foramen, a slight groove, 9, marks the passage of some vessels and a nerve, the rest of the surface being rough, for the insertion of the pterygoideus internus. The anterior border of each ramus is nearly vertical in its direction, and terminates in a pointed extremity, named the *coronoid process*, 10; it is grooved at its commencement, for

the attachment of the buccinator muscle. The posterior border is also almost vertical in adults; but in children and edentulous subjects it departs considerably from this direction, and approaches that of the base of the bone. This border is surmounted by a constricted part, 11, which appears as if compressed from before backwards, and is called the *neck* of the bone. It is slightly depressed at its fore part, and gives insertion to the external pterygoid muscle. Now the neck supports the articular head of the bone, 12, (the *condyle*,) which is convex and oblong, its greatest diameter being from without, inwards; the direction of its axis is oblique, so that, if prolonged, it would meet with that of its fellow of the opposite side at the anterior margin of the foramen magnum. The interval between the condyle and the coronoid process, deeply excavated, is called the *sigmoid* notch, and if viewed when the bones are *in situ*, it will be found to form a complete circle with the arch of the zygoma.

155. *Attachments of muscles.*—To the incisor fossa, the levator menti; to the external oblique line, the depressor labii inferioris, depressor anguli oris, and a small part of the platisma myoides. To the upper tubercles on the inner surface of the symphysis, the genio-hyo-glossi; to the inferior ones, the genio-hyoidei; to the depression beneath these, the digastricus; to the internal oblique line, the mylo-hyoideus, and posteriorly a small part of the superior constrictor of the pharynx. To the external surface of the ramus, the masseter; to the lower part of the inner surface, the pterygoideus internus; to the neck of the condyle, the pterygoideus externus; to the coronoid process, the temporal.

Developement.—The growth is here effected from two osseous points, one in each lateral half.

OS HYOIDES.

156. This is the U-shaped bone, fig. 49, so named from some resemblance to the Greek letter υ. It is occasionally called the lingual bone, from its important relations with the tongue; it is situated at the base of the tongue, and may be felt between the chin and the thyroid cartilage. It consists of a body,

Fig. 49.

two cornua, and two cornicula. The body or central piece, 1, is small, quadrilateral in its form, and appearing as if compressed from before backwards; hence the direction of its plane is nearly vertical; but the great cornua seem as if compressed from above downwards, so that their plane appears horizontal. The anterior surface of the body is convex, and marked at the middle by a vertical line, on each side of which are depressions for the attachment of muscles; its posterior surface is concave, and corresponds with the epiglottis. The cornua, 2, project backwards, and end in a rounded point. The cornicula, 3, short, irregularly conical in their form, and oblique in their direction, are placed at the junction of the body with the cornua, and give attachment to the stylo-hyoid ligament; they continue for a long time movable, as the cartilage which connects them remains unossified to an advanced period of life.

157. *Attachments of muscles and ligaments.*—The stylo-hyoid ligaments, to the cornicula; the thyro-hyoid, to the cornua. The anterior surface gives attachment to the stylo-hyoid, sterno-hyoid, and digastric muscles; the superior border, to the mylo-hyoid, genio-hyoid, genio-hyo-glossi, lingualis, hyo-glossus, and the middle constrictor of the pharynx; its lower border, to the omo-hyoid and thyro-hyoid muscles, and more internally to the thyro-hyoid membrane.

THE SUTURES.

158. The bones of the skull, and those of the face, are joined together by seams or sutures. The cranial sutures are commonly said to be five in number, of which three are termed true, as the margins of the bones are, in a manner, dovetailed one into another; and two are called false, or squamous, as they merely overlap one another, like the scales of fishes. The true sutures are, the coronal, the lambdoidal, and the sagittal. These names are obviously ill-chosen; they convey no notion of the position which the sutures occupy in the skull, or of the bones which they connect.

159. The *coronal* suture (sutura coronalis) has been so named from being situated where the ancients wore their garlands (coronæ). It connects the frontal with the two parietal bones, and hence it may with more propriety be called "fronto-parietal." It commences at each side about an inch behind the

external orbital process of the frontal bone, where the anterior inferior angle of the parietal articulates with the great wing of the sphenoid bone. From this point it mounts rather obliquely up towards the vertex, having an inclination backwards. The dentations are better marked at the sides than at the summit of the head, for in the latter situation the suture approaches somewhat the squamous character, to allow the frontal bone to overlap the parietal. A similar change takes place at its lower part or commencement, with this difference, that there the parietal bones are made to overlay the frontal.

160. The *lambdoid* suture (sutura lambdoidalis) is situated between the occipital and the parietal bones, its form resembling somewhat that of the Greek letter Λ, whence its name has been taken. It begins at each side on a line with the posterior inferior angle of the parietal bone, and thence inclines upwards and forwards to the point at which the two parietal bones are joined by the sagittal suture. It thus represents two sides of a triangle. It is often interrupted by accessory osseous deposits (ossa Wormiana). From its position and relation this suture may be named "occipito-parietal."

161. The *sagittal* suture (s. sagittalis—sagitta, an arrow) extends directly backwards, from the middle of the coronal to that of the lambdoid suture, and connects the two parietal bones, from which circumstance it may be called the "interparietal" suture: in children, and occasionally in adults, it is prolonged through the frontal bone, even to the root of the nose. The serrated appearance of the sutures is perceptible only on the external surface of the bones; the internal surface, or table of each, as it is called, being merely in apposition with the contiguous bone.

The line of union between the occipital and the temporal bone at each side used to be considered as a continuation of the lambdoid suture, or as an appendix to it, and was accordingly named *additamentum suturæ lambdoidalis*. It may, however, be named *temporo-occipital*, as it connects the mastoid and petrous parts of the temporal bone with the occipital—principally its basilar and condyloid portions. In this suture there are no regular dentations; in a great part of its extent the margins of the bones are merely in apposition.

162. The *squamous* sutures (suturæ squamosæ) are arched,

and mark the junction of the lower borders of the parietal bones with the squamous parts of the temporal, their edges being so bevelled off as to allow the latter to overlay the former. At the point of junction between the squamous and mastoid parts of the temporal bone, the true squamous suture ceases; but from thence a short suture runs backwards to the lambdoid, connecting the mastoid part of the temporal with the postero-inferior angle of the parietal. This is termed *additamentum suturæ squamosæ:*—both together form the "temporo-parietal" suture.

The line of direction of the sutures (particularly the lambdoid and sagittal) is not unfrequently interrupted by additional bones, inserted between those hitherto enumerated. These, from being sometimes of a triangular form, are called *ossa triquetra*, and also *ossa Wormiana.*

163. The cranial bones are joined to those of the face by sutures, which are common to both sets of bones. The *transverse* suture, observable at the root of the nose, extends across the orbits, and connects the frontal with the nasal, superior maxillary, ossa unguis, ethmoid, sphenoid, and malar bones. The *zygomatic* sutures are very short; they are directed obliquely downwards and backwards, and join the zygomatic processes of the temporal with the malar bones. The *ethmoid* suture surrounds the bone of the same name; so does the *sphenoid;* they are necessarily complex in consequence of the many relations of these bones. The lines of connexion between the nasal and maxillary bones, though sufficiently marked, have not received particular names; but those observable between the horizontal lamellæ of the latter, and those of the palate bones, may be termed the palato-maxillary sutures.

REMARKS ON THE GENERAL CONFORMATION OF THE SKULL.

164. After having described, in detail, the separate bones of the head and face, it becomes necessary to review them collectively. The description of these bones forms the most difficult part of human, as well as of comparative osteology, as they are the most complex in the whole skeleton; but a correct knowledge of them is indispensable, in consequence of the many important parts which they serve to sus-

tain and enclose; viz. the cerebral mass, with its nerves and vessels; the organs of sight, hearing, smell, and taste; part of those of mastication and deglutition, as well as of voice. To facilitate the description of the numerous eminences, depressions, cavities, and foramina of the skull, anatomists examine successively its external and internal surface: the former may be considered as divisible into five regions, three being somewhat of an oval figure, and situated, one superiorly, another at the base, the third in front, including the face; the others comprise the lateral parts, and are somewhat flat and triangular.

165. The *superior region* extends from the frontal eminences to the occipital protuberance, and, transversely, from one temporal ridge to the other; it thus includes the upper broad part of the frontal, almost all the parietal, and the superior third of the occipital bone, which together form the vaulted arch of the skull. It is divided into two symmetrical parts by the sagittal suture and its continuation when it exists; it presents no aperture or other inequality deserving of particular notice; it is covered by the common integument and occipito-frontalis muscle, on which ramify branches of the temporal, occipital, and auricular arteries, as well as filaments of nerves from the frontal branches of the fifth and portio dura, and also from the occipital nerve.

166. The *inferior region*, fig. 50, also oval in its outline, is the most complex of all, as it includes the entire base of the skull, extending from the incisor teeth to the occipital protuberance, and transversely, from the mastoid process and dental arch on one side, to the corresponding points on the other. It may be considered as divisible into three parts. Of these, one corresponds with the extent of the arch of the palate; it is divided into two parts by a line, 1, extending from before backwards, and marking the junction of the palate processes of the superior maxillary and palate bones; this is intersected by another, 2, running transversely between each palate bone and the corresponding maxillary bone. Anteriorly, and in the middle line, is a foramen, 3, (the *anterior palatine*,) which in the floor of the nares is double, but becomes single

Fig. 50.

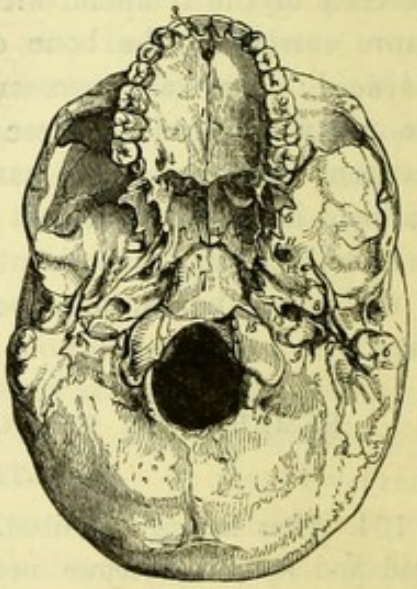

inferiorly, and transmits the naso-palatine nerve; posteriorly, on each side, and at the base of the alveolar border, is another foramen, 4, (*posterior palatine,*) for the posterior palatine nerves and artery. The middle, or guttural region, is bounded at each side by a line extended from the pterygoid process, 5, as far as the mastoid process, 6, thus including the posterior aperture of the nares, and the central part of the base of the skull. In the centre is situated the basilar process, 7, of the occipital bone, marked by slight inequalities, for the attachment of muscles, and towards its posterior extremity the anterior condyloid foramina, which transmit the ninth pair of nerves. On each side is the pars petrosa, 8, of the temporal bone, in which may be observed the styloid and vaginal processes; more posteriorly is the jugular fossa, which is completed into a foramen, 9, (*foramen lacerum posterius basis cranii,*) by the border of the occipital bone. This is divided into two parts by a spicula of bone, or a fibrous band, the internal and anterior one serving to transmit the glosso-pharyngeal, par vagum, and spinal accessory nerves; the other the jugular vein. Between the apex of the pars petrosa, and the side of the basilar process, and the body of the sphenoid bone, is the *foramen lacerum anterius basis cranii*, 10, which is closed inferiorly by a thin plate of cartilage: across its area, as viewed at its upper or cerebral aspect, runs the internal carotid artery in its passage from the carotid canal in the temporal bone to the side of the sphenoid, and also the Vidian nerve, after it has passed backwards through the pterygoid foramen, and is proceeding to reach the groove in the upper surface of the pars petrosa. Between the contiguous margins of the pars petrosa and the great ala of the sphenoid bone is a groove, which leads backwards and outwards, and lodges the cartilaginous part of the Eustachian tube; and above the osseous part of that tube, and separated from it by a thin lamella of bone, is the orifice of the canal which transmits the tensor tympani muscle. The foramina of this region, taken in their order, from within outwards and backwards, are, the foramen ovale, 11, foramen spinosum, 12, foramen caroticum, 13, and stylo-mastoideum, 17.

The anterior part of this region is continuous with the posterior aperture of the nares, which is divided into two parts by the vomer, 14. It is bounded above by the body of the sphenoid bone, below by the palate plates of the ossa palati, and on the sides by the pterygoid processes. The pterygoid groove, in each of these processes, is completed inferiorly by the pyramidal process of the palate bone; near its junction with the body of the bone is the scaphoid fossa, for the origin of the circumflexus palati; and at its inferior termination is the

hamular process, round which the tendon of that muscle is reflected. Between the base of this process and the posterior palatine foramen is situated a smaller foramen, leading down from the posterior palatine canal, and which transmits the middle palatine nerve.

The posterior part of the inferior region includes all that is situated between the occipital protuberance and a line connecting the mastoid processes. It is divided into two lateral parts by a ridge, extending to the foramen magnum from the occipital protuberance, from which two rough curved lines branch outwards, giving attachment to muscles; so does the space between the lines, and that between the inferior one and the foramen magnum. At the margin of the foramen, but nearer to its anterior termination, are the condyles, 15, of the occipital bone, which articulate with the first vertebra; behind each is a depression, 16, (*condyloid fossa,*) and usually a foramen (*posterior condyloid foramen*), which transmits a small vein and artery. Before and a little to the outer side of each, in a spot also retiring and depressed, is the opening of the *anterior condyloid foramen*, which looks obliquely outwards and forwards, and transmits the lingual nerve.

167. The *anterior region* of the skull is of an oval form, and extends from the frontal eminences to the chin, and from the external border of the orbit and ramus of the jaw, on one side, to the corresponding points on the other, so as to include the whole of the face. The eminences, depressions, fossæ, and foramina, observable in this region, are as follow: viz. the frontal eminences, more or less prominent in different individuals, bounded inferiorly by two slight depressions, which separate them from the superciliary ridges; these curve outwards, from the nasal process of the frontal bone. Beneath the superciliary ridge, on each side, is the margin of the orbit, marked at its inner third by a groove, or a foramen, which transmits the frontal nerve and supra-orbital artery; and also by a slight depression, which gives attachment to the cartilaginous pully of the trochlearis muscle. At an interval corresponding with the breadth of the orbit is another ridge, forming its inferior margin; under which is situated the infra-orbital foramen, for the passage of the superior maxillary nerve; and still lower down, the fossa canina, which gives attachment to the levator anguli oris muscle; it is bounded below by the alveolar border of the upper jaw, and surmounted by the malar tuberosity. Towards the middle line, and corresponding with the interval between the orbits, is the nasal eminence of the frontal bone, which is prominent in proportion to the developement of the frontal sinuses over which it is situated. This is bounded by the transverse suture,

marking the root of the nose. Beneath the nasal, and between the contiguous borders of the superior maxillary bones, is a triangular opening which leads into the nasal fossæ; it is broad below, and there its edge is surmounted by a prominent process, the nasal spine. Laterally it presents two sharp curved borders, which gradually incline inwards as they ascend to the nasal bones, so as to narrow it somewhat. Below the nasal aperture is a slight depression (myrtiform fossa), at each side of the middle line over the alveolus of the second incisor tooth. Farther down is the transverse rima of the mouth, between the alveolar borders of the jaws. In the inferior maxillary bone, besides some muscular impressions, is the mental foramen, which transmits the terminal branches of the dental nerve and artery.

168. The two *lateral* regions of the skull are somewhat of a triangular figure, the apex of the triangle being at the angle of the lower jaw, the base at the temporal ridge, and the sides formed by two lines drawn, one upwards and forwards, over the external orbital process, the other upwards and backwards, over the mastoid process. In consequence of the great irregularity of the surface, it is necessary to subdivide each of these regions into three; the part above the zygoma being called the temporal region or fossa, that beneath it the zygomatic, the remainder being named the mastoid.

The *temporal* region, or fossa, being bounded by the temporal ridge above, and by the zygomatic arch below, is of a semicircular form, and extends from the external angular process of the frontal bone to the base of the mastoid process. It is filled up by the temporal muscle, lodges the deep temporal vessels and nerves, and is formed by the temporal, parietal, frontal, sphenoid, and malar bones.

The *mastoid* region is bounded before by the transverse root of the zygoma, above by the horizontal one and the additamentum suturæ squamosæ, behind and inferiorly by the additamentum suturæ lambdoidalis. Proceeding from behind forwards, we observe the mastoid foramen, the process of the same name; anterior to which is the aperture of the meatus auditorius externus, which is circular in young subjects and somewhat oval in adults, the greatest diameter being from above downwards. The osseous tube continuous, externally, with the fibro-cartilage of the ear, and bounded, internally, by the membrana tympani, is directed, obliquely, forwards and inwards, and is somewhat broader at its extremities than in the middle. Anterior to the meatus is the glenoid fossa, which is bounded before by the transverse root of the zygoma, behind by the meatus, and internally by the spinous process of the sphenoid bone. It is divided into two

parts by a transverse fissure (*fissura Glasseri*), the anterior portion being smooth, for its articulation with the condyle of the lower jaw; the posterior, rough, lodges part of the parotid gland. This fissure gives entrance to the laxator tympani muscle and a small artery, and transmits outwards the chorda tympani nerve.

The *zygomatic* region, situated deeply behind and beneath the orbit, is bounded before by the convex part of the superior maxillary bone, and is enclosed between the zygoma and the pterygoid process. The posterior surface of the maxillary bone is pierced by some small foramina, opening into canals, for the transmission of the superior dental nerves. Between the superior border of this bone, and the great ala of the sphenoid, is a fissure (*spheno-maxillary*), which is directed forwards and outwards, and communicates with the orbit; and between its posterior border and the pterygoid process is another (*pterygo-maxillary*), whose direction is vertical. The angle formed by the union of these fissures constitutes the *spheno-maxillary fossa*, which is situated before the base of the pterygoid process, behind the summit or posterior termination of the orbit, and immediately external to the nasal fossæ, from which it is separated by the perpendicular plate of the palate bone. Into this narrow spot five foramina open, viz. the foramen rotundum, which gives passage to the second branch of the fifth pair; the foramen pterygoideum, to the Vidian or pterygoid nerve and artery; the pterygo-palatine, to a small artery of the same name (sometimes called also the superior pharyngeal); the posterior palatine foramen, leading to the canal of the same name; and the spheno-palatine, which transmits the spheno-palatine nerve and artery.

169. The *internal surface* of the skull may be divided into its arch and its base. The arch extends from the base of the perpendicular part of the frontal bone, as far as the transverse ridge on the inner surface of the occipital bone. Along the middle line, and corresponding with the direction of the sagittal suture, is a shallow groove, marking the course of the superior longitudinal sinus. Several slight irregular depressions may also be observed, for the cerebral convolutions, and some tortuous lines for the branches of the meningeal artery; and in many cases irregular depressions over the points occupied by glandulæ Pacchioni. The surface is more or less depressed so as to form fossæ at the points corresponding with the frontal and parietal eminences, and also above the internal occipital ridge, where the posterior lobes of the brain are lodged.

170. The *base* of the skull presents the several eminences, depres-

sions, and foramina, which have been already enumerated in the description of the separate bones. Three fossæ may be observed at each side, differing in size and depth.

The *anterior fossa*, formed by the orbital plate of the frontal bone and the smaller wing of the sphenoid, serves to support the anterior lobe of the brain: it is marked by eminences and depressions corresponding with the cerebral convolutions and sulci; and, posteriorly, by a transverse line, indicating the junction of the bones just mentioned.

The *middle fossa*, formed by the great ala of the sphenoid, the squamous part of the temporal, and the anterior surface of the pars petrosa, lodges the middle lobe of the brain. It is marked by linear impressions for the meningeal artery, and by shallow pits for the cerebral convolutions; anteriorly it opens into the orbit by the sphenoidal fissure, sometimes called foramen lacerum anterius to distinguish it from those placed farther back, and already noticed; it transmits the third, the fourth, and the sixth nerves, together with the ophthalmic branch of the fifth and the ophthalmic vein. Behind this is situated the foramen rotundum for the second branch of the fifth, the foramen ovale for the third, and, lastly, the foramen spinosum for the middle meningeal artery. Where the summit of the pars petrosa approaches the body of the sphenoid bone, there the internal orifice of the carotid canal opens. On the anterior surface of the pars petrosa, and directed obliquely backwards, there is a slight groove, leading to the hiatus Fallopii, and transmitting the Vidian nerve.

The *posterior fossa*, deeper and broader than the others, gives lodgment to the lateral lobes of the cerebellum. In the posterior surface of the pars petrosa, which forms the boundary of this fossa, may be observed the internal auditory foramen, and, within a few lines of it, a triangular fissure, which opens into the aquæductus vestibuli, and towards its inferior margin part of the groove for the lateral sinus, which leads down to the foramen lacerum posterius. Along the middle line, and taking the parts situated in the base of the skull from before backwards, we observe the crista galli of the ethmoid bone, and on each side the cribriform lamella of that bone; farther back, a slightly depressed surface, which supports the commissure of the optic nerves; and on each side the optic foramina. Behind this is the pituitary fossa, situated on the body of the sphenoid bone, bounded before and behind by the clinoid processes. Leading downwards and backwards from these is the basilar groove, which supports the pons Varolii and medulla oblongata, and terminates at the foramen mag-

num; at each side of this foramen are the condyloid foramina, and behind it a crista, leading upwards to the occipital ridge, and giving attachment to the falx cerebelli.

The Orbits.

171. The form of the orbits is that of a quadrilateral pyramid, whose base is directed forwards and outwards, and apex backwards and inwards, so that if their axes were prolonged backwards they would decussate on the body of the sphenoid bone.

The *roof* of each orbit forms part of the floor for the brain; it is concave, and composed of the orbital process of the frontal, and the smaller wing of the sphenoid bone: at its anterior and inner border may be observed a depression for the attachment of the pulley of the trochlearis muscle; externally, and immediately within the margin of the orbit, a shallow depression for the lachrymal gland; at the anterior border, a groove, sometimes a foramen, which transmits the supra-orbital or frontal nerve and artery; and posteriorly, at the apex of the cavity, the optic foramen, transmitting the optic nerve and ophthalmic artery. The *floor* forms the roof of the maxillary sinus: it consists of the orbital processes of the malar and maxillary bones, and of the small portion of the palate bone which rests on the latter; towards the inner and anterior border, near the lachrymal canal, may be observed a slight roughness, for the attachment of the obliquus inferior muscle; posteriorly, a groove, terminating in the infra-orbital canal, which runs nearly horizontally forwards. The inner side or wall of the orbit runs directly backwards, being parallel with the corresponding side of the other orbit, and is composed of the ascending process of the maxillary bone, the os unguis, the os planum of the ethmoid, and part of the body of the sphenoid bone. Near the anterior border is situated the *lachrymal canal,* which is formed, for the most part, between the ascending process and body of the maxillary bone, the remainder being made up by the groove in the os unguis, and a small process of the inferior spongy bone; this canal, a little expanded at its extremities, is directed downwards, backwards, and a little outwards. The *outer* side of the orbit, composed of the orbital plates of the malar and sphenoid bones, presents some minute foramina, which transmit small nerves from the orbit to the temporal fossa.

The *superior internal angle,* formed by the junction of the orbital process of the frontal bone with the os unguis and os planum, presents two foramina *(foramen orbitale internum, anterius, et posterius),* which give transmission, the anterior to the nasal twig of the ophthal-

mic nerve, the posterior to the ethmoidal artery. The *internal inferior angle* is rounded off so as to be scarcely recognised; it is formed by the union of the os unguis and os planum with the orbital plates of the superior maxillary and palate bones. In the *external superior angle*, formed by the malar, frontal, and sphenoid bones, is observed the sphenoidal fissure, of a triangular form, situated obliquely, its base being internal and inferior, the apex external and superior. In the *inferior external angle*, formed by the malar, the great ala of the sphenoid, the maxillary, and palate bones, is situated the sphenomaxillary fissure, inclined at an angle with the former, and communicating with it, but of a different form, being broad at its extremities and narrow at the centre,

172. The *anterior extremity*, or *base*, of the orbit, is directed outwards and forwards; and, as if to provide for a free range of lateral vision, the external wall retreats in some degree, and does not extend as far forward as the internal. The inner termination of the cavity, representing the summit of a pyramid, to which it has been likened, corresponds with the optic foramen. In each orbit, parts of seven bones are observed, viz. the frontal, ethmoid, sphenoid, os unguis, malar, maxillary, and palate bones; but as three of these, viz. the ethmoid, sphenoid, and frontal, are common to both, there are only eleven bones for the two orbits.

The Nasal Fossæ.

173. These fossæ, fig. 51, are two cavities, placed one at each side of the median line, separated by a flat vertical septum. They communicate, by foramina, with the various sinuses lodged in the frontal, the ethmoid, and superior maxillary bones, and open anteriorly, on the surface, by the nares, and posteriorly into the pharynx. The roof, the floor, the inner and the outer walls of these cavities, require a separate consideration.

Fig. 51.

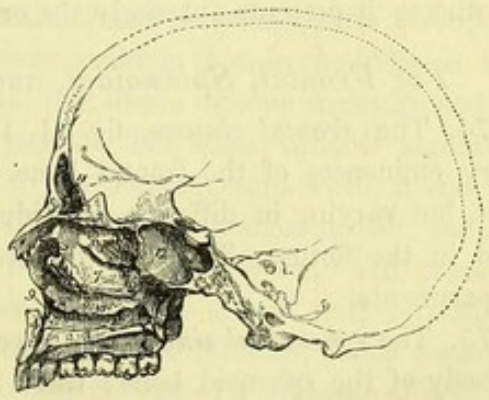

The *roof* is flat at its middle part, and sloped before and behind it; is formed in front by the inner surface of the nasal bones, 1, behind by the body of the sphenoid, 12, and in the middle by the horizontal or

cribriform lamella of the ethmoid bone, 2. The *floor*, smooth, concave from side to side, and formed by the palate plates of the maxillary and palate bones, 3, extends backwards, and a little downwards, from the nares to the pharynx. Towards the anterior opening may be observed the superior orifice of the anterior palatine canal, 4. The *internal wall*, or septum narium, which extends from the roof to the floor of the cavity, is flat, nearly vertical (the deviation, if any, being usually to the left side), and composed of the perpendicular plate of the ethmoid bone, the vomer, and the nasal cartilage. The *external wall* is formed by the ethmoid, superior maxillary, os unguis, inferior spongy, and palate bones. The posterior and inferior parts of this surface are marked by a number of inequalities, whilst the superior and anterior are comparatively even. In the latter situation may be observed, first, the smooth surface just mentioned; and, secondly, passing downwards and backwards, three, and frequently four, arched and convoluted bones (spongy bones), beneath which are grooves (*meatus*) leading from before backwards. The superior spongy bone, 5, is much shorter than the others; beneath it is the *superior meatus*, 6, into which will be found opening, anteriorly, a foramen from the posterior ethmoidal cells, and, posteriorly, the spheno-palatine foramen. The middle spongy bone, 7, overhangs the *middle meatus*, 8, which communicates with the anterior ethmoidal cells; one of these curves forwards and upwards, and is continuous with the frontal sinus; more posteriorly is situated the opening of the maxillary sinus. The *inferior meatus*, 9, situated below the inferior spongy bone, 10, between it and the floor of the nasal cavity, is necessarily longer than the others; it presents anteriorly the orifice of the nasal canal.

The Frontal, Sphenoidal, and Maxillary Sinuses.

174. The *frontal sinuses*, fig. 51, 11, correspond with the superciliary eminences of the frontal bone. Of considerable size in the adult, but varying in different individuals, they are not at all developed in the fœtus. They are divided into two, sometimes three, compartments.

175. The *sphenoidal sinuses*, 12, two in number, are placed within the body of the sphenoid bone; these also cannot be said to exist in infancy. They are separated by a partition. Above, behind, and on each side, they are bounded by the body of the sphenoid bone, and in front by two small spongy bones (cornua sphenoidalia).

176. The *maxillary sinus* (antrum Highmori) is a large excavation in the body of the superior maxillary bone. It appears at an

earlier period than any of the other sinuses, the developement commencing about the fourth month of fœtal life. Its form is irregularly pyramidal, the base being towards the nasal cavity, the apex corresponding with the malar tuberosity. Superiorly, it is enclosed by the orbital plate of the maxillary bone; and inferiorly by its palate plate: internally, it opens into the middle meatus of the nasal cavity by a foramen, which, though it appears very large in the dry bone when separated from its connexions, is in the natural state small, being little more than sufficient for the admission of a probe; this diminution of size is caused by the lower edge of the ethmoid, the inferior spongy and the palate bones, and also by a fold of the mucous membrane.

Analogy between Cranial Bones and Vertebræ.

177. Anatomists have at all times perceived and recognised the analogy between the movable and motionless pieces of the spine—between those of the lumbar and dorsal regions, and those of the sacrum and coccyx: in the one, as well as in the other, similar organic elements are observed to exist, variously modified, in order to suit special purposes; but it is only of late years that any adequate attention has been directed to the points of similitude which exist between vertebræ, properly so called, and the cranial bones. Many persons who adopt, without hesitation, the terms false or pelvic vertebræ, as applied to the sacrum and coccyx, feel a repugnance to use the word false or cranial, as applied to the pieces of the skull; and deny, perhaps without examination, the analogy upon which it is founded, as being unnatural or far-fetched. We have numerous instances of the harmony that subsists between containing and contained parts throughout the economy; in no case is it more striking than in the relation that obtains between the fundamental part of the osseous structure and the central mass of the nervous system. The spinal canal is accurately adapted in its different parts to the nervous cord which it encloses. In the pelvic region, the canal, at least in the human subject, becomes narrow, as it merely encloses nerves, whilst the body and processes take on a particular developement to meet a special purpose, that of forming a basis of support for the rest of the column. This seems to result from the working of what may be termed a principle of compensation in the growth, as well as in the action of parts; for when one part of a given whole is developed to excess or to a maximum, others will remain at a minimum or atrophied: thus the spinal canal and the arches are at their minimum in the sacrum and coccyx, for the contained parts are there at a low point of developement; but at the

opposite end of the column the reverse obtains; the contained parts, viz. the central parts of the nervous system, are evolved in the human subject to the greatest extent, and so must the containing parts also be. The portion of the osseous system which corresponds with the bodies of the vertebræ can, therefore, hardly be recognised; whilst that which is analogous to the arches is expanded so much as to retain but a slight similitude to them.

If we take the occipital bone, and examine it attentively, we shall readily perceive in it all the elements of a vertebra. The foramen magnum is the counterpart of the ring of a vertebra, and has a similar relation to the spinal cord; the basilar process represents the body; the condyles are true articulating processes; the rough surfaces external to them, and which give attachment to the recti laterales, correspond to the transverse processes; the vertical ridge extended backwards along the median line, from the foramen to the occipital protuberance, is, in the human subject, merely a rudiment of a spinal process; but in the dog, bear, and badger, it forms a sharp prominence well deserving the name of spine, and the likeness is still more striking in osseous fishes: finally, the broad plates on each side of the spine represent the arches. In this view of the matter, the occipital bone forms the first false vertebra of the cranial region.

In the second cranial piece or vertebra, it must be admitted that the analogies are not so striking; but when we recollect that the cavity of the skull, if examined in the different orders of animals, enlarges in proportion as the brain acquires an increase of developement, and that this enlargement attains its maximum in the human subject, we shall at once find sufficient reason to expect that the parts corresponding with the vertebral arches should, in this region, be greatly evolved, while the rest are in a manner atrophied. The parietal bones, with the squamous part of the temporal and the great wings of the sphenoid, taken together, represent the arches, whilst the posterior part of the sphenoid bone (such as it exists in the human fœtus before its ossification is complete, and such as it continues permanently in several lower animals,) is the counterpart of the body; the mastoid processes of the temporal bones with the glenoid fossæ serve as transverse and articulating processes. These, together, form the middle cranial piece, which may be termed the spheno-temporo-parietal cranial false vertebra.

The frontal bone, the ethmoid, and the anterior division of the sphenoid (which is that part of the body that sustains the smaller wings), form the third vertebra; the part of the sphenoid just named,

together with the crista galli and the perpendicular plate of the ethmoid bone, form the body, which is here reduced to a rudimentary state, just as the coccygeal bones are at the opposite end of the column, of which it may be considered a repetition. The lateral and expanded parts of the frontal bone are the arches, and the external orbital processes may be likened to transverse processes.

We have here used the term false vertebra as applied to the cranial pieces; perhaps it would be better to use the word zone, as sanctioned by the authority of Cuvier. The passage in which he recognises the principle of developement here indicated, as well as the application of it, (which appears to have been first inculcated by Dumeril, and traced in all its details by Geoffroy Saint-Hilaire,) is as follows: — "Le crâne se subdivise comme en trois ceintures, formées—l'antérieure par les deux frontaux et l'éthmoide, l'intermédiaire par les pariétaux et le sphénoide, la postérieure par l'occipital." *

Man adapted to the erect posture.

178. Every part of the conformation of the human subject indicates its adaptation to the erect position. The feet are broader than those of any other animal proportionally to its size; the tarsal and metatarsal bones admit of very little motion; and the great toe is on the same plane with the others, and cannot be brought into opposition with them. The foot is thus fitted to sustain the weight of the body, but not to grasp or seize objects presented to it. The hands, on the contrary, though so well adapted for these purposes, are ill calculated for affording support; so that man is truly "bimanous" and "biped." † The tibia rests perpendicularly on the astragalus, and the os calcis projects backwards for the purpose of increasing the base, and also of lengthening the lever to which the strong muscles of the calf of the leg are attached. The whole extent of the tarsus, metatarsus, and phalanges, in man, rests on the ground, which does not obtain even in apes, the end of whose os calcis is somewhat raised, so as to form an acute angle with the bones of the leg. In dogs and digitated quadrupeds, the carpus and tarsus are considerably elevated from the ground, so that the body rests on the toes; and in the horse, and other solid-hooved animals, the third phalanges only rest on the ground, the os calcis being raised nearly to the perpendicular direction.

The femur, placed securely beneath the pelvis, affords a firm support during progression. The great breadth of the pelvis serves to

* Règne Animal, tom. i. p. 63. † Règne Animal, tom. i. p. 82.

enlarge the base on which the trunk rests; and this is farther increased by the length of the cervix femoris. This peculiarity in the neck of the femur renders it necessary that the body of the bone should incline inwards, in order that its axis should approach the central line, and so support the centre of gravity. If its articular head be viewed in profile, it will be observed that the cartilaginous coating is distributed for the most part on its upper and inner aspect, showing its adaptation as a pillar of support in the erect position.

The bones of the pelvis in the human subject are distinguished from those of other animals by some marked peculiarities. The sacrum is remarkably broad and expanded, so as to form a firm support for the spinal column which rests upon it; its lower part is curved and articulated with the coccyx, so that both incline forwards and enclose the pelvic cavity, constituting a support for the viscera when pressed down by muscular action. If a different arrangement of these bones obtained—if they were continued downwards in a straight line, they would project beyond the ischia, and render the sitting posture irksome or impossible.

The spinal column, which is supported on the pelvis, is peculiarly adapted to the erect attitude. Its pyramidal form and enlarged base fit it to sustain the superincumbent weight; and by means of the different curvatures which it presents, a considerable range of motion is allowed to the trunk, the centre of gravity being still supported within the base. The form of the thorax is also peculiar. Shallow and compressed from before backwards, it is broad and expanded from side to side; by which means the preponderance of the trunk forwards is considerably lessened. The sternum, though broad, is very short, so that a considerable space intervenes between it and the pubes, which is occupied solely by muscular parts. But in quadrupeds, the thorax is compressed and flattened laterally, becoming gradually narrower towards the sternum, which is prominent and keel-shaped, so that the breadth from this latter bone to the spine is much greater than that from side to side. This conformation, together with the absence of clavicles in true quadrupeds, enables the anterior extremities to approach closely together, and fall perpendicularly downwards beneath the trunk, so as to give it a steady support. The sternum is elongated in these animals, and the ribs pass from the spine to that bone so directly, without making any angle, that they approach near to the crista of the ilia, and thereby increase the extent of firm support necessary to sustain the weight of the viscera. Even with these advantages, the muscles of the abdomen would be inadequate to the

support of its contents, were they not assisted by a layer of elastic substance, which is placed over their entire extent, and which of itself marks their destination for the prone position.

Though the upper and lower extremities present several points of similitude, they yet may be contrasted so as to show that they are adapted to totally different purposes. It is quite obvious that the scapula and os innominatum, the humerus and the femur, the bones of the fore-arm and those of the leg, the hand and the foot, are respectively constructed on the same plan; but the differences which they present indicate a difference of function.

The scapulæ, placed on the supero-posterior part of the trunk, are borne off by the clavicles; their glenoid cavities are directed forwards and outwards, so that the arms, which are, as it were, appended to them, are fitted to enjoy a considerable degree of motion in the anterior and lateral directions. But in true quadrupeds the glenoid cavities look downwards, and are approximated closely together, so that the thoracic limbs, which are articulated with them, descend beneath the fore part of the trunk; and, as they are thus calculated to support its weight, they possess little lateral motion. The glenoid cavity in man is quite shallow, so that the globular head of the humerus is merely applied to its surface; but the acetabulum is a deep cup-like cavity, indicating a quite different destination in the two joints. The breadth of the articular surfaces of the knee-joint, and the peculiar conformation of the ankle-joint, as contrasted with the elbow and wrist, are abundantly sufficient to show that fixity and strength have been designed in the one, mobility in the other. This difference is, if possible, more strongly marked in the conformation of the hand and foot: the latter, as has been already observed, being intended to support the body, is placed at right angles beneath the leg; the former is continuous with the line of direction of the fore-arm, otherwise it could not be guided with sufficient precision to the different objects which it is intended to seize. The tarsal bones are large, firm, and strong; those of the metatarsus are also thick and large, and placed all in a line. That which supports the great toe being the stoutest of all, and almost immovable, ranges with the others. But the metacarpal bones are quite differently disposed; that which supports the thumb admits of considerable motion in every direction, so as to perform a complete circumduction, and is placed so much out-of line with the others that it can be opposed to them, as ingrasping different objects. The hand and foot may be considered as divisible each into two parts, differing in their degrees of mobility, viz. the digital pha-

langes, and the row of bones which sustains them. The movable phalanges of the hand are as long as the carpal and metacarpal bones taken together; but in the foot, they are not a third of the length of the tarsal and metatarsal bones.

179. No part of the osseous system of man affords more striking evidence of his adaptation for the erect posture than the cranium. Resting on the summit of the vertebral column, the line of its base forms a right angle with that of the column itself, which thus affords it a firm support. The condyles, or points of articulation, are situated very near the centre of its base, being, however, a little nearer to the occipital protuberance than to the anterior surface of the jaws; by this arrangement, very little active power is required to maintain it *in equilibrio.** In other animals the condyles are placed much further back; so that, instead of resting on the column, the skull is, as it were, appended to its extremity, and is sustained by an elastic substance, (ligamentum nuchæ,) which is attached by one extremity to the spinous processes of the vertebræ, and by the other to the occipital protuberance. The head, as has been already observed, is composed of two parts, the cranium and face; the one being intended to contain the brain — the material instrument of the mind; the other to enclose the organs of sight, smell, and taste. The more the organs of smell and taste are developed, the greater is the size of the face, and the greater its relative proportion to the cranium. On the contrary, the larger the brain, the greater must be the capacity of the skull, and the greater its proportion to the face. On this principle, a large cranium and a small face indicate a large brain with a restricted developement of the sense of smell and taste; but a small cranium and a large face mark an opposite conformation. The character and nature of animals is determined by the degree of energy with which their different functions are performed; they are guided and impelled by some leading propensity or disposition; and as the cranium and face bear to the brain and organs of sense the relation of containing and contained parts, the study of their relative proportions is one of great interest to the naturalist, inasmuch as they serve as indices of the faculties, instincts, and capabilities of different individuals, as well as of classes.

180. Several methods have been suggested for determining the proportion of the cranium to the face; the simplest is that of Camper. If a line be drawn upwards from the side of the chin, over the most prominent part of the forehead, it will form an angle with a horizon-

* Lawrence on the Characters of the Human Head, passim.

tal line drawn backwards over the external auditory foramen from the margin of the anterior nares; the size of the angle will indicate the degree of developement of the cranium and brain, as compared with that of the face and organs of sense. In the crocodile these lines are so nearly coincident, that there is scarcely any appreciable angle.

In the Horse it measures*	23°
Ram	30
Dog	35
Ouran-outang	56 to 60
European adult	85

Thus we find man at the top of the scale of animated beings, distinguished from all the rest, as well by his external conformation as by his internal organisation. When the mind has passed in review the many links of the chain which connects the lowest with the highest—the mere animated dot, with man the lord of the creation, it cannot fail to be struck with astonishment at the immense chasm which separates them. Yet, when each link of the chain is compared with that which precedes and follows it, the transition from the one to the other is found to be so gradual as to be almost imperceptible. So easy are the steps of ascent from the organisation of the higher orders of the quadrumana, up to the human species, that even Linnæus felt it difficult to assign the specific characters by which man is distinguishable from all others; but any doubt that may have existed on this subject has been long since removed. The physical and moral attributes of man are universally recognised as sufficient to elevate him much further from the higher mammalia than these are from the classes beneath them; and in the opinion of Cuvier,† he should be considered not merely as a distinct species, but even as forming a separate order by himself. Whether, then, with the zoologist, we consider the physical conformation of man as compared with that of other animals, or, with the moralist, reflect on his mental powers and high destination, we can scarcely refrain from saying, with the poet,

> Sanctius his animal mentisque capacius altæ
> Deerat adhuc, et quod dominari in cætera possit,
> Natus est homo.

---

* Cuvier, Leçons d'Anatomie Comparée, tom. ii. p. 8.

† Règne Animal, tom. i. p. 81.

THE TEETH.

181. The adult human subject is furnished with thirty-two teeth, sixteen in each jaw, arranged so that eight are placed on each side of the symphysis, in the upper and lower maxillæ. To facilitate their description, it is usual to consider a tooth as divisible into its *crown*, or that part projecting externally; the *root*, or that contained within the alveolus; and the *neck*, or part intermediate between the two. The root and central part of each tooth are composed of dense and hard osseous matter; and the projecting part, or crown, is, moreover, encased by a layer of white and excessively hard laminated substance, called enamel; at the superior and lateral parts of the crown the layer of enamel deposited upon it is thick, but gradually becomes thin at the neck, and disappears at the commencement of the root. The root and body of each tooth present a cavity, lined by a membrane (pulpa dentis), on which the nutritious vessels and nerves ramify, after having entered through the foramina in the apices of the roots.

The teeth differ in size, form, manner of insertion, and mode of action, so that they are divisible into four sets, each of which has received a particular denomination, viz. incisores, cuspidati, bicuspidati, and molares.

182. The *incisor*, or cutting teeth, (dentes incisores,) four in number in each jaw, are placed at the fore part of the mouth, forming the convex prominent part of the dental arch; their projecting part is wedge-shaped, the anterior and posterior surfaces being compressed, so that their free border is thin and sharp; this part of the tooth is convex in front, flat or concave behind, where it slopes upwards and forwards from a small elevation, which surmounts the neck. Those in the upper jaw, particularly the central pair, are larger than those of the lower. The roots of all are single, elongated, and tapering: the inserted as well as the projecting part of an incisor tooth is wedge-shaped, the former being compressed from side to side, the latter from before backwards.

183. The *canine* teeth (dentes cuspidati, canini) are two in number in each jaw, and come next in order after the lateral incisors. In these the projecting part is convex anteriorly, concave and sloping behind, and tapers towards its summit, where it ends in a blunted point: the root is longer and sinks deeper

into the alveolus than that of any other teeth; it is single, conical, compressed at the sides, and marked by a slight groove, running its whole length from its apex to its summit. This is a trace or a rudiment of that division into processes which obtains in the molar teeth.

184. The *small molar*, or bicuspid teeth, (dentes bicuspidati,) four in number in each jaw, are so named from usually having a divided root. They are intermediate in size as well as in situation between the cuspidati and molares. Their crown, compressed laterally where it is in apposition with the other teeth, is rounded on the external and internal sides, so that its depth from without inwards is greater than that of the incisores or cuspidati, whilst its breadth from side to side is less. The cutting extremities present two tubercles, one internal, the other external; in the lower jaw the internal tubercle is but very slightly prominent. A section of the neck presents an oval form, the root is single till near the apex, where it is usually bifid, particularly in the posterior bicuspidati; the groove at its sides is deeper than in the cuspidati.

185. The *large molar*, or true grinding teeth, (dentes molares,) are larger and placed farther back than the others; the crown, or projecting part, is compressed from before backwards, as well as at the sides, so as to assume a cuboid form; its free surface, which is intended for trituration, is surmounted by four tubercles, separated by depressions, which so intersect one another as generally to assume a crucial form. There are six molares in each jaw when the set is completed: the first and second are the largest of all the teeth, and in the upper jaw are usually furnished with three roots, very seldom with four, whilst in the lower jaw there are but two. The disposition of the roots deserves attention. In the upper jaw two of the roots are placed external, and parallel in their direction, whilst the third projects inwards from them at a slight angle; in the lower jaw the roots are placed one anterior, the other posterior. The last of these molar teeth are the smallest, and, as they appear at an advanced period of life, are named *dentes sapientiæ*. The root is often single and tapering, but marked by two grooves, indicating, as it were, a tendency to separation; in the upper jaw we frequently find it bifid, with traces of a still further subdivision.

The dental formula for the adult is as follows: — incisors $\frac{4}{4}$, canine $\frac{2}{2}$, bicuspidati $\frac{4}{4}$, molares $\frac{6}{6}$.

What has been here stated applies altogether to the permanent teeth. The temporary or deciduous teeth which precede them are fewer in number, being twenty in all when complete; they are also smaller, and more delicate in their texture.

The formula for these is thus expressed: — incisors $\frac{4}{4}$, canine $\frac{2}{2}$, molares $\frac{4}{4}$.

The incisors and cuspidati are supplanted by permanent teeth of the same name: the bicuspid, which do not previously make their appearance, occupy the place of the temporary molares, so that the permanent molares will necessarily protrude at points farther back. The sockets into which the teeth are inserted are called alveoli; their form, number, and size, being determined by that of the roots, which they lodge and receive; the alveolus being divided into two or three pits when the insertion of the tooth requires it, and being but a simple tapering fossa when a simple conformation obtains. The texture of the bone along the alveolar arches is porous and open, particularly in the transverse plates which separate the alveoli. In the natural state, each of these cavities is lined by a prolongation of the periosteum, which invests the maxillary bones, and which extends into them as far as their apices, where it is reflected on the roots of the teeth so as to form a special investment for them.

THE THORAX.

186. Into the composition of the thoracic portion of the skeleton, fig. 52, enter the sternum and ribs, which are proper

Fig. 52.

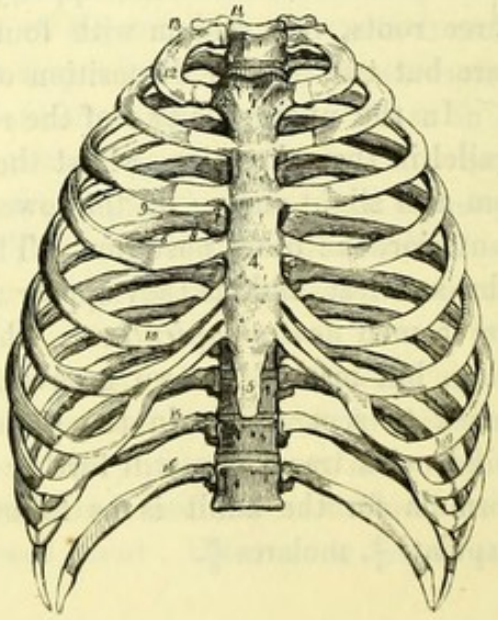

and peculiar to it, and the vertebræ, which are common to it and other parts. The latter have been already described, Sect. 103—110.

THE STERNUM AND ENSIFORM CARTILAGE.

187. The sternum is situated in the median line, at the fore part of the thorax, 1, 4: it is flat and narrow, but not of equal width in its entire extent, being broad at its upper part, then narrowed somewhat, after which it widens a little; finally it becomes compressed and narrow where it joins the ensiform cartilage. Its direction is oblique from above downwards and forwards; which, together with the curve backwards in the dorsal part of the vertebral column, causes a considerable increase in the antero-posterior diameter of the thorax inferiorly. We have to consider successively its surfaces, extremities, and borders.

The anterior surface, slightly convex, and subjacent to the skin, gives attachment to the aponeurosis of the pectoralis major and to the sterno-mastoid muscles, and is marked by four transverse lines, indicating its original division into five pieces. The union between the first and second of these pieces (corresponding with the insertion of the second costal cartilages) is frequently cartilaginous even in adult age.

The posterior surface looks backwards, towards the cavity of the thorax, and gives attachment, superiorly, to the sterno-hyoideus and sterno-thyroideus muscles; inferiorly, to the triangularis sterni. Along the middle line it corresponds with the interval left by the divergence of the two pleuræ (anterior mediastinum).

The borders are thick, and marked on each side by seven angular depressions for the reception of the cartilages of the true ribs, which give them a notched or serrated appearance.

The superior extremity, broad and thick, is slightly excavated from side to side, and presents at each corner a depression for the reception of the sternal end of the clavicle.

188. The sternum, in early infancy, is divided into several pieces, but in adult age two only remain distinct. The first division of the sternum, 1, is larger and thicker than the other; its form is nearly square; its lateral margins, thin and oblique, present each an oblong depression, 2, which receives the cartilage of the first rib; and at each inferior angle may be observed

an articular half notch, which articulates with the second rib. The superior border is hollowed, and at the angles which bound it are the fossæ, 3, which articulate with the clavicles, as has been already stated; the inferior is straight, and united to the extremity of the second piece.

The second piece, 4, much longer than the first, is marked on its anterior surface by some transverse lines, which indicate its original division into separate portions. Both surfaces are nearly flat. The upper border is narrow, corresponding in breadth with the termination of the first bone, with which it is connected by cartilage. The lateral margins present each five notches for the reception of the cartilages of the five lower true ribs, and a half notch superiorly, which, with a similar depression in the first piece, forms a cavity for the second costal cartilage. The five inferior notches approach one another more closely in proportion as they are situated lower down, and part of the last is occasionally made up by the ensiform cartilage.

189. The inferior extremity of the sternum, thin and elongated, gives attachment to a cartilaginous appendix, 5, called the *ensiform* or *xiphoid* (ξιφος, a sword; ειδος) cartilage, which in most cases remains in the cartilaginous state until an advanced period of life. It is sometimes bent forwards, sometimes in the opposite direction, and sometimes pierced by a hole at its centre. Its form varies considerably in different individuals: it gives attachment to the aponeuroses of the abdominal muscles.

Articulations.—This bone articulates by its sides with the true ribs,—by its upper angles with the clavicles, and by its lower end with the ensiform cartilage. When examined at an early period, it exhibits usually eight or nine ossific centres. When sawed across, the sternum presents a considerable quantity of loose spongy texture in its interior, with a very thin lamella of compact tissue on its outside;—hence it is very light.

THE RIBS AND THEIR CARTILAGES.

190. The *ribs* (costæ) extend from the dorsal portion of the vertebral column to the sternum, forming arches, which enclose the lateral parts of the thorax. They are twelve in number at each side, of which the seven superior pairs, which are united by means of cartilaginous prolongations to the sternum, are called *sternal* or *true ribs;* the remaining five, which are not

prolonged to the sternum, being denominated *asternal* or *false ribs.*

The ribs do not arch uniformly from the vertebral column towards the sternum : the greater number consist of parts of two circles or arches of different diameters, the anterior being much the larger. Thus the rib, directed at first backwards from its connexion with the bodies of the vertebræ, reaches and is supported by the transverse process (which in the dorsal region is inclined backwards) ; after leaving the extremity of this process, it turns abruptly outwards, and finally is directed forward towards the sternum.

In their length, breadth, and direction, these bones present several varieties. From the first to the eighth their length successively increases, whilst from the ninth to the twelfth they gradually decrease, so that the last is very little longer than the first.

Their breadth, considered in the whole series, diminishes gradually from the first to the twelfth ; but in each rib it is greatest towards its external extremity.

As to their direction in reference to the vertebral column, the first forms almost a right angle with it, and the succeeding ones gradually incline downwards, so that their anterior extremity is lower than the posterior. The body of all the ribs, except the first, is, as it were, twisted on itself, so that their two extremities cannot be made to rest at the same time on a plain surface.

These bones present two surfaces, two borders, and two extremities.

The external surface is convex and smooth. The internal is concave, and corresponds with the pleura.

The superior border, smooth and rounded, gives attachment to the intercostal muscles ; the inferior is marked on its inner aspect by a groove, fig. 52, 6, which is commonly said to be for the lodgment of the intercostal vessels, and also gives attachment to the intercostal muscles.

The posterior extremity, 7, somewhat rounded and thicker than the other parts of the rib, and hence denominated its *head*, presents (except in the instances to be presently stated) two articular faces (separated by a slight ridge) which articulate with the corresponding small surfaces on the bodies of the dorsal

vertebræ ; the head is supported by a narrow round part, 8, or *neck*, terminated externally by a tubercle, 9, which is smooth in one part for its articulation with the transverse process of the lower of the two vertebræ to which the head is connected, and rough in the other for the insertion of the posterior costo-transverse ligament.

The anterior extremity is broad, flat, and hollowed at its tip into an oval pit, into which is implanted the costal cartilage.

Between the tuberosity and the most convex part of the body of each rib is a rough line, marking what is termed its *angle*. The distance of the angle from the tuberosity increases gradually from the second to the eleventh inclusive. In the last it is not perceptible: in the first it is not distinguishable from the tuberosity.

The first two and the last two ribs present some peculiarities deserving of notice.

191. The *first* rib, 12, is shorter and broader than either of the succeeding ones, its direction is nearly horizontal ; its body not being twisted, as is the case in other ribs, it lies evenly when placed on a plain surface. One surface looks upwards, and is marked by two very slight depressions (over which slide the subclavian vessels), and an intervening roughness, sometimes well marked, which indicates the attachment of the scalenus anticus muscle. The other surface looks downwards, towards the cavity of the thorax. The external border, convex and rounded, is surmounted by the tuberosity, 13 ; the internal is thin, and forms the margin of the superior aperture of the thorax. The anterior extremity is broad and thick ; the *head*, which articulates with the first dorsal vertebra, 14, is small, presents an undivided articular surface, and is supported by a slender neck.

The *second* is longer than the first, and presents externally a prominent line for the attachment of the serratus magnus ; its internal surface is somewhat grooved posteriorly.

The *eleventh*, 15, has no groove on its inferior border, nor a tubercle, as it is not articulated with the transverse process ; its angle is scarcely perceptible, and the head has but one articulating surface.

The *twelfth*, 16, differs little from the preceding one, except in being shorter ; it has neither angle, tubercle, nor groove, and

as its anterior extremity, which is pointed, seems loose and unattached, it is called the floating rib.

The ribs grow from three osseous points, one in the body, one in the head, the third being at the tuberosity.

COSTAL CARTILAGES.

192. These cartilages (fig. 52, 10,—the numbers are omitted upon the others to avoid complexity in the drawing,) are twelve in number, like the ribs, of which they form the elastic continuation; their breadth diminishes gradually from the first to the last, whilst the length increases as far as to the seventh, after which it becomes less in each succeeding one. Their line of direction also varies considerably. The second is horizontal, the first descends a little, and all the rest ascend more and more as they are situated lower down. The external or costal extremity, convex and unequal, is implanted into the end of the corresponding rib. The internal extremities of the cartilages of the true ribs, smaller than the external, and somewhat pointed, are articulated with corresponding angular surfaces on the sides of the sternum; each of the cartilages of the first three false ribs, becoming slender towards its extremity, is attached to and blended with the lower border of that which is next above it; in the two last it is pointed and unattached.

Attachments of muscles.—The two layers of intercostals to the contiguous borders of all the ribs; the scaleni to the first and second; the pectoralis major to the cartilages of the true ribs, except the first; pectoralis minor to the bodies of the third, fourth, and fifth; rectus abdominis to the cartilages of the last three true ribs and ensiform cartilage; obliquus externus to the last three true ribs, and all the false; the internal oblique and transversalis to the cartilages of the four or five false ribs; the diaphragm to the ensiform cartilage, and to those of the last six ribs.

The serratus magnus to the nine superior ribs; latissimus dorsi to the four inferior; serratus posticus superior to the third, fourth, and fifth true ribs; serratus posticus inferior to the three last; sacro-lumbalis to the angles of all the ribs; levatores costarum a little beyond the tuberosities.

BONES OF THE SUPERIOR EXTREMITY.

The upper extremity consists of the shoulder, the arm, the fore-arm, and the hand. The shoulder consists of the scapula and clavicle; the arm of the humerus; the fore-arm of the radius and ulna; and the hand of the carpus, metacarpus, and fingers.

SCAPULA.

193. This bone, fig. 53, is placed upon the upper and back part of the thorax, occupies the space from the second to the seventh rib, and forms the posterior part of the shoulder.

Fig. 53.

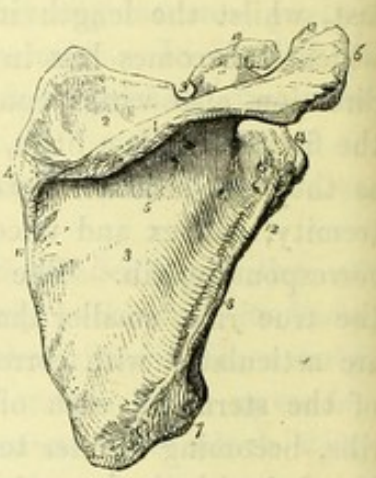

Its form is irregularly triangular and flat. It presents for examination two surfaces, three borders, and three angles.

The anterior surface, called also *fossa subscapularis*, looks towards the ribs, is triangular, slightly concave, intersected by prominent lines, directed from within outwards and upwards, and therefore crossing the direction of the ribs.

The posterior surface (*dorsum scapulæ*) is divided into two parts, but unequally, by a prominent ridge, 1 (the spine): of these, the superior one, 2, is called fossa supra-spinata; the inferior, 3, fossa infra-spinata.

Of the spine.—The spine of the scapula is a prominent ridge of bone, flattened from above downwards, commencing at the posterior border of the scapula, with a smooth flat triangular surface, 4, from which it becomes gradually more elevated as it proceeds forwards, until it terminates in an elongated process, 6, (acromion,) which surmounts the shoulder-joint. The form of the spine, considered by itself apart from the acromion is triangular; hence we have to notice its two surfaces and three borders. Its superior surface is concave, and, conjointly with the superior part of the dorsum of the scapula, forms the fossa supra-spinata. The inferior surface is irregularly triangular, constitutes part of the infra-spinous fossa, and in its middle may be

observed a small foramen, 5, for a nutritious vessel. On the projecting border of the spine, which is rough and broad, may be noticed two margins, of which the superior one gives attachment to the trapezius, the inferior to the deltoid muscle: the intervening edge is subcutaneous. The anterior or attached border, or base, is united with the dorsum of the bone. The external border, which is short, round, and somewhat concave, approaches the neck of the bone, and is continuous with the under surface of the acromion.

Of the acromion process.—This considerable eminence, 6, is flattened in the direction opposite to that of the spine, and, projecting outwards and forwards, forms the summit of the shoulder-joint; hence its designation (ακρον, a summit; ωμος, the shoulder). Its posterior and upper surface, convex and somewhat rough, is subcutaneous; the anterior and inferior one, concave and smooth, is in relation with the supra-spinatus muscle, and overlays the capsular ligament of the shoulder-joint; the superior border presents, anteriorly, a narrow oval surface for its articulation with the external extremity of the clavicle, and its summit affords attachment to the coraco-acromion ligament.

194. The *fossa supra-spinata*, 2, wider towards its vertebral than the other extremity, is filled up by the supra-spinatus muscle. The *fossa infra-spinata*, 3, much larger than the preceding, is convex in the middle, somewhat concave, or rather grooved, inferiorly. Between the latter part and the axillary border is a slightly raised and elongated ridge, 8, which extends from the glenoid cavity obliquely downwards to within an inch of the posterior angle of the bone, where it subsides into a flat and nearly quadrilateral surface, 7. This latter part it is that gives origin to the teres major muscle, and over it slides the latissimus dorsi. Along the upper and rounded part arise the fibres of the teres minor; whilst the line of division between them marks the attachment of an aponeurosis, common to these muscles and to the infra-spinatus, which occupies the remainder of the fossa.

Of the three *borders* of the scapula, or costæ (as they are sometimes called), the *superior* is the shortest; at its outer part is situated a lunated notch, 9, (lunula; incisura semilunaris,) which is converted into a foramen by a ligament, and is

traversed sometimes by the supra-scapular vessels and nerve, but usually by the nerve alone. In front of this opening it is surmounted by the *coracoid* process, 10, which being thick, elongated and curved on itself, is named from some fancied resemblance to a crow's beak (κόραξ, a crow; εἶδος, like). This process, superiorly convex and unequal, gives attachment to the coraco-clavicular ligament; anteriorly to the pectoralis minor muscle; posteriorly to the coraco-acromion ligament; and by its extremity to the biceps and coraco-brachialis muscles. The *posterior*, or vertebral border, 11, named also the "base" of the scapula, is the longest of the three; superiorly it approaches to the vertebral column, inferiorly it is more removed from it. The portion of this border which is above the spine will be observed to incline a little outwards. For the purpose of more easily assigning the attachments of the several muscles which are connected with it, we may regard it, though very thin, as divisible into two margins, with an inter-space; these are stated in the enumeration of the muscular attachments. The *axillary* border is inclined downwards and backwards from the lower margin of the glenoid cavity to the inferior angle of the bone; hence it is named the *inferior costa* of the scapula. It is of considerable thickness, being surmounted posteriorly by the ridge above noticed as giving origin to the teres minor. The edge itself presents a shallow groove running along the greater part of its extent. It corresponds with the lower border of the subscapular muscle. For about an inch beneath the glenoid fossa there is a well-marked linear impression, 12, which gives origin to the long head of the triceps muscle.

The postero-superior *angle* is formed by the junction of the base with the superior costa of the scapula; it is somewhat inclined outwards. The inferior angle is placed at the union of the base with the axillary or inferior border of the bone; upon it may be observed an elongated flat surface, 7, which gives origin to the teres major, and over which slides the latissimus dorsi muscle. At the convergence of the superior and inferior borders may be observed a narrow constricted part, 13, denominated the *neck* (cervix scapulæ). The neck is bounded by a slightly raised rim, 14, which gives attachment to the fibrous capsule of the shoulder-joint; and finally the rim surrounds the articular surface of the bone which is called the *glenoid* cavity

(γληνη, a superficial cavity; εἰδος). This is a shallow, oval depression, broader below than above, covered with cartilage in the fresh state, and deepened somewhat by a fibro-cartilaginous margin, which passes round it from the long tendon of the biceps muscle, whose origin is at its upper margin; its greatest diameter is perpendicular, its direction outwards and forwards. In this last respect, however, it varies considerably; for during the more extended motions of the humerus, the scapula is made to turn, as it were, on a pivot driven through the centre of its dorsum, by which means the glenoid cavity is kept constantly in apposition with the head of the humerus, which is the chief security against its dislocation.

The scapula articulates by its glenoid cavity with the humerus, and by the acromion process with the clavicle; it affords attachment to the following muscles :—

The sub-scapular fossa (the anterior or costal surface of the bone) to the sub-scapularis muscle. Posterior or dorsal surface,—the spine (by its border and the acromion) superiorly to the trapezius, inferiorly to the deltoid: the fossa supra-spinata, by its posterior two-thirds, to the muscle of the same name: the fossa infra-spinata, in the greater part of its extent, to the infra-spinatus; by a slight oblique line situated near the inferior angle, to the aponeurosis common to the infra-spinatus, teres minor, and teres major; by a narrow rounded surface, near the axillary border, to the teres minor; by the flat surface, at its inferior angle, to the teres major.

The superior border, near the margin of its notch, to the omo-hyoideus; the coracoid process, anteriorly, to the pectoralis minor, by its summit to the biceps and coraco-brachialis. The posterior border or base, anteriorly, to the serratus magnus; posteriorly, to the supra-spinatus and infra-spinatus; in the inter-space to the rhomboidei and to the levator anguli scapulæ. The inferior, or axillary border, at its upper part by a rough ridge to the long portion of the triceps extensor; posteriorly, by an unequal surface, to some fibres of the teres minor; inferiorly, to the teres major.

The inferior angle to the teres major, and occasionally to some fibres of the latissimus dorsi; the anterior angle, (glenoid cavity,) by its upper margin, to the long head of the biceps muscle.

Developement.—When the scapula is examined at a very early period, it appears as a thin lamella without any elevation corresponding with the spine. Soon after an osseous centre is seen towards the middle of its dorsum, one in the coracoid process, and in the acromion. The base and the inferior angle also commence by separate points.

THE CLAVICLE.

195. The clavicle (*clavis*, a key), or, as it is popularly called, the collar-bone, is extended, transversely, between the acromion process of the scapula and the summit of the sternum, which it serves to connect; its direction, however, is not exactly horizontal, the acromial end being slightly elevated. This bone is curved somewhat like an italic *f*, the degree of the curvature being less in young and female subjects than in male adults; it is rather thick and somewhat triangular towards its sternal end, but broad and flat towards the scapular extremity; it presents for our consideration a body and two extremities. The superior surface of the body is principally subcutaneous. The inferior surface presents, near the sternal extremity, inequalities for the attachment of the costo-clavicular ligament; in the centre, a longitudinal depression, giving attachment to the subclavius muscle, the foramen for the entrance of the medullary vessels, and, more externally, a rough oblique line, to which the coraco-clavicular ligaments are attached; this surface corresponds internally to the first rib, externally to the coracoid process and the shoulder-joint, and in the middle to the axillary vessels and brachial plexus of nerves. The anterior border is broad and convex towards the sternal, thin and concave towards the scapular extremity; the posterior border presents, of course, the opposite arrangement of curvatures. The internal extremity is inclined downwards and forwards; it is considerably thicker than the other parts of the bone, and terminates in a triangular unequal surface, which is convex from above downwards, concave from behind forwards; this is tipped with cartilage, and articulates with the sternum, the articular surface of which it much exceeds in size; its entire circumference gives attachment to ligaments. The external or scapular extremity, compressed and flattened, inclines a little backwards and upwards, and articulates

with the acromion by a narrow oblong surface which is covered with cartilage.

Attachments of muscles.—The clavicle gives attachment, by the superior surface of its sternal extremity, to the sterno-cleido-mastoid; the longitudinal depression on its inferior surface, to the subclavius; the anterior border, by its sternal half, to the pectoralis major; by its acromial third, to the deltoid; the posterior border, by its acromial third, to the trapezius.

Articulations.—The clavicle articulates with the sternum and the acromion process of the scapula.

Developement.—The division of the bone above indicated into body and extremities is merely technical, being intended to facilitate its description. It consists of one piece, and grows from one ossific centre.

THE HUMERUS.

196. The humerus or arm-bone, fig. 54, (os humeri,) the largest bone of the upper extremity, extends from the scapula to the bones of the fore-arm, with each of which it is articulated. Its direction is vertical, with an inclination inwards towards the lower end. Long and irregularly cylindrical in form, the humerus is divisible into a body and two extremities.

Fig. 54.

197. The *body* or shaft of the bone, 1, thick and rounded superiorly, is somewhat expanded, and triangular inferiorly. It is divided into two nearly equal surfaces by two longitudinal lines, of which one is external and anterior, 2, the other internal and posterior, 3. These lines may be considered as rising, the former from the external, the latter from the internal condyle, near to which they are well marked, but gradually subside as they proceed upwards on the body of the bone: they afford attachment to the inter-muscular aponeuroses. The external one is interrupted about the middle, 4, by an oblique depression, or groove, which runs from above downwards and marks the course of the musculo-spiral nerve and superior profunda artery; the surfaces separated by these

lines are named posterior and anterior. The *posterior* surface is round superiorly, and inclined a little inwards; in the lower part it is broad, flat, and turned rather outwards; it is covered in the entire of its extent by the triceps extensor muscle, and towards its middle may be observed a small foramen for the medullary vessels. The *anterior* surface is divided superiorly into two unequal portions by a longitudinal groove, 5, directed obliquely downwards and inwards, for about one-fourth of the length of the bone; this lodges the long tendon of the biceps muscle, and is therefore named the *bicipital* groove; its anterior margin, 6, gives attachment to the pectoralis major; the posterior, 7, to the latissimus dorsi and teres major. The portion of the anterior surface which is internal to this groove is smooth in the greater part of its extent, and presents, towards its middle, a linear elevation for the insertion of the coracobrachialis, and lower down an oblique medullary foramen, 8; externally to the groove, and a little above the middle of the bone, may be observed a broad rough eminence, 9, for the insertion of the deltoid muscle, beneath which runs the oblique depression already noticed as corresponding to the course of the musculo-spiral nerve and the accompanying artery.

198. The *superior extremity* of the bone presents a large hemispherical eminence, 10, covered with cartilage in the fresh state, and directed backwards and inwards to the glenoid cavity of the scapula, with which it articulates; this is called the *head* of the humerus. It is bounded by a slightly depressed groove, sufficiently marked on the upper, not on the under aspect, denominated the *neck* of the bone. A little beneath, and to the outside of the head, are two eminences, which project from the ends of the shaft of the bone, and, from their relative size, are named the greater and lesser *tuberosities* (tubercula). The greater tuberosity, 12, is external and posterior in its situation, convex in its outline, and marked on its upper border by three flat surfaces for the insertion of the external rotator muscles. The smaller tuberosity, 13, rounded and more prominent than the other, gives attachment to the sub-scapularis muscle. They are separated by the bicipital groove. Towards its lower third the bone widens, and appears compressed and somewhat twisted from behind forward; its greatest diameter is transverse; it presents internally a considerable projection, 14, the *inner condyle*,

which is inclined backwards, and gives attachment to the internal lateral ligament of the elbow-joint, and to a tendon common to the greater number of the anterior muscles of the foramen. Externally is situated another smaller process, 15, (*external condyle*,) to which are attached the external lateral ligament and a tendon common to the muscles of the posterior and external surfaces of the fore-arm. Between the condyles is placed the inferior articular surface, which is inclined somewhat forwards. Proceeding in the enumeration of the parts which enter into its composition from the radial to the ulnar side, we observe a rounded eminence, 16, placed rather on the anterior surface of the bone, and articulating with a cavity observable on the superior extremity of the radius, calculated to allow of all that freedom of motion which the radius enjoys, viz. flexion and extension on the humerus, and pronation and supination by rotation on its own axis;—a slight groove or depression corresponding with the circumference of this eminence, a semicircular ridge, which is lodged in the space intervening between the radius and ulna;—a wide and deep groove which receives the prominent part of the larger sigmoid cavity of the ulna; and, lastly, a prominent ridge, which is received into the internal part of the same cavity. This prominence descends much lower than the external portion of the articular surface, and determines an obliquity in the direction of the humerus, when its lower extremity is made to rest on a plain surface. The groove, with its margins, forms a well-marked pulley-like surface, 17, on which the sigmoid cavity of the ulna moves in flexion and extension; hence it is termed the *trochlea*. At the fore part of the inferior extremity of the bone, and immediately above the trochlea, is a superficial depression, 18, which receives the coronoid process of the ulna during flexion, and posteriorly a more considerable fossa, which lodges the olecranon during the extension of the fore-arm.

A modification of the nomenclature applied to these different eminences has been proposed by Chaussier: retaining the term trochlea for the surface of articulation with the ulna, he calls that which articulates with the radius, the condyle, (it is sometimes called the *small head*;) and for the two lateral eminences of insertion, now named condyles, he substitutes the terms *epi-trochlea* and *epi-condyle*.

199. *Attachments of muscles.*—The posterior surface gives attachment to the triceps; the anterior (by the posterior margin of the bicipital groove) to the teres major and latissimus dorsi; in the middle, by a slightly-marked line, to the coraco-brachialis; inferiorly, to the brachialis anticus;—the external portion of the same surface, superiorly, by a rough eminence, to the deltoid; by the anterior margin of the bicipital groove, to the pectoralis major. The greater tuberosity gives attachment, by the three flat surfaces on its upper border, to the supra-spinatus, infra-spinatus, and teres minor muscles; the lesser tuberosity to the sub-scapularis. The inferior extremity, by its outer border, to the supinator radii longus, and, by its external condyle, to the extensor carpi radialis longior and brevior, extensor communis digitorum, extensor carpi ulnaris, anconeus and supinator radii brevis; by the internal condyle, to a tendon common to the pronator radii teres, flexor carpi radialis, palmaris longus, flexor carpi ulnaris, and flexor digitorum sublimis.

Articulations.—The humerus articulates with the glenoid cavity of the scapula, and with the ulna and radius.

Developement.—The shaft of the bone grows from one ossific centre; the head and the two tuberosities have each their own points. So have the two condyles and the trochlea.

THE RADIUS.

200. The radius, fig. 55, 1, shorter than the ulna by the length of the olecranon process, is placed at the external side of the fore-arm, extending from the humerus to the carpus. It is broader below than above, slightly curved in its form, and divided into a body and two extremities. As the body is somewhat triangular, we observe on it three surfaces, bounded by three margins, or ridges. The *anterior* surface, 1, expands towards the lower part, and is marked along its middle by a longitudinal groove for the flexor pollicis longus; superiorly is situated the foramen, 2, for the medullary vessels, its directien being from below upwards; and inferiorly a flat surface, 3, corresponding with the pronator quadratus. The *posterior* surface, convex in the greater part of its ex-

Fig. 55.

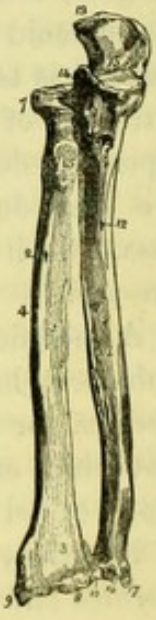

tent, is grooved at its central third, for the origin of the extensors of the thumb; the *external* surface, round and convex, is marked towards its middle by a rough impression, 4, which gives insertion to the pronator radii teres. Of the margins separating these surfaces, the posterior is distinct only at the middle part; the external is round, and becomes smooth towards the lower extremity; whilst the internal is acute and sharp, for the attachment of the inter-osseous ligament. The body is terminated superiorly by a rough prominence, 5, (tuber radii,) termed the *bicipital tuberosity*, from its giving insertion to the biceps muscle.

Above the tuberosity the bone becomes narrowed and constricted into the form of a *neck*, which is again surmounted by the *head*, 7, intended by its extremity to articulate with the round convex part of the lower extremity of the humerus, its small head (condyle, Chauss.), while its margin rolls on the lesser sigmoid cavity of the ulna. The margin is smooth and convex; the upper surface, also smooth, is a shallow cup-like cavity; and both are covered with cartilage in the recent state.

201. The radius at its lower part becomes broad and thick; the anterior surface is flat and expanded, being covered by the pronator quadratus muscle; it is bounded below by a prominent line, 8, which gives attachment to the anterior ligament of the wrist-joint. The posterior surface is convex, and marked by grooves which transmit the tendons of the extensor muscles; of these, one which is very narrow and oblique in its direction, and nearly in the middle line, lodges the tendon of the extensor pollicis (secundi internodii). At the inner or ulnar side of this is placed another, much broader, which transmits the tendons of the extensor communis and indicator; and at its outer side, a third, divided into two parts by a linear impression, marks the passage of the flexor carpi radialis, longior and brevior. Corresponding with the external border of the bone, is another groove, directed obliquely forwards, and divided into two parts, for the tendons of the extensores—primi internodii, and ossis metacarpi pollicis. The outer side of the bone, particularly the part corresponding with the ridge which separates the two latter grooves, is prolonged downwards, and named the *styloid process*, 9; it affords attachment to the external lateral ligament of the wrist-joint. On the inner side of the bone is situated a

small cavity, 10, (semi-lunar), covered by cartilage, which articulates with the inferior extremity of the ulna. At its inferior extremity the radius presents its carpal articulating surface, scaphoid; (navicular), which is included between the base of the styloid process and the oval cavity just mentioned, bounded before and behind by two rough margins for the attachment of the radio-carpal ligaments. It is divided from before backwards, by a line, into two unequal portions, of which the external is triangular, and articulates with the scaphoid bone; the internal is square, and articulates with the semi-lunar.

Attachments of muscles.—The anterior surface of the body, by its grooved part, to the flexor longus pollicis; by the oblique line, leading from the tuberosity to the insertion of the pronator radii teres, to the supinator brevis and flexor sublimis; its inferior fifth to the pronator quadratus; the posterior surface, by a slight concavity in the middle, to the extensores pollicis; the external margin, by a rough surface, to the pronator teres; inferiorly, to the pronator quadratus and the supinator radii longus; whilst the posterior part of the bicipital tuberosity gives attachment to the biceps muscle.

Articulations.—The radius articulates with the humerus, the ulna, the scaphoid and semi-lunar bones.

Developement.—It has a centre of ossification for its body, and one for each extremity.

THE ULNA.

202. The ulna, fig. 55, (ωλενη, cubitus,) is placed at the inner side of the fore-arm; it is a long and rather irregular bone, larger at the upper than at the lower extremity,—a conformation the reverse of that which obtains in the radius. Its body, or shaft, is marked off into three surfaces by three prominent lines. These are all broader above than below, in consequence of the decreasing size of the bone. The anterior surface, 11, slightly depressed, is grooved longitudinally for the origin of the flexor profundus, and marked at its upper third by a foramen, 12, directed obliquely upwards for the medullary vessels. The internal surface, smooth and somewhat excavated superiorly, is covered in the greater part of its extent by the flexor profundus muscle; it becomes round inferiorly, where it is subcutaneous. The external

surface, rough and irregular, is divided into two parts, of which one, of small extent, corresponds with the superior extremity of the bone, and forms an elongated depression for the anconeus muscle; the other, reaching to the lower extremity, gives origin to the extensors of the thumb and the supinator radii brevis. Of the three margins, the internal and posterior are round, and for the most part smooth; the external is sharp, and gives attachment to the inter-osseous ligament.

203. At the superior extremity of the bone are situated two eminences, so placed as to bound the cavity by which it articulates with the humerus. Of these, one called *olecranon*, 13, (ωλενη, ulna; κρανιον, the head,) is nearly on a line with the shaft of the bone; the other, the *coronoid process*, 14, (κορωνη, a crow's beak; ειδος, like,) projects from its anterior surface. The olecranon terminates in a rough tuberosity and an obtuse point; the former giving insertion to the triceps extensor; the latter being lodged, when the arm is extended, in the posterior cavity at the end of the humerus. Anteriorly, this process is smooth and hollowed out, to form part of the surface of articulation with the humerus; posteriorly, it presents a flat triangular surface, which is subcutaneous. The coronoid process, by a gentle ascent, rises upwards and forwards from the anterior surface of the bone, and terminates in a sharp ridge, which overhangs the articular surface, and is received during flexion into the anterior depression in the humerus; its anterior surface, rough and triangular, gives insertion to the brachialis anticus muscle; its upper aspect is smooth and excavated: its inner border gives attachment to the internal lateral ligament; the external is hollowed into a smooth depression, the *smaller sigmoid cavity*, which articulates with the head of the radius. The *great sigmoid cavity*, 15, formed by the junction of the smooth surfaces of these two processes, has been so named from some supposed resemblance to the form of the Greek letter Σ (σιγμα, ειδος, like), as it was originally written. Covered by cartilage in its entire extent, it is divided into two parts (but unequally, the inner one being the larger) by a smooth ridge running downwards from the peak or point of the olecranon to that of the coronoid process. This ridge and the concavities beside it correspond, the one with the groove, the others with the lateral

parts of the trochlea. At the margins of the sigmoid cavity may be observed two notches which mark off the parts of the surface which belong to the olecranon and the coronoid process respectively.

204. At the inferior extremity of the bone, which is small and rounded, are situated two eminences, of which the external one, named the *head* of the ulna, 16, round and covered with cartilage, presents two aspects, of which one, nearly circular in its form, looks towards the wrist-joint, and corresponds with the triangular fibro-cartilage of that articulation ; whilst the external one, narrow and convex, is received into the semi-lunar cavity in the contiguous border of the radius. The internal eminence, 17, named the *styloid process*, projects on a line with the posterior and inner surface of the bone ; it is elongated in its form, and gives attachment to the internal lateral ligament of the joint. The head and the styloid process are separated posteriorly by a groove, which is traversed by the tendon of the extensor carpi ulnaris, and inferiorly by a depression at the base of the styloid process into which the triangular fibro-cartilage is inserted.

Attachments of muscles. — The anterior surface, superiorly, and in the middle, gives attachment to the flexor digitorum profundus ; inferiorly, to the pronator quadratus ; the posterior surface, to the anconeus, the extensor carpi ulnaris, supinator radii brevis, the extensores pollicis, and the extensor indicis ; by the posterior longitudinal line, to an aponeurosis common to the flexor carpi ulnaris, flexor digitorum profundus, and extensor carpi ulnaris. The superior extremity, by the summit of the olecranon to the triceps brachialis ; the coronoid process, by its anterior rough surface, to the brachialis anticus ; and by its internal side, to the second origin of the pronator teres.

Articulations.—The ulna articulates with the humerus and the radius ; it has no point of contact with the carpal bones, but it is brought into relation with the cuneiform bone by means of the inter-articular fibro-cartilage.

Developement.—The shaft of the ulna, as in other long bones, has its own osseous centre ; so has the lower extremity or head, as well as the olecranon process.

HAND.

The hand is composed of the carpus, meta-carpus, and fingers.

CARPUS.

205. The first or superior part of the hand is named the carpus or wrist, fig. 56; it is placed between the fore-arm and the meta-carpus, and composed of eight small bones, which are disposed in two ranges, each consisting of an equal number. Proceeding in the enumeration from the radial to the ulnar side, the bones which constitute the first or superior range are thus named from their shape—scaphoid 1, semi-lunar 2, cuneiform 3, and pisiform 4; those of the second or inferior range are the trapezium 5, trapezoid 7, os magnum 8, and unciform 9. The dorsal surface of the carpus is convex, the palmar concave and irregular, and marked by four bony prominences, across which is stretched the anterior annular ligament, so as to form a canal for the transmission of the flexor tendons.

BONES OF THE FIRST ROW.

THE SCAPHOID BONE.

206. The scaphoid or boat-shaped bone, fig. 56, 1, (*σκαφη*, a boat,) is the first of this row, and the largest. Its position is oblique, so that its broad end is directed towards the trapezium and root of the thumb, whilst the narrow one inclines inwards and upwards to the middle of the articular surface of the radius. It is convex on one side, concave on the other. The concave or hollowed surface (scaphoid) looks obliquely inwards and forwards, and is that which determines the form and gives name to the bone. Its upper articular surface, convex and triangular, is applied to the radius; the lower, also convex, articulates with the trapezium and the trapezoid bone. Its concavity receives part of

Fig. 56.

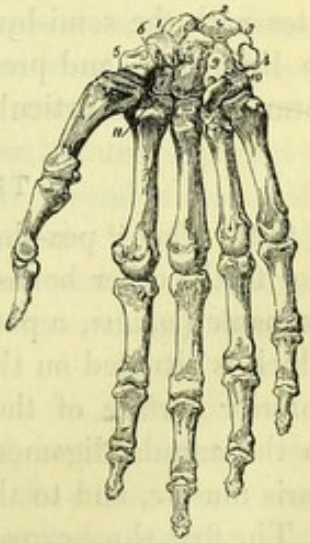

the head of the os magnum ; close to this is a narrow articular surface which is in contact with the semi-lunar bone ; on its radial side is a rough surface, to which is attached the external lateral ligament of the wrist-joint : posteriorly is a narrow grooved surface for the attachment of ligaments ; and anteriorly is a rough surface, the inner or ulnar half of which is narrow and slightly grooved, whilst the outer is prominent and tuberculated for the attachment of ligaments. It articulates with five bones.

THE SEMI-LUNAR BONE.

207. The name of this bone, 2, is taken from its being concave or crescentic on its inferior surface. Irregularly triangular in its form, convex superiorly, it articulates with the square part of the articular surface of the radius ; inferiorly concave, with the os magnum and the unciform ; on the ulnar side with the cuneiform ; on the radial side with the scaphoid ; anteriorly and posteriorly it gives attachment to ligaments. It articulates with five bones.

THE CUNEIFORM BONE.

208. This is the " wedge-shaped" bone, 3 ; sometimes also it is named from its form " pyramidal ;" superiorly, it is in relation with the inter-articular fibro-cartilage of the wrist-joint ; inferiorly, it articulates with the unciform bone ; on the ulnar side, gives attachment to ligaments ; on the radial side, articulates with the semi-lunar bone ; anteriorly it affords attachment to ligaments, and presents a small articular surface for the pisiform bone. It articulates with three bones.

THE PISIFORM BONE.

209. The " pea-shaped" bone, 4, is placed on a plane, anterior to the other bones of the carpus. Its form is indicated by its name (*pisum*, a pea). It presents but one articular surface, which is situated on the posterior part, or base, and rests on the anterior surface of the cuneiform bone ; it affords attachment to the annular ligament of the carpus, to the flexor carpi ulnaris muscle, and to the abductor of the little finger.

The first three carpal bones form, when in apposition, a rounded convex surface, which corresponds with the concavity pre-

sented by the radius and the inter-articular cartilage; but their lower surface constitutes a deep hollow, which receives the head of the os magnum and the unciform bone.

BONES OF THE SECOND ROW.

THE TRAPEZIUM.

210. The name of this bone, 5, is taken from its presenting four unequal edges at its posterior aspect. It is placed at the radial border of the carpus, between the metacarpal bone of the thumb and the scaphoid bone. It is known by the angular appearance of its dorsal surface, and by the tubercle and groove at its palmar aspect. Superiorly concave, it articulates with the scaphoid bone; inferiorly, concave from behind forward, and convex transversely, with the first metacarpal bone; on the ulnar side, with the trapezoid bone, and by a small surface situated more inferiorly, with the edge of the second metacarpal bone; on the radial and posterior sides it gives attachment to ligaments; anteriorly it presents a groove, 6, traversed by the tendon of the flexor carpi radialis, and a tubercle to which the annular ligament of the carpus is attached. It articulates with four bones.

THE TRAPEZOID BONE.

211. This is a small bone, 7, compared with those between which it is placed, viz. the trapezium, scaphoid, and os magnum; in form and position it has some resemblance to a wedge, and but little to a trapezium, except that its posterior surface is bounded by four unequal edges. It articulates superiorly with the scaphoid bone; inferiorly, with the second metacarpal bone; on the ulnar side, with the os magnum; on the radial side, with the trapezium: the anterior and posterior surfaces afford attachment to ligaments. It articulates with four bones.

OS MAGNUM.

212. This, 8, is the largest of the carpal bones; its form is oblong, round superiorly, cubic inferiorly; the superior surface, named its "head," (whence it is sometimes called os capitatum,) is supported by a narrowed portion, named the "neck;" its

greatest convexity is in the antero-posterior direction, where it is received into a cavity formed by the scaphoid and the semi-lunar bone; it articulates, inferiorly, by three distinct surfaces, of which the middle is the largest, with the second, third, and fourth metacarpal bones; on the ulna side, with the unciform bone; on the radial side, with the trapezoid bone: the anterior and posterior aspects are rough (particularly the former) for the attachment to ligaments. It articulates with seven bones.

THE UNCIFORM BONE.

213. The "hook-shaped" bone, 9, (uncus, a hook,) is readily distinguished from the rest by the curved process, 10, upon its palmar surface: it articulates, superiorly, with the semi-lunar bone; inferiorly, by two distinct surfaces, with the fourth and fifth metacarpal bones; on the ulnar side with the cuneiform bone; on the radial side with the os magnum: anteriorly its hooked process affords attachment to the anterior annular ligament of the carpus; posteriorly a rough surface also gives attachment to ligaments. It articulates with five bones.

THE META-CARPUS.

214. This forms the second or middle portion of the hand, being situated between the carpus and the phalanges; it is composed of five bones, which are named first, second, &c. in their numerical order, the enumeration being commenced at the radial side. These bones are placed parallel one with the other, and nearly on the same plane, with the exception of the first, which is more anterior than the rest, and alters its relative position to them in its various movements. They vary in size, the first being thicker and shorter than the others; and these gradually diminish in length from the second to the fifth. They are all slightly concave on the palmar surface, convex on the dorsal, larger at their extremities than in the bodies or middle part, terminated at the carpal extremity by an unequal eminence, and at the digital by a rounded head.

The bodies are lengthened and somewhat compressed, but may, in each, be regarded as presenting a palmar, a dorsal, and two lateral surfaces. The palmar surface is narrow, and presents in the middle a prominent line, which separates the attachments of the inter-osseous muscles, and corresponds with the tendons of

the flexor muscles; as also, in the first, to the opponens and flexor brevis pollicis, and in the third to the origin of the adductor pollicis.

The dorsal surface, convex and smooth in the first, presents, in the second, third, and fourth, a longitudinal line, which, bifurcating, forms the sides of a triangular surface, extending over two-thirds of their length; in the fifth, also, is observed a prominent longitudinal line, directed, obliquely, from the ulnar to the radial side. The lateral surfaces afford attachment to the dorsal inter-osseous muscles; broad in the four last bones, these surfaces are narrowed, and form merely borders in the first.

The carpal extremity presents, in each, some peculiarities which render a separate description necessary; on the first is observed a surface, which is concave in the antero-posterior, and convex in the opposite direction, which articulates with the trapezium; — in the second, a concave surface articulates with the trapezoid bone, and on the radial side, a small surface, with the trapezium; at the ulnar side, its margin is extended obliquely backwards, so as to become wedged in between the trapezium and the third metacarpal bone, and articulates by its tip with the os magnum; — on the third, a nearly plain surface articulates with the os magnum; on the radial and ulnar sides are surfaces for articulation with the contiguous metacarpal bones; — on the fourth, two articular surfaces move upon the os magnum and unciform, on the radial side there are two surfaces, and on the ulnar side one, for articulation with the corresponding surfaces of the bones on each side; —on the fifth, a concave surface, directed outwards, corresponding with the unciform bone; and, on the radial side, a surface for the fourth metacarpal bone.

The anterior, or digital, extremities of all are convex, and articulated with the phalanges, the smooth surfaces extending farther on the palmar than on the dorsal aspect of the bones; and on the margins of these are inequalities for the attachment of ligaments.

BONES OF THE FINGERS.

215. These are fourteen in number; each, with the exception of the thumb, having three separate pieces (*phalanges*, *internodia*). Of these the first is longer than the second, and the second than the third. Like other long bones, each is divided

into a body and two extremities, of which one represents the base and the other the head. Winslow and some other anatomists, reckon three phalanges in the thumb, as they conceive that its posterior, or most movable bone, resembles the first phalanges of the fingers, rather than the metacarpal bones. But if its conformation be examined with attention, more especially that of its anterior extremity, and also its mode of articulation with the bone in front of it, its analogy with the metacarpal range will appear more striking than with the first digital phalanges; and so it is considered by Meckel, Portal, H. and J. Cloquet. The bodies of the first row or phalanx are convex on the dorsal surface, and flat from side to side on the palmar, but arched from before backwards; the palmar surface is bounded by two margins which give insertion to the fibrous sheaths of the flexor tendons. The larger, or posterior extremities present an oval smooth surface, whose greatest diameter is from side to side, intended to receive the convex heads of the corresponding metacarpal bones. The anterior extremities, smaller than the other, end in two small lateral condyles, with a slight groove between them, both being adapted to the base of the contiguous bones, so as to form ginglymoid, or hinge-joints. The articular surface is prolonged farther on the palmar than on the dorsal aspect, which allows a more free range to the motion of flexion. The margins of the articular surfaces are rough and prominent for the attachment of ligaments.

The second row consists of four bones, the thumb having only two pieces corresponding with those of the first and last phalanx. Smaller than the preceding set, they still resemble them in their general outline. The broader, or posterior extremity, ends in an articular surface, divided by a slight ridge extending from before backwards, the lateral parts being concave, for the reception of the two eminences on the contiguous bone; the anterior extremity is divided into two lateral convex surfaces, which are lodged in depressions in the base of the last phalanx.

The third row (*phalanges unguium*, Sœmm.) consists of five pieces, that of the thumb being the largest. They are convex on the dorsal, flat on the palmar surface, rough at the summit, which corresponds with the points of the fingers, and at the base, for the attachment of ligaments and the flexor tendons. The articular surface, at the base, resembles that of the base of

the second phalanx, in having two shallow concavities divided by a central convex line.

Attachments of muscles. — 1. To the carpal bones. The *pisiform* bone gives origin to the abductor minimi digiti, and insertion to the flexor carpi ulnaris; the *trapezium* to the opponens and abductor pollicis; the *trapezoid* to part of the flexor brevis pollicis; the *os magnum* to part of the same; the *unciform* to the flexor brevis (minimi digiti) and to the adductor.

2. To the metacarpal bones. The *first*, or that of the thumb, gives insertion to the extensor ossis metacarpi pollicis and to the opponens pollicis, and origin to part of the abductor indicis: the *second*, or that of the forefinger, to the flexor carpi radialis at its palmar end, and to the extensor carpi radialis longior on the dorsal surface of its base, and by its lateral surfaces, to the two first dorsal inter-ossei muscles and one palmar: the *third*, to the extensor carpi radialis brevior, to the adductor pollicis, and also to two dorsal inter-ossei: the *fourth*, to two dorsal inter-ossei and one palmar: the *fifth*, to the extensor carpi ulnaris, and the adductor or opponens minimi digiti, to one dorsal and one palmar inter-osseous muscle.

3. To the bones of the fingers. Those of the *first* range of the four fingers give attachment by their lateral borders to the tendinous sheaths of the flexor tendons; their dorsal surface is covered by the expansion of the extensor tendons. The bones of the *second* row give insertion at their dorsal surface to the tendons of the extensor communis; the tendons of the flexor sublimis are inserted into their bases at the palmar surface: the *third* set gives insertion to the tendons of the flexor profundus; the fibres of the extensor communis are also continued on their dorsal aspect.

The *first* phalanx of the thumb gives insertion to the extensor primi internodii, to the flexor brevis, to the adductor and abductor pollicis: the *second* phalanx to the flexor longus, and to the extensor secundi internodii.

OF THE PELVIS.

216. The pelvis, or "basin-shaped" cavity, is placed, at the lower extremity of the trunk, being formed by the union of the ossa innominata, the sacrum, and the coccyx. Its form is some-

what circular; its size presents many varieties, dependent on the sex and age of the subject, as well as on individual conformation. In young subjects the two large lateral bones, the ossa innominata, are divided each into three pieces, the ilium, ischium, and os pubis; the sacrum consists of five pieces, resembling in some respects the bones of the vertebral column, and hence called false vertebræ; these in adult age become united into one. The coccyx, or caudal prolongation, consists of four pieces.

THE SACRUM.

217. The sacrum, fig. 57, when the body is in the erect position, is placed at the superior and posterior part of the pelvis, beneath the last lumbar vertebra, above the coccyx, and between the ossa innominata, between which it is inserted, in some measure like a key-stone into an arch.

Fig. 57.

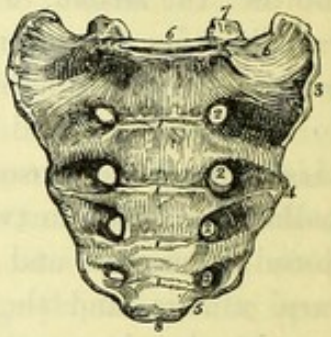

Its figure is triangular in its general outline; concave anteriorly, convex posteriorly. We consider successively its surfaces, borders, and extremities.

The anterior or pelvic surface, which is here shown, is nearly flat from side to side, concave from above downwards, and marked by four transverse lines, 1, indicating its original division into five pieces; laterally it presents four foramina, 2, (anterior sacral,) for the transmission of the anterior branches of the sacral nerves. These are directed outwards, and diminish gradually in size from above downwards; external to these the surface gives attachment to the pyramidalis muscle.

The posterior or spinal surface is convex, and presents along the median line four small eminences, usually connected so as to form a ridge; these are rudiments of the spinous processes; and beneath them is a triangular groove, or rather an opening, marking the termination of the sacral canal. The margins of the opening present two tubercles, which give attachment to the ligament that closes in the canal. The inferior pair (sacral cornua) articulate with the horns of the coccyx. At each side of the median line are two grooves, pierced by the posterior

sacral foramina, which are much smaller than the anterior, and transmit the posterior branches of the sacral nerves.

The borders, or lateral surfaces of the sacrum, present two distinct parts, one superior, 3, (iliac,) large and irregular, which in the fresh state is covered with cartilage, and articulated with the ilium ; the other inferior, 4, thin and narrowing to a point, gives attachment to the sacro-sciatic ligaments. A small indentation, 5, terminates this border, which, with the corresponding extremity of the coccyx, forms a notch for the transmission of the fifth sacral nerve.

The *base*, or superior extremity, broad and expanded, presents, 1st, towards the middle line, an oval surface, 6, cut off obliquely, and tipped with cartilage for its articulation with the last lumbar vertebra ; behind this is a triangular aperture marking the orifice of the sacral canal. 2nd, on each side a smooth convex surface, inclined forwards, and continuous with the iliac fossa ; an articular process, 7, concave from side to side, which looks backwards and inwards, and receives the inferior articular process of the last lumbar vertebra. Before each articular process is a groove, forming part of the last inter-vertebral foramen, and behind them is a curved, sharp, and depressed border which bounds the sacral canal, and therefore corresponds with the lateral arches of the vertebra, and gives attachment to the last ligamentum subflavum.

The *apex*, or inferior extremity, 8, directed downwards and forwards, presents an oval convex surface, which articulates with the coccyx.

The sacrum in its interior contains much loose spongy substance, and its exterior layer is but moderately compact. Its central part is also hollowed into a canal (sacral), which curves from above downwards as the bone does ; hence it is of a triangular form, and gradually narrows as it descends.

Attachments of muscles.— The sacrum gives attachment, by the lateral parts of its anterior surface, to the pyramidales muscles ; by its posterior surface at each side to the gluteus maximus, sacro-lumbalis, longissimus dorsi, and multifidus spinæ ; by the inferior part of each border to part of the coccygeus.

Articulations.— The sacrum articulates with the last lumbar vertebra, the two iliac bones, and the coccyx.

Developement.—In the first three pieces there are found five bony points, one being in the body, two at the sides in front, and two posteriorly in the arches. Analogy would lead us to admit two more in each body corresponding with its upper and lower surfaces, and one in the spinous process; in all eight. In the two lower false vertebræ there appear to be but three, one being in the body and one at each side.

OSSA COCCYGIS.

218. These bones, when united together, which is usually the case in advanced life, are supposed to resemble a cuckoo's bill, and are therefore called coccygeal (κοκκυξ, a cuckoo). Most commonly there are four of them, sometimes but three; in a few instances five have been found. They diminish gradually in size from above downwards, which gives them, when taken together, a pyramidal form. As they are placed in a continuous line with the inferior third of the sacrum, they form a slightly concave surface anteriorly, a convex one posteriorly.

The first of these bones resembles, in some measure, the last false vertebra of the sacrum. Its body is small and concave at its upper aspect, which articulates with the extremity of the sacrum; posteriorly, two small processes, termed cornua, project, which rest upon the sacral cornua. The second bone of the coccyx is somewhat square, the third oblong, and the fourth a small rounded nodule of bone.

Attachments of muscles.—The coccyx gives attachment to the gluteus maximus, and to the coccygeus of each side, and by its point to the sphincter ani. Its base articulates with the sacrum.

Each of these pieces has a separate osseous centre.

OS INNOMINATUM.

219. This bone, fig. 58, is of so complex and irregular a form, that it bears no perceptible resemblance to any other known object, and therefore remains "unnamed" and unnameable. The two bones thus distinguished by the negation of a name are situated at the inferior and lateral parts of the trunk, extending from the sacrum forwards to the median line, where they are connected together. Through the intervention of the sacrum, which is wedged in between them, they receive the

weight of the body, from the vertebral column, and transmit it to the lower extremities; thus placed, and being somewhat curved in their general outline, they circumscribe the greater part of the cavity of the pelvis, the sides and fore-part of which they form.

Fig. 58.

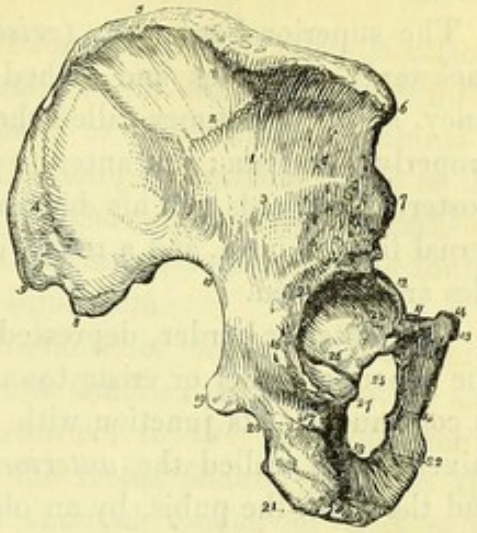

To facilitate the description of this very irregular bone, it is convenient to consider separately each of the parts into which it is found divided in early life, viz. the ilium, os pubis, and ischium.

220. The *ilium* (os ilii), or iliac portion of the os innominatum, constitutes the upper part of the bone where it is broad and expanded; it is situated at the superior and lateral part of the pelvis. Its surfaces, borders, and angles must be considered successively.

The external surface (*dorsum*), 1, convex before, concave posteriorly, is marked by two curved lines running from before backwards; the superior one, 2, commencing at the anterior superior spinous process, arches downwards to the margin of the sacro-sciatic notch. A space, narrowed before, and wider posteriorly, is included between the line just noticed, the margin of the crista ilii, and the border of the rough surface for the attachment of the gluteus maximus; from this space the gluteus medius arises. The inferior curved line, 3, is shorter and less strongly marked than the superior; it commences at the anterior inferior spinous process, and inclines backward to the sacro-sciatic notch. The space between these lines gives origin to the gluteus minimus. On its posterior and superior part is observed a rough surface, 4, which gives attachment to the gluteus maximus muscle. The internal surface of the ilium is divided into three parts. One anterior, smooth, concave, and of considerable extent, is called the *iliac fossa;* the posterior one is rough and uneven, and serves for its articulation with the sacrum; whilst the third is smooth, much smaller than the others,

and is the only part that enters into the formation of the true pelvis.

The superior border, 5, (*crista ilii*,) extending from before backwards, is convex and arched; it forms an epiphysis in infancy, and is sometimes called the *spine* of the ilium, but more properly its crista; its anterior extremity curves inwards, the posterior outwards. This border presents an external and internal lip (*labium*), and a rough interval, to each of which muscles are attached.

The anterior border, depressed and excavated, descends from the superior border or crista towards the os pubis, with which it is continuous; its junction with the crista is marked by a prominent point, called the *anterior superior spinous process*, 6; and that with the pubis, by an obtuse elevation, common to the two bones, called the *ilio-pectineal* eminence, 12. This border presents two excavations, separated by a prominent point, called the *anterior inferior spinous process*, 7. The interval between the latter and the ilio-pectineal eminence gives transmission to the iliacus and psoas muscles, and that between the spinous processes transmits the external cutaneous nerve, and gives origin to some fibres of the sartorius.

The posterior border also presents two notches, separated by a prominent point of bone, called the *posterior inferior spinous process*, 8; above which is another bony eminence, called the *posterior superior spinous process*, 9; of the notches, the inferior and larger one, 10, contributes to form the sacro-sciatic notch.

Of the three angles of the bone, the two superior ones correspond with the spinous processes (anterior and posterior); the inferior is represented by the constricted part of the bone. Here we observe three surfaces (when the ilium is separated from the os pubis and ischium): one external, smooth, concave, forming part of the *acetabulum*, the deep cavity which receives the head of the femur; one anterior, small and triangular, marking the junction with the os pubis; a third posterior, the junction with the ischium.

Attachments of muscles. — To the interval between the crista and the superior curved line on the dorsal surface, is attached the gluteus medius; to the space between the curved lines, the gluteus minimus; to the posterior rough surface, the

gluteus maximus; to the internal surface, or iliac fossa, the iliacus muscle.

To the anterior half of the external lip of its crista is attached the obliquus externus abdominis; to the posterior third of the same lip, the latissimus dorsi; to the anterior two-thirds of the interval between the lips, the obliquus internus; and to the remainder, the erector spinæ; to the anterior three-fourths of the inner lip, the transversalis abdominis; to the posterior fourth of the same lip, the quadratus lumborum.

To the external surface of the anterior superior spinous process is attached the tensor vaginæ femoris; to the process and the notch beneath it, the sartorius; to the anterior inferior spine, the straight tendon of the rectus femoris; and to the brim of the acetabulum, the external tendon of that same muscle.

Articulations.—This bone articulates with the sacrum, and joins by bony union with the os pubis and the ischium.

OS PUBIS.

221. The pubic bone forms the anterior and inner part of the os innominatum; and is usually divided into two portions, one superior and thick, called the body, the other inferior and thin, the ramus.

The *body*, fig. 58, 11, horizontal in its direction, presents three surfaces, separated by three prominent lines. The superior surface, slightly depressed, is covered by the pectineus muscle; the internal is smooth, and forms part of the pelvic cavity; the external or inferior is somewhat grooved transversely, overhangs the obturator foramen, and looks downwards to the top of the thigh.

The external extremity of the bone is thick, and presents three faces; one, concave, forms part of the acetabulum; another, superior, connects it with the ilium (the junction being marked by a rounded elevation, 12, called the *ilio-pectineal eminence*); the third, inferior, is joined with the ischium. The internal extremity, 13, flat and compressed, is joined to the corresponding part of the opposite bone by an intervening cartilage, the junction being termed the *symphysis pubis* (συμφυμι, to grow together). Leading outwards from the symphysis, whose direction is vertical, may be observed another margin, nearly an inch in

length, which is placed horizontally, and named the *crista*. The angle formed by the crista and symphysis, is termed the angle of the pubes, 14; the crista is terminated externally by a projecting nodule of bone—the *tuberosity* or spine, from which runs outwards a sharp line, (*ilio-pectineal line*,) giving attachment to Gimbernat's ligament, and to the pectineus muscle, and marking the margin or upper boundary of the true pelvis.

The *ramus*, or branch of the bone, 15, inclines outwards and downwards from the body, forming an angle with it, becomes thin, and unites with the ascending ramus of the ischium. Its inner surface is smooth; the external is rough, for the attachment of muscles. One of its borders, thick and rough and somewhat everted, forms with the opposite bone an arch, called the *arch of the pubes*; the other border, sharp and thin, forms part of the margin of the obturator foramen.

Attachments of muscles.—To the crista are attached the pyramidalis and rectus abdominis; to the tuberosity and anterior surface, the obliquus externus; to the pectineal line, the pectineus and Gimbernat's ligament; to the crista, and part of the same line, the obliquus internus and transversalis.

To the external surface, at the angle, the adductor longus; to the space between this and the border of the obturator foramen, the adductor brevis; to the line of the symphysis and the ramus, the gracilis; and to the whole margin of the foramen, the obturator externus. To the inner surface, part of the obturator internus and levator ani.

ISCHIUM.

222. The *ischium* forms the posterior and lowest part of the os innominatum; it consists of two parts, a body and a ramus, united at an angle, so as to give the bone somewhat the figure of a hook. The *body*, fig. 58, 16, or larger part, short, thick, and somewhat triangular in form, presents three surfaces or aspects which look in different directions; there are three borders, and two extremities. On its external surface may be observed a smooth concave part, which forms more than two-fifths of the acetabulum, and is surrounded by a curved prominent line, which forms the lower border of that cavity; beneath this is a groove, 17, directed horizontally backwards, corresponding with the tendon of the obturator externus muscle; and still lower a

rough line, 18, which bounds the tuberosity of the ischium, and gives attachment to the quadratus femoris. The internal surface of this portion of the bone is smooth, and forms part of the cavity of the pelvis. This is broad at its upper part, as it comprises the interval between the spine or spinous process, 19, and the margin of the obturator foramen. Below this process it becomes narrowed, constricted, and rounded off at its back, so as to form a pulley-like surface, 20, in the interval between the spine and the tuberosity where the obturator internus muscle winds round its border. The posterior surface, broad at its upper part where it comprises the space between the spine and the margin of the acetabulum, then becomes narrowed and depressed, finally ends in a rough and rather prominent surface bounded by well defined borders, which is the tuberosity of the ischium.

The *tuberosity*, 21, (*tuber ischii*,) thick and rounded, forms the part on which the body is supported in the sitting position. This rough prominence presents three impressions upon it, corresponding with the points of attachment of the three long flexor muscles of the leg.

The superior extremity of the bone (if it be examined in early life, when the bone can be detached from the ilium and os pubis, or after a section has been made of the os innominatum, so as to divide it into its three parts,) presents three surfaces, of which two are flat and triangular, and mark its junction with the ilium and os pubis ; the other, concave and smooth, forms part of the acetabulum. The inferior extremity of the body of the bone is identified with the tuberosity. The *ramus*, 22, of the ischium is the flat, thin part, which ascends forwards and inwards from the tuberosity, towards the ramus of the os pubis with which it is united. One margin of the ramus, thick, rough, and somewhat everted, forms part of the inferior outlet of the pelvis ; the other, thin and sharp, bounds the obturator foramen ; its external surface looks outwards and downwards, is rough for the attachment of muscles ; the inner surface forms part of the lower circumference of the pelvis.

Attachments of muscles.—To the outer border of the tuberosity and the contiguous part of the ramus, the adductor magnus ; to the inner margin of the tuberosity at its fore-part, the erector penis ; to the adjacent margin of the ramus, the trans-

versus perinæi; the internal obturator muscle to the inner surface of the bone behind the thyroid or obturator foramen.

To the posterior surface of the tuberosity, the three flexors of the leg, scil. the biceps, semi-tendinosus, and semi-membranosus; to the rough line on the outer surface which bounds the tuberosity, the quadratus femoris; to the external surface of the spine, the gemellus superior; to the adjacent border of the tuberosity, the gemellus inferior; to the internal surface of the bone, the levator ani; and to the spinous process, the coccygeus.

Developement.—The three pieces which form the os innominatum commence each with a separate point of ossification, and the extension of the osseous deposit proceeds in each towards the acetabulum as a common centre, so that when completed it is found to consist of a portion of each. Besides these, the spine of the ilium and the tuberosity of the ischium are formed separately.

223. *Acetabulum.*—At the junction of the three pieces of the os innominatum, 23, is situated the cavity which articulates with the head of the femur. It is called *acetabulum*, also the *cotyloid*, or cup-shaped cavity (κοτυλη, a cup; εἰδος, like). Of this the ischium forms somewhat more than two-fifths, the ilium somewhat less than two-fifths, the remainder being made up by the os pubis. It is surrounded in the greater part of its extent by a margin or supercilium, 24, which is most prominent towards the superior and external part; but at the opposite point, or towards the obturator foramen, it is deficient, leaving a notch, 25 (*cotyloid notch*, sometimes also called *incisura acetabuli*). The greater part of the cavity is covered with cartilage in the natural condition; but towards the notch there is a part depressed beneath the rest, 26, and which corresponds with the passage of the round ligament, and lodges some synovial cryptæ: this has no cartilaginous coating.

224. When we examine the pelvis as a whole, we observe that these articulating cavities, placed in the lateral walls of the pelvis, look outwards and forwards, and that they rest, when the body is erect, upon the globular heads of the thigh bones, which they lodge. The margin of each cavity is rough and uneven; but in the recent state it is rendered smooth, and the depth of the cavity is increased, by a fibro-cartilaginous rim, which runs

round it, and increases its depth. Where the osseous margin is deficient (at the cotyloid notch), its place is supplied by a fibrous band, so stretched across, as not altogether to fill it up, but rather to bridge it over, leaving a space beneath it for the entrance of vessels into the interior of the joint.

To the inner side of the acetabulum is found, in the dried bone, a large aperture, 27; which, however, in the natural condition, is almost completely closed by a fibrous membrane. It is called *foramen obturatorium*, perhaps more properly *obturatum*, from the circumstance of its being closed by a membrane or ligament. It is also called *foramen thyroideum* (shield-shaped, θυρεος, a shield), from its shape; and not unfrequently *foramen ovale*. It is somewhat of an oval form in the male, its greatest diameter being extended obliquely downwards and outwards; in the female it is a three-sided figure, with rounded angles.

GENERAL CONFORMATION OF THE PELVIS.

225. The *pelvis*, or basin-shaped cavity, which is thus made up of the ossa innominata, the sacrum, and coccyx, deserves to be attentively examined, not merely as to the details of the parts which compose it, but as to its general conformation. Taking the objects which are deserving of notice on the external surface, from before backwards, and beginning at the median line, we observe the *symphysis* pubis, or the line of junction between the two bones of that name; its direction is vertical, its depth greater in the male than in the female; beneath it is an angular space, the *pubic* or *sub-pubic arch*, bounded by the rami of the ossa pubis and ischia at each side. On each side of the arch is the *thyroid* or *obturator* foramen above noticed, and still more laterally the *acetabulum*, above which rises the broad convex part of the ilium (dorsum ilii). Posteriorly, along the middle line, are situated the tubercles or spinous processes of the sacrum; external to these, the posterior sacral foramina, and next, a broad, unequal surface, to which the sciatic ligaments and gluteus maximus are attached; and lastly, the large deep excavation (*sacro-sciatic notch*), bounded by the margins of the sacrum and os innominatum.

The internal surface is divided into two parts by a prominent line (*linea ilio-pectinea*) leading from the tuberosities of the ossa

pubis, outwards and backwards, to the prominent point of the sacrum (*promontorium*). This constitutes the margin or brim of the *true* pelvis, all the part above it being called the *false* pelvis; as in reality it belongs to the abdomen.

The superior circumference of the false pelvis is formed on each side by the crista ilii; posteriorly may be observed a deep notch, which is divided into two parts by the base of the sacrum, and anteriorly (in the interval between the anterior-superior spinous processes of the ilia) the margin of the bone subsides, so as to present a deep excavation, which in the natural condition is filled up by the soft parietes of the abdomen. Along this margin are placed the anterior-inferior spinous processes of the ilia, the ilio-pectineal eminences, the spines or tuberosities of the ossa pubis, with their cristæ and angles. The inferior circumference or outlet of the pelvis presents three bony eminences (the tuberosities of the ischia on the sides, and the coccyx behind in the middle line). These are like so many promontories, separated by deep excavations. The anterior one (*pubic arch*), triangular in its form, is bounded on each side by the rami of the ischia and ossa pubis, extending upwards and inwards, from the tuberosities of the ischia to the symphysis pubis. The two other notches (*sacro-sciatic*) are placed behind and above the tuberosities, and correspond with the interval between the sacrum and os innominatum. When examined in the dried bones, their extent is considerable; but in the natural condition they are divided into lesser spaces by the sacro-sciatic ligaments.

226. The size and conformation of the pelvis differ very remarkably in the two sexes. In the female the bones are thinner, more smooth on the surface, the muscular impressions being less strongly marked, and, though its perpendicular depth is less, its breadth and capacity are greater. The alæ of the iliac bones are more expanded; the upper aperture is more nearly circular, the projection of the sacrum less perceptible; and the space between the tuberosities of the ischia greater. The depth of the symphysis pubis is less in the female than in the male, whilst the breadth of the pubic arch is greater.

227. In the erect attitude of the body, the direction of the pelvis is oblique, its upper aperture being inclined forwards; so much so, that if a line be drawn from the upper border of the symphysis pubis, backwards to the sacrum, it rests against the

middle of that bone. In consequence of this inclination, the central line, or axis of the inlet, differs very decidedly from that of the outlet; the former, if drawn from above downwards, reaches the lower third of the sacrum; the latter, if drawn from below, backwards and upwards, touches the promontory of the sacrum; both therefore decussate towards the centre of the pelvic cavity. The different dimensions of the male and female pelvis are stated as follows, by Meckel, Cloquet, and Burns:—

	Meckel.		Cloquet.	Burns.
	In the male pelvis.	In the female pelvis	Female.	Female.
	inch. lines.	inch. lines.	inch. lines.	inch. lines.
Between the anterior-superior spinous processes of the ilia	7 8	8 6	10 0	10 0
Between the middle points of the cristæ of the ilia	8 3	9 4	11 1	11 1
The transverse diameter of the inlet	4 6	5 0	5 6	5 6
The oblique of the inlet	4 5	4 5	4 7	5 5
The antero-posterior of the inlet	4 0	4 4	4 4	4 0
The transverse diameter of the cavity	4 0	4 8	—	—
The oblique of the cavity	5 0	5 4	—	—
The antero-posterior of the cavity	5 0	4 8	—	—
The transverse of the outlet	3 0	4 5	4 4	4 0
The antero-posterior of the outlet	3 3	4 4	4 4	4 0

The last may be increased to five inches in consequence of the mobility of the coccyx.

BONES OF THE LOWER EXTREMITY.

228. The lower extremity is made up of three parts; the thigh, leg, and foot.

The osseous part of the first consists of one bone—the femur; that of the leg, of two—the tibia and fibula. The adjacent extremities of these, together with the patella (a sort of sesamoid bone), form the knee.

The foot is composed of three parts; the tarsus, metatarsus, and phalanges.

THE FEMUR.

229. The femur or thigh-bone, fig. 59, (*os femoris*,) the longest bone of the skeleton, is situated between the pelvis and the tibia. In the erect position of the body, its general direction is not vertical; it gradually inclines inwards towards the

Fig. 59.

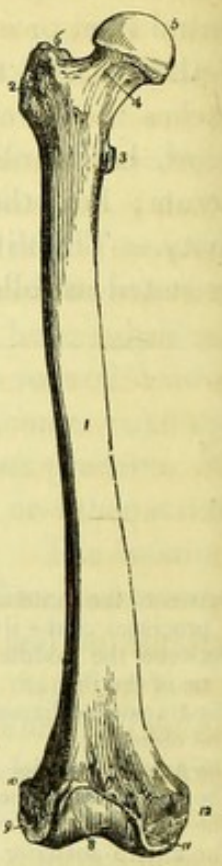

lower part, so that the bones of opposite sides, though separated at a considerable distance where they are connected with the pelvis, approach each other inferiorly, and come nearly in contact. The degree of this inclination varies in different persons, and is more marked in the female than the male. The femur presents a central part, or body, and two extremities.

The *body*, 1, or shaft, as it is sometimes called, compressed, but nearly cylindrical towards the centre, and at the same time slightly convex or arched forwards, is expanded superiorly and inferiorly. Its anterior surface, convex and smooth, is broader towards the lower than the upper extremity. Both its lateral surfaces are compressed and somewhat flat; but it may be observed that the external is somewhat concave; it affords attachment to the vastus externus muscle. The surface, which superiorly looks inwards, is in the lower third of the bone, inclined somewhat backwards, and gives attachment to the vastus internus. The anterior surface is separated, though not in a very marked degree, from the lateral surfaces by two lines, which may be traced upwards from the condyles, towards the superior extremity of the bone; but posteriorly, at the union of the two lateral surfaces, is a rough and prominent line (*linea aspera*,) which gives attachment to several muscles.

The *linea aspera* is most prominent towards the centre of the bone, and, when examined with attention, presents two margins and a rough interstice, each giving attachment to muscles. Above and below the centre, it subsides as it were towards the extremities, and also becomes bifurcated. The two superior divisions or branches of the line terminate, the one (internal and somewhat shorter) at the lesser trochanter; the other, external, at the greater trochanter; in the course of the latter a rough strongly-marked impression exists, which gives insertion to the gluteus maximus. The inferior divisions spread more asunder, and terminate at the condyles, enclosing between them and the

margins of these prominences, a flat triangular portion of the bone, which corresponds with the popliteal vessels. Towards the superior part of the linea aspera may be observed a foramen directed from below upwards, which transmits the medullary vessels.

At the superior extremity of the bone is placed its neck, which is directed upwards and inwards, so as to form an obtuse angle with the body or shaft; at its point of union with the latter are two eminences (*trochanter*, major and minor), one on the outer, the other on the inner side; it is from between these that the neck arises.

The *trochanter major*, 2, is prolonged from the external surface of the body of the bone, and nearly in a line with its axis. This apophysis, quadrilateral in its form, is convex and rough on its external surface, which is marked by a line directed obliquely downwards and forwards for the attachment of the gluteus medius; the internal surface, of less extent, presents at its base a pit, 6, (*trochanteric* or *digital fossa*,) which receives the external rotator muscles; its superior, or terminal border, is flat and straight, and the posterior thick and rounded. At the posterior aspect of the great trochanter may be observed an oblique and prominent line, directed downwards and inwards, and terminating in the trochanter minor.

The *trochanter minor*, 3, a conical rounded eminence, projects from the posterior and inner side of the bone, and gives attachment to the tendon of the psoas and iliacus muscles.

230. The *neck* of the femur, 4, which is so named from its constricted appearance and supporting the head, forms an obtuse angle with the body of the bone; it is compressed from before backwards, so that its diameter in this is much less considerable than in the vertical direction, in which greater power of resistance is required, for sustaining the weight of the body; its anterior surface is broad and smooth; the superior, inclined upwards, is short and somewhat concave; the inferior is the most extensive. The union of the neck with the rest of the bone is marked by the trochanters and two intervening oblique lines, (*inter-trochanteric*,) of which, the anterior one is rough, and but slightly prominent; the other, situated posteriorly, forms a smooth projecting ridge, which overhangs the trochanteric fossa.

The neck is surmounted by the globular *head*, 5, which forms a considerable segment of a sphere, is tipped with cartilage in

the fresh state, and lodged in the acetabulum. A little beneath its most prominent point is a small cavity, which gives attachment to the round ligament.

231. The *inferior extremity* of the bone, much thicker and broader than the superior, is terminated by two eminences, separated posteriorly by a deep fossa; these are named *condyles*, of which one is internal, the other external.

The external condyle, 7, is larger, and projects forwards more than the internal; its articulating surface also is broader, and mounts higher up anteriorly; its external surface, rough and unequal, presents a deep pit, 9, inferiorly, which gives attachment to the tendon of the popliteus muscle; and immediately above it, a projection, 10, (*external tuberosity*,) which gives attachment to the external lateral ligament of the knee-joint.

The internal condyle, 11, appears longer, and also to descend lower down than the other; but this is rather apparent than real, for, by means of the obliquity of the shaft of the bone, both condyles are brought to the same plane. The internal condyle presents at its inner side a tuberosity, 12, which gives attachment to the internal lateral ligament of the knee-joint and the tendon of the adductor magnus. In the fossa, between the condyles, posteriorly, are implanted the crucial ligaments.

The articular surfaces of both condyles, covered with cartilage in the fresh state, are united anteriorly where they form a pulley-like surface, 8, concave from side to side, on which the patella glides. Inferiorly, these surfaces diverge as they pass backwards, and when they terminate at the posterior surface of the bone, are separated by a considerable interval.

Articulations. — The femur articulates superiorly with the acetabulum; by its condyles with, inferiorly, the tibia, and, anteriorly, the patella.

Attachments of muscles.—To the anterior surface the crureus; to the two lateral and to both lips of the linea aspera, are attached the vastus internus and externus; to the centre of that line, the adductors and the short head of the biceps flexor; to the superior border of the trochanter major, the gluteus medius; to its anterior border, the gluteus minimus; to the fossa, at its posterior surface, the external rotators; to the lesser trochanter, the tendon of the psoas and iliacus; to the line between the trochanters, posteriorly, the quadratus femoris; to the line

below the lesser trochanter, the pectineus; to the rough impression beneath the great trochanter, the gluteus maximus; just above the inner and outer condyle, the corresponding heads of the gastrocnemius; to the external condyle, the plantaris; to the fossa beneath the external tuberosity, the popliteus.

Developement.—The femur grows from five osseous centres; one being in the middle of the shaft, which appears very early; the two trochanters and the head commence by separate points; and there is one at the lower extremity, which is evolved into the two condyles.

THE PATELLA.

232. The patella (rotula, knee-pan,) is situated at the anterior part of the knee-joint, being attached by a ligament (*ligamentum patellæ*) to the tibia, so that its position with regard to the joint varies according to the movements of that bone. Compressed and somewhat triangular in its form, its anterior surface is convex, and covered by the expanded fibres of the extensor tendons; the posterior, smooth and covered with cartilage for its articulation with the condyles of the femur, is divided into two parts by a vertical line, the external being the broader. Beneath these is situated a small irregular depression, corresponding with the apex, or narrowest part of the bone, which gives attachment to the ligamentum patellæ. The superior extremity, broad and rounded off at its margin, gives attachment to the extensor muscles; the inferior, narrow and pointed, to the ligament already named; the lateral borders are convex, the external being thinner than the internal.

THE TIBIA.

233. The tibia, next to the femur, is the longest bone in the skeleton; situated at the anterior and inner side of the leg, it alone receives from the femur (under which it is placed vertically,) the weight of the trunk, and communicates it to the foot. Like the other long bones, it is divided into a body and two extremities.

The *superior extremity*, fig. 60, 1, much thicker and more expanded than any other part of the bone, (being proportioned in size to the lower extremity of the femur), is broader from side to side than from before backwards; its circumference is somewhat rounded and convex in front and at the sides, but

Fig. 60.

slightly hollowed posteriorly; at the fore-part, a little below the head, is situated an eminence, 2, sometimes called the anterior tuberosity, more properly the *tubercle*, which is somewhat rough at its lower part, for the attachment of the ligament of the patella, and smooth superiorly, where it corresponds to a small synovial bursa, intervening between that ligament and the bone. On the sides, and above this, are two rounded eminences (*tuberosities*), the external one, 3, being somewhat smaller than the other, 4, and marked posteriorly by a flat surface, which articulates with the head of the fibula; these processes give attachment to the lateral ligaments of the knee-joint. On the superior aspect of this portion of the bone may be observed two concave cartilaginous surfaces, 5, 6, (*condyles*,) which sustain the condyles of the femur; the internal one is somewhat the deeper; its greatest diameter is from before backwards; the external one is nearly circular. In the interval between the articular surfaces is situated a pyramidal eminence, 7, the summit of which is usually divided into two tubercles; it is named the spine or spinous process of the tibia; before and behind this are two irregular depressed surfaces, which give attachment to the crucial ligaments and to the semi-lunar cartilages.

The *lower* or *tarsal* extremity of the bone is much smaller than the upper, and nearly quadrilateral in its form; the anterior surface, convex and smooth, is bounded below by a slightly rough margin which gives attachment to the anterior tibio-tarsal ligament; the posterior is flat, and marked by a groove for the flexor longus pollicis; the external, slightly concave, is rough superiorly, for the attachment of the transverse ligament, and smooth below, to receive the extremity of the fibula. From the inner border of this end of the bone projects downwards a triangular aphophysis, 8, the *internal malleolus;* the inner surface of which is convex, and covered merely by the skin, the external is smooth, and articulates with the side of the astragalus; the anterior forms a rounded border, whilst the posterior is marked by two grooves for the tendons of the tibialis posticus, and

flexor longus digitorum; to the most dependent part of the process is attached the internal lateral ligament. The lower articular surface of the tibia, 9, or that part which enters into the formation of the ankle-joint, consists of two parts, one vertical, just described as being situated at the outer side of the malleolus; the other horizontal in its direction, concave and quadrilateral in its form, divided into two parts by a slightly raised line; of these two surfaces, which are united at a right angle, and tipped with cartilage in the fresh state, the latter rests on the dorsum of the astragalus, the former is applied to its inner flat border.

The *body* of the tibia, triangular in its form, diminishes gradually in size for about two-thirds of its length, after which it increases somewhat towards its lower extremity. The internal surface, 10, is convex and subcutaneous, except at the upper part of its extent, where it is covered by the tendons of the sartorius, semi-tendinosus, and gracilis muscles. The external surface, slightly hollowed above, 11, where it gives origin to the tibialis anticus, is convex, and somewhat inclined forwards below, 12, where it is covered by the extensor tendons. The posterior surface is very deeply seated; not so uniform in its outline as the others, it is marked at its upper third by a line extending upwards and outwards to the external tuberosity; the part above this is triangular, and gives attachment to the popliteus muscle; that below it to the tibialis posticus and flexor digitorum; and from the line itself arises the soleus. Near this line may be observed a medullary foramen of large size, whose direction is from above downwards.

The surfaces here indicated are separated by an equal number of borders. The anterior border, 13, more or less sinuous in direction, sometimes considerably curved, is for the most part subcutaneous; sharp and prominent, especially towards the middle, and hence named the *crista* or *spine* of the tibia; it subsides towards the lower end of the bone, as if to allow a smooth surface for the passage forwards of the vessels and muscles, which superiorly are placed on the outer side. The inner border, thick and rounded, gives attachment to the soleus and flexor longus digitorum; whilst the external, 14, somewhat sharp, divides inferiorly into two lines, which diverge towards the surface of articulation with the fibula. The inter-osseous

ligament is inserted into this external border. The body of the tibia is slightly twisted, so that the internal tuberosity inclines a little backwards, and the internal malleolus forwards, which conformation deserves attention in the diagnosis and adjustment of fractures.

Articulations. — The tibia articulates with the femur, the fibula, and the astragalus.

Attachments of Muscles.—To the external surface and external tuberosity, the tibialis anticus; to the latter also, the head of the extensor longus digitorum; to the inner surface, the sartorius, gracilis, semi-tendinosus, and semi-membranosus; the popliteus to the triangular space on the posterior surface; the soleus, tibialis posticus, and flexor longus digitorum to the rest of its extent, and, through the medium of the patella and its ligament, it may be said to give insertion to the extensors of the leg.

Developement.—There is an osseous centre in the body of the bone, and one at each extremity.

THE FIBULA.

234. This bone (fibula, peroné, περονη, a clasp,) is situated at the external side of the leg; it is nearly equal to the tibia in length, but is much more slender. When the fibula is placed beside the tibia in its natural position, its lower extremity will be found a little farther forward than the upper one, and its shaft inclined backwards and a little inwards so as to be convex in that direction.

The *body* of the bone, irregularly triangular in its form, presents three prominent lines bounding three surfaces; the anterior, fig. 60, 15, or most prominent line, gives origin to muscles in the superior part of its extent, and bifurcates towards its lower extremity, so as to enclose a slightly concave triangular surface, 16, which is subcutaneous; the internal one also gives attachment to muscles, and inferiorly, where it inclines forwards, to the inter-osseous ligament. The *internal* surface, 17, looks backwards for about a third of its extent, and somewhat forwards in the rest, and is divided, but unequally, into two parts, by a slightly marked longitudinal line, to which the inter-osseous ligament is attached for about two-thirds of its length; the part of the surface behind this is grooved,—it gives

attachment to the tibialis posticus muscle; the anterior portion, the smaller, to muscles placed in front of the leg. The *external* surface, 18, concave in the greatest part of its extent, gives origin to muscles,—towards its lower extremity, this surface is inclined backwards, conforming with the peronei muscles, which are connected with the superior part of the bone, and incline in that direction to pass behind the external malleolus. The *posterior* surface, convex and smooth, affords attachment to muscles, and presents towards its middle a small foramen, directed obliquely downwards for the transmission of the medullary vessels; in the lower part it inclines inwards, and is terminated by a rough surface connected with the tibia.

The *superior* extremity of the bone, 19, called also the head, is smaller than the inferior one; it presents on the supero-internal part a small oval and nearly flat surface, for its articulation with the corresponding part of the external tuberosity of the tibia; the remainder is unequal, and gives insertion to the biceps flexor cruris, to the external lateral ligament of the knee-joint, and to those which connect the tibia and fibula. The *inferior*, or tarsal *extremity*, 20, forms the external malleolus, which is longer and more prominent than the internal one: in front it receives the insertion of ligaments; behind is situated a shallow groove traversed by the tendons of the peronei muscles; the outer side is convex and subcutaneous; the inner presents a small triangular surface, convex in the perpendicular, and nearly plain in the antero-posterior direction, which articulates with the astragalus, and is bounded posteriorly by a rough depression, affording attachment to the transverse ligament of the ankle-joint, whilst the apex gives origin to the external lateral ligament.

Articulations.—The fibula articulates at both extremities with the tibia, and at the inferior one with the outer border of the astragalus.

Attachments of muscles.—The internal surface, by its anterior portion, to the extensor communis digitorum, extensor proprius pollicis, and peroneus tertius; by the depression on its posterior part, to the tibialis posticus: the external surface, to the peronei; the posterior surface, to the soleus and flexor longus pollicis; its head, to the biceps flexor cruris.

Developement.—The fibula has an osseous centre for its body, and one for each extremity.

BONES OF THE FOOT.

The foot is composed, like the hand, of three parts, viz. the tarsus, meta-tarsus, and toes; their upper and under aspects are shown in fig. 61 and 61*.

TARSUS.

235. The tarsus is composed of seven bones, viz. the os calcis, astragalus, naviculare, cuneiforme internum, cuneiforme medium, cuneiforme externum, and cuboides.

THE CALCANEUM.

236. This bone, fig. 61, (os calcis—calcaneum,) is situated at the posterior and inferior part of the tarsus, and forms the heel by its projection backwards; elongated in that direction, and compressed laterally, it is the largest of the bones of the foot. Superiorly it presents (taking the objects successively from behind forwards,) a concave portion, 1, intervening between the insertion of the tendo Achillis into its posterior border, and the surface which articulates with the astragalus; then the last-named surface, which is bounded by a rough depression for the insertion of a ligament (inter-osseous), and lastly a narrow concave surface, which also articulates with the astragalus. On the inferior surface, which is narrower than the preceding, and broader behind than before, are observed posteriorly two tubercles, 2, 3, (the internal being the larger,) serving for the attachment of the plantar fascia and the superficial plantar muscles; between them a depression for the origin of the long plantar ligament, and in front another eminence, 4, giving attachment to the inferior ligament (calcaneo-scaphoid) connecting this bone with the scaphoid. The anterior surface, the smallest, is slightly concave, and articulates with the cuboid bone. The posterior surface, convex, presents, inferiorly, inequalities, 5, for the attachment of the tendo Achillis; and, superiorly, a smooth surface, 6, separated from that tendon by a synovial bursa.

Fig. 61.

Fig. 61.*

The external surface, broader behind than before, presents in the latter direction, superficial grooves, 7, for the tendons of the peronei muscles, and is subcutaneous in the rest of its extent. The inner surface, 8, deeply concave, is traversed by the plantar vessels and nerves, and the tendons of the flexor muscles. A groove, 9, runs along at its upper edge, and under the tubercle which surmounts it, for the tendon of the flexor longus pollicis. The calcaneum articulates with the astragalus and the cuboid bone.

THE ASTRAGALUS (*αστραγαλος*, a die).

237. The astragalus is situated at the superior part of the tarsus; its form is irregular; it appears as if twisted on itself. The upper surface presents, in front, a rough and slightly excavated part, 10, serving for the attachment of ligaments; and behind it a large convex cartilaginous surface, 11, which is longer and more prominent on the outer than on the inner side, broader before than behind, and articulated with the lower extremity of the tibia. On the outer and inner sides are situated two smooth surfaces, 12, 13, (the former the larger,) which are continuous with the preceding, and articulated with the inferior extremities of the tibia and fibula (the *malleoli*). On the inferior surface are observed, in front, and somewhat internally, a narrow convex surface, and behind, a broad concave one, both articulating with the os calcis; these are separated by a groove, which receives the ligament that proceeds upwards from the last-named bone. The anterior surface, 14, convex, is received into the hollow in the scaphoid bone; it is called the *head*, and the constricted part by which it is supported, the *neck* of the astragalus. The posterior surface, or rather border, is grooved and traversed by the tendon of the flexor longus pollicis. The astragalus articulates with the tibia and fibula above, with the os calcis below, and with the scaphoid in front.

THE CUBOID BONE.

238. This bone, (*os cuboides*, *cuboideum*,) is situated at the external side of the tarsus; its form is indicated by its name. The superior surface, 15, rather rough, inclined obliquely outwards and upwards, gives attachment to ligaments. The inferior surface presents, in front a depression, 16, traversed by the tendon of the peroneus longus muscle, in the middle a transverse ridge, (tuberosity,) 17, and behind it an irregular surface 18, both of which give attachment to the calcaneo-cuboid ligament; the former also to some fibres of the ligamentum longum plantæ. At the anterior aspect of the bone is a smooth surface, directed from without inwards and forwards, and divided into two parts, the internal one being square, the external triangular, and articulated, the former with the fourth, the latter with the fifth metatarsal bone; at the posterior is a surface by which it articulates with the os calcis. The external border, which is short and rounded, presents a groove, 19, continues with that on the inferior surface, and serving for the transmission of the tendon of the peroneus longus muscle. On the internal surface may be observed, towards its middle, an elongated smooth, and nearly flat portion, 20, which articulates with the third cuneiform bone, the part before and behind it being rough for the attachment of ligaments. The cuboid articulates with the fourth and fifth metatarsal bones before, with the os calcis behind, with the external cuneiform, and sometimes with the scaphoid.

THE SCAPHOID BONE.

239. The scaphoid or navicular bone, 21, so named from its excavated form (*σκαφη*, *navis*,) is placed at the inner border of the foot, between the astragalus and the cuneiform bones. It presents a concave surface which looks backwards, and a convex one which is turned forwards. Its inner margin projects in the form of a tubercle, 22, toward the sole of the foot. Upon its upper and inner surface are inequalities for the attachment of ligaments,—behind, a concavity for the head of the astragalus, —in front, three distinct surfaces for articulation with the three cuneiform bones; at its lower and inner border is the prominence or tubercle, above noticed, which gives attachment to the

tibialis posticus muscle; on the outer side, in some instances, is a small articular surface, by which it is united to the cuboid bone. It articulates with the three cuneiform bones, with the astragalus, and sometimes with the cuboid.

THE CUNEIFORM BONES.

240. These bones, 23, 24, 25, (ossa cuneiformia, wedge-shaped,) constitute the anterior and inner part of the tarsus; the name expresses their form. In number three, they are distinguished by their numerical order from within outwards. The first is the largest, and has its base or broad border turned down into the sole of the foot,—the second, or middle, the smallest. The base, or broad border, of the second and third is at the upper or dorsal surface of the foot, and contributes to give it its arched form. They articulate behind with the navicular, and in front with the first, second, and third metatarsal bones. In consequence of their excess in length over the second, the first and third, in addition to articulating laterally with the corresponding sides of that bone, are in apposition with the base of the second metatarsal bone, which is inserted between them. The inner side of the first is subcutaneous, and the outer side of the third articulates, by a smooth flat surface with the cuboid, and by a small linear facette with the fourth metatarsal bone.

Attachments of muscles.—The os calcis, by its dorsal surface, to the extensor brevis digitorum pedis; the inferior half of the posterior surface to the common tendon of the gastrocnemius and soleus (*tendo Achillis*), and to that of the plantaris; the inferior surface on the inner side, to the flexor accessorius, and part of the abductor pollicis: on the outer side, to the abductor digiti minimi; and between the two abductors, to the flexor brevis digitorum.

The cuboid bone, by the inferior surface, to a portion of the adductor pollicis.

The scaphoid bone, by its tuberosity, to a portion of the tendon of the tibialis posticus.

The cuneiform bones. The first, by its base, to portions of the tendons of the tibialis anticus and posticus, and the second and third to part of the flexor brevis pollicis.

Developement.—These bones have each a separate centre of

ossification. The os calcis has a second in its posterior part or tuberosity.

THE META-TARSUS.

241. The second, or middle portion of the foot, is analogous to the corresponding portion of the hand (meta-carpus), and like it is composed of five bones placed parallel one with the other. They are named according to their numerical order, from within outwards. The first, or that supporting the great toe, is the shortest, but it exceeds all the others very considerably in thickness. The second is the longest, and the rest decrease successively in length. In all, the thickness of the extremities, particularly of the tarsal ends, is greater than that of the bodies. The bodies of these bones elongated and somewhat compressed, like the metacarpal bones, may be considered as presenting a dorsal, a plantar, and two lateral surfaces. The dorsal surface of all is covered by the tendons of the extensor muscles, the extensor brevis digitorum, and the vessels and nerves; that of the first is broad, inclined inwards, and bounded externally by a prominent line; in the last it looks outwards, and is bounded on the inner side by a like line. In the others are observed analogous lines, placed in the middle, and separating the attachments of the interossei muscles. The plantar surface corresponds to the deep-seated muscles of the foot, and to ligaments serving to connect those bones. That of the first is broader than any of the others. The lateral surfaces form the interosseous spaces, and give attachment to the interosseous muscles. The tarsal extremity presents, in the first, an oval concave surface, broader above than below, articulating with the first cuneiform bone, and inferiorly a tuberosity for the attachment of the peroneus longus; that of the second metatarsal bone, triangular in its form, is, in consequence of the shortness of the corresponding cuneiform bone, impacted between the two other bones of that name; it gives attachment to ligaments, articulates behind with the second cuneiform bone, on the inner side with the first metatarsal bone, and on the outer with the second. The tarsal end of the third, also triangular, and smaller than the preceding, receives the insertion of ligaments on its upper and under surfaces, and articulates posteriorly with the third cuneiform bone, on the inner side with the second meta-

tarsal bone, on the outer with the fourth. The extremity of the fourth metatarsal bone, cubical in its form, is connected by ligaments to the adjacent bones, and articulates with the cuboid posteriorly, on the inner side with the third metatarsal and third cuneiform bones, on the outer with the fifth metatarsal. The posterior extremity of the fifth metatarsal bone, pyramidal in its form, articulates behind, by an oblique surface, with the cuboid, and on the inner side with the fourth metatarsal bone; on its external and lower side is a rough tuberosity, which forms a considerable projection on the external border of the foot, and gives attachment to the peroneus brevis, and to part of the abductor minimi digiti.

The anterior extremities of the metatarsal bones are convex, and rounded into the form of heads, flattened at the sides and elongated from above downwards. The head is bounded by a groove, or neck, better marked on the upper than on the under surface. These extremities are received into shallow depressions in the first phalanges, with which they are articulated.

PHALANGES OF THE TOES.

242. The toes, which form the last part of the foot, are composed each of three phalanges or rows, except the first, which has but two. The body of the *first* presents three surfaces: one inferior, or plantar, is flat; the others, lateral, are smooth and convex, and meet on the dorsum in a rounded border; they are contracted towards the middle, somewhat rough and broad at the extremities for the attachment of ligaments; concave towards the sole of the foot, and convex superiorly. The posterior extremities, broader than the anterior, are concave, and receive the head of the metatarsal bones. The anterior terminate in two rounded heads, with an intervening pulley-like surface, the lateral parts being received into depressions, in the contiguous extremities of the second phalanges, whilst the middle groove lodges a prominent line marked on the latter.

The bones of the *second phalanx*, much smaller than the first, are somewhat hollowed on the lower surface, and convex on the upper one; their borders are flat and compressed. The posterior extremities are terminated by two small concave articular surfaces separated by a prominent line, by which means they are adapted to the inequalities observed on the contiguous extremi-

ties of the first phalanges. The anterior extremities present two small condyles, which articulate with the third phalanges.

The third set are somewhat conical in their figure ; the posterior extremities, or base, being hollow for their articulations with the ends of the second phalanges, whilst the anterior is rough and scabrous.

Attachments of muscles. — To the metatarsal bones. The *first* gives attachment to the prolonged tendon of the peroneus longus, to the transversalis pedis, and the first dorsal inter-osseous muscle ; the *second* to the first and second dorsal inter-ossei ; the *third* to part of the adductor pollicis, to three inter-ossei, and part of the transversalis pedis ; the *fourth* to three inter-ossei also ; the *fifth* to the peroneus brevis and tertius, the transversalis pedis, part of the flexor brevis minimi digiti, to the fourth dorsal and third plantar inter-osseous muscle.

To the bones of the toes. The *first* phalanx of the great toe gives insertion to the abductor, flexor brevis, and adductor pollicis ; the *second* phalanx to the extensor proprius pollicis and flexor pollicis longus ; the *second* phalanges of the other toes receive the insertion of the tendons of the flexor sublimis ; and the *third* those of the flexor profundus, and of the extensors.

OSSA SESAMOIDEA.

243. These do not properly form part of the skeleton ; they may be considered as accessories to the tendons of muscles, and are found only in the limbs, never in the trunk. In the superior extremity, two are always found in the articulation of the metacarpal bone of the thumb with its first phalanx. In the lower extremity, two are frequently found behind the femoral condyles, and constantly beneath the first joint of the great toe, as well as in the tendons of the tibialis posticus and peroneus longus. They are situated in the direction of flexion (the only exception being the patella, which belongs to this class of bones), and serve the purpose of increasing the power of muscles, by removing them farther from the axis of the bone on which they are intended to act.

CHAPTER III.

ARTICULATIONS.

244. The different pieces of the osseous system being connected together so as to form a skeleton, their modes of union must be as various as their forms and uses. When the union is not immediate, as is the case in the cranial bones, it is effected by means of different substances, such as ligament, cartilage, fibro-cartilage, and fibrous membrane, variously arranged and disposed, so as to permit, in some instances, no perceptible motion; whilst in others a free and extended range is allowed in every direction. Still, all the varieties, however numerous, are usually included under the general term "articulation."

245. The articulations are divided into three classes; viz. the immovable, the movable, and mixed; the last being intermediate in degree between the others. The first form obtains where flat and broad bones are united to enclose cavities for the lodgment of important organs, as in the cranium and pelvis. In some instances the surfaces are indented and reciprocally impacted one into the other, so that complete solidity is insured by the structure of the part; and, as this mode of union occurs only amongst flat bones, their deficiency in extent of contact is compensated by the indentations in their margins. There is another set of immovable articulations, in which the surfaces are merely in apposition with one another, yet total immobility is secured by what may be termed a mechanical contrivance. Thus, though the squamous part of the temporal bone merely rests against the inferior border of the parietal, no motion can exist between them, in consequence of the manner in which the petrous portion of the former bone projects into the base of the skull.

246. All the bones of the head and face, except the lower jaw, are joined by immovable articulation, or *synarthrosis* (*συν, together; αρθρον, articulation*), of which there are several forms.

1. The first is called *suture* (sutura, *a seam*). In the true suture the union is effected by indentations in the contiguous margins of bones which are mutually received into one another, as may be seen between the two parietal, the occipital, and frontal bones; any varieties that occur being referrible to the form of the prominences. Thus, when they are tooth-shaped, the suture is termed *sutura dentata;* if like the teeth of a saw, *sutura serrata;* if the adjacent borders be bevelled off, as where the temporal and parietal bones are applied to one another, it is called a squamous suture (*sutura squamosa*). In some parts it may be observed that the mode of union and adaptation are alternated, in order to increase their power of resistance. Thus, at the superior part of the arch of the skull, the frontal overlays the parietal bones, and rests on them; but inferiorly and laterally the reverse takes place, where the parietal rests against the frontal.

When the surfaces are merely placed in apposition with one another, as in the superior maxillary bones, the union is called *harmonia* (ἁρμω, *to adapt*).

When a ridge in one bone is received into a groove in another, the articulation is called *schindylesis* (σχινδυλησις, a *slit* or *fissure*). The rostrum of the sphenoid, and the descending plate of the ethmoid bone, are joined in this way with the vomer. When a conical surface is impacted into a cavity, the term *gomphosis* (γομφος, *a nail*,) is adopted, which may be exemplified by the manner in which the teeth are lodged in the alveoli.

247. In the mixed form of articulation, or *amphi-arthrosis*, the bones are connected by an intermediate substance, which allows some degree of motion. The articulations between the bodies of the vertebræ, the union at the pubic symphysis, and that between the two first bones of the sternum, are all constructed on this principle. As the surfaces in these cases are flat and plain, they possess, in themselves, no mechanical advantage; so that their union is maintained partly by the cartilages interposed between them, and partly by ligamentous and fibrous structures disposed round the articulations.

248. In the movable articulations, or *diarthrosis* (δια, *through;* αρθρον, *articulation*), as the surfaces are merely in contact with one another, the connexion between the parts is

maintained by means of ligaments and fibrous membranes; for, though cartilages are interposed between their adjacent extremities, they do not form a bond of union between them; on the contrary, they are calculated to facilitate motion, rather than to restrain it. But the muscles which surround the different movable articulations contribute materially to retain the articular surfaces in their natural situations, and to prevent displacement. This is particularly evident in the shoulder-joint, in which the head of the humerus is kept in contact with the glenoid cavity of the scapula not so much by the fibrous capsule, which is weak and loose, as by the surrounding muscles; for if these be weakened by paralysis, luxation may be readily produced. The joints in the extremities are all referrible to the movable class; so is that of the lower jaw with the skull, and of the latter with the vertebral column. In the greater number of instances one of the articular surfaces is convex, the other concave; but each of these forms exhibits some varieties of conformation, which are marked by particular names. Thus, an articulating surface, which is rounded and globular, so as to represent a segment of a sphere, is called a *head;* but if it be elongated, the term *condyle* is used. These are in some cases supported by a contracted or thin portion (*neck*), which connects them with the body of the bone. If two condyles be placed in apposition, so as to leave a fossa between them, and constitute a pulley-like surface, it is termed *trochlea*. When plain even surfaces articulate, it is not necessary to mark them by any particular name; in describing them they are referred to generally as articulating surfaces. Some of the articulating depressions have also received names taken from certain peculiarities in their conformation. Thus, the superior extremity of the ulna, which receives the trochlea of the humerus, is called the sigmoid cavity, from some resemblance to the Greek letter Σ (*σιγμα*, *ειδος*, *like*); others are denominated from their greater or less degree of depth or shallowness. The deep cup-shaped cavity which receives the head of the femur is called cotyloid (from *κοτυλη*, *a cup*, and *ειδος*, *like*); and the shallow oval depression to which the head of the humerus is applied, receives the name of *glenoid* cavity (from *γληνη*, *a shallow cavity*, and *ειδος*, *like*).

The varieties of diarthrosis are:—1. *Enarthrosis* (*εν*, *in*; *αρθρον*, *a joint*), which in common language is called the "ball-

and socket" joint; such as we see in the hip and shoulder. In these great freedom of motion is provided for.—2. *Arthrodia*, which comprises joints with a limited motion, as in the case of the carpal and tarsal bones, which merely slide for a little way upon each other. The articulations between the tubercles of the ribs and the transverse processes of the vertebræ, and those between the articular processes of the last-named bones, also come under this head.

249. As the extent and form of the articulating surfaces of joints, as well as their ligamentous connexions, vary in different instances, so must their degrees of solidity and mobility: and on a review of the whole of the articulations, it may be laid down as a general principle, that the greater their mobility, the less their solidity; or, in other words, that the one is inversely as the other. All the motions, however, which are admissible in joints may be arranged under four heads, viz. motions of gliding, angular movement or opposition, circumduction, and rotation.

1st. The contiguous surfaces of every movable articulation admit a certain degree of *gliding* motion upon one another, so that it may be regarded as common to all; but in some cases it is the only one which takes place, for instance, between the different bones of the carpus and tarsus. We thus observe that some joints admit of all the motions here indicated; some are deprived of rotation, retaining the rest; whilst in others nothing more than a mere gliding can take place between the surfaces; so that a regular gradation is established in their degrees of mobility between the most movable and those which are least so. The shoulder-joint admits of the greatest extent and variety of movement; those between the carpal and tarsal bones are exceedingly limited in these particulars; and finally, between the latter and those which are altogether immovable, an intermediate grade may be traced, of which the pubic symphysis presents an example.

2nd. The *angular* movement, or opposition, can only take place between long bones. If these be made to move in opposite directions, as from extension to flexion, or from abduction to adduction, they form with one another angles varying in degree according to the extent of the motion. This, in some cases, as in the elbow and knee, is confined to flexion and ex-

tension, which makes them strictly ginglymoid or hinge-joints (*γιγγλυμος*, a hinge); in others the motion is general, and extends to four opposite directions, including each of the points intermediate between them, as may be observed in the shoulder, in the hip, and the metacarpal joint of the thumb, all which joints admit of a circumduction in the part to which they belong.

3rd. The motion of *circumduction* is performed when the shaft of a bone is made to describe a cone, its summit corresponding with the superior articulation, the base being at the inferior extremity of the bone. While this motion is being executed, the limb passes successively through the states of elevation, abduction, depression, adduction, and of course through all the intermediate points; and if a pencil be held between the fingers, and its point applied to any plain surface, such as a wall, it will trace a circle corresponding with the base of a cone, whose summit is at the shoulder-joint, whilst its side coincides with the line described by the out-stretched limb as it traverses the different points just enumerated.

4th. *Rotation* differs altogether from circumduction. In the latter the bone suffers a change of place as it moves from one point to another; in the former, it merely turns on its own axis, and therefore retains the same relative situation with respect to the adjacent parts. This movement, however, admits of two varieties; in one, it is performed on a pivot, as in the motion of the axis on the vertebra dentata; in the other there is a sort of compound motion, for instance, where the radius rolls on its own axis at one end, whilst at the other it moves upon the extremity of the ulna, by which its lower part describes a segment of a circle, and therefore changes place to a certain extent. The femur and humerus also admit of a rotatory motion; in the latter, as the head is closely applied upon the shaft, the axis of motion nearly coincides with that of the bone; but in the former, in consequence of the length of the neck, and of the angle which it forms with the bone, the rotation is performed round an imaginary axis, which may be conceived to pass from the globular head to the condyles.

250. There are but two articulations in which all the motions of opposition, circumduction, and rotation, can be performed, namely, the hip and the shoulder joint. In these a convex

surface is applied to one which is concave, the former being hemispherical, which is essentially necessary to such a freedom of motion. As joints constructed on this principle are more liable to displacement than any others, their security is in a great measure provided for by their being placed at the superior extremity of the limb, by which they are withdrawn from the influence of external forces. This arrangement is made subservient not to the security of the joint solely, but also to a very important purpose in the functions of the limb. For as these free and extended motions are performed in the superior articulation, their effect is communicated to the whole limb, so as to compensate for the more restricted movements in the lower joints.

251. Though all the motions above mentioned take place in the hip and shoulder joints, each of them, considered singly, is not performed with equal facility in both. Thus, circumduction is executed with greater ease in the shoulder than in the hip. Rotation, on the contrary, is more free and perfect in the latter than in the former. Circumduction can be executed with ease only when the axis of motion coincides (or very nearly so) with that of the lever to be moved, as is the case in the humerus; but in the femur, the length of the neck of the bone removes the axis of motion considerably from that of the shaft, and thereby impedes circumduction in proportion as it facilitates the rotation of the limb. These differences of structure in the superior joints of the two extremities bear a direct relation to the conformation of their other articulations, and to the purposes for which they are adapted. For, as the inferior extremity is intended to sustain the weight of the body and for progression, the bones of the leg must be securely fixed, which could be effected only by diminishing their mobility; on this account no rotation or supination is allowed between the tibia and fibula; but, to compensate for this deficiency, rotation is permitted in the hip. But as the superior extremity, on the contrary, is fitted for the prehension of objects, and for quick and varied movements, free motion is allowed between the bones of the fore-arm, and between the latter and the carpus, in order that the hand and fingers may be more readily directed and applied to such objects as are required to be seized for different

purposes ; and the power of pronation and supination, thus conferred, more than compensates for any deficiency in the rotatory motion of the humerus.

252. It has been already observed, that rotatory motion in a bone presupposes the existence of a globular head, placed so that its axis shall form an angle with the shaft. Wherever this requisite is wanted, motion is confined to opposition and circumduction, as occurs in the articulation of the thumb with the carpus, in the phalanges with the metacarpal bones, and in the clavicle with the sternum. In these joints, the articulating surfaces are placed at the ends of the more movable bones ; and as their axes coincide with that of motion, rotation is prevented, but circumduction and opposition are freely performed. When these are limited in extent, as in the sterno-clavicular articulation, it arises rather from the accessory ligaments of the part than from any impediment in the surfaces of the bones ; and if motion in one direction be more free than in another, as in the digital phalanges with the metacarpus, where flexion and extension are more free than abduction and adduction, it proceeds partly from the existence of the lateral ligaments, and partly from the great power possessed by the flexor and extensor muscles compared with those which perform the other movements. Though in the knee and elbow the axis of motion coincides with that of the bones, yet their movement is confined to two directions, viz. to flexion and extension. In these joints, all other motions besides those just mentioned are prevented by the breadth of the articulating surfaces, and by their mode of adaptation : however, when they are flexed, some degree of lateral motion, and also of circumduction, can be performed ; as any individual may ascertain by resting his elbow on a table, when he will find that the fore-arm may be made to describe a cone with its summit at the olecranon and base towards the fingers.

ARTICULATIONS OF THE SPINE.

253. The different pieces of the vertebral column are connected together by ligaments, by fibro-cartilage, and in some parts by synovial membranes ; the former serving to retain them in their situation, the latter to facilitate motion between the

different bones. The bodies are joined by two ligamentous bands, extending the whole length of the chain, and also by the inter-vertebral substances.

i. The *anterior common ligament*, fig. 62, 1, (ligamentum commune anterius, Sœmmering; fascia longitudinalis anterior, Weitbrecht,) is a strong band of fibres which is placed on the front of the bodies of the vertebræ, and reaches from the axis to the first bone of the sacrum, becoming broader as it descends. It consists of longitudinal fibres which are dense, firm, and well-marked. The superficial fibres extend from a given vertebra to the fourth or fifth below it; the set subjacent to these passes from the body of one to about the third beneath it; whilst the deeper ones pass only from one vertebra to that next it. The fibres are thicker towards the middle of the bodies of the vertebræ than at their margins, or over the inter-vertebral cartilages; by which means their transverse depressions are filled up, and the surface of the column rendered even. It may also be observed that they adhere more closely to the margins of the bones than to the middle of their bodies, and still more closely to the inter-vertebral cartilages. Upon the sides of the vertebræ, there are some fibres which are thin and scattered, and reach from one bone to the other.

Fig. 62.

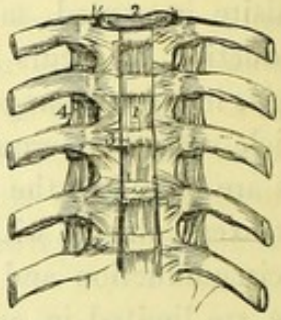

ii. The *posterior common ligament*, fig. 63, (ligamentum commune posterius, Sœmm.; fascia longitudinalis postica, Weit.) is situated within the spinal canal, and attached to the posterior surface of the bodies of the vertebræ, extending from the axis to the sacrum. It is smooth, shining, and broader opposite the inter-vertebral cartilages than opposite the bodies of the bones, so that its margins present a series of points or dentations with intervening concave spaces. In the greater part of its extent it adheres firmly to

Fig. 63.

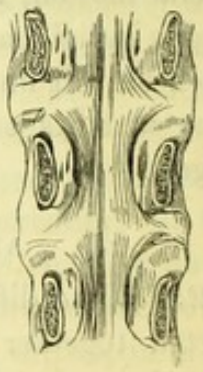

the fibro-cartilages and to the bodies of the vertebræ, and is separated by loose cellular tissue from the prolongation of the dura mater which lines the canal.

iii. The *inter-vertebral substance* (ligamenta inter-vertebralia, Weit.) is a plate or disc of fibro-cartilage, fig. 62, 2, placed between the bodies of each pair of vertebræ, from the axis to the base of the sacrum. They correspond in shape to the parts of the vertebræ between which they are interposed, and, like them, increase in thickness from the upper to the lower end of the column. The thickness of these plates is not, however, uniform in their entire circumference. As they contribute to the production and maintenance of the curves which naturally exist in the spine, they are thinnest anteriorly, in the dorsal region, where its concavity looks forward, and, on the contrary, thicker in front, in the neck and loins, where the convexity of the column looks in that direction. They are covered anteriorly and posteriorly by the common ligaments which are intimately adherent to them; in the dorsal region they are connected laterally, by short ligaments, to the heads of all the ribs, which articulate with two vertebræ. The inter-vertebral substance is composed, towards its circumference, of thin plates of fibro-cartilage, resting on their edges, and placed one within the other, as it were, concentrically. Thus the outer plate like a rim runs round the disc, its lower edge resting on the vertebræ beneath it; its anterior or convex surface being subjacent to the anterior common ligament, whilst its concave surface is in apposition with the plate next within it. They are not however so broad as that their upper edges may reach the vertebra above them, nor are they exactly perpendicular; they incline inwards a little, so as to allow other plates to be in a manner piled upon them; each cartilage being in fact composed of two or three tiers of very narrow plates thus disposed. The interstices between the plates are filled by a pulpy and apparently elastic substance; and as the number of the plates gradually decreases towards the centre, whilst the pulpy matter increases, the quantity of the latter is such, that when the pressure which confines it is taken off by cutting through the inter-vertebral substance, it will rise up so as to assume a conical form.

254. The *articulating processes* of the vertebræ are con-

nected by irregular fibrous bands (ligamenta processuum obliquorum, Weit.), forming a capsule outside the synovial membranes. These are longer and more loose in the cervical than in the dorsal or lumbar regions.

255. The arches, or plates of the vertebræ, are connected by the *ligamenta subflava*, fig. 64, (ligamenta vertebrarum subflava, Weit.) as their bodies are by the inter-vertebral cartilages. These consist of yellow elastic fibres, almost perpendicular in their direction, as they pass from the inferior border of one arch to the adjacent border of that immediately below it. They extend from the root of the transverse processes at each side backwards to the point where the two arches converge at the origin of the spinous processes, where the margins of each lateral half of the ligament may be observed to be merely in contact. The superior border of the ligament is attached, not to the margin exactly of the arch, but rather higher up on its anterior surface; whilst the inferior border is prolonged a little on the posterior surface, as well as the margin of its corresponding arch. They do not exist between the occiput and the atlas, or between the latter and the axis; common fibrous membrane supplies their place in these two spaces. They are most distinctly seen when the pedicles and arches are detached from the bodies of the vertebræ, so that they may be viewed from within the theca vertebralis as in this drawing. At the posterior aspect of the spine they appear short, and, as it were, overlaid by the arches. See fig. 72, 3; lower down, the position of the inter-spinous ligaments is indicated, 2.

Fig. 64.

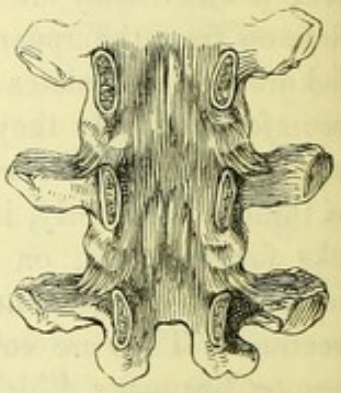

256. The *articulation of the spinous processes* is effected by means of the supra-spinous and inter-spinous ligaments. 1. The *supra-spinous ligament* consists of small, compressed bundles of longitudinal fibres, which connect the summits of the spinous processes, and form a continuous chain from the seventh cervical vertebra to the spine of the sacrum. See fig. 72, 1. The posterior fibres pass down from a given vertebra to the third

or fourth below it; those more deeply seated reach only from one to the next, or the second beneath it. 2. The *inter-spinous ligaments*, thin and rather membranous, extend from the root to near the summit of each spinous process, connecting the inferior border of one with the superior border of that next below it. They exist in the dorsal and lumbar regions only, and are intimately connected with the extensor muscles of the spine. The *inter-transverse ligaments* are found only between the transverse processes of the inferior dorsal vertebræ, and even there very indistinctly, for they are united so intimately with the sacro-lumbalis muscle, that their fibres are quite confused.

Articulations of the two upper vertebræ.

257. The articulation of the axis with the atlas is effected by means of their articulating processes, also (in the place of intervertebral substance, which would be altogether incompatible with the requisite movements) by the odontoid process of the former, which is connected in a particular manner with the arch of the latter, and constitutes the pivot on which the head turns in its rotatory motions. There are three ligaments and four synovial membranes in this articulation.

Fig. 65.

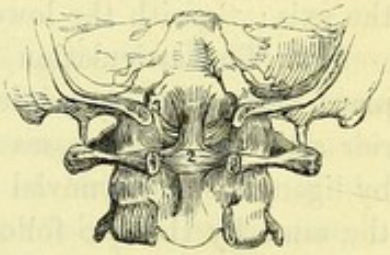

The *transverse ligament*, fig. 65, 2, (ligamentum atlantis transversum, Weit. Sœmm.) is a strong, thick fasciculus of fibres, compressed from before backwards, arched in its direction, and attached on each side to the inner border of the superior articulating processes of the atlas. It is broader and thicker at the middle than at its extremities. From the middle of its posterior surface a short thin bundle of fibres passes down to be attached to the root of the odontoid process, whilst another passes up to the basilar process. These appendages form a cross with the transverse ligament, and serve to bind the occiput to the two first vertebræ; from this is derived the term *cruciform*, which is sometimes applied to the transverse ligament. To bring these structures into view, the posterior part of the vertebral arches must be removed, as indicated in this drawing.

Fig. 66.

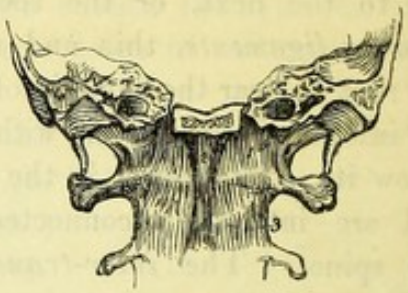

The *anterior atlo-axoid ligament* passes from the border of the anterior arch of the atlas, and its tubercle, to the body of the axis and the root of its odontoid process. It is thin and membranous, fig. 66, 3.

The *posterior atlo-axoid ligament* connects the posterior arch of the atlas with the plates of the axis, fig. 67, 2. Thus the interstices between the plates or arches, which in all the other vertebræ are filled by the ligamenta subflava, are occupied by a loose membrane between the second and first, as well as between the latter and the occiput, 1. The edges of the articulating processes are connected by irregular fibres passing from one to the other.

Two synovial membranes are placed between the articulating processes of the atlas and axis. One between the odontoid process and the transverse ligament, another between it and the arch of the atlas.

ARTICULATIONS OF THE CRANIUM.

258. The cranium is articulated, 1, with the atlas; 2, with the axis; 3, with the lower jaw.

259. The articulation of the cranium with the atlas takes place between the condyles of the occipital bone and the superior articulating processes of that vertebra, which are connected by ligaments and synovial membranes; it is also connected with the same by the two following ligaments.

The *anterior occipito-atloidean ligament*, fig. 66, 1. (membrana annuli anterioris vertebræ primæ,) extends from the anterior border of the occipital foramen, between the condyles, to the margin of the arch of the atlas between its superior articulating processes. This is thin, broad and membranous; but in the median line, a sort of accessory ligament, 2, is placed in front of it, which is thick, round, and composed of vertical fibres, attached above to the surface of the basilar process, and below to the small tubercle on the front of the atlas. The anterior surface of these ligaments is covered by the recti antici

muscles, the posterior covers the odontoid process and its ligaments.

Fig. 67.

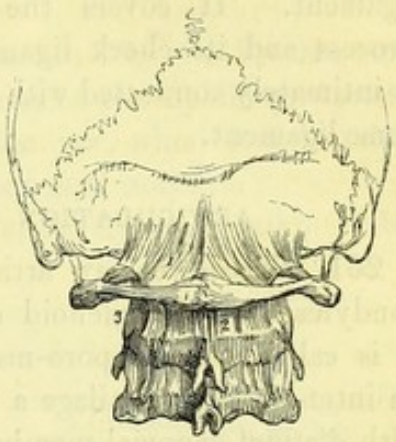

The *posterior occipito-atloidean ligament*, fig. 67, 1, also broad and membranous, is attached superiorly to all that part of the margin of the occipital foramen which is behind the condyles, and inferiorly to the adjacent border of the posterior arch of the atlas. It consists of two lamellæ, which are united at their superior attachment, but soon divide, one becoming blended with the dura mater, which lines the vertebral canal, whilst the other is inserted into the arch of the atlas. The posterior surface of the ligament is in apposition with the posterior recti and superior oblique muscles, the anterior looks towards the vertebral canal; at each side near the articular processes, the ligament forms part of the foramina through which the sub-occipital nerves and vertebral arteries pass.

260. The articulation of the occipital bone with the axis is effected through the medium of ligaments, as no part of their surfaces comes into contact.

The *odontoid ligaments*, fig. 65, 3, (ligamenta alaria,) are two thick bundles of fibres attached below to each side of the summit of the odontoid process, and passing up diverging to be implanted into the rough depressions at the inner side of the condyles of the occiput, and also to a small part of the margin of the occipital foramen. Their direction, therefore, is obliquely upwards and outwards; the triangular interval which they thus leave is filled by some thin fibres passing almost perpendicularly from the margin of the foramen to the summit of the process. These are strictly check ligaments; the middle set, last described, prevent what may be termed a retroversion of the head, whilst the lateral pair check its rotatory motions.

The *occipito-axoidean ligament*, fig. 68, seems to be a prolongation of the posterior common ligament; it is attached above to the inner surface of the basilar groove, from which

it descends perpendicularly, becoming narrow, and opposite the axis is blended with the posterior common ligament. It covers the odontoid process and its check ligaments, and is intimately connected with the transverse ligament.

Fig. 68.

ARTICULATION OF THE LOWER JAW.

261. The lower jaw articulates at each side by one of its condyles with the glenoid cavity in the temporal bone; hence it is called the temporo-maxillary articulation. By means of an inter-articular cartilage a double joint is formed at each side, with distinct synovial membranes.

The *external lateral ligament*, fig. 69, 1, is a short fasciculus of fibres, attached above to the external surface of the zygoma, and to the tubercle at the bifurcation of its root; below, to the external surface and posterior border of the neck of the condyle, its fibres being directed downwards and backwards. Externally it is covered by the parotid gland, internally it is in relation with the inter-articular cartilage and synovial membranes.

Fig. 69.

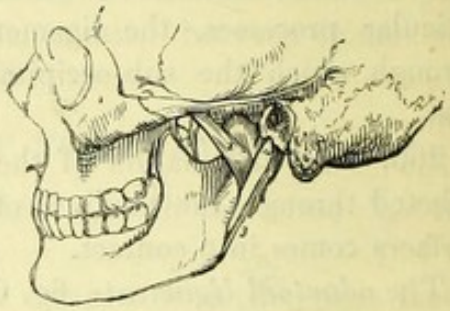

The *internal lateral ligament*, fig. 70, thin, loose, and elongated, extends from the spinous process of the sphenoid bone downwards, and a little forwards, to be attached to the inferior maxillary bone at the lower border of the dental foramen, where it is somewhat expanded. Its external surface is in relation superiorly with the external

Fig. 70.

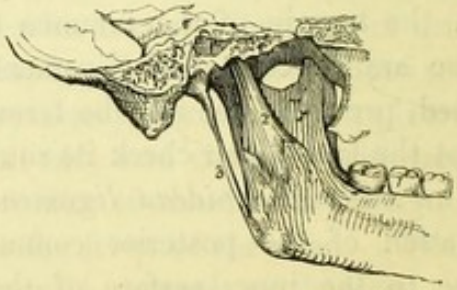

pterygoid muscle, and in the rest of its extent with the ramus of the jaw, from which it is separated by the internal maxillary artery and dental nerve. Its inner surface is concealed by the internal pterygoid muscle.

The *stylo-maxillary ligament*, figs. 69, 70, 71 ; 3, thin and aponeurotic, passes from near the point of the styloid process to the inferior border of the angle of the jaw, where it is inserted between the masseter and internal pterygoid muscles.

The *inter-articular fibro-cartilage*, fig. 71, 4, is a thin plate, placed horizontally between the articular surfaces of the bones ; it is of an oval form, and somewhat thicker at its margins than at its centre, where it is sometimes perforated. Its inferior surface, which is in contact with the condyle, is concave ; the superior is alternately concave and convex when taken from before backwards, conforming in some way with the outline of the articular cavity. Its circumference is connected at the outside with the external lateral ligament, and anteriorly with the external pterygoid muscle.

Fig. 71.

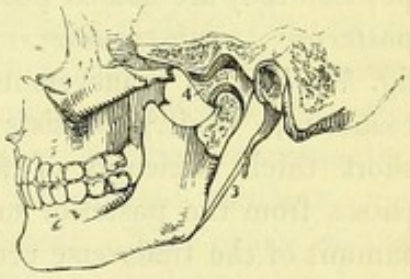

The synovial membrane, after lining the superior surface of the inter-articular cartilage, is reflected upwards on the external lateral ligament, and over the smooth part of the glenoid cavity ; a similar membrane is interposed between the inferior surface of the cartilage and the condyle, so as to constitute a double joint.

ARTICULATIONS OF THE RIBS.

262. The ligaments of the ribs may be divided into three sets : those which connect them—1, with the bodies of the vertebræ ; 2, with their transverse processes ; 3, with the sternum.

The *costo-vertebral ligaments* (lig. capitulorum costarum) consist : 1. Of an anterior ligament which connects the head of each rib with the sides of the bodies of the vertebræ, fig. 62, 3 ; its fibres, flat and radiated, are divided into three bundles, of which the middle one passes horizontally forwards upon the corresponding inter-vertebral cartilage, whilst the superior ascends to the body of the vertebra above it, and the inferior

descends to that below. From the divergence of its fibres, this is usually called the *stellate ligament*. 2ndly. Of an *inter-articular ligament*, which is a thin and short band of fibres which passes transversely from the ridge separating the two articular surfaces on the head of the rib to the inter-vertebral substance, and dividing the articulation into two parts, each lined by a separate synovial membrane. This ligament does not exist in the articulation of the first, eleventh, or twelfth ribs, and in consequence there is in them but one synovial capsule.

The *costo-transverse ligaments* connect the tubercles of the ribs with the transverse processes of the vertebræ; from their position they are named posterior, middle, and anterior. 1. The *posterior costo-transverse ligament*, fig. 72, 5, (lig. transversum externum costarum, Weit.) consists of a very short thick fasciculus of fibres which passes from the posterior surface of the summit of the transverse process, to the rough unarticulated part of the tubercle of the rib. Those of the superior ribs ascend, those of the inferior descend somewhat. 2. The *middle costo-transverse ligament* consists of a series of very short parallel fibres, which unite the neck of the rib to the anterior surface of the contiguous transverse process. These fibres are seen by removing horizontally a portion of the rib and transverse process, and forcibly drawing one from the other. 3. The *anterior costo-transverse ligament*, figs. 62, 72; 4, (lig. transversum internum costarum, Weit.) is usually divided into two fasciculi of fibres, both nearly in apposition, and on the same plane. They pass from the neck of the rib obliquely upwards and outwards to the lower margin of the transverse process next above it. These do not exist in the articulations of the first and last ribs. The articulations between the tubercles of the ribs and the transverse processes are provided with synovial capsules.

Fig. 72.

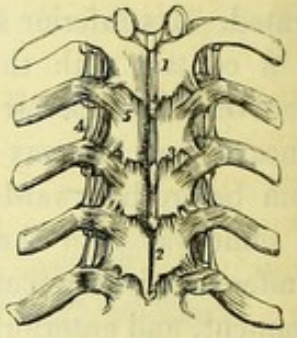

The *costo-sternal articulations*, situated between the anterior extremities of the cartilages of the ribs and the fossæ, in the margins of the sternum, are covered and supported by, 1, an anterior set of ligamentous fibres, fig. 73, 6, thin, scattered, and

Fig. 73.

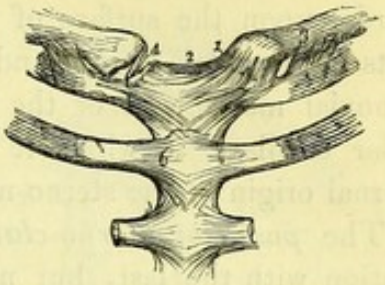

radiated, passing from the extremity of the cartilage to the anterior surface of the sternum, where they interlace with those of the opposite side, and are blended with the aponeurosis of the pectoralis major muscle; 2, a posterior set of fibres similarly disposed, but not so thick or numerous, connecting the thoracic surfaces of the same parts; 3, a synovial membrane, interposed between the ends of each true rib and the sternum, and also between the margins of each pair of false ribs, where they articulate with one another. These can be readily demonstrated by slicing off a little of the anterior surface of the sternum and cartilages. A thin fasciculus of fibres connects the cartilage of the seventh rib with the xiphoid cartilage, and thence called the *costo-xiphoid ligament*. The pieces of the sternum are connected by a layer of fibro-cartilage, placed between their contiguous borders; and, on the anterior and posterior surfaces, some scattered ligamentous fibres may be observed running longitudinally, which serve to strengthen their connexion. These are sometimes called the anterior and posterior sternal ligaments.

ARTICULATIONS OF THE SUPERIOR EXTREMITIES.

263. These may be arranged under the following heads, taking them in their anatomical order, from above downwards: 1, the articulation between the sternum and clavicle; 2, that of the scapula and humerus; 3, of the elbow; 4, of the wrist; 5, of the hand; 6, of the fingers.

The superior extremity has but one point of bony attachment to the trunk, namely, that at the sterno-clavicular articulation, the scapula being connected with the trunk by muscles only. The clavicle articulates with the first bone of the sternum, and is connected with its fellow of the opposite side, and the first rib, by ligaments.

264. The *sterno-clavicular* articulation consists of an anterior and posterior ligament, an inter-articular cartilage, and two synovial membranes.

The *anterior sterno-clavicular ligament*, fig. 73, 1, passes from the inner extremity of the clavicle, downwards and inwards, upon the surface of the sternum. It is broad, and consists of parallel fibres, and corresponds, internally, with the synovial membranes of the articulation, and with the inter-articular cartilage to which it is adherent; externally, with the sternal origin of the sterno-mastoid muscle.

The *posterior sterno-clavicular ligament*, of similar conformation with the last, but not so broad or strongly marked, is placed between the same bones lying at the thoracic aspect of the joint. Its posterior surface is in relation with the sterno-hyoideus and sterno-thyroideus muscles.

The *inter-articular fibro-cartilage*, 4, nearly circular in its form, and thicker at its border than at the centre, is interposed between the articulating surfaces of the sternum and clavicle. Towards its superior and posterior part it is attached to the margin of the clavicle, and at the opposite point to the cartilage of the first rib. In the latter situation it is thin and somewhat prolonged, so that the inferior border of the clavicle rests upon it.

Synovial membranes.—In this articulation, as in that of the lower jaw, there are two synovial membranes, of which one is reflected over the sternal end of the clavicle and adjacent surface of the fibro-cartilage, the other is disposed similarly between the cartilage and the articulating surface of the sternum.

The *inter-clavicular ligament*, 2, is a dense fasciculus of fibres, placed transversely between the contiguous extremities of the clavicles. Its fibres do not pass directly across from one to the other; they dip down, and are attached to the upper margin of the sternum, by which it is rendered concave from side to side.

The *costo-clavicular ligament*, 3, (ligamentum rhomboides, Weit. Sœmm.) does not properly form part of the articulation; yet it contributes materially to retain the clavicle in its situation. It is attached inferiorly to the cartilage of the first rib near its sternal end, and passes obliquely backwards and upwards, to be fixed to a roughness at the under surface of the clavicle.

265. The *scapulo-clavicular articulation* is effected between the acromion process of the scapula and the external end of the

Fig. 74.

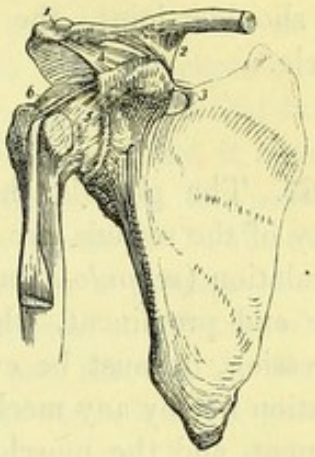

clavicle. These points are connected, 1st, by a *superior ligament*, fig. 74, 1, which is a strong broad band of fibres, passing from the superior surface of the acromion to the adjacent extremity of the clavicle; 2ndly, by an *inferior ligament* similar to the preceding, and placed at the under surfaces of the same bones; 3rdly, by a synovial membrane lining the two articular surfaces of the bones. As there is an inter-articular cartilage, there are sometimes two narrow synovial sacs, disposed in the same way as those in the sterno-clavicular articulation.

The *coraco-clavicular ligament*, fig. 74, 2, which connects the clavicle with the coracoid process of the scapula, presents two parts, each marked by a particular name. There is, however, no division between them, nor other distinction than that they look different ways.

The *posterior* or *internal fasciculus*, (conoid ligament,) broad above, narrow below, is attached, inferiorly, to the root of the coracoid process; superiorly to a rough space at the inferior surface of the clavicle, its fibres being directed backwards and upwards. The *anterior* or *external fasciculus* (trapezoid ligament) passes from the superior surface of the coracoid process upwards, to an oblique line extending outwards from the tuberosity into which the conoid ligament is inserted; with the latter it unites at an angle, one of its aspects being directed forwards and upwards, the other downwards and backwards.

266. There are two ligaments proper to the scapula: 1. The *coracoid ligament*, 3, (ligamentum proprium posterius,) is a thin flat band of fibres, attached by its extremities to the opposite margins of the notch at the root of the coracoid process, which it thus converts into a foramen for the transmission of the supra-scapular nerve, the artery most commonly passing external to it. 2. The *coraco-acromion ligament*, 4, (ligamentum proprium anterius,) is a broad, firm, triangular fasciculus, attached by its broader extremity to the coracoid process, and by

the narrower to the acromion, between which it is stretched almost horizontally. Its inferior surface looks downwards upon the shoulder-joint, the superior is covered by the deltoid muscle.

THE SHOULDER-JOINT.

267. The globular head of the humerus and the glenoid cavity of the scapula are the osseous parts which compose this articulation (*scapulo-humeral*). As the head of the humerus is large and prominent, whilst the cavity is merely a superficial depression, it must be evident that they are retained in their situation not by any mechanical contrivance, but by the capsular ligament, and the muscles which are attached to the two tuberosities of the humerus.

268. The *capsular ligament*, fig. 74, 5, is attached superiorly round the margin of the glenoid cavity, and inferiorly round the neck of the humerus. It is broader in the latter than in the former situation ; and its laxity is such, that if the muscular connexions of the humerus be detached, this bone drops away from the glenoid cavity. The superior and inner part of this membrane is covered and strengthened by a bundle of fibres, 7, passing outwards and forwards from the coracoid process to the great tuberosity of the humerus (*coraco-humeral ligament*). Besides this, it receives additions from the tendons of the supra and infra spinatus muscles, from the teres minor and sub-scapularis, which are intimately connected with it, as they proceed to be attached to the tuberosities of the humerus. Thus its superior part is thick and firm, the inferior comparatively thin and weak. Its internal surface is lined by the synovial membrane ; the external, besides the muscles already mentioned, is covered by the deltoid ; inferiorly, it is in relation with the long head of the triceps and the circumflex vessels. The insertion of its inferior border is interrupted to give passage to the long tendon of the biceps muscle.

269. The *glenoid ligament* appears to be continuous with the tendon of the long head of the biceps muscle : this at its point of attachment to the superior margin of the glenoid cavity, separates into two sets of fibres, which, after encircling it, meet and unite inferiorly. These fibres, by elevating the border of the cavity, render it a little deeper.

270. The *synovial membrane* lines the glenoid cavity, and is reflected over its lower margin until it reaches the inner surface of the fibrous capsule, on which it is prolonged as far as the neck of the humerus, where it separates from the capsule, and is applied upon the articular surface of the head of that bone, giving it a smooth investment. Viewed in this way, it appears a simple shut sac; and such it would be but for the peculiar relation of the long tendon of the biceps muscle to the shoulder-joint. The tendon is in fact enclosed in a tubular sheath, formed by an offset or process of the synovial membrane, which is reflected upon it where it is about to pass through the fibrous capsule, and is thence continued up to the summit of the glenoid cavity, where it is continuous with that part of the membrane which invests it. By this provision the integrity of the articulation and of the membrane is preserved.

On the superior and external surface of the capsule a considerable bursa mucosa is situated, by means of which the contiguous surfaces of the coracoid and acromion processes, and of the coraco-acromion ligament, are rendered smooth and lubricated, to facilitate their movements on the subjacent capsule.

271. The *coraco-humeral*, or accessory ligament, 6, above noticed, extends obliquely over the upper and outer part of the articulation; it is attached to the coracoid process, and thence descends, intimately connected with the capsule, to the greater tuberosity of the humerus.

THE ELBOW-JOINT.

272. The lower extremity of the humerus is connected with the ulna and radius at the elbow, so as to form a hinge-joint. The sigmoid cavity of the ulna articulates with the trochlea of the humerus, so as to admit of flexion and extension only, while the cup-shaped depression on the head of the radius can turn freely on the rounded tuberosity to which it is applied. The bones are connected by four ligaments and a synovial membrane.

273. The *internal lateral ligament*, fig. 75, 1, composed of diverging and radiated fibres, presents two parts, each with a different aspect, one looking obliquely forwards, the other backwards. The anterior part is attached above, where it is narrow

and pointed, to the front of the internal condyle of the humerus; its fibres, as they descend, become broad and expanded, and are inserted into the coronoid process, along the inner margin of the sigmoid cavity. The posterior part, of the same form (triangular), passes from the under and back part of the same process of bone downwards to the inner border of the olecranon; the superior fibres of this portion extend transversely between the points just named, the rest become successively more and more oblique.

Fig. 75.

Fig. 76.

274. The *external lateral ligament*, fig. 76, 2, shorter and much narrower than the internal, is attached superiorly to the external condyle of the humerus, and inferiorly becomes blended with the annular ligament of the radius; none of its fibres are prolonged to the surface of that bone, for if they were they would check its rotatory motion. It is intimately connected with the tendinous attachment of the extensor muscles, on which account, when dissected, it presents a jagged irregular appearance.

275. The *anterior ligament*, fig. 75, 3, is a broad thin membrane, placed in front of the joint, extending from the rough margin of the fossa, which receives the coronoid process during flexion, downwards to the anterior border of the coronoid process, and to the annular ligament of the radius. Some of its fibres are directed obliquely downwards and outwards, others are vertical.

276. The *posterior ligament*, fig. 76, 4, loose and weak, consists of fibres proceeding in opposite directions; thus some pass transversely between the adjacent margins of the fossa which receives the head of the olecranon; whilst others, subjacent to these, but not very well marked, pass vertically from the superior concave margin of that fossa to the extremity of the olecranon.

Though these structures are described and named as separate ligaments, it will be found, on examination, that they form a continuous membrane placed round the joint, as fibrous capsules usually are, except only that the irregularity of the surfaces to which they are attached prevents their continuity from being readily perceived, and gives them the appearance of distinct ligamentous connexions passing from one point of bone to another.

The upper Radio-ulnar articulation.

277. The head of the radius articulates with the small sigmoid cavity of the ulna, on which it rolls when it is made to turn on its axis. These surfaces are covered with cartilage, and invested by the synovial membrane of the elbow-joint. The radius is connected to the ulna by an annular ligament.

The *annular* or *orbicular ligament*, figs. 75, 76; 5, is a strong band of circular fibres, which, by being attached to the borders of the small sigmoid cavity, forms a ring, encircling the head of the radius, and binding it firmly in its situation. Its

external surface is in apposition with the external lateral ligament of the elbow, whose fibres are inserted into it; the internal is smooth and lined by the synovial membrane.

278. The *synovial membrane* of the elbow-joint, after having covered the articular extremity of the humerus, is prolonged a little on the anterior surface of that bone, as far as the attachment of the anterior ligament, where it is reflected, and applied to the internal surface of that membrane, lining it as far as its radio-cubital insertion; at that point the synovial membrane leaves the fibrous one, and invests the articular surfaces of the radius and ulna, and is extended over them until it comes into apposition with the posterior ligament, by which it is guided to the extremity of the humerus; in the same way, it lines the lateral ligaments. Besides these reflections, the membrane forms two pouches, one by being prolonged into the small sigmoid cavity, the other where it passes between the annular ligament and the contiguous surface of the head of the radius.

When the joint is laid open, and the bones extended, it will be observed that the head of the radius is not in contact with the rounded articulating process of the humerus. On which account, in the extended state of the limb, the rotatory motions of this bone are performed with much less ease than in that of flexion, from its wanting support at its upper end. The part of the humerus here referred to is moreover covered with cartilage only on its anterior aspect, indicating that the radius moves on it only when in the flexed position.

The middle Radio-ulnar articulation.

The interval between the radius and ulna in the fore-arm is filled up by an inter-osseous ligament and a round ligament, which serve to connect them together, and form what is called the middle radio-ulnar articulation.

279. The *inter-osseous ligament*, figs. 75, 76; 6, (membrana inter-ossea,) is a thin, flat, fibrous membrane, the direction of its fibres being obliquely downwards and inwards, from the inner sharp border of the radius to the contiguous one of the ulna. It does not reach the whole length of the bones, as it commences about an inch below the tubercle of the radius. The surfaces of this membrane are intimately connected with the deep-seated muscles of the fore-arm, serving to increase their points of origin

as well as to connect the bones. Inferiorly, it leaves an opening for the transmission of the anterior inter-osseous vessels; superiorly, there is another, but much larger interval, through which the posterior inter-osseous vessels pass.

280. The *round ligament*, fig. 75, 7, in some measure supplies the deficiency left by the inter-osseous ligament at the superior part of the arm. It is a thin narrow fasciculus of fibres, extending obliquely from the coronoid process, downwards and outwards, to be attached to the radius, about half an inch below its tubercle. The direction of its fibres is therefore altogether different from that of the fibres of the inter-osseous ligament.

The lower Radio-ulnar articulation.

281. At the lower or carpal end of the radius and ulna, the former rotates on the latter as its point of support, the articulating surface of the radius being concave, that of the ulna convex. The bones are connected anteriorly and posteriorly by some fibres passing between their extremities, so thin and scattered as scarcely to admit or require description, but internally they are joined by a fibro-cartilage and a synovial membrane.

282. The *fibro-cartilage*, placed transversely between the bones, is attached by its base to a rough line separating the carpal from the ulnar articulating surface of the radius, and by its summit to a depression at the root of the styloid process of the ulna. Its superior surface looks towards the head of the ulna, the inferior to the cuneiform bone; both are smooth, and lined by synovial membrane; the inferior one by the large membrane of the wrist-joint, the superior by a small one peculiar to the radio-ulnar articulation. Its two borders are connected with the carpal ligaments. As the radius rolls on the ulna, this cartilage is carried with it, and forms its chief bond of union with the latter bone.

The *synovial membrane* is frequently called *membrana sacciformis*, though there is nothing in its conformation which distinguishes it from other synovial sacs. It may be considered as presenting two parts, one projecting perpendicularly upwards into the articulation of the radius and ulna, lining the contiguous surfaces of each; the other placed horizontally between the head of the ulna and the corresponding surface of the fibro-cartilage,

lining them also; both, however are formed by a continuous membrane.

THE WRIST-JOINT.

283. This articulation (*radio-carpal*) is formed above by the radius and triangular fibro-cartilage, and the first three bones of the carpus below. The articular aspect of the former, when viewed in the fresh state, presents an oval and slightly concave surface, its greatest breadth being from side to side. The surface of the radius is divided into parts, by a line extending from before backwards; so that these, together with the cartilage, present three articular surfaces, one for each carpal bone. The scaphoid, semi-lunar, and cuneiform bones are articulated together, so as to form a rounded convex surface, which is received into the concavity above described. Four ligaments and a synovial membrane retain these parts in their situation, as follow:—

284. The *internal lateral ligament*, figs. 75, 76, ; 8, passes directly downwards, from the extremity of the styloid process of the ulna, to be attached to the cuneiform bone; it also sends some fibres to the anterior annular ligament and the pisiform bone. Its form is that of a rounded cord; its inner surface is in contact with the synovial membrane of the radio-carpal articulation.

285. The *external lateral ligament*, 9, extends from the styloid process of the radius to a rough surface on the outer side of the scaphoid bone, some of its fibres being prolonged to the trapezium, and also to the annular ligament of the wrist.

286. The *anterior ligament*, 10 (*radio-carpal*,) broad and membranous, is attached to the rough border of the carpal extremity of the radius, and to the base of its styloid process, from which its fibres pass down to be inserted into the anterior surface of the scaphoid, semi-lunar, and cuneiform bones. It is pierced by several foramina for the transmission of vessels: one of its surfaces is lined by the synovial membrane of the joint, the other is in contact with the tendons of the flexor nuscles.

287. The *posterior ligament*, 11, extends obliquely downwards and inwards, from the extremity of the radius to the posterior surface of the semi-lunar and cuneiform bones; its fibres appear to be prolonged for some way on the carpal bones. One surface is in contact with the synovial membrane, the other with the extensor tendons.

The *synovial membrane*, after having lined the articular surface of the radius, and the triangular fibro-cartilage, is reflected on the anterior and posterior ligaments, and thence over the surface of the carpal bones.

ARTICULATIONS OF THE CARPAL BONES.

288. The bones of the carpus consist of two sets, each united by its proper connexions, so as to form a row; and the two rows are connected by fibrous bands and a synovial membrane, so as to form between them a joint. The connexions proper to the first row are inter-osseous fibro-cartilages, and ligaments placed on their dorsal and palmar surfaces.

The *inter-osseous fibro-cartilages* are two lamellæ, one placed at each side of the semi-lunar bone, connecting it with the scaphoid and cuneiform bones. The carpal extremity of these is smooth, and lined by the synovial membrane of the wrist-joint.

289. The *palmar ligaments* are two, one extending from the scaphoid bone to the semi-lunar, the other from the semi-lunar to the cuneiform, their direction being transverse, and as their fibres are partly united, they may be considered as a continuous band connecting these bones.

290. The *dorsal ligaments* are also two, disposed similarly and connecting the same bones on their posterior surfaces. The pisiform bone stands out of the range, and rests on the palmar surface of the cuneiform, with which it is articulated by an irregular fibrous capsule and a synovial membrane.

291. The carpal bones of the second range are also connected by similar means. Three *dorsal and palmar ligaments* pass transversely from one bone to the other. There are, however, but two *inter-osseous fibro-cartilages*, placed one at each side of the os magnum, connecting it with the trapezoid externally, and the unciform internally. Such are the means of connexion peculiar to each row.

292. The ligaments which connect the upper to the lower row of bones are placed at their palmar, dorsal, and lateral aspects.

The *lateral ligaments* are placed one at the radial, the other at the ulnar border of the carpus; the former connects the sca-

phoid bone with the trapezium, the latter the cuneiform with the unciform.

The *palmar* or *anterior ligament* consists of short fibres, which pass obliquely from the bones of the first to those of the second range. The *posterior* is similar in structure and arrangement.

Synovial membrane. — It may be observed, that the first range of carpal bones forms a concavity; the second, particularly the os magnum and unciform, a convexity, which is received within it: by these means a ball-and-socket joint is formed, which is completed by a synovial membrane reflected over the articular surfaces of the different osseous pieces which compose it. The membrane, moreover, sends two processes between the three bones of the first row, and three between those of the second, so as to facilitate their respective motions.

CARPO-METACARPAL ARTICULATIONS.

293. The last four metacarpal bones are connected with those of the carpus by means of two sets of fibrous bands, situated one on the palmar, fig. 75, 12, the other on the dorsal surface, fig. 76, 13, the latter being better marked. All but the fifth metacarpal bone receive two bands. Thus, to the second, or that of the fore-finger, a thin fasciculus of fibres passes from the trapezium, another from the trapezoid bone; the third receives one from the latter, and also from the os magnum; the fourth from the os magnum and also from the unciform; but the fifth is connected to the latter only. On the palmar surface a similar mode of connexion exists, but the fibres are not so well defined.

294. The *carpal extremities* of the last four metacarpal bones are bound together by three transverse fibrous bands, 14, on the palmar, and the same on the dorsal surface, passing from one to the other; they are slight, and often ill-defined.

295. The *digital extremities* of these metacarpal bones are connected at their palmar aspect by a flat band passing across them, and closely connected with the head of each; this is called the *transverse ligament;* its place is indicated, fig. 75, 15; but it is better shown, though not numbered, in fig. 76, at the metacarpo-phalangal joints.

296. The *metacarpal bone of the thumb* is articulated on quite a different principle from the others; for, as it admits of all the motions except rotation, it is connected to the trapezium by a capsular ligament, 16, which passes from the rough border bounding its articular surface to the trapezium: these parts are lined by a synovial membrane.

ARTICULATION OF THE PHALANGES WITH THE METACARPAL BONES.

297. The rounded head of each of the last four metacarpal bones being received into the slight concavity situated in the extremity of the first phalanx, is maintained *in situ* by two lateral ligaments, an anterior ligament, and a synovial membrane.

298. The *lateral ligaments* consist of dense fasciculi of fibres, fig. 75, 17, attached by one extremity to the sides of the metacarpal bones, by the other to the contiguous extremity of the phalanges, the direction of the fibres being forwards and downwards. The *anterior* ligaments occupy the interval between these on the palmar aspect of the joints; they are thin and membranous. The synovial membrane invests the surfaces of the heads of the bones, and is reflected on the ligaments which connect them.

The phalanges are articulated with one another, 18, on the same principle as that which obtains in the articulation between their bases and the metacarpal bones; it is therefore unnecessary to repeat what has been just stated on that subject.

There are some other fibrous and ligamentous structures which deserve to be noticed in this place, but not as being connected immediately with the joints; they are rather accessories to the tendons of the muscles. Thus along the margins of the phalanges, on their palmar aspect, are attached the *vaginal ligaments*, which form sheaths for the flexor tendons, and bind them securely in their situation; these are thick and firm along the body of the phalanges, but over the flexures of the joints they are thin, so as not to impede their movements; their inner surface is lined by a fine membrane resembling the synovial class, which is reflected over the tendons, giving to each a smooth and shining appearance.

299. The *posterior annular ligament* of the wrist is continuous with the fascia of the fore-arm, of which it may be con-

sidered a part. It extends from the extremity of the radius, at its outer border, to the inner border of the ulna and the pisiform bone, and serves to bind down the extensor tendons.

300. The *anterior annular ligament* is a dense fasciculus of fibres, extended across the carpus from the pisiform and unciform bones to the trapezium and scaphoides, so as to form a canal which transmits the flexor tendons, retains them in their situation, and modifies their direction and power of action on the hand.

ARTICULATIONS OF THE PELVIS.

301. The os sacrum, considered as the common point of support of the vertebral column above, the os coccygis below, and ossa innominata on each side, is connected with each of these in the following manner :—

Sacro-vertebral articulation.—The base of the sacrum is articulated with the last lumbar vertebra by means similar to those which connect the different pairs of vertebræ throughout the column ; 1, by an inter-vertebral substance placed between their oval surfaces ; 2, by the continuation of the anterior and posterior common ligaments ; 3, a ligamentum subflavum connecting the arches of the last vertebra with the posterior border of the sacral canal ; 4, an inter-spinous ligament ; 5, two synovial membranes between the articulating processes ; and lastly, a sacro-vertebral ligament. All these, except the last, being similar to the connecting media throughout the column, require no farther description in this place.

The *sacro-vertebral ligament*, fig. 79, 1, extends obliquely from the transverse process of the last lumbar vertebra downwards to the depressed lateral surface at the base of the sacrum ; its form is triangular, as its fibres diverge and expand towards the sacro-iliac symphysis.

The *ilio-lumbar ligament*, 2, is extended horizontally between the summit of the transverse process of the last lumbar vertebra and the posterior extremity of the crista of the ilium, where its fibres expand somewhat, so as to give it a triangular form. This is the only bond of union between the true vertebræ and the os ilium.

302. The *sacro-coccygean articulation* is effected by, 1, an *anterior ligament*, fig. 77, 3, consisting of irregular fibres, placed

in front of these bones, subjacent to the rectum ; 2, by a *posterior ligament* more strongly marked, composed of fibres which descend upon the bones of the coccyx, from the margin of the inferior orifice of the sacral canal, which it serves to close in and complete ; 3, by a thin *fibro-cartilage* interposed between the contiguous extremities of the sacrum and coccyx with a synovial membrane which continues in the female to an advanced period of life.

The several pieces of the coccyx are connected one to the other by a continuation of the anterior and posterior ligaments which unite the sacrum and coccyx, and by very thin interposed fibro-cartilages. In the adult male the union between the sacrum and coccyx, and that between the pieces of the latter, are usually ossific ; but in the female this change most commonly does not occur till a very advanced period of life, and the mobility increases during pregnancy.

The *sacro-iliac articulation*, often named the sacro-iliac symphysis, or synchondrosis, is formed between the rough lateral surfaces of the sacrum and ilium closely applied to one another, and connected by an irregular lamella of a cartilaginous structure. In addition to these means of union, the pelvic bones are connected by the following ligaments :—

303. The *posterior sacro-sciatic ligament*, figs. 77, 78 ; 4, (ligam. sacro-ischiadicum majus, Weit., Sœmm.) elongated, broad, and triangular, is placed at the inferior and posterior part of the pelvis, whose lower aperture it assists materially in closing. Its base or broader part is attached to the postero-inferior spine of the ilium and to the side of the sacrum and coccyx ; whilst its other extremity is fixed along the inner margin of the tuber ischii, where it expands somewhat, and sends upwards and forwards along the margin of the ramus of that bone a falciform process, which presents one surface looking towards the perinæal space, and the other resting on the internal obturator muscle and pudic

Fig. 77.

artery. The posterior surface of this ligament gives origin to part of the gluteus maximus; the anterior is covered partly by the small sacro-sciatic ligament.

304. The *anterior*, or *small sacro-sciatic ligament*, 5, (lig. sacro-ischiadicum minus, internum, Weit., Sœmm.) is attached by its base to the side of the sacrum and coccyx, where its fibres are blended with those of the great ligament, and by its apex to the spinous process of the ischium; its form is triangular, the direction of its fibres forwards and outwards. The spinous process of the ischium, its tuberosity, and these two ligaments, bound an oval interval, through which pass the obturator internus muscle, and the internal pudic vessels and nerve; but above the border of the anterior ligament is a large oval opening, (bounded before and above by the margin of the ilium and ischium, and behind by the great ligament,) which transmits the pyramidalis muscle, the great sciatic nerve, the gluteal and ischiadic vessels and nerves.

305. The *posterior sacro-iliac ligaments* consist of three or four sets of short irregular fibres, extended between the posterior rough portion of the surface on the side of the sacrum and the corresponding part of the ilium. Some of the fibres pass horizontally between the bones, others obliquely: of the latter, one band, fig. 78, 6, extending downwards from the posterior superior spine of the ilium to the tubercles on the third or fourth piece of the sacrum, is described separately, under the name of (from its direction) the *oblique*, or (from being situated superficially to the others) the *posterior sacro-iliac ligament*. They are all placed deeply in the groove formed by the ilium and sacrum, and covered by the origin of the lumbar muscles. The *anterior sacro-iliac ligament* consists of some thin irregular fibres, fig. 77, 79; 7, placed at the anterior aspect of the sacro-iliac symphysis, and attached to the pelvic surfaces of the sacrum and ilium.

Fig. 78.

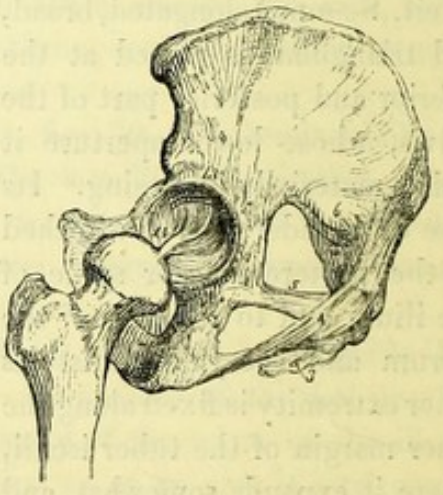

306. The *pubic articulation* (symphysis pubis) is formed by the junction of the ossa pubis in the median line anteriorly. This is effected by an elongated piece of fibro-cartilage, interposed between their surfaces, and connected to each. It consists of concentric lamellæ, as indicated in fig. 77, is thicker anteriorly than posteriorly, and frequently projects beyond the level of the bones in the latter direction. A provision is made in this part for a slight degree of movement, which, however, is more perceptible in the female than in the male. Each pubic bone, properly speaking, has its own plate of fibro-cartilage. These plates are connected by fibres passing transversely from one to the other at the fore part as well as at the upper and lower border; but at the middle and back part they are smooth, and often lined by a slight synovial membrane. The union between the bones is strengthened, 1st, by an *anterior pubic ligament*, fig. 79, 8, which consists of irregular fibres, passing obliquely across from one bone to the other, and decussating on the anterior surface of the fibro-cartilage; the fibres are intermixed with those of the aponeuroses of the external oblique muscles of the abdomen; 2ndly, the *sub-pubic ligament*, fig. 79, 9, (ligamentum triangulare, arcuatum,) thick and triangular, which is placed beneath the symphysis, its sides being attached to the rami of the pubis, its base free and slightly concave, directed, downwards and backwards to the perinæal space; 3rdly, by some indistinct fibres which are situated on the posterior surface of the articulation, and others placed on its upper border: these may be named from their position.

Fig. 79.

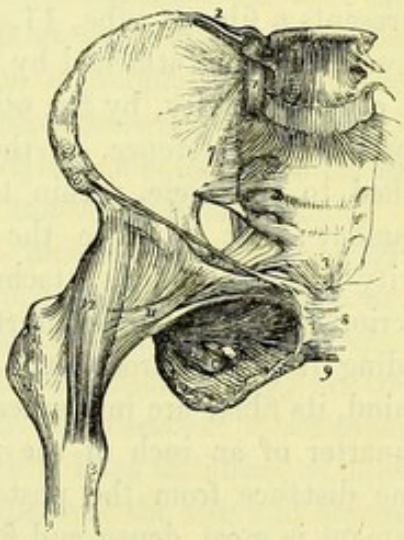

307. The *obturator ligament*, figs. 77, 79; 10, (membrana obturans foraminis thyreœidis, Sœmm.) is properly a fibrous membrane, inserted into the border of the obturator foramen, which it closes in its entire extent, except at the upper and outer part of its circumference, where a small oval aperture is

left for the exit of the obturator vessels. The obturator muscles are attached to its surfaces.

THE HIP-JOINT.

308. This is a true ball-and-socket joint, in which the globular head of the femur is received into the acetabulum or cotyloid cavity. The articulating surfaces are covered by cartilage in the greater part of their extent. It is deficient, however, at the bottom of the cavity, and also a little beneath the central point of the head of the femur; the latter marking the insertion of the round ligament, the former a shallow fossa for the lodgement of the structure which has been called the synovial gland. The connecting means in this articulation are three ligaments, viz. a capsular, cotyloid, and inter-articular ligament, together with a synovial membrane.

309. The *capsular ligament*, dense and firm in its texture, represents a fibrous tube, 11, whose direction is downwards and outwards; being attached by one extremity round the margin of the cotyloid cavity, by the other to the neck of the femur. Its superior circumference, in the greater part of its extent, is attached to the bone, within two or three lines of the cotyloid ligament; but opposite the notch, where the margin of the cavity is deficient, it is attached to the transverse ligament. Its inferior circumference is inserted in front into the oblique line leading from one trochanter to the other; but superiorly and behind, its fibres are implanted into the neck of the bone, within a quarter of an inch of the trochanteric fossa, and about the same distance from the posterior inter-trochanteric line. The ligament is most dense and firm towards the superior and anterior part of the articulation; inferiorly, its fibres are comparatively thin. A firm fasciculus, 12, of fibres extends obliquely downwards in front of the joint intimately connected with the capsule, being calculated to strengthen it, hence it is called its "accessory" ligament; but as one extremity of it is attached to the anterior inferior spinous process of the ilium, and the other to the anterior trochanteric line, it may be called the *ilio-femoral* ligament.

310. The *cotyloid ligament* is a fibro-cartilaginous ring, fig. 78, 13, placed round the cavity, and serving the purpose of

increasing its depth, and completing its border, where it is deficient. The broader part or base of this structure is attached to the bone, its thin edge is free, and both its surfaces are covered by the synovial membrane, the external being in contact with the capsular ligament, the internal with the head of the femur. Its fibres are not continued all round; they rather pass obliquely from without inwards, over the margin of the cavity, one extremity being attached to the outer, the other to its inner surface. At the cotyloid notch these fibres are continued from side to side, crossing one another, so as to render the circumference complete. Some additional fibres are superadded in this part; from which circumstance, as well as its being stretched across from one margin of the notch to the other, it is usually named the *transverse ligament*. Subjacent to the transverse portion an interval is left for the admission of the articular vessels.

311. The *inter-articular ligament*, fig. 78, 14, is not unfrequently called the "round" ligament (ligamentum teres capitis femoris, Weit. Sœmm.) It is a thick dense fasciculus of fibres, implanted by one extremity, which is round, into the fossa in the head of the femur; by the other, where it is broad, flat, and bifid, into the margins of the cotyloid notch, where its fibres become blended with those of the transverse ligament.

312. The *synovial membrane* lines the contiguous surfaces of all the parts which enter into the composition of the articulation, giving them a smooth and shining appearance. From the margin of the articular surface of the femur, it may be traced along the neck of that bone as far as the insertion of the capsular ligament, the inner surface of which it lines as far as its superior attachment. There it turns inwards over the cotyloid ligament, and dips into the cavity, lining its entire extent, and finally guided as it were by the inter-articular ligament (which it invests by a funnel-shaped process), it reaches the head of the femur, and invests it as far as the border of its cartilage, whence we proceeded in tracing its reflections.

THE KNEE-JOINT.

This is a ginglymus, or hinge-joint, formed by the condyles of the femur above, the head of the tibia below, and the patella in front, the contiguous surfaces of each being tipped with cartilage, and invested by a common synovial membrane. The fol-

lowing ligaments enter into the composition of the articulation: the ligamentum patellæ, the external and internal lateral, a posterior, a transverse, and two crucial ligaments; besides these, may be enumerated two semi-lunar fibro-cartilages, and some folds of the synovial membrane, which have received names, viz. the ligamenta alaria and mucosum; but the term ligament cannot with propriety be applied to any other than fibrous structures which connect parts together.

313. The *ligamentum patellæ*, fig. 80, 1, is a flat strong band of tendinous fibres, which connects the patella with the anterior tuberosity of the tibia. Its superior extremity is attached to the apex of the patella, and to a depression on its posterior surface; its superficial fibres pass upwards on the anterior aspect of the bone, and become continuous with those of the tendon of the rectus femoris; the inferior extremity is a little expanded; towards the middle its borders are slightly tucked in. The anterior surface of this ligament is subcutaneous in its whole extent; the posterior rests on the synovial membrane of the knee-joint, from which it is separated by some adipose substance, as it is inferiorly from the head of the tibia by a synovial bursa.

Fig. 80.

314. The *internal lateral ligament*, figs. 80, 81; 2, broad and flat, connects the tuberosity of the internal condyle of the femur with the inner surface of the head of the tibia. It becomes broad inferiorly, where it is covered by the tendons of the sartorius, gracilis, and semitendinosus muscles; internally it rests on the synovial membrane, and is attached to the internal semi-lunar cartilage.

Fig. 81.

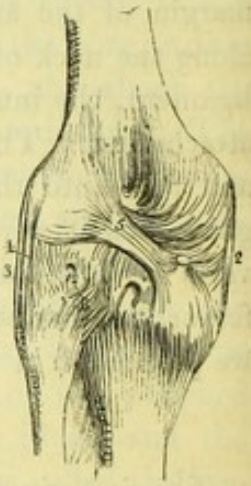

315. The *external lateral ligament*, 3, is a rounded cord-like fasciculus of fibres, which passes from the tuberosity of the external condyle of the femur, to the head of the fibula; its direction is almost vertical; it is placed nearer the posterior than the anterior surface of the joint; its internal surface corresponds with the synovial membrane and the external articular

arteries, the external being covered by the tendon of the biceps flexor cruris, and the expanded fascia of the extensor muscles. Posterior to this, but parallel with it, another ligament, fig. 81, 4, is placed, connecting the same points of the femur and fibula; it is called the *short external lateral ligament*.

316. The *posterior ligament*, fig. 81, 5, (ligamentum posticum Winslowi,) broad and expanded, is a flat plane of fibres, stretched obliquely behind the articulation from the internal tuberosity of the tibia to the external condyle of the femur. The direction of the greater part of its fibres is from below upwards and outwards, running diagonally across the joint, being evidently continuous with the tendon of the semi-membranosus muscle, of which they may be regarded as a prolongation. This ligament, however, cannot be considered as formed solely by a reflection of the tendon of the semi-membranosus, or merely as the third insertion of that muscle; for several transverse and perpendicular fibres are observed in it, distinct from those of the reflected tendon. Some apertures may be observed between its fibres, which transmit the posterior articular vessels.

317. The *crucial* or *oblique ligaments* (ligamenta cruciata) are placed at the posterior part of the joint, external to the synovial membrane, but partially invested by it. As the name imports, their direction is oblique, so that they cross or decussate somewhat like the lines of the letter X; the posterior one, however, approaches more nearly a perpendicular direction: of these one is anterior, the other posterior. The *anterior ligaments*, fig. 82, 6, is fixed by its lower extremity to a pit, situated before the spine of the tibia, where it is connected with the anterior cornu of the internal semi-lunar cartilage; its upper extremity is inserted into the inner side of the external condyle of the femur; hence its direction is upwards, backwards, and outwards. The *posterior ligament*, 7, is attached inferiorly to the pit behind the spine of the tibia (where it is intimately connected with the posterior cornu of the external semi-lunar cartilage), and superiorly, to the side of the inner condyle;

Fig. 82.

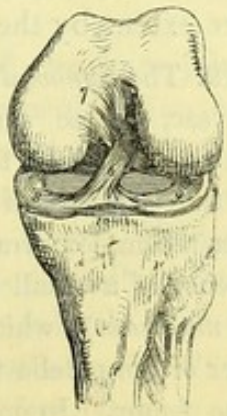

its fibres being directed upwards and a little forwards. Its interior surface is in contact with the last-mentioned ligament, and the posterior with the ligamentum posticum. Both are thus implanted into the fossa between the condyles.

318. The *semi-lunar cartilages* are two crescent-shaped lamellæ of the fibro-cartilage, placed on the articulating surfaces of the head of the tibia, interposed between them and the condyles of the femur. The outer border of each is thick and convex, the inner thin and concave, leaving the central part of the superior surface of the tibia uncovered.

The *internal semi-lunar cartilage*, fig. 82, 8, elongated from before backwards, is nearly of a semi-circular form; its anterior cornu is connected with the anterior crucial ligament, and is inserted into the pit before the spine of the tibia; the posterior is attached behind the spine, and is in relation with the posterior crucial ligament; its thick border is connected with the internal lateral ligament, the thin one is free and unattached.

The *external semi-lunar cartilage*, 9, forms nearly a complete circle; its two cornua, fixed one before, the other behind the spine of the tibia, are so close at their insertion, that they may be said to be interposed between the insertions of the internal semi-lunar cartilage. Its external border is connected behind with the tendon of the popliteus muscle, and in the middle with the external lateral ligament. Towards the front of the joint the convex borders of the inter-articular cartilages are connected by a slight transverse band, 10 (*transverse ligament*). The superior surface of the fibro-cartilages is concave, and in apposition with the condyles of the femur; the inferior plane rests on the head of the tibia: both surfaces are invested in nearly their entire extent by the synovial membrane.

319. The *synovial membrane*, like all similar structures, forms a shut sac, whose surface is continuous throughout its entire extent, and as it lines the contiguous surfaces of all the parts entering into the composition of the knee-joint, it must necessarily present rather a complex arrangement. This complexity is increased by the existence of a small funnel-shaped fold (improperly named *ligamentum mucosum*), which is stretched across the joint from the lower border of the patella to the margin of the fossa, between the condyles of the femur. In order to exhibit the arrangement of the membrane, the joint should be laid open by a vertical incision carried along the

inner margin of the patella and its ligament, leaving the ligamentum mucosum untouched. A lateral view of the joint being thus obtained, all the parts remaining in their natural position, it will be observed that the synovial sac is intersected and in a manner divided into two parts by a tranverse funnel-shaped process *(ligamentum mucosum)*; the superior one, elongated and pyramidal, projects by its summit more than an inch above the patella, its base corresponding with the breadth of the process just named. The inferior division of the membrane is quadrilateral, one side being made up of the lower border of the same process, and the smooth surface of the femur with which it is continuous; another by the articulating surface of the tibia; posteriorly it corresponds with the posterior crucial ligament, and anteriorly with the part of the membrane reflected on the ligamentum patellæ.

If we commence at the superior border of the patella to trace the reflections of the membrane, we find that it descends, lining its articulating surface; below its inferior border it corresponds with the ligamentum patellæ, from which it is separated by a considerable quantity of adipose matter; on reaching the margin of the tibia, it is reflected over its articulating surfaces, and also on both aspects of the semi-lunar cartilages, giving them a smooth investment; round the crucial ligaments also, it forms partial investments, enclosing them as far as their attachments to the femur. The membrane will thus be found to be guided to the articulating surface of that bone at several points, viz. by the two crucial ligaments, by the funnel-shaped process, and by the external margin of the semi-lunar cartilages; from these points it expands over the condyles, and after ascending for some way in front of the femur (forming a cul-de-sac between it and the tendon of the extensor muscles), it passes downwards to the margin of the patella, from which we proceeded to trace its reflections. At the sides of the patella the membrane forms two slight folds which are named "*alar*" ligaments (ligamenta alaria).

In the enumeration of the ligaments of the knee-joint, no mention has been here made of a fibrous capsule, as an investment distinct from the other fibrous structures of the joint. It is not usually described in anatomical demonstrations, and no notice of it occurs in the works of Meckel, Portal, Cloquet, or B. Cooper. A capsular ligament is, however, attributed to this articulation by Sœmmering, Weitbrecht, and Fyfe. The capsular ligament or membrane (membrana capsularis articuli genu) is said to arise in front from the whole circumference of the articulating extremity of the femur, at some distance from its

cartilaginous coating, and behind from the border of the inter-condyloid fossa, from which it descends, to be inserted into the rough border which surrounds the head of the tibia. The membrane is also inserted into the margins of the patella and its superior and inferior ligamentous connections, so that this bone forms part of the capsule of the joint. "It is very thin, but is strengthened by the fascia of the limb, and the surrounding aponeurotic structures."

These are pretty nearly the words employed by Fyfe; the last clause approaches somewhat to a correct expression of the fact. The fascia lata is prolonged from the lower part of the thigh to the head of the tibia, and extends backwards upon the condyles, and forwards to the margins of the patella and its ligament; thus forming an exterior investment for the joint and its synovial membrane. The ligamentum posticum supplies its place at the back of the articulation.

PERONEO-TIBIAL ARTICULATION.

320. The superior and inferior extremities of the tibia and fibula are connected by ligaments and synovial membranes, and the shafts of these bones are moreover maintained in relation by an inter-osseous ligament.

The contiguous extremities of the bones present superiorly two flat oval surfaces covered with cartilage, which are closely applied to one another, and retained *in situ*, 1, by an *anterior ligament*, figs. 82, 11; 83, 1, which is a broad flat band of fibres, passing obliquely upwards and inwards, from the head of the fibula to the internal tuberosity of the tibia; it is covered and strengthened by the tendon of the biceps flexor cruris; 2, by a *posterior ligament*, fig. 81, 12, similarly disposed behind the articulation, but stronger and thicker; 3, by a *synovial membrane*, which lines the articulating surfaces of the bones and ligaments.

321. The *inter-osseous ligament*, fig. 83, 2, which connects the bodies of the tibia and fibula, flat and membranous, is composed of a series of parallel fibres, extending obliquely between the external ridge of the tibia, and the ridge on the adjacent surface of the fibula. Most of the fibres run outwards and downwards, others cross them; and the membrane they compose is broader above than below, and presents in the former situation

Fig. 83.

an elongated opening for the transmission of the anterior tibial vessels, and inferiorly a small aperture for the passage of the anterior branch of the fibular artery.

322. The inferior extremities of the tibia and fibula present two articulating surfaces, of which that of the former is concave, and receives the latter, which is convex, both being for a little way covered with cartilage; these are connected by four ligaments and a synovial membrane.

1. The *anterior ligament* (tibio-fibular), fig. 83, 3, is a flat band of fibres, extended obliquely between the heads of the bones, the direction of its fibres being downwards from the tibia to the fibula.

2. The *posterior ligament*, fig. 84, 1, somewhat triangular, is similarly disposed behind the articulation; its external surface is covered by the peronei muscles.

3. The *transverse ligament*, fig. 84, 2, longer but narrower than the former, with which its fibres are closely connected, extends from the head of the fibula to that of the tibia; it forms the posterior boundary of the ankle-joint.

4. The *inferior inter-osseous ligament* consists of some short dense fibres, which connect the heads of the bones, as the great inter-osseous ligament does their bodies; it cannot be seen until the anterior and posterior ligaments are removed, and the bones in some degree separated.

THE ANKLE-JOINT.

323. This articulation consists of the inferior extremities of the tibia and fibula, united so as to form an arch, into which the superior convex surface of the astragalus is received. Their contiguous surfaces are covered with cartilage, lined by a synovial membrane, and retained in contact by the following ligaments. The *internal lateral ligament*, figs. 83, 4, and 84, 3, (ligamentum deltoides,) is a broad flat fasciculus of fibres, one extremity of which is attached to the inferior border of the internal malleolus, the other to the inner side of the

astragalus and os calcis. It is broader below than above; its cutaneous surface is covered by the tendon of the tibialis posticus muscle; the articular one is lined by the synovial membrane.

Fig. 84.

324. The *external lateral ligament* consists of three distinct fasciculi of fibres, separated by intervals, and disposed in different directions. 1. The central one, figs. 83, 5; 84, 4, *(ligamentum fibulæ medium)*, descends perpendicularly from the extremity of the fibula, and is inserted into the middle of the external surface of the os calcis. 2. The anterior fasciculus, fig. 83, 6 *(ligamentum fibulæ anterius)*, passes obliquely forwards from the inferior extremity of the fibula, to the anterior border of the articular surface of the astragalus; it is the shortest of the three. 3. The posterior, fig. 84, 5, *(ligamentum fibulæ posterius)*, the strongest of the three ligaments, passes obliquely backwards from the extremity of the fibula towards the posterior surface of the astragalus, where it is inserted into the border of the groove for the tendon of the flexor longus pollicis.

325. At the anterior aspect of the joint is a broad thin membranous band, fig. 83, 7, composed of irregular fibres, extended obliquely from the border of the articulating surface of the tibia to the margin of the pulley-like surface of the astragalus. This is usually called the *tibio-tarsal ligament;* it is covered by the tendons of the extensor muscles.

326. The *synovial membrane*, after having invested the articulating surface of the astragalus, is reflected upwards at each side upon the lateral ligaments, and at the anterior and posterior part of the joint, upon the corresponding fibrous structures, so as to reach the articulating surfaces of the tibia and fibula by several points at once. These it lines in their entire extent, and also sends upwards between the bones a process which reaches as far as the inferior inter-osseous ligament; so that the inferior articulation between these bones may be said to form part of the ankle-joint, as both are lined by the same synovial membrane.

ARTICULATIONS OF THE FOOT.

327. The foot is constructed on the principle of an arch, being concave inferiorly, where it rests on the ground, and convex superiorly, where it receives the weight of the body, transmitted to it by the bones of the leg. The posterior extremity, or heel, is narrow, thick, and rounded; the anterior, flat, thin, and expanded, being composed of the digital phalanges. The internal border, longer than the external, thick, and nearly straight, is composed of the inner border of the calcaneum, the scaphoid, first cuneiform, and first metatarsal and digital bones of the great toe: the external, shorter and thinner, consists of the calcaneum, the cuboid, the fifth metatarsal, and corresponding digital bones.

The foot being divided into the tarsus, metatarsus, and phalanges, its different parts are respectively bound together by ligaments, and all are united so as to form a whole.

The seven bones of which the tarsus consists may be divided into two sets, the os calcis and astragalus forming the first, the scaphoid, cuboid, and three cuneiform bones, the second.

Articulation of the astragalus with the calcaneum.

328. The astragalus is connected to the calcaneum by three ligaments, the chief of which is situated between the bones, and unites them somewhat after the manner that bivalve shells are connected by their muscle. This is termed the *inter-osseous ligament;* its breadth from side to side is more than an inch; the fibres of which it is composed pass perpendicularly between the bones, one extremity being fixed to the groove between the articulating surfaces of the calcaneum, the other to a corresponding depression in the astragalus. The *posterior ligament*, fig. 84, 6, connects the posterior border of the astragalus with the upper surface of the calcaneum; its fibres are oblique, its length and breadth not more than three or four lines. The *external ligament* is a slight fasciculus which descends perpendicularly from the under surface of the astragalus to the external side of the calcaneum; its direction is parallel with the external lateral ligament of the ankle-joint. It may be farther observed, that as the astragalus is wedged in between the malleoli, and as the

lateral ligaments pass downwards from these to the os calcis, they must contribute somewhat to retain the astragalus in its proper position with regard to the latter bone.

Articulation of the calcaneum with the scaphoid bone.

329. This is effected by means of two ligaments, their surfaces not being in contact. Of these ligaments, the inferior, or plantar one, fig. 85, 1, (*ligamentum calcaneo-scaphoideum inferius*, Meckel,) much the larger, passes forwards and inwards from the extremity of the calcaneum to the inferior surface of the scaphoid bone; its fibres are flat and horizontal, and in contact inferiorly with the tendon of the tibialis posticus muscle; superiorly they form part of the fossa which receives the head of the astragalus. The *external* or *dorsal ligament* (lig. calcaneo-scaphoideum externum) forms the external boundary of the cavity just mentioned; its fibres, very short, are directed from behind forwards between the contiguous extremities of the bones.

Fig. 85.

Articulation of the astragalus with the scaphoid bone.

330. The astragalus forms with the scaphoid bone a ball-and-socket joint. The anterior articulating surface of the calcaneum, and the inferior calcaneo-scaphoid ligament, also may be said to enter into this articulation, as all the parts here mentioned are lined by a common synovial membrane. On the dorsum of the foot the astragalus is retained in its situation by the *ligamentum astragalo-scaphoideum*, a broad band of fibres extending obliquely forwards from the anterior extremity of the astragalus to the superior surface of the scaphoid bone. It is covered by the extensor tendons. The necessity for an inferior ligament between these bones is removed by the existence of the calcaneo-scaphoid ligament. The *synovial membrane* lines the concave surface of the scaphoid bone, the calcaneo-scaphoid ligament, and the elongated articulating surface of the calcaneum; from these it is reflected to the under surface of the astragalus and its

scaphoid ligament, and so to the bone of that name from which we began to trace it.

Articulation of the calcaneum with the cuboid bone.

331. The connexion between these bones is maintained by three ligaments and a synovial membrane. The *superior calcaneo-cuboid ligament* is a broad flat band of fibres, which connects the anterior and superior surface of the calcaneum with the adjacent part of the cuboid bone. The *inferior* ligament consists of two distinct fasciculi of fibres, differing in form and attachments; of which one is superficial, the other deep-seated. The superficial one, called the *long plantar ligament*, fig. 85, 2, (ligamentum longum plantæ,) is the longest of the tarsal ligaments. Its fibres, attached posteriorly to the inferior surface of the calcaneum, pass horizontally forwards, and become intimately connected with the rough tuberosity on the under surface of the cuboid bone; the greater number of them are continued forwards, and terminate at the base of the third and fourth metatarsal bones. The *deep-seated calcaneo-cuboid ligament*, 3, lies close to the bones, being separated from the former by some cellular tissue; its breadth is considerable, its length scarcely an inch, one extremity being attached to the calcaneum before the long ligament, the other (somewhat expanded) to the under surface of the cuboid bone. A synovial membrane lines the contiguous surfaces of the two bones, and is necessarily reflected upon the articular aspects of the superior calcaneo-cuboid ligament and the deep-seated ligament just noticed.

Articulations between the second set or range of tarsal bones.

332. The second range of the tarsal bones, viz. the scaphoid, cuboid, and three cuneiform, are connected together in the following manner, so as to form separate articulations between each pair of them.

1. The *scaphoid* and *cuboid* bones, when in contact, which is not always the case, present two small articulating surfaces, at their edges covered with cartilage, and lined by a synovial membrane. They are connected by a *dorsal ligament*, composed of short thin fibres, extended obliquely between the two bones; and *a plantar*, situated in the sole of the foot, and composed of transverse fibres.

2. The *cuboid* and *the external cuneiform bones* are connected by a *dorsal* ligament, which is a thin fasciculus of fibres extended between them, and a *plantar ligament*, whose fibres are transverse.

3. The *scaphoid* and *the cuneiform bones* are held together by dorsal and plantar ligaments. It will be recollected that the scaphoid bone articulates with the three cuneiform, by the smooth faces on its anterior surface. The *dorsal* ligaments, three in number, pass from the superior surface of the scaphoid to the first, second, and third cuneiform bones, into which they are inserted. The *plantar ligaments* are similarly disposed on the under surface of the bones, but not so strongly marked.

4. The three *cuneiform* bones are connected by two dorsal and two plantar ligaments extended transversely from side to side; the internal one is broader and stronger than the other. The contiguous flat surfaces of the bones are lined by synovial membranes.

Articulation of the tarsus and meta-tarsus.

333. The four anterior bones of the tarsus, viz. the three cuneiform and the cuboid, articulate with the meta-tarsus. The first and third cuneiform bones project beyond the others; so that the anterior extremity of the tarsus is very irregular. The first meta-tarsal bone articulates with the internal cuneiform; the second is wedged in between the first and third cuneiform; the third meta-tarsal bone articulates with the extremity of the corresponding cuneiform, and the two last with the cuboid bone. The articular surfaces of the bones are lined by synovial membranes, and they are held in contact by *dorsal* and *plantar* ligaments. These are flat, thin bands of parallel fibres, which pass from behind forwards, connecting the contiguous extremities of the bones just mentioned. Thus the first meta-tarsal bone receives a broad thin band from the corresponding cuneiform bone; the second receives three, which converge to its upper surface, one passing from each cuneiform bone; the third has one from the third bone of that name: and, finally, the two last are bound by a broad fasciculus to the cuboid bone. The plantar set is similarly disposed; the first and second are more strongly marked than the corresponding ligaments on the dorsal surface.

Articulations of the meta-tarsal bones with one another.

334. The five elongated bones which form the meta-tarsus are connected by ligaments, so as to form an integrant part of the foot. At their posterior or tarsal extremity two sets of ligaments are situated, one on the dorsal, the other on the plantar surface. These consist of three short thin bands of fibres, which pass transversely across the contiguous extremities of the four last meta-tarsal bones; the plantar set, fig. 85, 4, is similarly disposed; but no such connection exists between the first and second bones. At the anterior, or digital extremity, the five bones are connected by a *transverse* ligament, 5, 5, which is a flat thin band of fibres, passing across from the extremity of one bone to the other; it is situated on the plantar surface of the meta-tarsus.

Articulations of the meta-tarsal bones with the digital phalanges.

335. The anterior extremities of the meta-tarsal bones are connected with those of the phalanges by two lateral ligaments, an inferior ligament, and a synovial membrane, similar in every respect to those of the hand.

The articulations of the phalanges with one another are also constructed on the same principle as those of the superior extremity. In each, the bones are held in contact by two lateral ligaments, fig. 85, 6, and an anterior ligament which is thin and membranous; the surfaces being lined by a synovial membrane.

CHAPTER IV.

OF THE MUSCLES.

336. The muscles are divisible into a number of groups, which occupy different regions of the body, and combine in various ways for the performance of its actions. We shall in the first place name the individual muscles included in each group, then indicate the method of dissecting or exposing them to view; the detailed description of each shall follow, and the rationale of their actions conclude the section.

EPICRANIAL REGION.

337. On the roof of the skull we find but one muscle, viz. the occipito-frontalis.

Dissection.—Care must be taken in making the first incisions to expose this muscle, particularly along the vertex; for the peri-cranium or tegument is very thick, and at the same time firmly adherent to the thin aponeurosis of the muscle, which is by almost every beginner detached with the tegument: this is the more likely to happen, as the aponeurosis is lifted up from the bone in the effort made to render the tegument tense. The better plan, therefore, is, to commence the dissection in such a way as to expose the fleshy fibres of the muscle; and then, taking these as a guide, to elevate the tegument from before and from behind upwards to the vertex from off the aponeurosis. Place

Note.—When proceeding with the dissection of a body, the examination of its upper and lower half is, for obvious reasons, carried on at the same time by different persons. Begin the dissection of the upper half with the epicranial region, (sect. 337,) then take the auricular; observe the temporal fascia and muscle; then, without delay, open the skull, as the brain speedily decomposes, and proceed with the examination of its membranes, vessels, and internal structure (*see* Brain, dissection of). When this is concluded, let the dissection of the different groups of muscles in the face, orbit, and neck, be continued in the order here set down. Do not pass over, or neglect the brief directions given for the examination of each region.

Those to whom the lower half of the body is allotted should commence with the abdominal muscles. These are confessedly of great importance; but still no time should be lost in inspecting them, as it is necessary, as soon as it can be effected, to proceed to the abdominal viscera. The perinæal muscles should in the next place engage attention, as they too become, in a short time, pale and

a high block under the back of the neck so as to raise the head nearly into the vertical position,—or, if the subject be turned prone, place the block under the chin. Make an incision across the forehead, about an inch above the upper margin of the orbit, and extending from the middle line outwards to the temple. Then a second incision may be carried from the inner termination of the one just indicated, upwards, over the middle of the forehead to the vertex; raise the skin at the angle formed by the junction of these incisions, and cautiously dissect it upwards and outwards, which will expose the fleshy fibres of the frontal part of the muscle. Having proceeded so far at the fore part, make a transverse incision from the occipital protuberance to the root of the mastoid process, a little above, but parallel with the superior curved line of the occipital bone. Another incision may be drawn at right angles with this from the occipital protuberance upwards to the vertex; and from the angle of union of these incisions begin and continue the dissection, raising the skin from the occipital part of the muscle, and so proceeding from the fleshy fibres upwards to the crown of the head. In conducting this dissection, the superficial filaments of the supra-orbital nerves will be seen in front, the temporal branches of the portio dura at the sides, and the ascending branches of the posterior divisions of the cervical nerves behind; also the branches of the temporal and occipital arteries. When it is not deemed necessary to retain the large flap of tegument thus dissected off, and reflected down over the ear and side of the neck, it can be readily detached by an incision carried from the outer angle of the orbit backwards to the mastoid process.

flaccid. Then take the muscles of the lower extremity in the order in which they are here placed.

If a student in his first essay at dissection has proceeded in this way, I would suggest to him to begin the second (its upper half) with the muscles of the back, which are usually left untouched till they are unfit for any purpose. As to the lower half, let that commence, for the like reason, with the gluteal and posterior femoral regions.

The remarks on the actions of muscles had better be passed over by junior students, until they become accurately acquainted with their points of attachment,—their form, and their lines of direction with regard to the axes of the bones. A perusal of them will then serve the purpose of a repetition, and suggest a strong motive to make another and a more careful dissection than could be expected in a first attempt. In doing this it will not suffice merely to trace the outline of each muscle; its points of attachment should be exactly defined by carefully removing the cellular tissue and every extraneous substance which obscures them. (See the Table of Muscles, in the order of Dissection, at the end of this chapter.)

338. *m. Occipito-frontalis* (epi-cranius) is a flat, thin digastric muscle, fig. 86, 1, 1, extended from the occiput to the forehead (from which circumstance its name is derived), and placed immediately beneath the cranial integument, to which it closely adheres, at the same time that it rests upon the arch of the skull over which it slides. It consists of two broad but short fleshy bellies, united by an intervening aponeurosis. The posterior fleshy portion is attached to the external two thirds of the superior curved line of the occipital bone, and to the mastoid portion of the temporal bone. The fleshy fibres, which are about an inch and a half in length, proceed forwards and upwards, and soon terminate by becoming continuous with the aponeurosis. The aponeurosis consists, for the most part, of longitudinal fibres, which form a plane corresponding with the roof of the skull, over which it slides, and ends by giving attachment to the anterior fleshy part of the muscle. The fleshy fibres, of which the frontal portion is composed, extend downwards and forwards on the frontal bone; they are longer than those of the occipital part; their upper margin, being their junction with the aponeurosis, presents a curved line, which is a little below the coronal suture; the inner fibres, corresponding with the median line, descend vertically, and become continuous with the pyramidalis nasi, 3: the middle fibres, longer than the others, terminate by becoming blended with the orbicularis, 2, and corrugator supercilii; and the external fibres curve inwards somewhat, and become blended with those of the orbicularis palpebrarum over the external angular process. The posterior attachment of the muscle lies immediately above the attachment of the trapezius, splenius capitis, and sterno-mastoid, to the superior curved line of the occipital bone; the anterior corresponds with the superior margin of the orbit. The external border of the aponeurosis

Fig. 86.

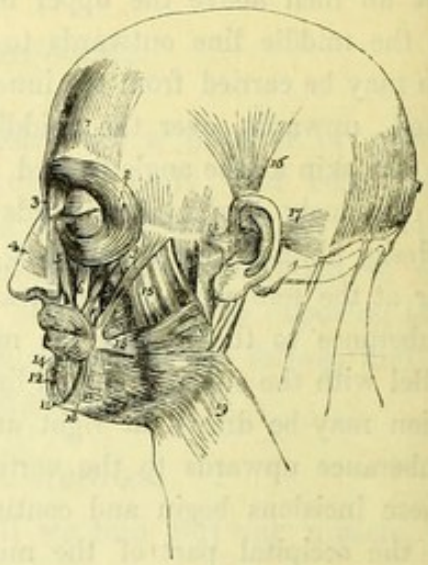

presents an arched margin, which overlaps that of the temporal muscle; but over the roof of the skull, the aponeurotic expansions from the two muscles of opposite sides are united, so as to form a continuous lamella.

Some anatomists consider this to be a four-headed muscle, having two fleshy portions behind, one on each side of the median line, and two similarly disposed in front, all connected by a single layer of aponeurosis, which rests on the cranium, and is therefrom named *galea* capitis. Others view it in a different way, the fleshy parts being taken as separate muscles, and named from their position, the anterior one being the "frontal" muscle, the posterior the "occipital." At an early period of the developement there is a digastric muscle at each side of the median line, composed of a fleshy part before and behind, joined by an intervening aponeurosis, and so we have here described it. But when the union along the vertex is completed, the aponeuroses become joined, no trace of their original separation remaining.

Actions.—These two muscles having one broad common aponeurosis, act together: their first effect is to draw up the eye-brows, the next to throw the skin of the forehead into transverse folds or wrinkles. Some persons possess the power of moving the hairy scalp backwards and forwards, by bringing the occipital and frontal parts of the muscle alternately into action.

MUSCLES OF THE FACE.

339. The muscles of the face are easily and conveniently arranged in groups, each occupying what may be called a region. The circumference of the orbit with the eye-brow and eye-lids forms the palpebral region; the side of the nose—the nasal; the cheek, or side-face—the superior maxillary; the circumference of the mouth, and the space between the jaws—the intermaxillary; that corresponding with the lower jaw—inferior maxillary. The interior of the orbit forms a separate region—the orbital; so does the space round the ear—the auricular; that of the temple and side of the jaw, the temporo-maxillary; finally, the region of the pterygo-maxillary fossa. To expose the muscles of the front and side of the face, proceed as follows:—

The *dissection of the face* may be commenced by making an incision

from the vertex along the middle line of the forehead and nose, taking care that it barely divides the skin. From this, two lines may be drawn outwards, one over the eye-brow to the side of the head, the other over the zygoma to the ear. The interval intercepted between these two parallel lines may be intersected, midway between the ear and orbit, by a perpendicular line drawn from one to the other. A square (*palpebral region*) is thus marked out over the orbicularis muscle, the skin of which should be carefully reflected from its borders and angles. The dissection is continued from its outer and upper border or circumference, the point of the scalpel being made to trace the course of the curved fibres of the muscle as far as the margin of the eye-lids. The external flap may then be reflected back over the ear, so as to expose the temporal fascia, artery, &c. The skin, in the next place, is to be carefully raised and dissected off the frontal muscle, from below upwards over the forehead as far as the vertex.

The fibres of the orbicularis, after being carefully examined, particularly at the inner border of the orbit, may now be divided along the eye-brow, so as to expose the corrugator supercilii; and if the lowe. border of the orbicularis be raised, it will expose the origin of the elevator of the lip, which will afford a guide to the dissection of that muscle, as well as of the common elevator of the lip and nose, down to their termination (*nasal region*). The transversalis nasi is partly concealed by the latter, but it emerges from under its inner border as it advances upon the side of the nose.

In order to expose the muscles and vessels of the lower part of the face, an incision may be made from the most prominent point of the cheek downwards to the margin of the jaw, from which the skin may be reflected backwards off the masseter muscle and parotid gland, taking care not to injure the duct of the latter, or the nerves and artery which accompany it; but the other flap of skin is to be carried obliquely inwards to the lip, in the direction of the zygomaticus. By this measure, the last-named muscle, and the levator anguli oris, and also the facial artery, will be exposed; and, by removing some adipose substance, the buccinator will be brought into view (*inter-maxillary region*). By turning aside the elevator of the lip, the second branch of the fifth nerve and the infra-orbital artery will be seen emerging from the foramen of that name.

PALPEBRAL REGION.

340. We have here four muscles, which act on the eye-lids, two being placed outside the orbit; viz. orbicularis palpebrarum

and corrugator supercilii; and two within it, viz. levator palpebræ and tensor tarsi.

341. *m. Orbicularis palpebrarum*, fig. 86, 2, (naso-palpebralis,) is situated at the base of the orbit, forming a thin flat plane of elliptic fibres, which is placed immediately under the skin of the eye-lids, resting on the eye-brow above, and spreading outwards somewhat on the temple, and downwards on the cheek. It is superficial in its entire extent, and closely adherent to the skin. The only points of fixed attachment (to bone) which its fleshy fibres possess are at the inner margin of the orbit; they are free in the rest of their extent, except along the eye-brow, where they are blended with the occipito-frontalis and corrugator supercilii. The fibres of the muscle form an ellipsis, whose great axis extends horizontally across the orbit from its inner angle to the temple, and corresponds with the fissure between the eye-lids. At the inner commissure of the eye-lids is a small tendon (*tendo palpebrarum*), which is often obscured by the fibres of the muscle, but is rendered apparent by drawing the lids outwards: this tendon is about two lines in length, and one in breadth; it is attached to the anterior margin of the lachrymal groove, from which it runs horizontally outwards to the inner commissure of the eye-lids, where it divides into two thin fibrous lamellæ, which diverge as they pass outwards in the substance of the eye-lids, and terminate in the tarsal cartilages. One surface of the tendon is subcutaneous, the other crosses the lachrymal sac a little above its centre, and from it a thin but firm fascia is given off, which spreads over the lachrymal sac, and adheres to the margins of the groove which lodges it. The muscular fibres are attached, 1st, to the upper margin and ante-surface of the tendon just described; 2nd, to the surface of the nasal process of the superior maxilla, near the anterior margin of the lachrymal groove; 3rd, to the nasal process of the frontal bone. The fibres of the orbicularis muscle thus arising arch upwards and outwards in the direction of the eye-brow and upper lid, and thence descend over the external angle of the orbit, returning to the points above stated. The external or orbital part of the muscle consists of distinct and well-marked fibres, whilst those of the tarsal or inner part are pale and thin; but all describe concentric curves, the centre of which bounds the aperture of the eye-lids. The anterior surface of the muscle

is subcutaneous in its entire extent; the posterior rests upon the lower border of the frontal muscle and the corrugator, with both of which it is intimately connected; farther down it rests upon the upper eye-lid and the tarsal cartilage. The lower segment of the muscle rests on the origin of the elevator of the upper lip, and on the zygomatic muscles; and internally, on part of the common elevator of the lip and nose, and the lachrymal sac; also externally for a little way on the temporal fascia. The fibres of the orbicularis are thin and pale where they correspond with the eye-lids; they are also less curved; but those which rest on the cheek and margin of the orbit are well developed, and describe considerable curves, the concavities of all being directed towards the fissure of the eye-lids.

342. *m. Corrugator supercilii* (fronto-superciliaris) is a small pyramidal muscle, placed in the eye-brow, whose direction it takes, being altogether concealed by the orbicularis palpebrarum and occipito-frontalis. It arises from the inner extremity of the superciliary ridge of the frontal bone, from which its fibres proceed outwards and a little upwards, and end at the middle of the orbital arch, by becoming blended with those of the orbicularis and occipito-frontalis lying between them and the bone. Its anterior surface is covered by the muscles just named; the posterior rests upon the frontal bone and crosses the frontal branch of the ophthalmic nerve and the accompanying artery as they emerge from the orbit; its inner extremity is somewhat thicker than the external one, which gradually narrows to a point.

343. *m. Levator palpebræ*, fig. 89, 1, (orbito-palpebralis,) is concealed, in the greater part of its extent, within the orbit; it arises above and before the margin of the optic foramen, from which it passes forwards and outwards, mounting over the globe of the eye, and separated from the roof of the orbit only by the frontal nerve. It is very narrow and tendinous at its origin; it soon becomes fleshy and widens; finally it ends in a broad fibrous expansion, which curves downwards in the substance of the upper eye-lid, to be inserted into the margin of the tarsal cartilage.

344. *m. Tensor tarsi* is a very thin, small muscle, placed at the inner side of the orbit, its outer surface resting against the lachrymal sac and the commissure of the eye-lids, the inner

being in contact with the conjunctiva; its fibres arise from the posterior margin of the lachrymal bone, and as they pass forwards they divide into two narrow processes, which diverge and become attached to the tarsal cartilages near the puncta lachrymalia.

Actions.—The corrugator muscle being fixed by its inner extremity, draws the eye-brow and eye-lid inwards, and throws the skin into perpendicular lines or folds, as in frowning. The occipito-frontalis will, on the contrary, elevate the brow, and wrinkle the skin transversely; which actions are so frequently repeated by most persons, and so constantly by some of a particular temperament, that the skin is marked permanently by lines in the situations just referred to. The orbicular muscle is the sphincter of the eye-lids. It closes them firmly, and at the same time draws them to the inner angle of the orbit, which is its fixed point of attachment. The levator palpebræ is the direct antagonist of the orbicular muscle; for it raises the upper eye-lid, and uncovers the globe of the eye. The tensor tarsi draws the eye-lids towards the nose, and presses the orifices of the lachrymal ducts closely to the surface of the globe of the eye. It may thus facilitate the entrance of the tears into the ducts, and promote their passage towards the nose.

NASAL REGION.

345. We here find four muscles, viz. the pyramidal muscle of the nose, the compressor, the elevator, which is common to the lip and the nose, and the depressor of the lip and nose.

346. *m. Pyramidalis nasi*, fig. 86, 3, (more properly triangularis, naso-frontalis,) rests on the nasal bone, and appears like a prolongation of the occipito-frontalis, with whose fibres it is intimately connected, as well as with those of the corresponding muscle. It extends from the root of the nose, where its fibres are continuous with the occipito-frontalis, to about half-way down, where it becomes tendinous and unites with the compressor nasi. The two pyramidal muscles diverge as they descend, leaving an angular interval between them, and each terminates in a thin fibrous lamella, which covers the side of the nose. At its outer border the fleshy fibres are connected with those of the orbicularis palpebrarum. It is covered by the common tegument, and rests upon the nasal part of the frontal bone and the os nasi.

Its chief effect seems to be that of giving a fixed point of attachment to the frontal muscle; it also wrinkles the skin at the root of the nose.

347. *m. Compressor nasi*, fig. 86, 4, (transversalis nasi,) is a thin small muscle, which lies close upon the superior maxilla and the side of the nose, the direction of its fibres being transverse from without inwards and upwards; it is concealed at its origin by the proper elevator of the lip, and is crossed by the common elevator. It *arises* narrow and fleshy from the canine fossa in the superior maxillary bone, from which its fibres proceed inwards and upwards, gradually expanding into a thin aponeurosis, which is partly blended with that of the corresponding muscle of the opposite side and that of the pyramidalis nasi of the same side, and partly attached to the fibro-cartilage of the nose.

348. *m. Levator labii superioris alæque nasi*, fig. 86, 5, (common elevator of the lip and nose,) lies along the side and wing of the nose, extending from the inner margin of the orbit to the upper lip. It *arises* by a pointed process from the upper extremity of the nasal process of the superior maxillary bone, and as it descends separates into two fasciculi; one of these, much smaller than the other, becomes attached to the wing of the nose, whilst the other is prolonged to the upper lip, where it is blended with the orbicular and elevator muscles. It is subcutaneous, except at its origin, where the orbicularis palpebrarum overlaps it a little.

349. *m. Depressor labii superioris alæque nasi* (m. myrtiformis) is a small flat muscle, extended from a slight pit (myrtiform fossa) near the alveolar border of the upper jaw to the lateral cartilage of the nose; it lies between the mucous membrane and the muscular structure of the lip, with which its fibres are closely connected; this double connexion enables it to depress the lip as well as the nasal cartilage.

SUPERIOR MAXILLARY REGION.

Here are four muscles, viz. the elevator of the upper lip, the elevator of the angle of the mouth, and the two zygomatici.

350. *m. Levator labii superioris*, fig. 86, 6, (the proper elevator of the upper lip,) extends from the lower border of the

orbit to the upper lip, lying close to the outer border of the common elevator, with which it is blended inferiorly. It *arises* immediately above the infra-orbital foramen, where its fibres are attached, partly to the superior maxillary bone, partly to the malar. Its direction is downwards and a little inwards, ceasing at the upper lip, where it unites with the rest of the muscular apparatus of that part. At its origin, this muscle is overlapped by the orbicularis palpebrarum, but its lower part is subcutaneous; it partly conceals the levator anguli oris, and the compressor nasi.

351. *m. Levator anguli oris*, fig. 86, 7, (musculus caninus; the elevator of the angle of the mouth,) lies beneath the preceding, and partly concealed by it. It *arises* immediately below the infra-orbital foramen, from the canine fossa, whence the name *caninus*, and is inserted into the angle of the mouth. It is broader above than below, and inclines outwards somewhat as it descends; it lies at the middle of the face, deeply behind the outer border of the elevator of the upper lip. Its anterior surface supports the infra-orbital nerve and artery, which separate it from the preceding muscle; the posterior lies on the superior maxilla and on the orbicularis and buccinator muscles with which its fibres become united.

352. *m. Zygomatici* are two narrow fasciculi of muscular fibres, extended obliquely from the most prominent point of the cheek to the angle of the mouth, one being larger and longer than the other. The *zygomaticus minor*, fig. 86, 8, (when it exists, which is not always the case,) *arises* from the anterior and inferior part of the malar bone, and inclines downwards and forwards to terminate at the angle of the mouth. It lies along the superior and inner border of the succeeding muscle. The *zygomaticus major*, 9, arises from the malar bone near the zygomatic suture, from which it descends, lying inferior and external to the smaller muscle of the same name, to be inserted into the angle of the mouth. These muscles, at their origin, are concealed a little by the orbicularis palpebrarum, but become subcutaneous in the rest of their extent. The larger one crosses, just below its origin, a part of the masseter and buccinator muscles, and at its insertion its fibres are intimately blended with the triangularis oris, and the other muscles of the lip.

INFERIOR MAXILLARY REGION.

This space contains three muscles, viz. the depressor of the angle of the mouth, the depressor of the lower lip, and the elevator of the lower lip.

353. *m. Triangularis oris*, fig. 86, 10, (depressor anguli oris:—maxillo-labialis,) lies at the side and lower part of the face, being extended to the angle of the mouth from the lower jaw. It arises from the external surface of the inferior maxillary bone, particularly from the oblique line which is marked upon it. Its name expresses its form: the base of the triangle which it represents corresponds with its origin, and its apex with its insertion into the angle of the mouth. Its fibres pass upwards, gradually contracting so as to form a narrow process, which is inserted into the angle of the mouth, by becoming blended with the orbicular and great zygomatic muscles, and also with the termination of the levator anguli oris. It is covered by the skin, and, at its insertion, by the zygomaticus major, under which its fibres pass; it conceals part of the buccinator and of the depressor of the lower lip.

354. *m. Depressor labii inferioris*, fig. 86, 11, (quadratus menti; mento-labialis,) is a small square muscle, lying nearer to the symphysis of the chin than the preceding muscle, by which it is partly concealed. It *arises* from the fore part of the inferior maxillary bone, and thence ascends to be inserted into the lower lip, its fibres becoming blended with those of the orbicularis oris, and also having previously united with those of its fellow of the opposite side. It presents rather a peculiar appearance when dissected, owing to a quantity of yellow adipose matter being deposited in the interstices of its fibres.

355. *m. Levator labii inferioris*, fig. 86, 12, arises from a slight pit a little below the alveolar border of the lower jaw, near the symphysis. This pair of muscles occupies the interval between the two depressors of the lower lip. They are small, short, and somewhat tapering, being narrow at their point of origin, from which they increase in breadth towards their insertion. They incline downwards and a little forwards to reach the tegument of the chin, into which they are inserted.

Actions.—The names of most of the muscles included in the three foregoing groups sufficiently indicate their actions upon the lips,

the nose, and the mouth. It will be found in conducting their dissection that they are intimately connected with the skin which covers them. Hence they are enabled to give to the face all those changes of state which are necessary for the expression of passion and feeling.

INTER-MAXILLARY REGION.

At each side of the face, in the part called the "cheek," is a muscle—the buccinator, and round the margin of the mouth, one—the orbicularis oris.

356. *m. Buccinator*, fig. 86, 13, (alveolo-labialis,) is a thin flat plane of muscular fibres, occupying the interval between the jaws; it is of a quadrilateral figure, all its sides being attached. Thus, its upper and lower borders are attached to the alveolar margins of the maxillary bones, from the first molar tooth in each, as far back as the last; the anterior border is blended at the commissure of the lips with the orbicular muscle; whilst the posterior is fixed to a narrow fasciculus of tendinous fibres, extended from the internal pterygoid plate to the posterior extremity of the mylo-hyoid ridge of the lower jaw, close to the last dens molaris. This tendinous band, from its attachments, has been called the *pterygo-maxillary ligament*, fig. 93, 2; one of its surfaces looks towards the mouth, and is lined by the mucous membrane; the other is separated from the ramus of the jaw by a quantity of adipose substance; the anterior border gives attachment, as has been here stated, to the buccinator muscle, and the posterior, to the superior constrictor of the pharynx. It is this connexion between the muscles just named which establishes a complete continuity of surface between the cavity of the mouth and that of the pharynx. The internal surface of the buccinator is lined throughout by the mucous membrane of the mouth; the external is overlapped by the triangularis oris, the terminal fibres of the platysma myoides, and by the labial artery and vein; also by the masseter and zygomatici, from which it is separated by a quantity of soft adipose tissue, of a peculiar character. Opposite the second dens molaris of the upper jaw, its fibres give passage to the duct of the parotid gland.

357. *m. Orbicularis oris*, fig. 86, 14; fig. 93, 3, (m. labialis,) belongs to the class of sphincter muscles, and like them is

elliptic in its form, and composed of concentric fibres so placed as to surround the aperture of the mouth. It is flat and thin; its inner surface being in contact with the mucous membrane, the external with the skin and the fibres of the different muscles which converge towards the margin of the mouth. The longer axis of the ellipse is transverse, so as to correspond with the fissure between the lips; the curves described by the fibres of the upper segment look downwards, and those of the lower one upwards; hence they are often found to decussate at the angles of the mouth. One border of each segment is free, and corresponds with the red part of the lip; the other is blended with the several muscles which converge to the mouth from different parts of the face.

Actions.—The aperture of the mouth is susceptible of considerable dilatation and contraction, the former being effected by the different muscles which converge to it, and which may be compared to retractors drawing with different degrees of obliquity the lips, or their angles, in the direction of their respective points of attachment. The elevators are necessarily placed at the upper part of the face, the depressors in the opposite situation, and the proper retractors on each side, and these are the zygomatici and the buccinators. The buccinators also contract and compress the cheeks; this power is brought into play when any substance becomes lodged in the interval between them and the jaws. The fibres of the muscles are then elongated and pressed outwards; but when they begin to act, they form a flat plane, which is pressed inwards, and so forces the substance back into the cavity of the mouth. It is obvious that the orbicular muscle must be the direct antagonist of all those that converge to it. When describing the muscles, we may commence at the lips as a common point of departure, and trace their fibres from thence as they diverge, radiating to their respective attachments.

TEMPORO-MAXILLARY REGION.

358. This space, extending from the side of the head to the angle of the jaw, contains the temporal and masseter muscles.

Dissection.—To expose the masseter muscle, and with it the duct and the surface of the parotid gland, it will suffice to reflect back the skin from the lines of incision indicated in the previous dissections. In doing this, a large branch of the facial nerve will be found accom-

panying the parotid duct. This will serve as a clue to the trunk of that nerve, by following it back through the substance of the parotid gland; and when the trunk is found, there can be no difficulty in pursuing all its branches, as they diverge from that point in three different directions over the face and side of the head. The superficial temporal vessels are at the same time brought into view. Cut the duct across, raise it and the accompanying piece of the parotid gland together, and draw it out towards the ear. This will expose the anterior margin of the gland and its relations to the ramus of the jaw. A little more dissection is required to get a view of its posterior border, and of its relations to the parts deeply seated between the jaw and the ear.

The next thing to be done is to get at the insertion of the temporal muscle, and at the same time bring into view the pterygo-maxillary region: proceed as follows:—

The masseter muscle and parotid gland having been examined, the parts concealed inside the ramus of the jaw may be brought into view in the following way:—With a sharp chisel and mallet the zygoma may be divided at both extremities, and the attachment of the temporal fascia to its upper border severed. The bony arch, with the masseter still connected with it, may be drawn down to the angle of the jaw, the fibres of the latter being at the same time detached from the ramus. In the next place, with Hey's saw, the ramus of the jaw may be divided by a perpendicular cut, carried from just before its condyle to a level with the alveolar border, and there met by another line carried forwards to the latter, so as to insulate and detach all that part of it which belongs to the coronoid process. This being done, the piece of bone, with the temporal muscle attached, may be drawn upwards, so as fully to expose the two pterygoid muscles (*pterygo-maxillary region*), the internal maxillary artery, the gustatory and dental nerves, and the pterygo-maxillary ligament, which gives attachment to the buccinator and superior constrictor muscles.

359. *m. Masseter*, fig. 86, 15, (zygomato-maxillaris,) is extended from the malar bone and the zygoma to the angle of the lower jaw. Its form is that of an oblong square; its direction downwards and a little backwards. It is a thick, compressed mass of fleshy and tendinous fibres, arranged so as to form two bundles, differing in size and direction. The *external*, or larger portion of the muscle, arises from the lower border of the malar bone, and somewhat from the malar tuberosity of the superior

maxilla, from which its fibres proceed downwards, and a little backwards, to be inserted into the lower half of the ramus of the jaw, extending as far as its angle. The *internal*, or smaller part, consists of fibres, whose direction is for the most part vertical, some inclining a little forwards. It arises by fleshy and tendinous fibres from the lower border of the zygomatic process of the temporal bone (extending as far back as its tubercle), and is inserted into the upper half of the ramus of the jaw. This part of the muscle is concealed, in the greater part of its extent, by the larger portion, with which its fibres become united at their insertion; part, however, projects behind it, and is covered by the parotid gland. The external surface of the masseter muscle is covered in the greater part of its extent only by the skin and fascia; it is, however, overlapped above by the zygomaticus, below by the platysma, and behind by the parotid gland, whose duct also crosses it; the branches of the facial nerve and the transversalis faciei artery also rest upon it. Its inner surface overlays the buccinator, from which it is separated by some soft adipose tissue; also the tendinous insertion of the temporal muscle into the coronoid process; and is in intimate contact with the ramus of the jaw.

360. *m. Temporalis* (temporo-maxillaris) is placed at the side of the head, occupying the whole extent of the temporal fossa; it is of considerable size, being broad, thin, and expanded above, where it is attached to the side of the skull, but it becomes thick, compressed, and narrowed to a point below, at its insertion. The fibres of the muscle present a radiating appearance; they are concealed from view by the temporal fascia, which must be removed before they can be seen. It *arises* from the whole of the temporal fossa, its fibres being implanted into all that depressed surface which extends from the external angular process of the frontal bone backwards to the root of the mastoid process, and from the curved line marked upon the parietal and frontal bones downwards to the ridge on the sphenoid bone which separates the temporal fossa from the zygomatic. The fibres from this extensive origin converge as they descend, some being directed from before backwards, a considerable number obliquely forwards, whilst those in the middle descend almost vertically; but all terminate in a tendon whose fibres, at first radiating like those of the muscle itself, gradually become aggre-

gated, so as to form a thick flat fasciculus, which is implanted into both surfaces as well as the anterior border of the coronoid process of the lower jaw-bone. The upper part of this tendon is in a great degree concealed by the muscular fibres, many of which descend to be implanted into its external surface, whilst the deep-seated fibres come forward from the lower part of the fossa to be attached to its inner surface; the lower part, or insertion of the tendon, is altogether concealed by the zygoma and the masseter. The muscle is covered and bound down by a remarkably dense firm membrane (*temporal fascia*), which is attached inferiorly to the upper margin of the zygoma, where it is separated from the muscle by some loose adipose and cellular tissue; but higher up, the fascia expands, and becomes closely connected with the muscular fibres, and is attached along the curved line bounding the temporal fossa, where it gives origin to many of the superficial fibres of the muscle. The external surface of the fascia is overlaid above by the aponeurosis of the occipito-frontalis muscle, before by the orbicularis palpebrarum; moreover, two muscles of the ear—the attollens and attrahens, rest upon it, and the temporal artery and vein, with the ascending branches of the facial nerve, cross it as they pass up towards the arch of the skull.

PTERYGO-MAXILLARY REGION.

361. *m. Pterygoideus internus*, fig. 87, 2, and 88, 2, (pterygo-maxillaris major,) is applied closely to the inner surface of the ramus of the jaw, somewhat as the masseter is to its outside. It is flat and elongated; its form, like that of the masseter, being an oblong square. It *arises* from the pterygoid groove, or fossa, its fibres, tendinous and fleshy, being attached to the inner surface of the external pterygoid plate of the sphenoid bone, and to the grooved surface in the tuberosity of the palate bone which is inserted between the pterygoid plates. From these

Fig. 87.

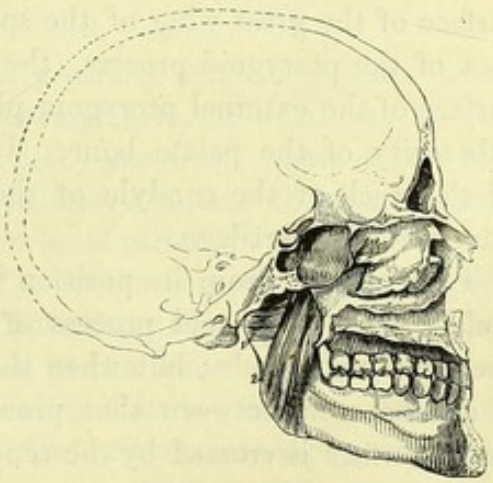

KING'S COLLEGE HOSPITAL LIBRARY Medical School

points of attachment the muscle inclines downwards, backwards, and outwards, to be inserted into the inner surface of the ramus of the jaw, for about an inch above its angle. The external surface of the muscle rests against the bone, from which it is separated by the internal lateral ligament, and by the dental artery and nerve. Its inner surface, whilst placed in the pterygoid groove, is in contact with the tensor palati muscle, and lower down with the superior constrictor of the pharynx.

Fig. 88.

362. *m. Pterygoideus externus*, figs. 88, 87, 1, (pterygomaxillaris minor,) is placed deeply in the zygomatic fossa, extending horizontally backwards and outwards from the process of that name to the condyle of the lower jaw. Its form is somewhat triangular, its base corresponding with its origin, and the apex with its insertion. The two extremities are tendinous, the rest of the muscle being a short, thick, fleshy, mass, the upper fibres of which descend a little and the lower ascend as they pass between their points of attachment, whilst those in the middle are horizontal. At its base or origin it appears to consist of two fasciculi, separated by a cellular interval; the upper fasciculus is attached to that part of the external surface of the great wing of the sphenoid bone which is near the root of the pterygoid process, the other is attached to the outer surface of the external pterygoid plate, and to a small part of the tuberosity of the palate bone. It is inserted into the fore part of the neck of the condyle of the lower jaw, and also into its inter-articular cartilage.

This muscle, from its position in the zygomatic fossa, is concealed by the coronoid process of the jaw, and the insertion of the temporal muscle; but when the masseter is removed, part of it can be seen between that process and the condyle. Its external surface is crossed by the tendon of the temporal muscle as it passes to the coronoid process, and is further covered by the masseter; the inner surface rests against the upper part of the internal pterygoid muscle, whose direction it crosses, also the internal lateral ligament of the lower jaw, and the inferior maxil-

lary nerve: the lower border is free and unattached, the upper is in contact with the great wing of the sphenoid bone, where it forms part of the zygomatic fossa. As the pterygoid muscles diverge to their destinations, they leave between them an angular interval, which transmits the gustatory and dental nerves, and the internal maxillary artery.

Actions.—The lower jaw is elevated by the temporal, masseter, and internal pterygoid muscles, which conspire to this end. If the two first act together, the elevation is direct; but if the two last act, the obliquity of their direction enables them to carry the angle of the jaw a little forwards. The triturating movement is performed exclusively by the external pterygoid muscles. If both act together, they draw the condyles, and therefore the whole jaw, directly forwards, so as to make the lower teeth project beyond the upper; but when only one acts at a given time, it draws the corresponding condyle forwards, the other remaining fixed, and so makes the symphysis of the jaw deviate to the opposite side. A similar movement can be given by the corresponding muscle, and the alternation of these horizontal motions constitutes trituration.

AURICULAR REGION.

363. In the space round the external ear are placed three small muscles, which in the human subject may be considered rudimentary, as they are not required to perform any action. They are attached by small tendons to the fibro-cartilage of the ear, and are quite superficial.

Dissection.—These muscles are generally removed together with the skin, when their dissection is attempted in the usual way by the beginner, who seeks to expose the fleshy part first: better at once reverse the process — seek for the tendons, and take them as guides. For this purpose, draw the pinna or broad part of the ear downwards; a very small tense cord will be felt under the skin, where it is reflected from the head to the ear, running from above downwards to the upper bulging part of the concha. This is the tendon of the attollens. Cautiously divide the skin by an incision drawn over the tendon from below upwards; reflect it to each side, and continue the process thus upwards from the tendon to its muscular fibres, which spread upon the temporal fascia. Proceed in the same way to expose the two other muscles—draw the pinna forwards, and the tendon of the retrahens will be readily perceived where it is inserted into the bulging

part of the concha behind. Let a hook be inserted into the extremity of the helix at the point corresponding with the line of the zygoma. When the helix is drawn backwards, the tendon of the attrahens muscle is rendered tense, and can be exposed and dissected as in the previous instances.

364. *m. Superior auris*, fig. 86, 16, (attollens aurem, temporo-auricularis,) is the largest. It arises from the temporal fascia, where it expands on the side of the head; its fibres, though delicate, being broad and radiated. The muscle ends in a compressed tendon, which is inserted into the upper and anterior part of the cartilage of the ear.

365. *m. Posterior auris*, 17, (retrahens aurem, mastoido-auricularis,) consists of two or three thin fasciculi, ranged one over the other; they arise from the mastoid process by short aponeurotic fibres, and are inserted into the back part of the concha.

366. *m. Anterior auris*, 18, (attrahens aurem, zygomato-auricularis,) is a narrow, fleshy, and tendinous fasciculus, which is attached to the temporal fascia above the zygoma, and passes backwards, to be inserted into the fore part of the helix.

ORBITAL REGION.

367. This consists of the orbit which lodges the eye, and its appendages. The muscles which it encloses are eight, viz. levator palpebræ, four recti, two obliqui, and tensor tarsi.

Dissection.—It is here taken for granted that the arch of the skull has been previously removed in order to dissect the brain. Now to gain a clear view of the contents of the orbit, it is necessary to remove the greater part of its roof, and the whole of its outer wall. With this intent the malar bone may be sawed through on a level with the floor of the orbit, and as far back as the spheno-maxillary fissure. The orbital plate of the frontal should in the next place be cut through with a chisel along its inner third, and back to the anterior clinoid process: this incision should be continued along the floor of the middle fossa of the skull, close to the outside of the foramen rotundum and ovale, and thence back to the pars petrosa, so as to cut through the great wing of the sphenoid bone and the squamous part of the temporal bone. When this has been done, the whole may be pressed down and detached, by cutting along the base of the skull, from within outwards, the knife being inserted into the fissure thus made. These measures

should first be considered, and marked out on the dried skull. A complete lateral view is thus obtained of the divisions of the fifth nerve, of all those in the cavernous sinus, as well as of the parts in the orbit.

Puncture the optic nerve with a coarse needle near the globe of the eye, and push it on into the latter, so as to make a free passage into it, through which you may convey a curved blow-pipe, and with a little air distend the globe; ligature the extremity of the nerve to prevent the air from escaping. Draw the eye-lids forward, fill them with a little cotton, and apply a few points of suture along their margins. The eye-lids and the globe can now be drawn gently forward, which will put all the muscles on the stretch; and their dissection merely consists in taking out cautiously the fat which fills the orbit.

368. The four recti muscles at their origin surround the optic nerve, and at their insertion correspond with the opposite points of the globe of the eye; each of them has a double name, one being founded on its situation, the other on its action.

369. *m. Rectus superior*, fig. 89, 2, (attollens,) arises close by the foramen opticum, and beneath the levator palpebræ, 1: it passes over the globe, and is inserted tendinous into the sclerotica, about two lines behind the cornea.

Fig. 89.

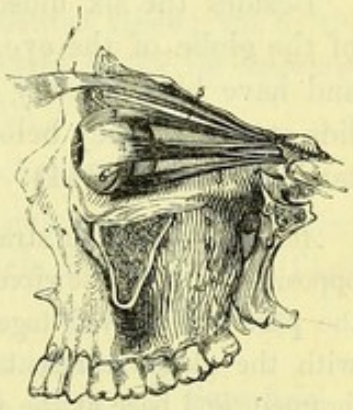

370. *m. Rectus inferior*, 3, (depressor,) *m. rectus internus* (adductor), and *rectus externus*, 4, (abductor,) all arise by a common tendon, which is attached to the bony lamella that separates the foramen opticum from the sphenoidal fissure; but the external rectus has another attachment besides that of the common tendon. Its second head arises from the margin of the sphenoidal fissure, near the superior rectus. Between these heads is a narrow interval, which gives transmission to the third and sixth nerves and the nasal branch of the fifth. The four recti, thus attached posteriorly, pass forwards diverging, and are inserted into the sclerotica, about the same distance from the cornea as the superior rectus.

371. *m. Obliquus superior*, 5, (trochlearis,) arises about a line from the optic foramen at its upper and inner part. From

thence it proceeds towards the internal angular process, and terminates in a round tendon, which passes through a fibro-cartilaginous ring, or pulley, that is attached to the inner margin of the orbit. To facilitate movement, a delicate synovial sheath lines the contiguous surfaces of the pulley and the tendon. At this point the tendon is reflected outwards and backwards, passing between the globe and the superior rectus, to be inserted into the sclerotica, midway between the superior and external recti muscles, and nearly equi-distant from the cornea and the entrance of the optic nerve.

372. *m. Obliquus inferior*, 6, arises from a minute depression in the orbital plate of the superior maxillary bone just within the inferior margin of the orbit, and close by the external border of the lachrymal groove. The muscle inclines outwards and backwards between the inferior rectus and the floor of the orbit, and ends in a tendinous expansion, which passes between the external rectus and the globe to be inserted into the sclerotica, at its external and posterior aspect.

Besides the six muscles here described as the special motors of the globe of the eye, two others are found within the orbit, and have been already described with the muscles of the eyelids, to which they belong, viz. the levator palpebræ and tensor tarsi (sect. 343, 344).

Actions.—The four straight muscles are attached in such a way at opposite points of the circumference of the globe of the eye, that, when the parts are viewed together in their natural position, the muscles with the globe represent a pyramid, whose summit is at the optic foramen, and base at the points of insertion. Now, as these points are anterior to the transverse diameter of the globe, and as each muscle, to reach its insertion, curves over the convexity of the eye, it will be obvious that, when in action, their effect must be to turn or rotate the globe, so that the cornea will be directed by them either upwards or downwards, outwards or inwards, as their names severally express. This will be better seen if a needle be inserted into the middle of the cornea, and each muscle be pulled by holding it with a pair of forceps near its origin. If any two recti act together, the cornea will be turned to a point intermediate between those to which they direct it separately. Thus the superior and external recti acting together turn the cornea upwards and outwards, the inferior and internal recti downwards and inwards. By this succession, combination, and alternation

of action, the recti are enabled to direct the eye with the minutest precision to every point in the field of view. Sir E. Home attributes to them also the power of compressing the globe so as to lengthen its antero-posterior diameter, thereby becoming the principal means of its adjustment to seeing at different distances.

What is the action of the obliqui? They were at one time supposed to serve as antagonists to the recti, and to draw forward the globe of the eye, after it had been retracted into the orbit by the latter muscles. This cannot be the case; for they exist in animals in which the globe cannot be retracted, and they receive no increase of developement in those which possess a large retractor muscle in addition to the recti. The obliqui perform all the involuntary and revolving movements; the recti all those which are governed by the will. When volition is suspended in sleep, or during coma, the cornea is observed to be turned upwards under the upper eye-lid; and when the lid descends, as in winking, the globes revolve upwards at the same time, and for a special purpose. When the eye-lid descends like a curtain over the globe, it brings down any extraneous matters which may have lodged upon it. These would necessarily be collected into a line across the centre of the cornea and obstruct vision; but by the revolving motion, the cornea is carried upwards as the lid descends, and all extraneous matters are brushed away.

Muscles of the Neck.

373. The muscles of the neck are numerous, and at first sight appear to be rather complex in their distribution. They may be grouped into sets as follows:—

1. The muscles placed along the side of the neck being, at least comparatively, superficial, viz. the platysma myoides, and sterno-mastoideus .	Superficial region.
2. Those placed obliquely at the upper part of the neck, viz. digastricus, stylo-hyoideus, stylo-glossus, stylo-pharyngeus	Sub-maxillary region.
3. Muscles placed towards the fore part, and above the os hyoides, viz. mylo-hyoideus, genio-hyoideus, hyo-glossus, genio-hyo-glossus, and lingualis	Genio-hyoid region.
4. The muscles placed in front, lying beneath the os hyoides, viz. sterno-hyoideus, sterno-thyroideus, thyro-hyoideus, crico-thyroideus, and omo-hyoideus	Sterno-hyoid region.

5. Those placed deeply at the side and front of the vertebral column, viz. scaleni, rectus lateralis, rectus anticus, major and minor, and longus colli . . . . . } Anterior vertebral region.

All these are in pairs at each side.

Dissection of the Neck. — The head being allowed to hang over a block placed behind the neck, and the side of the latter being turned forward, we may proceed to examine it as a surgical region. In this view it presents itself to our notice as a quadrilateral space, bounded below by the clavicle, above by the margin of the jaw, and a line continued back from it to the mastoid process; before, by the median line, extended from the chin to the sternum, and behind, by another from the mastoid process to near the external end of the clavicle.

The *dissection may be commenced* by making two incisions through the skin, corresponding with the two last-mentioned lines. Now, the whole space is divided into two triangles by the sterno-mastoid muscle, which runs diagonally through its area, each of which requires a particular examination; for in the upper triangle, whose base corresponds with the margin of the jaw, and whose apex lies at the sternum, is lodged the carotid artery; and in the external and inferior space, the base of which corresponds with the clavicle, the subclavian artery is placed in the situation in which it may be compressed or tied. When *proceeding with the dissection*, an incision may be made through the skin in the course of the sterno-mastoid, so that the angular flaps thus marked out may be raised and reflected, one upwards over the face, the other down on the chest. This will expose the platysma in its entire extent; the direction of its fibres should be carefully considered in reference to the operation of opening the jugular vein. If the point of the lancet be directed upwards and forwards in the course of its fibres, it will merely make a fissure between them, and when withdrawn they will contract and close over the wound in the vein; so that the operation is rendered ineffectual, and probably an ecchymosis will be produced. But if it be directed upwards and outwards, the fibres will be cut across and retract, so as to expose the vein and the aperture made in it.

The platysma should be reflected from below upwards over the face, beginning at the clavicle, by which means, particularly if the trapezius be turned back, the cervical fascia will be fully exposed. When the platysma is dissected off the sterno-mastoid, we see lying on it the ascending nerves of the cervical plexus, and passing downwards the descending set. In the area of the superior triangular

space will be found the submaxillary gland and digastric muscle; and lower down the sheath of the vessels, enclosing the carotid artery, jugular vein, and vagus nerve. On the sheath the descendens noni lies, and behind it the sympathetic nerve.

The inferior triangular space will be found divided into two parts by the omo-hyoideus passing across it; the upper division containing the cervical plexus, the lower the axillary plexus and the subclavian artery. The upper belly of this muscle also divides the superior space by passing across the sheath of the vessels; all that part of the carotid below it being deeply seated and covered by muscles, whilst the rest is comparatively superficial. When these parts have been examined, the jaw may be sawed through, both at the symphysis of the chin and at the margin of the masseter muscle, the mylo-hyoideus having been previously detached from its connexion with the os hyoides. These being removed, the side of the tongue, the gustatory nerve, the sublingual gland, and the hypo-glossal nerve, are brought into view, together with the muscles.

When describing the fascia, mention has been made of the fact, that processes pass inwards, investing the muscles in front of the larynx; similar lamellæ are also extended to the cervical glands. Now, enlargements of the latter often simulate the characters of aneurismal tumours of the contiguous artery, so that their diagnosis is difficult. The facts, however, just alluded to, will go some way to clear up the difficulty; for if the patient be desired to make an effort as if to swallow, the larynx will ascend, and with it the fascia, by reason of their connexion, and the latter will at the same time draw up the tumour, if it be merely glandular; when the effort ceases, these parts will again subside. The fascia is described sect. 469, 470.

SUPERFICIAL CERVICAL REGION.

Two muscles are extended beneath the skin, along the side of the neck:—

374. *m. Platysma myoides*, fig. 86, 19, (cutaneus,—peaucier,) is a flat thin plane of muscular fibres, forming a fleshy membrane, placed immediately beneath the skin of the neck. Its fibres, which are pale and thin in their entire extent, commence in the cellular tissue, covering the upper part of the deltoid and pectoral muscles, and thence proceed upwards and inwards over the clavicle, and upon the side of the neck, gradually converging to the muscle of the opposite side. They pass over the margin of the inferior maxillary bone; some of them adhere to its ex-

ternal oblique line, becoming blended with the triangularis oris, others incline inwards and mingle with those of the opposite platysma in front of the symphysis of the jaw, whilst others farther back are prolonged upon the side of the cheek as far as the angle of the mouth, where they become blended with the muscles in that situation. This part of the muscle, from its effect on the mouth, was formerly called *risorius Santorini.* In some subjects, a few fibres may be traced higher up on the face to the zygomatici muscles, or even to the margin of the orbicularis palpebrarum. The platysma is covered by the skin, to which it is connected by cellular tissue, usually called the superficial fascia of the neck. It covers slightly the pectoralis major, its upper or clavicular portion, as well as the clavicular part of the deltoid, also the clavicle; higher up it lies upon the sterno-mastoid muscle, external jugular vein, the sheath of the great cervical vessels, the submaxillary gland, labial artery, the body of the jaw-bone and side of the cheek.

Fig. 90.

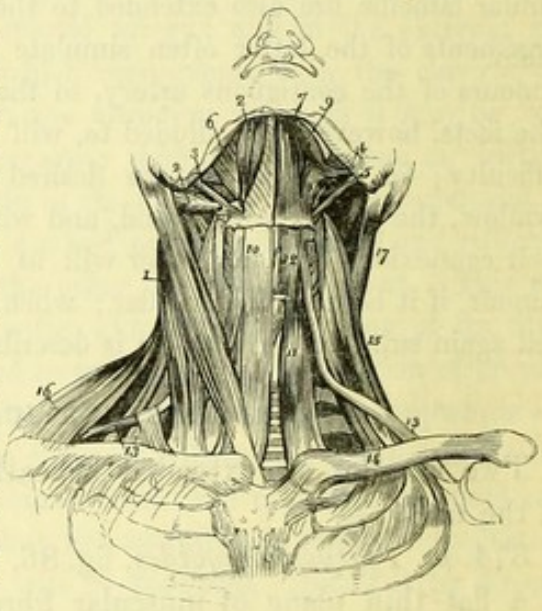

375. *m. Sterno-cleido-mastoideus*, fig. 90, 1, is extended, as it were, diagonally across the side of the neck, from the top of the sternum to the mastoid process behind the ear: it is thick and rounded at the middle, so as to be at all times prominent, particularly when in action, but becomes broader and thinner at its extremities. It *arises* from the top of the sternum and inner third of the clavicle, the attachment to the former being by a thick, rounded fasciculus, composed of tendinous fibres at its cutaneous aspect, the rest being fleshy. The clavicular portion is flat, and in form somewhat triangular; it is composed of fleshy and aponeurotic fibres, which pass perpendicularly upwards, whilst the sternal part inclines backwards as it ascends, so that both become inseparably blended, below the middle of the neck, into a thick rounded

muscle, which is finally inserted into the anterior border and external surface of the mastoid process, and for some way into the rough ridge behind it, by aponeurotic fibres. The external surface of the muscle is covered by the platysma in the middle three-fifths of its extent, its upper and lower portions being left uncovered, so that its sternal origin and its insertion are covered only by the fascia and skin; part of the parotid gland overlaps it superiorly. In the middle it is crossed by the external jugular vein, and by the ascending superficial branches of the cervical plexus. It rests on part of the sterno-hyoid and sterno-thyroid muscles, crosses the omo-hyoid muscle, covers the cervical plexus of nerves and great cervical vessels in the lower part of the neck, and in the upper part the digastricus and stylo-hyoideus muscles, and spinal accessory nerve, which pierces it. The two sterno-cleido-mastoidei are placed closely together at their sternal attachment, whilst their insertions are separated by the whole breadth of the basis of the skull.

Actions.—The lower part of the platysma can exert no action of much importance in the human subject; it may be considered as a rudiment of that broad fleshy lamella which is placed beneath the skin in the lower animals. The upper part of the muscle may assist in depressing the angle of the mouth; and when its action is general the skin of the neck becomes slightly creased or wrinkled. When the two sterno-mastoid muscles act together, they bow the head forwards; but if one acts by itself, it is enabled by the obliquity of its direction to turn the head, and therefore the chin, to the opposite side. It has been said that this muscle can draw the head down to its own side, approximating the ear to the shoulder. But to effect this, its action must be combined with that of some other muscle, as the splenius; for then, as the latter arises from the spinous processes, whilst the former comes from the sternum, both converging to the mastoid process, the head may, by their combined effort, be drawn down to the point intermediate between their attachments, namely, to the shoulder.

SUB-MAXILLARY REGION.

376. *m.* ***Digastricus***, fig. 90, 2, 2, (biventer maxillæ, mastoido-mentalis,) is placed in a curved direction across the upper part of the neck, a little below the margin of the jaw-bone. As its name implies, it consists of two fleshy bellies, united by a

rounded middle tendon, each of which parts has a separate attachment. The posterior belly, which is longer than the anterior, arises from the digastric groove in the temporal bone behind the mastoid process: the anterior is inserted into a slight depression at the inside of the lower border of the jaw-bone, close to its symphysis, whilst the tendon is connected with the side of the os hyoides by a dense fascia, and by the fleshy fibres of the stylo-hyoideus muscle, 3, through which the tendon passes. The posterior, or sub-mastoid portion, descends inwards and forwards, gradually tapering until it ends in the tendon; the anterior, or sub-mental portion, arising from the tendon, passes upwards and forwards, gradually widening towards its insertion, where it is in contact with the digastricus of the opposite side. Now, as the side of the os hyoides is beneath both points of attachment, and nearly in the middle between them, the fleshy bellies, where they end in the tendon, must form an angle with one another, which, if stretched, the whole muscle will describe a curve. The anterior belly lies immediately under the skin, and rests on the mylo-hyoideus muscle, being in close contact with its fellow of the opposite side; the posterior is covered by the sterno-mastoid, and crosses both carotid arteries and the jugular vein. Its upper margin bounds the sub-maxillary gland.

377. *m. Stylo-hyoideus*, figs. 90, 3; 91, 1, lies close to the posterior belly of the preceding muscle, being a little behind and beneath it. It *arises* from the middle of the external surface of the styloid process of the temporal bone, from which it inclines downwards and forwards, to be inserted into the os hyoides at the union of its great cornu with the body. Its fibres are divided into two fasciculi near its insertion, for the transmission of the tendon of the digastricus. Its upper part lies deeply, being covered by the sterno-mastoid and digastricus muscles, and by part of the parotid gland: the middle crosses the carotid arteries; the insertion is comparatively superficial.

378. *m. Stylo-glossus*, figs. 90, 4; 91, 2, lies higher up, and is also shorter than any of the three muscles which arise from the styloid process. Its direction is forwards and a little downwards, so that it becomes nearly horizontal. It *arises* from the styloid process near its point, and from the stylo-maxillary ligament, to which the greater number of its fibres are attached

by a thin aponeurosis, and is inserted along the side of the tongue, its fibres expanding somewhat as they become blended with its substance; they overlay those of the hyo-glossus muscle.

379. *m. Stylo-pharyngeus*, figs. 90, 5; 91, 3, is larger and longer than the other styloid muscles, and also more deeply seated; it extends from the styloid process downwards, along the side of the pharynx. It *arises* from the inner surface of the styloid process, near its root, from which it proceeds, downwards and inwards, to the side of the pharynx, where it passes under cover of the middle constrictor muscle, with which its fibres contract some connexion, but are finally prolonged to the posterior border of the thyroid cartilage, into which they are inserted. The external surface of the muscle is, in the upper part of its extent, in contact with the styloid process and stylo-hyoideus muscle and external carotid artery; in the lower, with the middle constrictor of the pharynx; the internal rests on the internal carotid artery and jugular vein; but, in the lower part of its extent, it is in contact with the mucous membrane of the pharynx.

Actions.—The stylo-hyoidei and stylo-pharyngei conspire in elevating the base of the tongue and the bag of the pharynx at the moment when deglutition is taking place, the latter pair of muscles tending at the same time to widen the pharynx. The peculiar mechanism of the digastric muscles enables them to contribute to the elevation of the os hyoides also; for when the two fleshy parts contract together, they come nearly into a straight line, and thereby draw up the bone just named, by means of the connexion of the middle tendon of the muscle with its cornu. As a preparatory measure, the mouth must be closed, and the lower jaw fixed, which is one of the first steps in the process of deglutition. If the os hyoides be kept down by the sterno-hyoideus, the anterior belly of the digastricus will serve to depress the lower jaw. The stylo-glossi muscles retract the tongue; they also act on its margins, and elevate them; if the génio-hyo-glossi, fig. 91, 7, come into action at the same time, and draw down its raphé, or middle line, its upper surface will be converted into a groove, fitted to convey from before backwards to the fauces any substance required to be swallowed.

GENIO-HYOID REGION.

380. *m. Mylo-hyoideus*, fig. 90, 6, is a flat, triangular muscle, placed immediately behind the anterior belly of the digastricus, and extended from the inside of the maxilla inferior to the os hyoides; its base, or broader part, being above, the apex being below. It *arises* from the mylo-hyoid ridge, along the inner surface of the lower jaw. The posterior fibres incline obliquely forwards as they descend to be inserted into the body of the os hyoides; the rest proceed, with different degrees of obliquity, to join at an angle with those of the corresponding muscle, forming, with them, a sort of raphé along the middle line, from the symphysis of the jaw to the os hyoides. The external surface of the mylo-hyoideus (which in the erect position of the head is inferior) is covered by the digastricus and sub-maxillary gland; the internal, which looks upwards and inwards to the mouth, conceals the genio-hyoideus and part of the hyo-glossus and stylo-glossus, and also the gustatory nerve; its posterior border alone is free and unattached, and behind it the duct of the sub-maxillary gland turns in its passage to the mouth.

The two muscles of this name, by their junction in front, and by the inclination of the plane which they form, support the mucous membrane of the mouth and the tongue, constituting a muscular floor for that cavity.

381. *m. Genio-hyoideus*, fig. 90, 7; fig. 91, 5, is a narrow, rounded muscle, concealed by the preceding, and lying close to the median line. It *arises* from the inside of the symphysis of the chin (its inferior sub-mental tubercle), and thence descends (separated from the corresponding muscle only by a narrow cellular interval), to be inserted into the body of the os hyoides. This pair of muscles lies between the mylo-hyoideus and the lower or free border of the genio-hyo-glossus.

382. *m. Hyo-glossus*, fig. 90, 8, is a flat, thin band of muscular fibres, extended upwards upon the side of the tongue from the lateral portion of the os hyoides. It *arises* from the great cornu of the os hyoides its whole length, and from part of the body of that bone. From this the muscular fibres incline upwards and outwards, to be inserted into the side of the tongue, where they expand, becoming blended with its substance: the direction of this muscle is almost vertically upwards, and that of

the stylo-glossus horizontally forwards, so that they decussate upon the side of the tongue.

Fig. 91.

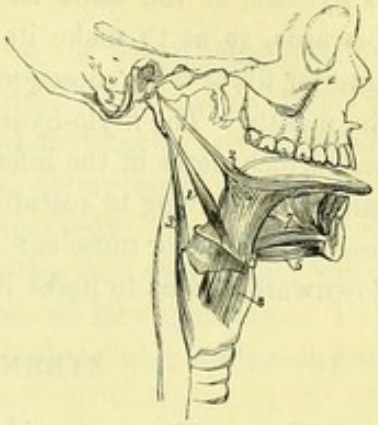

383. *m. Genio-hyo-glossus*, fig. 91, 7, is so called from its triple connexion with the chin, os hyoides, and tongue. The muscle forms a flat, triangular plane of fleshy fibres, placed vertically in the median line, the apex of the triangle being represented by its origin from the inside of the symphysis of the lower jaw, the base by its insertion along the whole length of the tongue from its point to its root, for the fibres spread out radiating like the ribs of a fan; one of the sides (the lower one) corresponds with the border which extends from the symphysis to the os hyoides, the other (upper and anterior) with the frænum linguæ. Its inner surface is in contact with the corresponding muscle, the external being covered by those last described. It *arises*, by a short, pointed tendon, from the superior sub-mental tubercle on the inside of the symphysis of the chin. To this the fleshy fibres succeed and diverge from one another, the inferior ones passing down to the os hyoides, the anterior forwards to the tip of the tongue, and all the rest proceeding with different degrees of obliquity to the under surface of the tongue, with which they are blended in its entire length from base to apex. The internal surface of the muscle is in contact with that of its fellow, from which it is at first separated slightly by some cellular tissue, but both become closely adherent towards their termination. The external surface is in contact with the lingualis, hyo-glossus and stylo-glossus, the sub-lingual gland, and lingual artery.

384. *m. Lingualis*, fig. 90, 9, is a thin, narrow band of fleshy fibres, extending along the under surface of the tongue in its entire length. It lies close to the outer side of the genio-hyo-glossus, between it and the hyo-glossus; one extremity of its fibres is connected to the os hyoides, and the other prolonged to the tip of the tongue, being blended inseparably with its substance.

Actions.—The muscles that pass from the jaw-bone to the os hyo-

ides are ordinarily employed in elevating the latter, and with it the base of the tongue, more particularly in deglutition. The genio-hyoglossi, by means of their posterior and inferior fibres, can draw up the os hyoides, at the same time bringing it and the base of the tongue forwards, so as to make its apex protrude beyond the mouth. The anterior fibres will, subsequently, act in retracting the tongue within the mouth. The mylo-hyoidei may be compared to a movable floor or bed, which closes in the inferior and anterior part of the mouth, at the same time serving to sustain the body of the tongue. The linguales resemble retractor muscles: they shorten the tongue, and draw its apex downwards, so as to make its dorsum convex.

STERNO-HYOID REGION.

385. *m. Sterno-hyoideus*, fig. 90, 10, lies at the fore part of the neck, close to the middle line, and immediately beneath the skin and fascia, being extended from the thoracic surface of the sternum to the os hyoides. It *arises* from the first bone of the sternum (its thoracic surface), from the posterior clavicular ligament, and from the cartilage of the first rib. It forms a flat, narrow band of muscular fibres, which ascends nearly in contact with its fellow or corresponding muscle, to be inserted into the lower border of the body of the os hyoides. It is concealed below by the sternum and sterno-mastoid; higher up it is concealed only by the skin and fascia. It lies on the sterno-thyroideus muscle, which it partly conceals; its inner border is in contact with that of the corresponding muscle, and the outer one with the superior part of the omo-hyoideus.

386. *m. Sterno-thyroideus*, fig. 90, 11, broader and shorter than the preceding, behind which it lies, *arises* from the thoracic surface of the first bone of the sternum, lower down than the sterno-hyoideus, from which it ascends, diverging a little from the corresponding muscle, to be inserted into the oblique line on the side of the ala of the thyroid cartilage. The greater part of its anterior surface is concealed by the sternum and the preceding muscle, as well as by the sterno-mastoid; the posterior rests on the vena innominata, the lower part of the common carotid artery, the trachea, and the thyroid gland.

387. *m. Thyro-hyoideus*, fig. 90, 12; fig. 93, 8, appears like a continuation of the preceding muscle, as it arises from the oblique line on the side of the thyroid cartilage, and thence

passes up to be inserted into the lower border of the great cornu of the os hyoides. It is concealed by the sterno-hyoid and omo-hyoid muscles, and rests on the ala of the thyroid cartilage, and on the thyro-hyoid membrane.

388. *m. Crico-thyroideus*, fig. 93, 9, is a remarkably short muscle, placed below the preceding, and, as its name implies, is attached to the cricoid and thyroid cartilages; its direction being obliquely upwards and outwards, diverging from its fellow of the opposite side. By this arrangement the crico-thyroid membrane is left uncovered, except by the skin and fascia, where it is to be punctured in the operation of laryngotomy. This muscle is concealed by the sterno-hyoideus and sterno-thyroideus.

389. *m. Omo-hyoideus*, fig. 90, 13, (scapulo-hyoideus,) is in structure a digastric muscle, as it consists of two bellies, united at an angle. One of these (the upper and inner one) lies close to the external border of the sterno-hyoideus muscle, and is covered only by the platysma and fascia; the other is deeply seated, being concealed, in the greater part of its extent, by the clavicle and sterno-mastoid. It *arises* from the upper border of the scapula, near the supra-scapular notch, and from the ligament which crosses it. From thence the muscle, forming a narrow, flat fasciculus, inclines forwards across the root of the neck, where it suddenly changes its direction, ascending almost vertically, to be inserted into the lower border of the os hyoides, at the union of its body and cornu. The two parts of the muscle here described form an angle, where they lie behind the sterno-mastoid, and are connected to each other by a tendon, which varies much in length and form in different subjects. The tendon is enclosed within two lamellæ of the deep cervical fascia, which, after forming a sort of sheath for it, are prolonged down and become attached to the cartilage of the first rib. It is by this mode of connexion that the angular position of the muscle is maintained.

Actions.—All the individuals of this group of muscles take their fixed point below, and therefore conspire in being depressors of the larynx and os hyoides, for they draw down these parts as deglutition is being performed. As a preparatory measure to swallowing, the pharynx is drawn up, so also is the os hyoides; and, moreover, as a means of security, the larynx at the same moment is made to ascend,

so as to be brought under cover of the epiglottis. After the ascent has been effected, the parts do not return to their original position by the mere relaxation of the elevators; they are drawn down by the action of the five muscles just described. The thyro-hyoideus is the only one of them that can act as an elevator; for when the os hyoides ascends, this muscle can draw upwards the thyroid cartilage with it.

VERTEBRAL REGION (LATERAL).

390. *m. Scalenus anticus*, fig. 90, 14; fig. 92, 1, lies deeply at the side of the neck, behind and beneath the sterno-mastoid muscle. It *arises* by a flat, narrow tendon, from the inner border and anterior surface of the first rib, from which its fleshy fibres ascend vertically, to be inserted into the anterior tubercles of four cervical vertebræ, from the third to the sixth inclusive. The lower part of the muscle separates the subclavian artery and vein. It is overlapped by the sterno-mastoid muscle (a small part only projecting behind its outer border), and crossed by the omo-hyoideus, with which and the clavicle it bounds an angular interval, in the area of which lie the subclavian artery and commencement of the axillary plexus of nerves.

Fig. 92.

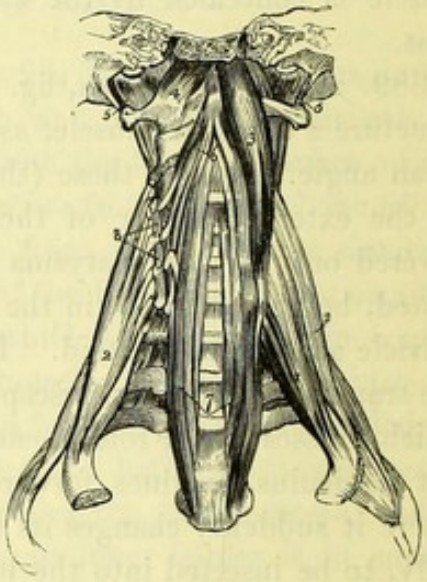

391. *m. Scalenus posticus*, fig. 90, 15; fig. 92, 2, is larger and longer than the preceding muscle, from which it is separated below by the subclavian artery, and above by the cervical nerves, as they issue from the inter-vertebral foramina. It *arises* from the first rib, about an inch behind the other muscle of the same name, and also from the second near its tubercle. The fleshy fibres ascend along the side of the vertebral column, and are inserted, by tendinous processes, into the posterior tubercles of all the cervical vertebræ except the first. The two origins of the scalenus posticus are separated at first by a cellular interval, which has given occasion to the division of the muscle

into two parts, the larger one being, from its situation, named *scalenus medius*, the smaller the *scalenus posticus*.

Actions.—These muscles draw down the transverse processes of the cervical vertebræ, and thereby bend that part of the spinal column to one side. The inter-transversales, 8, and rectus lateralis, 5, of each side act in the same way, all conspiring to incline the head as well as the vertebræ laterally. This movement may be alternated by bringing the opposite muscles into action. If both act together, the head and spine will be maintained erect. When the scaleni take their fixed points above, they draw on the first ribs, rendering them fixed, as a preparatory step to making a forcible inspiration.

VERTEBRAL REGION (ANTERIOR).

This includes the muscles placed in front of the spine upon the cervical and upper dorsal vertebræ ; viz. the rectus capitis anticus major and minor, with the longus colli.

392. *m. Rectus capitis anticus major*, fig. 92, 3, appears like a continuation of the scalenus anticus, being prolonged upwards from the points at which it ceases. This muscle *arises* from the anterior tubercles of the transverse processes of four cervical vertebræ (from the third to the sixth inclusive) by so many tendinous processes. It ascends, converging somewhat to the corresponding muscle, and is inserted into the basilar process of the occipital bone, in front of the foramen magnum. It is tendinous and fleshy in its structure ; its anterior surface supports the pharynx, the sympathetic nerve, and the great cervical vessels, viz. the carotid artery, the jugular vein, and the vagus nerve, or rather the sheath which encloses these. Its posterior surface overlays part of the longus colli, and the rectus anticus minor, also the articulation of the second with the first vertebra and of the latter with the occipital bone.

393. *m. Rectus capitis anticus minor*, fig. 92, 4, is a short, narrow muscle, lying behind the superior part of the preceding. It *arises* from the fore part of the lateral mass of the atlas and a little from the root of its transverse process, and is inserted into the basilar process, between the margin of the foramen magnum and the preceding muscle, but a little farther out than the latter.

394. *m. Rectus lateralis*, fig. 92, 5, is a short flat muscle placed between the transverse process of the atlas and the occipital

bone. It *arises* from the upper surface of the transverse process of the atlas, and is inserted into the rough ridge, external to the condyloid process of the occipital bone. It completes the series of the inter-transversales muscles, 8; its anterior surface supports the internal jugular vein at its exit from the skull, and the posterior is in relation with the vertebral artery.

395. *m. Longus colli* rests on the fore part of the spinal column, from the atlas to the third dorsal vertebra. It is narrowed and pointed at its extremities, but becomes wider along its middle part; it is compressed throughout, and appears to consist of two portions, differing in length and in the direction of their fibres. One of these, fig. 92, 6, superior and external to the other, *arises*, by a narrow, tendinous process, from the anterior tubercle of the atlas, from which its fibres descend obliquely outwards, to be inserted into the fore part of the transverse processes of the third, fourth, and fifth cervical vertebræ. The other part of the muscle commences at the depression in the body of the axis; its fibres also arise from the bodies of the third and fourth cervical vertebræ, and from the transverse processes of the fourth and fifth. The tendinous and fleshy fibres, 7, derived from these attachments, pass vertically downwards, to be inserted into the bodies of the three lower cervical vertebræ and the three upper dorsal. The two muscles of this name are smooth and compressed at their anterior aspect. They consist of tendinous and fleshy fibres; the former occupy the anterior surface, particularly at the extremities; some are also deep-seated; and the fleshy fibres, which are in general short, are placed obliquely between them. They support the pharynx, the œsophagus, the sympathetic nerves, the carotid arteries, and the eighth pair of nerves.

Actions.—The anterior recti muscles are the natural antagonists of those placed at the back of the neck. They restore the head to its natural position when it has been drawn backwards by the posterior muscles, and, continuing their effort, bow it slightly forwards. Beneath the base of the skull, and at opposite points, we find short and straight muscles, two in front (recti antici), two behind (rectus posticus, major and minor), one on each side (rectus lateralis), which are the direct agents in the restricted motions that take place between the head and the first vertebra. The horizontal movement of the head is effected by the obliqui, particularly by the inferior one. It is obvious

that if it acted by itself, the first vertebra only would be rotated on the second, the head remaining unmoved; but the recti minores and the superior oblique muscle conspire to fix the skull on the first vertebra, and thereby communicate to it any movement impressed on the latter by the inferior oblique muscle.

PHARYNGEAL REGION.

396. We have here the following muscles forming a hollow bag, the pharynx; viz. constrictor superior, constrictor medius, constrictor inferior, together with the stylo-pharyngeus and palato-pharyngeus.

Dissection.—After having examined the sides and fore part of the neck, when you are about to dissect the pharynx, larynx, and soft palate, proceed as follows:—Cut across the trachea and œsophagus a little above the sternum, and draw both together forwards. There then can be no difficulty in detaching the pharynx from the muscles in front of the vertebral column, as they are merely connected by loose cellular tissue. When this is done, a piece of cloth should be carried deeply to the base of the skull, and drawn across the pharynx, to serve as a retractor whilst the saw is being used. The edge of the saw should, in the next place, be applied behind the styloid processes, so as to cut through the base of the skull, from below upwards, thereby detaching the face, with the pharynx and larynx all pendent from beneath it. The pharynx should be stuffed, to render its muscles tense. When its exterior is sufficiently examined, a longitudinal slit made along the middle line posteriorly, will expose its cavity, and that of the mouth and larynx.

397. The pharynx is a musculo-membranous tube, extended from the centre of the base of the skull to the œsophagus, with which it is continuous. It lies behind the nasal fossæ, the soft palate, the isthmus of the fauces, and the larynx, which open into it,—before the vertebral column, and between the great vessels of the neck. The posterior and lateral parts of the pharynx are loosely connected to the adjacent structures by cellular tissue, but anteriorly it presents the several apertures that lead into the nose, mouth, and larynx. Its structure is made up, externally, of muscular fibres, (disposed in a very peculiar way, being formed into three lamellæ on each side, partially overlapping one another,) and, internally, of mucous membrane,

prolonged from the mouth and nares. These layers of muscle are called the constrictors of the pharynx.

398. *m. Constrictor inferior*, fig. 93, 10, arises from the external surface of the cricoid cartilage, and from the oblique ridge on the side of the great ala of the thyroid. From these attachments the fibres curve backwards and inwards, converging to those of the corresponding muscle of the opposite side, with which they unite along the middle line. The direction of the inferior fibres is horizontal, concealing and overlapping the commencement of the œsophagus; the rest ascend with increasing degrees of obliquity, and overlap the lower part of the middle constrictor.

Fig. 93.

399. *m. Constrictor medius*, fig. 93, 11, is smaller than the preceding: it *arises* from the side of the great cornu of the os hyoides, also from its lesser cornu, and the stylo-hyoid ligament. From these points of attachment the fibres proceed backwards, diverging from one another, and are blended with those of the corresponding muscle along the middle line. The lower fibres incline downwards, being concealed by the inferior muscle; the middle run transversely; the rest ascend, overlap the superior constrictor, and are prolonged, by a narrow slip of white fibres, to the basilar process of the occipital bone.

400. *m. Constrictor superior*, fig. 93, 12, is attached slightly to the side of the tongue, and to the extremity of the mylo-hyoid ridge, also to the pterygo maxillary ligament, 2, and the lower third of the internal pterygoid lamella. From these different points the fibres of the muscle curve backwards, becoming blended with those of the corresponding muscle along the middle line, and are also prolonged, by means of the posterior aponeurosis, to the basilar process of the occipital bone. Thus, by the peculiar mode of attachment of these muscles, the bag of the pharynx is completed on the sides and posteriorly, and left open in front; and by the connexion of the upper constrictor with the pterygo-maxillary ligament, and of the latter with the buccinator, a continuous smooth surface is established from the

commissure of the lips along the side of the mouth and fauces. Besides these, we find at each side, in the pharynx, two other muscular fasciculi, one being derived from the stylo-pharyngeus, 5, which is insinuated between the adjacent borders of the superior and middle constrictor, and which has been already described. (Sect. 379.) The other lies more internally, being the palato-pharyngeus, which shall be described with the muscles of the palate. (Sect. 406.) It may be observed, that as the lateral attachment of the superior constrictor is no higher than to about a third of the internal pterygoid plate, whilst the insertion is into the basilar process, the fibres of the muscle, as they pass between these points, leave a small interval, in which the mucous membrane is uncovered.

Actions.—The pharynx is drawn up when deglutition is about to be performed, and at the same time dilated in opposite directions. It is widened from side to side by the stylo-pharyngei, which are farther removed from one another at their origin than at their insertion, and can thereby draw outwards the sides of the cavity; and as the os hyoides and larynx are carried forwards in their ascent, the breadth of the pharynx from before backwards is also increased, inasmuch as its fore part is drawn in the same direction, by reason of its connexion with the larynx. When the morsel of food is propelled into the pharynx, the elevator muscles relax, the bag descends, and then the fibres of its own muscular wall begin to contract, and force the mass down into the œsophagus.

When we contrast the structure of the pharynx with that of the œsophagus, comparing the complex arrangement observable in the one with the simplicity of the other, we see abundant evidence of its being intended for something more than a mere recipient and propellent of such matters as are to be conveyed to the stomach. It exerts an important influence in the modulation of the voice, being brought into action in the production of its higher tones.

The description of the muscular structure of the pharynx may be given briefly as follows: it may be considered as a single muscle, consisting of two symmetrical halves, united by a raphé posteriorly along the middle line, the union extending from the basilar process to the œsophagus. The superior fibres curve downwards and outwards, to be fixed to the lower third of the internal pterygoid plate, to the pterygo-maxillary ligament, and to the mylo-hyoid ridge and side of the tongue; the middle set of fibres, broad, and expanded posteriorly

at the line of junction, converge as they proceed forwards to be attached to the cornu of the os hyoides and the stylo-hyoid ligament, and are so disposed, that part is concealed by the succeeding set, whilst others overlap the preceding muscle. The lower fibres proceed forwards in the same way, to be attached to the side of the cricoid and thyroid cartilages. The tube is thus shown to be complete posteriorly and at the sides, being open in front, where it communicates with the nose, mouth, and larynx.

When the pharynx is slit open, we expose the cavities just mentioned, and the apertures which lead into them, as well as the orifices of the Eustachian tubes.

PALATAL REGION.

401. The soft or pendulous palate (*velum pendulum palati*) forms a partial and movable curtain between the mouth and the pharynx. Its upper border is straight, and attached to the posterior margin of the palate bones; the lower presents, when viewed from before, a curved or arched border at each side, and in the middle a conical depending process, called the *uvula*. From this, as from a common point of departure, two curved lines will be observed to extend, one at each side, and proceed downwards and forwards, to the side of the tongue. These correspond with the lower or free border of the palate, and mark the limits of the cavities of the mouth and pharynx, for they represent a narrowed or constricted line between them, which is termed the *isthmus* of the fauces. Farther back is another pair of curved lines, one at each side, which also commence at the uvula, and extend downwards and backwards along the sides of the pharynx. They diverge from the preceding curved lines so as to leave between them an angular interval, in which is lodged the *tonsil* or *amygdala*. The curved lines here described are usually called the *arches* of the palate, one pair being anterior to the other, and also more prominent.

The soft palate consists of five pairs of muscles, enclosed by mucous membrane.

Dissection.—When the pharynx has been dissected and examined, as directed in section 396, it may be opened by an incision along the middle line or raphé; this will expose the soft palate; let the uvula be drawn down so as to render it tense; then the small muscles of the palate are at once exhibited by detaching the mucous membrane.

The levatores palati are brought into view by merely removing the mucous membrane from the posterior surface of the soft palate; the circumflexi will be found along the internal pterygoid plates: their aponeuroses, which form the principal support of the soft palate, will be seen in front by dissecting off a thick layer of granular substance, which is continued downwards upon it beneath the mucous membrane.

402. *m. Levator palati*, fig. 94, 1, (peri-staphylinus internus, περι, about or near, σταφυλη, the uvula,) is a long, thin, flat muscle, placed at the posterior surface of the soft palate under cover of the mucous membrane, which arises from the extremity of the petrous portion of the temporal bone, before the orifice of the carotid canal, and from the cartilaginous part of the Eustachian tube. The two muscles converge, as they descend, to become blended at the middle of the soft palate with the other muscles, viz. the levator palati of the opposite side, the azygos uvulæ, and the tendon of the circumflexus palati.

Fig. 94.

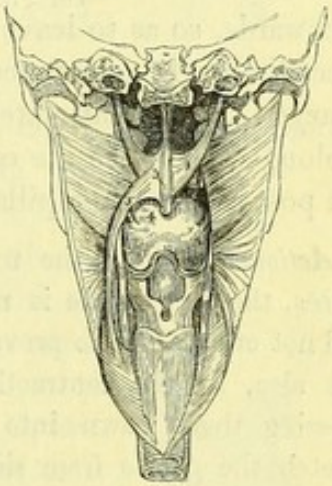

403. *m. Circumflexus*, or *tensor palati*, fig. 94, 2, (peri-staphylinus externus,) presents two portions which differ in their direction and relations. The muscle arises from the small fossa (*navicularis*) at the root of the internal pterygoid plate of the sphenoid bone, also from the anterior surface of the cartilage of the Eustachian tube. From these points it descends perpendicularly between the internal pterygoid muscle and the osseous lamella of the same name, and ends in a tendon, which winds round the hamular process; there it inclines inwards and expands at the same time into a broad aponeurosis, the fibres of which are inserted into the transverse ridge on the under surface of the palate process of the palate bone, and on reaching the middle line they unite with the aponeurosis of the corresponding muscle of the opposite side.

404. *m. Azygos uvulæ*, fig. 94, 3, (palato-staphylinus,) was so called from its having been supposed to be a single muscle; but

there are really two thin fasciculi, separated by a slight cellular interval above, which usually unite towards the lower part. Each arises from the pointed process (spine) of the palate plate, and descends vertically, becoming blended with the other structures in the uvula.

405. *m. Palato-glossus*, or *constrictor isthmi faucium*, fig. 94, 4, inclines from the uvula forwards and outwards to the side of the tongue, where it may be considered as inserted. It is merely covered by the mucous membrane, which it renders prominent, so as to form the anterior arch of the palate.

406. *m. Palato-pharyngeus*, fig. 94, 5, arches downwards and backwards, so as to leave an angular interval between it and the preceding. It commences at the uvula, and descends into the pharynx, being intimately connected with its muscles, and is prolonged as far as the cornu of the thyroid cartilage. It forms the posterior arch or pillar of the velum palati.

Actions.—When the mass of food is carried back towards the fauces, the soft palate is raised nearly to a level with the hard one, and not only serves to prevent the ingesta from passing into the nares, but also, by the contraction of its two arched muscles, assists in pressing them down into the pharynx. The circumflex muscles stretch the palate from side to side, and render it tense, whilst the proper elevators raise it up, and then the palato-glossi and palato-pharyngei, taking their fixed points below, are enabled, by depressing the palate, to force down the food into the cavity ready to receive it.

LARYNGEAL REGION.

407. We have here several pairs of small muscles, which move the cartilages of the larynx, and are thereby concerned in the production of voice.

Dissection.—When the pharynx has been opened, as directed in the previous dissections, the cavity of the larynx is brought into view. The muscles are readily exposed by removing the mucous membrane which alone conceals them. It is necessary to detach and evert the wing of the thyroid cartilage, in order to see the lateral crico-arytænoid muscle, and the thyro-arytænoid, as seen in fig. 96.

The proper muscles of the larynx may be divided into two sets, viz. dilators and contractors of the rima of the glottis. One

pair of the dilators has been already described as being seated outside, viz. the crico-thyroidei (Sec. 388). The others are the crico-arytænoidei postici.

408. *m. Crico-arytænoidei postici*, fig. 95, 1.—These rest posteriorly on the broadest part of the cricoid cartilage, covering by their origin the whole of it, except the middle perpendicular line. Their fibres converge, as they proceed upward and outwards, to be inserted by a narrow process into the bases of the arytænoid cartilages by their external borders. They are merely covered by the mucous membrane.

Fig. 95.

The contractors are the following:

409. *m. Crico-arytænoidei laterales*, fig. 96, 2, are extended obliquely backwards and upwards, from the upper border of the cricoid cartilage on each side, to the base of the arytænoid cartilage. They lie in the interval between the alæ of the thyroid cartilage and the glottis, concealed by the lining membrane.

Fig. 96.

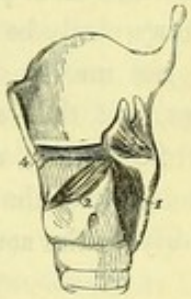

410. *m. Thyro-arytænoidei*, fig. 96, 4, are placed immediately above the preceding, and are united with them at the point of insertion; they are stretched from before backwards, between the inner surface of the thyroid cartilage at its angle, and the base of the arytænoid cartilages at their anterior border. They lie parallel with the rima.

Some muscular fibres may also be traced from near the origin of the preceding, which ascend to the margin of the epiglottis. These are described by some anatomists as *thyro-epiglottidæi*, or *depressores epiglottidis*; but it may be observed, that the closure of the aperture by means of the epiglottis, is effected by the ascent of the whole larynx, by which the rimæ is drawn as it were under cover of its operculum, and not by the descent of the latter upon it. Some muscular fibres are also occasionally found in the folds of mucous membrane stretched between the arytænoid cartilages and the epiglottis. These have been named *arytæno-epiglottidæi*.

411. *m. Arytænoideus*, figs. 95; 96, 5, consists of oblique and

transverse fibres intimately blended together, and laid upon the posterior concave surface of the arytænoid cartilages. Albinus and Winslow, from a consideration of the difference in the direction of its fibres, divided the muscle into three, viz. two oblique, and one transverse; but as all conspire in their actions, and are inseparably connected together, most modern anatomists describe them as a single muscle. The oblique fibres pass from the base of one cartilage towards the apex of the other, crossing in the middle. The transverse fibres pass from one border to the other, and are partly covered by the oblique.

Actions. — The arytænoideus contracts the base or widest part of the rima, rendering it an elongated chink, and is therefore the direct antagonist of the posterior crico-arytænoid muscles, which draw the basis of the cartilages outwards, and widen the interval between them. These cartilages are, on the contrary, drawn forwards (and the antero-posterior extent of the aperture thereby diminished) by the lateral muscles, which pass to them from the cricoid and thyroid cartilages. It may easily be shown that the fibres of the thyro-arytænoid muscles are not merely stretched from before backwards, between the cartilages, but that some of them are attached at different points to the chordæ vocales, and so may act as stops on a musical string, limiting the extent of the part which vibrates at a given moment, and thereby modifying the sound.

Muscles of the Back.

412. The muscles placed along the posterior part of the trunk are found to be arranged in layers, or strata, placed one over the other, and differing materially in extent, attachments, and use. The superficial muscles are so broad as to cover all the others; and, as their extent is considerable, their number is proportionably diminished, being only two, viz. the trapezius and latissimus dorsi. We shall here place them in the order in which we find them in our dissections, proceeding from the tegument to the spine and ribs. Those in each group or layer diminish in size as they increase in number.

In the first layer are the trapezius and latissimus dorsi.

In the second, the rhomboidæi and levator scapulæ.

In the third, the splenii and serrati postici.

In the fourth, the erector spinæ, cervicalis ascendens, transversalis colli, trachelo-mastoideus, and complexus.

In the fifth, the semi-spinales dorsi and colli, recti and obliqui.

In the sixth, the inter-spinales, inter-transversales, multifidus spinæ, levatores costarum.

Dissection. — The subject being turned prone, the chest and abdomen should be supported by blocks, and the arms allowed to hang over the sides of the table. An incision may be made through the integument, along the spinal column, from the occipital protuberance to the sacrum. This should be bounded at its superior extremity by a transverse incision, carried outwards to the mastoid process, and below by another extended along the spine of the ilium. The intervening space may, in the next place, be intersected by two lines; one drawn from the first dorsal vertebra, over the spine of the scapula, the other commencing at the last dorsal vertebra, and carried horizontally outwards.

As the space here marked out is so very extensive, it may be advisable to make an incision obliquely upwards from the last dorsal vertebra to the spine of the scapula, which will correspond with the lower border of the trapezius muscle; and the dissection may be commenced by raising the angular flap of skin thus included, proceeding in the direction of the fibres of that muscle, that is to say, from below upwards and outwards. The other portions of integument should be successively raised, taking care to expose accurately the tendinous fibres where they arise from the spinous processes, as they afford a guide to the fleshy part of the muscle.

When the latissimus and trapezius have been exposed and examined in their entire extent, which will take some time, in consequence of the quantity of surface that is to be gone over, they are to be removed, in order to bring into view the muscles that lie beneath them.

FIRST LAYER OF DORSAL MUSCLES.

413. *m. Trapezius*, fig. 97, 1, (cucullaris, Sœmm.; occipito-dorsi-acromialis,) is a flat thin triangular muscle of considerable extent, which is placed immediately under the skin along the posterior part of the neck, as well as of the back and shoulder. If the two muscles of this name be taken together, they represent a four-sided figure (hence the name), two angles of which correspond with the points of the shoulders, one with the occipital protuberance, and the fourth with the spinous process of

Fig. 97.

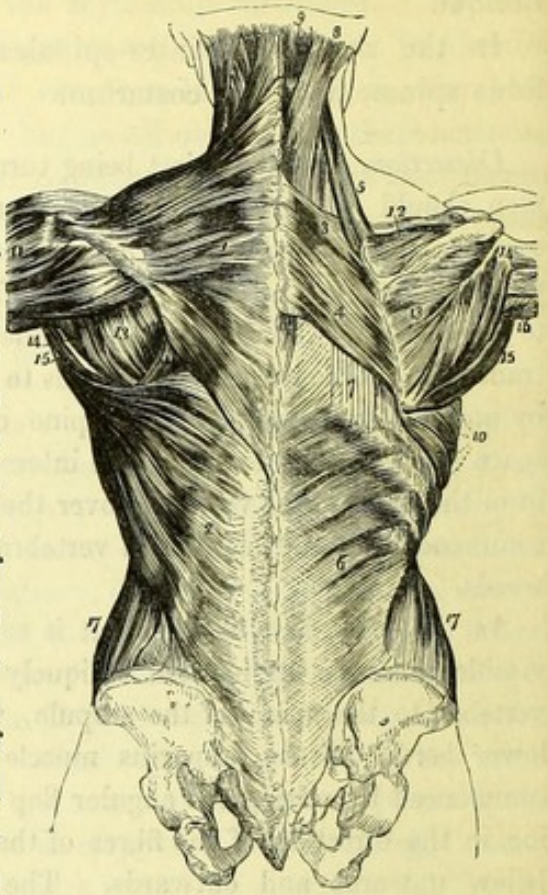

the last dorsal vertebra. The trapezius *arises*, 1, from the occipital protuberance, and from about a third of the curved line, extending forwards from it; 2, in the cervical region, from the fibres of the corresponding muscle, both being blended together, and from a tendinous band, called *ligamentum nuchæ;* 3, from the spinous process of the last cervical, and all those of the dorsal vertebræ, as well as from the supra-spinous ligament. From these different points of origin the fibres proceed towards their insertion into the clavicle, the acromion process, and the spine of the scapula, following very different directions; those from the occiput inclining downwards and outwards, and those from the lower part of the back upwards and outwards, the obliquity of each set diminishing, so that those intermediate between the two extremes become horizontal. The superior fibres turn forwards a little, and are inserted into the external third of the clavicle; the middle pass transversely to the upper border of the acromion process; whilst the inferior ones ascend to reach the upper border of the spine, to which they are attached as far back as the triangular surface at which it commences. The tendinous fibres by which the muscle arises are rather short along the interval from the last dorsal vertebra as high as the fourth; there they lengthen gradually, but opposite the fourth cervical vertebra they again acquire about the same extent, so that in the interval between these points, the union of the muscular with the tendinous fibres forms a crescent, and if the two muscles be dissected together they will represent an oval.

From the line of union of the two trapezii along the neck, a band of condensed cellular membrane, mixed with tendinous fibres, projects forwards, so as to reach the spinous processes of the vertebræ, forming a septum between the sets of muscles on each side of the middle line. It is attached by its upper extremity to the occipital protuberance, by the lower to the spinous process of the seventh cervical vertebra; its posterior border is blended with the fibres of the trapezii, whilst the anterior is fixed to the spinous processes of the cervical vertebræ. This is usually called *ligamentum nuchæ*. In the human subject it can only be considered as a rudiment of that peculiar elastic band which serves to sustain the weight of the head in the lower animals.

Structure—the trapezius is fleshy in the greater part of its extent, and tendinous at its attachments: relations—by its posterior surface with the skin, beneath which it lies in its entire extent; the anterior one covers part of the complexus, 9, the splenii, 8, levator anguli scapulæ, 5, the supra-spinatus, 12, infra-spinatus, 13, slightly, the rhomboidei, 3, 4, and the upper part of the latissimus dorsi, 2. Where the inferior fibres slide over the triangular surface between the base and spine of the scapula, in order to reach the upper border of the latter, a synovial bursa is interposed.

414. *m. Latissimus dorsi*, fig. 97, 2, (dorsi-lumbo-sacro-humeralis,) as its name implies, is of considerable extent, for it occupies the whole of the posterior part of the lumbar region, and the lower half of the dorsal. It is flat, broad, and thin in the greater part of its extent, but it gradually becomes contracted into a narrow fasciculus towards its insertion into the humerus. It arises by tendinous fibres, 1, from the spinous processes usually of the six lower dorsal vertebræ, from all those of the lumbar region and of the sacrum, and from the supra-spinous ligament; 2, from the external border of the crista ilii (its posterior third); 3, by fleshy digitations from the three or four last ribs, where they are interposed between similar processes of the obliquus externus. The tendinous fibres from the two first lines of origin form by their intertexture, or union, a broad aponeurosis, from which the fleshy fibres proceed, converging towards the axilla. The fibres at the upper part are the shortest, and pass almost horizontally outwards; those lower down become longer and incline from below upwards, gradually in-

creasing in the degree of their obliquity; finally, those which are attached to the ribs ascend almost vertically. By this convergence, the fibres form a narrow and thick fasciculus, which slides over the inferior angle of the scapula, from which it sometimes receives a small accessory muscle. In this situation it rests on the teres major, 15, which it accompanies towards the axilla, but gradually turns, as it were, on itself, so as to get to the anterior aspect of that muscle, and is inserted into the posterior border of the bicipital groove in the humerus. The flat tendon by which the latissimus dorsi is inserted becomes united, particularly by its lower border, with that of the teres major; it ascends higher than the latter, and also lies nearer to the brachial vessels. It is sometimes connected to the pectoralis major by a fleshy fasciculus extended across the axillary space.

Structure—tendinous along its point of origin from the spine and the ilium, broad and aponeurotic in the lumbar region,—tendinous at its insertion,—fleshy in the rest of its extent, where it lies over the ribs, the angle of the scapula, and the fold of the axilla: relations—it is covered by the trapezius at its dorsal origin, and subcutaneous in the rest of its extent, except where it ascends into the axilla. The anterior surface rests on part of the rhomboideus major, 4, infra-spinatus, 13, teres major, 15; the serratus posticus inferior, 6, and on part of the deep lumbar muscles, 7; its internal border is blended with the fibres of the corresponding muscle, along the middle line, the inferior intermixes with those of the gluteus maximus. The superior border is free, and describes a slight curve, whose concavity looks upwards; the anterior one, also free in the greater part of its extent, slightly overlaps the obliquus externus, 17, below, and higher up the serratus magnus, 10.

Actions.—The trapezius and latissimus dorsi direct or influence the motion of several parts, as must be evident from the extent of their attachments. If the shoulders be fixed, the trapezii muscles acting together, draw the head directly backwards; but if only one of them acts, it inclines the head to the corresponding side. If the head be fixed, the superior part of the trapezius elevates the point of the shoulder, and sustains it in that position, as when a burden is supported upon it; but if the effort required be considerable, or if it must be continued for any length of time, the co-operation of the serratus magnus becomes indispensable. It would appear at first sight, from

a mere inspection of the fibres of this muscle, that those in the middle part of it could draw the scapula directly backwards, and the lower ones draw it downwards. This, however, is far from being the fact. As the muscle is attached to the spine of the scapula and the acromion, it will rather, in consequence of the obliquity of the direction of these processes, communicate a certain degree of rotatory motion to the whole bone, by means of which, when the acromion ascends, the posterior angle descends, and the inferior one comes forward; and should the acromion be made to resume its previous position, the inferior angle will move backwards, the superior one upwards. The scapula, then, in its movements, cannot be made to ascend or descend, to go backwards or forwards, in such a way that the direction of its different parts may remain exactly parallel, in their new situations, to those which they had previously occupied:—This bone will, on the contrary, be found to rotate, as it were, on a pivot driven through the centre of its dorsum. To draw the scapula directly backwards requires the combined effort of the trapezius and rhomboid muscles; for, as their fibres decussate, the direction of the one being obliquely downwards, that of the other upwards, the bone, by their combined action, is made to move in the direction of the diagonal of their forces, that is to say, towards the spinal column.

The latissimus dorsi, when it acts on the shaft of the humerus, necessarily draws it downwards, and gives it at the same time a rotatory motion on its own axis, particularly if it had been previously everted, or turned outwards. When the shoulder and arm are rendered fixed, the muscle acts in various ways on the trunk. Thus it assists in forcible inspiration, by drawing on the lower ribs and elevating them. By conspiring with the abdominal and great pectoral muscles, it elevates and sustains the body in the effort of climbing; and when an individual is constrained to resort to the assistance of crutches, the latissimus and pectoralis major are the chief agents in progression.

The trapezius and latissimus dorsi, more particularly the latter, can act under certain circumstances on the spine, preparatory to which the shoulder and arm must become (at least relatively) the fixed points of their attachment. When a man walks close to the margin of a raised foot-path, or of a curb-stone, and happens to incline a little beyond it, the body becomes curved to that side, and by its own weight would carry him over it, if a particular effort were not made to prevent such an occurrence. For this purpose the arm of the opposite side is, as it were, instinctively thrown out somewhat from the

body, so as to render the insertion of the latissimus dorsi into that bone its fixed point of attachment. Thus sustained, the fibres of the muscle are enabled to act on the spine, and, by pulling on those parts of it which are curved, they draw them into a right line with the rest, and so restore the equilibrium of the body.

SECOND LAYER.

Dissection.—To expose the rhomboid muscles and the levator scapulæ, the trapezius must be removed. For this purpose, the fibres of the trapezius may be detached from their connexion with the clavicle and spine of the scapula, and reflected back to the spine. This will be found easier than the usual plan of detaching it from the latter, both because it is there very thin, and also because its fibres are connected with those of the rhomboid muscle. Its dorsal portion conceals the rhomboidei, and part of the latissimus dorsi; and the cervical, the levator scapulæ, the splenius, and complexus. These may be dissected in the course of their fibres, as the trapezius is being reflected back towards the middle line, where it may be separated from its fellow of the opposite side along the cervical region, so as to expose the ligamentum nuchæ. In doing this, insert the edge of the knife under the muscle at the occiput, and draw it from above downwards, in the line of the spinous processes.

The *rhomboideus muscle* (dorso-scapularis) is usually divided into two muscles, though they lie on the same plane, are similar in structure and use, and differ only in size. The two parts of the muscle are separated by a slight cellular interval. It is extended obliquely from the spinous processes of the lower cervical and upper dorsal vertebræ, to the base of the scapula.

415. *m. Rhomboideus minor*, fig. 97, 3, *arises* from the spinous process of the seventh cervical vertebra, and from the ligamentum nuchæ, its fibres being also closely united with those of the trapezius. It inclines downwards and outwards, to be inserted into that part of the base of the scapula which corresponds with the triangular surface from which the spine commences.

416. *m. Rhomboideus major*, 4, three or four times broader than the other, is placed in close contact, and immediately below it. It *arises* from the spinous processes of the four or five upper dorsal vertebræ, and their inter-spinous ligaments, and is in-

serted into that part of the base of the scapula included between its spine and inferior angle. Direction—downwards and outwards: structure—muscular in the greater part of its extent, tendinous at its origin: relations—it is covered by the trapezius in the greater part of its extent, and towards the lower part by the latissimus dorsi; but when the arm is drawn away from the side, a small portion is left uncovered by these muscles, where they diverge at the base of the scapula.

417. *m. Levator anguli scapulæ*, 5, (trachelo-scapularis,) is placed along the side and posterior part of the neck, forming a long and rather thick fasciculus of fleshy fibres. It *arises* from the posterior tubercles of the three or four superior cervical vertebræ, by so many tendinous points. From these the fleshy fibres proceed, being at first slightly separated, but soon united to form a flat muscle, which is inserted into that part of the base of the scapula included between its spine and superior angle. Direction — downwards and a little backwards; structure — fleshy in the greater part of its extent, tendinous at its origin: relations — it is covered by the sterno-mastoid muscle above, and by the trapezius below; it rests on the splenius colli, transversus cervicis, and serratus posticus superior.

THIRD LAYER.

Dissection.—After having examined the muscles of the second layer, they must be removed in order to gain a view of those underneath them. For this purpose, the rhomboidei may be detached from the base of the scapula, and reflected backwards, which is the easier mode of attaining the end desired, and avoids any risk of raising with them the serratus superior, which is intimately connected with their origin. The aponeurosis of the latissimus dorsi may be divided by an incision carried from above downwards, along its middle; and as the external half is reflected outwards, its intimate connexion may be observed with the obliquus abdominis, along the border of the deep lumbar muscles. The other portion of the aponeurosis may be drawn back towards the spine, by which means the serratus posticus is left untouched. The serrati and their connecting membrane may then be inspected.

418. *m. Serratus posticus superior* (cervici-dorso-costalis) is placed under cover of the rhomboideus; it is flat, and very thin. It *arises* from the spinous process of the last cervical, and from those of two or three upper dorsal vertebræ, by a thin aponeu-

rosis, which inclines downwards and outwards, soon becoming muscular, and is inserted by four fleshy digitations into the bodies of the second, third, fourth, and sometimes fifth ribs, a little beyond their angles. Its direction is obliquely downwards and outwards, resting on the deep muscles and the angles of the ribs.

419. *m. Serratus posticus inferior*, fig. 97, 6, (dorsi-lumbo-costalis,) is broader than the preceding muscle, from which it is separated by a considerable interval, as one of them corresponds with the upper, the other with the lower ribs. It *arises* from the spinous processes and inter-spinous ligaments of the two last dorsal, and two or three upper lumbar vertebræ, by a thin aponeurosis. This ends in a fleshy lamella, which is inserted by four digitations into the bodies of the four last ribs. Its direction is upwards and outwards: structure — partly muscular, partly aponeurotic: relations—its posterior surface is covered by the latissimus dorsi; the anterior rests on the deep lumbar muscles.

420. On the same plane with the serrati, and connecting their borders, may be observed a thin, semi-transparent lamella (*vertebral aponeurosis*), which forms a septum between the third and fourth layer of muscles. Its fibres are for the most part transverse; some, however, take a contrary direction. As the muscles, with their connecting aponeurosis, are stretched from the spinous process to the angles of the ribs, they form with the vertebral grooves a sort of angular canal, in which are lodged the long extensor muscles.

421. The *splenius muscle*, fig. 97, 8, is placed obliquely along the posterior part of the neck; it is usually divided into two parts, one being extended from the spinous processes of the upper dorsal and lower cervical vertebræ, to the side of the base of the skull, the other to the transverse processes of three or four superior cervical vertebræ. This separation of the muscle at its superior attachment has given occasion for its division into two parts, the lower being named splenius colli, the upper splenius capitis.

m. Splenius colli (dorso-trachelius) arises from the spinous processes of four dorsal vertebræ, from the third to the sixth inclusive: the fibres ascend, forming a flat, muscular plane, which is inserted by separate points into the transverse processes of the

three or four superior cervical vertebræ, close to the origin of the levator anguli scapulær.

m. Splenius capitis (cervico-mastoideus) differs from the preceding in situation, being placed superior and internal to it, and is also somewhat broader and thicker. It arises from the spinous processes of the two superior dorsal vertebræ, and of the seventh cervical, also from the ligamentum nuchæ opposite the sixth, fifth, and fourth. From these points its fibres proceed upwards and outwards, to be inserted into the external part of the mastoid process, and also into part of that rough surface on the occipital bone, which is included between its curved lines. Direction—obliquely upwards and outwards; structure—tendinous at its attachments, fleshy in the rest of its extent; relations—its posterior and external surface is covered by the trapezius, sterno-mastoid, and levator anguli scapulæ; the other rests on the complexus, trachelo-mastoid, and longissimus dorsi.

Actions.—The levator anguli scapulæ conspires with the rhomboideus in one of its more obvious actions. When the acromion process is elevated, the posterior angle of the scapula is depressed, and the inferior one carried forwards; but as soon as the more powerful muscles cease to act, the levator draws upwards the posterior angle of the bone, whilst the rhomboid carries backwards and upwards the inferior angle, thus giving a slight rotatory motion to the whole bone, and at the same time depressing the acromion and point of the shoulder. If the shoulder be fixed, the levator may incline the neck down to the same side, just as the trapezius draws the head under the like circumstances. If the rhomboid muscle conspires with the middle and lower part of the trapezius, the base of the scapula will, by their joint effort, be carried directly towards the spine.

The serrati postici, in their action on the thorax (which from their size is necessarily insignificant), are antagonists. The inferior one is enabled by the direction of its fibres to depress the ribs, and to assist in expiration; but the other elevates the ribs, into which it is inserted.

If the splenii muscles of both sides act together, they draw the head directly backwards, in which they conspire with the complexus and trapezius. When those of one side act separately, they incline the head laterally, giving it at the same time a slight rotatory motion. The complexus, too, by reason of the oblique direction of its fibres, can give a certain degree of horizontal motion to the head, but in a

direction contrary to that of the splenii, as must be evident from the fact, that the fibres of the one incline outwards as they ascend, and those of the other inwards.

FOURTH LAYER.

422. The term *erector spinæ* may with much propriety be applied to that long, intricate interlacement of muscular fibres, which in the lumbar region forms a thick mass that fills up the vertebral groove, but which along the back becomes divided into two parts, viz. the sacro-lumbalis and longissimus dorsi. The muscle arises, 1, from all the spines of the sacrum, as well as its lateral parts; 2, from the spinous and transverse processes of the four inferior lumbar vertebræ, and the inter-spinous ligaments; 3, from the sacro-iliac ligaments, and from the posterior third of the crista ilii. At its origin from the sacrum, it is tendinous: where it corresponds with the loins, the external half is fleshy, the internal aponeurotic. Opposite the last rib, the muscle becomes separated into the parts above mentioned by a cellular interval.

Dissection.—When you have sufficiently examined the muscles of the third layer, divide the serrati and their aponeurosis in the middle, and reflect the pieces, one inwards, the other outwards. When this is done, the sacro-lumbalis and longissimus dorsi may be traced from below upwards, by merely passing the handle of the scalpel along the cellular interval which separates them. The next step is to detach the splenii at their origin by an incision carried from above downwards close to the spinous processes. These muscles diverge at their upper part, and leave between them an interval in which the complexi are seen. When the splenius has been detached from the vertebræ and reflected outwards, the transversalis colli and trachelo-mastoideus can be followed along the neck, taking them as continuations of the long dorsal muscles. Examine the complexus, then pass the handle of the scalpel under its inner border; draw it outwards so as to get the scalpel deeply under it, and detach it from the transverse processes, cutting from within outwards. Reflect it up to the head, by which means the recti and obliqui capitis are exposed, and also the spinalis colli. Finally, the spinalis dorsi will be observed between the longissimus dorsi and the spinous processes; and when these muscles are removed, that series of oblique muscular and tendinous fibres is exposed which constitutes the multifidus spinæ. When examining the muscles here

noticed, you will find not a few variations in their points of attachment in different subjects. I lately saw the trapezius extend only to the seventh dorsal spine; and the deeper seated muscles are much more liable to present changes in the number and extent of the points to which their fibres are fixed.

Fig. 98.

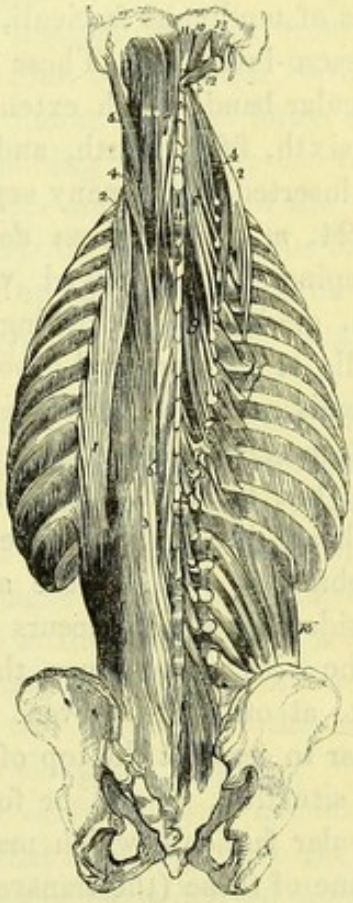

423. *m. Sacro-lumbalis*, fig. 98, 1, or rather (if its attachments be considered) the *sacro-costalis*, proceeds upwards, forming the exterior part of the erector spinæ, inclining a little outwards as it ascends, at the same time becoming narrower, inasmuch as it deposits, as it were, upon each rib part of its fibres. These end in tendinous processes, which are inserted into the angles of the six or seven lower ribs, and so the muscle (at least the part of it that can be traced up from the lumbar region) should be considered as terminating, but that a series of accessory fibres (*m. accessorius ad sacro lumbalem*) begin to be placed along its inner side, by which it is prolonged to the neck. These bundles of fibres, which are overlapped by the insertions of the muscle itself, commence at the angles of the ribs by tendinous points, which soon become fleshy, and pass up over one or two intercostal spaces, to be inserted successively into the angles of the superior ribs, and into the transverse process of the last cervical vertebra; and so the chain of continuity is maintained along the thorax.

Intimately united with these may be observed another and larger fasciculus of fibres, by which the muscle is prolonged into the neck, and which on that account has been called "cervicalis ascendens," from its resembling a process sent up into the neck

from the sacro-lumbalis; whilst others have applied to it the term cervicalis descendens, from the circumstance that its more fixed point of attachment is at the transverse processes of the cervical vertebræ, from which it passes down along the angles of the ribs, and intermingles with the fibres of the sacro-lumbalis. Be this as it may, the cervical prolongation of the sacro-lumbalis, 2, *(m. cervicalis ascendens; cervicalis descendens,) arises* from the angles of the sixth, fifth, fourth, and third ribs, by a series of tendinous fasciculi, which are blended with the fibres of the sacro-lumbalis. These gradually unite to form a thin, short, muscular band, which extends along the transverse processes of the sixth, fifth, fourth, and third cervical vertebræ, into which it is inserted by so many separate digitations or points.

424. *m. Longissimus dorsi*, 3, or inner division of the erector spinæ, is prolonged vertically upwards from the lumbar mass, gradually diminishing in size as it ascends. It lies in the middle of the vertebral groove, intermediate between the sacro-lumbalis and the semi-spinalis dorsi, from which it is separated by deep cellular intervals. The posterior surface is smooth and even, but from the anterior a number of processes are sent off, which are inserted into the transverse processes of the dorsal vertebræ, as well as the adjacent rough surface of the ribs. Considerable variety occurs in the number of these attachments to the ribs; sometimes they can be traced to only seven or eight, at others to eleven. The muscle would at first sight appear to cease at the top of the thorax; but when examined in that situation, it will be found connected intimately with two muscular fasciculi, which may be considered as accessories to it. By one of these (the transversalis colli) it is prolonged into the neck, and connected with the transverse processes of the cervical vertebræ; by the other (the trachelo-mastoideus), with the mastoid process and the base of the skull.

425. *m. Transversalis colli*, 4, (transversus cervicis, Sœmm.) *arises* from the transverse processes of the four or five upper dorsal vertebræ, by so many separate points, which are connected with the fibres of the longissimus dorsi: these form a flat irregular fasciculus, which is prolonged upon the transverse processes of the cervical vertebræ, and inserted by a series of tendinous and fleshy points into their posterior tubercles, from the sixth to the second inclusive. The muscle must, from its mode

of origin and insertion, be thinner towards its extremities than in the middle. Its external side is in contact with the cervicalis ascendens and splenius colli, which rest upon it; the internal one lies on the complexus and trachelo-mastoideus, being, in most instances, so closely united with the latter, that they are with difficulty separated.

426. *m. Trachelo-mastoideus*, 5, is the cranial prolongation of the longissimus dorsi; it is also sometimes called "complexus minor." It arises by a series of distinct fasciculi from the transverse processes of the three or four upper dorsal vertebræ, and the three lower cervical. The union of these forms a flat and thin muscle, which ascends, inclining somewhat outwards, to be inserted into the posterior border and surface of the mastoid process. Its internal surface rests on the complexus for the greater part of its extent; farther up it crosses over the obliquus capitis (superior and inferior), and covers the origin of the digastricus.

427. *m. Spinalis dorsi.* Between the inner border of the longissimus dorsi and the spines of the vertebræ is placed a series of tendinous and fleshy fasciculi, 6, attached by their lower extremities to the first two lumbar and the three contiguous dorsal vertebræ, and by the upper to the eight or nine superior dorsal spines. The fasciculi thus attached at their extremities are free in a great measure towards the middle, and form a separate muscle called spinalis dorsi. The two muscles of this name, when exposed together, represent an elongated ellipse.

428. *m. Complexus*, 7, (trachelo-occipitalis,) is a thick and rather broad muscle, situated somewhat obliquely upon the posterior part of the cervical region. Its name is derived from the peculiar manner in which tendinous and fleshy fibres are intermixed in its structure. It arises from the transverse and articulating processes of the four or five superior dorsal vertebræ, and from the transverse processes of the four inferior cervical, by a series of tendinous points. These are soon aggregated into a mass, which proceeds obliquely upwards and inwards, converging to the corresponding muscle of the opposite side, and finally is inserted into the irregular surface between the curved lines on the occipital bone. At their origin, the two muscles of this name are separated at a considerable interval, but at their insertions they are in close contact. The posterior or external

surface of each, which is inclined obliquely outwards, is in immediate contact superiorly for a short way with the trapezius; in the middle of the neck, the splenius rests upon it, and lower down the trachelo-mastoideus. The anterior, or inner surface rests on the semi-spinalis colli, and higher up on the rectus capitis major, and on the obliqui.

Close by the inner border of the complexus, and in most cases forming a part of it, is a long fasciculus, consisting of two fleshy bellies united by a tendon, and hence named *m. Biventer cervicis.* Inferiorly it presents two or three tendinous and fleshy points attached to as many transverse processes of the dorsal vertebræ from the fourth to the sixth or seventh, and superiorly inserted into the occipital bone near the complexus.

FIFTH LAYER.

429. The *semi-spinalis muscle* is so named from its fibres being placed obliquely between the transverse and spinous processes of the vertebræ. It consists of two parts, one in the cervical, the other in the dorsal region; hence they are described and named as if they were two separate muscles, viz. semi-spinalis colli and semi-spinalis dorsi.

m. Semi-spinalis colli, fig. 98, 8, arises by four or five fasciculi from the transverse processes of the four or five superior dorsal vertebræ. These, having united, incline inwards as they ascend, and are inserted usually by four separate points into the spinous processes of the cervical vertebræ, from the fifth to the second inclusive. Its fibres at their origin are covered by those of the longissimus dorsi, and in the neck by the complexus: its inner surface rests on the termination of the spinalis dorsi, and higher up on the inter-spinales cervicis.

m. Semi-spinalis dorsi, 9, is placed in a continuous line immediately beneath the preceding muscle, and intimately united with it. It arises from the transverse processes of the dorsal vertebræ, from the eleventh to the fifth inclusive, by so many distinct fasciculi. These, having united, pass upwards, and are inserted into the spinous processes of the four superior dorsal and two lower cervical vertebræ. Its fibres, at their origin, are concealed by the longissimus dorsi, and at their insertion, for some way, by the semi-spinalis colli; in the interval they lie

between the longissimus dorsi and the spinous processes of the vertebræ.

430. *m. Rectus capitis posticus major*, 10, (axoido-occipitalis,) is situated along the middle line, close to the vertebræ, extending from the spinous process of the axis to the under surface of the base of the skull. It arises by a pointed origin from the process just mentioned, and, gradually enlarging as it ascends, is inserted into the inferior curved line of the occipital bone. It diverges somewhat from the corresponding muscle of the opposite side, and is covered by the complexus.

431. *m. Rectus capitis posticus minor*, 11, (atlo-occipitalis,) extends from the atlas to the base of the skull, being smaller every way than the preceding. It arises from the posterior border of the atlas, and is inserted into the rough surface between the inferior curved line on the occipital bone, and the foramen magnum. It lies nearer to the middle line than the preceding muscle, and can therefore be seen without disturbing it.

432. *m. Obliquus capitis inferior*, 12, (axo-atloideus,) is placed obliquely between the first two cervical vertebræ. It arises from the spinous process of the axis, between the origin of the rectus posticus major and the insertion of the semi-spinalis colli, and is inserted into the extremity of the transverse process of the atlas.

433. *m. Obliquus capitis superior*, 13, (atlo-post-mastoideus,) extends from the atlas to the lateral and inferior part of the base of the skull. It arises from the extremity of the transverse process of the first cervical vertebra, inclines from thence obliquely upwards and inwards, expanding somewhat as it ascends, and is inserted, close behind the mastoid process, into the interval between the curved lines of the occipital bone. These two muscles are covered by the complexus, and correspond, the one with the first inter-vertebral space, the other with that between the atlas and occiput.

434. *m. Inter-spinales*, 14, as their name implies, are short fasciculi of fleshy fibres, placed between the spinous processes of the contiguous pairs of vertebræ. They are well marked and defined in the neck, in the lumbar region they are seldom distinct, and in the dorsal can scarcely be said to exist. As each passes from the upper border of a particular spinous pro-

cess in the neck, to be inserted into that next above it, it must consist of two parts, one for each tubercle, inasmuch as the spinous processes in this region (except the first and last) are bifid at their extremities. Their points of attachment at once indicate their extent and relations.

435. In close contact with the inter-spinales, and placed along their posterior border, may be observed, in most instances, some thin bundles of fibres, which cannot be said to lie within the interval of the spinous processes. On the contrary, they extend from the summit of one to the next, or second next, above it. From this circumstance they have been called *supra-spinales ;* and as they increase gradually from below upwards, being situated in the median line, they may be considered as analogous to the recti capitis postici.

When proceeding with the dissection of the muscles here noticed, you will meet with the elevators of the ribs, a series of fleshy and tendinous bundles extended downwards and forwards from the transverse processes of the vertebræ to the margins of the ribs ; for these see section 499.

436. *m. Inter-transversales* are placed between the transverse processes of the cervical vertebræ ; they can seldom, if ever, be demonstrated in the dorsal or lumbar region. As the transverse processes of the vertebræ in the neck are bifid, the muscles disposed between each pair of them are arranged in two planes, one before the other, so that the cervical nerves, at their exit from the vertebral column, necessarily pass out between them.

437. *m. Multifidus spinæ*, 15, extends along the spinal column from the sacrum to the axis, filling up the deepest part of the groove between the transverse and spinous processes. It is made up of bundles of fleshy and tendinous fibres, intermixed rather confusedly together. The direction of these is more or less oblique, but their length varies considerably, as they are found to reach from the transverse process of a particular vertebra to the spinous process of that immediately above it, and, in other instances, to those higher up by one or two spaces. Thus formed, the structure here described should be considered not as a single muscle, but rather as an aggregate of many, which conspire in their general action on the vertebral column, by reason of the separate influence which each can exert on individual pairs of vertebræ. The first of these

fasciculi extends from the side of the sacrum to the spinous process of the fifth lumbar vertebra, the last from the transverse process of the third cervical vertebra to the spine of the axis. The muscle gradually diminishes in bulk as it ascends; its fibres are intimately blended with those of the semi-spinalis dorsi et colli.

Combined actions. — The sacro-lumbalis, longissimus dorsi, and multifidus spinæ, conspire in fixing the spinal column, and thereby maintaining the trunk erect. If they continue their effort, the body will be drawn somewhat backwards, as may be observed when a considerable weight is suspended from the neck, or in persons who have become excessively fat. In both these cases, the extensor muscles are required to make increased efforts to counterpoise the influence of the weight appended to the fore part of the body. As these muscles have to sustain the trunk in the sitting as well as in the standing posture, it might be supposed that they scarcely admitted of any relaxation, and therefore are kept almost constantly in action. But it does not appear necessary, except in making great efforts, that all of them should be in action at the same moment, and even the different parts of the same muscle must, in most cases, act successively. Thus the lower fibres of the multifidus spinæ pass from the sacrum to the lumbar spines, and materially assist the quadratus lumborum and other muscles in fixing the lumbar vertebræ. These, or rather their transverse processes, become the fixed points from which the succeeding parts of the multifidus act on the spines throughout the entire length of the column, so that a succession of efforts is propagated from below upwards by a sort of vermicular motion. When by such an arrangement the action of one set of fibres succeeds that of another, each will have its alternations of contraction and relaxation, as well as the fibres of those muscles in which the change is more perceptible. The sacro-lumbalis can draw down the lower ribs; and if the effort be continued, this influence must speedily be propagated to the spinal column, which is thus bent towards the side by means of the intimate connexion between the heads of the ribs and the vertebræ. The longissimus dorsi conspires to produce the same effect. The spine admits, to a certain extent, of a rotatory movement. Thus the head may be carried round by a horizontal motion, until the chin comes nearly on a line with the point of the shoulder, after which the spine may be made to turn on its own axis, until the face shall have completed almost a semi-circle, from the point at which its first movement began. The latter move

ment is effected by that peculiar action of the multifidus spinæ above alluded to; but it is the muscle of the opposite side from that towards which the movement takes place, that produces the rotation, assisted by the obliquus externus abdominis.

The influence of the sacro-lumbalis in depressing the lower ribs must be evident from its mode of attachment to them. But its accessory muscle (cervicalis ascendens), by taking its fixed point at the cervical vertebræ, is enabled to draw up, and therefore elevate, the ribs into which it is inserted.

Muscles of the Upper Extremity.

438. The muscles of the upper extremity, taken in the order of their situation, may be divided into four groups, viz. those placed on the shoulder, those on the arm, on the fore-arm, and on the hand. We must, however, commence the description of the moving powers of the limb with that of the two pectoral muscles and the serratus magnus.

Dissection of the upper arm.—The subject being laid on its back, and the arm drawn away from the side, an incision may be made through the skin, commencing at the middle of the clavicle, and extending down to the centre of the axilla. From this another line may be drawn, downwards and inwards, along the lower border of the pectoralis major. The angular flap thus included should then be raised from off the muscle just named, its dissection being conducted from without inwards to the fore part of the sternum, so as to expose the muscle. It may be necessary to make another incision through the skin, along the clavicle, to the sternum, from the point above indicated. The external flap of the skin may then be dissected off the remainder of the pectoral muscle, and part of the deltoid. When the external surface of the pectoralis major has been examined, it may be detached easily by drawing forwards its lower border, and inserting the scalpel between it and the costal cartilages, and cutting through its attachments to them, as well as to the sternum and clavicle, successively. The muscle may then be drawn outwards, and the fold in its tendon examined. The pectoralis minor is thus exposed, and the axillary vessels partly. The costal attachment of this muscle may be separated in the same way as the other. The axillary vessels are by these measures brought fully into view, little else remaining to be done than to remove the cellular tissue in which they are imbedded. For the Axillary Artery,—the Vein,—and the Plexus of Nerves, see subsequent sections.

When commencing the dissection of the arm, an incision may be made from the middle of the interval between the folds of the axilla, and thence drawn down to the middle of the space between the condyles of the humerus. This indicates the course of the brachial artery. It should barely divide the skin, care being taken not to injure the fascia beneath it. It will be found convenient to bound it below by a transverse incision; after which, the skin may be cautiously raised from the fascia all round the arm. In order to expose the deltoid, it will be necessary to make an incision through the integument, commencing at the external third of the clavicle, and extended along the acromion and spine of the scapula; after which, it may be dissected off the muscle, proceeding from above downwards and outwards, until the whole flap of skin is removed. When the muscle has been examined, it may be easily detached from its origin, and reflected down on the arm, by inserting the scalpel under its posterior border, and cutting from within outwards, close along the margin of the spine of the scapula, and so successively along the acromion and clavicle. This will expose the circumflex vessels and the external rotator muscles.

The fascia of the arm may in the next place be divided, and reflected in the same way as the integument. In doing so, care should be taken not to injure the internal cutaneous nerve. As the fascia is being reflected, the biceps muscle and the brachial artery and the nerves, except the circumflex and spiral, are brought into view. Their relative position, particularly at the head of the arm, should be attentively considered. If the arm be rotated outward, the direction of the spiral nerve and profunda artery can easily be traced, for some way, between the heads of the triceps muscle. At the outer side of the arm, the nerve will be found in the deep sulcus between the brachialis anticus and supinator longus, after it has made its turn behind the humerus. The external cutaneous nerve also has to reach the external side of the arm, but it runs in front of the humerus, piercing the coracobrachialis muscle, and then lying between the biceps and brachialis anticus. The examination of the triceps had better be conducted from below upwards, following the plan adopted in the description given of it; and when its three heads have been carefully traced out, a longitudinal incision may be made through the substance of the muscle; after which, when the two parts are drawn back, the manner in which the fleshy fibres proceed to the bone, from its tendon or aponeurosis, will be distinctly seen.

THORACIC REGION (ANTERIOR).

439. *m. Pectoralis major*, fig. 99, 1, (sterno-costo-clavi-humeralis,) is placed on the anterior and upper part of the thorax,

Fig. 99.

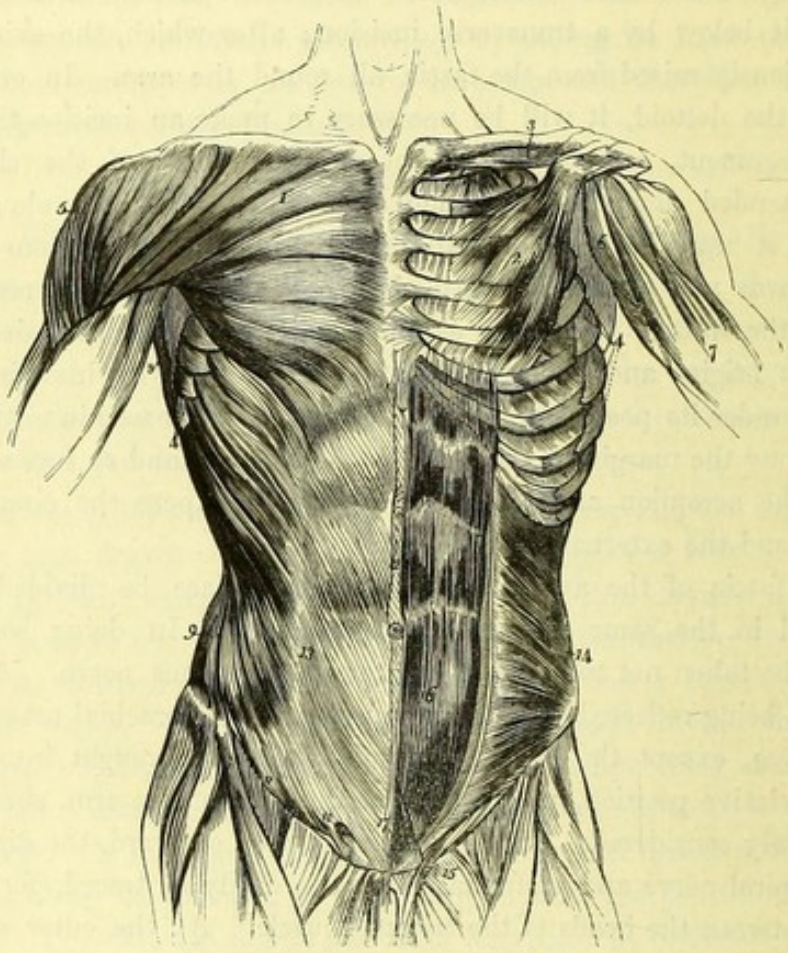

and in front of the axilla. It is broad and expanded at the former situation, narrowing gradually towards the latter, and *arises* from the sternal half, or a little more, of the clavicle, from the anterior surface of the sternum, extending as far down as the insertion of the cartilage of the sixth rib, and from the cartilages of the true ribs, except the first and last. In some cases, also, a fleshy slip is derived from the aponeurosis of the obliquus externus abdominis, where it covers the rectus muscle. From this extensive origin the fleshy fibres proceed, converging towards the tendon of insertion; those from the clavicle, which are usually separated from the rest by a cellular interval, pass downwards and outwards; those from the lower cartilages obliquely

outwards; the middle set horizontally. The muscular fibres become continuous with those of the tendon, and still retain their original direction as they proceed to their respective points of insertion into the humerus; and as the superior fibres descend, whilst the inferior ones ascend, the latter passing behind the former, their arrangement gives to the muscle a folded or twisted appearance along its axillary border. The flat portion of the muscle here described, after being extended across the axilla, is inserted into the anterior border of the bicipital groove in the humerus, its cutaneous surface being muscular, the axillary tendinous. Direction—the superior fibres descend as they pass outwards; those immediately below them are horizontal; the rest ascend with increasing degrees of obliquity: structure—aponeurotic at its internal and external attachments, fleshy in the rest of its extent:—relations—the aponeurotic fibres of its internal border decussate with those of the corresponding muscle in front of the sternum; the inferior border overlaps the serratus magnus, and the superior runs parallel with that of the deltoid muscle, from which it is only separated by the cephalic vein and a small artery. The anterior surface is subcutaneous in the greater part of its extent, being only covered by some of the fibres of the platysma myoides, and by the mamma. The posterior surface, besides the sternum, clavicle, and ribs, is in relation with the pectoralis minor, subclavius, and serratus magnus muscles, which it covers, and also with the axillary vessels and nerves. The lower border of this muscle is at first separated from that of the latissimus dorsi by a considerable interval, in which may be observed the fibres of the serratus magnus; but they gradually converge towards the axilla, forming its folds or borders.

440. *m. Pectoralis minor*, fig. 99, 2, (costo-coracoideus,) lies at the superior part of the thorax, covered by the preceding muscle, and extended obliquely across the axilla. It *arises* from the external surface of the third, fourth, and fifth ribs, near their cartilages; its margin being usually dentated, so that some of the older anatomists named it "serratus anticus minor." The fleshy fibres, as they proceed obliquely upwards and outwards, converge to a narrow tendon, which is inserted into the inner and upper border of the coracoid process near its extremity. Its direction and structure have been here sufficiently indicated.

Relations — the anterior surface is covered by the pectoralis major, the posterior crosses the axillary vessels and nerves.

441. *m. Subclavius*, fig. 99, 3, (costo-clavicularis,) is placed under the clavicle, in the interval between it and the first rib. It *arises* by a small short tendon from the cartilage of the first rib, close to the rhomboid ligament, from which it is directed outwards beneath the clavicle, forming a rounded fleshy fasciculus, which is inserted into the grooved and rough surface, along the costal aspect of the clavicle, for nearly half its length. Relations—its upper surface is covered by the clavicle, a small part beneath it being overlapped by the pectoralis major, but which is at first not perceptible, until a dense fascia that covers it is dissected off; the costal surface lies in front of the subclavian vessels as they pass down from the neck.

THORACIC REGION (LATERAL).

442. *m. Serratus magnus*, fig. 99, 4, (costo-basi-scapularis,) is placed upon the upper and lateral parts of the thorax, between the ribs and the scapula, being deeply seated in the greater part of its extent. Its anterior border presents eight or nine fleshy points or digitations, giving it a serrated appearance, whence its name is taken. By these, as its points of attachment, it *arises* from the surface of the eight superior ribs; for it is generally found that two of the processes come from the second rib, or, at all events, the one arising from it is larger than any of the others, and not unfrequently of a deeper colour. From this extensive origin, the fibres of the muscle, forming a flat thin plane, converge as they proceed backwards, and are inserted into the base of the scapula, being interposed between the subscapularis on the one side, and the rhomboidei and levator anguli scapulæ on the other. Structure—fleshy in its entire extent. If the muscle be put on the stretch by drawing the scapula backwards, its fibres will be observed to be arranged in flat fasciculi, traceable from its serrated border, and distinguished from one another by deep linear impressions. Relations—one surface rests on the superior ribs, the intercostal muscles, and part of the serratus posticus superior; the other is subcutaneous in the angular interval between the pectoralis and latissimus dorsi; higher up it is covered by both the pectoral muscles; in the rest of its extent it is in relation with the subscapular muscle

and the axillary vessels. The greater number of its fibres will be observed to converge towards the angles of the scapula, particularly the lower one.

Combined actions.—The most obvious actions of these muscles are exerted upon the shoulder and arm, as being their more movable points of attachment. The pectoralis major, conjointly with the latissimus dorsi and teres major, depresses the humerus, if it has been previously elevated; it then conspires with them in pressing the arm closely to the side, and, continuing the same effort, will by itself trail it along the side and front of the chest. The pectoralis minor draws the point of the shoulder downwards and inwards to the thorax. If the arms be fixed, these muscles act on the ribs and assist in dilating the chest. This is frequently observed during the forcible efforts at inspiration made by asthmatic persons; the arms are rendered fixed, by seizing hold of some object, and then every muscular effort is called into play which can elevate the ribs.

When the scapula is rendered fixed by the trapezius and rhomboid muscles, the serratus acts on the chest in the same way as the pectoral muscles do; but its most ordinary action is to draw the base and inferior angle of the scapula forwards, so as to elevate the point of the shoulder by means of the rotatory motion it can impress upon it conjointly with the trapezius, as has been observed when treating of the latter muscle. The continuation of the same effort retains the shoulder elevated, as when a burden is sustained upon it; but, as a preparatory measure, the thorax must be fixed. Whilst any important muscular exertion is being performed, the thorax must be fixed, and retained so by preventing the escape of the included air. This may be inferred from observation on what takes place under such circumstances, but was reduced to the test of experiment by M. Bourdon.* He opened the trachea, or larynx, of a dog that had been in the habit of jumping and tumbling when bidden; after which, the animal was no longer able to make any similar efforts, though evidently willing to do so. But when the aperture was closed, by drawing the margins of the wound together, the lost power was instantly restored.

ACROMIAL REGION.

443. *m. Deltoideus*, fig. 99, 5, (sub-acromio-humeralis,) is situated at the superior and external part of the arm, covering in

* Mémoire sur les Efforts.

the shoulder-joint; its form is triangular, the base above, and the apex below. It *arises* from the external third of the clavicle, from the lower border of the acromion, and from the spine of the scapula, as far back as the small triangular surface in which it terminates; and is inserted into the rough prominence on the middle of the outer side of the humerus. Direction — the middle fibres descend perpendicularly, the anterior and posterior converge to these as to a common point: structure — fleshy and tendinous at its base, tendinous at its apex, fleshy in the rest of its extent: relations — by the outer surface, with the platysma myoides and integuments; by the inner surface, with the tendon of the pectoralis major, the circumflex vessels and nerves, the outer side of the humerus, the fibrous capsule of the shoulder-joint, the coracoid process, the pectoralis minor, coraco-brachialis, biceps, subscapularis, coraco-acromion ligament, the external rotator muscles, and the triceps; by the anterior border, with the pectoralis major (from which it is separated by the cephalic vein), and more inferiorly with the biceps: the posterior border is free.

SCAPULAR REGION (POSTERIOR).

444. *m. Supra-spinatus*, fig. 97, 12, is placed at the superior part of the shoulder, in the supra-spinous fossa of the scapula. Its form is elongated and triangular. It *arises* from the posterior two-thirds of the fossa above mentioned, and is inserted into the superior surface of the greater tuberosity of the humerus. Direction — oblique from behind forwards: structure — tendinous at the humeral end, fleshy in the rest of its extent: relations — by the outer surface, with the trapezius, coraco-acromion ligament, and deltoid; by the inner surface, with the scapula and the ligamentum proprium posticum, with the supra-scapular nerve and vessels, the omo-hyoideus muscle, and the fibrous capsule of the shoulder-joint, with which it is intimately united.

445. *m. Infra-spinatus*, fig. 97, 13, occupies the chief part of the infra-spinous fossa, and *arises* from the lower surface of the spine of the scapula, and from all the convex part of its dorsum. The fibres converge to a tendon, at first concealed in a great degree within the substance of the muscle, but which afterwards proceeds forwards over the capsular ligament of the joint, to be inserted into the upper border of the great tuberosity of the

humerus. Direction—from behind forwards, the superior fibres being nearly horizontal, the inferior ones converging to meet them: structure—tendinous at the humeral end, and for some way along its centre, fleshy in the rest of its extent: relations—the posterior surface is covered, partly by the deltoid, the latissimus dorsi, and trapezius, a small part also being subcutaneous; the anterior rests on the bone and capsular ligament. The lower border is in contact with the teres minor, being united posteriorly with it and the teres major.

446. *m. Teres minor*, fig. 97, 14, lies along the inferior border of the scapula; its form is elongated, narrow, and round. It *arises* by a series of oblique fibres from the dorsal surface of that ridge which surmounts the axillary border of the scapula, and from two aponeurotic septa, placed between it and the infra-spinatus and teres major muscles. Its insertion lies immediately below that of the infra-spinatus, into the greater tuberosity of the humerus. Direction—oblique from behind forwards and upwards: structure—tendinous at its humeral end, fleshy in the rest of its extent: relations—by the outer surface with the integuments and deltoid muscles; by the inner with the scapula, the posterior or dorsal branch of the sub-scapular artery, the long head of the triceps muscle, and the fibrous capsule of the shoulder-joint. The upper border lies in contact with the infra-spinatus; the lower with the teres major, but is separated anteriorly from it by the long head of the triceps; the posterior extremity is, as it were, inserted between the teres major and infra-spinatus, being connected with both, as has been above stated.

The three flat surfaces marked on the upper border of the great tuberosity of the humerus give insertion to these three muscles, taken in their regular order, from above downwards.

447. *m. Teres major*, fig. 100, 1, extends from the inferior angle of the scapula to the humerus, contributing to form the posterior border of the axilla. It is rather broad and compressed than round, as its name would imply. It *arises* from the flat expanded surface placed at the inferior angle of the scapula, and from the septa interposed between it and the teres minor and infra-spinatus. Its insertion takes place by a broad flat tendon into the posterior border of the bicipital groove in the humerus, being in close contact with the tendon of the latissimus

dorsi. Its direction must necessarily vary according to the different positions of the scapula and humerus. Towards their insertion its fibres appear to descend somewhat, whilst those of the latissimus ascend, so that its border is placed lower down than that of the latter muscle. Structure — tendinous at its insertion, fleshy in the rest of its extent: relations — its posterior surface is covered by the latissimus dorsi and integument, and crossed by the long head of the triceps; the anterior, in part of its extent, is in contact with the latissimus (in consequence of the change of direction of the latter), and slightly with the coraco-brachialis and brachial vessels.

SCAPULAR REGION (ANTERIOR).

448. *m. Sub-scapularis*, fig. 100, 2, fills up the hollow of the scapula, lying between that bone and the thorax, from which, however, it is separated by the serratus magnus muscle. It *arises* from the entire surface of the sub-scapular fossa, its fibres being divided into two or three bundles by aponeuroses connected with the prominent lines marked on the bone. From this extensive origin the fibres converge to a thick tendon, which, after being intimately united with the capsular ligament, is inserted into the lesser tuberosity of the humerus. Direction — from behind forwards, the superior fibres being nearly horizontal, the inferior ascending obliquely: structure—tendinous at its humeral extremity, fleshy in the rest of its extent: relations—by the outer, or posterior surface, with the scapula, and the fibrous capsule of the shoulder, to which it is intimately adherent; by the inner, or anterior surface, with some loose cellular tissue separating it from the serratus magnus, and the brachial plexus of nerves.

Fig. 100.

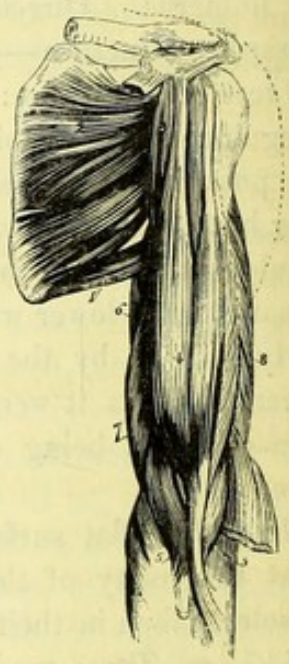

Actions. — The deltoid can raise the arm directly from the side, so as to bring it at right angles with the body; after which, by means

of its anterior and posterior fibres, it can carry the limb alternately backwards and forwards, being assisted in the former movement by the teres major and latissimus dorsi, in the latter by the pectoralis major. The mass of its muscular fibres is so considerable, that it is enabled, by pressing down the head of the humerus, to make it glide upon the surface of the glenoid cavity of the scapula, and then, by continuing the effort, to raise the limb directly upwards, so as to bring it to the vertical position. Its only assistant in elevating the arm is the supra-spinatus (whose power in this respect must be trivial, as it is inserted so near the centre of motion).

The supra-spinatus, infra-spinatus, and teres minor, are the external rotators of the arm, whilst the sub-scapularis rotates it inwards; for, as they are opposed in situation, so they are antagonists in action. The power of these muscles is increased in no small degree by passing over the globular head of the humerus, and also by being inserted into the prominent processes of bone which remove the line of their direction to a distance from the axis of the humerus. The teres major conspires with the latissimus dorsi in its actions; it depresses the arm, if raised, and rotates it on its axis. If the arm be fixed, as when, in the reclining posture, the elbow is removed from the side, these muscles, particularly the teres major, assisted by the long head of the triceps, can approximate the lower border of the scapula to the shaft of the humerus, thus conspiring with other muscles, viz. the pectoralis and latissimus dorsi, to trail the body after the out-stretched limb.

HUMERAL REGION (ANTERIOR).

449. *m. Coraco-brachialis*, fig. 100, 3, is placed along the superior and inner part of the arm for about half its length. It *arises* from the coracoid process of the scapula, between the pectoralis minor and the short head of the biceps, also from the tendon of the latter, with which it is intimately united for some way. The fleshy fasciculus thus formed passes downwards and a little outwards, to be inserted into the inner side of the humerus about its middle, where it is interposed between the brachialis anticus and the triceps. Direction — nearly vertical: structure—aponeurotic at its attachments, fleshy in the middle: relations — its anterior surface is covered above by the deltoid and pectoralis major, and at its insertion is crossed by the brachial artery. The posterior surface runs over the tendon of the sub-scapularis, and those of the latissimus dorsi and teres

major, the axillary vessels intervening; one border is in apposition with the biceps, the other with the brachial artery; its belly is usually pierced by the external cutaneous nerve.

450. *m. Biceps flexor cubiti*, fig. 100, 4, (coraco-scapulo-radialis,) lies along the anterior part of the arm for its entire length. Superiorly it is divided into two heads, whence its name is derived. Of these, the *internal* or short *head*, *arises*, conjointly with the coraco-brachialis, from the extremity of the coracoid process, from which it descends, and unites at an acute angle with the *external* or long head, which *arises* from the upper border of the glenoid cavity, where it is also connected with the fibrous rim which surrounds that cavity. The tendon passes over the globular head of the humerus, enclosed in a sheath formed by the synovial membrane of the joint, and, after piercing the fibrous capsule, and descending some way in the groove appropriated for it, unites, as above stated, with the short head. The long, rounded, fleshy belly thus formed ends near the bend of the arm, in a flat tendon, which sinks deeply between the muscles of the fore-arm, and is inserted into the posterior part of the tubercle of the radius. Direction—vertical: structure—tendinous at its extremities, fleshy in all the rest of its extent. From the tendon of insertion a fibrous expansion, presenting an arched border, is sent off, as it is about to sink between the muscles of the fore-arm. This process passes obliquely downwards and inwards, and becomes blended with the fascia of the fore-arm somewhat below the inner condyle; it is stretched across the brachial artery, median nerve, and part of the pronator teres muscle. Relations—the anterior surface is overlapped superiorly for some way by the deltoid and pectoral muscles; but in all the rest of its extent it is subcutaneous. The posterior surface, for about half its length, rests on the humerus and shoulder-joint, and in the rest on the brachialis anticus, being separated from the latter by the external cutaneous nerve. The inner border is in contact with the coraco-brachialis for half its length, and with the brachial artery for the rest.

451. *m. Brachialis anticus*, (humero-cubitalis,) fig. 100, 5, lies under cover of the biceps, along the lower half of the arm. It is somewhat compressed in its form, and broader in the

middle than at the extremities. It *arises* from the fore part of the humerus, commencing at the insertion of the deltoid, which it embraces by two angular fleshy processes, and extending nearly to the border of the trochlea. Some fibres also arise from the inter-muscular septa at each side. These, after passing in front of the elbow-joint, end in a thick fasciculus of tendinous fibres, which is inserted into the rough surface on the fore part of the coronoid process of the ulna. Direction—the middle fibres are vertical, those on each side converge a little to them: structure —tendinous at its insertion, fleshy in the rest of its extent: relations—the posterior surface rests on the bone and capsular ligament; the anterior, partly concealed by the biceps, projects somewhat at each side of it, and supports the brachial artery and median nerve.

Combined Actions.—The most obvious action of the biceps is that of flexing the fore-arm, in which it conspires with the brachialis anticus; it also serves to render tense the fascia of the arm by means of the process which connects its tendon with that membrane. If the arm be placed in the prone position, the biceps can turn it supine, being in this particular the direct antagonist of the pronator radii teres. When the fore-arm is rendered fixed by holding some firm object, the biceps and brachialis muscles can draw on the humerus, and bend it forwards on the arm, which is exemplified in the effort of climbing. They also can move the humerus on the scapula; but their influence in this respect must be very limited, as they run parallel with the axis of the bone. When the humerus is fixed, these muscles, by drawing on the coracoid process, move the scapula, and therefore the glenoid cavity on the head of the bone, so that the latter may receive support from the former, rather than that it should be pressed up against the capsular ligament solely.

HUMERAL REGION (POSTERIOR).

452. *m. Triceps extensor cubiti* rests against the posterior surface of the humerus in its entire length, being the only muscle that lies behind the bone and inter-muscular septa. Superiorly it is divided into three processes or heads, whence its name is derived, whilst its lower half, or more, remains single and undivided. In order to facilitate its description, we shall adopt Bichât's plan, and commence at the lower extremity of

Fig. 101.

the muscle. The triceps, fig. 101, then, is attached to the summit and sides of the olecranon by a strong tendon, which gradually expands into a wide aponeurosis, that covers the posterior aspect of the muscle for about half its length. From the anterior, or humeral surface of this aponeurosis, the fleshy fibres arise and proceed, with varying degrees of obliquity, to be inserted into the posterior surface of the humerus and of the inter-muscular septa, thus forming a thick fleshy mass, which continues undivided as far as the middle of the bone. There it begins to be separated into its three heads. Of these, the *posterior* or *long head*, 1, ascends vertically, and narrows into a flat fasciculus (fleshy and tendinous), which is inserted into the lower border of the scapula, immediately behind the glenoid cavity. The *internal*, or *short head*, 3, that is to say, the fibres which compose it, ascend along the inner margin of the humerus, and are inserted into each and every point of it, as far as the lower border of the teres major, where they end in a pointed process. Lastly, the *external head*, intermediate in length between the two others, proceeds along the external border of the humerus, gradually diminishing in size, until it ceases also by a pointed process, just below the insertion of the teres minor into the greater tuberosity. Direction—vertical: relations—its posterior surface is covered merely by the skin and fascia of the arm; the anterior rests against the humerus, from which it is separated, for an inch above the elbow-joint, by a cellular interval, and higher up, by the spiral nerve and profunda artery. These vessels also separate the second from the third head; and, where they pass between the former and the bone, they are protected from pressure by some tendinous fibres that arch obliquely over them. The long head is overlapped, near its insertion, by the deltoid, and is there interposed between the teres major and minor.

Actions.—When the fore-arm is flexed, the triceps, by drawing on the extremity of the ulna, is enabled to extend it on the humerus,

and so bring both parts of the limb into a right line. In situation, as well as in action, it is thus the direct antagonist of the biceps and brachialis anticus. When the arm is in the extended position, the long head of the triceps may assist, in some degree, the teres major and latissimus in carrying it backwards. If the elbow be fixed, the scapula becomes relatively the more movable point of attachment of the muscle, and then its long head, by acting on the lower border of that bone, can approximate it to the shaft of the humerus.

Muscles of the fore-arm.

453. The muscles of the fore-arm are very numerous, and their relations complex. In order to facilitate the examination of them, we shall divide them into groups, according to the positions which they occupy. The tendon of the biceps muscle, together with the brachial vessels, as they dip down at the bend of the elbow-joint, separate the mass of muscles into two parts, one being placed to the inner or ulnar side, the other to the outer or radial; the former being attached to the internal condyle of the humerus, the latter to the external; so that they are obviously separated at their upper part or origin. Another set of muscles, which likewise admits of subdivision, is placed at the posterior aspect of the limb.

BRACHIAL REGION (INNER AND ANTERIOR).

454. The muscles here placed are disposed in two sets, one being superficial, the other deep-seated.

The *dissection* of the fore-arm may be commenced by making an incision through the skin, from the middle of the interval between the condyles of the humerus to the root of the thumb; this marks out the course of the radial artery, and may be bounded by a transverse incision at each extremity. If the integument be drawn tightly forwards, and reflected inwards, the cutaneous nerves may be seen running in the cellular tissue between it and the fascia; and when once found, there can be little difficulty in tracing them in their entire extent, as they can be made to rest on the fascia, which gives them a firm support, whilst the scalpel is carried from above downwards along their cutaneous surface. After the superficial nerves and veins have been examined, the fascia may be dissected off the muscles. The examination of the muscles should be conducted in the order in which

they are described, commencing with those attached to the inner condyle.

The *superficial* muscles of the anterior and inner part of the fore-arm are, the pronator radii teres, flexor carpi radialis, palmaris longus, flexor carpi ulnaris, and flexor digitorum sublimis. These are all intimately united at their origin from the *inner condyle*, to which they are attached by a *common tendon* that gives a fasciculus of fibres to each, and also sends septa between them.

455. *m. Pronator radii teres*, fig. 102, 1, is extended obliquely across the front of the arm at its upper third. It *arises* by two distinct heads; one, large and superficial, is derived from the common tendon, from the fascia of the fore-arm, and the septum between this muscle and the flexor carpi radialis; the other head is a thin fasciculus which lies deeply (coming from the margin of the coronoid process), and joins the other at an acute angle, being previously separated from it by the median nerve. The fleshy belly thus formed proceeds outwards and downwards, to be inserted tendinous into the outer border of the radius about its middle. Direction — oblique from above, downwards and outwards: structure — tendinous and fleshy: relations — its anterior surface is superficial in the greater part of its extent; but towards its insertion it is crossed by the radial artery and nerve, and the supinator longus muscle. Its ulnar border is in contact with the flexor carpi radialis and palmaris longus: the radial border bounds, with the supinator longus, an angular space, in which are placed the brachial artery, the median nerve, and the tendon of the biceps muscle.

Fig. 102.

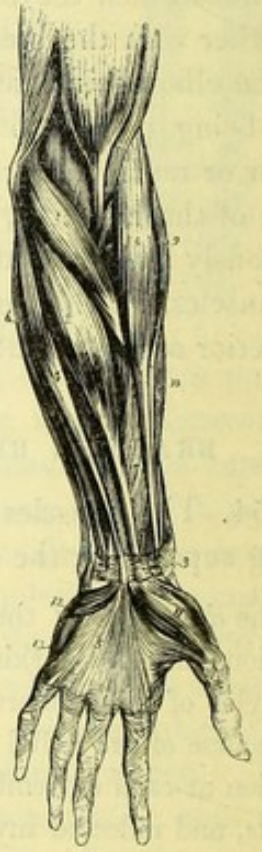

456. *m. Flexor carpi radialis*, fig. 102, 2, is situated in front of the fore-arm, being extended from the inner condyle towards the root of the thumb. It *arises* from the inner condyle by

the common tendon, from the fascia of the arm, and from the inter-muscular septa placed between it and the pronator teres on one side, the palmaris longus on the other, and the flexor sublimis posteriorly. Its tendon passes beneath the anterior annular ligament of the wrist, and runs through a groove in the os trapezium (to which it is bound by a thin fibrous sheath, lined by a synovial membrane), to be inserted into the extremity of the second metacarpal bone. Its anterior surface is covered by the fascia and integument; the posterior rests on the flexor sublimis, the flexor pollicis longus, pronator quadratus, and wrist-joint. Its tendon lies between those of the supinator radii longus and palmaris longus.

457. *m. Palmaris longus*, fig. 102, 4, lies along the middle of the fore-arm, on the ulnar side of the preceding muscle. It *arises* from the inner condyle and the inter-muscular septa; the small fleshy belly, which it presents superiorly, soon ends in a long slender tendon, which is inserted into the annular ligament of the wrist, and the palmar fascia, 5. When present, which is not always the case, this muscle is placed between the flexor carpi radialis and ulnaris, resting on the flexor sublimis.

458. *m. Flexor carpi ulnaris*, fig. 102, 6, lies superficial along the ulnar border of the fore-arm, being extended from the inner condyle to the inner margin of the wrist. It *arises* by two short processes, the angular interval between which transmits the ulnar nerve. One of these is attached to the inner condyle, the other to the border of the olecranon. The muscle is also connected, for some distance, to the inner side of the ulna by a dense fascia. The muscular fibres from these different points of attachment terminate in a tendon, which is inserted into the pisiform bone, and slightly into the base of the fifth metacarpal bone. Relations—the anterior surface is covered by the skin and fascia, the posterior rests on the flexor profundus, and overlaps the ulnar nerve and artery.

459. *m. Flexor digitorum sublimis, vel perforatus*, fig. 102, 7, is placed at the anterior part of the fore-arm, between the preceding muscles and the flexor profundus. It is flat and broad in the upper part, but inferiorly divides into four tendons. It *arises* from the inner condyle, by the common tendon, from the internal lateral ligament, from the anterior surface of the

coronoid process, and from the oblique line extended from the tubercle of the radius to the insertion of the pronator teres. The fleshy belly enlarges towards the middle of the arm, but diminishes somewhat before its division. The four tendons pass under the annular ligament of the wrist, resting on the flexor profundus; and diverge as they proceed to their destinations. Each of these, accompanied by a tendon from the flexor profundus, enters a fibrous sheath that binds it down to the palmar surface of the finger, and opposite the first phalanx it presents a fissured interval, which transmits the tendon of the deep flexor. Finally, after expanding somewhat, and forming a groove, by its palmar surface, which partly encloses the accompanying tendon, it is inserted into the fore part of the second phalanx. The same arrangement obtains in each instance. The direction and structure of the muscle have been here sufficiently indicated. Relations—superiorly concealed by the other muscles of this set, it rests on the flexor pollicis longus and flexor profundus, separated from the latter by the median nerve. In the palm of the hand, its tendons are covered by the palmar fascia, the superficial palmar arch of arteries, and the branches of the median nerve. Where the tendons slide beneath the annular ligament, they are invested by a synovial membrane, to facilitate their movements.

The *deep-seated* muscles, on the anterior surface of the fore-arm, are the flexor profundus, flexor pollicis longus, and pronator quadratus.

Dissection.—When the superficial muscles have been examined, consisting of the pronator teres, flexor radialis, palmaris longus, flexor ulnaris, and flexor sublimis, their common origin may be divided, and the whole mass drawn down towards the hand, which will expose the flexor profundus and flexor pollicis longus, as well as the median nerve and ulnar artery. The inter-osseous nerve and artery will at once be found between the two muscles last mentioned.

460. *m. Flexor digitorum profundus vel perforans*, fig. 103, 1, lies deeply along the ulnar border of the fore-arm, covered by the preceding muscles. It is compressed above, presents in the middle a fleshy belly of considerable size, and inferiorly is divided into four tendons. The muscle *arises* from the hollow at the inner side of the olecranon,—from the inner border and

Fig. 103.

anterior surface of the ulna, to within a few lines of the edge of the pronator quadratus, and from the ulnar half of the inter-osseous ligament. The four tendons, by which the muscle is continued into the palm, pass beneath the annular ligament, interposed between those of the flexor sublimis and the carpal bones, and maintain the same relation to the latter as they pass along the metacarpal bones and digital phalanges. Opposite the first phalanx of each finger, its tendon passes through the fissure formed for its transmission in the tendon of the flexor sublimis, and proceeds (still bound down by fibrous sheath) to be inserted into the base of the last phalanx. It is unnecessary to add anything more as to its direction or structure. Relations—its upper extremity in a manner embraces the insertion of the brachialis anticus ; the posterior surface rests on the ulna, inter-osseous ligament, and pronator quadratus ; the anterior is covered by the ulnar artery and nerve, the median nerve, and the other flexor muscles. The external border is parallel with the flexor pollicis longus, from which it is separated by the anterior inter-osseous artery.

461. *m. Flexor pollicis longus*, fig. 103, 2, lies on the same plane as the flexor profundus, resting on the radius. It *arises* from the grooved surface on the fore part of the radius, commencing just below the oblique line which extends from its tubercle to the insertion of the pronator teres, and reaching nearly to the edge of the pronator quadratus, also from the adjacent part of the inter-osseous ligament. The fleshy fibres come forward to a tendon, which, after passing beneath the annular ligament of the wrist, turns outwards, lying between the two heads of the flexor brevis and the sesamoid bones, then enters a fibrous sheath similar to those for the other flexor tendons, and finally becomes inserted into the base of the second phalanx of the thumb. Relations—its anterior surface is

covered by the flexor carpi radialis, flexor sublimis, and somewhat by the pronator teres, also by the radial vessels. Towards the lower part of the arm, its fibres can be readily perceived between the tendon of the supinator longus and flexor carpi radialis.

462. *m. Pronator quadratus*, fig. 103, 3; fig. 107, 1, is extended across the radius and ulna, immediately above their carpal extremity; it is flat and thin, and about two inches in breadth. Its origin, or fixed attachment, is from the inner border of the ulna, in the situation and extent just mentioned. The fibres pass directly across, to be inserted into the fore part and anterior surface of the radius. Its structure is fleshy; one surface rests on the bones and inter-osseous ligament, the other is covered by the muscles and vessels that pass into the palm of the hand.

Combined Actions.—These muscles act on the fore-arm, the hand, and the digital phalanges. The radius is made to turn on the ulna, and the hand thereby pronated by the pronator teres and quadratus, which take their fixed points, the one on the humerus, the other on the ulna, and draw the radius inwards across the latter bone. Should the pronator teres, after having effected so much, continue its action, it becomes virtually a flexor, and will assist the other muscles in bending the fore-arm on the arm. So also the flexors of the fingers, after having bent the phalanges towards the palm, begin to act on the wrist, and then contribute to the flexion of the fore-arm by means of the mechanical advantage they derive by passing under the annular ligament of the wrist. The flexores carpi, too, after having bent the wrist, become subsequently flexors of the fore-arm. The flexion of the phalanges is obviously effected by the superficial and deep common flexors, and by the flexor pollicis.

RADIAL REGION.

The muscles placed along the outer side of the fore-arm are the supinator radii longus and brevis, the extensor carpi radialis longior and brevior.

Dissection.—These muscles are readily exposed by reflecting the skin and the fascia outwards from a few inches above the external condyle down to the wrist; the preceding dissections obviously mark out the way of conducting this.

463. *m. Supinator radii longus*, fig. 102, 8; fig. 104, 1, is the most prominent muscle of this set, and lies upon the radial border of the arm, extended from nearly the middle of the humerus to the end of the radius. It *arises* from the external condyloid ridge of the humerus, nearly as high up as the insertion of the deltoid, where it is interposed between the brachialis anticus and the external inter-muscular septum, to which also its fibres are attached. The rounded, fleshy belly, thus formed, descends upon the anterior and outer border of the arm, and, about its middle, ends in a flat tendon, which, continuing the same course, is inserted into the external border of the radius, close to the base of its styloid process. This muscle is covered only by the skin and fascia; it rests on the humerus, extensor carpi radialis (longior and brevior), the insertion of the pronator teres, and the supinator radii brevis. The inner border is in contact, above the bend of the elbow, with the brachialis anticus, from which it is separated by the spiral nerve and the accompanying artery; along the arm it is in contact with the radial artery and nerve.

Fig. 104.

464. *m. Extensor carpi radialis longior*, fig. 102, 9; fig. 104, 2, is partly covered by the preceding muscle, but its external border projects beyond it. It *arises* lower down than the supinator longus, from the external condyloid ridge as well as from the inter-muscular septum. After passing along the outside of the articulation, it ends, at the upper third of the arm, in rather a broad, flat tendon, which descends along the outer and back part of the radius; passes conjointly with the following muscle, in a groove in the lower extremity of that bone; and is inserted into the base of the metacarpal bone of the fore-finger. The fleshy part of the muscle lies between the supinator longus and extensor carpi radialis brevior, but is concealed only in part by them; its tendon passes beneath the

extensors of the thumb, and the posterior annular ligament of the wrist.

465. *m. Extensor carpi radialis brevior*, fig. 102, 10; fig. 104, 3, lies along the posterior and external aspect of the radius. It *arises* from the extremity of the outer condyle of the humerus, and from the external lateral ligament of the elbow-joint. The fleshy belly, lying behind the preceding muscle, ends in a flat tendon, which remains closely applied to that of the latter, and with it proceeds in the groove in the radius, and under the annular ligament, where it diverges somewhat, in order to be inserted into the base of the metacarpal bone of the middle finger.

Combined Actions.—These are the direct antagonists of the pronators of the hand and flexors of the wrist. If the hand be previously pronated, the supinators, by rolling the radius on the ulna, turn the palm supine; but the extent and power of action of each differ considerably. The supinator longus, notwithstanding its length and size, can act but feebly in supinating the hand, inasmuch as its direction is parallel with that of the radius; its direction and attachments indicate it to be a flexor of the fore-arm. The supinator brevis (sect. 474), both by its direction and mode of attachment, is by far the more efficient agent in moving the radius on the ulna. The action of the radial extensors is fully indicated by their name; if their effort be continued, they assist in extending the fore-arm on the arm.

BRACHIAL REGION (POSTERIOR AND SUPERFICIAL).

The muscles situated on the posterior aspect of the fore-arm are the anconeus, the extensor communis digitorum, extensor carpi ulnaris, and extensor minimi digiti, which are superficial; whilst the rest are deep-seated, viz. the three extensors of the thumb, the extensor indicis, and the supinator radii brevis.

Dissection.—The muscles on the posterior side of the fore-arm are numerous, and closely connected together, so that their dissection and arrangement are sometimes deemed difficult. An incision may, in the first place, be made from the olecranon to the middle of the back of the hand, which should be bounded at each extremity by a transverse incision. The skin having been thus divided, may be reflected off the fascia in its entire extent; and when the fascia has been ex-

amined, it may be divided in the same way as the skin, and dissected off the muscles, which will be facilitated by proceeding from below upwards, taking the different tendons as guides to their respective muscles, until all of them are exposed, and their borders defined. When this has been effected, little difficulty will be experienced in distinguishing them from one another, if the first line of the description given of them be attended to, as it indicates the situation and direction of each; and when the name of a muscle is known, everything relative to its anatomical characters will be found in the section which treats of it.

466. *m. Anconeus*, fig. 104, 4, is placed immediately behind and beneath the elbow-joint, being a small triangular muscle. It *arises*, by a tendinous and fleshy point, from the extremity of the outer condyle of the humerus, at its posterior aspect. From this the fibres proceed, diverging from one another, the upper ones being horizontal, the rest passing with increasing degrees of obliquity; but all are inserted into the radial aspect of the olecranon and the adjacent border of the ulna itself. It is superficial in its entire extent, and lies below the triceps extensor, with which it conspires in its action.

467. *m. Extensor communis digitorum*, fig. 104, 5, lies along the posterior part of the fore-arm. It *arises* by a tendon common to it, the extensor carpi ulnaris, and extensor carpi radialis brevior, also from the fascia of the arm, and the septa between it and the last-named muscles. Somewhat below the middle of the fore-arm the muscular part ends in four tendons, which, after passing beneath the posterior annular ligament of the wrist, diverge as they proceed along the carpus and metacarpus. Each of these expands on reaching the fingers, forming a fibrous sheath, which encases the back of the first and second digital phalanges, and terminates upon the third, into which they are thus inserted. Opposite the second joint, the tendon appears to divide into two fasciculi, which leave an elliptic interval between them, into which the knuckle may protrude when the finger is bent. The tendon, however, is not deficient at this part; it is much thinner than at the sides, and the thin part is inserted into the base of the second phalanx. The same arrangement obtains at the third joint. At its origin this muscle lies between the extensor carpi radialis brevior and extensor carpi ulnaris, and maintains the same relation as it descends

towards the wrist. It covers the supinator radii brevis, and the extensors of the thumb at their origin ; and as the tendons pass along the metacarpal bones, the two inner ones are connected to one another by slips of communication passing obliquely between them. A synovial membrane encases the tendons as they pass under the annular ligament.

468. *m. Extensor digiti minimi*, fig. 104, 6, is usually united with the common extensor, and has been considered by some as a part of it. It is placed between the muscle last named and the extensor carpi ulnaris. It *arises* in common with the extensor communis, and presents, as it descends along the arm, a thin fleshy belly, which ends in a tendon that passes through a ring in the annular ligament appropriated to itself. This will be observed to join with the fourth digital tendon of the common extensor, conjointly with which it expands upon the posterior surface of the phalanges of the little finger.

469. *m. Extensor carpi ulnaris*, fig. 104, 7, lies towards the ulnar border of the fore-arm, being extended from the external condyle to the root of the little finger. It *arises* from the posterior surface of the external condyle by a tendon common to it, the extensor communis, and extensor carpi radialis ; some fibres are also derived from the septa that lie between it and these muscles, as well as from the fascia of the arm. The muscle inclines somewhat inwards, and ends in a tendon, which runs through a groove appropriated to it in the carpal end of the ulna, and, after passing between the carpus and annular ligament, is inserted into the posterior extremity of the metacarpal bone, sustaining the little finger. It is covered only by the skin and fascia.

BRACHIAL REGION (DEEP, POSTERIOR).

The deep-seated muscles on the back of the arm are all less in size and length than the superficial set, from which they are readily distinguishable by the obliquity of their direction.

Dissection.—When the long extensors which arise from the external condyle have been examined, they may be detached from their origin, and drawn outwards, so as to expose those which lie deeply between, or on the bones. The supinator brevis and anconeus, both short muscles, and oblique in the direction of their fibres, will be seen

close below the elbow-joint, whilst the extensors of the thumb, and the indicator, lie obliquely over the middle and lower part of the radius.

470. *m. Extensor ossis metacarpi pollicis*, fig. 105, 2, (abductor longus pollicis, Sœmm.) This muscle, the extensor of the metacarpal bone, descends obliquely over the bones of the fore-arm, lying immediately below the border of the supinator brevis. It *arises* from the external surface of the ulna, as well as from the inter-osseous ligament and radius, as it crosses each; its fleshy belly ends in a tendon, which passes through a groove in the outer border of the radius, common to it and the extensor of the first phalanx of the thumb, and is inserted into the base of the metacarpal bone of the thumb. The origin and upper part of the muscle are concealed by the common extensor, but it becomes superficial where it lies on the external border of the radius; and whilst passing over the carpus, its tendon crosses those of the radial extensors.

Fig. 105.

471. *m. Extensor primi internodii* pollicis, fig. 105, 3, (the extensor of the first phalanx,) is much smaller than the preceding, and lies close to its lower border. The muscle *arises* from the inter-osseous ligament and radius, and slightly, if at all, from the ulna; it takes the same direction as the abductor, which it accompanies through the groove in the radius, and over the corresponding border of the carpus; its tendon proceeds onwards to the thumb, and is inserted into its first phalanx.

472. *m. Extensor secundi internodii* pollicis, fig. 105, 4, (the extensor of the second phalanx) is much larger than the preceding muscle, which it partly covers; its direction is obliquely downwards and forwards from the ulna to the thumb. It *arises* from the back part of the ulna, immediately below the great abductor, and from the adjacent part of the inter-osseous

ligament. The fleshy belly derived from these attachments soon ends in a tendon, which, like the others, is bound down by the annular ligament, and runs through the narrow oblique groove at the middle of the carpal end of the radius, and is finally inserted into the base of the second phalanx of the thumb. Whilst passing along the groove, its tendon is separated from those of the other extensors of the thumb by the breadth of the interval which lodges the radial extensors; but it gradually inclines towards them as it proceeds to its destination.

473. *m. Extensor indicis*, fig. 105, 5, (indicator,) is nearly of the same size as the preceding muscle, whose lower border it accompanies. It *arises* from the posterior surface of the ulna, about its middle, also from the inter-osseous ligament. The tendon, which is continued from the muscular part, passes, together with the common extensor, beneath the annular ligament, comes in contact with the digital tendon of the latter, which is destined for the index finger, and unites with it to form the tendinous expansion by which both are inserted into the posterior surface of the phalanges.

474. *m. Supinator radii brevis*, fig. 105, 1, is a short triangular muscle, lying in close contact with the bones, and extended obliquely from the outer condyle of the humerus over the upper third of the radius. It *arises*, by a short tendon, from the external condyle, and from the external lateral ligament, as far as its insertion into the annular ligament of the radius, also from a rough ridge on the back part of the ulna, and, in the interval between the bones, from a slight band of tendinous fibres stretched from the ridge just mentioned to the condyle. The fibres of the muscle, from these points of attachment, pass obliquely over the head and upper part of the radius, and are inserted into the oblique ridge that leads from the tubercle of that bone downwards and outwards to the insertion of the pronator radii teres. It is altogether concealed by the supinator longus and the extensors.

Combined Actions.—These muscles act on the fingers and hand in the first instance, and then, by a continuance of their effort, on the fore-arm, which they assist in extending. The common extensor, as well as those of the thumb, the fore-finger, and little finger, are, from their situation and attachments, the direct antagonists of the flexors;

the latter, however, being, from their size and number, the more powerful agents. If the bones of the thumb be drawn inwards to the palm, as when an object is firmly grasped, their extensor muscles may, by reason of the obliquity of their direction, assist in supinating the hand. Their names indicate their more ordinary action. The anconeus assists the triceps in extending the fore-arm. The supinator brevis turns the radius on its axis, so as to bring the hand into the supine position.

Muscles of the Hand.

The muscles of the palm of the hand admit of being divided into three sets or groups, viz. those of the thumb, those of the little finger, and thirdly, those placed in the middle of the palm. The extensors, which have been described in the foregoing sections, and the dorsal inter-ossei, are the only muscles on the back of the hand.

Dissection.—The first step in the dissection of the hand consists in exposing the palmar fascia in its entire extent (for its description see section 581). For this purpose a transverse incision may be made at the wrist, down to the annular ligament; for, as the fascia arises from it, it affords an easy guide to that membrane. The integument may then be raised, and reflected forwards to the fingers, or to either side. When the fascia has been examined, it may be detached from its connexion with the annular ligament, and removed altogether; by which means the flexor tendons, the superficial arch of arteries, and the branches of the ulnar and median nerves, are brought into view. The digital prolongations of these different structures can, in the next place, be traced along the fingers by merely removing the integument. The short muscles of the thumb, and those of the little finger, may next engage attention. But it will not be necessary to add anything to what is stated in the description of the muscles, as they are placed in their anatomical order, care being also taken to indicate their situation and general characters, so that no mistake can occur. Deep in the palm of the hand are situated one set of inter-ossei muscles; these cannot be seen until the flexor tendons are all removed. The extensor tendons must be displaced, in order to expose fully the dorsal inter-ossei. Particular attention should be paid to the position of the superficial palmar arch of arteries, as well as to its digital branches.

EXTERNAL PALMAR REGION (MUSCLES OF THE THUMB).

The fleshy mass which forms the ball of the thumb consists of four muscles, which are inserted into its metacarpal bone and the first phalanx.

475. *m. Abductor pollicis*, fig. 106, 4, is a flat, narrow muscle, placed immediately beneath the skin. It arises from the annular ligament of the wrist, 3, and from the os trapezium, and proceeds outwards and forwards, to be inserted, by a short thin tendon, into the base of the first phalanx of the thumb, at its radial border. The muscle is superficial in its entire extent, and rests on the opponens pollicis.

476. *m. Opponens pollicis*, fig. 106, 5 ; fig. 107, 2, is placed beneath the preceding, but its borders project laterally, so as to be perceptible at each side of it. The fibres of the muscle arise from the annular ligament and from the os trapezium, and thence proceed outwards and forwards, to be inserted into the whole length of the metacarpal bone of the thumb, at its radial border. One surface is covered by the abductor and integument, the other rests on the short flexor.

Fig. 106.

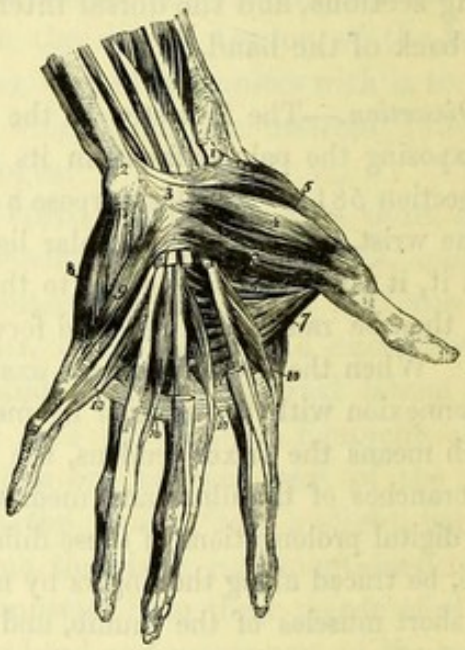

477. *m. Flexor brevis pollicis* is larger than either of the preceding muscles, beneath which it is placed. Its carpal extremity is divided into two processes or heads, 6, 6, the interval between which transmits the tendon of the long flexor. One of these, which is anterior, and therefore superficial, relatively to the other, arises from the inner surface of the annular ligament, and from the os trapezium ; the other is attached to the os trapezoides and os magnum. The fleshy fibres from these points of origin soon unite to form a single mass, which, however, again resolves itself into two short processes, which are inserted into

the opposite borders of the base of the first phalanx of the thumb. In each of these tendinous heads a sesamoid bone is placed, where it passes over the first joint of the thumb.

478. *m. Adductor pollicis*, fig. 106, 7 ; fig. 107, 4, is placed still more deeply than the short flexor, being extended from the metacarpal bone that sustains the middle finger, to the base of the first phalanx of the thumb. Its form is triangular, the base being attached to the former bone, the apex to the latter. It arises from the palmar border of the third metacarpal bone, from which its fibres proceed outwards, converging to a short tendon, which is inserted into the base of the first phalanx of the thumb, where its fibres are blended with the inner insertion of the short flexor, fig. 107, 3.

Combined Actions.—The names applied to the muscles of the thumb sufficiently indicate their actions and use ; they are eight in all, and may be arranged as follows. In the first place, it should be recollected that there are three movable osseous pieces in the thumb, so articulated as to admit of the four movements of extension, flexion, abduction, and adduction. There are three extensors, one for each bone, viz. the extensor of the metacarpal bone, and those of the first and second phalanges ; these are long muscles, placed on the dorsal aspect of the fore-arm and hand. Opposed in situation and action to these are the three flexors, lying on the palmar aspect of the thumb, viz. the opponens (which may be considered a flexor of the metacarpal bone), the flexor brevis, or flexor of the first phalanx, and flexor longus, which is the flexor of the second phalanx. There remain the abductor and adductor, which likewise are opposed to one another in situation and action ; one being superficial and external, and therefore well calculated to draw the thumb away from the fingers, whilst the other is internal and deep-seated, and thereby enabled to approximate it to them. If these moving powers be made to act successively, circumduction is performed ; or, in other words, the thumb moves so as to describe a cone, whose summit is at its carpal articulation, and base at the line traversed by its extremity.

INTERNAL PALMAR REGION (MUSCLES OF THE LITTLE FINGER).

The thick fleshy mass at the inner border of the hand also consists of four muscles, one of them being cutaneous ; the others are the proper muscles of the little finger.

479. *m. Palmaris brevis*, fig. 102, 12, forms a thin plane of pale fibres placed immediately beneath the skin. It arises from the annular ligament and palmar fascia, from which its fibres proceed inwards, diverging, and are inserted into the skin along the inner border of the palm of the hand. It is superficial to the palmar fascia, as well as to the muscles of the little finger.

480. *m. Abductor digiti minimi*, fig. 106, 8, runs along the ulnar border of the palm of the hand, arising by tendinous fibres from the pisiform bone, 2, and annular ligament, where they are blended with the insertion of the flexor carpi ulnaris. The fleshy belly, of which the muscle consists, ends in a tendon, which is inserted into the base of the first phalanx of the little finger at its ulnar border. The muscle rests on the fifth metacarpal bone, and on the opponens or adductor of the little finger, and is covered by the palmaris brevis and palmar fascia.

481. *m. Flexor brevis digiti minimi*, fig. 106, 9, is placed on the same plane with the abductor, lying close to its palmar border. It arises from the anterior surface of the annular ligament, and from the unciform bone, and is inserted into the base of the first phalanx of the little finger. In some instances the flexor does not exist, in which cases the abductor is found larger than usual. From this circumstance, as well as from its position and direction, it may be inferred that, in addition to its ordinary action of abduction, the last-named muscle can become also a flexor.

Fig. 107.

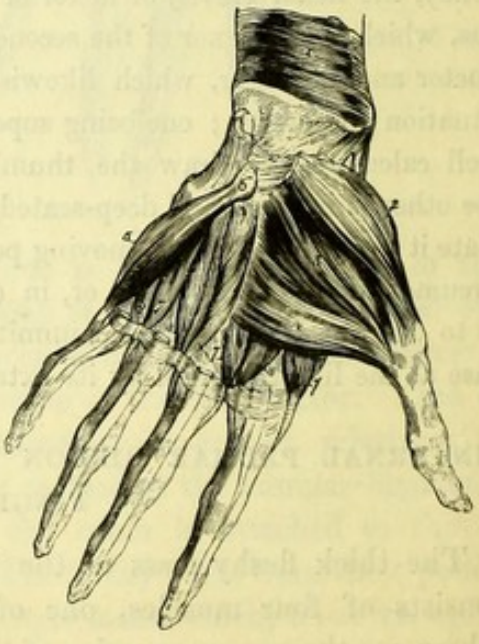

482. *m. Adductor vel opponens digiti minimi*, fig. 107, 5, is somewhat triangular in its form, and placed under cover of the others. It arises from the annular ligament, and from the hooked process of the unciform bone, 6, from which the fibres incline forwards and inwards, to be inserted into the whole length of the fifth metacarpal bone.

MIDDLE PALMAR REGION.

The muscles placed in the space intervening between the two borders of the hand, are the lumbricales and inter-ossei.

483. *m. Lumbricales*, fig. 106, 10, are four tapering, fleshy fasciculi, extended from the tendons of the flexor profundus to the first digital phalanges, and are therefore but accessories or appendages to that muscle. They arise by fleshy fibres from the outer or radial border of the flexor tendons, and proceed forwards to the corresponding sides of the fingers, where they are inserted into the tendinous expansion covering the dorsal aspect of the fingers. They are covered by the palmar fascia, and partially by the tendons of the flexor sublimis.

The *inter-ossei* are divided into two sets, viz. those which are perceptible at the dorsal aspect of the metacarpus, and those placed in the palm.

484. The *dorsal inter-ossei*, fig. 105, 9, 6, 6, are four in number, one of them being usually known as the abductor indicis, and placed amongst some of the other groups of muscles, though in position, mode of attachment, and structure, it is strictly an inter-osseous muscle. The general characters of these muscles are, that they lie between the metacarpal bones, and appear on their dorsal aspect, yet project into the palm where they are shown, fig. 107, 7, 7. They arise from the contiguous sides of the bones, between which they are placed, by fibres that converge to a common tendon ; each is, moreover, bifid at its carpal extremity.

485. The *first dorsal* inter-osseous muscle, fig. 105, 9, (*abductor indicis*,) is larger than the others, and lies in the interval between the thumb and the index finger. It arises by two heads, of which one, external and larger, is attached to the ulnar border of the first metacarpal bone, the other to the contiguous margin of the second, the angular interval between them serving to transmit the radial artery into the palm of the hand. Both soon unite, and become inserted, by a thin tendon, into the base of the first phalanx of the index finger, where its fibres also unite with those of the extensor tendon. The *second* dorsal inter-osseous muscle lies in the second metacarpal space. It arises from both bones, and is inserted tendinous into the radial border of the extensor tendon, covering the first phalanx of the middle

finger, and into the base of that phalanx. The *third*, similarly placed in the third metacarpal space, is inserted into the opposite or ulnar border of the tendinous expansion of the extensor communis, which covers the middle finger; and the *fourth*, lying in the corresponding space, is inserted into the ulnar side of the ring finger, by becoming attached to the tendinous expansion that covers it. These are also connected with the bases of the first phalanges.

486. The *palmar inter-ossei* lie rather on the palmar surface of the bones than in their intervals, fig. 107, 8. They are three in number, and are undivided at their origin. The *first* palmar inter-osseous muscle arises along the ulnar border of the second metacarpal bone, and is inserted at the same side of the base of the first phalanx of the index finger, where the fibres of its tendon are blended with those of the extensor communis. The *second* arises from the radial border of the fourth metacarpal bone, and is inserted into the base of the first phalanx of the ring finger, by its radial border. The *third* arises from the radial side of the fifth metacarpal bone, and is inserted into the base of the first phalanx of the little finger, by its outer or radial border. The second and third, like the first, have also a connexion with the extensor tendons.

Thus, the index and ring fingers have each two inter-ossei muscles (one palmar, and one dorsal); the middle finger has two of the dorsal set, and the little finger has one of the palmar.

Actions.—All the inter-ossei muscles act on the first phalanges of the fingers. They obviously possess the power of adduction and abduction, according to the manner of their insertion, and so can make the fingers diverge from or approach to one another. The dorsal set may, to a certain extent, assist the extensor communis in extending or drawing back the fingers; and again, if the fingers be but slightly bent, as the direction of the inter-ossei in that position forms an angle with that of the phalanges, they may assist in drawing them to the palm of the hand, that is, in flexing them.

ABDOMINAL REGION.

487. The abdominal muscles consist of three broad lamellæ on each side, a pair (usually two pair) in front, flat, elongated, and enclosed within the aponeurotic expansions of the former;

and another pair, situated posteriorly, beside the vertebral column, which are contained within a similar expansion prolonged from one of the lateral muscles to the lumbar vertebræ.

Dissection. To expose the external oblique muscle:—When commencing the dissection of the abdominal muscles, an incision may be made through the skin from the ensiform cartilage to the umbilicus, and another from thence to the most depending part of the margin of the thorax. The angular flap of skin, bounded by these lines, may be easily reflected by commencing at its point, and taking the tendinous fibres of the external oblique muscle as a guide, each stroke of the scalpel being directed obliquely upwards and outwards. The flap should be reflected until its base, or attached border, is brought on a line with the ensiform cartilage, or somewhat higher, which is necessary in order to expose the digitated processes of the muscle and their intermixture with those of the serratus magnus. An incision may, in the next place, be carried horizontally inwards from the anterior superior spinous process of the ilium to the linea alba, and there met by another drawn down from the umbilicus. The enclosed flap of skin should be reflected back to the posterior part of the lumbar region. If it be required to exhibit the muscle in its entire extent, the portion of integument still remaining on the lower part of the abdomen may be divided by an incision drawn from the pubes upwards, and the flap reflected down over Poupart's ligament. For the present, however, we shall leave untouched the integument, muscle, &c. in the iliac region, as they will require to be examined attentively when treating of the dissection of the parts connected with hernia.

To expose the internal oblique muscle:—When the external oblique muscle has been examined, it may be detached and reflected so as to bring into view the one subjacent to it, by cutting through its muscular fibres midway between its digitations and the margin of the ribs. Its posterior, or free border, will be found extending from the last rib to the crista of the ilium, and can be readily distinguished from the internal oblique muscle by the different course of its fibres. When this is effected, the fleshy fibres can be dissected from the crista ilii, as far as its spine, and the whole plane of muscle turned over to the opposite side. The internal oblique is thus exposed for two-thirds of its extent.

To expose the transversalis muscle:—When the examination of the internal oblique muscle has been completed, it is said to be difficult to detach it without injuring the muscle beneath it; yet, if just above the spine of the ilium the fibres be rendered tense by pressing the

thumb and fore-finger of the left hand on them, and so straining the interval, they can be divided with perfect precision, without interfering with the subjacent muscle; for the fibres are retracted when divided, and, after about three parts are cut through, the cellular interval between the muscles begins to be perceived, which, with the difference in the direction of their fibres, affords an unerring guide to their line of separation. Moreover, near the spine and crista of the ilium, these muscles are separated by the circumflex (ilii) vessels; and this is the part usually selected for cutting through the internal oblique, in order to expose the transversalis. When the line of separation is found, the muscular fibres should be detached from the crista ilii far back towards the lumbar region; after which they may be dissected from the cartilages of the ribs by insinuating the scalpel between the two planes of fibres, and then turning it so as to cut outwards. In this way the internal oblique muscle may be detached from its connexions, and reflected to the opposite side, exposing the transversalis.

To expose the rectus muscle:—The sheath of the rectus muscle should in the next place be examined. Its mode of formation is fully described (sect. 492). Its anterior layer must be divided in its whole length, by an incision drawn down from the margin of the thorax to the pubes, and reflected off the rectus. By inserting the handle of the scalpel beneath the outer border of the muscle, it may be raised, and the posterior layer of the sheath brought into view. Lastly, if the muscle be cut across midway between the umbilicus and pubes, and the two parts drawn aside, the point at which the sheath is imperfect, posteriorly, can be determined by pushing the handle of the scalpel against it, so as to separate it from the subjacent membrane.

488. *m. Obliquus externus abdominis*, fig. 99, 9, (obliquus descendens; costo-abdominalis; ilio-pubi-costo-abdominalis,) is situated on the lateral and anterior parts of the abdomen; its form being broad, thin, and irregularly quadrilateral. It arises from the anterior surfaces of the eight inferior ribs, by fleshy fibres arranged in so many angular processes, named digitations, of which five meet an equal number of similar prolongations from the serratus magnus muscle, and three with those of the latissimus dorsi. The fleshy fibres from the last ribs pass down to be inserted into the external margin of the crista ilii, the anterior half of its length; all the rest pass downwards and forwards, and terminate in tendinous fibres, which form a broad

aponeurosis, 13, that covers the entire front of the abdomen, and terminates by uniting with that of the corresponding muscle along the median line, 12, from the ensiform cartilage to the symphysis pubis. The inferior fibres of this aponeurosis are closely aggregated together, and extended across from the anterior superior spinous process of the ilium to the os pubis, in the form of a tense band, 11, which is called *Poupart's ligament.* Near the pubes the fibres diverge from one another, leaving between them a triangular opening, 10, for the passage of the spermatic cord in the male, and the round ligament in the female. The direction of this opening, called the *external abdominal ring*, is upwards and outwards, its base being formed by the crista of the os pubis, and the sides by the two sets of diverging fibres, called its *pillars*, of which one is attached to the anterior surface of the symphysis pubis, interlacing with the corresponding fibres of the opposite muscle; the other, external and inferior, is fixed to the spinous process of the pubes; whilst a third portion, reflected backwards and outwards from the latter, is inserted along the pectineal line, being triangular in its form, and nearly horizontal in its direction, and ordinarily denominated *Gimbernat's ligament.* The direction of the fibres of this muscle is obliquely downwards and inwards: structure—fleshy where it is attached to the thorax and ilium, aponeurotic in the rest of its extent: relations—externally with the skin and superficial fascia, internally with the cartilages of the ribs, obliquus internus, rectus, and pyramidalis muscles; posteriorly, its border is overlapped a little by the latissimus dorsi.

489. *m. Obliquus internus*, fig. 99, 14, (obliquus ascendens; ilio-abdominalis; ilio-lumbo-costi-abdominalis,) placed under cover of the preceding muscle, is of an irregularly quadrilateral form. It *arises* inferiorly from the external half, not unfrequently from two-thirds of the inner surface of Poupart's ligament, from the crista ilii for two-thirds of its length, also from a thin aponeurosis, prolonged backwards to the lumbar vertebræ. This aponeurosis is attached below to the crista ilii, above connected with the serratus posticus inferior, and posteriorly, after contracting an intimate union with the latissimus dorsi, becomes exceedingly thin, and in a manner identified with the aponeurosis of the latter, with which it extends back to the spinous processes of the lumbar vertebræ. From these attachments, the

fibres of the muscle pass with different degrees of obliquity, to be inserted as follows: those from Poupart's ligament arch downwards and inwards, to be fixed into the crista of the pubes, and also for some way into the pectineal line, conjointly with those of the transversalis muscle; or, more strictly, into Gimbernat's ligament, where it is inserted into that line. The fibres, from the anterior part of the crista ilii, pass horizontally inwards, whilst the rest ascend obliquely, and terminate, some in an aponeurosis expanded in front of the abdomen, the rest at the lower margin of the cartilages of the last four ribs, on a plane corresponding with the intercostal muscles. The aponeurosis divides at the outer border of the rectus muscle into two lamellæ, one passing before, the other behind it, and reuniting at its inner border, so as to enclose it in a sheath. The anterior lamella becomes identified with the aponeurosis of the external oblique muscle. The upper border of the posterior lamella is attached to the margin of the first false and the last true ribs, and also to the ensiform cartilage. At the inner border of the rectus muscle, this aponeurosis joins with that of the opposite muscle, and with the external oblique, so as to form with them the linea alba. Direction—obliquely upwards and inwards in the greater part of its extent; some of its fibres are horizontal, the rest are arched downwards: structure—fleshy at the sides, aponeurotic anteriorly and also posteriorly, where it becomes connected with the lumbar vertebræ: relations—by one surface with the obliquus externus, by the other with the transversalis; anteriorly with the rectus and pyramidalis, which its aponeurosis serves to enclose, posteriorly with the latissimus dorsi and the deep-seated lumbar muscles.

490. *m. Cremaster*, fig. 99, 15. Though the cremaster, or suspensory muscle (κρεμαω, to suspend) of the testis, does not form a part of the abdominal parietes, its description usually follows that of the internal oblique, in consequence of the intimate connexion which subsists between them. It is ordinarily said to arise from the inner surface of Poupart's ligament, and from the lower border of the internal oblique muscle, a few fibres also appearing to come from the transversalis; from these origins the fibres pass downwards on the spermatic cord, and are lost on the tunica vaginalis testis. When examined with attention, the cremaster appears to consist of two fasciculi; of which

the external and longer descends from the lower border of the internal oblique muscle, the other, internal and smaller, being attached to the crista of the os pubis. From these points of attachment the fibres descend through the external abdominal ring, converge and unite so as to form arches whose convexity looks downwards, their degrees of obliquity increasing as they descend. The cremaster does not exist as a distinct muscle before the descent of the testis.* In the fœtus of five months old, the inferior fibres of the internal oblique arch downwards and inwards, from Poupart's ligament to the crista of the pubes, passing over a delicate greyish fasciculus, the gubernaculum testis, which alone occupies the inguinal canal at that period. The gubernaculum is intimately connected with these fibres of the internal oblique, and if it be drawn downwards, they may be made to descend through the ring, and if retained in this situation they will strictly resemble the cremaster in direction and attachments. This experiment at once points out the manner in which the cremaster is produced; it shows that the fibres of which it consists were originally part of the inferior oblique muscle, and that, as the testis passes from the abdomen into the scrotum, they are drawn along with it, by reason of the intimate connexion subsisting between them and its gubernaculum. The testis sometimes passes between the fibres of the internal oblique; when this occurs, some will lie behind the cord, others (usually the greater number) before it, so that it is completely invested by them.

491. *m. Transversalis abdominis* (transversus abdominis, Sœmm.; lumbo-abdominalis).

Dissection.—A membranous prolongation from the transversalis muscle forms an investment for the quadratus lumborum, (sect. 494,) similar in many respects to the sheath of the rectus. Let us suppose that it is intended to examine this structure on the right side; it will be found convenient to lay the subject on the left, and to have it secured in that position. If the internal oblique be traced back, its muscular fibres will be found to end in an aponeurosis, which becomes intimately connected externally with the latissimus dorsi, close to the border of the deep lumbar muscles, and internally with the transversalis. Now, if the aponeurosis of the latissimus be divided in the

* Recherches Anatomiques sur les Hernies, par Jules Cloquet.

middle of its breadth, by an incision drawn from the ilium to the last rib, and the two parts reflected, the thick mass of lumbar muscles will be exposed; and if the handle of the scalpel be inserted beneath their outer border, they will be found to lie on a membrane, which is connected with the lumbar vertebræ on the one hand, and with the abdominal muscles on the other, being, in fact, a prolongation of the latter. The mass of lumbar muscles may now be cut across by two incisions, one opposite the last rib, the other at the crista ilii, and then removed altogether. When this is effected, if attention be directed to the internal oblique muscle, it will be found that the aponeurosis, in which it ends posteriorly, after contracting adhesion to the transversalis, as above stated, becomes connected with the aponeurosis of the latissimus dorsi, and with it prolonged to the spinous processes of the vertebræ behind the lumbar muscles. In this stage of the dissection, a thin lamella will be found stretched back from the transversalis to the transverse processes of the lumbar vertebræ. If this be divided by a perpendicular incision from the last rib to the ilium, the quadratus lumborum will be exposed; and if the external border of this muscle be raised, another thin layer will be found resting on its abdominal surface, and connected with the roots of the transverse processes. Thus, the posterior aponeurosis of the transversalis muscle, by dividing into two lamellæ, encloses the quadratus as in a sheath. We have thus traced four layers of fibrous structure, connected with muscles in the lumbar region, viz. the thick broad aponeurosis of the latissimus dorsi, the thin one of the obliquus internus, and that of the transversalis, which divides into two. The term *fascia lumborum* is applied by some to the aponeurosis of the latissimus, by others to the lamellæ prolonged back from the internal oblique and transversalis. It is not applicable to either, and conveys no definite idea of any of the parts seen in this region.

When this part of the dissection has been completed, the subject may be turned on its back, in order that the inguinal region may be examined, which is an indispensable preliminary to a correct knowledge of the structure of the parts connected with those intestinal protrusions to which the term hernia is applied (ἔρνος, *a tumour*). It will be recollected, that the dissections made with a view to exhibit the abdominal muscles (sect. 487) may be so conducted as to leave an angular flap of integument covering the inguinal region. The skin alone should be raised over this part, and reflected down on the fore part of the thigh, for about three inches below Poupart's ligament, without disturbing the layer of cellular membrane that lies beneath it.

This we shall describe as the superficial fascia of the abdomen (sect. 592), to which the reader is referred; and for the surgical anatomy of inguinal hernia to sect. 593.

The transversalis muscle, fig. 108, 4, is subjacent to the internal oblique, and of the same form; it arises from the iliac half of Poupart's ligament, from the inner margin of the crista ilii for three-fourths of its length, from the cartilages of the six or seven last ribs, and, in the space intermediate between the crista and the ribs, from an aponeurosis (see Dissection) which is attached to the transverse processes of the lumbar vertebræ. From these different points of origin the fibres pass horizontally forwards, and near the border of the rectus muscle end in an aponeurosis, 5, which joins with the posterior layer of the internal oblique, and, together with it, is inserted into the whole length of the linea alba; the inferior fibres curve downwards, and are inserted into the crista of the os pubis, and into the pectineal line. This insertion is so intimately connected with that of the internal oblique, that both together have received the name of the conjoined tendon, 6, or aponeurosis, of these muscles. At its attachment to the cartilages of the ribs, it digitates with the diaphragm, and is continuous with it in the two last intercostal spaces. Relations — externally, with the obliquus internus; internally, with the fascia transversalis, which separates it from the peritonæum: structure—muscular at the sides; aponeurotic anteriorly and also posteriorly, where it is prolonged to the vertebral column, and forms a sheath for the quadratus lumborum.

492. *m. Rectus abdominis*, fig. 99, 16; fig. 108, 3, (sterno-pubius,) long, narrow, and flat, is situated at the fore part of the abdomen, close to the linea alba. It *arises* from the anterior surface of the ensiform cartilage and its external ligament, also from the cartilages of the fifth, sixth, and seventh ribs, by separate fleshy points, and is inserted by a strong flat tendon into the crista of the os pubis, its fibres being extended perpendicularly between these points. They are, however, interrupted by irregular tendinous intersections (*lineæ transversæ*), varying in number from three to five. One of these corresponds with the umbilicus, another with the ensiform cartilage, the third intermediate between them, and if a fourth exists, it is placed below the umbilicus; so is the fifth. These lines do not usually penetrate the whole substance of the muscle, and some of them

extend only half-way across it. This muscle is enclosed in a sheath (*sheath of the rectus*), formed by the aponeuroses of the abdominal muscles, in the following manner: the aponeurosis of the internal oblique, on arriving at the external border of the rectus muscle, divides into two lamellæ, of which the anterior one passes in front of the rectus, together with the aponeurosis of the external oblique, whilst the other passes behind it, conjointly with that of the transversalis, becoming again united along the linea alba. This arrangement obtains from the margin of the thorax, as far as to midway between the umbilicus and the pubes, but at this point all the aponeuroses pass in front of the rectus; so that the posterior part of its sheath is deficient in the lower third, the muscle being separated from the peritonæum by the fascia transversalis only. The deficiency in the sheath here indicated is marked by a well-defined lunated edge, whose concavity looks downwards towards the pubes.

493. *m. Pyramidalis*, fig. 99, 17, triangular in its form, and situated close to the linea alba, arises from the crista of the os pubis, and, becoming narrow as it ascends, is inserted into the linea alba about midway between the umbilicus and pubes; its internal fibres are vertical in their direction, the others more or less oblique. It is covered in front by the aponeuroses of the other muscles, and posteriorly rests on the rectus, of which it may be regarded as an accessory; its more direct action is that of a tensor to the linea alba.

494. *m. Quadratus lumborum*, fig. 98, 16, (ilio-costalis,) situated deeply in the lumbar region close to the vertebral column, is in form irregularly quadrilateral, being somewhat broader below than above. It arises by tendinous fibres from the crista of the ilium for about one-fourth of its extent, and from the ilio-lumbar ligament; it is inserted into the inferior border of the last rib for about half its length, and by four tendinous points into the transverse processes of the four superior lumbar vertebræ. This muscle is enclosed in a sheath (*sheath of the quadratus*) not unlike that of the rectus, but not so dense or firm in its structure. The posterior or lumbar aponeurosis of the transversalis divides into two layers near the border of the quadratus, one of which is prolonged backward behind the latter muscle, to be attached to the apices of the transverse processes of the lumbar vertebræ, and the other before it to be fixed

at the roots of these processes. Now, the lower border of this layer is attached to the inner margin of the crista ilii (its posterior fourth), and the upper one is stretched across from the anterior surface of the last rib to the root of the transverse process of the first lumbar vertebra. This latter part, from its mode of attachment and relation to the broad muscle of the diaphragm, has been named by some ligamentum arcuatum externum (sect. 501).

Along the fore part of the abdomen some tendinous structures exist which require a special notice, viz. the linea alba, lineæ semi-lunares, and transversæ.

495. The *linea alba* may be considered as a tendinous cord, fig. 99, 12, formed by the juncture of the aponeuroses of the two obliqui and transversales muscles, and extended perpendicularly downwards from the ensiform cartilage to the pubes. It is covered in front by the common integument; posteriorly it rests on the fascia transversalis, which separates it from the peritonæum, and on each side it is enclosed by the recti muscles; it is therefore broader above than below, as these muscles diverge from one another in the former situation. In the middle of the linea alba is situated the umbilicus, which in the fœtal state is a foramen for the transmission of the umbilical vein and arteries, but afterwards becomes obliterated.

496. The *lineæ semi-lunares* are two curved lines extending from the cartilages of the eighth rib, on each side, to the tuberosity of the os pubis. They thus correspond with the external borders of the recti muscles (the enclosed space being broad above and narrow below), and are formed by the aponeurosis of the internal oblique on each side, as it divides to enclose the rectus muscle.

The *lineæ transversæ* have been already noticed with the rectus muscle, in the substance of which they are situated (sect. 492).

Actions.—The muscles here described not only enclose and support the abdominal viscera, but by their contractile power are capable of acting successively on them, on the thorax, and on the pelvis. When the pelvis and thorax are fixed, the abdominal muscles can constrict the cavity and compress its viscera, particularly if the diaphragm be made to descend at the same time, as occurs in vomiting, or in the expulsion of the fœtus, of fæces, or urine. If the vertebral

column be fixed, these muscles compress the lower border of the thorax, and so contribute to expiration. When it is intended to continue the effort, so as to produce a forced expiration, the quadratus lumborum draws down the last rib, and makes it relatively the fixed point to which all the rest are drawn by their inter-costal muscles; but if the vertebral column be not fixed, the thorax may be bent directly forwards, when the muscles of both sides act; or it may be rotated to either side, should they act alternately. Thus, if the external oblique of the right side be made to act on the thorax, the first effect appears to be that of drawing its margin down towards the pelvis; but if the effort be continued, the trunk will be rotated towards the opposite side. The left internal oblique will co-operate in this action, for the direction of its fibres coincides with that of the right external oblique. The pyramidales also contribute to the same effect, by rendering the linea alba tense. If the thorax be fixed, the abdominal muscles may be made to act on the pelvis; thus, in the action of climbing, the trunk and arms being elevated and fixed, the pelvis is drawn upwards, either directly, or to one side, as a preparatory step to the elevation of the lower limbs. A similar effect may be produced when the trunk is in the horizontal position, for the pelvis may be drawn forward and flexed upon the vertebral column by the recti and pyramidales.

COSTAL REGION.

Between the ribs we find a series of flat planes of muscular fibres filling up the intervening spaces, hence named "inter-costal,"— upon the ribs posteriorly the levatores costarum, and at their inner surface, and in front, the triangulares sterni.

It is not necessary to prescribe any particular mode of examining these, as they are necessarily exposed when the pectoral, the serratus, and external oblique muscles are removed.

The inter-costal muscles are disposed in the form of two thin planes, one external, the other internal.

497. *m. Inter-costales externi* are placed between the contiguous borders of each pair of ribs. There are, therefore, eleven such muscular lamellæ on each side, the direction of the fibres of all being obliquely downwards and forwards, fig. 108, 1. Their extent in each instance is from the tubercles of the ribs nearly to the external extremity of their cartilages. From this point a thin fascia is continued forwards to the sternum, overlaying the inner inter-costals.

498. *m. Inter-costales interni*, commencing at the sternum, in the spaces between the true ribs and in the rest, from the anterior extremities of their cartilages, extend as far back as their angles, the direction of their fibres being obliquely downwards and backwards, fig. 108, 2; thus they decussate or cross the former.

Fig. 108.

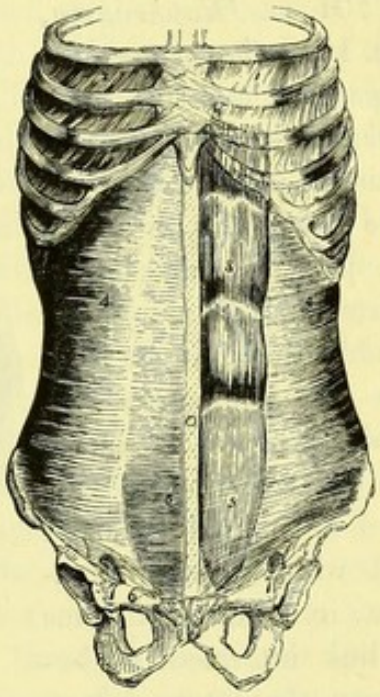

499. *m. Levatores costarum*, fig. 98, 17, are narrow, tendinous, and fleshy fasciculi, which extend obliquely downwards and forwards (in this particular resembling the external intercostals) from the extremities of the transverse processes of the dorsal vertebræ, to be inserted into the margins of the ribs, between their angles and tubercles. Their fibres spread out and become flat at their insertion.

500. *m. Triangularis sterni* is a thin flat plane of muscular and tendinous fibres, placed within the thorax, immediately behind the costal cartilages. It arises from the inner surface of the ensiform cartilage, and of the lower third of the sternum, from which its fibres pass outwards and upwards, diverging, to be inserted into the lower borders and inner surface of the cartilages of the true ribs, from the sixth to the third inclusive. One surface of the muscle is thus in apposition with the parts just mentioned, the other partly with the pleura, which is reflected upon it, and partly with the pericardium and the cellular interval called anterior mediastinum.

Actions.—The two planes of inter-costals act simultaneously; and as they decussate with one another, the ribs on which they act are made to move in the direction of the diagonal of the moving powers, that is to say, directly upwards when the first rib is relatively the more fixed point, and downwards when the last happens to be so. In drawing up the ribs, they slightly rotate their bodies, and evert their lower borders; at the same time the middle and lower inter-

costal spaces are widened, for the ribs are spread asunder somewhat like those of a fan. This arises from the peculiar mode of attachment of the last rib, which is prevented from ascending with the rest by the manner in which the quadratus lumborum binds it to the ilium, so that it serves to spread or separate them from one another.

501. *m. Diaphragma*, fig. 109, (διαφραττω, to separate,) is a thin muscular and tendinous partition, placed between the thorax and abdomen. It presents two lateral parts, united along the middle line, but the parts are not symmetrical, on which account it cannot be classed with the muscles of animal life, nor yet with those of organic: in structure it forms a link intermediate between these two orders, and in function partakes of the properties of both, being involuntary in its ordinary actions, yet not altogether withdrawn from the control of the will. The diaphragm, viewed as a whole, consists of three portions, two of which are muscular — the third, which forms the connexion between them, being tendinous. It is broad and expanded at its upper part, and takes the form of the base of the thorax, to which it is attached; therefore its extent, from side to side, is greater than from before backwards. At its inferior and posterior part it becomes constricted into two narrow processes or crura, by which it is attached to the lumbar vertebræ. Its inferior surface is concave, forming an arch which overhangs the cavity of the abdomen; the superior one is convex, but not equally so at both sides, for it ascends higher into the right side of the thorax than into the left. Both surfaces are lined by serous membrane, the inferior by the peritonæum, the superior by the pleuræ at the sides and the pericardium in the middle.

Fig. 109.

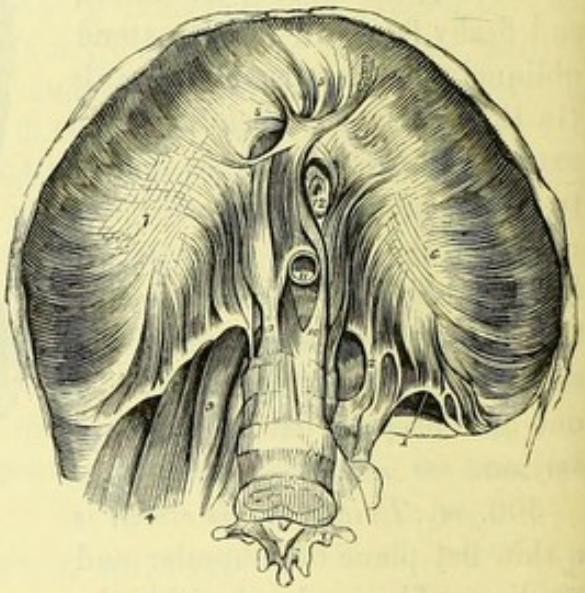

The muscular fibres attached to the margin of the thorax vary in length and direction. Anteriorly at the middle line, the fibres, few in number and short, *arise* from the inner surface of the ensiform cartilage; this narrow fasciculus is separated at each side by a cellular interval from the fibres attached to the cartilage of the seventh rib. The muscular fibres of each lateral part arise from the inner surface of the cartilages of the ribs, from the seventh to the twelfth inclusive, and from the anterior surface of the body of the last rib for about a third of its length; finally in the interval between the part of the last rib here indicated and the transverse process of the first lumbar vertebra, they arise from a fibrous band, stretched between these points, which is sometimes termed *ligamentum arcuatum* (see sect. 494). But Haller* very properly distinguishes this from another tendinous lamella, 2, which arches obliquely over the psoas muscle, being attached by one extremity to the transverse process of the first lumbar vertebra (where it is blended with the preceding), and by the other to the body of the second. This he terms "arcus interior:" it may be named *ligamentum arcuatum proprium.* The fleshy fibres from these different points of attachment proceed to their destination in different directions: those in front pass backwards, those at the sides directly inwards, the intermediate ones being oblique; but the fibres from the ligamentum arcuatum externum pass directly upwards, all becoming *inserted* into, or continuous with, the fibres of the central aponeurosis.

502. The *central aponeurosis* (central tendon, cordiform tendon, phrenic centre) is composed of tendinous fibres interwoven in every direction. Its narrow extremity or foot-stalk is turned towards the spine, the wider (which is divided into three processes) towards the margin of the thorax; hence it was compared by Winslow to a trefoil leaf. The central leaflet or process, 5, is the largest; the left the smallest, 7; the right, 6, being intermediate in size between them. Between the right and middle processes, a little anterior to the spine, is an opening, 8, (*foramen quadratum venæ cavæ,*) for the vena cava; it is somewhat of a square shape, and resembles rather a canal than a foramen.

503. The *lumbar portion* of the muscle consists of two thick

* Icones Anatomicæ.

fleshy processes, *crura* or *pillars*, placed at each side of the middle line. The right crus, broader and longer than the left, is attached to the fore part of the bodies of the vertebræ, and to the inter-vertebral fibro-cartilages, whilst the latter inclines rather to their sides. The right crus, 9, arises by fleshy fibres from the three upper lumbar vertebræ, and by a firm tendinous process from the inter-vertebral substance between the third and fourth. The left, 10, does not extend so far down by the breadth of half a vertebra. As they ascend, they leave an interval between them, which lodges the aorta, and opposite the first lumbar vertebra the fibres of each crus proceed to three different destinations. The greater number pass forwards and upwards, to be inserted into the central aponeurosis; those placed towards the sides of the vertebra incline outwards, and terminate upon the surface of the ligamentum arcuatum proprium; but the internal fasciculus of each passes in front of the aorta, so as to complete the canal (*hiatus aorticus*, 11,) which transmits it. The fasciculi decussate at this point; the one from the right side being the larger. After their decussation, the fasciculi are continued obliquely upwards, forming the margins of the opening for the œsophagus (*foramen œsophageum*, 12,) and are ultimately inserted into the central aponeurosis. The œsophagean opening is narrow and elliptical in its form, its greatest diameter being from before backwards, and about an inch and a half in length. It lies a little to the left of, and anterior to, the aortic opening, and transmits the œsophagus with both the vagus nerves. The aortic opening corresponds with the middle line, and gives passage to the aorta, thoracic duct, and also, in most instances, to the vena azygos. The opening for the vena cava lies before and to the right of that of the aorta.

Actions.—The diaphragm is of an arched form, the concavity of the arch looking down into the abdomen. When its fibres contract, the muscle descends, and becomes an inclined plane, whose direction is downwards and forwards. By these means the abdominal viscera are pressed against the lower and fore part of the parieties of the cavity, so that the capacity of the abdomen is diminished in proportion as the thorax is enlarged. Should the abdominal muscles and the diaphragm be both brought into action together, the viscera will be compressed between them, and forced towards the lower part of the cavity, as occurs in the expulsive efforts of accouchment, &c. After

a complete expiration, the upper surface of the diaphragm is on a level with the lower border of the fourth rib.

PERINÆAL REGION.

504. This is the space included between the rami of the ischia and ossa pubis at the sides, the symphysis pubis in front, and posteriorly by two lines drawn from the tubera ischii to the coccyx. The muscles contained within this area are divisible into two groups, one connected with the generative organs, and subservient to their peculiar function, the others are attached to the anal extremity of the intestine, and control its excreting action. The genital muscles in the male consist of the erector penis, accelerator urinæ, transversus perinæi, compressor urethræ, compressor venæ dorsalis penis; in the female, of the erector clitoridis and constrictor vaginæ. These are all disposed in pairs. The anal muscles are the sphincter externus and internus, levatores ani, and coccygei.

Dissection of the perinæum.—When viewed externally, this restricted space is observed to be divided into two equal parts, by a continuation of that vertical line which indicates the original division of the body into two symmetrical halves, and which here, as elsewhere, is called the raphé.

To expose the superficial fascia:—A little below the fold of the scrotum, an incision may be made through the skin along the raphé, down to the margin of the anus. At its upper extremity a transverse incision may be made, extending outwards, on the thighs, at each side, for two inches. The flaps of integument may, in the next place, be reflected outwards to the flexures of the thighs, and pinned back. By raising the integument round the anus, the external sphincter muscle will be exposed. The superficial fascia, which is, in fact, nothing more than the sub-cutaneous cellular tissue, having been exposed, its attachments and mode of distribution deserve attention. If it be divided along the middle line, and carefully reflected to each side, it will be found firmly attached to the rami of the ischia and ossa pubis. If traced upwards, or if air, or a jet of water, be passed beneath it, it will be found to be continuous with the sub-cutaneous investment of the scrotum, viz. the dartos, and also with the superficial fascia of the abdomen. A little below the transversus perinæi muscle the superficial fascia will be observed to pass back and become identified with the deep-seated fascia, after which both may be traced

beneath the superficial sphincter. When extravasation of urine takes place into the perinæum, the attachments of this fascia will influence the direction in which the fluid proceeds, should its quantity increase. Though its natural tendency is backwards to the anus, or downwards along the inside of the thighs, its progress in these directions is interrupted by the adhesion of the membrane to the rami of the ischia and pubes at each side, and to the deep fascia posteriorly; but towards the scrotum no impediment exists; and so we find that effusions gradually make way upwards to the groin, or even on the front of the abdomen, their progress being preceded by a red erysipelatous blush on the skin.

To expose the superficial vessels and muscles.—Divide the superficial fascia from above downwards in the middle line, and having drawn it aside, and pinned it back on the reflected integument, the superficial perinæal artery will be found running in the angular interval between the accelerator urinæ and erector penis. Midway between the margin of the anus and the bulb of the urethra, a narrowed point (fibrous or fibro-cellular) exists, which forms the *common centre* of the perinæal muscles: to it converge the transversi muscles from the sides, and the sphincter from behind, and from it the lower fibres of the acceleratores diverge. The last-named muscles should be attentively examined, and their description (sect. 506) read, after which they may be divided along their raphé, or common line of junction, and reflected carefully outwards, so as to expose the bulb of the urethra, which will be found invested by a thin smooth lamella, prolonged upon it from the margin of the deep perinæal fascia, through which the canal of the urethra must necessarily pass when emerging from the pelvis into the perinæum. The sphincter ani will be observed surrounding the margin of the anus in the form of a thin flat plane of muscular fibres, similar to orbicular muscles in other situations. On raising its external border, the fibres of the levator ani will be observed passing downwards to the margin of the anus; and further back, in the interval between the posterior margin of that aperture and the tip of the coccyx, the two levatores will be found to form a raphé or line of junction; before the anus their fibres join at the common central point above noticed. To expose the external surface of the levator, all the cellular tissue which fills up the deep interval between the margin of the anus and the tuber ischii must be removed.

To expose the attachments and relations of the levator ani, the interior of the pelvis must be laid open. For this purpose saw through the os pubis half an inch external to its symphysis (say at the right

side), the abdominal viscera and peritonæum being previously removed. With your scalpel carefully detach the pelvic fascia from the side of the pelvis, and reflect it inwards, together with the thin membranous muscle you will find attached to its external surface rather low down. When this is done, saw through the right sacro-iliac symphysis, and so remove the whole limb of that side. Let an assistant hold up the levator ani, which you have retained as above directed, and you can easily trace its fibres to the side of the bladder, rectum, and coccyx. And when you have gone so far, draw the bladder away from the left side, and trace down the fascia iliaca upon the side of the pelvis; you will see how it turns inwards to the side of the bladder and rectum. Now, close by these organs you will perceive that behind the fascia there is a thin plane of muscular fibres, the levator ani, of considerable extent, from before backwards, being from the pubic symphysis to the spine of the ischium. If you carefully remove the fascia (proceeding from below upwards) from the muscle, you will see that it is attached to the two points of bone just named, and in the intervening space to the angle of union of the pelvic and obturator fascia. (See description of the deep perinæal fascia, sect. 599, and remarks on catheterism and lithotomy, sect. 600.)

The genital muscles are as follow:

505. *m. Erector penis*, fig. 110, 1, (ischio-cavernosus,) is a thin, flat, long muscle placed on the ramus of the ischium and on the crus of the penis, extending from the inner and upper part of the tuberosity of the ischium to the side of the penis. It is narrow at its extremities, but widens somewhat towards the middle. It arises from the inner border of the tuber ischii, from which its fleshy fibres proceed obliquely upwards and forwards, and become tendinous on reaching the corpus cavernosum, into whose fibrous sheath they are inserted. The inferior surface of the muscle is covered by the skin and the superficial fascia; the superior is in contact with the crus and body of the penis, whilst between its inner margin and the accelerator muscle a groove exists, in which the superficial perinæal vessels are lodged.

506. *m. Accelerator urinæ*, fig. 110, 2, (bulbo-cavernosus,) is so disposed as to surround the bulbous part of the urethra. We may consider it as a single muscle consisting of two symmetrical halves, united so as to form a tube surrounding a part of the urethra, and connected, anteriorly, by two diverging processes,

with the corpora cavernosa, and posteriorly, at the central point of the perinæum, with the sphincter ani, and the transverse muscles, whilst its inferior fibres are extended obliquely outwards at each side to the rami of the ossa pubis. Its analogy with the constrictor vaginæ would lead us to consider it in this way. In conformity with usage, however, we shall describe each lateral half as a separate muscle.

The fibres of the accelerator muscle, forming a thin plane, are blended with those of the corresponding muscle along the middle line, beneath the bulb of the urethra. Their junction extends forwards for three quarters of an inch from the central point above referred to. The fibres from this line of origin proceed in three different directions: the inferior set pass obliquely outwards, and are attached to the angle of union formed by the deep perinæal fascia with the ramus of the pubes; the anterior set incline upwards and outwards, to be inserted into the corpus cavernosum; whilst the intervening or middle fibres coil round the canal of the urethra, and become tendinous on reaching its upper surface, upon which they unite with those of the corresponding muscle, thus forming a tube. If an incision be made over the bulb, so as to cut through the fibres of the muscle, and if one half be then carefully reflected outwards, its points of attachment will be readily seen; after which, if the urethra be cut across and reflected downwards, the union of the middle part of the muscle on its upper surface will be brought into view.

507. *m. Transversus perinæi*, fig. 110, 3, (ischio-perinæalis,) is a narrow fleshy fasciculus, which inclines forwards and inwards across the perinæum, being extended from the inner border of the tuber ischii at its junction with the ramus, to a point midway between the margin of the anus and the bulb of the urethra. The muscles of the opposite sides arise from the inner margin of the tuberosities and the rami of

Fig. 110.

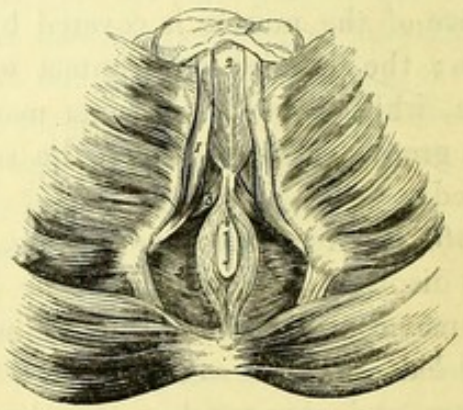

the ischia, and proceed with an inclination forwards, to the point just indicated, where they are blended with the sphincter ani and acceleratores urinæ. Another muscle of this name is occasionally found at each side, lying anterior to the one here described, and called *transversus perinæi alter;* the fibres of the latter are usually thin and pale.

508. *m. Compressor urethræ* (Wilson), compressor prostatæ (Sœmm.), is a narrow fasciculus that arises close by the pubic symphysis, immediately before the anterior fibres of the levator ani, and from which it is merely separated by a small vein and a little cellular tissue. The muscle descends close to its fellow of the opposite side, and, beneath the membranous part of the urethra, both of them having become tendinous, unite so as to support it in a sling. Many persons consider this as but a part of the levator ani.

509. *m. Compressor venæ dorsalis penis* is a small muscle lately demonstrated and described by Mr. Houston.* Cuvier noticed it briefly, and the late Mr. Shekleton showed it to Mr. Houston. It is a thin fasciculus, composed partly of tendinous, partly of fleshy fibres, placed beneath the pubic arch, and above the root of the penis. Its fleshy fibres are attached to the inner margin of the ramus of the os pubis, immediately above those of the erector penis; from this point the fibres ascend, at the same time inclining forwards and inwards, and end in a thin tendon, which unites with that of its fellow of the opposite side, at the median line, just over the dorsal vein. The length of each muscle is about an inch, its breadth about half an inch. As the conjoined tendon of these two muscles overlays the dorsal vein, they can, when in action, compress it against the root of the penis, so as to prevent the return of blood by the vessel, and so keep up the distension of the organ during the venereal orgasm. The general conformation of the muscle corresponds with what has been just stated. There are, however, some peculiarities in different animals which deserve notice. In the dog the tendon presents a transverse slit through which the vein passes; in the horse, the dorsal veins pass backwards in separate trunks, and the tendon is found subdivided into fasciculi, of which some pass over, some under

* Dublin Hospital Reports, vol. v.

and between the vessels. In the bear and monkey, the whole of the tendon overlays the vein. When proceeding to expose the muscle, we may take advantage of the circumstance of its tendon coming forwards upon the root of the penis, a little anterior to the symphysis pubis. Trace back the dorsal vein, carefully divide the fibrous expansions of the suspensory ligament, draw the penis tightly forwards, and the tendon of the compressor will be brought into view by a little cautious dissection. Taking the tendon as a guide, trace the muscular fibres outwards and downwards, detaching at the same time the crus penis from the ramus for some way from above downwards. Having proceeded so far, cut through the pubic symphysis, saw through the ramus close above the fibres of the muscle, and the body of the bone about its middle, and remove it altogether. The muscle will be fully exposed. This plan will do very well in the dog, or in a fresh muscular subject; but if the fleshy fibres are pale, and those of the tendon discoloured, the mode pointed out by Mr. Houston* had better be adopted: "Detach the bladder and levator ani from one side of the pelvis; with a saw divide the pubis and ischium about an inch from the symphysis, and break the bones at the sacro-iliac articulation. Next dissect away carefully the remaining part of the pubis from the symphysis, periosteum, and crus, then the compressor will be exposed without difficulty."

The perinæal muscles in the female correspond so nearly with those of the male in their number, general conformation, and attachments, that it is unnecesary to treat particularly of more than two of them.

510. *m. Erector clitoridis* (depressor, Meckel) resembles the diminutive of the erector penis; it arises from the ramus of the os pubis, and is inserted into the body of the clitoris.

511. *m. Constrictor vaginæ* (perinæo-clitorius) resembles an orbicular muscle, being composed of two narrow fasciculi, united before and behind the vagina by two commissures, and leaving between them an elliptic interval corresponding with its circumference. The two muscles of this name may be said to arise posteriorly at a point which is common to them) to the sphincter ani and transversi muscles; after diverging to enclose the vagina,

* Loc. cit.

they unite in front of it into a tendinous process, which connects them to the corpus clitoridis.

The anal muscles are as follow:—

512. *m. Sphincter ani externus*, fig. 110, 4, (coccygeo-analis,) is a flat elliptic muscle, placed immediately beneath the skin surrounding the margin of the anus. It is attached posteriorly to the coccyx by a narrow fasciculus of tendinous fibres, and anteriorly becomes blended, about midway between the anus and the bulb, through the medium of a common fibrous point, with the transversi and acceleratores muscles, whilst the intervening part is disposed like orbicular muscles elsewhere, being composed of fleshy fibres curving round the intestine, and united by commissures before and behind it. One surface of the muscle is covered by the skin, the other rests on the internal sphincter, and on some cellular tissue which separates it from the levator ani.

513. *m. Sphincter ani internus* is a flat muscular ring, surrounding the anal extremity of the rectum; it is about four or five lines in breadth, and two thick. It obviously consists of the circular fibres of the intestine much more developed than elsewhere, and projecting lower down than the longitudinal fibres.

514. *m. Levator ani*, fig. 110, 5, (sub-pubio-coccygeus,) is a thin broad muscle, placed obliquely across the outlet of the pelvis, which it assists in closing. Its origin cannot be distinctly stated without making reference to two membranes between which it is placed, and from whose line of union most of its fibres are derived. The obturator internus muscle occupies the whole space from the internal border of the obturator foramen to the sciatic notch. The upper half of this muscle is lined by the pelvic fascia, prolonged down as far as to a line extended from the symphysis pubis to the spine of the ischium, where it is reflected upon the levator ani, which guides it to the side of the rectum and bladder. The lower part of the obturator muscle is also covered by a fascia, but more dense and firm, which is prolonged upwards upon it from the edge of the falciform process of the great sacro-sciatic ligament, which is attached along the rami of the ischium and os pubis. This fascia becomes united to the fascia pelvica along the line above indicated, and may be said to determine its point of flexion; and from the

angle which they form by their union, arises the middle part of the levator ani. This fact may be easily ascertained by dividing the obturator fascia for an inch, or little more, and then passing a probe between it and the obturator muscle. It will then be found as the instrument is being moved backwards and forwards, that the greater part of the levator ani is attached only to these membranes.

The *levator ani* then *arises*, anteriorly, from the os pubis, near its symphysis, and immediately above its arch; posteriorly, from the spine of the ischium, and along the intervening space from the angle formed by the union of the obturator and pelvic fasciæ. From this extensive origin the fibres proceed downwards and inwards, the posterior set being fixed to the side of the coccyx; those next them in order unite by a raphé with the corresponding muscle, in the interval between the coccyx and the margin of the anus; the middle fibres are inserted into the extremity of the rectum, becoming connected with those of the internal sphincter, and the anterior ones pass on the side of the prostate, some of them uniting with those of the corresponding muscle beneath the membranous part of the urethra. In the female, the fibres of this muscle, previously to reaching the rectum, descend by the vagina, and become intimately connected with it.

515. *m. Coccygeus* (ischio-coccygeus) is placed deeply at the back part of the outlet of the pelvis, which it assists to close, by being stretched from the spinous process of the ischium to the side of the sacrum and coccyx. It is made up of tendinous and fleshy fibres, forming a flat triangular plane, the apex of which is attached to the spine of the ischium, and the base to the border of the coccyx and lower part of the sacrum. The internal, or pelvic surface, supports the rectum; the external is covered by the sacro-sciatic ligaments.

Actions.—The transverse muscles conspire to fix the common point of attachment of the perinæal muscles, and so increase their power. The action of the sphincter ani is sufficiently obvious. The accelerator muscle, by surrounding the bulbous part of the urethra, and by the increased power it acquires from its many points of attachment, is enabled forcibly to propel any fluid that may be lodged within the canal in that situation. The levator ani, in position and direction, is opposed to the diaphragm, and as the latter forces down the intestines

by its descent, the former, as its name implies, can elevate at least the lower part of the intestinal canal. The compressors of the dorsal vein have some analogy in form to the accelerator urinæ, for the muscles of opposite sides unite in the middle line and form a tube which surrounds the vein, as the fibres of the accelerator do the canal of the urethra. The name expresses their apparent use; they constrict the vein, and prevent the return of blood by it, so as to continue the distension of the parts during the venereal orgasm. The compressor urethræ supports the membranous part of the canal, as in a sling; it can also elevate it, and so, by drawing up the under surface, close it altogether.

Muscles of the inferior extremity.

ILIAC REGION.

In the iliac fossa, and along the upper border of the pelvis, we find placed the iliacus and psoas muscles. We need not give any particular directions for their dissection, as it is never undertaken until the abdominal muscles have been examined and the viscera removed, and then they are at once brought into view, being merely concealed by the fascia iliaca.

516. *m. Psoas magnus*, figs. 109, 3; 113, 1, (præ-lumbo-trochantineus,) is situated along the side of the lumbar vertebræ, the margin of the pelvis, and deeply at the superior part of the thigh, extending from the last dorsal vertebra to the small trochanter of the femur. Form—thick and round at the centre, diminishing in size towards the extremities. It *arises* from the sides of the bodies of the last dorsal and of the first four lumbar vertebræ, and the interposed fibro-cartilages, also from the roots of the transverse processes of the last-named vertebræ. From these attachments, which are separated by the branches of the lumbar plexus of nerves, the muscle passes across the brim of the pelvis, beneath Poupart's ligament, and ends in a tendon, which is inserted into the small trochanter of the femur. The direction of the muscle, in the greater part of its extent, is nearly vertical; it has, however, a slight inclination outwards—and its lower part passes backwards to reach its destination; structure—fleshy in the centre, tendinous at its insertion: relations—vary in the different parts of its extent: its posterior surface corresponds above with the transverse processes of the

lumbar vertebræ, the lumbar plexus of nerves, and the quadratus lumborum muscle, from which last it is separated by the anterior lamella of the aponeurosis of the transversalis muscle; in the middle, with the margin of the pelvis; farther down, with the os pubis and the capsular ligament of the hip joint; the anterior surface, placed behind the peritonæum, is in relation above with the ligamentum arcuatum and diaphragm, the renal vessels and ureter, the sympathetic nerve and its ganglia; in the middle it is covered by the iliac fascia, farther down by the femoral artery which rests upon it; and, finally, by the deep-seated vessels of the groin, inguinal glands, &c. The inner border is in relation superiorly with the bodies of the vertebræ, from the middle of which it is separated by the lumbar arteries and branches of communication between the spinal and sympathetic nerves; in the pelvic region with the iliac artery; and in the femoral with the pectineus muscle, from which it is separated by the internal circumflex artery. Its outer border is in relation with the inner border of the iliacus muscle from which it is at first separated by a slight cellular interval, and then by the lumbar nerves.

517. *m. Psoas parvus*, fig. 113, 2, (præ-lumbo-pubius,) is situated (when it exists, which is not always the case) along the anterior side of the psoas magnus. Form—long and thin. It *arises* from the body of the last dorsal and first lumbar vertebra, and soon ends in a flat tendon, which passes along the anterior and inner side of the psoas magnus, to be inserted into the ilio-pectineal eminence. Direction—vertical: structure—muscular and tendinous: relations—it rests on the psoas magnus in the whole of its extent; and is covered by the fascia iliaca,—crossed at its origin by the diaphragm, and lower down by the renal vessels.

518. *m. Iliacus*, fig. 113, 3, (iliacus internus, Albinus, Sœmm.; ilio-trochantineus,) is situated in the iliac fossa, which it fills up, and at the upper and fore part of the thigh. Form—compressed and somewhat radiated. It *arises* from the upper two-thirds of the iliac fossa, from the anterior-two-thirds of the inner margin of the crista ilii as far as its two spinous processes, and posteriorly from the ilio-lumbar ligament. From these different origins the fibres pass down, the greater number inclining obliquely inwards, to be inserted into the tendon com-

mon to this muscle and the psoas magnus, some of them being prolonged into the oblique line which leads downwards from the small trochanter. Structure—fleshy in almost all its extent: relations—posteriorly with the ilium and capsular ligament of the hip-joint, anteriorly with the iliac fascia, which separates it from the peritonæum, and by its inner border with the crural nerve and psoas muscle; it is subjacent to the cœcum at the right side, and to the sigmoid flexure of the colon on the left. This muscle is even still called iliacus internus, though there is now no correlative term in use, no muscle being called iliacus externus. Cowper, and some of the older anatomists, called the pyriformis by that name.

Combined actions.—The psoas and iliacus, when they take their fixed point above, can bend the thigh on the pelvis, and rotate the limb somewhat outwards,—the latter power being derived from the direction of their common tendon and the mechanical advantage given them by the projection of the trochanter minor. These muscles assist materially in maintaining the erect position of the body, in which case they take their fixed point at their insertion into the femur, and then act upon the pelvis and spinal column, drawing them forwards so as to keep them erect upon the thighs. If this action be continued, the trunk may be bent forwards as in bowing. It is scarcely necessary to add, that this bending of the body will be directly forwards if the muscles of opposite sides act together, and obliquely to one side if they act separately.

GLUTEAL REGION.

519. In this space, which comprehends the posterior and external surface of the pelvis, we find the glutei, and the external rotator muscles of the thigh.

Dissection.—The subject being placed in the prone position, and the abdomen supported on a high block, the foot should be rotated inwards, and the limb abducted, in order to put the gluteus on the stretch. An incision may be made through the skin, from the coccyx obliquely upwards over the side of the sacrum and posterior spine of the ilium, and as high as its crista; from which point draw another obliquely downwards over the great trochanter. The flap thus included should be dissected cleanly off the muscle in the course of its fibres, that is to say, downwards and outwards. The remainder of

the skin which covers the pelvis may be reflected upwards and outwards, the fascia serving as a guide. This will expose the tensor vaginæ and part of the gluteus medius. The rest of the latter can be seen only when the gluteus maximus is detached. To effect this, let its lower border be drawn a little forwards, and the scalpel be inserted beneath it, so as to raise it from the sciatic ligament, and so successively from the side of the coccyx, sacrum, and ilium, proceeding from below upwards. When the muscle is detached, and turned down on the femur, the external rotators and gluteus medius come into view, and require little further dissection. As the gluteus medius covers the third muscle of that name, the easiest mode of reflecting it is by cutting through its tendinous insertion, and drawing it upwards. The external rotators should be attentively examined, more particularly the two obturator muscles. The internal one cannot be fully seen until the pelvis is divided; but the direction of its two parts, and the peculiar appearance presented by its tendon, where it slides over the ischium, can be observed by cutting it across near its insertion, and reflecting it outwards.

Fig. 111.

520. *m. Gluteus maximus*, fig. 111, 1, (ilio-sacro-femoralis,) is situated behind the pelvis, at the nates, the prominence of which it forms. It extends from the back part of the ilium, the sacrum, and the coccyx, to the rough ridge at the upper and back part of the femur beneath the great trochanter. Form — broad, thick, and irregularly quadrilateral. It *arises*, 1, from the posterior fifth of the crista of the ilium, and the irregular rough surface subjacent to that part; 2, from the posterior surface of the sacrum below the ilium, and from the side of the coccyx in its whole length; 3, from the posterior or great sacro-sciatic ligament. From these origins, the coarse thick fibres of which the muscle consists converge as they pass downwards and outwards, and terminate in a broad strong tendon, whose external surface is rough and irregular, but the internal is smooth, and lined by a bursa mucosa, where it

corresponds with the great trochanter. This tendon is *inserted*, between the vastus externus and adductor magnus, into that rough longitudinal impression which descends from a little way beneath the great trochanter to the linea aspera. Direction—downwards, forwards, and outwards: structure — aponeurotic along its line of origin, tendinous at its insertion, fleshy in by far the greatest part of its extent. The fibres of origin are blended with those of the aponeurosis of the sacro-lumbalis and latissimus dorsi. The fleshy fibres are thick and coarse, those at the anterior border are shorter than those in the middle, and the latter than those along the posterior border. The fleshy fibres, which immediately succeed to the aponeurotic attachments superiorly, are arranged in parallel lines and aggregated into large distinct bundles, separated by cellular membrane. These fleshy bundles successively terminate at the posterior border of a strong common tendon, which extends from opposite the upper part of the great trochanter, where it is broad, and confounded with the fascia lata, to the line of attachment just described. Relations—the external surface is covered by the fascia lata, which here is very thin; the upper and anterior border is firmly connected by that membrane with the gluteus medius; the posterior is on the same plane, and somewhat identified with the common origin of the sacro-lumbalis and longissimus dorsi muscles; the inferior border (the longest) is free, and forms the fold of the nates. When the muscle is separated from its superior connexions and reflected downwards, it will be found that its inner surface covers, and is therefore in relation with, the ilium, sacrum, and coccyx, the great sciatic ligament, the gluteus medius, the gluteal, sciatic, and pudic vessels, the external rotator muscles, the great sciatic nerve, the trochanter major, the tuberosity of the ischium, and the superior extremities of the semitendinosus and biceps muscles.

521. *m. Gluteus medius*, fig. 111, 2; fig. 112, 1, (ilio-trochantereus major,) is situated on the external surface of the pelvis, partly covered by the preceding muscle, partly by the skin and fascia. It is broad, and, as it were, radiating at its upper part, but narrow and thick at its lower extremity. It *arises* by short aponeurotic fibres from the anterior four-fifths of the crista ilii, (its outer margin,)—from the rough line which bounds the surface on the back part of

Fig. 112.

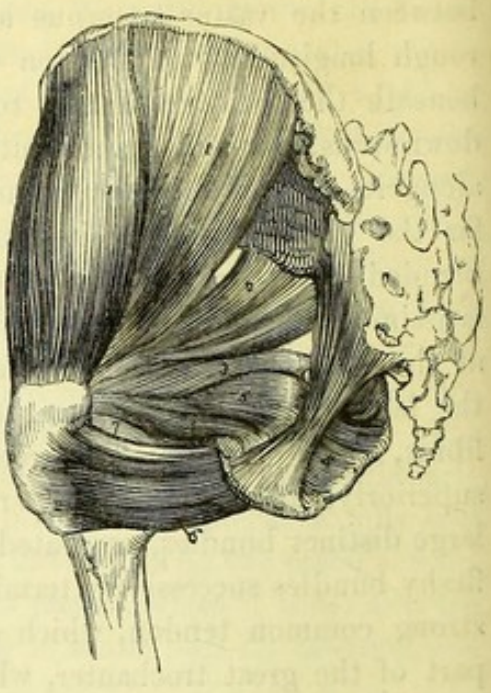

the ilium whence the gluteus maximus arises, — from that part of the external surface of the ilium which extends from the crista ilii, and the line just named, down to the superior curved line, also from the latter. From this extensive origin the fleshy fibres as they descend converge to a short thick tendon, which is blended anteriorly with that of the gluteus minimus, and posteriorly, in many instances, with the pyriformis; after which its fibres are inserted into the broad external surface of the trochanter major, and somewhat into its upper border. Direction—the anterior fibres extend obliquely backwards, the posterior obliquely forwards, the middle perpendicularly: structure—tendinous at the inferior attachment, fleshy in the rest of its extent: relations—part of the external surface is covered by the gluteus maximus, the rest by the fascia lata; the inner surface rests on the ilium, the gluteus minimus, and the branches of the gluteal vessels; the posterior border is in relation with the pyriformis muscle; the anterior is intimately connected with the tensor vaginæ femoris, by means of the fascia lata.

522. *m. Gluteus minimus* (ilio-trochantereus minor) is situated on the inferior part of the dorsum ilii. Form — radiated, broad above, narrow below. It *arises* from all that space on the dorsum ilii between the superior curved line and the inferior one, which runs above the brim of the acetabulum. From this origin the fibres converge as they descend, and end in a short tendon, which is *inserted* into the anterior border, and somewhat into the external surface of the great trochanter, where it is blended with that of the gluteus medius. Direction — the middle fibres are vertical, the anterior are inclined backwards, the posterior forwards, converging to the common tendon: structure—fleshy in the greater part of its extent, tendinous at its insertion: relations — by its external surface with the gluteus

medius; by the internal with the dorsum ilii, with the external tendon of the rectus femoris, and with the fibrous capsule of the hip-joint.

Actions.—The glutei act alternately on the femur and pelvis, according as the one or the other becomes relatively their fixed point of attachment. All three act as abductors; the anterior fibres of the gluteus medius and minimus draw the trochanter forwards, the posterior backwards, giving it a slight rotatory motion. The gluteus maximus is a powerful abductor, and by the direction of its fibres is calculated to draw the femur backwards, at the same time that it rotates the whole limb outwards if it be kept extended. When the thighs become the fixed points, these muscles act on the pelvis. The great glutei draw it backwards, and maintain it and the body in the erect position; in this they are assisted by the semi-tendinosus, semi-membranosus, and biceps of each side, which act on the tuberosities of the ischia, and draw them downwards, so as to elevate the fore part of the pelvis. The gluteus medius and minimus are chiefly called into action in progression, and in standing on one leg; they draw the pelvis towards the femur, which is fixed, and by this action counterbalance the weight of the trunk, and maintain it erect on the limb. This alternation of action of the muscles of opposite sides during progression, gives to the pelvis that rotatory motion so perceptible in those who walk irregularly, and which is strikingly evident in females, in consequence of the great breadth of the pelvis.

The external rotator muscles form a group by themselves, being placed deeply at the back of the pelvis. They are the pyriformis, two gemelli, two obturators, and quadratus femoris.

Dissection.— Most of these are exposed by the removal of the gluteus maximus. The origin of the obturator internus cannot be seen until the pelvis is opened.

523. *m. Pyriformis*, fig. 112, 2, (pyramidalis, sacro-trochantereus,) is situated at first within the pelvis, and afterwards on its posterior and external surface, extending from the anterior surface of the sacrum through the great sacro-sciatic notch to the great trochanter of the femur. Form—elongated and tapering, as its name imports. It *arises*, by three fleshy and tendinous digitations, from the second, third, and fourth divisions of the sacrum, interposed as it were between the anterior sacral foramina; a few fibres are also connected with the inner surface

of the ilium, near its lower curved border. From these attachments the muscle passes out of the pelvis by the great sacro-sciatic notch, and is *inserted* into the posterior border of the great trochanter by a rounded tendon, whose fibres are blended somewhat with those of the gluteus medius. Direction—downwards and outwards: structure—fleshy and tendinous: relations—within the pelvis it is placed behind the sciatic plexus of nerves, the internal iliac vessels, and the rectum (the last more especially at the left side). Outside the pelvis one surface rests on the ischium and the fibrous capsule of the hip-joint, the other is covered by the gluteus maximus; its superior border is parallel with the gluteus medius, from which it is separated by the gluteal vessels as they emerge from the pelvis, the inferior is a little above the gemellus superior and crosses the great sciatic nerve. The separation always existing at its points of origin sometimes continues to be apparent even after the muscle has passed out by the pelvis: when this is the case, the interval gives passage to one of the divisions of the great sciatic nerve.

524. *m. Gemelli* (ischio-trochanterei) are two small narrow fasciculi stretched nearly in the horizontal direction from the spinous process of the ischium and its tuberosity to the trochanteric fossa. They are named, from their position, superior and inferior, the latter being the larger. The superior one, fig. 112, 3, *arises* from the spinous process of the ischium; the inferior, 4, from the upper and back part of the tuberosity of that bone; and both are *inserted* into the digital or trochanteric fossa, together with the tendon of the obturator internus, which they enclose and almost conceal. Direction—transversely outwards from the ischium to the trochanter: structure—tendinous at their insertion, fleshy in the rest of their extent: relations—their posterior surface is crossed by the sciatic nerve, and covered by the gluteus maximus muscle; the anterior surface rests on the ischium and fibrous capsule of the hip-joint; the smaller gemellus corresponds by its upper border with the pyriformis; the larger by its lower border with the tendon of the obturator externus, the contiguous borders of each being intimately connected with the tendon of the obturator internus, which runs between them.

525. *m. Obturator internus*, fig. 112, 5, (sub-pubio-trochan-

tereus,) is situated chiefly within the pelvis, a small part only being placed on its external surface. Form—flat and triangular. It *arises* by tendinous and fleshy fibres from the inner flat surface of the os pubis, extending from near its symphysis as far as the margin of the obturator foramen,—from the obturator membrane, except where it is pierced for the transmission of the obturator vessels,—and from the inner flat surface of the ischium as far back as the sciatic notch, on a level with a line drawn from the upper margin of the obturator foramen backwards to that of the notch. The fibres converge to a tendon, which passes out of the pelvis by the inferior sciatic notch, and is inserted into the trochanteric fossa between the gemelli muscles. Direction—it at first passes backwards, then is reflected over a pulley-like surface on the ischium, situated between the spine and tuberosity of that bone, after which it proceeds horizontally outwards, so that the internal and external portions form a considerable angle with one another: structure — fleshy whilst within the pelvis; its tendon, flat and uniform on its posterior surface, presents at its anterior aspect four small tendinous bundles, which slide upon the smooth surface of the ischium above noticed: relations—within the pelvis it is covered by the internal pudic artery and the obturator fascia, which separates it from the levator ani muscle; its tendon lies on the ischium and fibrous capsule of the hip-joint, being covered by the great sciatic nerve and gluteus maximus muscle; its borders are enclosed between the gemelli.

526. *m. Quadratus femoris*, fig. 112, 6, (tuber-ischio-trochantereus,) is placed deeply at the upper and back part of the thigh, extending from the external margin of the tuber ischii outwards to the posterior border of the great trochanter. It is short and flat, its form being that of an oblong square. It *arises* from the external curved border of the tuber ischii, and is *inserted* into the lower half of the posterior border of the great trochanter; its middle corresponding with a smooth rising or tuberosity observable in that border. The line of insertion of this muscle may properly be called *linea quadrati*, to distinguish it from the inter-trochanteric line, the latter being oblique in its direction, the former vertical. Direction—horizontally outwards: structure—fleshy and very slightly tendinous at its attachments, fleshy in the rest of its extent: relations—by its posterior sur-

face, with the great sciatic nerve, the gluteus maximus and semi-membranosus muscles; by the anterior, with the obturator externus, the lesser trochanter, and part of the insertion of the psoas magnus muscle; its upper border is in relation with the inferior gemellus, the lower with the adductor magnus.

527. *m. Obturator externus*, fig. 112, 7, (sub-pubio-trochantereus externus,) is situated deeply at the anterior and external aspect of the pelvis, and superior part of the thigh. Form—flat and triangular. It *arises* from the external flat surface of the os pubis,—from the rami of the os pubis and ischium, as far as the margin of the obturator foramen, and from about half the surface of the obturator membrane. From this extensive origin the fibres pass outwards, converging to a tendon, which is directed behind the neck of the femur, to be *inserted* into the lower part of the trochanteric fossa, beneath the inferior gemellus. Direction—obliquely outwards, winding round the posterior part of the neck of the femur: structure—tendinous at its insertion, fleshy in the greater part of its extent, with a slight mixture of aponeurotic fibres at its origin: relations—its anterior surface, which in the erect position of the body is also the inferior one, is covered by the adductor brevis and pectineus muscles, also by the obturator vessels; the posterior one corresponds with the os pubis, its ramus, and that of the ischium, as well as the obturator membrane; one surface of its tendon is in close contact with the fibrous capsule of the hip-joint, the other is covered by the quadratus femoris.

Actions.—The transverse direction of these muscles, and their mode of insertion into the trochanter, together with the great mechanical advantage afforded them by the length of the cervix femoris, enables them to act powerfully in rotating the thigh, and therefore the whole limb, outwards. In position, direction, and action, they are analogous to the muscles which pass from the dorsum of the scapula to the great tuberosity of the humerus; the latter, however, are nearly equalled in strength by their antagonist, the sub-scapularis; but the external rotators of the thigh are very feebly opposed by the tensor vaginæ femoris, and the anterior fibres of the gluteus medius, which alone act directly in rotating the limb inwards, if we except the semi-tendinosus, which may, under some circumstances, co-operate in this action. If the femur be bent on the pelvis, the line of direction of these muscles nearly coincides with the axis of the bone; their

power of rotation then ceases, but they may in a slight degree become abductors; at least this may be said of the pyriformis, both from its direction and point of insertion.

ANTERIOR FEMORAL REGION.

528. At the fore part of the thigh we find immediately beneath the skin and fascia, these muscles, viz. the tensor vaginæ femoris, sartorius, rectus, vastus externus and internus, crureus.

Dissection.—To expose the fascia lata :—In the first place, let the knee be slightly bent,—the limb rotated outwards and supported on a block. And, as in this position the course of the femoral artery is indicated by a line extended from midway between the anterior superior spine of the ilium and the pubic symphysis to the lower border of the patella, the first incision through the skin should be made to the same extent, and in the same direction. In order to reflect the integuments with facility, a second incision may be made transversely at the junction of the upper with the middle third of the thigh; and finally, another in the same direction at the junction of the middle with the lower third; this marks the termination of the femoral artery. The flaps of skin thus formed are to be dissected back, so as to expose the fascia lata. This membranous investment should be attentively examined in its entire extent, particularly at the upper part; the differences of texture and thickness which it presents in different parts should also be carefully noted.

To expose the muscles :— In prosecuting the dissection, in order to expose the muscles on the fore part of the thigh (and it is with these the dissection usually commences), nothing more is necessary, after the skin has been removed, than to pinch up the fascia with the blades of the forceps, divide it with your scalpel, and reflect it from above downwards, in the direction of the fibres of each muscle. After the sartorius and rectus have been dissected in their entire length, and their attachments and relations attentively examined, the former may be cut across in the middle, and the parts drawn aside; the latter too may be divided near its origin, and turned down on the leg. The triceps extensor is thus brought fully into view, so that its three parts (the two vasti and the crureus) may be inspected successively, at the same time that it is considered as a whole. The muscle in fact may be compared to a hollow splint, encasing the anterior and lateral surfaces of the shaft of the femur, leaving unoccupied only the linea aspera and its bifurcations (superior and inferior).

To detach the vasti:—A perpendicular incision may, in the next place, be made through the muscle, extending from one extremity to the other over the middle of the femur. If the margins of the incision be drawn aside, a clear view will be obtained of the manner in which the fibres pass to be implanted, by so many separate points, into the surface of the bone. Holding the border of the incision tense, and with the blade of the scalpel placed in the horizontal position, the muscle may be detached from the bone inwards as far as the insertion of the adductors, and outwards to the attachment of the gluteus maximus, and the short head of the biceps, so as to denude the front and sides of the thigh-bone. Having proceeded so far, cut from within outwards through the vasti, so as to detach them altogether. When this is done, the two parts thus separated may be turned down on the leg, still left connected with the patella.

By these measures we shall bring into view the inferior attachments of the next set of muscles (adductors), which would otherwise lie in a great degree concealed.

Before the extensors are detached and reflected, the form and boundaries of the opening for the femoral vessels should be attentively examined, as the vastus internus constitutes a part of it; nor should the fascia be omitted which passes from the latter muscle to the adductors, covering the vessels.

529. *m. Tensor vaginæ femoris*, fig. 113, 5, (ilio-aponeurosi-femoralis,) is situated at the upper and outer part of the thigh, extending obliquely downwards, outwards and backwards, from the anterior superior spinous process of the ilium to about three inches below the great trochanter. Form—elongated and flat, broader at the lower than at the upper extremity. It *arises* from the external surface of the anterior superior spinous process of the ilium, between the gluteus medius, 4, and the sartorius, 6, and terminates about three inches below the great trochanter of the femur, its fleshy fibres being received between two laminæ of the fascia lata, into which they are thus inserted. Direction — as above stated: structure — aponeurotic in its origin, fleshy in the rest of its extent: relations—its external surface is covered by a layer of the fascia lata; the internal is also embraced by another process of the same membrane, which separates it from the rectus femoris and the vastus externus. Its anterior border is at first close to the sartorius, but lower down it diverges and leaves an angular interval occupied by the rectus

femoris. Its posterior border is for some way applied to the gluteus medius, but lower down they are separated by an interval.

Actions.—As its name imports, the direct action of this muscle is to render the fascia tense, and thereby assist the other muscles. If this effort be farther continued, the obliquity of its direction will enable it to rotate the whole limb inwards, provided the other muscles remain quiescent. In the erect position, by taking its fixed point below, it will act on the pelvis.

Fig. 113.

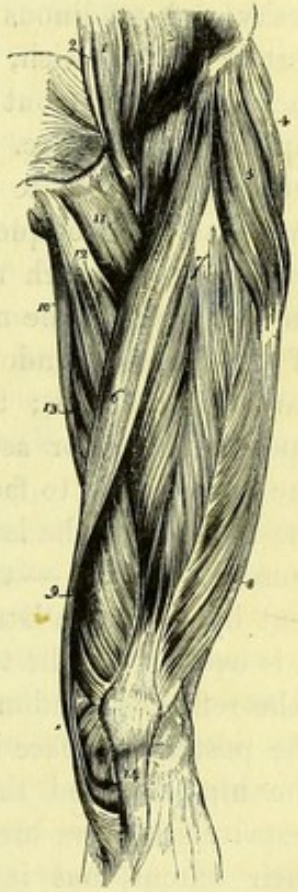

530, *m. Sartorius*, fig. 113, 6, (ilio-præ-tibialis,) is situated at the anterior and inner aspect of the thigh; it is a long, flat, narrow muscle, which extends from the anterior superior spinous process of the ilium down to the inner and fore part of the tibia. It *arises* from the curved margin of the ilium, between its anterior superior and inferior spinous processes, and from the former point of bone, and is *inserted* by an expanded aponeurosis into the upper and inner side of the tibia, just below its tuberosity. Direction — obliquely downwards and inwards in the upper third of its extent, then vertical as far as the knee, where it turns obliquely forwards to its point of attachment: structure — fleshy, except at the extremities, which are tendinous. The inferior tendon, broad and expanded, covers those of the gracilis and semi-tendinosus, and sends off an expansion which strengthens the fascia of the leg, by becoming identified with it. Relations — by the anterior surface with the fascia lata; by the posterior, with the iliacus, psoas, and rectus femoris muscles, the femoral vessels, the adductor longus, adductor magnus, vastus internus, gracilis, and semi-tendinosus muscles. Its internal border bounds, with the adductor longus, a triangular space in the upper third of the thigh, through the centre and apex of which the femoral artery passes.

531. *m. Rectus femoris*, fig. 113, 7, (ilio-rotuleus,) is situated in front of the thigh, being extended in a straight line from the pelvis to the patella. Form—elongated, smaller at the extremities than in the middle. It *arises* by two tendons, one of which embraces the anterior inferior spinous process of the ilium; the other, reflected outwards, is attached along the brim of the acetabulum. The tendons unite at an angle; from their union the muscle descends, gradually increasing in breadth and thickness towards its middle, from which it diminishes again towards its lower part. It is *inserted* into the patella, in conjunction with the triceps extensor. Direction — vertical: structure — fleshy and tendinous at the extremities, fleshy at the middle part or belly, which, though compressed somewhat from before backwards, swells out at the sides so as to assume a fusiform or tapering appearance. The muscular fibres are disposed in two sets, united at acute angles along the middle line, from which they pass off obliquely, diverging to the borders. From this arrangement, which resembles that of the lateral fibrillæ of a quill or feather, the muscle is said to be penniform. The fibres of the superior tendon run down a considerable way on the fore part of the muscle; those of the inferior tendon are prolonged upon its posterior aspect. This arrangement is calculated, in the former case, to facilitate the movement of the sartorius upon the rectus—in the latter, that of the rectus itself upon the crureus. Relations — the anterior surface is covered in all its extent by the fascia lata, except a small portion superiorly, where it is overlaid by the tensor vaginæ, iliacus, and sartorius muscles (the reflected tendon is covered by the gluteus minimus); by the posterior surface it is in relation with the fibrous capsule of the hip-joint and the triceps extensor muscle, upon which it rests: its borders are free and unattached in the greater part of their extent, but inferiorly they become united with the two vasti, between which it lies.

532. *m. Triceps extensor cruris* (tri-femoro-rotuleus) is a considerable mass of muscle which encircles all the body of the femur, except the linea aspera and the spaces between its bifurcations. Superiorly, it presents three portions or heads, whence its name; inferiorly, these are attached by a common tendon to the patella, which we shall consider as their common origin. This tendon, at first confounded with that of the rectus muscle,

soon separates from it, and, ascending a little way on the femur, gives off three processes, corresponding with the three divisions of the muscle, viz. the vastus externus, the vastus internus, and crureus; from the tendon, moreover, a fascia or aponeurosis is sent down over the knee-joint, which strengthens the articulation, and is inserted into the head of the tibia. Each of these parts of the triceps is usually described as a distinct muscle.

533. *m. Vastus externus*, fig. 113, 8; fig. 111, 3, is situated on the outside of the femur, larger above and in the centre than below; its fleshy fibres *arise* from the outer side of the common tendon, and pass to their insertion with varying degrees of obliquity. The inferior fibres pass almost transversely outwards, to about the middle of the line leading from the outer condyle of the femur to the linea aspera; those higher up are inserted into the external margin of the linea aspera and its superior bifurcation; the rest are implanted into the external surface of the bone, as far as the base of the great trochanter. Direction — the lower fibres are transverse, the rest oblique: structure — fleshy and aponeurotic: relations — anteriorly, with the fascia lata; posteriorly, with the femur; its external border is in apposition with the short head of the biceps and the gluteus maximus; the internal with the crureus, with whose structure it is identified.

534. *m. Vastus internus*, fig. 113, 9, is situated on the inner side of the femur. Form—elongated, broader below than above. It *arises* from the inner side of the common tendon, from which its fibres, like those of the preceding muscle, pass obliquely to their insertion; the inferior fibres terminate above the middle of the oblique line leading from the inner condyle to the linea aspera; those higher up are implanted into the inner margin of the linea aspera itself, the rest being inserted into the surface of the bone, as far as the base of the lesser trochanter. Direction —the lower fibres run almost transversely; the rest obliquely, upwards and inwards: structure — fleshy and aponeurotic: relations — by its anterior and inner surface with the fascia lata, the sartorius, and femoral vessels; the posterior surface rests on the femur; the inner border is in contact with the adductor magnus, longus, pectineus, and psoas muscles; the external is blended with the crureus.

535. *m. Crureus* is situated along the middle of the anterior

surface of the femur, between the two vasti, with which it is intimately blended. It *arises* from the centre of the common tendon, which is prolonged for some way upon its fore part; its fleshy fibres are inserted into the upper three-fourths of the anterior surface of the femur, ceasing at the anterior intertrochanteric line. Direction—vertical: structure—tendinous and fleshy: relations—its anterior surface is covered by the rectus, the posterior rests on the femur, its two borders being blended with the vasti.

Actions.—The rectus, vasti, and crureus, are named by Sœmmering quadriceps extensor, their intimate union and similarity of action being sufficient reasons for considering them as a single muscle consisting of four parts. The most ordinary action of these muscles is to extend the leg upon the thigh, which they are enabled to do by their connexion with the patella and its ligament, fig. 113, 14, the latter being inserted into the tibia. The immediate action of the sartorius is to bend the leg upon the thigh.

If the leg be fixed, as in the standing posture, the extensor muscles, taking their fixed point below, will act upon the femur and keep it perpendicularly on the condyles of the tibia, so as to counteract the influence of the weight of the body, which tends to flex the knee as well as the other articulations. The rectus and sartorius assist materially in maintaining the erect position of the body, for instance when we stand on both legs, for they act on the pelvis and draw it forwards, so as to keep it fixed and upright on the femur; in this they become assistants to the psoas and iliacus. It may be observed that the oblique direction of the sartorius enables it to give a slight rotatory motion to the pelvis when we stand on one leg, by drawing the spinous process downwards and inwards.

INTERNAL FEMORAL REGION.

536. Along the inside of the thigh we find the following muscles, viz. the gracilis, pectineus, adductor longus, adductor brevis and magnus. The pectineus at its origin is rather at the fore part of the limb, but at its insertion it lies to the inner side.

Dissection.—To expose the muscles of this group, nothing more is required, after examining the extensor muscles, than to remove the fascia from the inner and fore part of the thigh. The direction and

attachments of the adductor longus, running obliquely from the angle of the os pubis to the middle of the thigh, are at once obvious. The gracilis, too, will be observed running along its inner border. If the thigh be abducted, the fibres of these muscles will be rendered tense, and their dissection facilitated.

When proceeding with the dissection, the adductor longus may be severed from its superior attachment, and drawn downwards on the femur. In doing this, its posterior surface will be observed to be connected to the adductor magnus for a little way before their fibres reach the bone. The pectineus, lying to the outer side of the adductor, may in the next place be examined, and reflected after the same manner, which will bring into view the adductor brevis and the obturator externus.

Whilst these measures are being executed, both surfaces of each muscle should be dissected, or, in other words, all the cellular tissue connected with them should be removed by successive strokes of the knife, the edge being carried in the course of the fibres; and when their attachments, external conformation, and structure have been thus fully made out, each of them may be again restored to its place, that their mutual relations and bearings may be reconsidered. It is usual to direct that muscles, more especially the long ones, should be divided in the centre, and the two portions reflected. But if this precept be followed, it will be observed that students seldom examine, with any degree of accuracy, the points of attachment of muscles, without a precise knowledge of which it is quite impossible to reason correctly on their actions and uses. When a student is performing the dissection of the limb for the first time, it may be well if he confine his attention to the muscles, observing merely the general outline of the vessels and their branches; after which they may all be dissected away, in order to obtain an uninterrupted view of the muscles in their whole extent.

537. *m. Gracilis*, fig. 113, 10; fig. 111, 4, (pubio-præ-tibialis,) is situated along the inner border of the thigh, extending from the os pubis and its ramus to the inner and upper part of the tibia. It is flat and thin; broad at its upper extremity, narrow and tapering at the lower. It *arises* by a thin aponeurosis from the body of the os pubis, close to its symphysis (the lower half of its depth), also from the border of its ramus, and is *inserted* by a tendon (which is at first round, but afterwards becomes flat) into the inner side of the tibia, close below its

tuberosity, on the same plane with the semi-tendinosus, and under the expanded tendon of the sartorius. Direction—vertical; at the lower extremity it inclines a little forwards to the point of attachment: structure—aponeurotic superiorly, tendinous in the inferior third, and fleshy in the rest of its extent: relations—its inner surface is covered by the fascia lata, except a small part inferiorly, where it is overlapped by the sartorius; the external rests against the adductor longus, magnus, and semi-membranosus, the knee-joint, and its internal lateral ligament.

538. *m. Pectineus*, fig. 113, 11, (pectinalis; pubio-femoralis,) is situated at the superior and fore part of the thigh, being extended from the body of the os pubis (its upper surface) to the oblique line below the small trochanter. Form—flat and nearly triangular. It *arises* from the ilio-pectineal line, between the eminence of the same name and the spine of the os pubis, and is *inserted* into the line which connects the smaller trochanter to the linea aspera of the femur, immediately below the united attachment of the psoas and iliacus muscles. Direction—downwards, outwards, and backwards; opposite the smaller trochanter it turns on itself, so that the anterior surface looks somewhat outwards: structure—fleshy, except at the attachments, which are aponeurotic: relations—by the anterior surface, with the fascia lata and femoral vessels; by the posterior surface, with the obturator vessels and nerves, and the external obturator and adductor brevis muscles; by the outer border with the psoas magnus, by the inner border with the adductor longus.

539. *m. Adductor longus*, fig. 113, 12, (adductor primus; pubio-femoralis,) is situated at the superior and inner part of the thigh. It is flat, irregularly triangular, and extends obliquely from the body of the os pubis (its inner extremity) to the middle of the linea aspera of the femur. It *arises* from the external surface of the angle of the pubes, between its spine and symphysis, and is *inserted* into the middle third of the linea aspera, between the vastus internus and the adductor magnus; its direction between these points being downwards, outwards, and backwards: structure—tendinous at its origin, fleshy in the middle, aponeurotic inferiorly. From the aponeurosis several fibres are detached, which unite with those of the adductor magnus: relations—its anterior surface is covered by

the fascia lata, the sartorius, and femoral vessels; the posterior rests on the two other adductor muscles. The external border is parallel with the pectineus (a small portion of the adductor brevis being observable behind and between them); the inner border, which is much the longest, is in apposition with the gracilis.

540. *m. Adductor brevis* (adductor secundus; sub-pubio-femoralis,) is situated rather deeply at the upper and inner part of the thigh. Form—nearly triangular, being thick and narrow at its upper part, but gradually becoming broader and thinner towards its insertion. It *arises* by a narrow origin, beneath the preceding muscle, from the external surface of the os pubis, and is *inserted* into the oblique line leading from the base of the lesser trochanter of the femur to the linea aspera, immediately behind the insertion of the pectineus. Direction—outwards, downwards, and a little backwards: structure—fleshy, except at its attachments, which are somewhat aponeurotic: relations—by the anterior surface, with the pectineus and adductor longus; by the posterior, with the adductor magnus; by the external border, with the obturator externus, and the tendon of the psoas and iliacus; by the inner border, with the gracilis in part of its extent, the rest being concealed between the two other adductors. This muscle is pierced by some of the perforating branches of the profunda artery.

541. *m. Adductor magnus* (ischio-femoralis) is situated deeply at the posterior and inner part of the thigh; hence but a few of its fibres, 13, can be seen in this view:—It extends from the tuberosity and ramus of the ischium to the whole length of the linea aspera of the femur, and to its inner condyle. It *arises* from the ramus of the os pubis and that of the ischium, also from the border of the tuberosity of the latter bone. The muscular fibres diverge from their origin, somewhat like the ribs of a fan from their central pivot; those from the os pubis, shorter than the rest, pass transversely outwards, and are-inserted into the rough line prolonged from the linea aspera directly upwards; others pass with varying degrees of obliquity downwards and outwards, to be inserted into the whole length of the linea aspera, and a small part of its internal bifurcation, where they end in a pointed process; finally, some of the fibres descend almost vertically, forming the inner border of the muscle, and terminate in

a rounded tendon, which is inserted into the tuberosity on the inner condyle of the femur. The muscle thus presents two parts; one a flat broad plane, inserted into the linea aspera, and forming a septum between the anterior and posterior muscles of the thigh; the other being the elongated part which goes to the condyle. Between these an angular interval is left for the transmission of the femoral vessels backwards into the popliteal space. Direction—the fibres pass obliquely from within outwards and downwards, radiating as from a common centre: structure—fleshy in the greater part of its extent, aponeurotic where it arises from the ischium, and tendinous where it is inserted into the condyle: relations—the superior, or shortest border, is parallel and on the same plane with the quadratus femoris; the internal, or longest border, is covered by the fascia lata, the gracilis, and sartorius; the external border (its femoral attachment) is interposed between the two other adductors and the vastus internus, which lie in front of it, and the gluteus maximus, and short head of the biceps, which separate it from the vastus externus. The posterior surface is covered by the great sciatic nerve and ham-string muscles; the anterior by the sartorius, the adductor brevis and longus, and the femoral vessels. The anterior surface of the muscle is intimately blended with the adductor longus before it reaches its insertion; it also sends off an aponeurosis, which passes in front of the femoral vessels, and becomes blended with the vastus internus; finally, its prolonged portion is intimately connected with the last-named muscle. The interval left between the two parts of this muscle for the passage of the femoral vessels is triangular in its form, and fleshy and tendinous in its structure, when viewed from behind; but at its anterior aspect it is altogether tendinous in its entire extent, and oval in its form, its margins being formed of the following parts, viz. the prolonged tendon of the adductor magnus internally, the vastus internus externally, the superior border corresponding with the conjunction of the adductor longus and magnus; the inferior with the point of union between the prolonged tendon of the last-named muscle and the vastus internus.

Actions.—These are the direct adductors of the femur, and their force must be considerable, both from their strength and number. As

the linea aspera projects from the shaft of the bone, the adductors are removed proportionally from its axis, and so are enabled to rotate it outwards, thus conspiring with a distinct class of muscles, the external rotators. If the whole limb be in the extended position, they will draw it inwards, the gracilis assisting. The femur is bent on the pelvis by the action of the pectineus (and slightly by the adductor longus and brevis), thus conspiring with the psoas and iliacus. When the lower extremities are firmly fixed on the ground, these muscles contribute to maintain the body in the erect position, by taking their fixed point below, and thence acting on the pelvis. If this effort be continued, the pectineus and adductor longus may be made to flex the pelvis on the femur, by drawing the os pubis downwards.

POSTERIOR FEMORAL REGION.

542. At the back of the thigh are placed the three long flexor muscles of the leg, viz. the biceps, semi-tendinosus, and semi-membranosus. They are immediately subjacent to the skin and fascia, except at their superior attachment.

The *dissection* of this group should follow that of the muscles in the gluteal region, the subject continuing in the position indicated in sect. 519. From the middle of the incision made along the fold of the nates, or, what will answer just as well, from opposite the middle point between the tuber ischii and the great trochanter, carry an incision through the skin straight down along the back of the thigh and popliteal space, so as to mark out the median line of both. Let this extend to about three inches below the flexure of the knee-joint, and be there bounded by a transverse incision five or six inches in length. Make a similar transverse incision at the union of the middle with the lower third of the thigh. Now with your forceps pinch up the angles of these flaps of skin, and carefully dissect them off the subjacent fascia, which you will recognise as a smooth shining membrane. Examine this carefully in its whole extent. At the lower part of the thigh you will see it stretched tightly across from side to side, covering an angular space (popliteal space, or the ham in popular language), enclosed by the flexor or ham-string muscles, viz. those which you are now about to examine. Make an incision through the fascia from above downwards, along the middle of this space; bound it above and below by two transverse cuts. Pinch up the flaps of fascia tightly, and dissect them off the muscles, and so proceed down-

wards to their insertion into the tibia and fibula: continue the same process upwards, until you expose the muscles in their entire extent.

The origin of the flexors from the tuber ischii may be readily defined; and when their respective insertions are made out, that of the semi-membranosus should be particularly attended to, as it is attached to three distinct points. To gain a clear view of these attachments, the muscle may be cut across in the ham and drawn down, when, by holding it tense, one set of fibres will be observed to pass along the inner tuberosity of the tibia, another obliquely behind the joint, whilst the third goes perpendicularly downwards, which, after being fixed to the posterior surface of the tuberosity of the tibia, sends a dense fascia over the popliteus muscle, which is ultimately continuous with the deep fascia of the leg.

543. *m. Biceps femoris* (biceps flexor cruris; ischio-femoro-peronealis) is situated at the posterior part of the thigh. Form —elongated, divided above into two portions, or heads, of which one, the ischiadic, is long and rounded; the other, femoral, flat, and somewhat shorter. The long head, fig. 111, 5, *arises* by a tendon common to it and the semi-tendinosus from the upper and back part of the tuberosity of the ischium,—the femoral portion, 6, (or short head,) from the linea aspera of the femur, between the adductor magnus and vastus externus muscle, nearly as high up as the insertion of the gluteus maximus. These two parts, having united and become tendinous, are *inserted* into the head of the fibula: the tendon, whilst being attached, separates into two portions, which embrace the external lateral ligament of the knee-joint. One of these passes forwards upon the articulation of the fibula with the tibia: from the other an expansion is given off, which strengthens the fascia of the leg. Direction—vertical: relations—posteriorly with the gluteus maximus and fascia lata; in front with the semi-membranosus muscle, the sciatic nerve, and adductor magnus; inferiorly with the gastrocnemius externus, and external articular arteries.

544. *m. Semi-tendinosus*, fig. 111, 7, (ischio-præ-tibialis,) is situated at the posterior and inner part of the thigh. Form—elongated. It *arises* from the posterior part of the tuber ischii, close to the inner side of the biceps, and continues to arise from the tendon of that muscle for three inches lower down, somewhat in the same way as the coraco-brachialis does from the

biceps of the arm. A little below the middle of the thigh it ends in a long round tendon, which, passing along the inner side of the popliteal space, is reflected forwards, to be inserted into the inside of the upper part of the tibia, about two inches below its tuberosity, where the tendon is on the same plane, and beneath that of the gracilis. Direction—nearly vertical: structure—as its name implies, fleshy in half its extent, tendinous in the rest: relations—its posterior surface, except where it is slightly overlapped by the biceps, is covered by the fascia lata; the anterior surface rests on the semi-membranosus in the greater part of its extent; towards its termination, it runs beside the knee-joint; its insertion is covered by that of the sartorius.

545. *m. Semi-membranosus*, fig. 111, 8, (ischio-poplito-tibialis,) is situated obliquely at the posterior and inner part of the thigh. It *arises* from the posterior part of the tuberosity of the ischium, in front of the biceps and semi-tendinosus and behind the quadratus femoris, and is inserted by three portions, of which the middle one is fixed to the tibia, behind its inner tuberosity, and sends an expansion which covers the popliteus muscle; the internal portion passes forwards under the internal lateral ligament, and is inserted along the side of the inner tuberosity of the tibia; the third, broad and expanded, is reflected backwards and upwards behind the joint, and is inserted into the external condyle of the femur, becoming identified with the ligamentum posticum, fig. 116, 1. Direction—nearly vertical: structure—fleshy in the middle, tendinous at its extremities: relations—by the posterior surface with the biceps, semi-tendinosus, and fascia lata; by the anterior surface with the quadratus femoris, adductor magnus, the popliteal artery, inner head of the gastrocnemius and knee-joint; by the inner border with the gracilis and fascia lata; by the outer border with the sciatic nerve.

Combined actions.—These are usually called the ham-string muscles, as they enclose the ham, or space at the posterior aspect of the knee-joint; the biceps being placed at its external side, the other two at the internal. Their direct action is that of flexing the leg on the thigh, and this they do directly backwards, when they conspire in their action; but if they be made to act alternately, the leg will be

rotated slightly inwards or outwards; the latter motion, however, can only take place in the semi-flexed position of the limb. In the standing posture, these muscles, by taking their fixed point below, will act on the pelvis so as to prevent its flexion forwards; and if the effort be continued, they will draw it directly backwards, and commence that series of muscular actions observable in tumbling and other feats of activity, in which the body is thrown backwards so as to form an inverted arch.

Muscles of the Leg.

ANTERIOR TIBIO-FIBULAR REGION.

546. In the interval between the tibia and fibula we find three long muscles, viz. tibialis anticus, extensor proprius pollicis, and extensor communis digitorum.

Dissection. To expose the fascia.—The subject being placed on its back, bend the knee and place under it a high block, so that the leg should form an inclined plane; turn the foot inwards, and fix it in that position. Now, make an incision through the skin, beginning above at the middle point, between the head of the fibula and the spine of the tibia, and continue it straight down over the middle of the ankle-joint and dorsum of the foot. As this is a very long incision, intersect it by a transverse one at each end, and another in the middle; raise the flaps of skin tightly, you will see the dense fascia of the leg beneath it; dissect back the flaps, and expose this membrane in its entire extent.

To expose the muscles.—Divide the fascia along the leg as you did the skin, but opposite the flexure of the ankle-joint leave undivided a band of it about an inch wide, where it stretches across obliquely from one ankle to the other, forming the anterior annular ligament. Beginning a little above the ankle, raise the fascia from the tendons, and, taking them as your guide, dissect it from below upwards from the muscles. (For the description of the annular ligament see sect. 480.)

The muscles of the leg, taken altogether, may, to facilitate their classification, be divided into sets, each consisting of three. Thus, on the fore part of the leg, and lying between the tibia and fibula, we find the tibialis anticus, the extensor communis, and extensor pollicis, being the group which we are now examining. On the external side of the leg, and in close contact with the fibula, are placed

the peroneus longus and brevis. The third muscle of this name is, in reality, a part of the extensor communis, and is separated from the other two by the breadth of the fibula. It still, however, is described as a separate muscle, probably to keep up the ternary division. Posteriorly, there are two sets, one being superficial, consisting of the gastrocnemius, soleus, and plantaris; and the other deep-seated, viz. tibialis posticus, flexor longus digitorum, and flexor longus pollicis.

547. *m. Tibialis anticus*, fig. 114, 1, (tibio-super-tarseus,) is situated at the front of the leg and the inner part of the foot, being extended from the upper end of the tibia to the first cuneiform bone. Form—elongated, thicker above than below. It *arises* from the external tuberosity of the tibia, and from about two-thirds of the flat surface beneath it,—from a small portion of the inter-osseous ligament,—from the fascia of the leg, and an aponeurotic septum placed between it and the extensor digitorum communis muscle; it is *inserted* into the internal surface of the first cuneiform bone, and the contiguous extremity of the first metatarsal bone. Direction—downwards, and a little inwards; structure—fleshy in the two upper thirds, tendinous in the lower; relations—the upper, or fleshy portion, corresponds in front with the fascia of the leg, to which it is adherent superiorly, behind with the inter-osseous ligament, on the fibular side with the extensor digitorum communis and extensor proprius pollicis, from which it is partly separated by the anterior tibial vessels. The tendon crosses obliquely, in front of the lower end of the tibia, the ankle-joint, and the anterior and inner part of the tarsus, being bound down by the anterior annular ligament, 2, which gives it a separate sheath.

Fig. 114.

548. *m. Extensor proprius pollicis*, fig. 114, 3, is situated between the tibia and fibula, at the fore part of the leg and on the dorsum of the foot along its inner border. Form—elongated,

flat, and compressed in the middle, pointed at the extremities. It *arises* from the internal surface of the fibula, for about the middle third of its extent, and from the contiguous surface of the inter-osseous ligament, nearly as far as the ankle; the fleshy fibres run obliquely forwards into a tendon placed at the anterior border of the muscle, which, after passing beneath the annular ligament and along the dorsum of the foot, is inserted into the base of the second phalanx of the great toe, having also an intimate connexion with the first: structure—tendinous below, fleshy superiorly: relations—by the outer surface with the extensor digitorum communis, by the inner surface superiorly with the tibialis anticus and the anterior tibial vessels; the anterior border is overlapped for some way by the muscles just named, and is covered inferiorly by the anterior annular ligament, under which it passes in a separate groove, and by the integuments; the posterior border corresponds with the fibula and the inter-osseous ligament, and passes over the broad flat part of the tibia, the ankle-joint, the anterior tibial vessels, and dorsum of the foot.

549. *m. Extensor digitorum longus*, fig. 114, 4, is situated at the fore part of the leg and on the dorsum of the foot, extending from the head of the tibia to the toes. Form—elongated, flattened from side to side, but inferiorly it divides into four tendons. It *arises* from the external tuberosity of the tibia, from the anterior surface of the fibula for about two-thirds of its length; also from the inter-osseous ligament, from the aponeurotic septa intervening between it and the muscles, on either side, and from the fascia of the leg. The fleshy fibres from this extensive origin pass obliquely into three flat tendons placed on the fore part of the muscle; these descend beneath the annular ligament, in the same sheath with the peroneus tertius; and on the dorsum of the foot the inner one divides into two parts, so as to constitute four tendons, corresponding in number with the four smaller toes, into the last phalanges of which they are inserted; towards their termination each of the tendons expands into an aponeurosis, covering the upper surface of the phalanges; and this is strengthened by the tendons of the extensor brevis, and gives attachment also to the lumbricales and inter-ossei. Structure—fleshy and tendinous: relations—it is covered in front by the fascia of the leg, the

annular ligament and integument; posteriorly it rests on the fibula, the inter-osseous ligament, and the tibia; then crosses the ankle-joint, and the extensor brevis digitorum; externally it is in relation with the peronei muscles, internally with the tibialis anticus and extensor proprius pollicis; along its lower border lies the peroneus tertius.

550. *m. Peroneus tertius* (called also *anticus*, from its position with regard to the fibula) is placed along the fore part of the fibula at its lower third. It lies just below the extensor longus, with which its muscular fibres, 5, are united, and of which it is really but a part. Form—elongated and flat. It *arises* from the lower third of the fibula, being attached to the anterior border and inner surface of the bone; also from the inter-osseous ligament, and an aponeurosis which connects it on the outer side with the peroneus brevis; and is inserted inferiorly into the external surface of the tarsal end of the fifth metatarsal bone. Direction—vertical in the leg, obliquely forwards and outwards on the foot. Structure—fleshy in the upper portion, tendinous in the lower. Relations—the posterior border corresponds with the fibula, inter-osseous ligament, and peroneus brevis; the outer surface is covered by the fascia of the leg; the inner is confounded with the extensor digitorum communis. It passes, in conjunction with the common extensor, under the annular ligament, and is invested by the same synovial membrane; on the foot it is placed on the extensor digitorum brevis and last metatarsal bone.

551. *m. Extensor brevis digitorum*, 6, is situated on the dorsum of the foot. Form—broad and thin; narrow and undivided at its origin; it separates into four parts in front. It *arises* from the dorsal surface of the calcaneum, and from the ligament connecting that bone with the astragalus, and terminates in four tendons, the first or most internal of which is inserted into the tarsal end of the first phalanx of the great toe; the other three become severally united to the outer border of the extensor tendons, proceeding to the three next toes. Structure—fleshy and tendinous. Relations—it is covered by the tendons of the long extensor and peroneus tertius, and rests on the tarsus, metatarsus, and the dorsal inter-osseous muscles.

Actions.—A very slight effort of the extensor communis and extensor proprius pollicis extends the digital phalanges, and if their

action be continued, they will be made to bend the foot upon the leg. This they are enabled to do by the manner in which their line of direction is altered by the annular ligament of the ankle-joint, as it gives them all the mechanical advantage of a pulley. The tibialis anticus and the peroneus tertius are the direct flexors of the foot on the leg, and if either act separately, it will give a slight inclination towards the corresponding side. In the erect position, these muscles take their fixed point below, and, by drawing on the bones of the leg, keep them perpendicular on the foot. The extensor brevis is obviously but an accessory to the long extensor; but, from the obliquity of its direction, it is fitted not only to extend the toes, but also to draw them somewhat outwards.

552. *m. Peroneus longus*, fig. 114, 7, (peroneo-sub-tarseus,) is situated at the outer side of the leg, and under the foot. Form—very long and narrow, reflected on itself inferiorly. It *arises* from the upper third of the external surface of the fibula—from a small part of the external tuberosity of the tibia, and from the fascia of the leg; also from aponeuroses interposed between it and the contiguous muscles, viz. the extensor communis digitorum on one side, and the soleus and flexor longus pollicis on the other. Proceeding from these attachments, it descends and becomes tendinous; the tendon passes, with that of the peroneus brevis, in a groove on the posterior surface of the external malleolus, where they are covered by a fibrous lamella extended from the end of the fibula to the calcaneum, and invested by a common synovial membrane. The tendons then separate; that of the peroneus longus proceeds in another groove on the external surface of the calcaneum, to which it is connected by a separate fibrous band. It then enters a groove on the cuboid bone, where it changes its direction, and inclines forwards and inwards beneath the foot, to be inserted into the tarsal end of the first metatarsal bone. Structure—tendinous at the lower, aponeurotic at the upper extremity, fleshy in the middle. Relations—in the leg it corresponds, by the outer surface, with the fascia of the leg; by the inner surface, with the fibula, extensor digitorum communis, and peroneus brevis; by the posterior surface, with the soleus superiorly, and flexor longus pollicis inferiorly. When passing across the foot, the

tendon runs close to the bones, and therefore above all the plantar muscles.

553. *m. Peroneus brevis*, fig. 114, 8, is situated at the external side and lower part of the leg, and at the outer part of the dorsum of the foot. Form—similar to that of the preceding muscle, but not so long. It *arises* from the external surface of the fibula for about the lower half of its extent, and from the inter-muscular septa which dip in between it and the contiguous muscles. The tendon passes behind the external malleolus in the same groove and sheath, is invested by the same synovial membrane with the preceding muscle, and is inserted into the base of the last metatarsal bone, after having traversed a separate groove in the calcaneum, situated above that for the tendon of the peroneus longus. Structure—tendinous at the lower extremity, fleshy superiorly: relations—by the outer surface, with the peroneus longus and the fascia of the leg; by the inner surface, with the fibula, the extensor digitorum longus, the peroneus tertius, and flexor longus pollicis muscles.

Actions.—The peroneus longus and brevis, by the change of their direction, after turning behind the external ankle, are enabled to draw the foot back, and so extend it on the leg. The peroneus tertius is, on the contrary, a flexor of the foot; it lies before the fibula, and combines with the extensor communis. The peroneus longus is enabled to evert the sole of the foot, by means of the mechanical advantage which it derives from turning round its external margin. This, however, is not readily perceptible in the natural condition of the limb; but, if the fibula be fractured, and the check afforded by the external ankle be in consequence diminished, it will take place to a considerable extent. When the peronei take their fixed point below, they act on the bones of the leg, and assist in maintaining them erect on the foot. This power is chiefly called into action when we stand on one leg. The weight of the body must then tend to incline the leg inwards; but the peroneus longus, acting from its fixed point in the sole of the foot, with the additional power given it by the pulley round which it turns, draws on the external side of the bones of the leg, and prevents them from obeying the influence which otherwise would incline them inwards.

POSTERIOR TIBIO-FIBULAR REGION (SUPERFICIAL).

554. On the posterior part of the leg there are two sets of muscles, one superficial, the other deep-seated. The former consists of the gastrocnemius, the soleus, and plantaris; the latter of the popliteus, tibialis posticus, flexor communis digitorum, and flexor longus pollicis.

Dissection.—The gastrocnemius may be exposed without any difficulty, by dissecting off the fascia, commencing where it is continuous with that covering the popliteal space; after which, the internal head of the gastrocnemius may be raised, and its border reflected outwards. By this expedient the thin tendon of the plantaris will come into view, and afford a guide to its muscular belly, which may otherwise be raised with the external head of the gastrocnemius, with which it is closely in contact. The soleus may in the next place be detached, taking the inner surface of the tendo Achillis as a guide; previously to which, attention should be directed to the structure of that part of its upper border, between its tibial and fibular origins, which is arranged for the transmission of the posterior tibial vessels.

555. *m. Gastrocnemius*, or *gemellus*, fig. 115, 4, (bi-femoro-calcaneus,) is situated at the posterior aspect of the leg, forming the greater part of what is named the calf (γαστηρ, a belly; κνημη, the leg). Form—very thick and convex behind, plane in front, divided longitudinally at the upper extremity into two portions or heads, of which the inner is thicker and longer than the other. From their relative situations, they are named the outer and inner heads of the muscle; they leave an angular interval between them, which forms the lower part of the popliteal space. Each head of the muscle *arises* from the upper and back part of the corresponding condyle of the femur; their fleshy fibres descend converging, and both become gradually united, so as to form a thick muscular mass. Below the middle of the leg, the muscular structure ends in a broad strong tendon

Fig. 115.

(tendo Achillis) which is inserted into the lower part of the posterior extremity of the os calcis. Direction—vertical: structure—tendinous at the lower extremity, aponeurotic and fleshy at the upper, fleshy in the middle: relations—the posterior surface is covered by the fascia of the leg, the anterior rests on the popliteus, plantaris, and soleus muscles, and popliteal vessels; where its heads pass over the condyles, they are guarded by synovial membranes.

556. *m. Soleus*, 5, (tibio-peroneo-calcaneus,) is situated at the posterior part of the leg, of which, in conjunction with the preceding muscle, it forms the calf. Form—nearly oval, being much thicker and broader in the middle than at the extremities. Like the preceding muscle, it presents superiorly two attachments, though by no means so distinctly separated. Of these, the external one, longer and larger, *arises* from the posterior part of the head of the fibula, and from the surface beneath it for about a third of its extent; the inner portion arises from the middle third of the tibia, commencing below the oblique line which gives insertion to the popliteus; finally, in the space intermediate between the bones, the muscular fibres are attached to a tendinous band extended from one to the other, over the posterior tibial vessels, which it secures from pressure or injury. The fleshy fibres descend lower than those of the gastrocnemius, and end in a flat tendon, which soon becomes blended with the tendo Achillis. Direction—the muscular fibres converge to a species of aponeurotic raphé, which exists along the middle of the muscle: structure—aponeurotic and fleshy at its origin, fleshy in the middle, tendinous inferiorly: relations—behind with the gastrocnemius and plantaris muscles; in front, with the tibia and fibula, the peroneus longus, the flexor longus pollicis, tibialis posticus, and flexor longus digitorum muscles, and the posterior tibial vessels. The soleus and gastrocnemius, having but one common attachment inferiorly (tendo Achillis), and being fixed by three heads superiorly, form in reality one muscle, which is named by Meckel and others, triceps suræ.

The *tendo Achillis*, 6, formed by the junction of the tendinous structures in which the two preceding muscles terminate inferiorly, is situated at the posterior and inferior part of the leg; and is by far the thickest and strongest tendon in the body. Form—elongated, narrower in the middle than at the extremi-

ties, of which the superior is much broader than the inferior; where it passes over the posterior surface of the calcaneum, it is separated from the bone by a synovial membrane. It is covered behind by the skin and fascia of the leg; its anterior surface is separated by a considerable quantity of cellular tissue from the deep-seated muscles.

557. *m. Plantaris*, 7, is situated immediately behind the knee-joint and leg, between the gastrocnemius and soleus; it consists of a very long thin tendon, and a small pyriform muscular part, about two inches in length. It *arises* from the femur just above the external condyle, and from the posterior ligament of the knee-joint, where it is covered by the corresponding head of the gastrocnemius, and soon ends in a delicate tendon, which inclines inwards between the two large muscles of the calf of the leg, and running along the inner border of the tendo Achillis is inserted conjointly with it into the posterior surface of the calcaneum. Its direction, structure, and relations are here sufficiently indicated.

Actions.—The power of these muscles, as they are exerted successively in standing, walking, running, &c. is very considerable.

In walking, the gastrocnemius and soleus take their fixed point above, and by drawing on the os calcis lift it from the ground, so that the foot is made to represent an inclined plane. By this action an impulse is communicated to the body, and a direct tendency is given to progression. When the body is thus supported on the elevated foot, the opposite limb can be carried forward to its destination unimpeded by the inequalities of the surface over which it has to pass.

In standing, the soleus takes its fixed point at the os calcis, and, by drawing on the bones of the leg, retains them perpendicularly on the foot, thus preventing them from obeying the influence of the weight of the body, which constantly tends to bend them forwards. If this effort be carried as far as it will admit of, the gastrocnemius and popliteus will bend the femur on the tibia, and if at the same time the semi-tendinosus, semi-membranosus, and biceps, be made to act on the ischium, so as to draw it downwards and backwards, the commencement of that series of muscular actions is made by which the body is retroverted, and carried towards the ground, as we see when a tumbler or mountebank makes an inverted arch of his body, the head and heels being brought to the same plane.

POSTERIOR TIBIO-FIBULAR REGION (DEEP-SEATED).

558. The muscles here placed are in close contact with the bones; they are the popliteus, flexor longus digitorum, flexor longus pollicis, and tibialis posticus.

Dissection. To expose the deep fascia.—Detach the two heads of the gastrocnemius from the condyles, also the plantaris: then separate the soleus from the tibia and fibula, proceeding from below upwards. When this is done, turn these muscles down towards the foot, and you will find behind and just beneath the knee-joint the popliteus muscle; and you will observe, that this as well as the long muscles, which lie lower down, and the posterior tibial vessels, are bound down by a thin fascia (the deep-seated fascia of the leg). This membrane extends down from the tendon of the semi-membranosus muscle, becoming connected on each side with the borders of the bones, and towards the ankles with the sheaths of the tendons; and if traced along the interval between the inner ankle and the heel, it will be found to cover the vessels, and to terminate at the internal annular ligament.

To expose the deep-seated muscles.—Pinch up the fascia with your forceps, and detach it from the tendons of the muscles behind the ankles:—taking these as a guide, proceed upwards to the popliteus. In this way the deep-seated set of muscles become exposed, (viz. the flexor communis, placed along the tibia, the flexor pollicis on the fibula, and the tibialis posticus between both, and partly concealed by them,) and also the vessels which rest upon them.

559. *m. Popliteus*, fig. 116, 4, is situated immediately behind and beneath the knee-joint, extending from the outer surface of the external condyle of the femur downwards and inwards to the tibia. It is flat and somewhat triangular in its form, for it gradually widens as it descends. It *arises* by a flat, thick tendon, about an inch in length, from a depression on the outer side of the external condyle, beneath the attachment of the corresponding lateral ligament of the knee-joint, and is inserted into all that triangular surface of the tibia which is above the posterior oblique line. Direction — obliquely downwards and inwards: structure — tendinous at its attachment to the femur, aponeurotic and fleshy in the rest of its extent: rela-

tions—behind, with an expansion continued over it from the semi-membranosus muscle, also with the popliteal vessels and the plantaris and gastrocnemius muscles; in front with the knee-joint, the tibia, and tibialis posticus muscle. The tendon by which it is connected to the femur adheres by its anterior surface to the external semi-lunar cartilage, (which sometimes is grooved for it,) and is invested by the synovial membrane of the knee-joint: its posterior surface is crossed by the external lateral ligament of the knee-joint and by the biceps flexor muscle.

Fig. 116.

Actions.—The popliteus assists in flexing the leg on the thigh, and vice versâ; but when the leg is flexed, it draws the inner border of the tibia backwards, turning it in such a way that the toe is inclined towards the foot of the opposite side.

560. *m. Flexor longus digitorum pedis*, fig. 116, 5, (flexor perforans,) is situated deeply at the posterior part of the leg, from which it is prolonged forwards into the sole of the foot. It extends from the upper part of the tibia to the phalanges of the toes. The muscle at its commencement is thin and pointed, but gradually increases, and then diminishes again as its fibres end in a tendon. Finally, the tendon becomes divided into four slips previously to its insertion. It *arises* from the posterior surface of the tibia, below the oblique line which gives attachment to the popliteus and soleus, and continues its attachment to within three inches of the inner ankle; some fibres also arise from an aponeurosis which connects it with the tibialis posticus and flexor longus pollicis. The fleshy fibres pass obliquely backwards into a tendon situated at the posterior aspect of the muscle. The tendon passes behind the internal malleolus, along a groove common to it and the tibialis posticus (the latter being next to the bone); thence it is directed beneath the arch of the os calcis, obliquely forwards and outwards, into

the sole of the foot, where it crosses the tendon of the flexor longus pollicis, with which it is connected by a transverse tendinous slip. The tendon, fig. 118, 2, then divides into four processes, corresponding with the four smaller toes, and as they run along their under surface, they are bound down to the phalanges by fibrous sheaths; opposite the second phalanx, each tendon passes through a fissure in the tendon of the flexor brevis, 5, (whence the term perforans is applied to the one, perforatus to the other,) and, finally, they are inserted into the bones of the third phalanges.

Previously to its division, the tendon of the flexor longus gives insertion to an accessory muscular structure (flexor accessorius), which connects it with the calcaneum, and materially modifies the direction of its action on the toes. Close to the point of division the tendons give origin to four small muscles (lumbricales) which may also be considered as accessories to the flexor longus.

Though in the dried bone only one impression is marked for the tendons of the tibialis posticus and flexor longus, behind the malleolus, the fibrous sheath which retains them in their situation is divided into two parts by a septum, or partition, so that each runs in a separate groove lined by a distinct synovial membrane. The direction is vertical in the leg, horizontal in the foot: structure — fleshy and tendinous: relations—in the leg it is bound down by the deep fascia, and covered by the posterior tibial vessels, which separate it from the soleus; its anterior surface rests against the tibia, and overlaps the tibialis posticus muscle; in the foot its tendon lies between those of the flexor longus pollicis, which is above it, and the flexor brevis digitorum, which lies beneath it.

561. *m. Flexor longus pollicis pedis*, fig. 116, 6, is situated close to the fibula, along the external side of the leg, and at the under and inner part of the foot. It *arises* from the posterior surface of the fibula (its inferior two-thirds), also slightly from the inter-osseous ligament, and from the intermuscular septa interposed between it and the peronei externally, and the flexor longus digitorum and tibialis posticus internally. The fleshy fibres, continuing to arise nearly as far as the external ankle, pass obliquely backwards into a tendon placed on their posterior surface; the tendon traverses a groove on the tibia, external to

that which transmits the tibialis posticus and flexor digitorum, then passes through another in the posterior border of the astragalus, in which it is retained by a fibrous band and a synovial membrane. It then runs in a groove beneath the tubercle at the inner edge of the os calcis, and so reaches the sole of the foot, where, after being connected to the common flexor by a tendinous slip, it turns forwards beneath the metatarsal bone of the great toe, fig. 118, 1, and between the two heads of the flexor brevis pollicis, and after running through a fibrous sheath which binds it to the first phalanx of the great toe, is inserted into the base of the second. Structure—fleshy in the greater part of its extent, tendinous inferiorly: relations—in the leg it is bound down by the deep fascia which separates it from the soleus; its anterior surface rests on the fibula, and overlaps the tibialis posticus muscle and the peroneal artery: its relations in the sole of the foot have already been sufficiently indicated.

562. *m. Tibialis posticus*, fig. 116, 7, (tibio-sub-tarseus,) lies deeply behind the bones of the leg and the inter-osseous ligament, and between the two preceding muscles, but commences about three inches higher up. Its superior extremity is divided into two short processes, or heads, by an angular interval for the transmission of the anterior tibial artery and vein. It *arises* from the posterior surface of the tibia, beginning along the oblique line of insertion of the popliteus, its fibres continuing to be attached to the bone for some way down, also from the posterior and inner surface of the fibula and from the inter-osseous ligament for two-thirds of its length; some fibres arise also from the inter-muscular septa, between it and the flexor muscles. The muscular fibres end in a flat strong tendon, which winds round the internal malleolus close to the bone, and in a sheath appropriated to itself, whence it is directed forwards, beneath the tarsus, to be inserted into the tuberosity on the plantar surface of the scaphoid bone, several fibres being also prolonged to the first cuneiform bone, and some obliquely into the sole of the foot, as far as the second and third metatarsal bones. Direction—vertical in the leg, horizontal in the foot: structure—fleshy along its points of attachment to the tibia and inter-osseous ligament, aponeurotic for the most part where it arises from the fibula, the aponeurosis being usually continued down for some way upon its posterior surface; its lower part is

altogether tendinous: relations—in the leg it is overlapped and concealed in the greater part of its extent by the two flexor muscles, but superiorly the part which is left uncovered by them supports the posterior tibial vessels; its anterior surface rests against the inter-osseous ligament and the tibia and fibula, from which it arises; its tendon runs close to the inner ankle and tarsal bones, and where it slides under the astragalus is thickened by a cartilaginous or bony deposit within its fibres, analogous, in form and use, to the sesamoid bones in other situations.

Actions.—Like their antagonists on the fore part of the leg, the two flexor muscles act, in the first instance, on the phalanges of the toes, which they curve or bend, and then, by continuing their effort, they act on the foot. The latter effect they are enabled to produce by means of the mechanical advantage afforded to them by the pulley-like surface on which they slide as they pass from the leg into the sole of the foot. By this provision the flexor muscles conspire with the soleus and gemellus in extending the foot on the leg, for instance in the effort to stand on tip-toe.

The direct agent in extending the foot upon the leg is the tibialis posticus; but from its position it is also enabled to incline the foot inwards, thus antagonising the peroneus tertius, which tends to turn it outwards. It may also, by elevating the inner border of the foot, turn the sole inwards; which action is directly opposed to that of the peroneus longus, which tends to incline it outwards.

It may be observed, that the toes would, in all cases, be drawn inwards whilst they are being flexed by the flexor communis, in consequence of the oblique direction of its tendon, but for the influence exerted upon it by the accessory muscle, which is connected with it in the sole of the foot. The direction of the latter being from behind forwards, it is well fitted by its contraction to modify the action of the long flexor on the toes, and to draw them towards the heel, where its fixed point of attachment is situated.

The action of these muscles may be reversed; for they may take their fixed points below at the foot, and from thence draw on the bones of the leg, so as to keep them in the erect position and prevent their inclining forwards.

Muscles of the Foot.

563. The only muscle on the dorsum of the foot is the extensor brevis digitorum, which has been already described (sect.

551), together with the extensor longus, as they conspire in their actions; the present section therefore includes only the muscles in the sole of the foot. These may be considered as divisible into three regions, corresponding with the two borders and the intermediate space; the internal set consisting of the muscles of the great toe, the external those of the little toe, those in the middle being common to all. But in order to facilitate the examination of the parts contained in the sole of the foot, it is found more convenient to divide them into layers, lying one beneath the other; more particularly as, like the muscles on the back part of the leg, they are found to be separated into a superficial and deep set by a layer of fascia interposed between them and binding down the latter.

Dissection. To expose the plantar fascia.—The subject, or the limb, if it be detached, being placed in the prone position, lay the dorsum of the foot on a high block, so as to bring the sole fully into view; secure it in that position. Make an incision from behind forwards in the middle of the sole, beginning over the heel. Cut down through the thick skin and the cushion of granular fat at the heel, until you see the white fibres of the fascia: then taking these as a guide, and everting the margins of the incision, lateralise your knife and dissect the skin off the fascia from behind forwards. You will observe its middle part to spread out beneath the metatarsus, and to give off five processes, which run along to the extremities of the metatarsal bones: the external portion, which binds down the muscles of the little toe, is thick and firm; but the internal one, which corresponds with the muscles of the great toe, is a thin membrane which appears to be prolonged from the fascia on the dorsum of the foot, and not to be properly an offset of the true plantar fascia (see its description, sect. 590).

To expose the first layer of muscles, fig. 117.—These are three, viz. the abductor pollicis at the inner side, the abductor of the little toe at the outer, and the short flexor of the toes in the middle. The abductor pollicis is readily brought into view by raising the thin fascia which covers it, and dissecting it off, beginning over its tendon and thence proceeding backwards. The abductor of the little toe is exposed by raising the outer division of the plantar fascia from its attachment to the fifth metatarsal bone and reflecting it backwards. Now observe that the broad part of the fascia appears as if tucked in at its sides by processes or septa, which separate the middle from the lateral groups of muscles. Insert the knife under the fascia, raise it from the mus-

cles a little, and then cautiously detach it from them, proceeding from before backwards. When severed from the calcaneum, you may carry it forwards, still leaving it attached by its digital processes. By these means you bring into view the short flexor muscle.

Fig. 117.

564. *m. Abductor pollicis*, fig. 117, 1, is placed along the inner side of the sole of the foot. It *arises* from the inner border of the protuberance of the calcaneum, from the internal annular ligament (sect. 588), from the septum between it and the flexor brevis digitorum, and from the superior surface of the plantar fascia. The fleshy fibres end in a tendon, which, after uniting with the external head of the flexor brevis pollicis, is inserted into the inner border of the base of the first phalanx of the great toe. Direction—parallel with the inner border of the foot: structure—fleshy and tendinous: relations—its plantar surface is covered by the skin and fascia, the superior surface is in contact with the tendinous insertion of the tibialis posticus, with the flexor brevis pollicis with which it is identified, and with the internal plantar vessels.

565. *m. Flexor brevis digitorum*, 2, (flexor perforatus,) is placed in the middle of the sole of the foot, in intimate contact with the plantar fascia. It *arises* from the plantar surface of the calcaneum, immediately before its internal or greater tuberosity, from the plantar fascia, 3, and the intermuscular septa on each side. It soon terminates in four thin tendons corresponding with the four lesser toes; and opposite the extremity of the first phalanx each tendon divides into two fasciculi, so as to leave a fissure for the transmission of the tendon of the flexor longus, after which the fibres unite again into a broad lamella which is inserted into the under surface of the second phalanx. Direction—from behind forwards: structure—tendinous and fleshy behind, fleshy in the middle, tendinous in front: relations—the lower surface is in intimate contact with the plantar

fascia, the upper with the flexor accessorius, with the tendons of the flexor longus digitorum, the lumbricales, and the plantar vessels.

566. *m. Abductor digiti minimi*, 4, is placed along the external border of the foot. It *arises* from the external border and under surface of the calcaneum, immediately before its external or smaller tubercle, and from the upper surface of the process of the plantar fascia, which extends from that tubercle to the base of the fifth metatarsal bone. The fleshy fibres end in a tendon, which, after sliding along a smooth impression on the inferior surface of the head of the fifth metatarsal bone, is inserted into the external surface of the base of the first phalanx of the little toe. Its direction and structure are here sufficiently indicated. Relations—the inferior surface is covered by the plantar fascia; the superior is in contact with the external head of the flexor accessorius, the ligamentum longum plantæ, and the flexor brevis digiti minimi.

Dissection.—To *expose the second layer* of plantar muscles, fig. 118. Separate the two abductors and the short flexor from the calcaneum by inserting the knife under the border of each successively, and cutting obliquely backwards close to the bone. Then draw them forwards, leaving them still attached by their insertions, in order that you may restore them to their original positions, and inspect their attachments and relations again.

When these muscles are removed, a thin lamella (*deep plantar fascia*) of membrane will be observed, extending across from one side of the foot to the other, separating the first from the second layer of muscles, consisting of the tendons of the flexor longus pollicis, those of the flexor communis, and its accessories, viz. the flexor accessorius and lumbricales. The long tendons will be observed to cross one another at an acute angle, that of the flexor pollicis inclining inwards, and placed on a plane superior to the tendon of the flexor communis, whose direction is obliquely outwards, as if towards the base of the fifth metatarsal bone.

567. *m. Flexor accessorius* is not unfrequently termed *massa carnea;* but its structure does not at all warrant such an appellation, as one of its origins is tendinous, and at its point of union with the flexor longus it is for the most part tendinous. It is divided posteriorly into two heads, fig. 118, 3, 3, of which the internal or larger one *arises* from the inner or concave surface

Fig. 118.

of the calcaneum; the external, flat and tendinous, arises from the plantar surface of that bone, a little before its external tubercle. These origins unite at an acute angle, and form a flat fleshy mass, which becomes united to the posterior border, as well as to the two surfaces of the tendon of the flexor longus at its point of division. It may be observed, that the fibres of the accessory muscle, where they enclose the tendon of the long flexor, are tendinous, and so arranged as to form a groove, within which it is lodged.

568. *m. Lumbricales*, fig. 118, 4, 4, are four small tapering muscles, in form like worms, whence their name is derived; they *arise* from the tendons of the flexor communis digitorum at their point of division; from which they pass forwards to the inner side of each of the lesser toes, where each becomes a thin tendon, which is inserted into the base of the first phalanx at its inner border, and also becomes united to the tendinous expansions of the extensor muscles on the dorsal surface of the phalanges.

Dissection.—Cut the flexor tendons across, detach the flexor accessorius from its origin, and draw them forwards or over the sides of the foot. When these muscles are removed, the third layer is exposed, filling up the deep irregular part of the sole of the foot.

569. *m. Flexor brevis pollicis*, fig. 119, 1, is single and pointed behind, but divided into two parts or heads in front. It *arises* by a flat tendinous process, which extends along the greater part of its upper surface, from the inner border of the cuboid bone, slightly from the contiguous margin of the external and middle cuneiform bones, and from the tendinous fibres sent into the sole of the foot from the tendon of the tibialis posticus. These origins can be best perceived when the muscle is cut across and detached carefully from before backwards. The fleshy mass presents two heads, which are inserted, one into the inner, the other into the external border of the base of the first phalanx of the great toe; each head is also intimately connected

with one of the sesamoid bones beneath the articulation. Moreover, before reaching its points of insertion, an intimate union is established between this muscle and the abductor pollicis on the one side, and adductor on the other. The tendon of the flexor longus runs along the interval between the heads of the short flexor.

Fig. 119.

570. *m. Adductor pollicis pedis*, fig. 119, 2, is situated obliquely in the sole of the foot, forming a short, thick, fleshy mass. It *arises* from the cuboid bone, from the tarsal extremity of the third and fourth metatarsal bones, also from the sheath of the peroneus longus muscle, 7, and is inserted, conjointly with the external head of the flexor brevis pollicis, into the base of the first phalanx of the great toe.

The adductor of the great toe and its short flexor are thus found to be intimately united at their insertion, and if they be cut across about an inch behind the first joint, and reflected forwards, two small sesamoid bones will be found connected with their tendons, just as the patella is in the extensor tendons of the knee-joint. Like the latter bone, one of their surfaces is smooth, and enters into the composition of the articulation, being lined by the synovial membrane, and, like it, they are developed in the substance of the tendons, to increase their power of action.

571. *m. Transversus pedis*, fig. 119, 3, is a narrow flat fasciculus of fleshy fibres, stretched beneath the digital extremities of the metatarsal bones, being interposed between them and the flexor tendons. Its external extremity is attached usually to the lateral ligament, connecting the fifth metatarsal bone with the first phalanx of the little toe; sometimes it commences at the fourth; it passes from without inwards, its fibres being connected with the heads of the fourth, third, and second metatarsal bones, or rather with the ligaments passing from them to the phalanges. It thus reaches the ball of the great toe, where it becomes blended with the fibres of the adductor pollicis.

572. *m. Flexor brevis digiti minimi*, fig. 119, 4; fig. 118, 7, is placed at the external side of the sole of the foot; it arises tendinous from the base of the fifth metatarsal bone, and from the sheath of the peroneus longus; the fleshy fibres terminate in a tendon, which is inserted into the base and external border of the first phalanx of the little toe. Direction—horizontally forwards: structure—fleshy in the middle, tendinous at the extremities: relations—its superior surface is in contact with the fifth metatarsal bone; the inferior is covered partly by the abductor digiti minimi, partly by the plantar fascia.

573. *m. Inter-ossei*, as their name implies, are placed between the metatarsal bones, filling up the intervening spaces. There are seven in all. On the dorsal aspect of the metatarsus four of these muscles are perceptible, but still they dip down into the sole of the foot, where the other three are altogether situated; hence it is that in the latter situation their appearance and arrangement are somewhat complex.

574. The *dorsal* or *superior inter-ossei* closely resemble one another in appearance and mode of attachment. Their fibres arise from the contiguous surfaces of the bones between which they are placed, and pass obliquely forwards to a slight tendon that runs along the centre of each, so that they form a double penniform muscle, the posterior extremity of which is bifid, leaving an angular interval for the passage of the perforating branches, which pass from the plantar to the dorsal arteries. The two first dorsal inter-ossei belong to the second toe, being inserted, the one into the internal, the other into the external side of its first phalanx, and into the margins of the extensor tendon as it expands upon its dorsal surface. The third is inserted into the external side of the first phalanx of the third toe, and the fourth terminates in like manner in the first phalanx of the corresponding toe, fig. 119, 5, 5.

575. The *plantar* or *inferior inter-ossei* are not, strictly speaking, situated between the metatarsal bones; they are placed rather beneath the third, fourth, and fifth metatarsal bones, inclining somewhat towards their inner border.

The *first* plantar inter-osseous muscle arises along the inner border of the third metatarsal bone. The fleshy fibres end in a tendon, which is inserted into the base of the first phalanx of the third toe, becoming blended with the tendinous expansion of the extensor communis.

The *second* plantar inter-osseous muscle, fig. 119, 6, arises from the inner side of the fourth metatarsal bone, and is inserted into the inner border of the first phalanx of the corresponding toe and the extensor tendon.

The *third* plantar inter-osseous muscle, fig. 119, 6, arises from the inner side of the fifth metatarsal bone, and is inserted into the base of the first phalanx of the little toe and the extensor tendon.

Actions.—Several anatomists name the different inter-osseous muscles, not from their numerical order, first, second, third, &c. but from their actions and uses. Thus, the second, third, and fourth of the dorsal set are abductors of the corresponding toes, inasmuch as they are inserted into the external side of their phalanges; but the first dorsal and the three plantar muscles are adductors, so that, if all four act together, they will draw the four lesser toes to the great one.

TABLE OF THE MUSCLES

IN THE ORDER OF DISSECTION.

THE student, to whom the head and neck are allotted, will find sixty-six muscles at each side, disposed in sets or groups in particular parts, technically termed regions. He will find it convenient to dissect them in the following order. When a muscle forms part of two regions, it is enumerated in each, but is included within brackets ( ).

MUSCLES OF THE HEAD AND NECK.

Epicranial Region (sect. 337).

Occipito-frontalis.

Auricular Region (363).

Attollens aurem.
Retrahens aurem.
Attrahens aurem.

MUSCLES OF THE EYE-LIDS AND ORBIT.

Palpebral Region (340).

Orbicularis palpebrarum.
Corrugator supercilii.
(Levator palpebræ.)
(Tensor tarsi.)

Orbital Region (367).

Rectus superior.
——— inferior.
——— internus.
——— externus.
Obliquus superior.
——— inferior.
Levator palpebræ.
Tensor tarsi.

MUSCLES OF THE FACE.

Nasal Region (345).

Pyramidalis nasi.
Compressor narium.
Levator labii superioris alæque nasi.
Depressor labii superioris alæque nasi.

Superior Maxillary Region (350).

Levator labii superioris.
——— anguli oris.
Zygomaticus major.
——— minor.

Inferior Maxillary Region (353).

Triangularis oris.
Depressor labii inferioris.
Levator labii inferioris.

Inter-maxillary Region (356).

Buccinator.
Orbicularis.

Temporo-maxillary Region (358).

Masseter.
Temporalis.

Pterygo-maxillary Region (361).

Pterygoideus internus.
——— externus.

MUSCLES OF THE NECK.

Superficial Region (374).

Platysma myoides.
Sterno-cleido-mastoideus.

Sterno-hyoid Region (385).

Sterno-hyoideus.
Sterno-thyroideus.
Thyro-hyoideus.
Crico-thyroideus.
Omo-hyoideus.

Submaxillary Region (376).

Digastricus.
Stylo-hyoideus.
Stylo-glossus.
Stylo-pharyngeus.

Genio-hyoid Region (380).

Mylo-hyoideus.
Genio-hyoideus.
Hyo-glossus.
Genio-hyo-glossus.
Lingualis.

Muscles of the Pharynx (396).

Constrictor inferior.
——— medius.
——— superior.
(Stylo-pharyngeus.)
(Palato-pharyngeus.)

Muscles of the Soft Palate (401).

Levator palati.
Circumflexus palati.
Azygos uvulæ.
Palato-glossus.
(Palato-pharyngeus.)

Muscles of the Larynx (407).

(Crico-thyroideus.)
Crico-arytænoideus posticus.
Crico-arytænoideus lateralis.
Thyro-arytænoideus.

Arytænoideus.
Arytæno-epiglottideus.
Thyro-epiglottideus.

Vertebral Region (390).

Scalenus Anticus.
Scalenus posticus.
Rectus capitis anticus major.
——————— minor.
Rectus lateralis.
Longus colli.

MUSCLES OF THE UPPER EXTREMITY.

There are fifty-three muscles in each limb (including the pectorales, subclavius, and serratus), which may be examined one after another, in the order here set down.

Anterior Thoracic Region (439).

Pectoralis major.
——— minor.
Subclavius.

Lateral Thoracic Region (442).

Serratus magnus.

MUSCLES OF THE SHOULDER.

Acromial Region (443).

Deltoideus.

Scapular Region, posterior (444).

Supra-spinatus.
Infra-spinatus.
Teres minor.
—— major.

Scapular Region, anterior (448).

Sub-scapularis.

MUSCLES OF THE ARM.

Humeral Region (449).

Coraco-brachialis.
Biceps flexor cubiti.
Brachialis anticus.
Triceps extensor cubiti (452).

MUSCLES OF THE FORE-ARM.

Brachial Region, inner and anterior (454).

Pronator radii teres.
Flexor carpi radialis.
Palmaris longus.
Flexor carpi ulnaris.
—— digitorum sublimis.
——————— profundus.
(Lumbricales.)
Flexor pollicis longus.
Pronator quadratus.

Radial Region (463).

Supinator radii longus.
Extensor carpi radialis longior.
——————— brevior.
Supinator radii brevis.

Brachial Region, posterior (466).

Anconeus.
Extensor digitorum communis.
——— minimi digiti.
——— carpi ulnaris.
——— ossis metacarpi pollicis.
——— primi internodii pollicis.
——— secundi internodii pollicis.
——— indicis.

MUSCLES OF THE HAND.

Palmar Region (475).

Abductor pollicis.
Opponens pollicis.
Flexor brevis pollicis.
Adductor pollicis.
Palmaris brevis.
Abductor digiti minimi.
Flexor brevis digiti minimi.
Adductor digiti minimi.
Lumbricales.
Inter-ossei.

MUSCLES OF THE TRUNK.

Omitting the pectorales, subclavius, and serratus magnus, which are usually taken with the upper extremity, we find in the trunk of the body ninety muscles at each side, together with the diaphragm and levator ani, which are single.

MUSCLES OF THE ABDOMEN.

Abdominal Region (487).

Obliquus externus abdominis.
——— internus.
Cremaster.
Transversalis.
Rectus abdominis.
Pyramidalis.
Quadratus lumborum

MUSCLES OF THE THORAX.

Anterior Thoracic Region (439).

(Pectoralis major.)
(Pectoralis minor.)
(Subclavius.)

Lateral Thoracic Region (442).

(Serratus magnus.)

Costal Region (497).

Inter-costales [externi, interni].
Levatores costarum.
Triangularis sterni.
Diaphragma.

MUSCLES OF THE PELVIS AND PERINÆUM.

Iliac Region (516).

Psoas magnus.
—— parvus.
Iliacus.

Perinæal Region (504).

Sphincter ani.
Transversus perinæi.
Accelerator urinæ.
Erector penis.
Levator ani.
Coccygeus.
Compressor urethræ.
(Erector clitoridis.
Constrictor vaginæ.)

MUSCLES OF THE BACK.

These are arranged in layers.

Dorsal Region (413).

1. Trapezius.
   Latissimus dorsi.
2. Levator anguli scapulæ.
   Rhomboideus minor.
   ———— major.
3. Serratus posticus superior.
   ———— inferior.
   Splenius colli.
   ——— capitis.
4. Sacro-lumbalis.
   Cervicalis ascendens.
   Longissimus dorsi.
   Transversalis colli.
   Trachelo-mastoideus.
   Spinalis dorsi.
   Complexus.
5. Semi-spinalis dorsi.
   Semi-spinalis colli.
   Inter-spinales.
   Inter-transversales.
   Multifidus spinæ.
   (Levatores costarum.)
   Rectus capitus posticus major.
   ———— minor.
   Obliquus capitis superior.
   ———— inferior.

MUSCLES OF THE LOWER EXTREMITY.

In each limb there are fifty-six muscles, which may be dissected in the following order.

MUSCLES OF THE THIGH.

Femoral Region, anterior (528).

Tensor vaginæ femoris.
Sartorius.
Rectus.
Crureus.
Vastus externus.
——— internus.

Femoral Region, internal (537).

Gracilis.
Pectineus.
Adductor longus.
———— brevis.
———— magnus.

Gluteal Region, superficial (519).

Gluteus maximus.
——— medius.
——— minimus.

Gluteal Region, deep-seated (523).

Pyriformis.
Gemellus superior.
Obturator internus.
Gemellus inferior.
Quadratus femoris.
Obturator externus.

Femoral Region, posterior (543).

Biceps femoris.
Semi-tendinosus.
Semi-membranosus.

MUSCLES OF THE LEG.

Tibio-fibular Region, anterior (546).

Tibialis anticus.
Extensor pollicis.
——— digitorum longus.
Peroneus tertius.
(Extensor digitorum brevis.)
Peroneus longus.
———— brevis.

Tibio-fibular Region, posterior superficial (554).

Gastrocnemius.
Plantaris.
Soleus.

Deep-seated (558).

Popliteus.
Flexor longus digitorum pedis.
——————— pollicis pedis.
Tibialis posticus.

MUSCLES OF THE FOOT.

Dorsal Region (551).

Extensor digitorum brevis.

Plantar Region (563).

Abductor pollicis.
Flexor brevis digitorum.
Abductor digiti minimi.

Flexor accessorius.
Lumbricales.

Flexor brevis pollicis.
Adductor pollicis.
Flexor brevis digiti minimi.

Transversus pedis.
Inter-ossei.

TABLE OF THE MUSCLES,

ARRANGED AFTER THE MANNER OF DR. BARCLAY, ACCORDING TO THEIR ACTIONS.

THE HEAD IS MOVED

Forwards by

Platysma myoides
Sterno-mastoideus
Rectus anticus major
——————— minor,

Assisted (when the lower jaw is fixed) by

Mylo-hyoideus
Genio-hyoideus
Genio hyo-glossus
Digastrici.

Backwards by

Part of trapezius
Splenius capitis
Complexus
Trachelo-mastoideus
Rectus posticus major
——————— minor
Obliquus capitis superior.

To either side by

Platysma myoides
Sterno-mastoideus
Part of trapezius
Splenius capitis
——————— colli
Trachelo-mastoideus
Complexus.

THE NECK IS MOVED

Forwards by

Platysma myoides
Sterno-mastoideus
Digastricus
Mylo-hyoideus
Genio hyoideus
Genio-hyo-glossus
Omo-hyoidei
Sterno-hyoidei
Thyro-hyoidei
Rectus anticus minor
Longus colli.

Backwards by

Part of trapezius
Rhomboideus minor
Serratus posticus superior
Splenius capitis
——————— colli
Complexus
Trachelo-mastoideus
Transversalis colli
Interspinales colli
Semi-spinales colli
Rectus posticus major
——————— minor.
Obliquus capitis superior
——————— inferior
Scaleni postici
Levator scapulæ.

Laterally by

Various combinations of those muscles which separately move it forwards and backwards, assisted by the scaleni, inter-transversales, and recti laterales.

THE TRUNK IS MOVED

Forwards by

Rectus abdominis
Pyramidalis
Obliquus externus abdominis
——————— internus
Psoas magnus
——————— parvus,

Assisted (when the arms are carried forwards) by

Pectoralis major
——————— minor
Serratus magnus.

Backwards by

Trapezius
Rhomboideus major
Latissimus dorsi
Serratus posticus superior
——————— inferior
Sacro-lumbalis
Longissimus dorsi
Spinales dorsi
Semi-spinales dorsi
Multifidus spinæ
Inter-transversales dorsi et lumborum.

Laterally by

Obliquus externus
——————— internus
Quadratus lumborum
Longissimus dorsi
Sacro-lumbalis
Serrati postici
Latissimus dorsi.

THE SCAPULA IS MOVED

Upwards by	*Downwards by*	*Forwards by*	*Backwards by*
pezius	Lower part of trapezius	Pectoralis minor	Part of trapezius
vator scapulæ	Latissimus dorsi	Serratus magnus.	Rhomboidei
omboidei.	Pectoralis minor.		Latissimus dorsi.

THE HUMERUS IS MOVED

Forwards by	*Backwards by*	*Inwards by*	*Rotated inwards by*
rt of deltoid	Part of deltoid	Part of pectoralis major	Subscapularis,
rt of pectoralis major,	Teres major	Latissimus dorsi.	*Assisted occasionally by*
ssisted in some circumstances by	—— minor		Pectoralis major
ceps	Long head of triceps		Latissimus and teres major.
raco-brachialis.	Latissimus dorsi.		*Outwards by*
			Supra-spinatus
			Infra-spinatus
			Teres minor.

THE FORE-ARM IS MOVED

Forwards by	*Backwards by*	*Rotated inwards by*
Biceps	Triceps	Pronator teres
Brachialis anticus	Anconeus.	Flexor carpi radialis
Pronator teres,		Palmaris longus
Assisted by		Flexor sublimis
Flexor carpi radialis		Pronator quadratus.
—— sublimis		*Outwards by*
—— ulnaris		Biceps
Supinator longus.		Supinator brevis
		Extensor secundi internodii.

THE CARPUS IS MOVED

Forwards by	*Backwards by*	*Outwards by*	*Inwards by*
lexor carpi radialis	Extensor carpi radialis longior	Flexor carpi radialis	Flexor sublimis
almaris longus	——— brevior	Extensor carpi radialis longior	—— carpi ulnaris
lexor sublimis	Extensor secundi internodii	——— brevior	——— profundus
—— carpi ulnaris	Indicator	Extensor ossis metacarpi	Extensor communis digitorum
—— profundus	Extensor communis digitorum	——— primi internodii.	——— minimi digiti
—— longus pollicis.	——— proprius pollicis.		——— carpi ulnaris.

THE THUMB IS MOVED

Inwards and forwards, across the palm, by	*Outwards & backwards by*	*Upwards & forwards, away from the other fingers, by*	*Backwards and inwards, to the other fingers, by*
pponens pollicis	Extensor ossis metacarpi pollicis	Abductor,	Adductor
lexor brevis	——— primi internodii	*Assisted by part of the*	Extensor primi internodii
—— longus.	——— secundi internodii.	Flexor brevis.	—— secundi internodii.

THE FINGERS ARE MOVED

Forwards, or flexed, by	*Backwards, or extended, by*	*Outwards, to radial border, by*	*Inwards by*
Flexor sublimis	Extensor communis	Abductor indicis	Abductor digiti minimi
—— profundus	——— minimi digiti	Adductor digiti minimi	Inter-ossei.
Lumbricales	Indicator.	Inter-ossei.	
Inter-ossei			
Flexor brevis digiti minimi			
Abductor digiti minimi.			

THE THIGH IS MOVED

Forwards by	*Backwards by*	*Inwards by*	*Outwards by*
Psoas magnus	Gluteus maximus	Psoas magnus	Tensor vaginæ femoris
Iliacus	Part of gluteus medius	Iliacus	Gluteus maximus
Tensor vaginæ femoris	Pyriformis	Pectineus	—— medius
Pectineus	Obturator internus	Gracilis	—— minimus
Adductor longus	Part of adductor magnus	Adductor longus	Pyriformis.
—— brevis.	Long head of biceps	—— brevis	
	Semi-tendinosus	—— magnus	
	Semi-membranosus.	Obturator externus	
		Quadratus femoris.	

THE THIGH IS ROTATED

Inwards by	*Outwards by*
Tensor vaginæ femoris	Gluteus maximus
Part of gluteus medius,	Part of gluteus medius
And, when the leg is extended, by	Pyriformis
	Gemellus superior
Sartorius	Obturator internus
Semi-tendinosus.	Gemellus inferior
	Quadratus femoris
	Obturator externus
	Psoas magnus
	Iliacus
	Adductor longus
	—— brevis
	—— magnus
	Biceps cruris, slightly.

THE LEG IS MOVED

Backwards, or flexed, by	*Extended by*
Semi-tendinosus	Rectus
Biceps	Crureus
Semi-membranosus	Vastus externus
Gracilis	—— internus.
Sartorius	
Popliteus.	

THE FOOT IS MOVED

Forwards, or flexed, by	*Backwards, or extended, by*	*Inclined inwards by*	*Outwards by*
Tibialis anticus	Gastrocnemius	Extensor proprius pollicis	Peroneus longus
Extensor proprius pollicis	Plantaris	Flexor longus digitorum	—— brevis
—— longus digitorum	Soleus	—— pollicis	Extensor longus digitorum
Peroneus tertius.	Flexor longus digitorum	Tibialis posticus.	Peroneus tertius.
	—— pollicis		
	Tibialis posticus		
	Peroneus longus		
	—— brevis.		

THE TOES ARE MOVED

Backwards, or flexed, by	*Forwards, or extended, by*	*Inclined inwards by*	*Outwards by*
Abductor pollicis	Extensor longus digitorum	Abductor pollicis	Adductor pollicis
Flexor brevis digitorum	—— proprius pollicis	Inter-ossei.	—— digiti minimi
Abductor minimi digiti	—— brevis digitorum.		Inter-ossei.
Flexor longus pollicis			
—— digitorum			
Flexor accessorius			
Lumbricales			
Flexor brevis pollicis			
Adductor pollicis			
Flexor brevis minimi digiti			
Inter-ossei.			

CHAPTER V.

FASCIÆ.

We have here grouped together the different fasciæ, or membranous investments of parts which are of importance, more particularly those which have relation to the surgical anatomy of different regions.

CERVICAL FASCIA.

576. The neck is enclosed by a membranous investment, similar in its general conformation to those of the extremities, though not so firm in its structure. It is called the *cervical fascia*. We may observe, *in limine*, that a layer of cellular tissue lies beneath the skin, disposed in the same way as the subcutaneous cellular membrane in other situations, but which is here termed the *superficial cervical fascia*. Its chief peculiarity is, that at the sides of the neck the cutaneous muscle (platysma) is developed in its interior, dividing it into two lamellæ, but before and behind that muscle it is single and undivided, as elsewhere, being continuous superiorly with the cellular tissue on the face, and below with that on the thorax. (See Dissection of the neck, Sect. 373.)

577. The *deep*, or *proper cervical fascia*, encases the neck all round, from the ligamentum nuchæ to the middle line at the fore part of the neck, where the two lateral portions are united from the chin to the sternum. When fully exposed, by removing the platysma and superficial cellular membrane, and turning back the trapezius muscle, we find its conformation to be as follows: Commencing posteriorly at the middle line, the fascia will be found to bind down the splenius and second layer of muscles as far as the external border of the sterno-mastoid muscle. It there divides into two layers, one placed before, the other behind that muscle, and uniting again at its inner border, so as to form a sheath for its investment. From this point the fascia is prolonged, in front of the trachea and its

muscles, to the middle line, when it unites with the corresponding portion of the opposite side. Whilst passing over the muscles just referred to, it sends thin lamellæ between them, which form the cellular sheaths that enclose them, and become attached to their respective points of insertion.

If traced upwards, the lamella on the cutaneous surface of the sterno-mastoid will be found to pass over the parotid gland, and to be thence prolonged over the side of the face, becoming thin, and gradually degenerating into cellular tissue. But externally it is attached to the cartilaginous tube of the ear, and higher up to the zygoma. The deep layer inclines inwards, and becomes connected with the styloid process, from which it is again reflected to the angle of the lower jaw, forming a broad lamella, extended between these points, which constitutes a septum between the parotid and sub-maxillary glands, and is usually described as the *stylo-maxillary ligament.*

578. When examined at the lower part of the neck, the fascia will be found strained tightly across from one sterno-mastoid muscle to the other, and thence extended down to the top of the sternum, where it divides into two lamellæ, one being continued on its cutaneous, the other on its thoracic surface, where they are firmly attached. This part of the fascia may be said to complete the wall of the thorax, and to bear off the pressure of the atmosphere from the air-tubes. External to the sterno-mastoid, the superficial layer of the fascia passes over the clavicle, and is continued down, becoming thin and cellular on the pectoral muscle. But the deep-seated lamella, after having sent back a process which forms a sheath for the tendon of the omo-hyoideus, reaches the border of the subclavius, where it divides into two layers, of which one passes before, the other behind that muscle, so as to invest it. At its lower border both these unite again, and become attached to the coracoid process on the one hand, and the cartilage of the first rib on the other, forming a dense lamella in front of the subclavian vessels, and called the *costo-coracoid membrane* or *ligament.* At first sight it appears to cease at this point by a lunated border, but on closer inspection it will be found to be prolonged down over the thorax, becoming thin and cellular as it descends.

FASCIA OF THE ARM.

579. The upper extremity is invested by a fascia, or membrane, analogous in its general formation to that of the lower, though by no means so dense or firm. If examined towards the bend of the elbow, it will be found to form a complete sheath for the arm, investing it all round. In this situation the fascia is continuous with a similar investment of the fore-arm, which may thus be said to be prolonged downwards from it. The fascia is also connected intimately with the condyles of the humerus, and also with the ridges which extend upwards from them, by two membranous septa (*inter-muscular ligaments*) prolonged from its inner surface to the bone, and separating the anterior from the posterior muscles. The one on the outer side of the arm extends up to the insertion of the deltoid muscle, the other reaches to that of the coraco-brachialis. When traced upwards, the fascia becomes thin and weak where it covers the deltoid, but yet it can be easily recognised as far as the spine of the scapula, into which it may be said to be inserted. Internally it is connected somewhat with the tendons of the pectoralis major and latissimus dorsi, and stretches across the folds of the axillary space, but gradually becomes thin, and degenerates into cellular substance, where it is prolonged towards the serratus magnus.

580. The *fascia of the fore-arm* is continuous all round with that of the upper arm, but is much more dense and firm, being composed of fibres that interlace in almost every direction. Posteriorly, it is thick and firm, and binds down the extensor muscles, being intimately connected with their fibres, as well as with the inter-muscular septa placed between them; anteriorly it covers the two groups of muscles placed on the ulnar and radial borders of the fore-arm, being at the same time stretched across that angular interval into which the brachial vessels and the tendon of the biceps sink as they proceed to their destinations. In this situation it is strengthened by a process derived from that tendon. Inferiorly it may be said to terminate by becoming inserted into the annular ligaments of the wrist (anterior and posterior).

581. The hand is also covered by a membranous investment, which on the dorsal surface is thin and weak, being prolonged

to the phalanges of the fingers from the posterior annular ligament. But that in the palm is dense and firm, and called the *palmar fascia*, being analogous to the fibrous structure which sustains the muscles in the sole of the foot. The palmar fascia, fig. 102, 5, is attached to the anterior annular ligament, where its fibres are collected into a thick and rather narrow fasciculus. As it extends over the palm of the hand, its fibres gradually diverge, so as to form rather a broad membrane. Its anterior border presents four processes, corresponding with the metacarpal bones of the fingers, and at their digital extremities each divides into two thin fasciculi, which diverge to be inserted into the lateral ligaments of the first joints of the fingers, and into the heads of the metacarpal bones. The angular interval formed by the divergence of these processes serves to transmit the flexor tendons and the digital branches of the vessels.

FASCIA LATA.

When the common integument has been dissected off and removed from the lower extremity, it will still be found invested by a membrane of a glistening white colour, close in its texture, and composed of fibres crossing in various directions. Anatomists have named it the fascia lata of the thigh. The leg is enclosed in a similar investment, and so is the foot. But each presents certain peculiarities, which require a separate consideration.

582. The *fascia lata* of the thigh may be considered as its special or immediate investment, not only enclosing it in its entire extent from the knee to the pelvis and Poupart's ligament, but also sending processes inwards in several situations, which form septa between the muscles. The thickness of this membrane varies in different parts. It is considerable along the external side of the thigh, it is less so on its posterior aspect; but superiorly, at the inner side, it is in some places so thin as to require great care in dissecting off the skin, else the fascia will be removed with it. When examined towards the lower part of the thigh, it is found to be prolonged over the knee-joint, and to be continuous with the fascia of the leg. It has at the same time a connexion more or less intimate with all the bony prominences round the articulation, viz. with the condyles

on each side, with the tuberosities of the tibia below, with the head of the fibula to the outer side, to which it is guided by the biceps muscle, and finally, after being stretched across the popliteal space, it is prolonged over the gastrocnemius muscle, and so becomes continuous with the fascia of the leg at the back part.

When traced upwards over the thigh, it is found not only to encase it, but also to send processes inwards between the muscles. The most dense and remarkable of these is one which passes in between the vastus externus and the short head of the biceps, and is attached to the linea aspera in its whole length, as far as the insertion of the gluteus maximus. Along the internal side of the thigh it invests the muscles, and merely gives attachment to some thin cellular lamellæ which lie between them ; but along the course of the sartorius, particularly in the lower two-thirds of its extent, an investment or sheath is formed for it, which serves to maintain it in its place, notwithstanding the obliquity of its direction.

Its points of attachment at the superior part of the limb are so numerous, that it becomes necessary to examine each of them in detail, more especially as one portion of the membrane bears an important relation to the parts connected with Hernia. Thus, 1st, at the external and posterior sides of the limb, the fascia, after having been intimately connected with the insertion of the gluteus maximus, is prolonged backwards and upwards on the cutaneous surface of that muscle, and, though very thin and weak, it may with care still be traced as far as to the side of the sacrum and coccyx, and also to the crista of the ilium, to which it is firmly attached, after having passed over the upper part of the gluteus medius. The fascia in the latter situation becomes very dense and firm, and is intimately connected with the fibres of that muscle. Still more externally it divides into two lamellæ, which embrace the inferior termination of the tensor vaginæ femoris, to which it in this manner gives insertion. These two lamellæ become united into one along the posterior border of the muscle, which, by being prolonged over the gluteus medius, (to whose fibres it gives attachment by its inner surface,) passes to be inserted into the crista of the ilium and its spinous process. 2nd, Along the inner side of the thigh the fascia passes upwards over the adductor muscles, and becomes

attached to the tuberosity of the ischium and its ramus, as well as to that of the os pubis, as far as its spinous process. 3rd, The most important part of the membrane—that which has claimed the greatest share of attention from anatomists and surgeons, remains now to be considered, namely, the part immediately below Poupart's ligament, and which extends from the spinous process of the ilium to that of the pubes.

It will be recollected that the membrane forms an uninterrupted sheath, until it comes within a little more than an inch of Poupart's ligament. There a division takes place, and an opening is established for the transmission of the superficial vessels. The saphenous vein, in its whole course, from the inner ankle to the knee, and thence to the top of the thigh, lies superficial to the fascia. The superficial lymphatic vessels are similarly situated; the superficial epigastric vessels also descend over the abdominal muscles; and as all these converge to one point, in order to communicate with the deep-seated vessels, an opening must be established for them in the fascia lata. The existence of this opening has caused a division of the anterior portion of the fascia into two parts, one external, the other internal.

583. The *external* or *iliac* portion passes upwards, lying on a plane anterior to the vessels, and becomes attached to the lower border of Poupart's ligament, with which it continues to be thus united as far as the spinous process of the pubes. Whilst it is being prolonged in front of the femoral vessels, this part of the membrane, by reason of its inclination from below upwards and inwards, must necessarily present a curved or falciform appearance, one extremity of it being at the lower border of the saphenous opening, the other at the spinous process of the os pubis. Now, as the membrane stretches between these two points, its border becomes folded on itself, not ceasing abruptly at the margin of the opening, as at first sight may appear. On the contrary, it is reflected on itself, and the reflected part becoming very thin, and degenerating into cellular tissue, passes outwards on the sheath of the vessels with which it is identified; but towards its superior termination it turns under the border of Poupart's ligament, and adheres to that of Gimbernat, with which it is inserted into the pectineal line.

584. The *pubic* or *inner* portion of the fascia (so called from

its situation) lies on the pectineus muscle, and therefore is on a plane posterior to the femoral vessels. Superiorly, it terminates at the pectineal line, to which it is guided, as it were, by the muscle of that name; externally, it passes behind the vessels and their sheath, and, on reaching the border of the psoas muscle and its tendon, divides into two lamellæ. Of these, one, rather dense and firm, passes deeply behind the tendon, and becomes attached to the fibrous capsule of the hip-joint; the other, lying more superficially, unites, along the border of the psoas magnus, with a membrane covering the muscle just named. This cannot be the fascia iliaca, as is usually stated. That membrane extends no farther than Poupart's ligament, in all that part between the spine of the ilium and the femoral vessels. In the rest of its extent, it forms part of the sheath of these vessels, behind which the pubic part of the fascia lata lies. The membranous structure then, with which the pubic part of the fascia lata becomes blended at the border of the psoas, is a deep-seated layer of the fascia lata, prolonged upwards upon the iliacus and psoas muscles, and which finally unites with the under surface of the fascia iliaca, where the latter turns forwards to be connected with Poupart's ligament.

Now, the iliac and pubic parts of the fascia lata are continuous, and united at the lower border of the opening which their junction serves to form, and over which slides the saphenous vein. Though the fascia, in the situation here referred to, appears to present a defined, concave border (the concavity looking upwards), it still will be found not to cease abruptly; on the contrary, it is folded on itself like the external margin of the opening, and reflected down on the sheath of the vessels, on which it is gradually lost. The oval aperture here described, from its transmitting the saphenous vein, is called the *saphenous opening* (*foramen saphenum*), and its curved external margin has been named by Mr. Burns the *falciform process*.

585. *Saphenous opening.—Dissection:* The description here given of this opening, and the statements concerning the manner in which the external and inferior parts of its border are folded and reflected, may be verified by dissecting it in the following way: We shall suppose for a moment that the skin has been carefully removed from the upper part of the fascia, so as to exhibit its two parts. The opening,

however, is not defined, nor is its border distinctly seen. This is owing to the existence of a thin lamella, which is laid across the opening, and connected at each side with its borders. It is evidently of a reticular texture, and pierced by numerous small foramina, which transmit the superficial vessels; hence it is named by some persons *fascia cribriformis*. It is considered as a part of the fascia lata, which, however, cannot be the fact; for the lower border of the opening is reflected down upon the sheath of the vessels, and the external one is reflected outwards upon it, whilst the inner part is prolonged altogether behind it. Hence no part of the membrane can be extended upwards in this situation. If the saphenous vein be cut across an inch below the opening, and the fascia carefully divided by a transverse incision a little below its margin, the reflected layer can be observed as it passes down on the sheath of the vessels. Again, if from this incision another be made at right angles with it, and carried up to Poupart's ligament, the thin, reflected lamella sent outwards from what is called the falciform process, will be distinctly seen. If then, by the reflection of this border on the vessels, and the transmission of the pubic part behind them, the whole of the fascia is, as it were, accounted for, it follows that no third part remains to cover the opening, or to form what has been termed the cribriform fascia or lamella. What this really is, will appear when we shall have examined the superficial fascia; it is in fact derived from that membrane, and forms part of it. (Sect. 592.)

FASCIA OF THE LEG.

586. The lower part of the limb, from the knee to the ankle, is encased by a membrane similar in structure and use to that of the thigh. Posteriorly it is continuous with that part of the latter which covers the popliteal space; externally it contracts a firm adherence to the head of the fibula, where it is strengthened by additional fibres, given off from the biceps muscle; and internally it receives an expansion from the sartorius. If traced down from these different points, the fascia will be found to invest the muscles, and also to send processes inwards between them, more particularly between the extensor communis and tibialis anticus in front, and on the outside between the peroneal muscles. These intermuscular septa serve to increase the number of points to which the muscles are attached; for it will be observed that their fibres arise from them, as well as from the

inner surface of the fascia for some way down the leg. The fascia is thin posteriorly over the gastrocnemius, but is dense and firm where it covers the extensors, more particularly at the upper part; and will be found so firmly united along the anterior angle of the tibia, that it cannot be detached so as to be traced over its cutaneous surface. If traced along the posterior aspect of the leg, the fascia will be observed to pass over the tendo Achillis, and to be connected with the malleoli on each side, and also with the fibrous sheaths which bind down the tendons passing behind them. On the inner side it joins the internal lateral ligament, externally it is continuous with the fascia covering the side of the foot, and in front becomes identified with the anterior lamella of the anterior annular ligament.

FASCIÆ OF THE FOOT.

The fasciæ of the foot consist of two parts, differing in density and texture as well as in situation, one being a dense fibrous structure placed in the sole of the foot, the other a thin membrane covering its dorsum. Previously to examining the latter, it becomes necessary to describe a band of fibres which is strained across the bend of the ankle, and serves to bind down the tendons of the muscles.

587. The *anterior annular ligament* is attached by one extremity to the external malleolus and to the depression on the upper surface of the calcaneum, from which points the fibres of which it consists pass obliquely inwards, and divide into two fasciculi on reaching the border of the peroneus tertius and common extensor, one of them passing in front, the other behind the tendons of these muscles. At their inner border the fasciculi become united again, thus forming a tube or sheath for the transmission of the tendons. A similar arrangement of these fasciculi obtains as they cross the tendons of the extensor proprius pollicis and tibialis anticus, so that each is made to pass through a separate tube; and, finally, the fibres of the ligament, after having been thus successively separated and united again, are inserted into the internal malleolus. Now the fasciculus of this band, or ligament, which lies in front of the tendons, is continuous by its upper border with the fascia of the leg, and by the lower with that on the dorsum of the foot, all three lying on the same plane beneath the skin.

588. The *internal annular ligament* is attached, by one extremity, to the inner malleolus and to the fibrous sheath of the muscles passing behind it, by the other to the inner margin of the calcaneum. Its superior border is continuous with the fascia of the leg, the inferior gives origin to part of the abductor pollicis; one surface is subcutaneous, the other is in contact with the vessels and tendons of the flexor muscles, which pass under cover of it into the sole of the foot.

589. The *fascia on the dorsum of the foot* is a thin lamella which covers the extensor tendons, being prolonged from the lower border of the annular ligament forwards to the digital phalanges. When traced towards the external border of the foot, it is found to be attached to the head of the fifth metatarsal bone. Behind that point it becomes blended with the corresponding margin of the plantar fascia, and before it the membrane folds over the abductor and short flexor of the little toe, and unites with the digital process of the plantar fascia that lies beneath them. When traced along the inner border of the foot, we find the membrane passing over the fleshy fibres of the abductor pollicis. Posteriorly, it is attached to the calcaneum; but in all that part called the hollow of the foot, after covering the muscle just named, it is folded round its outer border, and, for part of its extent, passes deeply towards the tarsal bones, becoming blended with a septum sent upwards by the plantar fascia; farther forwards it unites with the first digital process of the fascia just named.

The examination of the fascia in this situation is easily conducted by dissecting it from the tarsal bones, and tracing it over the border and plantar surface of the abductor muscle, when its termination and attachments will be found to be as above stated.

590. The *plantar fascia* is a dense firm layer of fibrous structure, extended from the calcaneum to the heads of the metatarsal bones, along the sole of the foot. Its fibres are white and glistening; most of them are longitudinal in their direction. The transverse fibres by which these are woven into a layer increase somewhat in strength at the fore part, particularly where the digital processes are given off. The fascia is attached behind to the posterior tubercles on the plantar surface of the calcaneum, where its fibres (the greater number of which are longitudinal) are aggregated into a narrow, thick fasciculus. From

this point the fibres, as they proceed forwards, diverge and arrange themselves into two parts, separated by a depressed interval, one corresponding with the muscles of the little toe, the other with the middle of the tarsus and the whole width of the metatarsus. The external, or narrow part, after being connected firmly with the fifth metatarsal bone, sends forwards some thin fibres which unite with the last digital process of the larger portion. By its outer border it gives attachment to the fascia of the dorsum of the foot; from the inner it sends a process upwards to the tarsal bones, which contributes to form a septum between the plantar muscles. The broad portion of the fascia becomes thin as its fibres diverge, and ultimately resolves itself into five processes corresponding with the metatarsal bones. Each process, on reaching the digital extremity of these bones, divides into two fasciculi, which separate and become attached to their sides, and to the lateral ligaments, thus leaving an angular interval for the transmission of the flexor tendons and the vessels to the phalanges of the toes. From each border of this part of the fascia a membranous partition is given off, which separates the mass of muscles placed in the middle of the foot from those which are situated along its borders, and belong to the great and little toes. These septa are not merely interposed between the lateral and middle bundles of muscles;—a thin fascia will be found passing across from one to the other, separating the three superficial muscles from those which are deeper seated, and at the same time combining, with the septa at the sides and the plantar fascia beneath, to form a sort of sheath for each of the three muscles alluded to.

If the middle or broader portion of the fascia be divided by an incision carried from behind forwards, and the two parts reflected to each side off the flexor brevis, the septa will be observed passing upwards; and if that muscle be drawn aside, the *deep fascia* will come into view.

It may be proper to observe, that the plantar fascia is usually said to consist of three portions, the lamella which covers the great toe being considered as one. But this will be found, if examined in the way already pointed out (589), to be a prolongation from the fascia on the dorsum of the foot, to which its structure is strictly analogous, and therefore altogether different from that of the plantar fascia.

591. The muscular parietes of the abdomen, it will be recollected, consist of three lamellæ at each side, placed one over the other. The arrangement of their fibres, in the greater part of their extent, is well calculated to support the viscera, and prevent their protrusion. The external set incline downwards and inwards, those subjacent to them run in the opposite direction, whilst the internal ones take a transverse course; so that they afford to each other a mutual support.

But this arrangement does not obtain throughout the entire extent of these muscles. At the lower part of the abdomen, in the part generally known as the "inguinal region," or "abdomino-inguinal," (meaning thereby the part just above Poupart's ligament,) the fibres of the muscles are quite differently disposed; they all incline downwards and inwards, and thus lose the advantage obtained by the arrangement above noticed. The fibres also of the two inner muscles, in this part, are thin and pale, and, moreover, an interstice exists beneath their lower border for the passage of the spermatic cord of the male, and the round ligament of the female. In the external muscle, also, an aperture is formed for the transmission of the same parts. Again; Poupart's ligament being merely stretched across from the spinous process of the ilium to the os pubis, can only be contiguous to, or in apposition with, the parts which pass beneath it from the abdomen down to the thigh, viz. the psoas and iliacus muscles and the femoral vessels. These are obviously so many sources of weakness—so many deficiencies in the structure of the part, which, if not guarded against by some additional provision, would leave us constantly exposed to the occurrence of intestinal protrusions both above Poupart's ligament and below it. Such a provision appears to be made by means of a lining, which is placed at the inside of the abdominal muscles; but its description can be more conveniently given farther on (sect. 592), as we here take the different textures found in the inguinal region as they present themselves, layer after layer, in our everyday examinations of them.

Dissection.—Make an incision through the skin directly inwards from the anterior superior spine of the ilium to the middle line of the

body (linea alba); carry another thence down to the pubes.—Reflect this angular flap of tegument down upon the thigh, without disturbing the loose cellular layer beneath it. This is called the superficial fascia —it requires a detailed notice.

592. The *superficial fascia* (fascia superficialis) is a layer of cellular membrane placed between the skin and the external oblique muscles in their entire extent, and which is moreover prolonged upwards over the thorax, down on the thighs, and backwards into the loins. It is in fact part of the subcutaneous cellular membrane which we find all over the body; but in the region here referred to, it deserves particular attention, from its forming one of the coverings of hernial tumours. In the human subject it can add little to the strength of the abdominal parietes; but in animals, particularly in the larger quadrupeds, its place is occupied by a membrane of a yellow colour, firm texture, and quite elastic, which assists the muscles materially in supporting the viscera. Its structure in these cases is analogous to that of the ligamenta subflava of the vertebræ, or to the middle coat of arteries, according to the opinion of those who deny their muscularity.

Dissection.—The superficial fascia increases in thickness towards the lower part of the abdomen, and in its substance may be observed to run the superficial epigastric vein and artery, so that along their course it may, by a little care, be separated into two layers, one being behind, the other before these vessels; but on each side of the vessels it remains single and undivided. Taking the vessels as a guide, the anterior layer of the fascia can be dissected off them as far down as the saphenous opening in the fascia lata, and thence downwards uninterruptedly over the thigh. Externally, where the membrane is undivided, it can be traced over the iliac part of the fascia lata, and internally over the spermatic cord, and so to the scrotum, forming one of its layers, and thence down into the perinæum. When raised from the aponeurosis of the external oblique muscle, and reflected down, together with the small vessels which lie upon it, we find it closely connected by cellular bands with the line of junction between the iliac portion of the fascia lata and Poupart's ligament, and further down it becomes connected with the borders of the saphenous opening,—that layer of it which lies behind the vessels being stretched across from one border to the other, so as to form the *cribriform fascia* or *lamella*

through which the superficial vessels pass, and which, for the reasons already stated when describing the fascia lata, cannot be considered as a part of that membrane. (Sect. 585.)

593. The *aponeurosis* of the external oblique muscle being exposed by the removal of the superficial fascia, the fibres which compose it will be observed gradually to separate as they approach the crista of the os pubis, and to be aggregated into two bundles, leaving an interval between them, as they pass, the one to the symphysis pubis, the other to its tuberosity. This interval must therefore be of a triangular form, its base corresponding with the crista of the os pubis, and the sides with the two bundles of fibres above referred to. This has been called the *external abdominal ring*,—a term evidently ill-chosen, if its form be considered, more particularly as its bounding lines are named *pillars*. Towards the crista of the os pubis a rounded cord (*spermatic*) projects through the opening, but its borders or pillars are not distinctly defined, which is owing to the circumstance of a membrane being stretched across from one to the other, and also prolonged on the cord.

594. *Inter-columnar fascia.*—If the surface of the aponeurosis of the external oblique be examined, a series of fibres will be observed running upon it and describing arches, the convexities of which look downwards and inwards. As they approach the triangular aperture they become more closely aggregated together, and lose their fibrous character, so as to assume that of a smooth membrane, which passes thence downwards on the cord, forming one of its investments. Whilst resting on the fibres of the muscle, this structure is called the "inter-columnar fascia," and where it comes into contact with the cord it receives the name of *fascia of the cord*, or *fascia spermatica*.

In order to exhibit clearly the margins or "pillars" of the ring, this thin fascia may be detached from the cord by holding the cord forwards, and lightly drawing the edge of the scalpel all round it, so as to divide the fascia, after which it can be readily pushed upwards.

Dissection.—The aponeurosis of the external oblique muscle may, in the next place, be divided by an incision carried horizontally inwards from the anterior superior spine of the ilium to the linea alba,

from the termination of which another should be drawn down to the pubes. The angular flap thus included may then be reflected down on the thigh, by which means the internal oblique muscle is brought into view, and also the cremaster, which is given off from its lower border, and thence prolonged upon the cord, with which it passes through the opening in the external oblique muscle. The cord lying undisturbed in its situation, will be observed to rest (so far as it is exposed by reflecting the external oblique) upon the fibres of the internal oblique, after having passed beneath its lower border. For the same extent it is covered by the aponeurosis of the external oblique, and inferiorly it is supported by the groove formed by the lower fibres of the latter, as they turn obliquely backwards and inwards to reach their second and third insertions. Supported in this groove to the point at which it passes through the external ring, the cord will be observed to incline a little outwards after its exit, and to lie to the outside of the tuberosity of the os pubis.

The next step is to *expose the cord in the rest of its extent;* to effect which it becomes necessary to detach the fibres of the internal oblique muscle from the inner surface of Poupart's ligament, and to draw them inwards, together with the cremaster, towards the middle line. This requires to be done with care, in order to separate them from the transversalis muscle, whose fibres in this part run in the same course, both being also inseparably united previously to their insertion into the crista of the os pubis. When this is effected, the cord will be found to pass beneath the lower fibres of the transversalis muscle, where they form an arched border over it; and if these fibres be carefully pushed upwards, by passing the handle of a scalpel beneath them, a thin membrane will be brought into view, on which the muscle last named rests. Through this membrane the cord passes; in doing so, however, it does not pass through it as it might be supposed to do through a hole in a sheet of paper, or, in other words, through an aperture with a sharp and defined border. On the contrary, the cord in its passage carries with it, from the margin of the opening, a prolongation which runs down upon it, enclosing it all round, and gradually narrowing so as to become of a funnel-shape.

Now, if the fibres of the transversalis muscle be detached a little farther, an artery (the epigastric) will be observed running from below upwards, lying to the inner side of the cord, at the point where the latter pierces the membrane. This, it may now be observed, is called the *fascia transversalis*, from lying behind the muscle of that name, and forms part of a general lining placed within the abdominal parietes.

595. *Inguinal canal:*—The spermatic cord, then, in its passage, lies in an oblique canal (inguinal) formed for it in the wall of the abdomen; it presents an inlet, an outlet, and an intervening space, viz. the canal itself, each of which requires a special notice.

Abdominal ring—internal:—The inlet, or inner aperture of the canal, is called "the internal abdominal ring;" it is situated in the fascia transversalis, being that part of it through which the cord passes as it is about to emerge from the cavity of the abdomen. It corresponds with the middle point between the anterior superior spinous process of the ilium and the symphysis pubis, being about half an inch above the margin of Poupart's ligament. Its existence may be determined, and its margins defined, or rather margins may be given to it, by holding the cord forwards, and cutting across the prolongation which it receives from the fascia. When the cord is relaxed, the aperture becomes apparent.

Abdominal ring—external:—The outlet, or the inferior and external opening, fig. 99, 10, is called "the external abdominal ring;" it is the triangular interval left between the fibres of the external oblique muscle, which has been already described (593).

The *inguinal canal* is the interval between the two apertures here noticed, its direction being downwards, inwards, and a little forwards. Its length may be said to be from an inch and a half to two inches; as it varies in different instances, being greater in the female than in the male subject, and in adult age than in infancy. To understand rightly the nature of this canal, and the structures in which it may be said to be formed, we must consider the course of the spermatic vessels in their progress from the abdomen down to the scrotum, and the relations which they bear successively to the fascia transversalis, and the transversalis muscle,—to the internal oblique muscle and also to the external oblique; for these are placed and adjusted in a manner so peculiar, that the vessels in passing to their destination bear to each a special relation in the different parts of their course. How they are made in this short interval to pass through, beneath, upon, and between the contiguous surfaces and borders of the structures above named is shown in the next paragraph.

596. *Spermatic cord—its coverings and relations:*—At the

point above indicated, viz. midway between the anterior superior spine of the ilium and the pubic symphysis, the spermatic vessels and the vas deferens meet at an angle. They there pass *through* the fascia transversalis, as has been already stated, and receive from it their first investment, viz. the funnel-shaped process given off from the margin of the internal ring. Thus enclosed, they turn downwards and inwards, under cover of the transversalis muscle, and then under the internal oblique. During this part of its course, which is about one-third of the length of the canal, the cord rests *upon* the fascia transversalis, and is covered immediately by the muscles just mentioned. It then passes *beneath* the lower border of the internal oblique muscle, and receives its second covering, viz. the cremaster; and during the rest of its course it lies *between* the contiguous surfaces of the internal and external oblique muscles. For it rests upon the conjoined fibres of the internal oblique and transversalis muscles (where they turn down to be inserted into the crista of the os pubis and the pectineal line), and is covered by the aponeurosis of the external oblique. Finally, it passes through the external ring, where its third investment is placed upon it, viz. the inter-columnar fascia, or fascia of the cord, after which it becomes covered by the superficial fascia and the common integument.

These different structures are examined with attention by anatomists, not so much from a consideration of any importance or interest they possess in the natural or healthy condition of the parts, but in consequence of the relation which they bear to hernial tumours when they occur in this situation. Five lamellæ, it will be recollected, have been here enumerated as forming the investments of the cord. They have been taken in the order in which the cord and testis come into contact with them whilst passing from the abdomen down into the scrotum. Should a portion of intestine be forced through the internal ring into the canal, and so down into the groin, it will, during its progress, clothe itself in these same investments, having previously derived another from the peritonæum, which it pushes before it at the moment of its exit. Hence it is that the anatomist describes these structures in the order in which they are super-imposed upon the cord or hernial sac; the surgeon, on the other hand, enumerates them in the order in which they

successively present themselves to his scalpel whilst he is dividing them during an operation.

597. *Oblique inguinal Hernia—situation of:*—When the intestine follows the course of the spermatic cord through the inguinal canal, the tumour which it forms is denominated, from its situation and direction, "oblique inguinal hernia." In such cases, the neck of the hernial sac lies close to the external side of the epigastric artery, on which account Hesselbach has applied the term "hernia externa" to that form of the affection now under consideration.

598. *Direct inguinal Hernia—situation of:*—At the inner side of the epigastric artery a *triangular space* will be observed, its sides being formed by that vessel and the external border of the rectus muscle, and its base by the crista of the os pubis and the part of Poupart's ligament intercepted between its tuberosity and the epigastric artery. Should the intestine protrude in this situation, it must either distend and push before it the conjoined fibres of the transversalis and internal oblique muscles, or it may rupture some of them, and escape through the interval. In either case it passes directly forwards through the external ring, and hence has been denominated *direct inguinal hernia.* But Hesselbach calls it *hernia interna*, from its relation to the epigastric artery.

Dissection.—Across the area of this space are stretched the conjoined fibres of the internal oblique and transversalis muscles, which, even with the addition of the fascia transversalis, would form an inadequate support to the viscera in this situation, particularly as the external oblique cannot lie evenly upon them, owing to the interposition of the cord. By a little attention a number of white tendinous fibres may be observed to pass obliquely upwards and inwards from about the inner fourth of Poupart's ligament, as well as from the crista of the os pubis; and after crossing the area of the triangular space, to terminate by being inserted into the linea alba. These by being stretched between the points just referred to, and by running across the fibres of the internal oblique and transversalis muscles, with which they are in close contact, tend materially to support them. But this is not the only influence they seem to exert. If the fibres of the external oblique be cut through, so that no part be allowed to remain but the external pillar of the ring and Poupart's ligament, it is clear that no direct communication any longer exists between the

latter and the linea alba. Now if the linea alba be pushed to the opposite side, or if it be cut across and drawn in different directions, by being held in the forceps, Poupart's ligament will be made tense and elevated by the traction exerted upon it through the medium of the oblique fibres here described. These fibres, then, serve not only to strengthen the part over which they are extended, but also to connect the linea alba and Poupart's ligament, somewhat on the principle of a diagonal brace, and by means of their elasticity tend to weaken the force of any pressure made upon the part by diffusing it over a greater extent of surface.

A correct and clear knowledge of the direction and formation of the inguinal canal can alone enable the surgeon to apply the taxis judiciously in cases of oblique hernia. And a knowledge of the precise situation of the internal ring is no less necessary to point out the exact spot on which the pad of a truss should be applied to prevent the recurrence of a hernial protrusion.

FEMORO-INGUINAL REGION.

The groin or inguinal region is divisible into two parts —the division being established by the line of Poupart's ligament. The portion above the ligament may be called the "abdomino-inguinal" region. It is the seat of the oblique and direct forms of hernia, as well as that peculiar variety of the former which occurs in infancy, and is thence termed "congenital" hernia. Now the space just below Poupart's ligament,—that which intervenes between it and the saphenous opening in the fascia lata, may be named the "femoro-inguinal region." It is the seat of that form of hernia which so frequently occurs in females, and which is usually called "femoral" from its protruding at the top of the thigh.

599. *Dissection.*—After having examined all that part of the inguinal region which lies above Poupart's ligament, reflect the skin down from the front of the thigh for about four or five inches—reflect the superficial fascia also, and accurately define the saphenous opening. In the next place, separate the iliac portion of the fascia lata from the lower margin of Poupart's ligament by an incision carried from without inwards, and draw it down. The lower border of the ligament may in the next place be defined by passing the handle of a scalpel beneath it, and then a funnel-shaped membranous tube will be observed pass-

ing down behind it, narrowing as it descends, and investing the femoral vessels. If some of the superficial inguinal glands have been retained, their vasa efferentia may be readily seen (by drawing the glands down, so as to render the vessels tense) to pierce the inner side of the tube, and render it cribriform. This tube, by a little care, can be insulated from Poupart's ligament, which lies before it, from the border of Gimbernat's ligament, which is situated at its inner side, and from the pubic portion of the fascia lata, on which it rests; and if it, together with the enclosed vessels, be cut across two inches below Poupart's ligament, they may easily be drawn up towards the abdomen. These facts bear materially on the anatomy of the parts connected with femoral hernia.

When the examination has been conducted thus far, lay open the abdomen by making an incision from the umbilicus to the anterior superior spine of the ilium, and another down to the pubes, then draw the flap down on the thigh. The intestines should, in the next place, be removed, and the peritonæum carefully detached from the iliac fossa, and from the inner surface of the flap above described, as well as from the lumbar region.

Cellulo-fibrous lining—general idea of:—When these measures have been taken, the inner surface of the parietes of the abdomen will be found to be lined throughout its entire extent by a smooth shining membrane, which appears to be placed there for the purpose of strengthening them where they are most in need of support, and of connecting them together where, from the fact of their being merely contiguous, they are liable to be separated from each other, and so leave spaces into which the intestines may be protruded. This membrane is exceedingly thin at the upper part of the abdomen, where it may be said to degenerate into mere cellular tissue, but it gradually becomes more dense towards the lower part — in the inguinal region, and is very firm and resisting where it rests on the iliacus muscle. Its *structure* may be said to be *cellulo-fibrous;* its external surface is in intimate contact and even union with the muscular parietes of the abdomen, whilst the inner one is in apposition with the serous investment (peritonæum) of the viscera.

At a first inspection, this cellulo-fibrous lining would appear to form a cul-de-sac, its closed extremity being placed at the lower part of the cavity — one side of it being prolonged upwards behind the transversalis muscle, the other backwards upon the iliacus, the juncture or seam marking the union of the two being at Poupart's ligament. However, when examined with attention, it will be found not to form a complete

shut sac at the lower part of the abdomen, for a prolongation of a tubular form descends from it round the femoral vessels, so as to become continuous with the sheath which invests them in the rest of their extent. Again, where the spermatic vessels pass from the abdomen into the inguinal canal, they also receive a tubular investment, which accompanies them. Both these, it will be recollected, have been brought into view during the progress of the dissections already directed.

Cellulo-fibrous lining — its division into parts: — The membranous lining is not usually described in this way as a continuous whole. Its different parts are examined separately and with much detail, so that students are apt to regard them as distinct structures, and probably intended for different purposes, more especially as each has been designated by a particular name. For instance, all that part of the membrane which lies above Poupart's ligament, and lines the transversalis muscle, has been from this circumstance named the *fascia transversalis*. The posterior part, which rests on the iliacus muscle, has been, doubtless for a similar reason, called the *fascia iliaca;* and where the membrane is prolonged over the margin of the pelvis it receives the name of *fascia pelvica*. Finally, where it becomes reflected upon the sides of the rectum and bladder, some have gone so far as to call it the *vesical fascia*. These, it may be observed, are anatomical or topographical names taken from the situation of the different parts of the membrane. There are others, however, which have a surgical origin (if such an expression be allowable), inasmuch as they are derived from their connexion with pathological conditions of the parts, or, in other words, with certain forms of hernia. Thus the tubular prolongation, already noticed as descending with the femoral vessels, has been termed the *fascia propria* of femoral hernia; and that which passes along the spermatic cord has been by some considered as the *fascia propria* of inguinal hernia. With this general view of that structure, which we have here ventured to term the membranous lining of the abdominal parietes, we proceed to describe, *seriatim et singulatim*, the different portions into which it is usually divided.

600. The *fascia transversalis* has been so called by Sir Astley Cooper (who discovered it), from its being placed behind the transversalis muscle, which it lines. Some degree of confusion occasionally arises from the use of this term. For whilst describing the different parts of this region, we are obliged to speak of the transversalis muscle — the conjoined fibres of the transversalis and internal oblique — the aponeurosis of the transversalis, and, finally, of the fascia transversalis. The repeated use of the same term, in so many different acceptations,

produces no small degree of perplexity, particularly to students at the commencement of their pursuits. We may then take one step at least towards removing a source of embarrassment to ourselves, at the same time that we make a due acknowledgment to the individual whose researches have thrown so much light on the anatomical structure of the parts connected with hernia; and as he was the first who discovered and described the membrane now under consideration, it may with great propriety be called *fascia Cooperi*. The fascia transversalis, or fascia Cooperi, then, is a thin smooth membrane, closely adhering to the transversalis muscle; along whose inner surface it may be traced, in many instances, upwards, as far as the margin of the ribs, gradually becoming thinner as it ascends above the umbilicus; downwards it reaches to Poupart's ligament and the pubic symphysis, and outwards it extends to the crista ilii (to which it is firmly attached). Finally, if examined above this point of bone, it will be found prolonged deeply into the lumbar region, where it gradually degenerates into cellular tissue. As the membrane extends inwards to the middle line (for we here confine our attention to one lateral half of it), it becomes closely adherent to the aponeurosis of the transversalis muscle, and where it lies behind the rectus it becomes thin and weak. If from this point it be traced downwards, it will be found, after lining the rectus, to pass along the inner surface of the pubic symphysis, and thence down to the point at which the urethra escapes from the pelvis, where it is reflected backwards upon the upper surface of the neck of the bladder, on which it is gradually lost. Along the lower border of the abdomen the membrane may be said to terminate at Poupart's ligament, at least in all that part of its extent which is included between the anterior superior spine of the ilium and the exit of the vessels, where, by uniting with the fascia iliaca, it forms a complete cul-de-sac, the junction being indicated by a white line running from without inwards; but this does not exactly correspond with the margin of Poupart's ligament. Now in the space which is included between the external border of the femoral artery and the base of Gimbernat's ligament, the membrane cannot pass backwards to join the fascia iliaca, inasmuch as the vessels are interposed between them. Hence it is prolonged down behind Poupart's ligament, guided as it were by the vessels, and forms the anterior half of the membranous tube that invests them, and which has been already more than once alluded to.

It will be recollected that the fascia transversalis forms the entire of the tubular prolongation that invests the spermatic vessels, as they escape through the internal ring. When describing the last-named

opening, no mention has been made of its boundaries, or its pillars, as they have been called. It is difficult to conceive the existence of anything so dense or defined as to resemble a pillar, in a membrane so thin and uniform in its structure. Most probably a consideration of the structure of the external ring led to the idea that it was necessary to institute an analogy between it and the internal one, and so to assign pillars to the one as well as to the other; however, taking it to be elliptical in its form, its long diameter being from above downwards, it will be found that it is more dense and firm along the inner segment of the ellipsis than at the external one.

601. The *fascia iliaca* is more dense and firm than the membrane just described. It is in close contact with the iliacus muscle, and, like it, is attached to the inner margin of the crista ilii from the anterior superior spine backwards for three-fourths of its extent, and so far it is continuous with the fascia transversalis, which has been described as being inserted along that line. When traced inwards, it is found to pass behind the iliac vessels and over the psoas muscle, along the inner border of which it sinks into the pelvis. Round the margin of this cavity the fascia becomes closely connected to the bone by means of dense cellular fibres; after which it descends, lying upon the inner surface of the obturator internus muscle, until it comes to a level with an oblique line extended from the symphysis pubis to the spine of the ischium. At the point here indicated the fascia turns inwards, guided by the pelvic surface of the levator ani muscle, and so reaches the side of the rectum and bladder, with which it becomes identified. In the interval between the spine of the ischium and the promontory of the sacrum, the fascia stretches across the great sciatic notch, covering over the parts which escape through it; and as it lies behind the internal iliac artery, it is pierced by its different branches, giving to each a tubular prolongation. On reaching the surface of the sacrum the fascia becomes continuous with that of the opposite side.

It may thus be observed that the psoas muscle is covered by the fascia as well as the iliacus. We have as yet traced it upon the former no higher than where it is on a line with the crista ilii. But the fascia does not cease at this point; it extends upwards on the psoas muscle, being prolonged, from its surface, inwards upon the lumbar vertebræ, whilst, along its external border, it is united with the anterior lamella of the lumbar aponeurosis of the transversalis muscle, and terminates superiorly by being inserted into the ligamentum arcuatum proprium. Thus we find that the numerous interstices, apertures, and foramina, which occur in this extensive region, are covered over

by this membrane. We now proceed to examine that part of it which is more immediately connected with the anatomy of femoral hernia.

FEMORO-INGUINAL REGION—SURGICAL ANATOMY OF.

602. When traced to the lower part of the iliac fossa, the fascia iliaca is found to turn forwards a little, and to become blended with the fascia transversalis in all that part of its extent which intervenes between the superior spine of the ilium and the exit of the femoral vessels. But in the interval between this point and the base of Gimbernat's ligament the fascia cannot come forwards so as to form a junction with the fascia transversalis, in consequence of the interposition of the vessels; on which account it passes down behind them, forming the posterior part of their funnel-shaped sheath. Now, having already derived the part of this membranous tube or sheath that lies before the vessels from the fascia transversalis, and that which is behind them from the fascia iliaca, it remains only to add, that, in order to complete the tube, the membranes unite externally along the side of the artery, and internally at the base of Gimbernat's ligament. The tube is wide above, but gradually narrows as it descends. The external border runs straight downwards along the artery, to which it is closely applied; the internal one inclines obliquely downwards and outwards, from the base of Gimbernat's ligament, so as to reach the vessels. The external part of it only is thus found occupied by the vessels, the remainder is unoccupied (except by lymphatic glands), and presents an oval opening called the *femoral ring*, which is the only outlet that exists behind Poupart's ligament through which a portion of intestine can be protruded. Such an accident cannot happen immediately in front of the vessels; for we find interposed between them, and connecting the anterior to the posterior sides of the tube, a firm process of membrane preventing their separation. Moreover, the sub-serous cellular tissue, which lies upon the iliac vessels in their entire course, becomes dense and firm near their exit, as it is being reflected from them to the anterior wall of the abdomen.

603. *Femoral arch.*—It may here be observed that the term *femoral arch* is applied to the whole space between the anterior superior spine of the ilium and the angle of the os pubis, its

boundaries being the irregularly curved border of the os innominatum, and Poupart's ligament, which stretches across it. Through this space pass the psoas and iliacus muscles, the femoral vessels and nerves, which, with the peculiar arrangement of the membranes above described, effectually prevent the protrusion of a hernia between the spine of the ilium and the femoral vein:—

Femoral ring.—But such an occurrence may happen to the inside of that vessel, the intestine passing into the femoral ring, whose boundaries (bearing in mind that it is lined by the membranous sheath above described) may be thus enumerated: anteriorly it is bounded by Poupart's ligament, posteriorly by the os pubis, internally by the base of Gimbernat's ligament, and externally by the femoral vein.

Femoral canal.—This ring forms the inlet to a canal whose outlet is the saphenous opening in the fascia lata, and through which the intestine descends, behind Poupart's ligament, into the upper part of the thigh, constituting *femoral hernia.* The ring does not at first distinctly appear, even after the removal of the peritonæum, as its margin is still obscured by a layer of the sub-serous cellular tissue, which in this situation is rather thick and dense; this, however, can be readily removed.

It may not be altogether out of place to observe that we are constantly in the practice of using the word *crural* as if it were synonymous with *femoral*, when treating of the different structures here noticed. We say crural ring—crural arch—crural nerve—crural hernia—which necessarily produces not a little confusion, as crus means the leg, not the thigh, and is synonymous with κνημη, tibia.

The relation of the vessels to the ring requires to be attentively considered. The external iliac vein and artery lie to the outside of the ring, and therefore of a hernial sac, should it occupy that situation. The epigastric artery, arising from the iliac, runs obliquely along the external border of the femoral ring, and must bear the same relation to a hernial tumour. Continuing to ascend, this vessel lies to the inner side of the spermatic artery and vas deferens, and therefore will be similarly placed with regard to the neck of an oblique inguinal hernia. When the obturator artery arises from the epigastric, which is not an unusual occurrence, it passes downwards and inwards into

the pelvis. If it arises by a common trunk with the epigastric, or starts from that vessel close to its commencement, its course, as it descends, will lie obliquely along the lower half of the external border of the ring. In such a case this aperture, if viewed from within, the vessels having been injected, will present the form of an ellipse, its greater diameter being from before backwards, the external side being formed by the two arteries diverging to their destinations and the internal one by the curved base of Gimbernat's ligament. But should the obturator artery arise from the epigastric higher up, its direction will then correspond with the superior and inner border of the ring, which will therefore be nearly surrounded by vessels. This, however, is a rare occurrence.

DIFFERENT FORMS OF HERNIA.

604. Having thus examined the disposition and mutual relations of the different structures of which the abdominal parietes are composed, we proceed to make a few remarks on the practical application that may be made of the facts which we have here reviewed in detail. We shall suppose that the subject lies on the table, and that the different processes of dissection above pointed out have been conducted on one side, the other remaining untouched. It may in the first place be observed, that if a hernial tumour has occurred towards the lower part of the abdomen, the intestine must have escaped either immediately above Poupart's ligament, or below it. In the former case it is termed *inguinal hernia,* in the latter *femoral.* It must obviously be a matter of the first consequence to determine this point with certainty, and without any delay; for on it depends, not only the success of the efforts made to reduce the hernia by what is called the taxis, but also the propriety and manner of performing every step of the operation requisite for the relief of a strangulated intestine, from the first incision through the skin to its final completion. This question can be determined only by ascertaining with accuracy the position of the neck of the tumour, and then carefully tracing out its relation of place, or its position with regard to Poupart's ligament. If the tumour be of moderate size, so that the finger may be passed along the ligament, from the tuberosity of the pubes outwards, little doubt can remain as to whether it lies below or above its border. But a large inguinal hernia will obscure this part by its descent, and a large femoral one by its ascent; for when the latter has passed down for some way, it turns up towards the abdomen, lying on Poupart's liga-

ment, and so occupies the situation of the other species. But if such a tumour can be drawn down a little, by making it slide between the skin and fascia, its point of attachment can at once be determined. And if, in the other form of the disease, the tumour be pushed a little upwards and inwards, so that the situation of its neck can be ascertained, and the ligament defined, as above suggested, a satisfactory conclusion will at once be arrived at. Suppose it to be decided that the tumour lies above Poupart's ligament, and therefore that it is an inguinal hernia, we have seen that its descent may be along the course of the inguinal canal, or it may pass straight forwards through the external ring,—constituting, in the former case, an *oblique*,—in the latter, a *direct inguinal* hernia. It is indispensably necessary, as well in reference to the taxis as to the operation, to distinguish even these, though so closely allied. The situation of the spermatic cord, the direction of the tumour, and also its form, furnish sufficient data on which the diagnosis may be established. In the oblique hernia, the tumour inclines upwards and outwards, in the direction of the spine of the ilium, the vas deferens, and the spermatic vessels lying behind it. In the direct descent, the tumour may be traced upwards in the direction of the umbilicus, and the cord will be found to its external side, and partly in front of it.

605. The *taxis—principle of*.—Now, if the previous question here raised be determined, and if the case has been decided to be an oblique inguinal hernia, it remains for the surgeon to restore the intestine, by the taxis, if possible; if not, by an operation. Previously to making any effort at reduction, the abdominal muscles should be relaxed as much as possible, which can be done by approximating their points of attachment. With this view, the body being placed in the recumbent posture, the shoulders should be raised and supported, and the thighs bent on the pelvis, that of the affected side being also inclined a little inwards to lessen the tension exerted on Poupart's ligament by the iliac portion of the fascia lata. So far, a knowledge of the anatomical connexion of the parts points out the propriety of placing the body and the limbs in a particular position, rather than in any other. In the next place, the tumour being taken hold of steadily with one hand, and elevated somewhat towards the ring, compression should be made on its neck with the first two fingers and thumb of the other, followed by an effort to push it upwards and outwards, that is to say, in the direction of the inguinal canal. These measures should be employed until hopes of success fail, or until it is no longer safe to continue them, from their tendency to excite or increase inflammation

in parts placed under circumstances which dispose them to run very speedily into that condition.

Operation.—When all efforts at reduction prove fruitless, the operation must necessarily be resorted to, and the sooner it is done the better. When placed on the operation table, the shoulders should be raised in the same way as whilst the taxis was being performed, but the legs must be allowed to hang over the margin of the table. In the first place, the skin may be made tense over the tumour, by straining it between the fore-finger and thumb of the left hand, if the tumour be small; or, if it be large, by supporting it in the palm of the hand, and drawing the skin from behind. The integument may then be divided by an incision drawn over the convexity of the tumour, beginning at its upper extremity, or even a little above it, and continued down to the lower, unless it be very large. Another mode of making the first incision is, by pinching up the skin into a fold, running transversely with regard to the tumour, and dividing it down to its base, or point of reflection. When this is done, and the skin is allowed to return to its original position, the line of the incision through it will be found to correspond with the direction of the tumour. This incision will divide the skin and superficial fascia, and also a small vessel, which sometimes requires to be secured, viz. the superficial or external pudic artery. The fascia of the cord becomes by these means exposed, a small piece of which should be pinched up between the blades of the forceps, and cut off close to their points, so as to make an aperture barely sufficient to admit the director. The instrument being passed upwards to the ring, the fascia is to be divided upon it by running the scalpel along its groove, and then downwards to the extent of the external incision. The cremaster is thus brought into view, and is to be divided with equal caution, and after the same manner. The hernial sac, however, is not yet laid bare; it remains covered by the prolongation given off from the margin of the internal ring, and by what we have already alluded to as the sub-serous cellular tissue, and which, as it descends, gradually becomes thin and weak. This "must be cautiously cut through," by employing the forceps, director, and scalpel, as above stated, and so the peritonæal investment, or the proper hernial sac, is exposed; to open which requires "the utmost caution." The operator should "nip up a small portion of the membrane, over the inferior and anterior part of the tumour, between the fore-finger and thumb of his left hand, and then, by gently rolling it between them, he easily distinguishes if any intestine be included: if

so, he raises a fresh portion."* The slight rotatory motion of the fingers here directed will in most cases suffice to insulate the membrane from the intestine; and when this is done, the fold compressed between the fingers may be divided by the scalpel, or scissors, so as to make a small opening for the admission of the director. Whilst the director is being introduced and passed up towards the ring, its grooved border should be carefully kept in close apposition with the inner surface of the sac, lest by any means a part of the intestine should insinuate itself between them, and be divided, as the scalpel runs along the groove.

The stricture—its divisions.—It now only remains, so far as the operative part is concerned, to ascertain the seat of the stricture, and to divide it. For this purpose the fore-finger of the left hand is passed into the hernial sac, to the point at which it becomes constricted, which will be found in one or other of the three following situations, and may be stated in the order of their frequency as follows: 1. At the internal ring in the neck of the sac; 2. In the canal itself, about an inch or a little more within the external ring, the compression being formed by the lower border of the internal oblique and transversalis muscles, where they arch over the neck of the tumour; 3. At the external ring, which is less frequent than the others. The finger having reached the strictured part, a probe-pointed bistoury is to be passed along it, its side resting on the palmar surface of the finger; and when it has been conducted beneath the stricture, the edge should be turned forwards, " so that the division of the structure should be made in a direction parallel with the linea alba, that is to say, *directly upwards.*"

Precautions.—In performing this part of the operation, the only thing to be apprehended is the division of the epigastric artery. It will be recollected that this vessel lies to the inside of the neck of the tumour in cases of oblique inguinal hernia, and on the outside in the direct hernia. If the diagnosis, in a given case, were so clear as to leave no room for doubting whether the descent was oblique or direct, the position of the artery would at once be determined with regard to the neck of the tumour, and the direction in which the stricture should be divided may be indicated with certainty. In the oblique form, the artery may be effectually avoided by cutting outwards; in the direct, by inclining the incision inwards; and in recent cases doubts

* Sir Astley Cooper's Lectures, edited by F. Tyrrell.

seldom arise on the question. But when a hernia has been of long standing, the weight of the tumour, by drawing on its neck, and therefore on the internal ring, approximates it to the external one, by which means it occupies the situation of a direct hernia. If, on examination, such a case were pronounced to be a direct descent, and if, on such an assumption, the incision were made inwards, the artery must be divided. Such an occurrence can only be avoided by adopting the precept laid down by Sir Astley Cooper, viz. of cutting upwards in all cases of inguinal hernia, whether they be direct or oblique.

In cases of direct inguinal hernia, the coverings of the sac are the skin and superficial fascia, the fascia of the cord, the conjoined fibres of the internal oblique and transversalis (if they be not ruptured), together with the fascia transversalis. The cremaster muscle forms only a partial covering, near the external ring, for there the cord and the tumour come into contact; but they instantly diverge, one passing upwards into the abdomen, the other outwards in the course of the canal. The division of the different structures above enumerated is to be conducted on the same principle as in the oblique descent, but with a degree of caution the more as the tumour has a covering the less.

FEMORAL HERNIA.

606. *Progress of the intestine.* — When a portion of intestine passes into the femoral ring, it necessarily pushes before it that part of the peritonæum which lines the aperture, and, thus invested, descends into the tubular sheath sent down round the femoral vessels, from the fascia transversalis and iliaca; in other words, into the femoral canal. After descending for about an inch and a half, its progress downwards is arrested; and if the quantity of intestine protruded increases, the tumour turns forwards through the saphenous opening in the fascia lata. There its direction becomes altered again, as it is made to ascend obliquely inwards, lying in front of the iliac portion of the fascia lata (its falciform process), and even of Poupart's ligament; so that it forms, by its different turns, a curve whose concavity looks upwards.

Having thus described the progress of the intestine, we are prompted to inquire what are the circumstances in the structure of the parts through which it passes which determine these changes in its direction? Having descended to the point above indicated, the tumour is checked by the narrowing of the tube in which it is enclosed. This,

though wide above, where its inner border is separated at a considerable interval from the femoral vessels, gradually contracts, so as soon to come into close contact with them; and where it does so, it must become intimately connected with them by the *vasa vasorum*. The lower border of the saphenous opening is also closely applied to the sheath of the vessels in this situation; and as the pubic portion of the fascia lata passes behind, whilst the iliac lies in front of it, any extraneous substance that may pass down in the sheath would be constricted by that arrangement of the fascia, even if the connexion between the vessels and the sheath were not sufficient to produce such an effect. These causes limit the descent of the intestine, and determine its passage forwards through the saphenous opening, where comparatively little resistance is given.

But, it will be asked, why does the hernia turn upwards? why does it not rather descend in front of the thigh, lying between the skin and the fascia lata, more especially as, from its exit out of the abdomen, down to its first turn, it had been lying on the pubic portion of that fascia? The impediment to its descent in that way is produced, partly by the manner in which the superficial fascia is connected to the margin of the saphenous opening, but chiefly by the superficial epigastric vessels which run on its surface. With these the tumour comes into contact, after emerging through the opening, and though, by the firmness of their connexion with the deep vessels, they resist its descent, they offer no obstacle to its ascent, so that during this part of its course it necessarily passes up between the superficial fascia which lies in front of it, and the fascia lata lying behind.

607. *The taxis—principle of.*—To restore to its natural situation an intestine so placed, it becomes necessary to make it retrace its steps, as it were, describing successively, but in a retrograde course, the different turns it had made in its passage. With this view, after having adjusted the body so as to relax the abdominal muscles, and to take off all tension from Poupart's ligament, the patient being placed with the affected side close to the side of his bed, the surgeon draws the tumour downwards into the hollow at the upper part of the thigh, so as to bring it opposite the saphenous opening. This being done, it should be pressed backwards, as if into that aperture, and upwards, with a slight inclination outwards, so as to avoid any impediment that may be presented by Gimbernat's ligament. Should these and the other usual expedients fail, the operation must be resorted to, even still more speedily than in cases of inguinal hernia.

Femoral hernia—operation.—When commencing the operation, the

first step (after the body has been properly placed) consists in dividing the skin by a transverse incision carried over the middle of the tumour from one side to the other, parallel with Poupart's ligament, and of course below it. This incision may be made by pinching the skin into a fold parallel with the femoral vessels, and cutting down to its base; after which, when allowed to return to its natural situation, it will be found divided in the extent and direction above indicated. This should be met at right angles by another incision, begun about an inch and a half above the femoral arch, so that both together shall stand thus ⊥. Many surgeons, it may be observed, commence with a crucial incision. Dupuytren usually does so. Sabatier discountenanced the practice, through a fear that if the vertical incision were carried below the horizontal one, so as to form a cross, the saphenous vein might be wounded. If the tumour be very small, such an accident may arise from prolonging the incision below the middle part of it; but when it increases, and comes forward, through the saphenous opening, it lies on a plane anterior to the vein, which therefore is out of all danger. In the transverse incision through the skin, the superficial epigastric artery is divided, but that is of little consequence. The angular flaps of integument having been reflected, the superficial fascia becomes exposed, and should be divided to the same extent. It is much thicker than where it forms a covering for inguinal hernia, and contains, moreover, some of the superficial lymphatic glands. The tubular sheath of the femoral vessels, or *fascia propria*, next comes into view, which is to be cautiously divided by pinching up a small piece between the blades of the forceps, and cutting it off close to their points, thus making an aperture sufficient to admit a director. When the fascia propria is divided, the hernial sac is, in most cases, still obscured by that thick lamella of cellular tissue which lies across the femoral ring, and has been pushed down before the peritonæum, as the hernia descends. It is scarcely necessary to add, that this also must be divided; after which, whilst the proper sac, or peritonæal covering of the intestine, is being opened, the same precautions should be observed that have been already suggested when describing the operation for inguinal hernia.

The stricture—seat of.—When the contents of the sac are exposed, the operator has to divide the stricture, which obviously includes a consideration of the place at which the division should be made, and the manner of making it. The finger being introduced into the sac, and passed upwards along its anterior and inner side, for the purpose of ascertaining the seat of the stricture, it will be found, according to

the testimony of our highest authorities, either at the arched border of the saphenous opening, at the edge of Poupart's ligament, or in the neck of the hernial sac. Should a stricture be found at the border of the opening in the fascia lata, a bistoury may be introduced on the finger, and its division effected by directing the edge of the instrument obliquely upwards and inwards. This part can be the seat of stricture only when the tumour is sufficiently large to turn forwards and upwards; and it not unfrequently happens, that though it be divided, still the reduction of the intestine cannot be effected. The stricture must then exist higher up, in one or other of the situations above indicated, to remove which, different modes of proceeding have been recommended, all, however, having a common object, viz. to widen the opening through which the intestine had escaped in the first instance, and which it necessarily must repass whilst it is being restored. The anterior boundary of the femoral ring being Poupart's ligament, and the internal one that of Gimbernat, the proposed end must be attained by the division of one or other. Sir Astley Cooper is of opinion that Gimbernat's ligament cannot be the seat of stricture; for "if strangulated femoral hernia be examined in the dead body, and that ligament cut through, the hernia is not liberated by such a division."

The stricture—division of.—If it be on these grounds concluded that the stricture is situated at the border of Poupart's ligament, or in the neck of the sac, the same incision will necessarily divide both. But in what direction should it be made? This question must be determined by a reference to the position of the vessels or parts which lie contiguous to the margin of the ring. If the incision were directed upwards in a male subject, the spermatic vessels and vas deferens must be wounded, should it be carried beyond a very few lines. In the female, the round ligament only would be endangered, which is of comparatively little importance. To avoid these consequences, Sharpe recommended the edge of the bistoury to be inclined upwards and outwards, by which means its direction will be parallel with that of the cord; but then the epigastric artery lies exactly before it. Though this fact would seem rather decisive against adopting the practice, Dupuytren prefers it to any other, and no vessel appears to have been wounded in any of his operations; doubtless from the fact, that it is only necessary to divide a few fibres of the ligament. One point then remains, in which the stricture may be divided without risk, viz. by inclining the edge of the bistoury, after it has been introduced, obliquely *upwards and inwards.* On this but one contin-

gency rests, and that an extremely remote one, namely, when the obturator artery arises from the epigastric in such a way that, as it descends into the pelvis, it runs along the anterior and inner side of the ring. For full information on this important subject the reader will consult the following works:—Sir Astley Cooper's *Treatise on the Anatomy and Surgical Treatment of Hernia;* Lawrence *on Ruptures;* Sir A. Cooper's *Lectures on Surgery,* edited by F. Tyrrell; and Scarpa *on Hernia.*

SURGICAL ANATOMY OF THE PERINÆUM.

The subject is placed on its back, and drawn to the edge or end of the table; its foot is tied to the hand at each side, and the knees held apart. A curved staff or catheter is introduced into the bladder. The penis and scrotum are drawn up towards the abdomen, so as to expose the perinæal space. The first steps of the dissection have been already pointed out (see Dissection, sect. 504). The superficial fascia, its structure, attachments, and relations, will also be found described with sufficient detail, as well as the perinæal muscles. These things being premised, we now proceed to the structure which comes next in order, viz. the deep perinæal fascia.

608. The *deep perinæal fascia* is a thin, yet firm membrane, which fills up the interval between the rami of the ossa pubis and ischii, and is thereby rendered triangular in its form. In its mode of attachment and general characters it presents some similitude to the obturator fascia, which fills the foramen of that name. It should be observed, that this structure has been variously denominated by different writers. Camper* and Douglas named it *ligamentum triangulare.* M. Velpeau† has devised or adopted the term *recto-vesical aponeurosis.* The terms ligament, tendon, aponeurosis, and fascia, appear to be ordinarily used, as if they were synonymous. It would be well to confine each of them to particular forms of structure. A ligament is properly a fasciculus of tendinous fibres connecting bones, and for the most part entering into the formation of joints; a tendon is the cord-like prolongation of a muscle; an aponeurosis is the expanded fibrous lamella prolongated from a broad muscle; whilst the term fascia, in strictness, denotes a

* Fasciculi Anatomico-pathologici. † Anatomie des Regions.

membrane serving to invest parts, or to support them. In this sense we here apply the term to the fibro-cellular lamella which fills up the outlet of the pelvis, and assists in supporting its viscera: it is also called the deep fascia, to distinguish it from the superficial one already noticed. (See sect. 504.)

The deep perinæal fascia is attached on each side to the osseous boundaries of the perinæal space, which thus determine its form; and, if examined beneath the pubic arch, will be found to consist of two lamellæ, which on approaching the base of the sub-pubic ligament, separate, one passing on its cutaneous, the other on its pelvic surface, where they terminate by gradually becoming thin and cellular. Where the membrane is strained across the interval between the bones, it at first sight appears to terminate by a lunated border, whose concavity looks towards the rectum; but we find that its continuity is not interrupted at this point, as it can be traced downwards round the margin of the rectum, and on the levator ani, gradually, however, becoming thin and indistinct.

609. *Urethral canal.*—About half an inch below the base of the sub-pubic ligament, and, therefore, an inch below the arch, the deep fascia presents a foramen, or rather forms a canal, for the transmission of the urethra. If the latter be drawn forwards it will be found to be invested by a tubular prolongation derived from the margin of the foramen, and continuous with the perinæal or external lamella of the fascia. A similar prolongation is reflected backwards from the posterior or pelvic lamella which invests the membranous and prostatic portions of the canal, and extends as far as the neck of the bladder. When the parts remain undisturbed, the surface of the fascia is quite flat; and if the urethra be cut across close to it, the aperture will be found barely sufficient to transmit it. But if the penis be drawn obliquely upwards, the fascia is rendered tense, and convex forwards, by means of the traction exerted on it through the medium of its tubular prolongation. Should the experiment be then made of cutting off the urethra close to the fascia, the foramen will be found much wider, for the tube had been previously rendered, as it were, trumpet-shaped, and so it will be when the urethra is rendered tense during the introduction of a catheter.

It may now be observed that the urethra, whilst the penis

remains pendulous, forms two curves, the concavity of one looking down towards the perinæum, that of the other up towards the pubic arch. The first of these is owing to the fact, that the penis is attached on each side of the arch of the pubes by its crura, and by its triangular ligament to the symphysis, from which it hangs downwards, carrying the urethra with it. From the angle thus formed by the body of the penis with the fore part of the pubes, the urethra has to descend about an inch, to get to a level with the urethral foramen in the perinæal fascia; and, finally, having passed through the foramen, it inclines a little upwards behind the symphysis. This latter curve is very trifling in the adult, but is considerable in the young subject, owing to the position of the bladder. When, preparatory to the introduction of a catheter, the penis is drawn upwards on a line with the abdomen, the first or anterior curve no longer exists, and so the canal presents but a single curve, corresponding with that of the instrument.

610. *Catheterism.*—If the integument, superficial fascia, and muscles be removed from the penis and perinæum, we can observe what takes place on the introduction of a catheter. No impediment occurs during its passage through that part of the tube which corresponds with the corpus spongiosum, for there it is supported by the body of the penis, and is also quite straight. But where it corresponds with the bulb, it is comparatively unsupported, and also is slightly dilated at its lower surface. On arriving close to the perinæal fascia, should the point of the catheter deviate to either side, or be elevated or depressed too much, it will miss the foramen, carrying the urethra with it, and so the latter will be pinched between the margin of the foramen and the instrument. If, in such a position of the parts, force be used, or if the catheter be depressed, with a view to make it correspond with the curve of the urethra, the latter must be torn through or considerably injured. A catheter in its construction resembles an angular lever, though not intended to act as such; but it virtually becomes such, if, after its progress is impeded, and it is thereby rendered fixed, an effort be made to depress the handle, for then the beak is made to move in the opposite direction, and will readily tear through the urethra. The effect of drawing the penis upwards may be exemplified in this way: when the catheter has reached the bulb, (the urethra and perinæal fascia being fully exposed,) if it deviates to either side, the point will be observed to catch

on the margin of the foramen; but if the urethra is drawn upwards, the impediment will be removed by the widening of the aperture in the foramen.

It has been contended rather strenuously by some persons, that the direction of the urethra becomes horizontal, and its canal straight, when the penis is drawn directly forwards. It will, however, be found, that when the penis is so placed, the urethra has to descend nearly an inch to reach the urethral foramen, after which it turns somewhat upwards. Moreover, the part of the urethra between the root of the penis and the neck of the bladder will be found loose and relaxed, no matter with what degree of force the penis be drawn forwards, for that will affect only the part of the urethra which corresponds with the body of the organ, as must be evident when the attachments of the latter to the bones, by its suspensory ligament and crura, are considered. The tension will, by these attachments, be confined to the spongy portion of the canal, and cannot be propagated thence to the bulbous or membranous. This constitutes the principal impediment in the use of straight catheters.

611. *Different modes of operating—Historical sketch of.*—Having noticed the boundaries of the perinæum considered as a surgical region, and having enumerated the different structures included within it, as well as their mutual relations, we may now observe that, narrow as this space is, there is scarcely a direction possible to be conceived in which it has not been traversed by incisions made to open a way through it into the bladder for the extraction of calculi.

The operation of Celsus.—Taking these different modes of proceeding in their historical order, the first we find recorded is that of Celsus.* The patient was placed in the lap of an assistant, who was required to keep his legs bent so as to expose the perinæum. If the patient was large, or very robust, two assistants were strapped together by the thighs, and each held the leg next to him, whilst the body was supported between them. The surgeon passed the index and middle fingers of his left hand into the rectum, with a view to press against the stone and force it forwards into the neck of the bladder, making it thereby prominent in the perinæum. This being done, he made a lunated incision about midway between the margin of the anus and the bulb of the urethra, the concavity of the curve looking down to the former, its extremities being directed towards the ischia—"cornibus ad ischia spectantibus." In this way he cut down upon

* Lib. vii. cap. 26.

the stone, and sought to push it through the wound; but if that did not succeed, he used a hook to assist in its extraction. This mode of operation was subsequently called "cutting on the gripe;" and from the fewness of the instruments required for its performance, it was described as the *apparatus minor*, to distinguish it from another in which several were employed. The parts divided in the incisions were—the skin and superficial fascia, part of the fibres of the accelerator muscles, and the transverse muscles; finally, the prostatic part of the urethra, the lower half of which was thrown down in the form of a flap. It is not at all unlikely that the urethra was in many cases cut across, and severed altogether from the bladder. Heister says, that the stone was made prominent at the left side of the perinæum, and that an oblique incision was then made down upon it. The line of incision marked in his plate corresponds exactly with that of the lateral operation as now performed; so that he must have taken his delineation from the mode of operation practised in his own time, and not from that described by Celsus.

The operation of Romanus.—After the revival of letters, when every dictum of Hippocrates passed for doctrine, a method of operation was devised by one Johannes Romanus, founded on a dogma of the father of physic, "that wounds of membranous parts do not unite." Its description was subsequently given by one of his disciples, named Marianus Sanctus, from which circumstance it was afterwards called "sectio Mariana," but is better known as the *apparatus major*, from the variety of instruments it required. When the perinæum was exposed, a grooved staff was introduced, and an incision made with a razor along the middle line, extending from beyond the bulb to within a finger's breadth of the margin of the anus. A second incision laid open the bulbous part of the canal, which concluded the cutting part, as all the rest was to be done by dilatation; for though the rules of art forbade the division of membranous parts, they laid no injunction against their being stretched. Hence the operation was of a mixed character, founded partly on the necessity of resorting to incisions, and partly on the equally imperative necessity of deferring to authority. When the urethra was laid open, dilators were introduced, in order to distend the canal sufficiently to admit the forceps; but, as may be concluded from a consideration of its structure and width, laceration was the immediate result, and not simple dilatation. The after consequences may be readily inferred.

Operation of Frère Jacques.—At a subsequent period, a method of operation was projected and carried into execution by a monk,

named Frère Jacques, who appears to have been altogether unacquainted with anatomy, and even otherwise illiterate, and yet his plan must be admitted to have paved the way for the introduction of that which is now most generally employed. Having introduced a common catheter (not grooved), he therewith caused the bladder to be made prominent in the left side of the perinæum: he, in the next place, inserted a long bistoury between the anus and tuber ischii, but nearer the latter; and, directing it upwards and forwards, he entered the bladder at its side, and cut through the neck, "without injuring* any other part of the urethra." When the operation was performed on the dead subject, it was found that "the integument having been divided for about two fingers' breadth, the wound next passed between the accelerator and erector muscles without injuring either, and had penetrated the neck of the bladder, and part of its body, for about an inch."† This was subsequently termed the *lateral operation,* both because the incision was parallel with the side of the perinæal space, and also because it opened its way into the side of the bladder. This plan was acted on, but modified and improved, by Ravius, or Raw, in Holland, and by Cheselden in this country, both of whom used a grooved staff.

Cheselden's operation.—Mr. Cheselden, in his first operations, entered the bladder at the side, and then divided its neck, by drawing the scalpel from within outwards, or towards the surface. It must be very difficult to extract, without laceration, a stone of any size through an incision placed so deeply, and corresponding with the side, and not with the most depending point of the bladder: for this reason, as well as from its having been followed by sloughing of the cellular substance round the rectum, caused by infiltrations of urine, this method was soon abandoned. An objection of another sort may also be taken to it, derived from a consideration of the direction in which the incision in the bladder is made. The point of the scalpel is entered at a part comparatively unsupported and movable, and is thence directed towards the neck, which, by means of its attachments, is held fixed,—a mode of proceeding which is contrary to an obvious principle in the making of incisions. This Cheselden effectually remedied, by entering his scalpel into the groove of the staff, where it lies in the membranous part of the urethra, and passing it from before backwards, so as to divide the prostate gland and neck of the bladder.

* Heister, System of Surgery. † Ibid.

The operation, as devised by this eminent surgeon, and practised at the present day, may be performed as follows (attention is here confined to the operative part exclusively, all other details and preliminaries being foreign to our present purpose):—A grooved staff, corresponding in size with that of the urethra, is in the first place introduced, and so placed that its concavity lies close beneath the pubic arch, whilst its convexity is turned somewhat towards the left side of the perinæum. The edge of the scalpel is then laid on the skin, close to the left side of the raphé, at about fourteen lines before the margin of the anus, and is thence drawn downwards and outwards to the interval between the margin of the anus and the left tuber ischii, inclining a little nearer to the latter; this divides the skin and superficial fascia. The second incision, commencing a quarter of an inch, or a little more, according to the size of the bulb, below the upper end of the first, is carried downwards in the same direction and extent, and so divides the lower fibres of the accelerator muscle, the transversus perinæi muscle and artery, with part of the levator ani and deep perinæal fascia. The staff should now be sought for at the upper angle of the incision; if the bulb be large, it will be necessary to press it aside with the index finger of the left hand. The point of the scalpel being elevated, by depressing its handle, and throwing the hand a little back, it is made to enter the groove of the staff, its lodgement therein being ensured by moving it slightly from side to side, and then is passed along the groove, so as to lay open the membranous part of the urethra. When this has been effected, the operator draws downwards to himself the handle of the staff (its concavity being held securely beneath the pubic arch), by which means its beak is made to move upwards and backwards, and thereby removed from the rectum. Whilst this is being done, the scalpel (previously lateralised, so that the direction of its edge shall correspond with that of the external incision,) is made to slide along the groove, dividing in its passage the prostatic part of the urethra and of the neck of the bladder. After this has been completed, the scalpel is withdrawn a little, and carried obliquely downwards in the direction of the first incision, so as to divide any septa that may lie across the wound, which usually consist of part of the fibres of the levator ani, and of the transversus perinæi, if not severed in the second incision. The advantage, or rather the necessity, of freely dividing the membranous part of the urethra, previously to depressing the staff, has been put in a very clear point of view by Mr. Colles:—"If you have entered your knife into the urethra high up in the perinæum,

and, while the point of the knife is lodged there, should depress the staff, and attempt the division of the prostate, you will have to make it describe a portion of a circle at the same time that it is dividing very resisting parts."

The operation of Celsus revived.—M. Chaussier in his lectures frequently commented on the curved-lined incision through the perinæum indicated by Celsus, and appears to have sanctioned this method of operating. Two of his pupils made it the subject of their theses; but it does not appear to have been reduced to practice, or to have met with any general approval as to its principle. Some years ago M. Dupuytren conceived it practicable to modify and improve the method of Celsus so as to render it safe and easy of execution. The principal difficulty to be got over is that of making the final incision through the prostate gland exactly to correspond with the curved direction of the first and second incisions through the skin, muscles, and fasciæ. When this is attempted with the scalpel or lithotome, two separate incisions must be made, one along the left side, the other at the right, the staff being inclined alternately each way so as to serve as a guide to the cutting instrument. In making the second incision the operator is very liable to direct it so as to cut a narrow angular flap in the prostate rather than the broad segment which is intended. To avoid these inconveniences, M. Dupuytren performs the section of the prostate with a double-bladed lithotome caché, so constructed that the blades by being curved in the direction of their planes shall, when pressed out from their sheath, cut obliquely outwards and downwards.

Dupuytren's operation (la taille médiane périnéale; sectio bilateralis).—The method of proceeding is as follows:—The patient is placed in the usual position, and a grooved staff is introduced into the bladder, which is entrusted to an assistant, who at the same time holds up the scrotum. The operator renders the skin of the perinæum a little tense by pressing it down with the fingers of his left hand placed at the anus, and then with a scalpel a curved incision is made through the tegument, commencing at the right side between the ischium and the anus, and terminating at the corresponding point at the opposite side. The concavity of the curve thus described looks downwards to the anus, and its convexity upwards to the bulb of the urethra, its centre being about five or six lines above the former point. A second incision is made in the same direction and to the same extent through the muscles and the deep fascia. In the next place the operator, with the index finger of his left hand, feels

for the curve of the staff in the urethra at the top of the wound, and there he enters the point of his scalpel. When secure of its position, he runs it in the groove from before backwards, for four or five lines, so as to divide the membranous part of the urethra. This being effected, the point of the double lithotome is placed in the groove of the staff, its concavity being turned up towards the pubic arch; then the operator, taking hold of the handle of the staff, draws it down towards him and passes the lithotome back into the bladder. The staff is withdrawn, and the lithotome turned so that its concavity shall look downwards. Its blades are expanded to the required extent, and the instrument drawn steadily outwards, its handle being at the same time a little depressed, so that it is made to cut outwards and downwards. In this way the prostate gland and the neck of the bladder are divided at each side, and a lunated flap, composed of the lower segment of these structures, is formed. This will give sufficient space for the easy extraction of a calculus, unless it be of unusually large size, or the pubic arch be very narrow. This operation is termed "bilateral," not only because the first incision extends into both sides of the perinæal space, but because both sides of the prostate gland are incised by a double-cutting instrument. In this method of proceeding no risk is incurred of wounding the rectum, and the pudic arteries can only be endangered by making the blades of the lithotome spread out to an extent altogether unnecessary.

The *recto-vesical* operation consists in laying open the bladder in the middle line by cutting from below upwards, beginning in the rectum, and so laying the two cavities into one. I mention it merely because it has been practised by M. Sanson in Paris, and M. Vacca Berlingieri in Pisa. It is not sanctioned by any surgeon in this country, nor is it likely to meet with much approval, as it contravenes one of the first principles of surgery, which prescribes that we are not to wound any important parts which can be avoided.

Lithotomy—its difficulties.—This brief historical notice shows us at one view the various routes that have been chosen at different times to reach the bladder through the perinæum: narrow as the space is, it is surrounded with parts on every side that must be avoided. The rectum lies beneath the line of incision, the pudic artery outside it, and the artery of the bulb above it; and again, whilst passing into the bladder, the incision must be so made as to avoid the ejaculatory ducts. Notwithstanding these difficulties, if the parts were unvarying in their relations, the execution of the operation might be made comparatively easy, by performing it a number of times on the dead sub-

ject. But, in addition to the complexity of the lines of incision, and their close contiguity to parts which should not by any means be wounded, there is another source of difficulty which is seldom attended to, and which arises from the fact, that the depth, as well as the dimensions of the perinæal space, vary in different individuals far more than could at first sight be supposed. It is usually said, that the space is included within three lines, each three inches long, so that it is an equilateral triangle; and, as the operation is now performed, the left lateral half of that triangle is alone interested. The extent of the space here indicated is more than the average. Professor Dupuytren measured the distance between the tuberosities of the ischia in twenty-three subjects, taken indiscriminately from the dissecting rooms, and found that in some it was not more than two inches, but in others was as much as three and a half. Again, by placing one branch of a pelvimeter at the surface of the perinæum, and the other at the neck of the bladder, it was ascertained that the distance between them, or, in other words, the depth of the perinæum, was in some instances only an inch and some lines, in others four inches and a quarter.

CHAPTER VI.

OF THE ARTERIES.

612. We here enter on the description of the arteries, having already given their general anatomy, and an outline of the vascular system, p. 73, et seq.

AORTA.

613. The aorta (*αορτη*, quasi *αηρτηρη*, scil. *μεγαλη*, the great artery, in contradistinction to *τραχεια αρτηρια*, the rough artery, or air-tube,) is the main trunk of a series of tubes which convey red blood to the different organs of the body. It commences at the left ventricle of the heart, with which it is connected by the lining membrane on the inside, by the serous pericardium externally, and by a cellulo-fibrous ring, which extends from the indented border of its middle coat (p. 80,) to the margin of the ventricle. From the ventricle the vessel

Fig. 120.

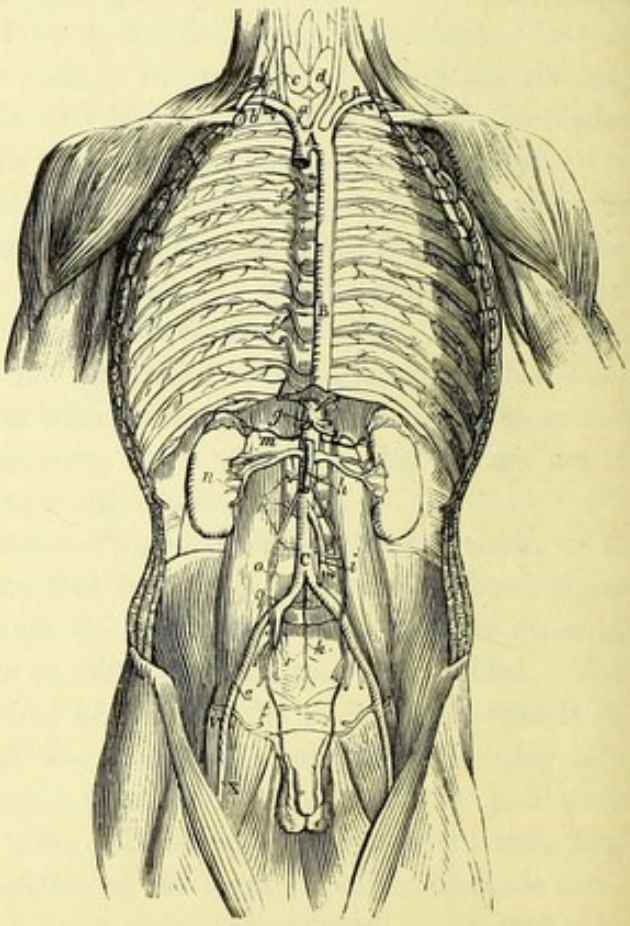

extends as far as the fourth lumbar vertebra, where it divides into the common iliac arteries. But though it remains an undivided trunk to the point just indicated, different parts of it have received different names, from their position and relations, as well as to facilitate their description; the short curved part, A, which reaches from the ventricle to the side of the third dorsal vertebra is the "arch" of the aorta. The straight part, B, which extends from the vertebra just named to the diaphragm, is called the thoracic aorta; and the remainder, C, down to its bifurcation, is spoken of as the abdominal aorta.

Dissection. — In order to expose this vessel within the thorax, after having dissected the pectoral muscles, cut through the intercostal spaces and ribs, from the first to the ninth, beginning at the origin of the anterior scalenus, close to its inner border, and ending at the middle of the ninth costal cartilage. Pass a scalpel inwards at the bottom of the thorax, and detach its lower margin, consisting of the costal cartilages and the ensiform cartilage, from the diaphragm. These, together with the sternum, form a sort of operculum, which covers in the thorax. When thus detached below and at the sides, draw them upwards, and saw across the first bone of the sternum immediately below the clavicular articulations, by which means the relative position of the vessels at the upper aperture of the thorax will be more accurately exhibited. Perhaps it may not be out of place to suggest, that, previously to removing the sternum and cartilages as here directed, a satisfactory view can be obtained of the internal mammary artery, by cautiously dissecting away the intercostal muscles along the margin of the sternum, and continuing their removal outwards as far as the costal ends of the cartilages. When sawing across the sternum, near its upper border, care must be taken not to wound the brachio-cephalic veins, which lie close behind it. Some persons remove the sternum altogether, by dividing the clavicular articulations.

Examine the pericardium and pleura attentively, then open the pericardium by two incisions, one from above downwards, the other transverse, and evert the flaps. If these in any way incommode you, cut them away, leaving merely a narrow band above, where the membrane becomes adherent to the vessels. Having by these means fully exposed the heart and its investment, observe its position, relations, and direction (see Heart, dissection of); note the arrangement of the large vessels at its base; then, higher up, see how the veins

converge and form the superior cava; observe the relative position of these vessels with regard to the large arteries which ascend to the head and upper extremities. The phrenic and the vagus nerves can also be traced without difficulty.

In order to see the descending or straight part of the artery, turn the left lung over to the right side, and fix it in that position with hooks and a chain; you will see the vessel lying along the spine, and, as it descends, gradually getting in front of the column. Dissect off the pleura, which is reflected upon it, and you at once expose it.

614. The aorta, the primary systemic artery, arises from the upper part or base of the left ventricle of the heart, where its margin is guarded by three semi-lunar valves, which prevent the reflux of blood projected into the vessel. At its origin it is not exactly cylindrical, for there are three small bulgings externally, corresponding with as many dilatations within, each lying external to one of the valves. These dilatations are named *sinus minores*, or sinus Morgagni. If a probe be passed directly backwards from the upper border of the fourth costal cartilage of the left side, at its junction with the sternum, it will impinge on the junction of the vessel with the ventricle; and if pushed further back, it will touch the fourth dorsal vertebra a little to the left of the median line. The aorta at its origin lies behind the pulmonary artery which overlays it, and before the left auriculo-ventricular opening. Its course is at first upward, forwards, and to the right side, until it gets on a level with the second costal cartilage; it then alters its direction, turning from right to left, becoming transverse, at the same time inclining backwards, being on a level with the second dorsal vertebra: but it soon makes another turn, and changes its direction so as to incline inwards and downwards upon the left side of the third dorsal vertebra, where the curved part of the artery (*arcus aortæ*) ceases.

Some persons restrict the term "arch" to the transverse portion (crosse de l'aorte). We, however, here apply it to the whole space included between the base of the ventricle and the lower border of the third dorsal vertebra; and between these points it will be observed that the artery describes a curve, whose convexity is directed upwards, forwards, and to the right side, the concavity of course in the opposite way.

The terms "ascending" and "descending" aorta are not in strictness applicable to the conformation of the vessel in the human subject; they were adopted by some of the older anatomists, whose dissections were for the most part confined to inferior animals, in many of which the vessel, instead of forming a curve, divides into two trunks, one descending to supply the posterior parts, the other ascending to the head and anterior extremities. But in order to facilitate the description of the *arch*, and to mark more precisely its relations, it is convenient to consider it as divisible into three portions, an ascending, transverse, and descending.

The ascending part of the arch has before it, for a short way, the pulmonary artery, the right auricula also overlapping it; but as it ascends and comes forward, it approaches the sternum, from which it is separated by the pericardium and the cellular tissue lodged in the mediastinum. Posteriorly, it is supported by the right branch of the pulmonary artery; on its right, lies the descending vena cava, on the left—the pulmonary artery. This part, from two inches to two and a quarter in length, is enclosed within the pericardium. The transverse part lies behind the sternum (at the junction of its first and second pieces), from which it is separated, at least in part, by the left brachio-cephalic vein, which lies along its upper border, and overlaps it a little,—before the trachea, and above the bifurcation of the pulmonary artery, to which its concavity is connected by the ductus arteriosus: finally, at its left extremity, where it turns downwards, the vagus nerve crosses it in front, and the recurrent coils upwards and inwards behind it. The descending part of the arch, as it sinks backwards, recedes from view, having before it the left bronchus and left pulmonary artery, behind it the body of the third dorsal vertebra, to the right the œsophagus and thoracic duct, and to the left the pleura, which is reflected upon it. If the pulmonary artery be cut across at its root and drawn upwards, it will be seen that the curve of the aorta in a manner encloses the right pulmonary artery, the left bronchus, the left auricula, the ductus arteriosus, and the recurrent nerve.

Aorta—its branches.—The branches given off by the arch of the aorta are five in number, viz. two to the heart, and three which supply the upper extremities, with the head and neck.

The branches which go to the heart are called coronary (à *corona*), from the manner in which they encircle the base of the ventricles; and cardiac (κηρ, καρδια, the heart), from their destination. They are named, the one right, the other left, from their direction. The other branches are, the brachio-cephalic or arteria innominata, which is distributed to the right upper extremity, and the corresponding side of the head and neck, the left carotid, and the left subclavian.

CORONARY ARTERIES.

615. *Arteria coronaria dextra*, about the size of a crow's quill, is seen just close to the right border of the pulmonary artery, being lodged in the groove which separates the right ventricle from the corresponding auricle. It arises from the aorta just above the free margin of the right semilunar valve, and runs obliquely outwards and downwards to the right side, lodged in the groove just mentioned. Having passed the right border of the heart, it continues its course in the same way at the posterior aspect of that organ, until it reaches the line indicating the position of the septum ventriculorum, where it divides into two branches: one, superior and transverse, runs a little way into the groove which separates the left ventricle from the contiguous auricle, and anastomoses with the left coronary artery; the other takes a different course, assumes the longitudinal direction, running from above downwards along the posterior border of the septum, giving ramusculi on each side to the ventricles, and terminating towards the apex of the heart by anastomosing with the descending anterior branch of the left coronary artery.

In its course, this vessel gives several small off-sets, some of which pass upwards into the fleshy substance of the auricle, others downwards upon the ventricle, one or two also, near its origin, to the pulmonary artery. Opposite the right or thin margin of the ventricle, a considerable branch runs downwards towards the apex, sending at the same time ramifications to the anterior and posterior surfaces of the ventricle. Finally, the terminal part of the artery, as it lies in the groove between the left auricle and ventricle, gives small branches to both.

616. *a. Coronaria sinistra* is smaller than the preceding, but arises from the aorta higher up by a line or two. It is seen at

the left side of the pulmonary artery, between it and the left auricula. At first its direction is downwards and a little forwards, as if to reach the line which marks the septum ventriculorum anteriorly, where it divides into two branches, of which one, superior, very small, continues to pursue the transverse direction, inclining outwards and to the left side between the left ventricle and auricle, and, soon after arriving at the posterior aspect of the heart, anastomoses with the transverse terminal branch of the right coronary artery; the other, much larger, runs from above downwards along the line of the septum, anteriorly, towards the apex, and anastomoses with the long descending branch of the right coronary artery.

This artery, near its origin, gives off some small branches to the pulmonary artery, the aorta, and auricula. As it passes along the groove, several others are distributed to the left ventricle and auricle, and its long descending branch freely supplies both ventricles as it lies between them, and sends some branches also deeply into the septum.

BRACHIO-CEPHALIC ARTERY.

617. *a. Brachio-cephalica* (innominata) is a short trunk, fig. 120, *a*, which divides so as to supply the right upper extremity and the corresponding side of the head and neck; hence its name. There is no sufficient reason for continuing to call it the "unnamed" artery, when, so far from being unnameable, it has received a very appropriate name. Its diameter is greater than that of either of the vessels which arise from the arch of the aorta; its origin is at the junction of the ascending with the transverse parts of the arch, from which point it passes obliquely upwards, and to the right side, until it reaches the sterno-clavicular articulation, where it divides into the right subclavian, *b*, and right carotid artery, *c*. Its length is generally from an inch to an inch and a quarter; but in some cases it is a little longer, and ascends higher into the neck; its point of bifurcation may be transfixed by a probe passed backwards through the cellular interval between the sternal and clavicular portions of the sterno-mastoid muscle. This artery lies behind the first bone of the sternum, from which it is separated above by the sterno-hyoid and sterno-thyroid muscles, and below by the left brachio-cephalic vein, which crosses it. It rests on the

trachea, over which it passes obliquely; to its right side is the right brachio-cephalic vein, and to the left the thymus gland, or the cellular tissue, into which it degenerates. No branches arise from this vessel in their ordinary or regular distribution; whenever any are seen to issue from it, they are found to be some which ordinarily come from other sources, for instance, the left carotid, or the thymic or inferior thyroid.

618. The left carotid artery, *d*, arises from the arch of the aorta close by the brachio-cephalic; as it ascends to gain the top of the thorax, it inclines outwards, resting on the trachea, and covered by the first bone of the sternum (the left brachio-cephalic vein, with the sterno-hyoid and thyroid muscles interposing); opposite the left sterno-clavicular articulation it appears in the neck. The left subclavian artery, *e*, is the third vessel which regularly comes from the aortic arch; it ascends almost vertically from the most depending part of the arch, and therefore lies very deep, being covered by the left lung and pleura until it gets on a level with the first rib, where it inclines outwards. These vessels are for the present merely alluded to; their detailed description shall be resumed after we have noticed the varieties and anomalies of the arch and its branches, and pointed out the general law of organisation by which their occurrence admits of explanation.

619. *Varieties.*—The direction and relations of the aorta, and the arrangement of its primary branches, are usually found in the human subject to be conformable with what has been here stated. It may therefore be taken as the type or normal condition of these vessels, so that any other which may occur in particular instances is considered a variety. We are not, however, to regard such deviations as total departures from the laws of organisation; many of them are obviously but repetitions of the ordinary arrangement in some of the lower animals,* whilst others are referable to a union of parts generally separate, or a division of such as are usually joined. The modes of internal organisation in the different classes of animals are exceedingly various,—so are the vital phenomena which they manifest.

* See Otto's Compendium of Pathological Anatomy, translated by J. F. South; Meckel, Manuel d'Anatomie générale et descriptive, par Jourdan, tom. ii. p. 318, et seq.; Tiedemann, Tab. Arteriarum; or the same work reduced to the quarto size, and published in fasciculi by Dr. Knox; An Account of the Varieties in the Arterial System of the Human Body, by P. H. Green, M. B.

When investigating these phenomena, we must not confine our attention exclusively to any particular class of beings, or to any one mode of existence; we must review the different modifications which they present in the animal series; for the human body itself is but a particular instance of living form and vital manifestation.

In many of the mammalia the aorta has the same general conformation as in man. It is so in monkeys and carnivora; but in the ruminantia and solid-hoofed animals, and in some pachydermata, as the hog, peccari, and rhinoceros, it divides,* near its origin, into two trunks, one of which passes forwards, and gives off the carotids and subclavians, whilst the other turns backwards, and so becomes the descending aorta. On this has been founded the division of the vessel adopted by the earlier anatomists into ascending and descending, for their dissections were confined to inferior animals. The aorta of the human subject presented a conformation precisely similar to this in a case cited by Meckel. The vessel did not form an arch; for, soon after its origin, it divided into two trunks, of which one ascended and gave off the subclavian and carotid arteries, whilst the other inclined backwards, and assumed the position and relations of the descending aorta.

In birds, the aorta, near its origin, divides into three large vessels, of which one, lying to the right side, inclines backwards, and becomes the posterior or descending aorta, and is placed to the right of the œsophagus; the two other arteries are the subclavians; and from them arise the carotids. A case is cited by Meckel from Fiorati, which conformed to this rule—the aorta turned suddenly downwards, and ran along the right side of the spinal column to the bottom of the thorax. Mr. Abernethy has related a case nearly analogous to this; the aorta curved back over the right bronchus, but as it descended it assumed its ordinary position with regard to the spine, having inclined to the left, behind the œsophagus and left bronchus.

These two varying degrees of inclination to the right side may be considered as so many transition links between the natural conformation of the vessel and that extreme change in its position which is termed the lateral inversion, and which can occur only in cases of inversion or transposition of all the viscera. In a subject some time since brought to the College, and which is now preserved in the museum, the axis and apex of the heart were found inclined to the right side, the three-lobed lung lay to the left, so did the large lobe of

* See Tiedemann's plate, or Fasciculus II. fig. 3, of Knox's edition of that work.

the liver with the gall-bladder. The spleen, with the large extremity of the stomach, was lodged in the right hypochondrium, the valvula coli lay in the left iliac fossa, and the sigmoid flexure in the right; the aorta ran upon the right side of the spine, the cava being to the left. This individual was well known during his life. A case, in every particular similar to this, was found rather accidentally in the dissecting room of the College of Surgeons in Dublin, by the late Mr. Shekleton, by whom it was prepared, and put up in the museum of the college; and another, beautifully prepared, is in the possession of Sir Astley Cooper.

In the tortoise, the systemic artery, after arising from the heart as a single trunk, soon divides into two large vessels, which at first ascend diverging, and then turn inwards and backwards so as to converge and form the descending aorta.* In the body of a robust man, Malacarne found the aorta similarly disposed. At its origin were five semi-lunar valves; the division took place soon after; and when the two vessels united (after having left an oval interval between them) they formed the thoracic aorta. Tiedemann has copied Malacarne's drawing. There is another nearly similar case reported by Hummel; the aorta divided in the same way, and united again, so as to form a ring or ellipsis, which included the trachea and œsophagus.

The arteries which arise from the aorta occasionally vary from the normal standard, Meckel says about once in eight cases. We have not, however, as yet collected sufficient data to warrant any rigorous inference on this point.

The coronary arteries have been observed in a few instances to commence by a common trunk, from which they diverged and proceeded to their usual destinations. Camper found the vessels so disposed in an elephant, and Cuvier considered it to be their normal state in that animal. We may take this as the result of a particular dissection, and refrain from saying anything positive upon it, until some other examinations shall have been recorded. The existence of three coronary arteries is not a very rare occurrence, the third being small, and arising close by one of the others. Meckel, in one instance, observed four, the supernumerary vessels appearing like early divisions of the regular ones.

The primary trunks which issue from the transverse part of the arch may deviate from the normal standard in their arrangement and conformation, even though there be no more than three, or they may be more or fewer in number; and many of these deviations

* Tiedemann, plate iv. fig. 6, 7.

will be found to correspond with fixed modes of distribution in inferior animals. So far as observation has as yet gone in these inquiries, the number has been found more frequently increased than diminished.

620. *Varieties with three primary trunks.*—In the elephant three trunks arise from the aorta, the subclavian arteries being placed to the right and left, whilst between them stands a single vessel which soon bifurcates into the two carotids. A corresponding conformation occurs, but very rarely, in the human subject. Tiedemann delineates one,* taken from the body of a person over twenty years of age.

The brachio-cephalic artery has been seen to arise, in some instances, from the left side of the arch. But the aorta, in the case delineated by Tiedemann, appears to have presented that deviation above noticed, in which it inclined suddenly backwards and to the right side, so that the position of its primary trunks became in a manner transposed, the innominata being turned towards the left side.

The brachio-cephalic, after giving off both carotids close to its origin, has been seen to continue its course as the right subclavian artery, whilst the left vertebral occupied the second place, and the left subclavian the third, as they arose from the arch.

The right subclavian artery has arisen from the most depending part of the arch, and thence passed across to the right side, behind the trachea and œsophagus, so as to assume its usual position. I met with an instance of this variety some years ago, but, if I recollect rightly, the vessel lay between the trachea and œsophagus. Mr. Harrison† cites "the case of a woman in whose throat a small bone had stopped, and, having perforated the œsophagus, wounded the vessel, which took the course here indicated." When the left carotid ‡ is a branch of the brachio-cephalic, it necessarily lies across the trachea in the neck. If in such a case tracheotomy were to be performed, and the operator were not aware of the possibility, however remote it may be, of such a variety existing, the most destructive consequences might follow.

Varieties with four primary vessels. — Of this there are various modes. The two subclavian and carotid arteries may stand in a row, issuing from the top of the arch, the two former being at the sides, and the latter in the middle. But in one case the subclavians stood

* Plate iii. fig. 2. † Surgical Anatomy of the Arteries, vol. i. p. 13.

‡ Plate ii. fig. 2.

KING'S COLLEGE HOSPITAL LIBRARY Medical School

second and fourth, the carotids first and third. Or, the right subclavian may arise from the front of the arch, near its termination, and then pass across the carotids to the right side. Again, the supernumerary vessel may be one of the vertebral arteries, or the inferior thyroid, which ascends from the arch between the brachio-cephalic and the left carotid, lying on the trachea and therefore exactly in the line of incision in tracheotomy.

Varieties with five primary vessels.—In addition to the carotid and subclavian arteries placed separately, the left vertebral and inferior thyroid may arise also from the arch by a common trunk, or one of the last-named vessels separately. The three primary vessels may exist in their usual position, both vertebrals being added as branches of the arch; or the additional vessels may be the internal mammary of the right side with the inferior thyroid.

Tiedemann delineates * the variety with six primary vessels. Both carotids and subclavians come off separately, the vertebrals being interposed at each side between the subclavian and carotid.

Varieties with two primary trunks.—In the chiroptera two short vessels (innominatæ) arise from the arch, and bifurcate into the subclavian and carotid arteries of each side. This, according to Cuvier, is the case in the porpoise. Tiedemann observes that it generally occurs in animals with short necks. A similar conformation has been observed twice by Malacarne in the human subject. Tiedemann refers † to another case which he saw in the museum in Berlin.

The two trunks may be ‡ the brachio-cephalic, placed as usual (but giving off the left carotid), and the left subclavian. Meckel states that he saw this distribution twelve times. It is the normal conformation in very many animals—in several of the quadrumana, of the glires, in the lion, hyæna, bear.

COMMON CAROTID ARTERY.

621. *A. Carotis communis vel primitiva.*—The two carotids, whilst in the neck, are, as nearly as may be, similar in their course, size, and relations; but they differ in their length and mode of origin, as shown in fig. 120. The vessel on the right side commences opposite the sterno-clavicular articulation, being the point at which the brachio-cephalic divides into the carotid and subclavian arteries, whilst that of the left arises from

* Plate iv. fig. v. op. cit. † Plate ii. fig. 2. ‡ Plate ii. fig. 5.

the arch of the aorta, and is necessarily longer, and at first more deeply seated. That portion of the left carotid which intervenes between the arch of the aorta and the sterno-clavicular articulation, is covered by the upper part of the sternum, by the muscles arising from its posterior aspect, and is crossed by the brachio-cephalic vein of the left side; posteriorly, it corresponds to the trachea, to the œsophagus (which, in this situation deviates to the left side), and the thoracic duct. The description of the cervical portion of one artery will suffice for both, fig. 121.

Fig. 121.

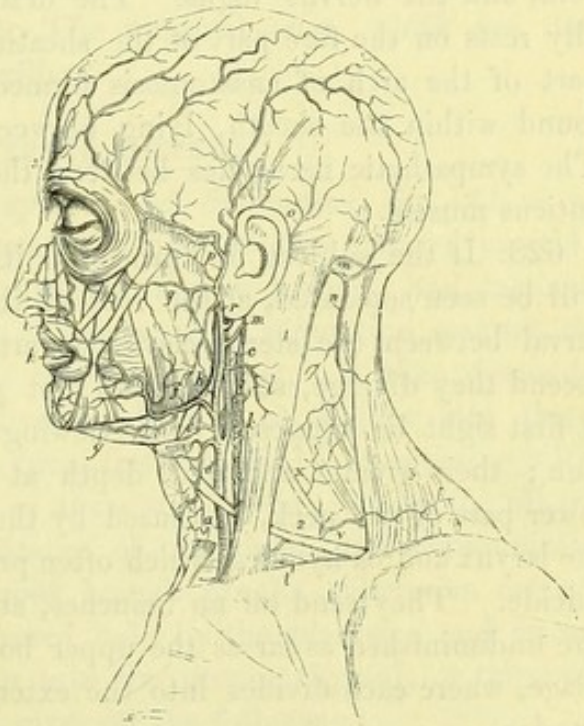

622. The common carotid artery, *a*, ascends obliquely upwards and outwards, its direction coinciding with that of a line drawn from the sterno-clavicular articulation to midway between the angle of the jaw and the mastoid process. Opposite the upper border of the thyroid cartilage, the vessel divides into two great branches, of which one, *b*, is distributed by its ramifications to the cranium and face, the other, *c*, to the brain and the eye; hence, from their destination, they are named the external and internal carotid arteries. The common carotid artery is covered below by the skin and fascia, also by the sterno-mastoid, 1, sterno-hyoid, and sterno-thyroid muscles, and crossed by the omo-hyoideus, 2, opposite the upper rings of the trachea, or the lower border of the cricoid cartilage. But from this point to its bifurcation the vessel is covered only by the skin, platysma, and fascia, owing to the fact that the sterno-mastoid and omo-hyoideus, by diverging to their respective destinations, cease to cover it, and

so leave it comparatively superficial. It has behind it the vertebral column, from which, however, it is separated by the longus colli and rectus anticus muscles, and inferiorly by the recurrent laryngeal nerve and inferior thyroid artery. The inner side of the vessel is in close relation below with the trachea, higher up with the thyroid gland (which often overlaps it), the larynx, and pharynx; along its external side are placed the internal jugular vein and the vagus nerve, the latter being behind and between both vessels. The artery will be found enclosed in a sheath, composed of condensed cellular membrane, which forms an investment common to it, the internal jugular vein, and the nervus vagus. The descendens noni nerve usually rests on the fore part of the sheath; but in some instances part of the arch of anastomosis formed by this nerve will be found within the sheath, lying between the artery and vein. The sympathetic nerve lies between the sheath and the rectus anticus muscle.

623. If the subject be turned on its back, the two carotids will be seen separated, at the root of the neck, only by the interval between the sterno-clavicular articulations, but as they ascend they diverge, still they do not pass backwards, as may at first sight be supposed from viewing the parts in this position; their greater apparent depth at the upper than at the lower part of the neck, is caused by the projection forwards of the larynx and os hyoides, which often protect them in attempted suicide. They send off no branches, and therefore retain their size undiminished as far as the upper border of the thyroid cartilage, where each divides into the external and internal carotid arteries.

EXTERNAL CAROTID ARTERY.

624. *a. Carotis externa*, fig. 121, *b*, smaller than the other in infancy, but of equal size in adult age, extends from the point of division above indicated, to the neck of the condyle of the jaw, or a little lower, where it divides into the temporal, *p*, and internal maxillary arteries, *r*. At first it lies before and to the inner side of the internal carotid, but soon crosses it, inclining backwards, after which it curves somewhat as it ascends to its point of division. For a quarter of an inch after its origin it is covered only by the skin, platysma, and fascia;

it is then crossed by the stylo-hyoid and digastric muscles, also by the lingual nerve, and finally becomes embedded in the parotid gland. The stylo-glossus and stylo-pharyngeus muscles, with the glosso-pharyngeal nerve, run between it and the internal carotid artery, and support it, at least partially, until it reaches the gland, in the substance of which the artery is crossed by the portio dura, which is placed superficially to it. It gives off eight branches, including the pair into which it ultimately divides, which may be arranged into sets as follows: — 1. The anterior branches, consisting of the superior thyroid, the lingual, and the facial. 2. The posterior set, viz. the occipital and posterior auris. 3. The internal, being the pharyngea ascendens. 4. The terminal ones, which are the temporal and internal maxillary.

THYROID ARTERY.

625. *a. Thyroidea superior, vel descendens*, fig. 121, *d*, is given off close to the commencement of the external carotid, immediately below the cornu of the os hyoides, and inclines downwards and inwards, somewhat in a serpentine manner, to the upper border of the thyroid cartilage. It then descends a little to reach the thyroid gland, and divides into three branches, one of which runs transversely to anastomose with the corresponding vessel of the opposite side, whilst the others ramify freely in the substance of the gland, and communicate with the ascending thyroid branch of the subclavian artery. The vessel is at first covered only by the platysma and fascia. Previously to its division into the proper thyroid, or terminal branches here noticed, it gives off the following:

Ramus hyoideus—a small branch, which passes just below or upon the os hyoides, and forms an arch with its fellow of the opposite side, sending at the same time ramusculi to the adjacent muscles and integuments.

r. Descendens superficialis passes down, and divides into several ramusculi, which supply the thyroid muscles, the sterno-mastoid, the platysma, and integument.

r. Laryngealis inclines inwards with the superior laryngeal nerve, and in most instances pierces the thyro-hyoid membrane, but in some it passes through a foramen in the thyroid cartilage. In either case, on reaching the inside of the larynx, it divides into ramusculi, which

take different directions for the supply of the small muscles and lining membrane of the organ.

LINGUAL ARTERY.

626. *a. Lingualis*, fig. 121, *e*, inclines forwards and inwards to the upper margin of the cornu of the os hyoides, where it passes between the hyo-glossus and the middle constrictor of the pharynx. So far the direction of the vessel is horizontal, but it soon ascends almost perpendicularly, being covered by the digastric, mylo-hyoid, and genio-hyoid muscles; and finally changes its course, to run directly forwards beneath the tongue, where it assumes the name of ranine artery. Its branches are the following:

Ramus hyoideus takes the direction of the os hyoides, running on its upper border, and forming an arch by anastomosis with the corresponding vessel of the opposite side; it gives ramusculi to the contiguous muscles and the tegument.

r. Dorsales linguæ.—One or two branches arise where the artery is deeply seated, and incline backwards and upwards, covered by the hyo-glossus muscle. These are called the "dorsal" branches, from their destination, for they supply the substance and upper part of the tongue, ramifying as far back as its root. At the anterior border of the hyo-glossus the lingual artery may be said to divide into the ranine and sublingual arteries.

r. Raninus, in direction, is its proper continuation; it proceeds forwards beneath the lingualis muscle, and close to the outside of the genio-hyo-glossus; and, finally, near the tip of the tongue, forms an arch, by anastomosing with the corresponding artery of the opposite side. The ranine arteries of opposite sides are placed at each side of the frænum linguæ, under cover only of the mucous membrane.

r. Sublingualis passes between the mylo-hyoid muscle and the sublingual gland, giving branches to both; one also reaches the chin, where it ramifies in small ramusculi. In its course it supplies the sublingual gland, as well as the muscles passing from the chin and jaw to the tongue: its size varies in different instances, so does its origin, for it often comes from the submental branch of the facial.

FACIAL ARTERY.

627. *a. Facialis*, fig. 121, *f*, (labialis; maxillaris externa)

extends from the carotid artery, along the side of the face, towards the root of the nose. It is usually the largest of the anterior branches, and arises higher up than the lingual. It ascends in rather a winding course, so as to get deeply under cover of the jaw-bone, and then inclines down, running in a groove in the upper surface of the submaxillary gland, as far as the margin of the jaw, over which it turns, to reach the side of the face. In its ascent, the artery is concealed by the platysma, the tendon of the digastricus, and the stylo-hyoideus; but where it rests on the external surface of the jaw-bone, it is covered only by the integument and platysma, lying close to the anterior border of the masseter, where its pulsation can readily be felt. The artery thence ascends, inclining towards the angle of the mouth; it rests on the buccinator muscle, and is crossed by the zygomatici. And, finally, becoming much diminished in size by having given off several branches, it ascends under the name of *ramus angularis* by the side of the nose, covered by the common elevator muscle, and terminates at the angle of the eye by two or three very small ramusculi, which anastomose with the nasal branches of the ophthalmic artery.

Its branches are numerous, and may conveniently be divided into two sets, the first consisting of those given off before the vessel reaches the jaw, being usually three or four, the second of those distributed to the face, varying from five to six, as follows:

Ramus palatinus inferior ascends between the stylo-glossus and stylo-pharyngeus, reaching the pharynx close by the border of the internal pterygoid muscle. After having given small twigs to the tonsil, the styloid muscles, and Eustachian tube, it divides near the side of the levator palati into two ramusculi, of which one follows the course of the circumflexus palati muscle, and ramifies in the soft palate and its glands, whilst the other passes to the tonsil, supplying it, and anastomosing with the following branch.

r. Tonsillaris ascends by the stylo-glossus to the side of the pharynx, and terminates by dividing into several ramusculi, which are distributed to the tonsil and side of the tongue.

r. Glandulares: a fasciculus of small branches passes into the substance of the submaxillary gland, whilst the artery is in contact with it; some of these are prolonged to the side of the tongue.

r. Submentalis, g, departs from the artery near its turn round the jaw, and runs forwards between the mylo-hyoideus and digastricus, close to the margin of the bone. At the symphysis of the chin it divides (after having previously given offsets to the submaxillary gland and muscles) into two branches, one of which, more superficial than the other, passes between the depressor labii inferioris, and the skin supplying both, whilst the other lies between this muscle and the bone, sending twigs to the substance of the lip, and communicating with the following branch. The submental artery will sometimes be found of considerable size, and then it gives off the sublingual.

r. Labialis inferior, vel superficialis, inclines inwards, sending ramusculi to the muscles of the lower lip, and anastomosing with the r. coronarius inferior, with the submental, and the termination of the dental artery.

r. Coronarius labii inferioris, h, arises near the angle of the mouth, and takes a transverse and tortuous course upon the mucous membrane covered by the muscles of the lip, at the middle of which it inosculates with the corresponding artery of the opposite side. Some of its ramusculi pass upwards into the orbicular and depressor muscles, others downwards to the chin, communicating with the branches that ramify there.

r. Coronarius labii superioris, i, is larger and more tortuous than the preceding, above which it arises, taking a similar course as it proceeds inwards, across the upper lip. It passes under cover of the zygomaticus and orbicularis, and forms an arch by inosculation with the corresponding artery of the opposite side. In addition to several small twigs to the muscles of the lip, it gives two or three to the nose. One of these (*r. nasalis septi*) proceeds along the septum to the extremity of the nose; the other (*r. nasalis lateralis*) ramifies on the side of the nose, and forms a minute net-work on its ala, to which the nasal branch of the ophthalmic artery also contributes.

The facial artery is the chief medium of communication between the superficial and deep branches of the external carotid, by means of its anastomosis with the infra-orbital, dental, and nasal branches. Also between the external and internal carotids, by its anastomosis with the ophthalmic artery.

ASCENDING PHARYNGEAL ARTERY.

628. *a. Pharyngea ascendens,* fig. 121, *k,* lies deeply and

concealed from view until some of the branches of the carotid artery and the stylo-pharyngeus muscle are drawn aside. It arises near the lingual artery, or even from the bifurcation of the common carotid, and is the smallest of the branches of the external carotid. It rests on the rectus capitis anticus, close to the surface of the pharynx, and is directed up as if towards the foramen lacerum posterius. Its branches are necessarily small — they are mere ramusculi. We may, however, from a consideration of their destination, divide them into three sets.

Pharyngeal branches. — These pass inwards to the pharynx. One or two small and variable branches ramify in the middle and inferior constrictors. Higher up than these is a larger and more regular branch, which runs upon the upper constrictor, and sends delicate ramifications to the Eustachian tube, the soft palate, and the tonsil.

The external branches consist of some small and irregular twigs, which are given to the first cervical ganglion, to some of the cerebral nerves as they issue from the skull, and to the conglobate glands of the neck.

Meningeal branches. — The terminating branches are those which pass through the holes at the base of the skull; one or two of them accompany the internal jugular vein through the foramen lacerum posterius, and ramify in the dura mater. Another passes through the foramen lacerum medium basis cranii, and is similarly disposed of.

OCCIPITAL ARTERY.

629. *a. Occipitalis*, fig. 121, *m*, *m*, runs a long and tortuous course deeply at the upper part of the neck and base of the skull, and finally arches up towards the vertex, ramifying beneath the pericranium. This vessel passes backwards, from the external carotid, opposite either to the lingual or facial artery, and takes the direction of the posterior belly of the digastricus, to reach the interval between the atlas and mastoid process, where it runs in a groove behind the latter. In this course it crosses the internal carotid artery, the vagus nerve, and jugular vein; the lingual nerve will be observed to hook round it; it is covered in the first place by the sterno-mastoid muscle; then it passes under the trachelo-mastoid, the splenius, and frequently the complexus, and is separated from the occipital bone by the fibres of the obliquus and rectus superior. The artery

then changes its direction, and runs upwards, piercing the cranial attachment of the splenius and trapezius, and mounts beneath the integument, freely distributing branches. In its course the following branches are given off:

r. Musculares.—Small twigs to the digastricus and stylo-hyoideus, and some of a larger size to the sterno-mastoideus.

r. Auricularis. — An auricular branch to the back part of the concha of the ear, and two or three to the splenius and trachelo-mastoid.

Ramus princeps cervicis, n, is of variable size, being in some cases a small branch, and sometimes nearly as large as the continuation of the artery itself. When this is the case, it descends beneath the complexus, towards the lower part of the neck, and anastomoses freely with the r. cervicalis profundus of the subclavian artery. Some branches of this vessel pass outwards to the transverse processes of the vertebræ, communicating with the r. cervicalis ascendens and the external ramifications of the vertebral artery.

r. Meningeus runs up with the internal jugular vein, enters the skull through the foramen lacerum posterius, and ramifies in the dura mater investing the cerebellum.

The *superficial* or cranial branches of the occipital artery pursue rather a tortuous course, and as they proceed forwards on the skull separate into three divisions, which ramify upon it; these communicate with the branches of the corresponding artery of the opposite side, with those of the posterior auris, and with the temporal artery in front. Some of these are given to the fleshy fibres of the occipitalis muscle, others to the skin, and one (*r. mastoideus*) enters the mastoid foramen, and ramifies in the dura mater.

POSTERIOR AURICULAR ARTERY.

630. *a. Auricularis posterior* is a small vessel, which arises sometimes from the occipital artery, but in most instances from the carotid, a little higher up than the latter. It ascends, under cover of the parotid gland, in the direction of the fold or angle formed by the cartilage of the ear with the side of the head, and finally, after having passed above the mastoid portion of the temporal bone, it divides, fig. 121, *o*, into two sets of ramusculi, of which one inclines forwards to anastomose with the ramifications of the temporal artery, the other backwards to

communicate with the occipital. In its course the following branches are given off:

Some small twigs to the parotid gland and digastricus.

r. Stylo-mastoideus enters the foramen of that name, and, on reaching the tympanum, divides into delicate ramusculi, which pass, some to the mastoid cells, others to the labyrinth. One branch will constantly be found, in young subjects, to form, by uniting with a twig that enters the fissura Glasseri, a sort of coronary artery round the osseous ring of the meatus auditorius, from which delicate offsets pass inwards upon the membrana tympani. This sometimes arises from the occipital artery.

One or two branches ramify on the posterior surface of the concha.

With the posterior branches of the carotid, viz. the occipital and posterior auris, a small vessel is frequently enumerated and called *sterno-mastoid* from its destination; it is marked *l*, fig. 121.

Opposite the neck of the condyle of the lower jaw, the external carotid artery divides into two terminating branches, one being superficial, the other deeply seated.

TEMPORAL ARTERY.

631. *a. Temporalis*, fig. 121, *p*, is at first embedded in the substance of the parotid gland, where it lies in the interval between the tube of the ear and the condyle of the lower jaw. It soon turns forwards to reach the cutaneous surface of the zygoma, on which it may be readily compressed, being merely covered by the integument, the prolonged part of the cervical fascia, and the thin tendon of the attrahens aurem muscle. Continuing to ascend, the artery lies beneath the skin, supported by the temporal muscle and its fascia, and divides into two sets of arching branches, which ramify beneath the integument. In its course it gives off:

Some small twigs to the parotid gland.

One or two to the masseter muscle (*masseterici*).

Ramus transversalis faciei, *q*, arises whilst the artery is deeply seated, and inclines upwards and forwards through the substance of the parotid gland, so as to get between its duct and the zygoma, resting on the masseter muscle, and accompanied by one or two transverse branches of the facial nerve. It sometimes gives off some

masseteric branches, and divides into three or four ramusculi, which are distributed to the side of the face, anastomosing with the infra-orbital and facial arteries.

r. Temporalis medius vel profundior dips beneath the temporal fascia, and inclines forwards between it and the muscle of the same name, sending branches into the latter, which communicate with the deep temporal branches, whilst others extend to the external angle of the orbit, where they meet some ramifications of the ramus lachrymalis. Soon after its origin, this vessel usually gives some twigs to the meatus externus of the ear (*r. auriculares anteriores*).

r. Temporalis anterior inclines forwards as it ascends, and ramifies extensively over the forehead, supplying the orbicularis and occipito-frontalis muscles, and communicating with the frontal branches of the ophthalmic artery.

r. Temporalis posterior, vel occipitalis, inclines back on the side of the head, and seems to be the continuation of the original vessel; its branches ramify freely, both upwards to the vertex, where they communicate with those of the corresponding vessel of the opposite side, and backwards, to meet those of the occipital artery.

INTERNAL MAXILLARY ARTERY.

632. *a. Maxillaris interna*, fig. 121, *r*; fig. 122, *a*; is larger than the temporal, and follows a serpentine and complex course from its commencement to its termination, changing its direction several times. On leaving the external carotid it inclines downwards and inwards, so as to get under cover of the ramus of the jaw, and, in the next place, proceeds inwards, between the two pterygoid muscles. Opposite the pterygoid process it ascends perpendicularly, passing between the two heads of the pterygoideus externus, and thus reaches the spheno-maxillary fossa, where it makes its final turn, forwards and inwards, becoming horizontal. Having assumed this direction, the artery, considerably dimi-

Fig. 122.

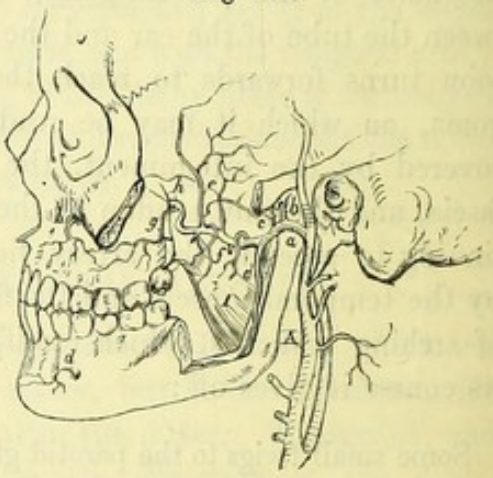

nished in size by having given off many branches, passes directly forwards beneath the orbit lodged in the infra-orbital canal, and finally emerges on the face, where it terminates by several small ramusculi. It will thus be observed, that the artery in its course is successively in relation with the ramus of the jaw, the pterygoid muscles, the spheno-maxillary fossa, and the floor of the orbit. As at each of these stages of its progress it gives off branches, we may divide them into four sets, corresponding with the points above referred to.

633. 1. Branches of the internal maxillary artery given off near the ramus of the jaw:

Ramus tympanicus passes deeply behind the articulation of the lower jaw, and enters the fissura Glasseri, supplying the laxator tympani, and ramifying in the cavity of that name, as well as on its membrane.

r. Meningeus medius, vel magnus, fig. 122, *b*, is by far the largest of the branches given to the dura mater. It passes directly upwards to the foramen spinale in the sphenoid bone, which transmits it to the interior of the skull, where it will be observed to run in a groove marked on the great wing of the sphenoid bone, the squamous part of the temporal, and the inferior angle of the parietal. From the last point it branches out, its ramifications corresponding with the arborescent lines traced on the cranial bones, but intimately connected with the dura mater; so that if the latter be detached from the skull, the artery and its branches will be carried with it.

r. Meningeus parvus, c, sometimes arises from the preceding branch, or from one of those given to the pterygoid muscles. It ascends between the pterygoid plate and the circumflexus palati, and enters the skull through the foramen ovale, to supply the dura mater.

r. Maxillaris inferior, vel dentalis, d, d, enters the dental canal, accompanied by the nerve of the same name, and runs from behind forwards to the foramen mentale, through which it escapes on the face. In its course, the vessel lies beneath the roots of the teeth, and gives off at intervals small twigs, which ascend and enter the minute apertures in their points, and finally ramify in the pulp of each tooth. Near the foramen mentale a branch passes forwards beneath the incisor teeth, which it supplies, and inosculates, at the symphysis of the chin, with a corresponding artery from the opposite side. Its terminal branches on the face anastomose with the coronary and submental arteries.

634. 2. Branches given off whilst the artery is between the pterygoid muscles:

r. Temporales profundi, e, are two or three branches which ascend between the temporal muscle and the cranial bones, along which they ramify, freely supplying that muscle.

r. Pterygoidei: some small and short ramusculi, *f,* pass to the pterygoid muscles, which they supply.

r. Massetericus is a small but regular branch which passes from within outwards through the sigmoid notch in the lower jaw, and is distributed to the masseter muscle.

635. 3. The branches given by the internal maxillary artery whilst opposite the pterygo-maxillary fissure:

r. Buccalis passes obliquely forwards upon the buccinator muscle, to which, and to the other muscles of the cheek, it distributes twigs, and anastomoses with the facial artery.

r. Alveolaris vel dentalis superior, g, turns forwards on the border of the superior maxillary bone, and gives off several small twigs, some of which pierce the bone, and reach the antrum maxillare, where they ramify freely, whilst others penetrate to the alveoli by similar foramina, and enter the roots of the upper teeth to supply their lining membrane.

r. Infra-orbitalis, h, h, turns horizontally forwards from the artery when it has reached the spheno-maxillary fossa, and enters the infra-orbital canal, when it sends some twigs into the orbit to supply the inferior oblique muscle and the lachrymal gland. It emerges on the face after having traversed the canal, and sends twigs upwards and inwards to the lachrymal sac and angle of the orbit, which communicate with the r. nasalis lateralis, whilst others descend, covered by the elevator of the lip, and anastomose with the transversalis faciei and buccal branches.

636. 4. The branches given off in the spheno-maxillary fossa:

r. Palatinus superior vel descendens is one of the three branches into which the artery may be said to divide at the point just indicated. It passes perpendicularly downwards through the posterior palatine canal, and so reaches the arch of the palate, along which it ramifies, supplying the gums and soft palate, and anastomosing with the nasal artery by a branch sent up through the foramen incisivum. At its point of origin a reflected branch passes directly backward to enter the vidian canal with the nerve of the same name.

Hence it is termed the *vidian,* or pterygoid branch. It is distributed to the Eustachian tube and top of the pharynx.

r. Pterygo-palatinus is a very small ramusculus, which passes backwards and upwards to reach the pterygo-palatine foramen, by which it reaches the top of the pharynx, where it freely ramifies, after having given some twigs to the Eustachian tube and sphenoidal cells.

r. Nasalis vel spheno-palatinus enters the foramen of that name, by which it reaches the cavity of the nose at the posterior part of the superior meatus. There, lying between the mucous membrane and the bone, it divides into two or three ramusculi; one of these ramifies on the septum narium, the others on the spongy bones, some twigs being sent into the posterior ethmoidal cells as well as the antrum.

637. The vessels here described as arising from the external carotid, present several varieties in their mode of origin in different instances, and some also as to the relative size of the branches which two or more of them send to the same parts. If the supply from one quarter be greater than usual, that from another will be proportionally diminished, by the operation of a principle of compensation so constantly observable in the distribution of vessels. These arteries are not merely branches issuing from a common trunk, for, if viewed in a general way, it will be found that each of them is intended for a particular organ or system of organs, and therefore should be treated as a trunk in itself, or a special source of supply to the parts to which it is distributed. Thus, the vocal and part of the respiratory apparatus are supplied by the superior thyroid artery, ramifying on the exterior, as well as in the interior of the larynx. The upper part of the digestive tube derives its blood from the lingual, the palatine, and pharyngeal arteries. The face, including the organs of expression and mastication, receives supplies from several vessels, the facial and internal maxillary arteries being the chief, whilst the occipital and temporal ramify on the cranium. This arrangement was first suggested by Bichât, and is one of the many instances which may be cited of his constant anxiety to make physiology the basis of his classifications.

Varieties.—The principal varieties presented by the carotid arteries at their origin have been already noticed. Their bifurcation may take place lower down or higher up than the margin of the thyroid

cartilage. Burns recites a case in which it occurred as low as the fifth or sixth cervical vertebra; and Meckel mentions one in which its division was opposite the styloid process, and another in which the deviation went still farther, no bifurcation having taken place, for the common trunk gave off those branches to the external parts which usually issue from the external carotid, and then continued its course, assuming the direction and destination of the internal carotid.

Varieties frequently occur in the branches of the external carotid. The superior thyroid artery may arise by a branch common to it and the lingual, or may come from the common carotid at its bifurcation. One or two cases have been cited in which it did not exist, at least at one side, its place being supplied by the inferior thyroid.

The lingual artery may arise conjointly with the superior thyroid, but much more frequently with the facial. In the facial artery two varieties very frequently occur, not only in different individuals, but even at opposite sides of the same subject. It has been found very small in some cases, not extending beyond the jaw; but, as if to supply its place, the masseteric and transverse facial branches were unusually large.

The auricular may arise from the occipital, and the latter has in some cases come from the internal carotid.

638. *Operations.*—The *common carotid artery* may be exposed and tied in the upper part of its course, viz. after it has passed the omo-hyoideus, by proceeding in this way:—The chin being turned to the opposite side, and pushed upwards so as to extend the parts, an incision may be made along the inner border of the sterno-mastoideus, beginning on a level with the cricoid cartilage, and extending upwards for two inches and a half towards the angle of the jaw. The skin being divided, the platysma is to be cut through to the same extent, and afterwards the cervical fascia; in doing which, a portion of the membrane should be pinched up by the forceps, and cut across, so as to make a small opening for the introduction of a director, on which it is to be slit up. This will expose the sheath of the vessels, which may be opened with the same precaution, care being taken to avoid the descendens noni nerve. When passing the ligature, it will be found convenient to pinch up the inner margin of the divided sheath with the forceps, and draw it forwards. The point of the needle may then be applied closely to the outer side of the artery, by which means the vagus nerve and jugular vein are excluded, and the instrument will be made to slide smoothly between the artery and its sheath.

When proceeding to expose the artery in the lower part of the neck, the incision through the integument should commence on a level with the cricoid cartilage, and extend for fully three inches down towards the sterno-clavicular articulation, along the inner margin of the sterno-mastoid muscle. The skin, platysma, and fascia, being successively divided, the head must be slightly elevated in order to relax the muscles and allow of their being drawn aside. The sterno-mastoid is drawn to the outside, and the sterno-hyoid and sterno-thyroid to the inner side of the wound. Some fibres of the latter may require to be divided in order to bring the sheath of the vessels fully into view. When this is effected, the subsequent steps are the same as in the higher operation.

INTERNAL CAROTID ARTERY.

639. *a. Carotis interna*, having commenced at the division of the common carotid, opposite the upper border of the thyroid cartilage, inclines at first somewhat backwards and outwards, but soon turns forwards and inwards, and ascends to the base of the skull to reach the carotid foramen in the temporal bone. In this course the artery is accompanied by the internal jugular vein, which lies external to it, and by the vagus and sympathetic nerves, to which it is closely united by cellular tissue. The hypo-glossal nerve at first lies behind the artery; but as it descends it inclines to its outer side, and finally passes in front of it as well as of the external carotid artery. The artery is supported by the rectus anticus muscle, and is crossed by the digastricus and stylo-hyoideus muscles, and the lingual nerve. Higher up, the stylo-pharyngeus and stylo-glossus, together with the glosso-pharyngeal nerve, pass also in front of it, interposed between it and the external carotid artery. On reaching the lower margin of the canal appropriated to it in the pars petrosa of the temporal bone, the internal carotid artery ascends perpendicularly a little way, and then inclines forwards and inwards, its direction being influenced by that of the osseous tube which encloses it. It soon, however, ascends somewhat to reach the posterior clinoid process, close by which it pierces the deep lamella of the dura mater, which forms the cavernous sinus, but does not enter the cavity of the latter, as it becomes invested by a reflection of its lining membrane. The artery, in the next

Fig. 123.

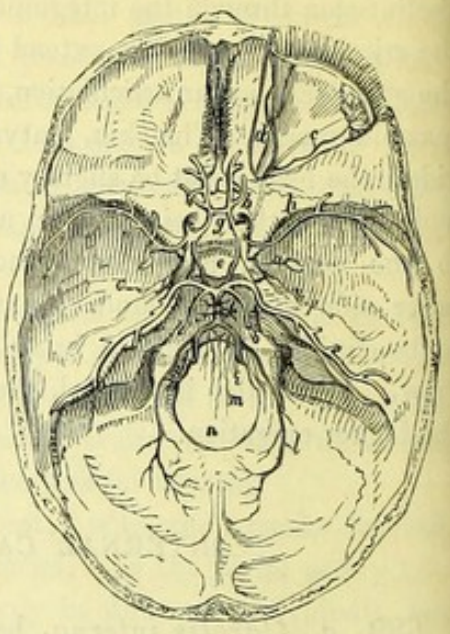

place, fig. 123, *a*, passes horizontally forwards to the base of the anterior clinoid process, where it curves upwards, and pierces the superficial or cerebral lamella of the cavernous sinus: finally, becoming invested by the arachnoid membrane, it reaches the fissure of Silvius, in which it divides into its terminal branches. Whilst in the canal, the artery is enclosed in a plexus formed by the sympathetic nerve, and gives off a small branch, which enters the tympanum, and anastomoses with the stylo-mastoid and tympanic arteries. Whilst at the sinus it gives a small twig to the dura mater (*r. meningeus anterior*). The ophthalmic artery is given off close by the anterior clinoid process.

OPHTHALMIC ARTERY.

640. *a. Ophthalmica*, fig. 123, *b*, passes forwards from the internal carotid artery, where it lies by the anterior clinoid process, and enters the orbit by the foramen opticum, placed inferior and external to the optic nerve. It soon changes its direction, passing above and to the inside of the nerve, to reach the inner wall of the orbit, along which it runs, and finally terminates by branches that ramify on the side of the nose.

Its branches are very numerous, being intended to supply the eye and its appendages.

Ramus lachrymalis, c, is a long branch which passes forwards, while the artery lies to the outside of the optic nerve. It runs close by the upper border of the external rectus muscle, which guides it to the lachrymal gland, to which the greater number of its branches are distributed; some, however, pass onwards to the eye-lids, and one or two delicate vessels pierce the malar bone to reach the temporal fossa.

r. Centralis retinæ is a very small branch, which pierces the substance of the optic nerve, and runs embedded within it until it arrives

on a level with the retina, where it divides into minute branches, which ramify in the anterior or vascular lamella of that membrane; a minute branch will be observed also to pass through the vitreous humour, and to reach the posterior surface of the capsule of the crystalline lens.

r. Supra-orbitalis, d, ascends to get above the muscles, and in its course forwards to the supra-orbital notch lies immediately beneath the roof of the orbit. The artery mounts towards the forehead, and distributes several branches, which communicate with those of the temporal artery.

r. Ciliares are divisible into three sets; viz. short, long, and anterior ciliary arteries. The short ciliary arteries vary from twelve to fifteen in number, and will be found to enclose the optic nerve as they pass forwards to reach the posterior aspect of the sclerotica, which they pierce about a line or two from the entrance of the optic nerve. These ramify minutely in the choroid membrane. The long ciliary arteries, two in number, lie one at each side of the globe, as they pass forwards between the choroid membrane and the sclerotica. Each of them passes through the ciliary ligament, and divides into two branches, which, by anastomosing with one another and with the anterior ciliary arteries, form a vascular zone round the circumference of the iris. From this, minute branches pass inwards, again subdividing and anastomosing, the last circle corresponding with the margin of the pupil. The anterior ciliary arteries are derived from some of the muscular branches; they pierce the sclerotica within a line or two of the margin of the cornea, and communicate with the preceding as they ramify in the iris.

r. Musculares are subject to many varieties in their course and distribution, like all muscular vessels: they supply the muscles of the orbit.

r. Ethmoidales are two in number; one passes through the posterior foramen in the inner wall of the orbit, and having given some small branches to the posterior ethmoidal cells, enters the skull, and sends minute filaments through the foramina of the cribriform lamella to the nasal fossæ. The other branch passes with the nasal division of the ophthalmic nerve through the anterior foramen, and having given ramusculi to the anterior ethmoidal cells and frontal sinuses, reaches the skull, and, like the preceding, sends its ultimate branches through the cribriform lamella to the nose.

r. Palpebrales (superior et inferior) arise usually in common, but soon diverge as they pass forwards, one lying above, the other below

the tendon of the orbicularis muscle: they are distributed, as their names imply, to the eyelids, branches being also sent to the caruncula and lachrymal sac.

r. Nasalis passes forwards to the root of the nose, and there ramifies minutely, maintaining a free communication with the termination of the facial artery.

r. Frontalis runs close to the preceding, but on reaching the margin of the orbit turns upwards on the forehead, where it anastomoses with the supra-orbital artery.

After having pierced the inner lamella of the dura mater, the internal carotid artery gives off the following branches:

Ramus communicans posterior, fig. 123, *e*, runs directly backwards, parallel with its fellow of the opposite side, so that they enclose within them the infundibulum, with the corpora mammillaria, and both terminate in the posterior cerebral arteries; thus forming the sides of the circle of Willis. In some instances I found two communicating branches, one being very small—about the size of a horse-hair. In some cases, there are two at the right side and one only at the left.

r. Cerebri anterior, *f*, arises from the division of the internal carotid opposite the inner termination of the fissure of Silvius. From this point it inclines forwards and inwards to reach the margin of the longitudinal fissure between the cerebral hemispheres, in which it is connected with its fellow of the opposite side by a branch, *g*, not more than two lines in length (*r. communicans anterior*). The two arteries, in the next place, lying close together, turn around the anterior border of the corpus callosum, and, on reaching its upper surface, run from before backwards upon it, overlapped by the cerebral hemispheres. In this course numerous branches are given off to the cerebral convolutions.

r. Cerebri medius, *h*, inclines obliquely outwards, taking the course of the fissure of Silvius, within which it divides into several branches, for the supply of the anterior and middle lobes of the brain. Some of these branches, as they ramify in the pia mater, turn forwards to the substantia perforata antica; and one or two will also be observed to enter the fissure between the middle lobe and the crus cerebri, to reach the descending cornu of the ventricle, where they are distributed to the plexus choroides (*rami choroidei*).

641. A remarkable inosculation exists between the branches

of the vertebral and carotid arteries, by which the circulation in the brain is equalised, and any deficiency that may arise from the obliteration of one, or even two of the vessels, is speedily supplied by the others. This inosculation, which is known as the circle of Willis, results from a direct communication between the following branches. The anterior cerebral arteries, as they converge, are connected by their anterior communicating branch. These, or rather the trunk from which they arise, are united by the posterior communicating branches with the posterior cerebral arteries, and the two latter are united with the basilar artery at its point of termination. Within the area thus included will be observed the commissure of the optic nerves, the infundibulum and tuber cinereum, the corpora mammillaria, and the origins of the third pair of nerves.

ARTERIES OF THE UPPER EXTREMITY.

642. The arterial trunk which supplies the upper extremity continues undivided from its commencement as far as the bend of the elbow; but, like that of the lower extremity, different parts of it have received different names, according to the regions in which they are seated. Whilst in relation with the clavicle, which comprises all that part of the vessel intercepted between its commencement and the lower border of the first rib, it is called *subclavian;* from the point just indicated, to the border of the axilla, it is named *axillary;* and from thence to the bend of the elbow, *brachial.* This mode of division is analogous to that of the inferior arterial trunk into iliac, femoral, and popliteal; and the analogy is completed by the fact, that as the one ultimately divides into the radial and ulnar branches, so does the other into tibial and fibular. As the subclavian artery commences on the left side at the arch of the aorta, and on the right at the division of the brachio-cephalic artery, opposite the sterno-clavicular articulation, the vessels of opposite sides must differ materially in length and relations to contiguous structures in the first part of their course. They both agree, however, in arching upwards and outwards across the lower part of the neck, and in descending beneath the clavicle and subclavius muscle, as far as the lower border of the first rib, where they assume the name of axillary.

SUBCLAVIAN ARTERY.

The two vessels of this name differ in length, relations, and size, in which particulars they may be compared and contrasted as follows:

643. *a. Subclavia dextra*, fig. 120, *b*, which is usually a little larger than the left, having commenced at the division of the brachio-cephalic artery, behind the sterno-clavicular articulation, arches upwards and outwards to reach the margin of the scalenus anticus. It there inclines outwards and downwards, beneath the clavicle and subclavius muscle, becoming continuous with the axillary artery, at the lower border of the first rib. The vessel lies on a plane anterior to that of the left side, inasmuch as the brachio-cephalic artery from which it arises, is borne forwards by the trachea; in its course it describes a curve, whose convexity looks upwards, approaching the lower nerve of the brachial plexus, whilst its concavity looks downwards, resting on the pleura and first rib. The subclavian vein lies on a plane anterior to the artery, being separated from it by the scalenus anticus muscle, but is somewhat lower down, so as not to obscure or overlap it, except when much distended.

644. *a. Subclavia sinistra*, fig. 120, *e*; fig. 121, *t*, arises from the transverse part of the aortic arch at its most depending point, and thence ascends, almost perpendicularly, to get to a level with the first rib, lying close to the vertebræ, and supported by the longus colli muscle. It is overlapped by the upper lobe of the left lung and the reflected part of the pleura, and crossed at its lower part by the nervus vagus (which had previously been parallel with it), and above by the left brachio-cephalic vein, and by the sterno-thyroid and sterno-hyoid muscles: all these are interposed between it and the sternum. The artery lies parallel with, and close to the œsophagus. On reaching the margin of the first rib it turns suddenly outwards, behind the scalenus anticus, and thenceforward follows the same course, and maintains the same relations as the right subclavian. But up to that point it lies so deeply, and changes its course so suddenly when passing outwards behind the scalenus,

Now, previously to reaching the scalenus, the artery is covered by the skin, the cervical fascia, and by the origin of the sterno-mastoid muscle, and is overlapped by the sterno-hyoideus and sterno-thyroideus muscles; it is also crossed by the nervus vagus, (whose recurrent laryngeal branch passes behind it,) by some branches of the sympathetic nerve, and more externally by the internal jugular vein. In the next part of its course (where it lies behind the scalenus anticus) the artery is still covered by the sterno-mastoid to an extent dependent on the breadth of the clavicular attachment of that muscle: the subclavian vein and the phrenic nerve are here anterior to the artery, but separated from it by the scalenus anticus, on which they rest. But externally to the scalenus, the artery, though still deeply seated, is covered only by the skin, platysma, and fascia (superficial and deep-seated), and by some cellular membrane. Here it will be found lodged in a triangular interval, the base of which is formed by the clavicle, and the sides by the scalenus anticus and omo-hyoideus muscles. In the space just indicated, the external jugular that it is found impossible to apply a ligature upon it previously to reaching that muscle,—an operation which has been performed with success on the corresponding part of the right subclavian artery.

vein opens into the subclavian, and sometimes forms, with branches from the neighbouring parts, a venous plexus, embarrassing to the operator. Two arterial branches (posterior scapular and supra-scapular) pass transversely outwards in the same situation—the latter being usually behind the clavicle; the brachial plexus of nerves lies superior and external to the artery, one branch being in close relation to it; the subclavian vein is, as has been above stated, anterior but at the same time inferior to the artery. This is the situation in which the artery can be most easily compressed or ligatured.

645. Seven branches proceed from the subclavian artery, each to a different destination; three of these, however, in most cases, arise by a common trunk.

The vertebral artery passes up almost in the course of the original vessel, and is conducted by the foramina in the transverse processes of the cervical vertebræ to the base of the brain; the internal mammary artery turns downwards and forwards; the thyroid inclines upwards and inwards to the fore part of the neck: the supra-scapular and the posterior scapular pass outwards across the lower part of the neck, whilst the deep cervical and the superior intercostal pass backwards, and lie deeply, to gain their respective destinations.

VERTEBRAL ARTERY.

646. *Ramus Vertebralis* is a principal branch of the subclavian artery. It enters the foramen in the fifth or sixth cervical vertebra, and ascends vertically along the canal formed by the chain of foramina in the transverse processes, as far

as the axis, at which point it inclines outwards, n consequence of the greater width of the atlas. Having passed through the latter, it winds backwards round its articulating process, lying in a shallow groove behind it; and having pierced the dura mater, enters the skull through the foramen magnum. The vessel finally passes forwards, fig. 121, *i*, converging to that of the opposite side, and unites with it, their conflux forming the basilar artery.

647. The *basilar artery*, fig. 121, *k*, is so named from its lying on the basilar process of the occipital bone: its length corresponds very nearly with the breadth of the pons Varolii, beneath which it lies, and at whose anterior border it divides into four branches, two for each side.

The vertebral artery in its ascent is accompanied by a vein of the same name, which commences by branches at the base of the skull, and comes into contact with the artery at the first vertebra. Both vessels lie anterior to the series of cervical nerves, which they cross at right angles.

The branches of the vertebral artery in the neck consist of small twigs given off at different points of its course to the dura mater of the spine, and some of variable size to the deep-seated cervical muscles; those within the skull are the following:

r. Meningeus posterior, which is a small branch that arises when the artery is opposite the foramen magnum, and ramifies upon the neighbouring part of the dura mater.

r. Inferior cerebelli, fig. 121, *l*, arises at the side of the medulla oblongata, and turns backwards and outwards beneath the corresponding lobe of the cerebellum, to which it distributes numerous ramifications, some of which extend to the inferior vermiform process, and to the fourth ventricle, through the medium of its choroid plexus.

r. Spinalis posterior, *m*, inclines backwards round the medulla oblongata, to reach the posterior surface of the medulla spinalis, along which it descends parallel with its fellow of the opposite side, as far as the second lumbar vertebra, where it terminates in ramifications on the cauda equina. Both these vessels are long and tortuous, and maintain frequent communications by transverse branches.

r. Spinalis anterior, *n*, smaller than the preceding, descends in front of the medulla oblongata, and unites with the corresponding

branch of the opposite side, immediately below the foramen magnum, so as to form one long vessel, which descends in the middle line in front of the medulla spinalis, at the extremity of which it passes through the nervous filaments forming the cauda equina, and terminates at the lower part of the canal in delicate ramifications. This and the preceding branch give numerous ramusculi to the spinal cord and its nerves, and communicate with the branches which enter through the intervertebral foramina.

The branches of the basilar artery are the following :

Several ramuli are given to the cerebral protuberance and adjacent nerves : one also accompanies the acoustic nerve into the labyrinth of the ear.

Ramus cerebelli superior, fig. 121, *o*, turns backwards and outwards round the upper margin of the pons Varolii, to reach the superior surface of the cerebellum, upon which it ramifies freely.

r. Posterior cerebri, *p*, is larger than the preceding, and separated from it by the third nerve ; it turns round the crus cerebri, and inclines backwards to the posterior lobe of the cerebrum, along which it distributes numerous branches, for the supply of its substance. At the point where this vessel turns backwards, it receives the communicating artery from the internal carotid, and so contributes to form the circle of Willis.

INFERIOR THYROID ARTERY.

648. *R. thyroideus inferior* (ascendens).—The inferior thyroid artery is not unfrequently called *thyroid axis*, because, immediately after its origin, it divides into three branches, which diverge in different directions, viz. the inferior or ascending thyroid, the transversalis colli, and transversalis humeri. It springs from the upper surface of the subclavian artery at a point nearly opposite to that from which the internal mammary artery arises, and to the inner side of the anterior scalenus. At first it presents the appearance of a short stunted trunk ; but a line or two from its origin it greatly diminishes in size, owing to its giving off the branches above named. It passes upwards, resting on the longus colli, but soon turns inwards, behind the sheath of the cervical vessels and the sympathetic nerve, directing its course to the thyroid gland, in which its final branches ramify, and where they com-

municate freely with those of the superior thyroid artery, derived from the carotid.

ramulus cervicalis ascendens :—At the point where the inferior thyroid changes its direction, a small branch (ascending cervical) usually arises from it, and proceeds upwards, on the line of junction formed by the scalenus anticus and rectus anticus major, ramifying on these muscles, and communicating with the ramusculi sent outwards from the vertebral artery.

r. Glandulares are the terminal branches given to the thyroid gland.

SUPRA-SCAPULAR ARTERY.

649. *R. Supra-scapularis* (transversalis humeri) is smaller than the succeeding branch (r. scapularis posterior); it arises almost constantly from the thyroid artery, seldom from the subclavian. It runs from within outwards, lying deeply at the root of the neck, and rests at first upon the scalenus anticus, then crosses the subclavian artery, taking a transverse course under cover of and parallel with the clavicle, to reach the root of the coracoid process of the scapula. At this point it is separated from the corresponding nerve by the ligament stretched across the supra-scapular notch, as the nerve usually passes through the foramen.

ramulus supra-spinalis :—On reaching the supra-spinous fossa, the artery lies close to the bone, and sends outwards a branch (supra-spinal) which ramifies in the supra-spinatus muscle.

r. Infra-spinalis :—Continuing to descend, the artery in the next place passes through the interval between the glenoid cavity and the spine of the scapula, resting on the neck of that bone, and so reaches the infra-spinous fossa, where it supplies the muscle of that name, and at the same time communicates with the dorsal branch of the sub-scapular artery, and the termination of the scapularis posterior. These two branches are seen in fig. 125, *a*, *a*.

r. Musculares :—In its course across the neck some ramuli are given by this vessel to the muscles by which it passes.

r. Acromialis :—A small though regular branch will also be found to pass obliquely downwards to reach the cutaneous surface of the acromion, on which it distributes several twigs, which anastomose with those of the thoracico-acromial branch.

POSTERIOR SCAPULAR ARTERY.

650. *R. Scapularis posterior*, fig. 121, *v*, (transversalis colli,) is much more frequently derived from the subclavian itself than from the inferior thyroid; it runs directly outwards across the lower part of the neck, resting on the scaleni muscles and the axillary plexus of nerves, but sometimes passing through the divisions of the latter. On reaching the posterior angle of the scapula it changes its direction, and turns downwards, along the base of that bone, so far as its inferior angle, where it freely anastomoses with the sub-scapular branch of the axillary artery. It lies deeply in its entire course, and gives off several branches.

r. Cervicalis superficialis:—Opposite the anterior border of the trapezius a branch passes upwards, becoming superficial (hence its name), and distributes ramusculi in the interval between the trapezius and sterno-mastoid muscles, supplying both, as well as the cervical glands and integuments.

r. Posterior scapulæ:—The proper *posterior scapular* branch, fig. 125, *b*, is in fact the continuation of the vessel, and will be found at the posterior angle of the scapula under cover of the levator anguli muscle, and subsequently under the rhomboidei, to which it gives several branches, as well as to the latissimus dorsi and intercostal muscles, anastomosing at the same time with the intercostal arteries. Towards the inferior angle of the scapula its terminating branches will be found to establish a free anastomosis with the sub-scapular artery and its dorsal branch.

DEEP CERVICAL ARTERY.

651. *R. Profundus cervicis* is subject to many varieties, in its point of origin as well as size. It frequently arises by a short trunk common to it and the superior intercostal artery, or may come even from the thyroid or vertebral. It passes backwards in the interval between the transverse processes of the sixth and seventh cervical vertebræ, and on reaching their dorsal aspect ascends, still deeply seated, between the semi-spinalis colli and the complexus, and sends off several branches to the surrounding muscles. Some of these communicate with ramusculi sent outwards from the vertebral artery, whilst others

ascend, fig. 121, *x*, to anastomose with the descending branch *(princeps cervicis)* of the occipital artery.

INTERNAL MAMMARY ARTERY.

652. *R. Mammarius internus* turns forwards from the subclavian to reach the inner surface of the first rib, and then descends between the pleura and the costal cartilages, as far as the cartilage of the seventh rib. At this point it divides into two branches, one of which inclines outwards, along the margin of the thorax, the other continues in the original direction of the vessel, down to the abdomen. Its branches, including the two just alluded to, are the following:

ramulus comes nervi phrenici is a very small branch, which joins the phrenic nerve where it passes over the mammary artery, or a little lower, and accompanies it to the diaphragm, to which its ramusculi are distributed, anastomosing with the phrenic arteries derived from the abdominal aorta, as well as with the phrenic branches given off by the musculo-phrenic division of the internal mammary.

ramuli mediastini:—Several small branches pass inwards to the cellular tissue in the anterior mediastinum, and also some to the anterior part of the pericardium.

r. Thymici:—One or more small branches are given off to the thymus gland.

r. Pericardiacus is a branch of variable size, which passes backwards into the upper part of the pericardium. Its lower part receives twigs from r. musculo-phrenicus.

r. Intercostales anteriores pass outwards, at each intercostal space, between the pleura and internal intercostal muscles, then between the two layers of the latter, and inosculate with the vessels of the same name, derived from the aorta, maintaining communications at the same time with the thoracic branches of the axillary artery. We usually find two branches in each intercostal space.

r. Musculo-phrenicus is the external division of the mammary artery. It inclines outwards, in the direction of the cartilages of the false ribs, sending branches, backwards into the diaphragm, and downwards to the abdominal muscles, whilst others pass outwards, in the intercostal spaces, being disposed in the same way as those which come higher up from the mammary artery itself.

r. Epigastricus superior continues in the direction of the mammary

artery, passing behind the seventh costal cartilage to reach the parietes of the abdomen. It there lies between the rectus muscle and its sheath; it ramifies freely in the muscles, and anastomoses with the inferior epigastric branch, which comes up from the external iliac artery.

SUPERIOR INTERCOSTAL ARTERY.

653. *R. Intercostalis superior* turns backwards, immediately after its origin, from the posterior aspect of the subclavian, and reaches the inner surface of the first rib, beneath which it sends outwards an intercostal branch, similar in course and distribution to those derived from the aorta. Opposite the second intercostal space another branch is given off, after which it terminates by a small ramulus that communicates with the first aortic intercostal branch. Some twigs are given to the upper part of the œsophagus, and some also enter the intervertebral foramina, to ramify on the dura mater of the spinal canal.

Varieties.—The branches of the subclavian artery present numerous variations in their mode of origin. The thyroid is of considerable size when it gives off the supra-scapular and posterior scapular branches, but is much reduced when it is merely a single vessel for the supply of the thyroid gland. In some cases which have been cited it did not exist; in others it arose from the arch of the aorta, and ascended upon the trachea to its destination. The possibility of such a distribution points out at once how necessary it is to be cautious in performing the operation of tracheotomy.

The posterior scapular branch very frequently comes off singly from the subclavian, in the latter part of its course, where it turns down upon the first rib. The first intercostal and the deep cervical frequently arise by a common trunk. We have already seen that the vertebral has been found arising from the aortic arch. A very singular variety is delineated by Tiedemann, in which the vertebral artery of the left side had two origins; one from the aortic arch, between the left carotid and left subclavian arteries, and the other from the latter vessel, which united and formed the vertebral opposite the fifth cervical vertebra. The mammary artery is very constant; in a few cases it has been known to come from the aortic arch or from the brachio-cephalic.

Operation.—In order to expose and ligature the subclavian artery

external to the scalenus anticus muscle, the subject should be placed in the horizontal position, and the head turned to the opposite side to that which is about to be operated on. Commencing over the external margin of the sterno-mastoid muscle, an incision three inches and a half in length should be made outwards, close above the clavicle, and parallel with it. The platysma and fascia having been successively divided on a director in the same direction and extent, a blunt probe should be employed to tear through the cellular membrane that fills up the triangular interval in which the vessel is lodged. The external jugular vein will be found close along the margin of the sterno-mastoid muscle, and should be carefully avoided. The subclavian vein will be observed, after the division of the fascia, behind the clavicle, alternately swelling and subsiding. This arises both from the natural flow of the current within it, as well as from the reflux caused by the action of the auricle. The hurried and agitated state of the respiratory action also exerts a considerable influence, both on the quantity of blood in the subclavian vein, as well as on that which flows from the cut extremities of the smaller veins, which are of necessity divided. If this becomes embarrassing, the operation may be suspended for a moment, and the patient slightly elevated, so as to allow him to make a full and easy inspiration, after which the regurgitation from the mouths of the vessels will cease, and the tension of the large vein will be diminished. When the omo-hyoideus is brought into view, the thin fascia which binds down its tendon may be torn through, after which the artery can be felt pulsating where it rests against the first rib. When attempting to pass the ligature, its point should be directed from before backwards, and then made to turn from below upwards behind the artery, care being taken to keep it close to the vessel, so as to avoid the pleura, on which it lies, and the nerves which are placed close above it.

AXILLARY ARTERY.

654. *A. Axillaris* lies obliquely across the superior and lateral part of the thorax, extending from the lower border of the first rib as far as the inferior margin of the tendons of the latissimus dorsi and teres major. In this short course the direction of the vessel is outwards, downwards, and a little backwards, so that when the arm hangs freely by the side, it describes a curve whose convexity looks towards the acromion, and concavity towards the chest. It is accompanied by the

axillary vein and brachial plexus of nerves, which lie at different sides of it; hence, in order that we may state precisely the relation of these vessels, as well as of the muscles, to the artery, it becomes necessary to consider it, not as a cylindrical tube, but as if it were compressed so as to present four sides. The acromial side at first corresponds with a small cellular interval that separates it from the plexus of nerves, then with the divisions of the plexus which are in close contact with it, and lower down with the tendon of the sub-scapular muscle, and, finally, at its termination, with the coraco-brachialis, which is interposed between it and the humerus. The thoracic side of the vessel rests on the first intercostal space, then on the first digitation of the serratus magnus muscle. When it passes off the chest into the axillary space, it lies in the cellular interval between the serratus and sub-scapularis, and becomes supported by the nerves which here surround the vessel. The anterior surface is covered by the pectoralis major and costo-coracoid ligament or membrane in the space between the subclavius and pectoralis minor, then by the latter and the pectoralis major together, and, finally, by the last-named muscle, which covers it to its termination. Its posterior surface is supported by some cellular membrane and the deep divisions of the brachial plexus of nerves. The axillary vein, at first separated from the artery by the insertion of the scalenus anticus muscle, lies inferior and internal to it, that is to say, to its thoracic side; lower down it comes in front of the artery, and conceals it from view when we look into the axillary space.

The space here referred to, when cleared of the cellular tissue and glands which fill it, is of a pyramidal form, the summit being at the interval between the scaleni muscles, and the base at the borders of the pectoralis and latissimus dorsi; its sides are formed as follow, viz. by the pectoral muscles in front, by the latissimus and teres behind, the serratus magnus internally, and the sub-scapularis and head of the humerus externally. The brachial plexus of nerves is situated above, and to the outer side of the artery at its commencement; at about the middle of its course, the nerves surround it (the vessel being between the two roots of the median nerve); lastly, the branches proceeding from the plexus are disposed with regard to the artery as follows: the external cutaneous nerve and one root

of the median lie at its outer side; the internal cutaneous, the second root of the median, and the ulnar, at its inner side; and behind it the circumflex and musculo-spiral.

The axillary artery, fig. 124, A, gives off seven branches, which are named as follows; premising, at the same time, that considerable variety obtains in their mode of origin.

Fig. 124.

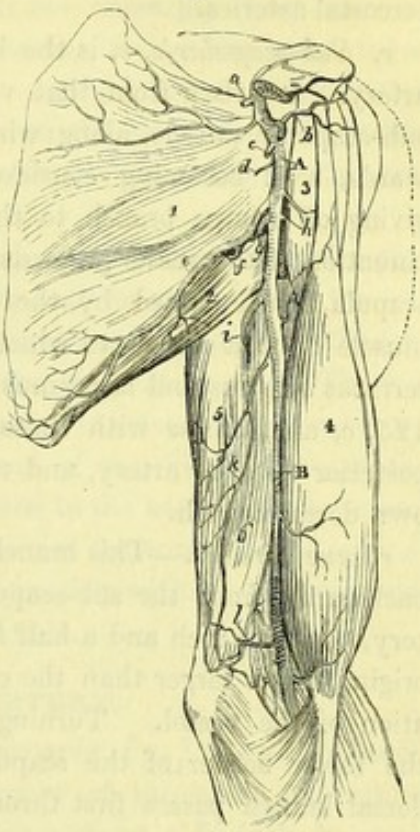

ramulus thoracicus supremus, a, is a very small twig which arises just above the border of the pectoralis minor, from the axillary artery itself or from the thoracico-acromial branch. It inclines forwards and inwards, getting between the pectoral muscles, to which its ramifications are distributed; some of them also go to anastomose with those of the internal mammary and intercostal arteries.

r. Thoracico-acromialis, b, arises from the fore part of the axillary artery, being rather a large branch. It projects forwards at the upper border of the pectoralis minor, and soon divides into branches which take opposite directions. One set inclines inwards to the thorax, the other outwards to the acromion, whence the vessel derives its name. The thoracic branches are three or four in number, and are distributed to the serratus magnus and pectoral muscles, their extreme terminations communicating with those of the other thoracic branches, as well as with the intercostal branches of the internal mammary artery. The acromial branches incline outwards, and subdivide into a descending and transverse set. The latter proceed towards the acromion, and are distributed partly to the deltoid muscle; whilst others upon the upper surface of that process, maintain an anastomosis with branches of the supra-scapular and posterior circumflex arteries. The descending branch passes down in the interval between the pectoralis major and deltoid, and ramifies in both.

ramulus thoracico-alaris, d, is very small and variable in size, and altogether unimportant; it is merely distributed to the glands and cellular tissue in the axilla.

r. Thoracicus longus, c, passes downwards and inwards along the lower border of the pectoralis minor, and is distributed to the mamma, (hence it is often called external mammary,) to the serratus and pectoral muscles, and anastomoses with the external branches of the intercostal arteries.

r. Sub-scapularis, e, is the largest branch given off by the axillary artery. It arises from that vessel, close by the lower border of the sub-scapular muscle, along which it proceeds downwards and backwards, soon becoming considerably diminished in size, owing to its giving off a large branch to the dorsum of the scapula. The continuation of the vessel proceeds down towards the inferior angle of the scapula, accompanied by the sub-scapular nerve, and lying on the muscle of that name, to which it gives branches, as well as to the serratus magnus and latissimus muscles. Its final ramifications, fig. 125, *c,* anastomose with those of the posterior scapular artery, and with its own dorsal branch.

Fig. 125.

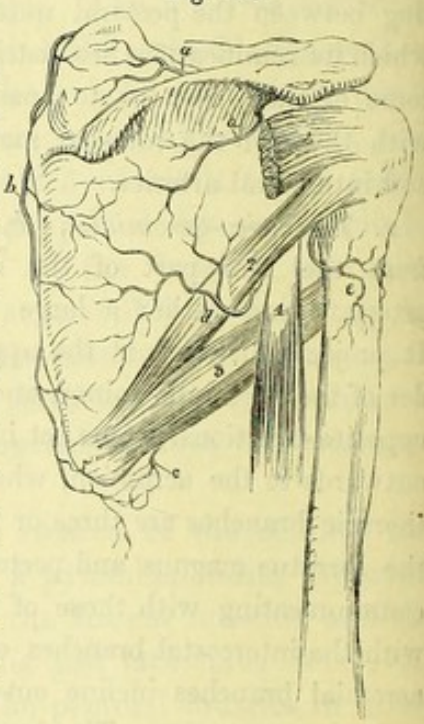

ramus dorsalis.—This branch passes backwards from the sub-scapular artery, about an inch and a half from its origin, and is larger than the continuation of the vessel. Turning round the lower border of the scapula, the dorsal branch passes first through the interval between the sub-scapularis and latissimus dorsi muscles, and then between the teres major and minor, and may be always found, fig. 125, *d,* in the fissure between the last-named muscles, immediately behind the long head of the triceps. It gives branches to these muscles, and, on reaching the dorsum of the scapula, ramifies extensively upon it, supplying the infra-spinatus muscle, and anastomosing with the supra-scapular and posterior scapular arteries.

The two following branches are called "circumflex" from the manner in which they pass, one before and the other behind the shaft of the humerus. They come off close to the lower border of the axilla as the axillary artery is about to merge in the brachial. They vary much in their mode of origin; they often arise by a common stem

from the axillary artery or from its sub-scapular branch; sometimes the posterior one comes from the upper deep branch of the brachial artery.

r. Circumflexus posterior, fig. 124, *g*, is not so large as the sub-scapular, near which it arises. It passes backwards immediately after its origin, winds round the shaft of the humerus, lying between the bone and the long head of the triceps, having the teres major muscle below, and the teres minor above it, fig. 125, *e*; it terminates by ramifying in the deltoid muscle and on the shoulder-joint, having previously communicated by branches with the anterior circumflex and supra-scapular arteries.

r. Circumflexus anterior, fig. 124, *h*, is much smaller than the preceding. It passes from within outwards and forwards, under the coraco-brachialis and inner head of the biceps muscle, resting on the fore part of the humerus, until it reaches the bicipital groove. There it divides into two branches, or, in some cases, into two sets of branches: of these, one ascends by the long head of the biceps through the groove in which it runs, and is distributed to the head of the bone and the capsule of the joint; the other continues outwards, in the original direction of the vessel, and after anastomosing with the posterior circumflex branch, is lost in the deltoid muscle.

BRACHIAL ARTERY.

655. *Arteria Brachialis vel humeraria*, fig. 124, B, is placed along the internal and anterior aspect of the arm, extending from the lower border of the axilla to about a finger's breadth below the bend of the elbow. Its direction is downwards, outwards, and forwards, and may be marked out by a line drawn from midway between the borders of the axilla to the middle point between the condyles of the humerus; so that in the first part of its course the vessel is situated at the inner side of that bone, and inferiorly on its anterior aspect. The artery may be said to be superficial in its whole course, inasmuch as it can be exposed without dividing any muscular fibres, being covered merely by the skin and fascia.

The brachial artery in the upper part of its course rests on the triceps muscle, the spiral nerve, however, and the profunda artery intervening; in the middle of the arm, it crosses over the insertion of the coraco-brachialis muscle, and lies from thence to its termination on the brachialis anticus. Its external side is in apposition, in the upper half of the arm, with the coraco-brachialis, in the lower with the biceps, the border of which

muscles somewhat overlap it. The venæ comites are in close contact with the artery, short transverse branches of communication passing from one to the other, so as at many points to encircle it: the basilic vein is parallel and superficial to it, sometimes in its entire extent. The median nerve, though its two roots embrace the axillary artery, lies at first to the acromial side of the brachial; but as it descends it inclines in front of the vessel, crossing it about the middle of the arm, so that at the elbow it lies to the inner side of the artery, and on the same plane, both being supported by the brachialis anticus muscle. The nerve usually crosses in front of the artery, but in some instances behind it. The internal cutaneous nerve is superficial to the artery, but it does not lie exactly in front of it; for, at the elbow, the nerve is to its inner side, and maintains a similar relation higher up.

At the bend of the arm the artery sinks deeply into an angular interval, enclosed between the pronator teres and supinator radii longus, fig. 126, 3, 2. In this situation the vessel is covered by the fascia of the arm, and crossed by the fibrous process which passes from the tendon of the biceps to that membrane, and separates the artery from the median basilic vein; it rests on the brachialis anticus muscle, having the tendon of the biceps on the radial, the median nerve on the ulnar side, and finally, opposite the insertion of the brachialis anticus, it divides into the radial and ulnar arteries. The position of the artery with regard to the shaft of the humerus deserves particular attention. Superiorly it is parallel with, and to the inner side of the bone, and inferiorly lies directly in front of it. In the former situation, therefore, in order to compress the vessel, the pressure must be directed from within outwards; in the latter, from before backwards; and at the intermediate point the direction of the pressure must also be intermediate, that is to say, backwards and outwards.

The brachial artery in its course gives numerous branches to the muscles by which it passes; none but the following have received names, or require description.

ramus Profundus superior, fig. 124, *i*, having started from the back part of the artery, just below the border of the teres major, inclines downwards and outwards, to reach the interval between the second and third heads of the triceps. In this course it is accompanied by

the musculo-spiral nerve, and both, continuing the same oblique direction, pass between the second head of the triceps and the bone, to reach its external and anterior aspect. In the latter situation, the artery lies deeply in the fissure between the brachialis anticus and supinator longus muscles, considerably diminished in size, by having given off several branches, and descends to the elbow, where it anastomoses with the recurrent branch of the radial artery. The only offset from this artery that requires a special notice, is one which descends perpendicularly from it, when lying behind the middle of the humerus, and proceeds between the triceps muscle and the bone to the back part of the elbow-joint, where it anastomoses with the inter-osseous recurrent branch. This vessel is sometimes given off by the sub-scapular artery or by the posterior circumflex.

ramulus nutritius.—This is a very small branch given off by the brachial artery about the middle of the arm, or by one of its collateral branches. It inclines downwards and enters the oblique canal in the humerus near the insertion of the coraco-brachialis muscle, and is distributed to the medullary membrane.

r. Profundus inferior, fig. 124, *k,* is of small size, and arises from the brachial artery, a little below the middle of the arm. Its direction is downwards and inwards, from the point just indicated, to the back part of the inner condyle of the humerus; to gain which, it, in the first place, pierces the intermuscular ligament or septum, and then lies on the inner surface of the triceps (its third head), to which it gives branches. In this course the artery lies parallel, and on the same plane, with the ulnar nerve, and enters the interval between the olecranon and inner condyle, where it terminates by anastomosing with the posterior recurrent branch of the ulnar artery.

ramulus anastomoticus, fig. 124, *l,* though a very small branch, is almost constant in its occurrence; it arises from the brachial artery, about two inches above the bend of the arm. Resting on the brachialis anticus, this little vessel descends towards the inner condyle, and divides into two sets of ramifications. Of these, one lies in front of the articulation, and after supplying the brachialis anticus and pronator teres muscles, anastomoses with the anterior ulnar recurrent, whilst the other passes backwards, comes into relation with the ulnar nerve, and communicates with the branches of the r. ulnaris recurrens and of the r. profundus inferior.

656. It must be obvious, that the terms applied to the branches of the brachial artery are rather ill chosen. The r.

inferior profundus, though beneath the fascia, can hardly be called deep-seated; and the property of anastomosis is common to all, as well as the small branch called anastomoticus magnus or major. The first branch may, with propriety, be named "profundus," from its situation; or "spiral," from its direction; and the two others "collateral," from their relation to the artery itself; so they were named formerly by Winslow, and still by Boyer.

Varieties.—The description above given of the course, relations, and mode of division of the brachial artery, is conformable with what obtains in the greatest number of instances. Some varieties, however, occur which deserve notice. The vessel not unfrequently divides as high as the middle of the arm, or even higher, or rather gives off one of its two terminal branches, which most commonly is the radial. On this subject, Meckel states, as the result of his observations, that when the radial artery arises in the arm, it usually commences towards the middle point; but that the anomalous division of the ulnar, though less frequent in its occurrence, takes place in most instances higher up, even as high as the point at which the axillary terminates in the brachial. I found in the dissecting-room a few years ago a variety not hitherto noticed. It was at first taken for the ordinary high division of the ulnar artery. The two vessels descended from the point of division at the border of the axilla, and lay parallel with one another in their course through the arm; but instead of diverging, as is usual, at the bend of the elbow, they converged and united so as to form a short trunk, which soon divided again into the radial and ulnar arteries in the regular way. The femoral artery presented a conformation in every particular similar to this in the person of an individual who was the subject of popliteal aneurism, for which an operation was performed by Sir Charles Bell. The pulsation was not stopped when the ligature was applied to the vessel. When the radial arises high up from the brachial artery, it may be situated parallel and internal to that vessel, or may turn suddenly outwards across it, becoming in a manner superficial to it, but still covered by the fascia. Tiedemann says that in such cases the "radial artery is either enclosed by the aponeurosis of the arm, or, perforating it, runs with the cephalic vein immediately under the skin." The latter case must be of rare occurrence. In some instances the radial artery, instead of continuing

its course to the lower part of the radius, inclines outwards and backwards a little below the middle of the fore-arm, and so descends along its outer border, superficial to the extensor tendons. When the radial artery arises thus high, and runs superficial, the external or radial recurrent is a branch of the brachial artery, or more rarely of the ulnar.

When the origin of the ulnar artery takes place high in the arm, it lies beneath the fascia as it descends, and runs superficial to the flexor muscles. In one instance of a high division, Tiedemann observed a cross branch connecting the ulnar and brachial. In a few cases an anomalous branch has been observed to pass down from the brachial and end in the radial, or in the brachial itself. This appears to be but a minor degree of that division, and subsequent re-union, instances of which in the brachial and femoral arteries have been above noticed.

The inter-osseous artery, in two or three cases (at least there are no more recorded), arose from the brachial about the middle of the arm. Its position was internal, and posterior to the main artery; and on reaching the bend of the elbow, passed deeply between the muscles, and assumed the usual position of the vessel. A superficial anterior inter-osseous artery sometimes exists, which arises a little below the elbow-joint, and takes the course of the median nerve to the palm of the hand, where it terminates by inosculation in the palmar arch.

Operations. — The *brachial artery* may be exposed and tied in any part of its course, the border of the biceps and coraco-brachialis serving as a guide to its situation. When the arm is drawn away from the side, and slightly everted, the hand being supinated, the seat of the operation is fairly brought into view. The first incision through the skin should be about two inches in length, along the border of the biceps muscle. This will expose the fascia, which is to be divided to the same extent. Now, if the operation be performed low down, the median nerve will be found to the inner side of the artery; if in the middle, it lies in front of the vessel, or crosses immediately behind it; whilst in the upper part of the arm, the nerve lies to the outer side of the artery. These facts should be recollected when the endeavour is being made to separate the nerve from the artery, preparatory to passing the ligature round the latter. If the fore-arm is a little bent, the biceps muscle and the nerves become relaxed, and may readily be

drawn aside, so as to facilitate the separation of the artery from the veins which accompany it previously to passing the ligature round it.

The brachial artery, when arrived opposite the insertion of the brachialis anticus muscle, divides into the ulnar and radial arteries.

ULNAR ARTERY.

657. *Arteria ulnaris*, fig. 126, B, inclines, in rather a curved direction, downwards and inwards, passing under cover of the superficial muscles which arise from the inner condyle, viz. the pronator teres, 3; flexor carpi radialis, 4; palmaris longus, 5; and flexor sublimis, 6; until it reaches the flexor carpi ulnaris, 7. About the same point, that is, at the junction of the upper with the middle third of the fore-arm, the artery comes into contact with the ulnar nerve, which had previously been separated from it by a considerable interval, having lain behind the inner condyle, but here approaches it, lying to its ulnar side. Thus placed, they both descend towards the inner border of the palm of the hand. In the first part of its course the artery is covered by the muscles above enumerated; in the middle of the arm it is overlapped by the flexor carpi ulnaris; and in the lower, it runs parallel, and in close relation with the outer border of its tendon. In this part of its course the vessel is covered only by the common integuments, the fascia of the arm and a thin layer, by which it is connected to the muscles behind it. For two-thirds of its extent it lies on the flexor profundus muscle; in the rest, on the pronator quadratus and annular ligament. It is accompanied, in its entire extent, by two veins, which lie one on each side. At its origin the artery is in close relation with the median nerve, from which, however, it is soon separated by the origin of the pronator teres from the coronoid process of the ulna; inclining inwards, it approaches the ulnar nerve, and by it is accompanied in the lower two-thirds of its course,—the nerve lying on the ulnar side of the artery.

658. *Palmar arch* (superficial).—The ulnar artery, guided as it were by the tendon of the flexor ulnaris muscle, reaches the radial border of the pisiform bone, where, accompanied by the nerve, it passes over the cutaneous surface of the annular

ligament of the wrist. At this point the artery begins at once to change its direction, by running outwards and forwards, across the palm of the hand; and on arriving about midway between the flexure formed by the bend of the first joint of the thumb and that of the fore finger, it terminates by inosculating with a branch (*superficialis volæ*) sent forwards by the radial artery, to unite with it. The vessel thus describes a curve, fig. 126, D, whose convexity looks forwards. This curved part of the artery is called the *superficial palmar arch.* (arcus volæ superficialis,) to distinguish it from the deep-seated one formed by the radial artery. It rests on the annular ligament of the wrist at its commencement, and afterwards on the tendons of the flexor sublimis; and is covered, for a short way, by the palmaris brevis, and afterwards by the palmar fascia and integument. The vessel, in the palm, is usually somewhat tortuous; and presents some varieties in its course and mode of termination, which will be found enumerated in sect. 660.

Fig. 126.

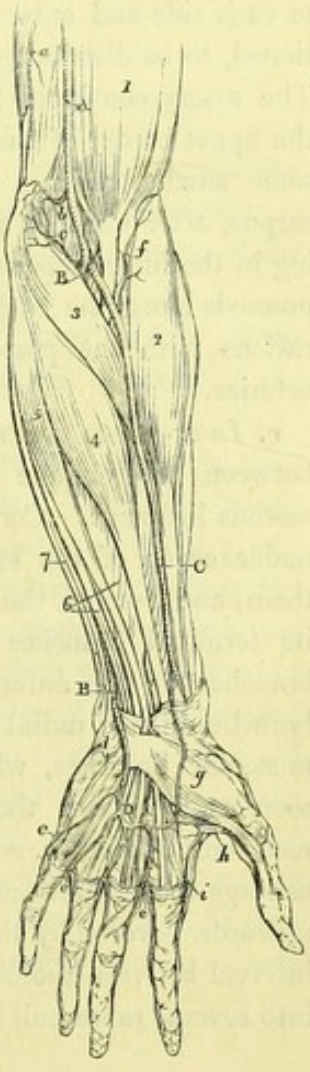

The branches of the ulnar artery in the fore-arm are the following:

ramus recurrens anterior, fig. 126, *c*, arches inwards from the ulnar artery, near its origin, running on the brachialis anticus muscle, and covered by the pronator teres, to both of which it sends ramusculi. On reaching the inner condyle, it anastomoses with the ramus profundus inferior and anastomoticus, *b*, derived from the brachial artery.

r. recurrens posterior is larger than the preceding, and comes off lower down; but not unfrequently they both arise by a small common trunk. It runs backwards somewhat, and ascends upon the posterior aspect of the inner condyle; and in the interval between that process and the olecranon, anastomoses with the r.

profundus inferior, some of its banches extending outwards, so as to communicate with those of the r. profundus superior and recurrens inter-osseus.

r. Inter-osseus (communis) is of considerable size, and is sometimes called the common inter-osseous artery, from the circumstance of its dividing into two vessels bearing that name which lie on the opposite surfaces of the inter-osseous ligament or membrane. This vessel inclines somewhat backwards after its origin, to reach the upper border of the inter-osseous ligament, where its division takes place.

r. Inter-osseus anterior proceeds downwards, lying on the anterior surface of the inter-osseous ligament, and is accompanied by the inter-osseous branch of the median nerve, and overlapped by the contiguous borders of the flexor profundus and flexor longus pollicis. Thus placed, it gives off some muscular branches, and the two nutritious arteries (r. medullares) to the radius and ulna. These incline to each side and enter the oblique foramina in the bones just mentioned, to be distributed to the medullary membranes in their interior. The artery continues its course directly downwards until it reaches the upper border of the pronator quadratus muscle, where it gives off some small branches to supply that muscle, and ramify upon the carpus, after which it passes from before backwards, through an opening in the inter-osseous ligament; and, on reaching its dorsal surface, proceeds along the back of the carpus, where it maintains communications with the posterior carpal branches of the radial and ulnar arteries.

r. Inter-osseus posterior passes backwards, through the interval left between the oblique ligament and the upper border of the inter-osseous ligament. Continuing its course downwards, along the arm, under cover of the extensor muscles, it gives several branches to them, and reaches the carpus considerably diminished in size, where its terminal branches anastomose with the perforating or terminal branches of the anterior inter-osseous artery, and with the carpal branches of the radial and ulnar arteries. In addition to numerous muscular branches, which require no special notice, this artery, as soon as it reaches the posterior surface of the ligament, gives off a recurrent branch (*r. recurrens inter-osseus posterior*), which is nearly as large as the continuation of the vessel. This branch passes directly upwards, covered by the supinator brevis and anconeus, to reach the interval between the olecranon and external condyle, where it divides into several ramusculi that anastomose with the terminal branches of

the r. profundus superior and inferior, as well as of the posterior ulnar recurrens.

r. Musculares.—Several branches are distributed to the muscles by the ulnar artery in its course along the arm.

r. Carpi dorsalis is a branch of variable size, which inclines backwards from the ulnar artery a little before it reaches the pisiform bone. It winds back under the tendon of the flexor carpi ulnaris, and reaches the dorsal surface of the carpus; there it gives some ramuli which anastomose with similar offsets from the metacarpal branch of the radial artery, after which it runs along the metacarpal bone of the little finger, and forms its dorsal branch. From the arch of anastomosis just referred to, the second and third dorsal interosseous branches are derived.

r. Carpi palmaris is a very small twig, which runs on the anterior surface of the carpus, and anastomoses with a similar offset from the radial artery.

BRANCHES GIVEN OFF BY THE PALMAR ARCH.

r. communicans, fig. 126, *d*, arises a little beyond the pisiform bone, and sinks deeply between the flexor brevis and the abductor of the little finger; it inosculates with the termination of the radial artery, and thereby completes the deep palmar arch.

ramuli palmares.—From the concavity and dorsal surface of the palmar arch, small branches are given to the parts in the palm of the hand.

r. Digitales, four in number, *e, e*, proceed forwards from the convexity of the palmar arch, to supply the fingers. The *first* branch inclines inwards to the ulnar border of the hand, and after giving ramusculi to the small muscles of the little finger, runs along the inner margin of its phalanges. The *second* runs along the fourth metacarpal space, and at the root of the fingers divides into two ramusculi, which proceed along the contiguous borders of the ring and little fingers. The *third* is similarly disposed of to the ring and middle fingers, and the *fourth* to the latter and the index;—the radial side of the index finger and the thumb are supplied from the radial artery. Each pair of collateral branches, on arriving at about the middle of the last phalanx of the finger, converge and form an arch, from the convexity of which small ramusculi run forwards to its termination.

RADIAL ARTERY.

659. *Arteria radialis*, fig. 126, c, in direction, though not in size, appears to be the continuation of the brachial. Its direction is from the point of division above indicated towards the styloid process of the radius, lying obliquely along the anterior aspect of the fore arm, its course being indicated by a line drawn from the middle of the bend of the elbow to the narrow interval between the trapezium bone and the tendons of the extensors of the thumb. These can be readily felt towards the outer border of the wrist. The artery is covered by the fascia of the arm and integument, and for some way is overlapped by the fleshy part of the supinator longus, 2, which must be drawn aside in order to expose it. It is at first supported by the branches of the musculo-spiral nerve, and some cellular tissue, which separate it from the supinator radii brevis muscle; it then passes over the insertion of the pronator teres, and the radial origin of the flexor sublimis; after which, it lies on the flexor pollicis longus and pronator quadratus, until it reaches the end of the radius. To its inner side lies the pronator teres in the upper part of its course, and the flexor carpi radialis in the rest; its outer side being in apposition with the supinator longus all the way down. Two venæ comites run parallel with the artery. The radial branch of the musculo-spiral nerve lies to its radial side during the middle third of its extent; but above that part the nerve is separated from it by a considerable interval, and lower down it turns backwards to reach the dorsal aspect of the arm, and loses all anatomical relation to it. Opposite the end of the radius the artery inclines outwards, passing between its styloid process and the trapezium, and beneath the two first extensors of the thumb. It then runs forwards for a short way (lying in the angular interval between the tendons of the two first extensors of the thumb and that of the third), to gain the angle between the two first metacarpal bones, and makes its final turn into the palm of the hand, by passing between the heads of the abductor indicis muscle.

Palmar arch (deep-seated).—The terminal part of the artery (*arcus volæ profundus*) runs transversely across the palm of the hand, lying on the heads of the inter-osseous muscles (to which it gives branches) and the carpal extremities of the metacarpal

bones, and opposite the fourth bone of that name inosculates with the communicating branch from the ulnar artery, which completes the deep palmar arch. This differs from the superficial arch, not only in being more deeply seated (being covered by all the flexor tendons), but also in retaining its size almost undiminished, and lying nearer the carpus.

The radial artery gives off the following branches :

ramus recurrens, fig. 126, *f*, arches upwards from the artery soon after its origin, running between the branches of the spiral nerve. It lies on the supinator brevis, covered by the supinator longus ; and opposite the external condyle anastomoses with the terminal branches of the r profundus superior, having in its course given ramuli to the extensor and supinator muscles.

ramuli musculares.—Several unnamed branches are given to the muscles on the fore part of the arm.

r. Superficialis volæ, *g*, proceeds directly forwards from the artery, where it is about to turn towards the back of the hand, and seems like the proper continuation of that vessel in direction, though not in size, as it is usually small and tapering. In this respect, however, it is subject to many varieties. This branch runs over the small muscles of the thumb at their origin, lying upon the annular ligament, to which it is bound down by a thin process of fascia, and terminates by inosculating with the radial extremity of the superficial palmar arch, which it thus completes.

r. Carpi posterior (r. dorsalis carpi radialis) arises close by the tendons of the radial extensor muscles, beneath which it runs upon the dorsal surface of the carpus, to anastomose with a similar branch, proceeding from the ulnar artery.

r. Carpi anterior.—A small branch will be found also on the anterior surface of the carpus, arising from the radial artery somewhat higher up. It is usually called *ramus anterior carpi radialis*, to distinguish it from a similar branch of the ulnar artery, with which it anastomoses.

r. Metacarpi.—When under the extensors of the thumb, a branch goes off obliquely forwards as if to gain the interval between the second and third metacarpal bones. It gives from its ulnar side one or two ramuli, which join with small branches from the posterior carpal branch of the ulnar artery, and form an arch or network of vessels upon the carpus. The continuation of the metacarpal branch runs upon the second dorsal inter-osseous muscle ; at

the cleft between the fingers it gives off ramuli to the dorsal surface of the middle and fore-finger, and communicates with the palmar digital branch at its point of division. This part of the artery is sometimes called the first dorsal inter-osseous branch, the second and third being derived from the arch of arteries above noticed.

r. Dorsales pollicis are two, which sometimes arise separately, at others by a common trunk, which divides into two ramusculi that run along upon the dorsal aspect of the bones of the thumb, one at its radial, the other at its ulnar border.

r. Dorsalis indicis arises lower down than the preceding, and after sending ramusculi to the abductor indicis, runs along the dorsal surface of the index finger. Its size is very variable.

r. Princeps pollicis, h, commences where the artery is about to turn across the palm of the hand, and after proceeding forwards between the abductor indicis and adductor pollicis, divides, near the extremity of the first metacarpal bone, into two ramusculi, which run along the borders of the phalanges of the thumb at its palmar aspect. These form its collateral branches, and unite by anastomosing upon its second phalanx, in the same way as those of the other fingers derived from the superficial palmar arch.

r. Radialis indicis.—Close to the preceding, a branch, *i,* arises, variable in size, but very regular in its course. It runs along the external border of the index-finger, and on its last phalanx anastomoses with the corresponding collateral branch, derived from the superficial palmar arch.

ramuli recurrentes. — From the concavity of the deep palmar arch ramuli proceed backwards, and communicate with the carpal arteries.

r. Interossei.—From the convexity of the arch others run forwards along the metacarpal spaces, supplying the inter-osseous muscles, and anastomosing with the digital branches of the ulnar artery.

r. Perforantes.—These are small ramuli, usually three in number, which pass backwards through the metacarpal spaces at their posterior extremities, and inosculate with the dorsal inter-osseous branches.

660. *Varieties.*—The distribution of the arteries in the hand presents, in very many instances, deviations from the arrangement here indicated. We occasionally find the superficial palmar arch formed by the ulnar artery alone, the superficialis volæ branch being too small to extend farther than the muscles of the thumb,

upon which it is expended. In such cases the digital branches of the thumb, as well as those of the other fingers, are derived from the ulnar artery, which is necessarily a little larger than usual.

In other instances the ulnar artery forms but half the palmar arch. In these the superficialis volæ is larger than usual, and, on reaching the palm, inclines inwards, so as to meet the ulnar artery about the middle line. The digital branches of the fingers are derived from the arch thus formed, and those of the thumb generally from the superficialis volæ by means of a short vessel which it gives off previously to its junction.

The ulnar artery is sometimes found to incline very little towards the radial side of the hand, and to supply no more than the little finger, the ring finger, and one side of the middle finger; the rest of the digital branches being derived from the superficialis volæ; here there is in strictness no palmar arch, and there is no direct connexion between the superficialis volæ and the ulnar artery. The ulnar artery has been observed to incline obliquely across the palm, being directed from the pisiform bone to the root of the fore-finger, supplying the usual number of digital branches. In some of these cases a connexion is formed between it and the superficialis volæ, if the latter be large, by a small transverse branch passing from the one to the other a little before the annular ligament.

The ulnar artery on reaching the palm has been found so diminutive as to terminate in a few offsets upon the muscles of the little finger, being incapable of supplying any digital branches. It may perhaps give one branch to the inner border of the little finger. Here all the collateral branches of the fingers are derived from the deep palmar arch of the radial artery. The inter-osseous branches of the latter, on reaching the cleft of the fingers, divide and run along their margins, occupying the position of the branches ordinarily supplied by the superficial palmar arch.

A superficial inter-osseous artery has been observed to run along the fore-arm in the course of the median nerve, and, after passing into the palm of the hand, to join the palmar arch formed in the usual way. But, in some rare instances of this sort, the ulnar artery was found smaller than it generally is, and the thumb, and the fore-finger, and one side of the middle finger, were supplied by the inter-osseous branch. The ulnar artery passed obliquely forwards and gave off the remaining digital branches.

The deep palmar arch varies much in its size. The radial artery may in this part be larger than usual, and may give off, as above stated, the collateral branches to the fingers, or it may be smaller and form only half the deep arch, the rest being made up by the communicating branch of the ulnar artery.

Finally, the greater part of the arch may be formed by the ulnar artery, the radial being so small when it reaches the palm of the hand that it opens into the ulnar at the root of the thumb. Here the size of the vessel which forms the arch diminishes as it runs from the ulnar towards the radial side of the metacarpus.

THORACIC AORTA.

661. *Thoracic aorta:—(its straight portion).*—The aorta having completed its curve or arch at the lower border of the third dorsal vertebra, descends along the spine to the fourth lumbar vertebra, where it divides into the common iliac arteries. Its direction is not vertically downwards, for as its course is influenced by the spine, upon which it rests, it is necessarily concave forwards in the dorsal region, and convex forwards in the lumbar. Again, its commencement is at the left side of the spine, its termination also inclines a little to the left, whilst about the last dorsal vertebra it is nearly upon the median line. From this arises another curve, the convexity of which is to the right side, and the concavity to the left. Within the thorax it diminishes little in size; in the abdomen the diminution is considerable, in consequence of its giving off large branches soon after its entrance into that cavity.

The thoracic aorta, fig. 120, B, lies in the posterior mediastinum, being before the spine, and behind the root of the left lung and the pericardium; its left side is in contact with the corresponding pleura, the right with the vena azygos major, the thoracic duct, and œsophagus. The latter tube, however, as it descends, inclines in front of the artery, and near the diaphragm gets to its left side.

The branches which it gives are numerous but small.

rami pericardiaci are some very small and irregular vessels which pass forwards and ramify on the pericardium.

r. Bronchiales are the proper nutritious arteries of the substance of the lung; they accompany the bronchial tubes in their ramifi-

cations through the organ. They vary much in their mode of origin, and also in their number; in some instances there being two, in others three, four, or even five. Thus two small vessels arise from the aorta, about an inch below the arch, which diverge, inclining forwards and outwards, each being directed to the corresponding bronchus, whose course it takes, dividing and subdividing with the minuter bronchi into the substance of the lung. These are the *superior* bronchial arteries; they occasionally issue from a small common trunk. Lower down, two others (*r. bronchiales inferiores*) come off, which apply themselves to the bronchi and take a similar course. The right bronchial artery often arises from the first aortic intercostal. The left has been seen to arise from the subclavian, and, in a few rare instances, from the inferior thyroid.

r. Œsophageales are also variable in size and number; there are usually four or five, which arise from the fore part or right side of the aorta, and run obliquely downwards upon the œsophagus, freely supplying its substance. The lower branches of these vessels anastomose with the ascending offsets of the coronary artery of the stomach, whilst the upper ones communicate in a similar way with the branches of the inferior thyroid.

r. Intercostales, fig. 120, *f, f*, (inferiores,) arise from the posterior part of the aorta, and run at first outwards and upwards upon the bodies of the vertebræ, after which they lie along the intercostal spaces. Their number varies; there are usually eight or nine at the right side, for the two or three first intercostal spaces are supplied by the superior intercostal artery, derived from the subclavian; on the left side there are generally ten. Owing to the position of the aorta with regard to the spine, the right aortic intercostals are a little longer than the left. As these vessels pass outwards, they are covered by the pleura, and crossed by the sympathetic nerve; those of the right side also pass behind the œsophagus, the thoracic duct, and the vena azygos major. When arrived in the intercostal space, the corresponding vein being above it and the nerve below it, the artery gives off its posterior branch, which passes directly backwards, and is ultimately distributed to the muscles of the back which are lodged in the vertebral groove; previously to which, it gives ramusculi to the body of the vertebra upon which it passed, and also one which enters the intervertebral foramen and ramifies upon the membranes of the spinal cord. The continuation of the vessel is placed at first between the

pleura and the external intercostal muscle, and then between the two planes of muscles of that name. It divides into two branches, which diverge at an acute angle and then run along parallel to one another, taking the course of the margins of the ribs between which they lie. The inferior or smaller branch inclines downward, and approaches the border of the rib which lies below its intercostal space, and, after giving small twigs to the bone and the intercostal muscles, anastomoses with some of the superficial vessels. The superior or larger branch inclines towards the border of the rib which lies above its intercostal space, and, after giving branches to the intercostal muscles and communicating with the preceding branch, anastomoses with the anterior intercostal branches derived from the internal mammary artery, and with the thoracic branches of the axillary artery. The first aortic intercostal artery has an anastomosis with the vessel of that name, which comes from the subclavian artery, and the three last are prolonged amongst the abdominal muscles, where they communicate with the epigastric artery in front, the phrenic internally, and the lumbar branches of the abdominal aorta inferiorly.

ABDOMINAL AORTA.

662. The Aorta, after having passed between the crura of the diaphragm, rests on the bodies of the lumbar vertebræ as far as the fourth, where its division takes place. Its anterior surface is successively in apposition with the liver, the pancreas, duodenum, and mesentery. The vena cava accompanies it, lying at its right side, and it is surrounded by a mesh of nerves derived from the sympathetic.

The abdominal aorta, fig. 120, c, gives branches which are divided into two sets:—1. Those which arise from its fore part and singly, viz. the cœliac, and the superior and inferior mesenteric. 2. Those which pass off in pairs, viz. the phrenic, capsular, renal, spermatic, and lumbar.

CŒLIAC ARTERY OR AXIS.

663. *Arteria Cœliaca*, fig. 120, *g*; fig. 127, *b*, arises from the aorta whilst between the crura of the diaphragm, and as soon as it becomes apparent in the cavity of the abdomen. In the erect position of the body its direction is nearly horizontally

forwards, but it is not more than half an inch long. It is concealed by the small omentum, and lies close to the left side of the lobulus Spigelii, and above the pancreas, the two semi-lunar ganglia being in apposition with it on either side. It gives off three remarkable branches; viz. the coronary artery of the stomach, the hepatic, and splenic.

Fig. 127.

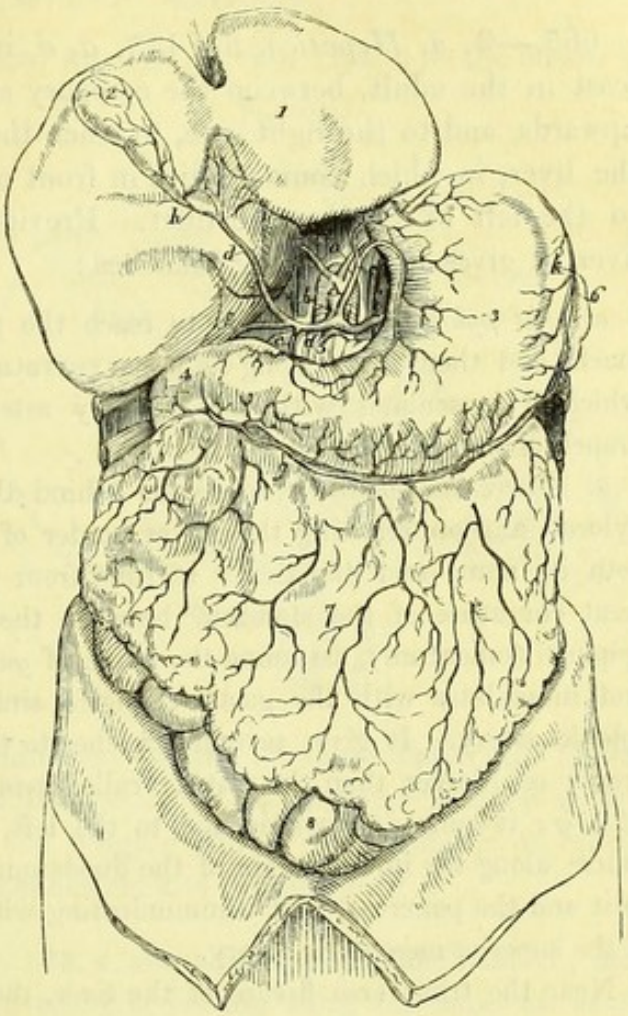

[In fig. 127, the liver is marked 1, the gall-bladder 2, the stomach 3, its pyloric extremity 4, the pancreas 5, the spleen 6, the great omentum 7, and the small intestines 8.]

CORONARY ARTERY OF THE STOMACH.

664.—1. *a. Coronaria ventriculi*, fig. 127, *c*, the smallest of the three, inclines upwards, and to the left side, to reach the cardiac orifice of the stomach. At this point some ramuli are sent upwards on the œsophagus, which communicate with the aortic œsophagean branches; others pass before and behind the cardiac extremity of the stomach, which they coil round. The continuation of the vessel inclines from left to right along the upper curvature of the stomach, gives branches to its coats, and inosculates with the pyloric branch of the hepatic artery.

HEPATIC ARTERY.

665.—2. *a. Hepatica*, fig. 127, *d*, *d*, intermediate in size, at least in the adult, between the coronary and the splenic, passes upwards, and to the right side, to reach the transverse fissure of the liver, in which course it lies in front of the vena portæ and to the left of the hepatic duct. Previously to reaching the liver, it gives the following branches:

arteria pylorica, *e*, descends to reach the pyloric end of the stomach, and then turns along its upper curvature, about the middle of which it inosculates with the coronary artery: it is sometimes a branch of the following.

a. Gastro-duodenalis, *f*, descends behind the duodenum near the pylorus, and on reaching the lower border of the stomach, changes both its name and direction. It runs from right to left along the great curvature of the stomach, between the lamellæ of the great epiploon (omentum), assuming the name of *gastro-epiploica dextra*, *g*, and inosculates with the gastro-epiploica sinistra derived from the splenic artery. It gives several branches to the duodenum and pancreas; one, larger than the rest, is called *pancreatico-duodenalis*, fig. 128, *g*; it runs downwards and to the left, forming a curve in its course along the inner margin of the duodenum, distributing branches to it and the pancreas, and communicating with some small branches of the superior mesenteric artery.

Near the transverse fissure of the liver, the hepatic artery divides into its right and left branches, which are intended for the supply of the corresponding lobes of that organ. The left, or smaller division, lying in front of the vena portæ, diverges at an acute angle from the other branch, and turns outwards to reach the left extremity of the transverse fissure of the liver, where it enters its substance, divides and subdivides into minute ramusculi, ramifying in the intimate texture of the organ.

The right or larger branch inclines outwards to the right extremity of the transverse fissure. When crossing behind the cystic duct, it gives off a branch, *h*, (*ramusculus cysticus*,) which turns upwards and forwards upon the neck of the gall-bladder, and divides into two ramusculi, of which one ramifies between its coats at its depending surface, the other between it and the liver. The right hepatic artery then divides into two or three branches, which enter the liver by its transverse fissure, and ramify in its substance, accompanying the divisions of the vena portæ and hepatic ducts.

666.—3. *a. Splenica*, fig. 127, *i;* fig. 128, *i*, in the adult, is the largest branch of the cœliac axis, from which it runs outwards, backwards, and to the left side. This artery will be found waving and tortuous in its course, as it passes along the upper border of the pancreas, to which it gives ramuli, and near the spleen divides into several branches.—Some of these enter the fissure in that organ, and are distributed to its substance; three or four are reflected towards the bulging end of the stomach, in which they ramify. Its branches are the following:

Fig. 128.

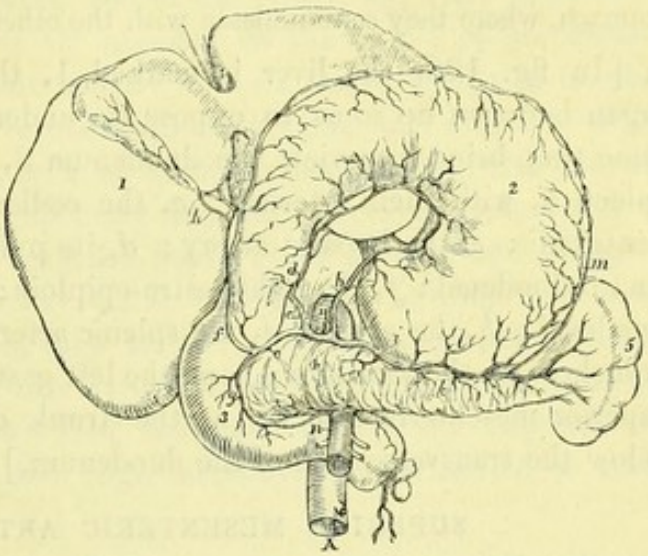

rami pancreatici, fig. 128, *k*, are variable in size and number; they are given off whilst the artery is passing along the pancreas, in the substance of which they ramify. One of larger size not unfrequently runs from left to right, in the direction of the pancreatic duct, and is called *r. pancreaticus magnus.*

r. Splenici are the proper terminal branches of the artery; they are five or six in number, and vary in length and size; they enter the spleen by the hilus or fissure in its concave surface, and divide within the organ until they become capillary.

The other branches of the splenic artery are reflected from it, and run a retrograde course.

r. Gastrici, l, (*vasa brevia,*) vary from five to seven in number; they run from left to right, some issuing from the trunk of the splenic artery, others from its terminal branches. Enclosed within the splenic omentum, they reach the left extremity of the stomach, where they divide and spread out between its coats, communicating with the coronary and epiploic arteries.

r. Gastro-epiploicus sinister turns forwards and downwards from the splenic, being at the same time reflected from left to right along the great curvature of the stomach, fig. 128, *m*, 127, *k*, where it inosculates with the right gastro-epiploic branch. In its course, this vessel lies between the layers of the great omentum, to which it gives several long branches; many also pass upwards from it to both surfaces of the stomach, where they communicate with the other gastric arteries.

[In fig. 128, the liver is marked 1, the stomach 2; this organ is drawn up so as to expose its under surface, and at the same time bring into view the duodenum 3, the pancreas 4, the spleen 5, with their arteries. *a*, the cœliac axis; *b*, coronaria ventriculi; *c*, the hepatic artery; *d*, its pyloric branch; *e*, the gastro-duodenal; *f*, the right gastro-epiploic; *g*, the pancreatico-duodenal; *h*, the cystic; *i*, the splenic artery; *k*, its pancreatic branches; *l*, the vasa brevia; *m*, the left gastro-epiploic; *n*, the superior mesenteric artery; A, the trunk of the aorta cut off below the transverse part of the duodenum.]

SUPERIOR MESENTERIC ARTERY.

667. *a. Mesenterica superior*, fig. 120, *h*; fig. 129, A, arises from the fore part of the aorta, a little below the cœliac. Its root lies beneath the pancreas, and above the transverse part of the duodenum; and its continuation is enclosed between the lamellæ of the mesentery. This vessel at first inclines downwards, and to the left side, but afterwards changes its direction, running

Fig. 129.

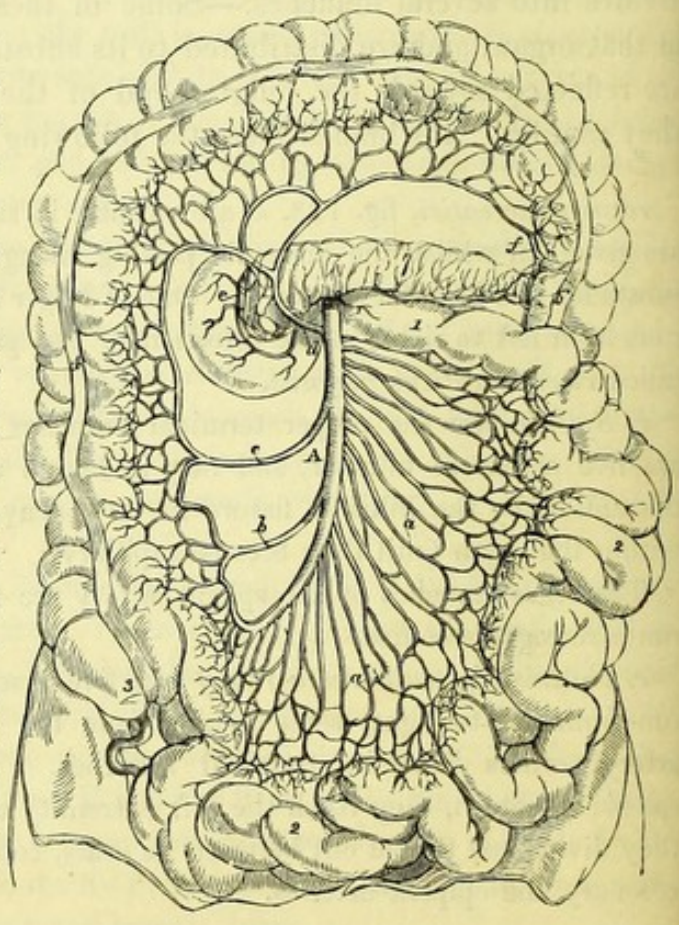

transversely towards the right iliac fossa, opposite to which it inosculates with the ilio-colic branch. It thus describes a curve, whose concavity looks to the right side, so that its branches may be divided into two sets, viz. those which arise from its convexity and those from its concavity. Those which spring from the convex side of the vessel, fig. 129, *a*, *a*, (*rami intestini tenuis*,) are all intended for the supply of the jejunum and ilium. They are usually from sixteen to twenty in number. They run parallel to one another for some way, and then divide into two branches, each of which forms an arch, with a similar offset from the neighbouring branch. From the summit of the first set of arches branches issue, which divide, and recommunicate in the same way, until, finally, after forming four or five such tiers of arches, each smaller than the other, the ultimate ramusculi proceed directly to the intestines, and ramify in their coats. The branches from the right side of the mesenteric artery are given to the large intestine, *arteriæ colicæ*, or rather *rami colici.*

ramus ilio-Colicus, *b*, which is the first of these, (taking them in their order from below upwards,) inclines downwards, and to the right side, towards the ilio-colic valve, near which it divides into two branches; of which one arches down, to inosculate with the termination of the mesenteric artery itself, and from the convexity of the arch branches go off towards the junction of the small with the large intestines, particularly to the valve; the other division ascends, and inosculates with the following branch:—

r. Colicus dexter, *c*, passes transversely to the middle of the ascending colon, opposite to which it resolves itself into two branches, of which one descends to communicate with the preceding vessel, whilst the other ascends to join in an arch with the succeeding:—

r. Colicus medius, *d*, passes upwards to the transverse colon, and divides in a manner exactly similar to the vessels just noticed. One of its branches inclines to the right, where it inosculates with the preceding vessel; the other descends to the left side, and maintains a similar communication with the left colic branch, *f*, derived from the inferior mesenteric artery. From the arches of inosculation thus formed ramusculi pass to the intestine, for the supply of its coats.

[In fig. 129, the transverse part of the colon is drawn up, and the anterior layer of the meso-colon and mesentery is removed to

bring the arteries into view :—1, is the termination of the duodenum ; 2, 2, the convolutions of the small intestines ; 3, the cœcum ; 4, the ascending colon ; 5, the transverse colon ; 6, the descending ; 7, the pancreas.]

INFERIOR MESENTERIC ARTERY.

668. *a. Mesenterica inferior*, fig. 120, *i* ; fig. 130, *d*, arises from the aorta, about an inch above its termination. It inclines downwards to the left iliac fossa to reach the sigmoid flexure of the colon, from which it descends into the pelvis, and under the name of " superior hæmorrhoidal" artery, runs down behind tha rectum. Its branches are :

Fig. 130.

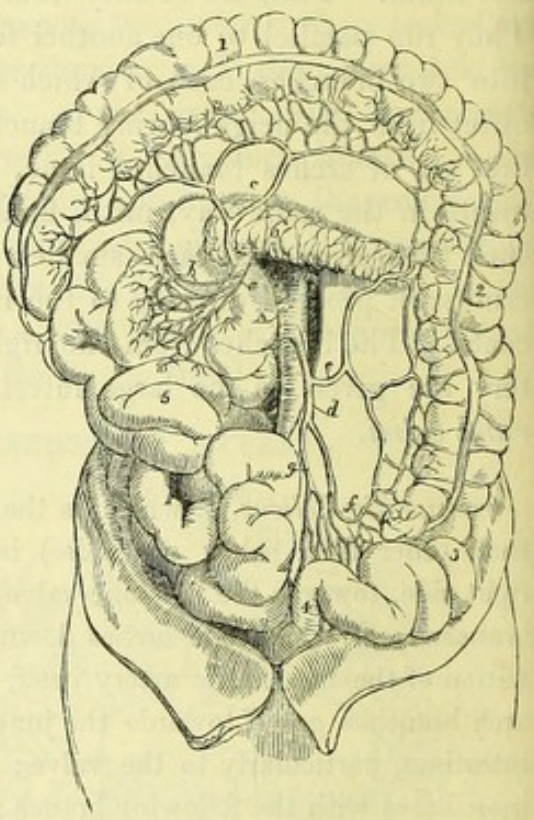

ramus Colicus sinister, fig. 130, *e*, which, close by the descending colon, divides into two branches, similar to those of the colic vessels of the opposite side. One of these branches passes upwards along the colon, and inosculates with the descending branch of the middle colic ; whilst the descending branch passes along the sigmoid flexure, to which it sends ramusculi. It anastomoses with the sigmoid branch.

r. Sigmoideus, f, runs obliquely outwards to the sigmoid flexure of the colon ; it divides into branches, some of which incline upwards and form arches with the preceding vessel, others turn downwards to the top of the rectum. From both, ramuli pass into the coats of the intestine.

r. Hæmorrhoidalis superior, g.—The continuation of the vessel having assumed the name of the superior hæmorrhoidal artery, lies in the fold of the meso-rectum, and ramifies in the coats of the intestine communicating with the middle and inferior hæmorrhoidal arteries.

We shall find, on even a slight inspection, a continued chain of anastomosis from one end of the alimentary canal to the other. The colic arteries form a vascular circle along the great intestine. The branches from the convex side of the mesenteric artery establish another range of arches along the small intestine, which is connected to the former by the ilio-colic artery. The superior mesenteric again anastomoses by some branches near its root with the pancreatico-duodenalis; the latter, at its commencement, is in a manner continuous with the pyloric artery; and so on, through the coronary and its ascending branches, a similar connexion is formed with the œsophageal branches, even up to the pharynx.

The middle sacral artery is the last of the single branches.

MIDDLE SACRAL ARTERY.

669. *a. Sacra media*, fig. 120, *k*, (r. sacer medius) is a small vessel about the size of a crow-quill, which arises from the extremity of the aorta, just at its bifurcation. From this point the artery proceeds downwards upon the last lumbar vertebra, and over the middle of the sacrum, as far as the coccyx, where it forms small arches of anastomosis with the lateral sacral arteries. From its anterior surface some ramusculi come forwards within the folds of the meso-rectum, and ramify upon the posterior surface of the intestine, and on each side others spread out upon the sacrum, and anastomose with the lateral sacral arteries, occasionally sending small twigs into the anterior sacral foramina.

The branches of the abdominal aorta, which arise in pairs, are, the phrenic, capsular, renal, spermatic, and lumbar.

PHRENIC ARTERIES.

670. *a. Phrenicæ*, fig. 120, *l*; fig. 127, *a*, are two small vessels which usually arise from the aorta, on a level with the inferior surface of the diaphragm. They are very close at their origin from the fore part of the aorta, but instantly diverge, cross the crura of the diaphragm, and proceed upwards and outwards upon its central tendon and broad muscle. That of the left side having passed behind the œsophagus, runs up to the left of the œsophageal opening, whilst the right phrenic artery, after having passed behind the liver and the vena cava, lies to

the right side of the opening in the diaphragm which transmits the latter. Each of these arteries divides into two branches before it reaches the central tendon of the diaphragm, of which one runs forwards towards the anterior margin of the thorax, distributing branches to the diaphragm, and finally anastomosing with the musculo-phrenic branch of the internal mammary artery. The other pursues a transverse direction towards the lateral margin of the thorax, and communicates with the termination of the intercostal arteries. Each phrenic artery gives small branches to the supra-renal capsule of its own side, and to the crus of the diaphragm; the left sends some to the œsophagus, and the right to the termination of the cava.

CAPSULA OR SUPRA-RENAL ARTERIES.

671. *a. Capsulares*, fig. 120, *m*, are two very small vessels which arise from the aorta, on a level with the superior mesenteric artery, and incline obliquely outwards upon the crura of the diaphragm to the supra-renal capsules to which they are distributed, anastomosing at the same time with the branches derived from the phrenic artery.

RENAL OR EMULGENT ARTERIES.

672. *a. Renales*, fig. 120, *n*, arise from the sides of the aorta, a little below the superior mesenteric artery, that of the right side being somewhat lower down than the left. The direction of each is outwards transversely, so as to form nearly a right angle with the aorta, but it has at the same time an inclination backwards and downwards. In consequence of the position of the aorta upon the spine, the right renal artery has to run a somewhat longer course than the left to reach the kidney; in most cases it crosses behind the vena cava, and is overlapped by its accompanying vein. Previously to reaching the concave border of the kidney, each artery divides into four or five branches, the greater number of which usually lie intermediate between the vein and the pelvis of the kidney, the latter being posterior, the former anterior. These branches, after having passed deeply into the fissure of the kidney, divide into ramusculi, which diverge, and mutually anastomose, forming a vascular interlacement round the conical masses into which the

tubuli uriniferi are aggregated; and so, when reduced to the size of capillaries, they constitute, with the ultimate radicles of the renal veins, the proper cortical or secreting structure of the kidney.

SPERMATIC ARTERIES.

673. *a. Spermaticæ*, fig. 120, *o*, are two very small vessels which arise from the fore part of the aorta, a little below the renal arteries. In the fœtus they are very short, as the testes are placed immediately beneath the kidneys; but the arteries acquire a proportional elongation as these organs remove from the lumbar region down into the scrotum. The direction of each spermatic artery is outwards and downwards, crossing the ureter, resting on the psoas muscle, and, after passing over the external iliac artery, turns forwards to the internal abdominal ring, where it comes into contact with the vas deferens, with which it descends through the canal, forming part of the spermatic cord as far as the testis, to the tubular structure of which it is distributed.

In the female these arteries do not pass out of the cavity. Their origin, direction, and relations, in the first part of their course, conform to what obtains in the male; but at the margin of the pelvis they incline inwards and backwards, so as to get between the layers of the broad ligaments of the uterus, by which they are guided to the ovaries, to whose structure they are finally distributed. Some of their ramusculi can also be traced along the round ligament into the inguinal canal, and others as far as the uterus, to which they are conducted by the Fallopian tubes.

LUMBAR ARTERIES.

674. *r. Lumbales*, fig. 120, *p*. are analogous to the intercostal arteries, for they are not only similar in their mode of origin, direction, and size, but also, like them, are intended for the supply of the lateral parts of the trunk. Moreover, as the intercostals, by communicating with the internal mammary arteries, form a vascular ring round the thorax, the lumbar arteries, by anastomosing with the epigastric, bear a similar relation to the walls of the abdomen. The lumbar arteries, when they arise singly from the aorta, which is not always the case, are

five in number; the first three pass outwards under the crus of the diaphragm, the sympathetic nerve, and the psoas muscle, the two last under the latter. Those of the right side pass behind the vena cava. In the first part of their course, they rest on the bodies of the vertebræ as they run towards the intervertebral spaces, where they give off two sets of branches, which take different directions; one being posterior, the other internal.

r. Muscularis.—The posterior branch of each artery turns directly backwards, between the transverse processes of the vertebræ, and is distributed to the deep-seated lumbar muscles.

r. Spinales.—The internal branches, usually two, or one which soon divides into two, enter the intervertebral foramina, and terminate in ramuli, of which some ramify upon the spinal cord and its membranes, communicating with the other spinal arteries; others supply the osseous structure, entering some of the foramina observable upon the surface of the bone, and may be called its nutritious branches (r. *nutritii*).

The artery itself, after giving off these branches, runs outwards transversely, maintaining its original direction, and after having passed first between the psoas and quadratus lumborum muscles, it gets between the layers of abdominal muscles and divides into branches, which supply these muscles, and also maintain various anastomoses; for they communicate with the branches of the epigastric and mammary arteries in front, with the terminal branches of the intercostals superiorly, and with those of the ilio-lumbar and circumflex ilii inferiorly.

Varieties in the distribution, mode of origin, and relative size of the branches of the abdominal aorta, are of frequent occurrence.

The phrenic arteries, in some instances, arise not separately, but by a common trunk, from the fore part of the aorta; in others, whilst one comes off as usual from that vessel, the other issues from the cœliac, the coronary, the renal, or conjointly with the capsular. These variations, however, seem to exert little influence on their course and distribution.

The hepatic artery, instead of arising from the cœliac, has, in a few instances, been seen to come from the aorta, and in one case from the superior mesenteric. It is much more usual to find two arteries entering the liver in the ordinary way, which, instead of

arising by a common trunk, come off separately, one from the coronary, the other from the cœliac or mesenteric. Dr. Green cites a case in which he found three hepatic arteries, "the left from the cœliac, in common with the coronaria ventriculi; another in the middle from the cœliac, also in common with the gastro-epiploica dextra; and a left (qu. right?) hepatic from the superior mesenteric, which gave off the cystic artery."

We frequently find the kidney at one or both sides receiving more arteries than one, but their size is diminished, from which it would appear that the deviation has gone merely a degree beyond that in which the single artery becomes divided into branches soon after its origin. The additional arteries in these cases come from the lower part of the aorta, or from the common iliac. When a kidney is placed lower than usual, for instance when situated in the pelvis, its artery is derived from the internal iliac or hypogastric. Meckel found in one case the two renal arteries of opposite sides arising by a common trunk from the fore part of the aorta.

The spermatic arteries occasionally arise by a common trunk, somewhat as the phrenics do; not unfrequently one of them is a branch of the renal.

The lumbar arteries of opposite sides, instead of arising separately from the aorta, may occasionally commence by a common trunk, whose branches pass out laterally, and continue their course in the ordinary way. The first lumbar not unfrequently arises conjointly with the last intercostal, and, in some instances, the last is a branch of the common iliac, or of the middle sacral.

The middle sacral artery represents the caudal prolongation of the aorta, but is necessarily diminutive in man, as the coccygeal vertebræ are merely rudimentary or atrophied. It sometimes deviates a little to the side, and proceeds, not from the bifurcation of the aorta, but from one of the common iliac arteries, usually from that of the left side.

675. The abdominal aorta terminates by dividing into two trunks, called the common iliac arteries, which diverge at an acute angle. This bifurcation usually takes place on the body of the fourth lumbar vertebra, a little to the left of the middle line. The point here indicated will be found on a level with a line drawn from one crista ilii to the other, and may be transfixed by another passed horizontally backwards from the left margin of the umbilicus to the vertebral column, in the erect posi-

tion of the body. It should, however, be observed, that the division not unfrequently takes place higher up or lower down by about the breadth of half a vertebra.

COMMON ILIAC ARTERIES.

676. *Arteriæ Iliacæ communes*, fig. 120, *q*, commence at the bifurcation of the aorta, and diverge as they pass downwards and outwards to the sacro-iliac symphysis, where each of them divides into two primary branches,—the internal and external iliac arteries, the former being distributed to the viscera of the pelvis, and the soft parts on its external surface, as well as to the perinæum, whilst the latter is prolonged into the lower extremity, after having sent two important branches to the parietes of the abdomen.

The common iliac arteries of opposite sides present some differences in their direction, length, and relations to contiguous parts, which deserve notice. The vessel on the right side passes off more abruptly than the left, and is somewhat longer, as the division of the aorta occurs to the left of the middle line. The right one also lies obliquely on the last lumbar vertebra, from which it is separated by both the common iliac veins, as they terminate in the vena cava. Both these vessels are covered by the peritonæum, and crossed by the ureters just at their point of division; the right being also crossed by the intestine ilium, where it is about to pass into the large intestine; whilst the left lies behind the sigmoid flexure of the colon. To the inner side of the left iliac artery, and supported on the last lumbar vertebra, lies its accompanying vein; on the right side the vein lies nearly behind the artery.

No branch that has received a name or deserves notice is given off by the common iliac trunks; but on reaching the sacro-iliac symphysis, as has been observed, each divides into the internal and external iliac arteries. We shall commence with the description of the internal iliac artery, chiefly because the parts which its branches supply, viz. the pelvic viscera and the perinæum, require to be examined at an early period.

Dissection.—In order to trace the branches of the internal iliac

artery, it is necessary to obtain a lateral view of the parts within the pelvis. Previously to taking measures for this purpose, the perinæum should be dissected, and the pudic artery examined at the same time (see Perinæum, dissection of). When this has been done, saw through the os pubis a little outside the symphysis, also the sacro-iliac symphysis of the same side; detach the peritonæum and viscera from that side, and push them to the opposite: by these means the whole limb, and the lateral part of the pelvis, can be removed, leaving the contained organs with their vessels, and one side of the cavity, undisturbed. When the parts are sponged, the arteries can be easily traced by commencing with the trunk and proceeding along the branches. In order to expose the branches of the gluteal and ischiadic arteries outside the pelvis, the gluteus maximus muscle must be dissected, detached from its origin, and reflected downwards.

INTERNAL ILIAC ARTERY.

677. *a. Iliaca interna*, fig. 120, *r*, (hypogastrica; pelvica,) in the fœtus, both from its direction and size, appears to be the continuation of the common iliac trunk. It is nearly double the size of the external iliac artery; but in the adult the relation in this particular is reversed, the external iliac being larger. As the vessel in the fœtal state differs from that in the adult subject so materially, in length, relations, size, &c. it becomes necessary to describe its condition in the former, previously to considering its course and distribution in the latter.

Internal iliac artery in the fœtus.—When the vessels in the fœtus are injected (part or the whole of the umbilical cord remaining attached), it will be found that the internal iliac artery proceeds from the point at which the common trunk divides (sacro-iliac symphysis) forwards and a little downwards, to reach the side of the bladder. In this course the artery descends very little, as the body and fundus of the bladder project into the abdomen in early life. Guided by the side and fundus of the bladder, it reaches the inner surface of the parietes of the abdomen, along which it ascends to the umbilicus, converging to the vessel of the opposite side. When arrived at that aperture, the two arteries come into contact with the umbilical vein, round which they coil in a peculiar manner, until

they reach the placenta, in the spongy texture of which their branches ramify until they become capillary. To that part of the vessel which intervenes between the sacro-iliac symphysis and the side of the bladder, the term *hypogastric* can in strictness be applied; the remainder thence onward through the umbilicus to the placenta, being the proper *umbilical* artery, which performs an important part in carrying on the fœtal circulation. In the first part of its course the vessel lies along the margin and side of the pelvis, covered by the peritonæum, then between that membrane and the side of the bladder, to which it gives branches (*superior vesical*), and finally, between the peritonæum and the fascia transversalis, which separates it from the rectus muscle and its sheath. After birth, when the placental circulation is no longer carried on, the umbilical arteries gradually contract, become impervious, and reduced to the form of mere ligamentous cords, extending from the side of the bladder to the umbilicus. The remaining part, which still continues pervious, presents a diminution in size proportioned to the decrease in the quantity of blood circulated through it.

678. The *internal iliac artery in the adult* is a short stunted trunk, extending from the sacro-iliac symphysis to the sacro-sciatic notch, opposite to which it may be said to terminate by dividing into branches. The external side of the artery just at its origin, is in contact with the inner border of the psoas muscle; lower down it rests against part of the sacral plexus. Behind it, is situated the internal iliac vein, and the communicating branch which passes from the lumbar to the sacral plexus; in front it is crossed by the ureter, which separates it from the peritonæum. When the depth at which this vessel is situated is duly considered, as well as its close connexion with the different parts here enumerated, we can form some idea of the difficulty of passing a ligature round it in the living subject, without including the nerve, or injuring the vein. Its branches, though constant and regular in their existence and general distribution, still vary much in their origin. Some, which are rather small and variable, are distributed to the parts or organs within the pelvis, viz. the surface of the sacrum, the rectum, bladder, uterus, and vagina, whilst others of larger size are sent for the most part to the muscles within the cavity of

the pelvis, and upon its outside. Viewing the internal iliac artery as we usually do after making a lateral section of the pelvis, it will be observed in most cases to present two primary branches at its point of division, one anterior, the other posterior: the latter gives off the ilio-lumbar, obturator, gluteal, and lateral sacral arteries; whilst from the anterior branch arise the umbilical (being originally its proper continuation), the ischiadic, and the pudic, which usually furnishes the vesical, uterine, and middle hæmorrhoidal arteries.

ILIO-LUMBAR ARTERY.

679. *r. Ilio-lumbalis* (iliaco-muscularis) resembles the lumbar branches of the aorta in direction and distribution. It passes outwards beneath the psoas muscle and external iliac vessels, to reach the margin of the iliac fossa, where it divides into two sets of branches. Of these, one passes upwards, ramifying in the psoas and quadratus muscles, where some of them communicate with those of the last lumbar arteries, whilst others enter the inter-vertebral foramina, and supply the parts lodged in the vertebral canal. The rest of its branches turn downwards and outwards, either in the substance of the iliacus muscle, or between it and the surface of the ilium. Some of these reach the crista and spine of that bone, where they anastomose with the circumflex ilii, and, if followed with attention, some can be traced forwards through the abdominal muscles, which they supply, and in which they communicate with the external branches of the epigastric artery.

OBTURATOR ARTERY.

680. *r. Obturatorius* (sub-pubio-femoralis), usually arises from the posterior branch of the internal iliac, but not unfrequently from the epigastric. The course and length of the internal or pelvic portion of the vessel will vary materially in these cases; the external or femoral is generally uniform. According to J. Cloquet,* who noted its distribution in more than two hundred instances, the number in which it arises from the iliac, as compared with that from the epigastric, may be stated as three to one. When the obturator artery arises from the internal iliac, it passes forwards close to the obturator internus

* Recherches Anatomiques sur les Hernies.

muscle, and a little beneath the nerve of the same name, with which it gradually comes into contact. Both pierce the pelvic fascia, pass through a cellular interval between the pubic and ischiadic portions of the obturator muscle, and finally appear at the top of the thigh, after having made their way through the oval aperture in the thyroid or obturator membrane. In this course the nerve lies above the artery, both being placed between the pelvic fascia and peritonæum, as they run along the inner side of the pelvis. But when it arises from the epigastric artery, it has to pass downwards and inwards into the pelvis, in order to reach the thyroid foramen; and in doing so its course must lie along the margin of the crural ring, and must be placed close to some part of the neck of the hernial sac, should a portion of intestine be protruded through that aperture. If the obturator artery arises near the origin of the epigastric, or by a short trunk common to it and that vessel, it will be placed across the external side of the crural ring; but if it starts from a point higher up, as it has to incline inwards whilst descending into the pelvis, it will be found along the superior and internal border of the ring, and therefore almost surrounding the neck of the sack. This, however, is rather an unusual occurrence; Breschet* appears to have met only a single instance of it. When the obturator artery has reached the thigh, it is supported on the external obturator muscle, and covered by the pectineus; it soon divides into two branches, one external, the other internal. The *external* branch inclines backwards and outwards, sending off branches, some for the supply of the obturator and quadratus muscles, whilst one or two, in some instances, reach the notch in the acetabulum, through which they pass, and are distributed to the hip-joint. The *internal* branch passes downwards between the adductors, supplies them as well as the pectineus and gracilis and communicates with branches of the internal circumflex artery.

GLUTEAL ARTERY.

681. *r. Gluteus* (la fessière, Chauss.) is the largest branch of the internal iliac artery; it inclines downwards and outwards, so as to reach the border of the great sciatic notch,

* Thèses présentées et soutenues publiquement devant les Juges du Concours. Paris, 1819.

beneath which it turns in order to appear on the dorsum of the pelvis. Its trunk will be found, accompanied by the gluteal vein and nerve, in the interval between the contiguous borders of the gluteus medius and pyriformis muscles; but it instantly divides into branches, one of which runs between the gluteus maximus and medius, and is superficial relatively to the other, which is placed between the latter muscle and the gluteus minimus. The first or superficial branch sends off in its course several ramusculi, which are distributed, some inwards (after piercing the tendinous origin of the gluteus maximus) to the side of the sacrum, anastomosing with the posterior branches of the sacral arteries; others, of considerable size, pass outwards between the gluteal muscles which they supply. The second or *deep* branch situated between the gluteus medius and minimus, runs in an arched direction forwards, and may be said to divide into two branches. The superior one, holding the course of the vessel from which it arises, proceeds beneath the gluteus medius and tensor vaginæ femoris, towards the anterior spine of the ilium, and anastomoses with the circumflex ilii and the ascending branches of the external circumflex artery, after having freely supplied the muscles between which it passes. The other branch descends towards the great trochanter, supplies the gluteal muscles, and anastomoses with the external circumflex.

SACRAL ARTERY (LATERAL).

682. *r. Sacro-lateralis* is generally a small single vessel; sometimes there are two, running parallel in the usual direction, which is downwards and inwards, in front of the anterior sacral foramina, resting upon the origin of the pyriformis muscle and the primary branches of the sacral nerves. It lies about an inch outside the middle sacral artery, having between them the sympathetic nerve, and runs as far as the coccyx, where it arches inwards to anastomose with the middle sacral and the lateral sacral of the opposite side. Sometimes it enters the third or fourth sacral foramen, and ramifies in the interior of the canal. Branches pass off anteriorly from this artery to the back part of the rectum and bladder; others, more considerable, incline backwards, and after giving ramusculi to the pyriformis and sacral nerves, enter the foramina, and are distributed to the nerves within the canal, some being prolonged backwards

through the posterior sacral foramina, so as to terminate upon the dorsal surface of the sacrum.

ISCHIADIC ARTERY.

683. *r. Ischiadicus* is smaller than the gluteal, and arises somewhat lower down. It occasionally forms a common trunk with the pudic artery, in other instances it gives off that vessel when it is about to leave the pelvis. Placed for some way upon the pelvic surface of the pyriformis muscle and the sciatic plexus of nerves, it soon turns backwards beneath the border of that muscle, passing between it and the superior gemellus. In this situation it lies in the interval between the tuber ischii and great trochanter, covered by the gluteus maximus. It gives off several muscular branches, to supply the external rotators on which it lies, as well as the gluteus which conceals it. Two only of its numerous branches have received names, or require a particular notice. An internal branch, the coccygeal (*ramus coccygeus*) inclines inwards, and pierces the great sacro-sciatic ligament, and so reaches the posterior surface of the coccyx, and supplies the coccygeus and levator ani muscles. A descending branch (*comes nervi ischiadici*, Murray, Harrison,) runs downwards, accompanying the sciatic nerve, and sends a long branch into its interior, which passes some way along with it in its course through the thigh. Besides these, some branches, after supplying the upper part of the flexor muscles, anastomose with the gluteal, the circumflex, and superior perforating arteries.

PUDIC ARTERY.

684. *r. Pudicus internus* (artère honteuse interne). The parts contained in the perinæum are supplied with blood from the internal pudic artery. This vessel usually arises as a distinct branch from the internal iliac artery, but occasionally is derived from a trunk common to it and the ischiadic. It inclines downwards and outwards to reach the spine of the ischium, lying at first on the sacral plexus, but afterwards passes between the pyriformis and coccygeus muscles, to gain the point just referred to. Having thus passed out of the pelvic cavity, it rests upon the external surface of the spine

of the ischium, beneath which it turns inwards through the lesser sciatic notch, and proceeds towards the inner surface of the tuber ischii. In this situation it lies on the obturator internus muscle, to which it is bound down by the obturator fascia, between which structures it lies, in its course forwards and upwards, along the rami of the pubes and ischium, towards the pubic arch. On approaching the latter, the artery pierces the fascia, and becomes placed between the crus penis and the bone, where it divides into its two ultimate branches, viz. ramus dorsalis penis and r. corporis cavernosi. In the first part of its course, whilst within the pelvis, the artery lies behind the bladder and vesiculæ seminales, and is supported by the pyriformis muscle and the sacral nerves; whilst outside the cavity it is placed between the sciatic ligaments, and rests upon the spine of the ischium. With these parts of the vessel we have nothing to do, in a practical point of view; but as soon as it reaches the perinæal space, it enters into new and important relations. Its direction is forwards, upwards, and inwards, taking the direction of the rami of the os pubis and of the ischium, fig. 131, *a*. It rests against the obturator internus muscle, which separates it from the bone, being at first about an inch, or somewhat more, higher up than the margin of the tuber ischii, in which situation it is concealed and bound down by the obturator fascia. In the rest of its course, where it corresponds with the rami, it has the bone to its outside, the falciform process of the great sciatic ligament beneath, and the obturator fascia internally. In the course of the artery numerous branches are given off: we may divide them into three sets, viz. the pelvic, the perinæal, and the terminal. The pelvic branches consist, in the first place, of some small unnamed ramusculi given to the coccygeus, pyriformis, and obturator muscles; and, secondly, of some which pass inwards to the rectum, prostate, and bladder, and are named from the parts which they supply, viz. vesical, vaginal, uterine, and middle hæmorrhoidal. But as these sometimes come from the ischiadic, or internal iliac arteries, we must notice them separately, and not merely as branches of the pudic. The perinæal branches are the following:

Fig. 131.

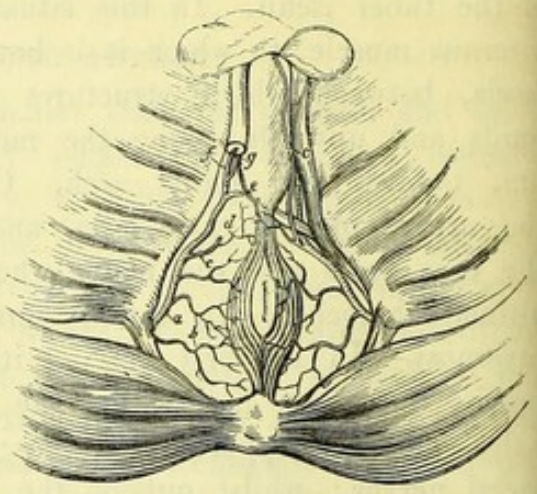

rami hæmorrhoidales externi, fig. 131, *b*, two or three in number, incline inwards from the pudic artery, when it has reached the tuber ischii, and must necessarily pierce the fascia which binds it down, in order to reach the perinæum. They lie embedded in a quantity of adipose substance, lodged in the interval between the ischium and the sphincter ani, and soon branch out into ramusculi, which are distributed to the parts about the margin of the anus.

r. Perinæi superficialis, *c*, is a long, small, but still regular artery, which supplies the scrotum and upper part of the perinæum; it pierces the fascia a little higher up than the preceding, and then turns upwards close by, and parallel with, the rami of the ischium and pubes: it crosses the transversus perinæi muscle, and finally lies in a groove between the erector penis and accelerator urinæ. In this course, it gradually becomes superficial as it ascends, and in the male is distributed to the scrotum, in females to the labium. It not unfrequently gives off the following artery:

r. Transversus perinæi, *d*, arises either from the pudic artery, or from the preceding branch, when on a level with the transversus perinæi muscle. As its name implies, it runs across the perinæum, and terminates in small twigs, which are distributed to the parts between the anus and bulb. Its size is very small.

r. *Corporis bulbosi*, *e*, passes horizontally inwards from the pudic artery when it is on a level with the bulb of the urethra, on reaching which it divides into ramusculi, that soon become capillary, and spread out into the erectile tissue constituting the bulb and corpus spongiosum.

r. *Corporis cavernosi*, *f*, is one of the terminal branches of the internal pudic. It turns forwards, and enters the body of the corpus cavernosum, in which it ramifies somewhat in the same way as the preceding vessel does in the corpus spongiosum and bulb.

r. Dorsalis penis, g, passes upwards between the crus penis and the pubic symphysis, and, having pierced the suspensory ligament, runs forward parallel with its fellow of the opposite side, freely supplying the integument in its course. Near the corona glandis, each of these arteries branches out into ramusculi, some of which pierce the glans, whilst others supply the prepuce.

The pudic artery sometimes takes a different course from that here described. Instead of passing out by the sciatic notch, it inclines inwards to the side of the bladder, runs along by the prostate gland, and escapes from the pelvis beneath the pubic arch; it thus gains the upper surface of the penis, and in the rest of its course represents the dorsal artery. Tiedemann gives a drawing of this variety: Burns met four cases of it. Mr. Harrison, after alluding to one which he had dissected, observes,* "Should such a variety exist in one who was to become the subject for the lateral operation of lithotomy, I fear this artery must be wounded; and, judging from its size and situation in those cases in which I have seen it take this course, I should apprehend very serious consequences from its division. It is not improbable but that some of those alarming and fatal cases of hæmorrhage which have occurred even to the best operators, may have depended on this variety."

The dorsal artery of the penis has been observed to arise not from the pudic, but from the a. profunda femoris, from which it passed obliquely upwards and inwards to reach the root of the penis. Tiedemann gives a drawing of this variety.

685. *a. Hæmorrhoidalis media* is usually a small long vessel derived from the pudic artery; but it may come from the ischiadic or internal iliac. It inclines inwards as it descends, and at the same time comes forwards to gain the side and fore part of the rectum, to which it gives ramusculi, some being prolonged under the peritonæum to the base of the bladder and the vesiculæ seminales. The branches of this vessel form a link of connexion between the external hæmorrhoidal artery derived from the pudic artery, and the superior one, which comes from the inferior mesenteric.

686. *a. Vesicales*, two or three in number, are derived from the pudic, from the middle hæmorrhoidal, or the ischiadic. They diverge as they pass forwards, one being directed down-

* Surgical Anatomy of Arteries, vol. ii. p. 124.

wards to the base of the bladder, upon which its ramusculi are lost; the other a little upwards to the side of that viscus. The latter may be called middle vesical, to distinguish it from those of the preceding vessel, as well as from some small branches which are situated higher up, and are derived from the internal the internal iliac artery itself, or from the umbilical.

687. *a. Uterina* is usually a branch of the pubic, or of the middle hæmorrhoidal, sometimes of the internal iliac. It is very small, and becomes tortuous as it approaches the uterus, to which it is guided by the fold of the broad ligament within which it lies. Its ramusculi ramify in the proper structure of the uterus, some being continued upwards to the ovarium.

688. *a. Vaginalis* arises not unfrequently in common with the uterine, or may come singly from the pubic or middle hæmorrhoidal. It runs forwards and inwards to reach the side of the vagina, and then inclines to its upper surface, to which it gives several ramusculi, some extending to the bladder.

EXTERNAL ILIAC ARTERY.

689. *a. Iliaca externa* (arteria cruralis in pelvi, Sœmm.) Previously to entering on its description, we may observe, that the vessel whose branches supply the lower extremity continues an undivided trunk from the point already indicated (*sacro-iliac symphysis*) as far as the lower border of the popliteus muscle, where it divides into the anterior and posterior tibial arteries; but though it continues thus undivided, different parts of it have received different names, taken from the anatomical regions through which it passes. Whilst within the pelvis, and running along the iliac region, it is named *iliac;* in the upper two-thirds of the thigh, *femoral;* from thence to the lower boundary of the ham, *popliteal.* Each of these divisions (which are really artificial, being intended merely to facilitate the description of the vessel) is marked by some change in direction, in relation to contiguous parts, and also by a diminution in size, proportioned to the decrease in the quantity of contained fluid consequent on the giving off branches of supply at different intervals.

Dissection. — As the external iliac artery and its branches are usually studied immediately after the abdominal viscera have been examined, very little dissection is required to expose them in their

entire extent. If the lower part of the parietes of the abdomen be turned down on the thigh, after the viscera have been removed, nothing more is necessary than to gently elevate the peritonæum from the iliac fossa, and draw it inwards towards the pelvis. The trunk of the vessel will then be observed resting on a smooth dense membrane (*fascia iliaca*) which is placed behind it, separating it from the psoas muscle; it is, however, bound down to the fascia by the sub-serous cellular tissue, which adheres firmly to it on each side of the vessel. The epigastric artery, if injected, may also be exposed in the lower and more important part of its course in the same way, namely, by removing the peritonæum from the fascia transversalis, which at once shows its relation to the cord and internal ring; to trace it higher up, the sheath of the rectus must be opened. If the abdomen be not opened, it will be necessary to cut through the three layers of abdominal muscles, in order to reach the epigastric artery. The direction of the vessel may be indicated by drawing a line a little from the pubic side of the middle point, between the superior spine of the ilium and the symphysis pubis, upwards to the side of the ensiform cartilage.

690. The *external iliac artery*, fig. 120, *s*; fig. 132, A, extends from the sacro-iliac symphysis to Poupart's ligament, its direction being obliquely downwards and outwards, so as to reach the middle point between the anterior superior spinous process of the ilium and the symphysis pubis. In this course the vessel presents a slight curve, being at first depressed a little backwards into the pelvic cavity; but lower down, where it passes over the brim of the pelvis and is supported by the psoas muscle, it comes a little forwards. It gives no branch of any consequence until it arrives within a few lines of its termination. It at first rests somewhat on the external iliac vein; as it descends it receives some support from the psoas muscle being closely applied to its inner margin, and finally rests upon it for some way, the fascia iliaca interposing. To its external side lies the psoas muscle in its whole course, which separates it from the anterior crural (femoral) nerve; the internal branch of the genito-crural nerve, as it passes inwards to its destination, runs in front of the artery. Anteriorly, the external iliac artery is covered by the peritonæum; internally, it is accompanied by the vein of the same name, which at first is placed rather behind it, but gradually comes forward, so as to lie on the same plane when they have

reached Poupart's ligament. The artery at this point is supported by the inner side of the psoas muscle, the vein by the os pubis, where a small part of its upper surface remains uncovered by muscular fibre, between the contiguous borders of the psoas and pectineus, but between the vessels and the bone and muscle just named, the prolonged part of the fascia iliaca is interposed. (Sect. 601.)

Just before its termination the artery gives its two branches, viz. the epigastric and circumflex ilii.

EPIGASTRIC ARTERY.

691. *r. Epigastricus*, fig. 120, *t*; fig. 132, *a*, is situated obliquely at the inferior and anterior part of the abdominal parietes. It arises from the external iliac artery, usually about two or three lines above the margin of Poupart's ligament; in some instances it comes off on a level with it, or even lower down. In the first case, it inclines downwards and inwards, so as to get on a level with the ligament, after which it changes its direction, passing obliquely upwards and inwards, being placed between the fascia transversalis and the peritonæum, until it reaches midway between the umbilicus and pubes, where it enters the sheath of the rectus, in which it ascends above the umbilicus, and terminates in several small branches that anastomose with the terminal branches of the internal mammary and inferior intercostal arteries; in its course it has communication also with some of the lumbar arteries. The epigastric artery is accompanied by one or two veins. In the male it is crossed by the vas deferens, in the female by the round ligament of the uterus. At first the duct lies in front of the artery, then turns round its external side as it descends to-

Fig. 132.

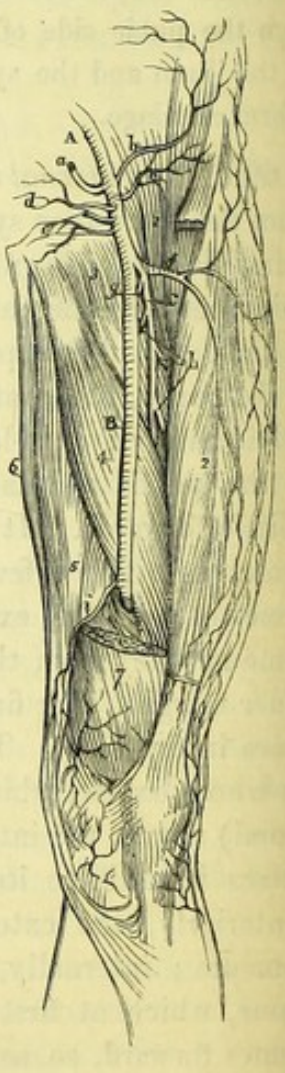

wards the pelvis. The vessel is therefore placed at the inner side of the internal abdominal ring, through which the spermatic cord passes. Its branches are the following:

r. Cremastericus.—A small branch descends along the spermatic cord beneath the cremaster muscle, passes through the external abdominal ring, and, after supplying the parts in the cord, anastomoses with the proper spermatic artery.

r. Musculares.—Several muscular branches pass from its inner and outer sides to the parts along which it runs; some of the latter communicate with the branches of the lumbar arteries and of the circumflex ilii.

r. Anteriores.—Some small ramuli come forwards through the muscle, become sub-cutaneous, and communicate with the superficial epigastric artery.

r. Terminales.—The terminal branches ascend in the substance of the rectus muscle, and anastomose with the internal mammary and inferior intercostal arteries.

CIRCUMFLEX ILII ARTERY.

692. *r. Circumflexus ilii*, fig. 120, *v*; fig. 132, *b*, smaller than the preceding, is placed obliquely along the lower border of the abdomen, lying at first within its parietes, and then between the muscular layers which form them. It arises from the external side of the iliac artery, on a level with Poupart's ligament, whose direction it takes as it runs upwards and outwards to the anterior superior spine of the ilium, where it turns along its crista, and divides into several branches, which are distributed to the abdominal muscles. About an inch after its origin, this artery pierces the fascia iliaca, and runs for some way between it and Poupart's ligament (corresponding with the line of insertion of that membrane); but opposite the superior spinous process of the ilium it gets between the transversalis and internal oblique muscles, to which it is finally distributed. It sends off:

Some slight twigs, which pierce the muscles, and along the groin anastomose with the superficial circumflex ilii, which comes from the femoral artery, and, farther on, with the branches of the gluteal artery; several smaller branches pass inwards to the iliacus muscle, and anastomose with the ilio-lumbar artery; its terminal branches communicate in the substance of the abdominal muscles with the lumbar arteries on the one hand, and the epigastric on the other.

Operations.—In order to expose and tie the external iliac artery in the living subject, it becomes necessary to divide the muscular parietes of the abdomen without injuring the peritonæum, after which this membrane must be pushed upwards from the iliac fossa. For this purpose, Mr. Abernethy made an incision about four inches long over the course of the artery. As the aorta divides on the fourth lumbar vertebra, and as the external iliac artery terminates midway between the anterior spine of the ilium and the pubic symphysis, it would at first sight appear that a line drawn from the umbilicus to the latter point would sufficiently indicate the course of the vessel, which in this, as in all other operations, it is a matter of great consequence to determine accurately. But this line would fall to the inner side of the vessel, more particularly at the right side, in consequence of the transverse direction of the common iliac artery. Hence the sacro-iliac symphysis, being the commencement of the external iliac artery, is the point over which the line must pass, in order that it may coincide with the direction of the vessel. If then, from midway between the anterior superior spine of the ilium and the symphysis pubis, a line be drawn upwards to about an inch to the outside of the umbilicus, it will mark the course of the external iliac artery. The incision through the integuments (the patient being placed in the horizontal position) should begin four inches and a half above Poupart's ligament, and end within half an inch of that line. This exposes the aponeurosis of the obliquus externus, which is to be divided in the same direction and extent. The fore-finger of the left hand should in the next place be insinuated beneath the lower border of the obliquus internus and transversalis muscles, in order to detach them from the peritonæum; but some difficulty will be experienced in effecting this, as it is necessary to tear through the fascia transversalis, which is rather firm in this situation. When the muscles have been elevated for some way, they are to be cautiously divided by a probe-pointed bistoury, carried along the finger. It then only remains, in order to obtain a view of the artery, to push the bag of the peritonæum from below upwards and inwards, towards the margin of the pelvis. It should, however, be recollected, that as the artery is in some measure bound down to the fascia iliaca by the sub-serous cellular tissue, which adheres rather firmly to that membrane, it becomes necessary to free it from this connexion, by carefully scraping, with the extremity of a probe or with the nail, before the needle can be passed round it. As the vein lies close to the artery

on its inner side, the needle must be insinuated between them, and passed from within outwards. No nerve, except a small branch of the genito-crural, is implicated in this operation, the anterior crural being separated from the artery by the breadth of the psoas muscle.

The mode of incision here pointed out, by cutting across the fibres of the abdominal muscles, necessarily weakens them where they most require to be strong. Its chief recommendation is, that it enables the operator to place the ligature higher up on the vessel than he could do otherwise; on which account it may be the only operation admissible in certain cases, for instance, where an aneurismal tumour has extended as far as Poupart's ligament, or a little above it. It may be farther observed, that whilst the operation is being performed in this way, much difficulty is experienced in keeping the vessel exposed after the peritonæum and intestines have been pushed up, as they are continually forced down by the descent of the diaphragm; and as the sides of the wound are held apart by two retractors, it is difficult to apply a third at its superior angle, so as to bear off the peritonæum and viscera.

Sir Astley Cooper adopts quite a different method of operation; his incision is somewhat transverse with regard to the course of the artery. Commencing about half an inch above, and to the pubic side of the spine of the ilium, he divides the skin in a direction parallel with that of Poupart's ligament, the incision being prolonged somewhat farther than midway between the spine of the ilium and symphysis pubis. The point specified is the inner margin of the abdominal ring; but this is not a good point of reference, as it is not perceptible or tangible before the incision is made. The fibres of the external oblique muscle are in the next place to be divided to the same extent; and when the lunated flap thus formed is elevated, the lower border of the obliquus internus and transversalis is exposed, as well as the spermatic cord, as it passes beneath them. The cord will then serve as a guide to the epigastric artery, in front of which it lies, and this vessel to the iliac artery, which can be detached from its connexions without any farther dissection. With this view the finger is passed along the cord, and through the fascia transversalis, or rather through the opening in it, which transmits the cord; the artery is then felt pulsating, and may be secured in the way recommended in the other mode of operation.

FEMORAL ARTERY.

693. *a. Femoralis* (femoralis communis; f. superficialis) is placed along the anterior and inner side of the thigh, extending from Poupart's ligament, where it is continuous with the external iliac, as far as the junction of the middle with the inferior third of the thigh, at which point the vessel changes its name and relation to the bone, becoming *popliteal.*

To expose the artery in the upper third of the thigh.—In the first place, let the knee be slightly bent and the limb rotated outwards. And as in this position the course of the femoral artery is indicated by a line extended from midway between the anterior superior spine of the ilium and the pubic symphysis, to the lower border of the patella, the first incision through the skin should be made to the same extent, and in the same direction. In order to reflect the integuments with facility, a second incision may be made transversely at the junction of the upper with the middle third of the thigh; and finally, another in the same direction opposite the termination of the femoral artery. The flaps of skin thus formed are to be dissected back, so as to expose the fascia lata. Whilst doing this, you will observe the superficial epigastric artery running upwards over Poupart's ligament upon the external oblique muscle and the superficial pudic branch, inclining inwards to the pubes. In the next place, the fascia may be divided to the same extent as the skin, so as to expose the muscles, which are to be dissected carefully. A pudic branch will be found running inwards on the pectineus, and the circumflex ilii outwards in the direction of Poupart's ligament. These are all small branches. Lower down you will see a much larger vessel derived from the arteria profunda, viz. the external circumflex, which runs outwards beneath the sartorius and rectus, its trunk affording a clue to its different branches, which can be traced without any difficulty after the vessel has once passed the crural nerves. The dissection of the femoral artery in the upper part of the thigh requires some care, as it is embedded in a quantity of cellular tissue, and gives off its more important branches. The profunda and femoral veins also, which here lie close to it, together with their different branches, pour out blood when divided, which embarrasses the young dissector. Hence it often becomes necessary to divide the veins and remove them, after which the parts may be sponged and the dissection proceeded with.

Before this measure is resorted to, the sheath of the vessels should be laid open, and the relative position of the vein and artery considered attentively.

To expose the artery in the middle third of the thigh.—In the middle third of the thigh, little more is necessary in order to exhibit the vessel, after the fascia has been removed, than to turn the sartorius outwards; the course of the artery is then readily perceived, though it is bound down by the firm fascia already noticed, as passing across it from the adductors to the vastus. The relation of the saphenous nerve and vein to the femoral artery should be noted carefully, and its depth from the surface considered, which will at once point out the difficulty of cutting down upon and tying it in this situation, and the comparative facility with which it can be reached in the upper third of the thigh.

To expose the deep-seated artery (a. profunda).—When the femoral artery has been sufficiently examined, attention should be directed altogether to the deep-seated artery (a. profunda) and its branches. To expedite the dissection, the femoral artery and vein, and also the deep veins, had better be removed; and if, after this, the adductor longus be detached from its origin, and reflected outwards over the vastus, the deep-seated artery will be fully exposed. Little difficulty can occur in tracing the external circumflex branch; but as the internal one sinks deeply between the muscles, it becomes necessary to divide the pectineus at its origin, and turn it outwards on the thigh, after which the artery can be traced as far as the neck of the femur; its terminating branches can be seen only when the posterior part of the thigh has been dissected. In this dissection the crural nerve and its branches should be attended to. They will be observed spreading out into a lash of filaments, which are distributed to the different muscles on the front and inner side of the thigh, whilst a few descend along the course of the artery.

To expose the perforating branches at the back of the thigh.—When the subject is turned on its face, in order to dissect the posterior part of the limb, an incision may be carried through the skin from midway between the tuber ischii and trochanter major to the middle of the popliteal space. This may be met by two transverse incisions, similar to those made on the fore part of the thigh. When the flaps of integument are reflected, and the fascia examined, the latter may be divided to the same extent, which will expose the

flexor muscles. These may be easily separated and drawn aside, after which the distribution of the perforating branches can be readily examined, as they lie on the adductor magnus, before their final termination. The anastomoses of the circumflex branches shall be considered after we have described the gluteal and sciatic arteries. As the incision through the integument here indicated corresponds with the course of the great sciatic nerve, it may be well to observe its relation and connexions whilst prosecuting the dissection of the arteries.

694. Resuming our description of the femoral artery, fig. 132, B, we remark *in limine*, that if the knee be semi-flexed, and the limb rotated outwards so as to turn the flat or inner side of the thigh somewhat forwards, the course of the vessel may be marked out by a line drawn, or a cord extended, from midway between the anterior superior spine of the ilium and the symphysis pubis, to the lower border of the patella. In this position of the limb, the vessel cannot be said to incline inwards; but if the subject be laid on the back, and both legs be placed closely together, the arteries of opposite sides will be nearer to one another, and therefore to the median line, in the popliteal space, than when under Poupart's ligament, which indicates a slight inclination inwards. A cursory inspection would, however, lead us to suppose the inclination to be greater than it really is, which is owing to the oblique direction of the femur. This is by no means a matter of indifference in a practical point of view. The superficial vein (vena saphena) has been wounded in a few instances during the operation for tying the femoral artery. This accident may happen to any individual who, from supposing that the artery inclines inwards as it descends, makes his first incision oblique, so as to correspond with such a direction of the vessel. It has been said,* that if a line be drawn from midway between the spine of the ilium and the symphysis pubis, down to the middle of the popliteal space, it will indicate the course of the vessel. This is nearly correct; but as this line runs along the inner surface of the thigh, its course is rendered much more oblique than that of the vessel, which is placed so much nearer the shaft of the femur. In

* Boyer, Traité d Anatomie, tom. iii.

the skeleton, whilst the femur hangs freely, a plummet line suspended from midway between the pubic symphysis and spine of the ilium, will drop exactly between the condyles of the femur, and mark out the general direction of the artery. In the upper third of the thigh it is directly downwards; some slight deviation inwards may occur in the middle third, where the vessel is borne off from the bone by the vastus muscle; but this cannot be so great as to require any obliquity in the direction of an incision made with the view of exposing it.

695. The direction of the vessel may then be said to be downwards, along the anterior and inner side of the thigh, becoming gradually deeper as it descends; and in its course it lies first on the psoas muscle (supported on its inner border), which separates it successively from the os pubis, the brim of the acetabulum, and the hip-joint. Below this, the vessel rests on some branches of the arteria profunda and its accompanying vein, embedded in cellular tissue; these separate it from the pectineus, 3, and adductor brevis; it then passes over the adductor longus, 4; and finally over the conjoined tendons of the latter and adductor magnus, 5. Internally, it is in contact with the femoral vein, both vessels lying on the same plane in the first instance, where they are supported by the os pubis; but when the vein sinks behind the artery, the latter comes into contact with the adductor longus and sartorius muscles. Externally, it at first rests against the psoas muscle, which separates it from the anterior crural nerve; but after that muscle has passed backwards to its insertion, it rests against the vastus internus; three or four branches of nerves will here be observed in contact with the sheath of the vessels.

696. The anterior surface of the artery in the upper third of the thigh is covered only by the common integument, the superficial fascia, the inguinal glands, and the fascia lata; so that it is comparatively superficial, and may be easily compressed against the os pubis or the brim of the acetabulum. In the middle third of the limb the vessel is more deeply seated, as in addition to the parts already mentioned, it is covered by the sartorius muscle, beneath which may be observed a fascia, composed of oblique fibres, passing from the

adductor muscles to the vastus internus. This is thin superiorly, beginning where the sartorius overlaps the vessels, but gradually becomes dense and firm as it approaches the point at which the vessel passes through the opening in the adductor magnus. At Poupart's ligament the femoral vein lies close to the inner side of the artery, and on the same plane with it; it rests on that part of the brim of the pelvis which corresponds with the interval between the contiguous borders of the psoas and pectineus muscles, separated from the bone by the prolonged part of the fascia iliaca, which passes down behind the vessels; when distended, it overlays some of the outer fibres of the pectineus. As the vein descends, it gradually inclines backwards, coiling round the artery, so that on reaching the popliteal space it is situated to the outer side and behind that vessel. The anterior crural nerve, at its exit from the abdomen, lies about three quarters of an inch to the outside of the artery, being separated from it by the breadth of the psoas muscle; but when the muscle sinks backwards towards the trochanter minor, two or three branches of the nerve incline towards the artery, and accompany its sheath for some way; of these, the largest, which from its ultimate distribution is called nervus saphenus, is found at the superior and external side of the artery during the middle part of its course, whilst the vein is situated posteriorly and internally for the same extent. This nerve does not accompany the artery and vein as they pass backwards through the adductor magnus; it continues directly downwards to the inner condyle of the femur, and may be found between the tendons of the gracilis and sartorius muscles.

Branches of the Femoral Artery.

697. The femoral artery gives off its chief branches in the superior part of its course, whilst it is yet uncovered by muscle. Some of these, small and unimportant, are distributed to the inguinal glands and adjacent muscles; others, though small, have received names, and require a separate notice, viz. the external pudic (superior and inferior), the superficial epigastric, the superficial circumflex ilii, and, finally, a branch of considerable size—a. profunda femoris.

Rami pudendi externi, fig. 132, *c*, arise, either separately or by a

common origin, from the internal side of the femoral artery. The *superior*, or more superficial one, passes upwards and inwards to the spine of the os pubis, crosses the situation of the external abdominal ring, and is distributed to the integuments at the lower part of the abdomen, and the external parts of generation. The *inferior* and deeper-seated one passes inwards, resting on the pectineus, and covered by the fascia lata, which it pierces on reaching the ramus of the os pubis, and is distributed to the scrotum in the male, or labium in the female, its branches inosculating with those of the superficial perinæal artery. The superior branch is necessarily cut across whilst the integuments are being divided in the operation for inguinal hernia.

r. Epigastricus superficialis, d, is larger than the preceding branch; it arises from the femoral artery, about half an inch below Poupart's ligament, passes forwards through the saphenous opening in the fascia lata; after which it changes its direction, and runs perpendicularly upwards on the abdomen, in the superficial fascia covering the obliquus externus. Its terminal branches, ascending as high as the umbilicus, anastomose with those of the proper or deep epigastric and internal mammary arteries. The rest of its branches ramify in the cellular tissue and superficial fascia, on the lower part of the abdomen. This vessel must be divided by the transverse incision made through the integuments in the operation for femoral hernia.

r. Circumflexus ilii superficialis, e, runs outwards and a little upwards, taking the direction of Poupart's ligament, to the spine of the ilium, across the psoas and iliacus muscles, to which it gives some branches. It terminates in several small twigs, which pierce the fascia lata, and anastomose with similar branches from the deep circumflex ilii, the external circumflex, and gluteal arteries.

DEEP-SEATED FEMORAL ARTERY.

698. *a. Profunda femoris*, fig. 132, *c*, may be considered as the proper nutritious vessel of the thigh, its branches being distributed to it exclusively, whereas the femoral artery passes onwards to supply the leg and foot, giving off very few (and these insignificant) branches whilst it corresponds with the femur. In this view of the destination of these vessels, the terms applied to them by Murray seem sufficiently appropriate. The short trunk intervening between Poupart's ligament and the origin of the profunda, he names *a. Femoralis communis;* the continua-

tion of the vessel as it passes along the thigh, *a. Femoralis superficialis;* and its deep-seated branch, *a. Femoralis profunda.* The profunda artery arises from the external and posterior surface of the femoral, usually from an inch and a half to two inches below Poupart's ligament. It at first inclines outwards in front of the iliacus muscle, but soon changes its direction, running downwards and backwards behind the femoral artery. Opposite the junction of the upper with the middle third of the femur, the profunda passes beneath the adductor longus muscle, and inclining outwards to the linea aspera of the femur, soon divides into its terminal branches, which pass between that ridge of bone and the adductor magnus, to reach the posterior part of the thigh, where they are distributed to the long flexor muscles. The trunk of the profunda in this course lies at first on the psoas and iliacus muscles after their junction, then on the pectineus and adductor brevis, finally on the adductor magnus. In the first part of its course it is separated from the femoral artery by the profunda and femoral veins, and by a quantity of cellular tissue, in which all these vessels lie embedded; lower down, the adductor longus is interposed between them. In addition to a number of small and nameless branches, the profunda gives off the following, which deserve particular notice.

Ramus Circumflexus externus, f, arises from the profunda whilst it rests on the iliacus muscle, and after passing outwards for a short way beneath the sartorius and rectus muscles, and through the divisions of the anterior crural nerve, it gives off branches, which may be divided into three sets, from the directions which they take. The first continue transversely outwards in the course of the vessel, and after passing over the crureus, 2, pierce the vastus externus, so as to get between it and the bone just below the trochanter major, and so reach the posterior side of the thigh, where they anastomose with the internal circumflex branch, also with the gluteal and ischiadic. The ascending branches pass upwards beneath the sartorius and rectus, and finally under the tensor vaginæ femoris, where they communicate with the terminal branches of the gluteal, and with some of the external descending branches of the circumflex ilii. The descending set pass outwards and downwards upon the extensor muscles, covered by the rectus. These are usually three or four in number, some being of a considerable size; most of them are distributed to the muscles on the fore part of the thigh, but one or two can be traced as far as the

knee where they anastomose with the superior articular branches (internal and external) of the popliteal, and with the anastomotic branch of the femoral.

r. Circumflexus internus, g, arises from the inner and posterior side of the profunda, and turns directly backwards between the pectineus and psoas muscles, so that only a small part of it can be seen without disturbing these muscles. On reaching the tendon of the obturator externus muscle, which in a manner guides it to the posterior part of the thigh, it divides into two branches, or rather sets of branches. One of these ascends, and is distributed partly to the adductor brevis and gracilis, and partly to the external obturator muscle, where it anastomoses with the obturator artery; the other branch passes backwards above the trochanter minor, and appears on the posterior aspect of the limb, between the quadratus femoris and adductor magnus, where it anastomoses with the sciatic and superior perforating branches. When this transverse branch of the internal circumflex arrives opposite the hip-joint, it sends into it, through the notch in the acetabulum, an articular vessel, which passes beneath the transverse ligament, and after supplying the adipose substance in the depth of the articulation, is guided to the head of the femur by the round ligament. In some instances this vessel is derived from the obturator artery; sometimes the joint receives one from both.

r. Perforantes, h, so called from piercing the adductor muscles, are three or four in number. The *first* passes backwards between the pectineus and adductor brevis, sometimes through the fibres of the latter, and finally through the adductor magnus, after which it immediately divides into branches, which are distributed to the adductor magnus, the biceps, and gluteus maximus, communicating with the ischiadic and internal circumflex arteries. The *second*, considerably larger than the first, passes through the adductor brevis and magnus, after which it divides into an ascending and descending branch; the former, passing up on the adductor, supplies the posterior muscles, and anastomoses, towards the great trochanter, with the circumflex and ischiadic arteries; the latter descends, and is distributed to the flexor muscles, where it communicates with the terminal branches of the profunda. A branch of this vessel usually enters the medullary foramen of the femur. The *third* perforating artery passes back from the profunda, when it has got under cover of the adductor longus, pierces the adductor magnus, and, like the others, is distributed to the long flexor muscles.

[In fig. 132, 1 marks the conjoined fibres of the iliacus and psoas; 2, the crureus, exposed by cutting away the rectus at its tendon; 3, the pectineus; 4, the adductor longus; 5, the adductor magnus; 6, the gracilis; and 7, the lower part of the vastus internus, the rest being removed.]

699. The profunda, after having given off these different vessels, becomes considerably diminished in size, and passes backwards close to the linea aspera, where it divides into branches, some of which are distributed to the short head of the biceps, the rest to the other hamstring muscles. These terminal branches do not pass to their destination exactly in the same way as the perforating set do: the latter pierce through the fibres of the adductors about an inch, or a little less, from their insertion; the former pass close to the linea aspera, between it and some tendinous fibres which arch over the vessels, and protect them from compression by the muscle. At these points the muscle is attached, not to the bone, but to the tendinous fibres just referred to. A similar provision will be found in several other parts of the body, for instance, where the r. profundus humeri passes beneath the triceps muscle, &c.

The femoral artery in its course along the thigh gives branches to the contiguous muscles, but none of them merit a particular name or description. Close to its termination a small but regular branch arises from it,—

Ramus anastomoticus, fig. 132, *i*, descends from the femoral, as it is about to pass into the popliteal space, in a line continuous with that of the trunk, from which it arises. It pierces the tendinous fascia which binds down the femoral artery, and gives off two or three branches, whilst the vessel itself passes down to the inner condyle, guided by the prolonged tendon of the adductor magnus, and there anastomoses with the internal articular artery. Its branches pass obliquely outwards through the substance of the vastus internus, and communicate with the long descending branches of the external circumflex artery.

700. *Varieties.*— It may be observed, that considerable variety obtains in the mode of origin of the branches of arteries here described. Meckel justly observes, that the varieties in the arterial system are not less numerous than those of the venous, which is not generally supposed to be the case. But as these branches are intended

to carry on the collateral circulation after the main vessel has been obliterated, their course and distribution are usually regular and uniform. The profunda artery very seldom comes off lower down than two inches from Poupart's ligament. Whenever it deviates from this rule, it, in the great majority of cases, separates from the femoral higher up, either close under the ligament, or even within the pelvis. In an individual who was the subject of popliteal aneurism, for which the usual operation was performed, it was found that the ligature when tied did not control the pulsation in the tumour; still a coagulum formed; but the patient died of another disease; and when the limb was dissected, two arteries, of nearly equal size, appeared, occupying the situation of the femoral. A division had taken place high up, and a reunion in the popliteal space just above the tumour. The preparation is preserved in the anatomical museum of University College. A similar conformation of the brachial artery has been already indicated. Meckel cites a case in which the femoral artery divided into the anterior and posterior tibial arteries at the top of the thigh at one side, the division being in its regular situation at the other.

Operations.—The femoral artery may be tied in the upper or middle third of the thigh; the former situation is now universally preferred, because the operation in the latter is considerably more difficult of execution, without securing any equivalent advantage. The limb being placed in the position pointed out at the commencement of section 693, an incision is made through the integuments, beginning two inches below the middle point of Poupart's ligament, and carried perpendicularly downwards for three inches, or a little more, in a muscular fat subject. Previously to commencing this incision, it may not be amiss to place a scalpel, or a probe, along Poupart's ligament, and mark upon it the middle point; if the external end of the instrument be depressed, so that it should lie horizontally across the thigh, the incision through the integument should be made so as to form with the instrument thus placed a right angle. This suggestion is intended only for those who are about to perform the operation on the dead subject, or who may be planning the execution of it. The fascia lata being exposed, a small part of it should be pinched up with the forceps, and cut across, so as to form a small opening, into which a director is to be passed, in order that the fascia may be safely divided upon it. The sheath of the vessels is thus brought into view, a small part of which should be raised by the forceps and divided, the knife being held in the horizontal position. The vein in this situation will

be found behind, and a little to the inner side of the artery; on which account, in carrying the needle round the latter, its point is to be directed from within outwards, and cautiously insinuated between them, its surface being held close to the artery. Some difficulty is generally experienced in effecting this step of the operation. The point of the needle is said to be hitched on some tough cellular membrane, which is pushed onwards, and requires to be divided before the needle can be fairly protruded. This resistance is owing to the sheath of the vessels, now loose after its division, and readily caught into a fold by the point of the instrument. In operating on the dead subject, this impediment is readily removed, by pinching up the external flap of the sheath, and holding it tight with the forceps, whilst the needle is passed round the artery. The nerves which here lie external to the sheath, will by the same expedient be held out of the way. The ligature of the carotid artery is facilitated by the same means. Would such a measure be advisable in operating on the living? It is not altogether undeserving of attention.

POPLITEAL ARTERY.

701. *a. Poplitea*, fig. 133, A, is that part of the arterial trunk which extends from the opening in the adductor magnus to the lower border of the popliteus muscle, being continuous superiorly with the femoral, and inferiorly with the anterior and posterior tibial arteries, into which it divides.

Dissection.— The subject being turned on its face, an incision should be made through the skin, along the middle of the popliteal space, extending from the lower third of the thigh as far as the upper fourth of the leg, which corresponds with the length of the popliteal artery. A transverse incision should be made right across this at each extremity; the flaps thus marked out being reflected, and the fascia exposed, this membrane is to be divided and reflected in the same manner. By these means the muscles bounding the popliteal space are exposed. The interval which they enclose is of a quadrilateral figure, two sides being formed by the hamstring muscles diverging to their insertions, and two by the heads of the gastrocnemius converging to their point of union. Through the centre of this space, from its superior to its inferior angle, runs the popliteal artery; but to expose it fully, the mass of adipose matter by which it is concealed must be dissected away, in order that its relation to the vein and nerve may be clearly discerned. To follow it up in the superior part of its course nothing more is necessary

than to draw aside the flexor, or hamstring muscles, as they are merely connected by some cellular tissue, which retains them in apposition with one another. But as the lower part of the vessel is covered by the gastrocnemius, it will answer all purposes to divide the inner head of that muscle near the condyle, and then reflect and carry it outwards, which will expose it as far as its bifurcation.

The direction of the artery is downwards and a little outwards, running through the centre of the popliteal space. In this course the vessel rests on, or corresponds for some way to, the flat surface of the femur (a quantity of adipose substance interposing), then on the posterior surface of the knee-joint, and finally on the popliteus muscle, 2. Its posterior surface is covered for some way by the semi-membranosus muscle, 1 ; in the ham it is covered only by the skin, fascia lata, and a quantity of adipose matter in which it is embedded, but lower down it is concealed by the gastrocnemius. On either side of it lie the hamstring muscles above, and the heads of the gastrocnemius below. The artery is accompanied by the popliteal vein and the sciatic nerve, the vein being posterior and a little external to it, the nerve still more posterior and external, that is to say, lying nearer to the skin and to the head of the fibula. The popliteal artery gives off five articular branches, two above and two below the joint, and one which passes into it,—also some large muscular branches to the gastrocnemius, hamstrings, &c.

Fig. 133.

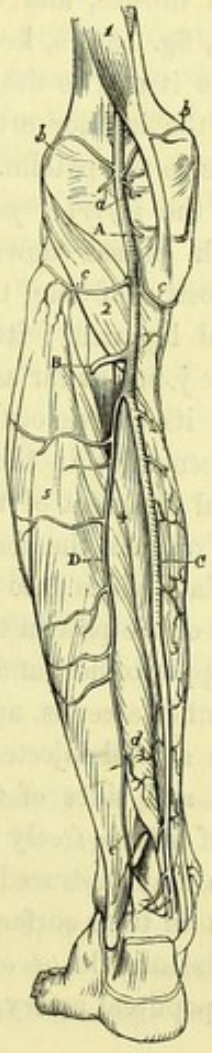

Rami musculares, fig. 133, *a*, are superficial, and come distinctly into view when the fascia is removed. Some of them are small, and are seen passing out at the point of divergence of the hamstring muscles; others, of considerable size, and three or four in number, will be observed between the heads of the gastrocnemius, two or three being distributed to its fleshy substance, and one rather long, and tapering in many

cases, descends vertically in the middle line, resting on its posterior surface.

Rami articulares. — Two of these pass away nearly at right angles from the popliteal artery above the flexure of the joint, and two below it; hence they are named internal and external.

Of the *superior pair*, fig. 133, *b*, *b*. — The *internal* branch turns round the inner side of the femur just above the condyle; and, passing under the tendon of the adductor magnus and vastus internus, divides into branches, of which one, comparatively superficial, fig. 135, *a*, enters the substance of the vastus, which it supplies, at the same time anastomosing with the r. anastomoticus, and with the inferior internal articular artery. The other branch runs close to the femur, gives ramusculi to it, also to the structures in the knee-joint, and keeps up a communication with the superior external articular artery.—The *external* branch passes outwards, a little above the external condyle of the femur, crossing under cover of the biceps muscle, and divides into a superficial and deep branch; the latter, fig. 135, *b*, keeps close to the femur, and, after giving ramusculi to it and to the articulation, anastomoses with the preceding and with the inferior articular branch; the former descends through the vastus to the patella.

Of the *inferior pair*, fig. 133, *c*, *c*; fig. 135, *c*, *d*. — The *internal* branch passes downwards and inwards below the corresponding tuberosity of the tibia, lying between the bone and the internal lateral ligament; its branches ramify on the anterior and inner part of the joint, as far as the patella and its ligament.—The *external* one takes its course outwards under cover of the external head of the gastrocnemius in the first instance, and afterwards under the external lateral ligament of the knee, and the tendon of the biceps muscle; it thus reaches the fore part of the joint, and near the border of the patella divides into branches, of which one descends along the ligament of the patella to communicate with the inferior articular artery of the opposite side, and with the recurrent branch from the anterior tibial; the other ascends, and anastomoses with the superior articular arteries.

In a well-injected limb, the four articular branches form at the front and sides of the joint a complete mesh by their ramifications, all of which freely communicate with one another; and several of them may be traced into the substance of the bones through the foramina on their surface.

The middle or *azygos* branch passes from the anterior surface of the popliteal artery, opposite the flexure of the joint, and about mid-

way between the superior and inferior articular arteries; it pierces the posterior ligament of the joint, and divides into minute ramifications for the supply of the crucial ligaments and the other structures within the articulation.

POSTERIOR TIBIAL ARTERY.

702. *a. Tibialis postica* is situated along the posterior part of the leg, between the superficial and deep muscles, being firmly bound down to the latter by the deep fascia.

Dissection.—When describing the method of exposing the popliteal artery, it was stated that this could be effected by merely dividing the inner head of the gastrocnemius, and turning the corresponding venter of it somewhat outwards. A small part of the posterior tibial artery, which is the continuation of the popliteal, is at the same time brought into view; but as the rest of it lies deeply beneath the soleus, this muscle must be detached wholly or in part, in order to trace the course of the vessel. As the vessels are here bound down to the deep-seated muscles by the deep fascia, and as that membrane exerts an important influence on the progress of operations executed on these arteries, it is advisable to leave it untouched whilst the superficial muscles (those of the calf of the leg) are being removed. This end can only be attained with facility by proceeding with the dissection of the muscles from below upwards. An incision may with this view be made through the strong external fascia of the leg, along the borders of the tendo Achillis. If the tendon be then drawn backwards, and held on the stretch, the deep fascia will be readily exposed, from the ankle, as far as the belly of the soleus muscle. When this is effected, there can be no difficulty in detaching the muscular fibres from the tibia and fibula, as the fascia serves as a guide, indicating the line of separation between the superficial set of muscles which are to be removed, and the vessels and deep-seated muscles that are to be left untouched.

The posterior tibial artery, fig. 133, c, extends from the lower border of the popliteus muscle, where it is continuous with the popliteal artery (of which it may be regarded as the continuation from its direction and course), as far as the inner border of the calcaneum, where it terminates, by dividing into the plantar arteries. The course of the vessel is obliquely downwards and inwards, being placed above, midway between

the bones of the leg, and below, between the inner ankle and the prominence of the heel. Its anterior surface rests successively on the tibialis posticus, the flexor longus digitorum, and inferiorly, for about two inches, on the tibia, separated from it by some cellular tissue; posteriorly, it is covered by the gastrocnemius and soleus (the deep fascia being interposed), and, farther down, by the fascia of the leg, as it is stretched from the tendo Achillis to the inner border of the tibia. On each side lie its accompanying veins, and along its external or fibular side runs the posterior tibial nerve. It will be recollected, that in the hollow between the internal malleolus and the calcaneum run three tendons, as well as the posterior tibial vessels. Their relative position may be stated as follows: the tibialis posticus and flexor longus digitorum run close to the inner malleolus; a quarter of an inch behind these is the tibial artery, the nerve being a little posterior to it; and finally, about half an inch further back towards the heel, is the tendon of the flexor longus pollicis. It gives off many branches:

r. Musculares.—In its course along the leg, this artery gives several unnamed branches to the contiguous muscles, particularly to the tibialis posticus, 4, and the long flexors.

Ramus nutritius tibiæ.—In the upper third of its extent, a considerable branch passes forwards to the tibia, and then, by an oblique course through the nutritious foramen in that bone, reaches the medullary membrane, on which its branches ramify.

The chief branch of the posterior tibial is the following:

PERONEAL ARTERY.

703. *a. Peronea*, fig. 133, D, is situated deeply along the posterior part of the leg, taking the direction of the fibula: hence it is sometimes called *fibular*. It arises from the posterior tibial, from an inch to two inches below the lower border of the popliteus muscle, 2, and descends almost perpendicularly towards the external ankle. Running for a while parallel and on the same plane with the posterior tibial artery, it lies on the tibialis posticus muscle, and is covered for the same distance by the soleus; as it descends, it inclines outwards to the fibula, and corresponds with the angle of union between it and the interosseous ligament. In this part of its course it is concealed from

view by the flexor longus pollicis, to which it gives branches, as well as to the adjacent muscles, and also one to the substance of the fibula (*ramus nutritius fibulæ*). On reaching the lower extremity of the inter-osseous ligament, which is about two inches, or a little more, above the external ankle, the artery usually divides into two branches, named, from their situation, anterior and posterior peroneal.

Ramus peroneus anterior, fig. 133, *d;* 135, *m,* passes forwards through the aperture in the inter-osseous ligament, and so reaches the fore part of the leg; it then descends along the border of the peroneus muscle, and sends branches outwards to the external ankle, which there anastomose with the external malleolar branch of the anterior tibial, and some forwards on the dorsum of the foot, to communicate with the r. dorsalis pedis of the same artery. Some of its ramifications also extend to the outer border of the foot, where they communicate with the external plantar and posterior peroneal arteries.

r. Posterior, e, continues in the original course of the artery, running downwards behind the external ankle, to reach the outer surface of the calcaneum. On arriving at the latter situation, it divides into ramusculi, some of which pass backwards to anastomose with the posterior tibial artery, others downwards to the border of the foot, and terminate in the muscles of the little toe, the rest forwards on the tarsus, communicating with the anterior peroneal branch, and with the tarsal branches of the anterior tibial artery.

704. *Varieties.* — The size and distribution of the fibular artery vary considerably in different instances; in some the posterior tibial is wanting, the popliteal appearing to divide into anterior tibial and fibular, the latter being double its usual size. In such cases, when the vessel reaches the lower part of the leg, it sends inwards a considerable branch, which, taking the course of the posterior tibial artery round the inner ankle, terminates in the plantar branches. In other instances, the anterior tibial artery is very small, and its dorsal branch necessarily too diminutive to carry on the circulation on the foot. The anterior fibular branch is then of considerable size, and supplies its place.

Operations.—The posterior tibial artery, in the lower part of its course, where it runs in the depression between the inner ankle and the heel, can be exposed and secured without much difficulty. Towards the middle of this interval, but nearer the prominence of the inner ankle than that of the heel by a finger's breadth, the vessel may be observed to pulsate, if the foot be extended so as to relax the fascia

and integuments. An incision should be made about two inches and a half in length, beginning near the inner border of the tendo Achillis, and extended downwards and forwards over the point just indicated. The integuments being thus divided, and the strong fascia of the leg exposed, it is in the next place to be laid open to the same extent, after which a deep fascia comes into view, being a continuation of that above described as binding down the deep muscles and vessels. A small piece of this being pinched up by the points of the forceps, it is cut through so as to allow a director to be inserted beneath it, on which it is to be divided. The vessels are thus laid bare; so that the artery, after having been separated from the nerve and veins with the same precautions as in other situations, may be readily tied, the point of the needle being directed from below upwards and inwards towards the ankle, to avoid the nerve.

In the interval between the lower part of the calf of the leg and the inner ankle, the artery may be exposed in the following way: an incision should be made parallel with the inner border of the tendo Achillis for about the same length, and through the same structures (the skin and two layers of fascia) as in the preceding operation. This will bring the artery into view.

Few operations on arteries present more difficulties than that of tying the posterior tibial while it is under cover of the soleus and gastrocnemius. The tibial origin of the former must be detached from the bone; and if, during this step of the operation, the deep fascia be torn, or the muscles rendered in any way confused, there remains no guide to the situation of the artery. In order to relax the muscles as much as possible, the knee must be slightly bent, and the foot extended so as to elevate the heel. If the limb be then placed on its outer side, and the knee supported, the seat of operation will be fairly brought into view. The incision through the skin must be very long, as the vessel lies so deeply; it may vary from four to five inches, according to the thickness of the muscles. It is usually directed to be made along the inner border of the tibia, so as to expose the margin of the gastrocnemius. In doing this the saphena vein can be easily avoided, as its course is quite apparent. When the soleus is exposed, its border is to be detached from the tibia, proceeding from below upwards, so as, if possible, to get a clear view of the deep fascia. If this be once obtained towards the lower part of the incision, a director can without much difficulty be insinuated between the membrane and the muscle, preparatory to the division of the fibres of the latter. When, by means of a retractor, the muscles are drawn back, so as to open the wound, its breadth will be found diminished by the posterior

border of the incision in the integument; for it will be recollected that its direction coincided, in the first instance, with that of the border of the muscle where it is attached to the bone; but it will no longer do so when the muscle is drawn backwards. In other situations, where deep incisions are required, both margins of the wound can be held aside by the retractors, but here the posterior one only admits of their application, as the other coincides with the tibia. The necessity of some change in the line of the first incision is obviously suggested by these facts; and we believe that M. Lisfranc makes his incision rather obliquely, its direction being from above downwards and backwards, so that when the muscles are retracted, their border may coincide with that of the skin.

PLANTAR ARTERIES.

705. When the posterior tibial artery reaches the hollow of the calcaneum, and gets under cover of the internal annular ligament, and of the origin of the abductor pollicis, it divides into the *plantar* arteries, which, from their position, are named internal and external.

Fig. 134.

The *dissection* of the plantar arteries includes that of the sole of the foot. When the thick skin and cellular texture are removed, and the plantar fascia fully exposed, the external plantar artery may be readily brought into view by cutting through a few fibres of the fascia, along the depression which separates the middle from the external portion of it; for when it has got on a line with the head of the fifth metatarsal bone, the vessel is almost superficial, though in the rest of its extent it is covered deeply by the muscles. The internal plantar artery can be laid bare merely by dividing the thin membrane which covers the abductor pollicis, and turning aside the external border of that muscle. When the plantar fascia and flexor brevis are detached and reflected from the calcaneum, the vessels can be easily traced in the rest of their extent.

706. *a. Plantaris interna*, fig. 134, *a*, much smaller than the other, turns directly forwards, so as to form, when the body is in the erect position, a right angle with the vessel from which

it arises. Placed at first above the abductor pollicis, and afterwards between it and the short flexor, it gives branches to both, and also some which incline towards the inner border of the foot, and communicate with branches of the dorsal arteries. On reaching the extremity of the first metatarsal bone, the internal plantar artery, considerably diminished in size, terminates by running along the inner border of the great toe, anastomosing with its digital branches. The direction of the artery corresponds with that of the line which separates the internal from the middle set of plantar muscles.

707. *a. Plantaris externa*, *b*, in size and direction appears to be the continuation of the posterior tibial. In its course it at first inclines outwards and forwards, to reach the base of the fifth metatarsal bone, where it changes its direction, arching inwards across the foot, to gain the interval between the first and second metatarsal bones, where it joins by a communicating branch, *c*, with the dorsal artery, which completes the plantar arch. The vessel first passes between the calcaneum and the abductor pollicis, then between the flexor brevis digitorum and flexor accessorius; as it turns forwards it lies in the interval between the former muscle and the abductor of the little toe, corresponding with the line separating the middle from the external portion of the plantar fascia; but its transverse part is deeply covered by the flexors of the toes and the lumbricales. The convexity of the arch is directed forwards and outwards, the concavity in the opposite way, and from it are given off numerous branches, varying in size and importance. Of these some pass outwards over the border of the foot, and anastomose with the dorsal arteries; others go back to supply the parts in the hollow of the foot, and several down to the fascia, integument, and subcutaneous cellular substance; these are too irregular to admit of being named or described; but from its superior and anterior surfaces branches are given off which deserve notice:

Rami perforantes posteriores, *d*, (perforating branches,) three in number, pass upwards between the metatarsal bones, through the posterior extremities of the dorsal inter-osseous muscles, and, on reaching the dorsum of the foot, inosculate with the dorsal inter-osseous arteries.

Rami digitales (digital branches) are four in number, and from

the order in which they arise from the arch, counting from without inwards, they are commonly named, first, second, &c.; but we shall name them from their relations to the metatarsal bones. The *fourth* digital branch curves outwards, to gain the external border of the fifth metatarsal bone; for it will be recollected that the most external part of the plantar arch corresponds with the fourth metatarsal space. In its course this vessel crosses under the abductor of the little toe, and then runs along the border of its phalanges, on the last of which it terminates. The *third* digital branch passes forwards along the fourth metatarsal space, and at the cleft between the toes divides into two twigs, which take the contiguous borders of the fifth and fourth toes, and end on the last phalanges; the *second* digital branch is similarly disposed of on the fourth and third toes; and the *first* on the third and second. Near the point of bifurcation, each digital artery sends upwards through the corresponding metatarsal space a small branch, which communicates with the digital branches of the metatarsal artery. These are called the *anterior perforating* branches, to distinguish them from those which come from the arch itself, and pass upwards between the posterior extremities of the metatarsal bones, to inosculate with the dorsal inter-osseous branches. The digital arteries, which, from their relation to the phalanges, are sometimes called collateral, at their final termination incline towards one another, and form arches by inosculation, from the convexity of which minute vessels pass forwards to the extremities of the toes. It will be observed, that in this way both sides of the three outer toes, and one side of the second toe, are supplied by branches derived from the plantar arch, in the ordinary distribution of the vessels; whilst both collateral branches of the great toe, and the inner one of the second, are furnished by the dorsal artery.

ANTERIOR TIBIAL ARTERY.

708. *a. Tibialis antica* is placed along the fore part of the leg in the inter-osseous space, at first deeply seated, but as it descends it gradually becomes comparatively superficial; it extends from the division of the popliteal artery to the bend of the ankle, from which it is prolonged to the interval between the first and second metatarsal bones, under the name of *dorsal* artery.

Dissection. — The course of the anterior tibial artery, and that of

its continuation, the a. dorsalis pedis, may be marked out by a line drawn from the inner border of the head of the fibula to the middle of the bend of the ankle, and thence continued onwards to the first metatarsal space. To expose the vessel, an incision should be made through the skin, corresponding with this line. Its commencement may, in the next place, be crossed by another, extending from the head of the fibula to the inner tuberosity of the tibia; a similar transverse incision is to be made at the ankle, and, to evert the skin conveniently, a third will be found necessary about midway. The flaps of integument being reflected, the one inwards on the tibia, the other outwards over the fibula, and the fascia exposed, the intervals between the muscles at once become apparent, where their tendons shine through the fascia. This membrane should now be divided in the same extent and direction as the skin, and the artery will be brought into view by separating the muscles, which can be done without the least difficulty by proceeding from below upwards.

Fig. 135.

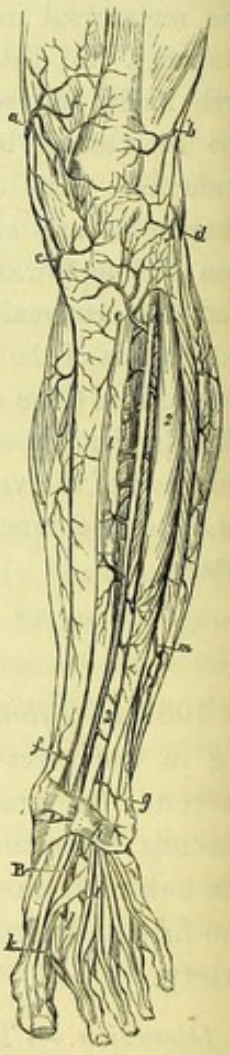

The dorsal artery, being placed between the tendon of the extensor proprius pollicis and that of the extensor communis, and uncovered by any structure except the skin and fascia, may be laid bare by an incision carried along the external or fibular border of the tendon of the extensor proprius, for about an inch and a half, or two inches. Above the bend of the ankle the incision must be somewhat longer, say two inches and a half, and the vessel will be found on the tibia, lying under the inner border of the extensor proprius.

709. The anterior tibial artery, fig. 135, A, at starting, turns horizontally forwards to reach the anterior surface of the inter-osseous ligament. In doing so, it passes between the heads of the tibialis posticus muscle, and through the interval between the bones left unclosed by the ligament. In its course it rests for two-thirds of its extent on the inter-osseous ligament, and for the rest on the anterior surface of the tibia. In the upper part of its extent it is deeply seated, and is overlapped and concealed by the tibialis anticus, 1,

and extensor longus digitorum, 2; the former being on its tibial, the latter on its fibular side. Lower down, it lies between the extensor pollicis, 3, and tibialis anticus, 1; but as towards the ankle these muscles incline inwards, the one to the tarsus, the other to the first metatarsal bone, whilst the artery continues directly onwards, it necessarily passes beneath the extensor pollicis, and is placed between the tendon of this muscle and that of the extensor communis digitorum. In this situation it is covered only by the skin and fascia of the leg. The anterior tibial artery is accompanied by two veins (*venæ comites*); the anterior tibial nerve lies to its fibular side for some way, as being derived from the peroneal nerve, it inclines inwards, so as to get in front of the artery in the middle of the leg, but turns outwards again as it descends lower down. Its branches are the following:

r. Musculares.—Small muscular branches are given to the tibialis posticus, as it passes between its heads, and as it runs down the leg several branches pass off to the tibialis anticus, extensor communis digitorum, and extensor pollicis.

Ramus recurrens, fig. 135, *e.*—On reaching the front of the leg, it sends upwards a pretty large and regular branch called "recurrent," because it is reflected up towards the knee from the point where the artery is turning downwards. This branch passes through the fibres of the tibialis anticus, and soon divides into several ramifications, which on the lateral and fore parts of the knee-joint anastomose with the inferior articular branches of the popliteal artery; and in its progress downwards between the extensor muscles, it gives on each side several muscular branches.

r. Malleolares, f, g.—Near the ankle-joint two malleolar arteries are given off; the *internal* one having passed beneath the tendon of the tibialis anticus, reaches the inner ankle, and ramifies upon it, supplying the surrounding textures, and communicating with branches of the posterior tibial artery; the *external* malleolar branch bears a similar relation to the outer ankle; having passed under the tendon of the common extensor, it anastomoses with the posterior peroneal artery, and also with some ascending or reflected branches from the tarsal artery.

DORSAL ARTERY OF THE FOOT.

710. *a. Dorsalis pedis*, fig. 135, B, is the continuation of the anterior tibial artery, extending from its termination at the bend of the ankle to the posterior extremity of the first metatarsal space, where it divides into two branches, of which one proceeds forwards in the first inter-osseous space, whilst the other dips into the sole of the foot, and terminates by inosculating with the plantar arch. Its course is forwards and inwards, running over the astragalus, the scaphoid, and internal cuneiform bones; it is covered by the skin and fascia, its line of direction corresponding with the interval between the tendons of the extensor proprius pollicis and extensor communis. The principal branches of the dorsal artery are directed outwards and forwards upon the tarsus and metatarsus, and are named accordingly. Some small vessels also run obliquely inwards upon the inner side of the foot, where they terminate in minute ramusculi.

Ramus tarseus, fig. 135, *h*, arises from the artery usually where it crosses the scaphoid bone, but its point of origin varies in different instances. It inclines forwards and outwards, describing a slight curve as it runs upon the tarsal bones covered by the extensor brevis muscle, to which it gives ramusculi; some also, of small size, sink deeply into the tarsal articulations, for the nutrition of the different structures which compose them. The artery, having curved backwards to the cuboid bone, divides into branches which take different directions; some forwards, to anastomose with the divisions of the metatarsal artery; others outwards, to communicate at the border of the foot with branches of the external plantar artery; whilst a third set anastomoses with branches of the external malleolar, and with those which the fibular gives to the outside of the calcaneum.

r. Metatarseus, i, is usually smaller than the preceding, and comes off farther forward. Its direction is also outwards and forwards under the extensor brevis. Sometimes there are two metatarsal arteries, the second being of smaller size, and not unfrequently, when there is but a single vessel of this name, it arises in common with the tarsal artery. Its direction is necessarily influenced by these circumstances, being oblique when it arises far back, and

almost transverse when its origin is situated farther forwards than usual. Ramusculi pass off in different directions for the supply of the surrounding structures; and some curve backwards, to form anastomoses with those of the tarsal artery; the inter-ossei only deserve notice.

r. Inter-ossei.—These branches are named "inter-osseous," from their position between the metatarsal bones. These are small straight vessels which pass forwards, resting each upon one of the dorsal inter-osseous muscles, and at the cleft between the toes each divides into two ramusculi which run along the contiguous borders of the toes, forming their dorsal collateral branches. From the external inter-osseous artery a small branch is given off, which inclines outwards to gain the external border of the little toe, upon which it lies, forming its first collateral branch. In this way we find that the inter-osseous branches derived from the metatarsal supply the dorsal surfaces of the three outer toes, and one side of the second. Now each of these vessels at its point of bifurcation communicates with the plantar artery by means of the anterior perforating branches; and again, at the posterior extremity of the inter-osseous spaces, they receive the posterior perforating branches. These are usually small branches of communication; but sometimes they are of larger size, and on reaching the upper surface of the foot, form the inter-osseous arteries, the metatarsal branches being reduced to small ramusculi, which terminate in them.

711. When the dorsal artery of the foot has reached the posterior extremity of the first metatarsal space, it gives off a branch, *k*, which runs along the outer surface of the first metatarsal bone, and which, from its analogy to the inter-osseous branches derived from the metatarsal artery, may be called the first inter-osseous branch, but is commonly called *r. dorsalis pollicis*, for, on reaching the fissure between the toes, it divides so as to form a collateral branch for the inner side of the second, and for the outer side of the great toe.

After giving off this branch, the artery, *l*, dips into the first inter-osseous space, and divides into its two ultimate branches. One of these, about two or three lines in length, inclines outwards, and terminates by inosculating with the external plantar artery, so as to complete its arch; the other passes forwards beneath the outer border of the first metatarsal bone, towards the fore part of which it sends inwards a branch which becomes the

internal collateral branch of the great toe; after which, on reaching the anterior extremity of the first metatarsal space, it divides into branches which run along the contiguous borders of the first and second toes.

The arteries of the foot are subject to several variations, and none so much so as those of the great toe. When the dorsal artery is small, the digital branches at the plantar surface of the great toe are derived from the vessels in the sole of the foot. When the inter-osseous branches of the metatarsal artery are small, their place is supplied by the posterior perforating arteries.

712. *Anastomoses.*—We have made frequent mention of the anastomoses between the different branches of the arteries in the lower extremity. It now becomes necessary to take a general view of them, in order that we may understand the important influence they exert in maintaining the circulation in the limb, when the principal artery is obliterated by an operation, or by disease. It will be recollected, that branches from different directions converge towards the posterior part of the hip-joint. The circumflex arteries (internal and external) turn round the shaft of the femur, one from within, the other from without; the gluteal and ischiadic arteries run from above downwards, and the superior perforating branches from below upwards, towards the same point. So that if the supply from one quarter be diminished or cut off, the loss is speedily made up from some other, the vessels taking on an increase of size and action proportioned to the increased demand upon them. This may be termed the *ilio-femoral anastomosis.* At the anterior and upper part of the limb, a similar mode of connection occurs, but by no means so extensive, between the ilio-lumbar artery and the circumflex ilii, and again between the latter and the external circumflex on the one hand, and the epigastric on the other.

Round the knee-joint a very free communication exists between the four articular arteries (converging to its fore part) and the recurrent tibial from below, and the descending branches of the external circumflex, from the opposite direction. This may be named the *femoro-tibial anastomosis;* and if we examine the condition of the vessels in a well-injected limb, we shall find it connected with the ilio-femoral anastomosis by the descending branches of the external circumflex artery in front, and by the series of perforating branches behind.

713. The ankle-joint is surrounded by a corresponding distribution

of vessels. The posterior tibial artery and the peroneal communicate before they proceed to their final destination. In front of the joint, the anterior peroneal branch anastomoses with the tarsal and external malleolar arteries; the latter communicating again with the posterior fibular, whilst the internal malleolar maintains a similar relation with the posterior tibial or its branches. This forms the *tibio-tarsal anastomosis.*

This freedom of anastomosis between the capillary terminations of different vessels, may be considered as a provision against the consequences that must otherwise follow the obliteration of any of the main vessels of a limb by an injury or by operation. If the external iliac artery is tied for an aneurism high up in the thigh, an increased quantity of blood is at once thrown on the internal iliac artery and its branches, which thus become distended and enlarged. Whilst this is taking place, the femoral artery and its branches empty themselves of their blood, forcing it on into the veins by their contractile power, at the same time that they receive none in their natural course. But after a while they become filled again, and circulate blood, though in a direction exactly opposite to that in which it had previously flowed in them. The capillary terminations of the circumflex arteries receive from those of the gluteal, sciatic, and obturator, the increased current which is thrown upon them, and convey it thus into the femoral artery below the tumour for which the operation was performed; and so, in the new order of things, the blood flows from branch to trunk, conducted through the devious route of the collateral vessels, and maintaining the vitality of the limb by what is termed the *collateral circulation.* The anterior and lateral parts of the abdominal parietes, it will be recollected, are supplied by the epigastric and circumflex ilii arteries. When the regular source of their supply is cut off by the obstruction in the iliac artery, gangrene would speedily supervene if the circulation were not restored from some other quarter. A recurrence to the anastomoses of these vessels at once reminds us, that the circumflex ilii artery communicates with the epigastric on the one hand, and the ilio-lumbar on the other, and forms a ready medium of communication between them, when the latter, after the application of the ligature, receives part of the increased current propelled into the internal iliac artery, from which it arises. We need not extend these remarks farther for the present. The anastomoses round the knee and ankle must be sufficiently obvious from what has been already stated. As, however, the subject is one, not only of deep interest, but of great consequence in a practical point of view,

we can scarcely refrain from raising this question, What is the condition of the vessels of a limb which has been the subject of an operation for aneurism? We reply, in the words of an eminent authority—"In twelve or fourteen months after a ligature has been applied on the femoral artery, it becomes completely obliterated, as far up as the profunda, and down to the origin of the anterior tibial artery, the remnant of the vessel being a mere cord. The circumflex vessels become enlarged, and convey blood to the rectus, sartorius, and vasti, which had previously been supplied by the femoral. The articular arteries round the knee are also enlarged and tortuous; they receive blood, not from the popliteal, but from the communicating vessels of the profunda." After some general remarks on the effect of ligatures, the description of the limb, which formed the subject of the memoir here referred to, proceeds as follows: "The profunda, which formed the new channel for the blood, was considerably enlarged in diameter, and sent branches larger than usual to the flexor muscles. Just midway on the back part of the thigh, it gave off those branches which became the chief support of the new circulation. The first of the newly-established vessels went down to communicate with the superior articular artery, on the inner side of the articulation. Another, guided by the biceps muscle, opened into a muscular branch on the gastrocnemius. Between these, a third vessel passing along in the course of the sciatic nerve, divided into several branches, communicating with the inferior articular vessels, with the origin of the anterior and posterior tibial arteries, and with some of their muscular branches, in such a way as to form a vascular plexus in the popliteal space. The external circumflex artery was considerably enlarged, and freely supplied the muscles on the fore part of the thigh. The obturator artery did not appear larger than usual, nor could any enlarged communicating branches be traced between the ischiadic and profunda arteries."*

* Dissection of an Aneurismal Limb, by Sir Astley Cooper. Med. Chir. Trans. vol. ii.

CHAPTER VII.

OF THE VEINS.

714. Though the veins diffused throughout the body form one system, and serve for one especial purpose—that of returning the effete or residual blood to one common recipient (the right auricle) by means of their great trunks (venæ cavæ), still they admit of a division into compartments, in consideration of certain peculiarities which they present. The veins within the cavity of the cranium and spine form a group, in a manner apart from the others; so does the vena portarum, which ramifies in the liver; and perhaps the pulmonary veins may be admitted as a third, from the circumstance of their conveying red blood. Even before the announcement of Harvey's discoveries, anatomists perceived how objectionable it was to classify these vessels with other veins, and sought to mark the distinction between them, by calling them *arteriæ venosæ*; and, for the like reason, the pulmonary artery was named *vena arteriosa*.

We shall commence the description of the veins with those which form the superior vena cava, or, more properly, with those which, commencing by minute ramusculi in the head, neck, the upper extremities, and the walls of the thorax, form so many tributary streams, gradually increasing in size as they diminish in number, until they are finally united into one current, that of the superior vena cava. The cerebro-spinal veins may be considered an offset connected with this part of the venous system, as their contents are, for the most part, poured into it. The venous ramifications, which terminate in the inferior vena cava, come next in order; to this the vena portarum is an adjunct. The veins of the heart open directly into the right auricle itself, and so cannot be said to belong to either venous trunk; the vena azygos (major and minor) is a tributary to the superior vena cava, at the same time that it serves as a substitute for both these vessels within the thorax, and also as a medium of connexion between them.

The veins of the head are divided, like the arteries, into two sets,—those which ramify on its exterior, and those placed in its interior; and a sufficient correspondence exists between the ramifications of both orders of vessels to warrant us in saying generally, that the one returns the residue of the blood circulated by the external carotid artery, the other by the internal. The veins on the exterior of the head converge and unite, so as to form two trunks, the facial and the temporal.

FACIAL VEIN.

715. The facial vein, fig. 136, *a*, (*vena facialis*,) lies obliquely along the side of the face, extending from the inner margin of the orbit downwards and backwards to the anterior edge of the masseter muscle. Resting on the same plane as the facial artery, but farther back, and less tortuous, it still maintains very nearly the same relations. It may be said to commence at the side of the root of the nose by a vein formed by the conflux of branches from the forehead, the eye-brow, and nose, and to increase by receiving others at each step of its course.

Fig. 136.

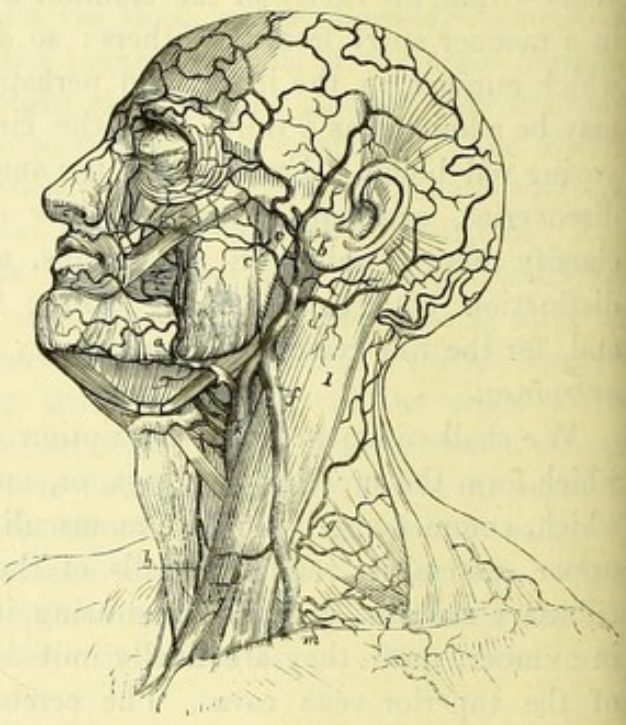

The frontal vein (*vena frontalis*) commences on the roof of the skull by ramusculi, which pass obliquely downwards and forwards upon the forehead, maintaining communications in their course with the anterior branches of the temporal vein. By gradually converging, these branches form a vein of some size, which descends vertically, parallel with the corresponding vessel of the opposite side, with which it is connected by transverse branches. In some instances both unite and form a

short trunk, which again divides at the root of the nose, its branches diverging as they descend, so as to become continuous with the angular vein. When descending from the forehead, it receives a branch from the eye-brow, and some, of smaller size, from the nose and upper eye lid.

The supra-orbital vein *(vena supra-orbitalis, v. supercilii)* runs transversely inwards in the direction of the eye-brow, covered by the occipito-frontalis muscle. Its radicles are connected externally with those of the external palpebral and superficial temporal veins; in its course it receives branches from the contiguous muscles and tegument, and at the inner angle of the orbit it inclines downwards, to terminate in the frontal vein. The supra-orbital and frontal veins, by their junction, form the angular vein *(vena angularis)*, which is perceptible beneath the skin as it runs obliquely downwards and outwards by the inner margin of the orbit, resting against the side of the root of the nose. This small vessel receives by its inner side the *nasal veins*, which pass upwards obliquely to join it from the side and ridge of the nose; whilst some small palpebral veins open into it from the opposite direction. When arrived on a level with the lower margin of the orbit, the angular vein may be said to terminate by becoming continuous with the facial vein.

716. The facial vein, commencing as has been just stated, gradually increases, by receiving ramusculi from the lower eye-lid and from the ala of the nose; also from the upper lip branches arise, which, after a short course, open into it. By its outer side it receives a vein *(v. palpebralis inferior, externa)*, which is formed by small branches derived from the lower eye-lid, from the external side of the orbit, and the prominence of the cheek. The direction of this vessel is obliquely inwards above the zygomaticus muscle, beneath which it turns previously to its termination. When on a level with the angle of the mouth, the facial vein is further increased by branches from the lips, which perhaps may be called coronary veins, and from the cheek *(venæ buccales)*, and still lower down from the masseter muscle on the one hand, and the chin on the other. When arrived at the lower border of the jaw, the vein inclines outwards and backwards, covered by the cervical fascia and the platysma muscle, and soon unites with a large branch of communication derived from the temporal vein, to form a vessel

of considerable size, which opens, at an acute angle, into the trunk of the internal jugular vein, *k*.

Previously to its termination, the facial vein receives the following veins :—viz. *Vena ranina*, a small vessel which lies along the under surface of the tongue, close by the frænum linguæ, in apposition with the artery of the same name; its course is backwards and outwards, between the mylo-hyoideus and hyo-glossus muscles, to open into the facial vein, or sometimes into the lingual :—*Vena submentalis ;* this vessel, larger than the preceding, commences by radicles derived from the sublingual gland, from which it passes backwards in the course of the duct ; it receives branches from the submaxillary gland, and from the mylo-hyoideus muscles, and, keeping close under cover of the margin of the jaw-bone, it joins the facial vein ; but in some instances it pours its contents into the lingual or superior thyroid vein. *Vena palatina* returns the blood from the amygdala and soft palate ; it passes downwards, deeply seated by the side of the pharynx, to join one of the preceding veins, or terminate in the facial separately.

TEMPORAL VEIN.

717. The temporal vein, fig. 136, *b*, (*vena temporalis*,) is a vessel of considerable size, whose trunk passes almost perpendicularly downwards before the external auditory tube, extending from the zygoma, upon which it rests, to the angle of the jaw, whilst its branches spread out upon the side of the head, some being superficial, others deeply seated. The superficial branches commence by minute ramifications upon the arch of the skull, where they communicate with the radicles of the frontal and occipital veins, as well as with those of the corresponding vein of the opposite side. Those from the fore part incline downwards, and a little backwards, those seated posteriorly run forwards over the ear, all being placed between the skin and the temporal fascia. Converging in this way, they unite at an angle above the zygoma, and at their junction commences the trunk of the temporal vein. To this same point also passes a large branch, which may be called the middle temporal vein, to distinguish it from those which are still deeper seated, and open into the internal maxillary vein. This vessel arises in the substance of the temporal muscle, from which

the branches emerge, and form a vessel of some size upon its surface; the vessel pierces the fascia at the upper border of the zygoma, and opens into the commencement of the common trunk, formed as has been above stated. The temporal vein gradually sinks into the substance of the parotid gland as it descends behind the ramus of the jaw. When under cover of its angle, it divides into two vessels, of which one, ordinarily the larger, inclines inwards to join with the facial vein, whilst the other turns backwards, and becomes continuous with the external jugular vein, *f*. The branches which open into the temporal vein in its course are numerous:—from the parotid gland several ramusculi (*venæ parotideæ*), from the articulation of the jaw (*vena articularis*), from the external ear (*vena auricularis anterior*), from the side of the face a vein of some size (*vena transversalis faciei*). This vessel corresponds, *c*, with the artery of the same name, by receiving branches from the parts it supplies. Its direction is transversely outwards from the side of the face to the temporal vein. From the opposite direction is received the *vena auricularis posterior*, *d*, which is increased by the stylo-mastoid vein. Besides these, a vein of considerable size joins the temporal whilst embedded in the parotid gland, viz. the internal maxillary vein. —*Vena maxillaris interna*, fig. 136, *e*, corresponds in direction, position, and relations, with the artery of the same name. Three or four temporal branches descend from the fossa, deeply seated, others come from the pterygoid muscles, some from the surface of the upper jaw, and one, of large size, from the lower one, emerging from the dental foramen (*vena dentalis inferior*). All these unite to form a short trunk, which joins nearly at right angles with the temporal vein.

The vessel formed by the junction of these different veins from the temple, jaw, and face, may be called the *temporo-maxillary* vein; it descends in the interval between the ramus of the jaw and the mastoid muscle, and terminates in the external jugular vein, *f*, or partly in it, and partly in the internal jugular vein.

EXTERNAL JUGULAR VEIN.

718. *Vena jugularis externa*, fig. 136, *f* (trachelo-subcutanea).—This vein commences on a level with the angle of the

jaw, where it receives the termination of the temporo-maxillary vein. The latter passes downwards and forwards obliquely to the point above stated, from beneath the ear, in the space between the jaw and the mastoid muscle. The external jugular vein assumes at once the perpendicular direction, lying between the platysma and sterno-mastoid. In consequence of the obliquity of the muscle last named, the vein gets to its outer border, close by which it descends to the lower part of the neck, where it inclines inwards behind the muscle, to terminate (either as a single trunk, or by two or three branches) in the subclavian vein, *m*, near its junction with the internal jugular. In this course it receives one or two large branches from the back of the neck ; one of these, *g*, (*vena cutanea posterior*,) lying at first between the splenius and trapezius, passes down at the outside of the jugular vein, and below the middle of the neck opens into it. Some superficial branches also join it from the fore part of the neck (*venæ cutaneæ anteriores*). Some of these commence over the submaxillary gland, some under the chin ; by converging, they often form a vein of considerable size, *h* ; when this is the case, it is called the anterior jugular vein : it lies along the inner border of the sterno-mastoid muscle. This vessel terminates either by inclining outwards to join the external jugular vein, or, after giving to it a branch of communication, it sinks under the sterno-mastoid muscle, and opens into the internal jugular vein. Previously to the termination of the external jugular vein, two large veins open into it, derived from the region of the scapula, *i*, (*vena supra-scapularis*, et *vena posterior scapulæ*.) Their direction is transverse from without inwards, lying parallel with the arteries of the same name.

INTERNAL JUGULAR VEIN.

719. *Vena jugularis interna*, fig. 136, *k*.—The blood from the brain and cranial cavity is received by the internal jugular veins, which are continuous at their upper extremities with the lateral sinuses ; whilst inferiorly they terminate in the innominata, or brachio-cephalic veins. The junction of the vein with the sinus is at the broad part of the foramen lacerum (*fossa jugularis*), beneath which it is supported by the rectus lateralis muscle, and lies close at the outer side of the internal carotid artery, as far as the cornu of the os hyoides. Now, as the part

of the vessel which extends from the skull to this point corresponds with the internal carotid artery, and receives its residual blood, it may with much propriety (and also with advantage, as tending to render the nomenclature uniform) be called *vena carotis interna*. Some confusion would arise from calling it "cephalica," as the external superficial vein of the arm has, without any proper reason, received that name. Again, the short vessel which extends downwards from the junction of the facial and temporal veins and joins the preceding, may, for the like reason, be called *vena carotis externa*; and finally, the trunk which results from the conflux of these vessels, and which extends thence down to the inner end of the clavicle, should be called *vena carotis communis*. At present, the entire length of the vessel included between the point just named and the base of the skull, is known as the internal "jugular" vein, as if it belonged to the throat, and had no correspondence in its divisions and distribution with the artery which it accompanies. However, we must defer to usage, and continue for the present so to name it.

The internal jugular vein having passed down to a level with the os hyoides, receives the common trunk formed by the facial and temporal veins, and then becomes considerably enlarged. It descends parallel with the common carotid artery, lying at its outside enclosed in the same sheath, together with the vagus nerve, and at the root of the neck joins nearly at a right angle with the subclavian vein, and so forms the innominata, or brachio-cephalic. Previously to its junction with the facial vein, the internal jugular receives branches from the tongue, pharynx, and occiput:—*Vena lingualis* commences at the side and upper surface of the tongue, passes backwards, receiving branches from the sublingual gland; occasionally the ranine vein joins it, sometimes also the pharyngeal. In either case it passes backwards between the mylo-hyoideus and hyo-glossus muscles, to open into the jugular vein. *Vena pharyngea* commences at the back and sides of the pharynx, and terminates in the lingual, or separately in the jugular vein. *Vena occipitalis*, fig. 136, *l*, corresponds in its course, and in the distribution of its branches, with the artery of the same name. It communicates with a plexus of veins on the outside of the occiput, and terminates occasionally in the external jugular vein, but more frequently in the internal.

Vena laryngea is a small vessel whose branches come out of the larynx through the thyro-hyoid membrane ; they unite and form one vein, which opens into the internal jugular (its anterior or facial division) : sometimes it terminates in the superior thyroid vein.

Vena thyroidea superior arises by ramusculi, which ramify in the thyroid gland, in company with the branches of the superior thyroid artery. These unite and form a single vessel, which runs transversely outwards, and opens into the jugular vein (its common trunk). Lower down we find another branch coming from the same source (*vena thyroidea media*).

Veins of the Upper Extremities.

Fig. 137.

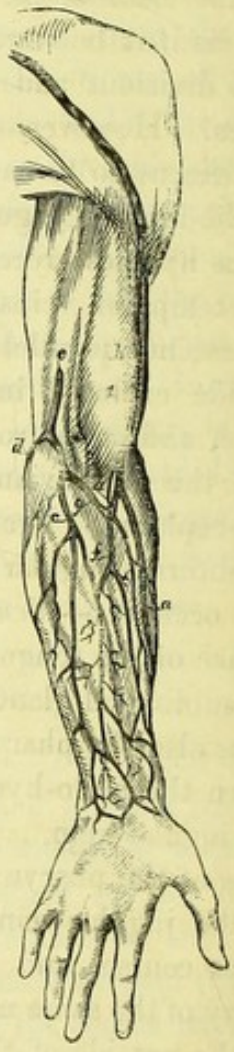

The veins of the upper extremity are divisible into two sets, one being superficial, the other deep-seated. The superficial veins are much larger, and lie between the skin and fascia. They commence on the dorsal surface of the fingers, and as they converge and communicate with one another on the back of the hand, they form a sort of venous plexus, from which issue two chief veins, that take, one the radial, the other the ulnar border of the fore-arm.

720. *Vena radialis cutanea*, fig. 137, *a*.—The radial cutaneous vein commences by ramusculi placed on the dorsal surface of the thumb and fore-finger. These ascend upon the outer border of the wrist, and form by their union a pretty large vessel, which passes along the radial border of the fore-arm, receiving numerous branches from its anterior and posterior surfaces. At the bend of the arm it receives a division of the median vein, and then continues its course at the outer side of the upper arm, and is named the *cephalic* vein, *b*. The cephalic vein thus formed ascends along the external border

of the biceps muscle, and then in the interval between the pectoralis major and deltoid, and finally terminates in the axillary vein, between the coracoid process and the clavicle.

721. *Vena ulnaris cutanea, anterior et posterior.*— There are two ulnar cutaneous veins, one on the anterior, the other on the posterior surface of the fore-arm. The posterior ulnar vein, *d*, begins on the back of the hand by some ramusculi, which unite to form a vein placed over the fourth metacarpal space, and called by some of the older anatomists "salvatella." This proceeds along the ulnar border of the fore-arm, at its posterior aspect, and, somewhat below the bend of the elbow, turns forwards to join with the anterior ulnar cutaneous vein. The anterior ulnar vein, *c*, commences upon the anterior surface of the wrist, and thence ascends along the fore-arm, communicating by branches with the median vein on the one hand, and the posterior ulnar cutaneous on the other. After having received the posterior ulnar it ascends, and from the bend of the elbow upwards the posterior ulnar cutaneous vein assumes the name of "basilic vein."

722. *Vena basilica*, *e*, is usually of considerable size; it receives at its origin a division of the median vein, *g*, (median-basilic,) and ascending along the inner border of the biceps muscle, in front of the brachial artery, terminates in one of the venæ comites of that vessel, or in the axillary vein. The position and relations of the veins here described are sufficiently expressed by calling them radial and ulnar cutaneous whilst in the fore-arm, and internal and external brachial in the upper arm. The terms "basilic" and "cephalic" serve no useful purpose.

723. *Vena mediana*, *f*.—The median vein results from the union, on the anterior part of the fore-arm, of several branches. It is a short trunk, which serves as a means of communication between the ulnar and radial veins on each side, as well as between the superficial and deep veins of the arm. Its length is subject to many varieties; it terminates by dividing into two branches, which diverge at an angle; one inclining inwards to join the basilic vein, and thence named *median-basilic*, *g*, passes in front of the brachial artery, from which it is separated by the fibrous offset given by the tendon of the biceps muscle to the fascia covering the flexor muscles; it is crossed by twigs of

the internal cutaneous nerve: the other division, *h*, (*median-cephalic*,) directed outwards, unites with the cephalic vein; this is crossed by branches of the external cutaneous nerve. The termination of the median vein is also connected with the deep veins by a short branch, which sinks between the muscles, to the veins accompanying the brachial artery. The nomenclature may be simplified by considering these three as communicating branches, and so naming them internal, external, and middle.

Of the deep-seated veins.—The brachial artery, its branches, and their several divisions, are each accompanied by two veins, hence named *venæ comites.*

724. The *deep ulnar veins* (venæ comites arteriæ ulnaris). —On the palmar surface of the hand the incipient ramusculi disposed along the borders of the digital phalanges become united at the cleft between the fingers into one small vessel, which, with one similarly formed from the contiguous border of the next finger, run along the inter-osseous spaces, and terminate in the superficial palmar arch of veins, from which two branches proceed at each side of the wrist, the external following the course of the superficialis volæ artery, whilst those on the inner side accompany the ulnar artery. The deep ulnar veins, commencing thus at the inner side of the superficial palmar arch, pass in front of the wrist, where they communicate with the inter-osseous and the superficial veins; then proceeding upwards along the inner side of the fore-arm, in apposition with the ulnar artery, they receive several branches from the neighbouring muscles; and lastly, being joined by the vessels which accompany the inter-osseous and ulnar recurrent arteries, unite with the deep radial veins to form the venæ comites of the brachial artery.

725. The *inter-osseous veins* (v. com. art. inter-oss.) consist of two sets (anterior and posterior), corresponding to the arteries with which they are associated. The anterior take their rise in front of the wrist-joint, where they communicate freely with the deep radial and ulnar veins. In their course upwards they are joined by several small branches, and are connected at the lower part of the fore-arm with veins situated posteriorly, by means of branches which pass through the inter-osseous

membrane near the elbow-joint; after being joined by the posterior inter-osseous veins, they open into the venæ comites of the ulnar artery. The veins which accompany the posterior inter-osseous artery, previously to passing from behind to join with the anterior, communicate by their incipient radicles with the ulnar cutaneous veins, and through branches accompanying the recurrent inter-osseous artery, with the cephalic vein.

726. The small radicles which give rise to the deep radial veins (*venæ comites art. radialis*) run upon the inter-osseous muscles of the hand; they are united in front with the digital veins previously described, and, at each end of the space separating the metacarpal bones, are connected by perforating branches with small vessels situated on the back of the hand; by uniting across the carpal end of the metacarpus, they form an arch corresponding with that formed by the radial artery. This deep venous arch communicates on its inner side with the superficial palmar arch, and from its radial side proceed what may be considered properly the venæ comites of the radial artery. These vessels, when passing upwards to the fore-arm, receive at the wrist a dorsal branch, and one which passes over the small muscles of the thumb, with the superficialis volæ artery; then pursuing the course of the radial artery, they are joined by small veins from the surrounding parts, and end in the venæ comites of the upper arm.

727. The accompanying veins of the brachial artery (*venæ comites arteriæ brachialis*), resulting from the union of the deep ulnar and radial veins just described, follow, like the several vessels of the same class, the course of the artery with which they are associated. They are joined in their progress, from the bend of the elbow upwards on the arm, by the veins which are distributed with the branches of the brachial artery, namely, the anastomotic and the two deep or collateral arteries of the arm. At the lower margin of the axillary muscles, the brachial veins unite to form the axillary; not unfrequently, however, one of them will be found to come forward and unite with the basilic, which soon becomes continuous with the axillary vein.

Between the several veins of the upper extremity hitherto described, numerous connexions exist in their whole course. Thus, those placed immediately under the integument are con-

nected by branches arching in different directions from one to the other over the hand and fore-arm; each pair of venæ comites are united by short transverse vessels crossing the artery which they accompany, whilst between those attending the different arteries frequent communications exist; moreover, as has been in many instances specially indicated, the different series of vessels, namely, those situated superficially and more deeply, communicate freely, especially in the neighbourhood of joints. This disposition prevents the occurrence of any impediment to the course of the circulation, by reason of muscular action, or the frequent and varied motions of the joints.

AXILLARY VEIN.

728. *Vena axillaris.*—The axillary vein arches like the corresponding artery, from the margin of the axillary muscles to the lower border of the first rib; it is covered by the pectoral muscles and the costo-coracoid membrane, and is placed internal and anterior to the axillary artery. The branches which open into the axillary vein are very numerous. It results, as above stated, from the union of the venæ comites of the brachial artery; it receives the veins of the arm (the basilic at its commencement, the cephalic towards its termination); it is also joined by the several veins corresponding with the branches of the axillary artery, viz. the two circumflex and the subscapular from the shoulder, the alar from the axilla, and the inferior, the superior, and acromial thoracic veins from the side of the chest. The axillary vein, therefore, returns all the blood from the superior extremity; its size is very considerable.

SUBCLAVIAN VEIN.

729. *Venæ subclaviæ*, fig. 138, *d* (dextra et sinistra).—The subclavian veins are the continuation of the axillary. Each extends from the lower margin of the first rib to the inner end of the clavicle, behind which it is joined by the internal jugular vein, *c*, the union forming the vena innominata, or brachio-cephalica, *e*. The subclavian vein arches over the first rib; it is covered by the clavicle, the subclavius, and the sterno-mastoid muscles, and lies on a plane anterior to the corresponding ar-

tery, from which, while resting on the rib, it is separated by the scalenus anticus muscle and the phrenic nerve. — On the outer side of the last-named muscle it receives the external jugular vein, and on its inner side becomes united with the internal jugular; in their course to join it, both these veins pass in front of the subclavian artery, and add to the difficulty of placing a ligature on that vessel. The subclavian vein also receives the following as so many branches:

Fig. 138.

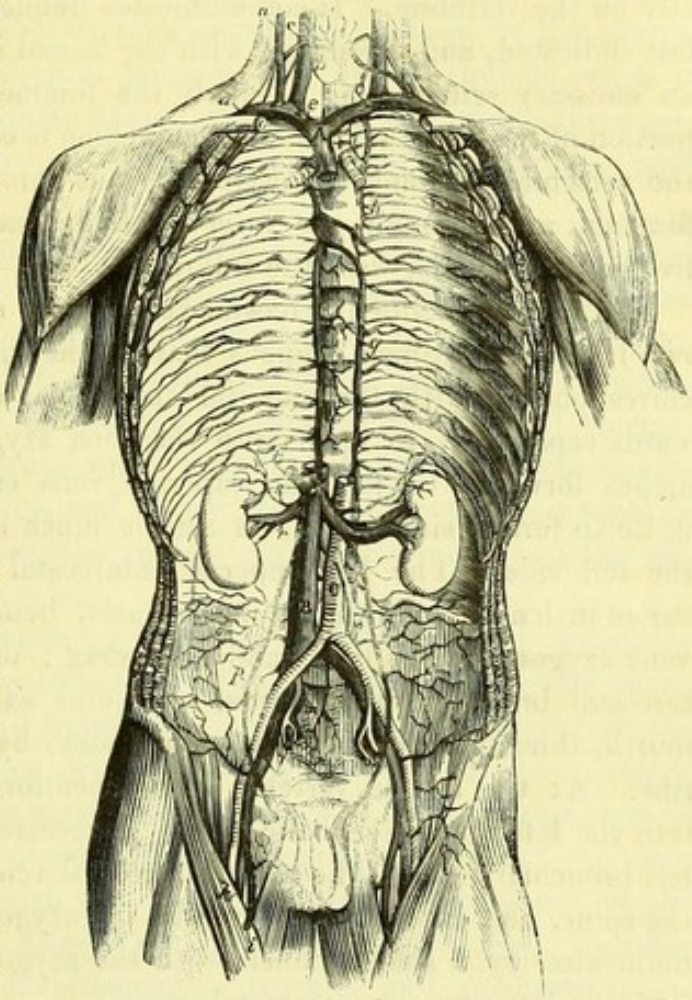

730. *Vena vertebralis.*— The vertebral vein takes its rise from several ramusculi proceeding from the pericranium and the deep muscles lying behind the foramen magnum of the occipital bone; having passed from thence outwards and downwards to reach the foramen in the transverse process of the atlas, it comes into relation with the vertebral artery, with which it descends through the canal formed by the corresponding foramina of the other cervical vertebræ as far as the sixth. Here it emerges and joins the subclavian vein; a small branch or division sometimes passes through the foramen in the seventh vertebra, and opens separately into the same vein. It is joined in its course by several branches proceeding from the neighbouring muscles, also immediately before its termination by a vein corresponding

to the ramus profundus of the subclavian artery, and in the same situation by another of considerable size, which runs longitudinally on the vertebræ. It communicates frequently with the vein last indicated, and through it with the lateral sinus, by means of an emissary vein passing through the foramen in the mastoid portion of the temporal bone ; a connexion is established between the vertebral vein and the occipital sinus through the condyloid foramen, and through the intervertebral foramina it maintains free communication with the following :

731. The superior intercostal vein (*vena intercostalis superior*). It sometimes happens that at the right side the veins corresponding with the superior intercostal artery pass downwards separately, to open into the vena azygos, as that vessel arches forwards to join the superior vena cava. When they unite to form a single vein, its size is much inferior to that on the left side. The left superior intercostal vein, fig. 138, *h*, varies in length in different individuals, being small when the vena azygos minor is large, and *vice versâ ;* usually the fifth intercostal branch turns upwards, and joins with or receives the fourth, third, second, and first, as it passes by the heads of the ribs. At the second vertebra it inclines forwards, and opens into the left brachio-cephalic vein. It receives in its course the left bronchial vein. The sixth intercostal vein generally crosses the spine, and opens separately into the azygos major ; it communicates by a small branch with the azygos minor, and also with the left superior intercostal vein.

BRACHIO-CEPHALIC VEIN (VENA INNOMINATA).

732. The blood returned from the superior extremities through the subclavian veins, and from the head and neck by the jugular veins, is poured into two trunks, which may therefore be named brachio-cephalic. These vessels, fig. 138, *e*, *e*, (*venæ innominatæ*, v. *brachio-cephalicæ*,) resulting from the union of the subclavian with the internal jugular vein at each side, extend from the inner extremities of both clavicles to beneath the cartilage of the first rib on the right side, where, by uniting, they form the superior vena cava, A. In consequence of the situation of the point at which they meet, the brachio-cephalic veins differ considerably in direction, length, and relations ; that of the right side is very short, and nearly

vertical in its direction. The vein of the left side, about three times longer than the preceding, is directed transversely to the right, at the same time inclining downwards: it crosses behind the first bone of the sternum, separated from it by the sterno-hyoid and sterno-thyroid muscles, and by the thymus, when it exists, or some cellular tissue: it lies in front of the three primary branches given off from the transverse portion of the arch of the aorta.

733. The inferior thyroid veins (*venæ thyroideæ inferiores*) emerge from a sort of venous plexus on the thyroid body—those of opposite sides communicate by small branches across the trachea. The vein of the left side descends in front of the trachea, behind the sterno-thyroid muscles, and ends in the left brachio-cephalic or innominata vein: that of the right side inclines outwards in some degree, and opens into the corresponding brachio-cephalic vein, or into the angle of union between it and the vessel of the opposite side.

734. *Venæ mammariæ internæ.* — The internal mammary veins follow exactly the course of the arteries of the same name. They arise by small branches, derived from the fore part of the walls of the abdomen, where they anastomose with the epigastric veins; from thence proceeding upwards behind the cartilages of the ribs between them and the pleura, they receive the veins which correspond with the anterior intercostal branches of the internal mammary artery (*v. intercostales anteriores*), together with some small diaphragmatic, thymic, and mediastinal ramusculi, and finally terminate—that of the left side in the left brachio-cephalic vein, that of the right side usually in the vena cava.

VENA CAVA SUPERIOR.

735. The *vena cava superior*, fig. 138, A, conveys to the heart the blood which is returned from the head, the neck, the upper extremities, and the thorax. It extends in nearly a vertical direction from opposite the cartilage of the first rib on the right side of the sternum to the base of the heart, where it opens into the right auricle; at about an inch and a half above its termination, it is invested by the fibrous layer of the pericardium, the serous membrane being reflected over it. The

superior cava lies immediately in front of the right pulmonary vessels, and between the right lung and the aorta, which partly overlap it. It receives several small veins from the pericardium and the mediastinum, and lastly is joined from behind by the vena azygos.

VENA AZYGOS.

736. *Vena azygos* (v. sine pari).—The name given to this vein signifies that it has no fellow or corresponding vessel (*α* priv. *ζευγνυμι*); but it cannot be applied with propriety, inasmuch as there is a similar vessel on the opposite side, though of smaller size (azygos minor). The incipient radicles of the vena azygos major, fig. 138, *f*, issue either from the inferior cava, where that vessel turns forwards to reach the opening in the diaphragm, but much more frequently from one of the lumbar veins of the right side, sometimes from the renal vein. The vein passes from the abdomen into the thorax, through the aortic opening in the diaphragm, or more externally through the fibres of that muscle, and ascends on the bodies of the dorsal vertebræ, until it arrives opposite the root of the right lung: here it arches forward above the bronchus, and opens into the superior vena cava, immediately above the point at which that vessel is invested by the pericardium. When passing through the opening in the diaphragm, this vein is in company with the thoracic duct, and both are situated on the right side of the aorta: in the thorax, maintaining the same position with respect to the duct and the œsophagus, it crosses in front of the intercostal arteries, and is covered by the pleura. It receives the several veins which accompany the aortic intercostal arteries of the right side (*v. intercostales posteriores*), and, at about the fifth dorsal vertebra, the v. azygos minor: it is also joined by several œsophageal and other small veins, and near its termination by the bronchial vein of the right lung. It is connected with the commencement of the left superior intercostal vein; and as it communicates with the inferior vena cava, while it terminates in the superior, it forms a connexion between both these vessels. Meckel in one instance found the azygos terminating in the subclavian vein.

737. *Vena azygos minor*, fig. 138, *g*, commences from one

of the lumbar veins, or from the left renal vein, and having entered the thorax with the aorta, or through the crus of the diaphragm, runs on the spine, and opens into the preceding vein, opposite the fifth or sixth dorsal vertebra. It receives the lower intercostal veins of the left side.

738. The bronchial veins (*venæ bronchiales*) return the residue of the blood employed in the nutrition of the lungs. They commence in the minute texture of these organs by radicles corresponding with those of the bronchial arteries. Their course is determined by that of the bronchi, which in a manner support them, as they pass towards the back part of the lungs. That of the right side opens into the vena azygos major near its termination, that of the opposite side ends in the superior intercostal vein.

Veins of the Spine and Cranium.

739. The part of the venous system contained within the skull and spinal canal, presents certain peculiarities deserving especial notice. In the skull we find a series of sinuses, representing at once reservoirs and canals, interposed between the small veins which directly receive the blood from the arteries, and the large trunks (jugular veins) which transmit it towards the heart. The sinuses in the skull are formed within the layers of the dura mater, their cavities being lined by a continuation of the inner coat or membrane of the veins: they are very numerous, and vary considerably in form and size. In the spinal canal a chain of venous tubes runs along its whole length, which present some analogy to the cranial sinuses, but still differ in such a way that we may consider them as a transition-link between the veins diffused throughout the body and the sinuses.

The veins within and upon the spinal column may be arranged under the following heads :—viz. 1. Those placed deeply in the vertebral grooves, having close relation to the spines and arches of the vertebræ; 2. The veins of the spinal cord itself; 3. Two long veins, or rather chains of veins, extended the whole length of the canal; 4. Veins lodged within the bodies of the vertebræ; 5. Branches of communication which connect all these together; and, finally, another set, by

which they are brought into connexion with the general venous system.

Preparation and Dissection.—The long spinal veins were first described by Chaussier; the veins of the cranial and spinal bones, as well as of the osseous system generally, were subsequently examined with great care by Dupuytren, and demonstrated in his lectures on anatomy. Breschet subsequently took up the subject.* In order to inject these vessels, an old and emaciated subject should be chosen, as the venous system becomes more developed in advanced age; it should be placed in a warm-bath in the usual way, and thoroughly warmed previous to injection. As the vessels cannot be filled from any single vessel, advantage must be taken of their numerous connexions to inject them from different points. With this view, an injecting pipe must be inserted into the superior longitudinal sinus, another into the vena azygos major, also into the superior and inferior cava. Through all these vessels the injecting fluid should be conveyed, and through at least two or three of them, if possible, at the same time. The posterior and external veins (if the injection has succeeded) are to be traced through the mass of dorsal muscles; those within the spine are best seen by making a vertical section of it and of the skull, dividing it into two lateral halves: or the arches may be cut out, and the cavity exposed.

740. *Venæ dorsi-spinales* (Dupuytren, Breschet). The blood is received and returned from the muscles and tegument placed along the back part of the spine, by a series of short veins, which run horizontally forwards and terminate in some of the larger veins within the spine; hence they are named as above. Commencing by small ramusculi, they gradually increase as they run forwards, close by the spinous processes; and on reaching the interval between the arches of the vertebræ, they pierce the ligamenta subflava, to terminate in a venous plexus within the canal. Towards the external part of the intervertebral grooves another set of veins arise, which pass obliquely inwards, through the inter-transverse spaces, in company with the posterior branches of the lumbar and intercostal arteries, and open into the veins which accompany these vessels.

* Essai sur les Veines du Rachis. 4to.—Traité Anatomique sur le Système Veineux. Fol. avec planches.

741. *Venæ medulli-spinales* (Breschet).—These appertain solely to the spinal cord and its nerves, upon which they are placed, enclosed within the tube of the dura mater. Though they communicate by branches with the other spinal veins, they are not injected concurrently with them, even when the injecting process above described is most successful. Breschet gives the following as the best method of demonstrating them :

Preparation.—Let the injection consist of a strong solution of isinglass, coloured with indigo or Prussian blue ; open the spinal canal in the lumbar region, slit up the dura mater, and search for one of the largest of the veins which rest upon the cord ; into this pass the point of a very small syringe—a silver injecting pipe would answer better—then cautiously introduce the injection, for the coats of the veins are exceedingly thin and weak.

The medulli-spinal veins are very small, long, and tortuous ; they run upon both surfaces of the cord, where they form a diffused plexus or net-work, by mutually giving and receiving branches. The general direction of these vessels is from below upwards, but still they do not increase as they approach the base of the skull, on the contrary their size is smaller than in the lumbar region. This arises from the fact, that the blood brought into these superficial vessels, by the small veins which open into them from the substance of the cord, is sent outwards directly by the branches which accompany the nerves towards the intervertebral foramina, where they pour it into the great spinal veins. Near the base of the skull the medulli-spinal veins unite, and form two or three small trunks, which maintain, by transverse branches, communications with the vertebral veins, after which they terminate in the inferior cerebellar veins, or in the petrosal sinuses.

742. *Venæ basis vertebræ.*—The large apertures observable in the bodies of the vertebræ lodge veins of corresponding size ; any arterial branches which may enter by them are very small. In the posterior flat surface of these bones, and equi-distant from their upper and under margins, we find a large foramen leading into a canal, which, running forwards for two or three lines, divides into two similar tubes of smaller size. Each of the latter turns inwards and unites with its fellow, forming an arch, from the convexity of which small branches pass obliquely

forwards. Some of these terminate in the cancelli of the bone, others are prolonged to its convex surface, where they anastomose with some of the superficial veins. Whilst the final ramifications of these venous canals terminate, as has been just stated, or rather (taking it in the course of the current) commence, the trunk of each when it reaches the spinal canal divides into two branches, which diverge and terminate in the large spinal veins.

743. The blood collected by the different vessels here described is poured by them into two large veins, or rather tortuous venous canals which extend the whole length of the spine lodged in its interior. These vessels may be named the great spinal veins; Chaussier and Breschet call them *veines meningo-rachidiennes;* but they are not enclosed within, or formed by, the dura mater (μηνιγξ), therefore the name is not well chosen. They do not present the appearance of continuous tubes: for, from space to space, they are alternately constricted and enlarged, so as to resemble a series of links, the constricted points corresponding with the intervertebral foramina, where they are drawn forwards, and in a manner secured by the branches of communication which pass outwards. They lie behind the bodies of the vertebræ, occupying the interval at each side between the intervertebral foramina and those in the centre of the bodies of these bones. In some parts the links of the chain which they form are double, or even triple, and occasionally detached from any connexion with the link above or that below, which shows that each portion is, as it were, a separate trunk by itself, receiving the blood, and conveying it outwards into the general circulation, for the current does not ascend or descend along the column which the series of veins forms. Each of these venous trunks is as long as the interval between two intervertebral foramina. In the thoracic region their communicating branches open into the intercostal veins, in the loins into the lumbar veins, in the neck for the most part into the vertebral.

744. A complex interlacement of tortuous veins is established along the inner surface of the arches of the vertebræ. In the lower part of the canal the interlacement is not so close as in the upper portion, where it usually conceals (if the injection has run minutely) the whole surface of the dura mater. These veins also converge to the intervertebral fora-

mina, and open by rather narrow channels into the intercostal veins. From a consideration of the connexion and arrangement of the different parts of this complex apparatus, it would appear that the blood at each stage flows through them from behind forwards horizontally. The dorsi-spinal veins pour their blood into the plexus inside the arches of the vertebræ, from which it is collected by two or three small branches, that converge to the intervertebral foramina, and open into some of the præ-vertebral veins (lumbar, azygos, or cervical). Into these also the contents of the great spinal veins are conveyed by the short communicating branches already noticed.

This adjustment of the venous tubes necessarily determines the course of the current; but it will naturally be asked, what is the agency which propels it, seeing how many obstacles tend to retard its flow? The "vis à tergo" from the arteries could not be sufficient of itself, where everything seems to favour stagnation: it necessarily assists; but the chief propelling power seems to be the physico-mechanical influence exerted by the expansion of the thorax; by means of which the pressure on the venous trunks within the chest is diminished, whilst that on all other parts remains undiminished, and so the current is made to flow towards that point where it meets the least resistance.

745. *Cerebral veins.*—The part of the venous system contained within the skull consists of veins, properly so called, and sinuses, which resemble so many recipients or reservoirs. The veins which return the blood from the cerebral mass are divisible into two sets, one being superficial, the other deeply seated. The superficial veins of the brain branch out upon every part of its surface, their ultimate radicles dipping into its substance, whilst their large extremities terminate in the different sinuses. Upon the upper surface of the hemispheres the veins will be seen lodged in the sulci, between the convolutions, which give them a waving direction. They are not, however, confined to the sulci; for some of the branches will be observed to pass over the convexity of the convolutions. On reaching the margin of the great fissure between the hemispheres, (their general direction being for the most part transversely inwards,) they receive the branches which come up from the inner flat surface of the hemisphere, become invested by a tubular sheath of the

arachnoid membrane, and turn forwards in such a way as to open obliquely into the superior longitudinal sinus.

The veins at the sides, and under the surface of the brain, are similarly placed; but their direction is outwards, to open into the lateral sinuses at each side.

The deep-seated or internal veins commence within the ventricles of the brain. Upon the surface of the corpus striatum several minute venous branches are seen, after having emerged from its interior. Most of these converge, and form a slender vein (*vena corporis striati*), which runs along the groove between the corpus striatum and optic thalamus, to open into one of the veins of the choroid plexus. The minute veins spread out in the choroid plexus pass backwards, and incline towards the middle line from each side, so as to form, by their union, two veins (*venæ Galeni*). These, lying parallel, run directly backwards, enclosed within the velum interpositum, and escape from the ventricle by passing through the great fissure between the under surface of the corpus callosum and the tubercula quadrigemina. In this way they reach the anterior margin of the tentorium cerebelli, at its angle of union with the falx, where they terminate by opening into the straight sinus.

746. The veins of the cerebellum (*venæ cerebelli*) are disposed in two sets, not merely from a reference to their position, but also from a consideration of their direction and termination. Those of the upper surface incline inwards and forwards for the most part, and so will be found to run upon the superior vermiform process, over which they ascend a little to reach the straight sinus, in which they terminate; some, farther forward, open into the venæ Galeni. Those at the under surface run transversely outwards, and pour their contents into the lateral sinus.

CEREBRAL SINUSES.

747. The sinuses placed within the cranial cavity, and which are interposed between the veins above noticed and the internal jugular veins which receive the blood from them, are numerous; and, by reason of a difference in their position, admit of being divided into two sets, viz. those placed in the prominent folds of the dura mater, and those disposed at the base of the skull.

The form and size of these reservoirs are various; but all are lined by a continuation of the inner membrane of the veins, the dura mater serving as a substitute for their fibrous coat, which extends no farther than the base of the skull.

The sinuses which are formed in the prominent processes of the dura mater converge to a common point, which corresponds with the internal occipital protuberance, and is called the *conflux of the sinuses*, or *torcular Herophili*, fig. 139, *a*; fig. 140, *i*: its form is very irregular. If a square piece of bone be removed, and the dura mater laid open at the point above referred to, the apertures of the following sinuses will be observed opening into it:

Fig. 139.

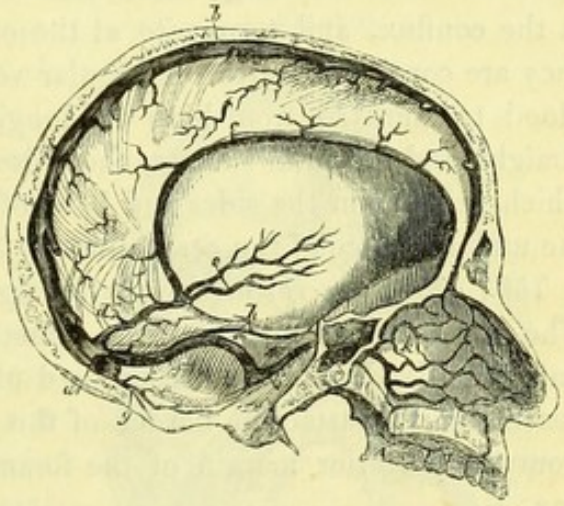

748. *Sinus longitudinalis*, fig. 139, *b* (s. falciformis superior).—The superior longitudinal sinus, commencing at the crista galli, extends from before backwards, in the upper border of the falx, gradually increasing in size as it proceeds. Across its cavity, which is triangular, several bands (*chordæ Willisii*) extend obliquely. The veins from the cerebral surface open into this sinus in such a way that the apertures of the greater number of them are directed from behind forwards, contrary to the direction of the current within it; so that though regurgitation may take place into the sinus, it does not follow that it shall extend into the brain, as the blood in the sinus, by its pressure will close the mouths of the veins, by reason of the peculiar arrangement just noticed.

749. *Sinus longitudinalis inferior*, fig. 139, *c* (s. falciformis inferior). — The inferior longitudinal sinus is very small, and circular in its form; its diameter is inconsiderable. Placed in the inferior concave border of the falx, it runs from before backwards, and opens into the straight sinus on reaching the anterior margin of the tentorium.

750. *Sinus rectus*, fig. 139, *d* (s. quartus; s. tentorii).—The straight sinus may be considered as the continuation of the inferior longitudinal sinus; it runs backwards in the direction of the base of the falx cerebri, gradually widening as it approaches the conflux, where it terminates. Its form is triangular; some transverse bands cross its interior. Besides the inferior longitudinal sinus, the venæ Galeni, *e*, and the superior veins of the cerebellum, open into it.

751. *Sinus lateralis*, fig. 139, *f*; fig. 140, *h* (s. transversi).—The lateral sinuses are of considerable capacity. Their direction conforms to that of the groove marked along the interior of the occipital bone, from opposite the internal occipital protuberance to the foramen lacerum posterius. The sinus of the right side is usually larger than that of the left; both commence at the conflux, and terminate at the outlet just noticed, where they are continuous with the jugular veins. In addition to the blood transmitted from both the longitudinal sinuses, from the straight and occipital sinuses, they also receive that of the veins which arise from the sides and base of the brain, and also from the under surface of the cerebellum.

752. *Sinus occipitalis posterior*, fig. 139, *g*; fig. 140, *g*.—The posterior occipital sinus is sometimes a single canal, not unfrequently double, as if composed of two compartments. It lies along the attached border of the falx cerebelli, extending from the posterior margin of the foramen magnum to the conflux.

The sinuses placed at the base of the skull are as follows, taking them in their order from before backwards:

753. *Sinus circularis*, fig. 140, *a* (s. coronoideus; s. Ridlei).—The name expresses its form; its position is round the margin of the pituitary fossa. It is not always a complete ring, as it represents sometimes a semicircle, placed usually before the gland, sometimes behind it. This little reservoir takes up the blood from the pituitary body by minute veins. It communicates at each side with the cavernous sinus.

754. *Sinus cavernosi*, fig. 140, *b*, are two in number, placed at the sides of the body of the sphenoid bone, and of a very irregular form, but of considerable size. Each receives the ophthalmic vein at its fore part, communicates internally with the circular sinus, and posteriorly with the petrosal sinuses. The

name given to this sinus seems to have been adopted from the winding complex appearance which its interior presents. The dura mater at the side of the body of the sphenoid bone divides into two layers; one of these rests on the bone, whilst the other is stretched from the margin of the sphenoidal fissure backwards, to the upper border of the pars petrosa; so that they leave an interval between them, constituting the sinus. The membrane which lines the ophthalmic vein and the circular sinus, when prolonged into the cavity now under consideration, is considerably dilated; it is intimately connected with that layer of the dura mater which forms the inner wall of the sinus, but is separated from the outer one by an interval which lodges the carotid artery, with the third, fourth, ophthalmic division of the fifth, and the sixth nerves.

Fig. 140.

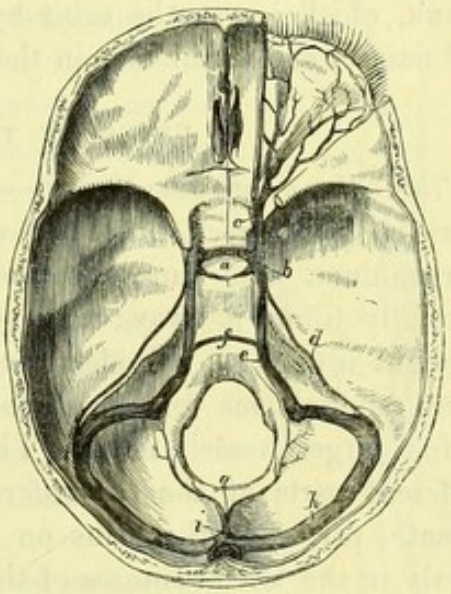

755. *Sinus petrosus superior*, fig. 139, *h*; fig. 140, *d*, represents a narrow canal, running along the upper angle of the pars petrosa. Commencing at the posterior part of the cavernous sinus, its direction is outwards and backwards in the attached margin of the tentorium cerebelli; it descends a little, and ends in the curved part of the lateral sinus, where it lies upon the temporal bone.

756. *Sinus petrosus inferior*, fig. 139, *i*; fig. 140, *e*, at its inner extremity is near to the preceding; it passes downwards and a little outwards, taking the direction of the inferior angle of the pars petrosa, where it is in apposition with the basilar process of the occipital bone; it opens into the lateral sinus near its termination.

757. *Sinus occipitalis anterior*, fig. 140, *f* (s. basilaris).—This is placed at the fore part of the basilar process of the occipital bone, extended transversely, so as to establish a communication between the sinuses just described.

OPHTHALMIC VEIN.

758. *Vena ophthalmica*, fig. 140, *c*.—This vessel may be placed in connexion with those of the cranial cavity, as it opens into the cavernous sinus. Its branches and radicles ramify in the different structures contained within the orbit, in company with the branches of the ophthalmic artery. Minute ramifications arise from the palpebræ, where they communicate with those of the angular vein; those which accompany the supra-orbital artery have similar connexions with the external veins of the forehead. These pass backwards, converging to form others of larger size. The branches arising from the lachrymal gland, from the different muscles, from the ethmoidal cells, those from the globe of the eye itself, all taking the names of the arterial branches which they accompany, join to form a short single trunk, which leaves the orbit by the inner part of the sphenoidal fissure, and terminates in the cavernous sinus.

VEINS OF THE DIPLOE.

759. *Venæ ossium cranii*.—In order to demonstrate the position and direction of the veins of the diploe, detach the pericranium, and remove the external table of the skull by carefully filing it away; the vessels thus named will then be brought into view. Lodged in grooves hollowed in the bone, their ramifications form a series of irregular areolæ, from which a few larger vessels issue. These are directed downwards at different parts of the circumference of the cranium, and terminate, partly in the veins on the outer surface of the bones, partly in the lateral sinuses of the dura mater.

Of the Veins which form the Inferior Vena Cava.

760. These consist of the vessels which return the blood from the lower extremity from the viscera of the pelvis and of the abdomen. The veins of the lower extremity, as in other parts of the body, are divisible into two sets, of which one is deeply seated, whilst the other runs superficially between the common integument and fascia. Immediately under the integuments on the dorsum of the foot there exists a series of small veins disposed in meshes; from these issue two principal trunks (saphenous), which are named, from their relative po-

sition, internal and external, or from their relative length, the greater and smaller.

761. *Vena saphena major*, vel *interna*, fig. 141, extends from the ankle to within an inch and a half of Poupart's ligament; in this course it lies superficially between the integument and fascia. Taking rise from the plexus previously indicated, it passes upwards in front of the inner malleolus, and thence along the corresponding border of the tibia, accompanied by the internal saphenous nerve. At the knee, the vein inclines a little backwards, as it passes by the internal condyle; after which it ascends along the inner and anterior side of the thigh, and terminates in the femoral vein, after passing through an aperture, 1, in the fascia lata, which, from this circumstance, has been termed the saphenous opening. It is joined in this long course by numerous cutaneous branches, and near its termination receives the *superficial epigastric*, *a* ; *pudic*, *b* ; and *circumflex ilii veins*, *c* ; the former passing down from the abdomen between the lamellæ of the superficial fascia, the latter from the groin and pubes.

Fig. 141.

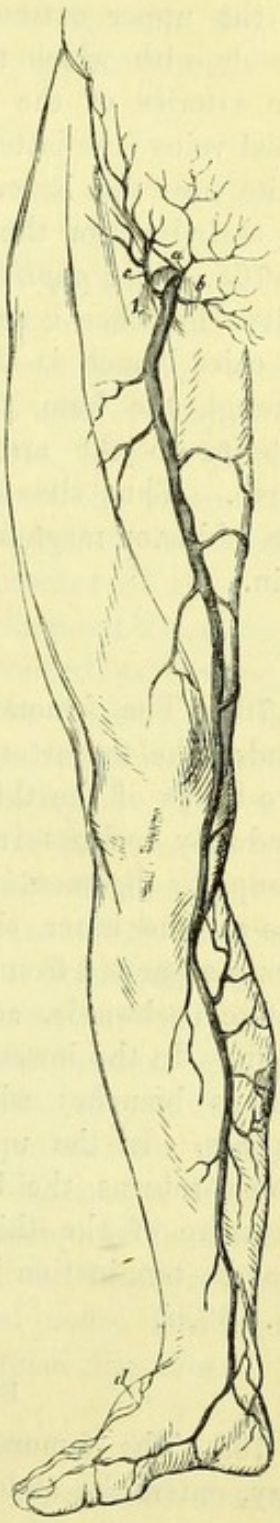

762. *Vena saphena externa*, vel *minor*, proceeds from branches, *d*, which arise along the outer side of the dorsum of the foot, and passes behind the outer ankle, gradually inclining backwards to the tendo Achillis. Passing along the border of the tendon, it gets on the belly of the gastrocnemius muscle, on which it ascends, accompanied by the external saphenous nerve, with which it runs between the heads of the gastrocnemius, and pours its contents into the popliteal vein.

The deep veins of the lower extremity accompany the arteries and their branches, following exactly their distribution. Those below the knee being for the most part disposed in pairs, and presenting the disposition described in the corresponding veins of the upper extremity, are named the *venæ comites* of the vessels with which they are associated. The venæ comites of the arteries of the leg, namely, the anterior and posterior tibial veins (the latter having previously received the peroneal), unite near the lower border of the popliteus muscle, and form by their junction the popliteal vein.

763. *Vena poplitea.*—The popliteal vein, thus formed, receives branches corresponding with the articular vessels; but its chief branch is the external saphenous vein. In its course through the ham, the popliteal vein is placed posterior and exterior to the artery, that is to say, between it and the nerve. Thus situated, it passes up through the aperture in the adductor magnus, and becomes continuous with the femoral vein.

FEMORAL VEIN.

764. The femoral vein, fig. 138, *k*, (*vena femoralis,*) extends, like the artery which it accompanies, through the upper two-thirds of the thigh. Placed at first behind that vessel, it gradually inclines inwards and forwards, so that on reaching Poupart's ligament (where it terminates in the iliac vein), it lies on the inner side, and on the same plane as the artery, being separated from it only by a slight lamella that passes from before backwards, across the membranous tube which invests them. In the lower part of its course, the vein receives all the venous branches which accompany the ramifications of the arteries. In the upper part, the profunda vein opens into it, which returns the blood from all that part of the muscular structure of the thigh supplied by the profunda artery; and near its termination it is joined by the internal saphenous vein, fig. 138, *i*.

EXTERNAL ILIAC VEIN.

765. The femoral vein, placed at the inner side of the artery, enters the abdomen through the femoral ring, and assumes the name of *external iliac vein*, fig. 138, *l*. This ves-

sel, lying at first on the inner side, and on the same plane with the artery of the same name, gradually inclines somewhat behind it as it approaches the sacro-iliac symphysis, where it joins the internal iliac vein, to form with it the common iliac vein. Near its commencement at Poupart's ligament, the external iliac receives the circumflex ilii and epigastric veins.

INTERNAL ILIAC VEIN.

766. *Vena iliaca interna*, fig. 138, *m*.—All the branches of the internal iliac artery are accompanied by veins except the umbilical, whose corresponding vein passes in the fœtus upwards to the liver, these several veins give rise to the internal iliac. The vessel thus formed lies behind the corresponding artery in front of the sacro-iliac symphysis, and, after a very short course upwards to the margin of the pelvis, joins with the external iliac vein. It returns the blood from the organs contained within the pelvis, and from the large mass of muscles which occupy its outer surface. The branches of this vein being remarkable for their size and their frequent interlacings one with the other, they have been described as forming a series of plexuses, severally named from the organs on whose surface the interlacement occurs: thus the vesical, hæmorrhoidal, or uterine plexus, are not unfrequently mentioned. The only branch which requires more detailed notice is that named vena dorsalis penis in the male. This vessel is of considerable size. Commencing by a series of ramusculi which issue from the glans penis, we find in the first instance one at each side of the median line, in the dorsal groove of the penis: here they communicate with branches which accompany the internal and external pudic arteries. Proceeding backwards, they unite and form a short trunk which passes under the compressor muscle, and enters the pelvis beneath the sub-pubic ligament. Here it divides, its branches from thence passing obliquely downwards and backwards over the prostate and neck of the bladder, where it anastomoses with branches of the vesical veins, forming a sort of plexus, and finally opens into the internal iliac vein.

COMMON ILIAC VEIN.

767. The common iliac vein (*vena iliaca communis*), formed by the confluence of the two iliac veins, passes upwards, con-

verging towards the corresponding vessel of the opposite side, and both unite at the junction of the fourth with the fifth lumbar vertebræ, a little to the right of the middle line, where they terminate in the inferior or ascending cava. The right is shorter, and nearly vertical in its direction, and both pass under the right common iliac artery.

INFERIOR VENA CAVA.

768. The *inferior vena cava*, fig. 138, B, returns the residue of the blood circulated by the abdominal aorta. It commences at the conflux of the two common iliac veins on the side of the fourth lumbar vertebra, and thence ascends along the right side of the aorta, as far as the posterior border of the liver; it there becomes lodged in a groove in that organ, after which it inclines forwards to reach the opening in the diaphragm appropriated to it, and immediately terminates in the right auricle of the heart. In its course it receives the veins corresponding with the lumbar and renal arteries; also the spermatic, capsular, and inferior phrenic; and, finally, the hepatic veins, which, through the medium of the vena portæ, return the blood from the chylopoietic viscera. In a case reported by Meckel,* the inferior vena cava followed the course usually taken by the azygos vein, and terminated in the superior cava. The hepatic veins united into a single trunk, which assumed the ordinary position of the inferior vena cava, passed through its foramen in the diaphragm, and opened into the right auricle.

769. *Vena sacra media.*—This vein, fig. 138, *n*, taking its course upwards on the anterior surface of the sacrum, opens into the commencement of the vena cava, or more usually into the left common iliac vein as it passes obliquely to its junction with the corresponding vein.

770. *Venæ lumbales*, fig. 138, *o*.—The lumbar veins commence by small branches in the muscles of the back and abdomen, where they communicate with the epigastric and other veins in the neighbourhood; arrived at the spine, they proceed forward behind the psoas muscle, those on the left side passing also behind the aorta, and terminate in the vena cava. Some of these veins are frequently found to unite into one trunk before their termination.

* Med. Gaz. 1830.

771. *Venæ spermaticæ*, fig. 138, *p*, *q*.—Proceeding upwards from the testis, and forming one of the constituents of the spermatic cord, each spermatic vein enters the abdomen, and ascends on the psoas muscle behind the peritonæum. Below the external ring the veins are numerous, branched and convoluted; they have valves, but still may be injected from above downwards. These branches gradually unite, and form a single vessel, which opens on the right side into the vena cava, on the left into the renal vein. The spermatic veins sometimes bifurcate before their termination, each division opening separately; in this case, that of the right side may be found communicating with the vena cava and the renal vein.

772. *Venæ renales*, vel *emulgentes*, fig. 138, *r*.—These veins are short, but of very considerable calibre. That of the left side is longer than the right, and passes generally in front of the aorta. They join the vena cava at nearly a right angle. The renal veins usually receive branches from the supra-renal capsules; the left has also opening into it the spermatic vein of the same side.

773. *Venæ capsulares*, fig. 138, *s*.— The veins of the supra-renal capsules are very small; they usually join on the right side with the vena cava, on the left with the renal veins.

774. The *venæ phrenicæ inferiores* follow exactly the course of the arteries supplied to the diaphragm by the abdominal aorta.

Veins of the Liver.

775. In the adult, as well as in the fœtus, the veins of the liver present peculiarities which in a manner mark them off as a separate compartment of the venous system. For here a vein seems to assume the functions of an artery, and to convey the materials from which the peculiar secretion of the organ is elaborated. The *vena portæ*, or vein of the gate, has been so called from its entering the transverse fissure of the liver, which was likened to a gateway, the minor lobes placed before and behind it representing its pillars. This vessel conveys to the liver the residual blood from all the chylopoietic viscera. The veins from these different sources unite into two principal trunks, viz. the splenic and superior mesenteric; from the conflux of these proceeds the vena portæ, which again spreads out and ramifies in the liver, so that it may be said to have two sets of branches,

viz. the incipient in the intestines, and the terminal in the liver, both being connected by an intermediate trunk.

776. *Vena splenica*, fig. 142, *b*.—The splenic vein is a vessel of very considerable size, for it returns the blood not only from the spleen, but also from the pancreas, duodenum, the greater part of the stomach and omentum, the left colon, and part of the rectum. It commences by five or six branches which issue separately from the fissure of the spleen, but soon join to form a single vessel. Its direction is then transverse from left to right, embedded in the substance of the pancreas, in company with the splenic artery, beneath which it is placed. On reaching the front of the spine it joins the superior mesenteric vein, nearly at a right angle. It receives branches from the pancreas (*venæ pancreaticæ*), from the duodenum (*v. duodenales*), from the left extremity of the stomach, which, from the arteries they accompany, may be called *v. gastricæ* or *vasa brevia*, and the *left gastro-epiploic vein*, *c*; also the two following, which require a more detailed notice:

Fig. 142.

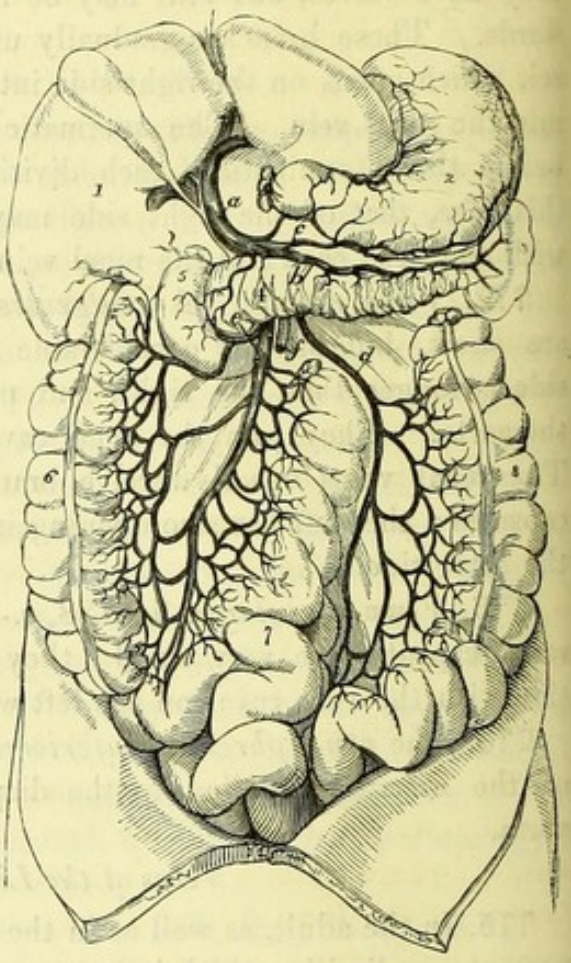

777. *Vena mesenterica inferior*, fig. 142, *d*.—The branches of this vein correspond with the ramifications of the artery of the same name. They commence behind and at the sides of the rectum, from which they ascend and unite to form a single vessel, towards the sigmoid flexure of the colon. From this point it passes upwards and inwards along the lumbar region, behind

the peritonæum, and runs between the transverse meso-colon and the spine; sometimes it lies farther to the left, but in either case it passes under the pancreas, so as to reach the splenic vein, in which it terminates.

778. *Vena coronaria ventriculi.*—This vein lies parallel with the artery of the same name. Its size is inconsiderable, and its direction transverse from the cardiac to the pyloric part of the stomach, along the lesser curvature. On reaching the latter point it turns downwards, and opens into the splenic vein, or in some instances into the trunk of the vena portæ.

779. *Vena mesenterica superior*, fig. 142, *e*, corresponds with the artery of the same name, lying to its right, and somewhat anteriorly, and returns the blood from the same parts, viz. the small intestine, and the ascending and transverse parts of the duodenum and behind the pancreas, where it joins with the colon. The trunk formed by the union of these branches inclines upwards and to the right side, passing in front of the transverse part of the splenic vein.

[In fig. 142, the liver is marked 1, the stomach 2, the spleen 3, the pancreas 4, the duodenum 5, the ascending colon 6, the small intestines 7, the descending colon 8.]

VENA PORTÆ.

780. The trunk of the vena portæ, fig. 142, *a*, commencing at the junction of the splenic and mesenteric veins, passes upwards, forwards, and a little to the right, to reach the transverse fissure of the liver, being about three inches in length. It comes into intimate relation with the biliary vessels, being placed closely behind, and in a manner between the hepatic artery and the hepatic ducts. It is surrounded by the filaments of the hepatic plexus of nerves, together with lymphatics. All these are embedded in loose cellular tissue, and enclosed within the layers of the gastro-hepatic omentum. When near to the right extremity of the transverse fissure, the vena portæ divides into two branches. That of the right side directly enters the substance of the corresponding lobe of the liver, and spreads out into branches, each of which is accompanied by a branch of the hepatic artery and of the hepatic duct. The left branch, which is smaller, but necessarily longer, passes across to gain the left extremity of the fissure, where it enters and ramifies like the preceding branch. The blood conveyed to the liver by

this vessel is collected again and returned into the current of the circulation by the hepatic veins.

781. *Venæ hepaticæ*, fig. 138, *t*, commence by radicles, which communicate (as may be shown by injection) with the terminations of the vena portæ. These gradually enlarge as they pass upwards, converging to the point at which the vena cava passes behind the liver, and pour their contents into that vein. There are usually three sets, proceeding to a common point; those from the right and left lobes being oblique in their direction, those from the lobulus Spigelii and middle of the liver occupying an intermediate position.

Veins of the Heart.

782. *Vena cordis maxima.* — This vessel is of considerable size, and from the way in which it coils round the left side of the base of the heart, or rather of the ventricle, it may be named "coronary." Its chief branch runs along the groove at the anterior convex surface of the heart, corresponding with the septum ventriculorum. Commencing at the apex, it gradually increases as it approaches the base of the ventricles, receiving branches from both, particularly from the left. It then inclines backwards and to the left side, running in the groove between the left auricle and ventricle, but prolongs its course a few lines beyond this to open into the right auricle, close to the septum auricularum. In this course it receives branches from the ventricles, also from the left auricle; and when it passes by the thick margin of the left ventricle, it receives a vein of some size, which ascends to join it.

Vena cordis media. — The term "coronary" cannot be applied to this vessel with any propriety, as its direction is altogether straight, running along the groove between the ventricles at the posterior surface of the heart. It commences by small branches at the apex, communicating with those of the preceding vein, ascends to the base, receiving ramusculi from the fleshy substance of both cavities, and opens into the vena maxima, near its termination.

Venæ cordis parvæ.—Several small branches arise from the anterior surface of the right ventricle, from which they pass upwards and outwards, to open separately into the right auricle, after having crossed over the groove which separates it from the ventricle.

Venæ cordis minimæ. — Under this name are included those minute vessels whose orifices are observable in the interior of the right auricle, which, from having been noticed by an old anatomist, Thebesius, are generally called *foramina Thebesii.*

THE ABSORBENTS.

783. The absorbing vessels, considered as a system or whole, are divisible into two sets: 1, those which return the chyle from the alimentary canal; and 2, those which take up the lymph or residue of nutrition from all the other parts of the body: both are connected in their course with ganglia or glands. We shall here describe their course and position, having, in the article on the general anatomy of absorbents, indicated their conformation and structure. The chyle vessels, by their union, form a large trunk (thoracic duct), which is a common reservoir for receiving their contents, as well as those of the lymphatics, which come—from both the lower extremities,—from the cavity of the abdomen and its viscera, except the right lobe of the liver, — from the walls of the abdomen at both sides, and from the surface of the left side of the thorax, — from the left lung, the left side of the heart, and left side of the diaphragm, — from the left upper extremity, and from the corresponding side of the head and neck. But the lymphatic vessels which arise from the right upper extremity, the right side of the head and neck, from the right lung, and from the corresponding half of the liver and diaphragm, pour their contents, by a short trunk, into the conflux of the right subclavian and internal jugular veins. This vessel may be called the right lymphatic duct; it is commonly named the right thoracic duct, though no part of it lies within that cavity. The duct of the left side is not entirely thoracic; for its commencement is in the abdomen, and its termination in the neck.

784. *Vasa lactea*, vel *chylifera.* — These vessels commence in the intestinal canal, from which they extend to the thoracic duct, in which they all terminate. They are much more numerous in the small intestine than in the large; hence they exist in greatest number in the mesentery, particularly in that part of it which corresponds with the jejunum and duode-

num. We find two sets of these vessels along the tube of the intestine, taking a different direction, and lying on different planes. One runs longitudinally in the course of the canal, lying beneath its peritonæal coat; whilst the other, placed between the muscular and mucous coats, is transverse, being directed from the intestine along with its nutritious vessels, and, like them, enclosed within the folds of the peritonæum. It was at one time supposed that the superficial absorbents here noticed were lymphatics, and that the others were lacteals; the distinction, however, is not tenable; both seem to communicate and anastomose. "The lacteals (says Cruikshank) absorb chyle when it is presented to them; and at other times they absorb other fluids."* The deep-seated lacteals, when they enter the mesentery, take the course of the vessels, passing through the lymphatic glands, of which many are placed within its folds. They gradually unite as they proceed, two or three perhaps converging to form one; and so they become diminished in number, until finally, towards the root of the mesenteric artery, two or three trunks shall have resulted from the junction of all. Sometimes, however, six or seven of these vessels open separately into the commencement of the thoracic duct. In this way the lacteals, from the whole of the small intestine and from the cæcum, together with the ascending and transverse parts of the colon, terminate; those from the descending colon and its sigmoid flexure usually join some of the lumbar lymphatics, or turn upwards, and open by a single vessel into the lower end of the duct. To the same point we trace, from below upwards, the lymphatic vessels, from the two lower extremities; so that the thoracic duct may be said to commence at the conflux of those just named with the common trunk of the lacteals.

785. The *thoracic duct*, fig. 143, *b*, is from eighteen to twenty inches long in the adult, for it extends usually from the second lumbar vertebra to the root of the neck. Its commencement, however, is often opposite the third lumbar vertebra; in some cases as high as the first, or even the last dorsal. Here there is usually a dilatation, which varies considerably in degree, being in some cases scarcely perceptible, in others considerable. This part of the

* Anatomy of the Absorbing Vessels, p. 161.

duct is called *receptaculum chyli*, fig. 143, *a*; but the term is not well chosen, as it receives lymph as well as chyle, nor is it always applicable, for there may be no dilatation. It lies to the left side and behind the aorta, and is about three lines in diameter; but as it ascends it passes to the right side of that vessel, getting into contact with the right crus of the diaphragm, and so reaches the thorax, where it is placed at first upon the fore part of the dorsal vertebræ, between the aorta, 1, and the vena azygos major, 8, the latter being to its right side. It ascends gradually inclining to the left, at the same time diminishing in size until it reaches the third dorsal vertebra, where, after passing behind the arch of the aorta, it comes into contact with the œsophagus, lying between its left side and the pleura. Continuing its course, it ascends into the neck, supported by the longus colli muscle, until it comes on a level with the upper border of the seventh cervical vertebra, where it changes its direction and comes forwards, at the same time inclining downwards and inwards, so as to describe a curve, *d*, previously to its termination at the external angle formed by the union of the subclavian and internal jugular veins, 6, 7. The duct does not always remain single in its whole extent; it frequently divides opposite the seventh or eighth dorsal vertebra into two branches, which unite again; sometimes in its course it separates into two or three branches, which afterwards unite, and enclose between them so many spaces or islets. Mr. Cruikshank in one case found the duct

Fig. 143.

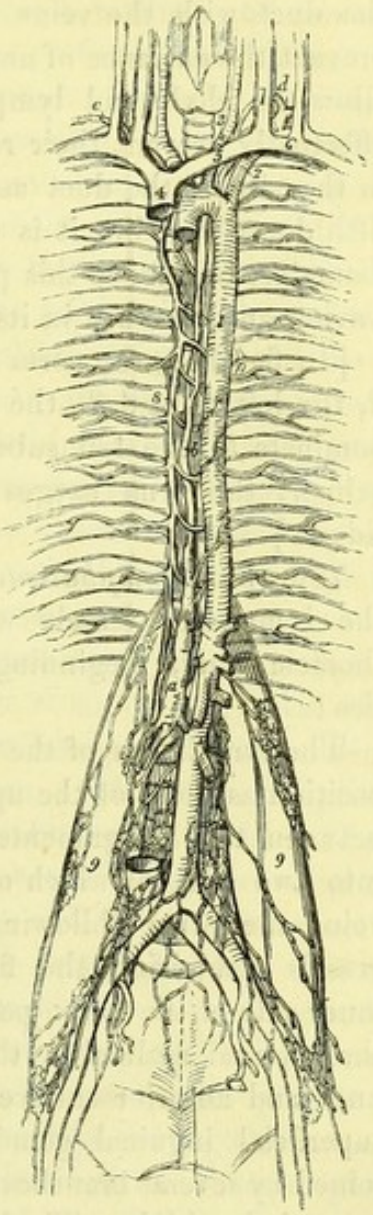

double in its entire length; "in another triple, or nearly so." When in the neck, it often divides into two or three branches, which in some instances terminate separately, but in others join again previously to their termination. At the junction of the duct with the veins there are two valves so placed as to prevent the entrance of any blood into the duct, and whilst they allow the chyle and lymph freely to pass into the veins, they effectually prevent their return into the duct. The diminution in the size of the duct as it ascends has been noticed; at the fifth dorsal vertebra it is often no more than about two lines in diameter, but above this point it enlarges again. It is generally waving and tortuous in its course.

[In fig. 143, the aorta is marked 1, the left subclavian artery 2, the left carotid 3, the superior vena cava 4, the left vena innominata 5, the left subclavian vein 6, the left internal jugular vein 7, the vena azygos major 8, the psoas muscle at each side 9.]

786. *Vasa lymphatica.* — We shall trace up the course of the lymphatic vessels which pour their contents into the thoracic duct, beginning with those of the lower extremities:

The lymphatics of the lower extremity present the same disposition as those of the upper. The superficial series, disposed between the integuments and fascia of the limb, are arranged into two sets, of which one accompanies the internal saphenous vein, the other following the course of the external. The vessels composing the first set take rise on the dorsum and inner side of the foot: passing partly in front and in part behind the internal malleolus, they ascend along the inner side of the knee and anterior surface of the thigh, and terminate in the superficial inguinal glands. In their course these vessels are joined by several branches proceeding from the integuments of the leg and the thigh. The lymphatics, which constitute the second division of the cutaneous series, are much less numerous than those just described. Commencing from radicles which occupy the outer margin of the foot, they pass behind the external malleolus, and ascend along the posterior part of the leg; here they get under cover of the fascia, and proceed between the heads of the gastrocnemius muscle to terminate in the popliteal glands.

This course corresponds to that of the smaller saphenous vein, which these lymphatics accompany.

The deep-seated lymphatics, associated in their whole course with the arteries and their branches, consist in the leg of three divisions, namely, anterior tibial, posterior tibial, and peroneal. In the leg, neither these nor the superficial vessels meet with any lymphatic gland, with the exception of those accompanying the anterior tibial artery, which occasionally pass through one: this gland when it exists, which is not always the case, is situated on the inter-osseous ligament, about the middle of the leg. The several sets of deep lymphatics here pointed out, after ascending with the blood-vessels, unite in the glands situated in the popliteal space. These (the popliteal lymphatic glands) are usually very small, and four or five in number; they surround the popliteal vessels, and are embedded in a quantity of loose fat. The popliteal glands receive the deep-seated lymphatics of the leg, and those which accompany the external saphenous vein, and from them proceed vasa efferentia, which ascend with the femoral artery to the glands of the groin.

The inguinal glands, like the lymphatic vessels, are, from their relative position, divisible into a superficial and a deep set; the former being placed immediately under the integuments, the latter under the fascia lata. The superficial glands are larger than the others; their number varies much, but may be stated to average about eight or ten; they are disposed irregularly about Poupart's ligament and the saphenous opening of the fascia; a few sometimes extend for two or three inches downwards on the saphenous vein. The deep-seated glands are placed around the femoral artery and vein, immediately behind the preceding. In addition to the lymphatics of the inferior extremity already described, the inguinal glands are joined by some superficial vessels from the external generative organs, from the lower part of the abdominal parietes, and several which proceed from the integuments covering the outer side of the pelvis. The deep lymphatics, which are derived from the mass of the muscles on the pelvis, and many proceeding from the adductor muscles of the thigh, accompanying respectively the gluteal, sciatic, and obturator arteries, enter the cavity of the pelvis with these vessels, and proceed in

a series of glands situated in the neighbourhood of the trunk by which the vessels are given off. The vasa efferentia of the superficial inguinal glands perforate the fascia, come into connexion with those situated deeply, pass into the abdomen by the side of the blood-vessels, and terminate in a chain of lymphatics lying along the external iliac artery, and communicating with the lumbar glands.

787. *Lymphatics of the abdomen and pelvis.* — The lymphatic vessels of the abdominal parietes consist of several groups, proceeding in different directions, but all referable to the arteries supplied to the different regions. A superficial series, derived from the integuments covering anteriorly the lower part of the abdomen (from the umbilicus downwards), descends, converging to the superficial inguinal glands; and those deeply seated in the same situation, pursuing a similar direction, join glands situated on the external iliac artery, both following respectively the superficial and deep epigastric blood-vessels. The other lymphatics, proceeding from the lateral and posterior part of the parietes of the abdomen, pass inwards between the fibres of the muscles; a small portion then winds round the crista of the ilium, meeting in their course one or two small glands, and proceed along Poupart's ligament with the circumflex ilii artery, to terminate in the external iliac glands; while the greatest number, directed backwards with the lumbar and ilio-lumbar arteries, and being joined by radicles from the large muscles of the back, pass behind the psoas muscle to the vertebral column, where they end in glands surrounding the large blood-vessels.

788. *Lymphatics of the pelvic viscera.* — The course of these, as of the lymphatic vessels in other parts, is indicated by that of their arteries and veins. The lymphatics of the bladder, taking rise from the entire surface of that organ, join the glands placed about the internal iliac artery: with these are associated the lymphatics of the prostate gland and of the vesiculæ seminales.

Those of the rectum are frequently of considerable size: immediately after leaving the intestine, some pass through small glands which lie contiguous to it; finally, they pass to glands situated in the hollow of the sacrum; some to those in the lumbar region.

In the unimpregnated state of the uterus, its lymphatics are

small, but during the period of gestation they become of considerable size. Issuing from the entire substance of the organ, the greatest number descend, unite with those of the vagina, and, passing backwards, join the internal iliac glands; thus pursuing the direction of the principal uterine blood-vessels. Others springing from the superior part (fundus) of the uterus, pass outwards in the folds of peritonæum which constitute its broad ligaments, and join with lymphatics derived from the ovarium and Fallopian tubes. The united vessels now ascend with the ovarian (in the male, spermatic) arteries, and, at the point where these take their rise, become connected with the lymphatics placed on the aorta and vena cava.

789. The *lymphatics of the penis* consist of superficial and deep sets, which pursue different courses. Those placed superficially usually form three vessels, two being placed laterally, the other superiorly. Commencing in the prepuce, they pass backwards, and generally unite on the dorsum penis, and, again subdividing, send branches on each side to the inguinal glands.

The *lymphatics of the scrotum*, together with those from the integuments of the perinæum, may be associated; for all, guided, as it were, by the superficial pudic vessels, join the inguinal lymphatic glands. The deep-seated lymphatics of the penis accompany the internal pudic vessels, and unite with glands on the internal iliac artery. The lymphatics of the labia, clitoris, &c. in the female, present a disposition entirely similar to that here described in the male organs.

790. *Lymphatics of the testis* commence by radicles issuing from the substance of the testis, and from the tunica vaginalis. Collected into several trunks of considerable size, they ascend, with the other constituents of the spermatic cord, to the internal abdominal ring, and finally accompany the spermatic vessels to enter the large lumbar lymphatic glands.

791. *Lymphatics of the kidney.*—Those placed superficially are very indistinct; they become united with the deep-seated set, at the inner margin (hilus) of the kidney, from which they incline inwards to the lumbar glands. The lymphatics of the supra-renal capsules unite with those of the kidney. The lymphatic vessels of the ureter are numerous; they communicate with those of the kidney and the bladder, and for the most part terminate with the former.

792. *Lymphatics of the stomach.*—These at first are disposed into two planes, one lying under the peritonæal coat, the other between the muscular coat and the mucous lining; by taking the direction of the vessels they become aggregated into three fasciculi. One set takes the direction of the coronary artery, receiving, as it runs from left to right, branches from both surfaces of the organ, and at the pylorus turns backwards to join some of the larger trunks. Another, from the left extremity of the stomach, follows the vasa brevia, and unites with those of the spleen; whilst the third, guided by the right gastro-epiploic vessels, inclines from left to right along its great curvature, from which they pass backwards, and at the root of the mesentery terminate in one of the principal lacteal vessels.

793. *Lymphatics of the spleen and pancreas.*—Some of the lymphatics of the spleen lie immediately under its peritonæal covering, others in the substance of the organ. Both converge to the inner side of the spleen, come into relation with the blood-vessels, and, accompanying them, pass through a series of small glands, and finally become connected with the lymphatics of the digestive organs.

Lymphatics emerge from the pancreas at different points, and join those last described.

794. The *lymphatics of the liver* are divisible into three principal sets — those upon its upper surface, those on the lower one, the third being diffused throughout its substance with the hepatic vessels. Those upon the upper surface, though spread out pretty equally upon it, incline in their course to different points, and so become distinguishable into groups, of which four are ordinarily enumerated. Thus, from the middle of the great lobe, five or six branches run obliquely upwards to the suspensory ligament, where they form a large trunk, which passes between the fibres of the diaphragm, behind the ensiform cartilage. When in the mediastinum, they pass along the chain of glands which accompany the internal mammary vessels, and so they are conducted to the root of the neck, generally at the right side, where they terminate in the lymphatic trunk of that side. The second group consists of vessels which incline upwards and outwards to the right lateral ligament, opposite to which they unite into one or two of

larger size, which pierce the diaphragm, and run upon its convex surface to join the preceding trunk in the mediastinum. In some cases, however, these, instead of passing into the thorax, turn backwards and inwards on reaching the posterior border of the liver, and, running upon the crus of the diaphragm, open into the thoracic duct at its commencement. A similar fasciculus is formed upon the left lobe of the liver, which, after passing through the left lateral ligament, pierces the diaphragm, upon which they ascend to the glands above noticed. Finally, towards the lower sharp border of the liver, at each side, some vessels will be observed also to turn downwards and join those placed upon its under surface.

A diffused plexus is formed by ramifications upon the concave surface of the liver. On the right lobe they will be found running downwards over the surface of the gall-bladder to the transverse fissure, where some join the deep-seated set, and others, after passing through a few glands, are, as it were, guided by the hepatic artery to the right side of the aorta, where they terminate in the thoracic duct. Branches also proceed to the concave border of the stomach, between the folds of the small omentum, to join with the coronary lymphatics of the stomach.

The deep-seated lymphatic vessels of the liver accompany the ramifications of the vena portæ in the interior of the organ, from which they escape by the transverse fissure. After communicating with the superficial vessels, and also with those of the stomach, they pass backwards, and, at the side of the cœliac artery, join with one of the lacteal trunks, previously to its termination in the thoracic duct.

795. *Mesenteric glands.* — These bodies vary in number from one hundred and thirty to a hundred and fifty; and in the healthy state are seldom larger than an almond. They are most numerous in that part of the mesentery which corresponds with the jejunum. Through these the lacteals may be said to pass in their course to the thoracic duct; they seldom occur nearer to the attached border of the intestine than two inches. Small glands are also disseminated irregularly between the folds of the peritonæum connected with the large intestine; they are not numerous, and require no special consideration.

Lymphatic Glands of the Abdomen.

796. The lymphatics of the lower half of the body have been traced into the abdomen, to a series of glands situated in front of the vertebral column and the sacrum. Though these are connected by vessels passing from one to the other, forming a sort of chain in the situation indicated, yet as they are more numerous, or as it were aggregated together at particular points, they are divisible into different series. In the pelvis, some of the glands are placed behind the rectum in the hollow of the sacrum, and are hence named sacral glands; others situated more externally, surrounding the internal iliac artery, are denominated the internal iliac glands. It does not appear necessary to name them separately; they receive the lymphatics corresponding to the branches of the internal iliac artery, and communicate upwards with the lumbar glands.

The *lumbar lymphatic glands* are very large and numerous; they are placed in front of the lumbar vertebræ, surrounding the aorta and vena cava. To them we have traced the lymphatics which accompany several of the branches of the abdominal aorta, those of the inferior extremity being also connected with them. The vessels passing between the glands here described, progressively increasing in size, while their number diminishes, at length form the trunks which, with those of the lacteals, give rise to the thoracic duct.

797. The lymphatics of the thorax are divisible into two sets, viz. those of its parietes and those of the contained viscera. The former are arranged in two distinct planes, one lying between the skin and the muscles, the other being deeply seated. The superficial lymphatics at the front of the chest run upon the pectoralis major muscle, for the most part outwards and upwards, to reach the axilla, where they open into the glands. Those on the posterior surface lie upon the trapezius and latissimus dorsi: some incline downwards, others upwards, some transverse — all converging to the axilla, where, through the medium of the glands, they join with the lymphatics of the upper extremity. The deep vessels at the fore part of the chest correspond, in their general distribution, with the internal mammary artery; for they commence in the muscles of the ab-

domen, run upwards through the cellular interval, between the fibres of the diaphragm at their attachment to the ensiform cartilage, and so they ascend behind the costal cartilages to the summit of the thorax. In their course they receive branches from the anterior part of the intercostal spaces, and ultimately terminate, that of the left side in the thoracic duct, whilst the corresponding one ends in the right lymphatic trunk.

The lymphatics placed deeply at the sides and back part of the chest follow the distribution of the aortic intercostal arteries; for they receive branches from the dorsal muscles, which come forwards through the inter-transverse spaces, and others from the sides running along the intercostal spaces. All these incline inwards to the spine, and terminate in the thoracic duct.

798. The *lymphatics of the lungs*, as in other organs, are disposed in two planes, one being superficial, the other deep-seated. Those at the surface run beneath the pleura, where they form a diffused net-work by their anastomoses. Their number is considerable, but they cannot be demonstrated with equal facility in all cases. "I have been able,"* says Cruikshank, "at one time to show the whole external surface of the lungs covered with absorbents I had injected; at another time I have not been able to find one." One of the easiest methods of finding them is to inflate the lungs of a still-born child from the trachea; the air passes from the cells into the absorbents, and enables us to see those on the surface: if a puncture be made into one of them with a lancet, the air will partially escape, and then the injecting pipe, containing a column of quicksilver, can be introduced.† Most of these converge to the root of the lungs, and terminate in the bronchial glands.

The deep lymphatics of the lungs run with the vessels along the bronchi, communicating freely with those at the surface, and at the root the lungs open into the bronchial glands. From these, two or three trunks issue, which ascend along the trachea to the root of the neck, and terminate at the left side in the thoracic duct, at the right in the corresponding lymphatic duct.

799. *Lymphatics of the thymus gland.*—On the spinal surface of the thymus, Sir Astley Cooper‡ observes, "numerous

* Anatomy of the Absorbents, p. 194. † Loc. cit.

‡ Anatomy of the Thymus Gland, p. 14.

absorbent glands are found; and if these be injected, many absorbents are discovered. But upon the posterior surface of the cornua and cervical portion, two large vessels proceed on each cornu, and the side of the trachea, towards the junction of the jugular veins with the superior cava. They are sufficiently large to admit a pipe to throw in coarse injection, and I can readily inject them with wax, dissect and preserve them, so as to make very interesting preparations of them. They pass nearly straight upon the spinal surface of the cornua, converging a little as they proceed towards the sternum, and terminate in the jugular veins by one or more orifices on each side."

800. *Lymphatics of the thyroid gland.*—From each lateral lobe of this organ some absorbing vessels arise, which converge and unite to form one short trunk, that opens at the right side into the right lymphatic duct, at the left into the thoracic. They may be demonstrated by inserting the injecting pipe into the substance of the gland, when the mercury, by its weight, will force its way into the lymphatics.

801. *Lymphatics of the heart.*—These follow the coronary vessels, from the apex of the organ up to its base. Those of the right side converge to the origin of the aorta; a trunk of some size is thus formed, which runs upwards over the aortic arch, gets between the carotid and brachio-cephalic arteries, where it sinks backwards to the trachea, by which it ascends to the root of the neck, to terminate in the right lymphatic trunk. The left lymphatic branches ascend to the base of the heart; where they also communicate with the preceding, and then proceed, having united into a single vessel, along the pulmonary artery, towards its bifurcation. At this point it gets behind the arch of the aorta, passes through some lymphatic glands, and finally ascends by the trachea to terminate in the thoracic duct.

802. *Lymphatics of the œsophagus.*—Along this tube a plexus is formed by absorbing vessels, which pass upwards upon it, traversing the glands which lie in their course; and after having communicated by anastomoses with the lymphatics of the lungs, at the root of that organ, and also higher up, finally terminate in the thoracic duct.

803. *Lymphatic glands of the thorax.*—In the description of the vessels, we have noticed the ovoid bodies with which

they are connected. Thus, six or seven small glands are placed in the course of the internal mammary vessels, and through which the lymphatics pass; they may be named the *anterior mediastinal* glands. Three or four lie behind the aortic arch, and one before it, (*cardiac glands*,) having a similar relation to the lymphatic vessels; some, also, are found along the œsophagus, varying from fifteen to twenty in number (*œsophageal glands*). At the root of the lungs ten or twelve similar bodies are placed of larger size, and usually named *bronchial glands*. The largest of these occupy the interval between the bronchi at their bifurcation, whilst others of smaller size rest upon these tubes for some way within the lungs. In early infancy their colour is pale red; towards puberty, we find them verging to gray, and studded with dark spots; at a more advanced age they are frequently very dark. In chronic diseases of the lungs they become enlarged and indurated, so as to press on the air-tubes, and cause much irritation. They are frequently the seat of tubercular deposits.

804. *Lymphatics of the superior extremity.* — These are divisible into two series, one of which is superficial, the other deeply seated; the former accompanying the cutaneous veins, the latter following the course of the deep vessels.

The *superficial lymphatics* commence by two divisions. Of these, one corresponds with the branches of the ulnar cutaneous vein, which its different ramusculi accompany, from the inner border of the hand, along the anterior and inner surface of the fore-arm as far as the bend of the elbow. In this course they receive numerous branches from the surrounding parts, and join at the point just indicated with a portion of those which constitute the second or external division. Some now enter a lymphatic gland situated in front of the inner condyle of the humerus; continuing their course upwards from thence, they terminate either in glands placed along the brachial artery, or in those of the axilla, where they unite with the deep lymphatics. Those which constitute the second division are less numerous than the preceding. Proceeding from the integuments on the outer margin and back of the hand, they follow the course of the radial cutaneous veins to the bend of the elbow; here the greater number become united to the preceding series,

whilst a few accompany the cephalic vein, ascend on the external side of the arm, pass with that vessel between the deltoid and great pectoral muscle, and end in one or more lymphatic glands beneath the clavicle, communicating with those at the lower part of the neck.

805. The deep lymphatic vessels correspond exactly to the arteries which they accompany. In the fore-arm the deep lymphatics consist, therefore, of three sets, associated with the radial, the ulnar, and inter-osseous arteries; in their progress upwards, they maintain communication with those placed superficially. Some of them pass to the glands which lie near the brachial artery; finally, all end in the glands of the axilla.

The *glands of the axilla* are generally ten or twelve in number; in this, however, as well as in their size, they vary considerably in different individuals; they are placed along the axillary vessels, embedded in a quantity of loose cellular tissue. They receive the lymphatic vessels of the arm already described, as well as those proceeding from the integuments of the back, from the anterior surface of the thorax and mamma, and are therefore liable to be influenced by disease affecting any of these parts.

From the glands in the axilla, vessels, fewer in number, but larger in size, issue and proceed along with the subclavian artery, in some parts twining round it. From the top of the thorax they ascend into the neck, close to the subclavian vein, and terminate, those of the left side in the thoracic duct, those of the right side in the second or smaller lymphatic duct. These vessels sometimes unite into a single trunk, which opens separately into the subclavian vein near its termination.

Lymphatic Vessels and Glands of the Head and Neck.

806. The lymphatics of the head consist of those of the cranium and the face. The former commence by a series of minute radicles disseminated over the scalp; in their descent they diminish in number, increasing in size, and separate into an anterior and posterior division, which follow respectively the course of the temporal and the occipital arteries. The former pass in front of the ear; some at this point enter one or two glands

usually placed in the immediate neighbourhood of the zygoma, while others go to those situated on the parotid gland; finally all end in the lymphatic glands of the neck. The posterior division of the cranial lymphatics accompany the occipital artery, then pass to the glands situated behind the ear (over the mastoid process of the temporal bone), and thence join the superficial lymphatics of the neck. The superficial lymphatics of the face, more numerous than those of the cranium, descend obliquely in the course of the facial vein, and join the glands placed beneath the base of the lower maxillary bone; a few of these in their descent pass through one or two glands situated over the buccinator muscle. The deep-seated lymphatics of the face issue from the cavity of the nose, the mouth, &c. and proceed in the course of the internal maxillary artery; when arrived at the angle of the jaw, they join the glands which occur at this point. The lymphatic glands described as existing on different parts of the head are few and very small; those of the neck, on the contrary, are comparatively large and very numerous.

The *cervical glands* are almost all placed on the sides of the neck, and are divisible into a superficial and deep-seated series. Of the former, some lie along the base of the inferior maxillary bone; the remainder, disposed in the course of the external jugular vein, occur in greatest number in the angular space behind the lower end of the sterno-mastoid muscle, where the external jugular joins the subclavian vein; at the point indicated, they approach and communicate with the axillary glands. The deep-seated cervical glands are placed along the carotid artery and internal jugular vein, extending downwards on different sides of these vessels as far as the thorax. The lymphatic vessels of the cranium and face (already described), together with those of the pharynx, larynx, and other parts of the neck, being received into these glands, and again issuing from them, progressively diminish in number during their descent, and ultimately, at the bottom of the neck, unite into one trunk. This vessel usually pours its contents at the left side into the thoracic duct, immediately before its termination, and at the opposite side into the large right lymphatic duct; it, however, sometimes terminates separately at the confluence of the sub-

clavian and internal jugular veins, or in one of these vessels immediately beyond their point of junction.

807. *Right lymphatic duct*, fig. 143, *c*.—This is a short vessel, about a line or line and a half in diameter, and about three quarters of an inch in length, which receives the lymph from the absorbents of the right upper extremity, and corresponding side of the head and chest. It runs obliquely into the angle formed by the union of the right subclavian and internal jugular veins, where its orifice is guarded by two valves.

CHAPTER VIII.

OF THE VISCERA.

808. The internal viscera and organs of the body are so many instruments which perform special functions; as such they are divisible into two groups, one being subservient to the life and well-being of the individual, the other to the continuance of the species. The former is subdivided into the organs of assimilation, (viz. digestion, absorption, secretion, circulation, respiration, and innervation,) and those of external relation, viz. the senses and the vocal apparatus. The latter, also, includes two groups, one for impregnation, the other for the support of the new being. We shall describe the organs by which these various functions are performed in their order as here indicated, beginning with those of digestion.

ORGANS OF DIGESTION.

809. The digestive organs consist of a primary or fundamental part, the alimentary canal, and certain accessories, which are in a manner appended to it. Under this head are included the salivary glands (sublingual and submaxillary, parotid and pancreas), the liver, and the spleen. Though the canal (*canalis cibarius*) forms one continuous tube, from its commencement at the mouth to its termination at the anus, it presents numerous modifications in its dimensions and form in different parts; moreover, as one portion of it is lodged at the base of the skull, another in the neck and thorax, and a third in the abdomen, it becomes necessary to treat of each separately. To avoid unnecessary subdivision, we shall consider it as composed of two parts, one above the diaphragm, the other below it. The first division includes the organs of mastication and deglutition; the second, those of digestion properly so called, and of defæcation

The Mouth.

810.—The space included between the lips (*labia*) and the throat (*fauces*) is called mouth (*os ; cavum oris*). Its roof is the palate, its floor the tongue, its sides the cheeks (*buccæ*). Immediately within its external aperture (*rima*) are the dental arches. All these parts are coated with a mucous membrane, which has been already described (p. 68 et seq.). In the present section, therefore, it remains for us to notice some folds which are formed by its reflections, and which, from some assumed resemblance to check ligaments, have been called *fræna*. Inside each lip, at the middle line corresponding with the symphysis of the jaw-bones, a small vertical fold is placed (frænum labii superioris et inferioris). One of larger size extends from the under surface of the tongue downwards and forwards (frænum linguæ) ; when the point of the tongue is raised, the form of this fold is triangular, its base being forwards. At the root of the tongue we observe another, extended backwards from its upper surface upon the epiglottis (frænum epiglottidis). Most of the constituents of the other parts here enumerated have also been noticed; the muscles of the lips and cheeks (sect. 348-357), those of the palate (401-6), of the tongue (382-4) ; the osseous structure of the palate (166), the teeth (181).

The Tongue.

Fig. 144.

811. The tongue, fig. 144, (lingua,) is not only the proper organ of taste, but, by means of its great mobility, assists other parts in deglutition, in speech, in suction, &c. Its upper surface, or dorsum, is convex in its general outline, and marked along the middle by a slight groove, or raphé, which divides it into two symmetrical parts. About a quarter of an inch from its base will be observed a round hole, 1, (*foramen cæcum*,) which forms a sort of reservoir for some of the mucous follicles placed in considerable number in that situation. We speak of its point or anterior narrowed extremity, of its sides,

and of its base, which is in intimate connexion with the os hyoides. Upon its upper surface we find several projecting points, or *papillæ*, differing so far in size and number as to admit of being arranged as follows:—1. *Papillæ lenticulares*, 2, 2, which vary in number from ten to fifteen, are disposed in two lines, converging to an angle just before the foramen cæcum. They are rounded on their free surface, and resemble so many inverted cones, their summits being embedded in the substance of the tongue. 2. *Papillæ capitatæ*, vel *fungiformes*, are more numerous than the preceding, and also smaller. They are placed, for the most part, towards the borders and point of the tongue. They present each a rounded head, supported by a short thin pedicle. 3. *Papillæ conicæ*, vel *pyramidales*, are much more numerous than the others, and are diffused over the whole of the dorsum of the tongue, from the lenticular papillæ to its point. They are minute and tapering. A fourth class has been recognised by some persons (*papillæ filiformes*), but they are very few, and placed close to the apex of the tongue. The papillæ at the point and sides consist of the ultimate terminations of the gustatory nerve, surrounded by a delicate vascular plexus, and supported by cellular tissue.

Structure.—Beneath the mucous membrane is placed a thin but firm lamella of condensed cellular tissue, approaching in its characters to elastic tissue. If all the muscles ordinarily described as belonging to the tongue be dissected away, a considerable mass of fleshy substance will still remain, the fibres of which appear interlaced in such a way as to be with great difficulty traced. Upon the upper surface and sides of the tongue a thin stratum of fleshy fibres is placed, extending longitudinally from behind forwards. At the under surface, the fibres of the linguales muscles run in the same way, but that they form fasciculi, not a layer. If the genio-hyo-glossi be carefully dissected to their insertion, their fibres will be found to turn outwards, or to become blended with others which pass transversely from the raphé to the borders on each side. Both the planes of fibres here noticed are placed horizontally, one being at the upper, the other at the under surface; a third set seems to connect them, by passing vertically from one to the other.

The Soft Palate.

812. The soft palate (velum pendulum palati) forms a partial and movable curtain between the mouth and the pharynx. Its upper border is straight, and attached to the margin of the palate bones; the lower is divided into two parts by a conical, depending process, called *uvula*. From this, as from a common point of departure, two curved lines will be observed to extend at each side, one proceeding downwards and forwards to the side of the tongue, the other backwards to the pharynx; both being named, from their form, the arches of the palate. In the angular interval left by their divergence is lodged the tonsil, or amygdala; the interior arch is also called the *isthmus* of the fauces, as it marks the narrowed interval between the mouth and the throat, or pharynx. The soft palate consists of five pairs of muscles (sect. 401), enclosed by the mucous membrane.

Amygdala.— Between the arches of the soft palate, on each side, is lodged an elongated oval structure, about the size and shape of an almond, from which circumstance it is termed *amygdala;* in common language it is called *tonsil:* it seems to be composed of a great number of mucous follicles aggregated together into a mass. Its internal surface presents several small apertures, which lead into follicles, or cells, that secrete a mucous and viscid fluid. It is of a reddish gray colour, and exceedingly vascular. Before it, is the palato-glossus muscle; behind, the palato-pharyngeus: internally, the mucous membrane; externally, the stylo-glossus.

813. *Salivary glands.*— Three secreting organs, belonging to the class of conglomerate glands, are placed at each side in the region now under consideration, viz. the parotid, submaxillary, and sublingual glands. They differ in size and situation, but agree in being of a pale ash-colour, also in being composed of minute lobuli aggregated into bundles and lobes, and in secreting the salivary fluid, which is conveyed into the mouth by ducts that arise by radicles from the granular structure of each gland.

The Parotid Gland.

814. The parotid gland, fig. 145, 1, (παρα, near, ους, ωτος, the ear,) so called from its position with regard to the ear, is the largest of these. Its superficial extent is from the zygoma to a level with the angle of the jaw and mastoid process, and from the meatus externus of the ear and anterior margin of the mastoid process to the ramus of the jaw and masseter muscle, being also prolonged upon the latter by a process which accompanies its duct, and thence named *socia parotidis*, 2. The external surface of the gland is covered by the skin, and partially by the platysma muscle, and bound down by a prolongation of the cervical fascia. Its substance projects deeply towards the base of the skull, filling up the interval between the ramus of the jaw and the mastoid process, and necessarily maintaining various and complex relations with nerves and vessels therein situated. Thus, one process of it fills up the posterior part of the glenoid cavity, another passes behind and between the styloid muscles; a third, covered by the ramus of the jaw, rests against the pterygoideus internus. Through its substance pass the external carotid artery, with its accompanying vein, also the facial nerve; and close to its internal or deep-seated surface are placed the internal carotid artery, together with the internal jugular vein. Considering the complexity of these relations, is it possible in the living subject to dissect out the body of the gland and its various deep-seated processes? The duct of the gland, 3, (*ductus Stenonis*,) arises by minute radicles in the lobuli, and taking a transverse course passes forwards on the masseter muscle, 4, and pierces the buccinator muscle, 5, and the mucous membrane of the mouth opposite the second dens molaris of the

Fig. 145.

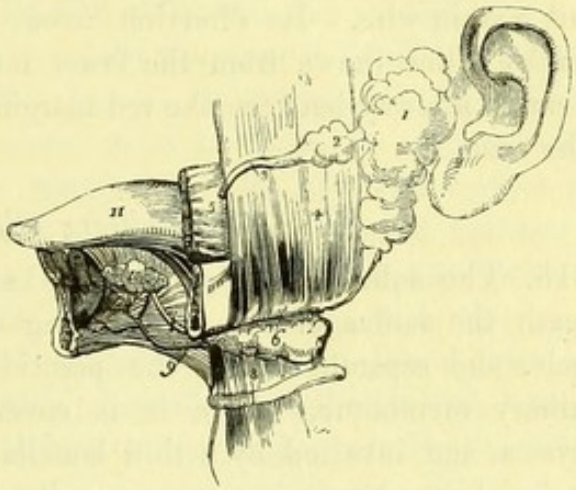

upper jaw. The duct is accompanied by a process of the gland already noticed; it is composed of two tunics, the external one being thick and fibrous in its structure; the internal one is a mucous lining prolonged into it from that of the mouth, and though it appears some lines in diameter, its calibre will barely admit a thin wire. Its direction across the face may be indicated by a line drawn from the lower margin of the concha of the ear to midway between the red margin of the lip and the ala of the nose.

The Submaxillary Gland.

815. The submaxillary gland, fig. 145, 6, lies behind and beneath the ramus of the jaw, resting on the mylo-hyoideus muscle, and separated from the parotid gland by the stylo-maxillary membrane, where it is covered by the skin and platysma, and invested by a thin lamella of cellular membrane. The facial artery runs in a groove on its upper surface. A process of the gland turns round the posterior border of the mylo-hyoideus muscle, lying beneath the mucous membrane. Its excretory duct, 7, is called *ductus Whartoni*, though it was known before that anatomist's time: in its passage to the mouth, it at first inclines backwards, to reach the posterior border of the mylo-hyoideus muscle; after which it runs forwards and inwards along the side of the hyo-glossus and genio-hyo-glossus muscles, towards the side of the frænum of the tongue, where it terminates.

The Sublingual Gland.

816. The sublingual gland, fig. 145, 10, is much smaller than the others, and of an oval form. As its name implies, it lies beneath the tongue, 11, close to the side of its frænum, resting against the genio-hyo-glossus muscle, supported by the mylo-hyoideus, and in close contact with the duct and deep process of the submaxillary gland. Its secretion is poured into the mouth by several minute orifices which open beneath the tongue on each side. Sometimes one or two small ducts join with that of the submaxillary gland.

The Pharynx.

817. The pharynx (fauces, throat) is a musculo-mem-

branous bag, extended from the centre of the base of the skull as far as opposite the fifth cervical vertebra, where it becomes continuous with the œsophagus. Its superior wall or roof consists of the osseous structure just named (lined by mucous membrane), and its sides and back part of three pairs of flat muscles (constrictors, sect.398-400), with two pairs of accessories, stylo-pharyngeus (379), palato-pharyngeus (406). It is more expanded in the middle than at its extremities, of which the lower one gradually tapers, so as to represent a funnel, when in connexion with the œsophagus. Its posterior surface rests against the spinal column; its sides are included between the great cervical vessels; anteriorly, it communicates with the nose by two apertures (posterior nares); with the mouth through the palatal arch (isthmus faucium); lower down with the larynx, by the glottis; laterally with the tympanal cavities of the ears by the Eustachian tubes; and inferiorly is continued into the œsophagus.

The Œsophagus.

818. The œsophagus (*οισω*, feram, *φαγω*, edo) is a musculo-membranous tube, extended from the pharynx to the stomach. It is the narrowest part of the alimentary canal, being about an inch in diameter; and, though far less curved than any other, it is not perfectly straight. As it lies along in front of the spine in the neck and thorax, it necessarily presents a slight concavity forwards in the latter region, corresponding with that of the spine. Besides this, it has two slight lateral curves, for its commencement lies upon the median line; further down, towards the root of the neck, it inclines to the left side; but thence to the fifth dorsal vertebra, it gradually resumes its position in the middle line; finally, when approaching the diaphragm, it deviates again to the left, at the same time coming forward to the foramen œsophageum of the diaphragm. The œsophagus is closely applied to the anterior surface of the vertebral column, being merely separated from it superiorly by the longus colli muscle, lower down by the thoracic duct, and towards its lower extremity by the aorta. In the neck it lies immediately behind the trachea, but inclining to the left side comes into relation with the left carotid artery: in the chest it is concealed by the remaining part of the trachea and by the

pericardium. The cervical portion has on each side the common carotid arteries; in the thorax, the aorta, except near the diaphragm, lies to its left side, and the vena azygos to the right; here the œsophagus is partially covered by serous membrane lying in the interval between the pleuræ (posterior mediastinum).

Structure.—The œsophagus consists of a muscular or external coat, and of a mucous lining. While in the thorax it receives its arteries from the aorta (r. œsophagei), in the neck from the inferior thyroid artery. The branches of the nervus vagus form a plexus upon it; and, superiorly, the recurrent nerve is in close relation to it. Its muscular coat consists of two sets of fibres, forming distinct planes, and taking different directions. Those of the external layer are well marked, all disposed longitudinally in the direction of its axis, and of considerable thickness; the inner fibres run in the opposite way, so as to form rings or circles round the tube; near its extremities they are quite transverse; in the intervening space they are somewhat oblique. At the commencement of the œsophagus its muscular fibres are blended with those of the pharynx, the circular set being, as it were, a continuation of the lower border of the inferior constrictor. But the longitudinal fibres present a peculiarity which deserves attention: they are disposed in three fasciculi, one at each side, which is blended with the inferior constrictor, and one in front, which is attached to the cricoid cartilage at the prominent ridge, between the crico-arytenoidæi muscles. At the lower extremity of the œsophagus its fibres become blended, or rather continuous, with those of the stomach. The lining membrane is continuous superiorly with that of the mouth and nose, inferiorly with that of the stomach; it is pale, but dense and firm. It presents several slight longitudinal folds, which disappear when the tube is distended. Its inner surface is coated by a prolongation of the epidermis, which can be recognised as far as the cardiac orifice of the stomach.

The part of the alimentary canal which is beneath the diaphragm consists of the stomach and intestines. Previously to describing them, it is necessary to notice the conformation of the cavity in which they are contained, viz. the abdomen.

THE ABDOMEN.

819. The abdomen (*abdere*, to conceal) is the largest cavity in the body.

Its extent and boundaries.—It extends from the diaphragm, which forms its upper boundary, to the levatores ani, and from the transversales muscles in front, to the spine, quadrati lumborum, and iliaci, behind. In these structures, which form the walls of the cavity, several apertures exist from the transmission of parts into and out of it. Superiorly, there are three in the diaphragm, for the aorta, œsophagus, and vena cava; inferiorly, there are two at each side, one for the femoral vessels, and one for the spermatic cord; in front there is one—the umbilicus, which, during fœtal life, transmits the umbilical arteries and vein. To these may be added the several interstices and apertures which give passage to the obturator, sciatic, pudic, and gluteal vessels.

Its contents.—The abdomen contains the greater part of the digestive organs, those for the secretion of urine, and part of those of generation. The first class includes the stomach and intestines, the spleen, the liver, the pancreas, and the lacteal vessels, with their glands; the second comprises the kidneys and supra-renal capsules, with the ureters and bladder; and the third the spermatic vessels and ducts, with the vesiculæ seminales in the male, and the uterus, with the ovaries and Fallopian tubes, together with the vagina, in the female.

Division into regions. — The great cavity which extends, as above stated, from the diaphragm to the levatores ani, presents a sufficiently obvious division into two parts, the upper or larger one being the abdomen, properly so called, the lower the pelvis, the crista of the pubic bones and the ilio-pectineal line, which extends backwards to the promontory of the sacrum, marking the boundary between them. Again, the larger or upper compartment is subjected to what may be called a technical subdivision into regions; not that there are any septa or partitions between them, but because of the many and important parts which are contained in it, and which require to be minutely described. Pathologists have also found it necessary, in order to give precision to their inquiries, as well as clearness

to the communication of the results of them to others, to adopt those subdivisions which anatomists had established for the purpose of facilitating their descriptions of parts.

820. With these views the cavity of the abdomen has been divided into three primary regions, a superior, an inferior, and a middle, which is intermediate between both. These may be marked out by two transverse lines, fig. 146, drawn round the body, as follows: one, having commenced at the most prominent point of the cartilages of the ribs at one side, is drawn across to the corresponding point on the opposite, and so continued round the spine to the place at which it began, thus completing the circle. The other line, proceeding from the crista of the ilium at one side, extends to that of the other, and so round the body, as in the former instance. The superior division, 1, or zone, is called, from its position, the *epigastric region* (*επι*, *above* or *upon*, *γαστηρ*, the *abdomen*). Its lower boundary corresponds with the line above indicated, the upper with the ensiform cartilage and the diaphragm. The inferior division has been named the *hypogastric region*, 3, (*ὑπο*, *under* or *beneath*; *γαστηρ*, the *abdomen*), which extends from the lower transverse line to the crista of the os pubis, and to Poupart's ligament on each side. The intermediate, or middle division, is called the *umbilical region*, 2, from the circumstance of the umbilical aperture being placed at its centre. These divisions not having been found sufficient for the purposes above stated, it became necessary to subdivide each of them into three minor regions, which may be done by drawing two lines parallel to one another, from the cartilage of the eighth rib at each side down to the centre of Poupart's ligament. By this expedient each primary region is divided into a central

Fig. 146.

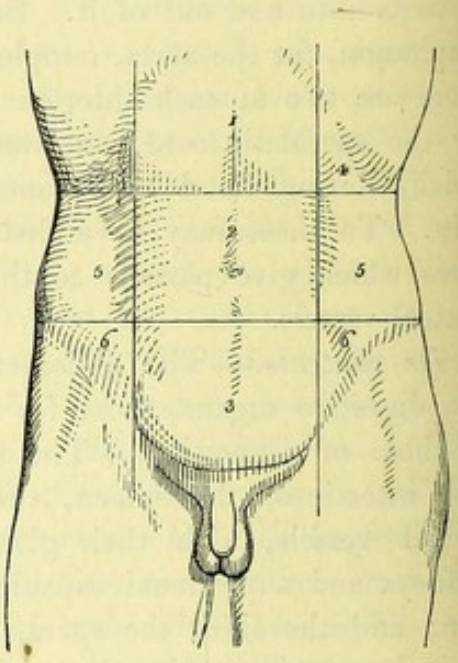

and two lateral ones. The epigastric region is thus resolved to the two *hypochondriac regions*, 4, 4, (*ὑπο, under; χονδρος*, the *cartilage*,) and the proper epigastric region, 1, which is sometimes called "scrobiculus cordis." The middle zone is divided into the proper *umbilical* region in the centre, 2, and the *lumbar* region at each side, 5, 5; and the inferior zone into the proper hypogastric or pubic region, 3, in the centre, and the *iliac* region at each side, 6, 6.

821. The mode of subdividing the primary regions here suggested differs from that adopted by others. The vertical lines are usually directed to be drawn from the most prominent point of the costal cartilages to the anterior superior spinous process of the ilium. It must be obvious that the very purpose and intent of marking out these lines show that they are not confined to the surface on which they are drawn. They are, on the contrary, supposed to be projected into so many planes, forming partitions, which divide the cavity into compartments, each containing a certain portion of the abdominal viscera. Now, if lines were drawn from the costal cartilages to the spine of the ilium, they would exert no influence on the hypogastric region, inasmuch as they cease at its upper boundary; and in the next place, if projected backwards, they would leave the lateral parts of the umbilical region far too small. These reasons are obviously sufficient to warrant a departure from usage and precedent.

The epigastric regions contain	The middle part of the stomach, with its pyloric extremity, the left lobe of the liver, the hepatic vessels, and lobulus Spigelii, the pancreas, the cœliac axis, the semilunar ganglia, part of the vena cava, also of the aorta, together with the vena azygos and thoracic duct, as they lie between the crura of the diaphragm.
The left hypochondriac . .	The large end of the stomach with the spleen and narrow extremity of the pancreas, part of the colon, the renal capsule, and upper part of the kidney.

Right hypochondriac . . .	The right lobe the liver, with the gall-bladder, part of the duodenum and of the ascending colon, the renal capsule, and part of the kidney.
Umbilical	Part of the omentum and mesentery, the transverse part of the colon, transverse part of the duodenum, with some convolutions of the jejunum.
Right lumbar	Ascending colon, lower half of the kidney, and part of the jejunum.
Left lumbar	Similar parts at the opposite side.
Hypogastric region	The convolutions of the ilium, the bladder in children, and in adults if distended, the uterus under like circumstances.
Right iliac fossa	The cæcum, ilio cæcal valve, the ureter and spermatic vessels.
Left iliac fossa	Sigmoid flexure of the colon, the ureter, and spermatic vessels.

As it is the usual practice to examine the serous membrane which invests the different organs here enumerated, and also lines the abdomen, we shall describe it in this place.

822. The *peritonæum: its general conformation.*—The name applied to this membrane has been taken from its relation to the abdominal viscera (*περιτεινω, to extend around*). It is the most extensive serous sac in the body, as it not only lines the parietes of the abdomen, but is also reflected over each of the organs it contains, at the same time that it forms several folds of considerable extent.

Preparation.—After the abdominal muscles have been dissected, the transversalis muscle should be carefully separated from the peritonæum, and removed altogether from it, commencing over the iliac region, and so proceeding up to the costal cartilages, and backwards, deeply into the lumbar region. The same should be done at the opposite side; but, along the middle line, part of the aponeurosis must be allowed to remain, in consequence of its firm adhesion to the membrane. This at once gives a general view of the membrane: it appears like a loose bag placed within the walls of the abdomen, forming a lining for them. The more usual mode however is, after dissecting

the muscles, to divide whatever remains of the parietes by a perpendicular and transverse incision, and reflect the flaps thus formed.

823. The student will find his progress facilitated if he will first make himself familiar with the names, position, and extent of the different folds of the membrane which have received names, and then proceed to trace their connexion and continuity as parts of a whole.

The drawing, fig. 147, will serve for both purposes; it is a diagram which represents the parts as they would be seen if a vertical section were made through the abdomen and its contents, so that they may be seen in a side view. L, is the liver; S, the stomach; C, the transverse colon; D, the transverse part of the duodenum; P, the pancreas; I, the small intestines; B, the bladder; U, the uterus; R, the rectum. —*e*, *f*, mark the great omentum; *d*, the small omentum; *k*, the mesentery; *g*, the transverse meso-colon.

Fig. 147.

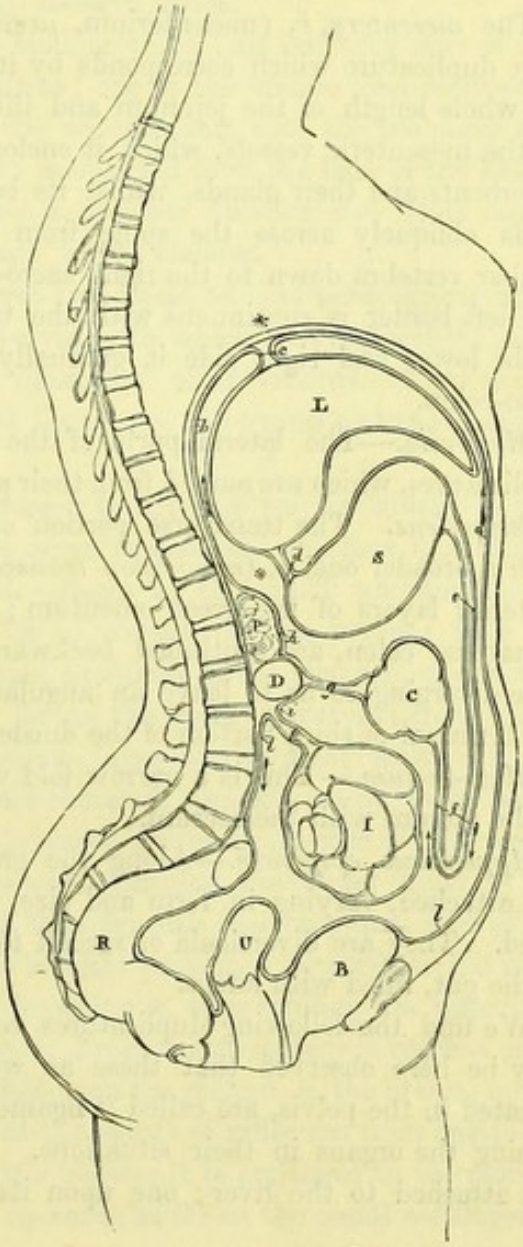

The folds or duplicatures, above alluded to, are as follows:

The *great omentum* (epiploon majus; epiploon gastro-colicum; επιπλεω, to float upon) is the broad floating process of peritonæum which lies loosely over the fore part of the small intestines, fig. 147, *e*, *f*. Its upper extremity is attached to the great curvature of the stomach, to the left of which it is continuous with the gastro-splenic omentum; at the right side it extends as far as the duodenum; it is in-

timately connected with the transverse colon, below which it floats loosely over the small intestines. It consists, at the lower part, that is to say, below the transverse colon, of four lamellæ.

The *small omentum* (o. minus ; epiploon gastro-hepaticum) extends from the transverse fissure of the liver to the concave border of the stomach, enclosing the hepatic vessels, fig. 147, *d*. At its right margin, the membrane is folded so that both layers are continuous, whilst the left extends over to the œsophagus. Behind this is a canal,*, which leads down behind the stomach into the bag of the great omentum. Through this, which is called *foramen Winslowi*, the great cavity of the peritonæum becomes continuous with that enclosed within the layers of the great omentum.

The *mesentery*, *k*, (mesenterium, *μεσος, εντερον*, intestine,) is the large duplicature which corresponds by its greater circumference with the whole length of the jejunum and ilium, to which it is conducted by the mesenteric vessels, which it encloses, together with the lacteal absorbents and their glands, whilst its base or point of reflection extends obliquely across the spine from the left side of the second lumbar vertebra down to the right sacro-iliac symphysis. Its upper and left border is continuous with the transverse meso-colon, whilst at the lower and right side it gradually spreads into the ascending meso-colon.

Meso-cola.—The lateral parts of the colon are bound down by duplicatures, which are named from their position *meso-colon ascendens, et descendens.* The transverse portion of that intestine is connected with a broader one, *g*, (*meso-colon transversum,*) continuous with the posterior layers of the great omentum ; for these, after enclosing the transverse colon, are continued backwards to the spine, at the same time diverging so as to leave an angular interval, across which runs the terminal or third portion of the duodenum.

Meso-rectum.— This is a narrow fold which connects the back part of the rectum with the sacrum.

Appendices epiploicæ.—Along the great intestine some processes are attached, varying in form and size, some fringed, others pediculated. They are diverticula or sacculi formed by the peritonæal coat of the gut, filled with adeps.

We find the following duplicatures connected with the liver. It may be here observed that these as well as other folds which are situated in the pelvis, are called " ligaments," from their effect in retaining the organs in their situations. There are four folds of this sort attached to the liver ; one upon its upper surface, connecting it

with the diaphragm, from which circumstance it is called its "suspensory ligament" (*ligamentum suspensorium*), but from its shape it is named "falciform process," or falx. It indicates the line of division between the left and right lobes of the liver; its lower border or base encloses the umbilical vein or the ligament into which it is converted. The folds which connect the lateral lobes of the liver at each side to the diaphragm, are called "lateral or triangular ligaments" (*ligamentum laterale dextrum, et sinistrum*); between these lies another towards the middle line, the "coronary ligament" (*ligamentum coronarium*).

In the pelvis there are some folds connected with the bladder, the rectum, and the uterus, which deserve notice.

From the summit of the bladder three long but very narrow folds extend upwards to the umbilicus; one in the middle line, corresponding with the urachus, and one on each side with the umbilical arteries. Where the peritonæum is reflected from the base of the bladder backwards upon the rectum, it presents two lunated folds usually called the "posterior ligaments" of the bladder.

From the sides of the uterus two broad folds of peritonæum extend outwards to the wall of the pelvis, with which they connect it; hence they are called the "broad ligaments" of the uterus. They enclose the uterine vessels, the round ligaments, the ovaria and the Fallopian tubes.

The student may now proceed to note the way in which the peritonæum is reflected from one organ to another, and how it is thrown into the folds here indicated. Begin at the small omentum, *d*, as a starting point: you find it to consist of two layers; take the upper one, trace it to the small curvature of the stomach, s, and then over its anterior surface as far as the great curvature; from this it reaches down, forming the upper layer of the great omentum, *e*, at whose lower border it becomes reflected, and returns up as far as the transverse colon, c: having invested the under surface of this part of the intestine, it passes backward, forming the under layer of the transverse meso-colon, *g*, and then beneath the transverse part of the duodenum, D; at this point it is again prolonged forwards to the small intestine, I, and returns after investing it, thus forming the upper and under layers of the mesentery, *k*. From the mesentery it reaches down in front of the spine at *l*, and then upon the rectum, R, the uterus, U, and the bladder, B, forming folds at the points of reflection from one to the other. From the summit of the bladder it is prolonged to the parietes of the abdomen at *l*, and so upwards as far as the costal cartilages at

a, where it comes into contact with the diaphragm, whose under surface it lines. From this it is reflected upon the liver at *c*, forming the upper layer of its coronary and lateral ligaments. It invests the upper and under surface of the liver, L, as far as the transverse fissure, where it is reflected down upon the portal vessels, forming the upper or anterior layer of the small omentum, to the point at which we commenced to trace its reflections and relations to the viscera. Now, beginning again at the small omentum, and taking its under layer, you trace it to the small curvature of the stomach, and thence along the under surface of this organ as far as its great curvature; from this point the membrane reaches down, forming the inner layer of the great omentum, *e*, at whose lower border it is reflected up to the transverse colon, C; after investing the upper surface of this part of the intestine it is reflected back towards the spine, forming the upper layer of the transverse meso-colon, *g*; it is thence prolonged at *h*, successively in front of the transverse part of the duodenum, D, the pancreas, P, and the crura of the diaphragm: from the diaphragm it is reflected to the liver at *c*, where it forms the under layer of its coronary and lateral ligaments: it invests the surface of the liver as far as the transverse fissure, where it is reflected down, forming the under layer of the small omentum, whence we set out in tracing its reflections.

It may here be observed, that it is difficult at first sight to conceive how the different vessels can reach the viscera without piercing the peritonæum, inasmuch as the trunks from which they proceed lie behind it. The aorta lies on the spine, behind the peritonæum; the kidneys, placed at the sides, are also behind that membrane; there can, therefore, be no difficulty in perceiving how their vessels reach them. The mesentery, consisting of two lamellæ, is reflected from the spine close to the origin of the superior mesenteric artery, which is thus placed between its layers. The inferior mesenteric artery, after running behind the peritonæum to the pelvis, lies between the sacrum and rectum, in the fold of the meso-rectum: the colic vessels are enclosed in the meso-cola. It remains for us first to consider, how the cœliac axis and its vessels lie with regard to the membrane; which can only be done with effect by examining the formation of what is called Winslow's foramen, which, properly speaking, is a canal or tube, not a perforation, as the term foramen would imply. If the finger be passed close by the neck of the gall-bladder, beneath the free border of the small omentum, the two lamellæ of the omentum, with the hepatic vessels enclosed, will lie upon the finger, and the ascending layer of the transverse meso-colon behind it. If an effort be made to pass

the finger down behind the stomach, it is at once checked by the manner in which the membrane is there reflected backwards and upwards. Just below the point of reflection stands the cœliac axis, so that its hepatic and coronary branches, by passing over this reflected part, can get between the layers of the small omentum, and thus reach their destinations. Now, the splenic artery runs along the pancreas, which has been shown to be posterior to the ascending layer of the transverse meso-colon, but on reaching the spleen it insinuates itsel between the layers of its epiploon (gastro-splenicum.)

THE STOMACH.

824. The *stomach* (*γαστηρ*, *ventriculus*,) is a hollow, musculo-membranous viscus, occupying part of the left hypochondriac and epigastric regions, fig. 148, 1. It is the largest or most distended part of the alimentary canal, being continuous, by one extremity, with the œsophagus, 2, which opens into it from above, and by the other with the duodenum, 5, which forms the first part of the intestines properly so called. Its form is somewhat conical, being also curved, so as to incline downwards and forwards; but its form and direction vary remarkably in different ages of life; in the fœtus it does not extend so transversely from left to right as is the case in the adult,

Fig. 148

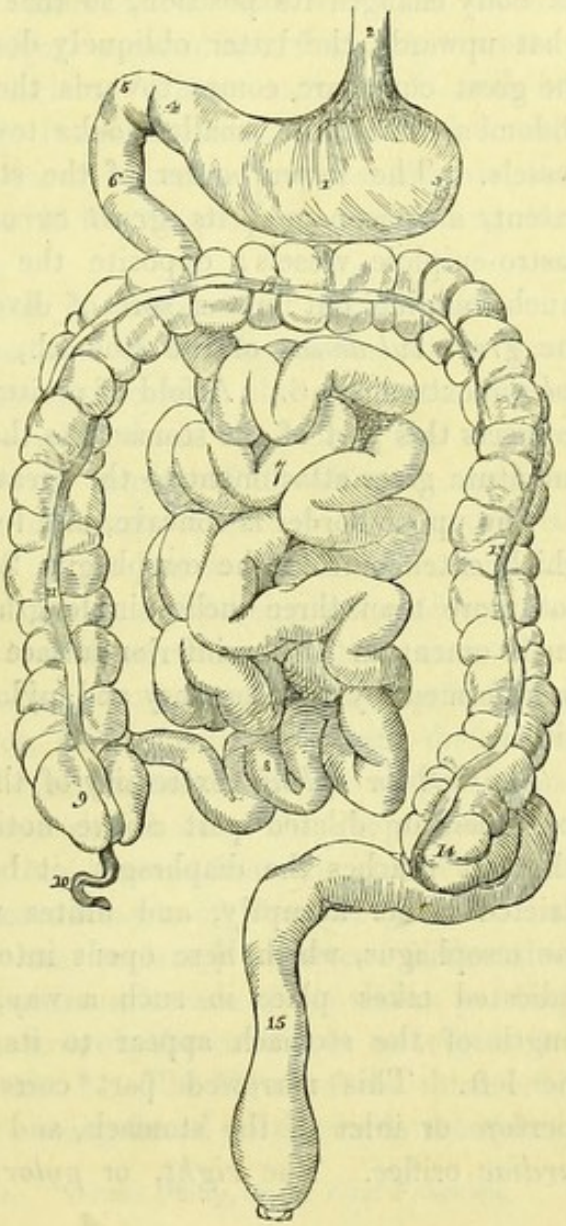

the pylorus is, on the contrary, placed with rather a slight obliquity beneath the cardia, the line of its axis being from above downwards.

The stomach is in intimate relation with many important organs; it lies beneath the diaphragm and liver, above the transverse colon, 12, having the spleen on its left, and the duodenum on its right, whilst its anterior surface is in contact with the wall of the abdomen, and the posterior rests on the pancreas and great vessels,—the ascending layer of the transverse mesocolon interposing. It is usual to consider successively its surfaces, borders, and extremities. When empty, one surface looks forwards, and the other backwards; but when distended its body changes its position, so that the former inclines somewhat upwards, the latter obliquely downwards, by which means the great curvature comes towards the anterior parietes of the abdomen, whilst the smaller looks towards the spine and large vessels. The lower border of the stomach is of considerable extent, and is named its *great curvature;* along it run the gastro-epiploic vessels; opposite the spleen it expands very much, bulging out into a sort of diverticulum, which is called the *great cul-de-sac* of the stomach, and sometimes its left or *splenic* extremity, 3. A fold of peritonæum (*splenic omentum*) connects this part of the stomach to the spleen; the rest of the curvature gives attachment to the great omentum.

The upper border is concave, and forms the *small curvature*, which extends from the œsophagus, 2, to the pylorus, 4, being not more than three inches in length; it is connected by the small omentum to the inferior surface of the liver, the vascular arch formed by the coronary and pyloric arteries being parallel with it.

The *left* or *splenic* extremity of the stomach comprises the expanded or dilated part above noticed; at its upper part, where it touches the diaphragm, it becomes, as it were, constricted rather abruptly, and unites with the termination of the œsophagus, which here opens into it. The junction here indicated takes place in such a way, that two-thirds of the length of the stomach appear to its right, and one-third to the left. This narrowed part corresponds with the upper aperture or inlet of the stomach, and is called *cardia*, or the *cardiac* orifice. The *right*, or *pyloric* extremity of the sto-

mach, 4, is elongated so as to represent the summit of a cone, to which this organ has been likened: it commences at a slight angular turn, marked by a crease or fold, where the great curve of the stomach ends at the right side, from which it ascends towards the under surface of the liver, at the same time inclining backwards, and ends at a circular constricted line, which can readily be perceived at the exterior, and which, when compressed between the fingers, gives the sensation as if a cord-like ring surrounded the interior of the tube. The point here indicated corresponds with the inferior opening of the stomach, by which it communicates with the duodenum; it is called the *pyloric* aperture, for it is surrounded by a ring of muscular fibres above alluded to, and which is termed *pylorus* (πυλη, a gate; ουρος, a guardian), from some resemblance to a sphincter muscle. When examined, it will be found so placed, that whilst its circumference is identified with the wall of the stomach, its free border projects towards the central line of the canal, as if for the purpose of retaining the food until it is digested.

Structure.—The stomach is composed of three coats, connected together by two lamellæ of cellular tissue, which were formerly enumerated also,—particularly the one between the middle and inner coats,—and which was called the nervous tunic, from being supposed to consist of the ultimate ramification of the nerves. The external, or *serous* coat, is derived from the peritonæum, and forms but a partial investment for this, as for other organs, inasmuch as by being reflected away at its curvatures, it leaves two linear intervals there uncovered. The second, or *muscular* coat, consists of thin and pale fibres, placed on different planes, and pursuing different directions. The fibres subjacent to the serous membrane are disposed longitudinally, being continuous with those of the œsophagus, from which they spread out, as they proceed from the cardiac towards the pyloric orifice; the second layer of fibres is circular; but though no individual fibre can be found to extend farther than from a third to a half of the circumference of the viscus, yet they can sometimes constrict it towards the centre, so as to give it a sort of hour-glass contraction.* The fibres of the third order are scattered and irregular; being found only towards the splenic

* Sir E. Home, *Phil. Trans.* Wilson Philip, *on the Vital Functions.*

end of the stomach, where they in a manner decussate with the circular fibres, which in that part are rather few in number. The internal coat, called *mucous*, from its peculiar secretion, and *villous*, from the numerous delicate papillæ, like the pile of velvet, that project upon it, forms part of the lining membrane of the alimentary canal. It has been already described in the section on the general anatomy of mucous membranes (sect. 46, et seq.)

Vessels and nerves.—The stomach derives its blood from two arterial arches, which correspond with its two curvatures; the upper one being formed by the coronary artery and the pyloric branch of the hepatic; the lower by the two gastro-epiploic branches; one being derived from the hepatic, the other from the splenic artery. Besides these, its splenic end receives the vasa brevia from the splenic artery. Its residual blood is conveyed by corresponding veins into the splenic vein; whilst its nerves consist of the terminal branches of the two vagus nerves, and of the stomachic plexus, which is derived from the great solar plexus.

THE INTESTINAL CANAL.

825. The intestinal canal extends from the pylorus to the anus, and in the human subject varies in different individuals; hence it has been variously stated as being from fifteen to twenty-seven feet by Meckel, and from ten to twenty-five by Cruveilhier. It is coiled on itself, so as to form folds or convolutions, and presents two parts, differing in size and situation, as well as in external conformation. Moreover, the division between them is marked by a peculiar valvular structure, which prevents a reflux of the ingesta after they have passed beyond it. The part of the canal between the pylorus and the valve just referred to is called the small intestine (*intestinum tenue*), the remainder thence onward to the anus, the large intestine (*intestinum crassum*). Anatomists have agreed to consider the small intestines as divisible into three parts, viz. the *duodenum*, *jejunum*, and *ilium*; premising, however, that they are but portions of a continuous tube, the lines of division between them being altogether arbitrary.

DUODENUM.

826. The duodenum has been so called from being in its length equal to about twelve fingers' breadth, fig. 148, 5, 6. Its diameter is greater than that of the jejunum or ilium; it is also more distensible. In its course it will be observed to curve on itself, so as to describe a considerable portion of a circle; for having commenced at the pylorus, it ends at the left side of the second lumbar vertebra, and is divisible into three portions, each presenting some circumstances deserving of notice. The first, which is the shortest, being about two inches in length, ascends a little, at the same time inclining backwards and to the right side so as to touch the gall-bladder: hence, soon after death, it becomes tinged yellow by the bile. Opposite the neck of the gall-bladder the intestine turns on itself, and descends perpendicularly in front of the right kidney as far as the third lumbar vertebra, where it again alters its direction, passing across the spine, ascending a little, so as to end at the left side of the second lumbar vertebra, where it is continuous with the jejunum. The concavity of the curve formed by the duodenum is turned to the left side, so as to enclose within it the head of the pancreas. Its transverse part is crossed by the mesenteric vessels, which necessarily separate it from the lower border of the pancreas. The ascending portion is not only shorter than the others, but is also of smaller diameter; it is covered in the greater part of its extent by peritonæum. The descending part is covered by it only on its anterior surface, whilst the transverse part has no immediate serous investment, as it merely lies in the divergence of the two layers of the transverse meso-colon. Its muscular coat is thick, the circular fibres being more strongly marked than the longitudinal. The internal surface presents a great number of transverse folds, called *valvulæ conniventes*. At the angle of union formed by the descending and transverse parts of the intestine, will be observed a small papilla, marking the orifice of the biliary and pancreatic ducts, which open at that point.

JEJUNUM AND ILIUM.

827. The jejunum and ilium are so called, the former from being usually found empty after death, the latter from

its position in the fossæ of that name. They occupy the interval from the duodenum to the ilio-colic valve, two-fifths of the whole length being assigned to the jejunum, 7, and three-fifths to the ilium, 8. The diameter of the tube diminishes gradually as it approaches the latter point. This part of the intestinal canal presents numerous coils or convolutions, which, taken together, are found in the umbilical region, at the same time extending laterally into the lumbar regions, and downwards into the hypogastric and iliac. Thus situated, the small intestine is in a manner enclosed within the curve formed by the colon. The outer surface is smooth, and free in its entire extent, except along its posterior border, where it is connected with the mesentery.

Structure.—The coats of the jejunum are thicker than those of the ilium, but they are similar in every other respect; the serous coat is derived from the mesentery, to the circumference of which these portions of the canal are attached; and the muscular coat presents some longitudinal and superficial fibres, the rest forming arches of circles, but not extending round the tube. The valvulæ conniventes, which are numerous at the commencement of the jejunum, diminish in number and size gradually towards the ilium, and cease in the lower part of the latter.

Vessels and nerves.—The duodenum receives its arteries from the pancreatico-duodenalis, from the pyloric and superior mesenteric arteries; its veins open into the coronary and superior mesenteric; its nerves are offsets from the mesenteric and solar plexus. The jejunum and ilium are supplied by the superior mesenteric vessels.

828. The *large intestine* presents on its exterior surface a sacculated appearance, and is fixed in its situation by folds of the peritonæum. Its length is to that of the rest of the canal as one to five, and is disposed so as to describe, whilst in the abdomen, an arch, the extremities of which are fixed in the iliac fossæ, the upper part or curve extending as high as the liver and stomach; whilst the terminal part descends into the pelvis, and describes another curve, corresponding with that of the sacrum. The large intestine consists of three portions differing in length and situation, viz. the cæcum, colon, and rectum.

CÆCUM.

829. The cæcum, fig. 148, 9, is fixed in the right iliac fossa, where it forms a sort of cul-de-sac, being a short, rounded pouch, extended down from the colon, with which it is continuous, and receiving at its left side the ilium, which opens into it at an angle, being directed from left to right, and from below upwards. It is sometimes called *caput coli*. It is covered by the peritonæum in front and at the sides, but posteriorly it is left uncovered, where the membrane is reflected away from it. To its lower and inner part is attached a round tapering process (*appendix cæci*), which, from its resemblance to an earth-worm, is also called *appendix vermiformis*, 10. This is about three inches long, and slightly convoluted, a small fold of peritonæum serving to retain it in that condition. Its coats are as thick as those of the cæcum, with which they are continuous, for both are lined with mucous membrane, and the muscular fibres of the one are prolonged to the other. In the early periods of fœtal life no distinction is perceptible between them; they form a long tube, projecting below the small intestine, and continuous above with the colon. But towards the time of parturition, this part of the canal becomes constricted for about two-thirds of its length, the rest retaining its natural size; and so that peculiar conformation is established which we find in after life, at least in man, and one of the higher species of the quadrumana, in whom it may be regarded as a rudiment of the tubular diverticulum which is found in the rest of the mammalia.

COLON.

830. The colon, by reason of the curve it describes, presents three parts: of these one, the right or ascending part (fig. 148, 11), passes up from the right iliac fossa, where it is continuous with the cæcum, as far as the inferior surface of the liver, supported on the quadratus lumborum muscle and the right kidney, its external border being in contact with the wall of the abdomen, the internal with the convolutions of the small intestines. Another part, 12, (middle or transverse,) passes across from right to left, beneath the liver and stomach,

concealed by the great omentum, and supported by the ascending layer of the transverse meso-colon. And the third portion, 13, (left or descending,) extends from the spleen to the left iliac fossa, where it makes a double curve, so as to resemble the letter S, placed horizontally, 14. Hence it is termed the *sigmoid flexure* of the colon. From the point just indicated, the intestine inclines inwards, passing over the border of the pelvis, and assumes the name of "rectum." This we shall describe separately, in consequence of the peculiarities of its structure and the importance of its relations.

831. *Structure.*—The large intestine is composed of three tunics, like the rest of the canal. The serous coat invests the ascending and descending portions of the colon only at the front and sides, as the posterior and inner border corresponds with the interval between the lamellæ of the meso-cola; and, as its transverse arch gives attachment to the great omentum and the transverse meso-colon, it is uncovered along these points. The external surface of the cæcum and colon is marked by three narrow lines running their entire length, composed of the external or longitudinal fibres of the muscular coat clustered together, and which, by being somewhat shorter than the intestine, draw it into folds or sacculi, commencing at the cæcum, and extending to the sigmoid flexure of the colon, the rectum not being marked by any such appearance; at different points are also placed appendices epiploicæ, noticed already in the description of the peritonæum. The inner surface of the large intestine presents prominent lines and sacculi, corresponding with those seen on the exterior; and at the junction of the ilium with the cæcum there is a valve, which deserves particular notice.

Valvula coli; v. ilio-colica; v. Bauhini.—When the large intestine is laid open along the right side, particularly if it has been partially dried, a narrow aperture, of an elliptic form, will be observed leading from the ilium, into the cæcum and colon at their junction. This narrowing of the canal is caused by two lunated folds which project into its interior, and form the valve. The lower fold is the larger of the two; its convex border is attached to the line of union of the ilium with the cæcum, that of the upper or smaller fold corresponds with its junction with the colon; whilst the straight margins of both

project inwards, and are in apposition one with the other. Each of these is made up of the mucous membrane, the submucous cellular tissue, and the circular fibres of the ilium and large intestine projected into the interior of the canal, whilst the longitudinal fibres and the serous coat are continued uninterruptedly from one to the other. If the two latter be divided all round externally at the angle of union, and the ilium drawn outwards, the valve will be effaced, and present a rounded or funnel-shaped opening.

Vessels and nerves.—The colon receives its arteries from the right side, or concavity of the arch formed by the superior mesenteric artery, and one also from the inferior mesenteric. Its veins terminate in those which accompany the two arteries just named. Its nerves are offsets from the mesenteric plexus (superior and inferior).

832. The *rectum*, fig. 148, 15, or terminal part of the great intestine, extends from the left sacro-iliac symphysis (where it is continuous with the sigmoid flexure of the colon) to the anus, its direction being at first obliquely from left to right, as it descends to gain the middle line of the sacrum. When deep in the pelvis, it changes its direction, in order to pass forwards in front of the lower part of the sacrum and the coccyx, and behind the bladder, prostate gland, and vesiculæ seminales in the male, or the uterus and vagina in the female. When opposite the prostate, it makes its final turn, inclining downwards somewhat, so as to leave an angular interval between its upper surface and the neck of the bladder. Thus the intestine presents a lateral inclination at its upper part from left to right, and also two curves, from which it is evident that the name (rectum) given to it is ill-chosen, and calculated to convey erroneous impressions. The curves here referred to may be said to indicate a division of the rectum into three parts, differing in situation and relation to contiguous organs. That part of the intestine included between the sigmoid flexure and the first turn, which is about half its length, is covered by peritonæum in front and at the sides, and also connected by its fold (meso-rectum), though loosely, to the sacrum. The middle portion, or that between the curves, is about three inches long, its direction being forwards and a little downwards; it rests on the lower part

of the sacrum, on the coccyx, and the coccygei muscles, whilst its upper surface lies immediately beneath the base of the bladder and the prostate gland, being separated from the former on either side by the vesiculæ seminales, and between them merely by some loose cellular tissue. This part is stripped altogether of the peritonæal coat at the side as well as posteriorly, and it remains only for a very little way upon its upper surface, for it becomes reflected off it opposite the points at which the ureters impinge on the base of the bladder. Now, in the situation here indicated, the peritonæum forms a small cul-de-sac as it is being reflected, the base of which projects forwards somewhat beyond the level of the ureters, forming a lunated fold (if the parts be viewed laterally), whose concavity looks forwards. The third portion of the intestine extends from opposite the prostate gland to the anus, its length being from an inch to an inch and a half, its direction downwards and backwards. At its commencement it is close to the under surface of the prostate gland; it soon becomes invested by the internal sphincter muscle, and embraced by the levatores ani, at the same time contracting its diameter towards its termination, where it is surrounded by the external sphincter muscle.

Structure.—The relation of the peritonæal coat to the intestine having been already sufficiently indicated, we may observe, with regard to the muscular tunic, that the longitudinal fibres, which are considerably developed, are not aggregated into fasciculi as in the colon, but disposed equally all round the tube of the intestine, just as they are in the œsophagus, so that in this particular not a little similitude exists between these two parts of the alimentary canal. At the lower portion of the gut the longitudinal fibres cease, whilst the circular set becomes proportionally developed, so as to form what is termed the internal sphincter muscle. The mucous membrane is thicker and much more vascular than it is in the colon, and presents three prominent folds at different points. One projects backwards from the upper and fore part of the tube, where it corresponds with the prostate gland, the second from its side at the second curve, the third higher. The position, and the degree of projection of these folds, should be attentively considered; they must necessarily exert a material influence on the

introduction of instruments.* No doubt they have been often taken for strictures. In reference to this matter also, the lateral deviation and the curves above noticed should likewise be studied.

Vessels and nerves.—The rectum receives arteries from three sources, from the inferior mesenteric, its superior hæmorrhoidal branches, from the internal iliac, or from one of its principal branches, the middle hæmorrhoidal, and from the pudic — the external hæmorrhoidal. The veins are very numerous, and form a complex interlacement (hæmorrhoidal plexus,) which communicates with the internal iliac vein by branches accompanying the middle hæmorrhoidal artery, and with the inferior mesenteric vein. The nerves are also numerous, and derived from two sources; from the cerebro-spinal system it receives several filaments, which come from the sciatic plexus, also from the pudic nerve. From the sympathetic system numerous branches also are derived, which come from the inferior mesenteric plexus, and also from the hypogastric plexus.

THE LIVER.

833. The liver (*hepar*, *jecur*) is of considerable size; it occupies the right hypochondriac, and part of the epigastric region, extending also somewhat into the left hypochondriac, and so will be found placed beneath the diaphragm, above the stomach and arch of the colon, behind the cartilages of the ribs, and before the spine—the aorta, the vena cava, and crura of the diaphragm being interposed. In this situation it is retained by four folds of peritonæum, called *ligaments*, viz. the falx, or falciform fold, on its upper surface, and the coronary, and two lateral ones, placed at its posterior border. These have been already described with the other processes of the peritonæum (sect. 823).

When examining the form of the liver, it is necessary to consider separately each of its surfaces, borders, and extremities.

The *superior* surface, smooth and convex in its general outline, corresponds with the arch of the diaphragm, and is divided by the falx into two parts or lobes, named, from their position, the *right* and *left* lobes, the former being considerably the larger.

The *inferior* surface is irregularly concave, and presents certain fissures, eminences, and depressions, deserving of notice.

* Mr. Houston—Dublin Hospital Reports, vol. v.

1. *Right and left lobes*, fig. 149.—The division of the liver into right and left lobes, which is indicated upon the upper surface by the falx or suspensory ligament, is here marked by a fissure which extends from the anterior to the posterior border. The right lobe, 1, is considerably larger than the left, 2; it occupies the right hypochondriac region, whilst the other is placed in the epigastric and left hypochondriac; the proportion as to size between the former and latter is about five or six to one.

Fig. 149.

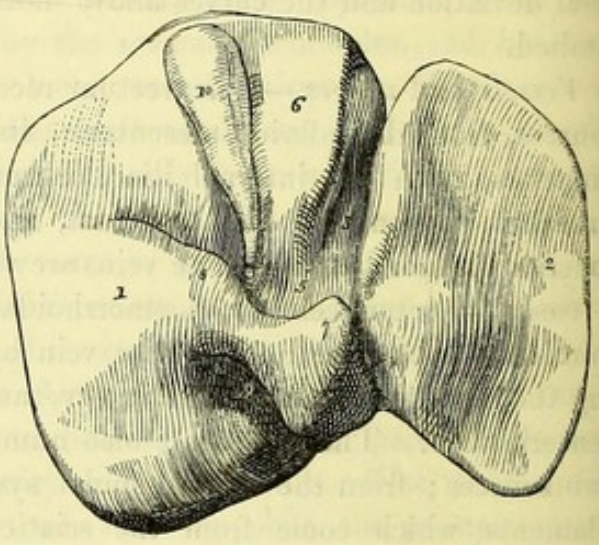

2. The *umbilical fissure*, 3.—Extending from before backwards, a deep groove or fissure will be observed (sulcus umbilicalis—longitudinalis, horizontalis), which in fœtal life lodges the umbilical vein in that part of its extent which reaches from the anterior border to the transverse fissure, whilst the remaining portion, 4, transmits the ductus venosus. In after life both these degenerate into ligamentous cords. This fissure is in some instances converted into a canal, by a portion of the substance of the liver being extended across it.

3. The *transverse fissure*, 5.—Running transversely with regard to the preceding, and at right angles with it, is a second fissure (sulcus transversus; s. venæ portæ). It occupies the middle third of the transverse diameter of the liver, being somewhat nearer the posterior than the anterior border. The older anatomists likened it to a gateway, which gave transmission to the portal vessels, as it lodges the vena portæ, the hepatic artery and biliary ducts, with the nerves and lymphatics.

4. The *square lobe*, 6.—In front of the transverse fissure a square piece is marked off (lobulus quadratus), which is bounded behind by the fissure just named, before by the margin of the liver, on the left by the longitudinal fissure, and on the right by the gall-bladder.

5. The *pyramidal* or *Spigelian lobe*, 7.—Behind the transverse fissure, and concealed by the hepatic vessels and small omentum, is situated another lobe (lobulus Spigelii) ; it projects in the form of a pyramidal mass, forming a sort of promontory between the three great veins, or rather the fissures which lodge them, viz. the vena portæ, vena cava, and the umbilical vein. Its base is connected with the right lobe by a process, which is named *lobulus caudatus*, 8. This lobule has before it the transverse fissure, and behind it another, 9, which lodges the inferior vena cava. The square and pyramidal lobes were formerly likened to the *pillars* of a gate, and the transverse fissure to a gateway (*porta*) for the entrance of the vessels ; from this the great vein, *vena portæ*, took its name.

Some confusion arises from applying the term "lobulus" to the portions of the liver here described, viz. lobulus Spigelii — quadratus — caudatus, at the same time that we speak of the "lobuli" or "lobules" of which these and all other parts of the liver are composed, and in which its secretion is elaborated. It would be better to restrict the term to the minute lobules, and call the masses above noticed minor lobes, which will sufficiently distinguish them from the great lobes (right and left), into which the liver is divided.

The depressions on the lower surface of the liver are very slight ; they merely correspond with the position of the contiguous viscera. In the left lobe a depression will be observed corresponding with the upper surface of the stomach ; on the right, one for the gall-bladder, and two others, very faintly marked, indicating the points of contact of the colon and the right kidney.

The *anterior border* of the liver, which lies beneath the margin of the chest, is sharp and thin, and presents a notch, indicating the commencement of the longitudinal fissure, and sometimes another, which lodges the fundus of the gall-bladder. The *posterior and superior border* is thick and rounded ; it is marked by two grooves, of which one, broad and superficial, indicates where it rests on the spine, the other transmits the vena cava. The right extremity is rounded and thick ; the left, on the contrary, is thin and oblique, being directed towards the cardiac orifice of the stomach and the spleen.

Structure.—The liver is invested by the peritonæum, except at the points of reflection of the falx, and of the lateral and coronary ligaments. Its surface is throughout smooth and shining, which is owing to its serous covering. Subjacent to this is a very thin lamella of cellular tissue, which invests the organ in its entire extent; on the surface it is not more developed than the sub-serous cellular tissue in many other parts. Opposite the transverse fissure, however, it becomes considerably increased in quantity, encases the hepatic vessels, and accompanies them throughout their ramifications, supporting them in their course, and constituting a nidus for them when they become capillary. The liver is dense and heavy, of a deep red colour, or a brownish red, with very frequently a slight purple tinge along its sharp margin. Its weight is about four pounds; its transverse diameter is from twelve to thirteen inches, its thickness about five or six. When torn or divided, the surface exposed by the fracture presents a granular appearance, as if it were made up of minute granules or lobules, from which circumstance the liver has been classed amongst the conglomerate glands. Its colour in some points is of a yellowish tinge, in others of a dusky red; the former being caused by the bile of the ducts exuding through their coats, the latter is obviously owing to the blood retained in greater or less quantity in the hepatic and portal veins.

At the outset of any inquiry into the intimate structure of this or of any other organ, it is necessary to ascertain the vessels which enter into it, their mode of distribution, and mutual relations. Those of the liver may be stated as follows: 1. The *vena portæ* conveys into it the residual blood from all the chylo-poietic viscera. Its branches (right and left) spread out like arteries in the corresponding sides of the liver, until they become capillary in its granular structure. 2. The *hepatic veins* commence by radicles continuous (as may be shown by injection) with the terminations of the vena portæ. These gradually enlarge as they pass upwards, converging to the point at which the vena cava passes behind the liver, and pour their contents into that vein. They are usually three in number; their direction is upwards and inwards, converging towards the sulcus which lodges the vena cava; and most of them have also an inclination from before backwards, inas-

much as they have to pass from the anterior surface to the posterior border. These veins are, moreover, so intimately connected with the substance of the liver, that they do not collapse when cut across; and finally, they proceed to their destination unaccompanied by any other vessel. From this it must be obvious that the hepatic veins cross those of the vena portæ, which not only diverge towards the lateral masses of the liver, but also have to come forwards to its anterior surface. 3. The *hepatic artery*, arising from the cœliac, ascends to the transverse fissure, where it divides into two branches, which accompany those of the vena portæ to their terminations. 4. The *nerves*, forming a plexus (*hepatic*) round the artery and veins, are derived from the great solar plexus. 5. The *lymphatics* are exceedingly numerous; some being extended upon its surfaces, others arising from its interior, the latter following the course of the blood-vessels. 6. The *hepatic or biliary duct* (ductus hepaticus—biliarius) arises by minute ramusculi in the lobules, where they are intimately connected with those of the vena portæ, whose branches they accompany as they converge towards the transverse fissure, out of which issue two branches, one for the left lobe, the other for the right; these soon unite, and by their union they form the duct. It consists of two coats or tunics, of which the external is fibrous and the internal mucous. 7. A lamella of cellular membrane encloses the vena portæ, the hepatic artery, and the duct, previously to their entrance into the fissure, and accompanies them to their final termination, loosely connecting them to the substance of the organ. This has been called the *capsule of Glisson*, who supposed it to possess a contractile, and even a muscular power, and on this hypothesis sought to explain the portal circulation.*

Such are the anatomical elements of which the liver is composed, its proximate constituents being the granules or lobules above noticed. These were supposed by Malpighi to be hollow in the interior, and to form follicles, or *acini*, interposed between the capillary terminations of the vena portæ and of the artery, and the incipient radicles of the hepatic duct;—a conjecture which is invalidated by the fact, that injections passed into the vein return by the duct without suf-

* Glisson, de Anatomiâ Hepatis.

fering extravasation. Ruysch, on the contrary, supposed them to be solid, and to consist of an interlacement formed by the capillaries of the different orders of vessels. Now, when we consider the course of the vessels, and of the fluids they contain, we perceive that two sorts of blood are brought to each lobule by the portal vein and hepatic artery, the former conveying materials for the secretion of bile, the latter for the nutrition of the organ; and that a different sort of blood is conveyed away by the hepatic vein, whilst at the same moment a new fluid (the bile) is received and carried down by the duct; so that each lobule forms the centre of a minute eddy within which the fluids turn; and where they not only change their direction, but also receive a total alteration of character.

The recent researches of Mr. Kiernan give a very clear view of several points connected with the distribution of the vessels in the liver, and particularly of the structure of the lobuli. It is obvious that the interior of the organ is channeled or hollowed into two sets of canals, the one giving lodgment to the hepatic veins, the other to the portal vein, its branches, and the accompanying arteries and ducts. At the transverse fissure the vein, duct, and artery divide into branches which enter the portal canals. These divide and subdivide into smaller branches, which enter the smaller canals; and every canal, however small, contains an offset from the portal vein, the hepatic artery, and the duct. These are enclosed by Glisson's capsule, which lines the portal canals, and forms sheaths for the larger vessels, and a web in which the smaller vessels ramify; it enters the inter-lobular fissures, forming capsules for the lobules, and finally extends into their interior, and with the blood-vessels expands itself over the secreting biliary ducts. "The capsule thus presents three portions—a vaginal—inter-lobular—and lobular portion; and as the vessels ramify in the capsule, their branches admit of a similar division."

The hepatic ducts can be traced along the canals, in the fissures between the lobules, and into the lobules where they form plexuses. "These may be called the lobular biliary or secreting plexuses, as being the immediate agents in the secretion of bile." The branches of the portal vein and the hepatic arteries also enter the lobules. The venous branches form a plexus which communicates with the incipient radicles of the hepatic vein; and the arteries, which are very few and very minute, are the nutrient vessels of the lobules, and pro-

bably terminate in the plexus of the portal vein. The branches of the artery ramify freely upon the coats of the portal vein, and on the hepatic ducts, furnishing materials for the nutrition of both, and to the latter for the secretion of mucus which lubricates their interior.

The trunks of the hepatic veins are lodged in the "hepatic venous canals." Their incipient radicles commence in the interior of the lobules, so that each lobule may be said to be "sessile" upon a minute venous branch. Hence when a hepatic vein is laid open, the orifice of each minute branch which terminates in it is seen to come out of the middle of a lobule; but the branches of the portal vein, when viewed in the same way, correspond with the interstices between the lobules.

Structure of the lobules.—Each lobule is found to consist of a reticulated plexus formed by the minute radicles of the biliary ducts. For these, when examined with a high magnifying power, are seen to divide and subdivide so as to form a mesh in its interior, which is supported by a nidus of cellular tissue furnished by Glisson's capsule. Upon this mesh or plexus is disposed another, formed by the terminal branches of the portal vein. This is the "lobular venous plexus," from which that formed by the ducts can be distinguished, as the latter presents somewhat the appearance of cells. The branches of the venous plexus converge from the circumference of the lobule towards its centre, and communicate with the incipient radicles of the hepatic vein.

It is difficult to inject the ducts, owing to their being filled with bile. Mr. Kiernan succeeds by first tying the portal vein and hepatic artery in a living animal after feeding it. By this expedient the secretion of bile is suspended, and that which the ducts contain is discharged. The ducts cannot be injected directly from the hepatic vein, for no branches of this vessel ramify on their coats. Whenever it does reach the ducts, it is only through the branches of the portal vein which spread upon them: and even when the ducts are injected from the portal vein or the hepatic artery, the fluid gets into their interior by rupturing their lining membrane.

The residue of the blood conveyed by the hepatic artery to the lobules, to the different vessels, and the ducts for their nutrition, is taken up by minute veins and conveyed into the portal vein, so that part of the blood from which bile is secreted is derived from the liver itself.—(See Mr. Kiernan's paper.*)

* Philosophical Transactions, 1833, part ii.

834. The *gall-bladder*, fig. 148, 10, (vesicula fellis,) is a membranous sac, of a pyriform shape, lodged in a slight depression at the inferior surface of the right lobe of the liver. Its position is oblique, so that its fundus inclines downwards, and to the right side, being on a level with the lower margin of the liver, whilst its body and neck are directed backwards, upwards, and to the left. Its neck tapers gradually, and is prolonged into a small tube, fig. 149ª, 5, (*ductus cysticus*, κυστις, vesica,) which at first inclines inwards and backwards, then descends and joins at an angle with the hepatic duct, 6, to form a common canal, 7, (*ductus communis choledochus*, χολη, bile, δεχομαι, to receive,) which lies on a level with the hepatic artery, and on the same plane, the vena portæ being behind and between both. The common duct is about three inches long, it descends behind the pylorus, insinuates itself between the descending part of the duodenum and the head of the pancreas, with whose duct it comes into contact, and both together pierce the coats of the duodenum, running for three quarters of an inch between them, previously to terminating on the inner surface of that intestine. The gall-bladder is composed of two coats, united by a lamella of cellular membrane: the external one is but a partial covering, being derived from the peritonæum; the internal is a mucous lining, continuous with that in the ducts. In the neck of the sac the mucous membrane projects inwards, so as to form folds, disposed spirally, and calculated not only to favour the ascent of the bile into its reservoir, but also to graduate its flow as it descends. If the pipe of a syringe be inserted into the hepatic duct, the duodenum being at the same time laid open, and the fundus of the gall-bladder cut off, water forced along it will be found to ascend into the latter almost as soon as it appears in the intestine. This would indicate a resistance to

Fig. 149ª.

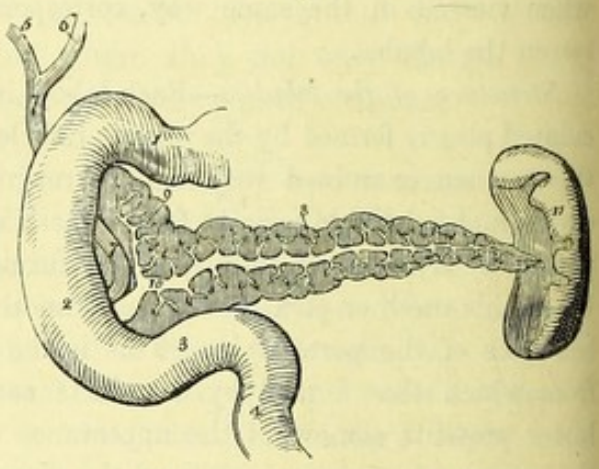

its course at the mouth of the common duct, which is produced by a small valvular fold of membrane, placed within the orifice. The effect of the spiral lamella in the gall-bladder can be readily perceived by the manner in which the fluid ascends contrary to its gravity.

THE SPLEEN.

835. The spleen, fig. 149[a], 11, (lien, splen,) is a soft, spongy, and exceedingly vascular organ, placed in the left hypochondriac region, between the diaphragm and the stomach, and beneath the cartilages of the ribs. Its colour is deeply red, with a tinge of blue, particularly round its margin. Its form is somewhat oval, being smooth and convex on the exterior, where it is in apposition with the diaphragm, and irregularly concave on the opposite side, which is divided into two parts, but unequally, by a transverse slit (*hilus lienis*) for the transmission of its vessels. The spleen has a peritonæal investment prolonged to it from the stomach, by which, as well as by vessels, it is connected to that organ; but it has also a smooth and fibrous tunic proper to itself. Its size is very variable, not only in different individuals, but also in the same person. Taking a general average, its greatest diameter measures about four inches, its breadth three, and its thickness from two to two and a half; its weight, from eight to ten ounces. Its consistence is so slight that it is easily torn, and in many cases it is found soon after death so soft as to be readily broken down by a slight pressure, when it appears a grumous, dark, confused mass.

Structure.—The fibrous or proper coat of the spleen is so firmly adherent to the serous investment, that they cannot be separated, except at its concave surface. From its interior, a multitude of cellular bands and fibres project, which form, by their intersections, cells of various forms and sizes. The splenic artery and vein are both of very large size compared with the bulk of the organ. They ramify minutely in its interior, and freely communicate, which is proved by the facility with which injections pass from one to the other. Its nerves are derived from the solar plexus forming an interlacement (splenic plexus) previously to their entrance into it; its lymphatic vessels are very numerous; but as there is no appreciable

product elaborated by this apparatus, it has no excretory duct; and as no necessary dependence or connexion has hitherto been established between it and any other organ (for it has been extirpated from dogs without causing death, or even, in some cases, any very material disturbance of their functions), the purpose which it serves in the animal economy remains altogether unknown. Besides the cellular structure and vascular arrangement above indicated, several minute granular bodies are scattered through the substance of the spleen, of a whitish colour, but variable in size and form.

THE PANCREAS.

836. The pancreas, fig. 149 [a], 8, is a conglomerate gland, being composed of a number of granules aggregated together; in which respect, as well as in its function, it resembles the salivary glands, with which it is classed. The greater part of it lies deeply in the epigastric region, resting on the spine, the great vessels interposing, and concealed by the stomach, one end being in contact with the spleen, and therefore lying in the left hypochondrium, the other surrounded by the curve of the duodenum, so that its direction is obliquely downwards, and to the right side. The gland is compressed and flat, and after the stomach is drawn upwards, it will be found still covered by the ascending layer of the transverse meso-colon. The superior mesenteric artery will be observed interposed between its lower surface and border and the transverse part of the duodenum, and along its superior and posterior margin run the splenic vessels. The left, or splenic extremity, is narrow and thin; the right is broader, and called the *head* of the pancreas; a small part of it is also detached somewhat from the rest, and called the *lesser pancreas*, 9. Its excretory duct, 10, (*ductus pancreaticus*,) commences by filaments which issue from the different granules, and gradually increases in size as it proceeds from left to right through the substance of the gland, and will be found nearer the lower than the upper border; near its extremity it is joined by the duct of the smaller pancreas. When arrived at the right border of the gland, the duct comes into close apposition with the ductus communis choledochus, with which it pierces obliquely the coats of the duodenum and becomes identified with it so that both terminate by a single

orifice which opens at the inner surface of the duodenum at the junction of its second and third portions, 2, 3.

Structure.—The globules of which this gland is composed are aggregated into bundles, and these connected so as to form a mass by cellular tissue, which, however, does not constitute a proper capsule for it. It is of a pale ash-colour, about six inches long, one and a half in breadth, and from half an inch to three quarters in thickness. Each granule seems to contain within itself all the elements of a secreting organ ; in its interior is a minute cell or cul-de-sac, being the ultimate radicle of the excretory duct ; around which is a minute vascular plexus —all supported and connected by cellular tissue, in which also run filaments of nerves. The arteries of the pancreas come from the splenic, pancreatico-duodenalis, and root of the mesenteric ; the veins open into the splenic ; the nerves are offsets from the solar plexus.

837. After the organs of digestion, those of absorption follow, when taken in their physiological order, as they take up the product of digestion and convey it into the current of the circulation. We have already described the absorbing vessels and their common trunk (thoracic duct), sects. 783 *et seq.*, so that we may now continue our route, and proceed to the circulating system.

We shall premise a few remarks on the thorax, previously to describing the organs which it contains.

THE THORAX.

838. The thorax is somewhat conical in its form, and intended to lodge the central organs of circulation and respiration. It is intermediate not only in size and situation, but also in the structure of its walls, between the abdomen and the cranium, the one being composed almost entirely of soft parts, and the other an osseous case, whilst the thorax consists of muscular and osseous parts in nearly equal proportions. The spaces between the ribs are filled by the intercostal muscles. The base is formed by the diaphragm. In the natural condition, when the scapula and arms are attached to the trunk, the top of the chest is wider than the bottom ; but when these parts are detached, and nothing remains but the walls of the cavity, the proportions are reversed, for it appears a truncated

cone, the summit being above. The upper aperture is bounded at each side by the first rib, before by the top of the sternum, behind by the spine. Its breadth from side to side is greater than its depth from before backwards. Its plane, or line of direction, is backwards and upwards; through it pass the great arteries and veins of the head and upper extremities, the trachea, œsophagus, vagus and sympathetic nerves, the thoracic duct, sterno-hyoid and sterno-thyroid muscles anteriorly, and the longi colli posteriorly. The base of the thorax is also oblique; its inclination, however, being from before backwards and downwards; hence the depth of the cavity is greater behind than before. The breadth of the base from side to side is greater than its depth. The thorax, in the natural condition, is divided into two lateral chambers by a partition (mediastinum) formed by the reflection of the pleuræ; it extends from the summit to the base of the cavity, and from the sternum back to the spine. It may be likened to a hollow partition, composed of two parallel planes, leaving an interval between them which lodges the vessels, nerves, and tubes above enumerated, and transmits those which pass down to the abdomen.

Dissection.—We have already pointed out the mode of opening the chest and pericardium, and of tracing the large vessels (sect. 613).

ORGANS OF CIRCULATION.

839. When treating of the general anatomy of the vascular system, we have given an outline of the apparatus of circulation. The arteries are described (sect. 50 and 54); the veins (53 and 63); our attention having been confined to the systemic or great circle, the pulmonary artery and veins shall be treated of with the lungs, as they form a circle by themselves. It remains for us in the present section to describe the central organ of the circulation (the heart), with its investing membrane (pericardium).

PERICARDIUM.

840. The pericardium, or "heart-purse," (περι and κηρ, the heart,) is a membranous sac which invests the heart, and the commencement of the large arterial and venous trunks which

are connected with it. It is composed of two layers, the external being fibrous, the internal serous; it is situated above the central aponeurosis of the diaphragm, behind the sternum and the cartilages of the third, fourth, and fifth ribs of the left side, before the bronchi, œsophagus, and descending aorta, and between the reflected layers of the pleuræ which separate it from the lungs. Though the two membranes of which the pericardium is composed are intimately united, still their general conformation, as well as their structure and properties, are so different that it is impossible to describe them together; we must, then, notice each separately.

The *fibrous* membrane, dense, thick, and unyielding, consists of fibres which interlace in every direction. Most of them are attached to the central aponeurosis of the diaphragm, and superiorly, where they embrace the large vessels, they form tubular prolongations, which, after passing for some way upon them, become blended with their external coats; of these, eight are usually enumerated, viz. one for the superior vena cava, four for the pulmonary veins, one for the aorta, and two for the right and left branches of the pulmonary artery. As the inferior vena cava opens into the right auricle as soon as it penetrates the diaphragm, it cannot be said to receive an investment in the same way as the other vessels.

The internal or *serous* lamella of the pericardium represents a shut sac partially inverted on itself, and so disposed as that the internal or inverted part embraces the heart, whilst the other lines the inner surface of the fibrous lamella. It was the great simplicity of arrangement observable in the serous pericardium, as contrasted with that of other membranes of the same class, that suggested to Bichât the idea of comparing it to a double night-cap; for if the heart could be drawn out of it without injury to its continuity, it would resemble an elongated sac closed on all sides, and we should then have demonstrative proof, that, though that organ is invested by the membrane, it is still without its proper cavity.

THE HEART.

841. The heart (cor, *κηρ*), the central organ of the circulation, is a hollow muscle, irregularly pyramidal in its shape,

which lies between the lungs, enclosed in its proper investment, the pericardium. It is placed so obliquely, that if a line corresponding with its axis were passed through it at the moment of its pulsation, its direction, taken from base to apex, would be downwards, forwards, and to the left side. The anterior surface of the heart is convex in its general outline; the posterior is flat and rests on the diaphragm: the lower, or right border, is rather thin, and longer than the upper, which is rounded. The heart's surface is marked on its anterior and posterior aspect by two lines, of which one runs transversely, the other from above downwards; their position indicates the division of the organ into four different compartments, or cavities. The base of the heart (which is comparatively thin and flaccid in its structure) consists of that part which is in immediate connexion with the veins *(pars cordis venosa)*, and is divided into two cavities, called auricles, from the fact that each is surmounted by an appendage resembling an ear *(auricula)*. It is separated from the lower or pyramidal part by a deep transverse groove *(sulcus auriculo-ventricularis)*. These circumstances are most distinctly observable when the heart is distended. The portion between the transverse sulcus and the summit is thick and muscular, and connected with the arterial trunks; it consists of two cavities (ventricles), the division between which is indicated by two slight grooves extending from the base to the apex, and lodging the descending branches of the coronary vessels.

When we consider the heart in its physiological relations, we adopt a different mode of division; for we find it to be a double organ, made up of two hearts, one for the pulmonary circulation (cor pulmonale), occupying the right side, and consisting of an auricle and a ventricle; the other for the system at large (cor systemicum), also consisting of two cavities of the same denomination. The pulmonic heart is the agent for the circulation of black blood, the systemic circulates red blood. Now, as no two of these cavities agree in form or in the arrangement of their components, it becomes necessary to describe each separately.

In fig. 150 the heart and lungs, with their vessels, are represented: 1, the right auricle of the heart; 2, the superior vena cava; 3, the inferior vena cava; 4, the right ventricle; 5, the

pulmonary artery issuing from it; 6, the left auricle; 7, the left ventricle; 8, the aorta arising from it:—*a*, *a*, the pulmonary artery (right and left) entering the lungs; *b*, *b*, the bronchi, or air-tubes, entering the lungs; *v*, *v*, the pulmonary veins issuing from the lungs:—9, the upper lobe of the left lung; 10, its lower lobe; 11, the upper lobe of the right lung; 12, the middle lobe; 13, the lower lobe.

The *right auricle*, fig. 150, 1, rests on the diaphragm, and forms the right and anterior part of the base of the heart. It presents two parts which, though not marked off by any precise line of division, yet differ in size and form. One of these, large and flaccid, occupies the interval between the venæ cavæ, so as to receive directly the blood which they convey, and is hence named *sinus venarum cavarum*. The other projects forwards and inwards, between the right ventricle, 4, and the root of the aorta, 8, like an appendage to the general cavity; and so it is sometimes named "auricular appendage," but more frequently *auricula*, from some resemblance to a dog's ear. It is triangular in form, compressed, and slightly dentated at its border. It is thicker and more fleshy than the sinus.

Fig. 150.

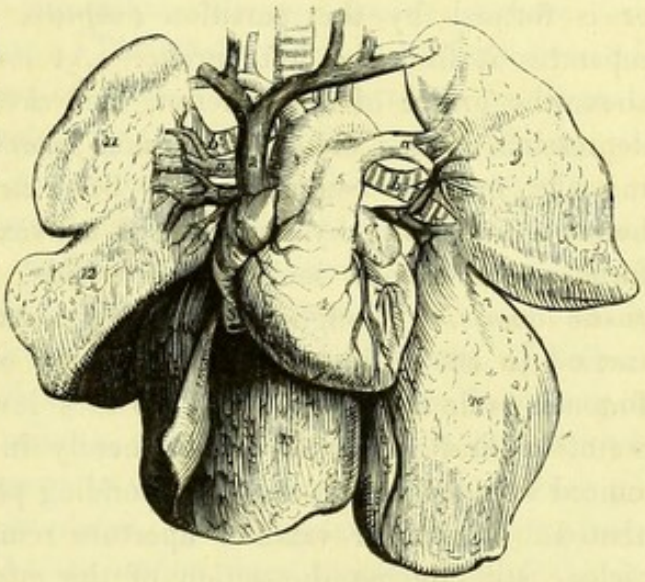

The external surface of the auricle, unattached in the greater part of its extent, is prolonged upwards, and to the left side, into its auricular appendage; inferiorly, it is connected with the right ventricle, internally with the left auricle: into its upper extremity opens the vena cava superior, 2, and into the lower the inferior vena cava, 3.

In order to examine the interior of the auricle, an incision may be made from the junction of the cavæ across to the au-

ricula, from the middle of which another may be carried upwards into the superior cava. If the lower border of this incision be drawn forwards, the cavæ will be observed to incline inwards at an angle, their conflux being marked by a slight elevation, called *Lower's tubercle* (tuberculum Loweri). The greater part of the cavity forms a pouch *(sinus)*, which is smooth, and but slightly muscular in its structure. The inner surface of the auricula is distinguished from the rest by several fleshy fasciculi, which run transversely upon it, called *musculi pectinati*. The inner side of the auricle is thin and smooth, it corresponds with or is formed by the partition *(septum auricularum)* which separates it from the left auricle. At its lower part, and just above the orifice of the inferior vena cava, is situated an oval depression, *(fossa ovalis, vestigium foraminis ovalis,)* indicating the original communication between the auricles: it is bounded superiorly by a prominent convex border of a lunated form, its concavity looking downwards, and named *annulus fossæ ovalis*. Though the development of the septum be carried to the full extent, that lamella of it which closes the foramen ovale having extended up to a level with the annulus, we often find its upper border merely in apposition, but not united by adhesion to the corresponding part of the septum, so that an oblique or valvular aperture remains between the auricles; still, during the action of the organ, there is sufficient provision against any communication between these cavities. At the line of union between the inferior cava and the auricle is situated a crescentic fold of the lining membrane, called *valvula Eustachii*. This in the fœtal state is large; in the adult it is comparatively diminutive, and often even perforated by several foramina. One border of the valve rests upon the wall of the auricle, with which it is continuous. Another is free and unattached, being of a crescentic form: its upper extremity blends itself with the inner border of the annulus ovalis, and the inferior with the corresponding part of the orifice of the vena cava inferior. Between this valve (its left side) and the ventricular opening is situated the orifice of the coronary vein, protected by a valve. Several minute foramina may also be observed in different parts of the auricle, resembling the orifices of small veins, and called *foramina Thebesii*. Placed obliquely between the appendix and the inferior cava, we observe the *auriculo-*

ventricular opening, of an elliptic form, and about an inch in diameter; round its circumference is attached the base of the tricuspid valve, the rest of which lies in the cavity of the ventricle.

The *right ventricle*, fig. 150, 4, (ventriculus pulmonalis,) extends from the base of the right auricle to the apex of the heart. Its form is somewhat triangular: to see its interior it will be found convenient to make an angular or V-shaped flap, by dissecting up its anterior wall. When this is done, we observe that the interior surface presents a number of rounded fleshy fasciculi, which are called *columnæ carneæ*, and are divisible into three orders. The first, adherent by both extremities, are free in the rest of their extent; others are but slightly prominent, being attached by their extremities, and also by the greater part of their circumference; the third set form three or four fasciculi, which are directed from the summit towards the base of the ventricle, where they are connected with the borders and apices of the tricuspid valves, through the medium of several tendinous processes, called *chordæ tendineæ*. The base of the ventricle is prolonged upwards; its surface becoming at the same time quite smooth, somewhat in the form of a funnel, where it gives attachment to the pulmonary artery; so that the mouth of this vessel is placed higher up, and to the left of the auricular opening. At its orifice three membranous folds are placed, called *sigmoid valves*. One border of these is attached at the line of union of the ventricle with the artery, the other is free in the cavity of the latter, and presents in its middle a small granule, called *nodulus* or *corpus aurantii*. The *tricuspid valve* is so called from its being divided into three points or processes, formed by the lining membrane of the auricle and ventricle. Each is triangular in its form; their bases, which are continuous and undivided from one another, being attached all round the circumference of the opening, whilst in the rest of their extent they lie within the cavity of the ventricle. One of them rests upon the septum, or corresponds with it; another with the anterior wall of the cavity; whilst the third or larger is inclined obliquely upwards, and, as it were, interposed between the auricular and pulmonary apertures. The free margin of each is a little thickened, and gives attachment to the chordæ tendineæ.

The *left auricle*, fig. 150, 6, (sinus pulmonalis,) is situated at the posterior part of the base of the heart, where the greater portion of it is concealed by the pulmonary artery and the aorta, which overlap it, the auricula alone being visible, without detaching these vessels, or inverting the position of the heart. When distended, it is of a square form, and into its angles open the pulmonary veins, those of the left lung being very close together. From its upper and left extremity projects the auricula, which is narrower, but longer and more tapering than that of the right side. Its margins are more deeply dentated, and present some angular inflections or zigzags. Its point rests on the root of the pulmonary artery. The interior of the left auricula presents musculi pectinati similar to those in the right, but the general cavity of the auricle is smooth. A slight depression may be observed in the septum auricularum, corresponding with the fossa ovalis. In the inferior part of the cavity is situated the *auriculo-ventricular opening*, the circumference of which gives attachment to the mitral valve.

The *left ventricle*, fig. 150, 7, (ventriculus aorticus,) occupies the left border of the heart, about one-third of its extent appearing on the anterior surface, the rest being placed posteriorly, owing to the obliquity of the septum ventriculorum. Its cavity can be conveniently exposed by making two incisions through its wall, parallel with the septum, and uniting at an angle near the apex. When the flap thus formed is drawn upwards, the great thickness of the walls of the cavity, as compared with those of the right ventricle, is rendered manifest. The columnæ carneæ resemble those of the right side, but are thicker, and directed for the most part from the base to the apex of the heart. Their intersections are exceedingly numerous at the summit of the cavity, and along its posterior wall, but the upper part of the anterior one is comparatively smooth. Two fleshy fasciculi of considerable size, commencing by smaller bundles, one from the anterior, the other from the posterior surface, pass upwards and terminate each in a blunted extremity, from which numerous chordæ tendineæ branch off to be inserted into the edges of the mitral valve. The auriculo-ventricular opening is guarded by a valve, similar in structure to that of the right side, but differing from it in presenting but two pointed processes; hence it has been termed the *mitral valve (valvula mitralis)*.

The larger division of it looks towards the aortic opening. To the right side of and before the large opening just noticed, is situated a smaller one, which communicates with the aorta, and is guarded by three valvular folds of the lining membrane, similar in structure and form to those of the pulmonary artery, and also called *sigmoid* or *semi-lunar valves.* In one instance I saw four semi-lunar valves, in another there were but two.

842. *Structure.*—The heart is covered by the serous layer of the pericardium, which is reflected upon it, and lined in its interior by a membrane of apparently similar structure, which not only serves as a coating for its proper substance, but also forms folds or valves at the auriculo-ventricular openings at each side, as well as the semi-lunar valves, where it is prolonged into the aorta and the pulmonary artery. Between the investing and the lining membrane is placed the proper muscular tissue of the organ. The muscular fibres of which the parietes of the heart are made up, differ not only in their quantity and number in each of its cavities, but also in their mode of arrangement. The smoothness of the heart's surface is obviously owing to the membrane which invests it. Within the cavities of the ventricles, and in the auricular appendages, we can readily see how the muscular fibres are disposed and interlaced, without disturbing the lining membrane; but to expose those on the outer surface, the investing membrane must be taken off. When this is carefully done, it will be found that the fibres of the ventricles run obliquely from above downwards to the left, and backwards, which disposition of them can be demonstrated even to the apex. M. Gerdy has shown that the fibres also form curves, whose convexity is turned forwards towards the apex; for if any given fibre commences at the surface, it will be found to dip in so as to become deeply seated at its termination, and *vice versâ*, by which means the bend of their curves will be turned as above stated. Owing to this disposition, the fibres of one ventricle are not all continued across into the other; many of them are seen to turn inwards at the septum, and mix with its substance. By following the course of these, we can separate the septum into two planes; but the greater part of its substance appears to belong to the left ventricle. The ex-

ternal stratum of fibres extends over the whole surface of the ventricles; within these is another plane (not, however, so extensive, as it does not reach much more than halfway to the apex), whose fibres take a different direction, so as to decussate with those of the outer layer; and, lastly, a third plane at the inner surface of the ventricles runs longitudinally from below upwards to the base, being continuous with the columnæ carneæ; but towards the apex they run in every possible direction, rendering the surface minutely reticulated.

But, it will be asked, have these fibres any common point of departure—an origin, as it is usually called? They will be found to commence at the base of each ventricle, deeply in the groove which separates it from the auricle. The examination of them is facilitated by filling all the cavities with plaster of Paris, and immersing the heart in boiling water for an hour or two; the serous pericardium can then be easily removed, and the muscular fibres traced deeply into the groove, where they will be found attached to a white tendinous, or rather cellulo-fibrous band of fibres. A fasciculus of this sort occupies the grooves at the anterior and posterior aspect, corresponding with the auriculo-ventricular openings; but it does not reach round their circumference; it seldom extends more than halfway. The two pair of fasciculi thus disposed are connected with a fibrous structure placed at the aortic aperture, at each side of which are two tendinous points, connected by a transverse band passing round the posterior segment of the aperture. To this band the fibrous fasciculi in the posterior grooves are attached, whilst the anterior pair are connected with the tendinous points. Taken altogether, this structure may be called apparatus tendinosus cordis. M. Gerdy* names it "tissu albuginé cardiaque," and Wolff "textus cartilagineus cordis." The muscular fibres of the auricles are thin, and in a manner scattered; most of those in the sinuses are transverse, but posteriorly, at the junction of the venæ cavæ in the right auricle, some run longitudinally; and higher up, at the orifice of the superior cava, they become circular, and seem as if prolonged a little way upon it.

* Mémoire sur l'Organisation du Cœur.—*Journal Comp. du Dict. des Sciences Médicales.*

843. During the progress of *post-mortem* examinations, it often becomes a question whether the heart of the subject is of its natural size—its walls of their proper thickness—its cavities of their normal capacity—or, in other words, does simple hypertrophy exist, or hypertrophy with dilatation, or the concentric hypertrophy described by Bertin?* Laennec has stated,† as the result of his observations, that the heart in its natural condition is about the same size as the closed hand of the individual. This cannot be considered a good standard of comparison, for no part of the body is so liable to be influenced by accidental circumstances as the hand. We must then resort to weight and measure to determine the point. Its weight is about ten ounces,‡ its length from the apex to the middle of the auricles averages five inches and a half, of which four appertain to the ventricles; the breadth of the ventricles is three inches at their base, and that of the auricles three and a half. The thickness of the walls of the left ventricle is a little more than double that of the right. Now the anterior wall of the left ventricle is five or six lines in thickness at the base, but scarcely three towards the apex. The thickness of the septum at its middle is about four lines. The results of measurement made by different persons to determine the capacity of these cavities are so various, that nothing positive can be stated upon it.

844. *Vessels and nerves.*—The heart receives its blood by the two coronary arteries; its veins terminate in the right auricle; its nerves come from the cardiac plexus, and appear very small as compared with the bulk and quantity of matter of the organ; a circumstance which was much insisted on in the discussion of the long-litigated question—Do the fibres of the heart possess their susceptibility to impression (irritability) *per se*, or do they derive it from the nerves?

We may, in concluding these remarks, observe, that those deviations from the normal condition of the heart which are congenital, and are ordinarily termed malformations, are referable to the general law which we indicated when treating of varieties in the distribution of arteries (sect. 619); for in many instances they are found to be but repetitions of some of the fixed modes of conformation in inferior animals, most com-

* Traité des Maladies du Cœur. † Traité de l'Auscultation Mediate, vol. ii.
‡ Meckel, vol. ii. p. 252 *et seq.*

KING'S COLLEGE HOSPITAL LIBRARY

monly that of reptiles. The degrees of deviation in different instances are various. In some the organ is altogether rudimentary, being "a mere expanded vascular trunk. To these follow the heart, with a very imperfect muscular structure, containing a single valveless cavity, with a very imperfect trace of an auricle; then such hearts as are occasionally formed with but a single ventricle and auricle, with a corresponding vascular trunk; succeeded by those which, having merely a single ventricle, are furnished with an auricle more or less perfectly divided by a partition into two cavities, whence the venous and arterial trunks simultaneously arise, either confounded together or distinctly divided. More perfect and more common are those formations of the heart in which, either by the increased capacity of the ventricles, or by the gradual developement of the partition, merely open at a single point, the division into two ventricles is effected, of which sometimes the right, sometimes the left, is imperfect. Lastly, we meet with hearts which depart from the normal structure merely so far as that the fœtal blood-passages remain open, the oval hole, or the ductus arteriosus, (one or both,) remaining unclosed."*

THE LUNGS.

845. The lungs (*pulmones*) constitute the organ of respiration, and are two in number; they occupy the lateral parts of the cavity of the thorax, which they completely fill. Each lung is of a conical figure, and rests upon the diaphragm, whilst its summit extends a little above the first rib. The external surface of the lung, smooth and convex in its general outline, corresponds with the arch of the ribs; the internal is compressed, and rests against the mediastinum, and at its middle third the bronchi and vessels enter its substance, forming, by their aggregate, what is called the *root* of the lung. The anterior border is thin and sharp, whilst the posterior is rounded and prominent, being received into the groove formed between the vertebral column and the ribs. The base, surrounded by a sharp border, is concave, and rests on the arch of the diaphragm, whilst the summit is tapering and rounded, where it ascends between the scaleni muscles. Each lung, fig. 150, is divided into lobes by a deep fissure, whose direction is from above down-

* Otto's Compendium of Pathological Anatomy, translated by J. F. South.

wards and from behind forwards; the lower lobe of each is thus quadrilateral in its figure, the upper conical. The perpendicular depth of the left lung is greater than that of the right, as the corresponding part of the diaphragm does not ascend so high; its inner border is also excavated to receive the pericardium and heart. The left lung has two lobes, 9, 10, divided, as has been above stated; the right presents three, 11, 12, 13, the third being intermediate in size and situation between the two others. It appears like an angular piece, detached by a groove from the anterior and inferior part of the upper lobe.

Each lung is invested by a serous lamella derived from the pleura; its interior is lined by a prolongation of mucous membrane, and the intervening structures form, by their aggregate, what is called the parenchyma of the organ.

THE PLEURA.

846. There are two membranes named *pleura*, each being thin, semi-transparent, and so disposed as to form a shut sac, thus conforming to the general law of serous membranes. Each membrane will thus be found to line the inner surface of the thoracic parietes, and to be reflected over the corresponding lung, giving it a smooth investment, the point of reflection corresponding with the root of the organ. Inferiorly, the membrane covers the convex surface of the diaphragm, and superiorly forms a small cul-de-sac at the bottom of the neck, over the summit of the lung. The part of the membrane which invests the lung is called *pleura pulmonalis*—that which lines the thorax, *pleura costalis;* it would be more correct to say, "pars pulmonalis," and "pars costalis." These two membranous sacs, by their apposition along the middle line, form a partition *(mediastinum)*, which divides the thorax into its two lateral chambers; it extends from the top of the thorax to the diaphragm, and from the spine to the sternum, with some inclination to the left side (inferiorly), owing to the position of the pericardium and heart. The interval between the two membranes in this situation gives lodgment, immediately behind the sternum, to the thymus gland and some cellular tissue; and lower down, to the pericardium and heart. Along the spine we find, similarly situated with regard to the membranes, the œsophagus, the vagus nerves, the descending aorta, thoracic

duct, vena azygos, and splanchnic nerves, with some lymphatic glands and cellular tissue. Now the bronchi and root of the lungs, by their transverse position, separate the mediastinal interstice into two parts, of which one is termed, ordinarily, the *anterior*, and the other the *posterior mediastinum*.

Structure.—The anatomical constituents of each lung are: 1. The bronchus and its ramifications. 2. The pulmonary artery and pulmonary veins. 3. Bronchial arteries and veins. 4. Lymphatics. 5. Nerves of the pulmonary plexus. These are enclosed in a quantity of cellular tissue, which forms a connecting medium between them.

THE TRACHEA AND BRONCHI.

The description of the bronchus considered as a constituent of the lung, includes that of the trachea, or rather presupposes a knowledge of it.

847. The *Trachea* (τραχεια αρτηρια, aspera arteria) is a cylindrical tube, which extends from the cricoid cartilage to the third dorsal vertebra, where its division into the bronchi takes place. It rests on the œsophagus, which, however, inclines somewhat to its left side. It is enclosed between the great vessels of the neck, and covered partly by the thyroid gland and its veins, also by the sterno-hyoid and sterno-thyroid muscles, and crossed by the brachio-cephalic artery, the left brachio-cephalic vein, and the arch of the aorta. The bronchi, fig. 150, *b*, *b*, commencing at the bifurcation of the trachea, incline laterally towards the lungs; the right one, larger but shorter than the other, inclines outwards, almost horizontally, and enters the lung on a level with the fourth dorsal vertebra; it is enclosed by the termination of the vena azygos, which hooks round it, and by the arch formed by the right pulmonary artery. The left bronchus, less in diameter, but longer than the right, inclines obliquely downwards and outwards to reach the lung. The arch of the aorta hooks round it, and the left pulmonary artery lies upon its superior and anterior border. Each bronchus, at its entrance into the lung, divides into two branches, one being intended for each lobe. The lower branch of the right lobe also subdivides, or rather gives off a branch to its middle lobe. Each bronchial ramification in its course gives off tubes of smaller size; and so, by a process of division and

subdivision continued through five or six successive stages of decrease, a series of tubes is formed, increasing in number as they decrease in size, until, finally, each becoming capillary, terminates in a minute cul-de-sac or air-vesicle, the aggregate of which constitutes the proper cellular structure of the lungs.

Structure of the trachea.—This tube is composed of fibro-cartilaginous rings, varying from sixteen to twenty in number, and of membranes which connect them. The rings do not extend all round the tube; they exist at the front and sides, but are deficient posteriorly. A thin, yet elastic, fibrous lamella forms the circumference of the tubes, serving to connect the cartilaginous rings, which seem as if developed in its interior, and also to complete the circuit posteriorly where these rings are deficient. Interiorly to these is situated the mucous lining, continuous superiorly with that of the larynx, and prolonged throughout the whole of the bronchial ramifications. Where the cartilaginous rings are deficient, the mucous membrane is supported by some longitudinal fibres, and beneath it we also find a series of muscular fibres resembling those of the intestinal canal. These are disposed transversely, so as to connect the extremities of the cartilaginous rings.

The bronchi and their primary ramifications are made up of the same constituents as the trachea, but the rings are found gradually to lose their annular form and to degenerate into lamellæ of irregular shape, placed in different parts of the circumference of the canal. At the several points of subdivision, however, they are still somewhat annular, so as to keep their orifices open. The rings thus gradually disappear, so that at the ultimate divisions of the bronchi they no longer exist, nor are they required, for the air which distends the vesicles is never altogether excluded from them. So far as the bronchi are cognizable by our senses, they appear to consist of materials analogous to those found in the larger tubes, but gradually reduced to the greatest degree of tenuity. If they be injected with quicksilver, the globular form of the vesicles, and the cylindrical form of the ultimate ramusculi which terminate in them, are rendered manifest; and as the mucous membrane is prolonged into the vesicles forming their lining, it is a legitimate matter of inference, from the various facts disclosed by the general anatomy of tissues, that the fibrous lamellæ and muscular structure

extend to them also. In support of this inference it may be urged, that if the lungs were simply passive, and therefore incapable of contributing to the expulsion of the air, the subsidence of the thorax upon them would only press the air out of the parts near their surface, but could exert little influence over those which are deeper seated. Besides, if one side of the thorax of a living animal be opened, the degree in which the lung becomes diminished is greater than that which is ordinarily produced by the weight of the atmosphere. This indicates a contractile, and even an irritable power in the organ.

PULMONARY ARTERY.

848. The *pulmonary artery*, fig. 150, 5, (arteria pulmonalis, vena arteriosa,) arises from the base of the right ventricle of the heart, from which it proceeds upwards and a little towards the left side for the space of about two inches, having a slight inclination, at the same time, from before backwards; opposite the concavity of the aortic arch, it bifurcates into its right and left branches, *a*, *a*. It partially conceals the aorta at its origin, and is connected with it by the serous lamella of the pericardium. At its point of bifurcation it is also connected to the concavity of the arch by the ductus arteriosus in fœtal life, and subsequently by the ligamentous remains of that vessel. The *right* branch, larger and longer than the left, inclines almost transversely towards the corresponding lung, which it reaches after passing behind the ascending aorta and the superior vena cava: it lies upon the right bronchus, but soon makes a turn so as to embrace it; after which it separates into three divisions. The *left* branch passes in front of the descending aorta, immediately beneath its arch, and, after reaching the upper border of the corresponding bronchus, divides into two branches. The primary and each succeeding division of the pulmonary arteries correspond with those of the bronchial tubes, whose course they follow to their final terminations in the air-vesicles, where they become capillary.

PULMONARY VEINS.

849. The *pulmonary veins*, fig. 150, *v*, *v*, (venæ pulmonales, arteriæ venosæ,) two in number at each side, commence by minute radicles, which are continuous with the capillary terminations of the arteries. They are found to converge to the

root of the lung from different parts of its structure, and in their course increase in size as they diminish in number. The veins of the right lung pass behind the right auricle and the superior vena cava; those of the left have a shorter course to run in order to reach the left auricle, which is their common destination; thus, the pulmonary, or smaller circulation, which commences at the right ventricle, and ends at the left auricle, is completed.

850. The *bronchial arteries* arise from the aorta (sect. 661); on reaching the root of the lungs each divides into small branches, which follow the divisions of the bronchi until they become capillary. The veins which return the blood of the bronchial arteries terminate at the right side in the vena azygos, at the left in the superior intercostal. Some of them, also, in their course appear to communicate with branches of the pulmonary veins. Some anatomists have been led to conclude, from a consideration of the size of the lungs, that they could not be dependent on the bronchial arteries alone for their nutrition. A similar idea seems to have been entertained concerning the nerves by Haller, who says, "neque multos nec magnos pulmonis nervos esse." But if we compare not the size, but the quantity of matter of the lungs, with that of any other organ, even with the liver, we shall find no reason to question the sufficiency of the bronchial arteries, or to doubt whether they are as well supplied with nerves as other parts.

851. The *nerves* of the lung are derived from the pulmonary plexus (anterior and posterior). The nervus vagus contributes much the greater share to the formation of the plexus, assisted by the sympathetic nerve. The branches of both form an inextricable interlacement exterior to the lungs, but are not found to anastomose within their substance. An opinion for some time prevailed, that the gangliac nerves were distributed exclusively to the vessels of the lung, and those of the nervus vagus to the bronchi. But Reiseissen,* after a most minute examination of this, and almost every other question that can be raised concerning the structure of the lungs, has come to the conclusion, that the branches derived from the nerves belong alike to the vessels as to the bronchi, and ramify indiscriminately on both.

* De Structurâ Pulmonum.

852. The *lymphatics* of the lungs are divisible into two sets; one being superficial, the other deep-seated. The superficial vessels run beneath the pleuræ, and after ramifying, so as to enclose areolar spaces, terminate in the bronchial glands at the root of the lung. The deep-set take the course of the veins; they enter the bronchial glands, and after having emerged from them again, they pass along the trachea; those of the left side terminating in the thoracic duct, those of the right in the lymphatic trunk of the corresponding side.

THE THYMUS GLAND.

853. The structure of this organ has been hitherto little known (thymus, *à θυμος*). The recent researches of Sir Astley Cooper have, however, exhibited every part of it in a perfectly clear point of view, and have thrown much light on the purposes which it appears to serve in the economy. "Perhaps," observes Sir Astley,* "no part of the body is more difficult of investigation than the thymus gland in the human subject. Its small size, the delicacy of its texture, its soft and pulpy nature, which renders it liable to tear under the slightest force, and the numerous small lobes which are combined to form it—all conspire to produce this difficulty, and to render it necessary to call in the aids which injection, hardening, unravelling, and the most careful and repeated dissecting can furnish." A leading peculiarity of this organ is, that its existence is temporary; it can be distinguished as early as the third month of fœtal life; it increases until birth, but its increase is not equable, being much more rapid during the seventh month than in the fifth or sixth. At birth, its weight is about half an ounce; it increases a little to the end of the first year, when it begins to decrease to the time of puberty, and is not only atrophied, but so far changes, as, "in after-age, to cease to have cavities, becoming a body of very small dimensions."†

The thymus is narrow and elongated, part being lodged in the thorax (in the mediastinum), close behind the sternum, and part extended upwards into the neck. Its colour is greyish, or rather ash-colour, with a reddish tinge; its consistence very

* The Anatomy of the Thymus Gland, by Sir A. Cooper.
† Op. cit. p. 19.

soft; its surface uneven and distinctly lobulated. It is not a single organ; for though it presents two lateral and nearly symmetrical parts, the only difference between them being, that the left is often larger than the right; still, as these parts "are generally separated from each other as regards glandular substance, they may properly be called a right and left thymus gland."* Sometimes a third thoracic lobe exists, which appears to join together those that are placed laterally, but by careful dissection they admit of being separated. Each lateral part may be said to present a base, a summit, two surfaces, and two borders. The base or broad extremity rests on the upper part of the pericardium, to which it is connected by cellular tissue; for at birth it reaches as low down as opposite the fourth rib. The summit extends as high as the thyroid gland; the anterior surface lies behind the first bone of the sternum and the upper part of the second, the origins of the sterno-hyoidei and sterno-thyroidei muscles interposing; in the neck, the latter muscles cover it. The posterior surface rests, while in the thorax, on the left brachio-cephalic vein, on the convexity of the aortic arch, and the origins of the large vessels (a thin layer of cellular tissue interposing); in the neck, it rests upon the front and sides of the trachea as far up as the thyroid gland. The inner borders are in apposition one with the other, whilst the external margins are enclosed within the interval between the internal mammary vessels and the layers of the mediastinum, and higher up between the great cervical vessels.

The thymus is surrounded by a layer of cellular tissue, which not only connects it with surrounding parts, but binds together the lateral masses that compose it. When this is removed, "the substance of the gland is exposed, which is found to be of the conglomerate kind, being formed of numerous lobes, connected together by a second covering of reticular tissue, uniting the lobes to each other."† Now, the size of the lobes varies considerably, some being as small as a pin's head, whilst others are as large as a pea. If a section of the gland be made, an elongated cavity will be found in its interior, containing an albuminous fluid, and round this the lobes are disposed in a peculiar way. In order to understand the relation which sub-

* Op. cit. p. 26. † P. 27.

sists between the cavity and the lobes, and the structure and mode of connection of the latter, it becomes necessary to unravel one of the lateral masses. In order to effect this, Sir Astley observes: * "to unravel it satisfactorily, it is necessary to dissect it, in part, in water, and then harden it in alcohol, when the dissection may be minutely pursued." After this is effected, it will be found that the lobes are connected by a strong fasciculus —a rope, in fact, round which they are attached like knots, and that "these ropes are disposed spirally around a central, or nearly central cavity." In this position they are retained by the cellular envelope externally, and the mucous lining of the cavity internally, as well as by the different vessels. Every lobe, or rather lobule, contains several small cavities, each of which resembles a small cul-de-sac, being "a secretory cell for producing the fluid" above alluded to. The cells of each lobule open into a small pouch at its base, and this, in turn, communicates with the large central cavity of the gland. "If a pipe be introduced into the gland, and alcohol be injected, and the organ then be immersed in strong spirit, or a solution of alum, a large cavity (that just referred to) will be filled, which I shall call the reservoir of the thymus."† The reservoir extends through the thoracic and cervical portions of the gland, being larger in the former. It is lined by a vascular mucous membrane, which is evidently prolonged through the pouches into the cells.

Vessels and nerves.—The thoracic part receives its arteries from the internal mammary artery; the cervical from the superior thyroid, and sometimes from the inferior thyroid. The veins run a different course from the arteries, and open, for the most part, into the vena innominata. The nerves are very minute; Haller thought they were derived from the phrenic; Sir A. Cooper says that he could not trace any branch from that nerve going to the gland; some evidently pass along it, and even through its cellular envelope, but they proceed on to the pericardium. He further observes, that a plexus is formed by branches from the sympathetic upon the internal mammary artery, and that filaments from this plexus pass along upon the thymic artery, which in a manner guides them to the gland. Besides this, "he has seen a filament from the junction of the

* Op. cit. p. 28. † P. 29.

par vagum and sympathetic pass on the side of the thyroid gland to the thymus." As to absorbents, Sir Astley has succeeded in injecting them only once in the human subject; but in the fœtal calf they pass nearly straight along the posterior surface of the gland, and terminate in the vena innominata. They are sufficiently large to admit an injecting pipe, and to receive ordinary coarse injection. The remarks upon them thus conclude: "These vessels, I consider, and shall name, the *absorbent ducts* of the gland; they are the carriers of the fluid from the thymus into the veins, at the lower part of the neck."*

Not content with stating the result of his researches, the distinguished author details his methods of conducting them, obviously to abridge the labour of those who are not as well versed as himself (and few are) in anatomical pursuits.

NERVOUS SYSTEM.

854. The different parts of this complex apparatus (see Nervous System, General Anatomy of, p. 108, et seq.) we shall describe in the following order (having first treated of the membranes which invest them): — 1. The spinal cord; 2. The brain; 3. The cerebral nerves, properly so called, viz. olfactory, optic, auditory; 4. The single-rooted motor nerves, viz. the third, sixth, ninth, and fourth; 5. The respiratory set of nerves, facial (portio dura), glosso-pharyngeal, nervus vagus, and accessorius; 6. The spinal nerves with two roots; and, 7. The sympathetic nervous system.

Membranes of the Brain and Spinal Cord.

The brain and the spinal cord are invested by three membranous lamellæ, namely, the dura mater, the arachnoid membrane, and the pia mater.

DURA MATER.

855. The *dura mater* (μηνιγξ σκληρη), which is the most external of the three, is thick, firm, and resisting, and belongs to the class of fibrous, or rather fibro-serous membranes, as it is in reality a compound structure; the outer lamella being

* Op. cit. p. 15.

fibrous, the inner serous and derived from the arachnoid membrane. It is in close apposition with the cranium, which it lines, at the same time that it invests the brain, and sends inwards processes, which are interposed between its different parts, serving to sustain them. It is, moreover, prolonged in a tubular form through the spinal canal, but is separated from the bones by a lamella of adipose tissue and the great spinal veins. It adheres closely to the arch of the skull, particularly along the sutures, but at its base the points of connexion are multiplied by its passing over the inequalities of the surface, and still more so by sending tubular prolongations through the different foramina, serving to enclose and protect the nerves which they transmit. Along the spinal column similar prolongations pass out with the nerves through the inter-vertebral foramina: these constitute its chief connexion with the bones. But towards the lower part of the sacral canal it is fixed by some irregular fibrous bands.

The processes formed by the dura mater are the following:

The *falx cerebri* is lodged in the longitudinal fissure between the hemispheres of the brain, forming a partition between them. It is narrow before, broad behind, and presents a curved border inferiorly, so that in shape it resembles a sickle: hence its name. It extends from the crista galli of the ethmoid bone, which is inserted between its lamellæ, to the internal occipital protuberance, on a level with which it branches out at each side, becoming blended with the tentorium cerebelli. It seems as if formed in the following manner:—The fibres of the dura mater, on approaching the sagittal suture from each side, divide into two lamellæ, one of which is continued uninterruptedly across, thereby maintaining the continuity of the membrane, but the other dips down, converging to that of the opposite side, by which means they enclose between them an angular interval, viz. the longitudinal sinus. After their union they continue to descend to the margin of the falx, where they separate, and unite again, so as to form the inferior longitudinal sinus. A section of the upper sinus is found to be triangular, of the lower circular. On the surface of the dura mater, in the sinus, or upon the cerebral hemispheres, small albuminous masses occasionally exist, called glandulæ Pacchioni, apparently resulting from morbid action.

The *tentorium cerebelli* spreads out from the base of the falx, and serves to support the posterior lobes of the brain: one border of it is attached all around to the lateral grooves on the occipital bone, and to the margin of the pars petrosa; the other, concave and free, encloses an oval interval, which transmits the crura cerebri, processus ad testes, and basilar artery.

The *falx cerebelli* is a narrow fold placed between the lobes of the cerebellum, extending vertically from the under surface of the tentorium to the foramen magnum; its base lodges the occipital sinuses. (The sinuses are described sect. 747 et seq.)

PIA MATER.

856. The *pia mater* (μηνιγξ λεπτη) in its anatomical characters differs considerably from the other membranes. It is made up of a thin lamella of cellular tissue, permeated by a multitude of minute capillary arteries, which ramify in it previously to their entrance into the cerebral substance. It invests the medulla spinalis, as well as the brain, and dips into the sulci between the convolutions of the latter: we also find it enclosed within the ventricles, where it is named "plexus choroides" (χοριον, ειδος). Its inner surface is in close contact with the cerebral substance; the external is in apposition with the arachnoid membrane on the surface of the convolutions, but loses all connexion with it after passing into the sulci.

Plexus choroides.—Fig. 153, *m*. In the fissure observable at the base of the brain, between the inner margin of its middle lobe and the crus cerebri, the pia mater, which invests the external surface, is continuous with that process of it (plexus choroides) which is found in the ventricles; so that when we trace it, we find it, as it were, entering at the inferior cornu of the ventricle, where it corresponds at first with the interstice between the corpus fimbriatum and the crus cerebri, and afterwards lies along the floor of the ventricle, in which it ascends upon the thalamus nervi optici, and unites at the foramen or fissure of Monro with the plexus of the other side. At its entrance into the ventricle the plexus is drawn together so as to resemble a small vascular bundle, and becomes invested by the arachnoid membrane, which, by its reflection from the sides of the ventricles to the plexus, maintains the integrity of the cavity.

857. Where the pia mater is prolonged on the medulla oblongata, it forms a small plexus, which enters into the fourth ventricle, and becomes also invested by a duplicature of the arachnoid. As the membrane descends into the spinal canal it becomes firm, resistent, and much paler in colour. Its inner surface is in close contact with the cord, the exterior is but slightly connected with the arachnoid; but the nerves, at the different points at which they pass outwards, derive from it their immediate investment, or neurilema. The difference of character here pointed out between the spinal and cerebral parts of the pia mater, appears to MM. Jules and Hippolite Cloquet sufficient to induce them to consider it as a distinct structure. But it would be difficult to show where the continuity of the membrane is interrupted; and as to any difference of character and consistence that may appear, they are merely such as may be supposed to arise from the different circumstances in which the membrane is placed. In the spine it is exposed, at least in some degree, to the influence of motion and pressure, which necessarily produce the same effect on it as on cellular textures elsewhere; that is to say, they render it thick and lamellar. Again, in the skull it is in contact with grey substance, in the spine with white; so that we can readily account for the difference of the vascularity in the membrane, by recurring to the relative vascularity of the structures with which it is in contact.

ARACHNOID MEMBRANE.

858. The serous investment of the brain and spinal cord is called the *arachnoid membrane*, from its tenuity (ἀραχνη, a spider's web; εἰδος). It is smooth and transparent, and, like all the other membranes to which it belongs, forms a shut sac; one part of it invests the cord and the brain, passing over its surface without dipping into the convolutions; the other lines the dura mater and its different processes, with which it is inseparably connected. Moreover, as the nerves and vessels pass across the intervals between their points of attachment to the cerebral substance, and those by which they escape from the cavity of the cranium, they are enclosed in tubular prolongations of the arachnoid membrane, which are continuous by one extremity with the portion investing the brain and the cord, and by the other with that which lines the dura mater. By

this arrangement the continuity of the membrane is maintained, at the same time that the apertures of transmission are closed. The arachnoid membrane is prolonged into the ventricles, lining them in their entire extent, and forming within them a remarkable duplicature (*velum interpositum*). By these means its arrangement is rendered as complex as that of the peritonæum; and were we, with the same view, and on the same principle, to "trace its reflections," they would be found as follow:—

We shall suppose, in the first place, a vertical section of the skull and the spine to be made, so as to lay open their cavities. Commencing then at the vertex, we trace the membrane along the upper and under surface of the anterior lobe of the brain, and thence downwards upon the crus cerebri and pons. We then follow it on the anterior surface of the medulla spinalis down to the extremity of the cauda equina, where it is reflected upon the different nerves which guide it to the contiguous surface of the dura mater, with which it becomes in a manner identified, forming a lining for it as far as the foramen magnum. From the foramen the membrane continues its adhesion to the dura mater, forwards upon the base of the skull, then up along its roof, and thence backwards to the occipital protuberance. At the latter point it is reflected over the tentorium, coating both its surfaces, and is thence prolonged down through the foramen magnum, still bearing the same relation to the fibrous membrane, as far as the extremity of the canal. At this point it is reflected forwards upon the medulla, which it invests in its entire extent. From the medulla oblongata it is, as it were, guided by the corpora restiformia to the cerebellum, and having invested both its surfaces, reaches the processus ad testes, on which it is continued, to the under surface of the cerebral hemisphere, and is thence prolonged to the vertex, that is to say, to the point from which we set out.

When the continuity of surface is thus shown at each side, the lateral parts of the membrane will be found continuous, by tracing them over the flat surfaces of the hemispheres, and down to the corpus callosum; so that, if a transverse section were made of the cerebral hemispheres, the part of the membrane which is reflected from their flat surfaces over the corpus callosum will represent a cul-de-sac.

But it will be asked, how and where can the external or investing part be shown to be continuous with that which lines the ventricles?

The fact can be demonstrated as follows:—If we trace the membrane along the posterior border of the corpus callosum, it will be found to turn beneath it, and to enter the ventricle through the fissure of Bichât. Again, the part of it which lies on the tubercula quadrigemina is also prolonged into the ventricles, lying, like the preceding, close on the cerebral substance, and constituting an investment for it. If the falx and tentorium have been left undisturbed, a tubular process of arachnoid membrane will be observed (by drawing aside the posterior cerebral lobes) passing out of the fissure, and directed backwards to the point at which the border of the falx joins with that of the tentorium. This process is prolonged from the velum interpositum, and encloses the venæ Galeni, which are two small veins that return the blood from the plexus choroides, and pass from before backwards, enclosed within the velum, to terminate in the straight sinus. We have then within the ventricles to examine a prolongation of the membrane which lines their surface, and another which is in a manner free and unattached (*velum interpositum*), each being continuous with the other, and both with the more extended serous surface already examined. That the membrane lines the roof of the ventricles, may be proved by cautiously dividing the fibres of the corpus callosum, and pushing them aside. A thin membranous lamella will be thus exposed, which, though diaphanous, is sufficiently firm to confine air or fluid passed into the ventricle. There are then two entering layers, one along the roof, the other on the floor of the ventricle, and a returning or tubular process continued back from these, and terminating as above stated. Their arrangement appears to be as follows:—the arachnoid membrane, after investing the surface of the corpus callosum as far as its posterior border, turns beneath it, passing through the foramen of Bichât. After lining the under surface of the fornix, it is reflected over its borders to the septum lucidum, upon which it is prolonged to the roof of the ventricles, and so to their outer margins. In this way it may be traced into the posterior and descending cornua as far as the points at which the plexus choroides of each side enters, on the upper surface of which it is reflected, to form the commencement of the velum interpositum. Now the part of the membrane that covers the tubercula quadrigemina, on reaching the interior of the ventricle, sends in the middle line a process into the third ventricle, which is prolonged in the form of a cul-de-sac downwards into the fourth ventricle, lining its walls and closing its cavity inferiorly. On each side the membrane extends along the floor of the ventricles to their outer margins, where it is continuous with the part already traced to these points.

It is similarly disposed of in the floor of the posterior and descending cornua; and on reaching the fissures which admit the plexus choroides at each side, it is reflected on the under surface of the latter, the part that lined the roof having been reflected on their upper surface; so that they are enclosed between two lamellæ of the serous membrane, in their entire extent, from the lateral fissures to the foramen Monroi. These lamellæ, from being stretched from side to side, betweeen the fornix and the third ventricle, constitute what is called *velum interpositum:* posteriorly, the velum is narrowed to a funnel-shaped process, which makes its exit through the fissure of Bichât, and on reaching the point at which the falx spreads into the tentorium, becomes continuous with the part of the membrane which lines these processes.

859. *Membrana dentata* (ligamentum denticulatum, vel serratum).—At each side of the spinal cord, along its whole length, is placed a shining, thin, but firm membrane, which is attached to the tube of the dura mater by a series of pointed processes, from which circumstance its name is derived. It extends from the border of the foramen magnum, to which its first dentation is attached, down to the first lumbar vertebra, in all which extent it is interposed between the anterior and posterior roots of the nerves, one of its surfaces looking forwards, the other backwards. The external or dentated border being attached (by so many points as there are dentations—about twenty in all) to the dura mater, the place of their attachment is midway, or very nearly so, between the foramina for the exit of the nerves. Its inner border, corresponding in position and direction with the lateral sulcus of the spinal cord, rests against the pia mater, which encloses the cord, and appears to be connected with it by delicate cellular tissue. As to its structure, some regard it as a production of the arachnoid membrane, others of the dura mater; whilst not a few contend, that it is fibrous or cellulo-fibrous in its texture, and distinct from the other appendages of the cord.

THE SPINAL CORD.

860. The spinal cord (chorda spinalis, medulla spinalis, cerebrum oblongatum) is that part of the cerebro-spinal mass which is enclosed within the spinal canal. The term "medulla," commonly given to it, cannot with propriety be retained,

as it obviously bears no similitude to the "marrow" of long bones; and it certainly is not a prolongation of the brain, which the name cerebrum oblongatum would imply, for its appearance and developement precede that of the brain. We must observe, that though, as the name implies, the greater part of the cord is enclosed within the canal, still a portion of it is prolonged into the skull, and rests on the basilar process of the occipital bone. On this is founded its division into *chorda spinalis* and *chorda oblongata* (medulla spinalis and medulla oblongata).

Spinal cord, dissection of.—In order to expose the cord, previously to examining its structure, it is necessary to saw through the broad part of the occipital bone down to the foramen magnum, and then to cut through the arches of the vertebræ at each side, along the whole of the column, with a knife, or chisel and mallet, as it is both tedious and troublesome to saw them. The arches being removed, the dura mater may be laid open in its entire length, and the description of the contained parts referred to. Slit open the tube formed by the dura mater, reflect the borders of it to each side, observe the roots of the nerves, the filaments which collect to compose them, and carefully note the ligamentum dentatum—its relations to the nerves and to the other membranes.

In the adult human subject, the cord extends from the lower border of the pons Varolii as far as the first or second lumbar vertebra. In the early periods of fœtal life it extends throughout the whole length of the spinal canal, conforming in this particular with the permanent condition of it in lower animals, in which it reaches even to the caudal prolongation of the column. As the process of growth and developement goes on, the relation of the cord to its osseous canal varies, so that ultimately it reaches only to the point above stated. Keuffel, however, saw it in one case end opposite the eleventh dorsal vertebra, and in another to reach as far as the third lumbar. Its form, considered in its general outline, is cylindrical; but its transverse diameter is somewhat greater than the antero-posterior, which gives it a flattened appearance in the former direction. The size of the cord is not the same from one extremity to the other; neither does it increase or diminish uniformly. Three distinct swellings are observable in different parts of its extent. Superiorly it is enlarged where it is in apposition with

the margin of the pons Varolii, but gradually diminishes as it approaches the foramen magnum. The second swelling corresponds with the interval between the third and sixth cervical vertebræ; the third with that between the tenth dorsal and the first lumbar. Its inferior termination is subject to considerable variety in different cases. It usually becomes fusiform, and terminates in a point a few lines below the lumbar swelling: in other instances it ends in a small bulb, slightly constricted at its centre; but any varieties of conformation presented by this portion deserve little attention, as none of the nerves arise from it.

861. When detached from its connexions, the cord is found to be divided into two lateral halves, by grooves (sulci) extending along its whole length, one situated on the anterior, the other on the posterior aspect; the anterior groove is wider and more distinct, though not so deep as the posterior, at least at the upper part of the cord; it penetrates to about one third of the diameter of the cord. The white substance which encircles these two lateral parts or fasces dips into the sulci; but it is somewhat remarkable that, in the anterior one, the fibres are observed to pass from side to side, and intermix along the median line so as to form a commissure (*commissura longitudinalis*) connecting the lateral halves of the cord; in the posterior one they all pursue the longitudinal direction. At each side of these grooves, two others (*fissuræ laterales—sillons laterales*) may be observed running parallel with them, being however but faintly marked. These indicate the lines in which the anterior and posterior roots of the spinal nerves are attached to the cord; that which corresponds with the posterior roots is sufficiently defined; the other scarcely, if at all; and, finally, along the lateral aspect of the cord, a slightly depressed line may be traced down as a continuation of that which separates the corpus restiforme from the olivare, gradually, however, becoming more faint, and ceasing to be perceptible about the upper part of the dorsal region.

Structure.—A transverse section of the spinal cord (fig. 151, *a*,) shows it to consist of a thin lamella of white matter, enclosing the gray or cineritious substance. The latter is disposed in a very peculiar way; it presents two lateral portions, each of a crescentic form, their concavities looking outwards; the

convex sides of each are turned towards the middle line, and are connected by a short transverse fasciculus of gray matter, somewhat in this way)-(; the transverse plate may be considered a commissure (*commissura grisea*) which connects the lateral portions of gray matter. The anterior cornua of the lateral masses are rather thick and rounded; the posterior extend as far as the collateral sulci, from which the posterior roots of the nerves arise. These facts, as well as the relation of the white to the gray matter, and the form of the latter, can be readily seen by making some transverse sections of the cord, particularly at the swellings which it presents.

862. *Spinal nerves.*—The spinal cord gives attachment to thirty-one pairs of nerves, which are regular, symmetrical, and double-rooted. One of the roots of each nerve arises from the anterior, the other from the posterior aspect of the cord. The fibres which form the latter pass outwards, converging towards one another, and in the tubular investment of dura mater, which encloses them, form a ganglion. The fibres of the anterior root pass to the same point, and, having united, join with the preceding, immediately external to the ganglion. The trunk thus formed is a compound nerve in structure and in function, sensation being transmitted, according to the researches of Sir C. Bell, by the posterior root, and the power of motion by the anterior. There are eight cervical pairs of nerves, the upper four of which form a plexus at the side of the neck (cervical plexus); the lower four, with the first dorsal, constitute the brachial plexus: the dorsal nerves are twelve in number; eleven of them correspond with the intercostal spaces. There are five pairs of lumbar nerves, and six sacral, which form each a plexus (lumbar and sacral plexus), but which are joined in such a way as to form one elongated interlacement (lumbo-sacral), from which issue the nerves of the lower extremity.

MEDULLA OBLONGATA.

863. The cranial portion of the cord (*chorda oblongata, medulla oblongata*), figs. 151, 154, is broad and thick superiorly near the pons Varolii, but tapers gradually towards the occipital foramen. It is about fifteen lines in length; its breadth at the upper parts nine, and its thickness six. Its anterior aspect is rounded, the posterior is somewhat flattened,

and each presents a continuation of the median sulcus (anterior and posterior), by which it is divided into two symmetrical parts. The lateral depressions, which correspond with the points of origin of the spinal nerves, are also continued upwards into the medulla oblongata. But though inferiorly the divisions established by these lines are so slightly marked as to have escaped notice, until Chaussier directed his attention to the subject, yet in the superior part (*medulla oblongata*) they are so well defined as to have been deemed deserving of particular names. The anterior and posterior pair have been called the anterior and posterior pyramids: the middle, from their shape, the corpora olivaria. These, according to Gall, are made up of the primitive or formative fibres of the cerebrum and cerebellum; for if they be traced upwards, the anterior pyramids and the corpora olivaria will be found continuous with the fibres which are expanded into the cerebral hemispheres, whilst the posterior pyramids (usually called, since Ridley's time, *corpora restiformia*) are evolved into the lobes of the cerebellum. Besides these parts, which have been noticed by all anatomists, Sir C. Bell has described another, which is situated between the corpus olivare and restiforme. This consists of a narrow line of white matter, which may be traced along the medulla oblongata, and from thence downwards between the anterior and posterior roots of the spinal nerves. It is but slightly marked in the lower part of its extent, but becomes more perceptible opposite the corpus olivare; after which it narrows, and ceases altogether at the margin of the pons, "not being continued upwards into the cerebral mass." This may be termed *tractus respiratorius*, as it gives origin to the class of respiratory nerves as established by Sir C. Bell.

The *anterior pyramids*, fig. 151, *b*, (corpora pyramidalia,) are close together, being separated only by the anterior sulcus, and extend, enclosed between the corpora olivaria, from the margin of the pons Varolii to the foramen magnum. Some of the fibres of each pyramid which are close to the sulcus pass across it obliquely, and so a decussation is produced between them about eight lines below the pons (*c*). The rest continue their course uninterruptedly, so that only a part of the pyramids change place, or decussate.

The *olivary bodies*, *d*, (corpora olivaria,) are so called from

their oval rounded form, like an olive ; they are placed external to the anterior pyramids between them and the restiform bodies. When stripped of their medullary lamella, they are found to consist each of an oblong mass of gray matter, surrounded by a fringed or scalloped border, and attached towards the middle line by a slight petiole. Owing to this arrangement, it presents, when divided by a transverse section, an arborescent appearance.

The *restiform bodies*, fig. 151, *e*, (corpora restiformia, Ridley ; posterior pyramids — pyramides postérieures, Gall,) correspond with the lateral and posterior parts of the medulla ; they diverge as they ascend towards the lobes of the cerebellum, fig. 154, *g*, *g* ; they were called at one time processus è cerebello ad medullam, when it was the usage to trace all these parts from above downwards ; but now they are taken in the opposite way, and as these bodies constitute the formative fibres of the cerebellum, according to the views of Gall, they may be named processus è medulla ad cerebellum.

The posterior aspect of the medulla oblongata is slightly concave, and presents the division into two lateral parts by the median sulcus. The restiform bodies as they diverge leave an angular interstice between them bounded by a slightly raised margin spreading out from the point of divergence like the branches of the letter V, fig. 154, *k*. Upon the surface at each side of the median line some fine medullary streaks (*l*) are seen, which run outwards obliquely and correspond with the origins of the auditory nerves. The older anatomists, dealing much in comparisons, likened the V-shaped divergence and the depressed surface to the point and body of a writing-pen, and the striated lines to the barbulæ or feathers, and so applied the term *calamus scriptorius* to the assemblage of these objects viewed in this way.

At each side of the median line, beneath the point of the calamus and between the restiform bodies, two narrow medullary fasciculi are placed. They have been named the "*posterior pyramids*," though that term has been for some time applied to the restiform bodies. They enlarge a little at their upper extremity, and seem to subside upon the restiform bodies. The white fibres seen here, and which lie in the calamus, reach upwards, and can be traced as far as the optic thalami. Rolando,

in his work on the structure of the cerebellum, has described and figured two slight fasciculi of fibres, whose direction is oblique or curved, lying at the side of the medulla oblongata, one running by the lower border of the olivary body, another above it, and reaching from the restiform body with which they are confounded downwards and inwards to the pyramid; in conformity with present usage, however, they are traced from the latter to the former, and so to the cerebellum.

The interior composition of the medulla oblongata may be examined in the same way as the cord, by transverse sections. One made at the lower end of it will show the arrangement and form of the white and gray matter to be as indicated in the rest of the cord; another may be made at the decussation of the fibres of the pyramids, and a third across the olivary bodies.

THE BRAIN.

864. The part of the central mass of the nervous system which is lodged within the skull, has been called from this circumstance "encephalum." It presents, even on a superficial inspection, a division into parts, which differ in position, size, and form, as well as in the arrangement of their components; these have been named cerebrum, cerebellum, (or great and little brain,) cerebral protuberance, and lastly, the connecting link between these and the spinal part, viz. the medulla oblongata.

Dissection of the Brain. — When proceeding to open the skull (the muscles having been previously dissected), it will be found convenient to saw through the external table of the bones all round, from the superciliary ridge to the occipital protuberance. When this has been done, the inner table may be broken through by employing a small mallet and chisel, or a strong knife made for the purpose. After the roof of the skull is removed, the chin should be supported on a block, and the dissection proceeded with. An incision may be made along the middle line, so as to lay open the longitudinal sinus; after which the dura mater may be divided by a horizontal incision carried along the whole length of one of the hemispheres, on a level with the section made in the bone. This portion of the membrane may then be drawn to the opposite side, which will expose the surface of the brain, the falx cerebri,

the fissure between the hemispheres, &c. All the parts here named should be examined attentively, the descriptions given of them in the different sections being at the same time read.

In the next place, let the hemisphere which is uncovered be drawn aside so as to expose the corpus callosum; after which its substance may be cut through, by passing down a scalpel to a level with the corpus callosum, and then directing its edge outwards and somewhat upwards, so as to avoid entering the ventricle.

To open the Ventricle.—The lateral ventricle may be opened by making an incision through the corpus callosum parallel with its raphé, and everting the external portion of it. The parts within the body and anterior and posterior cornua of the ventricle being examined, the descriptions given of their form, size, and position being read, the descending cornu should in the next place be traced by following the plexus choroides downwards into it; after which it can be fully exposed by making an incision through the substance of the optic thalamus down to the cornu, so as to remove the external two-thirds of it. If the cornu ammonis be drawn outwards, the point at which the plexus enters will distinctly appear, and also the change presented by the pia mater where it enters the ventricle. The greater part of the substance of the hemisphere may now be removed, and the tentorium cerebelli at the same time detached from the pars petrosa, and reflected backwards. This will expose the greater number of the cerebral nerves, and give a side-view of their course and relations within the cranium. Those within the cavernous sinus may be brought into view by following the third, fifth, and sixth through the foramina in the dura mater, and everting it as it is cut up.

865. The brain (*cerebrum*) forms the largest portion of the central mass of the nervous system, and occupies the principal part of the cranial cavity. It extends from the frontal bone to the occipital fossæ, resting on the orbital processes of the former, on the tentorium cerebelli posteriorly, and in the centre descends into the middle fossæ, at the base of the skull. Its superior surface is convex and arched, corresponding with the vault of the cranium, beneath which it is placed, and presents along the middle line a deep fissure, running from before backwards, by which it is divided into two equal parts (*hemispheres*). The surface of the brain is rendered unequal by several depressions and elevations marked upon it. The elevations are called

convolutions (*gyri*), and are situated between the depressions (*sulci*). The course of the convolutions is winding and tortuous, as their name implies, and their size presents many varieties in different places. It should be observed, that the anterior extremity of the brain, which corresponds with the frontal bone, is narrower than the posterior, which is in apposition with the occipital bone.

866. *Hemispheres.*—The external surface of each hemisphere is convex in its general outline; the internal, fig. 152, *a*, is flat and compressed, as it rests against its fellow of the opposite side, the falx major being interposed between them. The inferior surface presents several depressions and inequalities, corresponding with those of the base of the skull.

Lobes.—On the inferior surface of each hemisphere is observed its division into three *lobes*. The anterior lobe, fig. 151, *f*, rests on the orbital process of the frontal bone and the smaller wing of the sphenoid bone; the posterior, *g*, is supported by the tentorium cerebelli; and the middle, *h*, is received into the central fossa, at the base of the skull. The anterior is separated from the middle lobe by a deep fissure (*fissura Sylvii*, *i*,); but there is no precise line of demarcation between the latter and the posterior.

867. The *Brain — its external surface.* — The relation of size, form, and situation of the different objects seen on the external surface of the brain, should be carefully noted, as allusions are constantly being made to them during the description of the parts deeply seated, and also when tracing the progress of its developement in the human subject, or in the animal series, and particularly when, after the manner of Gall and Spurzheim, we follow the course of the nervous fibres through the successive steps of their expansion, as the phrase is, from the medulla upwards into the cerebral hemispheres. Nothing of consequence remains to be noticed on the superior and external surface, in addition to what has been already stated.

To examine the origins of the nerves and the parts at the base of the brain, it must be detached from its situation and inverted; but it is not necessary to repeat what has been already stated in our description of the exterior of the brain. Note first the parts which lie along the median line, beginning with the anterior sulcus, and proceeding with them from before backwards. Note their size and relations,

compare them with the descriptions. Then take the objects which are placed more externally. Observe the relative position, form, direction, and size of the different nerves. You will at once recognise the olfactory running forwards, in a manner embedded in a groove in the anterior lobe, about a finger's breadth outside the median sulcus. In the interval between these, at their roots, you recognise the commissure of the optic nerves, behind which is the tuber cinereum and the infundibulum; behind the tuber are the corpora albicantia, and then a small depressed triangular space, the locus perforatus, on each side of which is the crus cerebri. Attached to the crus, towards its inner side, is the third nerve, and upon its outer side rests the inner convolution of the middle lobe; evert the latter, and you see the fissure through which the pia mater enters the inferior cornu of the lateral ventricle. Whilst doing this, you recognise the optic nerve, rather soft and flat, resting on the crus cerebri, and curving forwards to its commissure.

Now, returning again to the middle line, you find behind the crura, and as if overlapping them at their commencement, the broad white lamella — pons Varolii; trace its fibres outwards, and you observe them to be continuous with the crus cerebelli at each side, which is concealed by some minor lobules. And here, at the junction of the pons with the crus, you see the fifth nerve. At the posterior border of the pons is the medulla oblongata, presenting the two pyramids close together, one at each side of the middle line; external to these are the olivary bodies, and still farther out the restiform. At the junction of the pyramid with the pons is the sixth nerve. Along the groove, between the pyramid and the olivare, are several delicate filaments, forming the origin of the ninth or lingual nerve. A little farther out you see a small nerve running parallel with the medulla, as it were, coming up from the foramen magnum—this is the nervus accessorius. Now look at the groove between the olivary and restiform bodies, and you will find in the first place, high up and close to the pons, the portio dura, a rounded small cord; immediately beneath it a very small nerve — the glosso-pharyngeal, to which succeeds a flat fasciculus, the nervus vagus. Evert the medulla a little, or draw it forwards — you see the calamus scriptorius — a groove and fissure like the point of a writing-pen; higher up, a few oblique lines faintly traced upon the surface, and then the portio mollis, or auditory nerve. Finally, draw the lobes of the cerebellum forward so as to invert it, you see a white lamella in front of it — the valve of Vieussens, and the fourth nerve attached to it.

868. The *Brain—its base or inferior surface*, fig. 151.—When we turn to the inferior surface, we observe that it presents in the middle line, and in front, a fissure, *k*, being the continuation of the longitudinal one, which establishes the separation between the hemispheres. It lodges the anterior extremity of the falx cerebri, its depth being limited by the corpus callosum, which passes across from one hemisphere to the other. The inferior surface of each anterior lobe, as it corresponds with the orbital plate on which it rests, is slightly concave.

Sulcus olfactorius.—A few lines external to the longitudinal fissure, and parallel with it, is a groove resembling one of the sulci, which lodges the olfactory nerve, 1, and at its posterior extremity is a rounded papilla, from which one root of that nerve is derived.

Fissure of Sylvius.—Posterior to the groove just noticed is the fissure, *i*, (fissura Sylvii,) which marks the separation between the anterior and middle lobes, and lodges the middle artery of the brain. It inclines from within outwards and upwards, and gradually terminates amongst the convolutions on the exterior of the hemisphere, its direction corresponding with that of the small wing of the sphenoid bone. At its internal termination it forms a right angle with another fissure, which extends from before backwards, and which is bounded externally by the middle lobe, internally by the crus cerebri and tractus opticus, and deserves notice because it transmits the pia mater from the external surface into the lateral ventricle.

The angular part of the anterior lobe, which is included between the internal termination of the fissure of Sylvius, the longitudinal fissure, and the commissure of the optic nerves, has been named by Vicq-d'Azyr *substantia perforata antica*, *m*, and by Reil *lamina cribrosa*, because it presents several foramina for the transmission of vessels. It deserves attention, inasmuch as the white lines seen at its inner border are continuous with those of the corpus callosum.

869. *Optic commissure*, *n*.—Between the fissuræ Sylvii, and corresponding with the interval between their internal terminations, is situated the *commissure of the optic nerves*. It is flat and quadrilateral in its form: one surface looks upwards to the brain, and is connected with the anterior termination of the

corpus callosum, which passes upon it in the form of a thin semi-transparent lamella; the other surface rests upon the depressed part of the sphenoid bone, which lies before the pituitary fossa; the lateral and anterior margins are free, but the posterior one is intimately connected with a delicate stratum of gray matter, which is inserted between the nerves as they converge to their commissure.

870. *Tuber cinereum.*—The piece of gray matter just referred to is called by Sœmmering *tuber cinereum*, figs. 151, 152, *o:* it extends from the posterior margin of the optic commissure to the corpora albicantia, gradually becoming a little thicker and firmer; for in front it is so thin as to be torn by the slightest touch. Its superior surface forms part of the floor of the third ventricle; the inferior one is slightly convex, and gives attachment by its centre to a funnel-shaped process, called *infundibulum* (tige pituitaire). This is a thin elongated process of reddish gray matter, inclined obliquely downwards and forwards from the tuber cinereum to the pituitary gland: its extremities are slightly expanded, and its centre constricted, which gives it an hour-glass shape.

871. *Pituitary gland* or *body*, fig. 152, *q.*—The pituitary gland appears to have received its name from its being supposed, in the infancy of anatomy, to communicate with the nose, and to secrete the viscid mucus (pituita) of that cavity; it is lodged in the excavation in the upper surface of the body of the sphenoid bone, and is unequally divided into two portions or lobes: the anterior, which is larger and more firm than the other, is convex in front, and concave behind, so as to receive the other, whose border is round and convex. The situation of the pituitary gland is peculiar: it is interposed between the two lamellæ of the fibro-serous membrane. The dura mater will be found to line the surface of the bone on which the gland rests; but the arachnoid membrane, after having formed a funnel-shaped process round the infundibulum, is reflected off from it at its lower extremity, and stretched across the upper surface of the gland until it reaches the clinoid processes, where it becomes continuous with the inner lamella of the fibro-serous membrane. When cut into thin slices, it appears to consist of two substances, one being reddish gray, the other white.

872. *Mammillary bodies.* — Immediately behind the tuber cinereum are placed two small bodies, called corpora mammillaria, figs. 151, 152, *p* (albicantia, pisiformia). Their size is about that of a pea, but they are not quite round, being slightly compressed on three sides. Placed in apposition with one another, they are connected by a delicate process of gray matter, of which substance the greater part of their mass consists; they are, however, invested by a lamella of white matter, derived from the anterior pillars of the fornix, of which they may be regarded as the termination.

Behind the mammillary bodies is situated a thin lamella of white substance, which is pierced by a number of foramina, for the transmission of vessels, and called *locus perforatus*, *q*, and sometimes *pons Tarini*. Its shape is triangular, the sides being formed by the crura cerebri, the base by the mammillary bodies, the apex being at the border of the pons Varolii; it forms part of the floor of the third ventricle.

873. The *crura cerebri*, *r*, are two thick rounded bodies, about three-fourths of an inch long, and situated towards the centre of the base of the brain, from which they project rather prominently. They are extended from the pons Varolii forwards and upwards to the under surface of the hemispheres, into which they seem as if inserted. They are nearly in contact behind, but diverge as they pass forwards, so as to leave an interval, which is occupied by the locus perforatus. The external surface of the crura consists of white matter, which is about two lines thick, and presents a distinctly fibrous character; within this is enclosed a quantity of gray substance, so dark as to have received the name of *locus niger*. The arrangement of these structures can be readily seen by making a transverse section of the crus: the dark part is found to be convex inferiorly, and concave above, so that the section of it presents a lunated form. The optic nerves rest upon the external surface of the crura as they pass forwards to their commissure.

874. The *great Commissure — corpus callosum*, fig. 152, *b*. —All the parts of the brain hitherto noticed can be examined without any division of its texture, as they are placed superficially; but several are enclosed within its interior, which cannot be seen without dissection. Between the hemispheres, and extending transversely from one to the other, is placed the *cor-*

pus callosum (mesolobe, commissura magna cerebri); its form is that of a broad layer of white fibres placed horizontally, but nearer to the anterior than to the posterior margin of the brain. Its extent from before backwards is about three inches, but its breadth from side to side cannot be assigned, as it becomes blended with the substance of the hemispheres. Its superior surface is convex in its general outline, and concealed by the hemispheres which overlap it. When these are removed, a superficial linear impression will be perceived exactly in the middle line, and at each side of it a slight longitudinal elevation. To this the term raphé, or suture, is applied, as it indicates the point at which the union of the hemispheres takes place when their developement is being completed. The fibres obviously are transverse from without inwards, for they commence at the circumference of the hemispheres, and terminate by their junction along the raphé. The inferior surface of the corpus callosum forms the roof of the lateral ventricles on each side, and towards the middle line it rests on the fornix, with which it is blended posteriorly: in front it gives attachment to the septum lucidum. Its anterior extremity, *c*, which, when viewed externally, presents a rounded border, is prolonged downwards and backwards to the base of the brain, where it forms a thin semitransparent lamella. This reflected part is nearly horizontal in its direction, so that it lies beneath the corpora striata, and above the commissure of the optic nerves, to which it adheres, but still passes backwards, and becomes continuous with the tuber cinereum in the middle line, whilst at each side its margins are blended with the substantia perforata. The posterior border, *d*, of the corpus callosum is thick and rounded at the middle line, its thickness being greater (as may be seen when it is cut through perpendicularly) than that of the anterior border, owing to its receiving a greater number of converging fibres from the posterior lobes. A little more externally, the border of the corpus callosum gives off at each side two fasciculi of fibres, which can be traced, one into the posterior, the other into the descending cornu of the ventricle; one of these forms the medullary investment of the hippocampus minor, the other that of the hippocampus major.

875. *Lateral ventricles*, fig. 153 (ventriculi tricornes).—Beneath the corpus callosum are situated the lateral ventricles,

occupying the interior of the hemispheres. Their shape is very irregular, and can scarcely be said to bear a resemblance to any known figure. Each of them may be considered as divisible into a body or central portion, and three cornua or diverticula, which pass away in different directions. The central part lies horizontally: one cornu extends forwards from it into the anterior lobe, another backwards into the posterior, and the third downwards into the middle one; each of these presents certain peculiarities referable to the parts seen within them, which deserve notice. In the central part will be observed the corpus striatum, and thalamus nervi optici, and between them the tænia semi-circularis; also the margin of the fornix, and part of the plexus choroides. These objects are for the present merely enumerated; each of them shall be noticed separately.

876. *Septum inter ventriculos.*—Previously to describing the objects just named, it may be observed that the lateral ventricles are separated by a partition (*septum lucidum*), fig. 153, *a*, fig. 152, *n*, which extends from the corpus callosum perpendicularly down to its reflected lamella in front, and to the fornix behind; it is round and broad before, but becomes narrowed to a point posteriorly. It consists of two thin lamellæ of white substance, between which is a fissure, or interval, called the *fifth ventricle.*

877. *Fornix.*—Beneath the corpus callosum and septum lucidum is a triangular lamella of white matter, which is extended from behind forwards over the third ventricle, and is thence termed *fornix*, fig. 153, *b*, *b*; fig. 152, *e*. Its upper surface gives attachment to part of the septum lucidum, and posteriorly becomes united with the corpus callosum; the inferior one overlays the third ventricle and the thalami nervorum opticorum, but is separated from them by the velum interpositum. Some oblique lines are traced on this surface, on which account it has been termed *lyra*, or *corpus psalloides.* The anterior extremity of the fornix is narrow, and divides into two fasciculi, fig. 153, *c*; fig. 152, *f*; fig. 154, *a*, (*pillars of the fornix*,) which curve downwards at the fore part of the third ventricle, immediately behind the anterior commissure, and terminate at the base of the brain by investing the corpora mammillaria. The base or posterior extremity of the fornix gives off at each angle a thin flat process, which passes into the

descending cornu of the ventricle, and assumes the name of *corpus fimbriatum.*

878. The *anterior cornu* of each ventricle, fig. 153, *d*, inclines forwards and outwards, diverging from its fellow of the opposite side; the corpus striatum (its fore part) projects a little into its floor: the remainder of it resembles a groove in the cerebral substance. The *posterior cornu*, *e*, called the *digital cavity*, converges towards that of the opposite side, and presents in its floor the *hippocampus minor*, *f* (calcar, unguis). This is a slight elevation, composed of a lamella of white matter (continuous with, or derived from, the corpus callosum), enclosing some cineritious substance; it gradually tapers to a point, and reaches to within an inch of the posterior extremity of the hemisphere.

879. The *inferior* or *descending cornu*, *g*, passes at first backwards and outwards from the body of the ventricle; but, after descending a little, it changes its direction altogether, and proceeds forwards and inwards, to terminate at the base of the brain, within a few lines of the fissure of Sylvius. This is the largest of the cornua; its convexity looks outwards and backwards, its concavity in the opposite direction; the under surface of the thalamus forms its roof, and the plexus choroides rests loosely on its floor, concealing the hippocampus major and corpus fimbriatum.

The *hippocampus major*, *h*, (cornu ammonis,) resembles in shape a cerebral convolution; it is curved so that its convex border looks outwards, and the concave inwards, conforming with the direction of the cavity in which it lies. Its anterior extremity expands somewhat, and presents two or three, and sometimes as many as five small prominences, separated by slight depressions, which make it to resemble somewhat the back of the hand when shut close. Some of the older anatomists called it *pes hippocampi*, from its resemblance to the clubbed foot of some of the lower animals. External to the part where the cornu makes its curve forwards, a slight elevation is observed, which is called *pes accessorius.*

Corpus fimbriatum.—Along the inner border of the cornu is a narrow falciform process of white substance (corpus fimbriatum), which is adherent by one edge to the floor of the cornu. It gradually becomes narrow, and ends in a point a little behind

the pes hippocampi. Near the inner border of the corpus fimbriatum a narrow line of cineritious substance (*fascia dentata*) is placed ; it is not perceptible until the middle lobe, together with the inferior cornu of the ventricle, is drawn outwards, as it is excluded from the cavity of the cornu by the reflection of the arachnoid membrane ; its free border is marked by several transverse notches, giving it a dentated appearance, from which its name is derived.

The cornu ammonis consists externally of a lamella of white substance, which, if traced upwards into the body of the ventricle, will be found continuous with the corpus callosum. The corpus fimbriatum, in like manner, will be found continuous with the fornix.

880. The *corpora striata*, fig. 153, *i*, fig. 154, *b*, (ganglions cérébraux supérieurs, Gall,) are two in number, situated one in the body of each lateral ventricle. Each of these bodies is pyriform in its shape, the larger extremity being turned forwards and inwards, the smaller backwards and outwards. The superior surface is smooth and slightly prominent in the cavity, all the rest being embedded in the substance of the hemisphere. Their position is so oblique, that though in front they are separated by not more than three or four lines, their posterior extremities are from an inch and a half to two inches apart, the interval being occupied by the optic thalami and the third ventricle. Their external surface is composed of gray substance, but internally the gray and white are intermingled, so as to produce a striated appearance, whence the name is derived. The white fibres here found are continuous with those of the anterior pyramids and of the crura cerebri. They spread out considerably as they pass through the mass of gray matter of which the corpora striata consist, and appear to be at the same time enlarged and increased. Hence these bodies are considered by Dr. Gall to be ganglia of increase placed in the course of the fibres which are diverging to form the cerebral hemispheres.

881. The *optic thalami*, fig. 153, *k* ; fig. 154, *c*, (thalami nervorum opticorum, ganglions cérébraux postérieurs, Gall,) are placed behind and between the corpora striata. The upper surface of each projects into the body of the corresponding ventricle ; the inferior one forms the roof of its descending cornu, and the external is blended with the corpus striatum and the sub-

stance of the hemisphere. The internal surface of each thalamus, which is contiguous to that of the opposite side, is united to it by a soft lamella of gray substance called the *soft commissure*, fig. 152, *i* (commissura mollis). The union, however, may be called partial, for before and behind the commissure a small interval exists, where the thalami are unconnected, being merely in apposition.

Corpora genicula.—On the posterior border of each thalamus are observed two slightly raised papillæ (*corpus geniculatum internum et externum*), which are connected by medullary striæ to the tubercula quadrigemina, the external one being also united to the origin of the optic nerve.

Tænia semi-circularis, fig. 153, *l*.—The contiguous borders of the optic thalamus and corpus striatum are separated by a thin fasciculus of nervous matter, of a pale straw colour (tænia semicircularis), commencing near the anterior pillar of the fornix; it extends from before backwards between the bodies just named, and can be traced as far as the posterior border of the thalamus, and for a little way into the roof of the descending cornu, where it seems to cease.

882. *Pineal gland and its peduncles.*—Along the inner margins of the thalami two delicate white fasciculi arise, and pass backwards, converging to the pineal gland, whose *peduncles*, fig. 152, *g*, they form, and at the same time constitute its only bond of connexion with the substance of the brain. The pineal gland is a small mass of gray substance of a conical shape, and is sometimes called *conarium*, *h*, occasionally also *acervulus*. Its base rests on the tubercula quadrigemina; it usually contains in its interior some sabulous matter; at its first formation it consists of two masses, which unite into one.

883. The *third ventricle.*—The optic thalami enclose between them a narrow cavity (*third ventricle*), fig. 154, *d*, which corresponds exactly with the middle line, and resembles a longitudinal fissure. Its sides are formed by the thalami, its floor by the locus perforatus and tuber cinereum; the velum interpositum and fornix cover it in. The anterior commissure, and the pillars of the fornix, bound it in front. Into this cavity leads an aperture, fig. 152, *j*, (*foramen commune anterius*, *foramen Monroi*), which is a rima between the anterior pillars of the fornix and the thalami, and which establishes a communication

between the third and the lateral ventricles; a foramen leads out of it downwards and forwards (*iter ad infundibulum*). It may be observed that the infundibulum becomes imperforate at its middle, which appears to be owing to a small cul-de-sac of arachnoid membrane which is prolonged into it. From the posterior extremity of the ventricle another foramen opens into a canal (*iter à tertio ad quartum ventriculum; aquæductus Sylvii*, fig. 152, *k*; fig. 154, *h*), which leads obliquely downwards and backwards into the fourth ventricle.

884. *Commissures, anterior and posterior.*—Two cord-like fasciculi are stretched across the extremities of the third ventricle, and prolonged into the hemispheres which they connect, serving as commissures. The *anterior commissure*, fig. 152, *l*, lies just before the pillars of the fornix, and as it extends laterally it will be found embedded in the substance of the corpora striata at each side, but does not become blended with them; its extremities arch backwards a considerable way, so as to form a curve whose convexity looks forwards. The *posterior commissure*, fig. 152, *m*; fig. 154, *e*, is much shorter than the preceding, and extends but a few lines on each side into the thalami: it lies behind the ventricle, before the tubercula quadrigemina, and above the aqueduct of Sylvius.

THE CEREBELLUM.

885. The second division of the central mass of the nervous system is the cerebellum, which differs in situation and size, as well as in the arrangement of its component parts, from the cerebrum. It is lodged in the recess formed between the tentorium cerebelli and the inferior occipital fossæ, its weight as compared with that of the brain being as 1 to 16 in the infant and as 1 to 8 in the adult. Its surface, instead of convolutions, is divided into a number of concentric lamellæ (*folia cerebelli*), placed perpendicularly on their edges, and enclosed one within the other. If, however, the sulci between them be opened, several other lamellæ will be found enclosed within them, but smaller, more irregular, and with various degrees of inclination.

Lobes.—The cerebellum is divided into two lateral lobes, fig. 151, *s s*, the division being established behind by a fissure,

which receives the falx cerebelli, and in front by a deep excavation, which lodges the medulla oblongata.

Superior vermiform process.—The superior surface of the cerebellum is slightly depressed on each side where the tentorium rests upon it, but along the middle line a rounded ridge (processus vermiformis superior) runs from before backwards, and seems as if produced by the rippling up or admixture of the lamellæ of the lobes as they extend from without inwards. There appear to be from sixty to seventy lamellæ on the upper surface of the cerebellum, which are aggregated into five fasciculi.

Inferior vermiform process, fig. 151, *t*.—The inferior surface is convex, and dips down into the occipital fossæ; along the middle line runs the *inferior vermiform process*, interposed between the lateral lobes; it resembles a lobule formed of short transverse plates; its anterior extremity has been compared to a mammillary process.

The mass of medullary matter enclosed within the cerebellum is connected with three pairs of medullary fasciculi; viz. processus è cerebello ad testes, corpora restiformia, and crura cerebelli, which require a detailed notice.

886. *Processus è cerebello ad testes*, fig. 154, *f f*. — From the interior of the lobes, two fasciculi of white fibres pass forwards and upwards to the lower pair of the tubercula quadrigemina; the name given to them indicates the points between which they lie; they converge in their ascent, and are connected by a semi-transparent medullary lamella, named the valve of Vieussens. The valve, fig. 152, *r*, (*valvula Vieusseni*,) presents on its upper surface a slight groove, running from above downwards, and sometimes a linear ridge, like a raphé; it overhangs the fourth ventricle.

Posterior pyramids, fig. 151, *e*, fig. 154, *g g* (corpora restiformia, pyramides postérieures).—Two white rounded processes pass obliquely upwards and outwards from the medulla oblongata into the cerebellum, named by Ridley "restiform" bodies, by Gall "posterior pyramids;" we have already noticed them as part of the medulla oblongata.

Peduncles of the cerebellum, fig. 151, *u* (crura cerebelli).—These are the largest of the fasciculi here referred to; they are at first concealed within the lobes, and even when about to

emerge from their substance, they are overlapped by some minor lobules. They incline forwards and inwards, descending somewhat, and become continuous with the fibres of the pons Varolii, which are thus divided from the crura cerebelli. The pons, from its mode of formation, bears the same relation to the cerebellum that the corpus callosum does to the cerebrum, as it is composed of converging fibres, and may therefore be called a commissure.

887. *Fourth ventricle*, fig. 154, *i*, fig. 152, *s*.—The cerebellum encloses a cavity called the "fourth ventricle," the roof of which is formed by the valve of Vieussens and processus ad testes, the sides by the lobes of the cerebellum; the dorsal surface of the medulla oblongata forms its floor, and it is completed inferiorly by a reflection of the arachnoid membrane: a process of pia mater projects into it at this situation, called *plexus choroides minor*.

Corpus dentatum.—If a vertical section be made of one of the lobes of the cerebellum, in such a way as that two-thirds of its breadth shall lie external to the incision, an oval nucleus of gray substance (corpus dentatum, vel rhomboideum, fig. 154, *m m*,) will be exposed: its texture is usually firm, and its border notched, so as to give it a dentated appearance. Gall considers it as a ganglion of increase to the formative fibres of the cerebellum. The surface of the section here indicated presents rather a peculiar appearance: the white substance will be found so disposed as to represent the stalk and branches of a tree, hence called *arbor vitæ*, fig. 152, *t*. The branches project into the lamellæ of the cerebellum, which are not unfrequently in figurative phrase termed *folia*, for the gray substance invests them so as to make them resemble pinnatifid leaves. If a horizontal section be made, so as to divide the lobe into two equal parts, the quantity of white substance will appear considerably greater than that of the gray.

CEREBRAL PROTUBERANCE.

888. The *cerebral protuberance*, fig. 151, *v*, (nodus cerebri, pons Varolii, protuberantia annularis,) is much the smallest portion of the central mass; its relative size being to that of the rest as 1 to 72. It is placed beneath the cerebrum, above the

medulla oblongata, and before the cerebellum, having intimate relations with each by continuity of substance; hence it has been termed *nodus encephali*. It is a square mass, its depth being about equal to its length. Its anterior surface is convex, and rests against the basilar process of the occipital bone, and is composed of the converging fibres of the cerebellum, disposed so as to form a portion of a ring, which encloses the contiguous extremities of the crura cerebri and medulla oblongata; — it is termed *protuberantia annularis*, or *pons Varolii*. Its upper border is bounded by a transverse line, marking its separation from the crura cerebri, and the lower by another line, which divides it from the medulla oblongata; along its middle is a shallow groove, running from above downwards, which corresponds with the basilar artery.

Tubercula quadrigemina, fig. 152, *u*, fig. 154, *n*, *n*.—Upon the posterior surface of the cerebral protuberance, which is almost entirely concealed by the cerebellum, are placed four white rounded bodies (tubercula, vel corpora quadrigemina), disposed in pairs, one above the other, and separated by two decussating lines. The upper pair are the larger, and called *nates*—the lower, *testes:* they are connected in front with the thalami, inferiorly with the processus ad testes and the valve of Vieussens, and between their upper surface and the corpus callosum is a rima or fissure (*fissure of Bichât*), through which the arachnoid membrane enters to line the ventricles.

889. *Communication between the ventricles of the brain.*—The irregular vacuities disposed in the interior of the cerebellum and brain communicate freely with one another by certain constricted portions, or foramina. If, whilst the brain and cerebellum remain *in situ*, the latter be divided by a vertical incision made from the valve of Vieussens downwards through its substance, the fourth ventricle will be exposed. This cavity contracts towards its upper part into a tube (aqueduct of Sylvius), which is directed upwards and forwards, under the tubercula quadrigemina and the posterior commissure, into the middle or third ventricle. The latter again communicates at each side with the lateral ventricles by a rima (*foramen Monroi*), situated between the pillars of the fornix and the thalami, on which they rest. When the ventricles have been distended with fluid, this rima assumes a rounded form, and then only represents a fora-

men. These vacuities, then, should be considered not as so many separate cavities, but as a series of compartments of one cavity contained within the cerebral mass; and this is the appearance they present during the earlier periods of fœtal life. The cavity, however, is not a shut sac, for the membrane which lines it is continuous with that which invests the external surface of the brain and cerebellum. It has been already stated, that the arachnoid membrane passes in through the fissure of Bichât. Two other fissures are situated, one on each side between the corpus fimbriatum and the crus cerebri, through which the pia mater enters, to form the plexus choroides. These may be considered as chinks between the portions of cerebral substance just referred to; but they are closed up by the manner in which the arachnoid membrane is reflected from the sides of the cornua of the ventricles upon the plexus choroides.

890. *Structure of the brain.*—The cerebral hemispheres are considered by Gall as resulting from an expansion or evolution of the fibres of the medulla oblongata, which he therefore terms primitive, or formative fasciculi.

891. *Diverging fibres.*—The fibres of the anterior pyramids, fig. 152, may be traced upwards to the margin of the pons, where they become somewhat constricted. By drawiug the pyramids apart from one another, about eight or ten lines below the pons, it will be seen, as indicated in fig. 151, *c*, that from the inner border of each, some fibres pass across the middle sulcus, and mutually change place, or decussate; those of the right side passing to the left, and *vice versâ*. If an incision, a line or two in depth, be made through the pons, so that one lateral half of it may be turned outwards, the fibres of the pyramid will be observed to pass into a quantity of gray substance lodged in the interior of the nodus encephali. In this situation the fibres diverge and separate, fig. 152, *w*, and are also considerably increased: at the upper margin of the pons they become continuous with the superficial fibres of the crus cerebri, *x*. Here an additional increase is derived from their passage through the gray substance lodged in the interior of the crus, after which they proceed through the inferior cerebral ganglion (*thalamus nervi optici*), and in the next place through the superior one (*corpus striatum*), being successively increased and rendered still more divergent, until finally they reach the anterior and

middle lobes, where they are evolved into their inferior, external, and anterior convolutions. The corpus olivare contains within itself a small ganglion; its fibres pass, without any decussation, into the gray substance lodged in the cerebral protuberance, where, like the pyramids, they receive additions, after which they pass into the crus cerebri, of which they form the posterior and inner part. Continuing their ascent, after being increased in the locus niger, they pass through the optic thalamus, and thence into the corpus striatum, receiving additions as they radiate through each, and finally are continued upwards into the convolutions at the summit of the hemisphere, and backwards into those of the posterior lobe. Previously to entering the optic thalamus, some fibres of the corpus olivare have been observed to turn inwards, so as to give to the tubercula quadrigemina their medullary investment, and also to unite with those of the opposite side, to form the valve of Vieussens. Finally, the diverging fibres traced up, as has been pointed out, through their successive steps of increase and expansion, terminate in the gray substance of the cerebral convolutions.

The fibres thus traced from the pyramids to the convolutions of the brain, may be termed the "cerebral fibres" of the anterior columns (Solly); taken in their whole extent, they constitute the tractus motorius (Bell). But, besides these, there are other fibres which pass from the pyramids in a different direction to reach the cerebellum. Of these Mr. Solly, in his treatise on the Brain, describes two sets; one superficial, one deep. The superficial fibres cross the surface of the cord in two sets, one immediately below the corpus olivare, and may be seen without dissection, particularly in the sheep, ox, and horse; they form a very thin layer emanating from the pyramid at each side. The other "run to the inner side of the corpus olivare," form the outer part of the restiform body, and with it reach the cerebellum. "The deep set of fibres from the antero-lateral columns to the cerebellum are the most posterior of the whole mass of fibres composing this portion of the spinal cord. They are separated from the posterior columns by the fissure from which the posterior roots of the spinal nerves emerge; this fissure they cross in their passage to the cerebellum, obliterating it entirely. The two first correspond with those described by Rolando as the curved or arched filaments."

892. *Converging fibres.*—Another order of fibres may be observed quite distinct from those above noticed, and taking a different direction. These are called the "converging fibres," as they commence at the peripheral terminations of the preceding set, and pass from without inwards to the middle line, so as to connect the lateral parts, and bring them into relation with one another; on which account they are called commissures. The anterior and posterior commissures are formed in this way, as is also the corpus callosum; though the greater number of the fibres which compose the latter are transverse, those towards its extremities are oblique. This is owing to the manner in which the converging fibres of the anterior lobe are constrained to pass from before backwards, and those of the posterior lobe from behind forwards, in order to gain the corresponding borders of the corpus callosum. By this arrangement a greater number of fibres is collected to its extremities, which renders them thicker (particularly the posterior one) than any other part of its extent. Some of the inferior fibres thus traced from without inwards, instead of uniting with the corresponding set along the middle line, become reflected downwards from the under surface of the corpus callosum to the fornix, and so form the septum lucidum. The convolutions of the posterior lobe are brought into relation with those of the middle one by means of the fornix, the fibres of which are stretched from behind forwards, in such a way, that whilst its body is in a manner unattached, the extremities are identified with the parts just referred to.

893. *Diverging fibres of the cerebellum.*—The formative fibres of the cerebellum are derived from the posterior pyramids, or corpora restiformia; they pass upwards and outwards, and soon meet the corpus rhomboideum, which is considered as the ganglion of the cerebellum: the fibres are supposed to proceed through the gray substance of which it is composed, though it is difficult to demonstrate the fact; after which they pass outwards, diverging into the lobes of the cerebellum.

Converging fibres. — From the peripheral terminations of the diverging fibres in the folia, a new set arise, which incline inwards towards the middle line. These are the converging fibres, which, by their union, form the crura cerebelli; and the fibres of each crus, expanding as they pass downwards and inwards, constitute by their junction the pons Varolii, which

brings the lateral lobes of the cerebellum into relation, and becomes thereby their commissure. The processus à cerebello ad testes bring the lobes of the cerebellum into intimate connexion with the cerebral hemispheres.

The weight of the brain in the adult is about three pounds; that of the cerebellum about four ounces and a half, and of the medulla oblongata half an ounce.

Vessels.—The brain is supplied with blood by the two internal carotid arteries, and the two vertebral; its residual blood is returned by the two internal jugular veins.

OF THE CEREBRAL NERVES.

OLFACTORY NERVE.

894. *Nervus olfactorius* (par primum), figs. 151, 152, 155, 1. — The olfactory, or, as it is frequently called, the first pair of nerves, lies in a longitudinal groove marked on the under surface of the anterior lobe of the brain, about half an inch exterior to the median fissure; when undisturbed it appears flat, but is really triangular in form, the upper angle being lodged in the groove just alluded to. The nerve is soft in its texture, not being invested by a membranous tube or neurilema; but the arachnoid membrane is stretched across its inferior surface, and so retains it *in situ*. The nerve arises by three roots, two of which are medullary, the third or intermediate one being cineritious. The external root, 2, is the longest, and may be traced in the form of a white line obliquely outwards along the border of the fissure of Sylvius, where it corresponds with the last convolution of the anterior lobe of the brain. The internal root, 3, shorter and broader than the preceding, arises, at the inner termination of the fissure of Sylvius, from the substantia perforata. By turning down the nerve from the groove in which it is lodged, we see the third origin, which is a delicate line of gray matter, derived from a papilla, 4, or slight bulb (bulb of origin), at the posterior extremity of the sulcus, or groove, just referred to. The first and second roots converge to the third, and the nerve thus formed passes forwards by the side of the crista galli, where it expands into an elongated bulb, 5, (*bulbus olfactorius,*) or *ethmoidalis*, from its situa-

tion. From the under surface of this structure numerous filaments, 6, descend through the cribriform lamella of the ethmoid bone, each of which is invested by a tubular prolongation of the dura mater, and also by one from the arachnoid membrane, which latter, after descending a little way, re-ascends, and becomes continuous with the serous lining of the dura mater. The filaments of the olfactory nerve are arranged into three sets: the internal set are lodged for a while in grooves upon the surface of the septum nasi, but soon ramify in the pituitary membrane; the external set descend upon the two superior turbinated bones, and upon the plain surface before them; but the middle ones are short, and confined to the roof of the nares. We speak of the "origin" of this nerve from the brain, and we indicate its "roots" as if it commenced there and terminated in the nose. But all that we know of its developement and of its function shows the reverse to be the fact. As it is a nerve of simple sensation, and as impressions are conveyed by it in one direction only, viz. from without inwards, it would be better to consider the so-called roots as its points of attachment and connexion with the brain.

Fig. 155.

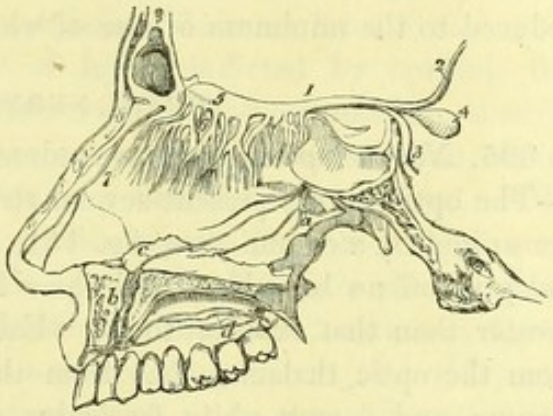

Though the whole of this tract is considered a nerve, the term in strictness applies only to the filaments which pass down into the nose from the bulb; the rest, or cranial part, appearing to be a prolongation of the cerebral substance itself,—of the gray as well as the white, which does not occur in the nerves. In fishes it obviously is a prolongation from the olfactory lobe —a continuation of its proper substance, and even in some cases the two olfactory nerves are connected by a transverse fasciculus like a commissure. It was usual to say that the external root of the nerve was connected with the under surface of the corpus striatum; but no relation exists between this body and

the nerve.* For though the latter is fairly developed in reptiles, the former is atrophied; and again, the corpus striatum exists in cetaceous mammalia, though, according to Cuvier, the olfactory nerve does not exist in them,—or, at all events, is reduced to the minimum of size of which it is capable.

OPTIC NERVE.

895. *Nervus opticus* (par secundum), fig. 151, 2, fig. 152, 2. —The optic nerves present several striking peculiarities. They are united by a commissure, fig. 151, *n*, are of considerable size, but give off no branches; and their length within the skull is greater than that exterior to it. Each optic nerve arises not from the optic thalamus, but from the corpus geniculatum externum, and from a white fasciculus sent downwards from the nates, or rather these are the points by which it is attached to the cerebral substance, and to which it conveys its impressions. The nerve, at first soft and flat, rests on the crus cerebri, and passes forwards, converging to its fellow of the opposite side, with which it unites before the pituitary fossa, and between the anterior clinoid processes. From the commissure each of the nerves proceeds forwards and outwards through the foramen opticum, where it is surrounded by the recti muscles; and having reached the posterior surface of the globe of the eye, pierces the sclerotic coat, after which it passes through the choroid, and finally becomes continuous with the retina.

The Optic commissure: its structure.—A considerable difference of opinion exists concerning the disposition of the fibrillæ of the optic nerves at their commissure. Some of the earlier anatomists supposed that they were merely applied one to the other, without any actual admixture of their substance; this opinion has now no supporters. Several physiologists are of opinion that a decussation between the nerves of opposite sides takes place, the fibres of that on the right side passing to the left, and *vice versâ*. Others, on the contrary, contend that the decussation, or crossing, exists only to a certain extent, being confined to the fibres on the inner side of each nerve, the rest passing on uninterruptedly. The anatomical examination of the fibrillæ, after the nerves have been macerated in dilute nitric acid, seems to indicate that those on the external border of each

* Serres, vol. i. p. 290.

of them proceed forwards without admixture, but that several pass obliquely inwards through the commissure, and afterwards form part of the fibres which proceed to the eye of the opposite side; this at least is the result of Caldani's observations. Little account can be made of conclusions deduced from experiments on animals; the quantity of injury inflicted by opening the skull, in order to divide the nerves or their commissure, is sufficient to confound all the sensations of the animal, and render any inferences nugatory that may be drawn from them. Observations on the morbid conditions of the nerves have been adduced in support of both opinions; thus, in a case in which the right eye had been destroyed, the optic nerve was found altered and wasted back to the commissure on that side, and thence to the brain at the opposite side; thus supporting the theory of decussation. Some cases have also occurred, in which blindness of one eye was traced to a morbid alteration of the nerve of the opposite side, at its origin from the brain. Some other instances, however, would go to prove that the decussation is only partial. In one instance in which the eye had been destroyed, and its nerve altered in texture for some way, it was found that the external fibres of the diseased nerve could be traced from the commissure directly backwards to the brain at the same side, so could the external fibres of the sound nerve; thus showing that no decussation took place between them; but the internal fibres of the diseased nerve could be traced obliquely through the commissure, and also backwards along the inner side of the opposite nerve to its origin, whilst the inner fibres of the sound nerve seemed, but not so distinctly, to cross also to the opposite side. Each of these opposing opinions, then, is borne out by the observations to a certain extent; so that the advocates of them are not warranted in concluding that either is universally true. Professor Meckel supposes that the anterior or orbital parts of the nerves issue from a common point (the commissure), produced by a union of the fibres which are prolonged from the brain, and that the mode of union is not quite identical in all cases, for that, in the different other structures which are joined along the middle line, varieties in the manner and degree of their union are constantly observed to occur.

Otto* remarks, that in cyclopic monsters, and in hemicephalic

* South's edition, p. 448.

cases, the optic nerves have been seen to run apart and without a commissure; and that in dropsy of the brain, the commissure has been observed torn asunder, and, instead of crossing, only connected by a transverse portion of nerve.

AUDITORY NERVE.

896. *Nervus auditorius*, fig. 151, 7, *y* (portio mollis paris septimi).—The auditory nerve is usually, since the time of Willis, called "the soft portion" of the seventh cerebral nerve. The use of such a name confounds all distinctions of structure, function, place of origin, and mode of termination; in each of which particulars these nerves differ from one another. One of them is subservient to a special sense—that of hearing, and is susceptible of no impression except that of sound: the other is altogether a nerve of motion, and has little, if any, sensibility. The auditory nerve is nearly as soft as the olfactory; the facial is a firm cord, like the motor oculi nerve. Now, as to origin, the facial arises from the groove between the corpus olivare and pyramidale, and forms the first of a series, which are associated at their place of origin, and combine in some remarkable particulars of function; viz. the glosso-pharyngeal, pneumo-gastric, and spinal accessory nerves; with these the auditory nerve obviously has nothing to do; for, to give an abridged expression of its commencement and termination, it extends from the floor of the fourth ventricle to the meatus auditorius internus, through which it is conducted into the internal ear. In this course it is in apposition with the facial nerve, which lies internal and anterior to it, and even compresses its surface so as to mark it by a slight groove. But what is its proper origin? It has been usual for a long time (ever since Picholomini pointed out a connexion between it and certain white striæ or lines traced upon the posterior surface of the restiform bodies) to say that this nerve arises from the floor of the fourth ventricle, by some white fibres, fig. 154, *l*, which lie obliquely upon it. This sufficiently indicates the place; but as to the mode of the connexion, that is another question. Wenzel showed that the fibres of the auditory nerve are traceable to the "loculus cœruleus" in the floor of the fourth ventricle. Serres calls it "ruban gris" when much developed. The origin of the nerve seems to be from the gray matter here

noticed, from the white lines which represent the barbulæ of the calamus, and from the restiform body.

It may perhaps appear an unnecessary refinement to say, as M. Serres does, that though the nerve is connected to the points here indicated, it still does not arise from them; for that it is but substituting the word "insertion" for "origin," leaving the facts to stand as before. It is sufficiently known that this nerve, as well as all others, is produced and grows independently of the brain and cord; that they are deposited by their own nutrient vessels, each in its proper place, and that their progress is from without inwards; consequently they do not "arise" from the brain in the same sense as plants arise from their roots. Now, when the auditory nerve grows inwards and comes into contact with the side of the ventricle, it contracts a union with it, which may be called organic, as the two structures are intimately blended. The white lines are developed subsequently, and so also is the gray matter, the "ruban gris."

As the auditory nerve inclines outwards to gain the meatus internus, it is, as has been above stated, in close contact with the facial nerve, from which it is separated by a small arterial branch derived from the basilar, or anterior cerebelli artery that accompanies it into the meatus. Within the meatus it divides into two fasciculi, and these again into a number of filaments which pass through the foramina in the cribriform lamella of bone that closes the passage, and so proceed to their destination, the cochlea, vestibule, and semi-circular canals of the ear. The distribution of the nerve shall be indicated when treating of the anatomy of the ear.

THIRD CEREBRAL NERVE.

897. *Nervus motorius oculi*, fig. 151, 3, fig. 152, 3 (motores oculorum, par tertium).—This nerve, which is the third in order when they are counted from before backwards, arises from the inner border of the crus cerebri, about two lines anterior to the pons Varolii. This is only the point at which the nerve issues from the cerebral substance, and becomes invested by its neurilema and a tubular sheath of arachnoid membrane, for its fibrillæ can be traced backwards into the gray substance within the cerebral protuberance, if the pons Varolii be removed. The nerve passes forwards, and a little outwards,

to enter a canal appropriated to it in the dura mater, close by the posterior clinoid process, at which point its serous investment leaves it, and becomes continuous with that which lines the dura mater.

As the nerve proceeds forwards, it lies along the external wall of the cavernous sinus, being at first placed superior and internal to the fourth, the ophthalmic branch of the fifth and the sixth nerves; as it approaches the sphenoidal fissure, it descends so as to become inferior to the other nerves, and as it is about to penetrate into the orbit it receives one or two delicate filaments from the cavernous plexus of the sympathetic and one from the ophthalmic branch of the fifth nerve; it then divides into two branches, which separately pierce the dura mater, and enter the orbit by passing between the heads of the external rectus muscle. The superior or smaller branch ascends so as to get above the optic nerve, and gives one or two ramusculi to the superior rectus muscle, the other being prolonged to the levator palpebræ; the inferior or larger branch lies beneath, and to the outside of the optic nerve, where it divides into three branches, one of which passes obliquely inwards to the rectus internus muscle; another descends and is distributed to the rectus inferior, whilst the third, longer than either, passes forwards between the inferior and external recti muscles, and terminates in the obliquus inferior; these several nerves enter the muscles at the surface which looks towards the eye-ball. The branch last described gives off a filament, which enters the inferior and posterior angle of the lenticular ganglion.

FOURTH NERVE.

898. *Nervus trochlearis*, fig. 151, 4 (nervus patheticus, par quartum). This is called the fourth, though it does not range in line with the others. It is the smallest of the cerebral nerves: it arises by two, and sometimes by three filaments, from the valve of Vieussens, immediately beneath the tubercula quadrigemina. Each nerve passes forwards on the side of the cerebral protuberance on a level with the margin of the tentorium cerebelli, and enters an aperture in the dura mater, a little inferior and external to that of the third pair: by this it is conducted into the cavernous sinus, along whose external wall it runs towards the sphenoidal fissure, through which it enters

the orbit, at the same time passing above the third nerve. The nerve finally inclines upwards and inwards, mounting over the superior rectus muscle and the levator palpebræ, and divides into two or three filaments, which enter the superior oblique muscle at its orbital surface. Whilst the nerve lies along the external wall of the cavernous sinus a small filament passes off from it, and is reflected back in the tentorium cerebelli as far as the lateral sinus.

SIXTH NERVE.

899. *Nervus abducens*, fig. 151, 6 (par sextum). — This nerve arises, close by the central line, from the superior extremity of the corpus pyramidale, where it joins with the pons Varolii. From this point the nerve passes forwards and upwards, to enter the cavernous sinus, by a foramen in the dura mater, where it rests against the outer side of the carotid artery, and whilst so placed receives two or three filaments of communication from the superior cervical ganglion, or rather from the carotid plexus. The nerve passes thence forwards to the sphenoidal fissure, separated from the cavity of the cavernous sinus by its lining membrane; and on passing into the orbit runs between the two heads of the external rectus, to which it is distributed by two or three filaments, which pierce the ocular surface of the muscle.

NINTH NERVE.

900. *Nervus lingualis*, or the ninth pair of nerves (n. hypoglossus, par nonum). It arises by several delicate filaments, fig. 151, 9, placed in a continued series along the sulcus between the corpus pyramidale and olivare of each side. These filaments converge and unite as they pass forwards to the anterior condyloid foramen, through which the nerve they form makes its exit from the cranium. The nerve at first is deeply seated, lying posterior and internal to the sympathetic and vagus nerves, with both of which and the first cervical nerve it communicates; but it gradually comes forwards as it descends, and after passing between the carotid artery and jugular vein, becomes more superficial than either of the nerves just mentioned, and lies a little below the posterior belly of the digastricus muscle. The nerve, fig. 156, 1, now inclines forwards and inwards, parallel with

Fig. 156.

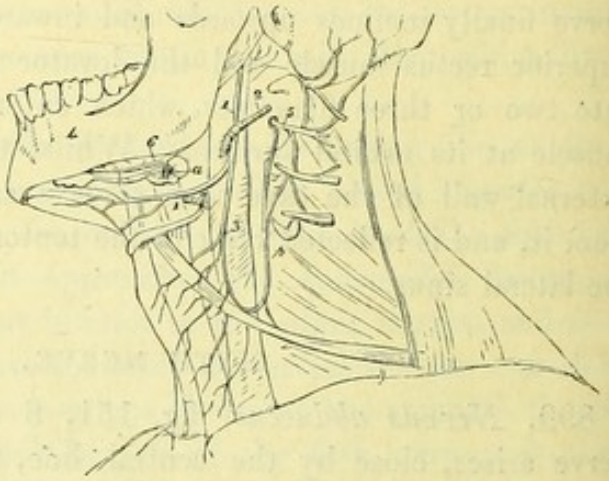

the cornu of the os hyoides, gets under cover of the mylo-hyoid muscle, and is separated from the lingual artery, 7, by the hyo-glossus muscle, at the inner border of which it ascends somewhat, and divides into several filaments, which are distributed to the genio-hyo-glossus and lingualis muscles.

Ramus descendens noni. — At the point where the nerve makes its turn forwards, it will be observed to hook round the occipital artery, 2, and then, where it crosses over the external carotid artery, to give off its chief branch, the *descendens noni*, 3, which inclines downwards and inwards in front of the sheath that encloses the carotid artery, and internal jugular vein, and at the middle of the neck curves outwards to form an inverted arch, by joining with two branches, 4, from the cervical plexus of nerves. The convexity of the arch looks downwards, and from it several long delicate filaments are given off, which descend upon the fore part of the neck, and are distributed to the sterno-hyoid and sterno-thyroid muscles, also to the omo-hyoideus. Previously to its ultimate division, the lingual nerve gives some filaments to the hyo-glossus muscle, and others to communicate with the gustatory nerve.

FACIAL NERVE.

901. *Nervus facialis* (portio dura paris septimi, sympatheticus minor).—The facial nerve, fig. 151, 7, *x*, arises from the sulcus between the corpora restiformia and olivaria, close by the lower margin of the pons Varolii, whence it passes forwards and outwards, closely applied to the portio mollis, which is slightly hollowed to receive it, whilst in the meatus it receives some filaments from the auditory nerve. (Cruveilhier.) Having reached the fundus of the meatus auditorius internus, the portio dura enters an osseous tube (*aqueduct of Fallopius*), through which it

is conducted, in a curved direction, outwards and backwards, to the stylo-mastoid foramen. After having passed about two lines into the tube just named, a small nerve (*Vidian*) becomes applied to its inferior surface, and accompanies it nearly to the point of its exit from the foramen above mentioned. The Vidian nerve there leaves it, and passes obliquely across the cavity of the tympanum, where it assumes the name of chorda tympani: its course and destination shall be particularly considered when treating of the gangliac system of nerves. While within its osseous canal, the facial nerve gives two small filaments, which enter the cavity of the tympanum, and are distributed to the tensor tympani and stapedius muscles; the former being given off at the commencement, the latter near the termination of this portion of its course.

After having issued from the stylo-mastoid foramen, the nerve, fig. 157, 1, sends off three small branches previously to its ultimate division.

Fig. 157.

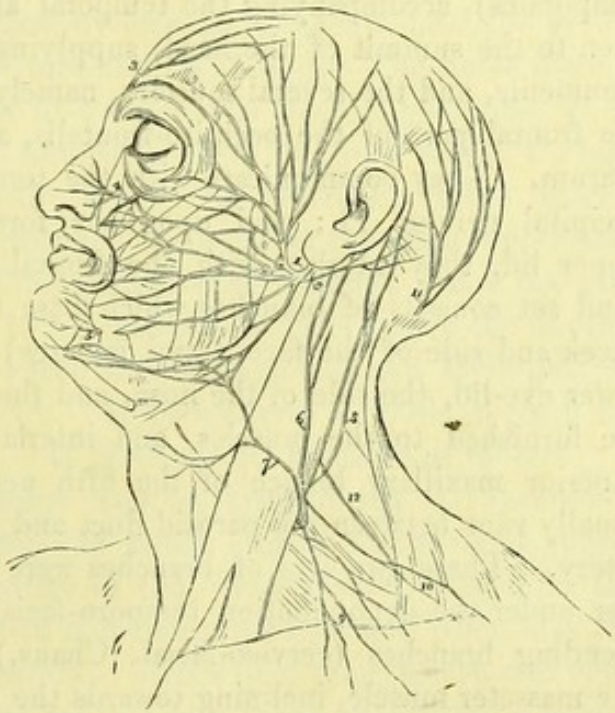

The *posterior auricular* branch, 2, (n. auricularis posterior,) inclines backwards and upwards in front of the mastoid process, and subdivides into two branches, one of which ramifies in the occipitalis muscle and the integuments, while the other gives twigs to the retrahens aurem muscle, to the pinna, and to the meatus externus. The *stylo-hyoid branch* (n. stylo-hyoideus) descends upon the stylo-hyoideus muscle, to which, and to the digastricus, it is partly distributed, the remainder of its filaments maintaining communication with the sympathetic nerve and the ascending branch of the cervical

plexus. The *digastric branch* (ramus digastricus) inclines outwards to the posterior belly of the digastric muscle, to which it distributes the greater number of its filaments, the remainder maintaining communications with the nerves emerging from the foramen lacerum, in front of the internal jugular vein.

The facial nerve, after giving off these branches, inclines forwards beneath the external meatus to the ramus of the inferior maxilla, lying deeply embedded in the substance of the parotid gland. Here it divides into two primary branches, which have been named from their destination temporo-facial and cervico-facial; sometimes as many as four, or even five, exist; these communicating one with another form a sort of plexus (plexus parotideus, pes anserinus), from which numerous branches are distributed to the temples, the face, and the neck. The branches from the plexus, formed as above, may be divided into three sets, differing in destination and direction.

The first ascend upon the zygoma in front of the ear (rami temporales), accompanying the temporal artery and its branches even to the summit of the head, supplying filaments to the integuments, and the several muscles, namely, those of the pinna, the frontal part of the occipito-frontalis, and orbicularis palpebrarum. They communicate with the terminal branches of the occipital nerves, 11; and upon the forehead, eyebrow, and upper lid, they interlace with the frontal nerves, 3. The second set consists of branches which pass transversely upon the cheek and side of the face (rami malares), ramifying upon the lower eye-lid, the side of the nose, and the lips, where filaments are furnished to the muscles, and interlace with those of the superior maxillary branch of the fifth nerve, 4: one of these usually runs between the parotid duct and the transversalis faciei artery. These two sets of branches were combined by Chaussier under the denomination temporo-facial. The third or descending branches (cervico-facial, Chaus.) run obliquely over the masseter muscle, inclining towards the base of the jaw-bone, beneath which some of them ramify in the platysma and the integuments, and communicate with the ascending branches, 7, of the cervical nerves; but others higher up are distributed in the depressor muscles of the lip, and maintain a similar connexion with the inferior maxillary branch, 5, of the fifth nerve, where it ramifies on the chin. Having stated the general plan,

according to which the distribution of the facial nerve takes place, it may be observed, that its filaments enter the substance of the muscles of the temple and eye-lids, those of the cheeks, lips, and nose. Now, it will be recollected that these are all supplied with branches from the different divisions of the fifth nerve also, which suggest the question — Do these parts receive merely an additional quantity of the same influence by their double supply of nerves, or do they derive from these sources an influence differing not in degree, but in kind?* The question has been decided by direct experiment. If the seventh nerve be divided, the muscles it supplies lose the power of motion, but retain their sensibility; but if the fifth nerve be cut across, motion is retained, though the sensibility is lost.

GLOSSO-PHARYNGEAL NERVE.

902. *Nervus glosso-pharyngeus*, fig. 151, 8, α, is a small nerve placed at its origin between the facial and the vagus nerve, its root being implanted by separate filaments into the groove between the corpus olivare and restiforme. The nerve inclines outwards and forwards to the foramen lacerum posterius, where it enters a small canal formed for it by the dura mater, through which it escapes from the skull. In its transit it lies internal and anterior to the jugular vein :—while in the canal it presents a slight gangliform swelling (ganglion petrosum); below the ganglion it descends, fig. 158, 1, almost vertically before the internal carotid artery, and between the stylo-glossus and stylo-pharyngeus, fig. 158, 2, muscles. It then curves forwards to reach the dorsum of the tongue. It gives several branches as follows :

The *tympanic branch* (ramus tympanicus, v. Jacobsoni) arises from the ganglion, and enters a canal in the bone appropriated to it. The orifice of the osseous canal is seen in the jugular fossa, from which it inclines upwards, and penetrates the inner wall of the tympanum. From this, three canals, still more minute, branch off: one inclines downwards to the carotid canal; a second forwards and upwards to the hiatus Fallopii; a third directly upwards behind the fenestra ovalis, to reach the upper surface of the bone, where it terminates in a groove internal to the hiatus Fallopii. Now, the nerve emerging from the ganglion

* Exposition of the Nervous System, by C. Bell.

enters the canal, and divides into three branches corresponding with those just indicated as existing in the bone. One descends to join the carotid plexus; of the others, one joins with the Vidian nerve in the hiatus, and the third terminates in the otic ganglion. Arnold, in his seventh plate, figures two other filaments; one going to the foramen rotundum, the other to the foramen ovale.

A branch passes off from the ganglion, and inclines downwards and outwards for a little way behind the styloid process; after which it curves up to join the portio dura, or facial nerve, as it issues from the stylo-mastoid foramen. This is the *ramus anastomoticus* ad nervum facialem. Another proceeds to the vagus and spinal accessory. Two or three descend upon the carotid artery, and join the nervus plexus upon it. A muscular branch is given off from the outer side of the nerve, which divides into two; one to the posterior belly of the digastric muscle — *ramus digastricus*, the other to the stylo-hyoid—*ramus stylo-hyoideus*. The pharyngeal branches are two or three which incline inwards, and ramify upon the superior and middle constrictors, contributing to form the pharyngeal plexus. Where the nerve lies close to the tonsil, it gives off some filaments which spread upon it as a plexus—*rami tonsillares*. Finally, on reaching the root of the tongue, the terminal branches of the nerves pass forwards, approaching the mucous membrane, to which and the follicles they seem to be distributed.

PNEUMO-GASTRIC NERVE.

903. *Nervus pneumo-gastricus; n. vagus* (par vagum, sympatheticus medius, pneumo-gastrique), fig. 151, 8, 6, arises immediately beneath the preceding, by eight or ten filaments placed closely together, so as to form a flat fasciculus. The nerve inclines outwards and forwards to the foramen lacerum, through which it escapes from the cranium, being in its passage separated from the jugular vein by a process of membrane or of bone, and from the nerves which take a similar course by a tubular prolongation of the dura mater which invests it. The filaments by which the nerve arises become aggregated together at the foramen, and within it the nerve presents a gangliform enlargement; as it emerges from the foramen, and descends beneath the base of the skull, a close communication by branches is established between it and the glosso-pharyngeal, lingual, and

sympathetic nerves. In the same situation, also, it presents an elongated swelling, resembling a ganglion in colour and consistence, fig. 158, 4.

Fig. 158.

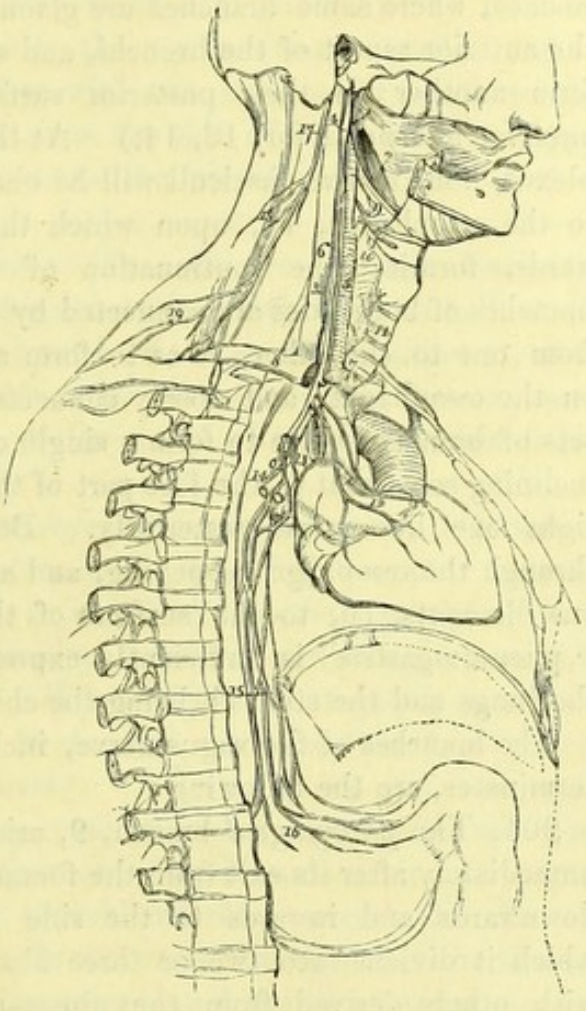

Soon after its exit from the skull, the nerve inclines outwards and a little backwards, supported by the rectus capitis anticus major; it assumes a vertical direction, and a fixed position or relation with regard to the cervical vessels; for as it continues its course along the neck, it is enclosed within the sheath of these vessels, lying between the carotid artery, 5, and jugular vein, 6, and with them overlaid by the sterno-mastoid muscle. Whilst within the jugular fossa, a branch is given off from the ganglion which lies between the jugular vein and the fore part of the fossa, and passes by a small aperture into a canal that leads to the aqueduct of Fallopius, where it joins the facial nerve. Beneath the base of the skull a branch of communication joins the nerve, derived from the spinal accessory, also from the lingual nerve where the latter is crossing in front of it. Filaments also connect it with the glosso-pharyngeal and the sympathetic. When entering the thorax, the nerve, 3, of the right side passes between the subclavian artery and vein, crossing the artery at right angles, and gives off a recurrent branch, 11, which, after turning behind the artery, 7, ascends by the trachea to the larynx. But at the left side the nerve descends parallel with the subclavian artery, to reach the

arch of the aorta, round which the recurrent branch takes its course. After having given the recurrent branch, the vagus nerve inclines inwards and backwards, to reach the side of the trachea, where some branches are given off to form a plexus on the anterior aspect of the bronchi, and a considerable number to form another on their posterior surface (*pulmonary plexus, anterior* and *posterior*, 13, 14.) At the lower extremity of the plexus, four or five fasciculi will be observed to pass backwards to the œsophagus, 15, upon which they are prolonged downwards, forming the continuation of the vagus nerve. The branches of both sides are connected by filaments, sent obliquely from one to the other, so as to form a sort of mesh. Resting on the œsophagus, and closely connected with it, each of these sets of branches unite to form a single cord, that of the left side inclining somewhat to the fore part of the œsophagus, whilst the right one lies more posteriorly. Both enter the abdomen through the œsophagean opening, and are distributed by numerous filaments, 16, to the surfaces of the stomach. The term "pneumo-gastric" is sufficiently expressive of its destination; the lungs and the stomach being the chief organs it supplies.

The branches of the vagus nerve, including those by which it terminates, are the following:

904. The *pharyngeal* branch, 9, arises from the vagus nerve immediately after its exit from the foramen lacerum, and inclines downwards and inwards to the side of the pharynx, behind which it divides into two or three filaments, which, conjointly with others derived from the glosso-pharyngeal, the superior laryngeal, and sympathetic nerves, form a plexus (*pharyngeal*) behind the middle constrictor muscle; several filaments will be observed to pass from this plexus to the other constrictor muscles also.

905. The *descending* or *superior laryngeal* nerve, 10, passes downwards and inwards behind the internal carotid artery, and divides into two branches, both being intended to ramify in the structures of the larynx. The *external* branch passes on the side of the larynx, and gives filaments to the sterno-thyroid, crico-thyroid, and thyro-hyoid muscles, and to the thyroid gland. The *internal* one pierces the thyro-hyoid membrane, together with the laryngeal artery, and divides into several small filaments, some of which incline upwards to the root of the

epiglottis, and ramify on its upper surface, and in the substance of the epiglottic gland: others proceed downwards;—of these, one or two, of very small size, pass through the arytænoid gland, and terminate partly in it, and partly in the mucous membrane; another goes to the arytænoideus muscle; and a third, after communicating with the inferior laryngeal nerve, runs along the groove between the side of the thyroid cartilage and the cricoid, to terminate in the crico-thyroid muscle,—this is a long slender twig.

906. Below the middle of the neck two or three filaments (*cardiac branches*, 12,) are given off, which unite with those of the superficialis cordis (a branch of the great sympathetic), and from the interlacement formed between them, branches are continued down to the arch of the aorta, where they terminate in the cardiac plexus.

907. The *recurrent* or *inferior laryngeal* nerve, 11, runs a very remarkable course; for, as its name implies, after leaving the pneumo-gastric nerve, it turns back into the neck again; but its point of departure, as well as its course and relations, are not the same at both sides. When the pneumo-gastric nerve of the right side is about to descend into the thorax, it passes before the subclavian artery. At that point the recurrent branch leaves it, and turns round the artery to gain its posterior aspect, after which it inclines obliquely inwards behind the common carotid and inferior thyroid arteries, to reach the side of the larynx. At the left side the nerve descends into the thorax parallel with the subclavian artery, and the recurrent passes in front of the arch of the aorta and turns behind it, inclining obliquely upwards and inwards, to reach the side of the trachea. Whilst making its turn, the recurrent nerve of each side gives off some filaments to the pulmonary plexus. When arrived at the top of the trachea, the recurrent gives some small filaments to the inferior constrictor of the pharynx, and then enters the cavity of the larynx, where it gives branches to the crico-arytænoid and arytænoid muscles, communicating at the same time with the superior laryngeal nerve. Both these nerves in their course give small branches to the œsophagus and under surface of the trachea; and some also descend in front of that tube, to join the anterior pulmonary plexus.

908. *Bronchial branches.* — We may so name several fila-

ments which pass inwards to the bronchus, some anterior to it, but still more behind it. Five or six small branches incline inwards from the nerve, immediately after it has got into the thorax, and, reaching the root of the bronchus, join with the filaments which come down from the recurrent, and form with them the *anterior pulmonary plexus*, 13. Continuing its course, the nerve sinks backwards, and applies itself to the posterior surface of the bronchus, where it appears at the same time to enlarge and assume the pearly tinge peculiar to the divisions of the sympathetic nerves. It gives off a great number of branches, which form a complex interlacement behind the root of the lung, and hence named *posterior pulmonary plexus*, 14. The plexus is further increased by filaments from the third and fourth thoracic ganglion of the sympathetic nerve. Its ramifications take the course of the bronchi through the lungs, even to the air-cells. Those of the anterior pulmonary plexus are similarly disposed. The anterior one, moreover, sends filaments to join with the cardiac plexus.

909. *Œsophageal branches.*—The nerve, after giving off the pulmonary branches, applies itself to the œsophagus, not, however, as a distinct trunk, but divided into from three to four or five branches; those of the left being anterior, and those of the right rather posterior to the tube; but they communicate by oblique and transverse branches. This interlacement is usually called the *œsophagean plexus*, 15. A little above the diaphragm the branches of the nerve join again, and form at each side of the œsophagus a short single nerve, which enters the abdomen, guided by the tube just named to the stomach.

910. The terminal branches of the vagus nerves ramify on the stomach. The *left*, on reaching the cardia, spreads out into branches on the anterior surface of the viscus; some of these run along the smaller curvature, where they communicate with those of the right vagus nerve, and finally several filaments are prolonged within the folds of the small omentum, to join with the hepatic plexus. The nerve of the right side, after forming a plexus round the cardia, distributes branches to the posterior surface of the stomach as far as the pylorus, where it communicates with the preceding nerve, and with the coronary plexus formed by the splanchnic nerve; and finally one or two branches pass backwards, leaving the stomach altogether, and join the solar plexus.

SPINAL ACCESSORY NERVE.

911. *Nervus accessorius.*—The *spinal accessory* nerve, fig. 151, 8, γ, ascends from the spinal canal into the cranium, and applies itself to the pneumo-gastric nerve—hence its name. It arises by several filaments from the side of the spinal cord, commencing opposite the fourth cervical vertebra. From this point the nerve ascends to the foramen magnum, lying between the ligamentum dentatum and the posterior roots of the spinal nerves; and having mounted into the cranium, it comes into contact with the pneumo-gastric nerve, close by which it passes through the foramen lacerum, but in a separate sheath of the dura mater. At the base of the skull this nerve is connected by filaments with the two preceding nerves, as well as with the lingual and sympathetic, after which it inclines outwards and downwards, fig. 158, 17, behind the internal jugular vein, and through the substance of the sterno-mastoid muscle, giving off at the same time several branches, 18, for its supply. Having emerged from the muscle at its posterior border, the nerve, fig. 157, 12, communicates with those which form the cervical plexus, and then continues its course obliquely downwards and outwards across the neck, until it gets under cover of the trapezius muscle, to which it is finally distributed by several filaments, 19.

PHRENIC NERVE.

912. *Nervus phrenicus* (diaphragmaticus) arises from the lower part of the cervical plexus, fig. 162, 2; its principal root comes from the fourth nerve; one higher up, of smaller size, issues from the third, and usually another from the upper part of the brachial plexus joins it. At first the nerve inclines inwards, descending between the contiguous terminations of the rectus anticus and scalenus anticus muscles, then gets upon the latter, and, so supported, reaches the top of the thorax, which it enters between the subclavian artery and vein, generally crossing the root of the internal mammary artery. It now inclines inwards and somewhat forwards, runs anterior to the root of the lung, insinuates itself between the pleura and the fibrous pericardium, by which it is guided to the diaphragm. Previously to reaching this muscle, the nerve divides into four or

five filaments, which pierce its substance, and spread out within it; some of small size also reach its inferior surface, and guided by the phrenic arteries, join the solar plexus; one or two at the right side pass down with the inferior vena cava.

FIFTH CEREBRAL NERVE.

We commence the description of the symmetrical nerves which have double roots with that which is commonly called the fifth cerebral nerve.

913. *Nervus trigeminus* (nerf trifacial, par quintum). This nerve in its structure and functions is analogous to the regular or symmetrical nerves. It consists of two parts, derived from distinct sources; one communicating sensation, the other the power of motion; and the former, like the posterior roots of the spinal nerves, forms a ganglion, whilst the latter passes beneath the ganglion, and is unconnected with it, but unites with the third division of the nerve soon after its exit from the skull. The fifth nerve, fig. 151, 5, issues from the cerebral substance about the middle of the crus cerebelli, close to its junction with the pons Varolii. The point here indicated marks the emergence of the nerve from the surface; but the filaments of both roots can be traced deeply; those of the sensitive or larger division can be followed downwards and backwards to the posterior columns of the medulla oblongata, whilst the other can be traced to the motor tract. It consists of from eighty to a hundred filaments, each invested by a neurilema. The filaments at the circumference receive their neurilema sooner than those of the centre, so that if the nerve be torn off, a sort of mammillary process remains, which seems as if it had been concealed in the interior of the nerve. The nerve, fig. 159, 1, thus constituted, passes forwards, and on the summit of the pars petrosa pierces the dura mater, and enters a canal formed for it in that membrane. At this point the portion derived from the posterior root alters its appearance; its fibres diverge as they run forwards, and form a compressed plexus of a semi-lunar shape, named *Casserian ganglion*, 2. It somewhat resembles a crescent, and from its anterior or convex border three branches are given off, one of which passes into the orbit, another proceeds forwards beneath the orbit to the face, and the third descends through the foramen ovale, to be distributed to the tongue, to the teeth, and to the

muscles of the lower jaw. The two former communicate sensibility only to the structures in which they ramify; but the latter gives the power of motion to certain muscles, and sensibility generally to all the organs to which it is distributed; hence it is a compound nerve, and its component parts can at once be recognised by drawing the plexus or ganglion forwards, which will bring into view a nervous cord that lies beneath it on the bone, and which, if traced backwards, will be observed to be continuous with the anterior root of the nerve, and if followed will be found to pass through the foramen, with the third division of the ganglion, and to unite with it immediately after its exit from the skull; the mode of union being perfectly analogous to that of the anterior and posterior roots of the spinal nerves.

OPHTHALMIC NERVE.

Fig. 159.

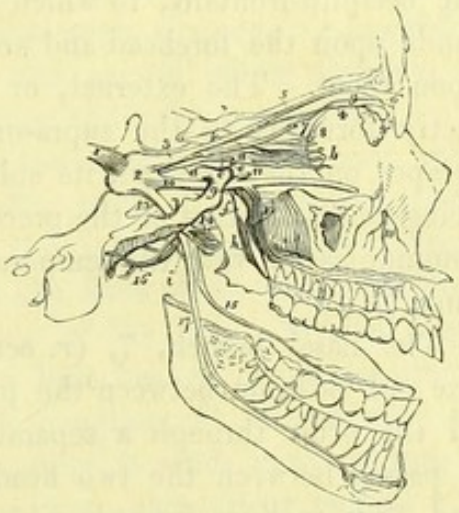

914. The first or ophthalmic branch, fig. 159, 3, (*ramus quinti paris primus*, v. *ophthalmicus*,) is the smallest of the divisions of the ganglion: it lies beneath and to the outside of the other orbital nerves, and receives, whilst lying along the outer side of the cavernous sinus, some filaments from the sympathetic. It divides into three branches, which separately pierce the dura mater to enter the orbit through the sphenoidal fissure. These branches, from their destinations, are called lachrymal, frontal and nasal.

The lachrymal branch, 4, (*nervus lachrymalis*,) which is smaller than the others, and also inferior to them, passes forwards between the orbit and the external rectus muscle, to the lachrymal gland, to which it distributes four or five filaments, that enter at its ocular surface; some are also prolonged to the external side of the orbit, and ramify in the orbicular muscle and integument; one or two delicate filaments are also reflected

inwards to the upper eye-lid. The lachrymal nerve, near its commencement, receives one or two filaments of communication from the superior maxillary nerve; and as it proceeds forwards, one or two delicate threads are given off, which pierce the malar bone, and anastomose with the deep temporal branches of the facial nerve.

The frontal branch, 5, (*r. frontalis*,) which is the largest offset of the ophthalmic nerve, inclines upwards and inwards, to get between the levator palpebræ and the orbit, being at first closely connected with the fourth nerve. About midway between the summit and base of the orbit, it divides into two branches, one lying internal to the other, but on the same plane; the internal or super-trochlear branch, 6, (r. supra-trochlearis, passes forwards to the point at which the trochlea or pulley of the superior oblique muscle is attached to the margin of the orbit, close to which it emerges on the forehead, lying between the muscles and the bone. It soon, however, pierces the occipito-frontalis, to which it distributes filaments, and ascends upon the forehead and arch of the skull, ramifying freely upon them. The external, or supra-orbital branch, passes directly forwards to the supra-orbital notch, through which it escapes on the forehead, its subsequent course and distribution being similar to that of the preceding. These nerves maintain communication with the temporal branches of the facial or portio dura.

The nasal branch, 7, (*r. oculo-nasalis*,) is intermediate in size and position between the preceding nerves. Having entered the orbit through a separate foramen in the dura mater, it passes between the two heads of the external rectus muscle, and then inclines inwards and forwards, rising over the optic nerve to reach the inner side of the orbit: whilst passing over the optic nerve it gives a small branch (r. ad ganglion), which terminates in the posterior and superior angle of the lenticular ganglion, *a*, and two filaments, 8, which pierce the globe of the eye, and are distributed in the same way as the ciliary branch derived from the ganglion. At the inner wall of the orbit the nerve divides into two twigs, one of which passes into the cavity of the nose (r. nasalis internus, v. ethmoidalis), the other, 9, issues from the orbit beneath the trochlea, and has on that account been called the infra-trochlear branch. The nasal branch passes inwards

to the cavity of the cranium, through the foramen orbitale internum anterius, and on reaching the side of the crista galli, runs forwards on the cribriform lamella, descending into the nose through its anterior foramen or fissure. In this situation the nerve divides into two filaments, of which one (ramus septi, fig. 155, 7) passes down upon the septum narium, on which it divides into two or three offsets; the other runs in a groove at the inner surface of the os nasi, and piercing the fibrous structure which connects it with the nasal cartilage ramifies upon the tegument of the tip and ala of the nose. The infra-trochlear branch, above referred to, 9, emerges from the orbit at the inner side and beneath the trochlea, where it divides into filaments, which are given to the upper eye-lid, the tensor tarsi muscle, and the root of the nose; some of them also extending to the lachrymal sac and caruncula lachrymalis.

SUPERIOR MAXILLARY NERVE.

915. The superior maxillary nerve, or second division of the fifth, fig. 159, 10, (*ramus quinti paris secundus ; r. maxillaris superior*,) is intermediate in size, as well as in direction and situation, between the ophthalmic and inferior maxillary nerves. It passes forwards, and leaves the skull by the foramen rotundum of the sphenoid bone, after which it crosses the spheno-maxillary fossa, and enters the infra-orbital canal, through which it is conducted beneath the floor of the orbit, and finally ramifies on the cheek and side of the face. Whilst passing across the fossa, it gives two branches of communication, *g*, which pass down to Meckel's ganglion, *f;* immediately after its exit from the foramen rotundum it sends upwards into the orbit a branch, 11, (*orbital, nervus subcutaneus malæ*,) which passes forwards, and forms an anastomosis with the lachrymal nerve, sending twigs to the lachrymal gland, some of which are continued along the outer margin of the orbit, to be distributed to the orbicular muscle and the integument; and also a filament which passes through the malar bone to the temporal fossa, and communicates with one of the deep temporal branches. The *posterior dental* branches, 12, three or four in number, descend upon the tuberosity of the superior maxillary bone, and enter the foramina observable on its surface: through these the filaments descend to the alveoli of the molar

teeth, in the pulp of which they ramify: one filament will be observed to run along the alveolar border of the superior maxilla, supplying the gums. Before it emerges on the face, the superior maxillary nerve sends downwards a branch (*anterior dental*), which divides into three or four filaments, for the supply of the bicuspid, canine, and incisor teeth. At its exit from the infra-orbital foramen, the nerve, 10, is concealed by the orbicularis and levator labii superioris muscles, where it divides into a number of branches, some of which incline inwards to the nose, and communicate with the nasal branch of the ophthalmic nerve; others pass downwards upon the cheek and upper lip; and a third set incline somewhat outwards, forming a complete mesh by their interlacement with the branches of the facial or portio dura nerve.

INFERIOR MAXILLARY NERVE.

916. The inferior maxillary nerve, fig. 159, 13, the third and largest branch of the fifth pair, (*ramus tertius quinti paris; r. infra-maxillaris*,) is made up, as has been said, of two portions, which issue from the cranium by the foramen ovale of the sphenoid bone, and become united immediately after their exit. A few lines beneath the base of the skull, in which situation it is under cover of the pterygoideus externus muscle, the nerve divides into two primary branches. One of these, which lies superior to the other, and also is smaller than it, soon subdivides into five offsets, 14, which are distributed to the deep-seated muscles as follow:—The deep temporal branches, two in number, (r. temporales profundi, anterior and posterior,) at first pass outwards between the external pterygoid muscle and the bone, one of them at the same time inclining forwards; they then ascend, and become applied to the inner surface of the temporal muscle, to which most of them are distributed; some, however, pierce its fibres and fascia, and becoming superficial, anastomose with the superficial temporal branches of the facial nerve. The buccal branch (r. buccalis) is longer than any of the others; it inclines downwards and forwards between the pterygoid muscles, and reaches the surface of the buccinator muscle, on which it spreads out into four or five filaments, which communicate with branches of the facial nerve, supplying the muscles of the cheek and lips. In its course it furnishes some

twigs to the external pterygoid and temporal muscles. This nerve is sometimes found to arise by a common trunk with, or to give off, one of the preceding (temporal) branches. The pterygoid nerve (n. pterygoideus) passes between the pterygoid and circumflexus palati muscles, to ramify in the internal pterygoid; there is frequently more than one pterygoid twig. The masseteric branch (r. massetericus) is directed transversely outwards in front of the glenoid fossa of the temporal bone, passes between the temporal and external pterygoid muscles, and finally escaping through the sigmoid notch of the lower maxillary bone, supplies the muscle from which its name is derived.

The remaining division of the inferior maxillary nerve subdivides into three branches, viz. the gustatory, auricular, and inferior dental.

917. The gustatory nerve, fig. 159, 15, (*n. gustatorius v. lingualis*,) immediately after its origin, sends a short branch, of considerable thickness, to the dental nerve: lying anteriorly to this, it then descends between the pterygoid muscles for some way, where it is joined at an angle by the chorda tympani nerve, *i*, which accompanies it whilst descending inside the ramus of the lower maxillary bone, but soon parts from it, to be distributed to the submaxillary gland. The gustatory nerve continues its course forwards, under the mucous membrane of the mouth, to reach the side of the tongue, passing between the hyo-glossus and mylo-hyoideus muscles, in company with the duct of the submaxillary gland. As it ascends by the side of the tongue, it gets above the sublingual gland, and divides into several minute filaments, which may be traced beneath the mucous membrane, gradually becoming soft and waving, until they reach the papillæ, where they terminate. The nerve, during its course, gives one or two filaments to the internal pterygoid muscle, also some which communicate with the hypoglossal nerve, and others to the sublingual gland.

918. The auricular or superficial temporal branch, 16, (*r. meatûs auditorii externi*, Meckel; *temporalis superficialis*,) often commences by two roots; it inclines outwards, to gain the interval between the condyle of the lower jaw and the meatus auditorius externus, where it divides into two branches, whilst lying deeply in the substance of the parotid gland. One of these branches ascends behind the neck of the condyle of the lower

jaw between the articulation and the meatus externus of the ear; gradually becoming superficial, it divides into offsets, which mount up in the temporal fossa, taking the course of the temporal artery, its filaments being traced to the tegument upon the side of the head; at its commencement it gives a branch which joins the facial nerve, and in its course one to the articulation of the lower jaw and the meatus auditorius. The inferior branch divides into offsets, which passing through the parotid gland reach the lobule and tegument of the ear, and communicate with the posterior branches of the second cervical nerve.

919. The inferior dental nerve, fig. 159, 17, (*n. dentalis*,) usually receiving at its commencement a short thick branch from the gustatory, arises as it were by two roots, (between which the internal maxillary artery passes,) and is the largest of the branches of the inferior maxillary nerve. It descends at first between the two pterygoid muscles close to the gustatory, then passes between the internal pterygoid and the ramus of the inferior maxilla, protected from the action of the former by the internal lateral ligament of the temporo-maxillary articulation, and arrives at the orifice of the dental canal which occupies the inner surface of the ramus of the inferior maxillary bone. At this point a long delicate branch (*ramus mylo-hyoideus*) is given off, which inclines downwards and forwards in a groove marked for it on the inside of the ramus of the jaw. This branch rests on the inferior surface of the mylo-hyoideus muscle, to which, as well as to the submaxillary gland and anterior belly of the digastricus, it gives filaments. The dental nerve, having entered the canal appropriated to it in the lower jaw, passes horizontally forwards about three lines beneath the roots of the teeth, to each of which it sends filaments, which incline obliquely upwards, and enter the foramina in their apices, to be distributed to their central pulp. When arrived opposite the foramen mentale, the nerve divides into two branches, one of which, smaller than the other, continues in the canal as far as the symphysis of the chin, where it anastomoses with the corresponding nerve of the opposite side; and from the arch thus formed filaments ascend to supply the canine and incisor teeth. The other division of the nerve (*ramus mentalis*) passes through the foramen, and appears on the face, where it ramifies freely in the muscles and integuments of the chin and lip, its filaments communicating with those of the facial nerve.

SPINAL NERVES.

920. The spinal nerves are thirty-one pairs in all; and each individual nerve is attached by two sets of filaments, one to the anterior, the other to the posterior surface of the spinal cord. These unite (sect. 862) into one short trunk, which, as it passes out of the intervertebral foramina, divides into two branches, one anterior, the other posterior, which are distributed respectively to the parts in front of and behind the vertebral column. The anterior branches are, with one or two exceptions to be noticed in the special description of the nerves, larger than the others, and form the several plexuses found in different situations. These nerves are usually arranged in four groups, from a consideration of the regions in which they are situated, viz. cervical, dorsal, lumbar, and sacral.

The cervical nerves are sometimes described as eight, sometimes as seven in number, the difference depending on the place assigned to that which emerges from the spinal canal above the first vertebra of the neck.

FIRST CERVICAL NERVE.

921. The first cervical nerve (*nervus sub-occipitalis*, *decimus cerebri*) is the smallest of the spinal nerves, except the last sacral. Willis and several succeeding anatomists considered it as one of the cerebral nerves, but Sœmmering, Meckel, and Bell have on just grounds associated it with those that arise from the spinal column, because, like them, it arises by two roots, presents a ganglion on the posterior one, and in its general distribution is analogous to those which succeed it. This nerve passes out between the arch of the atlas and the occipital bone, lying in the groove on the upper surface of the former, and reaches the triangular space bounded by the recti and obliqui muscles, where it divides into an anterior and a posterior branch. The latter resolves itself into four or five filaments, which are distributed to the small muscles just mentioned, and to the complexus. It may be here observed, that the posterior branches of the three upper cervical nerves mutually communicate by a filament sent from one to the other, previously to their final division, so that an interlacement is formed between them, though it does not receive the name of plexus. The *anterior* branch of the first

cervical nerve, smaller than the posterior, runs obliquely forwards upon the transverse process of the atlas, and, on reaching the anterior surface of the spinal column, descends and joins with a branch sent up from the second nerve, having previously given some filaments to the muscles by which it passes. At the point of union also some twigs are sent to communicate with the lingual and vagus nerves and the superior cervical ganglion, at the base of the skull; a slender filament descends with the vertebral artery in its canal.

SECOND, THIRD, AND FOURTH CERVICAL NERVES.

922. The second, third, and fourth cervical nerves may in their description be taken together, inasmuch as by their anterior branches they form the cervical plexus. Their posterior branches shall be described in the first instance.

Posterior branches.—The posterior branch of the second cervical nerve, of greater size than the anterior, passes backwards and upwards, covered by the complexus, and resting on the rectus posticus and obliquus inferior. To these, as well as to the splenius, it gives ramusculi, and finally, having pierced the fibres of the complexus, becomes subcutaneous, ramifying in the skin of the occiput. It communicates with the corresponding branches of the nerves next to it, namely, the first and third. The posterior branch of the third nerve, less in size than the anterior, passes backwards by the articulation of the second and third vertebra, anastomoses with the preceding branch, and supplies filaments to the muscles in its neighbourhood; finally it pierces the muscles and ascends, becoming subcutaneous, and ramifies on the back part of the head and neck. The posterior branch of the fourth is smaller than either of those above it, except the first. It passes directly backwards between the transverse processes of the third and fourth vertebræ, and having given several filaments to the complexus muscle, pierces the splenius and trapezius, supplying both, and ultimately terminates in the integuments of the neck.

Anterior branches.—The anterior branches of the second, third, and fourth nerves communicate by small twigs with the superior cervical ganglion, and will be observed, as soon as they appear on the fore part of the neck, to send filaments mutually one to the other, in order to form the cervical plexus.

The *cervical plexus*, fig. 156, 5, fig. 162, 1, thus formed, is placed at the upper and lateral part of the neck; it extends from the transverse process of the second to that of the fourth vertebra, resting on the fibres of the posterior scalenus and levator scapulæ muscles, and concealed by the sterno-mastoid. Its branches are divisible into a superficial and a deep set; the latter being placed under cover of the sterno-mastoid, whilst the former lie immediately beneath the fascia, some of them passing up towards the jaw and ear, others down to the clavicle.

1. *Superficial branches* (*ascending*).—These, as they issue from the plexus, are three in number. They turn round the posterior border of the sterno-mastoid muscle, and will be observed to differ in size and direction as they lie upon its cutaneous surface. The middle or largest branch, fig. 157, 6, (*nervus auricularis magnus*, Sœmm.; *zigomato-auriculaire*, Chauss.) ascends perpendicularly towards the interval between the lobe of the ear and the angle of the jaw, lying close to the external jugular vein, and, on reaching the parotid gland, divides into branches, one or two of which pass deeply into its substance and join with those of the facial nerve. The rest of the branches remain superficial, and ramify in the integument of the external ear, some at its facial, and one or two at its occipital aspect. The internal branch, fig. 157, 7, (*r. superficialis colli*,) inclines obliquely up towards the submaxillary gland, giving filaments to the platysma and digastricus, also one or two which join with the cervical branches of the facial nerve: it finally divides into delicate filaments, which interlace with those of the chorda tympani and of the gustatory, as they ramify on the sub-maxillary gland, forming a sort of plexus by their union. The *posterior* branch, fig. 157, 8, (*r. occipitalis minor*,) runs along the posterior border of the mastoid muscle, lying on the splenius, and terminates by three or four filaments in the integument of the occiput and ear, anastomosing with a branch of the portio dura.

Superficial branches (*descending*).—These as they come from the plexus will be seen in the interval between the contiguous borders of the sterno-mastoid and trapezius, diverging as they pass down to the lower part of the neck. They are embedded in a considerable quantity of cellular tissue, and as

they diverge to their destination, one set passes over the clavicle, fig. 157, 9, (*r. claviculares*,) and supplies the integument on the upper part of the thorax; another, 10, on the acromion (*r. acromiales*); whilst some lie rather deeply behind the clavicle, being distributed to the posterior belly of the omo-hyoideus and to the serratus magnus.

2. *The deep branches.*—A few pass backwards, communicate with the spinal accessory nerve, and ramify in the trapezius and levator anguli scapulæ muscles. The other branches of this series are arranged into two divisions; one of these consists of two filaments, fig. 156, 4, derived from the second and third nerves, which incline inwards as they descend in front of the sheath of the cervical vessels, to join the descendens noni, and form with it an inverted arch. From the convexity of this arch, which looks downwards, three or four long waving filaments proceed towards the front of the neck, where they are distributed to the sterno-hyoideus and sterno-thyroideus, as well as to the omo-hyoideus muscles. The other division consists of two branches, which converge and unite on the scalenus anticus to form the *phrenic nerve*, fig. 162, 2.

923. *The phrenic nerve.*—The branches which form it will be observed to come from the third and fourth nerves; but they are further increased by a branch derived from the fifth, as it descends to the axillary plexus. The phrenic nerve thus constituted lies on the scalenus anticus, near its inner border, and passes into the thorax, to be ultimately distributed to the diaphragm. It is described sect. 912.

FIFTH, SIXTH, SEVENTH, AND EIGHTH CERVICAL NERVES.

924. The four inferior cervical nerves, namely, the fifth, sixth, seventh, and eighth, divide, like the preceding, into anterior and posterior branches. The latter are small; they pass backwards from the intervertebral foramina, and supply the muscles and integuments at the lower part of the neck.

Brachial plexus.—The anterior branches of these nerves are of very considerable size, much larger than those which form the cervical plexus. After emerging from the intervertebral foramina, they receive some filaments from the inferior or middle cervical ganglia of the sympathetic; and, being joined by the

corresponding branch of the first dorsal nerve, unite in a peculiar way to form an interlacement called the *brachial* or *axillary plexus*, fig. 162, 3, which extends from opposite the sixth cervical vertebra to the coracoid process. In the neck, the branches which form it lie between the scaleni muscles; closely aggregated together, they pass downwards and outwards into the axillary space, between the subclavius muscle and the first rib, and are placed at the acromial side of the accompanying artery, fig. 160, 1.

925. The branches which form this plexus are said by Boyer, and other anatomists, to interlace inextricably. An arrangement of them, however, may be made as follows:—a probe may be previously passed across, through the primary divisions of the plexus, so as to divide them into an anterior and posterior set. The anterior branches of the fifth and sixth cervical nerves will be observed, after coming out of the intervertebral foramina, to unite and form a common trunk, which, after giving off the supra-scapular nerve, separates into two divisions. Of these, one, posterior in situation, descends to form the circumflex nerve, and gives a small slip to form the spiral: the anterior division unites with a similar one from the seventh, and the common trunk thus resulting gives at its upper side the external cutaneous nerve; at the lower, the outer head of the median. The first dorsal nerve ascends to join the last cervical, to form a common trunk, which also separates into two divisions. The posterior one unites with a similar offset from the seventh to form the spiral nerve; whilst the anterior, after giving off from its inner side the internal cutaneous nerve, divides ultimately into the ulnar nerve and the inner head of the median.

926. *Brachial plexus—its branches.*—From this nervous interlacement several nerves proceed, which may be divided into three sets:—1. The first consists of those which pass off rather higher up from the plexus, viz. the supra-scapular, the sub-scapular, and the thoracic, the latter consisting usually of three branches, all, however, going to nearly the same destination. Opposite the coracoid process, the plexus divides into six ultimate branches, for the supply of the limb, which may be resolved into—2, those which reach the hand and fingers, consisting of the ulnar, median, and spiral nerves; and 3, those which

do not extend so far, namely, the internal cutaneous, the external cutaneous, and the circumflex nerves.

NERVES OF THE SUPERIOR EXTREMITY.

The first set of these nerves, according to the division above indicated, consists of the supra-scapular, the sub-scapular, and the thoracic nerves or branches.

SUPRA-SCAPULAR NERVE.

927. The supra-scapular nerve, fig. 160, 2, (*n. supra-scapularis*,) passes off from the plexus as high up as opposite the sixth cervical vertebra. Its direction is backwards and outwards, as it descends to the superior border of the scapula. The nerve passes through the supra-scapular notch or foramen, and so reaches the dorsum of the scapula, where it gives branches, first, to the supra-spinatus muscle, and then continues its course upon the neck of that bone, until it arrives in the infra-spinal fossa, where it terminates by ramifying in the muscles.

SUB-SCAPULAR NERVES.

928. The sub-scapular nerves, fig. 160, 3, 3, (*n. sub-scapulares*,) pass backwards from the plexus, at first lying deeply in the axillary space; they are usually three in number. One, the smallest of the three, enters the sub-scapular muscle, and is distributed to its substance. The others not unfrequently arise by a common trunk, but sometimes separately; both proceed in the same course as the sub-scapular artery, one supplying the muscle of that name, as well as the teres major and minor; whilst the other, somewhat larger, pierces the teres major, and ramifies in the latissimus dorsi.

THORACIC NERVES.

929. The thoracic nerves (*n. thoracici*) are usually three in number. Of these, two may be observed to pass down on the fore part of the thorax, lying in front of the axillary vessels, and to terminate by ramifying in the substance of the pectoralis major and minor muscles. Another very long branch commences by two filaments, which soon unite to form a thin, flat nerve, that lies behind the plexus and the axillary vessels. It descends along the thoracic side of the axillary space, resting

upon the serratus magnus muscle, to which in its course it gives branches, and finally terminates by ramifying in the lower part of that muscle. This nerve, from its situation, is called the posterior thoracic branch. Sir C. Bell classes it amongst the respiratory nerves, as, according to his views, its function is to associate the muscle to which it is distributed with the general respiratory movements. From its situation it is named the *external respiratory nerve*, to distinguish it from the phrenic, which is placed within the thorax.

INTERNAL CUTANEOUS NERVE.

930. The internal cutaneous nerve, fig. 160, 4, (*n. cutaneus internus*,) commencing at the inferior and internal part of the plexus, descends along the inner side of the arm, being the smallest and most superficial of the nerves derived from the plexus. It lies for some way covered by the fascia of the arm, and divides, at a variable distance above the elbow, into two branches, which separately pierce the fascia. One of these may be observed to cross in front of the median basilic vein, and then to descend along the fore part of the arm, gradually inclining towards its inner side. It distributes several filaments to the skin, and maintains communications with the external cutaneous nerve on the one hand, and with the larger branch, or proper continuation of the internal cutaneous, on the other, and finally ceases at the wrist. The other division of the nerve is larger than the preceding, and lies nearer to the inner condyle of the humerus. At the bend of the elbow it inclines towards the ulnar border of the fore-arm, distributing filaments on each side as it descends, which freely ramify in the integument. Towards the carpus the nerve is necessarily much diminished, after having given off so many branches; its final ramifications may be traced as far as the skin over the inner border of the hand. Previously to reaching the elbow, and before its division, the nerve sends off several small and delicate branches to supply the skin that covers the biceps and triceps muscles.

EXTERNAL CUTANEOUS NERVE.

931. The external cutaneous nerve. fig. 160, 5, *musculo-cutaneous*, *nervus perforans Casserii*,) issues from the superior and external part of the plexus, being intermediate in size be-

Fig. 160.

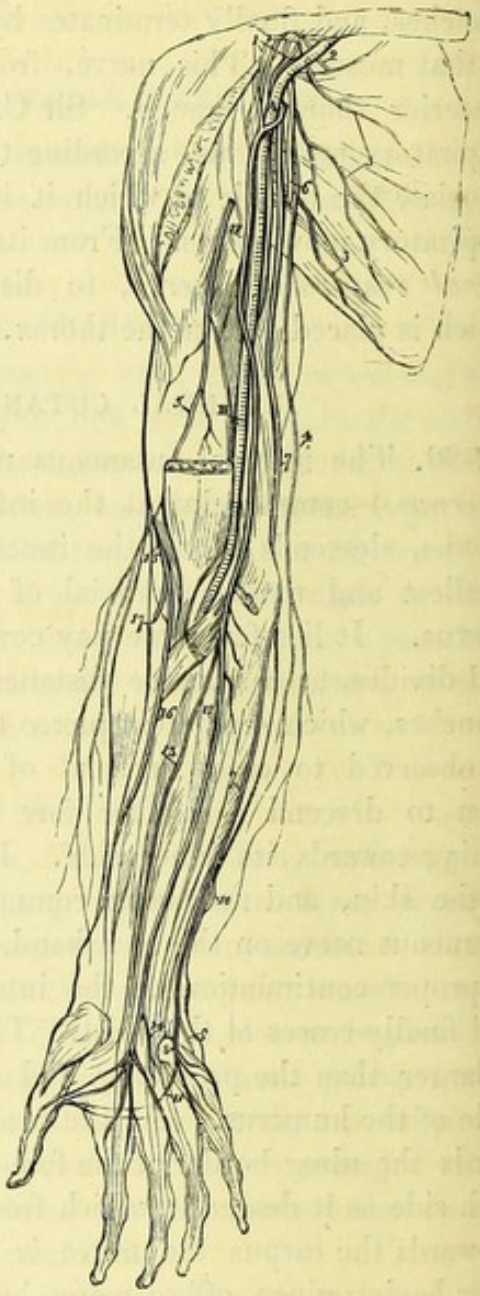

tween the preceding nerve and the ulnar. Its direction is outwards and downwards, so as to reach the border of the coraco-brachialis muscle, the fibres of which it in most cases pierces, but sometimes passes behind it. In either case, the nerve passes between the biceps and brachialis anticus muscles, where it gives off three or four branches to the muscles between which it lies, the continuation of the nerve being intended for the skin, whence its name, *musculo-cutaneous*. After this the nerve inclines outwards as it descends, reaches the outer border of the arm, and pierces the fascia, so as to come into contact with the median cephalic vein, behind which it lies. The nerve is thus placed between the fascia and integument, at the external or radial border of the fore-arm, along which it continues to descend as far as the wrist, where it terminates by dividing into two sets of filaments, one of which ramifies in the skin covering the anterior, the other in that on the posterior aspect of the carpus.

The branches given off by the nerve in its entire course are divisible into two sets, one muscular, the other cutaneous, whence its name. The muscular branches consist of three or four filaments distributed to the flexor muscles; one may be traced for some way in the interior of the coraco-brachialis,

arising from the nerve whilst passing through its substance, or beneath it; the others go to the biceps and brachialis anticus, one communicating with the median nerve. The cutaneous branches not only supply the integument of the forearm, but also maintain communications with the internal cutaneous nerve on the one hand, and the cutaneous branches of the spiral nerve on the other, by filaments which take a curved direction, and unite with similar offsets from the nerves just mentioned, so as to form arches, whose convexity, for the most part, looks down towards the hand. Finally, on the fore part of the wrist and root of the thumb, its terminal branches unite, in the same way with the cutaneous branches sent by the median nerve, to the integument on the palm of the hand.

CIRCUMFLEX NERVE.

932. The circumflex, or axillary nerve, fig. 160, 6, (*n. circumflexus brachis v. axillaris*,) is deeply seated, and altogether concealed by the plexus. It passes outwards and backwards immediately after its origin, and soon comes into contact with the posterior circumflex artery. The nerve and artery will be observed to run together close behind the shaft of the humerus, in order to reach its external aspect, where they both turn forwards somewhat, so as to lie between the bone and the deltoid muscle, to which the branches of both are finally distributed. The long head of the triceps lies behind the nerve in the first part of its course, and the sub-scapularis above it, the teres major being below it. To each of these filaments are given; and where it turns beneath the deltoid, a considerable branch descends, becoming superficial, and is distributed to the skin covering that muscle and the triceps extensor.

ULNAR NERVE.

933. The ulnar nerve, fig. 160, 7, (*n. ulnaris*,) intermediate in size between the external cutaneous and median nerves, is usually detached from the plexus opposite the lower border of the sub-scapular muscle. It inclines a little backwards as it descends along the arm, resting on the short head of the triceps, until it reaches the interval between the inner condyle

of the humerus and the olecranon. There the nerve, after passing through the interval between the heads of the flexor carpi ulnaris muscle, reaches the fore-arm, along which it descends close to its ulnar border, resting on the flexor proefundus muscle, and covered by the flexor carpi ulnaris. Towards the lower part of the fore-arm the nerve lies close to the radial border of the tendon of the last-named muscle, along which it runs, in company with the ulnar artery, to the pisiform bone and annular ligament of the wrist. Having passed in front of the latter, it divides into two branches, one being superficial, the other deep-seated.

The *superficial* branch, fig. 160, 8, the larger of the two, soon gives off, at its inner side, a considerable branch, 9, which inclines towards the ulnar border of the hand, lying upon the short muscles of the little finger, to which it gives filaments. On reaching the head of the metacarpal bone, it proceeds along the inner margin of the digital phalanges to their extremity, forming the internal collateral branch of the little finger. Continuing its course directly forwards, the superficial branch rests on the abductor muscle of the little finger, where it gives an offset, 11, from its radial side, which joins with the last digital branch of the median nerve; and, finally, on arriving opposite the heads of the metacarpal bones (fourth and fifth), it divides into two ramusculi, which run along the contiguous borders of the ring and little fingers.

The *deep-seated palmar* branch, 9, of the ulnar nerve becomes concealed from view by passing beneath the adductor of the little finger. It then inclines outwards across the metacarpus, covered by the flexor tendons, resting on the inter-ossei, and terminates by two or three filaments, which ramify in the adductor pollicis. The deep nerve, like the corresponding artery, forms an arch, whose convexity is turned towards the fingers, and, in its course, branches are given off on each side to the inter-ossei muscles, as well as to the small muscles of the little finger.

The ulnar nerve distributes several branches, which, if taken in the order of their occurrence, will be found as follows: 1, at the lower border of the axilla, one or two filaments are given to the teres major and latissimus dorsi; 2, in the arm a few branches pass into the substance of the long and short heads of

the triceps muscle, on which the nerve lies; 3, in the fore-arm, numerous branches are given to the contiguous muscles, viz. the flexor carpi ulnaris and flexor profundus, and also some filaments, which maintain communications with the branches of the median nerve; 4, at the union of the middle with the lower third of the fore-arm, a branch of considerable size, fig. 160, 10, inclines backwards from the nerve, and reaches the dorsal aspect of the limb, after having passed beneath the flexor ulnaris muscle. Continuing to descend, it lies superficial to the extensor carpi ulnaris, and so reaches the back of the hand, where it sends a branch along the inner border of the fifth metacarpal bone, which gives filaments to the abductor of the little finger, and finally runs along its ulnar margin as far as the last phalanx. The continuation of the nerve corresponds in its course with the fourth metacarpal space, giving off several small filaments to the skin and parts on the back of the hand, and, on reaching the heads of the metacarpal bones, divides into two branches which extend upon the contiguous margins of the little and ring fingers, in their entire length, forming their collateral branches. From the radial side of the nerve a branch not unfrequently is sent, which supplies also the external border of the ring finger, and the adjacent one of the middle finger. But it will sometimes be observed that this branch joins with some derived from the termination of the spiral nerve, and that from their union branches proceed to supply the contiguous borders of the ring and middle fingers.

MEDIAN NERVE.

934. The median nerve, fig. 160, 12, (*n. medianus*,) is so called from the position which it occupies in the fore-arm. It is of considerable size, and arises from the plexus by two fasciculi, or heads, which embrace the axillary artery, A. The artery, in this situation, is surrounded on every side by the divisions of the plexus. In front lies the median nerve, behind it are placed the circumflex and spiral, to the outer side one of the heads of the median, together with the external cutaneous nerve, and to the inner, the second head of the median, with the internal cutaneous and ulnar nerves. The median nerve inclines outwards at first, in order to come into contact with the coraco-brachialis muscle. Towards the middle of the arm it

crosses the brachial artery, B, usually in front, occasionally behind it, and becomes placed at its inner side, resting on the brachialis anticus. At the bend of the elbow the nerve sinks deeply into the interval between the pronator teres and the supinator longus muscles, and passes between the two heads of the pronator teres, and beneath the upper border of the flexor sublimis. Continuing its course, 12, along the fore-arm, the nerve lies between the muscle last named and the flexor profundus, with which it passes behind the annular ligament of the wrist, and so reaches the palm of the hand, where it divides into five branches.

935. The *first digital* branch proceeds outwards and forwards, lying upon the abductor and short flexor of the thumb, to both of which it gives filaments. It thus reaches the radial border of the thumb, and passes along its phalanges to their extremity.

The *second* branch is also intended for the thumb, being placed parallel with the preceding at its ulnar margin.

The *third*, larger than the preceding, sometimes forms, at its commencement, a common trunk with them. It proceeds directly forwards, giving some filaments to the abductor indicis, and one to the first lumbricalis muscle, and finally runs along the radial border of the phalanges of that finger.

The *fourth* branch, still larger, corresponds in its course with the second metacarpal space, where it gives a ramusculus to the second lumbricalis muscle, and finally divides into two collateral branches of equal size, which supply the adjacent borders of the fore and middle fingers.

The *fifth* digital branch lies in the third metacarpal space, where it communicates by a transverse slip with the ulnar nerve (its second digital branch). Like the fourth, it divides into two branches, which are placed along the contiguous margins of the middle and ring fingers.

In the arm the median nerve communicates with the musculo-cutaneous, and gives only a very few muscular branches, which are so small as scarcely to deserve notice; they are distributed to the muscles arising from the inner condyle of the humerus, opposite which they are given off. The most remarkable of these is the inter-osseous nerve, 13, (*n. inter-osseus anticus.*) This is of considerable size; immediately after its origin it

passes backwards to reach the anterior surface of the inter-osseous ligament, where it comes into contact with the artery of the same name. In this situation, the nerve is interposed between the flexor profundus and flexor pollicis longus, and so continues, as far as the upper border of the pronator quadratus muscle. Having passed under cover of the muscle just named, to which it gives some small filaments, the nerve turns backwards through the inter-osseous ligament, and so gains the dorsal surface of the hand, where it ramifies in several filaments.

At the lower part of the fore-arm, another branch is given off, called, from its ultimate destination, the *cutaneous palmar* branch, 14. This descends between the flexor tendons, passes in front of the annular ligament and palmar fascia, and divides into filaments, which supply the skin at the centre of the palm of the hand.

MUSCULO-SPIRAL NERVE.

936. The musculo-spiral nerve (*nervus radialis*, Sœmm.; *nerf radio-digital*, Chauss.) is, at first, the largest of those which issue from the plexus. Its direction is downwards, backwards and outwards, winding in a spiral manner round the bone, whence its name is derived. It lies in the cellular interval between the short and middle heads of the triceps muscle, accompanied by the superior profunda, or spiral artery. But, in order to reach the external and anterior aspect of the humerus, where it finally appears, the nerve passes between the second head of the muscle and the bone, lying in a canal formed for it by some tendinous fibres which arch obliquely over it. The nerve, fig. 158, 15, in the next place, lies deeply in the interval between the brachialis anticus and supinator longus, which overlap and conceal it, until it reaches the elbow-joint. There it divides into two primary branches, one being placed on the anterior and external part of the fore-arm, the other lying deeply at its posterior aspect.

The *anterior branch*, 16, resembles the continuation of the nerve in direction, though not in size. It proceeds directly downwards, guided by the supinator longus, giving several branches, usually five or six, which are distributed to the extensor and supinator muscles. In the middle third of the arm, the nerve, considerably reduced in size, comes into relation with

the radial artery, and lies to its outer side for some way. After a while it inclines outwards, beneath the tendon of the supinator longus, to reach the external border of the fore-arm, upon which it descends, lying superficial to the extensors of the thumb. Near the carpus it divides into two, or sometimes into three branches. One of these runs along the radial border of the thumb, forming its first posterior collateral branch. Another corresponds with the first metacarpal space, and divides, for the supply of the ulnar border of the thumb and the adjacent border of the fore finger. The third, after having given a branch from its ulnar side, which supplies the contiguous borders of the ring and middle fingers, proceeds forwards in the second metacarpal space, and divides into two collateral branches for the supply of the index and middle fingers (their adjacent borders). This branch of the spiral nerve will thus supply, besides the thumb, both sides of the index and middle fingers, and one side of the ring finger. In some cases, both sides of the latter receive their nerves from the ulnar, and, occasionally, its radial collateral branch is derived from an interlacement formed by the ramifications of the ulnar and spiral nerves.

The *branches* of the spiral nerve are numerous. Two or three of considerable size, are given to the triceps, whilst the nerve is in contact with it. One of these ultimately becomes cutaneous, and is sometimes called *nervus cutaneus externus superior*. It ramifies for some way in the integument covering the external and anterior part of the arm, and even of the fore-arm, where it communicates with the branches of the proper external cutaneous nerve. Then it gives the different muscular branches above mentioned to the supinators and extensors on the outer border of the fore-arm, and in the same situation its deep-seated branch. This branch, fig. 158, 17, (*ramus profundus* vel *muscularis*,) is larger than the continuation of the nerve. It inclines outwards as it descends, and after having passed beneath the supinator longus and the two radial extensors, pierces the substance of the supinator brevis, giving it several filaments. On arriving at the lower border of that muscle, the nerve gives off several branches, some being distributed to the long extensors of the fingers, others to those of the thumb. Finally, one rather remarkable by its size and regularity (*ramus inter-osseus posticus*) passes along the deep-

seated muscles (the extensors of the thumb and index finger), distributes branches to them, and extends as far as the carpus, ramifying on its posterior aspect.

INTERCOSTO-HUMERAL NERVES.

937. The superior extremity, in addition to the several nerves thus derived from the brachial plexus, receives three long branches, which come from the first, second, and third intercostal nerves. The branch derived from the first intercostal nerve passes out between the first and second ribs, and after giving filaments to the skin at the axilla, runs a little way in the integument of the inner and upper part of the arm.

The branch from the second intercostal nerve passes out from the second intercostal space, gives a filament or two which turn forwards to the skin upon the front of the chest, and after communicating with the first perforating branch just noticed, and the third which lies beneath it, as well as with the internal cutaneous nerve, it gives branches to the skin of the axilla, and terminates along the inner side of the arm. The branch from the third intercostal nerve, after piercing the muscles, gives filaments to the tegument below the axilla and along the lower border of the scapula. The origin and termination of these nerves are briefly indicated by the name given to them—"intercosto-humeral."

DORSAL NERVES.

938. The dorsal nerves (*nervi dorsales*, v. *intercostales*) consist of twelve pairs; the first issues through the inter-vertebral foramen, between the first and second dorsal vertebræ, the last between the twelfth and the first lumbar. The part of the spinal cord with which the cervical nerves are connected being nearly opposite the inter-vertebral foramen which gives them exit, the roots proceed almost horizontally outwards; those of the dorsal region, on the contrary, proceed obliquely downwards to leave the canal; and the degree of obliquity gradually increases from above downwards, so that the last deviates from the horizontal direction more than any of those above it. In size they are less than the inferior cervical, the lumbar, and the greater number of the sacral: this, doubtless, is owing to the parts to which the dorsal nerves

are distributed (the parietes of the thorax and abdomen) being less in extent than the upper and lower extremities, to which the others are given. Immediately after leaving the intervertebral foramina, they divide, as was described in treating of the cervical nerves, into posterior and anterior branches.

939. The posterior branches *(rami dorsales*, vel *postici)* pass backwards between the transverse processes, and are distributed to the dorsal muscles, some ramifying close to the spine, others near the angles of the ribs. This difference of distribution has given rise to these branches being considered divisible into an internal and an external series; both supply the erector spinæ and superficial muscles, namely, the rhomboidei, trapezius, and latissimus dorsi, and send filaments also to the integuments.

940. The anterior branches, fig. 162, *(rami intercostales,)* follow the intercostal spaces, lying, in the first instance, near the lower margin of the rib above them, but as they advance they gradually descend, and approach the inferior one, in this respect corresponding with the intercostal arteries which they accompany. Immediately after their commencement, the anterior branches communicate, each by one or two small filaments, with the neighbouring ganglion of the sympathetic nerve. Proceeding outwards, they at first lie between the pleura and external intercostal muscles; towards the angles of the ribs they pass between the two layers of intercostal muscles, furnishing them with several filaments, and at length each gives a large superficial branch. This is given off at about half the length of the intercostal space; or, as this does not apply except in the superior nerves, it will be more correct to state the point to be midway between the spine and the median line in front.

The further distribution of the nerves presenting some peculiarities in several, it is necessary to describe them specially.

The anterior division of the first nerve sends upwards over the head of the first rib a large branch to join with the brachial plexus, fig. 162, 3. The continuation of the intercostal nerves in the first seven spaces, that is to say, those which lie between the true or sternal ribs, after giving off each a superficial branch, pursue their original course forwards to the ster-

num, furnishing twigs to the intercostal muscles and triangularis sterni; and finally piercing them, they ramify in the pectoralis major and the integuments in the neighbourhood of the sternum. The four following intercostal nerves being those which correspond with the false or asternal ribs, after having furnished their superficial branches, approach the anterior extremity of the intercostal spaces, pass over the costal attachment of the diaphragm, and advance between the transversalis and obliquus internus abdominal muscles; to these they supply numerous twigs, and finally terminate in the substance of the rectus and the integuments covering it.

941. The superficial or external branches of the first, second, and third nerves pass across the axilla, and ramify in the integuments of the arm on its inner and posterior aspect; the former communicates with the internal cutaneous nerve. These are the *intercosto-humeral* branches. The corresponding branches of the dorsal nerves, from the fourth to the eleventh inclusive, pass through the external intercostal muscles, and are distributed to the superficial muscles of the thorax and abdomen; the superior supplying the pectoral muscles and the mamma, those lower down the serratus magnus and the external oblique abdominal muscles; and all send filaments to the integuments.

The anterior branch of the twelfth dorsal nerve, fig. 161, 12, passing below the last rib, cannot be named intercostal. At its commencement it sends a communicating branch to the first lumbar nerve (*dorsi-lumbar*): it then passes outwards, inclining obliquely down from the last rib, and lies in front of the quadratus lumborum. Near the outer margin of the last-named muscle, this nerve divides into deep and superficial branches, which are disposed in the same manner as those above it: thus the deep-set ramify between the transversalis and internal oblique muscles, and end in the rectus; while the superficial proceed along between the two superficial muscles, in which and the integuments they are expended.

LUMBAR NERVES.

942. The nerves which communicate the power of sensation and motion to the lower extremity, are derived from the lumbar and sacral plexus, that is, from a net-work or

interlacement which the anterior branches of the lumbar and sacral nerves form, after they have passed out of the spinal canal. As the entire of these nerves maintain thus an uninterrupted communication at their origin, and are distributed to similar structures, they have been associated under the general name "lumbo-sacral" plexus. This union resembles that which exists between the cervical and brachial plexus, being perhaps even more intimate.

943. The lumbar nerves, (*nervi lumbales*,) five in number, arise from the medulla spinalis by double roots. These, before uniting at the inter-vertebral foramen, proceed in a very oblique course, the last approaching to the vertical direction. Though exceedingly close, as it were compressed together within the spinal canal, the roots of different pairs have no communication one with the other; they form part of what is named the "cauda equina" of the spinal cord. The trunks formed by the union of each pair of roots pass through the inter-vertebral foramina, the first being transmitted through that between the first lumbar vertebra and the second, the fifth through that between the last and the sacrum. These trunks are very short, being not more than a few lines in length, as they immediately divide into two branches, called, from their direction, anterior and posterior.

944. The *posterior* branches of the lumbar nerves (*rami postici*, vel *dorsales*) pass backwards, immediately after their division, between the transverse processes of the vertebræ, and are distributed to the deep-seated extensor muscles situated along the spine, some of their branches extending as far as the skin. It may be observed, that they diminish gradually in size from the first to the last.

945. The *anterior* branches of the lumbar nerves (rami lumbales) increase in size from above downwards, and inclining outwards as they descend, become mutually connected by communicating filaments, sent from one to the other.

Lumbar plexus.—By the union in the way here indicated of the anterior branches of the first four lumbar nerves, fig. 161, 1, 2, 3, 4, (that of the fifth going to join the sacral,) a plexus or interlacement is formed (*plexus lumbalis*) reaching from the second to the fourth lumbar vertebra, resting on the junction of the transverse processes with their bodies, and co-

Fig. 161.

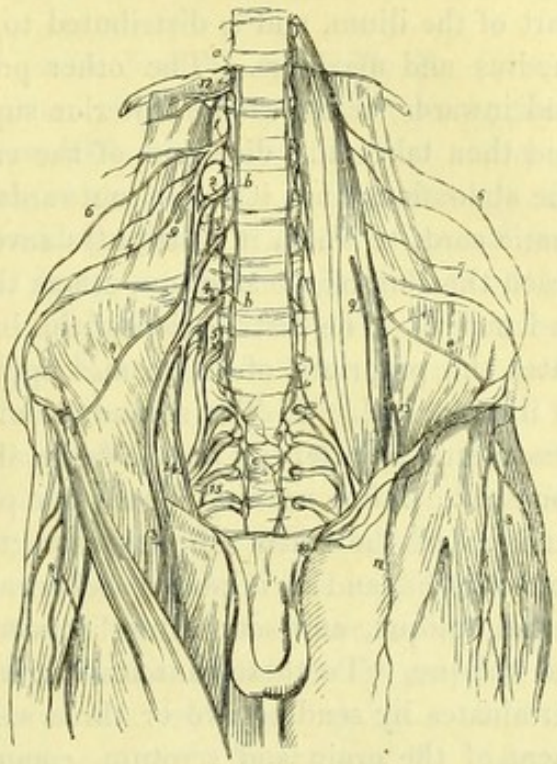

vered by the psoas muscle. In addition to this mutual communication, each nerve receives one or two small filaments from the lumbar ganglia of the sympathetic nerve, fig. 161, *b*, *b*. The plexus is moreover brought into relation with the dorsal nerves by a branch which the last dorsal, 12, sends down to the first lumbar, and also with the sacral nerves by the fifth lumbar, 5, which becomes associated with them. As the latter communicating branch, which is of considerable size, has been named *lumbo-sacral*, the former, though very small and delicate, may with equal propriety be termed *dorsi-lumbar*.

The lumbar plexus thus constituted gives off the following branches, which, if taken in the order of their origin, from above downwards, may be thus arranged: the musculo-cutaneous, external cutaneous, external pudic, the crural and obturator nerves, and lastly the lumbo-sacral or communicating branch.

946. 1. The *musculo-cutaneous* branches are usually two in number, fig. 161, 6, 7, and are derived either from the first lumbar nerve, or in some cases from the filament sent from it to the second. Both pass downwards and outwards through the upper part of the psoas muscle, supported on the quadratus lumborum, to the posterior part of the crista ilii. While in the lumbar region these branches run parallel, one being placed a little superior and external to the other. 1. The *external* branch (*ilio-scrotal*, or *ilio-inguinal*), on reaching the posterior part of the crista ilii, gets between the transversalis and internal oblique muscles, and divides into two ramusculi, one of which, after giving some twigs to the transversalis and iliacus, pierces

the abdominal muscles, becomes subcutaneous on the posterior part of the ilium, and is distributed to the skin over the gluteus medius and maximus. The other proceeds obliquely forwards and inwards, as far as the anterior superior spine of the ilium, and then takes the direction of the crural arch. On reaching the abdominal ring, it passes outwards, together with the spermatic cord, to which it distributes several filaments; some also reach the skin of the scrotum, others that on the pubes and labia in females. The distribution of the branches of this nerve indicates the propriety of the names applied to it, viz. ilio-scrotal, or ilio-inguinal. 2. The second, or more *internal* branch, after descending a little, lies on the fascia iliaca, covered by the peritonæum. After running for a while parallel to, and within half an inch of the crista ilii, it passes through the fibres of the transversalis, and so is placed between that muscle and the internal oblique, and soon after between the latter and the external oblique. To these muscles it gives delicate branches, and terminates by sending two or three which ramify on the integument of the groin and scrotum, communicating with the other cutaneous branches in these structures.

947. 2. The *external cutaneous* branch (inguino-cutanée, Chauss.), fig. 161, 8, proceeding from the anterior branch of the second, or from that between it and the third lumbar nerve, passes through the psoas muscle on a level with the crista ilii, runs from thence downwards and a little outwards, lying on the fascia iliaca. On reaching the anterior superior spinous process of the ilium, it emerges from the pelvis, by passing through the interval between that process of bone and the inferior one, after which the nerve divides into two ramusculi, which separately pierce the fascia lata of the thigh, and proceed to different destinations. 1. One of these, fig. 162, 2, inclines backwards, and, becoming subcutaneous, runs over the tensor vaginæ muscle, and along the external part of the thigh, placed between the fascia and the integuments, distributing filaments as it descends, until it ceases to be discernible about the union of the middle with the lower third of the thigh. 2. The *anterior* branch, fig. 162, 3, pierces the fascia from an inch and a half to two inches below the anterior superior spine of the ilium, becoming also subcutaneous, and ramifies as far as the external side of the knee, in numerous delicate filaments,

which will be found on the fascia covering the vastus externus muscle.

948. 3. The *external pudic* branch, fig. 161, 9, (nervus spermaticus externus, Sœmm.; pudendus externus; genito-cruralis,) arises from the second lumbar nerve, or from the communicating branch between it and the first, pierces through the fibres of the psoas muscle and the fascia that covers it, and then runs vertically downwards, lying on the anterior surface of that muscle. In this course it is covered by the peritonæum, and, on approaching the crural arch, it divides into two ramusculi, one being internal, the other external in its direction. 1. The *internal* ramusculus, 10, somewhat larger and longer than the other, turns forwards a little, so as to come into contact with the spermatic cord, or round ligament, which it accompanies through the abdominal ring, being distributed to the cremaster muscle and the investments of the testis in the male, some of its filaments extending also to the neighbouring parts of the groin, and in the female to the labia and pubes. 2. The *external* branch, 11, inclines, outwards in front of the external iliac vessels, just at their termination, passes beneath the crural arch, and divides into several filaments, which ramify in the inguinal region and in front of the thigh, some of them becoming subcutaneous.

949. 4. The *crural nerve*, fig. 161, 13, (nervus femoralis; femoro-præ-tibialis,) arises from the second, third, and fourth lumbar nerves, the greater part being derived from the two last; in some instances, also, it receives a small filament from the first, or from the communicating branch that passes between it and the second. The nerve thus formed is of considerable size, and is situated at first deeply in the sulcus between the contiguous margins of the psoas and iliacus muscles. As it descends it comes forwards somewhat, so as to become apparent, though it still remains covered by the fascia iliaca, and is guided to the crural arch by the psoas muscle (its external border), which separates it from the iliac artery. In this course the nerve gives from its external side several small filaments to the iliacus muscle; internally, some also pass over the iliac vessels, and others to the psoas muscle. Amongst the latter, one may be observed to take a retrograde course, running from below upwards on the muscle. Close to Poupart's ligament, or im-

mediately after it has passed beneath it, the anterior crural nerve, fig. 162, 4, spreads out and divides into a lash of branches, which diverge to their different destinations, and may be divided into a superficial and deep set, the former piercing the fascia, and becoming subcutaneous, forming the cutaneous nerves of the anterior and inner parts of the thigh, the latter remaining covered by that membrane.

950. The *superficial* branches are very slender, and usually two in number, fig. 162, 5, 6; sometimes there are more. They pierce the fascia from half an inch to an inch below Poupart's ligament, one just in front of the femoral artery, the other about midway between that point and the external border of the thigh. These may be called the anterior cutaneous branches, to distinguish them from the external cutaneous nerve and its branches, 2, 3, already described. One of these cutaneous branches, 6, passes down beneath the integument, lying on that part of the fascia which covers the rectus muscle, and may be traced as far as the front of the knee. The other, 5, runs more internal, distributing filaments as its descends over the sartorius and vastus internus, as far as the inner side of the knee-joint.

951. The *deep-seated* branches of the anterior crural nerve are very numerous, and admit of being divided into an external, internal, and long or descending set. The long descending branches are two in number; they both incline inwards as they descend, and come into contact with the sheath of the femoral vessels, where they are crossed by the sartorius muscle. One of these, 7, lies along the external side of the sheath of the vessels for some way, and distributes filaments to the sartorius as it descends; it soon, however, inclines outwards, and ramifies in the vastus internus as far as the knee. The other branch, 8, (*nervus saphenus major*, vel. *internus; tibio-cutané*, Chauss.) is larger and much longer than the preceding. It inclines inwards to get upon the sheath of the vessels; it then runs under cover of the fascia extended from the adductors to the vastus internus, and lies for about the middle third of the thigh towards the superior and external side of the artery. When the artery is about to pass backwards into the popliteal space, the nerve ceases to accompany it, and continues its course directly down to the knee, covered by the sartorius, to which it

gives some filaments. Opposite the inner condyle, the saphenous nerve may be found between the tendons of the sartorius and gracilis muscles. In this situation the nerve becomes subcutaneous, and applies itself to the saphenous vein, which it accompanies along the anterior and inner side of the leg, distributing filaments to the integuments as it descends. It passes with the vein in front of the inner ankle, and ramifies by several minute filaments upon the dorsum of the foot. At its origin, this nerve receives a branch of communication from the obturator. In its course along the thigh it is the collateral or satellite nerve of the femoral artery; and in the leg, of the saphena vein.

The rest of the deep-seated branches, 9, 9, are distributed almost exclusively to the muscles of the thigh, and may, as we have said, be divided (from a consideration of their direction) into an external and an internal set. The *external* branches incline outwards in front of the iliacus and psoas muscles, gradually diverging as they proceed. They get under cover of the sartorius, and give off three or four filaments for its supply, some of which pierce the fibres of the muscle, and ramify on its anterior surface; two of these, after piercing the sheath of the sartorius, become subcutaneous and reach as far as the patella. Other branches, still very numerous, pass beneath the rectus and tensor vaginæ femoris, supplying both; the remainder being distributed

Fig. 162.

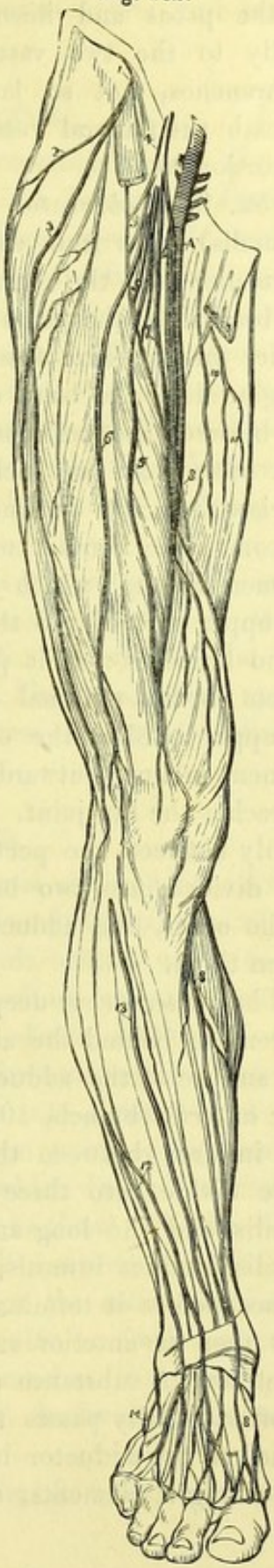

to the psoas and iliacus muscles after their junction, and finally to the two vasti and the crureus. The *internal* set of branches, not so large or so numerous, incline inwards beneath the femoral vessels, and supply the pectineus and adductor longus.

952. The *obturator nerve* (nervus obturatorius, sub-pubio-femoralis) arises from the third and fourth lumbar nerves, and is smaller than the crural nerve, from which it is separated by the breadth of the psoas muscle, one running along its external border in the iliac fossa, the other placed beneath its inner margin, along the brim of the pelvis. In this course the nerve lies between the peritonæum and the pelvic fascia, being situated about half an inch above the obturator artery, (when it arises from the internal iliac,) but gradually descends, so as to come into contact with it as they approach the obturator foramen, through which they pass out from the pelvis to reach the upper part of the thigh. Whilst within the pelvis it gives off no branches: as it passes out of the foramen it gives two offsets to the external obturator muscle, of which one enters its upper border, the other its anterior surface. From this a filament inclines outwards to the cotyloid notch, through which it reaches the hip-joint. On reaching the thigh, the nerve lies deeply between the pectineus and obturator externus muscles, and divides into two branches, one lying on a plane anterior to the other, the adductor brevis being in fact interposed between them.

The *posterior*, or deep branch, fig. 162, 11, passes backwards, descending behind the adductor brevis, and so reaches the anterior surface of the adductor magnus, to which it is distributed. The *anterior* branch, 10, will be observed to incline downwards and inwards between the pectineus and adductor brevis, and there divide into three offsets, which are distributed to the gracilis, and the long and short adductors. The branch to the gracilis inclines inwards, and runs for some way upon its inner surface before it terminates. The branch to the short adductor runs upon its anterior surface, and divides into filaments which penetrate its substance above its middle; from some of these an offset usually passes to join the saphenous nerve, 8. The branch to the adductor longus, after passing behind the muscle and giving it filaments, descends to the inner side of the thigh,

gives a connecting branch to the saphenous nerve, and can be traced to the inner side of the knee.

LUMBO-SACRAL NERVE.

953. The lumbo-sacral, or communicating nerve, (*nervus lumbo-sacralis*,) is the last offset from the lumbar plexus, and in size is larger than either of the preceding nerves. It is made up of the whole of the anterior branch of the fifth pair, and of the connecting branch sent down from the fourth. It passes backwards in front of the sacro-iliac symphysis to reach the pelvis, where it joins the first sacral nerve, and so contributes to form the sacral plexus, at the same time that it forms the connecting link between it and the lumbar plexus. Before its termination it gives off the gluteal branch, which is the only one that arises from it.

The *gluteal* nerve, fig. 163, 1, *(nervus gluteus superior)* turns outwards beneath the border of the sciatic notch, and above the pyriformis muscle. On reaching the exterior of the pelvis, the nerve immediately divides into filaments, which ramify over the dorsum ilii, supplying the two deep-seated gluteal muscles.

SACRAL NERVES.

954. The sacral nerves, five, and not unfrequently six in number, arise from the extremity of the medulla spinalis, which, it may be observed, ceases in the adult subject opposite the second lumbar vertebra. The fasciculi which compose the roots of these nerves must therefore descend almost vertically in the sacral canal, to reach the foramina through which they are transmitted; and as they are divided into a number of filaments, proceeding from a root or common point of attachment, they assume that peculiar appearance which has given rise to the term *cauda equina*, usually applied to them with the lower lumbar nerves, which present a like disposition, though in a less marked degree. While yet within the sacral canal, the two roots by which each nerve arises unite to form a common trunk, which soon divides into two branches that take quite an opposite course, one being directed backwards, the other forwards.

955. The *posterior* branches of the four superior sacral

nerves, like those of the lumbar set, are much smaller than the anterior. They pass backwards through the posterior sacral foramina, penetrate the tendinous origin of the sacro-lumbalis muscle, to which they distribute filaments in their passage, and become subcutaneous. Each of these branches inclines outwards, lying on the fascia that covers the gluteus maximus muscle, and is finally distributed to the skin covering the nates. The posterior branches of the two last sacral nerves are much smaller than any of the others; they pass downwards and forwards to supply the integuments round the margin of the anus. These several nerves have for the most part a communication from one to the other, each being connected with that which precedes and follows.

956. The *anterior* branches (*rami antici*) of the sacral nerves diminish in size from above downwards. They issue from the spinal canal through the anterior sacral foramina, and immediately each communicates with the neighbouring pelvic ganglion of the sympathetic nerve. The first three sacral nerves passing outwards and uniting with the communicating branch sent down from the fourth and fifth lumbar nerves, and having received some branches from the fourth sacral, form the sacral plexus, not as in other instances, by sending fasciculi from one to the other, so as to constitute an interlacement, but by a union of their fibres, forming a large compressed cord, from which nerves are given off. The anterior branch of the fourth sacral nerve, after passing through the fourth sacral foramen, communicates by a filament with the sympathetic, and gives some offsets, which, with similar branches from the third, go to the hypogastric plexus. It sends some filaments to the levator ani and coccygeus muscles, after which it terminates in the skin about the anus, and in the sphincter ani. The anterior branches of the fifth and sixth sacral nerves are very small, and do not enter into the formation of the plexus: they pass forwards, the first between the sacrum and coccyx, the second in a notch on the side of the latter, and are distributed to the muscles in their immediate neighbourhood, namely, the sphincter ani and coccygeus.

957. The *sacral plexus*, fig. 161, 15, (plexus sacralis, vel ischiadicus,) formed as aboves tated, is situated deeply at the posterior and lateral part of the pelvis, resting on the surface of the pyri-

formis muscle, crossed by some of the branches of the internal iliac artery, and covered (particularly at the left side) by the rectum.

The branches of the sacral plexus may be divided into two sets, one internal, the other external: the former consisting of the hæmorrhoidal, vaginal, uterine, vesical, and pudic, are distributed to the parts in the pelvis and perinæum; the latter, intended for the supply of the lower extremity, are two in number, and are named the small and the great sciatic nerves.

958. The hæmorrhoidal nerves *(nervi hæmorrhoidales superiores)* pass forward to the lower part of the rectum, and ramify in its muscular coat and mucous lining membrane, from the sphincter upwards to a considerable distance. These nerves interlace with branches of the sympathetic, and communicate with the vesical and vaginal nerves, which occasionally are even given off altogether from them.

959. Vaginal and uterine nerves.—Several slender twigs pass forward by the side of the rectum, and are distributed to the vagina; a few ascending reach the lower part of the uterus, anastomosing with the numerous branches of the sympathetic nerve supplied to that organ.

960. The vesical nerves, frequently confounded at their commencement with the two preceding series, proceed forwards to the lower part of the bladder, and ramify in its two internal coats. In their course they furnish twigs to the vesiculæ seminales and prostate gland in the male, and the urethra in the female.

961. The pudic nerve, fig. 163, 2, *(nervus pudendus,)* is derived principally from the third sacral; it inclines downwards and outwards from the plexus, so as to come into contact with the pudic artery as it is escaping from the pelvis, in the interval between the pyriformis and coccygeus muscles. Its course and distribution are similar in every respect to that of the artery. In company with it, the nerve returns to the pelvis through the small sciatic foramen, and gives off a superficial branch (perinæal nerve; n. pudendus inferior). This long branch, ascending on the inner side of the tuber ischii, sends one or frequently more twigs to the sphincter ani and margin of the anus (n. hæmorrhoidalis inferior); then it passes forward along the perinæum,

in the interval between the erector penis and accelerator urinæ muscles, and, after furnishing filaments to them and the transversus perinæi, terminates in the dartos and the integuments of the scrotum.

The continuation of the pudic nerve ascends on the rami of the ischium and os pubis, where it gives some filaments to the obturator internus muscle. The nerve in the next place reaches the dorsum of the penis by passing between the corpus cavernosum and the pubic symphysis; after which it passes forwards beneath the skin as far as the glans, where its filaments cease to be discernible; it distributes filaments during its course to the integuments and the urethra.

In the female the pudic nerve presents nearly a like disposition, but the superficial perinæal nerve is larger than the deep-seated one just described, because it is distributed to the labium, whilst the other supplies the clitoris.

962. The small sciatic nerve, fig. 163, 3, (*nervus ischiadicus minor*, v. *gluteus inferior*,) arises from the posterior and lower part of the plexus, from which it inclines backwards and downwards to reach the lower border of the pyriformis muscle, beneath which it escapes from the pelvis. In this situation it will be found on the same plane with the great sciatic nerve, but on its inner side, both resting on the superior gemellus, and covered by the gluteus maximus. Here the nerve receives a short twig

Fig. 163.

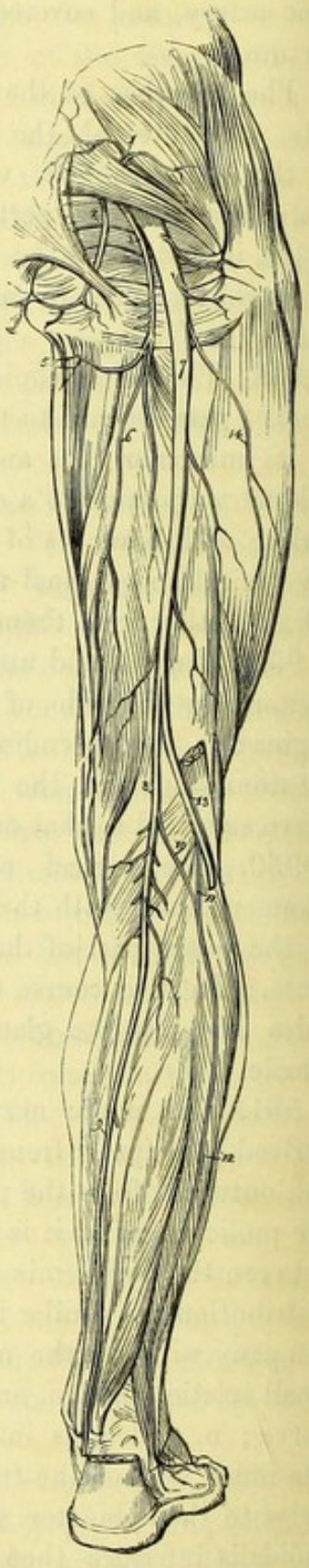

from the great sciatic, and may be said to divide into branches, which take different directions; one being directed outwards to the great gluteus, others inwards, and a third set downwards along the thigh. It is, however, more conformable with usage to consider the descending part as the proper continuation of the nerve, and the others as its offsets or branches. 1. The *inferior gluteal* branches may be so called to distinguish them from the superior gluteal nerve, 1, (a branch given from the lumbo-sacral, or communicating nerve,) from which, at their exit from the pelvis, they are separated by the breadth of the pyriformis muscle. The greater number of these branches are short, as they have merely to turn outwards a little, in order to reach the pelvic surface of the gluteus maximus, to which they are distributed. One of them, however, may be observed to curve round the border of the pyriformis, and proceed obliquely forwards beneath the gluteus, extending as far as its anterior border. 2. A branch, fig. 163, 5, (*posterior and internal cutaneous*,) inclines inwards beneath the tuber ischii, and divides into filaments, some of which are distributed to the gracilis, whilst others pierce the fascia, and become subcutaneous, ramifying in the integument that covers the upper and inner part of the thigh, as well as the perinæum and scrotum or labium. 3. From the posterior surface of the nerve proceeds the *middle cutaneous* branch, 6; this passes along the anterior surface of the gluteus maximus to its lower border; then, perforating the fascia, it continues to descend, distributing filaments to the skin, as far as the popliteal space, where it terminates. More cutaneous twigs derived from this nerve will frequently be found piercing the fascia at different points, together with others to be presently noticed, which are given off from the great sciatic nerve.

The continuation of the small sciatic nerve, as it descends, inclines inwards, covered by the fascia, and rests on the flexor muscles, to which it distributes branches, in its course towards the inner side of the popliteal space, where it usually ceases.

GREAT SCIATIC NERVE.

963. The great sciatic nerve, fig. 163, 7, (*nervus ischiadicus*, Sœmm.; *grand fémoro-poplité*, Chauss.) is the largest nerve in the body. From its size and direction it may be considered as the

continuation or prolongation of the plexus, it being impossible to determine where the one ceases or the other begins. The fasciculi which enter into its composition are derived from all the nerves which go to form the sacral plexus. Thus formed, the nerve emerges from the pelvis, beneath the lower border of the pyriformis muscle, (a portion sometimes passing through its fibres,) and lies in the interval between the trochanter major and tuber ischii, whence it proceeds almost vertically downwards to the popliteal space. In the upper part of this course it rests against the external rotator muscles, in the rest it is supported by the adductor magnus, and is covered for a short way by the gluteus maximus, and lower down by the flexor muscles of the leg; but in the ham it is placed in the interval between them, embedded in a quantity of adipose substance, and covered only by the fascia and integument. The branches of this nerve are necessarily very numerous:—1. As it emerges from the pelvis it sends a branch to the obturator internus, and another to join the nerve last described. 2. From its posterior surface some filaments pass to the gluteus muscle, whose size and number depend on that of the inferior gluteal branches, derived from the small sciatic nerve, being few and small when the latter are numerous, and *vice versâ;* for here, as elsewhere, in the nervous as well as in the vascular system, a principle of compensation obtains, by which, when the supply from one source is considerable, that from another admits of being proportionally diminished. Farther down it gives filaments to the flexor muscles, as they lie over it. From some of these branches, or from the trunk itself, one or two others pass backwards, and directly pierce the fascia; after which they proceed down towards the external side of the ham, ramifying in the integuments. These may be termed the posterior and *external cutaneous* branches, fig. 163, 14, to distinguish them from those that arise from the small sciatic nerve. 3. From its anterior surface branches proceed to supply the external rotators (a filament extending to the capsule of the hip-joint) and the adductor magnus, on which the nerve lies, and some pass outwards to the short head of the biceps muscle.

964. The sciatic nerve divides, generally about the middle of the thigh, into an external and internal branch,—the latter, in direction and size, being its proper continuation. This division

sometimes take place lower down than the point here indicated, and in many instances much higher, occasionally even within the pelvis. The internal or larger division lies behind and to the outer side of the popliteal artery, whilst in the popliteal space; hence during that part of its extent it may be called the popliteal nerve. According to the arrangement usually adopted, the nerve is considered as dividing into two branches, viz. the posterior tibial and fibular. But were we to adhere to this division, we should have no popliteal nerve, and it would evidently be a misnomer to speak of the posterior tibial in the popliteal space, and describe its relations to the popliteal artery. When treating of the external division, we cannot avoid this otherwise than by a periphrasis.

965. The internal or larger division of the sciatic nerve, fig. 163, 8, (*popliteal*, *nervus popliteus*,) passes directly downwards through the ham, covered by the fascia, and lying posterior and external to the popliteal vessels, from which it is separated by some adipose substance. After having passed below the joint, it rests on the popliteus muscle covered by the gastrocnemius. In this situation it inclines inwards, and, crossing the artery, lies to its inner side. Like the artery, the nerve, 9, assumes the name of posterior tibial (*nervus tibialis posticus*), when it has passed below the popliteus muscle. In the leg it resumes its original position with regard to the blood-vessels, being again placed externally to them; here it lies on or rather behind the tibialis posticus and flexor communis muscles, covered by the deep fascia which separates it from the soleus. Gradually inclining to the inner side of the leg, the posterior tibial nerve, as it descends, passes through that arched interval which separates the inner ankle from the calcaneum, and, like the artery which it accompanies, divides into its two terminal branches, viz. the internal and external plantar.

966. In this course the nerve gives several branches to supply the muscles along which it passes. A branch of considerable size, 10, (*nervus cutaneus longus posterior*, vel *communicans tibiæ*, Sœmm.) runs directly downwards between the heads of the gastrocnemius, and then over the posterior surface of that muscle, gradually inclining outwards to reach the external border of the tendo Achillis. In this course the nerve accompanies the external saphenous vein; and about the middle of the calf

of the leg, or sometimes lower down, it joins with a corresponding branch, 11, sent from the fibular nerve. The nerve, 12, resulting from this union may be called *external saphenous;* with the vein so named it passes down behind the external ankle, so as to reach the dorsum of the foot, where it divides into two branches, one running on the fourth, the other on the fifth metatarsal bone, and distributing filaments as far as the corresponding digital phalanges. The branch here described lies beneath the fascia in its course down the leg, but at different intervals sends through it filaments which ramify in the integuments, some of them descending as far as the bend of the ankle. Several muscular branches proceed from the nerve to the heads of the gastrocnemius, the plantaris, popliteus, and soleus muscles; and in the lower part of its course it supplies the tibialis posticus, and the long flexors, its filaments diverging and uniting again so as in some places to form a mesh round the posterior tibial artery. Some filaments are also distributed on the ligaments at the ankle, and on the bursa and fascia near the insertion of the tendo Achillis.*

When arrived at the hollow of the calcaneum, and lying under cover of the abductor pollicis muscle, the posterior tibial nerve sends off a filament which ramifies in the integuments of the sole of the foot, previously to its division into the internal and external plantar branches.

INTERNAL PLANTAR NERVE.

967. The internal plantar nerve (*n. plantaris internus*), the larger of the two, passes directly forwards beneath the tarsal bones, concealed by the abductor pollicis muscle, to which, as well as to the flexor accessorius and flexor brevis, it gives branches. It soon divides into, or gives off, four branches, intended to supply both sides of the great toe, and of the two next to it, as well as the inner side of the fourth. The first ramusculus is smaller than any of the others; it proceeds forwards and inwards beneath the flexor brevis pollicis, to reach the inner side of the great toe, forming its first collateral branch: the second, as it passes forwards, corresponds with the interval between the first and second metatarsal bones, where it gives filaments to the flexor brevis and the first lumbricalis, and on reaching the fissure

* Demonstration of the Nerves, by Mr. Swan.

between the toes, divides into two offsets, which run along the contiguous borders of the first and second toes: the third lies in the second metatarsal space, supplies the first plantar interosseous muscle, and, like the preceding branch, divides into two parts to supply the external border of the second toe, and the adjacent one of the third: the fourth ramusculus follows a similar course and distribution with regard to the third metatarsal space, and the digital phalanges of the third and fourth toes; it also joins with, or receives a filament from, the superficial branch of the external plantar nerve.

EXTERNAL PLANTAR NERVE.

968. The external plantar nerve (*n. plantaris externus*) proceeds forwards and outwards, lying between the flexor accessorius and flexor brevis digitorum. In this course it gives a branch which passes to the external border of the foot, and is distributed to the abductor minimi digiti, after which it divides into two branches, one being intended to complete the digital branches of the toes, the other to supply the deep-seated muscles in the sole of the foot. 1. The first of these, on reaching the extremity of the fifth metatarsal bone, sends along the outer border of the foot and of the little toe a collateral branch, similar to that which is given to the great toe by the internal plantar nerve. The continuation of the branch may be observed to correspond with the fourth metatarsal space, where it communicates by an oblique filament with the internal plantar nerve; after which it proceeds to the heads of the metatarsal bones, and divides into branches, which supply the external border of the fourth toe, and the adjacent one of the fifth. 2. The deep branch sends outwards a filament to the flexor of the little toe, and then proceeds almost directly forwards into the sole of the foot, where it divides into branches, which supply the abductor pollicis, the inter-ossei, and transversus pedis muscles.

FIBULAR NERVE.

969. The external division of the great sciatic nerve, fig. 161, 13, (*nervus peroneus, ramus peroneus nervi femoro-poplitei;*) inclines outwards as it descends from the point of division towards the external condyle of the femur, to which it is guided

by the border of the biceps muscle. It then proceeds obliquely forwards, lying in the interval between the external head of the gastrocnemius and the biceps, and reaches the posterior surface of the head of the fibula, where it may with propriety be named *fibular* or *peroneal*. The nerve continues to descend for a short way between the external surface of the bone and the peroneus longus muscle, where it is usually said to divide into two branches, one being named anterior tibial, the other the musculo-cutaneous. But as the latter, in size and direction, represents the continuation of the nerve, we shall so consider it, and treat the former as a branch, more especially as from its relations and course it is analogous to the inter-osseous branch in the fore-arm. The peroneal nerve, as it passes downwards, lies between the peroneus longus and the extensor communis, and afterwards between the latter muscle and the peroneus brevis, giving branches to each. Towards the middle of the leg, it escapes from under cover of the muscles, much diminished in size, descends for some way beneath the fascia, and divides into two branches, fig. 162, 12,—one being a little external to the other. The *external* branch, lying between the fascia covering the extensor tendons and the skin, passes over the bend of the ankle and dorsum of the foot, and divides into three ramusculi on reaching the latter situation. One of these is directed forwards, corresponding with the fourth metatarsal space, and ramifies in filaments on the dorsum of the little toe and outer border of the foot. In the latter situation its place is not unfrequently supplied by the external saphenous nerve. The next ramusculus passes along the interval between the fourth and third toes, supplying both; whilst the third, or most internal of them, is similarly disposed of on the phalanges of the third and second toes. The *internal* branch is directed towards the base of the first metatarsal bone, on which, after having given some filaments to supply the inner border of the foot, it divides into two ramusculi, which ramify on the upper surface of the first and second toes.

970. *Branches of the peroneal nerve.*—The peroneal nerve sends, in the popliteal space, a branch which supplies the short head of the biceps muscle, and terminates on the ligaments of the outer side of the knee-joint. Its chief branches, taken in their order from above downwards, are as follows:

1. A considerable branch is given off in the popliteal space, which descends between the external head of the gastrocnemius and the fascia, sending at intervals some branches which pierce the latter to supply the integuments. It finally divides into two or three branches, some of which ramify on the external side of the leg, whilst one joins with the superficial branch of the posterior tibial nerve, to form with it the communication alluded to in the description of the latter.

2. The anterior tibial, or inter-osseous nerve, fig. 162, 13, (*n. tibialis anticus*,) immediately after its origin below the head of the fibula, turns forwards and inwards between the surface of that bone and the peroneus longus and extensor communis muscles, giving branches to both. On reaching the inter-osseous ligament, it lies to the external side of the anterior tibial artery, but as it descends it inclines somewhat in front of that vessel, and so passes beneath the annular ligament of the ankle-joint to gain the dorsum of the foot. In this course the nerve gives off filaments to the muscles between which it lies, viz. the extensor proprius pollicis and tibialis anticus, and finally terminates in the situation just referred to by dividing into two ramusculi, of which one passes forwards and supplies the extensor digitorum brevis, and some of the inter-ossei, a few of its filaments uniting with the terminal branches of the peroneal nerve. The other division proceeds inwards over the first metatarsal bone, and ramifies on the first and second toes.

3. Several muscular branches are given by the peroneal nerve, in the upper part of the leg, to the peronei and extensor muscles; and, finally,

4. Some small cutaneous branches, which pass down towards the external ankle.

SYMPATHETIC NERVES.

971. The sympathetic nerves (*nervi intercostales; nerfs de la vie organique*, Bichât) form a system by themselves, characterised by many peculiarities which distinguish them from those nervous cords which are connected with the brain and the spinal cord. They extend from the cranium to the pelvis, lying along the vertebral column, and present a chain of ganglia connected by nervous filaments. In the infancy of anatomy the term "ganglion" was used to denote a swelling in the

thecæ of tendons, and even at the present day it is not unfrequently employed in the same sense. It was subsequently applied to the knotted appearance presented by certain nerves; but of late years a considerable latitude has been given to its signification by Gall and Spurzheim, who include within its comprehension the several masses of cineritious substance enclosed within the spinal cord and the brain, and which, according to their theory, are considered "ganglia of increase" to the formative fibres of the cerebral hemispheres.

Nervous ganglia may be divided into two orders: 1. Those observable on the posterior roots of the cerebro-spinal nerves, including that of the fifth nerve, as well as the swelling on the nervus vagus and glosso-pharyngeal. To this group may be added those connected with the branches of the cerebro-spinal nerves, such as the ophthalmic, otic, spheno-palatine, sub-maxillary, and naso-palatine ganglia. 2. The ganglia of the sympathetic nerves.

To the latter we confine our attention in the present section. Previously to Bichât's time, the sympathetic was considered as a nerve derived from the brain, and extended along the spinal column, presenting at stated intervals small knots or enlargements, but without interruption to its continuity. Bichât, however, supposed that the ganglia formed so many separate centres of nervous influence, and that each was connected with those near it by cords of communication. In this view of the matter, the sympathetic nerves may be compared to two chains, each made up of a number of separate links. The question then arises, whether the nervous filaments pass uninterruptedly through the ganglia or not? Lobstein examined a portion of the cord after having subjected it to maceration for a long time, and found that the filaments which issue from the first cervical ganglion passed without any interruption through the second and third, down to the first thoracic ganglion; moreover, that they continue still through the second, third, and fourth of this series, lying towards the inner side of each, mixed somewhat with other filaments, though not in any way interrupted. But what, it will be asked, are the "other" filaments here alluded to as being extraneous to those which pass down through the ganglia? Are they the terminations of the branches derived from the cerebro-spinal

nerves, according to the views of some anatomists, or the commencement of those which are given off from the ganglia to these nerves, according to others? This is altogether an open question — no answer can as yet be given to it. Each ganglion is invested by a thin investment of cellular tissue, which connects it with the surrounding structures, and forms a nidus for the vessels which supply its proper substance; but when this is removed, another lamella is found, forming an envelope for the filaments which enter and depart from the ganglion, as well as for that body itself. After long-continued maceration, we find the ganglion composed of delicate filaments, continuous at one extremity with the cord which enters it, and at the other with that which issues from it. The filaments seem as if unravelled, the interstices between them being filled with a greyish, semi-transparent, pulpy substance, which may be considered the peculiar matter of the ganglion. It has been supposed similar, if not identical with the cineritious substance of the brain; but that remains to be determined by future inquirers.

972. At one time the nervous cord now under consideration was said to arise from the sixth cerebral nerve, by filaments which pass down from it as it crosses the cavernous sinus; so that it would appear to be derived from the brain through the medium of the nerve just named. Some assign it a great number of roots derived from the spinal nerves, inasmuch as each of them is connected with it by filaments which appear to issue from them as they pass out of the intervertebral foramina. Were this opinion tenable, the sympathetic nerve may be likened to a creeping plant, which as it elongates acquires new joints, each of which takes root so as to form a new centre of increase. But we cannot now view the matter in this light. It is not at all correct to say, that this nervous cord arises, or starts from, or begins at, the sixth nerve; and nothing but the imperfection of language can justify the expressions, "the nerve arises from and proceeds to," or "the nerve gives off a branch which goes to form a plexus or a ganglion;" for every nerve, vessel, ganglion, or muscle — every organised part or structure, whether a compound organ or a simple filament—is secreted and deposited in its proper place by its own vessels, and no such elongation of it does or can take place as is implied by the

phrase, " it arises above, proceeds down, and terminates in such a manner." Now, as to the sympathetic nerve, so far from being in any way derived from the brain or the spinal cord, it is produced independently of either, and exists notwithstanding the absence of both. It is found perfectly formed in acephalous infants, therefore does not arise mediately or immediately from the brain; neither can it be said to receive roots from the spinal cord, for it is known to exist as early in the fœtal state as the cord itself, and to be fully developed even though the latter is altogether wanting.

It appears that whilst the organs of vegetative life are being formed, the sympathetic nerves are produced concurrently with them, and that as the growth of these parts proceeds from the circumference to the centre, and of the whole body from its lateral parts to the median line, the sympathetic nerves also conform to this general law. The two cords which represent them are placed one at each side along the sides of the spine; branches of communication connect them, on the one hand with the ganglia and plexus along the middle line in front of the spine, and on the other with the nerves of animal life. Thus we see that the sympathetic nerves, though forming a system in themselves, present two parts — 1. consisting of the ganglia and plexus in immediate connexion with the different organs, and placed in front of the spine, hence named prævertebral, viz. the semilunar ganglia in the abdomen, (and the plexus in connexion with it, viz. the mesenteric, hepatic, stomachic, aortic, &c.) the cardiac ganglion and pulmonary plexus in the thorax, and the pharyngeal plexus in the neck; 2. and another, represented by the two knotted cords extended along the sides of the spine connected with the preceding by numerous branches, and also with the nerves of animal life, being, as it were, interposed between the vegetative and the animal sphere, and most likely constituting the bond of sympathy between both, as well as between the different individual parts of the former.

973. When we examine these lateral cords, we find that they present each twelve knots or ganglia in the thorax, five in the abdomen, and four along the sacrum, with a single or azygos one at the extremity. So far they appear to correspond with the pieces of the spine. Seeing this in three regions of the body, we should be disposed to expect a similar conformity in the

cervical and cranial parts. We should perhaps be prepared to find the chain extended from the thorax along the cervical vertebræ, not in front, but at the sides of the bodies of the vertebræ, and therefore concealed from view by being enclosed within the foramina of the transverse processes. And in the cranial region we should feel disposed to keep up the analogy, by considering what is called the first or great cervical ganglion, as that which corresponds with the first cranial piece (the occipital bone); the spheno-palatine ganglion as being in relation with the second cranial piece; the ophthalmic with the third; and the naso-palatine as the counterpart at the anterior extremity of the osseous structure of the system, with the azygos already stated to exist at the extremity of the coccyx. Such a correspondence as this, however, cannot be fairly established. In the cranial region the approach to it is as near as could be expected, considering the difference of form and developement between the cranial and dorsal pieces; but in the neck we find but three ganglia, which are thrown forwards and out of line, so as to rank with the prævertebral rather than with the lateral part of the sympathetic system. And when we remove the anterior roots of the transverse process in the neck (which are but appendages to them, being in fact rudimentary ribs), we find upon the vertebral artery a plexus, but not a chain of ganglia. De Blainville says,* that in the elephant it has been found; but he does not give a reference to the person on whose authority the statement rests. Perhaps it may not be out of place to observe, that, as the organs of assimilation, secretion, and circulation, are placed in subordination to the sympathetic nerves, (or nerves of vegetative life, as they are frequently called,) the thoracic and abdominal parts of the sympathetic system are highly developed; and that the cervical is much less so, having fewer ganglia and smaller plexuses, whilst the nerves of animal life are numerous and large, inasmuch as the upper part of the alimentary canal and the larynx are strictly voluntary organs, and through the medium of their proper nerves are subjected to the immediate control of the will. Again, the small and large intestines are supplied exclusively by the sympathetic nerves, as far as the rectum; there the nerves of animal life begin to be received, and towards its

* Cours d'Anatomie et de Physiologie Comparée.

lower extremity predominate over the others, giving it, through the agency of its sphincters and levator, a strictly voluntary power. Concurrently with this change, as if by a principle of compensation, the sacral ganglia diminish in size, and become uncertain in their number.

974. The consistence of the sympathetic nerves is very variable, some being rather firm and dense, others so tender as to be easily torn, and so soft as to have received the name of "nervi molles." Their colour, and that of their ganglia, varies. They are not of that clear whiteness which the cerebro-spinal nerves present; their tinge is like that of mother-of-pearl. The thoracic ganglia are of the same aspect, but the semi-lunar and the first cervical are reddish, particularly the former, which in many cases looks almost fleshy.

975. In order to facilitate the description of the sympathetic nerves, it becomes necessary to consider them as divisible into superior, middle, and inferior portions, corresponding with the cervical and cranial regions, the thoracic, and the abdominal. As they are symmetrical, the description of one will suffice for both. Each nerve consists, in most instances, of three cervical ganglia, twelve dorsal, five lumbar, and four or five sacral, with their cords of connexion. To these should be added some small ganglia in the cranium; viz. the ophthalmic or lenticular in the orbit, the spheno-palatine or the ganglion of Meckel, the submaxillary, the otic or auricular as described by Arnold, the cavernous, the naso-palatine as indicated by Cloquet, and one described by Ribes as being placed on the branch of communication between the anterior cerebral arteries. We shall commence with the superior cervical ganglion.

SUPERIOR CERVICAL GANGLION AND ITS BRANCHES.

976. The superior, or great cervical ganglion, fig. 164, *a*, is elongated and fusiform, so as to extend from two or three lines beneath the base of the skull, to the transverse process of the third or fourth cervical vertebra. Its length varies considerably in different cases, being from an inch and a half to two inches, or even more. Lobstein found it in one case to measure thirty lines; its thickness is about two or three lines. It lies on the rectus anticus muscle, concealed by the jugular vein and carotid

Fig. 164.

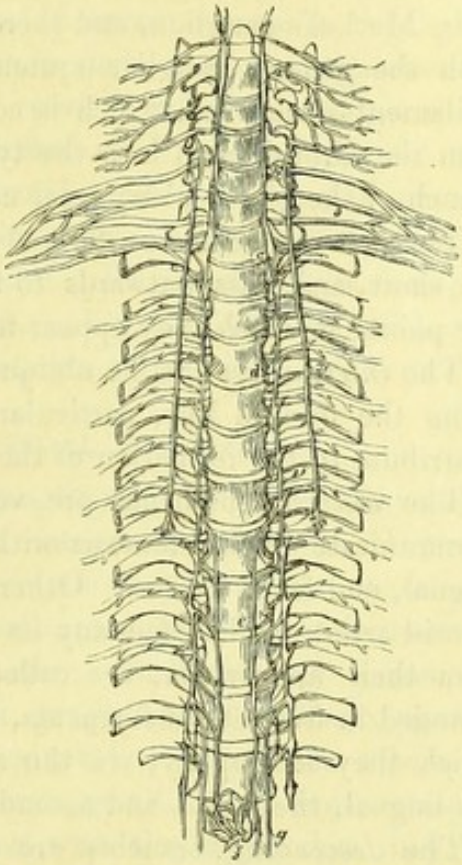

artery. Branches proceed from it in every possible direction, which may be arranged into sets as follow—ascending, descending, external, internal, and anterior.

The *ascending* branches are two in number: they enter the foramen caroticum, and form round the artery a plexus (*plexus caroticus*, v. *cavernosus*). Upon one of the filaments forming this plexus or interlacement round the artery, a ganglifform enlargement sometimes is seen at the first curvature of the vessel, and which has been termed the carotid ganglion (ganglion caroticum). From the plexus filaments are traced upwards connecting it with the sixth, fifth, and third nerves, and the ophthalmic ganglion, as follows:—two filaments pass upwards to communicate with the sixth nerve in the cavernous sinus;—one or two may also be traced along the carotid artery as far as the minute ganglion placed on the arteria communicans, and from this point filaments extend upon the coats of the artery throughout its ramifications; another terminates in the pituitary gland and infundibulum; one joins the third pair before it passes into the orbit, and one or two extend to the ophthalmic branch of the fifth. A filament also ascends to the nasal branch of the ophthalmic nerve, and is prolonged to the ophthalmic ganglion; and another communicates with the descending branch of the Vidian nerve. We may, however, consider these last-named branches as being derived, the one from the ophthalmic ganglion, and escorted for a while by the fifth nerve, in order to be ultimately prolonged to the carotid plexus, so as to connect the ganglion here named with the rest

of the system; and the other, viz. the inferior branch of the Vidian, as being continued to the same point, in order to associate Meckel's ganglion, and thereby the naso-palatine ganglion, with the general gangliac system. Finally, from the plexus a filament is derived, which is conducted by a minute aperture from the carotid canal into the tympanum to join the tympanic branch of the glosso-pharyngeal nerve.

The *external* branches derived from the first cervical ganglion are short, and pass outwards to the superior cervical nerves, at the points at which they appear in front of the neck.

The *internal* set incline obliquely inwards to the parts placed along the middle line, particularly to the pharynx, where they contribute to the formation of the pharyngeal plexus.

The *anterior* branches are very numerous; some of them communicate by anastomosis with the vagus, glosso-pharyngeal, lingual, and facial nerves. Others pass forwards on the external carotid artery, and accompany its different ramifications. These, from their appearance, are called *nervi molles;* they may be arranged in five sets of filaments, corresponding with the arteries which they accompany, viz. the superior thyroid, the laryngeal, the lingual, the labial, and ascending pharyngeal.

The *descending* branches are divisible into two sets. The first are two or three which unite to form the superficialis cordis nerve; the other is the cord by which the superior cervical ganglion is connected with the middle or inferior one, forming the continuation of the sympathetic nerve. It is in general a long and thin branch, but in some instances its place is supplied by two filaments running parallel. It descends behind the sheath of the vessels, resting on the rectus anticus and longus colli, and opposite the fifth cervical vertebra it joins the middle ganglion; but as this sometimes does not exist, particularly at the right side, the nerve continues its course to the third ganglion. This branch usually gives filaments which communicate with the second and third cervical nerves, with the par vagum and the cardiac nerves.

MIDDLE CERVICAL GANGLION.

977. The middle cervical ganglion, fig. 164, *b*, when it exists (which is not always the case), is small, and very variable in its shape. It will be found on a level with the transverse process of

the fifth or sixth cervical vertebra, where it is concealed by the sheath of the great vessels. It is so constantly in relation to the inferior thyroid artery, that Lobstein names it "ganglion thyroideum." It receives the branch of communication sent down to it from the superior cervical ganglion, and gives one which connects it with the inferior. From its external side branches pass to the third, fourth, and fifth cervical nerves; some proceed inwards upon the thyroid artery, others to communicate with the recurrent nerve. Finally, from its fore part issues the middle cardiac nerve, and some filaments which join the plexus on the subclavian artery.

INFERIOR CERVICAL GANGLION.

978. The inferior cervical ganglion fig. 164, *c*, is also variable in its form, being usually single, but sometimes double. It lies in the angle between the transverse process of the last cervical vertebra and the neck of the first rib, close by the vertebral artery, which almost conceals it from view. It receives the communicating branch from the middle ganglion, and sends down four or five, which pass, some in front, some behind the subclavian artery, and end in the first thoraic ganglion; in some instances it is placed in such close contact with the latter, that they become united inseparably, as if they were but one nervous mass. Some branches pass outwards, which soon join the spinal nerves that form the axillary plexus, particularly the seventh, eighth, and first dorsal; whilst others pass inwards, to contribute to the formation of the pulmonary plexus. An ascending branch enters the canal formed by the chain of foramina in the transverse processes of the cervical vertebræ, and forms a *plexus* (*vertebral*) upon the vertebral artery. The filaments of this interlacement can be traced upon the vessel up to the base of the skull, at each step of its ascent maintaining communications with the spinal nerves, from the fifth up to the first. Finally, the inferior cardiac nerve may be considered as the anterior branch of the ganglion.

Before we proceed to describe the thoracic portion of the nerve, it may be well to conclude our notice of the cranial part, by describing the ophthalmic ganglion, the spheno-palatine, the naso-palatine, otic, and submaxillary ganglia with their branches.

OPHTHALMIC GANGLION AND ITS BRANCHES.

979. The ophthalmic ganglion, fig. 159, *a*, is frequently called "lenticular" (lens or lenticula, a lentil-seed), and "ciliary" (ganglion ciliare) from the nerves which issue from it; it lies within the orbit, about midway between the optic foramen and the globe of the eye, and placed between the external rectus muscle and the optic nerve; it is very small, and not easily found, owing to its being embedded in the soft adipose tissue which fills up the interstices between the different parts within the orbit.

Its branches are the following:—From its anterior border from sixteen to twenty delicate filaments issue, which proceed forwards to the surface of the sclerotica, and pierce it through minute foramina: these are the *ciliary nerves*, *b*. In their course to the globe of the eye they are accompanied by one or two filaments derived from the nasal nerve, but they do not form a plexus or an interlacement; they become, however, disposed or divided into two fasciculi, one above, the other below the optic nerve, the latter being the more numerous. They pass along between the choroid membrane and the contiguous surface of the sclerotica, lodged in grooves in the latter; and on reaching the ciliary ligament they pierce it, some few of them appearing to be lost in its substance, whilst all the rest pass inwards, and ramify in the iris.

The posterior border of the ganglion, which seems as if terminated by two angles, receives two branches, of which one, *c*, passes downwards and forwards from the nasal branch of the ophthalmic nerve: the other branch, *e*, is shorter than the preceding, and is derived from the inferior oblique branch of the motor nerve of the eye; it joins the postero-inferior angle of the ganglion. A third branch, *d*, reaches the ganglion usually in company with the long or upper root, which appears to be the medium of communication with the rest of the gangliac system, being derived from the carotid or cavernous plexus.

SPHENO-PALATINE GANGLION AND ITS BRANCHES.

980. The spheno-palatine, or Meckel's ganglion, fig. 159, *f*, is very deeply seated, being placed in the pterygo-maxillary

fossa, close by the spheno-palatine foramen; its size is small, its colour reddish, and form variable, being sometimes triangular, but still convex upon its outer surface; sometimes it is heart-shaped. Its branches may be divided into the following sets: superior, inferior, internal, and posterior.

The superior branches are two, which pass downwards from the superior maxillary nerve as it passes across the pterygo-maxillary fossa previously to its entrance into the infra-orbital canal.

The *inferior* or *descending* branches, fig. 159, *h*, are three; they form the *palatine* nerves, which are so called from their destination.

The *great* palatine nerve passes directly down, to reach the posterior palatine canal. In its descent, whilst in the canal, one or two small filaments are sent off through the nasal plate of the palate bone, and ramify in the pituitary membrane; these lie between the inferior and middle turbinated bones; but lower down a small branch is given off, which, after passing through a similar osseous foramen, enters the velum palati and the amygdala. Finally, after having passed through the canal, the nerve turns forwards beneath the arch of the palate, where it divides into two branches, fig. 155, *d*, which ramify in the soft structures of the palate and gums, where they communicate with the terminal filaments of the naso-palatine ganglion.

The *middle* palatine nerve descends parallel with the preceding, but in a separate canal, which opens before the hamulus of the pterygoid process. The nerve on reaching this point divides into three or four filaments, which ramify in the soft palate and tonsil. The *small* palatine nerve runs in a similar direction, but further back, and is distributed to the same parts.

The *internal* or *spheno-palatine* branches, fig. 155, *a a*, three or four in number, pass inwards through the foramen from which they take their name, to reach the nasal fossæ. Two or three of these run upon the spongy bones; the other, *c*, from its destination is named "naso-palatine;" it passes obliquely downwards and forwards along the septum, and reaches the upper orifice of the anterior palatine canal, where it terminates in the *naso-palatine ganglion*, *b*. This ganglion is very small, and placed in the anterior palatine canal; it is a single or azygos

ganglion, and receives by its upper border the naso-palatine branch of each side, which converge to it; it gives off two or three small filaments, which descend to the membrane of the palate.

VIDIAN NERVE.

981. The *posterior* branch of Meckel's ganglion is called pterygoid, or Vidian; it passes back through the pterygoid or Vidian canal in the base of the process of that name. Having reached the foramen lacerum anterius, it divides into two branches, one of which inclines downwards and outwards, and enters the carotid canal, where it terminates in the carotid plexus, and so connects the spheno-palatine ganglion with the first cervical: the other branch enters the cranium, but does not pierce the dura mater. It runs outwards and backwards beneath that membrane, lodged in a groove on the upper surface of the pars petrosa, and having passed through the hiatus Fallopii, reaches the aquæductus Fallopii, where it becomes applied to the inferior surface of the facial or portio dura nerve, which it accompanies to within two lines or so of its exit from the stylo-mastoid foramen. The Vidian nerve at this point turns forwards into the tympanum, where it runs between the long process of the incus and the handle of the malleus, assuming the name of *chorda tympani.* In the next place the nerve descends, and escapes through the Glasserian fissure, inclining at the same time forwards and inwards, fig. 159, *i*, so as to come into contact with the gustatory nerve, which it accompanies along the inferior maxilla, until it approaches the submaxillary gland. When near the gland, the chorda tympani separates from the gustatory nerve, and descends upon the gland, and terminates in a small ganglion placed upon that body.

The *submaxillary* ganglion, fig. 151, *a*, so called from its position and relations, rests upon the gland just named; it is very small; receives the Vidian nerve at its posterior border, and two filaments from the gustatory nerve at its upper side; also one or two filaments from the sympathetic nerve, accompanying the facial nerve, pass upwards to join it. Two sets of filaments pass forwards from the ganglion; one joining the gustatory nerve, the other accompanying the duct of the submaxillary gland.

The Vidian nerve is here described as a continued thread ex-

tending from Meckel's ganglion to the submaxillary ganglion: this is done merely to give precision to its description and anatomical relations. But it is not to be thence inferred that it has no connexion with the portio dura and gustatory nerves, for in most dissections filaments appear to pass from the one to the other; neither has any question been raised as to the function of this nerve, or of the other branches of Meckel's ganglion.

THE OTIC GANGLION.

982. This body (*ganglion oticum*, v. *auriculare*) was discovered by Dr. Arnold of Heidelberg, and is sometimes named after him. It is a small reddish-gray, soft ganglion, situated a little below the foramen ovale, on the inner side of the third division of the fifth nerve, nearly at the point where its motor or smaller root joins the larger or sensitive one. Thus, whilst its outer side is supported by the nerve, the inner is in relation with the cartilaginous part of the Eustachian tube, and the origin of the circumflexus palati muscle; and the middle meningeal artery lies behind it. To the ganglion filaments are traced from three sources, which may be considered as its roots; 1st, from the fifth nerve, particularly its smaller division, also from its internal pterygoid branch; 2nd, from the sympathetic system a filament joins it, derived from the plexus that surrounds the middle meningeal artery; 3rd, the small petrosal branch, prolonged from the tympanic branch of the glosso-pharyngeal nerve, the course of which has been indicated in the description of the last-named nerve. From the ganglion, a branch passes backwards and upwards to the tensor tympani muscle, another obliquely forwards to the tensor palati, and two descend to anastomose with the anterior auricular nerve. (Arnold.)

THORACIC GANGLIA AND PLEXUS.

983. The thoracic portion of the sympathetic nerve comprises, first, a series of ganglia, twelve in number, disposed in a regular series upon the heads of the ribs or in the intercostal spaces, and connected by short nervous cords passing from one to the other; secondly, of the plexus, formed along the middle line, for the supply of the heart and lungs by the sympathetic and pneumo-gastric nerves, which present this remarkable dif-

ference, that the pulmonary plexus is formed for the most part by the latter, and the cardiac by the sympathetic nerves. The latter will be noticed first, from their connexion with the ganglia of the neck, already described.

CARDIAC PLEXUS AND GANGLION.

984. The heart receives its nervous influence by branches derived principally from the cervical ganglia at each side, to which are added others from the vagus nerve and the recurrent. The nerves of each side communicate variously with one another, and all by interlacing behind and upon the aorta form a plexus from which filaments descend to the substance of the heart. The plexus, from its situation, may be called "aortic," but from the destination is usually named "cardiac." The interlacement between the nerves is so complex and diffuse that it is considered by Mr. Swan and others as divisible into portions, or separate plexuses, viz. "the right and left lateral cardiac, the ventricular and auricular." By the cardiac nerves of each side an interlacement or plexus is formed behind the aortic arch, above the trunk of the right pulmonary artery,—plexus cardiacus magnus, profundus. "Anastomosis illa valdè insignis, quæ inter utriusque lateris cardiacorum nervorum truncos sub aortæ curvaturâ paulo supra cor conficitur."—Scarpa. At the concavity of the aortic arch, between it and the pulmonary artery, a similar interlacement exists; and in this situation, to the right of the ductus arteriosus, a gangliform enlargement is usually found, named by Wrisberg the cardiac ganglion (*ganglion cardiacum*). It is rounded and elongated, from half to three quarters of an inch long; it appears soft, but is of moderate consistence; its colour is that of mother-of-pearl.

From this plexus three orders of filaments proceed; some pass backwards, and join the pulmonary plexus, others turn forwards, to gain the fore part of the aorta; but the descending branches, by far the most numerous, pass to the heart itself, where they are disposed in two sets, which take the course of the coronary arteries, and are thence termed the coronary plexus. The branches of the *right* or *anterior coronary plexus*, pass forwards between the aorta and the pulmonary artery, and ramify on the right ventricle and auricle, the greater number of them being directed towards the right border of the heart, where they communicate with the branches of the posterior

plexus. The *posterior coronary plexus* will be found to ramify on the inferior and posterior surface of the left ventricle and auricle. These nerves were at one time supposed to be confined to the arteries which they accompany; but the researches of Scarpa have clearly shown that they pass away from the vessels in many places, and enter the muscular structure of the heart.

CARDIAC NERVES.

985. The cardiac plexus receives at its upper extremity the cardiac nerves of each side derived from the sympathetic, and some branches from the pneumo-gastric and its recurrent.

The superior cardiac nerve (*superficialis cordis*) commences by three or four filaments from the first cervical ganglion, and usually receives one or two from the trunk of the sympathetic nerve. It is very small and delicate; it descends along the neck behind the sheath of the vessels, taking the direction of the carotid artery; it crosses the inferior thyroid artery, forming a plexus upon it; it enters the thorax, crossing the subclavian artery, and is guided by the innominata to the aortic arch, where it terminates in the plexus. In its course the nerve anastomoses with the middle and inferior cardiac nerves, and with branches of the vagus and recurrent. In some instances the nerve is found to divide at the lower part of the neck into three branches, of which a very small one inclines inwards, and contributes to form a plexus round the inferior thyroid artery: some join the middle, or great cardiac nerve, whilst the remainder form with the recurrent nerve a plexus, from which branches descend to the great cardiac plexus. The middle cardiac nerve (*cardiacus magnus*) on the right side is the largest of the set; on the left it is sometimes wanting. It descends from the middle cervical ganglion, or from the trunk of the sympathetic, should the former be wanting, and after passing in front of the subclavian artery inclines backwards, to reach the posterior surface of the aortic arch, where it terminates in the cardiac ganglion. The *inferior* cardiac nerve arises from the last cervical ganglion, by several filaments which pass behind the subclavian artery, but afterwards cross in the front of the aorta, the greater number of its filaments reaching the anterior coronary plexus, the rest joining with the preceding. On the

left side the inferior cardiac nerve is sometimes larger than the others. We have here described the nerves and the ganglia as we ordinarily find them. The names employed, being taken from a general average of cases, will be found not to agree with the distribution in certain cases. Upon this point, Mr. Swan* has very justly remarked, "If the sympathetic and its ganglia corresponded in different subjects, and gave off similar branches to form the cardiac nerves, it would be in every respect advantageous to have a specific name for each nerve; but as there is so much uncertainty, particularly as to the extent both of the prolongations of the sympathetic and its ganglia, and consequently as to the situation and number of the branches given off from these, it will be much less perplexing to the student, and quite as conducive to every useful purpose, to call all the nerves arising from the sympathetic and par vagum in the neck, and proceeding to the heart and its large vessels, the right and left lateral cardiac plexus."

986. The thoracic ganglia, as has been said, lie on the head of the ribs or in the intercostal spaces, covered by the pleura. Considering each of them as a centre from which branches proceed, we observe a branch of communication passing upwards to the ganglion above it, and downwards to that below it, so as to continue the series. Externally one, or, more commonly, two filaments pass from each to the contiguous intercostal nerve, so as to connect the nerves of organic with those of animal life. The internal branches pass towards the middle line, some reaching the side of the trachea, and ending in the pulmonary plexus; others, ramifying on the œsophagus and aorta, form what may be called the thoracic plexus.

SPLANCHNIC NERVES.

987. Branches from the sixth to the ninth thoracic ganglia, and sometimes to the tenth inclusively, pass obliquely downwards and inwards on the sides of the bodies of the vertebræ, and unite into a single trunk, fig. 164, *e*, (*nervus splanchnicus major*,) which passes in a slight longitudinal fissure between the fibres of the crus of the diaphragm, and terminates in the semilunar ganglion, *f*. The anterior branches of the tenth and eleventh unite into a small nerve, *g*, (*splanchnicus minor*,) which

* A Demonstration of the Nerves of the Human Body, by Joseph Swan, p. 6.

pierces the crus of the diaphragm external to the larger nerve, with which it communicates by branches, and finally terminates in the renal plexus.

ABDOMINAL GANGLIA.

988. The abdominal part of the sympathetic nerve consists of the semi-lunar ganglia and solar plexus, with the primary and secondary plexus which issue from them; and, secondly, of the direct continuation of the nerve. The former may be called the prævertebral part, from its position before the spine. Its ramifications are extensive and numerous, being diffused throughout the whole of the chylopoietic viscera, all of them being either immediately or remotely connected with the semi-lunar ganglia and solar plexus, from which their nervous filaments spread out like rays from a common centre. Their arrangement, however, is very easily understood by any one who recollects the distribution of the arteries to the viscera, inasmuch as these vessels support and conduct the nerves in their passage to the different organs. The nervous filaments interlace in their passage, so as to form a plexus previously to entering the substance of the organ; and the plexus is named from the parts within or upon which its ramifications are spread. The continuation of the nerve itself lies along the lumbar vertebræ, at each side representing those two lateral cords which are placed along the spine within the thorax.

SEMI-LUNAR GANGLIA.

989. The semi-lunar ganglia are two small reddish masses, placed upon the crura of the diaphragm, close beside the cœliac artery. These are in the first place connected at their upper and outer borders with the great splanchnic nerves, which may be said to terminate in them — the point of junction being readily perceived by a marked difference of colour. The ganglia are connected by a transverse mass of similar structure, or are so close as to appear united at the lower surface of the cœliac artery. The upper border of each ganglion is concave, the lower convex; hence their name "semi-lunar." But the two bodies so named, and in which the great splanchnic nerves terminate, form only a part of the nervous structure placed in this situation. The anterior border of each will be found con-

nected with eight or ten smaller masses of a structure similar to themselves, which rest upon the crura of the diaphragm and the aorta, each being connected to the other by slips and by filaments, so as to enclose spaces. Now, to this aggregate of these islets of nervous substance the term *solar plexus* is applied, from which, as from a common centre of radiation, proceed filaments, accompanying the different arteries which spring from the aorta, constituting as many secondary plexus as there are organs to be supplied. These we shall arrange in the same order as the arterial branches :—

990. The *phrenic plexus* (sub-diaphragmatic) consists of filaments which accompany the phrenic artery. They will be found upon the crus of the diaphragm, passing upwards from the upper margin of the plexus ; they are usually three or four, and very delicate ; they form a slight interlacement with one another by small branches of communication, and with the phrenic nerve by a filament which joins it, or rather the terminal branch of it, which ends in the solar plexus. The phrenic plexus gives branches to the crura and broad part of the diaphragm.

991. The *cœliac plexus* consists of numerous large and close-set branches, which issue directly from the solar plexus, projecting forwards a little round the cœliac artery. Like the vessel just named, the plexus separates into three divisions, following the coronary, hepatic, and splenic arteries.

992. The *coronary* or *stomachic plexus* consists of numerous filaments, which are enclosed within the small omentum, and are guided by the coronary artery to the stomach. They form an interlacement by branches of communication one with the other, also with the terminal branches of the pneumo-gastric nerves, and finally spread out upon both surfaces of the stomach.

993. The *hepatic plexus* consists of a great number of branches, which accompany the hepatic and portal vessels, enclosed like them within the small omentum. These branches form a complex interlacement, which is joined by some filaments from the pneumo-gastric nerve. The greater part of the plexus reaches the transverse fissure of the liver, and there enters its substance, into which they can be traced for some way, apparently more connected with the arteries than with the veins. Another part of the plexus takes the course of the pyloric artery, and descends to the right extremity of the stomach. And a third

set of filaments, following the gastro-duodenalis artery, reaches the under surface and the great curvature of the stomach. Some of these incline outwards into the duodenum, and backwards to the pancreas, in company with the ductus choledochus. The cystic artery is also attended by some delicate branches, which ramify in the gall-bladder.

994. The *splenic plexus* consists of comparatively few branches, and the interlacement which they form is not so close as in the preceding instances. It accompanies the splenic artery, and gives off several filaments to the pancreas. Previously to its entering the spleen, some branches are reflected from it, along the vasa brevia, to the great curvature of the stomach.

995. The *aortic plexus* is the direct continuation of the solar; its branches form upon the aorta a complex net-work, which can be traced along the iliac vessels; its principal offsets are the following:—The *superior mesenteric plexus* is a broad, expanded, and complex interlacement of nervous filaments, enclosed between the layers of the mesentery, and accompanying the mesenteric artery to the small intestines on the one hand, and on the other to the cæcum and colon, guided by the colic arteries. The *inferior mesenteric plexus* follows the inferior mesenteric artery: at its commencement its branches communicate with those of the preceding plexus, and towards its lower part, where it descends into the pelvis, it receives an increase from the nervous interlacement upon the iliac vessels; and farther down, where it becomes lodged between the layers of the meso-rectum, it is connected with the hypogastric plexus.

996. The *renal plexus* of each side differs from the preceding, inasmuch as it receives, in addition to the branches which follow the renal artery, the small splanchnic nerve. Its divisions accompany those of the artery to the fissure of the kidney. A minor plexus, similarly formed, passes to the supra-renal capsule.

997. The *spermatic plexus* consists at each side of some minute filaments, traceable from the renal plexus, and also from the aortic; they accompany the spermatic arteries in their course and distribution.

LUMBAR GANGLIA.

998. Having traced the various ramifications of the prævertebral ganglia and plexus of the sympathetic nerves in the abdomen, we recur to the lateral cords. In the thorax we find the chain which they present at each side extended in such a way that the ganglia correspond with the heads of the ribs or the intervening spaces. When continued into the abdomen (which they enter by passing beneath the ligamentum arcuatum proprium), the two nerves incline forwards and inwards, so as to lie each along the inner border of the psoas muscle. The lumbar ganglia vary much in number: there are usually, however, four or five. They are tapering, and also smaller than those in the thorax, their connecting branches being at the same time longer and more slender. From space to space branches pass outwards from the ganglia, and, insinuating themselves under or between the fibres of the psoas muscle, join the anterior branches of the spinal nerves, which form the lumbar plexus. Another set of filaments passes inwards in front of the aorta, and joins the aortic plexus, which they in this way contribute to form.

SACRAL GANGLIA—HYPOGASTRIC PLEXUS.

999. From the last lumbar ganglion, at each side, nervous branches extend down over the border of the pelvis, inclining inwards as they descend upon the anterior surface of the sacrum. There are usually four, sometimes but three, sacral ganglia at each side, with a terminal or azygos one at the coccyx. The branches from the sacral ganglia proceed in opposite directions, like those of the preceding sets—some externally, to join with the branches of the sacral plexus, others internally, which are of little importance, as they merely establish a communication with the parallel cord of the opposite side. The anterior filaments are numerous and important, as they contribute to form the *hypogastric plexus*, from which the pelvic viscera receive branches. This is a complex and extended interlacement, placed deeply in the pelvis, part of it being contained within the mesorectum, where its fibres are continuous with those of the inferior mesenteric plexus, part in the false ligaments of the bladder, or in the broad ligaments of the uterus. In it we find a mixture of branches from nerves of both systems, viz. from the sacral ganglia, the inferior mesenteric, and aortic plexus; and in the next place

from the vesical, uterine, and hæmorrhoidal nerves, derived from the spinal nerve (sacral plexus). The offsets from the hypogastric plexus follow the arteries in their course to the pelvic viscera, viz. to the rectum, bladder, vesiculæ seminales, uterus, vagina, &c.

APPENDAGES OF THE EYE.

1000. Before we proceed to examine the globe of the eye, we have to notice and describe certain accessory structures which are placed in relation to it, and are called its "appendages." All these are lodged either within the orbit, or in its immediate vicinity. The orbit has been already described (sect. 171). The mode of opening the orbit, and of exhibiting these different parts, has been indicated (sect. 367); the muscles (369—343), the ophthalmic artery (640), the ophthalmic vein (758), the nerves (897—899, and 914—979).

The appendages of each eye, in addition to the muscles, ophthalmic artery, vein, and nerves already noticed, comprise the eye-brow, eye-lids, and the lachrymal apparatus.

EYE-BROWS.

1001. The eye-brows (*supercilia*) are the arched ridges which surmount the upper border of the orbits, extending from near the root of the nose to the temples. They consist of integument, rather thickened, and studded with short hairs, which are inserted obliquely into it; also of a lamella of adipose tissue, and of the orbicularis and corrugator supercilii muscles. They form the boundary between the forehead and the eye-lids.

EYE-LIDS.

1002. The eye-lids (*palpebræ*) are two thin movable curtains placed in front of the eye, and calculated to conceal it, or leave it exposed, as occasion may require. The upper lid, which is larger and more movable than the other, has a muscle exclusively intended for its elevation, whilst the lower one is raised up only by the action of the inferior half of the orbicular muscle. They are joined at the outer and inner angles of the eye (*canthi*); whilst in the interval they are separated by a transverse slit (*fissura palpebrarum*). Externally, the lids are covered by integument, which is thin and delicate; internally, they are

lined by the conjunctiva, which is more vascular than where it passes over the ball of the eye. Between these tegumentary membranes are placed the fibres of the orbicular muscle in both lids, and those of the levator palpebræ in the upper one, together with the tarsal cartilages, and along the margins of the lids the eye-lashes. The free margin of the eye-lids is straight, and rounded towards the inner angle for a distance of about two lines and a half, the caruncula lachrymalis being there interposed between them. At the point just indicated, the borders of the lids become thicker at the same time that their surfaces become arched, the external one being convex, the internal concave, inasmuch as it rests on the convexity of the globe of the eye. Now the borders of the lids in all this part of their extent, which is about four-fifths of their breadth from within outwards, are slightly bevelled off, so that when closed they come into contact only at the outer or cutaneous line. By this conformation a triangular groove is produced, whose sides are formed by the free margins of the lids, and base by the globe of the eye. Along this the tears appear to be conducted towards the inner angle, where the ducts are placed to receive them. At the union of the straight with the arched part of each lid will be seen a very small elevation, pierced by a minute foramen (punctum), which leads into the lachrymal ducts.

TARSAL CARTILAGES.

1003. The tarsal cartilages (*tarsi*) are two thin lamellæ of fibro-cartilage, placed one in each lid: the lower cartilage is narrow, about two lines in breadth, elongated, and nearly of equal breadth from side to side; that of the upper lid is four or five lines broad at the middle, but narrows to a point at the lateral margins. The ciliary, or contiguous margins of the cartilages are rather thick, bevelled off as above stated, and covered by the conjunctiva, where it is continuous with the external tegument; but the opposite margins are thin and attached to the orbit through the medium of a thin cellulo-fibrous lamella, prolonged obliquely to its border, where it becomes continuous with the periosteum, and is called the broad ligament. The cartilages extend inwards no further than the puncta, and there they become connected with the fibrous lamellæ, into which the tendon of the orbicularis muscle

divides; and externally they become gradually thinner, and are connected with a fibrous lamella, which attaches them to the margin of the orbit. These means of connection are sometimes called ligaments (*ligamentum tarsi, internum* et *externum*).

EYE-LASHES.

1004. Along the margin of each eye-lid, at the line of junction of the skin with the conjunctiva, are placed two or more rows of hairs, called *cilia*, or *eye-lashes*. They are more closely set, and also longer, in the upper than in the lower lid, and at the middle of each than towards their angles; they become thin and scattered in the interval between the puncta and the inner commissure. They are curved in such a way that those of the upper lid present a convexity directed downwards and forwards—those of the lower, upwards and forwards, by which they come into apposition sufficiently for the protection of the eye, even before the lids come into close contact.

MEIBOMIAN GLANDS (GLANDULÆ MEIBOMII).

1005. These are sebaceous follicles placed between the conjunctiva or lining membrane of the lids and the tarsal cartilages. They are very minute; their colour, or rather that of the secreted matter, being yellow, distinguishes them from the other structures. They are small culs-de-sac disposed in rows, running in parallel lines, and vertically from the attached to the free margin of each cartilage, along which they open by minute pores; the cartilages present grooves upon their surface corresponding with the rows of the follicles. There are usually from thirty to forty of them in the upper lid, and about half that number in the lower.

Along the line of the eye-lashes, the external tegument of the lids changes its appearance and characters; it becomes thin and soft, so as to resemble mucous membrane. It is obviously prolonged from the free margin to the inner surface of the lids, and from these it is reflected over the fore part of the globe of the eye. Moreover, through the puncta and lachrymal ducts above alluded to, it is prolonged into the nasal cavity. At the inner angle or commissure of the lids, which is more open than the external one, the conjunctiva forms a fold,

which encloses some fine cellular tissue, a delicate plate of fibrous structure, and also some mucous follicles, which, together, may be said to represent a third eye-lid in a rudimentary form. These are known as the plica semi-lunaris and caruncula lachrymalis.

PLICA SEMI-LUNARIS.

1006. This is a small angular fold of the conjunctiva, seen resting on the globe of the eye, at the inner commissure of the lids; its base, which is concave, looks outwards, the apex inwards. About a line to the inside of its base rises up the *caruncula lachrymalis*. Its form is conical; its summit corresponds with the inner angle of the lids; it looks red and fleshy. It consists of a cluster of delicate mucous follicles, from which an unctuous matter exudes; upon the surface are seen some minute hairs. The caruncula is not unfrequently included amongst the lachrymal apparatus, from its being supposed to assist in directing the tears into the puncta: such however, is not the use of the third lid, of which this is a rudiment.

LACHRYMAL APPARATUS.

The lachrymal apparatus consists of the lachrymal gland, puncta, and ducts, the lachrymal sac and its duct.

LACHRYMAL GLAND.

1007. The lachrymal gland is placed at the upper and outer part of the orbit, near its anterior border, corresponding with the lachrymal fossa in the orbital plate of the frontal bone. The gland is convex upon its upper surface, where it is in apposition with the wall of the orbit, and with which it is connected by a fibrous lamella, described by Sœmmering as a ligament; its under surface is concave, where it rests upon the globe of the eye, the recti muscles (superior and external) interposing. Its length is three quarters of an inch, its breadth half an inch; the inner border is compressed and thin, the external one being a little thicker. The gland is divisible into two lobes, which are so closely connected that the line of separation (which is not complete) is not at first observed. When the cellular tissue which invests it is removed, it is at once perceived to

belong to the class of conglomerate glands, being composed of a number of granules, each forming a secreting structure, which produces the tears. From the granules arise excretory ducts, which emerge from the gland at its anterior border, run downwards and inwards close to the conjunctiva, between it and the broad tarsal ligament, and open in a row upon its free surface, about three lines above the upper margin of the tarsal cartilage; these ducts are usually seven in number.

PUNCTA LACHRYMALIA AND LACHRYMAL DUCTS.

1008. Where the external margin of the caruncula is in apposition with each lid, a minute foramen will be observed (*punctum lachrymale*). The puncta are situated where the curved and straight parts of the lids meet, in the summit of a small papilla; they form the openings of two canals (*lachrymal ducts*, *canaliculi lachrymales*) which lead into the sac, or reservoir, for the reception of the tears. The superior canal is longer than the other: if a thin bristle be passed into it, it will be found first to ascend a little, and then to turn obliquely downwards and inwards. The inferior one descends a little, and then turns inwards with a very slight ascent: both open into the external and anterior side of the lachrymal sac, generally by two distinct orifices, which are close together, but sometimes by a common duct.

LACHRYMAL SAC.

1009. The lachrymal sac (*saccus lachrymalis*) is a membranous reservoir, placed in a groove formed for it in the os unguis and nasal process of the superior maxillary bone, at the inner canthus of the eye. Its form is oval, terminating superiorly in a cul-de-sac, but inferiorly it is prolonged into a tube (the nasal duct); at its superior and external side it receives the lachrymal ducts. The sac is crossed by the tendon of the orbicular muscle, being at the same time covered by its fibres as well as by its reflected tendon. It consists of two layers of membrane, united by cellular tissue, one of which is a mucous lining continuous below with that of the nasal fossæ, and above with the conjunctiva, through the medium of the lachrymal ducts; and the other a thin fibrous membrane, serving at the same time as periosteum for the bone in which it is lodged.

NASAL DUCT.

1010. The nasal duct (*ductus ad nasum*) is about six lines in length in the recent state, its direction being downwards, backwards, and a little outwards. Communicating above with the lachrymal sac, it terminates in the inferior meatus of the nose by an oblique slit or orifice, which is surrounded by a small fold of the pituitary membrane. It often appears as if constricted at the middle, at the same time that it presents a slight curve, whose convexity is turned forwards. The osseous structure here consists of the os unguis, the superior maxilla, and the inferior turbinated bone, which together form a complete canal.

GLOBE OF THE EYE.

1011. The globe of the eye is situated at the internal and anterior part of the orbital fossa, which lodges it and its appendages: its form is that of a spheroid, slightly compressed at the four opposite points of its circumference, which correspond with the insertion of the recti muscles. The direction of the axis of the globe of the eye does not correspond with that of the orbit; the axes of the eyes are parallel with one another, whilst those of the orbits diverge considerably in front, and if prolonged backwards would decussate behind the body of the sphenoid bone; hence, as the optic nerves coincide in their direction with that of the axes of the orbits, each of them enters the globe of the corresponding eye to the inner side of its axis, and consequently of the axis of vision. When viewed in profile, the globe appears to be composed of segments of two spheres, of which the anterior is smaller and more prominent; hence, when its different diameters are compared, it will be found that the antero-posterior exceeds the others by about a line. Anteriorly the globe of the eye is in relation with the conjunctiva, which is reflected from the eye-lids upon it; posteriorly with the vessels and nerves (optic and ciliary) which enter it, and with a quantity of adipose substance, in which it is in some measure embedded; round its circumference, with the six muscles inserted into it; superiorly, and towards its outer side, with the lachrymal gland; and internally with the caruncula, tensor tarsi, and lachrymal sac.

The globe, or, as it is often called, the ball of the eye, is composed of membranes, placed one within the other, and of humours or fluids which they enclose; the former are not unfrequently called coats or tunics; but as none of them forms a complete investment, the term is not so applicable as that here adopted. The membranes are the conjunctiva, sclerotica, cornea, choroid, retina, and iris, the capsule of the crystalline lens, the hyaloid membrane, and that of the aqueous humour. The humours are the aqueous, vitreous, and the crystalline lens.

Dissection.—The eye should be examined whilst fresh, as the humours soon become putrid, and the membranes alter in consistence and other properties. The eyes of animals will answer sufficiently well in the first instance; but the relative proportions of the different parts must be studied in the human eye before operations can be attempted with safety. In order to obtain correct notions of the situation and relation of the various structures, it is necessary to make several sections of the globe. Thus a vertical section, by dividing it into two equal parts, will show the relative extent of the cornea and sclerotica, their mode of connexion, and the varying thickness of the latter in different parts. If it be suspended in water, the relation of the iris to the ciliary processes may be observed, and also the manner in which the latter are continuous with the choroid membrane. If a transverse section be carried through the coats, and the posterior half of them be removed, leaving the vitreous humour resting on the anterior one, that disposition of the ciliary processes may be distinctly seen by which they are aggregated together so as to form a complete circle round the lens. When the ball of the eye is firmly compressed, the fluid within the lamellæ of the cornea is made to ooze out on its surface, and that membrane becomes opaque. The structure of the choroid membrane can be examined with most effect after the vessels have been filled with some fine injection, either from the internal carotid or ophthalmic artery. The size injection will answer sufficiently well for ordinary purposes.

In order to proceed with the examination, the fore part of the eye should be fixed: for this purpose a pin may be passed across the cornea, and the ends of it secured to a small plate of glass by a thread or cord. To keep the eye steady, it will be found useful to affix to the glass a lump of common wax, on the top of which the eye may be secured as above mentioned. Two incisions should then be

carried over the ball of the eye, decussating with one another at the optic nerve, and thereby dividing the sclerotica into four elliptic segments. These are easily everted, and drawn outwards after a little cautious dissection, by which means the choroid is exposed.

In order to exhibit the retina, the eye should be fixed, and the same incisions made through the sclerotica. The apparatus should then be immersed in a bowl of water, in order that the humours may be supported when the exterior membranes are removed. But in separating the choroid, two pairs of forceps should be used, one being employed to pinch up and hold a small portion of it, whilst it is torn with the other. This process may be continued until the whole of the vascular membrane is detached and everted, leaving the retina fully exposed.

THE CONJUNCTIVA.

1012. The conjunctiva (*membrana conjunctiva, sive adnata*) is included by some writers amongst the accessory structures of the globe of the eye, and not amongst its proper membranes; as if it were a tegument or means of connexion with adjacent structures, and did not form part of the organ itself, considered as an optical instrument. Be this as it may, the membrane lines the free border and inner surface of the eye-lids, from which it is reflected upon the globe of the eye, so as to cover its anterior third. Along the borders of the lids it is continuous with the skin, and by lining the *puncta lachrymalia*, forms a continuous surface with the mucous membrane of the lachrymal passages and nasal fossæ. It is red and vascular on the lids, but firm and pale on the sclerotica: it becomes thin and transparent on the cornea, so much so that some anatomists have doubted whether it extends over the entire of its surface. At present very few persons continue sceptical on this point; for even *à priori* we should infer its extension over the cornea, as every structure of the kind is known to require the protection of a tegumentary membrane. Moreover, in reptiles which cast their epidermis at stated times, the covering of the cornea comes away together with the rest; and finally, in the mus typhlus it is covered with hairs.

THE SCLEROTICA.

1013. The sclerotic, (*σκληρος*, hard; *cornea opaca*,) fig. 165, 1, belongs to the class of fibrous membranes; it is firm and resistant in its texture, and forms about four-fifths of the external investment of the eye, extending from the entrance of the optic nerve, 18, to the border of the cornea, 3. Its external surface is convex, and in relation with the conjunctiva, with the tendinous expansions of the muscles, and the vessels and nerves of the orbit: the internal surface is concave, and in apposition with the choroid membrane, with which it is connected by vascular and nervous filaments, and by some delicate cellular tissue. Posteriorly it is pierced by a small circular aperture for the transmission of the optic nerve, situated a little to the inner side of the axis of the globe; anteriorly it is truncated, so as to leave an aperture about six lines in diameter, but somewhat greater in the transverse than in the vertical direction. The inner edge of this aperture is slightly bevelled off, so as to allow the cornea to be inserted into it, somewhat as a watch-glass is into its case. The sclerotica being a fibrous membrane, its fibres interlace intimately, but do not assume any assignable direction. It is thicker posteriorly than towards its anterior part; but in this latter situation it is strengthened by the tendinous expansions of the muscles, which some anatomists have considered as a distinct membrane, and denominated *tunica albuginea*. At the back part of the globe it is about a line in thickness; at the insertion of the recti muscles it is scarcely half a line; but near the cornea it thickens somewhat. The aperture for the optic nerve is a little nearer to the nasal than to the temporal side of the globe, and is found to be divided by a number of septa, so as to constitute a *cribriform plate*, through which the pulp of the

Fig. 165.

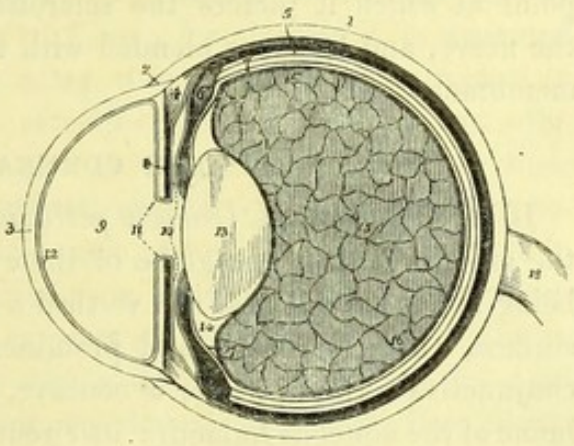

nerve may be made to ooze as if through minute pores. In the middle will be found one of these of larger size than the rest, which is named *porus opticus*. It gives passage to the centralis retinæ artery. At its exit from the skull the nerve receives an investment from the dura mater, which accompanies it to the point at which it pierces the sclerotica, where it separates from the nerve, and becomes blended with the substance of the latter membrane.

THE CORNEA.

1014. The cornea (*cornea pellucida*), fig. 165, 3, occupies the anterior fifth of the globe of the eye, its transverse diameter being about seven lines, the vertical a little less. The anterior surface, which is convex and prominent, is in contact with the conjunctiva; the posterior is concave, and is lined by the membrane of the aqueous humour: its circumference, nearly circular in the human subject, is received within or overlaid by the anterior border of the sclerotica, 2, with which it is so intimately united as not to be separable from it without long-continued maceration. Its degree of convexity varies in different individuals, and at different periods of life. It is composed of five or six concentric lamellæ, united by some connecting medium, probably a fine cellular tissue, the interstices of which contain an aqueous or serous fluid. It is thicker than the sclerotica, which may be readily seen by making a section of both; but it is by no means so dense; its layers will be found to slide almost upon one another when it is pressed between the fingers. The lamellated structure of the cornea is beautifully adapted to the functions of the eye. Were it fibrous, like the sclerotica, even though at the same time translucent, it would cause a dispersion of the rays of light, and thereby resolve them into their primitive or prismatic rays, which would necessarily produce a coloured and confused image. The effect may be readily exemplified by looking at a lighted taper through a feather: the flame will instantly appear surrounded by a halo of coloured images; and were the cornea made up of fibres woven ever so finely, the effect would be similar.

CILIARY LIGAMENT.

1015. The ciliary ligament (*orbiculus ciliaris*, Haller), fig.

165, 4, is a ring of light gray matter, about a line and a half in breadth, which is attached to the inner surface of the sclerotica, just at its junction with the cornea. Externally it is united, though slightly, with the sclerotica; posteriorly with the choroid membrane; and anteriorly with the iris, which may be said to be inserted into its substance. It adheres more firmly to the choroid than to the other textures; for though it is separated by a slight effort from the latter, it remains securely attached to the former. The ciliary arteries pass through it, and distribute some twigs to it, as do the ciliary nerves in their course to the iris. Its external surface or circumference presents a slight groove which runs around it, so that when in apposition with the sclerotica a minute canal is enclosed between them. Fontana appears to have been the first who noticed this circumstance; hence it has been named the canal of Fontana. Some anatomists have considered the ciliary ligament as a ganglion in which the ciliary nerves terminate, and from which branches proceed to the iris; but no instance can be adduced in which a nervous ganglion forms the medium of union and connexion between parts in the same way that this structure does, as we find it attached to the sclerotica, and giving attachment to the iris, choroid membrane, and ciliary processes.

THE CHOROID.

1016. The choroid membrane (*tunica vasculosa, choroidea*), fig. 165, 5, lies between the sclerotica and the retina, extending from the entrance of the optic nerve as far as the ciliary ligament. In the greater part of its extent it is connected, though loosely, to the sclerotica by cellular tissue, and by the vessels which pass from without to reach it; but anteriorly the union is established through the medium of the ciliary ligament. The inner surface is in apposition with the retina, or rather with Jacob's membrane. Posteriorly the choroid presents a foramen, with a well-defined margin, for the transmission of the optic nerve: anteriorly, after becoming connected with the ciliary ligament, it is prolonged inwards towards the axis of the eye, and is drawn into a number of delicate folds, the aggregate of which forms a complete circle, resting, like a collar, round the border of the crystalline lens, and the anterior surface of the

vitreous humour. In this manner are formed the ciliary processes, the aggregate of which has been variously named by different anatomists *(corpus ciliare, corona ciliaris)*.

The choroid membrane is essentially vascular in its structure, being composed of minute arteries and veins, united by cellular tissue. When the sclerotica is removed so as fully to expose the choroid membrane, we find lying upon its surface, if the dissection has been carefully executed, the ciliary nerves compressed and flat: their destination is the ciliary ligament and iris. Two long arteries will also be found (long ciliary arteries) passing horizontally forwards, maintaining little, if any, connexion with the choroid; for, after having pierced the sclerotica, they lie between the latter and the choroid, without giving branches to either; and when they reach the ciliary ligament, they turn inwards and divide into branches, which are exclusively distributed to the iris. These vessels are situated at opposite sides of the globe, nearly on a line with its axis; the external one, however, is a little above, the internal a little below it. But there is a set of vessels which are intimately connected with this membrane, being distributed to it exclusively, viz. the *short ciliary arteries*, which pierce the sclerotica nearer to the optic nerve than the long ones, and soon divide into branches; these run at first parallel with one another, and mutually send twigs of communication, so that they all freely anastomose, particularly towards the anterior part of the choroid, where they form a circle, consisting of a most minute interlacement of vessels. The veins are readily distinguishable from the arteries by their greater size, as well as by their peculiar arrangement. They extend from before backwards in a radiated form, describing arches as they converge to the posterior part of the eye, and form by this union three or four small vessels, which pierce the sclerotica, and open into some of the secondary branches of the ophthalmic vein. As the veins of the choroid membrane are disposed in whirls, they are usually denominated *vasa vorticosa;* they occupy for the most part the external, and the arteries the internal surface of the membrane. On this distribution of the vessels is founded the division of the choroid into two lamellæ, of which the internal is denominated *tunica Ruyschiana*, in compliment to Ruysch, who was the first that succeeded in demonstrating its structure by injection. The inner surface of the membrane,

from its villous or fleecy appearance has been called tapetum; when minutely injected, it is of a deep scarlet colour. It appears to secrete the colouring matter *(pigmentum nigrum)*, which is a viscid and apparently mucous secretion, deposited upon the anterior surface of the membrane. Its quantity varies in different parts, being more abundant anteriorly and in the interstices of the ciliary processes.

CILIARY PROCESSES.

1017. The ciliary processes, formed, as has been above stated, of the anterior margin of the choroid, are from sixty to eighty in number, fig. 165, 6. The form of each lamella, or process, is triangular; one side looks forward to the iris, the other backward to the vitreous humour, with which it is in contact; the third or internal one, the shortest, is free. The processes are alternately long and short, and in their arrangement resemble the plicæ observable on the under surface of a mushroom. The intervals between the processes are filled by a pigment similar to the pigmentum nigrum in every particular, which leaves on the surface of the lens and of the vitreous humour a number of dark striated lines, corresponding not with the processes, but with the intervals between them. When removing the ciliary processes, it will be observed that they are not merely in contact with the anterior part of the hyaloid membrane; minute plicæ of the latter project into the interstices between the processes, and seem to be connected with them. The name ciliary body (corpus ciliare) is usually given to the aggregate of the ciliary process.

RETINA.

1018. The retina *(tunica nervea)*, fig. 165, 7, is placed between the choroid membrane and the vitreous humour, with which it is merely in apposition. It extends from the bottom of the eye, where it is continuous with the optic nerve, forwards as far as the commencement of the ciliary processes, where it appears to terminate by a defined and rather prominent line. Its structure is soft and pulpy; in the living subject it is transparent, and so continues for some hours after death, but then becomes of a pale white colour. When the ophthalmic artery has been minutely injected, the membrane can be shown to consist of two lamellæ, of which the internal is vascular, and pre-

sents several small vessels, which arise from the centralis retinæ artery; the external lamella appears to consist of white nervous matter. If the eye be macerated for some days in water, the latter part of the retina can be washed away, leaving the vascular lamella in its natural position. About two lines outside the entrance of the optic nerve may be observed in the retina a small hole and a yellow spot, first described by Sœmmering, and named by him, the one *foramen centrale*, the other *limbus luteus*. The yellow spot appears to coincide with the axis of vision; the appearance which has been called a foramen is owing to a transparent point in the retina, and not to a perforation of its substance; the outer or medullary layer is merely deficient.

"Exclusively of the two layers here noticed, the retina is found to be covered on its external surface by a delicate transparent membrane, united to it by cellular substance and vessels. If the sclerotica be removed, and the choroid membrane carefully torn and averted, small portions of the structure here alluded to can be detached, or a globule of air, or even of quicksilver, may be insinuated beneath it, by which means it is raised, and can be seen distinctly if held towards the light."* This is now known as *Jacob's membrane*. It cannot be said to be a part of the retina, or to consist of its medullary lamella detached by the process resorted to in the dissection of the organ; for the yellow spot of Sœmmering is not distinctly seen until Jacob's membrane is removed; and when this has been effected, we can still show the retina to consist of its two lamellæ.

THE IRIS.

1019. The iris, fig. 165, 8, which presents the coloured circle seen through the transparent cornea, resembles a partition placed vertically so as to divide, but very unequally, the interval between the cornea and the lens into two parts. This interval is filled by the aqueous humour, so that the iris moves freely in the fluid. The space between it and the cornea, which is much the larger, is called the *anterior chamber*, 9; that behind it is the *posterior chamber*, 10: both communicate through the pupil. The iris presents two flat surfaces and two circumferences; on the anterior surface, which is differently coloured in different

* An Account of a Membrane now first described, by Arthur Jacob, M.D.—*Phil. Trans.* 1819.

individuals, may be observed two concentric rings, of which the external (annulus major) is broader than the internal, but not so deeply coloured: it is marked by several striated lines, which pass from the great circumference inwards to the pupil, where they seem to bifurcate. The inner ring (annulus minor) is more deeply coloured, and surrounds the pupil. The posterior surface contiguous to the ciliary processes is covered by a dark pigment similar to that of the choroid; it is usually called *uvea*. When this is washed off, a number of fine lines, or fibres, may be observed, with the assistance of a magnifying power, converging from the greater circumference to the pupil: these are distinct from one another in the former situation, but in the latter are blended so as to form a membranous zone.

The great circumference of the iris corresponds with the ciliary ligament, into which it may be said to be inserted: the smaller forms the border of the aperture called the *pupil* (pupilla), 11. The pupillary aperture is closed in the fœtus, up to the seventh month, by a delicate transparent membrane, called, from this circumstance, *membrana pupillaris*. If examined after the vessels of the eye have been injected, it will be found distinct from the iris, and appearing as if inserted into its margin, so as to cut off all communication between the two chambers. It becomes reticulated a little after the time referred to, then a few fragments of it only remain, and finally it disappears before birth. According to M. Jules Cloquet's account, it is a sort of mediastinum formed by the contiguous sides of two small culs-de-sac, one of which is the membrane of the aqueous humour continued across upon the front of the iris, the other the lining membrane of the posterior chamber; both being in apposition at the pupil.

The iris is abundantly supplied with nerves from the ciliary nerves: it receives the two long ciliary arteries which pass along between the choroid and sclerotica, and the smaller, or anterior ones, which pierce the ciliary ligament from without. These vessels approach the iris from four opposite directions, and at its greater circumference freely anastomose, so as to form the larger vascular circle of the iris. From this circle branches pass inwards, converging, and form at a little distance from the pupil another circle, by a second anastomosis. Finally, from this inner circle minute filaments pass inwards, and

seem to terminate at the pupillary margin of the iris. The veins, in general, take the same course as the arteries, but the greater number open into the vasa vorticosa. The ciliary nerves, after having passed through the ciliary ligament, incline inwards upon the anterior surface of the iris, where they divide into fine filaments, which soon elude our research, even with the aid of a microscope.

THE HUMOURS OF THE EYE.

1020. The *aqueous* humour is a thin, pellucid fluid, which fills up the two chambers of the eye, occupying the space between the cornea and crystalline lens. Its specific gravity and chemical composition differ little, if at all, from that of the vitreous humour; it is moreover enclosed in a thin transparent membrane, which secretes it in the first instance, and reproduces it when evacuated by accident, or during operations. This membrane, fig. 165, 12, usually called the *capsule* of the aqueous humour, lines the cornea and the anterior surface of the iris, but does not seem to extend into the posterior chamber.

CRYSTALLINE LENS.

1021. The crystalline lens, fig. 165, 13, is situated at the union of the anterior third with the two posterior thirds of the eye, lying behind the iris, surrounded by the ciliary processes, and embedded in the vitreous humour; it is perfectly transparent, soft in the greater part of its extent, but of high refracting power. The lens is doubly convex; but the posterior segment which is received into the vitreous humour is more convex than the anterior; the convexity of both is greater in infancy than in adult age. The greatest thickness of the lens is about two lines and a half; its circumference measures from twelve to fourteen. It consists externally of a soft and homogeneous substance, presenting no trace of organisation; but the central part, more dense and firm, is made up of concentric lamellæ.

The lens is enclosed in a delicate capsule, which invests it all round, but without any distinguishable adherence to it, and is thicker and firmer on the anterior than on the posterior surface. If a puncture be made in the membrane, a small quantity of a pellucid fluid, which is termed *liquor Morgagni*,

issues from the incision. When macerated in a dilute acid, or suddenly plunged into boiling water, the capsule becomes opaque and corrugated, presenting a pale, milky appearance. The lens, having its posterior segment embedded in vitreous humour, is retained in its situation so firmly that it requires some effort to detach it. This is accounted for by supposing that the lens and its capsule are both enclosed within a duplicature of the hyaloid membrane; or rather, after investing the vitreous humour, this membrane, as it approaches the circumference of the lens, divides into two lamellæ, of which one passes before, the other behind that body. By this arrangement an interstice of a triangular form is left, the apex of which is at the point of division of the membrane, the base at the margin of the lens; and as this is continued all round, it forms a canal, named the *canal of Petit*, fig. 165, 14. When distended with air, which can be easily done by puncturing it and inserting the point of a blowpipe, the canal presents the appearance of a chain of minute vesicles disposed round the lens, communicating freely, inasmuch as the air passes from one to the other. This is attributable to the existence of filaments or bands connecting the lamella which passes before with that passing behind the lens, so as to stricture the intervening space—the canal, from point to point. The formation of the canal, and the connection of the lens with the vitreous humour, has been accounted for in a different way from that here indicated. The hyaloid membrane, instead of dividing into lamellæ which encase the lens, may be said to pass altogether behind it, simply enclosing the vitreous humour, as in other parts of its extent. The zonula of Zinn is considered a distinct structure, being firmer than the hyaloid upon which it rests. It is a flat, thin, membranous lamella, whose inner circumference surrounds the lens, the outer being connected organically with the anterior edge of the retina; its anterior surface presenting a number of dark lines, being so many markings left by the pigment of the ciliary processes which rest upon it, as well as delicate folds which are received into the interstices between these processes, and form a connexion with them. This membrane, fig. 165, 17, supposing it to be a distinct structure from the hyaloid, may be said to retain the lens in its situation, and to form the anterior wall of the canal of Petit.

The capsule of the lens receives a minute branch from the

arteria centralis retinæ, which ramifies on its posterior segment, but none of its branches have been found to extend to the substance of the lens. The lens has been supposed to be muscular in its structure, and thereby to possess the power of altering its form, so as to adapt the eye to the different distances within which distinct vision obtains. This opinion was first promulgated by Dr. Pemberton,* in a thesis written at Leyden. Dr. Young † brought it forward again some years ago, and several physiologists have assented to it. Chemical analysis, however, has long since shown that the lens consists of pure albumen, some gelatine, and water, without the slightest admixture of fibrine, the essential constituent of muscle. Moreover, were it muscular, it must consist of fibres of some sort; and were these ever so minute or so fine, the density of the points corresponding with the fibres must be greater than that of the intervals, for intervals there must be where there are striæ or lines; and to suppose a muscle without lines and intervals, is to suppose what has not yet been seen in nature. Were such a structure as this made a medium for the transmission of light, the rays must be dispersed and resolved into their primitive or prismatic rays, producing of necessity a coloration of the image and indistinctness of vision. The remarks and the experiment above cited, to show that the cornea must be homogeneous, apply with equal force to the structure of the lens.

VITREOUS HUMOUR.

1022. The *vitreous humour* (humor vitreus, corpus vitreum) fills up the posterior two-thirds of the globe of the eye, fig. 165, 15. It consists of a thin transparent fluid enclosed in a fine membrane (*hyaloid membrane*); this not only invests it externally, but forms a number of processes, projecting inwards, and dividing it into detached masses, 16, 16, which may thus be said to be lodged within the areolar intervals of the membrane. Some anatomists suppose also that it forms a tubular fold which reaches from behind forward, enclosing the branch of the centralis retinæ artery which passes to the lens. This structure, though thin and transparent, is yet firm, particularly at the fore part. The

* Haller, Disputationes Anatomicæ, tom. vii. † Phil. Trans. 1809.

term *corpus vitreum* is sometimes applied to the fluid and the capsule taken together. Anteriorly, at the central part, is a slight depression which lodges the posterior segment of the crystalline lens, and farther out, where it corresponds with the ciliary processes, is an annulus, or disk, called the zonula of Zinn: we here observe a number of dark lines converging like radii, and disposed in the form of a disk round the lens. But besides the dark lines, which are merely streaks left by the pigment which had exuded from the intervals between the ciliary processes, there are also some delicate plicæ in the membrane itself; these project so as to be received between the contiguous ciliary processes, and form a connexion with them. This part of the membrane appears to differ somewhat from the rest of it, which induced Zinn to consider it a distinct structure; hence he called it "membranula," and the coloured disk and plicæ "zonula coronæ ciliaris."

When the eye is examined as an optical instrument, with a view to determine the influence which it can exert upon the rays of light, it becomes necessary to examine the dimensions, form, densities, &c. of its different components. The humours being so many media of transmission, their effects can be calculated only by knowing their density, refracting and dispersive powers. And as the membranes serve to enclose the area within which all the changes take place, the form of the space, its axis, and diameters, require to be subjected to accurate measurement. But these topics do not properly come within the scope of an elementary work on anatomy.

THE EAR.

1023. The organ of hearing is divisible into three parts, viz. the auricula, or external ear, which receives the impressions of sound; the tympanum, a middle chamber, which transmits them; and the labyrinth, or internal ear, which contains the sentient apparatus.

1024. The *auricula* (including under that term the pinna, or flat part; and the meatus auditorius, or the tube which leads from it to the tympanum) is placed at the side of the head, behind the jaw, and before the mastoid process.

The *pinna*, or flat part, is of an irregularly oval form, its superior extremity being broad, the inferior somewhat elon-

gated and narrow. Its surfaces are marked by some prominent lines and depressions which have received particular names. The semi-circular prominent line, fig. 166, 1, which runs round the border of the pinna, is called the *helix;* it may be said to commence at the centre of the concha, 8, above the meatus externus, and to terminate at the lobule, 5, after having formed the margin of the ear. Within this, and, as it were, enclosed by it, is another curved prominence, the *anti-helix*, 2, which begins above the concha by two slightly elevated lines, that converge and unite to form the line that bounds the concha, and finally terminates at the anti-tragus, 4. The *tragus*, 3, is a small triangular prominence, that projects over the anterior and external part of the auditory tube; its margin is covered with hairs; and opposed to it stands another, which is smaller, and called, from its position, *anti-tragus*, 4; it forms the termination of the anti-helix.

These parts owe their form and consistence to a firm lamella of fibro-cartilage, which constitutes their basis, and upon which the integument is reflected, giving it its exterior investment. The inferior and elongated portion of the pinna is called the lobule, 5 (*lobulus*). It is soft and pendulous, and differs in structure from all the rest, as it contains no cartilage, being composed merely of a thick lamella of condensed cellular and adipose tissue, subjacent to the common integument. Between the prominences above noticed three depressions are observable, differing very much in form and size. The helix and anti-helix are separated by a narrow groove, 6, sometimes called *fossa innominata.* The shallow depression, 7, between the two ridges presented by the anti-helix superiorly, is termed *fossa navicularis;* whilst the deep excavation, 8, bounded by the anti-helix, and leading into the meatus auditorius, is called *concha.* This is a deep depression, bounded above and behind by a crescentic prominent margin formed by the anti-helix; it is surmounted in front by the tragus, at the opposite point by the anti-tragus, and divided unequally by the ascending curve of the helix, which, as we have said, may be considered to arise out of it. The inferior, or larger fossa of the concha, leads forwards and inwards, to the meatus externus. The concha is necessarily prominent and convex posteriorly, and to this part the term *dorsum* is sometimes applied. When the integuments are removed, it will

be found that the cartilage is incomplete at some points, presenting fissures which are filled up by cellular or fibrous membrane. Between the tragus and the commencement of the helix, there is a large interval of this sort, and another between the inferior termination of the helix and anti-helix, where they surmount the lobule.

The pinna is retained in its situation not only by the integument and by its connexion with the meatus, but also by fibrous bands, which some have described as ligaments: one of these connects the tragus with the root of the zygoma, another passes from the convexity of the concha to the mastoid process, a third extends from the temporal aponeurosis to the upper part of the concha.

We have already described the muscles of the external ear (Sect. 364). These may be said to act on the pinna as a whole; there are others, however, which are calculated to move the different parts of which it is composed, but are so rudimentary in man as scarcely to deserve notice. It is usual to enumerate five of these, their names being taken from the parts of the pinna to which they are attached. As to their action, we may omit all mention of it in the human subject.

Musculus major helicis arises just above the tragus, runs upwards upon the helix, and terminates where it is about to curve backwards. *m. Minor helicis* commences in the concha close to the commencement of the helix, inclines upwards and forwards, and is lost upon the rim of the helix. *m. Anti-tragicus* commences at the posterior surface of the anti-tragus, upon which it passes upwards and outwards to terminate upon the helix, crossing the fissure between it and the anti-tragus. *m. Tragicus* consists of some fibres which are placed upon the tragus, extended from its base to its apex. *m. Transversus auriculæ* stretches from the convexity of the concha to that of the fossa innominata. To these Mr. Tod,* in his publication on the ear, has added two muscles not hitherto named: musculus obliquus auris, which extends from the dorsum of the concha to that of the scapha; and m. contractor meatus (trago-helicus), which ascends from the tragus obliquely to the anterior extremity of the helix.

* The Anatomy and Physiology of the Organ of Hearing, by David Tod.

1025. The *auditory tube*, 9, (meatus auditorius externus,) leads from the concha towards the cavity of the tympanum, from which it is separated by the membrana tympani: its direction is obliquely forwards and inwards, with a slight inclination at first upwards and then downwards, so that it describes a curve, the concavity of which looks downwards and a little forwards. The length of the tube is about ten or eleven lines, but its lower surface measures more than the upper, in consequence of the obliquity of the membrana tympani; its form is oval, for when a section is made of the tube, its greater diameter will be that from above downwards. Its capacity is not equal throughout its entire extent; it is wider externally where it passes off from the concha than internally at its termination, and about the middle point between these it is a little narrower than elsewhere. The meatus is made up partly of cartilage, and partly of a ring of bone, about six lines long, and placed between the mastoid process and the root of the zygoma, and above the glenoid fossa. In the adult it is identified with the temporal bone; in the fœtus it represents a thin osseous ring, connected with it chiefly by membrane, and somewhat by bone at its upper and outer part. The cartilaginous part is continuous externally with the concha, from which it is prolonged inwards, to be attached by some short irregular fibres to the rough margin of the osseous ring, with which it thus forms a continuous tube. The cartilaginous and osseous structure occupy each about half the length of the meatus. But the cartilage does not complete the tube in its external half; it may be said to

Fig. 166.

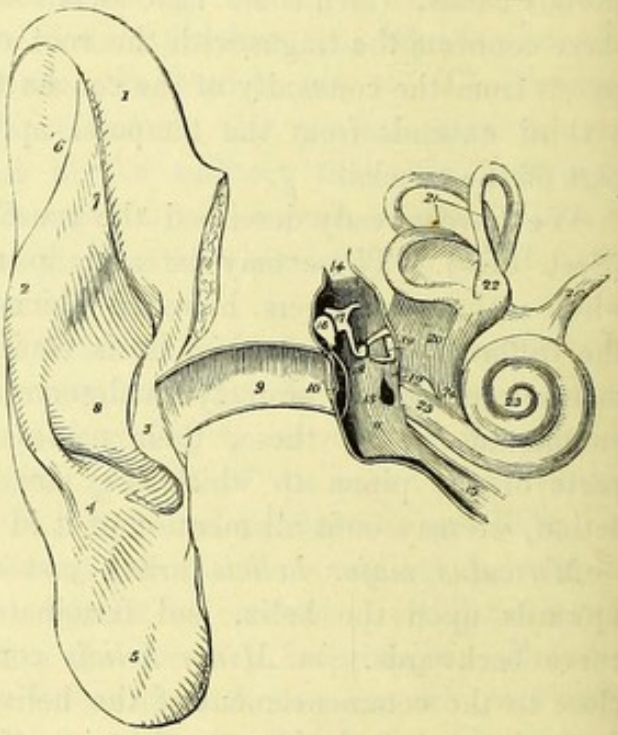

commence from the base of the tragus and the inferior and back part of the concha; proceeding inwards, it becomes curved upon itself so as to form the under and anterior portion of the tube, but is deficient at its superior and external part, where its place is supplied by dense fibrous membrane. The meatus is lined by a prolongation of the external tegument, which resembles a blind sac, like the finger of a glove, its termination being reflected upon the outer surface of the membrana tympani. The tegument gradually becomes thinner as it recedes from the concha, and when its cuticle is removed it presents a number of pores or apertures, being the outlets of the glands which secrete the cerumen of the ear.

MEMBRANA TYMPANI—THE TYMPANUM.

1026. The membrana tympani, 10, forms the inner boundary of the meatus externus, and separates it from the cavity of the tympanum. The membrane is inserted into the inner margin of the osseous tube, and is placed so obliquely in its situation that its external surface looks outwards, downwards, and forwards; it is, moreover, concave, whilst the internal surface, which looks to the cavity of the tympanum, is convex. The membrane consists of three lamellæ, one being proper to itself, and of a fibrous structure, the others being tegumentary membranes, reflected upon it, and derived, the one from the skin, which is prolonged in the form of a cul-de-sac into the auditory tube, whilst the other is continuous with the mucous lining of the tympanum.

Sir Everard Home advocated the opinion, that the proper or middle membrane of the membrana tympani consisted of muscular fibres, and supported his views by appealing to his dissection of the part in the elephant. No one is disposed to deny its being fibrous, but as to its being muscular, that forms an additional matter of inquiry. The fibres appear to converge from the circumference of the ring of bone towards the central line, and are connected intimately with, if not actually inserted into, the outer surface and apex of the long handle of the malleus, also into its short process. From this arrangement it results, that all that part which corresponds with the former is concave outwards; but the remainder, being about an eighth of the whole, is slightly convex. The form of the

membrane is an irregular oval in the fœtus, but in the adult it is nearly circular.

1027. The *cavity of the tympanum*, 11, is narrow and irregular in its form, and so placed in the pars petrosa that the meatus externus lies to its outside, the labyrinth to the inner side, with the mastoid cells opening into it posteriorly, and the Eustachian tube anteriorly. Its external wall is formed almost exclusively by the membrana tympani; the internal is composed of an irregular bony lamella, in which we observe the following elevations, openings, &c. The *promontory* (promontorium), a rounded bony eminence, 12, corresponding with the middle of the extent of the tympanum, if taken from before backwards. Above the promontory is situated an aperture, the *fenestra ovalis*, which leads into the vestibule, but is closed by a thin membrane, which prevents any direct communication between the cavities. The greater diameter of the fenestra is directed obliquely backwards and a little downwards. Beneath the promontory, and almost concealed by it, is another aperture, called *fenestra rotunda*, 13, though its form rather approaches that of a triangle: it corresponds with that part of the cochlea called *scala tympani*, and is also closed by a membrane.

When we examine the circumference of the tympanum, we find, at a point posterior and external to the promontory, and opposite to the inferior extremity of the fenestra ovalis, a small triangular bony process called the *pyramid*, the summit of which presents a minute opening, leading to a tube (*fistula*) in its interior, that lodges the stapedius muscle. Between the pyramid, the promontory, and fenestra ovalis, is a depression called sinus or sulcus tympani. Behind and beneath the pyramid is a minute foramen (*apertura chordæ*), which gives passage to the vidian nerve as it enters the tympanum from the aqueduct of Fallopius, and assumes the name of the chorda tympani. This bony canal is sometimes called iter ab aquæductu ad tympanum. A little above this orifice is a convex ridge, which runs upwards and forwards over the fenestra ovalis; it marks the course of the aqueduct of Fallopius. At the posterior and superior part of the cavity is situated an aperture, 14, leading into the interior of the mastoid process, which is hollowed into cells partially separated by bony septa, and lined by mucous

membrane prolonged from the tympanum; so that the mastoid cells may be considered as diverticula or prolongations from the latter cavity. In the anterior part of the floor of the cavity is the glenoid fissure, which transmits the chorda tympani nerve, the tensor tympani muscle, and lodges the processus gracilis of the malleus. Finally, at the inner and anterior part of the cavity are two orifices, with a small bony lamella (*processus cochleariformis*) interposed between them, which separates two canals into which these orifices lead: the superior or smaller one transmits the tensor tympani muscle, the other forms part of the Eustachian tube.

EUSTACHIAN TUBE.

1028. The Eustachian tube, 15, is from an inch and a half to two inches long, its posterior and external part being an osseous canal, the remainder composed of fibro-cartilage and fibrous membrane; its direction, as it leads from the anterior and inner part of the tympanum to the fauces, being forwards, inwards, and a little downwards. The osseous part narrows somewhat as it proceeds forwards; the cartilaginous, on the contrary, widens, so that the tube is constricted towards the middle, but is expanded at its extremities, particularly at the guttural one, which will be found thickened and trumpet-shaped. The osseous part of the tube occupies about one third of its extent, and is placed beneath the canal for the tensor tympani muscle, from which, and from the carotid canal, it is separated by a thin osseous lamella. The cartilage does not surround the tube; it forms the inner and upper side of it, and also part of the external, the remainder being made up of fibrous membrane. The tube thus formed is lined by mucous membrane prolonged into it from the pharynx, which thus becomes continuous with the lining of the tympanum.

BONES OF THE EAR.

1029. The bones of the ear (*ossicula auditûs*) form a chain consisting of three minute pieces, extended across the cavity from the membrana tympani to the fenestra ovalis, each being articulated with the other, so that the whole chain is moveable. A fourth is very generally enumerated — the os orbiculare; but Sœmmering and some other anatomists consider it

merely as a process of the incus. The bones are arranged in such a way that the malleus or external one is connected with the membrana tympani, whilst the stapes, which is placed internally, rests on the membrane of the fenestra ovalis, the incus being situated between both and articulated with them.

The *malleus*, 16, so called from some resemblance to a hammer, is the first or most external of the series, and presents a head, neck, and processes. The head or superior part is convex and round in the greater part of its extent, but presents at its inner and posterior aspect two slightly irregular surfaces, covered with cartilage, by which it articulates with the incus. The neck is the short constricted part that intervenes between the head and the processes. The handle (*manubrium*) is an elongated process, which, when the bone is *in situ*, inclines downwards and forwards, and terminates in a small rounded process, corresponding with the most prominent part of the membrana tympani, with which it is intimately connected. The short process inclines outwards at right angles, from the upper extremity of the handle, and lies in contact with the membrana tympani. The long process (*gracilis*, *anterior*) extends from the cervix obliquely downwards and forwards; it is very thin, and ends in a point which passes into the glenoidal fissure.

The *incus*, 17, is so called from some resemblance in shape to that of an anvil; it has been compared also to a molar tooth; but its similitude to either is very remote. This bone lies a little behind and to the inside of the malleus; it may be considered as divisible into a body and two processes. The body, compressed and somewhat square in its form, is directed forwards and upwards; and if its anterior border be viewed in profile, it will be found to present two surfaces, which meet at an angle, and are intended to articulate with the head of the malleus. One of the processes (*processus brevis*), shorter than the other, and also superior and posterior to it, is directed obliquely backwards towards the mastoid cells, where it terminates in a free point; the other process (*processus longus*) is longer but thinner than the preceding; it is directed forwards and downwards in the greater part of its extent, but near its termination it suddenly turns inwards, and ends in a small rounded

process or nodule, 18, which articulates with the head of the stapes. This is the part which is considered by some to be a distinct bone, and as such is named *os orbiculare*.

The *stapes*, 19, or stirrup-bone, is placed horizontally, with its base resting against the fenestra ovalis, and its head articulated with the round nodule at the extremity of the long process of the incus, which it receives in a small shallow cavity. The base of the bone is of the same form as the fenestra ovalis, on which it rests, its upper border being convex, and the lower straight. The anterior process is shorter and straighter than the posterior, and both are slightly grooved along their inner borders, where they give attachment to a membrane that fills the interval between them. The two processes converge and meet at a narrowed part, which is sometimes called the neck, and which is surmounted by a small tubercle or head. The head inclines outwards, and articulates, as above stated, with the incus.

INTERNAL MUSCLES OF THE EAR.

1030. These muscles, like the bones above described, are the smallest in the body: only four are usually enumerated, of which three are attached to the malleus. *m. Internus mallei* (tensor tympani) arises from the upper surface of the cartilage of the Eustachian tube, and also from the contiguous border of the pars petrosa; thence it inclines outwards and backwards in the osseous canal that runs parallel with the Eustachian tube, and becomes tendinous on entering the tympanum, where it is inserted into the short process of the malleus. *m. Externus mallei* (laxator tympani major) arises from the spinous process of the sphenoid bone, and soon becoming tendinous, passes through the glenoid fissure to be inserted into the processus gracilis of the malleus. *m. Laxator tympani minor* is very small, and so indistinct, that many anatomists have omitted it altogether; it arises from the upper border of the osseous part of the auditory tube, and descends to be inserted into the manubrium of the malleus, near its short process. *m. Stapedius* is lodged within the tube of the pyramid, from the summit of which a small tendon issues, to be attached to the neck of the stapes.

THE LABYRINTH.

1031. The labyrinth is so called from its complexity; it lies internal to the tympanum, and consists of three parts; viz. the vestibule, semicircular canals, and cochlea.

The *vestibule*, 20, is a small irregular cavity of an ovoid figure, bounded externally by that bony lamella in which we noticed the fenestra ovalis and promontory, internally by the cribriform lamella at the bottom of the meatus auditorius internus, posteriorly by the semicircular canals, and anteriorly by the cochlea. Along its upper surface runs the aquæductus Fallopii, an osseous tube which leads obliquely outwards and backwards from the meatus internus to the stylo-mastoid foramen, and lodges the facial and vidian nerves. The cavity is divided into two slight foveæ, or pits, one being circular, the other oval, and intended to lodge two sacculi, which enclose the expanded part of the auditory nerve. The vestibule is lined by a delicate membrane, which appears to be of the serous class, as it secretes a fine fluid (*liquor Cotunni*) which fills all the intervals left unoccupied by the expansion of the nerve. The following foramina are observable in the interior of the cavity: externally, the fenestra ovalis; internally, four or five minute holes, which transmit the auditory nerve. These are placed in the plate of bone (*lamina cribrosa*) which closes the meatus auditorius internus; at its posterior and external part, five openings, which lead into the semicircular canals, two of them opening by a common foramen; near the common orifice just mentioned is a small foramen leading into the aquæductus vestibuli, a small curved canal about four lines long, which leads outwards and backwards to open on the posterior surface of the pars petrosa: it transmits a small vein; at the anterior and inferior part of the cavity is the opening into the cochlea.

SEMICIRCULAR CANALS.

1032. The semicircular canals are three small osseous tubes, 21, curved so as to form a considerable segment of a circle. They are embedded in the substance of the petrous portion of the temporal bone, and therefore cannot be seen until its external plate is removed, and the reticular texture beneath it is pecked away. They are distinguished, by a consideration of

their position, into superior or vertical, external or horizontal, and posterior or oblique. They lie behind the vestibule, each being somewhat greater than a semicircle. The contiguous limbi of the posterior and superior canals become united for about two lines before they reach the vestibule. Each of the canals is lined by a fine membrane enclosing the expansion of the nerve, and at their vestibular orifice, or commencement, a slight dilatation, 22, (ampulla) will be observed, corresponding with a similar enlargement of the nerve.

COCHLEA.

1033. The cochlea, 23, has been so called from some resemblance to the shell of a snail. When insulated from the rest of the bone, it is of a pyramidal form, the base being turned to the meatus internus, the apex outwards, and a little downwards, so as to approach the horizontal part of the carotid canal. The cochlea consists of a spiral osseous tube coiled round a central axis (*modiolus*). The tube makes two turns and a half from the base of the cochlea to its summit, which is called the *cupola*. From its inner surface projects a thin bony lamella, which extends about half-way across its cavity, and gives attachment to a delicate membranous plate, which completes the separation of the spiral tube into two parts, called *scalæ*, or stairs. The separation between the scalæ is complete in the natural condition, except at the cupola, where the osseous part of the septum is deficient, and allows a communication between them. The septum consists partly of a bony plate, partly of membrane. The former is usually named *lamina spiralis;* it commences at the base of the cochlea, and coils round the modiolus nearly to its apex, where it ends in a hook-like process. The membranous part of the septum is a little broader than the lamina spiralis, from the border of which it extends outwards to the wall of the cochlea, to which it becomes attached, and so completes the partition between the two scalæ. One of the scalæ, 24, (*scala vestibuli,*) commences at the vestibule, and after making its two turns and a half, ends in the cupola; the other, 25, (*scala tympani,*) may be said to commence at the cupola, and after making its turns round the modiolus, to end at the fenestra rotunda. The base of the *modiolus* communicates with the meatus internus, and is pierced by minute fora-

mina, which give admission to the filaments of the nerve, and to some small blood-vessels: its summit opens into the cupola, where it is expanded, and thence termed *infundibulum*. In the scala tympani, near its termination at the fenestra rotunda, a minute foramen exists, which leads into a canal (*aquæductus cochleæ*). This canal is three or four lines long, and terminates at the posterior border of the pars petrosa, near the jugular fossa; it transmits a small vein.

1034. In our description of the nerves and vessels, we must notice the *osseous canals* which lodge or transmit them. The passages which convey the nerves from the cranium to the internal ear are the hiatus Fallopii, the auditory meatus, and the aquæductus Fallopii. The first of these is a fissure which leads obliquely backwards and outwards upon the anterior surface of the pars petrosa of the temporal bone, and which lodges the vidian nerve (Sect. 981). The meatus auditorius internus is an oblique canal in the posterior surface of the bone, from two lines and a half to three lines in diameter, and three lines in depth; its direction is outwards and forwards. It is bounded by a concave lamella of bone, and at first appears like a cul-de-sac, but the plate of bone is perforated by foramina. The meatus contains, in the natural condition, the proper auditory, 26, and the facial nerve, with a small vessel, a branch of the posterior cerebral artery. In the bottom of the meatus will be observed a slight ridge of bone, which divides it into two pits, the upper or smaller one being for the facial nerve, whilst the lower receives the auditory. A smaller foramen transmits the former, but for the latter there are several; hence the osseous plate is sometimes called lamina cribrosa, from its numerous perforations.

1035. The *auditory nerve*, whilst within the meatus, divides into several filaments, which separately pass through the foramina in its bottom; but they admit of being arranged in three sets, from a consideration of the parts of the labyrinth in which they ultimately terminate. One set passes directly into the base of the cochlea, and is lodged in the hollow of its central pillar or modiolus, from which the nerve proceeds by many minute pores to the scalæ, upon the entire surface of which it forms a delicate expansion, supported by the osseous and the membranous part of the septum. The second set of filaments

enters the vestibule, and forms an expansion supported by the lining membrane, which is dilated so as to resemble a sac (sacculus vestibuli). A third set, situated higher up than the preceding, enters the ampulla at the commencement of the superior semicircular canal. Here it loses its fibrous appearance, as if the nervous matter were formed into a tubular lamella prolonged through the canal, assuming its form, and supported by its lining membrane. Similar nervous expansions exist in the posterior and external semicircular canals.

1036. *Membrane of the labyrinth* (labyrinthus membranaceus).—The interior of the labyrinth is lined by a very delicate membrane, which necessarily takes the form of its different parts and recesses; it gives support to the nerves, and also serves to secrete a limpid fluid (aqua labyrinthi), which fills up the intervals left unoccupied by the membrane and the nerves. The fluid is one of the agents employed in conveying impressions from without to the sentient extremities of the auditory nerve. The vibrations of the air, agitated by sounding bodies, act upon the membrana tympani; its various changes necessarily influence the chain of ossicula; so that whatever motion is given to the malleus, is conveyed by it through the incus to the stapes, and so to the membrane of the fenestra ovalis. By means of the latter, the fluid of the labyrinth is compressed, and through it the nerves; when this is effected, the merely physical part of the function of hearing is completed. But a new chain of phenomena instantly succeeds. The impression received by the nervous expansions in the labyrinth is conveyed to the sensorium, by which means an internal sensation is produced, the character and intensity of the one being proportioned to that of the other. This, which may be considered the second link in the chain, gives still but a simple sensation. Memory and association, in other words previous experience, must lend their aid to enable us to establish that sort of connexion between the mere impressions received and various external agents, which is necessary in order that they should be made to stand in the relation of sign and thing signified.

1037. The *aqueduct of Fallopius* commences at the upper and inner part of the meatus internus; it is a small osseous tube lodged in the pars petrosa, through which it runs from the point just indicated to the stylo-mastoid foramen. At first, for about

two lines, it inclines forwards and outwards, then changes, so as to turn outwards and backwards, descending to the foramen above named. It transmits the facial nerve, and also the vidian, which joins the former where the canal changes its direction. In its passage, the nerve gives off some small filaments, which enter the tympanum, and supply its muscles. Mr. Tod observes that the chorda tympani gives branches to all the muscles in the tympanum, and "seems to be the nerve both of motion and perception to these organs."

The *vessels* of the tympanum, and of the labyrinth. — The stylo-mastoid branch (Sect. 630) and the ramus tympanicus (633) spread out in minute ramusculi in the tympanum. They are accompanied by veins which take a similar course. The labyrinth is supplied by the internal auditory artery, which enters the meatus internus, together with the nerves, and after passing through one of the foramina ramifies upon the lining membrane. The residual blood is returned by two veins, which are lodged in the minute canals called aquæductus vestibuli et cochleæ (121).

THE NOSE.

Having already described the nasal fossæ (173), the olfactory nerve (894), and the sphæno-palatine (980), it remains to notice the cartilages and the mucous lining membrane.

1038. *Cartilages of the nose.*—Of these five are usually enumerated. The *middle* cartilage (cartilago septi) is a flat triangular lamella placed vertically; its upper border articulating with the perpendicular plate of the ethmoid bone, the lower resting upon the vomer and maxillary bones, and the anterior supporting the lateral cartilages and the integument. The two *superior lateral* cartilages are of a square form, and extend from the nasal bones downwards, between the ascending processes of the superior maxillary bones, with each of which they articulate; and towards the middle line, along the ridge of the nose, they rest against the middle cartilage, which serves to support them. The two *inferior* cartilages form the alæ nasi; they unite superiorly with the preceding, externally with the maxillary bones, and in front with the middle cartilage; they are thin and curved, so as to form the arch of the anterior nares.

1039. The mucous membrane (*membrana Schneideriana, v. pituitaria*) lines and closely adheres to the bones which form the nasal fossæ — extending from the nostrils, where it is continuous with the skin, to the posterior nares, at which point it joins the mucous membrane of the pharynx. It is also continuous with the lining membrane of the several sinuses which open into the meatus narium, and (through the ductus ad nasum) with the conjunctiva. The pituitary membrane is of a red colour, of considerable thickness, soft, and villous on the surface, except towards the anterior nares, where it becomes thinner and the villi are less numerous. In the situation just mentioned it is studded with strong hairs (*vibrissæ*), which serve to prevent, during inspiration, the entrance of bodies floating in the air.

The membrane that lines the several sinuses differs remarkably from the preceding. It is pale, thin, and adheres very slightly to the surface of the bones.

THE TONGUE.

1040. The different components of the tongue have been already described: its muscles (378.382.405), its general structure (811), and the gustatory nerve (917). The aggregate of these forms the organ of taste.

THE LARYNX.

1041. The upper part of the air-tube being so constructed as to constitute the organ of voice, is named the larynx (λαρυγξ). It is placed at the upper and fore part of the neck (where it forms a considerable prominence), and between the large vessels. It is covered in front by the integument, and partly by some thin muscles; behind, it forms a boundary of the pharynx; superiorly, it is connected to the os hyoides, and communicates with the cavities of the nose and mouth, or rather with the pharynx, into which they open; below, it is continuous with the other part of the air-tube (the trachea).

The larynx is formed of, 1st, cartilages; 2nd, ligaments, by which these are connected; 3rd, muscles, which move them; 4th, a mucous lining membrane and some glands; together with (as in other organs) vessels and nerves.

CARTILAGES OF THE LARYNX.

Three of the cartilages are single and symmetrical, namely, the thyroid, the cricoid, and the epiglottis. The others are much smaller than the preceding, and occur in pairs, namely, the arytænoid, with their appendages (cornicula), and two small bodies, named the cuneiform cartilages.

1042. The *thyroid* cartilage (cartilago thyreoidea, *v.* scutiformis; θυρεος, a shield, and εἰδος, form) is the largest of the pieces composing the larynx, and forms almost exclusively its anterior and lateral boundary; but is altogether deficient behind. It consists of two flat lamellæ, united along the middle line, so as to form in front a projecting angle, fig. 163, 1, which is subcutaneous, and is named *pomum Adami*. This is much more prominent in the male than the female; an angular depression corresponds to it on the posterior aspect, to which are attached the epiglottis, together with ligaments and muscles connecting the thyroid and arytænoid cartilages. Each lateral half, 2, is somewhat of a square form; its internal surface is smooth, and receives inferiorly the insertion of the crico-thyroid muscle; the external is marked by an oblique line that gives attachment to the sterno-thyroid and thyro-hyoid muscles, while the smooth surface behind it gives origin to part of the inferior constrictor of the pharynx.

Fig. 163.

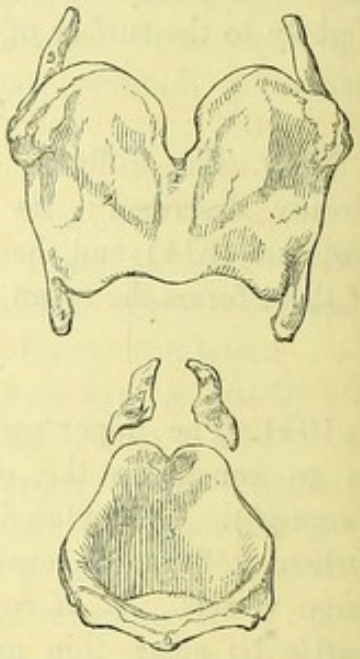

The superior border, which is slightly concave on the sides, and deeply notched in the middle, is connected to the os hyoides by a membrane (thyro-hyoid); the inferior presents a middle and two lateral concavities, all of which are united to the cricoid cartilage, the former by a membrane, the latter by muscles — both named from these attachments; the posterior border, rather thick and rounded, gives attachment to the fibres of the stylo-pharyngeus muscle, and is prolonged into

processes or cornua. The superior, or great cornu, 3, projects backwards, with an inclination inwards, and is attached by a round fibrous cord (thyro-hyoid ligament) to the extremity of the great cornu of the os hyoides. The smaller cornu, 4, is somewhat thicker, and presents towards its extremity, a slightly concave smooth surface, which articulates with the side of the cricoid cartilage.

1043. The *cricoid* cartilage, 5, so named from its annular shape (κρίκος, a ring; εἶδος), is the only one which bounds the tube in its entire circumference, being, however, more extensive behind, where the thyroid cartilage is deficient, than in front, in which situation it is very narrow; it forms the inferior, and a considerable portion of the back part of the larynx. The outer surface affords attachment in front of the crico-thyroid muscles; posteriorly, this surface is much expanded, and presents in the middle a slight vertical ridge, to which the œsophagus is connected; on each side of this is a depression for the crico-arytænoideus posticus, and more externally, a small rounded smooth surface for articulation with the inferior cornu of the thyroid cartilage. The inner surface is smooth, and lined by mucous membrane.

The lower border, which is horizontal, is connected to the first ring of the trachea. The superior border is united in front to the thyroid cartilage by a membrane which passes between them, and is named from this connexion; behind, this border projects upwards considerably, as if to support the arytænoid cartilages; for these it presents two convex oval articular surfaces, which incline somewhat outward; anteriorly to these the lateral crico-arytænoid muscles are attached.

1044. The *arytænoid* cartilages, 7, (cartilagines arytænoideæ v. pyramidales,) have been so called from some resemblance to a funnel (ἀρύταινα, a funnel; εἶδος). They may be compared to two triangular pyramids, resting by their bases on the posterior part of the cricoid cartilage, and in close relation one with the other by their inner borders. The posterior surface of each is smooth and excavated, so as to lodge the arytænoid muscle; the anterior, convex in its general outline, gives attachment to the thyro-arytænoid muscles; the internal being flat, is parallel and in apposition with that of the cor-

responding cartilage. The base is smooth, and slightly hollowed, for its articulation with the cricoid cartilage; in front of it is a projection for the attachment of the thyro-arytænoid ligament; behind and externally, a smaller tubercle, to which the crico-arytænoid muscles are connected. The summit of the cartilage becomes pointed, and is surmounted by a small appendage, called corniculum laryngis.

1045. The *cornicula* laryngis (*capitula*, Santorini) are two very small cartilages of a somewhat triangular shape. The base of each is united to the apex of the arytænoid cartilage by a smooth articular surface and some ligamentous fibres.

1046. Two small cartilaginous bodies (*cartilagines cuneiformes*) are sometimes found in the folds of mucous membrane which extend between the arytænoid cartilages and the epiglottis. These are somewhat curved, and broader towards their upper than their lower extremities; they are not directly connected to any of the other cartilages of the larynx.

1047. The *epiglottis* resembles in form a cordate leaf. It is a thin lamella of fibro-cartilage, projecting upwards from the superior and anterior part of the larynx, immediately behind the base of the tongue. In the ordinary condition the direction is vertical, but during deglutition the epiglottis is inclined back and downwards over the entrance into the glottis, which it covers,—hence its name (επι, upon; γλωττα). It is broad and somewhat round at its upper border, but inferiorly becomes pointed and prolonged, by means of a narrow fibrous band, to the angle of the thyroid cartilage, where it is attached.

The upper or lingual surface is free only in part of its extent, the rest being connected by the mucous membrane with the root of the tongue, so disposed as to form three small folds or frænа. The inferior or laryngeal surface is slightly concave from side to side, and convex from above downwards. The lateral borders are connected to the arytænoid cartilages by two folds of the lining membrane. The epiglottis is pierced by several foramina, and is marked on its surfaces by minute depressions which lodge small muciparous follicles.

LIGAMENTS OF THE LARYNX.

The ligaments of the larynx admit of being divided into, 1, those which unite it to contiguous parts (the os hyoides and the trachea); and, 2, those by means of which the several pieces are connected one to the other.

1048. Connexion of the larynx to the os hyoides and to the trachea.—From the upper border of the thyroid cartilage in its whole length, a broad fibrous lamella (*thyro-hyoid membrane*) passes to the os hyoides, to which it is attached, not at its inferior margin, but at the upper part of its posterior aspect; by this arrangement the top of the larynx, when drawn upwards, is allowed to slip within the circumference of that bone. The great cornua of the cartilage are also connected with those of the os hyoides by two rounded fibrous cords, in which small granular cartilages are deposited. The cricoid cartilage is united to the first ring of the trachea by the fibrous membrane which forms the greater part of that tube.

1049. The thyroid and cricoid cartilages are connected in front and on the sides; in the former direction by means of a fibrous yellow membrane (*membrana crico-thyroidea*) attached to the contiguous borders of both the cartilages. It is somewhat triangular in shape, and hence has been also named pyramidal. On its anterior surface a small branch of the thyroid artery runs transversely; the posterior is lined by mucous membrane. The articular surfaces on the small cornua of the thyroid cartilages, and those corresponding to them on the sides of the cricoid, are lined by synovial membrane, and covered by ligamentous fibres, which retain them in apposition.

1050. The arytænoid cartilages are united to the articular surfaces on the posterior and upper margin of the cricoid by a loose synovial capsule and thin fibres. The connexion between the arytænoid cartilages and the cornicula is of the same kind, but is frequently very indistinct.

1051. *Thyro-arytænoid ligaments. — Chordæ vocales.* — From the arytænoid to the angle of the thyroid cartilage there are extended on each side two bands, which, if regarded as means of connexion, may be termed the thyro-arytænoid ligaments; they are placed one beneath the other. The inferior

pair of fasciculi, more strongly marked than the others, consist of fibres stretched forwards from the anterior border of the arytænoid cartilages, near their bases. These converge, and meet at an angle, where they are implanted into the posterior surface of the thyroid cartilage, at the middle of its perpendicular depth. These ligaments, with the base of the cartilages to which they are attached posteriorly, bound a triangular interval called *rima glottidis*, and are, from their connexion with the special function of the organ, called the proper *chordæ vocales*. The superior bands consist merely of a duplicature of the lining membrane ; they contain no fibrous structure within them, and are therefore less tense and farther apart than the others. They are noticed chiefly because their appearance is constant, and also because they form the upper boundaries of two oval intervals placed between them and the preceding pair, which are named the sinuses, or *ventricles of the larynx*.

The *muscles* of the larynx have been already described. (Sect. 407, et seq.)

1052. *Glands of the larynx.*—The mucous follicles that exist at the upper part of the larynx being in some situations particularly numerous and aggregated together have received the name of glands. One of these is placed behind the os hyoides and tongue,—between them and the anterior surface of the epiglottis. It is named, from its connexion with the last named body, the *epiglottic gland* (glandula epiglottidea). This is contained in a considerable quantity of fat, and consists of several granules, from which ducts pass backwards through foramina in the epiglottis to open on its posterior surface. Another collection of follicles (*glandula arytænoidea*) is placed within the fold of mucous membrane in front of the arytænoid cartilage.

1053. *Lining membrane.*—The larynx is lined by a smooth, pale, mucous membrane, which is continuous with that of the mouth, as well as with that lining the pharynx and the trachea. Following it from the tongue, the membrane will be seen, when being reflected on the anterior surface of the epiglottis, to form on it three small folds (fræna), one of which is connected to its middle, the others to its borders. From the laryngeal surface of the epiglottis, the mucous mem-

brane continues downwards into the trachea, but on each side it forms a fold extending from the margin of the epiglottis to the arytænoid cartilage. At this point it descends over the posterior aspect of the larynx, and constitutes part of the lining of the pharynx.

The arteries of the larynx will be found in the division to which they belong (sect. 625); the nerves are supplied from the vagus (sect. 905—907).

1054. The larynx is similar in the male and female previously to the age of puberty. At this period a remarkable difference occurs, that of the male becoming suddenly more prominent and more perceptible at the upper part of the neck. This results from the thyroid cartilage, which previously was rounded in front (the permanent condition in the other sex), then projecting forward at the middle, so that its sides form an acute angle one with the other, and the notch on its upper border is deepened. The size of the larynx is at the same time generally enlarged, and its cartilages become thicker and stronger. In consequence of the angle of the thyroid cartilage advancing as stated, the distance between it and the arytænoid cartilages becomes greater, and the chordæ vocales are necessarily increased in length.

THYROID GLAND.

1055. The thyroid gland cannot be classed with any of the organs of the body, as its function remains still unknown. From its situation, some consider it as an appendage to the larynx. The propriety of the use of the term "gland" is questionable, as it possesses no excretory duct and elaborates no assignable product, though it is abundantly supplied with blood-vessels.

This body consists of two lateral parts, or lobes, and a transverse slip (isthmus) which connects them. When viewed as a whole, it is convex in front, and covered by the sterno-hyoid, sterno-thyroid, and omo-hyoid muscles; compressed or even concave posteriorly, where it rests against the trachea and larynx. Each lateral lobe is about two inches in length, and three quarters of an inch in breadth, the direction of the long diameter being from below obliquely upwards, or from opposite the sixth ring of the trachea to the inferior cornu of

the thyroid cartilage. The upper extremities of the lobes are generally, from their appearance, called cornua. The isthmus, which is from a quarter of an inch to half an inch in breadth, lies across the third and fourth rings of the trachea. From the middle of its upper border projects a small conical elevation of similar structure with the rest, and called the pyramid. To this part is attached a small band of muscular fibres, which descends from the thyroid cartilage, and has been considered by some as an elevator of the thyroid body or gland.

The colour of the thyroid body is dusky-red, its texture rather firm; it is surrounded with a thin lamella of condensed cellular tissue, which connects it with the adjacent parts, and gives support to the vessels which enter it and dip into its interior, separating it into small lobules or masses of very irregular form and size. From these, when divided, some glairy fluid oozes. Four arteries ramify in this substance, (the superior and inferior thyroid at each side,) also, in some cases, a single vessel of variable size, which ascends upon the trachea from the arch of the aorta. Besides the veins which accompany the arteries, two of considerable size descend and open into the brachio-cephalic veins. The nerves are derived from the pneumogastric and sympathetic.

CHAPTER IX.

THE URINARY ORGANS.

These consist of the organs by which the urine is secreted (kidneys), and those by which it is excreted, namely, the ureters, the bladder, and the urethra.

THE KIDNEYS.

1056. The kidneys (*renes*, *νεφροι*) are two in number; but this is not invariable, as in some rare cases three have been found, while in others but one existed. They communicate each by a separate duct (ureter), with a reservoir (the bladder), which receives the secretion of both. They are placed deeply at the posterior part of the abdomen behind the peritonæum, lying one on each side of the vertebral column, on a level with the two last dorsal and two first lumbar vertebræ; the right is, however, a little lower down than the left. The kidneys are covered by a quantity of loose cellular tissue, which sometimes contains much dense fat. They are of a deep red colour. Each measures about four inches in length and two in breadth; the form is peculiar,—being compressed and ovoid, the kidney presents for examination two surfaces and two borders.

The anterior surface, convex, lies behind the peritonæum, which separates it on the right side from the duodenum and ascending colon, and on the left from the descending portion of the latter; the posterior is embedded in cellular tissue and supported partly on the broad part of the diaphragm, partly on the quadratus lumborum, or rather on the anterior lamina of the fibrous membrane by which the transversalis abdominis muscle is connected to the spine; the external border is convex in its general outline, the internal concave, and excavated at the middle, where it presents a fissure for the transmission of the vessels. The superior extremity, which is thick, rounded, and inclined inwards, supports the supra-renal capsule: the inferior is smaller, somewhat flat, and diverges from the spine.

1057. *Structure.*—The surface of the kidney, fig. 164, is invested by a thin, yet firm membrane, 1, which turns over the concave border, and comes into contact with its pelvis, on which it is reflected, gradually degenerating into cellular tissue. If a section be made of the organ from the convex to the concave border, it is seen to be formed of two substances, differing materially one from the other; these, from their relative position, are usually named cortical and medullary.

Fig. 164.

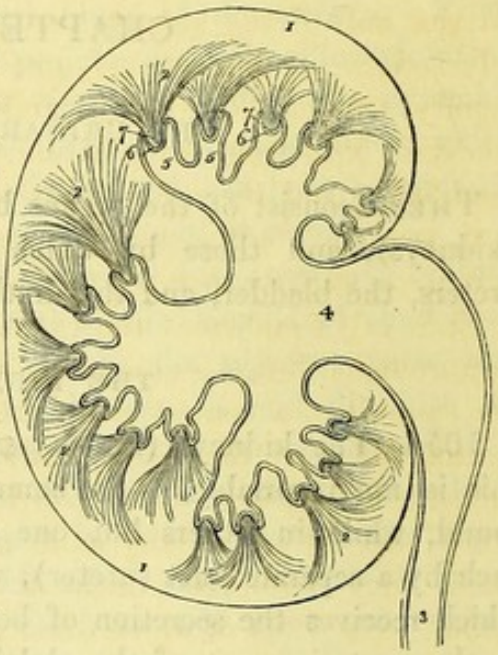

The *cortical substance* (substantia corticalis), placed immediately under the investing membrane, occupies the entire circumference of the organ, being about two lines in thickness, and sends inwards prolongations, between which the medullary portion is placed. It is of a deep red colour, easily torn, and is formed almost entirely by the capillary terminations of blood-vessels. The *medullary part* consists of a series of pyramidal or conical masses, 2, 2, 2, the bases of which are directed towards the surface of the kidney, and the small extremities towards its fissure; the cones are invested, except at their apices, by the cortical substance. The medullary substance is more dense than the preceding, and the colour is much less dark. From being made up of a series of minute tubes it is also named *tubular substance*, a term preferable to medullary, which is altogether objectionable.

In the kidney we follow, as in the liver, its component parts into the interior, with a view to ascertain their mode of arrangement, as on this its structure depends. The fissure of the kidney lodges the renal artery and vein, the nerves and lymphatics, together with the commencement of the excretory duct. This last (the ureter, 3) expands opposite the fissure of the kidney into an irregularly oval and compressed ampulla, 4, called

the *pelvis*, which is partly concealed by the vessels. If the ureter and pelvis be inflated, or, what is better, if they be distended with soft injection, it will be found, on dissecting off the anterior wall of the kidney, that on entering its substance the pelvis gives off three tubes, one corresponding with each extremity, and another with the middle of the organ ; these again subdivide into from seven to thirteen smaller tubes, 5, 5, (*infundibula*,) and the infundibula terminate in cup-like cavities, 6, 6, (*calices*,) formed by their extremities being depressed, or, as it were, slightly inverted on themselves.

Each calyx embraces the extremity, 7, of one, sometimes of more rounded processes (*papillæ*, *mammillæ*), and each papilla is the summit of a conical mass, whose base looks towards the circumference of the kidney, and is, together with the sides, embedded, as it were, in the cortical part of the kidney. The conical masses are usually more numerous than the calices, in which they terminate ; each is composed of minute tubes, (*tubuli uriniferi*,) of which one extremity opens on the surface of the papilla, and therefore pours its contents into the investing calyx, whilst the other, prolonged to the base of the cone, is there continuous with the capillary terminations of the arteries, from which it receives the secretion the moment it is elaborated ; and so the fluid is received, and passed on successively by the tubuli, calices, infundibula, and pelvis, whose structure is similar to that of the ureter, being but so many prolongations of it. Though the mucous membrane of each calyx appears to cease where it is reflected over the surface of the papilla, yet we can scarcely avoid coming to the conclusion that it is prolonged into the tubuli uriniferi, as there is no part of the economy in which an excrementitious fluid is allowed to rest on the structure of an organ unprotected by a tegumentary membrane. Again, though the fibrous investment of each infundibulum and calyx seems also to cease at the margin of the papilla, it is more than probable that it also is prolonged, so as to become continuous with the fibres which constitute the tubuli.

1058. *Vessels and nerves of the kidney.*—The renal *artery* is derived from the aorta, and divides into five or six branches previously to entering the fissure of the kidney ; its branches pass between the papillæ, and so continue until they reach the bases of the conical masses, where they divide and ramify, so as

to form a complete vascular net-work, encasing the inner or tubular structure, and so forming a cortex, or exterior investment for it. The capillary ramifications of the artery thus disposed communicate with the tubuli uriniferi, and also with the radicles of the renal vein, which reconveys the effete blood into the course of the circulation, opening into the inferior vena cava. The lymphatics of the kidney are very numerous. The *nerves* (which are derived from the renal plexus of the sympathetic system) are, on the contrary, comparatively few; their distribution has not been followed to any considerable depth in the substance of the organ.

During fœtal life, the surface of the kidney is marked by deep fissures, which indicate its division at that period into several lobules. These contain each the elements of a distinct organ; they gradually become united, and at length the kidney assumes the uniform appearance seen in the adult. The lobulated condition of the kidney is permanent in many of the lower animals.

SUPRA-RENAL CAPSULES.

1059. The *supra-renal capsules* are so named from surmounting the kidneys; other names have been given them from hypotheses concerning their use (atrabiliary capsules, renes succenturiati). Each of these bodies is compressed, and rather flat; the upper border is convex, the lower is excavated, and rests on the superior extremity and partly on the inner border of the kidney, to which it is united by cellular tissue. They are formed of two substances: an external, which is dark yellow in colour, somewhat dense and striated; and an internal, which is deep brown, soft, and pulpy. The interior is hollowed into a small triangular cavity, containing a viscid fluid. Some anatomists, however, believe that this cavity is produced by the decomposition of the pulpy substance in which it is found.

In early fœtal life the supra-renal capsules are granular in structure and exceed the kidneys in size; the latter, however, rapidly increasing, become much the larger towards the end of that period. After birth, the supra-renal capsules even become diminished, and apparently shrivelled. Their *arteries* are derived directly from the aorta, with a branch each from the phrenic and renal; the *veins* (of which there is usually but one

on each side) open, the right into the vena cava, the left into the renal vein.

The description of these bodies is placed in the present section in consequence of their connexion with the kidneys, and not from any consideration of their function, about which there has hitherto been nothing more than conjecture.

URETERS.

1060. The pelvis (renalis), which has been previously described, fig. 164, 4, as receiving all the urine from the calices, gradually becomes narrowed, and, opposite the lower border of the kidney, assumes the name of ureter, 3. This duct, fig. 165, 3, 3, extends from the point here indicated to the posterior and inferior part of the bladder, into which the canals from both kidneys open. Each thus averages about eighteen inches in length; its calibre is usually compared to that of a quill.

The ureter, in its whole course, lies behind the peritonæum; superiorly, it rests against the psoas muscle, and is crossed by the spermatic blood-vessels (these being in front): lower down it passes over the common iliac vessels; lastly, in the male, the vas deferens crosses to its inner side immediately before it terminates.

In opening into the bladder, the ureters pass obliquely between its muscular and mucous coats, before they end on its inner surface; this arrangement has a valvular effect, preventing the fluid from passing back towards the kidney. The structure is the same as that of the pelvis, and consists of an external fibrous tunic, lined by a thin mucous membrane.

URINARY BLADDER.

1061. The bladder (vesica urinaria), fig. 165, 1, is a musculo-membranous reservoir, placed deeply in the pelvis, behind the pubic symphysis, and before the rectum in the male, but separated from it by the uterus and vagina in the female. It receives the secretion of the kidneys by the ureters, and discharges it by the urethra.

In infancy the bladder is elongated and pyriform in its shape, and contained altogether in the abdomen. At this period it may be considered as divisible into three portions; the rounded or upper extremity being with propriety called

Fig. 165.

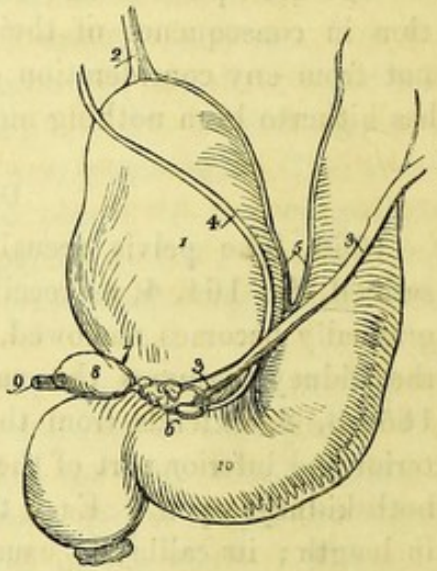

its *fundus*, the narrow tapering part the *neck*, the intermediate portion being the *body*. As the pelvis expands, the bladder gradually subsides into it, so as not to rise above its margin (at least in the adult) unless when distended, and at the same time assumes a remarkable change of form. It becomes a compressed oval, for the lower part of its body expands and subsides on the rectum, probably by the weight of the fluid it habitually sustains, and to this part is applied the term *base*, or "*bas-fond*." Thus we are obliged to recur to the original application of the terms, in order to explain an apparent inconsistency in those employed; and the inconsistency is heightened by making the term "fundus" and "summit" synonymous, at the same time that "fundus" and "base" are applied to different parts of the same viscus. Yet, so the nomenclature runs: that which was the fundus in the fœtal bladder is not unfrequently called "summit," because it is the highest part.

The direction of the bladder is oblique, being inclined somewhat forwards and upwards, from base to summit; and, as it is being gradually distended, it comes forward more and more, the neck being fixed, whilst the fundus and body curve forwards and upwards with the distension. If examined in this condition three ligamentous cords (viz. the urachus, 2, and the remains of the umbilical arteries) will be observed to pass from its summit obliquely upwards behind the recti muscles to the umbilicus. Into its base two tubes are inserted, viz. the ureters, 3; and at the sides the vasa deferentia, 4, pass obliquely backwards. Now all that part of the posterior surface and sides of the bladder included between these lines is covered by peritonæum, 5, the remainder being uncovered. Thus, at the fore part, from the point of attachment of the urachus down to the neck of the

bladder, no serous covering exists. In the collapsed condition all this lies behind the pubes; but, when distended, part of it rises above its margin, and is in contact with the recti muscles: inferiorly, from the entrance of the ureters to the urethra it is also uncovered, and on the sides from the vasa deferentia forwards to the surface of the pelvis.

1062. The base and neck are the parts which deserve the greater share of attention. The *base* is that depending part of the viscus which rests on the rectum. Attached to it we find the vesiculæ seminales, 6, and vasa deferentia, 4, so disposed as to leave between them an interval, in which the bladder is separated from the rectum only by some cellular tissue. This space is triangular in its form, the sides being formed by the vesiculæ converging to the prostate, whilst the base corresponds with the interval between the ureters. It is by no means so extensive when the parts are *in situ*, as may be inferred from viewing them after they are disturbed. The vesiculæ are in close contact for some lines before they reach the base of the prostate; and as the peritonæum is being reflected off the bladder at the entrance of the ureters, it forms a curved fold, whose convexity inclines forwards in the interval between them. The *neck*, 7, or constricted part at which the bladder is continuous with the urethra, 9, is usually compared to a truncated cone, longer below and at the sides than above. In infancy it is oblique, its direction being downwards and forwards, but in the adult it becomes almost horizontal. The posterior part of it rests on the rectum, the rest being encircled by the prostate gland, 8. In the female, the parts of the bladder last described are in close relation with the vagina, which is interposed between them and the rectum. Moreover, there are no organs appended to them, the vesiculæ and prostate being peculiar to the male.

1063. The *inner surface* of the bladder is lined by mucous membrane, continuous with that which is prolonged upwards along the ureters, and downwards through the urethra. When collapsed, it presents throughout the body and fundus slight rugæ, or waving lines, which exist no longer in the distended condition. But towards the lower part, and corresponding with what we described, externally, as the base, a smooth and slightly raised surface appears, in which no rugæ occur under any circumstances. The shape of this part is that of a triangle, its two

posterior angles being indicated by the openings of the ureters, and the anterior or apex by the commencement of the urethra: this part of the bladder is endowed with peculiar sensibility. It is the "*trigone vesical*" of Lieutaud and Camper;* its apex or anterior angle, from being slightly elevated, has also been named "*luette vesicale*" (*uvula vesicæ*). This corresponds to the third or transverse lobe of the prostate, which is placed beneath. Along the sides of the trigone, and under cover of the mucous membrane, muscular fibres extend from the prostate, diverging to the internal orifice of the ureters, and are fixed to both these points. The orifice of the ureters is not protected from the reflux of the urine by any valve; but the obliquity of their course through the substance of the bladder serves the purpose. Sir C. Bell supposes, that, as in contraction of the bladder, the point at which its outer coat is penetrated by the ureter is drawn towards the neck of the organ (its fixed point), and therefore opposite the internal orifice, the longitudinal fibres are intended to act on the latter at the same time; so that, drawing it proportionally forward towards the prostate, they may thus maintain the required obliquity.

1064. *Structure.*—The bladder, like the other hollow viscera, is composed of three coats or layers, united by cellular tissue. The peritonæal, or exterior coat, we have already noticed as forming a partial investment.

The *muscular* layer consists of pale fibres disposed in different directions, all of which are sometimes mentioned under the general name *detrusor urinæ*. The external fibres on the forepart may be seen to pass upwards from the neck to the summit, and thence downwards and backwards to the base of the prostate gland. On the sides they follow an oblique course. The internal set are for the most part transverse, and towards the neck so nearly assume a circular direction, that some anatomists have considered them as a sphincter muscle (*sphincter vesicæ*). These are disposed immediately behind the prostate, and therefore behind the opening of the seminal vessels: they are most apparent inferiorly. When the bladder is distended, intervals occur between the bundles of muscular fibres in which the inner tunic is seen. The protrusion of the latter in these inter-spaces forming a species of hernia of the mucous membrane, will con-

* Camper, Fascic. Anat. Pathol.

stitute what is called the sacculated bladder. The muscular fibres sometimes become much thickened (hypertrophied) by over-action, or in consequence of inflammation, and form considerable projections on the internal surface of the bladder, giving to it the peculiar appearance expressed among the French by the term "vessie à colonnes."

The *mucous* coat is smooth when distended, but corrugated when the bladder is contracted; its colour is pale, with a slight rose tint. The portion covering the "trigone" is smooth in all conditions of the organ, and paler than in any other part. The muscular and mucous membranes are united by a well-marked layer of cellular tissue, frequently mentioned as a separate coat, under the name vascular or nervous tunic.

Vessels and *nerves* of the bladder.—In early life, the bladder receives its arteries from the hypogastric; in the adult, it is supplied by the proper vesical arteries, and by twigs derived from the hæmorrhoidal and internal pudic vessels, the greater number being towards the neck and base. Its veins form a plexus at the same situation, and open into those of the internal iliac. The lymphatics follow a similar course. The nerves come from the sacral plexus of the cerebro-spinal system and the hypogastric plexus of the sympathetic.

1065. *Ligaments* of the bladder.—The bladder is retained *in situ* by certain membranous reflections called ligaments. The fascia iliaca, it will be recollected, descends into the pelvis, becoming adherent to its margin; thence it is prolonged downwards, under the name fascia pelvica, to a level with an oblique line extended from the pubic symphysis to the spine of the ischium. At that point it contracts a close connexion with the obturator fascia, after which it is continued on the inner surface of the levator ani, to the side of the bladder and prostate gland, with whose structure it becomes in a manner identified; from its destination, this last portion is sometimes called vesical fascia. A similar arrangement of the membrane takes place at the opposite side, and both are termed the *lateral ligaments* of the bladder. The fascia transversalis (sect. 600), it will also be recollected, is continued down behind the pubic symphysis, and on reaching the fore part of the neck of the bladder is reflected over the prostate on its upper surface. From the point of reflection two dense fasciculi of fibres (one at each side of the

median line, with a slight cellular interval between them) pass also upon the upper surface of the bladder; these are the *anterior ligaments*. They are considered by some anatomists as tendons of attachment for the muscular fibres of the bladder to the symphysis pubis.

As the peritonæum is being reflected to and from the bladder, it necessarily forms certain folds or duplicatures, which have been termed ligaments. Two of these will be observed extending from its sides to the iliac fossæ, and two posteriorly, corresponding with the course of the umbilical arteries; but, instead of checking its motions, they serve rather as provisions to admit of the changes consequent on distension, and therefore should not be called ligaments.

URACHUS.

1066. The urachus is a fibro-cellular cord, extending from the apex of the bladder upwards towards the umbilicus, lying behind the linea alba, and in front of the peritonæum. Inferiorly, it is connected with the muscular fibres of the bladder; the superior extremity, prolonged upwards to the umbilicus, becomes united with the fibrous tissue of the linea alba. In man, the urachus appears to be merely the rudiment of a tube which, in inferior animals, communicates with the allantois. It perhaps serves to maintain the proper position of the upper part of the bladder, and, during its distension, prevents the peritonæum from being insinuated between it and the abdominal parietes.

URETHRA.

1067. The urethra is a membranous tube directed in the median line from behind forwards, beneath the arch of the pubes; by one extremity it is continuous with the neck of the bladder, by the other it opens externally. In the female, it serves simply for the excretion of urine; in the male, it is the outlet also for the seminal fluid.

The *female urethra* is about an inch and a half in length, and is slightly curved, the concavity looking forward. It lies embedded in the upper wall of the vagina, under cover of the anterior ligament of the bladder. The external orifice (meatus urinarius) opens beneath the symphysis pubis, about an inch

behind the clitoris, and immediately above the inlet to the vagina. Its *structure* consists of a mucous lining membrane, covered by a layer of cellular tissue; these being unconnected with any dense or unyielding parts, the female urethra admits of considerable dilatation.

From the function and connexions of the *male urethra*, it may be associated with the organs of generation; moreover, as it is united to other parts (the prostate and penis), its description will be more conveniently placed after theirs.

THE MALE ORGANS OF GENERATION.

1068. The male organs of generation are situated for the most part on the anterior surface of the pelvis, differing in this respect from the corresponding parts in the female, the greater number of which are lodged in its cavity. They consist of, 1, the testes and their excretory ducts, the prostate and Cowper's glands (considered as accessory glands)—the urethra; 2, the penis.

In pursuing the physiological order, the organs should be examined as they are here enumerated; but as the urethra forms part of the urinary apparatus just treated of, we shall commence with it, premising the description of those parts of the generative system with which it is united, namely, the prostate and the penis.

THE PROSTATE GLAND.

1069. The prostate gland (prostata), fig. 165, 8, has been compared to a truncated cone, compressed from above downwards; but it more nearly resembles a chestnut both in shape and size. It usually measures a little more than an inch from side to side, an inch from before backwards, and half an inch in thickness. Situated deeply in the pelvis, behind the deep perinæal fascia and beneath the arch of the pubes, the prostate will be found to enclose part of the neck of the bladder and the commencement of the urethra at their junction; the tube, however, being so placed as that two-thirds of the substance of the gland lie beneath it. The prostate is also traversed by the common seminal ducts, which pass from behind forward through its substance and open into the urethra.

It lies immediately beneath the anterior ligaments of the

bladder, and rests on the middle portion of the rectum, to which it is united by means of dense cellular membrane. The posterior border is notched in the middle, and of considerable thickness; laterally it gives attachment to, or is, as it were, slung by, the anterior part of the levator ani. In consequence of their intimate connexion with the rectum, the inferior surface and posterior border are readily felt by the finger introduced into the intestine. The prostate is enclosed in a fibrous cover derived from the deep perinæal fascia; this membrane is frequently very dense, and affords considerable resistance in section of the gland during the operation of lithotomy.

Lobes—structure.—It consists of three lobes, two of which, placed laterally, are of equal size; the third (a small rounded body) is connected intimately with the others, lying behind and between them. The third lobe is exposed by turning down the vesiculæ and seminal ducts, being placed between the latter and the bladder, and corresponds to the elevation described as the luette vesicale. If enlarged, the third lobe forms a projection into the neck of the bladder, which would afford impediment to the evacuation of urine or the introduction of an instrument. The term luette vesicale, or uvula vesicæ, which has the same signification, would be more fitly applied to the diseased condition indicated than to the healthy state of the part.

The tissue of the gland is resistant, of a grayish colour, and consists of a series of follicles aggregated together. These secrete a whitish ropy mucus (liquor prostaticus), which is poured from ten or twelve orifices into the urethra on each side of the verumontanum.

THE PENIS.

1070. The penis, which supports the greater part of the urethra, is composed of vascular or erectile substance, occupying, as it were, three compartments, or forming three bodies, as they are termed. Of these, two are placed superiorly, one at each side of the median line (corpora cavernosa penis); the other is situated beneath the preceding, and more especially connected with the urethra, whence it is named corpus spongiosum urethræ. The entire, intimately connected one with another, are invested by integument, the peculiar disposition of which renders a special description necessary.

1071. The *integument—prepuce.*—The skin on the pubes is supported by a thick cushion of yellow adipose matter, and studded with hairs after puberty. It is prolonged (but much altered in character, inasmuch as here it is very thin, and fat is never deposited under it) on the body of the penis, forming a complete and close investment for it, as far as the extremity of the corpora cavernosa; at this point it is continued forwards, forming a loose and unattached fold called *prepuce*, which is intended to protect the glans. The margin of the prepuce terminates in a red line, where it becomes continuous with the mucous membrane. The latter may be traced down to the corona glandis, forming a lining for the prepuce, and thence over the glans to the orifice of the urethra, with whose lining membrane it becomes continuous. From beneath the opening of the urethra to the base of the glans, the membrane is thrown into a fold, called *frænum præputii.* These integuments derive their blood-vessels from the superficial pudic branches of the crural arteries, and from the dorsalis penis branches of the internal pudic. Their lymphatics terminate in the inguinal glands.

1072. The *corpora cavernosa* form the principal part of the body of the penis, and necessarily determine its form and consistence. They represent longitudinal sections of two cylindrical tubes, placed laterally with regard to one another, and intimately blended along the middle line for three parts of their length, whilst at the lower part they branch out into two processes, (crura,) so that the whole resembles the letter Y reversed. The *crura* are attached to the rami of the ischia and ossa pubis, and thence ascend, converging to the fore part of the pubic symphysis, where they become united. Along the middle line a vertical septum exists, which, however, forms but a partial separation, as it presents, more particularly towards the anterior extremity, many large foramina or fissures which admit of a free communication from side to side,—from this circumstance it is named *septum pecteniforme.*

The inferior surface of the penis presents, along the middle line, a groove, which partly lodges the canal of the urethra; the anterior extremity is rounded and supports the glans, with whose base it is firmly united. The upper surface, or dorsum, is also marked, but slightly, for the dorsal vein, and is attached to the symphysis pubis by a triangular *suspensory ligament.*

This is a dense lamella of fibres, so placed, that whilst the cutaneous border is free, the superior one is attached to the pubes, and the inferior to the body of the penis, where its fibres spread out, becoming identified with its structure.

1073. *Structure.*—The corpora cavernosa are composed of a fibrous sheath, enclosing a quantity of erectile tissue. The exterior investment is dense, elastic, and resisting, though composed for the most part of longitudinal fibres. From the inside of its circumference thin lamellæ project, forming partial septa, by means of which the shape of the part is maintained, more than a certain degree of distension is prevented, and the cavity is divided into several small cells. Within these is enclosed the intricate vascular interlacement just alluded to, which consists of numerous ramifications of blood-vessels, chiefly veins, forming complicated anastomoses.

A transverse section of the body of the penis will show the relation and connexion of its component parts. On the sides are two cylindrical tubes, formed by a fibrous membrane, enclosing a vascular mass in the interior, and divided along the middle line by a vertical septum ; beneath and between these runs the urethra, surrounded by its vascular investment. The vessels and nerves of the corpora cavernosa are derived from the internal pudic.

About an inch, or a little less, from the anterior margin of the prostate, the urethra comes into contact with what is called the bulb, which is succeeded by a prolongation, similar in structure, named corpus spongiosum, and the latter finally expands into the glans penis ; so that the canal is invested for three-fourths of its length by a vascular net-work, which, by being differently disposed in different parts, has received the names just mentioned. It consists of a minute interlacement of capillary vessels, connected together by cellular membrane, capable of receiving a considerable quantity of blood, and thereby assuming that state of tension which attends the venereal orgasm. Hence it has been termed erectile tissue.

The *bulb* is thick, and pendent from the under surface of the canal ; it is placed externally to the pelvis, being in front of the deep perinæal fascia which sends forwards on it a tubular investment. It rests on and is supported by the acceleratores urinæ, and lies immediately beneath the angle formed by the

junction of the corpora cavernosa. The bulb receives a large artery from the internal pudic.

The *corpus spongiosum*, extending between the bulb and glans, surrounds the urethra, but exists in greater quantity along its lower aspect; this is partly covered by the same muscles as the preceding.

1074. The *glans* (glans penis) forms the extremity of the penis; it is a conical prominence, slightly compressed from before backwards, presenting at its summit a vertical fissure, marking the termination of the urethra; its base is supported by the extremity of the corpora cavernosa, and presents a circular ridge (corona glandis). Behind the last-named part exists a circular constriction (cervix), in which are several follicles (glandulæ Tysoni), that secrete a substance of peculiar odour. The glans is covered by a thin dry mucous membrane, which is intimately adherent to the structure beneath it, and is continuous at the cervix with the inner layer of the prepuce, as well as with the lining membrane of the urethra at the orifice of the urethra. It is also protected by the prepuce.

URETHRA.

1075. The urethra is extended from the neck of the bladder to the extremity of the penis; its length has been very differently stated by different persons. It is usually set down as being from nine to twelve inches; but an examination of a considerable number of cases made to determine this point, gave, as the greatest length, nine inches and a half, and the least seven inches and a half.* Its diameter varies in different parts, being about four lines wide in the greater part of its extent, and from two and a half to three at its orifice.† The tube consists of two structures, one being the mucous lining, continuous with that of the bladder, the other a lamella of cellular membrane, resembling the sub-mucous tissue elsewhere, and which serves to connect it with the contiguous structures found along its course.

1076. The urethra is considered as being divisible into three portions, which are named according to the structures

* Whately on the Treatment of Strictures.

† Sir E. Home's Practical Observations on the Treatment of Strictures in the Urethra.

that surround them, each presenting some peculiarities deserving notice.

1. The *prostatic portion* (pars prostatica) is from twelve to fifteen lines in length; it is the widest part of the canal, being, however, larger in the middle than at its extremities. In the middle of its floor, or lower surface, projects a narrow ridge, of some lines in length, formed by an elevation of the lining membrane and subjacent cellular tissue. From its shape it has received the name of *caput gallinaginis*, or *verumontanum*. In the middle of its anterior part is a depression (sinus pocularis), close beside the margins of which are placed the openings of the two common seminal ducts (ductus ejaculatorii), one at each side. External to this ridge the surface is depressed a little into a groove (sinus prostaticus), and is pierced by several minute foramina, communicating with the cells in the substance of the prostate, and through which a viscid fluid is made to ooze if it be pressed.

2. The *membranous* part (pars membranosa) comprises the interval between the margin of the prostate and the bulb, being from ten to twelve lines in length. It is the narrowest part of the canal, and composed of the proper membranes only of the urethra,—hence its name; but it is encased by an offset from the deep perinæal fascia, which is continued backwards around it and the prostate, and is supported by the terminal expansions of Wilson's muscles. The membranous part is in close relation with Cowper's glands, and at its extremity passes through an aperture in the deep perinæal fascia, which, from this circumstance and its shape, is sometimes named the triangular ligament of the urethra.

3. The *bulbous* part of the urethra (pars bulbosa) dilates somewhat at its lower surface, but the diameter of the canal at this point does not exceed that of the following part by more than a line, under ordinary circumstances.

4. *Pars spongiosa* is from six to seven inches in length, and continues uniform in its size, being intermediate in diameter between the membranous and bulbous part, whilst in the glans another dilatation appears to take place, called *fossa navicularis*, previously to its narrowing into the orifice of the urethra. It has been contended by M. Amussat, that this dilatation is rather apparent than real, and that it is owing

to the fact that the glans, by its greater firmness of texture, draws the lining membrane outwards with it when the urethra is laid open, thereby making it appear wider than it is in reality.

Lining membrane. — *Lacunæ.* — The lining membrane is smooth and lubricated, as mucous surfaces usually are. Several minute foramina will be found to open into it, being the orifices of mucous follicles, or cryptæ, placed exterior to the mucous membrane, but lined by delicate processes prolonged from it into their interior. These are named *lacunæ;* they are inclined from behind forward, so that urine, when being evacuated, does not find ingress to them.

COWPER'S GLANDS.

1077. These are two small masses, about the size and shape of peas, placed immediately beneath the membranous part of the urethra, and behind the bulb. They consist of several small lobules, united by a membranous investment. Two ducts, from three quarters of an inch to an inch long, issue from them, and proceed forwards, to open into the urethra a little before the bulb. They are retained *in situ*, and supported, by a tubular prolongation sent forwards on the urethra from the deep perinæal fascia. The existence of Cowper's glands is not constant. In front of them a single small granule or glandular body is occasionally found.

THE TESTES.

1078. *Their change of situation,—descent* (*?*).—The testicles, (διδυμοι, *testes*,) the secreting organs of the seminal fluid, lie, in the earlier months of fœtal life, on the psoas muscles, near the lower extremities of the kidneys. Each of them is invested by a proper capsule, or fibrous tunic, and receives, moreover, a partial covering from the peritonæum, to about the same extent as the kidney does, as both are similarly circumstanced with regard to that membrane. It receives its artery from the aorta, close to which it lies, whilst the vein opens into the vena cava on the right side, and into the renal vein on the left. From the lower extremity its duct (vas deferens) will be observed to descend towards the neck of the bladder.

1079. *Gubernaculum testis.* — From the lower end of the

testis a cellulo-fibrous cord, of a very different character from that just mentioned, is extended down through the inguinal canal, to the external surface of the pubic symphysis. This has been called by Mr. Hunter gubernaculum testis; it appears a little broader above than below, and also to contain a minute canal.

In the seventh month of pregnancy the length of the gubernaculum is considerably diminished, as the testis has changed its place, having removed from the lumbar region to the iliac fossa. This in strictness cannot be considered a "descent:" for, in the ordinary position of the fœtus, the change is the reverse of that in which its gravity would draw it, and therefore it is rather an ascent. In the eighth month, the testis enters the internal ring, lying behind a process of peritonæum, which makes its exit from the abdomen by the inguinal canal; and at the ninth month it will be found at the bottom of the scrotum, bearing the same relation to its peritonæal investment that it had originally done to the whole membrane, that is to say, lying behind and exterior to its cavity, but still partially covered by it.

1080. The process of peritonæum that accompanies the testis in its course from the lumbar region to the scrotum, is an elongated cul-de-sac, somewhat like the finger of a glove, communicating at the inguinal ring with the general cavity of that membrane, and resting on the fore part of the testis and its cord, but closely adherent to both. By degrees its aperture is closed by the narrowing of the ring, and all communication with the abdomen is cut off, after which the part of the process which corresponds with the cord degenerates into cellular tissue, whilst that over the testis remains still a serous cavity. The position and relation of this organ to its serous investment may be illustrated by taking a small bladder, and pressing some elongated body, such as an almond, against its side, so as partially to invest it, the inverted portion being made to serve as an immediate though partial covering for the substance so placed, as a part must remain unconcealed along the lines of reflection. This is the way in which the *tunica vaginalis* is derived from the peritonæum, and the position in which the testis is placed with regard to it.

COVERINGS OF THE TESTIS AND CORD.

Whilst passing through the inguinal canal, the testis and cord become covered by offsets from the abdominal muscles; exterior to which lie the superficial fascia and the integument. These structures we shall now consider as they are found in the adult.

1081. *Scrotum.*—The testes are contained in a cul-de-sac, or purse-like investment (scrotum), which is short and corrugated in cold weather and in robust persons, but becomes elongated and flaccid in the opposite circumstances. The covering of the testes being composed of several strata, differing in structure, each requires separate examination.

The *skin* is of a darker colour than elsewhere; it is also thrown into several rugæ or folds, and marked along the middle line by a slightly elevated ridge or raphé, extending from the penis along the centre of the perinæum to the margin of the anus. It is furnished with several sebaceous follicles and some scattered hairs, the bulbs of which are distinctly perceptible when the scrotum is elongated.

1082. The *dartos* is a thin lamella of a peculiar texture, placed beneath the skin, and so disposed as to form two sacs, each containing the testis of the corresponding side, and both united along the median line,—thus forming a partition between them (*septum scroti*). This structure is vascular, and striated so as to resemble in some degree muscular fibre. It is confessedly contractile, and serves the purpose of drawing up and sustaining the testes, at the same time that it corrugates the skin; but when macerated, or tried by the usual tests, no trace of fibrine can be discovered in it. When examined with attention, it will be found that its texture gradually becomes assimilated to the superficial fascia which descends from the abdomen round the cord, and again, below the scrotum, it in the same way passes into the superficial fascia of that region. We may now call to our aid a few facts, which will assist in throwing some light upon, if they do not actually determine, a litigated question. That lamella which lies between the skin and abdominal muscles in the human subject is merely cellular membrane; in the larger quadrupeds a layer of elastic tissue (tissu jaune) is substituted, in order to support the weight of the

viscera. In the human subject such a support is not wanted for the abdomen, but the pendulous testes require something of the kind. When emaciation occurs, indicating a general diminution in the subcutaneous cellular deposit, the testes hang lower than they had previously done, owing to the absorption of the elastic tissue of the dartos, and its consequent conversion into mere cellular membrane; but when the *embonpoint* is restored, the testes rise to their usual level, by the restoration of the sustaining agent. In this view of the subject the dartos constitutes a transition structure between cellular membrane and elastic tissue.

1083. *Fascia of the cord, cremaster, &c.*—Beneath the dartos lies the thin fibrous expansion derived from the external abdominal ring (fascia of the cord, sect. 594): it is connected with that next in order. The cremaster (sect. 490), named also from its colour tunica erythroides (ερυθρος, red; ειδος), consists of muscular fibres arching downwards in front of the cord and testes, some being also placed behind. The fibres of the cremaster, where they are distinct one from the other (intervals existing between them) are connected by cellular tissue. Under the preceding is found a thin cellular investment, which is continued from the fascia transversalis at the internal abdominal ring (sect. 595). The three laminæ here described, namely, that given from the margin of the external ring, the cremaster, and the process derived from the fascia transversalis, are common to the spermatic cord and the testis; on the latter they are closely united one to the other, and to its serous tunic.

1084. *Vessels and nerves.*—The investments of the cord and testes are supplied with blood from three sources. 1. The external pudic artery (sect. 697) passes inwards from the femoral, and, crossing the cord, distributes branches to the anterior and lateral parts of the scrotum, as well as to the integuments of the penis and pubes. 2. More deeply seated than the preceding is situated a branch given from the epigastric artery (sect. 691). This supplies the cremaster, from which it is named *ramus cremastericus*, and sends ramifications to the integument of the scrotum and pubes. 3. The perinæal branch of the internal pudic (sect. 684) proceeds along the perinæum, from behind forward to the scrotum, in which it is distributed, especially towards the septum.

The *veins*, owing to the thinness of the skin of the scrotum, are apparent on the surface; they follow the course of the arteries. The lymphatics for the most part open into the inguinal lymphatic glands.

1085. The *nerves*, like the arteries, are three in number; one, the ilio-scrotal (sect. 946), proceeding from the musculo-cutaneous branch of the lumbar plexus, passes out of the external abdominal ring, and divides into filaments, which supply the integument of the scrotum. In some cases two small branches are found to follow the course here pointed out. 2. The genito-crural (sect. 948) proceeds also from the lumbar plexus. As its name implies, this nerve, dividing, sends one part to the integuments of the thigh, the other comes into contact with the spermatic cord at the internal abdominal ring. This latter, passing through the inguinal canal, sends many filaments to the cremaster, while others are given generally to the covers of the cord and testis. The third is the perinæal nerve (sect. 961). It accompanies the artery of the same name, and ramifies in the inferior and lateral parts of the scrotum.

TUNICA VAGINALIS.

1086. Under the parts described as forming investments common to the cord, fig. 166, 1, and the testis, lies the proper serous covering (*tunica vaginalis*) of the latter, 2. The manner in which this membrane is derived from the peritonæum, and the changes which occur subsequently to its being drawn down from the abdomen into the scrotum, have been already described (1079). In the adult it forms a shut sac, inverted on itself in such a way as that one part of it covers the body of the testis, 2, as well as the epididymis, 3, except where the vessels enter its posterior border; at which point the other part is reflected outwards, and becomes a lining to the preceding investments, to which it is closely adherent. From the

Fig. 149.

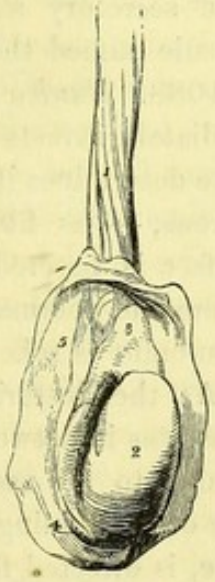

difference in the disposition or relations of both these parts of the membrane, they generally receive different names. One (that adherent to the testis) is called *tunica vaginalis testis*, fig. 167, 1; the other is named *tunica vaginalis reflexa*, fig. 167, 1, 166, 5.

Fig. 167.

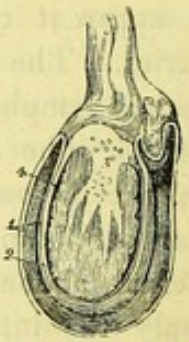

THE TESTES.

Their disposition and structure. — Having considered their change of position, and examined the various structures by which they are invested, we now proceed to the description of the organs themselves.

1087. The testes are suspended at unequal heights, that of the right side being higher than the opposite; this disposition prevents the inconvenience or injury that might result from one being pressed against the other in certain positions of the thighs. They are of an oval form, somewhat compressed laterally, and so placed by the manner in which they are suspended by the spermatic cords, that their upper extremities are turned obliquely forwards, and the lower in a corresponding degree backwards. The long diameter of each varies from an inch and a half to two inches; that from side to side is about an inch or a little more. Along the posterior border is placed an elongated appendage, called epididymis. The secretory structure of the testis is enclosed in a firm capsule named the tunica albuginea.

1088. *Tunica albuginea* (fig. 167, 2).—This membrane immediately invests the substance of the testicle, and at the same time determines its form. It is of a clear white colour, dense and fibrous, — its fibres interlacing in every direction. Its outer surface is covered by the tunica vaginalis, except posteriorly, where the spermatic vessels pass through it, at which point that membrane is reflected off.

At the posterior border of the testis the tunica albuginea separates into two laminæ; one of which, the external, is continued to the vas deferens (the excretory duct of the testis); the other, joining with a corresponding layer from the opposite side, is directed for the space of a few lines into the substance of the gland. This last part, 3, known by the name *corpus*

Highmorianum, forms an incomplete septum in the cavity of the tunica albuginea, and is thence named by Sir A. Cooper.* "mediastinum testis." Thus projecting from behind forwards, it is broader superiorly than at its lower extremity, and extends from the upper nearly to the lower end of the testis. Between the fibres of the mediastinum small intervals exist, which lodge seminal canals and blood-vessels, to be afterwards described. From its surface (which looks towards the cavity of the tunica albuginea) are given off fibrous processes that admit of being distinguished into two series. One of these consists of several slender cords or filaments, which, being also connected to the tunica albuginea at different points, serve to maintain the shape of the testis. The others, in the form of delicate laminæ, separate and support the several lobules into which the seminal vessels are divided.

1089. *Tunica vasculosa*, fig. 167, 4. — The inner surface of the tunica albuginea is lined by a delicate membrane formed of the ultimate ramifications of the spermatic blood-vessels, united by a minute portion of cellular tissue, and hence named tunica vasculosa.† This vascular membrane is also expanded over the fibrous processes already pointed out, and is thus brought into relation with each lobule of the testis.

1090. The tunica albuginea being removed, the *glandular structure* of the testis lies exposed. It has the appearance of a soft, pulpy, dark yellow mass, divided into lobes. This substance is, by injection, found to consist of vast numbers of minute tubes (tubuli seminiferi) which do not communicate one with the other. The lobes (*lobuli testis*) differ in size, some containing one, others a greater number of the seminal tubes. Their shape is somewhat conical; the large end of each is directed towards the circumference of the testis, the small one towards the mediastinum. They are supported by the fibrous expansions extended from the mediastinum to the tunica albuginea.

1091. The *tubuli seminiferi* (vascula serpentina) are the vessels in which the seminal fluid is secreted. According to Monro, their number is about three hundred, the length of each about sixteen feet, and the diameter $\frac{1}{200}$ of an inch.

* Observations on the Structure and Diseases of the Testis.

† Sir A. Cooper, loc. cit.

Each of these small vessels commences by a closed extremity towards the inner surface of the fibrous covering of the testis, and from this point proceed, inclining from side to side in a serpentine or zig-zag course, towards the mediastinum. It loses the convoluted disposition as it approaches that process, and, passing through its fibres, opens into the next order of vessels.

1092. *Vasa recta.*—The second order of seminal vessels are situated in the substance of the tunica albuginea, or rather amid the fibres of that process of it which has been termed mediastinum; of this they occupy but the anterior part, the posterior lodging the blood-vessels. The aggregate of them is named *rete testis.* Being less convoluted than the tubuli, though not straight, these vessels are named *vasa recta.* Their direction is backwards and upwards, to reach the posterior and upper part of the testis. The vasa recta are fewer in number, and larger than the tubuli seminiferi, from which they receive the secretion; and, on the other hand, are more numerous and smaller than the vessels into which they discharge it.

1093. *Vasa efferentia.*—The two preceding series of canals form, with the membrane in which they are contained, what is properly called the body of the testis; the next transmit the seminal fluid from it, (to its appendage, the epididymis,) and are in consequence named *vasa efferentia:* they are from twelve to fifteen in number, and open separately into a single vessel, of which the epididymis is formed. Being straight at the point at which they leave the testis, and very much convoluted towards their other extremity, they present a conical disposition, from which the name *coni vasculosi* has been applied to them.

1094.—The *epididymis* (επι, upon; διδυμος, testis) is placed along the posterior border of the testis, and is partially invested by the tunica vaginalis. Its upper or larger extremity, fig. 166, 3, is called the head or globus major; the lower, 4, is named its cauda or globus minor; and the narrow intervening part, the body. The epididymis consists of a single tube much convoluted, the several convolutions being united one to the other by small fibrous bands; the larger size of the upper part is owing to its connexion with the vasa efferentia. The seminal canal at the globus minor assumes the name of vas deferens.

1095. *Vas deferens.* — This is the excretory duct of the

testis; there are therefore two, one on each side. The tortuous condition, so well marked in the epididymis, gradually diminishes, and is entirely lost at a short distance from the commencement of the vas deferens. Each extends from the lower border of the epididymis to the prostatic part of the urethra, passing through the abdominal parietes; its length is very considerable, and its course necessarily complicated. Ascending behind the testes, the vas deferens comes into relation with the spermatic artery, veins, and nerves, constituting with them the cord. It lies behind the blood-vessels, and is readily distinguishable from them by its hard, cord-like feel. The direction of the spermatic cord is vertical from the testes upwards to the external abdominal ring; here it inclines obliquely outwards in the course of the inguinal canal. Arrived at the internal ring, the vas deferens turns away from the other vessels, and passes downwards into the pelvis. In descending, fig. 165, 4, it runs along the side of the bladder, and passing anteriorly to the termination of the ureter, reaches the inner border of the vesicula seminalis, with whose duct it unites to form the common seminal or ejaculatory duct. The vas deferens is formed of an external peculiarly thick and dense substance, and an internal mucous lining membrane; the calibre of its canal is very minute, especially towards its commencement.

VESICULÆ SEMINALES.

1096. The *vesiculæ seminales*, fig. 165, 6, are two narrow, membranous sacs, placed along the base of the bladder, and extended obliquely from the ureters to the base of the prostate gland. Their breadth is not more than three or four lines, their length two inches and a half. They converge anteriorly, and diverge behind, so as to include between them an angular space, in which the bladder rests immediately on the rectum. Each vesicula is convoluted, so as to appear much shorter than it really is, and consists of two lamellæ, the exterior one being dense and firm, whilst the internal is in every respect similar to mucous membrane, and thrown into folds, so as to divide the cavity into cells. The anterior extremity of the vesicula ends in a narrow tube, which unites with the vas deferens, forming a common duct.

1097. The common seminal ducts (*ductus ejaculatorii*) re-

sult from the union of the vas deferens and the tube from the vesicula on each side. Each is about an inch in length. They run forward parallel one to the other, lying between the middle and two lateral lobes of the prostate, then between the latter and the mucous membrane,—piercing which, they open into the urethra, beside the margins of the sinus which exists at the anterior part of the verumontanum.

1098. *Vessels and nerves of the testis.*—The vessels and nerves of the parts which cover the spermatic cord and testis have been already described; it remains to point out those which are furnished to the organ itself.

Artery of the vas deferens.—A long, slender branch, given off by a vesical artery, accompanies each vas deferens, ramifying in its coats, and hence named deferential.* It extends as far as the testis, and communicates with the vessel to be next noticed.

The *spermatic* artery (sect. 673) is slender and remarkably long. In early fœtal life the length is, however, no greater than ordinary, as at that period the testis is situated near the parts of the aorta from which the artery springs (1078). The spermatic artery, as it approaches the testis, gives off small branches to the epididymis, then perforates the tunica albuginea, and ramifies in the vascular membrane to supply the tubuli seminiferi.

The *spermatic veins* (sect. 771) commence by radicles from the different parts of the epididymis and testis; these unite into two or three vessels, which freely communicate one with the other, forming a sort of plexus. Following the course of the arteries, they unite in the abdomen into one trunk, which opens on the right side into the vena cava, and on the left side into the renal vein. The *lymphatics* consist at first of three or four vessels, which decrease in number as they ascend. They accompany the spermatic veins, and terminate in lymphatic glands, lying about the large vessels in front of the vertebral column (790).

The *nerves* are derived from the sympathetic system. The spermatic plexus (sect. 997) follows the course of the spermatic artery to the testis. It receives some additional filaments,

* Sir A. Cooper, loc. cit.

which accompany the artery of the vas deferens, from the hypogastric plexus.

FEMALE ORGANS OF GENERATION.

1099. The genital organs in the female are divisible, as are those of the male, into two classes: 1, those of formation (*organa generationis*, vel *formationis*), consisting of the ovaries, uterus, and Fallopian tubes; and 2, those of copulation, viz. the vagina and vulva. We commence with the latter, as they are usually first examined.

1100. *Vulva*, or *pudendum*, is a general term, which is considered as including all the parts perceptible externally; they are also sometimes called external genital organs, and consist of the mons Veneris, the labia, the hymen or carunculæ, the clitoris, and the nymphæ. The orifice of the urethra is also noticed in connexion with them, but solely from its situation.

1101. *Mons Veneris.* — The integument on the fore part of the pubic symphysis is elevated by a quantity of cellular and adipose substance deposited beneath it, and is studded with hair. This part, from its surmounting the labia, has been called mons Veneris. The *labia pudendi* (labia externa v. majora) extend downwards from the mons, gradually becoming thinner as they descend. They form two folds, so placed as to leave an elliptic interval (*rima*) between them, the external part of each being continuous with the skin of the thigh, and covered with scattered hairs, whilst the inner is lined by mucous membrane, forming the commencement of the genito-urinary mucous system. The labia unite both beneath the mons and before the perinæum, the points of union being called commissures; the inferior one has also received the name of *fourchette*. This is about an inch distant from the margin of the anus,—the interval being named the perinæum. Immediately above and on the inner side of the lower commissure, the labia are connected by a slight transverse fold (*frænulum pudendi*); the space between it and the entrance of the vagina has been called *fossa navicularis*.

1102. The *hymen* is a thin duplicature of the mucous membrane, placed at the lateral and inferior parts of the entrance of the vagina; its form varies very considerably in different persons, but is most frequently semi-lunar, the concave margin looking obliquely upwards. In the same situation are found, after the

rupture of the membrane, some small rounded masses called *carunculæ myrtiformes.*

1103. *Clitoris.*—Beneath the upper commissure, and within the labia, is the *clitoris*, a small elongated body, resembling in conformation and structure the diminutive of the penis: thus, it is sustained by two corpora cavernosa, separated by an incomplete septum, and attached by crura to the rami of the ossa pubis. It is also surmounted by a glans, though imperforate, from which depends a fold of membrane analogous to the prepuce, and acted on by a muscle (erector clitoridis, sect. 510).

Nymphæ—labia interna v. minora.—From the clitoris two folds of mucous membrane, in form not unlike a cock's comb, descend obliquely outwards, one on each side. These are the nymphæ. Their inner surface is continuous with that of the vagina, the external insensibly passes into that of the labia. They contain, between the laminæ of mucous membrane, a small quantity of erectile tissue, which appears continuous with that of the glans clitoridis.

The vestibule.—Between the nymphæ, and beneath the clitoris, is an angular interval called vestibule, at the centre of whose base is situated a circular orifice leading to the meatus urinarius. The membranous fold which surrounds the orifice of the urethra is rather prominent in some instances, so as readily to indicate its situation. The urethra has been already described (sect. 1067).

The *mucous membrane* may be traced inwards from the external labia, where it is continuous with the skin: it forms the nymphæ by being folded on itself, and is prolonged into the urethra and vagina. It is reddish in colour, is covered by epidermis, and beneath it lie a considerable number of mucous follicles.

1104. *Vessels and nerves.*—The parts here described are abundantly furnished with vessels and nerves. The arteries are the internal and external pudic. The veins and lymphatics correspond in their course with the arteries. The nerves proceed from the lumbar and the sacral plexus. Those from the former are the ilio-inguinal and external pudic branches (sect. 946, 947); from the latter, the internal pudic branch (sect. 961).

THE VAGINA.

1105. — The *vagina* is a membranous and dilatable tube extended from the vulva to the neck of the uterus, which it embraces; it rests on the rectum, supports the bladder and urethra in front, and is enclosed between the levatores ani. Thus placed, it is oblique from below upwards and backwards, its axis corresponding with that of the outlet of the pelvis. It is also slightly curved, the concavity of the curve looking upwards. Hence its length will be found greater if measured on the lower than on the upper surface, being in the latter direction about four inches and a half, while in the former it amounts to six and a half or seven. The extremities of the vagina are somewhat narrower than the middle part: the inferior is surrounded by a constrictor muscle (sect. 551): the superior embraces the uterus at a greater height behind than in front, and is covered by peritonæum.

On the *inner surface* of the vagina, along the superior, as well as the inferior wall, a slightly elevated line extends from before backwards, similar to the raphé in the middle line in other situations. Several transverse lines (*rugæ*) will also be observed, particularly in persons who have not borne children, running at right angles with those just mentioned. The rugæ are but folds of the mucous membrane, and are calculated to admit of the elongation of the vagina that occurs during the ascent of the uterus in pregnancy.

The exterior layer of which the vagina is composed is cellulo-fibrous in its structure, and contracts a close connexion superiorly with the fibrous structure of the uterus. It is thin, firm, and of a pale red colour. Round the lower part of the tube a lamella of erectile tisue is placed, which diminishes gradually in quantity from thence upwards, so that near the uterus little or none can be discovered. The arteries of the vagina arise from the internal iliac. It is furnished with nerves from the cerebro-spinal and the sympathetic systems (959 and 999).

UTERUS.

1106. The uterus (the womb; matrix) is the largest of the genital organs, and is fitted to contain and support the new being during the period of fœtal life. It lies between the

bladder and rectum, above the vagina, with which it is intimately connected, and enclosed in a fold of peritonæum, which, being extended laterally, connects it to the sides of the pelvis. In the ordinary condition, the uterus does not extend upward beyond the margin of the pelvis. The superior part inclines forwards, the inferior backwards; its direction thus corresponds to the upper axis of the pelvis, and forms an angle with that of the vagina. The average dimensions of the uterus may be stated to be about three inches in length, two in breadth superiorly, and one inch in thickness. The shape is somewhat triangular or pyriform, but compressed from before backwards, and is considered as presenting a fundus, a body, and a neck, with the enclosed cavity.

1107. The *fundus* is the broad part which projects above the attachments of the Fallopian tubes, surmounting the body; it presents a convex border, and is covered by peritonæum in its entire extent. The *body* tapers gradually as it extends from the fundus to the neck, its two sides being straight; its surfaces, however, are both convex. At the union of the sides with the rounded superior border or base are two projecting angles, into which the Fallopian tubes are inserted, the round ligaments being a little before, and the ligaments of the ovaria behind and beneath them. The *neck* (cervix uteri) is continuous with the body, narrowing gradually to the extremity; it is from six to eight lines long, and projects into the cavity of the vagina, which is attached around, by its line of union with the body of the organ, but extends upwards to a greater distance behind than in front. This part is sometimes named vaginal (pars uteri vaginalis). Its extremity presents a transverse fissure, by which the cavity of the uterus communicates with the vagina; this is named variously—os uteri, os uteri externum, and (from some supposed likeness of the part to the mouth of the tench fish) os tincæ. It is bounded by two lips (*labia*), which are distinguished by their relative position into anterior and posterior, the latter being the thinner and longer. The labia are smooth, but, after parturition, frequently become irregular, and sometimes present distinct fissures.

1108. The *cavity* is very small, in proportion to the size of the uterus. The part contained in the body of the organ is triangular, the base being directed upwards; at its two superior

angles will be observed two minute foramina, which lead into the Fallopian tubes. Where the neck is continuous with the body, the cavity is slightly constricted: this point is, in consequence, sometimes named the internal orifice (os uteri internum). The portion which corresponds to the neck is more properly a canal; it is slightly dilated in the middle, and opens inferiorly into the vagina at the os tincæ. The inner surface is marked by two slightly raised longitudinal lines, which run, one on the anterior, the other on the posterior wall; in the neck are also seen some slight rugæ directed obliquely from the former, and thus presenting an appearance not unfrequently named arbor vitæ uterinus.

The *mucous membrane* which lines the uterus is so closely adherent to the proper substance of the organ, that its existence has been doubted by some anatomists; it is continued from the vagina, and into the Fallopian tubes. In the cervix, especially towards its lower part, there are several mucous follicles. There are also occasionally found in the same situation some small vesicular bodies which, from an erroneous opinion as to their nature, have been named ova (ovula, Naboth). They appear to be mucous follicles altered by diseased action.

1109. *Proper tissue* of the uterus.—Though much difference heretofore existed concerning the nature of the proper tissue of this organ, it is now generally admitted to be muscular. The fibres are rendered distinct in cases in which the organ is enlarged, as during gestation, or when it contains a tumour. From the intricacy with which they interlace one with the other, it is difficult, if not impossible, to describe them more particularly than by assigning their general course. The muscular substance is most abundant towards the fundus of the uterus; the fibres are for the most part disposed in a longitudinal, a circular or transverse, and an oblique direction. The first appear to be the most numerous; those directed transversely are connected on each side with the Fallopian tubes and the round ligament. The *outer surface* of the uterus has been already stated to be closely invested by the peritonæum.

LIGAMENTS OF THE UTERUS.

1110. The *broad* ligaments.—The peritonæum, which covers the uterus on its anterior and posterior surfaces, is directed out-

wards to be connected to the sides of the pelvis. The part intervening between the uterus and the pelvis, on each side, is called the broad ligament (ligamentum uteri latum). Each consists of a fold of serous membrane, between the laminæ of which are situated the ovary, the Fallopian tube, the round ligament, and some blood-vessels.

The peritonæum, where it is reflected off from the uterus, in front to the bladder and behind to the rectum, is sometimes also regarded as constituting anterior and posterior ligaments.

1111. The *round ligaments* are cord-like fasciculi of fibres, attached to the angle of the uterus one on each side, immediately before the Fallopian tube. From this point the ligament passes upwards and outwards to reach the internal inguinal ring, and, after having passed through the canal of the same name, reaches the fore part of the pubic symphysis, where its fibres become expanded, and united with the substance of the labium and mons Veneris.

1112. The *arteries of the uterus* are very tortuous, and are four in number, viz. the two ovarian (which correspond to the spermatic of the male) and the uterine. The former pass in between the folds which constitute the broad ligaments, give branches to the Fallopian tubes, the ovaria, and uterus, and anastomose with the other uterine vessels. The uterine arteries are derived from the internal iliac. They become insinuated beneath the peritonæum, supply vessels to the vagina, and ramify in the uterus, communicating freely with each other, and with those which have been just described. The *veins* and *absorbents* follow the course of the arteries.

1113. *Developement.*—The uterus presents very considerable changes at different periods of life. In the fœtus it extends upwards into the abdomen, and is nearly vertical in direction. The situation and direction gradually altering, it assumes the position and inclination previously described. At the earliest period of developement it is divided superiorly into two distinct parts. The cornua, as they may be termed, gradually become united, and form an undivided organ with a single cavity. Such is the ordinary course; but cases occur in which the cornua remain permanently separate, constituting what is generally termed the double uterus. The state here referred to results from the non-union of the lateral halves, of which

the upper part of the uterus originally consists. It is worthy of remark, that this condition is permanent in some inferior animals.

Subsequently to the period first mentioned, (after the lateral parts become united,) the uterus is nearly cylindrical, being of equal dimensions at its upper and lower extremities. The fundus, however, gradually increasing in breadth, it assumes the pyriform shape, which is not completed till about the age of puberty. In old age the organ loses the triangular form, and becomes irregularly cylindrical, at the same time that it increases much in density.

During gestation, besides the remarkable increase of size and consequent change of situation, the muscular fibres become more perceptible; the arteries, veins, and lymphatics are greatly enlarged; the nerves, too, become more apparent. The substance of the organ is increased in thickness (to an inconsiderable degree) in the first instance, but, as the time of parturition approaches, it is somewhat thinner than in the unimpregnated condition.

OVARIES.

1114. The ovaries (*ovaria*) are two compressed and irregularly oval bodies, somewhat granulated on the surface, and enclosed between the folds of the broad ligaments. From the internal extremity of each descends a fibrous cord (the *ligament of the ovary*), which attaches it to the angle of the uterus, behind the insertion of the Fallopian tube — by one of the fimbriæ of which the outer extremity is supported. The ovarium is enclosed in a proper capsule, which is a thin cellulo-fibrous membrane; its proper structure presents, when divided, the appearance of a firm yet vascular mass giving lodgment to some small vesicles (*ovula Graafiana*). These, in females who have not had children, vary in number from about eight to fifteen or twenty.

1115. The *Fallopian tubes* may be considered as the excretory ducts of the ovaria, before and a little beneath which they are situated; they are about three inches in length. The attached extremity of each tube is narrow and cord-like; the unattached or free extremity is broad, and divided into a number of irregular processes (*fimbriæ*), one of which is longer

than the rest, and attached to the corresponding ovarium. The fimbriated border presents a fissure or opening (*ostium abdominale*), into which the impregnated ovum is received at the moment of its liberation from the ovarium, and thence conveyed along the tube, which opens into the uterus by another aperture (*ostium uterinum*). At this point it may be observed, that the serous membrane is in a manner continuous with the mucous, and consequently must be considered as interrupted, inasmuch as there is a real hilus along the fissured edge of the tube. Between the external serous covering and the lining membrane the tubes are composed of a thin layer of erectile tissue. The contained canal is very minute, particularly near the point at which it communicates with the uterus.

MAMMARY GLANDS.

1116. The mammary glands (*mammæ*) are accessory organs to the genital system, and, when fully developed after puberty, present the appearance of two rounded eminences placed one at each side on the front of the thorax, resting on the pectoral muscles. The base of the mamma is not exactly circular; it is rather ovoid or elliptical, the long diameter being directed obliquely upwards and outwards. A little below the centre of each projects a small conical body called the nipple, on which open several foramina that lead from the lacteal ducts. A coloured circle, or areola, surrounds the nipple, within which the skin is of a darker tinge than elsewhere.

Beneath the skin is deposited, in most cases, a considerable quantity of adipose substance, which surrounds the proper substance of the gland. The adipose tissue, which is firm, and of a yellow tinge, insinuates itself into the interstices between the lobules of the gland. It is supported by cellular tissue, which connects it with the muscle and the skin, and also with the gland; at the fore part, beneath the areola and nipple, the adeps does not exist, its place being supplied by the cellular tissue, which in this situation encloses and sustains the ducts of the gland.

Structure.—The mamma is a conglomerate gland, for it is found to consist of several small lobes, each being an aggre-

gate of a number of lobules (acini). Each lobule is about the size of a millet seed, oblong in its form, and hollow; its elements or components may be said to be a mucous lining, and an envelope of cellular tissue, in which the secreting vessels ramify. From the lobules thus formed arise the minute radicles of the lactiferous tubes (*tubuli lactiferi*), which receive the secretion when elaborated. The tubes converge towards the nipple, so as to become collected into a fasciculus beneath it, in which situation they are supported by some firm cellular tissue :—the number varies from twelve to fifteen, and each is found to belong to a particular lobe of the gland; its incipient radicles or branches commencing from the interior of the lobules which form it. In this way four, six, or eight minute ducts unite to form one lactiferous tube, which inclines towards the areola, where it dilates somewhat, particularly during the period of lactation; but at the base of the nipple it narrows again, and runs in a straight course from its base to its summit, where it terminates. The tubes are lined throughout by a tegumentary membrane (mucous), which extends inwards from the minute orifices in the nipple, and permeates their entire extent, even to the lobules; and this inner lining appears to be enclosed in another tunic, formed of condensed cellular tissue.

Upon the surface of the areola and nipple several minute orifices open, which lead into sebaceous follicles, the secretion of which exudes upon the skin, to protect it from irritation.

1117. *Analogy between the male and female organs of generation.*—Though the genital system appears to constitute a most marked distinction between the sexes, its component parts will be found to present so close an analogy in their general conformation, that we can scarcely avoid concluding that both have been formed according to a common type, of which the peculiarities in each constitute so many modifications, dependent on their respective degrees of developement. The analogy between the testes and ovaria is sufficiently obvious in form, function, and organic elements, as well as in their original position, both being lodged in the abdomen. The uterus and the prostate bear a marked similitude, more particularly in the early part of fœtal life, and subsequently

the mode of connexion and relation of the vasa deferentia to the one, resembles that of the Fallopian tubes to the other. The clitoris may be likened to the penis, and the labia to the scrotum; but it should be observed, that, the more early the period chosen to institute the comparison, the closer will the similitude appear; at the early part of fœtal life the distinction of sex is not perceptible.

INDEX.

Abdomen, 663.
Abdominal regions, 664.
Absorbents, 11, 94, 639.
——— of the abdomen, 644.
——————— arm, 651.
——— ——— head, 652.
——————— heart, 650.
——— ——————— kidneys, 645.
——————— leg, 642.
——— ——————— liver, 646.
——— ——————— loins, 644.
——————— lungs, 649.
——————— mesentery, 639.
——— ——————— neck, 652.
——————— œsophagus, 650.
——— ——————— pancreas, 646.
——————— pelvic viscera, 644.
——————— pelvis, 644.
——————— penis, 645.
——————— scrotum, *ib.*
——— ——————— spleen, 646.
——————— stomach, *ib.*
——————— testicle, 645.
——— ——————— thorax, 648.
——— ——————— thymus gland, 649.
——— ——————— thyroid gland, 650.
Acervulus, 734.
Adenology, 119.
Adipose tissue, 28.
Albumen, 21.
Amphi-arthrosis, 240.
Amygdalæ, 658.
Anastomoses, 76.
——————— lower extremity, 602.
Anatomy, human, 1.
——————— comparative, 2.
Angeiology, 119.
Angular motion, 242.
Annulus ovalis, 696.
Anti-helix, 840.
Anti-tragus, *ib.*
Antrum Highmori, 157.
Aponeurosis, 34.
Appendices epiploicæ, 668.
Appendix cæci, 677.
——————— vermiformis, *ib.*
Aquæductus cochleæ, 850.
Aqueduct of Fallopius, 851.
——————— Sylvius, 735.
Aqueous humour, 836.
Arachnoid membrane, 714.
Arbor vitæ, 737.
——————— uterinus, 891.
Arch—crural or femoral, 472.
Areola, 894.
Arteries, 11, 78, 492.
Arter. acromialis, 527.
——— alveolaris, 514.
——— anastomotica femoralis, 586.
——————— magna, 537.
——— angularis faciei, 507.
——— aorta, 492.
Arter. articulares inferiores, 590.
——————— superiores, *ib.*
——— articularis azygos, *ib.*
——— auriculares anteriores, 512.
——— auricularis posterior, 510.
——— axillaris, 531.
——— basilaris, 525.
——— brachialis, 535.
——— brachio-cephalica, 497.
——— bronchiales, 548.
——— buccalis, 514.
——— capsulares, 558.
——— carotis communis, 502.
——————— externa, 504.
——————— interna, 517.
——— carpalis ulnaris anterior, 543.
——————— posterior, *ib.*
——— carpi radialis anterior, 545.
——————— posterior, *ib.*
——— centralis retinæ, 518.
——— cerebelli inferior, 525.
——— ——————— superior, 526.
——— cerebri anterior, 520.
——————— media, *ib.*
——————— posterior, 526.
——— cervicalis ascendens, 529.
——————— profunda, 528.
——————— superficialis, *ib.*
——— choroideæ, 520.
——— ciliares, 519.
——— circumflexa anterior, 535.
——————— externa, 584.
——————— ilii, 575.
——————— interna, 585.
——————— posterior, 535.
——— coccygea, 568.
——— cœliaca, 550.
——— colica dextra, 555.
——————— media, *ib.*
——————— sinistra, 556.
——— comes nervi ischiadici, 568.
——————— phrenici, 529.
——— communicans cerebri anterior, 520.
——————— posterior, *ib.*
——— communicans palmaris, 543.
——— coronaria dextra, 496.
——————— labii inferioris, 508.
——————— superioris, *ib.*
——————— sinistra, 496.
——————— ventriculi, 551.
——— corporis bulbosi, 570.
——————— cavernosi, *ib.*
——— cremasterica, 575.
——— cystica, 552.
——— dentalis inferior, 513.
——————— superior, 514.
——— digitales manûs, 543.
——————— pedis, 596.
——— dorsales linguæ, 506.
——————— pollicis, 546.
——— dorsalis carpi radialis, 545.

Arter. dorsalis carpi ulnaris, 543.
——————— indicis, 546.
——————— pedis, 600.
——————— penis, 571.
——————— pollicis pedis, 601.
——————— scapulæ, 534.
——— emulgens, 558.
——— epigastrica, 574.
——————— superficialis, 583.
——— ——— superior, 529.
——— ethmoidales, 519.
——— facialis, 506.
——— femoralis, 578.
——— frontalis, 520.
——— gastricæ, 553.
——— gastro-duodenalis, 552.
——————— epiploica dextra, *ib.*
——————————— sinistra, 554.
——— glutæa, 566.
——— hæmorrhoidales externæ, 570.
——— hæmorrhoidalis media, 571.
——————————— superior, 556.
——— hepatica, 552.
——— humeraria, 535.
——— hyoidea, lingualis, 506.
——————— thyroideæ, 505.
——— hypogastrica, 563.
——— iliacæ communes, 562.
——— iliaca externa, 572.
——————— interna, 563.
——— ilio-colica, 555.
——————— lumbalis, 565.
——— infra-orbitalis, 514.
——— infra-spinalis, 527.
——— innominata, 497.
——— intercostales, 549.
——————————— anteriores, 529.
——— intercostalis superior, 530.
——— inter-ossea, 542.
——————————— anterior, *ib.*
——————————— posterior, *ib.*
——— inter-osseæ pedis, 601.
——— intestini tenuis, 555.
——— ischiadica, 568.
——— labialis, 506.
——————— inferior v. superficialis, 508.
——— lachrymalis, 518.
——— laryngealis, 505.
——— lingualis, 506.
——— lumbales, 559.
——— malleolaris externa, 599.
——————————— interna, *ib.*
——— mammaria interna, 529.
——— masseterica, 514.
——— maxillaris externa, 506.
——————————— inferior, 512.
——— ——————— interna, *ib.*
——— mediastinæ, 529.
——— meningea anterior, 518.
——————————— media v. magna, 513.
——— ——————— parva, *ib.*
——————————— posterior, 525.
——— mesenterica, 554.
——————————— inferior, 556.
Arter. metatarsea, 600.
——— musculo-phrenica, 529.
——— nasalis lateralis, 508.
——————————— septi, *ib.*
——— nutritia fibulæ, 593.
——————————— humeri, 537.
——————————— tibiæ, 592.
——— obturatoria, 565.
——— occipitalis, 509.
——— œsophageales, 549.
——— ophthalmica, 518.
——— palatina inferior, 307.
——————————— superior v. descendens, 514.
——— palpebrales, 519.
——— pancreatica magna, 553.
——— pancreaticæ, *ib.*
——— pancreatico duodenalis, 552.
——— perforantes femoralis, 585.
——————————— plantaris, 596.
——— pericardiacæ, 548.
——— perinæi superficialis, 570.
——— peronea, 592.
——————————— anterior, 593.
——————————— posterior, *ib.*
——— pharyngea ascendens, 508.
——— phrenicæ, 557.
——— plantaris externa, 596.
——————————— interna, 595.
——— poplitea, 588.
——— princeps cervicis, 510.
——————————— pollicis, 546.
——— profunda cervicis, 528.
——————————— femoris, 583.
——————————— inferior, 537.
——————————— superior, 536.
——— pterygoideæ, 514.
——— pterygo-palatina, 515.
——— pudendæ externæ, 582.
——— pudica interna, 568.
——— pulmonalis, 706.
——— pylorica, 552.
——— radialis, 544.
——————————— indicis, 546.
——— ranina, 506.
——— recurrens inter-osseæ posterioris, 542.
——————————— radialis, 545.
——————————— tibialis, 599.
——————————— ulnaris, anterior, 541.
——————————————— posterior, *ib.*
——— renales, 558.
——— sacra-media, 557.
——— sacro-lateralis, 567.
——— scapularis posterior, 528.
——— sigmoideæ, 556.
——— spermaticæ, 559.
——— sphæno-palatina, 515.
——— spinalis anterior, 525.
——————————— posterior, *ib.*
——— splenica, 553.
——— stylo-mastoidea, 511.
——— subclaviæ, 522.
——— sublingualis, 506.
——— submentalis, 508.

Arter. subscapularis, 534.
——— superficialis volæ, 545.
——— supra-orbitalis, 519.
——————— scapularis, 527.
——————— spinalis, *ib.*
——— tarsea, 600.
——— temporales profundæ, 514.
——— temporalis, 511.
——————— anterior v. frontalis, 512.
——————— media v. profunda, *ib.*
——————— posterior v. occipitalis, *ib.*
——— thoracica acromialis, 533.
——————— alaris, *ib.*
——————— longa, 534.
——————— suprema, 533.
——— thyroidea inferior v. ascendens, 526.
——————— superior v. descendens, 505.
——— tibialis antica, 597.
——————— postica, 591.
——— tonsillaris, 507.
——— transversa perinæi, 570.
——— transversalis colli, 498.
——————— faciei, 511.
——————— humeri, 527.
——— tympanica, 513.
——— ulnaris, 540.
——— uterina, 572.
——— vaginalis, *ib.*
——— (vasa brevia, 553.)
——— vasis deferentis, 886.
——— vertebralis, 524.
——— vesicales, 571.
——————— superiores, 564.
——— vidiana, 515.
Arthrodia, 242.
Articulations. See Joint, 239.
Arytænoid cartilages, 855.
——— gland, 858.
Atlas, 128.
Auditory tube, 842.
Auricles of the heart, 695, 698.
Auriculo-ventricular openings, 697, 698.
Base of the brain, 727.
Bladder, 865.
Bone—Analysis, 47.
——— growth, 48.
——— structure, 45.
Bones, 9, 39.
——— os. astragali, 233.
——— atlantis, 128.
——— axis, 129.
——— brachii, 197.
——— calcis, 232.
——— claviculæ, 196.
——— coccygis, 214.
——— costarum, 188.
——— cuboides, 234.
——— cuneiforme carpi, 206.
——————— externum tarsi, 235.
——————— internum, *ib.*
——————— medium, *ib.*
Bones, os. ethmoides, 150.
——— femoris, 223.
——— fibulæ, 230.
——— frontale, 137.
——— humeri, 197.
——— hyoides, 164.
——— ilii, 215.
——— innominatum, 214.
——— ischii, 218.
——— lachrymale, 159.
——— magnum, 207.
——— malare, 158.
——— maxillare superius, 155.
——————— inferius, 162.
——— metacarpi, 208.
——— metatarsi, 236.
——— nasi, 158.
——— naviculare, carpi, 205.
——————— tarsi, 234.
——— occipitale, 132.
——— palati, 159.
——— parietale, 135.
——— patellæ, 227.
——— phalangium manûs, 209.
——————— pedis, 237.
——— pisiforme, 206.
——— pubis, 217.
——— radii, 200.
——— sacrum, 212.
——— scaphoides carpi, 205.
——— tarsi, 234.
——— scapulæ, 192.
——— semi-lunare, 206.
——— sesamoidea manûs, 238.
——————— pedis, *ib.*
——— sphenoides, 145.
——— sterni, 187.
——— temporale, 140.
——— tibiæ, 227.
——— trapezium, 207.
——— trapezoides, *ib.*
——— triquetra, 154.
——— turbinatum superius, 153.
——————— inferius, 162.
——— ulnæ, 202.
——— unciforme, 208.
——— unguis, 159.
——— vertebrarum cervicalium, 125.
——————— dorsalium, 126.
——————— lumbalium, 127.
——— vomer, 161.
Brain, 723.
——— structure, 739.
Bronchus, 704.
Brunner's glands, 72.
Bulb of the urethra, 874.
Bulbous part of the urethra, 876.
Bulbus olfactorius, 742.
Bursæ mucosæ, 56.
Calamus scriptorius, 726.
Calices, 863.
Canal of Petit, 837.
Canthi, 821.
Capsulæ renales, 864.

Capsule of Glisson, 685.
Caput colli, 677.
—— gallinaginis, 876.
Cardia, 672.
Carpus, 205.
Cartilage, 37.
Cartilages:
——— cuneiform, 856.
——— inter-articular of the jaw, 253.
——— inter-articular of the wrist, 263.
——— semi-lunar, 276.
Caruncula lachrymalis, 824.
Carunculæ myrtiformes, 888.
Casserian ganglion, 760.
Catheterism, 484.
Cellular tissue, 23.
Cerebellum, 735.
Cerebral substance, 112.
Cerebral protuberance, 737.
Cerebrum, 723.
Cervical ganglia, 806.
Chordæ tendineæ, 697.
——— vocales, 857.
——— Willisii, 627.
Choroid membrane, 831.
——— plexus, 713.
Cilia, 823.
Ciliary ligament, 830.
——— processes, 833.
Circulation, adult, 73.
——— collateral, 77.
——— fœtal, 91.
——— portal, 78.
——— venous, 77.
Circumduction, 243.
Clitoris, 888.
Cochlea, 849.
Cœcum, 677.
Collateral circulation, 77.
Colon, 677.
Columnæ carneæ, 697.
Commissure, anterior, 735.
——— great, 729.
——— soft, 734.
——— posterior, 735.
Comparative anatomy, 2.
Conarium, 734.
Concha, 840.
Conglobate glands, 95.
Coni vasculosi, 884.
Conjunctiva, 828.
Convolutions, cerebral, 725.
Corium, 57.
Cornea, 830.
Cornicula laryngis, 856.
Cornu ventriculorum, 732.
Corona glandis, 875.
Corpora albicantia, 729.
——— cavernosa, 873.
——— mammillaria, 729.
——— olivaria, 721.
——— pyramidalia, *ib.*
——— quadrigemina, 738.
Corpora restiformia, 722, 736.
——— striata, 733.
Corpus aurantii, 697.
——— callosum, 729.
——— dentatum, 737.
——— fimbriatum, 732.
——— geniculatum externum, 734.
——— internum, *ib.*
——— Highmorianum, 883.
——— psalloides, 731.
——— rhomboideum, 737.
——— spongiosum, 875.
Cowper's glands, 877.
Cricoid cartilage, 855.
Crico-thyroid membrane, 857.
Crura cerebelli, 736.
——— cerebri, 729.
Crystalline lens, 836.
Cupola, 849.
Cuticle, 63.
Cutis, 57.
Cystic duct, 688.
Dartos, 879.
Dentes bicuspidati, 185.
——— cuspidati, 184.
——— incisores, *ib.*
——— molares, 185.
——— sapientiæ, *ib.*
Detrusor urinæ, 868.
Diaphragm, 388.
Diarthrosis, 240.
Digestion, organs of, 655.
Digital cavity, lateral ventricle, 732.
Dissection, 12.
——— of the abdominal parietes, 371.
——— aorta, 493.
——— arm, 346.
——— back, 329.
——— brain, 723.
——— buttock, 401.
——— eye, 827.
——— face, 289, 298.
——— femoral artery, 578.
——— foot, 436.
——— fore-arm, 359.
——— groin, 460.
——— hand, 371.
——— head, 286.
——— iliac artery external, 572.
——— internal, 562.
——— leg, 422.
——— neck, 308.
——— perinæum, 391.
——— peritoneum, 666.
——— pharynx, 321.
——— plantar arteries, 595.
——— popliteal artery, 588.
——— saphenous opening, 455.
——— soft palate, 324.
——— spinal cord, 718.
——— veins, 622.
——— thigh, 409.
——— posterior part, 419.

Dissection of tibial artery, anterior, 597.
——— posterior tibial, 591.
——— of hernia, femoral, 467.
——— inguinal, direct, 466.
——— oblique, 460.
Dissector, directions to the, 443.
Ductus ejaculatorii, 876, 885.
Ductus ad nasum, 826.
——— arteriosus, 89.
——— communis choledochus, 688.
——— cysticus, *ib.*
——— hepaticus, 685.
——— lymphaticus, 654.
——— pancreaticus, 690.
——— Stenonis, 659.
——— thoracicus, 96, 640.
——— Whartoni, 660.
Duodenum, 675.
Dura mater, 711.
Ear, 839.
Eccentric developement, 18.
Elastic fibrous tissue, 38.
Enarthrosis, 241.
Endosmosis, 53.
Ensiform cartilage, 187.
Epidermis, 63.
Epididymis, 884.
Epiglottic gland, 858.
Epiglottis, 856.
Epithelium, 73.
Erectile tissue, 100.
Eustachian tube, 845.
——— valve, 696.
Exosmosis, 53.
Eye,
—— brows, 821.
—— globe, 826.
—— lashes, 823.
—— lids, 821.
Facial angle, 182.
Falciform process, 455.
Fallopian tubes, 893.
Falx cerebelli, 713.
—— cerebri, 712.
Fascia brachialis, 451.
——— cervicalis profunda, 449.
——— superficialis, *ib.*
——— Cooperi, 470.
——— costo-coracoides, 450.
——— cribriformis, 456.
——— cruris, *ib.*
——— dentata, 733.
——— dorsi pedis, 458.
——— iliaca, 471.
——— inter-columnaris, 462.
——— inter-muscularis humeri, 451.
——— lata, 452.
——— manûs, 451.
——— palmaris, 452.
——— pelvica, 469.
——— perinealis profunda, 482.
——— superficialis, 391.
——— plantaris profunda, 459.
Fascia plantaris superficialis, 458.
——— propria, 469.
——— pubica, 454.
——— spermatica, 462.
——— superficialis, 461.
——— transversalis, 469.
——— vesicalis, *ib.*
Fasciæ, 449.
Fauces, 656.
Femoral arch, 472.
——— canal, 473.
——— ring, *ib.*
Fenestra ovalis, 844.
——— rotunda, *ib.*
Fibrine, 22.
Fibro-mucous membrane, 35.
—— serous, *ib.*
Fibrous membranes, 34.
——— sheaths, 36.
——— tissue, 32.
Fibro-cartilage, 37.
Fimbriæ, Fallopian, 893.
Fissure of Bichât, 738.
——— Sylvius, 727.
Fœtal circulation, 91.
Follicles, mucous, 72, 98.
——— Meibomian, 98.
——— ceruminous, 97.
——— sebaceous, *ib.*
Foramen centrale oculi, 834.
——— cæcum, 656.
——— commune anterius, 734.
——— of Monro, *ib.*
——— of Winslow, 668.
——— saphenum, 455.
Foramina Thebesii, 696.
Fornix, 731.
Fossa innominata, 840.
—— navicularis auris, *ib.*
——— urethræ, 876.
——— vaginæ, 887.
—— ovalis, 696.
Fourchette, 887.
Frænulum pudendi, *ib.*
Frænum epiglottidis, 656.
——— labii inferioris, *ib.*
——— superioris, *ib.*
——— linguæ, *ib.*
——— præputii, 873.
Frontal sinus, 176.
Ganglia, 113, 806.
——— cardiac, 814.
——— cervical, inferior, 809.
——— middle, 808.
——— superior, 806.
——— lumbar, 820.
——— sacral, *ib.*
——— semi-lunar, 817.
——— thoracic, 813.
Ganglion, azygos, 820.
——— caroticum, 807.
——— Casserian, 760.
——— lenticular, 810.
——— Meckel's, *ib.*

Ganglion, naso-palatine, 811.
——— ophthalmic, 810.
——— otic, 813.
——— spheno-palatine, 810.
——— submaxillary, 812.
Gall-bladder, 688.
Gelatine, 21.
Generation, female organs, 887.
——— male organs, 871.
Gland, epiglottic, 858.
——— lachrymal, 824.
——— parotid, 659.
——— pineal, 734.
——— pituitary, 728.
——— prostate, 871.
——— thymus, 708.
——— thyroid, 859.
Glands, absorbent, 95.
——— arytænoid, 858.
——— axillary, 652.
——— bronchial, 651.
——— Brunner's, 72.
——— cardiac, *ib.*
——— cervical, 653.
——— Cowper's, 77.
——— inguinal, 643.
——— lumbar, 648.
——— mammary, 894.
——— mediastinal, 651.
——— Meibomian, 823.
——— mesenteric, 647.
——— œsophageal, 651.
——— parotid, 659.
——— Peyer's, 72.
——— popliteal, 643.
——— salivary, 658.
——— secreting, 97.
——— sublingual, 660.
——— submaxillary, *ib.*
——— thoracic, 650.
——— thymus, 708.
Glandulæ Pacchioni, 712.
——— aggregate, 72.
——— agminatæ, 97.
——— Brunneri, *ib.*
——— Peyeri, *ib.*
——— solitariæ, 97.
——— Tysoni, 875.
Glans clitoridis, 888.
——— penis, 875.
Gliding motion, 242.
Glisson's capsule, 685.
Globus major epididymis, 884.
——— minor epididymis, *ib.*
Glottis, 858.
Gomphosis, 240.
Gubernaculum testis, 877.
Hair, 66.
Harmonia, 240.
Heart, 693.
——— its developement, 87.
Helix, 840.
Hepatic ducts, 685.
Hernia, crural or femoral, 478.
Hernia inguinal, direct, 466.
——— oblique, *ib.*
Hilus lienis, 689.
Hippocampus major, 732.
——— minor, *ib.*
Hyaloid membrane, 838.
Hymen, 887.
Ilio-colic valve, 678.
Ilium, 675.
Incus, 846.
Infundibula, 863.
Infundibulum, 728.
Inguinal, *see* Hernia.
——— canal, 464.
Inter-articular cartilage, jaw, 253.
——— sterno-clavicular, 256.
——— wrist, 263.
Intervertebral substance, 247.
Intestinal canal, 674.
Intestinum crassum, *ib.*
——— tenue, *ib.*
Iris, 834.
Iter ad infundibulum, 734.
——— à tertio ad quartum ventriculum, *ib.*
Jacob's membrane, 834.
Jejunûm, 675.
Joint, ankle, 279.
——— elbow, 259.
——— hip, 272.
——— lower jaw, 252.
——— knee, 273.
——— shoulder, 258.
——— wrist, 264.
Kidneys, 861.
Labia pudendi, externa, 887.
——— interna, 888.
Labyrinth, 848.
Lachrymal ducts, 825.
——— gland, 824.
——— sac, 825.
Lacteals, 94, 639.
Lactiferous ducts, 895.
Lacunæ 877.
Lamina spiralis, 849.
Larynx, 853.
Lenticular ganglion, 810.
Ligaments, 9, 36.
——— of the liver, 668.
Ligam. alaria axis, 252.
——— genu, 277.
——— annulare anterius carpi, 268.
——— posterius carpi, 267.
——— anterius tali, 457.
——— internum tali, 458.
——— anterior digitorum, 267.
——— anterius carpi, 264.
——— cubiti, 261.
——— arcuatum proprium, 389.
——— astragalo-scaphoideum, 282.
——— atlantis transversum, 249.
——— atlo-axoideum anterius, 250.
——— posterius, *ib.*
——— calcaneo-astragaloideum, anterius, 281.

Ligam. calcaneo astragaloideum, externum, 281.
——— cuboideum inferius, 283.
——— superius, *ib.*
——— scaphoideum externum, 282.
——— inferius, *ib.*
——— capsulare femoris, 272.
——— genu, 277.
——— humeri, 258.
——— pollicis, 267.
——— carpi dorsalia, 265.
——— palmaria, *ib.*
——— commune anterius, 246.
——— posterius, *ib.*
——— conoideum, 257.
——— coracoideum, *ib.*
——— coraco-acromiale, *ib.*
——— claviculare, 257.
——— humerale, 259.
——— costo-claviculare, 256.
——— sternalia anteriora, 254.
——— posteriora, 255.
——— transversum anterius, 254.
——— medium, *ib.*
——— posterius, *ib.*
——— vertebrale, 253.
——— xiphoideum, 255.
——— cotyloideum, 272.
——— cruciata, 275.
——— cruciforme, 249.
——— deltoides, 279.
——— denticulatum, 717.
——— dorsalia carpi, 265.
——— dorsalia tarsi, 281.
——— fibulæ anterius, 279.
——— medium, *ib.*
——— posterius, *ib.*
——— glenoideum, 258.
——— hepatis, 668.
——— ilio-femorale, 272.
——— lumbale, 268.
——— inter-articularia costarum, 254.
——— inter-claviculare, 256.
——— inter-osseum, astragalo-calcaneoides, 281.
——— peroneo-tibiale, 278.
——— inferius, 279.
——— inter-osseum, radio-ulnare, 262.
——— inter-spinalia, 249.
——— inter-transversalia, *ib.*
——— inter-vertebralia, 247.
——— laryngis, 857.
——— laterale carpi externum, 264.
——— internum, *ib.*
——— cubiti externum, 261.
——— internum, 259.
——— genu externum breve, 275.
——— longum, 274.
——— internum, *ib.*
——— maxillæ externum, 252.
——— internum, *ib.*
——— tali externum, 280.
Ligam. laterale internum, 279.
——— lateralia phalangium manûs, 267.
——— pedis, 285.
——— longum plantæ, 283.
——— metacarpi dorsalia, 266.
——— palmaria, *ib.*
——— metatarsi dorsalia, 284.
——— plantaria, *ib.*
——— mucosum, 277.
——— obturatorium, 271.
——— occipito-atloideum anterius, 250.
——— posterius, 251.
——— axoideum, *ib.*
——— orbiculare, 261.
——— palmaria carpi, 265.
——— patellæ, 274.
——— peroneo-tibiale superius et anterius, 278.
——— posterius, *ib.*
——— inferius et anterius, 279.
——— posterius, *ib.*
——— phalangium pedis, 285.
——— plantare longum, 283.
——— posterius carpi, 264.
——— cubiti, 261.
——— posticum Winslowii, 275.
——— processuum obliquorum, 248.
——— pubicum anterius, 271.
——— posterius, *ib.*
——— rhomboideum, 256.
——— rotundum, 263.
——— sacro-coccygeum anterius, 268.
——— posterius, 269.
——— sacro-iliacum anterius, 270.
——— obliquum, *ib.*
——— posterius, *ib.*
——— sacro-ischiadicum anterius, 270.
——— posterius, 269.
——— sacro-vertebrale, 268.
——— scapulo-claviculare inferius, 257.
——— superius, *ib.*
——— stellatum, 253.
——— sterno-claviculare anterius, 256.
——— posterius, *ib.*
——— stylo-maxillare, 253.
——— sub-flava, 248.
——— sub-pubicum, 271.
——— supra-spinosum, 248.
——— suspensorium penis, 873.
——— tarsea dorsalia, 281.
——— plantaria, *ib.*
——— teres, 273.
——— tibio-tarsale, 280.
——— transversa costarum externa, 254.
——— interna, *ib.*
——— metacarpi, 266.
——— metatarsi, 285.
——— transversum acetabuli, 273.
——— atlantis, 249.
——— genu, 276.
——— scapulæ, 257.

Ligam. atlantis tali, 279.
——— trapezoideum, 257.
——— triangulare, 271.
——— vaginalia, 267.
Ligature of the brachial artery, 539.
——————— carotid, 516.
——————— external iliac, 576.
——————— femoral, 587.
——————— posterior tibial, 593.
——————— subclavian, 530.
Limbus luteus, 834.
Linea alba, 385.
Lineæ transversæ, 383.
—— semi-lunares, 385.
Lips, 656.
Liquor Cotunni, 848.
—— Morgagni, 836.
—— prostaticus, 872.
Lithotomy, 485.
Liver, 681.
Lobuli testis, 883.
Lobulus auris, 840.
——— caudatus, 683.
——— quadratus, 682.
——— Spigelii, 683.
Loculus cœruleus, 746.
Locus niger, 729.
—— perforatus, *ib.*
Luette vesicale, 868.
Lungs, 702.
Lymphatic duct, 654.
Lymphatics, 94, 642.
Lymphatic vessels, *see* Absorbents, 639.
Lyra, 731.
Malleus, 846.
Mammæ, 894.
Marrow of bone, 29.
Matrix, 889.
Maxillary sinus, 176.
Meatus auditorius externus, 842.
——————— internus, 143.
——— urinarius, female, 870.
Meckel's ganglion, 810.
Mediastinum anterius, 704.
——————— posterius, *ib.*
——————— testis, 883.
Medulla, 31.
——— oblongata, 720.
——— Meibomian glands, 823.
Membrana dentata, 717.
——— pupillaris, 835.
——— tympani, 843.
Membrane, choroid, 831.
——— fibrous, 34.
——— hyaloid, 838.
——— Jacob's 834.
——— mucous, 68.
——— serous, 51.
——— synovial, 54.
Membranous part of the urethra, 876.
Mesenteric glands, 647.
Mesentery, 668.
Meso-cola, *ib.*
Meso-rectum, 668.
Metacarpus, 208.
Metatarsus, 236.
Mitral valve, 698.
Modiolus, 849.
Mons Veneris, 887.
Mouth, 656.
Mucous follicles, 72.
Mucous membrane, 68.
Mucus, 22.
Muscles, 9, 286.
——— tables of, 443.
Muscular system, 101.
—— fibre, 102.
Musculi pectinati, 696.
Musc. abductor digiti minimi, 374.
——————— pedis, 438.
——————— indicis, 375.
——————— oculi, 305.
——————— pollicis, 372.
——————————— pedis, 437.
——— accelerator, urinæ, 393.
——— accessorius, 438.
——— adductor brevis, 417.
——————— digiti minimi, 374.
——————— longus, 416.
——————— magnus, 417.
——————— oculi, 305.
——————— pollicis, 373.
——————————— pedis, 440.
——— anconeus, 367.
——— anterior auris, 304.
——— anti-tragicus, 841.
——— arytænoideus, 327.
——— arytæno-epiglottideus, *ib.*
——— attollens aurem, 304.
——————— oculum, 305.
——— attrahens aurem, 304.
——— azygos uvulæ, 325.
——— biceps femoris, 420.
——————— flexor cubiti, 356.
——— biventer cervicis, 342.
——— brachialis anticus, 356.
——— buccinator, 297.
——— cervicalis ascendens, 340.
——— circumflexus palati, 325.
——— coccygeus, 398.
——— complexus, 341.
——— compressor narium, 294.
——————— urethræ, 395.
——————— venæ dorsalis penis, 395.
——— constrictor inferior, 322.
——————— isthmi faucium, 326.
——————— medius, 322.
——————— superior, *ib.*
——————— vaginæ, 396.
——— contractor meatûs auris, 841.
——— coraco-brachialis, 355.
——— corrugator supercilii, 292.
——— cremaster, 380.
——— crico-arytænoideus lateralis, 327.
——————————— posticus, *ib.*
——————— thyroideus, 317.

Musc. cruræus, 413.
—— deltoides, 351.
—— depressor epiglottidis, 327.
—— labii inferioris, 296.
—— labii superioris alæque nasi, 294.
—— oculi, 305.
—— detrusor urinæ, 868.
—— diaphragma, 388.
—— digastricus, 311.
—— erector clitoridis, 396.
—— penis, 393.
—— spinæ, 338.
—— extensor carpi radialis brevior, 366.
—— longior, 365.
—— ulnaris, 368.
—— digiti minimi, *ib.*
—— digitorum brevis, 425.
—— communis, 367.
—— longus, 424.
—— indicis, 370.
—— ossis metacarpi pollicis, 369.
—— primi internodii pollicis, *ib.*
—— pollicis proprius, 423.
—— secundi internodii pollicis, 369.
—— flexor accessorius, 438.
—— brevis digiti minimi, 374.
—— pedis, 441.
—— carpi radialis, 360.
—— ulnaris, 361.
—— digitorum brevis, 437.
—— profundus, 362.
—— sublimis, 361.
—— longus digitorum pedis, 432.
—— pollicis pedis, 433.
—— pollicis brevis, 372.
—— pedis, 439.
—— longus, 363.
—— gastrocnemius, 423.
—— gemellus inferior, 406.
—— superior, *ib.*
—— genio-hyo-glossus, 315.
—— hyoideus, 314.
—— glutæus maximus, 402.
—— medius, 403.
—— minimus, 404.
—— gracilis, 415.
—— helicis major, 841.
—— minor, *ib.*
—— hyo-glossus, 314.
—— iliacus, 400.
—— indicator, 370.
—— infra-spinatus, 352.
—— inter-costales externi, 386.
—— interni, 387.
—— inter-ossei manûs dorsales, 375.
—— palmares, 376.
—— pedis dorsales, 441.
—— plantares, *ib.*
Musc. inter-spinales, 343.
—— inter-transversales, 344.
—— latissimus dorsi, 331.
—— laxator tympani major, 847.
—— minor, *ib.*
—— levator anguli oris, 295.
—— scapulæ, 335.
—— ani, 397.
—— labii inferioris, 296.
—— superioris, 294.
—— alæque nasi, *ib.*
—— palati, 325.
—— palpebræ, 292.
—— levatores costarum, 387.
—— lingualis, 315.
—— longissimus dorsi, 340.
—— longus colli, 320.
—— lumbricales manûs, 375.
—— pedis, 439.
—— mallei externus, 847.
—— internus, *ib.*
—— massetericus, 299.
—— multifidus spinæ, 344.
—— mylo-hyoideus, 314.
—— obliquus abdominis externus, 378.
—— internus, 379.
—— auris, 841.
—— capitis inferior, 343.
—— superior, *ib.*
—— oculi inferior, 306.
—— superior, 305.
—— obturator externus, 408.
—— internus, 406.
—— occipito-frontalis, 288.
—— omo-hyoideus, 317.
—— opponens digiti minimi, 374.
—— pollicis, 372.
—— orbicularis oris, 297.
—— palpebrarum, 291.
—— palato-glossus, 326.
—— pharyngeus, *ib.*
—— palmaris brevis, 374.
—— longus, 361.
—— pectineus, 416.
—— pectoralis major, 348.
—— minor, 349.
—— peroneus brevis, 427.
—— longus, 426.
—— tertius, 425.
—— plantaris, 430.
—— platysma myoides, 309.
—— popliteus, 431.
—— posterior auris, 304.
—— pronator quadratus, 364.
—— radii teres, 360.
—— psoas magnus, 399.
—— parvus, 400.
—— pterygoideus externus, 302.
—— internus, 301.
—— pyramidalis abdominis, 384.
—— nasi, 293.
—— pyriformis, 405.
—— quadratus femoris, 407.

Musc. quadratus lumborum, 384.
—— rectus abdominis, 383.
—— capitis anticus major, 319.
———————— minor, *ib.*
———————— posticus major, 343.
———————— minor, *ib.*
———————— femoris, 412.
———————— lateralis, 319.
———————— oculi externus, 305.
———————— inferior, *ib.*
———————— internus, *ib.*
———————— superior, *ib.*
———— retrahens aurem, 304.
———— rhomboideus major, 334.
———————— minor, *ib.*
———— sacro-lumbalis, 339.
———— sartorius, 411.
———— scalenus anticus, 318.
———————— medius, *ib.*
———————— posticus, *ib.*
———— semi-spinalis colli, 342.
———————— dorsi, *ib.*
———— semi-membranosus, 421.
———— semi-tendinosus, 420.
———— serratus magnus, 350.
———————— posticus inferior, 336.
———————— superior, 335.
———— soleus, 429.
———— sphincter ani externus, 397.
———————— internus, *ib.*
———————— vesicæ, 868.
———— spinalis dorsi, 341.
———— splenius capitis, 337.
———————— colli, 336.
———— stapedius, 847.
———— sterno cleido-mastoideus, 310.
———————— hyoideus, 316.
———————— thyroideus, *ib.*
———— stylo-glossus, 312.
———————— hyoideus, *ib.*
———————— pharyngeus, 313.
———— subclavius, 350.
———— superior auris, 304.
———— subscapularis, 354.
———— supinator radii brevis, 370.
———————————— longus, 365.
———— supra-spinales, 344.
———— supra-spinatus, 352.
———— temporalis, 300.
———— tensor palati, 325.
———————— tarsi, 292.
———————— tympani, 847.
———————— vaginæ femoris, 410.
———— teres major, 353.
———————— minor, *ib.*
———— thyro-arytænoideus, 327.
———————— epiglottideus, *ib.*
———————— hyoideus, 316.
———— tibialis anticus, 423.
———————— posticus, 434.
———— trachelo-mastoideus, 341.
———— tragicus, 841.
———— transversalis abdominis, 381.
———————— colli, 340.
Musc. transversus auriculæ, 841.
———————— pedis, 440.
———————————— perinæ, 394.
———————— alter, 395.
———— trapezius, 329.
———— triangularis oris, 296.
———————— sterni, 387.
———— triceps extensor cruris, 412.
———————— cubiti, 357.
———— vastus externus, 413.
———————— internus, *ib.*
———— zygomaticus major, 295.
———————— minor, *ib.*
Myology, 119.
Myolema, 101.
Nails, 67.
Nasal duct, 826.
—— fossæ, 175.
Nerves, 11, 742.
Nerv. abducentes, 749.
—— accessorius, 759.
—— acromiales, 770.
—— auditorius, 746.
—— auricularis anterior, 765.
———————— magnus, 769.
———————— posterior, 751.
—— axillaris, 775.
—— bronchialis, 757.
—— buccinatorius, 764.
—— cardiaci, 815.
—— cardiacus inferior, *ib.*
———————— magnus, *ib.*
———————— medius, *ib.*
———————— superior, *ib.*
—— cervicales, 768.
—— cervico-fasciales, 750.
—— chorda tympani, 812.
—— circumflexus, 775.
—— ciliares, 810.
—— circumflexus brachii, 775.
—— claviculares, 770.
—— communicans tibiæ, 797.
———————— peronei, 801.
—— cruralis, 787.
—— cutaneus externus brachialis, 773.
———————— externus lumbalis, 786.
—— cutaneus internus brachialis, 773.
———————— medii femoris, 788.
———————— posterior femoris, 795.
———————— radialis, 780.
—— decimus cerebri, 767.
—— dentalis anterior, 764.
———————— inferior, 766.
———————— posterior, 763.
—— descendens noni, 750.
—— diaphragmaticus, 759.
—— digastricus, 752.
—— digitales mediani, 778.
———————— plantaris, 798.
———————— radialis, 780.
———————— ulnaris, 776.
—— dorsales, 781.
—— dorsalis penis, 794.
—— dorsi-lumbalis, 783.

Nerv. ethmoidalis, 762.
—— facialis, 750.
—— femoralis, 787.
—— frontalis, 762.
—— genito-cruralis, 787.
—— glutæi inferiores, 795.
—— glosso-pharyngeus, 753.
—— glutæus superior, 791.
—— gustatorius, 765.
—— hæmorrhoidales inferiores, 793.
———— superiores, *ib.*
—— hepatici, 818.
—— hypo-glossus, 749.
—— ilio-scrotalis, 785.
—— infra-maxillaris, 764.
———— trochlearis, 762.
—— inguino-cutaneus, 786.
—— intercostales, 781.
—— intercosto-humerales, *ib.*
—— inter-osseus anticus, 778.
———— posticus, 780.
—— ischiadicus major, 795.
———— minor, 794.
—— lachrymalis, 761.
—— laryngealis inferior, 757.
———— superior, 756.
—— lingualis, 749.
—— lumbales, 783.
—— lumbo-sacralis, 785, 791.
—— massetericus, 765.
—— maxillaris inferior, 764.
———— superior, 763.
—— medianus, 777.
—— mentalis, 766.
—— molles, 806.
—— motores oculorum, 747.
—— musculo-cutaneus, 773.
———————— spiralis, 779.
—— mylo-hyoideus, 766.
—— nasalis, 762.
—— obturatorius, 790.
—— occipitalis minor, 769.
—— oculo-nasalis, 762.
—— œsophageales, 758.
—— olfactorius, 742.
—— ophthalmicus, 761.
—— opticus, 744.
—— orbitalis, 763.
—— palatinus magnus, *vel* posterior, 811.
———————— medius, *ib.*
———————— minor, *vel* anterior, *ib.*
—— palmaris cutaneus, 779.
———————— ulnaris profundus, 776.
———————————— superficialis, *ib.*
—— patheticus, 748.
—— perforans Casserii, 734.
—— perinæalis, 793.
—— peroneus, 799.
—— pharyngealis, 756.
—— phrenicus, 759, 770.
—— plantaris externus, 799.
———————— internus, 798.
—— pneumo-gastricus, 754.
—— popliteus, 797.
—— portio dura, 750.
———— mollis, 746.
—— pterygoideus, 765.
Nerv. pudendus externus, 787.
———————— inferior, 793.
———————— internus, *ib.*
—— radialis, 779.
—— recurrens, 757.
—— renales, 819.
—— respiratorius externus, 772.
—— sacrales, 791.
—— saphenus externus, 798.
———————— major, 788.
———————— minor, *vel* externus, 798.
—— spermatici, 819.
—— spheno-palatini, 811.
—— spinales, 767.
—— splanchnicus major, 816.
———————————— minor, *ib.*
—— splenici, 819.
—— stylo-hyoideus, 751.
—— sub-occipitalis, 767.
—— sub-scapulares, 772.
—— superficialis colli, 769.
———————— cordis, 815.
—— supra-orbitalis, 762.
———— scapularis, 772.
———— trochlearis, 762.
—— sympatheticus major, 801.
———————————— medius, 760.
———————————— minor, 750.
—— temporales profundi, 764.
———————— superficialis, 765.
—— temporo-fascialis, 750.
—— thoracici anteriores, 772.
—— thoracicus posterior, *ib.*
—— tibialis anticus, 801.
———————— posticus, 797.
—— trigeminus, 760.
—— trochlearis, 748.
—— ulnaris, 775.
—— uterini, 793.
—— vaginales, *ib.*
—— vagus, 754.
—— vidianus, 812.
Nervous system, 108.
———— tissue, *ib.*
Neurology, 119.
Nipple, 894.
Nodus encephali, 737.
Nose, 852.
Nymphæ, 888.
Œsophagus, 661.
Omentum, great, 667.
———————— lesser, 668,
———————— splenic, 672.
Omphalo-mesenteric vessels, 86.
Operation for hernia:
———————————— femoral, 479.
———————————— inguinal, direct, 476.
———————————————— oblique, *ib.*
Optic commissure, 727, 744.
—— thalami, 733.
Orbiculare, os. 847.
Orbits, 174.
Organised bodies, composition, 18.
———————— growth of, 19.
Os. *See* Bone.
Ossa triquetra, 154.
—— wormiana, *ib.*

Osseous system, 39.
Ossicula auditûs, 845.
Ossification, 48.
Osteology, 119, 120.
Os tincæ, 890.
— uteri externum, *ib.*
——— internum, 891.
Ostium abdominale, 894.
——— uterinum, *ib.*
Ovaria, 893.
Ovula Graafiana, *ib.*
Ovula of Naboth, 891.
Palpebræ, 821.
Pancreas, 690.
Papillæ capitatæ, 657.
——— conicæ, *ib.*
——— filiformes, *ib.*
——— fungiformes, *ib.*
——— lenticulares, *ib.*
Par vagum, 754.
Parotid gland, 659.
Pelvis, 211.
Penis, 872.
Pericardium, 692.
Perichondrium, 35.
Perinæum, 391, 482.
Periosteum, 34.
Peritonæum, 666.
Pes accessorius, 732.
— anserinus, 750.
— hippocampi, 732.
Peyer's glands, 72.
Pharynx, 660.
Phytotomy, 2.
Pia mater, 713.
Pigmentum nigrum, 833.
Pineal gland, 734.
Pinna, 839.
Pituitary gland, 728.
Pleura costalis, 703.
—— pulmonalis, *ib.*
Plexus, aortic, 819.
—— brachial, 770.
—— cardiac, 814.
—— carotic, 807.
—— cervical, 769.
—— choroides, 713.
———— minor, 737.
—— cœliac, 818.
—— coronary anterior, 814.
———— posterior, *ib.*
———— of the stomach, 818.
—— hepatic, *ib.*
—— hypogastric, 819.
—— lumbar, 784.
—— mesenteric inferior, 819.
———— superior, *ib.*
—— œsophagean, 758.
—— parotid, 750.
—— pharyngeal, 756.
—— phrenic, 818.
—— pulmonary anterior, 758.
———— posterior, *ib.*
—— renal, 819.
—— sacral, 792.
—— solar, 818.
—— spermatic, 819.
Plexus, splenic, 819.
—— submaxillary, 769.
—— tonsillaris, 753.
—— vertebral, 809.
Plica semi-lunaris oculi, 824.
Plicæ, 70.
Pomum Adami, 854.
Pons Varolii, 737.
Portal circulation, 78.
Portio dura, 750.
Porus opticus, 830.
Prepuce, 873.
Processus cochleariformis, 845.
——— è cerebello ad testes, 736.
——— vermiformis inferior, *ib.*
———— superior, *ib.*
Promontory, 844.
Prostate gland, 871.
Prostatic part of the urethra, 876.
Protuberantia annularis, 737.
Pudendum, 887.
Pulse, 84.
Puncta lachrymalia, 825.
Pupil, 835.
Pylorus, 673.
Pyramid, 844.
Pyramids, posterior, 722, 736.
Raphé corporis callosi, 729.
—— perinæi, 391.
Receptaculum chyli, 641.
Rectum, 679.
Rete mucosum, 61.
Rete testis, 884.
Retina, 833.
Rima glottidis, 858.
Ring, abdominal external, 462.
———— internal, 464.
—— femoral, 472.
Rotation, 243.
Ruban gris, 746.
Rugæ, 70.
Sacculus vestibuli, 848.
Salivary glands, 658.
Saphenous opening, 455.
Scala tympani, 849.
—— vestibuli, *ib.*
Schindylesis, 240.
Schneiderian membrane, 853.
Sclerotic coat, 829.
Scrotum, 879.
Semicircular canals, 848.
Semilunar cartilages, 276.
———— valves, 697.
Septum auricularum, 696.
—— lucidum, 731.
—— pectiniforme, 873.
—— scroti, 879.
—— ventriculorum, 698.
Serous membranes, 51.
Sigmoid valves, 697.
Sinus basilaris, 594.
—— cavernosus, 628.
—— circularis, *ib.*
—— frontalis, 139.
—— lactiferi, 895.
—— laterales, 628.
—— longitudinalis inferior, 627.

Sinus longitudinalis superior, 627.
—— maxillaris, 157.
—— occipitalis anterior, 629.
———— posterior, 628.
—— petrosus inferior, 629.
———— superior, *ib.*
—— pocularis, 876.
—— prostaticus, *ib.*
—— rectus, 628.
—— sphænoidalis, 146.
Skeleton, 39.
Skin, 57.
Skull, conformation of, 137.
Soft palate, 658.
Spermatic cord, 464.
Sphæno-palatine ganglion, 810.
Sphenoidal sinus, 176.
Sphincter vesicæ, 868.
Spinal cord, 717.
—— veins, preparation of, 622.
Splanchnology, 119.
Spleen, 689.
Spongy part of the urethra, 876.
Stapes, 847.
Steno's duct, 659.
Stomach, 671.
Sublingual gland, 660.
Submaxillary gland, *ib.*
Substantia perforata antica, 727.
Sudoriferous ducts, 60.
Sulcus longitudinalis hepatis, 682.
—— transversus, *ib.*
—— umbilicalis, *ib.*
Supercilia, 821.
Supra-renal capsules, 864.
Suture, 165, 240.
Sutures coronal, 165.
——— lambdoid, 166.
——— sagittal, *ib.*
——— squamous, *ib.*
Sympathetic nerves, 801.
Synarthrosis, 239.
Syndesmology, 119.
Synovial membranes, 54.
Tænia semicircularis, 734.
Tarsal cartilages, 822.
Tarsus, 232.
Teeth, 184.
(Dent.) bicuspidati, 185.
—— cuspidati, 184.
—— incisores, *ib.*
—— molares, 185.
Tegumentary membrane, 57.
Tendo Achillis, 429.
Tendon, 35.
Tentorium cerebelli, 713.
Testicles, 882.
———— descent, 877.
Thalami nervorum opticorum, 733.
Thoracic duct, 96, 640.
Thorax, 691.
Thymus gland, 708.
Thyro-hyoid membrane, 857.
Thyroid cartilage, 854.
——— gland, 859.
Tissue, adipose, 28.
——— cellular, 23.
Tissue, mucous, 68.
——— muscular, 101.
——— nervous, 108.
——— tegumentary, 57.
Tongue, 656.
Tonsils, 658.
Torcular Herophili, 627.
Trachea, 704.
Tractus respiratorius, 721.
Tragus, 840.
Tricuspid valve, 697.
Trigone vesical, 868.
Tuber cinereum, 728.
Tubercula quadrigemina, 737.
Tuberculum Loweri, 696.
Tubuli lactiferi, 895.
——— seminiferi, 883.
——— uriniferi, 863.
Tunica albuginea oculi, 829.
———— testis, 882.
——— erythroides, 880.
——— nervea, 833.
——— Ruyschiana, 832.
——— vaginalis, 881.
——— vasculosa testis, 883.
Tympanum, 843.
Tyson's glands, 875.
Unorganised bodies, increase of, 18.
Urachus, 870.
Ureters, 865.
Urethra, female, 870.
——— male, 870, 875.
Urinary organs, 861.
Uterus, 889.
Uvea, 835.
Uvula palati, 658.
—— vesicæ, 868.
Vagina, 889.
Valve, Eustachian, 696.
——— ilio-colic, 678.
——— of Vieussens, 736.
——— mitral, 698.
——— of the rectum, 680.
——— semilunar, 697.
——— sigmoid, *ib.*
——— tricuspid, *ib.*
Valvula Bauhini, 678.
Valvulæ conniventes, 70, 675.
Varieties in the abdominal arteries, 560.
———————— aorta, 498.
———————— brachial, 538.
———————— carotid, 515.
———————— femoral, 586.
———————— subclavian, 530.
Vas deferens, 884.
Vasa chylifera, 639.
—— efferentia, 95, 884.
—— inferentia, 95.
—— lactea, 639.
—— lactifera, 895.
—— lymphatica, 642.
—— recta, 884.
—— vasorum, 70.
—— vorticosa, 832.
Vascula serpentina, 883.
Vascular system, 73.

Vascular developement, 85.
Veins, 11, 93, 605.
Velum interpositum, 715.
——— pendulum palati, 658.
Ven. angularis, 607.
—— articularis maxillæ, 609.
—— auriculares anteriores, *ib.*
—— auricularis posterior, *ib.*
—— axillaris, 616.
—— azygos, 620.
———— minor, *ib.*
—— basilica, 613.
—— basis vertebræ, 623.
—— brachio-cephalica, 618.
—— bronchiales, 621.
—— buccalis, 607.
—— capsulares, 635.
—— carotis communis, 611.
———— externa, *ib.*
———— interna, *ib.*
—— cava inferior, 634.
—— cava superior, 619.
—— cerebelli, 626.
—— cerebri, 625.
—— cephalica, 612.
—— comites brachialis, 615.
———— inter-osseæ, 614.
———— radialis, 615.
———— ulnaris, 614.
—— cordis maxima, 638.
———— media, *ib.*
———— minimæ, 639.
———— parvæ, 638.
—— coronaria ventriculi, 637.
—— corporis striati, 626.
—— cutaneæ cervicis, 610.
—— dentalis inferior, 609.
—— dorsi spinales, 622.
—— duodenalis, 636.
—— emulgentes, 635.
—— epigastrica superficialis, 631.
—— facialis, 606.
—— femoralis, 632.
—— frontalis, 606.
—— Galeni, 626.
—— gastricæ, 636.
—— hepaticæ, 638.
—— iliaca externa, 632.
———— interna, 633.
—— iliacæ communes, *ib.*
—— innominatæ, 618.
—— intercostales, 620.
———— anteriores, 619.
—— intercostalis superior, 618.
—— jugularis externa, 609.
———— interna, 610.
—— laryngea, 612.
—— lingualis, 611.
—— lumbales, 634.
—— mammariæ internæ, 619.
—— maxillaris interna, 609.
—— mediana, 613.
———— basilica, *ib.*
———— cephalica, 614.
—— medulli spinales, 623.
Ven. mesenterica inferior, 636.
———— superior, 637.
—— nasalis, 607.
—— occipitalis, 611.
—— ophthalmica, 630.
—— ossium cranii, *ib.*
—— palatina, 608.
—— palpebralis, inferior, 607.
—— pancreaticæ, 366.
—— parotideæ, 609.
—— pharyngea, 611.
—— phrenicæ, 635.
—— poplitea, 632.
—— portæ, 635, 637.
—— posterior scapulæ, 610.
—— pudendæ externæ, 631.
—— pulmonales, 706.
—— radialis cutanea, 612.
—— ranina, 608.
—— renalis, 635.
—— sacra-media, 634.
—— salvatellæ, 613.
—— saphena major, *vel* interna, 631.
———— minor, *v.* externa, *ib.*
—— spermaticæ, 635.
—— splenica, 636.
—— subclaviæ, 616.
—— submentalis, 608.
—— supra-orbitalis, 607.
—— supra-scapularis, 610.
—— temporalis, 608.
—— thyroidea superior, 612.
—— thyroideæ inferiores, 619.
—— trachelo-subcutanea, 609.
—— transversalis faciei, *ib.*
—— ulnaris cutanea anterior, 613.
———— posterior, *ib.*
—— vertebralis, 617.
Venous system, 77.
Ventricles of the brain, 738.
—— fifth, 731.
—— fourth, 737.
—— lateral, 730.
—— third, 734.
—— of the heart, 697, 698.
———— larynx, 858.
Vermiform processes, 736.
Vertebræ, 122.
———— cervical, 125.
———— dorsal, 126.
———— lumbar, 127.
Vertebral column, 122.
Veru-montanum, 876.
Vesica urinaria, 865.
Vesiculæ seminales, 885.
Vestibule, 848.
Vestibulum vaginæ, 888.
Villi, 71.
Viscera, 635.
Vitreous humour, 838.
Vulva, 887.
Wharton's duct, 660.
Wilson's muscles, 395.
Zonula coronæ ciliaris, 839.
Zootomy, 2.

London: Printed by Samuel Bentley, Dorset Street, Fleet Street.

WORKS PRINTED FOR TAYLOR & WALTON,

BOOKSELLERS AND PUBLISHERS TO UNIVERSITY COLLEGE.

UPPER GOWER STREET.

SERIES OF TEXT-BOOKS.

DEMONSTRATIONS OF ANATOMY; BEING A GUIDE TO THE DISSECTION OF THE HUMAN BODY. By George Viner Ellis, one of the Demonstrators of Anatomy in University College. 1 vol. crown 8vo. 750 pages. 12*s*.

"We think Mr. Ellis's 'Demonstrations' are in every way fitted for the purpose for which they are intended, and we therefore strongly recommend the work to the notice of every member of the profession. We are convinced that it will quickly become the general text-book of every working student in anatomy."—*British and Foreign Medical Review*, January 1841.

ELEMENTS OF ANATOMY. FOR THE USE OF STUDENTS. By Jones Quain, M.D., Member of the Senate of the University of London. Fourth Edition, revised and enlarged. Illustrated with 140 Engravings on Wood, and Four Steel Plates. One thick vol. 8vo. 1*l*. 2*s*.

"This work may be, in short, recommended for giving a very just view of the present state of anatomical knowledge, and putting the English student in possession of the most important points of information contained in the best Continental Treatises. It constitutes, further, a very valuable and useful guide to the dissecting-room, by the number of specimens which it contains of the descriptive anatomy of the parts as they are brought into view."—*Edinburgh Med. and Surg. Journal*, Jan. 1, 1835.

ELEMENTS OF PHYSIOLOGY. BY J. MÜLLER, M.D., Professor of Anatomy and Physiology in the University of Berlin. Translated from the German, with Notes, by William Baly, M.D., Graduate in Medicine of the University of Berlin. Illustrated with Steel Plates and very numerous Wood Engravings. 2 vols. 8vo. Vol. I., 900 pages. Second Edition, 1*l*.

Volume II. will be published in the course of October.

"We *do*, however, recommend it very strongly, and we have no hesitation in saying that it will supersede all other works as a Text Book for Lectures, and one of reference for students. It steers a middle course between the superficial brevity of many of our modern works, and the pleonastic and metaphysical jargon of Burdach."—*Med. Chir. Review*, April 1838.

ELEMENTS OF CHEMISTRY. INCLUDING THE ACTUAL STATE AND PREVALENT DOCTRINES OF THE SCIENCE. By the late Edward Turner, M.D. Seventh Edition. Edited by Justus Liebig, M.D., Professor of Chemistry in the University of Giessen, and William Gregory, M.D., Professor of Chemistry in King's College, Aberdeen. One thick volume 8vo, *including the Oily Acids*, 1*l*. 5*s*.

"To the student in chemistry it is decidedly the best adapted of any manual in the English language. It is indeed a condensed epitome of the science. This is one of the greatest recommendations to those who wish to possess a work giving, in detail and consecutive connexion, the facts and doctrines of the science. Such is the work before us."—*The Chemist*, Jan. 1841.

*** A Second Supplement, completing the work, is expected very shortly.

Lately published.

THE OILY ACIDS, forming the First Supplement to the Seventh Edition. 8vo. 4*s*.

Part 3, No. 3 of the Sixth Edition, containing the same subjects. 4*s*.

A SERIES OF ANATOMICAL PLATES, IN LITHOGRAPHY,

with References and Physiological Comments, illustrating the Structure of the different Parts of the Human Body. Edited by Jones Quain, M.D., Member of the Senate of the University of London; and W. J. Erasmus Wilson, Lecturer on Anatomy and Physiology at the Middlesex Hospital.

This publication consists of a Series of Anatomical Drawings, selected from monograph treatises or from systematic works. In such of the departments as have been less ably and accurately delineated by early authors, or from their date may not appear adapted to the present state of improvement in anatomical science, the drawings have been taken from dissections and preparations made expressly for the work. The plates are accompanied by letter-press, containing detailed references to the various objects delineated, the names being set down in English, Latin, and French. The drawings are taken on stone by Mr. W. Fairland and Mr. Walsh, from drawings by Mr. J. Walsh and Mr. W. Bagg, and the printing executed by Hullmandel, Graf, and Fairland.

The Work consists of the following Divisions:

The Muscles. Royal Folio, 51 Plates. 2*l.* 16*s.* plain. 5*l.* 5*s.* full coloured.

The Vessels. Royal Folio, 50 Plates. 2*l.* 14*s.* plain. 3*l.* 18*s.* with the vessels coloured.

The Nerves. Royal Folio, 38 Plates. 2*l.* 4*s.* plain. 4*l.* 2*s.* full coloured.

The Viscera. Including the Organs of Digestion, Respiration, Secretion, and Excretion. Royal Folio, 32 Plates. Price 1*l.* 13*s.* plain. 3*l.* 10*s.* coloured.

The Bones and Ligaments, (in course of publication, in Monthly Fasciculi,) completing the Series.

*** *Any Volume may be purchased separately.*

THE SURGEON'S PRACTICAL GUIDE IN DRESSING, AND

IN THE METHODIC APPLICATION OF BANDAGES. By Thomas Cutler, M.D., late Staff-Surgeon in the Belgian Army. Second Edition, enlarged, illustrated by numerous Engravings on Wood. Foolscap 8vo, 6*s.* 6*d.* cloth.

"This appears to be a valuable little treatise. The Author seems to have spared no pains in procuring correct descriptions of all the surgical apparatus at present employed in bandaging and dressing, both at home and abroad. He has given numerous illustrations in the form of well-executed woodcuts, and has altogether produced what we conceive to be a very useful, and by no means an expensive publication."—*Medical Gazette*, Nov. 15, 1834.

FRACTURES OF THE EXTREMITIES, EXHIBITED IN

TWENTY PLATES; showing the Causes of Displacement; with an Explanation of the Appearances and Mode of Treatment. By G. W. Hind, M.R.C.S., formerly House-Surgeon to the Middlesex Hospital, and late Curator of the Museum of Anatomy in University College, London. Second Edition, with Woodcuts of the Appearances and mode of Bandaging. 1 vol. folio, price 1*l.* 4*s.* cloth.

"This volume forms a very splendid book, the result of much labour, and is calculated to answer every purpose that the practitioner can desire in a work of this kind."—*Lancet.*

ON THE CLASSIFICATION OF THE INSANE. BY M.

ALLEN, M.D., of High Beech, Essex. 8vo, 6*s.*

ACUTE HYDROCEPHALUS, OR WATER IN THE HEAD,

an Inflammatory Disease, and Curable by the same means with other Diseases of Inflammation. By David D. Davis, M.D., Professor of Obstetric Medicine in University College, and one of the Physicians to University College Hospital. 8vo, price 9*s.* 6*d.* cloth.

"—— In conclusion, we have only further to state our conviction that it is a treatise eminently calculated to exalt the high reputation which already distinguishes its author."—*Edinburgh Monthly Medical Journal*, January 1841.

TAYLOR AND WALTON, UPPER GOWER STREET.