

Nouveaux éléments de médecine opératoire : accompagnés d'un atlas de 20 planches in-4o gravées, représentant les principaux procédés opératoires et un grand nombre d'instruments de chirurgie / par Alf. A.L.M. Velpeau.

Contributors

Velpeau, A. 1795-1867.
Needham, Ewan Fraser, active 1889
Guy's Hospital. Medical School
King's College London

Publication/Creation

Paris : J. B. Baillière, 1832.

Persistent URL

<https://wellcomecollection.org/works/wvne2wrr>

License and attribution

This material has been provided by This material has been provided by King's College London. The original may be consulted at King's College London. where the originals may be consulted.

This work has been identified as being free of known restrictions under copyright law, including all related and neighbouring rights and is being made available under the Creative Commons, Public Domain Mark.

You can copy, modify, distribute and perform the work, even for commercial purposes, without asking permission.

**wellcome
collection**

Wellcome Collection
183 Euston Road
London NW1 2BE UK
T +44 (0)20 7611 8722
E library@wellcomecollection.org
<https://wellcomecollection.org>

KING'S
College
LONDON

Velpau Library
New elements of operative surgery...
1947
GH Fol. RD32. VEL

200912345 1



KING'S COLLEGE LONDON



Digitized by the Internet Archive
in 2015

<https://archive.org/details/b21298610>

NEW ELEMENTS
OF
OPERATIVE SURGERY:

BY
ALF. A. L. M. VELPEAU,

PROFESSOR OF SURGICAL CLINIQUE OF THE FACULTY OF MEDICINE OF PARIS, SURGEON OF THE HOSPITAL OF LA CHARITE,
MEMBER OF THE ROYAL ACADEMY OF MEDICINE, OF THE INSTITUTE, ETC.

CAREFULLY REVISED, ENTIRELY REMODELLED, AND AUGMENTED WITH
A TREATISE ON MINOR SURGERY;

ILLUSTRATED BY
OVER 200 ENGRAVINGS INCORPORATED WITH THE TEXT:

ACCOMPANIED WITH
AN ATLAS IN QUARTO OF TWENTY-TWO PLATES,
REPRESENTING THE PRINCIPAL OPERATIVE PROCESSES, SURGICAL INSTRUMENTS, &c.

FIRST AMERICAN, FROM THE LAST PARIS EDITION.

TRANSLATED BY
P. S. TOWNSEND, M.D.,

LATE PHYSICIAN TO THE SEAMEN'S RETREAT, STATEN ISLAND, NEW YORK.

AUGMENTED BY THE ADDITION OF
SEVERAL HUNDRED PAGES OF ENTIRELY NEW MATTER,
COMPRISING ALL THE LATEST IMPROVEMENTS AND DISCOVERIES IN SURGERY IN AMERICA
AND EUROPE, UP TO THE PRESENT TIME.

UNDER THE SUPERVISION OF, AND WITH NOTES AND OBSERVATIONS BY

VALENTINE MOTT, M.D.,

PROFESSOR OF THE OPERATIONS OF SURGERY WITH SURGICAL AND PATHOLOGICAL ANATOMY, IN THE UNIVERSITY OF NEW YORK; FOREIGN
ASSOCIATE OF THE ACADEMIE ROYALE DE MEDECINE OF PARIS, OF THAT OF BERLIN, BRUSSELS, ATHENS, ETC.

IN THREE VOLUMES.

~~~~~  
ATLAS.  
~~~~~

NEW YORK:
SAMUEL S. & WILLIAM WOOD,
No. 261 PEARL STREET.
1847.

RD32.VE

Entered according to Act of Congress, in the year 1847, by
SAMUEL S. & WILLIAM WOOD,
In the Clerk's Office of the District Court of the Southern District of New York.



EXPLANATION OF THE PLATES.

PLATE I.

MANNER OF HOLDING THE BISTOURY.

[SEE VOLUME I.]

Fig. 1. *Straight Bistoury with a Spring*.—Those bistouries that have the handle fixed, possess the inconvenience of not allowing of their being shut up. Those which have no spring, though they may perhaps be somewhat more easily cleaned, are handled with less facility, while this one might, if necessary, be substituted for all of them. A sliding button, such as exists on those made by M. Charrière, is moreover an excellent substitute for the spring.

Fig. 2. *Convex Bistoury*.—The cutting edge of this bistoury being uniform from the point to the heel, it is more convenient than those in which the blade, broader in the middle part than posteriorly, has a cutting edge only on one half of it, or on its two anterior thirds.

Fig. 3. *Bistoury with an English form*.—In England they scarcely make use of any other than small convex bistouries, movable on their handles. Their use, which is convenient when it is a matter of importance to keep the instrument at a very short distance from the parts to be divided, is never absolutely called for, and the French bistoury may always be substituted for them.

Fig. 4. *Straight Blunt-pointed, or Button-pointed Bistoury*.—This is the bistoury with which the tonsils are excised when we perform staphyloraphy, and the one with which we enlarge certain abscesses, fistulas, &c.

Fig. 5. *First Position*, or the convex bistoury held in the full hand, with its cutting edge downwards.

Fig. 6. The same position, or the bistoury held in the full hand with its cutting edge upwards.

Fig. 7. *Second Position*, the cutting edge of the bistoury held in the manner of a bow and facing downwards.

Fig. 8. The same position, with the cutting edge facing upwards.

Fig. 9. *Third Position*, or the bistoury held as a writing-pen, the cutting edge upwards.

Fig. 10. Same position, and the point of the bistoury turned backwards or towards the wrist.

Fig. 11. *Fourth Position*, the bistoury held as a pen, with the cutting edge upwards.

Fig. 12. Same position, and the point of the bistoury turned backwards.

Fig. 13. *Fifth Position*, the bistoury held as a bow, the cutting edge transversely.

SUTURES.

Fig. 14. *Simple or Interrupted*, (*à points séparés*) *Suture*.—A, A, A, Nooses [or points] of the suture. B, B, B, Rosettes, or bow-knots, which fix or fasten each of its points.

Fig. 15. *The Basting* (*en faufil*) *Suture*.—A, A, Extremities of the thread, and which are to be knotted separately, and which have been left free in order to comprehend the nature of the process better. B, B, B, Points of the suture.

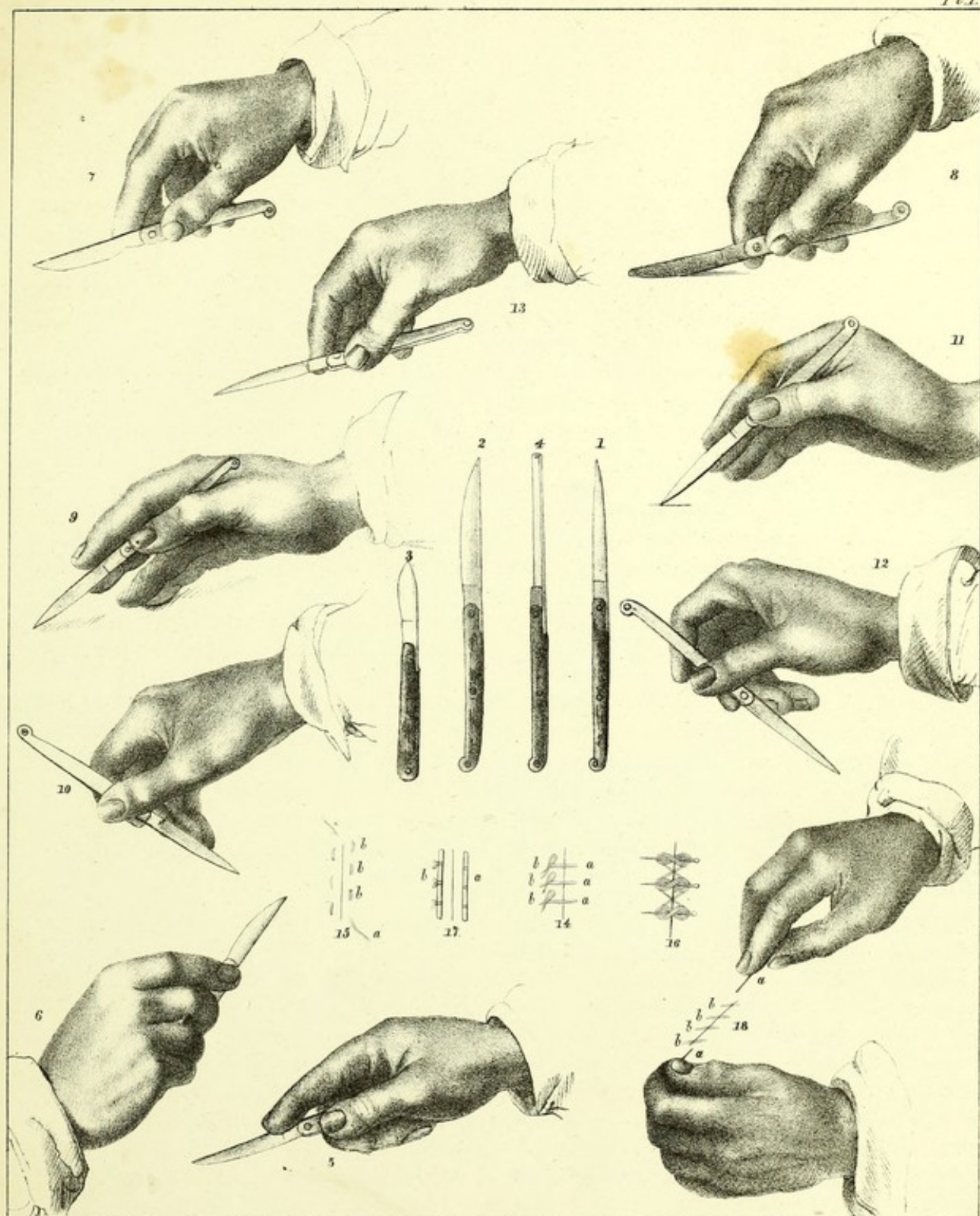
Fig. 16. *Twisted Suture*.

Fig. 17. *Quilled Suture*.—A, A cylinder of adhesive plaster, wood, whalebone, gum-elastic, or metal, fixed on one side of the wound by the nooses of each thread. B, Second cylinder of adhesive plaster, on which is to be fastened by a knot the free extremity of each point of the suture.

Fig. 18. *Spiral, Whip, or Glover's Suture*.—A, A, Extremities of the thread a little drawn upon in order to tighten their turns. B, B, B, Points of the suture.

POSITIONS OF THE BISTOURY-SUTURES

Pl. 1.



Published by S.S. & W. Wood, New-York.




PLATE II.

LIGATURE OF ARTERIES.

Fig. X. The arteries raised up, on as many sounds, are seen on this figure at the great majority of points where the surgeon is called upon to cut down to them. The patient is represented in a convenient position for a ligature upon each of them, except that we must suppose him to be lying horizontally for that upon the external iliac. The hands, instead of being placed from above downwards, should be in a contrary position for the carotid and subclavian, but if placed so here they would have concealed the parts of the figure too much. The other figures represent, of their natural size, each wound of the kind at present under consideration. They retain its number and form.

HEAD, NECK, AND UPPER EXTREMITY.

Fig. 25. Ligature upon the Temporal Artery

Fig. 26. Ligature on the Facial Artery.

Fig. 27. Ligature on the Lingual Artery.

Fig. 28. Ligature on the Occipital Artery.

Fig. 1. *Ligature upon the Carotid.*—1, 1, 1, The lips of the wound in the integuments properly separated apart. 2, The platysma myoides muscle divided and drawn aside with the skin. 3, The sterno-mastoid drawn outwards. 4, The omo-hyoideus crossing the artery and dividing the infra-hyoid region into two triangles. 5, The sterno-hyoid. 6, The sterno-thyroid. 7, The fibrous layer which separates the muscles from the vessels, incised vertically and turned back towards the inside, that is, toward the trachea. 8, The clavicle, which the skin allows of being perceived through it. A, The common carotid artery disengaged from its sheath in the omo-tracheal triangle and raised up by the extremity of a sound. V, The jugular vein pushed back to the outside. N, The pneumo-gastric nerve, situated between the vein and the artery, and naturally concealed by these two vessels. N', The descending branch of the ninth pair of nerves.

Fig. 2. *The Subclavian Artery outside of the Scalenus Anticus Muscle.*—1, 1, 1, 1, Contour and lips of the wound. 7, 7, Direction of the clavicle. 2, Cervical border of the trapezius muscle. 3, Clavicular root of the sterno-mastoid muscle. 4, Omo-hyoideus. 5, Scalenus anticus. 6, The aponeurosis freed of its adipose layer and of the lymphatic ganglions, and then divided and raised up. A, The subclavian artery issuing from the chest, raised up by a sound from before backwards and from within outwards, between the tubercle of the first rib or the scalenus muscle and the lower cervical branch of the brachial plexus. A', The posterior cervical artery, which passes between the nervous cords of the plexus in order to reach to the rear. V, The external jugular vein, which is very voluminous in this subject and situated very far posteriorly. V', The subclavian vein partly concealed by the clavicle, and proceeding to cross the anterior surface of the scalenus, in order to enter into the chest, while passing behind the sterno-mastoid muscle. N, N, N, Bundles which contribute to form the nervous plexus of the axilla. N', N', Descending superficial branches of the cervical plexus, otherwise called the supra-acromial nerves.

DESCRIPTION OF PLATE II—CONTINUED.

Fig. 3. *The Axillary Artery laid bare from before backwards.*—1, 1, 1, 1, Contour of the wound. 2, 2, The adipose and the aponeurotic layer. 3, 3, 3, Section of the pectoralis major divided in the direction of its fibres. 4, Upper border of the pectoralis minor—adipose pelotons and the deep-seated aponeurosis torn. A, The axillary artery brought forward by the sound, after having been disengaged from behind the vein, which is on the inside, and from the nervous branch nearest approximated to the chest, which is on the outside. A', A', The acromial and the anterior thoracic branch, which come by a common trunk from the principal artery. V, The axillary vein. V', The cephalic vein arriving from the arm in order to join the axillary. N, The first branch of the brachial plexus.

Fig. 4. *The Brachial Artery.*—1, 1, 1, 1, Contour of the wound. 2, 2, The enveloping aponeurosis. 3, 3, Another aponeurotic layer, which serves as a common sheath to the neurovascular fasciculus. 4, The fibrous partition which usually separates the artery from the median nerve. A, The brachial artery raised up from before backwards, that is, on its passage from the biceps muscle towards the inner portion of the triceps. V, V, Collateral veins. V', The basilic vein. N, The median nerve. N', The cutaneous nerve. N*, The ulnar (or cubital) nerve.

Fig. 5. *The Brachial Artery in the Fold or Bend of the Arm.*—1, 1, 1, 1, Contour of the wound. 2, 2, 2, The aponeurosis divided and turned back to the outside. 3, A portion of the brachialis internus muscle. 4, Sheath of the artery. A, The artery raised up from without inwards, above the aponeurotic expansion of the biceps. V, Its collateral [i. e. associate or accompanying] vein. N, The median nerve. N', A branch of the musculo-cutaneous nerve, separated aside by means of a hook, at the same time with the corresponding lip of the wound.

Fig. 6. *The Radial Artery above.*—1, 1, 1, 1, The contour of the wound. 2, 2, First layer of the aponeurosis, divided and turned back on its borders. 3, The inner border of the supinator radii longus muscle. 4, Second layer of the aponeurosis. 5, The flexor digitorum sublimis [or superior or superficial] muscle. 6, The tendon of the pronator radii teres muscle. A, The artery raised up between the veins. V, Collateral veins. V', N, superficial vein and nerve.

Fig. 7. *The Ulnar Artery above.*—1, 1, 1, 1, Contour of the wound. 2, 2, 2, First aponeurotic layer. 3, The flexor digitorum sublimis. 4, The flexor carpi ulnaris muscle. 5, 5, The second aponeurotic layer. A, The artery disengaged from its envelopes and brought forward. V, The collateral veins situated on the radial side. N, The ulnar nerve.

Fig. 8. *The Radial Artery below.*—1, 1, The contour of the wound. 2, 2, The aponeurosis. 3, Tendon of the flexor carpi radialis muscle. 4, The pronator radii quadratus muscle behind the vessels. A, The artery separated from its veins, V.

Fig. 9. *The Ulnar Artery below.*—1, 1, Contour of the wound. 2, 2, Aponeurosis. 3, The tendon of the flexor carpi ulnaris muscle pushed back to the inner side. 4, 4, The deep-seated layer of the aponeurosis. A, The artery, accompanied on its sides by the veins, V. N, Anterior branch of the ulnar nerve.

Fig. 30. *Ligature upon the Radial Artery between the Thumb and Forefinger.*

THE LOWER EXTREMITY.

Fig. 10. *The External Iliac Artery.*—1, 1, 1, Contour of the wound. 2, 2, Aponeurosis of the obliquus abdominis externus muscle. 3, 3, The obliquus abdominis internus muscle. 4, A

ganglion which is sometimes encountered in front of the artery. 5, 5, Borders of the fibrous sheath which separates the artery A from the nerve N, and from the vein V. A', The circumflex artery of the ilium. A'', The epigastric artery. A''', V, Artery and vein of the integuments.

Fig. 11. *The Femoral Artery above.*—1, 1, 1, Contour of the wound. 2, 2, The first layer of the aponeurosis. 3, The border of the sartorius muscle. 4, The second layer of the aponeurosis, or the arterial sheath. A, The femoral artery, accompanied on its outside by the crural nerve N, on its inside by the vein of the same name V, and crossed by the saphena nerve N', and the internal saphena vein V' enveloped in fat.

Fig. 12. *The Femoral Artery below.*—1, 1, 1, Contour of the wound. 2, The aponeurosis. 3, The sartorius pushed back to the outside. 4, The deep-seated aponeurosis, furnishing a sheath to the artery A, the femoral vein V, and the crural nerve N, on its inner side. A', The great anastomosing artery, which proceeds to ramify itself into the tendon of the adductor magnus muscle.

Fig. 13. *The Posterior Tibial Artery in the Calf.*—1, 1, 1, 1, Contour of the wound. 2, First aponeurotic layer. 3, The gemellus superior and the gemellus inferior muscles. 4, The cellular layer which separates the gemelli muscles from the soleus muscle. 5, 5, A section of the soleus muscle. 6, 6, The deep-seated aponeurosis. A, The tibial (posterior) artery, having a vein on each side. V, N, Posterior tibial vein and nerve. V', The internal saphena vein pushed forwards.

Fig. 14. *The Posterior Tibial Artery below the Calf.*—1, 1, Contour of the wound. 2, 2, First aponeurotic layer. 3, Second aponeurotic layer. 4, The tendo achillis placed between the two layers of the aponeurosis. A, The tibial (posterior) artery situated deeper down. V, Collateral veins. N, The posterior tibial nerve. V', Branch of the saphena vein.

Fig. 15. *The Posterior Tibial Artery behind the Malleolus.*—1, 1, 1, Contour of the wound. 2, 2, First aponeurotic layer. 3, The deep-seated aponeurosis. 4, The tendon of the tibialis posticus muscle, purposely laid bare. A, The artery. V, Veins. N, Tibial nerves. V', Subcutaneous veins.

Fig. 31. *Ligature on the Anterior Tibial Artery above.*

Fig. 32. *Ligature on the Anterior Tibial Artery below.*

Fig. 33. *Ligature on the Dorsalis Pedis Artery.*

INSTRUMENTS.

Fig. 16. The curved needle of Deschamps.

Fig. 17. The needle of J. L. Petit.

Fig. 18. The canulated or grooved ligature-holding sound.

Figs. 19 and 20. Other curved needles for passing ligatures.

Fig. 22. The needle, or eyed-probe.

Fig. 24. Desault's needle.

Fig. 21. A knot-tightener.

Fig. 23. Slide-forceps, (pince à coulisse.)

Fig 1

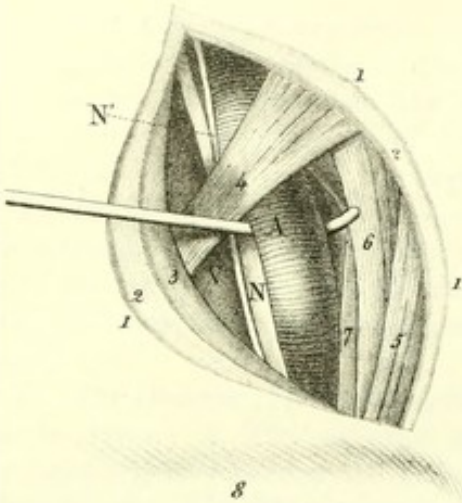


Fig 2

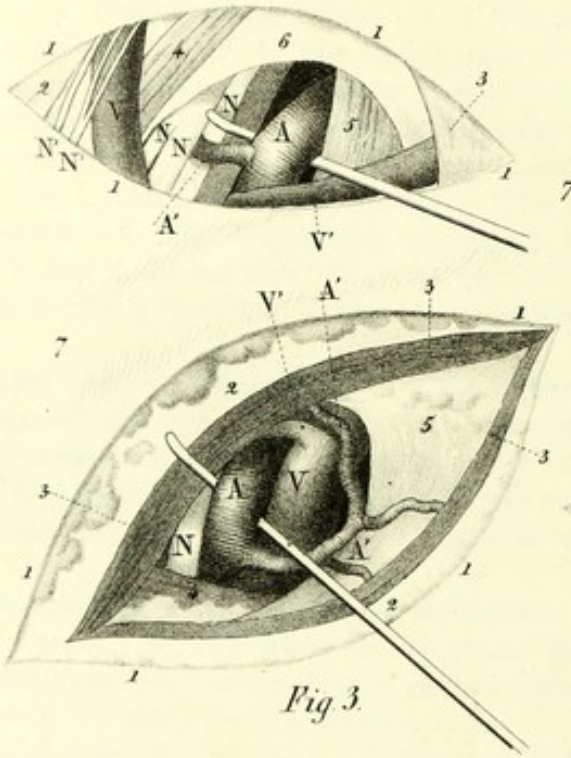


Fig 4

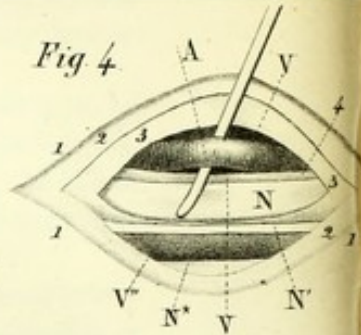


Fig 5

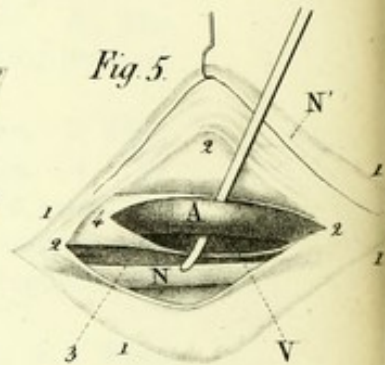


Fig 3

Fig 6

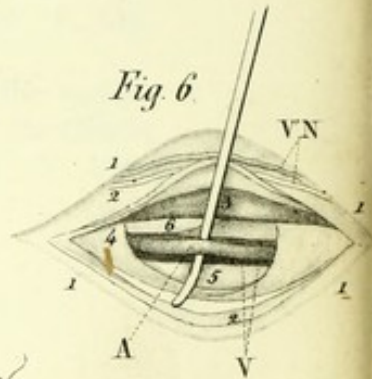
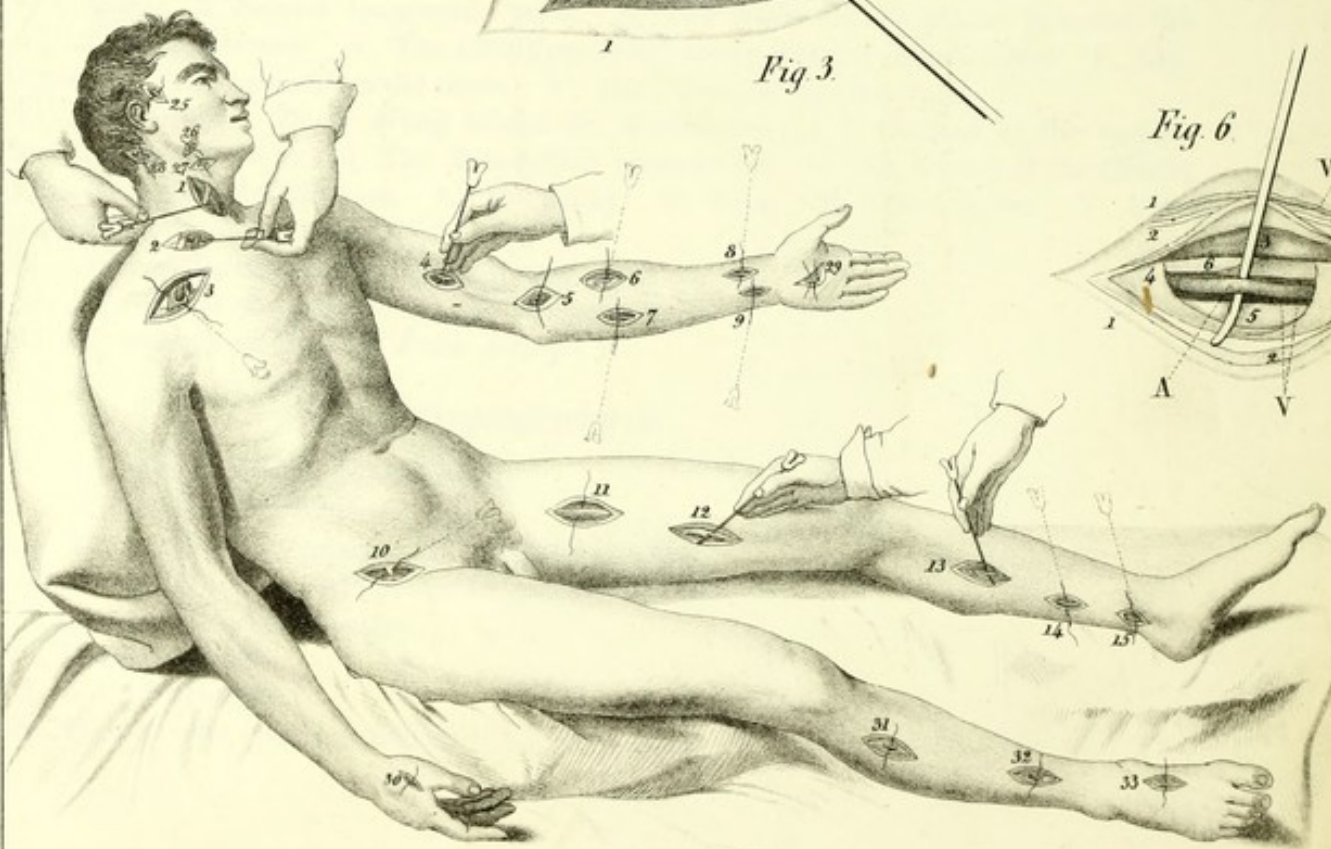
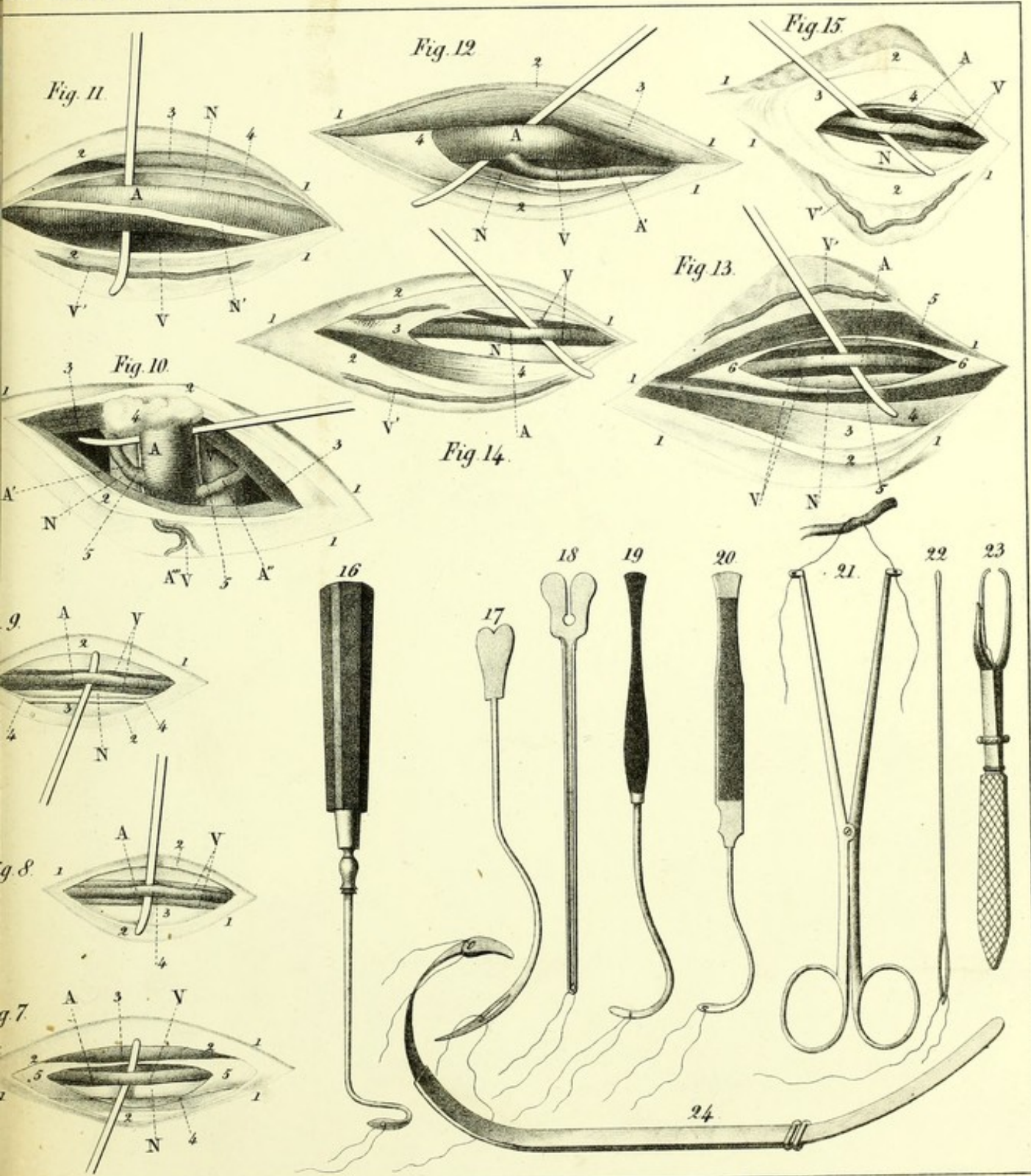


Fig X



En stone by F. Davignon.



Printed by J. Nagel, N.Y.


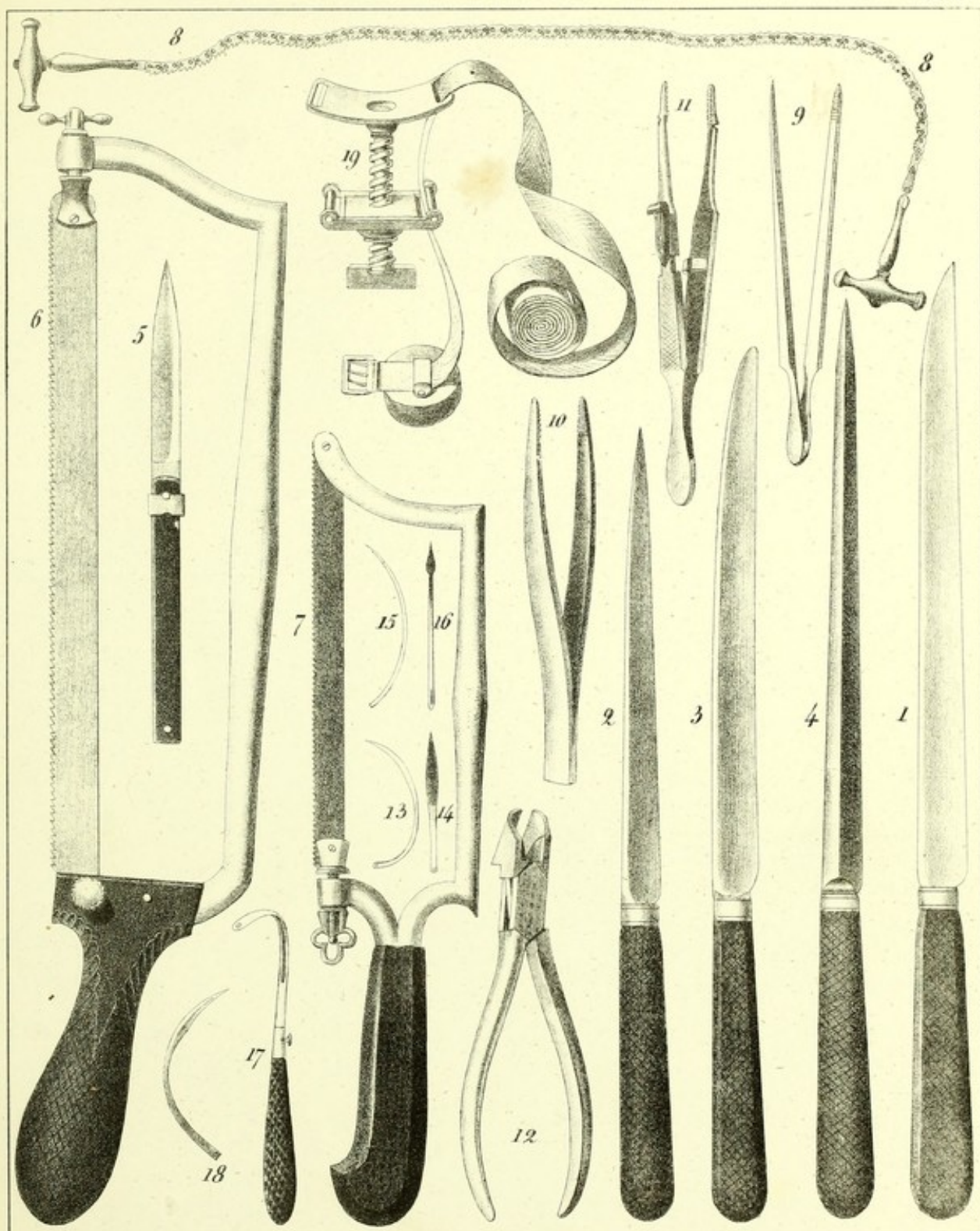


PLATE III.

- Fig. 1. Ordinary knife of medium size, and with its cutting edge uniformly straight.
- Fig. 2. Straight knife, without a heel, and slightly convex in approaching the point, as I prefer it, which may be had at M. Sirhenry's, (Paris.)
- Fig. 3. Straight knife, also without a heel, and the point of which is blunt.
- Fig. 4. Knife with a double cutting edge, or the ordinary interosseous knife.
- Fig. 5. Bistoury with a slide, (*à coulisse*,) which some have in the amputating case, but which has no real advantages over the ordinary bistoury.
- Fig. 6. Saw, and which may be had of M. Charrière, (Paris.)
- Fig. 7. Ordinary saw, here reduced to a little over half the size of the preceding.
- Fig. 8. The articulated or chain saw of Aitken or Jeffrey.
- Fig. 9. A ligature forceps whose form has always appeared to me to be very convenient.
- Fig. 10. Ordinary forceps.
- Fig. 11. Torsion forceps.
- Fig. 12. Cutting pliers, (*tenaille incisive*.)
- Fig. 13. Needle of a new form, seen on its side.
- Fig. 14. A needle seen on its face.
- Figs. 15 and 16. Ancient needles.
- Fig. 17. Another ancient needle, having the heel flattened laterally and the eye on the side.
- Fig. 18. Ordinary curved needle, with its cutting portion of triangular shape.
- Fig. 19. J. L. Petit's tourniquet, as modified, and having a movable pelote,



On Stone by F. Daignon.

Printed by L. Yagor.

APPENDIX



PLATE IV.

AMPUTATIONS.

UPPER EXTREMITY.

Fig. 1. *Amputation at the Wrist.—The Flap method.—Ordinary process.*—*a*, The right hand of the operator, holding the knife *b*, almost horizontally, to cut the palmar flap and to remove the hand *d*, which he supports and depresses himself with his left hand *c*. *e*, The dorsal flap raised up on the fore-arm. *f*, Adipose layer and anterior border of the wound. *g*, Dorsal aponeurosis of the metacarpus. *h, h, h, h*, Divided tendons of the extensor muscles. *l*, Radial and ulnar arteries divided. *k*, Head of the ulna.

The articulation having been divided, we perceive in front the head, *m*, formed by the union of the scaphoid, semilunar and pyramidal bone behind. *i, i*, The corresponding cavities presented by the radius and ulna, and then a little farther on, three fibrous sheaths, one radial, one ulnar, and the other a middle sheath, which are destined for the tendons of the three principal bundles of muscles employed in extending the hand or the fingers.


Fig. 2. *Amputation of the Fore-arm.—The Circular method.—Also the modification which consists in dividing the muscles from the bones to the aponeurosis.*—*a*, Right hand of the operator, holding the knife *b*. *c*, His left hand, supporting the wrist, *d*, of the patient. *e*, The part of the fore-arm which should be embraced by one of the hands of the assistant. *f*, Incision through the skin at two inches below the place where the bones are to be sawed. *g*, The muscular tissues and aponeurosis denuded of their integuments. *h*, Flap of skin with its cellular tissue, dissected and raised up in the form of a ruff. *i*, Place of entrance of the knife. *k*, Place of exit of the knife.

As it is the right limb, and which has to be turned in pronation, and the operator to be placed on the inner side, the skin must be kept raised up by an assistant. For the left fore-arm it would be the corresponding hand of the operator; the assistant then takes charge of the hand of the patient.

Fig. 3. *Disarticulation of the Arm.—Ovalar method.—Process of the author.*—The patient being seated, and the humerus disarticulated, the member is upon the point of being separated from the trunk. In place of being in front, the operator, if it is the left limb, would place himself behind.

a, The right hand of the surgeon acting on the knife *b*. *c*, The left hand, holding the arm *d* in such manner as to separate its upper extremity as much apart from the trunk as possible, with the view of favoring the passage of the instrument. *e, e, e*, The triangular flap of the deltoid, strongly depressed, in order to expose the bottom of the wound. *f, f*, The borders of the division reuniting above at an acute angle, a little in front of the acromion *g*, the summit of which ordinarily forms the point of departure for the wound. *h*, Glenoid cavity bordered with a remnant of fibrous capsule. *i*, Cartilaginous head of the humerus, surrounded near its neck *j* with a portion of the articular capsule. *k*, The body of the humerus exposed to view by the depression of the deltoid flap. *l*, The right hand of an assistant placed behind the patient, which assistant is to compress the axillary vessels while the operator is terminating the separation of the limb.

This manner of suspending the course of blood through the artery of the arm, and which is employed in almost all the other processes, and appears to date its origin as far back as to Le Dran, is always effected by the manipulation here described.



On Stone by F. Dargatzis

Printed by L. Nagel, NY




PLATE V.

AMPUTATIONS.

FINGERS AND LOWER EXTREMITY.

Fig. 1. *Amputation of the Fingers.—Ovalar method.—Process of M. Scoutetten.*—1, The right hand terminating the incision, 2, of the integuments, which incision the operator had commenced on the dorsum of the carpus, 3, in such manner as to surround the entire root of the finger. 4, Aspect of the wound immediately after the amputation. We perceive there from behind forwards the extensor tendon, the head of the bone, the cut surface of the ligaments, and the flexor tendon and its sheath. We are to suppose that an assistant is present to separate the other fingers apart, and that the left hand of the surgeon acts in a proper manner on that which he is amputating.

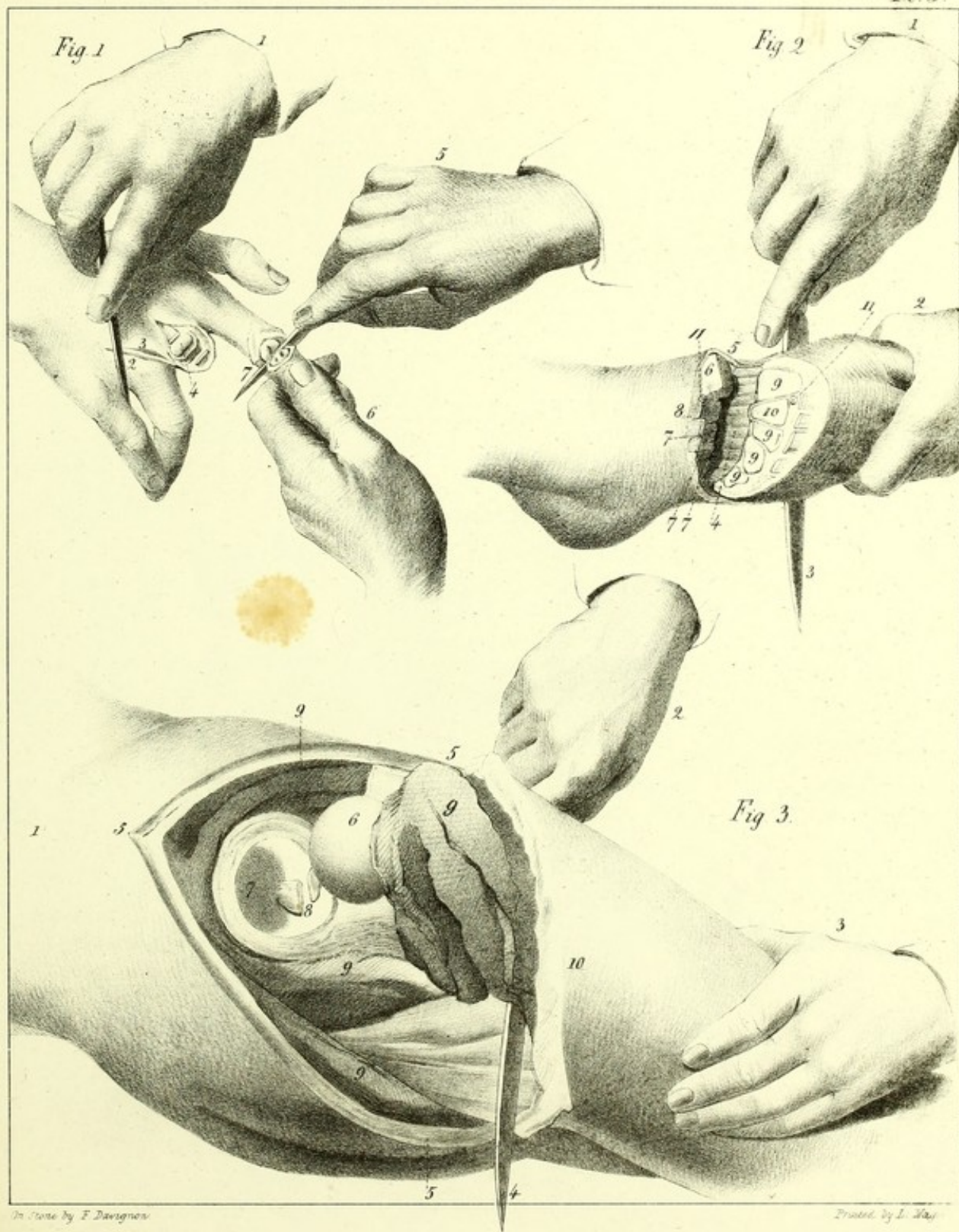
Amputation of the Phalanges.—The Flap method.—Ordinary process.—5, The right hand of the operator, holding the bistoury 7, and cutting out the anterior flap, [i. e. the palmar,] to separate the second phalanx from it, and which latter [i. e. the phalanx] the left hand, 6, causes to vibrate, (basculer,) and endeavors to remove from the first phalanx. An assistant should embrace with his left hand the root of this finger and the thumb, while with the right hand he keeps the three other fingers apart and flexed.

Fig. 2. *Disarticulation of the Metatarsus.*—1 and 2, The hands of the surgeon pressing on the point of the foot and on the knife 3, at the moment at which he is about to terminate the [planar] flap which is to cover the articular surface. 4, The bleeding surface of this flap. 5, The projection which is made on the inside by the first cuneiform bone. 6, The anterior articular surface (facette) of the same bone. 7, 7, 7, The articular surface of the three last cuneiform bones. 8, The bottom of the tarsal mortice destined for the reception of the extremity, 10, of the second metatarsal bone. 9, 9, 9, 9, The cartilaginous articulating surfaces of the four other metatarsal bones. 11, 11, The [cut] extremities of the dorsalis pedis artery.

Fig. 3. *Disarticulation of the Thigh.—Ovalar method.—Process of M. Cornuau.*—1, The haunch or hip of the patient, who is placed in a recumbent position on his sound side. 2, The right hand of the surgeon holding the knife 4, while the left hand, 3, supports the thigh 10, the separation of which from the trunk is upon the point of being accomplished. 5, 5, 5, The superior angle and lips of the wound. 6, The head of the femur, luxated and detached from the cotyloid cavity 7. 8, The inter-articular ligament divided. 9, 9, 9, 9, The cut surface of the different muscles. We must also suppose here that there is an assistant stationed behind, with his back turned towards the head of the bed, and supporting the diseased hip, while another assistant is charged with the leg.

AMPUTATIONS.

Pl. 5.



On Stone by F. Davignon

Printed by L. Hay




PLATE VI.

TREPHINING.—EXSECTIONS.

THE TREPHINE.

- Fig. 1. Shaft (arbre) of the trephine.
- Fig. 2. Crown of the trephine armed with its pyramid, (or point.)
- Fig. 3. The perforating trephine.
- Fig. 4. The crown of the trephine, encased in a protecting sheath.

THE SAW OF M. MARTIN.

- Fig. 5. The handle of the instrument.
- Fig. 6. The rod, (tige,) which in order to be put into action by its extremity 7, has this last inserted into the shaft of the trephine 1, [see fig. 1, above.]
- Fig. 8. A concave rowel saw, which the stem 6, fixed on the ball 9, moves in the handle 10, 10.
- Figs. 11, 11. Concave rowel crowns or saws, of different sizes.
- Fig. 12. A flat rowel crown or saw.

CHARRIERE'S SAW.

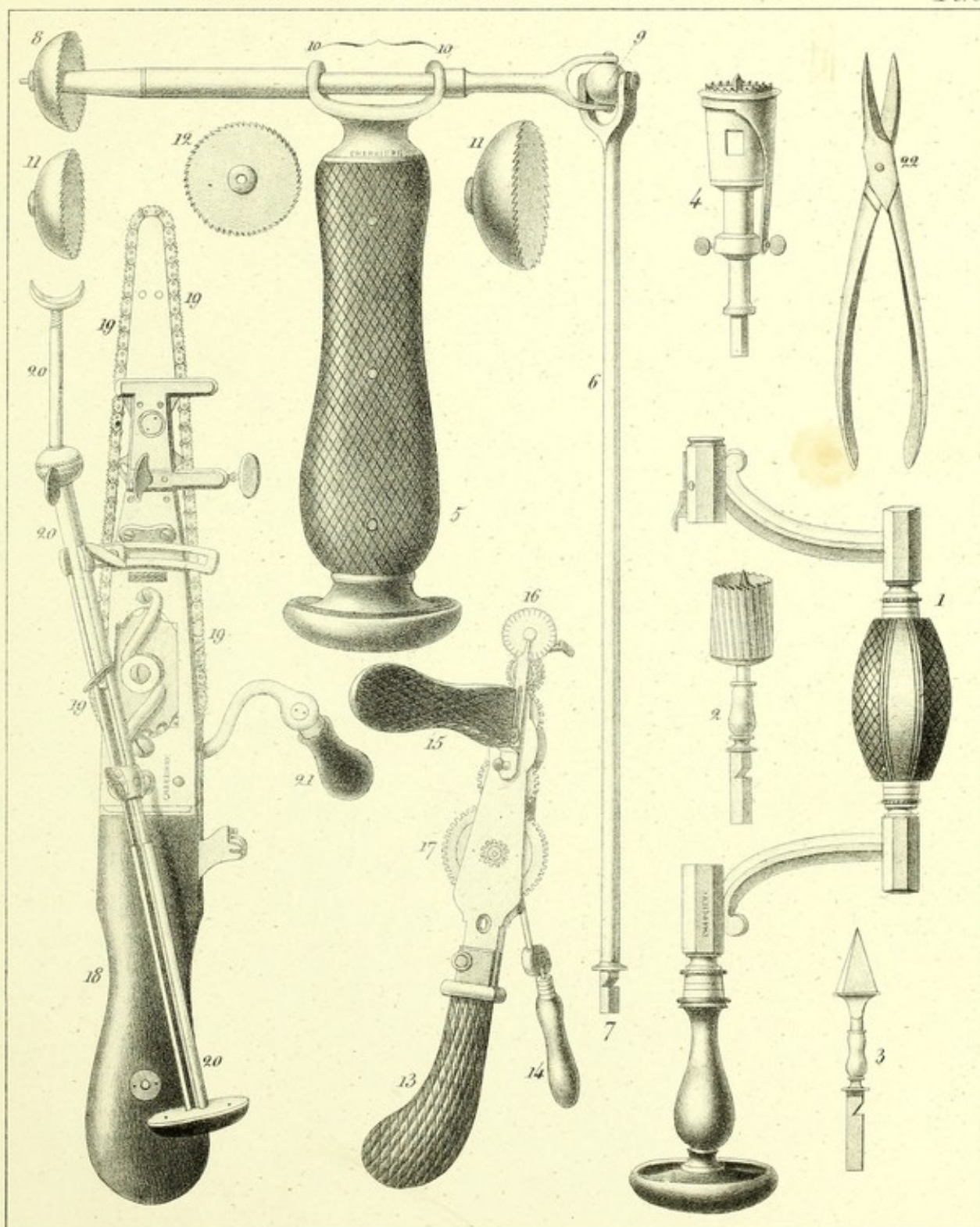
- Fig. 13. The handle, which is applied against the chest.
- Fig. 14. The crank, (manivelle,) which by means of the wheel 17, and those which follow, put into action the saw 16, while the left hand holds the instrument by the handle 15.

THE SAW OF M. HEINE.

- Fig. 18. The handle, which is to be embraced by the full grasp of the hand.
- Figs. 19, 19, 19, 19. The chain-saw, which is made to turn with the right hand by means of the crank 21.
- Figs. 20, 20, 20. The sliding rod, (tige à coulisse,) which allows of our taking a fixed point near the bone to be sawed during the course of the operation.
- Fig. 22. Scissors for the section of a toe or finger-nail imbedded in the flesh.

INSTRUMENTS for TREPHINING & EXSECTION.

PL 6



On Stone by F. Davignon.

Printed by L. Nagel.

Published by S.S. & W. Wood, New-York.

PLATE VII
EXPLANATION

1. The ...
2. The ...
3. The ...
4. The ...
5. The ...
6. The ...
7. The ...
8. The ...
9. The ...
10. The ...
11. The ...
12. The ...
13. The ...
14. The ...
15. The ...
16. The ...
17. The ...
18. The ...
19. The ...
20. The ...
21. The ...
22. The ...
23. The ...
24. The ...
25. The ...
26. The ...
27. The ...
28. The ...
29. The ...
30. The ...
31. The ...
32. The ...
33. The ...
34. The ...
35. The ...
36. The ...
37. The ...
38. The ...
39. The ...
40. The ...
41. The ...
42. The ...
43. The ...
44. The ...
45. The ...
46. The ...
47. The ...
48. The ...
49. The ...
50. The ...
51. The ...
52. The ...
53. The ...
54. The ...
55. The ...
56. The ...
57. The ...
58. The ...
59. The ...
60. The ...
61. The ...
62. The ...
63. The ...
64. The ...
65. The ...
66. The ...
67. The ...
68. The ...
69. The ...
70. The ...
71. The ...
72. The ...
73. The ...
74. The ...
75. The ...
76. The ...
77. The ...
78. The ...
79. The ...
80. The ...
81. The ...
82. The ...
83. The ...
84. The ...
85. The ...
86. The ...
87. The ...
88. The ...
89. The ...
90. The ...
91. The ...
92. The ...
93. The ...
94. The ...
95. The ...
96. The ...
97. The ...
98. The ...
99. The ...
100. The ...

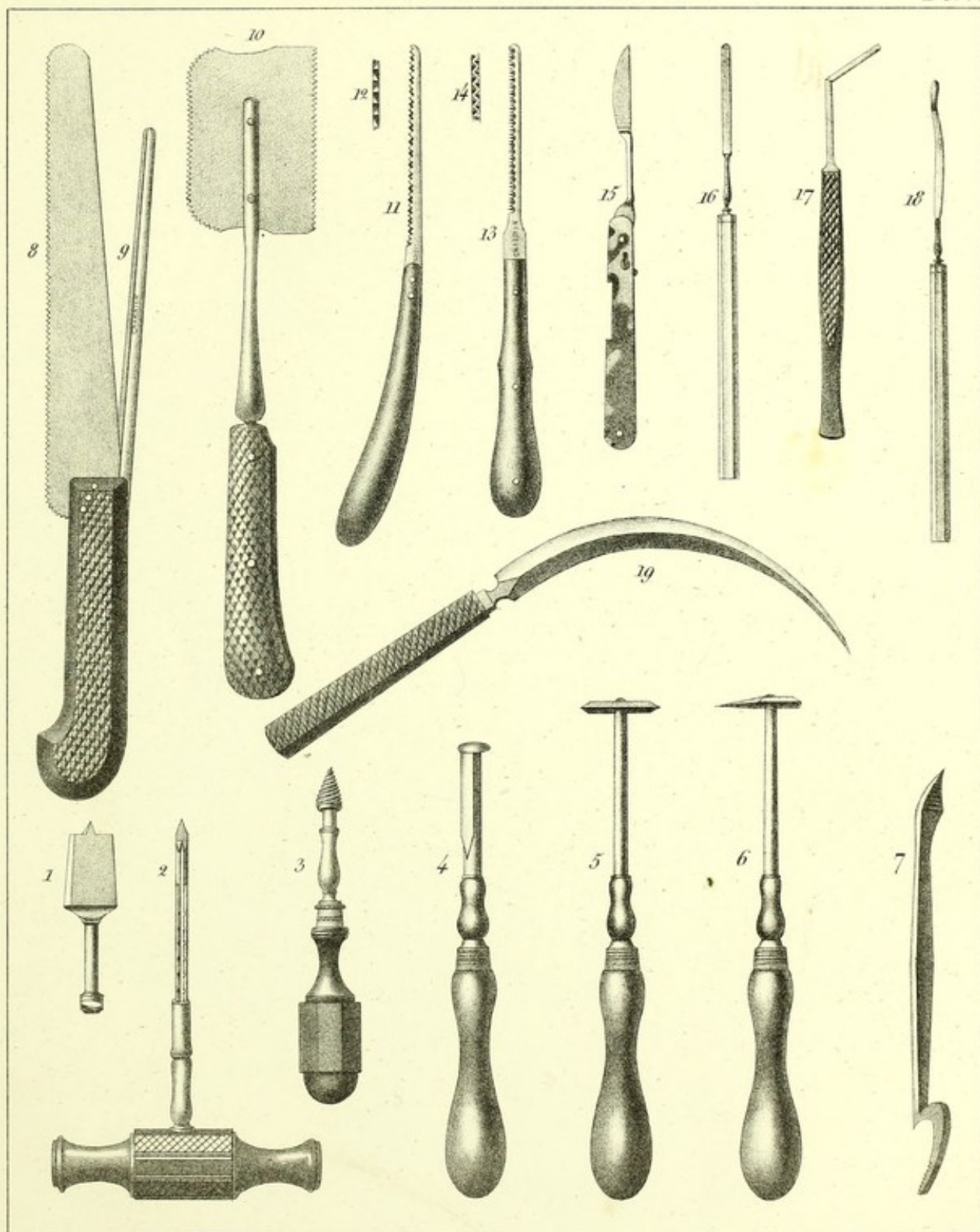
P L A T E V I I .

EXSECTIONS.—TENOTOMY.

- Fig. 1. The exfoliating trephine.
- Fig. 2. The shaft, handle or staff of a trephine.
- Fig. 3. The screw-drill (tire-fond) or turrel.
- Fig. 4. The lenticular knife.
- Fig. 5. The four-sided rasp.
- Fig. 6. Rasp with a point.
- Fig. 7. The elevator.
- Fig. 8. The saw with a movable back, 9.
- Fig. 10. The little hand-saw.
- Figs. 11, 12. The cultellaire saw of M. H. Larrey.
- Figs. 13, 14. The same of M. Raimbaud.
- Fig. 15. The tenotome of M. Duval.
- Fig. 16. The same of M. Bovièr.
- Fig. 17. The same of M. Stæss.
- Fig. 18. Another tenotome, with a blunt-pointed extremity, used by M. Guérin.
- Fig. 19. The curved amputating knife of M. V. Onsenoort.

VARIOUS INSTRUMENTS.

Pl. 7.



On Stone by F. Davignon.

Printed by L. Nagel.

Published by S. S. & W. Wood, New-York

PLATE VIII.

EXSECTION OF BONES.

Fig. 1. *Exsection of the Head of the Humerus.—Left Arm.—Process adopted by the author.*—In following this we make a large triangular flap, *h, h*, with its base above, and at the expense of the deltoid, which flap is then raised by the hand *i* of an assistant stationed behind. The surgeon, with his left hand, *g*, grasps the diseased arm *j*; divides on the head of the bone *a*, the same as for amputation of the limb, the capsule and tendons which surround it; luxates the humerus, and exposes to view the glenoid cavity *b*; causes the borders of the wound *f, f*, to be separated apart or depressed; finally seizes, with his right hand *e*, the saw *c*, in order to apply its blade *d* on the body of the bone, as low down as is required by the disease, and then to make it move in a slightly oblique direction from below upwards.

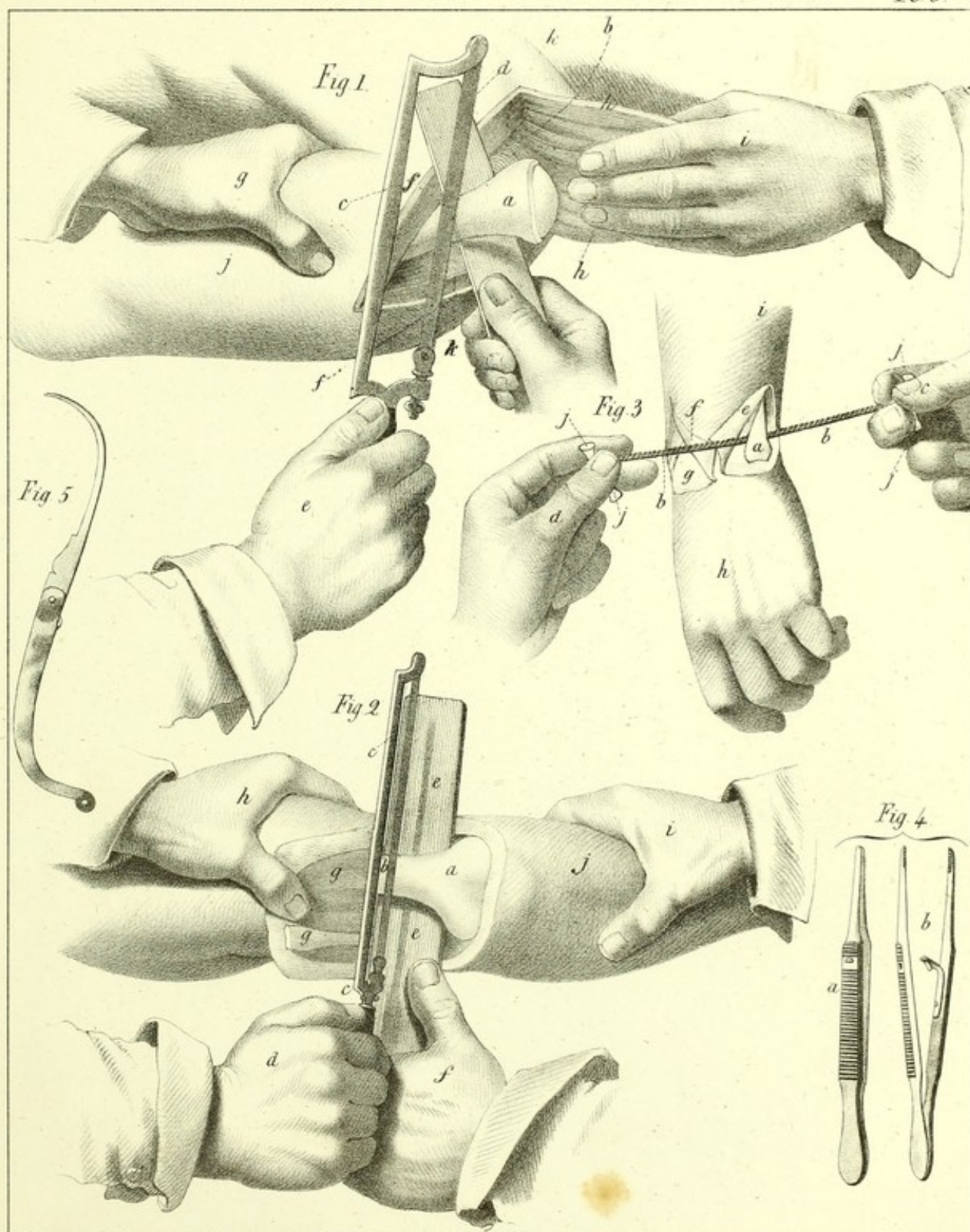
Fig. 2. *Exsection of the Lower Articular Extremity of the Humerus.—Ordinary process.*—The figure represents the left limb, and the patient is lying upon his belly. After having cut a quadrilateral flap, *g, g*, at the expense of the triceps muscle, which flap the left hand *h* raises up at the same time that it supports the arm, we detach the anterior muscular tissues in such manner as to be enabled to glide between them and the bone a plate *e, e*, of thin wood or paste-board, or even a simple long compress folded several times double, and which the hand *f* is charged with keeping in place. The saw *c, c*, is conducted in such manner by the hand *d*, that its blade *b* falls almost perpendicularly on the body of the humerus, while the hand *i*, acting on the fore-arm *j*, is prepared to adapt itself to its movements. Upon the supposition that it were required to excise also the extremity of the ulna and of the radius, there would be nothing more to be done than to prolong downwards the first lateral incisions, and to make a third from *a* to *j*, in order to have two lower flaps instead of one only, and then to perform on the fore-arm what we have just described on the humerus.

Fig. 3. *Exsection of the Carpal Extremities of the Fore-arm.—Process of Moreau.*—By means of an L incision we first cut on the dorsum of the limb *i* a triangular flap, *e*, or *f*. Having disengaged the contour of the ulna, *a*, from the soft parts, we glide under its deep-seated surface the dismounted saw *b, b*, either by means of a grooved sound, flexible probe, or curved needle. To put this saw into action, it is necessary that the hand *c* of the surgeon, and the hand *d* of the assistant, which hold the handles *j, j, j, j*, should move in concert with each other, and that the hand *h* of the patient should be directed outwards and backwards by the assistant who has charge of it. We proceed, in the last place, but in the same manner, to the extraction of the head *g* of the radius.

FORCEPS AND TENACULUM.

Fig. 4. This forceps, which by means of a hook or opening seen at *b*, is very readily shut up, as is shown by fig. *a*, and is at the same time opened with great facility. It is preferable to most of the slide or catch-forceps destined for the same purpose. It is found at the shop of M. Charrière.

Fig. 5. Tenaculum, such as is used in France.






PLATE IX.

CATARACT AND ARTIFICIAL PUPIL.

Fig. 1. *Cataract by Extraction at the moment when the operator is terminating the section of the Cornea.*—*a*, The right hand of an assistant, the forefinger of which, *b*, raises the upper eyelid, while the other fingers remain spread out upon the temple. *c*, The left hand of the surgeon, holding the keratotome *d*, in the manner of a writing-pen, and directing it slightly from above downwards, while the little finger of the right hand *h*, pressing upwards upon the ophthalmostat *e*, (of the author,) depresses the lower eyelid, and steadies the globe of the eye. The keratotome *d* traverses the anterior chamber through and through. The cutting edge *f*, of its point *g*, has emerged from the eye and arrived at the great angle, having glided under the border of the nail of the middle finger of the left hand, which nail thus serves for it as a point d'appui, and at the same time protects it from the surrounding tissues, until the section of the flap of the cornea is completed.

Fig. 2. *Cataract by Depression.*—The upper eyelid is raised up by the forefinger *b* of the left hand of an assistant, while the body of the same hand *a*, supports the head of the patient. The lower eyelid is depressed by the forefinger *d* of the left hand *c* of the surgeon, who spreads out the other fingers *e* upon the root of the nose, while with his right hand *f* he puts into movement the needle *g*, the handle of which *h* is supported on the forefinger of the same hand. This is at the moment when the needle having arrived into the pupil and lacerated the anterior capsule of the lens in a circular direction, is applied by its concavity upon the crystalline, in order to draw it downwards, backwards and outwards, by a simple vibratory or oscillating movement.

Fig. 3. *Artificial Pupil.—Corotomy and Corectomy.—Process of the author.*—The knife *a*, introduced in the same way as for cataract, has passed through and through the cornea. When its point has arrived at *b*, the flap *e* of the iris is found to be completely detached. The reason why the back of the knife is seen here is, because the natural pupil has been preserved. In withdrawing it from *b* to *a*, we take care not to cut through the point *d* of the flap of the cornea, which still remains adherent to the sclerotica. The globe is steadied by the rounded point *c*, of the ophthalmostat, 4.

Fig. 5. Physick's forceps, such as I have modified it.

Fig. 6. The pupil forceps of Dr. Maunoir.

Fig. 7. The small ocular forceps.

Figs. 8, 9. M. Furnari's lance for incising the cornea.

Fig. 10, 4. The ophthalmostat of the author, [Prof. Velpeau.]

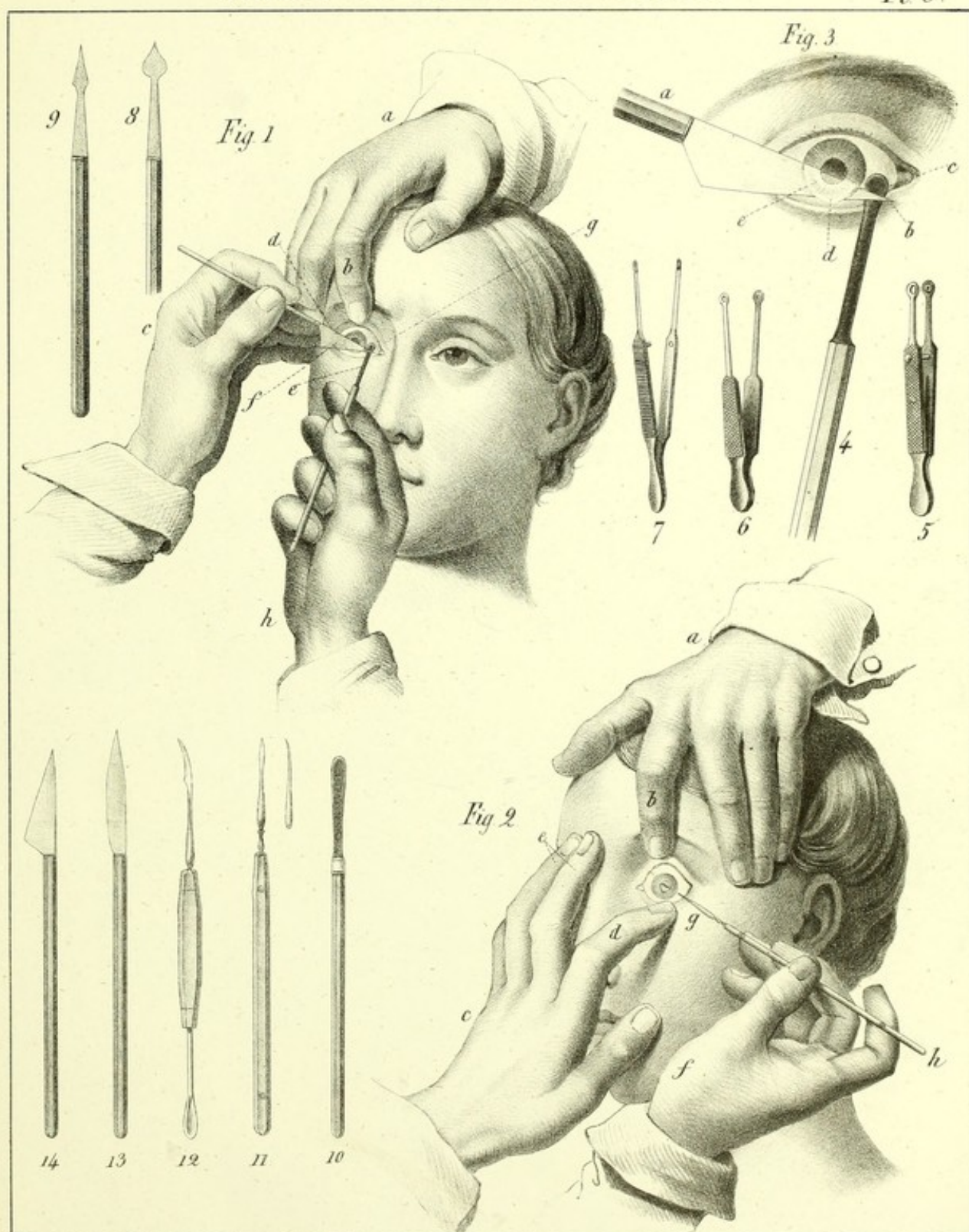
Fig. 11. Dupuytren's needle, seen on its face and side.

Fig. 12. Tenon's serpette, as modified by Boyer.

Fig. 13. The keratotome of Wenzel.

Fig. 14. The keratotome of Beer.





On Stone by F. Davignon.

Printed by L. Nagel.




PLATE X.

FISTULA LACHRYMALIS.

Fig. 1. This figure represents the first stage of the operation. The surgeon, with his right hand, *c*, withdraws the bistoury *e* from the wound *g*, while with his left hand, *d*, he inserts the canula *i*, by means of the stylet *f*. An assistant, stationed behind, steadies the external palpebral angle *h* with his left hand *b*, and with his right hand *a* supports the forehead of the patient. The whole process should be conducted in such manner that the canula shall penetrate in proportion as the bistoury is being withdrawn in the same direction in which it entered, and that it should also glide rather upon the back or posterior part of the blade of the bistoury than upon its anterior portion.

Fig. 2. The catheter of M. Serre of Alais.

Fig. 3. Catheter of M. Pirondi.

Figs. 4, 5, 6. Lead nails for dilating the nasal canal.

Fig. 7. Desault's probe, to clear out the nasal canal through the canula of Pamard.

Fig. 8. The probe of Anel.

Fig. 9. The syringe of the same author.

Fig. 10. Copper capillary wire, which is kept in the tube of the syphon to prevent its becoming obstructed when not used.

Fig. 11. Long canula to inject the Eustachian tube through the nasal passages.

Fig. 12. The syphon detached from its syringe.

Fig. 13. The canula of Laforest.

Fig. 14. Dupuytren's right-angled shape mandrin or stylet, designed for introducing the different descriptions of canulas that have circular rims, [bourrelets.]

Fig. 15. The blunt hook of Desgranges, convenient for withdrawing the conducting thread or stylet from the nasal fossæ.

Fig. 16. Jurine's instrument.

Fig. 17. The plates of Cabanis, destined for the same uses. They are half opened, and in the state in which they are placed to withdraw the stylet as soon as it is seized by them.

Fig. 18. The canula and spring of Pamard.

Fig. 19. Another mandrin mounted on an ebony handle.

Fig. 20. Lecat's sound, which is introduced through the nose, and the beak of which, having an eye, receives the thread in the ocular angle, in order to draw from above downwards the dilating meche, into the nasal canal.

Fig. 21. The canula of Foubert, such as it has been preserved in the cabinets of the Faculty. There exists in the museum of the School of Medicine a golden one, which has a bourrelet on its upper part, and has much more resemblance than the preceding to that of Dupuytren.

Fig. 22. Another canula of the same kind, but straight and much smaller.

Fig. 23. The perforator of M. Montain.

Fig. 24. A canula of the natural size, with a bourrelet or rim at its upper part.

Fig. 25. The canula of Pellier, as modified by M. Malgaigne.

Fig. 26. A canula as modified by the author, [M. Velpeau.]

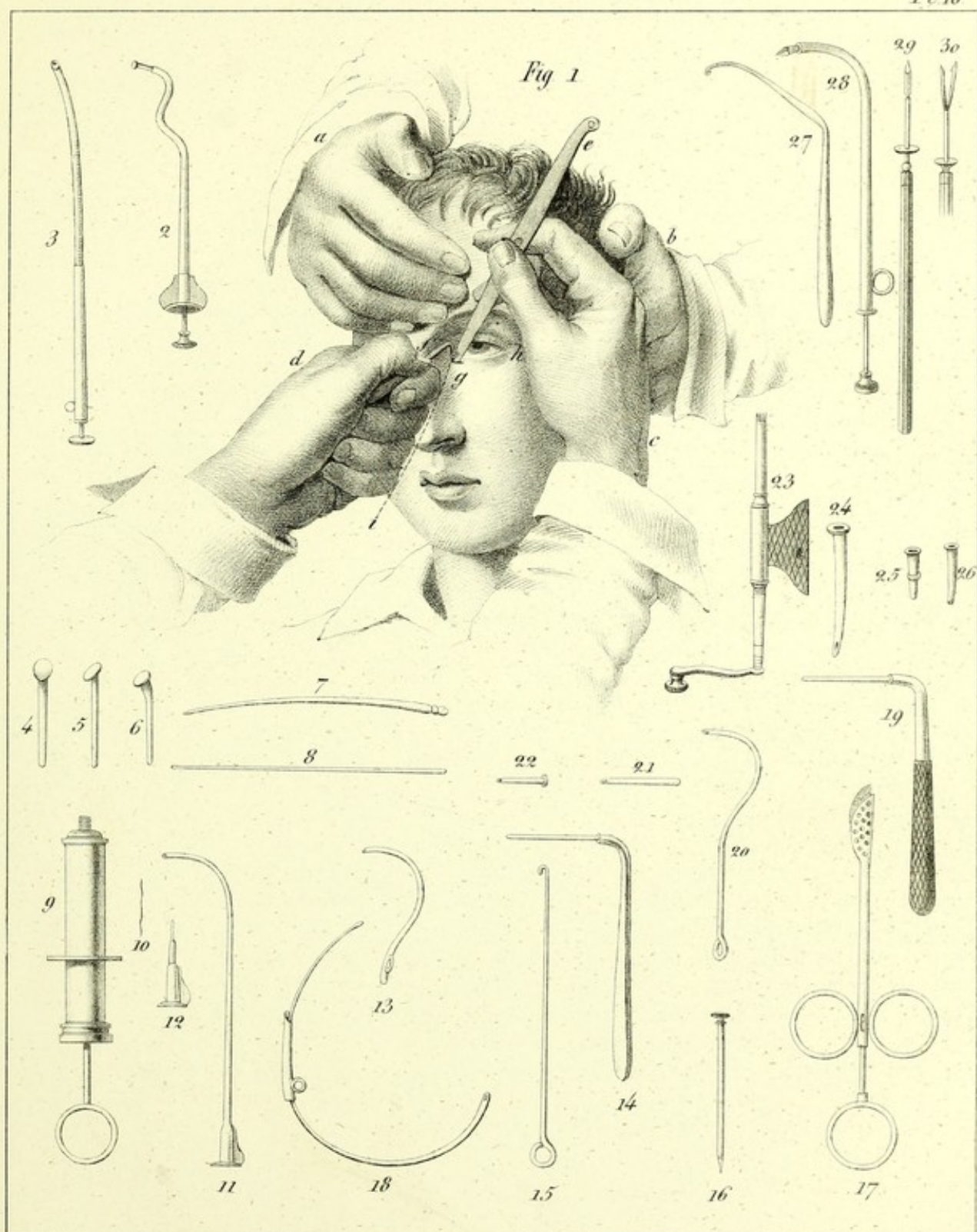
Fig. 27. The extracting hook of M. Cloquet.

Fig. 28. The instrument of M. Manec.

Figs. 29, 30. Needle of M. Gerdy, for the depression of the cataract.

FISTULA LACHRYMALIS.


PL 10.



On Stone by F. Davidson

Printed by L. Nagel

Published by S.S. & W. Wood, New-York.



PLAY THE X

CONSTITUTIONAL AND CIVIL RIGHTS AND ECONOMIC JUSTICE

THE PLAY THE X is a collection of essays and articles that explore the intersection of civil rights and economic justice. The collection is organized into three main sections: the first section focuses on the historical context of civil rights and economic justice, the second section explores the current state of civil rights and economic justice, and the third section offers solutions for addressing the challenges of civil rights and economic justice. The essays are written by a diverse group of authors, including scholars, activists, and policymakers. The collection is a valuable resource for anyone interested in the intersection of civil rights and economic justice.

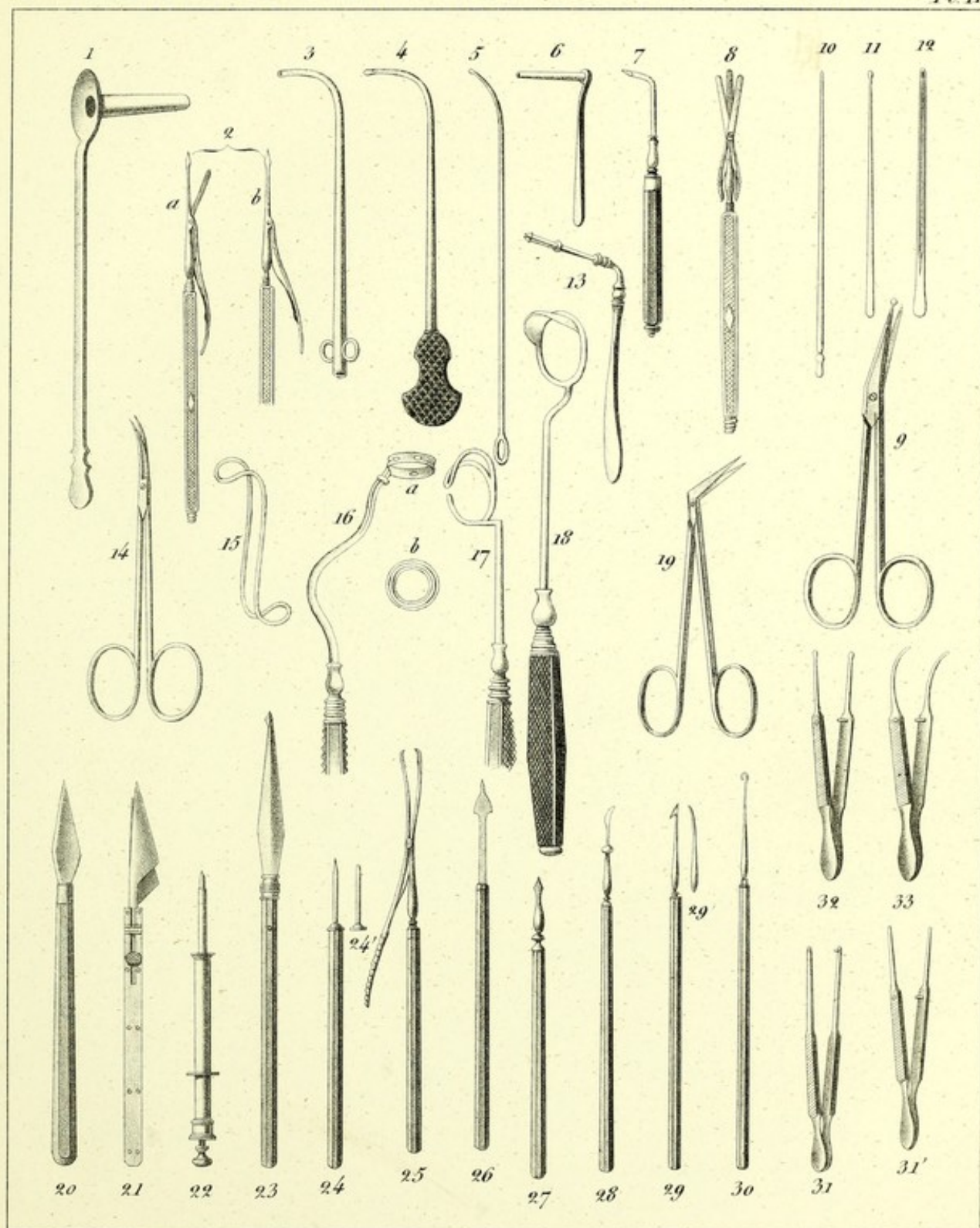
The first section, "Historical Context," provides a comprehensive overview of the civil rights movement and its impact on economic justice. It includes essays on the role of the federal government in the civil rights movement, the impact of the Supreme Court on civil rights, and the role of the private sector in the civil rights movement. The second section, "Current State," examines the current state of civil rights and economic justice in the United States. It includes essays on the impact of the 2008 financial crisis on civil rights, the impact of the 2010 health care reform on economic justice, and the impact of the 2012 immigration reform on civil rights. The third section, "Solutions," offers a variety of solutions for addressing the challenges of civil rights and economic justice. It includes essays on the role of the federal government in addressing civil rights and economic justice, the role of the private sector in addressing civil rights and economic justice, and the role of civil society in addressing civil rights and economic justice.

PLATE XI.

INSTRUMENTS FOR CATARACT, ARTIFICIAL PUPIL AND FISTULA LACHRYMALIS.

- Fig. 1. Protecting canula for cauterization of the os unguis.
Fig. 2. The needle-keratotome of the author.
Fig. 3. M. Gensoul's canula for cauterizing the nasal canal from below upwards.
Fig. 4. The solid sound of the same author.
Fig. 5. Another sound less curved and less commodious.
Fig. 6. Protecting canula for cauterizing the nasal canal.
Fig. 7. Pellier's punch (*poinçon*) for perforating either the os unguis or the lachrymal sac.
Fig. 8. The double keratotome of M. Carron du Villards.
Fig. 9. Button scissors for the pupil.
Figs. 10, 11, 12. Probes and grooved sound for clearing out the nasal canal from above downwards.
Fig. 13. Mandrin, or stylet, with an elastic and cleft head, for withdrawing Dupuytren's canula.
Fig. 14. Small scissors, concave on their border, for artificial pupil.
Fig. 15. Double silver wire, shaped into a double hook, and denominated Pellier's elevator, designed for raising the upper eyelid.
Fig. 16. M. Sanson's ring for cauterizing the conjunctiva around the cornea.
Fig. 17. The elevator of M. Luzardi.
Fig. 18. The ophthalmostat elevator of M. Fardeau.
Fig. 19. Pupil scissors of Dr. Maunoir.
Fig. 20. Keratotome of Richter.
Fig. 21. Double slide knife, or keratotome of Jæger.
Fig. 22. Kystitome of La Faye.
Fig. 23. The knife of Siegerist.
Fig. 24. Hey's needle, seen on its edge.
Fig. 24'. The same, seen on its face.
Fig. 25. M. Furnari's forceps for extracting the crystalline.
Fig. 26. Keratotome of M. Furnari.
Fig. 27. Straight, or lance-shaped needle, for incising, in various directions, the posterior capsule, after having extracted the crystalline, (Beer.)
Fig. 28. Instrument for breaking up the crystalline in the operation by keratonyxis. The border on its stem prevents it from entering too deep into the eye.
Fig. 29. The hook needle (*aiguille à crochet*) of Beer, seen on its face.
Fig. 29'. The same, seen on its edge.
Fig. 30. The *erigne* or *corioncion* of Walker.
Fig. 31. Wolf's teeth-forceps for the pupil.
Figs. 31', 32, 33. Various kinds of ocular forceps.

INSTRUMENTS for CATARACT, ARTIFICIAL PUPIL and FISTULA LACHRYMALIS. *Pl. II.*



On stone by F. Davignon.

Printed by L. Nagel.




PLATE XII.

I. STAPHYLORAPHY.

Fig. 1. The lips of the division *a, a*, have been excised, (*avivées*.) The three threads or sutures have been introduced. Their extremities *b, b*, hang out of the mouth, and their nooses are a little depressed towards the pharynx. Nothing more is to be done than to knot them, and thus close up the fissure.

Fig. 2. Angular scissors of M. Roux for commencing the excision of the fissure.

Fig. 3. Blunt-pointed bistoury, suitable for continuing from below upwards the incision begun near the uvula with the scissors.

Fig. 4. The needle-holder preferred by M. Roux. Its branches *a, a*, open in drawing upon the ring *b*, by means of the stem *c*, which traverses the handle, *f*, and by means of the button *d*. On the contrary, the branches are compressed together, and solidly hold the needle *e*, when we act upon this instrument in an opposite direction.

Fig. 5. The same needle by itself. Fig. 6. A needle used by M. Alcock at London in 1822.

Fig. 7. Needle of M. Ebel.

Fig. 8. Needle of M. Graefe, seen on its edge.

Fig. 9. The same, seen on its face.

Fig. 10. Another needle of the same author.

Fig. 11. The needle-holding forceps of M. Sotteau.

Fig. 12. Needle and needle-holder of M. Schwerdt, bent at an angle like the preceding. It is in other respects so constructed, that by pressing on the lateral stem *b*, its point *a* is opened, by means of the flexion of the spring *c*, which is thus brought near to the handle *d*.

Fig. 13. New needle-holder of M. Bourgougnon.

Fig. 14. Forceps of Graefe or Ebel.

Fig. 15. Uranotome of Dieffenbach.

Fig. 16. Knot-tightener of Graefe. While with one hand we draw upon the noose *a*, by its two branches *b, b*, the instrument, held by its handle, is pushed forwards with the other hand.

Fig. 17. The same instrument seen on its side.

Fig. 18. Needle and needle-holder of M. Donigès, curved, pierced, mounted on a handle, and strongly bent at an angle upon its handle.

Fig. 19. Principal needle-holder of M. Bourgougnon.

II. POLYPI.

Fig. 20. A knot-tightener, whose gutter (or groove) *b*, changes into a canal at its two extremities *a, a*.

Fig. 21. The knot-tightener of Desault, with its head *a* bent to an angle, and its plate *b* cleft.

Fig. 22. Another knot-tightener, which receives the ligature by its orifice *a*, and fixes it by means of its winch *b*.

Fig. 23. Polypus-forceps of M. Charrière. They are slender, elastic, and also exceedingly strong from their peculiar tempering, and crossed in such manner as to occupy but very little space in the opening of the nostrils.

Fig. 24. The chaplet knot-tightener of M. Mayor. *a*, A noose of thread passed into the piece *b*, and through the small balls *c, c*, the two branches *d, d*, of which thread, reunited in the cylinder *e*, are fixed upon the winch *f, g*.

III. EXCISION OF THE TONSILS.

Fig. 25. Tonsillotome of M. Fahnestock.

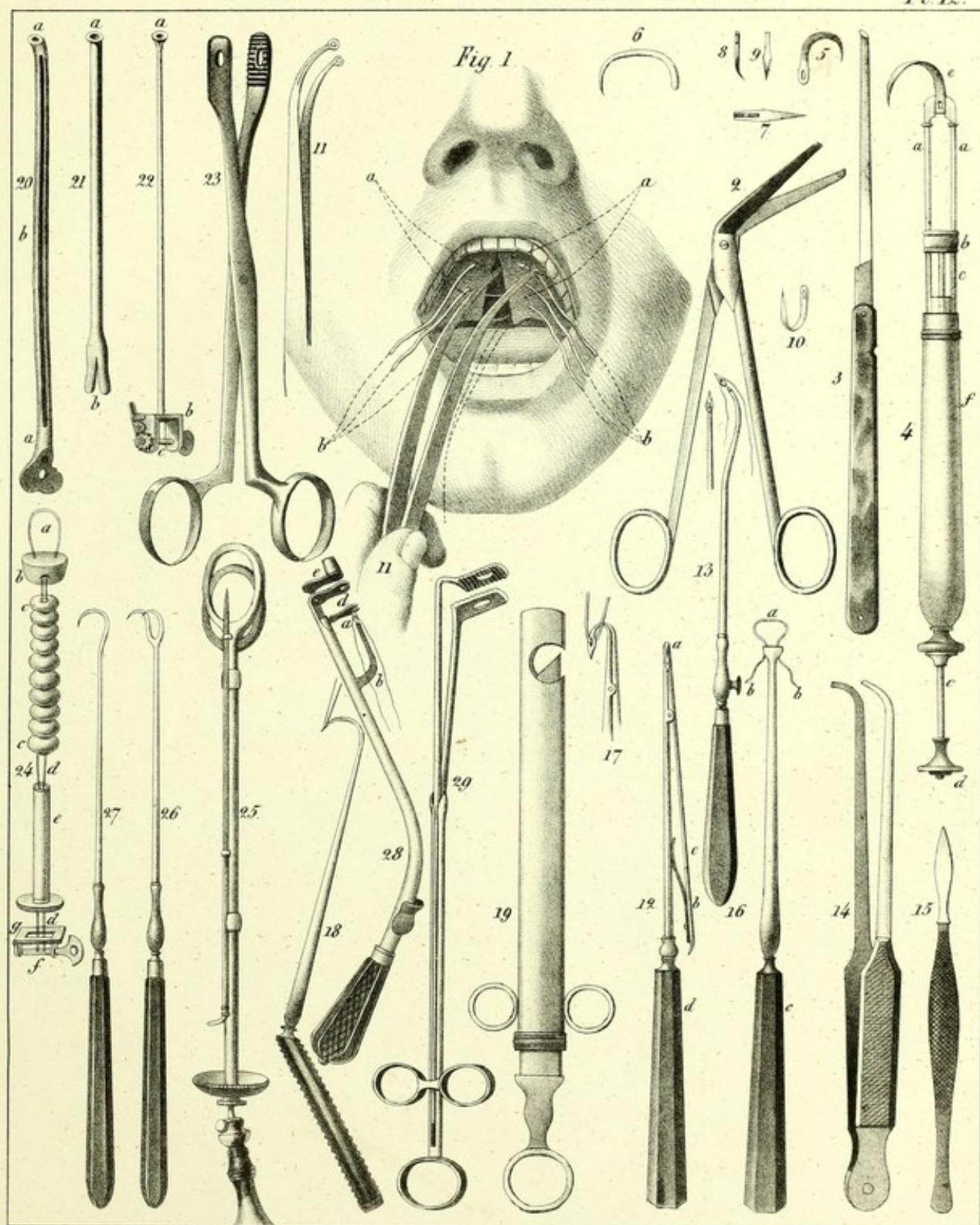
Figs. 26, 27. A simple erigne and double erigne.

Fig. 28. The kiotome of Desault.

Fig. 29. Tonsil forceps of M. Chaumet.

STAPHYLORAPHY — POLYPI of the NOSE.

Pl. 12.



On stone by R. Davignon

Printed by J. Nagel

Published by S. S. & W. Wood, New-York.




PLATE XIII.

I. TRACHEOTOMY.

Fig. 1. The head of the patient is slightly elevated. The lips of the wound are separated apart in order to expose to view more clearly the different layers which it is necessary to divide. The canula is placed with its concavity in front and downwards, as it was by M. Bretonneau on Mademoiselle Puységur. *a, a, a, a*, Angles and lips of the division of the integuments. *b, b*, Superficial layer of the cervical aponeurosis. *c*, Its deep-seated layer. *d, d*, The sterno-hyoid muscles. *e*, The lower rings of the trachea. *i*, The canula, with its two small rings, and seen at its larger extremity. *g*, One of the largest infra-hyoid veins divided. *h*, A portion of the thyroid body laid bare and pushed upwards by the canula.

Fig. 6. The instrument of Bauchot, which is a sort of flattened trochar, very short, and provided with a canula, and designed for performing the operation in a single movement by means of puncture.

Fig. 3. Two flattish canulas of M. Bretonneau, encased one within the other, and seen on their edge.

Figs. 4 and 8. Represent their openings and the rings seen in front.

Fig. 5. A small brush or swab (*écouvillon*) of metallic threads, used for cleansing out the interior of the canulas, when they are adjusted in their place, and for expelling all mucosities from them. (See Plate XV. fig. 4, Bivalve canula of M. Gendron, and the ordinary canula, fig. 5.)

II. ŒSOPHAGOTOMY.

Fig. 2. The division of the parts has been completed. The bistoury *b* is beginning to penetrate into the œsophagus *f*, facilitated as it is by the beak *g* of the sound *a*, which has been previously introduced through the mouth and pharynx, down as far as to the foreign body, with the view of making the œsophagus project outwards, and in order to disengage it from the enormous vessels by which it is surrounded. *d*, Angles and anterior lip of the wound of the integuments. *e*, The sterno-mastoid muscles on the outside, and the sterno-hyoid and sterno-thyroid muscles on the inside. *h*, The left lobe of the thyroid gland crossed by a branch of the superior thyroid artery. *i*, The omo-hyoid muscle, allowing a view of the portion *k* of the primitive carotid artery in front of the thumb of the right hand *c*, or on the back of the bistoury. *f, f*, The trachea lying on the anterior and left region of the œsophagus.

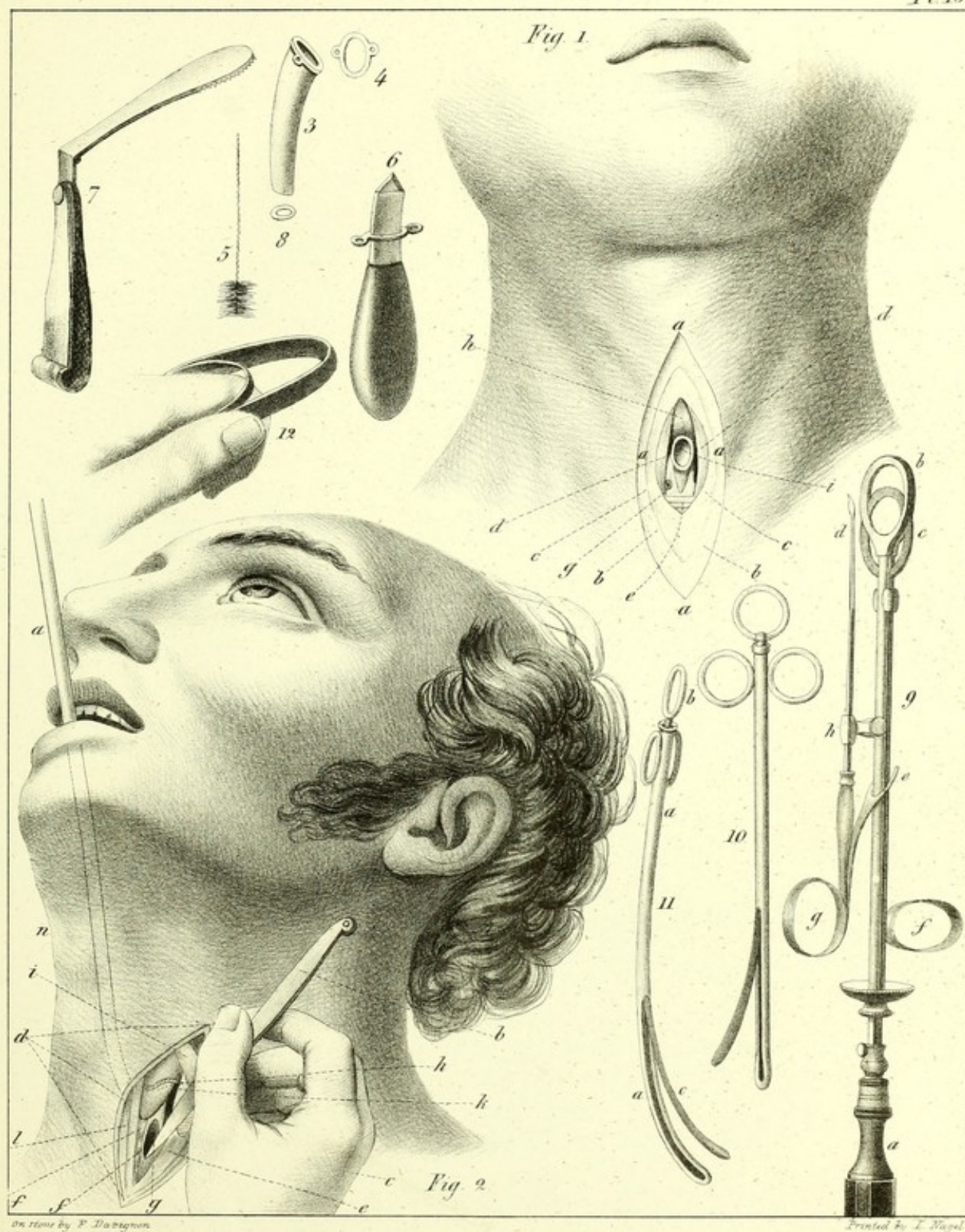
Figs. 10 and 11. Instruments of Vacca, one curved, the other straight. *a, a*, The conducting catheter. *b*, The ring of the elastic stem, which moves the branch *c*.

III. EXCISION OF THE TONSILS.

Fig. 7. Depressor of the tongue, (Colombat.)

Fig. 9. Tonsillotome of M. Velpeau, armed with its movable pique *d, g, h*.

Fig. 12. The inter-maxillary ring of M. Saint-Yves.






PLATE XIV.

HERNIA.

Fig. 1. A view of the track and envelopes of inguinal hernia. *a, a, a, a*, The integuments divided and thrown back on their external surface. *b*, A portion of the *fascia superficialis* dissected and drawn to the outside. *c'*, A flap of the aponeurosis *c* of the obliquus externus abdominis muscle turned down in order to expose to view the subjacent parts. *d*, A portion of the obliquus internus abdominis muscle *e*, cut and turned towards the median line. *f, f*, The *fascia transversalis*, the upper portion of which has been removed in order to show the *fascia propria* *g*, and the peritoneum. *h*, The epigastric vessels, passing underneath (au-dessous) and on the inner side of the cord, and situated in the tissue of the *fascia propria*, between the peritoneum and the *fascia transversalis*. *k, k*, The spermatic cord, traversing the *fascia transversalis*, which latter is purposely denuded from it a little lower down, the cord being enveloped by the cremaster muscle *j*, as far down as to the scrotum. *i*, The contour of the ring turned back and to the outside, and prolonging itself below, in order to form the fibrous envelope of the cord.

Fig. 2. A view of the femoral portion of the crural canal. A portion of the integuments has been removed. *g, g, g, g*, The contour of the wound which results from this incision of the integuments. *b*, The *fascia superficialis* raised up. *a, a, a*, The falciform layer of the *fascia lata*. *d, d, d*, Venous branches, proceeding to join the femoral vein *e*, through the opening *c* of the aponeurosis. *f*, Dotted lines, showing the track of the femoral artery. *h, h, h, h*, Contour of the anterior opening of the crural canal.

INSTRUMENTS.

Fig. 3. Pott's bistoury.

Fig. 4. Cooper's bistoury, whose concave border *b* has a cutting edge to the extent only of six or eight lines at *a*.

Fig. 5. The enterotome of M. Raybard.

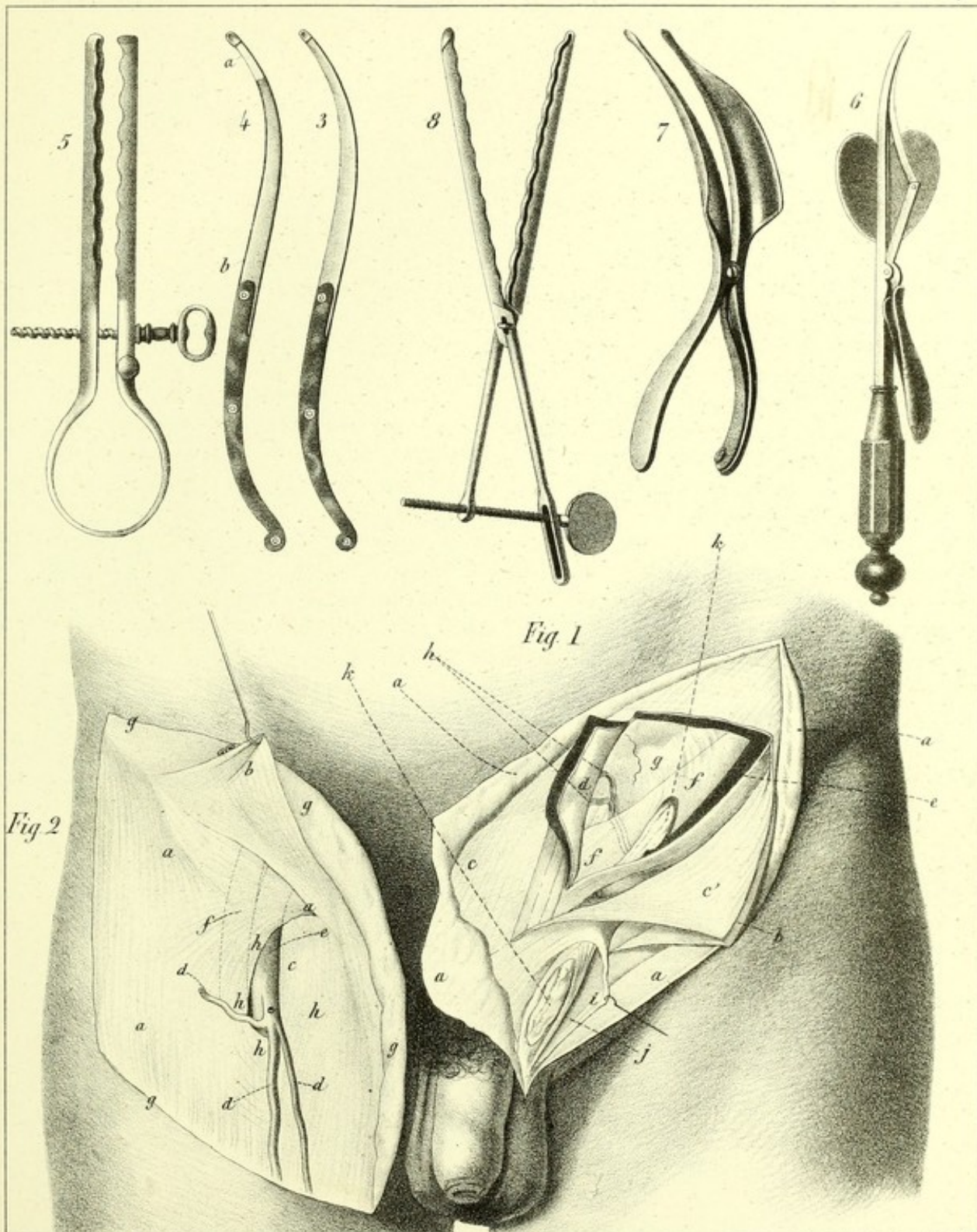
Fig. 6. The hernial bistoury of Le Dran.

Fig. 7. The dilating gorget of Le Blanc.

Fig. 8. Dupuytren's enterotome for artificial anus.

HERNIA.

Pl 14



Drawn on stone by F. Davignon

Printed by J. Bagel.

Published by S.S. & W. Wood, New-York.

PLATE VII

THE ORIGIN OF THE

The first of the three figures (Fig. 1) shows the origin of the three main branches of the tree. The second (Fig. 2) shows the origin of the three main branches of the tree. The third (Fig. 3) shows the origin of the three main branches of the tree.

The first of the three figures (Fig. 1) shows the origin of the three main branches of the tree. The second (Fig. 2) shows the origin of the three main branches of the tree. The third (Fig. 3) shows the origin of the three main branches of the tree.

Fig. 1. The origin of the three main branches of the tree.

P L A T E X V .

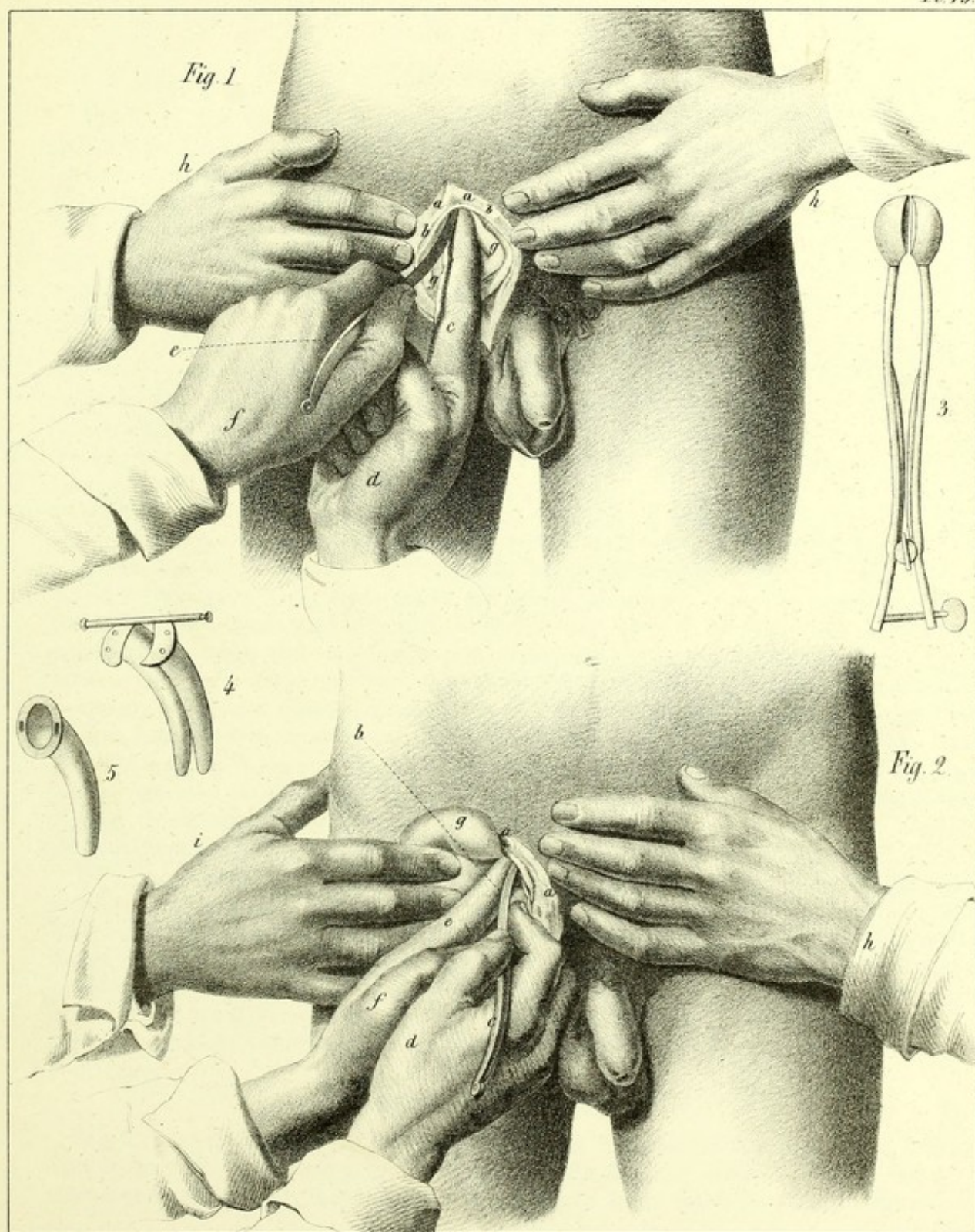
THE OPERATIONS FOR HERNIA.

Fig. 1. *Inguinal Hernia*.—*The right side*.—(See Vol. III.)—The skin and subjacent tissues, *a, a*, which have been freely incised, are strongly pushed aside by the hands *h, h*, of the assistant, who draws aside, in the same manner, the sac *b, b*. With his left hand *f* the surgeon glides Pott's bistoury *e* under the upper and outer angle of the ring, in order to incise upwards and outwards. The forefinger *c* of the right hand *d*, which supports the back of the instrument, is at the same time made to depress the intestines *g, g*. On the left side it would be the right hand which would conduct the bistoury, and the left forefinger which would push back the intestines.

Fig. 2. *Crural Hernia*.—*The right side*.—(See Vol. III.)—The hernial envelopes *a, a*, having been divided in the direction of the fold of the groin, are drawn to the inner side by the hand *h* of an assistant, who depresses, in a contrary direction, the intestines *g* with his other hand *i*. The cutting edge *b* of the bistoury *c*, held in the right hand *d*, in a direction almost horizontal, is placed upon the concave border of Gimbernat's ligament, which border it incises from without inwards, and slightly from above downwards. The forefinger *e* of the hand *f* pushes the intestines aside, and accommodates itself to the action of the instrument.

Fig. 3. The enterotome of Delpech.

Figs. 4 and 5. Canulas for the trachea. (See Plate XIII.)



On Stone by F. Davignon.

Printed by J. Nagel.

PLATE XVI.

INTESTINAL SUTURES.

Fig. 1. A, *The Glover's Suture*.—The borders of the wound situated *lengthwise*, with the gut, are turned inwards, after the process of M. Lembert. The two ends *b, b*, of the thread are to be brought forward and fixed outside, or are to be cut off very near the intestine, should we adopt the plan of leaving everything in the belly.

B, The same form of wound united together by the *suture of Le Dran*, whose borders *a* are also turned inwards. The nooses *b, b, b, b*, of the ligature, which are first rolled together separately, are afterwards seen to be all united together in *c*, which forms a cord, and which is to be fastened outside.

C, A complete section or division through the intestine. In place of invaginating them according to the method of M. Jobert, the two ends *f* of the intestine *b, b*, are simply turned inwards upon their mucous coat, according to the process of M. Lembert, (see above.) Three points *c* of the free suture unite the divided gut. The mesentery *a* has been divided transversely in a direction parallel with the vessels *d*, in order to give greater facility to the manipulations upon the wound of the intestine.

D, Transverse section or division of the gut, through and through, as in the last, (C.) The suture here is made with the three metallic rings of M. Denans, placed within the gut. These rings are here of gum-elastic. *a*, The central or internal ring, the external surface of which is perceived through a slight separation of the lips of the wound. *b, b*, The ends of the intestine, each of which is folded inwards upon a distinct ring, after which these ends are brought into approximation upon their rings, and thus maintained, supported as these ends are, upon the internal ring. *c*, A noose of thread which, after having passed through the interior of the innermost ring, pierces the intestine externally to the other two, and has its two ends firmly knotted, so as to keep the three rings close together. We see at *G*, one of the ends *e* of the divided intestine provided with its appropriate ring, and the serous or external surface of the end of the gut doubled or turned in upon the inner surface of the ring. *f*, The other end of the intestine, also turned in upon its appropriate ring, as in the last, exhibits also a portion of the common or internal ring *d*, on the point of being introduced into *e*, in order to terminate the operation.

E, A longitudinal wound of the gut, treated by the process of M. Raybard. A plate of thin wood or of gum-elastic, traversed in its middle by a noose of thread *i, i*, is to be first prepared. This plate is then to be glided into the intestine, the contour and position of the plate being designated by the dotted line *e, e, e*. Its thread is immediately passed from within outwards, in such manner as to perforate through the walls of the belly at *f, f*, before the extremities *f', f'*, of this thread are tied or twisted together. *a, a*, The right lip of the intestinal wound. *b, b*, The left lip of the same wound. *g, g, g, g*, The borders of the division through the walls of the belly.

LITHOTRITIC INSTRUMENTS.

Fig. 2. The straight catheter of Gruithuisen. *a, a*, The body of the catheter. *b*, The extremity of the stylet or mandrin *g, g*, uniting at *e* with the catheter, and moved by the ring *c*. *f*, A vacant space left to show that the instrument is shorter in the figure than in the original.

DESCRIPTION OF PLATE XVI—CONTINUED.

Fig. 3. The same catheter, with its mandrin terminated in the crown of a trephine *a*, for the purpose of breaking up calculi in the bladder. This mandrin, which three round pieces of leather *d, d, d*, prevent from deviating in the tube, has at its extremity *c* a pulley which receives the cord of the bow. The opening *b* is for the purpose of giving exit to the particles of the calculus, in proportion as they are detached from the principal stone. *e*, The space above mentioned.

Fig. 4. In fig. 4, the mandrin, which terminates in a spear or lance-shaped point *b*, also has a pulley at its extremity *c*, and contains within it a noose *a, a*, of brass wire, the two ends of which *d, d*, are seen at the other end of the instrument. *e*, The space above mentioned.

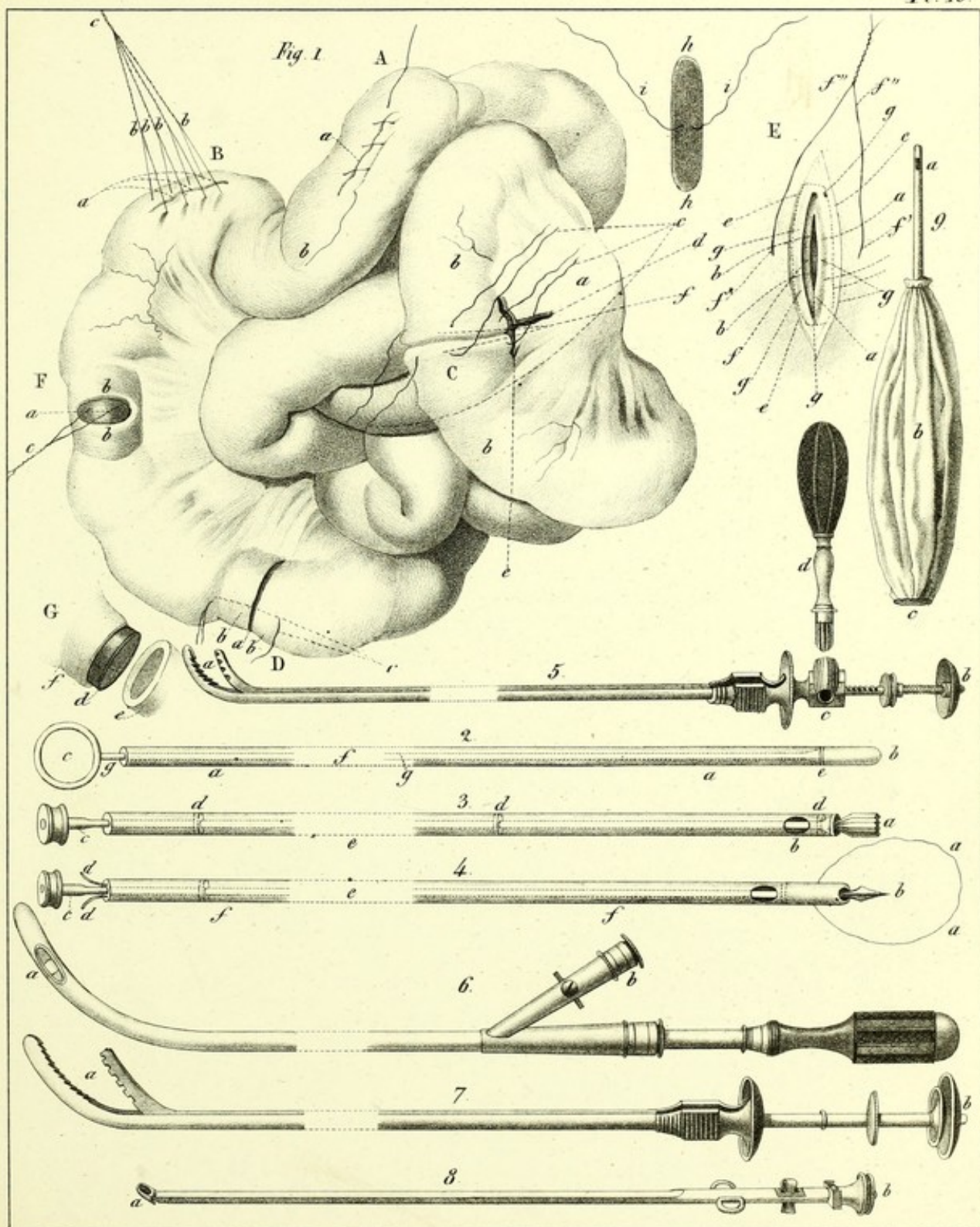
Fig. 5. The lithotritor *a, b, c*, of M. Charrière, that is, the *pignon-lithotritor*, with its key D.

Fig. 6. The *magazin catheter* of M. Leroy or M. Heurteloup.

Fig. 7. The *percussor* (percuteur) of M. Heurteloup, simplified.

Fig. 8. The *articulated scoop* (curette) of M. Leroy.

Fig. 9. The valve-canula of M. Raybard for empyema.



On Stone by F. Dartignou

Printed by L. Nagel.

Published by S. S. & W. Wood, New-York




PLATE XVII.

LITHOTRITY.

Fig. 1. *The method of M. Civiale.*—The patient is laid in a horizontal position, with his seat raised up by a cushion, and his legs half-flexed out of the bed. The calculus *b*, embraced by the three-branched forceps *a, a, a*, is seen through the bladder, at the moment at which the head-drill (foret-à-tête) *r* is beginning to perforate it. The left hand *q* of the surgeon keeps it steadily firm in the one direction against the external canula *s, s*, which latter, moreover, is fixed by the head *c* of the mandrel-lathe, and in the other direction on the free portion *f* of the litholabe, while his right hand puts the bow in motion. *m*, A portion of the rod of the drill, which is inserted by degrees into the protecting canula or sheath provided with its leather circular box *e*, in proportion as the twisted or cork-screw spring (ressort on boudin) concealed in the upper branch *k, l*, of the mandrel, pushes its free portion, and that the bow acts on its pulley *n*. *b, b*, The lower part of the mandrel, which an assistant holds solidly with his two hands *o, o*, placed underneath, and on which glides the portion *h*. The pressure-screw *j* is for the purpose of arresting, when we wish, the expansion of the cork-screw spring which presses against the drill, and the screw we notice at *i* is designed for adjusting the two portions of the instrument against each other, in the same way as the one marked at *d* fixes the litholabe in the interior of the external or sheath-canula.

Fig. 2. The simple percussor of M. Heurteloup.

Fig. 3. The *volant stone-breaker*, (brise-pierre à volant.)

Fig. 4. The duck-billed screw and percussion stone-breaker—the screw at *b*.

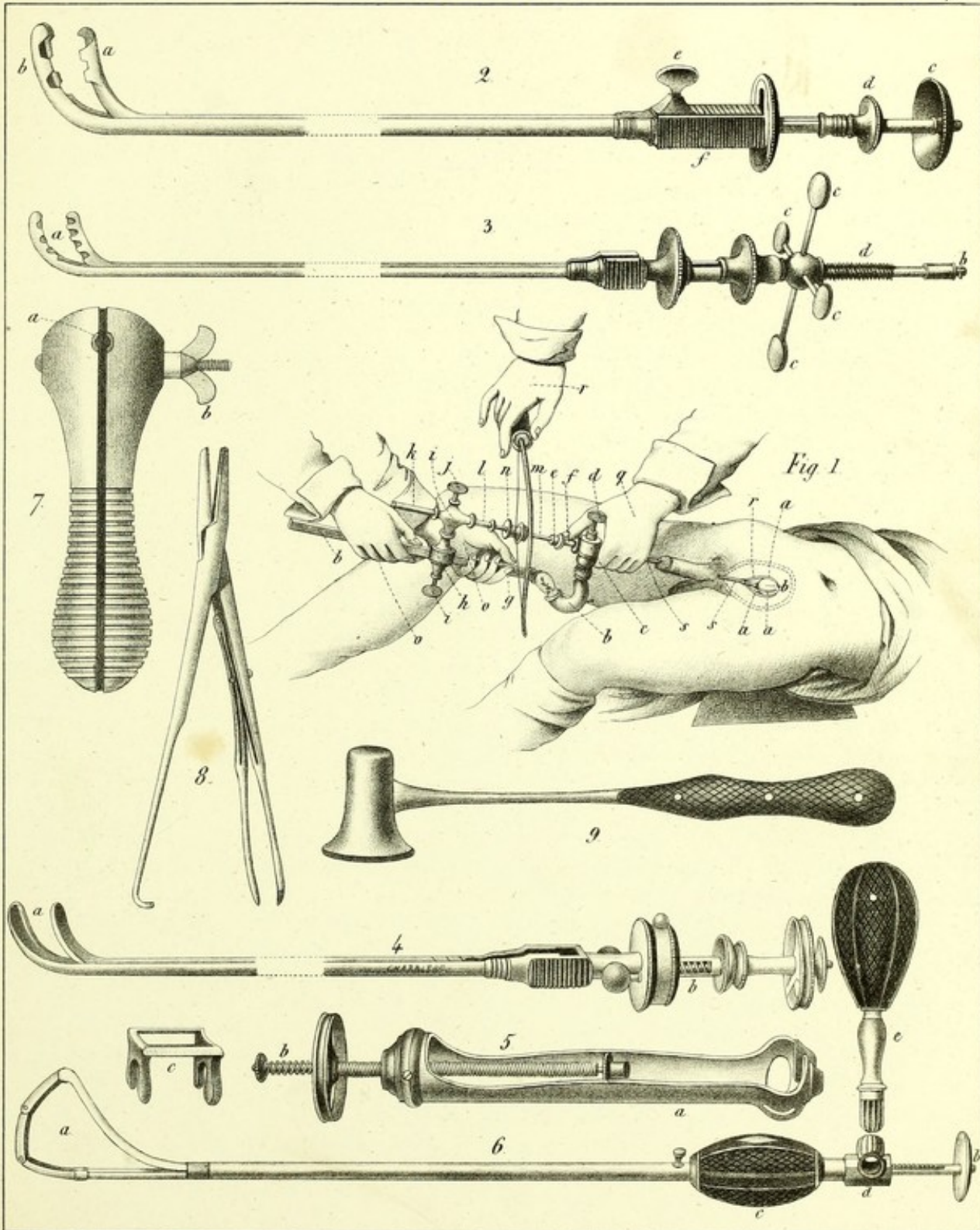
Fig. 5. The screw-socket or box which may be adapted to the preceding stone-breakers, and which resembles, in some measure, those that MM. Touzet, Leroy and L'Estrange have invented.

Fig. 6. The stone-breaker of M. Jacobson, modified as is seen at *b, c, d*, and *e*, by M. Charrière, after my suggestions.

Fig. 7. An ebony vice, which is opened or shut by relaxing or tightening the screw *b*. It is in its opening *a*, that we adjust that portion of the lithotritic apparatus which is embraced by the head *c* of the mandrel-lathe, as seen in fig. 1, but it possesses no merit.

Fig. 8. The urethral forceps of M. Civiale.

Fig. 9. The percussion hammer.



On stone by F. Davignon.

Printed by Nagel.




PLATE XVIII.

LITHOTRITY.—DISEASES OF THE URETHRA.

INSTRUMENTS OF DUCAMP.

Fig. 5. The apparatus open. *a, a*, The graduated gum-elastic conductor. Its vesical extremity is provided with a platina socket *b*, and its other end is fixed in a silver tube *c*. The cuvette *e* of the caustic-holder, pushed out of its conductor by the head of the forceps *d*. *f*, Represents the instrument shut up. The porte-caustic of Ducamp, which is still preferred by M. Pasquier, is of metal only near the ring and near the cuvette. A gum-elastic bougie constitutes its middle portion. In fig. 8, we see the exploring bougie *a*, provided at *b* with moulding wax, fixed on the portion of the instrument not graduated.

Fig. 1. The blunt-pointed stylette working in a catheter of gum-elastic, and designed for measuring the length of the contraction of the urethra, as had been already proposed by M. Bell and M. Van Welsnaer, for penetrating into the bladder in difficult cases. This stylette has been eulogized by M. Ségalas.

INSTRUMENTS OF M. LALLEMAND.

Fig. 13. A portion of the porte-caustic sound isolated.

Fig. 12. The instrument complete and open. *a, a*, The sheath, made of platina and provided with its running ring. *b*, The button, which may be removed at pleasure, and which allows of our pushing out or drawing in the button-cuvette *d* of the porte-nitrate. *c*, a small ball armed with a pressure-screw to graduate the movements of the central stem.

Figs. 19 and 21. The articulated mandrin of M. Tanchou, for straightening out the urethra and depressing the prostate. In fig. 21, it is seen on its side, while in fig. 19 we have its dorsal or concave face.

Fig. 14. A conical, dilated, emplastie bougie.

Fig. 15. A gum-elastic conical bougie, which is not dilated.

Figs. 18 and 20. Forceps for extracting small calculi from the urethra, or even from the bladder. We push it in shut up, as in fig. 20, by means of the ring, *a*. When it is open [as in fig. 18] and we wish to shut it up, all we have to do is, to draw back its root, *b*, into the canula, *c*, *c*.

Fig. 16. The forceps-head (seen edgewise) of the same part, seen [obliquely] at *d*, fig. 5.

Fig. 17. The antero-posterior porte-caustic of M. Leroy.

Fig. 2. The curved scarificator with one blade only, otherwise called the simple *uretrotome* of M. Ricord.

Fig. 10. M. Tanchou's conical dilated scarificator, with three or four cutting blades.

Fig. 11. M. Stafford's scarificator, with a lancet-shaped head and point.

Fig. 3. The lentil-head explorer or bridle-cutter of M. Leroy.

Fig. 4. M. Barré's instrument for cauterizing from before backwards.

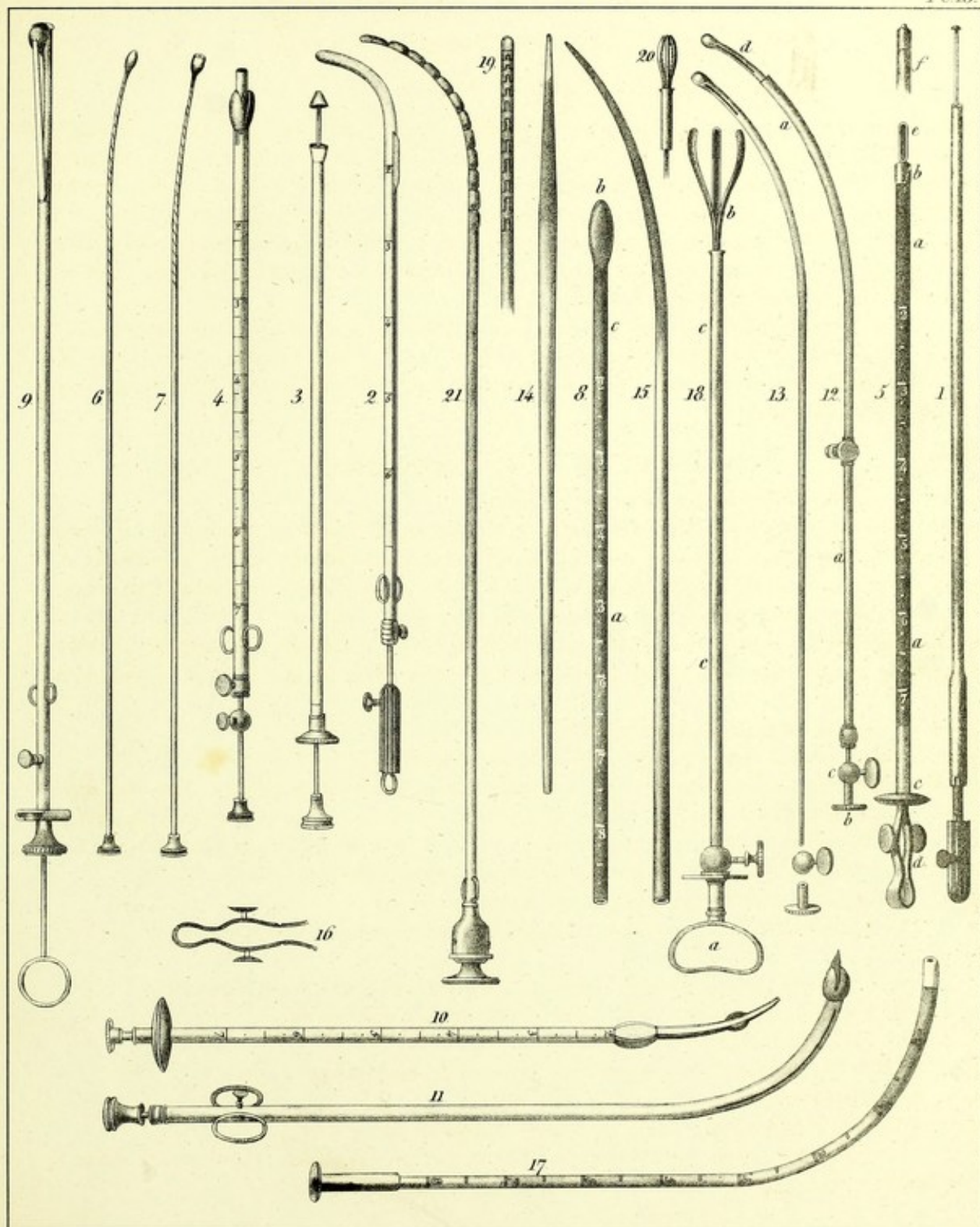
Fig. 7. A porte-caustic isolated from its sound, fig. 17.

Fig. 6. M. Leroy's button-headed stylette, made of twisted silver wire.

Fig. 9. An articulated scoop armed with a stylette, having a head to fix and extract calculi from the urethra, according to the process laid down by M. Bonnet, of Lyons.

DISEASES of the URETHRA.

Pl 18.



Des. from F. Dargren.

Printed by L. Nagel N.Y.

Published by S.S. & W. Wood, New-York.




PLATE XIX.

INSTRUMENTS FOR LITHOTOMY.

Fig. 1. A sound with an ebony handle, dilated in its curved portion, and having a button-like extremity, also with a wide [deep] groove upon it, like that of Dupuytren.

Fig. 2. The lithotome which Cheselden employed in the beginning.

Fig. 3. Pessary for the deviation of the neck of the womb.

Fig. 4. Desormeaux's bilboquet pessary.

Fig. 5. M. Tanchou's funnel-shaped pessary.

Fig. 6. The elytroidal pessary.

Fig. 7. Foubert's angulated knife for his lateral method.

Fig. 8. The lithotome of F. Come, as modified by M. Charriere. The handle of this has neither facettes (pans) nor numbers. We vary the degree to which its blade is opened, by advancing or drawing back the button which slides along the root of its bascule or movable piece, on the side of the instrument.

Fig. 9. The double lithotome of Dupuytren, the opening of the blades of which may be graduated and regulated in the same manner as in the last, and which lithotome has in various respects received important and ingenious modifications from the same cutler.

Fig. 10. M. Roux's gorget, scarcely differing from that of Scarpa.

Figs. 11 and 12. A male and female dilator, as formerly used in the great operation.

Fig. 13. M. Charriere's tenacula, (tenettes.) They are so constructed that in opening them to the greatest extent possible, they never make but a slight separation between the branches of their handle in the wound.

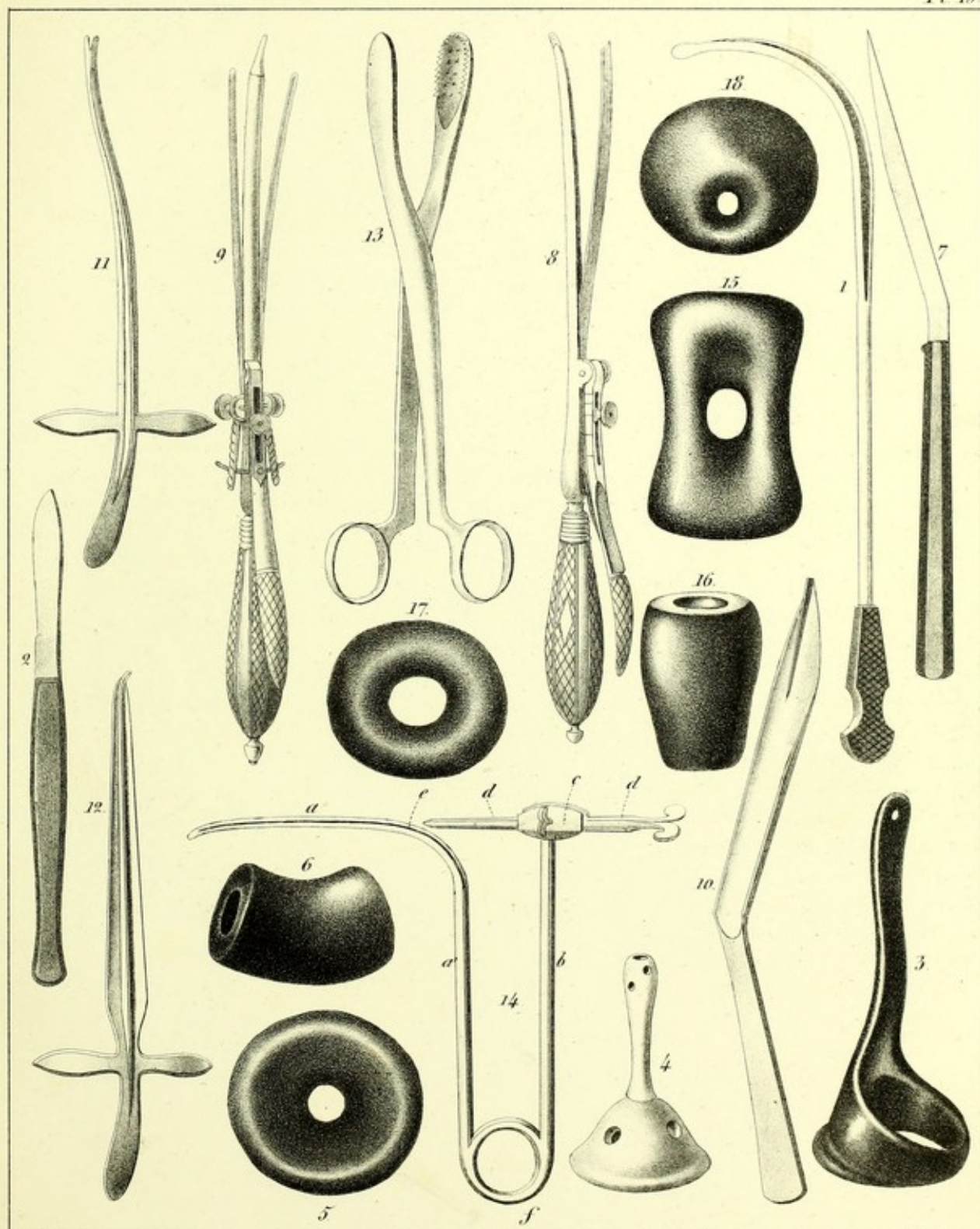
Fig. 14. Guerin's sound. *a*, its vesical and grooved portion, almost straight. *a'*, the portion which, being united at *f*, to the corresponding upright branch, *b*, terminates in the head, *c*. *d*, *d'*, a trochar which passes through the head, *c*, and at the perineum, falls at *e*, on the groove *a*, of the sound.

Fig. 15. Pessary in figure of 8.

Fig. 16. The *bondon* or bung pessary.

Fig. 17. The gimblet pessary.

Fig. 18. The funnel pessary (see fig. 5) seen at its lower end.



Engrav. by F. Dargatzis.

Designed by L. Magill, N.Y.

PLATE XX.

LITHOTOMY.

SURGICAL ANATOMY.—INSTRUMENTS.

Fig. 1. The object of this figure is to expose to view the parts that are wounded, or that may be wounded, in performing the operation of lithotomy. The subject is placed on his right side. All the left side of the abdomen, comprising with it the hip and breech [of that side] are removed, in such manner, however, that the separation is outside of the median line. The lithotome *j* of F. Côme, placed as it is, would almost unavoidably wound the termination of the rectum *l, l*, should we not take care to elevate its handle in withdrawing it. The uretro-anal triangle *k, k', k''*, represents, in its upper border *k, k'*, the line for entering [the bladder,] and by its lower border *k, k''*, the line for the withdrawal of the bistoury, which has performed the office of opening a passage for the concealed lithotome. The lower angle *k''*, [of this triangle] falls on the anus *i*, its deep-seated angle *k* on the neck of the bladder, and its anterior angle *k'* on the front part of the perineum. If the instrument were placed on the line *k, c, k'*, it would incise the prostrate without danger as far as to *b*; while in the position in which we see it, it would almost inevitably wound the intestine, if we should wish to extend the wound *c, c'*, to beyond *c'*. If the incision were commenced upon the membranous portion *d* of the urethra, it would present some advantages for the extraction of the calculus; but it would be difficult to avoid the bulb *e*, which has the appearance here of being strongly curved, in consequence of the remainder *f* of the urethra being left pendant, and the left corpus cavernosum being raised up.

The vesicula seminalis *u*, in reality runs no risk, except in recto-vesical lithotomy. Then, in fact, the incision, being restricted between the peritoneal cavity *n, n*, and the prostate *b*, when we follow the original process of M. Sanson, would expose to the risk also of wounding the vas deferens *p*, or the pouch, [i. e. the vesicula seminalis,] which runs along its outer side. The peritoneum *r, r, r, r, r, r, r*, which, from the front part of the rectum *l, l*, ascends upwards behind the bladder *a, a, a*, in order to line the posterior surface of the abdominal muscles *s*, leaves the ureter *o, o*, and the seminal duct outside of it and in the subjacent cellular tissue. They have been raised up in this plate, in order to expose the parts to the view better.

In hypogastric lithotomy, we first penetrate down to the cellular space *t*, and the bladder may afterwards be opened from the root of the urachus *v*, down to the sheath of the lithotome, opposite the section of the pubis *h*.

Fig. 2. The gorget of Hawkins. Its languette [or small blunt point] occupies the middle line of the termination of the blade, which last is regularly concave and cutting to a great extent.

Fig. 3. The sonde-à-dard of F. Côme.

Fig. 6. The cystotome-bistoury of M. Belmas.

Fig. 4. The lithotome-trochar of F. Côme. When the point *a* has arrived, by puncture, in the space *t* of fig. 1, the surgeon firmly holds its body *d* against the pubis *h*, while with the other hand he forcibly directs its bascule *b*, and cutting edge *c*, towards the umbilicus, as far as *s*.

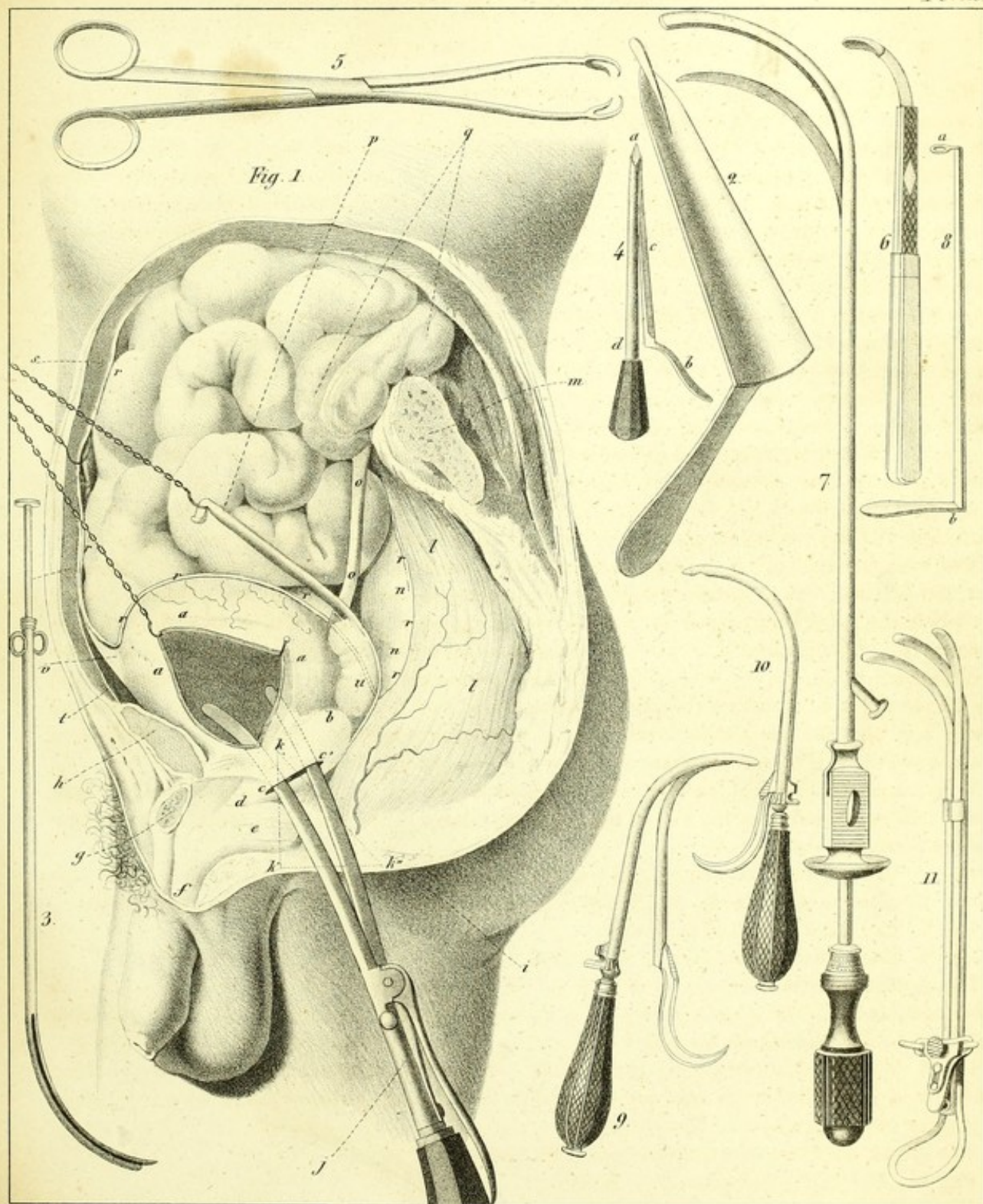
Fig. 8. The suspensory-crotchet of F. Côme. When its extremity *a* is once in the bladder, its handle *b* is confided to an assistant, whose duty it is to raise up the organ [the bladder] while it is being incised from above downwards.

Figs. 9 and 10. Suspensory cystotomes of M. Leroy.

Fig. 11. The tripliod suspensory of M. Leroy.

Fig. 7. The cystotome-sound of M. Leroy.

Fig. 5. Erigne-forceps of the author, for polypi and the neck of the uterus.



Des. et Grav. by F. Darnay.

Printed by L. Nodding.



PLATE XXI.

LATERALIZED LITHOTOMY.

Fig. 1. An assistant placed on the right, holds with his left hand *a*, the sound *c*, while inclining it a little to that side, while with his right hand *b*, he gently raises up the scrotum. The legs *i, i*, and the thighs *h, h*, flexed and separated apart, and strongly raised up, are held in this manner by two other assistants. With their hand *d, d*, they fix the knee *f, f*, against their chest; while with their other hand *e, e*, they embrace the foot *g, g*, by its inner border and plantar surface. The integuments and all the soft parts in this figure, are incised down to the bladder. The lithotome of F. Côme, introduced shut up, is opened, in order to incise the prostate from behind forwards. As the back of its sheath is made to rest against the right branch of the pubes, rather than directly against the symphysis or against the upper angle *q*, of the wound of the integuments, its blade thereby has almost a transverse direction towards the border *s*, and no longer towards the angle *r*, of that wound. Its bascule *n*, is held against the handle *m*, by the hand *k*, of the operator, who opens it in this manner, while his other hand *l*, embraces its articulation *o*, laterally, between the thumb and radial border of the flexed forefinger. The whole is a little more depressed here and more inclined than it should be, because the wound and instrument itself would otherwise have been, to a great extent, concealed by the hands of the surgeon.

INSTRUMENTS.

Fig. 2. *Form of the Ordinary Sound*.—Its plate, *a*, gives much more fatigue to the hand than if it were armed with a handle like that on Plate XVII. Its beak *b*, though blunted, is in no respect dilated, and its groove *c, c, c*, has much less width than in that of Dupuytren.

Fig. 3. Forceps for introducing lint, &c., upon the neck of the uterus.

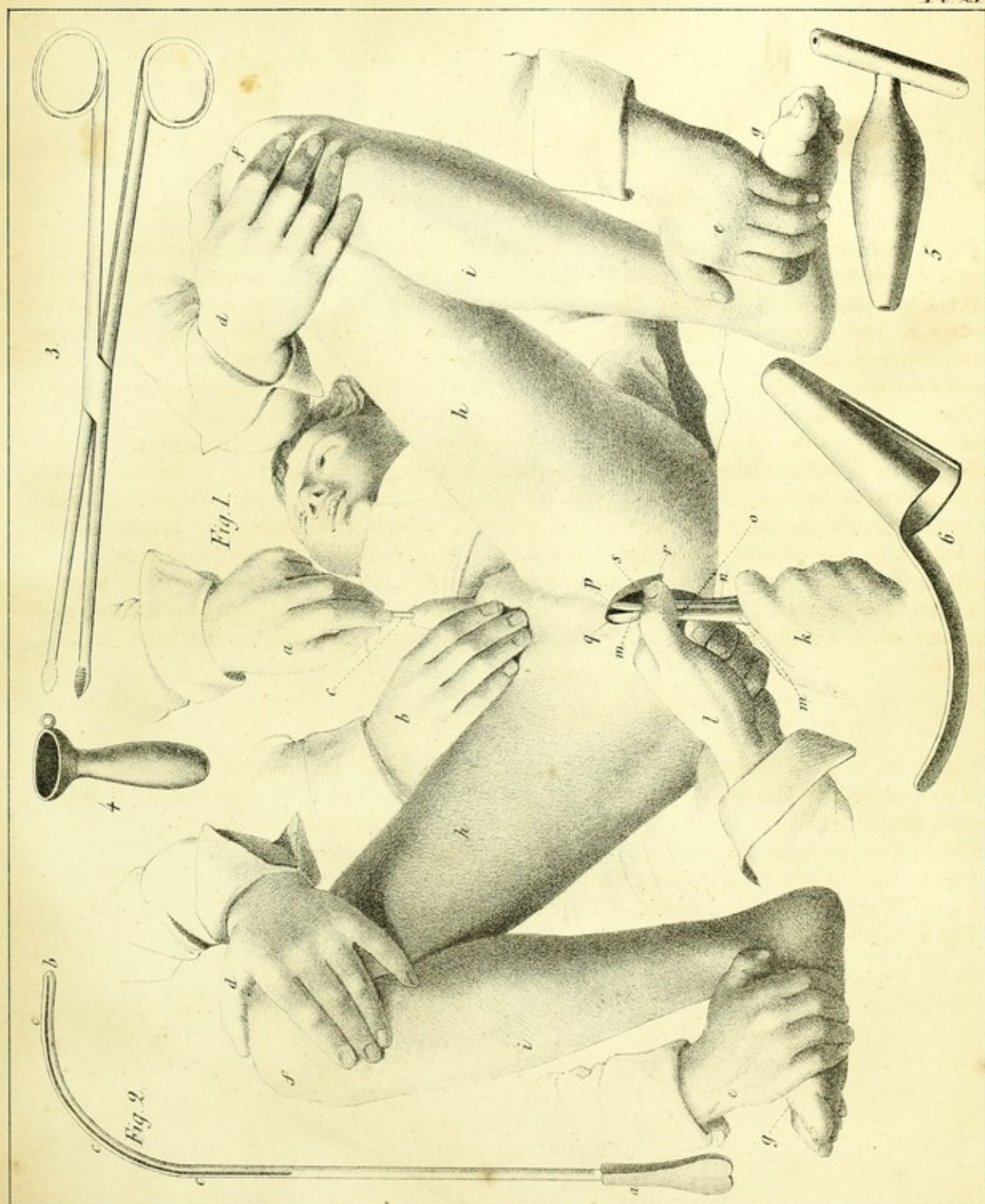
Fig. 4. Anal canula for preventing the rectum from re-contracting.

Fig. 5. The rectal spindle (fuseau) of English practitioners.

Fig. 6. Speculum ani, cleft on the back.

LATERALIZED - ANAL LITHOTOMY.

Pl 21



On Stone. by F. Darvagan

Printed by J. Neigel.

Published by S. S. & W. Wood, New-York.

PLATE XXII.

SEXUAL ORGANS OF WOMAN.

Fig. 10. *The trivalve and developing speculum of M. Charrière.*—This instrument appears to me the most perfect one we have at the present day. It is opened and shut up without the slightest noise, with the utmost ease, and almost imperceptibly.

Fig. 13. The speculum with four valves and a bascule, made by the same artist.

Fig. 14. Dugès' trellis (en treillage) speculum.

Fig. 11. A sort of piston, intended for introducing pomades or other medicated substances upon the neck of the uterus through the speculum, in which last, moreover, it may be used as a sort of mandrin or stylette.

Fig. 3. The womb laid open on its internal surface, and containing a pediculated polypus, upon which the ligature is being applied by the method of Desault. The two instruments brought from behind forwards, cross each other on the anterior region of the polypus *a*, in such manner that the thread *e, e*, may strangulate its pedicle. After having turned them once or twice on their axis, there is nothing more to be done than to loosen one of the threads, by pushing the stem *h* into the canula *i*, in order to open the forceps *f*. The thread-bearing tube *g* being removed, we apply the knot-tightener, and the operation stops there. Though applied very high up in the uterus, as is seen by its situation *e, e*, on the neck, the polypus nevertheless makes a considerable projection into the vagina *d, d*.

Fig. 4. The ligature applied to a polypus, after the process of M. Mayor of Lausanne. The ligature *c, c*, having been passed around the neck *a* of the morbid mass *b*, and supported thus far by the three small thread-bearing forks *e, e, e*, is not inserted into the cylinder *d* until after having been made to pass through the small balls of ivory or the chaplet, fig. 24 of Plate X.

Fig. 5. The double canula of Levret. When the noose *a* accurately embraces the polypus, we draw upon the threads *b, b*, in order to tighten it. These threads are afterwards attached to the rings of the canula, which latter also is to be turned on its axis when we wish to make still greater constriction.

Fig. 6. Ligature-bearing forceps of Desault, modified in this particular, that the ring *a* gives movement to it by means of a screw, and fixes it by means of the catch *b*.

Fig. 7. Ligature-bearing forceps of Levret.

Fig. 8. Dupuytren's screw-knot-tightener. The body *c* is slit throughout its whole length, in order to enable the fly *e*, which is lodged in it, to glide along freely. This fly, to which the thread *b* is fastened, tightens or loosens the noose *a*, as often as we act upon the plate *d*, and without deranging anything.

Fig. 9. The same instrument, armed with a ring *d*, and carrying at the extremity of its screw *b* a button *e*, instead of a plate.

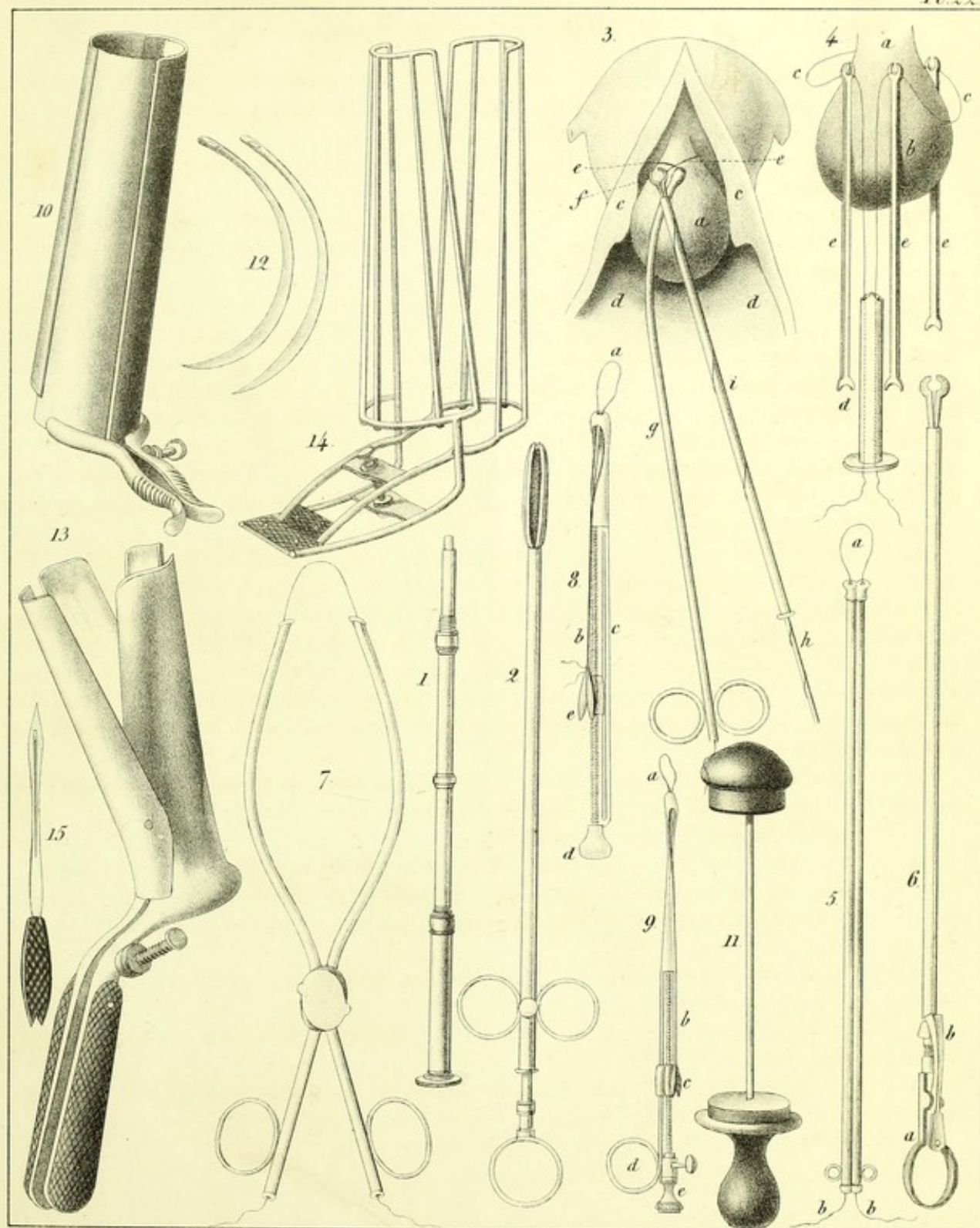
Fig. 1. Ordinary caustic-holder, (porte-crayon,) a little longer than usual, in order to touch the neck of the uterus with nitrate of silver.

Fig. 2. M. Ricord's three-branched forceps, to introduce the nitrate of silver without danger into the interior of the neck of the uterus.

Fig. 12. M. Roux's needles for suture of the perineum.

Fig. 15. M. Vidal's needle for the same operation.





En. Drawn by J. Paragore.

Printed by J. Nagel.

