

Plates of the arteries of the human body / after Frederic Tiedemann ; engraved by E. Mitchell, under the superintendency of Thomas Wharton Jones ; the explanatory references translated from the original Latin, with additional notes, by Dr. Knox.

Contributors

Tiedemann, Friedrich, 1781-1861.
Jones, Thomas Wharton, 1808-1891.
Knox, Robert, 1791-1862.
Mitchell, Edward, active 1814-1831
Denniston, J., active 19th century?
Guy's Hospital. Medical School
King's College London

Publication/Creation

Edinburgh : Maclachlan & Stewart, 1831.

Persistent URL

<https://wellcomecollection.org/works/bkpcd2cy>

License and attribution

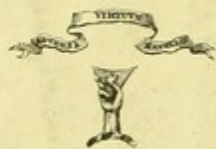This material has been provided by King's College London. The original may be consulted at King's College London, where the originals may be consulted.

This work has been identified as being free of known restrictions under copyright law, including all related and neighbouring rights and is being made available under the Creative Commons, Public Domain Mark.

You can copy, modify, distribute and perform the work, even for commercial purposes, without asking permission.

**wellcome
collection**

Wellcome Collection
183 Euston Road
London NW1 2BE UK
T +44 (0)20 7611 8722
E library@wellcomecollection.org
<https://wellcomecollection.org>



J. Denniston.

KING'S
College
LONDON

Tiedemann Library
Plates of the articles of the ...
1831
Glt QM191.TIE

200912346 0



KING'S COLLEGE LONDON



Digitized by the Internet Archive
in 2015

<https://archive.org/details/b21298609>

LV Botson 11
53-130T. L. 13.

PLATES

OF THE

ARTERIES OF THE HUMAN BODY;

AFTER

Frederic Tiedemann,

PROFESSOR OF ANATOMY AND PHYSIOLOGY IN THE UNIVERSITY OF HEIDELBERG.

ENGRAVED BY E. MITCHELL,

UNDER THE SUPERINTENDENCY OF

THOMAS WHARTON JONES, SURGEON.

THE

EXPLANATORY REFERENCES

TRANSLATED FROM THE ORIGINAL LATIN, WITH ADDITIONAL NOTES,

BY DR. KNOX,

LECTURER ON ANATOMY.

SECOND EDITION.

EDINBURGH :

PRINTED FOR MACLACHLAN & STEWART, EDINBURGH.

1831.

599255
31.1.1914
H. QM. 91. T. 1E

PLATES

OF THE

ARTERIES OF THE HUMAN BODY:

BY

Frederic Diebenmann

PROFESSOR OF ANATOMY AND PHYSIOLOGY IN THE UNIVERSITY OF HEIDELBERG

ENGRAVED BY E. MITCHELL

UNDER THE SUPERVISION OF

THOMAS WHARTON JONES, SURGEON

THE

EXPLANATORY REFERENCES

TRANSFERRED FROM THE ORIGINAL PLATE, WITH ADDITIONAL NOTES

BY DR. KNOX

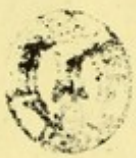LECTURER ON ANATOMY

SECOND EDITION

EDINBURGH:

PRINTED BY A. BALFOUR & CO., NIDDRY STREET, EDINBURGH.

1881



AUTHOR'S PREFACE.

ALTHOUGH there have been many anatomists who, from their acquaintance with the arteries of the human body, have most diligently described them, and very materially aided in enlarging and extending our knowledge of their distribution, yet it cannot be denied that the anatomical student, without the assistance of Plates, however zealously he may gather his information from various works, and however carefully he may endeavour to retain his knowledge thus obtained, will, unaided, make but little progress. I indeed allow that anatomical knowledge can, with far more advantage, and with much more prospect of its proving useful, be obtained by actual dissection than by the examination of plates: But this demands a daily and a careful investigation of many bodies, and a considerable share of manual dexterity; besides, bodies cannot be obtained always, and everywhere, with equal ease. In short, whoever he may be, he cannot prosecute those dissections provided with that share of anatomical information which the manuals of anatomical students require of those engaging in such pursuits. For this reason we owe a debt of deep gratitude to those great men who have handed down, for the use and advantage of the student, engravings of their investigations.

But there are few anatomists who have given us their plates either plainly executed, true to nature, or with accurate references. For the most, whether conscious of the paucity of their own ability, or panic-struck at the necessary load of labour, have either borrowed the plates of others, which they have transferred, rudely executed and inaccurately delineated, to their own works, or given us their own dissections so negligently engraved, and contrary to the order of nature, that they exhibit the figures of parts removed from their natural situation, and disagreeing much in proportion and arrangement. And no one will deny, that to the student of anatomy more loss than advantage will accrue from his investigation of plates imperfect in themselves and inaccurately represented.

Of the Plates of the Arteries already existing, those only are worthy of praise, or indeed anyways remarkable, which HALLER, CAMPER, SCARPA and SCÈMMERING have given to the world,—men widely celebrated, and deserving much from the student of anatomy. But it is to be regretted, that HALLER has taken the greater part of his plates from the bodies of children; that PETER CAMPER, in the *Anatomico-Pathological Demonstrations*, has only represented the arteries of the arm and pelvis; that the very elegant plates which the celebrated SCARPA has exhibited in his immortal work on Aneurism, merely represent the vessels of the arm and leg; and that the illustrious SCÈMMERING has confined his beautifully engraved plates to the arteries of the organs of the senses. Since, therefore, there is still a work much required in which all the arteries of the human body will be given delineated of their natural size, in their natural situation, and according to their regular distribution, I have ventured to produce these my Plates of the Arteries, with their explanations, equally adapted to the anatomist, surgeon, and student of medicine.

That I might, if possible, render my knowledge of the arteries fuller and more accurate than any one's, I have laboured with indefatigable zeal for sixteen years in investigating their origin and distribution; I have with my own hands dissected upwards of five hundred bodies, and examined with no small degree of diligence subjects of both sexes, and of all ages. How much time and labour this task necessarily required, those alone who have witnessed and properly considered of this work can be adequate judges. Indeed, I by no means would have engaged in an undertaking so arduous, and linked with so many difficulties, had I not been cheered by the advantage that would from thence accrue to medical science.

In preparing these plates I have endeavoured to follow as guides, and imitate in their vigour, ALBINUS, HALLER, CAMPER, SCARPA, and SCÈMMERING, who have merited so highly of anatomy. The plates represent the situation, connexion, and distribution of the arteries, that they may point out to the surgeon the high advantage resulting from a knowledge of the vessels of our body in the cure and healing of wounds, and that, from a comparison between the parts affected with disease or wounded, with these plates, he may more clearly understand how a flow of blood is to be dealt with, and where the vessels are to be compressed or tied. In performing operations, an examination of these plates, showing you parts with their accompanying arteries, layer after layer, is only requisite to enable you to avoid wounding the larger vessels.

In the explanations, I have always indicated the age and sex of the individual from whom the plate is taken, as the diameter of the arteries differ much according to the age and sex ; but their relations, curvatures, and direction are so constant, that it is of no moment whether the body has been male or female, young or old.

To those who have often investigated the constitution of the human body, an opportunity of seeing and observing such circumstances as tend to illustrate either the regular or irregular conformation of the body will have frequently presented itself. It is indisputably acknowledged, that no part of our frame varies so frequently, or in so whimsical a manner, in their origin, course, and distribution, as the blood-vessels. This fact is well established by the united testimony of many anatomists. Indeed it is difficult to establish, in any case, what variety would best suit the economy of an animal, what least ; nevertheless all are highly worthy the attention of the careful examiner into our constitution. As certainly a knowledge of the natural origin and distribution of the vessels may be reckoned the thing chiefly necessary, and deservedly too, to the surgeon or physician, yet the recollection of their variations is by no means without its utility, but renders us the more capable of mastering those difficulties which so easily arise to interrupt our prognosis, and foil us in our operations. Surgeons and physicians, from a knowledge of these varieties, may usefully elicit many salutary advantages to men who are either wounded or inflicted with disease. When I was yearly in the custom of dissecting a remarkable number of bodies, and of publicly and privately demonstrating their anatomy, and was engaged also in showing many young men how they should dissect, that they might obtain a knowledge of the structure and functions of the body, and become skilful anatomists, good surgeons, and able physicians, it could not happen but that I would meet with many points of use both to surgeons and physicians. I have carefully noted the varieties of the arteries from a great number of bodies which I examined for the purpose of perfecting this work ; and I have caused those, in particular, to be delineated which can either impede the functions of a part, or be of interest to the surgeon in the prosecution of his profession.

The celebrated ROUX, much skilled in engraving, has very accurately represented the true and proper structure, situation, figure, order, and connexion of each part, from dissections upon the body. In the muscles he has expressed the linearity of their fibres ; the arteries he has represented by transverse lines ; the nerves and glistening tendons by dotted points placed horizon-

tally : and shaded the remaining organs and parts in different ways, according to their natural appearance. The lithographic printers, among whom C. F. MULLER of Carlsruh is pre-eminent, have transferred these plates to stone under my own inspection, and after the most approved rules of the art.

When in any of the plates many arteries are represented, the branches are very often so small and frequent, that in linear plates it would be impossible to refer conveniently, by means of figures, to each individual one. I have, therefore, omitted referring to the smaller twigs, lest by too great a number of references I should impair the perspicuity of the whole. However, I deem it necessary to remind you, that if in any particulars the references may slightly differ, and not exactly fall upon the point indicated, this is owing to the barrenness of the minutiae ; in those places in which this could not be avoided, what is meant will be easily understood by men but moderately skilled in the science.

TO THE PUPILS ATTENDING MY LECTURES.

GENTLEMEN,

EVER since I had the honour of delivering Lectures on Anatomy, I have, as you, perhaps, are already aware, uniformly taught, that a vague and general acquaintance with Anatomy, (characterised by an indifference for minute research, a misapprehension of the exact relative position of the various organs of the body, and a premature grasping at practical results, which can only flow from a wide and extended inquiry into human structure,) was a kind of knowledge serviceable to no one.

On the other hand, I think I have also insisted on this, that whether your views were directed towards Surgery, Medicine, Physiology or general Philosophy, your researches into Anatomy ought to be minute and precise. Now, conformably to these principles and views, which have been approved of by you and by all who seriously reflect on what ought to be the nature of a medical education, I ventured to introduce last winter into the dissecting room, Engravings copied from the celebrated works of SCARPA, SÆMMERING, WALTHER, and others, in order to encourage the Student of Anatomy to aim at higher views in his dissections, and to adopt as his model of research, the minute and accurate dissections of SCARPA, rather than the meagre and but too often incorrect descriptions of the Dissecting-room Manual. The experiment (for it was one) was eminently successful; and it was easy to observe, that, by the use of such delineations and descriptions in the Practical Rooms, the general character of the dissections shortly became altogether different: thus, many attempted and succeeded in obtaining such an acquaintance with the anatomy and physiology of the Nervous System as is rarely met with in the mere Student of Anatomy. Now, whatever I have said with regard to the Engravings of the Nerves is *mutatis mutandis* strictly applicable to the Work which I now beg respectfully to dedicate to you. It cannot, I imagine, be necessary for me, or any one, to

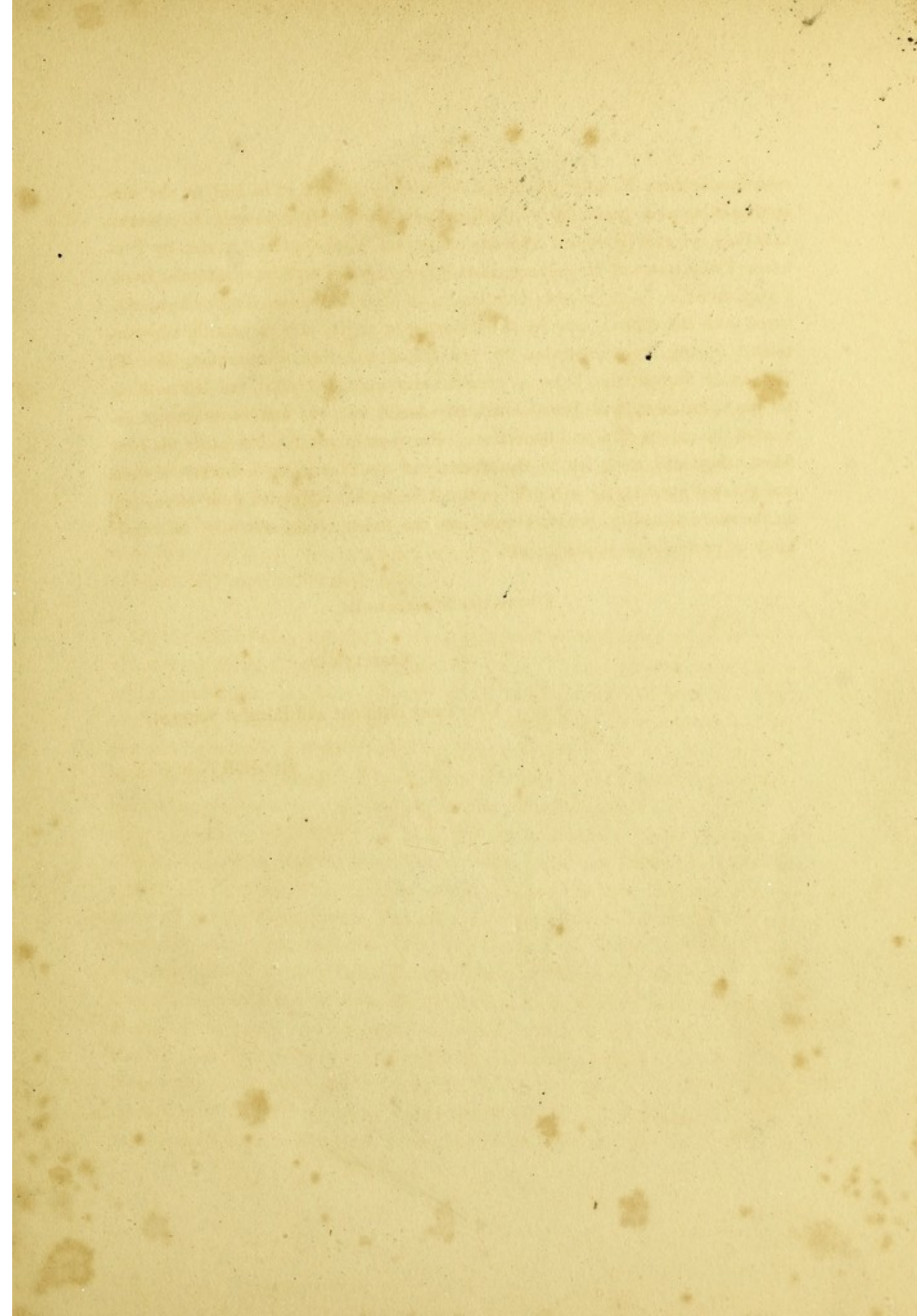
recommend these Engravings of the Arteries, (intended to be laid on the dissecting-table as a guide for your dissections,) farther than merely to observe that they are exactly copied from the celebrated Work on the Arteries by Professor TIEDEMANN of Heidelberg, than whom no more accurate anatomist lives. I may therefore be permitted, Gentlemen, to hope that these Engravings, executed with the utmost care by a distinguished artist, and constantly superintended during their execution by my friend and former assistant, Mr. T. WHARTON JONES, who, being at once the anatomist and artist, has left nothing for me to criticise, will prove eminently useful to you, and in no respect diminish the extent of actual dissection. Previous experience has made me confident they will not; for, if the anatomy of the Nerves be a matter of deep and general interest, the anatomy of the Arteries has claims on your attention, on the score of utility, which throw into the shade, comparatively, all other kinds of professional acquirements.

I have the honour to be,

GENTLEMEN,

Your most obedient and faithful Servant,

ROBERT KNOX.



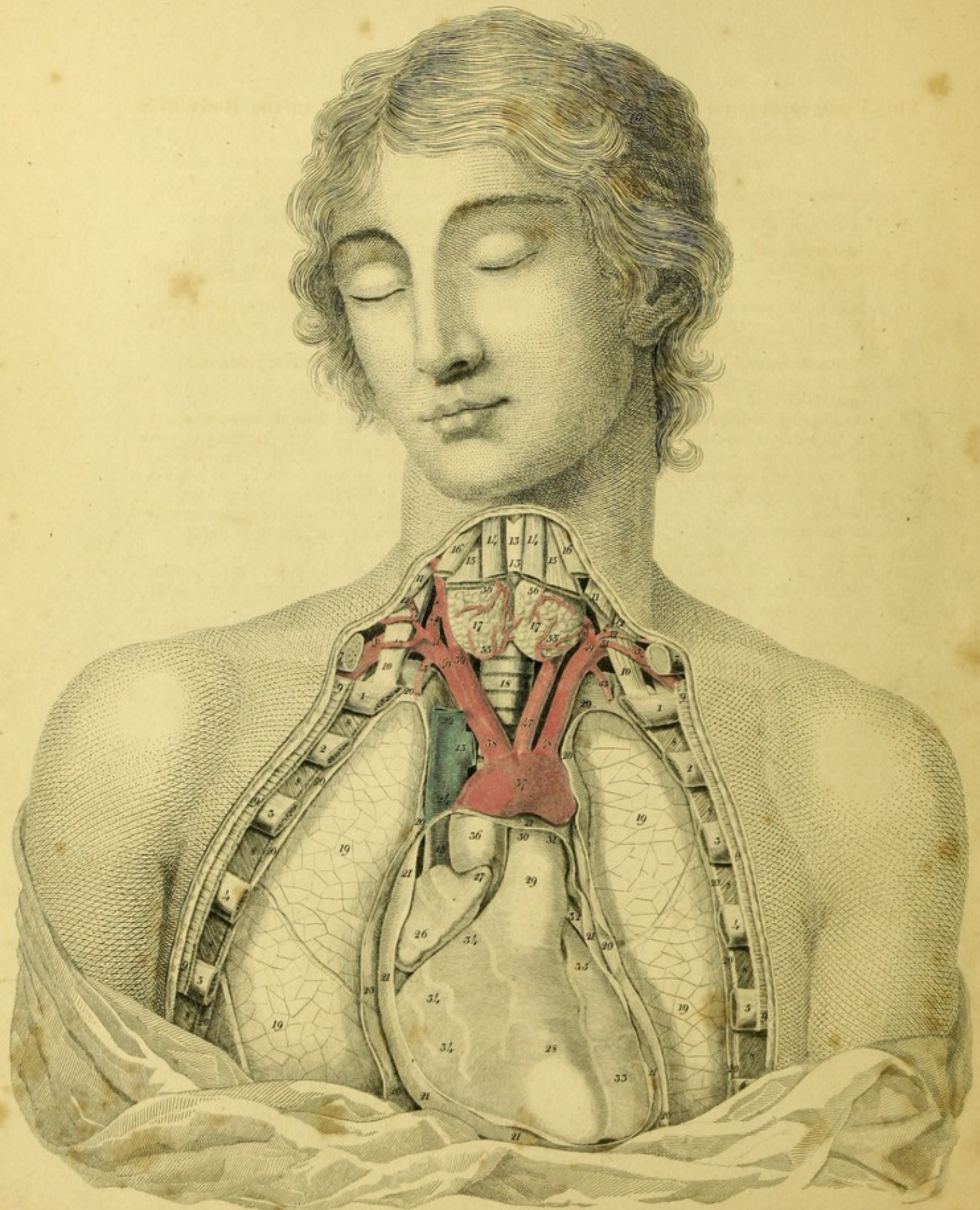


PLATE I.

This Plate represents the situation of the Heart and Aorta in the Body of a
Man 24 years of Age.

- | | |
|--|--|
| <p>1, 1, 2, 2, 3, 3, 4, 4, 5, 5, 6. Superior ribs of both sides, cut.</p> <p>7, 7. Clavicles cut.</p> <p>8, 8, 8, 8, 8, 8, 8, 8, 8. Intercostal muscles.</p> <p>9, 9, 9, 9, 9, 9. Great Pectoral muscles.</p> <p>10, 10. Anterior scaleni muscles.</p> <p>11, 11. Sternal portion of the sterno-cleido mastoid muscle, cut.</p> <p>12, 12. Clavicular portion of the sterno-mastoid muscle divided.</p> <p>13, 13. Thyroid cartilage.</p> <p>14, 14. Sterno-hyoid muscles, cut.</p> <p>15, 15. Sterno-thyroid muscles divided.</p> <p>16, 16. Omo-hyoid muscles divided.</p> <p>17, 17. Thyroid gland.</p> <p>18. Trachea.</p> <p>19, 19, 19, 19. Lungs.</p> <p>20, 20, 20, 20, 20, 20, 20. Pleurae.</p> <p>21, 21, 21, 21, 21. Pericardium laid open, in which the heart is seen.</p> <p>22. Common trunk of the right subclavian and jugular veins.</p> <p>23. Common Trunk of the left subclavian and jugular veins, or thoracic jugular vein.</p> <p>24. Trunk of the vena cava superior.</p> <p>25. Trunk of the same vein descending into the right sinus, the pericardium being turned back.</p> <p>26. Right sinus or atrium cordis dextrum.</p> | <p>27. Right auricle.</p> <p>28. Right or pulmonary ventricle.</p> <p>29. Pulmonary artery arising from the arterial cone of the right ventricle.</p> <p>30. Right branch of the pulmonary artery proceeding to the lung under the arch of the aorta.</p> <p>31. Left branch of the pulmonary artery.</p> <p>32. Left auricle.</p> <p>33. Left or aortic ventricle.</p> <p>34, 34, 34. Branches of the right coronary artery of the heart which the pericardium covers.</p> <p>35. Anterior branch of the left coronary artery of the heart running in the hollow between the ventricles to the apex of the heart.</p> <p>36. Trunk of the aorta ascending between the pulmonary artery and the right sinus.</p> <p>37. Arch of the aorta.^a</p> <p>38. Common trunk of the right subclavian and carotid arteries, anonymous trunk, or arteria innominata.</p> <p style="padding-left: 20px;">The length of the arteria innominata varies much in different individuals; I have seen it longer in tall people and shorter in those with a short neck.</p> <p>39. Right carotid artery.</p> <p>40. Right subclavian artery.</p> <p>† Vertebral artery.</p> <p>41. Trunk of the inferior thyroid artery.</p> |
|--|--|

^a Haller (de partium corporis humani praecipuarum fabrica et functionibus T. 4, p. 7.) speaks in the following manner of the branches arising from the arch of the aorta. "In man alone, of all animals I have yet examined, three distinct branches have arisen from the convexity of the great arch, so that, correctly speaking, we cannot use the word ascending aorta. The first of these trunks is the right subclavian, which gives off the right carotid; the second the left carotid; and the third the left subclavian of the same side."


I have distinctly observed the same origin of the vessels arising from the arch of the aorta in the simia aetheops, sciurea, and capucina, in the hedgehog, mole, rat, and mouse, beaver, three-toed sloth, and dolphin of the ancients.

Dubenton has seen this disposition of the vessels in the simia sciurea, (Buffon Hist. Natur. T. 15. p. 47.) capucina, (ib. p. 57.) rosalia, (ib. p. 113.) appella, (T. 15, p. 49.) lemur tardigradus, (ib. T. 13. p. 217.) racoon, (ib. T. 8. p. 348.) two-toed sloth, (ib. p. 56.) two-toed ant-eater, (ib. T. 10. p. 171.) hamster, (ib. T. 8. p. 130.) mus decumanus, (ib. T. 8. p. 212.) and beaver, (ib. p. 316.)

Ducrotay de Blainville, (Dissertation sur la place, que la famille des Ornithorinques et des Echidnes doit occuper dans les series naturelles, Paris 1812, p. 34.) has taken notice of the distribution of vessels in the ornithorynchi and echidnae. J. F. Meckel has seen it in the three-toed sloth, (Beiträge zur vergleichenden anatomie, B. 2. Heft. 1. S. 130.) and two-toed ant-eater, (Deutsch. Archiv für die Physiologie, B. 5. S. 59.)

But it is to be remarked, that the origin of the trunks arising from the arch of the aorta is subject to vary in mammalia as well as in men; for in the simia capucina and racoon I have seen only two branches proceeding from the arch, the first and greater of which consisted of the arteria anonyma, the posterior and smaller of the left subclavian.

42. Proper thyroid branch.
43. Transverse artery of the scapula.
44. Superficial cervical artery.
- †† Ascending cervical artery.
45. Internal mammary or thoracic artery.
46. Trunk of the subclavian artery, proceeding between the scalenus anticus and medius muscles.
47. Left carotid.
48. Left subclavian artery.
 - * Vertebral artery.
49. Inferior thyroid artery.
50. Thyroid branch.
- ** Ascending vertebral artery.
51. Transverse artery of the scapula.
52. Superficial cervical artery.
53. Left mammary artery.
54. Subclavian artery running between the scaleni and descending obliquely over the first rib.
- 55, 55. Branches of the inferior thyroid artery.
- 56, 56. Branches of the superior thyroid artery.



PL. II.

Fig 1.

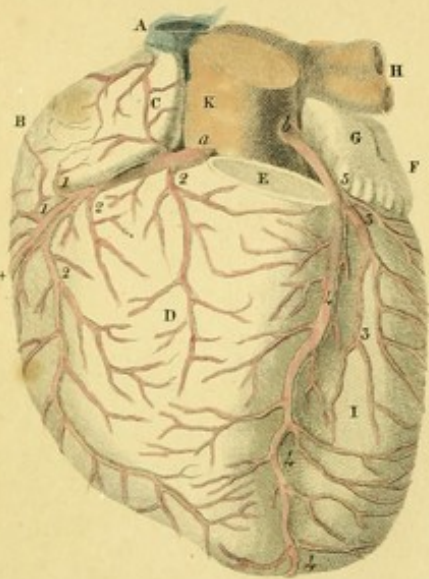


Fig 2.

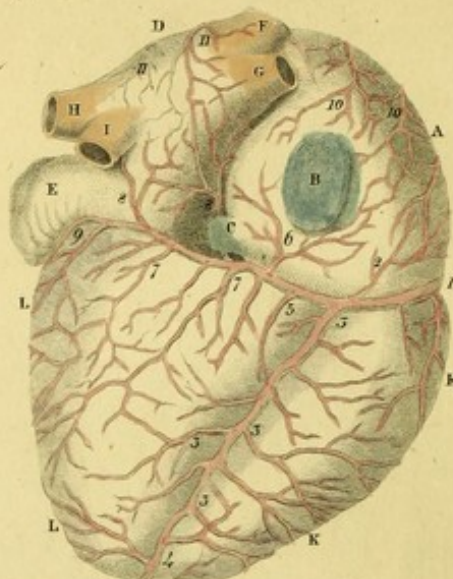


Fig 3.

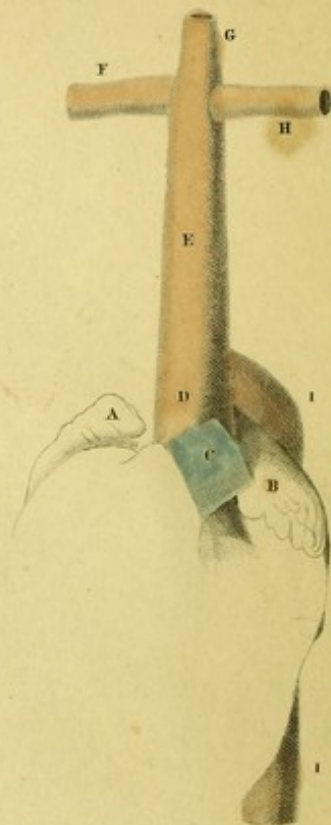


Fig 4.

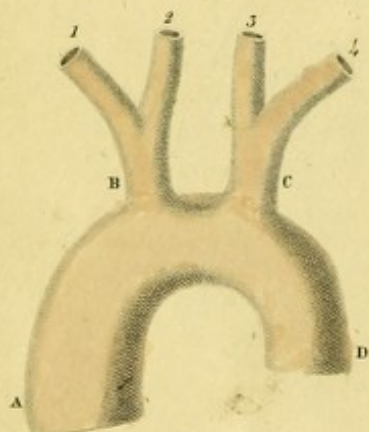


Fig 5.

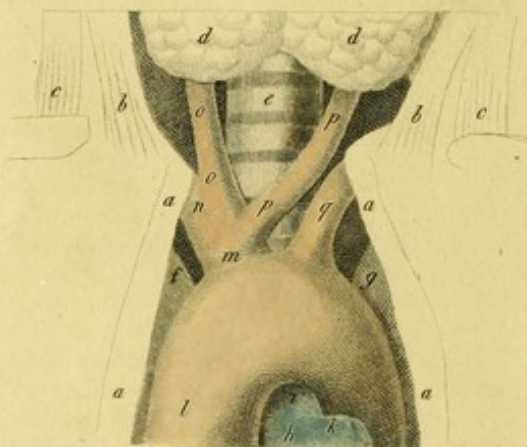


Fig 6.

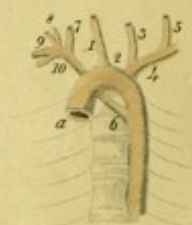

Fig 7.

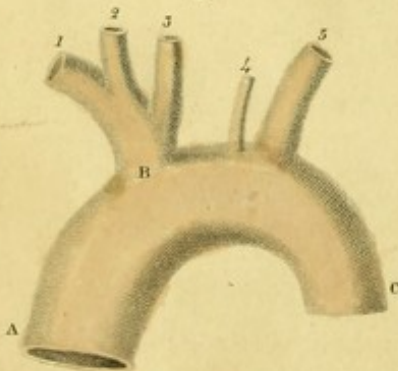


Fig 8.

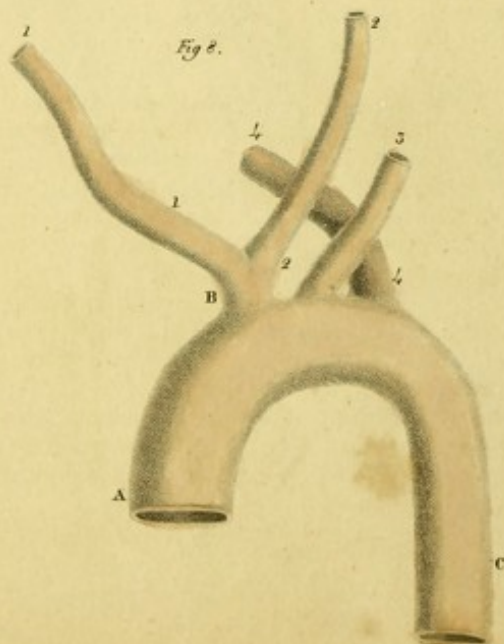


Fig 9.

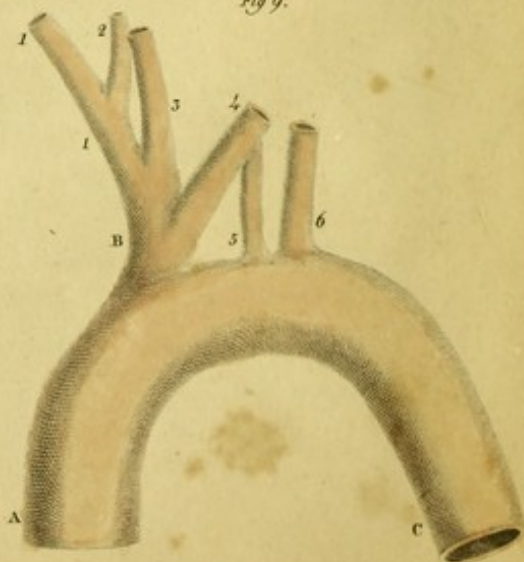


PLATE II.

FIGURE I.

Represents the Coronary Arteries of the Heart, or Cardiac Arteries, upon the Anterior surface of the Heart.

- A—Trunk of the vena cava superior, cut.
- B—Right sinus.
- C—Right auricle.
- D—Pulmonary ventricle.
- E—Arterial cone, with the pulmonary artery divided, that the origins of the cardiac arteries may be better seen.
- F—Left sinus.
- G—Left auricle.
- H—Left pulmonary veins.
- I—Aortic ventricle.
- K—Trunk of the aorta.
- a*—Right anterior or inferior coronary artery of the heart, escaping from the aorta, and running in the hollow between the base of the pulmonary ventricle and right sinus.
- b*—Left posterior or superior coronary artery of the heart arising from the aorta between the pulmonary artery and left auricle of the heart.
- 1,1,1.—Branches proceeding from the right coronary artery to the sinus of the venæ cavæ.
- 2,2,2.—Branches running to the right ventricle.
- *—Continuation of the right coronary artery upon the posterior surface.
- 3,3.—Branches of the left coronary artery to the left ventricle.
- 4, 4, 4.—Great anterior branch running in a winding manner in the hollow between each ventricle to the apex of the heart, and then reflected between the apices of both ventricles to the inferior surface of the heart.

- 5.—Tortuous branch proceeding to the posterior surface of the heart.

FIGURE II.

Represents the Cardiac Arteries upon the Posterior surface of the Heart.

- A—Right sinus.
- B—Mouth of the vena cava inferior.
- C—Trunk of the great coronary vein terminating in the right sinus.
- D—Left sinus.
- E—Left auricle.
- FG—Right pulmonary veins.
- HI—Left pulmonary veins.
- K. K.—Pulmonary ventricle.
- L L—Aortic ventricle.
- 1.—Posterior circumflex branch of the right coronary artery of the heart.
- 2.—Small twig to the right sinus.
- 3, 3, 3.—A branch descending between each ventricle, and giving branches to the posterior surface of the ventricles.
- 4.—A branch of the left coronary artery reflected between the apices of the ventricles, and entering into anastomosis with the descending branch.
- 5.—Continuation of the posterior circumflex branch.
- 6.—Small twig to the right sinus.
- 7, 7.—Twigs running to the left ventricle.
- 8, 8.—Small branches proceeding to the left sinus.
- 9.—Posterior anastomosing circumflex branch of the left coronary artery.
- 10, 10.—Small reflected branch of the right sinus.
- 11, 11.—Small twigs of the left sinus.

The coronary arteries of the heart sometimes differ in their number and distribution from what I have here represented. THEBESIUS^a has observed only one, though a large trunk, arising from the aorta, and immediately dividing into two branches. WINSLOW^b and FIORATI^c have both noticed three coronary arteries.

The following figures exhibit the principal varieties of the aorta, and of the branches arising from its arch: for, the branches of the aorta do not always originate in the same manner; nor are they distributed in all bodies after the same law, even although they do arise in the usual way. I have here laid down those varieties in the origin and course of the trunks arising from the arch of the aorta, which I have either myself observed,^d or seen depicted and described in the works of other anatomists.

FIGURE III.

Represents the most uncommon variation of the aorta, which KLINZ^e observed in the body of a soldier twenty years of age. The aorta forms no arch, but after emerging from the left ventricle immediately divides into an ascending and descending trunk, one of which gives off both carotids and subclavians.^f

- A—Right auricle of the heart.
- B—Left auricle of the heart.
- C—Pulmonary artery.
- D—Trunk of the aorta.
- E—Ascending aorta.
- F—Trunk of the right subclavian and carotid arteries.
- G—Left carotid.
- H—Left subclavian.
- I I—Descending aorta.

^a Diss. de Circulo Sanguinis in Corde. Lugd. Batav. 1716, 8, p. 6.

^b Exposition Anatomique de la Structure du Corps Humain. Paris, 1732, p. 366.

^c Atti della Academia di Padua, T. 3. P. 1. p. 38.

^d J. N. Bayer, praes. F. Tiedemann. Diss. de ramis ex arcu aortae prodeuntibus. Salzburg, 1817. 4. cum tab. lithograph.

^e Abhandlungen der Josephinischen Medicinisch-Chirurgischen Akademie. Wien. 1787. B. 1. S. 271. Taf. 6.

^f This distribution of the aorta occurs in animals of the order Pecora, in the sheep, goat, bull, stag, buck, reindeer, (Daubenton, l. c. T. 12. p. 182;) both varieties of the camel, (Daubenton, T. 11. p. 260, p. 432;) chamois, (Daubenton. T. 12. p. 182;) also in the solidungula, the horse, ass, and zebra, (Daub. T. 12. p. 17;) in most of the belluae, *v. gr.* in the boar, the pecari, and rhinoceros, (Cuvier Anatomie Comparée, T. 4. p. 248.) It is rarely observed in the mammalia of the order Glires and Quadrumana, yet I have seen it in the cavia agouti, and in the lemur mongoz. Daubenton has remarked it in the cavia cabybara (T. 12. p. 292.) and paca, (T. 10. p. 276,) in the lemur mongoz, (Tit. 13. p. 201,) and ring-tailed lemur, (ib. p. 189.)

This disposition of the vessels seems to be peculiar to those mammalia provided with a long neck; and from it seems to have arisen the vulgar division of the human aorta into ascending and descending, which we find so often mentioned in the works of the older Anatomists.

^g Osservazione in Chirurgia, Torino, 1784, T. 2. p. 119.

^h Observationes Anatomicae, p. 133.

I have remarked this distribution of the vessels in the bat; the left arteria anonyma was shorter than the right. Daubenton has observed it in the pteropus rufus, (T. 10. p. 70.) The other animals of the class Cheiroptera obviously have this arrangement of vessels. It is found also in the porpoise. (Cuvier. Anat. Compar. T. 4. p. 249.)

It would appear that this distribution is chiefly to be met with in those of mammalia with short necks.

FIGURE IV.

Sometimes two common or anonymous trunks arise from the arch of the aorta, one of which gives off the carotid and subclavian arteries of the right side, the other the same vessels of the left side. This variety has been twice observed by VINC MALACARNE,^g and once by BIUMI.^h I have seen it in the Anatomical Museum of Berlin.

- A—Aorta.
- B—Right common trunk.
- 1.—Right subclavian artery.
- 2.—Right carotid artery.
- C—Left common trunk.
- 3.—Left carotid.
- 4. Left subclavian.
- D—Descending aorta.

FIGURE V.

There are very often only two trunks originating from the arch of the aorta, the first and larger of which is composed of both carotid and right subclavian arteries, the second and smaller of the left subclavian.

- a, a, a, a.—Sternum of an adult cut in its middle part.
- b, b.—Sternal portions of the sterno-cleido mastoid muscles.
- c, c.—Clavicular portions of the same muscles.
- d, d.—Thyroid gland.
- e.—Trachea.
- f.—Right pleura.
- g.—Left pleura.
- h.—Trunk of the pulmonary artery.
- i.—Right pulmonary artery.
- k.—Left pulmonary artery.
- l.—Trunk of the aorta.
- m.—Arteria innominata, which is sometimes observed longer.

- n.—Right subclavian artery.
 o, o.—Right carotid artery.
 p, p.—Left carotid, passing obliquely across the trachea.
 q. Left subclavian.

This variety, which some of the older anatomists have either delineated or described as usual and regular, has been often observed in more recent times. PETSCHÉ^a has seen it once in the body of a female. NEUBAUER^b twice in adults, and once in a new born infant. J. J. HUNTER^c in a girl six years old, and in a boy of twelve. Besides, we have the authority of J. F. MECKEL,^d VINC. MALACARNE,^e WALTER,^f SCARPA, BURNS,^g RYAN^h and J. F. MECKEL, (the grandsonⁱ) in establishing this variation.

I have myself very often seen this disposition of these arteries in males as well as females, while studying at Landishut; but seldom in those bodies which I procured while at Marburg, Wirceburg, and Heidelberg.^k

The left carotid, when it arises from the arteria innominata always passes obliquely across the trachea between the manubrium of the sternum and the thyroid gland; for which reason the anterior surface of the neck, in performing the operation of tracheotomy, should be carefully examined by the surgeon lest he wound this artery.*

FIGURE VI.

A variety which I have remarked in a foetus of eight months. This foetus had a hare-lip.

- A—Aorta.
 1.—Right carotid.
 2.—Anonymous trunk.
 3.—Left carotid.
 4.—Left subclavian.
 5.—Vertebral artery of the same side.
 6.—Right subclavian artery arising from the thoracic aorta.
 7.—Right vertebral artery.
 8.—Inferior thyroid artery.
 9.—Transverse artery of the neck.
 10.—Internal mammary artery.

FIGURE VII.

Exhibits a variety, which I observed in the body of an adult man at Landishut.

- A—Aorta.
 B—Arteria innominata.
 1.—Right subclavian artery.
 2.—Right carotid.
 3.—Left carotid.
 4.—Vertebral artery of the left side.
 5.—Left subclavian.
 C—Thoracic aorta.

^a Sylloge Anatomicarum Selectarum Observationum. Hal. 1736, p. 14.

^b Descriptio Anat. Arteriae Innominatae et Thyroideae Imae. Jenae, 1772, § 11. Tab. 2. Fig. 1.

^c Act Helvetic, Vol. 8. p. 71. Tab. 3. Fig. 1.

^d Epistolae ad Hallerum, Vol. 3. p. 140.

^e Osservaz. in Chirurgia, P. 2. p. 128. Tab. 1. Fig. 3.

^f Nouveaux Memoires de l'Acad. de Berlin, Ann. 1785, p. 61. Tab. 2. Fig. 5. I am surprised that Walter has called this variety a very rare one.

^g Von den Herzkrankheiten, a. d. Engl. Lemgo, 1813, s. 324.

^h Diss. de Quarundum Arteriarum in Corpore Humano Distributione. Edinburg. 1812. 8. p. 2.

ⁱ Tabulae Anatomicae Pathologicae Fasc. 2. Tab. 10. Fig. 11. Handbuch der Pathologischen Anatomie. B. 2. Abth. 1. s. 131.

Meckel asserts that he has seen this distribution twelve different times.

^k In many animals I have observed both carotids and the right subclavian arising by a common trunk from the aorta. In animals of the order quadrumana, viz. in the simia satyrus, † whose heart I saw preserved in the celebrated museum of Sandifort at Leyden; in the simia entellus, the magot, sajou sai, coaita, green ape or callitriche, red ape of Senegal, simia artesus, brown baboon, and pigtailed baboon. Daubenton saw the same type or distribution of vessels in the magot, (l. c. T. 14. p. 119.) the pig-tailed baboon, (p. 183,) the cynomolgus, (p. 198,) the faunus, (p. 233,) the green ape, (p. 279,) the fuliginosa, (p. 250,) and coaita. (T. 15. p. 30.)

I have found the same disposition of vessels in the dog, (l. c. Fig. 3.) fox and wolf, and cat, (l. c. Fig. 5.) lion and weasel, (Fig. 4.) martin or polecat, and ermine, the yellow and red coats mundi, racoon and badger. Besides, according to Daubenton, it is met with in the hyæna, (l. c. T. 9. p. 285,) leopard, (p. 181.) ounce, (p. 212,) lynx, (p. 248,) caracal, (T. 12. p. 445,) civet or musc, common otter, (T. 7. p. 143,) and bear, (T. 8. p. 271.)

Finally, I have seen it in most of the Glires, v. gr. in the hare, (Fig. 6.) rabbit, porcupine, beaver, and alpine mouse. Daubenton described it in the sciurus palmarum, (T. 10. p. 135.) the Guinea pig, (T. 8. p. 11,) and didelphis, (T. 13. p. 98.) Pallas showed it in the daman of the Cape. (Miscellanea Zoologica, p. 43.)

(† I have followed the learned author in the text, in retaining the name of *Simia Satyrus*, though it is now tolerably well ascertained that the simia satyrus of naturalists, the animal described by Vosmaer and Camper, is only a young pongo. The heart preserved in the museum at Leyden may perhaps have belonged to the very specimen so ably dissected and described by Camper.—R. KNOX.)

(* There is a specimen of the distribution of vessels, described in the text, in my own museum. I owe the preparation to the kindness of Mr. Turnbull, one of my pupils.—R. KNOX.)

FIGURE VIII.

Shows the arch of the aorta, from which a trunk common to both carotids arises, and each subclavian formed by a trunk proper to itself, and originating in a singular manner, so that the left subclavian is situated in the middle, while the right is placed on the left side. This figure is taken from the observations of WALTER.

- A—Ascending aorta.
 B—Common trunk of the carotids.
 1, 1,—Right carotid.
 2, 2—Left Carotid.
 3—Left subclavian artery.
 4—Right subclavian artery behind those trunks proceeding to the right side.
 C—Portion of the thoracic aorta.

HUNAULD,^a HOMMEL,^b NEUBAUER,^c J. F. MECKEL,^d WALTER,^e and J. F. MECKEL, (the grandson^f) have each remarked the branches of

the arch of the aorta arising in this manner. The right-subclavian generally proceeds behind the oesophagus and trachea to the right arm; but, in the case which WALTER describes, it runs over the trachea.

FIGURE IX.

Represents a variety observed by WALTER,^g agreeing completely with Fig. vii.

- A—Aorta.
 B—Arteria innominata.
 1, 1.—Right subclavian artery.
 2.—Vertebral artery.
 3.—Right carotid.
 4.—Left carotid.
 5.—Left vertebral artery.
 6.—Left subclavian.

ED. SANDIFORT^h describes a similar case as occurring in the body of a female.

^a Hist. de l'Acad. des Sciences de Paris, an. 1737, p. 20, Nro. 7.

^b *Commercium Litterarium Norimberg.* 1737, p. 162, Tab. 2. Fig. 3, 4. e viro adulto.

^c *De Arteria Innominata*, § 12.


^d *Epistol. ad Haller.* T. 3. p. 141.

^e *Mem. de l'Acad. de Berlin*, 1785, T. 3. Fig. 3.

^f *Tabulae Anatomicae-Pathologicae*, Fasc. 2. Tab. 10. Fig. 2.

^g *l. c.* Tab. 3. Fig. 3.

^h *Observationes Anatomicae-Pathologicae*, Lib. 4. p. 92.



PL. III.

Fig. 1.

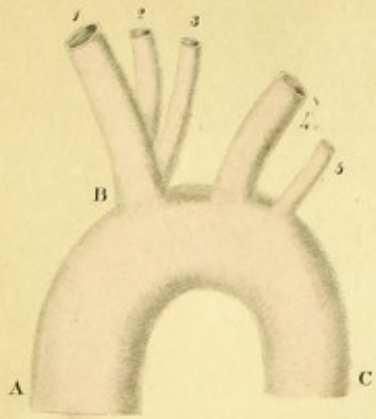


Fig. 2.

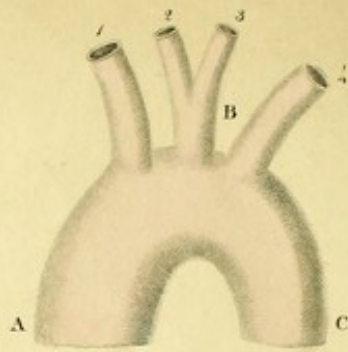


Fig. 3.

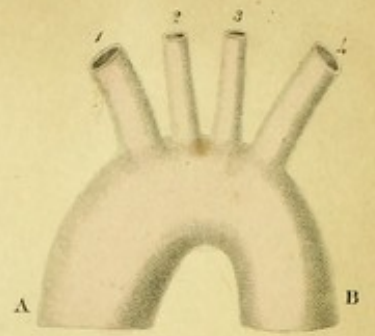


Fig. 6.

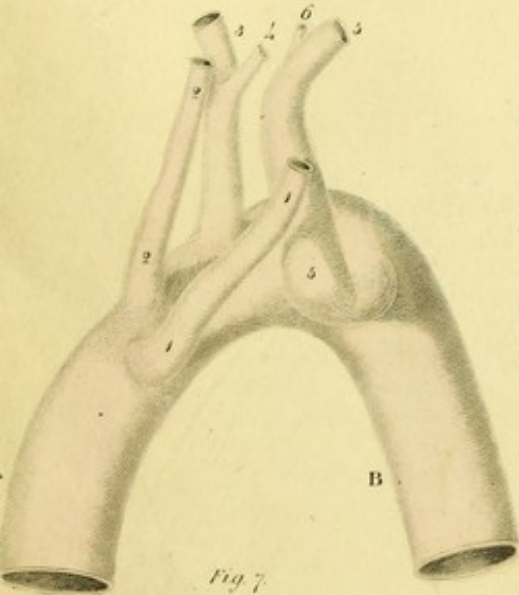


Fig. 4.

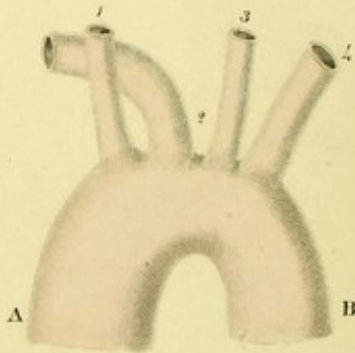


Fig. 5.

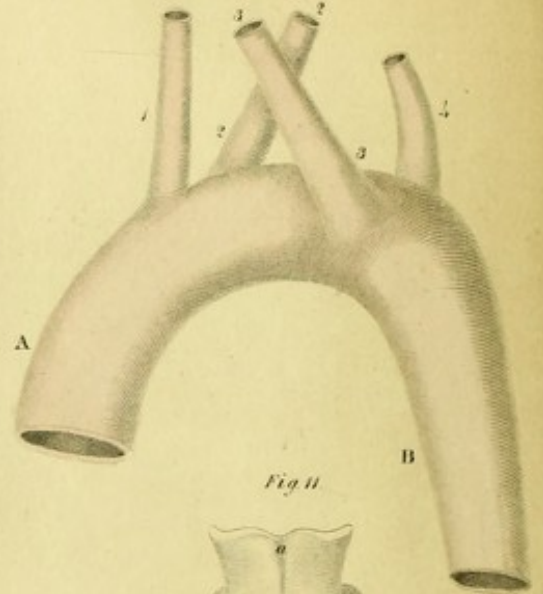


Fig. 8.

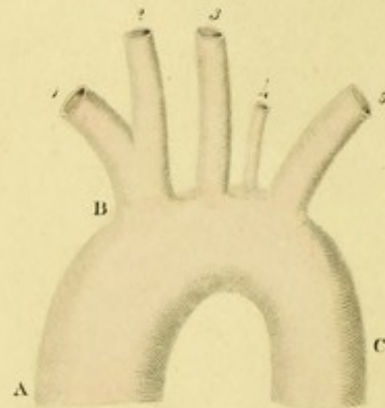


Fig. 11.

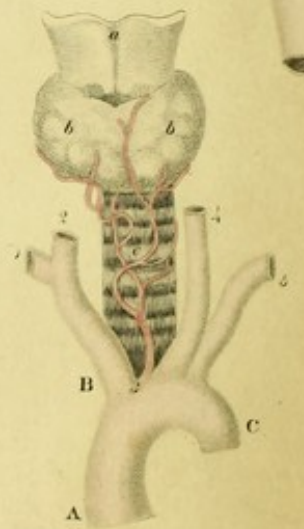


Fig. 7.

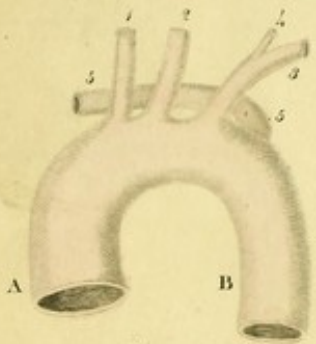


Fig. 9.

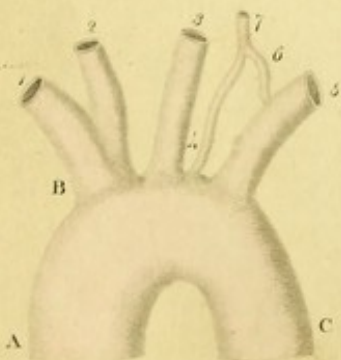


Fig. 10.

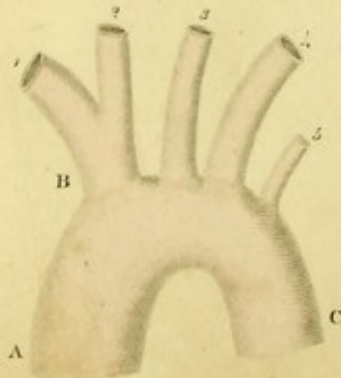


Fig. 12.

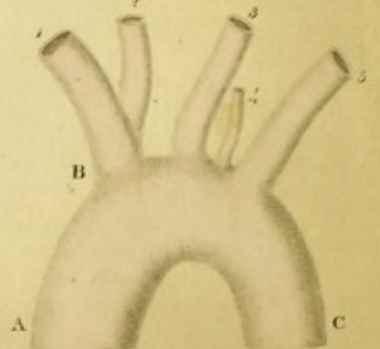


PLATE III.

FIGURE I.

- A. The aorta.
- B. The arteria innominata.
 - 1. Right subclavian artery.
 - 2. Right carotid artery.
 - 3. Left carotid.
 - 4. Left subclavian artery.
 - 5. Left vertebral artery arising from the arch of aorta.
- C. Thoracic part of the aorta.

I saw this disposition of the vessels in the body of a man forty years old; it is like that described by WALTER.*

FIGURE II.

This very rare variety occurred to me whilst dissecting the body of a young person aged twenty-two.†

- A. Ascending trunk of the aorta.
 - 1. Right subclavian artery.
- B. Trunk common to the two carotids.
 - 2. Right carotid.
 - 3. Left carotid.
 - 4. Left subclavian.
- C. Descending aorta.

* Museum Anatomicum, p. 237, No. 1447.

† This origin of the branches from the arch of the aorta is proper to the elephant.—See Cuvier, (l. c. Vol. 4 p. 249.)

FIGURE III.

It is not unusual for the number of trunks arising from the arch of the aorta to be increased. This is effected, partly, if the right subclavian and right carotid arteries form no anonymous trunk (*arteria innominata*), but arise separately, partly, if those branches which are commonly subdivisions of larger trunks arise from the arch of the aorta itself; thus four, five, or even six trunks may come off from it.

- A, B. Arch of the aorta.
 - 1. Right subclavian artery.
 - 2. Right carotid.
 - 3. Left carotid.
 - 4. Left subclavian.

HEISTER,¹ WINSLOW,² BALLAY,³ NEUBAUER,⁴ NEVIN,⁵ RYAN,⁶ J. F. MECKEL,⁷ ZAGORSKY,⁸ and FLEISCHMANN,⁹ have seen such a distribution of branches arising from the arch of the aorta.

¹ Compendium Anatomicum. Notæ, p. 123, in a female body.

² l. c. p. 364.

³ Journal de Medicine. Ann. 1758. Mois Avril.

⁴ l. c. § 14.

⁵ Edinburgh Med. Commentaries. Dec. 2. Vol. 9.

⁶ l. c. p. 3.

⁷ Patholog. Anat. B. 2. Abth. 1. S. 107.

⁸ Mem. de l'Academ. de Petersbourg, T. 1.

⁹ Leichen—Oeffnungen, S. 236.

Daubenton (l. c. T. 13. p. 420.) says, that four branches were found arising from the arch of the aorta in the *trichechus rosmarus*;* that they agree with the above however is not quite evident.

* This expression has been employed by different naturalists to designate different animals, as the walrus, the dugong, and the lamenteine.

FIGURE IV.

- A, B. Arch of the aorta.
1. Right carotid.
 2. The right subclavian going behind the carotid of the same side, on its way to the right arm.
 3. Left carotid.
 4. Left subclavian.
- J. J. HUBER* saw this disposition.

FIGURE V.

Exhibits a variety taken from †WALTER's Dissertation on the aberrations of the arteries.

- A, B. Arch of the aorta.
1. Right carotid artery.
 2. Left carotid artery.
 3. Right subclavian artery.
 4. Left subclavian artery.

FIGURE VI.

A similar variety taken from the observations of WALTER. †

- A, B. Arch of the aorta.
1. Right carotid.
 2. Left carotid.
 - 3, 3. Right subclavian.
 4. Vertebral artery.
 - 5, 5. Left subclavian.
 6. Vertebral artery.

FIGURE VII.

This figure is taken from the Programma of P. A. BOEHMER. †

- A, B. Arch of the aorta.
1. Right carotid artery.
 2. Left carotid.
 3. Left subclavian.
 4. Vertebral artery of the left side.
 5. Right subclavian running behind the œsophagus and trachea, on its way to the right side.

This anomaly of the vessels has been described by FABRICIUS,¹ MIEG,² LOESECKE,³ LUDWIG,⁴ POHL,⁵ NEUBAUER,⁶ MURRAY,⁷ SCHLEITZ,⁸ SANDIFORT,⁹ BAYFORD,¹⁰ HULME,¹¹ AL. MONRO,¹² AUTENREITH,¹³ ZAGORSKY,¹⁴ KOBERWEIN,¹⁵ HEROLD,¹⁶ FLEISCHMANN,¹⁷ OTTO,¹⁸ and J. F. MECKEL.¹⁹

The right subclavian artery immediately at its origin is bent towards the right, and proceeds obliquely or transversely to the right arm. In its course it either runs behind the œsophagus and trachea, as in the cases observed by BOEHMER, NEUBAUER, POHL, MURRAY, SCHLEITZ, AUTENREITH, FLEISCHMANN, and OTTO; or it passes between the œsophagus and trachea, as in the cases described by BAYFORD, MONRO, ZAGORSKY, and HEROLD. Some physicians, BAYFORD, HULME, MONRO, AUTENREITH, and MURRAY, relate that deglutition has been impeded by this irregular origin and course of the right subclavian artery, and they derive from thence a new sort of Dysphagia which they call *Lusoria*. But others, KOBERWEIN, OTTO, and FLEISCHMANN, have not observed Dysphagia to arise from this cause.

¹ Proemticum non nullas observationes anatomicas sistens ad diss. J. B. Hoffmann. Helmst. 1751. p. 10.

² Specimen Observationum Anatomicarum atque Botanicarum. Basil. 1753. Art. 8.

³ Observationes Anatomico-Chirurgico-Medicæ. Berolin, 1754. p. 26.

⁴ Programma observationes angiologicas tradens. Lips. 1764. p. 5.

The right mammary artery arose in the same subject from the right carotid.

⁵ Observationes Angiologicæ de Arteriis. Lips. 1773. p. 7.

⁶ l. c. § 13.

⁷ Abhandlungen der Schwed. Akadem. B. 30. S. 92.

⁸ Ib. p. 98.

⁹ Museum Anatomicum, Acad. Lugd. Batav. Tab. 106. Fig. 2.

¹⁰ Memoirs of the Medical Society of London, Vol. II. p. 271. In the body of a Female aged sixty.

¹¹ Ib.

¹² De Dysphagia. Edinb. 1797. Outlines of the Anatomy of the Human Body. Edin. 1813. Vol. III. p. 277. Plate 43.

¹³ Pfeleiderer Praes. Autenrieth, Diss. de Dysphagia Lusoria. Tubing, 1806, in a female body aged sixty. Reils Archiv. fur die Physiologie, B. 7. s. 145.

¹⁴ Mem. de l'Acad. des Sc. de St. Petersburg, 1810. T. 2. p. 318. Tab. 2. Fig. 7. From the body of a boy.

¹⁵ Diss. de vasorum decursu abnormi ejusque vi in omnem valetudinem varia. Vitenberg, 1810, p. 16.

¹⁶ Diss. exhibens Observationes quasdam ad Corp. Hum. Part. Struct. Marburgi, 1812, p. 7.

¹⁷ Leichenoffnungen. Erlangen, 1815, S. 213. From the body of a man aged fifty-nine.

¹⁸ Seltene Beobachtungen Zur Anatomie, Physiologie und Pathologie, Breslau, 1816, 4. S. 100.

¹⁹ Handbuch, der Patholog. Anatomie, B. 2. Abth. 1. S. 98.

* Acta. Helvetic. T. 8. p. 75. Fig. 3.

† Mem. de l'Acad. de Berlin, 1785. p. 62. Tab. 3. Fig. 5. From a male body.

‡ Ib. Tab. 3. Fig. 4.

§ De quatuor et quinque ramis ex arcu arteriæ magnæ ascendentes. Halæ, 1744, Fig. 1.

FIGURE VIII.

This shews an unusual origin of the left vertebral artery from the arch of the aorta between the left carotid and subclavian arteries, which I saw in the body of a man of fifty.

- A. Aorta.
B. Arteria innominata.
1. Right subclavian artery.
2. Right carotid.
3. Left carotid.
4. Vertebral artery of the left side.
5. Left subclavian artery.
C. Descending aorta.

This variety very frequently occurs. It has been observed by J. G. DE BERGEN,¹ PETSCHÉ,² TREW,³ LOESEKE,⁴ BOEHMER,⁵ MOREL,⁶ HUBER,⁷ MORGAGNI,⁸ WINSLOW,⁹ BARBAUT,¹⁰ MEKEL,¹¹ SANDIFORT,¹² NIEMEYER,¹³ and J. F. MECKEL the grandson.¹⁴ I have seen this anomaly five times in males as well as in females.

FIGURE IX.

Exhibits a very rare variety of the left vertebral artery, which HUBER* saw in the body of a boy.

- A. Aorta.
B. Arteria innominata.
1. Right subclavian artery.

¹ Acta Eruditor. Lips. Ann. 1698, p. 295. Tab. 7.

² l. c. pag. 14.

³ Commerc. Liter. Norimberg. Ann. 1737, p. 185, No. 2.

⁴ l. c. p. 26.

⁵ Observation. Anat. Rarior. Fasc. 1. p. 11. No. 15. In a female body.

⁶ Journal de Médecine, 1757. Dec.

⁷ l. c. He saw this structure in a new born infant, and in one fifteen days old, in a boy of one year, in a girl of two, and another of five years old, and in an old woman.

⁸ De Sedib. et Causis Morbor. Epist. 3. Art. 20, 21. Epist. 15, Art. 26. Epist. 56. Art. 10. and 21.

⁹ l. c. No. 21.

¹⁰ Angiolog. p. 387.

¹¹ Epistolae ad Hallerum. T. 2. p. 258.

¹² Observat. Anat. Patholog. Lib. 4. p. 92. In a female body.

¹³ De Fetu Puellae Abnorm. Hal. 1814, p. 7.

¹⁴ Hanb. der Patholog. Anat. B. 2. Abth. 1. s. 109.

Tabul. Anatomic. Pathologic. Fasc. 1. Tab. 1. Fig. 3. In the body of a young person of fourteen, who died of the blue disease, (*morbus caeruleus*.)

This distribution of the arteries from the arch of the aorta seems to be regular in the seal; for I observed it in three seals dissected by myself.

* l. c. p. 73.

2. Right carotid.
3. Left carotid.
4. The first left vertebral artery arising from the arch of the aorta.
5. Subclavian artery of the left side.
6. Another left vertebral artery coming off from the subclavian.

Both these, viz. that which is a branch of the aorta, and that which comes from the subclavian, joined into one at the transverse process of the fifth cervical vertebra.

7. Common trunk of the vertebral arteries.

HENKEL* likewise found two vertebral arteries on the left side, one of which, the smaller, came from the usual place; the other, the larger, arose from the aorta; they formed a common trunk in the canal of the transverse processes of the neck.

FIGURE X.

- A. Aorta.
B. Arteria innominata.
1. Right subclavian.
2. Right carotid.
3. Left carotid.
4. Left subclavian.
5. Vertebral artery deriving its origin from the arch of the aorta.

I saw this anomaly in the body of a man thirty years old. WINSLOW,¹ and J. F. MECKEL,² have observed a similar distribution.

FIGURE XI.

This figure exhibits the inferior thyroid artery, coming off from the arch of the aorta between the arteria innominata and the left carotid. NEUBAUER† was the first who described this.

- a.—Thyroid cartilage.
b, b.—Thyroid gland.
c.—Trachea.

- A. Aorta.
B. Arteria innominata.
1. Right subclavian.
2. Right carotid.

* Zweite Sammlung Medicinischer und Chirurgischer, Anmerkungen, S. 10. Fig. 4.

¹ l. c. p. 364.

² l. c. p. 109.

† De Arteria Innominata et Thyreoidea ima, § 8. Tab. 2. Fig. 2.

3. Inferior thyroid artery, sending small branches to the trachea and thyroid gland.
 4. Carotid of the left side.
 5. Left subclavian.
- C. Thoracic part of the aorta.

It is worthy of notice, that in this case the right inferior thyroid artery, a branch of the subclavian, gave no twigs to the thyroid gland; but that the scapular, the transverse cervical, and ascending cervical arteries, chiefly supplied it.

HUBER,¹ WALTER,² LODER,³ and HEROLD,⁴ have also observed this abnormal origin of the inferior thyroid artery. I happened once to see it in the body of an adult man. It merits the attention of the surgeon in performing the operation of tracheotomy.

¹ Act. Helvet. T. 8. p. 83.

² l. c. Tab. 3. Fig. 2.

³ Programma, in quo recensentur non nullae arteriarum varietates. Jenae, 1781, p. 4.

⁴ l. c. p. 12.

FIGURE XII.


This represents the inferior thyroid artery arising from the arch of the aorta, between the left carotid and subclavian arteries, which I found in the body of a female of forty.

- A. Aorta ascending to form the arch.
 B. Arteria innominata.
 1. Right subclavian artery.
 2. Right carotid artery.
 3. Left carotid artery.
 4. Inferior thyroid artery.
 5. Left subclavian artery.
 C. Descending aorta.

The inferior thyroid artery which came off from the left subclavian was small, and gave no branches to the thyroid gland, but it sent off the transverse scapular and ascending cervical arteries.

NICOLAI* has also observed this unusual origin of the inferior thyroid artery.

* De Directione Vasorum, Argentorati, 1726, p. 25.



PL. IV.

Fig. 1.

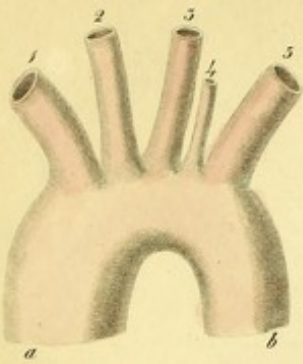


Fig. 2.

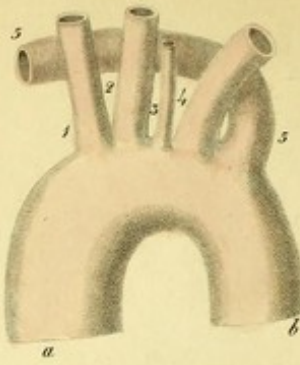


Fig. 3.

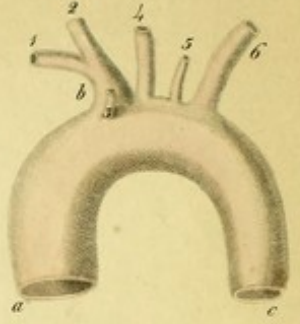


Fig. 4.

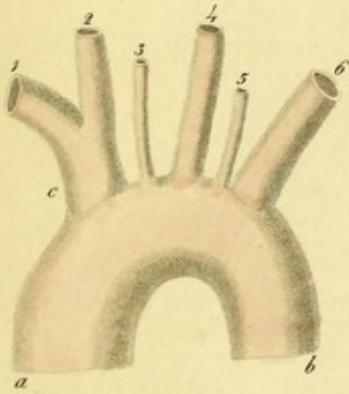


Fig. 5.

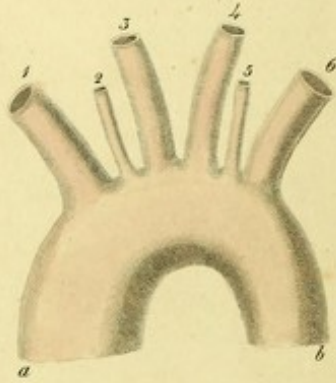


Fig. 6.

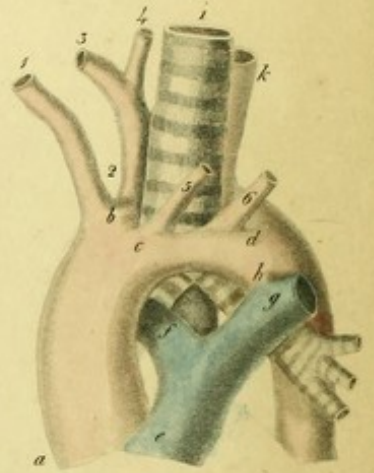


Fig. 8.

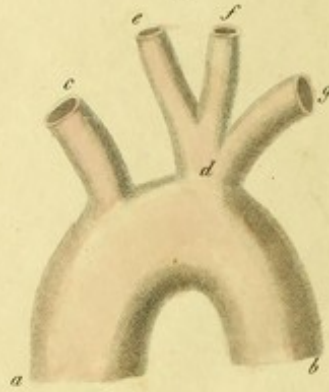


Fig. 9.

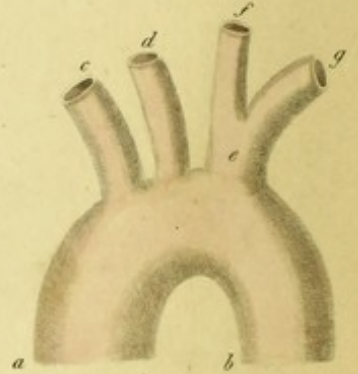


Fig. 7.

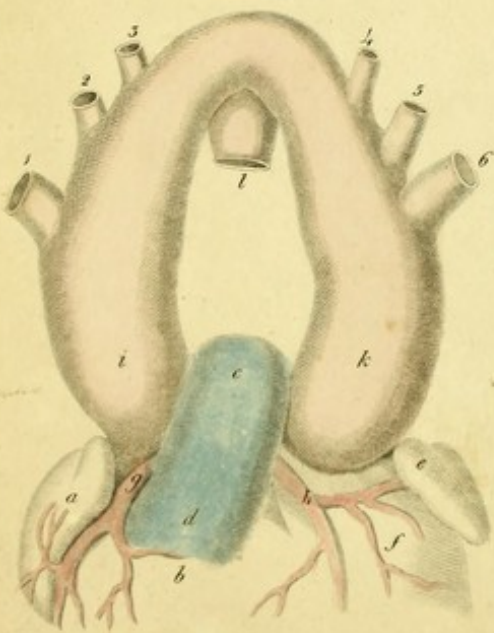


Fig. 10.

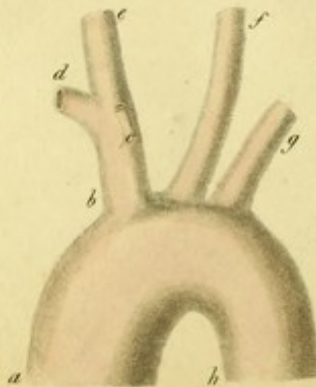


Fig. 11.

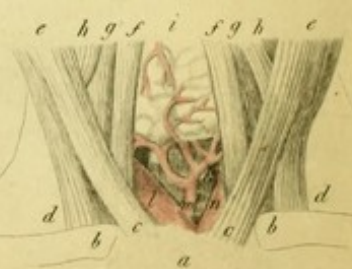

PLATE IV

FIGURE I.

Five branches arising from the arch of the aorta have also been observed.

- a, b.*—Arch of the aorta.
1. Right subclavian artery
 2. Right carotid artery.
 3. Left carotid artery.
 4. Left vertebral artery.
 5. Subclavian artery of the left side.

PETSCHÉ¹ and LODER² saw such a disposition of branches arising from the arch of the aorta.

FIGURE II.

- a, b.*—Arch of the aorta.
1. Right carotid.
 2. Left carotid
 3. Left vertebral artery.
 4. Left subclavian.
 5. Right subclavian going to the right arm behind the trunks arising from the arch of the aorta, and behind the oesophagus and trachea.
- KOBERWEIN³ has observed this variety.

FIGURE III.

In addition to the usual three branches, the right internal mammary artery sometimes

originates from the arch of aorta, and the vertebral artery of the left side arises between the carotid and left subclavian, of which BOEHMER¹ has delineated an example.

- a, c.*—Aorta.
- b.*—Arteria innominata.
1. Right subclavian.
 2. Right carotid.
 3. Right internal mammary, or thoracic artery
 4. Left carotid.
 5. Vertebral artery of the left side.
 6. Left subclavian.

Sometimes instead of the right mammary, the inferior thyroid artery takes its origin from the arch of the aorta. J. F. MECKEL² has observed this variety twice.

FIGURE IV.

Sometimes the vertebral arteries of both sides arise from the arch of the aorta. PENADA,³ FIORATI,⁴ and MECKEL,⁵ relate such cases.

- a, b.*—Arch of the aorta.
- c.*—Arteria innominata.
1. Right subclavian.
 2. Right carotid.
 3. Vertebral artery of the right side.
 4. Left carotid.
 5. Vertebral artery of the left side.
 6. Left subclavian.

¹ l. c. § 44. In a female body.

² l. c.

³ l. c.

¹ l. c. Fig. 2.

² Handbuch der Anatomie, B. 3. S. 83.

³ Saggio Terzo di Osservazioni e memoire Pathologico-Anatomiche. Padoua, 1801, p. 44.

⁴ Attii Della Academia di Padoua, T. 3. P. 1. p. 38.

⁵ In Reils Archiv. B. 6. S. 571.

FIGURE V.

Six branches very rarely arise from the arch of aorta. I once happened to see them in the body of a man of forty.¹

a, b.—Arch of the aorta.

1. Right subclavian.
2. Vertebral artery of the right side.
3. Right carotid.
4. Left carotid.
5. Vertebral artery of the left side.
6. Left subclavian.

FIGURE VI.

This exhibits a very rare variety of the aorta observed by HOMMEL,² in which the aorta is seen divided at the commencement of the arch, and again united at its termination. Through this ring, as it were, the trachea and oesophagus pass.

a.—Trunk of the ascending aorta cut near the heart.

b.—Posterior arch.

c.—Anterior arch.

d.—The reunion of both arches.

1. Right carotid artery.
- 2, 3, 4. Right subclavian artery.
5. Left carotid artery.
6. Left subclavian artery.

e.—Trunk of the pulmonary artery.

f.—Right branch of the pulmonary artery.

g.—Left branch of the pulmonary artery.

h.—The remains of the ductus arteriosus (Ligamentum arteriosum Botalli).

i.—The trachea.

k.—The oesophagus.

FIGURE VII.

This shows a remarkable aberration of the aorta described and delineated by VINC. MALACARNE.³ The aorta had scarcely emerged from the left ventricle before it was divided into two trunks. Five semilunar valves were placed at the commencement of the aor-

ta, which was very capacious. Each trunk, the right and left, gave off three branches to its own side, viz. the first the subclavian artery, the second the external carotid, and the third the internal carotid. After having given off these branches, the right and left arches joined together to form the descending or thoracic aorta.¹

a.—Right auricle of the heart.

b.—Pulmonary ventricle.

c, d.—Pulmonary artery.

e.—Left auricle.

f.—Aortic ventricle.

g.—Right coronary artery of the heart.

h.—Left coronary artery.

i.—Right trunk of the aorta.

k.—Left trunk of the aorta.

l.—Aorta descendens.

- 1.—Subclavian artery of the right side.
- 2.—Right external carotid artery.
- 3.—Right internal carotid artery.
- 4.—Left internal carotid artery.
- 5.—Left external carotid artery.
- 6.—Subclavian artery of the left side.

FIGURE VIII.

This shows a variety of the aorta which ZAGORSKY² has observed. The first trunk given off from the arch of the aorta directed its course to the right extremity only, but the second forming an anomalous trunk, divided into the two carotids and left subclavian.

a, b.—Arch of the aorta.

c.—Right subclavian artery.

d.—Anomalous trunk.

e.—Right carotid artery.

f.—Left carotid artery.

g.—Left subclavian artery.

FIGURE IX.

a, b.—Arch of the aorta.

c.—Right subclavian artery.

d.—Right carotid.

e.—Arteria innominata.

f.—Left carotid artery

g.—Left subclavian.

¹ Meckel relates a similar example which was observed by F Müller, (Handbuch der Anat. B. 3. S. 84.

² *Commercium Litter.* Norimberg, 1737. Hebdomas, 21. p. 161. Tab. 2. Fig. 1, 2.

³ *Osservazioni in Chirurgia.* Torino, 1784. P. 2. p. 119. Fig. 1, 2. From the body of a robust man of sixty, who died of apoplexy.

¹ This disposition of the aorta is not unlike that which occurs in Amphibia, lizards, tortoises, serpents and frogs.

² *Mem. de l'Acad. des Sciences de St. Petersburg,* 1809. T. 1. p. 384.

In a body dissected by BERNHARD,¹ the aorta having arisen from the left ventricle, first ascended in a straight direction as far as the region of the third or fourth dorsal vertebra; it was then inclined towards the right, so that it was bent over the right branch of the trachea, and in this manner turned its arch to the right side: it then descended behind the right branch of the trachea, on the right side of the bodies of the vertebrae. By this singular direction, the origin of the larger vessels coming from the arch of the aorta was also changed. Similar cases have been observed by CAILLOT,² J. F. MECKEL,³ and others.

FIGURE X.

This represents the irregular origin of the right mammary artery from the arteria innominata, which NEUBAUER⁴ and WALTER⁵ have described.

- a.—Aorta.
- b.—Arteria innominata.
- c.—The right internal mammary artery, a branch of the arteria innominata.
- d.—Right subclavian.
- e.—Right carotid.
- f.—Carotid of the left side.
- g.—Subclavian of the same side.
- h.—Thoracic aorta cut.

FIGURE XI.

This exhibits the inferior thyroid artery in the body of a boy, coming off from the arteria innominata. This variety which frequently occurs, was seen by HALLER,⁶ NEUBAUER,⁷ HUBER,⁸ LODER,⁹ and SOEMMERRING.¹⁰ I have observed it four times, in the body of a new born infant, in a boy three years old, also in the bodies of two men, the one of twenty the other of sixty years. The infe-

rior thyroid branches arising from the subclavian are generally seen to be small or wanting altogether. I once saw in the body of a man of fifty the inferior thyroid artery arising from the arteria innominata, and a small thyroid artery from the common carotid of the right side.

- a.—Superior part of the sternum.
- b, b.—The clavicles.
- c, c.—The sternal portions of the sterno-mastoid muscles.
- d, d.—Clavicular portions of the same muscles.
- e, e.—The sterno-cleido-mastoidei muscles dissected.
- f, f.—The sterno-hyoid muscles.
- g, g.—The sterno-thyroid muscles.
- h, h.—The omo-hyoid muscles.
- i.—The thyroid gland.
- k.—Trachea.
- l.—Common trunk of the right subclavian and carotid arteries.
- m.—The inferior thyroid artery sending small branches to the thyroid gland.
- n.—Left carotid.

Sometimes the inferior thyroid artery arises from the common carotid itself, which generally does not give off any branches.

NICOLAI,¹ HALLER,² BOEHMER,³ MECKEL,⁴ HUBER,⁵ NEUBAUER,⁶ and J. F. MECKEL⁷ have observed this variety. I have noticed it twice.

Lastly, it may be mentioned here that it is not uncommon for small arteries to arise from the arteria innominata, or from the anterior part of the arch of the aorta, which are distributed to the thymus gland and pericardium, or to the sterno-hyoid and thyroid muscles, or to the bronchia. RUYSCH, HALLER,⁸ J. F. MECKEL,⁹ NEUBAUER,¹⁰ and others, have seen such arteries, and they have occurred to me several times.

¹ De Arteriarum e corde prodeuntium aberrationibus. Bero- lini, 1818, 4 c. tab. aen. In the body of an infant which died a little after birth.

² Bulletin de l'Ecole de Medicine de Paris, 1807, p. 21.

³ Pathol. Anat. B. 2. Abth. 1. S. 97.

⁴ L. c. § 10. ⁵ L. c. Pl. 1.

⁶ Icon. Anatomic, Fasc. 8. p. 60. Note 30.

⁷ L. c. § 6. Tab. 6. He saw it thrice.

⁸ l. c. T. 8. p. 83. He observed it several times.

⁹ l. c. p. 4. Loder observed this variety twice; one ex- ample was in the body of an infant which died a short time after birth, another example was in the body of a woman about thirty years old.

¹⁰ De Corporis Humani Fabrica, T. 5. p. 123. nota q.

¹ De Directione Vasorum, § 7. not. q. p. 28.

² Element. Physiol. T. 3. p. 403.

³ Diss. de Confluxu Trium Cavarum in dextro Cordis atrio; resp. Nic. Theune. Hal. 1763.

⁴ Epistol. ad Hallerum, vol. II. p. 258. The inferior thy- roid artery arose from the left carotid.

⁵ l. c. p. 84. Huber saw this anomaly once in the left side, and thrice in the right.


⁶ l. c. § 7. He observed the inferior thyroid artery arise from the trunk of the right carotid in the body of an adult, as well as in that of a new born child.

⁷ Tabul. Anatom. Patholog. Fasc. 2. T. 10. Fig. 3.

⁸ Icon. Anat. Fasc. 3. p. 25. Fasc. 6. p. 3.

⁹ Epistol. ad Haller. T. 3. p. 80.

¹⁰ l. c. § 9.



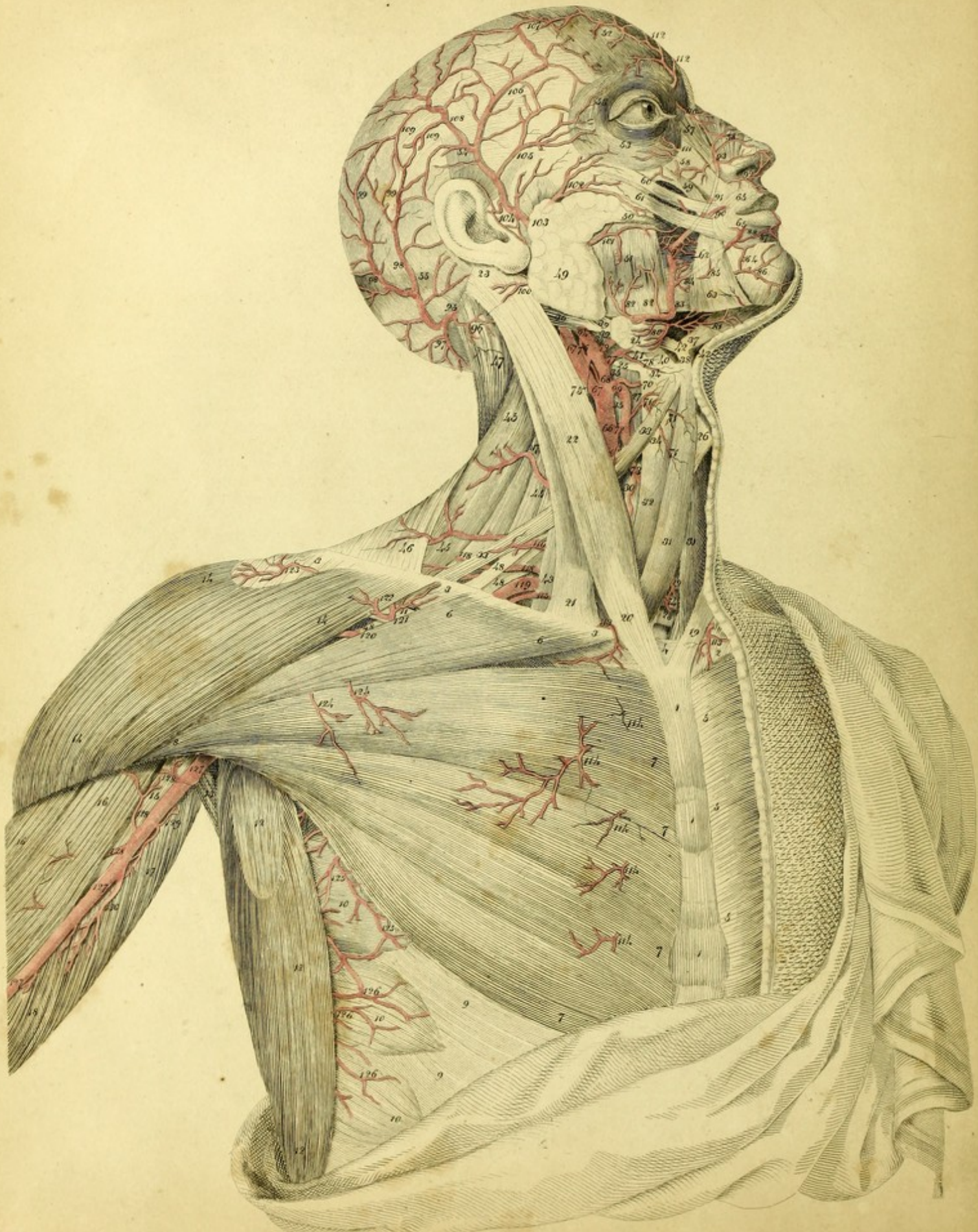


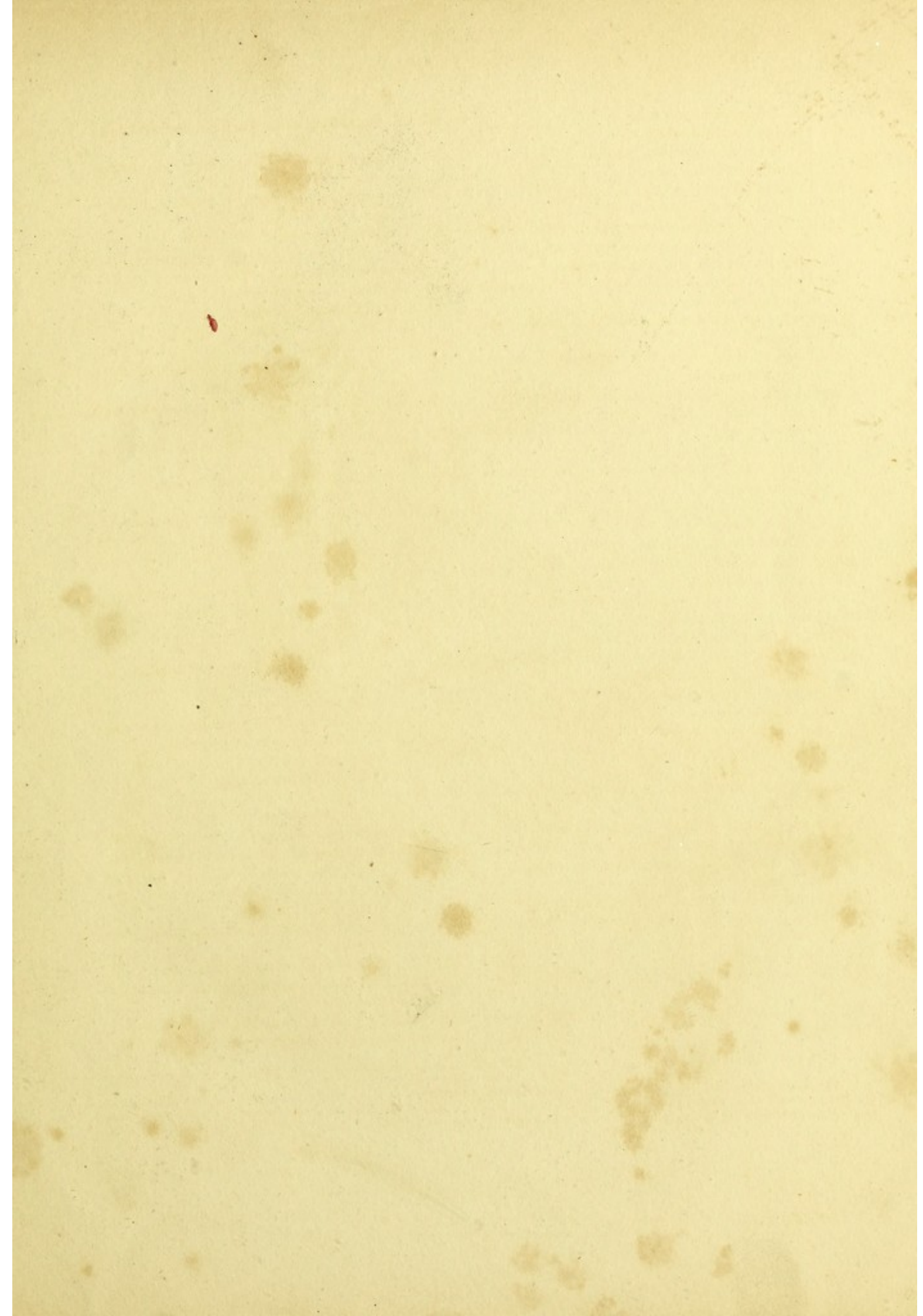PLATE V.

Exhibits the Arteries of the Thorax, Neck, and Head, seen on removing the Platysma Myoides Muscle.

- 1, 1, 1. Sternum
2. Left clavicle.
- 3, 3, 3. Right clavicle.
4. Interclavicular ligament.
- 5, 5, 5. Pectoralis major of the left side.
- 6, 6. Clavicular portion of the pectoralis major of the right side.
- 7, 7, 7, 7. Portions of the pectoralis major, arising from the sternum and costal cartilages.
8. Insertion of the pectoralis major.
- 9, 9. Superior digitations of the external oblique muscle of the abdomen.
- 10, 10, 10. Serratus magnus muscle.
11. Part of the subclavius muscle.
- 12, 12, 12. Latissimus dorsi.
13. Teres major muscle.
- * Teres minor —
- 14, 14, 14. Deltoid —
- 15, Coraco-brachialis —
- 16, 16. Biceps flexor cubiti.
17. Long head of the triceps extensor.
18. Short head —
19. Sternal portion of the left sterno-mastoid muscle.
20. Sternal portion of the right sterno-mastoid muscle.
21. Clavicular portion of the same muscle.
22. Middle part of the sterno-cleido-mastoid.
23. Insertion of the same muscle.
24. Submaxillary gland.
25. Os hyoides.
26. Thyroid cartilage.
27. Superior horn of the thyroid cartilage.
- 28, 29. Trachea.
30. Thyroid gland.
- 31, 31. Sterno-hyoid muscles.
32. Sterno-thyroid muscle.
- 33, 33. Omo-hyoid muscle.
34. Hyo-thyroid —
- 35, 35, 35. Inferior constrictor muscle of the pharynx.
36. Posterior belly of the biventer maxillae.
37. Anterior belly of the same muscle.
38. Aponeurosis of the biventer muscle descending to the hyoid bone.
- 39, 39. Stylo-hyoid muscle, through a slit in which the tendon of the biventer maxillae passes.
40. Tendon of the stylo-hyoid inserted into the hyoid bone.
41. Hyo-glossus muscle.
42. Mylo-hyoideus —
43. Anterior scalenus —
44. Middle and posterior scaleni muscles.
- 45, 45. Levator scapulae.
46. Trapezius.
47. Splenius capitis.
- 48, 48, 48. Inferior cervical nerves proceeding to the brachial plexus.
49. Parotid gland.
50. Steno's duct.
51. Masseter muscle.
52. Frontalis —
- 53, 53. Orbicularis palpebrarum.
54. Attollens auriculam.
55. Occipitalis muscle.
56. Compressor narium.
57. Levator labii superioris alaeque nasi.
58. Levator labii superioris.
59. Levator anguli oris.
60. Zygomaticus minor.
61. Zygomaticus major.
62. Buccinator muscle.
63. Depressor anguli oris.
64. Quadratus menti muscle.

- 65, 65. Orbicularis oris muscle.
 66. Common carotid artery.
 67, 67. Internal or cerebral carotid.
 68. External or facial carotid.
 69. Superior thyroid artery.
 70. Internal laryngeal —
 71, 71, 71. Superficial laryngeal branch, sending twigs to the sterno-hyoid, sterno-thyroid, omo-hyoid, and hyo-thyroid muscles.
 72. A small branch to the sterno-cleido-mastoid and omo-hyoid muscles.
 73. Proper thyroid branch distributed to the thyroid gland.
 74. Twigs of the inferior thyroid artery proceeding to the trachea.
 75. Branch to the sterno-cleido-mastoid muscle.
 76. Ascending pharyngeal artery.
 77. Lingual artery.
 78. Hyoid branch.
 79. Anterior facial, labial, maxillary, or external angular artery.*
 80. Branches to the submaxillary gland.
 81. Submental artery.
 82, 82. Twigs to the masseter muscle.
 83. Superficial labial artery.
 84. Coronary artery of the inferior lip.
 85. Small branch to the depressor anguli oris.
 86. Twigs to the quadratus menti and skin.
 87. Small artery to the orbicularis oris.
 88. Proper coronary branch of the inferior lip perforating the orbicularis oris.
 89. Coronary artery of the superior lip, ascending in a winding manner, and transmitting branches to the buccinator.
 90. Proper coronary branch.
 91. Lateral nasal artery.
 92. Small twig proceeding to the orbicularis oris and septum nasi.
 93. Branch running to the wing, dorsum, and apex of the nose, and anastomosing with the dorsal artery of the nose from the ophthalmic and infra-orbital.
 94. Trunk of the external carotid artery ascending and covered by the digastric muscle of the inferior jaw.
 95. Occipital artery.
 96. A branch running to the muscles of the neck.
 97. Another twig proceeding downwards to the neck.
- 98, 98. Ascending and superficial occipital branches.
 99, 99. Small arteries inosculating with the posterior auricular and temporal arteries.
 100. Posterior auricular artery, sending a twig to the sterno-mastoid muscle.
 101. Transverse artery of the face.
 102. Branch to the orbicularis palpebrarum, zygomaticus major and minor muscles.
 103. Superficial temporal artery.
 104. Anterior auricular arteries.
 105. Anterior temporal branch.
 106. Middle temporal branch.
 107. Twigs anastomosing with the frontal artery.
 108. Posterior temporal branch.
 109, 109. Small branches anastomosing with those of the occipital artery.
 110. Dorsal artery of the nose from the ophthalmic.
 111. Branches of the infra-orbital artery.
 112, 112. Frontal artery.
 113. Small branch of the internal mammary artery running between the sternal and clavicular portions of the sterno-cleido-mastoid muscle.
 114, 114, 114, 114, 114. External perforating twigs of the internal mammary artery, distributed to the pectoralis major muscle, mamma, and skin.
 115. Superior scapular or transverse scapular artery.
 116. Superficial cervical artery.
 117. Branch of the ascending cervical artery.
 118, 118. Transverse artery of the neck.
 119. Subclavian artery.
 120. Arteria thoracica humeraria.
 121. Acromial branch.
 122. Cutaneous twig divided.
 123. Small acromial branch.
 124, 124. Branches of the thoracic artery perforating the great pectoral muscle, and proceeding to the mammary gland.
 125, 125. Long thoracic artery.
 126, 126, 126. Thoracic branches of the subscapular artery.
 127, 127, 127. Trunk of the brachial artery.
 128, 128, 128. Small branches to the biceps and coraco-brachialis muscles.
 129. Small twig to the long head of the triceps.
 130. Arteria profunda humeri.

* The labial artery varies much in the size and distribution of its branches, as HALLER (l. c. Fasc. 3. p. 12. Fasc. 8. p. 12.) has correctly remarked. Sometimes it is so small that it does not even give off the superior coronary artery, at other times so large that all the arteries of the external parts of the nose, the palpebral arteries, nay even the frontal artery itself, are produced from it.



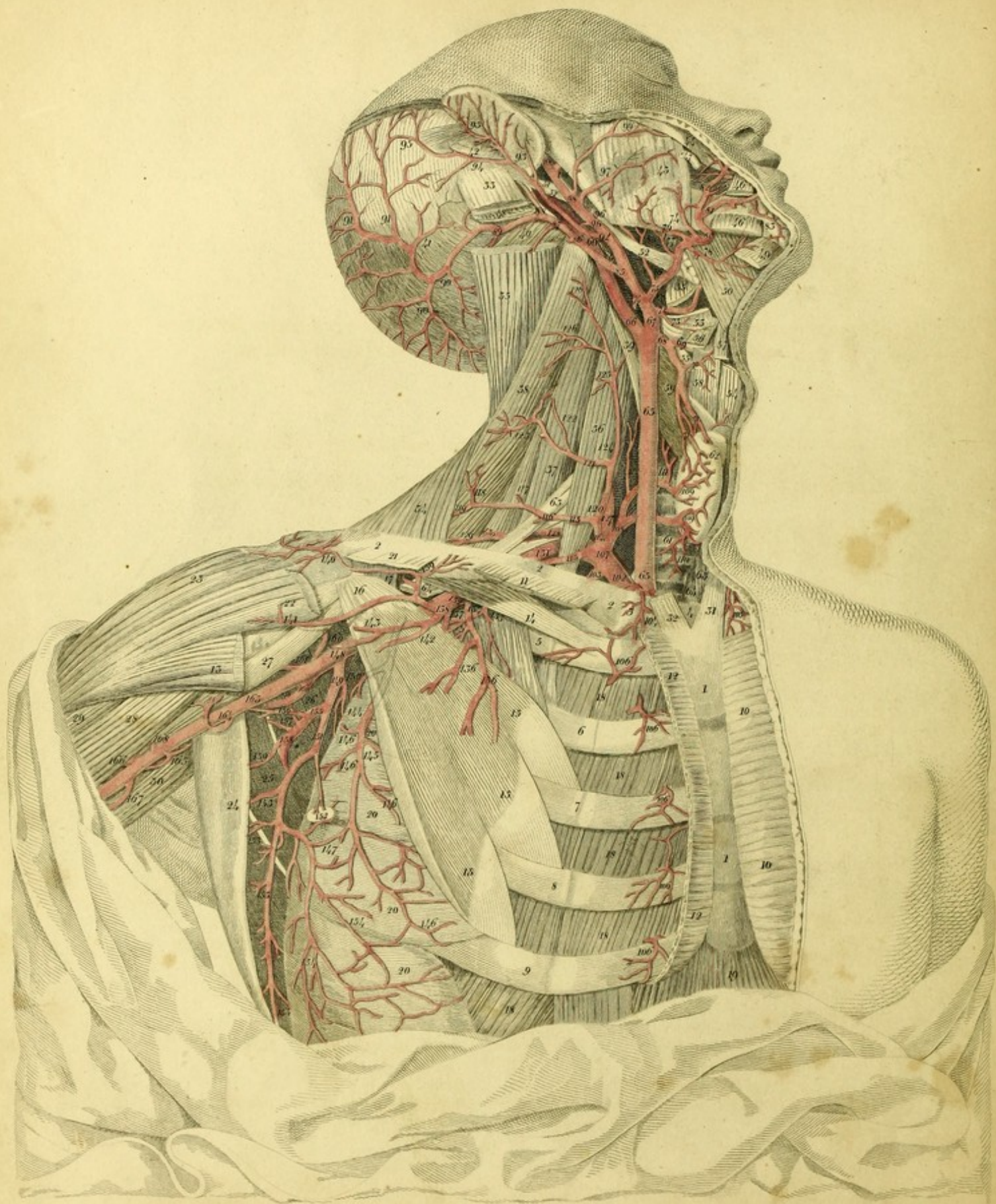


PLATE VI.

This Plate represents the Carotid and Subclavian Arteries, and the Branches which arise from them, according to their usual distribution.

- 1, 1. Sternum.
- 2, 2, 2. Right clavicle.
3. Articulation of the clavicle with the sternum.
4. Interclavicular ligament.
5. First rib.
6. Second rib.
7. Third rib.
8. Fourth rib.
9. Fifth rib.
- 10, 10. Pectoralis major muscle of the left side.
11. Clavicular portion of the pectoralis major of the right side, cut away.
- 12, 12. Sternal portion of the same muscle.
13. Termination of the pectoralis major.
14. Subclavius muscle.
- 15, 15, 15. Origin of the pectoralis minor muscle from the 3d, 4th, and 5th ribs.
16. The insertion of the same muscle into the coracoid process.
17. Anterior common ligament of the scapula.
- 18, 18, 18, 18. Intercostal muscles.
19. Portion of the rectus muscle of the abdomen.
- 20, 20, 20, 20. Serratus magnus muscle.
- 21, 22. Clavicular portion of the deltoid muscle.
23. Deltoid muscle.
24. Latissimus dorsi thrown aside.
25. Teres major muscle.
26. Subscapular muscle.
27. Coraco brachialis.
28. Short head of the biceps.
29. Its long head.
30. Long head of the triceps.
31. Sternal portion of the sterno-cleido mastoideus muscle of the left side.
32. Sternal portion of the right sterno-cleido mastoideus removed.
33. Insertion of sterno-cleido mastoideus.
34. Trapezius.
35. Splenius capitis cut through.
36. Scalenus anticus.
37. Scalenus medius and posticus.
38. The levator scapulæ.
39. Rectus capitis anticus major muscle.
40. Obliquus capitis inferior.
41. Occipitalis muscle.
42. The retrahentes muscles of the ear.
43. The masseter muscle.
44. Zygomaticus major.
45. The buccinator.
- 46, 46. Depressor of the angle of the mouth cut through.
47. Steno's duct dissected back.
48. Origin of the digastric muscle of the lower jaw removed.
49. Insertion of the same muscle.
50. Mylo-hyoideus muscle.
51. Styloid process.
- 52, 52. Stylo-glossus muscle.
- 53, 53. Hyo-glossus muscle cut through.
* Sublingual gland.
54. Thyroid cartilage.
55. Upper horn of the same.
56. Omo-hyoid muscle cut.
57. Sterno-hyoid muscle laid back.
58. Hyo-thyroid muscle.
59. Inferior constrictor of the pharynx.
60. Middle constrictor of the pharynx.
61. The trachea.
62. Thyroid body.
63. Sterno-hyoid muscle of the left side.

64. Sterno-thyroid muscle of the left side.
 65, 65. The common carotid artery.^a
 66, 66. The internal or cerebral carotid.
 67. The external or facial carotid.
 68. The superior thyroid artery.^b
 69. The superior laryngeal artery.^c
 70. Superficial branch which gives off twigs to the sterno-hyoid, omo-hyoid, and hyo-thyroid muscles.
 71, 71. Thyroid branches.
 72. Lingual artery.^d
 73. Hyoid branch.
 74. A small branch, truncated, which proceeded to the sterno-cleido mastoid muscle.
 75. Facial or external maxillary artery.
 76. Ascending palatine artery.
 77. Artery of the tonsil.
 78. Sub-mental artery.
 79. Branch sent to the masseter muscle.
 80. Superficial labial artery.
 81. Coronary artery of the lower lip.
 82. Coronary artery of the upper lip.
 83. A small branch of the inferior maxillary artery which passes through the mental foramen.

^a The common carotid artery sometimes divides much lower than the usual place opposite the horn of the hyoid bone. This unusual division occurs, at one time on both, at another only upon one side; sometimes on the right side, at the distance of not more than an inch from the arteria inominata; and sometimes in different places between this and the common point of separation. MORGAGNI (de Sed. et Causis Morborum, Lib. iii. Epist. 29. Art. 20.)—in a female subject, aged 50, observed the left common carotid artery divided into two branches, scarcely half an inch from its origin. BURNS, (l. c. p. 327.) and RYAN, (l. c. p. 4.) have seen a similar case.

^b The superior thyroid artery sometimes arises from the common carotid artery—(BURNS, B. c. p. 329.—J. F. MECKEL, Patholog. Anat. b. ii. Abth. 1. p. 112.—BARCLAY, a Description of the Arteries of the Human Body, Edin. 1812, S. p. 13.)—and sometimes forms a common trunk with the lingual artery, taking its origin either from the common carotid artery (BOYER,) or from the external carotid artery, (BURNS, l. c. p. 329.)

^c I have often seen the superior laryngeal artery coming off from the trunk of the external carotid. HALLER (Iconum. Anat. Fasc. ii. p. 4.) has observed this distribution five times.

It sometimes arises from the lingual artery, which I once happened to see in the body of a boy twelve years of age. It, for the most part, enters the larynx between the hyoid bone and thyroid cartilage, but seldom proceeds to the interior of it betwixt the thyroid and cricoid cartilage, as is represented by SABATIER, (Traité d'Anatomie, Paris 1781, S. t. 3. p. 15.) and MURRAY, (Descriptio Arter. Corp. Hum. in Tab. Redacta, Lips. 1794. p. 11;) or through the opening in the thyroid cartilage.—(SÖMMERING, l. c. p. 126.)

^d The lingual artery sometimes forms a common trunk with the labial or external maxillary. I have seen this variety ten times. HALLER (b. c. p. 5,) in seven out of 50 subjects, observed the lingual to arise in common with the labial. BURNS (b. c. p. 330.) asserts that he has seen a similar arrangement.

84. The ascending pharyngeal artery.^e
 85. The occipital artery.^f
 86. A small branch to the sterno-cleido mastoid muscle, cut.
 87. A small branch to the splenius capitis muscle.
 88. Stylo-mastoid artery.
 89. A deep branch going to the trachelo-mastoideus, complexus, and splenius colli muscles.
 90, 90. Superficial branches descending to the neck.
 91, 91. Proper occipital branches ascending in a serpentine course.
 92. Posterior auricular artery.^g
 93. Small twigs to the posterior surface of the external ear.
 94. An occipital branch.
 95, 95. Small branches inosculating with twigs from the occipital artery.
 96, 96. Branches of the parotid gland cut.
 97. Transverse artery of the face.^h
 98, 99. A branch sent to the orbicularis palpebrarum, and zygomatic muscles.
 100. Superficial temporal artery.
 101. Internal maxillary artery.
 102. The trunk of the subclavian artery.
 103. Internal mammary artery.
 104. A small branch of the same artery which runs around the clavicle to the pectoralis major muscle, between portions of the sterno-cleido mastoid muscle.
 105. The corresponding small branch of the left side.
 106, 106, 106, 106. The external branches of the internal mammary artery, perforating the intercostal muscles.

^e The ascending pharyngeal artery usually takes its origin either from the external carotid, or at the point where the common carotid divides. I have, however, repeatedly seen it arise from the occipital and superior thyroid. HALLER (l. c. p. 4.) has likewise observed the same arrangement. Sometimes there are two pharyngeal arteries present; one of these branching off from the above-mentioned angle; another immediately below or above the lingual, forms the second or third branch of the external carotid.

^f I have twice seen the occipital artery proceeding from the internal carotid. HALLER gives an account of a similar case, (l. c. p. 2.)

^g The posterior auricular artery frequently arises from the occipital, as HALLER has correctly observed, (l. c. p. 8.)

^h The distribution of the transverse artery of the face is so irregular, that, in the same head, it is seldom alike on both sides. Sometimes it is so large that it sends the whole of the small branches to the upper lip and nose, which commonly are given off by the facial.—(Vide HALLER, Icon. Anat. Fasc. 3, p. 12. Tabula Arteriarum faciei, ubi Arteriam Caronariam labii superioris, emittit.) Sometimes, also, it is so small that it only enters the orbicularis palpebrarum.

107. The inferior thyroid axis giving off the inferior thyroid, supra-scapular superficial, and ascending cervical arteries.
108. Inferior thyroid artery.^a
- 109, 109. Branches proceeding to the thyroid body.
110. A small branch sent to the trachea.
111. The inferior or ascending laryngeal artery.
112. A small branch to the longus colli muscle.
113. Supra-scapular artery.^b
114. The small trunk of the superficial and ascending cervical.
115. Superficial cervical artery.
116. A small branch to the omo-hyoid muscle cut.
- 117, 118. Small twigs proceeding to the levator scapulae.
119. A small branch to the trapezius.
120. Ascending cervical artery.
- 121, 122, 123. Branches running into the levator scapulae.
- 124, 125. Small branches to the scaleni muscles.
126. Small branches to the levator scapulae and muscles of the neck.
127. The vertebral artery.
128. Transverse artery of the neck, or dorsal artery of the scapula.^c
129. A branch running to the trapezius.
130. The trunk of the transverse artery of the neck dipping under the levator muscle of the scapula.
131. The subclavian artery, which, after escaping from between the clavicle and first rib, assumes the name of the axillary artery.
132. The axillary artery.
133. A small branch to the serratus magnus anticus, and first rib.
134. The short thoracic.
135. A twig sent to the lesser pectoral muscle.
- 136, 136. Branches to the pectoralis major muscle truncated.
137. A small twig to the serratus magnus anticus.
138. Humeral, or acromial thoracic artery.
139. A clavicular twig.
140. An acromial branch.
141. Small branch going to the deltoid muscle.
- 142, 143. Minute branches to the greater pectoral muscle cut.
144. The long thoracic.
145. Small branch to the pectoralis minor muscle.
- 146, 146, 146, 146. Small branches to the serratus magnus muscle.
147. A slender twig inosculating with the thoracic artery, which is given off from the subscapular artery.
148. The axillary artery descending between the pectoralis minor, and subscapularis muscles.
149. Subscapular artery.
150. Branch to the subscapular muscle.
151. Thoracic branch.
152. A slender twig to the axillary lymphatic glands.
- 153, 153, 153, 153. Branches which are sent to the latissimus dorsi muscle.
- 154, 154, 154. Small branches to the lower portions of the serratus magnus.
155. Circumflex artery of the scapula.
156. A slender twig to the teres major muscle.
157. Branches to the subscapular and teres minor muscles, and long head of the triceps.
158. Proper circumflex branch.
159. Small branch to the latissimus dorsi.
160. A slender twig to the coraco-brachialis muscle.
161. Anterior circumflex artery of the humerus.
162. Posterior circumflex artery of the humerus.^d
163. Humeral or brachial artery.
164. Branch to the coraco-brachialis and biceps.
165. A small branch to the long head of the triceps.
166. Branch to the biceps.
167. The superior profunda.
168. A small cutaneous branch cut.

^a This artery sometimes originates from the common carotid itself; as has been observed by NICOLAI, (l. c. p. 28.) HALLER, (Elem. Phys. T. iii. p. 403.) VINK, (Van. de Bloed Vaten, p. 50.) BÖHMER, (l. c. p. 81.) NEUBAUER, (l. c. § 7.) J. F. MECKEL, (Epist. ad Hallerum, T. ii. p. 258.) HUBER, (Act. Helvet. T. viii. p. 84.) J. F. MECKEL, (Grandson,) Tab. Anat. Pathol. Fasc. 2 T. x. Fig. 3.)

I have frequently observed this both in men and women. Some times two inferior thyroid arteries are present, either upon the right or left side, one of which arises as usual from the subclavian artery, and the other from the common carotid. BURNS once saw a pretty large artery, branching off from the subclavian, which ultimately separated into the inferior thyroid arteries of the right and left sides.

^b This artery, for the most part, arises from the inferior thyroid, rarely from the subclavian itself. I once saw it given off from the internal mammary artery.

^c The transverse artery of the neck, for the most part, takes its origin from the subclavian artery, seldom from the inferior thyroid.

^d The circumflex arteries of the humerus not unfrequently either arise from, or form a common trunk with, the subscapular artery.




Fig. 3.

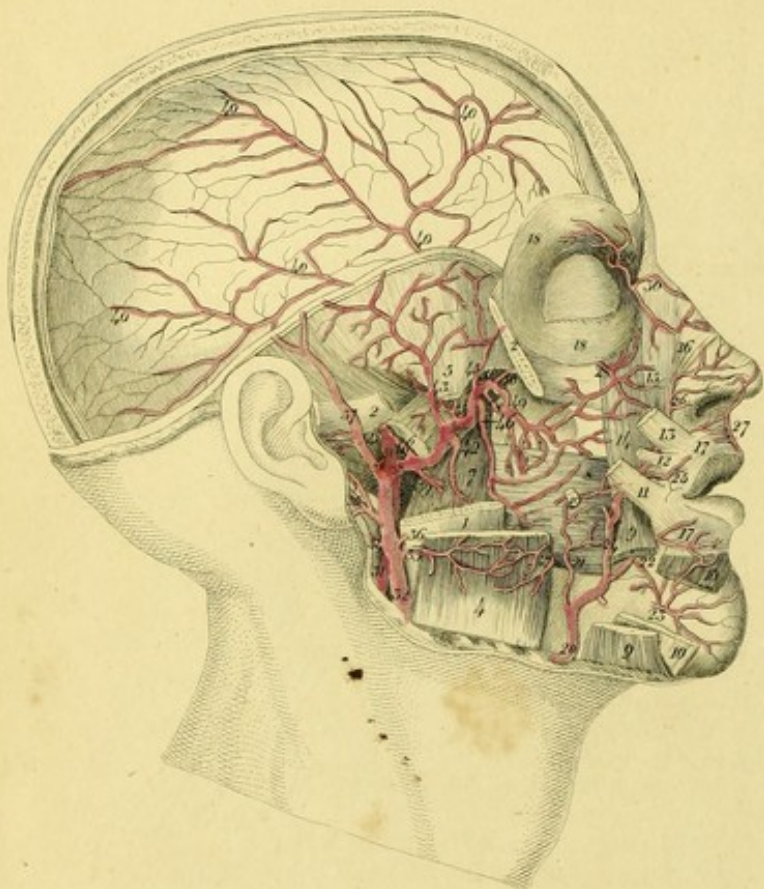


Fig. 2.

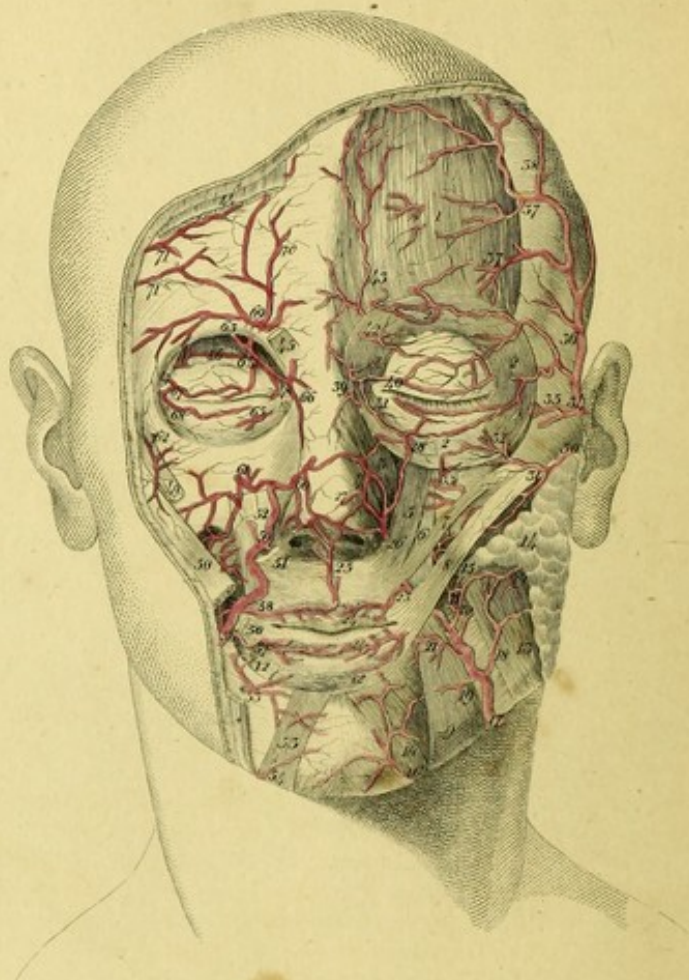


Fig. 1.

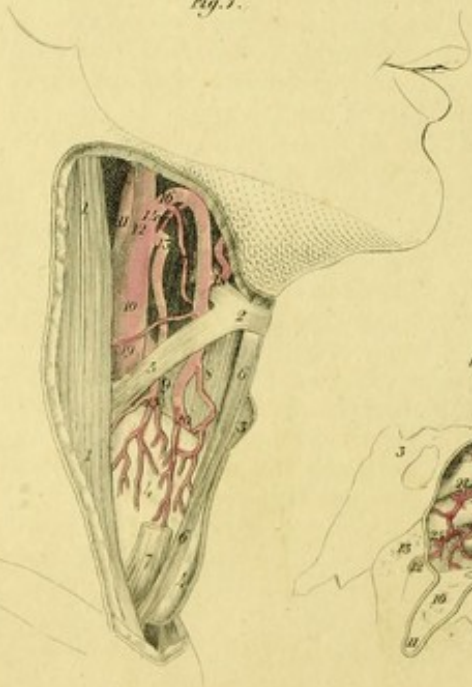


Fig. 4.

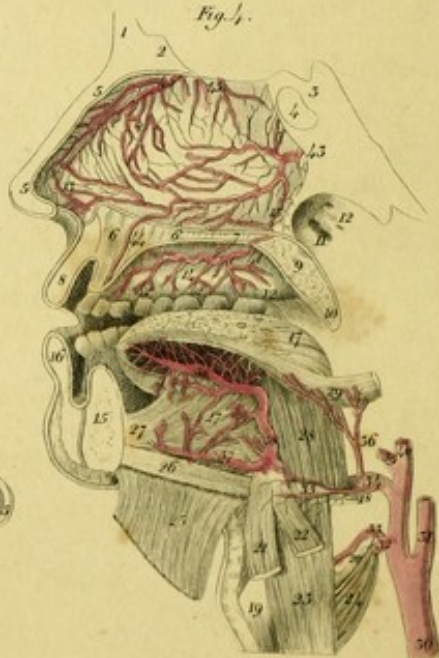


Fig. 5.

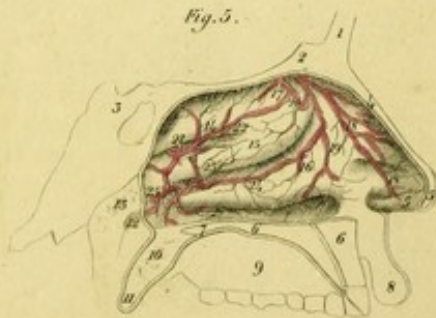


PLATE VII.

FIGURE I.

Exhibits a variety of the Superior Thyroid, and Lingual Arteries, which I observed in the body of a man who died of phthisis pulmonalis.

- 1, 1. Sterno-cleido-mastoideus muscle.
2. The hyoid bone.
3. Thyroid cartilage.
4. Thyroid body.
5. Omo-hyoid muscle.
6. Sterno-hyoid muscle.
7. Sterno-thyroid muscle cut.
8. Hyo-thyroid muscle.
9. Ascending horn of the thyroid cartilage.
10. Primitive carotid.
11. Internal carotid.
12. External carotid.
13. Superior thyroid artery.
14. Dorsal artery of the tongue.
15. Thyroid branches.
16. The other superior thyroid artery, from which are given off the laryngeal and lingual arteries.*
17. Superior laryngeal artery.
18. Lingual artery.
19. A small twig to the sterno-cleido-mastoid muscle.
20. Branches running to the thyroid body.

FIGURE II.

Represents the regular distribution of the Arteries of the Face.

1. The frontalis muscle.
- 2, 2, 2. The orbicularis palpebrarum.

* The superior thyroid artery is frequently to be met with double.

3. Levator labii superioris, alaeque nasi.
4. The compressor muscle of the nose.
5. Levator proprius of the upper lip.
6. Levator of the angle of the mouth.
7. Zygomaticus minor.
8. Zygomaticus major.
9. Depressor of the angle of the mouth.
10. Depressor of the lower lip, or quadratus menti muscle.
11. Buccinator.
12. Orbicular muscle of the mouth.
13. Masseter.
14. The parotid gland.
15. Steno's duct.
16. Small branch of the submental artery ascending to the chin.
17. Labial or external maxillary artery.
18. Slender twig to the masseter muscle.
19. Inosculation with the submental.
20. Small branch to the buccinator.
21. Small branch to the depressors of the angle of the mouth and lower lip.
22. Coronary artery of the lower lip.
23. Coronary artery of the upper lip.
24. Small twigs to the labial glands.
25. Branch to the septum of the nose.
26. Lateral nasal artery.
27. Small branches uniting with those of the right side, at the apex of the nose.
28. Slender branches to the lower eye-lid.
29. Small branch of the transverse artery of the face.
30. Transverse artery of the face.
31. Small branches from it to the zygomatic muscles.
32. Small branch to the lower eye-lid.
33. Small branches of the infra-orbital artery.
34. Superficial temporal artery.
- 35, 35. Small branches to the eye-lids.
36. Anterior temporal branch.

- 37, 37. Small branches to the forehead.
 38. A small ascending branch.
 39. The dorsal artery of the nose from the ophthalmic.
 40. A small cutaneous branch to the superior eye-lid.
 41. Cutaneous twig to the lower eye-lid.
 42. Small branch to the frontal artery sent to the skin of the superior eye-lid.
 43. Frontal artery.
 44. Right frontal muscle cut.
 45. Portion of the corrugator supercilii.
 46. Levator of the upper eye-lid.
 47. Lachrymal gland.
 48. Lachrymal sac with the lachrymal ducts.
 49. Portion of the zygomaticus minor.
 - 50, 50. Zygomaticus major cut through.
 51. Insertion of the levator of the upper lip.
 52. Levator of the angle of the mouth.
 53. Portion of the quadratus muscle of the chin.
 - * Depressor of the angle of the mouth cut.
 54. Small branch of the submental artery going to the chin.
 55. Small branch of the inferior maxillary artery which escapes from the mental foramen, and inosculates with the sub-mental artery and coronary artery of the lower lip.
 56. Labial or external maxillary artery.
 57. Coronary artery of the lower lip.
 58. Coronary artery of the upper lip.
 59. Lateral nasal artery.
 60. Small branch to the apex of the nose.
 61. Infra-orbital artery passing out through the infra-orbital foramen, and uniting with the coronary artery of the upper lip, the lateral nasal, and transverse artery of the face.
 62. Slender twig of the lachrymal artery perforating the zygomatic foramen.
 63. Ophthalmic artery.
 64. Superior palpebral artery.
 65. Inferior palpebral artery.
 66. Dorsal artery of the nose.
 67. Branch of the lachrymal artery to the upper eye-lid.
 68. Branch of the same artery to the lower eye-lid.
 69. Supra-orbital artery.
 70. Ascending branch.
 - 71, 71. Small branches of the temporal artery.
3. Styloid process.
 4. Masseter muscle.
 5. Temporal muscle.
 6. External pterygoid muscle.
 7. Internal pterygoid muscle.
 8. Buccinator.
 - 9, 9. Depressor of the angle of the mouth cut.
 - 10, 10. Quadratus menti muscle cut through.
 11. Part of the zygomaticus major.
 12. Part of the zygomaticus minor.
 13. Portion of the levator of the upper lip.
 14. Levator of the angle of the mouth.
 15. Levator labii superioris alaeque nasi.
 16. Compressor of the nostrils.
 - 17, 17. Orbicularis oris muscle.
 - 18, 18. Orbicularis palpebrarum.
 - 19, 19. Parotid duct, cut.
 20. Labial or external maxillary artery.
 21. Small branch to the buccinator.
 22. Coronary artery of the lower lip.
 23. Mental branch of the inferior maxillary artery.
 24. Trunk of the labial or external maxillary artery ascending to the upper lip and nose.
 25. Coronary artery of the upper lip.
 26. Lateral nasal artery.
 27. Small branch to the septum of the nose.
 28. Infra-orbital artery.
 29. Small branch of the frontal artery to the eye-brow.
 30. Dorsal artery of the nose.
 - 31, 31. Internal carotid.
 32. External carotid.
 33. Branch to the masseter muscle.
 34. Posterior auricular artery.
 35. Deep auricular artery, which often arises from the internal maxillary artery.
 36. The branch of the parotid gland, truncated.
 37. Superficial temporal artery.
 - * Transverse artery of the face, cut.
 38. Internal maxillary artery.
 39. Slender twig to the internal pterygoid muscle.
 - 40, 40, 40, 40. Middle meningeal artery, which enters the cranium through the spinous hole of the sphenoid bone, and there sends off branches to the dura mater.
 41. Tympanic artery, which enters the cavity of the tympanum through the glenoid fissure.
 42. Inferior maxillary artery, which enters the dental canal of the lower jaw, after having given off a small branch to the internal pterygoid muscle.
 43. The first or posterior deep temporal artery.
 44. Small branch to the external pterygoid muscle.
 45. Second or anterior deep temporal artery.
 46. Buccal artery.

FIGURE III.

Shows the course of the Internal Maxillary Artery.

1. The ramus of the lower jaw partly removed.
- 2, 2. Zygomatic arch cut through.

47. Small twig from the above artery to the masseter muscle.
48. Superior palatine artery descending to the pterygoid canal.
49. Alveolar artery.
50. Infra-orbital artery, which passes along the canal of that name to the face.
51. Posterior nasal artery, which enters the cavity of the nostrils between the palate bone and upper jaw.

FIGURE IV.

Gives a delineation of the Lingual Artery, the Descending Palatine, and the Arteries distributed upon the Septum of the Nostrils.

1. Frontal bone.
2. Crista galli of the ethmoid bone.
3. Sphenoid bone.
4. Sphenoidal sinus.
- 5, 5. The external nose cut.
- 6, 6. Upper jaw.
7. Palate bone.
8. Upper lip.
9. Soft palate, or velum pendulum.
10. Uvula.
11. Entrance to the Eustachian tube.
12. Orifices of several mucous follicles.
- 13, 13. Septum of the nose.
14. Palate.
15. Lower jaw.
16. Under lip.
17. The tongue.
18. Posterior horn of the hyoid-bone.
19. Thyroid cartilage.
20. Posterior horn of the same cartilage.
21. Portion of the sterno-hyoid muscle.
22. Part of the omo-hyoid muscle.
23. Hyo-thyroid muscle.
24. Inferior constrictor of the pharynx.
25. Mylo-hyoideus reflected.
26. Genio-hyoideus muscle.
- 27, 27. Genio-hyo-glossus.
28. Hyo-glossus.
29. Stylo-glossus.
30. Common carotid artery.
31. Internal carotid.
32. Thyroid artery, cut.
33. Superior laryngeal artery.
34. Lingual artery.
35. Hyoidean branch.
36. Dorsal artery of the tongue.
37. Sublingual artery.
- 38, 38. Ranine artery.

39. Labial, or external maxillary artery truncated.
40. External carotid artery, cut.
41. Superior or descending palatine artery, a branch from the internal maxillary.
- 42, 42. Small twigs to the gum.
43. Branch of the posterior nasal artery to the septum of the nostrils.
44. Small branch of the same artery, descending through the incisive canal to the palate.
45. 45. Ethmoidal arteries, which are from the ophthalmic, and inosculate with the posterior nasal artery.

FIGURE V.

Represents the Arteries ramified on the turbinated Bones and Meatuses of the Nose.

1. Frontal bone.
2. Part of the crista galli.
3. Sphenoid bone.
4. Nasal bone.
- 5, 5. Wing of the nose.
- 6, 6. Upper jaw.
7. Palate bone.
8. Upper lip.
9. Palate.
10. Soft palate, or velum pendulum.
11. Uvula.
12. Orifice of the Eustachian tube.
13. Mucous follicles.
14. Superior turbinated bone.
15. Middle turbinated bone.
16. Inferior turbinated bone.
17. Small branch of the ethmoidal artery to the septum, cut.
- 18, 18. Small branches of the ethmoidal artery, which proceed to the internal surface of the wing of the nostrils.
19. Small branch extending to the inferior turbinated bone.
20. Slender twig going to the middle turbinated bone.
21. Branch of the posterior nasal artery proceeding to the turbinated bones.
22. Small twig going to the upper turbinated bone.
23. Small branch to the middle turbinated bone.
24. Slender twig proceeding to the lower turbinated bone.
25. Small branch to the Eustachian tube.
26. Minute twig to the lower meatus of the nostrils.




Fig. 1.

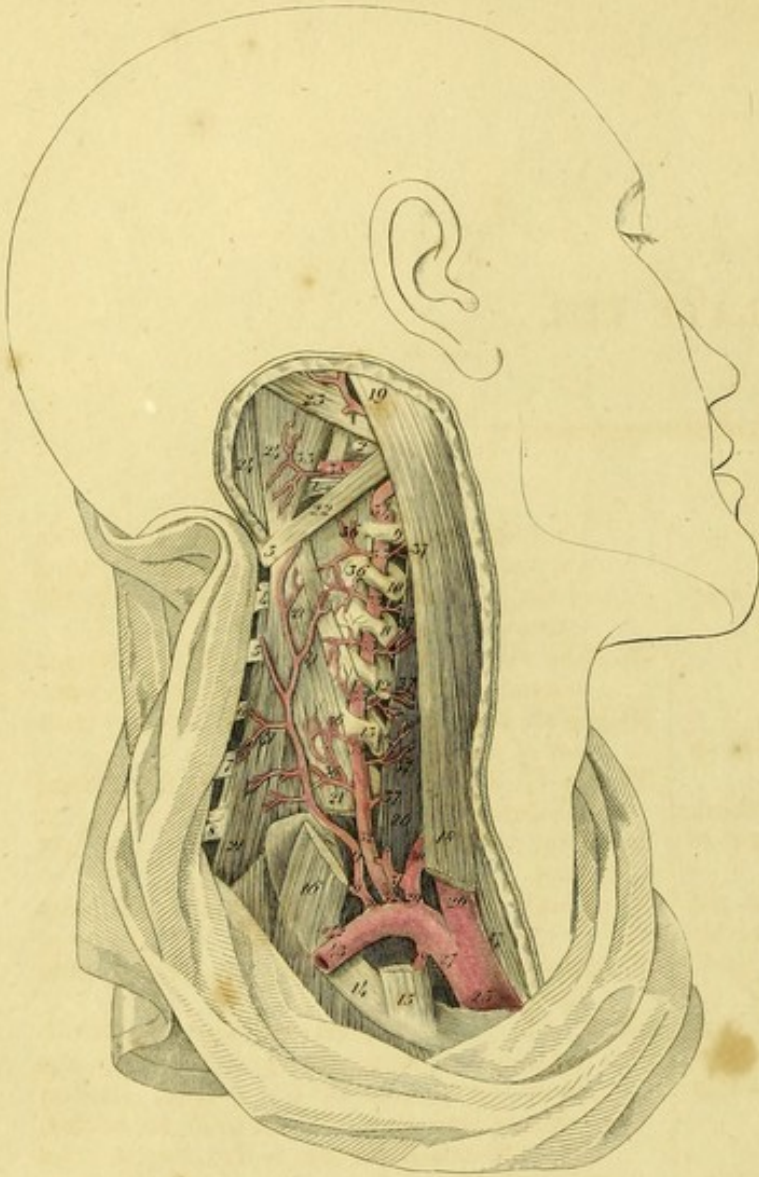

Fig. 2.

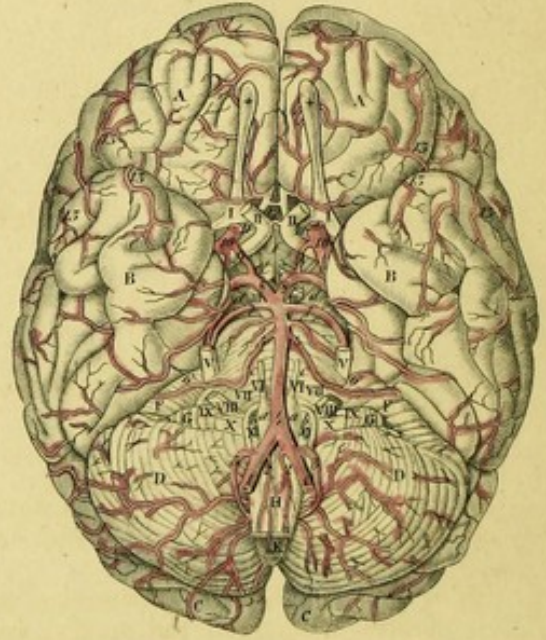


Fig. 6.

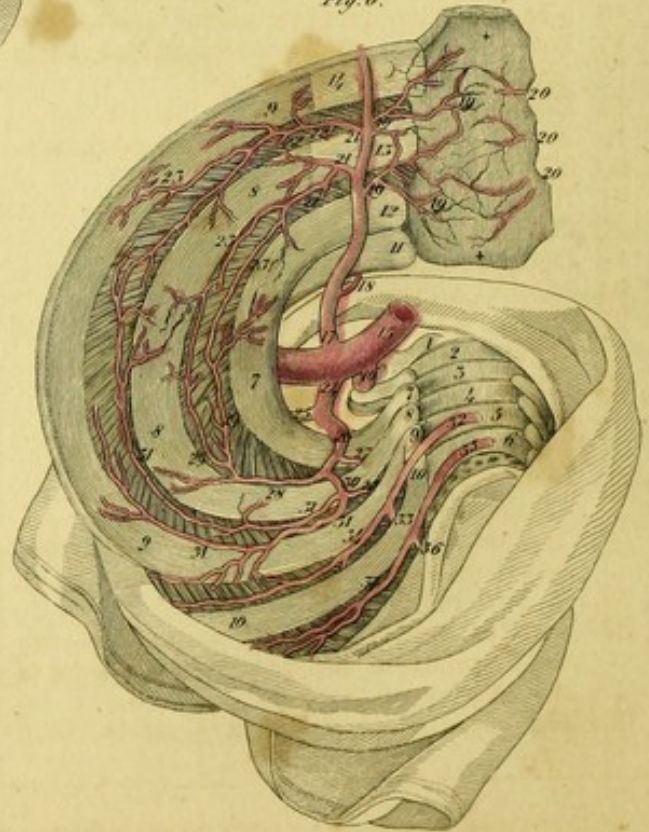


Fig. 3.

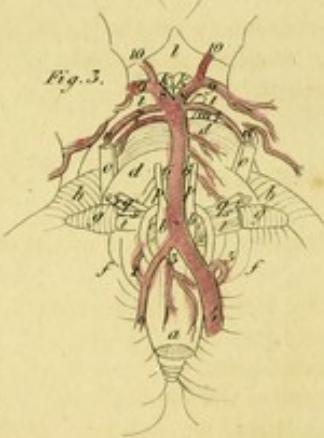


Fig. 4.



Fig. 5.

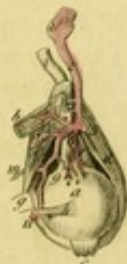

PLATE VIII.

FIGURE I.

Represents the Course of the Vertebral and deep Cervical Arteries.

1. Posterior arch of the atlas.
2. Transverse process of the same vertebra.
3. Spinous process of the second vertebra of the neck.
- 4, 5, 6, 7, 8. Spinous processes of the third, fourth, fifth, sixth, and seventh vertebrae of the neck.
- 9, 10, 11, 12, 13. Transverse processes of the second, third, fourth, fifth, and sixth vertebrae of the neck.
14. The first rib.
15. Insertion of the scalenus anticus muscle, cut.
16. The middle and posterior scalmi muscles, cut.
17. Sternal portion of the sterno-cleido-mastoid muscle.
18. Clavicular portion of the same muscle.
19. Insertion of the sterno-cleido-mastoid muscle.
20. The longus colli muscle.
- 21, 21, 21. Semi-spinalis colli.
22. Obliquus capitis inferior.
23. Obliquus capitis superior.
24. Rectus capitis posticus major.
25. Arteria innominata, or the common trunk of the right carotid and subclavian arteries.
26. The common carotid.
27. The subclavian artery.
28. Internal mammary artery.
29. Inferior thyroid axis.
30. Inferior thyroid artery.
31. The common trunk of the supra-scapular, superficial and ascending cervical, arteries.
- 32, 32. Vertebral artery.^a
33. Vertebral artery proceeding upwards through the foramina in the transverse processes of the vertebrae of the neck.
34. The curve which this artery makes, from

the point where it escapes from the hole in the transverse process of the second vertebra of the neck, till it arrives at the hole in the transverse process of the atlas.

35. The same artery proceeding to the foramen magnum between the atlas and occipital bone.
- 36, 36, 36, 36. Small branches to the deep muscles of the neck.
- 37, 37, 37, 37. Small branches to the longus colli, and rectus capitis anticus major muscles.
38. Twig to the posterior recti muscles of the head.
39. Trunk of the superior intercostal and deep cervical, arteries.^b
40. Superior intercostal artery descending into the thorax.
- 41, 41, 41. The deep cervical artery which directs its course to the neck, between the transverse process of the seventh cervical vertebra and first rib, and, in its ascent, gives off small branches to the deep muscles of the neck.
42. The transverse artery of the neck, or dorsal artery of the scapula, truncated.
43. Subclavian artery.

FIGURE II.

Exhibits the Arteries of the Base of the Brain.

- A, A. The anterior lobes of the cerebrum.
- B, B. The middle lobes.
- C, C. The posterior lobes.
- D, D. Hemispheres of the cerebellum.
- E. Vermiform process, or inferior commissure of the cerebellum.
- F, F. Lower surface of the anterior lobe of the cerebellum.
- G, G. The lobules of the pneumo-gastric nerves.
- H. Medulla spinalis, cut.

^a The vertebral artery sometimes enters the hole in the transverse process of the fifth, fourth, third, nay, even the second, but very rarely that of the seventh vertebra of the neck.

^b These arteries sometimes arise separately from the subclavian artery.

- a, a.* The corpora pyramidalia.
b, b. The corpora olivaria.
c, c. The pons Varolii, or tuber annulare.
d, d. The crura cerebri.
e, e. Eminentiae candicantes.
f. The infundibulum.
 I, I. The olfactory nerves.
 * * Olfactory bulbs.
 II, II. Optic nerves.
 III, III. The third pair, or common oculo-muscular nerves.
 IV, IV. The fourth pair, or trochleares, or internal oculo-muscular nerves.
 V, V. Fifth pair, or trifacial nerves.
 VI, VI. Sixth pair, or external oculo-muscular nerves.
 VII, VII. The facial nerves, or portiones duræ of the seventh pair.
 VIII, VIII. The auditory nerves, or portiones molles of the seventh pair.
 IX, IX. Glosso-pharyngeal nerves.
 X, X. The pneumo-gastric nerves.
 XI, XI. The ninth pair, or great hypoglossal nerves.
 1, 1. The vertebral arteries.
 2, 2. Anterior spinal arteries.
 3, 3. Inferior and posterior cerebellar arteries from which the posterior spinal arteries arise.
 4, 4. Basilar artery.
 5, 5. The inferior and anterior arteries of the cerebellum.
 6, 6. Arteries of the internal ear truncated.
 7, 7. Superior cerebellar arteries.
 8, 8. Deep or posterior cerebral arteries.
 9, 9. The communicating arteries.
 10, 10. Internal carotid arteries.
 11, 11. Anterior cerebral arteries, or arteries of the corpus callosum.
 12. Communicating branch.
 13, 13, 13, 13, 13. Small branches to the fossa of Sylvius.

FIGURE III.

Shows a Variety which I observed in the Vertebral Arteries of an Adult Male.

- a.* Medulla spinalis.
b, b. Corpora pyramidalia.
c, c. Corpora olivaria.
d, d. Pons Varolii, or tuber annulare.
e. Inferior vermiform process of the cerebellum.
f, f. The cerebellum.
g, g. The lobules of the pneumo-gastric nerves.
h, h. Anterior lobules of the cerebellum.
i, i. Crura cerebri.
k, k. Eminentiae candicantes.
l. Infundibulum.

- m.* Nerve of the third pair.
n, n. Fourth pair.
o, o. Fifth pair.
p, p. Sixth pair.
q, q. Facial nerves.
r, r. Auditory nerves.
s, s. Glosso-pharyngeal nerves.
t, t. Pneumo-gastric nerves.
u, u. Hypo-glossal nerves.
 1. Right vertebral artery, which is seen unusually small.
 2. Inferior and posterior cerebellar artery of the right side.
 3. Trunk of the anterior arteries of the medulla spinalis.
 4. Left vertebral artery, remarkably large.
 5. The left inferior and posterior cerebellar artery, larger than that of the right side.
 * Basilar artery.
 6, 6. The inferior and anterior cerebellar arteries, differing in magnitude, the right being larger than the left.
 7, 7. Superior cerebellar arteries.
 8, 8, 9, 9. Deep cerebral arteries.
 10, 10. The Branches communicating with the internal carotid arteries.

FIGURE IV.

Represents the Superior Branches of the left Ophthalmic Artery.

- a, a.* Orbicularis palpebrarum muscle.
b, b. Levator palpebrae superioris.
c. Rectus superior, or attolens oculum.
d. Rectus externus, or abductor oculi.
e. Rectus internus, or adductor oculi.
f. Superior oblique muscle of the eye.
g. Trochlea or pulley.
h. Tendon of the superior oblique passing through the trochlea.
i. The lachrymal gland.
k. The optic nerve.
 1. The last turn of the internal carotid artery, from which is given off the ophthalmic artery.
 2. Ophthalmic artery.
 3. Lachrymal artery.
 4. Twig proceeding to the abductor oculi.
 5. Slender branches going to the lachrymal gland.
 6, 6. Palpebral or tarsal artery, anastomosing with the superior palpebral artery.
 7. Trunk of the ophthalmic artery crossing the optic nerve.
 8. Posterior ethmoideal artery.
 9. Anterior ethmoideal artery.

10. Supra-orbital artery.
11. Small branch to the levator palpebrae superioris.
12. Ophthalmic artery proceeding to the inner canthus of the eye.
13. Dorsal artery of the nose.
14. Frontal artery.
15. Superior palpebral artery.
16. Inferior palpebral artery.

FIGURE V.

Shows the deep Branches of the Ophthalmic Artery.

- a. Ball of the eye.
- b. The attollens oculum, cut and reflected.
- c. Insertion of the same muscle.
- d. Abductor oculi.
- e. Depressor oculi.
- f. Superior oblique muscle.
- g. Trochlea.
- h. Tendon of the superior oblique.
- i. The optic nerve.
1. The flexure of the internal carotid.
2. Ophthalmic artery.
3. Central artery of the retina.
- * Slender twig going to the attollens oculum, cut.
4. Small branch to the same muscle and levator palpebrae superioris.
5. Lachrymal artery cut.
6. Inferior muscular artery.
- ** Ciliary arteries.
7. Trunk of the ophthalmic artery going across the optic nerve.
- * Posterior ethmoideal artery.
8. Small branch to the superior oblique muscle, as also the anterior ethmoideal artery.
9. Ciliary arteries.
10. Supra-orbital artery.
11. Continuation of the artery, cut.

FIGURE VI.


Exhibits the internal Mammary and Superior Intercostal Arteries, as they occurred in the body of a full grown man.

1. Seventh vertebra of the neck.

- 2, 3, 4, 5, 6. The upper dorsal vertebrae.
- 7, 7. First Rib.
- 8, 8, 8. Second rib.
- 9, 9, 9. Third rib.
- 10, 10. Fourth rib.
- ** The sternum.
11. The clavicle.
- 12, 13, 14. Costal cartilages.
15. Subclavian artery.
16. Vertebral artery.
17. Internal mammary artery.^a
18. Small branch which proceeds around the clavicle from the cavity of the thorax.
- 19, 19. Sternal branches.
- 20, 20, 20. Sternal branches of the left side cut, which inosculate with the former.
- 21, 21. Intercostal branches.
- 22, 22, 22. External thoracic branches which perforate the intercostal muscles.
- 23, 23, 23. Intercostal branches which anastomose with the proper intercostal arteries.
24. Trunk of the deep cervical and first intercostal arteries arising from the subclavian.^b
25. Deep cervical artery.
26. Superior intercostal artery crossing the first rib.
- 27, 27. Dorsal branches which perforate the intercostal muscles and proceed to the muscles of the back.
28. First intercostal artery.
- 29, 29. Superior and inferior branches.
30. Second intercostal artery.
- 31, 31, 31, 31. Superior and inferior branches.
32. Third intercostal artery arising from the aorta.
33. Dorsal branch of the same artery.
34. Proper intercostal branch.
35. Fourth intercostal artery.
36. Dorsal branch.
37. Intercostal branch.

^a The origin of this artery is sufficiently uniform, for it very rarely arises either from the arch of the aorta, or the arteria innominata. J. J. HUBER, (Act. Helv. T. 8. p. 92.) once saw it given off from the inferior thyroid artery. I have twice observed a similar origin.

^b They often arise separately from the subclavian artery.



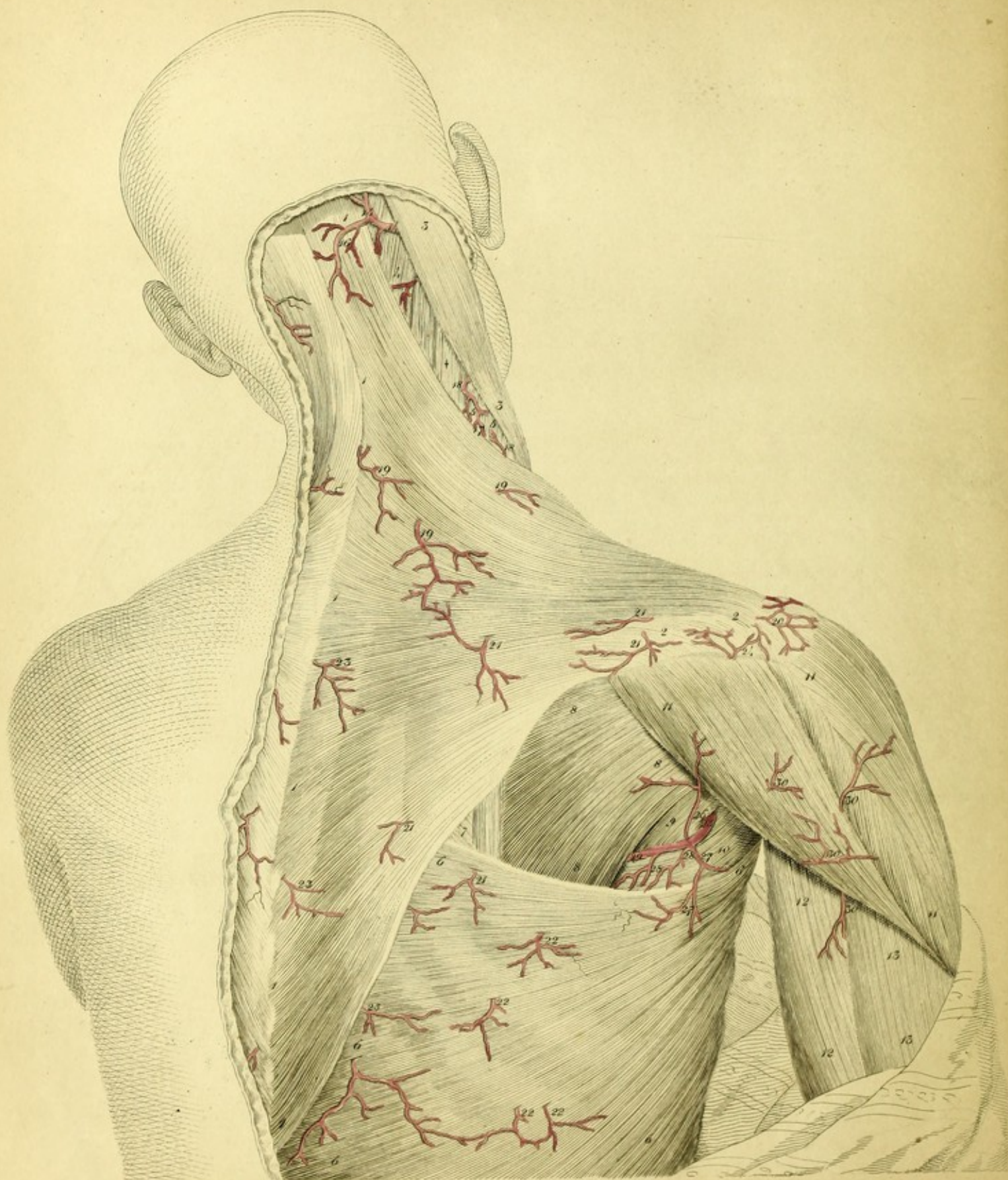


PLATE IX.

This Plate exhibits the Arteries of the Neck, Back, and Scapula, which are met with in the first layer of Muscles beneath the Skin.

- 1, 1, 1, 1, 1, 1. Origin of the trapezius muscle.
- 2, 2, 2. Insertion of the same muscle.
- 3, 3, 3. Sterno-cleido-mastoid muscle.
4. Splenius capitis.
- 5, 5. Levator scapulae
- * Scalenus posticus.
- 6, 6, 6, 6, 6. Latissimus dorsi muscle.
7. Rhomboideus major muscle.
- 8, 8, 8. Infra-spinatus.
9. Teres minor
10. Teres major.
- 11, 11, 11. Deltoid.
- 12, 12. Long head of the triceps extensor cubiti.
- 13, 13. Second or external head of the same muscle.
14. Occipital artery.
15. Proper occipital branch.
16. Superficial cervical branch.
17. Small branch of the ascending cervical artery to the trapezius.
- 18, 18. Small branches of the same artery to the levator muscle of the scapula and scalenus posticus.
- 19, 19, 19. Slender twigs of the superficial cervical artery to the trapezius and skin.
20. Minute ramifications of the supra-scapular and acromial arteries.
- 21, 21, 21, 21, 21. Small branches of the dorsal artery of the scapula to the skin, trapezius, and latissimus dorsi.
- 22, 22, 22, 22. Minute branches of the inter-costal arteries to the latissimus dorsi and skin.
- 23, 23, 23, 23. Dorsal branches of the inter-costal arteries.
24. Branch of the supra-scapular artery to the acromion.
25. Circumflex artery of the scapula.
26. Branch to the infra-spinatus and deltoid muscles.
- 27, 27. Branch to the latissimus dorsi muscle.
- 28, 28. Small branches to the teres major muscle.
29. Deep circumflex branch.
- 30, 30, 30, 30. Small branches given off from the posterior circumflex artery of the humerus to the deltoid and triceps muscles.

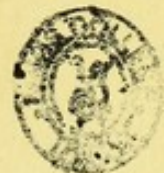

PLATE IX.

This Plate exhibits the Arteries of the Neck, Back, and Scapula; which are met with in the first layer of Muscles beneath the Skin.

- | | |
|---|--|
| <p>18. 19. 20. 21. 22. 23. 24. 25. 26. 27. 28. 29. 30. 31. 32. 33. 34. 35. 36. 37. 38. 39. 40. 41. 42. 43. 44. 45. 46. 47. 48. 49. 50. 51. 52. 53. 54. 55. 56. 57. 58. 59. 60. 61. 62. 63. 64. 65. 66. 67. 68. 69. 70. 71. 72. 73. 74. 75. 76. 77. 78. 79. 80. 81. 82. 83. 84. 85. 86. 87. 88. 89. 90. 91. 92. 93. 94. 95. 96. 97. 98. 99. 100.</p> | <p>1. 2. 3. 4. 5. 6. 7. 8. 9. 10. 11. 12. 13. 14. 15. 16. 17. 18. 19. 20. 21. 22. 23. 24. 25. 26. 27. 28. 29. 30. 31. 32. 33. 34. 35. 36. 37. 38. 39. 40. 41. 42. 43. 44. 45. 46. 47. 48. 49. 50. 51. 52. 53. 54. 55. 56. 57. 58. 59. 60. 61. 62. 63. 64. 65. 66. 67. 68. 69. 70. 71. 72. 73. 74. 75. 76. 77. 78. 79. 80. 81. 82. 83. 84. 85. 86. 87. 88. 89. 90. 91. 92. 93. 94. 95. 96. 97. 98. 99. 100.</p> |
|---|--|





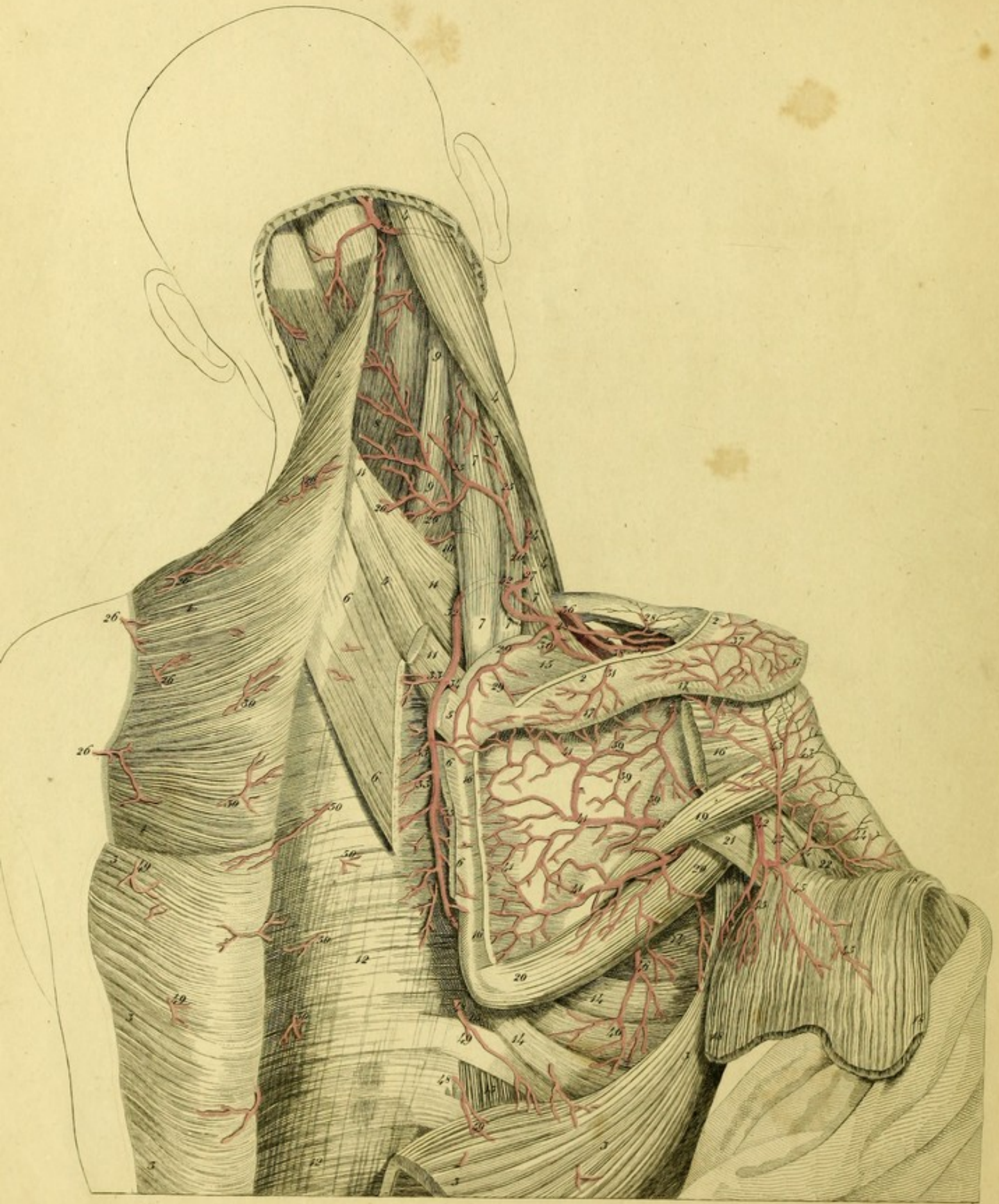



PLATE X.

This Plate represents the Ramifications of the Arteries distributed to the Muscles of the Neck, Back, and Scapula.

- 1, 1, 1. Trapezius cut through and reflected.
- 2, 2. Insertion of the same muscle.
- 3, 3, 3, 3, 3, 3. Latissimus dorsi divided and thrown aside.
- 4, 4. Sterno-cleido-mastoid muscle.
- 5, 5. Rhomboideus minor.
- 6, 6, 6, 6. Rhomboideus major cut through.
- 7, 7, 7, 7, 7. Levator Scapulæ.
- 8, 8. Splenius capitis.
- 9, 9. Splenius colli.
10. Transversalis colli.
- 11, 11, 11. Serratus posticus superior.
- 12, 12, 12. Vertebral aponeurosis binding down the long muscles of the back.
- 13, 13. External intercostal muscles.
- 14, 14, 14. Serratus magnus.
15. Supra spinatus.
16. Origin and insertion of the infra-spinatus.
17. Origin of the deltoid.
- 18, 18, 18. Deltoid divided at its origin, and drawn downwards.
19. Teres minor.
20. Teres major.
21. Long head of the triceps.
22. External or middle head of the triceps.
23. Occipital artery.
24. Superficial cervical artery.
- 25, 25. Small branches going to the levator muscle of the scapula and splenii muscles.
- 26, 26, 26, 26, 26. Slender branches distributed to the trapezius, cut.
27. Transverse artery of the neck, proceeding between the fasciculi of the levator of the scapula.
- 28, 28. A twig sent to the clavicle.
- 29, 29. Small branch to the supra-spinatus muscle.
- 30, 30, 30. Small branches distributed to the trapezius muscle.
31. Slender branch perforating the insertion of the trapezius, and crossing the spine of the scapula.
- 32, 32. Dorsal artery of the scapula.
- 33, 33, 33. Small branches which are sent to the rhomboideus major and serratus posticus superior muscles.
34. Branch descending under the scapula, and proceeding to the subscapularis muscle.
- 35, 35. Minute branches going to the subscapularis muscle.
36. Supra-scapular artery.
- 37, 37. Superficial scapular branch perforating the trapezius, and giving off twigs to the skin covering the upper part of the arm, and to the deltoid muscle. It anastomoses with the acromial artery.
- 38, 38. A branch descending through the great notch of the scapula to the fossa infra-spinata.
- 39, 39, 39. Small branches of the same artery which inosculate with the circumflex artery of the scapula.
40. Trunk of the subclavian artery.
- 41, 41, 41, 41, 41, 41. Branches of the circumflex artery of the scapula.
42. Posterior circumflex artery of the humerus.
- 43, 43, 43. Branches entering the infra-spinatus, teres minor, and articular capsule of the humerus.
- 44, 44. Slender branches to the periosteum of the humerus.
- 45, 45, 45. Small twigs going to the deltoid muscle.
- 46, 46. Branch of the long thoracic artery proceeding to the serratus magnus muscle.
47. Branch of the same artery sent into the latissimus dorsi muscle.
- 48, 49. Branches of the inter-costal arteries to the latissimus dorsi.
50. Dorsal Branches of the intercostal arteries.



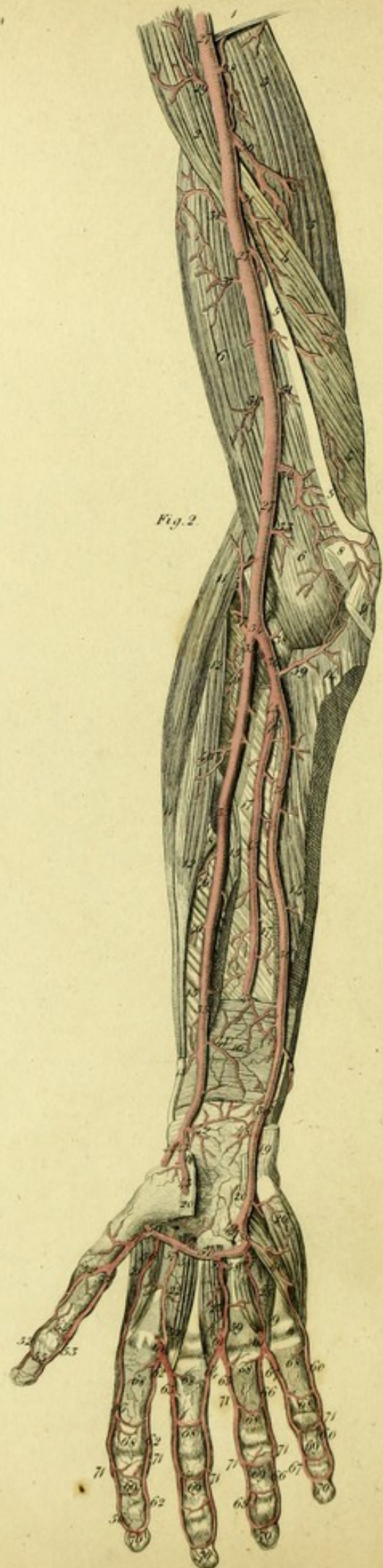
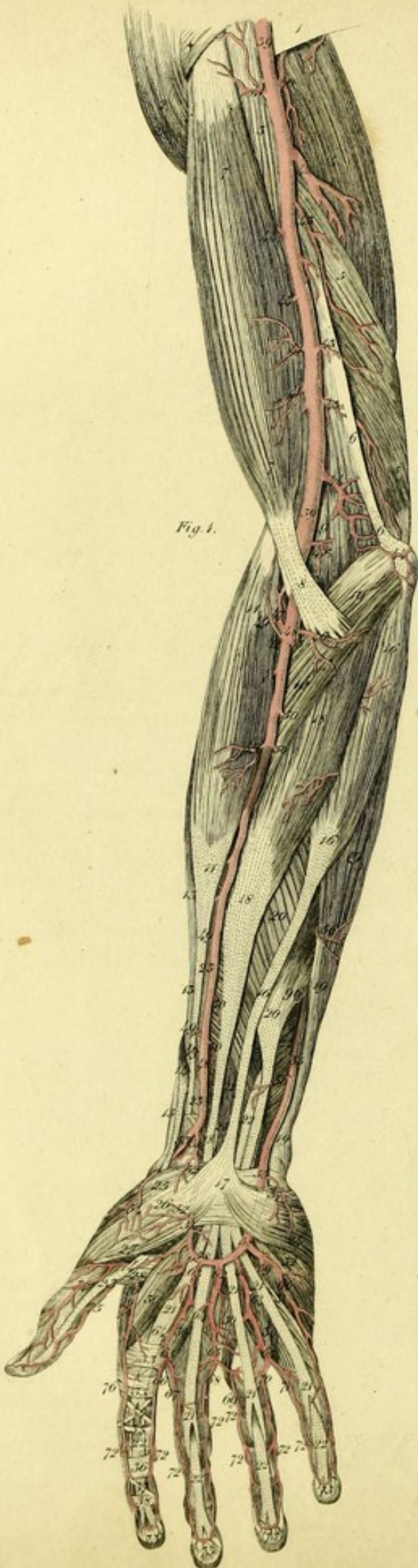


PLATE XI.

This exhibits, according to their regular order, the Arteries of the Anterior Aspect of the Superior Extremity, Right Side.

FIGURE I.

In this Figure are seen the Arteries which are situated beneath the Skin, and Aponeurosis of the Upper Extremity.

- | | |
|---|---|
| <ol style="list-style-type: none"> 1. Insertion of the latissimus dorsi muscle. * Termination of the pectoralis major. 2. The deltoid muscle. 3. Coraco-brachialis. 4. Long head of the triceps. 5. Short head of the same muscle. 6. Internal intermuscular ligament. 7, 7. Biceps flexor cubiti. 8. Aponeurosis of this muscle. 9. Brachialis internus. 10, 10. Pronator teres. 11, 11. Supinator radii longus. 12. Supinator brevis. 13. Extensor carpi radialis longior. 14. Extensor ossis metacarpi pollicis. 15. Extensor primi internodii pollicis. 16, 16, 16. Palmaris longus. 17. Palmar aponeurosis. 18, 18, 18. Flexor carpi radialis. 19, 19, 19. Flexor carpi ulnaris. 20, 20. Flexor communis digitorum sublimis
<i>seu perforatus.</i> 21, 21, 21, 21. The tendons of this muscle. 22, 22. Flexor communis digitorum profundus
<i>seu perforans.</i> 23, 23. Flexor longus pollicis. 24. Palmaris brevis. 25. Opponens pollicis. 26. Abductor pollicis. 27. Flexor brevis pollicis. 28. Adductor pollicis. 29. Abductor, or prior indicis. 30, 30, 30, 30. Lumbricales muscles. | <ol style="list-style-type: none"> 31. Flexor brevis minimi digiti. 32. Abductor minimi digiti. 33. Fibrous sheath which binds down the tendons on the first phalanx of the fore-finger. 34. Crucial ligament of the first phalanx of the fore-finger. 35. Transverse ligament _____ 36. Fibrous sheath of the second phalanx. 37. Oblique ligament of the second phalanx of the same finger. 38. Annular ligament surrounding the articulation of the second and third phalanges. 39, 39. The brachial or humeral artery, proceeding from the cavity of the axilla. 40. A small branch to the triceps. 41, 41, 41. Small twigs to the coraco-brachialis and biceps. 42. Arteria profunda, or great collateral artery descending between the two lower heads of the triceps. 43, 43. Branches to the triceps. 44, 44. Ramus anastomoticus, or ulnar collateral artery. 45. A small branch to the brachialis internus. 46. A twig to the pronator teres, and flexor carpi radialis. 47. Radial recurrent artery. 48, 48. Radial artery. 49, 49, 49, 49. Small branches to the supinator longus, extensor carpi radialis longior and brevis, likewise to the extensors, the abductor, and long flexor of the thumb. 50, 50, 50, 50. Twigs proceeding to the pronator teres, flexor carpi radialis, and the flexors of the fingers. 51, 51. Superficial volar artery. 52, 52. Twigs to the small muscles of the thumb. 53. Trunk of the radial artery passing to the back of the wrist. |
|---|---|


54. A slender branch to the abductor, opponens, and flexor brevis pollicis.
- 55, 55, 55. Ulnar artery.
56. 56, 56. Twigs sent to the flexor carpi radialis, flexor carpi ulnaris, palmaris longus, and flexors of the fingers.
57. A small branch to the palmaris brevis.
- 58, 58, The ulnar artery in the palm of the hand, forming, with the superficialis volae of the radial artery, the superficial palmar arch.
59. Deep palmar artery.
60. First digital artery.
61. Second digital artery.
62. Third digital artery.
63. Fourth digital artery.
64. Twigs to the skin of the palm truncated.
- 65, 65, 65. Subdivision of the second, third, and fourth digital arteries.
The fourth digital artery divides into
- 66 The digito-ulnar artery of the fore-finger, and
67. The digito-radial artery of the middle finger. The third digital artery divides into
68. The digito-ulnar artery of the middle finger and
69. The digito-radial artery of the ring-finger. The second digital artery divides into
70. The digito-ulnar of the ring-finger, and
71. The digito-radial of the little finger.
- 72, 72, 72, 72, 72. 72, 72, 72, 72. Twigs which the digital arteries send to the back of the fingers.
- 73, 73, 73, 73. The digital arteries forming arches.
- 74, 74. Anterior digito-radial artery of the thumb arising from the arteria magna pollicis.
75. Anterior digito-ulnar artery of the thumb coming off from the same artery.
- 76, 76. Anterior digito-radial artery of the fore-finger
- 14, 14. Part of the flexors of the fingers.
- 15, 15. Flexor longus pollicis.
16. Pronator quadratus.
- 17, 17. Interosseous ligament of the fore-arm.
18. Part of the tendon of the flexor carpi radialis.
19. Tendon of the flexor carpi ulnaris.
- 20, 20. Proper ligament of the carpus divided.
21. First external interosseous muscle.
- 22, 23, 24. Interossei muscles of the middle finger.
25. Adductor minimi digiti.
26. Abductor minimi digiti.
- 27, 27, 27. Brachial artery.
28. Branch to the triceps.
29. Branch to the coraco-brachialis.
30. Arteria profunda humeri.
- 31, 31, 31, 31, 31. Branches to the brachialis internus and triceps.
32. Ramus anastomoticus, or ulnar collateral artery.
33. Slender branch to the brachialis internus.
34. The division of the brachial artery into the radial and ulnar.
35. Radial artery.
- 36, 36, 36, 36. Ulnar artery.
37. Radial recurrent artery.
38. Small branch proceeding to the capsular membrane of the fore-arm.
39. Ulnar recurrent artery.
- 40, 40, 40, 40. Small branches given off from the radial artery to the muscles of the fore-arm.
41. A small branch to the pronator quadratus, inosculating with twigs of the anterior interosseal artery.
42. Anterior carpal branch, which, anastomosing with twigs of the ulnar and anterior interosseal arteries, forms a vascular network on the carpus.
- 43, 43. Superficial volar branch of the radial, truncated.
- 44 Radial artery proceeding towards the back of the hand.
- 45, 45. Interosseal artery.
46. Superior perforating artery.
* Branch of the anterior interosseal artery.
- 47 Inferior perforating interosseal artery.
** Dorsal ulnar artery.
48. Anterior carpal branches from the ulnar.
49. The superficial palmar arch cut away.
- 50, 50, 50, Deep palmar artery of the ulnar, which, by its anastomosis with the radial artery in the palm, completes the deep palmar arch.
51. Arteria magna pollicis.
- 52, 52. Anterior digito-radial artery of the thumb.

FIGURE II.

Shows the deep Arteries of the Superior Extremity.

1. Tendon of the latissimus dorsi.
2. Coraco-brachialis muscle.
- 3, 3. Long Head of the triceps.
- 4, 4. Short Head of the same muscle.
- 5, 5. Internal intermuscular ligament.
- 6, 6. Brachialis internus.
7. Tendon of the biceps.
- 8, 8. The pronator teres muscle cut at its origin.
9. Flexor carpi radialis and palmaris longus cut.
10. Supinator brevis.
- 11, 11. Extensor carpi radialis longior.
- 12, 12. Extensor carpi radialis brevior.
13. Tendon of the supinator longus.

- 53, 53. Anterior digito-ulnar artery of the thumb.
54. Anastomosis of the two last arteries on the first phalanx of the thumb.
55. Arch formed by the inosculation of the same arteries on the second phalanx of the thumb.
- 56, 56, 56. Anterior digito-radial artery of the fore-finger.
- 57, 57, 57. Palmar interosseal arteries.
- 58, 58, 58. Perforating interosseal arteries.
- 59, 59, 59. Anastomosis of the palmar interosseal arteries with the digital.
- 60, 60, 60. Anterior digito-ulnar artery of the little finger.
- *** Small branches from the deep palmar arch running to the anterior vascular network of the carpus.
- 61, 61, 61. The small trunks of the anterior digital arteries, which arise from the superficial palmar arch, cut.
- 62, 62, 62. Anterior digito-ulnar artery of the fore-finger.
- 63, 63, 63. Anterior digito-radial artery of the middle finger.
- 64, 64. Digito-ulnar artery of the same finger.
- 65, 65. Digito-radial artery of the ring-finger.
- 66, 66. Digito-ulnar artery of the same finger.
- 67, 67. Digito-radial artery of the little finger.
- 68, 68, 68, 68. Vascular plexus formed on the first phalanx of each finger by its digital arteries.
- 69 69, 69, 69. Similar anastomosis on the second phalanges.
- 70, 70, 70, 70. Arches formed on the third phalanges by the digital arteries. From these arches very small twigs arise.
- 71, 71, 71, 71, 71, 71, 71, 71. Small branches which the anterior digital arteries send to the backs of the fingers.



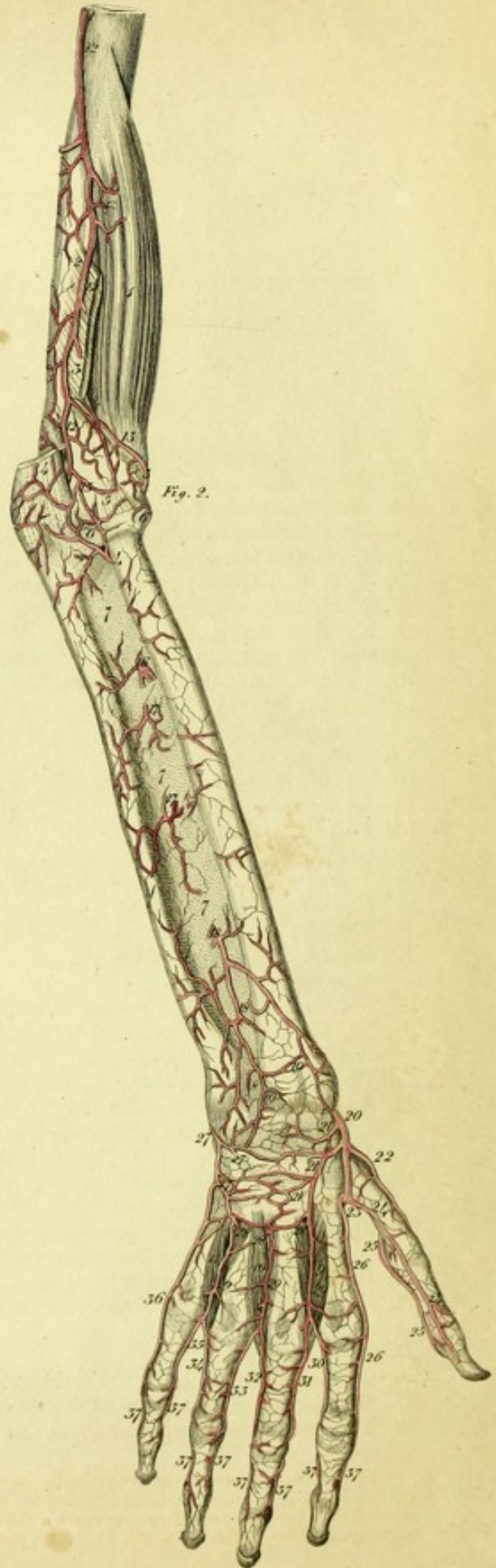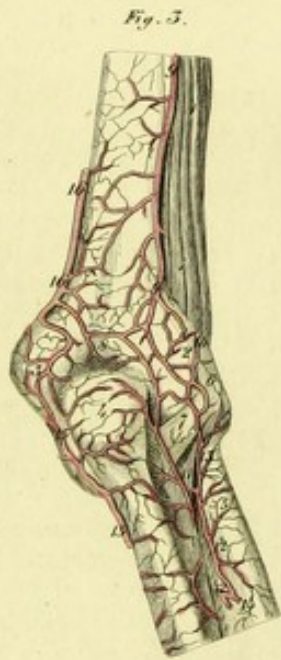
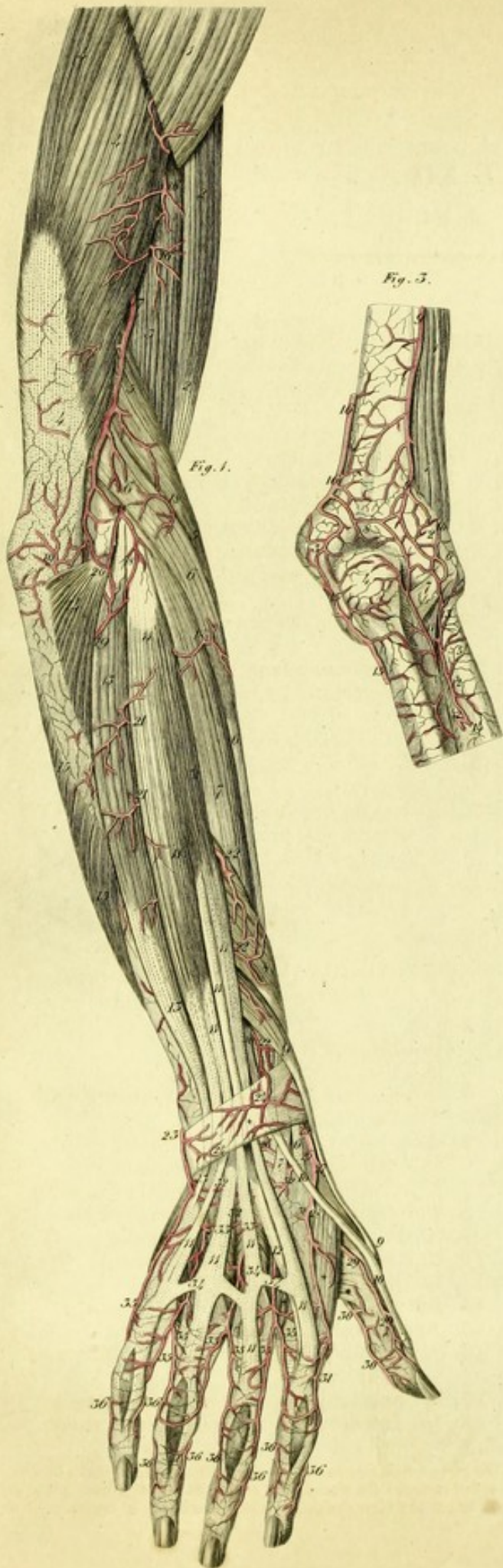


PLATE XII.

This represents the Regular Distribution of the Posterior Arteries of the Right Superior Extremity.

FIGURE I.

1. Deltoid Muscle.
2. Biceps flexor cubiti.
3. Brachialis internus.
4. Triceps extensor cubiti.
- 5, 5. Supinator longus.
- 6, 6, 6, 6. Extensor carpi radialis longior.
- 7, 7. Extensor carpi radialis brevior.
8. Extensor ossis metacarpi pollicis.
- 9, 9, 9. Extensor primi internodii pollicis.
- 10, 10, 10. Extensor secundi internodii pollicis.
- 11, 11, 11, 11, 11, 11, 11, 11. Extensor communis digitorum.
12. Extensor proprius indicis.
- 13, 13, 13. Extensor carpi ulnaris.
14. Anconeus muscle.
- 15, 15. Flexor carpi ulnaris.
- * Adductor pollicis.
- † † † † External interossei muscles.
- † † Abductor minimi digiti.
- † Posterior annular ligament of the carpus.
- 16, 16, 16. Muscular branches from the arteria profunda humeri.
17. Arteria profunda, or a great collateral artery.
- 18, 18, 18, 18. Twigs of the radial recurrent artery.
- 19, 19. Twigs of the interosseal recurrent artery.
20. Anastomosis between the arteria profunda and the radial and interosseal recurrent arteries.
- 21, 21. Muscular and cutaneous twigs of the superior perforating interosseal artery.
- 22, 22, 22. Muscular and cutaneous twigs of the inferior perforating interosseal artery.
23. Dorsal carpal artery from the ulnar.
- 24, 24. Superficial vascular net-work in the back of the carpus.
25. Radial artery.
- 26, 26. Dorsal carpal artery from the radial.
27. Dorsal digito-radial artery of the thumb.
28. The radial artery proceeding to the palm of

- the hand between the first external interosseous muscle and the metacarpal bone of the thumb.
- 29, 29. Dorsal digito-ulnar artery of the thumb.
 - 30, 30. Palmar digito-ulnar artery of the thumb.
 - 31, 31. Dorsal digito-radial artery of the fore-finger.
 - 32, 32, 32. Deep dorsal vascular net-work of the carpus.
 - 33, 33. Perforating branches of the palmar interosseal arteries, which join the carpal network.
 - 34, 34, 34. Dorsal interosseal arteries.
 - 35, 35, 35, 35, 35, 35, 35, 35. Dorsal arteries of the fingers.
 - 36, 36, 36, 36, 36, 36, 36, 36. Twigs which the anterior digital arteries send to the back of the fingers.

FIGURE II.

Represents the deep arteries on the posterior aspect of the superior extremity.

1. Brachialis internus.
2. Origin of the Supinator radii longus.
3. Origin of the extensor carpi radialis longior.
4. Tendon of the triceps.
5. External lateral ligament of the elbow joint.
6. Orbicular ligament of the radius.
- 7, 7, 7. Interosseous ligament of the fore-arm.
8. The capsular membrane of the wrist joint.
- 9, 10, 11. External interossei muscles.
- 12, 12, 12. Arteria profunda humeri.
- 13, 13. Radial recurrent artery.
14. Interosseal recurrent artery.*
15. Anastomosis of these arteries.
16. Superior perforating or posterior interosseal artery.
- 17, 17. Smaller perforating interosseal arteries.
- 18, 18. Inferior perforating interosseal artery.

* The interosseal recurrent artery generally comes off from the posterior interosseal artery after it has perforated the interosseous ligament; the artery marked 14 in the plate does not do so, but occupies the situation of a branch which I have found to come off from the ulnar, and then pass through the interosseous ligament to follow the course which this artery is represented to follow in the Plate.—Vid. fig. 3. No. 11, of this plate.—K,


- 19, 19. Twigs to the dorsal vascular net-work of the carpus.
20. Radial artery.
- 21, 21, 21. Dorsal carpal twigs.
22. Dorsal digito-radial artery of the thumb.
23. Continuation of the radial artery going to the palm of the hand.
- 24, 24. Dorsal digito-ulnar artery of the thumb.
- 25, 25. Anterior digito-ulnar artery of the thumb.
- 26, 26. Dorsal digito-radial artery of the forefinger.
- 27, 27, 27. Dorsal carpal artery from the ulnar.
- 28, 28, 28. Perforating branches of the anterior interosseal arteries of the hand.
- 29, 29, 29. Dorsal interosseal arteries of the hand.
30. Dorsal digito-ulnar artery of the forefinger.
31. Dorsal digito-radial artery of the middle finger.
32. Dorsal digito-ulnar artery of the same finger.
33. Dorsal digito-radial artery of the ring finger.
34. Dorsal digito-ulnar artery of the same finger.
35. Dorsal digito-radial artery of the little finger.
36. Dorsal digito-ulnar artery of the same finger.
- 37, 37, 37, 37, 37, 37, 37, 37. Twigs, which the anterior digital arteries send to the back of the fingers.

FIGURE III.

This represents the Posterior Vascular Net-work of the Elbow Joint.

- 1, 1. Brachialis internus.
2. External condyle of the humerus.
3. Internal condyle.
4. Olecranon of the ulna.
5. Upper part of the radius.
6. External lateral ligament of the elbow joint.
7. Orbicular ligament of the head of the radius.
8. Posterior vascular net-work of the elbow joint.
9. The arteria profunda.
10. Radial recurrent artery.
11. A branch from the ulnar, which passing through the upper part of the interosseous ligament, runs in a recurrent direction upwards, to enter into the vascular net-work on the back of the elbow joint.
12. Interosseal recurrent artery.
13. Twigs of the same artery.
14. Superior perforating or posterior interosseal artery, cut.
- 15, 15. Posterior ulnar recurrent artery.
- 16, 16. Ramus anastomoticus, or inferior collateral artery.*

* The explanation of this figure is omitted in the original.—K.



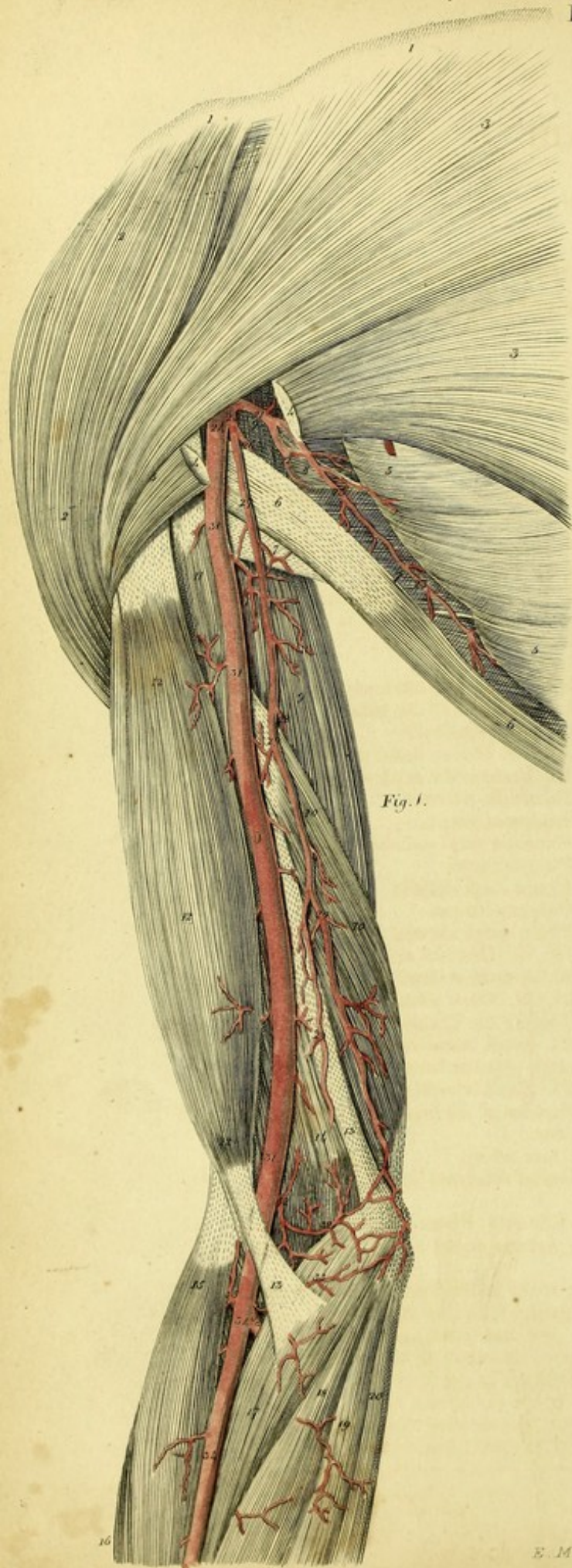


Fig. 1.

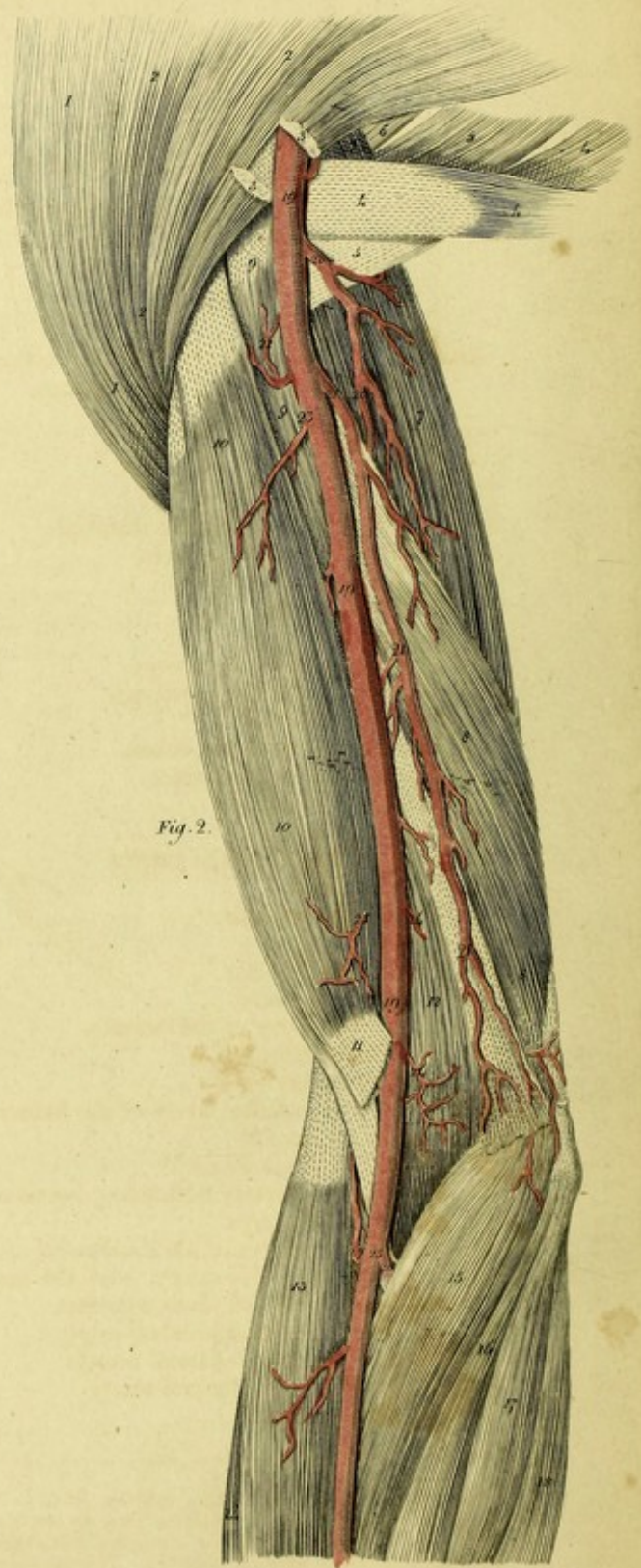


Fig. 2.

PLATE XIII.

This represents the Varieties of the Arteria Profunda Humeri and Ramus Anastomoticus or Ulnar Collateral.^a

FIGURE I.

Arteria Profunda, arising from the Posterior Circumflex Artery of the Humerus.

- 1, 1. Clavicle.
- 2, 2. Deltoid muscle.
- 3, 3, 3. Pectoralis major.
- 4, 4. Portion of this muscle removed.
- 5, 5. Serratus anticus muscle.
- 6, 6. Latissimus Dorsi.
- 7, 7. Teres major.
8. Teres minor.
- 9, 9. Long head of the triceps.
- 10, 10. Short head of the triceps.
11. Coraco-brachialis.
- 12, 12, 12. Biceps flexor cubiti.
13. Aponeurosis of this muscle.
14. Brachialis internus.
15. Supinator Longus.
16. Extensor carpi radialis longior.
17. Pronator teres.
18. Flexor carpi radialis.
19. Palmaris longus.
20. Flexor carpi ulnaris.
21. Subscapular artery.
22. Circumflex artery of the scapula.
- 23, 23. Thoracic branch.
24. Axillary Artery.
25. Posterior circumflex artery of the humerus.
26. Circumflex branch.
27. Arteria profunda humeri.^b
28. Branch of this artery descending between the heads of the triceps.
- 29, 29, 29, 29. Superior ulnar collateral artery.
30. Inosculation of this artery, with the second ulnar collateral and ulnar recurrent.
- 31, 31, 31. Brachial or humeral artery.
- 32, 32. Second ulnar collateral artery.
- 33, 33. Third ulnar collateral artery.
- 34, 34. Radial artery.

35. Radial recurrent artery.
36. Ulnar artery.

FIGURE II.

Exhibits an unusual variety of the Ulnar Collateral Artery.^a

- 1, 1. Deltoid.
- 2, 2, 2. Pectoralis major.
- 3, 3. Portion of this muscle cut out.
- 4, 4, 4. Latissimus dorsi.
- 5, 5. Teres major.
6. Teres minor.
- 7, 7. Long head of the triceps.
- 8, 8. Short head of the same.
- 9, 9. Coraco-brachialis.
- 10, 10, 10. Biceps flexor cubiti.
11. Its Aponeurotic expansion.
12. Brachialis internus.
13. Supinator longus.
14. Extensor carpi radialis longior.
15. Pronator teres.
16. Flexor carpi radialis.
17. Palmaris longus.
18. Flexor carpi ulnaris.
- 19, 19, 19. Brachial artery.
- 20, 20. Arteria profunda.
- 21, 21, 21. Great ulnar collateral.
22. Twig to the Coraco-brachialis.
- 23, 23. Small branches to the biceps.
- + Arteria nutritia humeri.
- 24, 24. Small branches to the brachialis internus.
25. Division of the brachial artery into radial and ulnar.
26. Ulnar artery.
27. Radial recurrent artery.

The following Plates show the varieties of the Arteries of the superior extremities.

No artery in the human body is more liable to irregularity than the axillary and humeral arteries. For the most part the axillary artery is continued into the brachial, which proceeds without dividing, to the bend of the arm, where it divides in the radial and ulnar. Very frequently, however, this division does not take place at the bend of the arm, but considerably higher, nay,

^a Barclay has mentioned these varieties (l. c. p. 108.) The profunda humeri rises sometimes from the scapular artery; sometimes from the scapular circumflex, and sometimes from the posterior or anconal circumflex. It is not only irregular in its origin, and mode of origin, but in its size, and in the number of its ramifications.

^b I have twice observed this unusual origin of the arteria profunda. It is by no means rare for the arteria profunda to rise from the scapular artery itself, as Haller has well remarked. (*Iconum Anatomicorum*, Fasc. vi. p. 18.)

^a This variety often occurs.

even in the axilla itself. Andrew Laurentius^a was the first who mentioned this variety, and described it as if regular. Bidloo^b observed the high division of the humeral artery so frequent that he considered it as regular, and reckoned the brachial artery when single as an anomaly. J. Palfyn,^c Laurentius Heister,^d Moebius,^e Elias Frid. Heister,^f Winslow,^g Petsche,^h Trew,ⁱ Hebenstreit,^k Sharp,^l H. F. de Dran,^m Schmied,ⁿ Winkler,^o Daubenton,^p Ph. C. Fabricius,^q Ph. A. Boehmer,^r and Haller have seen this distribution.^s Peter Camper^t has, with impropriety, called in question the high division of the brachial artery; for since that time it has been observed by Bidlay,^u C. G. Ludwig,^x Isenflamm,^y Pohl,^z Saba-

tier,^a Ed. Sandifort, Penchianat,^c J. C. A. Mayer,^d Ad. Murray,^e S. Th. Soemmering,^f Hildebrand,^g J. Bell,^h Portal,ⁱ Allan Burns,^k G. Ryan,^l Barclay,^m Al. Monro, jun.,ⁿ Fleischmann,^o and J. Meckel.^p

I have seen this variety very often, and I transmitted to the Academy of Sciences at Munich, eight years ago, several observations descriptive of it.^q

The high division of the humeral artery is frequently met with in both arms. Heister, Petsche, Monro, Meckel, and others, have seen this. I have several times observed it. Men of short stature are principally liable to this variety.

It is the duty of the surgeon to attend to this variety, either when he performs venesection, operates for aneurism, or amputates the arm. The high division of the trunk of the brachial artery is easily ascertained by the pulsation of the arteries. If the trunk of the brachial artery has reached the elbow without dividing, the pulsation of one artery only is felt in the middle of the arm; but if it divides above the bend of the arm, two arteries are felt pulsating. Those surgeons who wish to open the median vein ought to pay particular attention to these circumstances, lest they should wound either the one or the other of the arteries.

^a Historia Anatomica. Corp. Hum. Francof. 1600, Fol. p. 105. The subclavian artery, after it has reached the axilla is called the axillary artery, from which are given off the thoracic and basilic arteries. The thoracic is double, one branch of which is sent to the anterior muscles of the chest, the other to the posterior. The basilic is also perceived to consist of two portions, a deep and subcutaneous; each separates into various ramifications; there is, however, a small branch of the subcutaneous observable at the wrist in the part where the pulse is usually felt.

^b Idonis Wolf, Observ. Chirurgico-Medicæ Quædlinburg, 1704, 4.

^c Anat. Chirurgicale, Paris, 1726, T. ii. p. 272.

^d Compendium Anatomicum, p. 157, Not. 66, Acta Physico-Medica, vol. vii. Obs. 35, p. 34.

^e Obser. Medic. Miscellan. Theor. et Pract. Helmst. 1731.

^f Diss. Praes. Heister. de Nova Brachium Amputandi Ratione, no. 31.

^g Exposition Anat. de la Structure du Corps Hum. p. 377. sect. 143. It rarely happens that instead of this bifurcation, the brachial artery divides at its origin into two large branches.

^h Sylloge Observat. Anat. Select. Halae, 1736, § 54, 55.

ⁱ Commere. Litter. Noriberg, Ann. 1737, Hebd. 24, p. 186. Acta Physico-Medica, vol. x. App. p. 369.—History and Cure of a false Aneurism, caused by opening the Basilic Vein, Norimbergae, 1769, 4 c. Fig. TREW saw this distribution of the arteries several times.

^k De Arteriis. c. h. Confinius, Lips. 1739, p. 6.

^l A Treatise upon the Operations of Surgery, Lond. 1740, cap. 36, he says "If the humeral artery happens to divide above the elbow, which is not very uncommon, the prospect of cure is better, and the pulse will be stronger after the operation."

^m Traité des Operat. de Chirurg, Paris, 1742.

ⁿ De Varietate Vasorum Plurimque Magni Momenti. Erlang. 1745.

^o Diss. de Arteria Brachii, Goett. 1745, No. 49, 50.

^p Buffon, Histoire Naturelle avec la Description du Cabinet du Roy, Paris, 1749, T. iii. p. 159, No. 312.

^q Progr. ad Anatom. Anni, 1749, Helmst. 1749, p. 13.—Observationes Aliquæ Anatomicae, Helmst. 1754, 4.

^r Observation. Anatom. Rarior. Fasc. Halae, 1752, Fol. Prefat, p. 11. It is not unusual for the brachial artery to be divided into two.

^s Icon. Anat. Fasc. VI. Goetting. 1753, p. 34. Examples of this arrangement are rare.

^t Demonst. Anatomico-pathologic. Amstel. 1760. Lib. 1, p. 15. I doubt much its existence, for Eustachius, who is most correct regarding the varieties of the arteries, has not given a delineation of it; neither is it mentioned by Haller, who, next to Eustachius, has done most in this part of Anatomy; and if my authority is of any weight, I confess that I never witnessed a higher division into radial and ulnar than that which I have represented.

^u Sammlung. Anserlesener Wahrnehmungen aus der Arzneiwissenschaft, a. d. Französisch, Strasbourg, 1764, B. 8. s. 336.

^x Progr. de Variantibus Arteriæ Brachialis ramis in Aneurismatis Operatione Attendendis, Lips. 1767.

^y De Difficili in Obser. Anat. Epicrisi. Comment. 3, § 13.

^z Observat. Angiologicae de Arteriis, Lips. 1743, p. 8.

^a Traité Complet d'Anatomie, Paris, 1781, T. 3, p. 68. The humeral artery is one of those which presents the most varieties; it is often seen to divide at the middle part and at the upper part of the arm.

^b Observat. Anatomico-Pathologic. Lib. 2, p. 127, Lib. 4, p. 3.

^c Sur les Aneurysmes des Arteres du Bras. In Mem. de l'Ac. de l'urin, 1784, b. 177.

^d Beschreibung der Blutgefäße des Menschlichen Körpers, Berlin, 1788, s. 129.

^e Descriptio Arteriarum, c. h. Lips. 1794, p. 61.

^f De Corporis Humani Fabrica, T. v. p. 201.

^g Lehrbuch der Anatomie des Menschen, b. 4, s. 87.

^h Anatomy, Edin. 1797, vol. ii. p. 360.

ⁱ Cours d'Anatomie Medicale, Paris 1804, T. iii. p. 238.

^k Von Einigen der Häufigsten und Wichtigsten Herzkrankheiten, a. d. Engl. Lemgo, 1813, p. 336.

^l Diss. de Quarundam Arteriarum in Corpore Humano Distributione, Edin. 1812.

^m A Description of the Arteries of the Human Body, Edin. 1812, p. 100. The high division occurs so often that we can hardly, with any propriety, call it an anomaly.

ⁿ Outlines of the Anatomy of the Human Body, Edin. 1813, vol. iii. p. 303.

^o Leichenöffnungen. Erlangen, 1815, s. 230.

^p Ueber den regelwidrigen Verlauf der Armpulsadern. Im Deutschen Archiv für die Physiologie, b. 2, s. 117.—Tabula Anatomico-Pathologic. Fasc. 2, Tab. 11.

^q Beobachtungen über die hohe Theilung der Armschlagader in die Speichen- und Ellenbogen-Schlagader. In den Denkschriften der Akademie der Wissenschaften Zu München für die Jahre, 1816 und 1817, b. 6, s. 3.

The high division of the humeral artery occurs in several of the inferior animals. The very celebrated Cuvier (Anatomie Comparée, t. iv. p. 251,) observed this disposition in the didelphi and kangaroo. I have observed it in the simia capucina, apella, sabæa, sciurea, and lemur gracilis, (Ueber einen am oberarmbein bei mehreren geschwanzten affen vorkommenden kanal und eine damit in ver. bindung stehende Anordnung der Arterien und Nerven des Arms. Im deutschen Archiv für die Physiologie, b. 4, s. 544,) also in the civet, the dog, the fox, the wolf, and other mammalia.

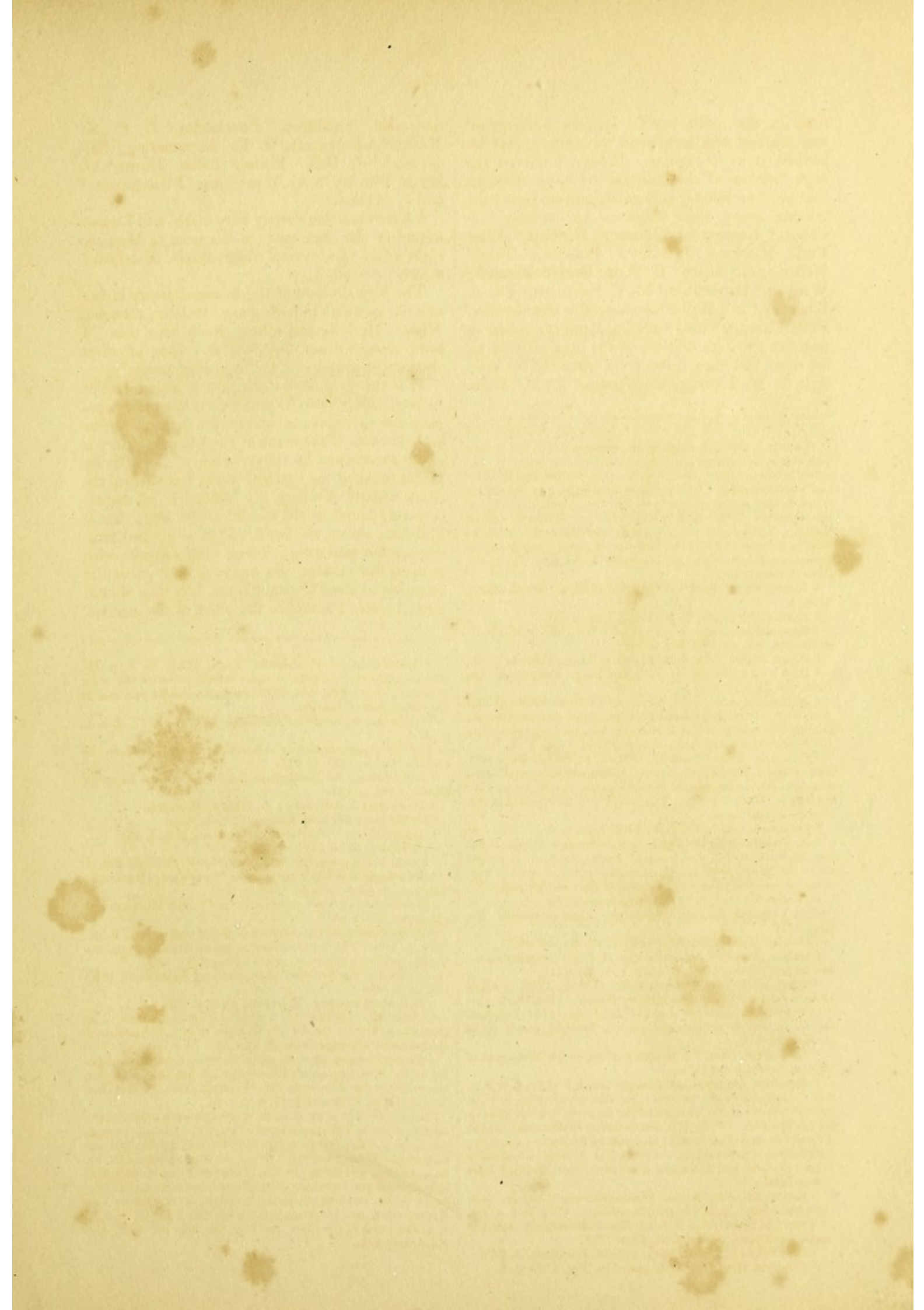


Fig. 1.

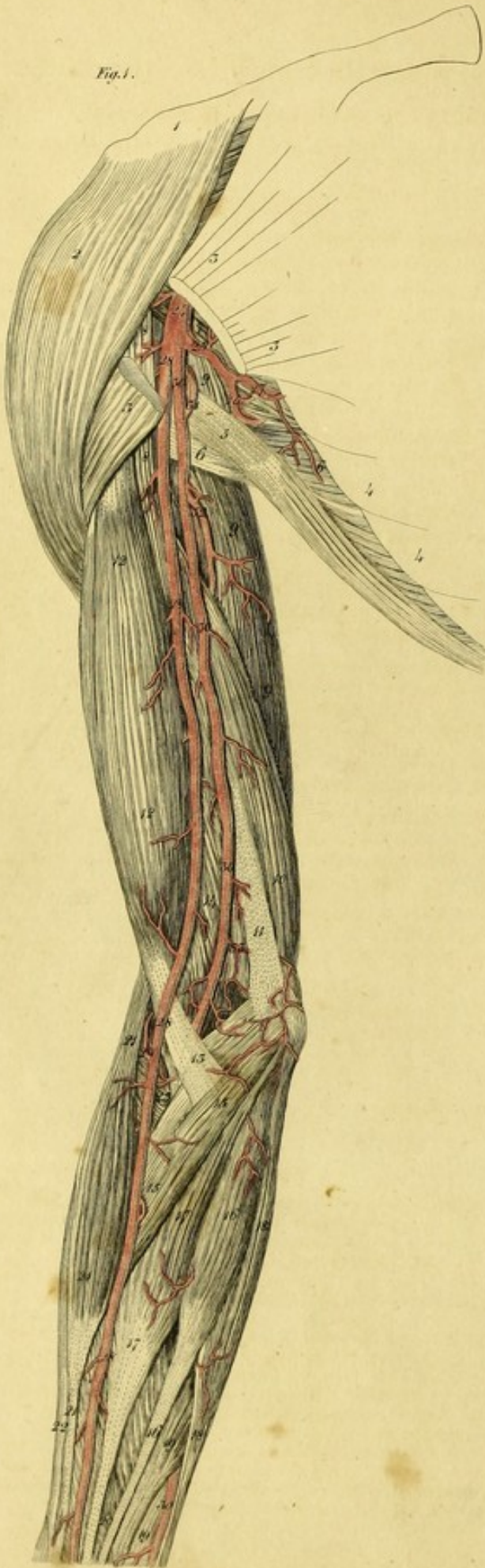


Fig. 2.

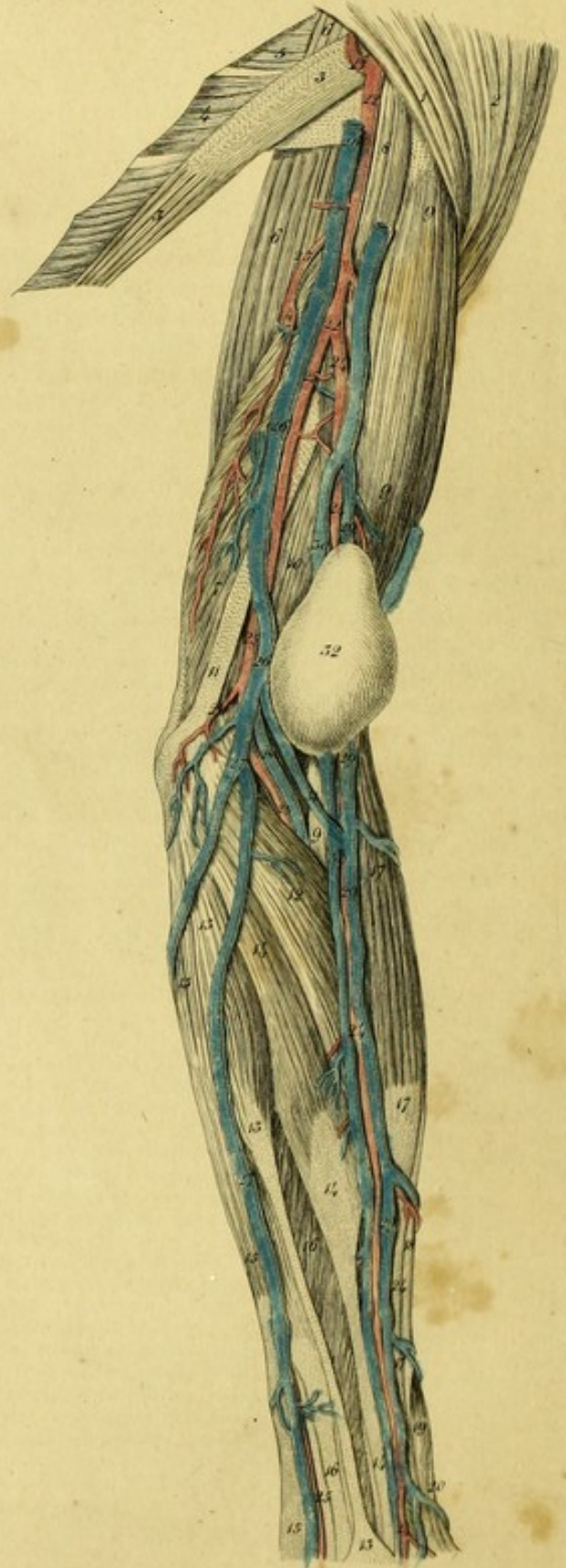


PLATE XIV.

FIGURE I.

This represents the Right Arm of a Man, in which the high bifurcation of the Axillary Artery is seen. The Radial Artery, in both arms, proceeded from the Axillary Artery, and ran between the Aponeurosis and Skin of the Arm.^a

1. The Clavicle.
2. The Deltoid muscle.
- 3, 3. The Pectoralis major.
- 4, 4. Serratus magnus.
5. Latissimus Dorsi.
- 6, 6. Teres major.
7. Teres minor.
8. Coraco-brachialis.
- 9, 9, 9. The long head of the triceps.
10. The short head of the triceps.
11. Intermuscular ligament of the arm.
- 12, 12. Biceps.
13. Aponeurotic portion of the same muscle.
14. Brachialis internus.
- 15, 15. Pronator teres.
- 16, 16. Palmaris longus.
- 17, 17. Flexor carpi radialis.
- 18, 18. Flexor carpi ulnaris.
- 19, 19. Flexors of the fingers.
20. Flexor longus pollicis.
- 21, 21, 21. Supinator longus.
22. Extensor carpi radialis longior.
23. Supinator brevis.
24. Axillary artery.
25. Subscapular artery.
26. Circumflex artery of the scapula.
27. Thoracic branch.
- 28, 28, 28, 28. Radial artery, arising from the axillary.
29. Radial recurrent artery
- 30, 30, 30, 30. Humeral artery, which ends in the ulnar.
31. Posterior circumflex artery of the humerus.
32. Profunda humeri.
33. Ramus Anastomoticus.

FIGURE II.

Shows the left arm of a woman, in which the radial artery came off from the humeral.^a The radial artery was wounded by the Surgeon when opening the cephalic vein, whence arose an aneurism.

1. The Pectoralis major.
2. Deltoid.
- 3, 3. Latissimus dorsi.
4. Teres major.
5. Teres minor.
- 6, 6. Long head of the triceps.
7. Short head of the same muscle.
8. Coraco-brachialis.
- 9, 9, 9. Biceps.
10. Brachialis internus.
11. Internal intermuscular ligament.
12. Pronator teres.
- 13, 13, 13. Palmaris longus.
- 14, 14, 14. Flexor carpi radialis.
- 15, 15, 15. Flexor carpi ulnaris.
- 16, 16. Flexors of the fingers.
- 17, 17, 17. Supinator longus.
18. Extensor carpi radialis longior.
19. Extensor ossis metacarpi pollicis.
20. Extensor primi internodii pollicis.
21. Posterior circumflex artery of the humerus.
- 22, 22. Humeral artery.
23. Arteria profunda humeri.
- 24, 24, 24, 24. Radial artery.
- 25, 25, 25, 25. Ulnar artery.
- 26, 26. Humeral vein.
- 27, 27. Basilic vein.
28. Ulnar vein.
- 29, 29, 29, 29. Cephalic vein.
30. Radial vein.
31. Median vein.
32. Aneurismal sac.

^a Laurence Heister (l. c.) and El. Fr. Heister (l. c. No. 31.) saw in the right arm of a woman, the radial artery arising from the axillary; Ph. Ad. Boehmer (l. c.), in the right arm of a male subject; Ludwig (l. c. p. 8.) saw, in the right arm of a female subject, the brachial artery running as usual, but at the bend of the elbow it formed a pretty large anastomosis, by which it was united to the radial; Sandifort (l. c. Lib. 4. p. 93.) remarked it in a right arm; Mayer (l. c.) also; Ryan (l. c.) saw five specimens of it in Dr. Monro's museum; J. Fr. Meckel (Archiv. B. 2. S. 127.) met with it three times. I have observed this unusual origin and course of the radial artery: in the right arm of a new born infant; in the right arm of a girl of four years; in the right arm of a boy; in the left arm of a woman; in the right arm of a woman; in the left arm of a young man; in both arms of a man of forty years old; in the right arm of a woman of sixty,—in the left arm of this subject the ulnar artery arose from the axillary.

The radial artery is either enclosed by the aponeurosis of the arm, or perforating it, runs with the cephalic vein immediately under the skin.

^a This variety very frequently occurs. It was seen, in both arms by Laurence Heister (l. c. not. 66.), by Moebius (l. c. obs. 8.), Trew (l. c. fig 5.), Petsche (l. c. No. 55.), Eschenbach (l. c. No. 1141.), Winkler (l. c. No. 50.), Schmiedel (l. c. No. 9.), Haller (l. c. p. 34.), Ernest. Hebenstreit (l. c.), Ludwig (l. c. p. 6.), Ballay (l. c. p. 336.), Penchianati (l. c.), Sandifort (l. c. lib. 4. p. 93.) in the right arm of a woman; by Soemmering (l. c. p. 301.), Ryan (l. c.), Monro (l. c. p. 301. pl. 44. fig. 3.), Burns (l. c.), Barclay (l. c. p. 104. This case is common), and J. F. Meckel (Tabula Anatomico-pathol. Fasc. 2. Tab. 11. Fig 5. 7.) I have observed it in both arms of a girl, in both arms of a woman of thirty years old, in both arms of a woman of sixty, in both arms of a young man, in both arms of a man of seventy, in the right arm of a woman, and in the left arm of a man. The radial artery is either covered by the brachial aponeurosis, or runs along with the cephalic vein between it and the skin.


Figure 1

This represents the right arm of a Man, in which the high bifurcation of the Axillary Artery is seen. The Radial Artery, in both cases, proceeded from the Axillary Artery, and ran between the Aponeurosis and Skin of the Arm.

Figure 11

Shows the left arm of a woman, in which the radial artery came off from the humeral. The radial artery was wounded by the surgeon when opening the capsule, &c. where there was an aneurism.

- 1 The Trachea major.
- 2 The Trachea minor.
- 3 The Arteria humeri.
- 4 The Arteria profunda.
- 5 The Arteria profunda.
- 6 The Arteria profunda.
- 7 The Arteria profunda.
- 8 The Arteria profunda.
- 9 The Arteria profunda.
- 10 The Arteria profunda.
- 11 The Arteria profunda.
- 12 The Arteria profunda.
- 13 The Arteria profunda.
- 14 The Arteria profunda.
- 15 The Arteria profunda.
- 16 The Arteria profunda.
- 17 The Arteria profunda.
- 18 The Arteria profunda.
- 19 The Arteria profunda.
- 20 The Arteria profunda.
- 21 The Arteria profunda.
- 22 The Arteria profunda.
- 23 The Arteria profunda.
- 24 The Arteria profunda.
- 25 The Arteria profunda.
- 26 The Arteria profunda.
- 27 The Arteria profunda.
- 28 The Arteria profunda.
- 29 The Arteria profunda.
- 30 The Arteria profunda.
- 31 The Arteria profunda.
- 32 The Arteria profunda.



This diagram illustrates the arterial supply of the right arm. The axillary artery bifurcates into the radial artery (1) and the ulnar artery (2). The radial artery runs along the outer side of the arm, while the ulnar artery runs along the inner side. The diagram also depicts the brachial plexus of nerves and the surrounding muscles and bones. The labels 3 through 32 correspond to the anatomical structures listed in the legend on the left.

This diagram illustrates the arterial supply of the left arm of a woman. The radial artery is shown coming off from the humeral artery. The diagram also depicts the brachial plexus of nerves and the surrounding muscles and bones. The labels 1 through 32 correspond to the anatomical structures listed in the legend on the left.




Fig. 1.

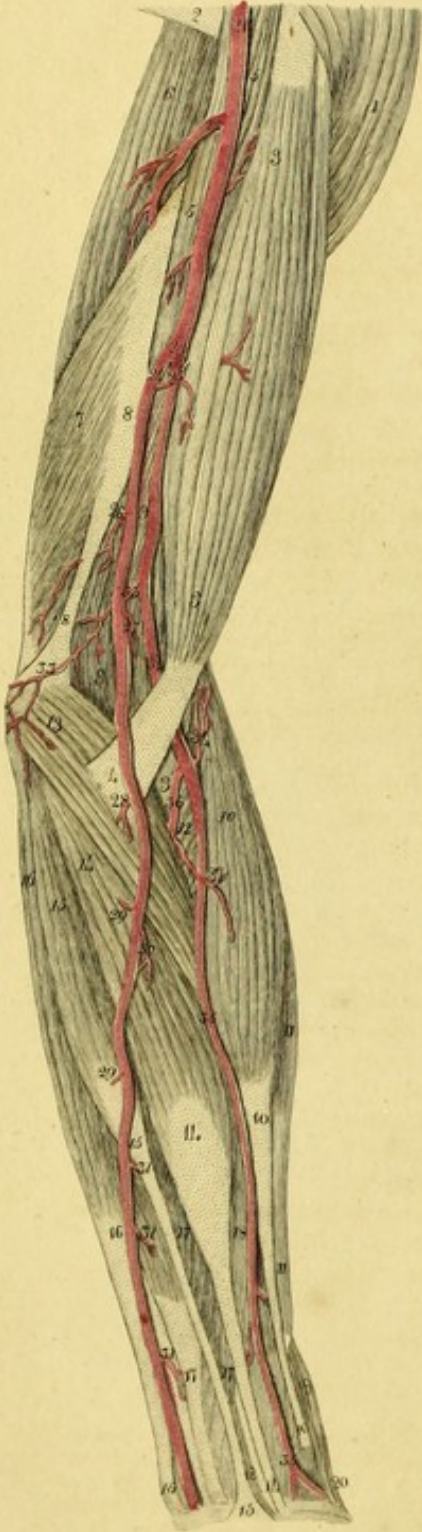


Fig. 2.

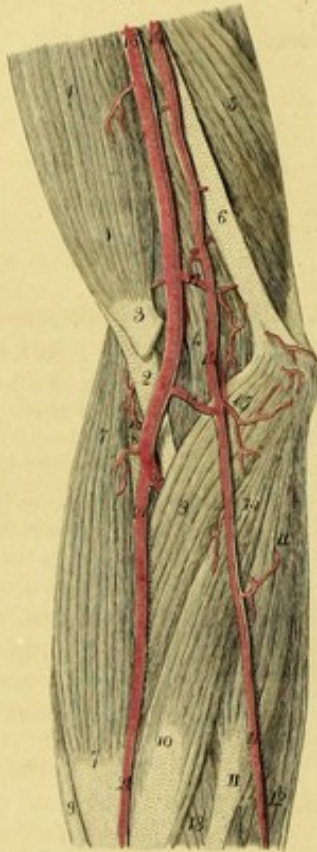

Fig. 3.

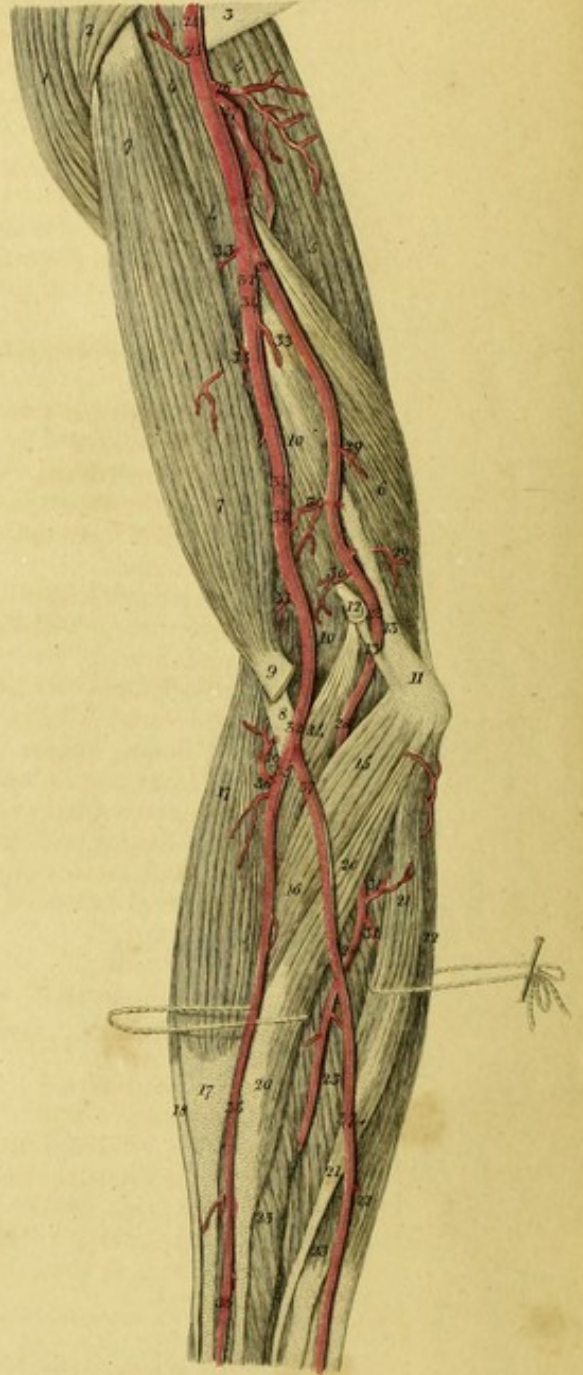


PLATE XV.

FIGURE I.

This shows the left arm of a man, in which the ulnar artery arises from the humeral.^a

1. Deltoid muscle.
2. Tendon of the latissimus dorsi.
3. Biceps.
4. Aponeurotic portion of this muscle.
5. Coraco-brachialis.
6. Long head of the triceps.
7. Short head of the same muscle.
- 8, 8. Intermuscular ligament.
9. Brachialis internus.
- 10, 10, 10. Supinator longus.
- 11, 11. Extensor carpi radialis longior.
12. Supinator brevis.
- 13, 13. Pronator teres.
- 14, 14. Flexor carpi radialis.
- 15, 15, 15. Palmaris longus.
- 16, 16, 16. Flexor carpi ulnaris.
- 17, 17, 17. Common flexors of the fingers.
- 18, 18. Flexor longus pollicis.
19. Extensor ossis metacarpi pollicis
20. Extensor primi internodii pollicis.
21. Humeral artery.
22. Arteria profunda.
23. Division of the humeral artery into the ulnar and radial.
24. Ulnar artery.
25. A twig to the biceps.
26. Ulnar collateral artery.
27. Twig to the brachialis internus.
28. Twig to the pronator teres.
29. Cutaneous twigs, cut.
30. Twig to the palmaris longus.
- 31, 31, 31. Twigs to the flexors of the fingers.

^a This variety is rare. It has been seen by Petsche, (l. c. § 55.) Pohl, (l. c. p. 9.) Sandifort, (l. c. p. 93.) and J. F. Meckel, (Deutsch. Archiv. f. d. Physiolog. B. 2. p. 127. Tabul. Anatomico-Patholog. Fasc. 2, Tab. 11, fig. 4.) I have seen this disposition in the right arm of a boy of twelve years old; the ulnar artery ran between the skin and the aponeurosis of the arm. The distribution of the arteries in the left arm was regular. I have moreover observed it in the left arm of a woman, and in the right arm of a man, in both which cases the ulnar artery was under the aponeurosis.

- 32, 32. Continuation of the humeral artery, which divides into the radial and interosseal arteries.
- 33, 33. Ramus anastomoticus magnus.
34. Radial recurrent artery.
- 35, 35, 35, 35. Radial artery.
36. Interosseal artery.
37. Twig to the supinator longus muscle.

FIGURE II.

Represents the ulnar artery given off from the axillary in the right arm of a man;^a there is a pretty large anastomosis between the ulnar and the humeral.

- 1, 1. Biceps.
2. Tendon of this muscle.
3. Aponeurotic portion.
4. Brachialis internus.
5. Short head of the triceps.
6. Intermuscular ligament.
- 7, 7. Supinator longus.
8. Supinator brevis.
9. Pronator teres.
- 10, 10. Flexor carpi radialis
- 11, 11. Palmaris longus.
12. Flexor carpi ulnaris.
13. Flexor sublimis digitorum.
- 14, 14, 14. Ulnar artery, which was given off from the axillary.
15. Ulnar recurrent artery.
- 16, 16. Humeral artery.
17. Ramus anastomoticus.
18. Anastomosing branch between the humeral and ulnar arteries.
19. Radial recurrent artery.
20. Interosseal artery.
- 21, 21. Radial artery.

^a The origin of the ulnar artery from the axillary is rather common. It has been seen by Mayer (l. c. p. 129.), Burns (l. c. p. 336.) Ryan (l. c. p. 12.) Monro (outlines pl. 44. Fig. 2.) Barclay (l. c. p. 104. This case is frequent.) Fleischmann (Leichenöffnungen, p. 228.) and J. F. Meckel (Archiv. B. 2, p. 126.) I have found it in the left arm of an infant, and in the right arm of a man.

FIGURE III.

Exhibits the right arm of a woman, in which the interosseal artery arose from the humeral.^a

1. Deltoid.
2. Insertion of the pectoralis major.
3. Termination of the latissimus dorsi.
- 4, 4. Coraco-brachialis.
- 5, 5. Long head of the triceps.
- 6, 6. Short head of the same.
- 7, 7. Biceps.
8. Tendon of this muscle.
9. Its aponeurosis.
10. Brachialis internus.
11. Internal condyle of the humerus.
12. An unusual excrescence from the humerus.
- 13, 13. Internal intermuscular ligament.
14. An unusual portion of the pronator teres arising from the osseous excrescence.

^a This rare distribution of the arteries of the arm has been observed by Ludwig, (l. c. p. 7.) in a female subject, whose bones were soft, Sabater, (l. c. p. 69.) Hildebrandt (l. c. B. 4. p. 87.) A. Monro (l. c. vol. iii, p. 304. The interosseous artery sometimes arises from the middle of the humeral artery,) and Barclay (l. c. p. 104. note u.) I have only seen it once.

15. Pronator teres.
16. Insertion of the pronator.
- 17, 17. Supinator longus.
18. Extensor carpi radialis longior.
19. Supinator brevis.
- 20, 20. Flexor carpi radialis.
- 21, 21. Palmaris longus.
- 22, 22. Flexor carpi ulnaris.
- 23, 23. Common flexors of the fingers.
24. Humeral artery.
25. Twig to the coraco-brachialis.
26. Twig to the long head of the triceps.
27. Profunda humeri.
- 28, 28, 28, 28. Interosseal artery coming off from the humeral.
- 29, 29. Twigs to the short head of the triceps.
- 30, 30. Twigs to the brachialis internus.
- 31, 31. Twigs to the palmaris longus.
- 32, 32, 32. Trunk of the humeral artery.
- 33, 33, 33. Twigs to the biceps and brachialis internus.
- 34, 34. Cutaneous twigs, cut.
- 35, 35, 35. Radial artery.
36. Radial recurrent artery.
- 37, 37. Ulnar artery running on the surface of the forearm.




Fig. 1.

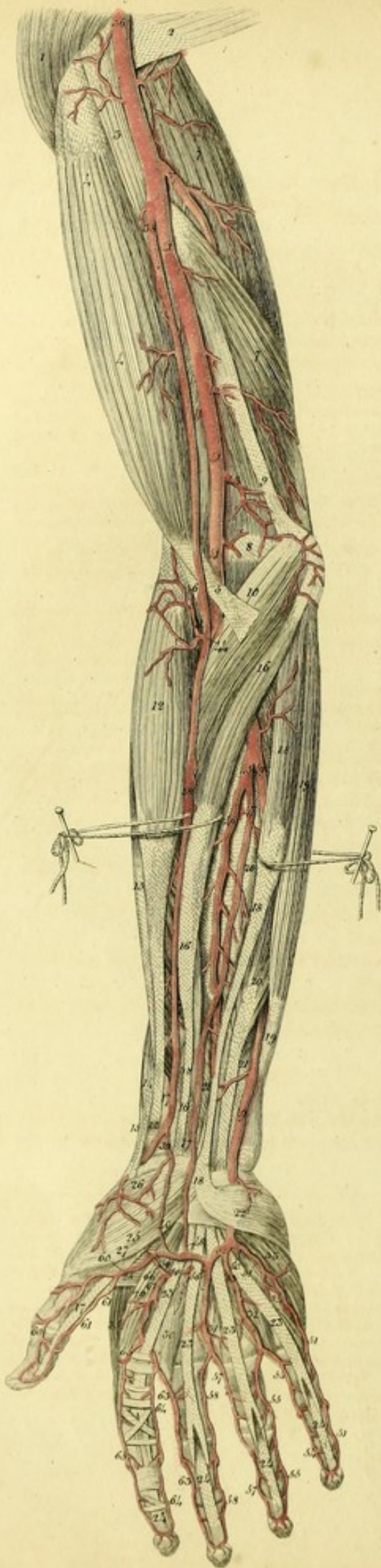


Fig. 2.

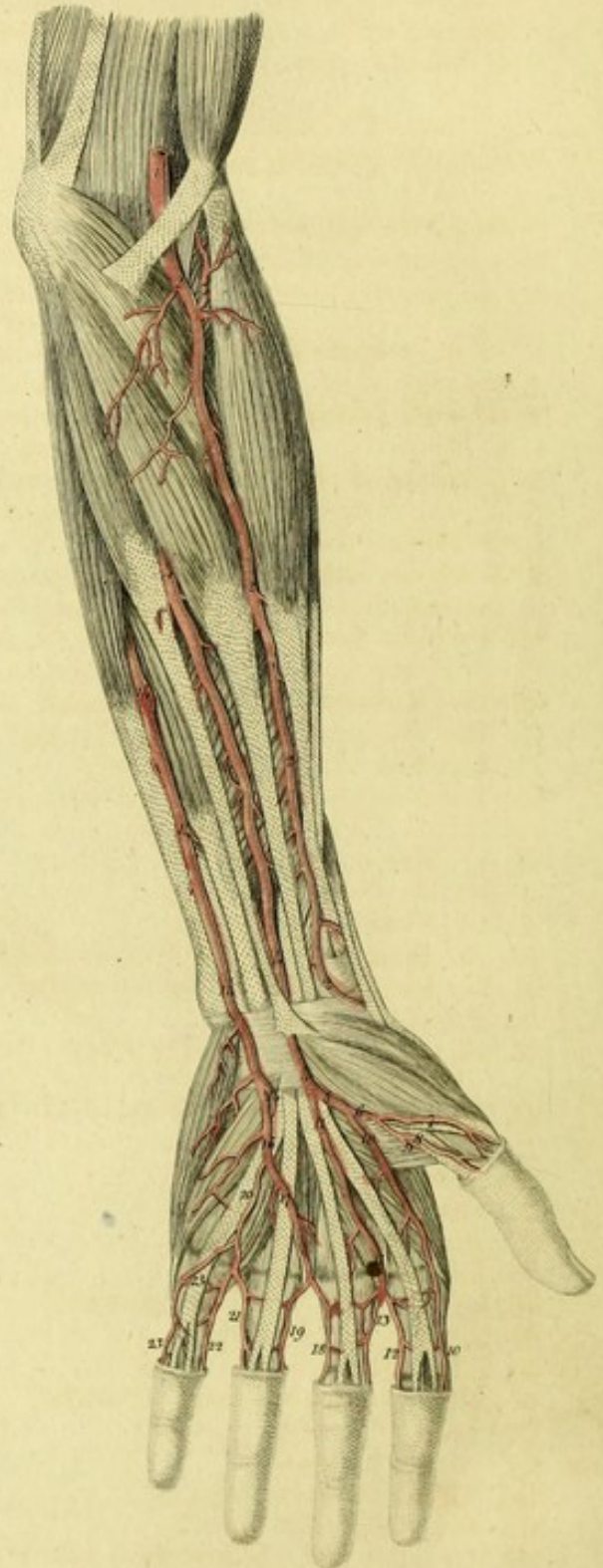

PLATE XVI.

FIGURE I.

Shows the right arm of a man in which the high bifurcation of the humeral artery, and an unusual artery are seen.

1. Insertion of the pectoralis major.
2. Insertion of the latissimus dorsi.
3. Coraco-brachialis.
- 4, 4. Biceps.
5. Aponeurotic portion of this muscle.
6. Tendon of the biceps.
- 7, 7. Triceps extensor cubiti.
8. Brachialis internus.
9. Internal intermuscular ligament.
10. Pronator teres.
11. Supinator brevis.
- 12, 12. Supinator longus.
13. Extensor carpi radialis longior.
14. Extensor ossis metacarpi pollicis.
15. Extensor primi internodii pollicis.
- 16, 16, 16. Flexor carpi radialis.
- 17, 17. Flexor longus pollicis.
- 18, 18, 18. Palmaris longus.
- 19, 19. Flexor carpi ulnaris.
- 20, 20. Flexor communis digitorum sublimis.
- 21, 21. Flexor communis digitorum profundus.
22. Palmaris brevis.
- 23, 23, 23, 23. Tendons of the flexor sublimis, or perforatus.
- 24, 24, 24, 24. Tendons of the flexor profundus or perforans.
25. Abductor pollicis.
26. Opponens pollicis.
27. Flexor brevis pollicis.
28. Adductor pollicis.
- 29, 30, 31, 32. Lumbricales muscles.
33. Abductor minimi digiti.
34. Flexor brevis minimi digiti.
35. First external interosseous muscle.
36. Humeral artery.
37. Arteria profunda.
- 38, 38, 38. Radial artery.
39. Superficial volar branch.
40. Its union with the superficial palmar arch.
- 41, 41, 41. Humeral artery continued into the ulnar.
42. Branch to the triceps.
43. Ramus anastomoticus magnus.

44. Radial recurrent artery.
45. Interosseal artery.
46. Anterior interosseal artery.
47. An unusual superficial interosseal artery.
48. Its anastomosis with the superficial palmar arch.
- 49, 49. Ulnar artery.
- 50, 50. Deep volar artery.
- 51, 51, 51. Digito-ulnar artery of the little finger.
52. Superficial volar artery.
53. Second digital artery, which divides into,
- 54, 54. The digito-radial artery of the little finger, and
- 55, 55. The digito-ulnar artery of the ring finger.
56. Third digital artery, which divides into,
- 57, 57. The digito-radial artery of the ring finger, and
- 58, 58. The digito-ulnar artery of the middle finger.
59. Arteria magna pollicis.
- 60, 60. Anterior digito-radial artery of the thumb.
- 61, 61. Anterior digito-ulnar artery of the thumb.
62. Fourth digital artery coming from the deep volar artery.
- 63, 63. Anterior digito-radial artery of the middle finger.
- 64, 64. Anterior digito-ulnar artery of the forefinger.
- 65, 65. Anterior digito-radial artery of the forefinger.
66. Communicating branch, with the deep volar artery, from the radial artery.

FIGURE II.

Exhibits the left arm of a woman, in which an unusual superficial interosseal artery is observed.^a

^a Haller (Icon. Anat. Fasc. 6. p. 33.) observed a similar case. He says: *Caeterum non penitus omittere visum est, mirificam varietatem, quam semel omnino anno 1745 M. Septembri vidi. Ex ipsa fere origine arteriæ interossee ramus provenit, sodalis mediani nervi, inter sublimem et profundum flexorem, quorum utriusque ramos dedit, venitque cum ipsis ad latus radiale medii digiti et ulnare indicis, dedit ramum pollicis abductoris, inosculatum radialis arteriæ pollicis, et una cum ea arteria ulnare pollicis et arteriam radialem volarem indicis constituit. Semel etiam ex ipsa origine arteriæ interossee ramum prodiisse vidi, qui ad volam venit, et superficialem arcum constituit, qui solet a radiali nasci.*

1. Humeral artery.
- 2, 2, 2. A radial artery of small size which sends no branch to the palm.
3. Radial recurrent artery.
- 4, 4, 4. Superficial interosseal artery, which might be called *median artery*, as it accompanies the median nerve.

Ludwig (l. c. p. 9,) described a similar variety: in an infant six months old, in whom the humeral artery gave off the radial at the usual place, which extended to the hand, but another radial came off from the side of the interosseal, descended on the inner side of the radius, and passed under the transverse ligament of the carpus to the palm of the hand.

Sabatier (l. c. T. 3. p. 69,) says: "J'ai vu l'artere humerale produire une radiale et une cubitale ordinaire, et une seconde cubitale qui descendoit derriere les tegumens le long du bord interne de l'avant-bras, jusqu'au poignet ou elle fournissoit l'arcade palmaire, pendant que la vraie cubitale s'y terminoit par des branches tres petites."

Allan Burns (l. c. p. 348,) has well described this disposition of the interosseal artery.

Barclay (l. c. p. 120,) says "Sometimes there are more interosseals than one, whether it arise from the humeral separately, or terminate the humeral along with the ulnar, or along with the radial, or along with the radial and ulnar together, is always seen on the thenal aspect in the middle, between the radius and ulna; always deeper than the sublimis, always extending some of its branches as far as the carpus, though seldom so far as the points of the fingers."

"In rare cases, where it runs immediately under the sublimis, and extends to the fingers, there is usually another interosseal artery, either a branch, or a separate trunk between the sublimis and the flexor longus pollicis."

- 5, 6. Arteria magna pollicis.
7. Dorsal digito-radial artery of the thumb.
8. Anterior digito-radial artery of the thumb.
9. Anterior digito-ulnar artery of the thumb.
10. Anterior digito-radial artery of the fore-finger.
- 11, 11. Digital artery, which divides into,
12. The anterior digito-ulnar artery of the fore-finger, and,
13. Anterior digito-radial artery of the middle-finger.
- 14, 14, 14. Ulnar artery.
15. Deep volar artery.
16. Small trunk of the digital arteries.
17. First digital artery.
18. Anterior digito-ulnar branch of the middle-finger.
19. Anterior digito-radial branch of the ring-finger.
20. Internal digital artery, which divides into,
21. Anterior digito-ulnar branch of the ring-finger,
22. Anterior digito-radial branch of the little-finger, and,
- 23, 23. Anterior digito-ulnar branch of the little-finger.




Fig. 1.

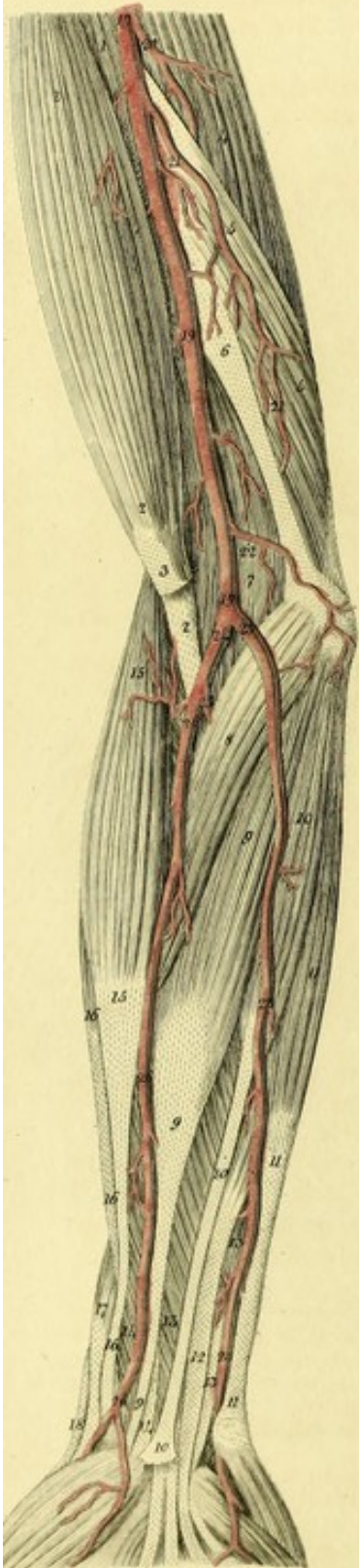


Fig. 2.

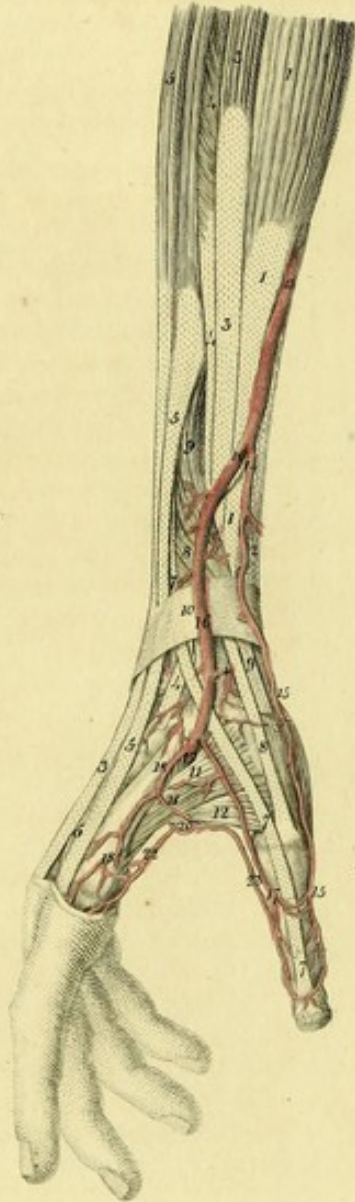


Fig. 3.

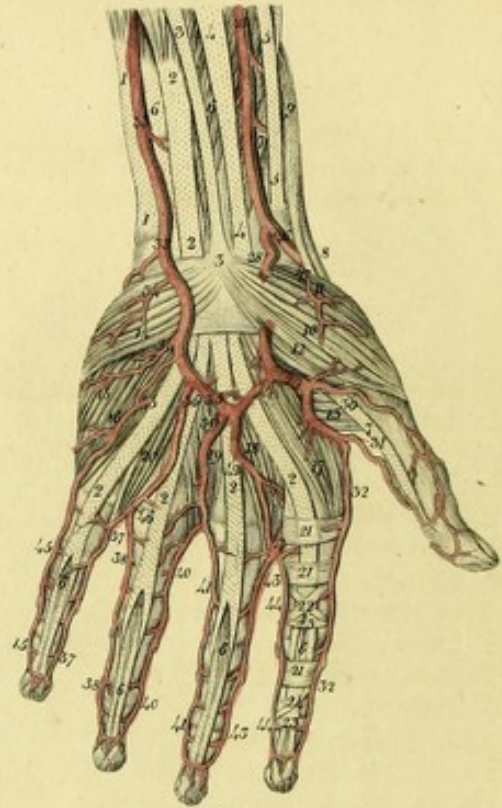


Fig. 4.

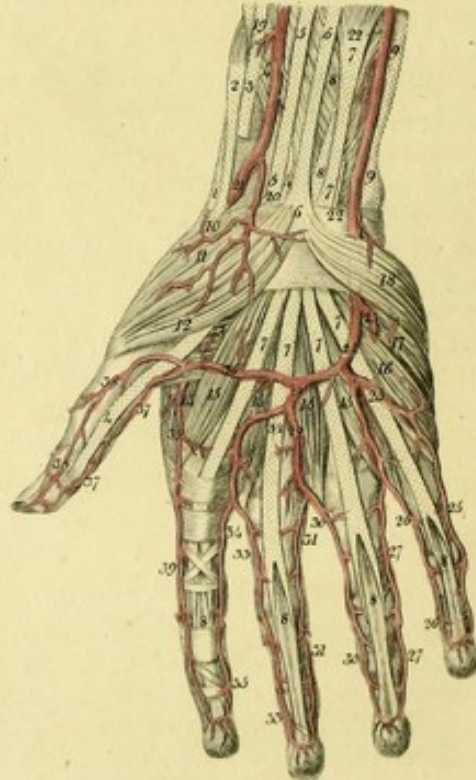


PLATE XVII.

FIGURE I.

Exhibits an unusual course of the ulnar artery in the right arm of a young man.^a

1. Insertion of the coraco-brachialis.
- 2, 2, 2. Biceps.
3. Aponeurotic portion of this muscle.
4. Long head of the triceps.
- 5, 5. Short head of this muscle.
6. Internal intermuscular ligament.
7. Brachialis internus.
8. Pronator teres.
- 9, 9. Flexor carpi radialis.
- 10, 10, 10. Palmaris longus.
- 11, 11, 11. Flexor carpi ulnaris.
12. Flexor communis digitorum sublimis.
- 13, 13, 13. Flexor communis digitorum profundus.
14. Flexor longus pollicis.
- 15, 15, 15. Supinator longus.
- 16, 16. Extensor carpi radialis longior.
17. Extensor ossis metacarpi pollicis.
18. Extensor primi internodii.
- 19, 19, 19. Humeral artery.
20. Arteria profunda.
21. An unusual ulnar collateral artery.
22. Ramus anastomoticus magnus.
- 23, 23, 23. Ulnar artery arising from the humeral at the bend of the elbow, and running superficially on the fore-arm.
24. Trunk of the radial and interosseal arteries.
25. Interosseal artery.
26. Radial artery.

FIGURE II.

Represents the right fore-arm of a man, in which the radial artery, at the middle of the radius, passed towards the back of the hand, superficially, over the supinator longus, extensor carpi radialis longior, extensor carpi radialis brevior, and extensor muscles of the

thumb. The superficialis volæ from the radial descended in its usual place.^a

1. Supinator longus.
2. Flexor carpi radialis.
- 3, 3. Extensor carpi radialis longior.
- 4, 4. Extensor carpi radialis brevior.
- 5, 5, 5, 5. Extensor communis digitorum.
6. Tendon of the extensor proprius indicis.
- 7, 7. Extensor secundi internodii pollicis.
- 8, 8. Extensor primi internodii pollicis.
- 9, 9. Extensor ossis metacarpi pollicis.
10. Posterior annular ligament of the carpus.
11. First external interosseous muscle.
12. Adductor pollicis.
13. Radial artery.
14. Superficialis volæ.
- 15, 15. Dorsal digito-radial artery of the thumb.
- †. Dorsal carpal branch.
- 16, 16. Continuation of the radial artery running superficially to the back of the hand.
17. Dorsal digito-ulnar artery of the thumb.
18. Dorsal digito-radial artery of the forefinger.
19. Deep volar artery.
20. Arteria magna pollicis.
21. Communicating branch with the dorsal artery of the forefinger.
22. Anterior digito-radial artery of the forefinger.
23. Anterior digito-ulnar artery of the thumb.

The following figures show the principal varieties in the arteries of the hand which I have observed.^b

^a Portal (*Anat. Medicale*, t. iii. p. 247.) has described this unusual course of the radial artery well. *L'artere radiale se detourne quelquefois; au lieu de passer sur le bord interne et antérieure du rayon, elle passe sur le bord arteriel externe, et il n'y a alors qu'une petite arteriole qui marche dans la direction du tronc.*

Allan Burns (*l. c.* p. 343.) has also described it.

I have frequently seen this unusual course of the radial artery. I once observed it in both arms of a man, labouring under hectic fever, where there was no pulsation perceived at the usual place.

^b The varieties of the arteries of the hand have been pointed out by Haller, (*Icon. Anat. Fasc. vi. p. 36, 41.*) Soemmering, (*De Corp. hum. fabrica t. 5. p. 204, 222.*) Allan Burns, (*l. c.* p. 344.) Ryan, (*l. c.*) Barclay, (*l. c.* p. 126.) J. F. Meckel, (*Handbuch der menschlichen Anatomie*, B. 3. S. 180, 190.) and others.

^a Allan Burns (*l. c.* p. 341.) observed this variety three times.

FIGURE III.

Represents the left hand of a man, in which the superficialis volæ is of a very large size. This variety often occurs.


- 1, 1. Flexor carpi ulnaris.
- 2, 2, 2, 2, 2, 2. Flexor communis digitorum sublimis.
- 3, 3. Palmaris longus.
- 4, 4. Flexor carpi radialis.
- 5, 5. Tendon of the supinator longus.
- 6, 6, 6, 6, 6, 6. Flexor communis digitorum profundus.
- 7, 7. Flexor longus pollicis.
8. Extensor primi internodii pollicis.
9. Extensor ossis metacarpi pollicis.
10. Abductor pollicis.
11. Opponens pollicis.
12. Flexor brevis pollicis.
13. Adductor pollicis.
14. Palmaris brevis.
15. Abductor minimi digiti.
16. Adductor minimi digiti.
- 17, 18, 19, 20. Lumbricales muscles.
- 21, 22, 23, 24. Ligamentous sheaths of the flexor tendons of the forefinger.
- 25, 25. Radial artery.
26. Trunk of the radial artery running towards the back of the hand.
27. Twig to the short muscles of the thumb.
28. The superficialis volæ of unusual size covered by the abductor pollicis.
29. Arteria magna pollicis.
30. Anterior digito-radial artery of the thumb.
31. Anterior digito-ulnar artery of the thumb.
32. Anterior digito-radial artery of the forefinger.
- 33, 33. Ulnar artery.
- 34, 34. Twigs to the palmaris brevis, the abductor and adductor minimi digiti.
35. Superficial palmar arch which is formed by the ulnar and radial arteries.
36. First anterior digital artery, which divides into,
- 37, 37. Anterior digito-radial artery of the little finger, and
- 38, 38. Anterior digito-ulnar artery of the ring finger.
39. Second anterior digital artery, which divides into,
- 40, 40. Anterior digito-radial artery of the ring finger, and
- 41, 41. Anterior digito-ulnar artery of the middle finger.
42. Third anterior digital artery, which divides into,
- 43, 43. Anterior digito-radial artery of the middle finger, and
- 44, 44. Anterior digito-ulnar artery of the forefinger.

- 45, 45, 45. Anterior digito-ulnar artery of the little finger coming off from the deep palmar arch.
46. 47. Palmar interosseal arteries communicating with the digitals.

FIGURE IV.

This exhibits the right hand of a man, in which the ulnar artery alone forms the superficial palmar arch. This variety frequently occurs.

1. Extensor primi internodii pollicis.
2. Extensor ossis metacarpi pollicis.
3. Tendon of the supinator longus.
4. Flexor longus pollicis.
- 5, 5. Tendon of the flexor carpi radialis.
- 6, 6. Tendon of the palmaris longus.
- 7, 7, 7, 7, 7, 7. Flexor sublimis digitorum.
- 8, 8, 8, 8, 8, 8. Flexor profundus digitorum.
- 9, 9. Tendon of the flexor carpi ulnaris.
10. Opponens pollicis.
11. Abductor pollicis.
12. Flexor brevis pollicis.
13. Adductor pollicis.
14. First external interosseous muscle.
- 15, 15, 15, 15. Lumbricales.
16. Abductor minimi digiti.
17. Adductor minimi digiti.
18. Palmaris brevis.
19. Radial artery.
20. Superficialis volæ, sent to the small muscles of the thumb.
21. Trunk of the radial artery turning towards the back of the hand.
- 22, 22. Ulnar artery.
23. Deep palmar artery.
24. Superficial palmar arch formed by the ulnar alone.
- + First digital artery, dividing into,
- 25, 25. The anterior digito-ulnar artery of the little finger,
- 26, 26. Anterior digito-radial artery of the same finger, and
- 27, 27. Anterior digito-ulnar artery of the ring-finger.
28. Trunk of the second and third digital arteries.
29. Second digital artery, which divides into,
30. The anterior digito-radial artery of the ring-finger, and
- 31, 31. The anterior digito-ulnar artery of the middle finger.
32. Third digital artery, which divides into,
- 33, 33. The anterior digito-radial artery of the middle finger, and
34. 35. Anterior digito-ulnar artery of the forefinger.
36. Arteria magna pollicis.
37. Anterior digito-ulnar artery of the thumb.
- 38, 38. Anterior digito-radial artery of the thumb.
- 39, 39. Anterior digito-radial artery of the forefinger.



PL. XVIII.

Fig. 1.

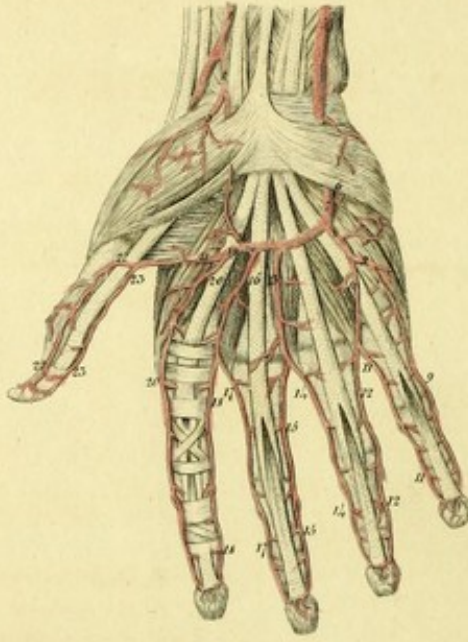


Fig. 2.

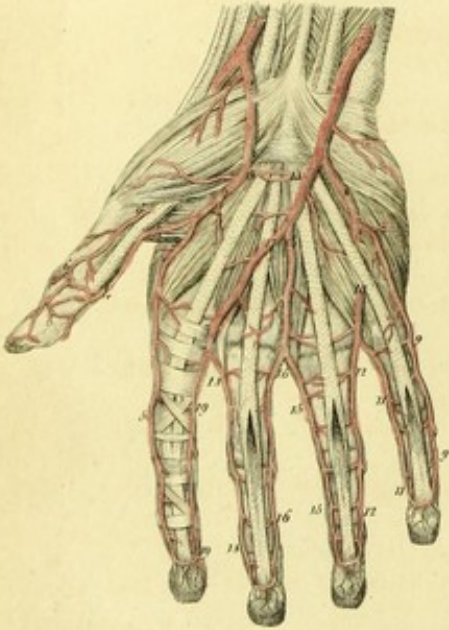

Fig. 3.

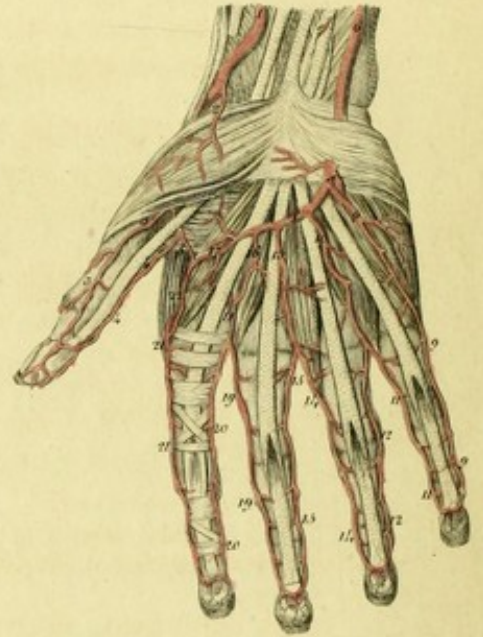


Fig. 4.

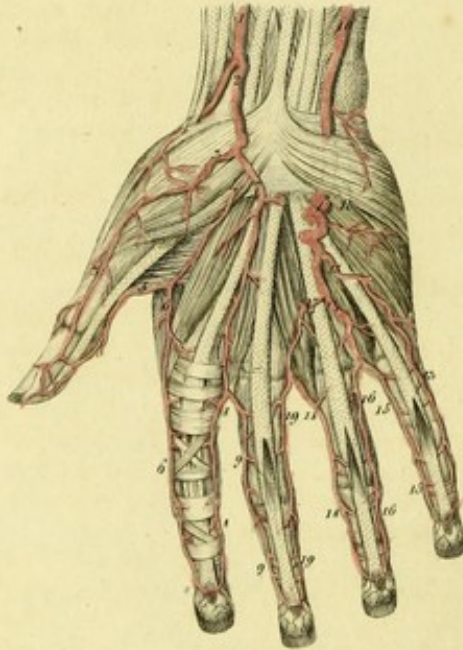


Fig. 5.

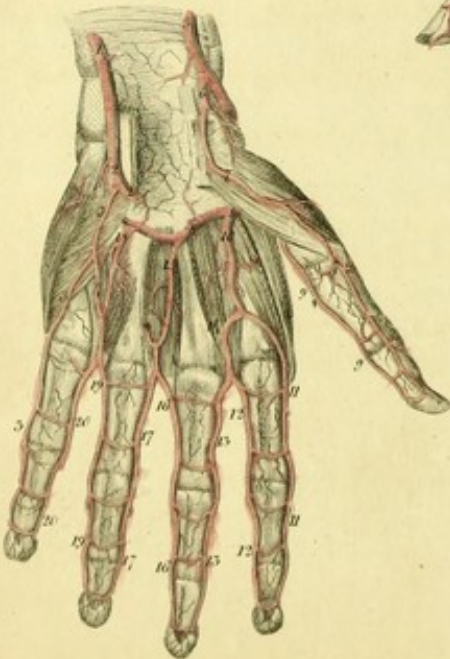


Fig. 6.

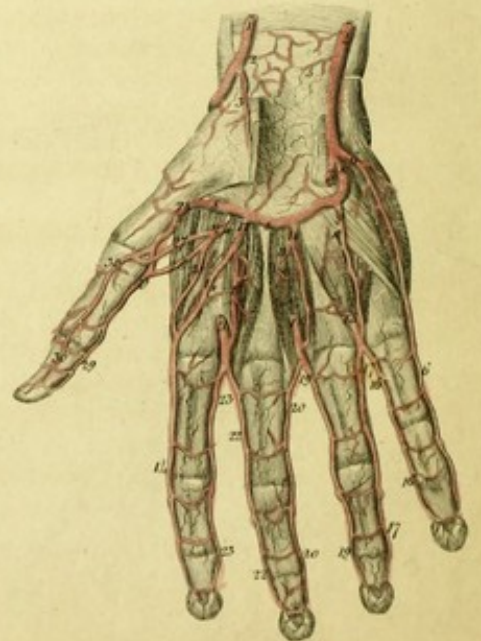


PLATE XVIII.

FIGURE I.

This shows a right hand, in which the superficial volar arch is composed of the radial and ulnar arteries. This disposition is frequent.

1. Radial artery.
2. Superficial volar branch.
3. Twig to the opponens, abductor, and flexor brevis, pollicis.
4. Anastomosis of the superficial volar branch, with the ulnar artery.
5. Ulnar artery.
6. Deep volar branch of the ulnar.
7. Superficial volar arch.
8. First digital artery.
- 9, 9. Anterior digito-ulnar artery of the little finger.
- 10, 10. Small trunk, which divides into
- 11, 11. The anterior digito-radial artery of the little finger, and
- 12, 12. Anterior digito-ulnar artery of the ring finger.
13. Second digital artery, which divides into
- 14, 14. The anterior digito-radial artery of the ring finger, and
- 15, 15. Anterior digito-ulnar artery of the middle finger.
16. Third digital artery, which divides into
- 17, 17. Anterior digito-radial artery of the middle finger, and
- 18, 18. Anterior digito-ulnar artery of the fore-finger.
19. Fourth digital artery, which divides into
- 20, 20. The anterior digito-radial artery, of the fore-finger, and
21. Arteria magna pollicis, which divides into
- 22, 22. The anterior digito-radial artery of the thumb, and
- 23, 23. Anterior digito-ulnar artery of the thumb.

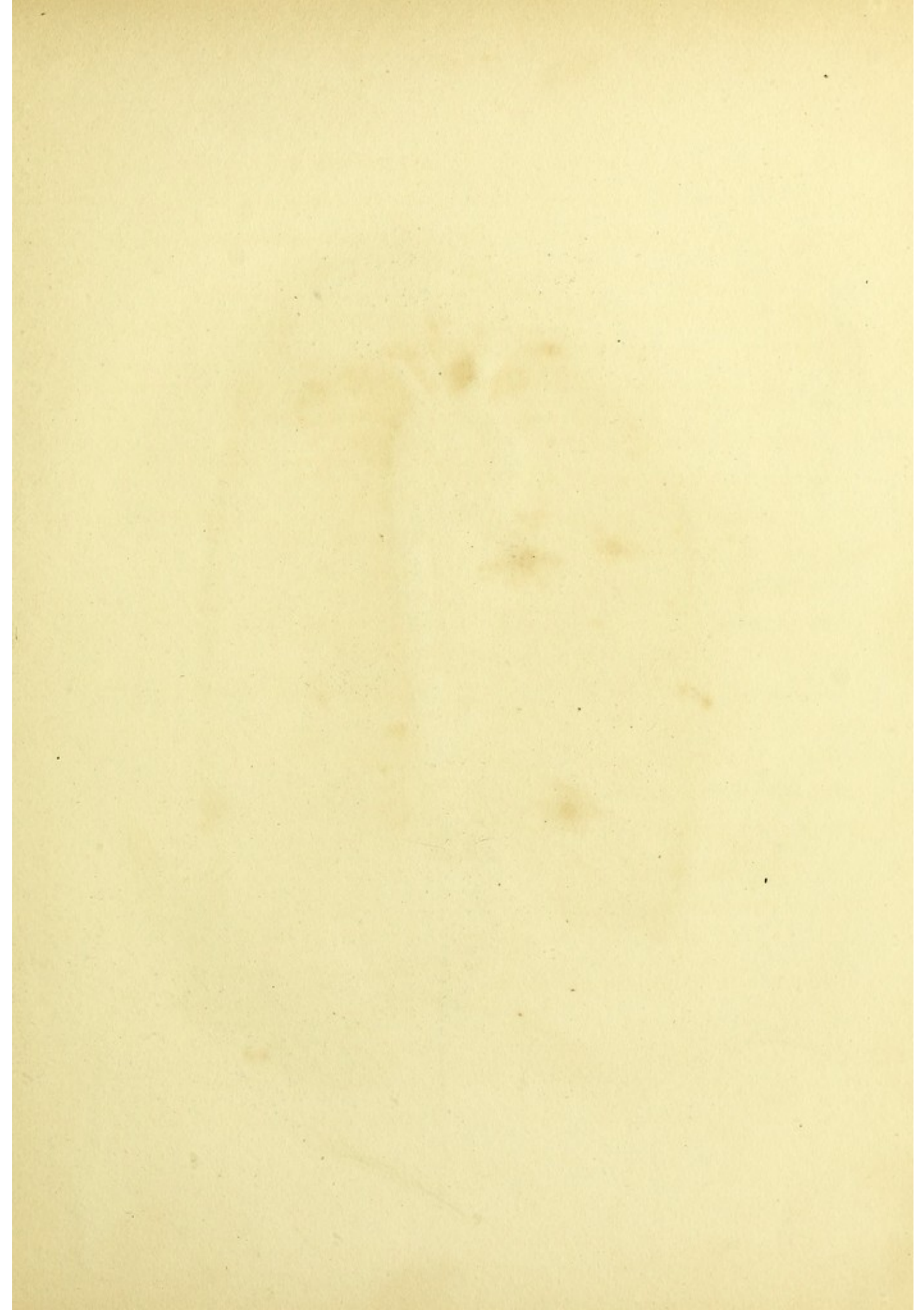
FIGURE II.

The right hand of a man, in which a rare disposition of the arteries is observed.

1. Radial artery.
- 2, 2. Superficial volar artery from the radial.
3. Anastomosing twig, with the ulnar.
- 4, 4. Anterior digito-ulnar artery of the thumb.
- 5, 5. Anterior digito-radial artery of the fore-finger.
- 6, 6. Anterior digito-radial artery of the thumb, from the deep arch.
7. Ulnar artery.
8. Deep volar artery.
- 9, 9. Anterior digito-ulnar artery of the little finger.
10. Small trunk, which divides into
- 11, 11. Anterior digito-radial of the little finger, and
- 12, 12. Anterior digito-ulnar artery of the ring finger.
13. Twig anastomosing with the superficialis volæ of the radial.
14. First digital artery from the ulnar in the palm, which divides into
- 15, 15. Anterior digito-radial artery of the ring finger, and
- 16, 16. Anterior digito-ulnar artery of the middle finger.
17. Second digital artery from the ulnar in the palm, which divides into
- 18, 18. Anterior digito-radial artery of the middle finger, and
- 19, 19. Anterior digito-ulnar artery of the fore-finger.

FIGURE III.

The right hand of a woman, in which an unusual distribution of the arteries is seen.



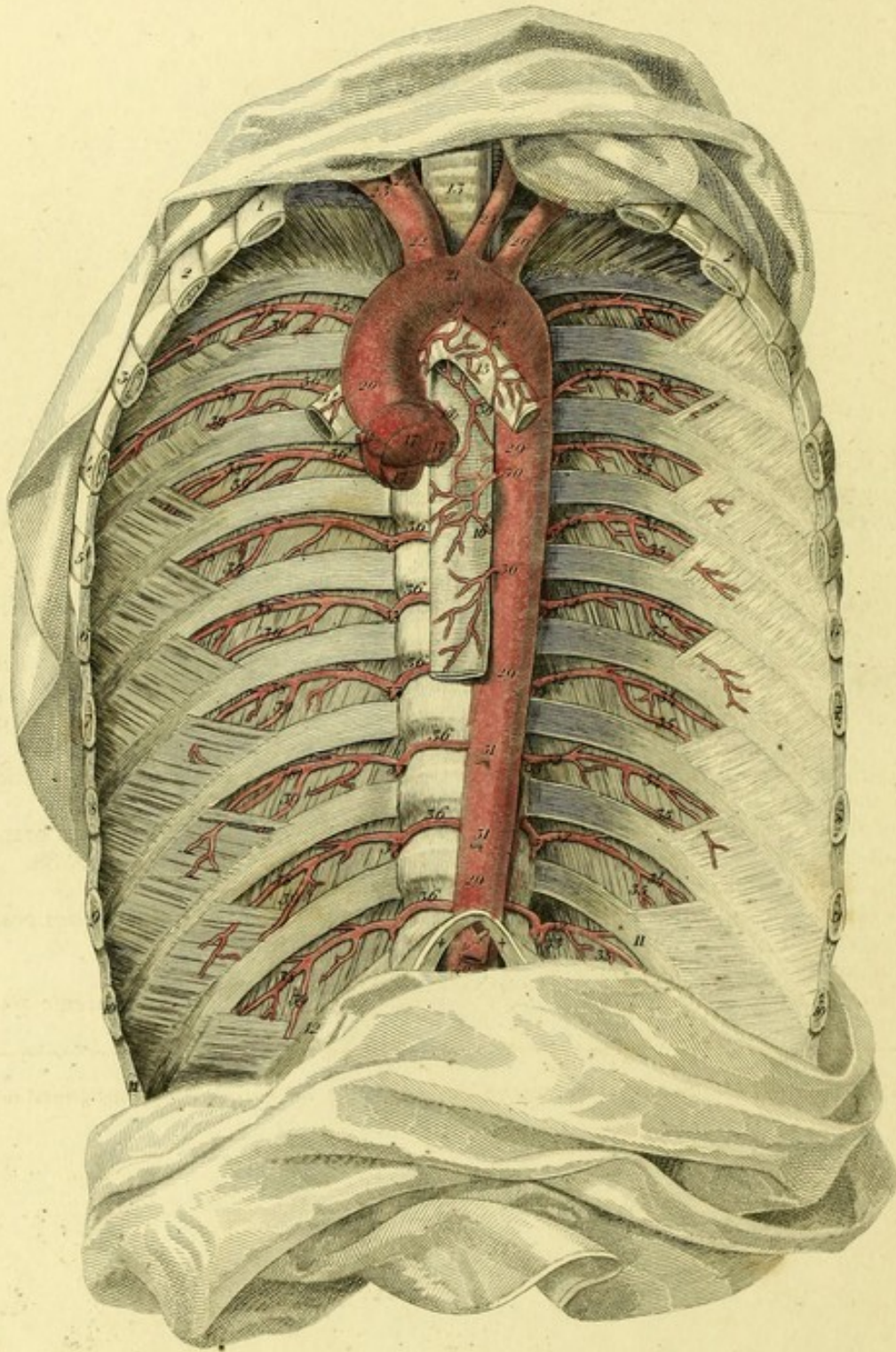



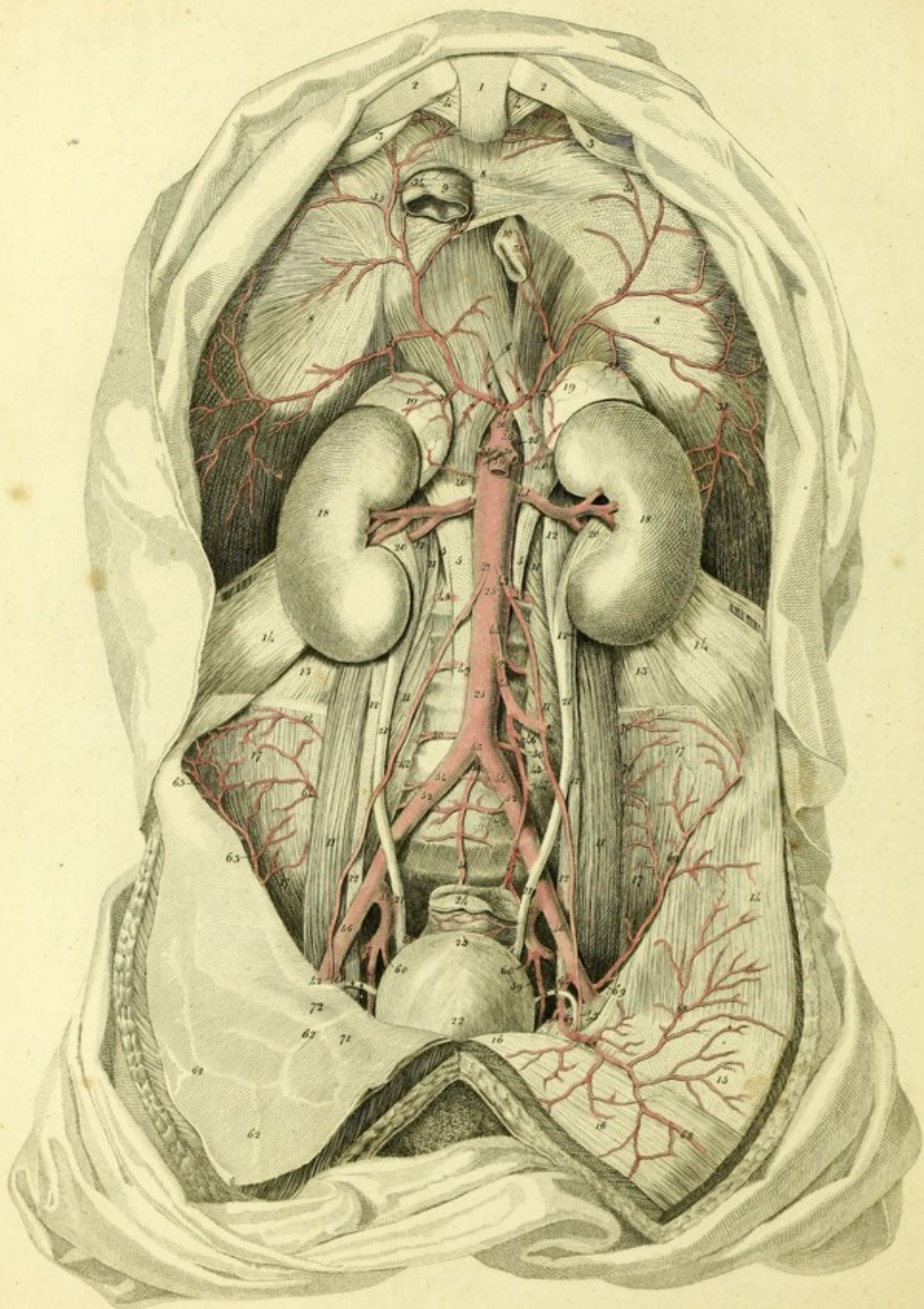
PLATE XIX.

Gives a Representation of the Thoracic Aorta.

- | | |
|---|---|
| 1, 2, 3, 4, 5, 6, 7, 8, 9, 10, 11, 12. The ribs. | 29, 29, 29. Descending aorta. |
| ++ Portion of the diaphragm. | 30, 30, 30. Œsophageal arteries. |
| 13. The trachea. | 31, 31. Œsophageal arteries truncated. |
| 14. Right bronchus. | 32, 32, 32, 32, 32, 32, 32, 32, 32. Left inferior or aortic intercostal arteries. |
| 15. Left bronchus. | 33, 33, 33, 33, 33, 33. Posterior or dorsal branches. |
| 16. Œsophagus. | 34, 34, 34, 34, 34, 34, 34. Inferior costal branches. |
| 17, 17, 17. Semilunar valves of the aorta. | 35, 35, 35, 35, 35, 35, 35. Superior costal branches. |
| 18. Origin of the right coronary artery of the heart. | 36, 36, 36, 36, 36, 36, 36, 36. Right aortic intercostal arteries. |
| 19. Origin of the left coronary artery of the heart. | 37, 37, 37, 37, 37, 37. Dorsal branches. |
| 20. Ascending aorta. | 38, 38, 38, 38, 38, 38, 38, 38, 38. Inferior costal branches. |
| 21. Arch of the aorta. | 39, 39, 39, 39, 39, 39. Superior costal branches. |
| 22. Trunk of the arteria innominata. | 40. Abdominal aorta. |
| 23. Right subclavian. | 41. Coeliac artery. |
| 24. The right carotid artery. | 42. Trunk of the inferior phrenic arteries. |
| 25. The left carotid artery. | |
| 26. Left subclavian artery. | |
| 27. Bronchial artery of the right side. | |
| 28. Left bronchial artery. (a) | |

(a) It is quite evident that the bronchial arteries vary very much, and scarcely keep to any general rule.





This shows the Abdominal Aorta and its Branches.

1. Ensiform process of the sternum.
- 2, 2. Cartilage of the seventh rib.
- 3, 3. Cartilage of the eighth rib.
- 4, 4. Costo-xiphoid ligaments.
- 5, 5, 5. Lumbar fasciculi of the diaphragm.
6. Union of the crura of the diaphragm.
- 7, 7, 7, 7. Costal fasciculi of this muscle.
- 8, 8, 8. Tendon of the diaphragm.
9. Foramen, through which the inferior vena cava passes.
10. Hiatus for the passage of the œsophagus.
- 11, 11. Psoæ magnæ muscles.
- 12, 12, 12, 12. Psoæ parvæ muscles.
- 13, 13. Quadrati lumborum muscles.
- 14, 14, 14, 14. Transversales muscles of the abdomen.
15. Membraneous tendon of the left transversalis muscle of the abdomen.
- 16, 16. Rectus abdominis of the left side.
- 17, 17, 17, 17. Iliaci interni muscles.
- 18, 18. Kidneys.
- 19, 19. Supra-renal glands.
- 20, 20. Pelves of the kidneys.
- 21, 21. Ureters.
22. Urinary bladder.
23. Urachus.
24. Rectum.
- 25, 25, 25. Abdominal aorta passing between the crura of the diaphragm.
26. Coeliac artery.
27. Inferior phrenic artery (*A. magna s. princeps*).^a
28. Left phrenic artery.
- ++++ Twigs to the crura of the diaphragm.
- 29, 29. Superior supra-renal branches.
- 30, 30. Œsophageal branch.
- 31, 31, 31. Anterior, external, and posterior branches.
32. Right phrenic artery.
- 33, 33. Superior supra-renal branches of the right side.
- 34, 34. Twigs to the vena cava inferior, ascending into the thorax by the foramen in the cordiform tendon of the diaphragm.
- 35, 35, 35. Anterior, external, and posterior branches.
36. Arteria coronaria ventriculi, cut.
37. Hepatic artery, cut.
38. Splenic artery, cut.
39. Trunk of the superior mesenteric artery.
- 40, 40. Middle capsular arteries.^b
- 41, 41. Renal arteries.^b
- 42, 42, 42. Right spermatic artery.^c
- 43, 43, 43. Left spermatic artery passing into the inguinal canal along with the vas deferens.
44. Inferior mesenteric artery.
45. Left superior colic artery.
46. Left inferior colic artery.
47. Superior or internal hæmorrhoidal artery.
- 48, 48. Second lumbar artery of each side.
- 49, 49. Third lumbar artery of each side.
- 50, 50. Fourth lumbar artery of each side.

^a This artery presents many varieties which Haller (Icon. Anat. Fasc. 3. p. 53.) has well described. There are either two phrenic arteries or a single one. In twenty-one bodies, a single phrenic artery occurred five times, thrice from the aorta, immediately above the coeliac, and twice from the latter artery itself. Sixteen times there were two: the coeliac gave them both off six times; the aorta twice; twice the coeliac gave off the right, and the aorta the left; twice the coronaria ventriculi gave off the right, and the aorta the left; twice the aorta gave off the right, and the coeliac the left; once the renal gave off the right, and the aorta the left; lastly, there were once four arteries, two of which were given off by the aorta, and two by the coeliac. I here omit another observation, in which, besides two phrenics from the aorta, one came from the coeliac.

To these varieties, all of which I have seen, I may add a

new one, viz. the phrenic artery formed a common trunk with the coronaria ventriculi which arose from the aorta.

^b These capsular arteries very often arise from the renal.

^c It is well known that the renal arteries vary very much.


^c The spermatic arteries vary as to number and origin. Generally two spermatic arteries arise from the aorta, or one which afterwards divides into two. Not uncommonly the left spermatic comes off from the aorta higher than the right, and *vice versa*. One spermatic often arises from the renal or capsular artery, (Haller Icon. Anat. Fasc. 3, p. 60.) or from the Hypogastric, (Mayer Beschreibung der Blutgefäße, p. 180.) and the other from the aorta.

Sometimes there are two on one or both sides, (Haller, L. c. Morgagni de Sed. et Causis, Morbor. T. 2. p. 348; Hunter Medical Commentaries, p. 78; Pohl Obs. Angiol. p. 12; Nicolai de direct. vasor. § 17; Huber Observ. Anat. in Halleri Thes. Diss. vol. i. p. 307; Otto Seltene Beobacht. Zur Anatomie, p. 101.

- 51, 51. Arteria sacra media.
- 52, 52. Fifth lumbar artery.^a
- 53. Abdominal aorta dividing into the common iliacs.
- 54, 54. Common iliac arteries.
- 55, 55. Hypogastric, or internal iliac arteries.
- 56, 56. External iliac arteries.
- 57, 57. Gluteal arteries.
- 58. Right sacro-lateral artery.
- 59, 59. Obturator arteries.
- 60, 60. Ischiatic arteries.

- 61, 61. Right epigastric artery.
- 62, 62, 62. Branches of this artery ascending behind the peritoneum.
- 63, 63. Right circumflex iliac artery.
- 64, 64. Twigs of the ilio-lumbar artery.
- 65. Left epigastric artery.
- 66. Twig to the inner surface of the os pubis.
- 67. Twig to the spermatic cord, forming the inferior spermatic artery.
- 68, 68, 68. Proper epigastric branches.
- 69, 69. Left circumflex iliac artery.
- 70, 70. Twigs of the ilio-lumbar artery anastomosing with the circumflex iliac artery.
- 71. Internal inguinal fossa.
- 72. External inguinal fossa.

^a This artery generally arises from the arteria sacra media, sometimes from the aorta, or common iliac.



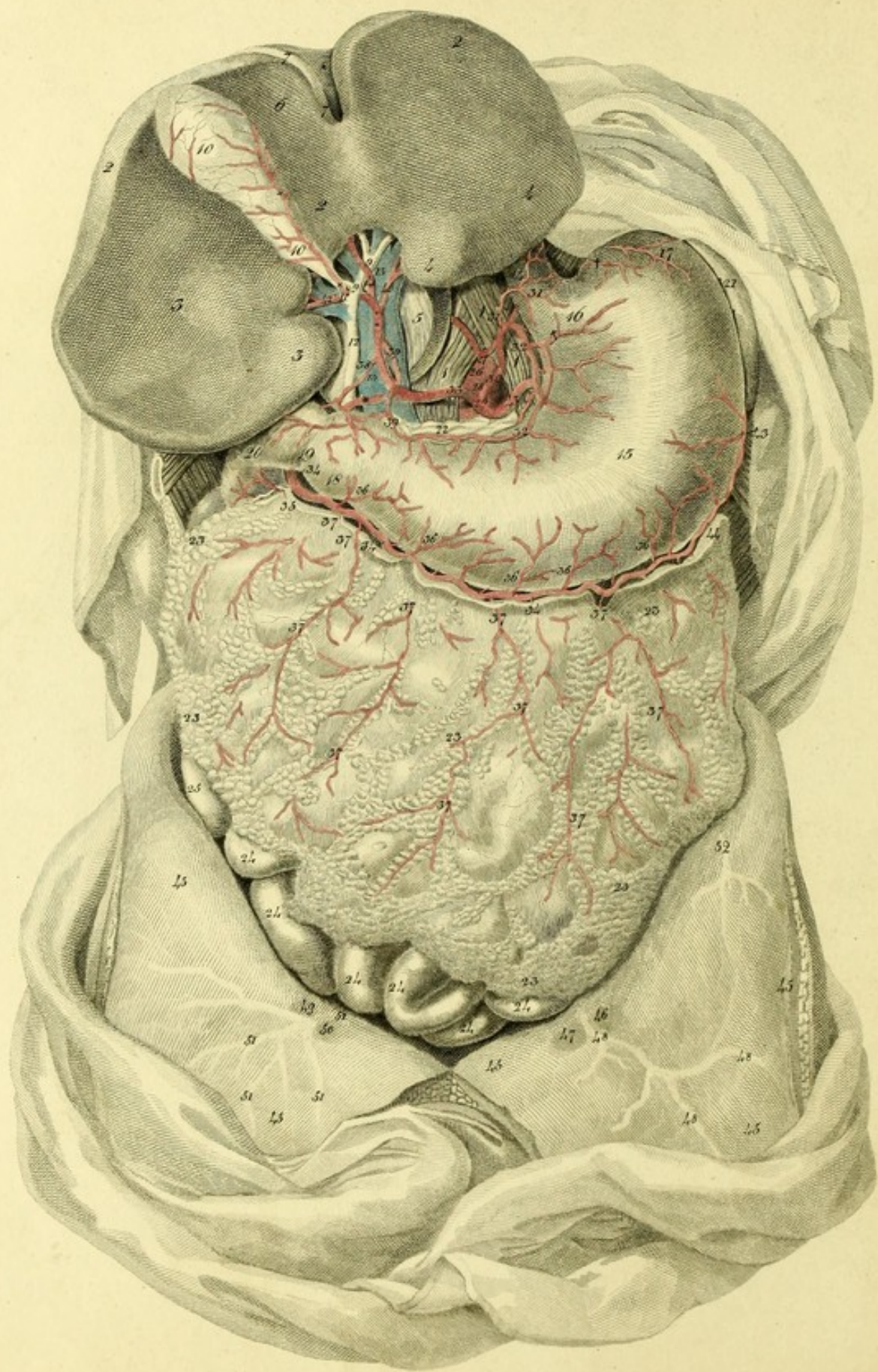


PLATE XXI.

This shows the Arteries of the Stomach and Liver.

- 1, 1, 1. Crura of the diaphragm.
- 2, 2. Liver drawn aside.
- 3, 3. Right lobe.
- 4, 4. Left lobe.
5. Lobulus Spigelii.
6. Lobulus quadratus.
7. Round ligament.
8. Suspensory ligament.
- 9, 9. Hepatic duct.
- 10, 10. Gall-bladder.
11. Cystic duct.
12. Ductus communis choledochus.
13. Vena portarum.
14. Oesophagus.
15. Stomach.
16. Cardia.
17. Great cul-de-sac of the stomach.
18. Small cul-de-sac of the stomach.
19. Pylorus.
20. Duodenum.
21. Spleen.
22. Pancreas.
- 23, 23, 23, 23, 23. Omentum majus.
- 24, 24, 24, 24, 24. Small intestines.
25. Cæcum.
26. Abdominal aorta.
27. Phrenic arteries arising from the aorta.
28. Cœliac artery.
29. The tripod of the cœliac artery.
30. Coronary artery of the stomach.
31. Inferior œsophageal artery.
- † † Twigs to the cardia and the great cul-de-sac of the stomach.
- 32, 32. Anastomosing coronary branch.

33. Hepatic artery.^a
- * Gastro-duodenal artery.
- 34, 34, 34. Right gastro-epiploic artery.
35. A twig to the duodenum.
- 36, 36, 36, 36, 36. Gastric twigs.
- 37, 37, 37, 37. Omental branches.
38. A twig to the pylorus.
- 39, 39. Pyloric artery which anastomoses with the coronaria ventriculi.
- ** Hepatic branch.
40. Left hepatic artery. ^b
41. Middle hepatic artery.
42. Right hepatic artery.
- † † † Cystic artery.
43. Left gastro-epiploic artery.
44. Anastomosis between the right and left gastro-epiploic arteries.
- 45, 45, 45, 45. Peritoneum.
46. External inguinal fossa.
47. Internal inguinal fossa.
- 48, 48, 48. Left epigastric artery covered by the peritoneum.
49. External inguinal fossa of the right side.
50. Internal inguinal fossa of the same side.
- 51, 51, 51. Right epigastric artery.
52. Twig of the circumflex iliac artery.

^a It seldom comes off from the aorta separately (Sandifort Obs. Anat. Path. L. 2. p. 126.) The hepatic artery is sometimes a branch of the superior mesenteric artery. Lastly, there may be several hepatic arteries, one from the usual place, the other from the coronaria ventriculi or superior mesenteric artery.

^b This very frequently arises from the coronaria ventriculi.

Fig. 1.

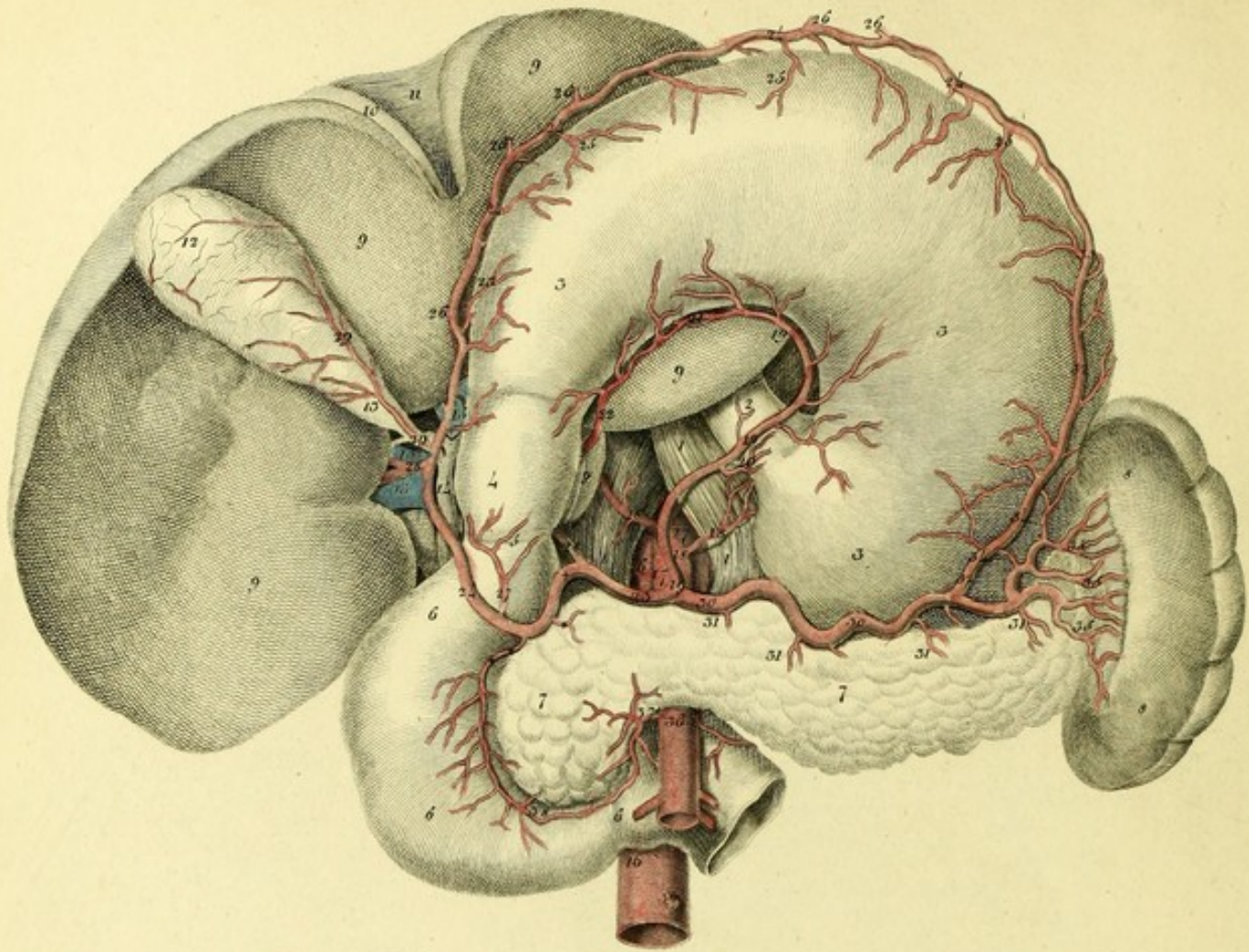


Fig. 2.

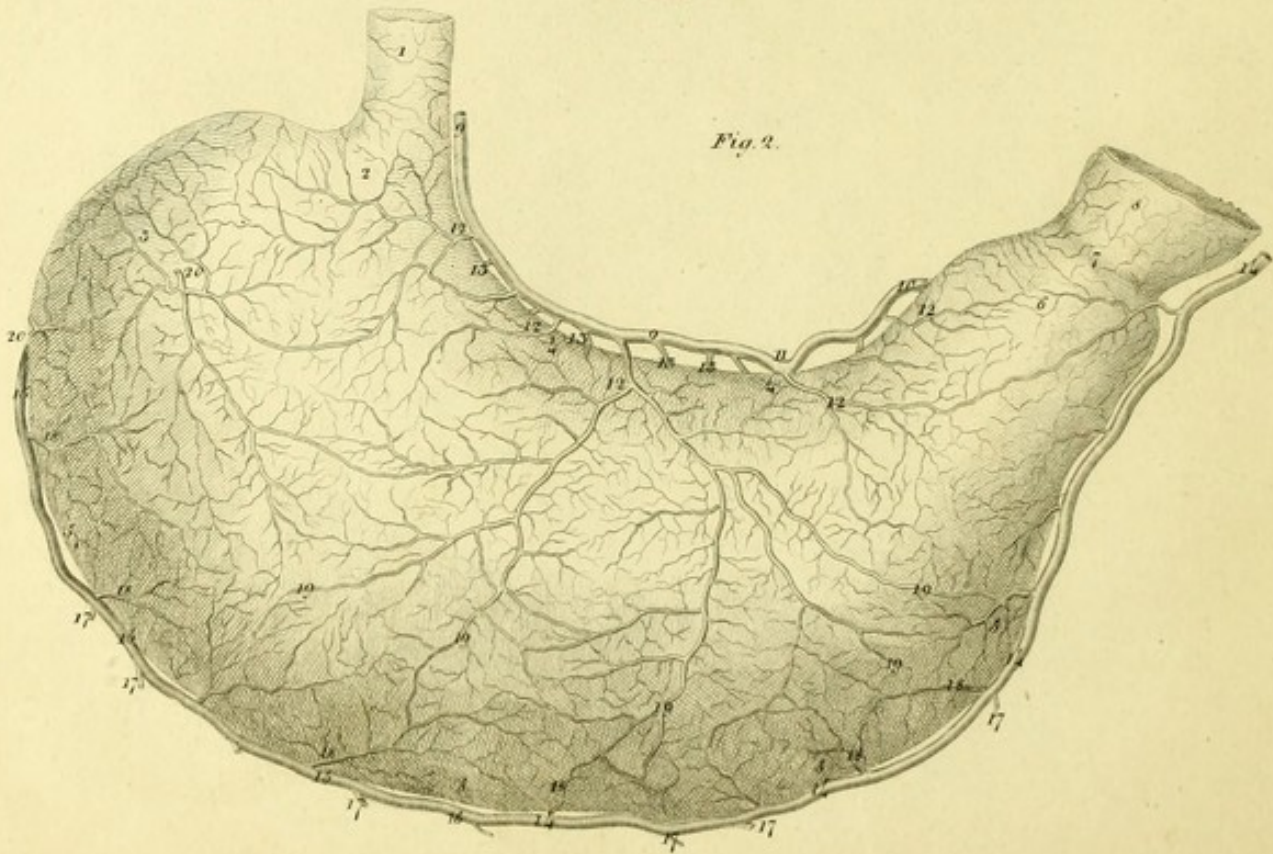


PLATE XXII.

FIGURE I.

Represents the arteries of the stomach, duodenum, pancreas, and spleen, The stomach is drawn aside.

- 1, 1, 1. Crura of the diaphragm.
2. Œsophagus.
- 3, 3, 3, 3. Posterior surface of the stomach reflected.
4. Small cul-de-sac of the stomach.
5. Pylorus.
- 6, 6, 6. Duodenum.
- 7, 7. Pancreas.
- 8, 8. Spleen.
- 9, 9, 9. Inferior surface of the liver drawn aside.
10. Round ligament of the liver.
11. Suspensory ligament.
12. Gall-bladder.
13. Neck of the gall-bladder.
14. Ductus communis choledochus.
- 15, 15, 15. Vena portarum.
- 16, 16. Abdominal aorta.
- 17, 17. Cœliac artery.
- 18, 18, 18. Inferior phrenic arteries.
- 19, 19, 19. Coronary artery of the Stomach.
20. Œsophageal branch.
21. Anastomosis of the coronaria ventriculi with the pyloric artery.
22. Pyloric artery from the hepatic.
23. Hepatic artery.
- † Gastro-duodenal artery.
- * Pancreatic branch.
- * * Superior pancreatico-duodenal artery.
- 24, 24, 24, 24. Right gastro-epiploic artery.
- 25, 25, 25. Gastric branches.
- 26, 26, 26, 26, 26. Omental branches, cut.
27. Inferior pyloric artery.
28. Hepatic branch.
29. Cystic artery.
- 30, 30. Splenic artery.
- 31, 31, 31, 31. Superior or middle pancreatic branches.
- 32, 32. Left gastro-epiploic artery.
33. Anastomosis between the left and right gastro-epiploic arteries.
- 34, 34. Vasa brevia.
- 35, 35, 35. Proper splenic branches.
36. Superior mesenteric artery.
37. Inferior pancreatico-duodenal artery.
38. Anastomosis of this artery with the superior pancreatico-duodenal.
39. Inferior mesenteric artery.

FIGURE II.

Exhibits the distribution of the arteries on the posterior surface of the stomach.

1. Œsophagus.
2. Cardia.
3. Fundus, or great cul-de-sac of the stomach.
- 4, 4. Smaller curvature.
- 5, 5, 5, 5. Greater curvature.
6. Small cul-de-sac of the stomach.
7. Pylorus.
8. Duodenum.
- 9, 9. Coronary artery of the stomach.
10. Pyloric artery.
11. Anastomosis between these arteries.
- 12, 12, 12, 12. Posterior gastric branches.
- 13, 13, 13, 13. Anterior gastric branches.
- 14, 14, 14, 14. Right gastro-epiploic artery.
- 15, 15, 15. Left gastro-epiploic artery.
16. Anastomosis of these arteries.
- 17, 17, 17, 17, 17. Omental branches cut.
- 18, 18, 18, 18, 18. Posterior gastric branches.
- 19, 19, 19, 19, 19. Great vascular net-work, which is formed by the anastomosis of these arteries with the superior.
20. 20. Vasa brevia from the splenic.

PLATE XXII

1. The first part of the plate shows the
 2. The second part shows the
 3. The third part shows the
 4. The fourth part shows the
 5. The fifth part shows the
 6. The sixth part shows the
 7. The seventh part shows the
 8. The eighth part shows the
 9. The ninth part shows the
 10. The tenth part shows the
 11. The eleventh part shows the
 12. The twelfth part shows the
 13. The thirteenth part shows the
 14. The fourteenth part shows the
 15. The fifteenth part shows the
 16. The sixteenth part shows the
 17. The seventeenth part shows the
 18. The eighteenth part shows the
 19. The nineteenth part shows the
 20. The twentieth part shows the
 21. The twenty-first part shows the
 22. The twenty-second part shows the
 23. The twenty-third part shows the
 24. The twenty-fourth part shows the
 25. The twenty-fifth part shows the
 26. The twenty-sixth part shows the
 27. The twenty-seventh part shows the
 28. The twenty-eighth part shows the
 29. The twenty-ninth part shows the
 30. The thirtieth part shows the

1. The first part of the plate shows the
 2. The second part shows the
 3. The third part shows the
 4. The fourth part shows the
 5. The fifth part shows the
 6. The sixth part shows the
 7. The seventh part shows the
 8. The eighth part shows the
 9. The ninth part shows the
 10. The tenth part shows the
 11. The eleventh part shows the
 12. The twelfth part shows the
 13. The thirteenth part shows the
 14. The fourteenth part shows the
 15. The fifteenth part shows the
 16. The sixteenth part shows the
 17. The seventeenth part shows the
 18. The eighteenth part shows the
 19. The nineteenth part shows the
 20. The twentieth part shows the
 21. The twenty-first part shows the
 22. The twenty-second part shows the
 23. The twenty-third part shows the
 24. The twenty-fourth part shows the
 25. The twenty-fifth part shows the
 26. The twenty-sixth part shows the
 27. The twenty-seventh part shows the
 28. The twenty-eighth part shows the
 29. The twenty-ninth part shows the
 30. The thirtieth part shows the


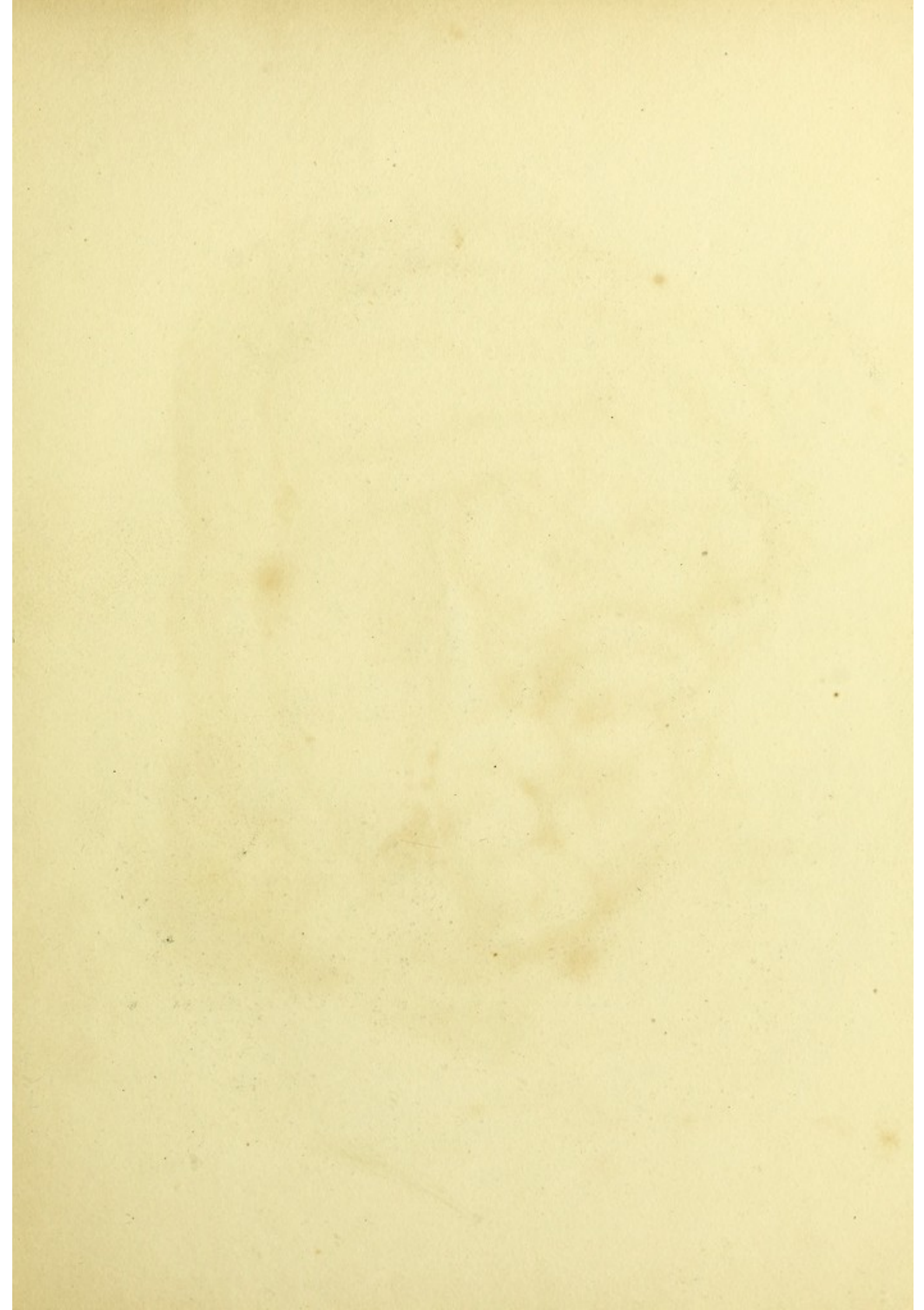


PLATE XXIII.

Shows the Superior Mesenteric Artery.

- 1, 1. The duodenum.
2. Beginning of the jejunum.
- 3, 3. Pancreas.
- 4, 4, 4, 4, 4, 4, 4, 4, 4. Small intestines.
- 5, 5. Termination of the ileum in
- 6, 6. The cœcum.
7. Vermiform appendix.
- 8, 8. Ascending colon.
- 9, 9, 9, 9. Transverse colon.
10. Descending colon.
- 11, 11, 11, 11, 11. Anterior bundle of longitudinal fibres,
- 12, 12, 12, 12, 12. Posterior lamina of the peritoneum.
13. Superior mesenteric artery.^a
- 14, 14. Inferior pancreatico-duodenal artery.
15. Superior pancreatico-duodenal artery.
- 16, 16, 16. Middle colic artery.
17. Anastomosis of this artery with the left colic.
18. Anastomosis with the right colic artery.
19. Trunk of the right colic and ileo-colic arteries.
20. Right colic artery.
21. Ileo-colic artery.
- † Cœcal artery.
- 22, 22, 22. Artery of the vermiform appendix.
- † † Branch to the termination of the small intestines.
23. Anastomosis of the ileo-colic artery with the intestinal artery.
- 24, 24, 24, 24, 24, 24, 24, 24, 24, 24, 24, 24, 24, 24, 24. Intestinal arteries.
- 25, 25, 25, 25, 25, 25, 25, 25, 25, 25, 25, 25, 25, 25. Anastomoses of these arteries of the first order.
- 26, 26, 26, 26, 26, 26, 26, 26, 26, 26, 26, 26, 26, 26. Anastomoses of the second order.
- 27, 27, 27, 27, 27, 27, 27, 27, 27, 27, 27, 27, 27, 27. Anastomoses of the third order.
- 28, 28, 28, 28, 28, 28, 28, 28, 28, 28, 28, 28, 28, 28. Intestinal twigs.

^a This rarely forms a common trunk with the cœliac artery. Haller (Icon. Anat. Fasc. viii. p. 35. No. 11.) once saw this disposition, which Galen, Riolan and others have described as regular.



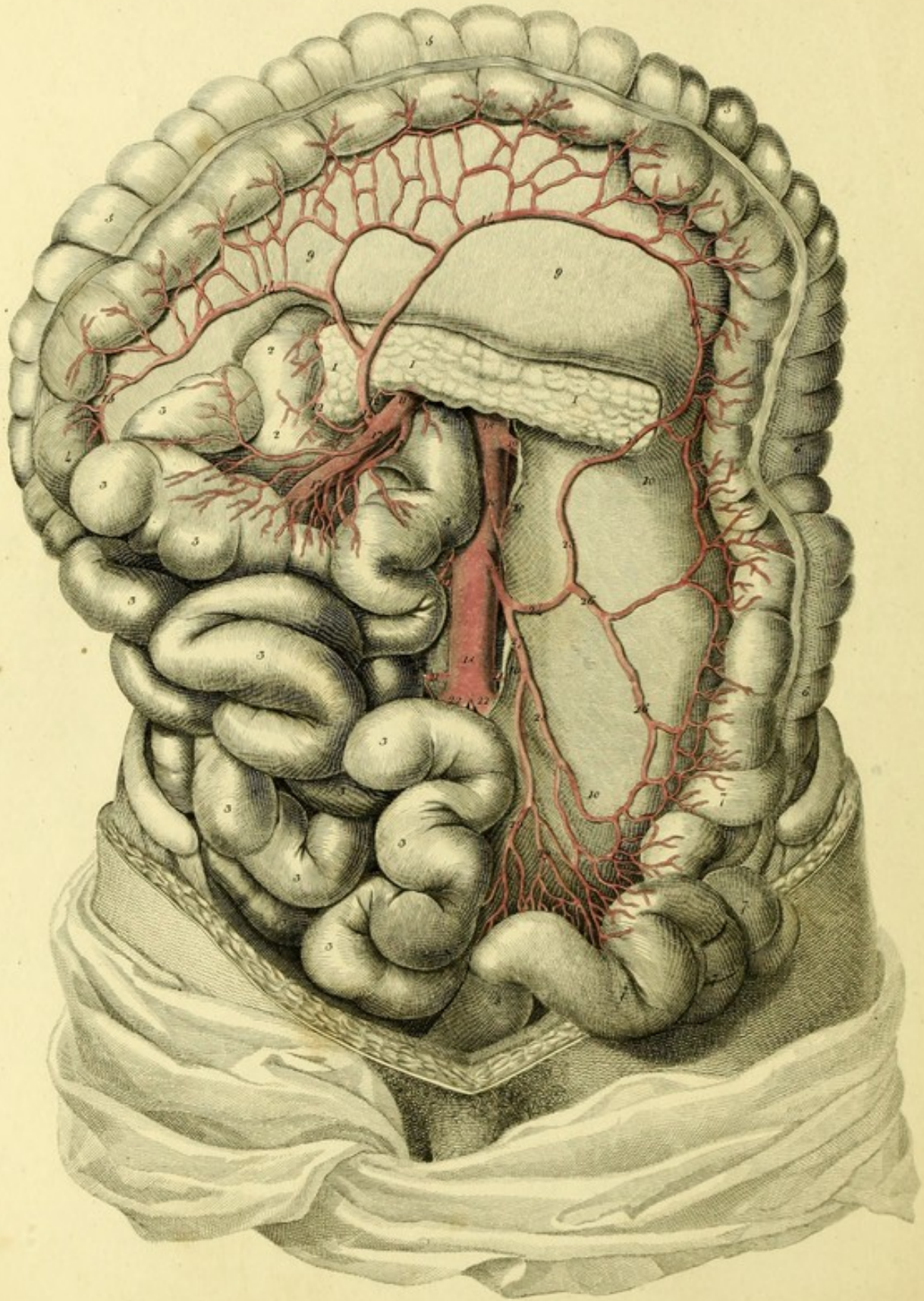


PLATE XXIV.

Exhibits the Inferior Mesenteric Artery.

- | | |
|--|--|
| 1, 1, 1. Pancreas. | 20, 20. Spermatic arteries. |
| 2, 2, 2. Duodenum. | 21, 21, 21. Lumbar arteries. |
| 3, 3, 3, 3, 3, 3, 3, 3, 3, 3, 3, 3, 3, 3. Small intestines. | 22, 22. Iliac arteries. |
| 4. Ascending colon. | 23. Inferior mesenteric artery. ^a |
| 5, 5, 5. Transverse colon. | 24. Left colic artery. |
| 6, 6. Descending colon. | 25, 25. Ascending or great anastomosing branch with the middle colic. ^b |
| 7, 7, 7, 7, 7. Sigmoid flexure of the colon. | 26, 26. Branch to the descending colon. |
| 8. Rectum. | 27. Internal or superior hæmorrhoidal artery. |
| 9, 9. Lamina of the peritoneum composing the transverse mesocolon. | 28. Branch to the sigmoid flexure of the colon. |
| 10, 10, 10, 10. Posterior lamina of the peritoneum which forms the descending mesocolon. | 29, 29. Branches to the rectum. |
| 11. Superior mesenteric artery. | |
| 12, 12. Inferior pancreatico-duodenal artery. | |
| 13. Superior pancreatico-duodenal artery. | |
| 14, 14, 14. Middle colic artery. | |
| 15. Anastomosing branch with the right colic artery. | |
| 16. Great anastomosing branch with the left colic artery. | |
| 17, 17, 17. Intestinal branches. | |
| 18, 18. Abdominal aorta. | |
| 19. Left renal artery. | |

^a Petsche (*Sylloge observationum anatomicarum selectarum* §. 76.) mentions a rare variety in the origin of the inferior mesenteric artery. In a preparation in which the left kidney was wanting, the aorta, after having given off the right renal artery, divided into two equal branches, from the left of which the inferior mesenteric artery arose, below this these two branches communicated together by another cross branch.

Fleischmann (*Leichen-Oeffnungen*, S. 239.) found in the body of an infant no inferior mesenteric artery arising from the aorta; the left colon and the rectum received branches from the superior mesenteric artery.

^b Vicq-d'Azyr (*Mém. de l'Ac. des Sc. Ann. 1776. p. 702.*) saw the anastomosis between the superior mesenteric and inferior mesenteric arteries entirely wanting.




Fig 1.

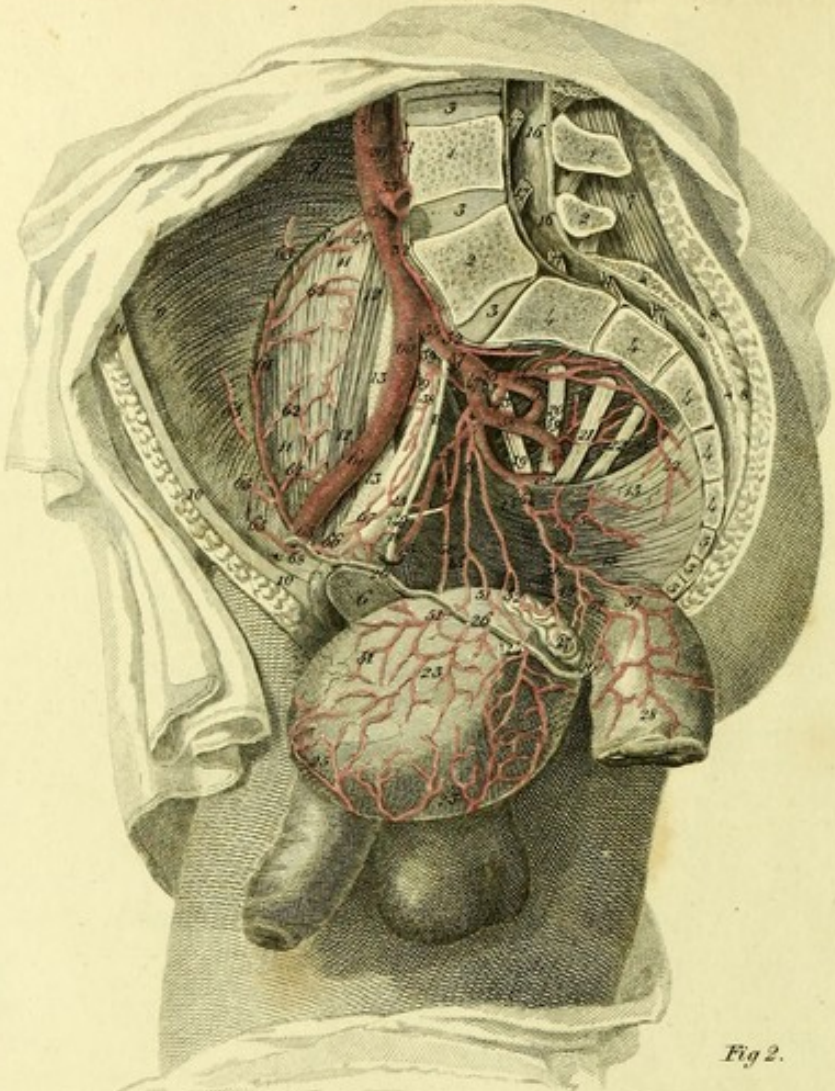


Fig 2.

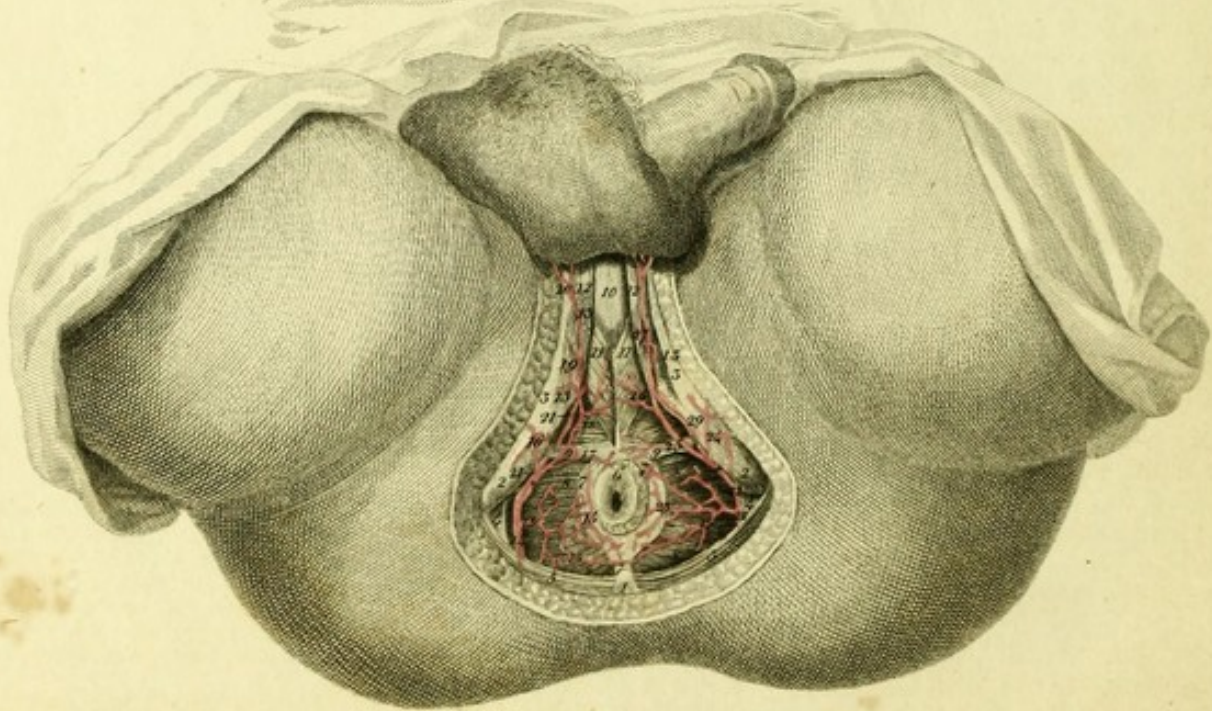


PLATE XXV.

Shows the Internal Iliac Artery of a Man.

FIGURE I.

Exhibits the pelvis cut perpendicularly, in which the branches of the internal iliac artery are seen.

- 1, 1. Fourth lumbar vertebra.
- 2, 2. Fifth lumbar vertebra.
- 3, 3, 3. Intervertebral cartilages.
- 4, 4, 4, 4, 4, 4, 4. Sacrum.
- 5, 5, 5. Ossa coccygis.
6. Symphysis of the bones of the pubes.
7. Longissimus dorsi muscle.
- 8, 8. Gluteus maximus muscle.
- 9, 9, 9. Transversalis abdominis muscle.
- 10, 10, 10. Rectus abdominis muscle.
- 11, 11. Iliacus internus muscle.
- 12, 12. Psoas magnus.
- 13, 13. Tendon of the psoas parvus.
- 14, 14, 14. Piriform muscle.
- 15, 15, 15, 15. Levator ani muscle.
- 16, 16, 16. Fibrous membrane of the spinal marrow.
- 17, 17, 17, 17, 17. Lumbar and sacral nerves.
- 18, 18. Obturator nerve.
19. Fifth lumbar nerve.
20. First sacral nerve.
21. Second sacral nerve.
22. Third sacral nerve.
- 23, 23. Urinary bladder drawn out of the pelvis.
24. Ureter.
25. Urachus.
- 26, 26, 26. Vas deferens.
27. Vesicula seminalis.
28. Rectum.
29. Aorta.
30. Inferior mesenteric artery.
31. Fourth lumbar artery.
- 32, 32. Middle sacral artery.
33. Left common iliac artery cut.
34. Right common iliac artery.
35. Internal iliac artery, which generally divides into an anterior and a posterior trunk.
36. Posterior trunk, which gives off the posterior branches.
- 37, 37. Ileo-lumbar artery.^a
38. Branch running along the linea innominata of the pelvis, and inosculating with a branch from the epigastric artery.

^a This artery sometimes arises from the common iliac, or from the external iliac, or from the gluteal, seldom from the fourth lumbar or middle sacral. There are often two smaller ileo-lumbar present.

- 39, 39. Twigs to the Psoas magnus.
40. Anastomosis of the ileo-lumbar artery with the circumflex iliac.
- 41, 41. Sacro-lateral artery.^b
42. Twig to the levator ani.
- 43, 43, 43. Obturator artery.^c
- 44, 44. Twig perforating the levator ani, and going to the obturator internus.
45. Twig anastomosing with the epigastric artery.
46. Gluteal artery.
47. Anterior trunk of the internal iliac, which gives off the anterior branches.
- 48, 48. Umbilical artery.
49. Part of this artery changed into a ligament.
50. Superior vesical artery.
- 51, 51, 51, 51, 51. Inferior vesical artery.^d
52. Branch to the seminal vesicle.
- 53, 53. Internal or common pudic artery.
54. Middle hæmorrhoidal artery.^e
55. Twig to the levator ani.
56. Twig to the vesicula seminalis.
- 57, 57. Branches distributed to the rectum.
- 58, 58. Ischiatic artery.
59. Twig to the pyramidalis muscle.
- 60, 60. External iliac artery.
- 61, 61. Circumflex iliac artery.
- 62, 62, 62. Twigs to the iliacus internus muscle.
- 63, 63, 63. Twigs to the abdominal muscles.
64. Anastomosis of this artery with the ileo-lumbar.
65. 65. Epigastric artery.
66. Obturator twig.
67. Union of this twig with the obturator artery.
68. Branch to the spermatic cord.

FIGURE II.

Shows the course of the common pudic artery.

1. Coccyx.
- 2, 2. Ischiatic tuberosities.

^b Two are very often present, one of which comes from the internal iliac, the other from the gluteal, or ileo-lumbar or ischiatic.

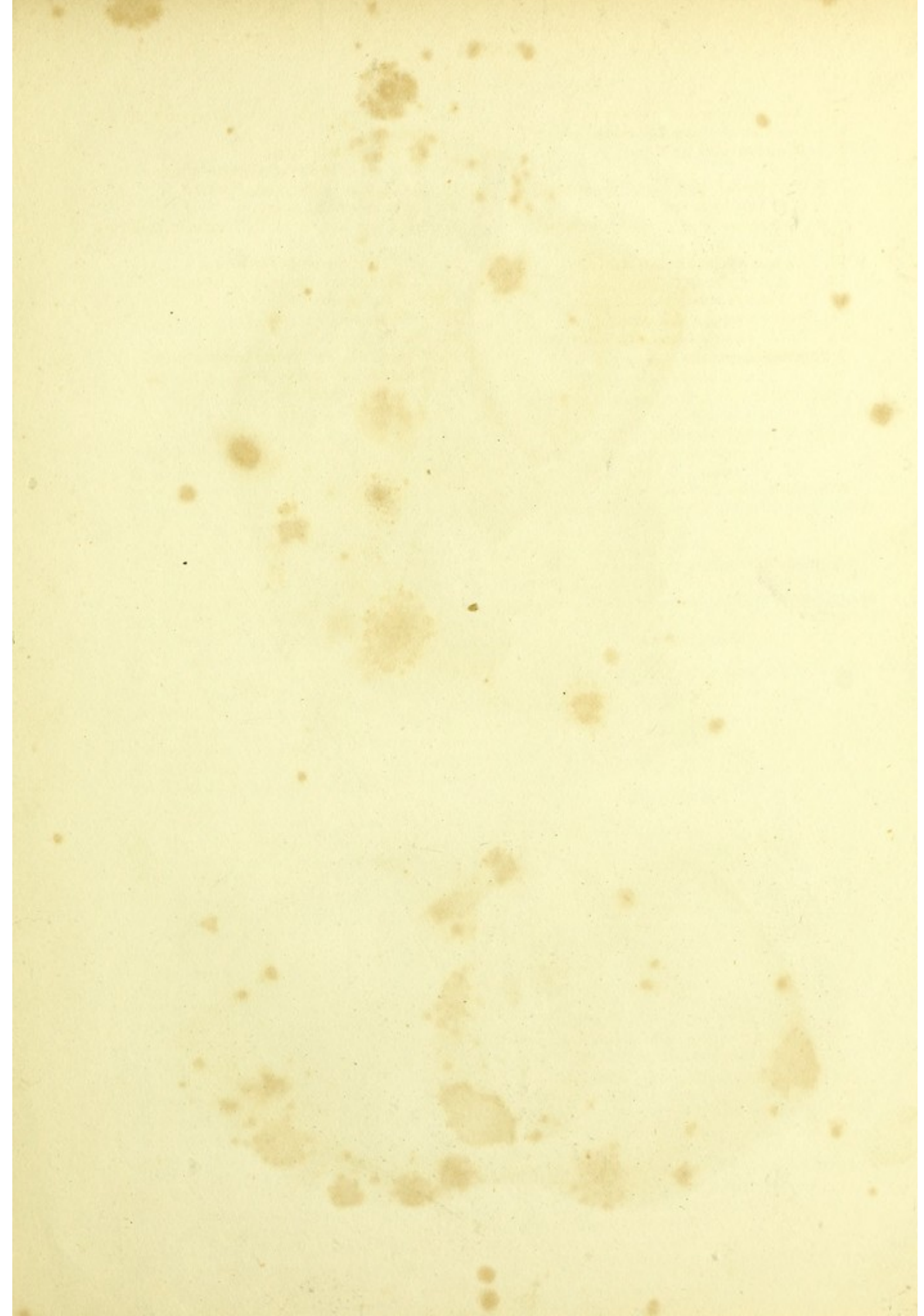^c The origin of this artery varies very much. It frequently arises from the anterior trunk of the internal iliac; not unfrequently from the external iliac, or from the epigastric artery. Another plate exhibits the principal varieties of this artery.

^d This artery varies as to its origin. It very often comes from the anterior trunk of the internal iliac artery, or from the common pudic artery, or from the ischiatic, or lastly from the middle hæmorrhoidal artery.

^e This generally comes from the pudic artery, sometimes however from the anterior trunk of the internal iliac, or from the ischiatic, or from the sacro-lateral.

- 3, 3. Ascending rami of the ossa ischia.
- 4, 4. Great sacro-sciatic ligaments.
- 5, 5. Glutei maximi muscles.
- 6. Anus.
- 7, 7, 7. External sphincter of the anus.
- 8, 8, 8, 8. Levatores ani.
- 9, 9. Transverse muscles of the perineum.
- 10. Urethra.
- 11, 11. Acceleratores urinæ muscles
- 12, 12. Crura penis.
- 13, 13. Erector muscles of the penis.
- 14. Right common pudic artery.
- 15, 15, 15. External hæmorrhoidal artery.
- † Superficialis perinei.

- 16. Twig descending to the tuberosity of the ischium.
- 17. Proper perineal twig.
- 18. Twig going to the accelerator urinæ.
- 19. Twigs sent to the erector penis.
- 20. Posterior scrotal artery.
- 21, 21. Deep branch of the common pudic artery.
- 22, 22. Left common pudic artery.
- 23, 23. External hæmorrhoidal artery.
- * Superficialis perinei.
- 24. Ischiatic twig.
- 25. Proper perineal twig.
- 26. Twig to the accelerator urinæ muscle.
- 27. Twigs to the erector penis.
- 28. Posterior scrotal artery.



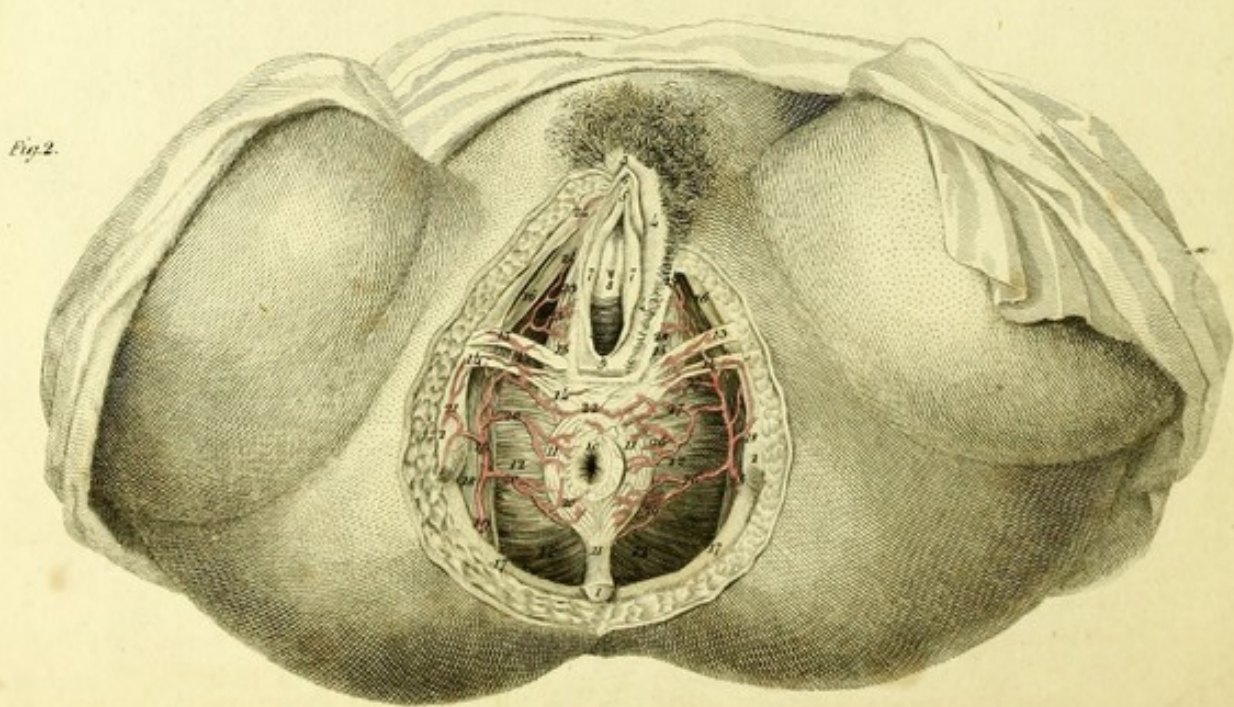
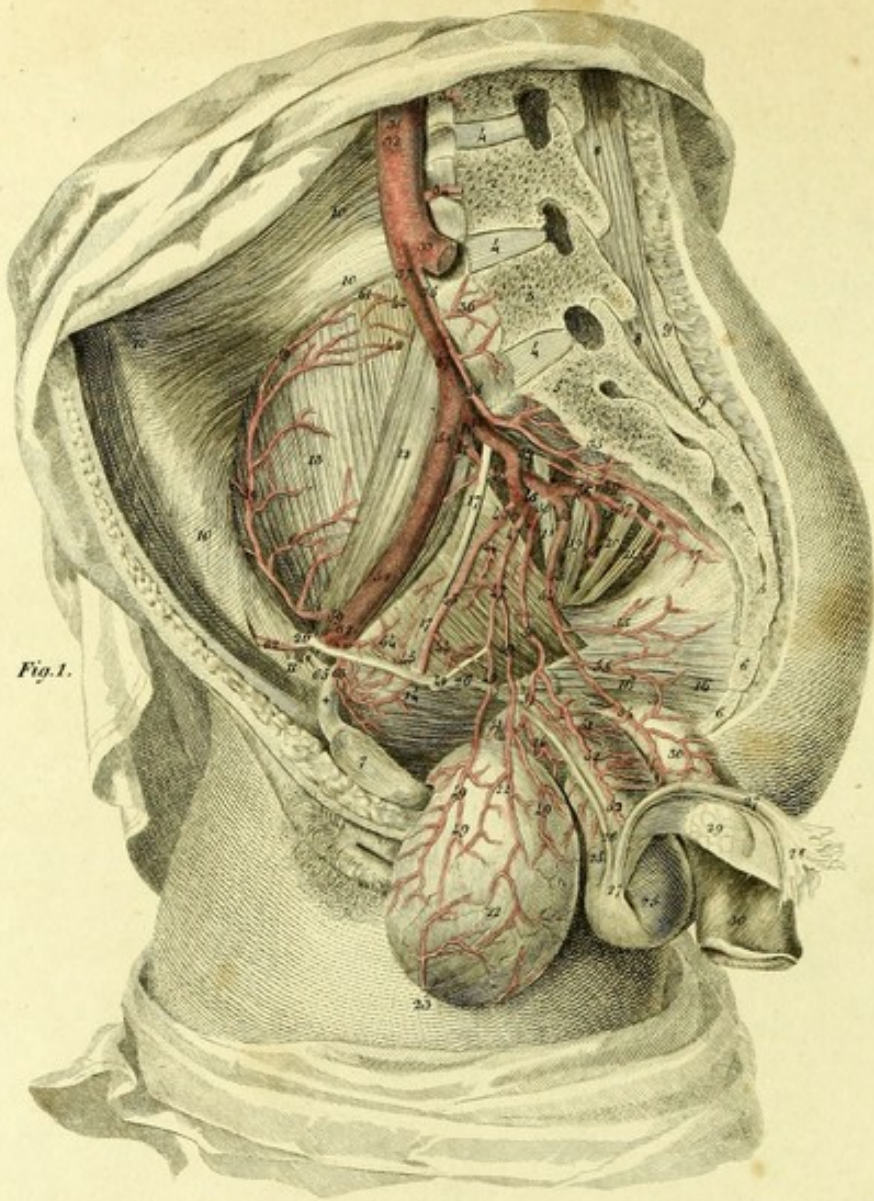


PLATE XXVI:

Exhibits the Course of the Internal Iliac Artery in the Female.

FIGURE I.

Shows the internal iliac artery in the female pelvis which is cut perpendicularly.

1. Third lumbar vertebra.
2. Fourth lumbar vertebra.
3. Fifth lumbar vertebra.
- 4, 4, 4. Intervertebral cartilages.
- 5, 5, 5. Sacrum.
- 6, 6. Ossa coccygis.
- † Horizontal ramus of the pubes.
7. Symphysis pubis.
- 8, 8. Longissimus dorsi muscle.
- 9, 9. Left gluteus maximus muscle, cut.
- 10, 10, 10, 10. Transversalis abdominis.
11. Internal aperture of the inguinal canal.
12. Psoas magnus muscle.
13. Iliacus internus muscle.
14. Obturator internus muscle.
15. Pyriform muscle.
- 16, 16. Portion of the levator ani.
- 17, 17. Obturator nerve.
18. Fifth lumbar nerve.
19. First sacral nerve.
20. Second sacral nerve.
21. Third sacral nerve.
22. Urinary bladder drawdown.
23. Urachus.
24. Vagina.
- 25, 25. Uterus drawn aside.
- 26, 26, 26. Round ligament of the uterus.
- 27, 27. Fallopian tube.
28. Fimbriated extremity of the tube.
29. Ovary covered by the broad ligament.
- 30, 30. Rectum.
31. Aorta.
32. Inferior mesenteric artery.
33. Left common iliac artery.
- 34, 34. Third and fourth lumbar arteries.
- 35, 35, 35. Middle sacral artery.
36. Fifth lumbar artery.
- 37, 37. Right common iliac artery.
38. Internal iliac artery.
- 39, 39. Sacro-lateral artery.
40. Ileo-lumbar artery.
41. Twig to the psoas magnus.
- 42, 42. Twigs to the iliacus internus muscle.
- 43, 43. Obturator artery.
- 44, 44. Twigs to the obturator internus muscle.
45. Twig anastomosing with the epigastric artery.
46. Gluteal artery.
- 47, 47. Umbilical artery.
48. Part of the umbilical artery changed into ligament.
- 49, 49, 49, 49, 49. Vesical arteries.

- 50, 50. Uterine artery.^a
- 51, 51, 51. Vaginal artery.
- 52, 52. Branch to the uterus.
- 53, 53. Common pudic artery.
- 54, 54. Middle hæmorrhoidal artery.^b
- 55, 55. Twigs to the levator ani.
- 56, 56. Ischiatic artery.
- 57, 57. Twigs to the anterior surface of the sacrum and sacro-sciatic ligaments.
- 58, 58. External iliac artery.
- 59, 59. Circumflex iliac artery.
- 60, 60. Twigs to the iliacus internus muscle.
61. Anastomosis of this artery with the ileo-lumbar.
- 62, 62. Epigastric artery.
63. Twig to the inner surface of the pubes.
64. Obturator twig.
65. Branch to the round ligament of the uterus.


FIGURE II.

Shows the course of the common pudic artery.

1. Apex of the coccyx.
- 2, 2. Tuberosities of the ischia.
3. Mons veneris.
- 4, 4. Labia majora.
5. Clitoris.
6. Prepuce of the clitoris.
- 7, 7. Nymphæ.
8. Orifice of the Urethra.
9. Entrance of the Vagina.
10. Anus.
11. External sphincter of the anus.
- 12, 12, 12, 12. Levatores ani.
13. Anterior transversalis perinei muscle.
14. Posterior transversalis perinei.
- 15, 15. Constrictor vaginæ
- 16, 16. Erectores clitoridis
- 17, 17. Glutei maximi muscles.
- 18, 18. Internal obturator muscles.
- 19, 19. Right pudic artery.
- 20, 20. External hæmorrhoidal artery.
21. Twig to the tuberosity of the ischium.
- 22, 22. Perineal artery.
- 23, 23. Posterior artery of the labium pudendi.
24. Artery of the clitoris.
25. Left pudic artery.
- 26, 26, 26. External hæmorrhoidal branches.
- 27, 27. Branches to the perineum.
28. Twigs to the labium majus.
29. Artery of the clitoris.

^a This often forms a common trunk either with the umbilical artery or with the middle hæmorrhoidal.

^b This sometimes arises as a peculiar branch from the internal iliac artery; or it comes from the ischiatic artery.



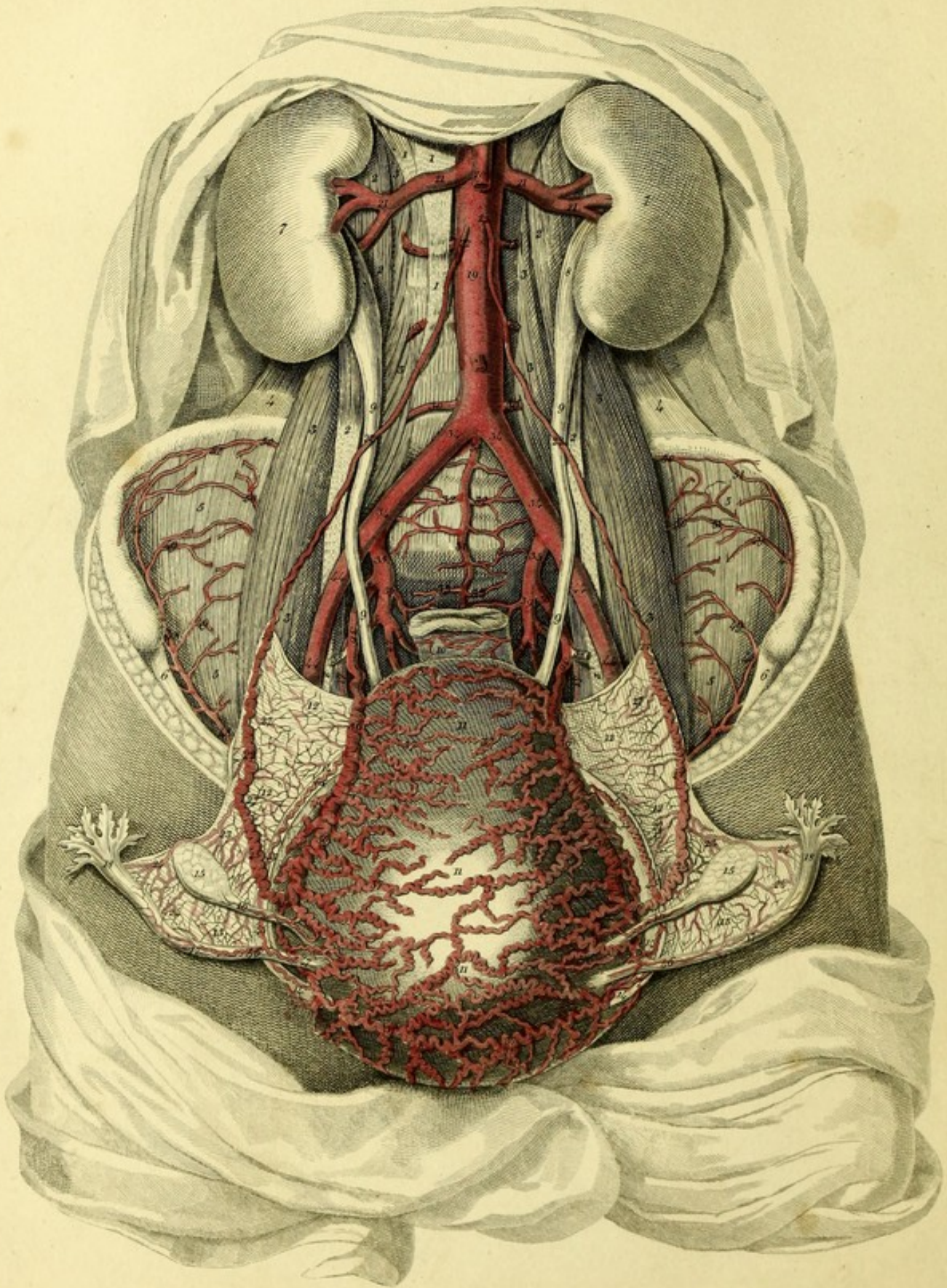



PLATE XXVII.

This exhibits the arteries of the uterus in a woman, who died six days after parturition.

- 1, 1, 1, 1. Crura of the Diaphragm.
- 2, 2, 2, 2, 2, 2. Psoæ parvæ muscles.
- 3, 3, 3, 3, 3, 3, 3. Psoæ magnæ muscles.
- 4, 4. Quadrati lumborum muscles.
- 5, 5, 5, 5. Iliaci interni muscles.
- 6, 6, 6. Ligaments of Poupart.
- 7, 7. The kidneys.
- 8, 8. Pelves of the kidneys.
- 9, 9, 9, 9. Ureters.
10. Rectum.
- 11, 11, 11. Uterus drawn forwards.
- 12, 12, 12, 12. Lamina of the broad ligaments of the uterus.
- 13, 13. Ligaments of the Fallopian tubes.
- 14, 14, 14, 14. Round ligaments of the uterus.
- 15, 15. Ovaries.
- 16, 16. Ligaments of the ovaries.
- 17, 17. Fallopian tubes.
- 18, 18. Fimbriated extremities of the tubes.
- 19, 19. Abdominal aorta.
20. Superior mesenteric artery.
- 21, 21, 21, 21. Renal arteries.
- 22, 22, 22, 22, 22, 22, 22, 22. Spermatic arteries.
- 23, 23. Branches sent to the ovaries.
- 24, 24, 24, 24. Branches to the Fallopian tubes.
- 25, 25. Continuations of the spermatic arteries, going to the uterus, the diameter of which is much increased during pregnancy.
- 26, 26. Their anastomosis with the uterine arteries.
- 27, 27, 27, 27. Twigs to the broad ligaments of the uterus.
- + Inferior mesenteric artery.
- 28, 28. Second lumbar artery of each side.
- 29, 29. Third lumbar artery of each side.
- 30, 30. Fourth lumbar artery of each side.
- 31, 31. Middle sacral artery.
- 32, 32. Fifth lumbar artery of each side.
- 33, 33. Sacral branches.
- 34, 34, 34, 34. Common iliac arteries.
- 35, 35. Internal iliac arteries.
- 36, 36, 36, 36, 36, 36. Uterine arteries.
- 37, 37, 37, 37, 37, 37. Tortuous branches going to the posterior surface of the uterus.
- 38, 38. Umbilical arteries.
- 39, 39. Lateral sacral arteries.
- 40, 40. Gluteal arteries.
- 41, 41. Obturator arteries.
- 42, 42. Internal pudic arteries.
- 43, 43. Ischiatic arteries.
- 44, 44, 44, 44. External iliac arteries.
- 45, 45, 45, 45. Arteries of the round ligaments of the uterus which come off from the epigastric arteries. These arteries become larger during pregnancy.
- 46, 46. Twigs to the tubes.
- 47, 47. Anastomosis with the uterine arteries.
- 48, 48, 48, 48, 48, 48. Circumflex iliac arteries.
- 49, 49, 49, 49. Twigs to the iliac muscles.
- 50, 50, 50, 50. Twigs of the ilio-lumbar arteries.
- 51, 51, 51, 51. Their anastomosis with the circumflex arteries.



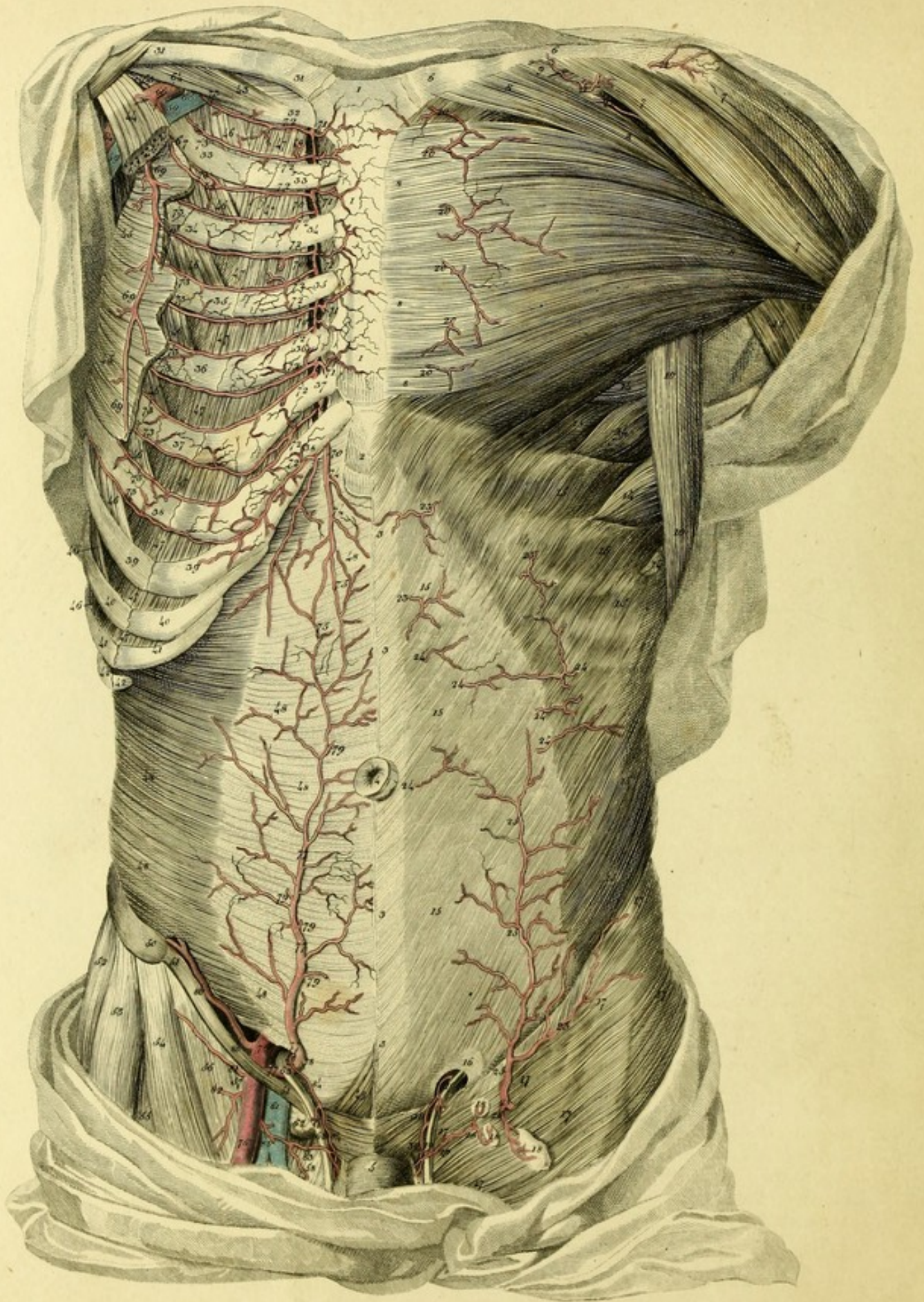


PLATE XXVIII.

Shows the Course of the Internal Mammary and Epigastric Arteries. On the Left Side are seen the first Layer of Muscles and the Superficial Arteries. On the Right Side, the first and second Layers of Muscles are removed, so that the situation and Anastomosis of these Arteries are seen.

1, 1, 1. Sternum.

2. Ensiform process of the sternum.

3, 3, 3, 3. Linea alba.

4. Umbilicus.

5. Penis.

LEFT SIDE.

6, 6. Left clavicle.

7, 7, 7. Deltoid muscle.

8, 8, 8, 8, 8, 8, 8, 8. Pectoralis major.

9. Subclavius muscle.

10, 10. Latissimus dorsi.

11. Teres major.

12. Triceps extensor cubiti.

13. Coraco-brachialis.

14, 14, 14, 14. Serratus magnus.

15, 15, 15, 15, 15, 15, 15, 15. External oblique muscle of the abdomen.

16. External abdominal ring.

17, 17, 17, 17, 17, 17. Fascia lata.

18, 18, 18. Superficial inguinal glands.

19, 19. Vas deferens.

20, 20, 20, 20, 20, 20. External perforating branches of the internal mammary artery which are distributed to the pectoralis major, mamma, and skin.

21, 21. Twig to the acromion.

22. Acromial thoracic artery.

23, 23, 23. Abdominal cutaneous twigs of the internal mammary artery.

24, 24, 24, 24, 24, 24. Cutaneous twigs of the epigastric artery.

25, 25, 25, 25. Superficial epigastric artery.^a

26. Twig to the superficial inguinal glands.

27. Branch of the external pudic artery.

28. Twig to the superficial inguinal glands.

29. Cutaneous twig.

30, 30. Spermatic artery.

RIGHT SIDE.

31, 31. Right clavicle.

32. First rib.

33, 33. Second rib.

34, 34. Third rib.

35, 35. Fourth rib.

36, 36. Fifth rib.

37, 37. Sixth rib.

38, 38. Seventh rib.

39, 39. Eighth rib.

40, 40. Ninth rib.

41, 41. Tenth rib.

42, 42. Eleventh rib.

43. Subclavius muscle.

44. Insertion of the pectoralis minor.

45, 45. Serratus magnus.

46, 46, 46, 46, 46, 46, 46, 46. External intercostal muscles.

47, 47, 47, 47, 47, 47, 47, 47, 47. Internal intercostal muscles.

48, 48, 48, 48, 48, 48, 48, 48. Transversalis abdominis.

49. Pyramidalis.

50. Crest of the ileum.

51, 51. Poupart's ligament.

52. Gluteus medius.

53. Tensor vaginae femoris.

54. Sartorius.

55. Rectus femoris.

56. Iliacus internus.

57. Psoas magnus.

58. Pectineus.

59, 59. Axillary vein.

60. Brachial plexus.

61. Femoral vein.

62. Deep inguinal glands.

63, 63. Vas deferens.

64, 64. Axillary artery.

65. Superior thoracic artery.

66. Acromial thoracic artery.

67. Third thoracic artery.

^a This artery always occurs, sometimes larger, sometimes smaller.

- 68. Anastomosis of this artery with the anterior intercostal branch of the internal mammary artery.
- 69, 69, 69. Long thoracic artery.
- 70, 70, 70, 70, 70, 70, 70. Internal mammary artery.
- 71, 71, 71, 71, 71, 71. External branches.
- 72, 72, 72, 72, 72, 72, 72, 72, 72, 72. Anterior intercostal arteries.
- 73, 73, 73, 73, 73, 73, 73, 73, 73, 73, 73, 73. Posterior intercostal arteries anastomosing with the anterior.

- 74, 74. Epigastric branch of the internal mammary artery.
- 75, 75. Anastomosis of this with the epigastric artery.
- 76, 76. Femoral artery.
- 77, 77, 77, 77. Epigastric artery.
- 78. Twig to the spermatic cord, cut.
- 79, 79, 79, 79. Perforating branches, cut.
- 80, 80. Circumflex iliac artery.
- 81. Muscular branch.
- 82. Superficial epigastric artery.
- 83. External pudic artery.
- 84, 84. Spermatic artery.

Fig 1.

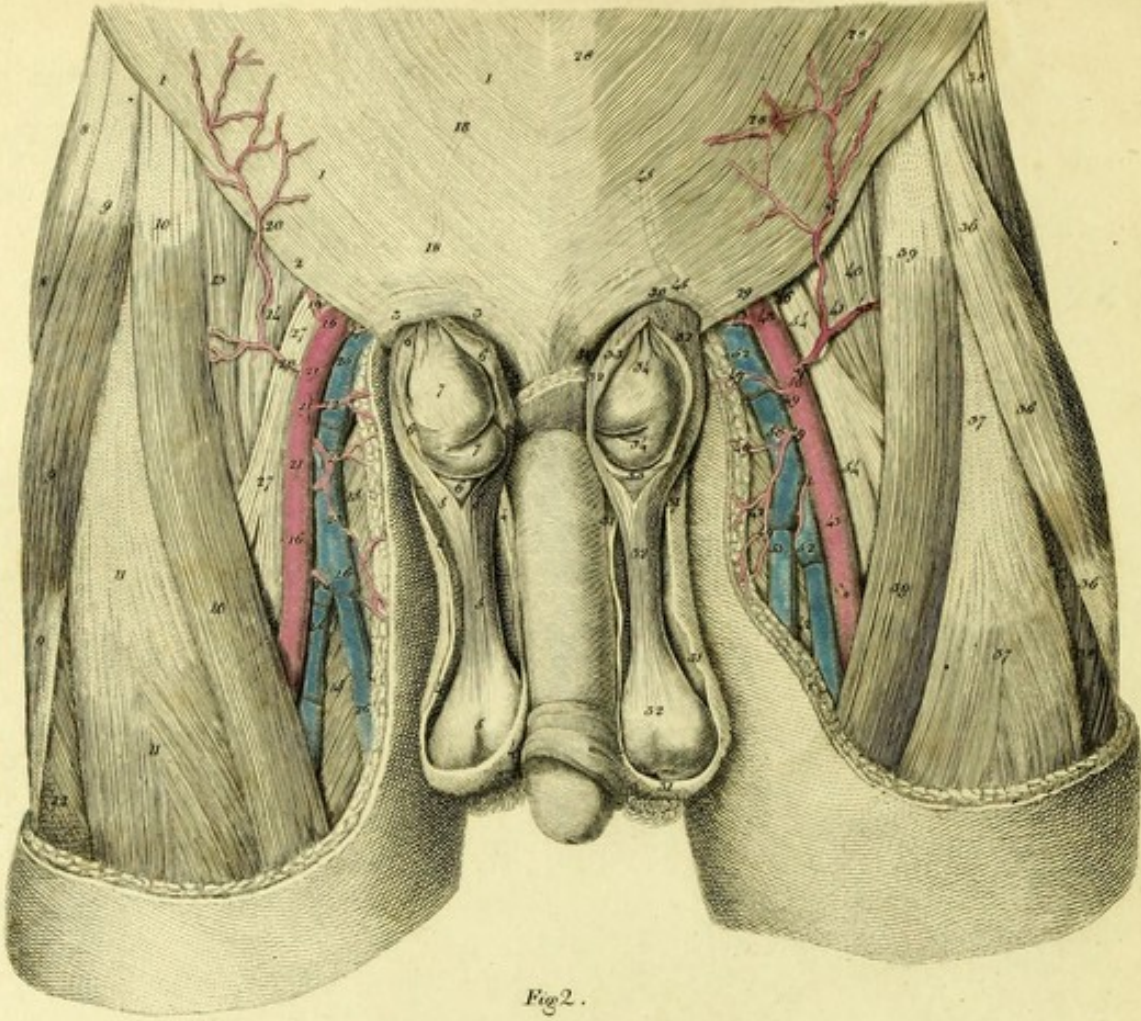


Fig 2.

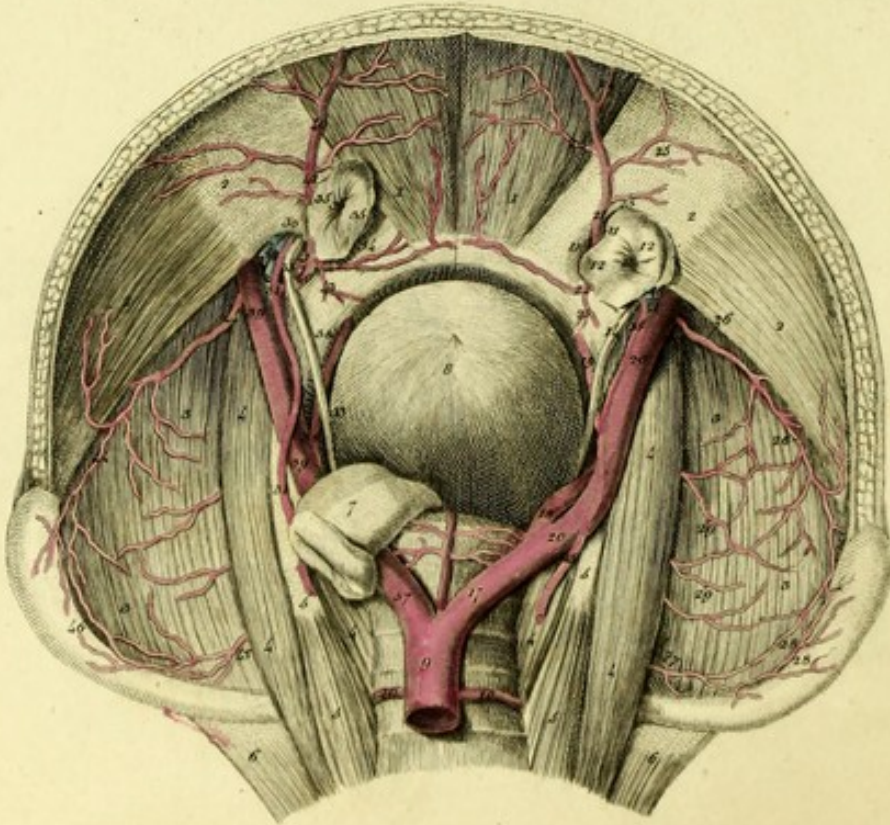


PLATE XXIX.

This shows the situation of the epigastric arteries in the body of a man who had an oblique or external inguinal hernia on the right side, and a direct or internal inguinal hernia on the left.

FIGURE I.

Represents the herniæ from the outside.

RIGHT SIDE

Shows the external inguinal hernia.

- 1, 1, 1. External oblique muscle of the abdomen.
- 2, 2. Poupart's ligament or crural arch.
- 3, 3. Abdominal ring expanded.
- 4, 4, 4, 4. Scrotum, cut.
- 5, 5, 5, 5. Common tunica vaginalis, with the cremaster muscle.
- 6, 6, 6, 6. The peritoneum, constituting the sac of the hernia, opened.
- 7, 7. Portion of the small intestine.
- 8, 8. Gluteus medius.
- 9, 9, 9. Tensor vaginae femoris.
- 10, 10. Sartorius.
- 11, 11. Rectus femoris.
12. Vastus externus.
13. Iliacus internus.
14. Psoas magnus.
- 15, 15. Adductors.
- 16, 16. Femoral artery.
17. Epigastric artery ascending behind the hernia.
- 18, 18. Course of this artery towards the umbilicus, marked by dots.
19. Circumflex iliac artery.
- 20, 20. Superficial epigastric artery.
- 21, 21, 21. Twigs to the inguinal ganglia and skin, cut.
22. First external pudic artery.
23. Second external pudic artery.
24. Third external pudic artery.
- 25, 25. Femoral vein.
- 26, 26. Great saphena vein.
- 27, 27. Femoral nerve.

LEFT SIDE

Exhibits the internal inguinal hernia.

- 28, 28, 28. External oblique muscle of the abdomen.
- 29, 29. Crural arch.

- 30, 30. Abdominal ring, dilated.
- 31, 31, 31. Scrotum, cut.
- 32, 32, 32, 32. Common tunica vaginalis and cremaster muscle.
- 33, 33, 33. Sac of the hernia, opened.
- 34, 34. Portion of the small intestine, protruded.
35. Gluteus Medius.
- 36, 36, 36. Tensor vaginae femoris.
- 37, 37. Rectus femoris
- 38, 38. Vastus externus.
39. Sartorius.
40. Iliacus internus
41. Psoas magnus.
- 42 42, Adductors.
- 43, 43, Femoral artery
- 44, 44. Epigastric artery ascending before the neck of the hernia.
- 45, 45. Course of this artery.
46. Circumflex iliac artery.
- 47, 47. Superficial epigastric artery.
48. Twig to the sartorius.
- 49, 49, 49, 49. External pudic arteries.
- 50, 50. Twigs to the skin and the inguinal glands, cut.
51. Twig to the adductor brevis.
- 52, 52. Femoral vein.
53. Great saphena vein.
- 54, 54. Femoral nerve.

FIGURE II.

This exhibits the epigastric arteries from the inside.

- 1, 1. Recti muscles of the abdomen.
- 2, 2, 2, 2. Transversales muscles of the abdomen.
- 3, 3, 3, 3. Iliac muscles.
- 4, 4, 4, 4, 4, 4. Psoæ magnæ.
- 5, 5, 5, 5. Psoæ parvæ.
- 6, 6. Quadrati lumborum.
7. Intestinum rectum.
- 8 Urinary bladder.
9. Aorta.
- 10, 10. Lumbar arteries.
- + Middle sacral artery.

External inguinal hernia and course of the arteries on the right side.

- 11, 11. Internal abdominal aperture.
- 12, 12. Peritoneum forming the hernial sac.
13. Entrance to the cavity of the hernial sac.
14. Vas deferens.
- 15, 15. Spermatic artery.
16. Spermatic veins.
17. Common iliac artery.
18. Hypogastric or internal iliac artery.
19. Obturator artery.
- 20, 20. External iliac artery.
- 21, 21. Epigastric artery running behind the hernial sac.
22. Branch running along the ramus of the os pubis.
23. Twig to the obturator hole.
- 24, 24. Twigs to the rectus abdominis
- 25, 25. Twigs to the transversales abdominis.
- 26, 26. Circumflex iliac artery.
27. Ileo-lumbar artery.
- 28, 28. Anastomosis with the circumflex iliac artery
- 29, 29. Twigs of the ileo-lumbar artery sent to the iliacus.

The internal inguinal hernia and course of the arteries on the left side.

- 30 Internal aperture of the inguinal canal.
31. 31. Spermatic artery.
32. Spermatic veins, or plexus pampiniformis.
- 33, 33. Vas deferens.
34. Aperture for the internal inguinal hernia which protrudes through a laceration in the tendinous lamina of the transversalis and obliquus internus muscles of the abdomen.
- 35, 35. Peritoneum forming the hernial sac.
36. Entrance to the hernial sac.
37. Common iliac artery.
38. Obturator artery.
39. Femoral artery.
- 40, 40. Epigastric artery which is situated on the outer and anterior part of the hernia.
41. External spermatic artery.
42. Branch running on the upper surface of the os pubis.
43. Twig to the obturator internus muscle.
- 44, 44. Circumflex iliac artery.
45. Ileo-lumbar artery.
46. Anastomosis of this artery with the circumflex iliac artery.




Fig. 1.

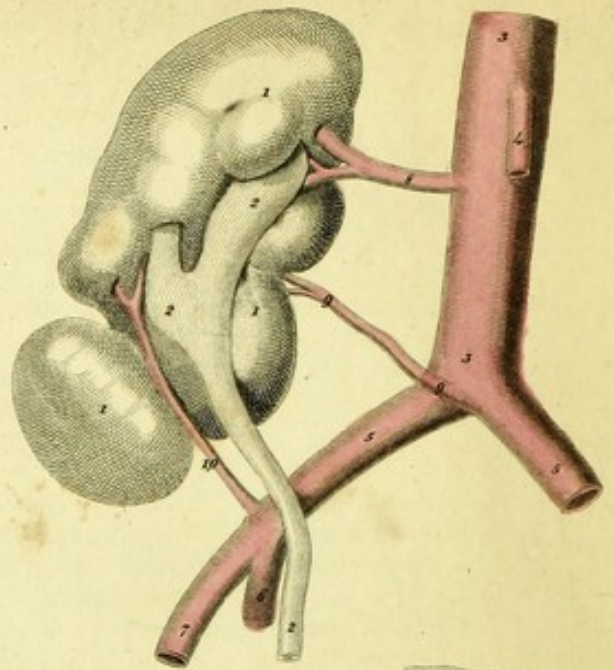


Fig. 3.

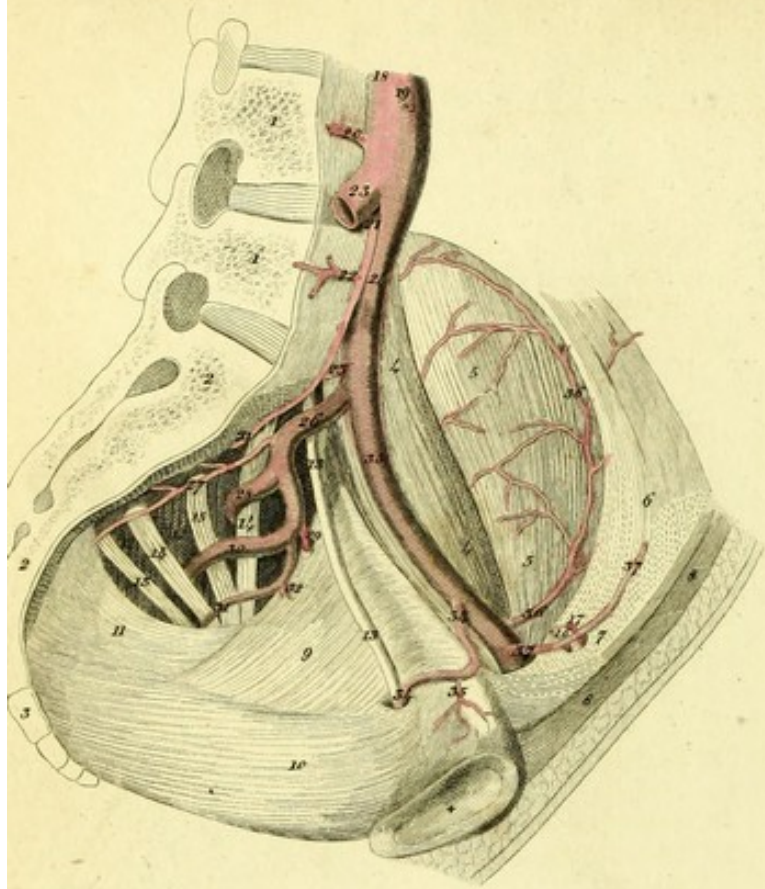


Fig. 2.

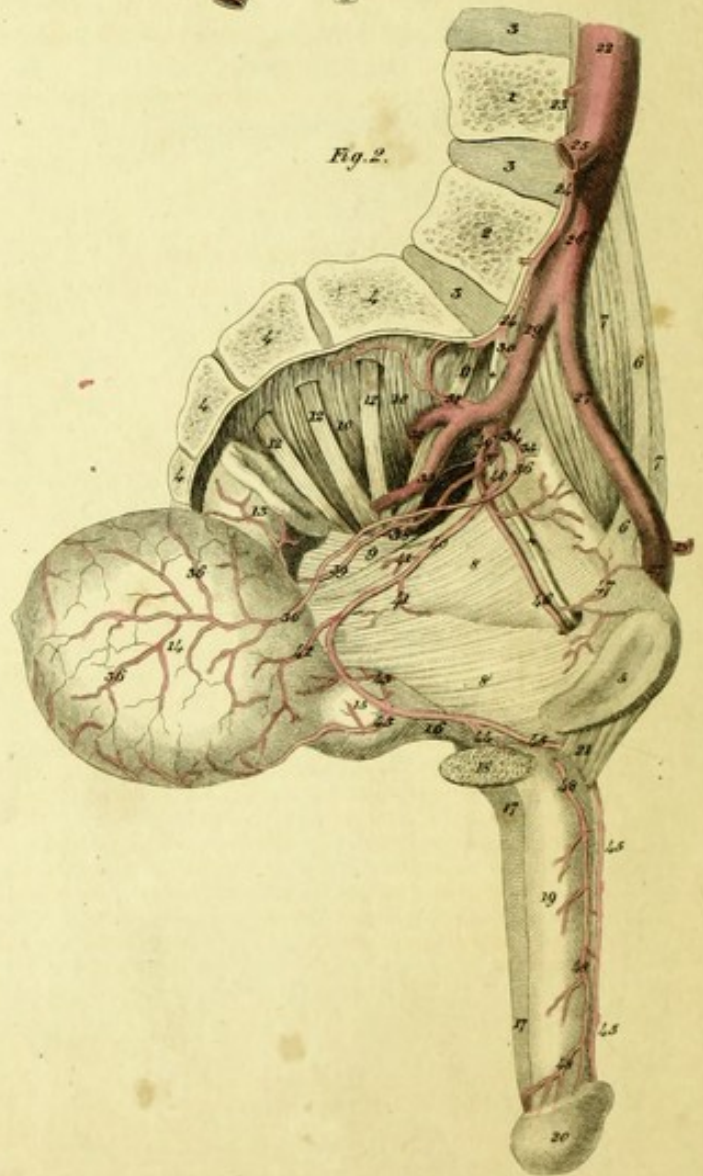


Fig. 4.

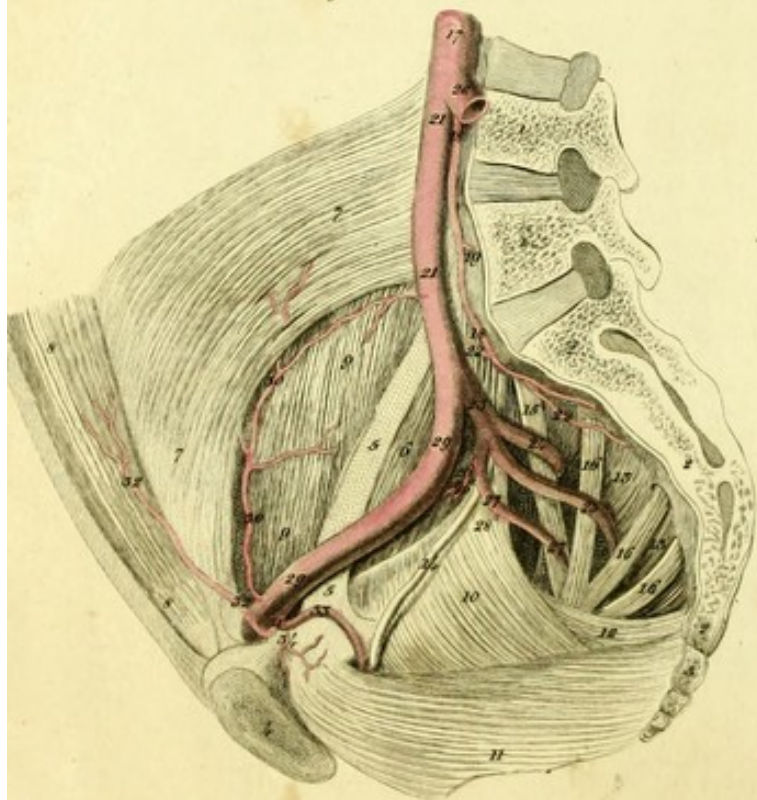


PLATE XXX.

FIGURE I.

This exhibits a rare variety of the renal arteries of the right side in the body of a man of sixty.^a

- 1, 1, 1. The right kidney, consisting of several lobes.
- 2, 2, 2. The ureter.
- 3, 3. Aorta.
4. Inferior mesenteric artery.
- 5, 5. Common iliac arteries.
6. Right hypogastric artery.
7. Right external iliac artery.
8. First renal artery.
9. Second renal artery arising at the point where the aorta divides.
10. Third renal artery arising from the common iliac.

FIGURE II.

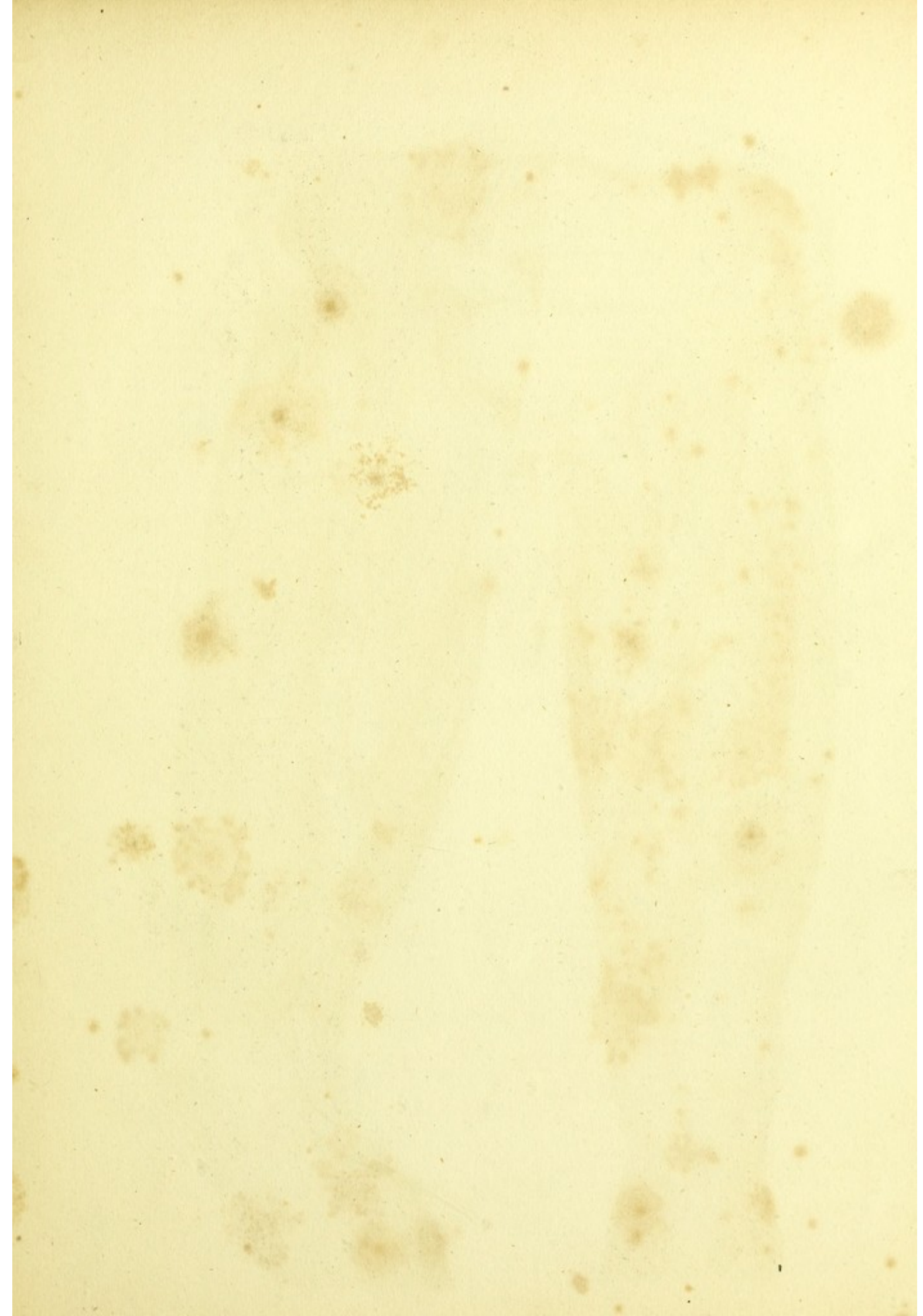
Here is seen an unusual course of the left dorsal artery of the penis, from the body of a man thirty-six years old.^b

1. Fourth lumbar vertebra.
2. Fifth lumbar vertebra.
- 3, 3, 3. Intervertebral fibro-cartilages.
- 4, 4, 4. Sacrum.

^a The renal arteries vary much in their origin, number, and division, and scarcely in any other part do varieties of the arteries present themselves so often as in the kidneys, Vide Eustachius, (Tab. anat. ; Tab. 3; Fig. 1, 2, 2; Tab. 12; Fig. 9, 10.) Boehmer, (Exercitat. acad. Praef. p. 11.) and Haller, (El. Physiol. T. 7, p. 260; Icon. anatom. Fasc. 3, p. 52.)

^b I have observed a similar occurrence on both sides in a man of twenty-eight and in a boy. I have, moreover, seen in the body of a virgin of eighteen, the artery of the clitoris running in a similar way. Burns, (l. c. p. 350,) mentions that he has seen this variety four times, and always in males. The older anatomists, Vesalius, Valverdus, Jac Sylvius, Bauhin, Vesling, Highmore, Winslow, and others have described this disposition of the dorsal artery of the penis and clitoris as regular.

5. Os pubis.
- 6, 6. Tendon of the psoas parvus.
- 7, 7. Psoas magnus.
- 8, 8. The levator ani stretched over the obturator internus muscle, and by a membranous beginning arising from its tendinous envelope.
9. Smaller sacro-sciatic ligament.
- 10, 10. Origin of the pyriformis muscle.
- + + Obturator nerve.
11. Fifth lumbar nerve.
- 12, 12, 12. Sacral nerves.
13. Rectum.
14. Urinary bladder.
15. Prostate gland.
16. Membranous part of the urethra.
- 17, 17. Urethra.
18. Right crus of the penis, cut.
19. Penis.
20. Glans penis.
21. Suspensory ligament of the penis.
22. Aorta.
23. Fourth lumbar artery.
24. 24. Middle sacral artery.
25. Right Common iliac artery.
26. Left common iliac artery.
- 27, 27. External iliac and femoral artery.
28. Epigastric artery.
29. Hypogastric artery.
30. Ileo-lumbar artery.
31. Lateral sacral artery.
32. Gluteal artery.
33. Ischiatic artery.
34. Umbilical artery.
35. Part of the umbilical artery changed into ligament.
- 36, 36, 36, 36. Vesical artery.
37. Trunk of the common pudic artery and middle hæmorrhoidal.
38. External hæmorrhoidal artery.
39. Middle hæmorrhoidal artery.
- 40, 40, Artery of the penis, which runs to that organ in an unusual way below the symphysis of the pubes.
- 41, 41. Twigs to the levator ani.



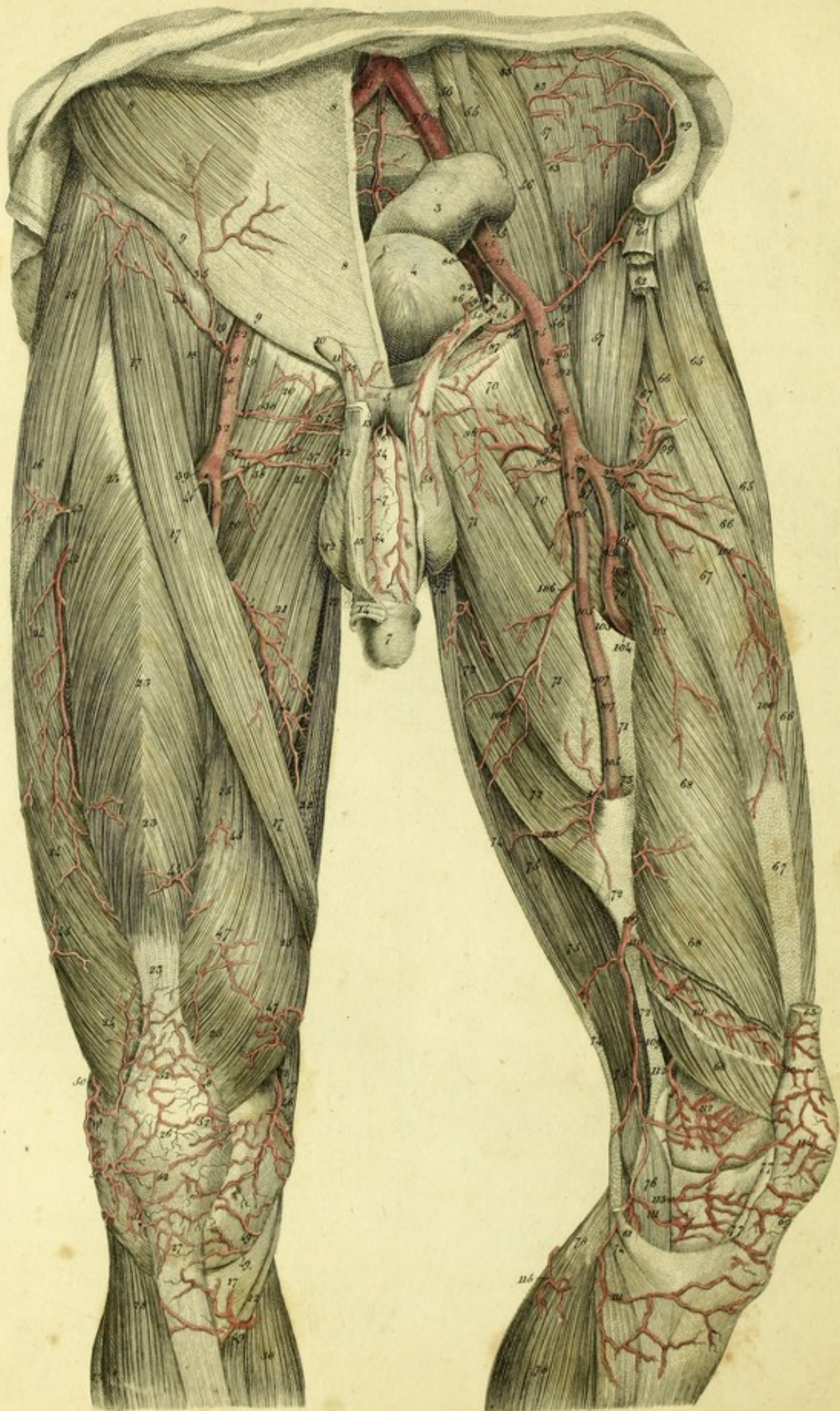


PLATE XXXI.

This exhibits the arteries of the anterior part of the thigh.

1. Division of the aorta into the common iliac arteries.
- 2, 2. Middle sacral artery.
3. Rectum.
4. Urinary bladder.
5. Symphysis of the pubes.
6. Suspensory ligament of the penis.
7. Penis.

RIGHT SIDE.

- 8, 8, 8. External oblique muscle of the abdomen.
- 9, 9. Poupart's ligament.
10. Abdominal ring.
11. Spermatic cord.
- 12, 12. Scrotum.
13. Skin of the penis cut and reflected.
14. The prepuce.
15. Gluteus medius.
16. Tensor vaginae femoris.
- 17, 17, 17, 17, 17. sartorius.
18. Iliacus internus.
- 19, 19. Psoas magnus.
- 20, 20. Pectineus.
- 21, 21. Adductor longus.
- 22, 22, 22. Gracilis.
- 23, 23, 23, 23. Rectus femoris.
- 24, 24, 24. Vastus externus.
- 25, 25, 25. Vastus internus.
26. Patella.
27. Ligamentum patellae.
28. Tibialis anticus.
- † Extensor communis digitorum.
29. Peroneus longus.
30. Internal head of the gastrocnemius.
31. Common iliac artery.
- 32, 32. Femoral artery.
33. Superficial epigastric artery.
34. Branch to the iliacus, sartorius, and tensor vaginae femoris.
35. Ascending cutaneous branch.
- 36, 36. Twigs to the inguinal glands, cut.
- 37, 37. External pudic arteries.
- 38, 38. Twigs to the inguinal glands and skin, cut.
39. Deep femoral artery.
40. Superficial femoral artery.
- 41, 41, 41. Internal circumflex artery of the thigh.

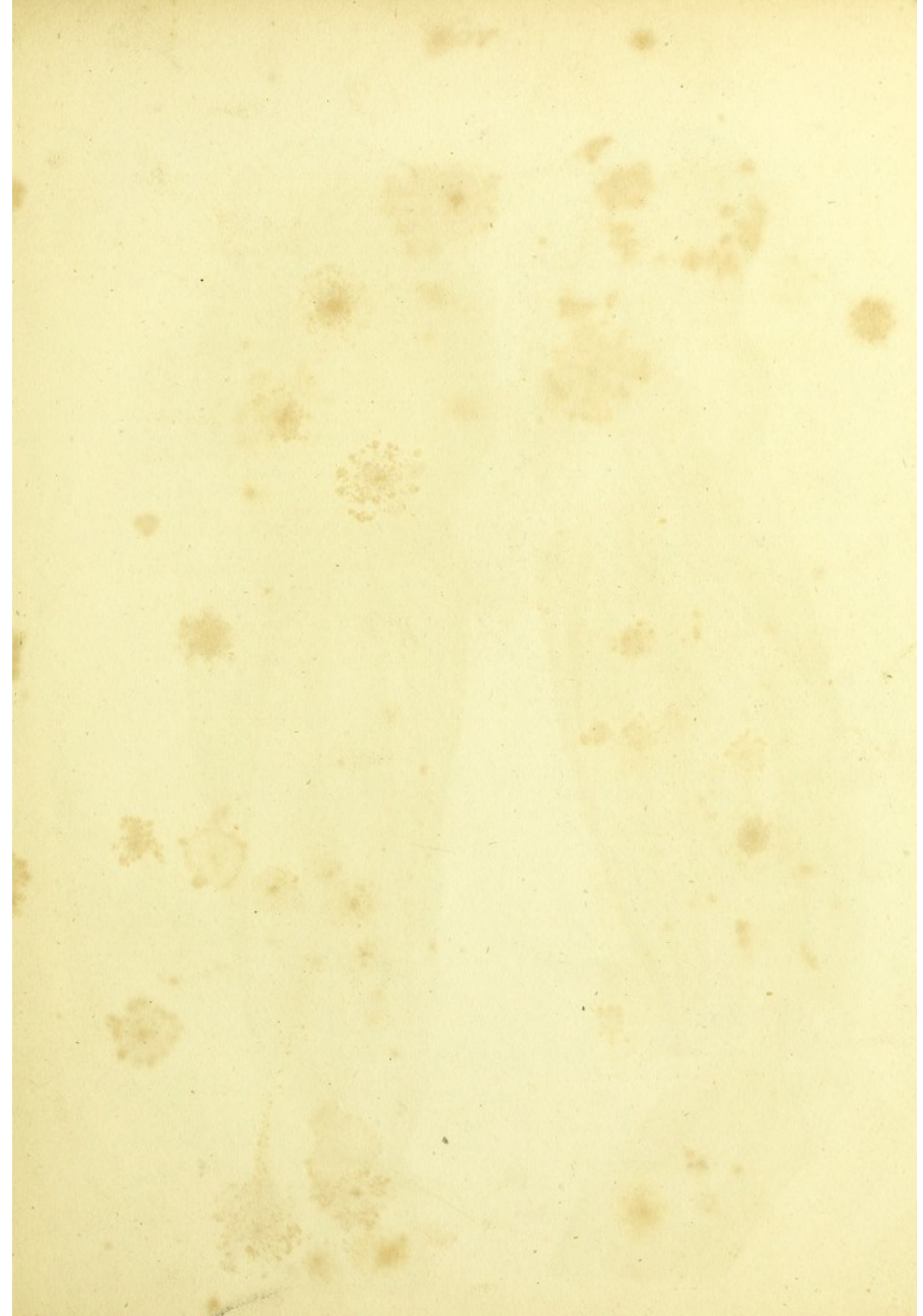
- 42, 42. Descending branch of the external circumflex artery of the thigh.
- 43, Branch of the external circumflex artery of the thigh to the tensor vaginae femoris.
44. Branch to the sartorius, gracilis, and adductors.
- 45, 45, 45, 45, 45. Small twigs to the skin and muscles.
46. Superior internal articular artery of the knee, which runs over the surface of the knee.^a
- 47, 47. Twigs of this artery which perforate the vastus.
48. Twig to the patella.
- 49, 49, 49. Inferior twigs of the same artery.
- 50, 50. External superior articular artery of the knee.
51. Twig of the recurrent branch of the anterior tibial artery.
- 52, 52, 52. Arterial network of the patella.
53. Twig of the epigastric artery to the tunica vaginalis.
- 54, 54. Arteria dorsalis penis.

LEFT SIDE.

- 55, 55, 55. Tendon of the psoas parvus.
- 56, 56, 56. Psoas magnus.
- 57, 57, 57. Iliacus internus.
- 58, 58. Spermatic cord.
59. Vas deferens.
60. Origin of the sartorius, cut.
61. Termination of the same muscle.
62. Origin of the rectus femoris, cut.
63. Termination of this muscle.
64. Gluteus medius.
- 65, 65. Tensor vaginae femoris.
- 66, 66, 66. Vastus externus.
- 67, 67, 67. Cruralis.
- 68, 68, 68, 68. Vastus internus.
69. Ligamentum patellae.
- 70, 70, 70. Pectineus.
- 71, 71, 71. Adductor longus.
- 72, 72, 72. Adductor magnus.

^a This artery, which sends twigs to the surface of the knee, is generally present. It is to be distinguished from the deep and internal superior articular artery of the knee.

73. Aperture through which the femoral artery descends.
- 74, 74, 74, 74. Gracilis.
- 75, 75, 75. Semimembranosus muscle.
76. Internal lateral ligament of the knee.
- 77, 77. Capsule of the knee-joint cut and reflected.
- 78, 78. Internal head of the gastrocnemius.
79. Common iliac artery.
80. Internal iliac or hypogastric artery.
81. Gluteal artery.
82. Obturator artery.
- 83, 83, 83. Branches of the ileo-lumbar artery.
84. Spermatic artery.
- 85, 85, 85. External iliac and common femoral artery.
- 86, 86. Epigastric artery.
87. Twig to the os pubis.
- 88, 88. External spermatic artery, or artery of the tunica vaginalis.
- 89, 89, 89. Circumflex iliac artery.
90. Superficial epigastric artery, cut.
- 91, 91. External pudic arteries, cut.
92. Twig to the inguinal glands and skin, cut.
- 93, 93. Deep femoral artery.
94. Internal circumflex artery of the thigh.
95. Deep circumflex branch.
- 96, 96. Superficial circumflex branch.
97. Twig to the pectineus and adductor muscles.
98. External circumflex artery of the thigh.
- 99, 99. Ascending branch.
- 100, 100, 100. Descending branch.
- 101, 101. Twig to the cruralis and vastus internus.
102. First perforating artery.
103. Second perforating artery.
104. Third perforating artery.
- 105, 105, 105. Superficial femoral artery.
106. Branch to the adductor longus, adductor magnus, and to the gracilis.
- 107, 107. Twigs to the sartorius, cut.
- 108, 108. Twig to the adductor magnus, semimembranosus, and gracilis.
- 109, 109. Superficial internal superior articular artery of the knee.
- 110, 110, 110. Twig perforating the vastus internus and proceeding to the patella.
- 111, 111. Twig proceeding to the inner surface of the leg.
- 112, 112. Deep internal superior articular artery of the knee.
- 113, 113. Branch of the internal and inferior articular artery of the knee.
114. Arterial net-work of the patella.
115. Twig to the gastrocnemius.



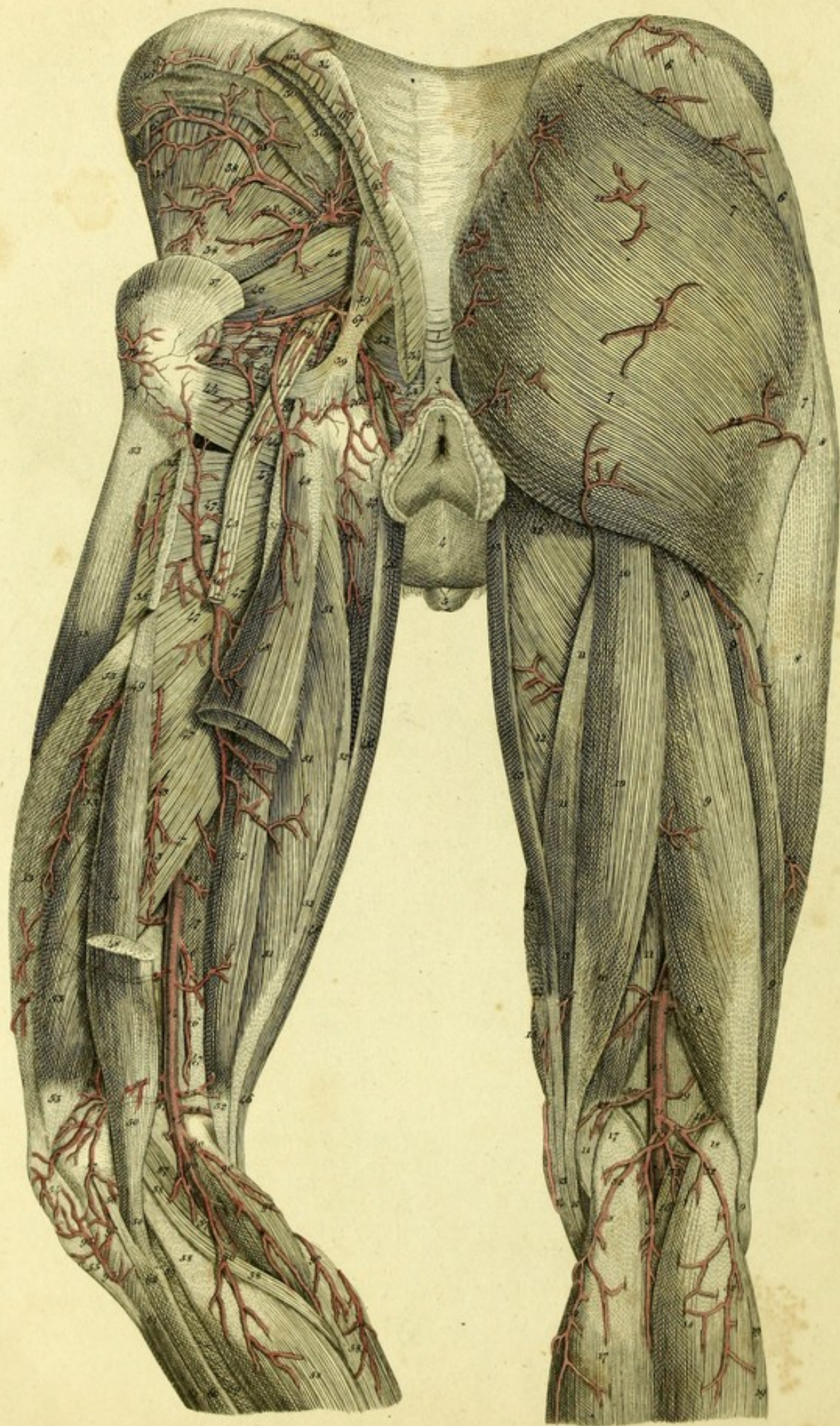


PLATE XXXII.

This represents the arteries of the posterior part of the pelvis and thighs.

1. Ossa coccygis.
2. External sphincter of the anus.
3. Anus.
4. Scrotum.
5. Glans penis.
- RIGHT SIDE.
- 6, 6. Gluteus medius.
7, 7, 7, 7, 7, 7, 7. Gluteus maximus.
8, 8, 8. Vastus externus.
9, 9, 9, 9, 9, 9. Biceps flexor cruris.
10, 10, 10, 10. Semitendinosus muscle.
11, 11, 11, 11, 11. Semimembranosus muscle.
12, 12. Adductor magnus.
13, 13, 13, 13. Gracilis.
14, 14, 14. Sartorius.
15. Vastus internus.
16, 16. Plantaris muscle.
17, 17. Internal head of the gastrocnemius.
18, 18. External head of the gastrocnemius.
19, 19. Soleus.
20. Twig of the ileo-lumbar artery.
21, 21, 21, 21, 21, 21. Twigs of the gluteal artery.
22, 22, 22, 22. Twigs of the ischiatic artery.
23. Twig of the internal pudic artery.
24, 24, 24. Twigs of the perforating arteries.
25, 25, 25. Popliteal artery.
26. Twig to the semitendinosus and semimembranosus muscles.
27. Internal and superficial superior articular artery of the knee.
28. Twig to the semimembranosus muscle.
29. External superior articular artery of the knee.
30. Deep internal superior articular artery of the knee.
31. Trunk of the sural arteries.
32, 32, 32, 32, 32. Superficial or cutaneous sural arteries.
33, 33, 33. Deep or muscular sural arteries.

LEFT SIDE.

- 34, 34, 34. Origin of the Gluteus muscle, cut.
35, 35. Insertion of this muscle.
36, 36, 36. Origin of the gluteus medius muscle, cut.
37, 37, 37. Insertion of this muscle.
38, 38, 38, 38. Gluteus minimus,
39, 39. Great sacro-sciatic ligament.
40, 40. Pyramidalis muscle.
41, 41, 41, 41. Obturator internus muscle.
42, 42, 42. Gemelli muscles.
43, 43. Levator ani.
44, 44. Quadratus femoris muscle.
45, 45, 45. Ischiatic nerve.
46, 46, 46, 46. Gracilis muscle.
47, 47, 47, 47, 47, 47, 47, 47, 47. Adductor magnus muscle.
48, 48, 48, 48. Long head of the biceps flexor cruris muscle.
49. Short head of the same muscle.
50, 50. Insertion of this muscle.
51, 51, 51, 51. Semitendinosus muscle.
52, 52, 52, 52, 52. Semimembranosus muscle.
53, 53, 53, 53, 53, 53. Vastus externus.
54. Patella.
55. Ligamentum patellæ.
56. External lateral ligament of the knee.
57, 57. Plantaris muscle.
58, 58, 58, 58, 58. Gastrocnemius muscle.
59, 59. Soleus muscle.
60, 60. Peroneus longus muscle.
61, 61. Extensor longus communis digitorum.
62, 62. Gluteal artery.
63, 63, 63, 63, 63, 63, 63, 63, 63. Superficial branches.
64, 64, 64, 64, 64. Deep branches.
65. Twig to the great sacro-sciatic ligament.
66, 66. Ischiatic artery.
67. Twig to the sacro-sciatic ligament.
68, 68, 68, 68, 68, 68. Branches to the gluteus maximus, cut.

- 69, 69. Twigs to the ischiatic nerve.
 70, 70. Branches to the obturator internus, gemelli and quadratus femoris muscles.
 71, 71. Branch descending to the flexor muscles of the leg.
 72, 72. Branch to the adductor muscles.
 73, 73. Internal pudic artery.
 74. Twigs to the obturator internus and gemelli muscles.
 75. External hæmorrhoidal artery.
 76, 76. Twigs to the tuberosity of the ischium.
 77, 77. First perforating artery.
 78. Twigs communicating with the external circumflex artery of the thigh.
 79. Twig of the external circumflex artery of the thigh.
 80. Twig to the ischiatic nerve.
 81, 81, 81, 81. Muscular twigs.
 82, 82. Second perforating artery.
- 83, 83. Third perforating artery.
 84, 84, 84, 84. Popliteal artery.
 85, 85, 85, 85, 85, 85, 85. Twigs to the muscles.
 86, 86. Superficial internal superior articular artery of the knee.
 87, 87, 87, 87. External superior articular artery of the knee.
 88. Deep internal superior articular artery of the knee.
 89. Middle or azygous articular artery of the knee.
 90, 90, 90, 90, 90. Superficial sural arteries.
 * Middle superficial sural artery.
 91, 91, 91. Deep sural arteries.
 92, 92. External inferior articular artery of the knee.
 93, 93. Recurrent branch of the anterior tibial artery.




Fig. 2.

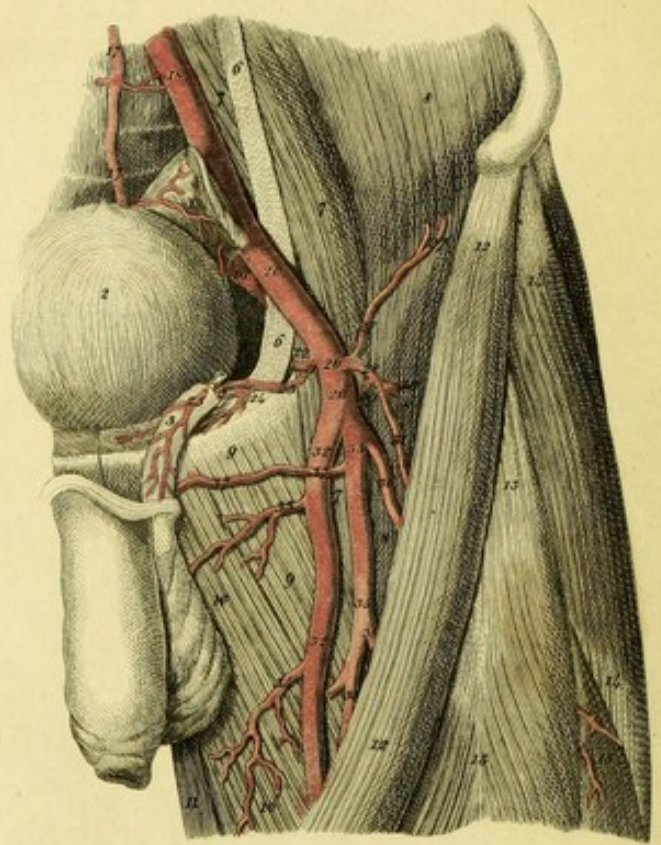


Fig. 1.

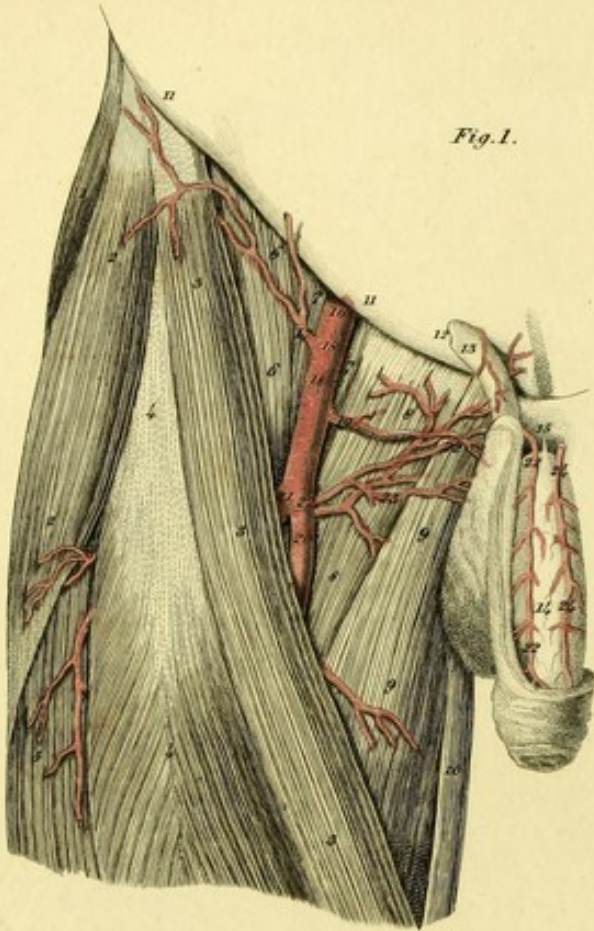


Fig. 3.

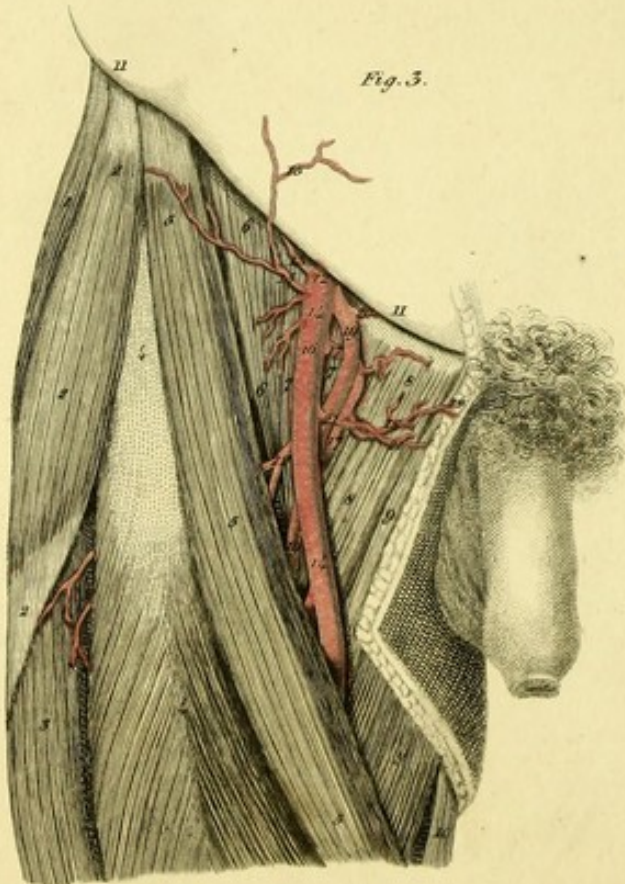


Fig. 4.

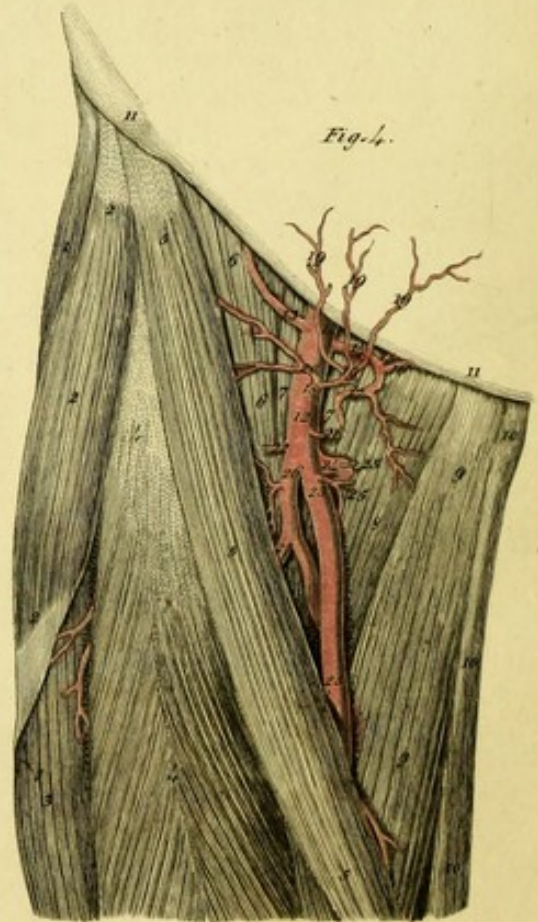


PLATE XXXIII.

FIGURE I.

Represents the unusual origin of the dorsal artery of the penis from the deep femoral artery, observed in the body of a man, twenty-seven years old.^a

1. Gluteus medius.
- 2, 2. Tensor vaginae femoris.
- 3, 3, 3. Sartorius muscle.
- 4, 4. Rectus femoris muscle.
5. Vastus externus.
- 6, 6. Iliacus internus.
- 7, 7. Psoas magnus.
- 8, 8. Pectineus.
- 9, 9. Adductor longus.
10. Gracilis.
- 11, 11, Poupart's ligament.
12. Abdominal ring.
13. Spermatic cord.
14. Penis.
15. Suspensory ligament of the penis.
16. Common femoral artery.
17. Superficial epigastric artery.
- 18, 18. Twigs to the inguinal glands.
19. First external pudic artery.
20. Superficial femoral artery.
21. Deep femoral artery.
- 22, 22, 22, 22. Dorsal artery of the penis.
23. Branch to the scrotum.
- 24, 24. Left dorsal artery of the penis.

FIGURE II.

In the body of a man thirty-four years old, the epigastric and obturator arteries formed a common trunk; and the circumflex iliac artery, arising from the common femoral artery below Poupart's ligament, sent off a large branch to the external side of the thigh.^b

^a I have also seen an unusual origin of the dorsal artery of the penis, from the common femoral on the right side of a man of thirty-six years old; also from the first external pudic artery in the body of a man forty years old, and in the body of a boy.

^b The circumflex iliac artery frequently arises from the common femoral artery below Poupart's ligament, and then generally gives off a branch to the muscles of the thigh. Burns (l. c. p. 362.) mentions such a case.

1. Rectum.
2. Urinary bladder.
3. Spermatic cord.
4. Vas deferens.
5. Spermatic artery.
- 6, 6. Tendon of the psoas parvus.
- 7, 7, 7. Psoas magnus.
- 8, 8, 8. Iliacus internus.
- 9, 9. Pectineus.
- 10, 10. Adductor longus.
11. Gracilis.
- 12, 12. Sartorius.
- 13, 13. Rectus femoris.
- 14, 14, 14. Tensor vaginae femoris.
15. Vastus externus.
16. Gluteus medius.
- 17, 17. Middle sacral artery.
18. Common iliac artery.
19. Hypogastric artery.
- 20, 20. External iliac artery and its continuation as the common femoral, which soon after its exit from the abdomen, divides into two trunks.
21. Common trunk of the epigastric and obturator arteries.
22. Epigastric artery.
23. Obturator artery.
24. Twig to the os pubis.
25. Artery of the tunica vaginalis.
26. Circumflex iliac artery.
- 27, 27. Proper circumflex branch.
28. Unusual external branch.
29. Twig to the inguinal glands, cut.
30. Superficial epigastric artery, cut.
31. Muscular branch.
- 32, 32. Superficial femoral artery.
33. Internal circumflex artery of the thigh.
34. Muscular branch.
- 35, 35. Deep femoral artery.
36. External circumflex artery of the thigh.
- 37, 37. External pudic artery.
38. First perforating artery.

FIGURE III.

Shows the rare origin of the epigastric artery from the deep femoral in the body of a man of twenty-four.^a

^a According to Barclay, (l. c. p. 232,) *Monro, jun.* observed a similar case. Other examples are not wanting, in which the epigastric artery arose from the femoral below Poupart's ligament. Burns, (l. c. p. 360,) remarked this variety, and *J. K. Hesselbach*, (l. c.) saw it thrice. It has occurred to me twice.


1. Gluteus medius.
- 2, 2, 2. Tensor vaginae femoris.
3. Vastus externus.
- 4, 4. Rectus femoris.
- 5, 5, 5. Sartorius.
- 6, 6. Iliacus internus.
- 7, 7. Psoas magnus.
- 8, 8. Pectineus.
- 9, 9. Adductor longus.
10. Gracilis.
- 11, 11. Poupart's ligament.
12. Femoral artery, which immediately after its exit from the pelvis, divides into superficial and deep arteries.^a
13. Circumflex iliac artery.
- 14, 14. Superficial femoral artery.
- 15, 15. Superficial epigastric artery.
16. Twig to the inguinal glands.
- 17, 17. Internal circumflex artery of the thigh.
- 18, 18. First external pudic artery.
- 19, 19. Deep femoral artery.
- 20, 20. Epigastric artery.
- 21, 21. Second external pudic artery.
- 22, 22. External circumflex artery of the thigh.

^a The common femoral artery generally divides into the superficial and deep femoral, two inches below the crural arch, on the extremity of the iliacus muscle, between the trochanter minor and pubes. This division sometimes occurs higher up, and according to my observation, more frequently in the female than in the male. Moreover, I have frequently seen this division in bodies of small stature. Nay, there are examples of the common femoral artery dividing into two trunks within the pelvis. Burns (l. c. p. 362), found this disposition in three bodies. I have seen the division of the common femoral artery above Poupart's ligament, on both sides in the body of a woman.

FIGURE IV.

Shows the rare origin of the epigastric and obturator arteries, from the common femoral below Poupart's ligament in the body of a woman.

1. Gluteus medius.
- 2, 2. Tensor vaginae femoris.
3. Vastus externus.
- 4, 4. Rectus femoris.
- 5, 5, 5. Sartorius.
- 6, 6. Iliacus internus.
- 7, 7. Psoas magnus.
8. Pectineus.
- 9, 9. Adductor longus.
- 10, 10, 10. Gracilis
- 11, 11. Ligament of Poupart.
- 12, 12. Common femoral artery.
13. Circumflex iliac artery.
14. Trunk of the epigastric and obturator arteries.
15. Epigastric artery.
16. Obturator artery.
- 17, 17. Twig to the psoas magnus and pectineus muscles.
18. Superficial epigastric artery.
- 19, 19, 19. Twigs to the skin of the abdomen.
20. Twig to the iliacus and sartorius muscles.
21. First external pudic artery.
22. Twig to the inguinal glands.
- 23, 23. Superficial femoral artery.
24. Internal circumflex artery of the thigh.
- 25, 25. Second and third external pudic arteries.
26. Deep femoral artery.
27. External circumflex artery of the thigh.



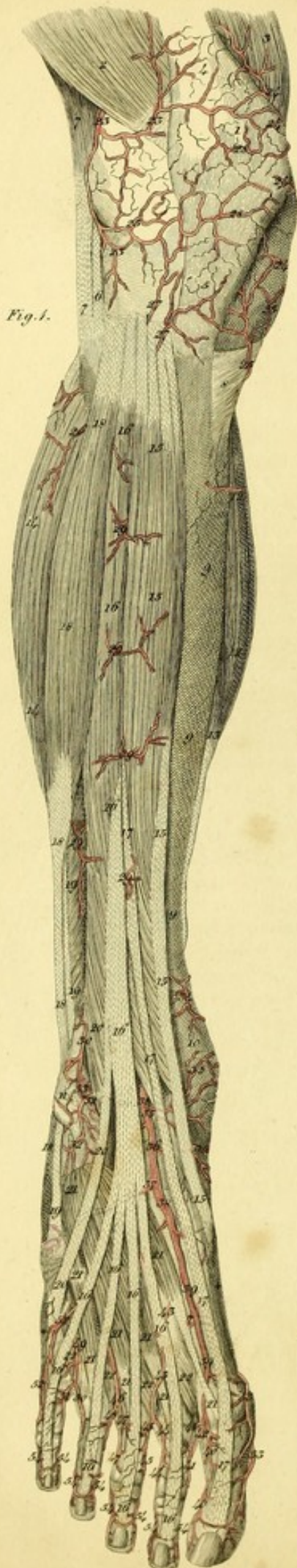


Fig. 1.

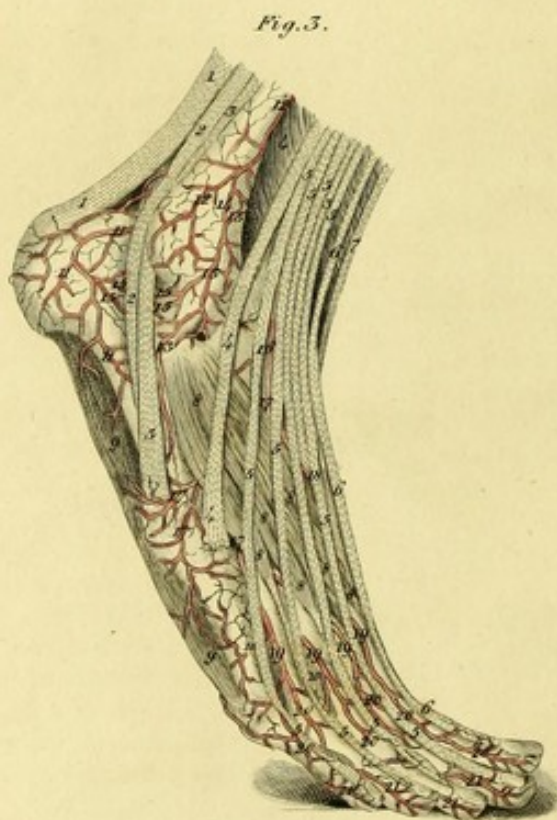


Fig. 3.

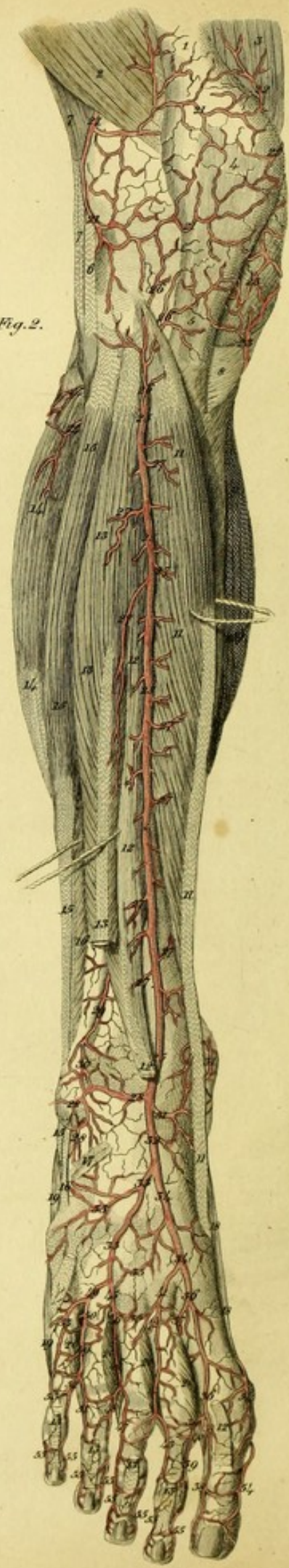



Fig. 2.

- 13, 13, 13, 13, 13, 13, 13. Extensor longus communis digitorum.
- 14, 14. External head of the gastrocnemius.
- 15, 15, 15, 15. Peroneus longus.
- 16, 16. Peroneus brevis.
17. Origin of the extensor brevis communis digitorum.
- 18, 18. Abductor hallucis.
- 19, 19. Abductor minimi digiti.
- 20, 20, 20, 20. External interossei muscles.
- 21, 21, 21, 21, 21. External superior articular artery of the knee.
- 22, 22. Branches of the internal superior articular artery of the knee.
- 23, 23. Branches of the internal inferior articular artery of the knee.
- 24, 24. Branches of the external inferior articular artery of the knee.
- 25, 25, 25, 25, 25. Anterior tibial artery.
- 26, 26, 26. Recurrent artery.
- 27, 27, 27, 27, 27, 27, 27, 27, 27. Muscular branches.
- 28, 28, 28. External anterior malleolar artery.
29. Anterior peroneal artery.
30. Anastomosis of the anterior peroneal artery, with the external malleolar.
- 31, 31. Internal anterior malleolar artery.
32. Dorsal artery of the foot.
- 33, 33, 33. External tarsal artery.
- 34, 34. Internal tarsal artery.
- 35, 35. Dorsal arch.
- 36, 36. First metatarsal or dorsal interosseous artery.
37. Great anastomosing branch, with the external plantar artery.
- 38, 38. External dorsal artery of the great toe.
- 39, 39. Internal dorsal artery of the second toe.
40. Anastomosing branch, with the plantar artery of the great toe.
- 41, 41. Second metatarsal or dorsal interosseous artery.
42. Anastomosis of this artery with the deep perforating branch from the plantar interosseal artery.
43. External dorsal artery of the second toe.
44. Internal dorsal artery of the third toe.
- 45, 45. Third metatarsal or dorsal interosseous artery.
46. Anastomotic perforating branch.
47. External dorsal artery of the third toe.
48. Internal dorsal artery of the fourth toe.
- 49, 49. Fourth metatarsal or dorsal interosseous artery.
50. Anastomosis of this artery with a perforating branch.
51. External dorsal artery of the fourth toe.
52. Internal dorsal artery of the fifth toe.
- 53, 53. External dorsal artery of the fifth toe.
- 54, 54. Internal dorsal artery of the great toe from the plantar artery.
- 55, 55, 55, 55, 55, 55, 55, 55. Anterior dorsal branches of the toes from the plantar arteries of the toes.

FIGURE III.

Shows the foot from the outside.

- 1, 1. Tendo Achillis.
- 2, 2. Tendon of the peroneus longus.
- 3, 3. Tendon of the peroneus brevis.
- 4, 4, 4. Peroneus tertius.
- 5, 5, 5, 5, 5, 5, 5, 5, 5, 5, 5. Tendons of the extensor longus communis digitorum.
- 6, 6, 6. Extensor proprius hallucis.
7. Tibialis anticus muscle.
- 8, 8, 8, 8, 8, 8, 8, 8. Extensor brevis communis digitorum.
- 9, 9. Abductor minimi digiti.
- 10, 10. External interossei muscles.
- 11, 11, 11. External artery of the calcaneum.
- 12, 12. Anterior peroneal artery.
- 13, 13, 13. External anterior malleolar artery.
14. Anastomosis of this artery with the anterior peroneal.
- 15, 15, 15, 15. Anastomosis of the external malleolar artery with the external artery of the calcaneum.
16. Dorsal artery of the foot.
- 17, 17, 17. External tarsal artery.
- 18, 18. Internal tarsal artery.
- 19, 19, 19. Metatarsal or dorsal interosseous arteries.
- 20, 20, 20, 20, 20. Dorsal arteries of the toes.
- 21, 21, 21, 21. Anterior dorsal branches of the toes.



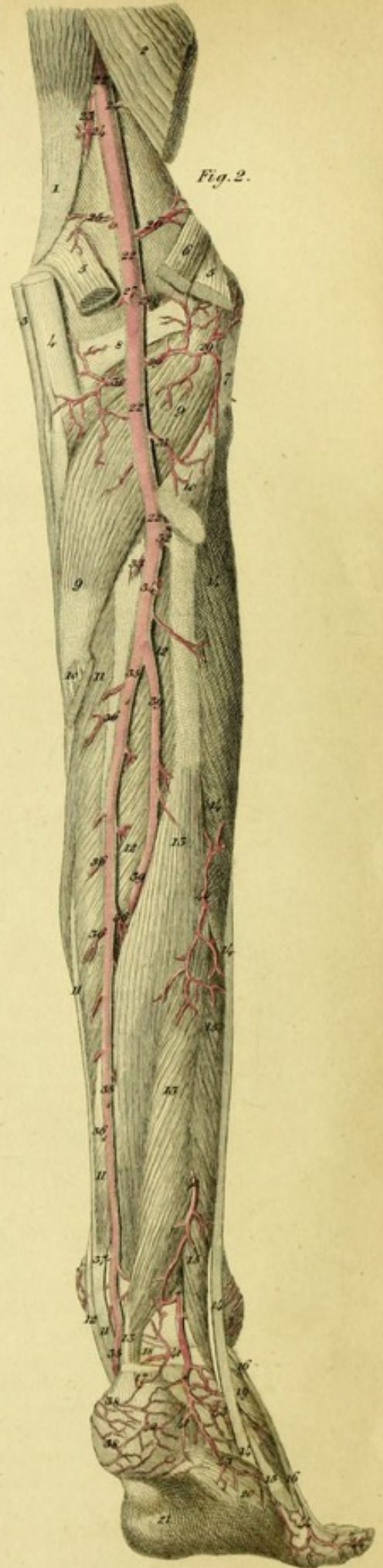
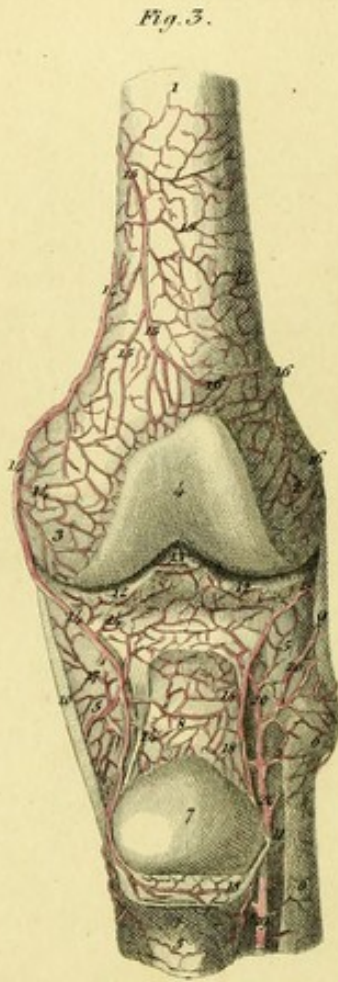
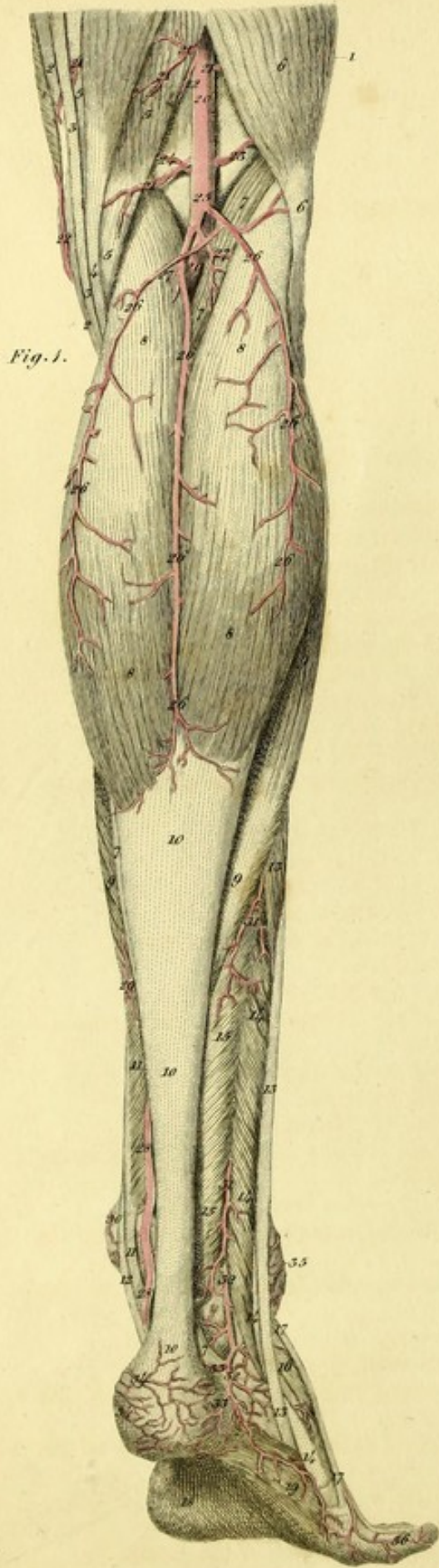


PLATE XXXV.

Exhibits the Arteries of the posterior part of the Leg.

FIGURE I.

Shows the superficial arteries.

1. Vastus externus.
- 2, 2. Tendon of the sartorius muscle.
- 3, 3. Tendon of the gracilis muscle.
- 4, 4. Semitendinosus muscle.
- 5, 5, 5. Semimembranosus muscle.
- 6, 6. Biceps flexor cruris.
- 7, 7, 7, 7, 7. Plantaris muscle.
- 8, 8, 8, 8. Gastrocnemius.
- 9, 9, 9. Soleus.
- 10, 10, 10. Tendo Achillis.
- 11, 11. Flexor longus communis digitorum.
12. Tendon of the tibialis posticus.
- 13, 13, 13, 13. Peroneus longus.
- 14, 14, 14, 14. Peroneus brevis.
- 15, 15. Flexor proprius hallucis.
16. Origin of the extensor brevis communis digitorum.
- 17, 17. Tendon of the peroneus tertius.
18. Plantar aponeurosis.
19. Abductor minimi digiti.
- 20, 20, 20. Popliteal artery.
- 21, 21, 21, 21, 21. Muscular branches.
- 22, 22. Internal superior articular artery of the knee running superficially.
23. External superior articular artery of the knee.
24. Deep internal superior articular artery of the knee.
25. Sural artery.
- 26, 26, 26, 26, 26, 26, 26. Superficial sural branches.
- 27, 27. Gastrocnemial arteries.
- 28, 28. Posterior tibial artery.
29. Muscular branch.
30. Internal posterior malleolar artery.
- 31, 31. Muscular branches arising from the posterior peroneal artery.
- 32, 32. Posterior peroneal artery.
- 33, 33. Twigs to the calcaneum.
- 34, 34. Twigs to the calcaneum from the posterior tibial artery.
35. Twigs of the external anterior malleolar artery.
36. External dorsal artery of the little toe.

FIGURE II.

Shows the deep arteries.

1. Insertion of the adductor magnus muscle.
2. Portion of the biceps muscle.
3. Tendon of the semitendinosus muscle.
4. Tendon of the semimembranosus muscle.
- 5, 5. Origins of the gastrocnemius.
6. Origin of the plantaris.
7. External lateral ligament of the knee.
8. Posterior ligament of the knee.
- 9, 9. Popliteus muscle.
- 10, 10. Origin of the soleus.
- 11, 11, 11, 11. Flexor longus communis digitorum.
- 12, 12, 12. Tibialis posticus.
- 13, 13, 13. Flexor longus pollicis.
- 14, 14, 14, 14, 14. Peroneus longus.
- 15, 15, 15, 15. Peroneus brevis.
- 16, 16. Tendon of the peroneus tertius.
17. Tendo Achillis.
18. Posterior ligament of the ankle joint.
19. Origin of the extensor brevis communis digitorum.
20. Abductor minimi digiti.
21. Plantar aponeurosis.
- 22, 22, 22, 22. Popliteal artery.
23. Superficial internal superior articular artery of the knee.
- 24, 24, 24. Muscular branches.
25. Deep internal superior articular artery of the knee.
26. External superior articular artery of the knee.
27. Sural artery.
28. Azygous articular artery of the knee.
- 29, 29. External inferior articular artery of the knee.
- 30, 30. Internal inferior articular artery of the knee.
31. Twig to the soleus.
32. Anterior tibial artery.
33. Great nutritious artery of the tibia.
34. Branch to the soleus muscle, cut.
- 35, 35, 35, 35. Posterior tibial artery.
- 36, 36, 36, 36. Branches to the muscles.

- 37. Internal posterior malleolar artery.
- 38. 38. Twigs to the calcaneum.
- 39, 39. Common peroneal artery.
- † † Posterior peroneal artery.
- 40, 40. Muscular branches from the common peroneal artery.
- 41, 41. Twigs to the calcaneum.
- 42. Vascular network of the calcaneum.
- 43, 43. Branches going to the outer surface of the foot.
- 44, 44. External dorsal artery of the little toe.

FIGURE II.

Represents the deep arteries of the knee and their anastomoses.

- 1. Lower part of the left thigh-bone.
- 2. External condyle.
- 3. Internal condyle.
- 4. Articular surface.
- 5, 5, 5. Tibia.

- 6, 6. Fibula.
- 7. Articular surface of the patella.
- 8. Ligamentum patellæ.
- 9. External lateral ligament of the knee.
- 10. Internal lateral ligament of the knee.
- 11. Interosseous ligament.
- 12, 12. Semilunar cartilages of the knee.
- 13. Anterior crucial ligament.
- 14, 14, 14, 14, 14, 14. Branch of the superficial internal superior articular artery of the knee.
- 15, 15, 15, 15. Deep internal superior articular artery of the knee.
- 16, 16, 16. Twigs of the external superior articular artery of the knee.
- 17, 17, 17. Internal inferior articular artery of the knee.
- 18, 18, 18, 18. External inferior articular artery of the knee.
- 19. Anterior tibial artery.
- 20, 20, 20, 20. Recurrent branch of the anterior tibial artery.




Fig 1

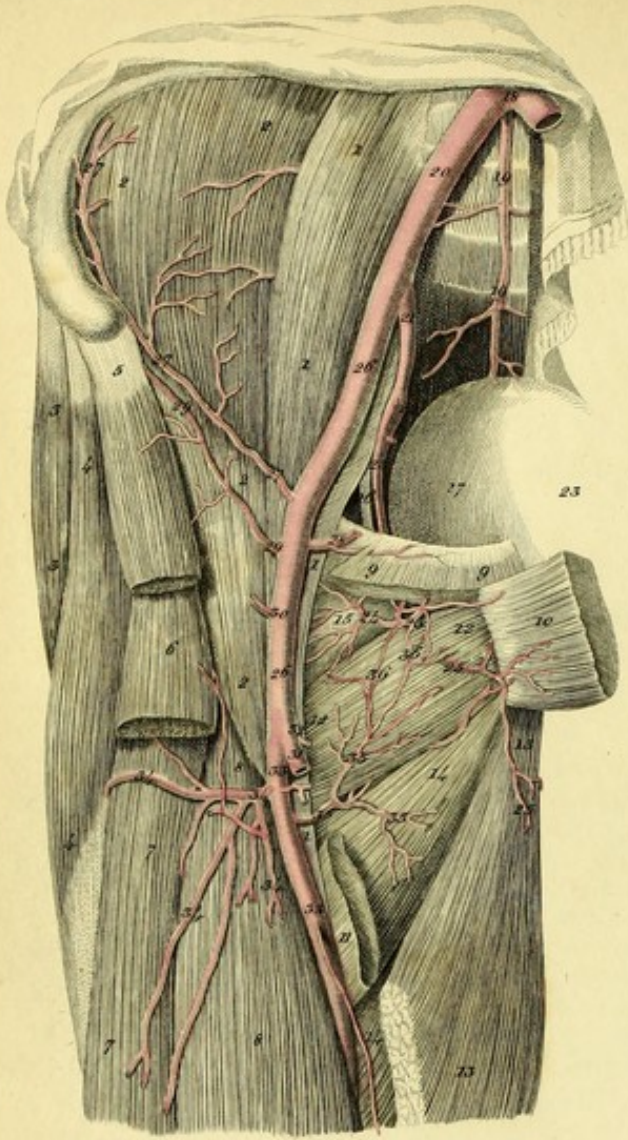


Fig 2

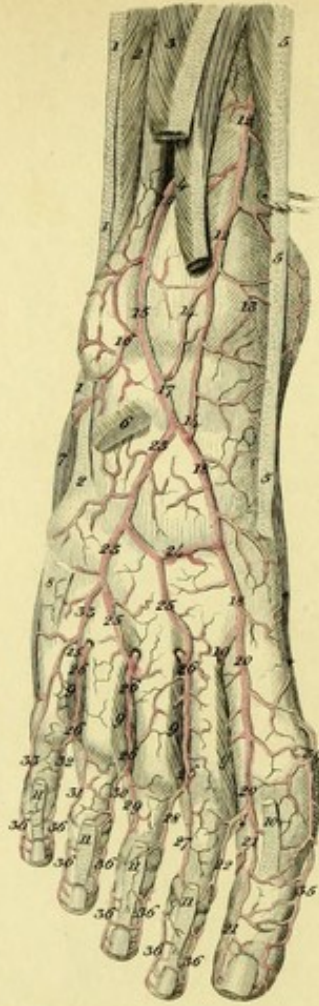


Fig 3

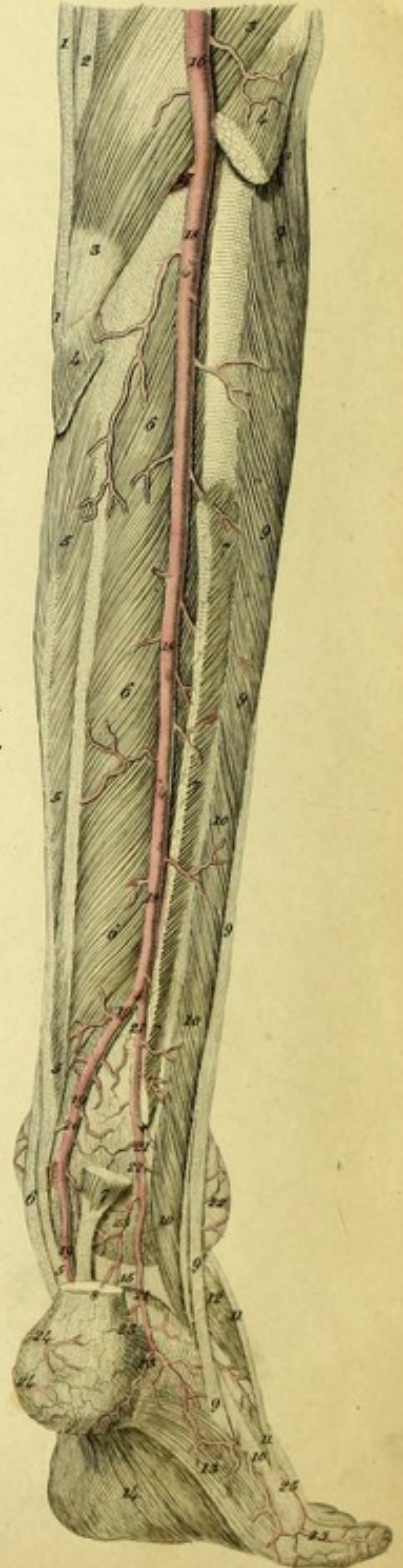


Fig 4

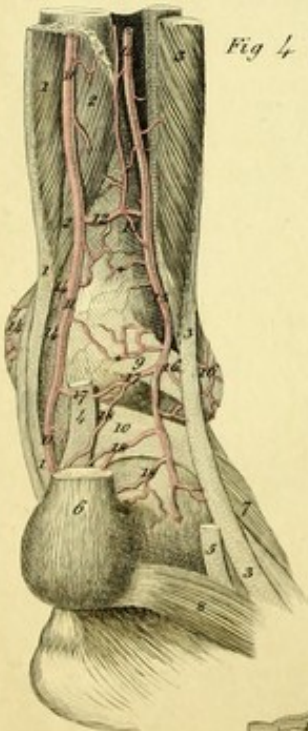


Fig 5

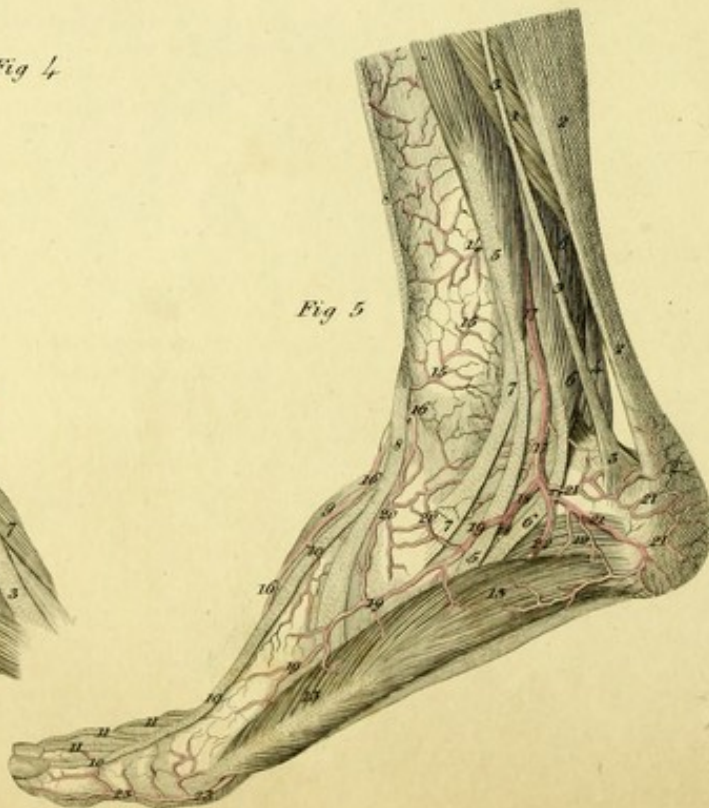


PLATE XXXVI.

FIGURE I.

Represents the obturator artery from the body of a man.

- 1, 1, 1, 1. Psoas magnus.
- 2, 2, 2, 2. Iliacus internus.
- 3, 3. Gluteus medius.
- 4, 4. Tensor vaginæ femoris.
5. Origin of the sartorius.
6. Origin of the rectus femoris muscle.
- 7, 7. Vastus externus.
- 8, 8. Cruralis muscle.
- 9, 9. Origin of the pectineus.
10. Head of the adductor brevis, reflected.
11. Insertion of this muscle.
- 12, 12. Obturator externus muscle.
- 13, 13. Adductor longus.
- 14, 14. Adductor magnus.
15. Capsular ligament of the hip-joint.
16. Obturator nerve.
17. Urinary bladder.
18. Division of the aorta.
- 19, 19. Middle sacral artery.
20. Common iliac artery.
21. Hypogastric artery.
22. Gluteal artery.
- 23, 23. Obturator artery.
24. Twig to the capsular ligament.
25. Twigs to the adductor muscles.
- 26, 26. External iliac artery, and its continuation as the common femoral.
- 27, 27, 27. Circumflex iliac artery.
28. Epigastric artery.
29. An unusual circumflex iliac artery
30. Superficial epigastric artery.
31. Trunk of the superficial femoral artery cut.
32. External pudic artery.
- 33, 33. Deep femoral artery.
- 34, 34, 34, 34. External circumflex artery of the thigh.
- 35, 35, 35. Internal circumflex artery of the thigh.
- 36, 36. Anastomoses with the twigs of the obturator artery.

FIGURE II.

Shows the right foot of a man, in which the anterior peroneal artery gives off the dorsal artery of the foot.^a

- 1, 1, 1. Peroneus longus muscle.
- 2, 2, 2. Peroneus brevis muscle.
3. Portion of the extensor longus communis digitorum muscle.
4. Portion of the extensor proprius hallucis.
- 5, 5, 5. Tibialis anticus.
6. Origin of the extensor brevis communis digitorum.
7. Abductor minimi digiti.
8. Tendon of the peroneus tertius.
- 9, 9, 9. External interossei muscles.
10. Tendon of the extensor hallucis.
- 11, 11, 11, 11. Tendons of the extensor longus communis digitorum.
- †† Abductor hallucis.
- 12, 12. Anterior tibial artery unusually small.
13. Internal anterior malleolar artery.
- 14, 14. Anastomotic branches of the anterior tibial artery, with the dorsal artery of the foot.
- 15, 15. Anterior peroneal artery larger than usual, forming the dorsal artery of the foot.
16. External anterior malleolar artery.
17. Dorsal artery of the foot.
- 18, 18. Internal tarsal artery.
19. Great anastomosing branch with the arch of the plantar artery.
- 20, 20. First metatarsal artery.
- 21, 21. External dorsal artery of the great toe.
22. Internal dorsal artery of the second toe.
- † Twig anastomosing with the plantar artery of great toe.
- 23, 23. External tarsal artery.

^a I have seen this disposition four times.*

* I have seen this disposition several times.—T. W. J.

24. Anastomosing branch between the external and internal tarsal arteries.
- 25, 25, 25. Anastomosing branches, with the perforating arteries from the plantar arch.
- 26, 26, 26. Very large perforating branches, constituting the dorsal interosseal, or metatarsal arteries.
27. External dorsal artery of the second toe.
28. Internal dorsal artery of the third toe.
29. External dorsal artery of the third toe.
30. Internal dorsal artery of the fourth toe.
31. External dorsal artery of the fourth toe.
32. Internal dorsal artery of the fifth toe.
- 33, 33. External dorsal artery of the fifth toe.
34. Internal dorsal artery of the great toe.
35. Anterior dorsal artery of the great toe.
- 36, 36, 36, 36, 36, 36, 36. Anterior dorsal branches of the toes.

FIGURE III.

Exhibits an unusual disposition of arteries on the posterior part of the right leg of a man twenty-seven years old.^a

1. Tendon of the sartorius.
2. Tendon of the gracilis muscle.
- 3, 3. Popliteus muscle.
- 4, 4. Origin of the soleus.
- 5, 5, 5, 5. Flexor longus communis digitorum.
- 6, 6, 6, 6. Tibialis posticus muscle.
- 7, 7, 7, 7. Flexor longus hallucis.
8. Tendo Achillis.
- 9, 9, 9, 9, 9. Peroneus longus.
- 10, 10, 10, 10. Peroneus brevis.
- 11, 11. Tendon of the peroneus tertius.
12. Extensor communis digitorum brevis.
13. Abductor minimi digiti.
14. Plantar aponeurosis.
15. Transverse ligament of the ankle joint.
16. Popliteal artery.
17. Anterior tibial artery.
- 18, 18, 18. Trunk of the posterior tibial and peroneal arteries.
- † Division of the trunk into posterior tibial and peroneal arteries.
- 19, 19, 19. Posterior tibial artery.
20. Internal posterior malleolar artery.
- 21, 21, 21. Posterior peroneal artery.
- * Anterior peroneal artery perforating the interosseous ligament.
- 22, 22. External posterior malleolar artery.
- 23, 23, 23. Branches to the calcaneum.
- 24, 24. Branches to the calcaneum from the plantar artery.
- 25, 25. External dorsal artery of the little toe.

FIGURE IV.

Here is seen another variety of the posterior arteries of the leg in the body of a woman thirty-five years old.

1. 1, 1. Flexor longus communis digitorum.
2. 2, 2. Tibialis posticus.
3. 3, 3. Peroneus brevis.
4. Tendon of the flexor hallucis.
5. Tendon of the peroneus longus.
6. Tendo Achillis.
7. Extensor brevis communis digitorum.
8. Abductor minimi digiti.
9. Posterior tibio-fibular ligament.
10. Transverse ligament of the ankle joint.
- 11, 11, 11. Posterior tibial artery.
12. Anterior peroneal artery, arising from the posterior tibial.
13. Anastomosing branch with the posterior peroneal artery.
- 14, 14, 14. Internal posterior malleolar artery.
- † Small anastomosing twigs with the posterior peroneal artery.
- 15, 15, 15. Posterior peroneal artery.
- 16, 16. External posterior malleolar artery.
- 17, 17. Great anastomosing branch between the peroneal and posterior tibial arteries.
- 18, 18, 18. Twigs to the calcaneum.

FIGURE V.

Shows the arteries of the inner side of the foot of a man distributed in the usual manner.

1. Soleus.
- 2, 2, 2. Tendo Achillis.
- 3, 3, 3. Tendon of the plantaris muscle.
4. Peroneus brevis.
- 5, 5, 5. Flexor longus communis digitorum.
- 6, 6, 6. Flexor longus hallucis.
- 7, 7. Tendon of the tibialis posticus.
- 8, 8, 8. Tendon of the tibialis anticus.
9. Extensor brevis communis digitorum.
- 10, 10, 10. Tendon of the extensor hallucis.
- 11, 11, 11, 11. Tendons of the extensor longus communis digitorum.
12. Flexor brevis communis digitorum.
- 13, 13. Abductor hallucis.
14. Internal posterior malleolar artery.
- 15, 15. Internal anterior malleolar artery.
- 16, 16, 16. Internal tarsal artery.
- 17, 17. Posterior tibial artery.
- 18, 18. Internal plantar artery.
- 19, 19, 19. External superficial lateral branch of the foot.
- 20, 20. Anastomosing twigs with the internal tarsal artery.
- 21, 21, 21, 21. Calcaneal branches.
22. External plantar artery.
- 23, 23. Internal dorsal artery of the great toe.

^a I have observed this variety twice: once in the right leg, once in the left.



Fig. 1.

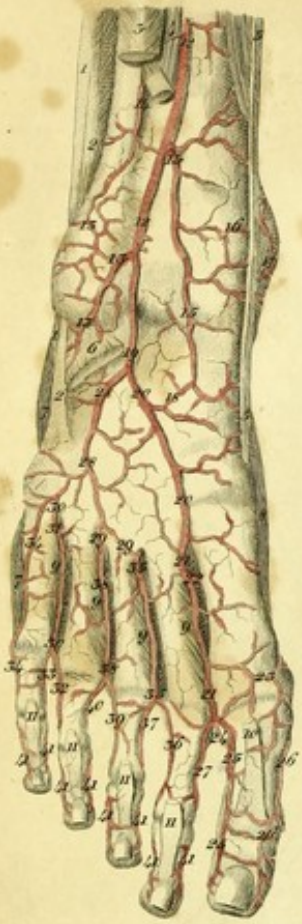


Fig. 4.

Fig. 2.

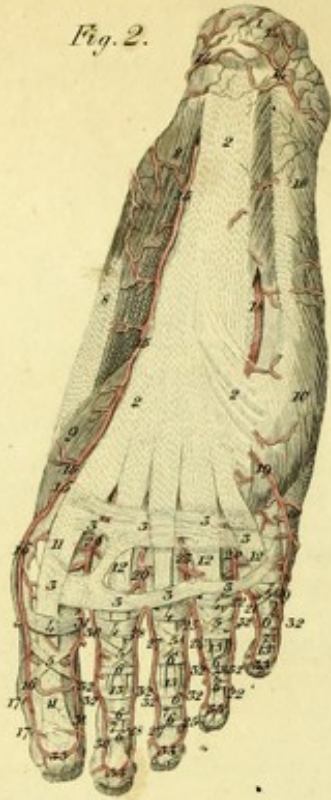

Fig. 3.

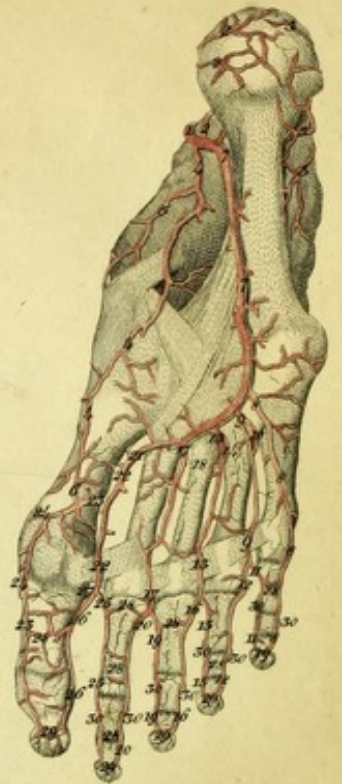
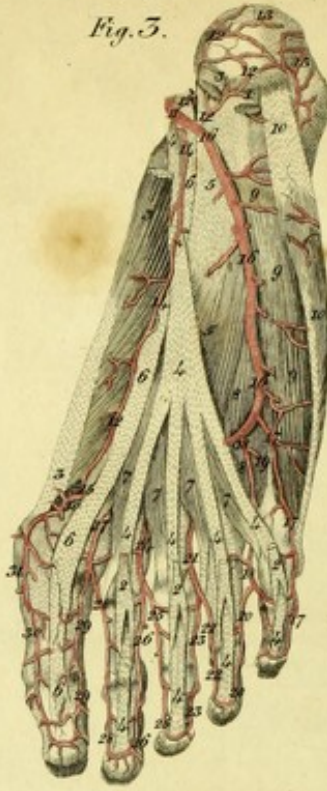

Fig. 5.

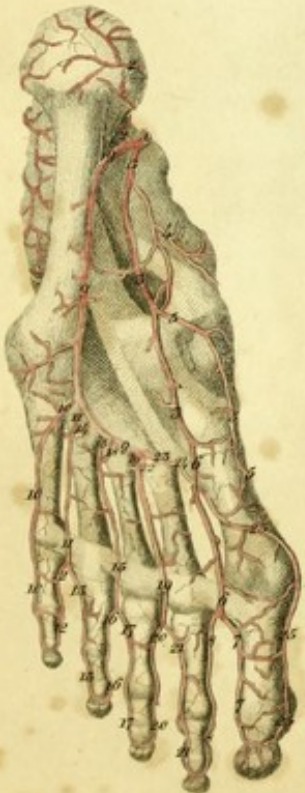

Fig. 6.

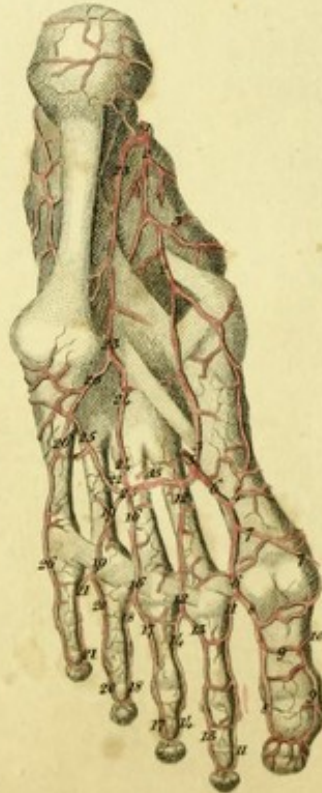

Fig. 7.

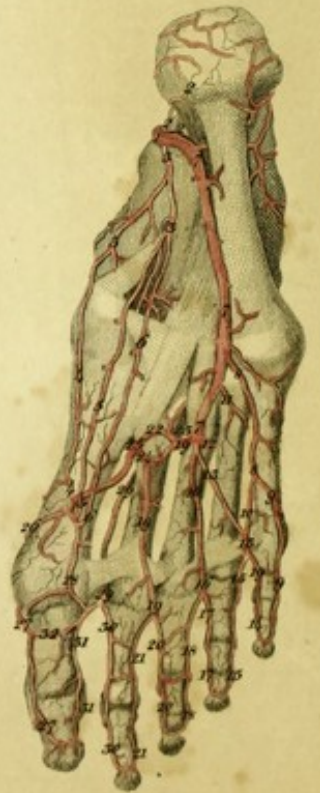

PLATE XXXVII.

FIGURE I.

This represents the right foot of a man forty-two years old, in which the arteries are irregularly distributed.

- 1, 1. Peroneus longus.
- 2, 2. Peroneus brevis.
3. Part of the extensor longus communis digitorum.
4. Part of the extensor proprius hallucis.
- 5, 5. Tibialis anticus.
6. Origin of the extensor brevis communis digitorum.
- 7, 7. Abductor minimi digiti.
8. Abductor hallucis.
- 9, 9, 9, 9. External interossei muscles.
10. Tendon of the extensor hallucis.
- 11, 11, 11, 11. Tendons of the extensor communis digitorum.
- 12, 12. Anterior tibial artery.
- 13, 13, 13. External anterior malleolar artery.
14. Anterior peroneal artery.
- 15, 15. An unusual branch.
16. Internal anterior malleolar artery.
17. Anastomosis with the internal posterior malleolar artery.
18. Anastomosis of the unusual branch with the internal tarsal artery.
19. Dorsal artery of the foot.
- 20, 20. Internal tarsal artery.
- 21, 21. First metatarsal artery.
- 22, 22. Great anastomosing branch with the plantar arch.
23. Internal dorsal branch of the great toe.
24. Small anterior anastomosing branch.
- 25, 25. External dorsal artery of the great toe.
- 26, 26. Internal anterior dorsal branch of the great toe.
27. Internal dorsal artery of the second toe.

- 28, 28. External tarsal artery.
- 29, 29. Anastomosing branches with the perforating arteries of the plantar, which form the second and third metatarsal arteries.
- 30, 30. Fourth metatarsal artery.
31. Perforating branch.
32. External dorsal artery of the fourth toe.
33. Internal dorsal artery of the little toe.
- 34, 34. External dorsal artery of the little toe.
- 35, 35. Second metatarsal artery.
36. External dorsal artery of the second toe.
37. Internal dorsal artery of the third toe.
- 38, 38. Third metatarsal artery.
39. External dorsal artery of the middle toe.
40. Internal dorsal artery of the fourth toe.
- 41, 41, 41, 41, 41, 41, 41, 41. Anterior dorsal digital branches.

FIGURE II.

Exhibits the regular distribution of the superficial arteries in the sole of the right foot, from the body of a man twenty-seven years old.

1. Tuberosity of the calcaneum.
- 2, 2, 2. Plantar aponeurosis.
- 3, 3, 3, 3, 3, 3, 3, 3. Transverse tendinous fibres connecting the flexor tendons.
- 4, 4, 4, 4. Ligamentous sheaths of the tendons.
- 5, 5, 5, 5, 5. Crucial ligaments.
- 6, 6, 6, 6, 6, 6, 6. Annular ligaments.
- 7, 7, 7, 7. Oblique ligaments.
- 8, 8. Abductor hallucis.
9. Flexor brevis hallucis.
- 10, 10. Abductor minimi digiti.
- 11, 11. Tendon of the flexor longus hallucis.
- 12, 12, 12, 12. Tendons of the flexor brevis communis digitorum.
- 13, 13, 13, 13. Tendons of the flexor longus communis digitorum.
- 14, 14, 14. Branches to the calcaneum.

- 15, 15, 15. Internal plantar artery.
 16, 16, 16. Internal plantar artery of the great toe.
 17, 17. Dorsal branches.
 18. External plantar artery.
 19, 19. External plantar artery of the little toe.
 20. First plantar interosseous artery.
 21. Internal plantar artery of the little toe.
 22, 22. External plantar of the fourth toe.
 23. Second interosseous artery.
 24, 24. Internal plantar artery of the fourth toe.
 25, 25. External plantar artery of the middle toe.
 26. Third interosseous artery.
 27, 27. Internal plantar artery of the middle toe.
 28, 28. External plantar artery of the second toe.
 29. Fourth interosseal artery.
 30, 30. Internal plantar artery of the second toe.
 31, 31. External plantar artery of the great toe.
 32, 32, 32, 32, 32, 32, 32. Anterior dorsal branches of the toes.
 33, 33, 33, 33. Arterial arches on the third phalanx of the toes.

FIGURE III.

Shows the usual course of the arteries of the sole of the foot. The plantar aponeurosis is cut, and the flexor brevis communis digitorum and flexor brevis proprius pollicis removed.

1. Origin of the flexor brevis communis digitorum.
- 2, 2, 2, 2. Tendons of this muscle.
- 3, 3, 3. Abductor hallucis.
- 4, 4, 4, 4, 4, 4, 4, 4. Flexor longus communis digitorum.
- 5, 5. Musculus accessorius of the flexor longus.
- 6, 6, 6, 6. Flexor longus hallucis.
- 7, 7, 7, 7. Lumbricales muscles.
8. Internal head of the flexor brevis minimi digiti.
9. External head of the flexor brevis minimi digiti.
- 10, 10. Abductor minimi digiti.
11. Plantar artery.
- 12, 12. Branches to the calcaneum.
- 13, 13. Branches to the calcaneum from the posterior peroneal artery.
- 14, 14, 14. Internal plantar artery.
15. Anastomosis of this artery with the internal plantar artery of the great toe.
- 16, 16, 16. External plantar artery.
- 17, 17. External plantar artery of the little toe.
- 18, 18. First plantar digital artery.

19. Perforating branch.
- † † Internal plantar artery of the little toe.
- 20, 20. External plantar artery of the fourth toe.
21. Second plantar digital artery.
- 22, 22. Internal plantar artery of the fourth toe.
- 23, 23. External plantar artery of the third toe.
24. Third plantar digital artery.
- 25, 25. Internal plantar artery of the third toe.
- 26, 26. External plantar artery of the second toe.
27. Fourth plantar digital artery.
- 28, 28. Internal plantar artery of the second toe.
- 29, 29. External plantar artery of the great toe.
- 30, 30. Internal plantar artery of the great toe.
31. Dorsal branches.

FIGURE IV.

Represents the deep arteries of the sole of the foot, the muscles being removed.

1. Plantar artery.
- 2, 2. Branches to the calcaneum.
- 3, 3. Branches from the posterior peroneal artery to around the calcaneum.
- 4, 4. Internal plantar artery.
5. Branch running to the inside of the foot.
6. Anastomosis with the internal plantar artery of the great toe.
- 7, 7, 7. External plantar artery forming the deep plantar arch.
- 8, 8, 8. External plantar artery of the little toe.
- 9, 9. First interosseal artery.
10. Perforating branch.
- 11, 11. Internal plantar artery of the little toe.
- 12, 12. External plantar artery of the fourth toe.
- 13, 13. Second interosseal artery.
14. Perforating branch.
- 15, 15. Internal plantar artery of the fourth toe.
- 16, 16. External plantar artery of the third toe.
- 17, 17. Third interosseal artery.
18. Perforating branch.
- 19, 19. Internal plantar artery of the third toe.
- 20, 20. External plantar artery of the second toe.
21. Great anastomotic branch of the first metatarsal artery.
- 22, 22. Fourth interosseal artery.
- 23, 23, 23. Internal plantar artery of the great toe.

- 24, 24. Dorsal branches of the great toe.
- 25, 25. Internal plantar artery of the second toe.
- 26, 26. External plantar artery of the great toe.
- 27. Anterior anastomosing branch of the first metatarsal artery.
- 28, 28, 28, 28, 28, 28. Anastomoses on the first and second phalanges of the toes.
- 29, 29, 29, 29, 29. Arterial arches on the third phalanx.
- 30, 30, 30, 30, 30, 30, 30, 30. Dorsal branches.

FIGURE V.

Shows a variety of the arteries in the sole of the left foot of a woman.

- 1. Plantar artery.
- 2, 2. Calcaneal branch.
- 3, 3, 3. Internal plantar artery.
- 4. Internal lateral branch.
- 5, 5, 5. Internal dorsal artery of the great toe.
- 6, 6. Fourth plantar interosseal artery.
- 7, 7. External plantar artery of the great toe.
- 8, 8. Internal plantar artery of the second toe.
- 9, 9. External plantar artery.
- 10, 10, 10. External plantar artery of the little toe.
- 11, 11. First interosseal artery.
- 12, 12. Internal plantar of the little toe.
- 13, 13. External plantar artery of the fourth toe.
- 14. Perforating branch.
- 15, 15. Second Interosseal artery.
- 16, 16. Internal plantar artery of the fourth toe.
- 17, 17. External plantar artery of the middle toe.
- 18. Perforating branch.
- 19, 19. Third Interosseal artery.
- 20, 20. Internal plantar artery of the middle toe.
- 21, 21. External plantar artery of the second toe.
- 22. Perforating branch.
- 23. Communication with the great anastomosing branch of the first metatarsal artery.
- 24. Great anastomotic branch of the first metatarsal artery.
- 25, 25, 25. Internal plantar artery of the great toe.

FIGURE VI.

Shows another variety of the arteries in the sole of the left foot of a man.

- 1. Plantar artery.
- 2, 2. Internal plantar artery.

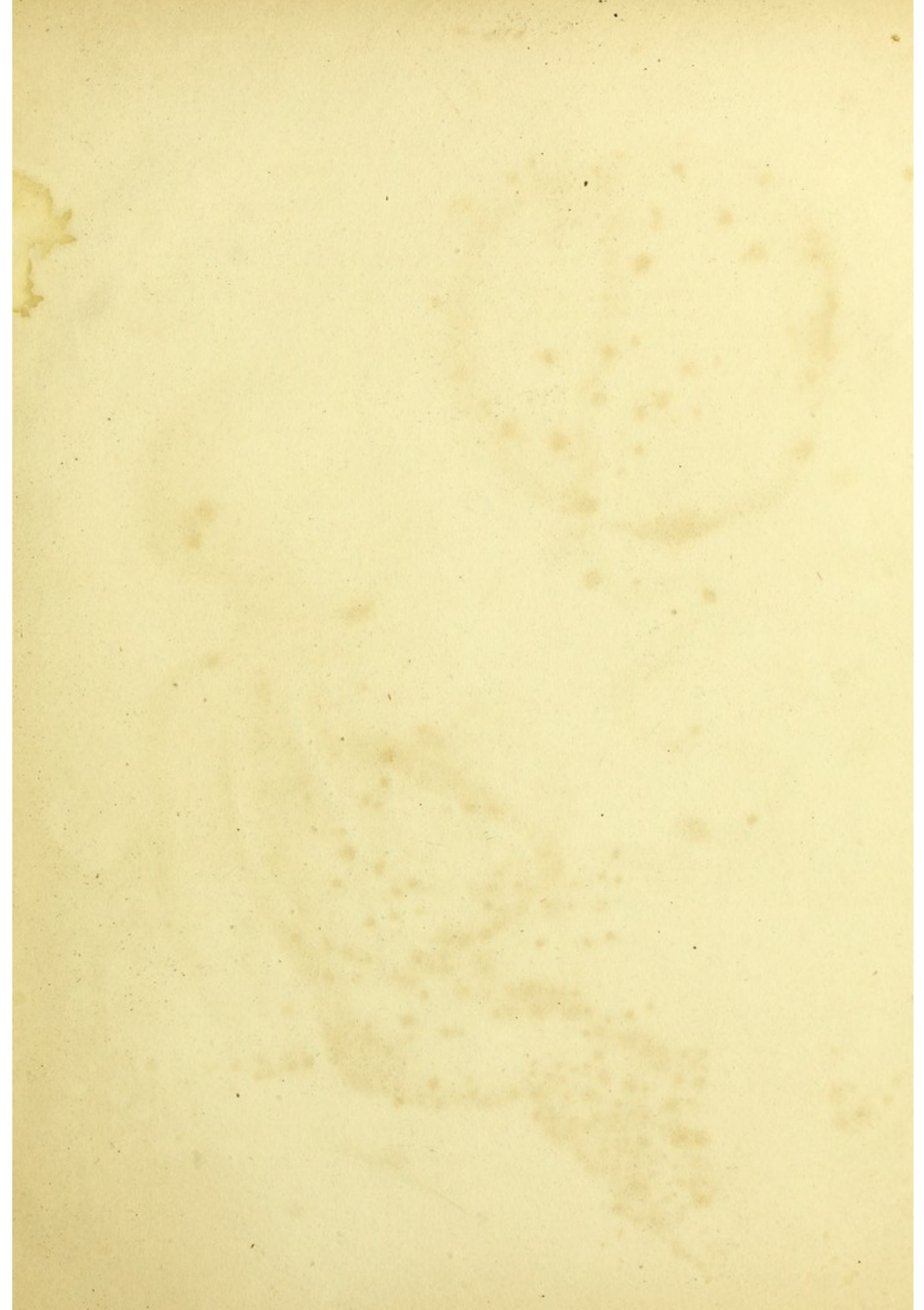
- 3. Anastomosis of this artery with the great anastomosing branch of the first interosseal.
- 4. Anastomosing branch with the first interosseal artery.
- 5. Great anastomosing branch of the first metatarsal artery, forming the deep plantar arch.
- 6, 6. First interosseal artery.
- 7, 7. Internal dorsal artery of the great toe.
- 8, 8. External plantar artery of the great toe.
- 9, 9. Internal plantar artery of the great toe.
- 10. Anastomosing branch with the internal dorsal artery of the great toe.
- 11, 11. Internal plantar artery of the second toe.
- 12, 12. Second interosseal artery.
- 13, 13. External plantar artery of the second toe.
- 14, 14. Internal plantar artery of the middle toe.
- 15. Perforating branch.
- 16, 16. Third interosseal artery.
- 17, 17. External plantar artery of the middle toe.
- 18, 18. Internal plantar artery of the fourth toe.
- 19, 19. Fourth interosseal artery.
- 20, 20. External plantar artery of the fourth toe.
- 21, 21. Internal plantar artery of the little toe.
- 22. Perforating branch.
- 23, 23. Small external plantar artery.
- 24, 24. First anastomosing branch with the deep plantar arch.
- 25, 25. Second anastomosing branch with the deep plantar arch.
- 26, 26. External plantar artery of the little toe.

FIGURE VII.

Here is seen a rare variety of the arteries of the sole of the right foot of a man.

- 1. Plantar artery.
- 2, 2. Calcaneal branches.
- 3, 3, 3. Internal plantar artery.
- 4, 4. First anastomosing branch with the plantar artery of the great toe.
- 5, 5. Second anastomosing branch with the plantar artery of the great toe.
- 6, 6. Third anastomosing branch with the plantar artery of the great toe.
- 7, 7. External plantar artery.
- 8, 8. Small trunk of the external plantar artery of the little toe, and the anastomosing branches with the first interosseal artery.
- 9, 9. External plantar artery of the little toe.
- 10, 10. Anastomosing branch.
- 11, 11. First perforating artery.

12. Second perforating artery.
13. First interosseal artery.
- 14, 14. Internal plantar artery of the little toe.
- 15, 15. External plantar artery of the fourth toe.
- 16, 16. Second interosseal artery.
- 17, 17. Internal plantar artery of the fourth toe.
- 18, 18. External plantar artery of the third toe.
- 19, 19, 19. Third interosseal artery.
- 20, 20. Internal plantar artery of the third toe.
- 21, 21. External plantar artery of the second toe.
22. First communicating branch with the great anastomotic branch of the first metatarsal artery.
23. Third perforating artery.
24. Second communicating branch with the great anastomosing branch of the first metatarsal artery.
25. Great anastomosing branch of the first metatarsal artery.
26. Internal dorsal artery of the great toe.
- 27, 27. Internal plantar artery of the great toe.
28. Branch anastomosing with the external plantar artery of the great toe.
- 29, 29. Fourth interosseal artery from the internal tarsal artery.
- 30, 30. Internal plantar artery of the second toe.
- 31, 31. External plantar artery of the great toe.



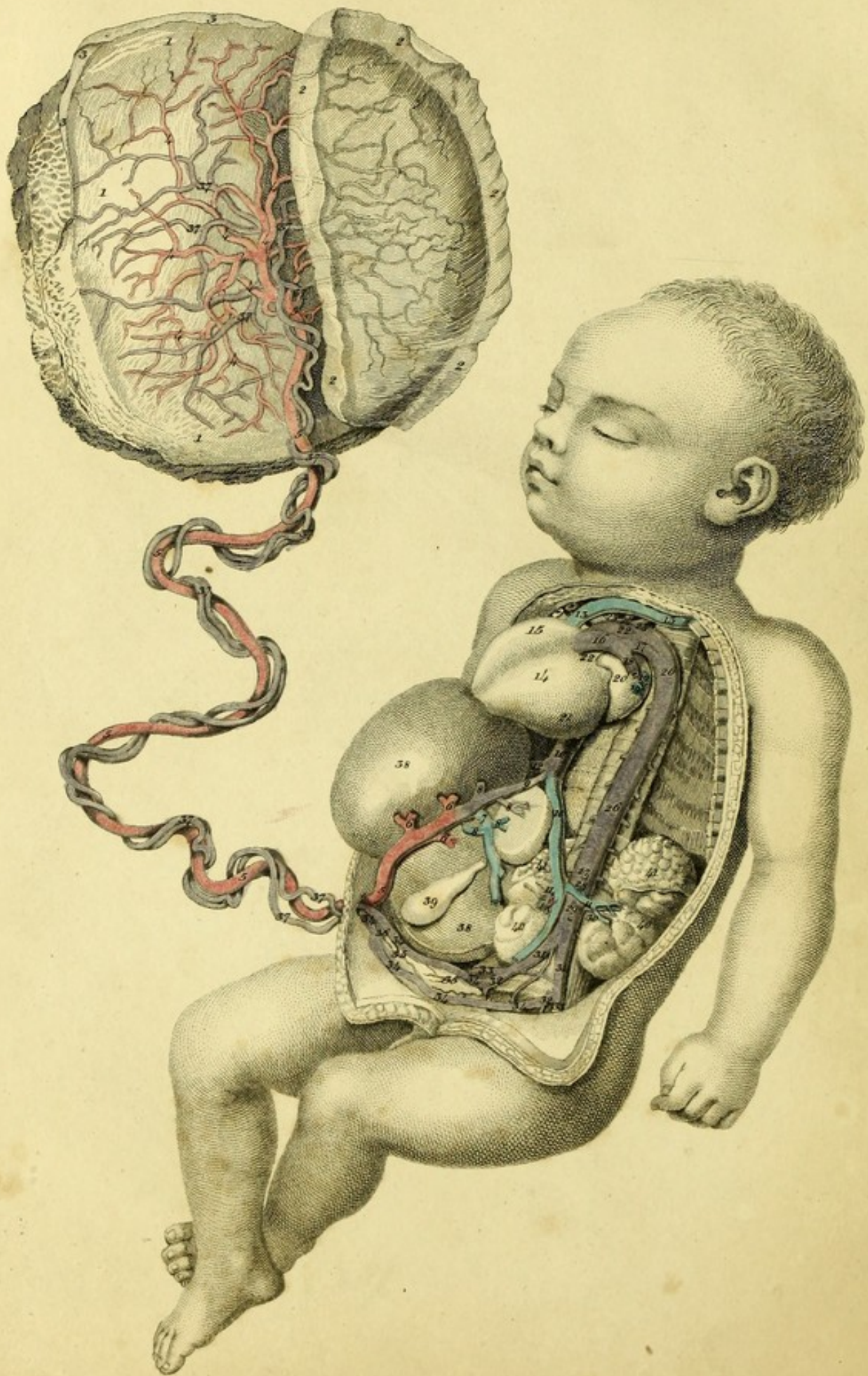


PLATE XXXVIII.

This represents the distribution of the vessels in the fœtus at the full time.
The difference in the colouring indicates that of the blood.

- | | |
|---|--|
| 1, 1, 1. Placenta. | 22, 22. Aorta. |
| 2, 2, 2, 2, 2. Part of the amnios covering the placenta. | 23. Arteria innominata. |
| 3, 3, 3. Portion of the chorion. | 24. Left carotid artery. |
| 4, 4, 4, 4, 4, 4, 4, 4. The veins of the placenta running into a trunk. | 25. Left subclavian artery. |
| 5, 5, 5, 5, 5, 5. Umbilical vein. | 26, 26, 26. Descending aorta. |
| 6, 6, 6. Branches of the umbilical vein sent to the liver. | 27. Cœliac artery, cut. |
| 7, 7. Vena portarum. | 28. Superior mesenteric artery. |
| 8, 8, 8, 8. Hepatic branches. | 29. Inferior mesenteric artery. |
| 9. Ductus venosus. | 30. Left renal artery. |
| 10, 10, 10. Vena cava inferior. | 31, 31. Common iliac arteries. |
| 11, 11. Renal Veins. | 32, 32. Hypogastric arteries. |
| 12. Hepatic vein. | 33, 33. External iliac arteries. |
| 13, 13. Vena cava superior. | 34, 34, 34, 34, 34, 34, 34. Umbilical arteries ascending towards the umbilical ring. |
| 14. The heart drawn to the right side. | 35, 35. Twigs to the urinary bladder. |
| 15. Right or pulmonary ventricle. | 36. Urachus. |
| 16. Pulmonary artery. | 37, 37, 37, 37, 37, 37, 37, 37, 37, 37. Umbilical arteries running to the placenta in a tortuous manner. |
| 17. Ductus arteriosus joining with the aorta. | 38, 38. The liver turned aside. |
| 18. Left pulmonary artery, cut. | 39. Gall bladder. |
| 19, 19. Left pulmonary veins. | 40, 40. Kidneys. |
| 20. Left or pulmonary auricle. | 41, 41. Supra-renal glands. |
| 21. Left or aortic ventricle. | |



PLATE XXXIII

This represents the distribution of the vessels in the heart at the full time.
The difference in the coloring between the two of the blood.

