The olfactory tracts and centers in teleosts / Ralph Edward Sheldon.

Contributors

Sheldon, Ralph Edward.
Sheldon, Ralph Edward
King's College London

Publication/Creation

Baltimore : Waverly Press, [1912]

Persistent URL

https://wellcomecollection.org/works/usxb2ex7

With regards of
R. E. Sheldon

The Olfactory Tracts and Centers in Teleosts

RALPH EDWARD SHELDON

Assistant Professor of Anatomy, the University of Pittsburgh
Medical School
From the Hull Laboratory of Anatomy of the University
of Chicago

Reprinted from THE JOURNAL OF COMPARATIVE NEUROLOGY,
Vol. 22, No. 3, June, 1912

Reprinted from The Journal of Comparative Neurology, Vol. 22, No. 3
June, 1912

THE OLFACTORY TRACTS AND CENTERS IN TELEOSTS

RALPH EDWARD SHELDON

Assistant Professor of Anatomy, the University of Pittsburgh Medical School
From the Hull Laboratory of Anatomy of the University of Chicago

ONE HUNDRED AND FORTY-TWO FIGURES

CONTENTS

I. INTRODUCTION

The information here added to that heretofore existing in the literature is derived largely from a study of the olfactory apparatus in the carp, Cyprinus carpio (L). The olfactory apparatus is highly developed in the cyprinoids which, therefore, lend themselves readily to its study. For the elucidation of difficult points, however, comparison has been made with Weigert and Golgi sections of the brains of the pike, Lucius lucius (L), the goldfish, Carassius auratus (L) and the catfish, Ameiurus nebulosus (Le Sueur).

I am indebted to Prof. C. Judson Herrick for helpful suggestions and criticism in every phase of the work, together with the opportunity to use his unexcelled neurological library and his personal material. Prof. R. R. Bensley likewise placed at my disposal all the facilities of the department, including the services of the artist, Miss Katharine Hill, who has drawn, with the most painstaking care, the larger portion of the figures. Through the kindness of Prof. Charles Brookover, of Buchtel College I have been able to examine preparations of the brain of Amia calva and to secure well preserved material for most of the Ramón y Cajal impregnations. Acknowledgments should also be made to Prof. B. G. Wilder of Cornell University, at whose suggestion this research was undertaken, and to Prof. S. H. Gage of Cornell University and Prof. E. L. Mark of Harvard University, in whose laboratories important parts of this investigation were conducted.

MATERIAL AND METHODS

The material used consists of the following eighty-three series of sections of the carp brain.

I. Weigert method

Inasmuch as the method used varies somewhat from that usually followed, and since it is very successful, it will be briefly outlined here. The fish are killed in a mixture of ether and water, the brain removed immediately and placed in 4 per cent formaldehyde for at least forty-eight hours. It is then washed in running water for a few hours and placed in Müller's fluid at a temperature of 40° C. for from eight to fourteen days. The fluid is changed every second day during this period. The brain is next washed, dehydrated, cleared in carbol-xylene and embedded in paraffine. After the removal of the paraffine from the mounted sections the slides are placed for twelve hours in a half-saturated solution of copper acetate, stained three to four hours in Weigert's hematoxylin, and differentiated in $2\frac{1}{2}$ per cent potassium ferricyanide with the addition of 2 per cent borax. Pal's modification was tried but rejected, as it was found that sections on the slide could not be evenly differentiated; moreover, the method outlined gives rather better results for the work in question, as it brings out the unmedullated tracts and the cell groups, which the Pal modification does not. There were stained according to this method:

Two series transverse sections of the entire brain.
Two series sagittal sections.
Two series frontal sections.
Six series through the olfactory bulbs and crura.

All of these were from carp 35 to 60 cm. in length and were cut at 15 micra. In addition there were prepared one transverse and one frontal series through the entire head of carp of 3 cm. in length. The method followed in this case is as follows; the fish are placed in Müller's fluid, changed every second day, for a month, and then decalcified for another month in Flemming's stronger fluid, changed each week. From this point on the method is similar to the one first outlined; viz., dehydration, clearing, embedding in paraffine, etc. Medullated fibers and nerves stand out very distinctly after the use of this method. Other methods of decalcification were tried but, as Herrick ('97) points out, the Weigert method will not 'take' after any of the ordinary processes of decalcification. Professor Herrick was kind enough to loan me, in addition, a series of transverse sections through the adult carp brain, stained by the Weigert-Pal method.

II. Chloral hematoxylin and eosin method

Entire carp, 1 cm. in length, decalcified.
Two series transverse sections.
Three series sagittal sections.
Two series frontal sections.

III. Toluidin blue method

The only fixing agent which gave uniformly good results with this stain was Graf's chrom-oxalic for twelve hours. This method was used for the differentiation of areas and the cytological structure of the nerve cells.

One series transverse sections.
One series sagittal sections.
One series frontal sections.

IV. vom Rath method

This was used for the unmedullated tracts, particularly in the olfactory bulbs, where two series of transverse sections were made. The method followed is that given by vom Rath ('95). This consists of fixation in the following solution for three days; saturated aqueous solution of picric acid, 200 cc., 10 per cent platinic chloride, 10 cc.; 2 per cent osmic acid, 25 cc.; glacial acetic acid, 2 cc. Next the specimens are placed in methyl alcohol for 15 minutes, 0.5 per cent aqueous solution of pyrogallic acid for two days, dehydrated for two weeks in the dark, cleared in carbol-xylene, embedded in paraffine and sectioned at 5 micra. This method is of particular value in tracing the course of the nervus terminalis.

V. Gold chloride method

This was used to bring out the unmedullated fibers, particularly in the olfactory bulbs; it is not of great value, however, owing to its low penetrating power. The method of fixation in formalin as given in Hardesty's 'Neurological technique,' was followed with the best results. Two series of sections of the bulbs were prepared by this method.

VI. Golgi method

- Individuals two to five centimeters in length.
    - Five series transverse sections.
    - One series frontal sections.
- Individuals twenty-five to forty centimeters in length.
    - Six series transverse sections.
    - One series sagittal sections.
    - Nine series cut in various oblique planes.
    - Fourteen series of the olfactory bulbs cut in various planes.

Two different methods were followed, both of which gave good results. With most of the Golgi material the fish were killed, the brains removed and placed for three to five days in a mixture of two parts of 3 per cent aqueous solution of potassium dichromate and one part of 1 per cent aqueous solution of osmic acid. Next they were rinsed in a $\frac{3}{4}$ per cent solution of silver nitrate in which they may remain indefinitely but are ready for dehydration and embedding in celloidin after two to four days. The second method was used for brains fixed in 4 per cent formaldehyde.

After fixation for forty-eight hours the brains were washed in running water for twenty-four hours and then placed in a 3 per cent aqueous solution of potassium dichromate at a temperature of 40° C. for six to ten days. They were next placed in the osmium-dichromate mixture and treated as outlined for the first method. In addition to the series noted above, Professor Herrick very kindly loaned me ten series of the brains of young carp cut in various oblique planes. The Golgi method was used chiefly for the study of the different neurones and the course, with particular reference to the direction, of the fiber tracts.

VII. Ramón y Cajal method

Two series transverse sections.
Three series frontal sections.
Five series sagittal sections, two of these partly oblique.

Some difficulty was experienced in getting good preparations, the following method giving the best results. Whole brains are fixed in 95 per cent ethyl alcohol, washed for two hours in running water, placed in a 1 per cent aqueous solution of silver nitrate at a temperature of 35° C. for three to five days, washed in distilled water, transferred to a 1 per cent aqueous solution of hydroquinone for twenty-four hours, washed in running water for twenty-four hours, dehydrated, cleared in cedar oil, mounted in paraffine and cut at ten to fifteen micra. Fixation in neutral or acid formalin gave poor results.

II. ANATOMY

The names applied to the different fiber tracts and cell areas have, so far as is consistent with their morphology, been taken from the literature. In a few cases such terms have been used in a sense slightly different from that assigned them by the original authors; whenever such is the case the fact has been noted. In several cases inappropriate terms of long use have been retained owing to their familiarity and common use. Where, however, a term is lacking in the literature, or where a previously used term is greatly at variance with the morphology, a new name has been selected. In this case the endeavor has been, as far as possible, to make such new name descriptive of the relationships involved, or else suggestive of a homologous structure in the nervous anatomy of higher forms. In the case of fiber tracts the customary methods of neurological nomenclature have been followed, viz., the application of a term which will include in itself full information as to the origin and termination of the fibers as well as their direction; as for example, the tractus intermedio-habenularis, originating in the nucleus intermedius and terminating in the habenula.

1. PERIPHERAL OLFACTORY APPARATUS

a. The olfactory capsules

The olfactory apparatus in the carp consists of the olfactory capsules with their lamellae, open to the exterior through two apertures; the olfactory nerves, bulbs, crura, centers in the cerebral hemispheres, epithalamus, medithalamus and hypothalamus, to which may be added the motor connections common to the olfactory and gustatory senses, etc. These latter will not be considered in this article.

Gross morphology. The two external apertures of the capsules are in close proximity, one rostro-medial of the other. They are separated by a grooved flap of skin so shaped that in forward movement water will be driven into the more rostral aperture. The lateral aperture opens caudally for the exit of water from the cup. Inside the capsule, and running caudo-laterally from the rostro-medial aperture, is a median ridge from which the lamellae radiate on either side and at its caudo-lateral end.

Microscopic anatomy. The lamellae are covered by the epithelium of the olfactory mucous membrane, consisting of the typical nervous olfactory cells, and the supporting cells. Goblet cells are particularly numerous in the epithelium of the central ridge, which is also slightly thicker than that of the lamellae (fig. 5). It resembles closely the respiratory epithelium of the Schneiderian membrane of mammals, as distinguished from the olfactory portion. It is probable, therefore, that there are found here two varieties of epithelium, similar to the condition in higher forms; an olfactory, concerned with smell and a respiratory, concerned, in this case, with the water current.

Innervation. From the olfactory cells arises the unmedullated fibers which, passing through the lamellae, form the olfactory nerve. Medullated fibers penetrate the central ridge, ending immediately underneath the epithelium (fig. 5). Such an innervation has been described in no other anamniote (Sheldon, '08 b), although it has long been known that in mammals, particularly in man, such fibers take part in the innervation of the nasal mucous membrane.

In 1903 Rubaschkin demonstrated their presence in birds. Practically all Amphibia and many fishes have been studied with reference to this point, but in no case have medullated fibers been demonstrated beyond doubt, although Aichel in 1895 believed that he found something of the kind in embryo teleosts. In six Weigert series through the olfactory capsules, bulbs and crura of the adult carp it has been possible to demonstrate the presence of medullated fibers in the tunica propria of the Schneiderian membrane, part of which evidently distribute to the epithelium, as they can be traced to the membrana propria itself. These latter probably end in free nerve terminations, as there are no special organs developed. Part of the fibers entering the tunica propria join the bundles of unmedullated fibers and apparently run to the mucous membrane of the lamellae with them. The remainder of the medullated fibers innervate the skin about the nasal capsule.

All of these medullated fibers are derived from the supraorbital trunk, which is made up of general cutaneous fibers from the Gasserian ganglion (nervus ophthalmicus superficialis trigemini) and sensory fibers from the facial (nervus ophthalmicus superficialis facialis). This latter nerve is composed partly of fibers from the dorsal lateralis ganglion, and partly of visceral sensory fibers from the geniculate ganglion. The fibers entering the tunica propria are certainly not acustico-lateral, since no canal or pit organs are developed in connection with the epithelium; the fibers are also smaller than are the lateralis fibers. They may, therefore, be either general cutaneous or visceral sensory, with the preponderance of evidence in favor of the former. This is due, in part, to the fact that in birds and mammals such innervation is trigeminal and partly because the weight of evidence in the teleosts is against the supposition that visceral sensory fibers are present in this region. Part of the branch entering the tunica propria goes to the skin, as already noted; the number of general cutaneous fibers in the supra-orbital trunk is much greater than the number of visceral sensory. If there are visceral sensory fibers going to the mucous membrane, they must be unspecialized, as there are no taste buds present; there is not the slightest evidence, however, that such fibers are here present. In their course from the supra-orbital trunk to the tunica propria the medullated fibers pass partly between the two bundles of the olfactory nerve and partly directly laterad into the median ridge.

Young gold fish and cod were studied with reference to the presence of medullated fibers in the mucous membrane, but none could be demonstrated. This may have been due, particularly, in the case of the gold fish, to the fact that the individuals were immature, as such fibers could not be found in young carp.

As the main current of water would be forced along the ridge thus innervated by general cutaneous fibers, it is probable that their function is that of tactile response for solid substances in the water or else with respect to the strength of the water current or both (see also Kappers, with respect to the 'Oralsinn,' and Sheldon, '09 b, on 'Chemical Sense').

b. The olfactory nerve

The olfactory fibers gather from the different lamellae in two main bundles. In general, the medial bundle is derived from the more rostral lamellae, while the lateral is derived from the more caudal. The fibers of the two bundles distribute to all parts of the rostral and lateral surfaces of each bulb, the lateral bundle causing a protuberance on the dorso-lateral surface of each bulb as shown in figs. 1, 6 (*a*). There is a quite general crossing of the fibers of the two bundles before they reach the bulb so that fibers from each reach all parts of the bulb (fig. 123). Apparently, however, the lateral bundle is more especially associated with the tractus olfactorius lateralis and to a somewhat less extent with the tractus olfactorius ascendens, while the medial bundle is most closely associated with the tractus olfactorius medialis. The olfactory bulb is closely applied to the caudo-mesal face of the capsule so that the nerve itself is very short, although individual fibers may be of some length.

c. Ganglion of the nervus terminalis

Lying between the two bundles of the olfactory nerve from the lamellae to the bulb are a number of large scattered ganglion cells forming the ganglion of the nervus terminalis. In the adult carp these cells are most numerous near the bulb and are apparently about a hundred in number. This is less than is the case in Amia as described by Brookover ('08, '10). Neurites from these cells run mesad to form a bundle of fibers on the mesal aspect of each bulb (figs. 7, 123, 124).

2. THE TELENCEPHALON

a. Olfactory bulb and crus

The olfactory bulb is ellipsoid in shape, about 1.5 mm. long and 1 mm. thick, in a 40 cm. carp. Rostrally and laterally it is covered by a mass of olfactory nerve fibers as noted above. At the rostral end of the bulb a circular constriction appears externally, separating the bulb proper from the olfactory nerve proper, which rostro-lateral to the constriction spreads out over the olfactory capsule. Caudally the bulb tapers down to the small, elongated crus on which it is borne in the cyprinoids. This is from three to four centimeters long in a 40 cm. carp, extending from the bulbs to the cerebral hemisphere (fig. 1). In young fry the bulbs are closely apposed to the hemispheres; but since the cranium grows faster than the brain as a whole, the crura elongate. Each crus is a hollow tube, the base of which is formed by the tracts connecting the bulb and hemisphere (figs. 2, 22, 23). Dorsally is an epithelial roof, a rhinotela, which is simply a rostral prolongation of the tela, or so-called pallium of the hemispheres, consisting of a layer of ependyma and one of pia. This covering arches over the solid base of the crus at its caudal end as shown in fig. 23, gradually decreasing in extent rostrad (fig. 22) until it forms only a roof for the trough-like cavity below. This cavity is morphologically a part of the ventricle of the hemispheres, extending, even a short distance into each bulb, as is the case with most vertebrates (Wiedersheim, '02).

Internal to the layer of olfactory nerve fibers occurs the formatio bulbaris, formed chiefly by the glomeruli. The glomeruli are of the usual type, consisting of the terminal end-brush of olfactory nerve fibers, mingled with the dendrites of mitral cells, chiefly. The central and mesal portion of the bulb is made up of a mass of cells, the nucleus olfactorius anterior, the lobus olfactorius anterior of Goldstein.

According to Golgi preparations, neurones of several different types are found in the olfactory bulb. The most conspicuous are the large cells with short, thick, many branched dendrites, the mitral cells (figs. 8 to 12). These are irregular in form and are situated largely in the peripheral portion of the bulb, with their long axes approximately parallel with the surface as figured by Johnston, Catois, etc. The mitral cells are very irregular in form; pyramidal, stellate and goblet shapes being the most numerous. The dendrites of these cells, as already mentioned, break up in the glomeruli and there come into relation with the terminals of the olfactory nerve fibers. Their neurites form the majority of the centripetal fibers of the tractus olfactorius lateralis and tractus olfactorius medialis. A dendrite of a mitral cell will often enter, also, into relation with one of the cells of the nucleus olfactorius anterior, usually a fusiform or stellate cell. The smaller cells of the bulb are more nearly central in position and make up most of the nucleus olfactorius anterior. Fusiform and stellate cells are the most numerous of these, with occasionally a pyramidal or goblet-shaped cell (figs. 13 to 20). The stellate cells, particularly of the types shown in figs. 14 and 17, are the most common, and are situated near the center of the bulb, with their many processes extending fan shaped toward the periphery, where many of them enter glomeruli (Johnston, '98, fig. 1). Other processes of these cells enter into relation with other cells of the nucleus olfactorius anterior. It is certain that a few of the stellate cells send their neurites into the hemispheres, but such could not be demonstrated with certainty for all. Many fusiform cells of the type shown in fig. 13 lie near the center of the bulb with two processes extending to either margin. These cells likewise send their neurites to the hemispheres (fig. 21). Cells of the types shown in figs. 15, 16, 18, 20 may be found in any part of the nucleus olfactorius anterior, with their processes extending nearly equally in all directions. Small granule cells, of the type shown in fig. 19, are common in the center of the bulb, where they apparently function as association cells, as no neurites entering the crura could be demonstrated. The mitral cells undoubtedly correspond with the mitral cells of all other vetebrates, so far as studied; there is some question, however, regarding the comparative morphology of the smaller cells throughout the vertebrate series. Apparently, as is shown also by Johnston, the stellate cells in lower vertebrates are connected with the glomeruli and hemispheres, much as are the mitral cells; as an ascent is made in phylogeny, however, these cells may either disappear or may metamorphose into mitral cells. The typical stellate cells of the carp as shown in figs. 14, 17, are undoubtedly similar to the stellate cells of the granular zone of Acipenser, as described by Johnston; there is the same relation to the glomeruli, the position in the bulb is the same, and the central processes take the same course. Fusiform cells of the type shown in fig. 13 are probably the homologues of Johnston's spindle cells of the granular zone, although no neurites were traced from these cells into the crura. The type found in figs. 15 and 20 probably corresponds to Johnston's cells with short neurites, Golgi type II cells. Cells of Cajal were not identified with certainty. The granule cells of the carp are apparently simply intrinsic association nerve cells, differing, therefore, from the granule cells of Acipenser.

The fiber tracts of the olfactory bulb will be taken up later, in connection with the fiber systems of the cerebral hemispheres.

b. The cerebral hemispheres

(*1*) *Gross morphology.* The cerebral hemispheres are of the typical teleostean type (figs. 1 to 4). They consist of paired solid basal lobes which contain chiefly the secondary olfactory centers, continuing caudo-ventrally over the optic chiasma as the pedunculi thalami, or praethalamus of C. L. Herrick. Dorsally and laterally, these are covered by a membranous roof, the so-called pallium, composed of adjacent layers of ependyma and pia. This tela is continuous rostrally with the membranous roof of each olfactory crus, the separation into two parts occurring just at the rostral margin of the basal lobes. This tela is attached at the ventro-lateral margin of each hemisphere, at which point its pia becomes continuous with that of the base of the brain, while its ependyma is reflected over the basal lobes (figs. 1, 2, 3, 4, 34). Immediately mesal to the attachment of the tela occurs a fissure, the fissura endorhinalis (figs. 4, 24, 25, etc.). This is the sinus rhinalis of Kappers ('06), the fovea endorhinalis externa of Kappers and Theunissen ('08), the fovea limbica of Goldstein and Edinger, the fissura ectorhinalis of Owen ('68), the fissura endorhinalis of many authors. This fissure holds a constant position throughout the vertebrate series, separating in the higher forms the basal olfactory centers from the pyriform lobe; it likewise bears a constant relation to the tractus olfactorius lateralis, as will be noted later.

The ventricle of the forebrain consists of the open space between the tela and the basal lobes. This forms a large, but shallow cavity, excepting between the two basal lobes where it is of some depth (figs. 24, 34, 35, etc.). It extends caudally to the velum transversum. Caudal to this velum, occurs a much convoluted epithelial sac extending rostrally over the tela proper; this is the dorsal sac, and is an evagination of the membranous wall of the diencephalon (fig. 68). Ventral to the velum transversum, the forebrain ventricle passes over into the third ventricle or diencephalic cavity.

Each basal lobe is separated by ependymal sulci on the dorsal, lateral and mesal surfaces into regions with characteristic internal structure and fiber connections (figs. 2 and 3). The deepest of these is the sulcus ypsiliformis, which arises from the ventrolateral border about three-fourths of the distance back from the rostral pole of the basal lobe, ascends to the dorsal surface and here divides into an anterior and a posterior limb, which enclose a central eminence. This eminence contains the palaeostriatum and the primordium hippocampi, the latter covering the dorsal surface of the palaeostriatum, especially on its mesal border. The posterior limb separates the posterior pole from the rest of the hemisphere; the anterior limb separates the central eminence from the tuberculum anterius and the tuberculum laterale, these comprising a part of the nucleus olfactorius lateralis. The remainder of the lateral olfactory nucleus is the nucleus pyriformis of the posterior pole.

The anterior limb of the sulcus ypsiliformis corresponds fairly closely with the sulcus palaeopallio-epistriaticus of Thynnus and the fovea endorhinalis interna of Amia, as described by Kappers and Theunissen ('08).

On the mesal aspect of each basal lobe, extending for almost the whole length of the lobe is a well defined sulcus of great morphological importance which has been ignored by other writers on the brains of fishes. It forms the dorsal boundary of the precommissural body and has some points of resemblance with the fissura limitans hippocampi (C. Judson Herrick, '10) in Amphibia and Reptilia, the fovea septocorticalis (Kappers and Theunissen) in Rana, and the fissura arcuata of Gaupp, with which, however, it is not fully homologous, as will appear beyond. It will be designated sulcus limitans telencephali.

Ventrally of this furrow lies the corpus precommissurale, termed the epistriatum by Kappers ('06), the lobus olfactorius posterior, pars medialis, by Goldstein, etc.

An examination of fig. 4 shows that the fissura endorhinalis on the ventral surface of the hemispheres forms an open V. It first appears rostrally at the point where the olfactory tract joins the hemispheres (fig. 24), gradually extending laterally until the base of the sulcus ypsiliformis is reached, whence it turns medially again. For the whole of its extent the tractus olfactorius lateralis lies immediately dorsal, giving off fibers to the nucleus olfactorius lateralis and nucleus pyriformis. Lateral to the caudal end of the fissura endorhinalis lies the nucleus teniae of Edinger, Kappers and Goldstein.

(2) *Nuclei.* The basal lobes are entirely separate, excepting ventrally, where they are joined by the lamina terminalis, which runs rostrally from the region of the optic chiasma. At a point approximately two-thirds distant from the rostral margin of the hemispheres, there lies embedded in the lamina terminalis, the large anterior commissure, connecting both lobes (figs. 34 to 61). Rostrally, the lobes overhang the olfactory tracts for a short distance (fig. 24), while caudally the hemispheres, spreading laterally over the optic tracts, are partly covered by the optic lobes (fig. 76).

The basal lobes contain, in teleosts, the secondary olfactory centers, one or more tertiary centers and the so-called corpus striatum, here designated the palaeostriatum. In the carp this receives, throughout most of its extent, secondary olfactory fibers.

(a) Corpus precommissurale. Extending from the rostral end of the hemispheres caudally into the diencephalon is a column of cells, bordering the medial cavity on either side. Its dorsal limit is indicated by the sulcus limitans telencephali and it is bounded laterally, throughout most of its more caudal portion, by the palaeostriatum.

This is the corpus precommissurale; the area olfactoria posterior medialis and epistriatum of Kappers, '06, but not of Kappers, '08, where this name is applied to the primordium hippocampi; the lobus olfactorius posterior, pars medialis of Goldstein; 'vordere nucleus,' partly, of Bela Haller. At the rostral end of the hemisphere this nucleus is largely ventral (fig. 25); toward the anterior commissure, however, it increases in dorso-ventral extent covering practically all the mesal surface of each hemisphere (fig. 35). The interposition of the fibers of the commissure separates the nucleus into two parts, a dorsal passing above the commissure, and a ventral composed of cells lying between its fiber systems (figs. 35, 36, 38, 55, 56, 61). Caudally of the anterior commissure, these two divisions of the nucleus remain distinct, one continuing ventrally, close to the median cavity, while the other remains dorsal, meeting the lateral olfactory area in the polus posterior of the hemisphere, and then continuing caudally under the habenula. This forking column of cells is, as will be brought out more clearly later, the morphological equivalent of the precommissural body or paraterminal body of Elliot Smith in mammals and reptiles, and is, therefore, here termed the corpus precommissurale. The rostral portion of the nucleus corresponds morphologically to the rostral part of the ganglion mediale septi of Gaupp, or the area precommissuralis septi of Kappers and Theunissen in the frog, and is called, therefore the nucleus medianus (fig. 25).

The portion of the nucleus extending into the commissure is simply the bed of the anterior commissure of Elliot Smith in reptiles and mammals and is called, therefore, the pars commissuralis. The arm of the precommissural body arching over the commissure presents points of resemblance to the pars fimbrialis septi of Kappers and Theunissen in the frog. It is here called the pars supracommissuralis (figs. 35, 36, 38, 55, 56, 61). Its extension caudad behind the commissure joining the lateral olfactory area is named the pars intermedia (figs. 66, 67, 68, 70). The commissure bed passes immediately caudad into a nucleus of small cells, bordering the ventricle, which is here termed the nucleus preopticus (figs. 61, 66, 67, 68, 70, 73, 76, etc.). This is composed of several different cell groups which will be taken up in greater detail later.

All parts of the corpus precommissurale appear very discrete in toluidin blue preparations. In the nucleus medianus, the cells are closely packed, but are arranged in groups or islands (figs. 25, 26). (See Calleja, '93.) Usually a clear zone of few cells surrounds the precommissural body particularly dorsally and laterally (fig. 38). In the pars supracommissuralis the cells are less closely packed (figs. 38, 46, 56), and have lost the island arrangement. The grouping in the pars commissuralis, is largely dependent on the position of the fiber bundles of the anterior commissure; the cells are, however, fairly evenly distributed (figs. 38, 56).

In the rostral part of the commissure bed is found the group of cells in which terminate the fibers of the nervus terminalis. The pars intermedia of the corpus precommissurale consists of a narrow column of cells, fairly closely packed and forming a distinct band across the ventral portion of the posterior pole of the hemisphere (figs. 66, 67, 68, 70). Its morphological relationships are obscure.

In Golgi preparations of different parts of the precommissural body some of the cellular relations are brought out more fully. In the nucleus medianus the cells are fairly large, fusiform, pyramidal or ellipsoid in shape, with almost all of their processes coming from the ends of the perikaryon as shown in figs. 28 to 31. A large proportion of these cells give rise to the fibers of the tractus olfactorius ascendens. The neurites are very delicate, possessing granular enlargements along their course. Smaller cells with a number of short, root-like dendrites and a single long neurite extending into the palaeostriatum, are not uncommon (fig. 43). Several varieties of small cells, apparently functioning as association cells, are found also in the nucleus medianus; these are chiefly stellate, or irregularly rounded (figs. 41, 42). In the pars supracommissuralis the cells are smaller; also rather more of the association cells of the type shown in figs. 41, 42 are found. Cells of type shown in fig. 43, sending fibers to the palaeostriatum, are more common than in the nucleus medianus. Many of the cells of this nucleus send their neurites into the tractus olfacto-thalamicus medialis. Such a cell is shown in fig. 40. Small stellate and small pyramidal cells are rather more common than the type illustrated.

(b) Primordium hippocampi. Dorsad of the sulcus limitans telencephali, appearing with especial distinctness rostrally, lies the primordium hippocampi, or nucleus olfactorius dorsalis. Between it and the corpus precommissurale may be seen a slight clear area, devoid of cells. The cells of the primordium hippocampi are rostrally slightly smaller than those of the nucleus medianus, while dorsal to the pars supracommissuralis they are very similar to those of the latter nucleus (fig. 46). Many of them resemble the dorsal cells of the nucleus olfactorius lateralis (figs.

48, 49, 56). The primordium hippocampi receives secondary olfactory fibers from the tractus olfactorius medialis and a few commissural fibers associated with the commissura corporium precommissuralium. The neurites of its cells descend partly with the tractus strio-thalamicus and partly with the tractus olfacto-thalamicus medialis, pars dorsalis. No tertiary olfactory fibers could be traced, in Golgi preparations, either from the lobus pyriformis or the corpus precommissurale to the primordium hippocampi. In Ramón y Cajal preparations, however, mingled with the fibers of the commissura corporium precommissuralium rostrally are a number of unmedullated fibers connecting the nucleus medianus with the primiordium hippocampi. From the conditions in amphibians, reptiles and mammals it seems extremely probable that these represent the tractus area-hippocampalis rectus of Kappers and constitute an association path between the precommissural body and the primordium hippocampi. The morphology of this region will be considered more in detail further on.

(c) Nucleus olfactorius lateralis. Laterally, extending from the extreme rostral end of each basal lobe to the extremity of the polus posterior, lies the lateral olfactory area; the area olfactoria of Edinger, the lobus olfactorius posterior, pars lateralis of Goldstein, area olfactoria posterior lateralis of Kappers ('06), area olfactoria lateralis of Kappers and Theunssen ('08). The nucleus olfactorius lateralis is here divided into itwo parts, both rostral to the sulcus ypsiliformis, and consisting of rather evenly distributed, somewhat scattered cells. The more rostral appears externally as the tuberculum anterius (figs. 2 and 3), while the more caudal presents superficially the tuberculum laterale. The nucleus olfactorius lateralis covers as a cap the entire rostrolateral surface of each basal lobe. At the extreme rostral pole it is restricted to the lateral aspect but passing caudally it gradually spreads dorsally covering the dorso-lateral aspect of each lobe, at the level of the sulcus ypsiliformis (figs. 25, 38).

The lobus pyriformis, so named since it is closely related to the pyriform lobe of mammals, consists dorsally and caudally, of evenly distributed scattered cells very similar to those of the nucleus olfactorius lateralis (figs. 38, 56, 66, 67). Ventrally, immediately lateral to the fissura endorhinalis, a portion of the nucleus pyriformis is specialized to form the nucleus teniae of Kappers, Goldstein, Edinger, the caudal portion of the hypostriatum of Catois, nucleus occipito-basalis of C. L. Herrick. This is a compact nucleus of rather small cells (fig. 57). Caudally it meets the pars intermedia of the corpus precommissurale, both being covered dorsally by the unspecialized cells of the lobus pyriformis (figs. 38, 56, 66, 67, 70).

In preparations by the Golgi method, this region is plainly marked. Throughout the whole lateral olfactory area, near the periphery of the lobes, one finds cells of the same general type, with fine processes, lightly spiny, and with small sized perikarya (figs. 32, 33, 48, 49, 52, 53). The perikarya vary considerably in shape, flask-shaped cells being most numerous, as shown in figs. 32, 33, from the rostral portion of the lateral area, figs. 48, 49 from the dorso-lateral part. Occasionally, small pyramidal cells of the type shown in fig. 53 may be found. Flask-shaped cells are particularly numerous close to the periphery of each lobe, with the rounded margin of the perikaryon directed toward the periphery and most of the processes arising from the mouth of the flask. A cell of this type is shown in fig. 52. Part of these processes extend laterally along the ventricular margin, while the neurite enters the basal forebrain bundle.

The cells of the nucleus teniae vary somewhat from the general type of the lateral olfactory area neurone but are recognizably similar. Many of the cells, as shown in figs. 59, 60, possess perikarya more nearly ovoid than flask-shaped; the processes are fine and bear inconspicuous spines, however, as do the other cells of the lateral olfactory area. Fig. 58 shows a cell nearly pyramidal in shape.

(d) Palaeostriatum. In the central part of each basal lobe is a region called by practically all writers on the teleostean brain the corpus striatum, here termed the palaeostriatum (figs. 25, 38, 56). It is bounded mesially by the precommissural body, dorsally by the primordium hippocampi and on the other sides by the lateral olfactory nucleus. Practically all parts of it receive olfactory fibers of the second order and it is largely, therefore, a portion of the mesal and lateral olfactory areas. The cells of the central part of this area are very large and conspicuous (fig. 44) and are quite scattered as compared with the cells of other areas of the basal lobes. In series stained by cytological methods, such as toluidin blue or thionin, it is easy to demonstrate that there is a gradual transition from these conspicuous cells to those typical of the lateral olfactory area.

According to the Golgi method, neurones of the central portions of the palaeostriatum appear very large, with comparatively enormous perikarya, and with long, thick, very thorny dendrites (figs. 50, 51). In shape, the perikarya vary from short, flask-shaped to pyramidal (fig. 45).

There is shown in Golgi preparations the same transition between the area olfactoria lateralis and the palaeostriatum, as in toluidin blue or thionin preparations. One may note a gradual change, in passing from the periphery centrally, from the small, flask-shaped cells with rather inconspicuous thorns, to the large cells, with enormous perikarya and thick, thorny processes; moreover, now and then, a cell of the palaeostriatal type will be found close to the periphery, or a small lateral area cell found in the palaeostriatum. A large proportion of the cells of both the lateral olfactory area and the palaeostriatum send their neurites into the basal forebrain bundle, the different parts of which will be taken up later. The neurites of the cells of the nucleus teniae, however, enter the tractus teniae. Many of the cells of these two areas are apparently association cells, functioning not only to bring different parts of the same area, but also adjacent areas, such as lateral olfactory area, palaeostriatum and corpus precommissurale, into relation. Such is apparently the function of some of the cells of the type shown in figs. 50, 51.

The word 'palaeostriatum' is not used in quite the same sense as it is used by Kappers, as will be noted from the preceding discussion. Kappers believes that the palaeostriatum is closely connected with the olfactory apparatus, but receives no somatic sensory connections from the thalamus, which it probably does receive in the teleosts. The term as here used indicates that a structure is found in the teleosts, closely related to the secondary olfactory centers, and morphologically related to a part, at least, of the corpus striatum of higher forms.

(e) Nucleus commissuralis lateralis. Situated in the ventromedial portion of each basal lobe, in the region of the anterior commissure, at either end of the commissure is a small compact nucleus of fairly large, closely packed cells (figs. 38, 56). No references to it in the literature have been noted; it has, therefore, been termed the nucleus commissuralis lateralis, owing to its location, laterally at the level of the anterior commissure.

(f) Nucleus preopticus. Immediately caudal to the anterior commissure there appears ventrally the recessus preopticus of the third ventricle (fig. 56). Surrounding this, on either side, and passing rostrally insensibly into the pars supracommissuralis, is the nucleus preopticus. This nucleus is composed of cells of two types; at the level of the caudal margin of the hemispheres is a dense mass of cells bordering the median ventricle; its cells are some of the largest in the brain (fig. 71), and are flask-shaped with their bases directed toward the ventricle and most of their processes extending laterally and ventro-laterally (figs. 67, 70, 71). This is here termed the pars magnocellularis of the nucleus preopticus. Rostral to this nucleus, continuous with the pars supracommissuralis, is a nucleus of small cells (fig. 64). This group of cells extends caudally, lateral to the pars magnocellularis, gradually curving around it caudally, thus enclosing the nucleus magnocellularis on three sides. In contradistinction to the nucleus magnocellularis this is called the pars parvocellularis of the nucleus preopticus. To the portions rostral, lateral and caudal to the pars magnocellularis are assigned the suffixes, anterior, lateralis and posterior, respectively (figs. 64, 66, 67, 70, 78). This nucleus extends caudally to the region of the fibrae ansulatae.

In Golgi preparations the pars parvocellularis shows cells of several types, resembling closely the various kinds of small cells of the corpus precommissurale.

The nucleus preopticus was recognized by C. L. Herrick in 1892. Herrick saw both the large and small cells and applied the name nidulus praeopticus to the larger portion of the nucleus; it is probable, however, that his nucleus postopticus contains a portion of the cells here included under the name nucleus preopticus. Bela Haller noted the same group of cells and termed it the nucleus posterior of the forebrain. Johnston ('98) and ('01) found a nucleus bordering the recessus preopticus and termed it the nucleus thaeniae owing to the fact that he observed fibers passing from it to the habenula, and that, therefore, it is ('98) "a nucleus corresponding to the nucleus occipito-basalis of (C. L.) Herrick and the nucleus thaeniae of Edinger" in reptiles. This view is untenable as will be pointed out later. Johnston probably recognized the fact, as he terms it nucleus praeopticus in his 'Nervous System' ('06). Kappers noted the large cells and, following Herrick, named the group, nucleus praeopticus. Goldstein, following the descriptions of Edinger for the brains of reptiles and birds, applied the names magnocellularis and parvocellularis strati grisei to the two components of the nucleus.

(g) Nucleus entopeduncularis. Appearing immediately caudal to the nucleus commissuralis lateralis is a group of very small cells (fig. 65), lying embedded in the basal forebrain bundle (figs. 66, 67, 68, 70). This is the nucleus entopeduncularis of Goldstein.

3. THE DIENCEPHALON

a. Rostral limits

The division of the vertebrate brain into transverse segments, with a clear definition of their limits, is a matter of considerable difficulty, particularly since, as Johnston and C. J. Herrick have pointed out, most of the important morphological centers and fiber connections are arranged in longitudinal columns. The question of the caudal boundary of the telencephalon ventrally is still unsettled, some authors considering the pedunculi thalami, caudal to the anterior commissure, part of the diencephalon, others placing the rostral limits of the 'tween-brain behind the optic chiasma in the adult. Dorsally the caudal margin of the velum transversum has long been considered the limit of the forebrain. Johnston recently ('09) has taken up the subject in some detail and his interpretation is here followed; according to which the caudal limits of the forebrain include the velum transversum and the optic chiasma. The pedunculi thalami, the praethalamus of C. L. Herrick, are included in the telencephalon, and their centers have already been described (nucleus preopticus and nucleus entopeduncularis).

Most writers on the brains of fishes have, however, included these structures in the diencephalon; in fact even under the interpretation here followed, the pars parvocellularis posterior of the nucleus preopticus extends into the diencephalon, since it reaches caudally to the level of the fibrae ansulatae.

b. Gross morphology

The diencephalon in the carp is of the typical teleostean type. Immediately caudal to the velum transversum, the diatela is thrown into a convoluted folded epithelial sac, extending rostrally over the membranous pallium of the hemispheres, forming the saccus dorsalis, post-velar arch, or Zirbelpolster (figs. 68, 73). This is an extremely vascular structure, formed by the covering of pia mater and a lining, continuous with the ependyma of the third ventricle. Arising immediately caudal to the saccus dorsalis, with the caudal wall of the one practically adherent to the rostral wall of the other, is the epiphysis or pineal body. This is a small elongated tubular organ extending rostrally, suspended in the folds of the dorsal sac. Its epithelium, while an extension of that of the ependyma, is glandular in type. Lying embedded in the membranous wall between the dorsal sac and the epiphysis, is found the commissura habenularum, or commissura superior. At the caudal base of the epiphysis is found the commissura posterior, between it and the tectum opticum.

The diencephalon is commonly subdivided into epithalamus, hypothalamus and thalamus. The latter has been divided by C. J. Herrick ('10), following Ramón y Cajal, into pars dorsalis (sensory correlation centers) and pars ventralis (motor correlation centers). The epithalamus of the carp is distinct; the other parts are so confused that further embryological study will probably be necessary to effect this separation; and the assignment of the different nuclei and fiber tracts to these regions in this paper must be regarded as provisional, particularly with respect to the centers lying within, and immediately dorsal to, the lateral parts of the inferior lobes.

The inferior lobes consist of an unpaired pars medialis, which is clearly hypothalamic, and paired partes laterales, the lateral lobes, which apparently belong chiefly to the pars ventralis thalami.

The lobi laterales are widely separated rostrally by the interposed lobus medius, while they meet one another caudal to it. Caudally a furrow appears on the ventral aspect of the lateral lobes, the sulcus mammillaris of Goldstein (fig. 4). The prominence of the lobes mesal to the two sulci, is due to the development dorsally of the corpora mammillaria of Goldstein (fig. 117). Laterally, each inferior lobe shows several lobes and sulci, varying somewhat in different individuals. Rostrally the great size of the nucleus prerotundus and nucleus rotundus causes the development of a slight protuberance, appearing on the outside of the lobe (fig. 3). Further caudally the nucleus cerebellaris hypothalami gives rise to a similar enlargement (fig. 3). The lobus medius consists of the tuber cinereum rostrally, and the pars infundibularis caudally.

Extending ventro-rostrally from the tuber is found the hypophysis, consisting of the two conspicuous solid lobes, separated by a circular constriction; a rostral pars glandularis and a caudal pars nervosa. Ventrally these are separated into symmetrical parts by a longitudinal median furrow (fig. 4). Extending caudally from the caudal margin of the pars infundibularis of the lobus medius is a narrow, thin, glandular, membranous sac, the saccus vasculosus, opening into the infundibular cavity (fig. 4).

The median cavity of the forebrain extends caudally and ventrally between the two pedunculi thalami and thalamus proper, giving rise to diverticula which penetrate the lateral lobes. (For a more detailed account of the ventricles of the teleostean inferior lobes see Goldstein ('05), pp. 189–195, figs. 13–19; Edinger ('08), fig. 171.)

(*1*) *Epithalamus.* The epithalamus of the carp is easily defined, consisting of the saccus dorsalis and epiphysis and the habenular centers, including the two habenular ganglia, the habenular decussation, or commissure and the nucleus posthabenularis, together with their connections.

The ganglia habenularum are very conspicuous in the carp, protruding for half their diameter into the median cavity (figs. 78, 81). Their cells are small and evenly distributed but thrown into groups or islands by the fibers of the tractus olfacto-habenularis and the fasciculus retroflexus (figs. 78, 81). As seen in Golgi preparations, the cells are very characteristic, of the type normal throughout the vetebrate series (fig. 75).

Nucleus posthabenularis. Immediately ventral to the habenular ganglia, the cells of the one continuous with the cells of the other, lies the nucleus posthabenularis, 'das posthabenulare Zwischenhirngebiet' of Goldstein, the 'posthabenulare Zwischenhirngegend' of Bela Haller, Meynert's nucleus of reptiles (figs. 78, 81). Rostrally, it becomes continuous with the nucleus intermedius (fig. 70), while caudally it extends beyond the level of the commissura posterior (fig. 84) always holding a position close to the median ventricle and ventral to the fasciculus retroflexus.

(*2*) *Thalamus.* At the level of the habenulae, there appear on either side, immediately ventral to the arch of the tectum, the corpora geniculata lateralia. Mesal to the lateral geniculate body lies the nucleus anterior thalami of Goldstein (figs. 78, 81). This is easily recognized, owing to its large size and its characteristic appearance, showing a ring of cells about its periphery (fig. 81).

Nucleus rotundus and associated centers. One of the most important parts of the thalamus, and at the same time one of the most difficult to understand in all its relations, is the region of the nucleus rotundus. Owing to its prominence, it has been noted by nearly every writer on the teleostean brain. It was described by Fritsch and called by him the nucleus rotundus; Bellonci used the same term, while C. L. Herrick termed it the nucleus ruber. Goldstein assigns the name nucleus ventralis thalami to this whole region, although he shows both in his figures and descriptions that it contains different groups of cells with different characteristics. Kappers ('06) pointed out that the center previously described as nucleus rotundus is really made up of several characteristic groups of cells. That

> situated most dorsally, proximally and laterally, is the *nucleus praerotundus*. This group . . . . gradually passes backward into a much larger group situated under and lateral to the level of the nucleus rotundus and ending where the real nucleus rotundus has its largest size. This latter group, which belongs entirely to the lobi inferiores, I shall distinguish as the *nucleus subrotundus* from the *nucleus rotundus proprius*, as it extends in part under the real nucleus rotundus so that the com. horizontalis, before it enters the lower border of the latter, lies for some distance over it and between it and the nucleus rotundus proprius.

This separation of the nucleus rotundus of the earlier authors into three different components is a matter of considerable morphological importance, as will be brought out later. Kappers' description applies in a general way to the relations in the carp, with some important modifications.

At the level of the rostral margin of the lateral lobes, the nucleus prerotundus appears ventro-laterally immediately ventro-lateral to the commissura transversa (fig. 78). It consists here of a fairly compact mass of irregularly shaped cells of medium size. A short distance further caudally this nucleus lies wedged in between the lateral lobe and the commissura transversa. Dorsolaterally it forms a small protuberance on the lateral surface of the brain (fig. 81). From this point the nucleus prerotundus extends caudo-mesially to the region of the nucleus posterior tuberis. It may be compared in shape to the caudate nucleus in the human brain, with a large and conspicuous head rostrally, gradually diminishing in size caudo-mesally (figs. 84, 89, 103, 106).

The nucleus rotundus proprius is by far the largest and most conspicuous nucleus of the thalamic region. It appears rostrally at about the rostral margin of the commissura posterior and extends caudo-mesally, lateral to the nucleus prerotundus, almost to the commissura ansulata, meeting the corpus mammillare ventro-mesially (figs. 84, 89, 103, 106, 117).

Ventrally of the nucleus rotundus, extending caudo-laterally from the level of the nucleus posterior tuberis, to the level of the caudal margin of the corpus mammillare, lies the nucleus subrotundus (figs. 106, 117).

When the three components of the nucleus are considered together, it is noted that the nucleus prerotundus forms a cap over the rostro-mesal surface of the nucleus rotundus (fig. 84), decreasing in transverse diameter as the latter increases in size (fig. 89). At approximately the level where the nucleus prerotundus ends, the nucleus subrotundus is beginning to appear, embedded in the nucleus rotundus ventro-laterally (fig. 106). Further caudally (fig. 117), since the nucleus rotundus extends caudo-mesally while the nucleus subrotundus extends caudo-laterally, the two come to lie approximately in the same horizontal plane, one lateral to the other, the nucleus rotundus merging into the dorsal margin of the corpus mammillare; the nucleus subrotundus similarly ending in the nucleus cerebellaris hypothalami and losing its typical shape and appearance (see figs. 136–140, for a horizontal projection of these nuclei).

In addition to their conspicuous size, the nuclei rotundi show a characteristic structure, hardly fully brought out in any of the drawings. The nucleus prerotundus throughout most of its extent is composed of rather large scattered cells, together with small numbers of various smaller sized cells (fig. 85) showing faintly between them. Several of the cells from Golgi preparations are shown in figs. 86 to 88. The cells of the nucleus rotundus are smaller and more nearly of the same size. They are always scattered in groups or islands, giving a characteristic appearance to the nucleus (fig. 90). Figs. 91 to 94 show several from Golgi preparations. The nucleus prerotundus and rotundus combined form the 'kleinzellige' portion of the nucleus ventralis thalami of Goldstein. The most easily recognizable of these nuclei is the nucleus subrotundus, owing to its extremely characteristic appearance near its rostral end, or head. There, as shown in figs. 106 and 107, it presents a circular appearance in transection, with its cells grouped in the center and surrounded by a clear peripheral area. The cells average larger than those of the remaining two nuclei and are noticeably so in its caudal part, where they become large, spindle shaped or pyramidal, as the nucleus cerebellaris hypothalami is approached. This nucleus corresponds to the 'grosszellige' portion of the nucleus ventralis thalami of Goldstein. By the Weigert or Ramón y Cajal methods the nucleus prerotundus and rotundus show a peculiar blotched appearance, due to the presence of small bundles of fine fibers scattered between the islands of cells; fig. 102 brings this out fairly well.

Nucleus posterior thalami. Lateral to the nucleus rotundus, at the level of the nucleus posterior tuberis, is a nucleus of very large ganglion cells, the nucleus posterior thalami, the 'Vereinsgebiet' of Bela Haller (figs. 103, 106, 117). This gradually increases in size caudally finally disappearing in the nucleus cerebellaris hypothalami. Its cells are particularly large as shown in fig. 109 from a toluidin blue preparation and figs. 110 to 113 from Golgi preparations.

Nucleus ruber tegmenti. Dorso-mesal to the caudal part of the nucleus posterior thalami, and dorsal to the nucleus subrotundus is a nucleus of extremely large cells, the nucleus ruber tegmenti of Goldstein (fig. 117).

The remaining centers of the thalami are omitted from consideration in this article as they have no special connection with the olfactory apparatus and are not necessary for purposes of orientation. This includes the *nucleus dorsalis of Goldstein*, the *nucleus corticalis of Kappers*, the *nucleus praetectalis*, and *nucleus intermedius of Goldstein.*

(3) Hypothalamus. The hypothalamus consists of the lobus medius and part of the lobi laterales of the inferior lobes (figs. 3, 4), together with their included centers and connections, and the hypophysis. The lobus medius consists rostrally of the tuber cinereum and caudally of the pars infundibularis. Ventro-rostrally, as previously noted, is given off the hypophysis, while extending caudally from the pars infundibularis, is found the saccus vasculosus.

Nucleus anterior tuberis. A single group of cells, the nucleus anterior tuberis, makes up the larger part of the rostral portion of the lobus medius (figs. 81, 84, 89). This is composed of small cells, appearing as a core in the center of the nucleus (figs. 84, 89). Rostrally, the nucleus anterior tuberis is continuous past the fibrae ansulatae, Herrick's commissure, etc., into the nucleus preopticus, pars parvocellularis posterior. Caudally, the nucleus ends at the level of the lateral ventricular diverticula, leading to the lobi laterales (figs. 100,101). See also Edinger ('08), fig. 171; Goldstein ('05), text-fig. 16.

Nucleus posterior tuberis. Dorsad of the diverticula the nucleus anterior tuberis passes caudally into the nucleus posterior tuberis, immediately ventral to the tuberculum posterius (Haubenwulst) (fig. 103). This is a nucleus of small cells, similar in appearance to those of the nucleus anterior tuberis, although its cells are more evenly distributed.

Nucleus ventralis tuberis. Appearing rostrally, immediately ventral to the commissura horizontalis, is a nucleus of enormous cells, not hitherto described in the literature, which is here termed the nucleus ventralis tuberis (fig. 78). It continues for a short distance caudally, lying close underneath the median ventricle and gradually diminishing in size (figs. 81, 84).

Nucleus lateralis tuberis Laterally, appearing immediately caudal to the commissura horizontalis, at the ventro-lateral margin of the nucleus anterior tuberis, occurs a closely packed group of large cells, the nucleus lateralis tuberis (fig. 84). This is found only for a short distance at the level of attachment of the hypophysis.

Nucleus ventricularis. Close to the median ventricle, particularly as far caudal as its diverticula, may be seen a layer of densely packed cells close against the ependyma. Similar cells may be noted adjacent to the median ventricle rostrally, even before the anterior commissure. The same condition holds also for the walls of the lateral diverticula into the lobi laterales. It is noticeable that wherever these cells are found the ependyma consists of higher columnar cells than in other regions. These probably belong to the apparatus, described by Johnston, for the regulation of blood pressure in the brain.

Nucleus diffusus lobi lateralis. Throughout the peripheral portion of the lobi laterales, particularly laterally and ventrally, is an evenly distributed area of small cells, forming the nucleus diffusus lobi lateralis of Goldstein, the substantia grisea lobi inferioris of Kappers, who divides it into a pars anterior and a pars posterior (figs. 78, 81, 84, 89, 103, 106, 117). The cells, as shown in Golgi preparations, possess elliptical or flask-shaped perikarya, with many finely spiny dendrites, resembling somewhat the undifferentiated cells of the area olfactoria lateralis. A number of the cells are shown in figs. 95 to 99. This undifferentiated area is evidently the primitive structure of the lateral lobes from which its nuclei have been gradually evolved. (Compare the condition of ganoids, according to Johnston.)

Nucleus cerebellaris hypothalami. Appearing rostrally, at approximately the middle of the longitudinal extent of the lateral lobes, occurs a nucleus of large evenly distributed, scattered cells, the nucleus cerebellaris hypothalami of Goldstein (fig. 89). This extends caudally and laterally, gradually increasing in size until it occupies a large part of the transverse diameter of each lateral lobe (figs. 89, 103, 106, 117). It extends practially to the caudal part of each lobe, laterally. A small area, under high power, is shown in fig. 108.

Corpus mammillare. The only remaining center of importance in the lobi laterales is the ganglion mammillare of Goldstein. Rostrally and dorsally it meets the tail of the nucleus rotundus; thence it extends caudally, always adjacent to the median wall of the caudal portion of each lobe (fig. 117), practically to the tip of the lobes. It is composed of very small, closely packed, evenly distributed cells of characteristic form (figs. 118, toluidin blue; 119 to 121, Golgi). Where this nucleus comes into contact with the nucleus rotundus the two may be easily distinguished by the difference in the size and arrangement of the cells.

In Weigert preparations the corpus mammillare is easily distinguished, owing to the large number of fine medullated fibers found in it, giving it a finely reticular appearance.

A number of the cell groups here introduced will not be further considered but have been mentioned in order to give an accurate understanding of the relations of the different centers.

4. THE FIBER TRACTS

a. Crural tracts

The olfactory neurones of the first order from the olfactory mucous membrane to the olfactory bulbs and their connections at that point have already been described. The connections between the bulbs and hemispheres will next be considered. It has long been known that the fibers of the olfactory tracts pass between the bulbs and olfactory lobes in two bundles; Bellonci was the first to divide the tracts into a medial and a lateral. C. L. Herrick in 1891 brings out clearly the morphological relations of these two tracts, which he calls the radix lateralis and the radix mesalis. He points out that the radix lateralis passes directly from the bulbs to the caudo-lateral part of each basal lobe, which he terms hippocampus, and that the radix mesalis decussates in the anterior commissure. Edinger ('96) figures a horizontal projection of the basal lobes of the carp, in which he traces the lateral tract, called by him the tractus bulbocorticalis, into a region termed the area olfactoria, while the median olfactory bundle, or tractus bulbo-epistriaticus, ends partly in the epistriatum of the same side, and partly decussates in the anterior commissure. Catois ('01) identifies the same two bundles as 'Le faisceau externe' and 'Le faisceau interne.' Catois is the first to point out that the medial tract consists of both centripetal and centrifugal fibers. He agrees with Edinger that it is partly crossed and partly uncrossed. Bela Haller likewise identifies the two tracts. Goldstein ('05) has worked out the relations of the bundles in more detail than his predecessors, and finds that the lateral tract, 'laterale Riechstrahlung,' originates in the lobus olfactorius anterior and ends, largely uncrossed, in the lobus olfactorius posterior, pars lateralis, while a few fibers decussate in the anterior commissure to end in the same area on the opposite side. The 'mediale Riechstrahlung' is formed, according to Goldstein, entirely from centripetal fibers, which run in several distinct bundles. The more lateral originates in the lobus olfactorius anterior, and decussates in the anterior commissure to end in the lobus olfactorius posterior, pars lateralis, of the opposite side. The remaining two bundles originate from the formatio bulbaris; the more medial forms the commissura olfactoria interbulbaris, while the more lateral ends in the lobus olfactorius posterior, pars medialis, in which are confused the precommissural body and the epistriatum of Edinger. Kappers ('06) observes two different conditions in the teleosts examined by him. The lateral tract, or radix olfactoria lateralis, always ends in the area olfactoria posterior lateralis (area olfactoria of Edinger); in Gadus, Thynnus and Lophius it ends on the same side, however, while in Salmo it decussates in the anterior commissure to end in the opposite side. Kappers also finds that the medial tract is composed of two parts, a medial tractus olfacto-lobaris medialis and a lateral radix olfactoria medialis propria. He finds that both sets of fibers decussate and that most of them end in the area olfactoria posterior medialis, here termed epistriatum, although a few in Salmo may end in the lateral area.

In none of the previous work on these tracts in fishes have all of the connections been brought out. This is undoubtedly due, in part, to the lack of a detailed study of the olfactory bulb and in part to a failure to learn the direction of the different components by the use of the Golgi method.

The olfactory crura in the carp, as previously noted, are very long and in transections at different levels, the apparent number of tracts varies considerably. In some sections only one or two bundles will appear, while in others ten or twelve may be seen. In order to determine the number and relations of these bundles, plots were made of several complete series of serial sections of the crura, showing the number of bundles appearing in each section and their relation to one another. Micrometer measurements were used to determine the relations in all doubtful cases; that is to say, whenever in one section two bundles were found, and in the next section three, measurements were taken if there was any doubt as to which of the two gave rise to the third. In this way, it is possible to determine the number of important fiber bundles in the crura and by tracing them to their origin and termination, learn their relation to the centers of the bulbs and basal lobes. Thus it is shown that instead of a radix medialis and a radix lateralis there are nine distinct fiber bundles running throughout the crura (figs. 123, 124, 22, 23).

(1) Tractus olfactorius lateralis. The lateral tract, the tractus olfactorius lateralis, consists of three bundles, a pars lateralis, pars intermedia and pars medialis. These are composed entirely of centripetal fibers, arising largely from mitral cells of the lateral part of each bulb. A few fibers, however, arise from stellate cells more centrally placed (fig. 124). The tractus olfactorius lateralis, pars lateralis originates, chiefly in this way, from stellate cells of the nucleus olfactorius anterior, a few of its fibers arising, however, from peripheral mitral cells (figs. 124, 137). The tractus olfactorius lateralis, pars intermedia is the largest and most important of the three. Part of its cells of origin lie in the nucleus olfactorius anterior, while the larger proportion are mitral cells from the lateral portion of the bulb rostrally and dorsally (fig. 6). One small bundle of fibers originates from the mesal part of the bulb, crossing dorsally to join the main tractus olfactorius lateralis, pars intermedia (fig. 6). The tractus olfactorius lateralis, pars medialis is small but extends throughout almost the entire length of the bulb, arising partly from mitral cells and partly from stellate cells of the nucleus olfactorius anterior (figs. 6, 124). The fibers of all three portions of the tractus olfactorius lateralis pass through the crura (figs. 22, 23), and gradually spread out above the fissura endorhinalis (figs. 24, 35) to end, without decussating, in the lateral olfactory area of the basal lobes (fig. 137), including all parts of the nucleus pyriformis and nucleus teniae. Fibers end throughout almost the entire length of the area, the fibers ending farthest rostrally arising from the tractus olfactorius lateralis, pars lateralis. All three tracts, however, give off fibers to all parts of the nucleus olfactorius lateralis, rostrally of the sulcus ypsiliformis. A larger proportion of the fibers of all three bundles end farther caudally, however, in the nucleus pyriformis, beyond the sulcus ypsiliformis, and in the nucleus teniae. Golgi preparations show that in all cases the fibers bend abruptly dorsad usually branching at their termination. The termination of the lateral tract in the

basal lobes of the carp is similar, therefore, to its ending in the majority of other teleosts; it has been possible, however, to demonstrate fibers from the tractus olfactorius lateralis in the dorsal and dorso-lateral region of the basal lobes, called by Johnston ('06) the epistriatum. This area is, therefore, simply a part of the lateral olfactory area.

(*2*) *Tractus olfactorius medialis.* The medial olfactory, described by the earlier workers as a single tract, and by the most recent as two, is really composed in the carp of five bundles of widely varying relationships (figs. 22, 23, 124, 136, 137).

Tractus olfactorius ascendens. The tractus olfactorius ascendens described by Kappers, in Salmo, Gadus, etc. (radix olfactoria medialis propria) as a centripetal tract is, in the carp, as shown by Golgi preparations, a centrifugal bundle, originating from cells in the nucleus medianus (figs. 27 to 31). Catois described the more medial portion of the medial tract as centrifugal, but other authors have been unanimous in considering all excepting a few commissural fibers as centripetal. The fibers of the tractus olfactorius ascendens gather from all parts of the nucleus medianus and extend rostrad to the bulb in two bundles which occupy the middle or intermediate portion of the base of each crus (figs. 24, 23, 22). On reaching the olfactory bulb the fibers gradually spread out, and end in the nucleus olfactorius anterior (figs. 124, 136).

Tractus olfactorius medialis. Medially in the bulb and crus is found the tractus olfactorius medialis. This originates almost entirely from mitral cells and contains the neurites from practically all the mitral cells far rostrally in the bulb; it may be traced much farther rostrally than any of the other tracts of the crus. Throughout most of the bulb three bundles, belonging to this tract may be identified (for two of them see fig. 6); near the caudal margin of the bulb, however, these three join to form two, which may be traced separately to their termination in the basal lobes. The two lateral bundles originate almost entirely from cells at the extreme rostral end of the bulb, joining to form the tractus olfactorius medialis, pars lateralis. This can be distinguished from the tractus olfactorius medialis, pars medialis throughout the entire extent of the crura; for a short distance at the rostral end of the basal lobes the two are so closely joined, however, that it is difficult to identify them (figs. 24, 34). As they come into proximity to the anterior commissure they again separate, the tractus olfactorius medialis, pars lateralis holding a position dorsal to its smaller companion tract (fig. 34). From this point caudad it extends slightly laterad until the anterior commissure is reached, when it largely decussates at about the middle of the commissure, to end in the lobus pyriformis of the opposite side (figs. 35, 36, 55, 137). This agrees with the more lateral portion of the 'mediale Riechstrahlung' of Goldstein but differs from the conditions observed by Kappers, excepting for a few fibers in the brain of Salmo. A small number of fibers, however, as shown by Golgi preparations, leave the tract before its decussation to end in the nucleus preopticus (fig. 137) and the primordium hippocampi. The tractus olfactorius medialis, pars medialis originates from mitral cells of the medial surface of the bulb, and extending to the basal lobes, decussates ventral to and slightly rostral to, the tractus olfactorius medialis, pars lateralis (figs. 34, 35, 136). This forms the commissura olfactoria interbulbaris of Goldstein, the commissural fibers connecting the two olfactory bulbs, which have been described by many writers. In Weigert preparations it appears as if these fibers actually form a commissure, but when the crossing is examined in Golgi and Ramón y Cajal material, it is found that a large part of the fibers decussate in the commissure and then end almost immediately, while a few terminate at the commissure, without decussation. Many fibers terminate, also, in the pars anterior of the nucleus medianus, the pars supracommissuralis of the corpus precommissurale and possibly in the primordium hippocampi of the same side. It can not be stated with certainty that no fibers pass around to the opposite bulb; commissural fibers have, therefore, been indicated on the diagram (fig. 124). Kappers, Edinger, Bellonci and others have noted fibers belonging to the medial olfactory tract, and ending in the hypothalamus. Such an appearance is likewise common in Weigert preparations, as the fibers of the tractus olfactorius medialis, pars lateralis appear to continue in the tractus olfacto-thalamicus medialis. Such a condition is deceptive, however, as no such fibers could be demonstrated in Golgi or Ramón y Cajal preparations. It is evident that the Weigert preparations, which fail to show the fine fibers as they approach their termination, are, therefore, unreliable in a study of the origin and termination of tracts, or the relations of two closely associated bundles.

(*3*) *Nervus terminalis.* Earlier a group of ganglion cells belonging to the nervus teminalis was described. As shown in fig. 124 the neurites of these cells pass mesad, lying for a distance between the two bundles of the olfactory nerve, along the mesal surface of the bulb. This has been demonstrated in Golgi preparations. In Weigert and vom Rath preparations, an unmedullated tract, undoubtedly formed by the central processes of these ganglion cells, extends from the same region to the hemispheres (Sheldon, '09, Sheldon and Brookover, '09). Rostrally this tract lies embedded in the tractus olfactorius medialis, pars medialis (fig. 6), on the medial aspect of the bulb. As it passes caudad throughout the crus, it still holds approximately the same position with reference to the tractus olfactorius medialis, pars medialis (figs. 22, 23). When the rostral part of the basal lobe is reached, the nervus terminalis gradually turns dorso-laterad through the tractus olfactorius medialis to lie between that and the tractus olfactorius ascendens (fig. 24). As the anterior commissure is reached, the unmedullated fibers separate from their companion tracts and decussate in the rostral part of the commissure, ending in the rostral portion of the pars commissuralis of the corpus precommissurale, as described for the nervus terminalis of selachians by Locy, and in Amphibia by Herrick (figs. 35, 136).

(*4*) *Distribution of secondary olfactory fibers in the forebrain.* It will have been noted that secondary olfactory fibers end in a very large part of the basal lobes. Fibers of the lateral olfactory tract end throughout the lateral, dorsal and latero-ventral portions of the basal lobes from the rostral end to the lobus pyriformis and nucleus teniae of the polus posterior. These fibers extend, also, into a large part of the central area formerly called striatum. The mesal tract, the tractus medialis, carries centripetal fibers to the nucleus medianus; nucleus supracommissuralis, nucleus preopticus and the primordium hippocampi, probably also to the nucleus commissuralis lateralis (*tr. olf. med.*); in addition to further fibers for the lobus pyriformis. The only portions of the basal lobes which do not receive secondary olfactory fibers are the nucleus entopeduncularis and, possibly, a small area in the center of the palaeostriatum. It can not be said with certainty, however, that this latter area receives no olfactory fibers of the second order; simply that such were not demonstrated.

b. The anterior commissure

The olfactory areas of the two basal lobes are connected by four sets of commissural fibers, crossing in five bundles. In the most rostral part of the anterior commissure are found numbers of fine fibers, partly medullated and partly unmedullated, bending sharply dorsad. The unmedullated fibers connect the mesal portions of the two primordia hippocampi, while the medullated join similar parts of the partes supracommissurales of the corpus precommissurale (Sheldon, '09 a, fig. 6). A short distance caudad, accompanied by unmedullated fibers, is a small commissure of medullated fibers connecting the lateral portions of the partes supracommissurales and nuclei dorsales or primordia hippocampi (figs. 35, 36). This latter bundle, as it presents points of resemblance with the commissura pallii anterior of reptiles, and the rostral portion of the commissura pallii or commissura dorsalis of Amphibia, is termed on the plates, commissura dorsalis. Morphologically, however, the fibers mentioned thus far are divisible into a commissura hippocampi, pars anterior, and a commissura corporium precommissuralium, each bundle consisting partly of each kind of fibers (fig. 138).

At the caudal part of the anterior commissure a few unmedullated fibers pass across to connect the rostral ends of the nuclei preoptici of the two lobes. This is termed the commissura nucleorum preopticorum (fig. 138).

The commissura dorsalis is closely associated with the decussation of the tractus hypothalamo-olfactorius medialis and also with a fourth commissure, entirely unmedullated, connecting the ventral parts of the two nuclei pyriformes, and here termed the commissura hippocampi, pars posterior. Its fibers are closely intermingled with those of the decussating tractus olfactorii mediales, partes laterales, distinguishable in Weigert preparations owing to their lack of medullary sheaths (fig. 138). See also Goldstein, Taf. 11, fig. 7; Goldstein terms this the commissura olfactorii internuclearis. This commissure is shaped like a bow, with either end bent caudally to terminate in the nuclei pyriformes (figs. 36, 37, 55). This is the hippocampal commissure of C. L. Herrick, probably also the commissura interolfactoria of Kappers. This commissure offers points of resemblance with the fibers of the commissura dorsalis, which connect the two occipital poles in the frog and with a part of the commissura pallii of Kappers in the frog.

It will be noticed that the anterior commissure complex contains two bundles connected with the primordium hippocampi, and one with the nucleus pyriformis, all of which are probably represented in the commissura dorsalis, or commissura hippocampi of amphibians. The morphological significance of the regions thus connected will be considered later.

These comprise all of the connections of the basal lobes excepting those bringing them into relation with the diencephalon, together with a few praethalamic connections which will be taken up later.

c. Diencephalic connections

(*1*) *The tractus olfacto-habenularis.* In 1892 Edinger described for selachians a tract between the basal lobes and the ganglia habenularum which he called the tractus ganglii habenulae ad proencephalon, stating, however, the possibility that its fibers might run in the opposite direction. Such a connection was also indicated by C. L. Herrick, in the same year under the name of taenia thalami. All recent writers have observed these fibers, and have shown that they are largely ascending, from the basal lobes to the habenular ganglia of the epithalamus. Catois traces the fibers of his tractus olfacto-habenularis from the caudal part of the hypostriatum (nucleus teniae) to the habenulae; Kappers and Goldstein make similar observations. Johnston, however ('98, '01, '02) in Acipenser and Petromyzon finds that the larger proportion of the fibers ascending to the habenulae arise from the nucleus preopticus, called by him the nucleus thaeniae ('98, '01, '02) and nucleus praeopticus ('06). Some fibers in Acipenser are traced from the nucleus postolfactorius ventralis and nucleus postolfactorius lateralis, corresponding largely to the corpus precommissurale and the area olfactoria lateralis, respectively. It will thus be noted, as Johnston himself pointed out, that the tractus olfacto-habenularis of Acipenser and Petromyzon is not the equivalent of that in teleosts, selachians, amphibians, reptiles and mammals. The conditions as observed in the carp explain this discrepancy, as in this form the tractus olfacto-habenularis is equivalent to both the tractus olfacto-habenularis of Edinger, etc., and of Johnston (figs. 140, 141, 142).

The tractus olfacto-habenularis of Catois, Edinger, Kappers, etc., the taenia thalami of Goldstein, appears conspicuously as a small, heavily medullated bundle, arising from the nucleus teniae, lateral to the fissura endorhinalis, at the level of the caudal margin of the anterior commissure. This is here termed the tractus teniae (fig. 55) and corresponds morphologically to the tractus cortico-habenularis lateralis of C. Judson Herrick in the Amphibia ('10).

It extends latero-caudad, dorsal to the bundles of the basal forebrain bundle (figs. 61, 68), where it receives a few unmedullated fibers from the nucleus intermedius, the tractus intermedio-habenularis, pars anterior (figs. 140, 141, 142), possibly homologous to the tr. septo-habenularis of Herrick. Slightly caudal to this point the tract receives a small number of unmedullated fibers from the nucleus entopeduncularis, extending dorsad from the praethalamus. This is termed the tractus entopedunculo-habenularis (fig. 72), and is probably the morphological equivalent of the lateral praethalamic portion of the taenia thalami of amphibians and reptiles. A large part of these fibers may be descending, corresponding to the tr. habenulo-thalamicus of Herrick ('10). Quite a number of fine unmedullated fibers arise from the nucleus preopticus, pars parvocellularis anterior, to join the main tract (figs. 73, 141, 142), termed the tractus preoptico-habenularis, pars anterior. Where the nucleus intermedius becomes continuous with the nucleus posthabenularis, it gives off a few unmedullated fibers to the tractus olfacto-habenularis, the tractus intermedio-habenularis, pars posterior (figs. 141, 142). The pars magnocellularis gives rise to two sets of fibers for the habenulae, both unmedullated, a diffuse fiber connection extending dorsad, close to the median ventricle, the tractus preoptico-habenularis, pars medialis (fig. 73), and a small compact tract, which passes lateral to the basal forebrain bundle, the tractus preoptico-habenularis, pars lateralis (figs. 74, 141, 142). Further caudally tracts join the main bundle from the pars parvocellularis, pars posterior, of the nucleus preopticus, the tractus preoptico-habenularis, pars posterior; and from the nucleus posthabenularis, the tractus posthabenulo-habenularis (figs. 141, 142). Part of this may also be descending and, therefore, homologous with the tractus habenulo-thalamicus of Herrick.

All of these fibers make up the tractus olfacto-habenularis. It will be noted that the only medullated bundle is the tractus teniae; this is likewise the most conspicuous of the different fiber systems which probably explains why it is the only one previously described in teleosts. The habenular ganglia, then, receive fibers from practically all parts of the caudal portions of both the lateral and medial olfactory columns. Laterally, fibers pass up from the nucleus teniae of the lobus pyriformis, medially from the nucleus preopticus, nucleus intermedius, nucleus entopeduncularis and nucleus posthabenularis. The lateral connection is the one observed by Edinger, Catois, Kappers, Goldstein, etc., while the medial is that found chiefly in Acipenser and Petromyzon by Johnston. Apparently the largest bundle in Petromyzon corresponds with the tractus preoptico-habenularis, pars lateralis, in the carp.

Practically all of the fibers of the tractus olfacto-habenularis decussate in the commissura habenularis, the commissura superior of many writers (figs. 76, 141, 142). It is possible that a few fibers end on the same side. It is likewise possible that there are a few commissural fibers connecting the two nuclei teniarum, taking this course, and running in the tractus teniae (Edinger ('08) fig. 231), as in the Amphibia. Such fibers would be comparable with the commissura pallii posterior (commissura aberrans) of lizards.

Several different fiber systems arising from cells in the habenular ganglia have been described. As indicated above, Edinger, in his earlier work, believed that the tractus teniae arose in the habenulae, the tractus ad proencephalon. He also describes in selachians a tract to the midbrain roof, the tractus ganglia habenulae ad mesocephalon dorsalis; a tract to the midbrain base, the tractus descendens ganglii habenulae, in addition to the long known Meynert's bundle, or fasciculus retroflexus, more recently described by Goldstein, Edinger, etc. under the name 'tractus habenulo-interpeduncularis.' Bela Haller observed fibers arising in the habenulae and entering the optic apparatus, 'Habenularwurzel des Opticus;' also a tract extending ventrad into the diencephalon, 'Hauben-Zwischenhirnbahn.'

(*2*) *Fasciculus retroflexus.* The fasciculus retroflexus in the carp is a strong, chiefly unmedullated tract, originating partly from cells of the habenulae (fig. 75) and partly from the nucleus posthabenularis, as pointed out earlier by Bela Haller and Goldstein (figs. 141, 142). From this point it extends caudad to the corpus interpedunculare, as described by practically all writers on the habenular connections (figs. 77, 79, 80, 82, 83, 100, 101, 102, 114, 115, 116, 122). As noted by Goldstein, it is surrounded by medullated fibers caudally. These originate from the nucleus posthabenularis and pass caudad to the commissura ansulata, which they appear to enter, turning laterad. Goldstein simply figures these fibers, giving no description of their connections.

(*3*) *Tractus habenulo-diencephalicus.* This tract arises in the habenulae and, descending into the more ventral diencephalic regions, is easily identified in the carp, as it is heavily myelinated. Haller traces it into the nucleus posthabenularis, while Goldstein thinks that it ends farther ventrally, possibly in his nucleus dorsalis. The tract, according to the conditions in the carp, contains both ascending and descending fibers and extends ventrocaudad from the habenular ganglia practically to the nucleus posterior tuberis. (Tractus habenulo-diencephalicus, figs. 77, 79, 80, 82, 83, 100, 101.) Excepting its most rostral part, it is closely associated with the medial forebrain bundle dorsally, which probably accounts for the rarity with which it has been reported. Apparently most of its fibers decussate in the habenular commissure, but such could not be demonstrated with certainty.

The tractus habenulae ad prosencephalon of Goldstein, the tractus ad proencephalon of Edinger, was not identified. Of course, it is quite possible that some of the fibers of the tractus olfacto-habenularis are ascending, as Goldstein believes.

No optic connections with the habenulae could be found, as Bela Haller describes. Large numbers of cells lying in the nucleus posthabenularis, particularly near the median ventricle, give rise, however, to fibers which pass directly laterad to enter, apparently, the optic apparatus as Haller notes (figs. 76, 77, 79, 83). These require further study. Considering the intimate relation between the nucleus posthabenularis and the ganglia habenularum, an optic connection, such as Haller describes, not improbably exists in some forms.

(*4*) *Posthabenular-preoptic connections.* In addition to the connections already described with the fasciculus retroflexus and the optic apparatus, the nucleus posthabenularis is placed in relation with the nucleus preopticus through three sets of diffuse unmedullated fibers, a tractus preoptico-posthabenularis, pars anterior from the nucleus magnocellularis to the nucleus posthabenularis; a tractus preoptico-posthabenularis, pars posterior from the nucleus parvocellularis posterior, and the tractus posthabenulo-preopticus from the nucleus posthabenularis to the nucleus parvocellularis posterior (fig. 140).

It is evident from its position and connections that the nucleus posthabenularis is closely related with the habenulae. The two are evidently a morphological entity, the habenular ganglia developing as specialized portions of the dorsal lamina of the thalamus.

(*5*) *Epiphyseal fibers.* Along the caudal wall of the epiphysis runs a small medullated bundle, which extends caudad to the posterior commissure. It is possible that it gives off fibers to the habenular ganglia as it passes them, but such could not be demonstrated with certainty.

(*6*) *Fasciculus medialis hemisphaerii.* This was observed first by Bellonci in Anguilla, and by him considered to be an olfactory tract of the second order from the olfactory bulbs to the nuclei rotundi. The question of the presence of such fibers in the carp has already been discussed. Edinger similarly traced a part of the fibers of the medial olfactory tract to the diencephalon, the tractus ad lobum inferiorem. C. L. Herrick identified the tract, but states that it originates in the mesaxial lobe (nucleus medianus and nucleus supracommissuralis of the corpus precommissurale), decussates as the axial commissure (anterior commissure), and then extends to the infundibulum. Herrick calls the rostral end the 'basal cerebral fasciculus,' while the diencephalic part he terms the fornix tract. Johnston ('98) describes the bundle as the tractus strio-thalamicus ventralis, passing caudad, without decussation, to end in the inferior lobes. In 1901 he points out that these fibers are largely descending, originating chiefly from the nucleus postolfactorius ventralis and to a less extent from the nucleus preopticus. It also contains ascending fibers from the corpus mammillare, most of which decussate in the anterior commissure to end in the epistriatum of the opposite side. Kappers describes the bundle in the teleosts as originating in his epistriatum (corpus precommissurale) and ending uncrossed immediately lateral to the nucleus rotundus. Goldstein gives the same origin for the fibers, but states that they decussate in the nucleus posterior tuberis. He notes also that the tract consists of more than one bundle, but fails to observe any difference in the connections of the different components.

A careful study of this tract in the carp shows that, instead of being a simple, single tract, it is really a complex of six fiber bundles each with a distinct course and connections. It likewise becomes apparent that Kappers, Goldstein, Johnston, etc., observed only a part of these components, which accounts for the differences in the course and connections of the tract as described by them.

The medial forebrain bundle first appears rostrally at the level of the anterior commissure, on either side of the mid-line. Immediately dorsal to the commissural fibers appears the tractus hypothalamo-olfactorius medialis, made up largely of fine, medullated fibers, between which are found many unmedullated in character (fig. 37). All of the fibers of this bundle are ascending, originating in the nucleus posterior tuberis (figs. 102, 104). Part of them decussate almost immediately, as shown in fig. 102, while the majority pass up on the same side to decussate in the anterior commissure, closely associated with the fibers of the commissura hippocampi, pars posterior and commissura dorsalis. Both sets of fibers terminate in the corpus precommissurale, largely in the pars supracommissuralis. This tract is that observed by Goldstein caudally, and called by him a descending tract.

Ventral to the fibers of the anterior commissure, at its level, may be seen another component of the median forebrain bundle, the tractus olfacto-thalamicus, pars ventralis (figs. 36, 37). The fibers making up this bundle appear very similar to those of the tractus hypothalamo-olfactorius medialis. They originate from the corpus precommissurale, largely in the pars supracommissuralis, and run caudo-ventrad, in a diffuse bundle, to terminate in the nucleus rotundus and the nucleus posterior thalami.

At the caudal margin of the anterior commissure a third component, the tractus olfacto-thalamicus, pars dorsalis, appears. This is a rather diffuse bundle, made up of fine medullated and intermingled unmedullated fibers, which originate largely in the supracommissural part of the precommissural body and terminate in the nucleus subrotundus. This bundle, together with the pars ventralis, was noted by Goldstein, rostrally (Taf. 11, fig. 7). He points out that one passes dorsal and one ventral to the tractus olfactorius medialis, pars lateralis, and that both originate in the medial olfactory nucleus. Apparently, however, he failed to follow all the fibers caudad, as in the more caudal region he observed only the tractus hypothalamo-olfactorius medialis, which tract he had not seen farther rostrally. The two parts of the tractus olfacto-thalamicus form the tractus olfacto-hypothalamicus medialis of Kappers, who failed to note the bundle from the nucleus posterior tuberis.

A short distance caudal to the anterior commissure, the medial forebrain bundle has increased largely in size (figs. 68, 69), due to the presence of a large number of short fibers, most of which are unmedullated. These are present throughout most of the extent of tract and are both ascending and descending, connecting and placing in relation the different parts of the precommissural body, nucleus preopticus and diencephalon. These fibers form the tractus olfacto-thalamicus, pars intermedia and tractus thalamo-olfactorius, pars intermedia (fig. 136).

Another factor in the increase in size of the median bundle consists in the addition to it of a few medullated fibers arising from the dorso-lateral part of the nucleus magnocellularis, forming the tractus preoptico-tuberis. These pass caudad mingled with the median forebrain bundle and end, apparently, partly in the nucleus posthabenularis, and partly in the nucleus posterior tuberis. These fibers may correspond to the 'Längsbündel' of Goldstein.

Slightly caudal to the level of the habenulae a seventh tract becomes closely associated with the median bundle, appearing to be a part of it. This is the tractus habenulo-diencephalicus of Goldstein and has already been described in connection with the habenular tracts (fig. 77).

When a careful study of the median bundle at different transsection levels is made, it is a simple matter to identify its components. Their relations rostrally have already been noted; as the tract is followed caudad it will be seen that there is a tendency for the longer components to arrange themselves in more compact bundles, with the more recently acquired fibers scattered about them (figs. 73, 74, 76). For some distance there is little change in the bundle (figs. 79, 80, 82). At the level shown in fig. 83, however, it will be noted that the fibers of the tractus olfacto-thalamicus, pars intermedia and tractus thalamo-olfactorius, pars intermedia, are decreasing in number. The remaining bundles of the complex are, at this point, separating from one another, all, however, turning ventrad (figs. 100, 101). The tractus habenulo-diencephalicus can be traced only a short distance caudal to the level shown in fig. 101, where it ends mesal to the nucleus rotundus at the level of the nucleus posterior tuberis. The tractus hypothalamo-olfactorius medialis holds a position near the median line at this point, while the tractus olfacto-thalamici, pars dorsalis and pars ventralis are looping ventro-laterally, to pass below the nucleus rotundus (fig. 101) to their termini in the nuclei subrotundus and posterior thalami, respectively (figs. 115, 116, 122, 139).

(7) *Fasciculus lateralis hemisphaerii.* This has been known from the time of the first workers on the microscopic anatomy of the teleostean brain. It has been called by various names since the time of Stieda: pedunculus cerebri, by the earlier workers, 'basale Vorderhirnbündel' by Edinger, 'faisceau basal' by Catois, 'tractus strio-thalamicus' by Johnston, Goldstein, Kappers, etc. In practically all forms it consists almost entirely of unmedullated fibers, although it is one of the largest and most constant bundles of the brain. Earlier workers considered that it was made up exclusively of descending fibers from the cells of the corpus striatum, ending in the diencephalon. Edinger ('88) states simply that the fibers originate in the 'Stammganglion' and end in the ventral part of the 'Zwischenhirn.' He thinks it very likely that part of the fibers decussate in the anterior commissure. C. L. Herrick ('91 and '92) divides the basal forebrain bundle into two parts, both descending, a ventral peduncle arising from the rostral part of each basal lobe and ending in the caudal part of the hypoaria, and a dorsal peduncle originating in the caudal part of each lobe, and ending largely in the nucleus ruber and subthalamicus (nucleus rotundus, sensu lato). Johnston ('98) identifies three sets of fibers in the bundle, a tractus strio-thalamicus medialis, lateralis and ventralis. Johnston here includes under the name tractus strio-thalamicus "all fibers connecting the forebrain with the ventral portion of the diencephalon." His tractus strio-thalamicus ventralis is evidently a part of the medial forebrain bundle, as is also a portion of the tractus strio-thalamicus medialis, consisting of ascending fibers from the thalamus to the epistriatum, decussating in the anterior commissure. John-

ston's tractus strio-thalamicus lateralis arises from cells of the nucleus postolfactorius lateralis, while the larger part of the tractus strio-thalamicus medialis arises from the striatum proper. In 1901 Johnston modifies these descriptions somewhat. He says that the ventral bundle is composed of ascending fibers, as noted above, which end in the epistriatum of the opposite side, together with descending fibers from the nucleus preopticus. He further adds that most of the ascending fibers arise from the dorsal and lateral walls of the mammillary bodies, and run in the medial bundle. Van Gehuchten ('94) also describes ascending fibers in the tractus strio-thalamicus, stating that the bundle is made up of two kinds of fibers, those which originate in the basal ganglia and end in the inferior lobes, and vice versa. Catois observed these same two fiber groups one of which is formed by 'fibers motrices descendantes,' the other by 'fibres sensitives ascendantes.' Catois states that the descending fibers lie external and dorsal to the ascending. The descending fibers he traces largely into the nucleus rotundus, and also farther ventrally, while a few fibers extend into the basal portion of the mesencephalon. The ascending fibers are traced by Catois from the region of the infundibulum, chiefly from the more rostral part. Catois includes here the medial forebrain bundle as a part of the tractus strio-thalamicus. Kappers traces the tractus strio-thalamicus from all parts of his striatum into the pedunculi thalami, ending uncrossed partly in the nucleus rotundus, but chiefly in the nucleus subrotundus. Kappers has, however, identified a tract arising chiefly from the lateral olfactory area, the tractus olfacto-hypothalamicus lateralis, which has been included with the tractus strio-thalamicus by other authors. This passes caudad, lying immediately dorsal to the tractus strio-thalamicus, and ending after decussation in the ventral portion of the inferior lobes. Goldstein has worked out the connections of the tractus strio-thalamicus in considerable detail and finds that it originates from all parts of the striatum and that part of its fibers decussate in the anterior commissure, as Edinger suggested in 1888. Goldstein states that the crossed fibers lie mesal to the uncrossed, and that the more dorsal fibers in the praethalamic part of the tract contain chiefly fibers from the more rostral part of the striatum. He traces strio-thalamicus fibers into the nucleus anterior thalami, nucleus dorsalis thalami, nucleus ventralis thalami, nucleus posterior thalami, nucleus anterior tuberis, nucleus lateralis tuberis, nucleus diffusus lobi lateralis. The tractus strio-thalamicus of Goldstein includes the tractus olfacto-hypothalamicus lateralis of Kappers. Johnston ('02) in Petromyzon states that the tractus strio-thalamicus is formed from the neurites of the cells of the striatum which end in the central gray of the thalamus. He also identifies fibers from the lateral olfactory centers, forming a part of his tractus olfacto-lobaris, which correspond to the tractus olfacto-hypothalamicus lateralis of Kappers.

As described here, the lateral forebrain bundle consists of the tractus strio-thalamicus, tractus thalamo-striaticus, tractus olfacto-hypothalamicus lateralis and tractus hypothalmo-olfactorius lateralis (fig. 139). Rostrally distributed through the central part of each lobe, almost at the tip of the basal lobes, may be seen in Weigert preparations many bundles of unmedullated fibers. Caudally, near the level of the anterior commissure, these bundles pass gradually ventrad, lying dorsal to the fissura endorhinalis (fig. 34). Thence these turn slightly mesad (fig. 35), constantly increasing in size through the accession of new fibers, until at the caudal level of the commissure the lateral forebrain bundle appears as a powerful tract containing many large bundles of mixed medullated and unmedullated fibers (fig. 36). As a usual thing the medullated fibers either form a sheath for the unmedullated or else form separate bundles, the two kinds of fibers being rarely intermingled in the same bundle. A large part of the fibers, as Goldstein describes, decussate in the caudo-ventral part of the anterior commissure (figs. 36, 37). Caudal to the commissure, the different bundles become more compactly arranged and extend through the pedunculi thalami close against their lateral margins (figs. 55, 61, 68).

The components of the tract, as it passes through the pedunculi thalami, are shown in fig. 139. It will be noted that the fibers are both ascending and descending and that the several bundles have somewhat different connections. In general it may be stated that the fibers connected with the more rostral part of the basal lobes lie ventrally and medially; that those belonging to the mid-portion of each lobe hold an intermediate position, while the more caudal fibers appear dorsally in the praethalamic bundle. It will be noted, also, that those which decussate in the anterior commissure are among the more caudal fibers, while those of the extreme caudal tip of the basal lobes occupy the extreme dorsal position and form the lateral hypothalamic tracts (figs. 36, 37, 55, 61, 68, 69, 72, 73).

The lateral forebrain bundle receives from, or sends fibers to, all parts of the basal lobes excepting the corpus precommissurale, nucleus medianus, nucleus supracommissuralis, primordium hippocampi, and possibly the nucleus preopticus. The fibers from the caudal part of the lobes belong to the nucleus pyriformis chiefly, although a few fibers are undoubtedly in connection with the lateral part of the nucleus intermedius; they, therefore, form a tract corresponding to the tractus olfacto-hypothalamicus lateralis of Kappers. Kappers, however, described this as a descending tract, while it here contains both ascending and descending fibers, which reach all parts of the nucleus pyriformis (figs. 69, 72).

A large part of the fibers of the tractus strio-thalamicus, or remaining portion of the lateral forebrain bundle, are ascending and are distributed to all parts of the palaeostriatum, nucleus olfactorius lateralis, including the dorso-lateral area of the basal lobes, called epistriatum by Catois and by Johnston ('06). Many of these ascending fibers enter into relation with large association cells of these areas, their neurites enclosing the perikarya of the cells (figs. 49, 50, 51). Other ascending fibers reach the peripheral area and branch dichotomously to form tangential fibers (fig. 39), here coming into relation with the association cells and their processes. Descending fibers of the tractus strio-thalamicus arise from cells found in all parts of the same areas, palaeostriatum, nucleus olfactorius lateralis, etc., already described. The nucleus olfactorius lateralis, and most, if not all of the palaeostriatum receive secondary olfactory fibers, while the palaeostriatum receives also processes from association cells of the corpus precommissurale (figs. 39, 139, *fib. precom. str.*). So far as the fiber connections are concerned, therefore, a definitely limited corpus striatum in the basal lobes can not be found, thus agreeing with the relations as shown by a cytological study.

In the pedunucli thalami, as was noted earlier, the fibers of the lateral forebrain bundle enclose the nucleus entopeduncularis, giving off collaterals to it (figs. 68, 69, 72, 139).

Throughout the extent of the pedunculi thalami little change takes place in the bundle; as it passes over the chiasma its components extend slightly ventrad, however, and now cover all of the lateral surface of the peduncles (figs. 73, 76). At the rostral margin of the lateral lobes the more ventral bundles become closely massed against the commissura transversa (figs. 77, 79), caudal to which they bifurcate, a few fibers entering the nucleus anterior tuberis (fig. 80), while many turn into the nucleus prerotundus (figs. 80, 82, 83, 100). The larger proportion of these two sets of fibers are ascending as Catois states (figs. 104, 105), although a part are certainly descending. Farther caudally the intermediate fibers of the bundle likewise turn ventro-laterad and enter the caudal part of the nucleus prerotundus, passing through it to distribute along the rostro-mesal aspect of the nucleus rotundus and to the ventral part of the nucleus diffusus lobi lateralis (fig. 83). Part of the nucleus prerotundus fibers are ascending, but a definite statement can not be made regarding those of the nucleus rotundus. In the latter case there is no doubt but that most of them are descending as C. L. Herrick, Catois and others describe, although the intermediate bundles certainly contain some ascending fibers. The fibers break up in the nucleus prerotundus and rotundus in a very characteristic manner, noted by the earlier workers on the teleostean diencephalon (see C. L. Herrick ('92), nidulus ruber). This was mentioned earlier and is shown in fig. 102. The dorsal bundles distribute caudally a few fibers to the nucleus subrotundus, nucleus posterior thalami, nucleus cerebellaris hypothalami and a large number to the nucleus diffusus lobi lateralis, ventrally and caudally. The tractus olfacto-hypothalamicus lateralis has practically the same distribution excepting that it sends no fibers to the nucleus subrotundus. These fibers are both ascending and descending, although most of the ascending fibers apparently arise from the nucleus diffusus. It is difficult to make positive statements regarding the cells of origin of the dorsal ascending fibers of the basal forebrain bundle owing to rather poor Golgi impregnations of adult brains in this region (fig. 139); there is no question as to their presence, however, as many such fibers can be seen leaving these bundles rostrally. In Golgi preparations of the brains of young carp fibers may be traced, nevertheless, from a nucleus apparently corresponding to the nucleus cerebellaris hypothalami into the tractus strio-thalamicus.

No strio-thalamicus fibers could be traced into the nucleus dorsalis, nucleus anterior thalami or nucleus lateralis tuberis, as Goldstein found in the forms studied by him. It is probable that the fibers which Goldstein traces into the nucleus lateralis tuberis really arise from the nucleus magnocellularis, as will be shown later. It will thus be seen that the lateral forebrain bundle contains throughout, both ascending and descending fibers connecting all of the lateral and intermediate portions of the basal lobes with practically all of the lateral and intermediate regions of the thalamus and hypothalamus, and also a part of the medial centers. It is not, therefore, the simple tract described by the earlier writers, but a complicated connection of paramount importance to the nervous mechanism.

(*8*) *The nucleus preopticus and its connections.* The fiber connections of this nucleus have been little understood by the different writers on the brains of the lower vertebrates. Johnston ('98), as noted earlier, traced fibers from it to the habenular ganglia; he also believed that secondary olfactory fibers terminate therein, although he could not demonstrate their presence. Johnston also observed fibers passing caudad, but could not trace them to their destination. In 1901 he observed fibers from it entering the tractus strio-thalamicus ventralis (tractus olfacto-thalamicus, probably pars intermedia). C. L. Herrick ('92) describes unmedullated fibers from the pars magnocellularis (nidulus praeopticus), which pass laterad into the optic tract region. Kappers notes similar fibers, which he traces ventrolaterad, and thence caudad into the tuber cinereum, and terms the tractus praethalamo-cinereus. Goldstein traces fibers from the pars magnocellularis caudo-dorso-laterad into 'Das posthabenuläre Gebiet,' the 'Längsbündel des grosszelligen Kerns des zentralen Höhlengraues.' From the pars parvocellularis a few fibers decussate ventrally to enter the nucleus of the opposite side, the 'Commissur des kleinzelligen Kerns,' evidently the functional equivalent of the commissura anterior, pars preoptica, previously described (fig. 138). He also finds other fibers which turn caudo-lateral, dorsal to the chiasma and postoptic commissures and end among the cells of the caudal portion of the nucleus in the rostral part of the hypothalamic wall. These fibers lie lateral to the fibers from the pars magnocellularis, and mesal to the lateral forebrain bundle. Goldstein believes that they constitute "ein Längscommissur der einzelnen Abschnitte des kleinzelligen Kernes des zentralen Höhlengraues." He likewise believes that these fibers are identical with the tractus praethalamo-cinereus of Kappers and the caudal fibers of Johnston in Acipenser. Bela Haller finds a part of these fibers, but believes that they are connected with the optic apparatus.

It was pointed out earlier that in the carp there are four different habenular connections from the nucleus preopticus, corresponding partly to the connections described by Johnston in Acipenser and Petromyzon. Olfactory fibers of the second order may be traced into both the pars parvocellularis anterior and pars magnocellularis, from the tractus olfactorius medialis, pars lateralis, just before its decussation. This agrees with Johnston's conjecture (figs. 137, 139, 141). Unmedullated fibers arising from cells in the nucleus medianus and pars commissuralis of the precommissural body respectively also extend caudad, placing these two areas in relation with the different parts of the nucleus preopticus (fig. 140, *tr. med. preopt. pars ant. and tr. med. preopt., pars post.*). The fibers of the tractus mediano-preopticus, pars anterior pass caudad, ventral to the crossing bundles of the anterior commissure (figs. 37, 54). From it and from the tractus mediano-preopticus, pars posterior fine fibers pass ventrad to end in either side or ventral to the recessus preopticus (figs. 54, 61). These are probably homologous with the 'Längsfasern des kleinzelligen Kerns' of Goldstein and are, perhaps, concerned with the movement of cerebro-spinal fluid.

Immediately ventral to the recessus preopticus Goldstein figures and describes a small tract (Taf. 11, fig. 7), the connections of which he was unable to identify. Fig. 62 shows a parasagittal section in which the relations of this tract are clearly shown (*tr. preopt. sup.*). It is entirely unmedullated and arises from small stellate cells (fig. 63) immediately ventral to the recessus preopticus, terminating partly in the nucleus parvocellularis posterior and partly in the nucleus magnocellularis.

The most important longitudinal caudal connection of the nucleus preopticus is the large unmedullated tractus praethalamocinereus. This originates largely from the nucleus magnocellularis as described by C. L. Herrick and Kappers, the fibers extending latero-ventrad (figs. 72, 73, 76). A part of the fibers, however, originate from cells of the nucleus intermedius and nucleus parvocellularis anterior (figs. 69, 72), while a few arise in the nucleus parvocellularis posterior (fig. 76). At first, the tract lies near the median line (figs. 69, 72, 73) but it gradually turns ventrolaterad (fig. 74) to lie ventral to the lateral forebrain bundle (figs. 76, 77, 79). As it is unmedullated and, therefore, of the same color as the tractus strio-thalamicus fibers, it is easily mistaken for a part of that tract and was undoubtedly so considered by the earlier authors. Immediately caudal to the postoptic commissures it bends ventro-mesad, entering the nucleus lateralis tuberis (fig. 80), where undoubtedly some of its fibers terminate, and where it probably also receives accessions. Goldstein describes and figures this tract but apparently considers it a part of the tractus strio-thalamicus, as he traces the latter tract, but not the former, into the nucleus lateralis tuberis. From this nucleus the tract extends ventrad into the nucleus ventralis tuberis (fig. 80) where it doubtless undergoes the same change as in the nucleus lateralis tuberis, thence passing on into the hypophysis, of which it forms the chief innervation, to terminate particularly in the pars glandularis (figs. 80, 82). Kappers traces this tract, as was previously noted, only as far as the region of the nucleus lateralis tuberis, which he fails to identify.

The "Längsbündel des grosszelligen Kerns des zentralen Höhlengraues" of Goldstein could not be identified with certainty. In sagittal sections a few medullated fibers arising from the dorso-lateral cells of the nucleus magnocellularis could be observed to pass caudad, closely associated ventrally with the medial forebrain bundle as was noted earlier, apparently ending in the nucleus posterior tuberis and the nucleus posthabenularis (figs. 136, 140, *tr. preopt. tub.*). Medullated fibers extending latero-caudad as Goldstein describes were not found. It is possible, however, that the unmedullated fibers of the tractus preoptico-posthabenularis, pars anterior may correspond to Goldstein's tract.

In addition to its longitudinal and habenular connections, the nucleus preopticus possesses a number of important short transverse, or dorso-ventral connections, all of which are composed of unmedullated fibers. Rostrally there are short connections, running in both directions between the nucleus parvocellularis anterior, and both the nucleus intermedius and nucleus commissuralis lateralis, the tractus preoptico-intermedius, pars anterior; intermedio-preopticus, pars anterior; preopticus lateralis; lateralis preopticus (figs. 68, 69, 140). Further caudally are found connections between the nucleus magnocellularis and the nuclei intermedius and entopeduncularis. The nucleus intermedius connections include a double tract medially (figs. 72, 137, 140, *tr. preopt. intermed., pars med. and tr. intermed. preopt., pars med.*) and an ascending tract passing dorsad, lateral to the lateral forebrain bundle, the tractus preoptico-intermedius, pars lateralis (figs. 69, 72, 137, 140). The short entopeduncular connections are shown in figs. 69, 72, 140, *tr. preopt. entoped. and tr. entoped. preopt.* Caudally the nucleus parvocellularis posterior and the nucleus magnocellularis are related to the nucleus posthabenularis through ascending fibers to the nucleus posthabenularis from both these nuclei, and descending fibers from it to the nucleus parvocellularis posterior (fig. 140, *tr. preopt. posthab., pars ant. and pars post. and tr. posthab. preopt., pars ant.*).

There are also ascending and descending unmedullated fibers running between the nucleus posthabenularis and the nucleus intermedius (*tr. intermed. posthab. and tr. posthab. intermed.*). Connections between the nucleus entopeduncularis and the nucleus intermedius may likewise be found (*tr. intermed. entoped. and entoped. intermed.*).

All of these latter short connections contain few fibers and in many cases form little more than a reticular network between different parts of closely related regions; they can not be demonstrated by means of Weigert preparations, but come out only in the silver methods, particularly the Ramón y Cajal. They are chiefly important in emphasizing the intimate relation between all parts of the brain, and particularly, closely related morphological areas, through the formatio reticularis.

This covers all of the direct olfactory connections which could be identified, but does not include the further connections of the different tertiary thalamic centers with other points in the diencephalon, mesencephalon, cerebellum, medulla and spinal cord. Some of these are shown, however, in the Weigert transections. It is expected that an article will appear later in which the morphological relations and functions of the different diencephalic centers will be taken up in detail, in which these further connections will be brought out. Until that time, it is not deemed wise to discuss in detail the morphological bearing of the thalamic olfactory connections, although some points will be taken up later in the interpretation of results.

5. THE CONDUCTION PATHWAYS

At this point it may be well to point out the different pathways which an impulse of a given character may follow. Of the various possible, anatomically demonstrated paths open to a given impulse, the one chosen under given conditions can be unquestionably accepted only when physiological evidence can be offered in support. Nevertheless, impulses must follow conduction paths, and we may, therefore, plot out anatomically extensive impulse pathways with an exceptional degree of accuracy, as is shown in the cases where a physiological check has been used.

Descending pathways

Nervus terminalis. In this case an impulse may travel from the periphery to ganglion cells situated among the olfactory nerve fibers and thence to a decussation among the rostral cells of the bed of the anterior commissure. Its further course is not known.

The olfactory neurones of the first order end throughout the lateral, rostral and rostro-medial face of the bulb. Fibers from all three areas form the tractus olfactorii lateralis, and medialis, pars lateralis, for the nucleus olfactorius lateralis and nucleus pyriformis of the basal lobes (fig. 137). From the lobus pyriformis originate the tractus teniae for the habenula of the opposite side, and the tractus olfacto-hypothalamicus lateralis for the nucleus cerebellaris hypothalami and the nucleus diffusus lobi lateralis of the same side (fig. 137).

The corpus precommissurale stands in relation, chiefly, with the more medial portion of the bulb, through the tractus olfactorius, pars medialis and pars lateralis, which terminate largely in the nucleus medianus of the same and opposite side, in the commissure bed, and in the pars supracommissuralis of the same side. The pars lateralis, after decussation, sends also a few fibers to the nucleus intermedius (fig. 137).

From the corpus precommissurale there are, likewise, two great pathways open. In one case cells with short neurites, forming the fibrae precommissurales striatici, transfer the impulse to the palaeostriatum, whence it is carried by the tractus strio-thalamicus to the nuclei anterior tuberis, prerotundus, rotundus, subrotundus, posterior thalami, cerebellaris hypothalami and diffusus lobi lateralis of the same side; and the nuclei rotundus, subrotundus, and diffusus lobi lateralis of the opposite side (fig. 139). The other connection is through the median forebrain bundle, which places the nucleus supracommissuralis chiefly, but other parts of the corpus precommissurale as well, in relation with the nuclei rotundus, subrotundus and posterior thalami. A third connection, less prominent but of considerable morphological importance, is with the nucleus preopticus. This receives two small bundles from the nucleus medianus, the tractus mediano-preoptici and also secondary olfactory fibers from the tractus olfactorius medialis, pars lateralis, before its decussation (fig. 136). It thus receives both secondary and tertiary olfactory fibers.

Very similar to the precommissural, and of great morphological significance, are the descending connections of the primordium hippocampi. The latter receives secondary olfactory fibers from the tractus olfactorius medialis, pars medialis, and gives rise to fibers for the tractus olfacto-thalamicus, pars dorsalis, for the diencephalon.

The important descending pathway from the nucleus preopticus is the tractus praethalamo-cinereus from the nucleus magnocellularis to the hypophysis, together with the nuclei lateralis and ventralis tuberis. Besides this there is the tractus preoptico-tuberis from the same nucleus to the region of the nucleus posterior tuberis and the nucleus posthabenularis. Both of these are probably neurones of the fourth order.

Important neurones, chiefly of the third order, connect the nucleus preopticus with the habenulae, originating from all parts of the nucleus (figs. 141, 142).

Neurones of the fourth order originate in the habenular ganglia and pass caudo-ventrad, the fasciculus retroflexus for the corpus interpedunculare, and the tractus habenulo-diencephalicus for the formatio reticularis in the region of the nucleus posterior tuberis (figs. 141, 142).

It will be noted, then, that the olfactory neurones of the first order, or olfactory nerve, carries impulses to all parts of the lateral, rostral and mesal aspects of the bulb. From the lateral part of the bulb, chiefly, but also from the mesal, impulses are carried by neurones of the second order to the lateral area of the basal lobes. Thence neurones of the third order carry the impulse either to the habenula, or else to the nucleus posterior thalami, or the diffuse cellular area of the caudal part of the inferior lobes. From the mesal portion of the bulb impulses are carried to all parts of the mesal olfactory area, or corpus precommissurale and primordium hippocampi, by neurones of the second order, which also reach the nucleus preopticus, further caudally. From the mesal area impulses may travel by neurones of the third order to the palaeostriatum, and thence by quaternary fibers of the tractus strio-thalamicus to practically all the nuclei of the thalamus and hypothalamus.

Or impulses will more usually take a tract of the third order, the median forebrain bundle, for the region of the nuclei rotundus, subrotundus, posterior thalami. Other impulses may continue into the nucleus preopticus with fibers of the third order, the tractus mediano-preoptici, or may reach the more rostral parts of the nucleus by means of fibers of the second order. Neurones of the third order, largely, carry impulses from all parts of the nucleus preopticus to the habenular ganglia. It is, therefore, probable that the nucleus preopticus stands in much the same relation to the habenulae as does the nucleus pyriformis. From the nucleus preopticus fibers of the fourth order reach the nucleus posterior tuberis and hypophysis, while from the habenulae such fibers pass to the corpus interpedunculare and the medial thalamus.

Motor correlation probably takes place through two connections; one of these is by means of the corpus interpedunculare, which sends fibers, according to Ramón y Cajal and Edinger, to the nucleus dorsalis tegmenti in higher forms, from which fibers undoubtedly pass into the great bulbar and spinal descending tracts for the transmission of somatic motor impulses. Other connections may also develop when this nucleus and its relations are more thoroughly worked out. Another connection is by way of the tractus thalamo-bulbares et spinales from the thalamus to the medulla and cord (Johnston, '06). In teleosts the more usual motor pathway for the simple direct olfactory impulses is probably by way of the corpus interpedunculare. This pathway is the more definitely laid down and involves the more direct connections. An impulse may pass to any part of the bulb, practically, from the olfactory mucous membrane, thence to the lateral olfactory area, thence by the definite, medullated tractus teniae to the habenular ganglia, thence by the powerful fasciculus retroflexus to the corpus interpedunculare and thence to the tegmental region of the mesencephalon, whence it may come into relation with the motor areas of the midbrain, medulla and spinal cord.

The olfactory connection with the thalamus is not so simple and direct. An impulse must pass from the corpus precommissurale by way of the comparatively few fibrae precommissurales striatici to the palaeostriatum and thence through the tractus strio-thalamicus, or else from the corpus precommissurale by way of the descending fibers of the medial forebrain bundle. In neither of these cases do we find so definite and compact a pathway as that first outlined, wherefore we may conclude that the first is the more usual path for the direct olfacto-motor reflexes. Another possible motor connection is through the preoptico-habenularis fibers to the habenular region, and thence through the fasciculus retroflexus, as above indicated. This is probably a very unusual pathway as the connections just mentioned are very diffuse and are undoubtedly simply the vestiges of a once powerful pathway, now of less functional importance (cf. Acipenser). The functions of these latter pathways will be considered later.

It is quite probable that there exist also somatic fibers connecting the epithalamic with the visual centers, although such were not demonstrated (Herrick, '10b, pp. 468–469). The relation between the ventral hypothalamic region and the visceral (gustatory) pathways in teleostean fishes will be brought out later (see also the discussion in the above mentioned paper of Herrick).

Ascending pathways

There is no evidence for the existence of centrifugal fibers in the olfactory nerve bundles. Ascending fibers from the diencephalon include fibers from the lateral and ventral portions of the inferior lobes to the nucleus pyriformis (tractus hypothalamo-olfactorius lateralis); fibers from the ventro-lateral part of the inferior lobes, the nucleus prerotundus and nucleus anterior tuberis especially, and possibly the nucleus rotundus to the palaeostriatum and nucleus olfactorius lateralis by way of the tractus thalamo-striaticus; and the fibers from the nucleus posterior tuberis to the corpus precommissurale. From the corpus precommissurale, nucleus medianus, fibers pass to the nucleus olfactorius anterior in the tractus olfactorius ascendens (figs. 136, 137).

C. Judson Herrick traces the gustatory fibers of the fourth order into the caudal portion of the inferior lobes; it is likewise probable that tactile and other general sensory fibers reach the dorsal thalamic region through the medial lemniscus fibers. It is, therefore, probable, as Johnston and Herrick have already pointed out, that the ascending fibers from the pars dorsalis of the thalamus and from the hypothalamus are in the nature of general somatic and visceral sensory forebrain connections, respectively. The relations of the nucleus posterior tuberis need to be better understood, however, before the function of this ascending tract can be stated positively. It may be a connection for the transmission of visceral and somatic sensory impulses to the olfactory bulbs through the tractus olfactorius ascendens.

Association connections

Cajal and Golgi preparations show that practically all parts of the brain are permeated by a closely meshed reticulum of fine fibers, the 'Punktsubstanz' or formatio reticularis. In certain preparations it is almost impossible to identify individual cells, so close is the fibrous mesh. All parts of closely related regions, such as the different nuclei of the corpus precommissurale, are also placed in relation by means of large numbers of short connections. The same holds true with respect to regions derived from the same morphological structure. This explains the connections between the nucleus intermedius and the nucleus posthabenularis, both of which are probably parts of the same dorsal olfactory column. It was noted earlier how the nucleus medianus separates into dorsal and ventral columns; how the dorsal continues caudo-laterad as the nucleus supracommissuralis, nucleus intermedius, nucleus posthabenularis and habenulae; and how the ventral continues as the pars commissuralis, nucleus medianus and the nucleus preopticus. It is, therefore, to be expected, after what has been said regarding the close connection of associated regions that these two dorsal and ventral columns would possess short association connections. Such is the case and, while these fibers have been given the name of tracts, they are really all a part of the same set of association fibers. The connections include all the nucleus preopticus-nucleus intermedius, posthabenularis, ganglia habenularum, nucleus commissuralis, nucleus entopeduncularis connections (fig. 140). Such connections also exist between the corpus precommissurale and the primordium hippocampi.

Commissural connections

These include the commissura interbulbaris between the two olfactory bulbs (?); the commissura hippocampi, pars anterior connecting the two primordia hippocampi or nuclei dorsales; the commissura hippocampi, pars posterior, joining the lobi pyriformes; the commissura corporium precommissuralium, between the partes supracommissurales; and the commissurae nucleorum preopticorum, all present in the anterior commissure. The pyriform lobes may also be connected through the superior or habenular commissure forming a commissura aberrans.

The formatio reticularis

In any discussion of the different pathways it must never be forgotten that the fine, reticular network of the formatio reticularis type is of great functional importance. In the past the tendency has been to consider only the tracts laid down in definite bundles. It is probable that in the phylogeny of a fiber tract the heavily myelinated bundle is the latest stage. In early stages, different areas are connected by a diffuse network of unmedullated fibers, through which impulses may take many courses. As phylogenetic development proceeds, impulses tend to take more and more definite paths through the maze of the reticulum; thus the diffuse unmedullated fiber connection is formed. Next this diffuse connection becomes more compact and usually myelinated. It should not be implied that the myelinated tract is more efficient for all connections, as it probably comes into existence chiefly when there is necessity for a stereotyped reflex; to prevent, possibly, 'loss of current' through diffusion, to use an electrical analogy. In spite of this, there is no question but that the more diffuse connections are of the utmost importance in putting into relation different parts of the nervous system, and in causing it to react as one correlated, organic whole.

6. THE MORPHOLOGICAL AREAS OF THE FOREBRAIN

On the basis of the facts brought forward in the previous discussion, the forebrain of teleosts may be divided into morphologically distinct centers, according to the following table:

- Telencephalon.
  - Bulbus olfactorius
  - Nucleus olfactorius anterior
  - Pars lateralis hemisphaerii (pars dorso-lateralis, Herrick)
    - Nucleus olfactorius lateralis
      - Tuberculum anterius
      - Tuberculum laterale
    - Lobus pyriformis
      - Nucleus teniae
  - Pars medialis hemisphaerii (pars ventro-medialis, Herrick)
    - Corpus precommissurale
      - Nucleus medianus
      - Pars commissuralis
      - Pars supracommissuralis
      - (Nucleus intermedius, in part, at least)
  - Primordium hippocampi, or nucleus olfactorius dorsalis (pars dorso-medialis, Herrick)
  - Palaeostriatum (pars ventro-lateralis, Herrick)
    - Nucleus commissuralis lateralis
    - Nucleus entopeduncularis
  - Nucleus preopticus
    - Pars parvocellularis
    - Pars magnocellularis

Johnston ('11) has made an important contribution to the morphology of the forebrain of fishes in his analysis of the 'somatic area' of selachians. This paper came into my hands after the present contribution was ready for the press, and I have not had an opportunity to make a thorough inquiry into the teleostean homologies of this selachian area. Pending further study of this question, I may say that it now seems probable that some or all of the following regions of the carp brain correspond with the selachian somatic area of Johnston: palaeostriatum, nucleus teniae, nucleus intermedius of the precommissural body, nucleus commissuralis lateralis and nucleus entopeduncularis. The fiber connections of several of these nuclei are still very imperfectly known and their morphological interpretation should therefore be considered purely provisional until this knowledge is extended.[1]

III. DISCUSSION

The structural plan of the teleostean diencephalon and telencephalon is very different from that of any other vertebrate type excepting the higher ganoids (notably Amia); but as we follow down the phylogenetic series through the lower ganoids to the generalized fishes, we approach progressively nearer to the common vertebrate type. When the development of the teleostean brain is more fully known it will probably prove easy to follow here also the sequence of form changes from a generalized type.

It is generally accepted that the primitive form of the vertebrate central nervous system was a simple epithelial tube and that from its rostral end two pairs of lateral vesicles were evaginated. One of these comes from the diencephalon to form the optic vesicles: the other comes from the telencephalon to form the cerebral hemispheres. The telencephalon must be defined, as taught by His and Johnston, as the rostral segment of the neural tube, including the hemispheres evaginated from it, and not as the hemisperes alone, as in the BNA tables.

There is the greatest diversity in different vertebrate types in the relative amounts of the telencephalic segment which are evaginated into the hemispheres, but in no case is the whole of this segment represented in the hemispheres. Accordingly, we subdivide the telencephalon into telencephalon medium and

---

[1] Johnston's still more recent paper on the telencephalon of ganoids and teleosts (Jour. Comp. Neur., vol. 21, no. 6, December, 1911). appeared while this contribution was in press. His results differ in some matters of fact and in several matters of interpretation from my own. So far as these concern the somatic or non-olfactory connections, they do not fall within the scope of this article. Some of his morphological conclusions I think rest upon an incomplete knowledge of the anatomical facts; but since the homologies of the telencephalic and diencephalic centers in the carp and other lower vertebrates will be fully discussed in a forthcoming paper, Johnston's conclusions will not be further considered at this time.

cerebral hemispheres, and recognize that in general the hemispheres increase at the expense of the telencephalon medium as we ascend the phylogenetic series. For further discussion of this question, see Johnston ('09) and Herrick ('10 b). The latter author, on the basis of the examination of a series of embryonic and adult brains of different vertebrates, has studied the method of evagination of the cerebral hemispheres in relation with the functional connections of the different parts of the neural tube involved in this process and has devised a schematic picture of the probable relations of the functional subdivisions of the neural tube in a primordial vertebrate whose optic and cerebral vesicles were still in the unevaginated condition ('10 b, fig. 72). See also Johnston ('11), fig. 82.

In such an ancestral type the sulcus limitans, terminating in the preoptic recess, separates the ventral lamina of the neural tube (Bodenplatte or hypencephalic region of His) from the dorsal lamina (Flügelplatte or epencephalic region). The ventral lamina therefore, ends in the chiasma ridge and all of the diencephalon and telencephalon dorsal and rostral to the sulcus limitans belongs in the primary dorsal lamina, i.e., to the sensory or receptive region. The chief sensory function of this region was, in the telencephalon, primitively, olfaction. The tissue in the ventral part of this region, which lies in contact with the ventral (efferent) lamina behind, secondarily assumed the function of motor correlation tissue, this part being usually above fishes separated from the dorsal part by a sulcus, the sulcus medius (sulcus Monroi of authors), which in higher forms extends caudad from the interventricular foramen. By a process of further differentiation the part above the sulcus medius becomes divided into epithalamus and pars dorsalis thalami, and the part below the sulcus medius into pars ventralis thalami and hypothalamus, the latter extending forward beyond the chiasma ridge into direct continuity with the preoptic nucleus.

The relations just described are preserved in the diencephalon of adult brains of many of the Ichthyopsida and are visible in embryos of many higher vertebrates. A transection taken through the rostral end of the diencephalon, accordingly, in these lower vertebrates shows, in addition to the membranous median plates in the roof and floor, four longitudinal columns or laminae on each side, viz., the epithalamus, pars dorsalis thalami, pars ventralis thalami and hypothalamus (fig. 128). The last two contain motor correlation tissue, with somatic and visceral elements, respectively, predominating.

In the primordial vertebrate these four columns probably extended forward into the telencephalon without fundamental change. In all existing vertebrate types variable amounts of this telencephalic tissue are evaginated to form the cerebral hemispheres. The olfactory bulb clearly formed the initial center of evagination. In cyclostomes the hemisphere is composed of olfactory bulb, with part of the secondary olfactory nucleus (these coming from the telencephalic extension of the pars dorsalis thalami), and a very small corpus striatum, this being an extension of the pars ventralis thalami. In the lower elasmobranchs the olfactory bulb is fully evaginated and the telencephalon medium greatly elongated, with great thickening and a very slight evagination of its rostral end. In the higher sharks the telencephalon medium is shortened in correlation with an increase in the thickening of the tissue about the lamina terminalis and the further evagination in this region of the secondary olfactory centers.

The Dipnoi show a very different line of specialization. The olfactory bulbs are in all cases fully evaginated. The telencephalon is not greatly elongated (except in adult Ceratodus) and its lateral walls are uniformly thickened and more or less completely evaginated to form the cerebral hemispheres, whose form and structure, especially in the case of Lepidosiren, are very close to those of Amphibia.

The morphology of the amphibian cerebral hemisphere has been fully discussed in the paper cited (Herrick, '10 b), the author showing that it is naturally divided into four parts (exclusive of the olfactory bulb), viz., (1) pars dorso-medialis (primordium hippocampi), (2) pars dorso-lateralis (primordium of the pyriform lobe), (3) pars ventro-lateralis (primordium of the corpus striatum) and (4) pars ventro-medialis (precommissural body and septum). He shows further that these four parts are the telencephalic extensions respectively of (1) the epithalamus, (2) the pars dorsalis thalami, (3) the pars ventralis thalami and (4) the hypothalamus and tissues surrounding the preoptic recess. The cerebral hemispheres of amniote vertebrates are modifications of this fundamental pattern.

The teleostean forebrain conforms neither to the selachian nor to the dipnoan and amphibian type. Further analysis of the series of ganoidean types and of the ontogeny of the teleosts will doubtless shed light upon the steps by which the teleostean pecularities have been acquired. The study of the form and fiber connections of the adult brain, together with the available data bearing on its phylogeny and ontogeny, suggests the following interpretation.

It is evident that the teleostean olfactory bulbs are completely evaginated and that they have carried out with them a small amount of secondary olfactory tissue, the nucleus olfactorius anterior. The remainder of the telencephalon remains unevaginated as the telencephalon medium, which is, moreover, considerably elongated. The failure of any considerable part of the telencephalon, except the olfactory bulbs, to evaginate laterally is the basis of its difference from that of the Dipnoi and Amphibia. The fact that the increase in its tissue takes place uniformly throughout its length or somewhat more at its caudal end instead of at its rostral end is the basis of its difference from the elasmobranchs.

The increase in the mass of the telencephalon occurs under the influence of two chief factors: (1) olfactory impulses coming in by way of the olfactory bulbs, (2) non-olfactory sensory impulses coming in for correlation purposes from the thalamus and hypothalamus. The correlation sought in the lower forms was exclusively with the olfactory apparatus; olfacto-somatic in the case of the thalamic tracts, and olfacto-visceral in the case of the hypothalamic tracts. In higher vertebrates the non-olfactory systems effect correlations *inter-se* thus giving rise to the neopallium; but little, if any of this sort of correlation occurs in fishes.

In the teleostean brain, as has been pointed out earlier, the arrangement of the telo-diencephalic centers in the form of longitudinal columns, is plainly evident. At the rostral end of the basal lobe the ventro-medial column appears in its primitive relations, forming here the nucleus medianus of the precommissural body. Passing caudad the nucleus medianus bifurcates at the anterior commissure into the dorsal pars supracommissuralis and the ventral pars commissuralis or commissure bed. The latter is directly continuous with the nucleus preopticus, which in turn grades almost insensibly into the hypothalamic nuclei. The pars supracommissuralis becomes continuous caudally with the nucleus intermedius. The cells of the latter nucleus likewise grade over into those of the nucleus posthabenularis and habenula, but this connection is probably secondary, as will be brought out later.

The other diencephalic columns are interrupted at the level of the velum transversum save for the fiber tracts of the basal forebrain bundles. Dorsal to the ventro-medial column lies the primordium hippocampi rostrally, immediately above the corpus precommissurale. This, the dorso-medial column of Herrick, is probably the telencephalic extension of the epithalamic habenula and nucleus posthabenularis of the diencephalon.

The nucleus entopeduncularis probably belongs to the same column as the pars ventralis thalami, the pars ventro-lateralis of Herrick, which expands rostrally to form the palaeostriatum. In the evaginated hemispheres of the Dipnoi and Amphibia the striatal complex is carried outward into the ventro-lateral wall of the hemisphere vesicle. In teleosts the wall as a whole does not evaginate in this way; but the striatum complex, with the associated lateral forebrain tract, moves outward within the solid basal lobe away from the ventricular surface and toward the lateral surface of the brain, a movement which has been carried to a greater extreme in the 'somatic area' of elasmobranchs (Johnston, '11). The precommissural body and the palaeostriatum are to be regarded as extensions of the hypothalamus and ventral part of the thalamus respectively and, therefore, as equivalent to the pars basalis, or pars subpallialis, of the amphibian hemisphere. The remainder of the basal lobe is the extension of the epithalamus and dorsal part of the thalamus and, therefore, is the equivalent of the pars pallialis of the amphibian brain.

The olfactory crus is attached to the rostral end of the basal lobe by two systems of tracts, a medial and a lateral. The former, as in Amphibia, connects chiefly with the precommissural body (tractus olfactorius medialis) and in smaller measure with the dorso-medial part of the basal lobes termed primordium hippocampi in this paper, this relation being in principle similar to that of Amphibia and higher forms. The closely associated nervus terminalis and tractus olfactorius ascendens have been discussed in another connection. The tractus olfactorius lateralis connects chiefly with the lateral part of the basal lobe, the nucleus olfactorius lateralis and the nucleus pyriformis. These nuclei correspond in a general way with the dorso-lateral part of the amphibian hemisphere, or primordium of the lobus pyriformis. Like the palaeostriatum, they tend to move laterad away from the ventricular and toward the lateral surface of the basal lobe.

In vertebrates with evaginated hemipheres the two dorsal parts (pars pallialis) lie on opposite sides of the lateral ventricle and in later phylogenetic stages become respectively the hippocampus and the pyriform lobe. In the teleosts these parts are very imperfectly separated, especially at the rostral end of the basal lobe; here both are parts of a common secondary olfactory nucleus. Incident to the progressive enlargement of the telencephalon without the evagination of its walls, the thickened secondary olfactory nucleus moves laterad, carrying with it the taenia, or line of attachment of the membranous roof, which accordingly becomes dilated laterally. (See figs. 126 to 134 illustrating the arrangement of these parts and the process of eversion.)

It will be observed that the teleostean form has not been reached by a simple process of eversion of the whole wall such as that suggested by Mrs. Gage ('92; see fig. 135); for that would bring the primordium hippocampi, which borders the taenia in Amphibia, far ventro-laterally in the teleosts. This appears not to be the case, but a portion of the dorsal secondary olfactory nucleus retains its dorso-medial position with reference to the other massive structures, in spite of the lateral movement of the taenia. The movement in question is not, in fact, a simple lateral bending of the whole wall at the sulcus limitans telencephali, but rather a gradual plastic movement of the material, such that, while the precommissural body and the medial part of the dorsal olfactory nuclei remain in the original position, the intervening portions of the lateral wall move toward the lateral part, thus bringing the dorsal olfactory nucleus and the precommissural body into contact at the sulcus limitans. The palaeostriatum moves laterad only a short distance, coming to occupy the middle of the basal lobe. But a portion of the dorsal olfactory nucleus and the whole of the lateral nucleus move to the extreme ventro-lateral margin, carrying the taenia with them, thus forming at the rostral end of the basal lobe the tuberculum laterale, and at the caudal end the nucleus pyriformis.

The tuberculum anterius, tuberculum laterale, and nucleus dorsalis are parts of the undifferentiated secondary olfactory nucleus. The precommissural body and pyriform nucleus are more highly differentiated parts of the secondary olfactory nucleus which have developed under the influence of ascending fibers of the medial and lateral forebrain tracts respectively. The palaeostriatum has become an efferent correlation center relatively free from direct olfactory connections. It is interesting to note that the termination of the lateral hypothalamic tract caudally in the teleosts has brought about the development of the nucleus pyriformis at that point, while in the selachians the more rostral ending of this connection (tractus pallii) has induced the formation of the nucleus olfactorius lateralis and primordium hippocampi in a correspondingly different position.

The selachians exhibit a considerably more highly differentiated condition of all of the forebrain centers than is found in the teleosts (cf. Johnston, '11). The selachian ascending tract from the hypothalamus to the primordium hippocampi (tractus pallii), in teleosts is probably represented in the tractus hypothalamo-olfactorius lateralis, a condition which resembles that of amphibians (Herrick, '10, p. 444).

The nucleus olfactorius dorsalis or primordium hippocampi receives some fibers from the tractus olfactorius medialis, and this connection is probably the reason why this portion of the undifferentiated secondary olfactory nucleus retains its dorso-medial position during the lateral eversion of the remainder of this nucleus. The adult configuration is such as to suggest that the nucleus dorsalis is homologous with the amphibian primordium hippocampi and the sulcus limitans telencephali with the fissura limitans hippocampi of Herrick (fissura arcuata of Gaupp). The latter homology is however, manifestly incomplete, for the fissura limitans hippocampi is a total fissure involving the whole wall of an evaginated hemisphere, while the teleostean sulcus limitans is an ependymal groove within the ventricle of the telencephalon medium. The two sulci in question separate homologous parts of the brain and are as nearly homologous as the topographic relations of these two types of telencephalon permit.

Some justification may be found for the homology of the nucleus olfactorius dorsalis with the primordium hippocampi of Amphibia, although the apparent resemblance in position is an argument rather against it than for it. It must not be forgotten that the nucleus dorsalis occupies a dorso-median position *below* the telencephalic ventricle, not above it, as in Amphibia. In the process of eversion, to which reference was made above, the whole of the dorsal nucleus might be expected to follow the taenia in its lateral movement. The fact that a part of this nucleus retains its position at the dorso-medial border of the basal lobe has been already explained as due to its connection with the tractus olfactorius dorso-medialis. This is a primary connection of the primordium hippocampi; cf. fig. 125 with C. J. Herrick ('10 b), figs. 72, 73, 83 and 84, the nucleus olfactorius dorsalis or primordium hippocampi of the teleost being the functional equivalent of Herrick's dorso-medial ridge in spite of its position far removed from the taenia. Nevertheless, the nucleus dorsalis shows few other resemblances with the primordium hippocampi. It has not been shown to receive large numbers of olfactory fibers of the third or higher orders; it sends very few fibers to the anterior commissure complex to form a commissura hippocampi and no clearly defined columna fornicis fibers appear to arise from it, though possibly the medial forebrain bundle may contain fibers of this type.

It is concluded, therefore, that the materials found in the amphibian primordium hippocampi are not completely separated in the teleosts from the other elements of the secondary olfactory nucleus, being represented chiefly in the nucleus olfactorius dorsalis or primordium hippocampi and to a less degree perhaps in the nucleus olfactorius lateralis and nucleus pyriformis.

The term 'epistriatum' has not been used in this article in the description of the telencephalic nuclei, owing to the fact that it has been applied by different authors, with resulting confusion, to morphologically different structures. It was originally used by Edinger ('96), to designate a structure found dorsal to the striatum in the lateral wall of the reptilian forebrain. Its connections here show clearly that it is morphologically a lateral structure, corresponding to the nucleus sphaericus of students of reptiles. The epistriatum of birds, as described by Edinger, is likewise a lateral structure. Turning to the so-called epistriatum of the anamniotes, a different condition is immediately noted. Edinger ('06a) and Kappers ('06) describes as epistriatum in teleosts a medial area reached by the tractus olfactorius medialis which seems to include a part of our precommissural body, but in their later works this name is applied to our nucleus olfactorius dorsalis. Catois uses the term for the dorsal portion of the palaeostriatum. Johnston ('06) places the epistriatum of teleosts on both the medial and lateral parts of each basal lobe, although these two areas belong to morphologically different structures. It is difficult to see how the term can continue in use without constantly increasing confusion. Even if all workers had clearly in mind the morphological characteristics of the different varieties of epistriatum, it would seem unwise to use the same name, even with a modifying adjective, as does Kappers in his later work, for such morphologically different structures.

From the preceding discussion it is clear that the localization of function in the telencephalon of teleosts has not advanced so far as in Amphibia and Dipnoi with more fully evaginated hemispheres. This is probably the explanation of the fact that the diencephalic regions are also far less clearly analyzed than in Amphibia, and that nearly all parts of the basal lobes seem to be connected with both hypothalamic and thalamic centers. But the discussion of these relations can be taken up more profitably after the connections of the diencephalic nuclei are more fully analyzed and particularly, after their embryological development has been studied.

Some comment should be made on the bearing which the data given in this article make with respect to the morphology of the forebrain tela. It is clear from the facts presented that the forebrain of the teleostean fishes contains primordial pallium and also the primordium of all important morphological structures found in the forebrain of higher vertebrates. The pallium of Rabl-Rückhard, then, is not the morphological equivalent of any portion of the wall of the forebrain of higher vertebrates but is simply a tela, derived from the Deckplatte of His. In fact there is no evidence anywhere in the phylogeny of the vertebrate brain that the Deckplatte gives rise to a nervous structure. The evidence which has been offered, then, gives additional support to the views of Studnička, already accepted by Kappers, Johnston, Edinger and Herrick.

Anatomical Laboratories,
The School of Medicine,
University of Pittsburgh.

LITERATURE CITED

All papers cited have been consulted, excepting those marked with an asterisk (*). The subject matter of articles so indicated was ascertained through reviews.

AICHEL, OTTO 1895 Kurze Mittheilung über den histologischen Bau der Reichschleimhaut embryonaler Teleostier. Sitzungsber. d. Gesellsch. f. Morphol. u. Physiol. i. München, Bd. 11, Hft. 2 u. 3, pp. 73–78.

BELLONCI, GIUSEPPE 1880 Ricerche comparative sulla struttura dei centri nervosi dei Vertebrati. Mem. d. r. Accad. d. Lincei, Cl. sc. F., ser. 3, vol. 5, pp. 157–182, figs. 1–58.

1885 Intorno all' apparato olfattivo-ottico (nuclei rotondi, Fritsch) del cervello dei Teleostei. Ibid., ser. 4, vol. 1, pp. 318–323, pl. 1.

BROOKOVER, CHARLES. 1908 Pinkus's nerve in Amia and Lepidosteus. Science, N.S., vol. 27, pp. 913–914.

1910 The olfactory nerve, the nervus terminalis and the preoptic sympathetic system in Amia calva, L. Jour. Comp. Neur., vol. 20, pp. 49–118, pls. 1, text figs. 32.

BURCKHARDT, R. 1892 Das Centralnervensystem von Protopterus annectens. Eine vergleichend-anatomische Studie. Berlin, Friedländer u. Sohn, Taf. 1-5, pp. 1-64.

CALLEJA C. *1893 La region olfatoria del cerebro en los urodelos. Madrid.

CATOIS, E. H. 1902 Recherches sur l'histologie et l'anatomie microscopique de l'encéphale chez les poissons. Bull. scientifique de la France et de la Belgique. Tom. 36, pp. 1-166, pls. 1-10.

EDINGER, L. 1888 Untersuchungen über die vergleichende Anatomie des Gehirns. I. Das Vorderhirn. Abhdlg. d. Senckenberg. Naturf. Gesellsch., Bd. 15, pp. 91-122, pls. 1-4.

1892 Untersuchungen über die vergleichende Anatomie des Gehirns. II. Das Zwischenhirn. Erster Teil. Das Zwischenhirn der Selachier und der Amphibien. Ibid., Bd. 18, pp. 1-55, pls. 1-5, text fig. 1.

1893 Vergleichend-entwickelungsgeschichte und anatomische Studien im Bereiche der Hirnanatomie. III. Riechapparat und Ammonshorn. Anat. Anz., Bd. 8, pp. 305-321, text figs. 6.

1894 Vergleichent-anatomische und entwickelungsgeschichtliche Studien im Bereiche der Hirnanatomie. IV. Die Faserung aus dem Stammganglion Corpus striatum. Vergl.-anat. u. exp. Untersucht. Verhandl. der Anat Gesellsch., pp. 53-60, figs. 1-4.

1896 Untersuchungen über die vergleichende Anatomie des Gehirns. III. Neue Studien über das Vorderhirn der Reptilien, Abhdlg. d. Senckenberg. Naturf. Gesellsch., Bd. 19, pp. 313-387, pls. 1-4, text figs. 14.

1896 a Vorlesungen über den Bau der nervösen Zentralorgane. Auf. 5. Leipzig.

1899 Untersuchungen über die vergleichende Anatomie des Gehirns. IV. Studien über das Zwischenhirn der Reptilien. Ibid., Bd. 20, pp. 161-197, pls. 1-3.

1908 Vorlesungen über den Bau der nervösen Zentralorgane des Menschen und der Tiere. Bd. 2, Auf. 7, pp. 12, 334, figs. 283. Leipzig.

FRITSCH, G. 1878 Untersuchungen über den feineren Bau des Fischgehirns. Berlin pp. 15, 94, pls. 1-13.

GAGE, SUSANNA PHELPS 1893 The brain of Diemyctylus viridescens from larval to adult life. Wilder Quarter Century Book, Ithaca, N. Y., pp. 259-314, pls. 1-8.

GAUPP, ERNST 1899 A. Ecker's und R. Wiedersheim's Anatomie des Frosches. Zw. Abth., Lehre vom Nerven- und Gefässsystem. Zw. Auf., Braunschweig, pp. 12, 548, figs. 146.

GOLDSTEIN, KURT 1905 Untersuchungen über das Vorderhirn und Zwischenhirn einiger Knochenfische. (Nebst einigen Beiträgen über Mittelhirn und Kleinhirn derselben). Arch. f. mikr. Anat u. Entw., Bd. 66, pp. 135-219, pls. 11-15, text figs. 23.

Haller, Bela 1898 Vom Bau des Wirbelthiergehirns. i Thiel. Salmo und Scyllium. Morph. Jahrb., Bd. 26, pp. 345–641, pls. 12–22.

Hardesty, I. 1902 Neurological technique, pp. 12, 183, Chicago.

Herrick, C. Judson 1897 Report upon a series of experiments with the Weigert methods, with special reference for use in lower brain morphology. State Hospitals Bull., Utica, N. Y., vol. 2, pp. 1–31.

1909 The nervus terminalis (nerve of Pinkus) in the frog. Jour. Comp. Neur., vol. 19, pp. 175–190, figs. 1–10.

1910 a The morphology of the cerebral hemispheres in Amphibia. Anat. Anz., Bd. 36, pp. 645–652, figs. 1–3.

1910 b The morphology of the forebrain in Amphibia and Reptilia. Jour. Comp. Neur., vol. 20, pp. 413–547, figs. 1–84.

Herrick, C. L. 1891 a The commissures and histology of the teleost brain. Anat. Anz., Bd., 6 pp. 676–681, figs. 1–3.

1891 b Contributions to the comparative morphology of the central nervous system. ii. Topography and histology of the brain of certain reptiles. Jour. Comp. Neur., vol. 1, pp. 14–27, pls. 3, 4, 9.

1891 c Contributions to the morphology of the brains of bony fishes. ii. Studies on the brains of some American fresh-water fishes. A. Topography. Ibid., pp. 228–245, pls. 19–21.

1891 d Contributions to the morphology of the brains of bony fishes. ii. Studies on the brains of some American fresh-water fishes. (Continued.) B. Histology of the rhinencephalon and prosencephalon. Ibid., pp. 333–358, pls. 24–25.

1892 a Additional notes on the teleost brain. Anat. Anz., Bd. 7, pp. 422–431, figs. 1–10.

1892 b Contributions to the morphology of the brain of bony fishes. ii. Studies on the brain of some American fresh-water fishes. (Continued.) C. Histology of the diencephalon and mesencephalon. Jour. Comp. Neur., vol. 2, pp. 21–72, pls. 4–12.

1892 c Notes upon the anatomy and histology of the prosencephalon of teleosts. Am. Nat., vol. 26, pp. 112–120, pls. 7–8.

Johnston, J. B. 1898 The olfactory lobes, fore-brain and habenular tracts of Acipenser. Zool. Bull., vol. 1, pp. 221–241, figs. 1–5.

1901 The brain of Acipenser. Zool. Jahrb., Abth. f. Anat. u. Ont., pp. 59–260, pls. 2–13.

1902 The brain of Petromyzon. Jour. Comp. Neur., vol. 12, pp. 1–86, pls. 1–8.

1906 The nervous system of vertebrates. Pp. 20, 370, figs. 1–180, Philadelphia.

JOHNSTON, J. B. 1909 The morphology of the forebrain vesicle in vertebrates. Jour. Comp. Neur., vol. 19, pp. 457–539, figs. 1–45.

1910 The evolution of the cerebral cortex. Anat. Rec., vol. 4, pp. 143–166, figs. 1–20.

1911 The telencephalon of selachians. Jour. Comp. Neur., vol. 21, pp. 1–114, figs. 1–85.

KAPPERS, C. U. ARIENS 1906 The structure of the teleostean and selachian brain. Jour. Comp. Neur., vol. 16, pp. 1–112, pls. 1–16.

1907 Untersuchungen über das Gehirn der Ganoiden Amia calva und Lepidosteus osseus. Abhdlg. d. Senckenberg. Naturf. Gesellsch., Bd. 30., pp. 449–500, pl. 18, text figs. 1–6.

1908 a (Mirwirkung von W. F. Theunissen) Die Phylogenese des Rhinencephalons, des Corpus striatum und der Vorderhirncommissuren. Folia Neuro-Biologica, Bd. 1, pp. 173–288, pls. 1–3, text figs. 1–5.

1908 b Weitere Mitteilungen über die Phylogenese des Corpus striatum und des Thalamus. Anat Anz., Bd. 33, pp. 321–336, figs. 1–6.

1908 c Eversion and inversion of the dorso-lateral wall in different parts of the brain. Journ. Comp. Neur., vol. 18, pp. 433–436, figs. 1–5.

1909 The phylogenesis of the palaeo-cortex and archi-cortex compared with the evolution of the visual neo-cortex. Archives of Neurol. and Psychiat., vol. 4, pp. 1–13, pls. 1–4.

KAPPERS, C. U. A., AND THEUNISSEN, W. F. 1907 Zur vergleichenden Anatomie des Vorderhirns der Vertebraten. Anat. Anz., Bd. 30, pp. 496–509, figs. 1–10.

KOELLIKER, A. 1896 Handbuch der Gewebelehre des Menschen. 6 Auf., Zw. Bd., Nervensystem des Menschen und der Thiere, pp. 8, 1–874, figs. 330–845. Leipzig.

LOCY, W. A. 1899 New facts regarding the development of the olfactory nerve. Anat. Anz., Bd. 16, pp. 273–290, figs. 1–14.

1903 A new cranial nerve in selachians. Mark Anniversary Vol., pp. 39–55, pls. 5–6.

1905 On a newly recognized nerve connected with the forebrain of selachians. Anat. Anz., Bd. 26, pp. 33–63, 111–123.

OWEN, RICHARD 1868 Anatomy of vertebrates, vol. 3, Mammals, pp. 10, 915, figs. 1–614. London.

RABL-RÜCKHARD, H. 1882 Zur Deutung und Entwickelung des Gehirns der Knochenfische. Arch. f. Anat. u. Physiol., Anat. Abth., pp. 111–138, pls. 6–7.

1883 Das Grosshirn der Knochfische und seine Anhangsgebilde. Ibid., pp. 279–322, pls. 12–13.

RABL-RÜCKHARD, H. 1884 Das Gehirn des Knochenfische. Biol. Centralbl., Bd. 4, pp. 499–510, 528–541, figs. 1–11.

1893 Das Vorderhirn der Cranioten. Eine Antwort an F. K. Studnička. Anat. Anz., vol. 9, pp. 536–547, figs. 1–16.

1894 Noch ein Wort an Herrn Studnička. Anat. Anz., Bd. 10, p. 240.

RAMÓN, PEDRO *1894 Investigaciones micrograficas en el encéfalo de los Batraceos y Reptiles. Zaragoza.

1896 L'Encéphale des amphibiens. Bibliographie anatomique, T. 4, pp. 232–252, figs. 1–15.

RAMÓN Y CAJAL, S. 1894 Notas preventivas sobre la estructura del encéphalo de los Teléosteos. Anal. d. l. Soc. Esp. d. Hist. Nat., Madrid. ser. 2, T. 13.

1899 Textura del sistema nervioso del hombre y de los vertebrados. T. 1. pp. xi, 566, figs. 1–206. Madrid.

1904 Ibid., T. 2, pp. 1–1209, figs. 207–887. Madrid.

RATH, O. VOM 1895 Zur Consirvirungstechnik. Anat. Anz., Bd. 11. pp. 280–288.

RUBASCHIN, W. 1903 Über die Beziehungen des Nervus trigeminus zur Reichschleimhaut. Anat. Anz., Bd. 22, pp. 407–415, figs. 1–4.

SHELDON, R. E. 1908 a An analysis of the olfactory paths and centers in fishes. Anat Rec., vol. 2, pp. 108–109.

1908 b The participation of medullated fibers in the innervation of the olfactory mucous membrane of fishes. Science, N. S., vol. 27, pp. 915–916.

1909 a The nervus terminalis in the carp. Jour. Comp. Neur., vol. 19, pp. 191–201, figs. 1–7.

1909 b The reactions of the dogfish to chemical stimuli. Ibid., pp. 273–311, figs. 1–3.

SHELDON, R. E. AND BROOKOVER, CHARLES 1909 The nervus terminalis in teleosts. Anat. Rec., vol. 3, pp. 257–259.

SMITH, G. ELLIOT 1895 The connection between the olfactory bulb and the hippocampus. Anat. Anz., Bd. 10, pp. 470–474, figs. 1–2.

1903 On the morphology of the cerebral commissures in the vertebrata, with special reference to an aberrant commissure found in the forebrain of certain reptiles. Trans. Linn. Soc., London, 2d Ser. Zool., vol. 8, pt. 12, pp. 455–500, figs. 1–36.

1908 The cerebral cortex in Lepidosiren, with comparative notes on the interpretation of certain features of the forebrain in other vertebrates. Anat. Anz., Bd. 33, pp. 513–540, figs. 1–18.

Sterzi, Giuseppe 1907 Il sistema nervoso centrale dei vertebrati. Ricerche anatomische ed embriologiche, vol. primo, Ciclostomi, pp. 731, figs. 194. Padova.

1909 Ibid., vol. 2, Pesci, Lib. 1, Selaci, Pt. 1, Anatomia. pp. 986, figs. 385. Padova.

Stieda, L. 1868 Studien über das centrale Nervensystem der Knochenfische. Zeit. f. wiss. Zool., Bd. 18, pp. 1–72, pls. 1–2.

1870 Studien über das centrale Nervensystem der Wirbelthiere. Zeit. f. wiss. Zool., Bd. 20, pp. 1–184, pls. 17–20.

1873 Über die Deutung der einzelnen Thiele des Fischgehirns. Zeit. f. wiss. Zool., Bd. 23.

Studnička, F. K. 1893 a Zur Lösung einiger Fragen aus der Morphologie des Voderhirnes der Cranioten. Vorläufige Mitteilung. Anat. Anz., Bd. 9, pp. 307–320, pls. 2–3.

1893 b Eine Antwort auf die Bemerkungen R. Burckhardt's zu meiner vorläufigen Mittheilung über das Vorderhirn der Cranioten. Ibid., pp. 691–693.

1894 Zur Geshichte des 'Cortex cerebri.' Verh. d. Anat. Gesellsch., 8. Vers. Strassburg, pp. 193–198, fig. 1.

1895 a Bemerkungen zu dem Aufsatze: 'Das Vorderhirn der Cranioten' von Rabl-Rückhard. Anat. Anz., Bd. 10, pp. 130–137.

1895 b Beiträge zur Anatomie und Entwickelungsgeschichte des Vorderhirns der Cranioten. Erste. Abth., Sitzungsber. d. Königl. Böhm. Gesellsch. d. Wissensch., math.-naturw. Klasse, pp. 1–42, pls. 1–7.

1896 Ibid., Zw. Abth. pp. 1–32, pls. 1–4.

1898 Noch einige Worte zu meinen Abhandlungen über die Anatomie des Vorderhirns. Anat. Anz., Bd. 14, pp. 561–569.

Van Gehuchten, A. 1890 Contributions à l'étude de la muqueuse olfactive chez les mammifères. La cellule, T. 6, fasc. 2, pp. 395–409, pl. 1.

1894 Contribution à l'étude du système nerveux des téleostéens (communication préliminaire). Ibid., T. 10, pp. 253–296, pls. 1–3.

1906 Anatomie du système nerveux de l'homme. 4th Edit., pp. 15, 999, figs. 1–848. Louvain.

Wiedersheim, Robert 1902 Vergleichende Anatomie der Wirbelthiere. 5 Auf., pp. 19, 686, figs. 379. Jena.

EXPLANATION OF FIGURES

All drawings are made from the brain of the carp, Cyprinus carpio L. The individual specimens from which these are made range from 15 to 30 cm. in length for the Golgi preparations; 25 to 40 cm. for those prepared with toluidin blue and the method of Ramón y Cajal, and 35 to 60 cm. for the Weigert preparations. Figs. 1 to 4 were drawn with the use of a dissecting microscope; for all others there were used a camera lucida and Zeiss microscope with the following objective and ocular combinations: compensating ocular 4*, objective A*; compensating ocular 8, objective A*; ocular 2, objective AA; ocular 4, objective AA; ocular 6, objective AA; compensating ocular 6, objective AA; compensating ocular 4, apochromatic objective 16 mm.; compensating ocular 4*, apochromatic objective 8 mm.; compensating ocular 18, apochromatic objective 4 mm.

On all figures from longitudinal sections an arrow (⟶) is placed always pointing rostrad. Where a double pointed arrow (⟵⟶) appears after the name of a tract it signifies that the tract in question contains both ascending and descending fibers; the name used on the figures is, however, always that of the descending tract. All figures from the Weigert or toluidin blue method are from transections; in the case of the latter every cell appearing in the section is drawn in with a camera lucida in order to obtain the proper grouping.

The eight diagrams, figs. 125, and 136 to 142, consist in each case of a basal diagram, the same in figs. 125 and 141, and in figs. 136 to 140, 142; to which is added in one or more different colors, the fiber connections. The two different basal diagrams are made from series of adjacent sections by the Weigert method, sagittal in the case of figs. 125 and 141, frontal in figs. 136 to 140, 142. These are drawn with the aid of a camera lucida, a Zeiss comp. oc. 4*, and objective A*, and are superimposed in such a way as to bring as many as possible of the structures to be considered into one figure. The relations are not, of course, accurate for any one given plane. The fiber tracts are represented by simple lines showing the course of each tract and its connections. The tracts so represented, are not, of course, equal in respect to number of fibers; some, such as the lateral forebrain bundle, are composed of an enormous number, while others, such as the tr. preoptico-habenularis, pars posterior, contain only a few.

PLATE 1

EXPLANATION OF FIGURE

1 Dorsal aspect of the brain of the carp. × 2.

a, dorsal-lateral protuberance on the surface of the olfactory bulb caused by the entering fibers of the olfactory nerve; *bulb. olf.*, bulbus olfactorius; *cbl.*, cerebellum; *crus olf.*, crus olfactorium; *gang. bas.*, ganglion basale of the cerebral hemispheres; *lob. fac.*, lobus facialis or tuberculum impar; *lob. vag.*, lobus vagi; *mesotela*, membranous roof of the mesencephalon; *rhinotela*, membranous roof of the cavity of the olfactory crus, the *rhinocele; sac. dors.*, saccus dorsalis, enclosing the corpus pineale; *sp. cord.* spinal cord; *tela.*, membranous roof of the fourth ventricle; *tectum*, tectum mesencephali; *torus long.*, torus longitudinalis; *valvula*, valvula cerebelli, showing through the membranous mesotela.

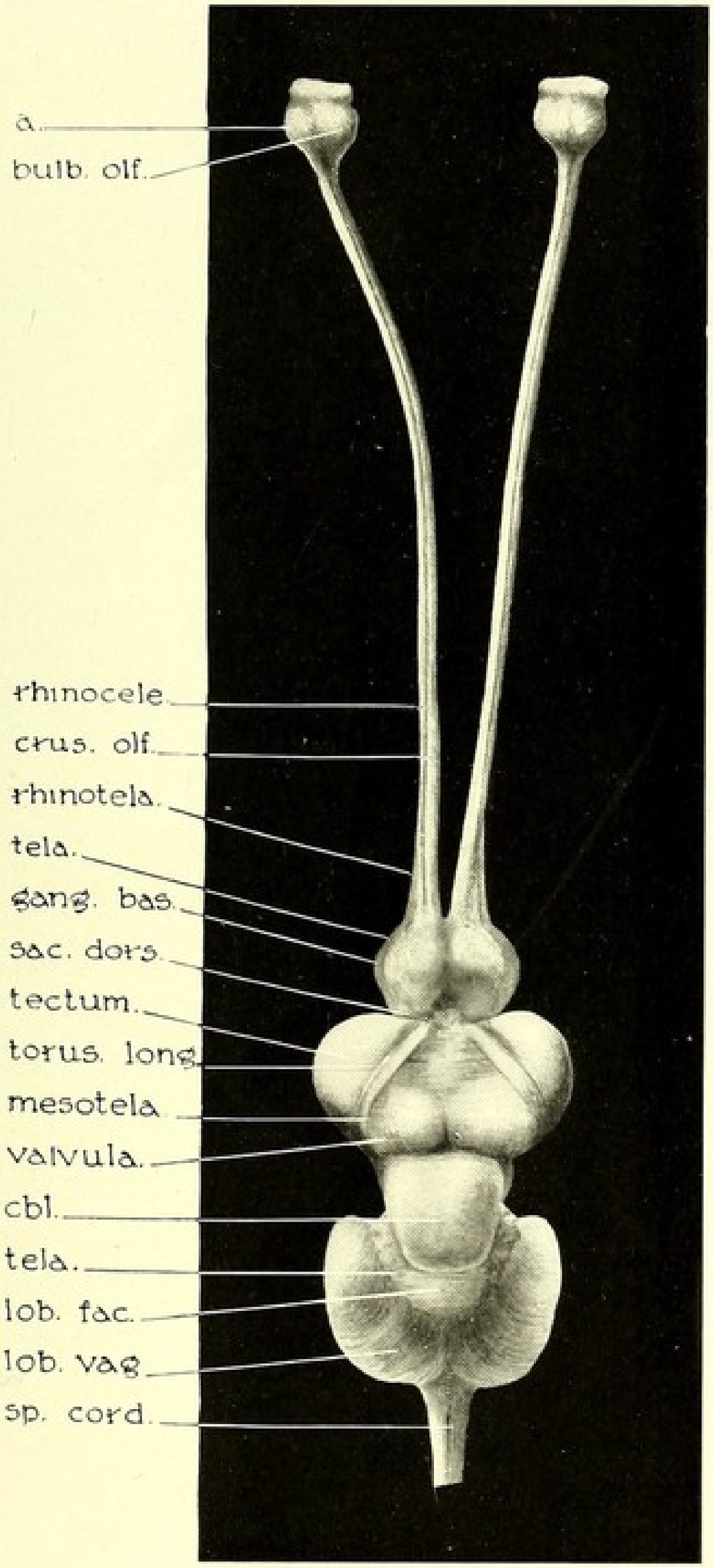

1

KATHARINE HILL, DEL.

PLATE 2

EXPLANATION OF FIGURES

2 Dorsal aspect of the rostral end of the brain. × 4. The optic lobes are removed and the tela of the cerebral hemispheres, the so-called pallium, is torn from the dorsal surface, exposing the basal ganglia.

3 Left lateral aspect of the rostral end of the brain. × 4. Optic lobes and tela as in fig. 2.

crus olf., crus olfactorium; *hyp., pars gl.*, hypophysis, pars glandularis; *hyp., pars. nerv.*, hypophysis, pars nervosa; *lob. inf.*, lobus inferior or hypoarium; *N. III*, nervus oculomotorius; *n. opt.*, nervus opticus; *n. cbl.*, protuberance caused by the development of the nucleus cerebellaris hypothalami of Goldstein; *n. prerot. + n. rot.*, protuberance caused by the development of the nucleus prerotundus and nucleus rotundus centrally; *s. ypsil.*, sulcus ypsiliformis of Goldstein, the rostral prolongation of which corresponds morphologically to the fovea endorhinalis interna of Kappers and Theunissen ('08); *tela*, this indicates the torn edge of the tela or pallium which covers the basal ganglia, extending rostrally over the olfactory tracts to the olfactory bulbs, and caudally between the two halves of the tectum, over the valvula; *tr. olf. lat.*, tractus olfactorius lateralis, the radix olfactoria lateralis of Kappers; *tr. olf. med.*, tractus olfactorius medialis, including also the tractus olfactorius ascendens and nervus terminalis; the corresponding tracts, according to Kappers are, tractus olfacto-lobaris medialis and radix olfactoria medialis propria; he failed to note the nervus terminalis; *tub. ant.*, tuberculum anterius; due chiefly, to the presence underneath, of the rostral end of the nucleus olfactorius lateralis ; *tub. dors.*, tuberculum dorsale, enlargement due to the development of the nucleus olfactorius dorsalis; *tub. lat.*, tuberculum laterale, caused by the development of the nucleus olfactorius lateralis; *tub. post.*, tuberculum posterius, due to the development of the nucleus pyriformis.

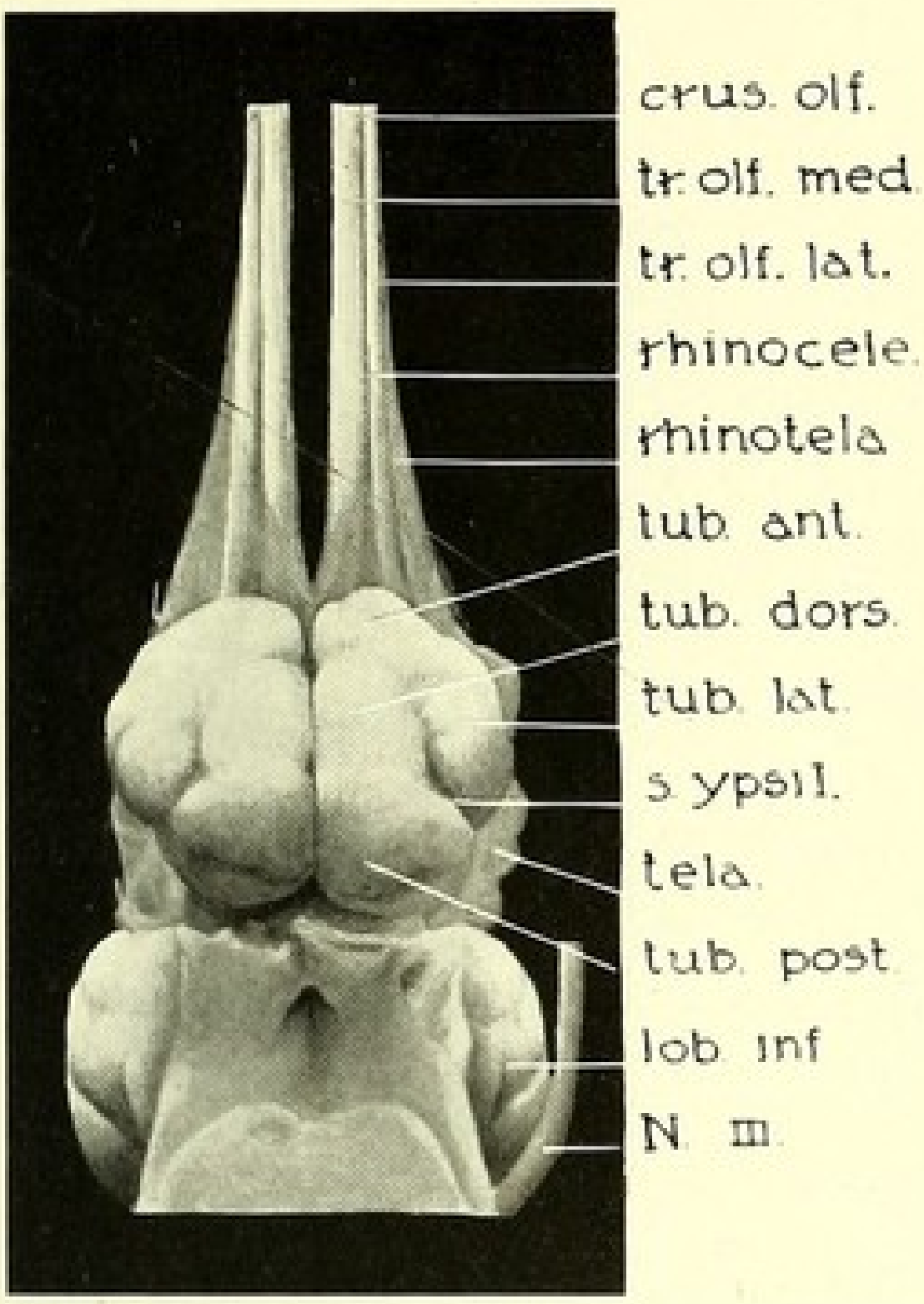

2

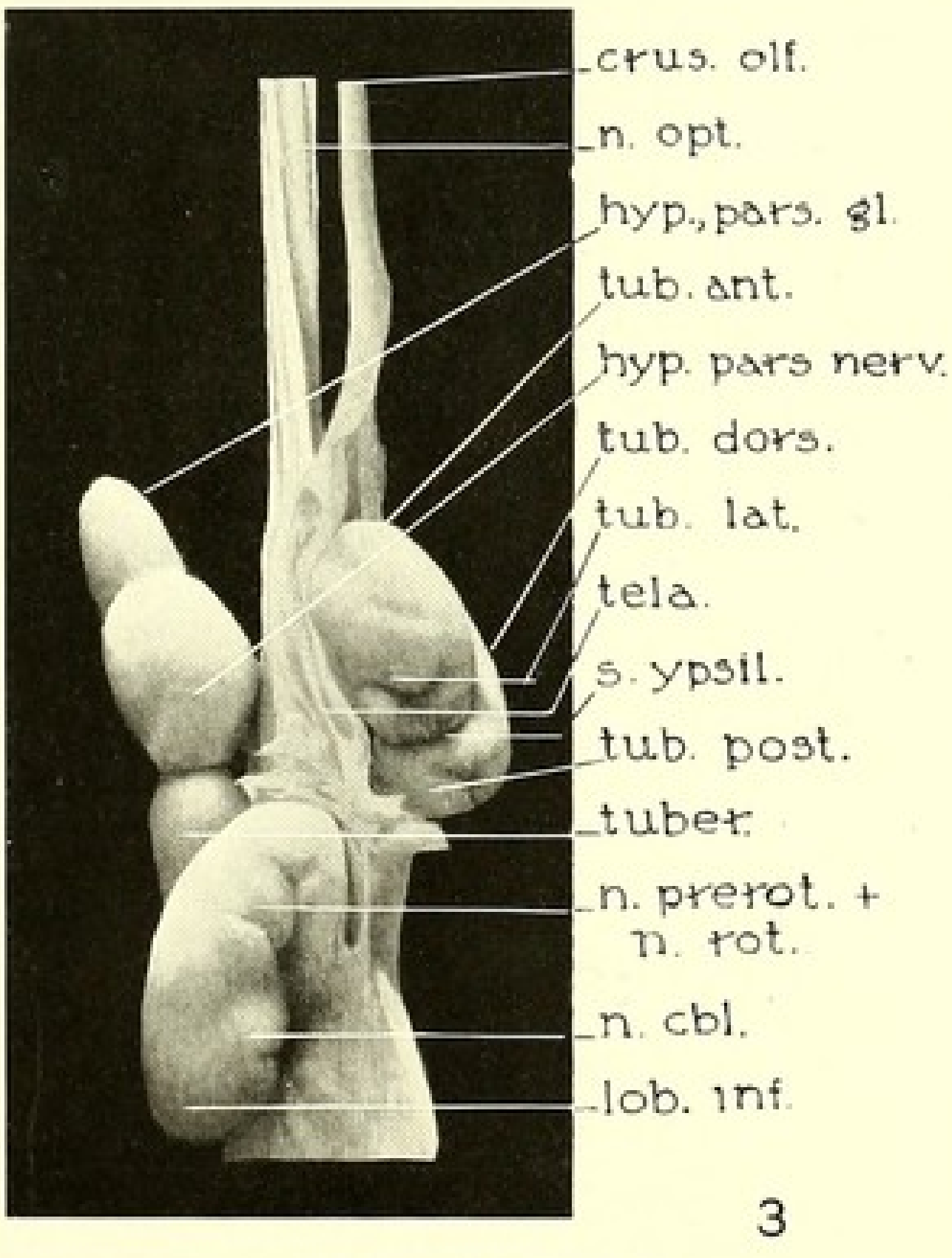

3

KATHARINE HILL, DEL.

PLATE 3

EXPLANATION OF FIGURES

4 Ventral aspect of the rostral end of the brain. × 4.

5 Transection through the median ridge of the olfactory mucosa to show its innervation by trigeminal nerve fibers. Weigert method. × 64. In adjacent sections the medullated fibers may be seen reaching the membrana propria. Note that the epithelium of the median ridge differs from that of the remainder of the Schneiderian membrane, particularly in the large number of goblet cells present. This is also a characteristic of the respiratory epithelium of mammals as distinguished from the olfactory epithelium, which lacks almost entirely the mucus secreting cells.

chias., optic chiasma; *c. mam.*, corpus mammillare of Goldstein; *fib. trig.*, fibrae trigemini; *f. end.*, fissura endorhinalis, the sulcus rhinalis of Kappers ('06), the fovea endorhinalis externa of Kappers and Theunissen ('08), the fovea limbica of Goldstein, the fissura ectorhinalis of Owen; *go. cells.*, goblet cells; *hyp., pars gl.*, hypophysis, pars glandularis; *hyp., pars nerv.*, hypophysis, pars nervosa; *lam.*, lamella; *lob. inf.*, lobus inferior; *lob. lat.*, lobus lateralis hypothalami; *lob. med.*, lobus medius hypothalami, of which the rostral part is the tuber or tuber cinereum and the caudal the pars infundibularis; *memb. olf.*, membrana olfactoria, or olfactory portion of the Schneiderian membrane; *memb. resp.*, membrana respiratoria, the respiratory part of the Schneiderian membrane; *n. opt.*, nervus opticus; *sac. vasc.*, saccus vasculosus; *s. mam.*, sulcus mammillaris of Goldstein, separating the region of the corpus mammillare from the remainder of the lobus lateralis; *tub. post.*, tuberculum posterius.

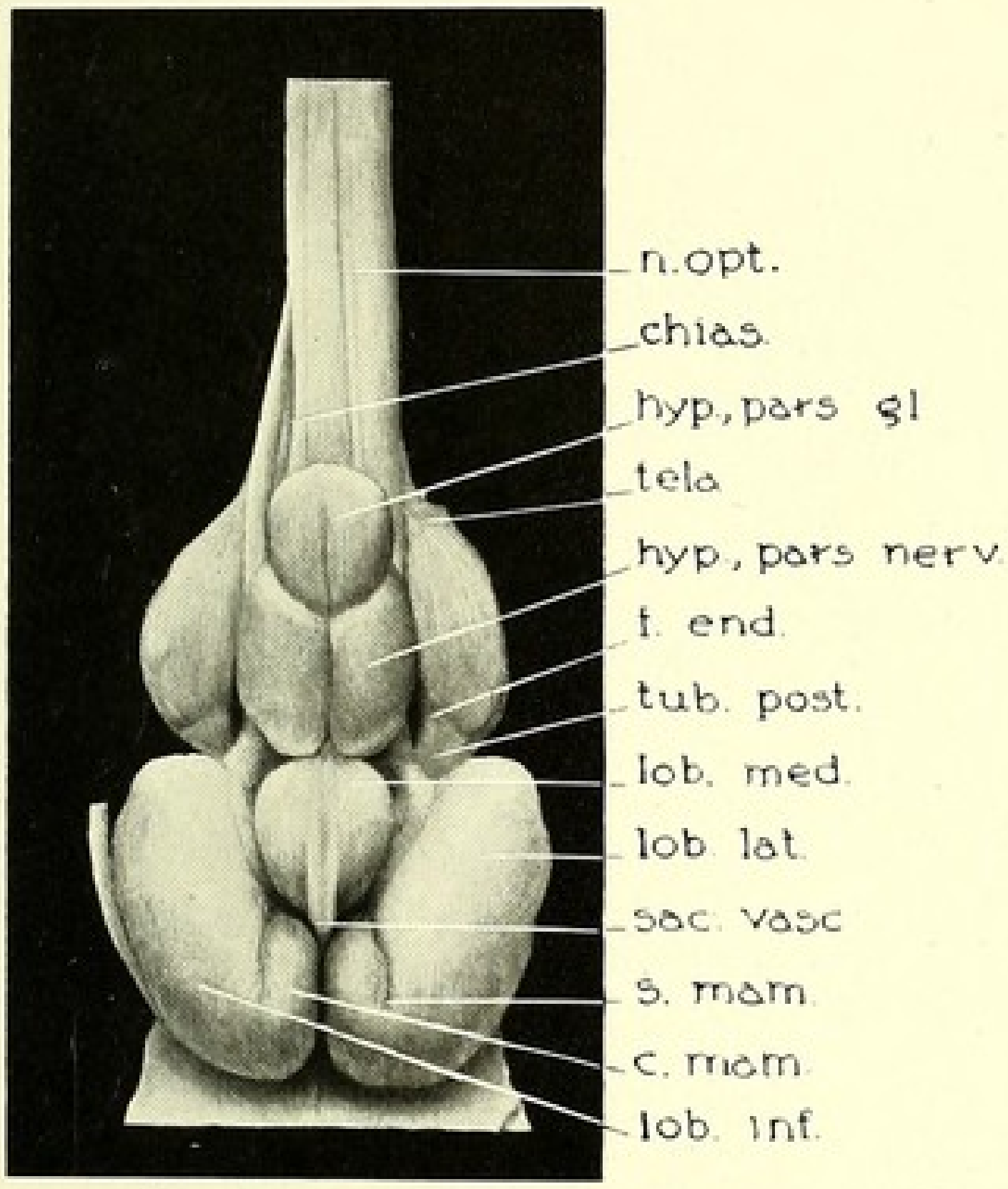
n. opt.
chias.
hyp., pars gl
tela
hyp., pars nerv.
t. end.
tub. post.
lob. med.
lob. lat.
sac. vasc
s. mam.
c. mam.
lob. inf.

4

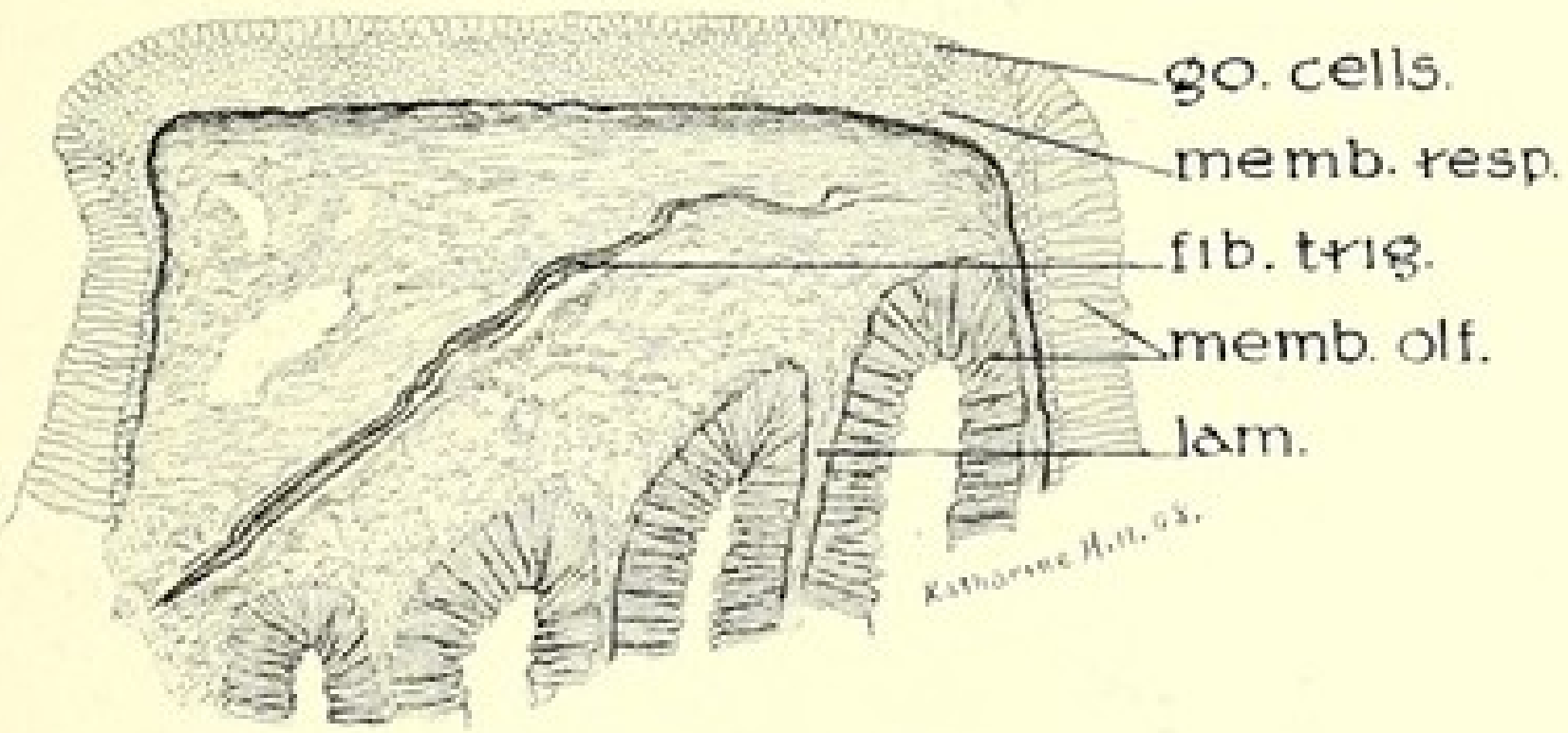
go. cells.
memb. resp.
fib. trig.
memb. olf.
lam.
Katharine H.H. 08.

5

PLATE 4

EXPLANATION OF FIGURES

6 Transection through the middle of the right olfactory bulb. Weigert method. × 31. Most of the stippled periphery is filled with the unmedullated fibers of the olfactory nerve which are ending in glomeruli in this region. An especially prominent mass of such fibers appears dorso-laterally, forming the protuberance '*a*,' as shown in fig. 1.

7 Ganglion cell of the nervus terminalis. Golgi method. × 93. See fig. 124 for the position of this cell.

8 to 12 Mitral cells of the olfactory bulb. Golgi method. × 93. In the cells from transverse sections an arrow points toward the center of the bulb; in sagittal or horizontal sections the arrow points diametrically away from the olfactory crus and toward the center of the bulb. Figs. 8 and 9 are from transverse sections, figs. 10 and 12 from longitudinal section of the bulb.

13 Fusiform cell from nucleus olfactorius anterior. Longitudinal section. Golgi method. × 93. Arrow as in figs. 8 to 12. This neurone extends diagonally across the bulb, one end entering a glomerulus.

14 Stellate cell from nucleus olfactorius anterior. Transverse section. Golgi method. × 93. Arrow as in figs. 8 to 12. Large numbers of these cells are found, most of which are connected with glomeruli; some of these glomeruli contain mitral cell dendrites, while many are small and are, apparently, formed only by stellate cell and olfactory nerve processes.

15 to 17 Neurones from the nucleus olfactorius anterior. Golgi method. × 93. Arrow placed as in figs. 8 to 12.

15 Stellate cell, connecting with a mitral cell glomerulus. From longitudinal section.

16 Stellate cell from longitudinal section. Shows one dendrite in connection with a glomerulus, while the neurite extends toward the center of the bulb.

17 Fusiform cell from longitudinal section.

dend., dendrite; *n. term.*, nervus terminalis; *neur.*, neurite; *olf. nerve*, olfactory nerve, fibers of which are scattered about the periphery at the points noted; *tr. olf. lat., pars intermed.*, tractus olfactorius lateralis, pars intermedia; *tr. olf. lat. pars. med.*, tractus olfactorius lateralis, pars medialis; *tr. olf. med., pars lat.*, tractus olfactorius medialis, pars lateralis; *tr. olf. med., pars. med.*, tractus olfactorius medialis, pars medialis.

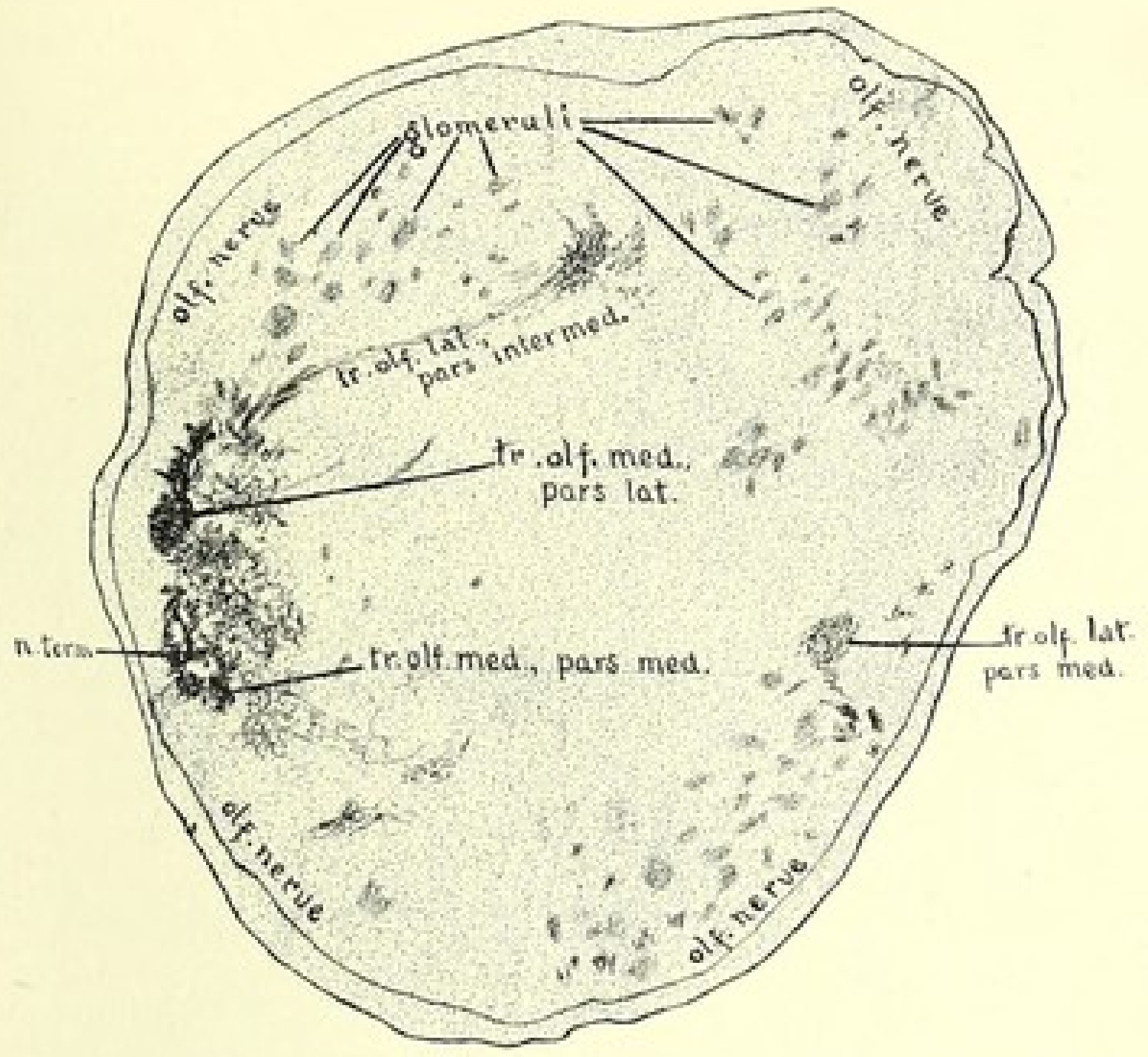

6



7

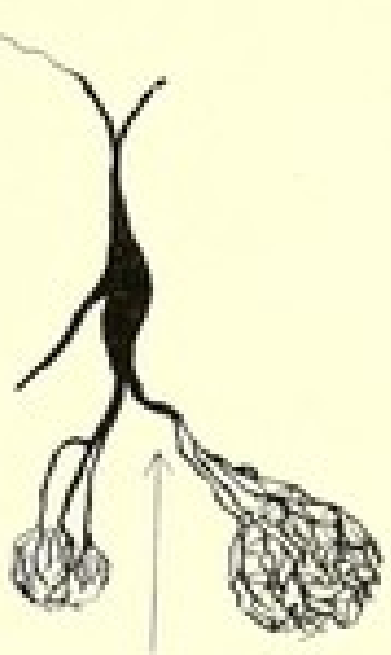

8



9

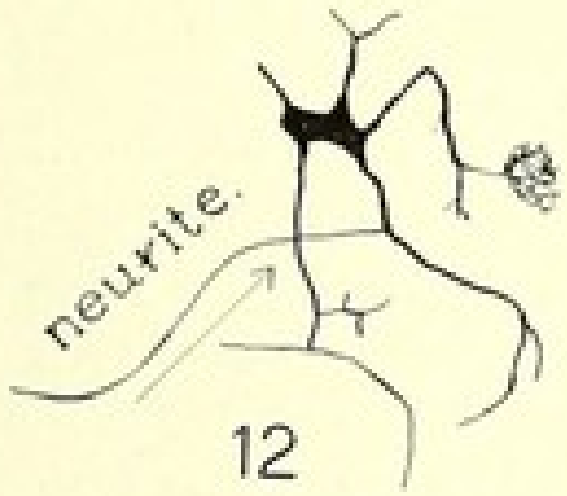

12

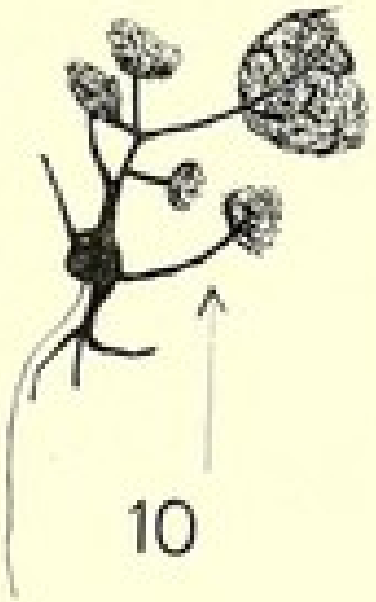

10

11

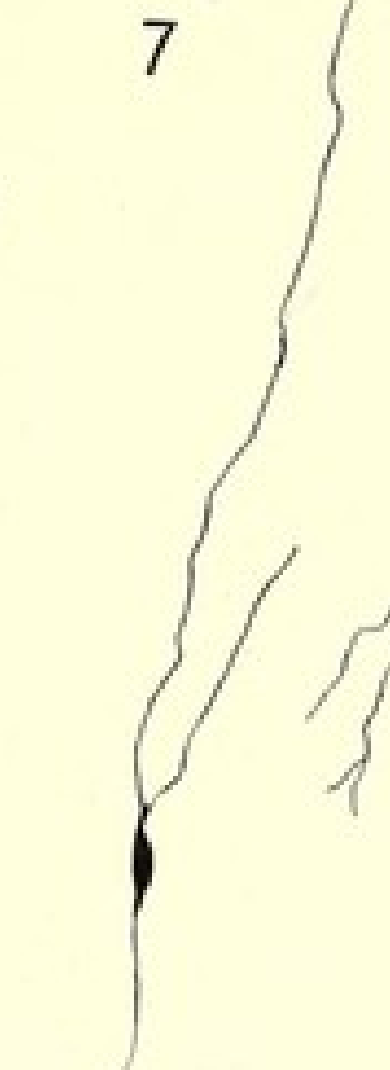

13

14

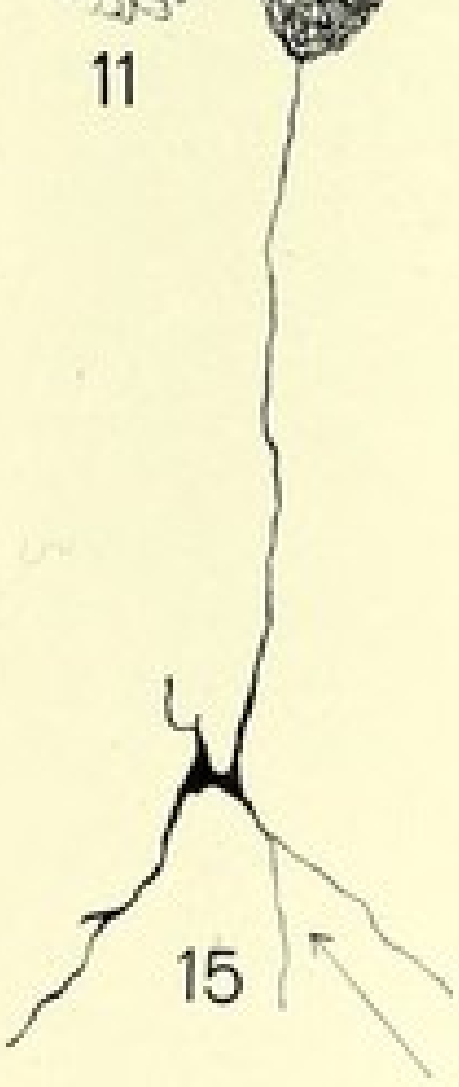

15

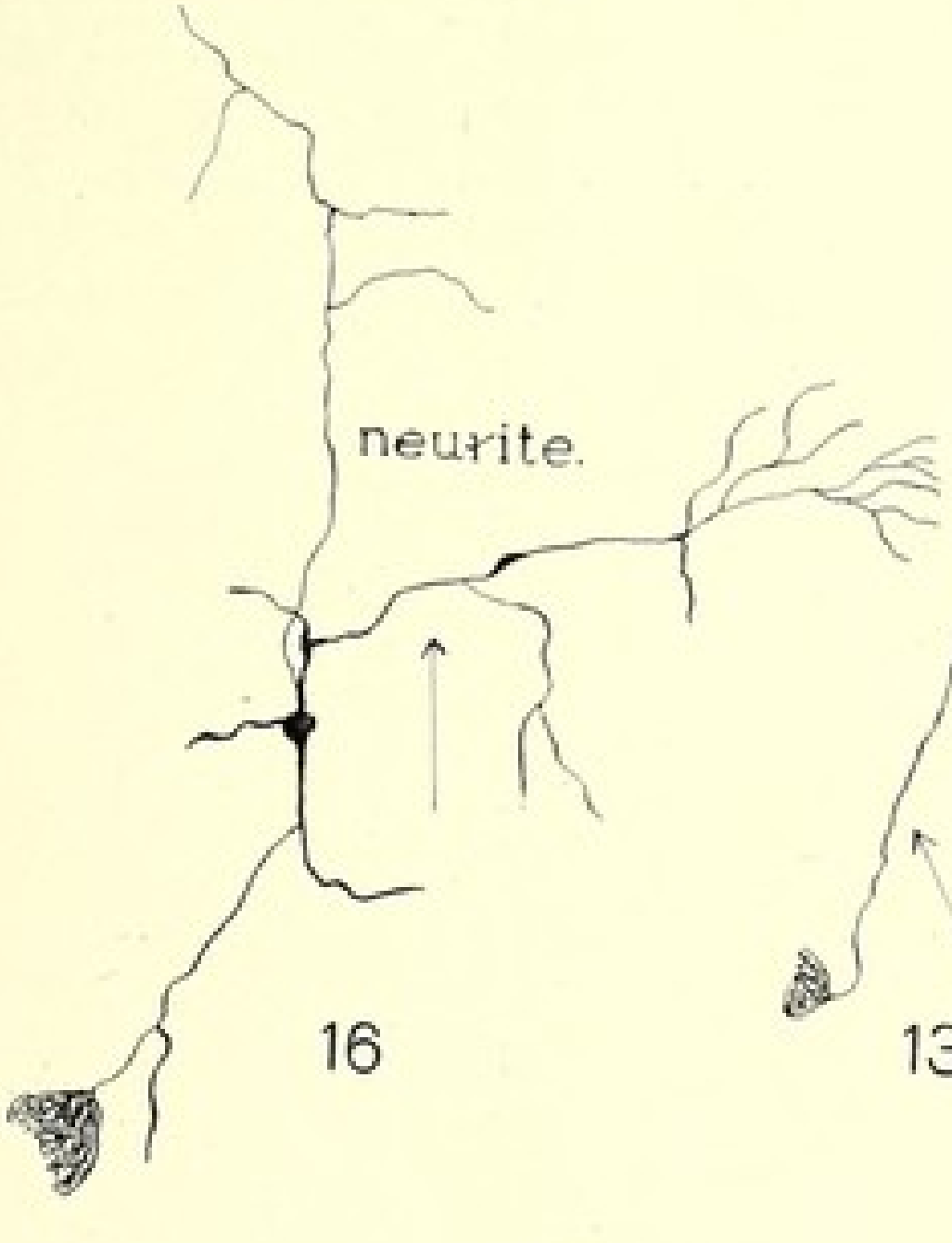

16

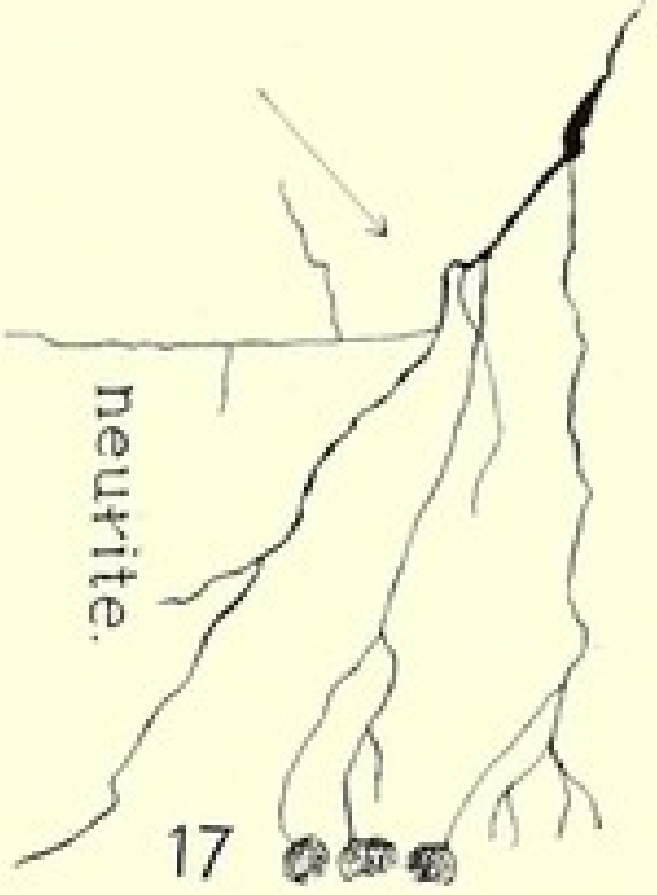

17

PLATE 5

EXPLANATION OF FIGURES

18 to 20 Neurones from the nucleus olfactorius anterior. Golgi method. × 93. Arrow placed as in figs. 8 to 12.

18 Goblet shaped cell from longitudinal section.

19 Fusiform granule cell from longitudinal section.

20 Stellate granule cell from longitudinal section.

21 Fusiform cell from sagittal section of the olfactory bulb, showing neurite entering the crus. Golgi method. × 93.

22 Transection through the middle of the right olfactory crus. Weigert method. × 33. This section was drawn to show, particularly, the nervus terminalis; the remaining fiber pathways do not come out so clearly as in other series.

23 Transection through the caudal part of the right olfactory crus, immediately rostral to the cerebral hemispheres. Weigert method. × 33.

24 Transection through the rostral portion of the cerebral hemispheres. Weigert method. × 17. This section shows the relation to the hemispheres, of the tracts of the crura.

bulb. olf., bulbus olfactorius; *crus olf.*, crus olfactorium; *f. endorh.*, fissura endorhinalis; *n. term.*, nervus terminalis; *neur.*, neurite; *tr. olf. asc.*, tractus olfactorius ascendens, the radix olfactoria medialis propria of Kappers; *tr. olf. asc., pars lat.*, tractus olfactorius ascendens, pars lateralis; *tr. olf. asc., pars. med.*, tractus olfactorius ascendens, pars medialis; *tr. olf. lat., pars intermed.*, tractus olfactorius lateralis, pars intermedia; *tr. olf. lat., pars lat.*, tractus olfactorius lateralis, pars lateralis; *tr. olf. lat., pars. med.*, tractus olfactorius lateralis, pars medialis; *tr. olf. med., pars lat.*, tractus olfactorius medialis, pars lateralis; *tr. olf. med., pars med.*, tractus olfactorius medialis, pars medialis.

18

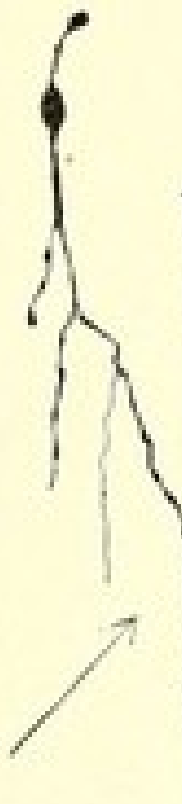

19

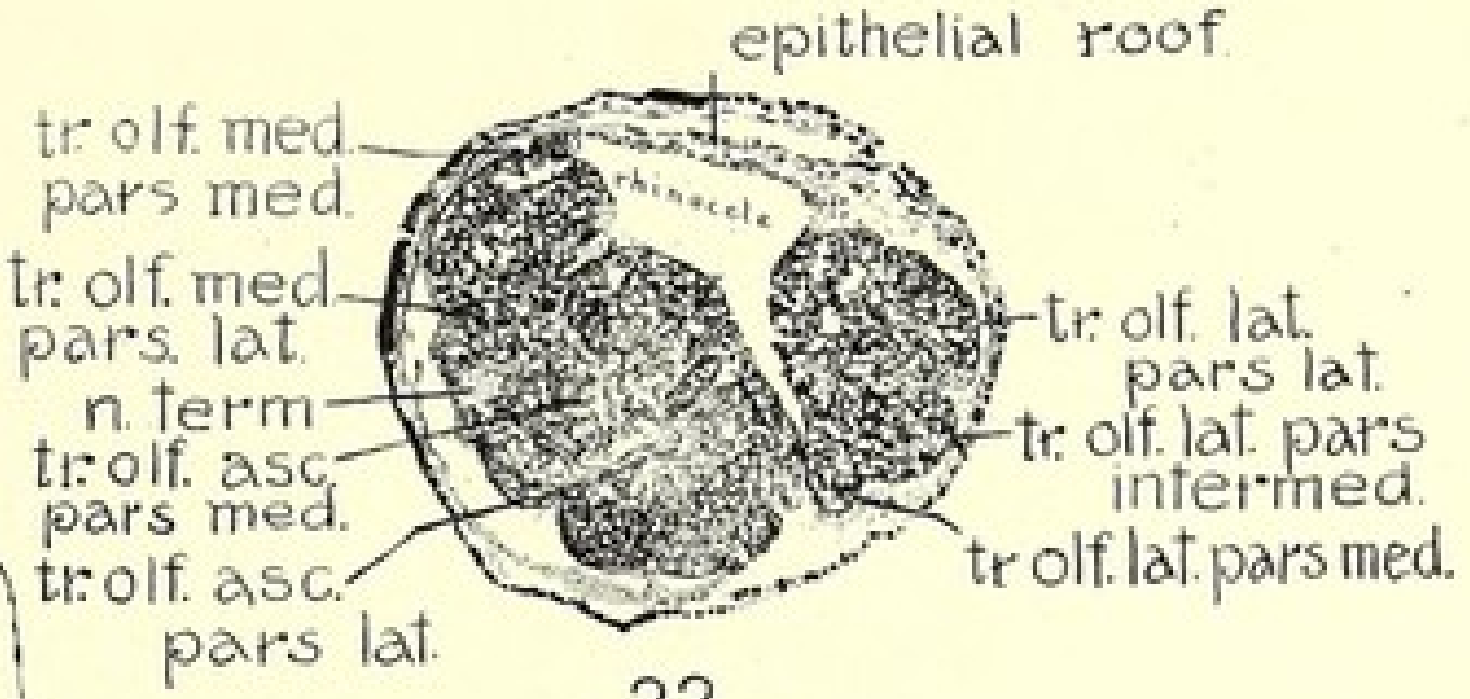

22

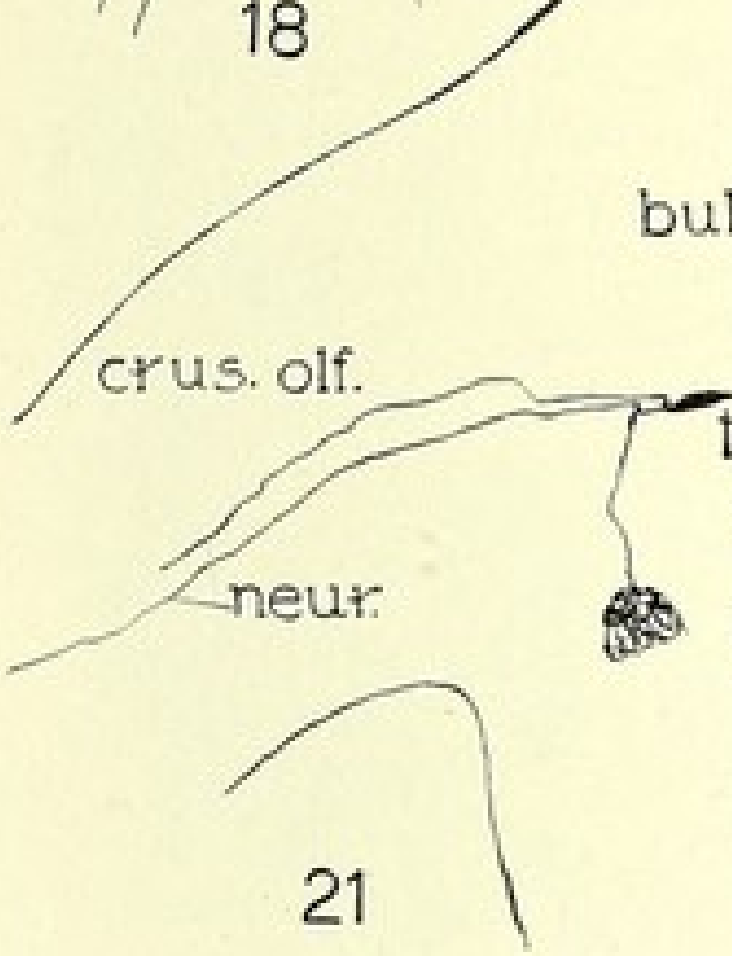

21

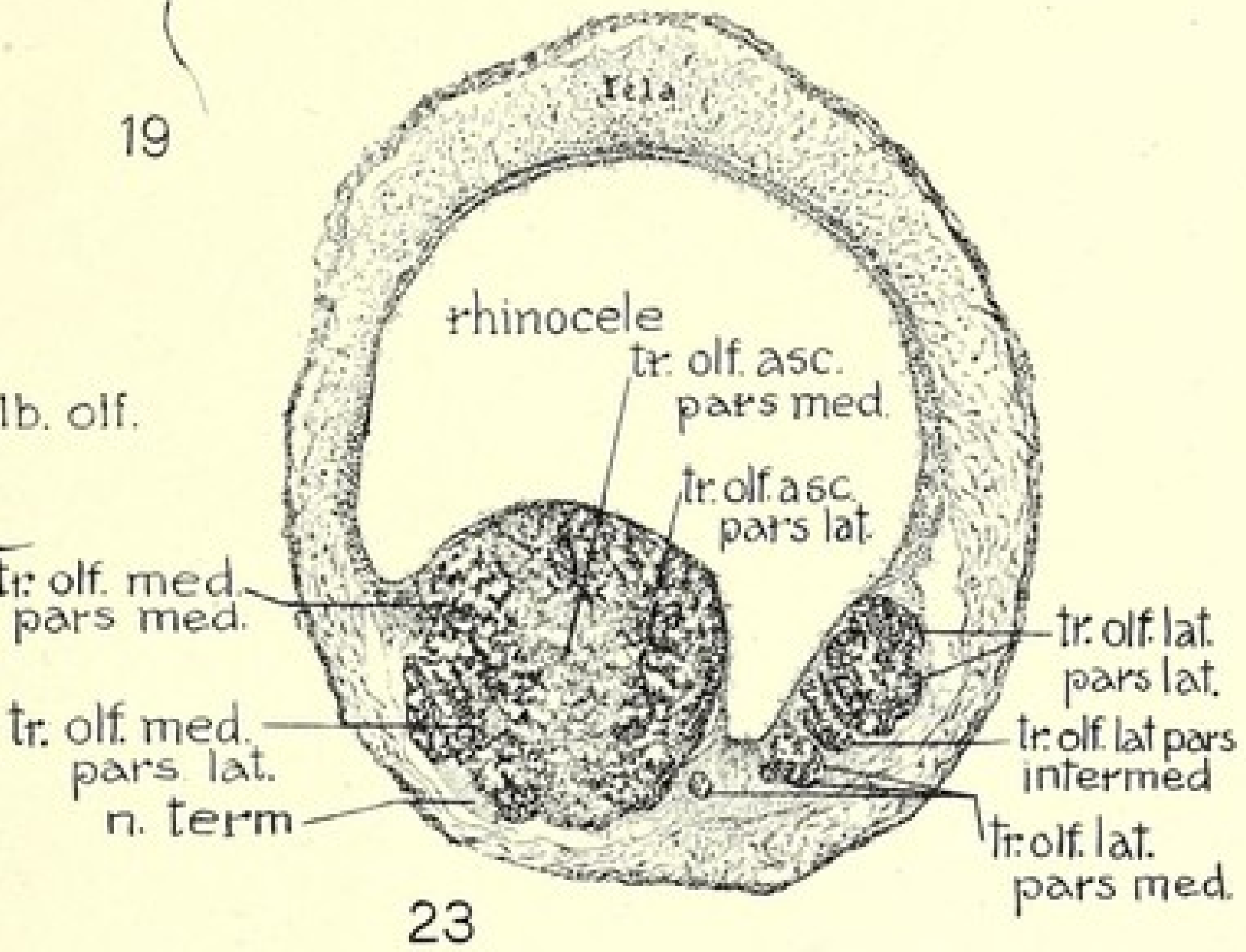

23

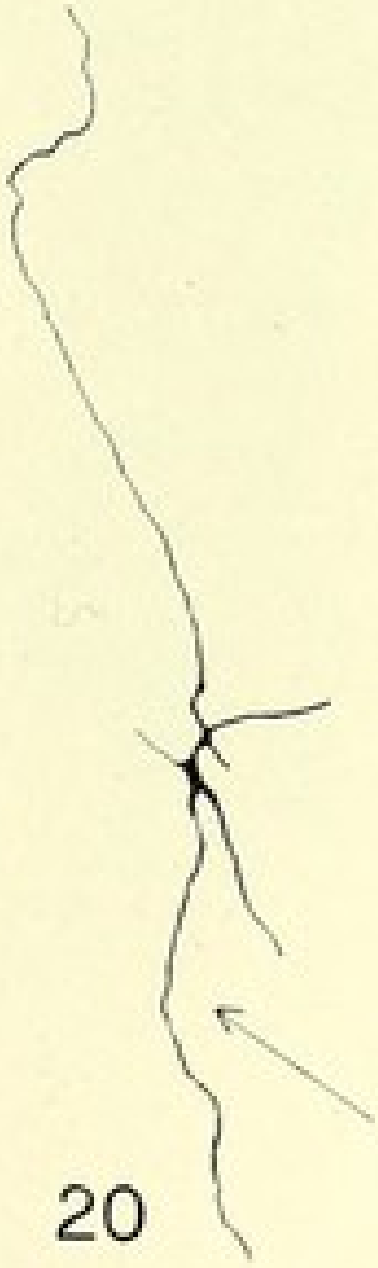

20

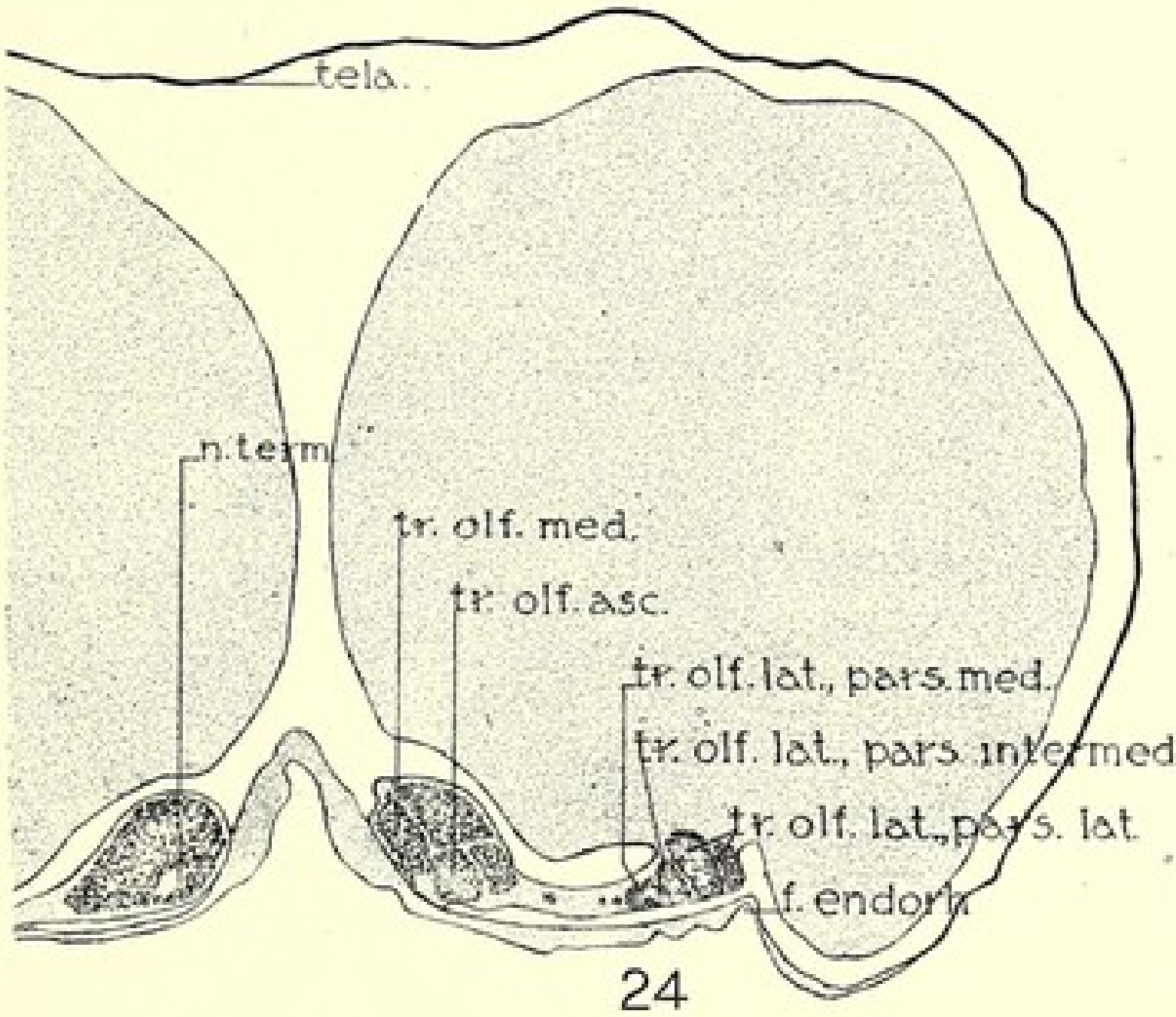

24

PLATE 6

EXPLANATION OF FIGURES

25 Transection through the rostral portion of the left cerebral hemisphere, slightly caudal to fig. 24. Toluidin blue method. × 46.

26 Cells of the nucleus medianus. Toluidin blue method. × 575. From transection. This nucleus is characterized by the arrangement of the cells in small, closely packed groups as shown in the figure. Compare fig. 25.

27 Oblique longitudinal section through the hemispheres showing the origin of the centrifugal fibers of the tractus olfactorius ascendens. Golgi method. × 9. The section is much nearer the frontal than the sagittal plane, as is shown by the inclusion of both olfactory crura, a portion of both optic nerves and much of the anterior commissure.

com. ant., commissura anterior; *corp. precom.*, *n. med.*, corpus precommissurale, nucleus medianus, this latter is the rostral end of the group of cells called 'lobus olfactorius posterior, pars medialis' by Goldstein; 'area olfactoria posterior medialis' and 'epistriatum' by Kappers ('06); 'area praecommissuralis septi' by Kappers and Theunissen ('08); 'ganglion mediale septi' by Gaupp ('99) and 'paraterminal body' by Elliot Smith ('03); *crura olf.*, crura olfactoria; *f. endorh.*, fissura endorhinalis; *hyp.*, hypophysis; *n. opt.*, nervus opticus; *nucl. olf. dors.*, nucleus olfactorius dorsalis; *nucl. olf. lat.*, nucleus olfactorius lateralis; *palaeostr.*, palaeostriatum; *s. lim. tel.*, sulcus limitans telencephali; *s. ypsil.*, *fur. ant.*, sulcus ypsiliformis, furca anterior, the fovea endorhinalis interna of Kappers; *tr. olf. asc.*, tractus olfactorius ascendens; *tr. olf. med.*, tractus olfactorius medialis.

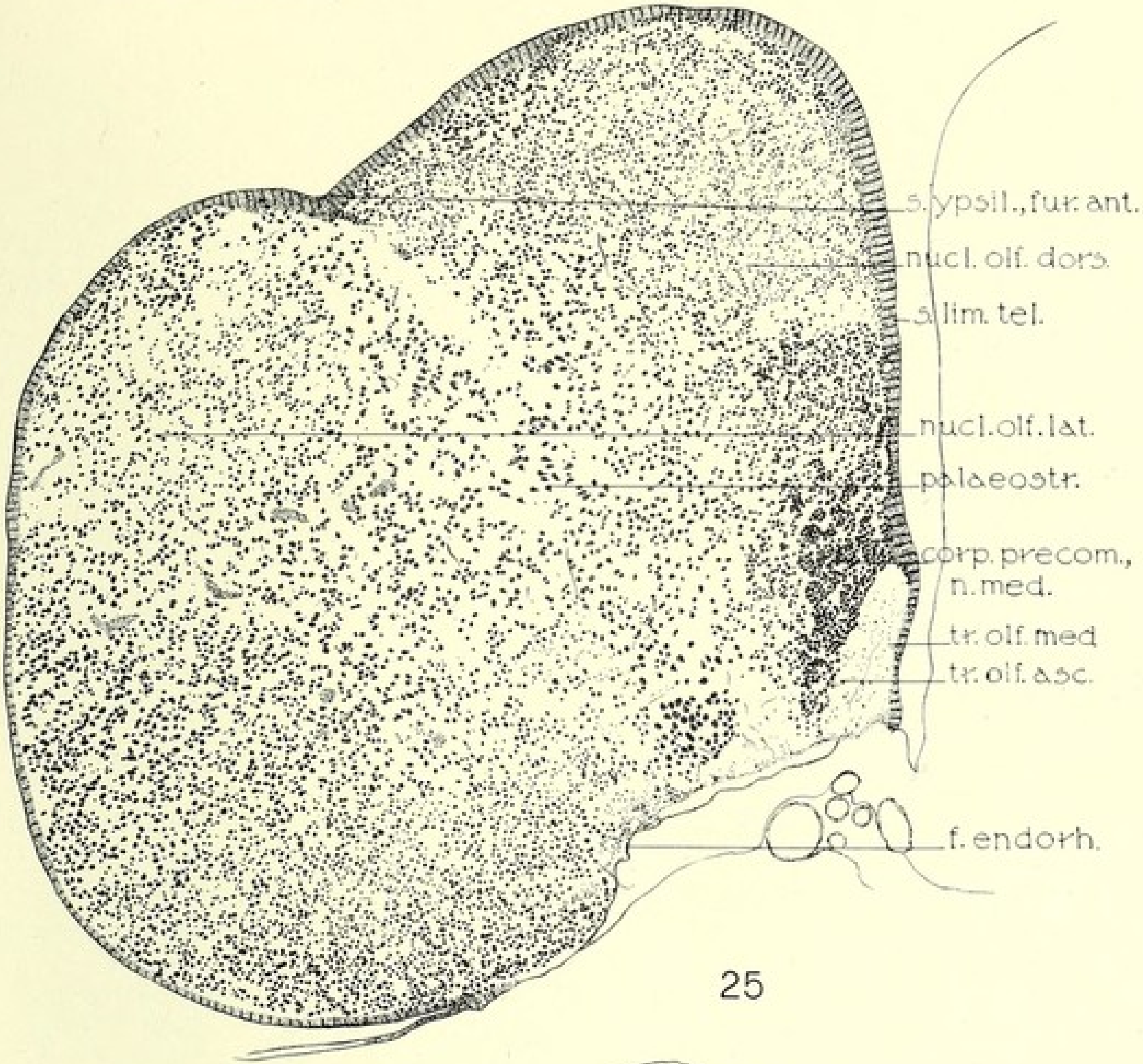
s. ypsil., fur. ant.
nucl. olf. dors.
s. lim. tel.
nucl. olf. lat.
palaeostr.
corp. precom., n. med.
tr. olf. med
tr. olf. asc.
f. endorh.

25

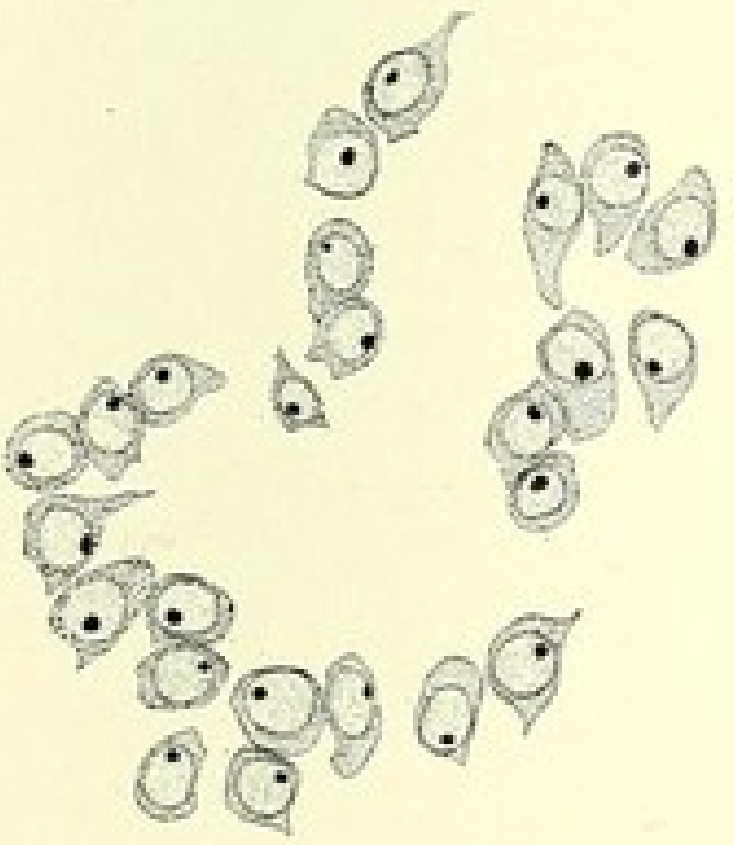

26

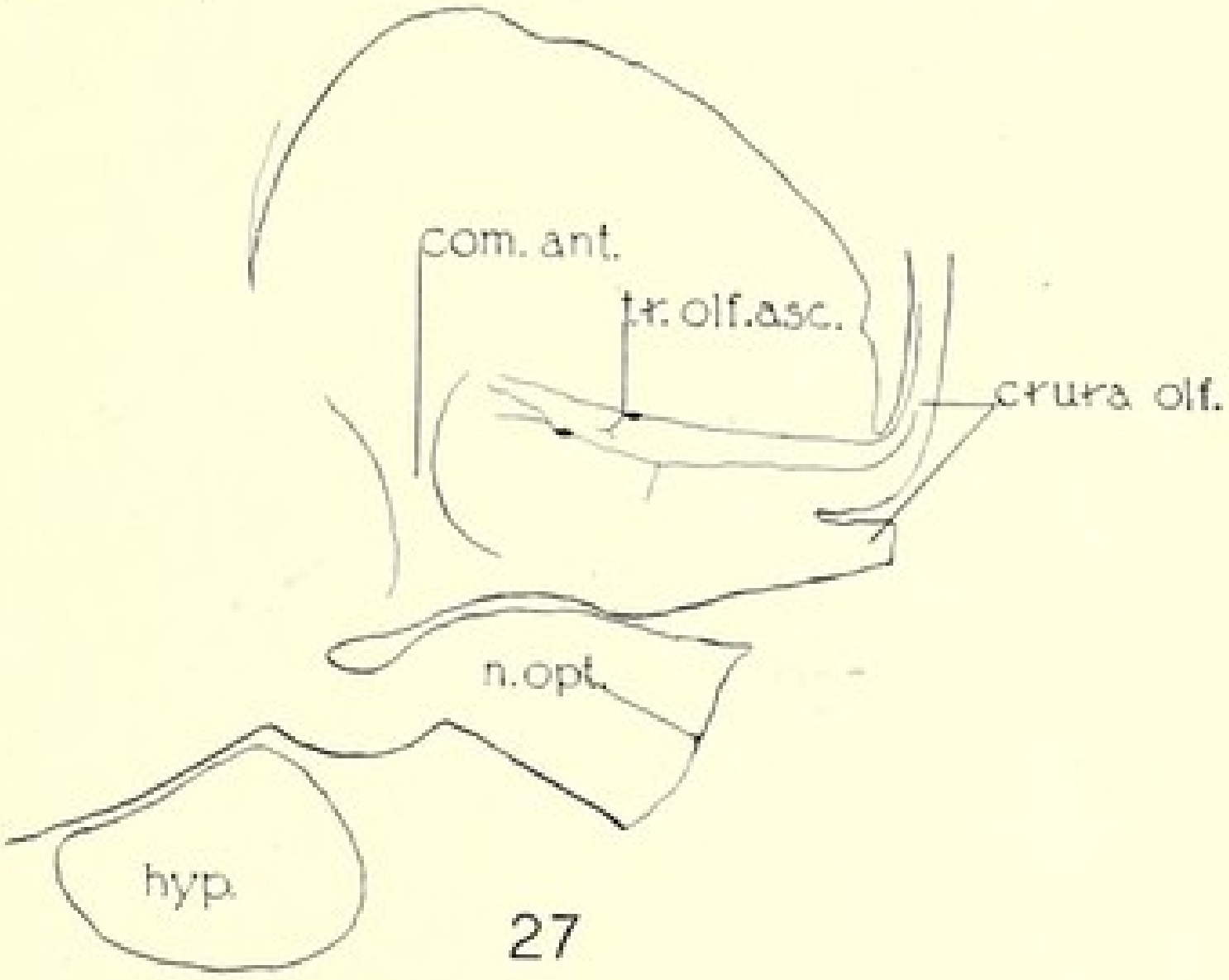
com. ant.
tr. olf. asc.
crura olf.
n. opt.
hyp.

27

PLATE 7

EXPLANATION OF FIGURES

28–30 Cells of origin of the fibers of the tractus olfactorius ascendens. Golgi method. × 93. These cells lie in the rostral portion of the precommissural body, in the nucleus medianus (see fig. 27). They are taken from a sagittal series and show the branching of the dendrites among the cells of the nucleus. The neurites terminate in the nucleus olfactorius anterior of the olfactory bulb.

31 Association cell of the nucleus medianus. Golgi method. × 93. From sagittal section.

32–33 Cells of the rostral part of the nucleus olfactorius lateralis. Golgi method. × 93. The neurite of fig. 32 enters the tractus strio-thalamicus, while that of fig. 33 apparently ends in the ventro-lateral portion of the hemisphere. The cells are taken from a sagittal series and occupy a position about midway between the dorsal and ventral surfaces of the hemisphere.

34 Transection through the cerebral hemispheres immediately rostral to the anterior commissure. Weigert method. × 17. The nervus terminalis is, at this level, separated from the tractus olfactorius medialis, preparatory to its decussation; the two components of the tractus olfactorius medialis likewise appear distinctly.

com. interbulb., commissura interbulbaris; *f. end.*, fissura endorhinalis; *n. term.*, nervus terminalis; *s. ypsil.*, *ant. limb*, sulcus ypsiliformis, anterior limb; *tr. olf. lat.*, tractus olfactorius lateralis spreading in the form of a crescent to end in the nucleus olfactorius lateralis, *tr. olf. med.*, *pars lat.*, tractus olfactorius medialis, pars lateralis; *tr. olf. med.*, *pars med.*, tractus olfactorius medialis, pars medialis; *tr. strio-thal.*, tractus strio-thalamicus; bundles appearing here are made up, mainly, of fibers which do not decussate.

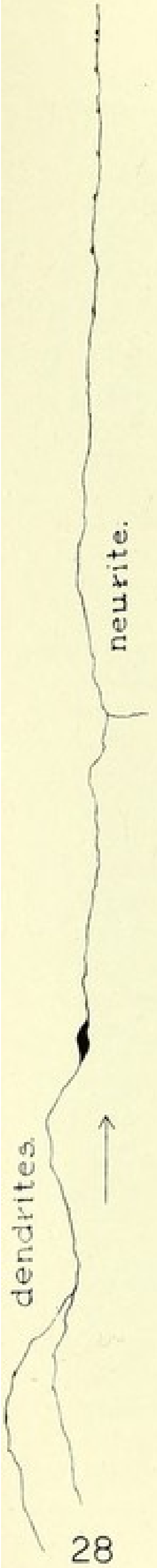

28



29

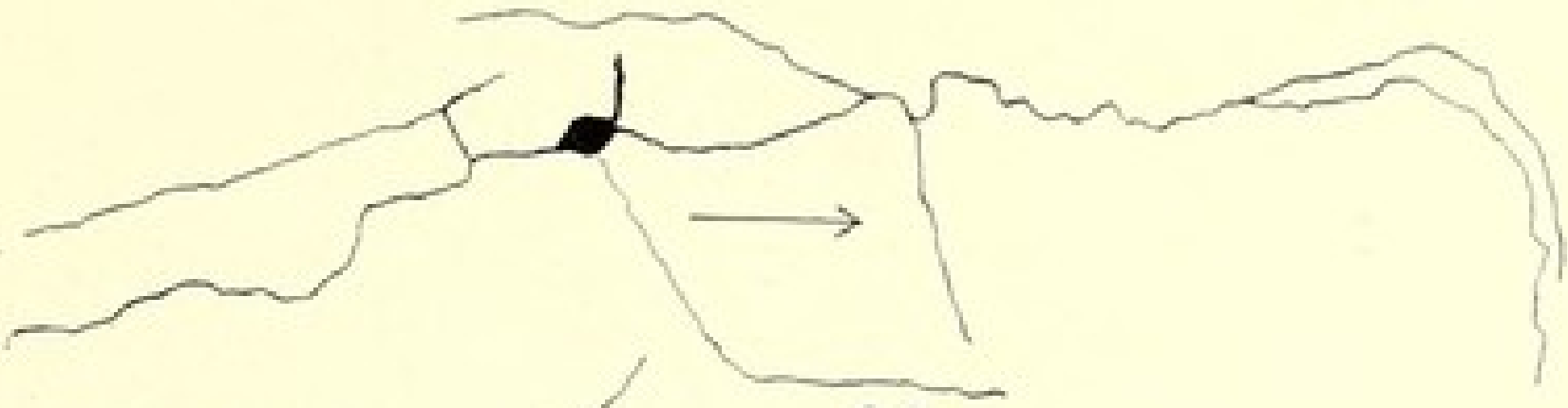

30

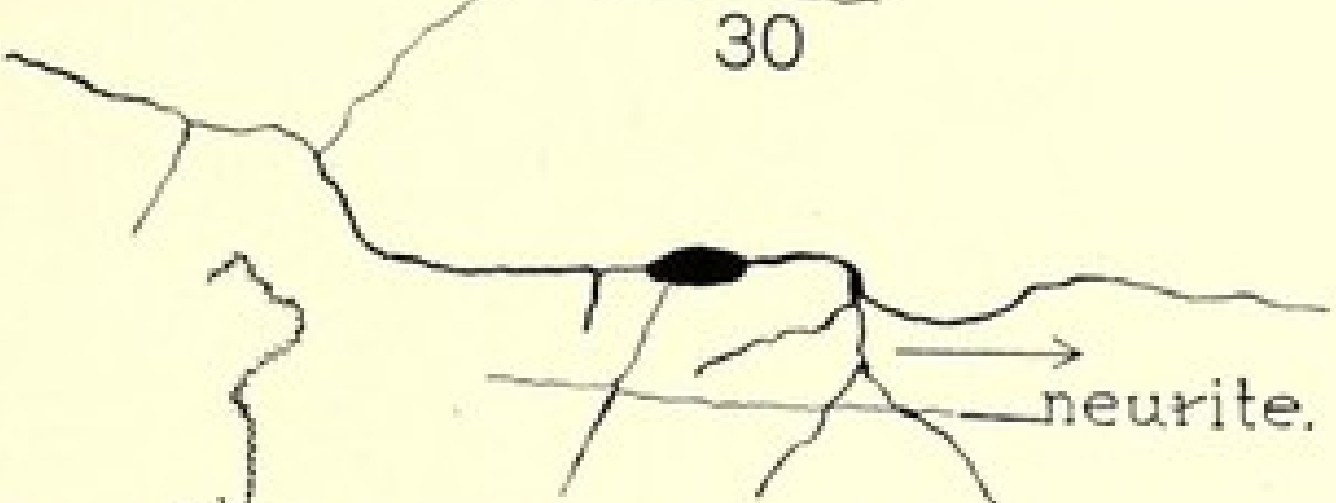

31

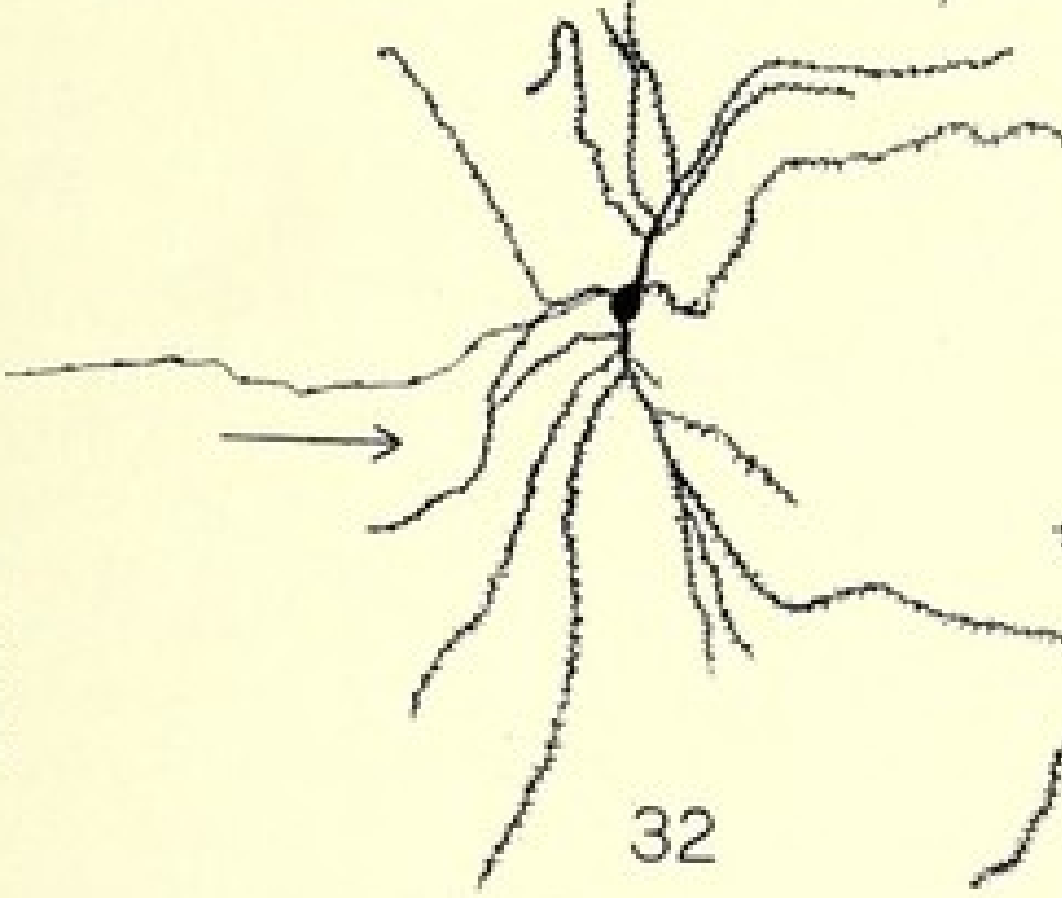

32

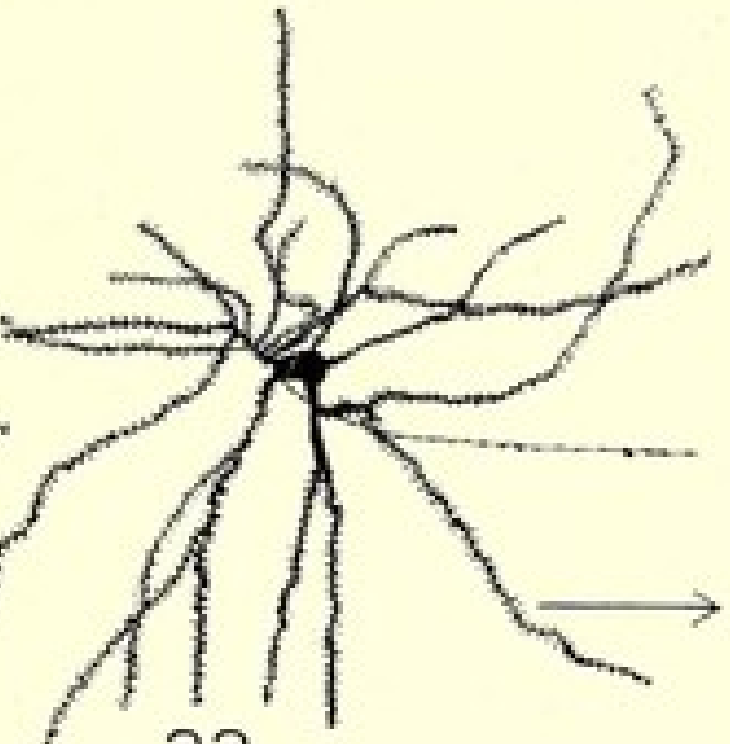

33

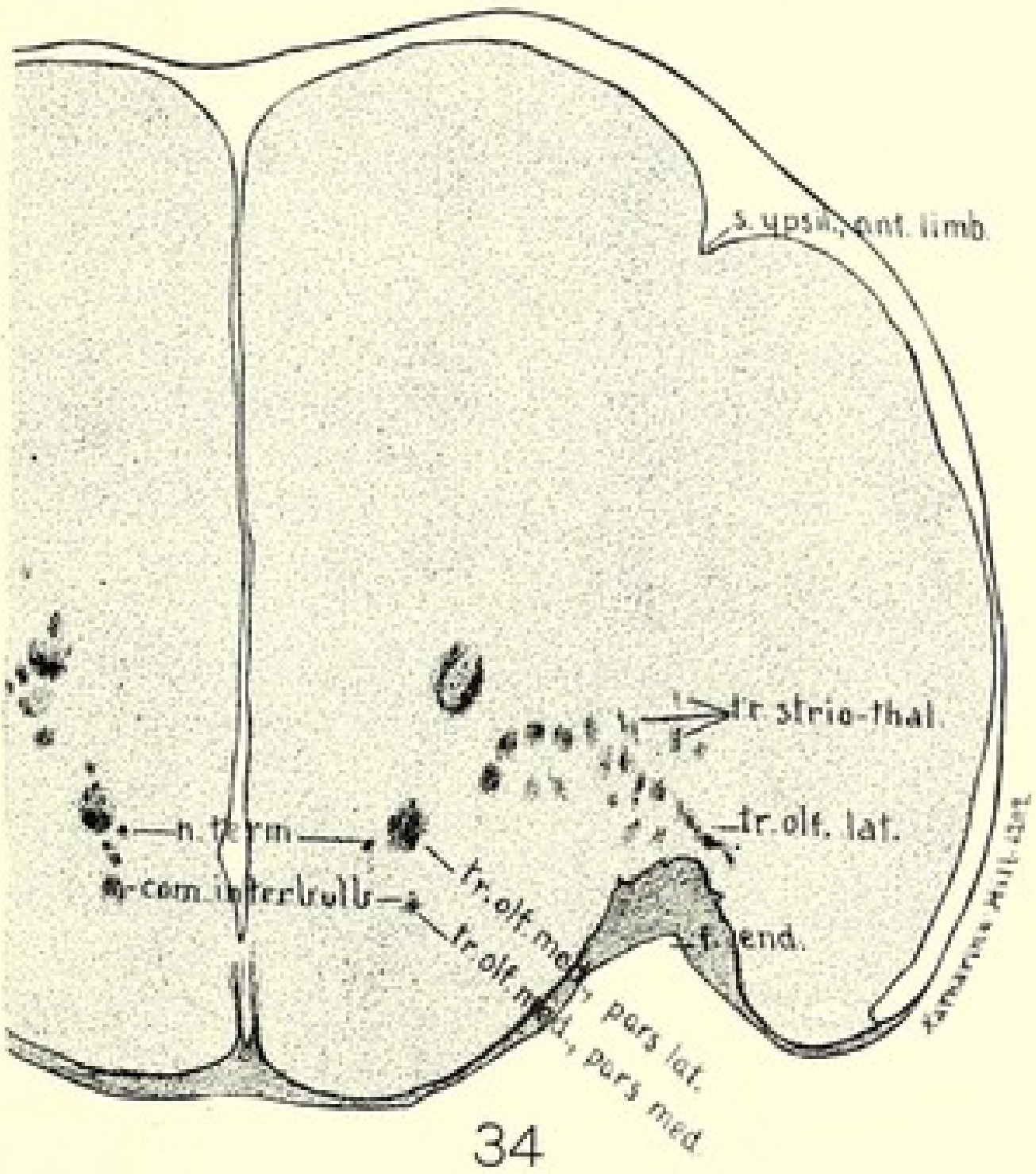

34

PLATE 8

EXPLANATION OF FIGURES

35 Transection through the hemispheres at the rostral margin of the anterior commissure. Weigert method. × 17. This section shows particularly the decussation of the nervus terminalis (see also Sheldon '09, figs. 6 and 7); also the commissura dorsalis, partly made up of fibers connecting the two partes supracommissurales of the precommissural body, partly of fibers connecting the two nuclei olfactorii dorsales (commissura hippocampi, pars anterior). The relation of the corpus precommissurale to the anterior commissure is brought out clearly, the pars commissuralis or commissure bed of Elliot Smith appearing ventrally and the pars supracommissuralis dorsally.

36 Transection through the middle of the anterior commissure. Weigert method. × 17. Shows especially the decussation of the tractus strio-thalamicus cruciatus and of the tractus olfactorius medialis, pars lateralis; also the commissura hippocampi, pars posterior, presenting points of similarity, morphologically, with the commissura dorsalis of Elliot Smith in amphibians, reptiles and mammals, the commissura pallii of Kappers and Theunissen in amphibians, the commissura pallii posterior of Edinger in reptiles, the commissura olfactorii internuclearis of Goldstein, and connecting the nuclei pyriformes of the two sides. This section also brings out several of the components of the medial forebrain bundle, the tractus olfacto-lobaris medialis of Kappers ('06). Dorsally, mingled with the fibers of the commissura dorsalis are the fibers of the tractus hypothalamo-olfactorius medialis. These are ascending fibers, part of which decussate in the anterior commissure and part in the region of the nucleus posterior tuberis (see figs. 102, 104, 105). This is the tractus olfacto-hypothalamicus medialis of Goldstein.

com. ant., commissura anterior; *com. dors.*, commissura dorsalis; *com. dors.+ dec. tr. hyp. olf. med.*, commissura dorsalis plus decussatio tractorum hypothalamo-olfactoriorum medialium; *com. hipp., pars post.*, commissura hippocampi, pars posterior; *com. interbulb.* (*tr. olf. med., pars. med.*), commissura interbulbaris (tractus olfactorius medialis, pars medialis, the fibers of the tract forming the commissura interbulbaris (aut); *corp. precom., pars com.*, corpus precommissurale, pars supracommissuralis; *dec. tr. olf. med., pars lat.*, decussation of the tractus olfactorii mediales, partes laterales; *dec. tr. strio-thal. cruc.*, decussation of the tractus strio-thalamici cruciati; *n. olf. lat.*, nucleus olfactorius lateralis; *n. opt.*, nervus opticus; *n. pyr.*, nucleus pyriformis—this, together with a part of the nucleus olfactorius lateralis, corresponds to the lobus olfactorius posterior or area olfactoria posterior lateralis of Kappers ('06), the lobus olfactorius posterior, pars lateralis of Goldstein, the lobus olfactorius of Edinger ('08), the area olfactoria lateralis of Kappers and Theunissen; *n. term.*, nervus terminalis; *palaeostr.*, palaeostriatum; *s. lim. tel.*, sulcus limitans telencephali; *s. ypsil., fur. ant.*, sulcus ypsiliformis, furca anterior; *tr. hyp. olf. med.*, tractus hypothalamo-olfactorius medialis; *tr. olf. lat.*, tractus olfactorius lateralis; *tr. olf. med., pars. lat.*, tractus olfactorius medialis, pars lateralis; *tr. olf. thal. med., pars vent.*, tractus olfacto-thalamicus medialis, pars ventralis—this latter component of the medial forebrain bundle is descending and made up of uncrossed fibers (see fig. 136), which, with the pars intermedia, and pars dorsalis, form the tractus olfacto-lobaris medialis or tractus olfacto-hypothalamicus medialis of Kappers; *tr. strio-thal.*, tractus strio-thalamicus.

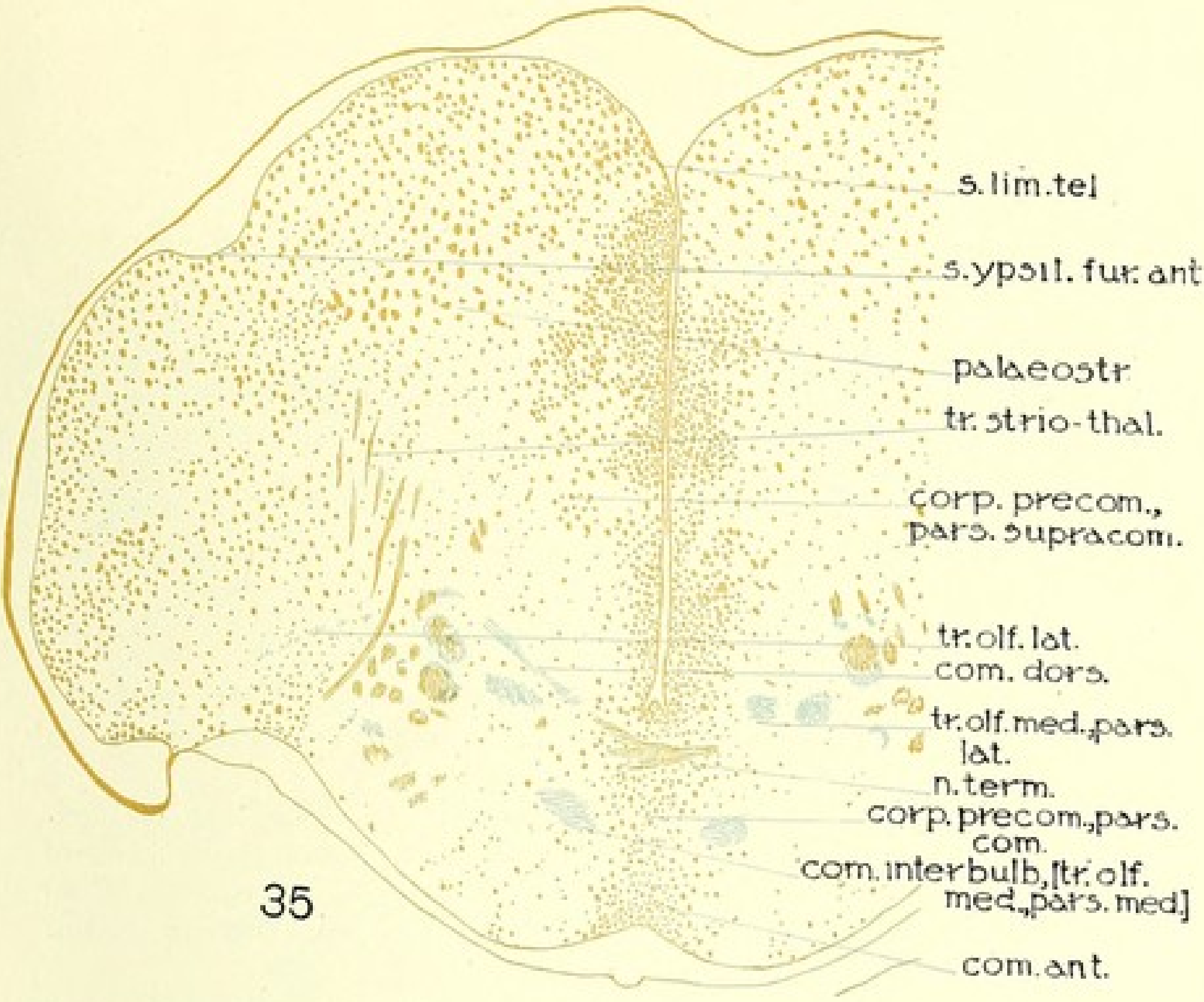
s. lim. tel
s. ypsil. fur. ant.
palaeostr.
tr. strio-thal.
corp. precom., pars. supracom.
tr. olf. lat.
com. dors.
tr. olf. med., pars. lat.
n. term.
corp. precom., pars. com.
com. interbulb, [tr. olf. med., pars. med]
com. ant.

35

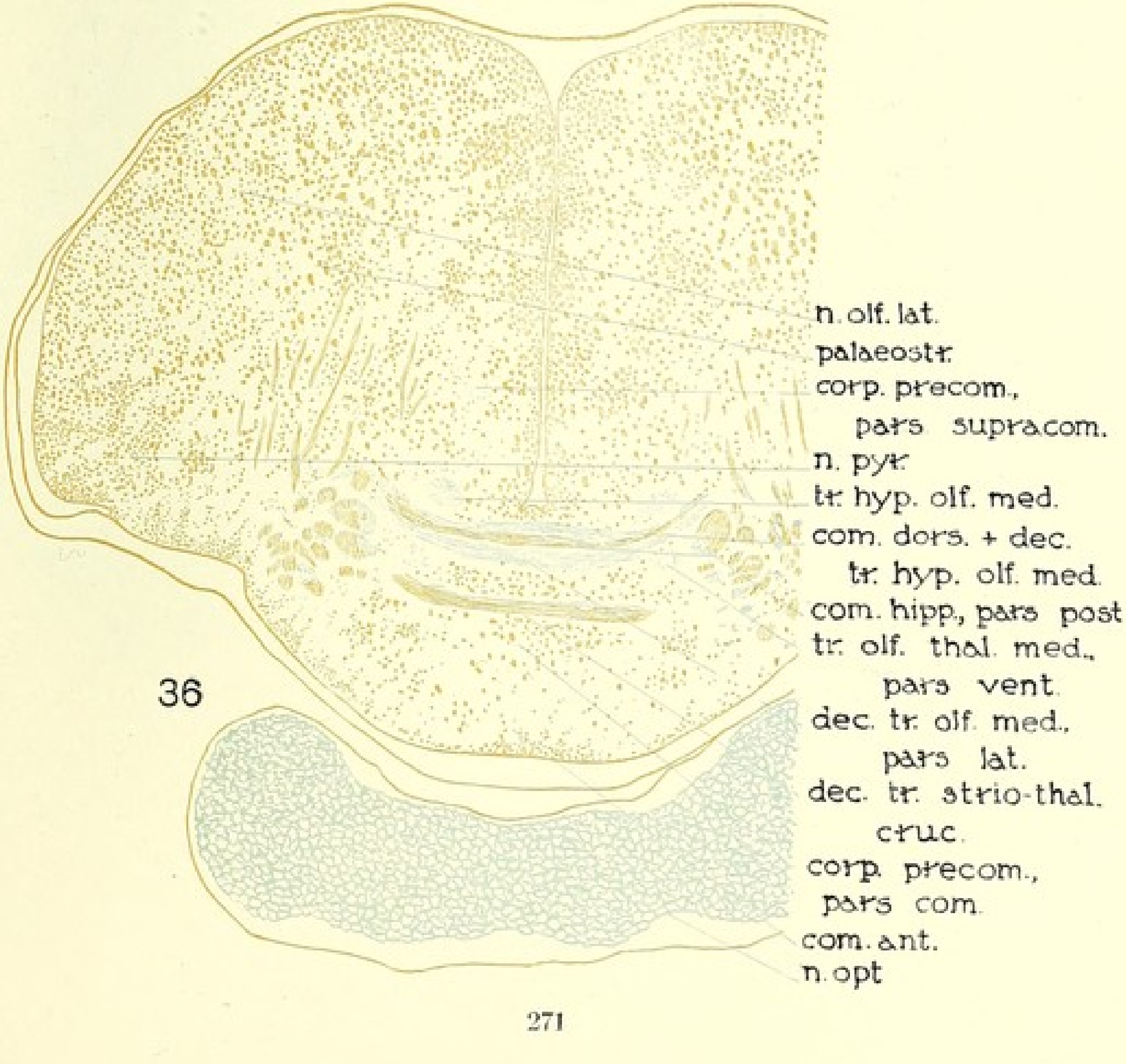
n. olf. lat.
palaeostr.
corp. precom., pars supracom.
n. pyr.
tr. hyp. olf. med.
com. dors. + dec. tr. hyp. olf. med.
com. hipp., pars post
tr. olf. thal. med., pars vent.
dec. tr. olf. med., pars lat.
dec. tr. strio-thal. cruc.
corp. precom., pars com.
com. ant.
n. opt

36

PLATE 9

EXPLANATION OF FIGURES

37 Transection through the anterior commissure. Ramón y Cajal method. × 46. Shows particularly the decussation of the tractus strio-thalamicus cruciatus.

38 Transection through the anterior commissure. Toluidin blue method. × 46. Shows with great clearness the limits of the pars supracommissuralis of the corpus precommissurale, the sulcus limitans telencephali, the nucleus olfactorius dorsalis and the bed of the anterior commissure, the pars commissuralis of the precommissural body.

corp. precom., pars com., corpus precommissurale, pars commissuralis; *corp. precom., pars supracom.*, corpus precommissurale, pars supracommissuralis; *dec. tr. hyp. olf. med. + com. hipp., pars post.*, decussatio tractus hypothalamo-olfactorii medialis plus commissura hippocampi, pars posterior; *dec. tr. strio-thal. cruc.*, decussatio tractus strio-thalamici cruciati; *necl. com. lat.*, nucleus commissuralis lateralis; *nucl. olf. dors.*, nucleus olfactorius dorsalis; *nucl. olf. lat.*, nucleus olfactorius lateralis; *nucl. pyr.*, nucleus pyriformis; *nucl. teniae*, nucleus teniae, the nucleus taeniae of Edinger, Kappers and Goldstein; *palaeostr.*, palaeostriatum; *rec. preopt.*, recessus preopticus; *s. lim. tel.*, sulcus limitans telencephali; *tr. hyp. olf. med.*, tractus hypothalamo-olfactorius medialis; *tr. olf. med., pars. lat.*, tractus olfactorius medialis, pars lateralis; *tr. olf. med., pars lat. + com. hipp., pars post.*, tractus olfactorius medialis, pars lateralis plus commissura hippocampi, pars posterior; *tr. olf. that. med., pars. vent.*, tractus olfacto-thalamicus medialis, pars ventralis; *tr. med. preopt., pars. ant.*, tractus medianopreopticus, pars anterior; *tr. strio-thal.*, tractus strio-thalamicus; *tr. strio-thal. incruc.*, tractus strio-thalamicus incruciatus.

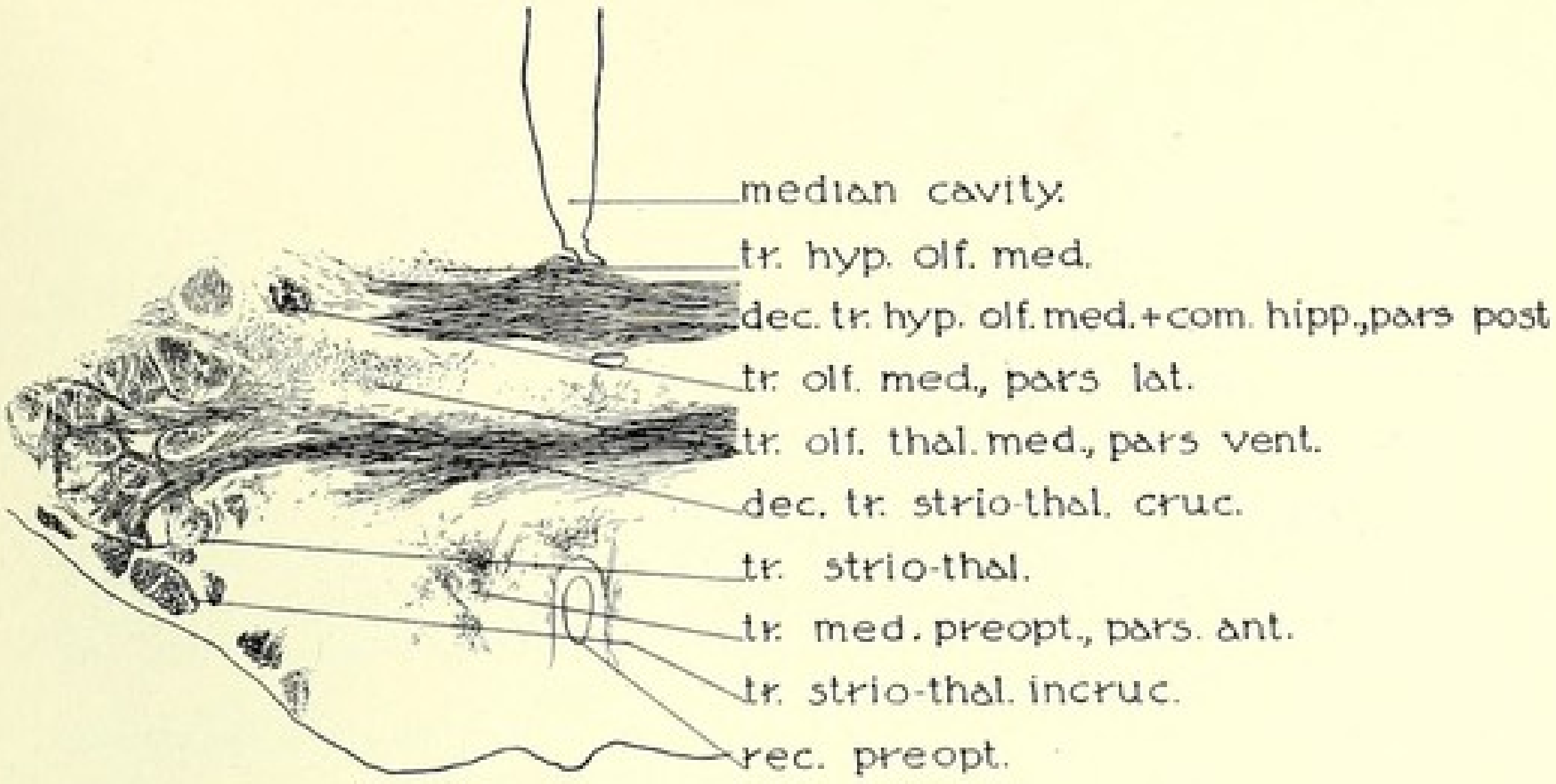
median cavity.
tr. hyp. olf. med.
dec. tr. hyp. olf. med.+com. hipp., pars post
tr. olf. med., pars lat.
tr. olf. thal. med., pars vent.
dec. tr. strio-thal. cruc.
tr. strio-thal.
tr. med. preopt., pars. ant.
tr. strio-thal. incruc.
rec. preopt.

37

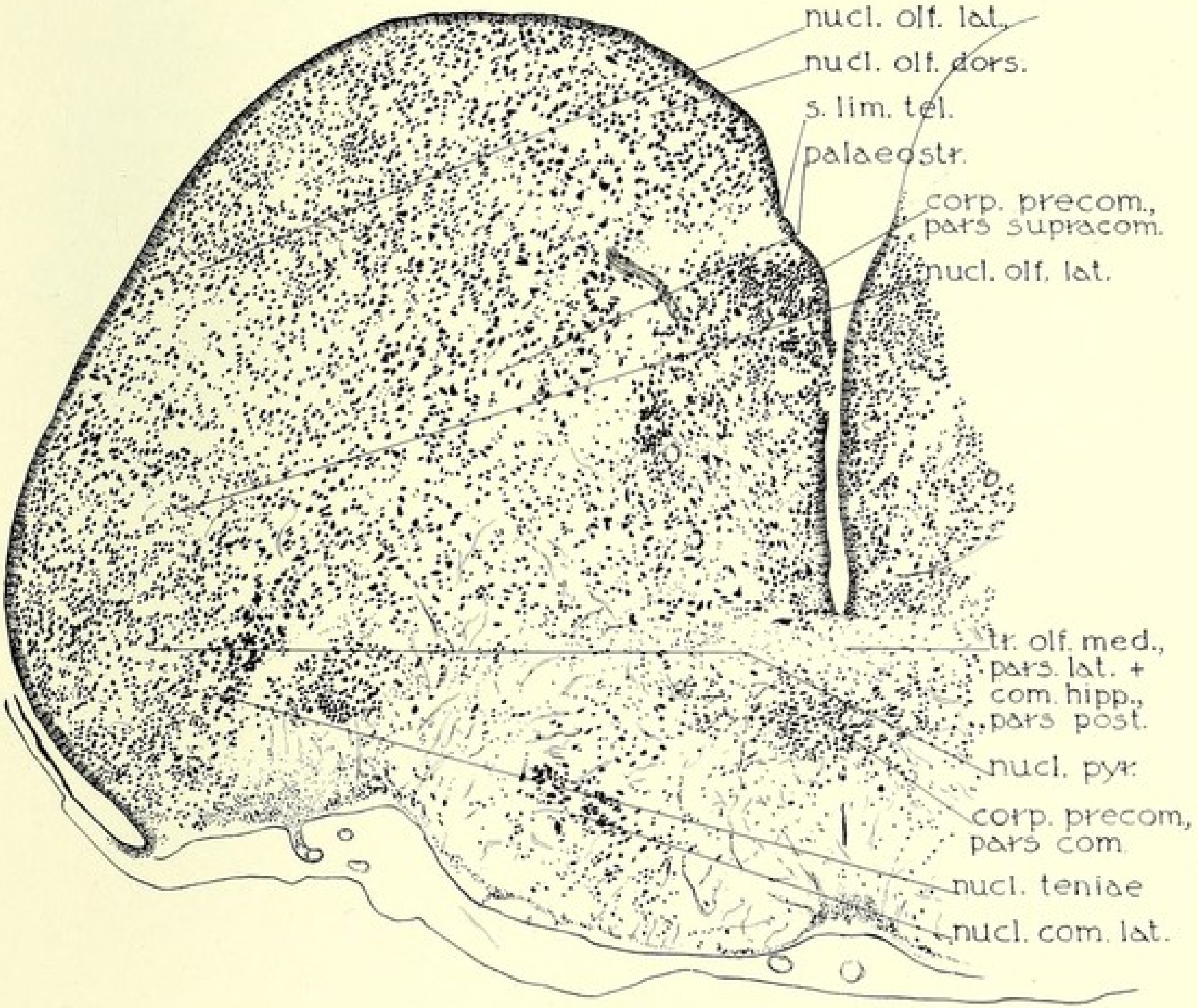
nucl. olf. lat.
nucl. olf. dors.
s. lim. tel.
palaeostr.
corp. precom., pars supracom.
nucl. olf. lat.
tr. olf. med., pars. lat. + com. hipp., pars post.
nucl. pyr.
corp. precom, pars com.
nucl. teniae
nucl. com. lat.

38

PLATE 10

EXPLANATION OF FIGURES

39 Sagittal section through the hemisphere. Golgi method. × 9. Shows cells of the corpus precommissurale sending axones, the fibrae precommissurales striaticae, into the palaeostriatum. Both ascending and descending fibers of the tractus strio-thalamicus are shown; note especially the dichotomous branching of the ascending neurites to form tangential fibers.

40 Cell of origin of the tractus olfacto-thalamicus medialis from the nucleus medianus. Golgi method. × 94. From sagittal section.

41–42 Association cells of the nucleus medianus. Golgi method. × 93. From sagittal section.

43 One of the neurones of the nucleus medianus, the neurite of which forms one of the fibrae precommissurales striaticae. Golgi method. × 93. (See fig. 39.) From sagittal section.

44 Cells of the palaeostriatum. Toluidin blue method. × 575. From transverse section.

45 Neurone from cerebral hemisphere. Golgi method. × 93. From sagittal section, neurite directed caudad, into tractus strio-thalamicus. This neurone can hardly be assigned to a definite region, as it lies about midway between the typical cells of the palaeostriatum and those of the area olfactoria lateralis. It will be noted that its perikaryon is larger than that of typical cells of the area olfactoria lateralis but that its dendrites do not show the conspicuous thorns of the typical palaeostriatal neurones.

46 Cells of the dorsal portion of the corpus precommissurale, pars supracommissuralis. Toluidin blue method. From transection. × 575.

47 Cells of the nucleus pyriformis. Toluidin blue method. From transection. × 575.

48 Neurone from the nucleus olfactorius lateralis. Golgi method. × 93. From sagittal section. This cell is found in the dorsal portion of the hemisphere, adjacent to the nucleus olfactorius dorsalis, but in the region called epistriatum by Johnston; its neurite enters the tractus strio-thalamicus.

49 Neurone from the nucleus olfactorius lateralis. Golgi method. × 93. From sagittal section. This is found in the rostro-lateral portion of the hemisphere; it comes into association with the ascending fibers of the tractus thalamo-striaticus as shown also in figs. 50 and 51.

fib. precom. str., fibrae precommissurales striatici; *hab.*, habenula; *tr. strio-thal.*, tractus strio-thalamicus; *tr. thal. striat.*, tractus thalamo-striaticus.

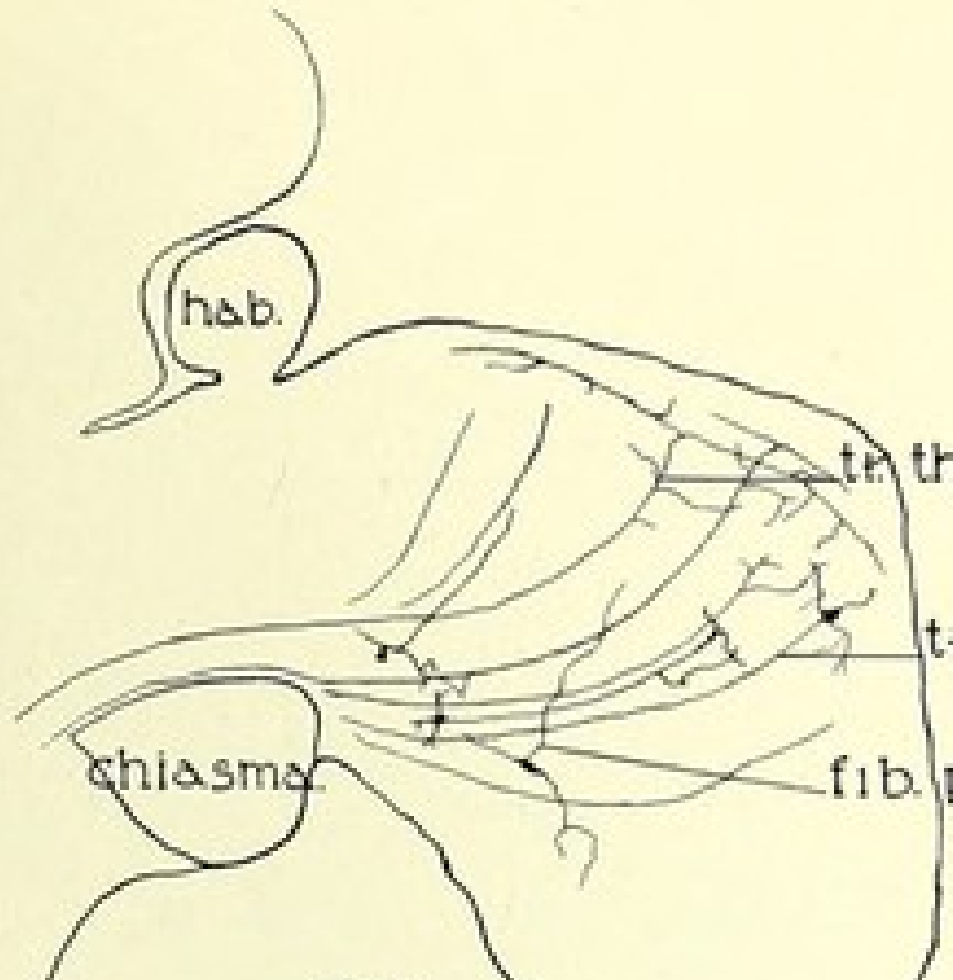

39

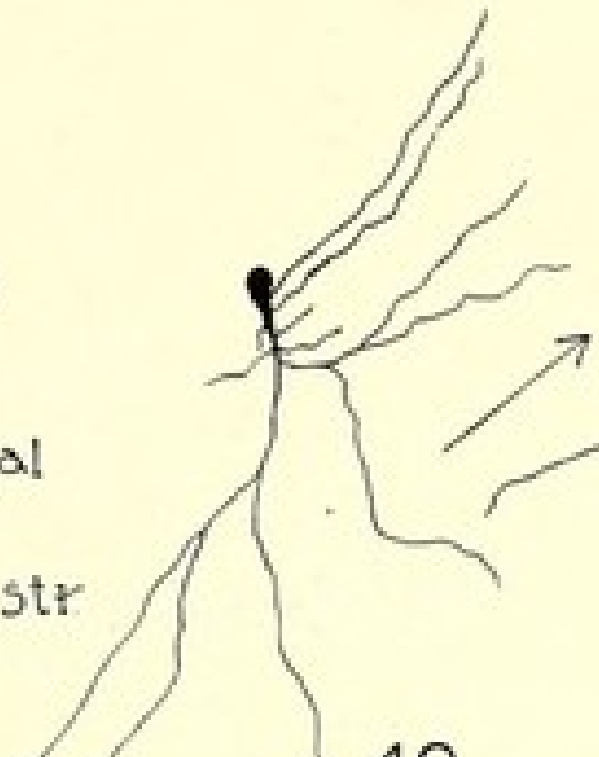

40

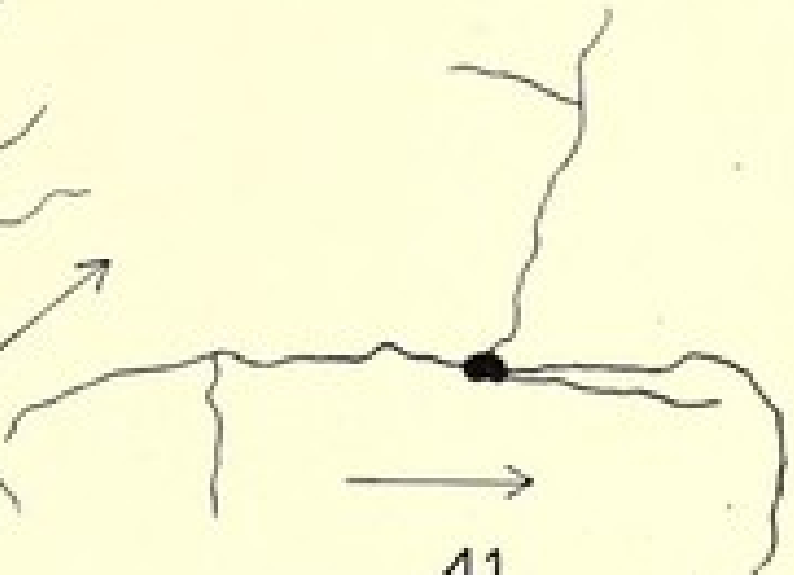

41

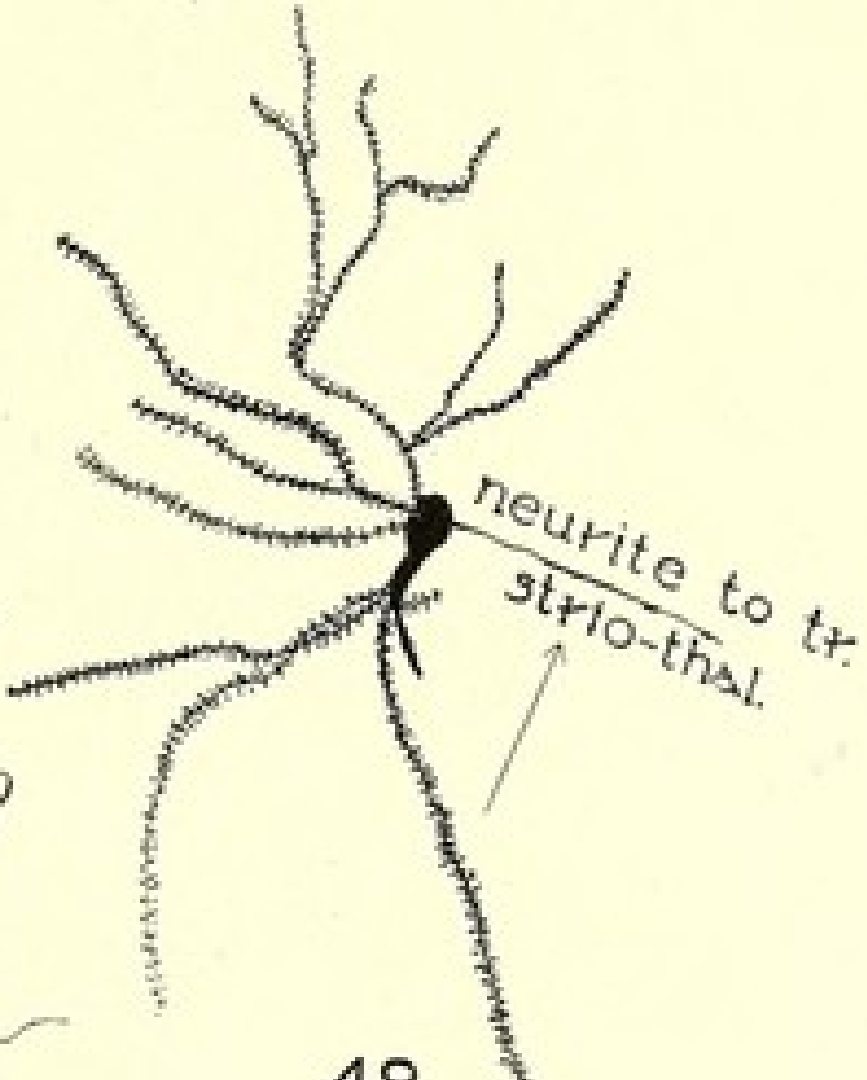

48

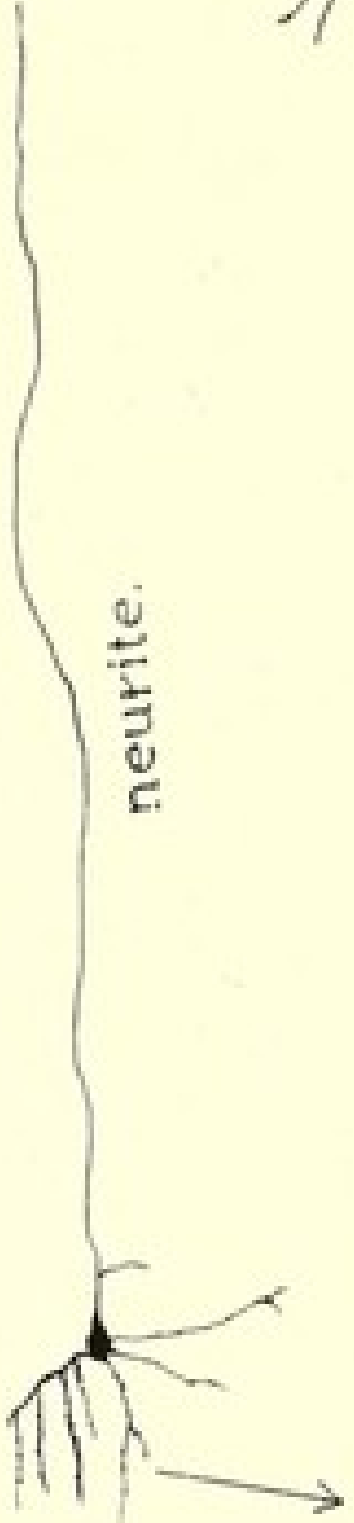

43

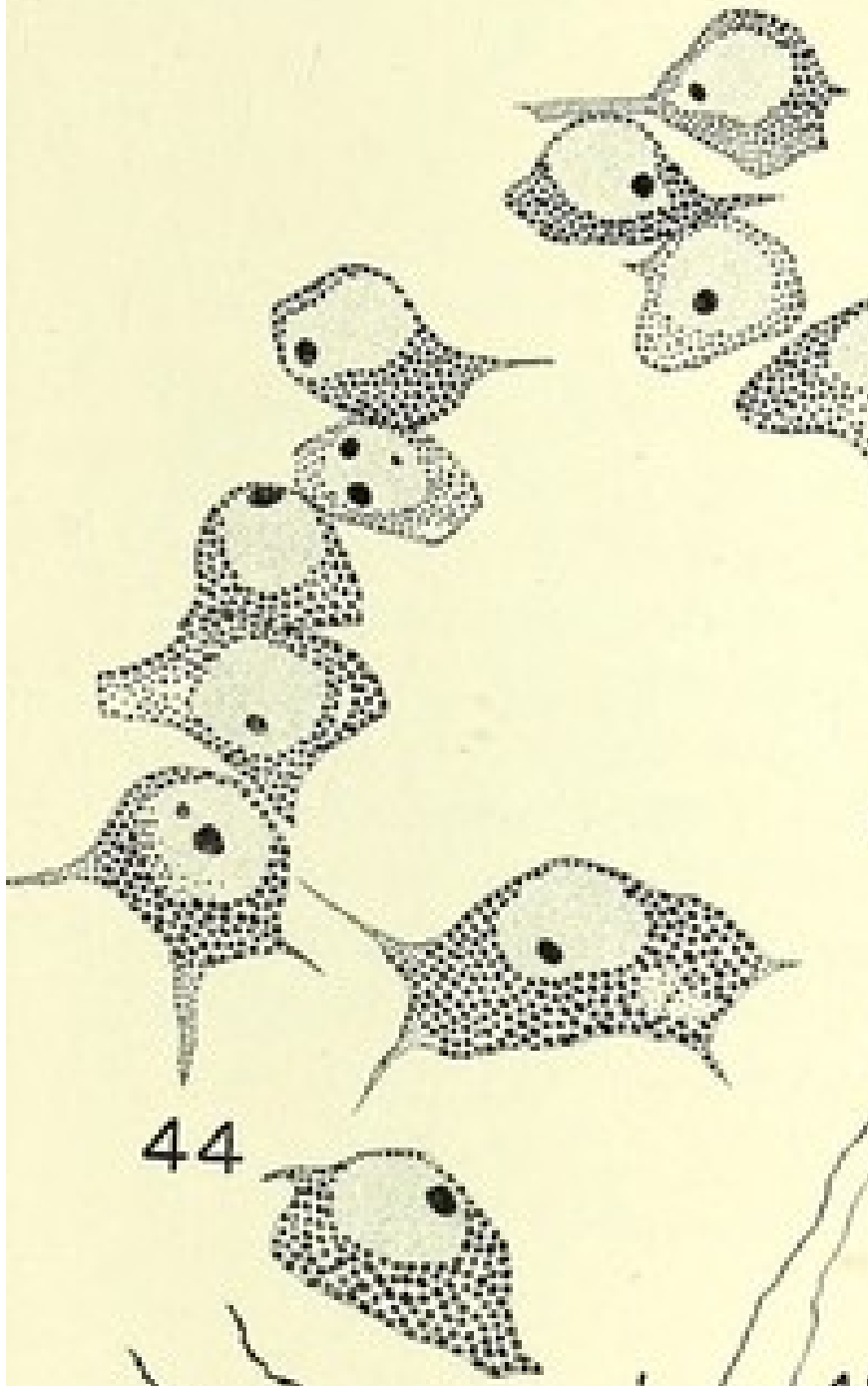

44

42

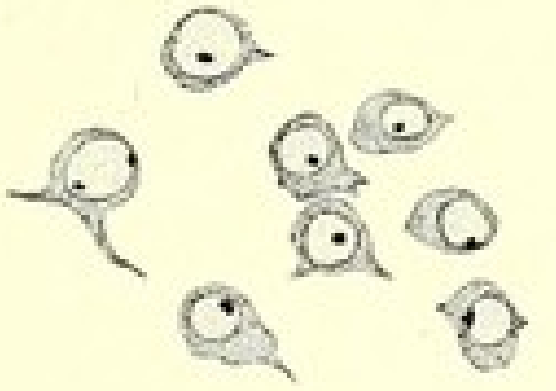

46

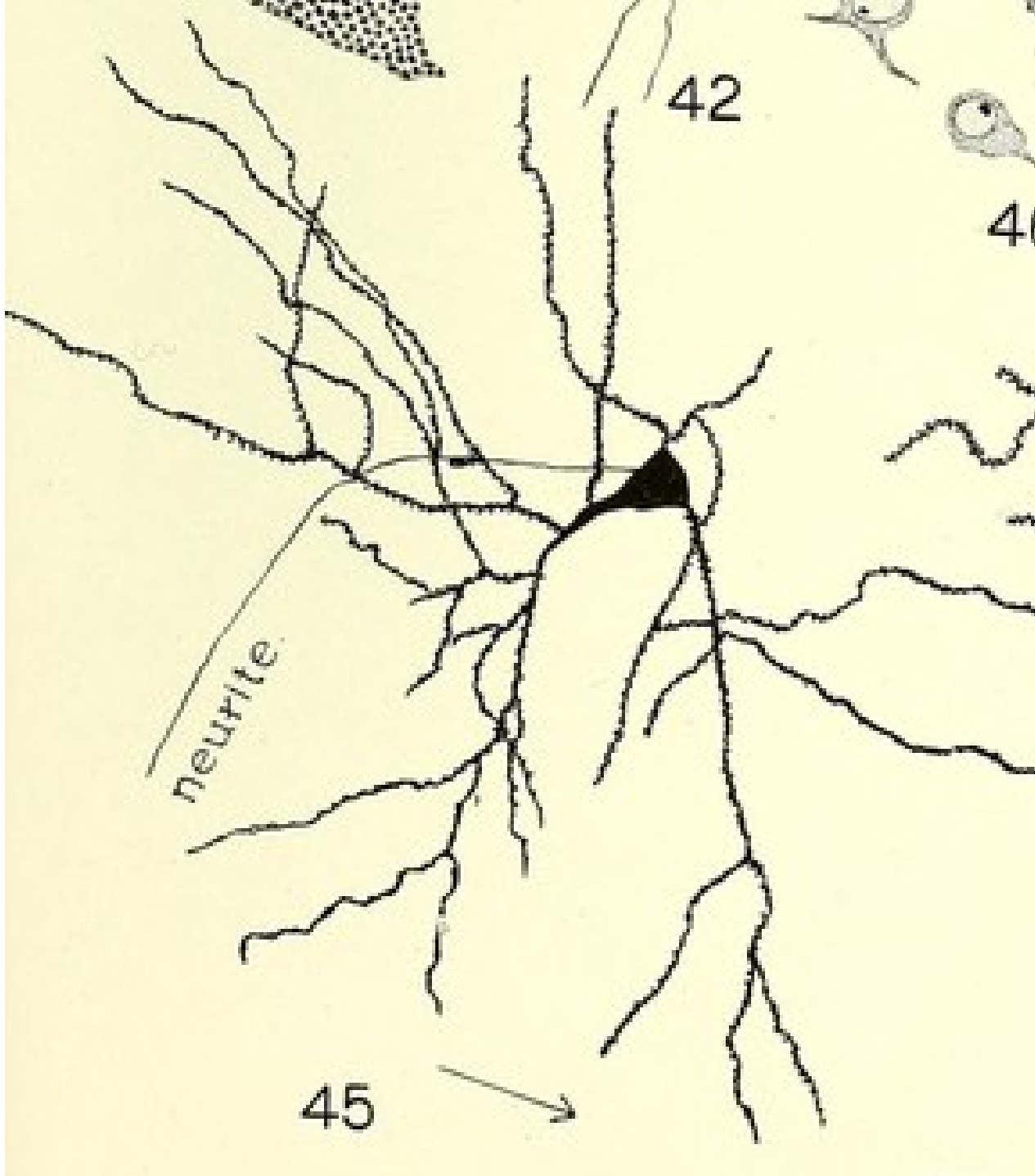

45

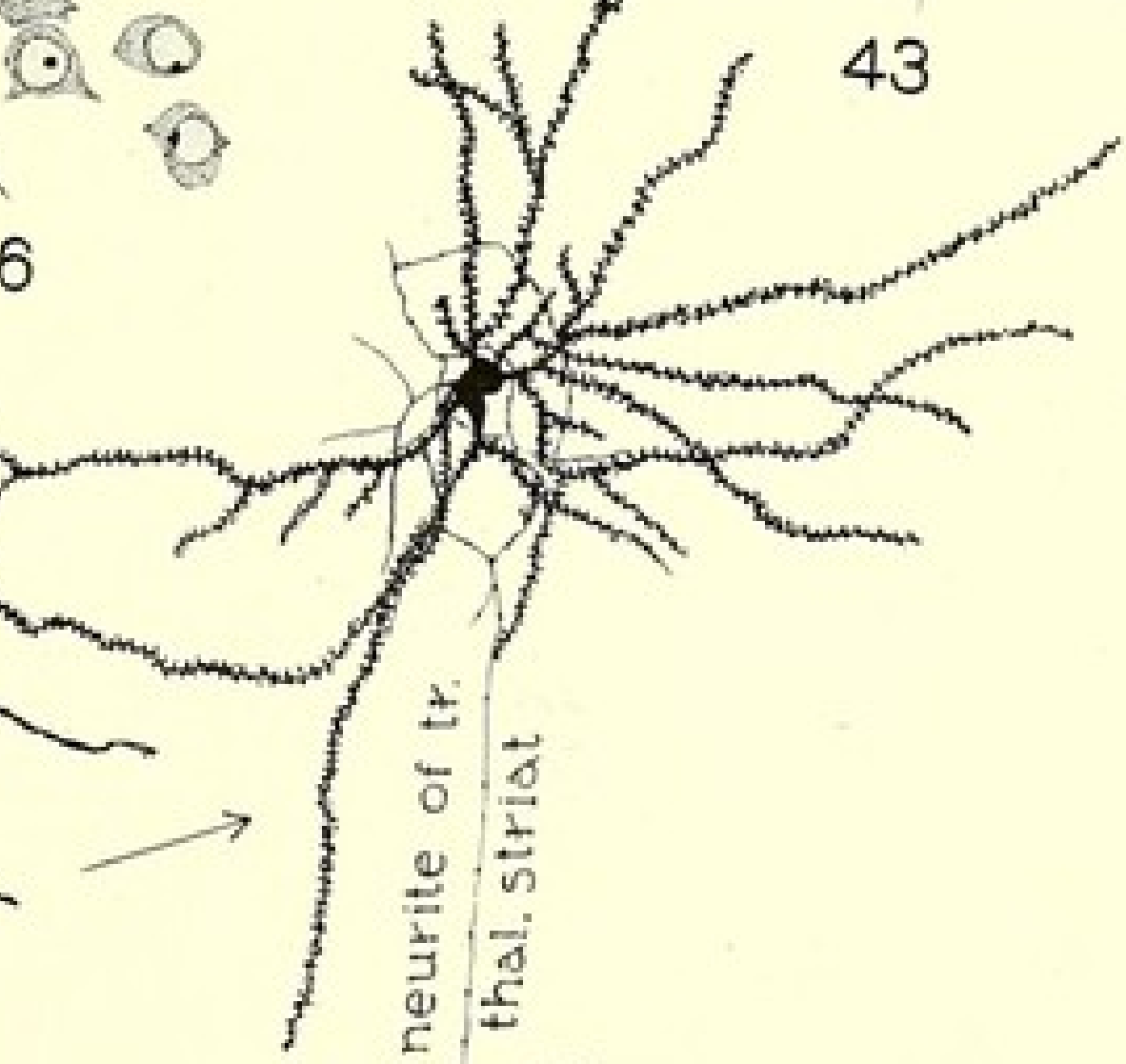

49



47

PLATE 11

EXPLANATION OF FIGURES

50–51 Neurones of the palaeostriatum. Golgi method. × 185. From sagittal sections. About the perikaryon of each neurone is a network formed by the terminal arborization of the neurites of the ascending fibers of the tractus strio-thalamicus. The larger portion of the cells of the palaeostriatum are very thorny, as shown in the cells drawn; a number of the neurones, however, particularly those giving rise to descending fibers of the tractus strio-thalamicus, resemble more closely fig. 45, with less conspicuous thorns and a larger perikaryon. The cells shown in figs. 50 and 51 are evidently association cells; their processes extend over a very large area, bringing different parts of the hemispheres into relation with one another, with the thalamus and hypothalamus, and with the olfactory apparatus through the precommissural body.

tr. thal. striat., tractus thalamo-striaticus.

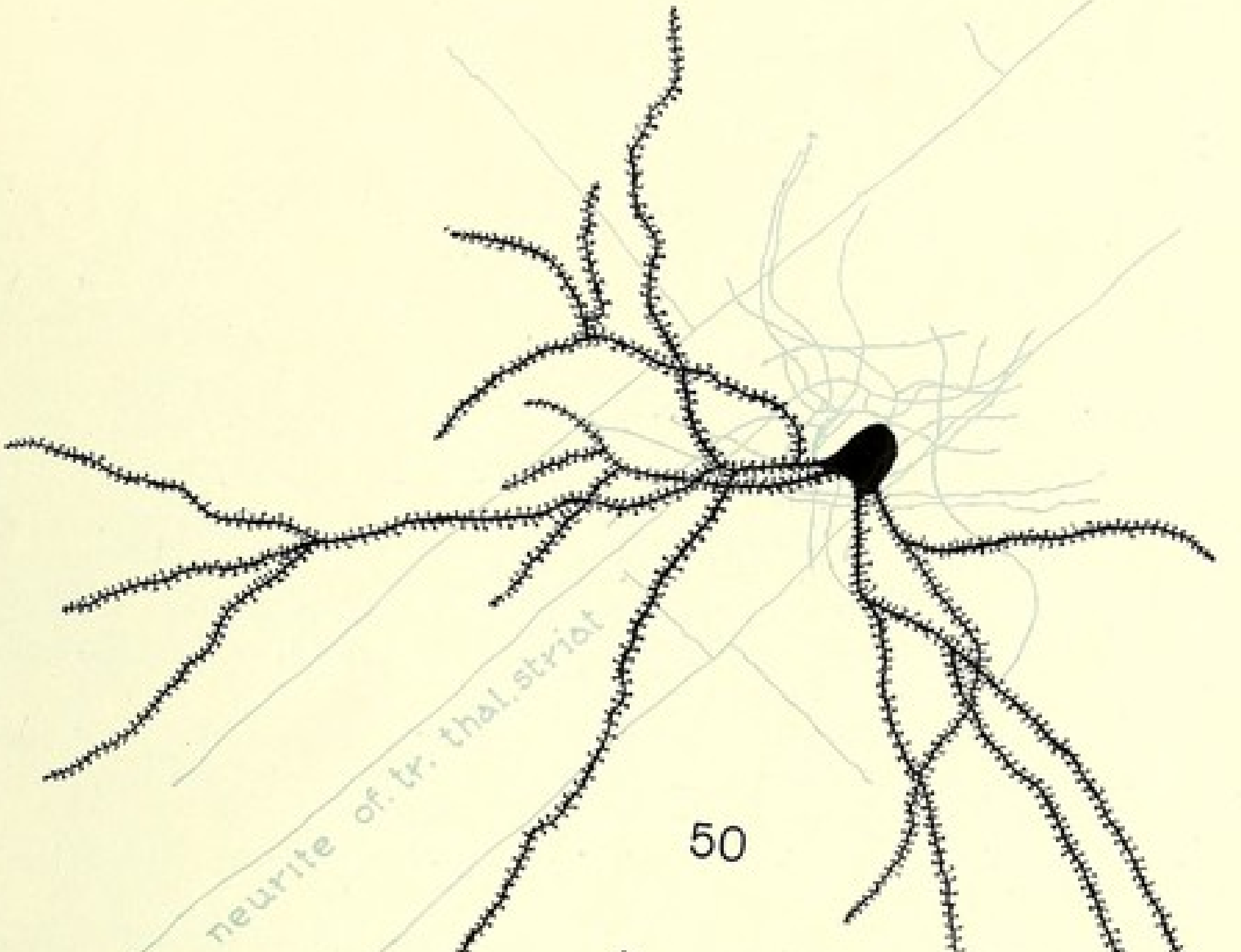

50

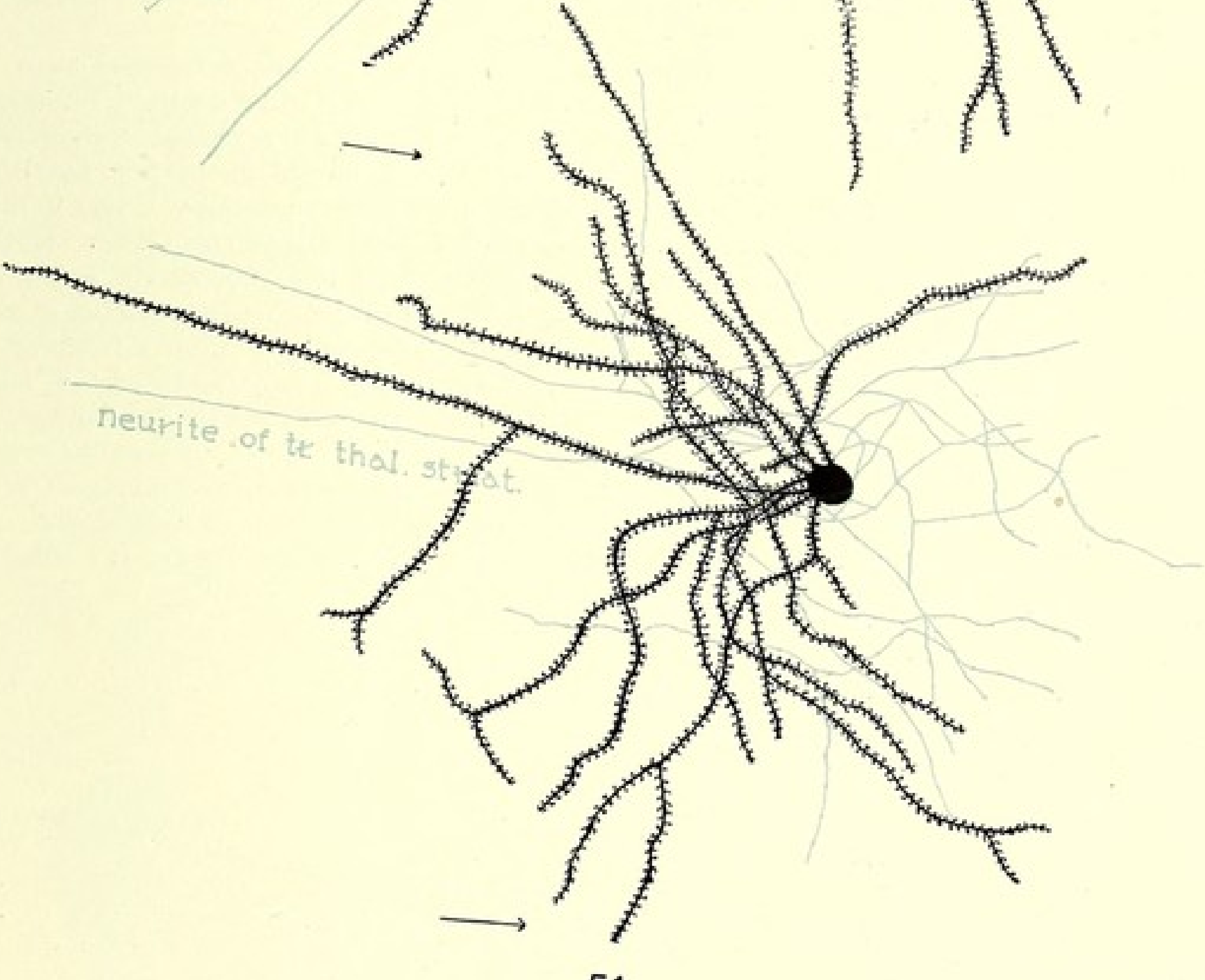

51

PLATE 12

EXPLANATION OF FIGURES

52 Neurone from the nucleus olfactorius lateralis. Golgi method. × 93. From sagittal section. This cell is found in the dorso-lateral portion of the hemisphere, its neurite enters the tractus strio-thalamicus.

53 Neurone of the nucleus pyriformis. Golgi method. × 93. From sagittal section. Most of the neurites from cells of this character and location enter the tractus olfacto-hypothalamicus lateralis.

54 Transection through the region of the recessus preopticus. Ramón y Cajal method. × 46.

55 Transection through the caudal part of the anterior commissure. Weigert method. × 17.

corp. precom., *pars supracom.*, corpus precommissurale, pars supracommissuralis; *n. opt.*, nervus opticus; *nucl. com. lat.*, nucleus commissuralis lateralis; *rec. preopt.*, recessus preopticus; *tr. hyp. olf. med.*, tractus hypothalamo-olfactorius medialis; *tr. med. preopt.*, *pars ant.*, tractus mediano-preopticus, pars anterior, consisting of fibers originating in the anterior part of nucleus medianus and terminating about the recessus preopticus; *tr. med. preopt.*, *pars post.*, tractus mediano-preopticus, pars posterior, consisting largely of fibers originating in the commissure bed and ending about the third ventricle in the region of the nucleus preopticus; *tr. olf. med.*, *pars lat.* + *c. hipp.*, *pars post.*, tractus olfactorius medialis, pars lateralis plus commissura hippocampi, pars posterior; *tr. olf. thal. med.*, *pars dors.*, tractus olfacto-thalamicus medialis, pars dorsalis; this component of the medial forebrain bundle appears in this section for the first time in the drawings; *tr. olf. thal. med.*, *pars vent.*, tractus olfacto-thalamicus medialis, pars ventralis; *tr. strio-thal. cruc.*, tractus strio-thalamicus cruciatus; *tr. strio-thal. incruc.*, tractus strio-thalamicus incruciatus; *tr. ten.*, tractus teniae, the tractus olfacto-habenularis of Kappers, Goldstein, etc.

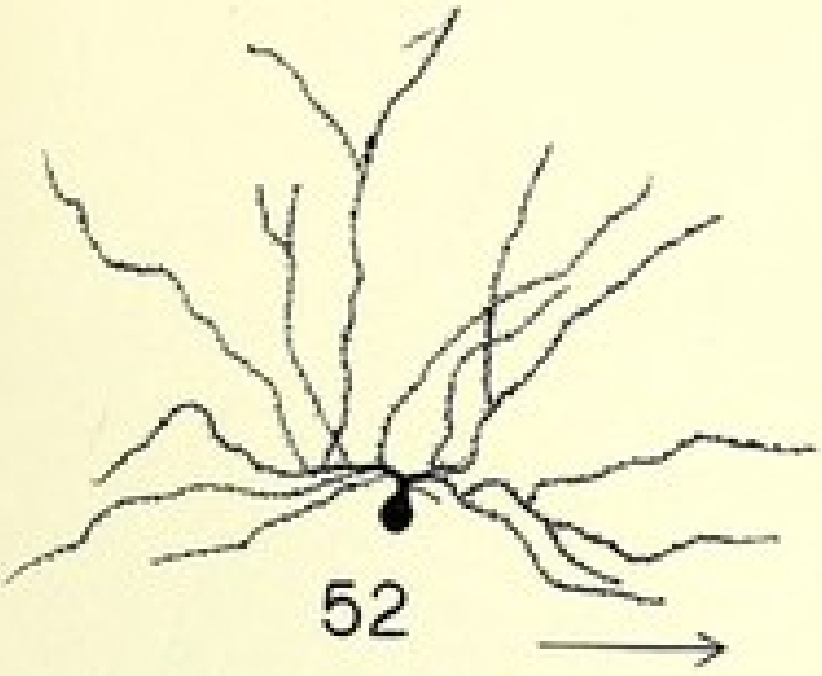

52

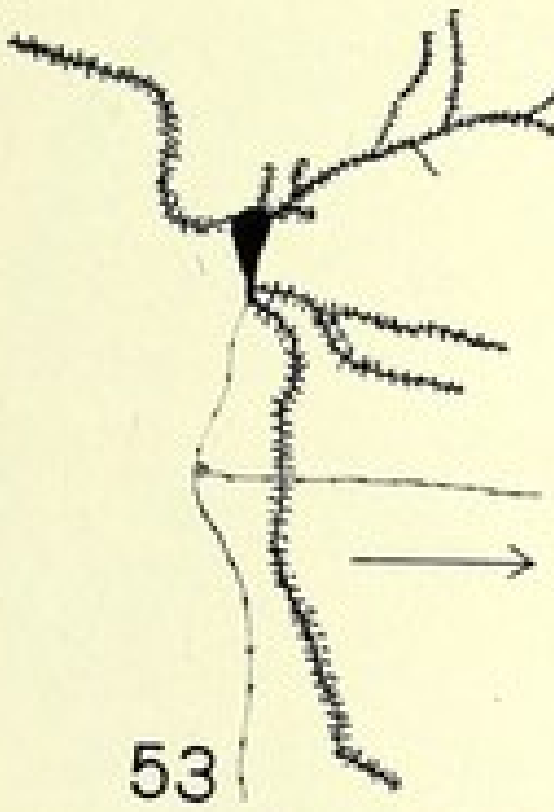

53

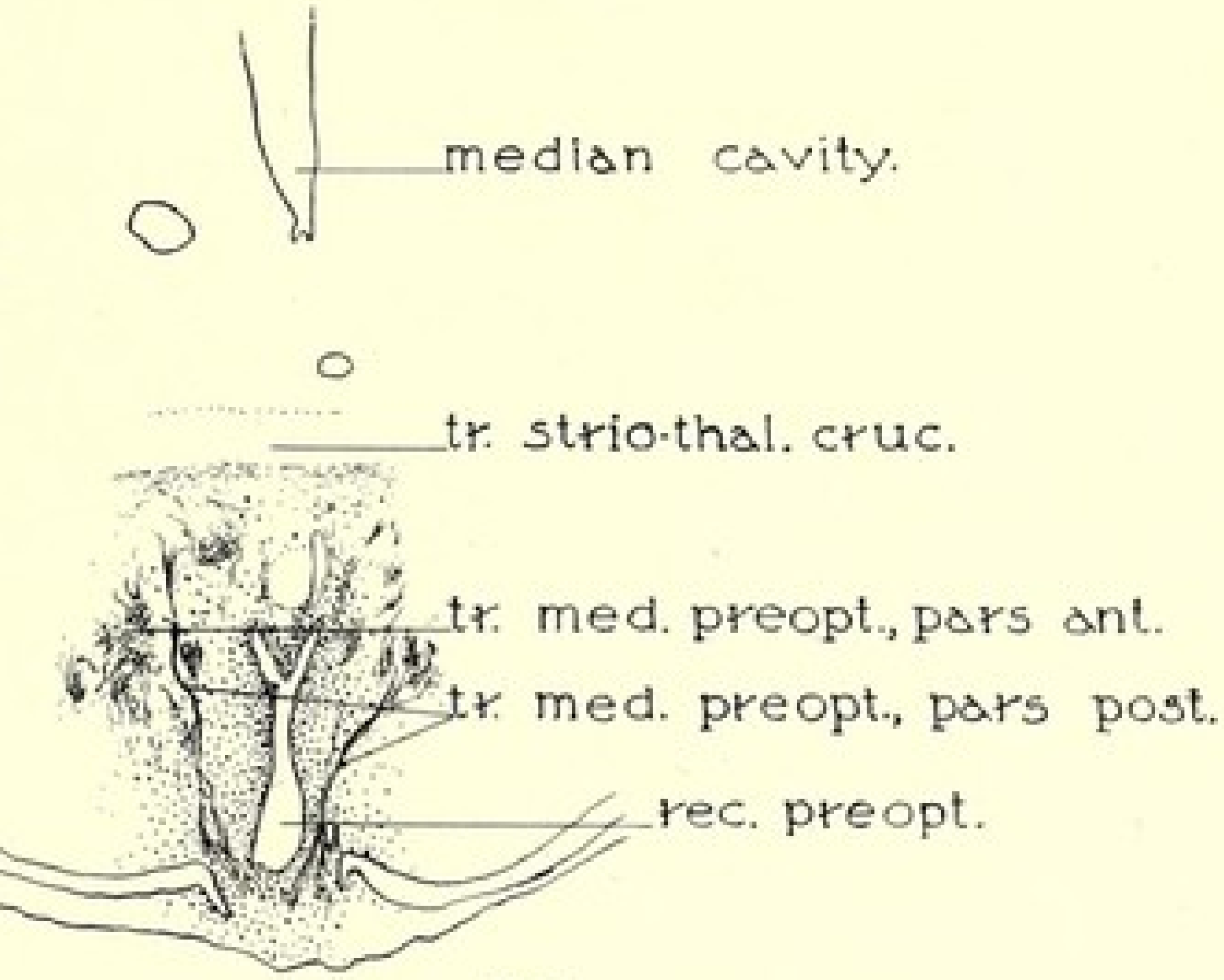
median cavity.
tr. strio-thal. cruc.
tr. med. preopt., pars ant.
tr. med. preopt., pars post.
rec. preopt.

54

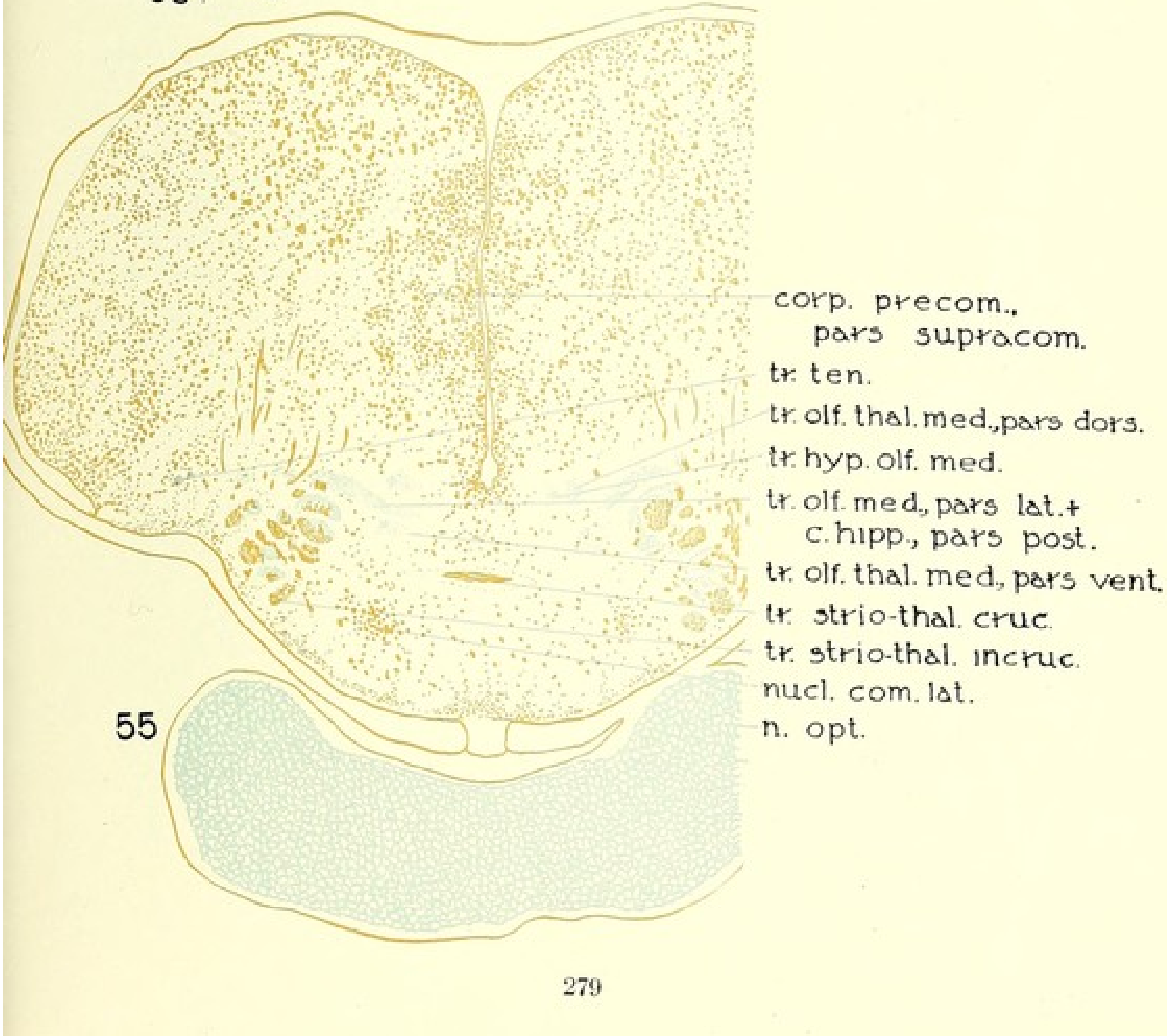
corp. precom., pars supracom.
tr. ten.
tr. olf. thal. med., pars dors.
tr. hyp. olf. med.
tr. olf. med., pars lat. + c. hipp., pars post.
tr. olf. thal. med., pars vent.
tr. strio-thal. cruc.
tr. strio-thal. incruc.
nucl. com. lat.
n. opt.

55

PLATE 13

EXPLANATION OF FIGURES

56 Transection through the caudal part of the anterior commissure. Toluidin blue method. × 46.

57 Cells of the nucleus teniae. Toluidin blue method. From transverse section. × 575.

58–60 Neurones of the nucleus teniae. Golgi method. × 93. From oblique sections, about midway between sagittal and transverse.

corp. precom., pars com., corpus precommissurale, pars commissuralis; *corp. precom., pars supracom.*, corpus precommissurale, pars supracommissuralis; *nucl. com. lat.*, nucleus commissuralis lateralis; *nucl. olf. dors.*, nucleus olfactorius dorsalis; *nucl. pyr.*, nucleus pyriformis; *nucl. ten.*, nucleus teniae; *palaeostr.*, palaeostriatum; *s. lim. tel.*, sulcus limitans telencephali.

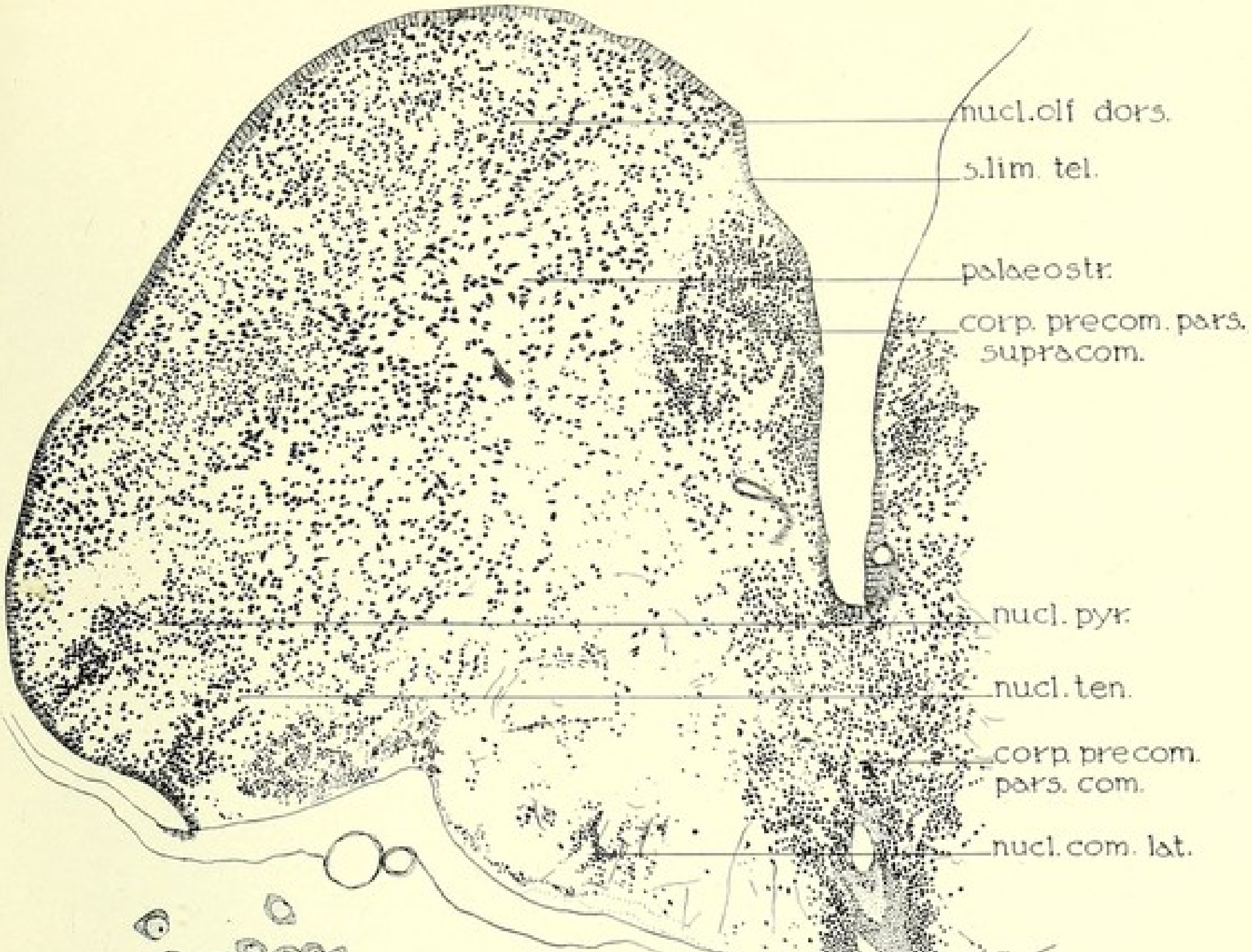
nucl. olf dors.
s. lim. tel.
palaeostr.
corp. precom. pars. supracom.
nucl. pyr.
nucl. ten.
corp. precom. pars. com.
nucl. com. lat.

56



57

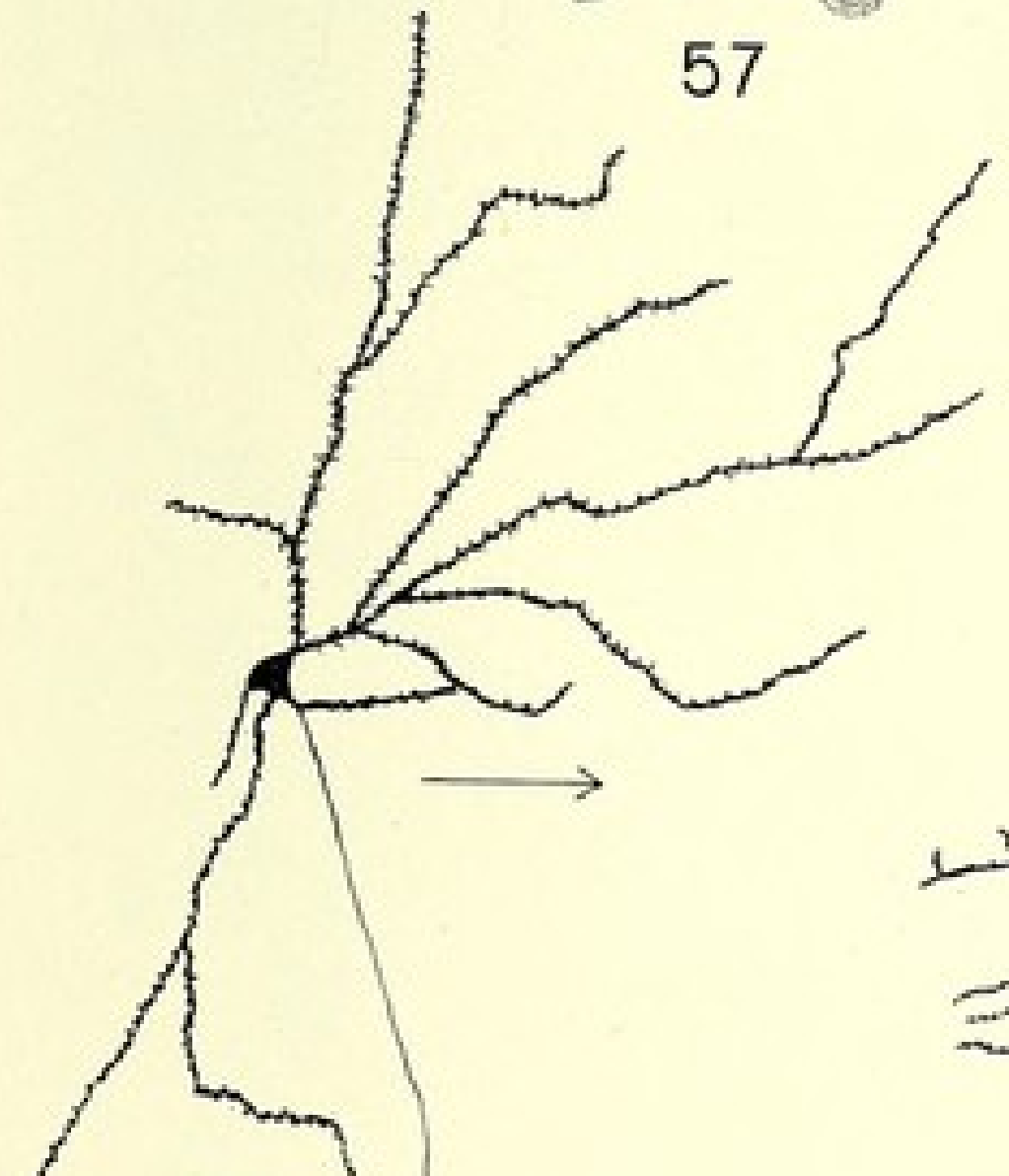

58

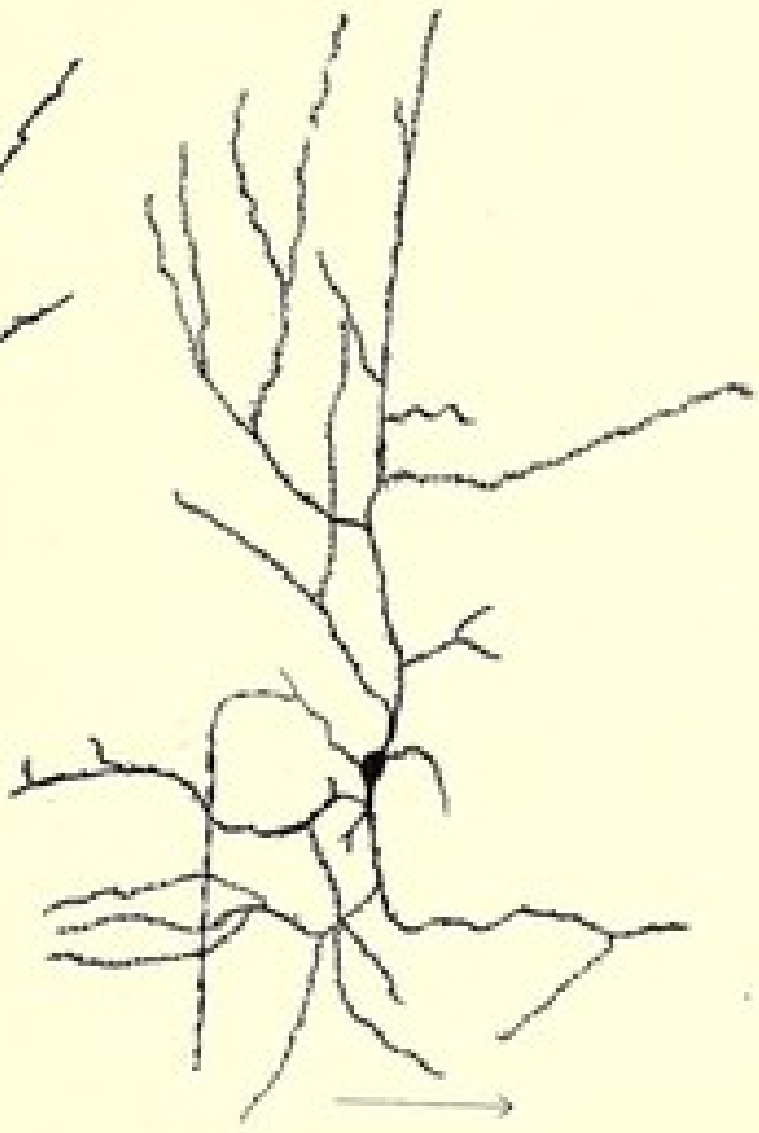

59

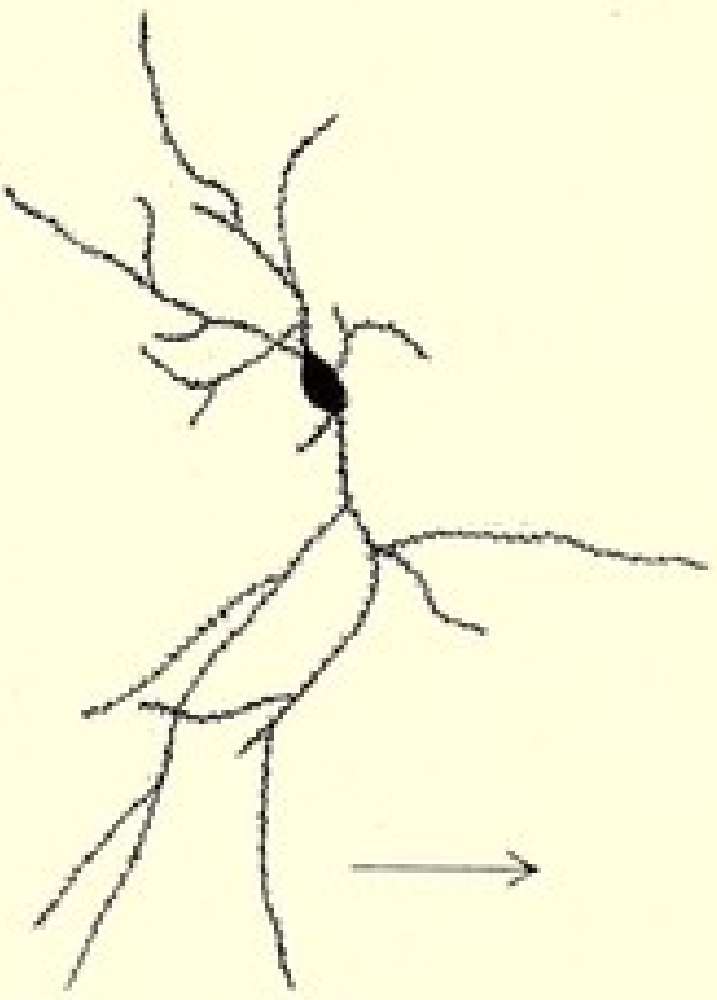

60

PLATE 14

EXPLANATION OF FIGURES

61 Transection through the caudal part of the anterior commissure. Weigert method. × 17.

62 Sagittal section slightly to one side of the median line, showing the tractus preopticus superior. Golgi method. × 46. The location of the different parts of the nucleus preopticus is indicated by broken lines.

63 Neurone of the tractus preopticus superior. Golgi method. × 93. From sagittal section. (See fig. 62).

64 Cells of the nucleus preopticus, pars parvocellularis anterior. Toluidin blue method. × 575.

65 Cells of the nucleus entopeduncularis. Toluidin blue method. × 575.

corp. precom., pars com., corpus precommissurale, pars commissuralis; *corp. precom., pars supracom.*, corpus precommissurale pars supracommissuralis; *fasc. med. hem.*, fasciculus medialis hemisphaerii; *n. opt.*, nervus opticus; *nucl. preopt., pars parvocell.*, nucleus preopticus, pars parvocellularis; *opt.*, optic chiasma; *pars magnocell.*, pars magnocellularis of the nucleus preopticus; *pars parvocell. post.*, pars parvocellularis posterior of the nucleus preopticus; *rec. preopt.*, recessus preopticus. *tr. hyp. olf. med.*, tractus hypothalamo-olfactorius medialis; *tr. olf. thal. med., pars dors.*, tractus olfacto-thalamicus medialis, pars dorsalis; *tr. olf. thal. med., pars vent.*, tractus olfacto-thalamicus medialis, pars ventralis; *tr. med. preopt., pars ant.*, tractus mediano-preopticus, pars anterior; *tr. preopt. sup.*, tractus preopticus superior; the connections of this tract are fully shown in the figure; it is apparently, Goldstein's tract × (Taf. 11, fig. 7); *tr. strio-thal. incruc.*, tractus strio-thalamicus incruciatus; *tr. ten.*, tractus teniae.

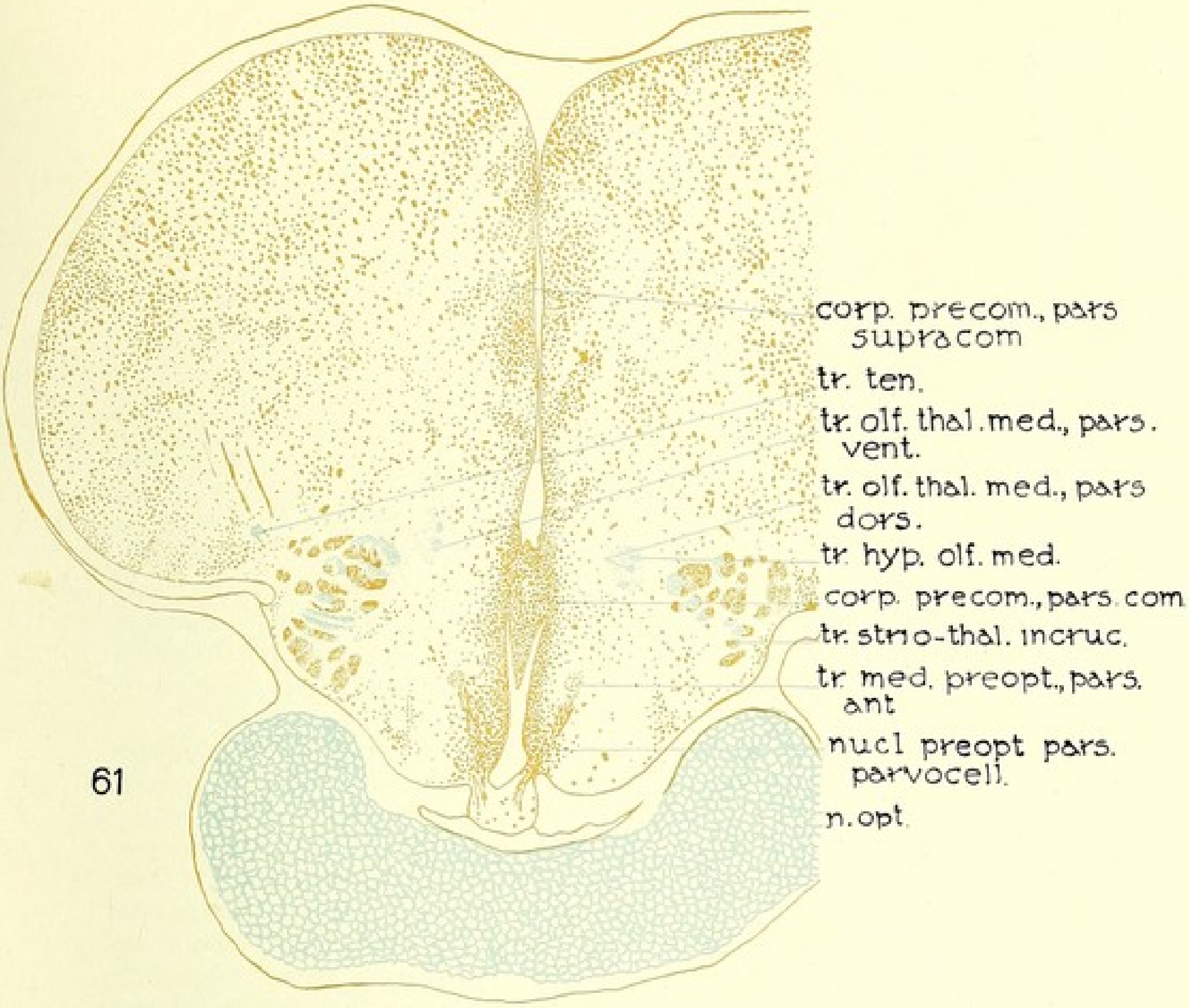
corp. precom., pars supracom
tr. ten.
tr. olf. thal. med., pars. vent.
tr. olf. thal. med., pars dors.
tr. hyp. olf. med.
corp. precom., pars. com
tr. strio-thal. incruc.
tr. med. preopt., pars. ant
nucl preopt pars. parvocell.
n. opt.

61

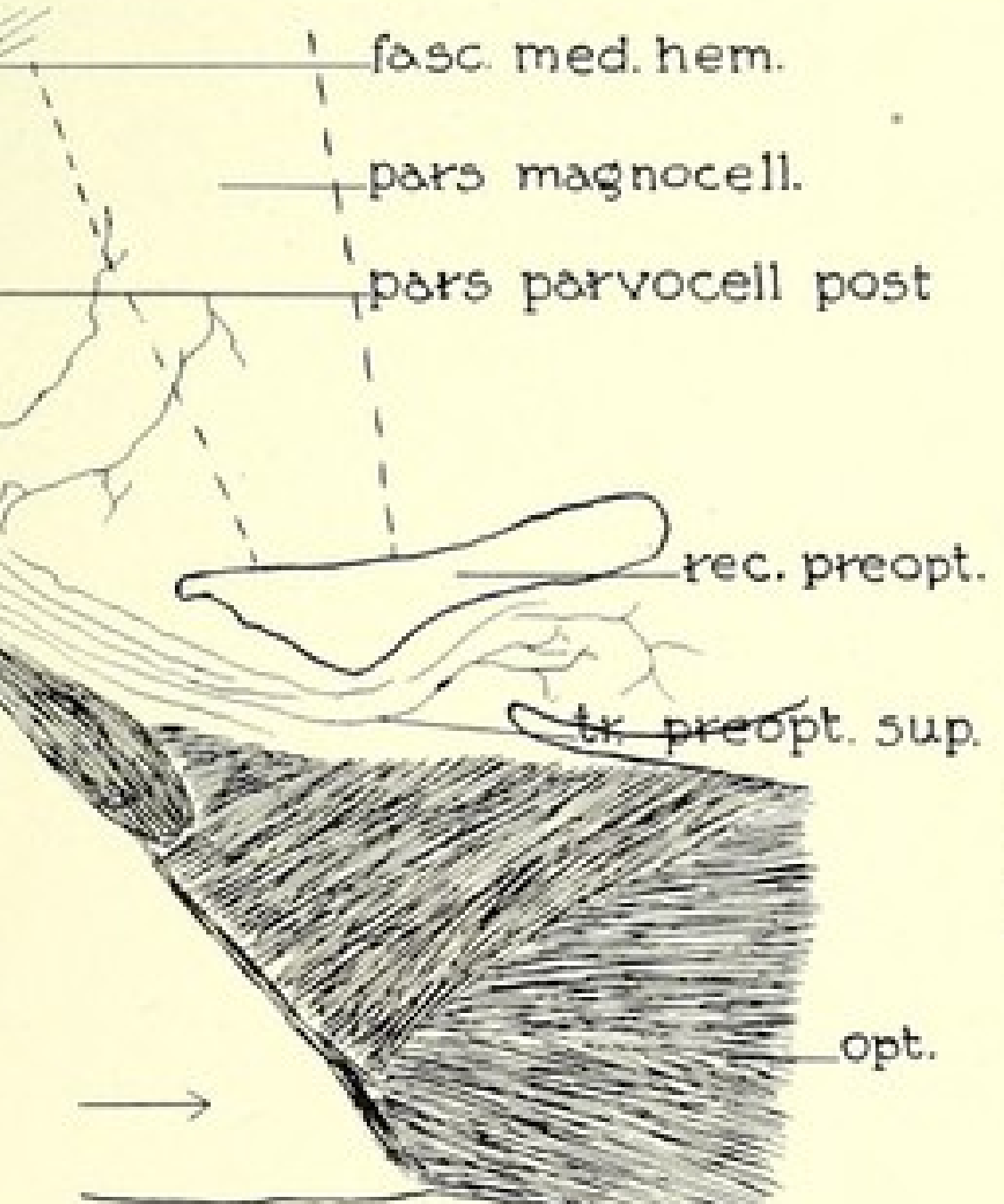
fasc. med. hem.
pars magnocell.
pars parvocell post
rec. preopt.
tr. preopt. sup.
opt.



65

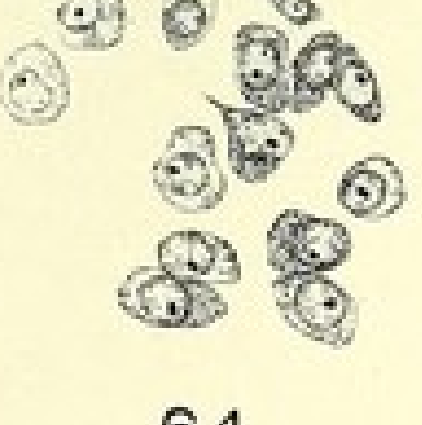

64

62

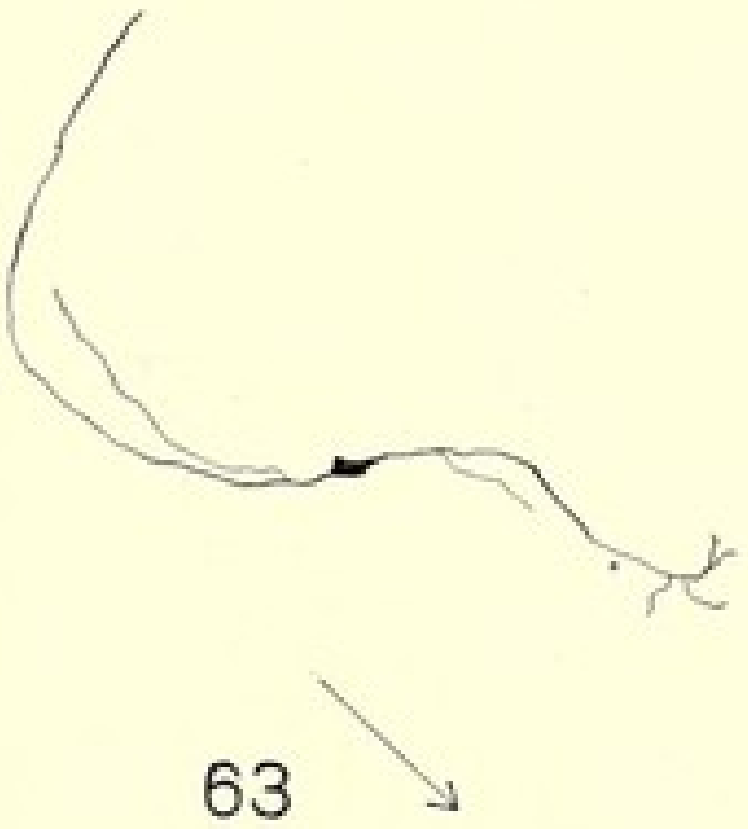

63

PLATE 15

EXPLANATION OF FIGURES

66 Transection through the cerebral hemispheres caudal to the anterior commissure. Toluidin blue method. × 46.

67 Transection through the cerebral hemispheres slightly caudal to the level shown in fig. 66. Toluidin blue method. × 46. Shows particularly the rostral portion of the pars magnocellularis of the nucleus preopticus and its relation to the pars parvocellularis.

corp. precom., pars intermed., corpus precommissurale, pars intermedia; this, the caudal prolongation of the pars supracommissuralis, meets the nucleus pyriformis at the posterior pole of the hemisphere, it likewise comes in close contact with the extension of the pars commissuralis caudally and ventrally, the pars parvocellularis of the nucleus preopticus; *fasc. lat. hem.*, fasciculus lateralis hemisphaerii, the lateral forebrain bundle; consisting of the tractus strio-thalamicus, tractus thalamo-striaticus, tractus olfacto-hypothalamicus lateralis and tractus hypothalamo-olfactorius lateralis; *fasc. med. hem.*, fasciculus medialis hemisphaerii, the medial forebrain bundle; *nucl. entoped.*, nucleus entopeduncularis; *nucl., preopt. pars magnocell.*, nucleus preopticus, pars magnocellularis; *nucl. preopt., pars parvocell.*, nucleus preopticus, pars parvocellularis anterior; *nucl. pyr.*, nucleus pyriformis; *nucl. ten.*, nucleus teniae; *s. lim. tel.*, sulcus limitans telencephli; *s. ypsil., fur. ant.*, sulcus ypsiliformis, furca anterior.

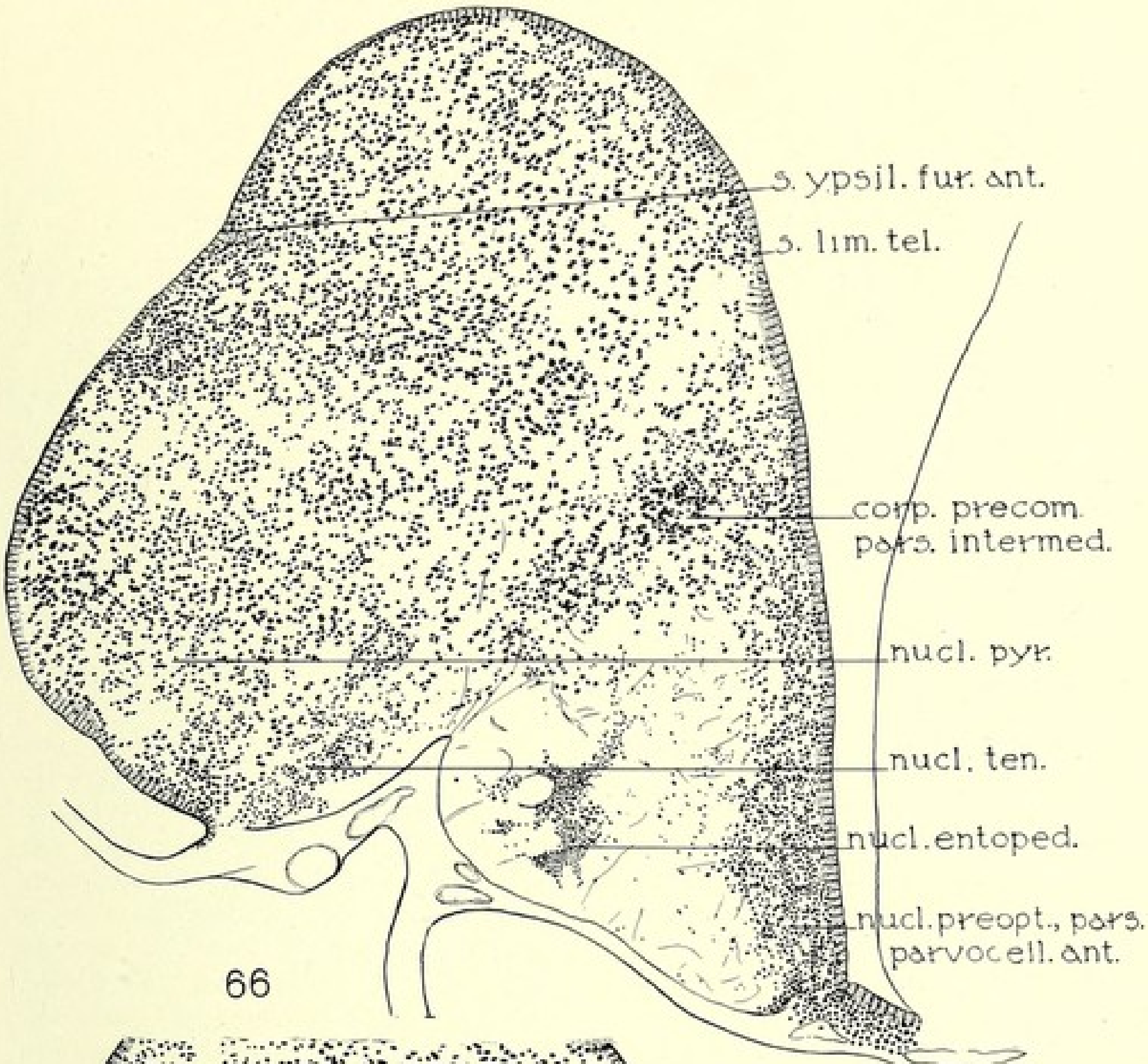
s. ypsil. fur. ant.
s. lim. tel.
corp. precom. pars. intermed.
nucl. pyr.
nucl. ten.
nucl. entoped.
nucl. preopt., pars. parvocell. ant.
opticus.

66

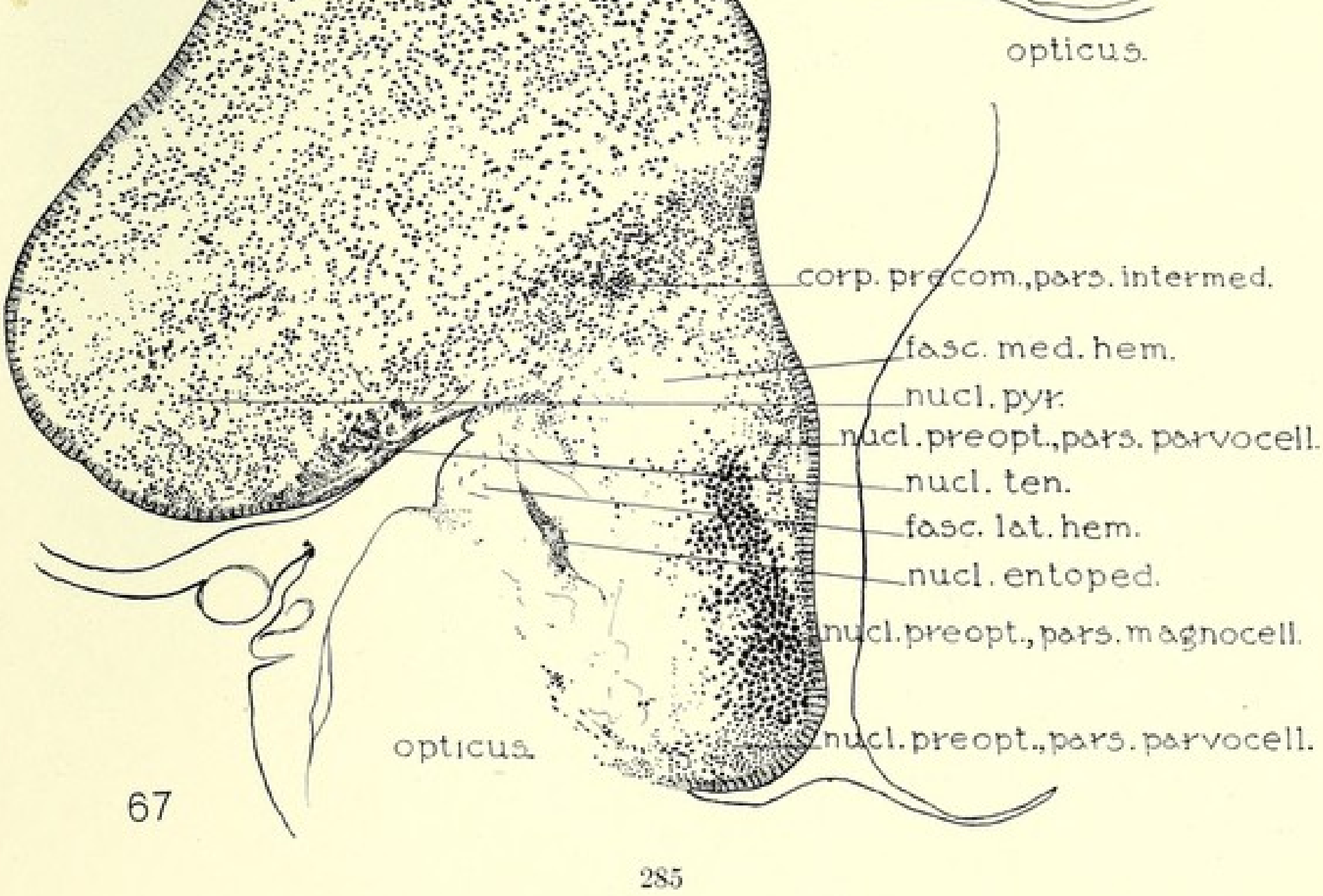
corp. precom., pars. intermed.
fasc. med. hem.
nucl. pyr.
nucl. preopt., pars. parvocell.
nucl. ten.
fasc. lat. hem.
nucl. entoped.
nucl. preopt., pars. magnocell.
nucl. preopt., pars. parvocell.
opticus.

67

PLATE 16

EXPLANATION OF FIGURES

68 Transection, at the level of the chiasma. Weigert method. × 17.

69 Transection at approximately the same level as shown in fig. 68. Ramón y Cajal method. × 46.

corp. precom., pars intermed., corpus precommissurale, pars intermedia; *fasc. lat. hem.* ⟷, fasciculus lateralis hemisphaerii; *fasc. med. hem.* ⟷, fasciculus medialis hemisphaerii; *nucl. entoped.*, nucleus entopeduncularis; *nucl. preopt., pars magnocell*,, nucleus preopticus, pars magnocellularis; *nucl. preopt., pars parvocell.*, nucleus preopticus, pars parvocellularis; *nucl. pyr.*, nucleus pyriformis; *sac. dors.*, saccus dorsalis; *s. ypsil., fur. post.*, sulcus ypsiliformis, furca posterior; *tr. hyp. olf. med.*, tractus hypothalamo-olfactorius medialis; *tr. olf. hyp. lat.* ⟷, tractus olfacto-hypothalamicus lateralis; *tr. olf. thal. med., pars dors.*, tractus olfacto-thalamicus medialis, pars dorsalis; *tr. olf. thal. med., pars vent.*, tractus olfacto-thalamicus medialis, pars ventralis; *tr. opt.*, tractus opticus; *tr. praeth. cin.*, tractus praethalamo-cinereus of Kappers; *tr. preopt. entoped.* ⟷, tractus preoptico-entopeduncularis; *tr. preopt. intermed., pars ant.* ⟷, tractus preoptico-intermedius, pars anterior; *tr. preopt. intermed., pars lat.*, tractus preoptico-intermedius, pars lateralis; *tr. strio-thal. cruc.* ⟷, tractus strio-thalamicus cruciatus; *tr. strio-thal. incruc.* ⟷, tractus strio-thalamicus incruciatus; *tr. ten.*, tractus teniae.

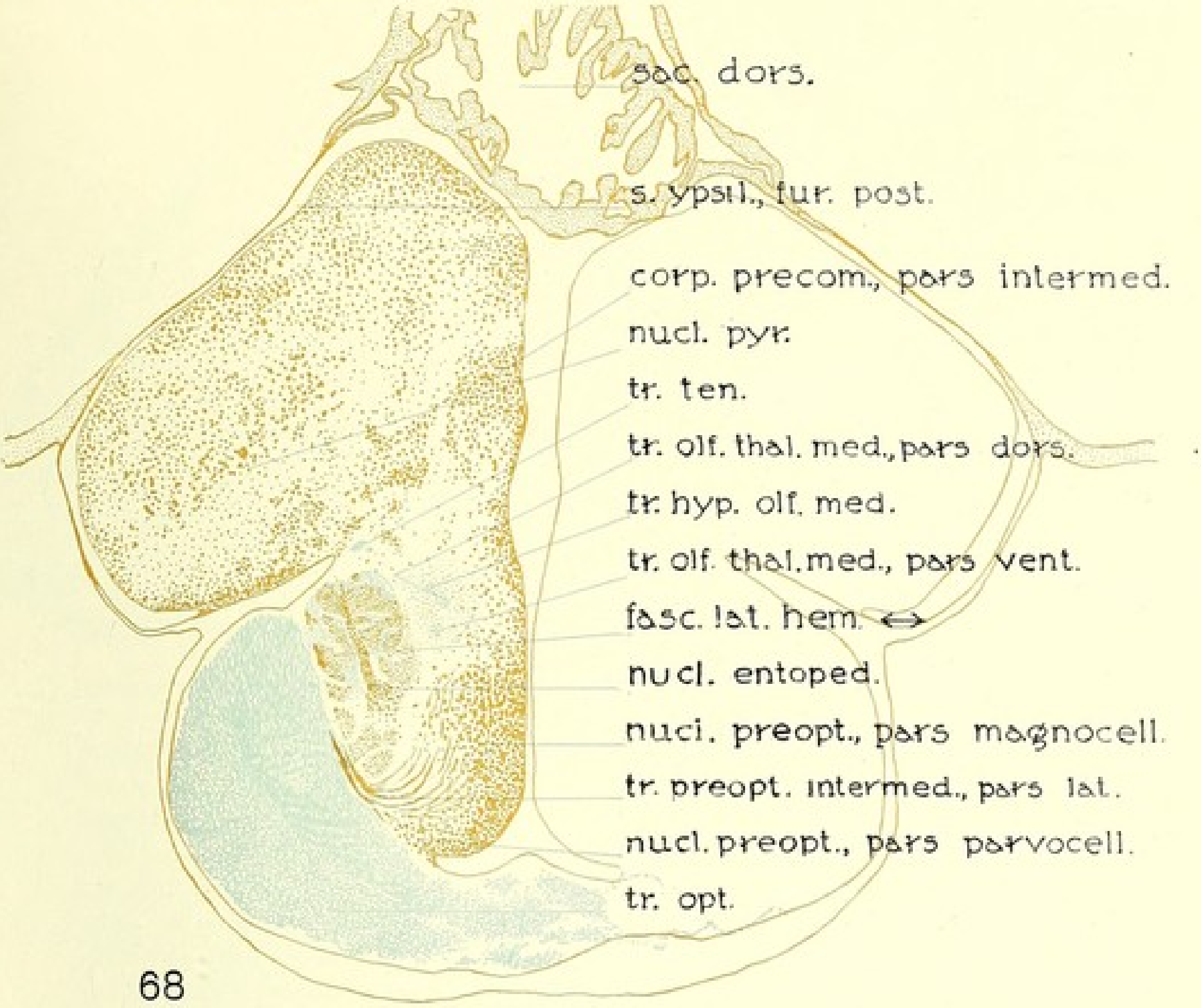
sac. dors.
s. ypsil., fur. post.
corp. precom., pars intermed.
nucl. pyr.
tr. ten.
tr. olf. thal. med., pars dors.
tr. hyp. olf. med.
tr. olf. thal. med., pars vent.
fasc. lat. hem. ↔
nucl. entoped.
nucl. preopt., pars magnocell.
tr. preopt. intermed., pars lat.
nucl. preopt., pars parvocell.
tr. opt.

68

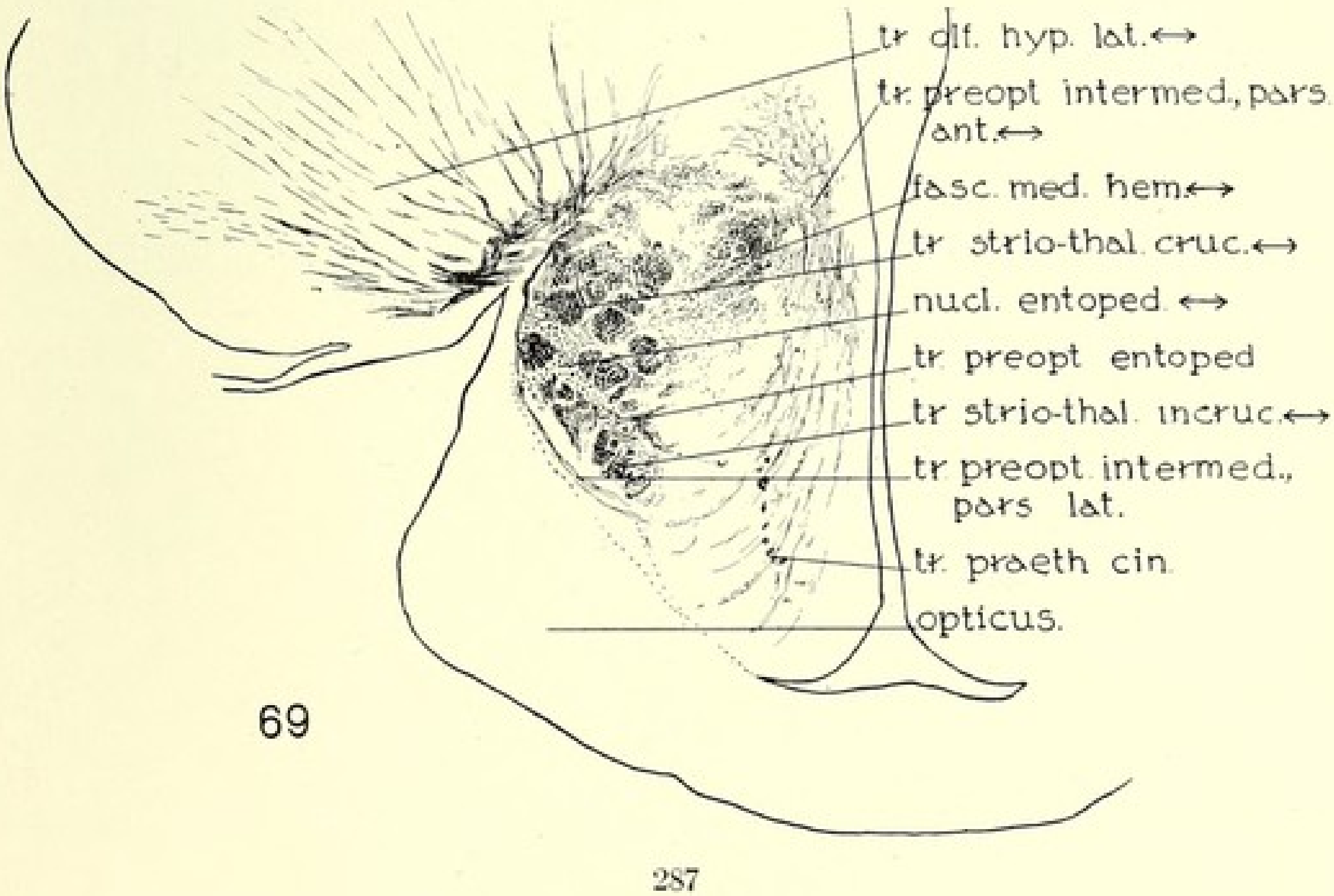
tr olf. hyp. lat. ↔
tr. preopt intermed., pars ant. ↔
fasc. med. hem. ↔
tr strio-thal. cruc. ↔
nucl. entoped. ↔
tr preopt entoped
tr strio-thal. incruc. ↔
tr preopt. intermed., pars lat.
tr. praeth cin.
opticus.

69

PLATE 17

EXPLANATION OF FIGURES

70 Transection through the posterior pole of the hemisphere and the nucleus magnocellularis. Toluidin blue method. × 46.

71 A group of cells of the nucleus magnocellularis. Toluidin blue method. × 575.

72 Transection slightly caudal to the level shown in fig. 69. Ramón y Cajal method. × 46.

fasc. med. hem. ⟷, fasciculus medialis hemisphaerii; *nucl. entoped.*, nucleus entopeduncularis; *nucl. intermed.*, nucleus intermedius; *nucl. preopt., pars magnocell.*, nucleus preopticus, pars magnocellularis; *nucl. preopt., pars parvocell. lat.*, nucleus preopticus, pars parvocellularis lateralis; *tr. entoped. hab.*, tractus entopedunculo-habenularis; *tr. olf. hyp. lat.* ⟷, tractus olfacto-hypothalamicus lateralis; *tr. praeth. cin.*, tractus praethalamo-cinereus; *tr. preopt. entoped.* ⟷, tractus preoptico-entopeduncularis; *tr. preopt. intermed., pars lat.*, tractus preoptico-intermedius, pars lateralis; *tr. preopt. intermed., pars med.* ⟷, tractus preoptico-intermedius, pars medialis; *tr. strio-thal. cruc.* ⟷, tractus strio-thalamicus cruciatus; *tr. strio-thal. incruc.* ⟷, tractus strio-thalamicus incruciatus; *tr. ten.*, tractus teniae.

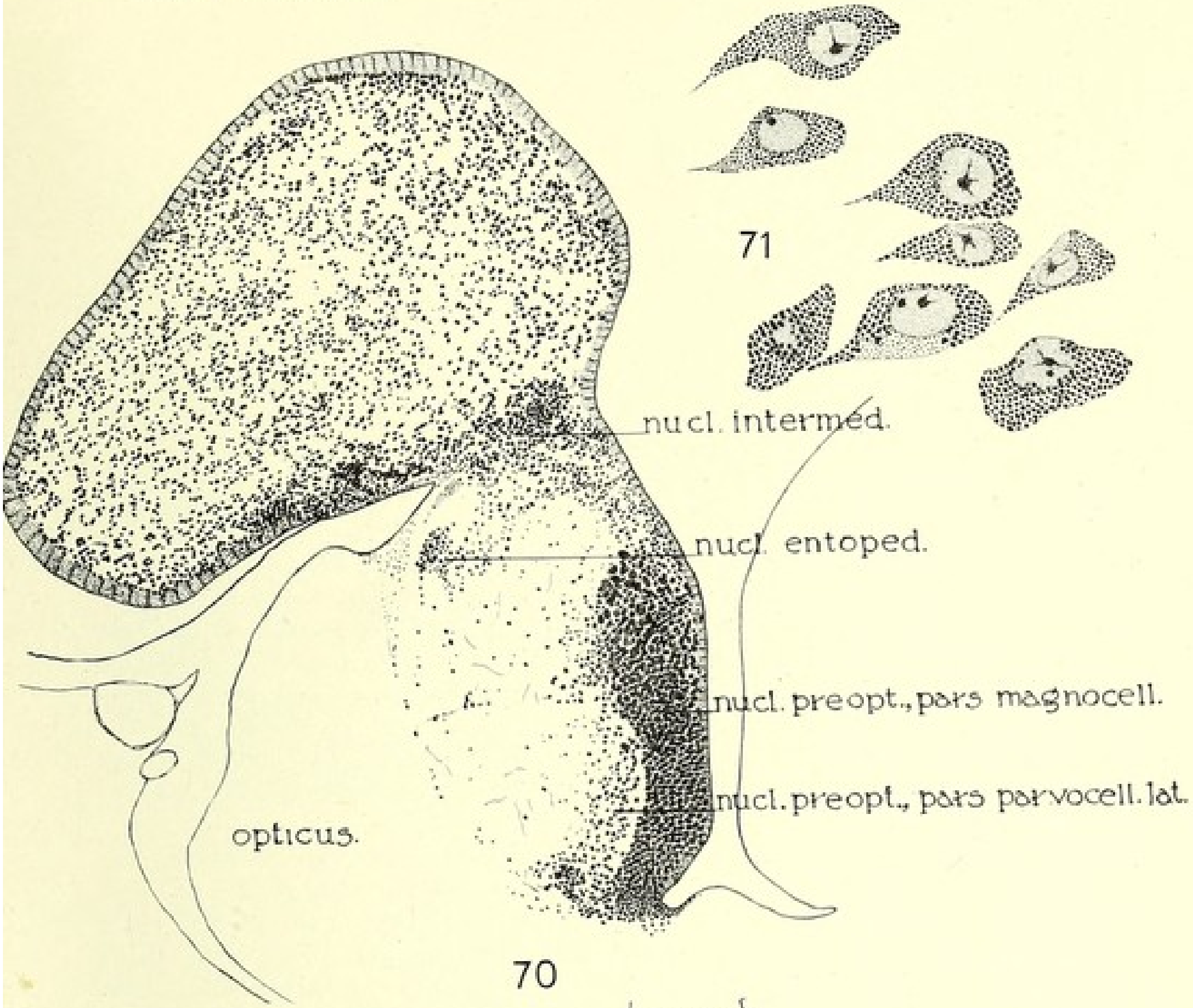

71

nucl. intermed.
nucl. entoped.
nucl. preopt., pars magnocell.
nucl. preopt., pars parvocell. lat.
opticus.

70

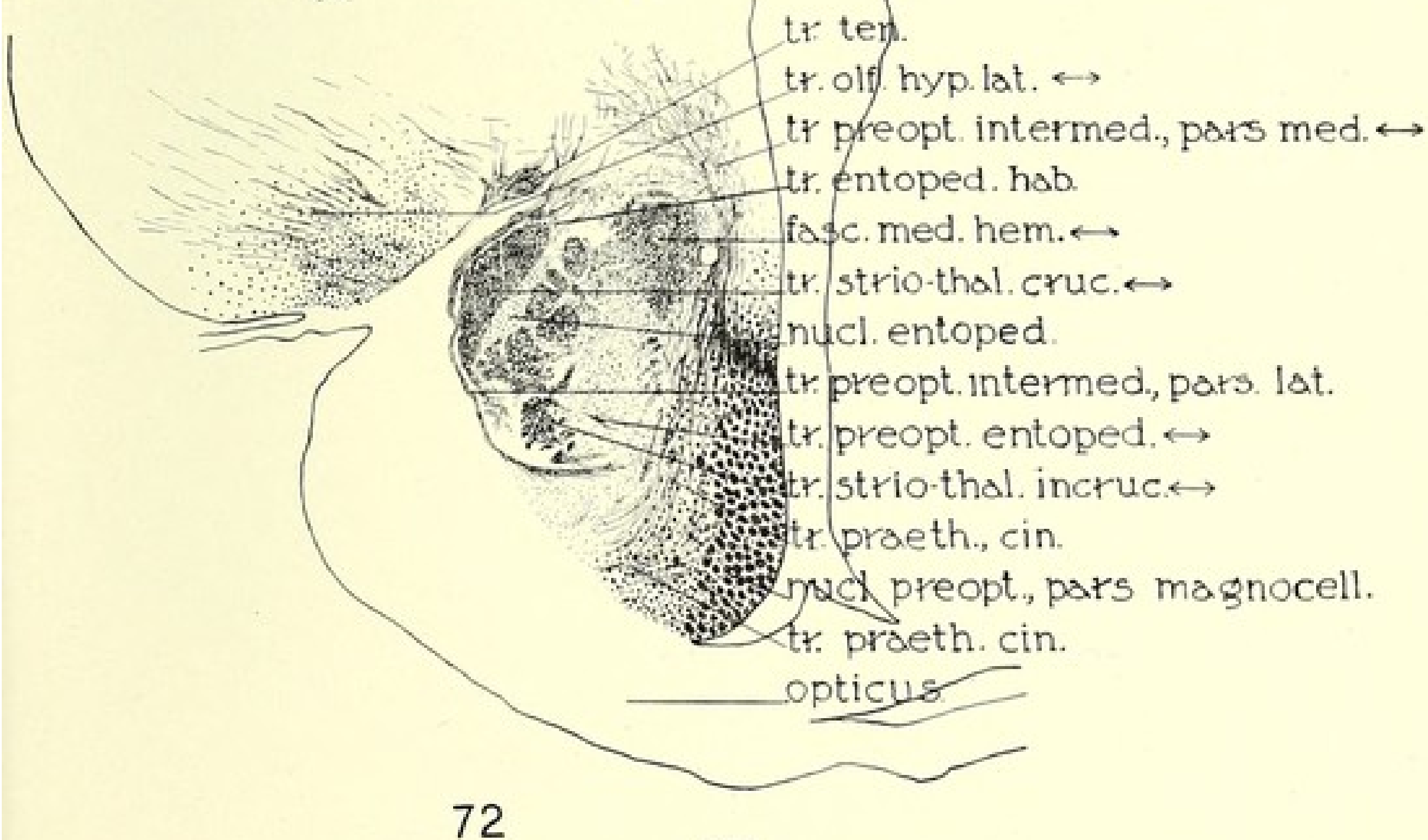
tr. ten.
tr. olf. hyp. lat. ↔
tr. preopt. intermed., pars med. ↔
tr. entoped. hab.
fasc. med. hem. ↔
tr. strio-thal. cruc. ↔
nucl. entoped.
tr. preopt. intermed., pars. lat.
tr. preopt. entoped. ↔
tr. strio-thal. incruc. ↔
tr. praeth., cin.
nucl. preopt., pars magnocell.
tr. praeth. cin.
opticus

72

PLATE 18

EXPLANATION OF FIGURES

73 Transection at the level of the commissura transversa. Weigert method. × 17.

74 Transection through the same region as is shown in fig. 73. Ramón y Cajal method. × 46. Shows particularly the tractus preoptico-habenularis, pars lateralis. In Petromyzon, according to Johnston ('02), a large portion of the fibers of his tractus olfacto-habenularis (my tractus preoptico-habenularis) take this course; as is also the case, but to a lesser extent, in amphibians and reptiles (Herrick, '10 b).

75 Cells of origin of the fasciculus retroflexus, or Meynert's bundle. Golgi method. × 93. One of the cells possesses a long neurite which may be traced into the fasciculus retroflexus.

com. trans., commissura transversa; *fasc. lat. hem.* ⟵⟶, fasciculus lateralis hemisphaerii; *fasc. med. hem.* ⟵⟶, fasciculus medialis hemisphaerii; *fasc. med. n. opt.*, fasciculus medialis nervi optici; *hab.*, habenula; *nucl. preopt., pars magnocell.*, nucleus preopticus, pars magnocellularis; *pol. post. hem.*, polus posterior hemisphaerii; *tr. hyp. olf. med.*, tractus hypothalamo-olfactorius medialis; *tr. olf. hab.*, tractus olfacto-habenularis; *tr. olf. thal. med., pars dors.*, tractus olfacto-thalamicus medialis, pars dorsalis; *tr. olf. thal. med., pars intermed.* ⟵⟶, tractus olfacto-thalamicus medialis, pars intermedia; *tr. olf. thal. med., pars vent.*, tractus olfacto-thalamicus medialis, pars ventralis; *tr. opt.*, tractus opticus; *tr. praeth. cin.*, tractus praethalamo-cinereus; *tr. preopt. hab., partes ant. et med.*, tractus preoptico-habenularis, partes anterior et medialis; *tr. preopt. hab., pars lat.*, tractus preoptico-habenularis, pars lateralis; *tr. preopt. hab., pars post.*, tractus preoptico-habenularis, pars posterior; *tr. preopt. intermed., pars. lat.*, tractus preoptico-intermedius, pars lateralis.

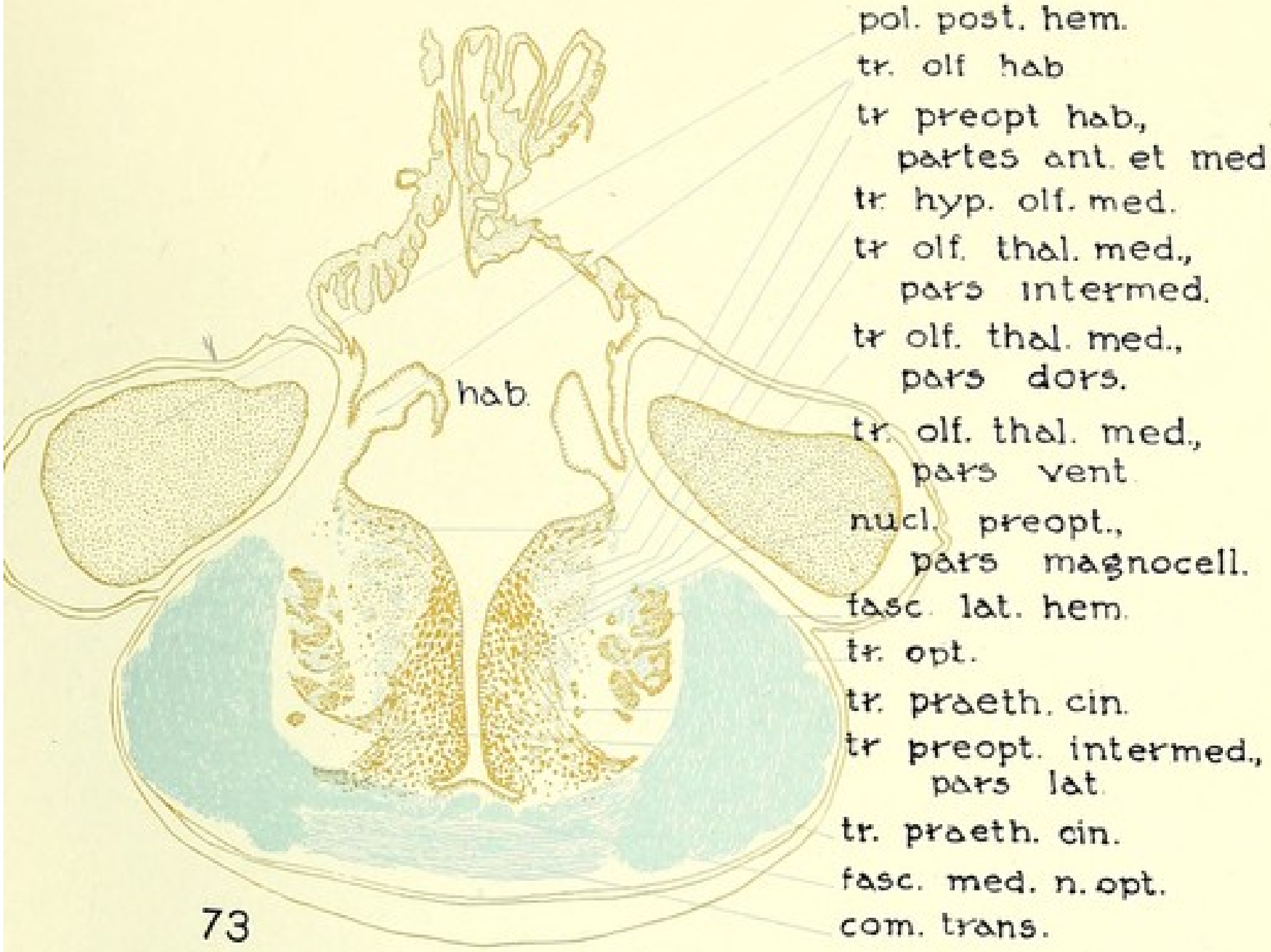
pol. post. hem.
tr. olf hab
tr preopt hab., partes ant. et med
tr. hyp. olf. med.
tr olf. thal. med., pars intermed.
tr olf. thal. med., pars dors.
tr. olf. thal. med., pars vent
nucl. preopt., pars magnocell.
fasc. lat. hem.
tr. opt.
tr. praeth. cin.
tr preopt. intermed., pars lat
tr. praeth. cin.
fasc. med. n. opt.
com. trans.
hab.

73

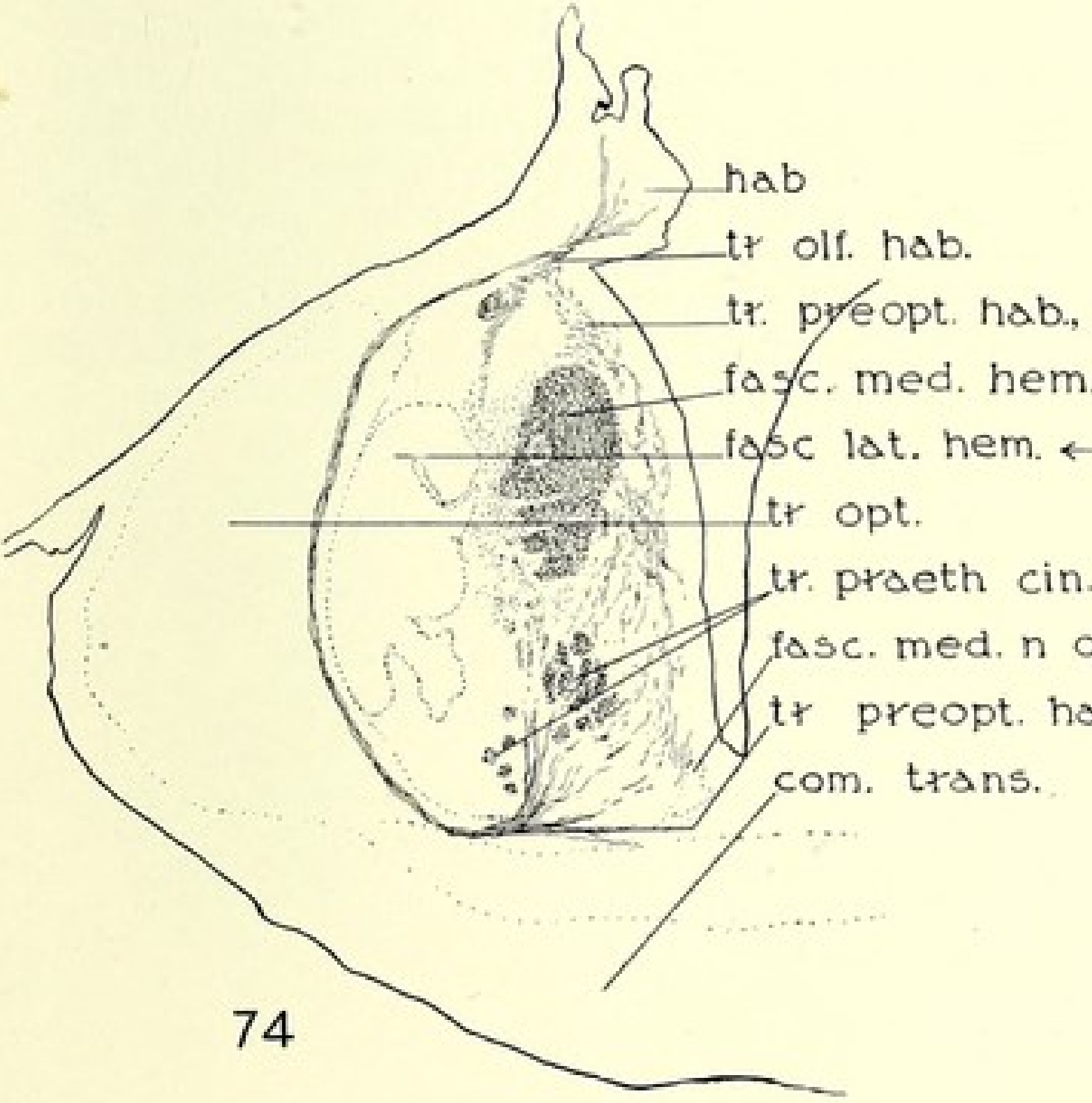
hab
tr olf. hab.
tr. preopt. hab., pars post.
fasc. med. hem. ↔
fasc lat. hem. ↔
tr opt.
tr. praeth cin.
fasc. med. n opt.
tr preopt. hab., pars lat.
com. trans.

74

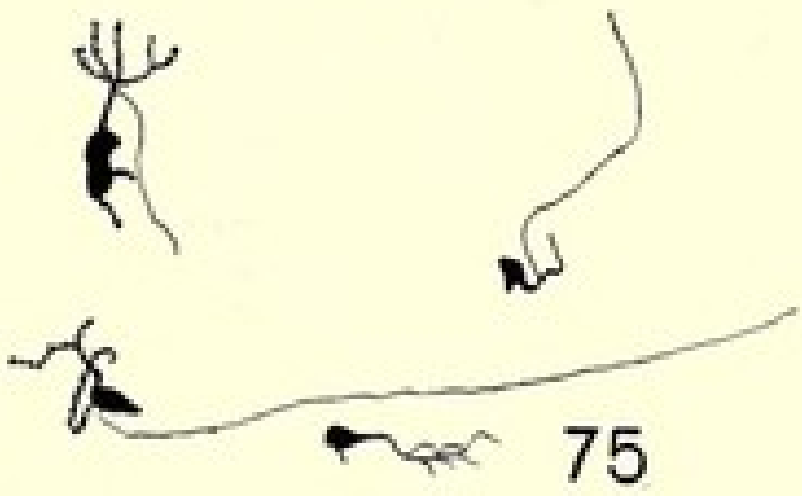

75

PLATE 19

EXPLANATION OF FIGURES

76 Transection through the ganglia habenularum. Weigert method. × 17.

77 Transection at the level of the commissura horizontalis. Weigert method. × 17.

a, fibers, originating largely in the nucleus posthabenularis and apparently entering the optic tract (described as an optic connection by Bela Haller); *com. hab.*, commissura habenularis, containing also decussating fibers of the two tractus olfacto-habenulares; *com. Herrick*, commissura Herricki; *com. horiz.*, commissura horizontalis of Fritsch; *com. trans.*, commissura transversa; *corp. gen. lat.*, corpus geniculatum laterale; *fasc. lat. hem.* ⟵⟶, fasciculus lateralis hemisphaerii; *fasc. med. n. opt.*, fasciculus medialis nervi optici; *fasc. retr.*, fasciculus retroflexus; *fib. tect. n. opt.*, fibrae tectales nervi optici (centrifugal); *hab.*, habenula; *lob. inf.*, lobus inferior; *nucl. preopt.*, *pars parvocell. post.*, nucleus preopticus. pars parvocellularis posterior; *nucl. prerot.*, nucleus prerotundus; *nucl. vent. tub.*, nucleus ventralis tuberis; *tr. hab. dien .* ⟵⟶, tractus habenulo-diencephalicus; this is the 'tractus habenula ad diencephalon' of Goldstein; *tr. hyp. olf. med.*, tractus hypothalamo-olfactorius medialis; *tr. olf. hab.*, tractus olfacto-habenularis; *tr. olf. thal. med.*, *pars dors.*, tractus olfacto-thalamicus medialis, pars dorsalis; *tr. olf. thal. med.*, *pars intermed.* ⟵⟶, tractus olfacto-thalamicus medialis, pars intermedia; *tr. olf. thal. med.*, *pars vent.*, tractus olfacto-thalamicus medialis, pars ventralis; *tr. opt.*, tractus opticus; *tr. praeth. cin.*, tractus praethalamo-cinereus.

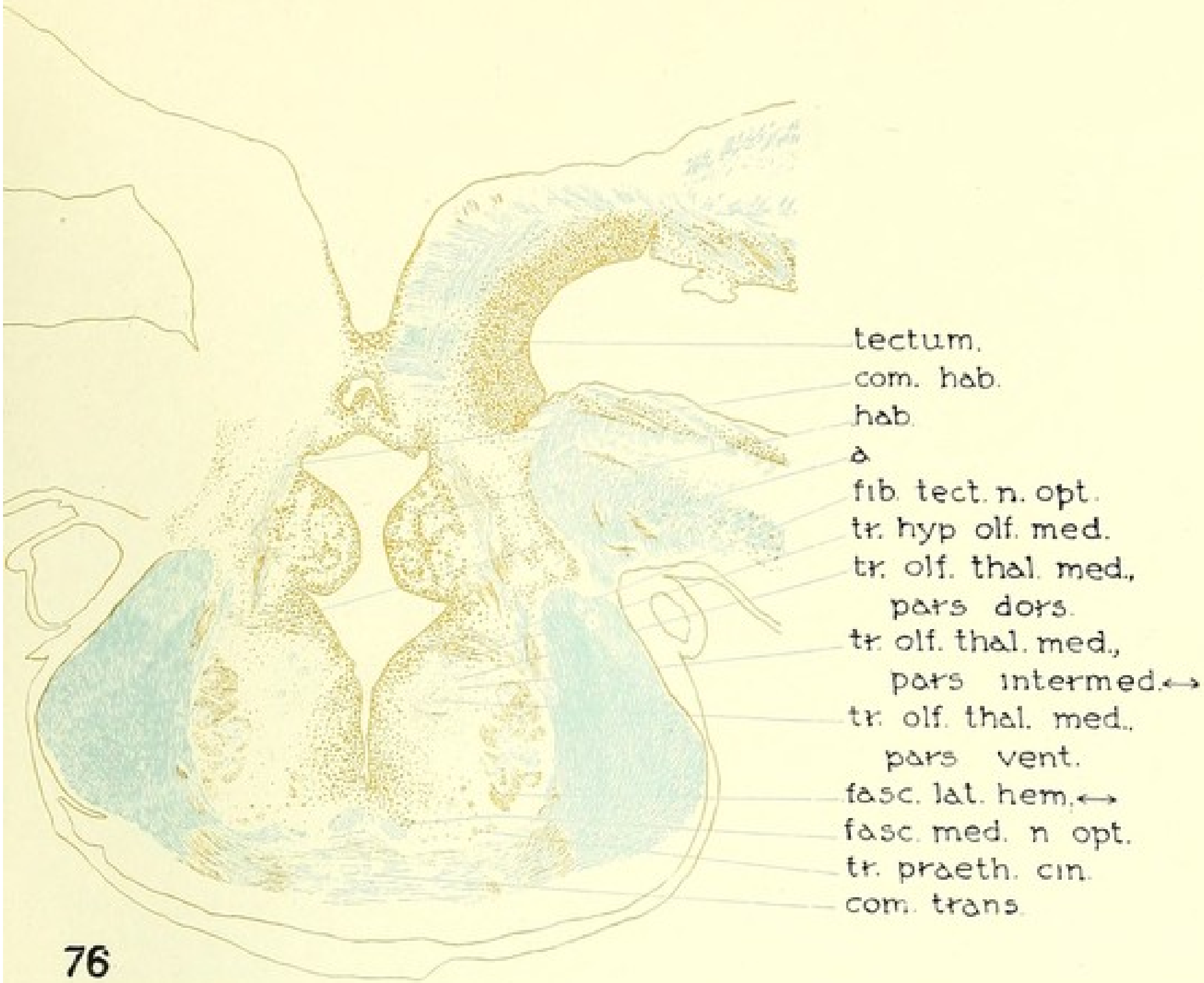
tectum.
com. hab.
hab.
a
fib. tect. n. opt.
tr. hyp olf. med.
tr. olf. thal. med.,
pars dors.
tr. olf. thal. med.,
pars intermed. ↔
tr. olf. thal. med.,
pars vent.
fasc. lat. hem. ↔
fasc. med. n opt.
tr. praeth. cin.
com. trans.

76

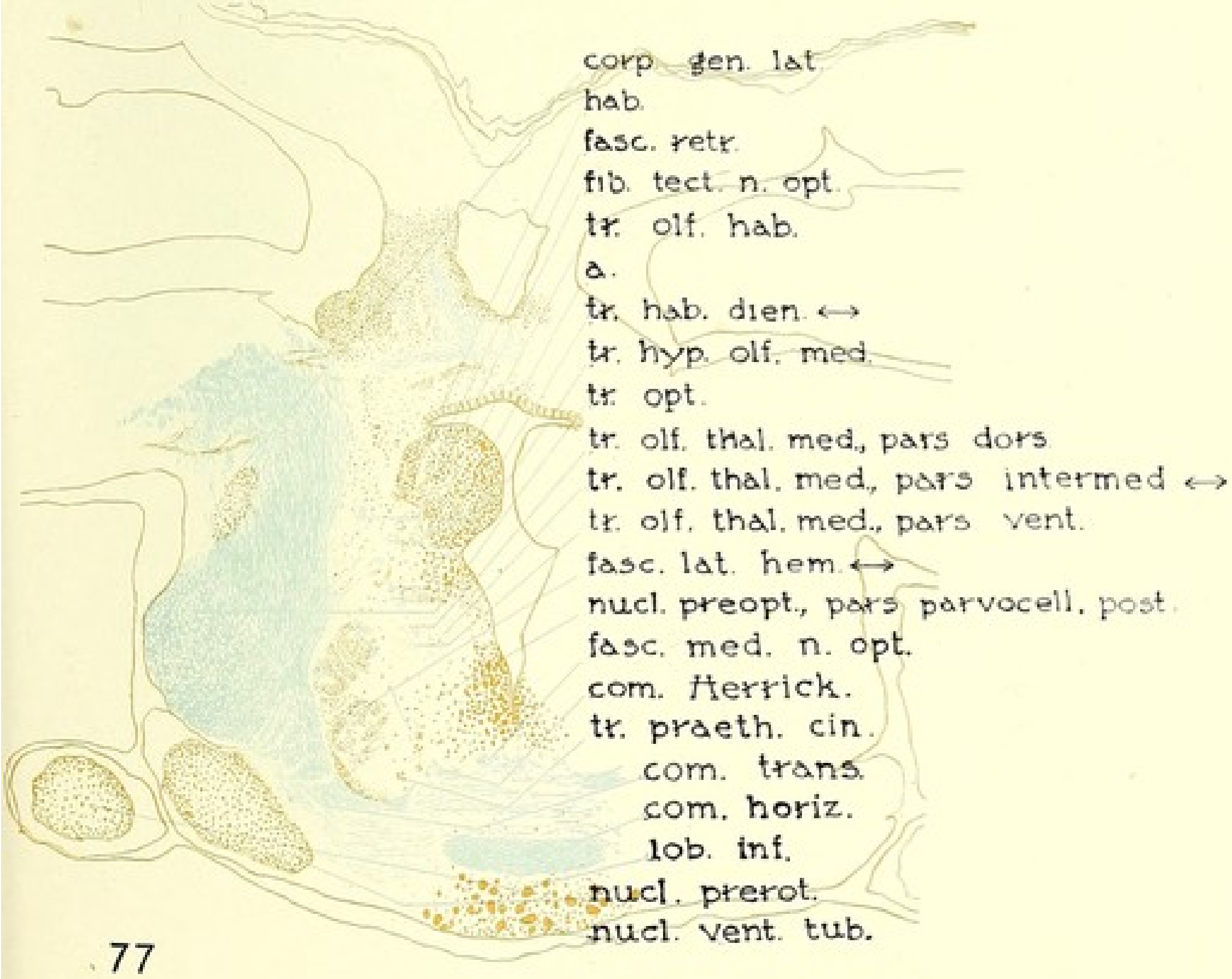
corp. gen. lat.
hab.
fasc. retr.
fib. tect. n. opt.
tr. olf. hab.
a.
tr. hab. dien. ↔
tr. hyp. olf. med.
tr. opt.
tr. olf. thal. med., pars dors.
tr. olf. thal. med., pars intermed ↔
tr. olf. thal. med., pars vent.
fasc. lat. hem. ↔
nucl. preopt., pars parvocell. post.
fasc. med. n. opt.
com. Herrick.
tr. praeth. cin.
com. trans.
com. horiz.
lob. inf.
nucl. prerot.
nucl. vent. tub.

77

PLATE 20

EXPLANATION OF FIGURES

78 Transection through the ganglia habenularum. Toluidin blue method. × 46.

com. horiz., commissura horizontalis; *corp. gen. lat.*, corpus geniculatum laterale; *fib. ans.*, fibrae ansulatae; *hab.*, habenula, showing characteristic arrangement of cells; *hyp.*, hypophysis; *lob. inf.*, lobus inferior; *nucl. ant. thal.*, nucleus anterior thalami of Goldstein; *nucl. posthab.*, nucleus posthabenularis, 'Das posthabenulare Zwischenhirngebiet' of Goldstein, 'Die posthabenulare Zwischenhirngegend' of Bela Haller; *nucl. preopt., pars parvocell. post.*, nucleus preopticus. pars parvocellularis posterior; *nucl. prerot.*, nucleus prerotundus; *nucl. vent. tub.*, nucleus ventralis tuberis.

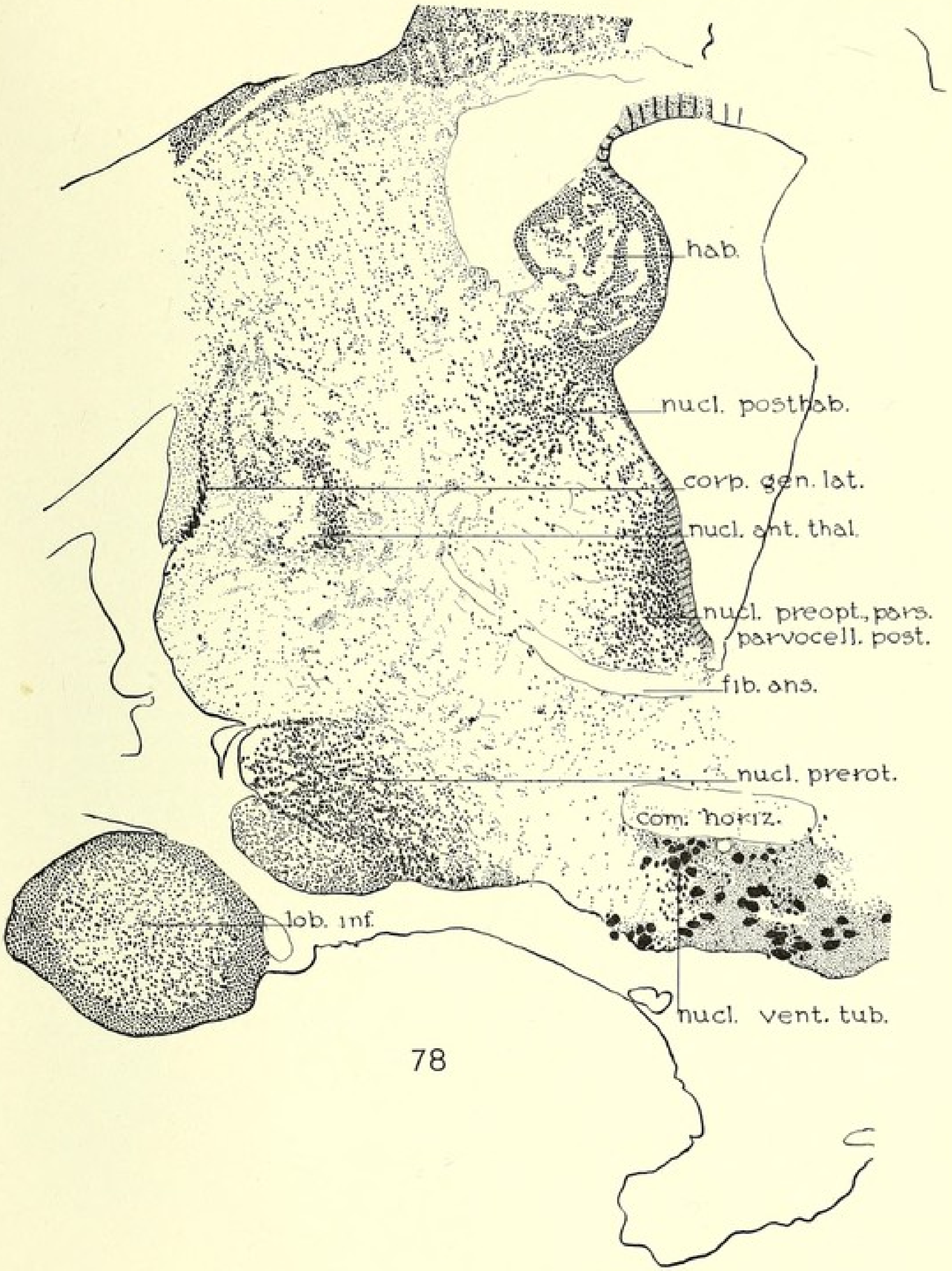
hab.
nucl. posthab.
corp. gen. lat.
nucl. ant. thal.
nucl. preopt., pars. parvocell. post.
fib. ans.
nucl. prerot.
com. horiz.
lob. inf.
nucl. vent. tub.

78

PLATE 21

EXPLANATION OF FIGURES

79 Transection slightly caudal to the level shown in fig. 77. Weigert method. × 17.

80 Transection through the nucleus anterior tuberis. Weigert method. × 17.

a, see fig. 76; *com. Herrick.*, commissura Herricki; *com. horiz.*, commissura horizontalis; *com. post.*, commissura posterior; *com. trans.*, commissura transversa; *corp. gen. lat.*, corpus geniculatum laterale; *fasc. lat. hem.*←→, fasciculus lateralis hemisphaerii; *fasc. med. n. opt.*, fasciculus medialis nervi optici; *fasc. retr.*, fasciculus retroflexus; *fib. ans.*, fibrae ansulatae; *fib. tect. n. opt.*, fibrae tectales nervi optici; *hab.*, habenula; *hyp.*, hypophysis; *lob. inf.*, lobus inferior; *nucl. ant. thal.*, nucleus anterior thalami; *nucl. ant. tub.*, nucleus anterior tuberis; *nucl. lat. tub.*, nucleus lateralis tuberis; *nucl. prerot.*, nucleus prerotundus; *nucl. vent. tub.*, nucleus ventralis tuberis; *tectum*, tectum opticum; *tor. long.*, torus longitudinalis; *tr. hab. dien.*←→, tractus habenulo-diencephalicus; *tr. hyp. olf. med.*, tractus hypothalamo-olfactorius medialis; *tr. olf. thal. med.*, *pars dors.*, tractus olfacto-thalamicus medialis, pars dorsalis; *tr. olf. thal. med.*, *pars intermed.*←→, tractus olfacto-thalamicus medialis, pars intermedia; *tr. olf. thal. med.*, *pars vent.*, tractus olfacto-thalamicus medialis, pars ventralis; *tr. opt.* tractus opticus; *tr. praeth. cin.*, tractus praethalamo-cinereus; *tr. strio-thal. incruc.*←→, tractus strio-thalamicus incruciatus; *tr. tub. dors.*, tractus tubero-dorsalis; *valvula*, valvula cerebelli.

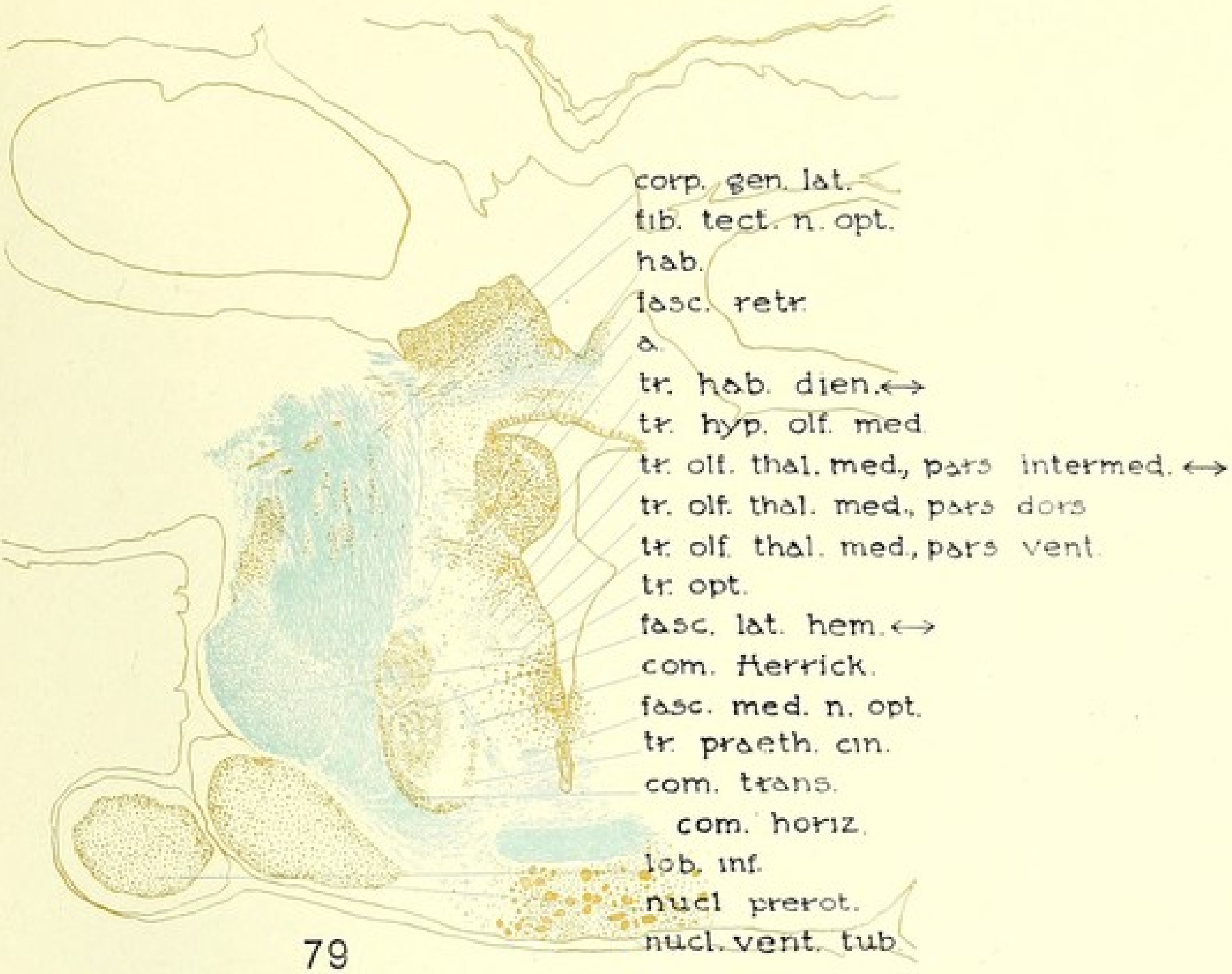
corp. gen. lat.
fib. tect. n. opt.
hab.
fasc. retr.
a.
tr. hab. dien. ↔
tr. hyp. olf. med.
tr. olf. thal. med., pars intermed. ↔
tr. olf. thal. med., pars dors.
tr. olf. thal. med., pars vent.
tr. opt.
fasc. lat. hem. ↔
com. Herrick.
fasc. med. n. opt.
tr. praeth. cin.
com. trans.
com. horiz.
lob. inf.
nucl. prerot.
nucl. vent. tub.

79

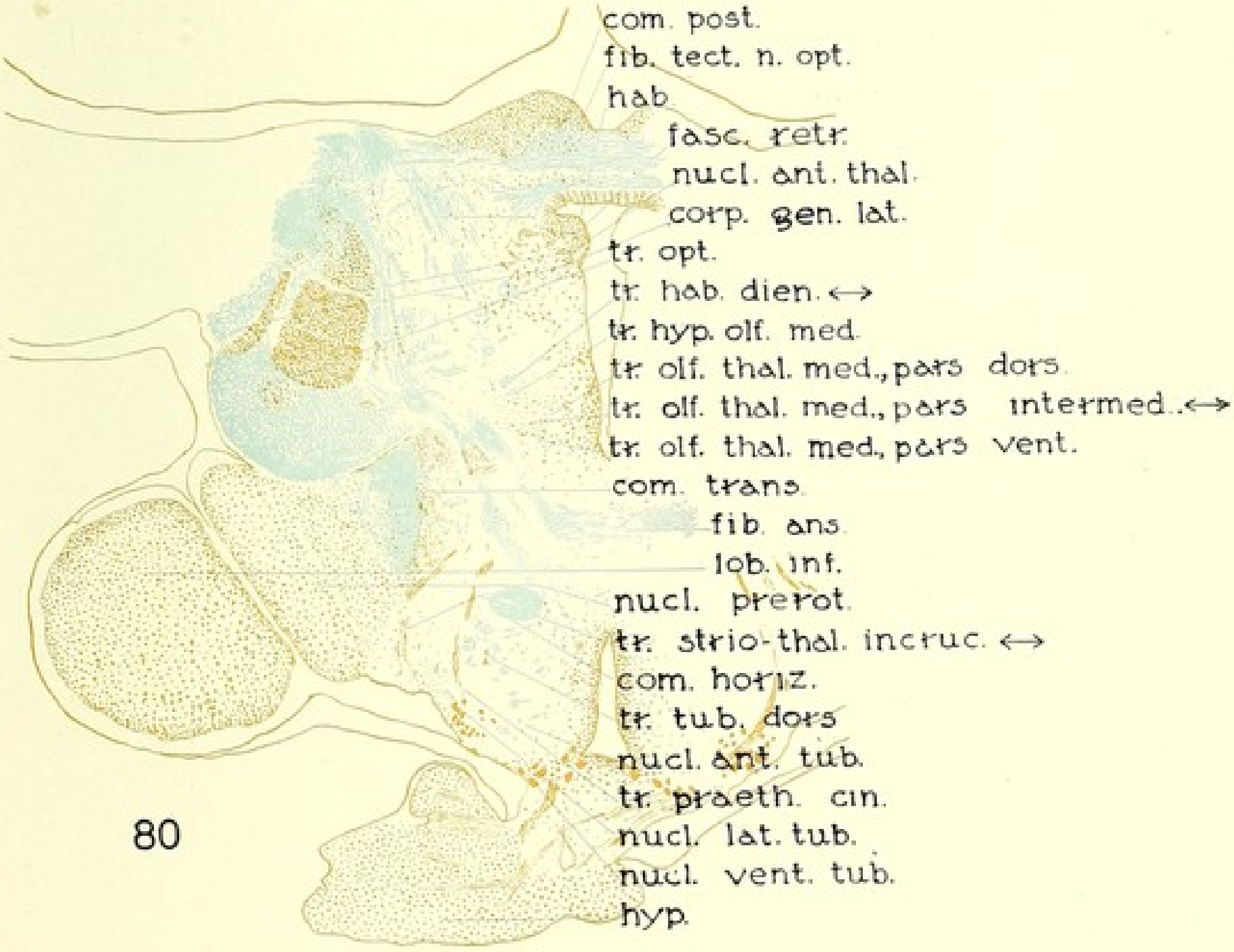
com. post.
fib. tect. n. opt.
hab.
fasc. retr.
nucl. ant. thal.
corp. gen. lat.
tr. opt.
tr. hab. dien. ↔
tr. hyp. olf. med.
tr. olf. thal. med., pars dors.
tr. olf. thal. med., pars intermed. ↔
tr. olf. thal. med., pars vent.
com. trans.
fib. ans.
lob. inf.
nucl. prerot.
tr. strio-thal. incruc. ↔
com. horiz.
tr. tub. dors.
nucl. ant. tub.
tr. praeth. cin.
nucl. lat. tub.
nucl. vent. tub.
hyp.

80

PLATE 22

EXPLANATION OF FIGURES

81 Transection through the nucleus anterior tuberis. Toluidin blue method. × 46.

com. trans., commissura transversa; *corp. gen. lat.*, corpus geniculatum laterale; *hab.*, habenula; *hyp.*, hypophysis; *lob. inf.*, lobus inferior; *nucl. ant. thal.*, nucleus anterior thalami; *nucl. ant. tub.*, nucleus anterior tuberis; *nucl. posthab.*, nucleus posthabenularis; *nucl. prerot.*, nucleus prerotundus; *nucl. vent. tub.*, nucleus ventralis tuberis; *tr. opt.*, tractus opticus.

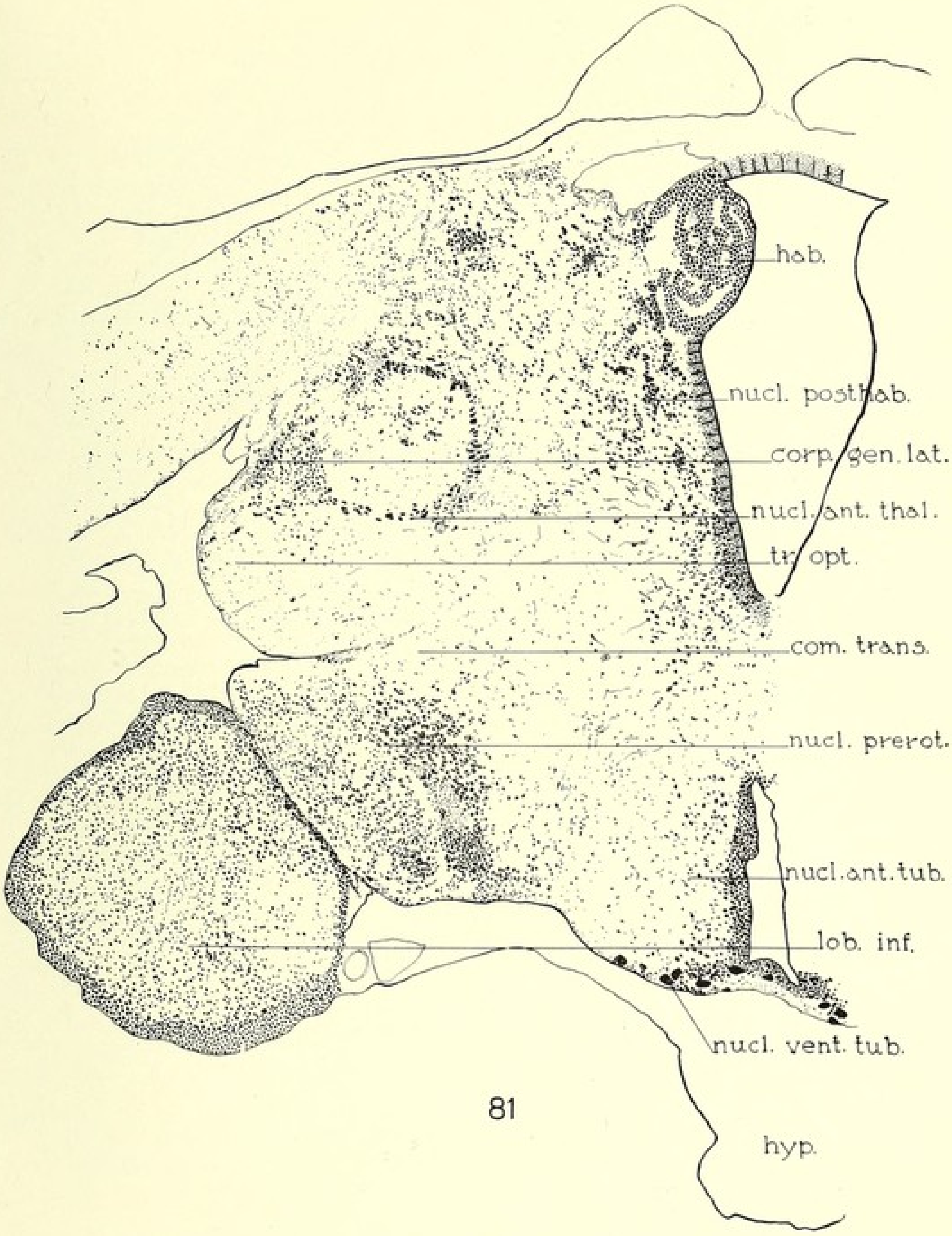
hab.
nucl. posthab.
corp. gen. lat.
nucl. ant. thal.
tr. opt.
com. trans.
nucl. prerot.
nucl. ant. tub.
lob. inf.
nucl. vent. tub.
hyp.

81

PLATE 23

EXPLANATION OF FIGURES

82 Transection slightly caudal to the level shown in fig. 80. Weigert method. × 17.

83 Transection through the rostral end of the nucleus rotundus. Weigert method. × 17. Shows particularly the connections between the fasciculus lateralis hemisphaerii and the nuclei prerotundus, rotundus and diffusus lobi lateralis.

a, (see fig. 76); *corp. gen. lat.*, corpus geniculatum laterale; *com. horiz.*, commissura horizontalis; *com. post.*, commissura posterior; *com. trans.*, commissura transversa; *fasc. retr.*, fasciculus retroflexus; *fib. ans.*, fibrae ansulatae; *fib. tect. n. opt.*, fibrae tectales nervi optici; *hyp.* hypophysis; *lob. inf.*, lobus inferior; *nucl. ant. thal.*, nucleus anterior thalami; *nucl. ant. tub.*, nucleus anterior tuberis; *nucl. lat. tub.*, nucleus lateralis tuberis; *nucl. prerot.*, nucleus prerotundus; *nucl. rot.*, nucleus rotundus; *nucl. vent. tub.*, nucleus ventralis tuberis; *tr. cbl. tect. + com. horiz.*, tractus cerebello-tectalis plus the commissura horizontalis; *tr. hab. dien.*⟵⟶, tractus habenulo-diencephalicus; *tr. hyp. olf. med.*, tractus hypothalamo-olfactorius medialis; *tr. olf. hyp. lat. + tr. strio-thal. cruc.*, tractus olfacto-hypothalamicus lateralis plus the tractus strio-thalamicus cruciatus; *tr. olf. thal. med., pars dors.*, tractus olfacto-thalamicus medialis, pars dorsalis; *tr. olf. thal. med., pars intermed.*⟵⟶, tractus olfacto-thalamicus medialis, pars intermedia; *tr. olf. thal. med., pars vent.*, tractus olfacto-thalamicus medialis, pars ventralis; *tr. opt.*, tractus opticus; *tr. praeth. cin.*, tractus praethalamo-cinereus; *tr. rot. lent.*, tractus rotundo-lentiformis (Kappers); *tr. strio-thal. incruc.*⟵⟶, tractus strio-thalamicus incruciatus; shows particularly the fibers innervating the nucleus diffusus lobi lateralis; *tr. thal. mam.*, tractus thalamo-mammillaris (Goldstein); *tr. thal. sp.*, tractus thalamo-spinalis (Kappers); *tr. tub. dors.*, tractus tubero-dorsalis.

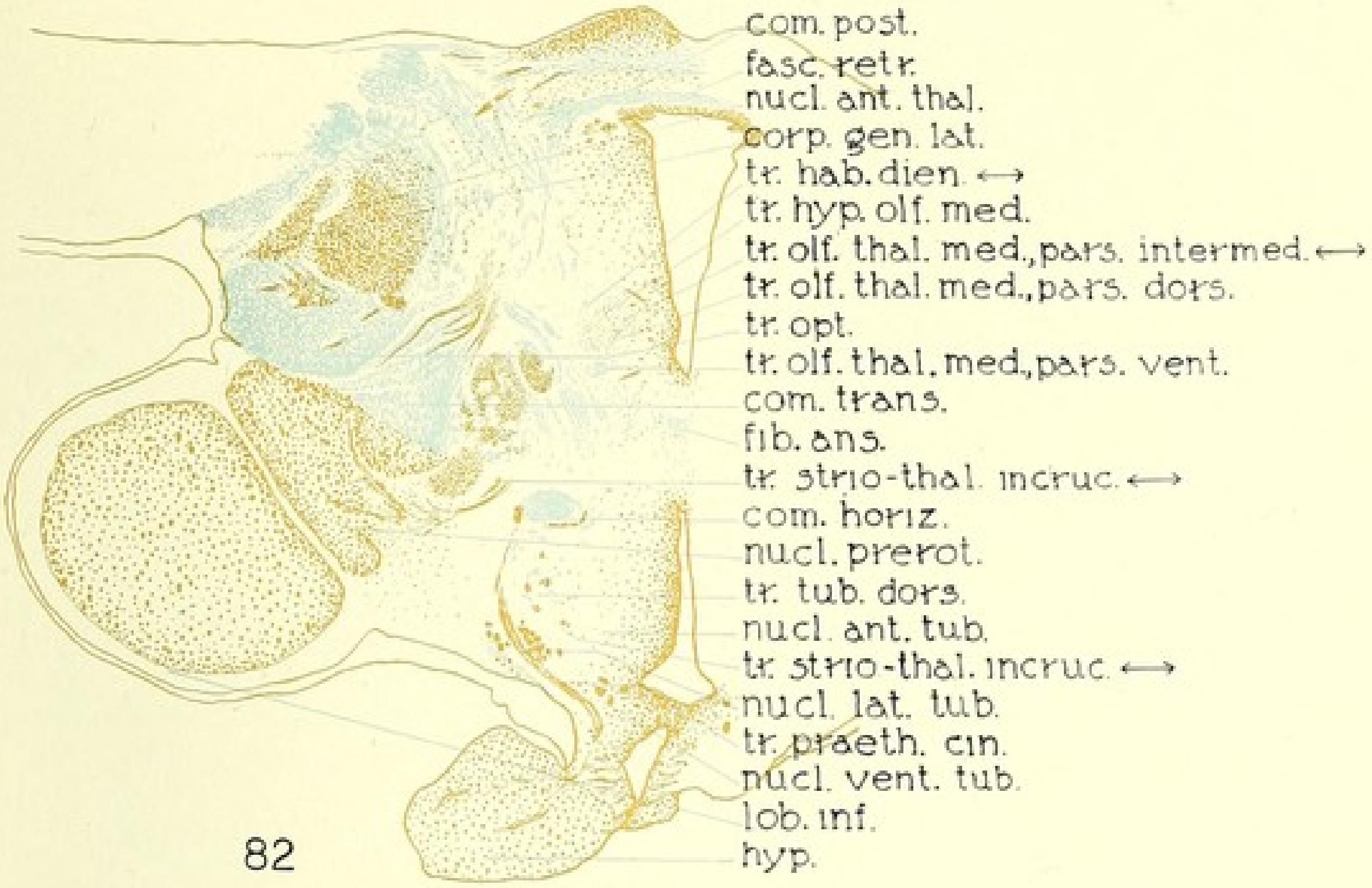
com. post.
fasc. retr.
nucl. ant. thal.
corp. gen. lat.
tr. hab. dien. ⟷
tr. hyp. olf. med.
tr. olf. thal. med., pars. intermed. ⟷
tr. olf. thal. med., pars. dors.
tr. opt.
tr. olf. thal. med., pars. vent.
com. trans.
fib. ans.
tr. strio-thal. incruc. ⟷
com. horiz.
nucl. prerot.
tr. tub. dors.
nucl. ant. tub.
tr. strio-thal. incruc. ⟷
nucl. lat. tub.
tr. praeth. cin.
nucl. vent. tub.
lob. inf.
hyp.

82

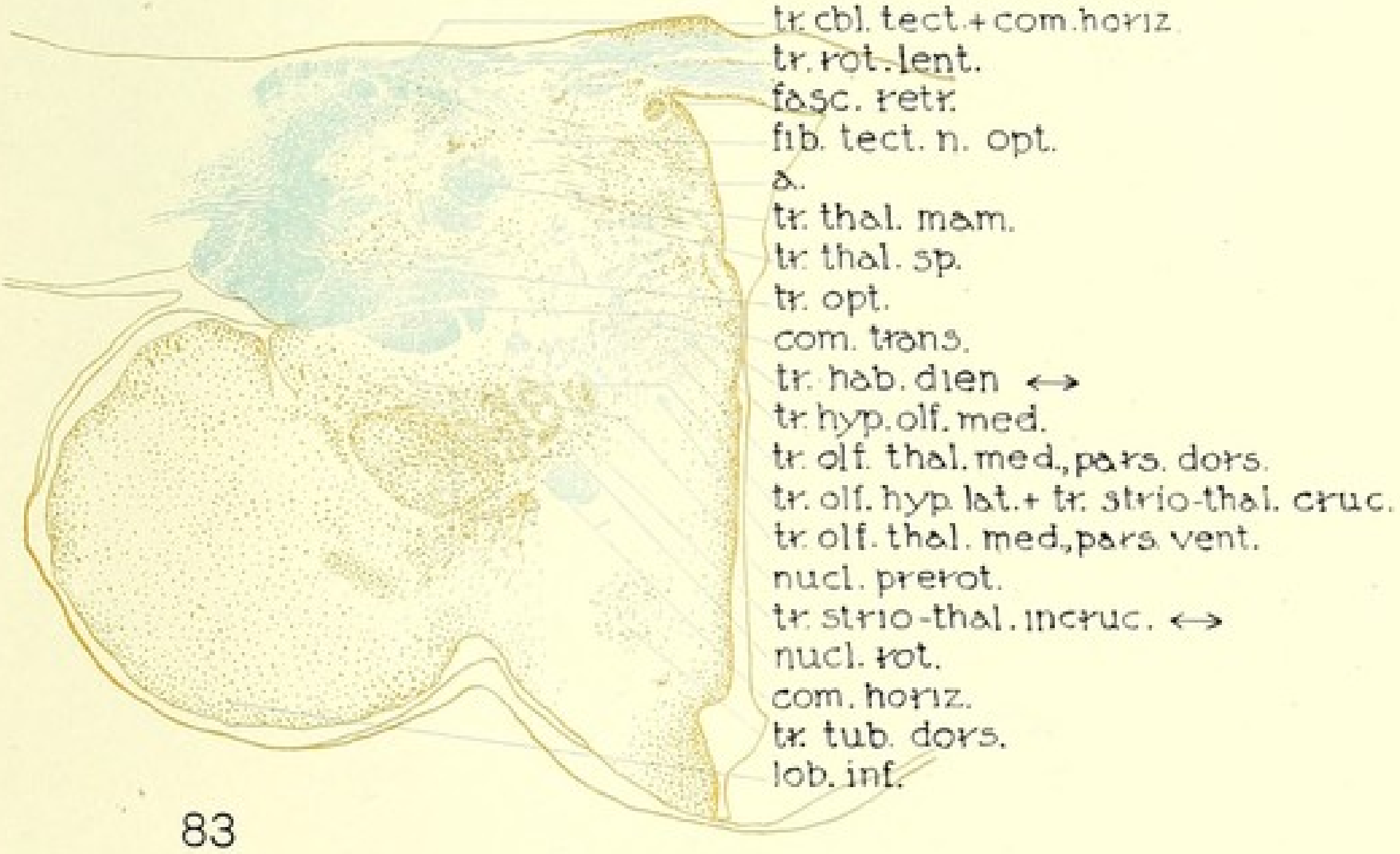
tr. cbl. tect. + com. horiz.
tr. rot.-lent.
fasc. retr.
fib. tect. n. opt.
a.
tr. thal. mam.
tr. thal. sp.
tr. opt.
com. trans.
tr. hab. dien ⟷
tr. hyp. olf. med.
tr. olf. thal. med., pars. dors.
tr. olf. hyp. lat. + tr. strio-thal. cruc.
tr. olf. thal. med., pars. vent.
nucl. prerot.
tr. strio-thal. incruc. ⟷
nucl. rot.
com. horiz.
tr. tub. dors.
lob. inf.

83

PLATE 24

EXPLANATION OF FIGURES

84 Transection through the rostral end of the nucleus rotundus. Toluidin blue method. × 46.

85 Cells of the nucleus prerotundus. Toluidin blue method. × 575. From the right nucleus. Shows the scattered arrangement of the cells and their difference in size.

86 Neurones of the nucleus prerotundus. Golgi method. ×93. From sagittal section.

b, cells adjacent to the recessus lateralis hypothalami (see fig. 87); *com. trans.*, commissura transversa; *fasc. retr.*, fasciculus retroflexus; *nucl. ant. tub.*, nucleus anterior tuberis; *nucl. dif. lob. lat.*, nucleus diffusus lobi lateralis; *nucl. lat. tub.*, nucleus lateralis tuberis; *nucl. posthab.*, nucleus posthabenularis; *nucl. prerot.*, nucleus prerotundus; *nucl. rot.*, nucleus rotundus ; *nucl. vent. tub.*, nucleus ventralis tuberis.

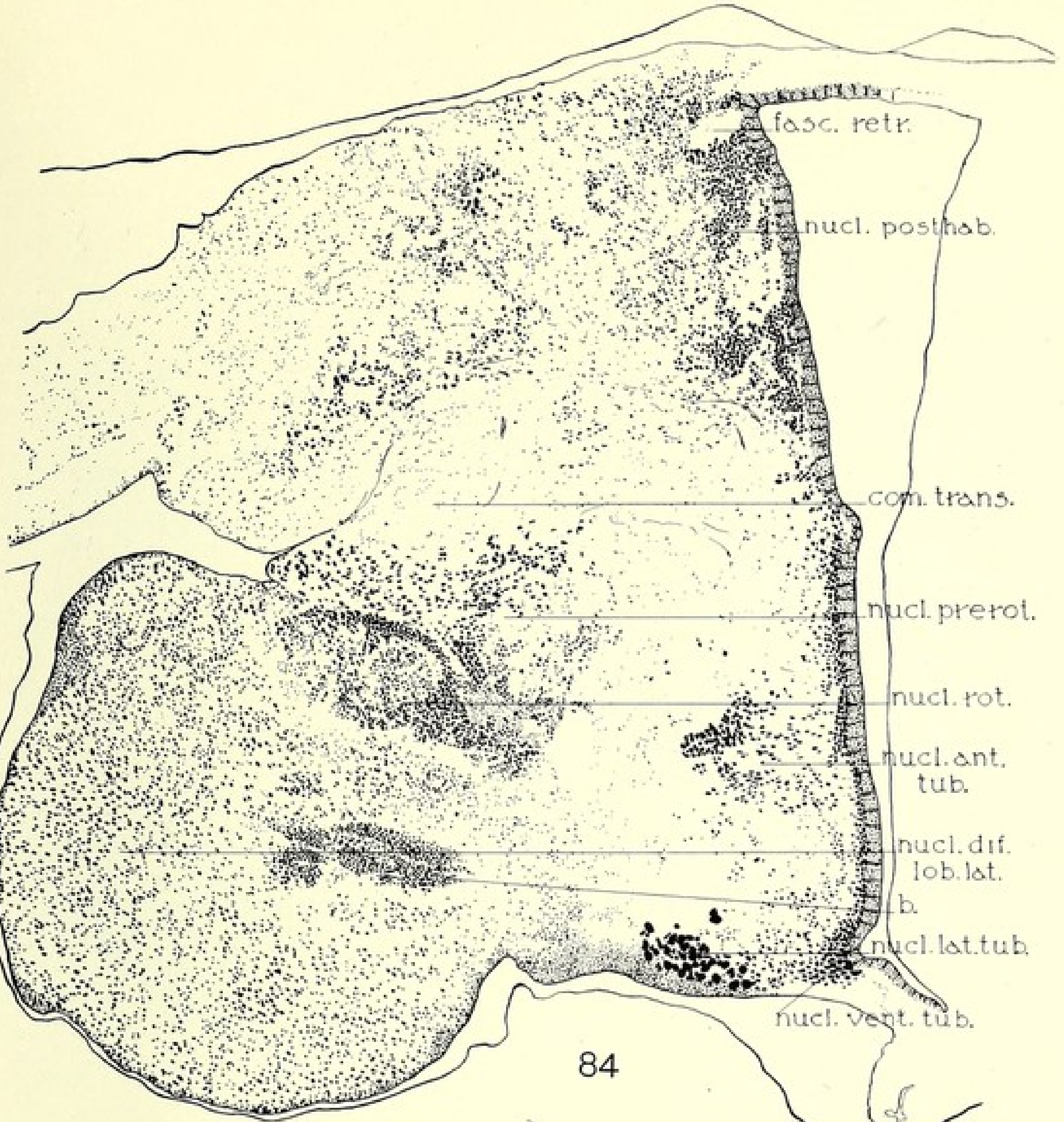
fasc. retr.
nucl. posthab.
com. trans.
nucl. prerot.
nucl. rot.
nucl. ant. tub.
nucl. dif. lob. lat.
b.
nucl. lat. tub.
nucl. vent. tub.

84

85

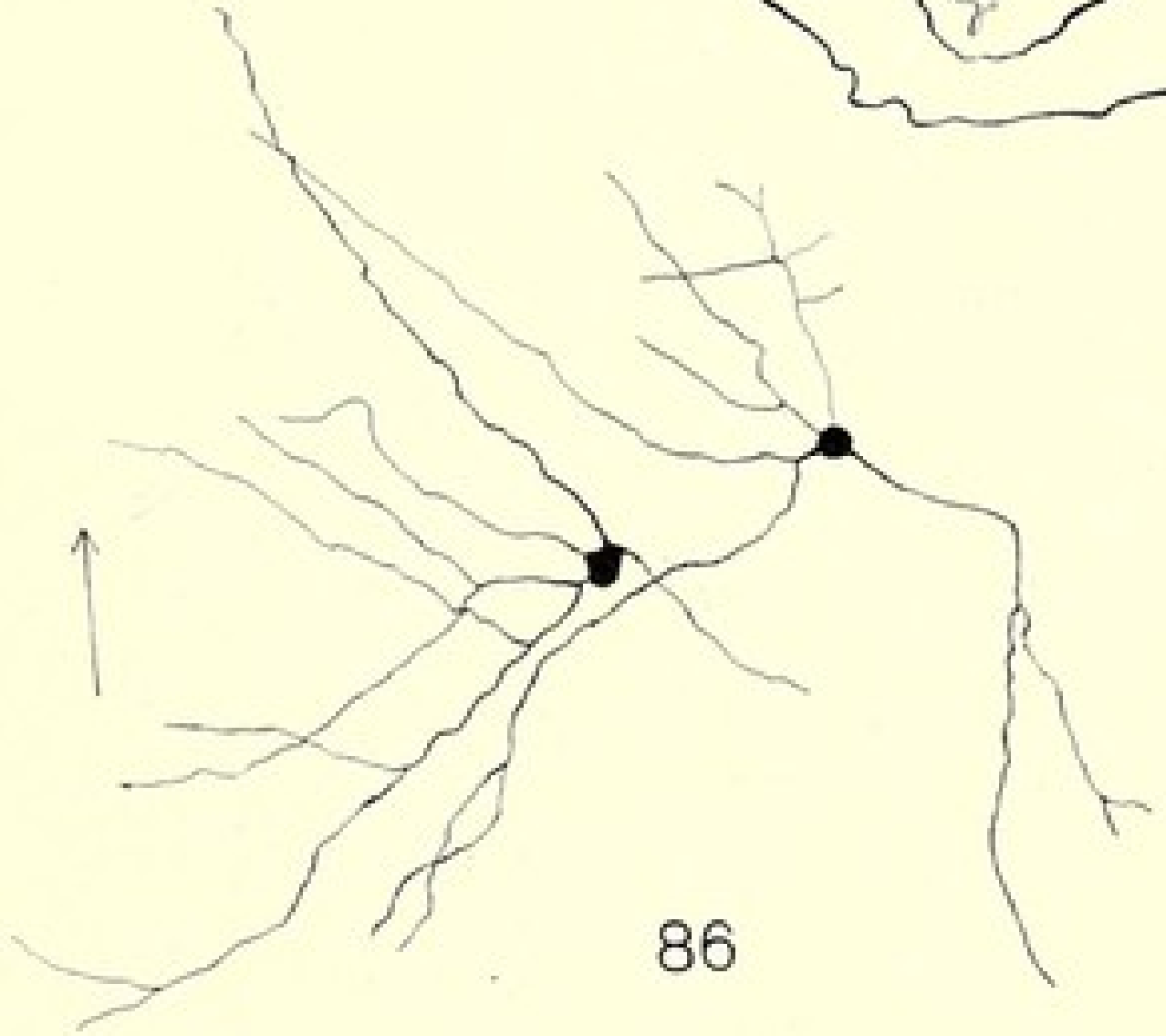

86

PLATE 25

EXPLANATION OF FIGURES

87–88 Neurones of the nucleus prerotundus, Golgi method. × 93. From sagittal sections.

89 Transection immediately caudal to the level of the commissura posterior. Toluidin blue method. × 46.

90 Cells of the nucleus rotundus. Toluidin blue method. × 575. Shows the typical arrangement of the cells in scattered groups.

com. post., commissura posterior; *fasc. retr.*, fasciculus retroflexus; *nucl. ant. tub.*, nucleus anterior tuberis; *nucl. cbl. hyp.*, nucleus cerebellaris hypothalami; *nucl. dif. lob. lat.*, nucleus diffusus lobi lateralis; *nucl. prerot.*, nucleus prerotundus; *nucl. rot.*, nucleus rotundus; *rec. lat. hyp.*, recessus lateralis hypothalami.

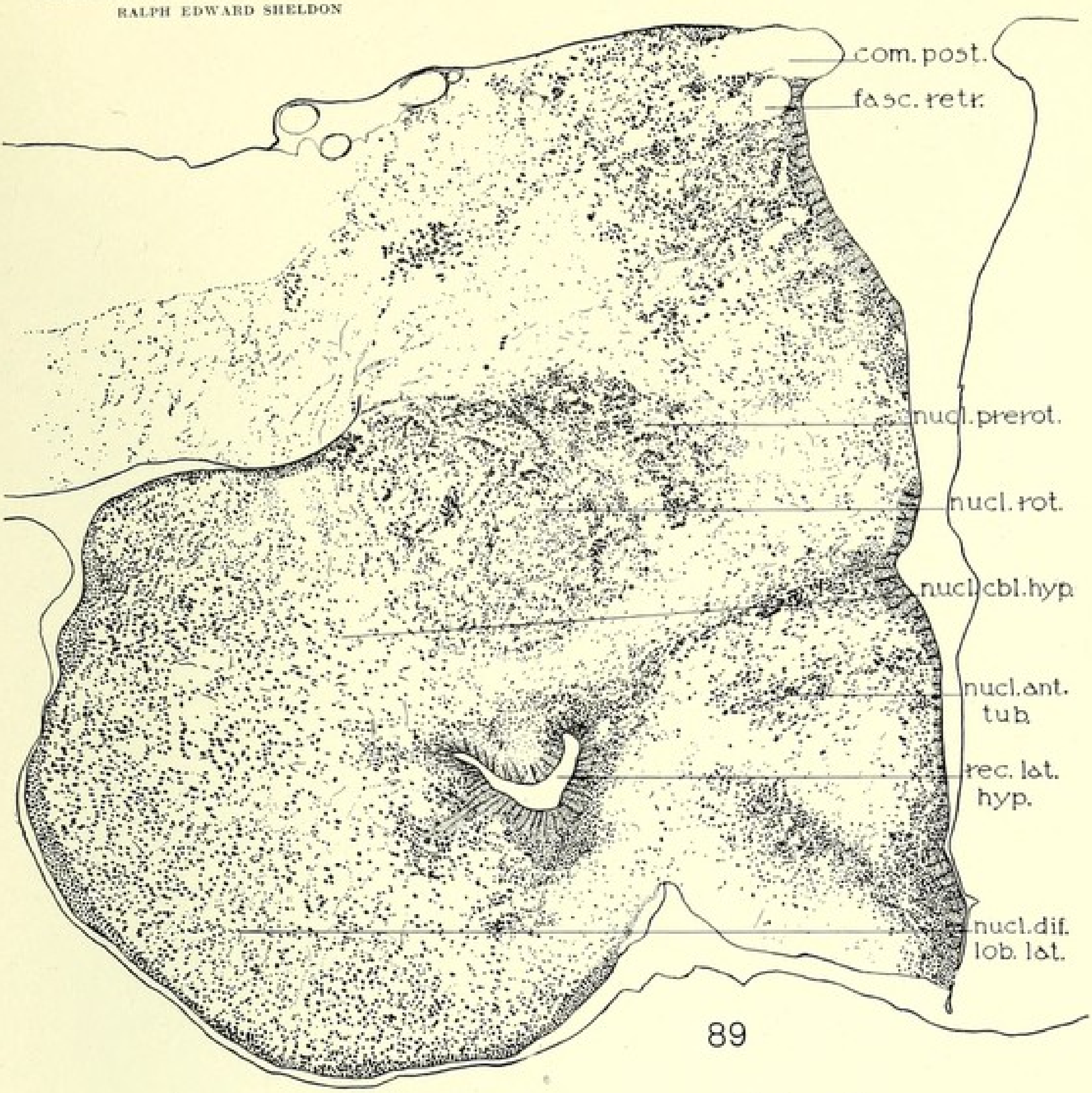
com. post.
fasc. retr.
nucl. prerot.
nucl. rot.
nucl. cbl. hyp.
nucl. ant. tub.
rec. lat. hyp.
nucl. dif. lob. lat.

89



87

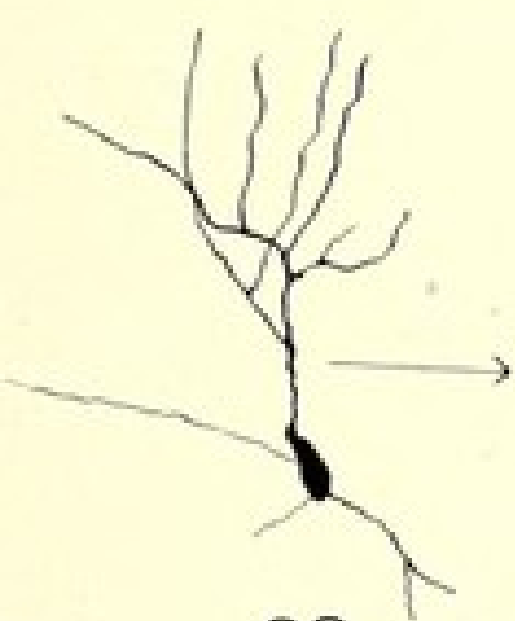

88

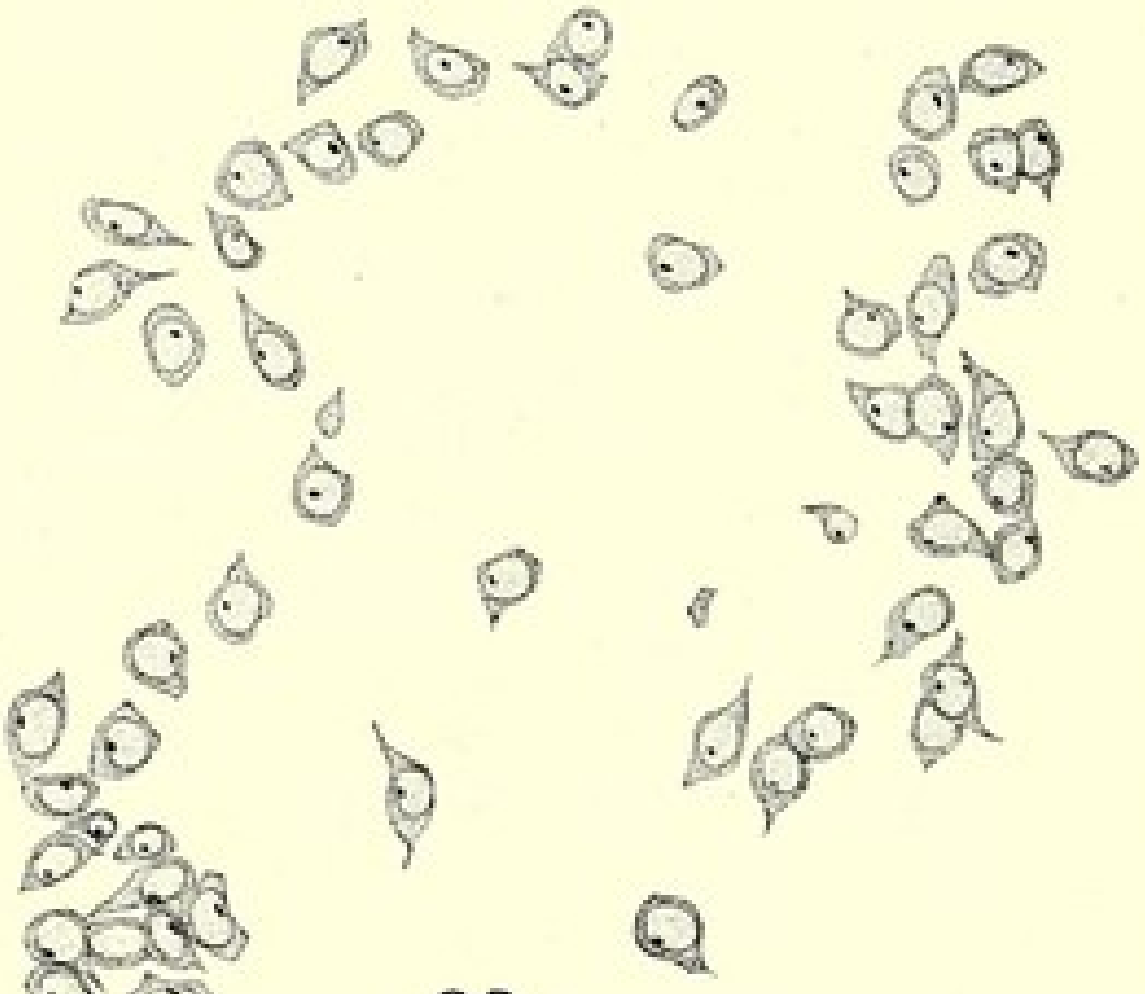

90

PLATE 26

EXPLANATION OF FIGURES

91–94 Neurones of the nucleus rotundus. Golgi method. × 93. From sagittal sections.

95–99 Neurones from different parts of the lobi laterales. Golgi method. × 93. From sagittal sections. Fig. 95 is taken from the caudal angle of the lobe, fig. 96 from the ventro-medial area, fig. 97 from the latero-medial, figs. 98 and 99 from the ventral area proper.

100 Transection at approximately the same level as that shown in fig. 89. Weigert method. × 17.

com. horiz., commissura horizontalis; *com. post.*, commissura posterior; *com. trans.*, commissura transversa; *fasc. retr.*, fasciculus retroflexus; *nucl. ant. tub.*, nucleus anterior tuberis; *nucl. dif. lob. lat.*, nucleus diffusus lobi lateralis; *nucl. prerot.*, nucleus prerotundus; *nucl. rot.*, nucleus rotundus; *tr. cbl. tect.* + *com. horiz.*, tractus cerebello-tectalis plus commissura horizontalis; *tr. hab. dien.* ⟵⟶, tractus habenulo-diencephalicus; *tr. hyp. olf. med.*, tractus hypothalamo-olfactorius medialis; *tr. olf. thal. med., pars dors.*, tractus olfacto-thalamicus medialis, pars dorsalis; *tr. olf. thal. med., pars vent.*, tractus olfacto-thalamicus medialis, pars ventralis; *tr. rot. lent.*, tractus rotundo-lentiformis; *tr. strio-thal. cruc.* + *tr. olf. hyp. lat.*, tractus strio-thalamicus cruciatus plus tractus olfacto-hypothalamicus lateralis; *tr. thal. mam.*, tractus thalamo-mammillaris; *tr. thal. sp.*, tractus thalamo-spinalis.

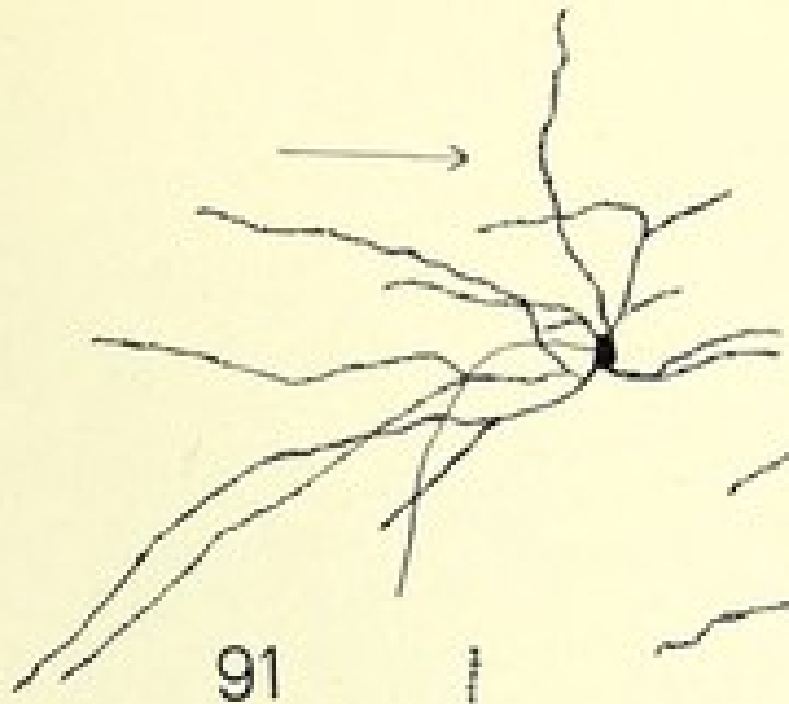

91

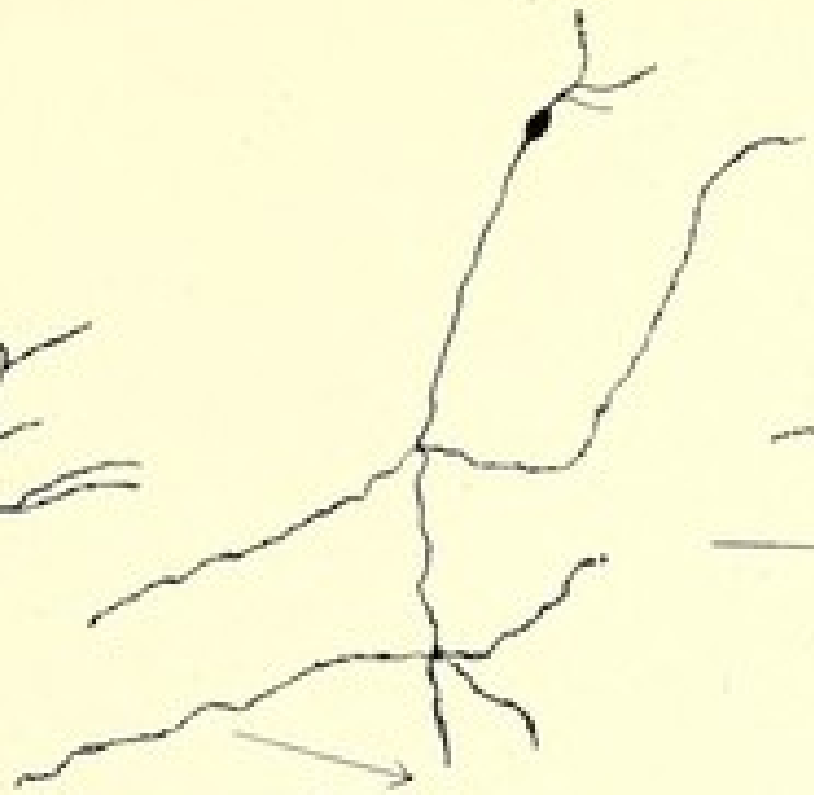

92

93

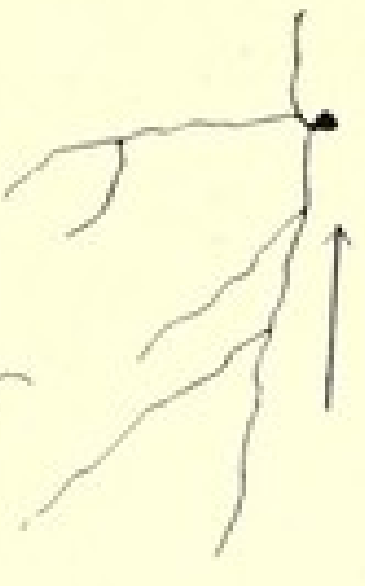

94

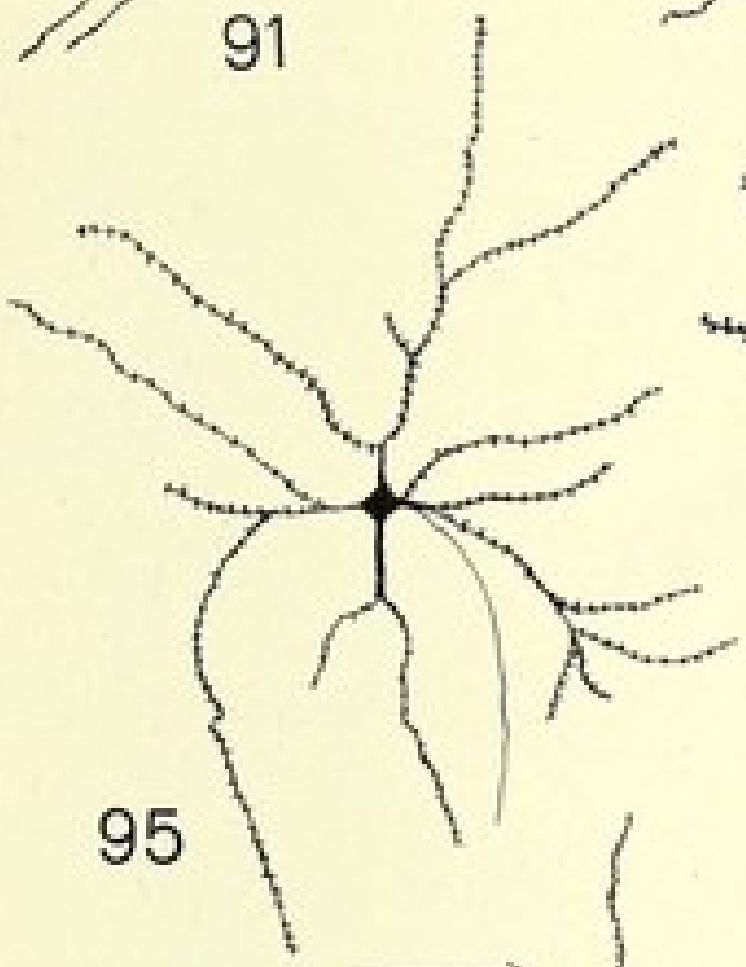

95

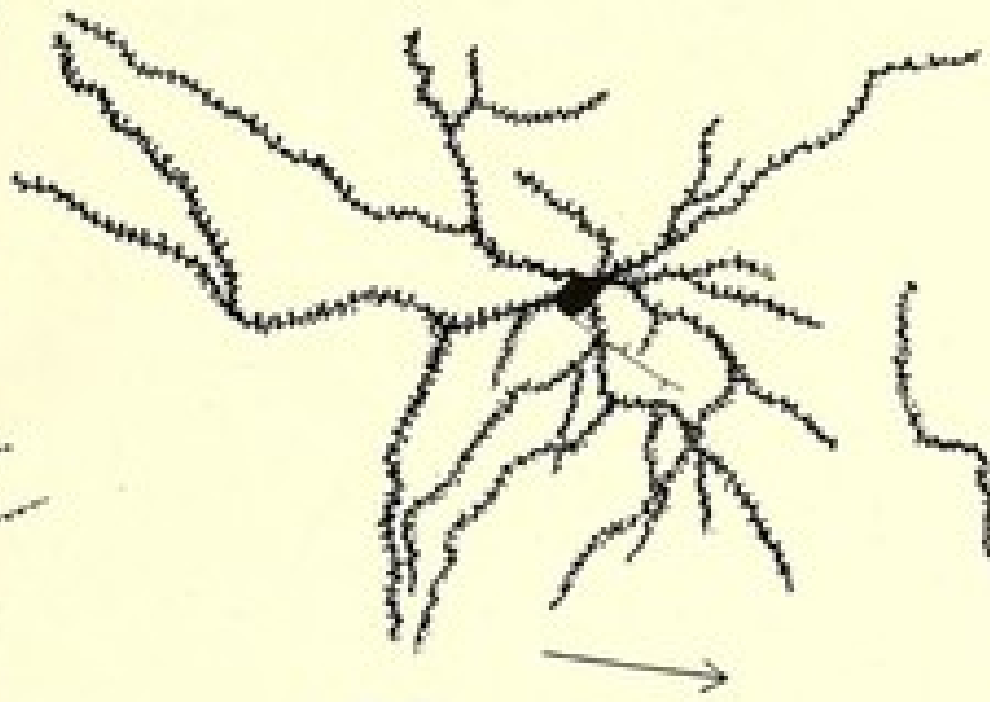

96

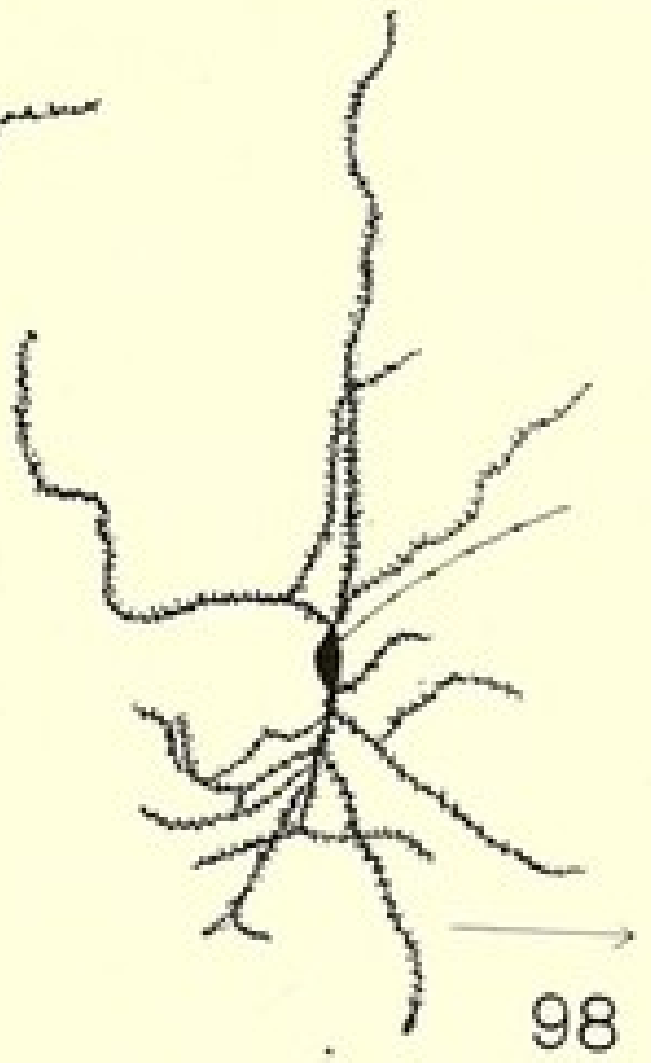

98

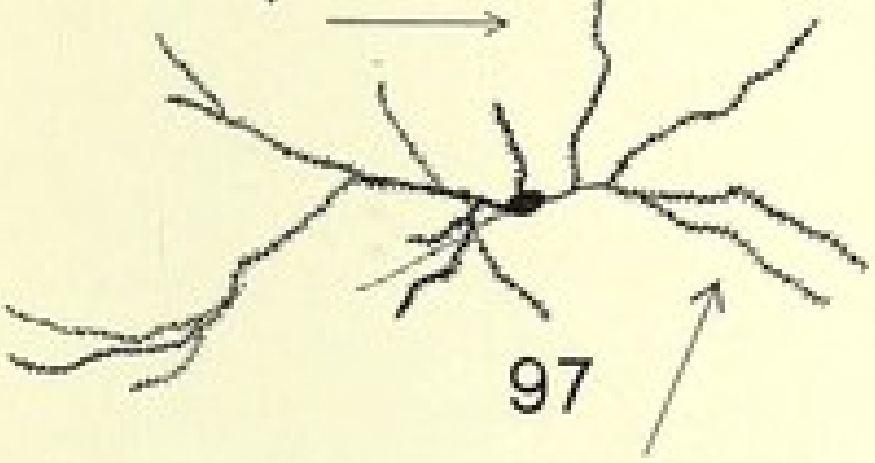

97



99

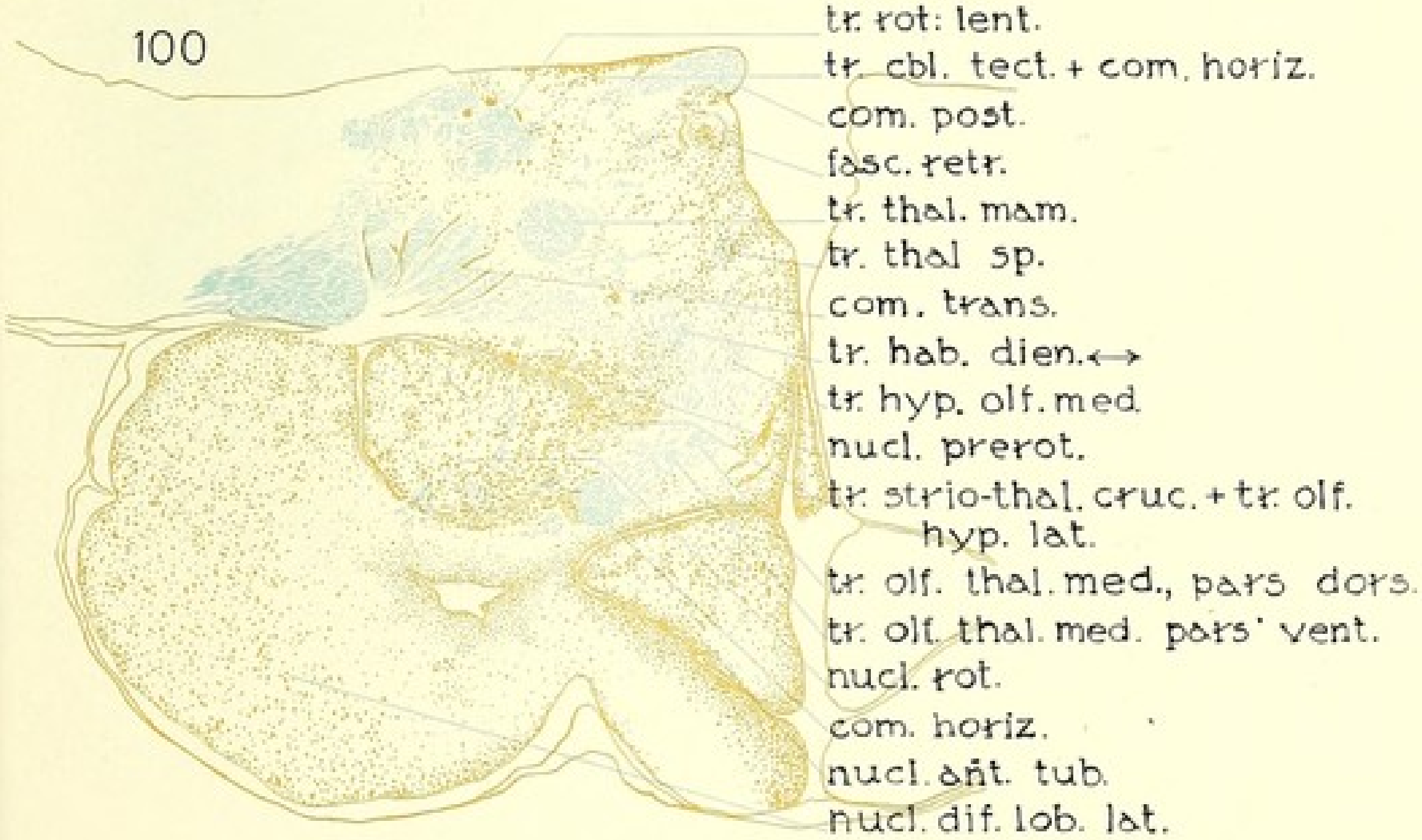

100

PLATE 27

EXPLANATION OF FIGURES

101 Transection slightly caudal to the level shown in fig. 100. Weigert method. × 17.

102 Transection through the decussation of the tractus hypothalamo-olfactorii mediales. Ramón y Cajal method. × 46.

com. horiz., commissura horizontalis; *com. post.*, commissura posterior; *com. trans.*, commissura transversa; *dec. tr. hyp. olf. med.*, decussatio tractorum olfactoriorum medialium; *fasc. retr.* fasciculus retroflexus; *lob. lat. hyp.*, lobus lateralis hypothalami; *lob. med. hyp.*, lobus medialis hypothalami; *nucl. dif. lob. lat.*, nucleus diffusus lobi lateralis; *nucl. prerot.*, nucleus prerotundus; *nucl. rot.*, nucleus rotundus; *nucl. subrot.*, nucleus subrotundus; *rec. lat. hyp.*, recessus lateralis hypothalami; *tr. cbl. tect.* + *tr. rot. lent.* + *com. horiz.*, tractus cerebello-tectalis plus tractus rotundo-lentiformis plus commissura horizontalis; *tr. hab. dien.*⟵⟶, tractus habenulo-diencephalicus; *tr. hyp. olf. med.*, tractus hypothalamo-olfactorius medialis; *tr. olf. thal. med., pars dors.*, tractus olfacto-thalamicus medialis, pars dorsalis; *tr. olf. thal. med., pars vent.*, tractus olfacto-thalamicus medialis, pars ventralis; *tr. rot. lob.*, tractus rotundo-lobaris; *tr. strio-thal. cruc.* + *tr. olf. hyp. lat.*, tractus strio-thalamicus cruciatus plus tractus olfacto-hypothalamicus lateralis; *tr. thal. mam.*, tractus thalamo-mammillaris; *tr. thal. sp.*, tractus thalamo-spinalis (Kappers).

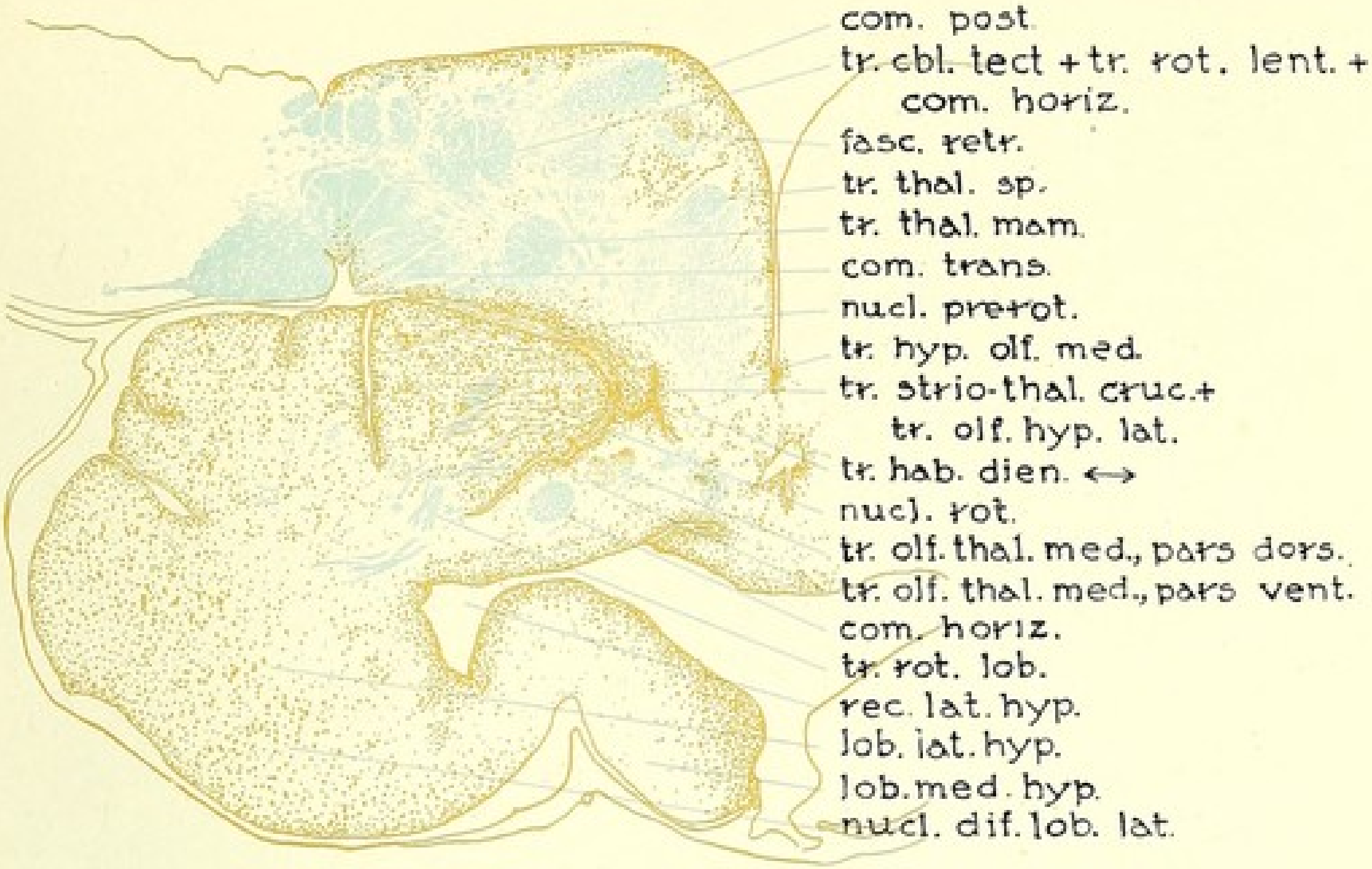
com. post.
tr. cbl. tect + tr. rot. lent. + com. horiz.
fasc. retr.
tr. thal. sp.
tr. thal. mam.
com. trans.
nucl. prerot.
tr. hyp. olf. med.
tr. strio-thal. cruc.+ tr. olf. hyp. lat.
tr. hab. dien. ↔
nucl. rot.
tr. olf. thal. med., pars dors.
tr. olf. thal. med., pars vent.
com. horiz.
tr. rot. lob.
rec. lat. hyp.
lob. lat. hyp.
lob. med. hyp.
nucl. dif. lob. lat.

101

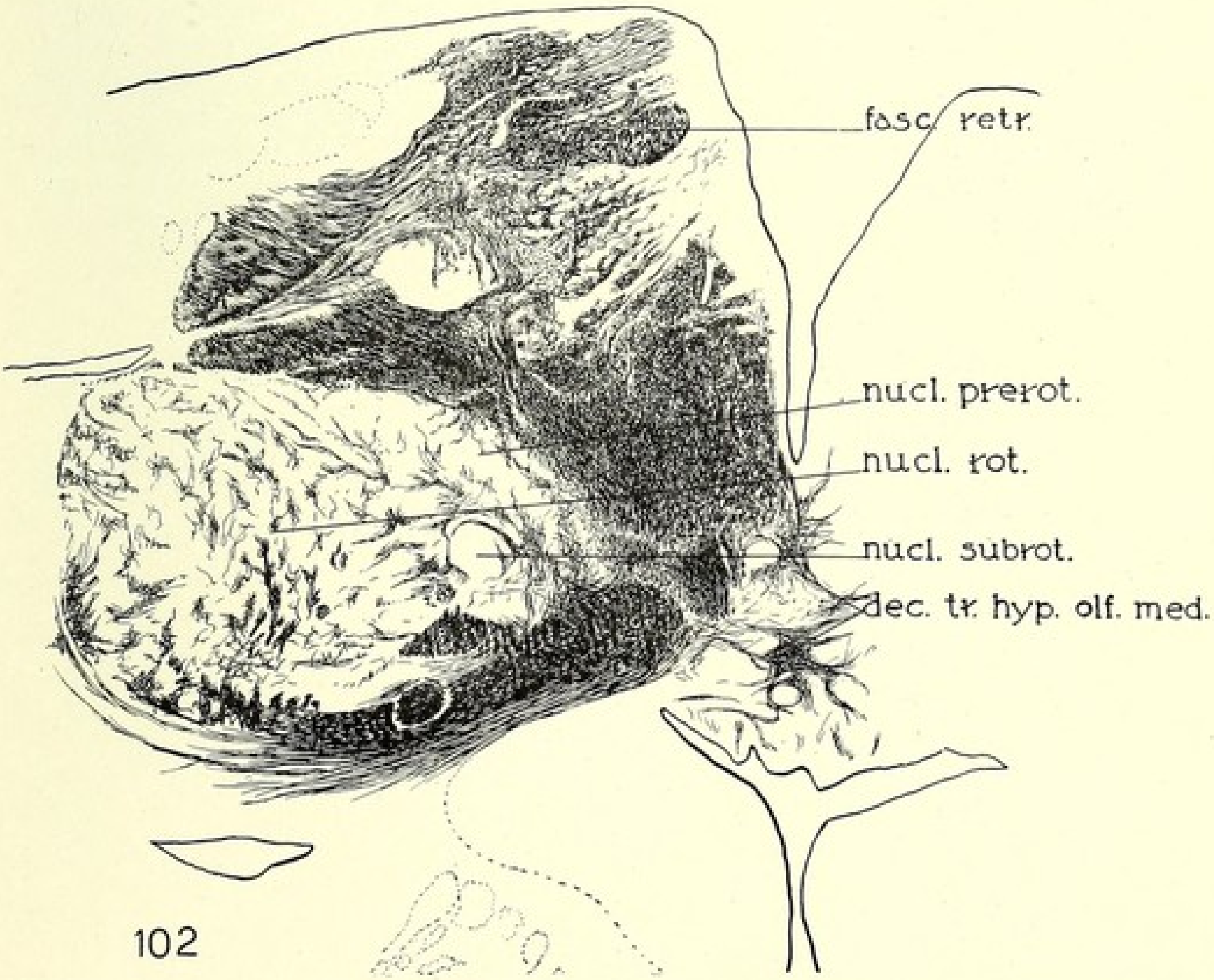
fasc. retr.
nucl. prerot.
nucl. rot.
nucl. subrot.
dec. tr. hyp. olf. med.

102

PLATE 28

EXPLANATION OF FIGURES

103 Transection through the nucleus posterior tuberis. Toluidin blue method. × 46.

104 Oblique longitudinal section showing the origin of the tractus hypothalamo-olfactorius medialis. Golgi method. × 9.

105 Neurone of origin of the tractus hypothalamo-olfactorius medialis. Golgi method. × 93. Taken from same section as fig. 104.

chiasma, optic chiasma; *corp. precom.*, corpus precommissurale; *crus olf.*, crus olfactorium; *n. opt.*, nervus opticus; *nucl. cbl. hyp.*, nucleus cerebellaris hypothalami; *nucl. dif. lob. lat.*, nucleus diffusus lobi lateralis; *nucl. post. thal.*, nucleus posterior thalami; *nucl. post. tub.*, nucleus posterior tuberis; *nucl. prerot.*, nucleus prerotundus; *nucl. rot.*, nucleus rotundus; *rec. lat. hyp.*, recessus lateralis hypothalami; *sac. vasc.*, saccus vasculosus; *tela*, membranous roof of forebrain; *tr. cbl. hyp.*, tractus cerebello-hypothalamicus; *tr. hyp. olf. med.*, tractus hypothalamo-olfactorius medialis; *tr. opt.*, tractus opticus; *tr. strio-thal.*, tractus strio-thalamicus; *tr. thal. str.*, tractus thalamo-striaticus; *valvula*, valvula cerebelli.

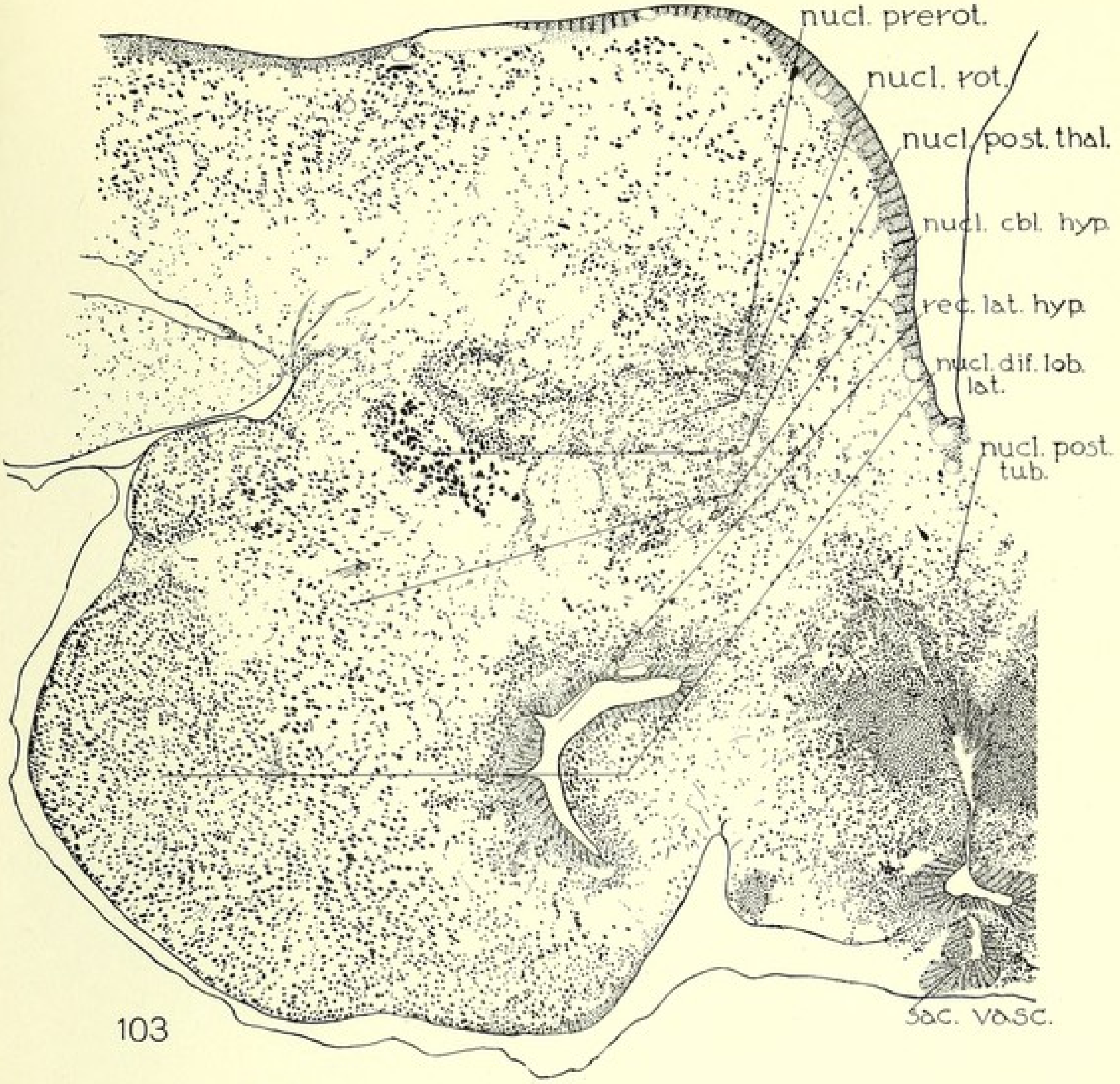
nucl. prerot.
nucl. rot.
nucl. post. thal.
nucl. cbl. hyp.
rec. lat. hyp.
nucl. dif. lob. lat.
nucl. post. tub.
sac. vasc.

103

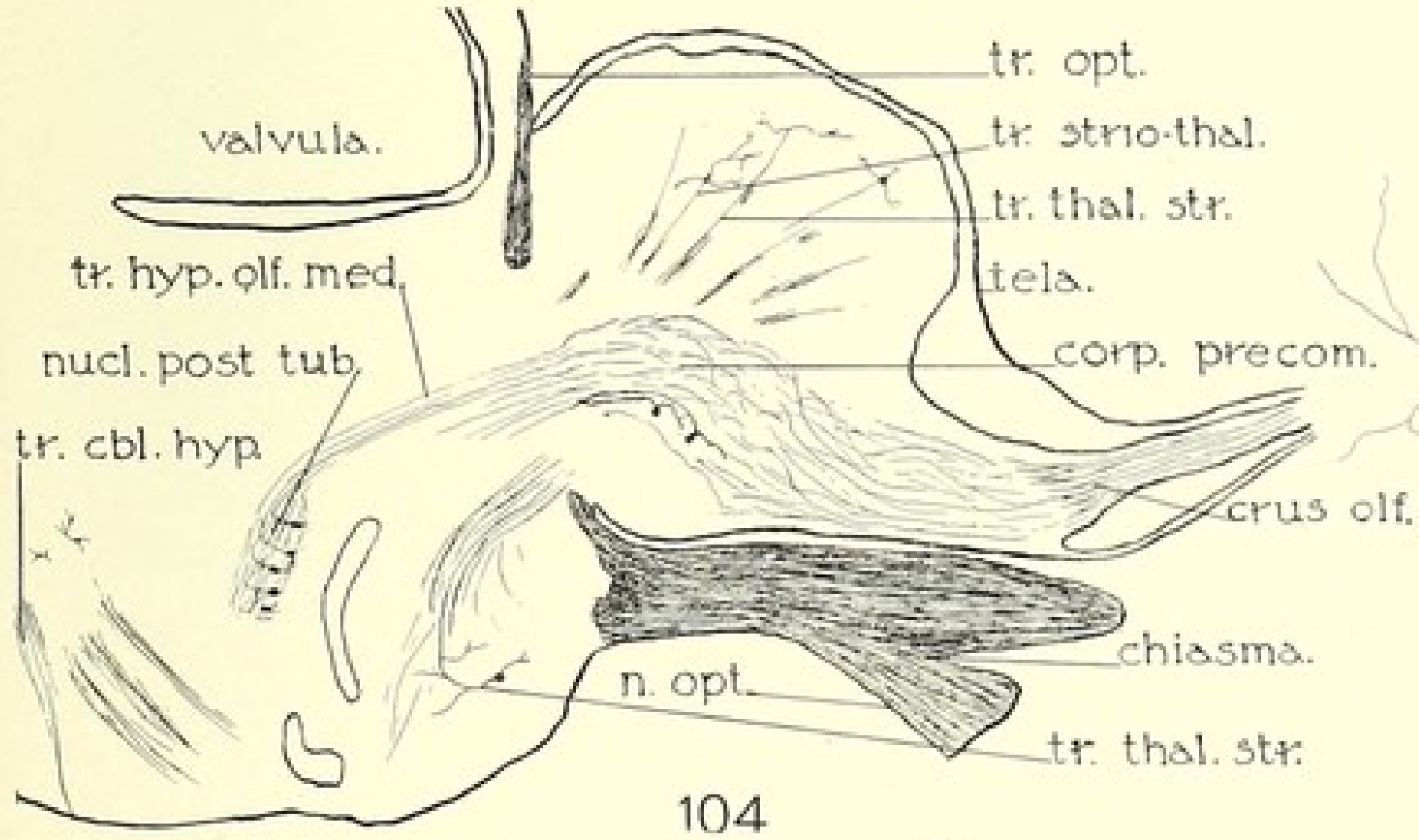
valvula.
tr. opt.
tr. strio-thal.
tr. thal. str.
tela.
tr. hyp. olf. med.
nucl. post tub.
tr. cbl. hyp.
corp. precom.
crus olf.
chiasma.
n. opt.
tr. thal. str.

104

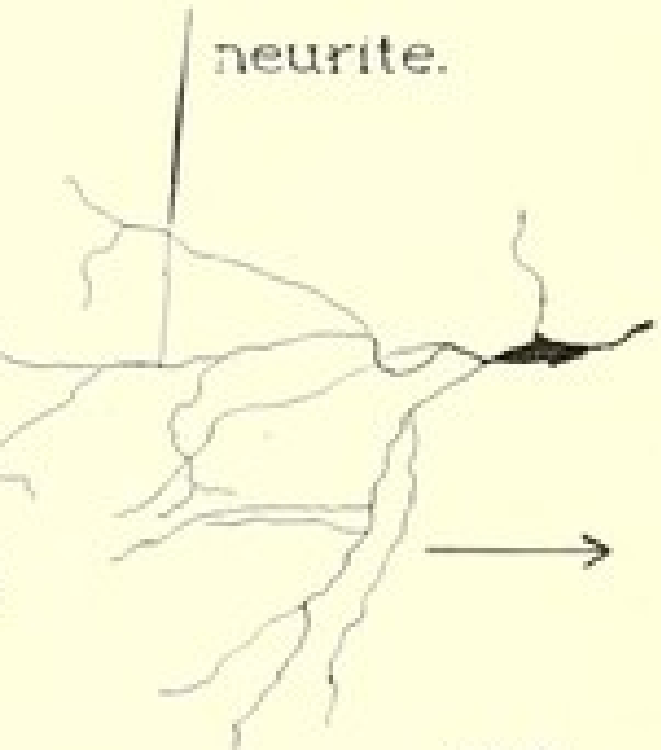
neurite.

105

PLATE 29

EXPLANATION OF FIGURES

106 Transection through the Haubenwulst. Toluidin blue method. × 46.

107 Transection through the nucleus subrotundus. Toluidin blue method. × 47. Detail cells. × 575. Shows the characteristic grouping of the cells in the center of the nucleus (see fig. 106). From right side.

108 Cells of the nucleus cerebellaris hypothalami. Toluidin blue method. × 575. Shows typical scattered arrangement of the cells (see figs. 103 and 106).

nucl. cbl. hyp., nucleus cerebellaris hypothalami; *nucl. dif. lob. lat.*, nucleus diffusus lobi lateralis; *nucl. fasc. long. med.*, nucleus fasciculi longitudinalis medialis; *nucl. post. thal.*, nucleus posterior thalami; *nucl. prerot.*, nucleus prerotundus; *nucl. rot.*, nucleus rotundus; *nucl. subrot.* nucleus subrotundus; *rec. lat. hyp.*, recessus lateralis hypothalami.

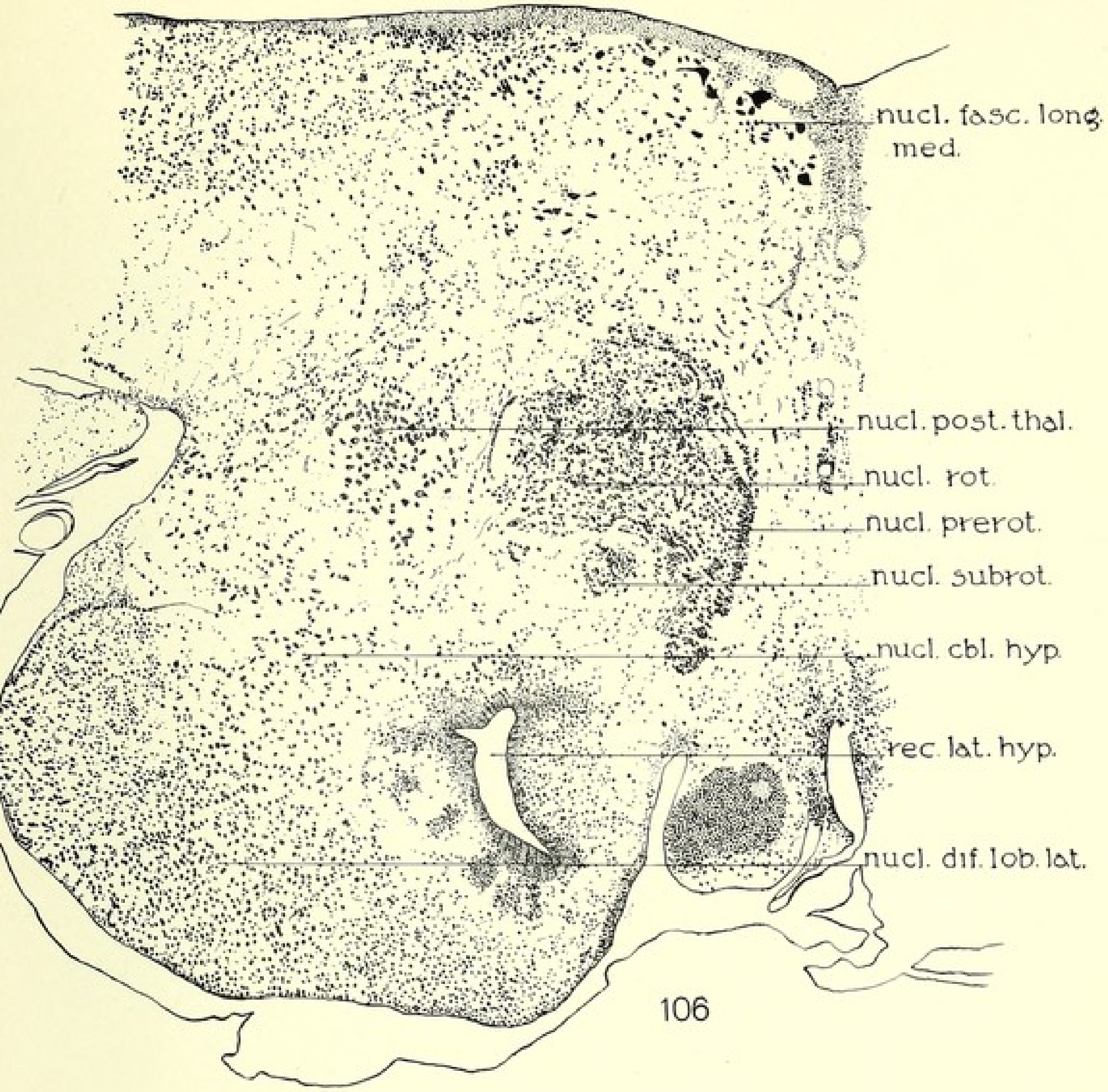
nucl. fasc. long. med.
nucl. post. thal.
nucl. rot.
nucl. prerot.
nucl. subrot.
nucl. cbl. hyp.
rec. lat. hyp.
nucl. dif. lob. lat.

106

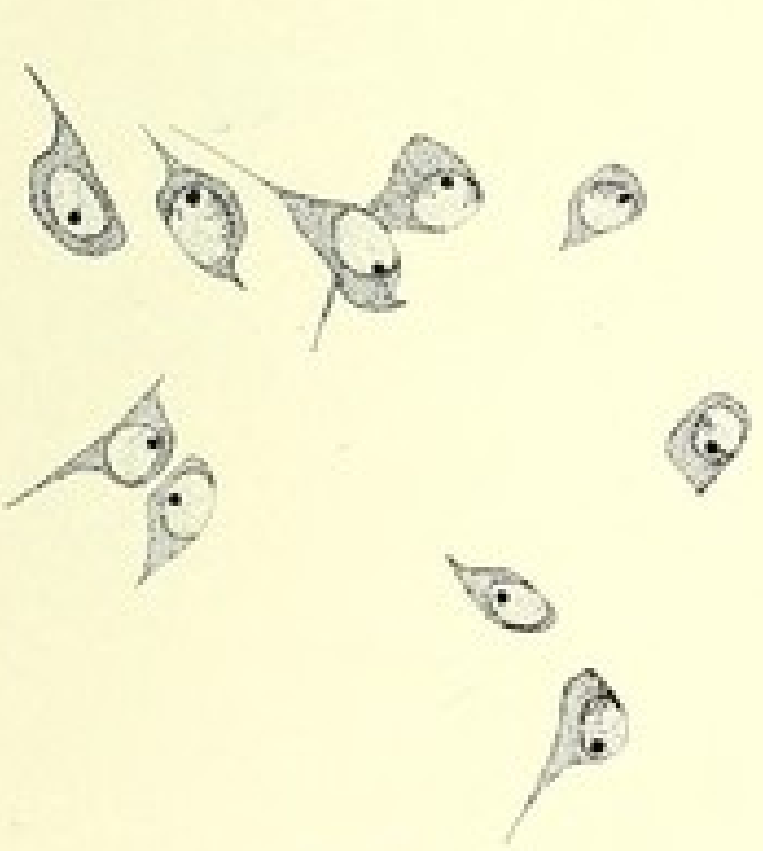

108

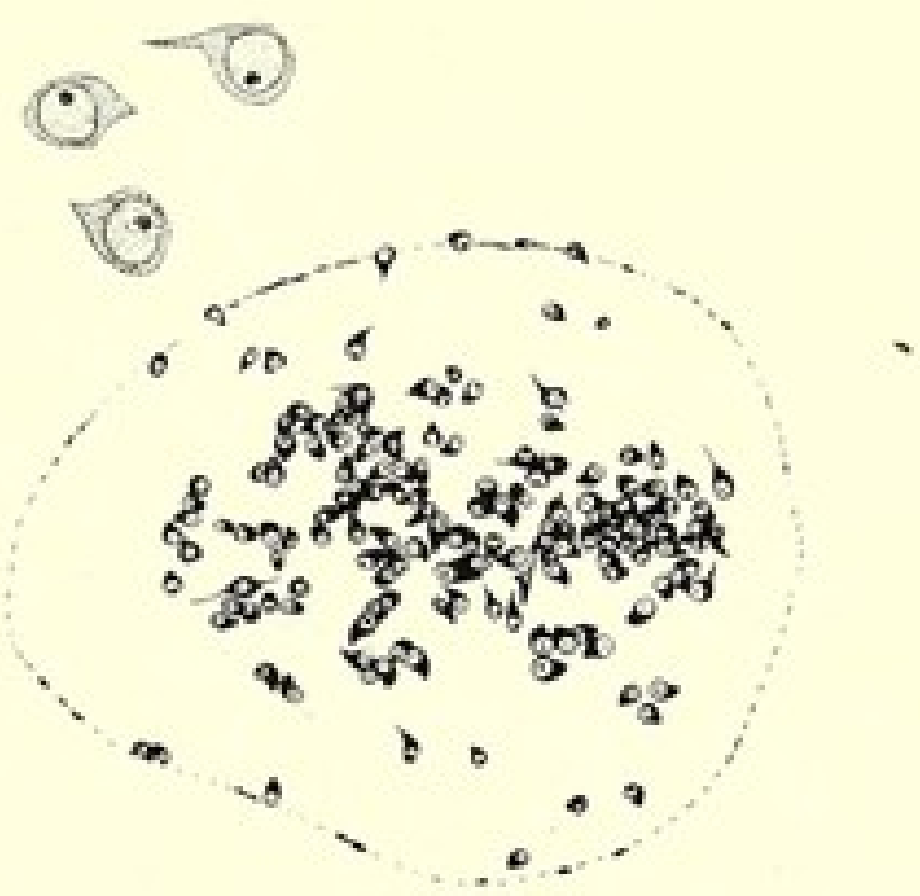

107

PLATE 30

EXPLANATION OF FIGURES

109 Cells of the nucleus posterior thalami. Toluidin blue method. × 575.

110–113 Neurones of the nucleus posterior thalami. Golgi method. × 93. From sagittal sections. As will be noted, the cells of this nucleus are very large. They appear larger in sagittal than in transverse sections, both in toluidin blue and Golgi material.

114 Transection at approximately the same level as that shown in fig. 106. Weigert method. × 17.

com. horiz., commissura horizontalis; *com. post.*, commissura posterior; *com. trans.*, commissura transversa; *fasc. retr.*, fasciculus retroflexus; *nucl. dif. lob. lat.*, nucleus diffusus lobi lateralis; *nucl. post. tub.*, nucleus posterior tuberis; *nucl. prerot.*, nucleus prerotundus; *nucl. rot.*, nucleus rotundus; *nucl. subrot.*, nucleus subrotundus; *sac. vasc.*, saccus vasculosus; *tr. cbl. tect. + tr. rot. lent. + com. horiz.*, tractus cerebello-tectalis plus tractus rotundo-lentiformis plus commissura horizontalis; *tr. cbl. hyp.*, tractus cerebello-hypothalamicus; *tr. olf. thal. med., pars dors.*, tractus olfacto-thalamicus medialis, pars dorsalis; *tr. olf. thal. med., pars vent.*, tractus olfacto-thalamicus medialis, pars ventralis; *tr. rot. lob.*, tractus rotundo-lobaris; *tr. thal. mam.*, tractus thalamo-mammillaris; *tr. thal. sp.*, tractus thalamo-spinalis (Kappers).

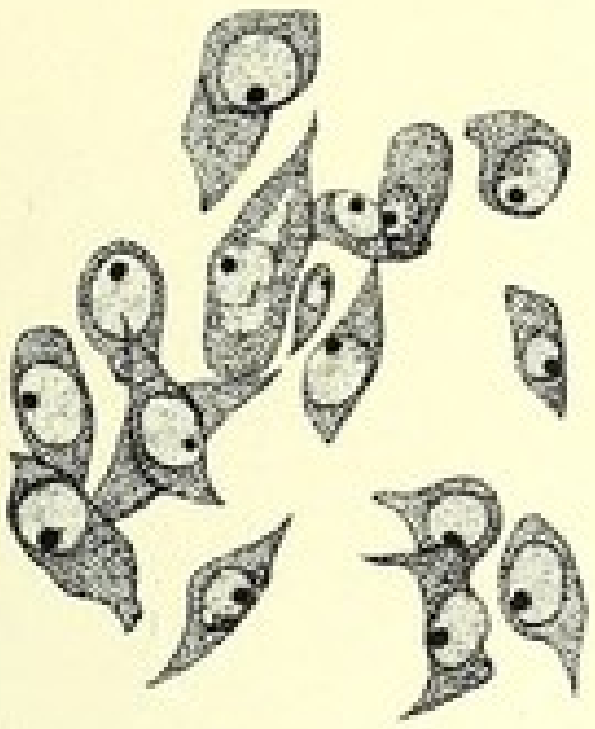

109

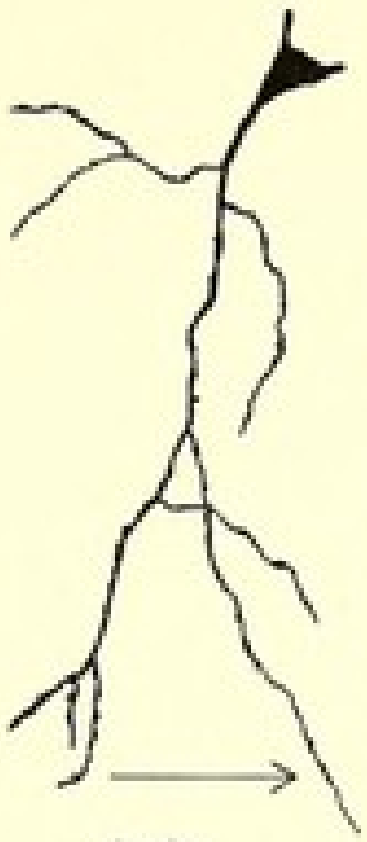

110

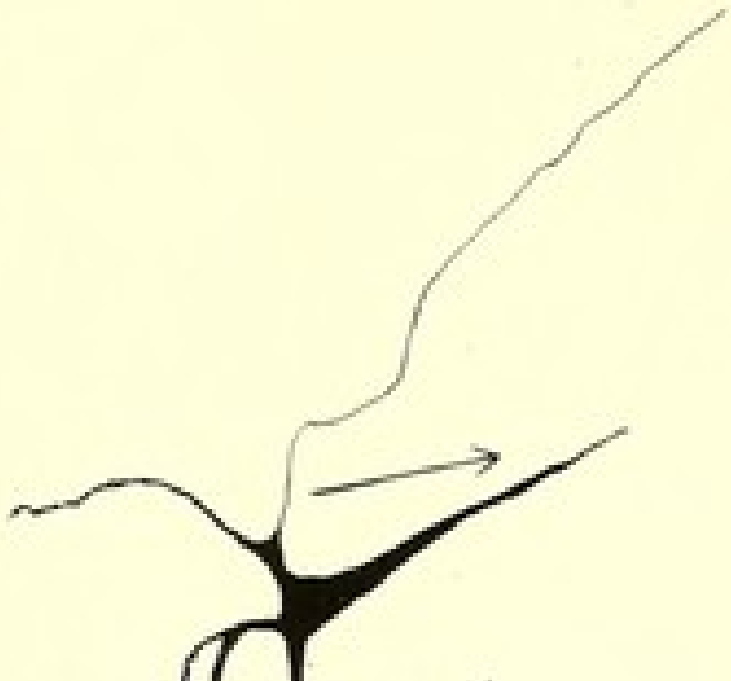

111

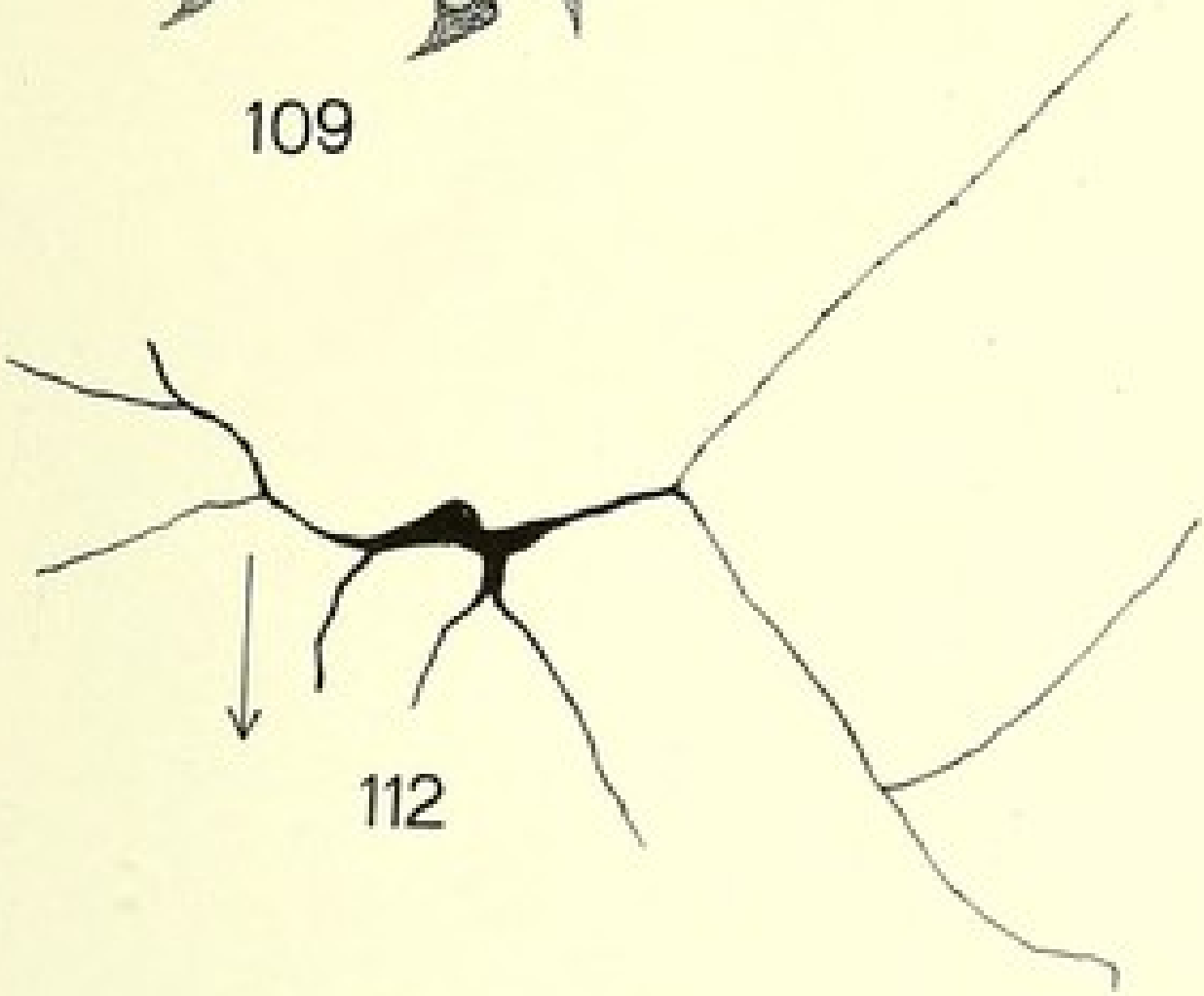

112

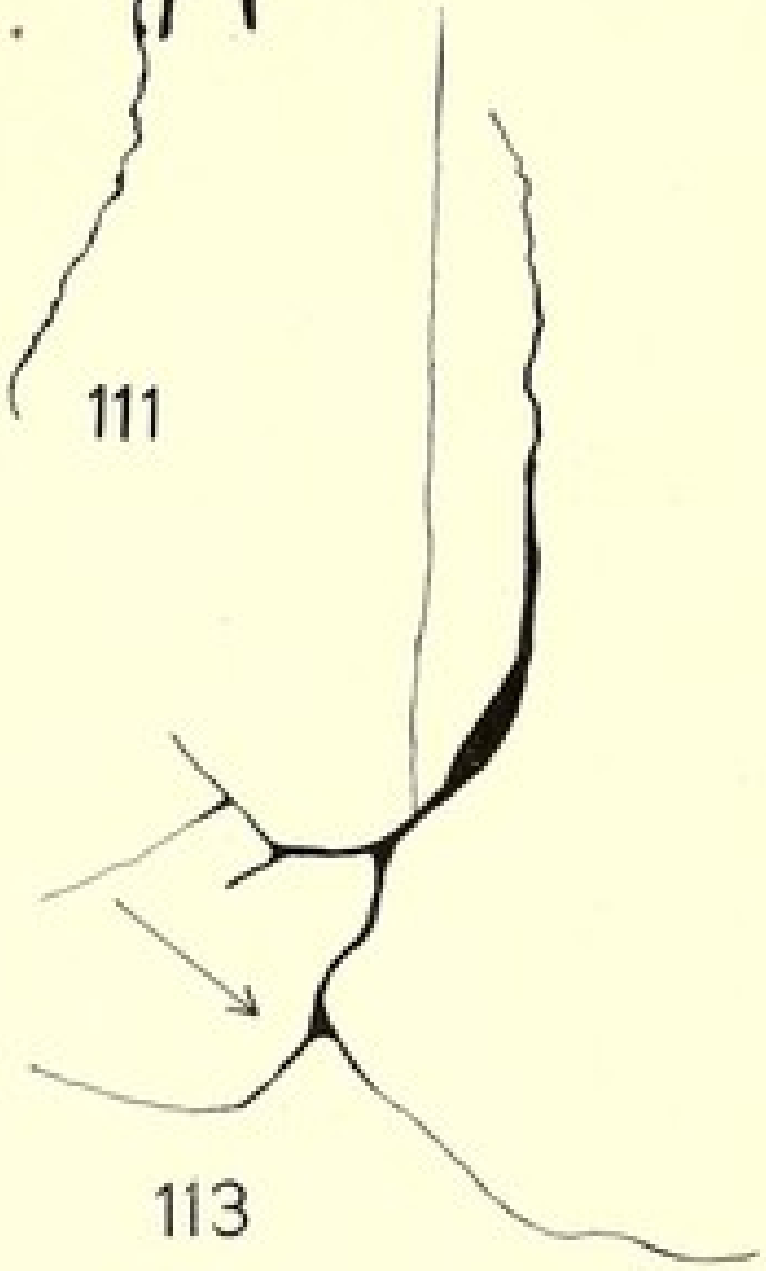

113

114

PLATE 31

EXPLANATION OF FIGURES

115 Transection slightly caudal to the level shown in fig. 114. Weigert method. × 17.

116 Transection slightly caudal to the level shown in fig. 115. Weigert method. × 17.

com. horiz. + tr. rot. lent., commissura horizontalis plus tractus rotundo-lentiformis; *com. trans.*, commissura transversa; *corp. mam.* (*G*), corpus mammillare, the ganglion mammillare of Goldstein; *fasc. retr.*, fasciculus retroflexus; *nucl. dif. lob. lat.*, nucleus diffusus lobi lateralis; *nucl. post. thal.*, nucleus posterior thalami; *nucl. post. tub.*, nucleus posterior tuberis; *nucl. prerot.*, nucleus prerotundus; *nucl. rot.*, nucleus rotundus; *nucl. subrot.*, nucleus subrotundus; *sac. vasc.*, saccus vasculosus; *tr. cbl. tect.*, tractus cerebello-tectalis; *tr. cbl. tect. + tr. rot. lent. + com. horiz.*, tractus cerebello-tectalis plus tractus rotundo-lentiformis plus commissura horizontalis; *tr. cbl. hyp.*, tractus cerebello-hypothalamicus; *tr. olf. thal. med., pars. dors.*, tractus olfacto-thalamicus medialis, pars dorsalis; its connection with the nucleus subrotundus comes out with great clearness in these figures; *tr. olf. thal. med., pars. vent.*, tractus olfacto-thalamicus medialis, pars ventralis; in fig. 116, immediately lateral to the nucleus rotundus, is shown the termination of this tract; *tr. rot. lob.*, tractus rotundo-lobaris; *tr. thal. mam.*, tractus thalamo-mammillaris; *tr. thal. sp.*, tractus thalamo-spinalis (Kappers.)

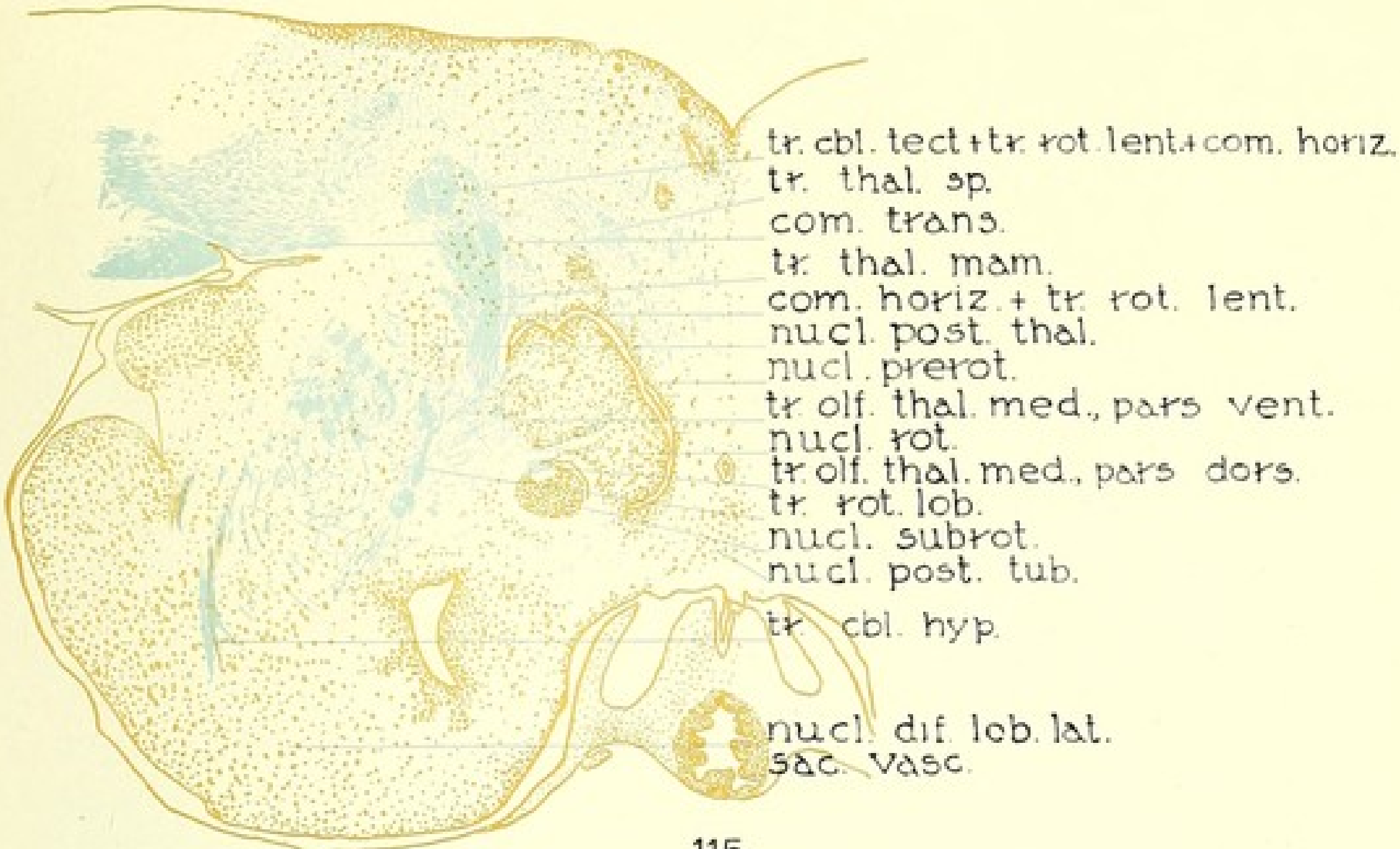
tr. cbl. tect + tr. rot. lent + com. horiz.
tr. thal. sp.
com. trans.
tr. thal. mam.
com. horiz. + tr. rot. lent.
nucl. post. thal.
nucl. prerot.
tr. olf. thal. med., pars vent.
nucl. rot.
tr. olf. thal. med., pars dors.
tr. rot. lob.
nucl. subrot.
nucl. post. tub.
tr. cbl. hyp.
nucl. dif. lob. lat.
sac. vasc.

115

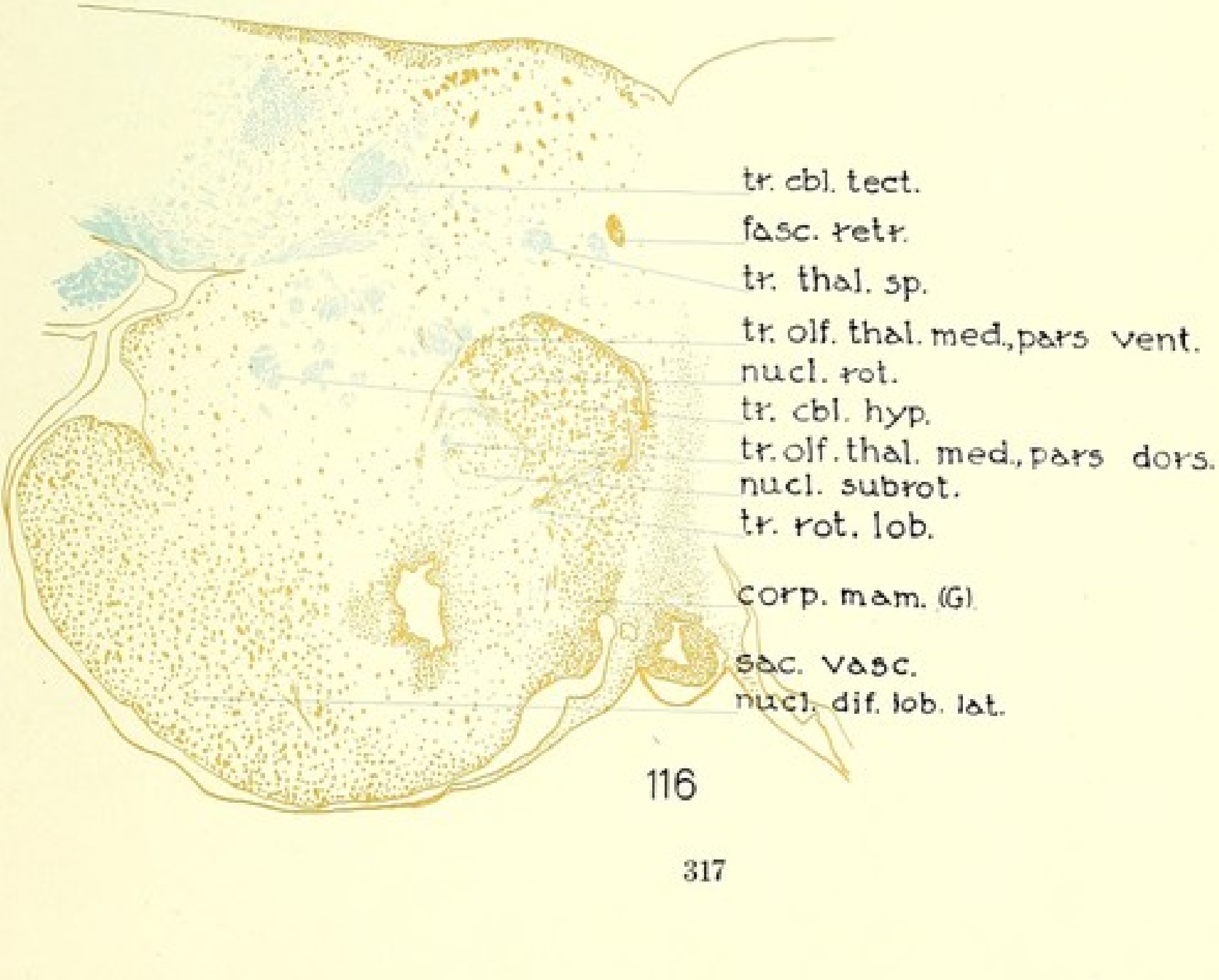
tr. cbl. tect.
fasc. retr.
tr. thal. sp.
tr. olf. thal. med., pars vent.
nucl. rot.
tr. cbl. hyp.
tr. olf. thal. med., pars dors.
nucl. subrot.
tr. rot. lob.
corp. mam. (G).
sac. vasc.
nucl. dif. lob. lat.

116

PLATE 32

EXPLANATION OF FIGURES

117 Transection through the corpus mammillare, the ganglion mammillare of Goldstein. Toluidin blue method. × 46.

118 Cells of the corpus mammillare. Toluidin blue method. × 575.

119–121 Neurones of the corpus mammillare. Golgi method. × 93. From sagittal sections. It will be noted from figs. 117 to 121 that the cells of the corpus mammillare are very small and closely packed.

corp. mam. (*G*), corpus mammillare, the ganglion mammillare of Goldstein; *nucl. cbl. hyp.*, nucleus cerebellaris hypothalami; *nucl. dif. lob. lat.*, nucleus diffusus lobi lateralis; *nucl. fasc. long.*, nucleus fasciculus longitudinalis medialis; *nucl. post. thal.*, nucleus posterior thalami; *nucl. prerot.*, nucleus prerotundus; *nucl. rot.*, nucleus rotundus; *nucl. rub.* (*G*), nucleus ruber of Goldstein; *nucl. subrot.*, nucleus subrotundus; *s. mam.*, sulcus mammillaris of Goldstein; *tr. cbl. tect.*, tractus cerebello-tectalis.

117

119

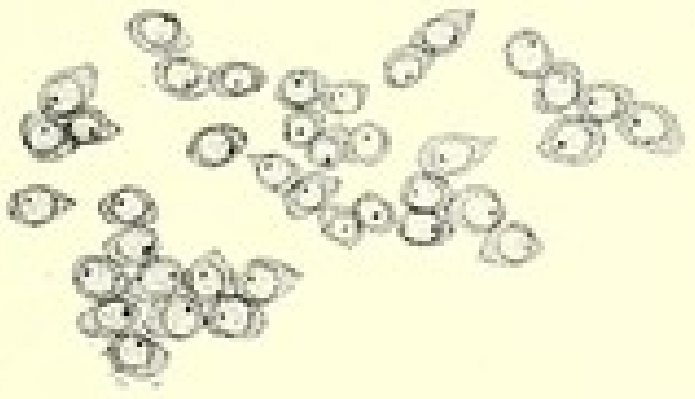

118

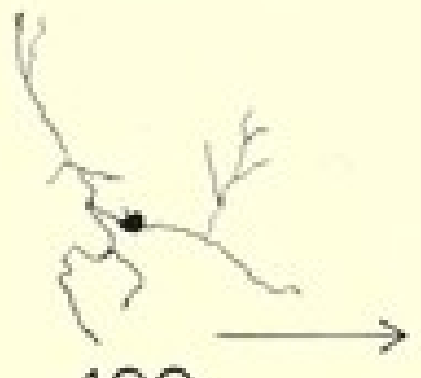

120

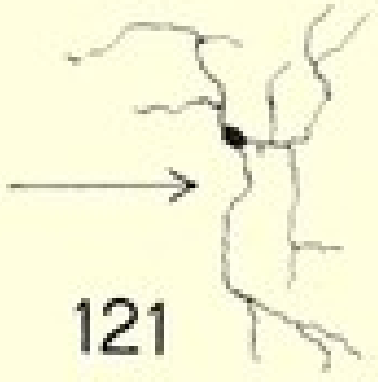

121

PLATE 33

EXPLANATION OF FIGURES

122 Transection through the corpus mammillare. Weigert method. × 17.

123 Diagram showing the two parts of the right olfactory nerve, and the relations of their fibers to the cells of the bulb and to the fibers of the olfactory tract.

124 Diagram of a horizontal projection of the right olfactory bulb showing the connections, in the bulb, of the different tracts of the crura.

corp. mam. (*G*), corpus mammillare (of Goldstein); *fasc. retr.*, fasciculus retroflexus; *fil. olf.*, fila olfactoria; *g.n. term.*, ganglion cell of the nervus terminalis; *gran. cell*, granule cell of the nucleus olfactorius anterior; *mitr. cell*, mitral cell; *nucl. cbl. hyp.*, nucleus cerebellaris hypothalami; *nucl. dif. lob. lat.*, nucleus diffusus lobi lateralis; *n. olf. ant.*, nucleus olfactorius anterior; *n. olf. lat.*, nervus olfactorius lateralis, consisting largely of fibers from the lamellae of the caudal and lateral portion of the olfactory capsule; *n. olf. med.*, nervus olfactorius medialis, formed largely from fibers originating chiefly in the rostral and medial portion of the capsule; *n. term.*, nervus terminalis; *nucl. prerot.*, nucleus prerotundus; *nucl. rot.*, nucleus rotundus; *nucl. subrot.*, nucleus subrotundus; *s. mam.*, sulcus mammillaris; *tr. cbl. tect.*, tractus cerebello-tectalis; *tr. olf. asc.*, tractus olfactorius ascendens, composed of centrifugal fibers from the corpus precommissurale, pars medianus; *tr. olf. asc.*, *pars lat.*, tractus olfactorius ascendens pars lateralis; *tr. olf. asc.*, *pars med.*, tractus olfactorius ascendens, pars medialis; *tr. olf. lat.*, tractus olfactorius lateralis, composed of the following three tracts, all centripetal, and practically all terminating, in the carp, in the nucleus olfactorius dorsalis and nucleus pyriformis of the same side; *tr. olf. lat.*, *pars. intermed.*, tractus olfactorius lateralis, pars intermedia; *tr. olf. lat.*, *pars lat.*, tractus olfactorius lateralis, pars lateralis; *tr. olf. lat.*, *pars med.*, tractus olfactorius lateralis, pars medialis; *tr. olf. med.*, tractus olfactorius medialis, the mesal part of the medial olfactory radix of authors, divided into the following; *tr. olf. med.*, *pars lat.*, tractus olfactorius medialis, pars lateralis, terminating, after decussation in the anterior commissure, in the nucleus pyriformis of the opposite side; *tr. olf. med.*, *pars med.*, tractus olfactorius medialis, pars medialis, forming the commissura interbulbaris of most authors which, as indicated in figs. 136 and 138, is largely a decussation and not a commissure; *tr. thal. sp.*, tractus thalamo-spinalis (Kappers).

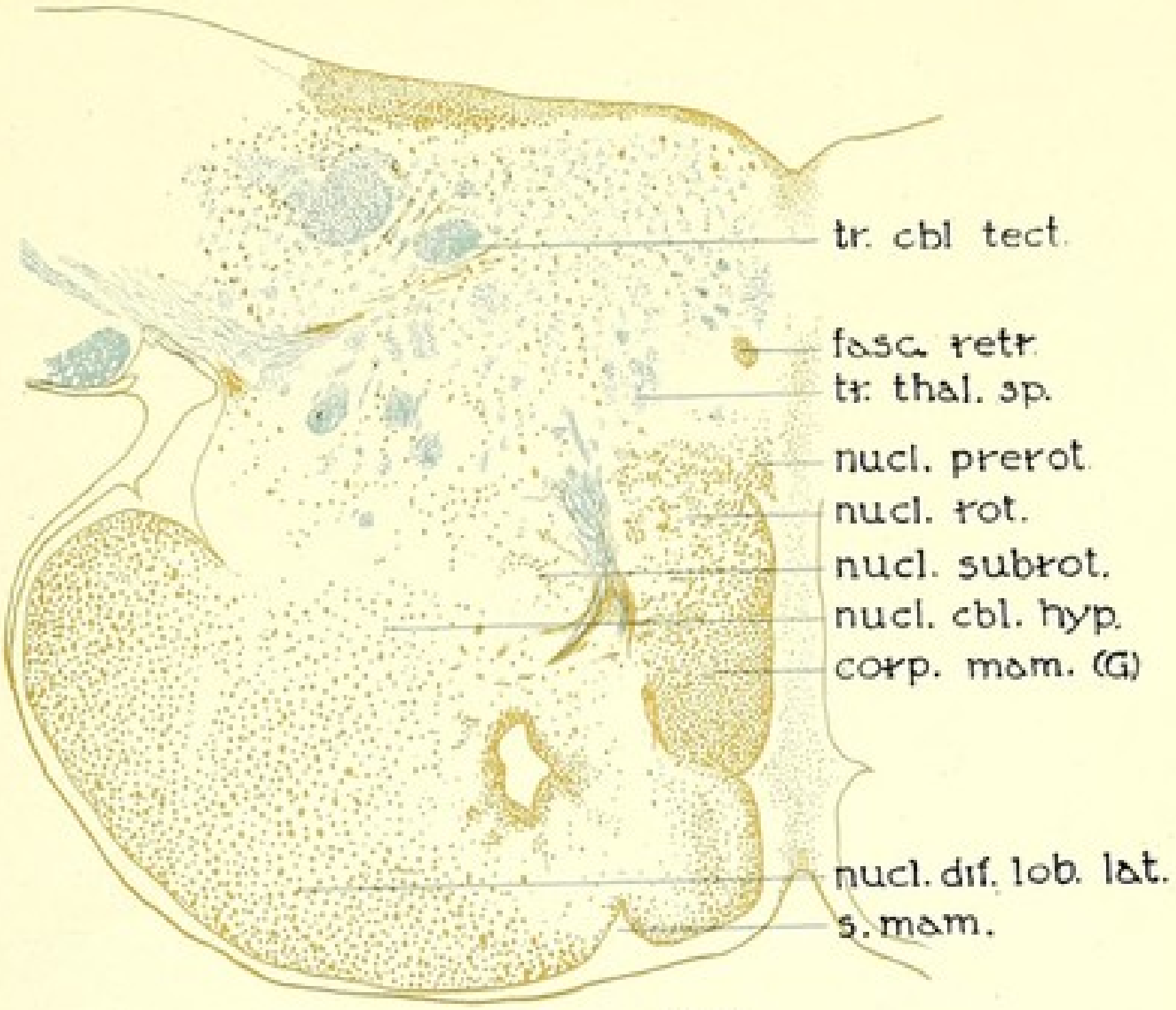
tr. cbl tect.
fasc. retr.
tr. thal. sp.
nucl. prerot.
nucl. rot.
nucl. subrot.
nucl. cbl. hyp.
corp. mam. (G)
nucl. dif. lob. lat.
s. mam.

122

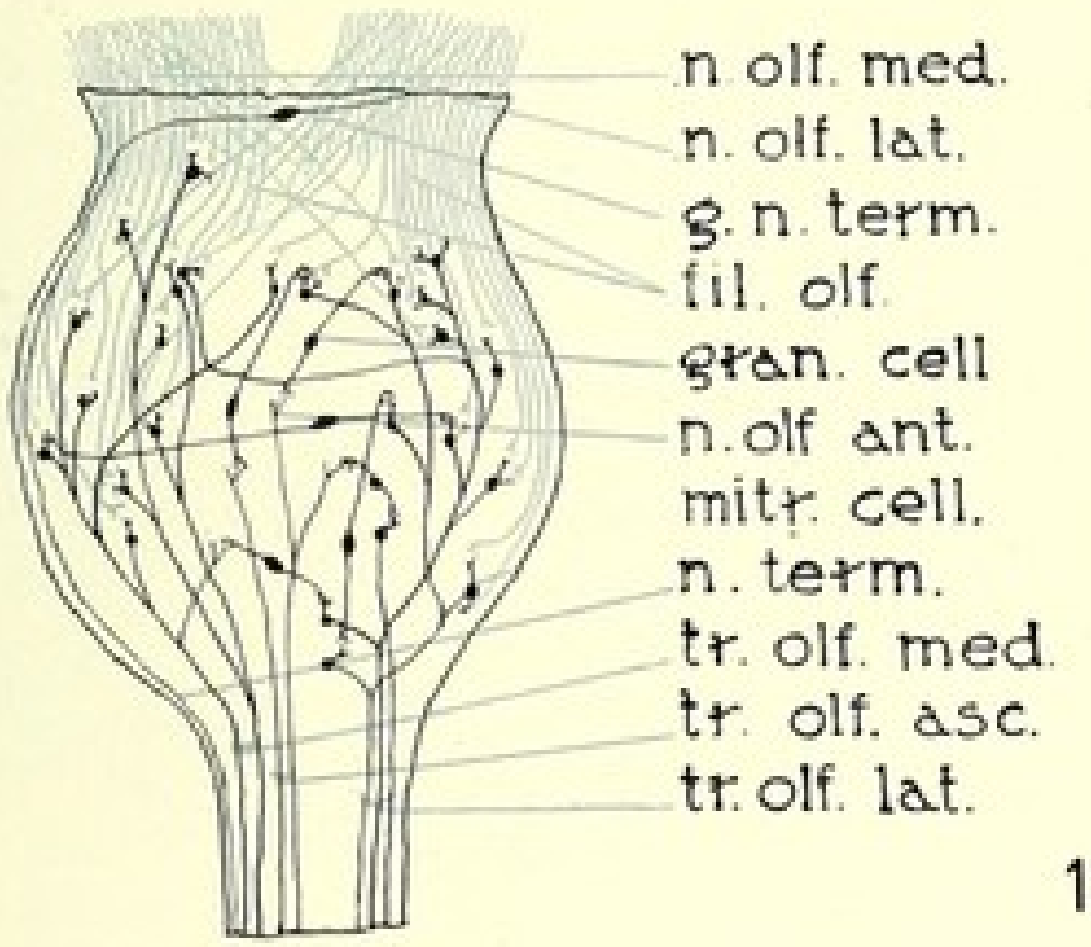
n. olf. med.
n. olf. lat.
g. n. term.
fil. olf.
gran. cell
n. olf. ant.
mitr. cell.
n. term.
tr. olf. med.
tr. olf. asc.
tr. olf. lat.

123

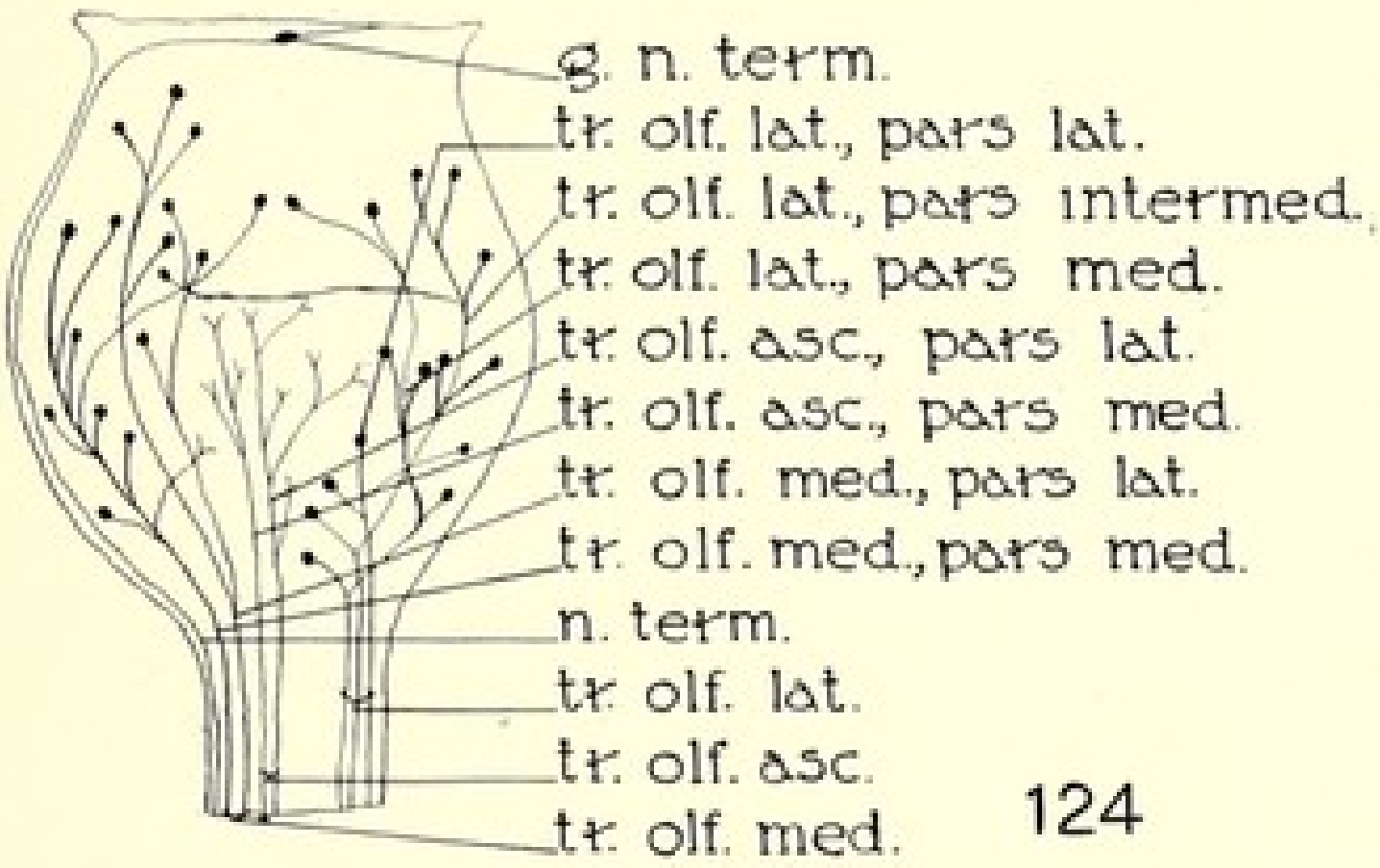
g. n. term.
tr. olf. lat., pars lat.
tr. olf. lat., pars intermed.
tr. olf. lat., pars med.
tr. olf. asc., pars lat.
tr. olf. asc., pars med.
tr. olf. med., pars lat.
tr. olf. med., pars med.
n. term.
tr. olf. lat.
tr. olf. asc.
tr. olf. med.

124

PLATE 34

EXPLANATION OF FIGURES

125 Diagram of a projection of the olfactory centers on a parasagittal plane, near the meson, showing the levels at which figs. 127 and 128 are taken and the relation of the different centers to the four primitive columns. × 11.

1, pars dorso-medialis hemisphaerii and epithalamus; *2*, pars dorso-lateralis hemisphaerii and pars dorsalis thalami; *3*, pars ventro-lateralis hemisphaerii and pars ventralis thalami; *4*, pars ventro-medialis hemisphaerii and hypothalamus; *tr. olf. lat.*, tractus olfactorius lateralis; *tr. olf. med.*, tractus olfactorius medialis. (For other abbreviations see explanation of fig. 141.)

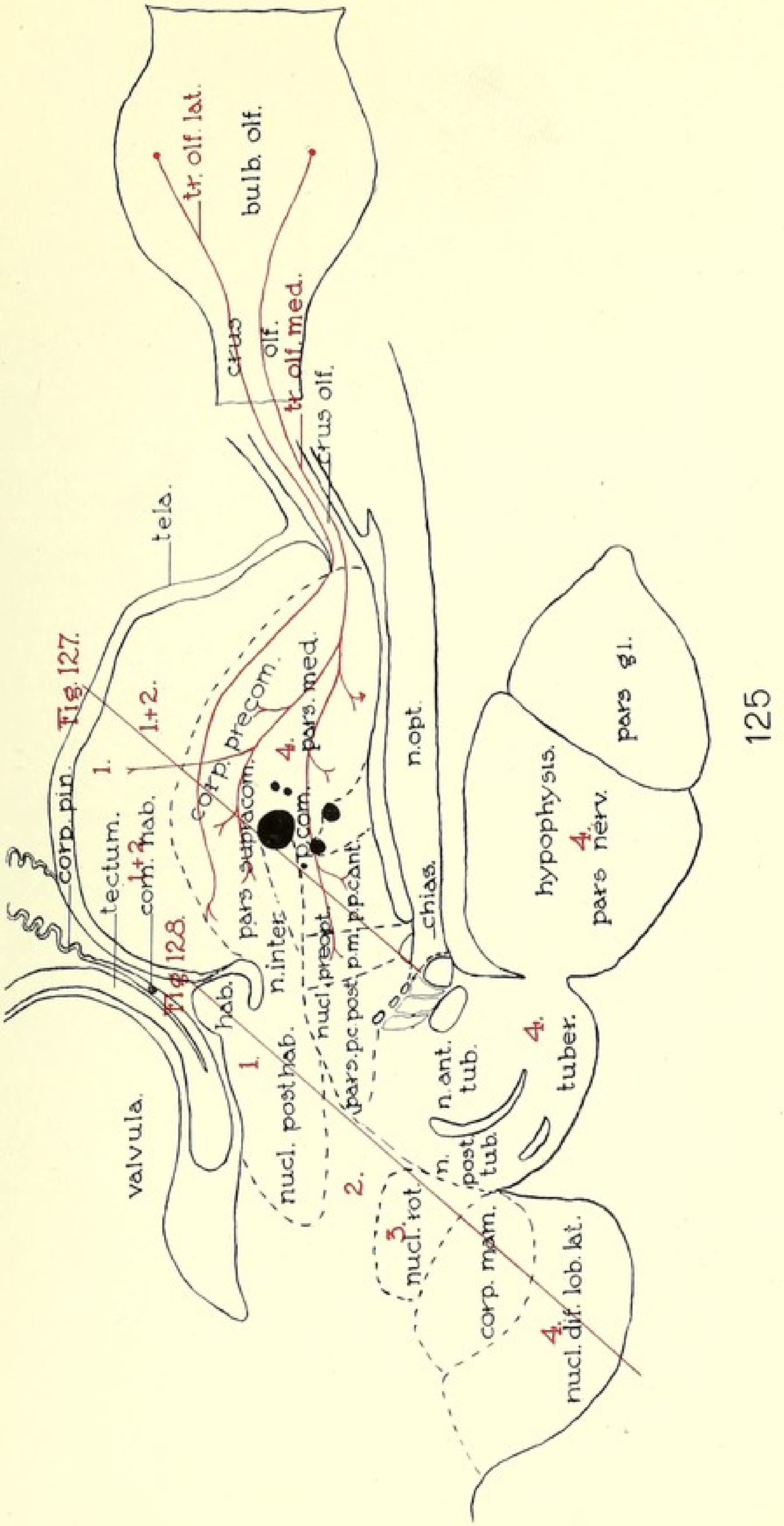
bulb. olf.
tr. olf. lat.
crus
olf.
tr. olf. med.
crus olf.
tela.
Fig. 127.
1.
1+2.
corp. precom.
pars. med.
4.
n. opt.
corp. pin.
tectum.
com. hab.
1+2
pars supracom.
p. com.
pars. p. p. cant.
pars. p. m. p. p. post.
nucl. preopt.
n. inter.
chias.
Fig. 128.
hab.
1.
pars. p. c. post.
n. ant. tub.
hypophysis.
4.
pars nerv.
pars gl.
tuber.
4.
valvula.
nucl. post hab.
2.
n. post tub.
nucl. rot.
3.
corp. mam.
nucl. dif. lob. lat.
4.

125

PLATE 35

EXPLANATION OF FIGURES

126 Diagram of a transection through the hemispheres of an embryonic teleost, showing the relations of the four primitive columns.

127 Diagram of a transection through the hemispheres of an adult teleost, showing the changes which have taken place through rearrangement of these columns. For approximate level see fig. 125.

128 Diagram of a transection through the diencephalon of an embryonic teleost, showing the relations of the same columns. Practically the same conditions hold in the adult. (For level see fig. 125.)

129–134 Diagrams of transections through the cerebral hemispheres of Ameiurus, at the level of the anterior commissure, showing the shifting which takes place with the gradual eversion of the tenia. Figs. 129 to 133 are camera lucida drawings obtained through the kindness of Dr. James M. Wilson, of Washington, D. C. Fig. 129, 5 mm. stage; fig. 130, 6 mm. stage; fig. 131, 9 mm. stage; fig. 132, 10 mm. stage; fig. 133, 12–13 mm. stage; fig. 134, adult.

135 Transection through the cerebral hemispheres of Amia calva in the region of the anterior commissure, to illustrate the eversion of the hemisphere wall, after Mrs. Susanna Phelps Gage ('93).

1, pars dorso-medialis hemisphaerii and epithalamus; *2*, pars dorso-lateralis hemisphaerii and pars dorsalis thalami; *3*, pars ventro-lateralis hemisphaerii and pars ventralis thalami; *4*, pars ventro-medialis hemisphaerii and hypothalamus; *epithal.*, epithalamus; *hypothal.*, hypothalamus; *pars dors. thal.*, pars dorsalis thalami; *pars vent. thal.*, pars ventralis thalami; *s. lim. tel.*, sulcus limitans telencephali; *sulc. dien. dors.* sulcus diencephalicus dorsalis; *sulc. dien. med.*, sulcus diencephalicus medialis; *sulc. dien. vent.*, sulcus diencephalicus ventralis.

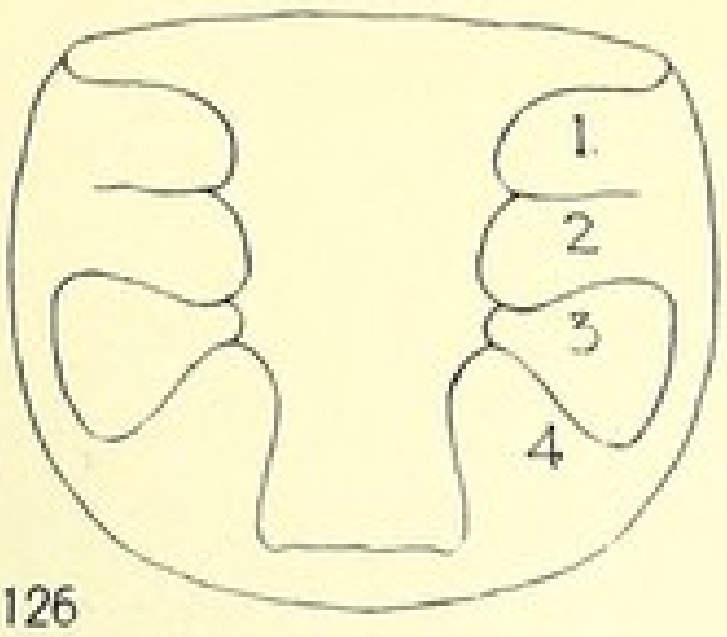

126

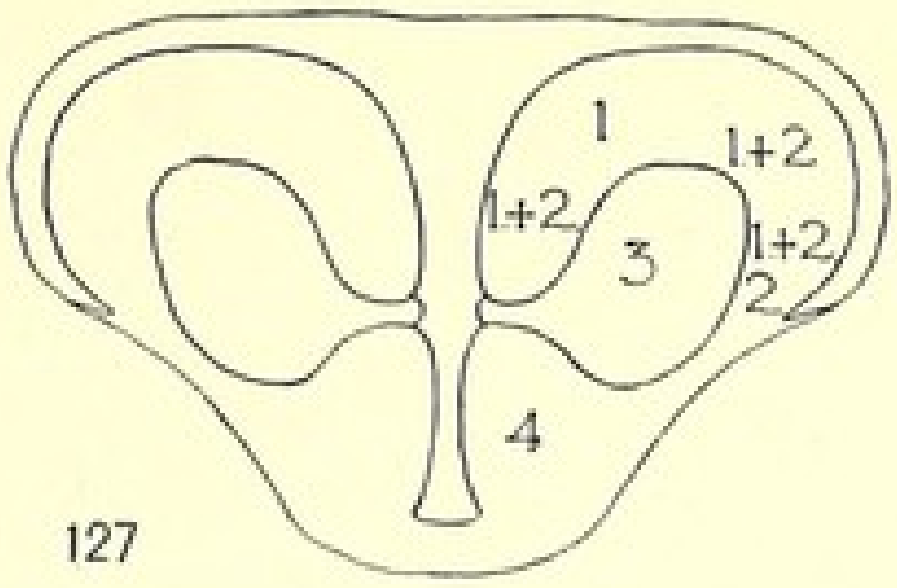

127

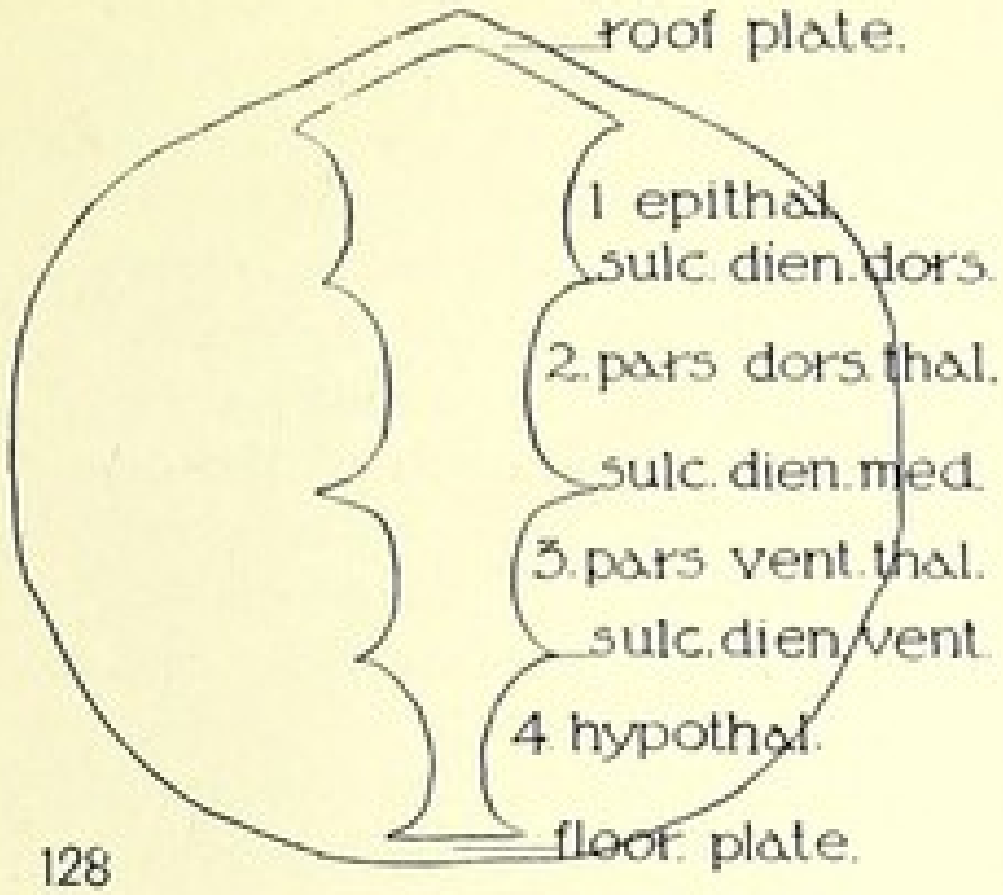

128

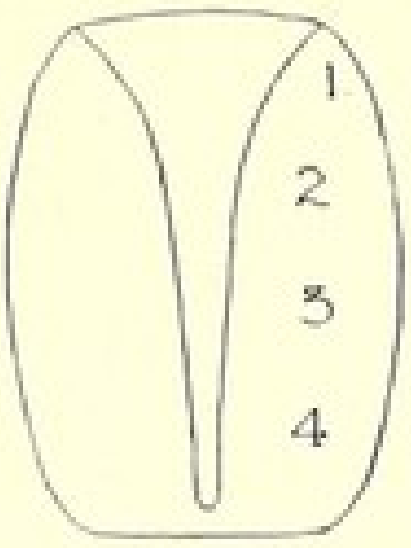

129

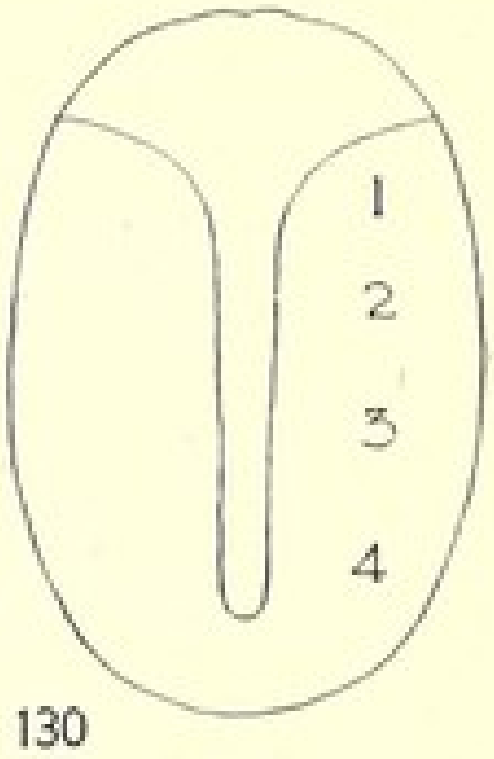

130

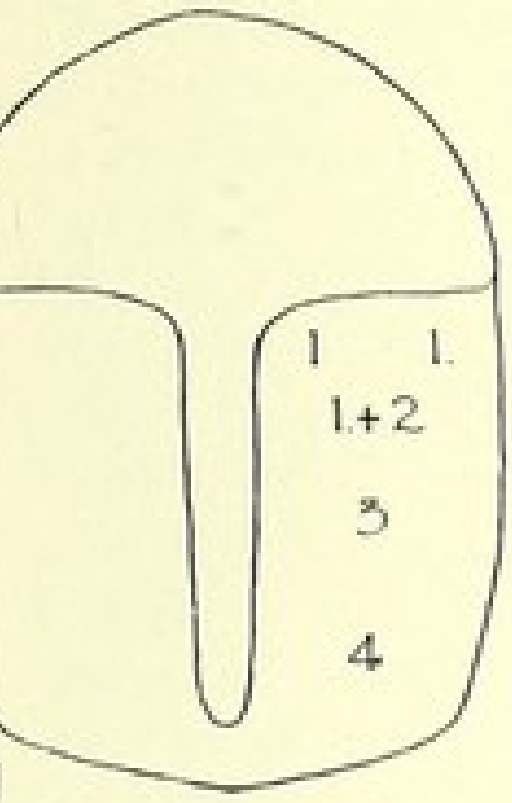

131

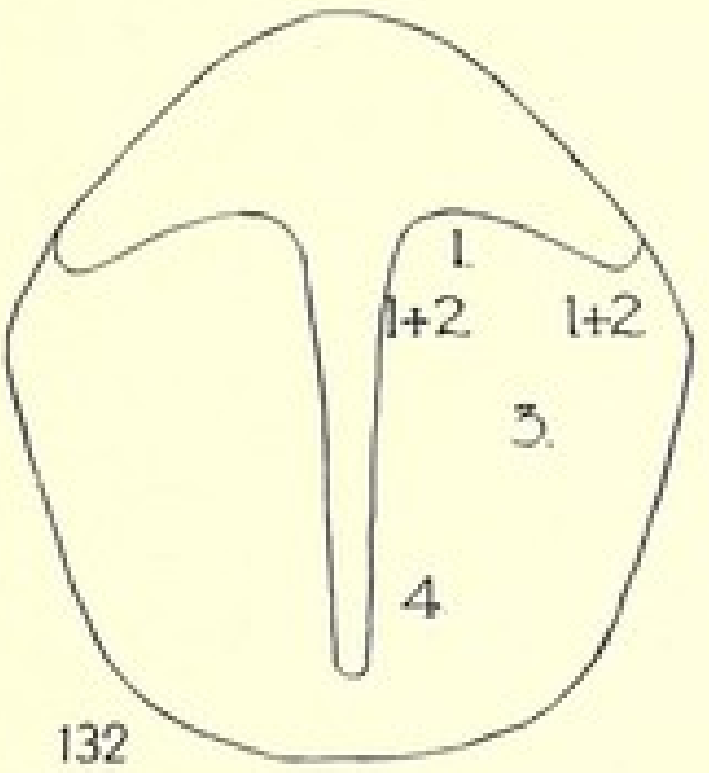

132

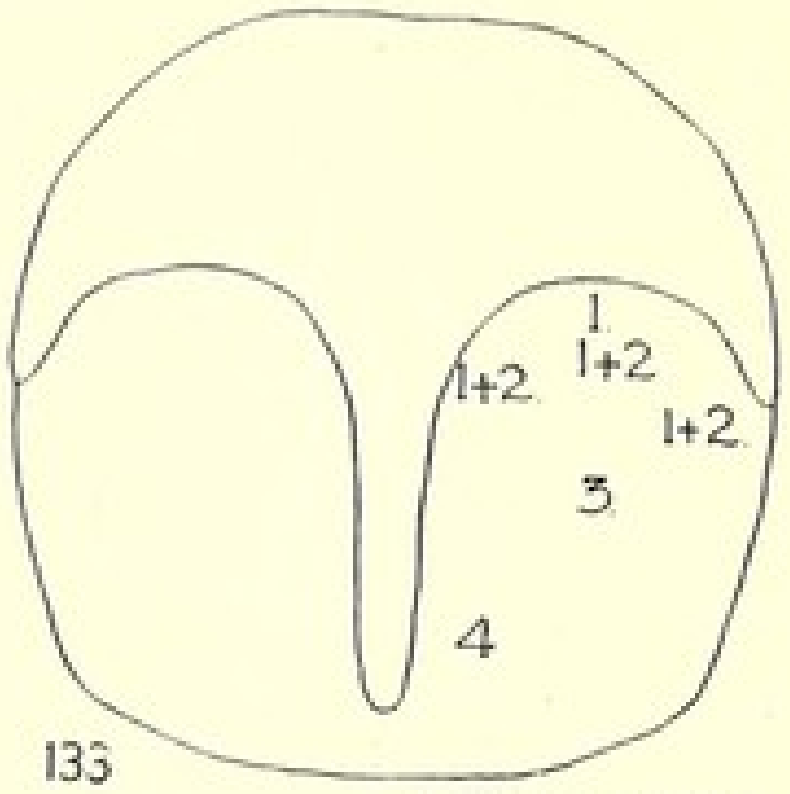

133

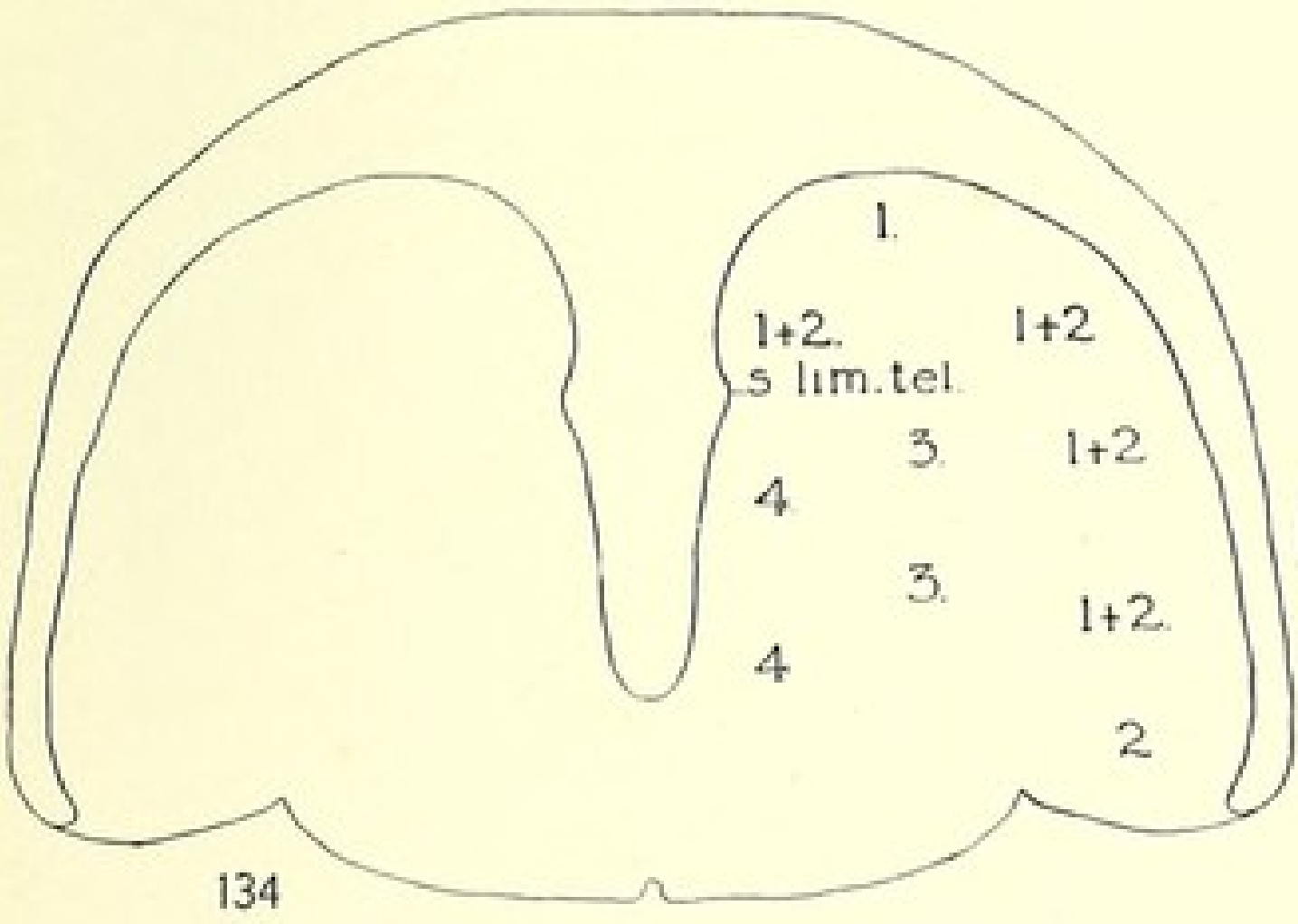

134

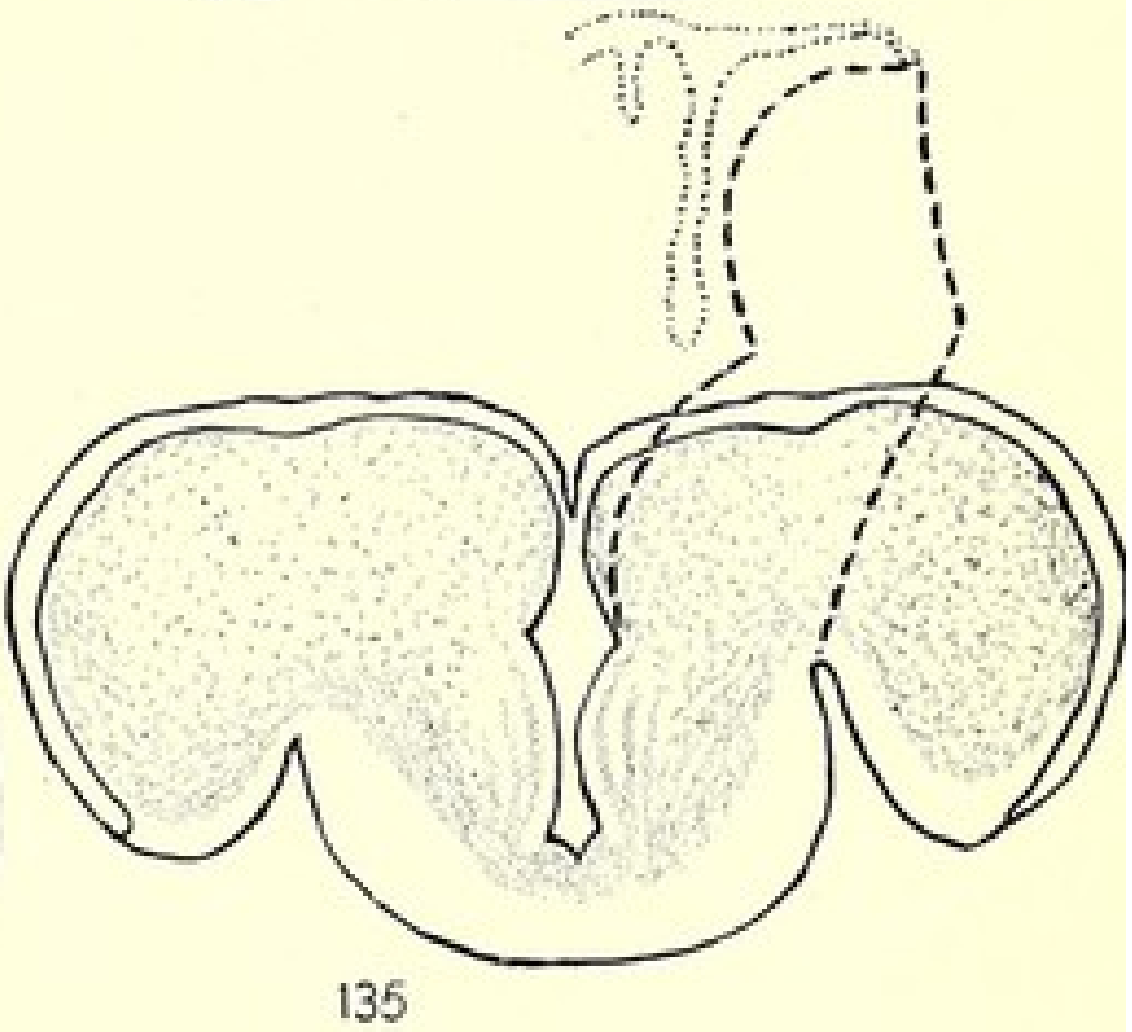

135

PLATE 36

EXPLANATION OF FIGURES

136 Diagram of a horizontal projection of the olfactory centers showing in blue the connections of the corpus precommissurale, together with the fiber components of the fasciculus medialis hemisphaerii and associated tracts. × 12.

bulb. olf., bulbus olfactorius; *c. mam.*, corpus mammillare, ganglion mammillare of Goldstein; *corp. precom.*, corpus precommissurale, consisting of the pars medianus, pars commissuralis, and pars supracommissuralis; *crus olf.*, crus olfactorium; *ent.*, nucleus entopeduncularis; *fib. precom. str.*, fibrae precommissurales striatici, running from the precommissural body to the palaeostriatum; *hab.*, ganglion habenulae; *hyp.*, hypophysis; *m.*, pars magnocellularis of the nucleus preopticus; *n. ant. tub.*, nucleus anterior tuberis; *n. cbl. hyp.*, nucleus cerebellaris hypothalami of Goldstein; *n.c.l.*, nucleus commissuralis lateralis ; *n. dif. lob. lat.*, nucleus diffusus lobi lateralis; *n. int.*, nucleus intermedius; *n. lat. tub.*, nucleus lateralis tuberis; *n. olf. lat.*, nucleus olfactorius lateralis; *n. posthab.*, nucleus posthabenularis; *n. post. thal.*, nucleus posterior thalami of Goldstein; *n. post. tub.*, nucleus posterior tuberis; *n. preopt.*, nucleus preopticus; *n. prerot.*, nucleus prerotundus; *n. pyr.*, nucleus pyriformis; *n. rot.*, nucleus rotundus; *n. subr.*, nucleus subrotundus; *n. ten.*, nucleus teniae; *n. term.*, nervus terminalis; *p.a.*, pars parvocellularis anterior of the nucleus preopticus; *paleostr.*, palaeostriatum, the striatum of most authors; *pars. com.*, pars commissuralis of the corpus precommissurale; *pars. med.*, pars medianus or the nucleus medianus of the corpus precommissurale; *p.p.*, pars parvocellularis posterior of the nucleus preopticus; *p. sup. com.*, pars supracommissuralis of the corpus precommissurale; *sac. vasc.*, saccus vasculosus; *tela*, the so-called pallium; *tr. hyp. olf. med.*, tractus hypothalamo-olfactorius medialis; *tr. med. preopt., pars ant.*, tractus mediano-preopticus, pars anterior; *tr. med. preopt., pars post.*, tractus mediano-preopticus, pars posterior; *tr. olf. asc.*, tractus olfactorius ascendens; *tr. olf. asc., pars lat.*, tractus olfactorius ascendens. pars lateralis; *tr. olf. asc., pars med.*, tractus olfactorius ascendens, pars medialis; *tr. olf., med., pars lat.*, tractus olfactorius medialis, pars lateralis; *tr. olf. med., pars. med.*, tractus olfactorius medialis, pars medialis; *tr. olf. thal. med., pars dors.*, tractus olfacto-thalamicus medialis, pars dorsalis; *tr. olf. thal. med., pars intermed.*, tractus olfacto-thalamicus medialis, pars intermedia (short descending association fibers); *tr. olf. thal. med. pars vent.*, tractus olfacto-thalamicus medialis, pars ventralis; *tr. opt.*, tractus opticus; *tr. preopt. tub.*, tractus preoptico-tuberis; *tr. thal. olf. med., pars intermed.*, tractus thalamo-olfactorius medialis, pars intermedia (short ascending association fibers).

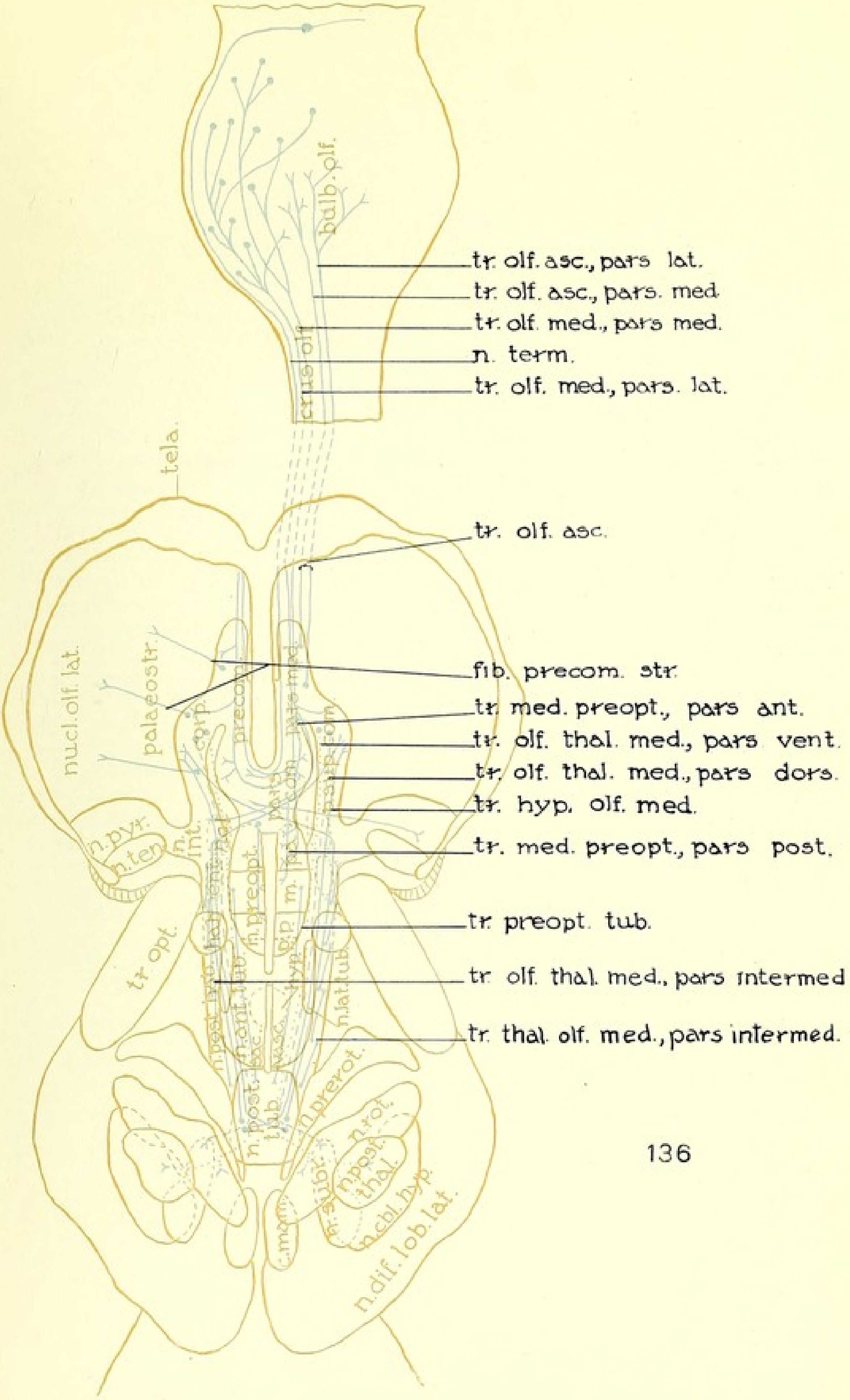
bulb. olf.
tr. olf. asc., pars lat.
tr. olf. asc., pars. med
tr. olf. med., pars med.
n. term.
tr. olf. med., pars. lat.
crus olf.
tela.
tr. olf. asc.
fib. precom. str.
tr. med. preopt., pars ant.
tr. olf. thal. med., pars vent.
tr. olf. thal. med., pars dors.
tr. hyp. olf. med.
tr. med. preopt., pars post.
tr. preopt. tub.
tr. olf. thal. med., pars intermed
tr. thal. olf. med., pars intermed.
nucl. olf. lat.
palaeostr.
corp.
precom.
n. pyr.
n. ten.
n. int.
n. preopt.
m.
e.p.
hyp.
tr. opt.
n. lat. tub.
n. ant. tub.
n. post. tub.
n. prerot.
n. rot.
n. post. thal.
n. cbl. hyp.
c. mam.
n. dif. lob. lat.

136

PLATE 37

EXPLANATION OF FIGURES

137 Diagram of a horizontal projection of the olfactory centers showing the connections of the nucleus pyriformis, nucleus teniae, nucleus olfactorius lateralis, and nucleus intermedius. On the right side are shown the tracts terminating in these nuclei, on the left side the tracts originating in them. × 12.

com. hab. (red), com. habenularum; *tr. entoped. intermed.* (red), tractus entopedunculo-intermedius; *tr. hyp. olf. lat.* (blue), tractus hypothalamo-olfactorius lateralis; *tr. intermed. entoped.* (red), tractus intermedio-entopeduncularis; *tr. intermed. hab., pars ant.* (red), tractus intermedio-habenularis, pars anterior; *tr. intermed. hab., pars post.* (red), tractus intermedio-habenularis, pars posterior; *tr. intermed. posthab.* (blue), tractus intermedio-posthabenularis; *tr. intermed. preopt. pars ant.* (red), tractus intermedio-precopticus, pars anterior; *tr. intermed. preopt., pars med.* (red), tractus intermedio-preopticus, pars medialis; *tr. olf. hyp. lat.* (blue), tractus olfacto-hypothalamicus lateralis; *tr. olf. lat.* (blue), tractus olfactorius lateralis; *tr. olf. lat., pars intermed.* (blue), tractus olfactorius lateralis, pars intermedia; *tr. olf. lat., pars med.* (blue), tractus olfactorius lateralis, pars medialis; *tr. olf. med., pars lat.* (blue), tractus olfactorius medialis, pars lateralis; *tr. posthab. intermed.* (blue), tractus posthabenulo-intermedius; *tr. praeth. cin.* (blue), tractus praethalamo-cinereus; *tr. preopt. intermed., pars ant.* (red), tractus preoptico-intermedius, pars anterior; *tr. preopt. intermed., pars lat.* (red), tractus preoptico-intermedius, pars lateralis; *tr. preopt. intermed., pars med.* (red), tractus preoptico-intermedius, pars medialis; *tr. ten.* (red), tractus teniae, the tractus olfacto-habenularis of Kappers, Goldstein, etc. (For other abbreviations see explanation of fig. 136.)

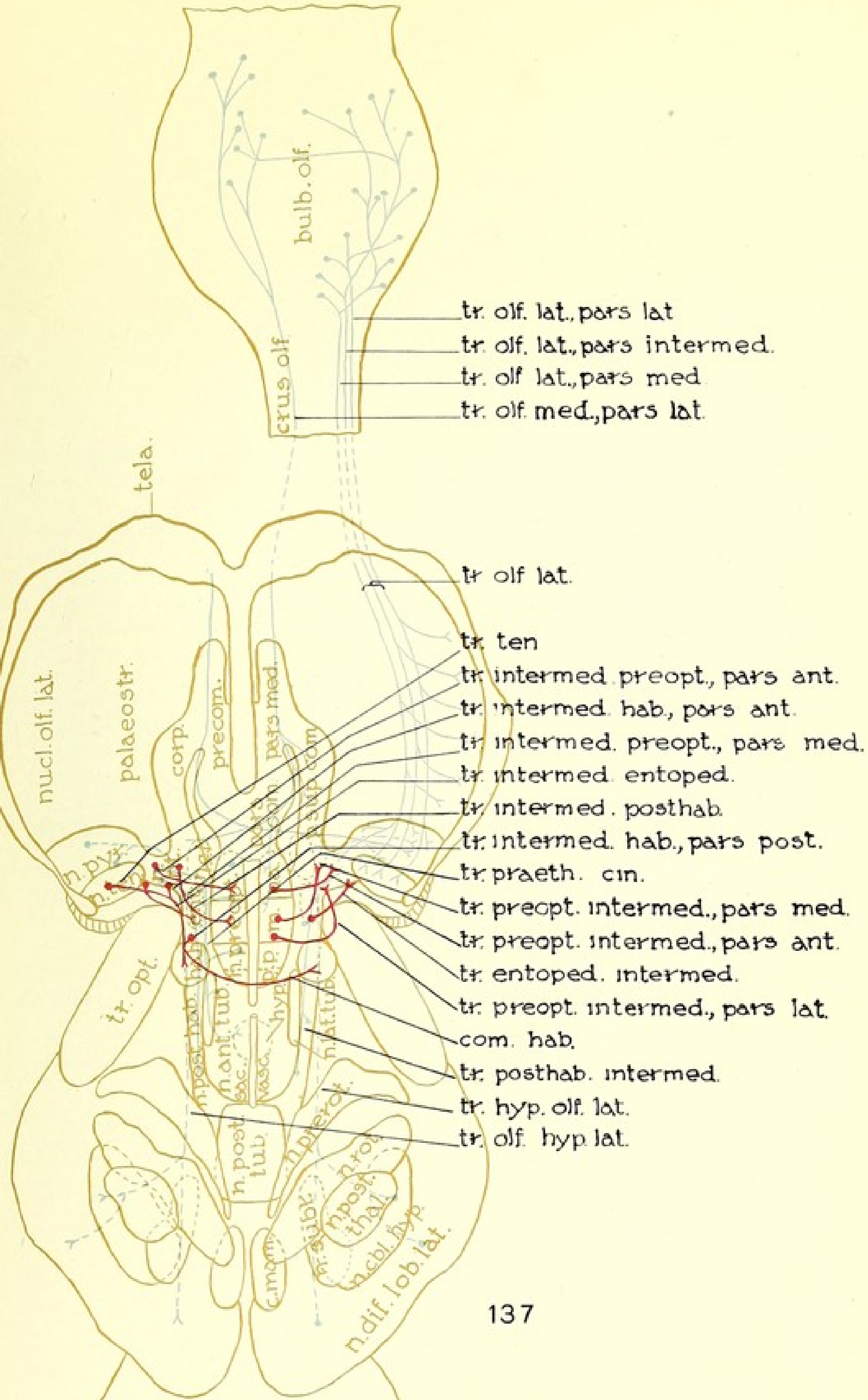
bulb. olf.
crus olf.
tr. olf. lat., pars lat
tr. olf. lat., pars intermed.
tr. olf lat., pars med
tr. olf. med., pars lat.
tela.
tr olf lat.
tr. ten
tr. intermed. preopt., pars ant.
tr. intermed. hab., pars ant.
tr. intermed. preopt., pars med.
tr. intermed. entoped.
tr. intermed. posthab.
tr. intermed. hab., pars post.
tr. praeth. cin.
tr. preopt. intermed., pars med.
tr. preopt. intermed., pars ant.
tr. entoped. intermed.
tr. preopt. intermed., pars lat.
com. hab.
tr. posthab. intermed.
tr. hyp. olf. lat.
tr. olf. hyp. lat.
nucl. olf. lat.
palaeostr.
corp.
precom.
pars med.
sup. com.
n. pyr.
tr. opt.
n. post. hab.
n. ant. tub.
sac.
vasc.
hyp.
n. lat. tub.
n. post. tub.
n. prerot.
n. rot.
n. post. thal.
n. subt.
c. mam.
n. cbl. hyp.
n. dif. lob. lat.

137

PLATE 38

EXPLANATION OF FIGURES

138 Diagram of a horizontal projection of the olfactory centers, showing the fibers entering into the composition of the anterior commissure, together with their connections. × 12.

com. corp. precom. (green), commissura corporium precommissuralium; *com. dors.* (green), commissura dorsalis; *com. hipp., pars ant.* (green), commissura hippocampi, pars anterior; connecting the two nuclei olfactorii dorsales or primordia hippocampi; *com. hipp., pars post.* (green), commissura hippocampi, pars posterior, the commissura internuclearis of Goldstein; *com. interbulb., (dec. tr. olf. med., pars med.)* (blue), commissura interbulbaris (decussation of the tractus olfactorii mediales, partes mediales); *com. nucl. preopt.* (green), commissura nucleorum preopticorum; *dec. n. term.* (blue), decussatio nervorum terminalium; *dec. tr. olf. med., pars lat.* (blue), decussation of the tractus olfactorii mediales, partes laterales; *gang. n. term.* (blue), ganglion cell of the nervus terminalis; *n. term.* (blue), nervus terminalis; *tr. hyp. olf. med.* (red), tractus hypothalamo-olfactorius medialis; *tr. olf. med.* (blue), tractus olfactorius medialis; *tr. olf. med., pars lat.* (blue), tractus olfactorius medialis, pars lateralis; *tr. olf. med. pars med.* (blue), tractus olfactorius medialis, pars medialis; *tr. strio-thal. cruc.* (red), tractus strio-thalamicus cruciatus (shown only on one side); *tr. thal. str. cruc.* (red), tractus thalamo-striaticus cruciatus, (shown only on one side). (For other abbreviations see explanation of fig. 136.)

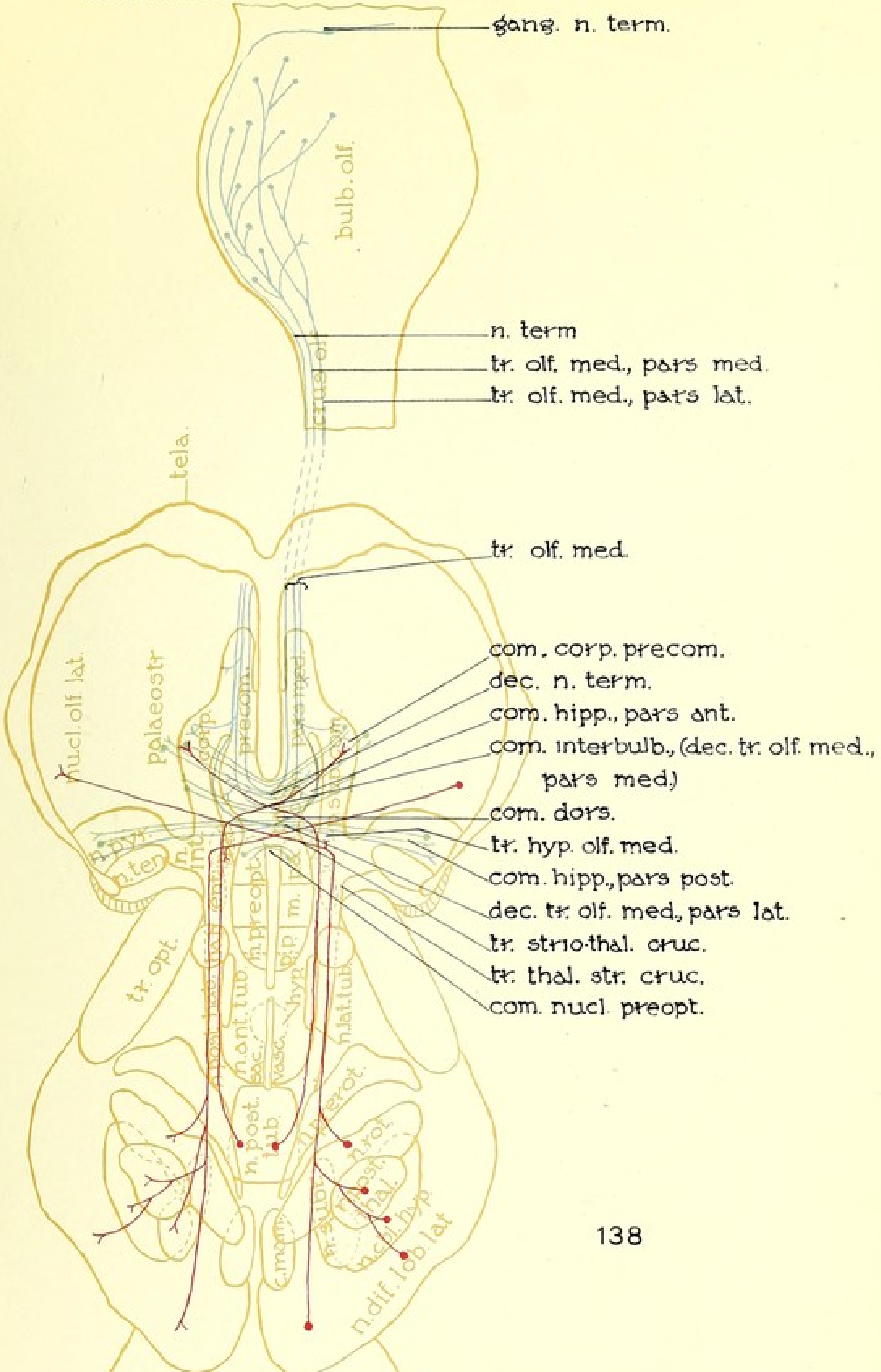
gang. n. term.
bulb. olf.
n. term
tr. olf. med., pars med.
tr. olf. med., pars lat.
crus olf.
tela
tr. olf. med.
com. corp. precom.
dec. n. term.
com. hipp., pars ant.
com. interbulb., (dec. tr. olf. med., pars med.)
com. dors.
tr. hyp. olf. med.
com. hipp., pars post.
dec. tr. olf. med., pars lat.
tr. strio-thal. cruc.
tr. thal. str. cruc.
com. nucl. preopt.
nucl. olf. lat.
palaeostr
precom.
pars med.
n. pyr.
n. ten.
n. int.
n. preopt.
m. preopt.
m.
e.p.
hyp.
tr. opt.
n. ant. tub.
n. lat. tub.
sac. vasc.
n. post. tub.
n. rot.
n. post. thal.
c. mam.
n. dif. lob. lat.

138

PLATE 39

EXPLANATION OF FIGURES

139 Diagram of a horizontal projection of the olfactory centers showing in blue the pathways of the fibers entering into the composition of the fasciculus lateralis hemisphaerii. The ascending fibers are shown on the right, the descending on the left. × 12.

fib. precom. str., fibrae precommissurales striatici; *tr. olf. hyp. lat.*, tractus olfacto-hypothalamicus lateralis; *tr. strio-thal. cruc.*, tractus strio-thalamicus cruciatus; *tr. strio-thal. incruc.*, tractus strio-thalamicus incruciatus; *tr. thal. str. cruc.*, tractus thalamo-striaticus cruciatus; *tr. thal. str. incruc.*, tractus-thalamo-striaticus incruciatus. (For other abbreviations see explanation of fig. 136.)

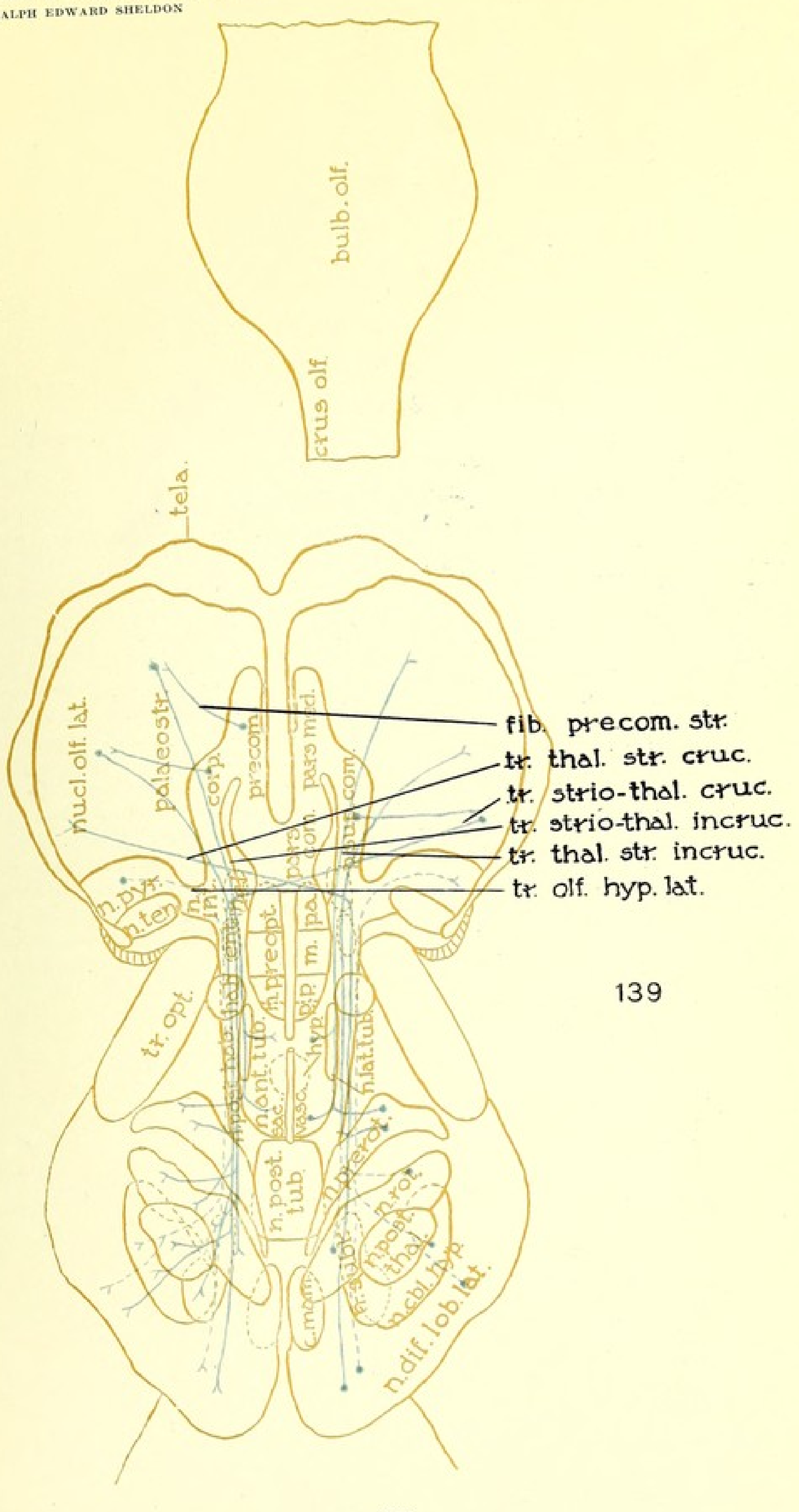
bulb. olf.
crus olf.
tela.
nucl. olf. lat.
palaeostr.
corp.
precom.
pars med.
pars com.
supr. com.
fib. precom. str.
tr. thal. str. cruc.
tr. strio-thal. cruc.
tr. strio-thal. incruc.
tr. thal. str. incruc.
tr. olf. hyp. lat.
n. pyr.
n. ten.
n. in.
n. ent.
n. pa.
m.
n. preopt.
p.p.
hyp.
tr. opt.
n. ant. tub.
sac.
vasc.
n. lat. tub.
n. prerot.
n. post. tub.
n. rot.
n. post. thal.
n. cbl. hyp.
c. mam.
n. dif. lob. lat.

139

PLATE 40

EXPLANATION OF FIGURES

140 Diagram of a horizontal projection of the olfactory centers showing the connections of the postcommissural olfactory nuclei, with the exception of the habenular fibers shown on fig. 142. Fibers which terminate in these centers are shown on the right, while those which originate from them appear on the left. × 12.

com. nucl. preopt. (red), commissura nucleorum preopticorum; *tr. entoped. preopt.* (red), tractus entopedunculo-preopticus; *tr. intermed. preopt., pars ant.* (red), tractus intermedio-preopticus, pars anterior; *tr. intermed. preopt., pars med.* (red), tractus intermedio-preopticus, pars medialis; *tr. lat. preopt.* (red), tractus lateralis preopticus; *tr. med. preopt., pars ant.* (blue), tractus mediano-preopticus, pars anterior; *tr. med. preopt., pars post.* (blue), tractus mediano-preopticus, pars posterior; *tr. olf. med., pars lat.* (blue), tractus olfactorius medialis, pars lateralis (see fig. 136); *tr. posthab. preopt.* (red), tractus posthabenulo-preopticus; *tr. praeth. cin.* (blue), tractus praethalamo-cinereus; *tr. preopt. entoped.* (red), tractus preoptico-entopeduncularis; *tr. preopt. intermed., pars ant.* (red), tractus preoptico-intermedius, pars anterior; *tr. preopt. intermed., pars lat.* (red), tractus preoptico-intermedius, pars lateralis; *tr. preopt. intermed., pars med.* (red), tractus preoptico-intermedius, pars medialis; *tr. preopt. lat.* (red), tractus preoptico-lateralis; *tr. preopt. posthab. pars ant.* (red) tractus preoptico-posthabenularis, pars anterior; *tr. preopt. posthab., pars post.* (red), tractus preoptico-posthabenularis, pars posterior; *tr. preopt. tub.* (blue), tractus preoptico-tuberis. (For other abbreviations see explanation of fig. 136.)

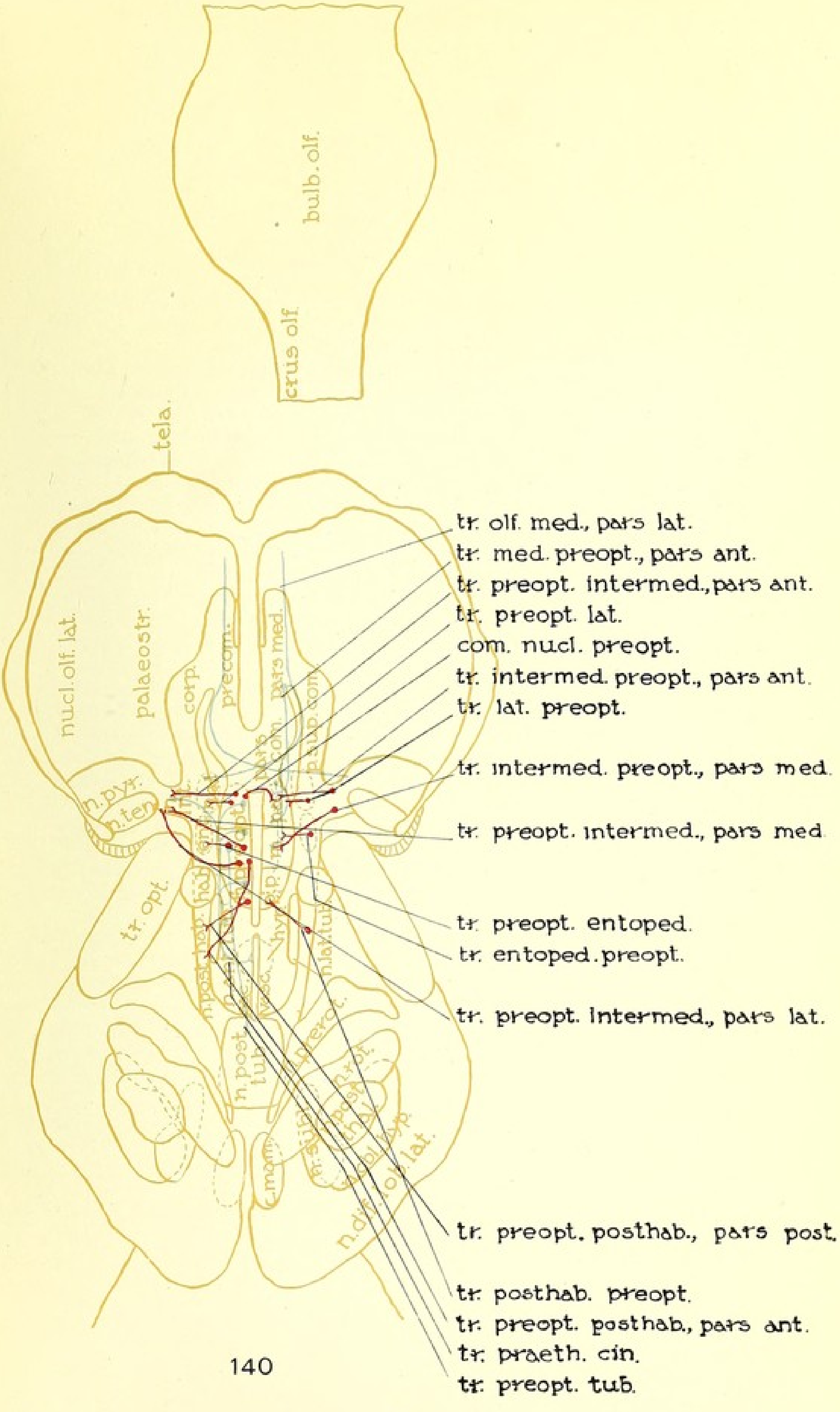
bulb. olf.
crus olf.
tela.
nucl. olf. lat.
palaeostr.
corp.
precom.
pars med.
n. pyr.
n. ten.
tr. opt.
n. post. tub.
n. lat. tub.
c. mam.
n. dif. lob. lat.
tr. olf. med., pars lat.
tr. med. preopt., pars ant.
tr. preopt. intermed., pars ant.
tr. preopt. lat.
com. nucl. preopt.
tr. intermed. preopt., pars ant.
tr. lat. preopt.
tr. intermed. preopt., pars med.
tr. preopt. intermed., pars med
tr. preopt. entoped.
tr. entoped. preopt.
tr. preopt. intermed., pars lat.
tr. preopt. posthab., pars post.
tr. posthab. preopt.
tr. preopt. posthab., pars ant.
tr. praeth. cin.
tr. preopt. tub.

140

PLATE 41

EXPLANATION OF FIGURES

141 Diagram of a projection of the olfactory centers on a para-sagittal plane near the meson, showing the components of the tractus olfacto-habenularis, and their connections, in black (*cf. Goldstein, Taf. 11, fig. 7*). × 12.

chias., optic chiasma; *com. corp. precom. + com. hipp. pars ant.*, commissura corporium precommissuralium plus commissura hippocampi, pars anterior; *com. hab.*, commissura habenularum; *com. Herrick*, commissura Herricki; *com. horiz.*, commissura horizontalis; *com. interbulb.* (*dec. tr. olf. med., pars med.*) commissura interbulbaris (decussation of the tractus olfactorii mediales, partes mediales); *com. nucl. preopt.*, commissura nucleorum preopticorum; *com. trans.*, commissura transversa; *corp. mam.*, corpus mammillare; *corp. pin.*, corpus pineale; *corp. precom.*, corpus precommissurale; *crus olf.*, crus olfactorium; *dec. n. term.*, decussatio nervorum terminalium; *dec. tr. hyp. olf. med. + dec. tr. olf. med., pars lat. + com. dors. + com. hipp., pars post.*, decussation of the tractus hypothalamo-olfactorii mediales, plus decussation of the tractus olfactorii mediales, partes laterales, plus commissura dorsalis, plus commissura hippocampi, pars posterior; *fasc. retr.*, fasciculus retroflexus; *fib. ans.*, fibrae ansulatae; *hab.*, ganglion habenulae; *n. ant. tub.*, nucleus anterior tuberis; *n. opt.*, nervus opticus; *n. post. tub.*, nucleus posterior tuberis; *nucl. dif. lob. lat.*, nucleus diffusus lobi lateralis; *nucl. posthab.*, nucleus posthabenularis; *nucl. preopt.*, nucleus preopticus; *nucl. rot.*, nucleus rotundus; *pars gland.*, pars glandularis of the hypophysis; *pars med.*, pars medialis of the corpus precommissurale; *pars nerv.*, pars nervosa of the hypophysis; *pars p.c. post.*, pars parvocellularis posterior of the nucleus preopticus; *p.m.*, pars magnocellularis of the nucleus preopticus; *p. p. c. ant.*, pars parvocellularis anterior of the nucleus preopticus; *p. supracom.*, pars supracommissuralis of the corpus precommissurale; *tectum*, tectum mesencephali; *tela*, so-called pallium; *tr. dien. hab.*, tractus diencephalo-habenularis; *tr. entoped. hab.*, tractus entopedunculo-habenularis; *tr. hab. dien.*, tractus habenulo-diencephalicus; *tr. intermed. hab., pars ant.*, tractus intermedio-habenularis, pars anterior; *tr. intermed. hab., pars post.*, tractus intermedio-habenularis, pars posterior; *tr. olf. hab.*, tractus olfacto-habenularis; *tr. posthab. hab.*, tractus posthabenulo-habenularis; *tr. preopt. hab., pars ant.*, tractus preoptico-habenularis, pars anterior; *tr. preopt. hab., pars lat.*, tractus preoptico-habenularis, pars lateralis; *tr. preopt hab., pars med.*, tractus preoptico-habenularis, pars medialis; *tr. preopt. hab., pars post.*, tractus preoptico-habenularis, pars posterior; *tr. strio-thal. cruc.*, decussation of the tractus strio-thalamici cruciati; *tr. teniae*, tractus teniae; *valvula*, valvula cerebelli. (See also fig. 125.)

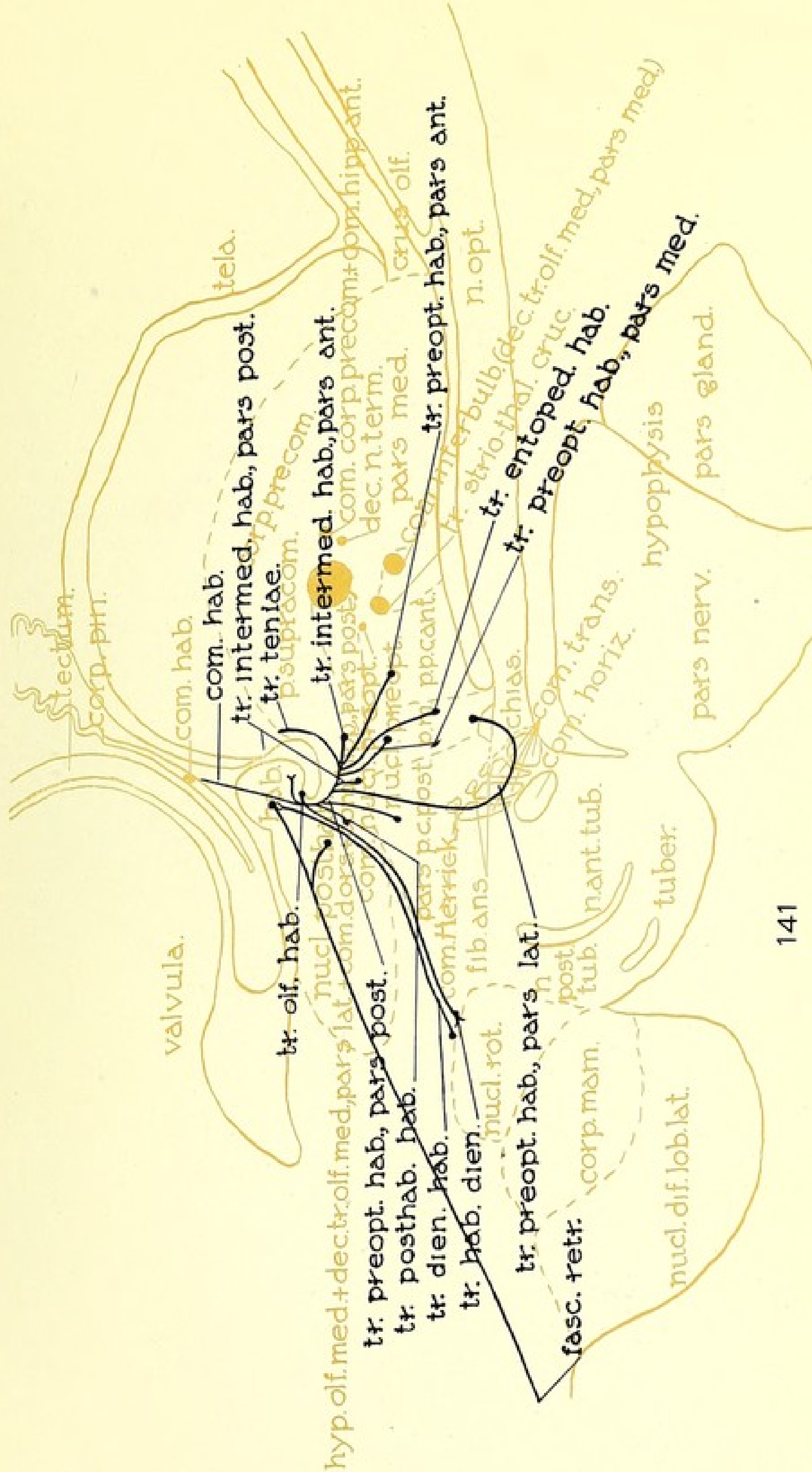
com. hab.
tr. intermed. hab., pars post.
tr. teniae.
tr. intermed. hab., pars ant.
tr. preopt. hab., pars ant.
tr. entoped. hab.
tr. preopt. hab., pars med.
tr. olf. hab.
tr. preopt. hab., pars post.
tr. posthab. hab.
tr. dien. hab.
tr. hab. dien.
tr. preopt. hab., pars lat.
fasc. retr.
tela.
tectum.
corp. pin.
com. hab.
valvula.
hab.
nucl. post. hab.
com. dors.
com. Herrick
fib. ans.
nucl. rot.
n. post. tub.
corp. mam.
nucl. dif. lob. lat.
tuber.
n. ant. tub.
com. horiz.
com. trans.
chias.
pars nerv.
hypophysis
pars gland.
n. opt.
tr. strio-thal. cruc.
tr. interbulb. (dec. tr. olf. med., pars med.)
crus olf.
com. corp. precom. + com. hipp. ant.
com. corp. precom.
dec. n. term.
pars med.
corp. precom.
p. supracom.
pars post.
nucl. preopt.
pars p.c. post.
pp. cant.
dec. tr. hyp. olf. med. + dec. tr. olf. med., pars lat.

141

PLATE 42

EXPLANATION OF FIGURES

142 Diagram of a horizontal projection of the olfactory centers showing, in red, the components of the tractus olfacto-habenularis and their connections. × 12.

com. hab., commissura habenularum, or commissura superior; *fasc. retr.*, fasciculus retroflexus, Meynert's bundle, tractus habenulo-peduncularis; *tr. dien. hab.*, tractus diencephalo-habenularis (a portion of the tractus habenulo-diencephalicus of Goldstein); *tr. entoped. hab.*, tractus entopedunculo-habenularis; *tr. hab. dien.*, tractus habenulo-diencephalicus; *tr. intermed. hab., pars. ant.*, tractus intermedio-habenularis, pars anterior; *tr. intermed. hab., pars post.*, tractus intermedio-habenularis, pars posterior; *tr. olf. hab.*, tractus olfacto-habenularis (under this name are included all the fiber systems which ascend into the habenula of either side); *tr. posthab. hab.*, tractus posthabenulo-habenularis; *tr. preopt. hab., pars ant.*, tractus preoptico-habenularis, pars anterior; *tr. preopt. hab., pars lat.*, tractus preoptico-habenularis, pars lateralis; *tr. preopt. hab., pars med.*, tractus preoptico-habenularis, par medialis; *tr. preopt. hab., pars post.*, tractus preoptico-habenularis, pars posterior; *tr. ten.*, tractus teniae (the tractus olfacto-habenularis of Kappers, Goldstein, etc.). (For other abbreviations see explanation of fig. 136.)

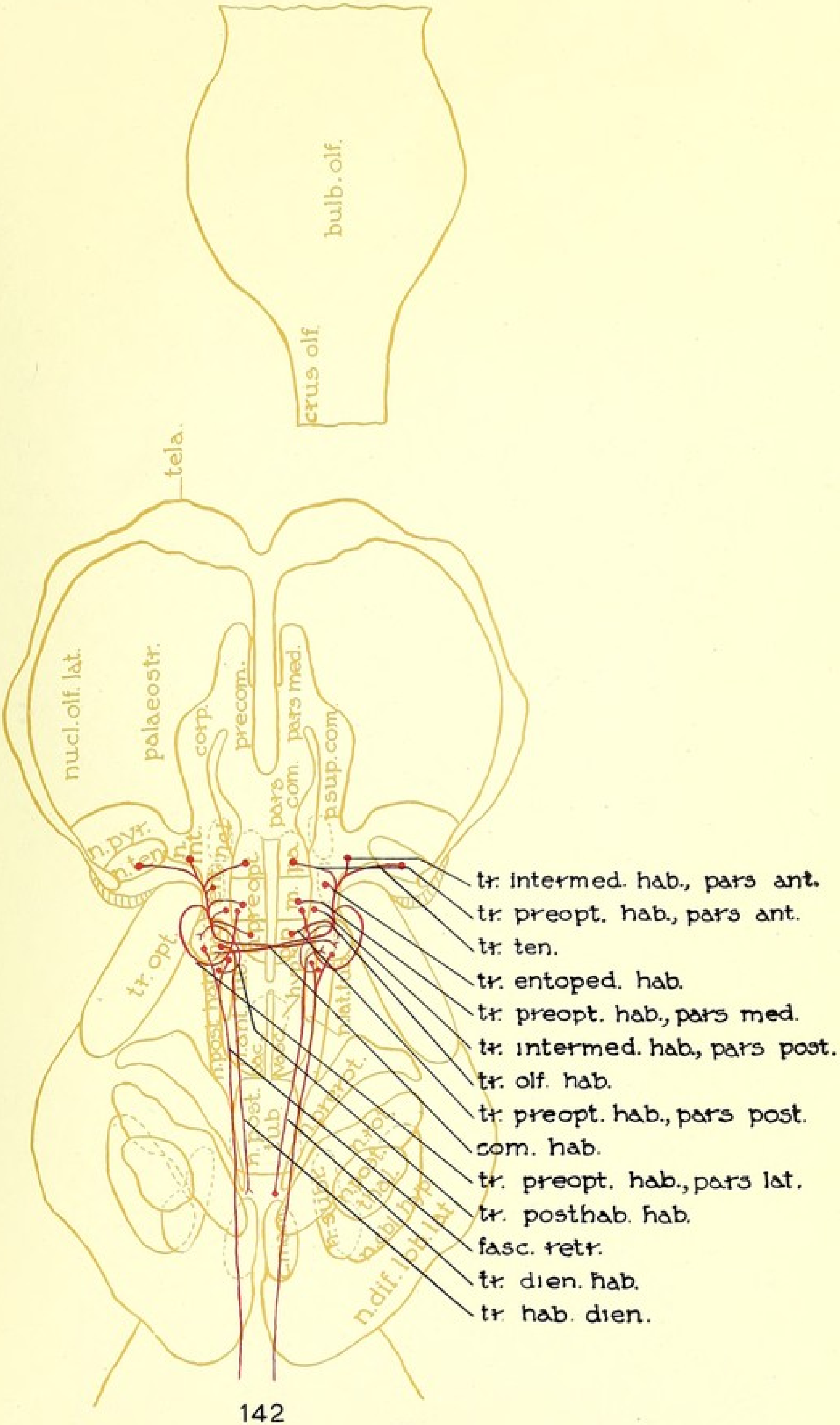
bulb. olf.
crus olf.
tela.
nucl. olf. lat.
palaeostr.
corp.
precom.
pars med.
p. sup. com.
pars com.
n. pyr.
n. ten.
n. int.
preopt.
tr. opt.
n. post. hab.
n. post. tub.
n. dif. lob. lat.
tr. intermed. hab., pars ant.
tr. preopt. hab., pars ant.
tr. ten.
tr. entoped. hab.
tr. preopt. hab., pars med.
tr. intermed. hab., pars post.
tr. olf. hab.
tr. preopt. hab., pars post.
com. hab.
tr. preopt. hab., pars lat.
tr. posthab. hab.
fasc. retr.
tr. dien. hab.
tr. hab. dien.

142

THE JOURNAL OF COMPARATIVE NEUROLOGY

VOLUME 22, NUMBER 3, JUNE, 1912

CONTENTS

THE WAVERLY PRESS
BALTIMORE, U. S. A.