The central course of the nervus octavus and its influence on motility / by C. Winkler.

Contributors

Winkler, Cornelis, 1855-1941.
Winkler, Cornelis, 1855-1941
Koninklijke Akademie van Wetenschappen (Netherlands)
King's College London

Publication/Creation

Amsterdam : Johannes Müller, 1907.

Persistent URL

https://wellcomecollection.org/works/uuv6jt22

License and attribution

This material has been provided by This material has been provided by King’s College London. The original may be consulted at King’s College London. where the originals may be consulted.
Conditions of use: it is possible this item is protected by copyright and/or related rights. You are free to use this item in any way that is permitted by the copyright and related rights legislation that applies to your use. For other uses you need to obtain permission from the rights-holder(s).

wellcome collection

Wellcome Collection
183 Euston Road
London NW1 2BE UK
T +44 (0)20 7611 8722
E library@wellcomecollection.org
https://wellcomecollection.org

200931500 6
INST. PSYCH.

UNIVERSITY OF LONDON
INSTITUTE OF PSYCHIATRY
DE CRESPIGNY PARK
DENMARK HILL
LONDON, SE5 8AF

LIBRARY

WINKLER, C.

The central course of the nervous octavus and its influence on motility. 1907.

h/Win
CLASS MARK .....
ACCESSION NUMBER .....

With compliments of the author.

The central course of the Nervus octavus and its influence on motility.

BY

C. WINKLER.

Verhandelingen der Koninklijke Akademie van Wetenschappen te Amsterdam.

(TWEEDE SECTIE.)

DEEL XIV. N°. 1.

(With 24 Plates).

AMSTERDAM,
JOHANNES MÜLLER.
1907.

Digitized by the Internet Archive
in 2015

https://archive.org/details/b21295712

INTRODUCTION.

After so many admirable researches as have been made of late about the mode of distribution of the N. octavus in the central nervous system, after all that has been brought to our knowledge from competent investigators, as to the influence exerted by this nerve on the muscular system in animals and in man, it may be considered an almost preposterous enterprise to publish another treatise, and moreover a monography, on the eighth cerebral nerve.

We may not expect — at least not if no new methods are employed — that we will find much to be added to what has been taught us by EWALD about the troubles of motion, observed in pigeons whose labyrinths have been removed on one or on both sides. Our knowledge of the function of the octavus-system has been settled for a long time by this eminent experimental essay.

Such is also the case with our anatomical notions. The investigations of HELD, of VAN GEHUCHTEN, of VON MONAKOW, LEWANDOWSKY and others form likewise in a certain sense a finished whole, accordant in many leading features.

These researches have shown the distribution of the Nervus octavus in the central system to be much more complicated than was surmised before. Still, though the whole appears thus complicated, the differences of opinion on cardinal points have diminished. Our knowledge having reached this stage, I am perfectly conscious of the impossibility that quite new views should be offered by this monography, in which the anatomy and the physiology of the nervus VIII are not studied by means of new methods.

Yet I believe that in a few points I have succeeded in obtaining definite results, going farther than those of my predecessors.

This was made possible only, because the functional effects, consequent on the isolated removal of the cochlea, or on the entire removal

of the labyrinth, or on the section of the Nervus VIII, or on that of the corpus trapezoides, or on that of the dorsal tract of the N. octavus, have been controlled regularly and minutely by the degenerative or atrophical changes, found after these operations in the central organ, and demonstrated by means of the methods either of MARCHI, of VON GUDDEN, of NISSL or of CAJAL, as may best fit the case. Though the experiments of EWALD deserve justly to be called masterly, yet there remains an incertitude adhering to the results they have produced. The anatomical control of his operations on pigeons, carried through in an admirable manner for the periferical-organs — the end-organ of the eighth cerebral nerve — was not attempted for its mode of distribution in the central system.

This is no imaginary objection. In some instances it becomes very palpable. When f. i. EWALD, speaking about his experiments on rabbits, writes: „Im ganzen eignen sich diese Tiere nicht sehr gut zur Untersuchung der Labyrinthstörungen" the importance of this objection becomes evident.

The real meaning of this sentence is doubtless, that rabbits, whose labyrinth has been removed, more especially if it has been removed on one side, show certain symptoms (rollings round the longitudinal axis, constraint-situation of the eyes) not shown plainly in pigeons, whilst other symptoms, appearing beautifully in pigeons (the progression of the paroxismally produced peculiar attitude of head and neck, the atony of the extremities on one side) either are shown differently, or else offer difficulties of demonstration in rabbits.

It would be just as right however to maintain, that for the same reason pigeons are animals less suited for experiments upon the labyrinth than rabbits.

Still both opinions would be inconsiderate. For the mode of distribution of the nervus octavus in the central nerve-system is so widely different in both species of animals, that we may not reasonably expect a *perfect* conformity in the symptoms of both species, when the labyrinth has been removed.

The more to be admired therefore is the perspicacity of EWALD, who apprehended how, in one respect, the functional loss, most conspicuous after the destruction of the labyrinth, was found to be accordant.

In demonstrating that a very serious atony of the extremities especially on one side is caused by removal of one labyrinth, EWALD has put a clue into the hands of anatomists, who know very well that in despite of all differences, there still exists a great conformity in the structure of the nervus octavus in the different animal species.

On the other hand, the anatomists who have studied after EWALD the central distribution of the octavus-fibres and who in the course of their labours, met with quite new views about the architecture of the medulla oblongata, have either quite neglected the results of the physiology of this nerve or else have taken these only into partial consideration.

In my opinion, a monography trying to establish a relation between the results of physiology (results that I dare say are settled permanently as regards cardinal points since EWALD) and those of anatomy, may vindicate a right to exist.

The task, enjoined on a complete monography about this subject, would be not only to treat different animals, representative of all the great families of the vertebrates, it should be written also for closely connected species of one family. This task however would exceed the power of one man.

Thus much I have learnt during my researches, that the course of the octavus-fibres and their distrubution towards different centra in the medulla oblongata, pons and mesencephalon is differing for rabbit, pigeon, dog, cat, mouse, horse and man, and that the function-trouble, consequent on section of the octavus in rabbit, pigeon, dog and cat is different too.

Not in the cardinal points, but in so many of the details, that the cardinal points are sometimes masked by them.

I will therefore take as basis for the description of the course of the primary and secundary octavus-tracts, and equally for the description of the function-troubles after their lesion, the nerve-system of the rabbit.

Only in as much as I think it necessary for the elucidation of a few important facts, I will also memorate details about this system in pigeons.

I have chosen the rabbit, because the oblongata of this species is best known. By far the greater number of investigators have studied the oblongata in this animal. For it is not the least important part of my purpose to consider the series of new facts, brought to our knowledge by the methods of CAJAL and MARCHI in their relation to the Octavus-question and to rely them to the physiologically proved disturbances in motion, consequent to the lesion of this nerve.

The long tracts, descending from mesencephalon, metencephalon and myelencephalon towards the medulla, ought to be examined as to their connection with the N. octavus. The results, obtained by MARCHI, THOMAS, VAN GEHUCHTEN, PROBST, JAMES COLLIER,

Lewandowski and others with the aid of Marchi's method, by Forel and Onufrowicz, Baginski, Von Monakow, Mingazzini, Ferrier, a. o. with the method of Gudden, by Cajal, Held a. o. with Golgi's method, by Flechsig, Bechterew, Held a. o. with the aid of the myelinisation of the embryonic nervous system, have certainly great importance in elucidating the question about the course of the N. octavus, and its primary and secondary distributions. All these are waiting for a connecting bond with the results of the physiologists, who have destroyed experimentally the N. octavus or its end-organs. On the other hand the question ought to be put again before the physiologists, *whether* the better knowledge of the mode of distribution of the N. octavus in the central organ can enable us to understand the influence exerted by the N. octavus on the muscular system.

If I am right in my surmise, that the mode of central distribution of the N. octavus does not allow a severe distinction between that of the N. cochlearis and that of the N. vestibularis, then it will be necessary to put again the question whether the N. cochlearis, whose end-organ is endowed with the function of hearing, does not exert a certain influence upon the muscular system, and whether the N. vestibularis, endowed with such an important significance for the motor disturbances and whose influence on the movements is universally acknowledged, does not contribute something to the function of hearing.

If I am right in my surmise that by the octavus-fibres, centra are innervated, whence originate long tracts towards the lateral and anterior columns of the medulla providing the motor centra of the cord with fibres, and that even primary octavus fibres, though in a slight degree, trace the same path, which is followed by the secundary, the prospect would be opened of obtaining a clearer comprehension of the motion-troubles after the lesion of the end-organs of the eighth nerve. The sensu-motor centrum of the N. octavus might in that case have become a more anatomically defined being, strictly separated from the psychical-system of it, but not by means of strict separation of the end-organs. Therefore I have endeavoured to establish a connection between the anatomy and the physiology of the N. octavus. In this manner I hope to contribute something towards smoothing the path, traced first by Ewald, a labour to wich Thomas, Marchi, Forel, Held, van Gehuchten, Cajal, von Monakow, Probst, Lewandowsky, and so many others have given and are still giving, all their energy.

Chapter I.

The removal of the rabbit-labyrinth. The section of the N. octavus and of its prolongation in the central nerve-system. The disturbances of motion following on these operations.

I. *A few technical remarks on the removal of the labyrinth in rabbits.*

Before trying to remove the labyrinth of rabbits, it is advisable to learn this operation on pigeons, all the while following strictly the technical directions, described with so minute a preciseness by EWALD, without neglecting any of the details given by him.

If the removal of the labyrinth is performed with the purpose of investigating, after a more or less prolonged duration of life of the animal, the secundary degenerations and atrophies in the central nerve-system by means of the methods of MARCHI or GUDDEN, it is of the utmost importance to take care that no accessory lesion may occur.

For the same reason, with pigeons likewise as with rabbits, the most careful antisepsis in the preliminary stage of the operation and the strictest asepsis during its course are necessary, and some subordinate parts of it ought to be executed with great circumspection. On the one hand, it is of absolute necessity to avoid any bleeding during the operation. On the other hand the method of the cauterizing the blood-sinus offers a danger, even when following strictly the rules prescribed by EWALD. This danger is that the heat, passing through the bone, may have scorched at a distance the surface of the cerebellum and may thus have created the origin of a secundary degeneration. And a pigeon, having a superficial lesion of the cerebellum even though this may not be betrayed

in the post-mortem by loss of substance or by softening seen with the naked eye, but only shown in microscopical investigation as the origin of a MARCHI degeneration, is no longer suited for following the course of the Nervus VIII by means of the MARCHI-method. Such pigeons are moreover likewise useless for the physiology of the Nervus VIII.

On pigeons the operation is more difficult than on rabbits, and even therefore it is necessary to make preliminary trials in removing the labyrinth on these animals, before experimenting on rabbits.

However, EWALD has described this operation on pigeons so minutely in all its subordinate parts, that, guided by him, it will be easy to obtain the experience that will be useful in experimenting on rabbits. Still, I am of opinion, like EWALD, that the success of the experiment i. e. the appearing of the functional troubles (that are always the same after extirpation of the labyrinth) depends, next to the post mortal assertion of the fact that only a lesion of the Nervus VIII has been produced, on asepsis and on the technics of the operation.

For my purpose five operations have been found necessary to elucidate the central course of the nerous VIII.

1°. the isolated removal of the cochlea,

2°. the removal of the cochlea together with the contents of the vestibulum,

3°. the operation mentioned sub 2° + the section of the N. octavus in the meatus auditorius internus,

4°. the section of the ventral octavus-tract (the corpus trapezoides),

5°. the amotion of the tuberculum acusticum and the nucleus ventralis N. VIII together with the dorsal octavus-tract (MONAKOW's stria medullaris in the rabbit).

The first four of these operations were performed through the bullea ossea, the last one from the 4th ventricle.

I will therefore begin with the description of the operations at the bulla ossea, before proceeding to that from the 4th ventricle.

It must be remarked previously, that all animals destined to be operated, are prepared the day before.

The skin over the region of the operation is shaven and carefully cleansed with soap, alcohol and sublimate. I hold a repeated disinfection of the skin on the day before the operation and immediately before operating, to be necessary. The great difficulty in these operations is the disinfection of the skin. It is to the minute skin-disinfection that I attribute the favorable results and the absolute aseptic woundhealing.

2. *The operations through the bulla ossea.*

If the bulla ossea is to be laid bare, a rather large area of operation must be prepared, having the shape of a rectangular trapezium, whose upright rectangle-side is in the cervical part of the mid-ventral line of the animal.

Cranialwards the boundary of this area is a line, starting from the lateral canthus of the eye and crossing the cheek, standing vertically on the mid-ventral line. It is the basis of the trapezium.

The dorsal boundary, is a line, drawn from the lateral canthus of the eye along the auricular root towards the mid-dorsal line.

The caudal boundary, the oblique side of the rectangular trapezium, is indicated by a line, starting from the mid-dorsal line a little way behind the ear and reaching the mid-ventral line at the manubrium sterni.

Nearly in the centre of this trapezium is found the angulus maxillae inferioris, serving as „point de repère".

Especial care is given to the disinfection of the roots of the ear and of the external auditory meatus, that after having been cleansed, are filled with Bruns's wadding.

Thus prepared, the animal is stretched with its back turned upward; and the head, retained in Czermak's trap, is placed in such a manner that the area of operation is turned upward.

After carefal re-disinfection of the area of operation, the stretched animal with its surroundings is wrapped up in sterile gauze, only the area of operation remaining visible and accessible to the operator.

The operator finds his way by the aid of the angulus maxillae inferioris, that may be felt through the skin.

The incision of the skin commences somewhat laterally from the lateral eye-canthus, passes midway between underjaw and ear, descending at first parallel to the ascending branch of the underjaw, till it has reached the angulus maxillae inferioris and until then it continues standing nearly vertically on the mid-ventral line.

It then commences to deviate slowly caudalward, forms a right angle with its original direction, courses parallel to the mid-ventral line, and terminates about 2 cM. from its bend. In this manner the skin-incision describes part of a circular line around the bony and the membranous auditory meatus, or, if one likes, above and over the bulla ossea lying in the depth.

This incision having been made, we meet in the caudal part of

the wound, the vena jugularis externa, that is generally much swollen by the turning of the head. (See fig. 1). This vena is supplied with blood by several venae from the face and from the auricle of the ear. Inconvenient among these may be the venae reaching the vena jugularis along the underjaw and also the venae auriculares, especially the vena auricularis posterior.

In the cranial part of the operative lesion is found the Nervus facialis, crossing the area of operation (See fig. 1).

First of all the vena jugularis has to be put aside. With a small blunt hook it is detached so far that it may be pushed behind the angulus maxillae inferioris. The venae auriculares posteriores are stretched by this proceeding, and it is therefore advisable to cut them between two ligatures, because rupture and bleeding in a later stage of the operation are to be avoided. With a blunt wound-hook the vena jugularis is now kept behind the ascending branch of the underjaw and both together are drawn aside by an assistant. During the further course of the operation this vena is seen no more.

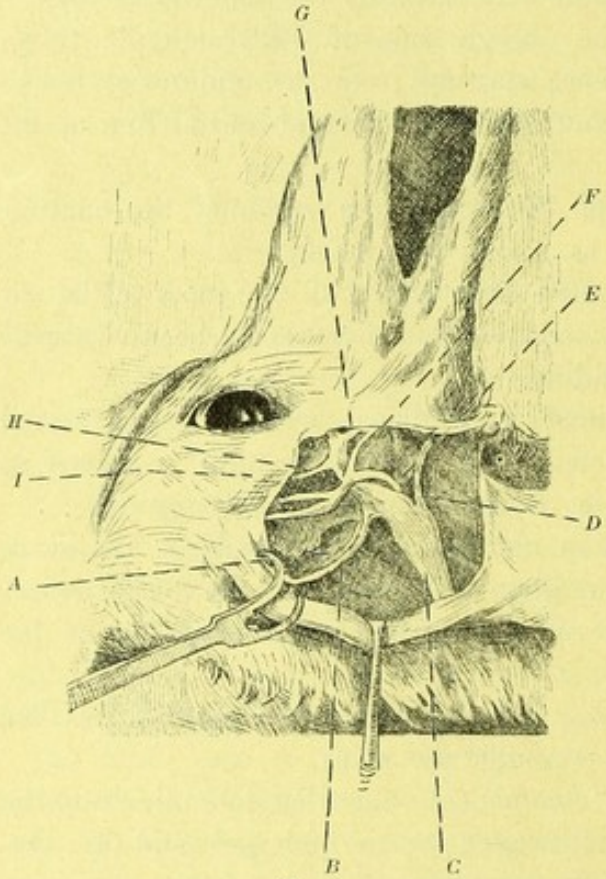

Fig. 1.

The skin and the superficial fascia being cleft, the situation of the venae appears.

A maxilla inferior, *B* vena maxillaris, *C* vena jug. ext., *D* vena auric. lat., *E* N. facialis, *F* r. auric. N. facialis, *G* vena auric. ant., *H* vena facialis, *I* r. zygom. N. facirlis.

Next the N. facialis has to be taken care of. This nerve, after having been isolated on the surface, is lifted upward by an assistant cautiously by means of a blunt wound-holder.

I don't hold it necessary to section the nerve in order to avoid degeneration in central direction, as has been done by VAN GEHUCHTEN. If carefully treated, there need not arise a degeneration. If the nerve be sufficiently protected, this does not occur, and the important advantage gained in this way is that no post-operative paralysis of the muscles of the face has to be combated. Once the

vena jugularis and the N. facialis having been preserved, the fascia is sectioned along the anterior border of the glandula parotis, that is pushed backward, under the root of the ear, by means of a third blunt wound-holder.

The operator now seeks his direction by the aid of the membranous auditory meatus, and determines the place where it passes into the bony part of it.

The periosteum lying on its surface is sectioned by means of a small, solid and sharp bone-knife and is pushed aside. Before proceeding directly to the bulla ossea, the periosteum along the anterior border of the processus mastoideus is removed, continually staying proximal to the place where the N. facialis leaves the bone, until the insertion of the m. biventer may be plainly seen. This insertion is lifted upward and is sectioned close to where it is affixed to the bone, (See fig. 2 and fig. 3). In this way a large space is obtained and the bony auditory meatus may be seen passing into the bulla ossea, this latter appearing as a smooth hemisphere of glossy white colour. (See fig. 3).

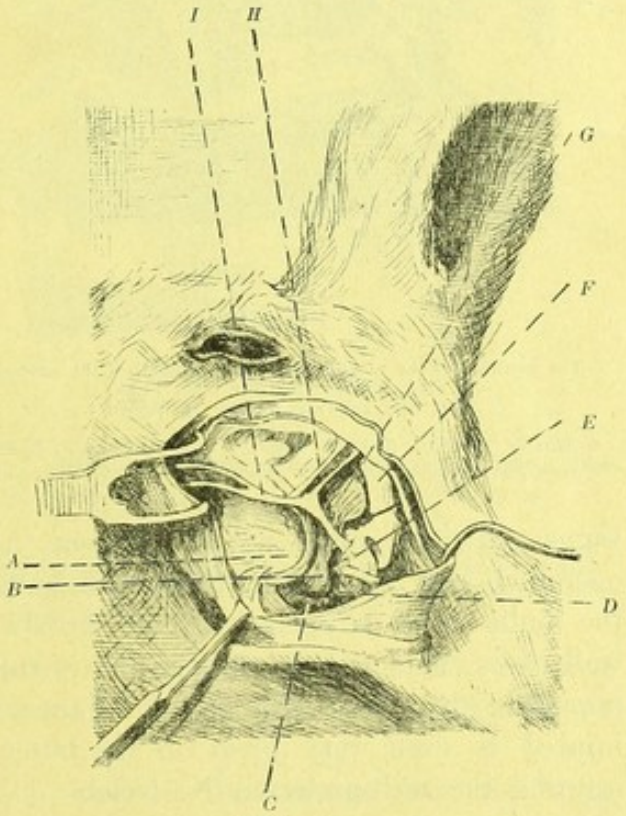

Fig. 2.

The vena jugularis is kept under the ascendent branch of the maxilla.
The m. biventer crosses the field of the operation. The N. facialis also crosses it.

A maxilla inferior, *B* bulla ossea, *C* musc. biventer, *D* Processus mastoideus, *E* Pars mastoidea *F* meat. audit. membranaceus, *G* meat. audit. osseus, *H* vena auric. ant., *I* N. facialis.

Next it is ascertained again that the vena jugularis and the N. facialis are not endangered. One must make likewise sure that nothing becomes visible, either of the arteria carotis or of the nerves leaving the bony skull at the posterior wall of the bulla ossea.

This latter point is of the utmost importance. For the sectioning of the m. biventer in order to obtain more space, simple though it may be for an experienced operater, may become an obstacle. If, in lying bare the processus mastoideus, the knife of the operator has

deviated too much towards the foramen of the occiput, after the section of the m. biventer, not only the bony auditory meatus with the anterior surface of the bulla ossea, but also the medio-distal wall of it becomes visible. Next to this latter is situated the foramen jugulare, and the operator will state to his dismay that as soon as the m. biventer is sectioned, the arteria carotis and the four nerves appear within the area of operation (See fig. 4).

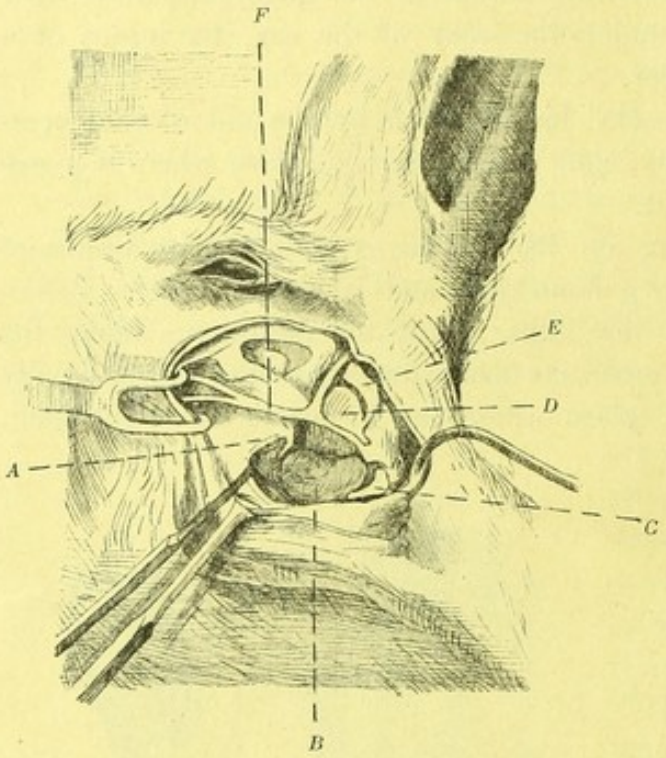

Fig. 3.

The position of the meatus auditoreus osseus, of the processus mastoideus and of the bulla ossea, after the cleaving of the m. biventer.

A maxilla inferior, *B* bulla ossea, *C* proc. mastoid., *D* meat. audit. osseus. *E* meat. aud. membranaceus, *F* N. facialis.

Beginning from the centre, these are the N. laryngeus superior, the N. hypoglossus, the N. sympathicus and the N. vagus. All these ought not to be seen, neiher in this stage of the operation nor afterwards, when the bulla ossea is opened. For if the bulla ossea is opened too far distalward, and the mediodistal wall does not remain firm, but is ruptured and has to be removed, the nerves will appear again. The danger of their being injured is even very great in the latter case, as well as that of injuring the well-protected N. facialis.

If one or several of these nerves are injured, the danger arises again of occasioning uncontrollabe retrograde degenerations. In a faultless operation however neither the arteria carotis nor one of the afore-said nerves may have been seen by the operator.

The anterior wall of the bulla ossea and the passage of the bony auditory meatus into the bulla ossea are now lying before the operator, who supports the bulla by wadding and either punctions the top of its hemisphere with a pair of small crooked nibling pincers or else opens it with a sharp chisel. The supporting of the bulla is necessary in order to prevent eventual fissures exten-

ding themselves unto the basis cranii and occasioning uncontrollable venal bleedings in the interior of the skull.

The aperture is widened further by means of a pair of small nibling pincers, whilst the utmost care is taken that a large part of the bulla towards the basis cranii may remain uninjured, until at last a full view is obtained in the cavum tympani.

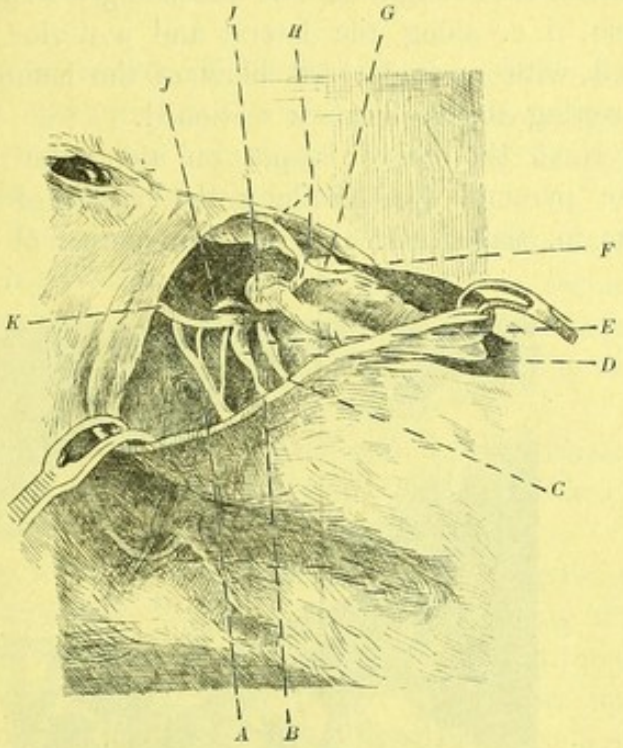

Fig. 4.

The position of the arteria carotis, of the N. laryngeus superior, of the N. hypoglossus of the N. vagus and of the N. sympathicus in relation to the bulla ossea.

A art. carotis, *B* N. sympathicus, *C* N. vagus, *D* Gangl. suprem. colli N. cympathici, *E* Gangl. N. vagi, *F* r. auric. N. facialis, *G* meat. audit. osseus, *H* N. facialis, *I* bulla ossea, *J* N. laryng. sup., *K* N. hypoglossus.

Here the way is easily to be found.

In the very first place the operator's attention is drawn to the large triangular orifice of the tuba Eustachii in the cavum tympani. From this orifice rises in a gentle declivity the triangular pyramid of the promontory, its apex being turned towards the orifice. On the basis of the pyramid and turned towards the operator is lying the foramen rotundum, whilst the foramen ovale, turned more backward, is not yet visible.

This latter becomes visible only if the passage from the bulla ossea to the bony auditory meatus is destroyed and the ossicles of the ear are removed. The glossy white sinew of the m. stapedium, lying enclosed in a spacious bony hole on the dorso-medial side of the promontorium is not seen if the bony auditory meatus remains uninjured and its bony hole is left unopened. The cavum tympani may now be surveyed.

a. The removal of the cochlea.

From the orifice of the tuba Eustachii towards the foramen rotundum runs the line, along which may be opened the thin

lamina of bone, constituting the promontory and covering the cochlea.

If the promontory be opened by means of the chisel, this instrument, that ought to be exceedingly sharp, is put on along this line, i. e. along the lateral and posterior border of the pyramid, and with a single, soft blow of the hammer the lamina of bone, covering the cochlea, is sectioned.

Next the chisel is put on along the most anterior nervure of the pyramid (partly along the border of the bony hole enclosing the m. stapedius), and the thin lamina of bone is sectioned again.

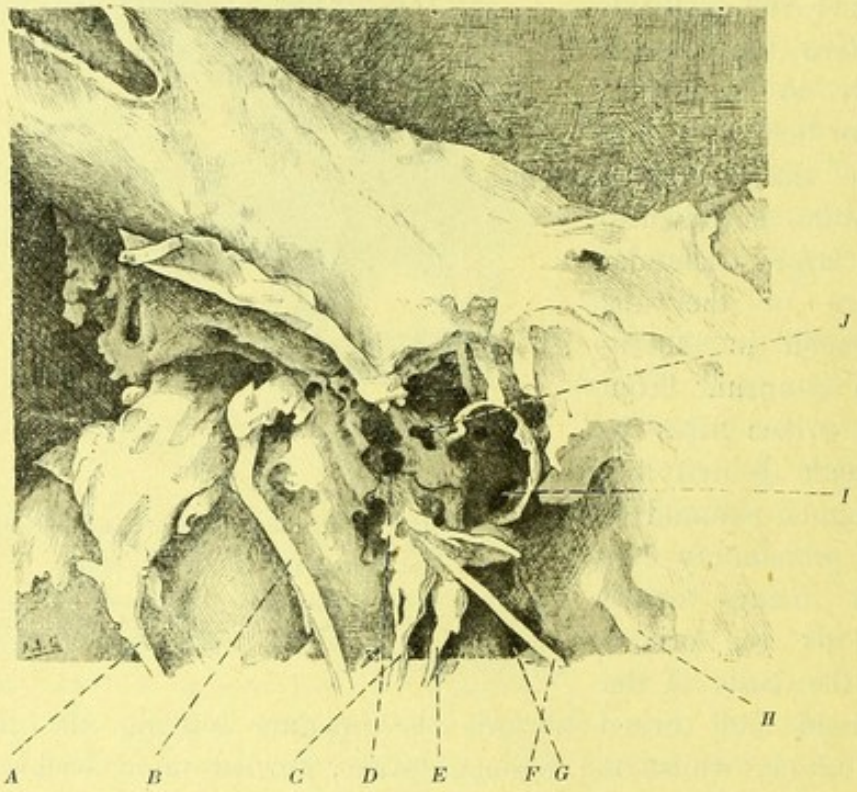

Fig. 5.

The bulla ossea is opened. The aditus ad tubam Eustachii, the promontorium, the foramen rotundum, the foramen ovale are seen.

A N. cerv. II, *B* N. cerv. I, *C* N. Vagus, *D* for. rotundum, *E* N. symp., *F* N. hypogl., *G* promont., *H* N. lar. sup., *I* tuba Eustachi, *J* for. ovale.

By a third stroke of the chisel both diverging lines of section are united straight before the foramen rotundum.

A very narrow lamina of bone, lying before it, remains uninjured.

The thin lamina of bone covering the cochlea is now detached, and may be removed with a pincet or an excavator.

If one does not dare to open the promontory with the chisel — for there is some danger that the thin lamina, covering the

cochlea, may be either ruptured or pressed downward — then the broad, flat edge of a small hook, having been bent vertically for this purpose, is introduced through the foramen rotundum.

This edge is pushed under the thin lamina of bone, which is then lifted up.

In most cases the lamina breaks off frontalward enough to offer sufficient space, and the aperture may be widened with excavators. Nevertheless a point de repère has been lost, because the foramen rotundum forms now part of the breach in the bone.

The lamina of bone having been removed, the convolutions of the cochlea are lying bare, and it offers no difficulty to extract these by means of an excavator or of a small, sharp spoon. The three convolutions being removed, we touch the petrous bone, forming the posterior wall of the cavity containing the cochlea.

The operation is now terminated. The cochlea and therewith the ganglion spirale N. cochlearis has been removed. The N. cochlearis degenerates within a week.

Endolymph is flowing forth. Perhaps the peripherical organs in the vestibulum may degenerate. Certainly the ganglia along the N. vestibularis do not so immediately. They are certainly without any lesion consequently of the cochlea-removal. It is therefore not only possible, but it follows necessarily, that the degeneration is confined to the N. cochlearis, if indeed this nerve does not exchange fibres with the N. vestibularis.

b. The removal of the entire labyrinth and the section of the N. octavus.

Generally however it is thought desirable to remove the entire labyrinth.

To this purpose the operation is commenced in the same way as described above. The bony lamella covering the cochlea is removed and the fenestrum rotundum is sought. After removing by means of an excavator the anterior wall, that had remained standing, a breach is made between fenestrum rotundum and foramen ovale in the bony wall covering the vestibulum. The stapes is extracted from the foramen ovale, without injuring the tympanum. The breach in the bone is enlarged as much as possible. Thus far the operation may be made easily without the aid of a lens. At this moment however it is preferable to examine the contents of the vestibulum with a lens. The anterior ampulla is caught in an iris-crotchet. The membranaceous anterior canal is cut through near the ampulla and with slight tractions the membranous contents of

the vestibulum are drawn out and removed. By this proceeding the membranous wall of the semicircular canals, lying enclosed in very hard bone, are stretched and ruptured above their ampullae, and it is advisable to help with a sharp excavator, and to section them, as they present themselves, in order to obtain their easily following the tractions. And yet it is very difficult to remove the vestibulum whith maculae and cristae as a whole. Ordinarily the anterior ampulla is breaking of. In that case the wall of the vestibulum again is caught in the iris-pincet, and the tractions are recommenced, until all ampullae are removed.

After the removal of the cochlea, of the vestibulum with its appendixes and of the ampullae, the trunk of the N. octavus is lying bare. The trunk may be sectioned at the interior auditory meatus, an operation that is often combined with the removal of the vestibulum and the ampullae.

For the removal of the cochlea is, in its relation to the central nerve-system, an operation very different from the removal of vestibulum and ampullae. With the cochlea the ganglion spirale is removed, but if the vestibulum with the ampullae is extracted, it does not follow necessarily that the ganglion vestibulare is totally extirpated. Therefore it is often thought desirable to destroy the trunk of the N. octavus, that becomes visible directly after the removal of the cochlea. For along this trunk in the meatus auditorius internus are situated continuously the nerve-cells forming the ganglion plexiforme Scarpae.

Only when the nerve has been sectioned between these cells and the central nerve-system, the N. vestibularis is in the same condition as that of the N. cochlearis after the removal of the cochlea. Only then there are no longer any cells between the lesion of the nerve and the central nerve-system. It is even questionable whether it be possible, in experimenting on rabbits, to section the N. vestibularis centralward from the ganglion vestibulare without injuring the medulla oblongata and the N. facialis is mostly injured in that case.

It is therefore rather easy to obtain isolated atrophy of the N. cochlearis. On the contrary it is impossible to obtain atrophy of the N. vestibularis, without injuring likewise the N. cochlearis. As soon as the vestibulum is removed, necessarily the N. cochlearis is damaged too.

In the course of the operation neither the nerves, running in the interior of the petrous bone, nor the N. facialis, nor the chorda tympani, become visible.

c. The sectioning of the corpus trapezoides.

Cochlea, vestibulum with ampullae having been removed and the trunk of the N. octavus lying before us, it is very easy, guided along by this trunk, to divide with a lanciform knife the dura mater and to damage the medulla oblongata.

This lesion of the medulla oblongata is produced invariably dorsal from the ramus spinalis N. V, and if due care be taken that the knife does not penetrate too far, the corpus trapezoides is cut from the nucleus ventralis N. VIII, without many complications. The knife enters the oblongata at the origin of the N. VIII, cuts generally the dorsal part of the ramus spinalis N. V., is introduced between it and the oval area of the corpus restiforme in the so-called interior part of this latter, and terminates more or less far dorsalward in this interior part (the corpus juxta-restiforme).

The destruction caused by the knife may be controlled post mortem when the medulla oblongata is examined in serial sections.

By this section the corpus trapezoides, at least in its distal portion is divided from the nucleus ventralis N. VIII dorsal (lateral) from the ramus spinalis N. V.

There is still another manner of sectioning the corpus trapezoides, without destroying the peripherical organs of the N. VIII and the octavus-roots. The bulla ossea having been opened, the promontory is left undamaged, but medio-ventral from the promontory, passing through the cavity (or next to it) that contains the M. stapedius (this latter being removed if necessary), the posterior wall of the bulla is punctured, and the glossy N. trigeminus does appear. Directing the knife by the aid of this nerve, the dura mater is cleft and the medulla oblongata is damaged, i. e. the corpus trapezoides medial from the ramus spinalis N. V. This lesion however is of less importance than the former operation.

d. The section at the dorsal octavus-tract. (VON MONAKOW's stria medullaris).

Next to the operations at the peripherical organs of the eighth cerebral nerve and to the section of the ventral systems of the root-fibres of this nerve, it may offer great importance to section their dorsal systems.

The section of the dorsal octavus-tracts, simple though it may be, must be attempted from the fourth ventricle. In operating on rabbits, under strict asepsis, it does not offer any great difficulty to lay bare in the mid-dorsal line the membrana atlantico-occipitalis, without any haemorrhage. This membrane being cleft, a view

is obtained of the interior of the 4th ventricle, bordered by the inferior peduncle of the cerebellum. On both sides the interior part of the corpus restiforme appears as protruding edges, that may be easily recognized. The interior part of the corpus restiforme may now be incised and with the corpus restiforme the stria acustica may be sectioned transversally at different places.

This may be done:

1ly more distally. The thin knife is introduced through the most lateral portion of the dorsal octavus-nucleus into the interior part of the corpus restiforme, cutting this in latero-distal direction, passing farther through the oval area of the corpus restiforme and the nucleus ventralis N. VIII and reaching the surface of the oblongata dorsal from the place of entry of the octavus-roots. If the operation is well done, the tuberculum acusticum and the nucleus ventralis N. VIII are separated from the medulla, the oval area of the corpus restiforme is sectioned but the two roots of the nervus octavus are often very slightly injured.

If the attempt be made imperfectly, the point of the knife remains within the juxtarestiform body.

2ly more proximally. Again the knife is introduced in lateral direction in the most lateral portion of the dorsal octavus-nucleus; but now it is turned somewhat more cranial, and is cleaving more cranialward the ped. cerebelli superior, reaching the lateral surface of the brain, a little above the pons in the lateral fillet.

Whilst by the former operation through the pedunculus cerebelli inferior, the stria medullaris was cut transversally in its more distal part, the cranial rest of the stria did remain uninjured.

This cranial rest, to be sure, is cut transversally in the second operation. But in the mean time this latter involves the section of the pedunculus cerebelli superior.

Both these operations are likewise necessary, in order to obtain orientation about the course of the secundary octavus-tracts. They must be repeated several times before their influence upon secundary degeneration may produce a uniform result.

2. *The acute motor-troubles arising after one-sided removal of the labyrinth.*

When, operating on rabbits in the above described manner, the cavum tympani has been opened, the bony wall of the promontorium removed, the spiral convolutions of the (thus opened) cochlea destroyed, the vestibulum having next been entered into and sac-

culus, utriculus and ampullae extracted (whilst, if necessary, the N. octavus has been sectioned at the interior auditory meatus), — then the one-sided destruction of the peripherical organ of this nerve is followed by tempestuous troubles of motility.

The eye on that side is jerked violently towards the nasal canthus (laterally) and remains fixed there, turned downward (ventrally) as far as possible. The slit of the eye is exceedingly narrowed, though there is protrusio bulbi.

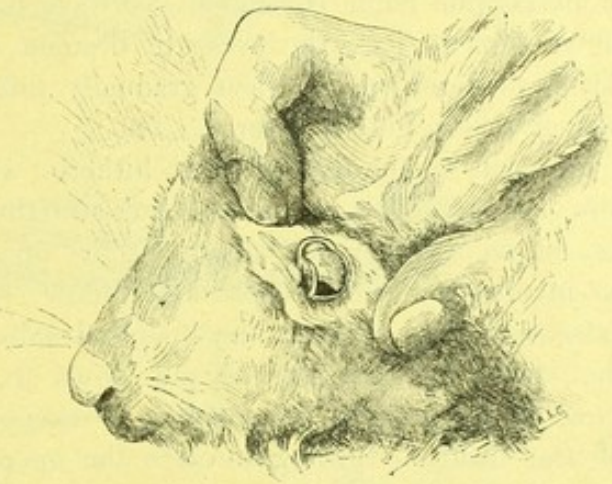

Fig. 6.

The opposite eye on the contrary is drawn towards the middorsal line, deviating likewise a little in nasal direction, the lateral edge of the sclera becoming visible, the more so because the eye protrudes from the widely opened eye-slit.

This characteristic position of the eyes, appearing directly after the operation, is maintained at its acme for a few moments only. After a few moments it is some what reduced, and during the reduction often the eyes are continually brought back into their first position by jerks, resembling those of nystagmus. But after some minutes the characteristic position of the eyes, not so intense however as immediately after the operation, has become permanent and continues for weeks, months or sometimes even years after the operation with small loss of intensity.



Fig. 7.

Position of the eyes in a rabbit.
Three weeks after the removal of the left labyrinth.

A glance on the subjoined photo may show better than any description, how the characteristic attitude of the eyes (reaching its acme again when the head is kept straight) presents itself, the head being put in a straight position, three weeks after the operation. (See fig. 6 and fig. 7).

As it is said already, the attitude of the eyes is slowly ameliorating, and when it has been somewhat reduced, occasional shocks of nystagmus recur continually, always in this manner that by an active violent jerk the eyes are brought again into their maximal deviation, and return then gradually into a yet evident deviation but of a less intense degree.

As soon as the animal (that hitherto was bound, and was therefore constrained to keep its head straight) has been loosened and set on its legs, or laid down on the operated side, a new tempest of involuntary movements does follow. The head is turned with extreme vigour towards the operated side, in such a manner that the cheek on that side is put down to the ground. Sometimes even the turning of the head is so excessive, that the dorsal part of the head — turning towards the operated side — touches the ground. Simultaneously with this movement of the head, the upper limb opposite to the operated side is extended and abduced as far as possible from the body. With this limb the animal is scratching the ground, as if trying to support itself by its leg in order to prevent further turning.

Generally however it does not succeed in this.

The animal is beating the air desperately with the foreleg opposite to the amoved labyrinth. This foreleg, still abduced and extended as far as possible, rises and rises (fig. 8 A--C), until at last it has got into a vertical stand. The dorsal part of the head touches the ground, at this moment, for the turning upward and the lifting of the opposite shoulder, subsequent to the turning of the head, is the cause of the motion of the foreleg. As soon as the foreleg has crossed the vertical level, another movement appears. The animal cannot maintain the hind-part of the body in the habitual attitude, now that the fore-part of the body is so far turned. It has done so, until the fore-leg had reached the vertical level, (or until the dorsal part of the head had touched the ground), but the turning of the head still continues. Now at once the animal subverts the hind-part of the body and also turns it to the operated side.

Doing so — the animal has then rolled round its longitudinal axis in the direction of the operated side, and it is not

rare to see this movement repeated several times. (See fig. 8).

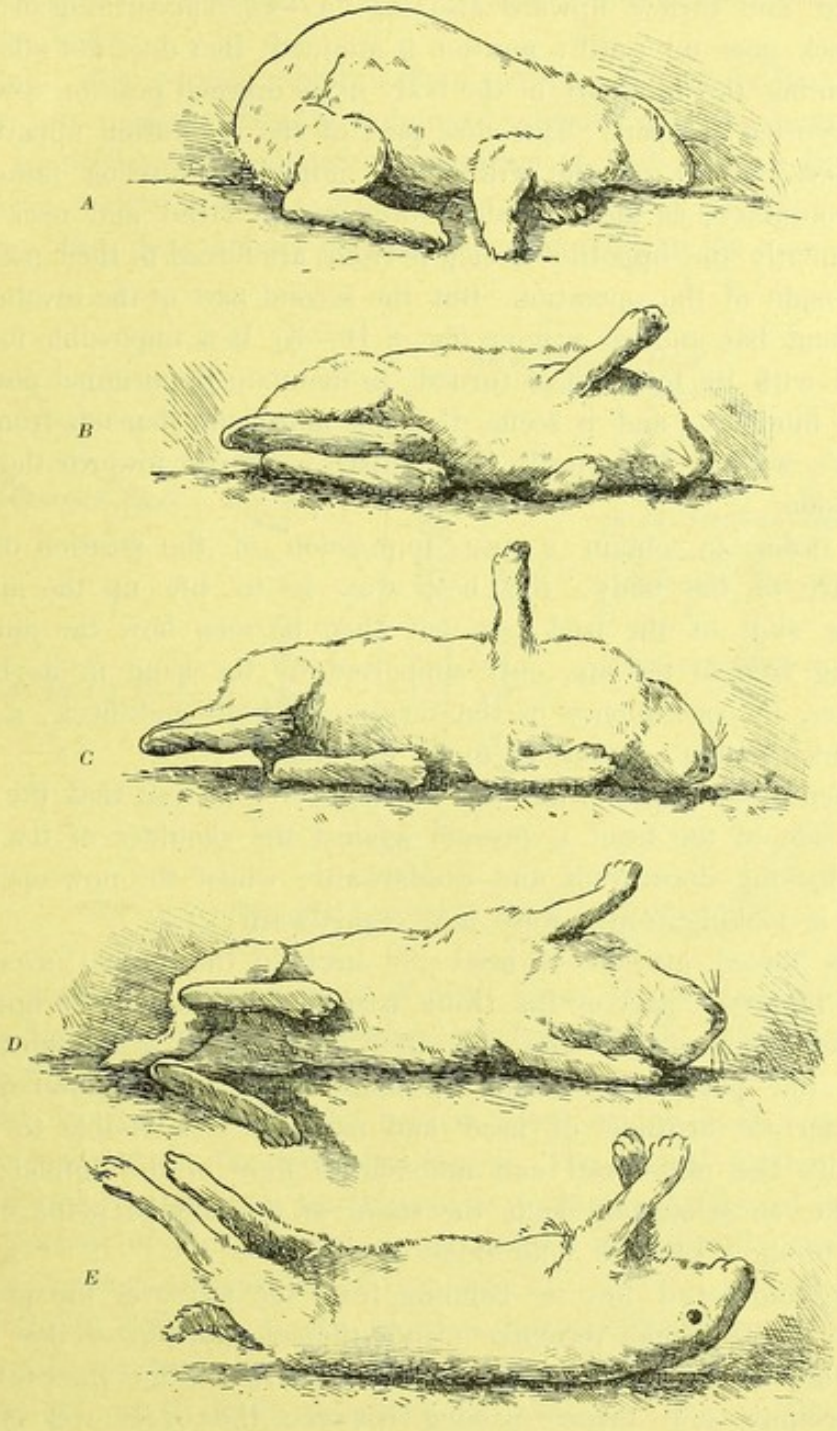

Fig. 8.

Different attitudes during the revolutions of a rabbit, after removal of the left labyrinth.

Every revolution is accomplished in two tempo's, or rather it may be decomposed into two semi-revolutions. By the first of these, head,

and neck are turned towards the operated side, the opposite shoulder is turned upward, subsequently the crossed fore-leg is extended and abduced and turned upward also (fig. A—C). The turning of head and neck goes on until a position is attained, that does not allow of maintaining the hindpart of the body in its original position towards the distorted forepart. This first part of the revolution apparently does not depend on the will of the animal, but seems rather to be involuntary, as an inevitable automatism. Head and neck (and subsequently the opposite foreleg is rised) are forced in their position to the side of the operation. But the second part of the revolution-movement has another origine (fig. 8 D—E). It is impossible for the animal with its fore-part so turned, to maintain the original position of the hindpart, and it seems that this movement depends from the animal's willing. Voluntarily the hindpart is thrown towards the operated side.

In order to obtain a just impression of the position of the fore-part of the body, the best way is to lift up the animal by the skin of the back. It may then be seen how the animal, hanging free in the air, only supported by the hand in its back, assumes, in consequence of the turning of head and neck, a very peculiar position, not easily to be described.

When observing it from the ventral side, we see that the operated side of the head is pressed against the shoulder of the same side, looking dorsalward and caudalward, whilst the now operated cheek is looking frontal-ward and cranialward.

This forced attitude of head and neck of the animal (even the upper (anterior) part of the trunk participating in it) is originated as suddenly as that of the eyes after the removal of the labyrinth.

To the purpose of giving a more minute description of the characteristic attitude of head and neck, it is advisable to draw mentally the mid-dorsal and mid-ventral lines of the animal, and to take as a starting-point the stand of the medial plane of the body brought through both lines.

The mid-dorsal line is running from the tail over the processi spinosi of the chest-vertebrae (caudo-thoracic portion of this line), over those of the neck-vertebrae (cervical portion of this line) towards the occiput, and thence passing between the eyes, over sagittal suture and dorsum nasi towards the middle of the upperlip (cranial part of this line).

The mid-ventral line goes from the middle of the underlip over the chin towards the larynx (cranial part of the mid-ventral line), thence it descends opposite the trachea to the manubrium sterni

(cervical part), and reaches the symphysis along the linea alba over the umbilic (caudo-thoracic part). The plane brought between both lines, divides the animal into two halves, and is the median plane of the body.

Now, if a normal rabbit is kept swinging free above the ground-plane, its median plane is standing vertically on this ground-plane. The caudo-thoracic and cervical portions of both median lines are running vertically to the ground-plane and are one another's prolongation. But their cranial portions, though lying in the same median

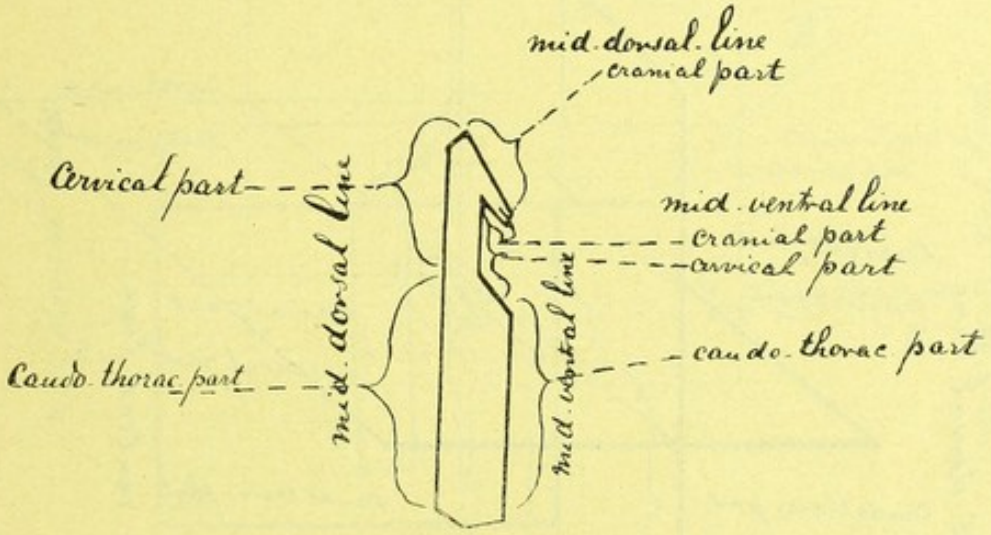

Fig. 9.

Scheme of the medial plane from a normal rabbit, swinging free above a horizontal plane. Seen laterally from the right side.

plane with the other portions of both lines, are forming with these latter an angle of 90° or even more. Consequently, when viewed in front the median part forms one line.

But viewed laterally, the median plane of the body appears as is represented in the adjoining figure. The cranial portion of the mid-dorsal line turning caudalward is looking ventralward, the cranial portion of the mid-ventral line turned caudalward, nearly touching the cervical portion of that line.

Entirely different is the position assumed by the rabbit whose labyrinth has been removed on one side, when kept swinging free in the air, as is shown in photo fig. 13.

In the caudo-thoracic portion both lines are still running straight upward. The median plane through both lines is standing vertically on the ground-plane, in the same way as with the normal rabbit.

But at the 7th cervical vertebra, in most cases even at more distal vertebrae, another position commences. The cervical portion

sometimes even also the thoraco-cervical portion of the median plane is turning towards the operated side.

Consequently the cervical portion of the median plane of the body is no longer lying in the prolongation of the caudo-thoracic portion of this plane. It is forming with this latter an angle of 90°, and runs therefore parallel again to the ground-plane, on

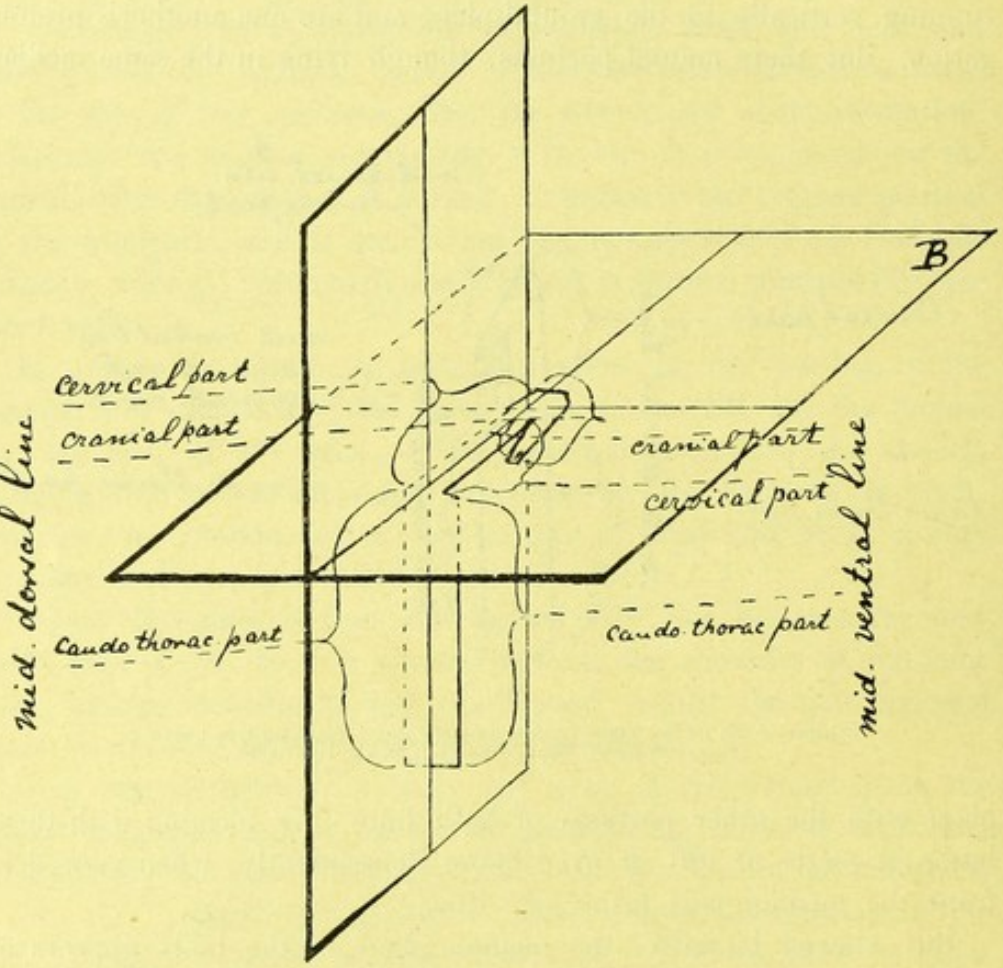

Fig. 10.

Scheme of the medial plane, if only its cervical part was turned 90°, and if its cranial part had retained its original position relative to its cervical part. Seen from the right side.

which the caudo-thoracic portion of the median plane of the body is standing vertically.

In the meantime however the cranial portion of the median plane of the body has also taken a turning, as it would not maintain its original position towards the cervical portion because of the changed position, assumed by this latter towards the caudo-thoracic portion. If its original position had been maintained, then the cranial and cervical portions of the median plan of the body would still form one plane, standing vertically on its thoraco-

caudal portion, but now parallel to the groundplane in a level B. The position would then be conform to the scheme, represented in fig. 10.

But such is not the actual position of the head. (See fig. 13). Neither is the change in position, suffered by the cranial portion of the median plane towards its cervical portion a simple moving parallel to itself, in such a manner that (as in fig. 11) the cranial portion, though standing vertically on the cervical portion, runs

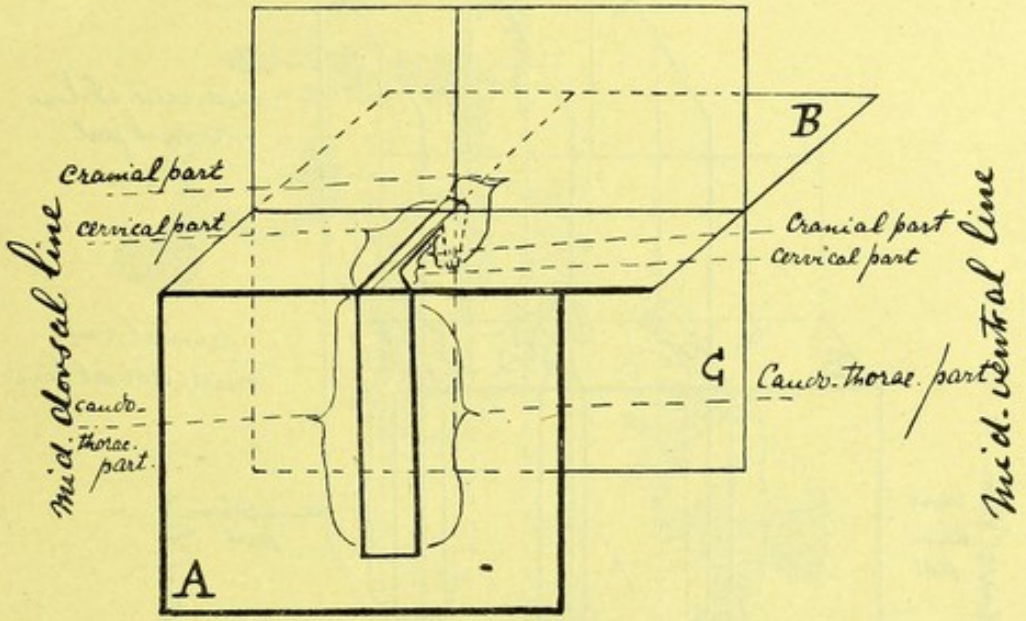

Fig. 11.

Scheme of the medial plane, if only its cervical part was turned 90° and if its craniel part had retained its original position relative to its caudo-thoracic part. Seen from the right side.

parallel to the thoraco-caudal portion that has retained its original position in a plane C, parallel to A, where the latter is found. This again is not the actual position of the head. (See fig. 13).

The cranial portion of the medial plane of the body has made a turning on its cervical portion and this movement has been made towards the operated side. The cranial portion is forming an angle of 90° or more with the cervical portion, and consequently a position of the head is shown, as represented in the scheme of fig. 12.

The caudo-thoracic portion of the median plane is still lying in A. The cervical portion is standing in a plane B perpendicular to A. The cranial portion of the median plane is lying in a plane C, standing vertically both on A and on B. Within this plane it may assume different positions, as shown in α, β and γ.

Rarely however positions, surpassing that which is represented in γ are found, because in that case the rolling round the horizontal axis becomes necessary.

Of course a scheme as represented here, has no further significance than that it may be of some aid to get a prompt orientation in the position of the operated animal. In the photo (fig. 13) the forced attitude, characteristic for the head and neck is represented, as shown when the animal is kept swinging free in the

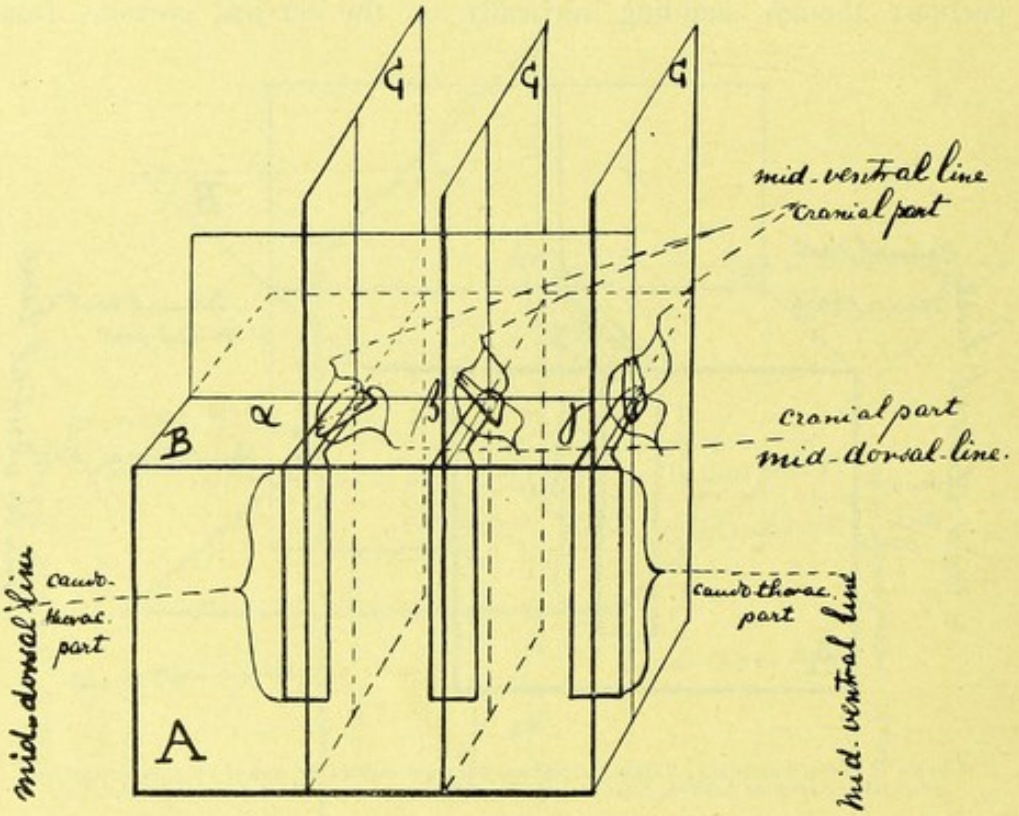

Fig. 12

Scheme of the medial plane from a rabbit, swinging free above a horizontal plane after removal of the left labyrinth. The cervical part is turned 90° upon the caudothoracic part, and the cranial part has turned upon the cervical in α 9°, in β 135°, in γ 180. Seen laterally from the right side.

air. Neither does this position change when the animal is sitting down on the ground. A comparison between fig. 13 and the position, designed in fig. 14, A—B, will easily enable us to form a just estinate of the attitude of head and neck, with the aid of the scheme and its description. More-over the conformity between the characteristic position of head and neck in rabbits and that shown by pigeons (see fig. 14, C) is so striking, that it may be presumed a similar mechanism is working in both. These latter figures however have been taken from animals, showing no longer any rollings around their longitudinal axis towards the operated side, 3 or 4 weeks after the operation.

For, besides the forced position of head and neck, the position

of the extremities directly after the operation is likewise characteristic.

When the animal is kept swinging free, the extremities on the operated side are hanging helplessly down, those of the opposite side are contracted. (See fig. 13).

Special description must be given of the opposite upper extre-

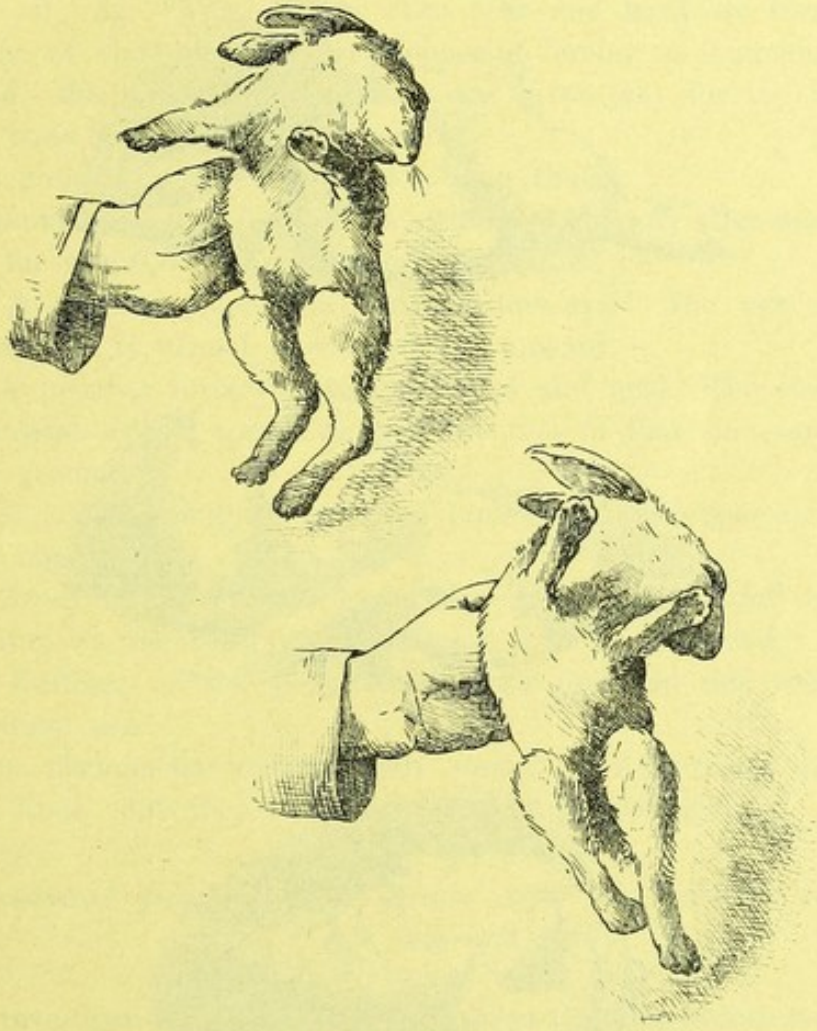

Fig. 13.

Copy of a photo from a rabbit swinging free above horizontal plane after removal of the left labyrinth.

mity, because it assumes a very peculiar position, hyper-extended and abduced from the body and in the meantime hypertonic.

During the first days after the operation the animal is beating and scratching the ground with this leg, in order to prevent the revolutions (fig. 8 A—D). Even in a period, when the turning of head and neck has already been much reduced, this leg is still kept extendend far from the body by the animal, partly because the shoulder is lifted up, perhaps also to compensate the forced

attitude of head and neck and to prevent rolling (fig. 14, A—B and fig. 15 A).

For the extremities on the operated side remain inactive during

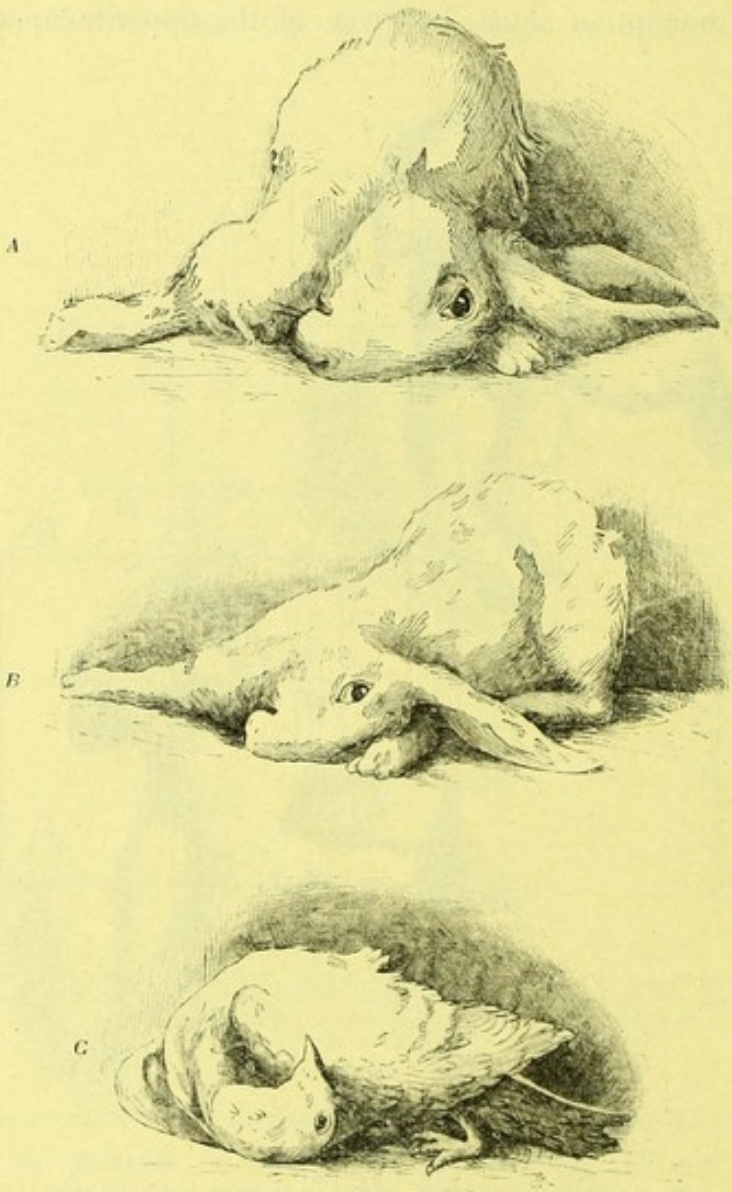

Fig. 14.

Copies of photo's from rabbits and from a pigeon after removal of the left (rabbits) and of the right (pigeon) labyrinth.

A. Rabbit's position a year after the removal of the left labyrinth.
B. Rabbit's position three weeks after the same operation.
C Pigeon's position three weeks after the removal of the right labyrinth.

the revolution round the longitudinal axis. They are lax, and the animal uses them far less than the opposite extremities, that are continually kicking. The upper extremity has been shoven under the body because of its laxity. It cannot bear the burden of the

body and one of the phenomena, characterising the typical position of the animal after the operation, is that this leg, having been shoven involuntarily foreward and outward, gets under the head and supports this latter (see fig. 14).

In this way the typical position of the rabbit after one-sided removal of the labyrinth, reproduced as it is by the photo's fig. 14 A—B, fig. 15 A, occurs. The neck and head are turned to the side of the operation, the opposite foreleg is extended and abduced, the equilateral, relaxed, has given way for the burden of the body and is shoven forward.

This position is permanent for a long time.

A summary of the phenomena, observed directly after the removal of the labyrinth, runs therefore as follows:

1°. A peculiar forced attitude of the eyes. The eye on the operated side is turned downward and inward.

2°. A peculiar forced attitude of head and neck. The cheek on the operated side is turned in the direction of that side, and laid on the ground.

3°. A peculiar abduced-extended position of the upper extremity on the opposite side.

4°. Atony of the extremities on the operated side, the opposite extremities on the contrary being more or less contracted.

5°. Rollings of the body towards the operated side round its longitudinal axis.

These phenomena are gradually losing their intensity up to a certain limit, but they never are entirely compensated.

3. *Permanent disturbances of motion after the one-sided removal of the labyrinth.*

An investigation of the further course of the tempestuous motions, following directly on the removal of the labyrinth on one side, is of course indicated. Not only it is an interesting question whether they are reduced at all afterwards, and if so in what measure, but besides it is of great importance to investigate, to which extent all these phenomena may be considered to be independent from one another, or if we find this is not allowable, in what manner they may be connected together.

We will therefore commence with:

a. The rolling of the body around its longitudinal axis in the direction of the operated side.

I have demonstrated already, that neck and head, shortly after

the operation, have been turned round in such a manner that for a normal animal it becomes impossible to remain seated on the ground with its lower extremities, its forepart having assumed a forced attitude, exceeding a certain degree. All the more so, because of the fact that this position does not retain permanently the same intensity, but is at intervals suddenly intensified.

If the rabbit, like the pigeon, did possess a long and easily movable neck, that could be laid down on the ground and find a support there, whilst the head was being turned upward, then the turning might perhaps, as it is in pigeons, still be checked, and the turning of the head only, might occur until 270° or even 360°.

Now this is impossible in rabbits. Therefore the animals roll. This rolling of the body round its longitudinal axis is therefore always accomplished in two tempo's. The first automatic tempo of the rolling is the same as it is observed in pigeons. The head is thrown vigorously towards the operated side, and turned so far, that its dorsal cranial plane touches the ground. The head then turns 180°. As is described already, at this moment the upper extremity of the opposite side, drawn by the movement of head and neck, is extended and abduced as far as possible from the body, and by scratching the ground tries to prevent a further turning of the head. But if once the head has been turned further, if its dorsal plane touches the ground, if the turning surpasses 180°, the aid of the upper extremity becomes useless. The extremity is itself turned upward, and at the moment when it does arrive in the vertical plane, (the turning of the head then reaches 270°) the second tempo of the rolling sets in with a vigorous jerk, and the hind part of the body is thrown round by the animal by an energetic voluntary movement. The fact, that the rolling of the body round its longitudinal axis is always preceded by a very intense turning of head and neck, supports the probability that the mechanism of the revolution may be a consequence of the automatic initial turning of neck and head.

After a few days however the rolling ceases. Then follows a period after the operation, wherein the rolling may be at any moment provoked again by laying down the animal on its non-operated side. The head is then jerked violently towards the operated side and the revolution follows. After a week perhaps this also ceases. It may still occur sporadically in the second week after the operation, but after three or four weeks the animal does no longer roll round its axis. Head and neck still are turned, but this characteristic position has no longer the same intensity it

had shortly after the operation. The turning of head and neck being thus gradually reduced, and at the same time the number of fits diminishing, in which an acute and excessive turning of the head called forth in periodical returns the acme, the rollings of the animal have ceased likewise and do not return. A permanent deviation of the head and neck of the animal remains, and in the rabbit this is never entirely compensated. The turning of the head on the cervical part of the body, towards the operated side, does again allow the animal to be sitting on its four legs.

The fact, that the revolutions cease, when the deviation of the anterior part of the body is corrected so far that sitting is made possible again, offers a strong argument for the presumption: that the revolution is quite dependent on the intensity of the turning of neck and head.

Still there is another, very important argument for this opinion. The animal, though rolling with the utmost violence, can be released immediately from these revolutions, if the other labyrinth is also removed. By this second operation the turned position of head and neck has likewise ceased as by enchantment, and also has the deviation of the eyes disappeared in consequence of it.

As soon as by an operation, removing both labyrinths, the innervation-defect has become nearly equal on both sides, the turning of head and neck does not appear, neither the revolution round the longitudinal axis of the body.

One of the phenomena described above, viz. the revolution round the longitudinal axis of the body, may therefore be considered as a consequence of the turning of head and neck; another, viz. the hyperextended-abduced position of the opposite fore-leg, may be necessitated partly by the changed upward position of the opposite shoulder, on the operated side the shoulder being turned downward.

Both phenomena are therefore dependent on the turning of head and neck, this latter may be said to belong to the primary disturbances of motion. Rolling and the characteristic position of the foreleg are secundary to it.

Not so easy it is, to elucidate if there is connection between the position of the head and neck and the deviation of the eyes.

b. Turning of head and neck and the deviation of the eyes.

After a complete removal of the labyrinth, head and neck are never to regain their original position. All phenomena that did appear directly after the operation, continue to exist in a lesser degree. The neck is bent on the trunk, the head is generally turned so far on the neck, that the cheek on the operated side is looking

towards the ground, resting on the atonic foreleg of that side which has been shoven forward, whilst the opposite fore-leg is hyper-extended and abduced. Only the revolutions have ceased.

With its twisted head however the animal continues to provide in all its habitual wants. It is eating, exerting coition, fighting with other animals, and does not give the impression of being dizzy, or of turning its head in order to compensate a sensation of dizziness.

If eventually in periods of rest, when left entirely to itself the animal is lifting its head, the orbital fissure on the operated side is opened somewhat wider, and the eye is no longer turned so far downward in the nasal corner as it was directly after the operation. The eye on the opposite side is likewise turned less far dorsalward.

When an animal has got into this stage, and is able again so sit on its four legs, we can try to put the head straight. A vigorous exertion is needed to do this. The animal offers violent resistance, but with some difficulty it may be done. If the head, after having been kept straight in this manner, is suddenly left free, it falls back with a vigorous jerk. It may even occur, that a single revolution reappears by this experiment.

Of even more importance is the fact, that with an animal in this stage, the deviation of the eyes, having also diminished somewhat already, at once become maximal, when the head is put straight. This position of the eyes lasts as long as the head is kept straight, sometimes the eyes relaxate, and in that case they are brought back into maximal deviation by a sudden shock, nystagmus is seen. These strokes of nystagmus often succeed one another with regular intervals.

The deviation of the eyes is therefore doubtlessly connected with the turned position of the head, in such a manner that the head follows the position of the eyes, this latter showing itself more plainly, if the head is prevented from following the eyes.

Evidently the eye on the operated side has assumed the most evident deviation, the opposite eye rather following the former. The eye on the operated side (see fig. 6 and 7) is drawn downward and nasalward. The head is following exactly the movements of this eye.

The neck being turned into the frontal plane, and the head being turned into a plane standing vertically on the former, the head follows the direction indicated by the turning of the eye on the operated side. Therefore the impression seems justified, that the involuntarily assumed position of neck and head is a movement made in compensation to the curious turning of the eye on the operated side.

Of course it would be very important if the deviation of the eye could be counterfeited experimentally.

The analysis of the opposite eye shows the following phenomena:

a. small orbital fissure.

b. protrusio bulbi.

c. maximal deviation in a direction downward (ventral) and in the nasal canthus (lateral) with a slight rolling of the eye.

All these phenomena may be the result of phenomena of paralysis, whereas the antagonistic innervation has been preserved or is even increased. In that case the paralytic phenomena must be:

a. paralysis of the m. levator palpebrae superioris.

b. paresis of several muscles of the eye with secundary exophthalmus paralyticus.

c. paralysis of the m. rectus superior-drawing the eye frontalward-, paresis of the m. rectus externus-drawing the eye lateralward-, paresis of the m. obliquus superior-drawing the eye downward and rolling it.

In connection with these paralytic phenomena we must admit a strong antagonistic action, exerted by the m. rectus internus and the m. obliquus inferior to develop the deviation of the eye.

Basing on this analysis, I now sectioned in rabbits isolated or in combination the m. rectus superior, the m. rectus externus and the m. trochlearis — all this being done easily by one single conjunctival lesion — and extirpated pieces from these three muscles, each piece being long at least 1 c.M.

After this operation however there is never observed any trace of a deviation of the operated eye. Perhaps the muscles are not rendered completely inactive, perhaps the antagonistic hyper-innervation is not excited, probable because under these conditions such an innervation would not serve to any purpose.

To conclude, I never did succeed in provoking any evident deviation of the bulbus by means of sectioning the bulbus-muscles, far less a position that might in any degree be compared to that, observed after destruction of the labyrinth.

It remained therefore impossible to decide whether an experimental deviation of the eyes was followed by a similar position of head and neck in the same direction, because such a position of the eyes could not be provoked experimentally.

Still the argument remains valid, that head and eyes compensate one another mutually by the deviations they assume, and this supports the opinion that the turning of head and neck may be a corrective for the position of the eyes.

A farther support to this opinion is given by the fact that both the deviation of neck and head, and that of the eyes, cease directly after the removal of the second labyrinth.

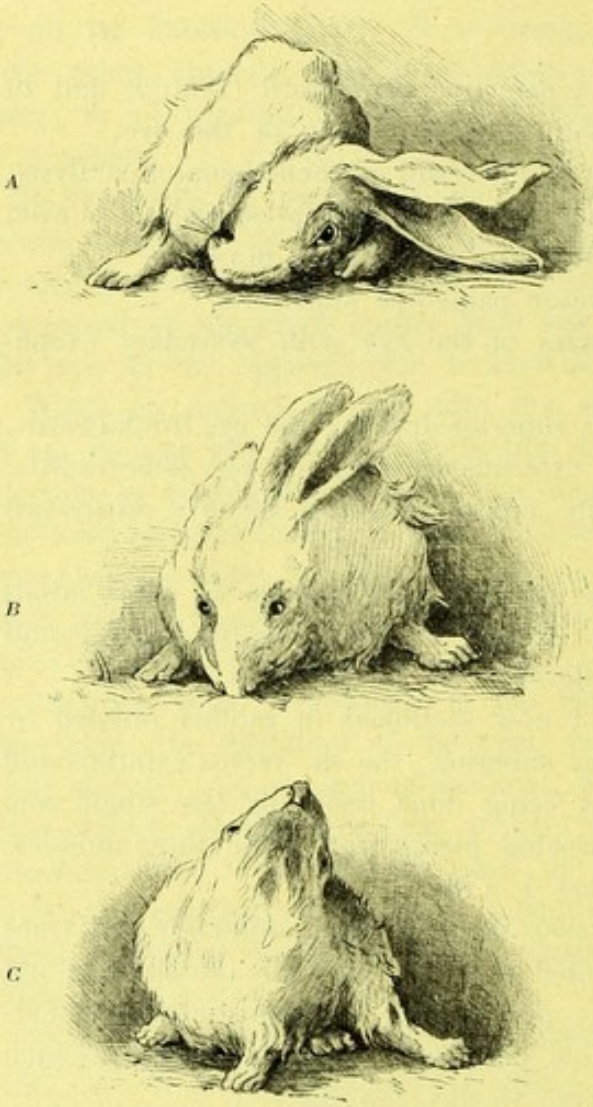

Fig. 15.

Copies of photo's.
A. A rabbit after removal of the left labyrinth.
B. The same rabbit after removal of both labyrinths.
C. The same rabbit staggering.

4. *The disturbances of motion in rabbits after the extirpation of the labyrinth on both sides.*

No result of any operation can be more striking than the result, following immediately on the removal of the second labyrinth, when this operation is made some weeks or months after the removal of the first labyrinth.

The animal, before being operated, bears its head obliquely, it presents the involuntarily assumed position of the eyes, the abduced-extended position of the opposite fore-leg, the atony of the homolateral extremities, but after the second operation it has become quite another animal (see fig. 15).

The oblique position of the head — the turning of head and neck — is suddenly changed. The animal bears its head straight. But in order to do this, its forelegs are widely extended (see fig. 15 B—C). The head is unsteady. It is hanging downward (see fig. 15 B).

Besides now and then fits occur, in which the head is thrown abruptly backward. The animal then staggers (see fig. 15 C).

The eyes are standing straight in the head. The orbital fissure

on the opposite side is narrowed, that on the operated side is widened by the second operation. There is no longer any deviation of the eyes (see fig. 16 A before and B after the second operation). On both sides however there is distinctly protusio bulbi, and the movements of the eyes are performed by strokes of nystagmus.

Peculiarly striking is the position of the back, it presents no longer a convex curve, as in the normal animal, on the contrary it is sunken in, and cannot assume the former rounded position again (see fig. 17).

Only with difficulty the animal is able to maintain itself on its four legs, that are placed in a singular position under the body.

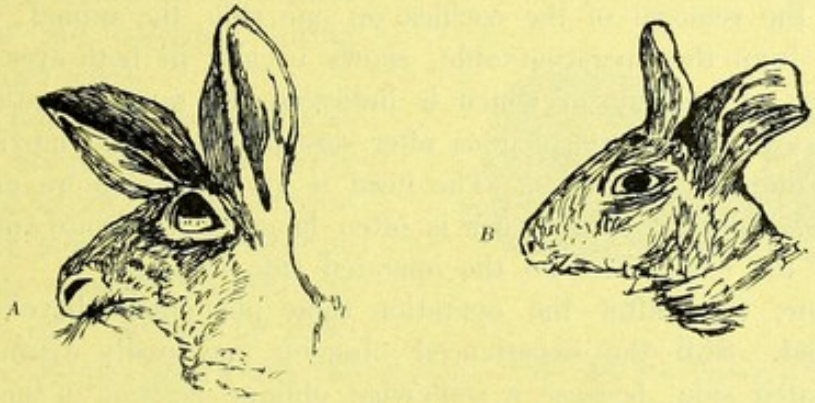

Fig. 16.

A. Position of the contra-lateral (left) eye after removal of the right labyrinths.
B. Position of this eye after removal of both labyrinths.

This latter is sunken in. At every moment it is slipping and there exists a great laxity of all extremities. The rabbit does no longer jump, it is creeping and faltering, and moves difficultly. Still it does not roll. In the lower extremities the atony is very strong, likewise in the fore-legs. The abduced-extended position has vanished. In order to maintain its equilibrium, the animal keeps its forelegs wide-extended. It does no longer react on sound-impresssions, and I could never keep them alive for more than two or three weeks after the second operation.

The results of the removal of the labyrinth on both sides are apt to support the opinion, that the symptoms of one-sided extirpation — the turning of head and neck and the deviation of the eyes-are connected symptoms, and that the rollings around the longitudinal axis are dependent on the turning of head and neck. But above all the results of the operation on both sides seem to prove that after the removal of the labvrinth on one side a one-sided spasm prevails, caused by destruction of innervations on the operated

side. If now these innervations are destroyed likewise on the opposite side, as is the case after the second operation, there is no longer any reason for the prevailing of tonic spasms on that side. The normal position is regained. But all movements are feebler, more unsteady, because they are supported by a reduced innervation. Head, neck and eyes seem therefore to be recovered, the extremities are atonic. The atony of the extremities exists on both sides, it is strongest in the upper extremities, but is very marked also in the lower ones.

5. *The results of destruction of the cochlea.*

After the removal of the cochlea on one side, the animal, when loosened from the operation-table, shows usually in both eyes some nystagmus, by means of which is indicated the same deviation of the eyes that is so conspicuous after destruction of the labyrinth, and in the same direction. The head is also poised more or less obliquely. The homo-lateral ear is often hanging downward and the atony of the extremities on the operated side is plain.

A short time after the operation these phenomena have much diminished. Still the experienced observer may easily distinguish the operated side, because a somewhat oblique position of the head is permanent, as is likewise a propensity to nystagmus or else to a deviation of the eyes, and also is the atony of the extremities on that side.

But all these phenomena are shown in a far lesser degree than after destruction of the labyrinth. It occurs rather often, that one or two weeks after the operation the animal begins to roll, whilst the involuntarily assumed position of the eyes, the turning of head and neck, and the atony of the lower extremities increase. This proves, that the discharge of endolymph — that will nearly always complicate the removal of the cochlea — has brought a complication by altering the contents of the vestibulum. In this manner the same complex of phenomena is brought about that appears after one-sided removal of the labyrinth.

The removal of both cochleae has the following effects:

1. The animal does no longer react on the sound-impressions.

2. It walks with wide-stretched legs, head and ears are hanging down, the back is sunken in. The head, though unsteady, is less unsteady than after removal of the labyrinth. The eyes are standing straight, but nystagmus is easily provoked by moving the head. Briefly, both after one-sided and after double-sided extir-

pation of the cochlea, all phenomena are shown that result from extirpation of the labyrinth, but they are not so intense and are much better restored.

In the first days after the removal of the cochlea on both sides, the animal is hardly to be distinguished from one, in which both labyrinths have been removed. Trough in the former case much more is restored, I could not find a great difference in the bearing of rabbits after double-sided removal either of the cochlea or of the labyrinth during the first week.

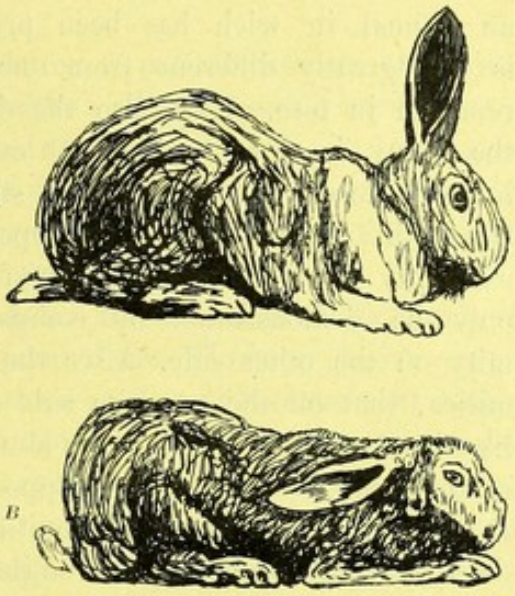

Fig. 17.

A. Position of a non-operated rabbit.
B. Position of this rabbit after removal of both cochleae.

In both cases sound-impressions are perceived very badly or not at all. The disturbances of motion resulting from double removal of the cochlea offer at first no difference at all; afterwards the difference is great, for two or three weeks afterwards, the atonic symptoms recover. Only the double operation is dangerous and badly supported. The difference seems to be a difference in degree. All that becomes atonic after extirpation of the labyrinth, becomes so likewise after extirpation of the cochlea. One-sided cochlea-operations are followed by fast recovery. Rolling never is obtained.

5. *The effects of the section of the dorsal secundary tracts of the N. octavus.*

As soon as in a rabbit the section in the IVth ventricle, described in the preceding chapter is produced, great care should be taken to keep the head fixed, in order to prevent the animal from damaging itself. For the lateral eye is jerked violently towards the lower nasal canthus and the opposite eye towards the dorsal (upper) canthus, the head turning at the same time with equal violence.

The animal after being loosened from the operation-table, rolls, the opposite upper extremity is hyper-abduced and extended and the animal is kicking continually with this leg. The lateral fore-leg,

and both lower extremities are atonic in the highest degree.

Gradually the rolling ceases. Permanently however the animal bears its head obliquely, the eyes retain their deviated position, changing with the position of the head. If this latter is put straight, the deviation of the eyes attains again its maximal degree. Briefly, an animal in wich has been produced a succesful dorsal section is not greatly different from one in wich the labyrinth has been removed in toto. Here also the difference is only in degree. Yet the atony is more evident. It exists on both sides and especially in both lower extremities it is stronger than after removal of the labyrinth. After this latter operation the atony of the lower extremity on the operated side often has to be sought for. It can only be demonstrated by comparing it carefully with the extremity on the other side. After the dorsal section both lower extremities, that on the opposite side also, are hanging helplessly down like inert masses. Though the atony is strongest in the extremities of the operated side, in the opposite legs it is still very important. It prevails in the lower extremities, so much that during the first days after the operation we might believe in paralysis of the hind-part of the body. But if the animal is left to itself, we find that it draws its hindlegs again under the body, though with some difficulty. As soon as it is frightened and changes its place, the lax lower extremities remain behind.

This appears to me being the cause that the rolling of the animal is performed with less vigour than after removal of the labyrinth. Generally it is confined to one single revolution, whereas after extirpation of the labyrinth several revolutions may take place, and do so as a rule.

This also seems the reason of a symptom, that rabbits present sometimes as a permanent symptom after the sectioning of the dorsal tracts.

It is the motion of the animal on the outline of a circle the centre of which is found on the operated side. In rabbits with one-sided removal of the labyrinth this manege-gait is not observed. I believe the cause from this fact to be that after the latter operation the atony in both lower extremities is never so much marked, that the hind-part of the body does no longer follow the fore-part of it. The fore-part during the gait, is deviating toward the side of the operation. This is also the case after the removal of the labyrinth. But after the sectioning of the dorsal secundary tract of the N. VIII, the weakness of the lower extremities is the cause that they remain on their place (the animal then moves as the

hand of a watch-work) or proceed but very little (and in such a case the animal moves with a manege-gait).

6. *A comparison between pigeons after one-sided removal of the labyrinth and rabbits after the same operation.*

In many respects the accordance is perfect between the disturbances of motion observed in rabbits after one-sided extirpation of the labyrinth, and those found in pigeons. Those in pigeons have been so carefully described by EWALD, that it is not necessary to describe them again, for I have nothing to add to the magistral picture, which that author has drawn.

Both animals present the peculiar turning of neck and head, the atony of the extremities at the operated side. However, there remains also an essential difference between the disturbances of motion observed in both animals. The rabbit, immediately after the removal of the labyrinth, shows the excessive deviation of the eyes and the excessive turning of head and neck with hyperextended and abduced position of the opposite upper extremity; it is rolling round its longitudinal axis in the direction of the operated side and both extremities on that side are atonic. Gradually these symptoms are to some degree corrected, the rolling ceases, and the animal continues its customary life with its twisted head, as if nothing had happened. The pigeon on the contrary offers but few phenomena directly after the one-sided removal of the labyrinth. It may walk somewhat unsteadily and with wide-extended legs, its head is unsteady and tottering, but the animal does not roll and shows no turning of neck and head. This turning does begin only after a few days, and the symptom is complete only with the 2^{d} and 3^{d} week after the operation. Moreover it is there no permanent symptom. Only the turning of the neck appears on the slightest occasion, though intervals occur during which the head is kept straight.

The maximal deviation of the eyes however does not exist in the pigeon, and rolling does never occur in uncomplicated cases. Nevertheless, in my opinion, these differences do not constitute an essential difference.

The pigeon does not roll round its longitudinal axis like the rabbit. But the pigeon has a long and easily movable neck, that may without any difficulty be laid down on the ground with its middle-part and so offer a support there, whilst the head is turned so far that the beak is looking upward, or even farther (see

fig. X). EWALD himself, thinks that the farther turning of the head is a voluntarily accomplished movement. It is easier for the pigeon, to have its head turned for 360° than for 180°, and the length of its movable neck permits it to do so.

That what the rabbit corrects by rolling round its longitudinal axis, the pigeon does in bending round its neck till 360°.

Besides, the peculiar anatomical relations of the octavus-system in the pigeon offer a clue to the behaviour of this animal shortly after one-sided removal of the labyrinth.

When observing attentively the newly-operated pigeon after one-sided removal of the labyrinth, we find that it presents a slight ressemblance with the pigeon, in which the labyrinth has been removed on both sides. At least the ressemblance is far greater than with itself after three weeks.

As a fact the one-sided extirpation of the labyrinth in a pigeon does signify for the central nerve-system a very grave lesion in the primary octavus-nuclei of the operated side and a less grave but important lesion in the primary octavus-nuclei opposite to the side of the operation. The pigeon, whose labyrinth has been removed on one side, is in the first days equivalent to an animal on which the removal of the labyrinth on both sides has been incompletely performed. It is only afterwards that gradually the preponderance of the one-sided disturbances appear in such an animal. Especially under the influence of emotions or other stimuli, the turning of head and neck occurs suddenly. If the characteristic turning of head and neck are seen they ressemble in all points that of the rabbit. But, and there lies the difference, it only appears by intervals. However the prevailing at the slightest occasion of the preponderance of the one-sided head-and neck-innervation is permanent in pigeons,as is likewise the atony of the extremities at the operated side.

In the rabbit, where the N. octavus does not end into the octavus-nuclei on both sides, as it does in the pigeon, the post-operative results are different. Here the operation produces a maximum of one-sided disturbance of innervation, not a double-sided disturbance. Therefore this disturbance attains its maximum directly after the operation, but gradually it diminishes. To a certain degree only it is compensated. The characteristic turning of head, neck and eyes remains for ever, though it also increases by intervals.

The pigeon has another anatomy of the VIIIth nerve as the rabbit. The one-sided removal of the labyrinth repercutes on both sides of the central system. Therefore in the first days there is a

slight loss of tonus in all extremities. But the animal, as the operative shock is gone, is not always able to compensate totally the preponderate disturbance of innervation at the operated side, and then the turning of the neck and head begins. Only when all around is quiet, the pigeon is able to master the turning of head and neck. Still ever and anon it is recurring by fits.

Ewald has even pointed out the memorable fact, that a pigeon, presenting the phenomena of a turning of head and neck recurring by fits, may lose again this involuntarily assumed position, if the labyrinth is again sought for, and the trunk of the N. octavus, whose terminal organ has once already been removed, is laid bare and a new lesion produced in it. In so doing, the Octavus-nuclei on both sides are damaged again by operative shock, and the results are once more the same as those of an imperfect double-sided operation. In all these cases however the turning of head and neck by fits returns gradually again.

For the rabbit things stand otherwise. Here we find in the first place the strong deviation of the eyes, that does not exist in pigeons, whose eyes are used for quite other purposes. Therefore in pigeons the eyes have a great influence on the correction of the deviation of the head. That also rabbits have not. So the turning of the head and neck and its consequence the rolling round the longitudinal axis, are the first symptoms of the rabbit.

Gradually the grave one-sided disturbance of innervation in the rabbit is corrected, but never to such a degree that the head may be borne erect, though it were only for a moment. From the very first the disturbance has too much prevailed on one side to allow this. The rabbit likewise is showing fits, in which all phenomena are aggravated, equivalent to the fits of turning of head and neck, observed in the pigeon.

But that, what in the pigeon is from the beginning a double-sided disturbance of innervation, changing gradually to a partial loss of innervation on each side, prevailing on that, where is operated, becomes unperceivable when the animal is perfectly quiet. In the rabbit, from the very first, a one-sided total loss of innervation exists, and though slightly diminishing afterwards, an always perceivable disturbance on one side remains.

The pigeon therefore, whose labyrinth has been removed on one side, is originally equivalent to an animal operated imperfectly on both sides, in which gradually is *prevailing* the one-sided disturbance — the turning of neck and head and the atony of the extremities — which is permanent.

The rabbit, whose labyrinth has been removed on one side, is an animal with a one-sided disturbance of innervation, a disturbance being at its maximum at the onset, and up to a certain degree compensated and corrected afterwards.

7. *Conclusions concerning the disturbances of motion found after extirpations of the labyrinth.*

The disturbances of motion, observed after extirpation of the labyrinth, may without any exception be considered as phenomena of „loss of function." It is not at all necessary to presume symptoms of irritation in order to explain them. In this respect I have nothing to add to the conceptions of EWALD. This opinion is proved irrefutably by the effect of the double-sided operation, that of all *apparent* symptoms of irritation, of all the spasms and forcibly assumed attitudes does leave nothing but only a most extensive muscular atony. All this may be demonstrated on the rabbit with still greater evidence than on the pigeon.

The identical disturbances of motion are shown further, though in a far feebler degree, after removal of the cochlea. They are then of the same kind as after removal of the entire labyrinth, and there is such a striking accordance between both cases, that we may only speak of a difference in degree, not of an essential difference. This fact may be explained in two different ways.

In the first place we may believe that the N. cochlearis, serving for the perception of sound, does not exert any influence on the muscular system. As in removing the cochlea, to all probability the contents of the vestibulum will be damaged in some measure by discharge of endolymph, it is to be expected that some slight disturbance of motion will occur. In that case the motion-symptoms would be dependent on the peripherical endings of the N. vestibularis. The Nervus cochlearis should have no influence on motion; the two nerves would be quite different nerves.

It is indeed not rare to find that, without any obvious cause, the far graver disturbances of motion, peculiar to destruction of the whole labyrinth, are gradually developing likewise after removal of the cochlea, and as in such cases the possibility of infection is excluded, this degeneration must originate in a slow secundary destruction of the vestibular endings.

This conception would be in accordance with the current opinions concerning the physiological signification of the cochlea for hearing and of the ampullae and maculae acusticae for the perception of equilibration.

But there may be given still another possible explanation of this fact. Leaving aside the specific perceptive functions belonging hypothetically to both terminal organs, it may still be imagined that both the N. cochlearis and the N. vestibularis should extend their fibres into the central nerve-system in a similar way, and are distributed in the same manner in relation to the motor nuclei situated there. Such being the case, the same disturbances of motion, that are manifested *completely* when the *entire* terminal organ is extirpated, would likewise be occasioned *in a lesser degree* (but still in quite the same way) by the incomplete removal of the terminal organ, as is done by destruction of the cochlea. As to the influence on motility, this conception is only seeing a quantitative difference between the two nerves. The N. cochlearis has an influence on motility in the same way, but not so intense as the N. vestibularis.

This conception may be argumented by the course of both nerves, because both are degenerating centralwards as a result of the lesion, and it is greatly supported in that way; but still it is not quite in accordance with the current opinion, that N. cochlearis and N. vestibularis are two nerves of entirely separate functions. A discussion about these opinions here however would lead me far beyond the limits put to this treatise, besides its being useless for my purpose.

For I think it is not proved, either that the vestibular-endings does not participate in the perception of sound, or that the cochlea may be neglected as being without any signification when investigating the causes of the spasms, the forced attitudes and the rollings. I doubt if a decisive argument may be given that hearing is not supported by the N. vestibularis, or that the N. cochlearis should have no influence on motion.

The animal, in which the cochlea has been destroyed on both sides, does not react on the violent sound-impressions of a Galton-whistle, blown above its head, as it did before the operation. It does not roll, but it always has in a slight degree the characteric deviations of head, neck and eyes.

But as soon as the experiments are made to aim directly at the solution of the question whether a remnant of sound-perception may still exist after removal of the cochlea, there arise such enormous difficulties, that I dare not draw any conclusion whatever from those experiments.

I will only just recall to mind that after the opinion of Ewald, pigeons whose labyrinth has been destroyed on both sides, still hear, i. e. that they reacted on sound-impressions, brought to act

upon these animals, whilst every precaution had been taken to prevent air-shakes. Without doubting in the least degree the correctness of the observations of such an investigator as EWALD, I believe that such observations go beyond the limits assigned to our judgment on the sense-perception of animals. I have believed to observe that rabbits, whose cochlea was destroyed, still did hear, but I wish expressly to leave this question undecided.

For the same reason I will only just recall the fact that the animal, chosen preferably to all others for demonstrating the degeneration of the labyrinth as the cause of disturbances of motion, the dancing Japanese mouse is at the same time deaf. I know of no instance wherein dancing mice have been described that could hear and I can assure that they have lost completely the primary nuclei of the N. VIII. As to deaf- and dumb creatures, whether they present disturbances of motion or not, it is my belief that the question whether in their case it is only the cochlea or the whole of the labyrinth that is damaged, is not yet resolved.

In this paper I carefully avoid to communicate anatomical investigations on the periferical endings of the eighth nerve. I prefer maintaining it between its proper limits. Therefore also I neglect experiments on sound-perceptions. I only have to study the influence that the N. octavus exerts on the motion of the animal.

That, what I wish to state here, is that the disturbances of functions, observed after removal of the cochlea and after extirpation of the labyrinth, show only a difference in degree, and that they leave room for the conception that there need not be assumed an essential difference in the mode of distribution in the central organ of the N. cochlearis and the N. vestibularis. This opinion is supported by the anatomical course of both nerves in the central nerve-system.

Chapter II.

On the distribution of the nervus octavus in the central nervous system in rabbits.

---

1. *Methods of investigation. Introduction.*

In order to investigate the central distribution of the nervus octavus it is necessary to use several methods of investigation.

From different species of animals the normal central nervous system must be compared, before beginning the researches in rabbits. Though this method of comparative anatomy need not be extended so far, as to apply it to nearly all vertebrates, it is necessary to examine the medulla oblongata of men, dog, cat, horse, mouse, rabbits, the amphibia and birds, which are common in our laboratoria, before examining foetal or experimentally prepared material of one species.

I even believe, that many questions, touched in this paper, will ask for a solution from the comparative anatomy of special animals or even of species, where an irregular differentiation of functions may be supposed. So for instance the examining of the medulla oblongata of the mole, the squirrel, the bat, of the cetacea, may teach us much about the auditory nervous system. But for my purpose the method of comparative anatomy is occupying only a second plan. My purpose aims the study of the N. octavus in rabbits. Therefore the method of comparative anatomy has the value of an introductory method, but other methods are more necessary. Absolutely necessary are embryological-investigations.

They may be applied in different ways, partly by studying the

myelinisation in foetal and young born animals, partly by studying GOLGI preparations.

I must avow, that I cannot support in every respect, the views of FLECHSIG, who sets too much value on the signification of the myelinisation-process in nerve-fibres. This method, though offering great advantages, offers great dangers too.

It may give evident results in some regards, as for instance, that the vestibular-nerve receives the medullated fibres at an earlier period of development than the cochlear nerve. But it may be very venturous to ascertain, that the vestibular nerve is myelinisated at a time when the cochlear is still quite exempt of medullated fibres.

Investigators, who have worked exclusively with this method will run a great chance to be induced into error, and it is my opinion that FLECHSIG himself has not been very happy in his description of the auditory tracts, especially in the separation of the primary and secundary paths. The study of the development of myelin may control other methods. Therefore it is of great value. But it is restrained between strict limits and ought to be controlled itself by the GOLGI-method and especially by the experimental methods.

The methods of experimental anatomy have been chiefly used in my investigations, either the method of VON GUDDEN or that of MARCHI.

GUDDEN's method of experimental secundary atrophy after lesions in the young-born animal is, if exclusively used, dangerous, nearly as dangerous as the myelinisation-method, but it cannot be totally substituted by the methods of secundary degeneration, for instance by the method of MARCHI.

For an experimentally produced atrophy, once provoked, is invariable. A nervous system sectioned in the young born animal will be found totally atrophied after a lapse of three months or longer.

But the dangers of VON GUDDEN's atrophy are evident. The method is giving too little and too much.

As soon as the atrophied fibres may be found distributed between intact fibres, they are not recognised. The judgment on the partially atrophied system is often a subjective judgment. In this respect the method gives too little.

Moreover nobody can foretell the extension of the atrophy in secundary and even in tertiary systems consequent to the atrophy of the insulted one. Neighbouring systems, completely independent of the one damaged, may, under circumstances, atrophy. In all these

regards, the method is giving too much, and is dangerous especially if the atrophy existed for a long time.

These objections to GUDDEN's method have discredited it, and in modern investigations the method of secundary degeneration, as it was used by MARCHI, is preferred.

To be sure, MARCHI's method is giving results in cases, wherein that of VON GUDDEN is impracticable.

Degenerated fibres distributed between intact fibres are easily found. When the method is used within a fortnight after the operation, the black granules in the degenerated fibres may be strictly limited to the damaged and degenerated system. Nevertheless grave objections are also to be made to the MARCHI-method.

1^{ly}. There must be certainty, that the experimental lesion, which is studied with MARCHI-tinction, has passed without any complication. A slight infection, the most superficial meningitis, etc. may be the cause of such an abundant overflowing of black granules in the nervous system, that all the results of the experiment are disturbed.

2^{ly}. The black granules do not remain strictly limited to the degenerated fibres, where they orinigated. The existence of neurophagic cells transporting the myelin-globules into the lymph-channels and the lymph-fissures is a grave complication. The black granules therefore are often found in places, independent of the original focus of degeneration. SUCH for instance is the case, in nearly all the roots of periferical nerves. Their entrance in the medulla oblongata is the favorite spot, where black granules are found. For instance, black granules are nearly always found at the entrance of the III^{d} nerve, consequently to every operation made in the oblongata or in the pons Varoli.

The quantity of the transported granules is increased in reason of the time that has passed after the operation.

3^{e}. Every small incision made in the central system, is surrounded by a (in MARCHI-tinction) white coloured mass, without black granules. The white-coloured mass in the neigbourhood of the wound must be added to the extent of the lesion.

4^{e}. The existence of the so called *retrograde* degeneration studied by VAN GEHUCHTEN and others. The retrograde degeneration (from the body of the cell, which axon was sectioned towards the section) begins after a fortnight.

5^{e}. Three weeks (and even earlier) after the operation, the degeneration in the sectioned system is complete. The degenerated fibres, though they may end in the nuclei by unfolding their terminal

collaterals (LEWANDOWSKY's Zersplitterung) or otherwise, can be traced to them. But at the same time, degenerated fibres, originated in the primary nuclei, are found. The question, whether those fibres may be the fibres of secundary systems or not, is as yet an open question. In respect of all these grave objections I believe that MARCHI's method must always be controlled as well by that of von GUDDEN, as by the method of myelinisation. Exclusively used, none of them is sufficient.

This is also the case with NISSL's method. It has to answer the question to what extent degenerative changes have occurred in the nerve-cells, but it is only adapted to the study of the relative fresh disintegration in cells, whose efferent axons are sectioned. It is nearly useless in the study of the changes in cells, receiving the degenerated collaterals of damaged systems.

And yet those cells may atrophy, as is taught by preparations treated with the carmin-method.

As we said before, the central course of the VIIIth nerve can only be elucidated by using all the different methods, and it is only with the aid of their mutual controlling that many dubious points may be ascertained.

There still is one important thing, that is often forgotten: The central system should always be examined in uninterrupted series of sections, and the direction of the sections should always be varied.

The frontal sections usually studied, often in incomplete series, are quite insufficient. Horizontal and sagittal series of sections are just as necessary as frontal series. Questions of great importance, that remain without solution in the frontal series, are immediately resolved in the horizontal or sagittal series.

With the aid of these methods the nervous system of rabbits, which had suffered different operations was studied and compared with embryonic material, as well as with the normal medulla oblongata of different animals, in order to form an opinion upon the central distribution of the VIIIth nerve.

2. THE ROOTS OF THE NERVUS OCTAVUS.

a. *The actual views upon the signification of the N. cochlearis and the N. vestibularis and their continuation in the lateral and ventral root.*

Generally the view is hold, that the centripetal prolongations of

the bipolar nerve-cells in the ganglion spirale cochleae are the medullated fibres composing the cochlear nerve and this nerve may be continued in the lateral (dorsal or distal) root of the nervus octavus.

Nevertheless it must be admitted that there exists a little nervous branch, gathering the fibres from the macula sacculi in a small proper ganglion. The central prolongations of the cells in this ganglion may also be traced in the cochlear nerve (RETZIUS, SCHWALBE a. o.).

On the other hand the macula utriculi and the cristae ampullae may receive the centrifugal prolongations of the bipolar cells composing the ganglion plexiforme Scarpae. In rabbits these cells are spread in the course of the vestibular nerve, and their centripetal prolongations pass through this nerve in the medial (ventral or proximal) root of the nervus octavus.

Both nerves together therefore are forming the nervus octavus, but, as is argued, cochlear and vestibular nerve are different nerves, different in structure, as well as in function. Their structure is different in many regards.

Firstly their relation to the periferical ganglia is not quite the same.

The ganglion spirale lies concealed in the lamina ossea of the cochlea. Therefore the cochlear-nerve, in its traject through the meatus auditorius internus, may be compared with a spinal root.

Not so the vestibular nerve. The cells are spread along this nerve and the so called ganglion vestibulare nearly touches the medulla oblongata. The vestibular nerve consequently may be partly compared with a spinal root, but partly also with a periferical nerve.

The degenerations in the nervus octavus after removal of the labyrinth may be influenced by this anatomical peculiarity.

For the removal of the cochlea includes necessarily the removal of the ganglion spirale and it is directly comparable with a root-section.

The removal of the contents of the vestibulum and even the section of the vestibular nerve in the meatus auditorius is not necessarily combined with a complete removal of the ganglion vestibulare. To do this, the vestibular nerve should be torn out and broken close to its entrance in the medulla oblongata, and it is hardly possible to do so, without lesion of the medulla.

But only the latter operation may be compared with a complete root-section. The removal of the vestibulum and the section of the vestibular nerve are operations partly comparable with a root-section, partly with the section of a periferical nerve.

This peculiarity influences the results of MARCHI-degeneration and offers an advantage as well as a danger.

Besides the somewhat different behaviour of the two nerves towards their periferical ganglia, they also show a certain difference in structure, the vestibular being composed mostly of thick fibres, the cochlear mostly of small ones. This difference is not caused by the circumstance that the cochlear-nerve contains root-fibres and the vestibular partly periferical and partly root-fibres, for then the same difference should be found in the roots. The dorsal root should be composed of small, the ventral of large fibres.

In this way the difference in the structure of the terminal organs (cochlea and vestibulum) should be reproduced in the structure of their centripetal nerves, as if a complete independency of the two organs and their nerves existed.

Yet this difference must not be thought too important. Firstly in rabbits the two nerves exchange many fibres. Consequently large fibres are found in the cochlear and in the dorsal root, small fibres in the vestibular and in the ventral root. In animals — for instance horse and sheep — where the nerves do not exchange fibres and where they run strictly separated, it is not otherwise, Sections perpendicular to the longitudinal axis of the root demonstrate with certainty, that there exists a certain prevailing of thick fibres in the ventral root above those in the dorsal root, but this difference in structure is only a relative difference.

Far more interesting than the supposed difference in structure of the two component branches of the nervus octavus is the nearly generally admitted opinion, that the cochlear and the vestibular nerve, after entering the medulla oblongata, pursue a completely different course in the central nervous system.

The cochlear nerve is continuated in the dorsal root and enters in the latero-dorsal layer of the corpus restiforme. It turns in this layer round the oval area of the restiform body, sending fibres during this traject in the ventral nucleus, in the tuberculum acusticum, perhaps also in the lateral part of the dorsal nucleus of the N. VIII.

The vestibular nerve however, continuated in the ventral root, finds its way between the restiform body and the spinal root of the Vth nerve, goes straight to the internal part of the corpus restiforme and dividing itself into a descending and an ascending branch ends in the nucleus dorsalis N. VIII, in the nucleus griseus rami descendentis radicis ventralis and in the so-called nucleus of BECHTEREW.

In this way the cochlear and the vestibular nerves, being pursued to different nuclei, originating out of different periferical

endings, presenting each a special arrangement of their periferical ganglia and showing a somewhat different structure in regard to the thickness of their fibres, should betray themselves, anatomically spoken, as complete independent nerves, though they compose together the VIIIth nerve.

But the distribution of the root-fibres in the central system is not exactly so, as the generally admitted opinions, described above, hold it to be. The greater part of my anatomical investigations will be consecrated to demonstrating that the root-fibres of both nerves, may be pursued in all the primary nuclei and in all the secundary systems of the nervus octavus. The difference in the central distribution of the cochlear and the vestibular nerve is a difference concerning the quantity of fibres thrown into the nuclei.

Therefore the complete independency of the two nerves, may be not so surely proved by their anatomy, as many investigators believe.

But not only strictly anatomical data are brought forward to prove that independency. The comparative anatomy also may furnish some arguments to defend this opinion.

Indeed, the comparative anatomy allows the assertion that the static organ is of a very old age in the phylogenetic history, for it is nearly everywhere present in lower animals as an organ bearing the otoliths.

Much later and gradually the cochlea has been differentiated from this static organ. In fishes scarcely existing, in birds representated by the lagaena with half a spiral convolution, it reaches in the mammalia its total development with its three characteristic convolutions. In the same series of ideas the embryonic argument may be ranged, that in the ontogenetic development the fibres of the phylogenetic much older nerve — the vestibular — begin their myelinisation at an earlier period of foetal life, than the fibres of the cochlear nerve.

This argument offers a support to the opinion that a certain independence of the two organs of the labyrinth and of their nerves exists, but nothing more.

My experiences are not at all in favour of the opinion, that the cochlear and vestibular nerves are myelinisated as if they were independent nerves.

Certainly the myelinisation begins at the radix medialis (ventralis) at an earlier period than in the dorsal root, still hardly the myelinisation of the former has become evident but there also appear medullated fibres in the cochlear.

Far more demonstrative power than anatomical proofs, physiological proofs may possess.

If it were demonstrated with certainty that the animal without cochlea, was deaf and without disturbances of motility, and on the other hand, that the animal without the static organ (contents of the vestibulum) was hearing but presenting characteristic motor symptoms — if this were surely demonstrated, the actual view of the complete mutual independency of the two nerves might have a firm base.

But, though this view is often defended, I hold it impossible to realise the experiments tending to prove it.

Our experimental methods are too rough for this purpose.

As is shown in the preceeding chapter, the animal without cochlea may present slight motor symptoms, not so grave as the characteristic disturbances after the total removal of the labyrinth.

And as to the hearing of the animal, I repeat, that EWALD thought pigeons were hearing, even after total removal of the labyrinth.

The enormous litterature on the functions of the otoliths demonstrates the influence that the static organ has on motility. But all this does not demonstrate, that the cochlea, after its differentiation from the static organ, has no longer any such influence.

Only it is evident, that in quantity its influence must differ from that of the whole labyrinth. Cochlea and vestibulum may be differentiated from a single more simple organisation — from a static organ. Possibly the one — the cochlea — obtained the qualities to prepare the psychical function of hearing. But there is not to be seen any reason, why it should have lost the quality — originally belonging to the whole organ — of acting automatically on a greater part of the muscles.

Possibly the other part — the static organ strictiore sensu — retained in a higher degree its original automatic influence upon the muscles. But it is not proved, why it never should have possessed or why it totally should have lost a function for the perception of shock and sound.

The experiences on dancing japanese mice show, that those animals, missing nearly completely the whole auditory system, have motor disturbances (are dancing) and are deaf.

The experiences on deaf-mutes do not contradict the opinion that both parts of the labyrinth or of their nervous system may be damaged, and in consequence cause deafness and unsteadiness in movements.

The anatomy of the auditory nervous system in rabbits now

may prove that the course of the root-fibres of the dorsal and the ventral root, is the same. Only the quantity of fibres, which are to be traced from the root in a distinct central part, does vary. Both roots innervate in larger or smaller quantity all the so-called primary nuclei, both are searching in larger or smaller quantity the same so-called secundary paths.

An endeavour to demonstrate this, I intend to make in the next paragraphs

3. The primary systems or the root-fibres of the nervus octavus

a. *The fresh degeneration in the root-fibres taking place after the isolated removal of the cochlea and the initial course of the dorsal (lateral) root in the central system.*

We have seen that it is possible in rabbits to remove the cochlea without damaging the vestibulum. We have seen that this operation is equal to a section of the cochlear nerve between the spiral ganglion and the medulla oblongata. A succesfully executed operation of this kind is always followed by a degeneration in the cochlear-nerve, within a week.

Marchi's method then gives in those cases an evident result.

The lateral (dorsal) root of the VIIIth nerve is covered with black grains, whereas the portion of the medial (ventral) root, that is found between ganglion vestibulare and medulla oblongata is totally exempt of them. (See fig. 1*a* on Plate I and fig. 2 on Plate II).

This fact does not prove that the degeneration in the lateral root is a complete one. There are reasons, as we will find, to admit that this is not the case.

But in this fact we have an expedient to study the fibres, taking their origin in the ganglion spirale, and to isolate them from the rest. Unfortunately it is not possible to remove the contents of the vestibulum without lesion of the cochlear nerve.

A comparison of the degeneration in the lateral root after removal of the cochlea may therefore only be made with the degeneration following the total section of the VIIIth nerve.

The degenerated fibres of the ganglion spirale (the cochlear root-fibres) throw themselves through the lateral root in the latero-dorsal layer of fibres, that turns round the oval area of the restiform body to reach the internal part of it. But after total section of the VIIIth nerve the number of degenerated fibres in the latero-dorsal

layer of the corpus restiforme has increased *and moreover they are lying in the inner part of this layer close to the corpus restiforme, where degenerated fibres are not found after the isolated removal of the cochlea* (see fig. 4 on Plate IV).

The common opinion that the stratum latero-dorsale of the corpus restiforme is only formed by the root-fibres of the cochlear-nerve is incomplete.

In fact the greater part of the lateral rootfibres continue their course in this stratum latero-dorsale corporis restiformis — as frontal sections through the medulla oblongata, touching the fibres of this layer longitudinally, demonstrate easily — but this stratum receives a considerable accres from fibres of the medial root. LEWANDOWSKY is right in this opinion.

With the Marchi-method it is easy enough, to follow the degeneration after the removal of the cochlea — the black granuled fibres of the lateral root — not only in the stratum latero-dorsale but also in other paths.

As soon as the degenerated dorsal root-fibres have reached in that case the medulla oblongata *they divide into three portions.*

1°. Some fibres leave the dorsal (lateral) root rectangularly in a ventral direction and passing directly in the corpus trapezoides may be followed across the raphe (see fig. 1*a* Plate I and Plate II fig. 2).

They are the root-fibres of the dorsal root, that are to participate in the formation of the „systema ventrale of the nervus octavus".

2° A few fibres — especially in the proximal region of the entrance of the lateral root — enter between the oval area of the corpus restiforme and the spinal root of the Vth nerve. They reach the portio interna of the restiform body. They form the most distally situated fibres among those, who are found between oval area and spinal root of the N. V. and bear themselves as the greater part of the root-fibres of the ventral (medial) root do (see fig. 2 on Plate II). They are the medial fibres of the dorsal root. This medial trunk of dorsal rootfibres is not very important.

3°. The greater part of those fibres pursue their way in a dorsal direction. Closely joined together, they penetrate through the nucleus ventralis nervi VIII, dividing it into a smaller medio-ventral, and a larger latero-dorsal part and reach the stratum latero-dorsale.

There they pursue their course, at first between nucleus ventralis and the oval area of the restiform body, afterwards between the tuberculum acusticum and the oval area. So they describe a curvature round the oval area, closely adossed to it in its ventro-distal part (see fig. 1*a* on Plate I), but as they advance dorsally and

proximally (see fig. 2 on Plate II), there appear normal fibres resting upon the lateral border of the oval area, which only may be brought to degeneration after the section of the eight nerve (see fig. 4 on Plate IV). On this traject the dorsal rootfibres enter into the ventral nucleus and the tuberculum acusticum in a way to be described further on and the remaining fibres reach also the portio interna of the corpus restiforme in its latero-dorsal part.

These remaining fibres are the root-fibres of the lateral root, which participate in the formation of the „systema dorsale nervi octavi".

Each of the three portions of these lateral root-fibres has its own adventures, and shall be separately described, as soon as the initial distribution of the ventral root-fibres is known. In the description of the initial ways of the lateral root-fibres here given I differ essentially from the opinion of VAN GEHUCHTEN, and approach to that of TRICOMI-ALLEGRA, not only because the Marchi-degeneration demonstrates it, but also because it is concordant with the results of other methods of investigation.

b. *The fresh degeneration in the root-fibres taking place after the section of the VIIIth nerve and the initial traject of the ventral (medial) root in the central system.*

The ventral root may be brought to degeneration, together with the dorsal root by sectioning the VIIIth nerve in the meatus auditorius internus.

The comparison of the degenerated fibres found after the removal of the cochlea, with those found after the section of the VIIIth may be used to study the course of the vestibular fibres and those of the ventral root.

This study teaches us, that the ventral root-fibres divide in three portions, exactly in the same manner as is done by the dorsal root-fibres.

1°. Some fibres, mostly thick fibres, leave the ventral root rectangularly, bending in lateral direction in the corpus trapezoides (see Plate VIII fig. 15 N°. 9, 10 and 11).

Those fibres increase the number of degenerated fibres entering there from the dorsal root, for after the section of the auditory nerve the degeneration in the corpus trapezoides is nearly doubled in intensity, as compared with that after removal of the cochlea.

Those fibres are the ventral root-fibres participating in the formation of the „systema ventrale nervi octavi".

2°. The principal portion of the degenerated fibres of the ventral root passes straight forward between the oval area of the corpus restiforme and the spinal root N. V to reach the portio interna corporis restiformis (corpus juxta-restiformis). There they occupy the medio-ventral part, resting upon the dorsal surface of the spinal root N. V. Immediately after their entrance they change abruptly their direction. The larger number of fibres turns downward (distally) — the radix descendens nervi octavi (see Plate V fig. 9) — and in a smaller quantity they turn upward (proximally) — the radix ascendens nervi octavi (Plate IV fig. 8, as well as Plate IX, X, XI, fig. 16 A—N).

For this reason their course is better studied in horizontal series of sections (Plate IX, X, XI fig. 16) than in frontal ones (Plate VIII and IX, fig. 15).

These are the medial root-fibres of the ventral root, forming the important medial trunk of the ventral root.

Many authors think that all the fibres found between area ovalis and spinal quintus root are ventral rootfibres. Marchi-degeneration has shown us in the preceding paragraph, that in the distal region a small portion of dorsal root-fibres take their course in the medial trunk.

Many authors also are of opinion, that all the ventral root-fibres may be continued among the here described fibres and that none of them take another way. But this certainly is not the case.

3°. Moreover an important number of ventral rootfibres passes in the stratum latero-dorsale corporis restiformis.

The capital situated part of this layer is nearly totally formed by ventral root-fibres. As we have seen in the preceding paragraph, a large number of dorsal root-fibres are also found in this layer, but in the dorsal and capital regions there always remain normal fibres (after removal of the cochlea) lying closely to the area ovalis. These fibres now degenerate after the section of the auditory nerve.

They turn in a curvature round the oval area of the restiform body, always touching it (see fig. 4 on Plate IV). On this way a part of them reaches the latero-dorsal part of the portio interna corporis restiformis, another part, perforating the oval area, and running transversally through it, also enters the portio interna. As soon as (in series of frontal sections) the oval area enters the cerebellum as its pedunculus inferior — in the most proximal regions of the octavus-entrance — the stratum latero-dorsale has disappeared and the medial root-fibres are the only remaining fibres or better the latero-dorsal and the medial trunk of root-fibres fall together, and there are no longer two trunks.

The fibres mentioned here sub 3 are the ventral root-fibres participating in the formation of the systema dorsale nervi octavi.

In this way the Marchi-degeneration demonstrates that 1° in the stratum latero-dorsale corporis restiforme root-fibres are to be traced as well from the cochlear, as from the vestibular nerve. They are ranged there in such a manner, that distally the number of cochlear fibres (dorsal root-fibres), proximally that of vestibular-fibres (ventral-root-fibres) prevails.

2° that between the oval area and the radix spinalis N. V. principally the fibres from the ventral may be traced. Only in the distal regions there are found dorsal root-fibres.

3° that in the corpus trapezoides thick fibres — principally ventral root-fibres — as well as small fibres, mostly dorsal root-fibres, may be pursued.

c. *The supposition that both roots send their fibres, though in different quantities, in the same paths, is confirmed by the study of the myelinisation of the roots in the rabbit.*

The Marchi-degeneration has shown us that the stratum latero-dorsale is not only the continuation of the dorsal rootfibres, but contains also ventral rootfibres (and as we shall see afterwards many other secundary auditory fibres), and that between oval area and spinal quintus root enter root-fibres of both roots as well as they do in the corpus trapezoides.

These conclusions are not accepted by the authors, who have studied the central distribution of the auditory nerve by means of the myelinisation-method.

So, for instance, the schema given by Bechterew is generally accepted, and it is taught, that the ventral nucleus should be an intervertebral nucleus, that the dorsal root may be continued in the stratum latero-dorsale and the ventral root between the oval area of the restiform body and the spinal root of the nervus trigeminus.

And, basing on Flechsig's investigations, it is usually taken for granted that the corpus trapezoides only contains fibres of the secundary auditory systems. Though these opinions are doubtless in contradiction with many of the results, mentioned in the excellent papers of Held, they are usually defended on the continent.

I must avow, that I fail to understand as yet, why the investigators, who have studied the auditory system by means of the myelinisation-method have not long ago stated the same conclusions, that are defended here as the results of the Marchi-method. For, as to my experience, the myelinisation of the root-fibres of

the auditory-nerve gives a very decisive answer in favour of the questions treated here.

Only it ought to be kept in mind that the ordinarily used frontal series of sections are not very apt to demonstrate the course of the root-fibres.

In a newborn rabbit it is nearly impossible (f. i. fig. 17. A and B on Plate XII, and fig. 5 on Plate I) to disentangle the fibres mixed together at the entrance of the two auditory roots. There the fibres of roots and of the corpus trapezoides are all medullated and mixed together in an inextricable mass.

Much easier the question is in sagittal sections. There the relation between the two roots and the corpus trapezoides is very clear (Plate VI fig. 19 A—B and Plate XIII fig. 18 A—D). Simpler as it is given in Plate VI fig. 19 A and in fig. 18 A on Plate XIII, the relation between the two roots may be hardly demonstrated. In fig. 18 A the section touches the superficial layer of the medulla oblongata. The entrance of the nervus trigeminus (N. V) is found most proximally. The proximal (medial or ventral) root of the VIIIth nerve with its thick fibres is distinctly separated from the distal (dorsal or lateral) root of the VIIIth nerve, having small fibres. But immediately it is seen that an intermedial rootlet passes from the ventral towards the dorsal root (Plate VI fig. 19 A and Plate XIII fig. 18 A r. interm).

By means of this intermedial rootlet fibres are passing from the ventral root into the stratum latero-dorsale, as it is found between the ventral auditory nucleus and tuberculum (Plate VI fig. 19 B and Plate XIII fig. 18 B). And in Plate XIII fig. 18 C it is clearly demonstrated that fibres of the ventral root, now found between the spinal root of the N. V. and the restiform body, perforate the latter (its oval area) to reach the stratum latero-dorsale. Those fibres, penetrating the corpus restiforme, may be found in all sagittal sections until the portio interna of the corpus restiforme is reached, at that moment a new bundle is found, close to the most medial limit of the oval area in the most lateral part of the portio interna of the restiform body. This latter bundle (fig. 18 D on Plate XIII in h. or HELD's interm. system) leaves the stratum latero-dorsale, and crossing the formatio gelatinosa of the spinal trigeminus-root, finds its way as well to the systema intermedium as even towards the corpus trapezoides. In a proximal situation to this bundle — the bundle of HELD — but medially from the oval area, communicating fibres from the ventral root to the latero-dorsal layer of the restiform body are still always to be seen, and

always crossing queer this body. It is not necessary to study younger foetus of rabbits in order to demonstrate, that fibres in important quantity are going from the ventral towards the dorsal root, and from the ventral root queer through the area ovalis towards the stratum latero-dorsale of the restiform body. Therefore I can only conclude that the fibres of the latero-dorsal layer, terminating as well in the ventral auditory nucleus as in the tuberculum acusticum, are originating of both roots of the VIIIth nerve.

The myelinisation-method at the same time confirms the opinion that rootfibres of the *ventral* root penetrate transversally through the oval area to reach the stratum latero-dorsale. Degenerate fibres after sectioning the VIIIth nerve, demonstrated with Marchi-method in the preceding paragraph (to compare Plate IV fig. 4, Plate VIII fig. 15 N°. 7 and 8 with Plate XIII fig. 18 C and D) may also be traced transversally through the oval area. There is shown, that they are not found after the removal of the cochlea.

Therefore, I think it evident, that the myelinisation-method supports in every way the supposition that the stratum-latero-dorsale and *the „systema dorsale nervi octavi" contain root-fibres of both auditory roots.*

But there is more. In the new-born rabbit and better still in younger foetus, it may be seen, that the myelinisated corpus trapezoides receives its fibres not only from the nucleus ventralis N. VIII (Plate XIII fig. 18 B) but from both roots (Plate VI fig. 19 B). Rootfibres pass directly into it.

This is so evident. that I also think it demonstrated by the myelinisation-method, *that the „systema ventrale nervi octavi" contains root-fibres of both auditory roots* as well as fibres of the secundary system.

d. *The supposition that both roots send their fibres in the corpus trapezoides is also confirmed by* Gudden's *method. The tuberculum acusticum and ventral auditory nucleus being removed in the young born aimal, without grave lesion of the auditory roots, the corpus trapezoides having lost its secundary only contains rootfibres.*

Van Gehuchten, who has published many excellent articles on the central course of the cerebral nerves, has in a recent paper revided the views previously originated in his laboratory as results of the researches of his disciple Tricomi-Allegra.

The isolated removal of the cochlea in two guinea-pigs caused Marchi-degeneration only in the dorsal root, which was only to be traced in the ventral auditory nucleus and the tuberculum

acusticum. VAN GEHUCHTEN therefore thinks erroneous the differing results of TRICOMI-ALLEGRA, who, experimenting principally on rabbits, assumes root-fibres entering the corpus trapezoides, and the cause of his error is by VAN GEHUCHTEN presumed to be a lesion of the facial nerve.

This nerve indeed crosses the area of operation and if injured, for instance by a slight traction, the lesion may be sufficient to cause a degeneration of the transversal fibres of the corpus trapezoides.

Moreover, there are, with the Marchi-method, often found some black stained granules at the entrance of the VIIth nerve and in its root-fibres.

Therefore, as argues VAN GEHUCHTEN, the slight tractions or other lesions of the facial nerve during the operation are the cause of the degenerated transversal fibres in the corpus trapezoides and the passage of auditory root-fibres therein is not proved.

Now I have already mentioned that Marchi-method offers dangers. One of these is, that the black granules — even within a few days after their appearance — are carried away by the lymph-current and that the roots, leaving the central systems, may be reckoned among the out-ways of the lymph-circulation. Indeed, black granules are often found there, where roots leave the system, and if a degeneration exists in the corpus trapezoides, they *must* be found at the issue of the facial nerve.

But if the presence of some granules at the entrance of the facial root-fibres is used — as is done by VAN GEHUCHTEN — to prove a lesion of the facial nerve I cannot entirely accept this view. They necessarily must be found there after each degeneration in the corp. trapezoides. And their presence in roots after degenerations in the central system only proves that Marchi-method is not a sovereign method and needs to be controlled. But in the preceding paragraph, I have established the fact that the myelinisation also gives arguments in favour of the opinion that root-fibres of the VIIIth nerve directly enter into the transversal fibres of the corpus trapezoides (Plate XIII fig. 19 B). Another experiment however may be taken, that demonstrates clearly the passage from the rootfibres in the corpus trapezoides, as well from the dorsal as from the ventral root.

In a new-born rabbit, the atlanto-occipital membrane may be opened in order to divide the lateral part of the medulla oblongata in such a manner that the ventral auditory nucleus and the tuberculum acusticum have lost all connections with the medulla. This operation may be done with a single draught of the thin knife,

without damaging the auditory root-fibres or with only a partial lesion of them.

The operation may seem difficult, but as a fact it is much simpler than it appears. In my possession are at least three series of post-mortem verified specimina wherein such an operation has succeeded.

Now one of these relates to an animal killed six months after such an operation. As I will show afterwards, in consequence of it an important atrophy of the corpus trapezoides was produced, as indeed was our purpose. The latter is now reduced to the fibres originating from the rootfibres, and to the fibres, originating from the medio-ventral part of the ventral auditory nucleus, that cannot be removed from the medulla oblongata, if the roots shall be spared.

Now the relations have become very transparent. Without any difficulty, the normal fibres of the dorsal, as well as of the ventral root, now may be followed in the transversal fibres of the reduced corpus trapezoides (as fig. 12 on Plate XXI demonstrate, where as fig. 28 A—E on Plate XXI show the extension of the lesion, wich is found as a port-mortem defect).

Therefore, as to my experience, it cannot be doubted that auditory root-fibres enter without ganglionic interruption between the transversal fibres of the trapezoid body. On the other hand I must concede to VAN GEHUCHTEN that in other animals — for instance in dogs — I found the extirpation of the cochlea not always followed by degenerations in the ventral systema, at least within a fortnight. Indeed I believe, that the difference between the root-systems and the secundary systems is not a very essential one. Not only, I am convinced with HELD, that primary (root-)fibres find their way in all the secundary systems, but I think even, that a primary system may be replaced by a secundary system and vice versa.

In rabbits however I argue that the Marchi-method of degeneration, the myelinisation and GUDDEN's atrophy-method all are concordant in the demonstration, *that root-fibres of both roots enter directly into the corpus trapezoides or better in the so-called „systema ventrale nervi octavi"*.

c. *The systema ventrale nervi octavi. The situation of the root-fibres in this system and their further course.*

With a small variation from the nomenclature given by EDINGER. I hence, forth will call the transversal fibres in the corpus trape-

zoides, that pass along the ventral margin of the medulla oblongata and belong to primary or secundary auditory systems „the systema ventrale nervi octavi". I have already mentioned that after sectioning the eighth nerve, thick fibres as well as small fibres are found degenerated among the transversal fibres of the corpus trapezoides.

The thick fibres principally originate from the ventral root, but they are also found after the removal of the cochlea in a smaller quantity (Plate I, fig. 1*a* and 1*b*. Plate II fig. 2).

The degenerated *thick* fibres have their proper situation and are found in the most ventral layers of the corpus trapezoides. At the ventral margin of the medulla oblongata, ventrally only covered by the free anterior pyramidal tract, they pass through the raphe (see Plate VIII and IX fig. 15. N°. 11, 12, 13, 14) and end in both nuclei trapezoides.

Only a small quantity ends in this nucleus of the same side in its latero-dorsal edge. By far the greater part of them reaches, after having crossed the raphe, the opposite trapezoid nucleus, entering at its medial hilus (Plate II fig. 2, Plate VIII and IX fig. 15, N°. 11, 12, 13, 14, fig. 16, A and B).

In frontal sections through the capital parts of the corpus trapezoides, those degenerated fibres, demonstrated with their black granules by the MARCHI-method seem to form a garland (Plate VIII and IX, fig. 15 N°. 11—14) thrown round the same-sided trapezoid nucleus and held at its top by the opposite one.

In the systema ventrale nervi octavi therefore there may be distinguished. 1° thick root-fibres from both roots to the nuclei trapezoides, especially to the opposite nucleus, situated among the most ventral transversal fibres of the corpus trapezoides and forming therein the stratum ventrale or the stratum *a* of the corpus trapezoides.

But fibres of small calibre are also found degenerated among the transverse fibres of the corpus trapezoides, as well after the removal of the cochlea as after sectioning the eighth nerve (Plate I fig. 1*a*, and 1*b*, Plate II fig. 2, Plate IX fig. 16 B and C).

They are found in deeper, more dorsal layers of it, pass close to the lateral facies of the spinal root of the nervus V and along to the facial nucleus. A few fibres terminate in the latter nucleus. I certainly accord with HELD in this regard (Plate I fig. 1*a* and 1*b*, Plate IX fig. 16 C and D), but I will come back on this question, when discussing the endings of the fibres of HELD (of the systema intermedium) in the VIIth nucleus.

After their passage ventrally from the facial nucleus, the majority

of these degenerated fibres enters into the medullary capsula surrounding the nuclei supra-olivares and para-olivaris of the same side (Plate II fig. 2 str. dors. corp. trap. *b*, Plate IX fig. 16, B, C, and D) at is lateral and ventral surface.

Notwithstanding the loss of fibres in the surrounding of the olivary nuclei of the same side, still an important number of them transgresses the raphe dorsally from the described thick fibres, reaches the opposite nucleus para-olivaris and ends there in the medial hilus of the medullary capsula of the opposite nucleus para-olivaris et supra-olivaris. In this way these small fibres represent another set of root-fibres, which also participate in the formation of the systema ventrale nervi octavi.

In the „systema ventrale nervi octavi" therefore may be distinguished: 2^{ly}. small root fibres from both roots to the ventral nuclei of the tegmentum on both sides, especially to the nucleus supra-olivaris and the nucleus para-olivaris of the same side. They are situated therein dorsally from the stratum *a*, described before and form the most ventral of the dorsal layers of the „systema ventrale", the stratum *b* of this system.

Now, it must be kept in mind, that a well defined corpus trapezoides is only present in its more distal parts. Especially its limitation dorsally towards the tegmentum is difficult.

Together with the root-fibres, fibres from the ventral auditory nucleus and from the tuberculum acusticum also participate in the formation of the transversal medullary fibres.

These secundary fibres are mixed with the root-fibres, and even when the most extensive degeneration after the section of the n. octavus is found, normal fibres may always be demonstrated between them in the distal part of the corpus trapezoides.

As soon as the oliva superior appears, the ventral part of the tegmentum, here characterised by the presence of a great number of transversal fibres passing the raphe and crossing there the opposite fibres, is no longer defined clearly towards the corpus trapezoides. But still always new fibres — now also originating from the olivary nuclei — are tending to augment these transversal fibres, and in sections through the middle of the olivary nucleus, the ventral part of the tegmentum so far as it is intercalated between them, is totally filled up with transverse fibres. The ventral tegmental transverse fibres between the olivary nuclei never degenerate after the section of the VIIIth nerve.

In that case, however, sections touching the proximal half of the olivary nuclei, demonstrate a new degeneration of root-fibres,

which crossing the raphe, seem to unite the two dorsal borders of the two nuclei. (Plate IX fig. 15 N°. 13 and Plate IX fig. 16 D in *h*). These fibres, also found in degeneration after removal of the cochlea, may scarcely still be reckoned to the transversal fibres of the corpus trapezoides. There will nevertheless exist a certain arbitrariness in judging which of the transversal fibres may be reckoned still to the fibres of the corpus trapezoides, and which of them deserve to be called ventral tegmental transverse fibres. In fact the dorsal border of the corpus trapezoides is not precisely defined, and therefore it is advantageous to reckon all transverse fibres in the ventral part of the tegmentum to the „systema ventrale nervi octavi" and to use no longer the term of corpus trapezoides.

In that case, the last-described root-fibres, which we will meet again when discussing on the „systema intermedium nervi octavi" and especially when their relation to the tracts of HELD and to the auditory fibres of VON MONAKOW has to be settled, form the utmost dorsal layer of the „systema ventrale nervi acustici".

In this way MARCHI-degeneration gives a special and very interesting analysis of this system. As we have seen in the course of this paragraph there are till now, demonstrated four portions in it.

Firstly, there are root-fibres to the trapezoid-nuclei (stratum *a* systematis ventralis).

Secondly, there are root-fibres to the nuclei supra-olivaris (stratum *b* systematis ventralis) and their surroundings. Both are degenerating after the section of the n. octavus.

Thirdly there are fibres, though partly mixed among the former two, forming a third, still more dorsal layer in the systema ventralis (stratum *c* systematis ventralis) not degenerating after the section of the N. octavus and consequently no rootfibres.

Fourthly, still more dorsally, a new small layer of rootfibres appear (stratum *d* systematis ventralis), belonging only partially to the systema ventrale, deriving for the greater portion their origin from the intermedial octavus-system. Their significance will be discussed, when treating of this latter. (Plate IX fig. 15 N°. 13 and fig. 16 D). They seem to unite the dorsal borders of the two nuclei olivares.

f. *The myelinisation-method offers the same results as the Marchi-method, as well in regard to the position of the transversal root-fibres in the systema ventrale nervi octavi, as to the position of the secundary fibres.*

The architecture of the systema ventrale N. octavi, as it has been described in the precedent paragraph, is not such, as is

usually taught by the authors, controversing the existence of root-fibres in the corporis trapezoides.

Ordinarily the opinion is defended, that the systema ventrale is composed only by fibres of the secundary system originating in the ventral auditory nucleus and in the nucleus olivaris superior.

However, the results of the myelinisation are in perfect concordance with those taught by the Marchi-degeneration, demonstrating different root-fibres in the systema ventrale.

Frontal sections through the oblongata of the rabbit, shortly before it is born, and even still the first days after birth may easily demonstrate this concordance. (Plate XII fig. 17 A, B and C).

And as the structure of the corpus trapezoides in the cat seems the same as in rabbits, frontal sections through the medulla oblongata of young born cat may be used likewise (Plate I fig. 5). Sagittal sections may also serve to this demonstration (Plate XIII).

In new-born animals the two auditory roots are both provided with medullated fibres, though the ventral root more than the dorsal. The systema ventrale is partly myelinisated, partly not. Intermittent strata of medullated and non medullated transversal fibres are found in it. In frontal sections one may distinguish in ventro-dorsal direction four layers.

Most ventrally a mighty layer of thick medullated fibres appears (Plate XII fig. 17 B, Plate I fig. 5, Plate XIII fig. 18 F the str. ventr. a.). limited dorsally by a second layer of much smaller, but also medullated and transversal fibres (the stratum *b* in the figures), among which many non-medullated fibres are found. More dorsally between the nuclei supra-olivares then comes a layer of non-medullated fibres (the stratum *c* in the figures) and still more dorsally at the boundary a fourth band of medullated small fibres is seen (the stratum *d* or the fibres of HELD in the figures). The latter fibres seem to unite the dorsal borders of the two nuclei supra-olivares.

In sagittal sections (Plate XIII fig 18 F) again these four layers may be seen, but here as strata of queer-sectioned fibres, and in such a way, that between the two ranks of superficical medullated queer-sections and those of HELD, the stratum of non medullated fibres is present.

There exists a striking resemblance between the frontal section through the oblongata of the new-born rabbit (Plate XII fig. 17 B) and that through the oblongata of the rabbit, treated with Marchi-method (Plate IX fig. 15 N°. 12 and N°. 13) within a fortnight after the rootsection. The medullated fibres in the systema ventrale

in the first case, are situated exactly at the same place, where the degenerated fibres in the second case are found, and the non-medullated fibres are corresponding with the non-degenerated. This accordance does not only prove the existence of root-fibres in the systema ventrale, but also puts it beyond doubt that they are situated there in three layers.

Now, if it were proved, that the Marchi-method demonstrated only root-fibres in degeneration within a fort-night after the root-section; if it were proved that simultanous myelinisation indeed occurred only in fibres of the same system — then to be sure the conclusion would be justified, that the quantity of root-fibres in the systema-ventrale of the VIIIth nerve was very important. But, because I believe, that even within a fortnight after the root-section, a certain quantity of fibres in the secundary system may degenerate and be demonstrated with Marchi-method, and that a certain quantity of fibres in the secundary system myelinisate simultanous with the root-fibres, I am not going so far as to declare that *all* the medullated fibres in the systema ventrale of the new-born rabbit are root-fibres.

As to the fibres of the secundary octavus-system originating in the ventral nucleus, the tuberculum acusticum and the nuclei supra-olivares, they for the greater part, do certainly not degenerate after root-section, and they have not all a myeline-sheath in the new-born rabbit.

These fibres are partly mixed between the medullated fibres (in the strata *a*, *b* and *d*) and partly they are collected in the stratum *c*.

The question remains whether it is proved, how many medullated fibres originate in the ventral nucleus and take their course in the systema ventrale.

If this be the case, such fibres will not be shown by frontal sections through the medulla of the not yet born or new-born rabbit.

In such sections there is only seen a field of medullated fibres near the entrance of the auditory roots (Plate XII fig, 17, A, B, C) which, medullated themselves, pass trough the myelinisated corpus trapezoides, to reach the ventral nucleus and the portio interna of the restiform body. I deem it impossible to decide here, whether medullated fibres are root-fibres or fibres from the nucleus ventralis. Even the argument, that there exists a disproportion between the quantity of medullated fibres in the auditory roots and that in the corpus trapezoides, appears more decisive than it really is, as it is not yet proved that the other roots (VII and V) do not at all enter into it. But yet I believe, that a certain quantity of

secundary fibres from the ventral nucleus towards the corpus trapezoides are myelinised in the new-born rabbit, because in sagittal sections indeed images may be seen (Plate XII fig. 18 B, Plate VI fig. 19 B) allowing the interpretation of a direct transition of medullated fibres from the ventral nucleus in the ventral system on one side, as well as on the other side of a transit of root-fibres in it.

But the accordance between the results of the myelinisation of the root-fibres, and their degeneration after root-section may be sufficient, to elucidate the situation of the root-fibres in the systema ventrale N. VIII, and to establish that, in rabbits their number is more important, than is thought generally.

g. *The secundary atrophy also confirms the existence of transversal root-fibres in the systema ventrale of the VIIIth nerve.*

If really the systema ventrale nervi octavi contains so many rootfibres as is affirmed here, a long controversed question in the central course of the nervus octavus ought to be settled. It is the question, whether the corpus trapezoides does undergo an atrophy or not, after the removal of the labyrinth in the young born animal.

The first investigators on this subject, Forel and Onufrowicz, supposed that the removal of the labyrinth in young rabbit was not followed by any atrophy, worth mentioning, in the corpus trapezoïdes. Baginsky, on the other hand, repeating the experiments, defended the view that the atrophy of this body, after three months, was important enough.

As to my experience, the opinion of Baginsky is right, and the reason of the discordance between his results and those of Onufrowicz may easily be understood.

For, it must be kept in mind, that the spiral and the vestibular are intercalated between the perifical labyrinth and the roots, that the spiral ganglion is necessarily removed with the cochlea, and that the vestibular ganglion remains untouched (unless its removal be intended for) when the contents of the vestibulum only are withdrawn.

Now Onufrowicz has not completely removed the contents of the vestibulum. He describes clearly enough, that the typical attitude of the operated rabbits was not obtained immediately, but weeks afther the operation, owing to a secundary lesion of the vestibulum. His drawings also demonstrate, that the ventral root was very little atrophied, instead of having disappeared.

Consequently the atrophy in the corpus trapezoides that might have been expected, was comparable to that, which follows the section of the dorsal root and must have been very slight.

Baginsky who has probably removed completely the contents of the vestibulum, did not intend to withdraw also the ganglion vestibulare. Consequently he found a more important atrophy in the corpus trapezoides, but not so intense as it ought to be after total disparition of the two roots.

Now this only occurs after the total destruction of the vestibular ganglion, an operation, hardly possible without lesion of the corpus trapezoides itself.

These being the facts, I believe, that the cases of atrophy of the corpus trapezoides observed months after labyrinth-lesions in young born rabbits will offer very great individual differences.

Total atrophy never will be found, because powerful secundary systems find a place in the corpus trapezoides. The different modus operandi used by different investigators, will more or less have exposed the vestibular nerve and its ganglion during the operation and makes the lesion more or less equal to a ventral rootsection. In the case that a true rootsection of both roots is made, both, the dorsal as well as the ventral root have completely lost their fibres, and in those circumstances the corpus trapezoides, or better, the systema ventrale nervi octavi, is always atrophied. This atrophy is chiefly confined to its distal part or at least it is rather easily demonstrable there, as the proximal portions of it are enclosing a larger quantity of fibres from secundary systems.

The figures 3*a* and 3*b*, 13*a* and 13*b* on Plate III are reproductions of frontal sections through the oblongata of a rabbit, which had lived one year after the removal of the labyrinth combined with section of the VIIIth nerve made on the young born animal.

If the left side (fig. 3*a* and 13*a*) is compared with the drawings (in fig. 3*b* and fig. 13*b* on Plate III) of sections at comparable levels on the non-operated right side of the same animal, it is immediately seen, that the distal part of the systema ventrale has totally disappeared, not because there might have been a displacement of the different parts in the central system, but because the roots are *completely* atrophied.

More proximally the systema ventrale reappears and soon it is no longer possible to give a judgment on its atrophy by comparing the two sides. But the atrophy in the distal end of the systema ventrale is not the only fact to be noticed in that case. There also exists a considerable atrophy of the nucleus trapezoides at the oppo-

site side of the operation. It has lost nearly all its fibres. Consequently the cells are lying closer together. The cells themselves have diminished in size, they are shrivelled, of irregulare shape, but none of them has disappeared.

The other ventral nuclei in the tegmentum do not present such intensive atrophy as the opposite trapezoid-nucleus. Yet the medullated surroundings of the nuclei olivares superiores and their accessory nuclei have lost a great deal of their fibres on both sides, but this loss is more apparent at the operated than at the opposite side. Cellular changes also are present in the olivary bodies, but in a slight degree.

Some cells may be diminished in size, perhaps some smaller cells may have disappeared but the cellular change is by no means so intensive as it is in the trapezoid nucleus. This nucleus has suffered an atrophy nearly as intensive as that of the ventral nucleus of the VIIIth nerve, which afterwards in the discussion of the „systema dorsale nervi octavi" will be described.

So, as to my experience, BAGINSKY is right. After complete root-section, the root-fibres disappear totally and with them the systema ventrale atrophies nearly completely in its distal end. After removal of the labyrinth the ventral root does not totally lose its fibres, and the atrophy of the ventral system is less intensive, may even be of small intensity, but in the distal end it is always present.

The atrophy of the systema ventrale is accompanied by a considerable atrophy of the crossed trapezoid nucleus, whose fibres are lost, whose cells are reduced in size, and with a remarkable loss of fibres in the medullary capsule of both nuclei supra-olivares and para-olivares, especially on the same side.

In this way the results of GUDDEN's method are accordant with those given by MARCHI's method and with those of the myelinisation-method.

h. *The most dorsally situated root-fibres (the stratum d) in the systema ventrale nervi octavi and their relation to the fibres of* HELD *or the „systema intermedium nervi octavi".*

As soon as, after section of the VIIIth nerve the degenerated transverse rootfibres of the ventral system, are studied in their course with MARCHI method on a series of horizontal sections of the medulla oblongata, the origin of the most dorsally situated fibres of this systema (the stratum *d*) may be settled with relative facility.

In fig. 16 A—I on plate IX reproductions are given of such a

series of horizontal sections. In fig. 16 A the thick degenerated fibres for the opposite nucleus trapezoides are found (the stratum *a*).

Somewhat more dorsally (in fig. 16 B) the degenerated smaller fibres for the ventral tegmentum-nuclei (the stratum *b*). In the figures 16 C and D the most dorsally situated degenerated root-fibres (the stratum *d*) appear. Expecially fig. 16 D is very demonstrative. From the dorsal border of the olivary body opposite to the rootsection part small degenerated fibres. They cross the raphe, go towards the dorsal part of the medullary capsule of the same sided oliva and reach from there the degenerated homolateral corpus trapezoides. These are the rootfibres in the stratum *d* from the systema ventrale nervi octavi.

But not all the transverse fibres here described take that way. A certain number of them do not enter into the corpus trapezoides, but are united at the dorsal top of the same sided olivary body into a separate bundle (Plate IX fig. 16 E in *h*). This bundle of now queer-sectioned degenerated nerves enters in the formatio gelatinosa of the Vth nerve (Plate X fig. 16 F in *h*). It passes the spinal root in a ventro-dorsal, and at the same time medio-lateral direction (Plate X fig. 16 G, H and I in *h*) until the portio interna of the restiform body is reached.

There, lying laterally from the radix descendens N. VIII, it is found at the medial border of the oval area, confining it against the portio interna and turning dorsally it disappears between the degenerated fibres of the stratum latero-dorsale at the dorsal border of the oval area of the restiform body (Plate XI fig. 16, K and L). The study of the horizontal sections shows, that, after the auditory root-section, the most dorsal layer of rooffibres — the stratum *d* — may not only be pursued in the corpus trapezoides (into the ventral system) but also into the stratum latero-dorsale of the corpus restiforme by means of an intermediary bundle of rootfibres.

This bundle, first discovered by Held, may be called the systema intermedium nervi octavi, for it unites fibres of the dorsal with fibres of the ventral system. This system contains partly root-fibres of both roots, partly fibres of a secundary system.

This intermedial system may be very well demonstrated in frontal sections of the normal animal, for instance in fig. 13*b* on Plate III, it is very well developed.

After removal of the cochlea, some fibres in this system are brought to degeneration and frontal sections are better adopted to demonstrate the course of the intermedial fibres in the latero-dorsal stratum of the restiform body.

As soon as the dorsal rootfibres and their continuation in the latero-dorsal layer are degenerated, a certain number of these fibres, lying upon the lateral border of the oval area of the restiform body, circle round it, first running dorsally, then turning round its dorsal border, and returning in ventral direction through the pars interna C. R. From here they perforate the grey matter of the spinal V^th^ root and reach the dorsal border of the oliva, and taking a medial direction, participate with the transverse fibres in the stratum *d*. (Plate I fig. 1*a*, Plate II fig. 2).

But only a few fibres in this intermedial system are brought to degeneration after the removal of the cochlea.

Much greater is the number of fibres degenerating in this system after root-section. I have already mentioned, how in that case, the number of degenerated fibres limiting the lateral border of the area has increased. Also I have shown, that many of them are seeking a shorter way to its medial border. They perforate the oval area instead of making a curve around its dorsal border.

Apparently those fibres — as described, they are the fibres passing from the ventral root in the stratum latero-dorsale — being themselves intermediary fibres between the roots, help in a considerable manner to augment the intermediary bundle to the stratum *d*. (Plate VIII fig. 15 N°. 5—11, especially fig. 15 N°. 9 und 11). After all, this intermedial system contains fibres of both auditory roots, and may be defined in the following way.

The root-fibres having entered the central system in dorsal direction, pass in the latero-dorsal layer, pass round or through the oval area of the corpus restiforme to gain the ventral direction in its pars interna. Penetrating there and through the spinal root of the Vth nerve, they reach the dorsal border of the facial nucleus and of the medullary surroundings of oliva superior and accessory nucleus on the same side. In these nuclei they send fibres, but the greater part now take a ventral direction and become the transverse fibres of the stratum *d* in the systema ventrale.

This stratum *d* therefore will afterwards be reckoned to the systema intermedium nervi octavi, a view, seeming perhaps arbitrary, as some of its fibres take their origin in the ventral system. But a severe separation is impossible here. For as we will soon demonstrate the intermedial system gives also fibres to the superficial (ventral) layers of the corpus trapezoides.

It has advantages to reckon all the dorsal root-fibres, the so-called fibres of Held, to the intermedial system. But this system not only contains root-fibres. There is also a secundary system and even

an important one, represented in it. A total degeneration of its fibres may only be brought about, after sectioning it at the dorsal border of the oval area. It is never found after root-section (to compare fig. 25. H on Plate XX).

It has been controversed, for instance by LEWANDOWSKY, that the rootfibres here mentioned, should enter in the nucleus of the VIIth nerve. I must, as regards this, be on the side of HELD. The fibres of the intermedial system enter in the dorsal border of the facial nucleus of the same side, as well as those of the ventral system enter it at the ventral border. But the greater number of them ends in the dorsal border of the oliva superior at the same side, and after having passed the Raphe in that of the opposite oliva.

In this way, the intermedial system provides with fibres the dorsal borders of the ventral tegmentum-nuclei, whose ventral, lateral and medial borders are provided by the ventral system of the VIIIth nerve.

k. *The longitudinal root-fibres of the ventral and intermedial systema ascending towards the cerebellum and towards the mesencephalon. Their situation in the lateral lemniscus. Their endings in the nuclei tecti cerebelli and in the nucleus of the corpus quadrigeminum posticum.*

As soon as the root-fibres of the intermedial system and those of the ventral system have met in the medullary field between the spinal quintus-root and the facial nucleus (respectively the superior olivary body) a small quantity of them deviate in longitudinal direction to form ascending and descending tracts, which now ask our attention. They contain rootfibres in a relative small quantity, still enough to be demonstrable, but they have a great importance, because they accompany important other secundary systems, taking the same course.

It is since long known, that in the foetal medulla oblongata, frontal sections may demonstrate between the spinal root of the Vth nerve and the facial nucleus or the olivary body a triangular field of queer-sectioned medullated nerve-fibres, that has obtained several names. It chiefly contains spinal fibres, which are situated there in the antero-lateral tract of GOWERS, and so this name is transferred to the field in the oblongata. Better it is to call it the ventral and ascending spino-cerebellar tract (the dorsal ascending spino-cerebellar tract being represented by FLECHSIG's Klein-Hirn-Seitenstrangbahn). This triangular medullated field found for a short time in the lemniscus lateralis, (Plate XII. fig. 17 A, B and C,

Plate I fig. 5 in l.l.) is named the antero-lateral spinal tract, GOWER's tract or the fasciculus spino-cerebellaris ascendens ventralis, but it must not be confounded with the more dorsally situated fibres (MONAKOW's aberrirendes Seitenstrangbündel with the so-called fasciculus rubrospinalis) between formatio gelatinosa N. V and nucleus N. VII or nucleus columnae lateralis and containing descending fibres. This bundle afterwards shall be recalled to mind.

The farther path of the fibres of the antero-lateral tract is also very well known.

Near the place, where the Vth root leaves the medulla those fibres bend in a dorsal direction (Plate XII. fig. 17 C, f. sp. c. v.) into the lateral fillet, close to the fibres of the bracchia pontis here embracing the medulla.

There they are somewhat dispersed by the appearance of the nucleus ventralis lemnisci (Plate XIII. D and E fig. 18) but reunite in the most lateral layer of the lemniscus lateralis, covering the pedunculus superior cerebelli.

Now they lie free at the surface on the dorsal back of the peduncle, only separated from the half-moon-shaped pendunculus cerebelli superior by the deeper layers of the fillet and by the nucleus dorsalis lemnisci, and their course till now having been always a course in proximal direction changes abruptly.

They now turn distally and medially, cross the dorsal border of the pedunculus cerebelli superior (Plate XV. fig. 14 D) and end in the nuclei tecti cerebelli of the same side, or after having transgressed the cerebellar medulla in those of the opposite side.

So the course of the antero-lateral spinal tract is described by many authors for instance after the hemisection of the cervical medulla.

But not all the fibres of this triangular field follow the here described way. They all bend dorsally at the entrance of the trageminus-root, but in the so-called lateral lemniscus a portion of the fibres have another situation. They also surround the ventral nucleus of the lemniscus, but in the medial medullar layers around it. They also reach the lateral lemniscus where it covers the cerebellar superior pedunculus but as the former tract turns distally, the latter tract still pursues its course (Plate XIII fig. 18 D) dorsally and slight proximally. They partly enter in the corpus quadrigeminum posticum. These fibres participate to the secundary auditory-system as FLECHSIG and those who studied the auditory system with the myelinisationmethod have taught.

Now indeed, rootsection of the nervus octavus within a fortnight

or three weeks after the operation, brings degeneration in fibres belonging to the two here described tracts.

In a frontal series after rootsection studied with MARCHI method it is easy to see (Plate VIII fig. 15 N°. 12 and N°. 13) that on the operated side, degenerated fibres detach themselves from the surroundings of the oliva superior (from the place, where ventral and intermedial system are meeting) and seek their way between the sensible and motor nucleur of the Vth nerve to the utmost lateral and superficial layer of the lemniscus covering the pedunculus cerebelli superior.

From there, turning distally, they may be traced (Plate VIII fig. 15 N°. 11, 10, 9 and 8) to the nuclei tecti mediales cerebelli at the same and at the opposite side. But, it may also be seen, that the root-fibres of the systema ventralis, having crossed the raphe (and on their way remaining for the greater part in the ventral tegmentum nuclei) still are present in the field between oliva superior and spinal root of the Vth nerve of the opposite side. There they meet again fibres of the intermedial system, which also have passed through the raphe. On this way also fibres are going into the opposite antero-lateral tract (Plate VIII fig. 15 N°. 12 and 11), however in much smaller quantity as at the same side.

More easily the degeneration in this tract after root-section may be traced in horizontal sections. (Plate X fig. 16 G, H and I, plate X fig. 16 K, L, M, N, Plate XIV and XV fig. 14 A—E). In fig. 16 at H, the entrance of the degenerated roots is found, covered with black granules. But the degenerated fibres in the lateral lemniscus have already appeared much more ventrally and in Plate IX fig. 16 E they detach themselves from the oliva superior.

These are crossed fibres from the systema ventrale.

But a new increasing of the degenerated fibres in the lateral fillet is found in Plate XI fig. 16 K. These homolateral fibres are coming from the stratum latero-dorsale along the queer-sectioned bracchium pontis. In a more dorsal section (Plate XI fig. 16 M in l.l.) the superficial layer of the lateral lemniscus, medially bordered by the nucleus dorsalis lemnisci, begins to cross the superior cerebellar peduncle and still more dorsally (Plate XI fig. 16 N). These fibres enters in the same-sided and opposite nuclei tecti mediales of the cerebellum.

In fig. 14 (Plate XIV and Plate XV) the direction of the horizontal section is better fit for demonstration. The preparation (Plate XIV fig. 14 A) at first touches the degenerated root-entrance, and degenerated fibres (entered in more ventrally situated sections) are already in the lateral lemniscus on both sides; lying close medial

to the bracchium pontis. To these fibres new ones are joined from the stratum latero-dorsale, and together they form the degenerated area, that may be traced (Plate XIV fig. 14 B and in Plate XIV fig. 14 C in l.l. and f. sp. c. v. a.) to the most lateral and superficial stratum of the lemniscus, separated from the pedunculus cerebelli superior by the nucleus dorsalis lemnisci. More dorsally (Plate XV fig. 14 D and E in f. sp. c. v. a.) they leave the lateral lemniscus, pass dorsally from the peduncle and reach the nuclei tecti cerebelli mediales.

As it is demonstrated these fibres pass on their way the two nuclei lemnisci, and it is not easy to say whether they enter in those nuclei.

As for the nucleus ventralis lemnisci the fibres surround it at its lateral, ventral and distal border, but as the number of degenerated nerves here even after rootsection is always small, I dare not say that they enter in this nucleus. I believe them to do so because after sectioning the tuberculum acusticum (as well as after hemisection of the lower part of the medulla oblongata) they certainly do.

As for the nucleus dorsalis lemnisci the question stands otherwise. The fibres pass this nucleus at its lateral border, but send no collaterals in this nucleus. In this way root-fibres of the ventral, intermedial (but also from the dorsal systema) nervi octavi, reach the nuclei tecti of the cerebellum, in the „fasciculus ascendens ventralis spino-cerebellaris".

But after root-section other fibres in the lateral fillet are brought to degeneration. They may be traced into the nucleus of the corpus quadrigeminum posticum (Plate VIII fig. 15 N°. 12, Plate IX fig. 15 N°. 13—16).

In frontal sections they also are found between the spinal root of the Vth nerve and the oliva, they also bend dorsally into the lateral lemniscus, near the departure of the Vth nerve, (but in a somewhat more proximal region as those, which enter in the cerebellar tract) and form there the medio-ventral surroundings of the nucleus ventralis lemnisci. Having left some fibres in this nucleus, they continue their dorsal direction (Plate IX fig. 15 N°. 15). In the lateral fillet they reach the nucleus of the corp. quadrigeminum posticum, embracing it at its ventral pole.

Studied in horizontal sections these fibres may be likewise demonstrated. As long as the ventral regions of the medulla are concerned, they are not separated from the fibres going to the nuclei tecti (Plate X fig. 16 E—I). In more dorsal sections they become

separated from them (Plate XI fig. 16 K—N, Plate XIV and Plate XV, fig. 14 A—E). They embrace the nucleus ventralis lemnisci, their number is augmented by root-fibres originating in dorsal transverse fibres and as soon as the cerebellar fibres leave the tegmentum to reach the nuclei tecti, (Plate XV fig. 14 D and E) the fibres to the corp. quadrigeminum posticum remain.

Though degenerating on both sides after one-sided root-section the greater quantity of these rootfibres is found on the opposite side.

After root-section of the VIIIth nerve therefore also ascendent tracts of root-fibres may be demonstrated with MARCHI method. There are two.

Rootfibres of the N. octavus are found in the „ascending ventral spino-cerebellar tracts" to the nuclei tecti mediales, especially in the homolateral tract.

Rootfibres of the N. octavus are also found in the lateral fillet to both corpora quadrigemina postica but chiefly in the lateral fillet of the opposite side. I repeat, that after rootsection, the number of degenerated fibres in those tracts is not very considerable, though they are evident.

After the removal of the cochlea the number is again diminished. Then they must be sought for attentively, and I believe that Marchi-method in such cases has nearly reached its utmost limits. For, even in a fortnight, the black granules, characterizing the degenerated fibres, are spread in the neighbourhood if there exists a localised degeneration, and the number found in the two described tracts after cochlea removal is very limited, especially in the cerebellar tract. None the less I am convinced that even after cochlea removal they may be demonstrated.

I therefore agree completely with HELD, who has long since defended the view, that primary fibres penetrate in all the secundary systems and accompany them, but I also think that the number of root-fibres entering in secundary systems is very different in different animals.

It is here perhaps the place to remark, how interesting it is, that the very great number of root-fibres existing in the ventral and intermedial system, is reduced to a very small quantity in the lateral fillet to the corpus quadrigeminum. Indeed, if they were not augmented considerably with rootfibres from the dorsal system, rootfibres to the corpus quadrigeminum would be rare.

There fore I believe that the root-fibres in the *ventral* system (the corpus trapezoides) have chiefly the significance to intercalate the ventral tegmentum nuclei in the reflex-system of the nervus octavus.

As I am convicted that fibres conducting sound must pass through the corpus quadrigeminum posticum, and as the greater part of the root-fibres to this nucleus originate in the intermedial and *dorsal* system, I believe that true auditory fibres must be sought in transverse *dorsal* fibres. They chiefly are as we will see afterwards MONAKOW's transverse fibres, and MONAKOW is right to call them the „auditory" fibres. And on the other hand, the views of FLECHSIG and other authors after him, holding that the ventral system is to be compared with the root-fibres in the chiasma nervorum opticorum, and that the corpus trapezoides forms a kind of semi-decussatio of the fibres towards the corp. quadr. posticum — those views appear to me not sufficiently founded. The relations of the primary auditory nuclei and the ventral tegmentum nuclei with the lateral fillet are too complicated to allow such comparisons.

1. *The rootfibres in the stratum latero-dorsale of the corpus restiforme. The nucleus ventralis nervi octavi, the tuberculum acusticum and the systema dorsale nervi octavi.*

More complicated than the ventral system, is the dorsal system of the eighth nerve.

As we have seen in the preceeding paragraphs, the important layer of fibres curving round the area ovalis of the corpus restiforme as a stratum latero-dorsale is not composed exclusively of dorsal root-fibres.

Dorsal fibres of the ventral root also participate in its formation, as is demonstrated equally by Marchi-method after rootsection and by the myelinisation-method.

In sections through the medulla oblongata of the foetal rabbit (Plate VI fig. 19 B, Plate XIII fig. 18 A and B) it is impossible to determinate, from which of the two rootlets — from the dorsal root or from the intermediary rootlet going from the ventral to the dorsal root — originate the medullated fibres, entering in the ventral nucleus and in the tuberculum acusticum.

MARCHI-method may teach us more. After removal of the cochlea there may be demonstrated an intense degeneration in the ventral nucleus and in the tuberculum acusticum. After section of the nerve there is a slight but strictly localisated increase of the degeneration in the ventral nucleus, where as the degeneration in the tuberculum acusticum is nearly as intensive in both cases.

Therefore it may be established, that the greater part of the dorsal root-fibres, degenerating after cochlea-removal are ending in

the ventral nucleus and in the tuberculum acusticum. In reference to this the ventral nucleus and the tuberculum acusticum may be called the nuclei of the dorsal root.

But only thus far I can accept the common view. To admit that these nuclei are exclusively the endings of the dorsal root, and to deny that the ventral send a few fibres to them, would be contrary to my experience. The study of the details of the degeneration in the ventral nucleus after removal of the cochlea, may establish that dorsal-root-fibres, then degenerating, enter it in its distal and ventral pole, and, united together to a rather sharply limited peduncle, penetrate it in a dorsal and slightly proximal direction.

In this way the ventral nucleus is divided in two portions, a distal and ventral one much smaller than the proximal and dorsal portion.

The dorsal root, the peduncle crossing the nucleus, now sends little bundles, containing 8—20 fibres each, like the radiation of a fan in both portions. Therefore the nucleus is making the impression, as if round the root-peduncle were a great number of little medullated nerve-bundles, and between these, the cells of the ventral nucleus are found. The little bundles have different directions. The more dorsally and proximally they are situated, the more their direction tends to become longitudinal.

Now it may be demonstrated in frontal sections (for instance in Plate II fig. 2 or Plate IV fig. 8) as well as in horizontal sections (for instance Plate V fig. 9, fig. 10, Plate XI fig. 16 K or Plate XIV fig. 14 A) that in the disto-ventral portion of the nucleus nearly all the little bundles are degenerated. Whether only the cochlea be removed or the root-sectioned the result in both cases is a very intense degeneration in the disto-ventral part of the nucleus. And after removal of the cochlea the degenerated fibres therein are so many, that an increase, even if it took place after octavus-section, would not be betrayed to the observator.

The disto-ventral portion of the nucleus surely seems to receive none but dorsal-root-fibres.

With the dorso-proximal portion of the nucleus it is otherwise. Indeed in this portion also degenerated fibres are found among the little bundles, which it contains.

But the farther distant the little bundles are from the root-peduncle, according to their situation dorsally and proximally, the more the number of degenerated fibres in them is reduced. (Plate IV fig. 8, Plate V fig. 9, Plate II fig. 2). In the dorso-proximal top of the

nucleus, there are always found normal fibres between the degenerated bundles, whether the cochlea may be removed or the nerve sectioned.

But in the latter case, the degeneration in the more dorsal and proximal parts of the nucleus appears more intensive as the comparison of. f. i. fig. 2 on Plate II (cochlea-removal) with the fig. 8 on Plate IV or fig. 9 and fig. 10 on Plate V (octavus-sectioning) may demonstrate.

But as in its dorso-proximal border in both cases the normal fibres reappear in the ventral nucleus, it may be stated, that the rootfibres chiefly enter at its disto-ventral pole, that the secundary fibres chiefly leave it at its dorso-proximal border, but in this manner that the entrance of root-fibres as well as the exit of secundary fibres principally take place along the medial border of the nucleus.

In fact the dorsal root meets the medulla somewhat distally from the nucleus, and the disto-ventral portion of it, is so intimately joined at the root, that it forms a part of the stratum latero-dorsale, which here, lying close to the area ovalis of the C. R. surely contains exclusively dorsal root-fibres.

As soon as the fibres of the stratum latero-dorsale, in their curvature round the area ovalis, have reached the dorsal border of this area, they begin to diverge from it. They spread themselves like a fan-radiation (see fig. 1*a* Plate I) between the tuberculum acusticum, the lateral portion of the dorsal nucleus of the eighth nerve and the pars interna of the corpus restiforme. Even in distal regions, but more easily distinguished in regions lying more proximally other fibres are running between the dorsal root-fibres in the stratum latero-dorsale.

We have already demonstrated that a little more proximally the dorsal root-fibres of the ventral root aid to increase the stratum latero-dorsale. They remain intact after cochlea-removal, and degenerate after section of the octavus (Plate VIII fig. 15 N°. 8, Plate IV fig. 8). The greater part of them hold themselves close to the oval area, and curving round its dorsal border or penetrating through it, they help to compose the systema intermedium nervi octavi.

Being composed distally of dorsal root-fibres, proximally of ventral rootfibres, this intermedial system originates from the most internal fibres of the stratum latero-dorsale, which may be considered as the beginning of the systema dorsale nervi octavi.

But a few fibres of the ventral root, may increase the rest of the dorsal root-fibres, which, having passed the ventral nucleus,

now are ranged in the lateral layer of the stratum latero-dorsale. There between the latero-dorso-proximal portion of the ventral nucleus (always providing this with fibres) and the oval area they run dorsally from this area, but soon diverging from it, they form the external radiation of the fan, radiating dorsally round the oval area.

These fibres of the external layer of the stratum latero-dorsale, bear as its stratum medullare profundum the tuberculum acusticum. They are degenerated in an intensive manner after removal of the cochlea (fig. 1*a* on Plate I) perhaps still more intensive after nerve section (Plate IV fig. 4) and in the distal regions of the stratum-latero dorsale, they a forming a second system of root-fibres.

Therefore now already two systems appear, participating to the systema dorsale nervi octavi dorsally from the oval area, and both being root-fibres.

Between the intermedial system curving closely round the oval area, and the rootfibres, which in distal regions form the stratum profundum medullare tuberculi acustici however new fibres make their appearance.

They are fibres, which do not degenerate, even after the section of the nerve (fig. 1*a* on Plate I in β).

They are found already in distal sections and increase in quantity proximally.

They are secundary fibres emanating from the dorsal and proximal border of the ventral nucleus and from the tuberculum acusticum.

They are mixed among the degenerated fibres of the two described layers but in the middle part of the radiation of the fan, they form a layer of intact fibres where nearly no degenerated fibres are found. But here no longer may be spoken of the stratum latero-dorsale, another portion of the systema dorsale nervi octavi has begun, usually called MONAKOW's stria medullaris acustica. As to its distal end, it is now composed of:

1° degenerated root-fibres of both roots, partly forming the intermedial system, the internal layer;

2° intact fibres of a secundary system;

3° degenerated root-fibres, chiefly belonging to the dorsal root, the external layer.

The latter fibres form the basis, on which the tuberculum acusticum is resting, and may be also called the stratum profundum medullare of this ganglion. They are sectioned longitudinally in frontal sections.

Perpendicular to the course of these fibres very small degenerated

collaterals now detach themselves and penetrate into the tuberculum. In frontal sections they appear situated as the spakes in a wheel. They are radial fibres to this ganglion which, sectioned frontally, has the shape of a circle segment. Those radial fibres are only traceable unto the level, where the great pyramide-shaped cells of the ganglion are found.

Now on horizontal sections again the fibres of the stratum medullare profundum are touched in a longitudinal direction and again the collaterals leave them perpendiculary.

In this way their situation is the cause of a very peculiar aspect of the degenerated ganglion, if coloured by Marchi-method.

It appears to be divided into two rings, the outer is quite free from degenerated fibres and extends to the layer of large cells. The inner ring is thickly specked with very small black granules — the degenerated collaterals — and radial fibres, also containing these black granules, are easily to be distinguished. The two rings are resting upon the deep medullary layer (fig. 1*a* Plate I, Plate VIII fig. 15 N°. 6, Plate XI fig. 16 L and M, Plate XIV fig. 14 C) and bordering the outer (non degenerated) as well as the inner (degenerated) ring the large pyramidal cells appear. In this way Marchi-degeneration divides the tuberculum acusticum into four or five layers (Plate VI fig. 6). Named from its centrum towards the periphery they are:

1°. The deep medulla or the stratum medullare profundum— containing root-fibres chiefly of the dorsal root.

2°. The deep grey matter or the stratum griseum profundum— containing degenerated collaterals of root fibres and small cells.

3°. The middle grey matter or the stratum griseum medium— containing the large nerve cells.

4°. and 5°. The superficial grey matter and fibres or the stratum griseum superficiale and the stratum medullare superficiale, where no degeneration is found after rootsection.

Moreover, in the same way as the nucleus ventralis, the tuberculum acusticum is receiving the greater part of the root-fibres at the distal end. At its dorsal and proximal end the black globules in the inner ring are less thickly spread and normal fibres mix between the degenerated of the stratum profundum medullare, seeking their way to the middle layer of the radiation found dorsally of the area ovalis.

Now, when following this radiation in proximal direction, the aspect changes, because the tuberculum acusticum gradually takes a more lateral instead of a dorsal situation. At the same place the

dorsal nucleus of the VIIIth nerve extends more laterally and the portio interna of the C. R. has become more extended in such a way, that the large cells of DEITERS, which in distal sections only were found at its latero-dorsal edge on the medial border of the oval area, now make their apperance on its dorsal border.

In this way the radiation of the fan is enlarged. Laterally always collaterals of the stratum medullare profundum enter into the tuberculum, but dorsally the radiation is now opened towards the lateral part of the dorsal nucleus n. VIII and towards the portio interna corporis restiformis. After removal of the cochlea, there are always found degenerated fibres here.

They are the dorsal root-fibres, remaining after the emission of the trunk to the ventral nucleus and the collaterals to the tuberculum acusticum.

Those fibres are tending for the greater part towards the lateral part of the dorsal or triangular auditory nucleus. Their number, is chiefly in proximal regions increased by root-section of the N. octavus. If I have rightly understood LEWANDOWSKI, those fibres would be represented in dogs by a contracted bundle, described by him under the name of the fasciculus solitarius of the eighth nerve. Apparently LEWANDOWSKI has had in mind a comparison with the fasc. solitarius nervi vagi. But in rabbits this radiation of root-fibres towards the lateral cells of the dorsal nucleus occurs continually and so there is no reason to speak of a fasciculus solitarius. The dorsal nucleus in rabbits extends rather far proximally, even so far, that when the fibres of the oval area have found their way to the cerebellum and no longer belong to the medulla (f. i. Plate VIII fig. 15 N°. 8—12), still the lateral part of the nucleus dorsalis exists.

Now continually fibres are running to this part. In the more distal part, they are chiefly rootfibres of the dorsal root, more proximally they are merely dorsal fibres of the ventral root, and as the corpus restiforme evades to the cerebellum the medial fibres of the ventral root enter in it.

But the distal fibres, we have here in view are chiefly dorsal rootfibres, degenerating after removal of the cochlea. They take different ways.

1°. They send collaterals in the lateral part of the dorsal nucleus to its lateral group of cells.

2°. A few fibres go farther between the dorsal nucleus and the portio interna corporis restiformis and become dorsal transverse fibres.

3°. A few fibres penetrate into the portio interna and augmented

with a few fibres from the internal layer of rootfibres, which leave the intermedial tract, they enter among the fibres of the descending ventral root.

The latter two systems will be studied afterwards, because they may better be demonstrated after section of the nervus octavus.

But after removal of the cochlea there is found an important degeneration in the dorsal systema, that in this way is composed of the following layers.

1°. rootfibres to the ventral nucleus.

2°. rootfibres to the tuberculum acusticum.

3°. rootfibres which reach more proximally and go, α to the lateral-cells of the dorsal nucleus, β between dorsal nucleus and portio interna to become transverse dorsal fibres that will be described afterwards, γ penetrating into the portio interna to the descending and ascending octavus-roots to be described afterwards.

4°. fibres, emanating from the ventral nucleus and the tuberculum acusticum.

5°. rootfibres forming the already demonstrated intermedial system.

The three last named fibres form together the layer at the dorsal border of the area ovalis, described by v. MONAKOW as stria acustica. It is increased by new fibres originating in the cerebellum and they all participate in the structure of the dorsal systema of the nervus octavus.

m. *The results of the secundary atrophy, as far as it may be applied to this question, allow the same views as those, which are defended in the preceedent paragraph, and the myelinisation-method also confirms the description given there of the achitecture of the systema dorsalis nervi octavi.*

I have demonstrated, that MARCHI-method allowed a division of the stratum latero-dorsale in several layers. Degenerated rootfibres formed an internal and an external layer, holding between them the non degenerate fibres of a secundary system (fig. 1*a* on Plate I by β). The secundary atrophy within the stratum latero-dorsale some months after the root-section in a young born animal enables to isolate therein all fibres that are no root-fibres.

For instance in fig. 3*a* and in fig. 13*a* on Plate III the atrophy in the distal end of the stratum latero-dorsale was drawn a year after the root-section in the young-born animal. In this case the two nerve-roots of the n. octavus have completely disappeared and as the comparison with the non-operated-side of the medulla demon-

strates immediately (drawn in fig. 3*b* and fig. 13*b* on Plate III), there is found an intense atrophy in the stratum latero-dorsale. At the non operated side, this layer may be found well developed with the tuberculum acusticum resting upon it. The stratum medullare profundum and the stratum griseum profundum of this nucleus — the inner ring — is richly endowed with medullated fibres.

At the operated side (fig. 3*a*) nearly all the fibres in the inner ring have disappeared. The stratum griseum profundum does scarcely exist, and the stratum medullare profundum also is much reduced. Because the root-fibres have disappeared, the medullated fibres now found in the stratum medullare profundum must belong to the system of secundary fibres. And these secundary fibres now form a small trunk of small fibres originating somewhat laterally from the ventral nucleus.

Here is isolated the trunk of the secundary system from the tuberculum acusticum (fig. 3*a* on Plate III).

But at the same time the ventral nucleus is much reduced in size, and especially its ventro-distal portion. Here also in the first place the fibres, constituting the rootbundles in this nucleus have completely disappeared, at least in its distal end, but at the dorsal and proximal border fibres reappear. Therefore at its medial border, increasing towards the dorsal and capital end of the nucleus, a relative strong bundle is found, a second trunk of secundary fibres.

Those two trunks meet each other at the dorsal border of the area ovalis (see fig. 3*a*), the external from the tuberculum, the internal from the ventral nucleus. They form together the much reduced stria acustica, but now a stria acustica, wherein no longer any root-fibres are exsiting.

It is true that in normal frontal sections also the two trunks of the secundary system may be demonstrated (compare fig. 13*b*) but not so evidently, because there they are complicated by the presence of the rootfibres.

However, from the atrophied radiation of the stria acustica, it is now possible to trace several systems of fibres, in their farther course.

For instance its internal layer may be traced round the area ovalis into the intermedial system. This system is much reduced, now that it has lost its rootfibres, but it contains a secundary system. Its outer layer may be traced in the transverse (see fig. 13*a* and fig. 13*b*) dorsal fibres, passing between the dorsal nucleus — which has lost many fibres — and portio interna. These fibres also are reduced in quantity (see fig. 13*a* and 13*b* str. dorsale), but enough of them are left to postulate an important secundary

system there. Between them many fibres still penetrate into the portio interna towards the region where the radix descendens of the n. VIII is found. They are less in number than at the other side.

Though the ventral root has completely lost its fibres, the descendent root — though its atrophy may be called very important — still contains many fibres. Therefore secundary fibres existing in this area may be presumed.

The atrophy method therefore makes from the stria acustica the exact reverse of what Marchi-method makes from it. The latter shows degenerated fibres on both sides of a normal secundary layer, the former shows the central layer without the rootfibres bordering it.

In the same way as the partial atrophy was formerly demonstrated in the corpus trapezoides, it is now found in the stria acustica. Indeed, between the stria acustica and the corpus trapezoides in many regards a paralel may be drawn.

Both are atrophying partially, both are possessing an important secundary system bordered on the two sides by root-fibres, both obtain secundary fibres from the same ganglia—ventral nucleus and tuberculum acusticum.

Frontal sections through the medulla of young born animals or of elder foetus, also show very clearly the existence of the different layers in the stratum latero-dorsale and in the stria acustica.

In the new-born cat (Plate I fig. 5 in β) for instance, two layers of medullated fibres, an internal and an external one are separated by a layer of non medullated fibres.

In the elder foetus of a rabbit (Plate XII fig. 17 A in β) the medullated internal layer forming the intermedial system, and the medullated external layer forming the stratum medullare profundum of the tuberculum are separated by a portion without medullated fibres.

If compared with the stratum latero-dorsale, as Marchi-method after cochlea-removal or root-sections shows it (fig. 1*a* on Plate I in β), the similitude is very striking.

The paralellism between the dorsal and the ventral systema again appears very clearly.

Both possess an external border of root-fibres, a secundary system and on their internal border the rootfibres of the intermedial system.

The atrophy in the primary nuclei, which accurs months after the rootsection in the young animal, is now chiefly characterised by an enormous loss of fibres, rootfibres as well as collaterals, but it is remarkable that the loss or the changes in the nervous cells of these nuclei is less evident. Firstly it may be called in mind,

that with NISSL's method used a fortnight after removal of the cochlea or after root-section, were not shown any degenerative changes in the cells of the nuclei, neither in the tuberculum, nor in the nucleus ventralis or in the olivae or nuclei trapezoides.

But in cases of atrophy the question stands otherwise. As regards the tuberculum acusticum, for instance there certainly never occurs any atrophy of the large cells.

A preparation made on purpose to judge the cells in that nucleus, for instance a NISSL preparation of the normal one (Plate VI fig. 6) may show, that 1° in the superficial medullated as well as in the grey layers, small cells of spherical and pyramidal shape are scattered.

2° the large pyramidal-shaped cells are found in the middle grey layer.

3° smaller pyramidal-shaped cells do appear in the deeper strata.

The more profoundly the layer is searched, the smaller the cells are found to be, their prevailing shape becoming spherical or elliptical, and their longest axis lying in the direction of the longitudually sectioned fibres of the stratum medullare profundum. These elliptical-shaped cells are increasing in number towards the distal pole of the nucleus, and in its neighbourhood, somewhat laterally situated between tuberculum and ventral nucleus, they are accumulated in such a manner that a true nucleus is formed. This accumulation is described as the „nucleus proprius rami dorsalis". This nucleus continues towards the stratum profundum of the tuberculum, it also sends prolongations along the lateral and medial borders of the ventral nucleus, embracing it, and at the distal end of this nucleus (Plate VII fig. 7 F and G) the number of the small cells is again much augmented.

In the ventral nucleus cells of triangular and multipolar shape are found, having nearly the same size of the larger pyramidal cells in the tuberculum.

Now, for the tuberculum acusticum I agree with nearly all the elder investigators, that in cases of atrophy after rootsection, I never have seen any change in the large pyramidal cells, ranged in radiar lines in the medial grey layer. On the contrary the small cells in the deeper layers are disappearing in great number and in the same time indeed nearly all cells of the nucleus proprius are gone.

In NISSL-preparations however the large cells of the tuberculum are not altered even months after rootsection. And yet after a section through the dorsal system in four days all these large cells are swollen, their tigroid is desintegrated, briefly they show chromatolysis.

Now GOLGI-method shows easily that the large pyramidal cells send their axones towards the stria acustica and VON MONAKOW

has proved, that they disappear totally after a partial section of the crossed lateral fillet.

For all these arguments it may be accepted as a certain fact, that from the large pyramidal cells in the tuberculum acusticum originates a secundary system. Why then, those cells do they not suffer any atrophy after root-section made long before? It appears to me, that the cause of this behaviour after rootsection may be found in the circumstance, that the collaterals of the rootfibres do not terminate directly at the large pyramidal cells. I believe that the small elliptical-cells in the deeper layers, the cells accumulated along the root-fibres, the cells of the proper nucleus of the dorsal root, are cells intercalated between the rootfibres and the secundary system.

And as for the ventral nucleus, it seems to me that the same view may be defended.

This nucleus is reduced very much in cases of atrophy, to $^2/_5$ of its original size as compared with that of the other side. Its ventro-distal end has suffered the greatest changes. The loss of fibres in this nucleus is enormous, and according to it the cells are lying close together. I cannot completely agree with Onufrowicz that the cells disappear in the nucleus, or that they are found to have diminished in size so very much as his drawings represents it.

This only is the case in its disto-ventral pole, where again the small elliptical cells are found. In the dorso-capital regions there are found a great many cells, which have degenerated not at all or very slightly, but they are lying closer together, because the bundles of root-fibres are gone. Here in this nucleus I believe that again the root-fibres do not immediately terminate at the larger cells, from which secundary systems originate, but by means of intercalated small cells.

And such may be also the case in the olivary bodies, where again small cells may disappear, but the larger ones are found unaltered. Only this is not the case in the cells of middle size from the nucleus corporis trapezoides. Here as Marchi-preparations show, the degenerated collaterals of the rootfibres fill up the nucleus. Moreover the peculiar terminations at the cells (the „Endfüsschen" of Held) in this nucleus is kwown. But in this nucleus — opposite to the rootsection — the cells are not only lying closer one to another than in the nucleus, corresponding to the undamaged root, but they are considerably reduced in size.

I believe that the dorsal root entering at the distal end of the nucleus ventralis, provides this nucleus with rootfibres, and afterwards entering in the deep medullar layer also provides the tuberculum acusticum, and that the ventral root only enters in these nuclei with a few dorsal

fibres. Between the endings of the rootfibres and the origin of new secundary systems however there must be intercalated small cells.

n. *The nucleus dorsalis nervi octavi.*

Before returning to the different root-fibres, which I left in the radiation at the dorsal border of the area ovalis, it now will be necessary to describe two very important parts of the auditory system, viz: the nucleus dorsalis nervi octavi and the portio interna of the corpus restiforme.

Else the nuclei situated therein, and the fibre-systems ending in them or passing through them, may not easily be understood.

Now the dorsal nucleus is the most extensive of the auditory nuclei. In frontal sections it begins already at a level with the clear nucleus of the Xth nerves and ends nearly at the entrance of the pedunculus superior cerebelli (see for instance Plate VIII fig. 15 N°. 4—11) in the metencephalon.

At its largest extensity it takes nearly the whole bottom of the 4th ventricle, between the genu of the VIIth nerve and the portio interna corporis rectiforme.

From the tuberculum acusticum, its lateral part is not always distinctly separated. If it is separated from it, the radiation of the dorsal systema at the dorsal border of the oval area confines laterally the nucleus. The large number of transverse fibres originating from this radiation and bending in medio-ventral direction, as transverse dorsal fibres, distinctly separate the nucleus from the portio interna.

In this way, laterally limited by the descending VIIIth root, ventrally by the formatio gelatinosa of the spinal Vth root, by the formatio reticularis and the genu of the VIIth, the dorsal nucleus obtains its triangular shape, its basis situated at the bottom of the 4th ventricle its apex resting upon the descendent root of the radix ventralis (f. i. Plate III, fig. 13*b*).

In the ventricle it is making three pro-eminencies. The most medial one, next to the raphe is in reality caused by the knee of the VIIth nerve. More laterally, the larger vault is made by the principal mass of cells of the dorsal nucleus, and a smaller, most laterally situated, is the expression of its lateral mass of cells (see Plate VII fig. 7. F and G). Now if the limits of the dorsal nucleus are not precisely defined, especially its relations towards the portio interna of the C. R., it afterwards may offer difficulties to fix the relations of the auditory root-fibres to it and to the nucleus of Bechterew. And in order to avoid the confusion which very often

has arisen amongst the authors concerning this region, I prefer giving a description of the cellular structure of the nucleus dorsalis N. octavi and its surroundings, before describing the entrance of root-fibres or the exit of the secundary fibres.

In a cell-preparation from the dorsal nucleus at its greatest extensity four groups of cells may be demonstrated (Plate III fig. 7A—H *a*—*e*).

a. a medial group (in *a*)

b. a principal, dorsal (in *b*) or central group

c. a lateral group (in *c*)

d. a ventral group (in *d*)

without reckoning to it a fifth group, the cells of the

e. nucleus nervi VI, which are closely allied to, and perhaps are a part of the dorsal nucleus (in *e*).

From these four groups, the three first named have nearly the same structure. Small cells are found in them, mostly elliptical or polygonal cells. Occasionally a larger pyramidal cell is found among the small ones. Together they allow the description as one single larger cell-mass. The principal or dorsal cellgroup was already present at the distal end of the nucleus, and as the nucleus exfoliated two alae were adjoined to it, the one medially, the other laterally, which again disappeared at the capital end. But as to the fourth group, it is quite another case. Its structure differs very much from the other three. The reason to distinguish the three former named one from another, is chiefly their relation to the auditory root-fibres.

1^{ly}. The medial group of cells (Plate VII fig. 7 A—H in *a*) has nothing to do with rootfibres. Situated, in distal sections, dorsally from the genu N. VII, in proximal sections, medially from it, it never is found covered with black granules, neither after cochlea-removal, nor after section of the nervus octavus.

2^{ly}. The lateral group of cells (Plate VII fig. 7 A—H in *c*) appears in the level of the tuberculum acusticum. It is laterally bordered by the smaller cells in the deep grey layer of this nucleus and medially by the cells of the principal group. But the separation between those cells is not very distinct.

As we have already seen, after removal of the cochlea, the degenerated root-fibres enter in its distal regions, from the outer layers of the radiation of the stratum latero-dorsale.

But as soon as the tuberculum acusticum does no longer cover dorsally the C. R. and has retired laterally (Plate VII fig. 7 H in *c*) this lateral group of cells is thrown more medially, because the portio interna of the C. R. is penetrating between it and the tub. acusticum.

For this portio interna has strongly increased in these regions. Partly because the nucleus of DEITERS has grown more extensive, partly because more and more ventral root-fibres have entered, partly because more and more fibres of the nuclei tecti cerebelli did find a place there.

Together with the portio interna the ventral group of cells in the dorsal nucleus is also increased and retiring laterally. It does no longer form the ventral border of the principal group only, as it was the case in distal sections, but it begins to border it also laterally. At the same time the lateral group has become smaller and is flowing together with the principal group.

3^{ly}. This dorsal or principal group (Plate VII fig. 7 A—H in *b*) is very important. As soon as after rootsection, the ventral fibres degenerate and with these the descending root of the ventral radix, it is easily demonstrated that degenerated collaterals leaving perpendicularly the descending root-fibres penetrate into it (Plate V fig. 9 and fig. 10). It is then very thickly specked with black granules.

The descending root however accompanies in its distal course, the ventral apex of the dorsal nucleus, and though it is situated in the medio-ventral part of the portio interna, it is surrounded by cells, forming a cellular nucleus, situated dorso-medially from the root-fibres.

The name of nucleus griseus radicis descendentis, given to it by LEWANSDOWSKI, is a most fit one. These cells are of very different size, but among them there are found many larger polygonal and pyramidal ones, not so large as the cells in the nucleus of DEITERS, a few of them reaching perhaps their size.

Those cells, now are hardly distinguishable from the cells in the ventral group of the nucleus dorsalis N. VIII.

4^{ly}. The ventral group of cells (Plate VII fig. 7 A—H in *d*), though containing cells of different size, possess among smaller ones many larger cells, a few of them also approaching the size of the large cells of DEITERS.

The ventral apex of the dorsal nucleus truly has quite another structure as its basis, rather the same structure as the nucleus griseus rami descendentis. Both receive a great quantity of root-fibres of the descending root, and both are passed by root-fibres, which must penetrate them, to reach the principal nucleus, as well as the lateral nucleus.

As soon as the tuberculum acusticum is gone laterally, and the ventral root has entered, a part of its fibres are tending proximally (as in Plate IV fig. 8 in a somewhat oblique frontal section is seen). I have demonstrated that, in the same moment the ventral

group of the dorsal nucleus is forming the lateral border of its principal and lateral cells. Here the nucleus griseus radicis descendentis is not yet gone, and is joined to the ventral group. A little more proximally the corpus restiforme (or its oval area) retires into the cerebellum, and nearly at the same moment the nucleus of DEITERS disappears. But the nucleus griseus of the ventral root-fibres together with the ventral group of the dorsal nucleus have remained, and are situated still laterally of the latero-dorsal cells of the dorsal nucleus. And on that plan cells of different, mostly of medial size, are forming a larger area (Plate IV fig. 8), which has been called since long the nucleus of BECHTEREW. It might have been called also the nucleus griseus of the ascending root.

It seems to me, that there exists some difficulty to define the nucleus of BECHTEREW. I only wish to state, that this nucleus certainly may not be identified with the proximal portion of the lateral groop of cells in the dorsal nucleus, as is done by some authors, f. i. LEWANSDOWSKI.

The relations of the ventral rootfibres to the nucleus griseus radicis descendentis and to the cells of the ventral apex of the dorsal auditory nucleus, during the whole course of the descending root are clear enough. They become still more transparent, as the nucleus of DEITERS has disappeared and the ventral rootfibres instead of forming a descending radix have a somewhat proximal direction (the ascending root), but the relation of the root-fibres to this nucleus, with its cells of midling size between small ones, has not altered. Only its name is here no longer „a nucleus of the ascending ventral rootfibres". This is the nucleus of BECHTEREW, lying between the corpus restiforme, as it retires towards the cerebellum, and the latero-dorsal cells of the dorsal nucleus, or between the nuclei tecti cerebelli and the motor nucleus of the nerve V in the lateral wall of the ventricle, characterized by cells of midling size scattered between small cells (Plate IV fig. 8 and Plate V fig. 9).

Now still remains the nucleus of the VIth nerve, as the last of the cell-groups entering into the surroundings of the nucleus dorsalis nervi octavi. (Plate VII fig. 7 A—H). The cells of this nucleus, scattered round the genu of the VIIth nerve, bordered, but not sharply, by the cells of the principal and the medial group of the dorsal nucleus, are found latero-dorsally from the genu N. VII in distal sections, latero-medially from it in proximal sections. In this way, they force the leaving root-fibres of the VIth nerve, to evade the genu, before taking their straight dorso-ventral direction.

The cells of this nucleus also receive rootfibres from the nervus octavus.

o. *The portio interna corporis restiformis (juxta-restiform body) and the root-fibres of the central root.*

As the portio interna, lying between the oval area of the C. R. and the dorsal auditory nucleus, is nearly everywhere passed by or composed with auditory root-fibres, it is necessary to give a minute description of its relations to these fibres.

In frontal sections, its distal end begins as soon as the nuclei of the posterior spinal columns reach their proximal endings. As soon as the dorsal ascending spino-cerebellar tract (FLECHSIG's Kleinhirn-Seitenstrangbündel), covering dorsally the spinal Vth root, attains its place in the oval area, grey matter appears at the medio-dorsal side of this tract. (Plate VIII fig. 15 N°. 1 and N°. 2). There it is situated laterally of the proximal ending of the nucleus of BURDACH, and as here the fibre-mass of the posterior spinal column soon has found an end, there appears rather abruptly an area of transverse sectioned nerve-fibres, united in little separate bundles, medio-ventrally from this grey matter. (see fig. 15 N°. 3 on Plate VII).

The grey matter is the nucleus proprius of the restiform body, the area with separated bundles contains the distal bundles of the radix descendens nervi octavi. (Plate VII fig. 15 N°. 3 in N. C. R. and in r. desc. N. VIII). Together they form the distal end of the portio interna.

As soon as the nuclei from the posterior columns have ended, at first laterally but soon dorsally of the nucleus of the Xth nerve (Plate VIII fig. 15 N°. 4. n. d. N. VIII) the dorsal nucleus also makes its appearance, and from that moment the different constituants of the juxta-restiform body are present. Bordered at its medial side by the dorsal nucleus and closely related to it, ventrally resting upon the Vth spinal root, laterally limited by the rapidly growing oval area, it extends proximally unto the entrance of the superior cerebellar peduncle.

Somewhat distally from the appearance of the tuberculum acusticum the nucleus of DEITERS is at first seen. The first large cells of this nucleus are always found in the dorso-lateral edge of the portio interna (Plate VII fig. 7 A—H) but as long as the tuberculum covers the oval area, those cells are not found dorsally from this area. As soon as the stratum latero-dorsale and the tuberculum are diverging from the area ovalis, DEITERS' nucleus is dorsally resting upon it and exfoliating laterally from it, it is crossed by root- and secundary fibres curving in the systema dorsale nervi octavi round the oval area.

The nucleus of DEITERS disappears when the oval area leaves the medulla and has become the inferior peduncle of the cerebellum, and as we will afterwards have much to do as well with this nucleus as with its position in the latero-dorsal quadrant of the portio interna, I memorate these long known facts here.

Rootsection of the nervus octavus now enables us to demonstrate other fields in the portio interna and divides it in degenerating and non degenerating portions.

After root-section, the medial octavus-trunk, the medial fibres of the ventral root, nearly totally degenerate.

They enter between oval area and spinal root of the Vth nerve, closely adossed dorsally to the latter (Plate VIII fig. 15 N°. 9) and having reached the medio-ventral edge of the portio interna, just there, where the ventral apex of the dorsal auditory nucleus, the medial edge of the Vth spinal root, and the portio interna meet, a great many of them bend downward in an angle of 90°.

This is the descending octavus-root, the degeneration of which after rootsection is shown very clearly in horizontal sections. (Plate V fig. 9). Plate X fig. 16 I. Plate XIV fig. 14 A), but is also easily distinguished in frontal sections, as an area of degenerated fibres, situated in the medio-ventral quadrant of the portio interna (Plate VIII fig. 15 N°. 8, 7, 6, 5, 4).

This area, composed of separated nerve-bundles, showing many degenerated fibres between non degenerated ones, may be traced until the proximal end of the nuclei of the posterior columns.

Now, they are not exclusively medial root-fibres of the ventral root, which compose this descendent tract, though they may form the greater part of it.

After removal of the cochlea there are also seen some fibres degenerating in it. These are firstly the few fibres running from the dorsal root into the medial trunk, but they mostly are belonging to the fibres of the stratum latero-dorsale, which have curved round the oval area, and passing obliquely through the nucleus of DEITERS also reach the medio-ventral edge of the portio interna.

These are the fibres, not very many, but yet demonstrable, which from the dorsal root do enter in the radix descendens. They never after cochlea-removal may be traced so far as to the nucleus of the Xth nerve.

But after root-section, the number of degenerate fibres in the inner layer of the stratum latero-dorsale being increased, not only the intermedial system is degenerated in a more important degree, but also many of those fibres, penetrating through the area ovalis,

go through the nucleus of DEITERS to the medio-ventral part of the portio interna in the descendent radix.

In this way the radix descendens contains different root-fibres. For the greater part they are fibres of the medial trunk originating in the ventral root. Some fibres nevertheless, reach it through the dorsal systema. They again are mostly fibres of the ventral root passing through the oval area. But some fibres of the dorsal root also attain the descendent radix by the two described paths, 1^{ly} as medial fibres of the dorsal root. 2^{ly} round the oval area.

After rootsection however degenerated fibres are found not only in the ventro-medial quadrant of the portio interna.

After rootsection the degenerate fibres in the stratum latero-dorsale are augmented, most in the inner layer, but also in the outer layer. They partly are ending in the lateral cells of the dorsal nucleus. But a rather important bundle goes on the latero-ventral border of this nucleus, through the cells of DEITERS, between this nucleus and the portio interna. As this bundle reaches the ventral apex of the dorsal nucleus, there, where it touches the nucleus griseus of the descendent root, it participates to the transversal fibres of this region, changing its direction into a medial one and going along the ventral border of the principal group and of the nucleus N. VI, it reaches the raphe.

These are the „transverse fibres of the systema dorsale n. octavi". Their number is increased by fibres of the medial trunk, there where it sends distally the greater mass of its fibres into the descending root, but they are not only fibres of the ventral root.

For after removal of the cochlea there are also found degenerated fibres in the transverse fibres of the dorsal systema.

Knowing now the degenerate fibres after root-section in the portio interna I am enabled to reconstruct the systema dorsale nervi octavi, where I left it.

This systema, by MARCHI-degeneration, has been divided in three layers, whilst it was contained in the stratum latero-dorsale.

An outer layer of degenerate root-fibres, a middle layer of normal fibres, and an inner layer again of degenerate root-fibres, radiate together towards the stria acustica.

But this dorsal system contains at least five bundles.

1^e dorsal rootfibres (from the two roots) to the lateral cells of the dorsal nucleus.

2^e dorsal rootfibres (from the two roots) to form dorsal transverse fibres.

3^e secundary dorsal transverse fibres.

4^{e} dorsal rootfibres (from the two roots) passing through the portio interna towards the descending root.

5^{e} dorsal rootfibres (from the two roots) forming the intermedial system.

Now, as soon as the corpus restiformis, deviates into the cerebellum the aspect of those fibres changes. The two slings of rootfibres, between which the area ovalis was enclosed, mix together, or rather the root-fibres penetrating through the oval area, found in the proximal sections (Plate VIII fig. 15 N°. 8 and N°. 9), are the preliminaries of the union of the dorsal and medial sling of root-fibres. And as the area leaves the medulla to become cerebellar inferior peduncle, (Plate IV fig. 8) the combined root-fibres go farther. They now have a somewhat proximal direction and may be called ascendent root. But they are originating from the two roots. The greater part may be medial fibres of the ventral root. The proximal dorsal fibres however participate to it and a smaller part of them may belong to the dorsal root.

As I have demonstrated, the nucleus of DEITERS has now disappeared, but the surroundings of these fibres have remained unchanged. They are surrounded by cells of the same shape and of medial size, like those which in more disal sections characterized the nucleus griseus round the descending root. But here the nucleus griseus of this ascending root is called nucleus of BECHTEREW.

It is not difficult (Plate IV fig. 8, Plate V fig. 10) to demonstrate the relations of the ascendent fibres to this nucleus. Many of them remain there, but a few exceed this nucleus towards the nuclei mediales tecti, from which the nucleus of BECHTEREW is less sharply marked off, as from the dorsal nucleus.

In this way the greater part of the root-fibres of the nervus octavus entering in the medial trunk between area ovalis and spinal Vth root, join a smaller part that has sought a dorsal way in order to reach the medio-ventral quadrant of the portio interna, forming a long tract, an ascending and a descending root of the nervus octavus.

This tract is surrounded by a long stretched nucleus.

In proximal sections it is called the nucleus of BECHTEREW, more distally the nucleus griseus of the descending root, still more distally it confluates with the proper nucleus of the corpus restiforme, and dorso-medially from this nucleus the dorsal nucleus of the nervus octavus appears, extending in a similar way. In this way, views closely allied to the elder views of ROLLER reappear.

Perpendicular collaterals part from this long tract during the whole of its course. They perforate the nucleus griseus and the

nucleus of DEITERS. They go at first ending tho the lateral and principal cells of the dorsal nucleus, and to the nucleus of the VIth nerve (Plate XIV fig. 14 A). Those nuclei are thickly specked with black granules after rootsection. Secondly an important number of these fibres are ending in the nucleus griseus. Round the nucleus of BECHTEREW and in the whole long nucleus griseus of the descendent root, ascending and descending rootfibres enter. They pass through the nucleus of DEITERS but they do not end among the large cells of it.

This nucleus is passed by all the rootfibres of the dorsal radiation, but yet there is found not a single symptom that rootfibres should be dissolved in collaterals or make any other contact with the cells, which certainly are not in direct contact with the root-fibres. Neither for the large cells of the tuberculum acusticum nor for the larger cells in the dorsal-proximal pole of the ventral nucleus a direct contact with rootfibres could be demonstrated, and in this regard the cells of DEITERS have not such a peculiar position among the secundary systems of the nervus octavus as often has been presumed. This however is a question, which afterwards will be discussed.

Until now the portio interna of the corpus restiforme contains at least three regions.

1°. a dorso-lateral quadrant—the nucleus of DEITERS.

2°. a ventro-medial quadrant—the descending root with its nucleus griseus.

3°. The medio-dorsal border of transverse dorsal root-fibres. They form part of the dorsal rootfibres passing the portio interna in every direction.

There still remain the non-degenerating fibres in the dorsal radiation.

That a secundary system passed into the intermedial system and into the descendent root I have already made probable. There also passes one in the dorsal transverse fibres.

But Marchi-method after rootsection leaves two large quadrants of the portio interna without degenerated fibres in the longitudinal axis of the medulla (Plate IV fig. 4).

The dorso-medial quadrant, where a great many secundary auditory fibres will soon be recognised, mixed with fibres originating from the cerebellum, and a ventro-lateral triangular area where again (between oval area and spinal root of the V) non degenerated fibres may be found.

The relations of the root-fibres to the dorsal nucleus n. octavi and the portio interna being such as described here, the farther course of the dorsal system may be studied.

p. *The portio interna in the embryo of the rabbit and its atrophy after root-section in the young born animal.*

Till now the Marchi-method has shown degenerated fibres in the intermediary and dorsal octavus-systems crossing the nucleus of DEITERS and in the descending root.

Now in the oblongata of the elder foetus of the rabbit (Plate XII fig. 17, A, B and C) are found likerwise medullated fibres, in the intermediary system (Plate XII, fig. 17 A, *h* = *s.* interm), in the dorsal system (Plate XII (fig. 17 A, B and C, fasc. dors. N. VIII) and in the descending root (Plate XII fig. 17 A r. desc. N. VIII), whereas in the area of DEITERS itself only a few medullated fibres, mostly passing through it, are seen.

In this way the portio interna appears to have medullated fibres in all systems, wherein Marchi-method demonstrates degenerate fibres after root-section.

And as in this still unborne young rabbit, the area ovalis, of the C. R., according to the medullated dorsal ascending spino-cerebellar tract, is partly myelinisated, its portio interna is clearly divided into four quadrants, among which the medio-dorsal and the triangular latero-ventral area's are not yet provided with medullated fibres.

Still more evident than in the rabbit (Plate XII fig. 17 A) this division is in the young born cat (fig. 5 on Plate I). There again the very powerful intermedial system, the very important system of transverse dorsal fibres, and also the descending root-fibres are medullated, the dorso-medial quadrant and the nucleus of DEITERS have only a few, the latero-ventral area between area ovalis and the Vth spinal root is without myelinisation.

Sagittal sections through the medulla of the rabbit demonstrate the same facts. Between the area ovalis and the Vth spinal root, a long stretched area is found (Plate XIII fig. 18 D), crossed proximally by the medullated intermedial system (Plate XIII fig. 18 D in *h* (HELD)). Medullated are also the medial (Plate XIII fig. 18 D) and the descending roots (Plate XIII fig. 18 E and F in rad. desc. N. VIII), whereas the medio-dorsal quadrant (Plate XIII fig. 18 E and F) dorsally from it is not.

The transverse dorsal fibres, also medullated (Plate VI 19 C) are best demonstrated on horizontal sections, where their whole course towards the fasciculus longitudinalis posterior may be seen.

Now if the frontal (Plate XII fig. 17 A) or horizontal (Plate VI fig. 19 C) sections through the medulla of the rabbit-foetus,

are compared with frontal (Plate I fig. 1*a* Plate II fig. 2) sections after cochlea-removal or after root-section (Plate IV fig. 4) or with horizontal sections after rootsection (Plate V fig. 9) treated with MARCHI, the similitude is striking.

Degenerated fibres are found situated at the place, where medullated fibres are seen, normal fibres there, where no myelinisation is found. In this way the dorsal and ventral systems present the same points of similitude.

Secundary octavus-fibres are not all medullated at birth. Some fibres are not. in the dorsal system these are the middle layer (Plate XII fig. 17 A in β, Plate I fig. 5 in β) and the latero-dorsal part of the portio interna. In the ventral system these are the stratum *c* in the corpus trapezoides.

If it were an established fact, that all medullated fibres in the elder foetus were only root-fibres, they should be present in the dorsal as well as in the ventral system in a rather abundant number. In regard to this question I at present only state, that MARCHI-method indeed shows degenerate fibres after rootsection at the same places, where medullated fibres are found, without more.

Now in the sections through the foetal medulla in this region there still are seen medullated fibres in two not yet described tracts, that may possibly contain rootfibres of the eighth nerve.

The first is the fasciculus longitudinalis posterior.

The second medullated bundle passes through or originates in the nucleus of DEITERS, and is known as the vestibulo-spinal tract, or better called — with LEWANDOSKI — the tractus DEITERS descendens. In frontal sections of rabbit (Plate XII fig. 17 A and B f. DEIT. desc.) and of cat (Plate I fig. 5 in f. DEIT. desc.) it leaves the nucleus of DEITERS, crosses the rootfibres of the nucleus of the VIIth nerve, which are forming the genu; afterwards, dorsally from the nucleus of the VIIth nerve, it bends into the longitudinal axis of the medulla, deviating slightly medialwards, but always situated laterally from the root-bundles of the XIIth nerve, this tractus may be traced into the spinal cord at the ventral border of the anterior and lateral collumns.

In sagittal sections the tractus DEITERS descendens (Plate XIII fig. 18 F in f. DEIT. desc.), its bending distally into the longitudinal axis of the oblongata, as is passes through the facial root-fibres is demonstrated very clearly.

Whether rootfibres also may be found in those two tacts will be discussed in the following paragraph. Here they are easily demonstrated as medullated tracts.

Thus far we may hold it to be proved in a sufficient way, that Marchi-method and myelinisation-method are tending to similar results.

And GUDDEN's method also rather confirms these results. A year after rootsection in the young rabbit it may be demonstrated that a large quantity of fibres has been lost in the dorsal radiation between tuberculum acusticum and oval area and that the intermedial system, the dorsal transverse fibres and the descending root are atrophied to an important degree (see Plate III fig. 13*a* and 3*a* compared with 13*b* and 3*b*). Still an important quantity of fibres have been left in these tracts — their secundary systems.

Fibres are lost also in the nucleus of DEITERS, in the nucleus of BECHTEREW, in the nucleus griseus of the descending root, in the lateral and ventral parts of the nucleus dorsalis N. VIII. And from the medial trunk of rootfibres there is left nearly nothing.

In such cases also cells have disappeared.

As is demonstrated (Plate VII fig. 7 A—H) before, there are found in the portio interna the large cells in the nucleus of DEITERS, the cells of small and midling size in the nucleus griseus, the ventral apex of the dorsal nucleus and in the nucleus of BECHTEREW, and the small cells along the fibres of the medial trunk between area ovalis and spinal V nerve. In the dorsal nucleus (except in the ventral apex and the nucleus of the sixth nerve) small cells are found to prevail.

Now I agree, with all the elder investigators, that no change is seen in the large cells of DEITERS. As fig. 13*a* demonstrates (if compared with fig. 13*b*, Plate III) clearly, those cells have suffered not the slightest alteration nothwithstanding the important atrophy of the fibres passing through the nucleus of DEITERS. Consequently they may lay more closely together than those of the other side, but they do not alter, even not in a year after rootsection on a young animal.

But this also is the case with the cells of midling and larger size, which are found in the nucleus of BECHTEREW, in the ventral apex of the dorsal nucleus, in the nucleus griseus radicis descendentis and in the nucleus N. VI.

Even a year after the operation, there may be found normal cells in large quantity in these nuclei. Still cells have vanished, but they are the small cells and among those of midling size, they are also the smaller specimina.

Those along the medial trunk of rootfibres are all gone. Many cells also have disappeared at the latero-ventral border of the dorsal

nucleus touching the portio interna. Therefore this part of the dorsal nucleus is found slightly atrophied, not only by loss of fibres (collaterals) but also by loss of cells. Cells in the nucleus of BECHTEREW, in the nucleus griseus radicis descendentis, in the ventral apex of the dorsal nucleus also have disappeared.

But only smaller cells, the larger cells are not altered. Here the same results reappear as were demonstrated in the nuclei of the ventral system a year after rootsection.

There these results were: No alteration in the large cells of the tuberculum acusticum; loss or atrophy of small cells in the deep grey matter. No alteration in the dorso-proximal pole of the ventral nucleus. Loss or atrophy of cells in the proper nucleus of the dorsal root of the smaller cells in the ventro-distal pole of this nucleus.

No alteration in the cells of the facial nucleus or in the larger cells of the olivary bodies. Loss or atrophy of cells in the small cells in their medullary surroundings and in the opposite nucleus trapezoides.

Here the results are: No alteration in the largest cells of DEITERS, or in cells of the large and middle-large size in the nucleus of BECHTEREW, the nucleus griseus + apex ventralis nuclei dorsalis, and in the cells of the abducent Nerve.

Loss or atrophy of cells in the proper nucleus of the medial trunk, in the ventral borders of the lateral and principal cell-groups of the nucleus dorsalis, and among the smaller cells of the nucleus of BECHTEREW, nucleus griseus + apex ventralis nuclei dorsalis.

Here as before I conclude, that the contact between root-fibres and cells, from which secundary systems originate is not a direct one. Small cells are intercalated. Here the cells of the medial trunk of rootfibres, the cells of the dorsal nucleus bordering the portio interna, a certain part of the cells in the nucleus BECHTEREW and in the nucleus of the descending roots.

And it is only through those intercalated cells, that the cells, in which originate the secondary systems — here the large elements in the nuclei of DEITERS, of BECHTEREW, in the nucleus griseus of the descending root and in the nucleus N. VI — are reached by the root-fibres.

These results, following inevitably, as well from MARCHI-method, as by GUDDEN's method, are not in contradiction with GOLGI-preparations.

q. *The descending root and the transverse dorsal fibres. The farther course of the systema dorsalis nervi octavi. Its ascending tracts and its descending tracts. Its relations with the nuclei of the VIth, IVth, III^{d} nerve.*

The degenerated descending root may now be traced in its distal course as well in frontal as in horizontal sections. In frontal sections this root is composed by a great many bundles of fibres, separated by grey matter (Plate IV fig. 4). Near its origin it is resting dorsally upon the spinal Vth root (Plate VIII fig, 15 N°. 7 and N°. 8), and in its bundles the degenerated fibres are found. More distally, as the spinal root of the Vth nerve takes a more lateral position, the descending radix, recognisable at its degenerate separated bundles, has not followed the nervus trigeminus. It is now resting upon the dorsal surface of the transparent nucleus nervi vagi (Plate VIII fig. 15 N°. 5). But here some degenerated fibres leave the radix descendens, to pursue their way in the fasciculus solitarius N. X, and may be traced far distally (Plate VIII fig. 15. N°. 5—N°. 1). In horizontal sections (Plate XIV fig. 14 A, Plate X fig. 16 H) in the same way the continuation of degenerated fibres from the radix descendens after rootsection, into the fasc. solitarius N. vagi may be seen.

In the transparent nucleus of the N. X, the fibres of the solitary tract are sending scarcely degenerated collaterals, parting from them in a perpendicular direction, in quite the same way as the descending root is giving collaterals to the dorsal nucleus of the VIIIth nerve.

Not long ago VAN GEHUCHTEN has emitted the view, that fibres going from the descending root in the fasc. solitarius N. X, may be fibres from the nervus intermedius WRISBERGII. VAN GEHUCHTEN has torn out the facial nerve with its ganglion geniculi and has concluded that the degenerations found after this lesion were caused by the lesion of the nervus WRISBERGII.

I can only state that without the least lesion of the facial nerve, the removal of the contents of the labyrinth and if necessary, rootsection is performed, and that, in cases of important degeneration of the descending root, always fibres in the solitary tract of the Xth nerve are found degenerated also. But the greater part of the fibres of the descending root may be traced distally otherwise.

As it is seen on Plate XIV fig. 14 A, the degenerated root-fibres, sending collaterals into the dorsal VIIIth nucleus and even directly to the nucleus of the VIth nerve, appear as if ending all in the

fasc. solitarius, but in frontal sections (Plate VIII fig. 15 N°. 5—1) there appears only a scanty number of them. As far as the field of separated bundles may be traced, that is to the proximal ends of the nucleus of BURDACH-MONAKOW a few degenerated fibres are seen. They probably provide the nucleus proprius of the restiform body till its most distal end.

Now the endings of the systema dorsale of the nervus octavus still remain to describe.

From this I have already demonstrated the intermedial system and found that it transported fibres from the dorsal system through the ventral ascending spino-cerebellar tract into the nuclei tecti and through the crossed lateral fillet to the corp. quadrig. postic. These two ascending tracts need here no farther description.

It only must be kept in mind, that in proximal sections, fibres of the ventral root continue in the ascending root and go directly to the nuclei tecti, without using the complicated way dictated by the ventral ascending spino-cerebellar tract.

But after having lost the intermedial system and the fibres to the descending root, the dorsal systema bends as transversal dorsal fibres between the dorsal nucleus and the portio interna. Arrived at the ventral apex of this nucleus or near to it, some degenerate fibres leave the dorsal systema and enter the formatio reticularis.

The most lateral of them following the edge between the Vth spinalroot and the nucleus of the VIIth nerve, reach there the field situated dorsally from the antero-lateral (GOWERS) tract, bend distally into the longitudinal axis of the medulla and give collaterals in the direction of the VIIth nucleus. (see fig. 1*a* on Plate I and fig. 15 N°. 11 on plate VIII). They reach a field, known as the „aberrirendes Seitenstrangbündel, or as MONAKOW's bundle, or as fasciculus rubrospinalis, or even as the dorsal descending spino-cerebellar(?) tract, that soon will claim a discussion. As soon as distalward the facial nucleus has disappeared, there may be found in frontal sections some black granules, more than usually (Plate VIII fig. 15 N°. 4) and in horizontal sections very few degenerate fibres medially from the spinal Vth root between it and the facial nucleus. But here Marchi-method reaches its limits. It only is interesting because afterwards we will have to discuss the question to what extent secundary fibres pass along this way towards the spinal cord.

More interesting are the fibres entering more medially into the formatio reticularis, and seeking dorsally from the facial nucleus the region, where the descending tract of DEITERS or the fasciculus

vestibulo-spinalis is found. They also bend distally in longitudinal direction and are represented by only a few fibres. In frontal sections distally from this nucleus, a few black granules are scattered here and there, within the area of this tract (Plate VIII fig. 15. N°. 5—N°. 1) and in horizontal sections (Plate X fig. 16 F) there are found a few longitudinal fibres degenerated. These fibres may become important, because they are found in the same area, where a considerable secundary system (already myelinisated in the elder foetus) will soon be demonstrated. Indeed I believe that a small number of rootfibres bends down, without interruption in the tractus Deiters descendens and may be traced towards the beginning of the spinal cord.

But the few fibres, that in ventral direction deviate in the formatio reticularis, do not much enfeeble the transversal dorsal fibres. Moreover these fibres have got a considerable increase in proximal regions from the straight entering ventral fibres and from the ascending root. They pursue their way, through the ventral apex of the dorsal nucleus, along the ventral border of the nucleus of the VIth nerve, giving collaterals to the principal and ventral cells of the dorsal nucleus and to the sixth nucleus. They still form a rather important bundle, as they reach the fasciculus longitudinalis posterior, and pass the raphe to send fibres into the opposite sixth nucleus, which is found blackened with globules, as well as that of the same side.

But at their passing the raphe a sufficient quantity of degenerated fibres, are bending in longitudinal direction to become ascending as well as descending fibres in the fasciculus longitudinalis posterior on both sides.

At first, more degenerate fibres are found in the opposite than in the homolateral fasc. longit. post, they go distally and proximally, providing the nucleus of the sixth nerve on both sides.

In this way the two nuclei of the sixth nerve, receive fibres of the dorsal systema. That of the same side recives them, 1^{e} from the descendent root (Plate XIV fig. 14 A), 2^{e} from the fasc. long. post. (Plate VIII fig. 15 N°. 8—N°. 11), that of the opposite side only from the fasc. long. post., but, the number of degenerate fibres in the opposite f. l. p. being greater than in that at the same side, the innervation of the two nuclei may not much differ.

Now a certain number of those fibres may be traced far more distally than the nucleus of the VIth (fig. 15 N°. 5—N°. 1). They are longitudinal fibres but have at the same time a slight inclination

in ventral direction. In this way there may pass a few of them in the so-called fasciculus praedorsalis.

The intermedial system however, at the moment of crossing the raphe, also sends a few of its fibres distally in a longitudinal direction.

Therefore in distally situated frontal sections of the oblongata, some degenerate fibres are found, in the region, that is called the area or fasciculus praedorsalis. Mostly they appear at the same side but a few in that of the opposite side of the root-section. In this area they are found in frontal sections as black globules, dispersed near the raphe, dorsally from the lemniscus medialis (principalis) and ventrally from the fasc. long. post. And in horizontal sections there are found scarcely longitudinal fibres, degenerated in this region near the raphe (Plate IX fig. 16 E, Plate X fig. 16 F and G).

Now it must be repeated that Marchi-method here has reached its limits, that the distal degeneration of longitudinal fibres in the fasc. long. post. and in the fasc. praedorsalis is not very important. But soon I will demonstrate, that a very important secundary way may be traced through the fasc. praedorsalis into the spinal cord.

In this way I believe root-fibres to be found as well in the distal path of the tractus Deiters descendens, as in that of the fasciculus longitudinalis posterior, tracts, which are both myelinisated in the elder foetus of rabbits.

A sufficiently large number of degenerate fibres however, enters in proximal direction among the longitudinal fibres of the fasc. long. posterior. These fibres are nearly all found homolaterally and may be followed to the same-sided nucleus of the IVth and that of the IIIth nerve, which in this way are connected with direct root-fibres of the N. octavus. But not in this way only.

Better than in frontal sections, it is seen in horizontal sections (Plate XIV fig. 14 B) of the normal, as well as of the young born animal, that other fibres of the tranversal dorsal layer, are going proximally towards the fasc. long. post.

In a slight ventrally curved proximal bundle, issued from the dorsal transverse fibres and medullated in the elder foetus of rabbit (which in distal sections reached the fasc. long. posterior in the level of the genu of the n. VII (Plate XII fig. 17, A, B and C)), somewhat laterally from the fasc. long. post. (Plate XII fig. 17 A. Plate VI 19 C) rootfibres reach the Nucleus N. IV and N. III, and provide in these nuclei. In this proximal bundle of the transversal dorsal fibres a slight but evident degeneration is found after root-section. The degenerate fibres lying there may be traced into the IVth and IIIth

nucleus (Plate XIV fig. 14 B, Plate XI fig. 16 K and L), following the path of the ascending tract of DEITERS. I will soon describe this bundle in a more minute way.

In this way the dorsal transverse root-fibres have relations with the nucleus N. VI, the nucleus N. IV and the distal end of the nucleus N. III of the same side and with the nucleus N. VI of the opposite side.

In this way the dorsal system of transverse rootfibres may be traced to its endings, towards all motor nuclei of the eye on the same side, towards the opposite nucleus of the VIth nerve, in the fasciculi longitudinales posteriores and in the area of the descendent tractus of DEITERS.

It remains however a remarkable fact, that after rootsection hardly any degenerated fibres or even none at all are found crossing the raphe, between the layer of dorsal transverse fibres and the layer of intermedial transverse fibres.

The so called auditory fibres of MONAKOW appear free from degeneration after root-section as likewise they are not all myelinisated in the elder foetal animal.

3. THE SECUNDARY SYSTEMS OF THE NERVUS OCTAVUS.

In using Marchi-method, after experimental lesions upon root-fibres, it should always be kept in mind, that together with the enormous advantages peculiar to this method, there also arise dangers, as soon as single degenerated fibres are to be traced with its aid.

It is possible, even probable, that an experimentally produced degeneration in a system of rootfibres, is not stopped by the first nucleus, which is intercalated in its course.

As well as by GUDDEN's method — experimenting on young born animals and studying their central system several months after the lesion — may be demonstrated the loss or the atrophy in the first nucleus and together with it the atrophy of the following system, Marchi-method — used a fortnight after the experimental lesion — may show a slight degeneration in the secundary system.

As soon as scarcely degenerated fibres are found with Marchi-method in a presumed secundary system, three possibilities exist to account for their presence there.

The first is to suppose, that true root-fibres pass without any interruption through the nucleus in the secundary system. I have accepted this interpretation when an important number of fibres

were found within a fortnight after the lesion, and if the myelinisation-method or Golgi-method confirmed its possibility.

The second is to suppose, that rootfibres having been stopped by a nucleus, where they find a preliminary end, (it may be indifferent whether cells are intercalated between them and the cells from which the secondary system originates, or not) damage the cells of that nucleus, after a longer or shorter lapse of time, and in this way cause a degeneration in the secundary system.

Or if the often controversed hypothesis of neurons coming into contact with the cells should prove false, if this hypothesis ought to be rejected and replaced by another, teaching an uninterrupted continuity of nervous fibrils, — it still may be presumed, that degenerated fibrils, degenerating through the cells of the nucleus reappear in the fibres of the secundary system and cause the degeneration of the fibre as a whole, made visible by Marchi-method.

In this way may be interpreted the fact, that the longer time has elapsed after the lesion, the greater is the number of degenerated fibres found in secundary systems, according to the theoretical views of the investigator and his defending the neuron-hypothesis or the hypothesis of the continuity of the nervous fibrils.

Now this danger of Marchi-method may under circumstances become an advantage. For if, after a long lapse of time rootsection can make visible degenerate fibres in secundary tracts, it may be, that a few degenerate fibres in a defined tract furnish an indication, a presumption that this tract might prove a secundary one.

Yet, this way may appear dangerous. The longer a degeneration has existed, the more are the chances that the altered myelin (the black globules) is spread and dislodged from the original to other places, and so no longer corresponds to the sought degeneration.

Therefore this use of Marchi-method was rejected.

I have preferred to study the degeneration or the atrophy, which occur after lesions in the central organ and to compare them with the degeneration or the atrophy after root-lesion.

I have destruated the nuclei to which the rootfibres go.

Such lesions however are always complicated, entailing more or less extensive destruction in other systems. It may occur that different systems degenerate in many directions and that it appears arbitrary to make a choice among them and to call the one or the other system the secundary system of the injured nucleus sought for. Yet if its results are interpreted with circumspection the method may be useful, for it permits to demonstrate secundary degeneration into a system, which otherwise can only degenerate indirectly.

a. *The secundary system participating in the systema ventrale nervi octavi and in the systema intermedium nervi octavi.*

In order to study the secundary systems entering in the ventral and intermedial system, it may be presumed, that they originate in the nucleus ventralis N. octavi, in the tuberculum acusticum in the nucleus of DEITERS and in the oliva superior with its adjoining nuclei.

I therefore have made two operations, described in the former chapter.

The first is the section of the corpus trapezoides or of the systema ventrale, laterally from the issue of the facial nerve.

The second is the ablation of the tuberculum acusticum and the nucleus ventralis.

As I have already described, each localised lesion in the central system is followed by a surrounding area, where the nervous elements are lost, not by means of simple degeneration, but (even with the severest asepsis) by means of irritation. Therefore each wound is surrounded by a more or less extensive area, not stained black with Marchi-method, but characterised as a spot of white colour, wherein here and there black globules are found.

The section of the lateral trunk of the systema ventrale is made at the entrance of the two roots, with a very thin knife, following the n. octavus through the meatus acusticus, and after some experience this may be done without lesion of the facial root, distally from the entrance of the nervus trigeminus, laterally from its spinal root.

Such a section is drawn in fig. 22 on Plate XVIII. The lesion itself is represented in *x* (Plate XVIII fig. 22 A, B, C, D). The incision enters (fig. 22 C) the medulla ventro-laterally and goes dorso-medially. After cleaving the trunk of the corpus trapezoides, it divides the oval area transversally, causing in this way a degeneration towards the cerebellum, that needs not be followed here. The surrounding area extends into the dorso-lateral part of the fibres (not into the formatio gelatinosa) of the Vth root, and causes a descending degeneration of the dorso-lateral fibres of this root, the ventro-medial fibres being normal (Plate XVIII (fig. 22 D—H). The surrounding area also extends into the latero-distal part of the portio interna, dividing the intermediary trunk, which is totally degenerated.

The incision has also divided the two entering roots. And consequently to this rootsection there exists a degeneration in the

systema dorsale and in the descending and ascending roots, which is nearly the same as after every rootsection. The nucleus of DEITERS (Plate XVIII fig. 22 D and E) is not sensibly injured.

A similar lesion was made in the case, from which the fig. 23 was taken.

Now in all cases, in which the lateral trunk of the ventral and intermedial system is sectioned there is found an intense degeneration in these systems. If compared with the degeneration after rootsection, the difference is marked in several respects.

1°. The degeneration in the systema ventrale and intermedium is now found in alle the layers of the transverse ventral fibres. In the layer of thick fibres (the stratum *a*) an enormous increase of degenerated fibres is found as compared with those degenerated in it after rootsection. (compare Plate XVIII fig. 22 B and Plate XXI fig. 23 with Plate VIII fig. 15. N°. 11, 12 and 13).

In the layer of small fibres (the stratum *b*) the same is the case there exists no longer a layer of normal fibres (the stratum *c*) between the ventral and intermedial degenerated systems, but a large quantity of degenerate fibres is found between the two olivary bodies. It is evident, that the at contra-lateral side to the operation this layer shows a more important degeneration than at the same side. (Plate XVIII fig. 22 B and Plate XXI fig. 23). And it is also evident, that the dorso-latero-ventral medullary surroundings of the olivary body present a very intensive degeneration at the operated side, where as on the contrary in the medial hilus of the nucleus olivaris of the opposite side it is more important than in the homo-lateral.

And the interpretation of these two facts is (a retrograde degeneration being excluded, because these degenerations are present within a week) that in the olivary body originates a new system, that leaves the nucleus at its medial hilus through the stratum *c*, to seek the opposite side, whereas the degenerated ventral and intermedial systems provide with fibres the homo-lateral oliva in its dorso-latero-medial surroundings, and crossing the raphe provide through the medial hilus the opposite one. The latter degenerated part of the system covers the non degenerated one. Therefore it has the appearance as if the medial hilus of the opposite oliva contains nearly all degenerate transverse fibres and the homolateral nearly all normal ones. Consequently there remains a layer of fibres in the systema ventralis not degenerating if the ventral nucleus and the systema intermedium be separated from the medulla.

The intermedial system (the stratum *d*) also presents a degene-

ration much more intensive than after root-section and therefore contains a secundary system, as well as all the other layers. It is however no longer differentiated from the ventral secundary system. The transverse fibres are so intermingled that it exists no longer as a system separated from the systema ventrale.

In this way it may be demonstrated, that a very important number of secundary fibres enters in the systema ventrale, from the ventral nucleus, and along the intermedial system, and that there still are found non-degenerate fibres originating in the oliva, leaving it through the medial hilus and going to the opposite side (the lateral fillet).

2. There is also found now a degeneration more intensive than after root-section in the region between the spinal root of the Vth nerve and the oliva superior. Not only at the operated side but also on the opposite side, and like the root-fibres (there are root-fibres among them), the now degenerated fibres may be traced into the two formerly described ascending tracts;

a. as to the ventral ascending spino-cerebellar tract, now also the homolateral degeneration is more intensive (Plate XVIII fig. 22 B) than that in the opposite bundle;

b. as to the degenerated fibres to the corp. quadrigeminum posticum through the lateral fillet, now again, like after root-section, the degeneration in the opposite tract is more important than that in the homolateral.

Though the number of degenerate fibres is now very (Plate XVIII fig. 22 A) much increased I was not able to trace them beyond the corp. quadr. posticum into its bracchium to the nucleus geniculatus medialis.

But in the here described case, there was found a thin bundle of degenerate fibres, forming a specimen of a commissural bundle between the two degenerated lemnisci, passing ventrally from the nucleus of the IVth nerve.

These fibres are probably the same commissural fibres seen also by PROBST in fillet-degeneration and that have been described as the bundle of PROBST (Plate XVIII fig. 22 A).

3. In the dorsal systema there also is found a degeneration, which as I have remarked, does not exceed very much that, found after rootsection. Yet, the two roots and the ventral end of the stratum latero-dorsale being sectioned, it may to a slight degree be increased.

In the fasciculus longitudinalis posterior therefore are found, rootfibres from the degenerated transverse dorsal fibres, going 1^{e} to the motor nuclei of the eye 2^{e} going distally.

These latter fibres do not remain there, but slightly deviating

in ventral direction they reach the fasc. praedorsalis in their distal course. They are found at both sides of the raphe.

At the same time, the intermedial transverse fibres, now intensively degenerated, send, near their passage through the raphe, a not unimportant number of fibres distally in the praedorsal tracts on both sides, but more in the homolateral than in the opposite side.

At the level of the facial nucleus (Plate XVIII fig. 22 C and D) the degenerated fibres (root-fibres) in the fasc. long. post. are separated from those (secundary fibres) in the fasc. praedorsalis. The two separated tracts unite more distally and at the level of the inferior olivary body, they have become one, along the raphe, dorsally from the stratum intra-olivare (medial fillet). The tracts may be traced dorso-laterally from the decussatio pyramidum, into the anterior columns of the spinal cord, where we afterwards will meet them again. But distalwards the degeneration in the opposite tract is found gradually diminishing and in the most distal sections (Plate XVIII fig. 22 F and H.) the homo-lateral tract is by far the most degenerate one.

Here for the first time a degenerated tract descending to the spinal cord is stated beyond doubt. It is composed, for the greater part, of secundary fibres — from the transverse fibres of the intermedio-ventral system — for the lesser part of rootfibres — from the dorsal transverse fibres.

It is a medial or anterior descending spinal tract from the octavus-system.

But it is also remarkable, that there now are found degenerate fibres dorsally from the nucleus N. VII in the field, where the tractus Deiters descendens is localised. As the degeneration in the transverse dorsal fibres does not much exceed that after rootsection, it is not very probable, that the degenerated fibres now found there in a number, sufficient to exclude every doubt as to their forming a slight tract, are all rootfibres. For, as is clearly shown by comparison with frontal sections after rootsection, the degenerate fibres in the region of the so-called fasc. Deiters descendens (fasc. vestibulo-spinalis) are now increased in an abundant manner.

The first presumption presenting itself, when we try to explain this fact, may be: the nucleus of Deiters, lying close to the surroundings of the incision, and being perhaps accidently injured, is sending degenerated fibres to this region.

But this presumption seems to be erronous. Firstly there is seen no lesion of the nucleus, and there are found no degenerated fibres issuing from it in the direction of the degenerated field —

yet it is very easy to trace these fibres to the nucleus of DEITERS when this nucleus is lesioned on purpose. Secondly the now degenerated fibres are not the large ones with voluminous black globules, which are characterising the degenerated thick fibres from the large cells of DEITERS.

Thirdly, they appear abruptly distally from the degenerated corpus trapezoides in the level of the nucleus of the VIIth nerve dorsally from it and fourthly they are found on both sides in the symmetrical field, though in lesser quantity on the opposite side.

More-over the degeneration in the fasc. DEITERS descendens being more intensive, than after rootsection, I therefore believe that from the intermedial and ventral systema a few degenerate fibres enter in the region dorsally from the facial nucleus, and bend distally in the formatio reticularis, to form a slight degeneration in a descending fasciculus, taking its way in the descendent tract of DEITERS.

This tract, the existence of which, after rootsection alone, may be doubtful, now appears clearly after section of the ventral + the intermedial systema, (though far less extensive as I soon will demonstrate it after section of the dorsal system with injury of DEITERS nucleus).

And in this way a medial descending spinal tract composed of a few rootfibres and a little more intermediary and ventral secundary fibres, may be observed. It exists on both sides, but is much more important at the side of the operation.

4 The most important descending degeneration however found in this case, is a very marked degenerated area suddenly appearing distally from the corpus trapezoides in the field between the spinal Vth root and the facial nucleus. (MONAKOW's aberrirendes Seitenstrangbündel).

A retrograde degeneration this cannot be, as it is found a fortnight after the operation.

In frontal sections it is first seen laterally and ventrally from the facial nucleus (see fig. 22 D and E). More distally it is retiring in a dorsal direction (see fig, 22 F) having now the shape of an equicrural triangle, one of its erect sides along the formatio gelatinosa, the other touching the lateral side of the nucleus of the lateral column, and its base resting on the periphery of the medulla. It leaves degenerate fibres into the nucleus funiculi lateralis.

During its further course, this tract maintains its situation medially and ventrally from the formatio gelatinosa of the Vth root, but the basis of the tract leaves the perifery as the ventral ascen-

ding spino-cerebellar tract (GOWER's tract) covers it. Besides the fibres of these two tracts intermingle. Arrived at the spinal cord (Plate XVIII fig. 22 H) it has found its place, ventro-laterally from the formatio gelatinosa of the cornu posterior, its top is found in the formatio reticularis of the cornu lateralis, and it leaves fibres in the lateral horn of the grey spinal substance.

Its degeneration is moderate, much more so than at the contra-lateral side. There also however, this descendent tract is clearly demonstrated by the black globules.

Now there is not the least doubt that this tract is the same, that has been described under many names, as rubro-spinal tract (PAWLOW, VAN GEHUCHTEN), as aberrirendes Seitenstrangbündel (MONAKOW) and others. As to its interpretation, it is allowed to presume that the lesion made in a more proximal level, may have damaged, the rubro-spinal tract in its course. But the most proximal end of the lesion does not extend far enough to damage the issuing root of the nervus trigeminus (Plate XVIII fig. 22 B) and neither the incision, nor its white surroundings (Plate XVIII fig. 22 C, D and F) transgress the fibres of the Vth root. The non injured formatio gelatinosa and the non injured ventro-medial fibres of the Vth root are separating in all levels the lesion from the presumed situation of the rubro-spinal tract. Therefore there is no reason to suppose an accidental lesion of this tract in its more proximal course. Moreover it is degenerated likewise, through in a less intensive degree, at the contro-lateral side.

I therefore believe, we encounter here a third descendent tract, that may be parallelised with the descendent tract of DEITERS and the descending praedorsal tract. Only this tract is more clearly degenerated after the section of the lateral trunk of the ventral system than after the dorsal section.

Besides I soon will have to discuss the further spinal course of these three descending tracts, but before doing so there still remains to be described another intermediary system that joins the ascendant tract of the ventral system towards the corpus quadrigeminum posterior after sectioning the dorsal system.

The section of the dorsal system is not so difficult as that of the ventral system. I have made it some twenty times, at one side and on both sides. If made aseptic, it is without danger for the animal.

The incision made, after opening the membrana atlantico-occipitale, has nearly always the same result. The tuberculum acusticum is ablated, the radiation dorsally from the area ovalis is devided. The

incision goes through the portio interna, damages partially or totally the nucleus of DEITERS, divides the area ovalis, consequently separates the intermediary bundle from its origin, cleaves often the stratum latero-dorsale and may damage the ventral auditory nucleus, running between its ventro-distal part and its latero-dorsal part. It may damage both roots, or one, or even none at all, this depends on its being made more or less deep. Only the beginner must take care, not to incide too far proximally, otherwise the pedunculus cerebelli superior may be lesioned, (which is not a great danger and may be done on purpose) and the end of the incision may be found in the lateral fillet.

Now in Plate XIX, XX, XXI fig. 25, Plate XVI and XVII fig. 20 and Plate XXI, XXII fig. 28 such dorsal sections are drawn. Plate XIX, XX, XXI fig. 25 represent the drawings of an oblongata wherein this section was made on the two sides.

In cases that the nucleus ventralis is touched — even if its ventro-distal end is not at all degenerated — the ventral system degenerates nearly as intensely as after section of its lateral trunk.

In that case, the degeneration is less intensive in its distal part. Even if the dorsal section be made on both sides a large number of intact fibres is found between the two olivary bodies (Plate XIX fig. 25 E, Plate XX fig. 25 F and G), probably those, which are not yet medullated at the animal's birth and do not degenerate or atrophy, unless the nucleus olivaris superior be lesioned.

Subsequent to this section, we meet for the first time with the degeneration a system of transverse fibres, originating in the dorsal system and joining the ventral system at its most proximal end.

They are the transverse fibres of MONAKOW, which leaving the dorsal system at the level of the nucleus of the VIth nerve, cross the raphe ventrally from the fasciculus longitudinalis posterior in a dorso-ventral oblique direction in order to reach the dorsal top of the contra-lateral oliva. In the medullary surroundings of this nucleus they may leave a part of them.

But the greater part of those fibres continues in the lateral layer of the olivary body and united with a part of the small transverse fibres from the ventral and intermedial system, they reach the medullary surroundings of the ventral nucleus lemnisci and bend upward.

In frontal sections this nucleus is seen as an acorn in a shell of degenerate queer-sectioned fibres, surrounding it from three sides, at the dorsal, ventral and lateral side (Plate XIX fig. 25 C, D, E).

The nucleus itself is filled up with degenerate fibres and dispersed black globules.

After a short longitudinal and proximal course those fibres bend dorsally into the lateral fillet (Plate XIX fig. 25 A, B).

In frontal sections through this part of the pons, where the pedunculus cerebelli superior begins leaving the cerebellum, the situation is now characteristic enough.

Dorsally and laterally of this peduncle the lateral fillet lays free at the surface (fig. 25, C) and its most superficial layer is totally degenerated. It here contains the ventral ascending spino-cerebellar tract (GOWERS tract), which has just entered in this place after its ventro-dorsal path through the lateral lemniscus, and leaves it soon again to seek the nuclei tecti.

But in these levels the degenerate layer round the ventral nucleus lemnisci begins to change its longitudinal into a dorsal direction. Embracing the nucleus ventralis lemnisci, its fibres never form the most lateral layer of the lateral fillet, even not after the disappearance of the antero-lateral spinal tract, but coursing towards the ventral pole of the nucleus of the corp. quad. postic., they end in this nucleus and I cannot trace them with certainty into the corpus geniculatum mediale.

These MONAKOW fibres, do not form a so sharply defined bundle crossing they raphe, as they seem to do in the dog. Between the fasc. long. post. and the place where the intermediary system passes, there are found many crossing degenerate fibres, uniting themselves in the degenerated area dorsally from the nucleus olivaris superior, and in the surroundings of the nucleus ventralis lemnisci.

In this manner there may now be distinguished, besides GOWERS' tract, at least four different kinds of fibres in the contra-lateral fillet.

1° rootfibres — because some of them are degenerated after root-section. They reach the fillet through the ventral and intermediary system.

2° secundary fibres issued from the ventral nucleus — because a greater number of fibres degenerate if rootsection is combined with section of they lateral ventral trunk. Those fibres, of course, also pass through the ventral and intermediary system.

3° secundary fibres issued from the tuberculum acusticum — because a still greater number of degenerate fibres is found there if degeneration in MONAKOW's fibres occurs.

They pass through the stria medullaris as MONAKOW's bundle and enter in the dorsal layer of the oliva superior and in the surroundings of the ventral nucleus lemnisci.

4° secundary fibres non degenerating after these operations and probably issued for the greater part from the contra-lateral oliva

from the same-sided nucleus trapezoides (?) and from the same-sided nucleus lateralis lemnisci.

Now from the degenerated fibres composing here the fillet, by far the larger portion is due to MONAKOW's fibres.

MONAKOW has proved evidently with GUDDEN's method, that, in the dog, after a section of the lateral fillet at one side, fibres are lost in the opposite stria acustica medullaris, together with a loss of nearly all the large pyramidal cells in the tuberculum acusticum.

He also distinguishes several layers in the lateral fillet, according to their origin from the opposite tuberc. acusticum, the dorsal border of the same-sided oliva, the nucleus ventralis lemnisci and the „aberrirendes Seitenstrangbündel."

Now it cannot be doubted that after a section through the dorsal system — including the stria medullaris — in the neighbourhood of the tuberculum acusticum, all the large cells in this nucleus are found in chromatolysis 5 days afterwards, whereas in the cells of the nucleus ventralis N. octavi (if it be spared) the chromatolysis is not so intensive. Three months after ablation of the tuberc. acusticum, there has remained nothing of it.

But it is very interesting to verify, to what extent GUDDEN's atrophy six months after the ablation of this nucleus, confirms the results of MARCHI-method. In the case here mentioned (Plate XXI and Plate XXII fig. 28 A—F) the ablation of the tuberculum was nearly a total one (fig. 28 A, B, C, D) from the ventral nucleus a ventro-distal end has been left (see fig. 28 B).

Consequently the same-sided corpus trapezoides has lost the greater part of its fibres (see fig. 28 D) at the operated side, only in the distal part fibres have remained.

The same-sided oliva has lost a large numbre of fibres in its dorsal and ventral layer. At the contra-lateral side the dorsal layer of the oliva superior has lost many fibres and on both sides the so called trunk of the olivary bodies is very clearly to be seen. (see Plate XXII fig. 28 G). As it has already been memorated the crossing fibres through the raphe do not form a very sharply defined bundle. Nevertheless from the stria medullaris originates (Plate XXII fig. 28 E) a large bundle and passes through the issuing facial root, which does not exist on the operated side. It enters into the formatio reticularis, where more transverse fibres are found than on the operated side.

Now on the contra-lateral side, the dorsal surroundings of the oliva superior are joined to the surroundings of the nucleus ventralis lemnisci. These surroundings have lost a great many fibres

and the „aberrirendes Seitenstrangbündel" (Plate XXII fig. 28 C) also has. Those different layers are forming the lateral fillet.

As soon as the contact with the cerebellum is lost, and the bracchia pontis surround the basis mesencephali (Plate XXII fig. 28 F) a very interesting aspect is found.

At the side of the operation, most superficially, laterally from the pedunculus cerebelli superior, separated from it by the dorsal nucleus lemnisci, the ventral ascending spino-cerebellar tract lays. Only for a moment, for it distally retires to the cerebellum in the nuclei tecti, and proximally (Plate XXII fig. 28 F) it gives its fibres to the ventral part of the tegmentum. This tract has lost here many fibres on the operated side, and is much smaller than that on the contra-lateral side.

But more interesting is the loss of fibres found now in the ventral parts of the lemniscus at the contra-lateral side (Plate XXII fig. 28 F). The nucleus ventralis lemnisci is atrophied. It has not only lost many fibres, but also a great many cells and they are much smaller than at the operated side. Its surroundings, still adjacent to its lateral, dorsal and ventral borders have lost fibres and are intensely atrophied.

There is an absolute ressemblance with the drawings of the MARCHI-degeneration, where these surroundings (the shell of the acorn) are degenerated (fig. XIX, XX fig. 25 A—G fasc. later. l. l.)

But medially from the nucleus ventralis lemnisci there appears another layer of fibres, on which the ventral end of the bracchium conjunctivum cerebelli reposes. This layer a continuation of the dorsal olivary surroundings has lost a great many fibres. If compared with the MARCHI-degeneration, the degenerate fibres found medio-dorsally and dorsally from the contra-lateral nucleus ventralis lemnisci are now intensely atrophied (on both sides in Plate XIX, XX fig. 25 A—F fasc. med. l. l. y and Plate XXII fig. 28 F).

These two layers — the fasciculus medialis lemnisci and the fasciculus lateralis lemnisci — embrace the nucleus ventralis lemnisci. They pass into the more internal layers of the lateral fillet, whose lateral surface remains free from degeneration or atrophy. They surround the distal pole of the corp. quadrigeminum. This part of the ganglion is atrophied — with GUDDEN's method — to a considerable degree. With MARCHI-method there also intense degeneration is found. A great many of the degenerate fibres however remain in the nucleus ventralis lemnisci and (Plate XIX fig. 25 B—G) the lateral layers round this nucleus, entering in internal layers of the fillet, are less intensely degenerated than those situated medially from it.

Thus far the results of atrophy and degeneration are wholly concordant as may be seen by comparing the figures given in fig. 28 and in fig. 25.

I believe with MONAKOW and contrary to the opinion of BECHTEREW, FLECHSIG and most modern authors, that the stria medullaris and MONAKOW's transverse fibres, have more to do with the auditory function, than the larger part of the ventral systema has, and that LEWANDOWSKI has not set value enough on MONAKOW's system here treated. There are reasons to think so.

For it seems probable to me, that the elder foetus or the new born rabbit, may posess medullated fibres in the roots and in the lower secundary reflex or automatic systems, but that medullated fibres are still wanting in the higher secundary systems, which have not yet functioned. Therefore I think we ought rather to seek the true auditory systems among those of the secundary octavus-systems which are not yet medullated at birth.

They are in the first place, a large part of the fibres in MONAKOWS' decussation corresponding to the nonmedullated central layer β in the stria medullaris, those at the dorsal proximal end of the oliva superior (fig. 17 and fig. 18 E.), the fibres in the stratum *c* of the ventral system and many fibres in the lateral fillet.

The ventral nucleus lemnisci is covered with medullated fibres at its disto-ventral pole, but sends only non medullated ones in the lateral fillet.

I do not reckon the ventral system of no importance for hearing. On the contrary I believe, that there are non medullated fibres enough in that system issued from the olivae. The stratum *c* may never be brought to total degeneration, even after sectioning the dorsal system with the greater part of the nucleus ventralis, as long as the olivary bodies remain intact.

MONAKOW's fibres, the non degenerate fibres between the olivae superiores in the stratum *c* and the non medullated fibres in the lateral fillet, though their relations to this fillet are very difficult to elucidate, probably form one system. Probably both nuclei olivares send fibres into it. MONAKOW in sectioning the fillet states a loss of cells in the medial leaf of the same-sided oliva. I, after sectioning the stria, found a like result in the same-sided oliva but in its lateral leaves. This part of the lateral lemniscus therefore seems a very complicated mixtum of fibres.

A few words still on this „aberrirendes Seitenstrangbündel" which here appears as a part of the fillet.

It hast lost a great many fibres as it enters into the opposite

lateral fillet (Plate XXII fig. 28 F) of which it forms the greatly atrophied most medial part.

More distally, where the Vth spinal root leaves the cord, its atrophy at the contra-lateral side also seems evident (fig. 28 E). In still more distal sections this is no longer the case and the region between the oliva superior and the fifth spinal root it even is smaller at the operated side (fig. 28 C).

To interprete the fact I remember that the ascending spino-cerebellar tract has lost fibres. I have shown its atrophy *at the same side* of the operation, there where it is lying free at the surface of the superior pedunculus cerebelli (fig. 28 F).

At the opposite side, there is again found atrophy of another part of the lateral fillet and of the „aberrirendes Seitenstraugbündel. This contra-lateral atrophy is found combined with an atrophy of transverse ventral fibres crossing the raphe at the operated side. (Plate XXIII fig. 28 F.) In this distal part of the decussatio ventralis tegmenti (Forel) there is also found degeneration in transverse fibres with Marchi. (Plate XIX fig. 25 A—D).

It is therefore doubtful whether this „aberrirendes Seitenstraug-bündel" that Monakow has isolated after transverse section of the oblongata (the ventral ascending spino-cerebellar tract having totally disappeared in such cases) contains only a rubro-spinal descending tract. There must still be found fibres of another origin.

The current view is that the rubro-spinal tract issued from the nucleus ruber after crossing in the ventral decussatio tegmenti (Forel) runs downward. Without contact with the red nucleus, there must still exist a crossed portion of that „aberrirendes Seitenstrangbündel" ascending to the medial part of the lateral fillet, and thence in the ventral fibres under the nucleus quadrigeminum posticum passing upward.

After all, there are entering two important systems into the lateral fillet — without reckoning the root-fibres — that accompany them.

The one, originating in the contra-lateral tuberculum acusticum, both olivary nuclei, and the same sided nucleus ventralis lemnisci lateralis, are not yet all medullated in the elder foetus or at birth. They go through the fibres of Monakow, the stratum *c* of the systema ventrale et intermedium into the lateral fillet.

The other originates in the contralateral nucleus of Deiters, the contralateral nucleus ventralis N. octavi, the contralateral nucleus griseus nervi descendentis, perhaps in the same-sided nucleus trapezoides. It passes through the ventral, intermedial and dorsal system of the nervus octavus and is medullated at birth.

In this way there may exist two systems, differentiated in the central secundary octavus-systems, the one to be used for the higher psychical function of hearing, the other for the automatic and reflex-functions, defining the influence upon movements, which the N. octavus has.

b. *The longitudinal secundary systems participating in the systema dorsale nervi octavi.*

As may be seen best in an horizontal section of an elder foetus of a rabbit (Plate VI fig. 19 C) the dorsal systema is forming a powerful mass of medullated fibres, spread over an extensive area.

A medullated bundle runs from it proximally (Plate VI fig. 19 C. syst. dors. N. VIII).

After rootsection (Plate XIV fig. 14 B, Plate XI fig. 16 K) in this tract, some degenerate rootfibres are found, which could be traced towards the nucleus of the IVth nerve.

After section of the dorsal system, this tract degenerates nearly totally.

Very instructive in this respect are here the results of the double-sided ablation of the tub. acusticum (Plate XIX, XX fig. 25 X—A).

There on the right side, the incision falls not so far proximalward as on the left side. The nucleus of DEITERS, on the left, has been totally destroyed. On the right its destruction is only complete at its distal end and at its proximal end some very well developed, normal cells are seen in it (Plate XIX, XX fig. 25 E, F at the right side).

Now from the proximal end of the damaged nucleus DEITERS on the left, there appears a large radiation of degenerated fibres (Plate XIX fig. 25 E). They radiate in medial direction, at first dorsally from the spinal fibres of the V$^{th.e}$ root, which is just preparing its issue from the central system. At its issue they pursue their medial course, now situated dorsally from the sensible and motor Vth nucleus. (Plate XIX fig. 25 D). They now bend in longitudinal direction, lying among the longitudinal fibres in the dorsal part of the formatio reticularis half way between the fasc. long. post. and the bracchium conjunctivum cerebelli (Plate XIX fig. 25 G). Slightly approaching the fasc. long. post., they touch its lateral border, and as ari united bundle the (degenerated) fasc. long. post. and that here described (Plate XIX fig. 25 B) pursue their common proximal course. Those degenerated fibres at first remain lateral from the fascic. long. post., but as the nucleus of

the IVth nerve appears, they surround this nucleus from its lateral side, lying now nearly dorsal from this fasc. long. post. (Plate XIX fig. 25 A).

Now on the right side, degenerate fibres taking the same way are also found, though in a smaller quantity, and they also may be followed through the proximal part of the stria medullaris, between the normal cells, which are left by the partial destruction of the right DEITERS nucleus.

This ascending tract in the dorsal system degenerating here on both sides, may be called the tractus DEITERS ascendens. Degenerating partially after rootsection, it does so totally within six days after the section of the dorsal systema, as DEITERS nucleus is incised. The tract gives an important number of fibres between the cells of the IVth nucleus, also to the distal end of the third nucleus and not only this, but within six days I found a very intense degeneration of the roots of the N. trochlearis.

On horizontal sections (Plate XVI fig. 20 D) the degenerated tract is also found after the division of the dorsal system. It is found degenerated on the operated side and forms a powerful bundle of fibres from the nucleus of DEITERS towards the same-sided motor nuclei of the eye.

However the tractus ascendens of DEITERS is only one of the many systems of fibres degenerating after the destruction of that nucleus.

In following (Plate XX fig. 25 F—L) the damaged nuclei DEITERS to their distal ends, there appears a new bundle of degenerate fibres. Apparently it accompanies for a short moment the descending root of the N. octavus, lying at its medial side (Plate XX fig. 25 F tr. DEIT. asc. + r. desc. N. VIII) but soon it leaves the root and radiates in a medio-ventral direction crossing the facial issuing root (fig. 25 F and G).

In horizontal sections this radiation is found as a field of degenerated queer-sectioned fibres medially from the facial root and surrounding it (fig. 20 E fasc. DEIT. desc.).

As the root is crossed it slightly bends distally until the root-fibres leaving the VIIth nucleus are reached (fig. 25 H). There the bundle forming an angle of nearly 90°, abruptly takes a longitudinal and distal course (Plate XX fig. 25 I L).

It is the tractus DEITERS descendens. Horizontal sections (Plate XVII fig. 20 E and F. tr. DEIT. desc.) are very useful to demonstrate this part of this tract and it may likewise be plainly demonstrated in the double-sided section of the dorsal systema, even better on the right, because the incision falling not very proxi-

mally, has not lesioned there completely the ventral root at its entrance and is consequently more or less isolating the tractus DEITERS descendens from the descending root (Plate XX fig. 25 G) at the beginning of its course.

The degenerated fibres of this tract are very thick fibres and may easily be followed towards the nucleus of DEITERS in case of partial destruction (in fig. 25 at the right side).

During its distal course this field of degenerate fibres is lying in the middle of the formatio reticularis. In frontal sections it has the form of a triangle, its top is directed dorsally and its base resting upon the facial nucleus.

More distally, the facial nucleus having disappeared it tends to take a more ventral position. In the level of the oliva inferior, it reaches the nucleus para-olivaris resting upon its lateral border. Medially the area is bordered by the issuing rootfibres of the XIIth nerve. There it reaches nearly the peripherical margin of medulla oblongata (Plate XX fig. 25 I and K).

At the distal end of the medulla oblongata it is found at the peripherical margin, bordered medially by the roots of the 1th spinal ventral root. Its form (Plate XX fig. 25 L) is still that ot a triangle, with its basis at the ventral margin of the lateral column, its short side towards the formatio reticularis of the cornu lateralis, to which it leaves collaterals.

At the entrance of the second spinal ventral root it has a position still more at the peripherical antero-lateral margo of the cord (Plate XXI fig. 25 M).

The diagram of the degenerated tract now has the form of a spherical obtuse-angled triangle, the basis of which lays at the antero-lateral margin of the cord, for its ventral edge now is no longer bordered medially by the entering roots and reaches into the columna anterior.

In this way the basis extends along the ventral third part of the lateral margin. There the short side of the triangle leaves the margin under an obtuse angle, curving towards the lateral cornu in a ventrally concave curvation. Its top now nearly reaches the ventral portion of the formatio reticularis of the lateral horn, and from there parts the long side of the triangle, sligtly arched and concentric to the border of the cornu antero-lateralis and concave towards the median line, it returns under a sharp angle, towards the ventral end of the basis.

During its distal course through the cord, the diameter of this degenerated area changes. In its way through the intumescentia

cervicalis it does suffer great alterations. (Plate XXI fig. 25 M—O). The dorsal obtuse edge, tending towards the lateral horn disappears and when the tract has reached the thoracic cord its much reduced diagram (Plate XVII fig. 21 D_4 D_8 D_{12}) has the form of a segment, lying at the peripherical antero-lateral margin and the issuing anterior roots pass between its degenerate fibres. In the lumbosacral intumescentia the edge towards the lateral horn reappears, now situated more medially and going along the roots. (Plate XVII fig. 21 L_4, S_2).

In this way the tract of DEITERS may be traced (Plate XVII fig. 21, Plate XVIII fig. 22 F. G. Plate XXI fig. 25 M—O) into the sacral cord, providing the antero-lateral horn with degenerate collaterals, but leaving the greater part of its fibres in the cervical cord, and giving more fibres to the intumescentiae than in the thoracic part of the cord.

For tracing the two tracts of DEITERS, MARCHI-method excels above all other methods, but it remains in perfect accordance with them.

The myelinisation-method in the new-born or elder foetus of rabbit is very appropriate to demonstrate the beginning of the descending tract, its relation to the facial root and the facial nucleus and rootfibres, and its curvation into the longitudinal axis (Plate I fig. 5. Plate XIII fig. 18 E and F).

In that stage it is medullated there among other non medullated fibres. But in the medulla it becomes more difficult to trace.

GUDDEN's method, as employed by von MONAKOW, has demonstrated, that after hemisection of the lower oblongata or in the cervical part of the cord, all the large cells in the nucleus of DEITERS disappear. In this case, like in that of the fillet-section with loss of the large cells in the tuberculum acusticum, there is demonstrated a total retrograde atrophy from a system lesioned not too far from its origin.

But by MARCHI-degeneration after the section of the dorsal systema more is shown.

In the beginning of their course, the fibres of the ascending and descending roots of the N. VIII are intermingled with those of the tracts of DEITERS in such a manner, that it is impossible to judge, whether the transverse dorsal fibres, now degenerated in a most intense degree take their origin in the nucleus of DEITERS or in other nuclei from the dorsal systema.

Some of those degenerate transverse dorsal fibres may be traced through the raphe, through the fasc. longitud. posterior,

among the transverse dorsal fibres on the other side. There they pass ventrally from the dorsal nucleus of the VIIIth nerve towards the opposite nucleus of DEITERS and bending distally, they follow in the contra-lateral half of the oblongata, a perfectly symmetrical course, forming a contra-lateral descending DEITERS tract, slightly yet evidently degenerated, though not in such intensity as the same-sided tract. (Plate XVII fig. 20 E and F). These transverse dorsal fibres I believe to originate in the destroyed nucleus of DEITERS at the opposite side.

However from the two tracts of DEITERS, as well from the ascending, as from the descending, many other transverse fibres originate. As is seen both in horizontal (Plate XVI fig. 20 D in tr. DEIT. asc.) and in frontal sections (Plate XIX fig. 25 A—E in tr. DEIT. asc.) the ascending tracts send transverse fibres crossing the raphe just ventrally from the fasc. long. posterior. As soon as, in frontal sections, this tract approaching the fasciculus longitudinalis posterior at its lateral side, has touched the grey matter round the aquaeductus Sylvii, there are seen always fibres leaving it, passing the raphe. These fibres find their way to the lateral fillet.

It has already been described that the lateral fillet here is composed of several layers, from which two were degenerated. The one, lateral from the nucleus ventralis lemnisci was formed by the decussatio of MONAKOW fibres in more distal regions, the other, also originated by these fibres did reach the dorsal layer of the oliva superior and increased with fibres arrived there from the ventral and intermedial systems, formed the medial bundle in this lateral fillet.

Into this medial bundle (Plate XIX fig. 25 C and D) the degenerated fibres above mentioned may be traced and this bundle is increasing in its proximal course.

These fibres, without any doubt being fibres going from the ascending tract of DEITERS to the medial bundle of the contra-lateral fillet, may be interpreted as more proximal situated MONAKOW's fibres and at the nucleus of the IVth nerve, where the ascending tract approaches its end, (it passes near to the nucleus of DARKSCHEWITSCH, but gives only a few fibres into it) the most proximal fibres of this system pass the raphe to the medial bundle of the lateral fillet.

In this way the tract described by PROBST as a commissure between the fillets, passing ventrally before the nucleus IV, may be a part of this system.

The relations between the descending tract of DEITERS and trans-

verse fibres are naerly the same as the above mentioned. At their origin from the degenerated mass of dorsal fibres, it cannot well be judged whence MONAKOW's fibres come, but as the DEITERS tract has loosened itself from this mass and crossed the facial root, a great many fibres issue from it in order to give an important number of fibres in MONAKOW's system.

In horizontal sections (Plate XVII fig. 20 E) this is easily demonstrated. Some of those fibres even bend proximally and, after having crossed the raphe, may again reach the medial bundle of the lateral fillet. The larger part follow the usual path of the MONAKOW fibres.

Therefore it appears, that the fibres issued from the large cells of the tuberculum acusticum, do not only follow the direct way into MONAKOW's decussation to reach the dorsal layer of the oliva superior and from there the medial layer of the fillet, but that they also enter in both tracts of DEITERS and remain there for a longer or shorter extension till they find, by means of a decussatio ventral from the fasciculus longitudinalis posterior, a direct way to this bundle. In this way the tub. acustic. may aid to the architecture of the DEITERS tract, and the nucleus of DEITERS, to that of the MONAKOW system to the lateral fillet.

Now leaving those tracts, still other important layers of degenerate fibres after the section of the dorsal systema ask a description.

1^{ly} in following the (degenerate) descending root, it appears that the layer of normal longitudinal fibres found after rootsection medially from the (degenerate) rootfibres (Plate V fig. 9 and fig. 10) between this root and the nucleus dorsalis N. octavi shows also degeneration (Plate XVI fig. 20 D). Subsequently this descendent tract, accompanying the descending root, intensely degenerated, may be traced very far distalward, constinuing with a part of its fibres in the fasc. solitarius N. vagi (Plate XVII fig. 20 E) and (Plate XX fig. 25 H) found there situated dorsally.

From this tract part an innumerable quantity of small collaterals perpendicular to its direction (Plate XVI fig. 20 D) ending in the nucleus N. VI, now totally blackened with black globules, in the nucleus dorsalis N. VIII, in the nucleus N. X and in the same-sided nucleus N. XII. The XIIth nucleus however is only very slightly connected with the secundary octavus-fibres, at least in a far less intensity than the upper part of the spinal cord. In this way as till now is demonstrated, there is only one motor nucleus, that of the Vth nerve, having no relation with them. Only not all are degenerated with the same intensity. The most interested nuclei at the operated side are:

The IVth and the distal end of the IIIth nucleus and that of the VIth nerve; in a lesser degree the facial nucleus, the motor nuclei N. X, and the nuclei funiculi lateralis; least that of the XIIth. Uninterested surrounded at all sides by a large quantity of degenerate fibres the motor quintus nucleus is lying.

2^{ly} from the descending root and also from the descending tract of DEITERS, there however originate dorsal transverse fibres, not ending in the described nuclei but passing the raphe.

They go ventrally and dorsally from the genu of the nervus VII, they even penetrate through it, pass the raphe, provide the contra-lateral nucleus of the VIth nerve withe a large quantity of fibres, pursue their course in the contra-lateral layer of transverse fibres and reaching there the portio interna, they accompany the descending rootfibres giving there again collaterals to the contra-lateral nucleus nervi VI (Plate XVI fig. 20 D).

In this way, the descending root of the opposite side receives a secundary system through the transverse dorsal fibres and in the same way as the secundary system in the contra-lateral descending DEITERS tract, it is less important than that of the same side.

3^{ly} a great many degenerate fibres of the dorsal transverse layer however, at their reaching the raphe bend in a longitudinal direction, forming in the fasciculus longitudinalis posterior an ascending and a descending tract.

After one-sided section of the systema dorsale it appears that the contra-lateral f. l. p. is degenerated more intensely. The same fact I have stated after rootsection on one side.

The proximal part of this tract, giving fibres to the contra-lateral nucleus N. VI diminishes rapidly. The contra-lateral VIth nucleus, as has been shown, now being provided from three sides, from dorsal transverse fibres after their crossing the raphe, from the contra-lateral fasciculus longitudinalis posterior and from the descending root, is degenerated to such an intense degree, that its degeneration hardly differs from that at the same side. The fasciculus longitudinalis posterior however do not leave all its degenerate fibres in this nucleus and in sections proximally from the levels of the VIth nucleus there are still found a few degenerate fibres in it. They may be followed to the IVth nucleus causing there a very slight degeneration (Plate XVI fig. 20 B). It is not quite clear however, where the larger part of those degenerate fibres remains.

Now, as it may be seen in fig. 20 G, the bracchium conjunctivum ped. cereb. sup. is divided. The subsequent degeneration is seen (fig. 20 D) in this bracchium towards the contra-lateral red

nucleus. It may be presumed, that the degenerated pedunculus cerebelli superior, after passing the raphe sends fibres into the fasc. longitudinalis posterior and in the fasc. praedorsalis backwards. My experience in regard to this is conform to that of VAN GEHUCHTEN. But this presumption does not enable us to interprete the prevailing of degenerate fibres in the contra-lateral fasc. long. post. in sections falling proximally from the nucleus of the VIth nerve after root-section. Even if (in the case drawn in fig. 20) fibres from the degenerated bracchium conjunctivum pedunculi cerebelli superior might have increased here the contra-lateral degeneration in the fasciculus longitudinalis posterior, it still would be too intense, to be caused by those fibres which only may exist in small number.

Therefore I believe that there exist fibres, issued from the nucleus ventralis nervi octavi and from the nucleus DEITERS of the opposite side, which take temporary a place in the contra-lateral fasc. long. post. to provide chiefly the nucleus VI of that side, in a far lesser quantity the nucleus IV and X, but leaving it also to reach the medial bundle of the lateral fillet.

All contra-lateral degenerated fibres in the fasc. long. post. remain within the medulla oblongata.

At the proximal top of the XIIth nerve, the degeneration prevails in the fasc. long. post. of the operated side, but these fibres have quite an other signification. Many transverse dorsal fibres namely have remained at the same side in the fasciculus longitudinalis posterior and bending distally they have a slight ventral inclination, in such a way that in proximal sextions being longitudinal fibres of the fasc. long. post. they gradually pass distally into the fasc. praedorsalis. Now from the degenerate transverse fibres in the decussatio of MONAKOW and from that of HELD, there also bend fibres in the homo-lateral fasc. praedorsalis and take a longitudinal course.

At the level of the XIIth nucleus (Plate XVIII fig. 22 F and G, Plate XX fig. 25 L, Plate VIII fig. 15 N°. 5—N°. 1) the fasciculus longitudinalis posterior and the fasc. praedorsalis are no longer differentiated. There now is in the medial field of the medulla oblongata, between the stratum interolivare (LEVANDOWSKI's lemniscus principalis) and the dorsal nuclei an intense degeneration at the same side and a much less intense, but still evident one, at the contralateral side.

At the end of the oblongata this degenerated tract is found in the anterior columna of the cord (Plate XXI fig. 25 M) at the sides of the decussatio pyramidum, and at the exit of the 2th ante-

rior root, it has a position in the columna anterior, between the anterior horn and the fissura anterior medullae. It rests upon the commissura anterior, and following the medial border of the horn, it is laterally limited by the most medial issuing rootlet.

This situation the degenerated field preserves in its course through the cervical medulla, giving fibres into the anterior horn. (Plate XXI fig. 25 N and O).

If one-sided section through the dorsal systema is made it prevails very much upon the operated side (Plate XVII fig. 21 C_4).

As it reaches the cervical intumescentia, it retires from the commissura and from the horn, takes a position at the peripheric margin of the cord along the fissura anterior and at the anterior margin. Extending more laterally, it soon touches the medial end of the tractus DEITERS descendens and together these two tracts now form a long peripherically situated degenerate small band, beginning at the commissura anterior, along the fissura anterior and the antero-lateral margin, untill the middle of the lateral column (Plate XVII fig. 21 C 7).

To reach the grey matter, their fibres often bend abruptly into a medial direction, crossing obliquely the columna.

This is the second long descendent tract, which unites the primary octavus-nuclei with the motor columns of the spine. Together they may be traced unto the sacral part of the cord (Plate XVII fig. 21 S_3). Thus it is found degenerated as well after section of the lateral trunk of the ventral system, (Plate XVIII fig. 22 H). as after section of the dorsal system (Plate XVII fig. 20 and fig. 21. Plate XXI fig. 25 M—O) and after section on both sides.

Through the existence of contra-lateral symmetrical tracts may not be denied, those on the same side are much more voluminous, as the intensy of their degeneration shows evidently.

There still remains to discuss the third long descendent path towards the spinal cord.

I already described its degeneration after the section of the lateral trunk of the ventral systema.

I saw it very intensely degenerated after the section of the dorsal systema (Plate XVII fig. 20 F and fig. 21 C_2—S_3) and in a less intense way after the double-section (fig. 25 M. N. O.)

It appears in the oblongata as soon as the voluminous degeneration of the corpus trapezoides has ended, as a degenerated area between the fifth root and the facial nucleus, extending ventrally of this nucleus at the peripherical margin. As GOWERS tract, with which its fibres are mixed, slightly bends medially and FLECHSIG's

tract begins the formation of the restiform body, the area must leave the peripherical margin. At the end of the oblongata it has the shape of an equal-sided spherical triangle. Its top is lying in the formatio reticularis lateralis medullae, one of its sides borders the formatio gelatinosa of the posterior cornu, the other borders the nucleus funiculi lateralis. (Plate XVIII fig. 22 H).

In the medulla the degenerated field preserves ist place, with the top in the formatio reticularis and resting upon the formatio gelatinosa cornu posterioris, bordered ventrally by the pyramidal tract in the lateral column, and laterally by FLECHSIG's Kleinhirn-Seitenstrangbahn (the dorsal ascending spino-cerebellar tract). This position (Plate XVII fig. 21 C 3) it retains, until the sacral part. It also has a tendency to reach the peripherical margin of the postero-lateral column, and in the middle of the thoracic part of the cord (Plate XVII fig. 21 D 4) the whole peripherical margin of the columna laterales et anteriores, may be formed by a small degenerated band, composed of fibres of our three descending tracts.

I believe this descendent tract for the greater part issued from the ventral nucleus n. octavi, because I have not found it degenerated in such an extensive degree after dorsal section as after section of the ventral systema.

It is found chiefly degenerated at the operated side, but slightly degenerated is also its contra-lateral partner in all cases.

But here a difficulty arises. The way traced out is the way of the descendent path in MONAKOW's „aberrirendes Seitenstrangbündel," which according to PAWLOW and VAN GEHUCHTEN might be a rubro-spinal path.

Certain it is, that in none of my cases the nucleus ruber is lesioned. But it is questionable whether by the dorsal section, the tract in its course from the contra-lateral nucleus ruber, crossing in the ventral decussatio tegmenti and reaching in such a way the „aberirrendes Seitenstrangsbündel" may be divided.

This rubro-spinal path exists, I do not doubt it, but the aberrirende Seitenstrangbündel reaches also the lateral fillet (Plate XXII fig. 28 E and F). There, lying still more medial than the medial bundle of this fillet, it is not only formed by the crossed fibres of the rubro-spinal tract, but it reaches probably much farther.

In the section of the dorsal system of fig. 20 (Plate XVI fig. 20 D) the lateral fillet in its dorsal regions has been touched, but in the section of the lateral trunk of the ventral system (Plate XVIII fig. 22 B) it is not, and in the double-sided lesion (Plate XX fig. 25 C—H) equally the fillet is intact. In the dorsal section of

fig. 20 and in the ventral section of fig. 22 the samesided degeneration in the rubro-spinal tract was very intense, in the double-sided it was only slight. I doubt, that the rubro-spinal path should have been damaged, but if in the medio-dorsal parts of the lateral fillet fibres are found, issuing from the c. quadr. posticum (or through the ventral fibre-layers of this ganglion from the corpus geniculatum or from the thalamus) and degenerating in descendent direction, it might have been possible, that, in the extensive dorsal section of fig. 20, a division of those fibres has been the cause of the intensive degeneration found in the rubro-spinal path.

Now as I find without lesion of the fillet a slight (Plate XXI fig. 25 M—O) or even a more intense (Plate XVIII fig. 22 G—H) degeneration in this tract (dorsally situated in the cord) according to dorsal or ventral section of the secundary systemata, I conclude that this tract also receives any fibres through the secundary octavus-systems and chiefly from the ventral systema. Here also the degeneration is found on both sides, but chiefly homolateral.

In this way I believe that the secundary octavus-systems are sending fibres to the medulla chiefly on the same side, along three ways. There are to distinguish 1^{ly} a praedorsal system or in reference to the cord, a ventral octavo-spinal way, 2^{ly} a tractus DEITERS descendens, or in reference to the cord, a lateral octavo-spinal way, 3^{ly} a smaller path in the „aberrirendes Seitenstrangbündel" or in reference to the cord a dorsal octavo-spinal way.

5. SUMMARY OF RESULTS.

I will close this chapter by giving the schemata, according to the results of these anatomical researches.

After removal of the cochlea, there is found an important degeneration in the dorsal root, the extra-medullar part of the ventral root however is found without degeneration.

After removal of the labyrinth, both roots are brought to degeneration, but a still more intense one takes place in the extra-medullar part of the dorsal root than after cochlea-removal.

Both roots, after having entered the oblongata, divide in three parts, a dorsal, a medial and a ventral trunk.

The dorsal root sends by far the larger part of its fibres into the dorsal trunk (stratum latero-dorsale C. R.), only a few fibres into the medial trunk, and also some fibres into the ventral trunk.

The ventral root sends the majority of its fibres into the medial trunk between the spinal root of the Vth nerve and the area ovalis

C. R., some fibres into the ventral trunk, but an important number of its fibres are by means of an intermediary bundle, directly or through the corpus restiforme, introduced into the dorsal trunk. In this way the course of the two roots does differ very much as to the quantity of the fibres, directed into the different trunks, but there are no paths, followed by one of them, wherein no fibres of the other appear.

Their course may now be illustrated by the adjoined schemata.

THE FIBRES OF THE DORSAL ROOT (cochlear-fibres).

(Schema A).

Most fibres of the dorsal root enter in

I. THE DORSAL TRUNK (stratum latero-dorsale corporis restiformis).

Those fibres perforate the ventral nucleus N. VIII and leave

1. *a great many fibres in the disto-ventral part of the ventral nucleus.*

Between the larger cells of this nucleus — from which secundary systems originate — and the rootfibres, small cells are intercalated (the nucleus proprius radicis dorsalis) and also

2. *many fibres in the dorso-proximal part of the ventral nucleus,*

After the perforation they form the external layer of the stratum latero-dorsale C. R. the beginning of THE SYSTEMA DORSALE NERVI OCTAVI. They divide into many bundles, radiating dorsally from the area ovalis C. R.

3. *the dorsal rootfibres in the stratum medullare profundum tuberculi acustici.*

From these rootfibres perpendicular collaterals enter in this nucleus and with the aid of small intercalated cells (in the stratum profundum griseum) the large radially situated cells are innervated — from which secundary systems originate.

4. *the dorsal rootfibres to the lateral part of the dorsal nucleus N. VIII.*

Collaterals end therein. The small cells therein may intercalate them to the nucleus of DEITERS.

Less in number but evident are:

5. *the dorsal rootfibres among the system of dorsal transverse fibres.*

They are much increased by ventral root-fibres. Only a few fibres go

α ventrally from the dorsal eighth nucleus to the VIth nerve, remaining in those nuclei. On this way very few are going.

β. to the formatio reticularis (descendent DEITERS *tract).*

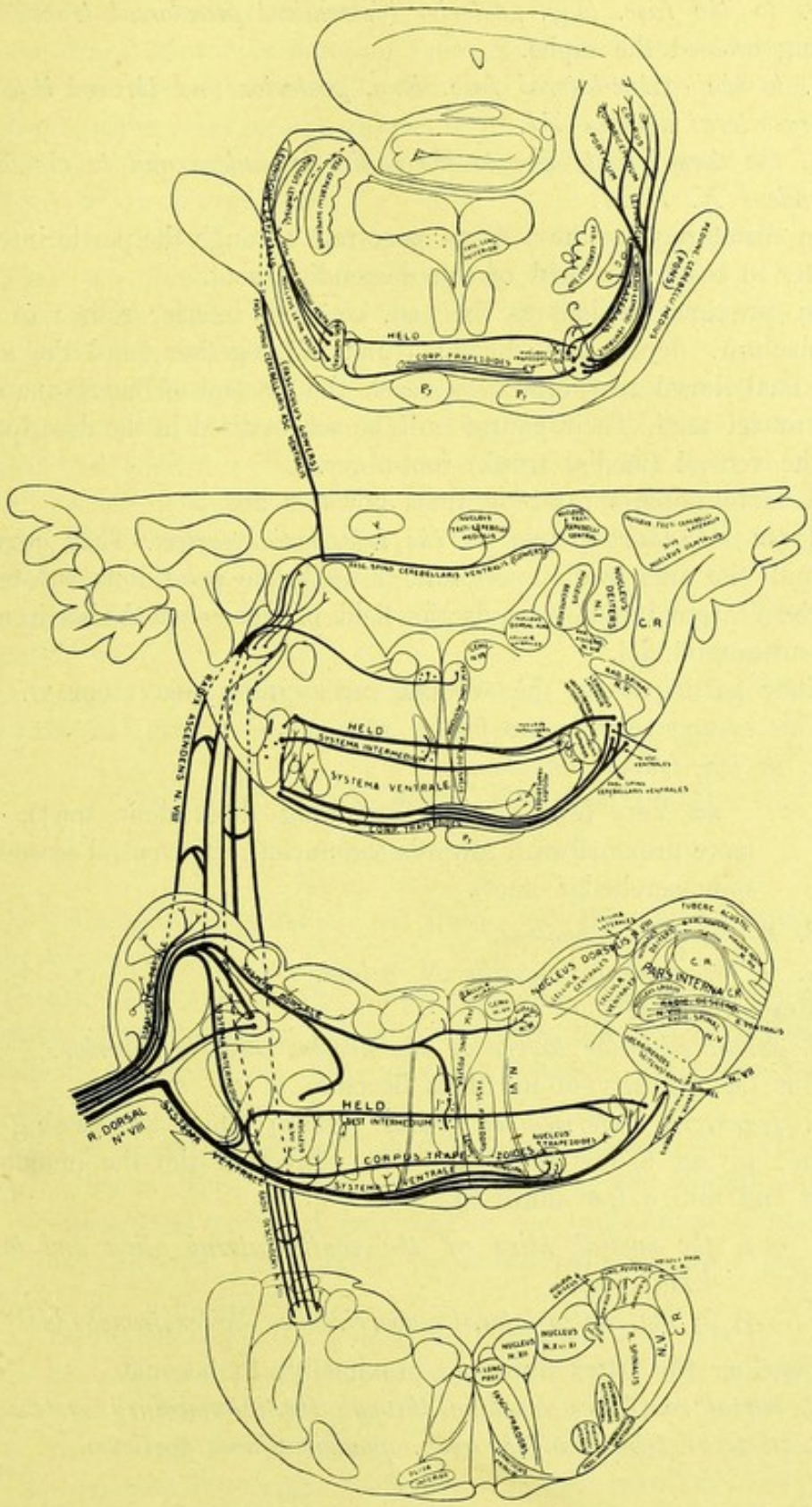

Fig. 18.

Schema *A*.

Scheme of the central path of the root fibres of the dorsal eighth root.

γ. to the fasc. long. posterior (descendent praedorsal tract) and having crossed the raphe.

δ. to the contra-lateral fasc. long. posterior and through it to the contra-lateral nucleus VI.

6. *the dorsal rootfibres to the radix descendens and to the radix ascendens N. VIII.*

In distal regions these fibres penetrate through the portio interna C. R. to reach the field of the descending root.

In proximal regions as the ped. cerebelli inferior retires to the cerebellum, dorsal and medial trunk fall together, and the most proximal dorsal rootfibres even reach the nucleus of BECHTEREW and the nuclei tecti. Their course will be schematised in the description of the ventral (medial trunk) root-fibres.

A more important set of fibres however are

7 *the dorsal rootfibres to the intermedial system.* They curvate around the area ovalis, perforate through the gelatinous substance of the Vth spinal root towards the field of the so-called aberrirendes Seitenstrangbündel.

They participate to the SYSTEMA INTERMEDIUM NERVI OCTAVI.

This system sends some fibres

α. in longitudinal direction.

αα Very few distally (beginning descendent tract), *ββ* more proximalward towards the nuclei tecti (ventral ascending spino-cerebellar tract).

β. in the facial nucleus.

γ. in the systema ventralis N. octavi.

More fibres in the

δ. dorsal medullar layers of the nucleus olivaris superior.

But the majority of its fibres become.

ε. transverse intermediary fibres (HELD) which are passing the raphe, giving a few fibres in distal direction tho the praedorsal tract and also a few fibres to

α the medial hilus of the contra-lateral oliva and to its dorsal layer.

β in the contra-lateral „aberrirendes Seitenstrangbündel".

Together the latter fibres go proximally, to become

ζ. dorsal rootfibres reaching through the intermediary system the contra-lateral fillet and the corp. quadrigeminum posticum.

II. IN THE MEDIAL TRUNK only a few fibres enter. They will be schematised in the description of the ventral rootfibres.

III. IN THE VENTRAL TRUNK.

The dorsal rootfibres entering there have the same course as the ventral rootfibres. Therefore for this part the schema of dorsal and ventral-rootfibres are nearly equal.

They participate to THE SYSTEMA VENTRALE NERVI OCTAVI.

They follow several ways.

1. *dorsal rootfibres to the contralateral nucleus trapezoides.*

They are thick, superficial, transverse fibres, from which some remain in the same-sided nucleus. The rest, after passing the raphe enter into the contralateral.

2. *dorsal root-fibres into the ventral system, to the nuclei ventrales tegmenti of the same side.* They leave collaterals into their lateral and ventral medullary layers and passing the raphe they are.

3. *dorsal root-fibres to the contra-lateral nuclei ventrales tegmenti.* They leave a few fibres in the medial hilus of the contralateral nucl. olivare superior, and the rest, united to the fibres of the intermediary system coming there, pursue their way in proximal direction as

4. *dorsal root-fibres, reaching through the ventral system the contralateral fillet and the corp. quadrigeminium porticum.*

THE FIBRES OF THE VENTRAL ROOT

(Schema B).

A considerable number of fibres of this root enters in

I ITS DORSAL TRUNK.

Directly or through the corp. restiforme the ventral rootfibres participate to the formation of the stratum latero-dorsale, forming chiefly its internal layer. They therefore also take part in THE SYSTEMA DORSALE NERVI OCTAVI.

To the ventro-distal part of the ventral nucleus N. VIII they give no fibres. They may give a few fibres to the ventral nucleus in its dorsal and proximal part and to the tuberculum acusticum, but they increase considerably the dorsal radiation upon the area ovalis C. R. thus giving.

1. *the ventral root-fibres to all cells of the nucleus dorsalis N. VIII.*

2. *the ventral root-fibres reaching the descending root* through the area ovalis corporis restiformis. These perforating fibres participate to

3. *the ventral root-fibres in the intermediary system.* Consequently to its increase by ventral rootfibres, THE INTERMEDIARY SYSTEM OF THE N. OCTAVUS is strengthened, and so are the ascending and descending tracts.

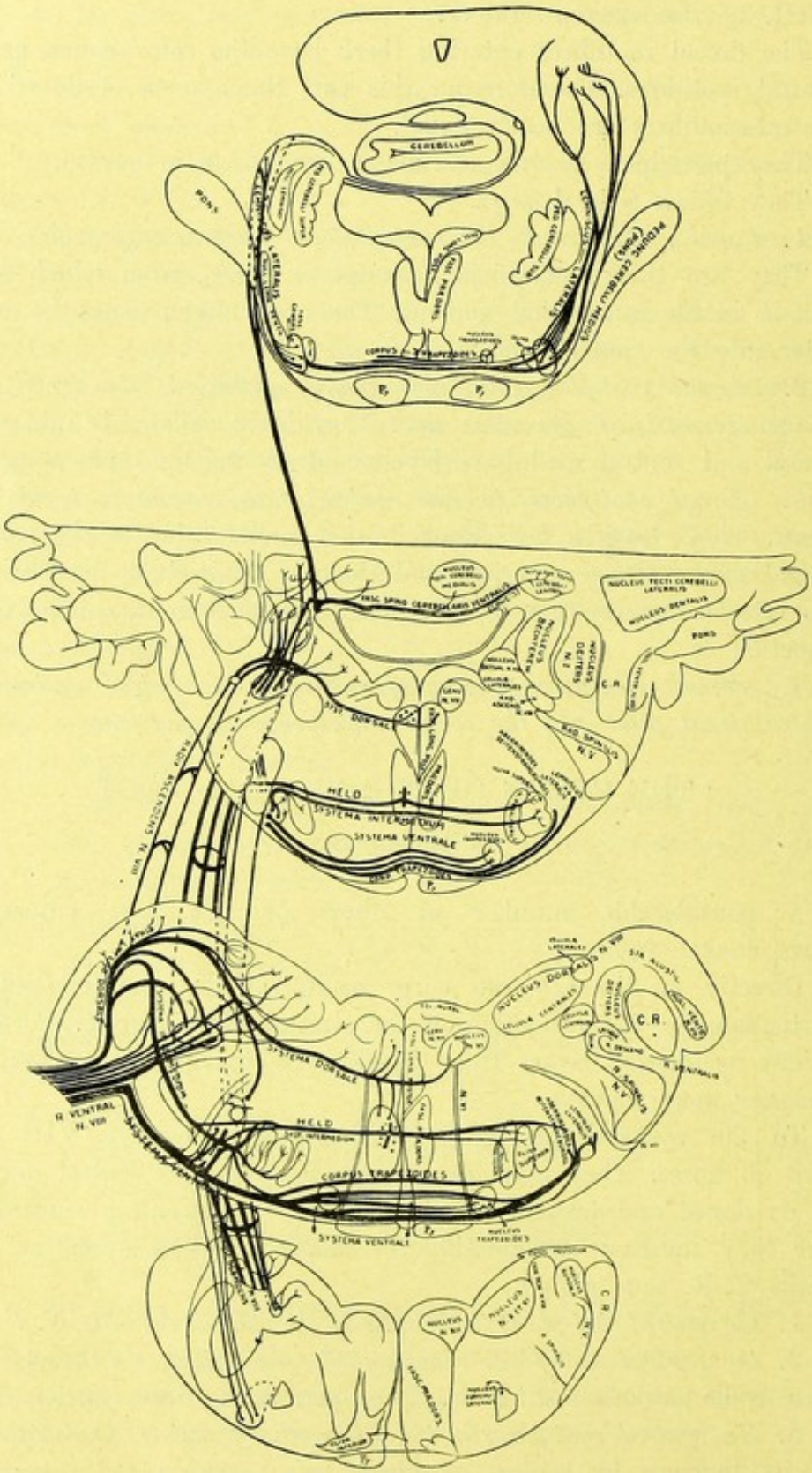

Fig. 19

Schema *B*.

Schema of the central path of the rootfibres of the ventral ligt root.

II ITS MEDIAL TRUNK however receives by far the larger portion of its fibres. They enter dorsally from the spinal Vth root, between it and the oval area C. R., and dorsally resting upon its medial end they bend distally (the descending root) and proximally (the ascending root). These fibres unite with dorsal and ventral root-fibres of the dorsal systema which have curvated round the corpus restiforme. As the restiform body retires into the cerebellum dorsal and medial trunk are no longer separated and form a single trunk.

In the ventral trunk small cells are intercalated (nucl. proprius radic. ventr.).

The descending rootfibres are accompanied by smaller and larger cells (the nucleus griseus radicis descendentis) united to the cells of the medial apex of the nucleus dorsalis.

This nucleus continues to accompany the ascending root and is called there the nucleus of BECHTEREW. The ascending and the descending root give rootfibres (far the greater part being ventral-rootfibres, the smaller part dorsal rootfibres) to many nuclei.

1. *ventral rootfibres to the nuclei tecti cerebelli.*

2. *ventral root-fibres to the nucleus of* BECHTEREW *and to the nucleus griseus radicis descendentis.*

3. *ventral rootfibres to all the cells of the dorsal nucleus N. VIII.*

In all these nuclei small cells are found to intercalate rootfibres with the large cells of DEITERS nucleus, which have no direct relations with any rootfibres.

4. *ventral rootfibres among the dorsal transverse fibres*, taking the way described in the schema of the dorsal root-fibres but providing now to a mere considerable degree the IIIth, the IVth and the VIth same-sided nuclei, the contralateral VIth nucleus and the beginning of the tractus DEITERS descendens and the tractus praedorsalis.

III ITS VENTRAL TRUNK

receives fibres taking the course described by the dorsal root-fibres.

THE ASCENDING FIBRES OF THE SECUNDARY SYSTEMS OF THE NERVUS OCTAVUS.

(Schema C).

Degeneration and atrophy after sections through the central system in rabbits and comparison with the foetal central system have taught, that from the nucleus ventralis, the tuberculum acusticum and DEITERS nucleus (+ large cells of the nucleus griseus

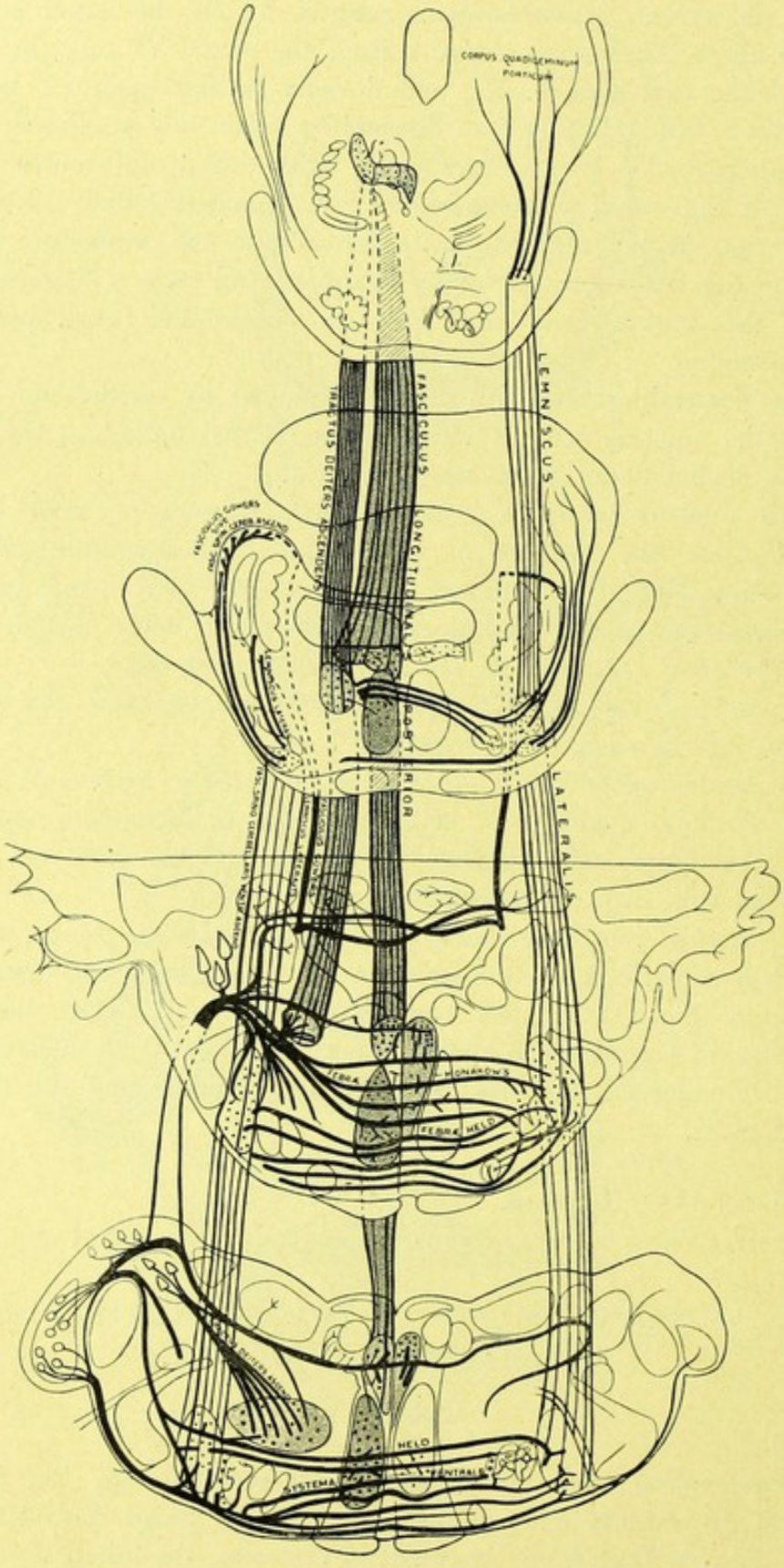

Fig. 20.

Scheme *C*.

Scheme of the ascending secundary octavus-fisres.!

and BECHTEREW) and from the olivary bodies issue secundary systems. Those systems (without those of the nuclei olivares superiores, nuclei paraolivares and nuclei trapezoides have been schematised).

They augment all the systems of rootfibres, and participate to the systema ventrale and intermedium, following the way traced by the root-fibres.

1. *The secundary fibres in the systema ventrale* are chiefly issuing from the ventral nucleus and are situated among all its layers. To this secundary system certainly is added an important one from the nuclei olivares especially in the stratum *c* of this system, probably following afterwards paths as the first.

2. *The secundary fibres in the systema intermedium* are also issuing from the ventral nucleus, but some of them may issue from the nucleus of DEITERS. To these secundary fibres the olivary bodies again add many fibres, not yet medullated at birth.

Those two systemata give now its origin to an ascendent, chiefly same-sided (but also contralateral) tract, which together with spinal fibres and octavus-rootfibres takes the way of the „vental ascending spino-cerebellar tract". Going proximally in the „aberrirendes Seitenstrangbundel" these primary and secundary octavus-fibres, they reach with the lateral fillet the outer layer of the pedunculus superior cerebelli, cross its bracchium conjunctivum and reach the nuclei tecti. Therefore in the

3. *ventral ascending spino-cerebellar tract* secundary as well as root-fibres of the n. octavus are found.

To this tract the olivary bodies, probably do not participate.

4. *The secundary fibres in the systema dorsale* issued from nucleus ventrale, tuberculum acusticum and nucleus DEITERS follow the dorsal way already traced by the root-fibres. But there parts from the stria medullaris a new very important system

5. MONAKOW's *transverse and ascendant secundary fibres.*

They cross the raphe ventrally from the fasc. long. post. reach the dorsal layer of nucleus olivaris superior, and that of the nucleus lemnisci ventralis.

This decussation of MONAKOW's fibres may be followed very far proximally, but in proximal regions (between the motor nucleus of the Vth and the nucleus of the IVth nerve) they exit from the tractus DEITERS ascendens. In distal regions DEITER's descending tract sends fibres among them.

Together with root-fibres and secundary fibres of the ventral and intermediary system, they go proximally in the lateral fillet in two distinct bundles. They unite there with

α. the lateral bundle from the nucl. ventr. lemnisci

β. the medial bundle from the dorsal layer of the nucleus olivaris superior

The latter fibres are strengthened by fibres from the tractus DEITERS ascendens.

Those fibres reach the corpus quadrigeminum posticum and probably still go farther.

This ascendent tract also is composed of rootfibres as well as of secundary fibres. But in this area of the lateral fillet there yet remain an important number of fibres, probably belonging to the octavus system, chiefly issued from the distal parts of the olivary nuclei, which are known insufficiently.

From the dorsal systema however a very important tract issues, containing

6. *The secundary fibres in the ascendent tract of* DEITERS.

They leave the nucleus of DEITERS, in proximal direction, bend medially and form the lateral part of the fasc. long. post. They end in the nucl. N. IV and III, whereas:

7. *The secundary fibres ascending in the fasc. longitudinalis posterior*, reach these nuclei united with the ascendent DEITERS tract. Nearly all the transverse fibres, issued from those two bundles to provide the nuclei (not those, reaching the medial bundle in the lateral fillet) are collateral fibres, and again their way is traced by the root-fibres of the nervus octavus.

THE DESCENDING FIBRES OF THE SECUNDARY SYSTEMS OF THE NERVUS OCTAVUS.

(Schema D).

The fibres of the dorsal system, composed of rootfibres as well as of fibres of the secundary system, also form descendent tracts.

1. *Fibres descending in the contralateral fasc. long. posterior.*

They form a contralateral rather important tract, providing the nucleus VI, and the distal end of the nucleus N. XII.

2. *Fibres descending in the same-sided fasc. long. posterior.*

Those fibres, slightly deviating ventrally in their distal course, unite with longitunal fibres, sent distally in the praedorsal tract, from the decussatio of MONAKOW and of HELD. Together they go towards the anterior column of the cord, where they are found along the fissura anterior and the ventral margin of the medulla.

It may be followed till the sacral part of it. The same tract is

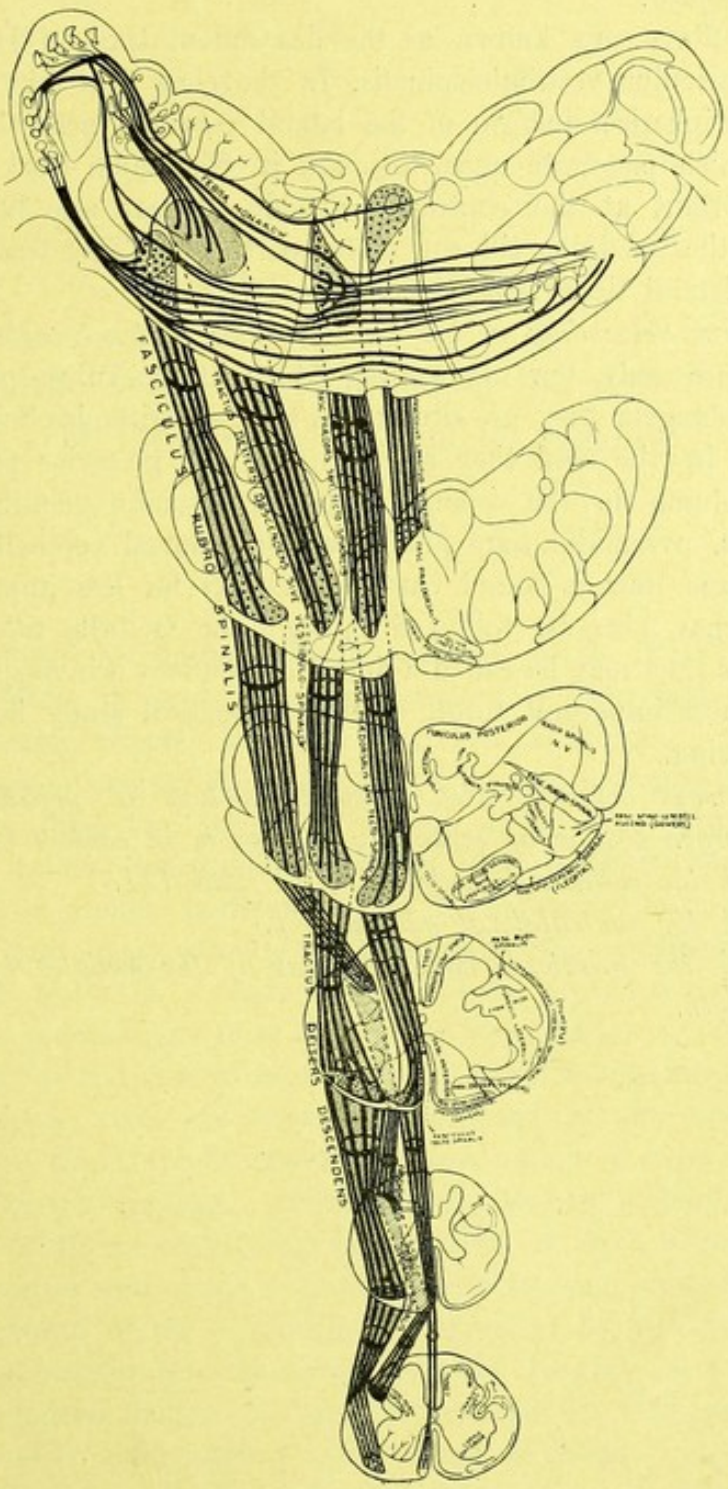

Fig. 21.

Scheme *D*.

Scheme of the descending secundary octavus-fibres.

found contra-lateral, but by far less important. It may be judged to be a ventral descending octavo-spinal tract.

3. *Fibres descending in the medial part of the formatio reticularis oblongata.*

These fibres are known as the descendent tract of DEITERS or as the fasciculus vestibulo-spinalis. In the cord they take a position at the peripherical margin of the lateral column, near the issuing roots, which penetrate queer through it. The same tract is by far less important at the contra-lateral side. It may also be followed through the medulla till the sacral part of it. This tract may be called a lateral descending octavo-spinal tract.

4. *Fibres descending in the „aberrirendes Seitenstrangbündel".*

They are only few descending fibres in the rubro-spinal tract. In the oblongata they are situated in the „aberrirendes Seitenstrangbündel". In the cord they are found in the posterior part of the lateral column in the triangle between formatio gelatinosa cornu posterioris, pyramidal tract and FLECHSIG's dorsal cerebellar tract.

The same tract is found contra-lateral by far less important.

They may also be followed through the medulla till its sacral part. This tract may be called a dorsal descendent octavo-spinal tract.

The most important result of this anatomical study however is, the following.

The nervus octavus, with a small portion of primary fibres with a larger postion of secundary fibres, is in contact chiefly.

1. *with the collateral nuclei VI, IV and III.*

2. *with the contralateral nucleus VI.*

3. *with the collateral motor columns of the medulla through its whole length.*

Chapter III.

On the central distribution of the root-fibres of the nervus octavus in pigeons.

The central distribution of the rootfibres of the VIIIth nerve in pigeons differs in many respects considerably from that, which in the preceeding chapter has been described in rabbits.

Therefore a comparison between the central system of the nervus octavus in these two species of animals is not very easy. It may even be called impossible, whithout homologizing the different fasciculi and nuclei, participating to the formation of this extensive system. And every attempt to homologize the octavus-nuclei of a bird with those of a mammalian will be proved a more or less subjective proceeding. It only may be tried, when a very minute knowledge of the central course of the rootfibres has been acquired.

My views upon the central distribution of the rootfibres in pigeons are based chiefly upon the examination of series of sections through their cerebrum, treated with MARCHI-method within a fortnight or three weeks after the removal of their labyrinth.

Those series were made in frontal, horizontal and sagittal direction.

The removal of the labyrinth was executed by strictly following the indications for this operation given by EWALD. As soon as the operated pigeon begins to turn its head the in IIIth position — generally after a fortnight — the animal is killed.

Now it must be observed, that in pigeons, the results of the MARCHI-method are often less sharply defined, as they usually are in rabbits. I believe that the rather high temperature of the blood in birds, may serve to explain the fact, that black globules are very often found every-where and in places, where they never might

have been expected after lesions in the root-fibres of the nervus octavus. Wherever a degeneration in the medulla oblongata is produced, nearly always black granules are found, for instance, in the intermedullary rootfibres of all the nerves and especially in those of the IIIth. The slightest degeneration in the oblongata suffices to bring forward black globules nearly every-where. I believe the reason of this fact, must be sought in the rapidity of the vital functions in birds. I think, that in an early period after the operation the dislocation of the degenerated myelin-products begins and that therefore the question whether there be a circumscript degenerated area or not may be more difficult to resolve in birds.

This observation however only relates to doubtful cases. Important and circumscript degeneration in the entering roots and in their initial paths after the removal of the labyrinth is found with equal certitude in pigeons as in rabbits.

1. *The entrance of the rootfibres of the nervus octavus in the medulla oblongata.*

Within a fortnight after removal of the labyrinth, in both roots of the VIIIth nerve many degenerate fibres are found. For in pigeons as in rabbits the VIIIth nerve enters into the medulla oblongata with two distinct roots. The one is the dorsal, distal or lateral root, the other the ventral, proximal or medial root. In both roots however, besides the degenerate fibres, many non degenerate fibres remain after the removal of the labyrinth.

In frontal sections it is now easily demonstrated that the distal root, lying laterally from the pedunculus cerebelli inferior, penetrates into a nucleus, immediately after its entrance in the medulla oblongata.

This nucleus covers the entering root like a dorsal cap, and according to the nomenclature adopted by Edinger and Wallenberg, it may be called the nucleus angularis — the „Eckkern" of these authors.

In this nucleus a large part of the degenerated dorsal rootfibres enter, and as they spread through the nucleus, this nucleus itself is intensely degenerated and found as a black spot after the removal of the labyrinth (Plate XXIII fig. 26 A).

In more distal regions, as long as the angular nucleus is resting upon the dorsal end of the dorsal root it is found laterally from the inferior cerebellar peduncle (fig. 26 A). In sections, falling more proximally (fig. 26 B and C) the nucleus retires at the dorsal end

of the inferior peduncle and the dorsal root, now still entering at its ventral pole, embraces the nucleus with its degenerate fibres, surrounding it ventrally and laterally, and giving it fibres, passing queer through the nucleus. Most of these fibres gather at the dorsal surface of the nucleus (fig. 26 A and B).

But at these levels, the ventral (proximal) root has also entered into the medulla oblongata. Its fibres — thick degenerated fibres after the removal of the labyrinth — perforate the inferior cerebellar peduncle. Its most dorsally situated fibres here approach the dorsal root-fibres and touch also the ventral border of the angular nucleus. Ventral rootfibres therefore here enter in the ventral surroundings of the nucleus angularis and continue to do so (Plate XXIII fig. 26 C and Plate XXIV fig. D) in more proximal levels, as the dorsal rootfibres have disappeared. They provide the proximal ventral border of it, until the nucleus joins the more lateral part of the nucleus pedunculi inferioris cerebelli, from which the angular nucleus is not distinctly separated.

Now the angular nucleus and its surroundings being provided in the manner here described, there remains at its distal end a bundle of degenerated fibres, chiefly dorsal rootfibres, that lying immediately below the ependyma of the IVth ventricle, takes a medial direction.

On the other hand, the greater part of the ventral rootfibres, which have passed queer through the pedunculus cerebellaris inferior (fig. 26 C) and continue to do so in more proximal levels, also take a straight medial direction.

These ventral root-fibres have lost some fibres in the ventral border of the angular nucleus, but on the other hand their number is increased by dorsal rootfibres, originating from the ventral surroundings of this nucleus.

In this way there are found in distal regions two degenerated bundles in the dorsal part of the oblongata.

The one, the dorsal bundle, leaves the dorsal surroundings of the angular nucleus, and directly be low its ependym, it runs parallel to the bottom of the IVth ventricle. In proximal levels it soon disappears.

The other, a ventral bundle, chiefly composed of the continuated ventral rootfibres, is much more important, as it may be traced in all proximal levels.

These two bundles (both composed of fibres of the two roots, but the dorsal chiefly of dorsal root-fibres, the ventral chiefly of ventral root-fibres) meet at the medullary surroundings of another nucleus, situated in the lateral wall of the IVth ventricle and the

aquaeductus, immediately below their ependyma. This nucleus, containing cells of middling and small size, may be called, conform to the nomenclature adopted by WALLENBERG, the nucleus parvocellularis of the nervus octavus.

It has the shape of a half moon or of a bean.

Its convex face, looking dorsally and laterally in distal levels is surrounded by a layer of medullated fibres. From its hilus a new fasciculus issues.

In distal regions this fasciculus, taking a ventro-medial direction towards the raphe, is small (fig. 26 A, B, C).

In proximal levels it is an important bundle.

But there the hilus also changes its position. Opening to the medio-ventral side in distal regions, it soon turns medially, and in the proximal end of the nucleus, the hilus is even found opening dorsally (fig. 26 D and E).

This new fasciculus forms a part of the systema dorsale nervi octavi, which soon will be discussed.

Now, as the drawings in fig. 26 demonstrate in a very evident manner, the two degenerated bundles of rootfibres may both be continued in the medullary surroundings of this nucleus. Those surroundings now are completely degenerated at the lateral side of the nucleus and among its cells every-where small black globules are found. In the fasciculus, issued from te hilus and forming a part of the systema dorsale n. octavi, there also are found several degenerate fibres but their discussion will take place in the following paragraph. At all events there may be spoken of a great contrast. The lateral surroundings of the hilus are intensely degenerated, the hilus itself is so in a far lesser degree.

Now, the ventral-root-fibres, in order to reach the parvocellular nucleus, must necessarily cross the area, which is found between this nucleus and the place, where they leave the fibres of the inferior cerebellar peduncle, perforated by them.

This area may be called the portio interna of the inferior cerebellar peduncle and the ventral bundle, crossing it far dorsally from the Vth spinal root, divides it into two unequal parts, a ventral one much more extensive than the dorsal one. (fig. 26 C).

This area moreover is sharply defined. It is bordered ventrally, by the spinal root of the Vth nerve and by a great many transverse dorsal fibres, to be discussed afterwards; laterally, by the fibres of the inferior cerebellar peduncle (here perforated by the entering root-fibres of the ventral root) and by the nucleus angularis; medially, by the fibres issuing from the nucleus parvocellu-

laris — which I, anticipating, now call the dorsal systema of the nervus octavus — and by this nucleus itself (in distal regions); the dorsal border of this area, in distal regions, is formed by the dorsal degenerated root-bundle and the angular nucleus. More proximally, this bundle having disappeared, there is found a new nucleus in the dorso-lateral part of this area, between the nucleus parvocellularis and the nucleus angularis. This nucleus is characterised by the presence of very large cells and adopting WALLENBERG's nomenclature, I will call it the nucleus magnocellularis nervi octavi. In this rather sharply defined area, in this portio interna of the restiform body, different parts may be distinguished, which as they comport differently to the root-fibres of the nervus octavus, may have a different signification.

1ly. The spinal fifth root and the fibres of the inferior cerebellar peduncle are diverging during their proximal course, leaving between them a triangular area, wherein fibres are found, showing an oblique direction in frontal sections. In this way, there appears in the latero-ventral edge of the portion a field of triangular shape, where after the removal of the labyrinth no degenerate fibres are found.

2ly. Between the dorsal systema and the (fig. 26 A—C) triangular area described here, there is found another field. It is of almost spherical shape (fig. 26 A—E) and after removal of the labyrinth several degenerated fibres — queer-sectioned in frontal sections — are found in it.

In distal regions this area is situated laterally from the nucleus of the N. X, and it is resting upon the dorsal face of the spinal root of the N. V (fig. 26 A). It retains its position in the ventro-medial edge of the portio interna in proximal regions. But it is soon bordered dorsally by the parvo-cellular and the magno-cellular nuclei, and latero-ventrally by the nucleus N. VI.

The degenerated longitudinal fibres, which in distal sections are very numerous here, may gradually be traced issuing from the ventral degenerated bundle of rootfibres (fig. 26 C and D). In this way these fibres appear to be descending rootfibres, bending in a longitudinal direction, and this area therefore may be compared with the descending root. And as the ventral bundle contains chiefly, though not exclusively ventral-root-fibres, it may be taken for granted that a few dorsal root-fibres, passing ventrally from the angular nucleus participate to these descendent fibres.

This area, that, conform to WALLENBERG's nomenclature, may be-called the „Acusticusfeld", thus contains a great many descending root-

fibres, most of them from the ventral, a few from the dorsal root.

In NISSL's or in carmin-preparations of this region, or in other preparations with succesful staining of the nerve-cells, it may be demonstrated, that in this area nerve-cells are very numerous. Cells of middling size are found along the fibres perforating the inferior cerebellar peduncle. Cells of small, of middling and even of large size are also found between the longitudinal fibres of this area.

Now Marchi-preparations after removal of the labyrinth show, that many of those descending fibres degenerate. In great number they are found there, where the ventral root enters (fig. 26 D). In more distal sections they seem to be gathered in two distinct area's, the one is found more laterally. the other more medially (fig. 26 C and B). The lateral field of degenerated descending fibres, if traced distally, disappears at the beginning of the nucleus N. X. A great many descending fibres apparently remain in the area itself, and after a descendent course of relative short duration end between the cells found there (fig. 26 C).

The more medial field of degenerated descending fibres may be traced far more distally. From those fibres also several remain in the area, but during their descendent course, they pass along the nucleus of the VIth nerve, sending fibres into it, and when the nucleus of the Xth nerve appears, these fibres, situated dorso-laterally from it (fig. 26 A) are giving fibres to this nucleus too. They have disappeared, when the latter is no longer seen.

These all are descending root-fibres.

But in tracing the ventral bundle of degenerate root-fibres in proximal regions, we find, that a part of them do not follow the straight medial path, but slightly bend proximally to form ascending degenerated fibres (fig. 26 D and E).

The ventral bundle, by which the portio interna was divided in two area's, the dorsal one being by far the smallest, and chiefly occupated by the magno-cellular nucleus, now divides. In its dorsal part, ventro-laterally of the nucleus magno-cellularis, a great many ascending degenerated fibres are found in proximal regions, but fibres going medially to the nucleus parvo-cellularis also exist here.

In this way the ventral bundle divides itself in three distinct portions of rootfibres.

There are 1^{ly} *descending rootfibres*. Most of these remain in the here described area among the cells found there. Other fibres go medialward to aid in the formation of transverse dorsal fibres, and provide the nucleus N. VI and that of the X (fig. 26 A—C).

2ly *ascending fibres.* Of these the greater part remain in the here described area, among the cells found there. Other fibres provide the proximal portion of the angular nucleus, and of the nuclei in pedunculus cerebelli (fig. 26 D—E).

3ly *transverse fibres.* Most of these participate to the formation of the surroundings of the nucleus parvo-cellularis N. octavi. But a great many of these fibres are going medialward.

To these latter other transverse fibres join, running in the same direction, but issued from the descendent and ascendent roots. All these fibres participate to the formation of the dorsal systema N. octavi, wich will be treated afterwards. (fig. 26 A—E).

The large area here described indeed is an area, into which most of the rootfibres enter. Together with the ventral bundle and with the systema dorsale N. octavi, it offers by far the most extensive, and perhaps also the most interesting part of the portio interna of the pedunculus cerebelli inferior.

4ly. In the dorsal border of the portio interna, however, is found the nucleus magno-cellularis already mentioned before.

This nucleus containing very large cells, and embraced by the transverse and ascending fibres of the ventral root — all degenerated after the removal of the labyrinth — is found without any degeneration if the labyrinth is removed.

The embracing rootfibres do not end in it. Perchance a single degenerate fibre may pass through it, but as a clear spot between the black degenerated nucleus angularis and nucleus parvo-cellularis, it is very distinctly marked in proximal sections. Distally the nucleus may be traced, in the dorso-lateral edge of the portio interna (fig. 26 B, C, D and E.), not so far as to the entrance of the distal root. Going from this entrance in proximal direction, at first the nucleus angularis, soon afterwards the nucleus parvo-cellularis and at last the nucleus magno-cellularis, appears, and it always retains its place between these two nuclei (fig. 26 B—E).

After all, a portio interna of the restiform body may be recognised in pigeons as well as in rabbits, and in this area are found different divisions differently behaving towards the octavus-rootfibres, and composed by root-fibres as well as by fibres of other origin.

b. *The rootfibres in the systema dorsale nervi octavi.*

It has been demonstrated, that the ventral bundle was divided in descending, ascending and transverse dorsal fibres. All those fibres, but chiefly the latter ones have contributed to the formation

of the surroundings of the parvo-cellular nucleus. Now from the ventral bundle an important number of fibres, takes a direct medial course in order to reach the raphe. Degenerate fibres leaving the (degenerate) surroundings of the parvo-cellular nucleus, and passing through the bundle leaving the hilus of this nucleus, join the degenerate transverse fibres, which also reach this bundle. All these fibres reach the raphe at the place where the fasciculus longitudinalis posterior is found, cross it, and continue their course in the same contra-lateral bundle towards the hilus of the contra-lateral nucleus parvo-cellularis. Together they form thy very important systema dorsale nervi octavi wherein many rootfibres, degenerating after the removal of the labyrinth, are found.

1^{ly}. An important number of degenerate fibres enter into the contralateral dorsal system, and may be traced into the hilus of the contra-lateral parvo-cellular nucleus. In distal regions there are not yet found many degenerate fibres, but their number increases rapidly in proximal sections (fig. 26 D, E). Here the contrast between the degenerated homo-lateral and contra-lateral nucleus is marked. The lateral surroundings of the homo-lateral nucleus are intensely degenerated, the hilus is so in a relative slight degree. The hilus of the contralateral nucleus is intensely degenerated, its surroundings are so only slightly (fig. 26 D E).

It is not only in this nucleus that degeneration is found. Here however it is intense. From thence a few degenerate fibres spread into the proximal part of the „Acusticusfeld" and though their number is small, they there take the same ascending and descending course as at the homolateral side.

In this way rootfibres not only reach the homo-lateral parvo-cellular nuclei, but a very important number of them, passing through the dorsal systema reach this contralateral nucleus (fig. 26 D, E and fig. 27).

2^{ly}. The here described path however is not the only one followed by the rootfibres in the systema dorsale. During their course towards the raphe many fibres leave the principal bundle. Fibres enter into the formatio reticularis. There they first go ventrally, gather dorsally from the facial nucleus and bend distally. But there these fibres soon disappear. At the distal end of the oblongata they cannot be distinguished with certainty among the small black granules, which are found here spread over the whole section and such is likewise the case in the spinal cord. It is impossible in pigeons to draw a conclusion concerning the existence of dispersed degenerated fibres.

3ly. Next to those fibres, other fibres leave the dorsal systema to enter in both nuclei N. VI. In pigeons this nucleus, reaching far ventrally, has a triangular shape and many fibres pass through it in all directions. The homolateral nucleus receives degenerated fibres from transverse dorsal fibres. In the contralateral nucleus they chiefly enter through the fasciculus longitudinalis posterior.

On both sides however the degeneration found in the VIth nuclei is only slight.

4ly. The greater number of the degenerate fibres of the systema dorsale enter in both fasciculi longitudinales posteriores and in the fasciculi praedorsales. They bend there in longitudinal direction going proximally and distally.

a. The ascending longitudinal fibres of the fasciculus longitudinalis posterior offer many interesting peculiarities.

At the entrance of the octavus-roots evidently the contra-lateral f. l. p. is much more intensely degenerated than the homo-lateral one. During its course next to the nucleus abducens fibres leave it to provide this nucleus with a few fibres, but more fibres leave it to gain the contra-lateral dorsal systema and the hilus of the parvo-cellular nucleus.

Proximal to the nucleus N. VI the fasc. long. post. has lost its degenerate longitudinal fibres, almost completely on both sides.

The proximo-dorsal shoots of the transverse dorsal fibres however, have not yet ended in these levels here. From those both fasciculi longitudinales posteriores soon receive new degenerate fibres.

At the distal end of the IVth nucleus again both fasciculi have degenerate fibres, obvious, though in small nnmber. They leave fibres in those nuclei and again the number of degenerated fibres is reduced, increasing at the distal end of the IIIth nucleus.

In all these nuclei there exists a slight degeneration. On the other hand the intermedullary root-fibres of these nuclei are covered with large black granules. I am convinced that many of those globules are situated in lymph-vessels and that they do not correspond with degenerate nerve-fibres, but I also believe that others represent degenerate fibres; as well as I am convinced, that in both fasc. longitudinales posteriores, true degenerated fibres enter and leave them again, because horizontal and sagittal sections demonstrate the black globules, ranged in longitudinal rows, which may only be interpreted as representants of degenerate fibres.

In the preceeding paragraph I have discussed the difficulties, which Marchi-method offers in pigeons.

It is impossible to interprete the true significance of all the

black globules, spread everywhere in the medulla oblongata, in all sections made through it. I believe that many of those black globules correspond with degenerate root-fibres situated in the dorsal part of the formatio reticularis and reaching in their course the fasc. long. post.

But I also believe, that a large part of them do not correspond to such fibres, but are transferred products of myelin-degeneration.

Therefore I only accept the slight but evident degeneration in both fasciculi longitudinales posteriores and I do not draw any conclusion as to the manner in which the fibres of the formatio reticularis enter into both.

I am unable to decide whether any degenerate root-fibres may reach the lateral part of the tegmentum, and as I have made no injuries in the central systems of pigeons I cannot give an opinion concerning this question.

b. The descending rootfibres. More interesting however are the degenerate fibres, descending in the fasciculus longitudinalis posticus and in the fasciculus praedorsalis.

They are found on both sides and, as has been described before, at the entrance of the roots, they are more numerous in the contralateral bundle. Followed in distal direction their number, however, rapidly diminishes. Therefore the number of degenerate fibres in the homolateral bundle soon prevails above that in the contra-lateral. This is the case at the proximal end of the nucleus of the Xth.

At the distal end of the medulla oblongata, as a distinct differentiation between the fasciculus longitudinalis and fasciculus praedorsalis no longer exists and as together they are forming the area along the raphe, ventrally from the nucleus of the XIIth nerve, this area contains a notable number of degenerate fibres at the operated side. In the contralateral area there are only a few.

Through this area the descending rootfibres may be continued in the funiculus anterior of the spinal cord. There they are situated along the fissura anterior and along the commissura anterior, at the operated side. They gradually enter in the antero-lateral part of the grey horn. Without doubt they provide in this manner the homolateral cervical horn and the grey matter in the cervical intumescentia. As to tracing them farther in the thoracical medulla, I dare not confirm their reaching it.

Moreover I am not sure that in the other funiculi of the cervical cord the presence of degenerate fibres, after removal of the labyrinth may be denied.

At the operated side, there are found at the peripherical margo of the lateral funiculus and along the exit of the anterior rootlets, without doubt more black globules than in other parts of the medullated parts of the medulla, but here again Marchi-method has reached its limits.

The only part, where degenerate fibres are found to a degree important enough to be admitted as consequence of the operation, is the anterior funiculus, though it is remarkable that in the lateral part of the formatio reticularis of the medulla oblongata and along the exit of the rootlets there always are found a few degenerate nervefibres.

5^{ly}. Returning now to the most proximal root-fibres of the dorsal system, I have already demonstrated, that they were not distinctly separated from the ascending rootfibres embracing the nucleus magnocellularis.

From the medial fibres found there, transverse fibres, passing through the surroundings of the proximal top of the nucleus parvocellularis or ventrally from it, contribute to the dorsal systema.

From the lateral fibres — the ending of which among the cells in the walls of the IVth ventricle, or in the most proximal part of the angular nucleus, or continuing their course in the nucleus pedunculi cerrebelli or even in the cortex cerebelli has been described — again transverse fibres go to the dorsal systema.

From these proximal dorsal fibres the greater number gain the fasc. long. posterior and they have found their description as ascending fibres therein.

In this way rootfibres form an important dorsal system, providing by means of the fasciculus longitudinalis posterior, both parvocellular nuclei, in a slighter degree the nucleus of the VIth nerve and the nuclei of the proximal eye-nuclei, whilst by means of the fasciculus praedorsalis a rather considerable number of them enter into the homolateral funiculus anterior of the cervical cord, going through this to the antero-lateral part of the horn.

c. *Comparison between the central octavus-rootfibres in pigeons and in rabbits.*

If a comparison of the central octavus-system in mammalia and in birds may be attempted, it is evident, that this attempt has no other value, than as a more or less fortunate endeavour to homologize the different fasciculi and nuclei, which together are forming this part of the central system.

Now in the first place, we must observe, that in pigeons — as likewise in other birds — there is not found any system, that may be compared with the ventral octavus-system in rabbits.

I cannot ascertain the existence of fibres forming a corpus trapezoides, neither can I find a nucleus olivaris superior, nor a nucleus para-olivaris, nor a nucleus trapezoides as differentiated nuclei. Moreover, there exists no trace of a ventral-trunk of the rootfibres of the N. octavus.

Therefore: *pigeons have no systema ventrale of the Nervus octavus.*

In accordance with this view, it might be supposed, that anything like the ventral nucleus N. octavi, from which the greater part of the corpus trapezoides originates, would not yet be differentiated, or would be missing completely. This opinion is supported by the situation of the angular nucleus, by its relation to the dorsal root, by its place relative to the magnocellular nucleus and to the cortex cerebelli, all these being identical to the relations of the tuberculum acusticum in rabbits.

The dorsal root enters in it at its ventral border with the greater number of its fibres, and continuates in a bundle found dorso-laterally from it. The distal portion of the ventral root also gives fibres to it. But the ventral root, perforating the fibres of the pedunculus cerebelli far dorsalward from the spinal root of the V^{the} nerve, may not be compared with the complete ventral root in rabbits. In rabbits the dorsal fibres of this root perforate the area ovalis of the corp. restiforme far dorsalward from the Vth nerve. At least in distal regions. And here again is an argument defending the view, that for the distal and ventral portions of the octavus-roots are much reduced in pigeons.

This however is no impediment for the existing rootfibres to take a course completely comparable, with that followed in rabbits.

In pigeons the rootfibres found in the ventral bundle, divide, into three parts: *a* descending rootfibres, *b* ascending rootfibres and *c* transverse fibres going straight to the nucleus parvocellularis (the ventral bundle sensu strictiori). The same is found in rabbits. Many of the descending as well as of the ascending rootfibres remain among the cells situated in the medio-ventral and central area of the portio interna pedunculi cerebelli.

These fibres are completely comparable with the descending rootfibres remaining among the cells of the nucleus griseus rami descendentis, or with the ascending rootfibres remaining among the cells of the aequivalent nucleus Bechterew found in rabbits.

Other descending fibres situated more medially in the portio

interna, send transverse fibres to the VIth nucleus, and going more distally even into the Xth nucleus. More proximally those transverse fibres either originate from the ventral bundle or from the ascending fibres and may be traced to the nucleus parvocellularis. To this nucleus also a portion of the dorsal rootfibres (the dorsal bundle) may be traced.

All these fibres follow the same course, which has been described in rabbits, and it is evident, that the parvocellular nucleus in pigeons has the same relation to these rootfibres, as in rabbits the nucleus dorsalis N. VIII has.

In this nucleus the dorsal and ventral bundle meet in a similar way as the systema latero-dorsale and the medial-roottrunk in rabbits are doing in the dorsal nucleus. Only in pigeons its distal end is reduced, but its proximal end again is provided for by transverse fibres of the ascending root, as in rabbits the proximal end of the dorsal nucleus is.

And if in pigeons the nucleus parvo-cellularis really represent the dorsal octavus nucleus, if the angular nucleus represent the tuberculum acusticum with the not yet differentiated ventral octavus-nucleus, if the cells in the medio-ventral and central area of the portio interna may be homologised with those in the nucleus griseus rami descendentis (in distal regions) or with those in the nucleus BECHTEREW (in proximal regions), then only one nucleus, the nucleus magnocellularis, remains to be homologized with the nucleus of DEITERS.

This magnocellular nucleus is situated in the dorsal edge of the portio interna, between the angular and parvo-cellular nuclei, it contains very large cells and after removal of the labyrinth, degenerate rootfibres, though distributed every where in the neighbourhood, may pass through it, but do not remain in it, as they do in the nuclei parvocellulares or angularis. Therefore its position, its structure, its relation to the rootfibres are all pleading in favour of the meaning, that this nucleus may represent, what in rabbits is called the nucleus of DEITERS.

Until now, there has been no great difficulty in comparing the roots and nuclei of the pigeon and the rabbit.

Pigeons have no ventral system, consequently no intermedial system is found, but a dorsal system they have.

In pigeons the ventral and distal portion are reduced, but the dorsal systema is considerably developed and is built in a similar manner as in rabbits.

Yet a very remarkable difference does exist.

From the nucleus parvocellularis a great number of fibres are issuing. They leave its hilus and enter in the important systema dorsale. After removal of the labyrinth these fibres degenerate contra-laterally and in that case the contro-lateral nucleus, especially its hilus, is degenerated nearly as intensely as the lateral surroundings of the homolateral nucleus.

Pigeons therefore, having no ventral octavus-system, receive by means of the systema dorsale nervi octavi *rootfibres to both nuclei parvocellulares.*

Each nucleus parvocellularis, a very important nucleus of the VIIIth *nerves receive a bilateral innervation of rootfibres from the n. octavus.*

The rabbit has not such a bilateral distribution of rootfibres towards the dorsal nucleus or towards any other of the octavus-nuclei.

After one-sided removal of the labyrinth in rabbits also fibres are found passing through the dorsal part of the raphe, but they only reach the nucleus of the VIth nerve.

The important bundle of root-fibres to the contralateral nucleus parvocellularis however is proper to pigeons. In rabbits it is missing. And this is a fact of physiological interest.

Now the dorsal system is not exclusively formed by this bundle. A great many transverse dorsal fibres enter from the portio interna, and increase the quantity of rootfibres in the dorsal systema.

These fibres offer again many points of comparison with those in rabbits.

Rootfibres in both animals are going to the homolateral nucleus of the VIth, in both fasc. longitudinales posteriores, and to the contra-lateral VIth nerve.

In pigeons however the direct innervation of the homolateral VIth nucleus is a slight one, and the innervation of the contra-lateral VIth nucleus through the fasciculus long. posterior is also slight, as the greater number of rootfibres, found here in the contra-lateral fasciculus longitudinalis posterior, retires towards the contra-lateral nucleus parvo-cellularis.

In this way, only a few rootfibres enter in both VIth nuclei.

At different levels however rootfibres enter again in both fasciculi longitudinales posteriores, going to both nuclei of the IVth and of the IIIth nerve. Only a few fibres are reaching those nuclei. Therefore in pigeons all motor nuclei of the eye on both sides are only to a slight degree provided with octavus-rootfibres.

In rabbits there is a notable quantitative difference as regards the innervation of the motor nuclei of the eye. As described there,

both nuclei of the VIth nerve are provided with a great many rootfibres. There also the intensity of the innervation is nearly the same on both sides.

But besides the less important innervation of the IVth homolateral nucleus through the fasciculus longitudinal posterior, there exists the important homolateral ascendant DEITERS tract, carrying rootfibres to the IVth and IIIth nuclei.

Therefore in rabbits is found an intense innervation of both nuclei N. VI, and a preponderant homolateral innervation of the IVth nucleus and the distal end of the IIIth nucleus.

This again is a difference of physiological interest. In pigeons rootfibres of the VIIIth nerve, go to all motor eye-nuclei. They are few in number, bilateral in their paths, and nearly equal in number on both sides.

In rabbits rootfibres of the VIIIth nerve also supply them. Many of them provide both VIth nuclei, but the homolateral IVth and IIIth nuclei are supplied by a much larger number of them than the contralateral.

As to the descendent rootfibres, the difference is less considerable. In rabbits as in pigeons there are found prepondering rootfibres in the homolateral fasciculus anterior of the cord, and in both it is doubtful whether there are found rootfibres in the descending tract of DEITERS in the lateral column.

Their path has been exactly described. The chief results therefore of the investigation of the rootfibres in pigeons are.

Pigeons have no ventral systema N. octavi. Their dorsal systema is very important. The angular, the parvocellular and the magnocellular nuclei are intercalated in it as the tuberculum acusticum, the dorsal nucleus N. VIII and the nucleus of DEITERS *are in mammalia.*

The former two receive the endings of rootfibres. Not the magnocellular nucleus.

Through the dorsal system the rootfibres of one N. octavus provide both nuclei parvo-cellulares.

Through the dorsal system the motor eye-nuclei receive a bilateral, symmetrical, but a very slight innervation of octavus-rootfibres.

Through the dorsal system the homolateral motor horn of the spinal cord — at least in its cervical part — receives a not unimportant innervation of root-fibres.

Chapter IV.

The influence exerted upon motility by the N. octavus in rabbits and in pigeons with regard to the central distribution of this nerve.

After the minute description of the anatomical details of the octavus-systems, given in the preceeding chapters, an endeavour may now be made to bring the central distribution of this nerve in connexion with the physiological facts found after its section. Especially the motor disturbances following its section on one side may now be proved to have a relative simple genesis.

The intact eighth nerve provides, as is generally admitted, the integrity of two functions.

The first of these, a true sensory function, is the function of hearing.

The other one, more difficult to define, has been called by a happy conception of EWALD, the tonic function of this nerve.

As regards hearing, there are strong arguments to postulate, that fibres of the octavus-systems, conducting centralward the impulses received by the irritation of ciliated cells in CORTI's organ, after having been interrupted many times f. i. in the ganglion of the corpus quadrigeminum posticum and of the corpus geniculatum mediale reach the temporal part of the cortex cerebri.

In that area of the cortex the perception of sound should be localisated.

In regard of the tonic function of the N. octavus, it has been the purpose of this monography to study the fibres of the octavus-systems in their central course to the motor nuclei in the mesencephalon, the medulla oblongata and the spinal cord.

In their psychological aspect however a striking difference does appear between these two functions.

Consciousness directly teaches us, that we hear. Everyone knows what is meant, when hearing is spoken of. The „perception of sound" is an expression with a definite meaning for everyone.

On the contrary consciousness teaches us nothing about a tonic octavus-function.

Nobody knows what is meant, when a perception of equilibration is spoken of.

This idea is a result from the penetrating researches of the physiologists.

Nobody knows the precise limits of the meaning of expressions, such as „perception of equilibrium" and „dizziness" are and as consciousness does not give us an immediate perception of the tonic function, it cannot be otherwise.

It is necessary to retain in mind, this simple though important and even fundamental psychological difference, which is too often forgotten.

For instance, often a question was laid before me, that demonstrates better than anything else the confusion around this matter.

If it is beyond doubt — so was asked — that the alterations produced in CORTI's cells by sound-waves, find their way to the temporal lobe of the cortex cerebri and consequently perception of hearing is localisated in this defined area of the cortex — in which part of the brain may then be localised the perception of equilibration.

Such a question should not be asked.

Wether a sharp difference between the functions of the cochlear and the vestibular nerve may be admitted or not, never a sensory function as the perception of sound — our hearing — is, ought to be compared, with the influence upon the motility exerted by the eighth nerve, even if there existed a conscious sensation of this sensu-motor or tonic octavus-function.

A similar opinion was held by one of the first investigators in this matter, by FLOURENS. This author, after describing the two nerves by which the nervus octavus is composed, and having postulated that the cochlear-nerve acts as a sensory nerve, preparing the function of hearing, speaks of the vestibular-nerve. He says: „l'autre nerf, le nerf des canaux-sémicirculaires, *n'est pas un nerf de sens;* il est doué de la faculté singulière d'agir sur la direction des mouvements."

GOLTZ also refers, in his sagacious deductions and experiments on the functions of the labyrinth, to the fundamental fact, that

in frogs, the specific disturbances of the equilibrium found after removal of the labyrinth, are not at all influenced by the removal of the prosencephalon.

The later minute experiments of EWALD upon dogs, teaching that the motor disturbances following the removal of the labyrinth, are compensated and corrected to a certain degree by the motor area of the cortex cerebri, are not in the least in contradiction with the here expressed opinion [1]).

All these authors are disposed to defend the view that the influence exerted upon motility by the N. octavus is merely an automatic function, playing beneath the cortex cerebri, without any direct participation of the cortex to its genesis and my anatomical researches also support this opinion.

Nevertheless it may be argued, that the octavo-motor innervations like all other sensu-motor innervations, though localisated in subcortical centres, may come to a vague perception.

I do not deny a priori the possibility of the perception of innervations. There may be alleged many facts in favour of the „Innervations-Gefühle" as they were called in german litterature, or of the „somato-psychic perceptions" as WERNICKE has called these perceptions in his eminent treatise on psycho-physics.

But even in that case no direct comparison is allowed between those complicated and little-known sensations, with the true sensory perceptions (the „allopsychic" perceptions of WERNICKE) as hearing, seeing, etc. are.

YVES DELAGE has demonstrated in a most proving way, that our orientation into space, depends not upon the altering periferical irritations in the labyrinth, but upon the altering tonicity in the muscles of the eyes and of the trunk.

These muscles are under permanent regulating control of optic and kinaesthetic impulses, as well as under the control of labyrinthic impulses.

But here we also meet with automatic control of equilibration.

In my country, at fairs or other popular amusements, there is often found a room with moveable walls, which may be turned round.

Benches are placed upon the unmoveable floor, wherein people take place. As soon as the turning of the walls begins, as the

---

[1]) These experiments may perhaps be a clue to the understanding of an inconstant result found sometimes, long after the removal of one labyrinth in young born rabbits. I stated once a total atrophy within the crossed motor area of the cortex, with a rather intense atrophy of the anterior pyramis-tract of that side, nearly a year after the operation. Less intensive atrophy of it was also seen.

attic displaces, it is very curious to see how people are thrown topsy turvy — though the floor does not move — and how their equilibration is disturbed, now that unusual optico-motor impulses are giving unusual irritation to the muscles of the eyes and trunk.

Optic impulses, when moving, greatly influence the movements of the eyes and the trunk.

Not only labyrinthic, but also optic and kinaesthetic afferent impulses are excercising a permanent control upon those movements in order to fulfil the purpose of maintaining the equilibrium. But this coordinate action is an automatic one.

There are no arguments to accept, that it is produced by an organon perceiving equilibrium and, after perception, correcting consciously the perceived faults in aequilibration.

The customary position of our body being regulated in the same way, by the same sensu-motor automatic innervations, there remains a large problem for anatomical investigations to elucidate the paths, by which the impulses parting from the periferical endings are directly and indirectly conducted towards defined motor nuclei.

As far as our knowledge goes till now, they do not pass through the cortex. Their being subcortical paths can be proved.

But if — as may be probable — the cortex should perceive the subcortical innervations, taking place in that extensive complex of tracts and centres, such a perception should be sought in the psycho-motor area of the cortex.

Not only EWALD's experiments point to this view.

There may exist a perception of the summary of all octavo-motor, optico-motor and kinaesthetic innervations, balancing each other and maintaining a resultant motor-innervation as a very vague sensation, not clear enough to speak to consciousness as the common sensory perception does.

Every sudden and important change in the whole of these subcortical innervations must necessarily cause disorders in the customary resultant motion or position, but on the other hand they may be the cause of a more or less intense perceived desorientation of these somato-psychic functions. The expression, we are accustomed to use in order to indicate every somato-psychical desorientation of this kind, is „dizziness" or „vertigo".

Therefore the vertigo is not the origin of motor disturbances, but every sensu-motor disorder of this kind may awake the somato-psychical desorientation, called vertigo.

All these questions however; whether there exists a perception of equilibrium? how that perception is altered? what vertigo may

be? are all merely psychological questions, and they are treated here to a certain degree conform whith the hypothesis defended by JAMES, LANGE a. o. in regard to the origin of psychical emotions in general.

But their elucidation may win nothing by treating here quite another question, which is often mixed up with them, but that in reality only regards the modus of stimulation of the periferical endings of the N. octavus.

Many sagacious reasonings have been used in trying to analyze the modus of stimulation of the cells found in the maculae and at the cristae ampullarum, since GOLTZ has called attention to the position of the semicircular channels and to the possibility that changes in the pression of the endolymph may act as a stimulus. Rotation-experiments initiated long ago by PURKINJE, repeated by BREUER, CRUM-BROWN, MACH a. o., extended by YVES DELAGE, KREIDL a. o. have worked out the ingenious presumptions of GOLTZ to a serious hypothesis. But rotation-experiments are experiments suited to study an irritation of the here analysed function. Interesting as they may be, they neither have a direct relation with the loss of function of the endings of the N. octavus as it is produced by the removal of the labyrinth, nor are they very well suited to study the perception of equilibration or the origin of vertigo.

They may teach that irritation of the end-organs alters their motor innervation in a distinct way, and what is of far more importance, they may prove the existence of mechanical stimuli adaequate to the ciliated cells in the vestibulum of another origin than sound-waves.

For instance, nobody may doubt that the loss of otoliths in lower animals (VERWORN, LOEB a. o.) may produce distinct motor disorders, comparable with those after removal of the labyrinth. Rotation now may perhaps prove that a dislocation of otoliths in a definite direction is the cause to irritation of distinct octavo-motor innervations, and even rotation-experiments may defend the existence of a definite direction of sliding of the otoliths in the maculae sacculi et utriculi. In that case I willingly accept, that the motion of the otoliths in the supposed definite direction is a stimulus adaequate to the cells in the maculae. But I only see in this modus of stimulation, the beginning of impulses given to octavus-fibres and conducted by them to the centre. Motor innervations are following these impulses. They are the cause of motor disorders, but there is not a single argument compelling us to accept, the changes in motion, seen in such cases, to be a consequence of altered perception.

In the same way the results of rotation-experiments may be

used to argue that variations either in the motion or in the pression of the endolymph may be stimuli adaequate to the ciliated cells upon the cristae ampullarum. Here again motor innervations may follow these stimuli after their being changed in nerve-impulses, conducted by octavus-fibres. Here again no single argument is delivered to prove that the changes in motility following them, should be produced consequent to an altered perception. For my purpose, that does not regard the modus of stimulation within the labyrinth adaequate to the there found nerve-endings, rotation-experiments are lying beyond the limits of my researches.

The adaequate stimuli cause the afferent impulses. These are given to octavus-fibres and bound to their central course.

Therefore the study of the central distribution of the N. octavus touches the questions mentioned above, but it remains within its own limits.

Now this study offers, as I have tried to demonstrate, no facts arguing a distinct separation in the way followed by the two octavus-roots.

On the contrary my researches in rabbits teach, that each of them, the cochlear as well as the vestibular root, after having entered the medulla, divides in three trunks of rootfibres (pag. 53—57).

The dorsal trunk (the stratum latero-dorsale C. R.) though composed for far the larger part, of dorsal rootfibres, receives a considerable number of ventral or vestibular-fibres. (The ramus intermedius N. octavi). The medial trunk, though composed nearly totally of ventral rootfibres, receives a few fibres from the dorsal root or cochlear-fibres. Both roots participate nearly equally to the ventral trunk (the corpus trapezoides).

From these trunks originate the rootfibres in the three important octavus-systems, and rootfibres together with fibres of secundary systems are constituating the dorsal, intermediary and ventral systems of the N. octavus.

After rootsection, the roots and the trunks of root-fibres, atrophy totally. Not so the systemata. They only partly — as far as root-fibres are contained therein — degenerate and their atrophy never is a total one (page 59 and 67).

With the roots and trunks however a great many of small cells atrophy or rather disappear.

They are found along the dorsal trunk (in the nucleus proprius of the dorsal root. in the disto-ventral portion and round the ventral octavus-nucleus, in the stratum latero-dorsale, in the deep layers of the tuberculum and in the lateral part of the dorsal

octavus-nucleus) along the medial trunk (in the nucleus proprius of the medial trunk) along its continuations, the descending and ascending roots (in the nucleus griseus rami descendentis, in the nucleus BECHTEREW, in the dorsal nucleus of the n. octavus) and along the beginning of the ventral trunk (in the olivary bodies).

These cells may be regarded as intercalated cells, making connection between primary rootfibres and greater cells from which secundary systems originate, helped sometimes for this purpose by direct collaterals of rootfibres.

For instance both nuclei of the N. abducentes are certainly innervated by direct collaterals of rootfibres of the descending root, the homolateral facial nucleus receives directly rootfibres of HELD's intermediary system. A few rootfibres innervate directly the proximal motor nuclei of the eye, by means of ascending rootfibres in the fasciculus longitudinalis posterior.

The larger cells in the tuberculum acusticum and in the dorsoproximal portion of the ventral nucleus, not disappearing after rootatrophy and in that case undergoing only slight atrophical changes after rootatrophy, receive root-collaterals but mostly are connected to the root-fibres by means of intercalate cells.

The gigantic cells in the nucleus of DEITERS, not or nearly not altering after root-atrophy, do not receive any direct collaterals of the roots. Their connections with rootfibres are only made by means of numerous cells found in the corpus juxtarestiforme (nucleus griseus rami descendentis, nucleus BECHTEREW) and in the dorsal octavus-nucleus, surrounding the nucleus of DEITERS on all sides.

These cells are forming links between rootfibres and the very important octavo-motor secundary systems, issued from the cells of DEITERS.

They are two important tracts. The one, the ascending DEITERS tract, connects those cells to the nucleus of the trochlear nerve and the distal part of the oculomotor nerve. The other, the descending DEITERS tract, connects them, to the nuclei of the VIth, VIIth, Xth, XIth, nerves, to the nuclei in the formatio reticularis lateralis of the oblongata and through the lateral column with the motor horn of the cervical cord. It may even be pursued, though much reduced, towards the sacral portion of the cord (page 119—125).

These secundary systems are chiefly homolateral tracts. A few of their fibres only enter in the homonymous contralateral tracts. They are accompanied by a few primary rootfibres.

In this way the first and most important octavo-motor system is constituted.

But it is not the sole octavo-motor system.

From DEITERS cells, from the large cells of the tuberculum acusticum and from the ventral nucleus new secundary systems issue. They all cross the raphe, be it either as transverse dorsal fibres, or as MONAKOW's fibres, or as HELD's intermediary fibres.

Before doing so, however, they send ascending fibres in the fasciculus longitudinalis posterior providing the nucleus of the N. abducens and the proximal motor eye-nuclei. They send also descending fibres to the nucleus of the XIIth nerve, and through the fasciculus praedorsalis, the anterior column and the anterior commissure towards the cervical part of the motor horn of the spinal cord, and though much reduced in number even to the thoracic and lumbo-sacral part of it. Moreover transverse dorsal fibres innervate the contra-lateral nucleus of the n. abducens to a considerable degree.

In this way new homolateral tracts, though they have a slight representation in the homonyme tracts of the opposite side, originate. They chiefly are composed of secundary fibres accompanied by a few rootfibres, in the beginning of their course. They may be considered as another homolateral octavo-motor system, not quite so important as the tract of DEITERS but still considerable enough to be mentioned.

There are however still other octavo-motor systems, perhaps of greater complexity.

We have seen a small quantity of rootfibres and of secundary fibres reach the homolateral ventral spinal cerebellar ascending tract (GOWER's antero-lateral tract) and seeking on this way, in the path followed by ascending spinal fibres, the homolateral as well as the hetero-lateral medial nuclei tecti. Moreover some rootfibres penetrating through BECHTEREW's nucleus directly enter into those nuclei.

NOW, as VAN GEHUCHTEN, controlling researches of RUSSELL, THOMAS, PROBST has proved [1]), from the medial nuclei tecti, a tract

[1]) I can completely affirm VAN GEHUCHTEN's statement, that after the medial transverse section of the cerebellum on both sides a tract degenerates, at first ascending along its internal border, then bending round the pedunculus superior, redescending lateraly from it, between the spino-cerebellar ascending ventral tract and bracchium conjunctivum pedunculi superioris to seek its place between area ovalis C. R. and the spinal root of the fifth nerve. It sends endings, methinks, among the nucleus BECHTEREW, DEITERS and nucleus griseus r. descendentis, and a few fibres (VAN GEHUCHTEN's bifurcation) may find their way in the descending tract of DEITERS; whereas other fibres still descend towards the nucleus of BURDACH.

I believe the here described tract to be a constituent of the congenial system of kinaesthetic nature, rather than of octavo-motor nature, and I therefore mean the experiments upon this bundle to be beyound the limits of these researches.

descends in the lateral fillet, medial from the ventral spino-cerebellar ascending tract, to the lateral part of the corpus juxta-restiforme, and having endings between the cells found there.

Here is another sensu-motor way, not so very important in regard to octavus-impulses, but very important in regard to the congenial kinaesthetic impulses, relying fibres from the two medial nuclei tecti with the corpus juxta-restiforme and the nucleus of DEITERS.

And at the same time we have seen a small quantity of fibres mostly secundary, descend homolaterally into another known way towards the horn of the spinal cord, in the so called rubro-spinal tract. Here is another sensu-motor way, not very important, I think, in regard to octavus-impulses, but touching to systems issued from the red nucleus, whose relation to optic impulses is probable, but as yet, insufficiently known.

Resulting from the details given in the second chapter, there are demonstrated in rabbits important, mostly secundary, but to a slight degree primary systems, forming connecting links between the end-organs of the N. octavus and different homolateral motor nuclei. The most important of them are the two first mentioned systems.

They connect the labyrinth-nerves to both nuclei of the N. abducens (ramus descendens N. octavi, fasciculus longitudinalis posterior and transverse rootfibres), to the homolateral trochlear-nucleus and the distal oculomotor-nucleus (tractus DEITERS ascendens, fasciculus longitudinalis posterior), to the homolateral motor nuclei in the medulla oblongata, to the cervical motor horn of the medulla spinalis and even to the thoraco-lumbal part of it (tractus DEITERS descendens, fasciculus praedorsalis and tractus rubro-spinalis).

In this way it may be understood, why after one-sided removal of the labyrinth or after rootsection, in rabbits motor disorders of the eyes appear, different on both eyes.

The homolateral eye misses the usual innervations of the N. abducens, N. trochlearis and a part of the N. oculomotorius. If this loss be complete, a forced position is seen towards the inner canthus and downward, if incomplete, jerks of nystagmus tend to produce this forced position. The influence of the remaining impulses upon the proximal motor eye-nuclei is sufficient to explain this position.

The contralateral eye only misses the usual innervation of its N. abducens. Under the influence of thé remaining impulses it is turned laterally or dorsalward (pag. 19).

And in the same way it may be understood, why rabbits having lost a preponderant innervation of the cervical motor spinal cord,

show the peculiar position of neck and head towards the operated side under the influence of the remaining contra-lateral impulses and are atonic at the homo-lateral, especially at the fore-leg.

The anatomy of the octavus-nerve may be fit to explain (p. 27) the facts, that physiologists have taught us to be consequent to its loss on one side, as regards the motor functions of the nerve.

Atony in all the homolateral muscles of head, neck and shoulder, together with an incomplete relaxation of eye-muscles, differing on both sides, may be sufficient to explain the forced position of head, neck and eyes towards the lost impulses. The correction of these forced attitudes, following immediately on the removal of the second labyrinth, their being replaced by a general atony in all muscles, is in perfect accordance with the here adopted anatomical views (p. 37).

All disorders of motility however are produced without any interference of a conscious sensation of equilibrium.

Anatomically spoken, they are produced in subcortical systems.

Physiologically spoken, they are automatic motions.

Moreover the anatomy teaches us, that rootfibres of both roots may contribute to the different octavo-motor subcortical systems.

Another important octavus-system however exists, the details of which are described in the second chapter, equally composed of different fibres and centra.

The greater part of all fibres composing it crosses the raphe before taking an ascending course.

From those the most interesting are MONAKOW's fibres. Issued from the dorsal system, and without any doubt being axons from the large cells in the tuberculum acusticum, they reach, through the dorsal layer of the crossed oliva superior, the medial bundle of the internal and lateral fillet. Before crossing the raphe they send descending fibres (collaterals) in the fasciculus praedorsalis of the octavo-motor system.

In the lateral fillet they meet with fibres of different origin, but taking all a part of their way in the ventral or in the intermediary octavus-system.

A few of them are rootfibres, more are originating in the crossed ventral octavus-nucleus, still more in the crossed oliva superior and nucleus para-olivaris. A great many of them issue from the homolateral nucleus trapezoides and from the homolateral nucleus ventralis lemnisci.

All together they participate to the very complicated tract, which is called the lateral fillet. The greatest number of them is medullated at birth (root-fibres, HELD's fibres, the layers *a* and *b* in the corpus trapezoides, and a part of MONAKOW's fibres), others have

not yet myelin at that time (the stratum *c* of the corpus trapezoides, a large part of MONAKOW's fibres).

The ventral spino-cerebellar ascending tract only for a short time is a constituent of the lateral fillet, as it soon takes its distal way to the nuclei tecti, and the descending hook-like bundle, descending from the nuclei tecti towards the corpus restiforme, also soon leaves it.

But the remainder of its fibres are going proximally, towards the nucleus corporis quadragemini posterioris, to the corpus geniculatum mediale and to the sub-thalamic region.

Whatever now may be the function, probable a very complicated sensu-motor function of the corpus quadrigeminum posterius is unknown. So much is sure, that its ablation never causes the forced attitude of eyes, head and neck, characterising the rootsection of the octavus, the ablation of the tuberculum acusticum, the lesion of the DEITERS-nucleus, shortly all operations in the region of the corpus juxta-restiforme. Nevertheless its ablation produces contralateral motor symptoms, different from those after rootsection, probable bound to proper afferent fibres

On the other hand it is stated, that in the corpus geniculatum mediale is the origin of direct centripetal fibres to the temporal cortex cerebri, where hearing is localisated, and therefore it is evident, that among the fibres in the lateral fillet must be sought those, whose function is to conduct true sensory or acustic impulses to the cortex.

As we have seen, this fillet system is chiefly a contra-lateral system.

It however has a homo-lateral representation. After lesions in the dorsal or ventral octavus-system its degenerations prevail contra-laterally, but are not missing homolaterally. The contrary was the case in the octavo-motor system. Degenerations in it were prevailing homolaterally but were not missing contra-laterally.

Therefore, we may speak of a differentiation within the central system between the chiefly homolateral octavo-motor system and the chiefly contra-lateral sensory octavus-system.

But it must be kept in mind, that this differentiation is not at all a sharp one. Both systems are originating from the dorsal, the intermediary and the ventral octavus-systems, and as we have seen, in describing details, often those octavo-motor and sensory-octavus systems are provided by the same fibres.

For instance, MONAKOW's fibres, true sensory-octavus fibres, send fibres (collaterals) in the octavo-motor system through the fasciculus praedorsalis, and on the contrary, from true octavo-motor tracts as the ascending and descending DEITERS tracts are, transverse fibres

(collaterals) issue taking their way through the raphe in MONAKOW's system. In relation with the anatomical views here defended it may be easily understood, that the removal of one cochlea needs give only very slight motor disorders, and that these disorders are necessarily of the same kind as those following the removal of one labyrinth, but less intense and of shorter duration.

For, the dorsal root is the smaller one of the two roots of the nervus octavus. The number of its fibres may be estimated to be one fourth of that of the ventral root. Moreover the greater part of the dorsal root fibres enters into the stratum latero-dorsale and the octavo-motor systems receive a much smaller quantity of fibres from this layer than from the medial trunk of the rootfibres.

No wonder that the motor symptoms following the one-sided loss of the dorsal rootfibres are less intense and more apt to correction by the remainings of the octavo-motor system, than those after the loss of the whole labyrinth on one side.

On the other hand the dorsal root prevails in the innervation of the ventral octavus nucleus and of the tuberculum acusticum above the ventral root, and it henceforth is evident, that the loss of fibres participating to the crossed octavus-system, may be intense after cochlea-removal. Ventral rootfibres participating to this system are however numerous enough to justify the presumption of their influencing to a rather important degree upon this system, the function of which was presumed to be the conduct of the perception of sound. I do not see any contradiction between the here defended views and the known facts.

From the contents of the vestibulum the macula sacculi has its own nerve and this nerve issues from the cochlear nerve. Hence this fact does not argue in favour of a sharp functional difference between the macula sacculi and the cochlea, and the macula sacculi has great morphological relations with the macula vestibuli.

The morphological differences between the roots founded upon the presence of thick or of small fibres found in them, are also relative.

It is easily assumed, that a differentiation of the static organ into a cochlea and a vestibular organ, did never lead to a total but only to a partial separation of two functions, existing both in the organ, from which the differentiation took place. Why should animals having no cochlea or an incomplete developed one, not perceive sounds?

Theoretically it offers no difficulties to assume, that the original static organ did not lose all its existing contacts with the sensory system, and that the new differentiated one, the cochlea, did retain

a rest of the existing contacts with the octavo-motor systems. The static periferical organ having the appropiate nerve-endings to be stimulated by mechanical blows brings a part of them — the sound-waves — to perception, and a farther developement of this perception was of great psychological importance.

Most of these however — sound-waves as well as all changes in endolymph or in otoliths — produce sensu-motor impulses, to wich only a vague perception is associated. From these no farther psychical developement took place, but they gave rise to an automatic motor function of high developement and of an enormous importance for the animal.

In this way I am viewing the functions of the labyrinth related to the central distribution of the N. octavus.

Now, as we have seen in the second chapter, in rabbits the octavo-motor systems were chiefly homo-lateral, and their slight contra-lateral representation was neglected. The sensory octavus-systems, neglecting their less numerous homo-lateral representation, were chiefly crossed systems.

The neglection of the homolateral or crossed systems however is no longer permitted in regard to the octavus-systems in pigeons. Their anatomical peculiarities, told in the third chapter were as follows.

Firstly, the dorsal root was unimportant, perhaps in account with the incomplete developed cochlea — the lagoena.

Secondly, and perhaps consequent to this, the tuberculum acusticum and the ventral octavus-nucleus were not yet differentiated. They were represented in pigeons by a relative important nucleus, the nucleus angularis, where as the ventral and the intermediary octavus-systems were totally or nearly totally absent.

Thirdly, the ventral root having an important radiation in the oblongata, together with the dorsal root, provides with direct root-fibres the octavus-nuclei — the so-called nuclei parvocellulares — of both sides. From these nuclei representing the dorsal octavus-nuclei an important systema dorsale nervi octavi issues, more considerable than in rabbits. Through this dorsal system direct rootfibres from one side reach as well the nucleus parvocellularis as the corpus juxtarestiforme at the other side.

Fourthly, the nucleus magnocellularis, representing DEITERS nucleus, and the „Acusticusfeld" representing the area of the radix descendens and ascendens, with its grey masses (BECHTEREW's nucleus), are without doubt similar organs, from which octavo-motor systems issue, as they are in rabbits.

In this way, in pigeons, one N. octavus influences upon the octavo-motor systems of both sides, though that influence is still prevailing upon the homolateral system. Consequently there must result a difference in their physiological behaviour after the loss of one labyrinth, if compared to rabbits.

From this anatomical view however a part of the motor disturbances, in pigeons different from rabbits may be understood.

In rabbits the loss of one labyrinth immediately after the operations causes grave disturbances, forced attitudes of head, neck and eyes to a maximal extensity and consequently rollings. Maximal after the operation, those disorders undergo correction until a certain amelioration is reached, nothing more. A part of the forced attitudes remains permamently.

In pigeons, the loss of one labyrinth, has no immediate effect. If it is sought for, atony may be found to prevail on the operated side, but the non-operated side being damaged by the operative shock to a rather important degree, is not yet capable of maintaining a forced attitude. If correction occurs, it first is observed at the less damaged side; and therefore at the third day, the forced attitudes begin.

The influence of the intact N. octavus upon the octavo-motor systems of both sides, though homolaterally prevailing, is important enough to maintain automatically the usual position and to prevent forced attitudes, sustained as it is by unaltered kinaesthetic and opticomotor impulses, as long as the animal is quite at ease. It does so, nonobstant the loss of one labyrinth.

But as soon as periferical stimuli (kinaesthetic, or optico-motor, or octavo-motor of the sound side) or central stimuli (volition, emotion) act, suddenly the different amount of innervation at the two sides becomes evident and suddenly the forced position of the head, not at all differing of that seen in rabbits, appears.

In this way during the first days after the removal of one cochlea a pigeon bears itself as if it were incompletely atonic on both sides, though atony at the operated side prevails. Afterwards it behaves at intervals, as if one side were atonic, but only in cases when the different amount of innervation of the two sides is brought forward by augmentation of stimulation.

In pigeons, each N. octavus, sends a not very important number of rootfibres towards all eye nuclei on both sides. They therefore never show such a peculiar forced attitude of each eye as rabbits do after the loss of one labyrinth.

That pigeons with their long neck, having lost one labyrinth, do

not roll like rabbits, but prefer, turning the head voluntary until 360° has been demonstrated long ago by EWALD.

As soon as both labyrinths are lost, the similarity of the motor disorders in the two species of animals is striking again. All muscles are atonic. To this in rabbits there is perhaps one exception difficult to explain, as the motor Vth nucleus stands unaltered among the degenerate fibres of the octavus-system.

In fact however, the difference of the motor disorders following the loss of one labyrinth, apparently so great between rabbits and pigeons, is in accordance with the different anatomical distribution of their nervi octavi.

There may arise many controversions upon the subject to what extent in different animals primary rootfibres are found in the secundary systems. I do not believe these controversions to have a fundamental value. The preponderance of the secundary systems augments with the relative high development of the whole octavus-system. They subentrate for the primary fibres.

For instance in dogs, there are found less numerous primary fibres between the secundary of the corpus trapezoides than in rabbits and if VAN GEHUCHTEN be right, in guinea-pigs they should be missed totally there.

I for myself believe, that even among animals of the same species the relation between rootfibres and secundary is different too. In rabbits for instance, in the corpus trapezoides, it may vary from a few only to very many, but I never missed them there.

Of more value and still more determining the physiological behaviour of one-sided operated animals, the correction of the motor disturbances seem to me. There may be a correction by means of the ameliorated function of the remainings of the damaged system, and there may be one, by means of substitution of quite other systems.

I do not believe that in rabbits the lost function is much restored neither by the same-sided cerebellum, nor by the motor area of the cortex cerebri, at least substitution of all lost function is impossible there. Yet I found — though not constant — atrophy of the same side of the cerebellum and of the motor area in the cortex, if new-born animals were operated long ago.

Such atrophies necessarily are tertiary atrophies and therefore they are inconstant. They may perhaps throw new light upon the different manners in which substitution of the motor disorders may occur after the loss of the labyrinth.

Explication of the Plates and description of the Figures and the abbreviations.

PLATE I.

Fig. 1*a*. A frontal section through the left half of the oblongata of a rabbit, at the entrance of the distal (dorsal) root 15 days *after removal of the left cochlea.*

Fig. 1*b*. A frontal section through the right half of the same oblongata at the same level (both treated with MARCHI). [1])

Py. = Pyramis anterior.
Lemn. med. = lemniscus medialis (principalis).
nucl. N. VII = nucleus of the facial nerve.
Ab. S. B. = MONAKOW's aberrirendes Seitenstrangbündel.
Tr. DEIT. desc. = tractus DEITERS descendens.
Corp. trap. = corpus trapezoides.
r. d. N. VIII = radix dorsalis nervi octavi.
Ar. ov. = area ovalis corporis restiformis (pedunculi cerebelli inferioris).
fibr. dors. trans. = fibrae transversae dorsales.
Port. int. C. R. = portio interna corporis restiformis.
Str. l. d. = stratum latero-dorsale.
Tub. ac. = Tuberculum acusticum.
Str. prof. tub. ac. = stratum profundum medullare tuberculi acustici.
β = area with normal fibres between the degenerated fibres in the stratum latero-dorsale.
str. l. d. e tub. ac. = stratum latero-dorsale e tuberculo acustico.
str. l. d. e. nucl. ventr. = " " " e nucleo ventrali nervi octavi.
a = inner layer of degenerated fibres of the stratum latero-dorsale, giving fibres to the intermedial system of the VIIIth nerve.

---

[1]) The lithograph has turned the original drawing. Therefore the left side has become the right one.

b = outer layer of those fibres, from which a part of the dorsal transverse fibres originate.
r. desc. N. VIII = radix descendens nervi octavi.
nucl. dors. N. VIII = nucleus dorsalis nervi octavi.
Nucl. ventr. N. VIII = nucleus ventralis nervi octavi.
f. l. p. = fasciculus longitudinalis posterior.
f. pr. d. = fasciculus praedorsalis.

The dorsal root is degenerated at the left side. Thedistribution of its degenerated fibres is described in Chapter II.

Fig. 5. A frontal section through the medulla oblongata of a foetal cat (just born) (treated with WEIGERT-PAL), at the entrance of the nervus octavus. The myelinisated fibres are blackened. The same indications are given as in fig. 1. Moreover, there are found:

c. trap. syst. ventr. a = Systema (ventrale) a in the corpus trapezoides.
c. trap. syst. dors. b = Systema (dorsale) b in the corpus trapezoides.
c. trap. syst. dors. c = Systema (dorsale) c in the corpus tradezoider.
syst. dors. d = syst. intm. = Systema (dorsale) d in the corpus trapezoides or the intermedial system of the nervus octavus.
nucl. trap. = nucleus trapezoides.
nucl. par. oliv. = nucleus para-olivaris superior.
nucl. ol. sup. = nucleus olivaris superior.
N. VI = abducens-nerve.
r. ventr. N. VIII = radix ventralis nervi octavi.
fibr. rad. N. VII = fibrae radiculares of the facial nerve.
nucl. DEITERS = nucleus DEITERS.
Tr. DEIT. desc. = tractus DEITERS descendens.
Str. sup. tub. ac. = stratum superficiale medullare tuberculi acustici.
r. sp. N. V. = ramus spinalis of the nervus trigeminus.
h = str. int. = fibres of HELD or the intermedial system of the nervus octavus.

PLATE II.

Fig. 2. A frontal section through the medulla of a rabbit *after removal of the left cochlea*, at the entrance of the ventral octavus root (treated with Marchi-method). The extramedullar ventral root is free of degeneration.

fasc. l. p. = fasciculus longitudinalis posterior.
genu N. VII = genu nervi facialis.
N. VII = radix nervi facialis.

nunc. dors.		= nucleus dorsalis	
r. desc.		= radix descendens	
a. = syst. interm.		= systema intermedium	
b. = syst. dors.	N. VIII	= systema dorsale	nervi octavi.
nucl. ventr.		= nucleus ventralis	
r. dors.		= radix dorsalis	
r. ventr.		= radix ventralis	

n. gris. r. desc. = nucleus griseus radicis descendentis.
str. med. = stria medullaris.

nucl. DEIT. = nucleus DEITERS.
Port. int. C. R. = portio interna corporis restiformis or corpus juxtarestiforme.
Ar. ov. C. R. = area ovalis corporis restiformis.
Tub. ac. = Tuberculum acusticum.
r. spin. N. V. = radix spinalis } nervi trigemini.
f. gel. N. V. = formatio gelatinosa radicis spinalis }
n. ol. sup. = nucleus olivaris superior.
n. par. ol. sup. = nucleus pára-olivaris superior.
n. trap. = nucleus trapezoides.
N. VI = Nervus abducens.
nucl. N. VI = nucleus Nervi abducentis.
str. ventr. a. } c. trap. = stratum ventrale a. } corporis trapezoides.
str. dors. c. } = stratum dorsale c. }
str. l. d. = stratum latero dorsale.
str. l. d. e. tub. ac. = stratum latero dorsale e tuberculo acustico.
str. l. d. e. n. ventr. = stratum latero-dorsale e nucleo ventrale.
Py. = Pyramis.
fasc. praed. = fasciculus praedorsalis.
lemn. med. = lemniscus medialis.

PLATE III.

Frontal sections through the medulla oblongata of a rabbit, one year after the removal of the right labyrinth, with octavus-section in the young born animal.

In fig. 3 A. A frontal section through the right (atrophied) tuberculum acusticum is drawed at the entrance of the dorsal root. (Preparation of WEIGERT-PAL).

In fig. 3 B. The corresponding frontal section through the left (normal) tuberculum acusticum at the same level. (Preparation as in fig. 3A).

In fig. 13 A. The frontal section through the right nucleus of DEITERS. (Preparation with picro-carminas ammoniae).

In fig. 13 B. The frontal section through the left nucleus of DEITERS (Preparation as in fig. 13A).

N. Dors. N. VIII. = nucleus dorsalis N. octavi.
Port. int. C. R. = corpus juxtarestiforme or portio interna corporis restiformis.
str. med. sup. Tub. ac. = stratum medullare superficiale tuberculi acustici.
str. med. prof. Tub. ac. = stratum medulare profundum tuberculi acustici.
str. l. d. = stratum latero-dorsale corporis restiformis.
R. lat. N. VIII } = radix lateralis (dorsalis) N. octavi.
R. dors. N. VIII }
R. Spin N. V. = radix spinalis N. quinti.
N. ventr. N. VIII = nucleus ventralis N. octavi.
Nucl. N. VII = nucleus N. septimi.
A. R. Ov. C. R. = Area ovalis corporis restiformis.
H. = fasc. interm. N. VIII = HELD's intermedial systema N. octavi.

N. Deiters. = Nucleus of Deiters.
N. Dors. (cell. lat. *c*) = nucleus dorsalis N. octavi (cellulae laterales).
N. Dors. (cell. ventr. *d*) = nucleus dorsalis N. octavi (cellulae ventrales).
N. Dors. (cell. centr. *b*) = nucleus dorsalis N. octavi (cellulae principales).
N. Dors. (cell. med. *a*) = nucleus dorsalis N. octavi (cellulae mediales).
Nucl. N. VI (*e*) = nucleus N. abducentis.
N. gris. r. desc. N. VIII. = nucleus griseus radicis descendentis N. actavi.
R. ventr. N. VIII = radix ventralis N. octavi.

Plate IV.

Fig. 4. An oblique and frontal section through the left half of the oblongata of a rabbit, 17 days after the removal of the left labyrinth. The section touches the entrance of the left (degenerate) dorsal root of the N. octavus.

Fig. 8. An oblique and frontal section at the entrance of the left (degenerate) ventral root (the medial trunk of rootfibres) of the same animal.

(Both preparations are treated with Marchi-method).

Pars. ventr.-med. n. ventr. N. VIII = Portio ventro-medialis nuclei ventralis N. octavi.
r. dors. N. VIII = radix dorsalis N. octavi.
Pars. dors.-lat. n. ventr. N. VIII = Portio dorso-lateralis nuclei ventralis N. octavi.
Str. pr. tub. ac. = stratum medullare profundum tuberculi acustici.
N. Deiters = nucleus of Deiters.
N. tecti = nuclei tecti cerebelli (lateralis = nucleus dentatus and mediales).
D. V. fibr. rad. e. r. ventr. N. VIII = degenerate fibres penetrating through the oval area from the radix ventralis N. octavi.
r. spin. N. V. = radix spinalis N. trigemini.
r. desc. N. VIII = radix descendens N. octavi.
st. = f. interm = Held's systema intermedium N. octavi.
N. dors. N. VIII = nucleus dorsalis N. octavi.
C. R. = corpus restiforme.
r. ventr. N. VIII = radix ventralis N. octavi.
P. cer. sup. (Bracch. conj.) = pedunculus cerebelli superior.
N. Bechterew = nucleus of Bechterew.
N. Dors. (cell. lat.) N. VIII = nucleus dorsalis N. octavi (cellulare laterales).
N. Dors. N. VIII (cell. princ.) = nucleus dorsalis N. octavi (cellulae principales).
N. gris. r. desc. = nucleus griseus radicis densendentis N. octavi.
Aquaeductus = Aquaeductus Sylvii.
Genu N. VII = genu N. facialis.
F. L. p. = fasciculus longitudinalis posterior.
N. N. VI = nucleus N. abducentis.

Plate V.

Horizontal sections through the right half of the medulla oblongata three weeks after the removal of the right labyrinth in a rabbit.

Fig. 9. This section touches the entrance of the ventral root and its division in a descending and in an ascending root.

Fig. 10. This section touches more dorsally the bracchium conjunctivum of the pedunculus cerebelli superior and its entrance in the mesencephalon.
(Both preparations are treated with Marchi-method).

R. dors. N. VIII = radix dorsalis nervi octavi.
P. ventr.-dist. n. ventr. N. VIII = portio ventro-distalis nuclei ventralis nervi octavi.
H = f. int. +r. dors. ad r. ventr. = HELD's intermediary system + fasciculis intermedius dorsalis ad radicem ventralem.
P. dors. lat. n. ventr. N. VIII = portio dorso-proximalis nuclei ventralis nervi octavi.
ar. ov. C. R. = Area ovalis corporis restiformis.
N. sens. N. V. = nucleus sensorius nervi trigemini.
Pes. cer. ad. pont. = Pes cerebelli ad pontem.
Nucl. ventr. lemn. l. = nucleus ventralis lemnisci lateralis.
L. L. = lemniscus lateralis.
nucl. gris. r. desc. N. VIII. = nucleus griseus radicis descendentis nervi octavi.
N. Dors. N. VIII = nucleus dorsalis nervi octavi.
N. DEITERS = nucleus DEITERS.
Syst. dors. N. VIII = systema dorsale nervi octavi.
nucl. Mot. N. V = nucleus motorius nervi trigemini.
form. ret. lat. = Area lateralis of the formatio reticularis.
f. l. p. = fasciculus longitudinalis posterior.
N. DARK. = nucleus DARKSCHEWITSCH.
Corp. restif. = corpus restiforme.
N. BECHTEREW = nucleus BECHTEREW.
Tr. DEITERS asc. = Tractus DEITERS ascendens.
r. desc. N. VIII = radix descendens nervi octavi.
L. L. ad c. q. p. = Lemniscus lateralis ad corpus quadrigeminum posticum.
N. dors. L. L. = nucleus dorsalis lemnisci lateralis.
Ped. cer. sup. = pedunculus cerebelli superior.

PLATE VI.

Fig. 19 A. B. Sagittal sections through the medulla of a not yet born rabbit near the entrance of the octavus-roots.
(WEIGERT-PAL preparations).

r. N. V = radix nervi trigemini.
r. N. VII = radix nervi facialis.
A. prox. (ventr.) N. VIII = radix proximalis (ventralis or medialis) nervi octavi.
r. dist. (dors.) N. VIII = radix distalis (dorsalis or lateralis) nervi octavi.
f. interm. rad. = intermedial rootlet going from the proximal to the distal octavus root.
c. trap. = corpus trapezoides receiving fibres from the distal and from the proximal root als well as from the.
n. ventr. N. VIII = nucleus ventralis Nervi octavi.
tub. ac. = tuberculum acusticum.

Fig. 19 c. A Horizontal section through the medulla of a not yet born rabbit at the level of the genu N. facialis. (WEIGERT-PAL preparation).

r. N. III = rootlets of the nervus oculomotorius.
tr. DEIT. asc. = tractus DEITERS ascendens.
f. l. p. = fasciculus longitudinalis posterior.
str. med. s. syst. dors. = stria medullaris sive systema dorsale nervi octavi.
l. lat. = lemniscus lateralis.
n. ventr. l. l. = nucleus ventralis lemnisci lateralis.
P. Var. = Pons Varoli.
f. sp. cer. ventr. = fasciculus spino-cerebellaris ascendens ventralis.
n. mot. N. V = motor nucleus nervi trigemini.
r. mot. N. V = motor radix nervi trigemini.
gen. N. VII = genu nervi facialis.
r. med. N. VIII = radix medialis nervi octavi.
r. dors. N. VIII = radix dorsalis nervi octavi.
n. ventr. N. VIII = nucleus ventralis nervi octavi.
corp. R. = corpus restiforme.
r. desc. N. VIII = radix descendens nervi octavi.
nucl. N. VI = nucleus Nervi abducentis.
f. sol. N. X = fasciculus solitarius nervi vagi.
r. spin. N. V = radix spinalis Nervi trigemini.
nucl. N. IX and N. X = nucleus Nervi glossopharyngei and nervi vagi.

Fig. 6. A Cell-preparation of the normal tuberculum acusticum (After a NISSL preparation).

n. pr. r. lat. N. VIII = nucleus proprius radicis lateralis nervi octavi.
cell. parv. str. med. t. ac. = cellulae parvae in the stratum griseum medium tuberculi acustici.
cell. parv. str. sup. t. ac. = cellulae parvae in the stratum medullare superficiale tuberculi acustici.
cell. magn. str. med. t. ac. = cellulae magnae in the stratum griseum medium tuberculi acustici.
cell. parv. str. prof. t. ac. = cellulae parvae in the stratum profundum griseum tuberculi acustici.
str. prof. med. t. ac. = stratum prof. medullare tuberculi acustici.
cell. DEITERS. = cellulae DEITERS.
ar. ov. C. R. = area ovalis corporis rectiformis.
cell. n. ventr. N. VIII = cellulae nuclei ventralis nervi octavi.

PLATE VII.

Fig. 7. A series of cell-preparations through the normal nucleus dorsalis nervi octavi, corpus juxtarestiforme and their neighbourhood. (After a NISSL preparation).

Fig. 7 A. Represents the most distal, fig. 7 H, the most proximal section of this series.

In all sections the figures mean:
n. dors. N. VIII = nucleus dorsalis nervi octavi.
a. = its medial group of cells.

b. = its dorsal (principal or central) group of cells.
c. = its lateral group of cells.
d. = its ventral group of cells.
e. = the nucleus nervi abducentis.
n. DEITERS = nucleus of DEITERS.
n. griseus r. desc. = nucleus griseus radicis descendentis nervi octavi.
tub. ac. = tuberculum acusticum.
n. ventr. N. VIII = nucleus ventralis nervi octavi.
r. ventr. N. VIII = radix ventralis nervi octavi.
r. N. VII = radix nervi facialis.
genu N. VII = genu nervi facialis.
N. V. = spinal root of the nervus trigeminus.
n. prop. n. ventr. N. VIII = nucleus proprius radicis ventralis nervi octavi.

PLATE VIII and PLATE IX.

Fig. 15. N°. 1—N°. 16. A series of frontal sections from the beginning of the medulla oblongata until the corpora quadrigemina anteriora in a rabbit, three weeks after the removal of the left labyrinth + the section of the left nervus octavus. (Treated with MARCHI-method). The root of the Vth is touched by the section.

The drawings are representing.
N°. 1 = the section through the medulla oblongata before the distal end of the ventriculus IV.
N°. 2 = idem through the medulla oblongata at the distal opening of the ventriculus IV.
N°. 3 = idem, as the dorsal ascending spino-cerebellar tract (FLECHSIG's Klein-Hirn-Seitenstrangbündel) changes its place and the area ovalis of the C. R. begins.
N°. 4 = idem, through the nuclei N. XII, the transparent nucleus N. X, the dorsal nucleus of the N. VIII and the distal end of the nucleus of DEITERS.
N°. 5 = idem, proximal from the nucleus N. XII, at the distal end of the nucleus N. VII.

The descending octavus-rootfibres, degenerated inthese sections, are described in Chapter II of the paper.

N°. 6 = idem, through the distal end of the tuberculum acusticum.
N°. 7 = idem, through the entrance of the distal (dorsal) root of the nervus octavus, showing its direct rootfibres to the medial nuclei tecti.
N°. 8 = idem, through the nucleus ventralis nervi octavi, with the fibrae perforating the oval area of the ventral root.
N°. 9 = idem, through the proximal (ventral) root of the nervus octavus.
N°. 10 = idem, through the nucleus of BECHTEREW, and the issue of the VIIth nerve.
N°. 11 = idem, through the corpus trapezoides, showing its degeneration and through the degenerate fasciculus spino-cerebellaris ascendens ventralis, free at the surface of the lateral fillet.
N°. 12 = idem, through the issue of the nervus trigeminus.
N°. 13 = idem, through the distal end of the corp. quadigeminum posticum.

N°. 14 = idem, through the corp. quadrig. posteriora. The bracchia cerebelli media are touching the med. oblongata.
N°. 15 = idem, through the distal end of the corpora quadrigemina anteriora showing the degenerate fibres in the crossed lateral fillet.
N°. 16 = idem, through the distal end of the nucleus N. IV.

The abbreviations here used are.

Py = Pyramis.
Ol = oliva inferior.
N. fun. l. = nucleus funiculi lateralis.
Fr. DEITERS desc. = tract. DEITERS descendens.
N. N. XII = nucleus nervi hypoglossi.
N. XII = nervus hypoglossus.
N. G. = nucleus of GOLL.
N. B. = nucleus of BURDACH.
N. C. R. = nucleus proprius corporis restiformis.
r. sp. N. V. = ramus spinalis nervi trigemini.
f. praed. = fasciculus praedorsalis.
n. N. X. = n. Nervi vagi.
f. sol. N. X. = fasciculus solitarius Nervi vagi.
f. DEIT. desc. = fasciculus DEITERS descendens.
F. l. p. = fasciculus longitudinalis posterior.
r. desc. N. VIII. = radix descendens nervi octavi.
N. N. VII = nucleus nervi facialis.
port. int. C. R. = portio interna corporis restiformis = corpus juxtarestiforme.
N. IX. = nervus glossopharyngeus.
Tub. ac. = Tuberculum acusticum.
ar. ov. G. R. = area ovalis corporis restiformis.
str. l. d. = stratum latero-dorsale corporis restiformis.
fibr. rad. perf. = fibres of the ventral root perforating through the oval area.
r. dors. N. VIII. = radix dorsalis
n. ventr. N. VIII. = nucleus ventralis } nervi octavi.
r. ventr. N. VIII. = radix ventralis
n. dors. N. VIII. = nucleus dorsalis
c. trap. = corpus trapezoides.
syst. dors. = systema dorsale Nervi octavi.
genu N. VII = genu nervi facialis.
f. sp. c. v. = fasciculus spino-cerebellaris ventralis.
N. BECHT. = nucleus BECHTEREW.
P. C. S. = pedunculus cerebelli superior.
n. mot. N. V. = nucleus motorius
r. spin. N. V. = radix spinalis } nervi trigemini.
N. V. = radix
n. sens. N. V. = nucleus sensorius
n. ol. sup. = nucleus olivaris superior.
n. par. ol. = nucleus para-olivaris.
n. trap. = nucleus trapezoides.
H = syst. interm. = HELD's systema intermedium nervi octavi.
c. q p. = corpus quadrigeminum posticum.
c. q. a. = corpus quadrigeminum anticum.
Br. pont. = pedunculus cerebelli medius.
R. N. IV = radix
N. IV = decussatio radicum } nervi trochlearis.
n. N. IV = nucleus
L. L. = lemniscus lateralis.

n. v. L. L. = nucleus ventralis lemnisci lateralis.

Mistakes are made in fig. 15 N°. 3 where r. d. N. VIII is found instead of ol. inf., in fig. 15 N°. 4 where f. praed. N. dors. N. VIII is found instead of n. dors. N. VIII, and in fig. 15 N°. 15 and N°. 16 where N. VI is found instead of N. IV.

Plate IX, X and XI.

Fig. 16 A—N. A horizontal series of sections through the central system of a rabbit, seventeen days after the removal of the left labyrinth + section of the left nervus octavus. The degenerate rootfibres are made visible with Marchi-method. The sections fall in a more or less oblique direction. The left side is touched in a more ventral level than the right half.

The drawings represent.

Plate IX.

Fig. 16 A = a horizontal section at the level of the most superficial layer of thick fibres (the systema *a*) of the corpus trapezoides.

Fig. 16 B = idem, through the ventral layer of small fibres (the stratum *b*) of the corpus trapezoides.

Fig. 16 C = idem, through the not degenerate layer (the stratum *c*) of te systema ventrale nervi octavi. The degenerate intermediary system is touched.

Fig. 16 D = idem, through the degenerate intermediary system of Held.

Fig. 16 E = idem, at the level where the facial nerve and more proximally the Vth nerve leaves the medulla.

Plate X.

Fig. 16 F = idem, touching the issuing root of the facial nerve (at the left side) just dorsally from its nucleus and from the olivary bodies.

Fig. 16 G = idem, falling through the ventral part of the nucleus motorius Nervi trigemini.

Fig. 16 H = idem, touching the genu N. VII and the nucleus of the nervus abducens, at the entrance of the distal (lateral) octavus-root.

Fig. 16 I = idem, at the level of the entrance of the proximal (medial) octavus-root.

Plate XI.

Fig. 16 K = idem, at the level of the dorsal nucleus, showing its innervation by the descending rootfibres.

Fig. 16 L = idem, at the level of the tuberculum acusticum.

Fig. 16 M = idem, through the inferior pedunculus cerebelli, at its union with the superior pedunculi cerebelli.

Fig. 16 N = at the level of the nuclei tecti.

The abbreviations are like those in the preceeding drawings moreover there are.

f. rtfl. = fasciculus retroflexus or Meynert's bundle.
n. med. th. = nucleus medialis thalami optici.
n. lat. th. = nucleus lateralis thalami optici.
c. g. l. = corpus geniculatum laterale.
tr. opt. = tractus opticus.
fimbr. forn. = fimbria fornicis.
c. g. m. = corpus geniculatum mediale.
f. ped. tr. = tractus interpeduncularis transversus.
N. N. III = nucleus nervi oculomotorii.

pulv. th. opt. = pulvinar thalami optici.
c. p. = commissura posterior.
g. hab. = ganglion habenulae.
g. interp. = ganglion interpedunculare.
N. R. = nucleus ruber.
Dec. Br. conj. = Decussatio bracch. conjunct. penduncul. cereb. superioris.

Plate XII.

Fig. 17 A, B, and C. Frontal sections through the medulla oblongata of a not yet born elder foetus of a rabbit. (a Weigert-Pal preparation) showing how far myelinisation of fibres has taken place. A is the most distal, C the most proximal section.

The abbreviations found here are the same as in preceeding drawings.

In fig. 17 A. The non medullated layer β is found between the two medullated layers of the systema dorsale (stria medullaris) nervi octavi.

In fig. 17 B. The non medullated layer (stratum *c* corp. tr.) is found between the medullated layers of the systema ventrale nervi octavi.

In fig. 17 C. The medullated triangular field of the fasciculus spino-cerebellaris ascendens, is making up to take its dorsal way in the lateral fillet.

Plate XIII.

Fig. 18 A—F. A series of sagittal sections through the central system of a not yet born elder foetus of a rabbit (a Weigert-Pal preparation) showing the myelinisation of the fibres at the time of birth.

The abbreviations found here are the same as in the preceeding drawings.

Fig. 18 A is a sagittal section just touching the lateral surface of the medulla. Most proximally the nervus trigeminus enters, distally at first the proximal octavus-root is seen, afterwards the distal octavus-root enters. Between them is found the fasc. intermedius radicum.

Fig. 18 B is a dito, somewhat more medially. The corpus trapezoides begins its exfoliation from the nucleus ventralis. The fasciculus intermedius is seen.

Fig. 18 C is a sagittal section, at the level where the dorsal spino-cerebellar tract (Flechsig's KleinHirn-SeitenstrangBündel) enters into the cerebellum. It is medullated, and crossed by medullated fibres of the ventral root going to the stratum latero-dorsale.

Fig. 18 D is a sagittal section, at the most medial region of the area ovalis, or at the most lateral region of the corpus juxta-restiforme. The medullated Held's intermediary system is touched as a bundle of longitudinal fibres, passing from the strat. latero-dorsale into the corp. trapezoides.

Fig. 18 E is a sagittal section, at the level of the facial nucleus. Held's system now is a field of queer-sectioned small fibres. The section demonstrates the beginning of the tractus Deiters descendens.

Fig. 18 F is a sagittal section through the lateral end of the genu Nervi facialis. It demonstrates the curvation in longitudinal direction of the tractus Deiters descendens.

Plate XIV and Plate XV.

Fig. 14 A—E. A series of horizontal sections, a fortnight after rootsection of the nervus octavus, through the central system of a rabbit. (MARCHI-preparation).

The abbreviations as in the preceeding drawings.

PLATE XIV.

Fig. 14 A. The section falls through the radix descendens radicis ventralis N. VIII and the genu of the N. VII. It demonstrates the degeneration of root-fibres in the ascending DEITERS tract, in the fasciculis long. posterior, in both fasciculi spino-cerebellares ventrales ascendentes, and round both nuclei ventrales lemnisci laterales. Still better it is demonstrated in.

Fig. 14 B. A horizontal section falling somewhat more dorsally.

Fig. 14 C. A horizontal section at the level of the tuberculum acusticum shows at the left side the union of the two bundles of the lateral fillet. The one, the fasciculus spino-cerebellaris ventralis ascendens, and the other the lemniscus ad corp. quadrigeminum posticum. At the right this union has not yet taken place.

PLATE XV.

Fig. 14 D and E = Horizontal sections through the nuclei tecti cerebelli, demonstrate, the distal end of the fasciculus spino-cerebellaris ventralis ascendens on both sides, their deviation into the nuclei tecti and their decussatio in the corpus medullare cerebelli.

PLATE XVI and PLATE XVII.

Fig. 20 A—F, Fig. 21. A series of horizontal sections through the brain and a series of frontal sections through the medulla of a rabbit ten days after a proximal section through the corpus juxtarestiforme.

The injury is found in fig. 20 A—D in X. Its most dorsal white surroundings are found in fig. 20 A. The incision enters medio-ventrally from the tuberculum acusticum in the nucleus of DEITERS, and from the IVth ventricle it goes proximally and laterally from the IVth nucleus in fig. 20 B.

The largest extension of the injury is found in fig. 20 C, where it nearly reaches the lateral fillet, and in fig. 20 D where it divides the Bracchium conjunctivum pedunculi cerebelli superioris, causing its centripetal degeneration. It touches the ventral part of the lateral fillet with its most ventral end in fig. 20 F.

From this injury many secundary degenerations exit.

Fig. 20 A. The root of the IVth nerve is sectioned. The decussatio and the opposite root of the nervus trochlearis is degenerated. The fasciculus spino-ventralis ascendens is degenerated on both sides.

Fig. 20 B. A horizontal section through the tuberc. acusticum. This is degenerated in all its layers. (The superficial as intensive as in the deep layers.) Both trochlearis nuclei are degenerated.

Fig. 20 C. A horizontal section somewhat more ventrally, demonstrating the degeneration in the tractus DEITERS ascendens.

Fig. 20 D. A horizontal section through the entrance of the octavus-roots and the knee of the facial nerve. The section demonstrates the degenerated tractus DEITERS ascendens, the degenerated fasciculus longitudinalis posterior and the transverse fibres, passing through the contralateral nucleus DEITERS and the beginning of the contralateral tract of DEITERS. with slight degeneration.

Fig. 20 E. A horizontal section touching the exit of the Vth nerve. It demonstrates the degenerate homolateral tract of DEITERS round the facial root, and more distally the degeneration in the praedorsal tract and in the rubro-spinal tract.

Fig. 20 E. A horizontal section touching the facial nucleus and olivary bodies, with degeneration in the three descendent longitudinal tracts, the praedorsal tract, the dsscending DEITERS tract, and the rubro-spinal tract.

Fig. 21. Sections at different levels of the medulla, to demonstrate the farther course of the descending tracts in the cord.

In these preparations, the lesion touches the fillet, and an injury of the rubro-spinal tract at the level of the issuing trigeminus-root cannot be excluded.

PLATE XVIII.

Fig. 22 A—H. A series of frontal sections, through the central system of a rabbit, eleven days, after a transverse section through the left lateral trunk of the corpus trapezoides.

In fig. 22 B—D the injury of the system is indicated by the letter X.

In fig. 22 A. The section falls through the corpora quadrigemina anteriora. In the right lateral fillet fibres to the ventral layer of the nucleus corp. quadr. posterioris are degenerated. A slight transverse degenerated layer of fibres ventrally from the nucleus or the IVth nerve is seen (PROBST bundle).

Fig. 22 B. This section, through the proximal parts of the olivary bodies, is touching the proximal end (by x) of the incision.

The corp. trapezoides and the systema ventrale nervi octavi is nearly totally degenerated.

Fig. 22 C. The section touches the injury by x. Between the lesion and the „aberrirendes Seitenstrangbündel" the intact medio-ventral end of the Vth spinal root is found. The dorso-lateral fibres of this root are sectioned and degenerated distally, as is seen in all distal sections. Here, in the aberrirendes Seitenstrangbündel, a tract degenerating distally is found (rubro-spinal bundle), and the slight degeneration in the descending tract of DEITERS and in the praedorsal tract is evident.

Fig. 22 D. The section touches the entrance of the ventral octavus-root.

Fig. 22 E. The entrance of the distal octavus root.

Fig. 22 F. A section through the proximal } part of the XIIth nucleus.
Fig. 22 G. A section through the distal }

Fig. 22 H. A section through the distal end of the oblongata.

In fig. 22 D—H. The area's of the rubro-spinal tract, of the descending tract of DEITERS and of the praedorsal tract, are marked by degeneration in the different levels, where the section touches them.

In this case it is not probable that the rubro-spinal

tract should have been directly damaged by the incision. Notwithstanding the rubro-spinal tract is degenerated in a rather important manner.

PLATE XXI.

Fig. 23. A frontal section through the oblongata of a rabbit 16 days, after the transverse division of the lateral trunk of the corpus trapezoides (by x), at the entrance of the octavus-roots, in order to demonstrate the degeneration in the corpus trapezoides.

PLATES XIX, XX at XXI.

Fig. 25 A—O. A series of frontal sections through the central system of a rabbit, eight days, after a double-sided ablation of the tuberculum acusticum. In fig. 25 E—I (by x) the double-sided injury is surrounded by a sharp line to make it demonstrable.

PLATE XIX.

Fig. 25 A. The most proximal section through the corpora quadrigemina anteriora.

There is an intense degeneration on both sides in the ventral layer of fibres of the nucleus corp. quadr. postici.

Moreover an intensive degeneration (more on the left than on the right side) in the fasc. long. post., here united with the ascending DEITERS tract, and in both nuclei of the IVth nerve.

Fig. 25 B. The section through the corpora quadrigemina posteriora and the lateral fillet.

There is an intense degeneration in the lateral fillet, especially in its medial bundle (f. m. l. l.), and in its lateral layer the fibres round the ventral nucleus have degenerated.

The fasc. long. post. begins its separation from the tract. DEITERS ascend. (The separation between the two tracts is distinct In fig. 25 c D and E) and fibres detach from the ascending DEITERS tract during its course to reach the medial bundle of the fillet. In the decussatio ventralis tegmenti another degeneration is found, reaching the place where the „aberrirendes Seitenstrangbündel" enters into the lateral fillet. The most lateral fibres of the fillet remain without degeneration.

Fig. 25 C. The section touches the place, where the pedunculi cerebelli medialis leave the medulla.

Degenerate fibres are found in 1^{ly} The fasciculus longitudinalis posterior, 2^{ly} the ascending DEITERS tract (which at this moment leaves the f. l. p. to deviate laterally). Both tracts send transverse fibres crossing the raphe, that may be followed in 3^{ly} the medial bundle of the lateral fillet.

4^{ly}. The lateral bundle of the fillet with the nucleus ventralis lemnisci. 5^{ly} transverse fibres in the ventral decussatio tegmenti towards the place of the „aberrirendes Seitenstrangbündel" 6^{ly} the fasciculus spino-cerebellaris ascendens ventralis.

Fig. 25 D. The section touches the middle of the nucleus ventralis lemnisci. There are found the same degenerations as in the former. The ventral decussatio tegmenti has ended, its degenerated area finds a place laterally from the nucleus ventralis lemnisci.

Fig. 25 E. The section touches at the right side the lesion. The pedunculus cerebelli inferior (its oval area) being cleft, this oval area is degenerating towards the cerebellum. Transverse fibres unite the two ascending DEITERS tracts. The medial bundle of the fillet touches the lateral bundle at the dorsal top of the distal end of the nucleus ventralis lemnisci. The systema ventrale nervi octavi is degenerated.

PLATE XX.

Fig. 25 F. The section touches the lesion in x on both sides. Degenerated are 1^{ly} the fasciculus longitudinalis posterior 2^{ly} the tractus DEITERS ascendens. 3^{ly} MONAKOW's decussation of transverse fibres going to the dorsal layer of the oliva superior (medial bundle of the fillet). 4^{ly} The systema ventrale nervi octavi.

Fig. 25 G. The section touching still in x the double-sided lesion falls through the exit of the VIIth nerve.

MONAKOW's transverse fibres towards the dorsal top of the nucleus olivaris superior are totally degenerate.

Fig. 25 H. The section touches the tuberculum acusticum and the nucleus ventralis. Degeneration is found in. 1^{ly}. The systema dorsale (MONAKOW's stria medullaris). 2^{ly}. HELD's intermedial system. 3^{ly}. The tractus DEITERS descendens. 4^{ly}. The systema ventrale.

Fig. 25 I. The section touches the nucleus facialis and the distal end of the tuberculum acusticum. On both sides is found degeneration in 1^{ly} the tractus DEITERS descendens. 2^{ly}. The fasc. long. post. and the fasciculus praedorsalis, 3^{ly} in the fasc. rubro-spinalis 4^{ly} in the nucl. facialis, 5^{ly} in the fibr. transversae dorsalis and 6^{ly} in the radix descendens N. VIII.

Fig. 25 K. The section falls through the XIIth nucleus, demonstrating the degeneration in the tracts descending towards the cord.

Fig. 25 L. The section through the distal end of the med. oblongata. The position of the tractus DEITERS descendens, the fasciculus praedorsalis and the rubrospinal tract.

PLATE XXI.

Fig. 25 M N and O. Sections through different levels of the cervical cord (C_1, C_2, C_3) to demonstrate the position of the f. praedorsalis, the descending DEITERS tract, and the rubro-spinal tract.

PLATE XXI and PLATE XXII.

Fig. 28 A—F and fig. 12. Series of sections through the medulla oblongata of the rabbit, six months after the ablation of the left tuberculum acusticum made in the young born animal. The lesion is found in fig. 28 in A—D. The nucleus ventralis is ablated, but the octavus-roots have but a slight atrophy. The series is drawn to demonstrate the atrophy of the systems in the fillet. (WEIGERT-PAL preparation).

PLATE XXI.

Fig 12. A part of the section in fig. 28 B, limited by a circle, is drawn by an enlargement of $^{150}/_{1}$. The nucleus ventralis and the larger part of the corpus trapezoides being lost, it is seen, that fibres of the octavus-root (the dorsal root) pass immediately into the corpus trapezoides.

Fig. 28 A. The section through the distal end of the tub. acusticum.

Fig. 28 B. The section through the middle of this nucleus. Those sections are drawn to demonstrate the extensity of the lesion.

PLATE XXII.

Fig. 28 C. The section through the distal end of the nuclei olivares superiores. It demonstrates:

The loss of fibres in the corpus trapezoides and the atrophy of the nucleus olivaris superior, at the operated side. The loss of the stria medullaris at that side and the loss of fibres of the „aberrirende Seitenstrangbündel" at that side:

Fig. 28 D. The section falls through the proximal end of the lesion The same fibres are atrophied as in fig. 28 C.

Fig. 28 E. The section falls through the genu N. VII. The crossed „aberrirendes Seitenstrangbündel" now has lost a great many fibres and so have the surroundings of the crossed nucleus ventralis lemnisci (atrophied itself).

Fig. 28 F. The section falls through the fillet. There is atrophy.

1 in the superficial layer of the fillet at the operated side.
2 in the nucleus ventralis lemnisci
3 in the medial bundle
4 in the lateral bundle
5 in the aberrirendes Seitenstrangbündel
} of the contra-lateral fillet.

The decussatio ventralis tegmenti contains less fibres at the operated side than contralaterally.

PLATE XXIII and PLATE XXIV. Fig. 26 A—E and fig. 27.

Fig. 26 A—E. A series of frontal sections through the medulla oblongata of a pigeon three weeks after the removal of the labyrinth, demonstrating the degeneration of root-fibres.

Fig. 27. A longitudinal section through the primary octavus-nuclei of a pigeon three weeks after the removal of the labyrinth. (These are Marchi-preparations).

The abbreviations used here are:

N. ang. N. VIII = nucleus angularis
r. lat. N. VIII = radix lateralis
r. desc. N. VIII = radix descendens
} nervi octavi.
r. N. X = radix nervi vagi.
r. spin. N. V = radix spinalis nervi quinti.
C. R. = corpus restiforme.
N. N. XII = nucleus nervi hypoglossi.
n. parvocell N. VIII = nucleus parvocellularis nervi octavi.
A. = „acusticusfeld".
r. med. N. VIII = radix medialis nervi octavi.
fibr. dors. = fibrae dorsales radicis nervi octavi.
$\times$ = trunc. med. = medial trunck of octavus-root fibres.
f. dors. N. VIII = systema dorsale nervi octavi.
f. l. p. = fasciculus longitudinalis posterior.
n. magno-cellul. N. VIII = nucleus magnocellularis nervi octavi.
n. cer. = nucleus pedunculi cerebelli.
N. VII = nervus facialis.
N. VI = nervus abducens.

Fig. 26 A. The section through the entrance of the dorsal (lateral) root and angular nucleus.

Fig. 26 B. The section through the entrance of the ventral (medial) root and the distal end of the nucleus parvo-cellularis.

Fig. 26 C. The section through the distal end of the nucleus magnocellularis.

Fig. 26 D. The section through the middle of the nucleus magnocellularis and the nucleus pedunculi cerebelli.

Fig. 26 E. The section through the proximal end of the medial trunk of rootfibres (the radix ascendens N. octavi)).

Fig. 27. A horizontal section through the nucleu angularis, parvocellularis, magnocellularis and pedunculi cerebelli.

List of books, consulted in studying the nervus Octavus.

G. Tricomi Allegra. Studio sperimentale sulla via acustica fondamentale. Le Névraxe. Vol. VII. 1906 p. 229—280.

Herm. Aubert. Physiologische studien über die Orientierung (1888). Unter Zugrundelegung von

Yves Delage. Etudes expérimentales sur les illusions statiques et dynamiques de direction pour servir à déterminer les fonctions des canaux sémicirculaires de l'oreille interne. (1886) mit einem Anhang.

Johann Purkinje. Ueber den Schwindel (1825).

Johann Purkinje. Beiträge zur näheren Kenntnisz des Schwindels aus heautognostischen Daten.
Med. Jahrbücher Bd. 6. 2. p. 79—125. Wien 1820.

B. Baginsky. Ueber den Ursprung und den centralen Verlauf des N. acusticus des Kaninchens.
Virchows Archiv. Bd. 105. 1886. S. 28.

B. Baginsky. Zur Kenntnisz des Verlaufs der hinteren Wurzel des Acusticus und des Verhaltens der Striae medullares. Sitz. der Berl. Ges. f. Psych. und Neur. 11 Nov. 1889.
Arch. für Psych. Bd. XXIII. p. 291—292.

B. Baginsky. Ueber den Ursprung und den centralen Verlauf des Nervus acusticus des Kaninchens und der Katze.
Virchows Arch. Bd. 119. 1890. S. 91.

B. Baginsky. Ueber die Folgen der Drucksteigerung in der Paukenhöhle und die Function der Bogengänge. Arch. f. An. und Phys. 1881. p. 201—235.

B. Baginsky. Zur Physiologie der Bogengänge. Arch. f. An. und Phys. 1885. p. 252—266.

B. Baginsky. Ueber den Ménièreschen Symptomen-complex. Berl. Klin. Wochenschrift. N°. 45 & 46. 1888.

W. Bechterew. Ergebnisse der Durchschneidung des N. acusticus, nebst Erörterung der Bedeutung der semicirculären Kanäle für das Körper-Gleichgewicht. Pflüger's Arch. f. d. ges. Phys. Bd. XXX. 1883. p. 312—347.

W. von Bechterew. Ueber die Bestandtheile der Hinterstränge des Rückenmarks auf Grund der Untersuchung ihrer Entwicklung. Neurol. Centrlblt. Bd. IV. N°. 2. p. 31—33. 1885.

W. von Bechterew. Zur Anatomie der Schenkel des Kleinhirns, insbesondere der Brückenarme. Ibidem Bd. IV. N°. 6. p. 121—125. 1885.

W. von Bechterew. Ueber die innere Abtheilung des Strickkörpers und den achten Hirnnerven. Ibidem. Bd. IV. N°. 7. p. 145—147. 1885.

W. von Bechterew. Ueber die Längsfaserzüge der formatio reticularis medullae oblongatae et pontis. Ibidem. Bd. IV. N°. 15. p. 337—336. 1885.

W. von Bechterew. Zur Frage über den Ursprung des Hör-Nerven und über die physiologische Bedeutung des N. Vestibularis. Ibidem Bd. VI. N°. 9. p. 193—198.

W. von Bechterew. Ueber den Schleifenschicht. (Sitz Ber. der Königl. sachs. Gesellschaft der Wissenschaften 4 Mai 1885). Ibidem Bd. IV. N°. 15. S. 356.

W. von Bechterew. Die Leitungsbahnen im Gehirn und Rückenmark. Leipzig 1894. (übersetzt von I. Weinberg). S. 65 u 7.

W. von Bechterew. Zur Frage über die Striae medullares des verlängerten Markes. Neur. Centrbltt. 1892. Bd. 11. S. 297.

Arthur Biedl. Absteigende Kleinhirnbahnen. Neur. Centrlbltt 1895. Bd. XIV. S. 434, 493.

Robert Boyce. Contribution to the study of descending degeneration in the brain etc.

Proceedings of the Royal Society Vol 55. 1894.
Phil. trans. Vol. 186. Part I. 1895.
Neur. Cent. Bltt N°. 13. 1894. S. 466.

ROBERT BOYCE. A contribution to the study of:
I. some of the decusating tracts of the mid-and interbrain and
II. of the pyramidal system in the mesencephalon and bulb.
Phil. Trans. Vol 188. 1897.

JOSEPH BREUER. Ueber die Function der Bogengänge des Ohrlabyrinthes. Medicinische Jahrbücher. Wien 1874. p. 72—124.
Beiträge zur Lehre vom statischen Sinne (Gleichgewichts-organ, Vestibularapparat des Ohrlabyrinthes). Medicinische Jahrbücher. Wien 1875 p. 87—156.

J. BREUER. Studien über den Vestibular-Apparat. Wien Sitz. Ber. (Abth. III) Bd. CXII. p. 353. 1903.

A. BUMM. Experimenteller Beitrag zur Kenntnisz des Hörnerven-Ursprungs beim Kaninchen.
Allgem. Zeitschrieft für Psych. Bd. XIV. 1889. S. 568 und Jahressitzung des Ver. deutsch. Irrenärtze im Bonn. 16 und 17 Sept. 1888. Neur. Ctbltt. 1888. S. 59.

CLARKE. Proceedings of the Royal Society 1861, p. 359
Philosophical transactions 1858 p. 231.

JAMES COLLIER and E. FARQUHAR BUZZARD. The Degenerations resulting from lesions of posterior Nerve Roots and from transverse lesions of the spinal cord in man. A study of twenty cases.
Brain 1903 Vol. XXVI p. 559.

JAMES COLLIER and E. FARQUHAR BUZZARD. Descending mesencephalic tracts in Cat, Monkey and Man; MONAKOW's Bundle etc. Brain 1901. Bd. XXIV p. 177.

CRAMER. Beiträge zur feineren Anatomie der medulla oblongata und der Brücke etc. Jena 1894.

A. CRUM BROWN. On the sense of rotation and the anatomy and the physiology of the semicircular canals of the internal ear
Proceedings of the Royal Society. Edinburgh T. VIII 19 Jan. 1874.

Journal of Anatomy and Physiology. Vol. VIII.

J. van Deen. Nieuw Archief v. binnen. en buitenlandsche geneeskunde etc. 1848 p. 304.

O. Deiters. Untersuchungen über Gehirn und Rückenmark der Säugethiere. Braunschweig 1865.

J. Déjérine. Anatomie des centres nerveux. Paris 1895, 1901.

L. Edinger. Vorlesungen über den Bau der nervösen Centralorgane des Menschen und der Thiere. 6ste Auflage, 1900.

L. Edinger. Ueber Ursprungsverhältnisse des Acusticus und die directe Kleinhirn Bahn. Neur. Centrbltt. 1886 Bd. VI p. 286.

L. Edinger. Untersuchungen über die vergleichende Anatomie des Gehirns. N°. 5 Untersuchungen über das Vorderhirn der Vögel. Abh. der Senckenberg naturf. Gesellschaft Bd. XX. 1903.

Th. W. Engelmann. Ueber die Function der Otolithen. Zoologischer Anzeiger N°. 258. 15 Aug. 1887 p. 439—444.

J. Rich. Ewald. Zur Physiologie der Bogengänge. Pflüger's Arch. f. d. ges. Phys. Bd. XLI. p. 463—483.

J. Rich. Ewald. Zur Physiologie der Bogengänge. Fortsetzung. Ueber Bewegung der Perilymphe. Pflüger's Arch. f. d. ges. Phys. Bd. XLIV. 1889 p. 319—326.

J. Rich. Ewald. Physiologische Untersuchungen über das Endorgan des N. Octavus. Wiesbaden 1892.

J. Rich. Ewald. Ueber die Beziehungen zwischen der excitabeln Zone des Groshirns und dem Ohrlabyrinth. Berl. Kl. Wochenschrift 1895. N°. 42. S. 929.

David Ferrier and W. Aldren Turner. A record of experiments illustrative of the symptomatology and degenerations following lesions of the cerebellum and its peduncles and related structures in monkeys. Phil. Trans. Bol. 185. p. 753. 1894.

P. Flechsig. Die Leitungsbahnen im Gehirn und Rückenmark des Menschen u. s. w. Leipzig. 1876.

P. Flechsig. Zur Lehre vom centralem Verlauf des Sinnesnerven.
Neur. Centrbltt. 1886. Bd. V· N°. 23. S. 545.

P. Flechsig. Weitere Mittheilungen über die Beziehungen des unteren Vierhügels zum Hörnerven. Ibidem 1890. Bd- IX N°. 4. S. 98.

P. Flechsig. Zur Anatomie des vorderen Sehhügelstieles, des Cingulums und der Acusticusbahn.
Ibidem 1897. Bd. XVI. N°. 7 S. 290—295.

A. Forel. Einige Hirnanatomische Betrachtungen und Ergebnisse. Archiv. für Psychiatrie. Bd. XVIII. 1887. p. 162—198.

A. Forel und B. Onufrowicz. Weitere Mittheilungen über den Ursprung des N. acusticus. Neur. Centrbltt. Bd. IV. 1885 p. 193.

A. Forel. Vorläufige Mittheilung über den Ursprung des Nervus Acusticus. Neur. Centrbltt. Bd. IV 1885. p. 191.

Foville. Traité complet de l'Anatomie et physiologie du système nerveux cérébro-spinal. Paris 1844 p. 503.

Fraser. An experimental research into the relations of the posterior longitudinal bundle and Deiters nucleus.
Journal of Physiology. Vol. 27. p. 327. 1901.

P. Flourens. Mémoire présentée à l'Académie des sciences Séance du 27 Dec. 1824.
Expériences sur les canaux sémicircularis de l'oreille chez les oiseaux. Séance du 11 Août 1828.
Annales des Sciences naturelles T. XV. p. 118.

P. Flourens. Recherches expérimentales sur les propriétés et les fonctions du système nerveux dans les animaux vertébrés 2de édition. Paris. 1842.

A. van Gehuchten. Nouveau procédé de section intracranienne du trijumeau du facial et de l'acoustique. Le Névraxe. Vol. II 1900. p. 45—55.

A. van Gehuchten. Recherches sur la voie acoustique centrale Le Névraxe. Vol. IV. 1903 p. 231—301.

A. van Gehuchten. Les connections centrales du noyau Deiters et des masses grises voisines. Le Névraxe. Vol. VI. 1904. p. 19—75.

A. van Gehuchten. Recherches sur la terminaison centrale des nerfs périphériques.
I. Le nerf intermédiaire de Wrisberg. Le Nevraxe. Vol. I. 1900. p. 3—13.
II. Le faisceau solitaire. Le Névraxe. Vol. I. 1900. p. 171—199.
III. La racine bulbo-spinale du trijumeau. Le Névraxe. Vol. II. 1901. p. 173—191.
IV. La racine postérieure des deux premiers nerfs cervicaux. Le Névraxe. Vol. II. 1901. p. 227—257.
V. La racine postérieure du huitième nerf cervical et du premier nerf dorsal. Le Névraxe. Vol. IV. 1903. p. 55—77.
VI. Le nerf cochléaire. Le Névraxe. Vol. VIII. 1907. p. 125—147.

A. van Gehuchten. Le corps restiforme et les connexions bulbo-cérébelleuses. Le Névraxe. Vol. VI. 1904.

A. van Gehuchten. Les pédoncules cérébelleux supérieurs. Le Névraxe. Vol. VII 1904 p. 29—87.

A. van Gehuchten. Le faisceau en crochet de Russell ou faisceau cérébello-bulbaire. Le Névraxe. Vol. VII. 1905 p. 117—161.

A. van Gehuchten. Anatomie du système nerveux de l'homme. 4e édition. Louvain. 1906.

F. Goltz. Ueber die physiologische Bedeutung der Bogengänge des Ohrlabyrinths.
Pflüger's Archiv. f. d. ges. Phys. Bd. III 1870. p. 172—192.

F. Goltz. Ueber die Verrichtungen des Groszhirns Bonn. 1881.

W. R. Gowers. Handbuch der Nervenkrankheiten. Übersetzt von Karl Grube. Bonn 1892.

Bernard von Gudden. Gesammelte und hinterlassene Arbeiten. Prof. Grashey 1889. Wiesbaden.

H. Held. Die centralen Bahnen des Nervus Acusticus bei der Katze. Archiv. für Anat. und Phys. 1891. p. 271—p. 288.

H. Held. Ueber eine directe akustische Rindenbahn und den Ursprung des Vorderseitenstranges beim Menschen. Ibidem 1892. p. 257—264.

H. Held. Die centrale Gehörleitung. Ibidem 1893 p. 201—248.

H. Held. Der Ursprung des tiefen Markes der Vierhügel-Region. Neur. Central Blatt. 1890. Bd. IX. S. 481—483.

W. His. Zur Geschichte des Gehirns, sowie der centralen und peripherischen Nervenbahnen, (Abh. der math. phys. Class. d. Königl. Sächsischen Gesellschaft d. Wissensch. 1888. Bd. XIV.

E. Hitzig. Untersuchungen über das Gehirn. Berlin 1874.

W. B. Hadden and C. S. Sherrington. On a case of bilateral degeneration etc. Brain 1886 Bd. VIII. S. 502.

S. Kirilzew. Zur Lehre vom Ursprung und centralen Verlauf des Gehörnerven. Neur. Centrbltt. Bd X. 1892. S. 669.

A. von Kölliker. Handbuch der Gewebe-Lehre etc. 6ste Auflage. II. Nervensystem. 1896. p. 262. etc.

Alois Kreidl. Beiträge zur Physiologie des Ohrlabyrinths auf Grund von Kranken und Taubstummen. Pflüger's Archiv f. d. ges. Phys. Bd. LI. 1891. p. 119—150.

Alois Kreidl. Weitere Beiträge zur Physiologie des Ohrlabyrinths. I. Versuche an Fischen. Sitz-Berichte der K. K. Acad. f. Wissensch. in Wien. Bd. CI. Abth. III 1892.

Alois Kreidl. Weitere Beiträge zur Physiologie des Ohrlabyrinths. II. Versuche an Krebsen. Wien Bd. CII Abth. III. 1893.

Alois Kreidl. Die Functionen des Vestibular-Apparates. Ergebnisse der Physiologie. Bd. V. 1906. p. 572.

Kohnstamm. Ueber Ursprungskerne spinaler Bahnen im Hirnstamm. 24ste Wandervers. Süd W. D. Neur. in Baden-Baden. Arch. f. Psych. und Nervenkr. Bd. XXXII. 1899. S. 682.

S. B. Laura. Nuove Richerche sulle Origine dei Nervi cerebrali. Torino. 1878.

M. von Lenhossek. Die Nervenendigungen in den Maculae and Cristae acusticae. VIIte Versammlung der Anatomischen Gesellschaft in Göttingen. 28 Mei 1893.

M. Lewandowsky. Untersuchungen über die Leitungsbahnen des Truncus cerebri und ihren Zusammenhang mit denen der Medulla spinalis und des Cortex cerebri. Jena. 1904 p. 80—91.

Longet. Anatomie et Physiologie du système Nerveux 1849. p. 67.

N. Löwenthal. La région pyramidale de la capsule interne chez le chien et la constitution du cordon antéro-latéral de la moelle.
Rev. méd. de la Suisse romande. 1886. 15 Sept.

L. Luciani. Das Kleinhirn. Neue Studien zur normalen und pathologischen Physiologie. Leipzig. 1893.

Vittorio Marchi e G. Algeri. Sulle degenerazioni discendenti consecutive a lesioni della corteccia cerebrale. Rivist: sperimentale di Frenatr. 1886. Bd. XI. p. 492.

V. Marchi. Sulle degenerazioni consecutive all' estirpazione totale e parziale del cerveletto. Rivist: sperimentale di Freniatr. 1886. XII. p. 50.

Vittorio Marchi. Sull'origine e decorso dei peduncoli cerebellari e sui loro rapporti cogli altri centri nervosi. Pubblicazioni del R. Instituto di studi superiori in Firence (Morena. Le Monnier. 1891).

P, Martin. Zur Endigung des Nervus Acusticus im Gehirn der Katze.
Anat. Anz. 1894 p. 181—184.

E. Mendel. Ueber den Verlauf der Fasern des Bindearmes. Berliner Klin. Wochenschrift 1878. S. 402. N°. 27. Vortrag in medic. psychol. Gesellschaft. Berlin 7 Januar.

Th. Meynert. Vom Gehirne der Säugethiere, in Stricker's Handbuch der Lehre von den Geweben 1870. Wien.

Th. Meynert. Skizze des menschlichen Groszhirnstammes etc. Arch. für. Psychiatrie Bd. IV.

E. Mach. Physikalische Versuche über den Gleichgewichtssinn der Menschen. Sitzber. der Wiener Academie 6 Nov. 1873. Bd. 68 p. 124—140.
Versuche über den Gleichgewichtssinn. Ibidem

Bd. 69. 1874 Ueber Gleichgewichtssinn Ibidem Bd. 78. Together they are found in.

E. Mach. Grundlinien der Lehre von den Bewegungs-Empfindungen. Leipzig 1875.

Middendorp. Het vliezig slakkenhuis in zijn wording en in den ontwikkelden toestand. Groningen 1867.

M. Magendie. Leçons sur les fonctions et les maladies du système nerveux. Paris. 1841. Tome I.

C. von Monakow. Zur Kenntnisz des „äusseren Acusticuskernes" und des corpus restiforme. Neur. Ctbl. Bd. I. 1882. p. 480—p. 482.

C. von Monakow. Experimenteller Beiträge zur Kenntnisz des corpus restiforme, des äusseren Acusticus-Kernes und deren Beziehungen zum Rückenmarke. Archiv. für Psych. Bd. XIV. 1883. p. 1—15.

C. von Monakow. Striae acusticae und untere Schleife. Archiv für Psychiatrie. Bd. XXII. 1890 p. 1—25.

C. von Monakow. Experimentelle und pathologisch-anatomische Untersuchungen über die Haubenregion etc. Archiv für Psychiatrie. Bd. XVII. 1895 p. 1—129, p. 386—479.

F. W. Mott. Die zuführenden Kleinhirnbahnen des Rückenmarks bei dem Affen. Monatschrift für Psych. und Neurologie 1897 Bd. T. S. 104.

E. Münzer und H. Wiener. Beiträge zur Anatomie des Central Nervensystems. Prager med. Wochenschrift 1895 N°. 14.

E. Münzer. Beitrag zum Aufbau des Central Nervensystems. Vortrag in Ver. f. Psych. und Neurol. Wien in Prag. 5 Oct. 1895. Neur. Centrlbltt. 1895 Bd. XIV. S. 956.

Mingazzini. Sulle degenerazioni consecutive alle estirpazione emicerebellari. Lab. di Anatomia normale della R. Universta di Roma. 1894.

F. W. Mott. Experimental inquiry upon the afferent tracts of the central nervous system of the Monkey. Brain 1895. Bd XVIII p. s.

H. Munk. Ueber die Functionen der Groszirn-Rinde. Berlin. 1890.

J. J. Muskens. Over degeneraties in het centrale zenuwstelsel na wegneming van den flocculus cerebelli. Versl. der K. Ak. v. Wet. Wis en Natuurk. Afdeeling. 24 Sept. 1904. Deel XIII. I. p. 267.

J. J. Muskens. Anatomisch onderzoek omtrent klein-hersen verbindingen. Hidem. 30 Dec. 1905. Deel XIV. II. p. 575.

J. J. Muskens. Waarnemingen omtrent de physiologie en de pathologie der dwangbewegingen en dwangstanden en daarmede verwante afwijkingen in de innervatie der oogballen. Handelingen der K. Ak. v. Wet. 2de Sectie Deel VIII. 1902 N°. 5.

H. Obersteiner. Anleitung beim Studium des Baues der nervösen Central Organe. Leipzig und Wien. 1888 und 1896.

B. Onufrowicz. Experimenteller Beitrag zur Kenntnisz des Ursprungs des N. acusticus des Kaninchens. Archiv für Psychiatrie. Bd. XVI 1885. p. 710—742.

W. Pavlow. Le faisceau de Monakow ou faisceau rubrospinal. Le Névraxe. Vol. I.1900 p. 151.

A. Pick. Beiträge zur Pathologie und pathologischen Anatomie des central Nervensystems, mit Bemerkungen zur normalen Anatomie des selben. Berlin. 1898.

Moritz Probst. Experimentelle Untersuchungen über die Schleifenendigung, die Haubenbahnen, das dorsale Längsbündel und die hintere Commissur. Archiv für Psych. Bd. XXXIII. Hft. 1.

Moritz Probst. Zur Kenntnisz des Bindearmes der Haubenstrahlung und der Regio subthalamica. Monatschrift f. Psychiatrie und Neurologie 1901.

Moritz Probst. Ueber die vom Vierhügel, von der Brücke und vom Kleinhirn absteigende Bahnen. (Monakow's Bündel etc.) 1899. Deutsche Zeitschrift für Nervenheilkunde. Bd. XV. p. 192.

Moritz Probst.	Zur Anatomie und Physiologie des Kleinhirns, Arch. für Psychiatrie 1902 Bd. XXXV. S. 692.
Santiago Ramon y Cajal	Textura del sistema nervioso del hombre y de los vertebrados. 1899—1904. Uebersetzt von Bressler 1899. Studium der med. Oblongata.
G. Retzius.	Das Gehör-Organ der Wirbelthiere. Stockholm. 1881—1884.
G. Retzius.	Die Endigungsweise der Gehörnerven. (Biologische Untersuchungen. Neue Folge III. Stockholm 1892).
Roller.	Die cerebralen und cerebellaren Verbindungen des III^{ten} bis XII^{ten} Hirnnerven. Die spinalen Wurzeln der Hirnnerven. Ztschrift für Psychiatrie Bd. XXXVIII. p. 230.
A van Rossem.	Gewaarwordingen en reflexen, opgewekt van uit de halfcirkelvormige kanalen. Diss. In. Utrecht. 1907.
Max Rothmann.	Ueber das Monakow'sche Bündel. Neur. Centrbltt. 1900. Bd. XIX. p. 41. Vortrag in Berl. ges. für Psych. und Nervenkrankheiten 12 Dec. 1899.
I. S. Risien Russell, F. E. Batten and James Collier.	Subacute combined degeneration of the spinal cord. Brain. 1900. Vol. XXIII p. 39.
I. S. Risien Russell.	The origin and destination of certain afferent and efferent tracts in the medulla oblongata. Brain. 1897. Bd. XX. Contributions to the study of some of the afferent and efferent tracts of the spinal cord. Brain 1897. Bd. XX.
I. S. Risien Russell.	Degenerations consequent on experimental Lesions of the cerebellum. Phil. transactions Vol. 186. Part. II. 1895.
L. Sala.	Sull' origine del nervo acustico. Archives Ital. de Biologie. Bd. XVI. 1892.
M. Schiff.	Lehrbuch der Physiologie. 1858.
J. S. C. Schroeder van der Kolk.	Anatomisch physiologisch onderzoek over het fijnere samenstel en de werking van het ruggemerg. A'dam. 1854.

J. S. C. Schroeder van der Kolk. Over het fijnere samenstel en de werking van het verlengde merg. A'dam. 1858.

Schrader. Zur Physiologie des Froschgehirns. Pflüger's Archiv. Bd. XLI. p. 75. 1887.

G. Schwalbe. Lehrbuch der Neurologie in Hoffmann's Lehrbuch der Anatomie des Menschen. Erlangen. 1880.

G. Schwalbe. Lehrbuch der Anatomie der Sinnesorgane. Das Gehörorgan. Erlangen. 1887. p. 288—p. 392.

Stanislaus von Stein. Die Lehren von den Functionen der einzelnen Theile des Ohrlabyrinths. Aus dem Russischen übersetzt von Dr. C. von Krzywicki. Jena. 1894.

Stanislaus von Stein. Ueber Gleichgewichtsstörungen bei Ohrenleiden. Sammelreferat. Internat. Centralbltt. für Ohrenheilkunde. Bd. III. N°. 12. p. 407.

J. Steiner. Die Functionen des Centralnervensystems und ihre Phylogenese. Braunschweig. 1885/98.

Stilling. Untersuchungen über den Bau und die Verrichtungen des Gehirnes. Theil I. Ueber den Bau des Hirnknotens oder der Varolischen Brücke. Jena. 1846.

André Thomas. Les terminaisons centrales de la racine labyrinthique. (C. R. de la Soc. de biologie. 1898. 12 févr.

André Thomas. Le cervelet. 1897.

Armin Tschermak. Ueber die Folgen der Durchschneidung des Trapeskörpers bei der Katze. Neur. Centr.-bltt. Bd. XVIII. 1899. S. 674—685, 731—741.

Max Verworn. Gleichgewicht und Otolithenorgan. Pflüger's Archiv f. d. Ges. Phys. Bd. L. 1891. p. 423—472.

A. Wallenberg. Die Secundäre Acusticusbahn der Taube. Anat. Anzeiger 1898. Bd. XIV. N°. 14.

A. Wallenberg. Giebt es centrifugale Bahnen aus dem Sehhügel zum Rückenmark. Neur. Centralbltt. 1901. Bd. XX. S. 50.

C. Wernicke. Lehrbuch der Gehirnkrankheiten. Bd. I. Anatom. Phys. Einleitung. Kassel 1881.

C. Wernicke. Grundrisz der Psychiatrie. Leipzig 1900. Psycho-physiologische Einleitung.

N. Wyrubow. Ueber die centralen Endigungen und Verbindungen des 7ten und 8ten Hirnnerven. Neur. Centralblt. 1901. Bd. XX. S. 434.

Th. Ziehen. Handbuch der Anatomie des Menschen, herausgegeben von Bardeleben. Das Central Nervensystem. Theil I. Jena 1899.

Th. Ziehen. Die Entwickelung der Leitungsbahnen in Oskar Hertwig's Handbuch der vergleichende Entwickelungslehre. 1906. Jena.

H. Zwaardemaker. Inleiding tot een bespreking van de ziekte van Ménière. XIde Nederl. Natuur- en Geneeskundig Congres. Leiden 6 April 1907.

INDEX.

pag.

INTRODUCTION 3

CHAPTER I. THE REMOVAL OF THE RABBIT-LABYRINTH. THE SECTION OF THE N. OCTAVUS AND OF ITS PROLONGATIONS IN THE CENTRAL NERVE-SYSTEM.

THE DISTURBANCES OF MOTION FOLLOWING ON THESE OPERATIONS.

1. *A few technical remarks on the removal of the labyrinth in rabbits* 6

2. *The operations through the bulla ossea* 9

a. the removal of the cochlea 13

b. the removal of the entire labyrinth 15

c. the sectioning of the corp. trapezoides 17

d. the section of the dorsal octavus-tract 17

2. *The acute motor troubles arising after one-sided removal of the labyrinth* 19

3. *Permanent disturbances of motion after the one-sided removal of the labyrinth* 29

4. *The disturbances in motion in rabbits after the extirpation of the labyrinth on both sides* 34

5. *The results of destruction of the cochlea* 36

5. *The effects of the section of the dorsal secundary tracts of the N. octavus* 37

6. *A comparison between pigeons after one-sided removal of the labyrinth and rabbits after the same operation* 39

7. *Conclusions concerning the disturbances of motion found after extirpation of the labyrinth* 42

pag.

CHAPTER II. ON THE DISTRIBUTION OF THE NERVUS OCTAVUS IN THE CENTRAL NERVOUS SYSTEM IN RABBITS 45

1. *Methods of investigation. Introduction* 45

2. *The roots of the nervus octavus* . . . . . .

a. The actual view upon the signification of the N. cochlearis and the N. vestibularis and their continuation in the lateral and ventral root 48

3. *The primary systems or the root-fibres of the nervus octavus*

a. The fresh degeneration in the root-fibres taking place after the isolated removal of the cochlea and the initial course of the dorsal (lateral) root in the central system 53

b. The fresh degeneration in the root-fibres taking place after the section of the VIIIth nerve and the initial traject of the ventral (medial) root in the central system 55

c. The supposition that both roots send their fibres, though in different quantities, in the same paths, is confirmed by the study of the myelinisation of the roots in the rabbit 67

d. The supposition that both roots send their fibres in the corpus trapezoides is also confirmed by GUDDEN's method 59

e. The systema ventrale nervi octavi 61

f. The myelinisation-method offers the same results as the Marchi-method, in regard to the position of the root fibres and secundary fibres in the systema ventrale nervi octavi 64

g. The secundary atrophy confirms the existence of rootfibres in the systema ventrale 67

h. The most dorsally situated root-fibres and HELD's intermediary system. 69

k. The longitudinal rootfibres ascending towards cerebellum and metencephalon 73

l. The rootfibres in the systema dorsale nervi octavi 77

m. The results of the secundary atrophy and of the myelinisation-method in regard to the systema dorsale nervi octavi 83

n. The nucleus dorsalis nervi octavi 88

o. The portio interna corporis restiformis 92

p. The portio interna in the embryo of the rabbit. Its atrophy after root-section 97

q. The descending octavusroot. The transverse dorsal fibres 101

4. *The secundary systems of the nervus octavus* 105

a. The secundary systems in the systema ventrale and in the systema intermedium nervi octavi 107

b. The longitudinal secundary systems from the systema dorsale nervi octavi 119

5. *Summary of results* 129

The fibres of the dorsal root 130

The fibres of the ventral root 133

The ascending secundary systems 135

The descending secundary systems 139

pag.

CHAPTER III. ON THE CENTRAL DISTRIBUTION OF THE ROOT-FIBRES OF THE NERVUS OCTAVUS IN PIGEONS 141

a. The entrance of the root-fibres 142

b. The rootfibres in the systema dorsale nervi octavi 147

c. Comparison between the central octavus rootfibres in pigeons and in rabbits 151

CHAPTER IV. THE INFLUENCE EXERTED UPON MOTILITY BY THE N. OCTAVUS IN RABBITS AND IN PIGEONS WITH REGARDS TO THE CENTRAL DISTRIBUTION OF THIS NERVE 156

EXPLICATION OF THE PLATES AND DESCRIPTION OF THE FIGURES AND THE ABBREVIATIONS 171

LIST OF BOOKS CONSULTED IN STUDYING THE N. OCTAVUS 187

C. WINKLER. NERVUS OCTAVUS.

Fig. 5.

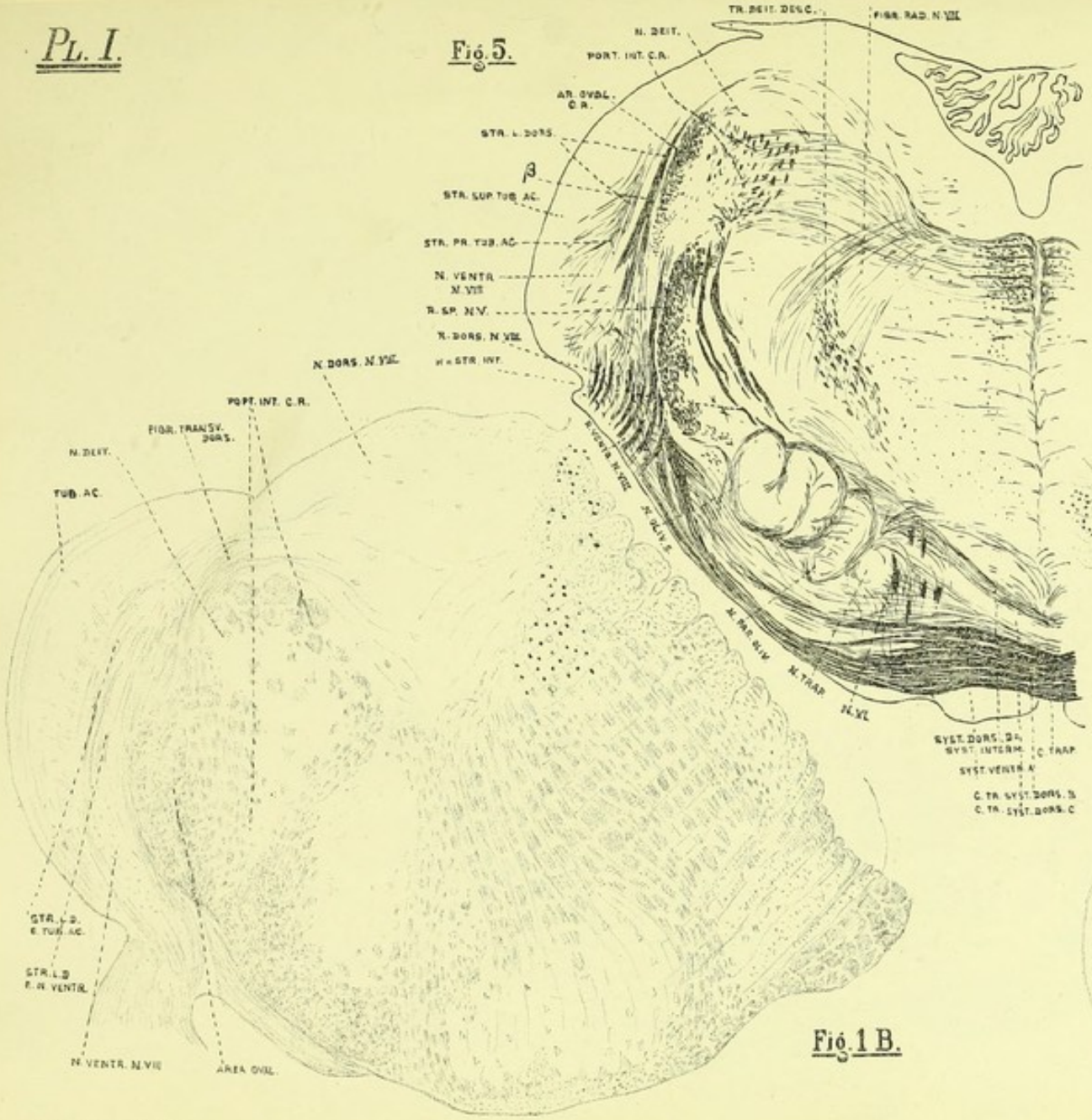

Fig. 1 B.

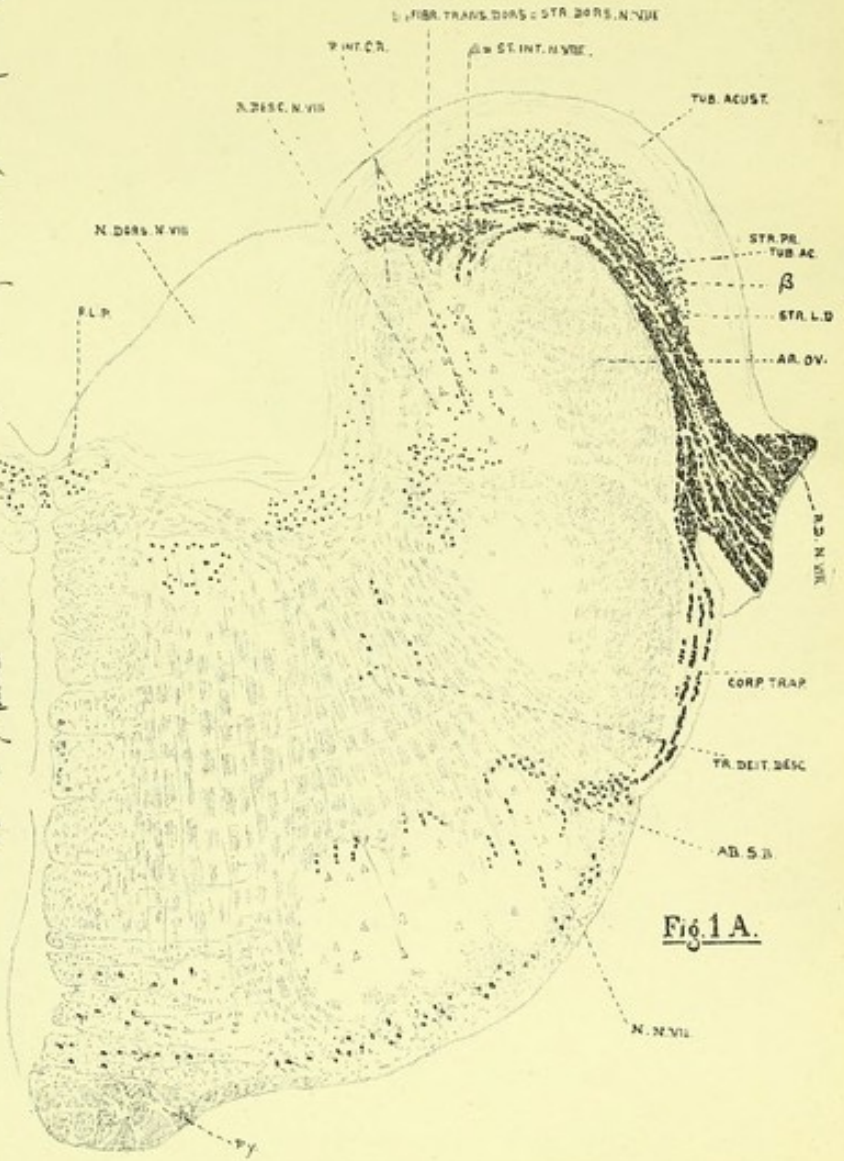

Fig. 1 A.

C. WINKLER. NERVUS OCTAVUS.

Fig. 2

PL. II

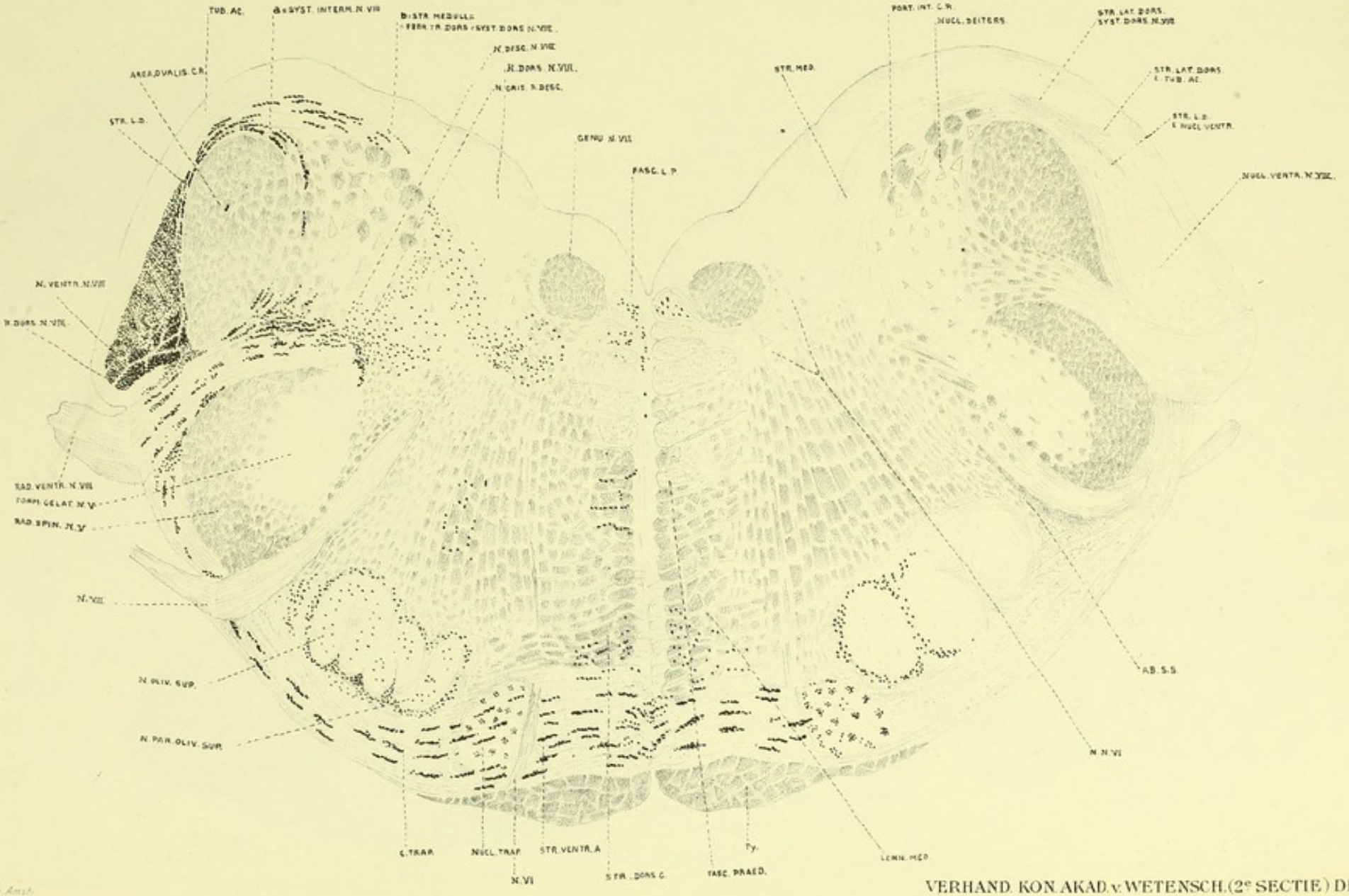

Lith. H. G. Wasmoeth, Amst.

VERHAND. KON. AKAD. v. WETENSCH. (2e SECTIE) DL. XIV.

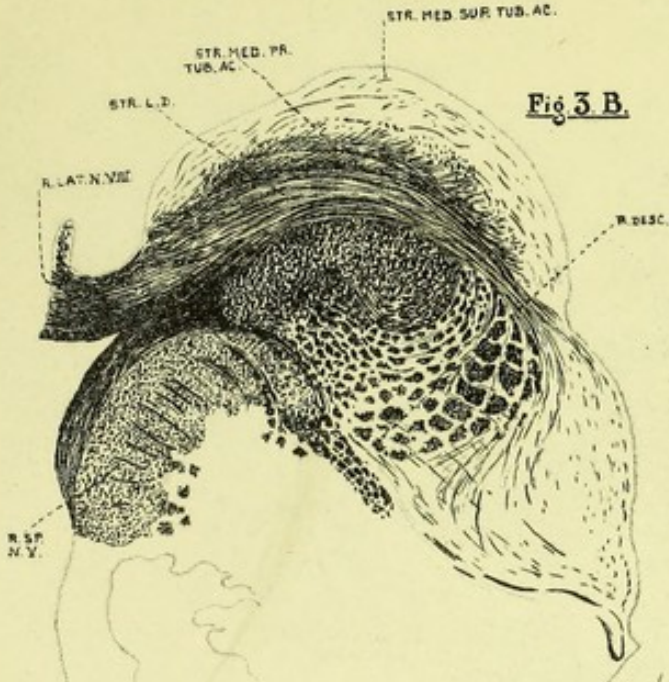

Fig. 3. B.

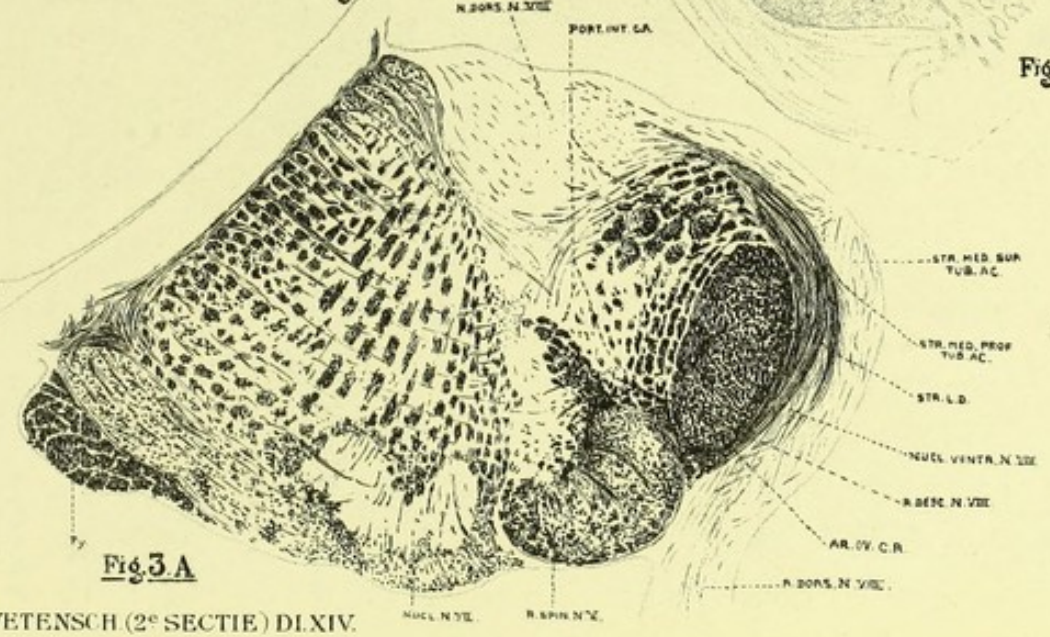

Fig. 3. A.

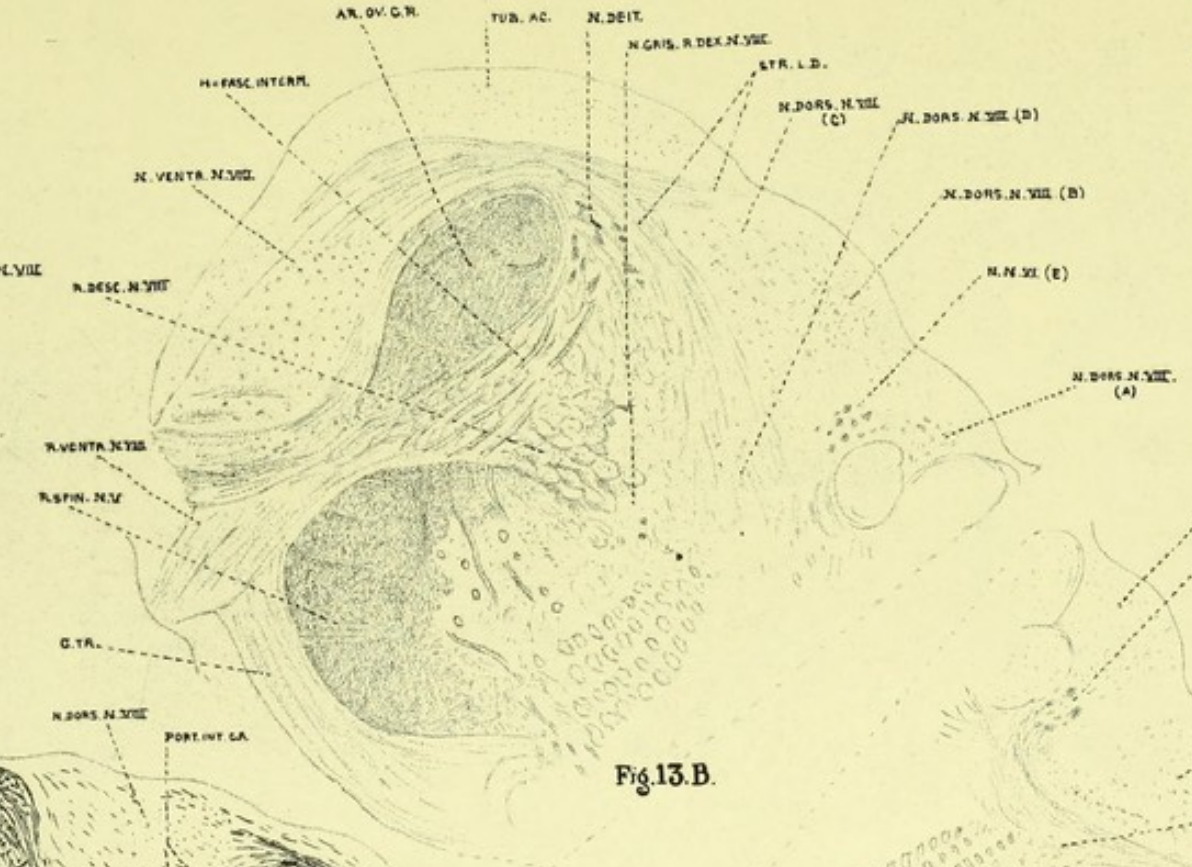

Fig. 13. B.

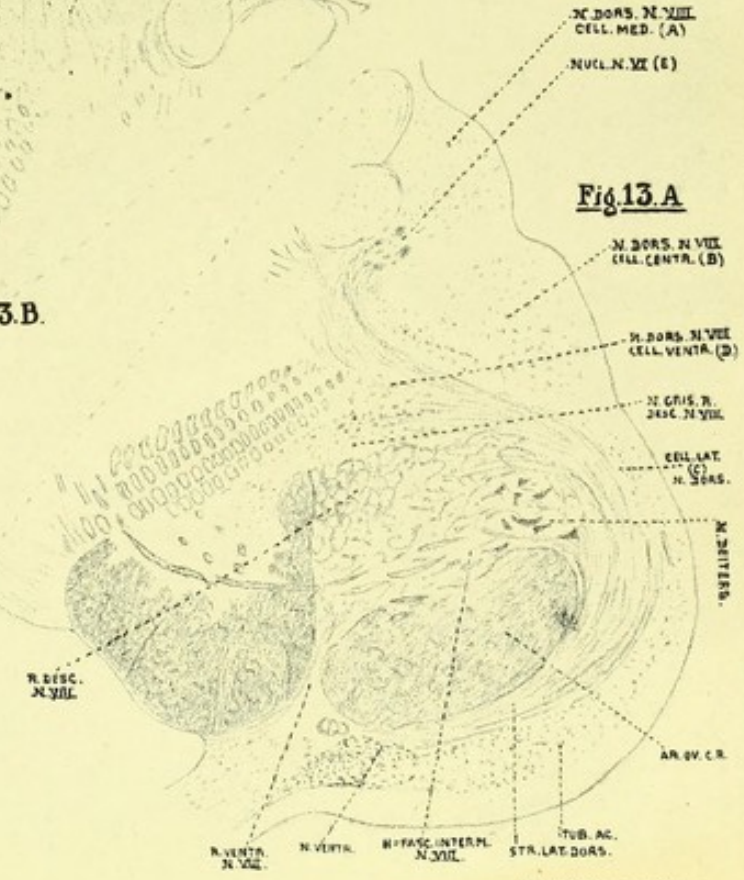

Fig. 13. A.

Lith. H. G. Waasmeer, Amst.

Fig. 4

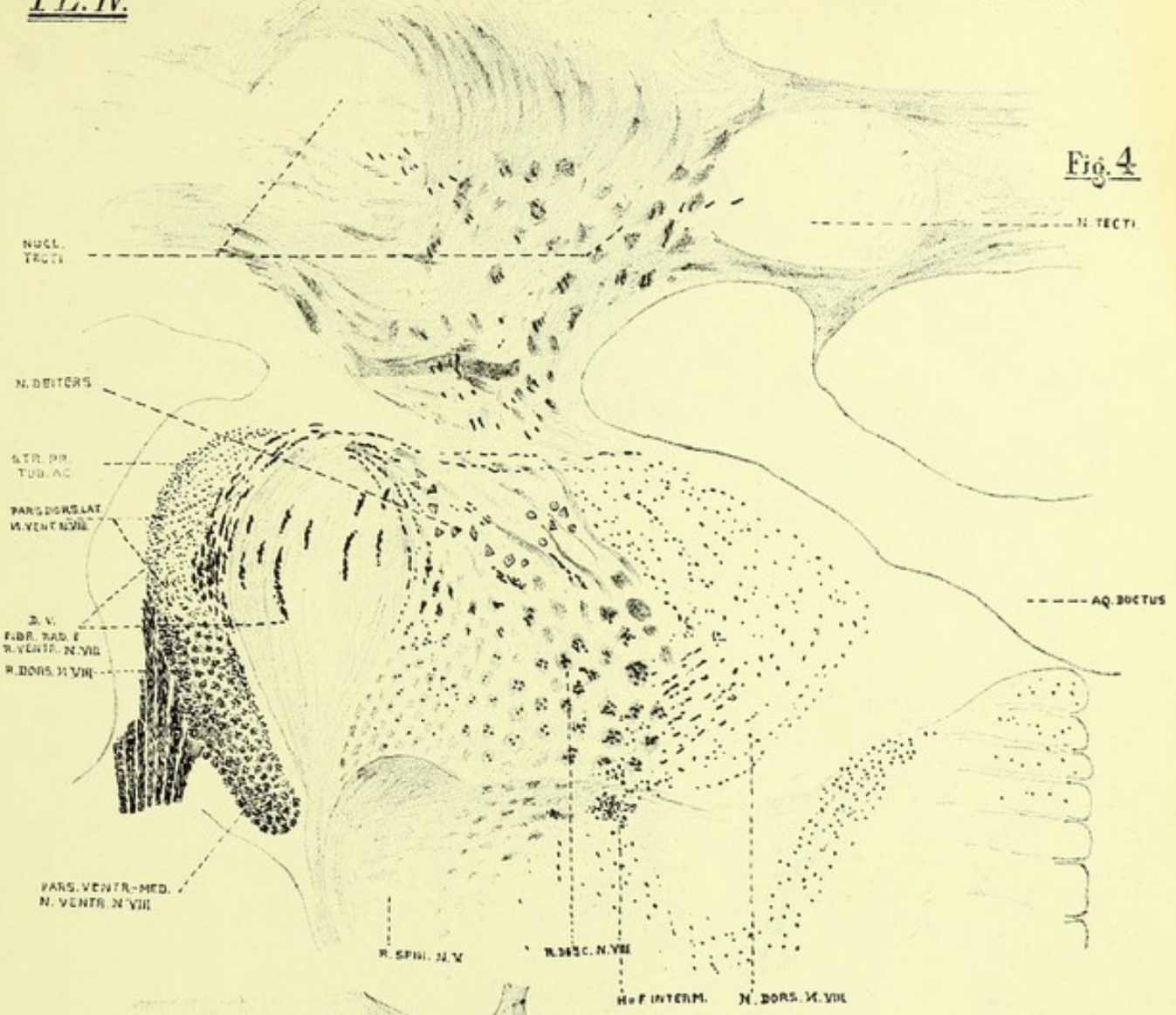

Fig. 8

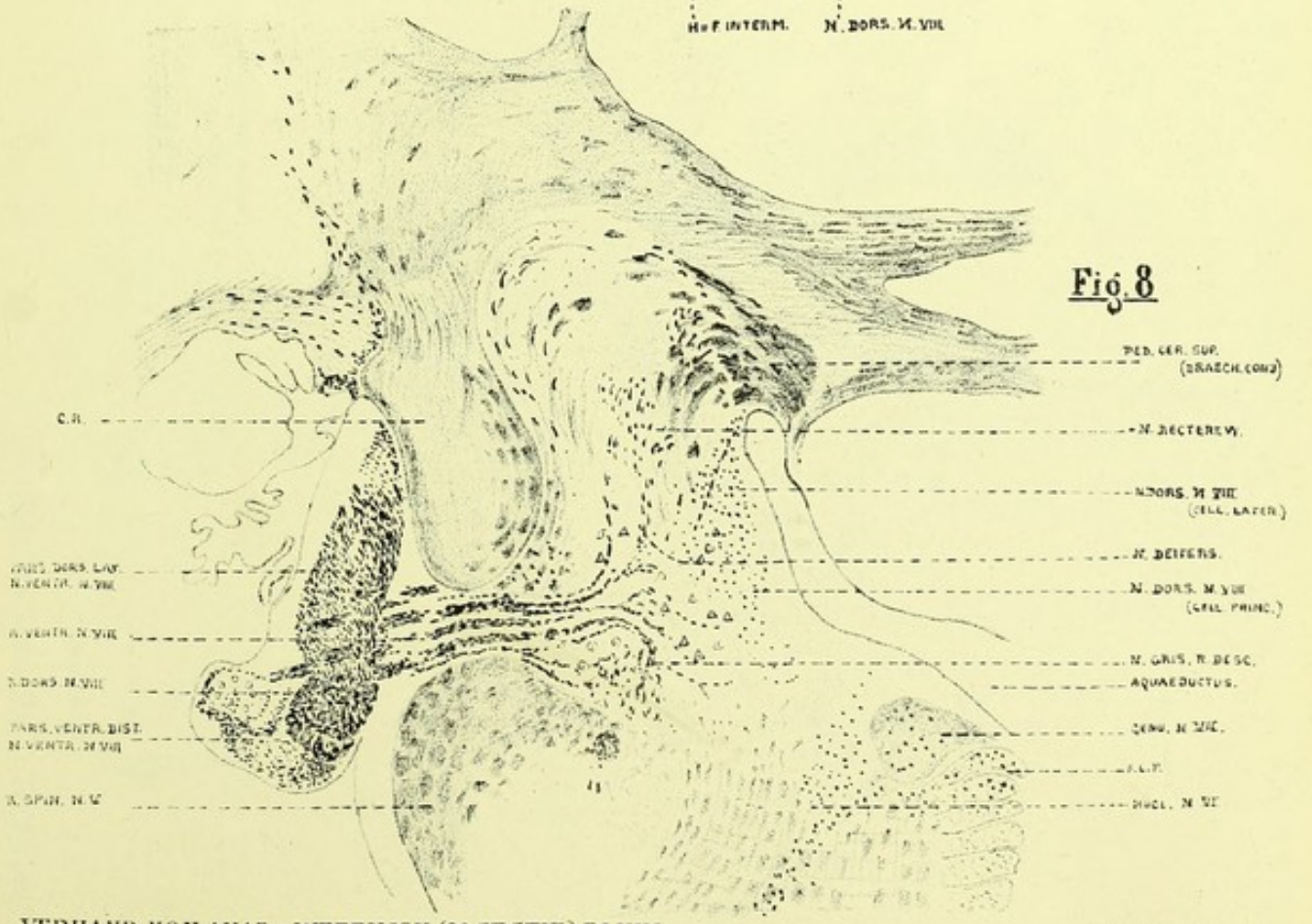

Lith. H. G. Wasmoeth, Amst.

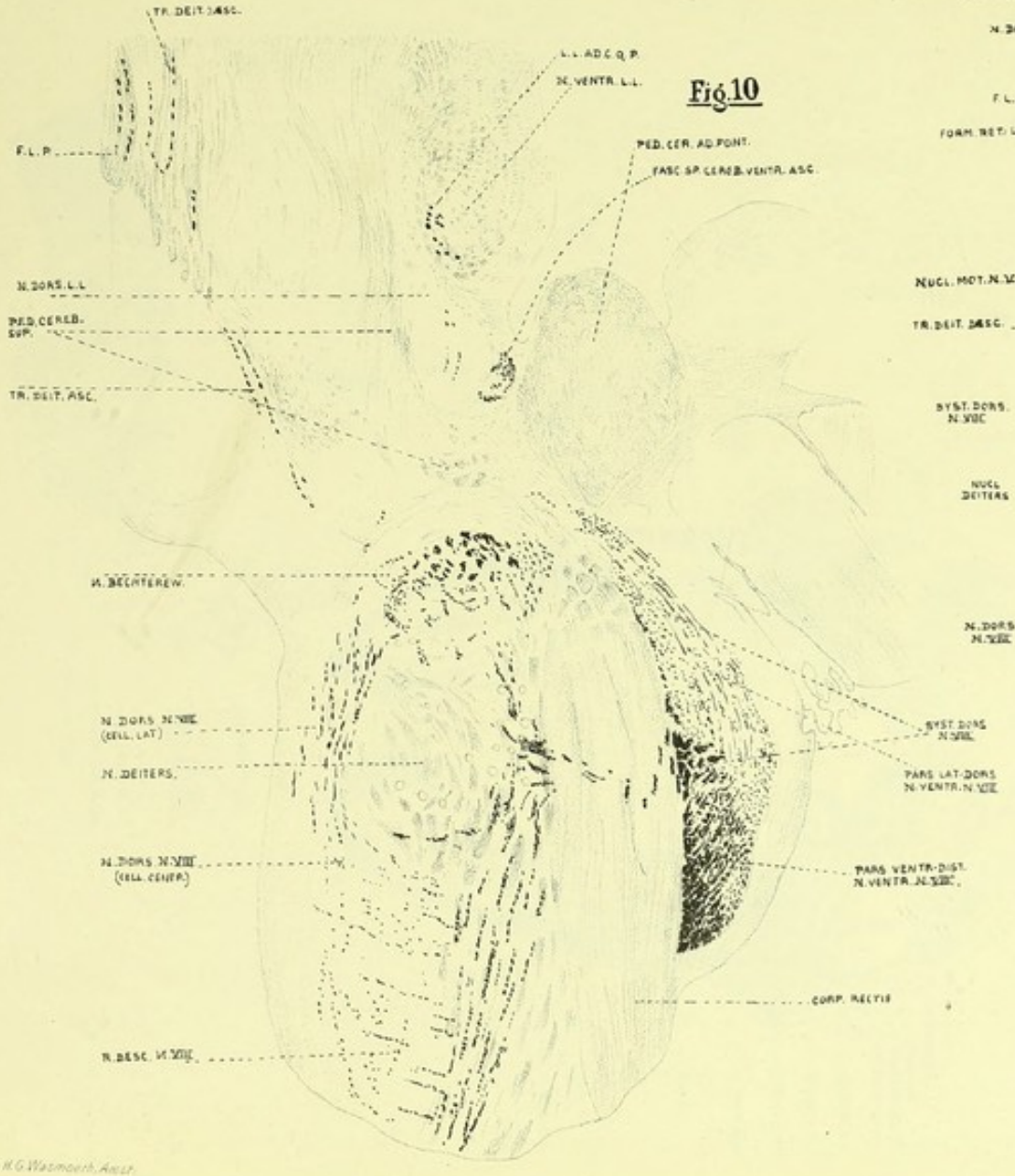
TR. DEIT. DESC.
L.L. AD C. Q. P.
N. VENTR. L.L.
F. L. P.
PED. CER. AD PONT.
FASC. SP. CEREB. VENTR. ASC.
N. DORS. L.L.
PED. CEREB. SUP.
TR. DEIT. ASC.
N. BECHTEREW.
N. DORS. N. VIII (CELL. LAT.)
N. DEITERS.
N. DORS. N. VIII (CELL. CENTR.)
SYST. DORS. N. VIII
PARS LAT-DORS N. VENTR. N. VIII
PARS VENTR-DIST. N. VENTR. N. VIII
CORP. RESTIF.
R. DESC. N. VIII

Fig. 10

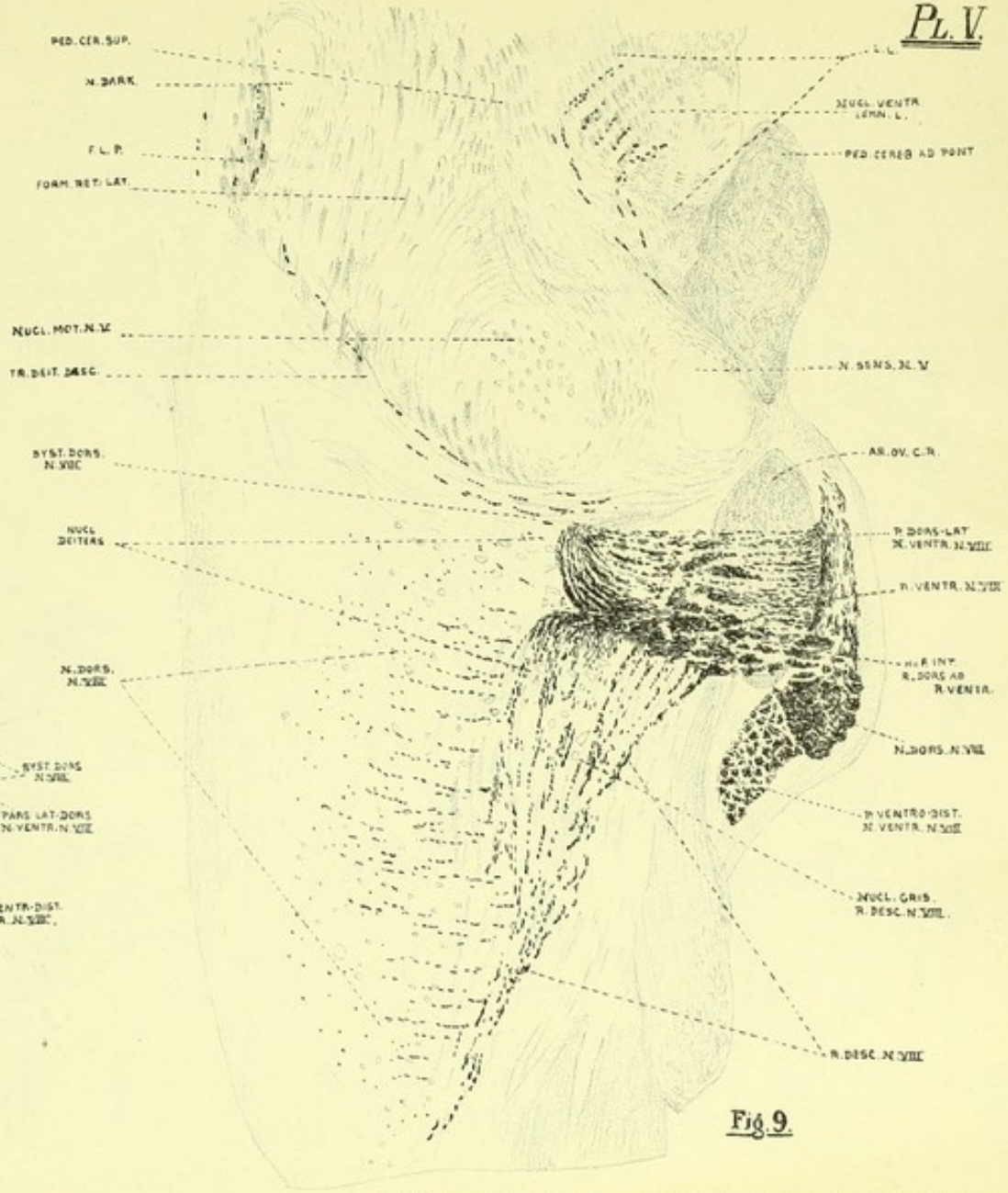
PED. CER. SUP.
N. DARK.
F. L. P.
FORM. RET. LAT.
L. L.
NUCL. VENTR. LEMN. L.
PED. CEREB. AD PONT.
NUCL. MOT. N. V.
TR. DEIT. DESC.
N. SENS. N. V.
SYST. DORS. N. VIII
AR. OV. C. R.
NUCL. DEITERS
P. DORS-LAT N. VENTR. N. VIII
N. VENTR. N. VIII
N. DORS. N. VIII
R. INT. R. DORS AB R. VENTR.
N. DORS. N. VIII
P. VENTRO-DIST. N. VENTR. N. VIII
NUCL. GRIS. R. DESC. N. VIII.
R. DESC. N. VIII

Fig. 9

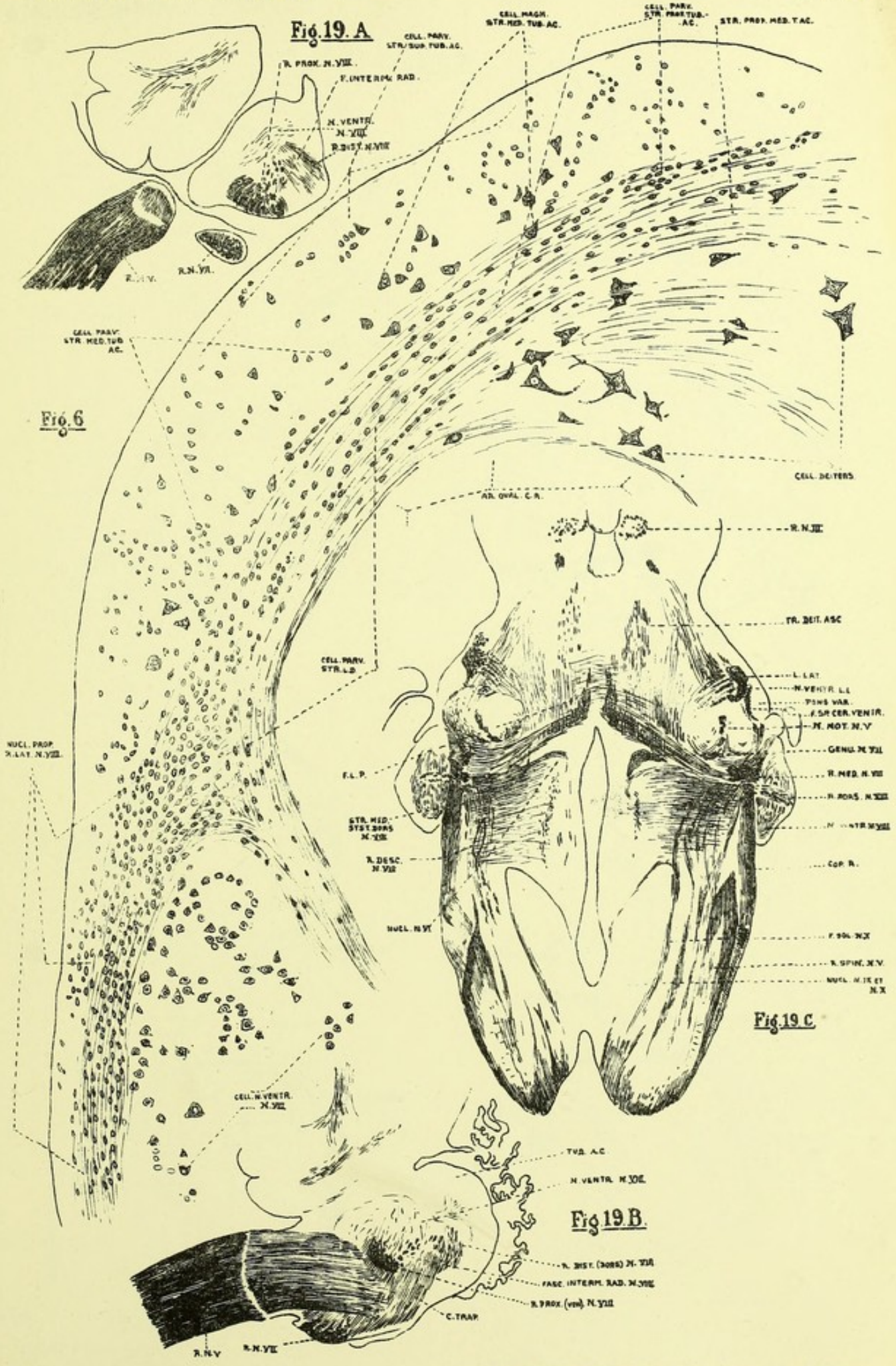
Fig. 19. A
CELL. PARV. STR. SUB. TUB. AC.
R. PROX. N. VIII.
F. INTERM. RAD.
N. VENTR. N. VIII.
R. DIST. N. VIII
R. N. V.
R. N. VII.
CELL. MAGN. STR. MED. TUB. AC.
CELL. PARV. STR. PROX. TUB. AC.
STR. PROX. MED. T. AC.
CELL. PARV. STR. MED. TUB. AC.
Fig. 6
CELL. DEITERS
AD. OVAL. C. R.
R. N. III.
TR. DEIT. ASC.
CELL. PARV. STR. L. D.
L. LAT.
N. VENTR. LL.
PONS VAR.
F. SR. CER. VENTR.
N. MOT. N. V
GENU N. VII.
R. MED. N. VIII
R. DESC. N. VIII
COP. R.
NUCL. N. VI
NUCL. PROP. N. LAT. N. VIII.
F. L. P.
STR. MED. SYST. DORS. N. VIII.
R. DESC. N. VIII
CELL. N. VENTR. N. VIII.
Fig. 19 C.
TUB. AC.
N. VENTR. N. VIII.
Fig. 19 B.
R. DIST. (DORS.) N. VIII
FASC. INTERM. RAD. N. VIII.
R. PROX. (ven.) N. VIII
C. TRAP.
R. N. V.
R. N. VII.

Fig. 7.

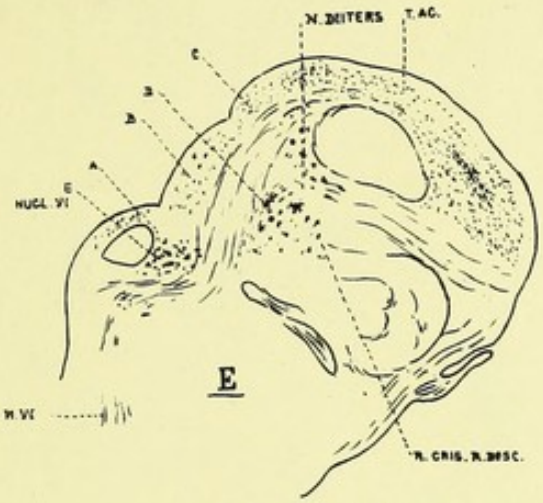

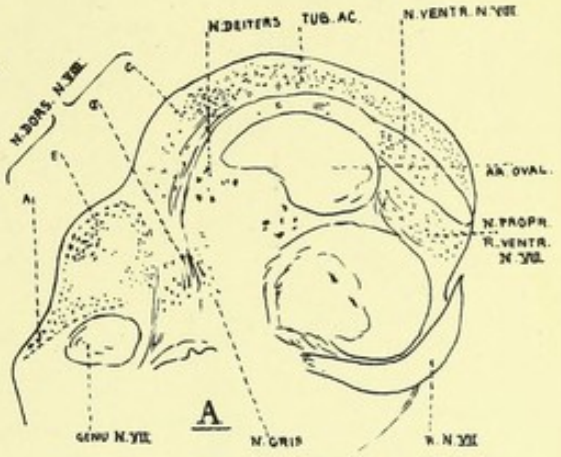

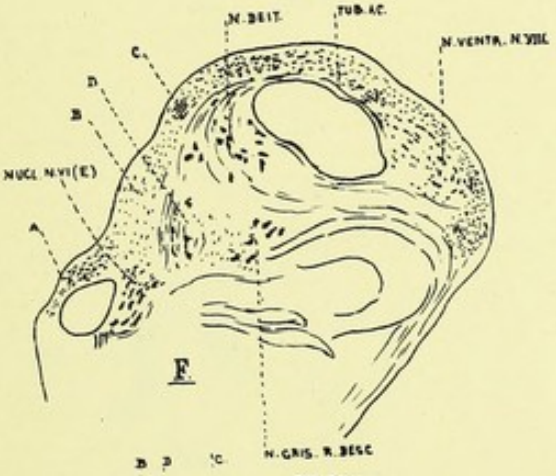

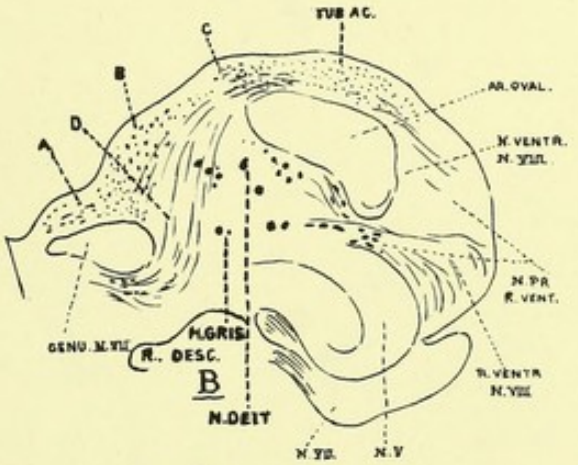

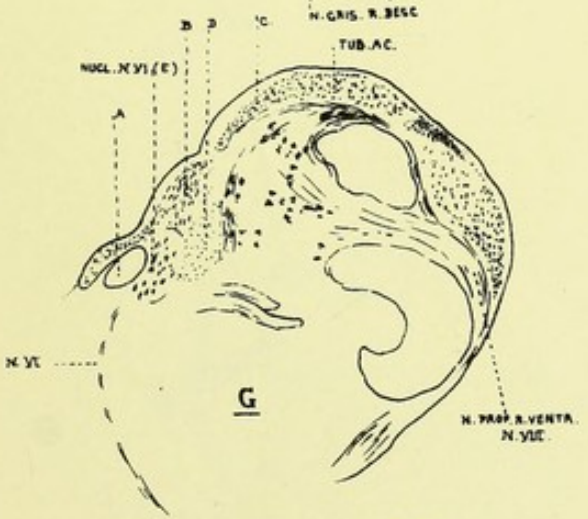

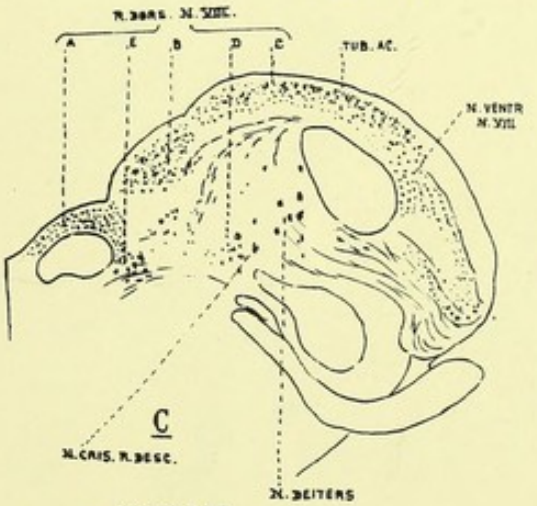

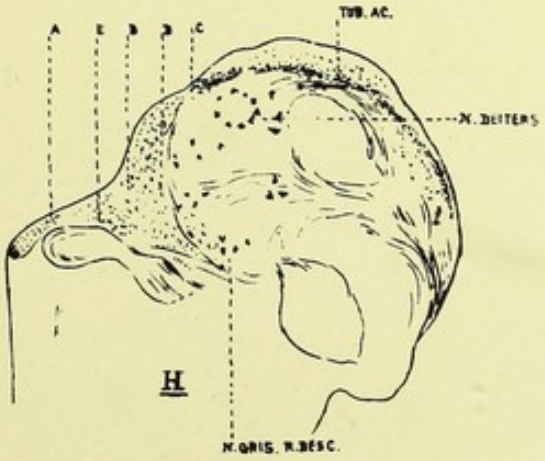

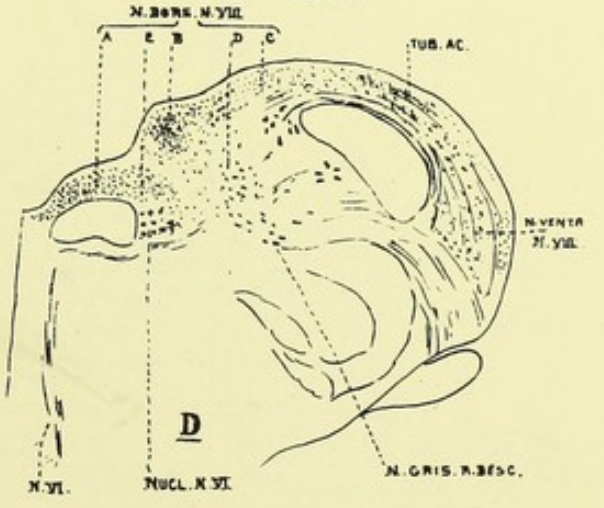

Lith. H. G. Waasmoeth, Amst.

Fig. 15.

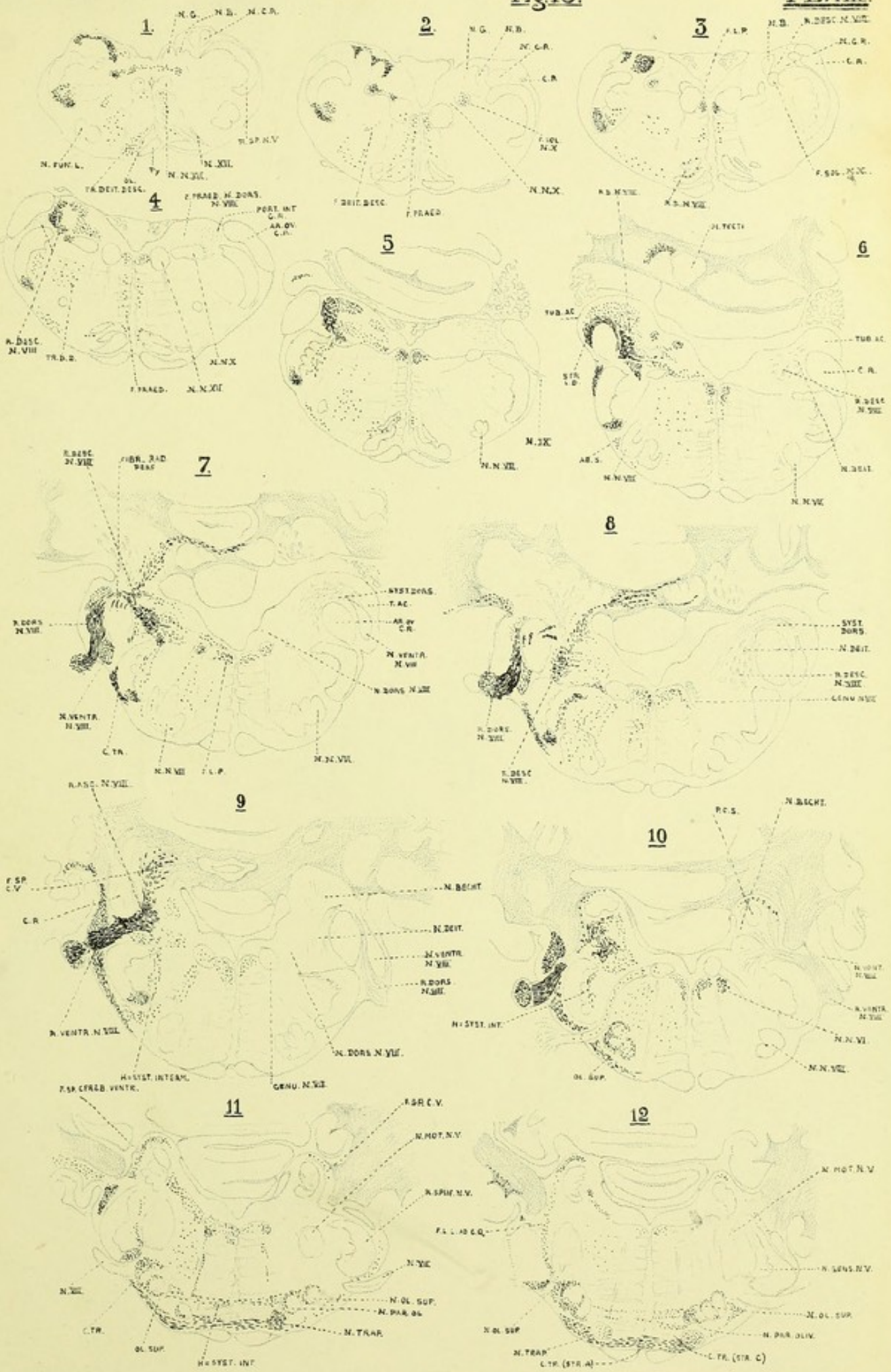

Fig. 15 N°13.

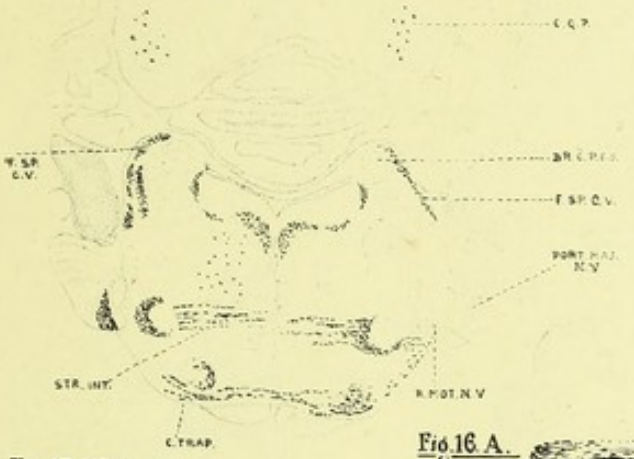

Fig. 15. N°14

Fig. 15. N°15

Fig. 16. A.

Fig. 15. N°16.

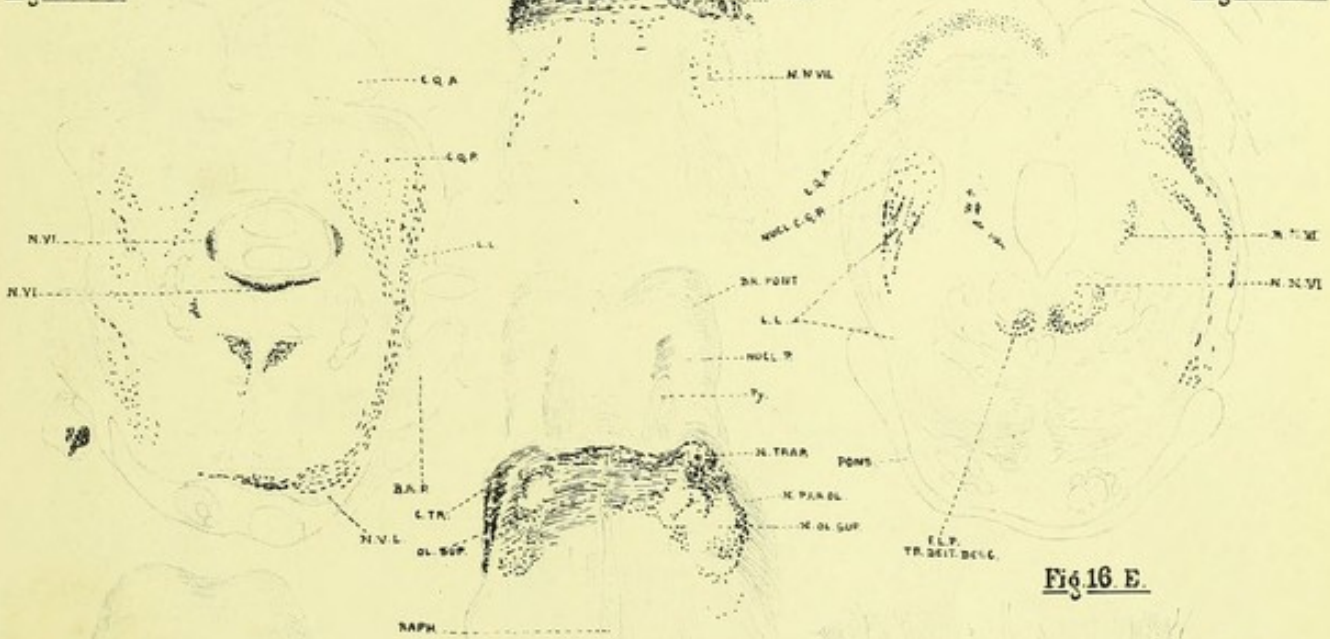

Fig. 16. E.

Fig. 16. B.

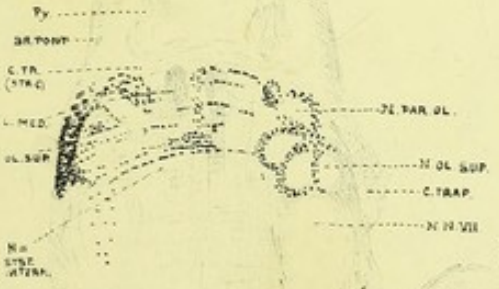

Fig. 16. D.

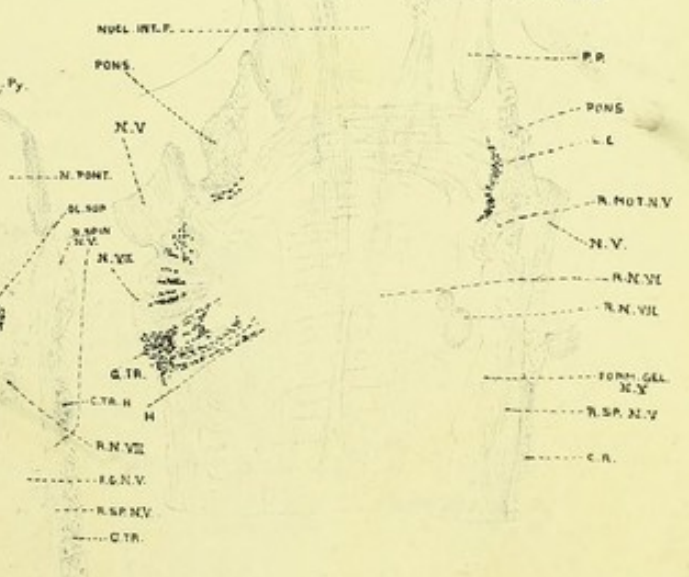

Fig. 16. C.

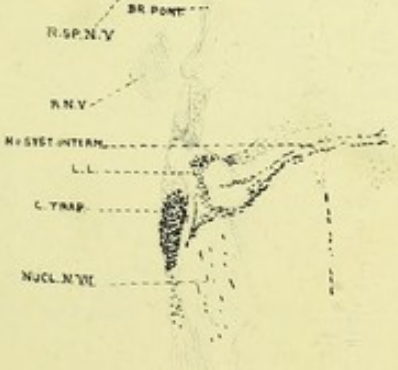

Fig. 16 F.

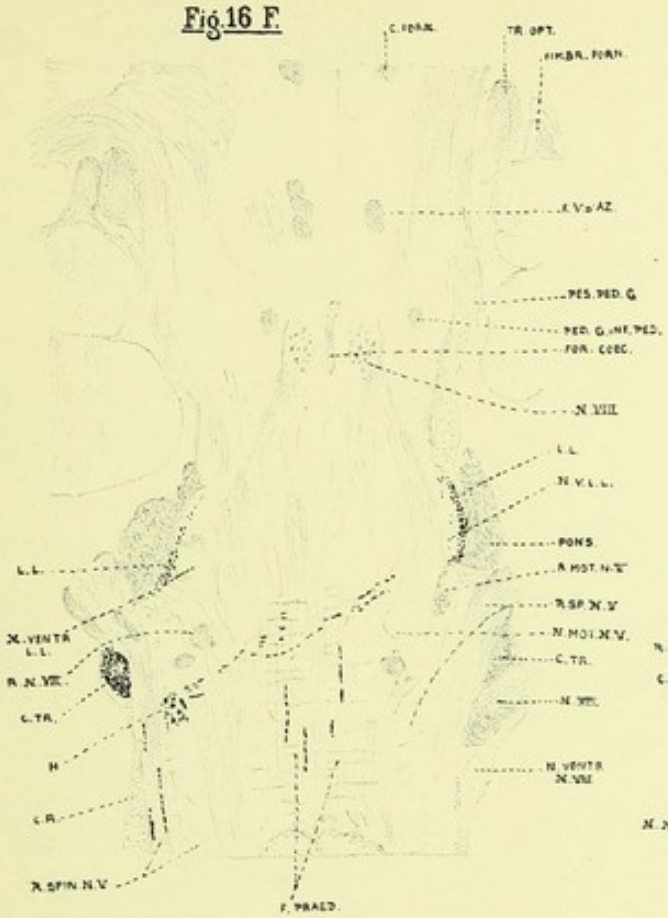

Fig. 16 G.

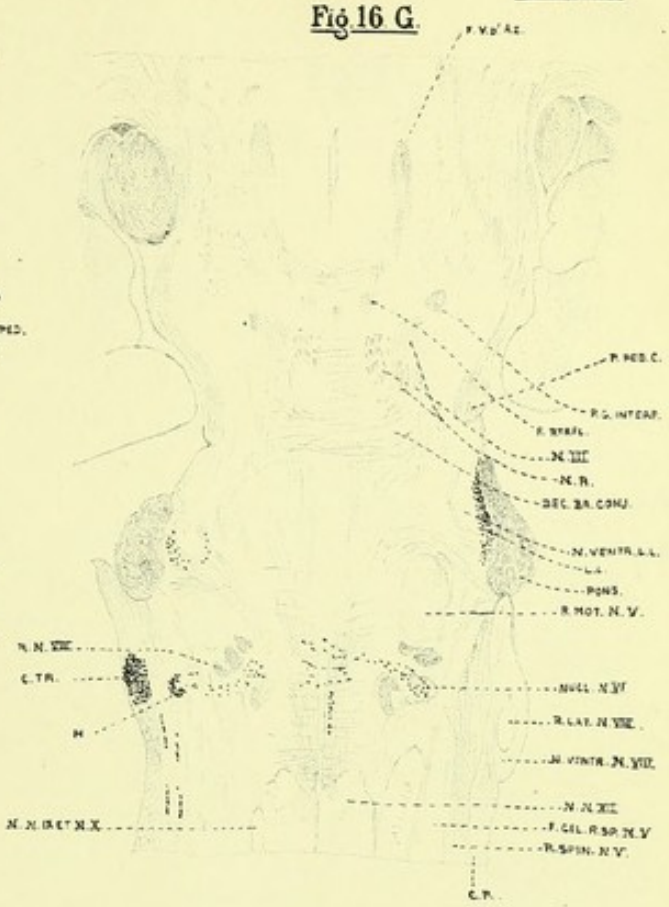

Fig. 16. H

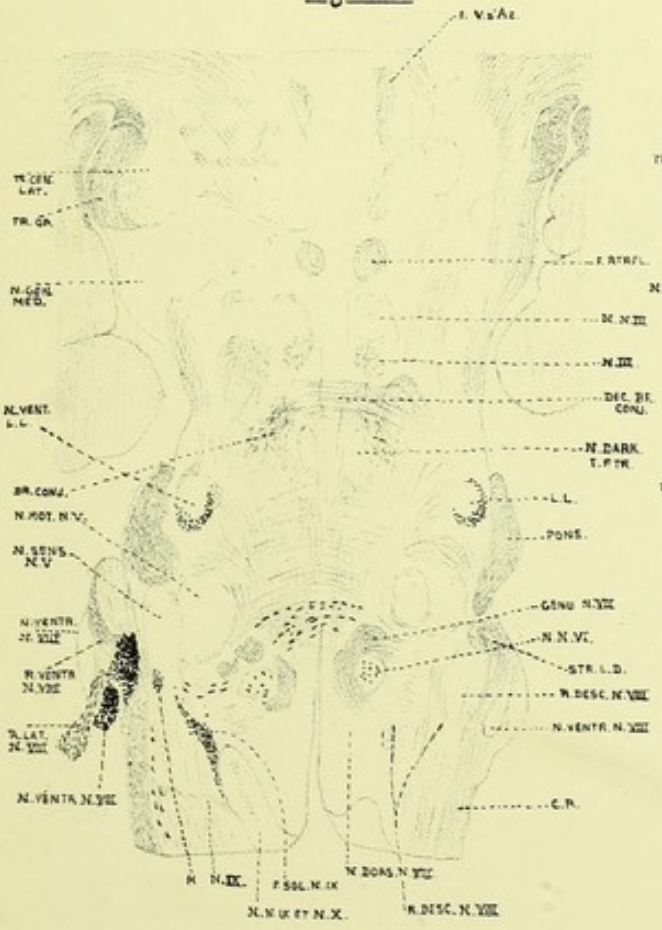

Fig. 16. I.

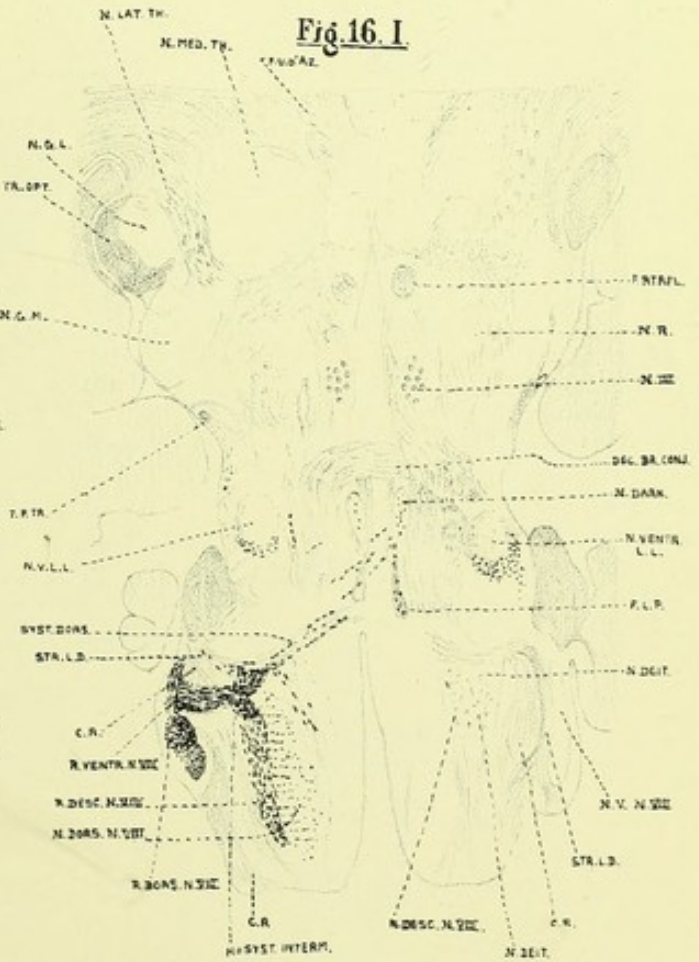

Lith. H. G. Wasmoeth, Amst.

Fig. 16. K.

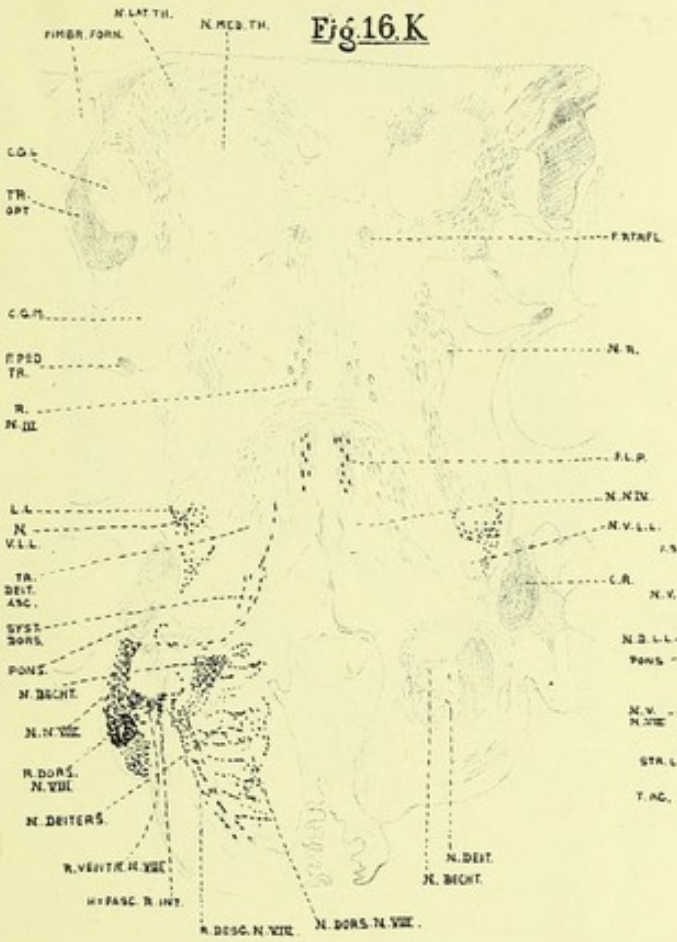

Fig. 16. L.

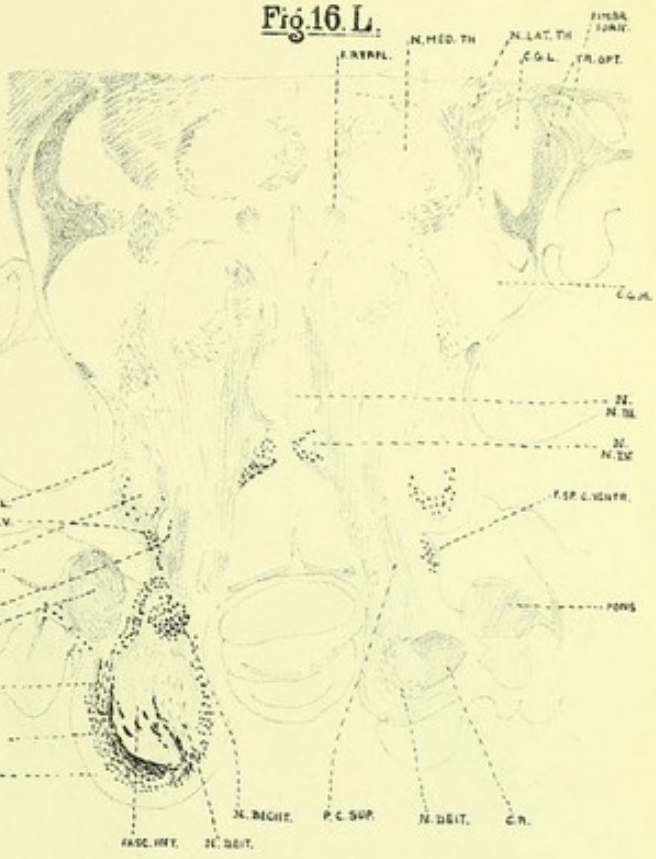

Fig. 16. M.

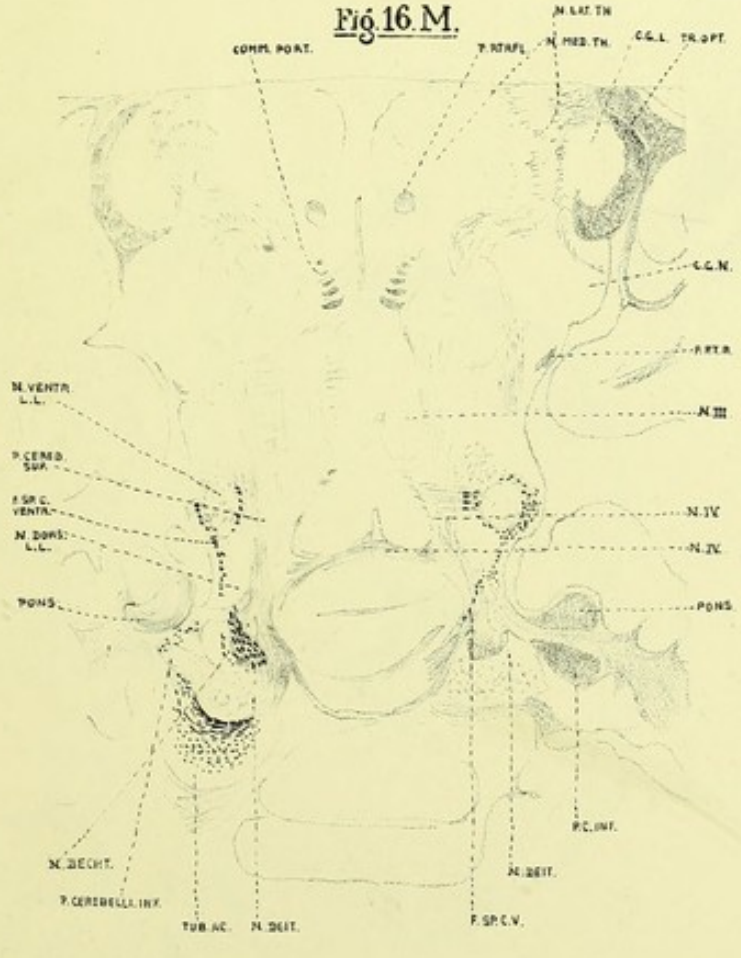

Fig. 16. N.

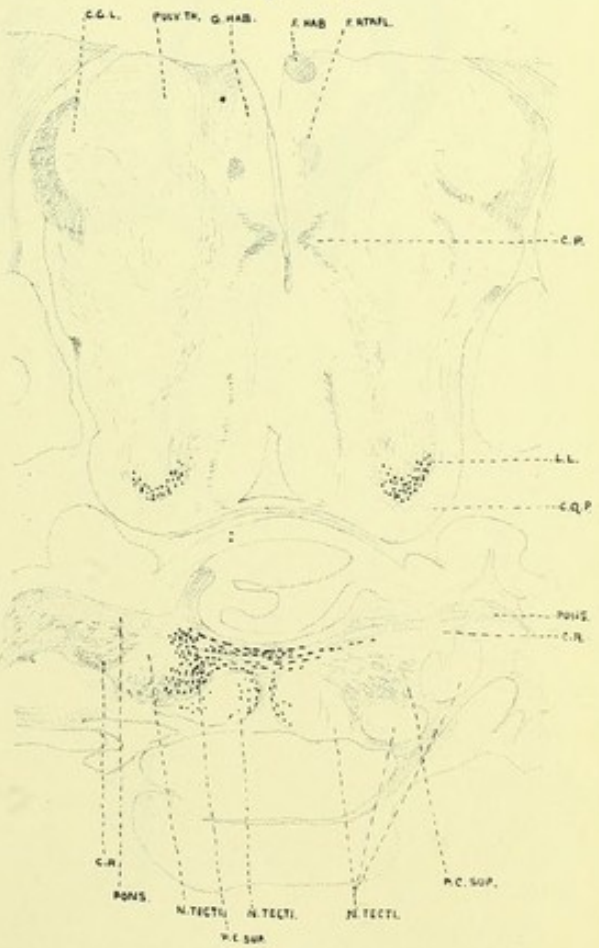

Lith. H.G. Vlasmoeth, Amst.

VERHAND. KON. AKAD. v. WETENSCH. (2e SECTIE.) DI. XIV.

Fig. 17 A

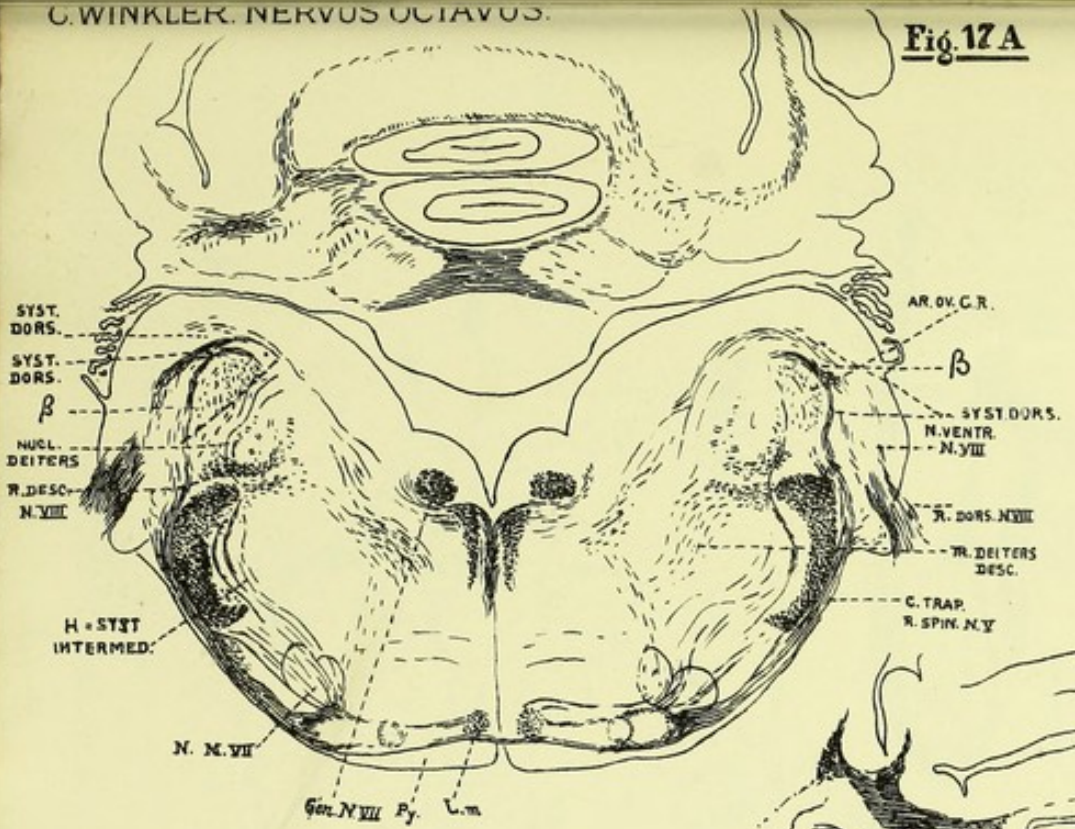

Fig. 17 B.

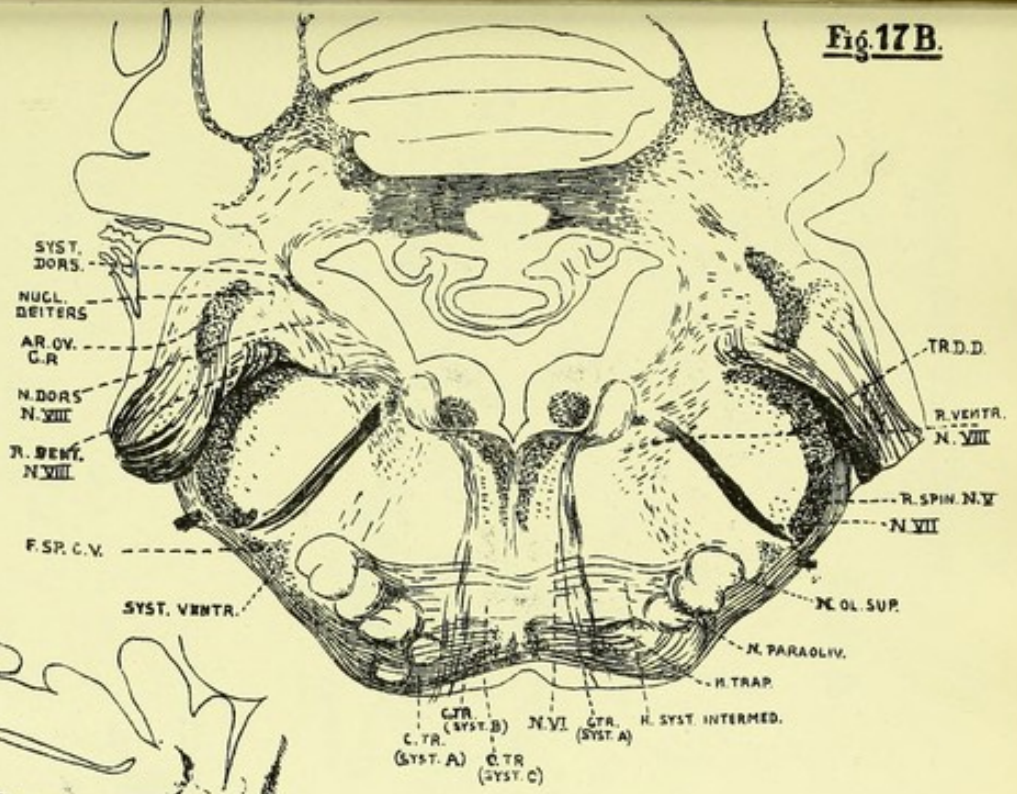

Fig. 17 C.

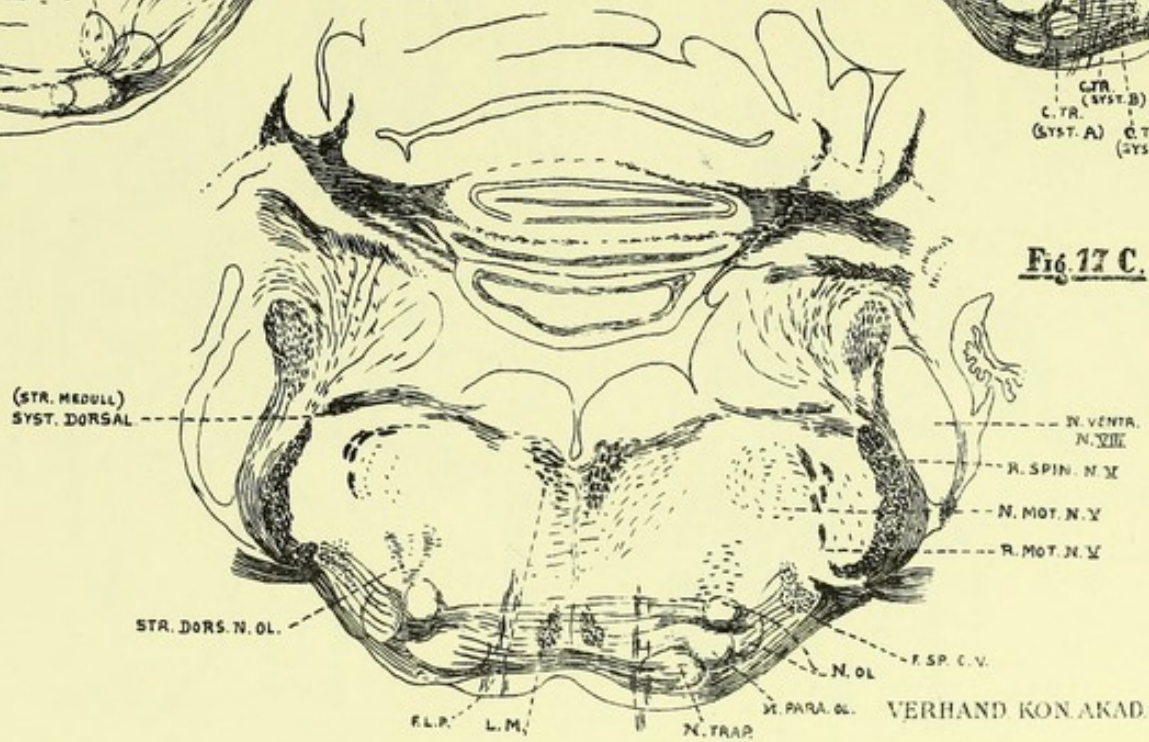

PL. XII.

PL. XIII.

Fig. 18 A.

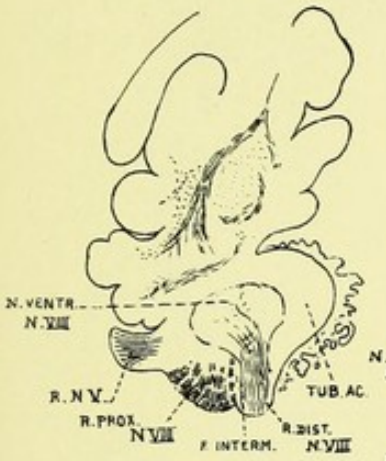

Fig. 18 B.

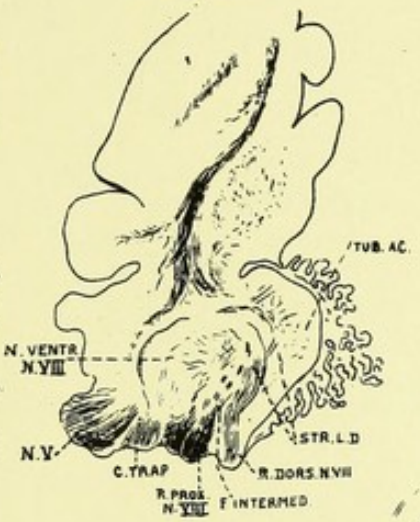

Fig. 18 C.

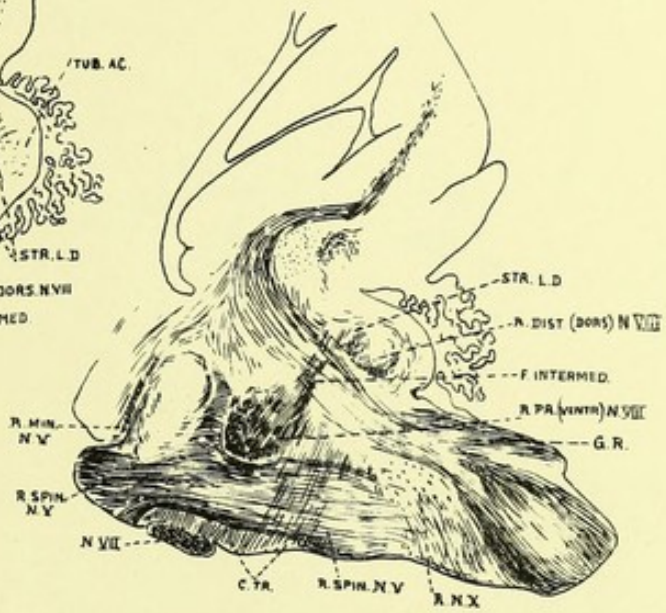

Fig. 18 D.

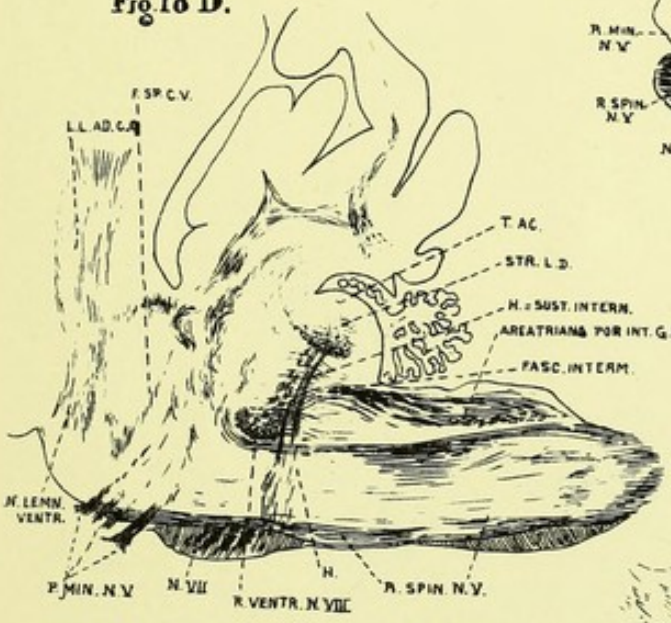

Fig. 18 E.

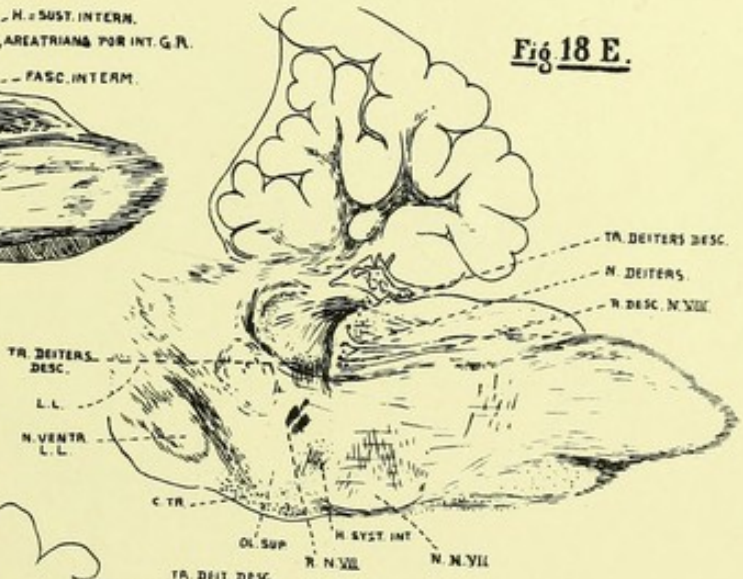

Fig. 18 F.

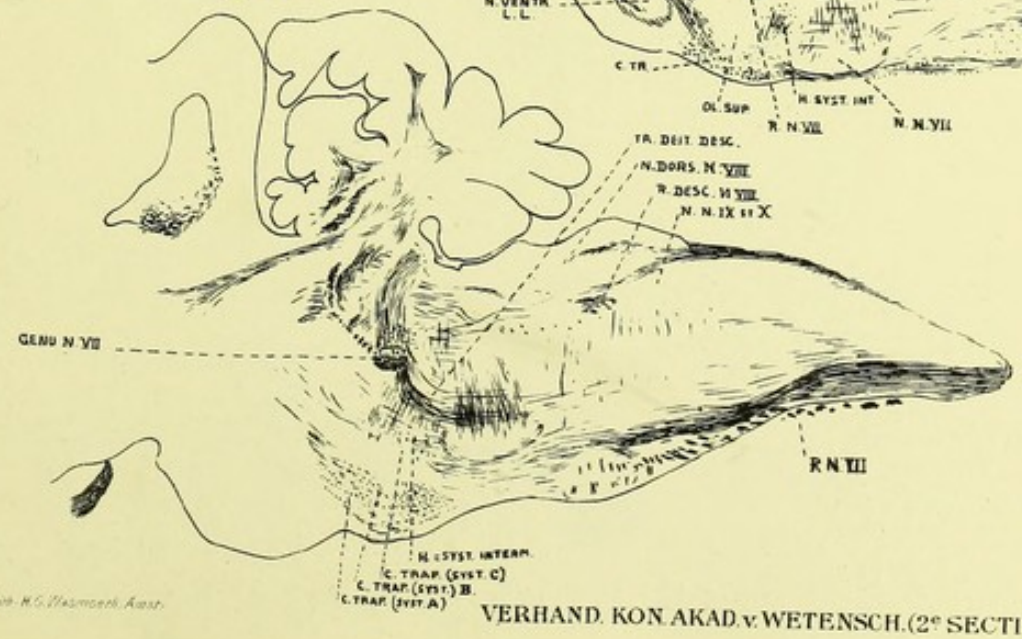

Fig. 14. A.

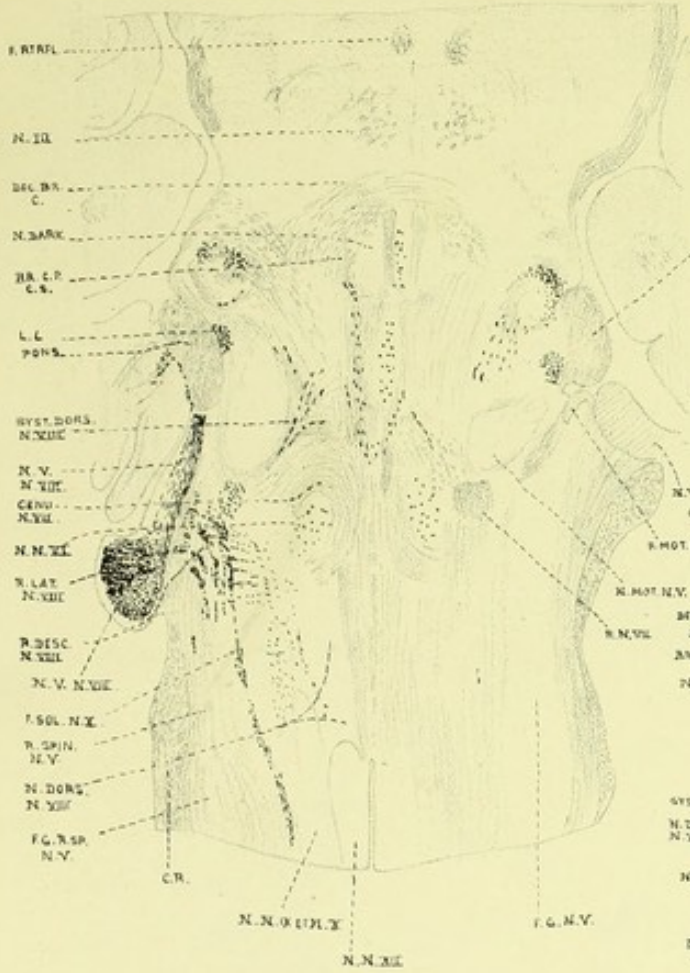

Fig. 14. B.

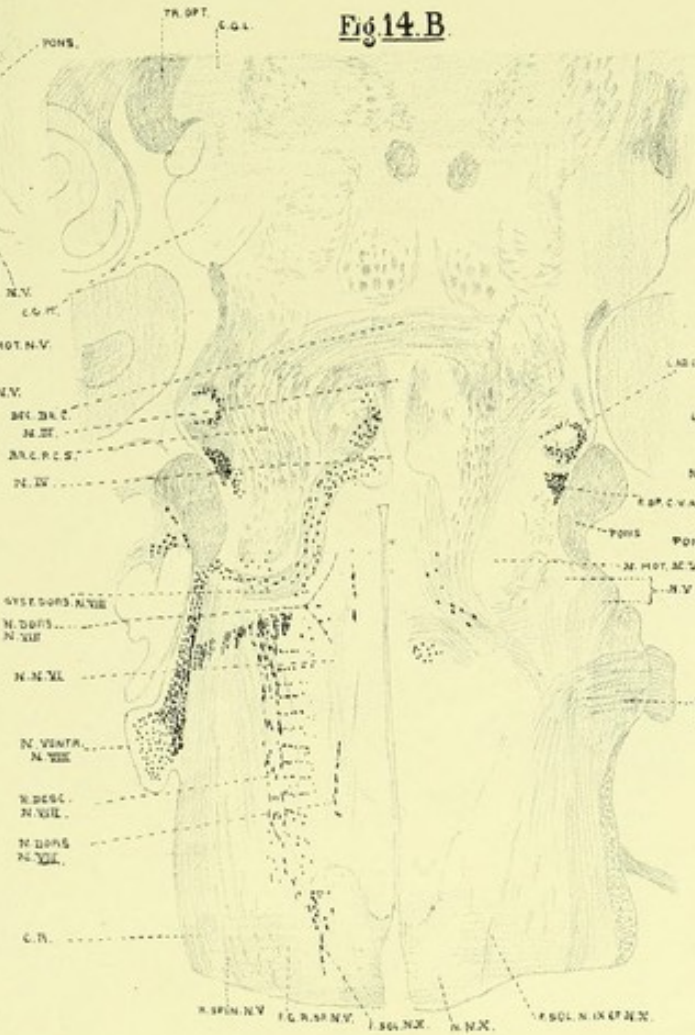

Fig. 14. C.

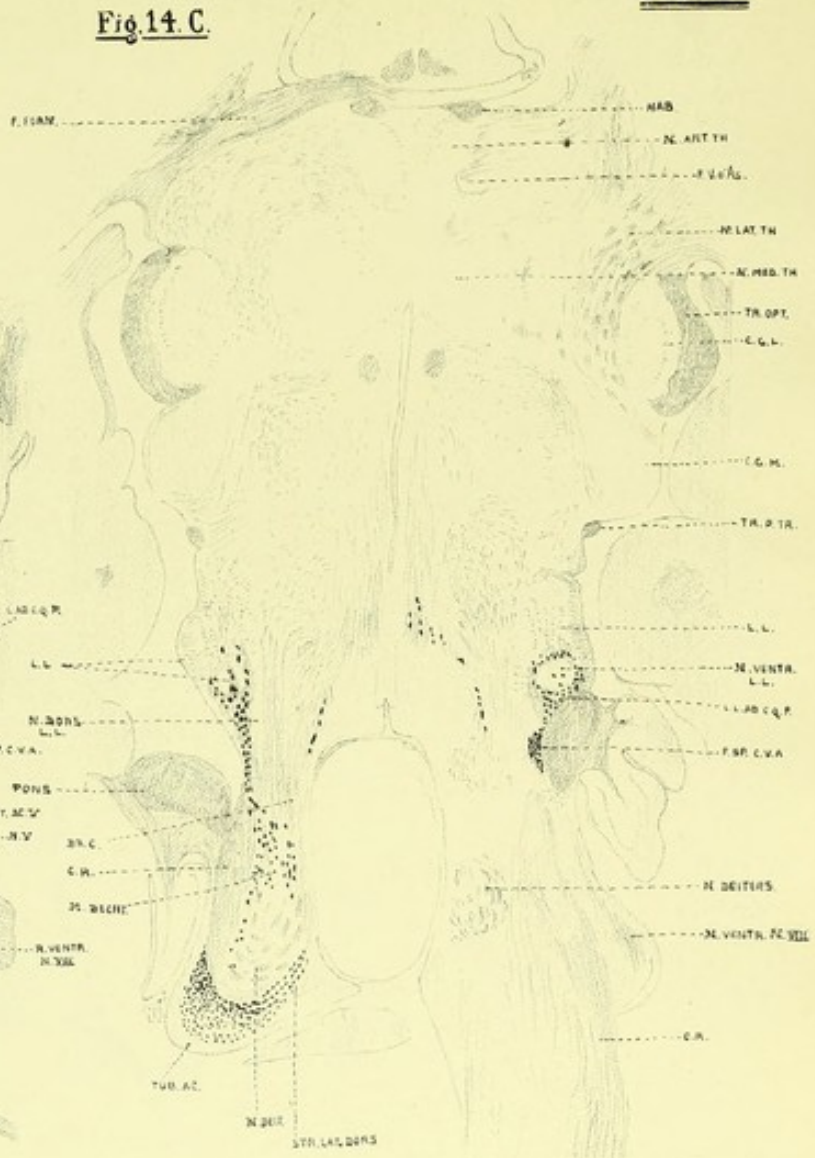

Lith. H. G. Waszmeth. Amst.

Fig. 14. E.

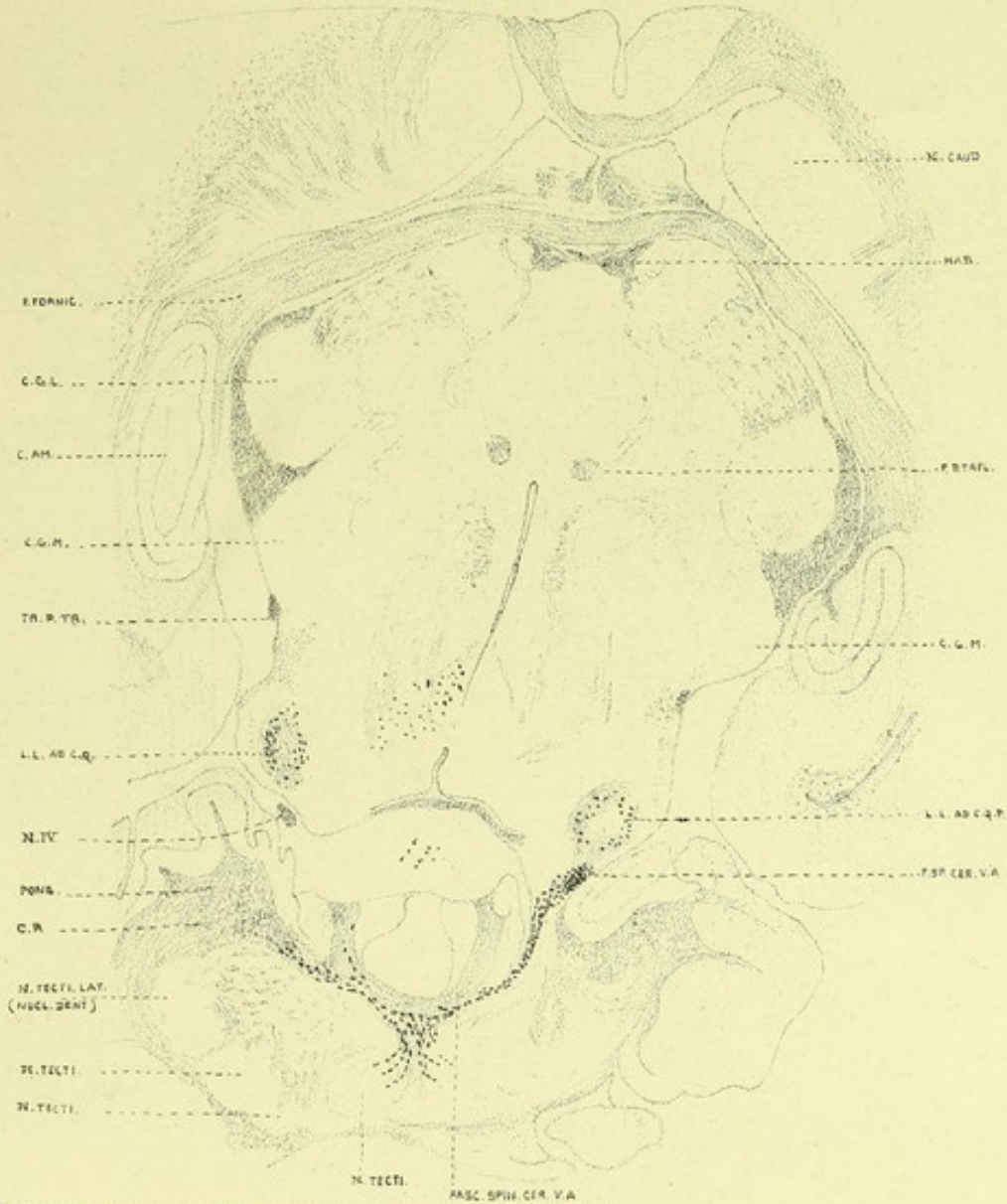

Fig. 14. D.

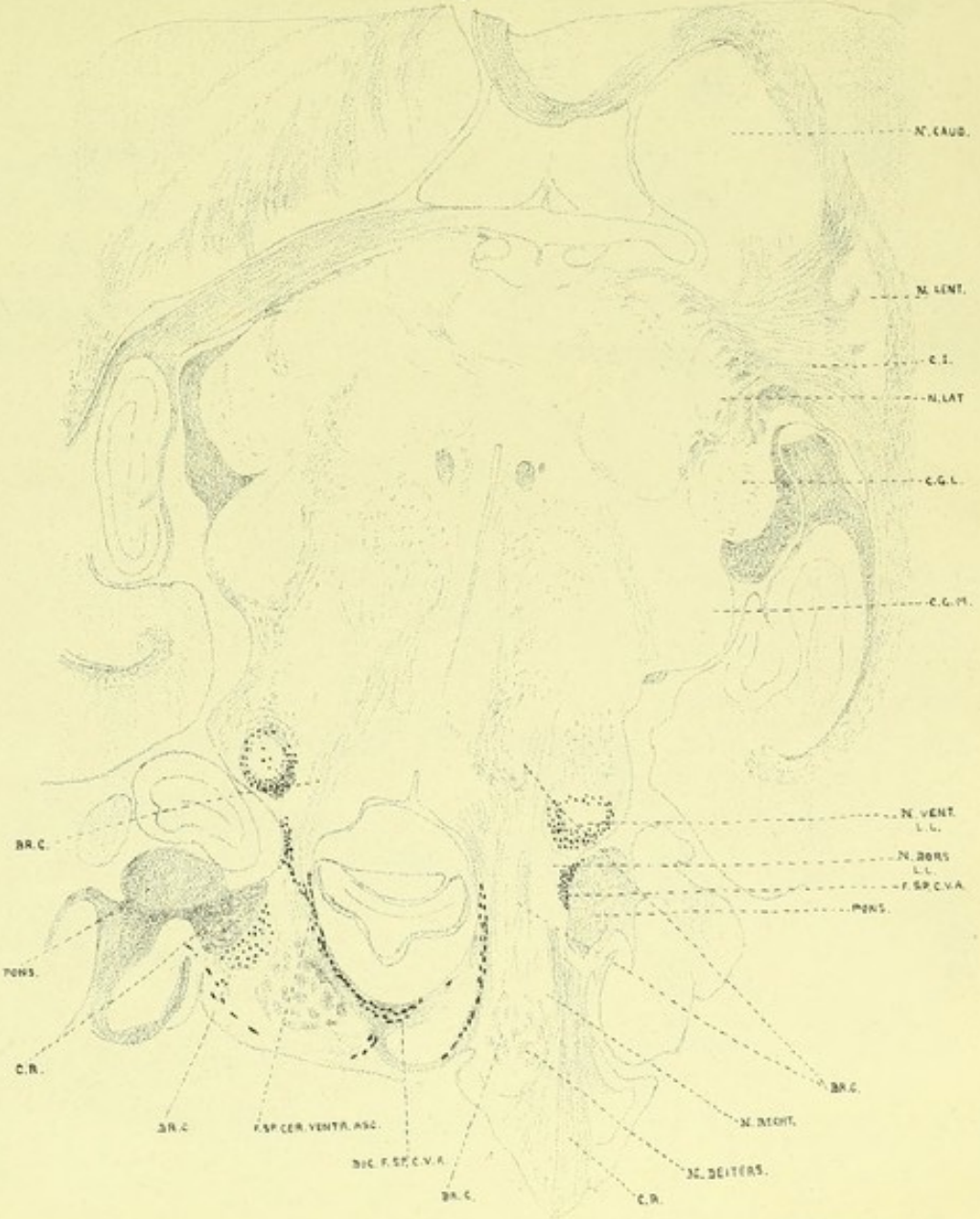

Lith. H. G. Waasmeer, Amst.

C. WINKLER. NERVUS OCTAVUS.

Fig. 20 E.

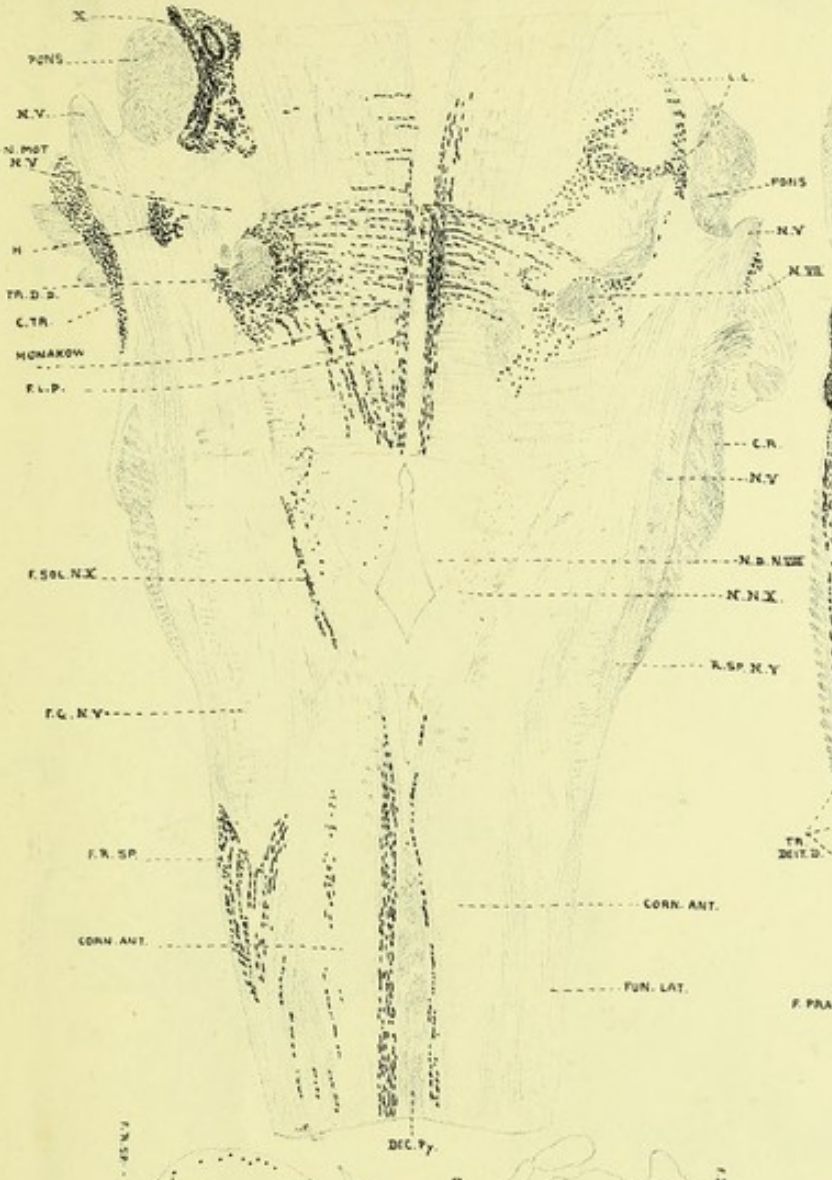

Fig. 20 F.

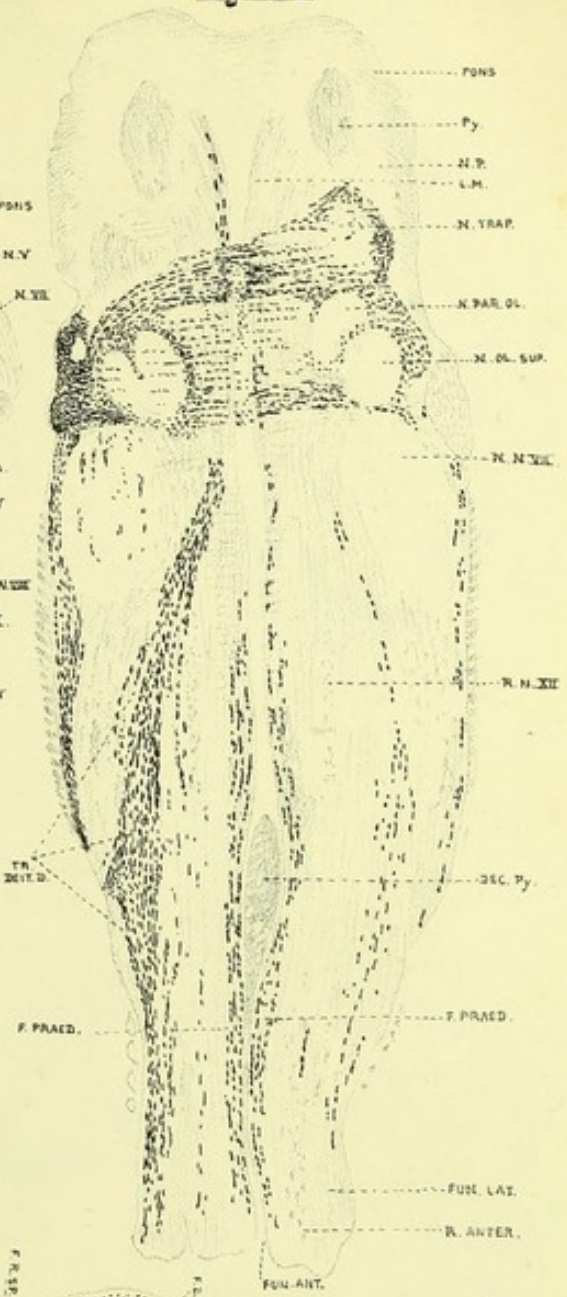

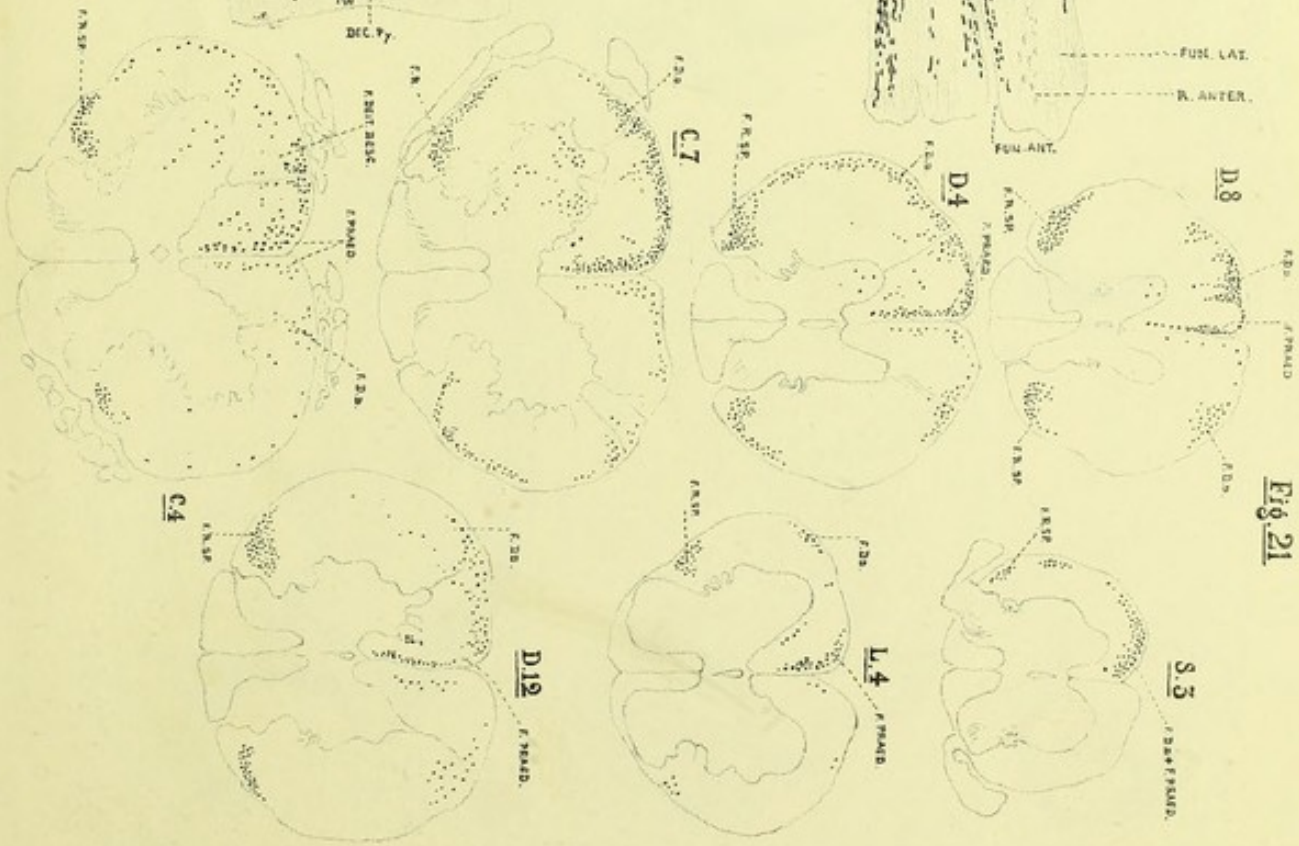

Fig. 21

Fig. 22 C.

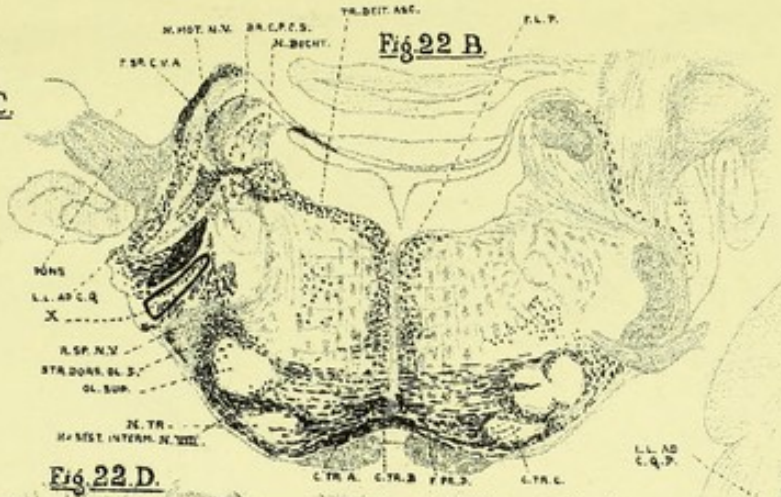

Fig. 22 B.

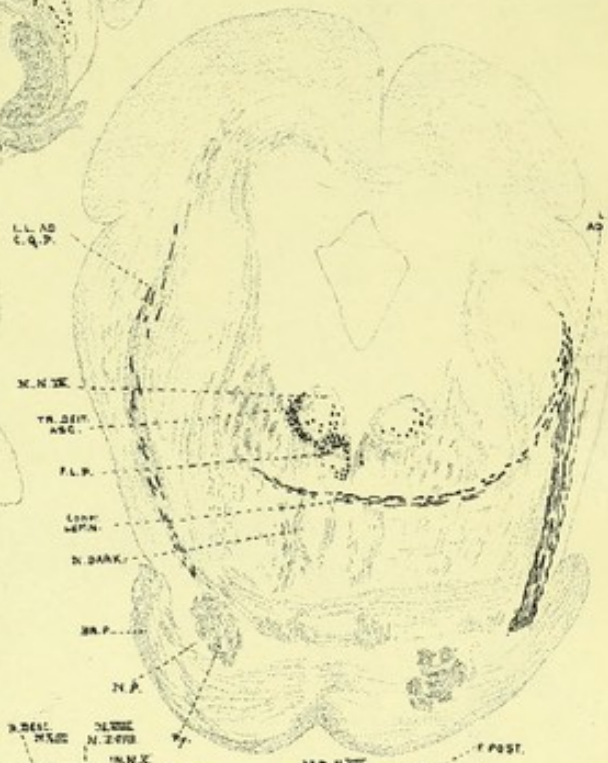

Fig. 22 A

Fig. 22 E.

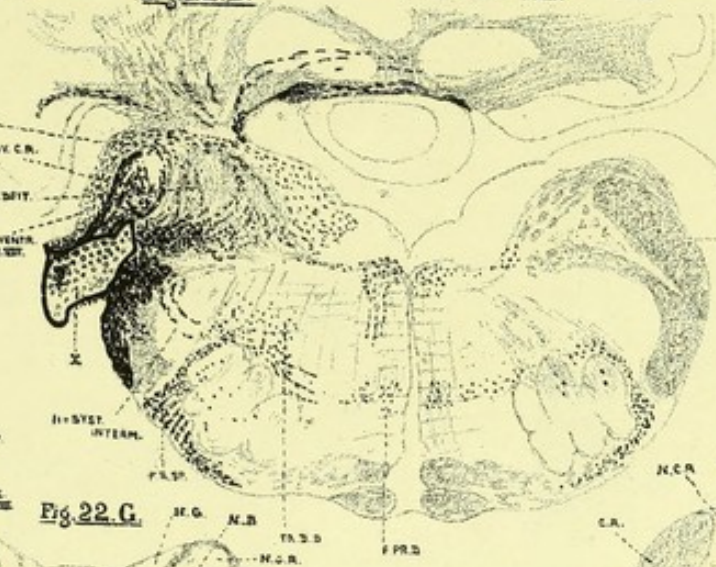

Fig. 22 D.

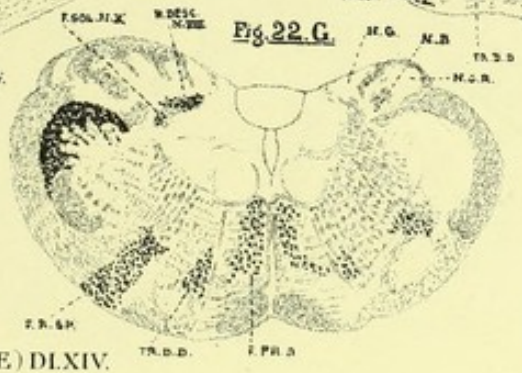

Fig. 22 G.

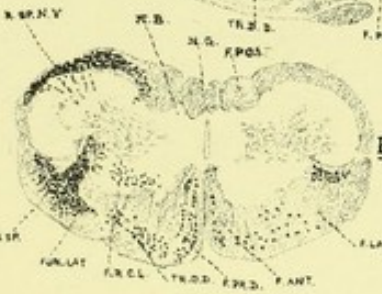

Fig. 22 H

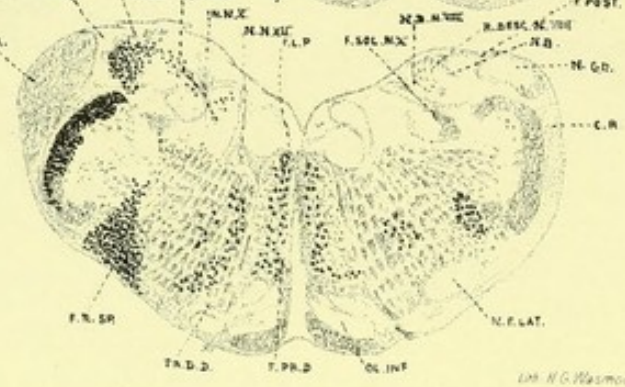

Fig. 22 F

C. WINKLER. NERVUS OCTAVUS.

PL. XIX.

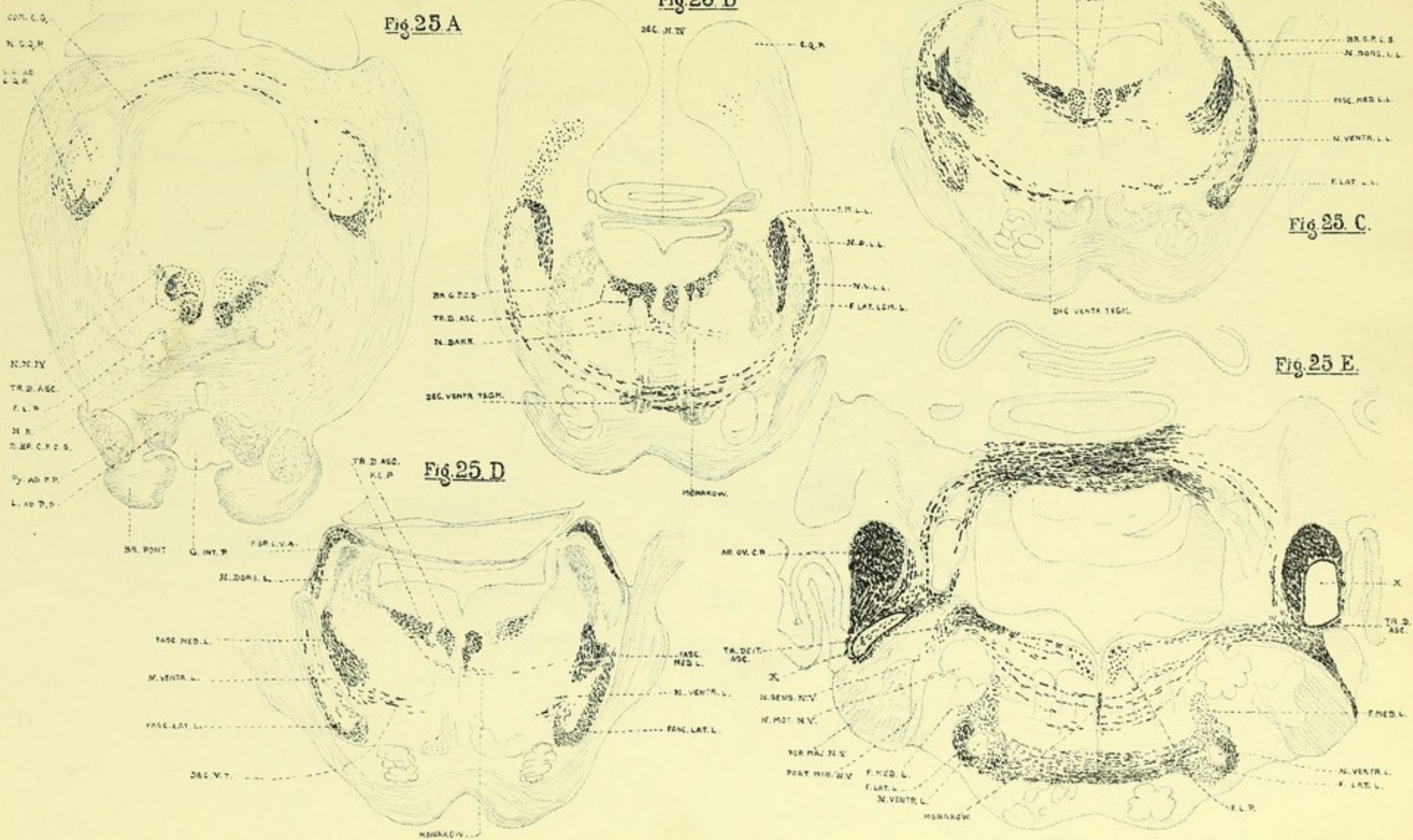

Lith. K. G. Wasmoeth, Amst.

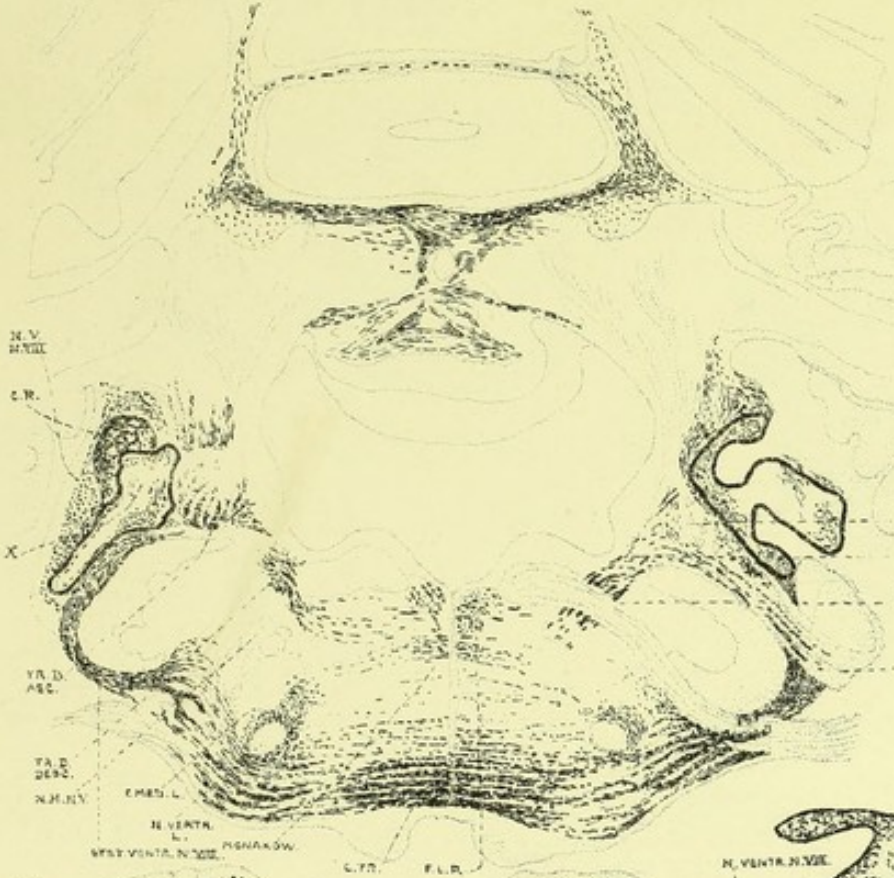

Fig. 25 F

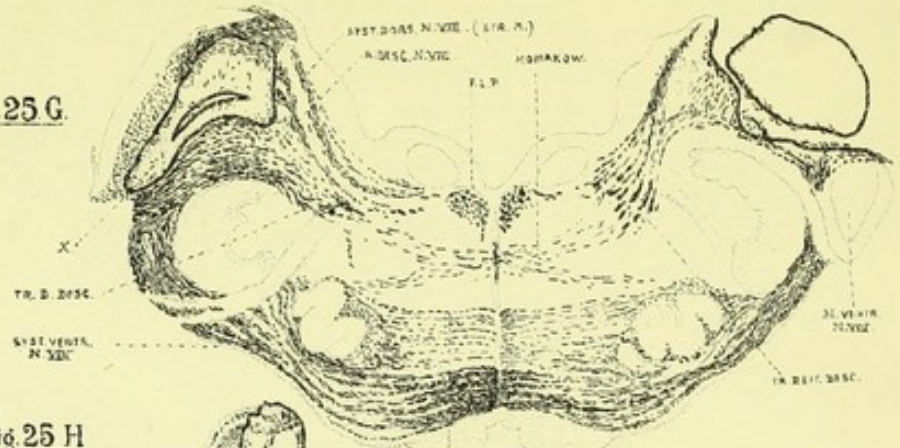

Fig. 25 G.

Fig. 25 H

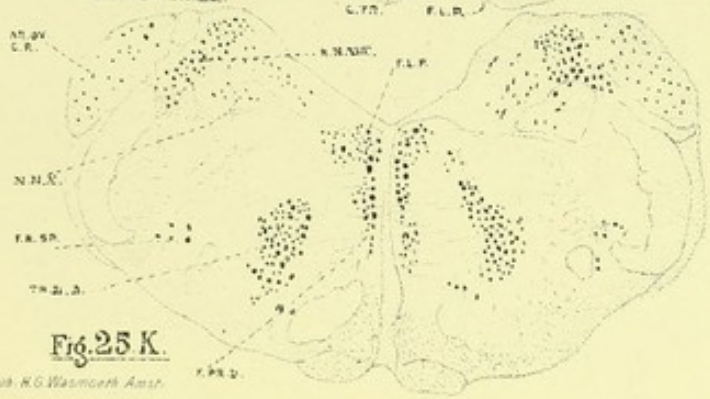

Fig. 25 K.

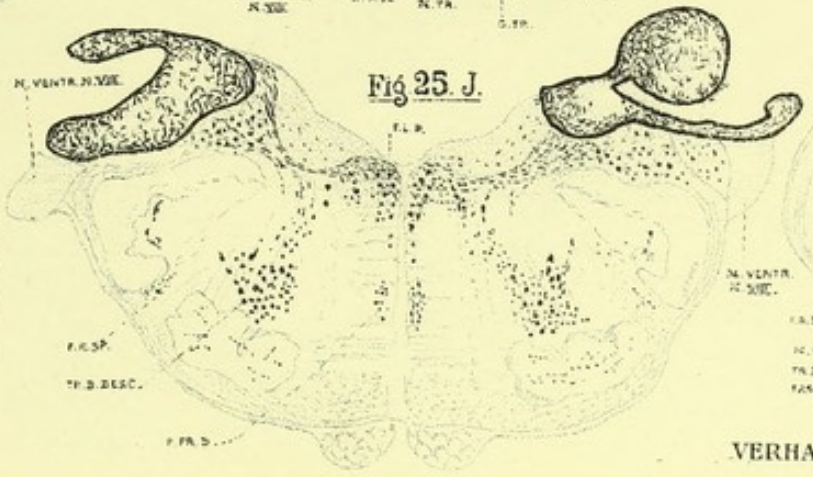

Fig. 25 J.

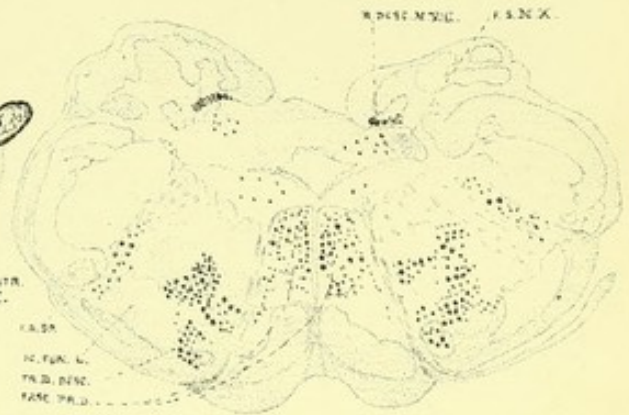

Fig. 25 L.

PL. XX.

Fig. 25 M

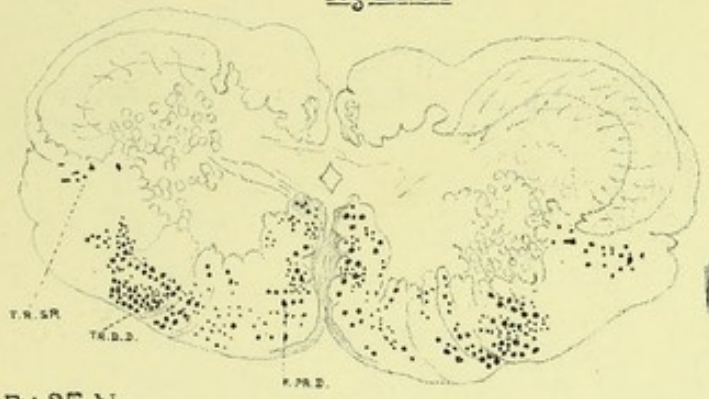

Fig. 25 N

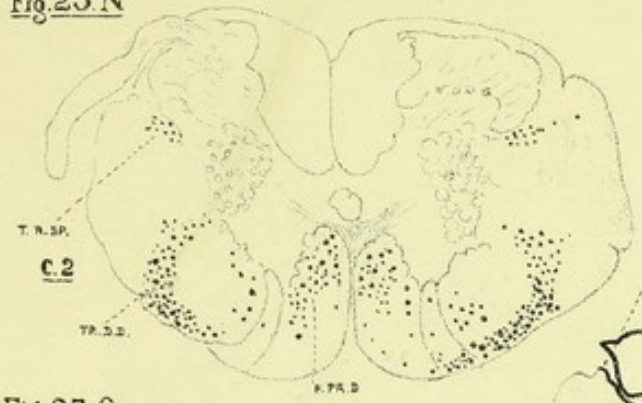

Fig. 25 O.

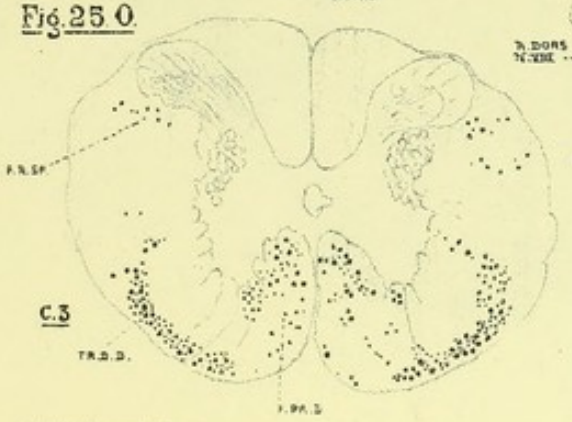

Fig. 12.

Fig. 23

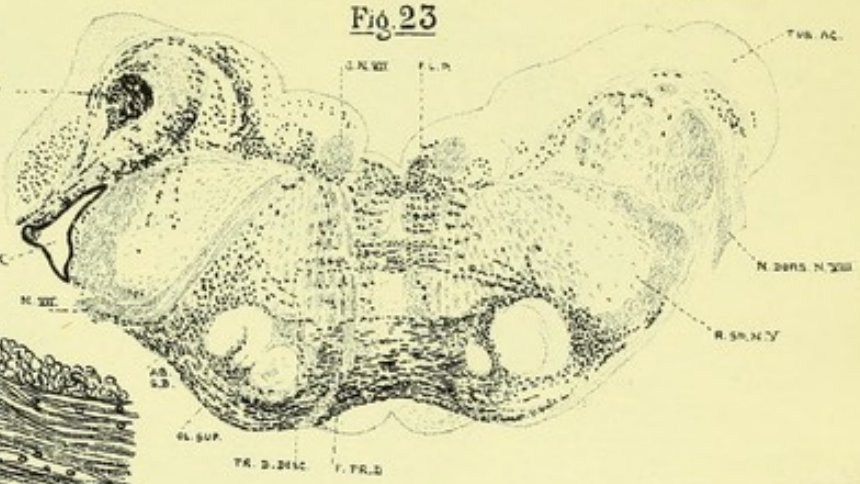

Fig. 28 B

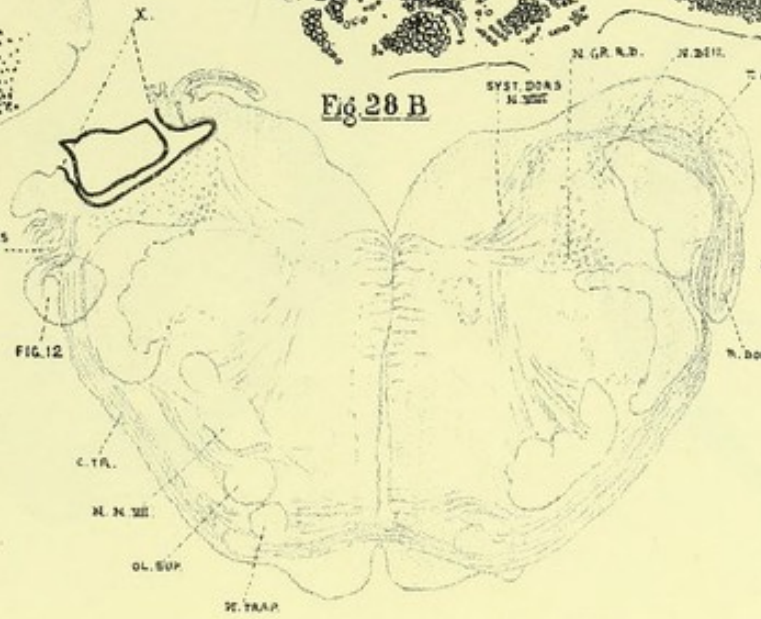

Fig. 28 A

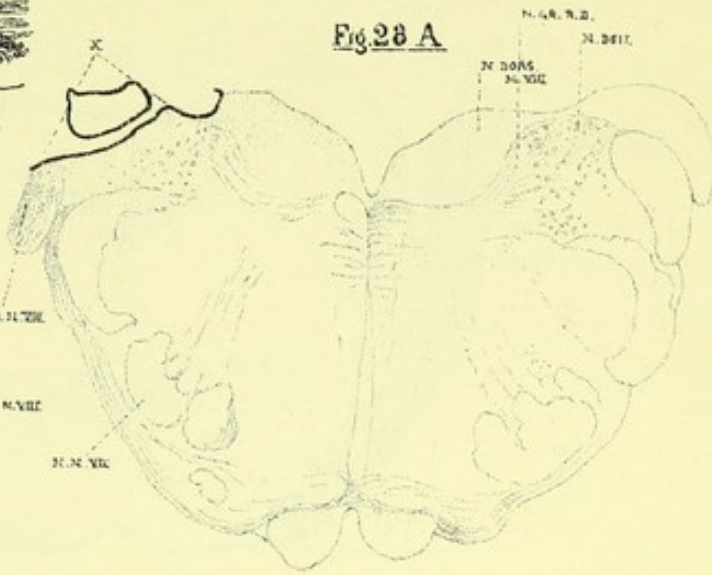

Fig. 28 D.

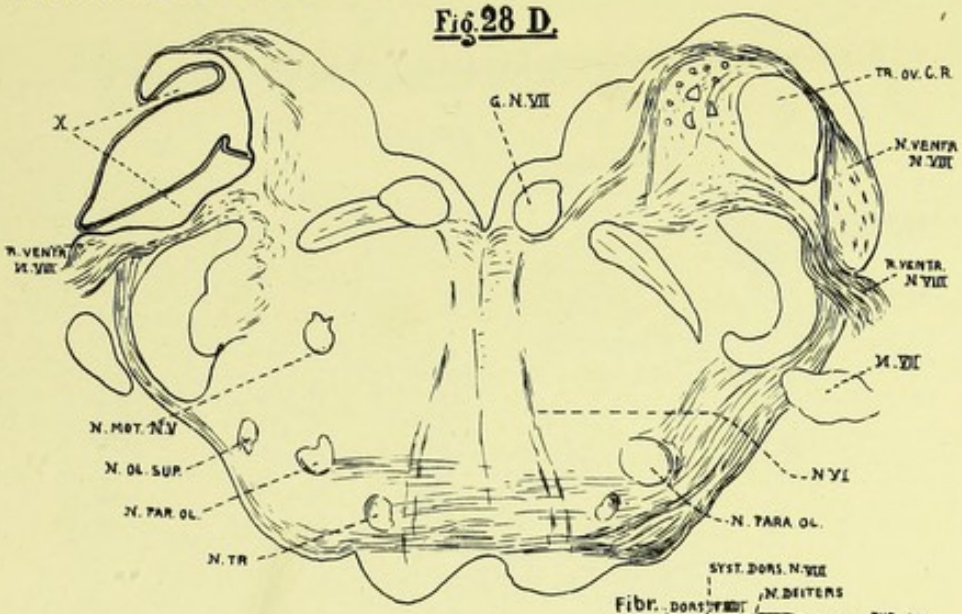

Fig. 28 C.

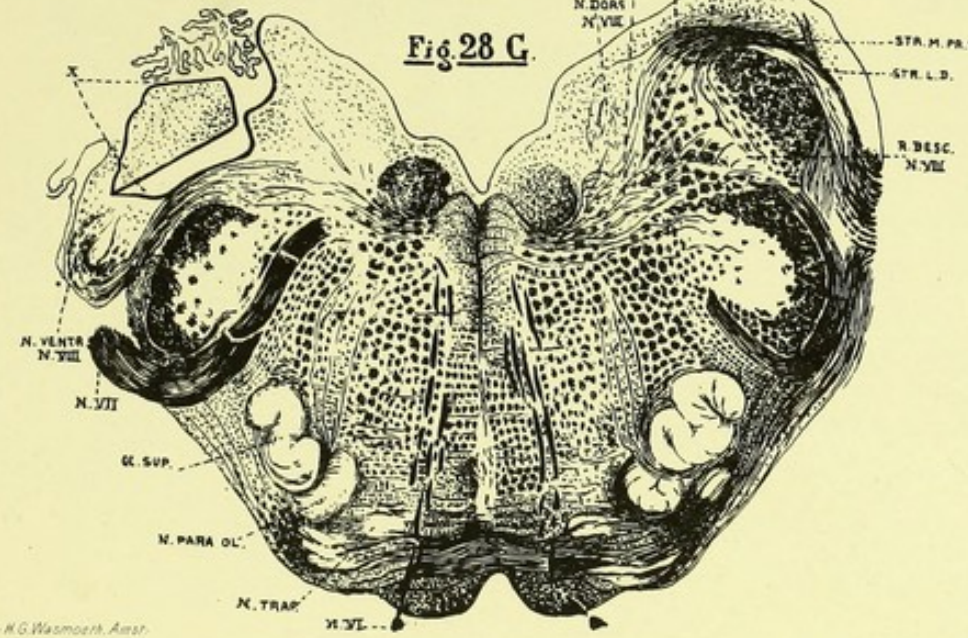

Fig. 28 E

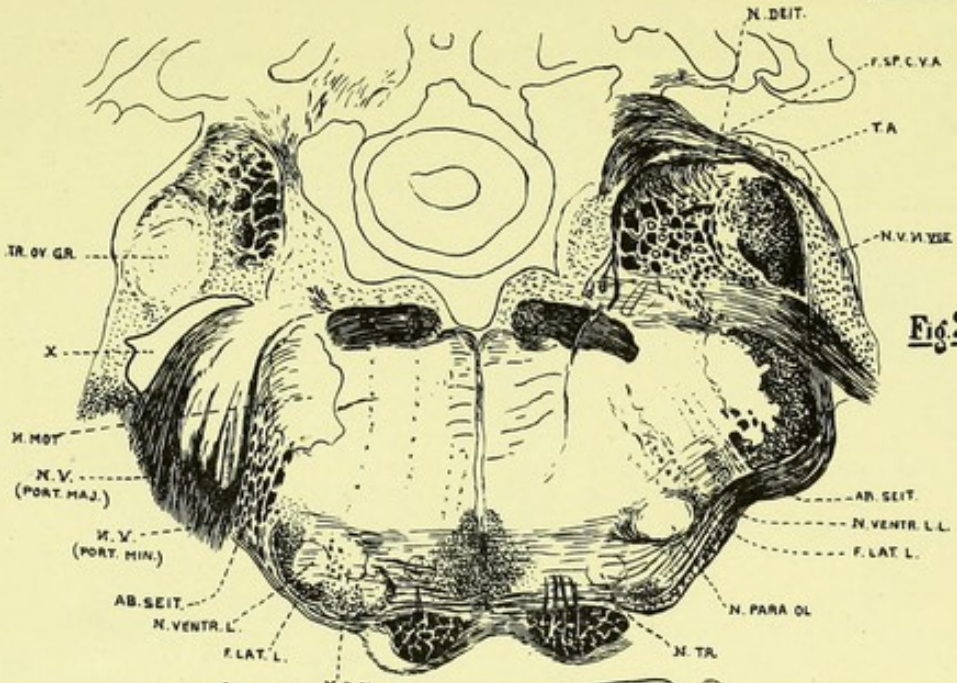

Fig. 28 F

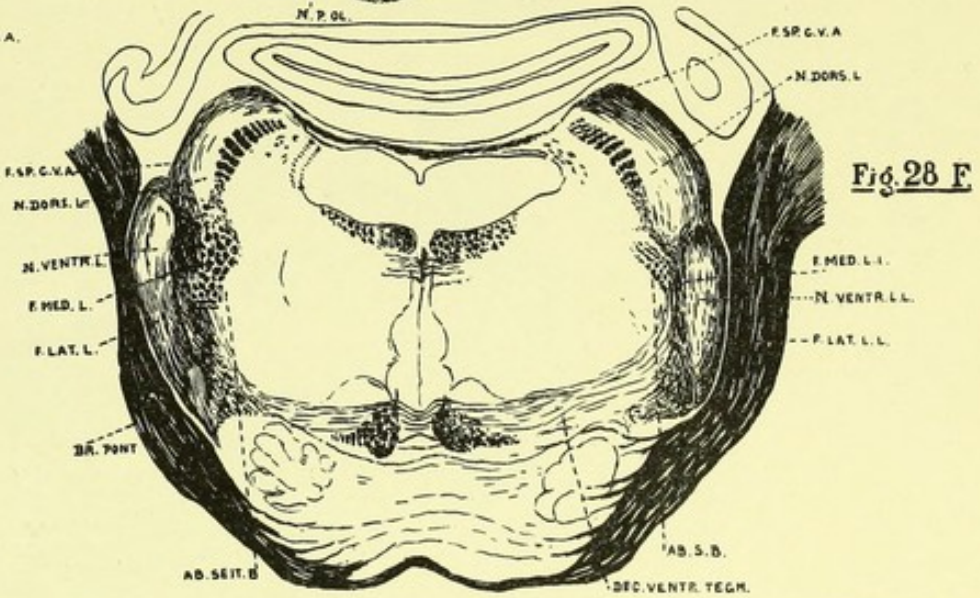

Fig. 26 A.

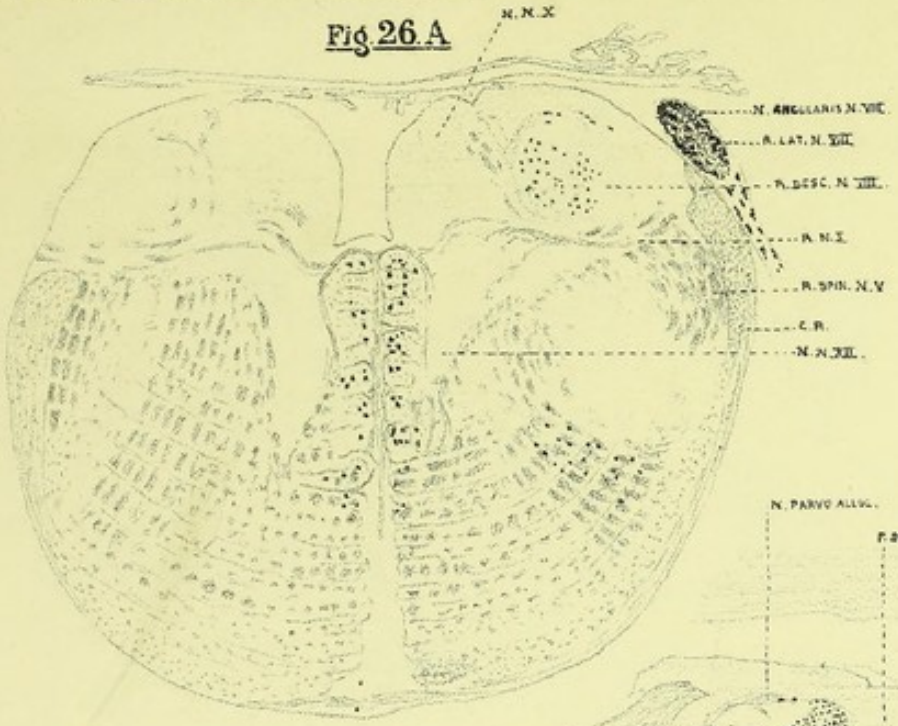

Fig. 26 B.

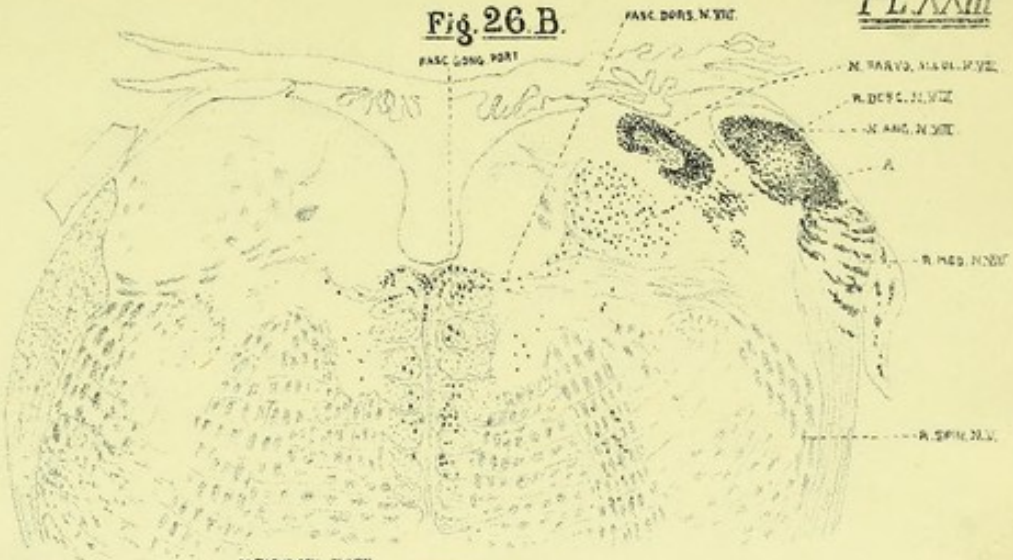

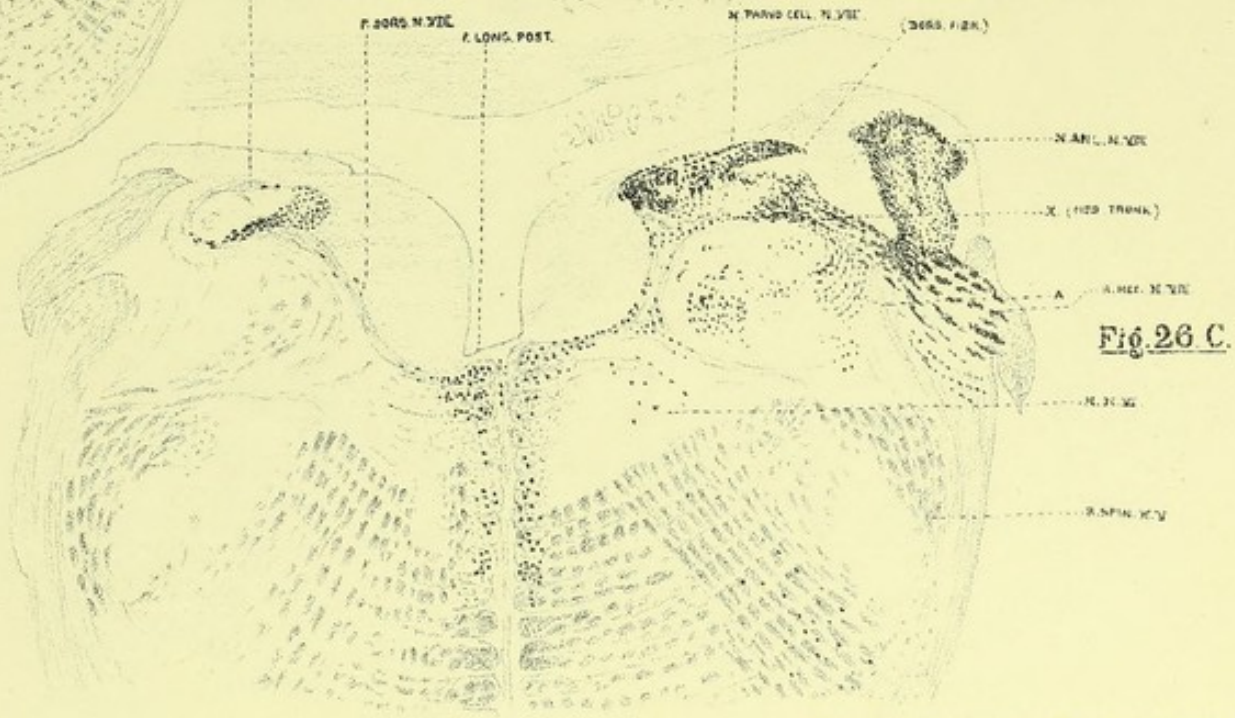

Fig. 20 A

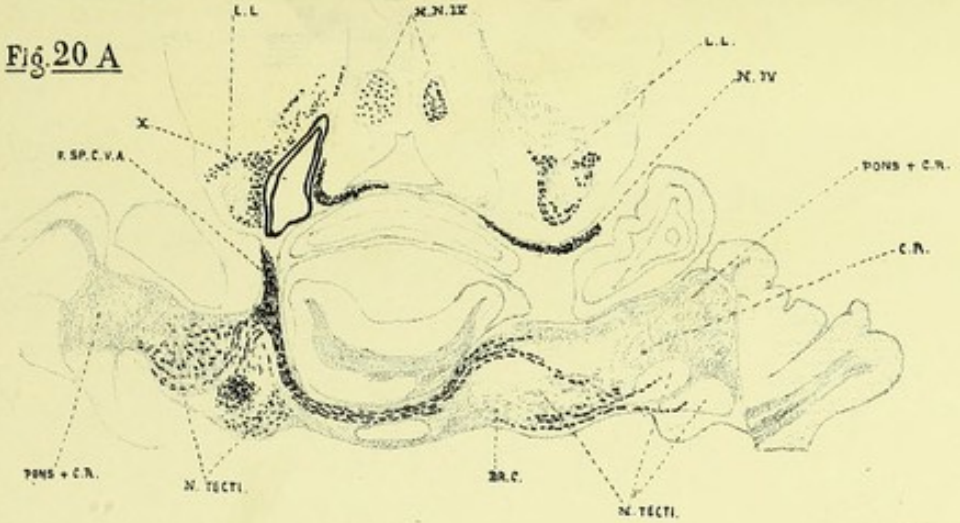

Fig. 20 B.

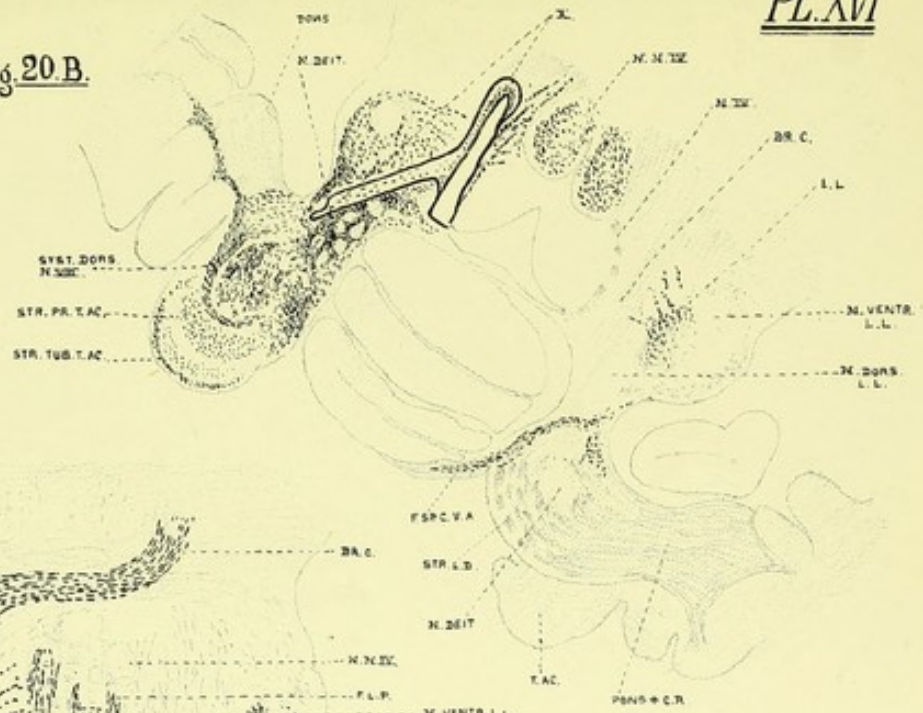

Fig. 20 C.

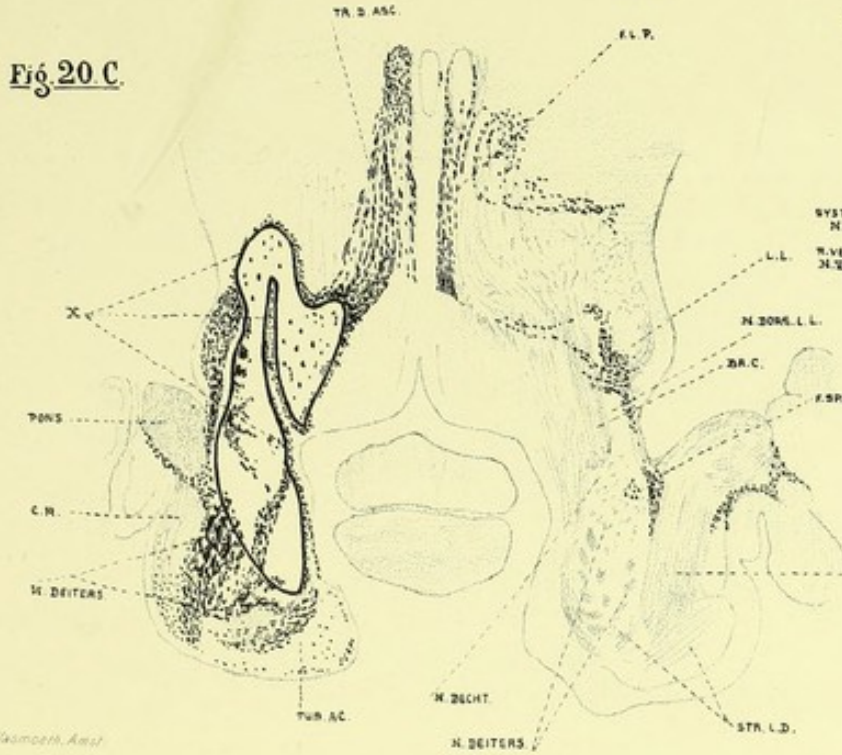
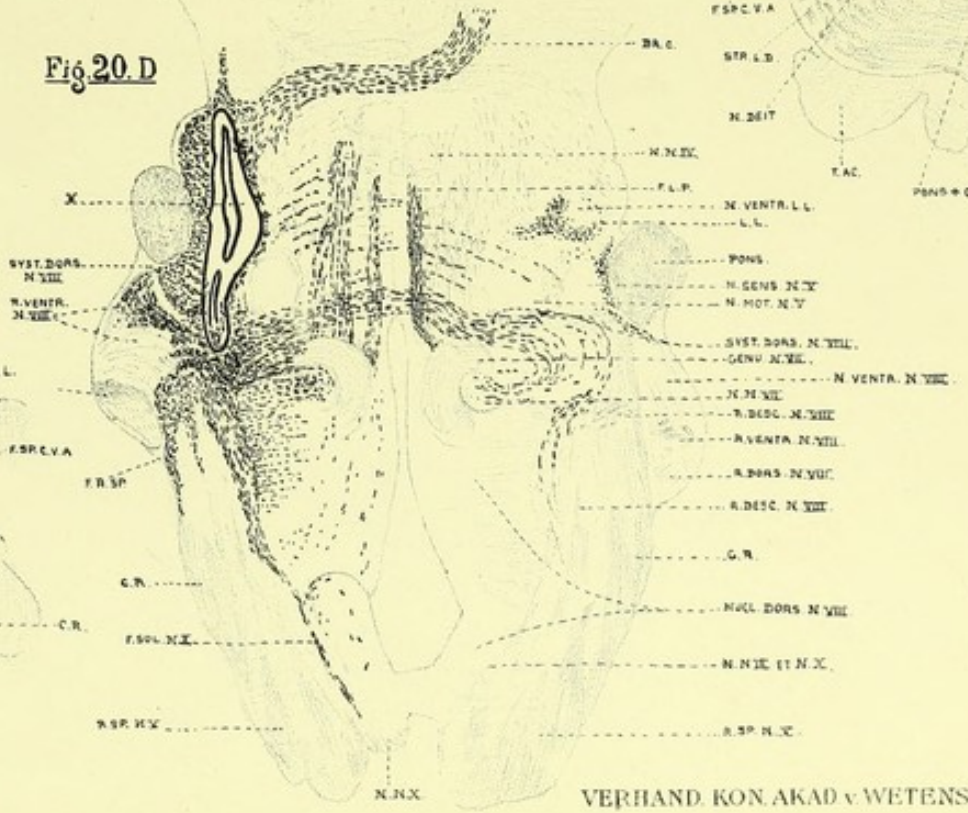
Fig. 20 D