

Orthopædic surgery : a textbook of the pathology and treatment of deformities / by J. Jackson Clarke.

Contributors

Clarke, J. Jackson.
Duff, A. P.
Jones, Arthur Rocyn
University College, London. Library Services

Publication/Creation

London : Cassell, 1899.

Persistent URL

<https://wellcomecollection.org/works/bk9gutb7>

Provider

University College London

License and attribution


This material has been provided by This material has been provided by UCL Library Services. The original may be consulted at UCL (University College London) where the originals may be consulted.

This work has been identified as being free of known restrictions under copyright law, including all related and neighbouring rights and is being made available under the Creative Commons, Public Domain Mark.

You can copy, modify, distribute and perform the work, even for commercial purposes, without asking permission.



Wellcome Collection
183 Euston Road
London NW1 2BE UK
T +44 (0)20 7611 8722
E library@wellcomecollection.org
<https://wellcomecollection.org>



Institute of Orthopaedics



Presented
by

Mrs. Arthur Rocyn Jones
from her late husband's
collection


Arch.

SC CUB CLA




Digitized by the Internet Archive
in 2014

<https://archive.org/details/b21290532>



ORTHOPÆDIC SURGERY



*At diff
from
J Jackson Clarke*

ORTHOPÆDIC SURGERY ¹⁵⁹

A TEXT-BOOK OF THE PATHOLOGY AND TREATMENT

OF

DEFORMITIES

BY

J. JACKSON CLARKE, M.B. LOND., F.R.C.S.

SURGEON TO OUT-PATIENTS AT THE NORTH-WEST LONDON AND CITY ORTHOPÆDIC
HOSPITALS, MEMBER OF THE COUNCIL OF THE BRITISH ORTHOPÆDIC SOCIETY,
LATE SENIOR DEMONSTRATOR OF ANATOMY, CURATOR OF THE MUSEUM,
AND PATHOLOGIST AT ST. MARY'S HOSPITAL

WITH 309 ILLUSTRATIONS

CASSELL AND COMPANY, LIMITED

LONDON, PARIS, NEW YORK & MELBOURNE

1899


ALL RIGHTS RESERVED

4225



961125

TO MY WIFE.



PREFACE.

FOR many years past it has been my intention to write a book on the Surgery of Deformities based upon their pathology, and giving in a systematised form an outline of the various therapeutic measures applicable to their treatment. In dealing with the special deformities, it has been my aim to begin with simple and familiar conditions in order to be able to explain more complex conditions by reference to them. The rich material of the North-West London and the City of London Orthopædic Hospitals has formed the basis of the clinical parts of the work, but I have taken information wherever I have found it, and it has been my endeavour in every case to acknowledge the sources to which I owe such gleanings.

Where obligations are many it may seem invidious to make special mention of but a few. I cannot, however, refrain from acknowledging in this place the debt I owe to Mr. William Adams and to Professor A. Hoffa. Mr. Adams has kindly allowed me to use many of the illustrations to be found in his classical works, and much of what knowledge this book contains can be traced to these works or to information generously given to me in conversation. To Professor Hoffa, too, I owe permission to

use several illustrations from his well-known "Lehrbuch der orthopädischen Chirurgie." The influence of this, the first of all systematic works on orthopædic surgery, will be felt in many parts of my book. To the President and Council of the Royal College of Surgeons of England I owe permission to reproduce illustrations of specimens in the Hunterian Museum, and to the Councils of the Royal Academy of Medicine in Ireland and of the Clinical Society of London the use of illustrations from their published Transactions. Mr. Frederick Treves has also kindly allowed me to reproduce some of the illustrations from his well-known works.

Some of the matter contained in this book has previously appeared in the medical journals, and I have to thank the editors of *The British Medical Journal*, *The Lancet*, *The Medical Press and Circular*, *The Practitioner*, *The Clinical Journal*, and other medical journals for permission to use illustrations and letterpress.

London, July 19, 1899.

TABLE OF CONTENTS.

	PAGE
INTRODUCTION.—Andry—Origin of the term "Orthopædic Surgery"— Scope of Orthopædic Surgery—Necessity for Orthopædic Depart- ments at Hospitals—Proper Relations between Surgeon and Instru- ment-makers—"Orthopædic Illusions"	1
PART I.—GENERAL PATHOLOGY AND PRINCIPLES OF TREATMENT OF DE- FORMITIES—Primary Congenital Deformities—Secondary Congenital Deformities—Acquired Deformities—Pressure Deformities—Vesti- mentary Deformities—Contractures—Anatomical Changes in Bones in Pressure Deformities—Meyer's Law—Wolff's Law	9
Rickets: Rachitis Adolescentium—Congenital Rickets—Achondroplasia— Syphilis—Fragilitas Ossium—Osteitis Deformans	25
Rheumatoid Arthritis—Chronic Dry Ulcerative Arthritis—Chronic Traumatic Arthritis Deformans—Rheumatoid Arthritis in Children —Rheumatism—Chronic Ankylosing Arthritis—Gout	35
Contractures: Dermatogenous, Desmogenous, Myogenous, Inflammatory Muscular, and Neurogenous—Causes of Paralytic Deformities— Arthrogenous Contractures—Ankylosis	47
General Prophylaxis and Therapeutics of Deformities—Statistics— Symptomatology—Diagnosis—Prognosis	60
General Treatment of Deformities: Massage—Gymnastics—Passive Exercises—Resisted Exercises—Electricity—Hydrotherapy	64
The Principles of the Treatment of Deformities by Instruments: Plaster of Paris—Hessing's Apparatus—The Rigid Splint—Scarpa's Shoe— Thomas's Splints—Chance's and Taylor's Spinal Splints—Springs and Elastic Traction	69
Correcting Manipulations: "Bone-Setting"—Forcible Stretching of Muscles—Orthopædic Operations on Skin, Fasciæ, Tendons—Repair of Tendons after Subcutaneous Tenotomy—Open Tenotomy—Opera- tions on Tendons other than Simple Tenotomy—Lengthening a Tendon—Shortening a Tendon—Tendon Transplantation—Tendon Grafting—Myotomy—Syndesmotomy	86
Open Division of Soft Parts—Operations on Joints: Osteoclasis—Osteo- tomy—Adams's Operation—Macewen's Operation—Oblique Osteo- tomy—Cuneiform Osteotomy—Curvilinear Osteotomy—Excision of Bones—Osteoplastic Operations—Arthrodesis	108
PART II.—SPECIAL ORTHOPÆDIC SURGERY	117
SECTION I.— <i>Deformities of the Fingers and Toes</i> : Hallux Valgus: Pathological Anatomy—Causation—Treatment—Operative Treat- ment—Hallux varus: treatment	127

	PAGE
Hallux Rigidus or Flexus: Symptoms—Pathology—Prognosis—Treatment	128
Hammer-toe: Anatomy—Pathology—Treatment—Illustrative Cases ...	130
Arthritic Deformities of the Toes: Contraction of the Digital Processes of Plantar Fascia—Ankylosis—Hallux Retractus—Paralytic Deformity of the Toes	134
Congenital Deformities of Fingers and Toes: Polydactyly—Bifurcated Hand—Suppression of Digits (Ectrodactyly)—Webbed Fingers and Toes (Syndactyly)—Treatment—Operations. Congenital Dislocations of the Fingers. Congenital Contracture of the Fingers: Diagnosis—Treatment	136
Acquired Deformities of the Fingers: Trigger Finger—Drop Finger—Writer's Cramp. Dupuytren's Contraction of the Fingers: Symptoms—Anatomy—Incidence—Pathology—Diagnosis—Prognosis—Adams's Operation—Illustrative Case—Other Operations	143
SECTION II.— <i>Deformities Affecting chiefly the Ankle and Tarsal Joints and the Corresponding Deformities of the Upper Extremities</i> ...	153
Introduction to Club-foot and Club-hand—Varieties of Talipes—Congenital Talipes Calcaneus: Symptoms—Anatomy—Diagnosis. Congenital Talipes Valgus—Congenital Talipes Calcaneo-valgus: Anatomy—Treatment—Illustrative Case	156
Paralytic Talipes Valgus—Paralytic Talipes Calcaneus: Treatment. Paralytic Talipes Calcaneo-valgus: Symptoms—Anatomy—Treatment. Nicoladoni's Operation	161
Congenital Talipes Equinus—Congenital Talipes Varus—Congenital Talipes Calcaneo-varus—Congenital Talipes Equino-valgus—Congenital Talipes Equino-varus: Degrees—Anatomy—Treatment—Gradual Method—So-called Relapsed Cases—Operations: Buchanan's—Phelps's. Osteotomy of Astragalus—Bradford's Operation—Fitzgerald's Operation	164
Acquired Talipes Equinus: Causes—Symptoms—Anatomical Changes—Treatment. Paralytic Talipes Varus—Paralytic Talipes Equino-varus—Talipes Cavus: Congenital—Acquired—Treatment. Congenital Flat-foot—Acquired Flat-foot (Talipes Valgus)—Varieties—Spasmodic Flat-foot (Illustrative Case). Static Flat-foot: Symptoms—Anatomy—Degrees—Treatment—Operations: Ogston's (Illustrative Case)—Stokes's Operation. Transverse Flat-foot—Metatarsalgia: Causation—Diagnosis—Treatment—Illustrative Cases	181
Deformities of the Hand: Congenital Club-hand—Congenital Dislocation of the Wrist—Acquired Spontaneous Subluxation of the Wrist—Paralytic Deformities of the Hand—Contractures and Ankylosis of the Wrist and Carpal Joints	215
SECTION III.— <i>Deformities caused by Changes in the Long Bones of the Extremities</i> —Spontaneous Arrest of Growth at the Epiphyseal Cartilages—Congenital Absence of Tibia—Congenital Defects of the Fibula—Rachitic Deformities of the Long Bones of the Lower Limbs: Periods of Life—Seat of the Changes in the Bones. Definition of Genu Valgum and Genu Varum: Varieties of Abnormal Curves in the Shafts of the Long Bones. Genu Valgum: Anatomy—Measurement of—Degree—Mode of Examination—Complications—	

Symptoms—Prognosis—Treatment—Ambulant—by Recumbency—Operative—Comparison of Results of Conservative and Operative Treatment. Genu Varum: Symptoms—Anatomy—Diagnosis—Prognosis—Treatment—Operative Treatment. Rachitic Deformities of the Shaft of the Femur—Outward Curves of the Leg Bones: Treatment. Anterior Tibial Curves—Treatment—Osteotomoclasia...	220
Rachitic Incurvation of the Neck of the Femur—Coxa Vara: Symptoms—Differential Diagnosis—Age of Onset—Pathology—Treatment. Rachitic Back-knee (Genu Retrorsum)	248
Deformities of the Long Bones of the Upper Limb: Treatment. Rachitic Deformities of the Bones of the Forearm—Deformity of the Forearm after Fractures	259
SECTION IV.— <i>Deformities Caused by Changes in the Large Joints of the Extremities, with a Consideration of the Surgical Aspects of Spastic Paralysis, etc.</i> —Traumatic Deformities of the Ankle-joint: Deformities due to Suppurative, Rheumatic, and Tubercular Affections of the Ankle. Deformities of the Knee-joint: Congenital Genu Recurvatum: Symptoms—Anatomy—Treatment. Congenital Contracture of the Knee-joint: Treatment. Congenital Affections of the Patella: Absence—Dislocation—Illustrative Case. Acquired Contracture and Ankylosis of the Knee—Paralytic Contracture of the Knee: Treatment—Illustrative Case. Paralytic Genu Recurvatum: Causation—Treatment. Paralytic Flail-joint at the Knee—Arthrogenous Contracture of the Knee: Treatment. Internal Derangement of the Knee (Hey's Joint). Deformities of the Hip-joint: Symptoms—Diagnosis and Method of Examination. Congenital Dislocation of the Hip: Anatomy—Causation—Frequency—Symptoms—Differential Diagnosis—Prognosis—Treatment—Reduction by Manipulation—Operative Treatment. Congenital Paralysis—Contracture of the Hip from Infantile Paralysis—Tubercular Coxitis ("Hip Disease"): Symptoms and Diagnosis—Hysterical Hip—Illustrative Case—Prognosis in Tubercular Coxitis—Treatment—Ambulant Methods—Complications. Non-tubercular Affections of the Hip—Deformities arising after Specific Fevers—Illustrative Case—Arthritis Deformans of the Hip: Symptoms—Diagnosis—Treatment—Illustrative Case. Sacro-iliac Disease: Pain—Abscess—Muscular Spasm—Diagnosis—Prognosis—Treatment	261
Congenital Defects of the Clavicle—Congenital Displacement of the Scapula—Deformities of the Shoulder-joint—Congenital Dislocation—Illustrative Cases—Congenital Paralysis of Shoulder-Muscles—Paralytic Deformities at the Shoulder: Diagnosis—Prognosis—Treatment. Contracture and Ankylosis at the Shoulder-joint: Symptoms and Diagnosis—Treatment. Deformities of the Elbow-joint: Congenital Dislocations—Symptoms—Causation—Treatment. Cubitus valgus and varus—Contractures and Ankylosis of the Elbow—Cicatricial Contracture—Ankylosis	312
The Surgical Aspects of Spastic Paralysis: Causation—Symptoms—Diagnosis—Prognosis—Treatment—Illustrative Case. Pseudo-hypertrophic Muscular Paralysis: Causation—Pathology—Symptoms—Diagnosis—Course—Treatment	319

	PAGE
SECTION V.— <i>Deformities of the Spine—Wry-neck and Deformities of the Thorax</i>	328
Preliminary Observations—Chief Varieties of Spinal Deformity—Method of Examination of the Patient	328
Congenital Deformities of the Spine: Thoracic Kyphosis, or Dorsal Excurvation of the Spine: Causation—Diagnosis—Treatment. Lordosis: Rachitic—Secondary—Causes—Treatment. Lateral Curvature of the Spine or Scoliosis: Frequency—Pathological Anatomy—Predisposing Causes—Exciting Causes—Experimental Investigation—Types of Scoliosis—Diagnosis—Method of Examination—Scoliometriety—Course and Diagnosis—Prognosis—Treatment—Preventive Treatment—Exercises—Instrumental Treatment—Forcible Correction	331
Rickets of the Spine—Rachitic Kyphosis: Symptoms—Differential Diagnosis—Prognosis—Treatment. Rachitic Lordosis—Rachitic Scoliosis—Rheumatoid Arthritis of the Spine: Types of Deformity—Age of Onset—Symptoms—Prognosis and Treatment. Other Forms of Non-tubercular Spondylitis: Syphilitic Disease—Rheumatism—Diagnosis—Post-scarlatinal—Gonorrhœal—Post-typhoidal and other Spinal Lesions	372
Neurotic Affections of the Spine: Forms—Treatment—Illustrative Case	380
Tuberculosis of the Spine—Tubercular Spondylitis: Pathology—Anatomical Effects—Tuberculosis of the Vertebral Arches—Recovery—Abscess—Secondary Effects on the Skeleton and on the Spinal Cord—Symptoms—Examination of the Back—Method of Recording Angular Deformity—Differential Diagnosis—Course and Prognosis. Complications of Tubercular Spondylitis: Abscess—Diagnosis of Abscess. Treatment of Tubercular Spondylitis: Recumbency—Mechanical Treatment—Forcible Correction of Deformity—Illustrative Case—Costo-transversectomy—Treatment of the Complications of Tubercular Spondylitis—Psoas Contraction—Treatment of Spinal Abscesses—Expectant Treatment—Illustrative Cases—Treatment of Sinuses—Paraplegia—Symptoms of Implication of the Spinal Cord—Operations in Paraplegia—Laminectomy	382
Malignant Disease of the Spine	419
Wry-neck or Torticollis: Acute or Rheumatic Torticollis: Causation—Course—Treatment. Ocular Torticollis—Chronic Torticollis. Congenital Wry-neck: Anatomy—Illustrative Case—Treatment. Articular and Osseous Torticollis—Spasmodic Wry-neck (Chronic Nervous Torticollis): Clonic Form—Varieties—Tonic Form—Varieties—Prognosis—Treatment—Operations—Hysterical Torticollis—Illustrative Case—Paralytic Torticollis	420
Deformities of the Thorax—Congenital Deformities—Acquired Deformities—“Pigeon Breast”—Retraction of the Lower Part of the Thorax from Respiratory Obstruction—Respiratory Exercises	437
Index to Subjects	443
Index to Authors	447

FIG.	PAGE
38. Ring-catch joint	77
39. Detachable joint	77
40. A method of elongating steel supports	77
41. Leg and foot in equino-varus	78
42. External malleable splint applied to same... ..	78
43. Antero-external malleable splint applied	78
44. Rectangular splint	79
45. The same used as a "Scarpa's shoe"	79
46. " holding the foot in a corrected position	79
47. Early form of "Scarpa's shoe"	80
48. Modern type of "Scarpa's shoe"	80
49. Walking-instruments and boots for equino-varus	81
50. H. O. Thomas's single hip-splint	83
51. " double hip-splint	83
52. Chance's spinal splint	84
53. Taylor's "	84
54. Boot and iron with toe-elevating spring	85
55. Prothero Smith's spinal support	86
56. H. O. Thomas's knee splint... ..	87
57. Prosthetic apparatus for use after amputation at or below the ankle	88
58. " " " through the leg	88
59. Tenotomes	94
60. Parker's tenotomes	95
61. Minute tissue changes in early stage of repair of tendon	97
62. Repair of rabbit's tendon—14th day	98
63. The same—histological appearances	98
64. Different methods of tendon suture	103
65. " " "	103
66. " " "	103
67. Lengthening a tendon by Z-shaped incision	104
68. " " by turning down flap	104
69. Tendon transplantation	107
70. Grattan's osteoclast	109
71. Adams's saw	110
72. Lower end of femur showing points to be observed in Macewen's operation	111
73. Macewen's osteotome	111
74. Osteotomes and chisels	111
75. Gighli's saw	112
76. Oblique osteotomy (Ollier)	112
77. " " "	112
78. Cuneiform osteotomy	113
79. Curvilinear osteotomy	114
80. " "	114
81. Hallux valgus	117
82. " "	117
83. Anatomy of hallux valgus	118
84. Meyer's plan for sole of boots	120
85. Sole of ordinary boot	120
86. Footprint of a child aged three years	121
87. Normal footprints, etc.	122

FIG.	PAGE
88. Footprints of feet deformed by fashionable boots	122
89. Bunion spring	123
90. „ lever	124
91. Bandage for hallux valgus	125
92. „ „	125
93. Hallux varus	127
94. Hallux rigidus: Position of the bones	129
95. Hammer-toe	130
96. „ The neighbouring toes held apart	130
97. „ Schematic section of	130
98. „ Adams's splint for	131
99. Outline of foot with deformities of toes and metal splint	133
100. Deformity of the third toe from wearing tight boots	134
101. Side view of a foot showing hallux retracts and flat-foot	134
102. The same foot after treatment	134
103. Casts of the foot of a boy showing clawed-toes	135
104. Bifurcated hand	136
105. Bones of a foot with six metatarsals and seven digits	137
106. Zeller's operation for webbed fingers	138
107. Didot's „	139
108. Method of adjusting flaps in same	139
109. Congenital contracture of fingers	142
110. Pen for writer's cramp	146
111. Dissection of Dupuytren's contraction	149
112. Dupuytren's contraction before operation	151
113. „ „ after operation	151
114. „ „ Splint for	151
115. Diagram showing the normal range of movement at ankle	154
116. The position of the feet in the later stages of utero-gestation	156
117. Dissection of congenital equino-valgus	159
118. Congenital talipes calcaneo-valgus	159
119. „ „ „ extreme case	160
120. „ „ „ partly corrected	160
121. „ „ „ after three months' treatment	161
122. Paralytic talipes calcaneus	161
123. Chinese lady's foot, dissected	162
124. „ „ „ external aspect	162
125. Apparatus for the gradual correction of pes cavus	163
126. Congenital talipes equino-varus, from behind	165
127. „ „ „ from before	165
128. „ „ „ dissected	166
129. „ „ „ Bones and joints in	166
130. Astragalus and scaphoid in congenital equino-varus	167
131. Bones of the foot in congenital equino-varus	168
132. Stages in the cure of congenital equino-varus	170
133. „ „ „ „	170
134. „ „ „ „	170
135. Impression of the soles after cure of congenital equino-varus	171
136. Feet of a child aged two years with so-called "relapsed" equino-varus	171
137. Diagram showing ligaments exposed by turning down the tendon of the tibialis posticus	174


FIG.	PAGE
138. Club-foot wrench (H. O. Thomas's)	175
139. „ wrenches (F. F. Baker's)	176
140. Congenital talipes equino-varus	178
141. Sole of the foot in the same case	178
142. Outer aspect of foot in the same case after treatment	179
143. Front view of the foot in the same case	179
144. Instrument applied to the foot in the same case	180
145. Fitzgerald's splint	181
146. Right-angled contraction of the ankle	182
147. Paralytic talipes equinus with total paralysis of extensors	183
148. „ „ with partial paralysis of extensors	183
149. Dissection of a foot affected by paralytic equinus	186
150. Paralytic equinus with shortening of leg	188
151. Little's night-shoe	189
152. Paralytic talipes equino-varus	190
153. Talipes cavus	193
154. Flat-foot	196
155. „ Appearance of the sole in	196
156. Footprint in an average case of flat-foot	198
157. „ „ extreme case of flat-foot	198
158. „ of a narrow foot with a medium degree of flat-foot	198
159. Radiograph of flat-foot viewed from side to side	199
160. „ „ „ dorso-ventrally	199
161. Photograph of feet showing extreme flat-foot on one side	200
162. Radiograph of extreme flat-foot	201
163. Diagram of the bones in extreme flat-foot	202
164. Plan of instrument for flat-foot	205
165. Whitman's metal valgus plate	207
166. Footprints of normal feet and in metatarsalgia	213
167. Congenital club-hand	215
168. Skeleton of foetal hand in congenital club-hand	216
169. Congenital club-hand with absence of radius	216
170. Skeleton in the same condition	217
171. Congenital absence of the tibia	221
172. Diagram of genu valgum	224
173. „ genu varum	224
174. Combination of genu valgum with external tibial curves	225
175. „ „ „ femoral curves	226
176. The bones in genu valgum	227
177. Radiograph of unilateral genu valgum	228
178. Tracings of the lower limbs in genu valgum	229
179. Thomas's splints for genu valgum	234
180. A case of genu valgum with anterior tibial curves	235
181. Case of genu valgum before operation	236
182. The same patient after operation	236
183. Radiograph of the same case before operation	238
184. „ „ „ after operation	239
185. Wooden splints for genu valgum (<i>bis</i>)	240
186. The legs of a patient aged five years, genu varum	241
187. The same with the legs crossed	241
188. Radiograph of genu varum	243

FIG.		PAGE
239.	Congenital malformation of vertebra	332
240.	Thoracic kyphosis	334
241.	Severe scoliosis	336
242.	Scoliosis of moderate degree	336
243.	Scoliotic skeleton, front view	337
244.	„ „ back view	338
245.	„ „ side view	339
246.	Scoliosis, flat-backed type	341
247.	„ „ „ side view	341
248.	Scoliosis of slight degree, showing inclination of the body	342
249.	Three dorsal vertebræ from a case of scoliosis	343
250.	Diagram of the thorax in scoliosis... ..	344
251.	Case of severe scoliosis, back view	351
252.	„ „ „ front view... ..	351
253.	The back in total left-convex scoliosis	353
254.	Tracings from the back and loins in scoliosis	354
255.	Radiograph of a case of scoliosis	355
256.	Primary left-convex cervico-dorsal scoliosis	357
257.	Chair and desk for use in school-room	361
258.	Adams's support for scoliosis	366
259.	Sheldrake's „ „	367
260.	Chance's „ „ (diagram)	368
261.	„ „ „ (photograph)	368
262.	Barwell's seat... ..	369
263.	Rachitic kyphosis (sitting)	372
264.	„ „ (lying prone)	373
265.	„ „ back board for	374
266.	Dorsal vertebræ in rheumatoid arthritis	375
267.	Side view of spinal column, rheumatoid arthritis	376
268.	Back of patient with scoliosis due to rheumatoid arthritis	377
269.	Hysterical dorsal kyphosis	381
270.	„ „ „ instrument used in	381
271.	Spinal column, showing the effects of deep and superficial spondylitis	383
272.	Side view of skeleton, showing high dorsal kyphosis	384
273.	„ „ „ „ low dorsal kyphosis	385
274.	Healed tubercular spondylitis (diagram)	386
275.	Section of spine in tubercular spondylitis (photograph)	387
276.	Sequestrum pressing on spinal cord	388
277.	Attitudes assumed in tubercular spondylitis	392
278.	Child with cervical disease of spine	393
279.	Tracings from cases of tubercular spondylitis	394
280.	Atlo-axoid disease	396
281.	Abscess beneath anterior common ligament in tubercular spondylitis...	397
282.	Psoas abscess	398
283.	Prone couch	401
284.	Case of severe dorsal deformity	404
285.	„ „ with felt jacket	404
286.	„ „ Chance's splint	404
287.	Section of spine showing effects of forcible correction of deformity	406
288.	Wullstein's apparatus for tubercular spondylitis	409
289.	Chance's splint with head-piece	410

LIST OF ILLUSTRATIONS.

xix

FIG.	PAGE
290. Vincent's case, showing method of draining abscesses ...	414
291. Patient after operation for lumbar abscess, wearing instrument ...	417
292. " " " without instrument ...	417
293. Method of applying extension to the head ...	422
294. Anatomy of congenital torticollis ...	423
295. Congenital torticollis before operation, front view ...	424
296. " " " back view ...	424
297. " " after operation, front view ...	425
298. " " " back view ...	425
299. Rack and pinion apparatus for wry-neck ...	427
300. Chance's apparatus for wry-neck ...	427
301. Mental torticollis ...	431
302. " " corrected ...	431
303. Spasmodic torticollis ...	433
304. " " ...	435
305. Hysterical wry-neck ...	436
306. Section of chest in pigeon breast ...	437
307. " " depressed sternum ...	437
308. Boy with pigeon breast and adenoids, front view ...	438
309. " " " side view ...	439



ORTHOPÆDIC SURGERY.

INTRODUCTION.

THE word "orthopædy" was invented by Andry, whose work, "*L'Orthopédie ou l'Art de prévenir et de corriger dans les Enfants les difformités du Corps*," was published in 1751. Andry explains the meaning of the word thus: "As to the term in question, I have formed it of two Greek words: to wit, *ὀρθός*, which means straight, upright, or free from deformity, and *παιδίον*, which means a child."

It seems necessary to give this simple piece of etymology because many well-informed medical men have asked me whether orthopædic surgery takes cognisance of anything besides the "feet." One learned man suggested that the word should be "orthopodic."

Andry's work dealt with a branch of preventive medicine rather than with surgery; his aim was to teach the different ways of preventing and correcting bodily deformities in children by methods within the reach of "fathers, mothers, nurses, and others entrusted with the bringing up of children." The importance of these preventive measures is so great that they should be familiar to every practitioner of medicine, and the spirit of Andry's work must animate everyone who is more closely responsible for the treatment of deformities, and thus the retention of the term orthopædic as qualifying a department of surgery is perhaps justified.

In most works on orthopædic surgery a variety of existing deformities, from wry-neck to hallux valgus, are described and, to some extent, the original meaning of the term orthopædic has become obscured. Orthopædic surgery,

properly understood, refers to the prevention of threatened deformities as much as the cure of those that already exist, and it regards the functions of the mechanical parts of the body even more than their form.

Although the scope of orthopædic surgery, as generally understood, is limited to the spine, the thorax, and the extremities, the principles of orthopædic surgery equally concern other parts of the organism and are applicable, for instance, to the surgery of the eye, of the nasal passages, of the uterus, and of the teeth. Thus, in its widest sense, orthopædic surgery embraces more than the limitations of practice enable one surgeon to perform with satisfaction to his patients and himself. In restricting a province of medicine, it is desirable not to carry the narrowing too far, and it is, in the writer's opinion, necessary for an orthopædic surgeon to be not only well versed in, but also by daily practice to be familiar with general surgery. Thus alone can he know with unfailing certainty when the time for conservative measures in any case is passed, and that for energetic and, if necessary, destructive interference is come.

A general idea of the conditions that come under the designation of deformities may be gathered from Volkmann's broad subdivision of orthopædic cases into two groups—firstly, deformities in the wider meaning of the term; and, secondly, deformities in the narrower sense. In the former group are included badly-set fractures, unreduced dislocations, and other traumatic cases; also rachitic deformities, ankyloses, contractures, and other definitely pathological conditions. In the second group are included deformities such as congenital club-foot, and cases of flat-foot, genu valgum, and scoliosis that arise in adolescence, and are attributable to the habitual assumption of certain attitudes. Whilst this rough classification gives a good idea of the scope of orthopædic surgery, and has the attractiveness that is found in the sharp differentiation of groups of phenomena some of the distinctions it affords can easily be pushed too far. In most cases of adolescent flat-foot, genu valgum, and scoliosis, among the causes that have combined to produce the deformity, a pathological element will usually

be found if carefully sought for; and the successful management of these cases demands a clear appreciation of all the factors that have a part in the production of deformity. In the present work I have attempted not only to give a scheme of classification, but also to sketch somewhat more fully than is usually done in similar works the pathological factors that enter into the various classes of deformity.

My own interest in deformities dates back to the year 1885, when my attention was drawn to them in the dissecting-room at St. Mary's Hospital, where, as demonstrator of anatomy, numerous opportunities of study came in my way, and still more during the five years that I held the post of pathologist and curator of the museum. After my appointment as surgeon to out-patients at the North-West London Hospital many cases of deformity came into my hands for treatment, but it was only after my appointment to the City Orthopædic Hospital that I found real satisfaction in the work. To deal successfully with the class of cases that are here in view requires an organisation which only many decades of continuous labour and experience can produce.

The necessity for such organisations has long been recognised in Germany, Austria, and America. In the metropolis of England, where some of the best work in this department of surgery has been done, there are well-organised orthopædic departments at only a few of the many metropolitan schools, and, at the same time, but few students apply for the post of clinical assistant to the special hospitals. The latter circumstance is explained by the practical absence of questions on orthopædic treatment from examinations in surgery. This condition of things is no doubt accounted for by the limitations of time and the ever-widening range of the subjects of medical education. Considering, however, the importance of a training in orthopædic work to all classes of practitioners, and especially to those engaged in general practice, it is hoped that now the five years' curriculum has been established, better arrangements will be made.

The severer cases of flat-foot, genu valgum, and scoliosis, which constitute a large proportion of those who come for

treatment to orthopædic hospitals, would not exist if the deformity were recognised early and the proper treatment adopted. The number of persons disabled by preventible deformities is very great, and entails a heavy burden upon the community as well as on the individual sufferers. The need of the periodical inspection of growing children by a medical man trained in orthopædic work is not sufficiently recognised either by the public or the profession. How many cases of deformity are first brought to the notice of the family doctor when they have advanced to a severe degree, and have become fixed by secondary changes in the form of the bones! A training in orthopædic surgery is necessary alike for the general practitioner and for the surgeon. There is an impression that an orthopædic case may be defined as one requiring instruments. This does not represent the facts and, indeed, the converse of this often holds good. In the various cases that still too often find their way to the bone-setter, it is the too prolonged use of splints, bandages, etc., that is usually at fault, and a period of study at a well-equipped orthopædic department would enable the practitioner to laugh at the empiric who in country work is too often a galling reality. At the same time, the question of instruments is a crucial one.

When I began my work as surgeon to out-patients I felt the lack of training in orthopædic surgery. For help with simple rachitic deformities I sent for an instrument-maker whom I knew to be employed at a large general hospital. I found that he usually made the instruments to *fit the deformity*, and so to exclude the possibility of any improvement being obtained. For cases of club-foot I sought the assistance of another instrument-maker, who had been recommended to me as being employed at a general hospital and a large special hospital for children. This man was always ready to air his views on the anatomy and pathology of the various kinds of club-foot. His pathology was grotesque, and the instruments he made were usually wrong in principle. It is not necessary to detail further the steps that led me to study for myself the principles of instrumental treatment. By testing the knowledge of a succession of house-surgeons trained in the various medical

centres of the three kingdoms, I found that my own case was not at all an isolated one. Some have shown a capacity for understanding the problems at issue, but none have given evidence of any training in orthopædic surgery. Not a few have evinced a superiority to the whole matter, and when I have asked them to measure a patient for a simple instrument, have replied: "This is *merely* mechanical treatment, for which the instrument-maker is responsible." Here is the fundamental error. In my opinion, the surgeon is responsible to his patient for knowing when an instrument is required, under what conditions it should be worn, and how soon it may be left off. The surgeon should be able to design any instrument and to make all the necessary measurements, to take contours, etc. The mechanician's work is to follow these directions, and if they are complete it should not be necessary for the instrument-maker to see the patient. On the other hand, the surgeon should never be pecuniarily interested in the price paid for the instrument by the patient.

That some misunderstanding exists in some quarters on this point is evidenced by a recent article,* from which the following passage is quoted:—

So far as regards the medical profession, its inclusion among the professions which accept commissions appears to be founded upon two statements received by the Committee. One was made by a pharmaceutical chemist, who wrote that "secret commissions are given by chemists to medical men on their prescriptions supplied to patients, in some cases amounting to from 25 to 50 per cent. on the price charged by the dispensing chemist." The other statement was from an "optician, jeweller, and silversmith," who said that he had about fifty years' business experience. He wrote that "it is an open secret that hospital doctors received commissions from makers of surgical instruments."

The surgeon's duty in this matter is merely to see that the patient is charged a fair price for the instrument and that the latter is satisfactory in every way.

Some instrument-makers, who have worked for a long time under orthopædic surgeons and for convenience have been entrusted with fitting and measuring patients, in time acquire a dangerously superficial knowledge of surgery, and

* *Brit. Med. Journal*, "Secret Commissions," March 11, 1899, p. 612.

on that presume to prescribe for different deformities. In the past, cases of deformity were handed by the physician to the instrument-maker, and from his love of mechanism and ignorance of physiology and pathology much unnecessary and injurious practice arose, to the discredit of orthopædic surgery. Many medical men, influenced by this tradition and from want of training in orthopædic surgery, still send patients directly to the instrument-maker, and leave the diagnosis and treatment of the case to him, and thus encourage a great deal of unqualified practice, which is against the true interest of the community, since it entails often defective or erroneous treatment, unnecessary and unnecessarily prolonged use of instruments.

There is evidence that these matters are becoming more generally understood, as may be shown by a quotation from a recent review:—

Even nowadays too many surgeons think that they have done all that is required of them when they send an orthopædic case to an instrument-maker. They themselves should provide the measurements and details of the instrument which is to be made, and unless they can do so they should not attempt to treat these cases.*

For the successful working of an orthopædic hospital department it is necessary that the surgeon should control every detail of the instrument-making.

An enthusiasm for the promiscuous use of instruments is almost as dangerous as an enthusiasm for surgical operations, and just as to those who are truly interested in medical education it seems a mistake to place the description of operations in the opening instead of the concluding chapters of a text-book on general surgery, so in a text-book on orthopædic surgery the section dealing with instruments should be placed after milder and more natural and before less conservative measures. Nothing has done more harm to the progress of orthopædic surgery in this and other countries than the advocacy of a certain mode of treatment as applicable to all cases of one or other deformity, to the exclusion of other means.

Success in orthopædic cases depends upon the most scrupulous attention to detail as well as a full under-

* Review of Moore's "Orthopædic Surgery," *Lancet*, Dec. 24, 1898.

standing of the pathological character of the case. Orthopædic work is most exacting in that it demands of the surgeon the closest personal attention to every detail of treatment. This necessitates the sacrifice of more time than is required in almost any other kind of clinical work. In many cases the treatment from the nature of the case must extend over a considerable period. This makes it necessary that very careful records, often aided by radiographs and photographs, must be kept in order to avoid errors of judgment as to the progress of a case. These errors are alluded to by De St. Germain* as follows:—

I must also carefully warn you against what are ironically termed "orthopædic illusions." You have all seen in surgery those tumours which when measured every other day were found to diminish 2 mm. each time, and, at the year's end, were half as large again! In orthopædic work one must, above all things, guard against this very human tendency to see an improvement where it does not exist, and to convert into reality the hope that is based upon any given therapeutic measure. There is another source of illusion. . . . How many times has not one been led to believe that one has been successful in curing an equinovarus when only the fore part of the foot had been raised, and the resistance of the tendo Achillis remained unchanged!

Only a thorough knowledge and a long experience of orthopædic work will enable the surgeon to avoid such errors.

Every student and practitioner of medicine is frequently confronted with orthopædic cases and has opportunities of studying the commoner deformities. Without some guidance much of the experience thus gained is wasted. The need of text-books dealing with this department of surgery cannot be disputed. In order to render such works as helpful as possible the simpler and commoner deformities should, I think, be discussed first, so that the more complex may be explained by reference to the simpler conditions: in the present work this idea has, as far as possible, been kept in view.

Readers of books devoted to orthopædic surgery will observe that certain congenital deformities, such as hare-lip and cleft-palate, are not, as a rule, included. Such deformities are fully considered in treatises on general

* L. A. De St. Germain, "*Chirurgie Orthopédique*," Paris, 1883, p. 33.

surgery, and rightly so; for the methods employed in their treatment are rather those of ordinary surgical than of orthopædic practice: in other words they are combated by direct operative measures, the aim of which is to obtain immediately the maximum of improvement, the same end not being arrived at nor contributed to by any form of gradual correction. These and other similar conditions are not dealt with in the present volume, in order that more space may be devoted to deformities that require a course of treatment that may occupy a much longer period than can be given by the average student to surgical clinical work.

It is in the more strictly orthopædic cases that the student is unable to follow the whole course of treatment and to witness the degree of improvement obtained: consequently it is in the same class of cases that occurs the error of deeming incurable a condition that at the time the opinion is expressed admits either of complete and permanent cure, or of distinct amelioration.

Part I.

INTRODUCTION TO THE GENERAL PATHOLOGY, PRINCIPLES OF TREATMENT, ETC., OF DEFORMITIES.

RATIONAL surgical practice depends so closely upon a knowledge of pathological anatomy and a correct appreciation of pathological processes that the fullest possible consideration is due to this aspect of the department of surgery with which this book is concerned; limitations of space, however, render it necessary to curtail into a single chapter matter which, if fully considered, would more than fill the whole book.

It is customary to describe instances of any abnormal condition in two categories: (1) Congenital and (2) Acquired. Whilst this subdivision is convenient, it may be at the same time misleading if it be taken to mean that there is something antithetical between the two sets of conditions. On the contrary, the effects of ante-natal adversity may be of the same character as those of untoward conditions of post-natal existence. Thus an accidental cramping of a limb within the uterus may produce deformity in precisely the same way as cramping of the toes by badly-fashioned boots will produce hallux valgus and other deformities after birth. In many particulars, however, developmental errors that result in deformity give a peculiarity to congenital cases and necessitate their separate consideration.

Primary congenital deformities are such as cannot be attributed to any simple mechanical or other recognisable

cause. They are sometimes termed "idiopathic." Some of these conditions depend upon peculiarities of the ovum or the sperm-cell. The exact character of these peculiarities, though doubtless of simple nature, if the structure of these cells were completely known, is at present not ascertained. To this class of cases belong peculiarities such as supernumerary digits. Some other conditions, at present included in this group, such as spina bifida, certain congenital dislocations, etc., may with further knowledge prove to be of mechanical origin.* When such a defect appears for the first time in a family it is designated a primary germ-variation, and when it has previously been observed in the same family it is termed a hereditary defect.

Allied to hereditary transmission of deformity is the occurrence of congenital deformity in several offspring of the same father or mother. The explanation of primary congenital defects involves the problems of evolution with which the name of Charles Darwin must ever be associated. It is of interest to recall the more recent work of Weismann,† who strongly opposes the view that accidental traumatic peculiarities may be transmitted.

It is probable that in many instances of supernumerary parts the underlying cause is akin to that

which gives rise to double monsters, the reduplication occurring at a later stage of ovum-segmentation, and affecting only one or more members of the embryo.

Hereditary primary malformations are not infrequently of various character

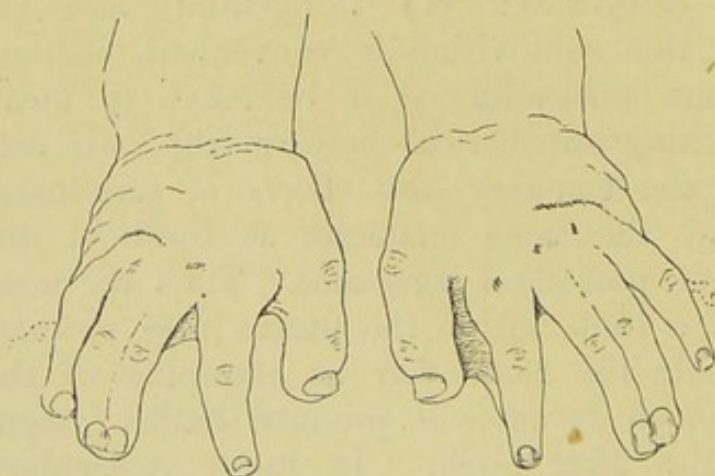


Fig. 1.—Webbed Fingers.

The dotted outlines represent supernumerary fingers that have been removed.


* See Dareste, "Production Artificielle de Monstruosités." Paris, 1877.

† Weismann, "Essays on Heredity" translated by Poulton.

in different members of the same family. As an instance of this, the history of the family in which occurred the case of webbed and supernumerary digits represented in Fig. 1 may be quoted.

CASES OF WEBBED FINGERS, SUPERNUMERARY FINGERS, WEBBED TOES, &c.*

Family History.



x Signifies congenital deformity. No history of deformity in the father's family.

ELIZABETH P., æt. 38 (mother of two following children):—

Right Hand.—Webbing half-way up between second and third fingers. Operated on when a baby; now webbing extends half-way up to the first inter-phalangeal joint.

Both Feet.—Both great toes webbed, and third and fourth toes webbed. "Only three toes on each foot."

ELIZABETH P., æt. 2 (daughter of above):—

- i. *Ear.*—On right side rudimentary: can hear a clock ticking. A rudimentary lobe is present in middle of the right cheek, like a red currant in size and shape.
- ii. *Double Squint.*
- iii. *Left Eye.*—Cataracta reducta.
- iv. *Right Hand.*—Third and fourth fingers joined whole length; fourth and little fingers webbed; one extra little finger.
- v. *Left Hand.*—Thumb and index webbed; third and fourth digits joined whole length; extra little finger.
- vi. *Right Foot.*—Three toes webbed together—second, third and fourth; and one extra toe.
- vii. *Left Foot.*—Extra toe and webbing of third and fourth.

MARY P., æt. nine months:—

One extra finger on left hand on ulnar side.

Both Feet.—Six toes: it looks as though patient had two great toes on each foot.

* For these notes I am indebted to Mr. M. Cecil Hayward, Senior Resident Medical Officer at the North-West London Hospital, 1898.

Hoffa notes the frequency of heredity in 100 cases of congenital deformity in the following table:—

70 cases of Scoliosis, of which 18 in 27·5 per cent. were hereditary.

7	„	Club-foot	„	2	„	27·5	„	„
7	„	Kyphosis	„	2	„	27·5	„	„
7	„	Congenital hip	}	1	„	14·3	„	„
		dislocation						
5	„	Deformity of	}	1	„	14·3	„	„
		the knee						
3	„	Flat-foot	„	1	„	14·3	„	„
1	„	Wry-neck	„	1	„	14·3	„	„

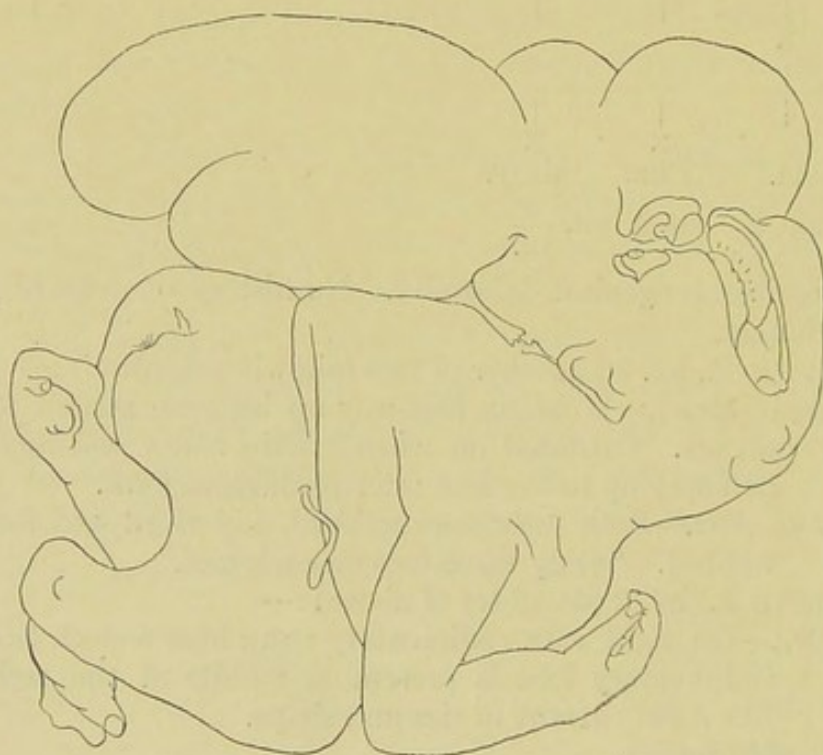


Fig. 2.—Single Monster with Amniotic Bands and Deformities attributable to want of Liquor Amnii.

Secondary congenital deformities are such as can be traced to mechanical causes, or to the effects of intra-uterine disease.

Among the causes of abnormal intra-uterine pressure during gestation some stand out prominently. Such are:— (1) a small amnion, or, what amounts to the same thing, a deficient amount of amniotic fluid; (2) multiple pregnancies; and (3) myomata in the uterus. As a marked example of many deformities associated with a total absence of liquor

amnii the specimen shown in Fig. 2 may be adduced. It is preserved in the museum of St. Mary's Hospital. The short description I gave of it in the catalogue reads:

537. A single monster, with total encephalocele, hare-lip, and cleft palate, spina bifida occulta, etc. The lower limbs are greatly deformed. The left testis was retained within the abdomen (No. 1277). The right had left the external ring, and been displaced outwards to the ant. sup. spine of the ilium.

From a woman who had previously borne five well-formed children. In this case the liquor amnii was absent. 1891.

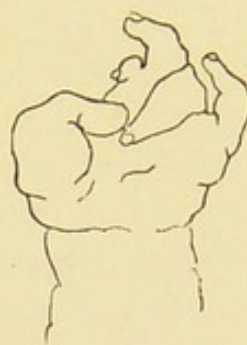

Fig. 3.—Left Hand of the Specimen shown in Fig. 2.

The absence of liquor amnii in this case was clearly ascertained by Mr. H. S. Collier, who was at the time obstetric officer and attended the labour. The amniotic and tegumental bands are referable to pressure of the amnion upon the skin and of the skin of the occiput upon that of the back. The flattened form of the left hand, Fig. 3, and the deformities of the lower limbs are also traceable to the same cause. In my opinion the same pressure of the amnion upon the embryonic head would account for the failure of the formation of the bones of the skull and for the deformed condition of the brain, and also for difficulty in the closure of the medullary groove, and thus for the occurrence of spina bifida. The retention of one and ectopia of the other testis would also be explained by the pressure of the thighs upon the inguinal canals.

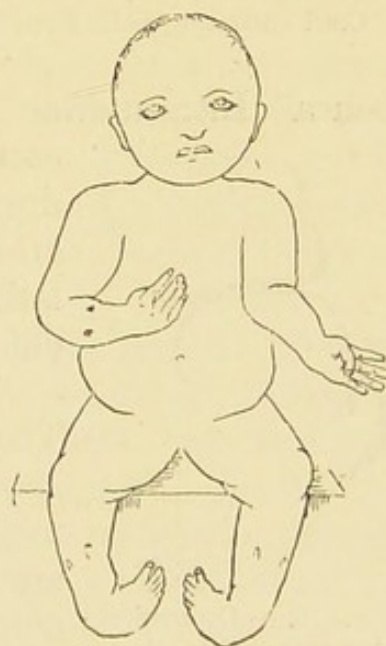

Fig. 4.—Infant with Congenital Deformities.

Less extreme results of abnormal intra-uterine pressure are not uncommon. The infant shown in Fig. 4 was brought to me for treatment of congenital club-foot. When I first saw the patient at the age of six months the thumbs were firmly adducted into the palms and the forearms were abnormally curved with a forward concavity. About the middle of the forearms and legs there were depressed

scar-like marks, one over the middle of each of the bones. The mother said that the birth was "very dry."

The dependence of congenital club-foot upon intra-uterine

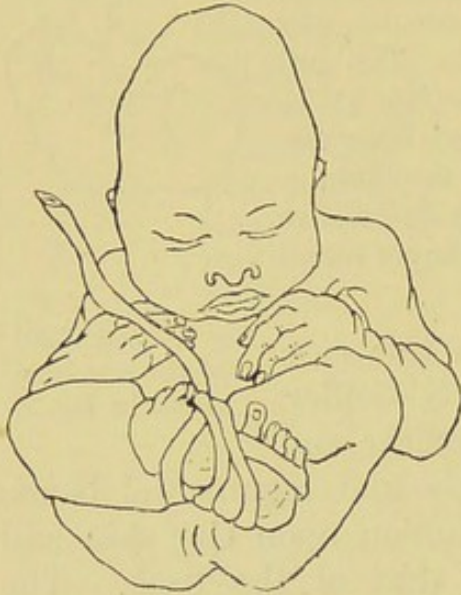


Fig. 5.—Sketch of a Baby, born dead at full term, with the Umbilical Cord encircling both Feet.

pressure* has frequently been observed. An instance in which this mechanical factor in the production of double club-foot consisted in the umbilical cord being securely tied around the feet and ankles is shown in Fig. 5. Intra-uterine amputations, constriction furrows around limbs (Fig. 6), and numerous other congenital errors are attributable to a similar constriction by the umbilical cord or an amniotic band.

Other deformities may be due to the normal intra-uterine pressure acting upon softened

bones. Intra-uterine fractures resulting in deformity may occur from injuries suffered by the mother during pregnancy. Achondroplasia and other foetal diseases account for a relatively small number of congenital deformities.

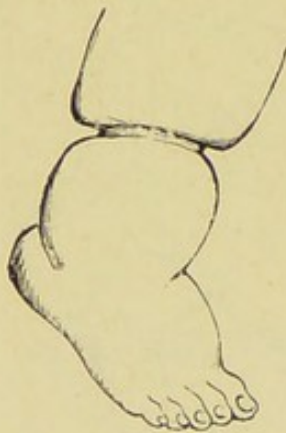


Fig. 6. — Congenital Annular Constriction.
(From Owen's "Surgical Diseases of Children.")

Deformities of Post-Natal Origin.—

The variety of deformities that may be acquired after birth is very great, and the modes of production of such deformities are correspondingly varied. Some of these deformities follow immediately upon an injury such as a fracture or a dislocation, and are termed "primary"; others are of gradual production, and are termed

"secondary." The physiological functions of the skeleton, muscles, and other parts of the locomotor apparatus of the body, as well as the pathological changes to which these parts are subject, have all to be borne in mind

* See Parker and Shattock, "Congenital Club-Foot," 1887.

when contemplating the origin of deformities. Many writers appear to dwell too exclusively upon the mechanical sources of deformity, others too exclusively upon the pathological loss of resisting power produced in the skeleton by disease. In every case the mechanical and the pathological factors must be duly weighed.

Pressure Deformities.—The mechanical factors come into play most prominently in what, since the views of Volkmann and Hueter were published, have been termed *pressure deformities*. The normal growth of the skeleton, ligaments and muscles is determined by healthy nutrition in the first place, and by a certain range of movement, and in the case of the bones by the regular daily transmission of force in certain directions for certain periods, alternating with periods of rest. A bone, even in a healthy state, will become altered in form and internal structure if its normal range of function is limited in a given direction. As examples of this the various *trade deformities* may be adduced. Many of these deformities are the result of the *fixation of a habitual attitude*. Thus, in a person whose days are spent in carrying heavy weights upon the shoulders with the dorsal spine curved forwards, the attitude becomes fixed from modifications of growth in bones and ligaments; in other words, a trade kyphosis results. If heavy weights are habitually carried upon one shoulder, as in millers, the spine is curved laterally, and a trade scoliosis results. When the nature of the occupation is very severe, as in coal-heavers, the effects are more akin to those of traumata, and, as Arbuthnot Lane has pointed out, ankylosis of the cervical vertebræ, and, in the lumbar region, spondylolisthesis may result. Bland Sutton has described similar effects in the dorsal and lumbar vertebræ of draught horses and in the cervical vertebræ of draught oxen. If in addition to modification of function disease such as rickets or osteoarthritis is present, the resulting deformities will be more severe.

If any one posture is habitually assumed for a disproportionately long period of time whilst the parts concerned are bearing the weight of the body, this posture tends to become fixed in the same way as and for similar reasons

to those just referred to as trade deformities. Thus the common occurrence of flat-foot in bakers, cooks, apprentices, and others is explicable. In school children flat-foot, knock-

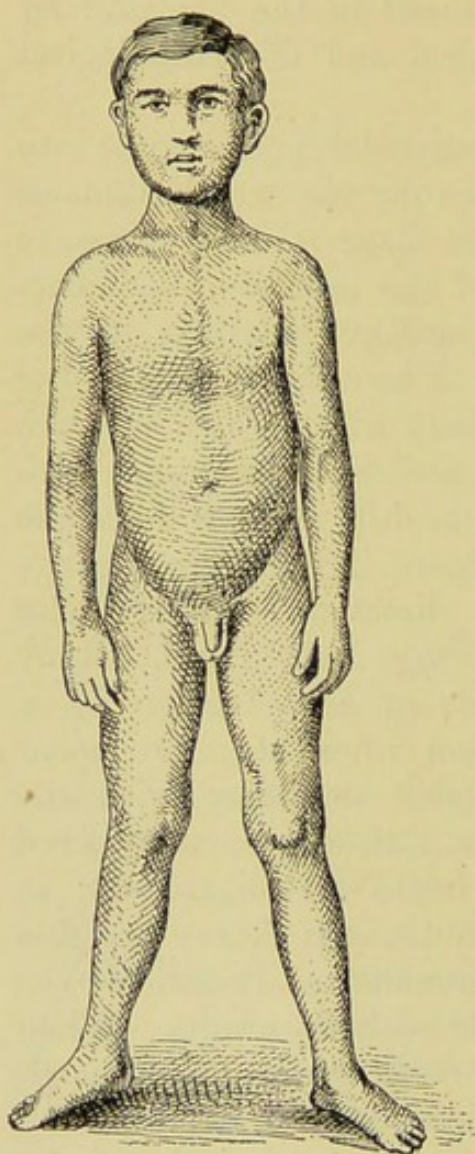


Fig. 7.—The "Attitude of Rest."
(From Hoffa, after Annandale.)

knee, etc., are frequently determined in the same way. In every case evidence of bone disease must be carefully excluded before the conclusion is arrived at that the deformity is due solely to mechanical apart from pathological causes. The mode of origin of many cases of flat-foot and knock-knee has been indicated by Annandale, who has attributed it to the long daily assumption of what he has designated the "attitude of rest" shown in Fig. 7.

In this posture the strain is on the ligaments on the inner side of the knee, ankle, and foot, in order to protect the muscles from excessive fatigue in long standing, and thus the growth of these ligaments is adapted to this mode of standing—they become elongated, and at the same time thickened. The danger of basing theories of deformity on anatomical researches alone is shown by the

fact that many deformities were formerly referred to changes in ligaments as a primary cause where it is merely a secondary effect. If the cause, that is the habitual posture, be not removed, alterations in the form of the bones and joints occur which *fix* the attitude, and permanent deformity results. In a similar way muscular fatigue or weakness may lead to scoliosis from the weight of the body being borne chiefly upon one leg for long periods together. Such is the "stand-at-ease" position, in which the pelvis is tilted laterally and

the spine is curved. Here, again, pathological processes must be considered, for such muscular weakness as is likely to cause the posture to be assumed is, in most cases, the outcome of a general state of malnutrition which affects the bones and ligaments, and renders them unduly soft. In other words, pressure deformities cannot be entirely separated from rachitic and other pathological groups. Deformities produced by the instinctive assumption of attitudes that can be maintained without muscular action are termed *habitual pressure deformities*. To this group are allied deformities produced by unequal growth in length in the radius and ulna or the tibia and fibula, or inequalities in the length of the lower limbs or again, deformities due to scars resulting from injuries in early life that offer one-sided resistance to the growth of a member, and result in its assuming an abnormal curve towards the side of abnormal resistance. These are the *static deformities*, a term which is often used to include also the habitual pressure deformities.

Vestimentary Deformities.—Among pressure deformities those due to badly-fashioned clothing are among the commonest. Narrowing of the thorax produced by tightly-fitting corsets, and hallux valgus and other deformities of the foot are familiar examples. The manner in which such deformities are brought about, *i.e.* by the prolonged and daily maintenance of parts in one position and the adaptation by growth of bones, ligaments, etc., to that position, is quite analogous to the production of congenital deformities by direct pressure of the uterine walls upon the foetus owing to lack of amniotic fluid. There are several important deductions to be drawn from this class of deformities, and chief among them is this: that if by continued daily maintenance of a part in an abnormal position a permanent deformity can be produced by adaptive growth, so by patient maintenance of a deformed part in a corrected position a permanent cure of deformity may be effected. This principle is of great importance in orthopædic surgery.

Contractures.—Deformities due primarily to shrinking of the soft parts are termed contractures, as distinguished from pressure deformities and from ankylosis, which is due to the union of two or more articular surfaces by interposed tissue,

so that movement is prevented between the bones concerned. A contracture by fixing a joint may in certain conditions lead to ankylosis by favouring the growth of

connective tissue between the articular surfaces. This I have observed in the case of the ankle and tarsal bones of an œdematous limb that was fixed in splints for four years on account of an ununited fracture. Contractures are named from the tissues primarily at fault: thus there are (1) *dermatogenous*, (2) *desmogenous*, (3) *myogenous*, (4) *neurogenous*, and (5) *arthrogenous* contractures.

Before passing to the consideration of the various forms of contracture, ankylosis, etc., it will be perhaps more profitable to pass in brief review some anatomical considerations and the pathological states that most frequently contribute to the onset of the pressure deformities. Among the latter rickets and what, for want of a better name, is known as rheumatoid arthritis or osteo-arthritis are prominent. In connection with these, for purposes of diagnosis, certain conditions that do not strictly belong to the domain of surgery will require mention,

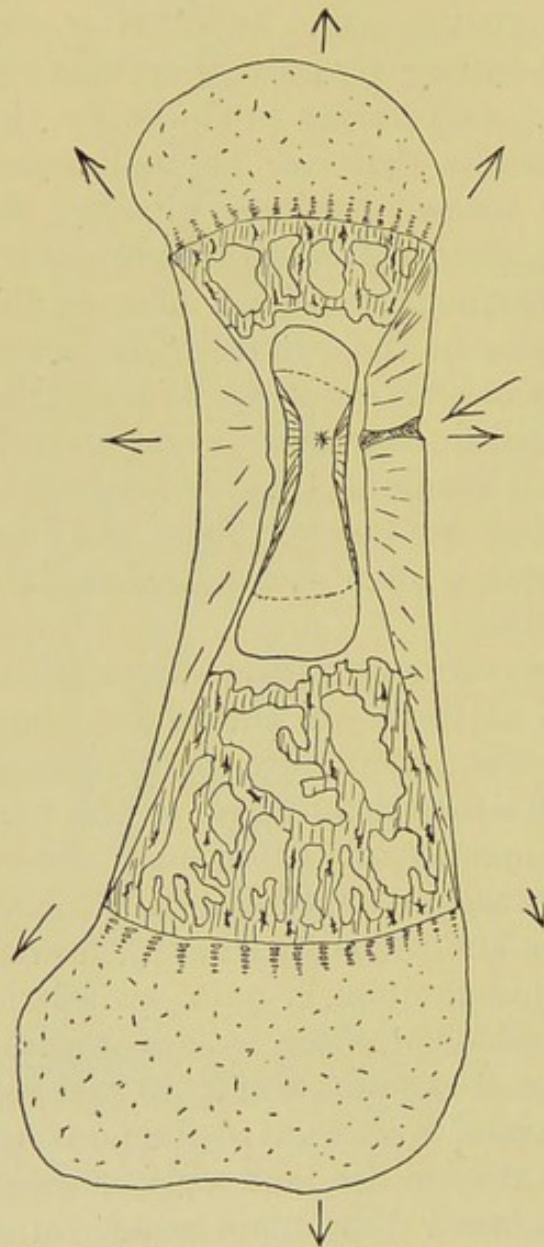


Fig. 8.—Diagram representing on an enlarged scale a Metacarpal Bone at Birth.

The small central figure shows the same bone at an early period of intra-uterine life. The ingoing arrow marks the medullary artery, and is directed towards a star which marks the centre of growth in the bone. (Modified from Kassowitz.)

if only to show the more clearly where the services of the surgeon cease to be required.

The Anatomical Changes produced in Bones Deformed as the Result of Pressure, etc.—The diagram, Fig. 8, will serve to indicate the complex mode of growth of a long bone, and as far as longitudinal growth is concerned it is sufficiently accurate, for it recalls the fact that the chief seat of longitudinal growth is at the extremities of the diaphysis where the latter abuts upon the epiphyseal cartilages, the "juxta-epiphyseal" region. At the same time the existence of a diffuse interstitial increase in all parts of the bone is not to be forgotten. It is important to consider the conditions of normal growth in bones. In clinical work some of these conditions may be learned by their absence. Thus, in cases of infantile paralysis the shortening of bones from retarded growth is often remarkable. In part this depends on defective circulation; in a large part also it is dependent upon the absence of function. That this is the case is shown by the increased growth of the bone that follows the application of a portable apparatus to a paralysed and previously long disused limb. After such a limb has been used again for walking for some time the growth-rate improves and ceases to lag so much behind that of the healthy limbs. The effect of muscular exercise on the nutrition of bones is well known. Besides increasing the bone-circulation, it calls into play the mechanical function of the bones and in so far stimulates growth. Intermittent strain and pressure within physiological limits produces increased growth in bone as in other tissues. A third factor is the altered innervation.

Volkmann* and Hueter explain certain static deformities by changes produced by pressure on the articular surfaces and the immediately adjacent bone. Thus Hueter† writes: "By the term 'joint-body' [Gelenkkörper] I mean the portion of cartilage, or, later in life, of bone that bears the articular surface, and hence gives to the joint its special functional form and arrangement"; and again "Just as by the development and growth of the bones changes are produced in their

* Richard von Volkmann, "Krankheiten der Bewegungsorgane," in V. Pitha and Billroth's "Surgery," 1865-1872.

† C. Hueter, "Klinik der Gelenkkrankheiten mit Einschluss der Orthopædie," Leipzig, 1876, pp. 14 and 19.

articular extremities, so, again, impediments to growth affect directly the articular extremities of the bones, and may alter the form of the intracapsular articular surfaces." According to this view, the deformity resulted from decrease of growth on the side of the joint on which the pressure was increased above the normal amount, and from a corresponding increase of growth in the bones on the side of the joint at which pressure is diminished below the normal amount. That this view is not universally applicable becomes clear when the joint is examined in, say, an average case of genu valgum. The joint surfaces are found to be practically normal, the deformity lying principally in the diaphyses of the bones. The mathematician Culmann* showed that the pressure upon the joint-surfaces is small or even *nil*, and that the greatest pressure is felt in the centre of the shafts of the long bones. And this agrees with the fact that in the chief deformities the first and principal change of form is in the diaphysis; the joint-surfaces are only secondarily changed. If, however, the same view be applied to the juxta-epiphyseal region, it will be seen to explain, in part, the change of form. In the case, again, of joints affected by severe osteo-arthritic changes, this view gives the best explanation of the deformities encountered. Thus, for example in dissecting the parts involved in a pathological dislocation of the hip due to osteo-arthritis, it is found that the upper part of the rim of the acetabulum has been flattened out and the head of the femur has been correspondingly changed. When, by pathological changes, the substance of the bone is softened so that pressure can obliterate the blood-vessels in the articulating surfaces of bones, this explanation of the resulting deformity holds good.

Hermann Meyer,† to whom science is indebted for consulting Culmann and obtaining his views, pointed out that fully formed bone in normal conditions, possesses a definite internal structure, which in every part represents the lines of greatest pressure or traction, and is so

* Culmann's researches are fully referred to in Wolff's work quoted below.

† H. von Meyer, "Die Architectur der Spongiosa." Reichert and Du Bois Reymond's Archiv, 1867, p. 627.

arranged as to give the greatest resistance with the smallest amount of material. The neck of the femur and the calcaneum were the bones examined by Meyer. His view was fully confirmed and shown to apply to all bones of the body.

Julius Wolff* showed that when fractures united with angular deformity the architecture of the bone became altered to correspond with Meyer's law. Wolff further showed that when a primary deformity occurs from pathological changes in a bone, the alteration in architecture is not limited to the bones immediately concerned, but extends to all those that are affected by the altered static condition. These observations were extended, and in 1892 Wolff formulated his "law," which has been paraphrased by Hoffa as follows:—

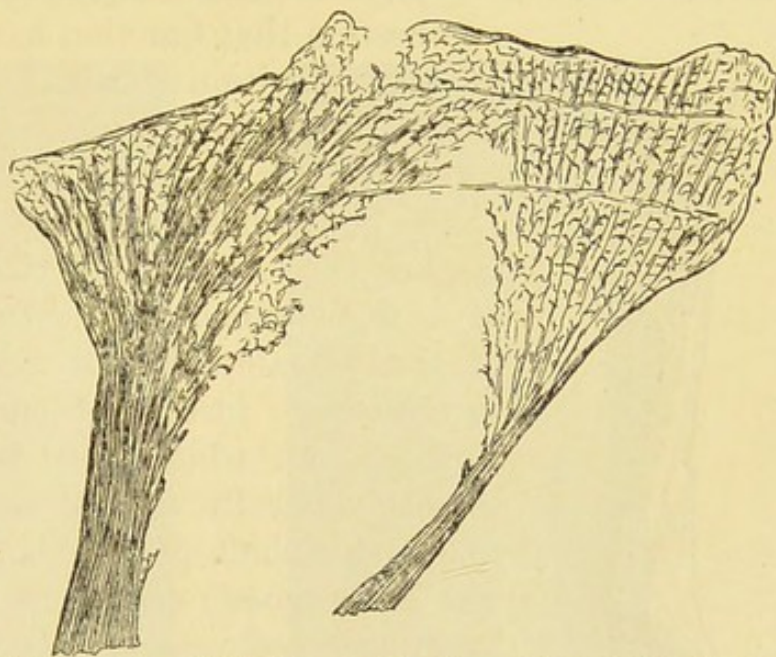


Fig. 9.—Frontal Section of the Upper End of the Right Tibia of an Adult in whom Genu Valgum had developed at puberty.

(From Hoffa's modification of Wolff's figure.)

Every change in the static relations of a bone not only leads to a corresponding change of internal structure, but also to a change of external form and physiological function.

According to this view, function alone is the one and only form-determining factor. Genu valgum is regarded by Wolff as a physiological accommodation to abduction of the legs, scoliosis to a twisted posture of the vertebral column.

Thus, in the upper end of a tibia from a marked instance of genu valgum, Wolff found the structure in a vertical

* Julius Wolff, "Das Gesetz der Transformation der Knochen," Berlin, 1892.

frontal section to be as shown in Fig. 9, in which the dark lines represent bony tissue.

In this case, in the outer half of the bone, where the pressure had been greatest, and where, according to the Volkmann-Hueter view, it should have been atrophied, the tissue is twice as dense as on the inner side. Hence Wolff rejected entirely their theory, and regarded such a deformity as the result of a physiological adaptation. There can be

no question that function has a great influence on bone-nutrition; still, it is not the only factor in producing deformity such as that shown in Fig. 9.

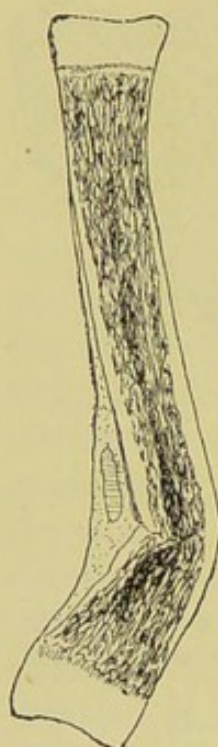

Fig. 10.—Section through the Radius of an Infant.

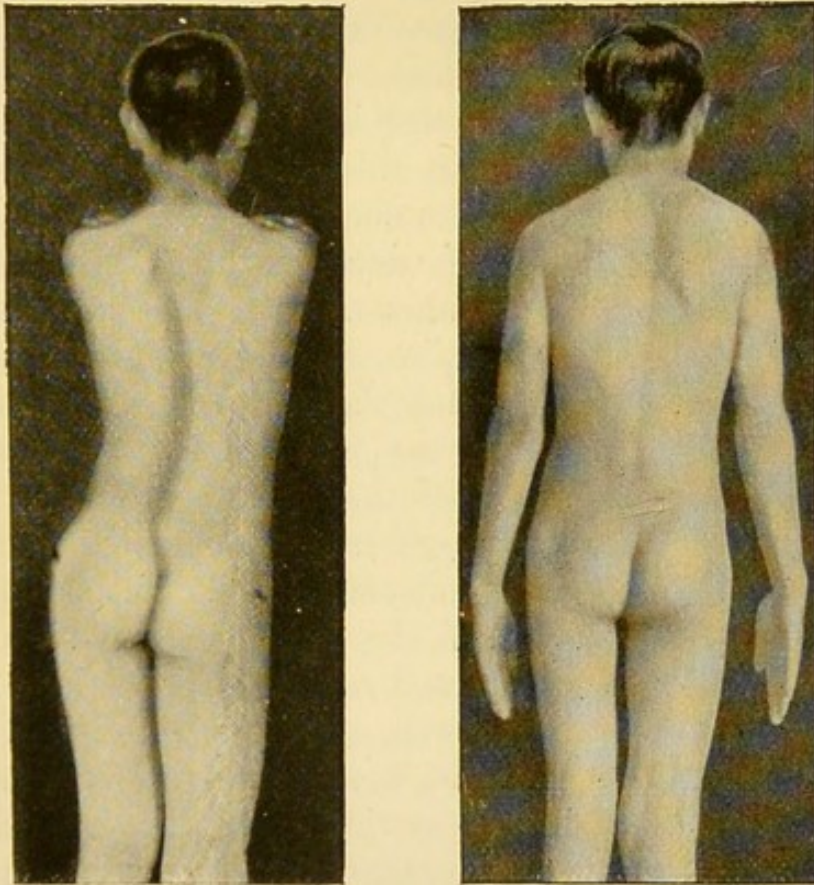
There is a greenstick fracture. In the concavity of the bend there is a formation of callus, part of which is a translucent bar of hyaline cartilage.

A pronounced instance of genu valgum implies the existence of rickets at the time of its development. In this disease the tissue of the juxta-epiphyseal regions is changed in character: instead of ending in a narrow surface, from which bone-forming capillaries project vertically against the epiphyseal cartilage, the shaft of the bone, whilst rickets was in progress, ended in a layer of long, irregular blood-vessels embedded in soft tissue of considerable depth. In the abducted position of the weight-bearing limb this layer of soft tissue would of necessity be altered in form, the outer side that bears the greater part of the weight being compressed, the inner side being stretched out. This alteration in form was made permanent by the calcification of the soft osteoid tissue. Thus, besides the physiological reason for the greater density of the concave side of a yielding, rickety bone, there is further a pathological one, the result of actual bending of the bone at moments when special stress is brought to

bear upon the limb. Each time that the patient's weight is brought to bear upon the limb there is an actual bending of the bone, and in rickets the bend is not recovered from as it would be in normal conditions, the elasticity of normal bone being wanting. Thus the gradual bending of bones

in severe rickets must be partly due to what amounts to a series of green-stick fractures.* Now in some examples of green-stick fracture the callus forms only in the receding angle of the bend (*see* Fig. 10). Looked at in this light, the thickening that takes place in the concavity of rachitic bones must be regarded, to a large extent at least, as an effect of repeated small traumata.

After early childhood, when the bones are sound, abnormal



Figs. 11, 12.—Back of a patient, aged nineteen, before and after correction of Ankylosis of the Left Hip in the position of Adduction and Flexion.

postures produce bony deformities only with extreme slowness. Thus a patient of mine, aged nineteen years, had worked as a barber for four years with the spine in the posture shown in Fig. 11, owing to the presence of ankylosis of the left hip. As soon as the latter deformity was corrected, the spine became straight, as shown in Fig. 12. In this case no appreciable change in the form of the bones had been produced

* Compare Virchow, "The Normal Growth of Bones and the Disturbance of the same by Rickets," *Virch. Archiv*, vol. 5, p. 470, 1853.

in the course of several years. If, however, the patient had been a young child, or had been the subject of rickets or some other condition entailing diminished resistance of the bones,

there is no doubt that the vertebræ would have been altered in form. It is to be remembered also that in many cases of flat-foot, scoliosis, etc., the deformity may develop rapidly and attain a severe degree before there has been time for any change in the form or structure of bones to take place.

Though it is necessary to emphasise again in this place the importance of the pathological factor in the production of deformity, the real value of Wolff's law must also be indicated. It is seen in cases of associated deformities that date from early childhood. When the bones are growing rapidly, the direction of increase in size is readily modified. Thus in congenital wry-neck that is left uncorrected, the half of the skull on the side of the contracted sterno-mastoid lags behind in growth, and the condition known as facial hemiatrophy develops. The lateral deviation of the head in congenital wry-neck also entails an asymmetrical position of the trunk, and in the course of growth a marked scoliosis is thus produced and the form and internal structure of the whole of the spinal column, the pelvis, and even of the lower limbs become modified.

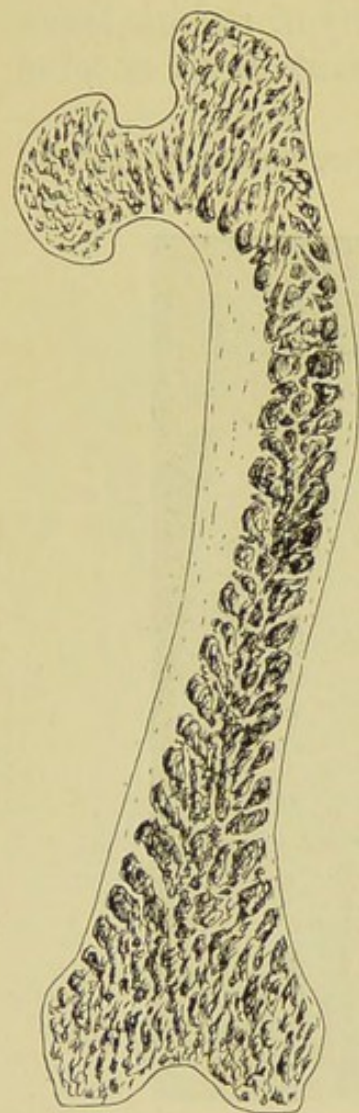


Fig. 13.—Vertical Section of Femur of Adult.

There is an old rachitic curve, and the bone of the concave side is greatly thickened. There is an incurvation of the neck of the bone.

In this instance the abnormal static condition dates from birth, and the secondary changes in the spine, etc., are due as much to modification in growth of cartilage and bone as to the adaptive processes referred to by Wolff. The purely adaptive changes in bone are best seen in the structure of bones deformed from rickets and examined

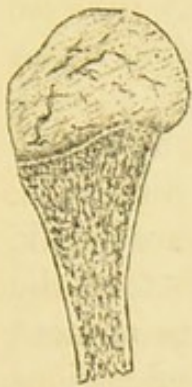

Fig. 14.—Vertical Section of Normal Humerus of Infant at Birth.

long after the disease has been recovered from. Thus in the femur represented in Fig. 13, the thickening of the concave side of the rachitic bend is as great as it was during the onset of the deformity. The nutrition of the thickened part of the bone has been *maintained* in accordance with Wolff's law, which, in the writer's opinion, does not give the complete explanation of the causation of the majority of static deformities, but affords an explanation of the permanence of many of them. The spontaneous

disappearance of deformity that is sometimes observed in the bones in rickets, may also be explained by the same law.

Further, when deformity has arisen, this transformation enables the skeleton to sustain the body-weight in its altered circumstances. The physiological accommodation in the vast majority of cases is an effect not a cause of deformity. As a remedial agent the transformation, save in early childhood, too often recalls in an altered sense, the ancient saying, "*Ars longa, vita brevis.*"

Rickets.—In England rickets accounts for more deformities than any other single affection. Thus it is impossible to omit a short notice of the disease in considering the pathology of deformities. It is known on the Continent as the "English disease," on account of the first thorough treatise on the disease being of English origin. In 1660 Glisson* described fully all rickety deformities and suggested their treatment by mechanical support and gymnastics.

* Francis Glisson was Professor of Medicine at Cambridge University.

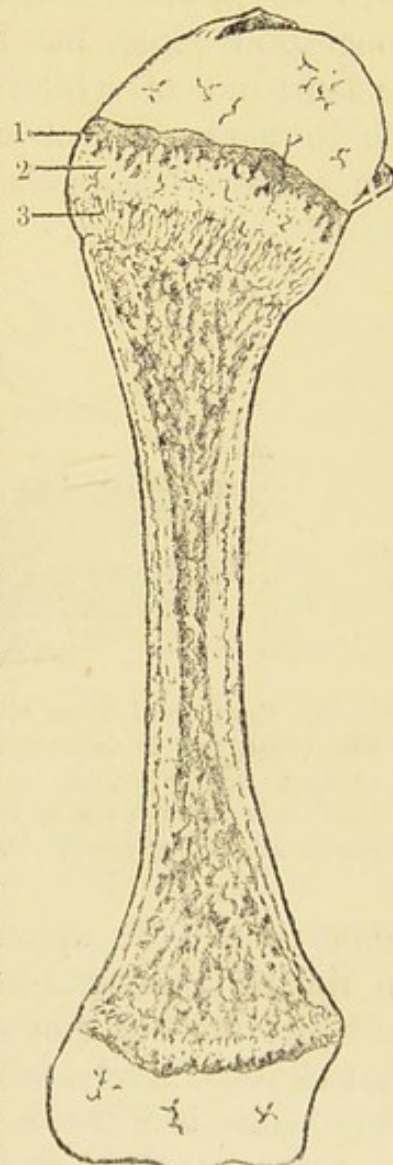


Fig. 15.—Vertical Section of Humerus of Child, aged two years, who had active Rickets.

1, zone of proliferating cartilage; 2, layer of osteoid tissue; 3, uppermost layer of the diaphyseal ossification.

Though the condition of the bones is of chief interest to the surgeon, there are many considerations that make it desirable to recall the general pathological changes as well.

The disease affects the alimentary tract and the whole organism as well as the bones. The abdomen is distended, the liver and spleen may be enlarged, muscles are weak, and there is often marked nervous irritability. Before the bones become altered sufficiently for the most prominent sign of rickets—the enlargement about the epiphyseal regions—to be produced, there is a condition of hyperæmia or congestion which has been observed on post-mortem examination, and of which there is sometimes evidence during life in tenderness of bones. When the extremities of the bones have become enlarged the malady has existed for

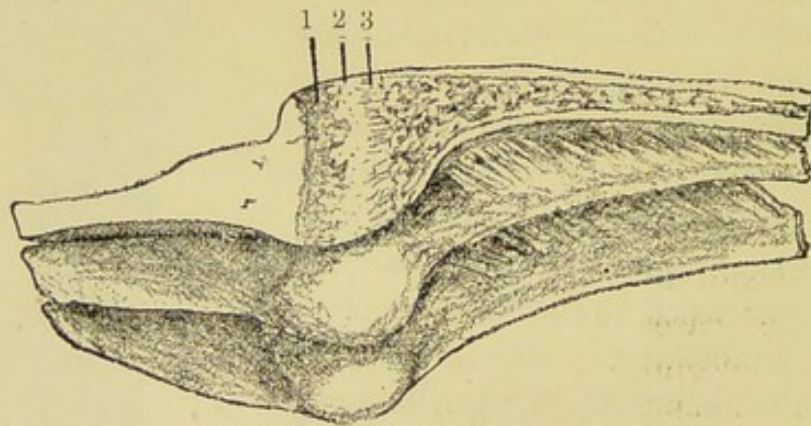


Fig. 16.—Portions of three ribs at the junction of shaft and costal cartilages. The "beading" is more marked on the pleural than on the superficial surface, owing to the sinking in at the junction of cartilage and bone. Section has been made through one of the ribs, and it shows zones 1, 2, 3 similar to those shown in the humerus in Fig. 15.

some time. To appreciate the kind of change that exists in rickets a normal bone may be compared with one that presents marked rickety enlargement, as shown in Figs. 14 and 15 respectively. The enlargement at the ends of the long bones is fully accounted for by the increase in amount of tissue at the epiphyseal line, and in a severe case like that from which the humerus, Fig. 15, was taken the greater part of the enlargement is found to consist of soft tissue; fine bony spicules can, however, be felt in the layer (3) by drawing the finger over the cut surface. On pressing upon the head of this humerus, the soft tissue

of the surface of the enlargement bulged forwards. The histological changes which lead to the formation of swellings at the junction of the ribs with the rib-cartilages, Fig. 16, are precisely similar to those observed at the juxta-epiphyseal regions of the humerus and other long bones.

In severe rickets marked changes occur in the bone of periosteal formation. This is more porous than the normal bone in texture. In Fig. 15 the superficial layer of periosteal bone is somewhat more porous than is normal. Sometimes the change in the periosteal bone is more marked than in the epiphyseal line. When this is the case there is a great deficiency of lime in the periosteal bone. Much of it is osteoid tissue. Occasionally in rickets islands of hyaline cartilage are formed from the periosteum. In rickety animals the formation of subperiosteal osteoid tissue is often very marked.

In membrane bones, such as those of the skull, changes occur similar to those described above in periosteal bone. This is especially noticeable at the sutures of the skull, where distinct thickenings from the formation of porous bone and osteoid tissue may arise. When this formation of bone extends over a considerable area of the skull, the latter has a resemblance to the nodes of congenital syphilis.

The seat of rachitic deformity in any individual is determined partly by the degree of pathological change in the different parts of the skeleton. In Fig. 15 the upper end of the shaft of the humerus is more extensively affected than the lower end. In the body of an infant aged one year and eight months, that I examined by the courtesy of my colleague, Dr. Leonard Guthrie, the rachitic changes at the costo-chondral junctions were very pronounced, in the bones of the limbs they were but slight, whilst in the spine they were only just beginning and were confined to the lower lumbar vertebræ. This child had suffered much from bronchitis and hence the ribs had been the seat of much motion and had felt the effects of atmospheric pressure, whilst the limbs and spine had been at rest in bed. Thus it may be inferred that the degree of rachitic change at any part will, in some measure, be proportionate to the amount of wear and tear of the part. With regard to

the pathological changes in other parts of the body the most important that I have found is a general increase of lymphoid tissue. This is marked in the bronchial and intestinal mucous membranes, in the liver, spleen, and lymphatic glands. The constancy with which post-nasal adenoid growths occur in rickets has suggested to me the probability that they are the expression of this same rachitic change. In other words, I believe that adenoid vegetations are often a symptom of rickets, though I do not suggest that the same hyperplasia may not sometimes arise from other causes. The association of rickets with "adenoids" is practically important, for patients relieved of nasal obstruction by removal of adenoids and enlarged tonsils usually require a course of medical treatment, and not infrequently deformities of the spine, thorax or limbs are present and demand orthopædic management.

Causation of Rickets.—The importance of diet in the causation of rickets cannot be over-estimated. The disease, it is true, is often observed in breast-fed infants, but the more marked cases are nearly always in children who have been brought up on artificial foods, which are less assimilable than the natural raw diet proper to infants up to the age of nine months. After this early age also the disease can be produced by errors of diet. The usual one consists of giving excess of starch and insufficient proteid and fat. Cheadle emphasises the importance of giving sufficient fat, and the value of cod-liver oil proves the necessity for this. Systematic sterilisation of milk as a preventive of tuberculosis plays a part in the production of rickets. That other factors besides diet contribute to the production of rickets is well known. Good hygiene is required as well as good food for the prevention and in the treatment of rickets. Another factor, namely, heredity, is, in my opinion, undoubtedly present in a fair number of cases and, as in other pathological conditions, must be regarded as a predisposing cause.

The *period of life* at which rickets becomes pronounced is usually the first few months after birth, and not many cases develop after the age of two years. In a few instances the onset of the disease has appeared to be as late

as seven or eight years. Another period of life at which skeletal deformities frequently arise is at the approach of puberty. These deformities are attributable in part to muscular weakness, but there is usually, in addition, a weakness of bone, a condition termed *rickets of adolescence*.

Rachitis Adolescentium.—This term is used somewhat vaguely. Distinction should be made between three conditions: (1) Persistence of rickets from infancy into adolescence; (2) recrudescence of rickets during adolescence after an interval of freedom from the disease; (3) rickets appearing for the first time during adolescence.

It is not uncommon to find among those who apply for treatment of deformities children of ten to twelve years who have every symptom of rickets: tumid abdomen, swollen epiphyses, disordered digestion, muscular weakness, etc. In some of these either a continuous history of rickets from infancy or a period of rickets during infancy followed by a period of comparative health can be obtained. In another class of cases there is no history of infantile rickets, but during adolescence osseous and muscular weakness, accompanied by anæmia and the occurrence of various deformities.

As a typical instance of the latter type of rickets of adolescence, the following case may be briefly noticed:—

A girl, I.V., of plump and well-nourished appearance, aged ten years. Always strong and active as a child. No traces of infantile rickets. Brought to the City Orthopædic Hospital for pain in the left hip and knee. She walked with a distinct limp. On examination distinct but moderate beading of the ribs and enlargement of the ends of the long bones was found. There was also fairly well-marked lateral curvature, evidently of recent date. All these symptoms appeared to have developed in two months. The patient was slightly anæmic, and her respiration was marked by an occasional deep inspiration followed by a sighing expiration. No sign of lung or other disease was present. The patient was growing rapidly in stature. Under treatment the anæmia, the enlargement of the ribs, and the pains in the limbs disappeared.

Mr. Clement Lucas* has observed cyclical albuminuria and a sexual neurosis in this class of case. As far as the rickets is concerned, these two symptoms would appear to me to be accidental concomitants, for in a marked case of

* *Lancet*, vol. i., 1883, p. 993; *Brit. Med. Journ.*, i., 1884, p. 852.

persistent rickets in a girl aged ten years I found the urine taken at different periods of the day to be free from albumen.

Albuminuria and neuroses are more commonly observed in rheumatoid arthritis, which is not unknown in childhood and adolescence and, by giving rise to flat-foot and other pressure deformities, may easily be mistaken for rickets.

Congenital Rickets.—Belief in the occurrence of intra-uterine rickets has to a large extent been lost in Great Britain owing to the fact that at least two other conditions—cretinism and achondroplasia—quite distinct from rickets, had been mistaken for this disease. Yet Kassowitz, in one of the most recent (1881) and most thorough investigations of the subject, says:—"But still it is not, I believe, sufficiently known that in the great majority of cases rickets begins in a very early period of intra-uterine development. Most authors still make the error of believing congenital rickets to be a rare condition, whilst, according to my experience,

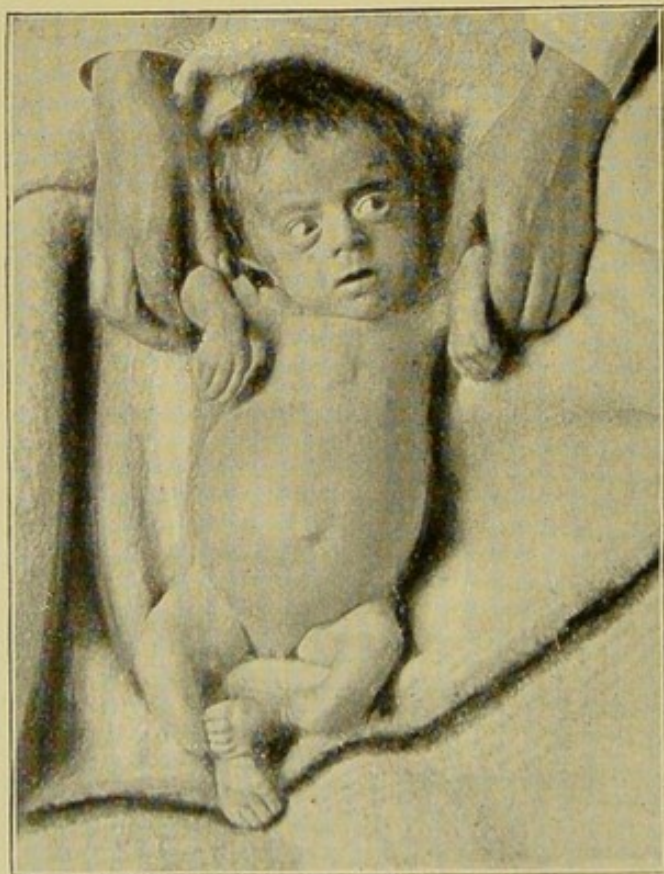

Fig. 17.—Dr. Railton's Case of Congenital Deformity.

this is by no means the case." This opinion is based on the careful histological examination of new-born children.

I have carefully examined the bodies of many stillborn infants, but I have never found any macroscopic rachitic changes in the bones.

A striking case of congenital deformity has been published by Dr. T. C. Railton, and by his courtesy and that of the editor of the *British Medical Journal* I am permitted to reproduce (Fig. 17), a photograph of the patient.

Dr. Railton* gave the following history of the case:—

A. W., aged seven months, was brought to the Clinical Hospital on April 24th, 1893, on account of certain deformities of the limbs, which are shown in the accompanying photograph [Fig. 17].

Personal History.—Her mother stated that these deformities were in existence at the time of her birth, and that the peculiar softness of the back of the head, to be presently mentioned, was remarked about the same time. The child had always sweated a great deal, and her limbs had been noticed to be tender when they were handled, especially the left arm. These points were, of course, carefully inquired into, and, apart from the evidence of the bones themselves, which one could hardly imagine to have become so completely and universally deformed had the rickets commenced after birth, there remained no reasonable doubt that the child had come into the world with the disease fully developed. She had been brought up at the breast until she was two months old, and subsequently she had been fed upon condensed milk. She had not cut any teeth.

Family History.—There was no family history pointing to syphilis; the mother certainly had miscarried once (after the birth of her second living child), but none of her children had shown any symptoms either of snuffles or rash. She herself had suffered from rickets in childhood, and as a consequence had bow legs and a somewhat contracted pelvis. Of the four other children of the family, I had the opportunity of examining one, aged two-and-a-half years, and found beading of the ribs, enlarged epiphyses of the radii, slightly bowed tibiae, but no signs of syphilis. The mother had not been in ill-health during the time she was carrying the patient.

Condition on Admission.—On her admission the following notes of the child's condition were taken:—She has an intelligent face, with good though very thin features, the sucking pads showing distinctly. Her height is eighteen inches instead of twenty-four, her weight six pounds instead of nineteen pounds. Her limbs and body, except the abdomen, are emaciated. There are no blood extravasations and no indications of cachexia. The forehead is rather bossy, but the vertex of the skull is not flattened. The anterior and posterior fontanelles

* T. C. Railton, *Brit. Med. Journ.*, June 16, 1894.

and the sagittal suture are widely open, and there are small lateral fontanelles at the inferior angles of the parietal bones. The membranous part of the occipital bone is quite unossified, so that it feels soft and yielding wherever pressure is applied. The neck is thin but not short, and there are no fatty swellings. The thyroid gland can be felt. The chest has the sternum thrown forwards, and there are well-marked beads at the junction of the ribs with their cartilages, and also smaller beads behind in the region of the angles. In front a deep transverse groove passes outwards and downwards from the ensiform cartilage. The abdomen is globular, and shows no enlargement of either liver or spleen. The patient moves both upper and lower extremities perfectly well. The arms are shortened by the extreme distortion of the humeri, so that the tips of the fingers barely reach the junction of the upper and middle third of the thighs. At the upper end of each humerus there is an abrupt bend, with the convexity turned towards the axilla, and the corresponding receding angle is visible on the outer side of the arm below the acromion process. There is no thickening of the shafts of the humeri or of any other bone. In each forearm there is a curvature of the radius and ulna, with the concavity forwards, especially marked on the left side. There is little or no enlargement of any epiphysis in the upper extremities. The hands are small, and have long, delicate, tapering fingers. The lower extremities are greatly shortened by their various curvatures, and are habitually folded in tailor fashion, much the same, I imagine, as they were in the womb. The lower epiphyses of the femora are enlarged. The femora themselves are much curved, with the convexity outwards. In the middle of the left femur there is a green-stick fracture, bending the lower half forwards and causing a projection behind and externally. The tibiæ are the most deformed bones in the body, the upper two-thirds in each leg being much curved, with the convexity forwards, while at the junction of the lower with the middle third, there is an abrupt bend backwards, leaving a strongly projecting angle in front. The lower third on each side has two curves, so that there is a convexity both forwards and outwards. On the left side this double curvature is exceedingly abrupt. The feet are small and well formed.

After-history and Treatment.—After admission it was observed that the child perspired profusely during sleep, so that the sweat stood in beads upon her forehead. She showed great tenderness in the limbs when they were handled.

The child improved under treatment, but after leaving hospital died of broncho-pneumonia.

The deformity of the lower limbs in this case recalls that seen in some instances of achondroplasia, and in all probability rickets was super-added after birth.

Achondroplasia is characterised by deformity of the foetal skeleton, affecting the bones of the limbs and the

base of the skull. The membrane bones of the skull and the clavicles are normal. The long bones are shortened and thickened, hard and compact. By the kind permission of the Council of the Clinical Society of London and Dr. Archibald E. Garrod, I am able to give an illustration of a typical case (Fig. 18).

Porak* is of opinion that achondroplasia undergoes its full evolution during the first half of pregnancy, whilst rickets develops during the second half of pregnancy, and is in full activity at the time of birth.

The accompanying sketch (Fig. 19), of the bones from a stillborn infant affected with achondroplasia is borrowed from Porak's memoir. The absence of cartilage in the bones is a striking feature.

Another condition not infrequently mistaken for rickets is a *dystrophy*, not as yet definitely named. The subjects of it are generally of stunted growth, and their joints possess remarkable mobility. The fingers, which tend to have a square shape, can sometimes be bent back almost

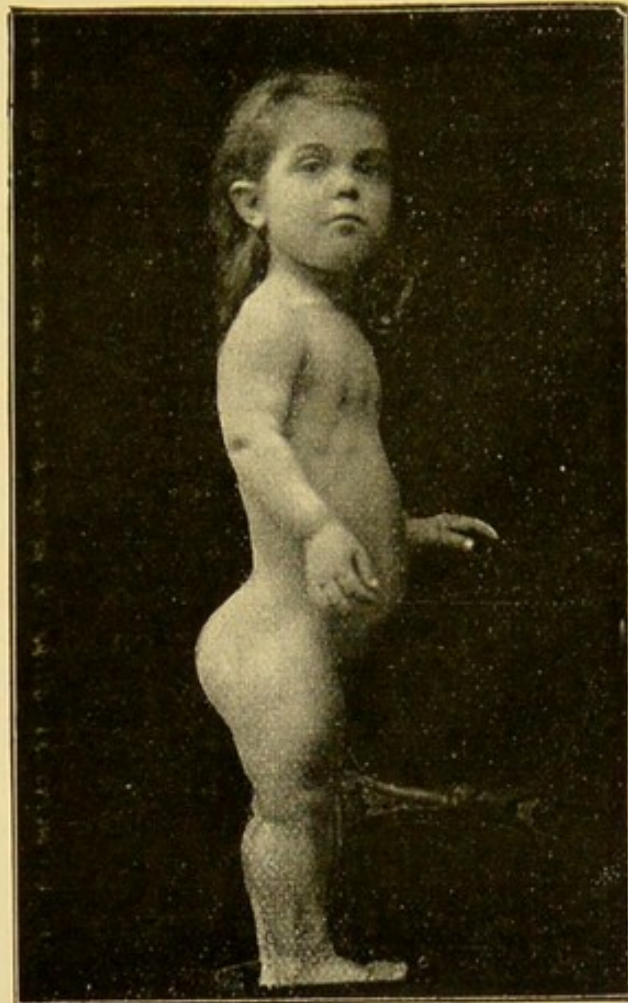


Fig. 18.—Achondroplasia in a Girl aged six years. (Dr. Archibald Garrod's Case.)

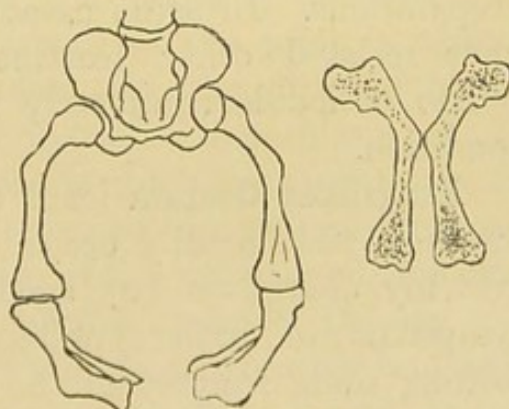


Fig. 19.—Bones of Lower Limbs of a Still-born Child, the subject of Achondroplasia.

(After Porak.)

* Porak, "L'Achondroplasie." *Nouvelles Archives d'Obstétrique et de Gynécologie*, 1890.

to touch the dorsum of the hand. In some of these cases kyphosis or contractures of the knee- and ankle-joints, in others genu valgum may be present. Many such patients are intelligent, other are idiots of the Mongolian type. In a case now under my care there was plain evidence of congenital syphilis. In these cases, which appear to have nothing to do with cretinism, not much can be promised in the way of improvement.

Syphilis.—In early infancy slight congenital specific enlargement involving the juxta-epiphyseal regions of several bones may mislead the observer into mistaking the condition for rickets. More pronounced syphilitic inflammation in the same regions will be readily distinguishable by the accompanying "pseudo-paralysis." Parrot confused the bone lesions of congenital syphilis with those of rickets. In orthopædic practice, as in other branches of medicine, the observer should be ever on the watch for evidences of syphilis, especially in aberrant cases. The anteriorly-bowed tibiæ that not infrequently occur in syphilitic children may be distinguished from those of rickets by their form and concomitant symptoms and by the thickening of the bone that occurs in the former condition. Tertiary syphilis has been recognised as the cause of some cases of spinal disease and deformity.

Syphilitic affections of joints are not always of the rapidly destructive character made familiar by pathological preparations. In some cases of chronic joint disability that have resisted other treatment, I have found a thorough course of iodide completely restore the part to its normal condition.

Fragilitas Ossium leads to deformity from the multiple fractures that readily occur. In a case that recently came into my charge—a boy aged ten and a half months—the symptoms of both syphilis and rickets were combined, lending some support to the suggestion made by Kassowitz, that congenital syphilis may in some cases be provocative of rickets by producing disturbance of nutrition.

Osteitis Deformans, osteomalacia, and other diseases of bones are usually of a progressive character, and offer but little scope to the surgeon.

Rheumatoid Arthritis.—Rheumatoid arthritis, or osteo-arthritis, is no more a joint disease than rickets is a bone disease. Indeed, in many ways these two affections resemble each other.

The influence of heredity is very marked, and although the grosser symptoms of the disease do not, as a rule, show themselves before adult life, cases of typical rheumatoid arthritis are met with among infants and children.

In osteo-arthritis, as in rickets, the nutrition of the whole of the body is deranged. The digestion is often seriously affected. The nervous organs are so far deranged that many observers attribute the articular changes to trophic nerve influence. Neuralgias, neurasthenia, etc., are of common occurrence.

Sometimes severe peripheral neuritis is observed, and may lead to serious deformity. Thus, in a case of rheumatoid arthritis that Dr. G. A. Sutherland brought to my notice complete paralysis of the tibiales and calf-muscles leading to a typical talipes calcaneo-valgus developed in fourteen days in a woman aged seventy-two.

Vasomotor disturbances, such as "dead fingers" and Raynaud's disease, are not infrequently seen. Some desmogenic contractures, *e.g.* Dupuytren's contracture, are at times part of a general rheumatoid arthritis.

With regard to the joints the chief changes are as follow :—The synovial membrane secretes an excess of viscid synovia. When this is in very great quantity the membrane is bulged out, and where the capsule of the joint is weakest this bulging is greatest, and may take the form of hernial protrusions. In many cases there is hyperplasia of the connective tissue of the synovial membrane resulting in the formation of numberless pear-shaped projections (*see* Fig. 20, 1), which remind the observer of the warty condition often seen in the skin about some chronic ulcers of the leg.

These hyperplastic synovial villi sometimes become separated from the membrane from which they spring, and so constitute one variety of loose bodies which occur in joints. They may become cartilaginous, and the cartilage in them may calcify. It occasionally happens that in dissecting a joint after death dozens of these calcified loose bodies fall out.

The articular cartilage, like the synovial membrane, undergoes inflammatory hyperplasia. The multiplication of the cartilage-cells loosens the fibres of the cartilage matrix, and

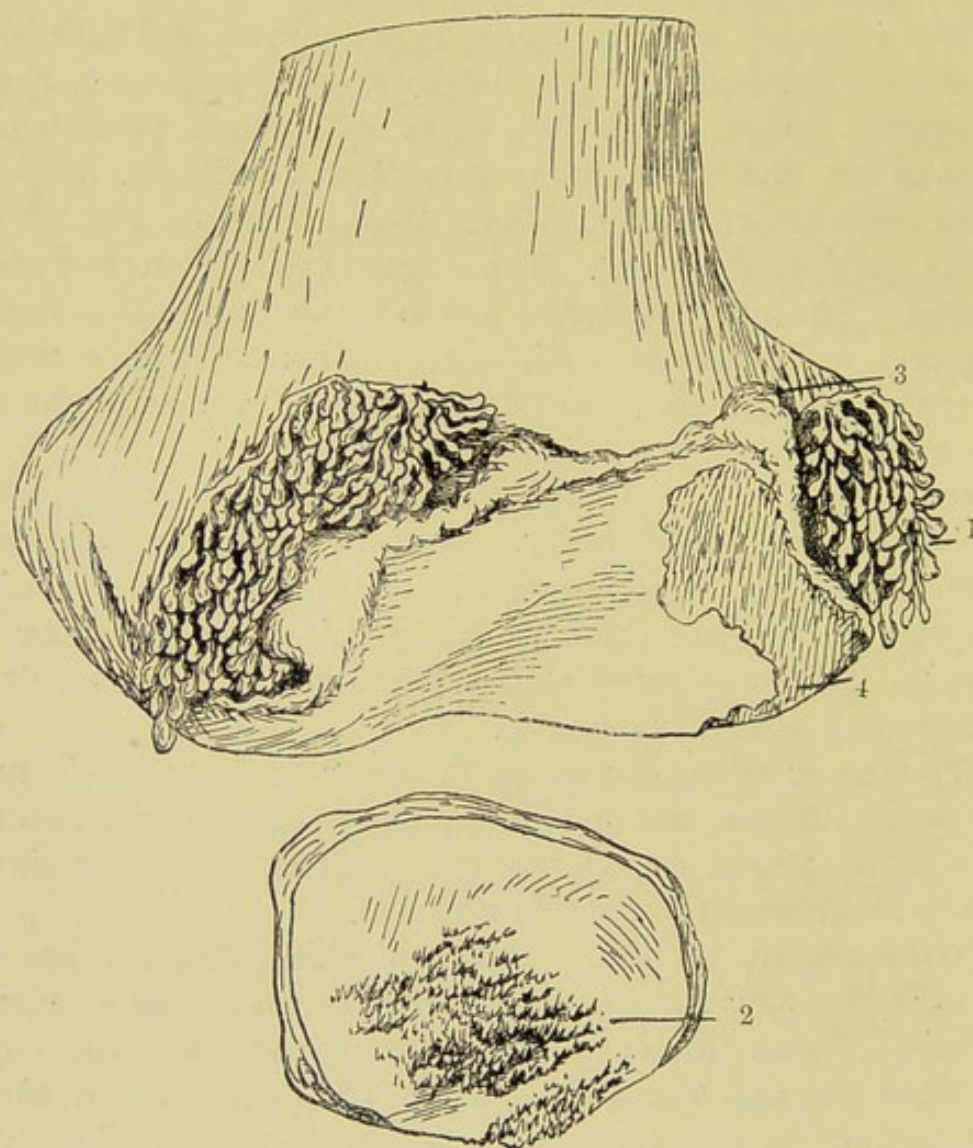


Fig. 20.—The Lower End of a Femur with the Patella, showing changes due to Osteo-arthritis.

1, part of the synovial membrane with fibrous projections; 2, cartilage over the patella showing the velvety condition; 3, part of the collar of ecchondrosis and exostosis growing beyond the margin of the articular cartilage; 4, part of the articular surface of the femur denuded of cartilage by friction. (*St. Mary's Hospital Museum, No. 460.*)

where the cartilage is exposed to friction the surface of the cartilage becomes fissured, and some of the cells escape into the joint-cavity. This gives the cartilage a velvety appearance (Fig. 20, 4). This velvety cartilage is readily worn away, exposing the bone, as at 2 (Fig. 20). The exposed bone, if the joint is much used, becomes grooved

from friction, and assumes a peculiarly increased density, which gives it an appearance like the glaze on porcelain. At its

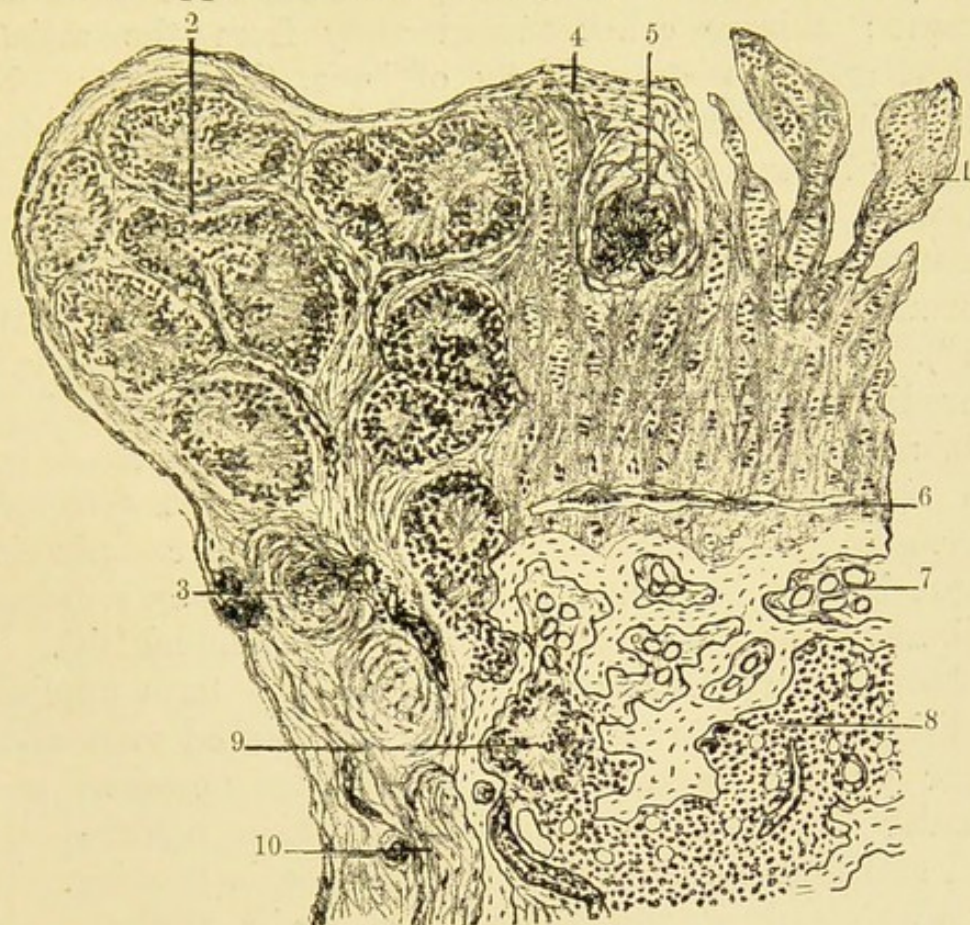


Fig. 21.—Section at the Margin of the Articular Surface of a First Metatarsal Bone from a case of Osteo-arthritis combined with Gout.

1, articular cartilage, the cells of which are proliferating, and the superficial layers of which are undergoing cleavage; 2, hyperplastic tissue of periosteal origin, consisting of areas of dense fibroid tissue surrounded by cells, some of which are multinucleated. These cells are supported by connective tissue continuous with the periosteum and containing newly formed capillaries. 3, commencing focus of inflammatory new tissue resembling those described under 2; 4, fibrous tissue derived from the synovial membrane growing for a short distance over the cartilage; 5, stellate cluster of urate of soda crystals in the articular cartilage; 6, cleft in the cartilage; 7, normal fatty marrow; 8, lymphoid marrow replacing the original fatty marrow; 9 (in the bone), focus of the newly formed fibro-cellular tissue resembling those forming "lip" at 2; 10, periosteum. In this instance the "lip" of new tissue consists neither of bone nor of cartilage, but resembles the inflammatory foci seen around gouty "tophi" in the soft tissues.

margin, where it is not exposed to friction, the cartilage from the inflammatory overgrowth forms a collar of ecchondrosis. Similar changes taking place in the bone beyond the cartilage there results a growth of bone (exostosis), on which that formed of cartilage rests. The histological structure in a case of osteo-arthritis combined with gout is shown in Fig. 21.

The "lipping" of the cartilages, as the formation of ecchondro-exostoses is commonly termed, is in some cases extreme; a large collar turned away from the articular surface, and consisting chiefly of bone, then exists. Now and again, in osteo-arthritis, the denuded bony surfaces, instead of becoming indurated (porcellaneous), are rarefied and worn away progressively, so that in this way deformity arises either by allowing displacement ("dislocation by deformation"), or by interlocking ("ankylosis by deformation"). Neither fibrous nor osseous ankylosis occurs in diarthrodial joints in osteo-arthritis, but the bodies of contiguous vertebræ may become joined together by bridges of bone. The changes in the vertebræ are known as *spondylitis deformans*. The histological changes of osteo-arthritis of infants include besides the changes in the joints excessive proliferation at the epiphyseal lines (osteo-chondritis).

Chronic Dry Ulcerative Arthritis is a term applied to conditions similar to osteo-arthritis, but marked anatomically rather by degenerative than proliferative processes in the articular cartilages, the matrix of which becomes fibrillated and fissured, whilst the proliferation is wanting. It is met with chiefly in the *malum coxæ senile*, and is regarded as a senile disturbance of nutrition. It is not clinically separable from osteo-arthritis.

Chronic Traumatic Arthritis Deformans.—Arthritis deformans may result from injury to a joint. Thus, after a slight injury to the hip-joint, deformity may gradually be produced, and in such cases medical men have been wrongly suspected of having overlooked a fracture.

Arbuthnot Lane* regards such a condition as simply traumatic. The close study of many such cases has convinced me that this view is untenable. After a period of rest in a simple traumatic case exercise of the joint improves the condition of the part instead of producing the changes that are correctly described by Lane in the hip-joint:—

If such a joint be examined after death, the head of the femur and the acetabulum are found to be completely altered in form and character. The opposing surfaces of the innominate bone and femur are rubbed down, sclerosed, and eburnated, while around these

* Arbuthnot Lane, "Clinical Lectures," 1897, p. 70.

eburnated surfaces there is an abundant deposit of more or less dense bone, whose obvious function is to compensate for the altering direction in which force is transmitted through the joint, and to render it as secure as possible under the circumstances. The capsule has become thin and lax, and has ceased to perform most of its normal functions. The synovial membrane in the joint is bulky, and contains an abnormal amount of synovia. The causation of the several changes here described is quite obvious. . . . The opposing surfaces of articular cartilage have been bruised sufficiently to interfere with their vitality, and there being no means of replacing the damaged tissue it is removed. The habitual transmission of force through the damaged joint results in the progressive destruction of the remainder of the articular cartilage, in the exposure, eburnation, and the progressive gradual destruction of the subjacent articular lamella of bone. These changes are followed by the others already described, the factors determining their evolution being solely mechanical.

In several cases of the kind that I have carefully watched I have been able to find the general symptoms of osteo-arthritis, though there were no pronounced anatomical changes in any save the injured joint.

On the other hand, in cases where, owing to traumatism of joints, fibrous ankylosis has occurred, it is familiar to all that after breaking down the adhesions movement forms the most important factor in the restoration of the joint to its normal form. It is therefore, in my opinion, probable that in all cases of deforming traumatic arthritis the trauma only serves to awaken into activity a local expression of a general pathological condition.

The essential nature of osteo-arthritis is disputed. The majority of observers regard it as an auto-intoxication. Recently Bannatyne* and Wohlmann have advanced the view that the more acute forms are due to infection, the more chronic to degeneration. In the course of making over 2,000 autopsies, I have frequently studied the pathological changes in this condition, which I regard as essentially a chronic inflammatory process, associated with degeneration in varying degree. Atheroma of arteries is often associated with the joint changes. The histological lesions of osteo-arthritis present both inflammatory and degenerative changes. The former are shown by proliferation of connective-tissue elements. (*See Fig. 21.*)

* Bannatyne, "Rheumatoid Arthritis," 1898.

The effect of these anatomical changes depends upon their degree. In the more advanced stages dislocation or interlocking may occur. The latter condition has been termed "ankylosis by deformation" (Volkmann). It closely resembles the effects of tabetic arthritis (Charcot's disease). Slight degrees of stiffness of joints are common in osteo-arthritis, and forcible passive movement is then sometimes advisable. This operation is sometimes spoken of as "breaking down adhesions," though it is to be remembered that true intra-articular adhesions do not form in osteo-arthritis. The resistance to movement is due to irregularities in the articulating surfaces and changes in the peri-articular structures.

The course of rheumatoid arthritis is chronic, and tends to be progressive, with intervals of remission of symptoms. By proper diet and medical treatment a great deal can be done to alleviate the sufferings of the patient, and especially in the young and neurasthenic diet is of the first importance.



The most difficult cases, as far as treatment is concerned, are those in which there is chronic effusion into the joints. As an instance, I may record the following case:—

Mrs. S., a Jewess, aged fifty-nine, came to the North-West London Hospital with great fluid swellings in both elbow-joints, of three years' duration; and pain and creaking in the knee-joints.

At the age of thirty-six, in spring, about six months after a baby was born, she was seized with a "rheumatic" attack in the right knee. The attack lasted some months. Towards the end the arms became affected. The doctor took the temperature, and found that there was some fever.

Three years later she was attacked in the arms, but did not feel feverish. She was ill for several weeks. An acquaintance recommended two ounces of mustard in half a pint of gin. Of this formidable remedy the patient took a wine glass twice a day for ten days. At the end of that time she felt well, and was free from pain for nearly twenty years. Her next attack occurred at the age of fifty-six. She had then been in London some years. The knees and arms were affected, the knees more severely than the arms. She had fourteen Turkish baths, and was relieved a little. The doctor ordered her cod-liver oil, maltine, and iron and quinine. Since this attack, which was eleven years ago, the patient has never been free from pain. During the last three and a half years the disease has progressed, chiefly in the elbows. The jaw has been stiff for three and a half years. A couple of sulphur baths were taken at ——— Hospital (London) but no good was obtained. The patient then tried the hot-air bath

six times ; no relief at all. She could not say that any kind of weather makes the condition better or worse. At — Hospital (London) blistering was tried three times ; it gave no relief. Iodine painting seemed to relieve, but caused eczema. Hutton (bone-setter) gave black liniment with CHCl_3 in it ; no relief. Rubbed by a nurse every day for fourteen days, Sundays excepted ; this made left elbow swell to double former size, and increased the pain. Went to Bath in March, 1894 ; remained four weeks ; first fourteen days had hot baths. This did her no good. Went into a Homœopathic Hospital, where she had "white powders" and six vapour baths. This did no good. She had no



Figs. 22, 23.—Greville Apparatus for localised Hot-air Bath to Thighs.

previous illness. Has pain in chest ; (?) indigestion ; no shortness of breath or swelling of legs.

Neither mother nor father had rheumatism. She is the only survivor of eleven children, the rest died in infancy and childhood. She has four children ; one has asthma and bronchitis, one healthy until two or three years ago, when he had slight stiffness in right arm. At one

time the patient had severe neuralgia right side of face ; for this, four teeth were taken out without relief. The pain yielded to medicine. Now she has pain about the affected joints, cramp in calves and feet.

I have given the chief points in the history of this case in order to emphasise the great difficulty there is in the treatment of obstinate rheumatoid arthritis.

The surgical bearings of rheumatoid arthritis are many. Spondylitis deformans, when severe and painful, may require the adaptation of a spinal support for the prevention of deformity and the arrest of pain. Arthritis of the hip and knee are also much benefited by rest, and not infrequently require supporting apparatus.

When joints are stiff and contracted forcible passive movement may be called for. This proceeding is made much easier and less painful to the patient by the use of the hot-air bath. The best form of this bath, where there is an available electric supply, is the "Greville," the value of which was demonstrated to me by Mr. William Armstrong, of Buxton. The heat is generated by electricity, and hence it has not the drawback of apparatus heated by gas. The temperature is regulated with great precision, and the apparatus for various parts of the body can be placed on the patient's bed. In Figs. 22 and 23 the apparatus is designed for application of heat to the thighs.

A temperature of from 300° to 340° F.,* continued for about forty minutes is the most useful, and the local effect in the way of increasing the mobility of joints is very great. This method of treatment should only be employed under close medical supervision.

Sometimes the pain in the neighbourhood of joints can be relieved by drilling the bone with antiseptic precautions. This simple procedure acts by relieving intra-osseous tension, as may be readily understood on noting the new inflammatory tissue shown in the interior of the bone in Fig. 21.

When obstinate effusion is present in one or two joints, aspiration, drainage, or even excision may be required.

* Dr. A. P. Luff (*Practitioner*, February, 1899, p. 173) points out that this temperature "as registered by the thermometer at the side of the bath is probably higher than that of the air close to the skin."

There is no affection in which there is more scope for co-operation of physician and surgeon than in this.

G. F. Still, in the "Transactions of the Royal Medico-Chirurgical Society, 1896," describes, as distinct from rheumatoid arthritis, a joint affection met with in children before the second dentition.

The disease may be defined as a chronic progressive enlargement of joints, associated with general enlargement of glands and enlargement of spleen.

The onset is almost always before the second dentition; ten out of twelve cases began before the age of six years, and of these eight began within the first three years of life; the earliest was at fifteen months.

Girls are more commonly affected than boys; seven of the twelve cases were girls, five were boys.

The onset is usually insidious; the child, if old enough, complains of stiffness in one or more joints, which slowly become enlarged, and subsequently other joints become affected; but occasionally the onset is acute, with pyrexia and, it may be, with rigors.

I wish to lay some stress on the character of the enlargement of the joints. It feels and looks more like general thickening of the tissues round the joint than a bony enlargement, and is correspondingly smooth and fusiform, with none of the bony irregularity of the rheumatoid arthritis of adults.

The absence of osteophytic growth and of anything like bony lipping even after years have elapsed since the onset, is striking.

There is, I believe, never any bony grating, although creaking, probably either of tendon or of cartilage, is frequently present. There is no redness or tenderness of the joints, except in very acute cases. The absence of pain is generally striking, but it may be present in slight degree, especially on movement. Limitation of movement, chiefly of extension, is almost always present; the child may be completely bed-ridden owing to more or less rigid flexion of joints.

The joints earliest affected were usually the knees, wrists, and those of the cervical spine; the subsequent order of affection being ankles, elbows, and fingers. The sterno-clavicular joint was affected in two out of twelve cases; the temporo-maxillary in three. The affection is symmetrical. There is no tendency to suppuration nor to bony ankylosis. The muscles which move the diseased joints show early and marked wasting, which contrasts often strongly with the good nutrition of the rest of the body.

The electrical reactions both to faradism and galvanism were brisk in three cases tested, but not otherwise altered.

Perhaps the most distinctive feature in these cases is the affection of the lymphatic glands. The enlargement is general, but affects primarily and chiefly those related to the joints affected.

A typical example of the kind of case under consideration is now under my care.

B. B., a girl, aged four, was brought to my out-patient department of the City Orthopædic Hospital suffering from the form of joint disease described by Still. There was no liquid effusion into the large joints, but enlargement of the ends of the long bones and beading of the ribs, and a painful angular curvature of the spine in the upper dorsal region. The general condition was one of severe anæmia and prostration. She

was admitted as in-patient under my colleague, Mr. John Poland, under whose treatment her condition improved greatly, so that she was able to leave the hospital. She now attends my out-patient department again. The anæmia has entirely disappeared, but the knees and ankles remain contracted and stiff, whilst there is great improvement in the deformity of the spine and the nodal swellings of the fingers and beading of ribs (see Fig. 24).

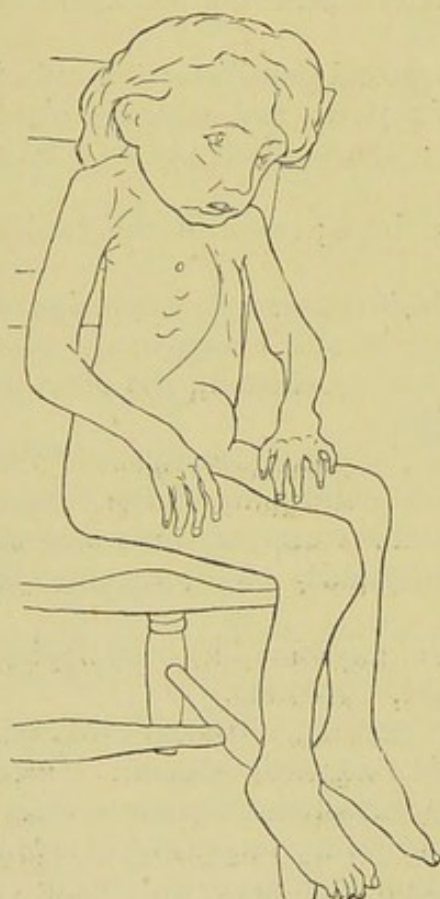


Fig. 24.—Sketch of B. B., aged four years, suffering from Rheumatoid Arthritis.

(From a Photograph.)

Whether the condition is distinct from rheumatoid arthritis is perhaps open to some doubt. One certainly sees in adults affected with undoubted rheumatoid arthritis similar ovoid swellings about the joints of the fingers, and also beading of the ribs is sometimes observed in older patients suffering from this affection; for example, in the case of a lady, aged thirty-five, sent to me by Sir William Broadbent for a painful condition of the right twelfth rib, which

presented a swelling near its free extremity. There were also oval swellings at other osteo-chondral junctions and a general condition of anæmia.

The pain arising from the twelfth rib was so severe that the patient asked to have it removed by operation. Seeing, however, that the affection was only one of several indications of a general condition, I advised the use of a small abdominal belt specially designed to steady the rib and

protect the swelling—a plan that proved completely successful.

Commenting upon Dr. Still's account, Dr. Bannatyne observes :—

The pure rheumatoid arthritis in children he considers to be characterised by bony thickening and lipping about the joints, and by the presence of bony grating and the absence of enlargement of the glands and spleen. Now, his description of the first class corresponds to my description of what we see in adults in the acute form of the disease, and also his second with the chronic form. To me he appears to be considering just the self-same forms of the disease. I do not believe that the first form he describes as peculiar to children differs in any respect from the acute form in adults except in the splenic enlargement, which may have been an accidental occurrence, so common in children ; but, of course, the question still remains, "Are these two diseases both in adults and in children?" Dr. Still's idea of what is pure rheumatoid arthritis is the popular one—that there must be bony enlargement. This, I would strongly urge on my readers, is not the case ; at least, not in the forms we most frequently see it in in Bath.*

Two other conditions that may give rise to contracture or ankylosis are to be distinguished from rheumatoid arthritis. These are true rheumatism and the peculiar affection termed "chronic rheumatic arthritis."

Rheumatism or Rheumatic Polyarthrititis, when acute, is associated with the general constitutional symptoms, the full consideration of which does not come within the scope of this work. Several joints become affected one after the other. The synovial effusion is marked by great pain and tenderness, and is accompanied by some para-arthritis. The distribution of rheumatic joint-effusions recalls those of pyæmia. And possibly the joint affections, which are not infrequently observed after the injection of antitoxic serum, throw some light on the nature of rheumatism, which may be the result of an intoxication. The tendency of acute rheumatism to simulate other affections and to become sub-acute or chronic, renders rheumatic affections of importance to the surgeon. In doubtful cases subcutaneous rheumatic nodules on the scalp, about the elbows, wrists, patella and ankles should be looked for.

Chronic Ankylosing Arthritis, or Chronic Rheumatic

* G. A. Bannatyne, "Rheumatoid Arthritis," 1898, p. 91.

Polyarthrititis (*arthrititis pauperum*). — This affection is marked by the joints of the body becoming ankylosed one after another. The disease may follow an attack of acute polyarticular rheumatism, or it may begin insidiously. Once begun it continues for the rest of the patient's life. The changes in the joint have some resemblance to those of osteo-arthritis, but differ in that the changes in the cartilage are accompanied by less pronounced cell-proliferation. The cartilages become villous and converted into fibroid tissue, which is replaced by vascular fibrous tissue, the blood-vessels of which are derived partly from the neighbouring synovial membrane, partly from the marrow-spaces of the underlying bone. Fibrous adhesions form between the articular surfaces. The remains of the articular cartilages become converted into osseous or osteoid tissue. The fibrous ankylosis once begun

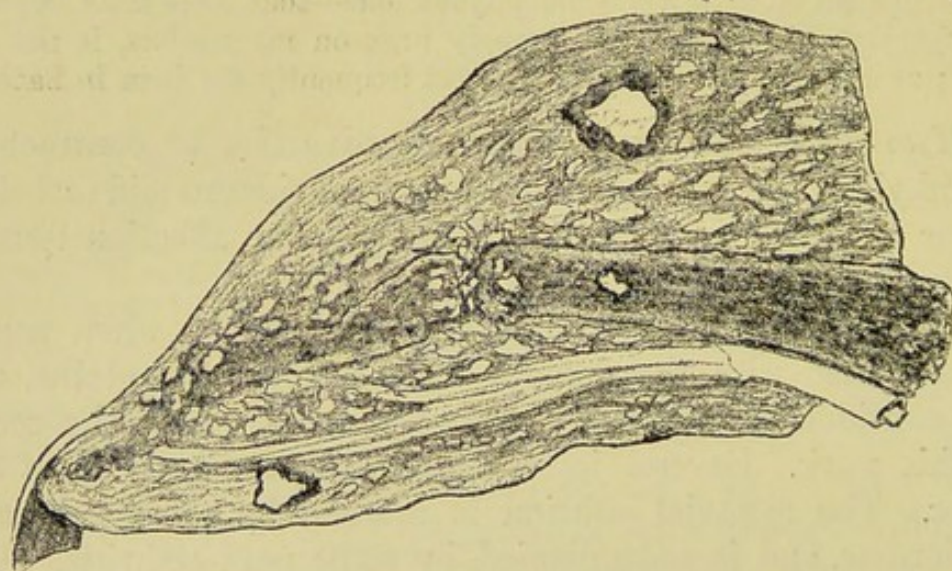


Fig. 25.—Section through a finger extensively disorganised by gout. The interphalangeal joints and their cartilages have been destroyed. Collections of urate of soda (tophi) are present in the ends of the bones and in the peri-articular and subcutaneous tissues.

becomes more extensive, and finally the fibrous adhesions become converted into bone. In old-standing cases this remarkable disease may result in bony ankylosis of every joint in the body. But little can be done to alleviate the disabilities of the patient in this condition.

Gout. — Of the anatomical changes in gout the most characteristic is the presence of urate of soda in the tissues. On opening a joint affected by gout, the articular surface may appear as if covered with a coat of white paint.

Without further marked change there may be, in addition, all the changes described under osteo-arthritis. Deposits of urate of soda in the soft parts (tophi) are sometimes very extensive, as in the instance shown in Fig. 25.

On histological examination, such collections are found to be deposited in degenerated tissue, and to be surrounded by a zone of inflammatory tissue,* exactly resembling that seen in osteo-arthritis (see Fig. 21).

Whether or not there is any relationship between gout and osteo-arthritis is disputed.† Even at the present time very different views are held—*e.g.* Sir Alfred Garrod (1859) described the condition as distinct from gout and rheumatism, thus agreeing with Heberden (1804), whilst Mr. Jonathan Hutchinson holds that rheumatoid arthritis is the inherited form of gout. In the course of making over 2,000 autopsies, I have very frequently observed the typical lesions of osteo-arthritis combined with gout, so that the two conditions have become closely associated in my mind. From a practical point of view, it is important for every surgeon to be on the watch for evidences of gout and granular kidney, with which it is often associated.

Myogenous and desmogenous contractures are of equally frequent occurrence both in gout and rheumatoid arthritis—*e.g.* Dupuytren's contraction of the palmar fascia may occur in either condition.

The arthrogenous deformities due to gout are similar in kind to those met with in osteo-arthritis, but they tend to be more severe. In gouty deformed hands the "seal-fin" type familiar in rheumatoid arthritis is often recognisable. Grave disorganisation, such as has been shown in Fig. 25, may demand amputation.

Rickets predisposes chiefly to pressure deformities, osteo-arthritis to both pressure deformities and contractures. The remaining conditions that more commonly cause contractures may now be briefly reviewed.

Dermatogenous Contractures are such as are due to cicatricial changes in the skin—*e.g.* from burns, ulcers, etc.

* See a paper by Berkart, *Brit. Med. Journal*, vol. i., 1895.

† A historical account, by Archibald E. Garrod, "Twentieth Century Practice of Medicine," vol. ii., 1895, may be consulted.

A large scar at the side of the neck may cause a dermatogenous wry-neck; a scar about the ankle may determine a dermatogenous club-foot.

Desmogenous Contractures result from shrinking of fascia—*e.g.* shrinking of the fascia lata may cause angular deformity of the hip-joint, and chronic inflammatory shrinking of the processes of the palmar fascia produces Dupuytren's contraction.

Myogenous Contractures are such as are due to primary shrinking of muscle. These are of various kinds. Certain habits may lead to shortening of muscles: thus, in coachmen, the fingers of the left hand are frequently contracted from holding the reins, and in time the power of straightening the fingers is lost. This is the *habit-contracture*. *Compensatory* muscular contracture is seen in some persons who, to overcome the disability of a short leg, hold the corresponding foot habitually in the position of club-foot. *Symptomatic* muscular contractures depend upon organic changes in the muscles. In the so-called "muscular rheumatism" the pathological condition and the contracture are usually of a temporary character. Such a condition causes acute torticollis, lumbago, and other local painful conditions. In applying massage to such muscles, knot-like, tender points are felt. When the condition is more chronic, the knot-like swellings are larger, and permanent contracture may remain. These conditions are probably more nearly related to "cramp" and lithæmia than to articular rheumatism.

Inflammatory Muscular Contractures.—Muscles involved in suppurative, tubercular, or syphilitic inflammation are partially destroyed, and undergo secondary cicatricial contraction of the fibrous tissue which takes the place of the destroyed muscular tissue. In this way, contracture of a finger after whitlow and contracture of a psoas muscle in tuberculosis of the spine become permanent.

Fibrous Myositis is a condition in which, as the result of inflammation akin to the chronic form of "rheumatic myositis," there is a new formation of interstitial fibrous tissue, either diffuse or insulated.

Ossifying Myositis.—This rare condition in its earlier phases may readily lead to errors in practice. It usually

commences before or about puberty, and is rather more common in males than in females. Inflammatory areas following the long axis of the fibres are succeeded by the formation of indurated bands in the substance of the muscle. The indurated areas finally become ossified. The muscles throughout the body become affected in turn. As a diagnostic feature shortening of the thumbs and great toes is to be remembered. The condition is very slowly progressive.

Ischæmic Myositis is the result of prolonged anæmia of muscle. It is commonly produced by tight bandaging or by swelling of a limb after splints have been applied. I have seen it follow ligature of the popliteal artery and vein. The deprivation of blood leads first to degeneration of muscle fibres, and this is followed by inflammatory infiltration, and subsequent induration and shrinking of the affected muscles. As this condition is of great practical importance, a typical example may be adduced.*

A boy, aged six years, was brought to me with a history that six weeks previously he had sustained a fracture at the lower end of the humerus that had been put up in splints and reset three days later. There had been much swelling of the elbow-joint, and for the first two or three weeks the boy had screamed if any of his fingers were touched, and he

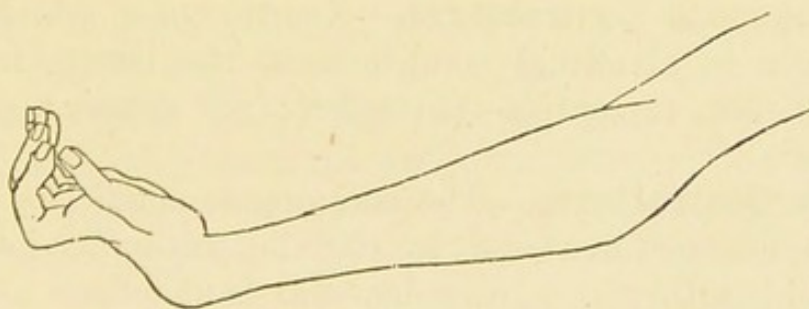


Fig. 26.—Ischæmic Contracture of the Hand.

was incapable of moving them. The swelling about the joint subsided in about five weeks, but left the joint immobile from adhesions that were broken down under chloroform. When I first examined the patient, there was no reaction in any of the muscles of the forearm to either galvanic or faradic currents, but after about a week's treatment with weak galvanism and massage, slight reaction was noticed. This was followed by reaction in some of the flexors of the wrist, but the

* For notes in this case I am indebted to Mr. Stroud Hosford, House-Surgeon at the North-West London Hospital, 1897.

flex. sub. digit., the pron. rad. teres, and the pron. quadrat. never reacted at all. The supinator longus always reacted. Sensation returned coincidently with the muscle reactions. Under this treatment he got back considerable power in the forearm, but the thumb muscles were very obstinate.

For some weeks he had fair use of the arm and hand, for he could grasp a knife or fork and even use dumb-bells. The whole arm then began to waste and stiffen, and became much more pronated, though sensation was perfect. A tendency to clawing of the hand was observed about four months after the original accident, and it increased in spite of regular massage.

The evidence in this case pointed to secondary shrinking of muscle. As soon as the deformity, which is represented in Fig. 26, had ceased to increase, I divided the flexor tendons above the wrist through a short longitudinal incision. This operation removed the whole of the deformity.

The various affections regarded as progressive myopathies—(1) pseudo-hypertrophic paralysis; (2) hereditary (or Erb's) muscular atrophy; and (3) the various forms of progressive muscular dystrophy may occasion deformities such as club-foot, and, in exceptional cases, orthopædic surgical measures may give temporary relief; but the full consideration of these conditions belongs to works devoted to the diseases of nerves.

Neurogenous Contractures.—Contractures which have their origin in abnormal conditions of the nerves fall into three different categories—(1) reflex; (2) spastic; and (3) paralytic.

Reflex Contractures.—The commonest conditions of this kind are contractures due to chronic joint-affections—*e.g.* rheumatoid arthritis. In tubercular and other forms of arthritis, reflex contracture also plays a large part in the production of deformity. In some cases of spasmodic flat-foot the painful contraction of the muscles is also of a reflex character.

Spastic Contractures are due in most cases to central nerve-lesions. Brain-lesions, whether hæmorrhage, syphilis, tumours, multiple sclerosis, or what not, are all frequently characterised by spastic conditions of the muscles, of which the innervation is disturbed. Cord-lesions, whether meningitis or myelitis, also produce the same effects. It is in *spastic*

paraplegia that the orthopædic surgeon more often witnesses spastic contractures. In post-mortems made in cases of this affection the crossed pyramidal tracts have been found to be degenerated secondarily to brain-lesions, such as meningeal hæmorrhage, caused by pressure of the mother's pelvis on the skull-bones of the infant during parturition; thrombosis of the superficial cerebral vessels, etc.

Paralytic Contractures.—Deformities due to paralysis of muscles form the largest class of contractures. In order to understand the different ways in which deformity may occur after paralysis, in the first place, the normal elasticity of muscles is to be remembered. Normally, within the body, the muscles are stretched to a slight extent. This enables a muscle to act immediately upon the points of its insertion when it enters into a state of contraction, and it also explains the immediate *retraction* of a muscle that occurs when it, or its tendon, is completely severed.

The retraction of a muscle that follows division of its tendon is gradually followed by further changes; the muscle retains its elasticity, and, if reunion of the divided tendon occurs, it recovers its functions, but with a somewhat shortened form, and hence a diminished range of action. In other words, the difference between its length when in full voluntary contraction and its length when in a state of rest is less than it was before the tenotomy was performed. If no union takes place between the ends of the severed tendon, the shortened muscle after a long time undergoes changes described above as "fibrous myositis." At the moment of division of a tendon of a muscle, or physiological group of muscles, the antagonistic muscle contracts actively and remains shortened on account of its elasticity. "Antagonistic muscles (Galen) are those which, during their action, have exactly the opposite effect of other muscles, *e.g.* flexors and extensors, pronators and supinators."* The shortening of the antagonist is not, however, as great as that of the muscle of which the tendon has been divided, because the antagonist, being intact, is involuntarily elongated by the action of adjacent muscles. Thus, as Hoffa† observes,

* Landois and Sterling, "Human Physiology," vol. ii., p. 676.

† Hoffa, "Lehrbuch der Orthopädischen Chirurgie," 1898, p. 37.

"If the flexor tendons of a finger are severed, the finger assumes an extended position. This position will, however, be frequently modified in the direction of flexion by the patient involuntarily using the other fingers to move the damaged one." When, however, the antagonist is not thus brought into physiological employment, it undergoes atrophy from disuse. The antagonist, though atrophied, retains permanently its power of voluntary contractility.

Complete Paralysis of a Muscle, *e.g.* from section of a peripheral nerve, has, as far as the antagonists are concerned,

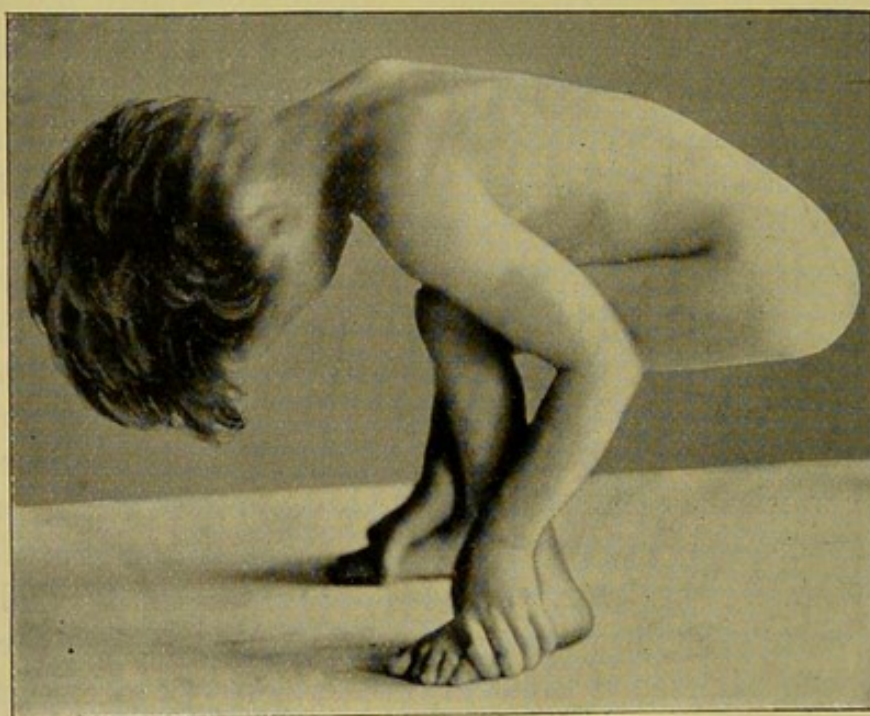


Fig. 27.—Attitude assumed by a Patient suffering from Paralysis of the Lower Extremities from the Hip-joint downwards.

practically analogous results—analogous to those that immediately follow complete division of tendon; thus, when the musculo-spiral nerve is severed, the extensors of the wrist are paralysed, and the antagonists, the flexors, contract, producing flexion of the wrist, which persists even in the supinated position of the limb; that is to say, the contraction of the flexors is capable of counterbalancing the weight of the hand, and hence is something more than is implied by the term "wrist-drop." In a similar manner, contracture of the knee

in the flexed position follows paralysis of the extensors, in spite of the counteracting force of the weight of the limb when the patient is in the erect position. This contracture of the antagonist to the paralysed muscles is increased by their voluntary contractions. If only a group of muscles acting laterally on a joint is affected, the resulting deformity is in the opposite direction; thus paralytic pes valgus results from paralysis of the tibiales muscles. These purely muscular contractures are modified by mechanical factors brought into play by the weight and use of the limbs. Thus, in the case of the little girl depicted in Fig. 27, I was at a loss to account for a marked flexion-contraction of both hips, for all the flexor and the extensor muscles were equally powerless from infantile paralysis. I found that the habitual posture of the patient was that shown in the figure. When thus arranged, with the thighs placed against the abdomen, the little girl, by the combined use of legs and arms, could move with remarkable celerity for very considerable distances. The contraction of the soft parts at the front of the hip-joints in this case was determined by this posture assumed as the only one that, before instruments were applied, made locomotion possible. Thus, when all the muscles acting on a joint are completely paralysed, what is termed a "flail-joint" results; but the movement of this flail-joint may become limited in one or other direction by secondary changes resulting from habitual posture, pressure, and other mechanical conditions.

When paralysis affects all the muscles about a joint, but is incomplete, the primary contraction takes place towards the side of the flexors because of the greater relative power of the latter.

The **Causes of Paralytic Deformities** are either peripheral or central. Peripheral nerve-lesions are (1) traumatic; (2) toxic neuritis, *e.g.* alcoholic and post-diphtheritic, gouty, etc. Central nerve-lesions are either cerebral or spinal.

Among **Cerebral Lesions**, some are congenital, such as some cases of hydrocephalus and porencephaly; others are acquired; *e.g.* traumatic lesions, hæmorrhage, tubercular and other tumours.

Spinal Lesions much more commonly give rise to

contractures. Spina bifida, the later stages of tabes dorsalis, compression-myelitis, syringomyelia, spinal meningitis, progressive muscular atrophy, and, above all, anterior poliomyelitis of both children and adults, may be given as examples of spinal lesions which are known to cause contractures.

Anterior Poliomyelitis is an inflammatory affection of the anterior horns of the grey matter. The destruction of the large motor cells leads to degeneration of the corresponding motor nerve-fibres and of the muscle-cells. The acute form of the affection known as infantile paralysis is marked by a sudden onset, fever, headache, pains in the loins and limbs, and, in children, convulsions. The sufferers have usually been in good health at the time of the attack. As the initial symptoms pass away, paralysis or paresis is noticed in one or more, sometimes in all the limbs; the muscles of the trunk may also be affected. The paralysis develops rapidly and reaches a maximum within a few hours of the attack. As a rule, much of the original paralysis is recovered from, especially under suitable medical treatment. Permanent paralysis may have a hemiplegic (unilateral or crossed), a paraplegic, or an irregular distribution. Extensor muscles are affected more commonly than flexors. The bladder and rectum, as well as the sensory nerves, escape. One important effect of extensive paralysis in children is a diminution in the rate of growth in the bones and all parts of the paralysed limb. Though the paralysis is purely motor subjective tingling is sometimes felt, and the affected muscles may be tender for a time.

In even partial paralysis of the extensors of the knee, the knee-jerk is lost. The important question for the surgeon is what is the period of time during which the case may be dealt with by the physician, aided by simple retentive splints designed to prevent the occurrence of deformity. The answer to this question amounts to a knowledge of the average course of the affection. Usually the paralysis remains stationary for from two to six weeks, and then improves, at first markedly, and then less rapidly, for three or four months. After six months, further spontaneous improvement is unusual.

An idea of the commoner modes of distribution of

paralysis may be gained from the following table, which is taken from Bradford and Lovett's work and is based on statistics given by Duchenne and Seeligmüller:—

One leg paralysed	74
One arm „	23
Both legs „	23
Both arms „	3
All four extremities paralysed	7
Hemiplegic paralysis	3
Crossed „	3
Paralysis of trunk and abdomen	1

137

In but a very few cases of infantile paralysis does the impairment become progressive. I have, however, observed this in one or two cases.

In such cases a chronic anterior poliomyelitis is ushered in by an acute attack instead of beginning, as it more commonly does, insidiously. The chronic affection is known clinically as *progressive muscular atrophy*.

Infantile paralysis being, as a rule, due to purely spinal lesions, is to be distinguished from spastic paralysis, which is usually the result of cerebral lesions. The chief effects of infantile paralysis are, besides the impairment of motor function, contractures such as club-foot or dislocations; proneness to ulcers from impairment of circulation are also to be remembered. These effects will be dealt with in detail in connection with the different regions of the body. The indications for mechanical treatment are (1) preventive; (2) corrective. In the latter case operative measures are often required in addition. It is a too common experience to find proper orthopædic treatment omitted altogether or too long delayed, with the result that avoidable deformities are allowed to develop, and unavoidable ones to become exaggerated.

Arthrogenous Contractures depend upon changes of a cicatricial character in the synovial membranes and peri-synovial tissues of joints. The ligaments of a joint, when attacked by gouty or tubercular inflammation, undergo cicatricial contraction. After fractures and other injuries in the neighbourhood of joints, intra-articular adhesions are of

common occurrence, and they frequently limit the range of movement in a joint or fix it in an abnormal position.

ANKYLOSIS.

Ankylosis differs from contractures in that it is a fixation of a joint by the union of the articular surfaces themselves by interposed connective tissue.

At the commencement the uniting tissue may be soft and yielding, when the ankylosis is termed incomplete.

In opening the ankle and tarsal joints in a limb amputated on account of an ununited fracture and œdema that had persisted for four years, I found that the processes that lead to ankylosis had been in progress, and that the first step consisted in the formation of a thin layer of plastic lymph between the articular cartilages. In joints in which the process was further advanced the articular cartilages had been perforated here and there by buds of granulation tissue which sent vascular buds into the lymph within the joint, meanwhile the cartilage was thinned by the deeper part being transformed to granulation tissue and to fibrous tissue. At the stage in which most of the articular cartilage remains whilst the amount of fibrous tissue is small, the term *ankylosis cartilaginea* has been applied to describe the condition. When much of the cartilage remains and the uniting fibrous tissue is more abundant the term *ankylosis fibrosa inter-cartilaginea* is employed. The latter is usually only a transitory state, for if the original cause of the disturbance continues in action the remainder of the cartilage is removed, and the condition becomes *ankylosis fibrosa inter-ossea*. *Osseous ankylosis* is produced in two different ways: (1) by ossification of the fibrous tissue formed as above described in *ankylosis fibrosa inter-ossea* after metaplasia of the cartilage, or (2) it may occur as a new formation of bone after destruction of the articular cartilage by inflammatory processes. Both these processes may occur in different parts of the joint. How complete the obliteration of a joint may be in bony ankylosis, is shown in Fig. 28. *Virtual osseous ankylosis* may result from the formation of uniting bridges of bone beyond the articular surfaces, as is seen in spondylitis deformans, in osteo-arthritis of the

temporo-maxillary joints and synarthrodial joints; or again from great alterations in the form of two articulating surfaces such as is often seen in osteo-arthritis and in tabetic arthropathy. To the latter condition Volkmann has applied the term "ankylosis by deformation." Congenital ankylosis from abnormal development or from intra-uterine pressure is also met with from time to time.

It has been maintained that fibrous ankylosis is only a passing stage of a process that would naturally terminate in osseous ankylosis. Seeing that in cases of un-united fracture an interval of fibrous tissue uniting two bony surfaces often shows no tendency to ossification, it would hardly be expected that the above rule should prove to be universally true.

Many instances might be quoted to prove that fibrous ankylosis may retain its character unchanged for many years. Thus, in the case of a lady aged twenty-eight whom, in conjunction with my colleague, Dr. W. K. Sibley, I operated on for fibrous ankylosis of both hips, the condition had been present for fourteen years, and dated from an inflammation of both joints that supervened after an attack of measles, and was treated for some months by extension. The flexion and abduction movements were greatly impaired, and a considerable degree of force was required to rupture the adhesions in each joint.

The causes of ankylosis are varied: traumatic conditions, suppuration in joints, gonorrhœal rheumatism, tubercular, and syphilitic inflammation are among the commonest. Long

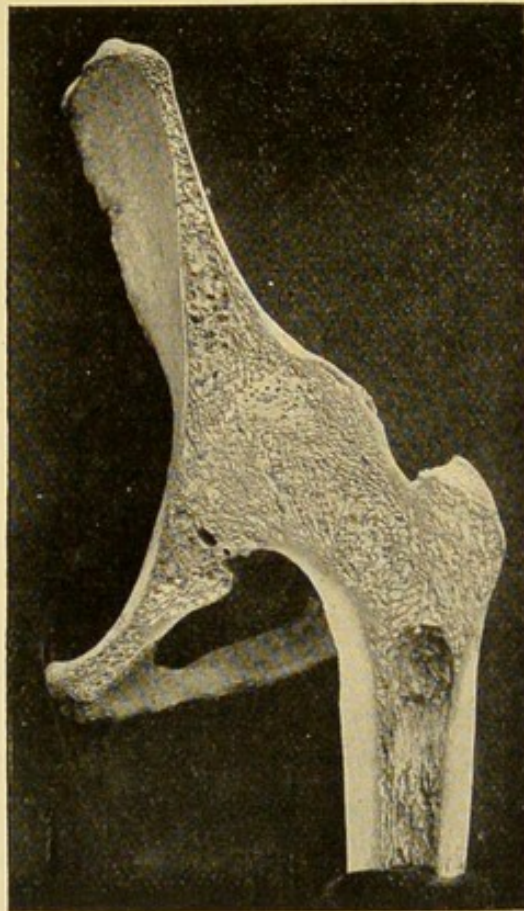


Fig. 28.—Osseous Ankylosis of the Hip.
(Royal College of Surgeons' Museum.)

fixation of a limb on a splint was once thought likely to lead to permanent ankylosis. In the case referred to on p. 56, this process had only begun at the end of four years, and then there was the presence of œdema to explain it. When a fracture occurs near a joint the formation of adhesions between the apposed surfaces of the folds of synovial membrane is likely to occur, and it must be guarded against as far as possible, and care should be taken to examine the joint carefully at the end of the treatment and to break down any adhesions that exist. The neglect of this on the part of the medical man is the golden opportunity of the "bone-setter."

The clinical aspects of different cases of ankylosis are of the highest importance and often require the closest attention and judgment in their management. In America, following the example of Sayre, orthopædic surgery is taken to include the whole of the surgery of joints. This course is, I think, unnecessary, since the more acute forms of joint-disease and their management is well described in works on general surgery. The more chronic cases are those that require orthopædic treatment, but in every case the surgeon must be prepared to relinquish conservative for active measures as soon as the indications for so doing are present. Of the various clinical groups of cases the following require special mention.

Traumatic Cases (non-septic).—These furnish a class in which simple manipulative measures are often of use, and whether the adhesions are few or many a good result may be anticipated. In many cases of the kind slight weakness of the joint remains for a period and calls for light support. This is most commonly seen in the knee.

Suppurative Arthritis.—In this class come most of the worst cases of joint-disability. Excluding cases that are secondary to acute osteomyelitis, there are traumatic and pyæmic suppurations, which may end in destruction of the endothelial surfaces and complete obliteration of the joint by dense scar-tissue or bony ankylosis. By means of prompt surgical treatment this result may frequently be averted, as is seen strikingly in the suppurative arthritis of children. The responsibility of the orthopædic surgeon begins when

the joint condition has reached a permanent state. The greatest caution is required in manipulating a joint that has been the seat of septic inflammation. Though every chance should be given to conservative treatment, excision is often to be preferred to forcible manipulation in such cases. Pyæmic conditions include arthritis following scarlet and other fevers, as well as gonorrhœal arthritis.

Tubercular Arthritis affects joints in various modes. The infection of the synovial membrane is often secondary to that of one or other of the articulatory bones. In children the primary seat of infection is frequently the juxta-epiphyseal extremity of the diaphysis. In adults, and occasionally in children, the cancellous tissue of the epiphysis itself may be first affected.

The synovial membrane is sometimes primarily affected. In a few cases a localised thickening of this membrane has been observed, and the spread of the disease to the rest of the membrane has been noted in the course of the case. A somewhat rare variety of tubercular infection of the synovial membrane of a joint might be termed an acute tubercular synovitis. In this condition the joint swells rapidly, and, upon opening it, a large quantity of opalescent fluid escapes, and the synovial membrane is found to be thickly studded in every part by recent miliary tubercles. In the vast majority of cases the course of tuberculosis is a chronic one, and no condition offers more problems to the surgical judgment than does this. The natural course of the affection varies according to the stamina and age of the patient, the particular joint affected, and the primary seat of infection. The prognosis of joint tuberculosis is much better in children than in adults. Howard Marsh* writes: "Indeed, recovery, when either the hip or the knee is attacked, in patients between thirty and sixty-five, very rarely takes place."

The majority of cases of tuberculosis of the hip- and knee-joint require a patient trial of orthopædic treatment. Perfect immobilisation, with complete relief from abnormal intra-articular pressure, gives, in average cases, the best chance of recovery with a useful limb. In many cases of undoubted tubercular arthritis these measures have resulted, not only

* "Diseases of Joints," p. 119.

in recovery from the disease, but in a restoration of mobility in the joint.

Deformity from tubercular arthritis is brought about by contracture, ankylosis, and dislocation. Contractures from this cause are fairly definite in direction, and are the result of muscular action, which is partly reflex spasm and partly

an involuntary adaptation with the object of protecting the joint from movement.

Ankylosis, following tubercular arthritis, may be either fibrous or osseous. The latter was formerly supposed to occur only after septic infection had supervened upon tuberculosis, but Howard Marsh has shown that bony ankylosis may occur in cases of tubercular arthritis apart from septic inflammation. The appearance of the macerated bones in a case of dislocation from tubercular coxitis is shown in Fig. 29.

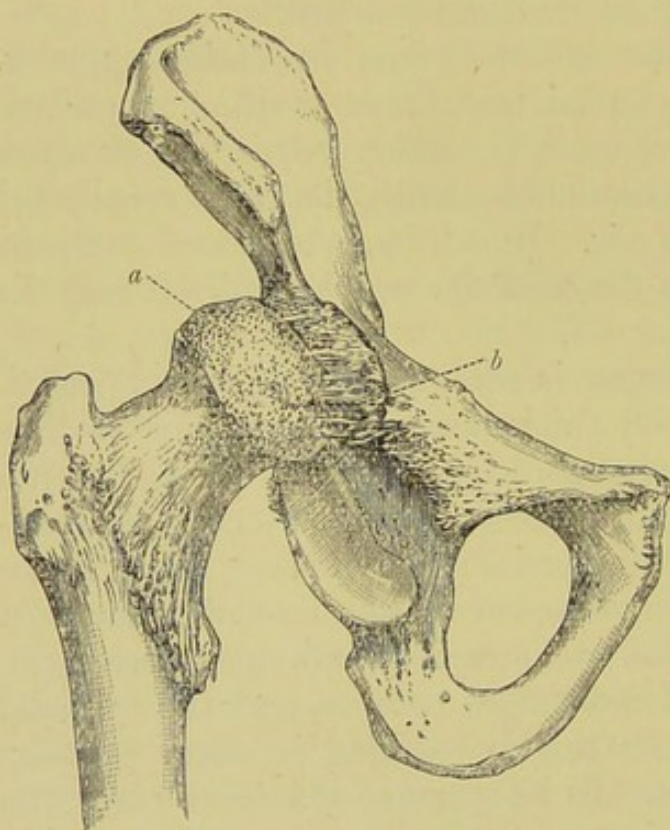


Fig. 29.—The Bones from a case of Tubercular Coxitis with Dislocation.

The head of the femur, *a*, has lost its cartilage; the articular surface is composed of porous, rarefied, cancellous tissue; the upper and posterior part of the acetabular rim has been absorbed by the joint action of the carious process and the continuous pressure of the head of the femur; *b*, buttress of bone, composed of sharp stalactitic osteophytes thrown out to support the dislocated head (*Pepper*).

The General Prophylaxis and Therapeutics of Deformities.—*Prophylaxis.*—To those who see regularly a large number of cases of deformity, it is striking what a considerable ratio of them might have been prevented.

Many phases of deformity are not preventible. Such are deformities that are present at birth. But even in these cases the future of a baby depends upon the early recognition and early treatment of conditions such as club-

foot or congenital dislocation. Thus, even when a deformity is present at birth, there may be scope for prevention, in the direction of preventing the deformity becoming permanent or aggravated. The examination of the new-born baby requires more than a superficial investigation, which would suffice to detect obvious malformation. The hip-joints, for instance, should be carefully examined, in order to ascertain whether a congenital dislocation is present.

In principle prevention is the same as early treatment.

A considerable proportion of acquired deformities is due to rickets. Therefore, of this class of cases, the prevention of deformities amounts to the prevention of rickets. Rickets is, to a large extent, a preventible disease. It has been shown that the young of certain animals, *e.g.* lions, can be made rickety by withholding milk and bones from their diet. Among the poor, prolonged suckling and ignorant feeding are the commonest causes. In a few cases I have observed rickets develop in the first months of life during suckling; in such cases the origin of the disease can only be attributed to some defect in the mother's milk, and in some cases circumstances have seemed to point to this defect, originating in indigestion in the mother.

Rickets is by no means confined to the poorer classes, and in its slighter forms is common among the children of the well-to-do and wealthy.

Nor is unwise and insufficient feeding confined to the poor. In too many public schools an ill-considered and often illiberal dietary accounts for many cases of deformity and prevents many a young fellow from entering the navy or the army.

It is a remarkable fact that in but few families is any arrangement made for the periodical inspection of growing children by the medical attendant of the family. Until such an arrangement becomes general, and until the methods of examination of children for incipient deformities are more systematically taught in the medical schools, it will be left to the tailor and the dressmaker to discover scoliosis, often when the deformity has progressed so far that a complete cure is impossible.

Statistics of Deformities.—A good and comprehensive

statistical statement of the various classes of orthopædic cases based on pathology and giving the results of modern treatment has yet to be made, and it is to be hoped that before many years elapse such statements will be forthcoming in Great Britain. Hoffa * records that out of 67,919 surgical cases treated at the Munich general hospital 1,449 were orthopædic cases. The ages of the patients were as follows:—

0—10 years	602	40—50 years	54
10—20 „	481	50—60 „	30
20—30 „	182	60—70 „	28
30—40 „	70	70—80 „	2

In this list the two sexes were about equally represented. The frequency of occurrence of the various kinds of deformity (where recorded) was as follows:—

Scoliosis	399	Hallux valgus	27
Pes valgus	338	Dupuytren's contraction ...	23
Pes equino-varus	171	Pes calcaneus	9
Tubercular kyphosis ...	142	Torticollis	7
Genu valgum... ..	119	Congenital hip-dislocation ...	7
Rachitic curves of the tibia	107	Genu varum	3
Pes equinus	52	Club-hand	1
Rachitic kyphosis	39		

The deformity was noted as congenital in 150, as acquired in 1,175 cases.

Symptomatology and Diagnosis.—The symptoms of deformity are not limited to alterations of external contour which “he who runs may read.” In many cases most careful examination is required before the kind and degree of deformity can be ascertained, and an exhaustive account of the history of the case must be taken before its pathological character can be decided upon.

The *subjective symptoms* are of most importance in the early stages of deformity.

Pain and Tenderness.—In the earliest period of the *habitual pressure deformities* dull aching pain is frequently complained of. The pain in rickety yielding of the neck of the femur (coxa vara) may closely simulate that of early

* Hoffa, *loc. supra cit.*, p. 51.

tubercular disease. Tenderness and neuralgic pain is a prominent feature of early rheumatoid arthritis, and in the spine these symptoms are more marked than they are in tubercular disease.

Alterations of Function are determined by several different factors: pain, muscular weakness, and alterations of structure may, separately or combined, produce alterations in function.

The Objective Signs.—The attitude of the patient, peculiarities of posture and gait, should all be observed before the part specially complained of is inspected. The deviations from normal form and size are to be noted, and when necessary, measured. Contours may be recorded by moulding a strip of tin or lead to the part and transferring the strip to paper and tracing with a pencil the contour obtained. For angular deformities various goniometers are in use.

Palpation gives valuable information as to the firmness or otherwise of muscles, the form of superficial bony structures and bands of fascia. The range of movements of suspected joints should be carefully ascertained by gentle manipulation, and if necessary an anæsthetic must be given to differentiate between limitation of movement due to organic changes and that due to muscular spasm. By manipulation also the degree of resistance to correction is to be observed.

In the differential diagnosis of certain conditions the Röntgen-ray process is of the greatest service.

Prognosis.—The first question raised in many cases is whether the deformity will disappear if left to itself. In the majority of cases in which this is predicted only disappointment ensues. Since the results of treatment will be discussed later in connection with the various deformities a few examples will suffice in this place.

Among congenital deformities club-foot, if properly treated from the first, is completely curable, and if the treatment is efficient, relapse is out of the question. Even congenital dislocation of the hip is curable if treatment is begun at the proper age. In some congenital affections, such as webbed fingers, the degree of perfection attainable depends upon the extent of the defect. Rachitic deformities of the bones of the

lower limbs can all be cured without operation if orthopædic treatment is begun sufficiently early. Among pressure deformities scoliosis, contrary to the opinion of some surgeons in Great Britain, is curable if efficient treatment is begun at the right time. In paralytic cases palliative measures are all that can be undertaken in most cases.

General Treatment.—The predisposing condition, whether this is rachitis, rheumatoid arthritis, or tuberculosis, must be treated by suitable hygiene, diet, and medicines. In children, cod-liver oil and iron, and cod-liver oil and hypophosphites of lime and soda; sea-salt baths and frictions are the more generally useful. The dress, the bed, and every detail of the patient's daily life and surroundings should be considered.

Massage.—The value of friction and manipulations in medicine have been recognised from the earliest times. Hippocrates (460–357 B.C.), in his work “De Articulis,” says, “The physician, besides being accomplished in many other ways, must also understand massage.”

As it is now understood, massage includes the following manipulations:—

(1) Centripetal stroking of the part with the finger-tips and palm of the hand (*effleurage*) empties veins and lymphatics and, by improving circulation, improves nutrition. The chief groups of muscles are followed with the flat of the hand, the thumb making firmer pressure.

(2) Centripetal kneading of muscles with the fingers of the hand placed transversely to the course of the muscle-fibres (*pétrissage*).

(3) Circular friction, combined with centripetal friction and kneading (*friction*). This manipulation is most useful for joints. It is done by pressing the fingers of one hand upon the skin of the part, and making them execute small circular movements, whilst the fingers of the other hand intermittently perform centripetal friction. Instead of the fingers, the thumb may be used to perform the circular movements, the fingers of the same hand being used as a “rest.”*

(4) *Tapotement* consists of a rapid series of slight blows, delivered by the backs of the two distal joints of the fingers,

* A. Symons Eccles, “Practice of Massage,” p. 11.

or by the ulnar border of the hand. The manipulation is used in muscular parts, the fingers being employed when the superficial, the inner borders of the hand when the deeper parts are to be influenced. This measure is most useful in spastic paralysis, and in other conditions, where the contractile property of the muscles is diminished.

(5) *Vibration* is a combination of *pétrissage* and *tapotement*, with a vibratory movement.

Among the physiological effects of massage, that of relieving muscular fatigue has been proved. Hence its utility in deformities due to habitual postures, assumed on account of muscular fatigue, might be inferred. Massage is also indicated in many cases in which any instrument that prevents the movements of a limb is required to be worn.

The effect of massage to improve the contractile power of muscle and its use in cases of spastic paralysis have also been proved. In helping to remove residual inflammatory effusions, as, for instance, after fractures and other traumatic conditions, massage has a well-recognised place. In muscular rheumatism and similar conditions, massage is used for this purpose. The place of massage in orthopædic surgery is often misunderstood. Thus, it is a not infrequent experience to come across a case of slight contracture or a case of spastic paralysis that has been treated with massage for many months without any real improvement, whilst with simple operative measures the condition has been easily remedied, and this done, massage has been employed with distinct advantage.

Gymnastics.—The value of systematically ordered movements of the body, or gymnastic exercises, as a factor in physical education and in the preservation of health, has been recognised in all civilised countries. In England, general exercises form a prominent feature of public-school life, and latterly the value of systematic outdoor sports is becoming recognised in the larger schools for girls. The value of systematic general exercises is illustrated by the good effect of the physical or “setting-up” drill upon young recruits. Apart from educational general exercises, the importance of remedial gymnastics has also, like massage, been recognised

from the earliest times. Galen (A.D. 130–200) distinguished clearly between active, passive, and compound movements, and his appointment as physician to the School of Gladiators at Pergamum gave him ample opportunities of studying the general effects of gymnastics.

The application of gymnastics to the treatment of deformities is a very wide one, and, like massage, they are more often of service in combination with other measures than when used alone. Before exercises are prescribed in any given case, the diagnosis must be made perfectly clear or much harm may be done—*e.g.* if severe exercises are ordered for a rapidly-growing girl, in whom the bones are softened by “rachitis adolescentium” and lateral curvature of the spine, genu valgum, and flat-foot are developing, these deformities will be aggravated. In the same way, the healthy general exercises of a public school will have a most deleterious effect on a weakly boy if he is compelled to do all that his stronger class-fellows perform.

Medical exercises, when carefully administered, are of the greatest service in the treatment of deformity, owing to dependence of proper postures upon healthy muscles and the influence of the muscles on the growth and form of bones. As an example of active remedial exercises directed to the correction of deformities that have arisen from faulty postures that have been assumed owing to weak muscles, Ellis’s tiptoe exercise for flat-foot may be taken. In this exercise the patient stands with the toes slightly turned in, rises on tiptoe, and returns at once to the original position. This is repeated a certain number of times according to the patient’s strength. The exercise brings into action chiefly the gastrocnemii, tibiales muscles, and the flexors of the toes, and tends to strengthen them, and so enable the patient to resist the tendency to eversion of the feet. Even this simple exercise may do harm if the condition of the bones and ligaments is one of greatly diminished resisting power, as is not infrequently the case.

Other simple postural exercises will be mentioned in the treatment of scoliosis.

Passive exercises are familiarly employed after injuries involving, or in the neighbourhood of, joints to prevent the

formation of adhesions, and in certain phases of rheumatoid arthritis. By passive movements the elasticity of muscles is exercised and the circulation is improved.

Resisted exercises constitute the original feature of the Swedish or Ling's system of gymnastics, established at Stockholm about 1813, and they remain as a valuable resource when divested of the extravagant and useless complexity into which Ling's methods degenerated. As applied to the limbs, they were named by their originator the "compound concentric" and the "compound eccentric" movements. An example given by Hoffa will best indicate the meaning of these terms:—

Let us suppose that it is desired to strengthen the biceps brachii muscle. It may be done in two ways. First, the patient may be told to bend the elbow, whilst the gymnast, holding the patient's wrist, offers resistance to the movement. The patient's biceps is seen to contract vigorously, and the gymnast's art consists in gradually diminishing his resistance till it is overcome by the contracting muscle. In this instance the patient performs an active movement whilst the gymnast offers passive resistance, in that he allows himself to be moved by the patient. The movement is thus termed active-passive. At the same time, the two extremities of the patient's biceps have been brought nearer to the middle of the muscle in the contraction of the muscle, so that the movement is described as concentric. Thus, gymnast and patient have effected what in Ling's terminology is termed a "compound active-passive, concentric, resisted movement." If now the patient, holding the elbow in the flexed position, is requested to keep the joint flexed whilst the gymnast endeavours to extend it, the patient offers passive resistance to an active extending force, and once more the biceps enter into marked contraction. Finally, the gymnast overcomes the resistance and extends the patient's elbow. The two extremities of the muscle, in spite of a series of small contractions on its part, have moved eccentrically from the middle point between them; in other words, a "compound passive-active, eccentric, resisted movement" has been effected.

Ling's system became extravagantly complicated; as Busch* observes:—

It was an error of Ling's to ascribe to every single muscular movement a special effect upon the general health; as, for example, when he believed that an arm movement while standing had quite a different effect from an arm movement while lying or sitting. From this assumption an extremely complicated system of gymnastics arose, which sharply differentiated the movements necessary in different cases.

* Busch, "General Orthopædics," 1885.

Thence arose the necessity for a considerable number of assistants, for four people might be required to hold the patient in a certain position, while the fifth—the gymnast proper—conducted the required movement.

The physiological effects of resisted movements are practically the same as active movements, and the chief indication for their employment is in conditions of muscular weakness, in which great care is required to prevent fatigue of muscles, and it is necessary at the same time to strengthen the muscles by exercises that are gradually increased as the

patient's strength increases.

In order to avoid the necessity of numerous assistants and the direct intervention of the "gymnast," Zander* more recently founded at Stockholm a medico-mechanical institute. There the resistances, etc., are obtained by mechanical means, and are so arranged that any set of muscles may be exercised, and the work

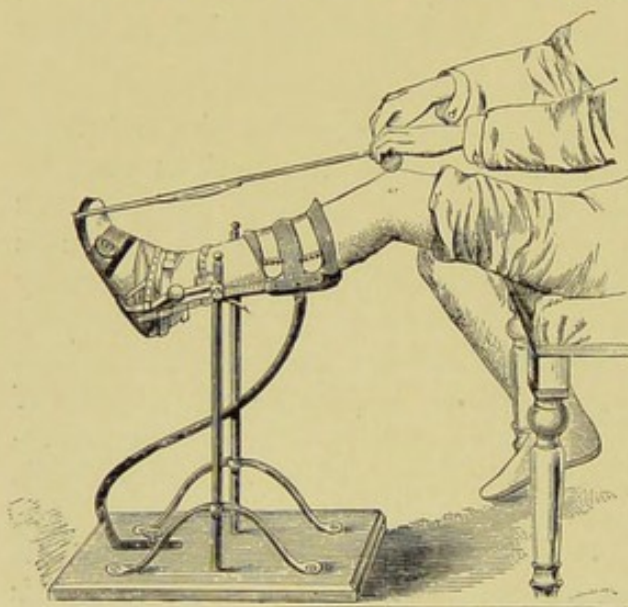


Fig. 30.—Bonnet's Apparatus for exercising the Ankle.

done may be graduated exactly according to the needs of each case.

Before Zander, Bonnet (see Fig. 30) and others had employed mechanical measures for self-exercising in orthopædic cases, and of late years the simple machines of Dowd and Whiteley have enabled physicians to prescribe for their patients home-exercises—the benefits of regular exercises without the expense entailed by the gymnastic institutes. Simple exercises with dumb-bells, bars, the trapeze, etc., are also of service in many cases; and the surgeon should thoroughly understand their influence in the treatment of deformities, and know what exercises to prescribe and what to avoid in a given case.

* Zander has described his methods in his book "Die Apparate für Mechanisch-heilgymnast und deren Anwendung," Stockholm, 1890.

Krukenberg* has introduced a system which combines active and passive movements by means of pendula. The part or limb below the joint to be exercised is fixed to a metal plate or socket, to which is attached a pendulum. The slightest movement of the joint on the part of the patient starts the pendulum, the swing of which is increased by each successive impulse, however small. Thus a passive movement is produced by the atrophied muscles about the joint.

Electricity.—In the diagnosis of nerve-paralysis electricity is of tried service. The value of electricity in the treatment of certain paralytic affections is estimated very highly by some, very slightly by others. The faradic current applied directly over the affected muscles is safe. Its use, according to some, consists in the local gymnastics it affords the affected muscles, enabling them to escape atrophy from disuse until the nerves have been afforded full opportunity of recovering their functions. The action of the constant current is more complex, and its application should be left to those who are well versed in its use.

Hydrotherapy.—Owing to the fact that many deformities are connected with gout, rheumatoid arthritis and other diseases, the patient often obtains much benefit from a course of treatment at one of the recognised Spas, such as Bath, Buxton, or Harrogate.

THE PRINCIPLES OF THE TREATMENT OF DEFORMITIES BY INSTRUMENTS.

The surgeon must have a taste for practical mechanical work. All the usual surgical dressing materials must be at his command. Bandages and adhesive plaster, used according to the indications in each particular case and not according to the examples figured in books on bandaging, will, together with the simplest instruments, *e.g.* tin splints often answer every purpose.

One important group of appliances is formed by the sheathing splints; plaster of Paris, poroplastic felt, leather, and many other materials are used for this purpose.

* H. Krukenberg, "Lehrbuch der Mechanischen Heilmethoden," Stuttgart, 1896.

Plaster of Paris may be used either in bandages or on house-flannel, as a single sheathing splint, *e.g.* Croft's, or again as the more convenient lateral splints. It is not necessary in this place to go into the details of the appli-

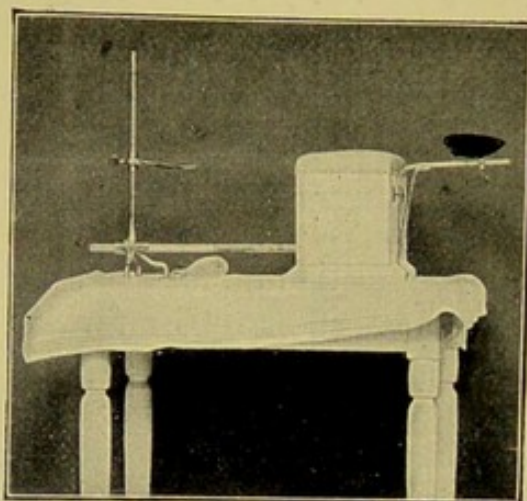


Fig. 31—Ulrich Grosse's Apparatus for applying Plaster of Paris Bandages to the Pelvis and Thighs.

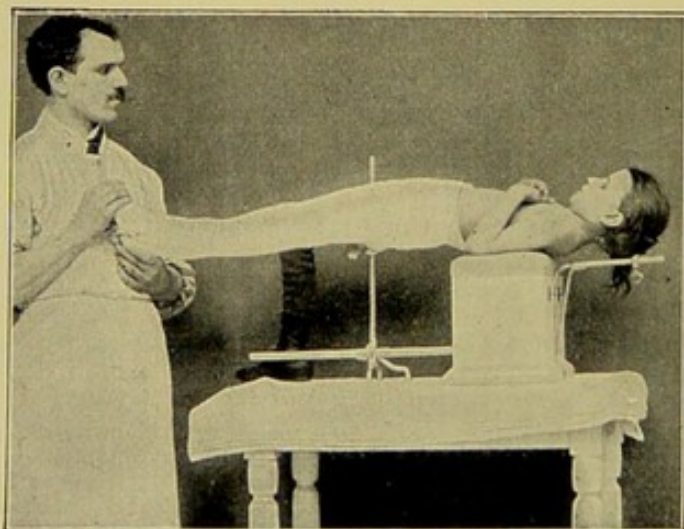


Fig. 32.—The same. The Bandage applied.*

cation of these familiar apparatus, but it is desirable to indicate what, in my opinion, is their scope in orthopaedic surgery. Plaster of Paris is suitable for the same purpose as a rigid splint, and is often the best form of splint to employ during the first week or more after an operation. Personally, I use plaster of Paris more for purposes of

* Figs. 31 and 32 are taken, by permission, from the *Centralblatt für Chirurgie*.

fixation than for reduction of deformity. Thus, after osteotomy, plaster splints, whether of Croft's pattern or as bandages, may be used either from the first or after the first splints have been left off; there is a period during which the union of the fragments of bone is weak and requires some support for the first few weeks during which the patient is allowed to walk. Although, as a corrective orthopædic apparatus, plaster of Paris has a more limited scope than many surgeons appear to think, its value as a temporary fixation appliance after operations cannot well be exaggerated. Thus any aid to the application of plaster of Paris bandages with precision and security against pressure sores is of importance. Ulrich Grosse (*Centralb. für Chirurg.*, July, 1898) recommends the simple apparatus shown in Figs. 31 and 32 for the application of plaster apparatus to the pelvis and thighs. In the bloodless reduction of congenital dislocation of the hip, and many other conditions, plaster splints are useful in the earlier part of the treatment.

By an ingenious device Mikulicz has used plaster as a means of correcting genu valgum, but much simpler and less irksome means being at hand in the simple splints shown in Fig. 34, it is unnecessary to employ it in this condition.

Many surgeons use plaster bandages as part of the means employed for the correction of congenital club-foot. The value of daily manipulations in these cases has made me relinquish the method in favour of malleable metal splints. The method of applying plaster bandages as a corrective measure in cases of congenital talipes equinovarus has been well described by Walsham and Hughes.*

The method of correcting the deformity by means of plaster of Paris bandages may be employed either with or without operative treatment. When employed alone without any operative measures the aim of the surgeon is gradually to stretch any resisting tendons, ligaments, and fasciæ, slowly to replace the displaced bones, and to mould those that are misshapen into their normal shape. The foot at each application is gently forced by the hand into the best position approaching the normal that it can be made to assume without causing pain, and is thus held whilst the plaster bandage is being rolled on and until the plaster has firmly set.

* "Deformities of the Foot," p. 146.

The plaster keeps the foot in the corrected position into which it has been forced by the hand till the next application, when further correction by the surgeon's hand is again made, and the foot retained by the plaster in the still further improved position. . . .

"The method of applying the plaster bandage.—A cotton-wool bandage is first evenly applied from without inwards to the lower half of the leg and foot, enclosing the ankle by figure-of-eight turns. The bandage is made by taking a sheet of cotton-wool and cutting it into strips three feet long and from three to five inches wide, according to the age of the patient. The strip of cotton-wool is next rolled up like an ordinary bandage, and is ready for use. The cotton-wool bandage having been applied, and the foot forced by the left hand of the surgeon, or by the hand of an assistant, into the improved position, we are now ready to put on the plaster of Paris bandage. After the bandage has been soaked in water it should be applied to the lower part of the foot, just to clear the phalanges. Beginning at the outer side, two turns should be taken round the foot, the bandage being kept taut all the time. No injurious effects will follow if the cotton-wool bandage has been carefully applied and the plaster bandage is kept quite flat and even. The bandage should be carried from the outer side of the foot to the inner side of the leg, well above the ankle, forming the first half of a figure of eight; then for a turn and a half round the leg. To complete the figure of eight, the bandage is carried from the outer side of the leg to the inner side of the foot. A turn and a half should now be taken round the foot at a higher point than the first turn, and so on as before until the whole foot and leg are covered in."

Poroplastic and other sheathing splints are open to some of the same objections as plaster of Paris.

In Germany the orthopædic instrument-maker, Hessing, has brought to great perfection the combination of sheathing-splints of leather with jointed metal splints. By confining the muscle and shutting in the perspiration, Hessing's apparatus has some of the disadvantages of plaster, but the metal supports and joints allow the joints to be free, and enable the surgeon to readjust the instrument from time to time. As applied to a case of one-sided congenital hip-

dislocation, it consists of a moulded corset for the trunk and hips, and others for the thigh, leg, and foot, all jointed together by steel bands. Hoffa records the case of a child who had worn this instrument for several years, and at the end of that time was so weak that she could scarcely stand. The apparatus so completely replaces the function of the skeleton that the bones tend to atrophy from disuse, and the muscles are weakened by compression and restricted movement. Of all Hessing's ingenious apparatus, his pelvic girdle for walking instruments is the most useful (Fig. 33). For the great majority of cases, I prefer the ordinary apparatus to that of Hessing, the chief value of which is, perhaps, in cases where extension is needed, and where the apparatus is required to act as an artificial limb.

For the construction of artificial limbs, some abdominal bands, knee supports, and other apparatus, it is sometimes necessary for the surgeon to make a plaster cast of the body. The new method of G. A. Peters gives very perfect results, but it is expensive, and for orthopædic work the older methods are sufficient. The following account is abbreviated from Hoffa's text-book. In order to take a rough plaster cast to show the contours of the part:—

1. Grease the skin.
2. Apply a strip of tin-plate if on body, a thin cord if on limbs, in the middle line.
3. Lay on several layers of plaster bandage. The case is cut up before drying, taken off when dry, wrapped in an ordinary bandage, and filled with plaster. For more perfect casts, the part is carefully greased with lard, mixed with petroleum, and a cast is taken in a box of stiff cardboard in the usual way. The surface of the edges of the first half of the mould is smoothed off, several hemispherical depressions

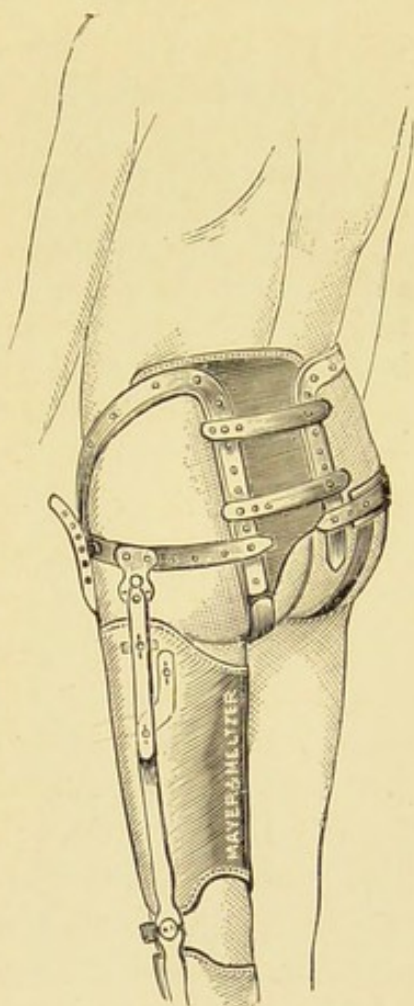


Fig. 33.—Hessing's Apparatus for the Pelvis.
(After Hoffa.)

being made in them. For very delicate casts Krukenberg's elastic material may be used.

R Gelatine	250
Oxide of zinc	175
Glycerine	400
Aq. Dest.	300

Rub up the zinc oxide with equal parts of glycerine. When the negative cast is set it is removed like a glove, and used to make a plaster cast.

Leather is treated with bichromate of potash to make it resistant to water. Calf leather is used for the foot, ox-hide for the limbs.

Models of paper are first cut, then the leather cut to this pattern is soaked in warm water, spread over the model, and fixed with brass tacks. This is called "fulling" the leather. It is dried in the sun. When half dry it is smoothed with a stick. When quite dry it is removed, rubbed with shellac, and spirit varnish, and lined with flannel; lacing is added.

The mechanical actions of any orthopædic appliance may be classed under one or more of the following three headings:—

(1) Retentive; apparatus designed to prevent threatened displacements.

(2) Reducing; designed to restore crooked parts to their normal form and function.

(3) Supplemental; apparatus such as springs and elastic bands that replace the action of paralysed muscles, and prosthetic apparatus that takes the place of amputated limbs, etc.

Whenever it is compatible with obtaining the best possible result, the instruments should be so constructed that they allow the patients to walk and follow the vocations proper to their age. The component parts of portable appliances are (1) the fixing, and (2) the active parts.

1. The Rigid Splint.—We may take as a familiar example of this, the simplest orthopædic appliance, that given by Andry* in his founding work on "Orthopædy." One of the quaint illustrations in this notable work represents a sapling with a bent stem which is bound to a strong stake at its middle and upper extremity, whilst the stake is fixed to the lower end of the tree by being thrust into the ground. In this instance the "deformity" of the trunk of the growing sapling is prevented from increasing, and if the

* Andry, "Orthopédie," 1741.

middle band were tightened from day to day the stem would gradually assume an erect position, and by daily increasing in thickness and strength would soon be enabled to maintain the upright form without the assistance of the supporting stake.

If instead of the curved stem of the sapling we take two common rickety deformities, such as outward bowing of the tibiae and knock-knee, we see that the same principle, that is, a rigid splint properly used, can be successfully applied during the period of the patient's growth. The splints employed for these conditions should have one most important feature; they are so constructed and applied that *the patient can walk about with perfect ease and comfort whilst wearing the splints.* This ambulant method of treating rickety deformities of the bones may seem to contradict the surgical axiom that in rickets, when the bones of the leg are yielding to pressure, the child should be kept "off its feet." There is no real contradiction, and treatment both by rest and by the ambulant method is frequently required in the same case. There is no difficulty in deciding when a child is fit to bear suitable "walking apparatus." He generally requires it as soon as he insists on walking.

Rest is required when the rickety process is most active. *i.e.* when the softening of the bones is very great. But rickets is not a matter of five or six weeks, or even as many months, under the best of treatment; in many cases the bones remain for years below their proper resisting power, and it is in cases of rickets, whether of moderate degree originally or remaining so after treatment of a more severe stage, that apparatus that admits of walking must be used.




Fig. 34.—Wooden Splints for Knock-knee.

The upper bandage does not pass in front of the body.

Mechanical treatment, always accompanied by proper diet and hygiene and medicinal remedies, allows of the child's going to school, and so removes a great additional disability. To consider more closely one example of the use of portable apparatus, a case of knock-knee may be taken. The simple

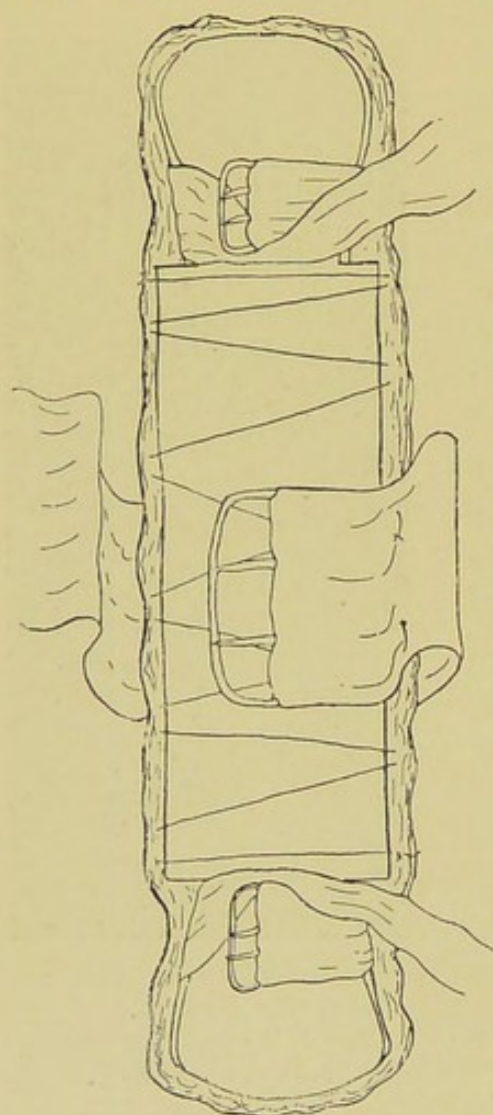


Fig. 35.—Wooden Splint for outward Tibial Curve.

wooden splints shown in Fig. 34 are those employed at the City of London Orthopædic Hospital. They are readily combined with the splint for outward bowing of the tibia (Figs. 35 and 36), a frequent concomitant of knock-knee.

Among the patients whom I have discharged as cured of this double deformity was a little girl aged five, who had worn the splints for two years. Not a trace of either deformity remained. The perfection of form resulting in this and many similar cases that have passed through my hands has convinced me of the undesirability of performing operations such as osteoclasis or osteotomy whilst rickets is still in progress and the patient is growing. Only when the disease has ceased and the bones have become hard should osteotomy be performed.

These simple and inexpensive wooden splints answer all the indications for surgical treatment, but still they are not so perfect of portability as well-constructed steel instruments. The chief points in an instrument of this class adapted to a case of knock-knee may now be examined (*see* Fig. 37).

The fixing parts of the apparatus are at the pelvis and the foot. There are joints opposite the hip and ankle. The

active part is opposite the knee, where the steel must be

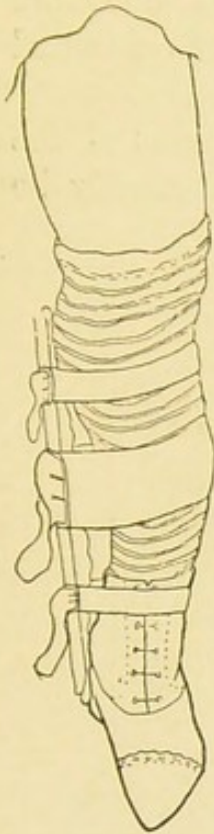

Fig. 36.—Wooden Splint for outward Tibial Curve, applied.

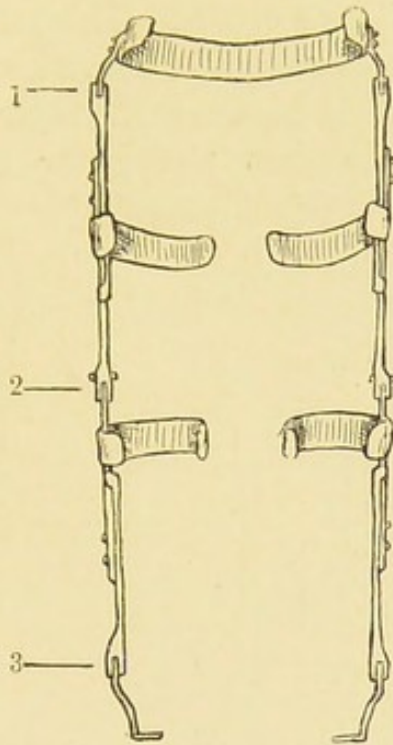


Fig. 37.—Metal part of the ordinary "Walking Instrument" for Knock-knee.

1, 2, 3, tenon joints; above 2 a ring-catch is shown in section.

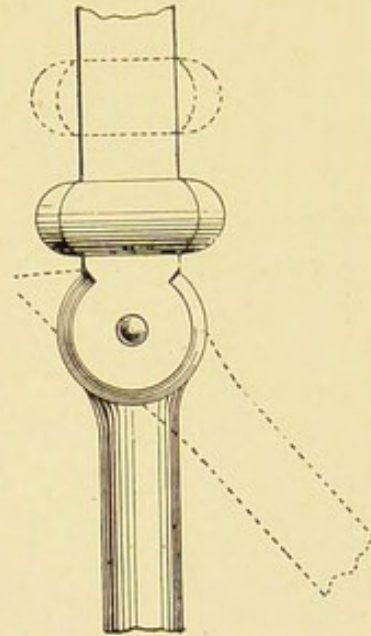


Fig. 38.—Ring-catch Joint.

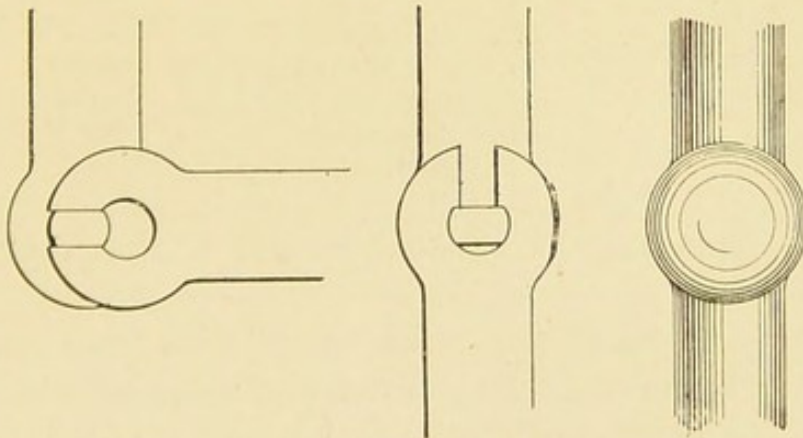


Fig. 39.—Detachable Joint.




Fig. 40.—The Method of elongating Steel Supports.

rigid when the child is standing, and the knee must be pulled outward to the splint by fastening the straps of a knee-cap.

In order to enable the patient to sit comfortably, there may be a joint at the knee, which can be locked and unlocked according as the patient stands or sits. This effect is obtained by the "ring-catch" joint as shown in Fig. 38.

A further convenience is to have the adjustment of the steel to the boot so made that the latter can readily be

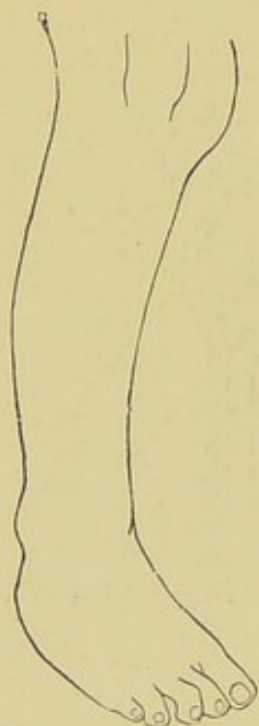


Fig. 41.—Leg and foot in Equinovarus, with Varus deformity partly corrected.

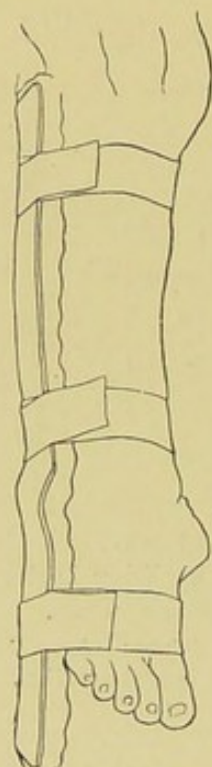


Fig. 42.—Malleable Metal Splint applied to the limb shown in Fig. 41.

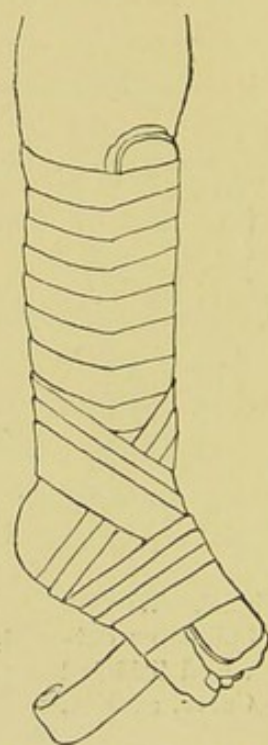


Fig. 43.—Antero-external Malleable Splint, applied in a case of Club-foot.

detached. This may be effected by use of the joint shown in Fig. 39.

In many forms of apparatus "stop-joints" are employed. Thus, after correction of a talipes equinus, the joint at the ankle should be so constructed that it permits of flexion but not of extension beyond a right-angle with the leg.

It may be asked whether a child does not soon grow out of the instrument. This is provided for by the structure of the thigh and leg pieces, which are made of overlapping rods of steel fastened by screws near the end of one and by a loop at the end of the other (see Fig. 40).

Another question I am frequently asked is, "Should the

instrument be worn at night?" The rate at which the deformity disappears is certainly increased by suitable instruments being worn at night. The steel apparatus should, however, be replaced by a simple splint for the night.

There are other refinements that might be mentioned in the structure of the steel walking apparatus, but the chief points have already been detailed, and space does not allow of more.

The principle of the rigid splint with the addition of

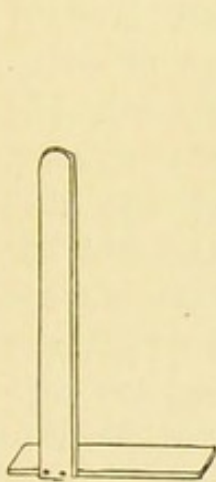


Fig. 44.—Rectangular Splint.

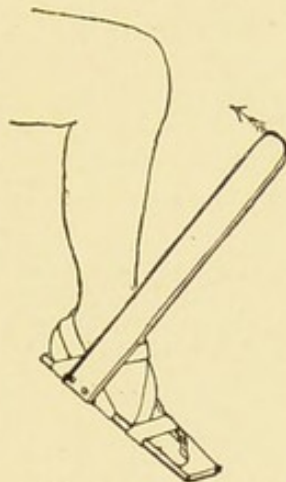


Fig. 45.—Foot-piece fixed to the foot by strapping.

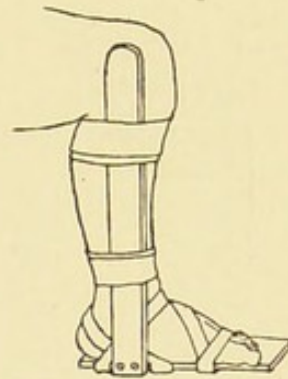


Fig. 46.—Leg-piece adjusted, holding the foot in a corrected position.

Figs. 44-46 illustrate the action of a simple "Scarpa's shoe" in a case of talipes equinus.

progressive alteration in form is seen in the useful "tin" splint. I have purposely put its rigidity as its most important feature; if such splints are made too flexible they do not answer their proper function. An example of the use of the splints may be taken in a case of congenital equino-varus in which treatment has been begun, as it should be, within the first few weeks after birth.

Even where this is not done, and treatment is neglected for a year or more, the eversion, much of the "cavus," and some of the "equinus" can be overcome by careful splinting. Such a case is shown in Figs. 41 and 42, at its middle stage of treatment.

When all the varus has been removed, an antero-external splint may be applied, as shown in Fig. 43, in order to remove any of the hollowness of the foot that remains, and some of the equinus.

It must be remembered that both these splints are used

as levers, and that their fulcra should be the sides of the leg and not the external malleolus or other bony prominence.

The Rigid Splint used as a Lever.—A good example of leverage obtained by means of a rigid splint is seen in the apparatus, termed generically "Scarpa's shoe," applied to the foot for talipes. In order to illustrate the mode of action of a "Scarpa's shoe" a case of equinus may be taken. A simple instrument made of oblong pieces of stiff board, joined at a right-angle (Fig. 44), would constitute a "Scarpa's shoe."

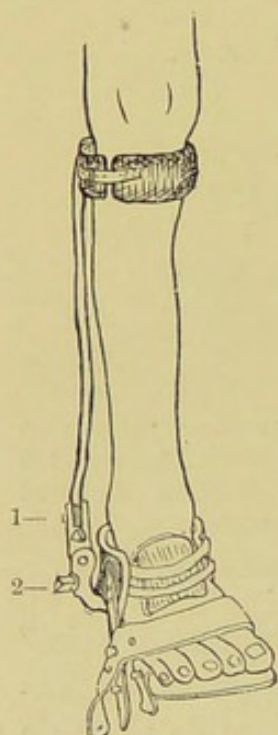


Fig. 47.—An early form of "Scarpa's shoe."

(1) Rack producing flexion at ankle; (2) rack for everting the foot.

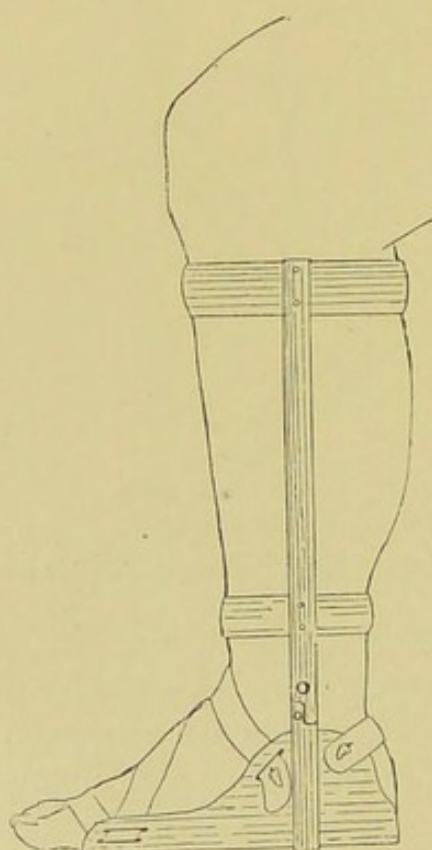


Fig. 48.—Modern type of Shoe applied after correction of Equino-varus.

The foot is fixed by strips of adhesive plaster, to the sole-plate (Figs. 44, 45, and 46), and when the foot has been firmly secured to the sole-plate in this way, the upright is secured to the outer side of the leg, and the foot is thus brought into a corrected position.

In the original "shoe" used by Scarpa for equino-varus the upright was applied to the outer side of the leg, as in the

apparatus shown in Fig. 47. In such instruments the leverage action as far as the varus part of the deformity is concerned, was lost, and had to be replaced by traction of a strap.

Other simple forms of apparatus are known as Taylor's and Bradford's shoes, much used in America. They consist of a steel sole-plate which reaches from the heel to the ball of the toes, and it has a raised edge and a jointed upright leg-iron on the side towards which the foot tends to turn.

When the foot is securely strapped to the sole-plate and the leg-iron is brought into place, a strong leverage action is brought into play (Fig. 48).

The more elaborate walking instruments which are commonly used in the after-treatment of club-foot, are on the same principle as the simpler splint just described. They also correct inversion at the knee and hip joints (Fig. 49.)

Progressive alteration in form of a rigid splint is frequently obtained by a rack-and-pinion movement (*see* Fig. 47). By means of an endless screw a lever may be made to incline in either of two directions in the same plane. The same effect can be obtained by using malleable rigid splints that can be bent by wrenches, and by using this simpler form of apparatus much expense is saved, since joints, and especially rack-joints, are the most expensive parts of instruments. In certain cases of club-foot, and contractures affecting the knee, hip, or other joints, a rack-joint is helpful to the surgeon by affording an easy means of gradually improving the condition by periodically turning the endless screw.

The success of any orthopædic appliance depends upon attention to every detail of structure and action, and the only effective appliances for the hip and the spine require on the part of the surgeon a familiarity with the principles of the appliance in order that he personally may re-adjust the instrument as the morbid condition improves under treatment.

Thomas's hip-splint may be described in some detail, as it is typical of the most useful class of orthopædic appliances. The hip-splint,* invented by the late H. O. Thomas, is



Fig. 49.—Walking Instruments for use after correction of Deformity in Double Equinovarus.

* An illustration of the hip-splint applied will be given on p. 300.

an example of a rigid splint capable of progressive alteration in form.

Although there are better ways of fixing the hip-joint by portable apparatus, it is a valuable aid when properly made and adjusted, but worse than useless when its mode of construction and of application is imperfectly appreciated. The principles involved in the designing, structure, and management of this instrument are instructive and important. It is on the constant attention on the part of the surgeon that success depends.

THE LATE MR. THOMAS'S ACCOUNT OF HIS SPLINT.*

We will suppose the patient, *æt.* ten, with right hip-joint disease. The surgeon requests him to stand on the left limb, and proceeds to measure him for the instrument. A block, or several, if necessary, are placed under the sole of his right foot, until the unsound limb is raised sufficiently to allow the spine to resume its natural form.

Now he takes a long, flat piece of malleable iron, one inch by a quarter for an adult, and three-quarters of an inch by three-sixteenths for children, and long enough to extend from the lower angle of the shoulder-blade in a perpendicular line downwards over the lumbar region, across the pelvis, slightly external, but close to, the posterior-superior spinous process of the ilium, and to the prominence of the buttock, along the course of the sciatic nerve, to a point slightly external to the centre of the extremity of the calf of the leg. The iron must be modelled to this track to avoid excoriations.

The lumbar portion of the upright must be invariably almost a plane surface, and rotated on its axis in the direction of the arrows (Fig. 50), more or less in proportion to the plumpness of the patient. This iron forms the upright portion. It is very necessary that it should come below the knee, to enable the surgeon to fix this joint.

Then measure round the chest, a little below the axilla, deducting, in the case of an adult, four inches from the chest circumference. This latter will be the measure for the upper cross-piece, which is made from a piece of hoop iron, one inch and a half by one-eighth of an inch. The hoop is firmly jointed to the top of the upright with a rivet (Fig. 50) at one-third of its length from the end next to the diseased side. It is important to give the upper crescent this oval shape to assist in arresting the machine from rotating from its position behind the body, and thus producing inversion of the limb. Another strip of hoop metal, three-quarters of an inch by one-eighth of an inch, and in length two-thirds of the circumference of the thigh, is fastened to the upright at a position from one to two inches below the fold of the buttock, then another piece of metal of like strength, equal to half the circumference

* H. O. Thomas, "Diseases of the Hip, Knee, and Ankle Joints, Treated by a New Method," 3rd Ed., 1876.

of the leg at the calf, is firmly riveted to the lower extremity of the upright.

The short portion of the top half circle is next to the diseased side, with a space intervening, while the long portion must be closely fitted to the sound side. If the machine should tend to rotate from the disused side, then daily contract the long wing of the crescents, and expand the short ones.

In applying the instrument with two uprights (Fig. 51), care should be taken to measure the distance between the tip of right and left posterior spinous processes, and then to set the uprights parallel and apart one inch more than such measurement, or it cannot be tolerated by the patient. The two uprights should be connected by a cross-bar when practicable, which is not possible when the double instrument is used for reduction of deformities; when used it will be found useful for the attendant to grasp in nursing.

The Rigid Splint applied to the Spinal Column.—Antero-posterior spinal splints have been used in orthopædic surgery for several generations, but the right method of their construction and application is largely due to the late E. J. Chance, of London, and the late C. F. Taylor, of New York.*

Bradford and Lovett state:

The first efficient and thorough adaptation of the principles of treatment by proper antero-posterior supports has been accomplished by Dr. C. F. Taylor, of New York. Since the use of certain appliances was advocated by him, some modifications have been introduced; but the principles under which he worked have remained much the same.

I shall, in the present place, first describe Chance's spinal splints, because I believe they were introduced prior to those of Taylor, and also because, in my opinion, they possess certain advantages over the latter. At the time that the late Sir

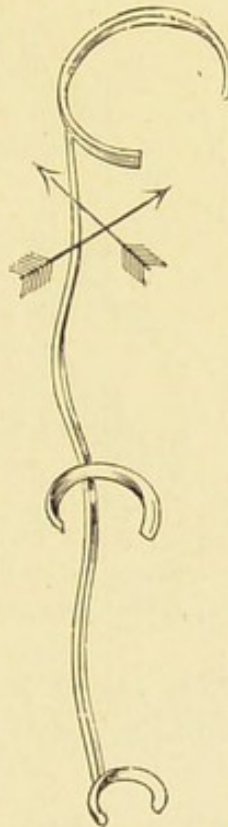

Fig. 50. — Single Thomas's Splint.

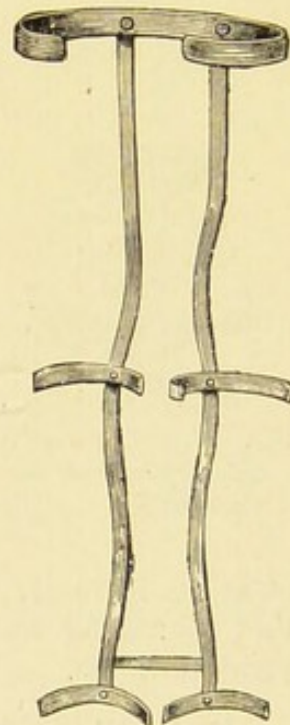


Fig. 51. — Double Thomas's Splint.

* C. F. Taylor, "The Mechanical Treatment of Pott's Disease," 1870.

John Erichsen selected Taylor's splint as the best for its purpose, there was in use in London a simpler and, in my opinion, for most cases a better apparatus. The late E. J. Chance began to employ his spinal splints at the City of London Orthopædic Hospital in 1852. As applied to a case of tubercular disease of the spine, their structure is shown in Fig. 52, and is thus described by Noble Smith.*

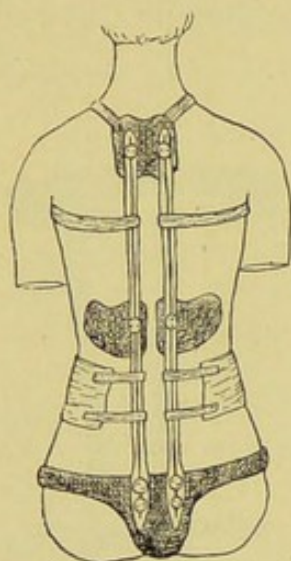


Fig. 52.—Chance's Splint for Angular Curvature.

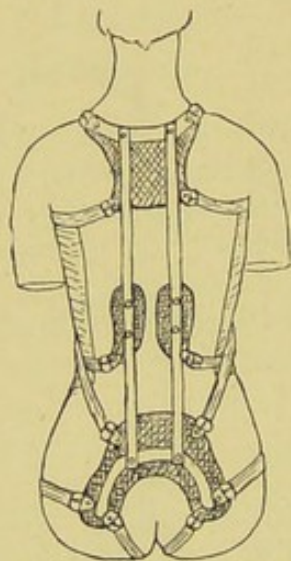


Fig. 53.—Taylor's Antero-posterior Spinal Support.

The Adaptable Metal Splint.—Soft shoulder-straps, placed round each shoulder, are drawn back and attached to a pad behind the shoulders. Light steel plates, padded, are adapted to the spine at the side of the angle, a space being allowed for the spinous processes to project between (Fig. 52). Two steel bars extend from the pad between the shoulders, upon each side of the spinous processes, to the level of the seat, where they are attached to a pelvic belt, the side plates also being

attached to them. The pelvic belt should be firm at the back, so that by resting on the seat it will support the whole body from that point upwards.

C. F. Taylor's spinal brace (Fig. 53) is thus described by Bradford and Lovett:—

The simplest antero-posterior apparatus consists of two uprights of annealed steel, three-eighths or half of an inch in width, and thick enough to be rigid. . . . These uprights should reach from just above the posterior-superior iliac spines to about the level of the second dorsal vertebra. The uprights are joined together below by an inverted U-shaped piece of steel, which runs as far down on the buttock as possible without reaching the chair or bench when the patient sits down. Or the brace may end in a waist-band. . . . The uprights are joined above by another U-shaped piece, the upper ends of which should pass over the anterior aspect of the elevation of the shoulders, or, rather, the root of the neck.

The uprights should be far enough apart to support the transverse processes of the vertebræ, and not the spinous processes. They should

* Noble Smith, "Spinal Caries," 2nd Ed., p. 83.

be bent according to a cardboard tracing of the back, taken as described, and then adjusted to the back. The neck and bottom pieces should be cut out in cardboard in pattern. The whole should then be riveted together and tried on the patient, who should be lying on his face in the recumbent position. . . . An accurate fit is essential, the covering is merely a matter of detail. . . . Pad plates, covered with felt or hard rubber, are needed. . . . Buckles are needed at the ends of the neck-piece, at a level with the axilla, opposite the middle of the abdomen, and at the lower end of the brace. . . .

It is, of course, essential that the trunk be properly secured to the brace. This can be done by means of an apron, which covers the front of the trunk, the abdomen, and the chest, reaching from the clavicles nearly to the symphysis pubis.

Springs and Elastic Traction.

—Steel springs may be used for various ends: as levers, as pressors, as tractors, as locks, etc.; elastic bands may be used instead of springs for many of these purposes. Although springs may be used for many of the same purposes as rigid splints, the latter are to be preferred in most instances.

The spring is used to replace functionless muscles, *e.g.* to replace the extensors of the toes in talipes equinus (Fig. 54), or the calf muscles in talipes calcaneus.

Springs are sometimes employed to press back the prominent sternum in pigeon-breast. Spiral springs or rubber cords may be used in place of a weight extension. Springs may take the place of rigid splints, *e.g.* in apparatus for club-foot or the spine. As an instance of the latter use of springs the spinal support invented by the late Dr. Prothero Smith* may be mentioned (*see* Fig. 55).

Mr. Barwell has applied elastic traction exerted by means of india-rubber rings to the treatment of lateral curvature of the spine, and Mr. Muirhead Little, in his

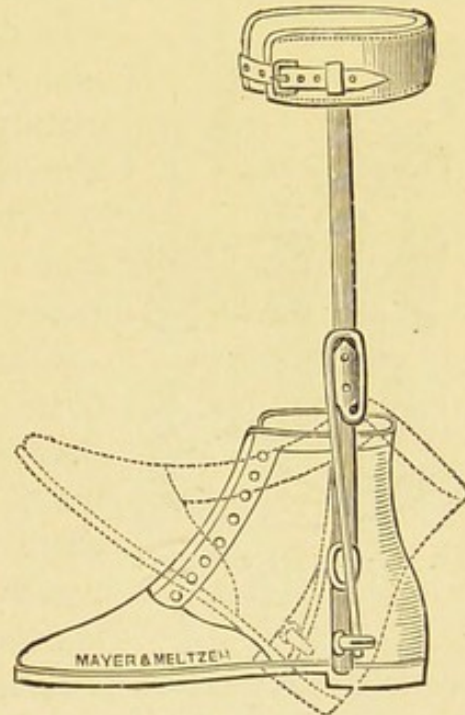


Fig. 54.—Boot and Iron, with Spring for elevating foot in Talipes Equinus.

* Prothero Smith, *Brit. Med. Journ.*, 31st Aug., 1878.

"concealed spring," has found a substitute for the rigid outside iron requisite in many cases of flat-foot.

The therapeutic properties of elastic traction were at one time extensively tried as a means of correcting paralytic club-foot without tenotomy. Mr. T. Holmes, at Great Ormond Street, showed that for this purpose no reliance was to be placed upon the method. In general, springs and elastic bands are less potent than suitable rigid apparatus

as corrective measures; their chief use is to supplement rigid splints as in the examples of club-foot apparatus given above.

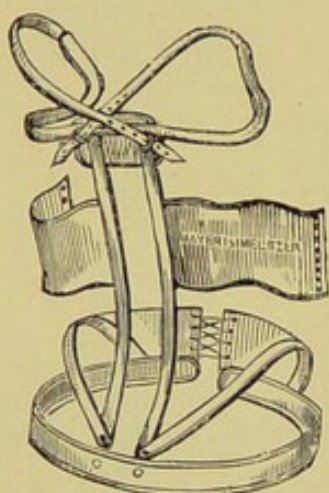


Fig. 55.—Prothero Smith's Spinal Support.

The great variety of *artificial limbs* and other prosthetic apparatus, though really belonging to this department of surgery, would require so much space that they cannot be fully considered in this work. One use of artificial limbs may, however, be mentioned. This is their employment as a means of giving rest to a diseased joint. A familiar instance of this valuable application of a prosthetic apparatus is seen in Thomas's knee-splint (Fig. 56). When this instrument is applied the whole of the lower limb is thrown out of use, the weight of the body being borne by the tuber ischii of the diseased side.

The principles of structure and of the working of artificial limbs are in the main similar to those of orthopædic ambulant apparatus, and they are of importance in general surgery. Thus, in planning an amputation, the life and safety of the patient are first to be thought of, after that the kind of prosthetic apparatus that will be required must be considered, and then such a stump must be devised as will enable the patient to use the apparatus with comfort. Examples of artificial limbs used after amputation below the knee are shown in Figs. 57 and 58.

Correcting Manipulations.—In orthopædic surgery there is much scope for the application of manual force for the temporary correction or diminution of deformity. Thus, in congenital club-foot, correcting manipulations should be

begun, as Sayre puts it, "as soon as the baby has been washed," and they should be continued daily in addition to other measures. The slight manual force applied acts by stretching the shortened and relaxing the lengthened structures, and enabling the surgeon to obtain a slightly improved position of the part each time the retaining apparatus is applied. In congenital wry-neck, scoliosis, genu valgum, and other rickety deformities, and in stiffness left after traumatic and inflammatory conditions, manipulations are often of very great assistance to the surgeon. In certain conditions the manipulative measures, after due instruction, may be left to the nurse or patient.

Manipulative Treatment of Stiff Joints—"Bone-setting."—The formation of adhesions within or about joints, tendon sheaths, etc., after traumatism, or non-traumatic conditions, is often the cause of much pain and crippling to the patient, and the frequency with which the cause of the disability is overlooked has proved the opportunity of the class of empirics known as "bone-setters," from their own mistaken ideas of the pathology of the conditions with which they deal.

The pathology of such conditions in purely traumatic cases is simple enough; it is the same as the formation of scar-tissue. Thus, for example, after a dislocation of, say, the shoulder-joint, more or less blood fills the potential pouch of synovial membrane, which forms when the arm is by the side. This blood clots and becomes organised in the usual way. By the fourth day new blood-vessels will begin to form, and by the eighth day the fibres formed from the

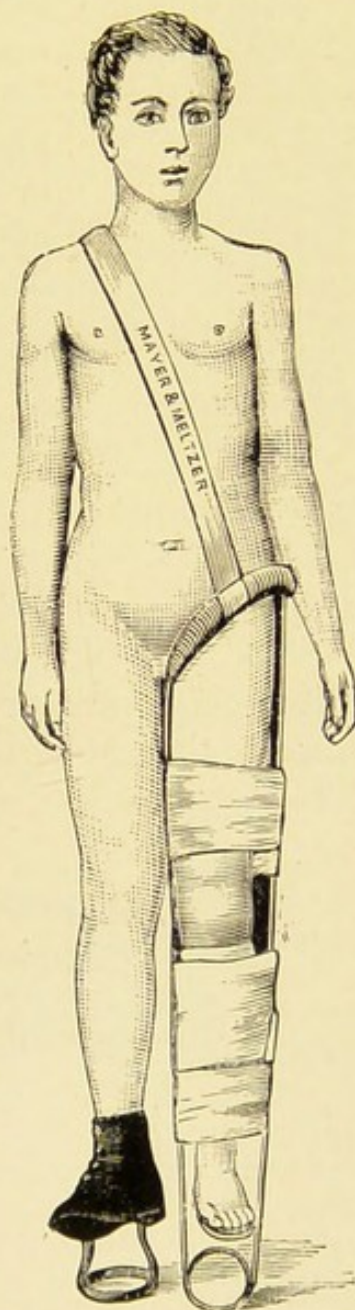


Fig. 56.—Thomas's Splint for Tubercular Disease of the Knee-joint.

fibroblasts of the granulation-tissue that now replaces the blood-clot and joins together the opposed surfaces, will be acquiring an increasing firmness. Thus, in order to prevent the formation of firm adhesions, passive movements should be begun and continued until repair is complete. In performing the necessary movements of the joint, the latter should be carefully supported, and firmly and evenly bandaged after each manipulation.

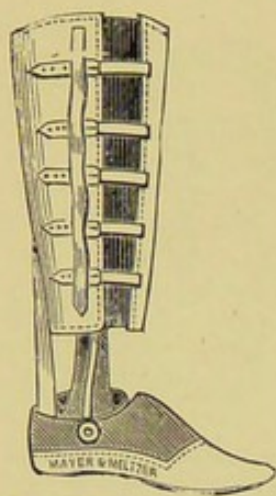


Fig. 57. — Apparatus for use after Amputation at Ankle or through Tarsus.

When there is a fracture in the neighbourhood of a joint, the proceedings for the prevention of adhesions must be delayed until the fragments are firmly united. Thus, in a Collis's fracture, the formation of adhesions in the tendon-sheath is provided against by leaving the fingers free, and by early passive movements of all the

digits. After five or six weeks, when a fair amount of union between the osseous fragments has taken place, the wrist-

joint should be fully flexed, extended, adducted, and abducted by one hand of the surgeon, whilst the other supports the end of the radius, and with thumb or fingers makes pressure upon any painful spots in the area of the synovial membrane of the joint. After this, re-formation of adhesions is prevented by daily manipulation and massage.

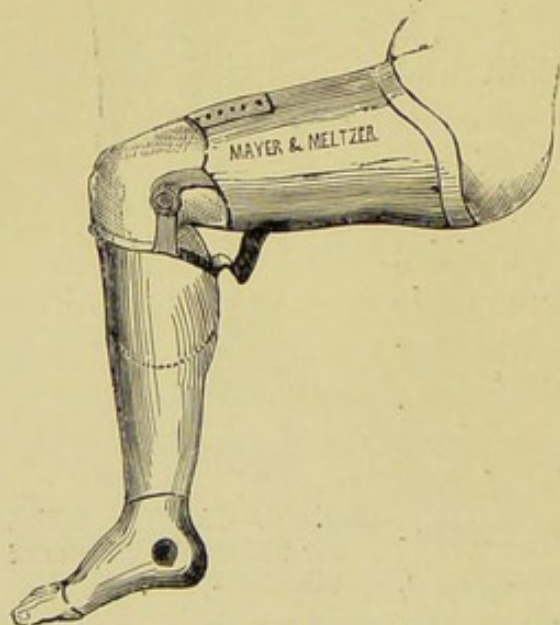


Fig. 58. — Artificial Limb for use after Amputation below the Knee.

As a typical example of the commonest kind of case that finds its way to

the bone-setter, the following may be given:—

A railway-porter, aged thirty-six, fell heavily on his shoulder on October 15th. He began to attend the casualty department of a hospital

on November 12th, the shoulder being then painful. He remained under treatment till May 5th, when he came to the City Orthopædic Hospital. The muscles around the joint were wasted, there was a tender point just below the acromion on the front of the joint, there was complete ankylosis of the joint as evidenced by the scapula moving in every direction with the humerus. The patient was put under gas, and with the left hand steadying the scapula and the left thumb making pressure on the tender point above mentioned, I produced full flexion and extension by my right hand holding the patient's arm just above the elbow. External and internal rotation, and finally circumduction, with the elbow well raised, whilst traction was made to prevent dislocation, were then performed. With every movement, loud creaking was elicited. The joint was then firmly bandaged. The patient had a good deal of pain for two hours. He was then sent home, and directed to remove the bandages at night, and next day to begin to use the arm. He was free from pain for four days, when he felt slight aching. On his second visit a week after the first, I found all the movements were free save that there was slight limitation of external rotation. On sharply moving the arm to the full in this direction, I felt a slight adhesion give way. After this, the patient had full use of his arm, and the muscles quickly regained their power, the patient returning to work in four weeks' time.

In other cases of similar character the symptoms are referred to parts at a distance from the joint, and a wrong diagnosis is easily made. Such a case may be briefly alluded to :—

M. O'D., aged forty-two. No previous illness, somewhat alcoholic in habit. February 8th, 1899 : Patient was carrying a heavy case when he fell on the outstretched right hand. Had severe pain about the shoulder, and in the upper part of the arm between the biceps and the bone ; severe pain was felt later about the right thumb and the back of the hand, and also along the ulnar nerve. The patient was unable to move the arm at the shoulder. He was treated for neuritis in the casualty department. February 18th : On examination I found the movements of the shoulder-joint were greatly limited. Gas was given by Mr. M. C. Hayward, and I broke down the adhesions, which were heard to give way. The pain immediately after this operation was severe, and was referred chiefly to the back of the hand. A quarter grain of morphia was given. February 22nd : Patient states that the pain entirely disappeared two hours after the operation, and has not since returned. He moves the arm better than before. February 25th : The movements in the arm are now nearly normal in every direction ; pain remains absent. The patient was recommended to use the arm as much as possible.

The various morbid states that are successfully treated by bone-setters are thus classified by Mr. Hood :—*

* Wharton P. Hood, "Bone-Setting," 1871, pp. 26, 27.

1. Stiffness and pain of joints following fracture. In this category are two classes of cases: (1) joints stiff from want of movement; (2) stiff and swollen joints, which have been implicated in the original injury.

2. Sprains that have been treated by long fixation or rest.

3. Joints that have been voluntarily kept at rest for the avoidance of pain, whether the latter is due to an intra-articular or an extra-articular cause.

4. Rheumatic and gouty joints.

5. Displaced cartilages.

6. Ganglia.

7. Subluxations of carpal or tarsal bones.

8. Displaced tendons.

9. Hysterical joints.

As may be imagined, these operations in the hands of men ignorant of pathology are occasionally performed in the wrong cases, and sometimes with disastrous results. Tubercular joints in which there is evidence of activity are especially liable to be made worse by the forced manipulations and subsequent movement. Although, as is well known, a quiescent tubercular joint may with due precautions be safely brought into a good position, it is necessary to apply a retentive apparatus and to diminish intra-articular pressure when the correction of the deformity has been effected. It is in the latter part of this method of procedure that the bone-setter fails.

Another large class of cases in which the bone-setter and even surgeons who give special attention to "bone-setters'" cases come to grief are those due to muscular contracture, such as talipes, paralytic contracture of the knee- or elbow-joint deformity from contracture of the triceps.

Again the bone-setter's success with rheumatic and gouty joints, ganglia, displaced cartilages, can only be of a transitory character.

On this subject the late H. O. Thomas* observed:—

This class of practitioners are not in possession of methods "not dreamt of in our philosophy." Frequently I have heard patients express themselves relieved in twenty-four hours, when, as a practical surgeon, I could plainly see that they were still sufferers.

The manipulations described in the case of fibrous anky-

* H. O. Thomas, *loc. cit. supra*, p. 109.

losis of the shoulder, described above, may be taken as a type of those required in similar cases. In every case the joint should be steadied by one or both hands whilst the manipulation is being performed. The tender spots in the joint over which the bone-setter makes pressure whilst the manipulation is being performed are the points of attachment of the principal adhesions, and by fixing them the synovial membrane to which they are attached is prevented from yielding, and so allowing the adhesion to resist the movement without undergoing rupture; it may also secure the rupture of the adhesions at some point distant from its attachment to the synovial membrane. In manipulations of this kind it is most important to secure free movement in the direction of the chief resistance. The bone-setter is frequently guided to use combination movements of joints by following this indication. Wharton Hood gives an instance of this in describing the manipulations as practised at the elbow-joint:—

In the case of the elbow-joint, the first care of the operator is to discover in what direction movement is most painful. For this purpose, the arm and forearm being each firmly grasped, he makes an effort at flexion with the hand carried towards the median line, and again with it carried outwards in the opposite direction. He inquires which movement is most painful, and when the pain is felt. The operator, placing the back of his left hand on the table, receives the elbow-joint in his palm and grasps it firmly, at the same time placing the left thumb steadily on the seat of pain. He then grasps the wrist with his right hand. If the most painful movement was flexion with adduction he twists the palm of the hand towards the median line and flexes the elbow sharply, at the same time bringing the hand across the chest. If flexion with abduction was most painful the palm is twisted outwards, and the forearm carried into the flexed position. In many cases both these manœuvres would be performed, the thumb-pressure being shifted to the spot especially painful in relation to each; and, lastly, complete extension and rotation would be made.

In applying these manipulative measures to the spine great care in the selection of cases is required. When pain and stiffness remain after a sudden twist of the spine—"ricked spine" as it is termed—suitable manipulation is often of service, but disasters have occurred from mistaking tubercular for simple traumatic conditions.

Of very great service before the application of these

manipulations is the use of the superheated air-bath (*see* p. 41). The pain that often follows the operation, and that felt during the operation, are frequently avoided by its use.

Massage is often of use in the after-treatment.

Forcible Stretching of Muscles.—This proceeding is of use as an element in the treatment of contractures, *e.g.* in diminishing adduction of the thighs and the adductor spasm in spastic paralysis. In slight cases of paralytic contracture of the knee it is also of service.

In performing the operation the patient is anæsthetised to full relaxation of the muscles. Then the joint is forcibly moved as far as possible in the desired direction. The amount of force employed must stop short of rupturing the muscle or its tendon. When the parts have been stretched as much as is safe the joint is fixed in plaster, and if full correction has not been obtained the plaster may be removed a few weeks after the first operation, and a further stretching effected.

In stretching the adductors in spastic paralysis it is of advantage to manipulate the stretched muscle by firm transverse massage.

Orthopædic Operations.—(1) *On the Skin.*—Deforming scars that resist treatment by massage, weight-extension, etc., may require operative treatment. Since the form and extent of scars vary widely, the exact method of dealing with them differs in each case. The various procedures are: (1) Excision; (2) plastic operations. Both these operations may be done with or without skin-grafting or flap-transplantation. Careful after-treatment is required to prevent re-contraction.

2. *Fasciæ.*—Contractions of the palmar or plantar fasciæ may be dealt with by simple transverse section of the bands correction of the deformity, and subsequent long maintenance of the part in the corrected position. The division of bands of fasciæ, contracted in a linear manner, requires avoidance of important vessels and nerves, but is otherwise simple. A small tenotome is inserted between the skin and the band, and its edge is so turned that it is vertical to the tissue to be divided. The band is then put on the stretch, and the division is continued until all resistance is overcome.

When wide areas of fascia are involved, as in contraction of the fascia lata in connection with tubercular disease of the hip or knee, simple transverse division is no longer sufficient, and the fascio-plastic operation introduced by V. Winwarter is employed. It consists in making a **V**-shaped section, including skin, fasciæ, and, if necessary, subjacent muscles. The base of the wedge is generally to be placed towards the proximal side, but when this procedure is employed in the treatment of Dupuytren's contraction the base of the **V** is placed distally. The section made and the deformity corrected, the wound is closed by sutures in such a way that the lines of sutures form a **Y**. In order to maintain the improved position the part is encased in a plaster of Paris case or a moulded splint for some weeks, and afterwards a suitable apparatus is worn to prevent recurrence of the deformity.

3. *Tendons*.—Subcutaneous tenotomy, established by Stromeyer in 1831 as a regular surgical procedure, remains to the present time as one of the most valuable of surgical resources. The only instruments required are tenotomes. Guérin's small narrow-bladed knives are those in general use. The two chief forms of tenotomes are the blunt and the sharp-pointed, as shown in Fig. 59. The sharp-pointed knives should not taper too much at the point and the latter should usually be in the central axis of the blade; in the case of the small fascia knife of William Adams, however, the cutting edge should be straight right up to the point. Most tendons may be safely cut with a pointed tenotome, but in the neighbourhood of large blood-vessels, as in the division of the sterno-mastoid, it is safer to puncture the skin and fascia with a sharp-pointed knife, which is then used as a director to guide a blunt-pointed tenotome, by means of which the section of tendon or muscle is done.

The slightly curved tenotome of Parker (Fig. 60) for cutting the tibialis-posticus tendon, ligaments, etc., below the internal malleolus, is also useful. Dieffenbach's sickle-shaped instrument is still used by some Continental surgeons, and some use a tenotome with a slight backward curve.

Tendons may be divided either by cutting from the superficial to the deep aspect, or *vice versâ*. In the former method

in the case of the tendo Achillis a fold of skin is pinched up over the narrowest part of the tendon, whilst the foot is held by an assistant, so that the tendon is relaxed. A sharp-pointed tenotome is then introduced on the inner side of the tendon and pushed on the flat between the skin and the tendon till its point can be felt under the skin projecting beyond the other side of the tendon. The tendon being put on the stretch by the assistant, the edge of the knife is then turned against the tendon. The assistant then increases the tension of the tendon, whilst the operator presses the blade of the tenotome against the tendon with

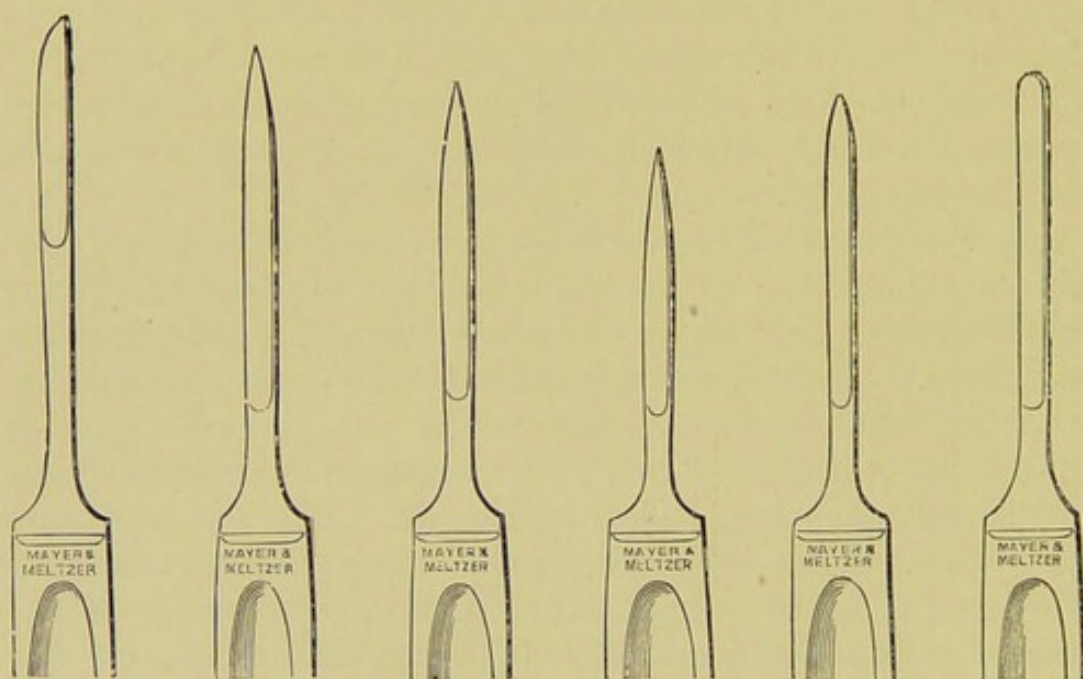


Fig. 59.—Tenotomes.

his left thumb, and with the right makes the blade execute a series of rocking movements, which cause a sort of grating sensation as the stiff tendon-bundles are successively cut. The completion of the division of the tendon is evidenced by a sudden yielding of the hitherto tense tendon. At the moment when this is felt the surgeon turns the knife again on the flat and withdraws it; the assistant at the same time relaxes the parts previously put on the stretch.

The second mode of dividing the tendon is to pass a sharp-pointed tenotome from the inner side, beneath the tendon, and the latter being put on the stretch, the tendon is cut through by rocking and sawing movements of the

knife. In Great Britain it is usual to have the patient lying on the face for this operation, and to use a sharp-pointed, straight tenotome. The best description of the operation is one given verbally to me by Mr. William Adams who recommends that the tenotome be passed through the skin near the inner border of the tendon and then under the latter at an angle of 45° ; the edge of the knife is then turned against the tendon which is divided by a succession of leverage movements of the knife against its under surface. If the knife is passed from the outer side, there is danger of puncturing the posterior tibial vessels. Some Continental surgeons have the patient lying on the back,

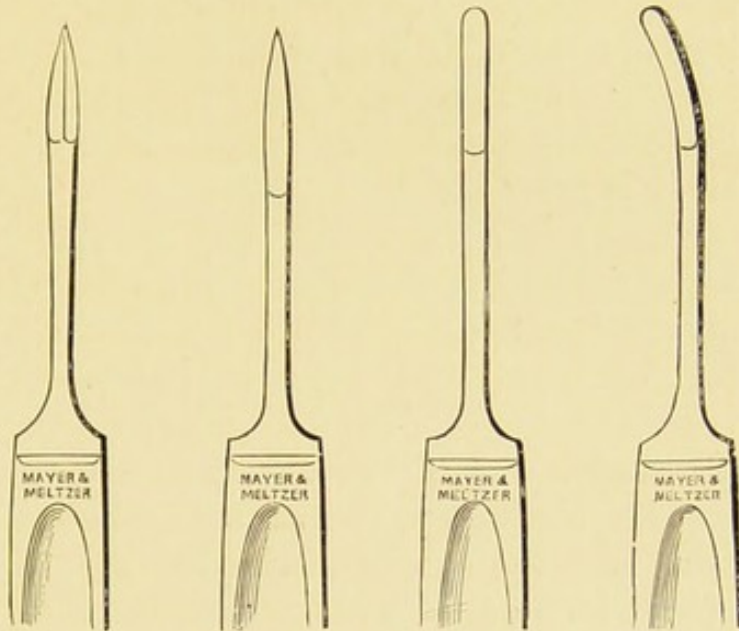


Fig. 60.—Parker's Tenotomes.

and pass a sickle-shaped tenotome from the outer side. During the division of the tendon by this means, the surgeon holds the patient's foot with his left hand; and, in operating on the feet of little children, it is always advisable for the surgeon to hold the foot, whilst the assistant steadies the leg.

Before passing to the consideration of tenotomy of other tendons, the process of regeneration of tendon may be briefly examined.

The *repair of tendon after division* may be studied in detail in the case of a tendon divided subcutaneously with antiseptic precautions. If the tendo Achillis of a rabbit is examined twenty-four hours after aseptic division, the clean-cut ends are seen to have separated about one inch, and to be coated with a thin layer of blood-clot. They are joined together, and for a short distance ensheathed by a jelly-like, straw-coloured coagulum, which is as large as the tendon, filling out the tendon-sheath.

The puncture in the tendon-sheath is closed by a little blood-clot which is adherent to the tissues outside. This uniting coagulum of "plastic lymph" is formed by the coagulation of lymph which has escaped from the divided lymphatics of the tendon, and from plasma which has escaped from the small blood-vessels injured by the operation. At the end of forty-eight hours the appearance to the naked eye is just the same as at the end of the first day, but if the tendon with the sheath and the uniting material be excised, hardened, and cut in sections, it is seen that active biological processes have occurred. The whole of the uniting bond is traversed by branched young connective-tissue cells linked together (see Fig. 61, 5), and careful examination reveals the fact that these cells are multiplying by indirect division, and also that other cells are being formed by the division of (1) the endothelial cells of the divided blood-vessels of the tendon, and (2) the connective-tissue cells of the sheath and of the interfascicular spaces of the tendon. Besides the newly-formed connective-tissue and endothelial cells are seen white blood-corpuscles, both the more numerous variety, with a subdivided nucleus, and the less numerous uni-nuclear variety, or lymphocytes. In the neighbourhood of the clot leucocytes of each variety may be found to have engulfed some of the red corpuscles. In the interior of some of the young connective-tissue cells both red and white blood-corpuscles are to be observed.

This activity of growth and multiplication of cells are caused in part by the presence of an unusual amount of food in the shape of serum, fibrin, and blood-corpuscles. The cells become predatory amœbæ. From their destination, which is about to be described, they are termed "fibroblasts" and "vasoblasts."

A divided tendon examined on the fourth day presents a new appearance. The uniting medium, though still jelly-like, is now everywhere traversed by red streaks, due to the formation of new blood-vessels. In other words, the *plastic lymph* has been transformed to *granulation tissue*. The newly-formed blood-vessels arise as buds from pre-existing capillaries. Examination of sections of the divided tendon on the fourth day affords evidence of the mode of formation

of new blood-vessels and also of the formation of new connective-tissue fibres from the young connective-tissue cells or fibroblasts.

Some other features in the structure of the new tissue

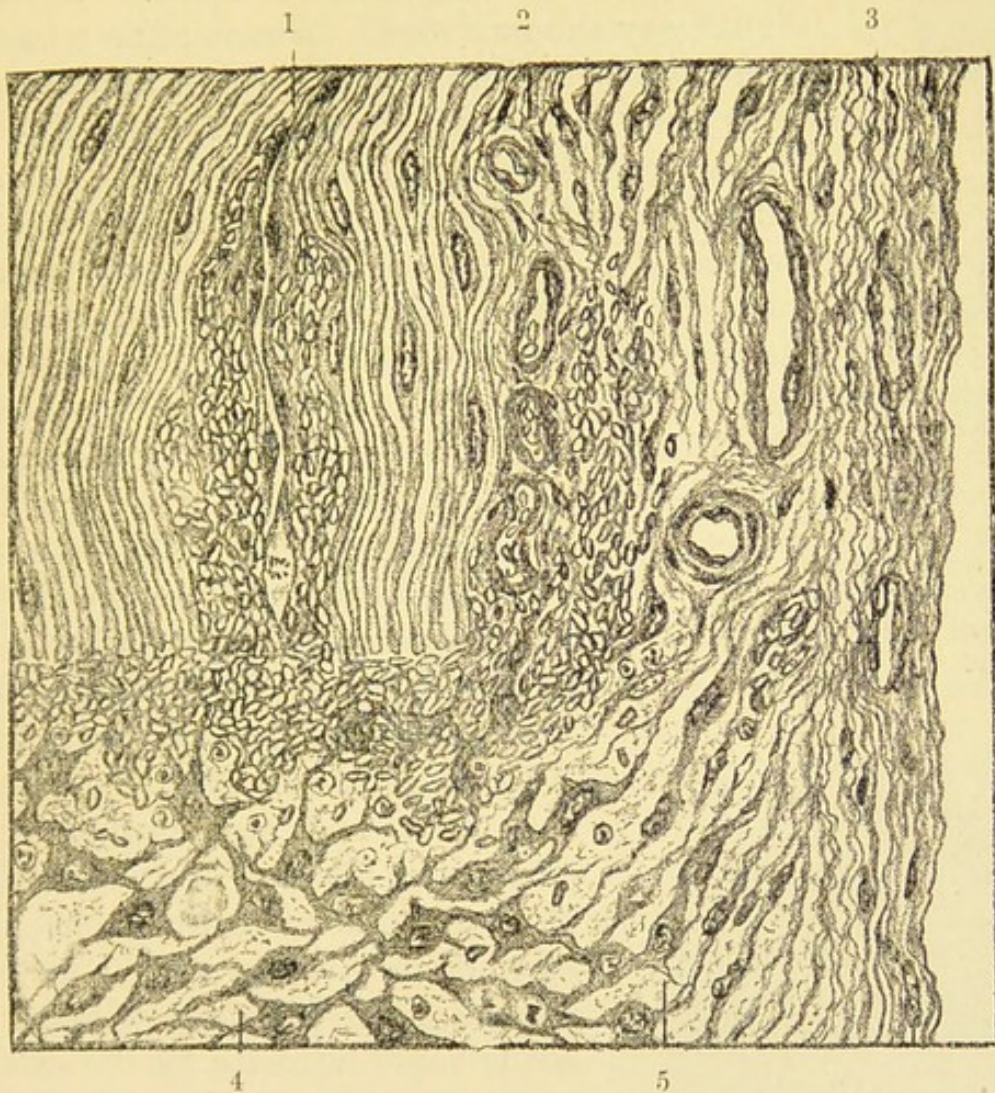

Fig. 61.—Part of a longitudinal section through one end of the tendo Achillis of a rabbit, forty-eight hours after operation. 1. A capillary lying between two bundles of tendon fibres. The cut (lower) ends of tendon fibres show no change; they are surrounded by effused red blood-corpuscles which extend upwards between the tendon fibres and also on the outer side of the tendon. 2. The inner part of the tendon-sheath where it closely invests the tendon and contains many small blood-vessels. 3. The outer part of the tendon-sheath which consists of fibrous tissues with some blood-vessels. 4. The inner aspect of the sheath with proliferating cells. 5. Young connective-tissue cells. $\times 500$ diams.

at this stage are worthy of note. The cut ends of the tendon still present no change, and the blood-clot adhering to them has been to a large extent removed. Traces of digested red blood-corpuscles reduced to hæmatoidin granules are to be

seen in some of the fibroblasts. The formation of fibrous tissue by the fibroblasts appears to occasion some shrinkage of the new tissue, for it contains in its central part clefts of relatively considerable size filled with serous liquid. By the eighth day the new tissue, as seen after removal from the body, has a greyish-pink appearance. It is now fairly firm, having lost its jelly-like character. The microscope shows it to be vascular throughout, and the fibrillation is still farther advanced; the fibroblasts are now closely packed, and, for the most part, are spindle-shaped. The cut ends of the tendon still present no marked change. On the fourteenth day the uniting bond consists of well-formed scar-tissue, and although to the naked eye the glistening white original tendon still contrasts sharply with the new material, as shown in Fig. 62, under the microscope, in parts where the fibres of the new scar-tissue continue the direction

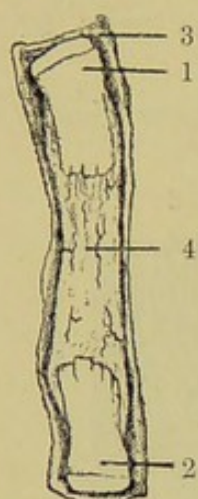


Fig. 62.—Severed ends of rabbit's tendon Achilles, 1 and 2; with the sheath, 3, and uniting tissue, 4. Fourteenth day.

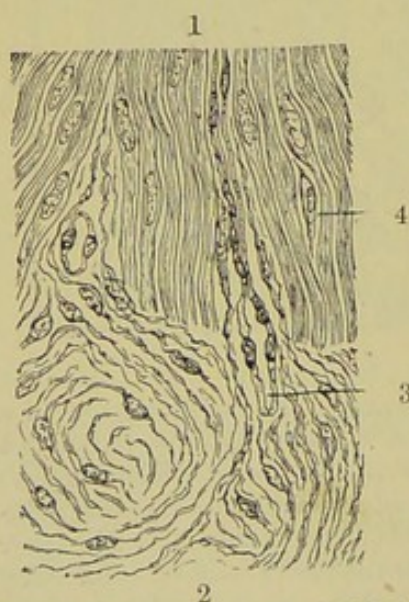

Fig. 63.—Junction of divided end of tendon, 1, with scar, 2. At 3 a capillary of scar extends into a cleft between the bundles; and a fibroblast, 4, is seen between the tendon fibres.

of the tendon-fibres, it is somewhat difficult to distinguish where tendon ends and scar begins; but where the fibres of the scar cross the cut ends of tendon-fibres the distinction is easy. The junction of the scar with the tendon is made more intimate by the extension of the former into the interfascicular clefts, as shown in Fig. 63. Moreover, fibroblasts find their way between the individual tendon fibres, as at 4 (Fig. 63).

After the second week a scar tends to contract owing to the progressive formation of fibres from the protoplasm of such fibroblasts as are not fully transformed. By this contraction the capillaries of the scar are narrowed and some of them are obliterated,

hence scars on the skin which are at first of a red colour become gradually white. Before contraction begins the formation of new fibroblasts in normal conditions comes to an end. The time occupied in the formation of scar-tissue is about the same in the rabbit as in man.

To recapitulate the steps in the formation of a scar:—

1. During the first few hours the effused blood and lymph collect between the severed tissues and coagulate, forming plastic lymph.
2. The cells of the areolar tissue, and of structures such as a tendon-sheath formed of connective tissue, begin to proliferate, and the new cells (fibroblasts) extend into the coagulum and, at the same time, the endothelial cells of the neighbouring capillary blood-vessels also begin to subdivide. These processes are well advanced at the end of the second day.
3. The fibroblasts form bundles of fibres by the conversion of their protoplasm into fibrils (the latter yield gelatine on being boiled). The cells resulting from the subdivision of the endothelial cells of the capillaries (vasoblasts) extend into the coagulum like the fibroblasts. They remain in continuity with the parent vessel, the lumen of which extends into them, forming at first blind capillary diverticula. These become new capillary loops by coalescing with neighbouring diverticula. These processes are well advanced by the fourth day.
4. The development of fibroblasts and the formation of fibrous scar-tissue is so far advanced by the ninth day that the scar has some degree of resisting power, so that stitches may be safely removed from skin wounds at this period.
5. By the fourteenth day the growth of scar-tissue is fairly complete, and changes which tend to cause contraction commence.

It is often of importance to allow scar-tissue to attain a certain degree of strength before allowing a patient use of a part that has been operated on. It may be concluded that in aseptic wounds this stage has been reached at the

end of five or six weeks.* Mr. A. H. Tubby found that the uniting tissue after section of the tendo Achillis in rabbits that were allowed to run about freely continued to elongate up to the end of the thirteenth month at which time it was nearly three inches in length.

Other modifications occur in the course of time induced chiefly by the physiological use of the repaired tendon. In the external part of the uniting bond, where it is attached to the sheath, from which it was largely generated, the fibres become drawn out by the alternate to and fro movement during the action of the muscle. At the same time the blood-vessels which pass from the sheath become elongated and attenuated, whilst those which pass into the uniting material from the interfascicular spaces of the tendon undergo compensatory enlargement. In some instances, where tendons have been divided and examined after death some years later, it has been found difficult to detect any difference between the old and the new material, although on closer scrutiny the parallel course of the fibres of the old tendon is seen to be interrupted where the scar-tissue joins together the two ends. In elongating by a **Z**-shaped section in an open wound the tendo Achillis of a man who had had an ordinary subcutaneous tenotomy performed twenty-five years previously, the new tissue was, I found, as strong as that of the original tendon, and to the naked eye was only distinguishable by adhesions which stretched from it to the sheath. The fibres of scars run in various directions, and the tissue which repairs the gap in a divided tendon is scar-tissue. These phenomena bear on surgical practice in regard to tenotomy, showing that though the ends of a tendon are separated for a considerable distance, good repair may ensue, and if the tendon-sheath is preserved intact, the lateral adhesions of the new piece of tendon will be limited to the sheath. It must be remembered that the new tissue is merely scar-tissue, and is capable of contraction or of elongation unless this is prevented for a sufficient length of time by suitable apparatus.

The old practice of putting up a limb after tenotomy

* This account is abbreviated from the author's "Surgical Pathology and Principles." Longmans & Co., 1897.

in the deformed position and subsequently gradually stretching the uniting bond has been proved to be unnecessary. A gap of three or four inches between the divided ends will in most cases be solidly repaired. It is important, however, to remember that the uniting material like all scar-tissue remains capable of being elongated by continuous traction for several months. Thus, in cases of club-foot, where multiple tenotomies have been performed, but the condition has been allowed to relapse for want of proper after-treatment, the deformity may often without further operation be corrected by patient stretching of the "callus" of the tendons as long as a year or more after the tenotomies have been performed. Thus in a child aged two years who had been operated on for equino-varus at the age of six months, I have found that the deformity was still uncorrected. In this case by gradual instrumental treatment I was able to correct the deformity completely in the space of four weeks.

The chief facts regarding the union of tendons divided subcutaneously were established by the classical work of William Adams.

The behaviour of the tendons of different muscles after subcutaneous section is a question of importance. Adams has shown that the tendons of the tibialis muscles undergo repair in a manner quite similar to that observed in the tendo Achillis. In some instances Adams noticed complete repair of the tendon of the posterior tibial muscle without any adhesions whatever. Similarly the tendons of the tibialis anticus, the flexor longus digitorum, the hamstrings and other muscles, readily undergo repair after tenotomy, whether done subcutaneously or by open incision. After division of the tendons of the fingers over the phalanges function is almost always lost by reason of adhesions that form between the divided ends of the tendons and the sheath. Dr. F. Wolter, in a very instructive article* points out that when the division has taken place over the first phalanx and tendon suture is performed, the prognosis is not so grave.

Precautions to be taken in performing tenotomy are

* F. Wolter, "The Functional Prognosis after Tendon Suture," *Arch. für klin. Chir.*, 1888.

the same as in other operations. Before deciding upon the operation care should be taken to make sure that the patient is not a "bleeder." Before and during the operation every detail of antiseptic surgery should be observed with as much completeness as though the peritoneal cavity were to be opened.

If these precautions are taken there are no complications to be feared after a skilfully performed operation.

The **causes of failure of tenotomy** are mainly three.

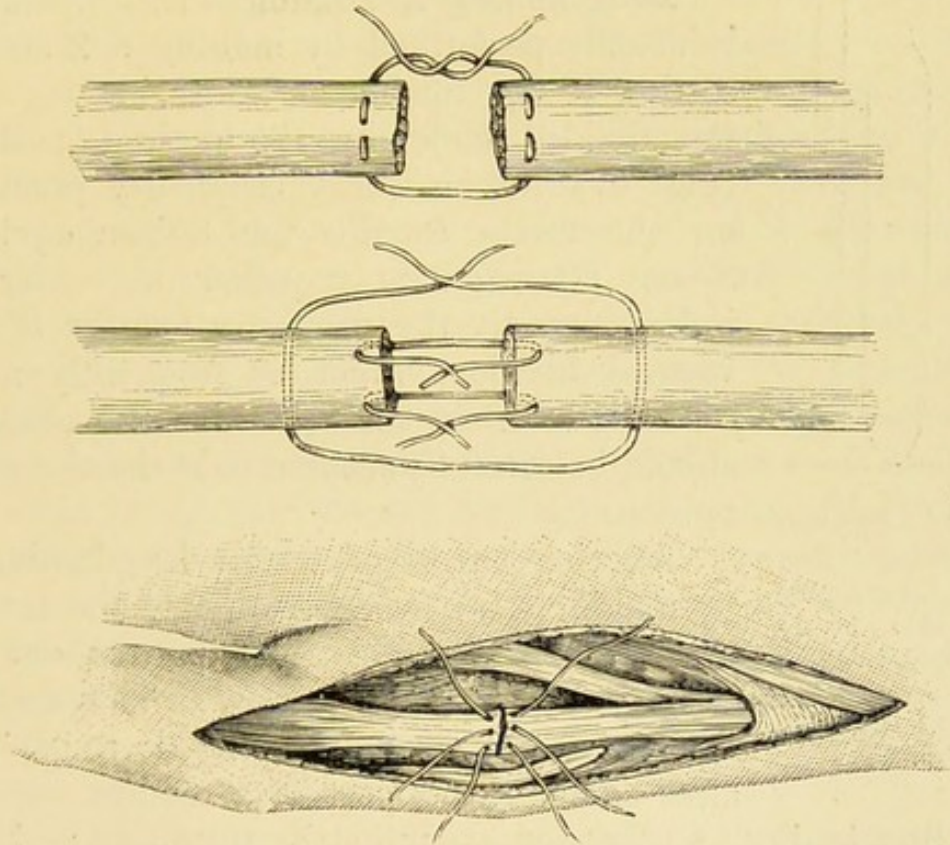
1. The presence of dense scar-tissue remaining from previous tenotomy. This is a frequent condition in the relapsed cases still so commonly seen. In such cases the method of gradual stretching should be patiently tried before any fresh tenotomy is decided on, and the open operation should be preferred.

2. Incomplete division of the tendons. This causes much pain to the patient, and results in imperfect correction of the deformity.

3. Ill-directed or insufficient after-treatment.

Open Tenotomy.—It is sometimes said that need of subcutaneous tenotomy has disappeared with the advent of antiseptic surgery. Though there is now no danger of septic complications of wounds, in cases where the simple section of a tendon is all that is required, it is still better to leave the skin intact for several reasons: firstly, with a view to minimising the extent of the wound; secondly, in order to prevent adhesion of the new piece of tendon to the wound in the skin, and subsequent stiffness when the patient begins to use the part. Still, if for any reason it may be desirable to operate by the open method, there need not be any hesitation in resorting to it. Thus, after division of the tibialis-posticus below the internal malleolus, in a case of talipes equino-varus, if it is necessary to divide also the flexor longus digitorum, I do so by a short incision a little above the base of the internal malleolus, and when the sheath of the muscle is exposed, I puncture the sheath with a sharp-pointed tenotome, which I then pass under the tendon to cut through the latter. The preservation of the sheath is of importance in securing, as far as possible, absence of adhesions between the new piece of tendon and

the surrounding parts. Where a tendon is in close relation to important structures it may be preferable to divide it by the open method. Again, when a tendon at the part at which it is desired to divide it sends off processes to the deep fascia, it may be desirable to make an open incision and to divide any offshoots of the tendon that resist correction of the deformity. This is the case with the biceps



Figs. 64, 65, 66.—Different Methods of Tendon Suture.
(After Duplay and Reclus, from Treves's "System of Surgery.")

femoris, of which the lower tendon sends from its posterior border strong fibres to the fascia lata.

Operations on Tendons other than Simple Tenotomy.

—Tenotomy is usually performed with a view to removing deformity by elongating the tendon. In certain paralytic cases, and more still in spastic conditions, it serves another purpose, namely, diminishing the range of movement of a muscle or set of muscles the contracting force of which predominates over the antagonistic muscle or muscles. Both these ends are equally well attained by elongating the tendons by a plastic operation. *Tendon suture* after rupture or

traumatic section of tendons is frequently required in ordinary surgery. The exact manner of passing the sutures will vary according to the character of the tendon in each case. Various plans of passing sutures are shown in Figs. 64, 65 and 66. For suturing tendons sterilised silk stitches are the best in my experience.

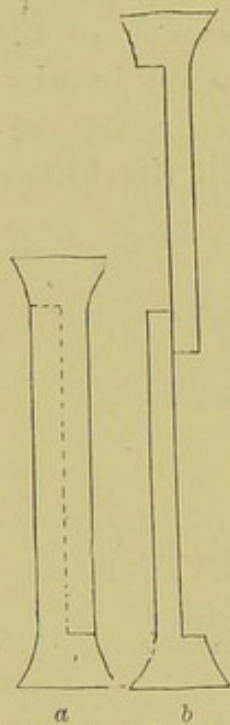


Fig. 67.—Diagram showing Method of Lengthening Tendon by Z-shaped Incision.
a, tendon before; b, tendon after elongation.

Lengthening a Tendon.—This operation is usually performed by making a Z-shaped section of the tendon and suturing together the divided ends in the desired position (Fig. 67). It is most frequently practised on the tendo Achillis for talipes equinus. Some attention is required in order to judge correctly the necessary lengths of the vertical incision, which is frequently made too short. After the operation the sheath* should be carefully sutured over the elongated tendon.

Another mode of tendon-lengthening is by making a transverse section of the tendon and then turning down a flap from one extremity, as shown in Fig. 68. This method is commonly employed to repair a gap left after sloughing of part of a tendon.

Shortening a Tendon. — Willett's operation :—† “A

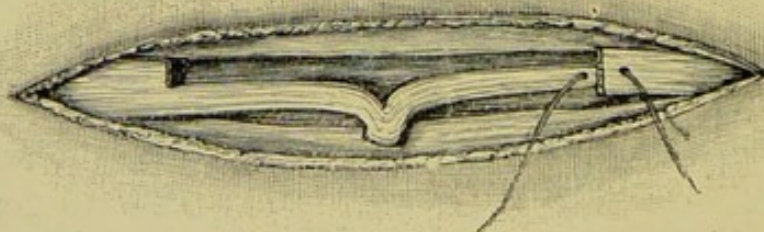


Fig. 68.—Lengthening Tendon by turning down Tendon flap.
(After Duplay and Reclus, from Treves's “System of Surgery.”)

* Some writers state that the tendo Achillis has no sheath. Though there is no firm fibrous sheath, there is a definite sheath with a smooth inner surface, and the proper management of this makes all the difference to the patient's comfort after the operation.

† St. Bartholomew's Hosp. Reports, vol. xvi., 1880, p. 309.

Y-shaped incision, some two inches in length, is made over the lower end of the tendo Achillis down to the tendon. At the lower or vertical portion of the incision the dissection is continued until the tendon is fully exposed over its superficial and lateral surfaces for the space of one inch in length, its deep connections being left undisturbed. The tendon is now cut across at the point of junction of the oblique portions of the wound with the vertical. Next, the proximal portion of the tendon is raised, with its superficial connections to the integuments undisturbed, to the extent of fully three-quarters of an inch, by dissecting along its deeper surface, *i.e.* by reversing the dissection made upon the distal segment. A wedge-shaped slice of the tendon is now cut off from both segments, that from the proximal being removed from the deep surface, whilst from the distal it is taken from the superficial, in both instances the bases of the wedge-shaped portions removed being at the point where the tendon has been divided. The heel being now pressed upwards, the proximal portion, including both skin and tendon, is drawn down and placed over the distal, thus bringing the prepared cut surfaces of the tendon into apposition. In this position they are held by an assistant, while four sutures, two on each side, are passed deeply through the integument, then through both portions of the tendon, and again out through the integument, and fastened. When the operation is completed, the united edges of the wound assume a **V**-shaped appearance, owing to the angle of the proximal portion being now attached to the terminal point of the distal portion of the original incision."

Gibney* has modified Willett's operation. He makes use of the same **Y**-shaped incision in the skin, but instead of removing a portion of tendon he makes a very oblique section and sutures the upper portion as low as possible to the lower, putting up the foot in a position of full plantar flexion.

Instead of either of the foregoing operations, the **Z**-shaped section may be made as for tendon-lengthening, and the

* Gibney, "Annals of Surgery," vol. xi., p. 241.

required amount cut off from each severed end, before they are united along every part of their cut surfaces.

Phocas* has practised the following operation: The tendo Achillis is laid bare by a median incision through skin and sheath and transfixed from side to side at the upper end of the denuded part; the knife is made to split the tendon so that the greater thickness of the latter lies superficially. This superficial (posterior) part is freed by cutting outwards at each end, whilst the anterior part is folded upon itself and fixed with sutures. The amount of shortening so obtained is equal to one half the length of the incision in the tendon.

Walsham† has practised transplantation of the tubercle of the os calcis with the view of producing the same effect as shortening the tendo Achillis without the risk of weakening the tendon. "A vertical incision, about four inches in length, is made over the centre of the lower portion of the tendon, and is carried downwards over the point of the heel. The sides of the wound are retracted; the lateral margin of the tendo Achillis immediately above its insertion into the bone is defined, and a director passed beneath the tendon. A key-hole saw is next slid along the groove of the director, its cutting edge turned downwards, and a portion about half an inch thick of the os calcis cut through, the saw emerging on the under surface of the bone. During this procedure the skin-flaps must be well retracted. To obtain enough room the first or skin incision must be carried sufficiently far forward along the under aspect of the heel. If this has not been done, it must at this stage be prolonged. It should have been carried through the fatty tissue of the heel down to the bone. The lower half inch or so of the posterior detached end of the os calcis is now cut off, and the upper end of this portion, to which the tendo Achillis remains attached, is drawn down and fixed by an ivory peg to the lower part of the section of the posterior part of the os calcis. Whilst this is being done the foot is held in the position of extreme plantar flexion. The wound should then be completely closed by sutures."

* *Revue d'Orthopédie*, 1894.

† Walsham and Hughes, "Deformities of the Foot."

The foot is dressed and put up for six weeks in plaster. In a case reported by Walsham and Hughes the transplanted bone was found to be firmly united at the end of this period.

Tendon Transplantation.—This operation (Fig. 69) was introduced by Nicoladoni for cases of paralytic calcaneo-valgus, the tendons of the sound peronei being divided at the ankle and attached near the insertion of the tendo Achillis. This operation may be profitably combined with shortening of the tendo Achillis by the **Z**-method. Mr. Frederick Eve* has applied the method of tendon transplantation to ordinary

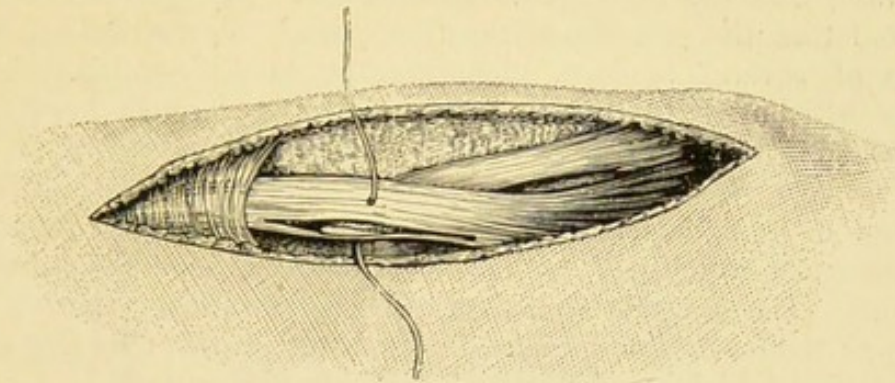


Fig. 69.—Tendon Transplantation.

The free end of divided tendon is being fixed in a slit made in another tendon, as suggested by Goldthwait.

(After Duplay and Reclus, from Treves's "*System of Surgery*.")

paralytic equino-varus and other conditions, but it remains to be seen whether the functional result in this class of cases is as good as that obtained by the ordinary methods.

Tendon Grafting.—A freshly isolated portion of tendon may sometimes be successfully grafted into the course of another tendon to fill a gap left by sloughing.

Myotomy.—The division of muscles like that of tendons may be done either subcutaneously or through an open wound, and repair, as in tendons, is effected by scar-tissue.

Another mode of altering the length of a muscle is by either subperiosteal detachment of its tendon of insertion or, better, by separation of the portion of bone into which its tendon is inserted (p. 106).

* Frederick Eve, Clin. Soc. Trans., 1898, p. 316.

Syndesmotomy, or section of ligaments, was introduced as a systematic proceeding by J. Guérin in club-foot. Langenbeck applied it to the treatment of knock-knee, dividing the external ligament. This latter operation has been rightly abandoned. In congenital club-foot properly treated from the first, the operation is, in my opinion, never necessary, whilst in neglected cases it is often of service. R. W. Parker gives the following indications for its employment:—

Division of ligaments is indicated (1) in a certain number of originally severe cases; (2) in some which have not been treated in early life; and (3) in some relapsed cases. In many cases it will be found that the position of the foot cannot be rectified even after section of several tendons, including the tendo Achillis. This is usually attributed to adhesions which have formed between the tendons and their sheaths, sometimes to inefficient operations, sometimes to other causes. In preceding chapters I have discussed the anatomy of this condition, and shown that it largely depends on the ligaments, which, like some of the tendons, have been developed too short. The extreme shortness and the unyielding nature of the ligaments render it almost impossible to lengthen them by any amount of stretching which can be tolerated by the living foot.

Open Division of all the Resistant Soft Parts.—Examples of this procedure are V. Volkmann's open operation for wry-neck and Phelps's open operation for club-foot.

These unsparing methods should only be adopted when there is no chance of obtaining a cure by gentler measures.

Operations on Joints.—Forcible correction of angular deformity due to fibrous ankylosis. An instance of this procedure has already been given on p. 89. Careful selection of cases should be made, since forcible correction has been known to re-awaken suppurative or tubercular activity in a joint. The operation consists of a breaking down of adhesions, and consequently entails some hæmorrhage into the joint. The blood thus poured out will certainly be transformed into fresh adhesions unless this is prevented by suitable after-treatment. After the operation the joint should be firmly bandaged in the corrected position and an opiate given, if necessary. The time at which passive movements should be begun varies in different instances. Where the adhesions are few in number the

patient may use the joint from the operation. If the previous condition of the joint has been an inflammatory one, and the adhesions are abundant, it is best to wait two or three days before performing passive movements, and gas may be given for the first movement of the joint. If a stiff joint in an improved position is all that can be hoped for, the joint must be fixed in the desired position for four or five weeks, and after that the patient may be allowed to get about with a support.

Forcible Correction of Bony Deformity or Osteoclasia.

—This operation is indicated in badly-set fractures, rickety deformity, and cases of osseous ankylosis where there is a bad position of the joint. The bone may require to be divided through the diaphysis, the epiphysis, or the epiphyseal line. The operation may be performed in slight cases by manual force. Green-stick fractures of rachitic children

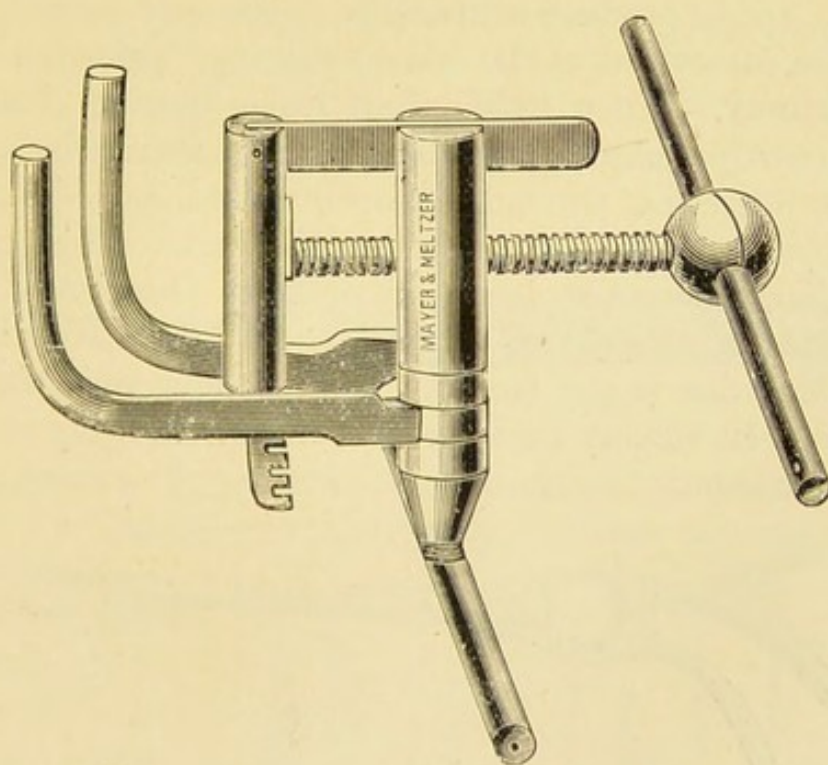


Fig. 70.—Grattan's Osteoclast.

are often overlooked, and receive no surgical treatment until the resulting deformity is accidentally discovered, and they furnish a large number of cases in which the deformity can be forcibly corrected without instrumental means. Thus

a green-stick fracture of the radius may often be straightened by the surgeon's two hands. In this instance the hands are used as a double lever.

Manual force may also be applied as a single lever, an assistant fixing the limb just above the spot where it is desired that the bone should be broken, whilst the surgeon uses as a lever the part of the limb below the point of fixation. Mechanical osteoclasis work on the same plan as these manual methods; a simple example of the two-armed lever as osteoclast is that of Rizzoli. An ingenious form of the two-armed osteoclast was invented by the late Mr. Nicholas Grattan, of Cork. The instrument is made of polished steel (Fig. 70), the two curved arms can be fixed at varying distances apart, and by means of a powerful screw the fulcrum can be brought to bear with any desired degree of force upon the middle of the convexity of a curved bone. The pressure of the fulcrum of machines of this type over the projecting angle of bone is apt to produce contusions of the soft parts, and for this reason osteoclasis of the one-armed type are safer.

Osteotomy.—Since 1826, when Rhea Barton* first performed intertrochanteric osteotomy of the femur for osseous ankylosis operating through an open wound, and V. Langenbeck subcutaneously through a small wound, the operation has to a large extent replaced osteoclasis. Osteotomy is now one of the commonest of surgical operations. This is to a great extent due to the freedom from danger that Listerism has given. In rickety cases there is now a tendency to abuse of the operation.

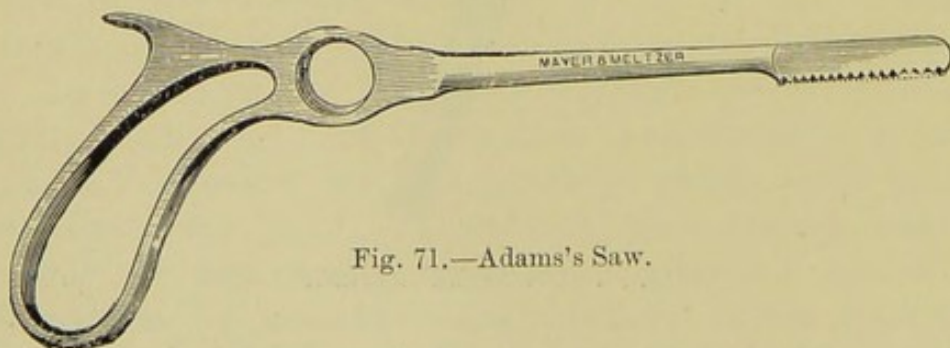


Fig. 71.—Adams's Saw.

In Great Britain William Adams and Macewen have done much towards the perfection of this operation, and the

* R. Barton: *N. American Med. and Surg. Journal*, iii., 1829, p. 279.

two chief modes of performing osteotomy may here be illustrated by Adams's operation for subcutaneous osteotomy of the neck of the femur in ankylosis of the hip and Macewen's osteotomy of the lower part of the shaft of the femur for old-standing genu valgum.

Adams's Operation (1869).—The patient lies supine. An incision is made through the soft parts down to the neck of the femur with a long narrow-bladed knife. The knife is then made to incise the periosteum, etc., along the anterior aspect of the neck of the bone, and before the knife is withdrawn the saw (Fig. 71) is passed along the blade. By short sawing movements the bone is almost completely divided, the division being completed by the posterior layers of bone being fractured by forcible abduction of the limb, which is then put up in the desired position.

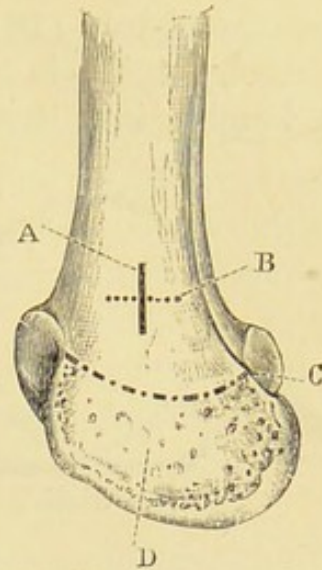


Fig. 72.—Lower end of Femur, showing—

A, line of incision in soft parts; B, line at which the osteotome is driven into the bone; line of epiphyseal cartilage is indicated at C; D marks the internal condyle of femur. (From Treves's "Operative Surgery.")

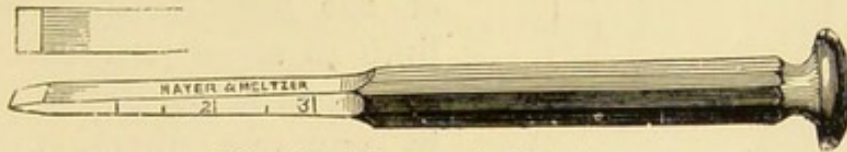


Fig. 73.—Macewen's Osteotome.

Macewen's Operation.—The method of osteotomy described by Macewen (1880) may be best appreciated by describing this surgeon's operation for genu valgum.

The limb is exsanguined, and a flat elastic tourniquet is applied to the middle of the thigh. The knee is bent and is laid on its outer side on a




Fig. 74.—Different sizes of Osteotomes and Chisels.

The two figures to the left show the difference between Chisel and Osteotome.

firm sand-bag (18 in. by 12 in.). The surgeon feels the adductor tubercle and the tendon of the adductor magnus. A longitudinal incision reaching down to the bone is made

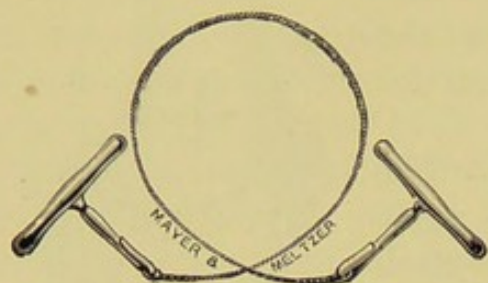


Fig. 75.—Gighli's Saw.

with its centre at the intersection of two lines, one a finger's breadth above the level of the upper border of the external condyle, the other (in the adult) half an inch in front of the adductor tendon. The osteotome is introduced along the blade of the knife, and

the latter is then withdrawn, and the edge of the osteotome is turned so that it rests on the bone at right angles to its long axis. The shaft of the osteotome is directed outwards towards a point a finger's breadth above the external condyle, and made to enter the bone by sharp taps of a mallet. The osteotome should be held firmly with the left hand, the inner border of the hand resting on the limb so as to prevent the instrument being driven too far in any one direction. The deeper part of the incision in the bone may be effected with a smaller instrument than that used at the beginning. The extent to which the bone must be divided varies according to its hardness. Usually two-thirds transversely is sufficient, the remainder should be broken by forcibly adducting the leg, the surgeon placing his left hand over the wound, which is covered by a sponge, whilst the right hand exerts leverage on the leg. If the bone should prove to be insufficiently divided, a few taps with a small osteotome on the posterior layers of the bone will usually render the completion of the operation easy.

Figs. 76, 77. — Illustrating Ollier's Method of Elongating a Limb by Oblique Osteotomy and subsequent Extension.

Fig. 76 before, Fig. 77 after, operation.

usually two-thirds transversely is sufficient, the remainder should be broken by forcibly adducting the leg, the surgeon placing his left hand over the wound, which is covered by a sponge, whilst the right hand exerts leverage on the leg. If the bone should prove to be insufficiently divided, a few taps with a small osteotome on the posterior layers of the bone will usually render the completion of the operation easy.

The chief points to be observed in this operation are shown in Fig. 72. Macewen's osteotome is shown in Fig. 73.

For performing osteotomies of various kinds, the surgeon should be provided with sets of chisels and osteotomes as shown in Fig. 74. These instruments should be carefully tempered and tested on ox-bone before being used in surgery.

Oblique section of bones in some instances gives a better correction of a deformity than simple transverse section. With care Adams's saw can be used for this purpose. Gighli's flexible wire saw (Fig. 75) renders section of the bone in any direction safe.

Ollier has suggested elongation of bones deformed by rickets after oblique section by means of continuous traction; and by this means he has obtained nearly $1\frac{1}{10}$ inch of length in a limb (*see* Figs. 76 and 77). This method has also been successfully applied for ankylosis of the hip with shortening, as will be described later.

Wedge-shaped Resection of Bones.—This is sometimes practised instead of transverse osteotomy, *e.g.* in the neighbourhood of joints for osseous ankylosis and in bones severely deformed by rickets (Fig. 78).

Curvilinear Osteotomy.—This operation was performed by Sayre (1869) for ankylosis of the hip with a view to the formation of a false joint in the intertrochanteric segment of the femur. It has also been performed at the knee and elbow for osseous ankylosis. A simple curved sawing of the bone may be done. Or a segment may be removed, as shown in Figs. 79 and 80. When it is desired to obtain a movable false joint passive movement must be begun about the tenth day. Operations for the re-formation of the hip-joint, as practised by V. Volkmann in hip ankylosis, by Hoffa and Lorenz in congenital hip dislocation, and by Arbuthnot Lane for pathological dislocation, belong to this category.

Chondrectomy is the name given by

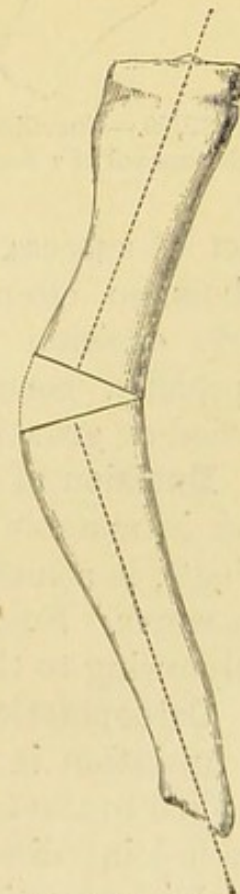
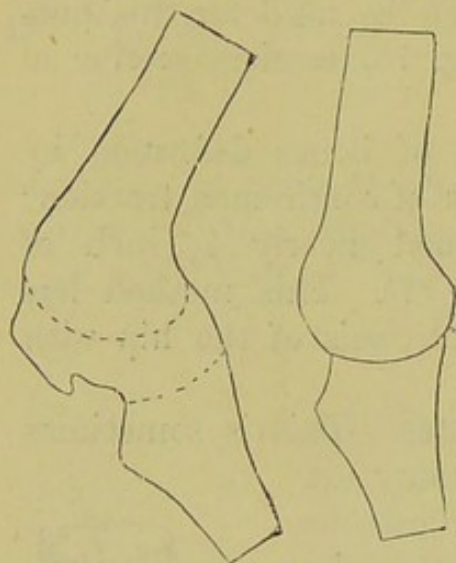


Fig. 78.—Cuneiform Osteotomy.

(From Treves's "Operative Surgery.")

Ollier to an operation consisting of the removal of an epiphyseal cartilage with a view to checking the rate of longitudinal growth of bone. It has been successfully employed at the lower end of the ulna in a case where the lower epiphyseal cartilage of the radius had been destroyed by acute osteomyelitis, and the hand had been deflected to the radial side. Chondrectomy should not be resorted to in cases where the epiphyseal cartilages lie within a joint.



Figs. 79, 80.—Curvilinear Osteotomy, with removal of a Segment of Bone.

Resection of joints, as a remedy for the results of deforming arthritis, or ankylosis, is sometimes employed as an orthopædic measure. In some cases the aim of the surgeon is to obtain a fixed, in others a free joint. If the former, the ligaments of the joint and the muscles that act upon it are to be spared as much as possible. This operation is not to be used in young growing subjects if more conservative measures hold out any prospect

of success. Orthopædic surgeons, perhaps more than others, so often witness the physiologically bad effects of early excision of the hip-joint that, in this articulation especially, conservative treatment is indicated during the period of growth.

Excision of bones, *e.g.* removal of the astragalus for severe and intractable equino-varus (Lund), or for severe flat-foot (Vogt), is sometimes employed in fault of more conservative measures. Such operations are called for but seldom, and only owing to the neglect of earlier treatment.

Osteoplastic Operations.—A striking example of this class of operation is the Wladimiroff-Mikulicz plastic operation, as applied to the treatment of shortness of one leg or to chronic ankle-joint disease. In this operation a talipes equinus is established artificially, in order to compensate for the shortness of the limb.

Arthrodesis, or the operation for producing artificial

ankylosis, was introduced by Albert in 1877. It is used in cases of flail-joint resulting from paralysis. The operation consists in opening the joint, removing the articular cartilages and a thin layer of bone, and then fixing the joint in the position that it is desired it should retain. The bony surfaces may be wired together, or fixed by ivory pegs, if it be thought necessary. A bony ankylosis is aimed at, but sometimes only fibrous results. Arthrodesis has been performed (1) at the shoulder-joint, when the shoulder-muscles are completely paralysed; (2) at the elbow-joint, when all the flexors are paralysed; (3) at the knee; and (4) at the ankle.

In most cases, in my opinion, suitable mechanical appliances afford the patient as much relief as the fixation of joints by ankylosis.

Part II.

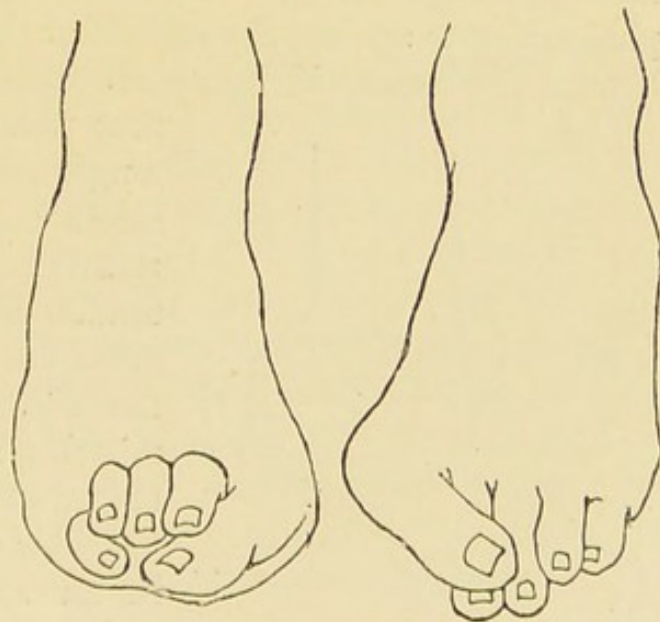
SPECIAL ORTHOPÆDIC SURGERY.

SECTION I.

DEFORMITIES OF THE TOES AND FINGERS.

Hallux Valgus.—In countries where boots are worn hallux valgus is the commonest of all deformities. In the normal foot the inner surface of the great toe is in the same plane with the inner border of the foot, as may be seen when the foot is placed firmly on the ground close to a wall. In those who wear sandals, or go with naked feet, the great toe may be slightly adducted and retain a share of the prehensile power seen in the hallux of the quadrumana.

Symptoms.—The appearance of hallux valgus is so familiar that it may be considered superfluous to give illustrations of the condition. There are, however, certain points in different cases that require attention. Thus, in the accompanying illustrations (Figs. 81 and



Figs. 81, 82.—Hallux Valgus.
(After Hoffa.)

82) it will be noticed that in the right foot the displaced great toe has passed beneath, whilst in the left it has passed above the second toe. In other cases, again, the

second toe is doubled back in the peculiar form known as hammer-toe (p. 130); or, again, the second toe may remain parallel with its displaced companion, being simply flattened against it. In this last instance either the outer, or more rarely the inner edge of the nail of the great toe may be forced into the soft tissues, constituting what is grievously misnamed "ingrowing toe-nail," a term implying a false accusation of active perversity on the part of the nail. This error of nomenclature is responsible for the misdirected surgical proceeding still much in vogue, namely, avulsion of part or the whole of the nail of the great toe.

In the more severe grades of hallux valgus the great toe may be almost at a right angle with the metatarsal bone, and much discomfort or pain is usually complained of. Indeed, the complicating bursa and other sequels of the deformity described below often render it a very serious affliction.

Pathological Anatomy.—In the slighter cases the altered position of the great toe may be described as eversion; but in the more advanced cases there is a subluxation of the metatarso-phalangeal joint. The inner edge of the base of the first phalanx rests against the middle of the head of the metatarsal bone. The sesamoid bones are displaced outwards with the

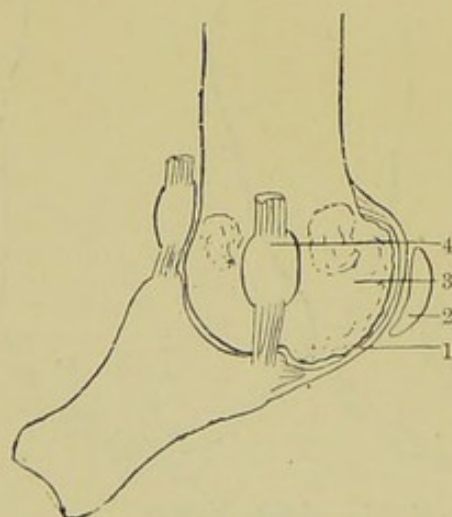


Fig. 83. — Diagram showing the changes of the chief parts concerned in Hallux Valgus.

- 1, internal lat. ligt. which is elongated;
- 2, bursa; 3, inner part of the head of the first metatarsal; 4, inner sesamoid bone displaced outwards.

first phalanx, and thus they no longer articulate with their proper facets on the head of the metatarsal bone (see Fig. 83). The tendon of the long flexor of the great toe and the attachment of the abductor pollicis and other muscles attached to the base of the first phalanx are also displaced, and these muscles, acting in an abnormal direction, tend to increase the displacement when once it is begun. The inner part of the head of the metatarsal bone is exposed to pressure of the boot and forms a prominence, to which the term

"bunion" is applied by the laity. This part of the head of the bone, and the facets for the sesamoid bones, in time lose their cartilaginous covering, and a groove forms from the pressure of the inner edge of the base of the first phalanx. This groove constitutes a further obstacle to reduction of the deformity. A bursa forms beneath the skin which covers the prominence, and the latter is thus increased in size, especially when the bursa is over-filled with fluid from inflammation. The skin over the bursa may give way and suppuration ensue in the bursa, which may extend to the joint, causing its disorganisation. A painful corn may form on the skin.

The internal lateral ligament, which is thickened in slight cases, is stretched and thinned in old-standing cases, and may become completely atrophied. When osteo-arthritic or other changes are present in the joint, there may be extensive ulceration of articular cartilage, and the inner border of the base of the phalanx may be found to have caused a deep groove upon the head of the metatarsal bone. Sometimes there is a similar condition at the inter-phalangeal joint, the terminal phalanx being displaced outwards.

Causation.—Hallux valgus is caused by pressure. Congenital cases are met with. At the present time I have under my care an infant of a few weeks whose right foot presents a well-marked hallux valgus, the second toe riding on the displaced hallux; the latter is, however, easily held in its place. In the same foot the little toe is displaced upwards and inwards upon the base of the fourth toe. Acquired hallux valgus is due to the use of boots or shoes that are pointed towards the middle line of the foot instead of being straight along the inner border. In infants and weakly children tight socks are sufficient to cause the displacement of the great toe outwards. High heels also favour the development of hallux valgus, by forcing the toes into the narrow part of the boot. When the affection arises in otherwise normal feet it is, like the Chinese lady's foot, an example of an alteration of form produced gradually by simple mechanical means. Alteration of the form of a part by long-continued slight pressure

is frequently aimed at in orthopædic surgery. In hallux valgus this displacement is produced in an abnormal direction, whilst in surgery similar forces are employed to rectify abnormal deviations from the natural direction of different parts of the body. When the ligaments of the metatarsophalangeal joint and the bones are softened by inflammation, whether of rheumatic, osteo-arthritic, gouty, or other nature, the displacement occurs the more readily. The outward displacement of the great toe necessitates alteration in the position of the second toe, and of all the other digits.

Treatment.—Preventive measures are readily to be deduced from a close study of the causation of hallux valgus. Medical men are frequently able to enforce such measures, especially in the case of young girls, and it is to be hoped that in time the absurd attempt of fashion to impose upon

the foot a unilateral instead of the more beautiful bilateral symmetry will be relinquished.

If the print of the sole of a normal foot is studied it will be seen that the shape of the sole of the boot should be as is shown in Fig. 84. It is sometimes very difficult to induce a bootmaker to understand this, even when the order is accompanied, as it should be, by a tracing of the sole of the foot and an outline of the shape that the sole of the boot is to have.

The principles of natural boot-construction have been

correctly laid down by Hermann Meyer: "A sole is of the proper construction when a line [Figs. 84 and 85] drawn at half the breadth of the toe distant from, and parallel to, the inner margin of the great toe shall, when carried backwards, pass through the centre of the heel. In the usual

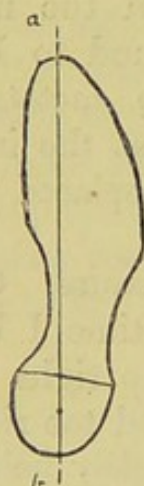

Fig. 84.

Meyer's scheme for the construction of a sole of a shoe or boot about a line (a b) passing through the middle of the heel and along the middle of the great toe when placed in its normal position.

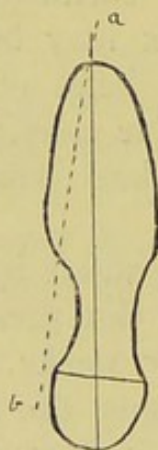

Fig. 85.

Plan of construction of an ordinary "shoe-manufacturer's" sole.

form of a sole this line passes out of the inner margin of the heel [Fig. 85].”*

A properly-shaped boot or shoe is in reality far more pleasing to the eye than a boot of the fashionable or deforming shape.

In children who have not worn shoes the toes are more outspread, and the boot or shoe should be relatively broader than for adults. (See Fig. 86).

Some boots said to be after the natural shape are aggressively straight right up to the tip of the great toe. There is no need for a well-fashioned boot or shoe to be anything but graceful and pleasing to the eye.

The general outline of the sole and the hollowing at the “waist” are shown in Fig. 87. Other features of importance are that the “upper” should not slope rapidly either at the toe or at the sides of the boot. The “waist” of the sole should be gently arched. The under surface of the heel and of the thick part of the sole should form one horizontal surface, *i.e.* when the wearer is standing on a level surface every part of the heel and of the thick part of the sole should touch the supporting surface. A sole that rises upward in front has been termed the “rocker” sole. With such a sole the toes are extended at the metatarso-phalangeal joints, and thus are predisposed to the condition of hammer or claw-toe.

Whilst the front part of the sole should be flat, the heel should be but very slightly higher than the soles. In persons who habitually wear very high heels a slight degree of talipes equinus, or non-deforming club-foot, not uncommonly results.

Royal Whitman (New York *Medical News*, August 14th, 1897) makes some practical remarks on shoes which deserve careful study: “The object of the shoe is to cover and to protect the foot, not to deform it or to cause discomfort;

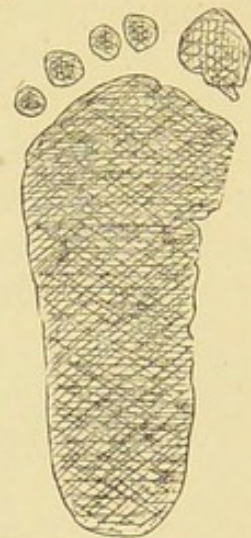


Fig. 86.—The normal footprint of a child, aged three years, who had not worn shoes.

* H. Meyer, translated by J. S. Craig, “Where the Shoe Pinches,” 1861.

therefore the one should correspond to the shape of the other. If the feet are placed side by side, the outline and the imprint of the soles will correspond to the accompanying diagram [Fig. 87]. The outline demonstrates the actual size and shape of the apposed feet, emphasised by enclosing them in straight lines. Thus each foot appears to be somewhat triangular, being broad at the front and narrow at the heel. The imprint shows the area of bearing surface, and,

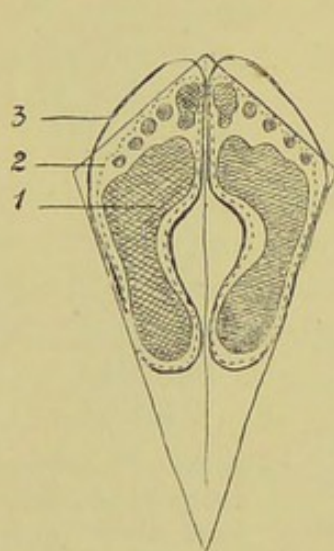


Fig. 87.

Shows (1) the impressions of normal feet, the tracing (2) obtained from such feet, and (3) the proper soles for normal feet.

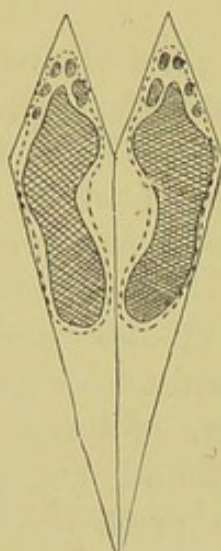


Fig. 88.

Shows the impression, etc., of feet deformed by wearing fashionable boots. (*Modified from Royal Whitman.*)

owing to the fact that but a small portion of the arched part of the foot rests upon the ground, it appears to be markedly twisted inward. The sole of the shoe, if it is to enclose and support the bearing surface, must also appear to be twisted inward in an exaggerated right or left pattern; it will be straight along the inner border, to follow the normal line of

the great toe, and a wide outward sweep will be necessary in order to include the outline, and thus to avoid compression of the outer border of the foot.

"I have found this statement of a self-evident fact and the demonstration of the true form of the foot to be almost an indispensable preliminary to an intelligent discussion of the relative merits of shoes, and, indeed, somewhat of a revelation to those who have thought of the foot only as it has been subordinated to the arbitrary and conventional standard of the shoemaker. This ideal, or shoemaker's foot, upon which lasts are fashioned, is much narrower than the actual foot; the great toe is not a powerful movable member, provided with active muscles, but is small and turns outward, so that the forefoot is somewhat pyramidal in form, and turns upward as if to avoid the contact with

the ground. This imaginary foot, drawn after the shape of the ordinary last, appears in the diagram [Fig. 88.] Upon it the sole of the shoe has been indicated to contrast it with the shape of that necessary to include the outline of the normal foot. The actual foot is thus compressed laterally by the shoe until the stretching of the leather during the 'breaking-in' process allows it to overhang the sole, the great toe is forced outward, and, with its fellows, is compressed, distorted, and lifted off the ground by the rocker-shaped sole, so that normal function is reduced to the smallest limit. Thus the foot, according to the age at which the re-shaping process is begun, and the constancy of the application, gradually approaches the ideal, and fits the shoe."

Additional points of importance in the proper shape of boots are mentioned by Parker Sims (*New York Medical Journal*, October 2nd, 1897) in an article on "Bunion." "The cause of this deformity is the wearing of shoes which are faulty in shape or are ill-fitting. A shoe that crowds the toes together or pushes the great toe backward will tend to produce this trouble. In this class are shoes with the following characteristics: First, shoes with narrow points, with the point in the median line; second, shoes that are too short; third, shoes that are so loose at the instep as to allow the foot to ride forward, and thus bring direct backward pressure on the toes; fourth, the worst of all, are shoes which combine two or all of these defects. Some pointed lasts are so constructed that the point is on the inner side of the shoe, and the toe is not necessarily displaced."

Curative Treatment.—In slight cases it is sufficient to order stockings with a separate stall for the great toe, and to see that the patient's boots are of the right shape. The toe should be drawn inwards several times twice a day.

When once the great toe has been brought into line with the inner border of the foot, the "tip-toe" exercise

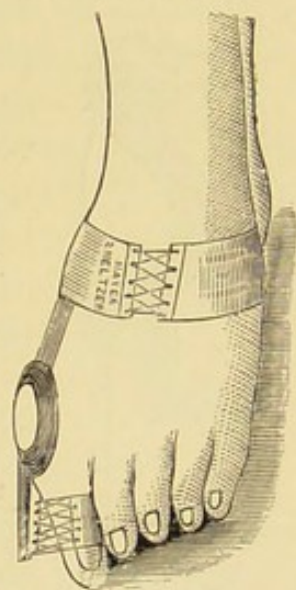


Fig. 89.—Bigg's Bunion Spring.

recommended by Ellis should be practised twice daily in order to strengthen the muscles and to render the joint firm. In more severe cases all the foregoing measures must be adopted, and in addition mechanical means must be taken to keep the toe in its place. There is a great variety of these to choose from. Perhaps the most familiar is Bigg's bunion spring (Fig. 89). This is practically an internal splint fixed to the foot round the instep by a band to which it is connected by a movable joint. A second

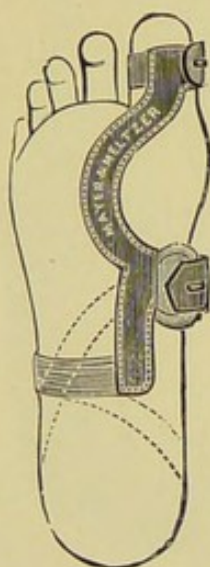


Fig. 90. — Bunion Lever.

band passes round the heel to prevent displacement forwards. The instrument is only suitable for wearing at night. A more convenient appliance, and one that can also be worn by day, is a lever (Fig. 90) having a broad, well-padded fulcrum about the middle of the first metatarsal at the inner border of the foot.

Sayre's plan consists in using a leather cap fitting over the great toe and secured by a tape which passes from the inner side of the leather cap along the inner border of the foot, where it is fixed by straps which pass round the instep and just behind the ball of the toes. A length of elastic webbing may be inserted into the tape if it is necessary. A metal or leather sole-plate, such as that shown in connection with hammer-toe (Fig. 99), may be worn both by day and at night. The idea of making a separate partition in the boot for cases of hallux valgus appears to have originated with an American surgeon, G. R. Fowler,* who writes: "A stocking of rather more than the ordinary width is chosen, and a double line of stitching run at the side of the interspace of the great and adjoining toes; by cutting accurately between the lines of stitching, a separate cot or receptacle was provided for the great toe, similar to the thumb portion of a mitten. . . . A last straight line along the inner edge is chosen. The partition separating the compartment for the great toe from the balance of the front of the shoe is made of two thicknesses of calf-

* G. R. Fowler, *New York Medical Record*, Sept. 7, 1889.

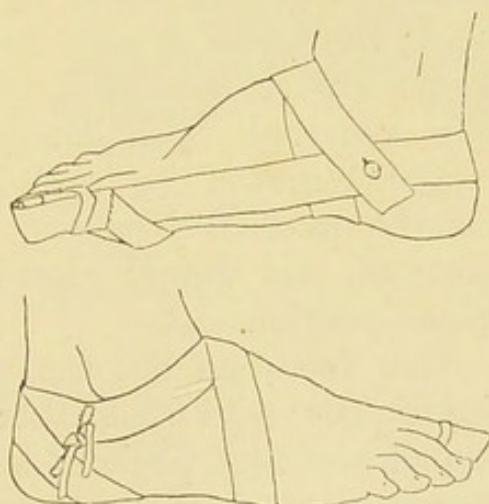
skin, and is secured in place in the following manner: The last is split, and the pieces of calf-skin from which the partition is formed are placed in position in the slot, a sufficient projection being left to pass through a slit in what is to be the inside sole of the shoe, in which latter location it is secured while still on the last. The shoe and welt are then 'lasted' in the ordinary manner, the reflected upper edges of the partition being stitched to the toe portion of the upper, and the shoe being arranged, in order to facilitate putting it on properly, to lace as low down as the site of the partition, which latter may be only just sufficiently deep to get a firm hold upon the toe—say, about one-third the depth of the interdigital space."

A similar idea has been embodied in the "toe-post." Many patients find the latter too rigid for comfort. The fact that proper sandals are an efficient preventive of hallux valgus suggests the use of sandals as a curative measure.

A stiff sole-plate with slots for tapes by which the toes are retained in good position is often the best appliance. If made of stiff thin leather it can be worn inside an ordinary stocking; if made of metal it must be applied over a digitated stocking and worn inside the boot.

Latterly I have recommended a method of bandaging the toe to avoid the use of rigid appliances. With slight modifications, according to individual needs I have found the plan answer in a considerable number of instances. The bandage consists of firm webbing $1\frac{1}{4}$ inch in width. An idea of the method of making and applying it may be gathered from Figs. 91 and 92.

Operative Treatment.—Very severe cases that have proved resistant to, or have been found to be unsuitable for, milder measures require operative treatment. Sometimes



Figs. 91, 92.—Bandage for Hallux Valgus.

subcutaneous division of the tendons, etc., attached to the outer side of the base of the first phalanx will enable the surgeon to correct the deformity under anæsthesia, and fix the joint in a good position. As in all orthopædic work careful after-treatment is required to secure a good result.

Partial excision of the head of the metatarsal bone is the operation I have most frequently adopted and found successful. In order to avoid having a scar on the inner side of the joint it is best to make a curved incision, the middle of which lies rather on the dorsal than the internal aspect of the joint. The latter is opened between the internal ligament and the dorsal expansion, and then with a small chisel; the outer part of the head of the bone beginning at the groove shown in Fig. 83, is separated and carefully removed with forceps. If a bursa is present it can be removed by careful dissection between the skin and the internal ligament. The deformity is now easily corrected, the wound closed, and the toe put up in the proper position.

This operation has the support of Mr. Arbuthnot Lane, who rightly says that after it has been performed, "the base of the first phalanx and the outer part of the head accommodate themselves to one another." G. R. Fowler has recommended opening the joint from the inner side:—

An incision was made from a point upon the dorsum of the foot somewhat below the level of the head of the first metatarsal bone, and just outside that portion of the tendon of the extensor brevis digitorum which goes to the great toe; this was continued to the bottom of the web between the first and great toes. A similar incision was made on the plantar surface of the foot slightly to the outer side of the line of the flexor longus pollicis.

Subcutaneous osteotomy of the neck of the first metatarsal bone, as described by Mr. A. E. Barker, allows the toe to be restored to a straight line with the inner border of the foot, but it leaves the altered relationship of the articulating surfaces unchanged, and hence it is, in my opinion, not advisable to use it in the advanced cases, which alone require operative measures.

Excision of the head of the metatarsal bone with resulting ankylosis of the joint has been recommended by William

Anderson,* amongst others, and it has given good results. Clutton has excised the entire joint.

Riedel (quoted by Hoffa†) and Davies-Colley recommend removal of the base of the first phalanx; this measure has the disadvantage of leaving the deformed head of the metatarsal bone.

The treatment of the complications of hallux valgus, such as inflammation and suppuration of the bursa, belong to general surgery. All concomitant deformities, such as hammer-toe and flat-foot must, of course, be treated at the same time as the hallux valgus.

Before deciding on any operation the general state of the patient's health, especially in relation to gout and granular kidneys, must be carefully considered.

Personally, I have never found it necessary to do more than chisel off the inner part of the head of the metatarsal bone. After this operation the toe is easily straightened, but, as is the case with all operations for hallux valgus, patient after-treatment is required to prevent a relapse.

When, as so frequently occurs, flat-foot is combined with hallux valgus the requisite measures are more complicated, and they will be described later under the heading of "Flat-foot" (p. 206).

Hallux Varus. — Hallux varus, also known as hallux malleus, is the converse of the condition last described. The great toe is bent inwards at the metatarso-phalangeal joint. In most cases of severe congenital equino-varus (see Fig. 127) this deformity is present as part of the general inward deviation of the foot, and not infrequently when the club-foot has been fairly corrected by orthopædic treatment some of the hallux varus persists as a trouble some remainder of the original deformity.

Sometimes congenital hallux varus is present without

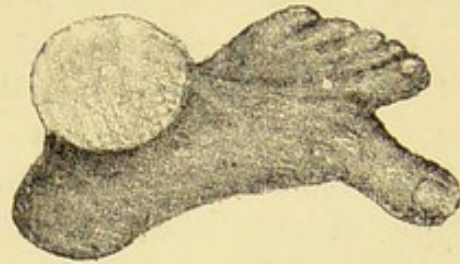


Fig. 93.—Foot with Six Digits, the innermost in the position of Hallux Varus.

(From a cast in the Museum of the City of London Orthopædic Hospital.)

* W. Anderson, "Fingers and Toes," 1897.

† Hoffa, "Orthopædic Surgery," 1890, p. 718.

any of the other deformities which are summed up as congenital equino-varus. Such cases are doubtless of similar causation to congenital club-foot. Paralysis of the adductor muscles may produce the deformity.

William Anderson* records a case in which the deformity was associated with macrodactyly. The patient was a boy, aged eleven years, who was unable to wear a boot on account of the deformity. The toe was straightened after subcutaneous section of ligaments, and three years later was found to be in a good position.

Treatment.—Slight cases will yield to a light splint worn for some months along the inner border of the foot and toe. More severe cases demand section of the internal lateral ligament of the metatarso-phalangeal joint, or excision of the head of the metatarsal bone or the base of the first phalanx.

Hallux varus is sometimes due to dichotomy of the great toe. In such cases the proper treatment consists in removal of the innermost toe. This was done by the late E. J. Chance on the two feet of the case from which Fig. 93 was taken, and both feet were thus rendered symmetrical and useful.

Hallux Rigidus or Flexus.—This condition, though far less common than hallux valgus, is met with more frequently than many writers would appear to think. It is not mentioned by many orthopædic authors. Mr. Davies-Colley first described it, in 1887, as "hallux flexus." This term has been objected to on the ground that the flexion constitutes but a minor part of the condition.

Simple hallux rigidus is seen chiefly in young subjects, and the condition should be distinguished from painful stiffness of the great toe, as it is seen in rheumatoid arthritis and gout.

Symptoms.—The great toe is slightly flexed at the metatarso-phalangeal joint, and attempts at passive extension cause pain to the patient. The position of the bones of the toe is shown in Fig. 94. The normal extent to which the great toe can be bent back varies in different individuals; in hallux rigidus this range is diminished.

* Anderson, *loc. cit.*, p. 121.

In many cases the toe cannot be brought into a straight line. The condition interferes greatly with walking; the patient limps on the outer border of the foot.

Pathology.—I have had an opportunity of examining the head of a metatarsal bone removed from a boy on account of this condition by Mayo Collier. It showed but a slight thinning of the articular cartilage where the margins of the sesamoid bones had rested upon it. In course of time this thinning of the cartilage might result in exposure of the bone and the occurrence of ankylosis. There may be also secondary shortening of the ligaments at a later stage of the disease. The term hallux rigidus should be restricted to such cases, to the exclusion of instances of rheumatic, osteo-arthritic, and gouty fixation of the joint. From the cases that have come into my hands, I conclude that the condition is usually secondary to slight flat-foot, which by elongating the foot causes tension of the tendon of the long flexor of the toes, and so flexes the great toe. In a few cases, however, I have not been able to detect even a slight degree of flat-foot.

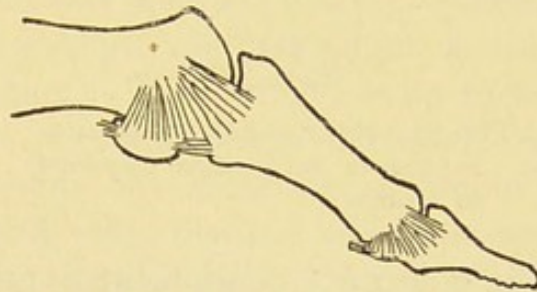


Fig. 94.—Position of Bones in Hallux Rigidus.

Prognosis.—There is a tendency to a natural cure in hallux rigidus. Davies-Colley is of opinion that the affection is often converted into hallux valgus. My experience is that this painful deformity, if left to itself, remains unchanged for many months.

Treatment.—In the earlier stages treatment of the flat-foot (p. 203), combined with passive movements, is sufficient; in the later stages forcible correction of the deformity under anæsthesia and subsequent fixation in the corrected position should be tried. Excision of the head of the metatarsal bone is required, after milder measures have had a fair trial and have failed. The results of this operation are very satisfactory, but in my experience the milder treatment is nearly always sufficient.

OTHER DEFORMITIES OF THE TOES.

Hammer-toe.—This deformity has already been mentioned in connection with hallux valgus. The term hammer-toe was first applied to the condition by Sir Astley Cooper.

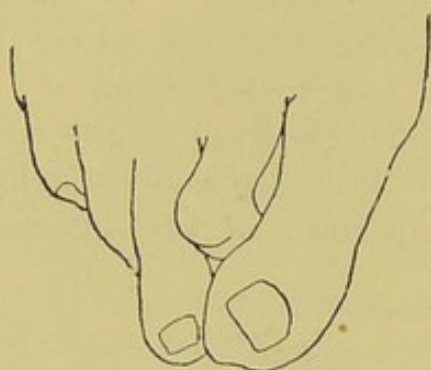


Fig. 95.—Hammer-toe, the remaining toes in the position they tend to assume.

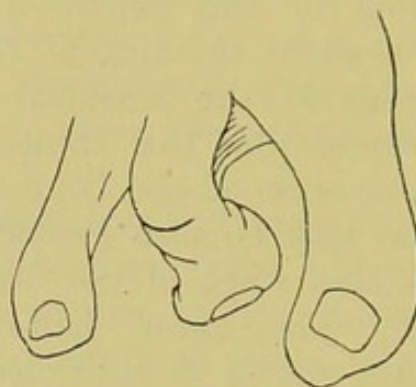


Fig. 96.—Hammer-toe, the neighbouring toes held apart.

The deformity consists in a permanent flexion at one of or both the inter-phalangeal joints. The second toe is by far the most commonly affected. The clinical appearance when the seat of the deformity is at the proximal inter-phalangeal joint is shown in Figs. 95 and 96.

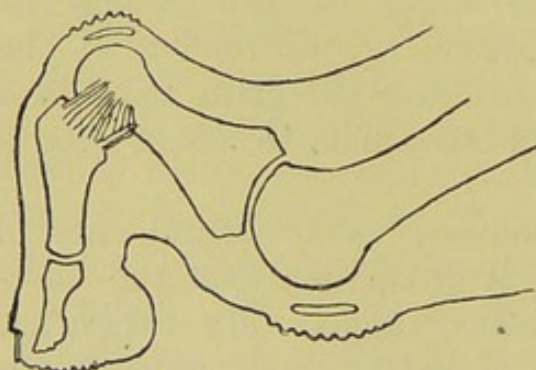


Fig. 97.—Schematic Section of Hammer-toe.

There are callosities and bursæ over the head of the metatarsal bone and first phalanx, and a callosity over the tip of the unguis phalanx.

In the early stages of the affection the deformity is readily overcome by manipulation, whilst in the later stages it is fixed by the rigidity of the parts concerned.

Anatomy.—Adams on clinical and Shattock on pathological grounds have shown the chief obstacle to

rectification to consist in a shortening of the lateral ligaments. This I have been able to confirm in the dissection of a hammer-toe, which I have thus described in the Catalogue of the Museum of St. Mary's Hospital: "A hammer-toe. The first inter-phalangeal joint is over-flexed; on straightening it the anterior fibres of the lateral ligaments became

tense." The chief points in the anatomy of the common form of hammer-toe are shown in Fig. 97.

In cases of old standing the skin on the flexor aspect of the contracted toe becomes atrophic and adds another obstacle to rectification.

Pathology.—Wm. Adams* describes hammer-toe thus: "Essentially it is a hereditary affection, frequently traceable through two or three generations, and when existing in a severe degree in one member of the family it may often be found, though to a less extent, in other children." Though it sometimes appears independently of hallux valgus and cannot be ascribed to badly-shaped boots, I am of opinion that in the majority of cases a slight hallux valgus is the determining cause of the affection. The patients who most frequently come for treatment are schoolboys destined for the army or navy, whose parents are desirous of removing an obstacle to their passing the medical examination. The deformity may not appear till old age. I have at the present time a lady, aged seventy-five, under my care for hammer-toe. The condition has been present only for one year, and hence had developed long after the growth of all the tissues had ceased. Anderson considers it to be analogous to the corresponding contraction sometimes observed in the fingers, and refers it to a primary want of growth on the part of the lateral ligaments of the first inter-phalangeal joint. That this may sometimes be the case I am ready to admit, but in the majority of cases the origin is in my opinion as stated above. Most of the cases that have come to my notice have been in growing boys or girls, many of whom have been slightly anæmic and delicate, and not a few have had definite signs of rheumatoid arthritis.

Treatment.—In the earlier stages, when the parts are still supple, corrective manipulations and the use of a simple splint at night will serve to check the tendency to deformity, if care is taken

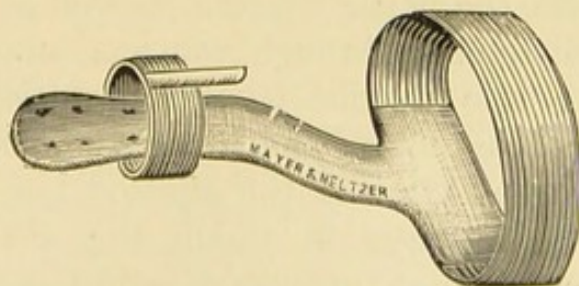


Fig. 98.—Adams's Hammer-toe Splint.

* Wm. Adams, "Finger Contractions and Hammer-toe," p. 124.

to secure the use of properly-shaped boots or shoes in the day. In more definite but still yielding cases, Adams's splint (Fig. 98) should be worn both day and night. It causes no inconvenience, and allows the patient to enjoy football and other athletic games.

When the flexed joint has become rigid operative treatment must precede the patient use of retentive apparatus. In cases where there is no great amount of shrinking of the skin, subcutaneous section of the lateral ligaments and of the lateral parts of the anterior ligaments, as recommended by Adams, is necessary before the toe can be brought straight. In practised hands this method is free from danger and gives excellent results if the after-treatment is properly carried out.

Adams's Operation.—"I use the smallest fascia knife, with a straight-cutting edge to the point, which is always preferable to the ordinary tenotomy knife with a central point, when any fascia or ligament has to be divided. I introduce the knife close to the angle of flexion in the concavity of the contraction and carry it under the skin with the blade flatwise, obliquely upwards and backwards towards the dorsal aspect of the first phalanx, just behind the head of the bone. I then turn the cutting edge of the knife directly towards the bone, and using chiefly the point, cut through the lateral ligament, and by repeated strokes also any fibrous bands connected with the capsular ligament that may be detected. I make sure of dividing everything down to the bone; and then, introducing the knife at a corresponding point on the opposite side, I repeat the same operation. The knife may also be entered at the middle of the flexion crease, and the whole of the anterior ligament with the flexor tendons, as well as the lateral ligaments, may be divided through the one puncture. The flexor tendons are also divided in this operation. It is requisite to have an assistant to hold the neighbouring toes apart while the surgeon steadies the affected toe with his left hand."

For cases in which the skin is shrunk Anderson's operation is preferable:—"An incision is made in the lateral aspect of the affected articulation, following the axis of the bones and exposing the lateral ligament, while leaving intact

the vascular and nervous trunks. The ligament is then divided by a touch of the knife, and by a forcible lateral movement the head of the proximal phalanx is made to protrude through the wound and is removed with a pair of bone-nippers. . . . After a fortnight's rest the patient is able to walk, the toe being extended upon a dorsal splint of flat steel. . . . The result is all that could be desired, and the relief immediate and permanent."

Hoffa recommends Petersen's plan, *i.e.* cutting deeply through the skin, tendons and capsule of the first inter-phalangeal joint, and leaving the open wound to granulate under an anti-septic dressing, a dorsal splint being applied to keep the toe in an extended position. The result is said to be good and lasting.

When several toes are affected a sole-plate with slots (Fig 99) must be worn night and day for some months until the tendency to deformity is overcome.

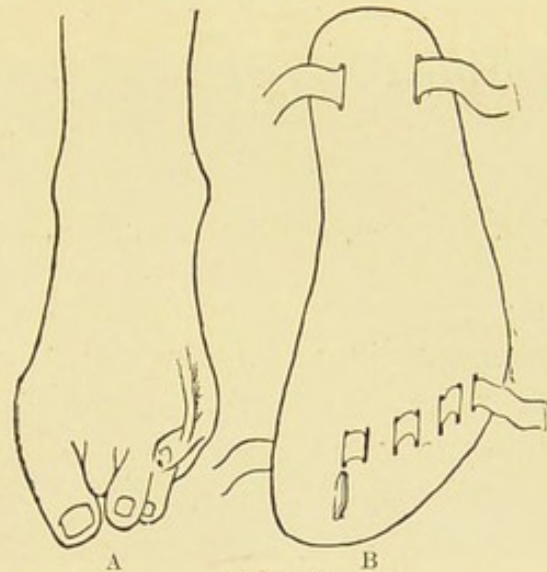


Fig. 99.

A, foot with hammer-toe, hallux valgus and congenital deformity of the fifth toe. B, sole-plate for the same, with "toe-post," slots and tape.

Illustrative Cases.—

CASE I.—A young gentleman, aged twelve, destined for the navy. Rather tall (5 ft. $\frac{1}{2}$ in.) for age, and somewhat anæmic. Slight flat-foot. Hammer-toe of usual type on both sides, and pronounced. Toes readily straightened by the fingers. Properly-shaped boots were procured, and plantar metal splints applied. Four months later the deformity was found to be corrected, and after removal of the splints the toes remained perfectly straight. The patient, though at school, had found no difficulty in applying the splints night and morning, nor in playing football with them on. When last seen, eight months after commencement of treatment, the toes remained straight.

CASE II.—An artillery officer, aged twenty-six. Marked deformity in both second toes. Congenital. Patient has had "rheumatism" in one knee. He had had much pain latterly in the affected toes. The latter were very rigid and the skin was contracted on both sides of the flexor aspect. In each toe I removed the head of the first phalanx, and

straightened the toes and applied a small metal splint. The stitches were removed on the eighth day, and on the tenth the patient was able to put on his boots, the toes being protected by small splints.

A very common mode of treatment for the condition is amputation. In my opinion this operation is rarely justifiable. Indeed, I

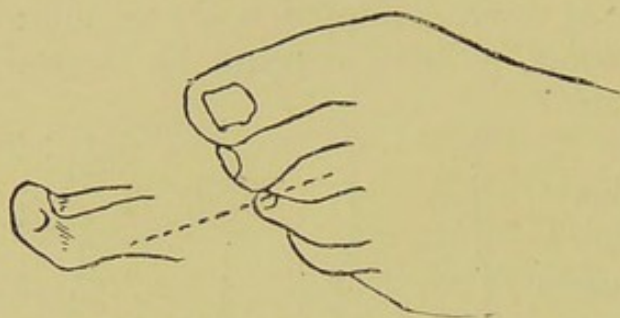


Fig. 100.—Deformity of a Third Toe from Wearing Tight Boots.

should not use this resource unless the toe were in a state of gangrene. In cases where the condition is due to hallux valgus, removal of the second toe makes the former condition worse, and

renders its successful treatment impossible. I have seen very many unfavourable results of amputation, and in only one instance have I seen the great toe remain straight after this operation.

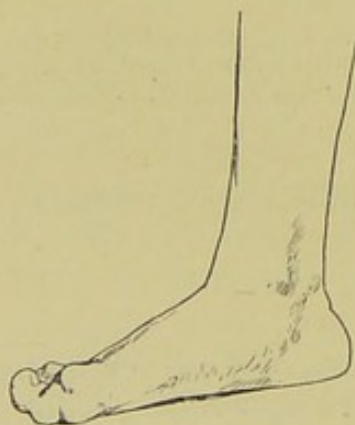

Fig. 101.—Side View of the Right Foot of a Man, aged thirty years, showing Deformity of the Great Toes and Flat-foot.

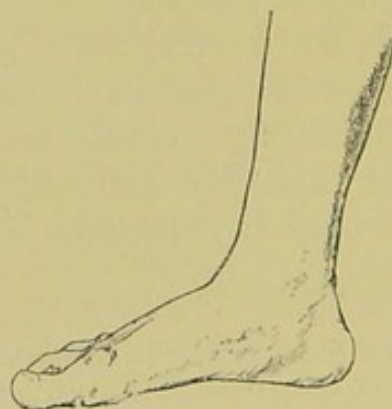


Fig. 102.—The same Foot after operations for Flat-foot and Retracted Toe.

(From Photographs.)

In some instances one of the outer toes is deformed from the compression of boots. Fig. 100 shows a deformity of the third toe from this cause.

Arthritic Deformities of the Toes are common in gouty or rheumatic subjects, and especially in those who suffer from rheumatoid arthritis. Arthritic hammer-toe is a common condition. The four outer toes are doubled back as in

ordinary hammer-toe, often with the addition of outward deviation of the toes. This condition differs from simple hammer-toe by reason of the pathological changes in the articular ends of the bones and in the ligaments. In advanced gouty conditions palliative and medical measures are, as a rule, all that can be adopted; but in the painful deformities of rheumatoid arthritis operations similar to those mentioned under hammer-toe may be required. In these arthritic cases the great toe is usually deformed. Hallux valgus is the commonest deviation.

Contraction of Digital Processes of Plantar Fascia.

—Some cases of contracted toes are similar in origin to Dupuytren's contraction of the fingers. Such cases have been recorded by Adams and Anderson. Their importance is not so great as in the

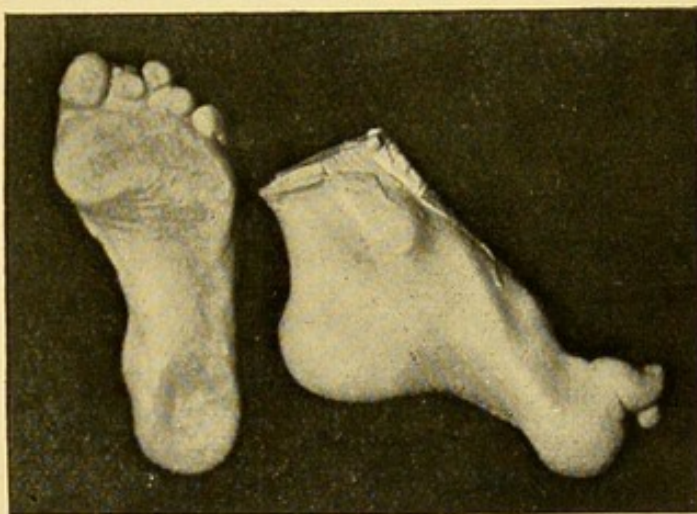


Fig. 103.

Gelatine casts of the feet of a boy suffering from a condition akin to Friedreich's disease. Both feet when left to themselves assumed the position of equinus, the toes becoming markedly clawed. The deformity was easily overcome, *e.g.* by the patient placing the foot on the ground, and with the disappearance of the equinus the toes came to their normal position, as shown by the cast of the sole of the foot. (*From a Photograph.*)

corresponding members in the upper extremity, owing to the smaller relative importance of the parts involved.

Ankylosis of the joints of the toes from traumatic inflammation, from nerve-lesions or chronic rheumatism, is often associated with rapid wasting of muscles, and may cause a considerable amount of lameness. Such conditions are often progressive and are then not amenable to treatment.

Hallux Retractus.—This term may be applied to a condition of the great toes seen in some cases of rheumatism and rheumatoid arthritis of the feet. An example is depicted in Fig. 101. In such cases the joint has been excised with success. Personally I have not found this measure necessary,

for I have found that section of the extensor tendon and lateral ligaments, and subsequent splinting, gives, as it did in the case referred to, satisfactory results.

Paralytic Deformity of the Toes.—In cases of talipes equinus, or its modifications, it is usual to find the toes "clawed," *i.e.* retracted at the metatarso-phalangeal and flexed at the inter-phalangeal joints. That Duchenne's theory of this being due to paralysis of the interossei does not apply to all cases is shown by a dissection made by Walsham and Hughes,* in which the interossei were found to be normal.

In the majority of early cases, whether the talipes is due to infantile paralysis or to some less promising condition, such as Friedreich's disease, the clawing of the toes disappears when the talipes is corrected, as shown in Fig. 103, taken from casts lent to me by Dr. G. A. Sutherland.

Treatment.—The importance of this fact is in its practical application to treatment. In other words, the deformity of the toes is to be treated by treating the equinus in such cases.

SOME CONGENITAL DEFORMITIES OF THE FINGERS AND TOES.

Supernumerary Digits, or Polydactyly.

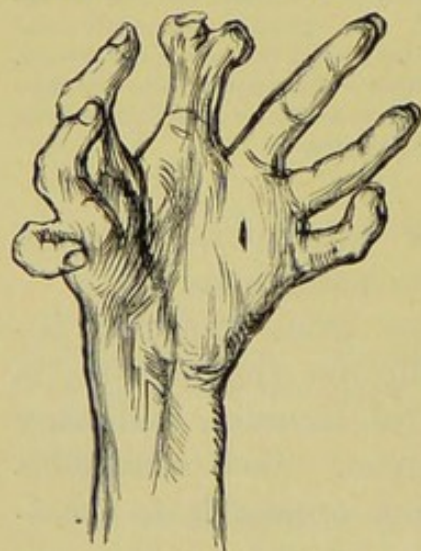


Fig. 104.—Bifurcated Hand.
(Clutton: Treves's "System of Surgery.")

is frequently hereditary. Cases may be arranged in various groups. Thus, (1) the extra digit may be rudimentary; in such cases it is usually attached to the outer or inner border of the hand, and is attached by a short pedicle; (2) the extra digit may possess all its complement of bones, etc., and it may either (*a*) be coherent with a neighbouring digit, or (*b*) free and functional; (3) in a few cases almost a whole hand has been reduplicated in development, there being eight fingers, with a little finger on each border, and the thumbs being absent (Fig. 104).

* Walsham and Hughes, "Deformities of the Human Foot," 1896.

Both hands and feet may be affected in the same case, or only one member may be affected. Thus, the anatomy varies widely in different cases. The skeleton of a foot dissected with seven digits and six metatarsals is shown in Fig. 105.

Treatment.—If the extra digit constitutes a useless and unsightly appendage it should be removed in infancy. When the extra digit is functional the patient must be advised according to his occupation.

Suppression of Digits (Ectrodactyly).—Suppression of a digit, or part of one, is of frequent occurrence, and is explicable on the same ground as other examples of intra-uterine traumatism or defective development. Sometimes there is, besides truncation, or absence of one or more digits, some peculiar conformation, such as the lobster-claw hand or foot. Sometimes the digits are represented by rudimentary knobs, consisting of skin and fat attached to a truncated limb.

In many of these cases a history of similar cases has been traced through many generations.

Treatment.—As a rule, little or no treatment is called for in this condition, because habit has given the member a good deal of functional utility that surgical interference might injure or destroy; but sometimes, and more particularly in the feet, it is permissible to operate for the purpose of lessening the deformity.

Syndactyly (Webbed Fingers and Toes).—Congenital fusion of the digits is frequently observed both in the hand and in the foot. The condition is of importance only when it occurs in the upper extremity, where it is frequently associated with other deformities, such as supernumerary digits, congenital hypertrophy, etc.

Anatomy.—The degree of fusion ranges from a thin, broad web, joining the fingers concerned, to complete fusion of two

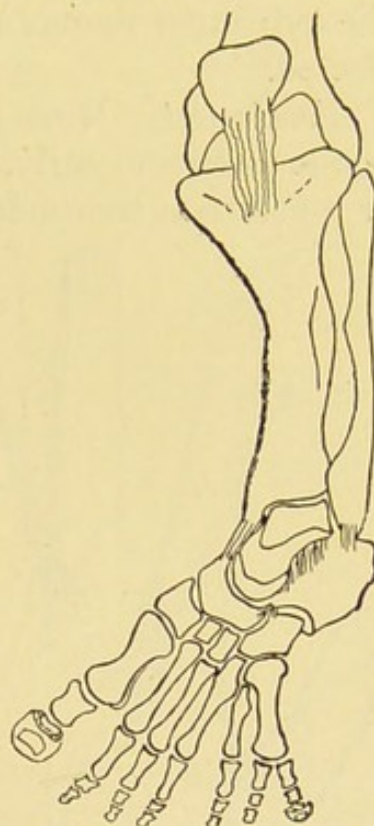


Fig. 105.—Bones of a Foot with six metatarsals and seven digits.

or more fingers with coalescence of more or fewer of the phalanges (see Fig. 1, p. 10). In the same hand the degree of fusion often varies between the different pairs of digits. The two inner fingers are the ones that are more commonly affected.

Treatment.—Most cases of webbed fingers are brought to the surgeon early, and the question of the proper age for operative treatment arises. I usually recommend the

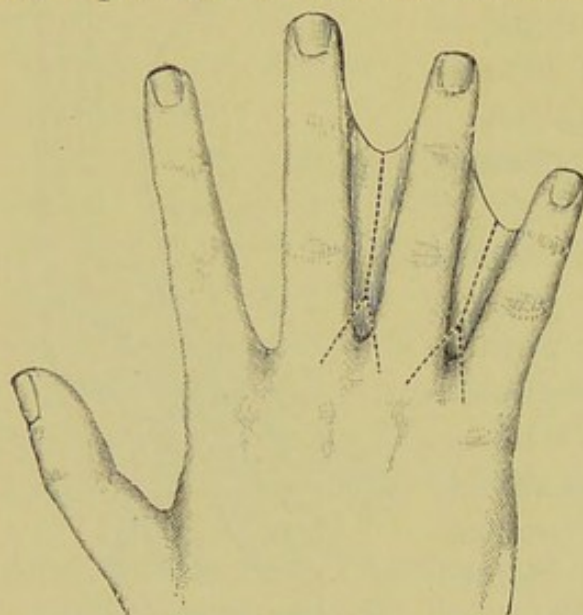


Fig. 106.—Zeller's Operation for Webbed Fingers.

The flaps should be made longer than in the Fig.
(From Treves's "Operative Surgery.")

parents to wait until the child is five or six years of age. If the web consists of a thin double layer of integument it may be simply divided, care being taken in dressing the wound that no adhesions form at the cleft between the fingers. In order to provide fully against this re-formation of the web various devices are in use. Thus, preliminary to division of the web, a permanent sinus may be made by perforating the web at

its base and inserting a small metal or rubber tube, which is retained until an epithelium-lined canal has been established. This somewhat tedious plan has, since the introduction of antiseptic surgery, been largely superseded by plastic methods, but it is still useful when the union between the fingers is very close.

Zeller's operation is applicable when the web is ample and thin. A triangular flap is made, with its base opposite the heads of the metacarpal bones and its apex at the level of the first inter-phalangeal joints (Fig. 106). The flap is dissected up, and the whole length of the web is divided, and the apex of the flap is stitched to the palmar aspect of the newly-made cleft between the fingers.

Norton's operation consists in making small dorsal and palmar flaps with rounded summits placed where the cleft is

to be formed between the fingers and their bases opposite the heads of the metacarpal bones. The flaps should be cut as thick as may be, and they should not be too wide. The

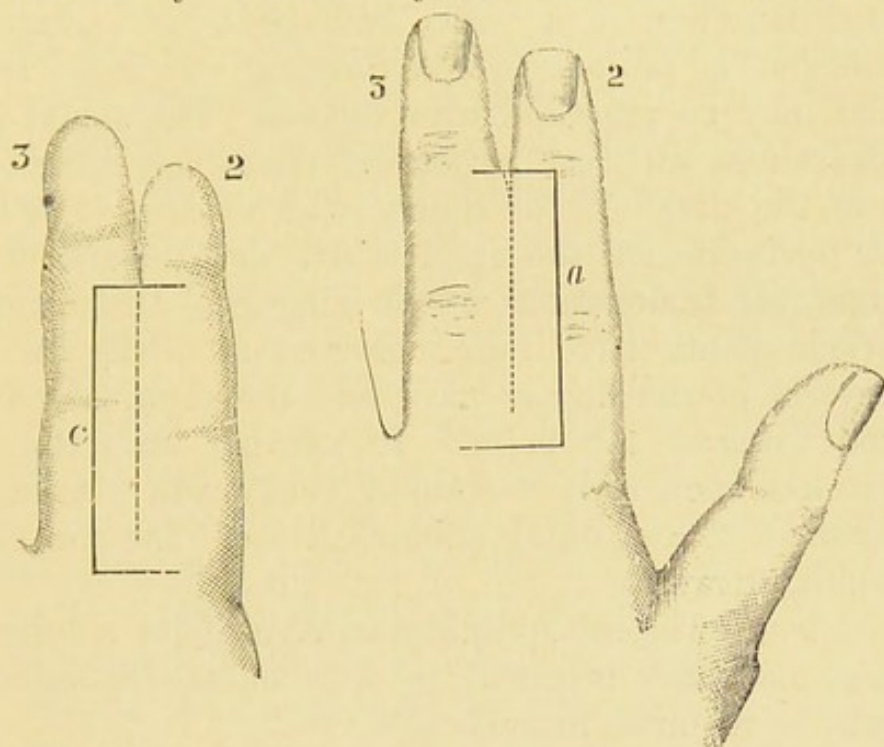


Fig. 107.—Showing the Method of cutting Flaps in Didot's Operation.
(From Treves's "Operative Surgery.")

web is divided, and the dorsal and palmar flaps are sutured together at their apices. This operation is suitable only when the web is wide.

Didot's Operation.—When the uniting membrane is thick and the fingers are close together this plastic operation should be used. An incision is made through the skin and far along the middle of the dorsum of one of the fingers, and another similar incision along the middle of the palmar aspect of the other finger. At the extremities of these incisions short cross-incisions are made to make rectangular flaps (Figs. 107 and 108).



Fig. 108.—Transverse Section showing the Method of adjusting the Flaps in Didot's Operation.

(From Treves's "Operative Surgery.")

The flaps are raised by dissection, and the remaining tissues are divided with great care in order to avoid injury to the digital nerves and vessels. The flaps are then carefully

sutured into place. At the bottom of the cleft the flaps must be carefully sutured together, so as to leave no raw surface to granulate. When the bones of the two fingers are fused together, it is often inadvisable to operate, but if the fusion is limited to the terminal phalanges Didot's operation may be practised with success. The age at which these operations are best performed varies according to the nature of the case. If the union is at all close it is better to defer operation till the child is five or six years old.

Congenital Dislocations of the Fingers.—Dislocations at the various joints have been observed at birth. In some cases several of the fingers have had the terminal phalanx displaced towards the palm. In another case the same phalanx has been seen dislocated backwards. Annandale has recorded a congenital subluxation of the fingers of both hands outwards.

Treatment.—Patient splinting, continued for a long time and when necessary preceded by a subcutaneous section of ligaments, is required in such cases.

Congenital Contracture of the Fingers.—In some families an abnormal condition of one or both little fingers is an inheritance. Adams found the condition more frequent in girls than in boys. The deformity may be present at birth or it may not be observed until the child is a year or two old. In some cases the onset of the affection may be as late as fifteen or twenty years. The ring finger and other digits sometimes share in the deformity. Adduction and flexion of the thumb may be present with or without deformity of the fingers. Lateral deviation is not infrequently combined with flexion of the fingers.

The deformity is not infrequently associated with hammer-toe.

Diagnosis.—These deformities must be distinguished from similar ones due to rheumatoid arthritis, gout, and similar conditions. The differential diagnosis will be given under "Dupuytren's contraction" (p. 149).

Adams,* to whom we owe a definite knowledge of congenital finger contractures, divides the affection into three stages.

* Wm. Adams, "Finger Contractions and Hammer-toe," 1892.

First Stage.—"The first indication observed is a dropping of the second and third phalanges of the little finger with some inclination to turn laterally inwards towards the median line of the hand; the third phalanx is rather more twisted than the second. There is no evidence of muscular contraction; no contracted band of fascia can be felt; no appearance of shortening of the skin on the palmar aspect of the fingers. The second and third phalanges can easily be restored by gentle manipulation to a straight position with the first; but they drop again as soon as the extending power is removed. There is a remarkably close resemblance to the first stage of hammer-toe."

Second Stage.—"In this stage there is no evidence of muscular contraction, but some contracted bands of fascia can be detected in most cases. The second and third phalanges generally remain on the same line, and become more or less rigidly flexed upon the first phalanx, which is usually drawn backward and hyper-extended. . . . The finger cannot be straightened by any moderate amount of force, and the resistance would seem to be partly in a contracted condition of the skin and fascia, and partly in the contracted condition by adapted shortening, during growth, of the articular ligaments."

In a case that came to my notice some years ago, the patient being a little girl aged six years, the little finger was bent to about 45° at the first inter-phalangeal joint. By using some force under an anæsthetic the finger could be straightened with a jerk, but the deformity readily returned. In this case the deformity appeared due to some abnormality in the first inter-phalangeal joint, and so the condition differed from that described as "trigger finger" (p. 143).

Third Stage.—"When the progress of the deformity is not arrested by Nature or by treatment the degree of flexion of the little finger increases, and the fourth and third fingers also become involved, and the utility of the hand is sensibly diminished. With the increase of deformity there is generally to be found a flat band of fascia opposite the flexor aspect of the first phalanges of the affected fingers. Adams regards this as due to shortening of those of the terminal fibres of the processes of the palmar fascia that are inserted into the skin."

Treatment.—In the first stage, as in the corresponding period of hammer-toe, preventive measures are alone required. The patient should wear a light metal splint, at first by day and night, and for a longer period, two or three years, at night

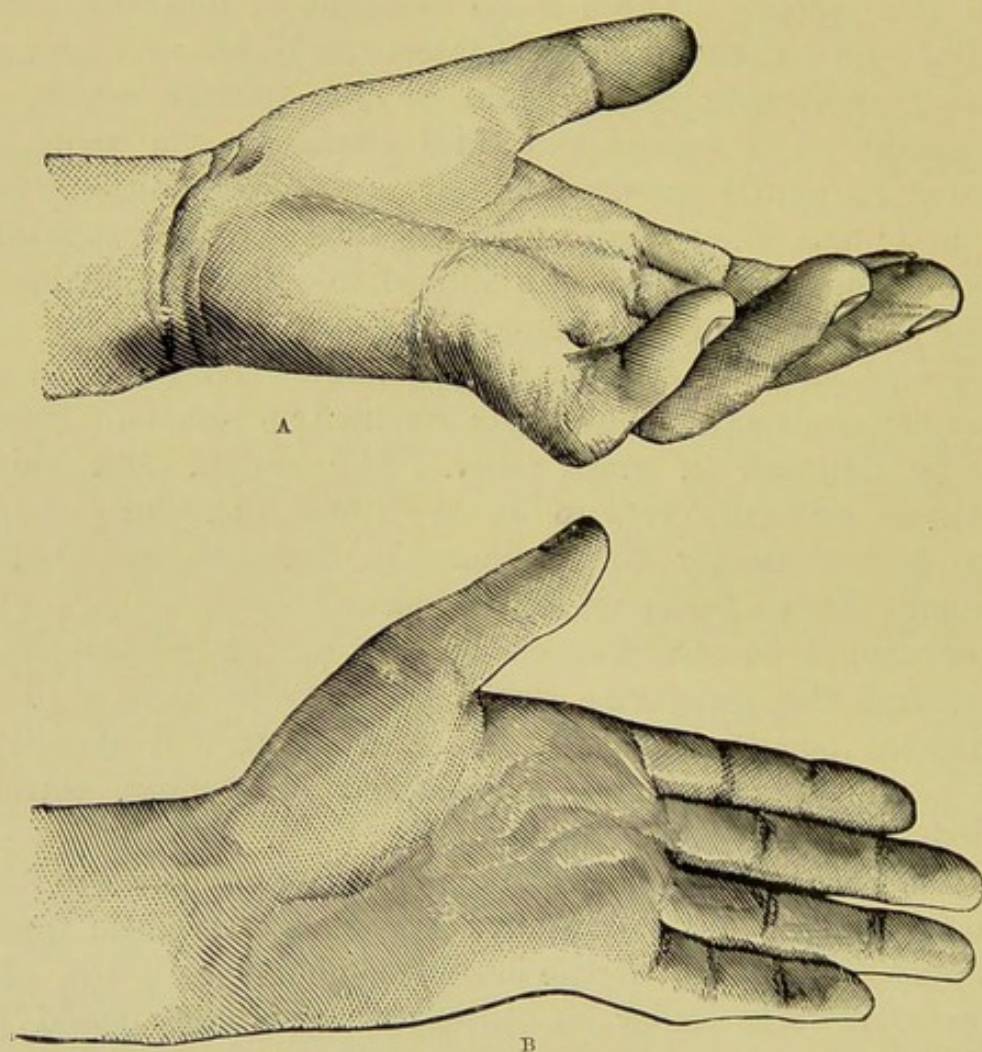


Fig. 109.—Congenital Contracture of the Fingers, before (A) and after (B) operation. (*W. Adams.*)

alone. In the second, any tense bands of fascia should be divided and the finger should be gradually brought straight by splinting, which should be continued for two or three years. Adams recommends division of the terminal cutaneous processes of fascia by passing a fine knife at several points under the skin and cutting horizontally. In the third stage, Mr. Adams, who has kindly allowed me to reproduce Fig. 109 from his work, describes the appropriate treatment as follows:—"All the fingers involved should be operated upon at the same time, a careful division being made of the longi-

tudinal bands running on either side of the median line of the first and second phalanges, and the terminal cutaneous fibres connected with them, which seem to give the appearance of an elongated, square, flattened band in the centre of each phalanx. The after-mechanical treatment is precisely similar to that described in the second stage, but the extension instrument should be worn night and day for a period of from three to six months, according to the severity of the case and the age of the patient."

If these measures, combined with passive movements in the day, do not suffice, the lateral ligaments of the flexed joints and any thickened bands of fascia that are present must be divided subcutaneously, and if after this any resistance should be felt when an attempt to straighten the finger is made, the tendons of the finger may be lengthened, as suggested by Anderson, by making a curved incision above the wrist, isolating the tendons, making Z-shaped sections, and suturing the ends together.

For the worst cases Vogt has recommended, and has found successful, a small plastic operation: dissecting up a triangular flap of skin, the attached base of the flap towards the palm, and after straightening the finger suturing the wound in such a way that the incision is converted into a Y-shaped one.

Lateral deviations of the fingers are remedied by adapting a light jointed splint for as long as may be necessary.

Some Acquired Deformities of the Fingers:—

Trigger Finger.*—This condition was first described by Notta in 1850. Clinically it is characterised by an impediment in either of or both the movements of flexion and extension. The movement of extension is more often at fault. On the patient closing the hand and then attempting to extend all the fingers, one of them remains flexed, and it can only be extended by using the other hand, when it becomes straightened out by a sharp movement resembling that of the blade of a clasp-knife. In many cases this "clasp-knife" action is repeated when the finger is bent.

Pathology.—In several cases thickening of the synovial

* Also known as Jerk, Snap, or Spring Finger. For full references to the literature up to that date, see Reeves's "Bodily Deformities," Lewis, 1892.

fringe covering one of the flexor tendons near the upper extremity of the fibrous digital sheath of the flexor tendons has been observed on making an exploratory operation. Such thickenings are most likely to occur in the course of rheumatoid arthritis. Such a case has been described by Budinge,* *Wien. klin. Woch.*, May 21st, 1896 :—

The patient was a woman aged sixty-eight, who fell in the street upon the abducted thumb of her outstretched right hand. Soon after she had much pain in the neighbourhood of the metacarpo-phalangeal joint, without swelling. There was marked crepitation on movement of the finger. In a few months the pain gave place to an impairment of the flexion and extension of the joint; eight weeks before admission the patient noticed that active extension of the flexed thumb had become impossible, but that when she pulled the last joint back forcibly with the other hand the obstruction to extension gave way with a sudden snap. Examination showed slight rheumatoid changes in the joints; flexion of the thumb was almost perfect, but caused the appearance at the base of the first phalanx of a hard, painless tumour, above which the skin was freely movable, and which could be felt to disappear with the sudden extension of the joint. An incision was made over the swelling from the volar aspect and the cause of the affection found to be that the tendon sheath folded up like a concertina during flexion, and caught the tendon so tight that it could only be released by a smart tug; the folding of the sheath was also the cause of the temporary swelling. The sheath was divided and tucked over, and the mobility of the joint perfectly restored. The two most important points in this case were the limitation of the "clasp-knife" action to extension, flexion being unimpaired; and the concomitant disappearance of the tumour.

In another case, a nodosity of the flexor profundus tendon where it enters the aperture in that of the flexor sublimis was found. In other cases no explanation of the condition has been arrived at. It may be remembered that alterations in the shape of the articular facets of the phalanges may produce similar symptoms. Carlier, quoted by Anderson, has advanced the view that spastic irregularities in the action of muscles may account for some of these cases.

Treatment.—This must be decided upon in each case after careful study. Massage and passive movements may be tried for a time. If a distinct swelling can be felt within the tendon sheath of the finger it is right to cut down, open the sheath and remove a hypertrophied synovial fringe, or whatever the enlargement may be.

* Quoted from the "Epitome" of the *Brit. Med. Journ.*

Drop Finger or Mallet Finger.—This condition is observed after an injury, which is usually a slight one, such as suddenly catching the finger in some part of the dress when dressing, or some similar act. The patient is incapable of extending the terminal joint of one or other of the fingers. Sometimes the last phalanx hangs helplessly at a right angle to the second.

Pathology.—The cause of the condition appears to be due to stretching of the expansion of the extensor tendon over the last joint of the finger. In my experience it is commonest in those who suffer from rheumatoid arthritis or gout, in whom the fibrous periarticular structures are weakened. It also occurs in healthy subjects.

Treatment.—The deformity is usually curable by splinting. A simple tin-plate splint covered with leather, and so applied that the last phalanx is slightly hyper-extended should be worn day and night for six weeks. Then passive movement of the joint should be begun, and the splint worn at night only. If this should fail an incision should be made over the joint, the tendinous expansion gathered up as well as may be and fixed to the base of the ungual phalanx by a fine catgut stitch which passes through the periosteum; after this operation, the nail is usually shed, but it is subsequently reproduced (Tubby).

Writer's Cramp.—Though the broad aspect of this affection belongs to medicine rather than to surgery, and pathologically to the central nervous system rather than the hand, yet in certain circumstances patients who suffer from this malady are so situated that they need mechanical aid, and therefore a note on the subject is required in this place. Three types of the affection are assumed: the spastic, the paralytic, and that marked by tremor.

Prognosis.—This is unfavourable. Even after months of rest from the particular vocation, and with massage, galvanism, etc., the affection returns with the patient's return to work. Hoffa accentuates the importance of looking for painful spots, and, if these are present, of adding to the massage of the muscles massage of the nerves from the point of origin of the brachial plexus above the clavicle downwards, following the course of the terminal branches of the nerves in the forearm and hand. To massage, gymnastics should be added. I

have found personally that when my right hand is fatigued with writing or drawing, a day's rowing on the river will restore its power. When the condition is sufficiently re-

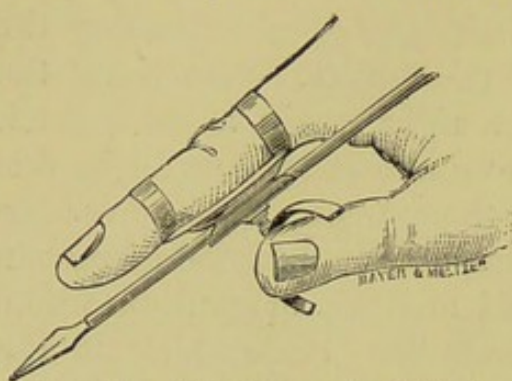


Fig. 110.—Pen for use in Writer's Cramp.

covered from the patient may return to light labour, aided by some apparatus, such as Nussbaum's "bracelet," which enables the wearer to write by using the extensor instead of the flexor muscles, or a pen such as the one shown in Fig. 110.

Dupuytren's Contraction of the Fingers.—This de-

formity, familiar to all medical men, bears the name of the French surgeon who first demonstrated that it was due to contraction of the processes of the palmar fascia, and not, as had previously been believed, to contraction of tendons.

Symptoms.—The first sign of the affection is a subcutaneous nodule which appears most commonly over the metacarpo-phalangeal articulation of the ring finger. The nodule is periodically the seat of slight tenderness, and during these periods the skin covering it may be red.

Sometimes the patient first notices a "stiffness" of the finger, owing to an inability to extend it fully. At this stage there is usually but little pain. On examining the palm, besides the simple nodule, rigid bands can be felt or seen, prolonged to one or more of the fingers. In course of time fresh nodules may appear, and several fingers become affected. In the later stages the bands stand out as rigid cords, so that it is easy to understand how they have been mistaken for tendons. At last several fingers may be drawn down so firmly that callosities or even ulcers form in the palm of the hand. In the middle stages the affection merely causes inconvenience. In the more severe degrees it is crippling and, to some extent, dangerous. Thus Adams* mentions the case of a gentleman whose fourth and fifth fingers in each hand were contracted. "In attempting to hold a restive horse, the contracted fingers on the right hand were suddenly torn open,

* Adams, "Finger Contractions and Hammer-toe," p. 12.

and the skin in the palm of the hand torn across. I saw him shortly after the accident, when the hand had been merely tied up by a handkerchief, and found a large gaping wound in the palm, reaching nearly half-way across. The palmar fascia had been torn across, together with the skin, but the sheaths of the tendons were not torn, and it was evident that these structures had not been implicated in the contraction. The tendons in their sheaths were seen lying at a depth from the surface. . . . I found, on attempting to extend the fingers, that the previously transverse wound assumed a lozenge-shape in a perpendicular direction. I therefore approximated the edges laterally, so that when sewn up it resembled a longitudinal instead of a transverse wound. The hand was firmly bound round with narrow strips of plaster, and bandaged to a splint with the fingers in an extended position. . . . The healing process proceeded without interruption, and the fingers remained nearly straight without their power of flexion being lost."

In the severest degree of the deformity all the digits, including the thumb, may be involved, and the inter-phalangeal joints become flexed, so that the nails may be pressed into the palm, causing callosities and even ulceration.

Anatomy.—The palmar fascia thinly covers the muscles, causing the thenar and hypothenar eminences, whilst it is dense and of triangular form in the middle of the palm, the apex of the triangle being at the wrist at the insertion of the palmaris longus tendon, while the base of the triangle opposite the metacarpo-phalangeal joints is subdivided into four processes which pass to the four inner digits, each process subdividing into two branches, from which short, strong, outer fibres pass to the sides of the metacarpo-phalangeal joints, their fibres partly blending with the ligaments of these joints and partly with the periosteum at the sides of the first phalanx, whilst the inner fibres pass along the fingers antero-laterally, giving off fibres to the deep parts and to the skin as far as the finger-tips. At the bases of the fingers the superficial fascia is thickened by transverse fibres: the superficial transverse ligament. From the palmar fascia and its chief divisions numerous processes pass to the skin and to the deeper parts of the hand. On dissection of hands affected with typical Dupuytren's

contraction it has been found that the main digital processes are usually most affected, but in advanced cases the processes passing to the second and third phalanx, to the skin, etc., are also affected. The great amount of fibrous tissue, both belonging to the superficial and in the deep fasciæ, readily explains the cases in which the malady begins opposite the base of the first phalanx, instead of in the usual site, *i.e.* opposite the metacarpo-phalangeal joint.

Incidence, etc.—Keen* tabulated 126 cases: out of these twenty, or nearly 18 per cent., were in women. In nine cases the thumb was involved. The cases that come for treatment are chiefly middle-aged men of the well-to-do classes.

Pathology.—The previously given clinical history shows that the condition is an inflammatory one. Adams† found the condition to be more common in butlers and indoor servants than in those who did hard manual work. He says: "The cases which have fallen under my observation have occurred in clergymen, barristers, medical men, officers of the army and navy, and merchants, the only condition common to the whole series being a disposition to gout."

One of the ablest clinical observers of the century, Mr. Jonathan Hutchinson, speaking recently at a meeting,‡ expressed it as his opinion that the condition was commonest in those who, descended from gouty patients, suffered from rheumatoid arthritis.

Lockwood has found a deposit of urate of soda in the nodular thickenings of the contracted palmar fascia.

Syphilis may account for a few cases, but the fact that cases have been improved by iodide of potassium must not be taken as proof that they were due to syphilis, since rheumatoid arthritis is often much benefited by the same drug.

Wm. Anderson supposes a microbic origin for the affection, but it must be remembered that recently bacteria have been described by Bannatyne and Wohlmann in rheumatoid arthritis. In my opinion this deformity is undoubtedly of arthritic origin, and the fact that some slight trauma often

* W. W. Keen, *Phila. Med. Times*, March 11th, 1882.

† Wm. Adams, *Brit. Med. Journ.*, June 29th, 1878.

‡ West District Met. Co. Br. B. M. Ass., May 26th, 1898. See also a recent paper by C. E. Hedges, *St. Bart.'s Hosp. Rep.* 1896, p. 119.

appears to be the starting-point of the lesion does not militate against this view.

The appearance of the dissected parts in a typical case is shown in Fig. 111.

Diagnosis.—The initial indurations have been mistaken for the results of the lodgment of foreign bodies in the palm. When well advanced the condition can hardly be misunderstood. The subcutaneous position of the contracted band and the puckered and adherent skin, serve to distinguish it from the results of tendon-contraction, and the mobility of the joints from ankylosis. The history of a case will serve to distinguish Dupuytren's from congenital contractures.

Prognosis. — This is more favourable in women than in men. If the patient will submit to a judicious diet, combined massage and medical treatment, the condition may be kept in check in its earlier stages. The use of a simple splint at nights will aid in this. After subcutaneous section relapses are not uncommon, but this is in most cases due to neglect of after-treatment or dietetic restrictions, and even a few years' relief from a severe deformity is quite sufficient justification for the operation.

Adams's Operation.—"When there is a tense cord extending from the contracted finger to the palm of the hand, I make the *first puncture* in the palm a little above the transverse crease and where the skin is not adherent to the fascia, or tightly stretched over the contracted cord, so that the fascia-knife can be readily introduced between the two. The

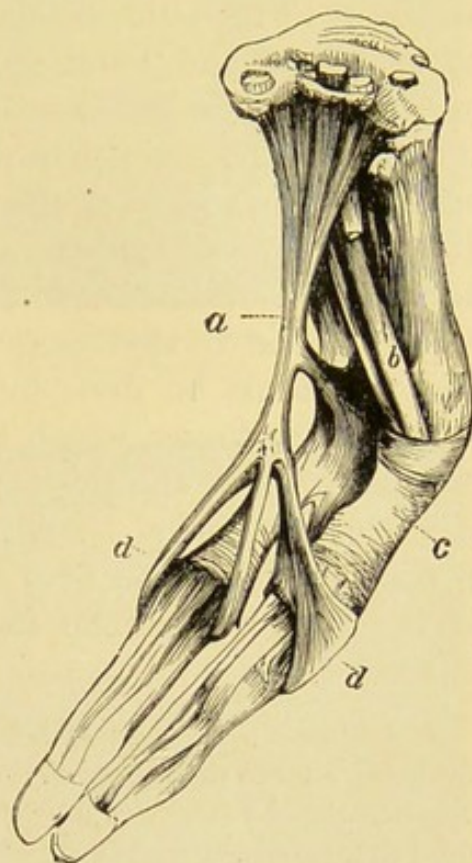


Fig. 111.—Dissection of Finger Contraction affecting the middle and ring fingers.

a, contracted band of palmar fascia; *b*, flexor tendons lying deeply close to the bones, bound down by their sheath, *c*; *d*, *d*, digital prolongations of the palmar fascia extending to the articulations between the 1st and 2nd phalanges. (After W. Adams.)

second puncture should divide the same cord as the first, between the transverse crease and the web of the fingers, thus leaving the contracted band in the palm of the hand, when adherent to the skin, isolated and cut off from its connections at its upper and lower extremities. The *third* and *fourth* punctures divide the lateral bands, or the digital processes of the palmar fascia, which pass from the central cord in the palm to the adjacent sides of the fingers. These must be divided very carefully so as to avoid cutting the vessels and nerves . . . Sometimes lateral bands of contracted fascia require to be divided near to the centre of the first phalanx, and this must be done by puncture, either near the dorsal aspect of the finger, which I prefer, or, if it cannot be reached from this point, the puncture must be made on the anterior aspect of the finger . . . Always avoid making central incisions in front of either the first or second phalanx, as the sheaths of the tendons or the tendons themselves may be readily injured"

Illustrative Case.—A gentleman, aged fifty-two. The ring finger of the left hand became stiff after a slight sprain, eight years ago. Patient had had "rheumatism" after sleeping out in South Africa on a campaign. The hand presented the appearance shown in Fig. 112. I performed Adams's operation under cocaine anæsthesia, straightened the fingers and applied a palmar tin splint. The immediate result of the operation is shown in Fig. 113, which was taken at the end of ten days when the punctures had healed. The patient was then recommended to wear the splint shown in Fig. 114 continuously for three weeks, with short intervals, twice a day, for the purpose of gentle corrective manipulation of the fingers after steeping the hand in warm water. At the end of this period the splint was worn at night for six months.

Open Operations.—*Busch's Operation.*—This consists in making a V-shaped section through the skin and fasciæ, and dissecting up a triangular flap of these tissues, the base of the triangle being opposite the metacarpo-phalangeal joints. The resisting tissues are divided until the finger or fingers can be straightened, and this done the flap is sutured with its apex lying a greater or lesser distance nearer the fingers than at first.

Excision of the chief contracted band of fascia and simple suture of the skin-wound has been tried, but owing to the cicatricial condition present in the skin in those cases that

require so severe a measure, this proceeding was often rendered unsatisfactory.

Plastic Operations.
—Anderson writes:—

“Plastic operations may be conducted under the same principles as those which guide the surgeon in the treatment of cicatricial contractions from burns or other causes. In cases of contraction at the metacarpophalangeal joint, where the skin is greatly involved, I have made a transverse incision through the integument and fibrous cord at the root of the finger and filled up the wide gap left on extending the joint by the transplantation of a flap from the side of the digit. The dissection of the flap must be carefully conducted in order to avoid injury to the digital nerves.”

When the patient's age and the degree of the deformity require operations, Adams's operation should have the preference. When there is widespread induration of the fascia excision of the altered tissue, combined with a plastic operation, may be required.

Congenital Hypertrophy, Macroductyly.—This condition

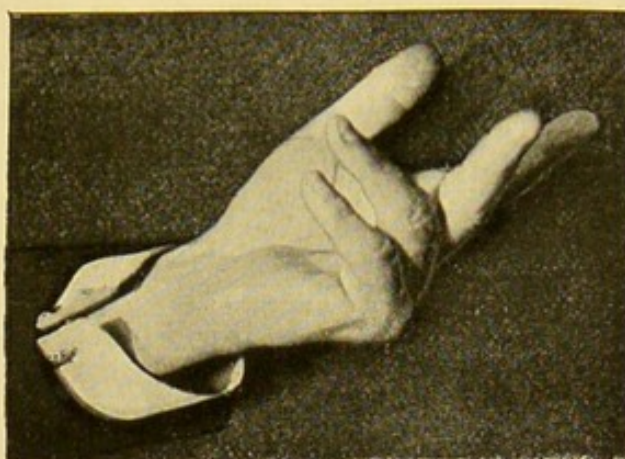


Fig. 112.—Showing Dupuytren's contraction of the fingers of medium severity.

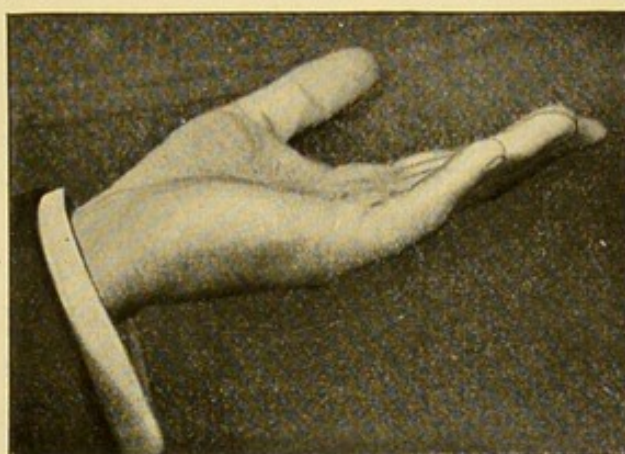


Fig. 113.—Same hand showing immediate result of Adams's operation.

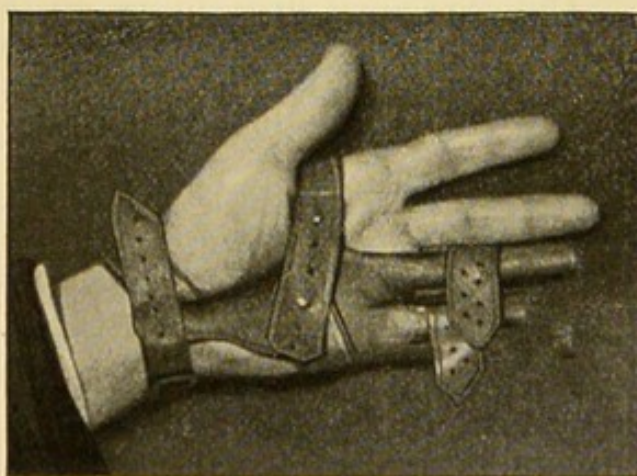


Fig. 114.—Splint applied after operation in this case.

is not infrequently brought to the notice of the orthopædic surgeon. For this reason it deserves mention, although in its wider bearings it belongs to general surgery.

Pathology.—The pathology of congenital hypertrophy is closely associated with that of lipomata, nævi, lymphangiomata and other growths. It may implicate any segment of the body exclusive of the viscera. Though more commonly affecting one extremity, it may implicate one half of the body, including the head, as in a case that came to my notice some years ago.

Symptoms.—As far as the digits are concerned, the majority of cases at first sight resemble somewhat widespread lipomata. On closer examination the bones can usually be ascertained to be hypertrophied. There are frequently areas of angiomatous and lymphangiomatous tissue. In the latter case periodic attacks of lymphangitis may be present.

Course ; Prognosis.—At birth the degree of enlargement is slight, and hence it is often overlooked. In some cases the overgrowth does not go beyond its original proportions, but sometimes rapid enlargement of the affected parts leads to gigantic deformity. Parts originally apparently normal may in the course of time become involved. In the case of a boy, aged twelve years, that came to my notice, the whole of the right lower extremity was greatly increased in size and the rapidly growing character of the growth became sarcomatous in the end.

The associated deformities are such as lateral deviations of the fingers and syndactyly. Deformities such as lateral curvature of the spine may arise from inequality of the lower limbs.

Treatment.—The only measures that can be adopted are directed to restrain associated deformities and when necessary to remove parts that are so disfiguring or inconvenient as to justify this proceeding.

SECTION II.

DEFORMITIES AFFECTING CHIEFLY THE ANKLE
AND TARSAL JOINTS, AND THE CORRESPONDING
DEFORMITIES OF THE UPPER EXTREMITIES.

INTRODUCTORY TO CLUB-FOOT AND CLUB-HAND.

A NUMEROUS class of deviations from natural form and function come under this heading. The chief of them are familiar as the forms of club-foot and club-hand. Under the latter designation the congenital deviations involving the wrist-joint are usually placed, whilst the deformities of the hand corresponding to the paralytic varieties of club-foot are not generally associated with the latter, but are placed apart, and so their clinical and pathological affinities are left out of sight. In the present work the effects of median, ulnar and muscular-spiral paralysis will be described in succession to talipes.

Preliminary Observations.—In order to render the meaning of various deformities of the foot more readily comprehensible, a few observations on the normal range of movements at the ankle and tarsal joints may be made. The diagram (Fig. 115) gives the movement allowed in a normal ankle-joint. It takes place wholly in one plane. In other words, the joint is a purely hinge-joint.

These movements are usually known as “extension” and “flexion” of the ankle, and since these terms are used in the opposite sense to that in which they are applied to the wrist-joint, instead of extension, the term “plantar flexion” may be used, and instead of flexion the term “dorsal flexion.” If the ankle, then, cannot be dorsal-flexed to the normal degree, there is so much *talipes equinus* present; and if it cannot be plantar-flexed to the normal extent, there is to that extent *talipes calcaneus*. The term “talipes,” from Lat. *talipedo*—I walk on the ankle—was formerly restricted to the severer forms of equino-varus. Dr. Little was the first to suggest its

being used to designate all forms of club-toot, as is now done by English writers.

The ankle-joint being normally a hinge-joint, no movement in it will account for the power we have of turning the sole of

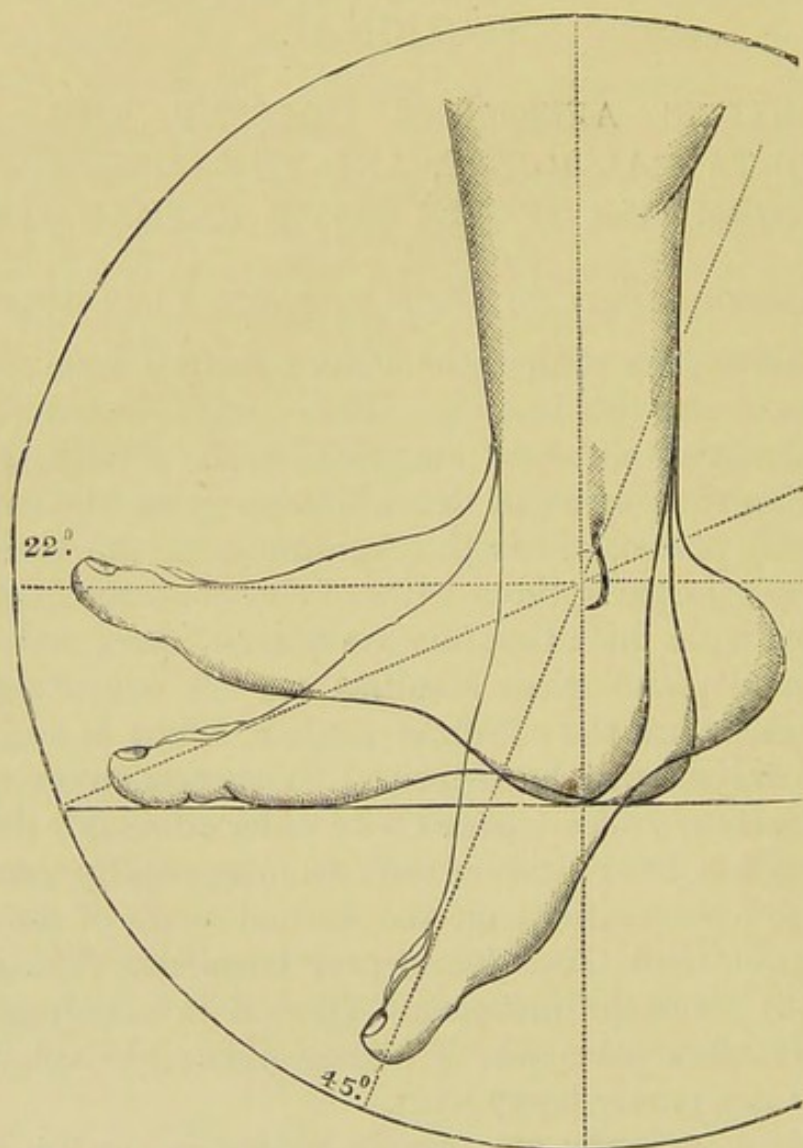


Fig. 115.—Diagram showing the Normal Range of Movement at the Ankle-joint. (Noble Smith.)

the foot, so that it is directed inwards when the leg is in a vertical position, and, to a much more limited extent, in the opposite direction. These movements are in Great Britain usually known as *inversion* and *eversion* of the foot respectively, and as far as possible I shall adhere to these terms. They are also known as adduction and abduction; and again by comparison with the movements of the hand, *supination* and *pronation* of the foot. Those who follow the example of

Lorenz in adopting the use of the latter terms, must remember that the mode of production of the movements is different in the two cases. In the case of the hand they are chiefly effected by virtue of the power of the radius to rotate through half a circle round the lower end of the ulna. In the case of the foot the seat of movement lies chiefly in the compound articulations between the astragalus on the one hand and the os calcis and scaphoid on the other; when those movements occur between these two bones, corresponding adaptive movements ensue in the calcaneo-cuboid and other articulations. In inversion, adduction, or supination of the foot, the scaphoid moves inwards and upwards over the head of the astragalus, in the line of action of the tibialis posticus muscle. This movement is effected partly by inward gliding of the bone as a whole, and partly by rotation in such a way that the tuberosity moves upward, whilst the outer end of the bone moves downward. The os calcis moves under the astragalus, partly gliding, partly rotating on the axis of the interosseous ligament in such a way that its anterior extremity follows the upward and inward movement of the scaphoid. The rotation movement of the latter bone is further assisted by a downward and inward gliding of the cuboid on the os calcis. If the inverted position of the foot is to any degree fixed, *i.e.* if the normal range of eversion is restricted, then to that degree *talipes varus* is present; and if the everted position is in any degree fixed, the foot is to that degree in a state of *talipes valgus*. Restriction of movement at the ankle-joint is very frequently accompanied by restricted movement in the tarsal joints, the resulting deformities being known as—

Talipes equino-varus.

" " valgus.

" calcaneo-valgus.

" " varus.

The normal arching of the bones of the foot may be increased; this condition is termed *talipes cavus*. With many of these deformities of the foot distortion of the digits is present.

Duval introduced the term strephopody as a substitute for talipes; thus, instead of talipes equinus he suggested

katastrephody, endostrephody for varus, and anastrephody for calcaneus, exostrephopody for valgus. Though Duval's nomenclature is more scientific than the terms commonly used, it has not been widely accepted.

It may be observed that many forms of club-foot belong to the class of *contractures*, being due to pathological changes in the muscles, skin, and other soft parts.

The corresponding deformities in the hand, owing to the relative smallness and the slight degree of mobility possessed by the carpal bones, show themselves by fixation and more or less flexion or extension of the wrist-joint, and by abnormal positions of the fingers.

The causes of talipes are varied. If an attempt is made to bring the various causal groups of club-foot into comparison with deformities of other parts the terminology may be changed, as in the following examples:—

1. Intra-uterine pressure deformities of the ankle and tarsal joints, or congenital talipes.

2. Neurogenic contractures of the ankle and tarsal joints, or paralytic talipes.

It is in some respects to be regretted that the popular term club-foot has been allowed to enter into surgical nomenclature. Walsham and Hughes would restrict the use of the term to talipes varus:—"In no sense, however, can flat-foot, talipes valgus, or spurious valgus, as it is sometimes called,

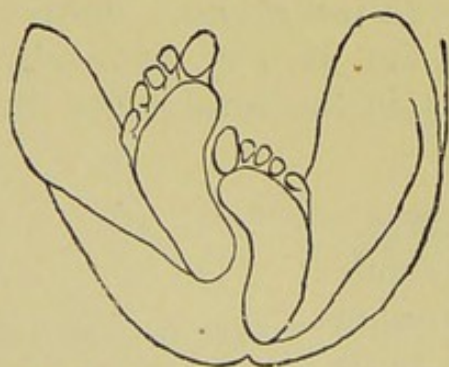

Fig. 116.—The position of the feet in the later weeks of gestation. (After Braune.)

be termed club-foot, and so with certain others of the deformities that will be hereafter described. The term 'club-foot' will be here* restricted to talipes varus."

Congenital Talipes Calcaneus.

—Since in normal conditions during the last stage of intra-uterine life the feet are held with the ankles dorsal-flexed, as shown in Fig. 116, a certain amount of talipes calcaneus is normal at birth.

This normal talipes calcaneus is corrected spontaneously by the movements of the foot after birth.

* Walsham and Hughes, *loc. supra cit.*, p. 46.

The more severe degrees of congenital talipes calcaneus nearly always combined with congenital valgus.

In a certain number of cases dorsal flexion of the ankle is the chief part of the deformity.

Symptoms.—In such cases the muscles are sound and the child moves the foot freely, but there is a variable degree of fixed dorsal flexion, and on attempting forcible plantar flexion the extensor tendons become prominent and prevent the movement being carried out to its full extent. Walsham and Hughes point out that the sole in cases of congenital talipes calcaneus may be directed more or less inwards. "Although the sole may look inwards, still the foot is, as a rule, quite flat, and the inner edge is more pronounced than normal, or even in some cases convex, especially in the region of the medio-tarsal joint. Here we not infrequently meet with a distinct prominence due to the projecting scaphoid. This condition of the inner edge of the foot may have given rise to the generally-accepted dictum that valgus is the common, if not universal, accompaniment of congenital calcaneus. But the inner edge is on a higher level than the outer, and although the scaphoid and astragalus are more prominent, they are elevated and not depressed, as in valgus."

Anatomy, etc.—As in other forms of congenital club-foot, there is at birth no evidence of disease of nerve or muscle. The deformity is the result of intra-uterine pressure and limitation of the range of intra-uterine movement normally enjoyed by the fœtus, and the anatomical changes are such as might be inferred. As far as the skeleton of the foot is concerned the astragalus and os calcis are the more frequently changed in form, but in slight cases they may be quite normal.

The changes in form that are present at birth must be distinguished from those that form later in untreated cases, when the child has used the deformed foot for progression. In these the astragalus is flattened and elongated, especially its neck, which presents on its upper aspect a cartilage-lined pit, formed by pressure against the anterior border of the lower articular surface of the tibia. In severe cases, the anterior part of the os calcis is increased, whilst the sustentaculum is diminished in size (Hoffa). The later changes have been described by Nicoladoni in the right foot

of a microcephalic boy who died at the age of fourteen years. The os calcis was placed vertically. The tendo Achillis was displaced inwards and the outer border of the foot was convex. On dissection the muscles were found to be wasted, but healthy. Seen from the inner side the tendon of the tibialis anticus and flexor longus pollicis were prominent. The scaphoid was approximated to the internal malleolus, whilst the latter and the anterior edge of the tibia overhung the neck of the astragalus. The tendo Achillis was displaced so far outwards that it was not visible from the inner side. The tendons of both peronei were dislocated forwards, so that they lay in front of the external malleolus.

Diagnosis.—Pronounced cases of this deformity are not common, but when they occur the absence of marked eversion of the foot serves to distinguish them from the commoner talipes calcaneo-valgus. In young infants it is easy to place the foot in the position it had *in utero*. In congenital calcaneus the back of the foot touches the front of the leg, whilst in calcaneo-valgus it lies against the outer side of the leg. This condition must be distinguished from the preternaturally mobile foot often seen in rickets.

Prognosis, treatment, etc., will be considered below.

Congenital Talipes Valgus.—Many authors describe congenital valgus as of frequent occurrence. On this point R. W. Parker observes: "I can only say that I have never seen an uncomplicated case in a young infant. Spurious forms occurring quite early in life in rickety children are common enough." My own experience is practically in harmony with this. I have, among some hundreds of cases of congenital club-foot, only seen one in which eversion of the foot was the only abnormal feature. The deformity, though rare, does, however, occur, and one example of it from a still-born child I placed in the museum of St. Mary's Hospital (Series I., No. 6). Such cases would probably yield readily to manipulative treatment. For an instance of valgus combined with equinus see Fig. 117.

Cases of congenital valgus complicated by absence of part or of the whole of the fibula are encountered from time to time, and will be considered (p. 221), with other complicated cases of club-foot.

Congenital Talipes Calcaneo-valgus.—Congenital calcaneo-valgus in the slighter degrees is not an uncommon condition, but it is not so frequently brought to the notice of the surgeon because it has a natural tendency to improve. In the moderately pronounced, *e.g.* Fig. 118, and severe cases, the appearance of the foot is characteristic. An extreme case now under my care is shown in Fig. 119.

Anatomy.—The anatomical changes are those described under the heading of congenital talipes calcaneus, combined with those that produce the valgus part of the deformity, as will be more fully described under the heading of talipes valgus acquisitus (p. 194). In Fig. 117 the altered position of the scaphoid is shown. The latter is displaced outwards, and rotated so that its outer is higher than is normal.

Treatment.—This consists of careful splinting and daily manipulation until the child is ready to walk, when boots and irons furnished with a front stop-joint should be applied. In applying the splint care must be taken that the bandages are applied in such a way that the heel is raised, otherwise the foot will become flexed at the medio-tarsal joint whilst the ankle remains fully dorsal-flexed. Tenotomy should not be performed until all the improvement that can be obtained by a patient course of splinting has been effected.

The tendons that may require section are those of the tibialis anticus, the extensor proprius hallucis, the extensor longus digitorum, and the peronei. These

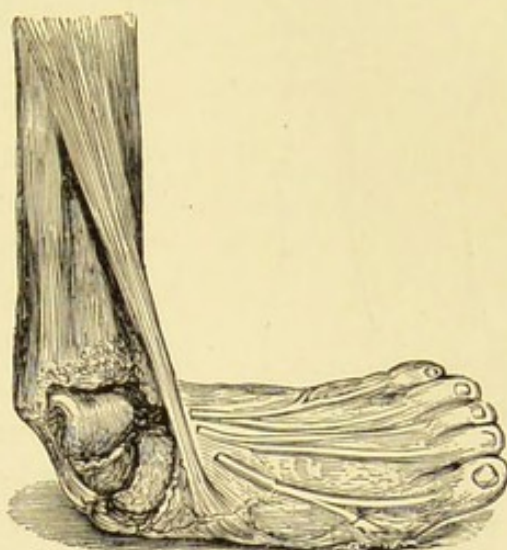


Fig. 117.—Dissection of a case of Congenital Equino-valgus, showing elevation of the Os Calcis (p. 157), oblique position of the Astragalus and outwardly displaced Scaphoid. (*After W. Adams.*)

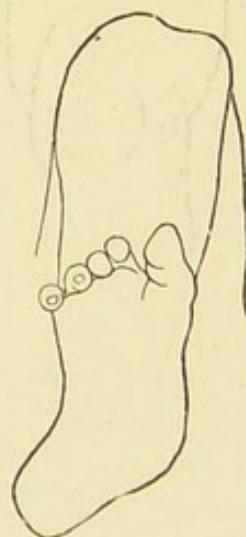


Fig. 118. — Congenital Talipes Calcaneo - valgus.

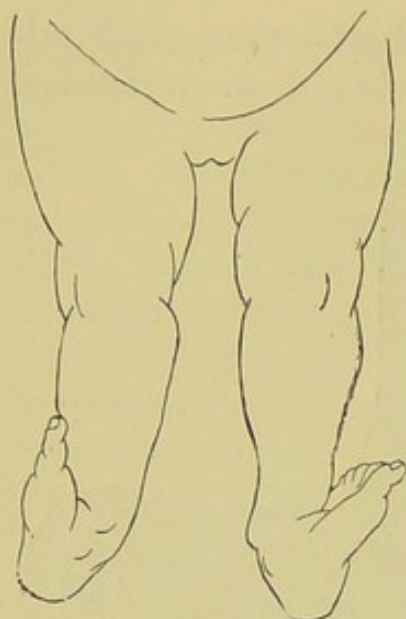


Fig. 119.—Original position of the feet in an extreme case of Congenital Talipes Calcaneo-valgus.

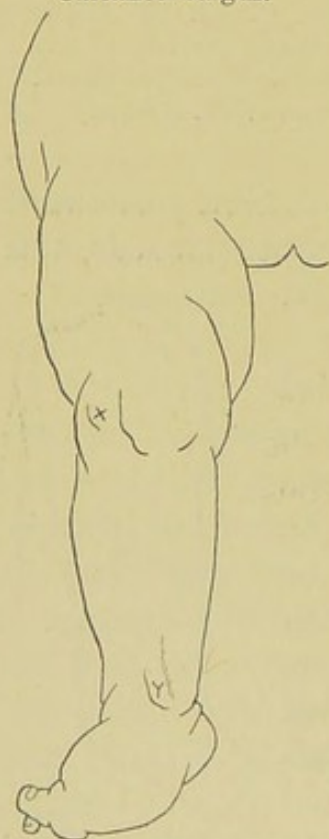


Fig. 120.—Position of the right foot after two months' treatment.

The position of the patella dislocated in the outer surface of the external condyle is indicated by x; y marks the internal malleolus.

tendons are best divided subcutaneously. Those of the tibialis anticus and extensor proprius are divided just below the ankle-joint, the tenotome being entered from the outer side. The extensor longus digitorum and peroneus tertius tendons may be divided together in front of the ankle-joint, the tenotome being entered on the inner side of the ankle-joint, and kept close to the inner edge of the tendon. It is seldom necessary to divide the tendons of the peronei longus and brevis, but they are easily cut close behind

the peroneal tubercle of the os calcis, where they lie in separate sheaths. Some surgeons divide them behind the external malleolus, where they lie one upon the other.

Illustrative Case.—In a marked case now under my care the appearance of the feet when the patient was first brought to me at the age of three months is shown in Fig. 119. The right foot was more severely deformed than the left, and the complete eversion of the foot was accompanied by outward rotation of the leg at the knee and a dislocation of the patella upon the outer condyle. The treatment adopted was the use of a metal splint bandaged to the inner aspect of the leg and foot and daily manipulations. By these means the appearance of the foot was brought to the position shown in Fig. 120 in two months. When the leg is rotated inwards as far as possible, the foot seen from the front has the appearance shown in Fig. 121. This patient has now been ordered irons reaching from the waist and extending to the inner side of the thigh and leg, and boots, in order to complete and consolidate the correction of the deformity, and the feet go

readily into the boots and are maintained in the corrected position. The dislocation of the patella has also been cured. The eversion was so great in this case that the feet seemed to be designed for the patient to walk backwards, the toes pointing more to the rear than to the front.

Paralytic Talipes Valgus.—The foot in cases of paralysis of the tibiales muscles has the same appearance as flat-foot from other causes, but as a rule is free from rigidity. The treatment required is to support the foot with a pad, outside iron and T-strap, as described under "Static Flat-foot" (p. 205).

Paralytic Talipes Calcaneus.—Complete paralysis of the muscles of the calf, the long flexor muscles, and the peronei, while some power remains in the extensor muscles, entails a marked deformity of the foot, as shown in Fig. 122.

The ankle-joint is fully dorsal-flexed, whilst the anterior part of the foot has dropped, making a sharp crease across the middle of the sole. Plantar flexion of the sole is termed pes cavus.

The production of cavus in paralytic pes calcaneus is chiefly effected by the plantar muscles, which, when the opposing force is removed by paralysis of the gastrocnemius, approximate the extremities of the plantar arch.

A second factor is present in many cases in the action of the peronei. These muscles, besides producing a valgus deformity of the foot, tend to increase the arch of the foot.

A third factor is the effect of gravity and of pressure of the bed-clothes at night depressing the fore part of the foot.

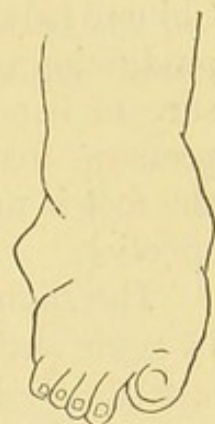


Fig. 121. — Appearance of the Foot after three months' treatment, the Leg being rotated inwards at the Knee.

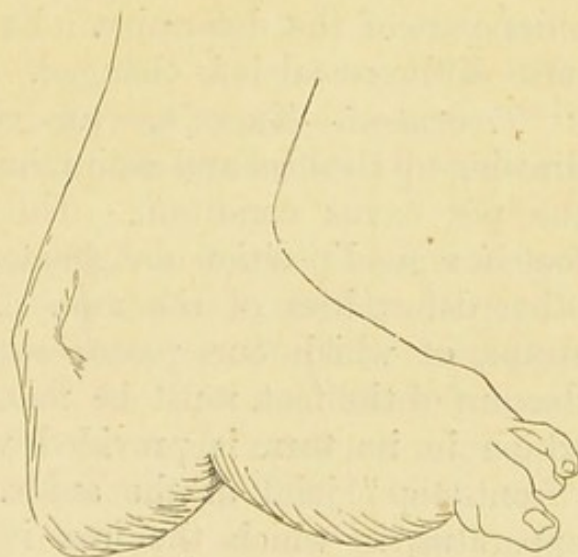
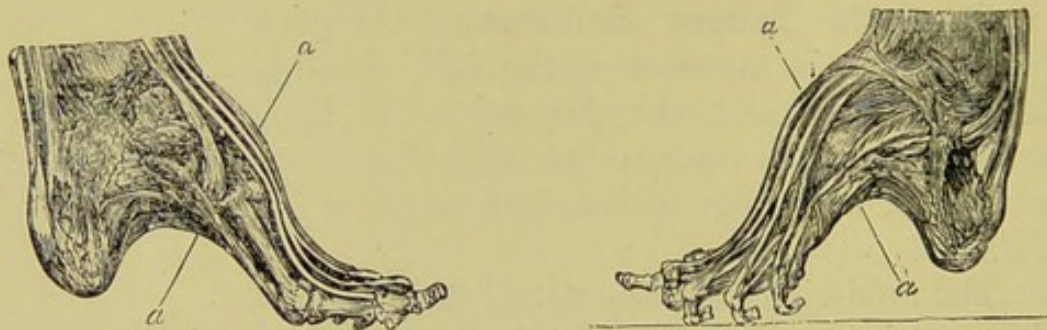


Fig. 122.—The Foot of a Girl aged six years, showing Paralytic Talipes Calcaneus.

The cavus met with in paralytic talipes calcaneus may be compared with the artificial talipes calcaneus exhibited in the Chinese lady's foot (Figs. 123 and 124). Although the mode of production of this intentional deformity is by continued pressure of bandages, resembling in character the intra-uterine pressure that determines congenital club-foot, the shape of the foot is more like that of the paralytic than the congenital affection.

The slighter degrees of paralytic calcaneus are designated by some authors following Nicoladoni as "*pes calcaneus sensu strictiori*." In such cases the "*pes cavus*" constitutes the



Figs. 123, 124.—Dissection of Foot of Chinese Lady. (*W. Adams.*)

chief part of the deformity. Even in these slight cases the form of the os calcis is changed.

Treatment.—There are two objects to be aimed at: first, drawing up the heel and maintaining it there; second, reducing the *pes cavus* condition. The difficulties of retaining the foot in a good position are greater than is the case with many other deformities of the foot. A metal sole-plate fixed by straps, of which one passes across the prominence of the dorsum of the foot, must be made and worn inside the boot, which in its turn is provided with an outside iron with a "front-stop" joint at the ankle. Instead of this, Judson's apparatus, in which the iron is fixed to the foot-piece and at a right angle to it, may be used. If there is any difficulty in reducing the deformity, measures should be adopted in order to overcome it before applying instruments which must be worn to prevent its return. When there is marked hollowing of the foot, it may require gradual correction by some such appliance as that shown in Fig. 125. When some sound muscular tissue remains in the calf-muscles, the

operations for shortening the tendo Achillis are useful in certain cases (*see* p. 104). A sufficient length of the tendon is removed, so that on joining the ends of the tendon the heel is drawn up to the desired amount. Walsham observes that this operation is useless when the gastrocnemius and soleus muscles are completely paralysed. The same surgeon has successfully substituted transplantation of the tubercle of the os calcis for shortening the tendo Achillis (*see* p. 106).

Paralytic Talipes Calcaneo-valgus.—When the calf muscles are paralysed and the peronei retain their power, the foot is everted in addition to the ankle being dorsal-flexed. In other words, the condition is one of calcaneo-valgus.

Symptoms.—The tendons of the peronei stand out prominently on the outer side of the ankle; viewed from the inner side, the foot has much the appearance shown above in Fig. 122; it is, however, more markedly everted.

Anatomy.—The chief alterations in the bones concern the astragalus and os calcis. In the former the tibial articular surface is extended forward upon the neck of the bone, whilst the posterior part of the surface loses its covering of cartilage.

The os calcis becomes modified in form. In severe cases, when the bone has been placed almost vertically, during life the anterior process of the bone may be completely atrophied.

Treatment.—The treatment for this condition is similar to that already described for paralytic calcaneo-valgus, but there is a further important resource in Nicoladoni's operation—transplantation of the tendons of the peronei. The latter are divided opposite the external malleolus, and the tendo Achillis is divided just above its attachment. The tendo Achillis may be shortened at the same time with advantage (*see* Fig. 69 and p. 107).

In Nicoladoni's operation a vertical incision four or five inches long is made along the anterior border of the peroneal tendons ending below at the external malleolus. From near

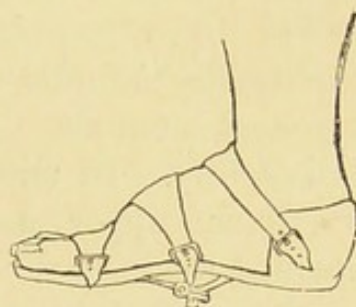


Fig. 125.—Apparatus for the gradual Correction of Pes Cavus. (*Heather Bigg.*)

the lower end of this incision a second is carried inwards at right angles, and a flap is made, exposing the peroneal tendons and the tendo Achillis. From the outer part of the latter a portion is removed, and thus a fresh surface is obtained to which the tendons of the peronei are sutured. In a small foot I have combined this with removal of a section of the tendo Achillis above the point of attachment of the peroneal tendons. The result of this operation was very satisfactory. In another case I adopted Goldthwait's plan of fixing the upper ends of the tendons of the peronei in an opening made at the lower part of the tendo Achillis.

Congenital talipes equinus is one of the rarest of congenital deformities. Cases have been recorded by Little, Adams, Walsham, Tubby, and others. I have seen several cases in which the equinus was the predominant deviation, but in all some share of varus could be distinguished. This accords with the experience of R. W. Parker, who writes :

This is so rare a form of congenital deformity that it may be dismissed with a mere mention. I have only seen one case that could with any propriety be called equinus. It will be observed that the foot is somewhat inverted, as well as extended. The inversion was easily overcome ; and the whole deformity yielded quickly, after section of the tendo Achillis.

Treatment.—The method to pursue is similar to that described below for congenital equino-varus. For some months after birth regular splinting and daily manipulation should be employed. In some cases a normal condition may be restored by these means alone. When necessary, the tendo Achillis should be divided.

Congenital Talipes Varus.—This term applies more properly to cases in which the foot is inverted without any elevation of the heel. Some confusion has arisen from the fact that many authors adhere to the old nomenclature and apply the term "varus" to cases that are better termed equino-varus in that the heel is drawn up in addition to the foot being everted. Although varus may occasionally be found without equinus, it is so rarely the case, and is so readily corrected, that no separate, detailed account of the condition is called for.

Congenital Talipes Calcaneo-varus.—The inversion of

the sole met with in some cases of congenital calcaneus has been referred to above (p. 157). Since the foot below the ankle is usually everted in such cases, the inversion probably depends on changes at or above the ankle, and the essential condition is, in my opinion, calcaneo-valgus. In other cases, however, the sole is inverted without there being any eversion of the foot below the ankle. Such cases are rare and of no great clinical importance.

Congenital Equino-valgus is occasionally met with.

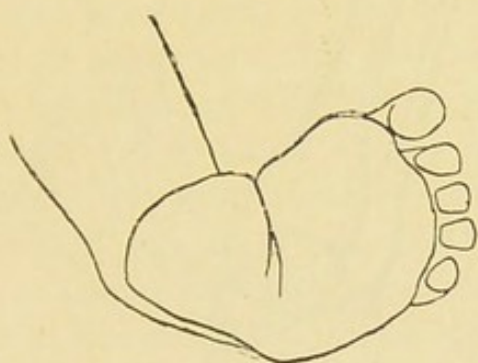


Fig. 126.—Foot of a newly-born Infant showing Congenital Talipes Equino-varus.

The transverse crease in the sole of the foot shows that there is a certain degree of pes cavus.

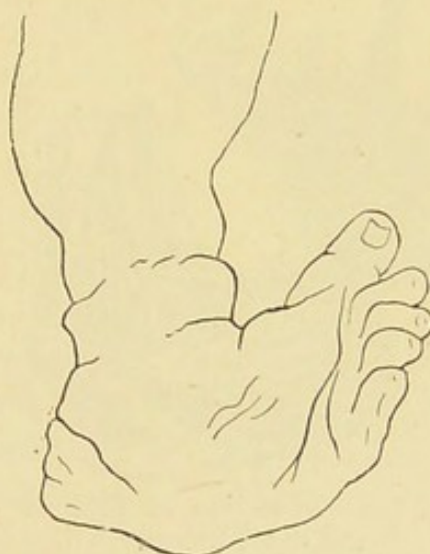


Fig. 127.—Similar Foot seen from the front.

There are furrows above the ankle from pressure of the umbilical cord.

Congenital Talipes Equino-varus.—Congenital talipes equino-varus, when severe, forms a well-marked deformity (see Figs. 126 and 127). Various degrees may be recognised: in severe cases the foot is rigidly fixed in the abnormal position which cannot be overcome by manual force; in medium cases the deformity is well marked, but the rigidity is not so great and the malposition can be greatly diminished by manual force; in slight cases there is but little rigidity, and the foot can be easily brought to its normal shape. The anatomy may be taken from a severe case. In infants who have not walked, the inner border of the foot is shortened, the outer shows signs of pressure, *i.e.* thinning of the skin over the outer malleolus and the prominent cuboid bone. The sole of the foot shows a transverse crease opposite the transverse tarsal joint, showing

that there is some flexion at this joint; in other words, some pes cavus is present. In older patients who have walked, callosities with underlying bursæ form over the outer border of the foot and a longitudinal crease develops in the sole.

Anatomy.—On dissection, all the structures from the skin to the bones are found to be changed in shape, but they are healthy in texture; there is no degeneration of muscle, as in paralytic talipes, and in life there is no active spasm of

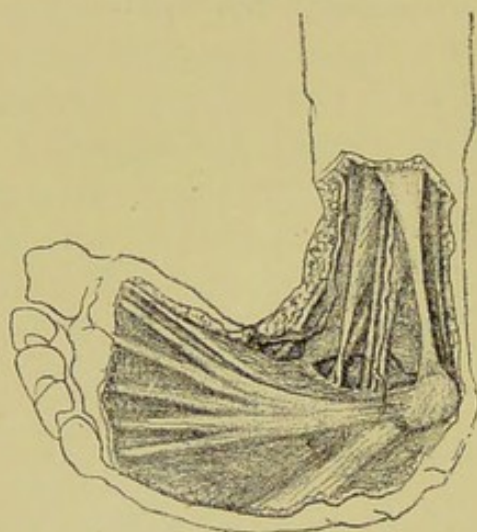


Fig. 128.—Dissection of Foot of still-born Infant.

Showing the attachment of the tendo Achillis; the tendons, vessels and nerves at the back of the ankle-joint; the internal saphena vein and the plantar fascia: congenital equino-varus.

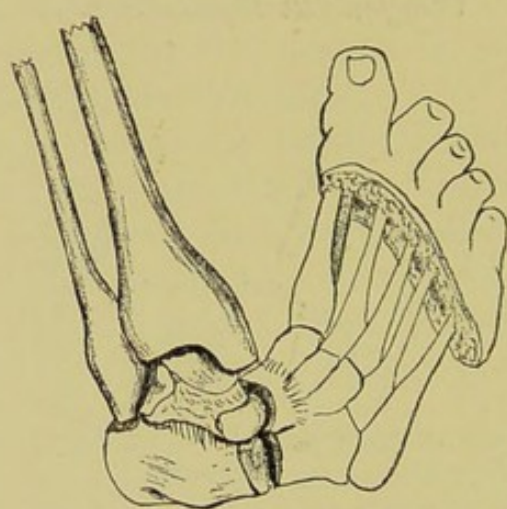


Fig. 129.—Bones and Articulations of a Foot to show the altered relations in Congenital Talipes Equino-varus.

muscles, as in spastic talipes. Before considering in detail the condition of the various tissues at the time of birth in cases of severe congenital talipes equino-varus, it is well to remember that no amount of operative interference can restore the part its normal shape. If every resistant part is severed, and the foot is placed in a position as nearly normal as possible, the altered form of the bones prevents a complete correction being attained. This fact will be referred to later in considering the treatment of the condition.

The *plantar fascia* in severe cases is shortened to suit the altered form of the foot; at birth the resistance to correction offered by the fascia is usually slight.

The Muscles.—The two tibiales, the long flexor muscles, and the gastrocnemius and soleus, and in the foot the adductor

pollicis, are all shortened, whilst the peronei muscles are elongated. It is noteworthy that when all the superficial tissues and the muscles have been removed, the deformity of the remaining structures still persists. This is owing to the alterations in the form of the ligaments and bones. The attachment of the tendo Achillis is displaced towards the inner side of the posterior extremity of the os calcis (Fig. 128), whilst the tuberosity itself is displaced outwards.

The Ligaments.—Those on the inner side of the foot are shortened, those on the outer side are lengthened. The posterior ligament of the ankle and the plantar ligaments are also shortened.

The *bones* of the foot in severe congenital equino-varus are all modified in form. The alterations in the astragalus and the os calcis are the most important, since they contribute most in producing the abnormal inversion of the foot; the anterior parts of both these bones are bent inwards as shown in Figs. 129 and 130. There are abnormal articulations between the scaphoid and the internal malleolus (Fig. 131), sometimes between the os calcis and the external malleolus (Fig. 129). Nor are the alterations always confined to the tarsus.

Changes in the Bones and Joints of the Leg.—These are of such a nature as to give rise to some inversion of the foot, and they are determined by the same constrained intra-uterine position of the limb that determines the changes in the foot just described. They may be enumerated as follows:

1. Pronation of the bones of leg, *i.e.* the lower end of the fibula is advanced forwards, whilst the lower end of the tibia is displaced backwards.
2. An inward twist in the shaft of the tibia.
3. The leg bones are rotated inwards at the knee, and at the same time there may be some over-extension of the knee-joint (*genu recurvatum*).
4. An inward twist in the axis of the femur.
5. Some forward bending of the neck of the femur.

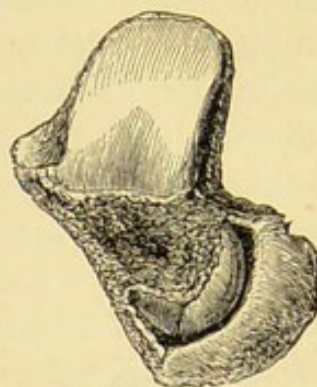


Fig. 130.—Astragalus and Scaphoid Bones from a Case of Congenital Talipes Equino-varus, showing inward deviation of the Neck of the Astragalus. (*W. Adams.*)

Treatment of Congenital Club-foot.—When the mechanical causation of this deformity is remembered, and when we recall the fact that at birth the whole of the tarsus, save for small nuclei in the os calcis and cuboid, and the epiphyses of the metatarsus, consists of cartilage, and much of this cartilage remains up to the age of puberty, it is recognised at once that

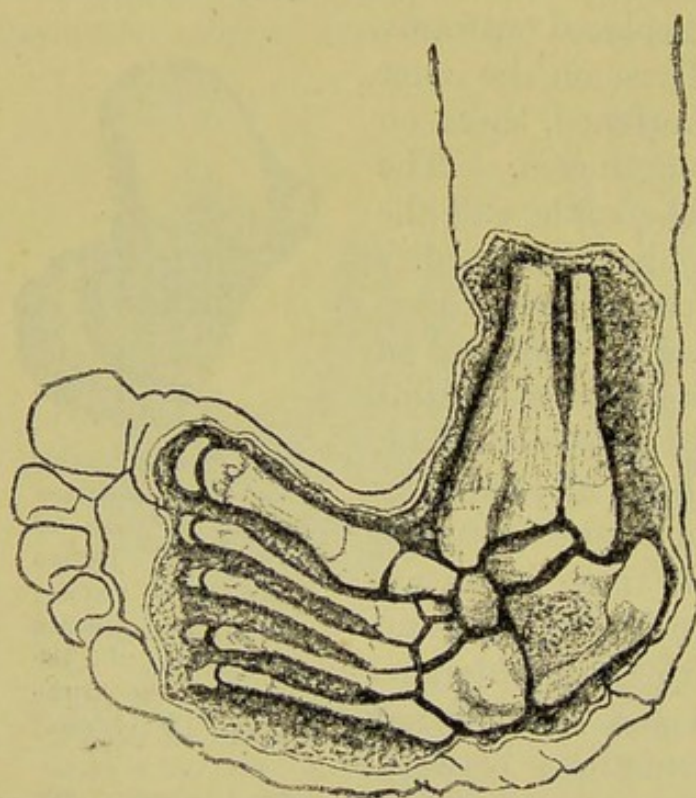


Fig. 131.—Bones in Congenital Equino-varus at Birth.

the conditions offer great scope for the guidance of growth in a normal direction, *i.e.* the true orthopædic treatment of the condition. Many surgeons recommend a rapid correction of congenital club-foot by tenotomy of the tendo Achillis and other tendons, section of ligaments, etc., followed by fixation in plaster of Paris, but after giving the method a thorough trial I

cannot recommend this process, and thus I will first give a detailed account of the method of treatment that I have found to give uniformly excellent results. The principles of the method were long ago established by Scarpa, who observes:—“The apparatus intended for correcting the deformity of congenital club-foot, which I am now to describe, consists of several springs, and, as the cure of this disease is divided into two stages, the elastic apparatus likewise consists of two parts. The first is intended merely for turning the fore part of the foot from within outwards, as far as its natural position and direction with the tibia. The second part of this apparatus is intended for retaining the fore part of the foot in its regained position with the tibia and with the external malleolus,

and for correcting the heel and retaining the tibia and fibula steadily perpendicularly to the astragalus.*

The first stage of treatment consists in the regular and systematic use of the adaptable† metal splint combined with simple massage and gentle manual wrenching. The treatment is begun as soon as possible after birth—"as soon as the baby has been washed," as Sayre has expressed it. The splint, well but firmly padded, is applied to the outer aspect of the leg by a flannelette bandage, which starts with a turn round the splint from without inwards and is continued in the same direction first round the leg and then round the foot, drawing the latter towards the splint. The splint is removed night and morning and the bandage is reapplied, and each time the splint is removed the limb is gently rubbed and the foot everted several times in succession. In the latter proceeding the surgeon supports the limb in the left hand by holding the ankle for some movements, and the lower part of the leg for others. The thenar eminence and the whole breadth of the flexed fingers must be used for holding the limb, and care should be taken not to dig in the tips of the fingers, for this causes pain to the child and awakens resistance. With the right hand abduction, eversion, and dorsal flexion are carried out several times in succession, first at the transverse tarsal, then at the sub-astragaloid, and lastly at the ankle-joint; finally, these movements are combined in circumduction of the foot outwards. After the manipulation, the splint is reapplied. For the first week the surgeon should himself perform these operations and apply the splint, meanwhile teaching the nurse or mother both how to manipulate the limb and apply the splint. After this, for a time the surgeon should see the patient twice a week to modify the shape of the splint from time to time, and to ascertain that treatment is being properly carried out. Later, less frequent visits will be sufficient. After a few weeks of this treatment, if it is begun soon after birth, the most rigid foot will become more pliable and the inversion and adduction

* "Memoir on the Congenital Club-foot of Children," translated by J. B. Wishart; Edinburgh, 1818.

† The tin splint is made of tinned iron of such a thickness that it can be readily bent to any desired shape by the surgeon, but retains its form, *i.e.* acts as a rigid splint when applied.

will be sensibly diminished (Figs. 132-4). After these displacements have been fairly overcome, a second tin splint can be added, bent at an angle and applied to the antero-external aspect of the limb (Fig. 43, p. 78). With ordinary care to protect the external malleolus from pressure, this mode of treatment is devoid of any risks, and in slight cases suffices to correct both the varus and the equinus. In more severe cases, after six months or more of this treatment, there will still remain some shortening of the calf muscles requiring division

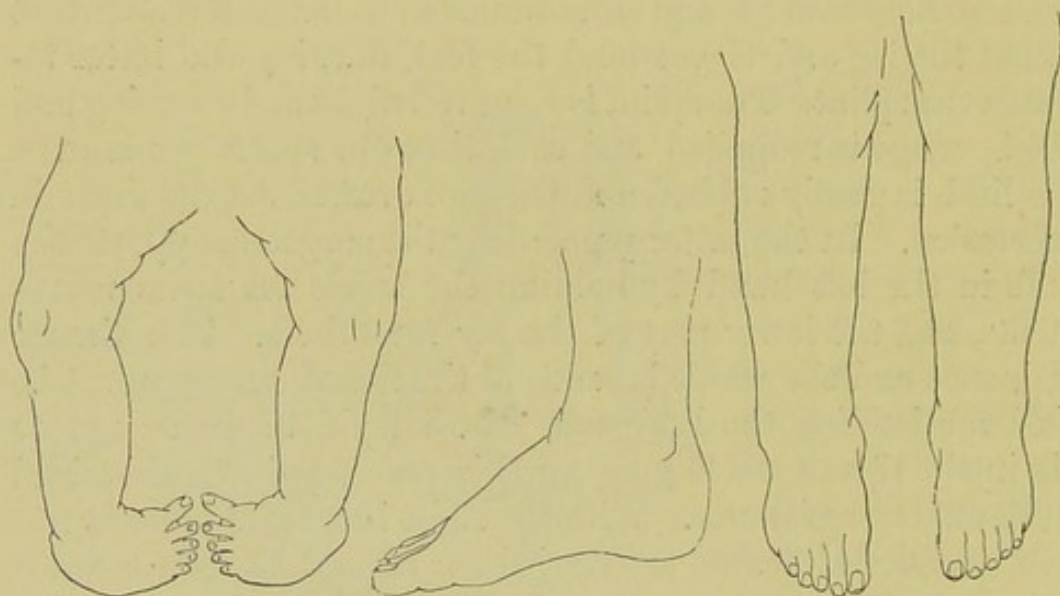


Fig. 132.—The Feet at the Beginning of Treatment.

Fig. 134.—One of the Feet after Section of the Tendo Achillis.

Fig. 133.—The same with the Varus corrected.

of the tendo Achillis. In very small feet this simple operation is in the hands of beginners not infrequently accompanied by division of the posterior tibial vessels, and though with the application of a pad the hæmorrhage is easily checked, and no ill results, it is still undesirable. The accident arises when the tenotome is introduced from the outer side of the tendo Achillis and is sloped too far backwards. The small size of the foot and the altered position of the tendo Achillis help to render the accident easy to make. The tenotome should be introduced from the inner side and be passed first at an angle of 45° , and then horizontally behind the tendon. As an illustrative example of this method of treatment, the one from which Figs. 132, 133, and 134 were taken may be cited.*

* This patient was shown before the Harveian Society, Feb. 2, 1899.

Treatment was begun at the age of six months. After five months of treatment, the varus was found to be corrected, and the tendo Achillis was cut. The feet for a few weeks were retained in position by simple metal shoes and then walking instruments were applied, as shown in Fig. 49. After wearing and walking in these instruments for one year, the impressions of the soles were as shown in Fig. 135, the deformity being completely cured; yet it was recommended that the instruments should be worn a year or two longer in order that the normal form of the bones should become completely restored before the instruments were left off. It will be noticed

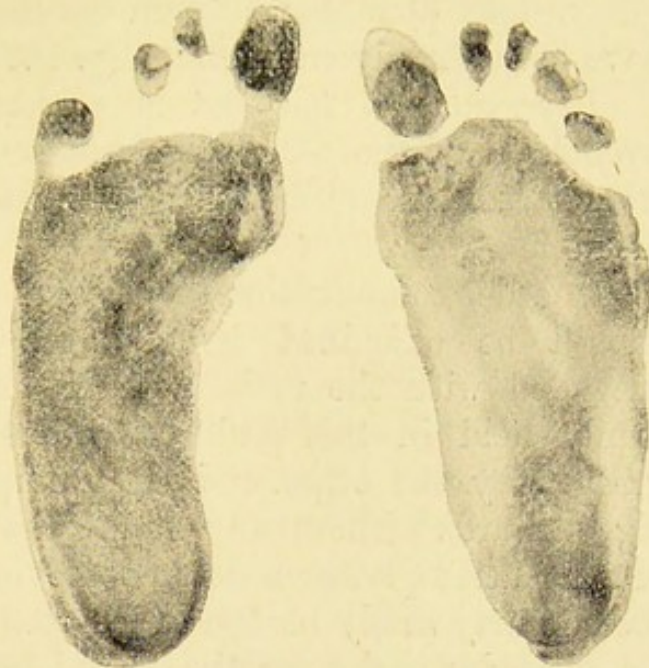

Fig. 135.—Impression of the Soles of the Feet after the Cure of Congenital Talipes Equino-varus.

that the instruments shown in Fig. 49 reach to the waist. The reason for this was that after correction of the talipes there was inversion of the feet owing to rotation inwards at the knee, and hip-joints. Had this not been the case, an apparatus ending below the knee would have sufficed.

Operation without Instrumental Treatment fails to cure Congenital Equino-varus.—As one of the very numerous cases illustrating this point that have come to my notice, I may refer briefly to that shown in Fig. 136. This patient was operated on at the age of six months by an experienced surgeon. A Phelps's operation being done on the left side, and extensive tenotomies, etc., on the left. Plaster bandages were used for six weeks, but after that no instruments were recommended. Much of the deformity remained.

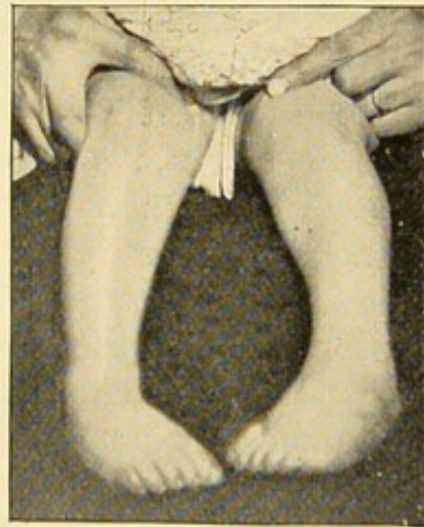


Fig. 136.—Feet of a Child aged two years who had been operated at the age of six months. In this case treatment by instruments had been omitted.

The *treatment of inversion of the limb* remaining after the cure of equino-varus requires more detailed description. The various possible factors in the causation of this inversion have been already enumerated (p. 167).

Inversion in the foot is corrected by the systematic wrenching of the foot, already described. If any inversion from this cause still remains, it will be controlled by the inside leg-iron.

In order to ascertain other causes of inversion, the patient should be examined lying down, with the lower limbs extended with the patellæ directed forwards. The thigh is firmly held in this position by one hand, whilst the leg is grasped by the other, and an attempt is made to rotate the leg outwards without any movement either at hip or ankle. If this attempt succeeds in removing the inversion of the foot, it may safely be concluded that the inversion is caused by inward rotation at the knee-joint; if the attempt fails, the conclusion is that the inversion is caused by one of three causes—*a*, pronation of the bones of the leg; *b*, torsion in the shaft or neck of the femur; *c*, torsion in the shaft of the tibia. A twist in the shaft or a forward bend in the neck of the femur is shown to exist when the normal range of eversion of the thigh is diminished. The remaining conditions are to be distinguished by a careful inspection.

When the inversion of the feet is due to laxity of ligaments at the knee-joint, it may be associated with a certain amount of *genu recurvatum* (see p. 261).

The Treatment of Inversion of the Foot in Congenital Talipes Equino-varus.—If the case has been undertaken at the proper age, that is, in early infancy, all the various factors which, singly or combined, may give rise to inversion can be successfully overcome without any operative measures.

During the course of splinting described above much can be done for defects at or below the knee-joint by using splints which reach to the middle of the thigh. Thus, if the splint is well secured to the outside of the thigh and then successively to the leg and foot, the latter are brought out to the line of the femur, and pronation of the leg bones is gradually corrected. If *genu recurvatum* is present, the metal splint can be cut so that the knee is kept in a slightly (25° to 35°) flexed position,

and thus the growth of the parts will be encouraged on the anterior, and diminished on the posterior part of the joint. As soon as the child begins to walk, towards the end of the first year, walking instruments should be prescribed and adapted.

Cases of congenital equino-varus in which early treatment has been improperly conducted or neglected require more severe measures. If the child is under five or six years, much can be done by patient mechanical treatment combined with operative measures. The pes cavus, the varus, and equinus must be attacked in turn and overcome. The use of some form of Scarpa's shoe is sometimes desirable instead of the simpler tin splints. I have, however, treated obstinate cases successfully, by using a simple metal sole-plate in addition to the ordinary tin splints. Where there is marked hollowness of the foot, it is desirable to use Adams's Scarpa's shoe, with a sole-plate, divided opposite the transverse tarsal joint to effect the correction of the cavus and varus.

With these or other instrumental aids operative measures must be undertaken. Such measures include wrenching, manual and instrumental, division of fascia, muscles, tendons, ligaments, and, in some instances, bones.

The plantar fascia and the adductor pollicis muscle most frequently require division in the sole. After section of these structures, a period of careful mechanical treatment should intervene. After the pes cavus is fairly overcome, and with it some of the varus will have disappeared, any varus that remains may be dealt with by section of the tibiales tendons, and, if necessary, the internal part of the anterior and the internal lateral ligaments* of the ankle and the superior astragalo-scaphoid ligament.

* Of the ligaments in congenital equino-varus R. W. Parker ("Congenital Club-foot," 1887) writes:—"Of first importance are those about the astragalo-scaphoid joint. In these cases there is a capsule made up above and internally by a blending together of the superior astragalo-scaphoid ligament with fibres from the anterior ligament, and the anterior portion of the deltoid ligament of the ankle-joint; below, with fibres from the inferior calcaneo-scaphoid ligament. To these are united fibrous expansions of the tendons of the anterior and posterior tibial muscles; together they form an unyielding capsule of great strength, which is attached to the several bones, not in the usual manner, but in adaptation to their altered relative positions. This I would name the 'astragalo-scaphoid capsule.' The tip and inner border of the inner malleolus

If the tendon of the tibialis posticus is divided immediately beneath the internal malleolus, the subjacent ligaments can readily be cut at the same time, as shown in Fig. 137.

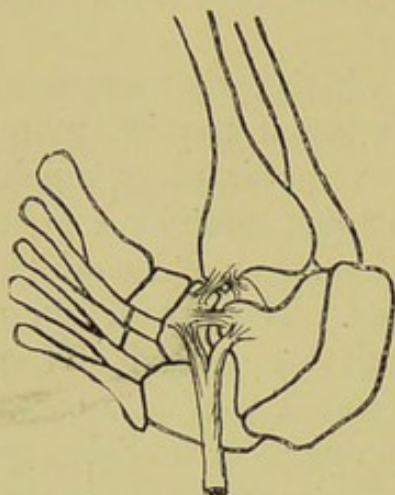


Fig. 137.

Diagram showing the tendon of the tibialis posticus turned down, in a case of congenital talipes equino-varus, exposing part of the internal ligament of the ankle and the inferior calcaneo-scapoid ligament.

After another interval of careful splinting, the tendo Achillis may be divided, and if the stages have been duly carried out the deformity will now be corrected, and as soon as this tendon has undergone repair, *i.e.* six or seven weeks, the patient may be fitted with boots and walking instruments. It may be noted that some surgeons prefer to divide the tendo Achillis quite early in severe cases. My own practice is founded on personal experience. The opinion of one who has done much for the surgery of club-foot may be quoted on the other side.

I have elsewhere mentioned that in congenital talipes, the tendo Achillis is attached quite close to the internal border

of the posterior surface of the os calcis, and that this fact accounts for some of the twisting and inversion of the sole of the foot. It is on this account that I think it well to cut the tendo Achillis quite early on in the treatment of these severe cases, for it is impossible properly to gauge the part played by other structures so long as the tendo Achillis remains uncut. The old argument, to leave it quite to the last, that it may serve as a *point d'appui* through which to exert mechanical force on the other structures, is wrong in principle since tenotomy has been introduced. When treatment was entirely mechanical, there was some reason in the argument. Now that section of the offending structures is regarded as the chief means of treating these deformities the assistance of the tendo Achillis should no longer be required; if it prove necessary in any given case, it may be taken for granted that the offending structures have not been divided.*

At all stages of treatment, in combination with other measures, *manipulation* or *wrenching* should be practised.

are generally in close contact with the scaphoid, a bursa intervening; in very severe cases I have seen the inner malleolus in contact with the internal cuneiform, a short, flat, ligamentous band of great strength passing from one to the other."

* R. W. Parker, "Congenital Club-foot," p. 95.

Manual wrenching is the most frequently applicable and usually all that is needed. In resistant cases, however, a greater mechanical advantage than that given by the hand is required. Many ingenious instruments have been devised to supply this. Of these the late H. O. Thomas's wrench (Fig. 138) is the most widely used.

Mr. William Thomas (Birmingham) has recently brought out a club-foot wrench that has certain advantages over that of the late Mr. H. O. Thomas. It consists of a strong metal quadrilateral with rounded sides, and capable of being narrowed or enlarged by a screw action of the long handle. The foot is placed in the quadrilateral space and firmly gripped by screwing up the handle; by which then a great leverage power can be obtained.

For equino-varus the instruments invented by Mr. F. F. Baker are extremely useful (Fig. 139).

Relapsed and unfinished Cases.—All orthopædic surgeons are familiar with cases which after much surgical activity and loss of time are no better off than when the surgeon's aid was first sought. There are very few of such relapsed cases that cannot be corrected in early childhood by the treatment described above. As far as the altered conditions will allow, this requires a longer time than if the proper treatment had been employed from the first, yet with patience a fair result will be obtained, unless the patient has been allowed to grow out of its infancy between the first and the second course of treatment. It cannot be too strongly urged that, if treatment is thorough, relapse is impossible, and in this place it may be

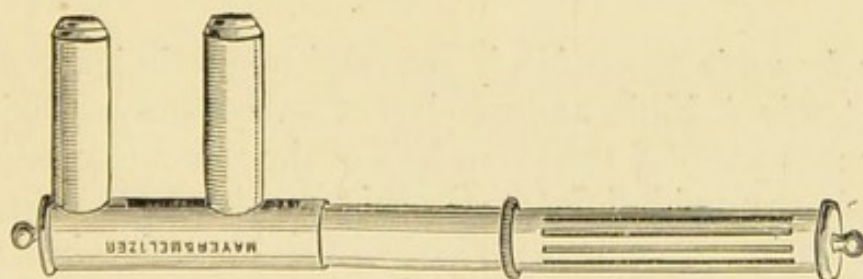


Fig. 138.—H. O. Thomas's Wrench.

observed that during the illnesses of childhood splinting may be continued without at all inconveniencing the patient.

Major Operations for Club-foot.—Two of these, Buchanan's

and Phelps's, have of late been extensively practised upon infants, and although I am convinced that such measures are undesirable in young subjects, the operations demand notice here.

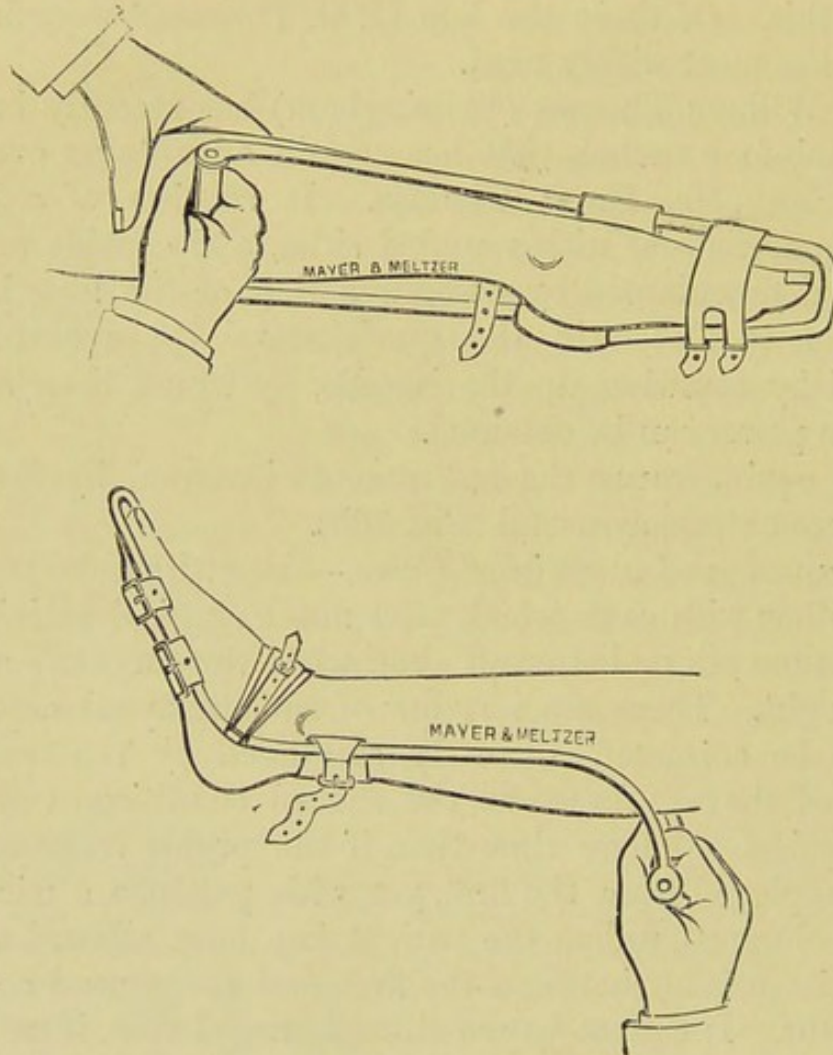


Fig. 139.—Baker's Wrenches for Equino-varus.

Buchanan's operation is preceded by preliminary division of the tendo Achillis, and consists of subcutaneous division of all the soft parts of the inner half of the sole and opening the astragalo-scapoid joint. Of this measure Walsham and Hughes write: "We have performed this operation in a few intractable cases of club-foot which seemed to us suitable. . . . We were disappointed with the result, and in one case had subsequently to remove the astragalus."

Arbuthnot Lane* has extended Buchanan's operation by

* *Lancet*, Aug. 19, 1893.

carrying the section of tissues even further than that recommended by Buchanan.

In criticising this operation, Walsham and Hughes observe: "Relapses . . . do occur. Such cases have come for further treatment to the orthopædic department of St. Bartholomew's Hospital. In these children, in addition to the deformity, there was felt beneath the skin a transverse gap in the muscles, at the bottom of which the tarsal bones could be felt apparently uncovered by soft tissues except the integuments."

*Phelps's Operation.**—The incision is made from a point midway between the tip of the internal malleolus and the scaphoid bone downwards over the inner border of the foot extending across the inner one-third of the sole. The abductor hallucis is seen and divided, exposing the internal plantar nerve and vessels, which are drawn aside. The tendons of the anterior and posterior tibial muscles, the internal lateral and calcaneo-scaphoid ligaments are cut through, exposing the head of the astragalus. The tendo Achillis is divided at the same time. The foot is then forcibly wrenched into the best possible position, and the gaping wound is packed with antiseptic gauze, and the foot is put up in plaster of Paris, the corrected position being maintained till the plaster has set.

Bessel Hagen has modified Phelps's operation by making a longitudinal incision which is afterwards closed by sutures. In order to prevent recontraction of the tissues after Phelps's operation, Arbuthnot Lane† has applied a skin-graft over the wound on the second day; for the same purpose T. H. Kellock‡ transplants a flap from the dorsum of the foot. William Gardner§ (Melbourne) fixes by wiring a wedge-shaped piece of decalcified bone between the astragalus and the scaphoid. Lastly, A. F. Jonas¶ makes a triangular skin-flap with its base corresponding with Phelps's incision, and its apex about the middle of the first metatarsal bone. I

* A. M. Phelps, *N. Y. Med. Record*, Sept. 24, 1881.

† Arbuthnot Lane, *Lancet*, Aug. 19, 1893.

‡ T. H. Kellock, *Ibid.*, March 30, 1893.

§ William Gardner (quoted by Tubby), *Australian Med. Journ.*, Sept., 1893.

¶ A. F. Jonas, "Annals of Surgery," April, 1899.

have only performed Phelps's operation in one case—a child aged three years, upon whom many tenotomies, etc., had been done before the patient came into my hands. The result was no better than might have been obtained by gradual methods. It may be that only bad results of this

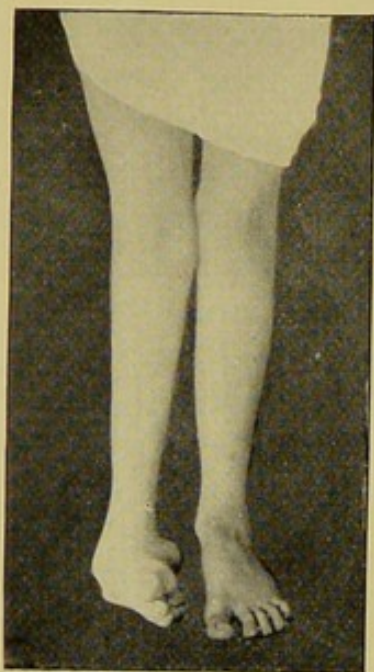


Fig. 140. — Congenital Talipes Equino - varus in a Boy aged nine years.

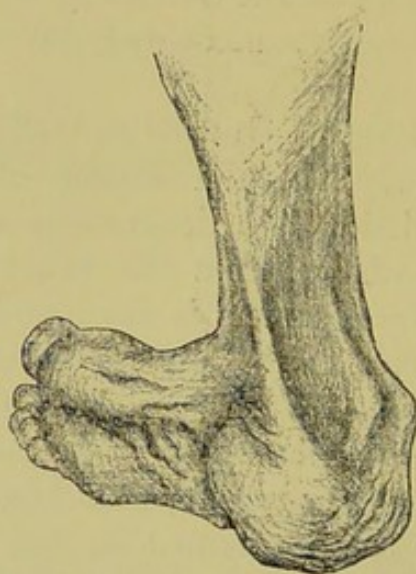


Fig. 141.—Sole of the Foot in the same Case (Fig. 140).

operation have come to my notice, but from what I have seen I can only condemn it as unnecessary and yielding bad physiological results in infants and young children. Patients who have been allowed to grow up with severe congenital club-foot are to be thought of in a totally different category from those who are brought to the surgeon in their infancy. The skeleton of the foot is no longer chiefly cartilaginous, but bony, and the original deformity of structure has not only been retained but increased by time. The soft ligaments and other soft parts, when once the period of rapid growth is passed, have become less amenable to correction than they were. If the patient is still young and growing, the gradual method of correction should be made to do all that it can before any osteoplastic or other operation is performed. Thus, in the case of a boy aged nine years who had been untreated for severe congenital

equino-varus (Figs. 140 and 141), I divided first the plantar fascia and the adductor pollicis, and after an interval the tibiales tendons below the internal malleolus, the flexor longus digitorum in the leg, and the flexor longus pollicis at the back part of the ball of the toe. The result is shown in Figs. 142 and 143. Here I decided not to do any osteoplastic operation, because the patient was still growing, and by the continuous use of the simple apparatus shown in Fig. 144 the form of the foot would improve still further.

When the bones are still further advanced in ossification, the foot should be corrected as much as possible by tenotomies, wrenching, etc., and then the necessary minimum of osteoplastic correction should be added.

The simplest bone operation is—

Osteotomy of astragalus, which consists in making an in-

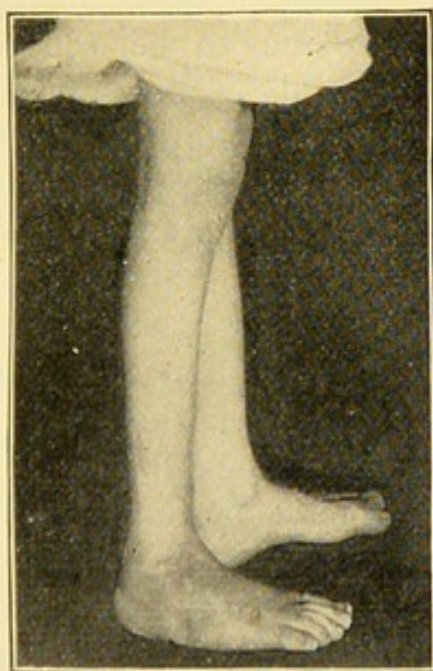


Fig. 142.—Outer aspect of the Foot in the same Case (Fig. 140) after operative treatment.

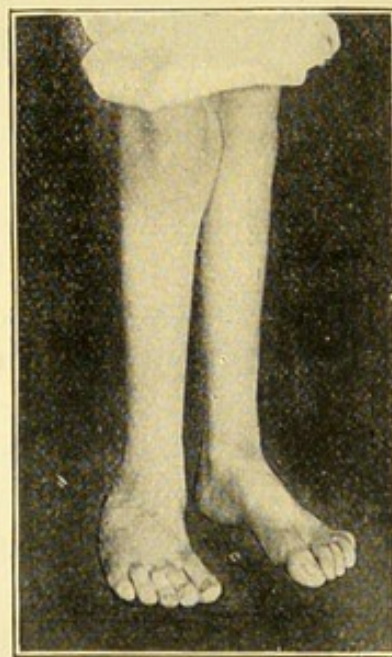


Fig. 143.—Front view of the Foot in the same Case (Fig. 140), showing Residual Adduction due to Alterations in the Shape of the Bones.

cision over the neck of the astragalus, dividing and separating the tissues till the bone appears. The osteotome may be applied either from the inner or the outer side. The difficulty is that of knowing exactly what part of the astragalus is cut by the osteotome.

Of the osteoplastic operations a great variety has been employed from time to time.

Solly,* at Little's suggestion, first removed a wedge from the tarsus. The patient recovered, but the operation was not

a great success owing to the defective apparatus for maintaining the foot in the corrected position.

Lund† removed the astragalus; Davy‡ the cuboid bone; Davies-Colley§ a wedge of the tarsus, irrespective of joints, etc.

Two of these osteoplastic operations appear to me to be especially useful. They are those of Bradford and Fitzgerald. The indications

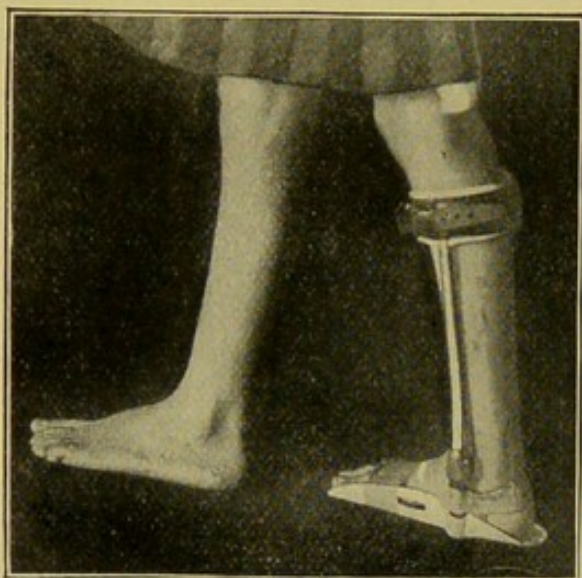


Fig. 144.—Metal Sole-plate applied to the Foot, to be worn inside the Boot.

in each case must be carefully studied before any operation is selected.

Bradford's|| operation is thus described by its inventor: "After complete stretching or division by tenotomy, force, or open incision of the contracted tissue on the inner and under side of the foot, tendons, ligaments, and fasciæ, if it is found that the front of the foot cannot be brought to a perfectly corrected or over-corrected position, an incision should be made on the outer side of the foot, passing from behind the external malleolus forward and downward. The incision should be a curved one, and the chief convexity should be at the forward part of the os calcis. This incision should reach to the bone, and should expose the peroneal tendons. These can either be drawn to the side or divided, to be stitched later. The upper portion of the incision should reach behind the external malleolus, and should extend far enough up to allow sufficient retraction of the flap to give room for the

* Adams's "Club-Foot."

‡ *Lancet*, Feb. 14th, 1888.

† Lund, *Brit. Med. Jour.*, Oct. 19th, 1892. § *Med. Chir. Trans.*, 1877.

|| E. H. Bradford, *Trans. American Orthopæd. Assoc.*, 1897

osteotomy. After the bone has been reached, the periosteum divided and pushed aside, an osteotome should be inserted sufficiently far back to remove a sufficient amount of bone. The direction of the insertion of the osteotome should be such as to allow the placing of the cuboid, after the bone has been removed, to a normal position. . . . It is of importance that the front plane of the bone after the wedge has been removed should be in the direction of the normal facet of the front of the os calcis. . . . The foot should be fixed in an over-corrected position by plaster bandages. . . . Whether the operation should be done in connection with an osteotomy of the neck of the astragalus . . . is a matter of judgment in each case. . . . It is desirable that a walking appliance should be used for six months following the operation."

*Fitzgerald's Operation.** — The limb is exsanguinated. The tendo Achillis, the tibiales tendons, abductor hallucis, plantar fascia, and other resistant soft parts are divided. An osteotome is introduced through an incision behind the calcaneo-cuboid articulation. The neck of the astragalus is divided, then the scaphoid is "freely broken up" with the osteotome, and the os calcis is divided obliquely immediately behind the posterior astragalo-calcaneal joint. The foot is forcibly moulded into shape, wrapped in a thick envelope of cotton-wool, and placed upon a special splint (Fig. 145).

Acquired Talipes Equinus.—The causes of talipes equinus are very varied. Among them (1) infantile paralysis must be given the first place, though many other affections may serve to produce it: for example, (2) pseudo-hypertrophic

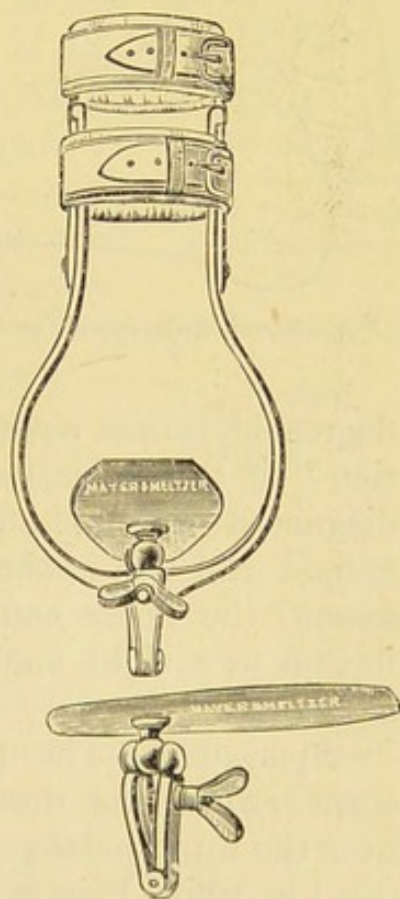


Fig. 145.—Fitzgerald's Splint.

* Fitzgerald, "A New Procedure for the Cure of Club-foot"; Melbourne, 1889.

paralysis, Friedreich's ataxy, and other myotrophic affections; (3) peripheral neuritis; (4) spastic paralysis. (5) Talipes equinus may arise as a reflex arthritic contracture in osteoarthritis, gout, and rheumatism; (6) in long maintenance of the foot in the plantar-flexed position,* as from faulty splinting after injuries to the leg or near the ankle-joint or in long illnesses from pressure of the bed-clothes; (7) from injuries to the extensor muscles or their tendons; (8)

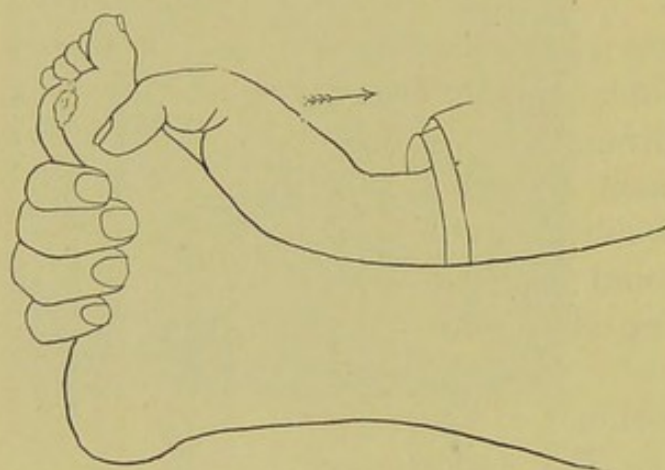


Fig. 146.—Right-angled Contraction of the Ankle.

from scars, *e.g.*, due to burns; (9) compensatory, *e.g.*, from the habit of walking on the toes adopted by persons who have one leg shorter than the other; (10) from disease or ankylosis of the ankle-joint.

Method of Examination. — The slightest recognised

degree of talipes equinus is termed "right-angled contraction" of the ankle, or "non-deforming club-foot." This is diagnosed by making the patient sit down and fully extend the knee, the surgeon then ascertaining to what extent the ankle can be flexed; if, as in Fig. 146, only flexion to a right angle is possible, 20° of talipes equinus is present.

Symptoms.—The patient usually complains of painful corns, either over the head of the first metatarsal bones or over the interphalangeal joints of the toes, which are "clawed" (*see* Fig. 103). Pain is also frequently present about the ankle, and also sometimes radiating up the leg. Pes cavus is often present as well as clawing of the toes.

In more severe talipes equinus due to *infantile paralysis* affecting the muscles of the leg, not only is there plantar flexion at the ankle-joint, but also at the transverse tarsal joint. Adams has pointed out that this *cavus* part of the

* I have observed several cases of talipes equinus which could only be traced to the habit of wearing very high-heeled shoes.

deformity may be more marked than the *equinus*. When this is the case, the elevation of the heel, may at first sight convey the impression that the ankle-joint is plantar-flexed more than is really the case. Since from the form of the articulating surfaces of the calcaneo-cuboid joint flexion there is accompanied by some inversion to a slight degree, the latter enters naturally into the severer degrees of talipes equinus, without, however, giving the foot the decided inversion that characterises equino-varus.

In most instances of severe acquired equinus, the patient walks on the ball of the toes, or, in other words, on the heads of the metatarsal bones. When the paralysis of muscles is very extensive, the fore part of the foot is greatly plantar-flexed, so that the patient walks on the dorsal aspect of the toes and sometimes of the metatarsus.

If a case of paralytic equino-varus of average severity is allowed to go on without treatment, the condition becomes much aggravated, and correction proportionately more difficult. The difficulty of correction is not to be gauged by the degree of the deformity, but by the rigidity of the parts. Thus, in some cases of pronounced deformity, and of old standing, there is but little rigidity owing to nearly all muscular power having been lost. From the completeness of the paralysis of the muscles, the foot assumes the form shown in Fig. 147, whilst if any power at all remains in the extensor muscles, they oppose the tendency to flexion of the toes, and the position assumed is that shown in Fig. 148. From the prognostic point of view, the latter of these two conditions is far the more hopeful, since by tenotomy,

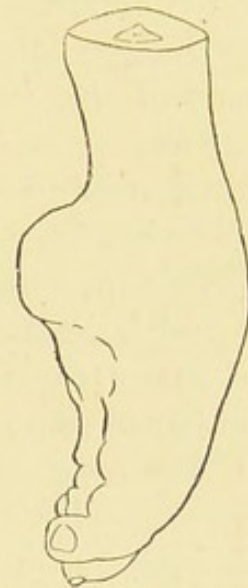

Fig. 147.—Paralytic Talipes Equinus with Total Paralysis of Extensors.

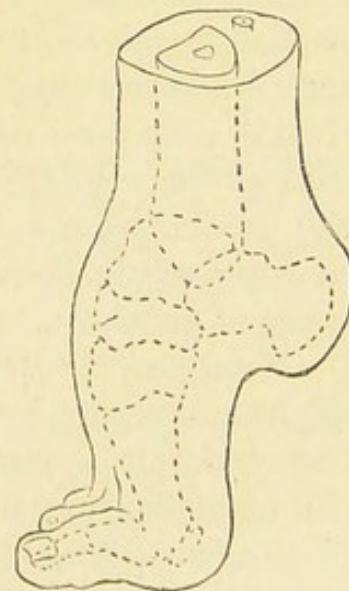


Fig. 148. —Paralytic Talipes Equinus from Partial Paralysis of Extensors, the Outlines of the Bones being indicated.

wrenching, and gradual correction, a good result is always to be obtained, and relapse is preventible by the use of simple instruments. Besides the equinus deformity, there are often secondary deformities present: of these the chief are hollow-ness of the foot, or *pes cavus*, and *clawing of the toes*.

Pes or talipes cavus is due to an increase in the longitudinal arching of the foot. In cases of equinus of long standing there is almost invariably some cavus present. The same conditions may arise independently of talipes equinus, and hence it will be described separately (*see p. 191*). In the treatment of many cases of talipes equinus, this complication is more obstinate than the original deformity.

Clawing of the Toes in Talipes Equinus and Equinovarus.—This condition has already been referred to. The clawing may be observed in the great toe alone, or all the toes may be affected. The first metatarso-phalangeal joint is dorsiflexed, and the two inter-phalangeal joints are plantar-flexed. This deformity can only arise when the anterior muscles retain a certain degree of power. The plantar-flexion of the ankle-joint separates the points of attachment of the extensors of the toes, and hence these muscles, being unable from partial paralysis to counterbalance the action of the calf-muscles in drawing up the heel, only succeed in drawing their digital insertions nearer to their origin from the fibula. The greater the amount of the power left in the extensor muscles, the greater, as a rule, is the amount of clawing of the toes; in other words, the deformity is most marked in the slighter cases of paralysis.

Anatomical Changes in the Bones in Talipes Equinus.—In slight and recent cases but little anatomical change is to be observed. In severe cases of long standing all the bones of the tarsus become modified in form to suit the altered shape of the foot. The general appearance of the bones in a severe case is indicated in Fig. 148, from the late E. J. Chance.* Some of the more practically important points are given by Chance as follows:—

The os calcis at first sight appears to be but little changed in its form, yet upon closer inspection you will observe that the articular surface for the os cuboides is directed obliquely downwards and

* Chance, "Bodily Deformities," 1862.

backwards, instead of perpendicularly downwards, a change in direction to correspond with the abnormal angle at which they are articulated together; while at the upper part of the articular surface there is situated an unnatural overhanging crest which would have afforded a very serious obstacle to the restoration of the joint into a proper position had the case been subjected to treatment.

The proofs of the existence of an altered relative position in the os calcis are, however, much more numerous than I have mentioned, for independent of its approximation and attachment to the scaphoid previously noticed, we find it almost in contact with the upper extremity of the fifth metatarsal bone; and upon its upper surface we observe an adventitious cartilaginous facet, which it is quite evident had abnormally articulated with the tibia.

Proceeding to the next bone, viz. the astragalus, we find it greatly modified in its general form, and its articulating surfaces changed, both in shape and direction; for example, the upper articulating surface—viz. that for the tibia—is evidently situated more posteriorly than it ought to be, and it is diminished in its size by a portion equivalent to the false articulating facet observed upon the os calcis: while the anterior articulating surface, for the scaphoid, looks directly downwards instead of forwards, and is supported on a neck which is both thickened and curved downwards in a corresponding direction.

The cuboid bone is absent; it is, however, evident that it had undergone a considerable modification in its form.

The scaphoid and cuneiform bones may be regarded as natural, with the exception of the posterior surface of the scaphoid, which is to articulate with the altered anterior articulating surface of the astragalus.

Passing from the tarsus to the metatarso-phalangeal articulations, we there observe that the head of each of the metatarsal bones has its articulating surface carried much farther back than usual, and that each articulating surface is surmounted by a thick crest, which juts against a corresponding crest developed upon the upper part of each of the first phalanges.

Walsham and Hughes found in their specimens that the posterior-articular facet of the cuboid was reduced to half its size, its upper part not being in contact with the os calcis.

On the whole, the alterations are not so marked as in severe congenital cases. The altered relationship of the bones to each other is a fixation and extension of the physiological position of extreme plantar flexion, combined with slight pressure deformities of the bones themselves. In recent cases of even severe equinus the foot can be immediately restored to its normal form on section of the tendo Achillis, showing that no change in the form of bones has as yet occurred. Besides being

elevated, the tuberosity of the os calcis is, according to Walsham and Hughes, drawn towards the fibular side of the leg, so that the posterior part of the os calcis lies behind the fibula and the tibio-fibular articulation. On the upper surface behind the posterior facet are two abnormal facets, one for the external malleolus, one for articulation with the posterior and external part of the trochlear surface of the tibia. The cuboidal articular surface is altered.

The *ligaments* are elongated on the dorsal and contracted

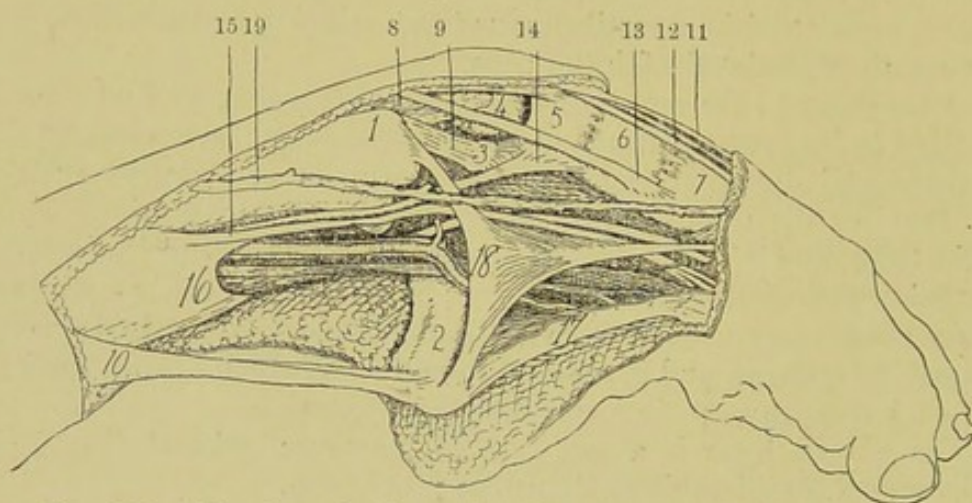


Fig. 149.—Dissection of a Foot affected by Paralytic Talipes Equinus.

- 1, internal malleolus; 2, os calcis; 3, sustentaculum tali; 4, astragalus; 5, scaphoid; 6, internal cuneiform; 7, 1st metatarsal; 8, anterior; 9, internal ligament of ankle; 10, tendo Achillis; 11, extensor longus digitorum; 12, exterior proprius hallucis; 13, tibialis anticus; 14, tibialis posticus; 15, flexor longus digitorum; 16 (on deep layer of fascia), flexor longus hallucis; 17, plantar fascia; 18, internal annular ligament and abductor hallucis; 19, internal saphena vein.

on the plantar aspect of the foot in old-standing cases. The plantar fascia is also contracted. The posterior ligaments of the ankle-joint and the posterior parts of the lateral ligaments are also shortened.

The *muscles* in cases of infantile paralysis are affected according to the extent of the nerve lesion. In some cases the whole of the leg-muscles, both flexors and extensors, are completely degenerated, and on dissection resemble soft, fatty tissue, with, perhaps, a few sparse streaks of healthy muscle-fibre remaining. In such cases the deformity is produced in a passive manner by the weight of the feet in sitting, by that of the bed-clothes at night. In other cases the anterior muscles are alone affected by partial or complete degeneration. In many cases, not of paralytic origin, the only change

observable may be wasting of muscles from disuse. Some of the chief structures concerned are shown in Fig. 149.

The Treatment of Talipes Equinus.—Since the causes and degrees of this condition vary so widely, the surgical measures required for the correction of deformity must be decided upon for each case separately. The treatment of congenital cases has already been considered (p. 168).

Paralytic Cases.—In slight cases, the right-angled contraction, it may sometimes be left to the patient to decide whether the slight lameness and disability experienced in walking are sufficient to warrant the simple operation of section of the tendo Achillis. When, however, in these slight cases, there is a secondary pes cavus and clawing of the toes, or neuralgic pains extending up the leg, or some lateral curvature of the spine, surgical treatment is necessary in order to prevent the development of a seriously crippling condition. The tendo Achillis is divided, and the foot is kept at a right angle with the leg for five or six weeks. The after-treatment depends upon the degree of paralysis in the extensor muscles. If the latter are extensively paralysed, the patient will have to wear a boot with an inside leg-iron and an outside T-strap, the recurrence of the deformity being prevented either by a "back stop" joint or a toe-raising spring.

In young subjects paralytic equinus is usually completely overcome by simple section of the tendo Achillis, and though the divided ends of the tendon may be two or more inches apart when the foot is placed in the corrected position, good union follows. The operation of tendon-lengthening (p. 103), is, in my opinion, to be preferred when the separation of the ends required for complete restoration of the foot is estimated to be more than one inch, and it may be done in any case as a substitute for simple tenotomy. Clawing of the toes usually disappears when the equinus is corrected, but in some cases the tendon of the extensor proprius hallucis requires division. In all cases careful after-treatment is required to prevent relapse (*see* p. 193).

Arthrodesis has been applied where there is paralysis both of the anterior and the posterior muscles, and a resulting flail-like ankle-joint. In my experience this operation is rarely necessary, since by the use of well-designed and well-made

instruments, the patients are assisted as well as by the operation. In old cases, where there are alterations in the bones and ligaments and marked pes cavus, more prolonged treatment is required. Subcutaneous section of the plantar

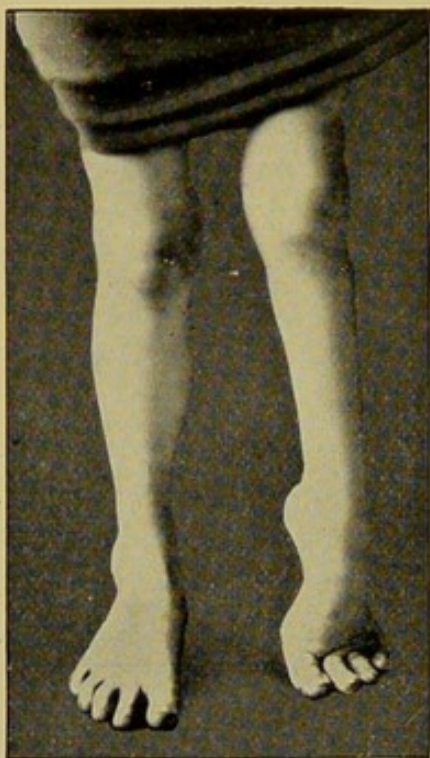


Fig. 150.—Legs and Feet of a Girl aged seven years.

There are marked paralytic equinus and two inches of shortening on the left side.

fascia just in front of its attachment to the os calcis, followed by daily manipulation and wrenching, will be advisable for some weeks preparatory to division of the tendo Achillis. After tenotomy there will be some difficulty in correcting the remaining deformity. Forcible rectification by one of the club-foot stretchers, or gradual correction by a Scarpa's shoe, will then be required. By these means, patiently applied, a good result may be obtained even in unpromising cases. Tarsal osteotomy and tarsectomy are, in my opinion, not justifiable in talipes equinus.

In many paralytic cases there is, combined with talipes equinus, a shortening of the limb from diminished growth. In such circumstances the equinus serves to

compensate for the shortness of the limb, and the question arises whether it is advisable to correct the equinus (see Fig. 150).

For generations orthopædic surgeons have treated some of these cases by the construction of a boot which will receive the foot in a position of equinus. If the equinus deformity were the whole of this disability, this simple mode of dealing with this combination of great shortening with talipes equinus might always be adopted. But it is to be remembered that in growing subjects with paralytic equinus not only the nutrition of the more or less damaged muscles on the front of the leg, but also of the sound muscles of the calf and of the bones of the leg, is interfered with by the loss of function in the part. In such cases the

relative shortening of the leg is still farther increased by the persistence of the equinus, and it has been observed that after correction of the deformity the difference in the growth-rate in the limbs has ceased or diminished. Thus, even where an equinus serves to compensate for a short leg, it is usually desirable to correct it during the period of growth. In adults in similar circumstances, when a fair amount of power remains in the muscles of the leg and progression is effected without discomfort, and the wasting of the remaining muscles is neither very marked nor progressive, the case may be treated by a proper boot without operation.

The treatment of spastic cases will be considered on p. 322

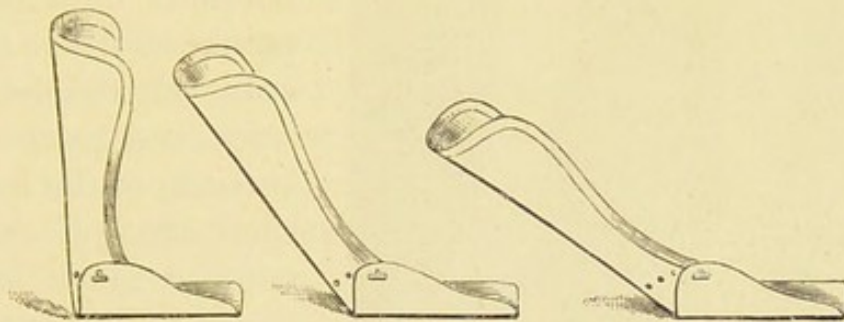


Fig. 151.—Little's Night-shoe. (*Noble Smith.*)

Deformity due to overgrowth of the tibia, disease of the ankle-joint, or loss of tissue in the neighbourhood of the ankle, must be dealt with according to the nature of the case. Supra-malleolar osteotomy of the tibia, or even amputation, may be required in certain cases.

After-treatment.—In paralytic and also in spastic cases it is not sufficient to correct the deformity, but the patient must be made to wear by day an apparatus of which an ordinary boot forms a part, and at night a simple padded tin splint or "night-shoe" (Fig. 151), in order to prevent a return of the deformity. It is the surgeon's duty to see that the boot and irons are of proper construction, and of as great a degree of lightness as is compatible with the requirements of each case. In most cases a single inside iron with a back-stop joint or a spring is sufficient (*see* Fig. 48). In cases where the extent of the paralysis gives the joint a flail-like character there should be an outside as well as an inside iron. When the patient is desirous of getting about before the end of the process of gradual correction that is necessary in inveterate

cases, a fixed rack-joint at the ankle may be substituted. Talipes of paralytic origin is so frequently combined with paralysis of the muscles acting on the hip- and knee-joint that walking instruments attached to a pelvic band may be required. The improvement in the nutrition of the leg and

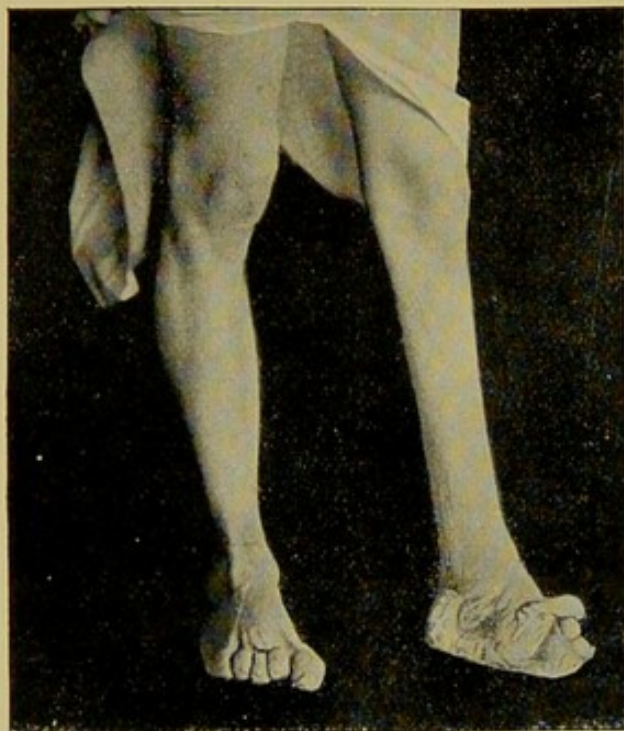


Fig. 152.—Paralytic Talipes Equino-varus.

This case was successfully treated by section of the plantar fascia and the tibialis posticus and subsequent plastic elongation of the tendo Achillis.

foot, always observed when function is restored, should be aided by regular massage and manipulation.

Paralytic Talipes Varus. — When the peronei muscles are paralysed, their opponents, the tibiales, contract and produce inversions of the foot. In such cases, if there is not too much adipose tissue in the part, the tense tendon of the tibialis porticus can be seen rounding the bend of the internal malleolus.

Treatment.—Division of the tendons of the contracted muscles combined with instrumental treatment—inside iron and outside T-strap—is required.

Paralytic Talipes Equino-varus.—This is a common deformity; in a marked case the position of the affected foot is shown in Fig. 152.

The treatment is a combination of that for equinus and varus (*q.v.*). In old-standing cases which have developed in infancy and have been left untreated for many years, alterations in the shape of the tarsal bones occur, and render complete restoration of the normal form of the foot a matter of some difficulty. But in most cases a good functional result is obtained without recourse to severe osteoplastic operations.

Talipes Cavus.—Talipes, or pes cavus,* has already been mentioned in connection with other affections of the foot.

Symptoms.—The degree of arching of the foot varies within normal limits, so that what constitutes talipes cavus, *i.e.* a pathological increase in the arching of the foot, in one may be normal in another individual. In the more marked degrees the footprint is altered; in such cases the outer border of the foot between the ball of the toes does not touch the ground, and so the middle part of the normal footprint is wanting. Pain in the instep and painful corns usually cause the patient to seek advice.

Anatomy.—In the early stages the deformity is the expression of an increased flexion at the transverse tarsal joint with hyper-extension of the metacarpo-phalangeal and flexion at the inter-phalangeal joints. Later, adaptive shortening of the plantar muscles and fasciæ occurs, and finally changes in the bones arise, produced by modified growth or by pressure effects from walking upon the ball of the toes.

The chief conditions in which talipes cavus occurs may be enumerated.

1. *Congenital.* (a) *Uncomplicated.*—Certain individuals are born with an abnormally high longitudinal arch in the foot, apart from any talipes equino-varus. Hoffa notes that such cases tend to be hereditary. (b) *Complicated*, as in cases of congenital equino-varus, when the talipes cavus is due to plantar flexion of the transverse tarsal and other joints from alteration in growth due to pressure.

2. *Acquired.* (a) *Uncomplicated.*—Certain cases of talipes cavus that develop after birth are independent of any contracture of the muscles of the calf. They are commonly attributed to paralysis of the extensor brevis digitorum, or

* Mr. R. Fisher, who is followed in this by Mr. Tubby, has suggested the advisability of dividing cases of talipes cavus into two categories: "The term talipes arcuatus is applicable to this raising of the arch of the foot when the heel and the balls of the toes are in a horizontal plane. If the balls of the toes fall below the level of the heel, and the arch is at the same time increased, then the condition known as talipes plantaris is present" (Tubby, "Orthopædic Surgery," p. 351). Seeing that the cause of the heel not reaching the ground is usually talipes equinus, to which the hollowing of the foot is secondary, it seems to me that this subdivision is rather misleading. Fisher's term, "talipes plantaris," might serviceably replace that of talipes cavus; but, as the latter is so well established, there is a strong reason for its retention.

the interossei. (b) Complicated. In paralytic equinus (Fig. 148) and equino-varus. Even the slighter degrees of equinus due to paresis of the extensor muscles, sometimes observed after febrile affections, may give rise to talipes cavus associated with clawed toes. The exact manner in which pes cavus arises in cases of paralytic equinus has not been satisfactorily explained. It is of practical importance to remember that in the early period of these associated deformities mere section of the tendo Achillis and correction of the talipes equinus also corrects the cavus and the clawing of the toes; the two latter malpositions would thus appear in some manner to be secondary to the equinus. Duchenne's hypothesis, that clawed toes and pes cavus are due to paralysis of the interossei, does not hold good for the majority of cases, at any rate, for both these deformities may be present when the interossei are intact.*

3. In paralytic calcaneus and calcaneo-valgus the talipes cavus observed in these conditions is due rather to the altered positions of the os calcis, which tends to become placed vertically, whilst the fore part of the foot drops, bringing the heads of the metatarsals on the same level with the tuberosity of the os calcis.

4. In spastic conditions, such as in post-hemiplegic spasm, spastic paralysis, and in the early stages of Friedreich's disease, etc. A suggestive argument on the occurrence of talipes cavus in these conditions has been advanced by Dr. James Collier,† who has confirmed Baginsky's observation that in certain nerve affections the flexion of the toes upon the metatarsus, which, save in the earliest infancy, is the initial movement of the normal plantar reflex, is replaced by extension of the toes upon the metatarsus.

Dr. Collier observes: "I have examined a large number of cases of hemiplegia and paraplegia of long duration with spastic lower extremities, and have found in all of them which showed an extensor response in the plantar reflex, a tendency to that position of the foot known as pes cavus." And again, "I have also had the opportunity of examining four cases of early

* Redard, "Orthopaedic Surgery," p. 839.

† James Collier, "An Investigation upon the Plantar Reflex, etc.," *Brain*, 1899, p. 71.

Friedreich's disease with commencing pes cavus. In all these cases the earliest sign of deformity was retraction of the great toe, and the second noticeable event was spasm of the tibialis posticus and peroneus longus muscles, as evidenced by the constant standing out of their tendons behind the internal and external malleoli respectively." In some of these con-

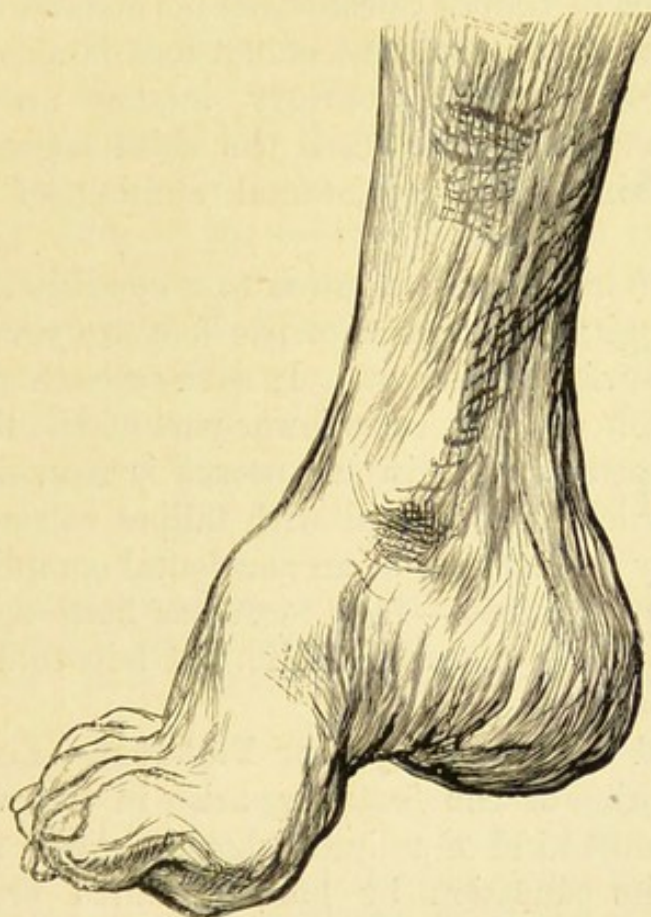


Fig. 153.—Talipes Cavus. (*Clutton: Treves's "System of Surgery."*)

ditions again the talipes cavus and clawing of the toes disappear when the foot is placed at right angles to the leg (*see* above, Fig. 103, p. 135), and it must be confessed that much work is yet to be done before the subject can be regarded as definitely cleared up.

Treatment.—This has already been touched upon in various places; here it is only necessary to summarise.

If there is a primary condition, such as talipes equinus or calcaneus, this should be first removed. It may then be found that the secondary condition has been cured. If this is not the case, gradual correction by means of a metal sole-plate with a strap over the instep, and slits with tapes to

hold down the toes, may be required either alone or after section of the plantar fascia flexor and extensor tendons, etc. In severe cases, in which the ligaments and bones are altered in form, repeated wrenchings or the application of one of the club-foot "stretchers" (Fig. 125) may prove of use.

Congenital Flat-foot.—At birth, as mentioned above, a certain degree of talipes calcaneus is normal, and it might be added that a certain amount of flat-foot is also normal, for the arches of the foot in early infancy are but feebly developed, and it is only when the child begins to use the feet in walking that the normal arching of the foot is evolved.

Küstner * has drawn attention to a condition in which at birth the longitudinal arches of the foot are reversed so that the plantar surface is convex. In such cases there is a depression in the soft parts over the lower part of the tibia, showing that a cramped position in the uterus is responsible for the condition which is combined with talipes calcaneo-valgus of which it may be regarded as an accidental complication.

Infantile Flat-foot.—This term has been applied to the condition in which the arch of the foot fails to develop when a child begins to walk.

Acquired Talipes Valgus or Flat-foot.—Fixation of the everted position of the foot may arise in very various ways. The commonest kind of talipes valgus is known as *static flat-foot*, from its causation by long-continued pressure, as in standing. Some authors use the term "spurious valgus" to designate acquired talipes valgus, but since the alteration in the form of the foot is essentially the same as that observed in congenital and paralytic cases (see pp. 158, 161), it is, in my opinion, a somewhat confusing distinction.

In *osteo-arthritic* and *rachitic* cases, though the weight of the body is the determining cause, as in the simpler cases, there is an osteopathic predisposing cause.

Congenital and *paralytic* talipes valgus have already been referred to.

Rheumatic Flat-foot is observed after some cases of rheumatic fever, and is marked by more effusion than ordinary cases of flat-foot.

* Quoted by Hoffa, *loc. cit.*, p. 680.

Gonorrhœal and post-scarlatinal rheumatism may produce similar effects.

In *Charcot's disease* sudden effusion into the tarsal joints may result in the same deformity.

Traumatic Flat-foot.—After injuries, such as crushing of the foot, falls from a height, and other injuries, obstinate flat-foot may remain. The everted position seen after cases of badly united Pott's fracture, also come under this heading.

Spasmodic Flat-foot or Spasmodic Talipes Valgus.—Spasmodic contraction of the peronei, whether of reflex or central origin, apart from paralysis of the opposing muscles, may result in the everted position of the foot being assumed. Some hysterical cases come under this heading.

This affection may be illustrated by a typical case. The condition in this instance was, in my opinion, of a hysterical character, though moral treatment and all measures short of tenotomy of the peronei longus and brevis proved ineffectual.

A housemaid, aged seventeen years, admitted into the North-West London Hospital, September 15, 1898.

Family History: Both parents healthy; five brothers and sisters healthy.

Previous Illness: Nil.

Present Complaint: A year ago, whilst going upstairs, patient felt a sudden pain in left knee and foot. She lay in bed for three days, and then went home and kept the foot at rest for three months. Pain continued, so patient became an out-patient at Chichester, and used liniment and a pad in the boot.

Condition on Admission: The left sole touches the ground all over in walking; arch is quite obliterated. Scaphoid bone touches the ground when patient is standing; the foot is everted. Patient suffers pain at night.

The right foot is in good condition.

September 22, 1898: Gas and ether administered. Patient's foot was then wrenched into good position; the foot was put up in plaster of Paris in a position with the sole much inverted.

October 24: As the eversion of the foot has returned to a certain degree, the peroneus longus and brevis were divided just above the external malleolus. (Gas was administered.)

October 26: It was noticed that the peroneus tertius is well developed and active. A boot with a pad sole inside and an external iron was provided, and patient discharged November 1.

There was no further tendency to recurrence of the deformity.

Static Flat-foot arises from prolonged standing, and is met with in young subjects whose occupation obliges them to stand for long periods of time. A predisposing cause is a long, narrow foot. In school children about the age of puberty who have this condition, it is generally possible to get a history of their having been delicate in infancy, and in

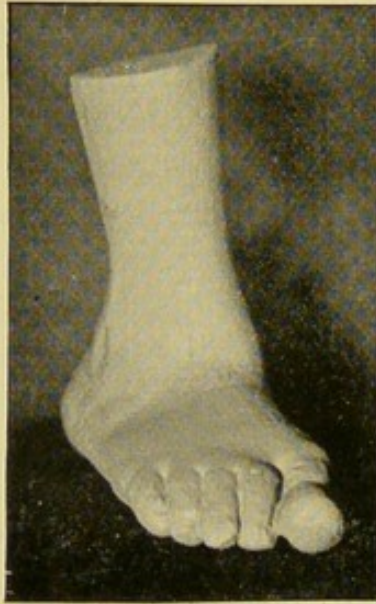


Fig. 154. — Flat-foot seen from the front and outer aspect.

(From a cast in the City of London Orthopaedic Hospital.)

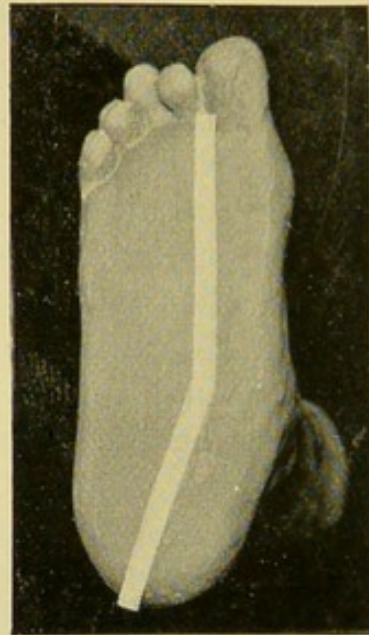


Fig. 155.—The Sole of the Foot with Strips of Paper pasted on to show the Degree of Abduction of the Fore Part of the Foot.

many are found the marks of infantile rickets in the shape of slight bow-legs or knock-knee, and thus such cases merge into the rachitic group. In the many porters, bakers, cooks, etc., who suffer from flat-foot, one often finds a general anæmic condition accompanied by coldness and hyperidrotic feet, so that here again a condition of malnutrition of bones and ligaments is present in addition to the fatigue of excessive standing. To Lorenz* belongs the credit of having shown that in the production of ordinary flat-foot there is something more concerned than muscular fatigue. All such cases are included with the static group in which there is no pronounced disease such as obvious rickets or rheumatoid arthritis present. When the production of flat-foot by the weight of the body is

* Lorenz, "Die Lehre vom erworbenen Plattfusse," 1883.

examined, the first condition to consider is the usual posture of those who have to stand for long periods together. This has been termed by Annandale "the attitude of rest" (see Fig. 7, p. 16). If such an attitude is persisted in too long, it will become a fixed position from adaptive growth of the ligaments and bones themselves, and thus the first stage of flat-foot and knock-knee will ensue, and continuance of the position will, when the nutrition of the tissues is impaired, go on to the establishment of graver degrees of deformity. If a definite disease affecting bones and periosteum or ligaments is present, the progress of the affection is more rapid and the onset of bone deformity is earlier and more marked.

In some traumatic conditions, *e.g.*, after Pott's fracture, there remains an eversion of the whole foot which aids in the production of flat-foot. In paralytic cases the counter-balancing effect of muscles is removed.

Symptoms.—The characters of an ordinary case of static flat-foot of average degree of severity are well marked. The instep is sunken, the hollow that should be found beneath the inner border of the foot when the patient stands up is diminished or lost, and the inner border of the foot may be convex inwards, presenting prominences corresponding to (1) the displaced head of the astragalus and (2) the tuberosity of the scaphoid bone. The skin is often thickened over this projection of the inner border. In most cases the internal malleolus is seen to be unduly prominent, and it appears to be displaced inwards, and below it the foot is bent outwards, *i.e.*, everted (see Fig. 154). This condition in slight cases is often designated as *weak ankles*. The sole of the foot loses its hollow on the inner side, and its fore part deviates outwards so that a line drawn from the posterior border of the foot forwards through the middle of the heel (Meyer's line) would pass to the inner side of the great toe instead of along its centre (see Fig. 155).

In severe cases the weight of the patient in walking is borne entirely by the inner edge of the feet, the outer edge being so far everted that it does not touch the ground. By the sinking of the longitudinal arches the foot is elongated. The sole of the foot has an ungraceful, flattened appearance,

and gives a characteristic impression (*see* Figs. 156 and 157), in which the normal hollow is lost. Hallux valgus is a frequent complication of flat-foot. In every case the degree of rigidity or resistance to manual correction of the deformity should be observed. Other points to be observed are the presence or absence of rickets or osteo-arthritis.

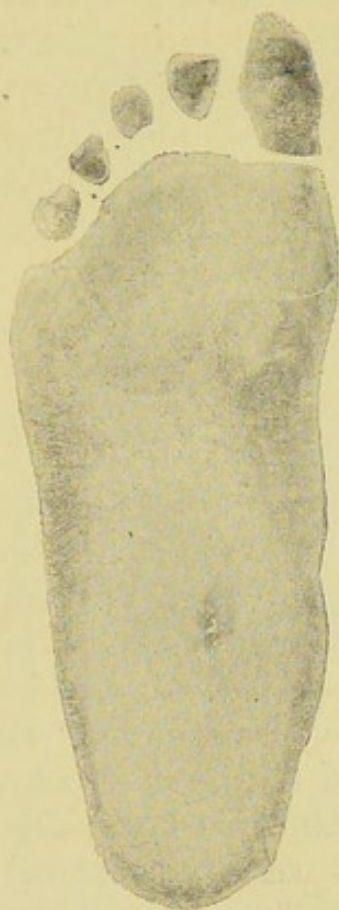


Fig. 156. — Footprint in an average Case of Flat-foot.

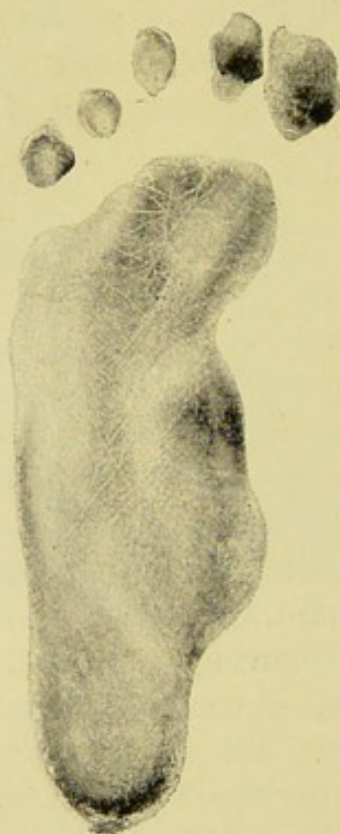

Fig. 157. — Footprint in an extreme Case of Flat-foot.

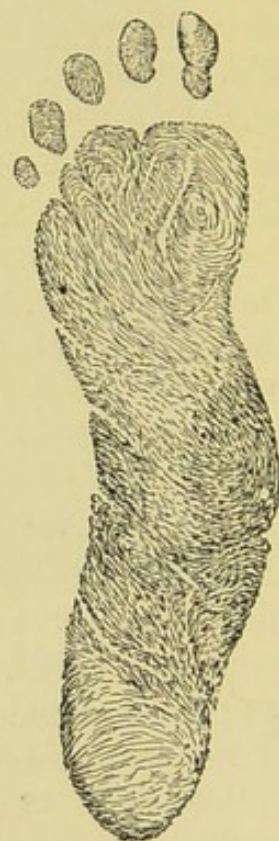


Fig. 158. — Footprint of an extremely narrow Foot, showing a Medium Degree of Flat-foot.

It is in long, narrow feet that the exact nature of the deviation from the normal can best be analysed by clinical examination or by radiographs.

The impression of the sole in such a case of medium degree is also greatly changed from the normal, as is shown in Fig. 158. The bulging on the inner side of the foot is here seen to be pronounced, and to be accompanied by an inbending of the whole of the foot. This footprint is that of a patient whose case may be quoted here:—

A girl, aged ten years, came under my care for lameness and painful feet. For the age and size of the patient the feet were remarkably long; they also showed an advanced condition of flat-foot, the whole of the inner border of the foot touching the ground when the patient stood up. The foot, naturally a long one, was still further

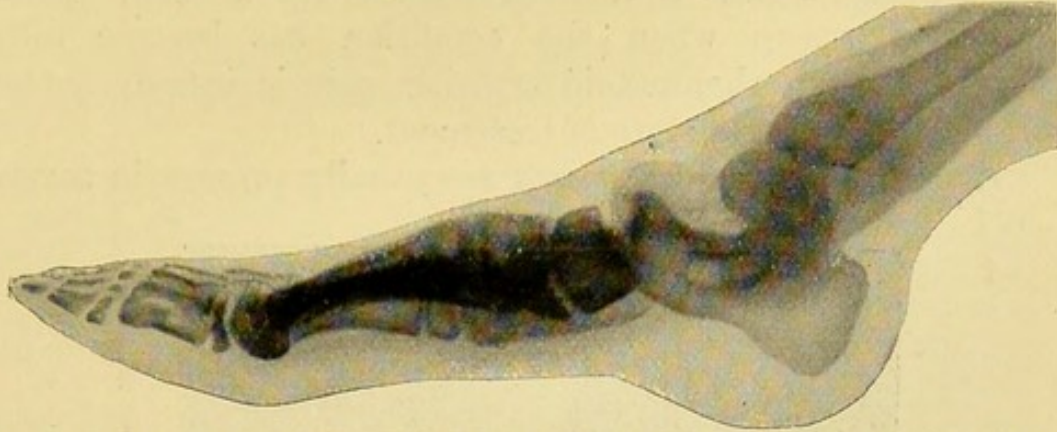

Fig. 159.—Radiograph of a Right Foot showing a Medium Degree of Flat-foot, viewed laterally.

The scaphoid is sunk below the head of the astragalus, which shows but faintly.

lengthened by the sinking of the longitudinal arches. The footprint, reproduced on a reduced scale in Fig. 158, measured $8\frac{3}{10}$ in. from front to back. Both feet were similarly altered in form and since they showed the condition uncomplicated by hallux valgus, &c., I thought radiographs

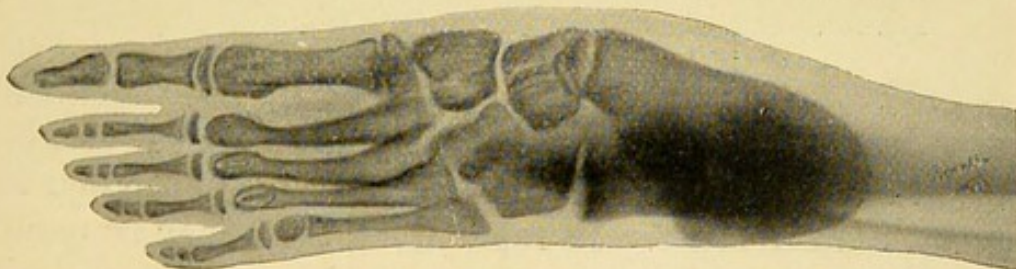


Fig. 160.—Radiograph of the Left Foot in the same Case (Fig. 159), showing Abduction of the Scaphoid upon the Astragalus.

would be useful in demonstrating the exact changes in the relative position of the bones. The radiographs (reproduced on a smaller scale in Figs. 159 and 160), were made for me by Messrs. Coxeter, the patient sitting down with the sole of the left foot placed flat on the plate whilst that of the right rested on its outer edge.

In a severer case of the same kind (Fig. 161), the footprint (Fig. 157) is even more abnormal, and the radiograph (Fig. 162) shows that the astragalus is placed with its head vertically downwards, just as it is in the severest forms of talipes equinus, but the os calcis in flat-foot does not follow the displacement

of the astragalus, which is turned inwards as well as downwards.

Pain.—The amount of pain present in flat-foot varies greatly. In the case of children it is usually absent. In most ordinary cases it is a marked feature for a time, but it frequently ceases when the condition has become fully established. In rheumatoid arthritis, pain is usually severe and may continue in spite of treatment.

Tenderness.—Tender points are usually present in severe

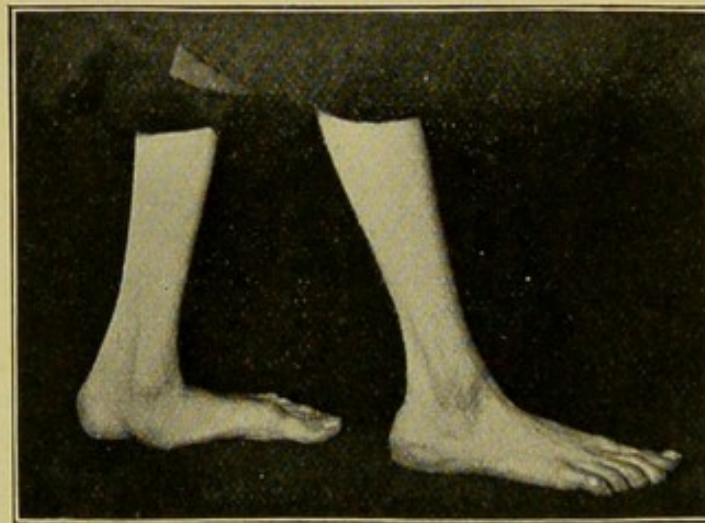


Fig. 161.—Photograph of the Feet of a Girl aged fourteen years.
The left foot shows an extreme degree of flat-foot.

cases. Their usual situations are over the astragalo-scaphoid joint, in front of the malleoli, and at the bases of the first and fifth metatarsal bones. In rapid cases there may be redness and swelling of the foot. In rheumatoid cases there may be effusion into the sheaths of the tibial muscles and the peronei, and swelling about the ankles.

The gait of one suffering from flat-foot is characteristic. The toes are directed outwards more than is normal; in walking the foot is placed on the ground in a flat, inelastic manner. In standing, the outer border of the foot may be actually raised from the ground.

Anatomy.—Some of the anatomical features have already been alluded to in connection with the radiographs. The altered positions in a marked and typical case, are chiefly as follows:—

1. The ankle-joint is extended or, to use a more correct

term, *i.e.* one less opposed to the term used to designate the movements of the wrists—plantar-flexed.

2. At the beginning of the displacement the foot is in the position variously termed “*eversion*,” “*pronation*,” or “*abduction*.” This is thus described by Arbuthnot Lane:—*

“Observe this foot in a position of abduction or of rest, and you see the head of the astragalus projecting inwards, and the calcaneo-scaphoid

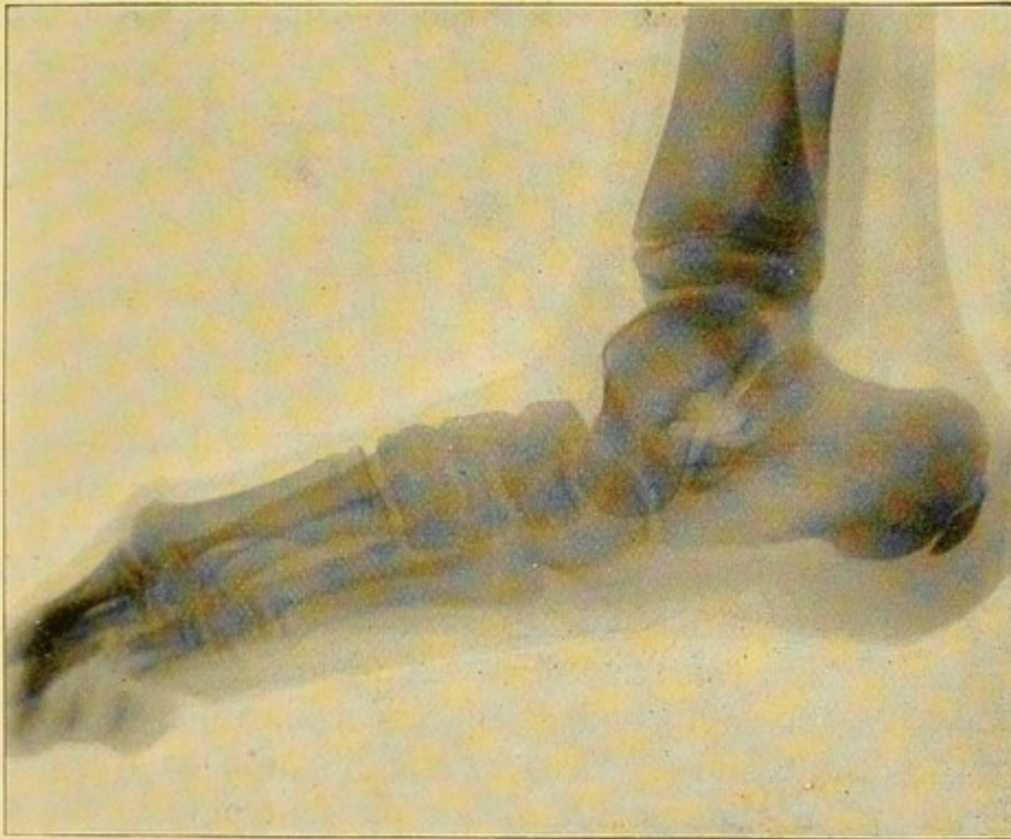


Fig. 162.—Radiograph of the Left Foot in the same Case (Fig. 161).

The astragalus is placed vertically as in severe talipes equinus, and its head is below the level of the scaphoid. (*Coxeter and Son.*)

capsule elongated to its utmost capacity; the scaphoid articulates with the outer segment of the head of the astragalus, while its tuberosity is separated by a considerable interval from the sustentaculum tali; the long and short plantar ligaments are arranged in their longest diameters, and the articular surfaces of the os calcis and cuboid are in accurate apposition, the cuneiform and metatarsal bones all being directed forwards and outwards.”

Later the astragalus becomes subluxated inwards from the os calcis, and the calcaneo-cuboid joint becomes subluxated dorsally, and in severe cases the metatarsal bone becomes

* Arbuthnot Lane, “Clinical Lectures.”

adducted. The sum of the changes results in giving to the longitudinal direction of the foot the aspect shown in the diagram (Fig. 163).

In the last stages the form of the foot is completely wrecked. The head of the astragalus reaches the lowest part of the fallen internal arch, and the inferior calcaneo-scaphoid ligament lies stretched out beneath it. In the worst cases, the outer arch is not only destroyed, but the lower end of the fibula forms a new joint with the os calcis, and the bones become gravely deformed.

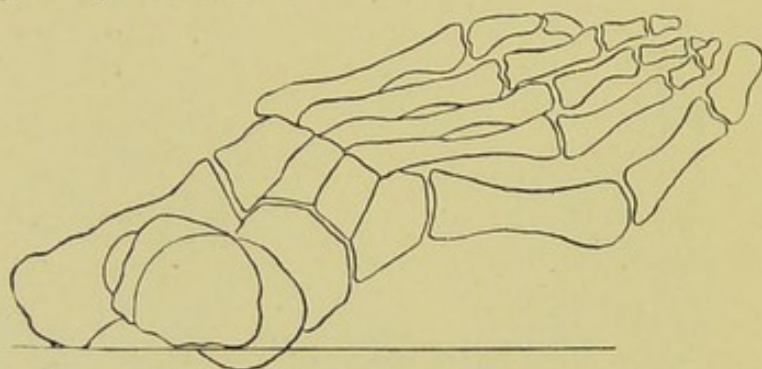


Fig. 163.—Diagram of the Bones in Extreme Flat-foot. (Lorenz.)

Degrees of Flat-foot.—It is usual and convenient to divide cases of flat-foot into several degrees.

1st degree, or "weak ankles." The deformity appears when the patient stands up, and disappears again when the weight is taken from the foot. Even in standing, the deformity disappears when the patient stands on tip-toe with the toes turned in (Ellis's exercise).

2nd degree. The deformity does not disappear when the patient sits down, nor when the patient attempts the tip-toe exercise, but if the surgeon takes the foot in his two hands, the fingers of one grasping the outer aspect of the heel, whilst its thumb rests on the head of the astragalus, the other hand holding the fore part of the foot and exerting steady force in the direction of inversion of the foot, the deformity is overcome. This is sometimes painful to the patient.

3rd degree. The deformity is usually reducible by manipulation under an anæsthetic. The resistance may be due to inflammatory stiffness, or adhesions, or to spasm of the peronei. In the last-named case the deformity reappears when the anæsthetic passes off.

4th degree—"osseous" flat-foot. In severe cases where the patients have been allowed to grow up without proper treatment, and in inflammatory conditions such as osteo-arthritis, the articulating surfaces have become changed and the deformity is extreme, the sole being convex downwards and the fore part of the foot raised from the ground. Such a foot can only be corrected by osteo-plastic operation.

Treatment.—The general condition of the patient must be carefully examined and suitable treatment adopted. Flat-foot is chiefly an affection of childhood and adolescence, though in some of its forms it may arise in adult life. Many of the younger patients are anæmic and require a liberal diet and iron. In rickets a sufficient supply of raw albuminous food and plenty of fat are required, with cod-liver oil and iron. It is to be remembered that the sterilisation of food required by the prophylaxis against tuberculosis favours the development of rickets. Slight cases of rachitic flat-foot will disappear in the course of a month from the beginning of a proper dietary. In this place one other practical point may be mentioned; that is, the value of iodide of potassium in moderate doses in flat-foot due to rheumatoid arthritis; in many cases the severe pain of this condition is at once relieved.

Local Treatment (Prophylactic).—1. Rest. — Rickety children and weakly adolescents who suffer from flat-foot should never stand and never walk when fatigued. The tone of the muscles should be improved by friction and douching, as well as by generous diet and tonics. Passive corrective movements should be practised daily. In order to secure complete rest in severe cases it is advisable to apply an internal splint similar to that used for Dupuytren's fracture, or, as some surgeons advise, to apply strapping or a plaster of Paris bandage.

2. Exercises.—When the muscular tone is sufficiently good, active exercises, namely, circumduction of the feet against resistance, walking on the outer border of the feet (Roth), rising on tip-toe with the feet slightly pointed inwards and the feet inverted (Ellis), should be gone through for three minutes twice a day.

It is somewhat difficult to teach young children to perform exercises. The majority of these early cases are, however,

rachitic, and will get well without exercises if proper general treatment is adopted, together with passive exercises.

Ellis's tip-toe exercise is the most generally useful. The patient should stand with the toes turned slightly inwards, rise in regular rhythm to tip-toe and return at once to the original position. It is not advisable for the patient to attempt to stand or walk on tip-toe, since, in doing this, strain is put upon the plantar ligaments, which may yield still farther. In certain cases, even after careful instruction, this exercise may make matters worse; it is, in my opinion, only to be advised when a fair amount of muscular vigour is present.

In performing the resisted inward circumduction exercise, the knee should be extended and the leg crossed over the opposite knee and rotated in (Walsham). Patients can readily be taught to replace the resistance of the surgeon's hand by a rubber cord with a suitable attachment.

The Outer-edge Exercise.—The patient stands as in Ellis's exercise, with the feet close together. At first it is sufficient for the patient to exercise for five minutes at a time by rhythmically rising on the outer edge of the feet and at once returning to the original position. When sufficient improvement has been obtained, he may be allowed to walk about on the outer edges of the feet. The exercises are best done with bare feet.

Foot-clothing in Flat-foot.—In every case of flat-foot it is of the greatest importance to see that the patient has roomy socks or stockings and properly-shaped boots, as described under the heading of "Hallux Valgus" (p. 120). Hallux valgus may play an important part in the production of flat-foot. The outward displacement of the first phalanx of the great toe entails some outward shifting of the tendon of the flexor longus hallucis and so weakens the support of the inner arch of the foot. The frequent combination of flat-foot with hallux valgus supports this view.

Mechanical Treatment.—The chief objects of mechanical treatment of flat-foot are to place and maintain the foot in an inverted position. A well-fashioned laced boot will itself tend to maintain the normal form of the foot and to prevent extreme eversion. In slight cases of flat-foot merely raising the inner

border of the heel and sole will suffice to arrest the progress of the deformity. This result is obtained by the slight inversion of the foot effected by the raising of the inner border. In inversion the astragalus is placed more nearly vertically above the os calcis, and hence, in standing, the action of gravity has less effect in tending to cause the astragalus to move forwards and inwards over the os calcis; it causes the outer border of the foot to bear its proper share of the weight of the body. The inner border of the foot may be raised either by thickening the sole internally or by the insertion of a pad into the boot. In some cases, in order to prevent the "waist" of the boot giving way, it is necessary to prolong the inner part of the heel to join the sole of the boot. These measures suffice only for the mildest cases. When the condition is at all severe, some leverage is required to prevent eversion of the foot. This is best obtained by an outside leg-iron which fits into the socket of an iron plate inserted into the heel and the back part of the sole of the boot. The boot being put on and laced up, the foot is inverted by placing the band at the upper end of the iron in position above the calf of the leg, *i.e.* with its upper edge below the head of the fibula. This leverage action is further maintained by an inside T-strap which encircles the iron above the malleoli* (*see* Fig. 164). The iron may be jointed opposite the ankle, or, when expense is an object, its lower end may be made to work freely in a round socket at the front of the heel, vertically below the malleoli, so avoiding the necessity of having a joint opposite the ankle. The efficacy of this mechanism is greatly increased by the addition of a properly-shaped valgus pad of vulcanised rubber within the boot. In a great number of cases this apparatus alone suffices to correct the deformity,



Fig. 164. — Diagram showing Construction of the Outside Iron, Valgus Pad and T-strap.

* In order that the T-strap may not be dragged backwards and forwards in walking, the boot-iron may be prolonged upwards beyond the ankle-joint, as suggested by Walsham.

and even in an extensive experience of severe cases of static flat-foot I have seldom known it to fail. In private practice, especially in the case of boys at public schools, there is often great objection to the wearing of any visible apparatus. For such cases Muirhead Little's "concealed spring" is of service.

Where hallux valgus is combined with flat-foot, the rubber pads may be fixed to a sole-plate of white metal furnished with a projection to keep the great toe in position. It has been objected to the use of valgus pads that they only act on the inner arch without affecting the outer, which is also depressed. The absolutely good results that I have seen in many cases of severe flat-foot obtained by this method have shown me that if the inner arch is restored the outer follows suit.

The appliances just described have the advantage of allowing the patients to pursue their usual vocations. In some cases laborious work has to be given up for a time in order to obtain a good result. Instead of the rubber pad, some surgeons recommend metal valgus plates. Hoffa recommends the use of Sidney Roberts's steel sole-plates, made upon a plaster model of the normally arched foot. They are slightly convex and cover the whole of the sole and the inner border of the foot. The metal is thin enough to retain a certain amount of spring. A serious drawback to steel plates is that they perish rapidly by rust. This can be to some extent provided against by giving them two coats of paint and covering them with leather. Whitman's metal valgus plates are shown in Fig. 165. They can be made of aluminium bronze to the shape of a plaster cast of the corrected foot. In some cases this apparatus answers admirably; in others, although made with equal care, it causes intolerable pain.

Elastic traction may be employed instead of solid pads. For this purpose Walsham recommends a modification of Nyrop's shoe: "In a properly-shaped boot provided with an outside leg-iron and calf-piece a rubber band is fixed so as to exercise elastic tension on the sunken arch. The band is firmly secured to the upper leather inside the boot, along the outer border of the sole, in such a position that, as

it crosses under the sole of the foot, its centre corresponds to the middle of the calcaneo-scapoid ligament. It is then carried up on the inner side of the foot to just above the top of the boot, and thence through the medium of a leather strap and buckle is secured to the calf-piece. A soft valgus pad can be slid over the rubber strap, and be so adjusted that it corresponds, when in position, to the situation of the yielding arch."*

Gradual Correction.—

In severe cases of flat-foot accompanied by marked rigidity and spasm the patient cannot be treated by ambulant methods throughout. For a time it is necessary for him to take to his bed or couch so that no weight is borne by the feet. After a period of rest, the foot should be wrenched and put up either on a suitable Scarpa's shoe or in plaster of Paris. Where the

former can be obtained, it is preferable, since it allows of daily improvement being obtained. The best form of shoe is that designed by Adams. It has a divided sole-plate, the front part of which allows of gradual inversion of the foot and carries a valgus pad at its upper and external angle. If plaster bandages are used, they should not be put on too thickly, and no additional plaster should be rubbed in, or much time is lost in changing the bandages. As an aid to the relaxation of the tissues of the foot, the hot-air bath (*see* p. 41) may be used for from one-half to three-quarters of an hour at a temperature of from 250° to 300° F. By persistent and continuous

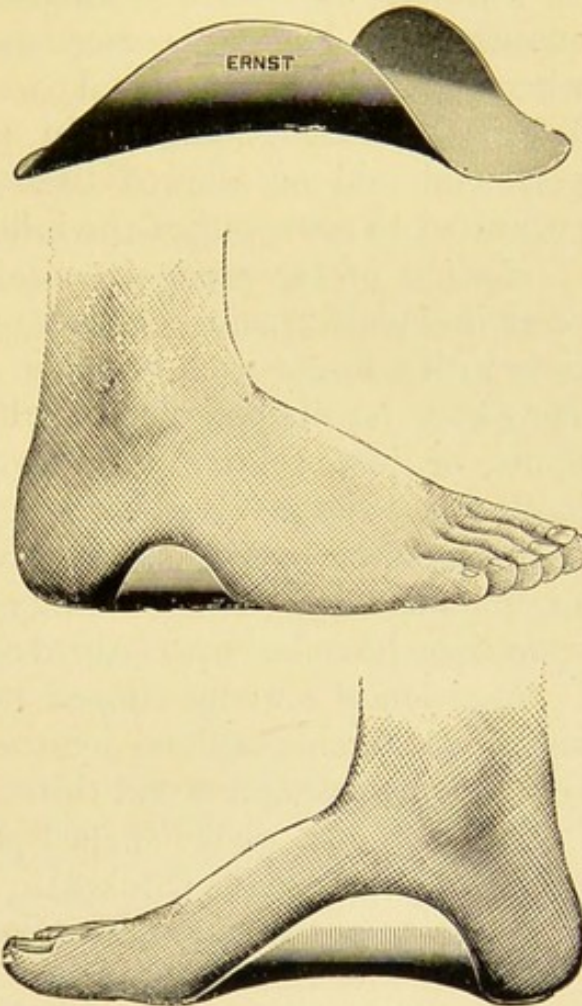


Fig. 165.—Whitman's Metal Valgus Plate.

* Walsham and Hughes, *loc. cit.*, p. 9.

treatment of this kind even unpromising cases are completely corrected. After correction has been obtained, the patient must be fitted with a valgus boot, as described above, or the deformed condition will return.

Forcible Correction.—This should be done under full anæsthesia. Manual correction is usually sufficient and where it fails instrumental wrenching usually fails also. When the foot is put up in plaster after wrenching, the plaster should be allowed time to set before the patient is permitted to come out of the influence of the anæsthetic.

Section of the peronei tendons may be required in some cases in which spasm of these muscles persists after correction, with a long period of rest in plaster of Paris or in a splint. They may be divided together behind the lower end of the fibula, or just below the external malleolus, or separately, just beyond the peroneal tubercle.

Osteoplastic operations are required in the severest cases accompanied by great deformity of bones. Many different operations have been performed:—

Excision of a wedge-shaped portion of the tarsus, including the astragalo-scaphoid joint and establishing an ankylosis between the astragalus and the scaphoid (Ogston).

Excision of a wedge-shaped portion (base inwards) of the neck of the astragalus (Stokes).

Excision of the astragalus (Vogt).

Excision of the scaphoid.

Linear osteotomy of the tibia and fibula above the ankle and fixing the limb with the foot inverted. The resulting position is the converse of the flat-foot which results from a badly-set Pott's fracture (Trendelenburg).

Transplantation of the posterior part of the os calcis (Gleich).

Ogston's and Stokes's operations deserve more detailed notice.

Ogston's Operation.—After the usual preparations, the foot is rendered bloodless by Esmarch's band placed upon its outer side and a longitudinal incision is made over the astragalo-scaphoid joint on the inner border of the foot. All the soft parts are divided down to the bones and the joint is opened. The opening is enlarged by cutting across the ligaments for

half an inch on each side of the longitudinal incision. With a half-inch chisel the articular cartilage and a thin layer of bone are removed from the head of the astragalus, leaving the latter convex. The articular surface of the scaphoid is then prepared in a similar way so that a concave surface is left. After washing away the bony fragments an attempt is made to reduce the deformity. If this is successful the bones are fixed together by two ivory pegs, which are driven, first, through the scaphoid and onward into the astragalus half an inch from one another. If after freshening the articular surfaces as described above, it should be still found impossible to reduce the deformity more bone must be sliced off from the lower part of the head of the astragalus until the scaphoid can be brought into its proper position.

After the fragments have been pegged together the skin incision is closed and the foot put up in the corrected position. Ogston obtained very favourable results. In the only case in which I have employed the operation it was completely successful.

Illustrative Case.—The patient was a man aged thirty, who had been invalided out of the army some years previously for flat-foot that developed suddenly during an attack of rheumatism. The foot had remained painful and deformed from this time. During the subsequent nine years the patient was unable to continue long in any situation on account of the pain he suffered. When he came to my out-patient department there was a pronounced condition of flat-foot combined with hallux retracts and clawing of the outer toes. The patient was admitted and several attempts were made to correct the flat-foot deformity by manual and instrumental wrenching under an anæsthetic, the foot being put in plaster in the intervals between each operation. No improvement was obtained, and I decided to perform Ogston's operation. After making the incision and opening the astragalo-scaphoid joint, the scaphoid was seen to be displaced downwards to a considerable extent. The articular surfaces were freshened and the deformity was corrected. The ivory pegs did not appear to hold the bones together very firmly, so that I thought it wise to stitch the divided ligaments and periosteum together with silkworm gut. The foot was put up in plaster and left untouched for two months. The result is entirely satisfactory, the foot being in good position and the patient has been able to walk about absolutely free from pain for the past twelve months. During his stay in hospital this patient suffered from several attacks of rheumatic iritis. (See Figs. 101 and 102, p. 134.)

Mr. Openshaw* has published a series of cases in which he dispensed with the step of pegging the bones together after Ogston's operation.

Hare's Modification of Ogston's Operation.—Hare exposes the astragalo-scaphoid joint through a 2-inch incision parallel to the tibialis-anticus tendon, and removes with a chisel portions of the astragalus and scaphoid, so that when the deformity is corrected the freshened surfaces of bone dovetail into each other. Additional security is obtained by stitching together the ligaments and periosteum.

Stokes's Operation.—An incision about one inch and a half is made over the most prominent part of the head of the astragalus, below and parallel to the tendon of the tibialis posticus. A second incision is made at right angles to the first, and joining it a little behind the astragalo-scaphoid joint; the two triangular flaps are dissected back exposing the bone. A wedge-shaped piece is next removed from the head and neck of the astragalus, and the foot is put up in plaster.

Transverse Flat-foot.—The transverse arch of the foot may give way alone, or more commonly in conjunction with the longitudinal arch in ordinary flat-foot. When the transverse arch alone is affected the foot has a peculiar broadened and flattened appearance in its anterior portion. The transverse arch is due to the form of the cuboid and three cuneiform bones behind and of the metatarsals in front.

Causes.—The deformity occurs in both sexes and at any age. Young women in my experience are the more commonly affected. In many cases the patient is subject to attacks of osteo-arthritis.

Symptoms.—Corns are frequently present over one or more of the heads of the 2nd, 3rd, and 4th metatarsal bones, evidence of their having become depressed towards the sole of the foot. On making an impression of the sole of the foot it is found that the usual appearance is changed; there is a bulging instead of there being a receding angle behind the part of the ball of the toes that corresponds to the heads of the second and third metatarsal bones. The symptom that usually causes the patient to seek medical advice is severe pain of a neuralgic character, starting near the heads of the

* Openshaw, *Clinical Journal*, Dec. 12, 1894.

metatarsal bones and radiating upwards. To this symptom the term *metatarsalgia* has been applied and the affection is usually discussed under that heading. But it is right to observe that transverse flat-foot can exist independently of metatarsalgia, which is only a common symptom of the deformity. The sinking of the transverse arch that occasions metatarsalgia is often partial in character, being limited to the downward displacement of the heads of one or two metatarsal bones, most commonly the 4th.

Metatarsalgia.—This symptom is of so characteristic a nature that it merits separate consideration. The affection was first described by Morton of Philadelphia in 1876, and the term “metatarsalgia” was first applied to it by Pollosson of Lyons in 1889.

The amount of pain varies. In the slightest degree of the affection it is only brought on by certain acts and ceases when the act is discontinued. Robert Jones* mentions riding and dancing as common provocatives. There is no tenderness to pressure in such cases.

In other cases the pain follows an injury and improves with rest and mechanical treatment. In the worst cases the pain is intense, arises spontaneously and does not yield to mechanical treatment.

Though the pain more commonly starts opposite the head of the 4th metatarsal bone, this is by no means always the case. Frequently there is tenderness over the 3rd as well as the 4th metatarsal head, and the pain sometimes originates near the 2nd or 5th metatarsal. There usually is a corn over the head of the offending bone or bones.

Causation.—From analysis of a carefully recorded series of cases, Morton concluded that the pain was due to pressure upon branches of the digital nerves between the head of the 4th metatarsal bone and the base of the 1st phalanx of the little toe. He found that the joints he examined were normal, with the exception that in one case there was an abrasion on the head of the 4th metatarsal which might have been caused by pressure of the 1st phalanx of the little toe.

* R. Jones, “Plantar Neuralgia,” *Liverpool Medico-Chirurgical Journal*, January, 1897.

Most subsequent observers agree in thinking that the origin of the mischief is a sinking of the transverse arch of the foot. Thus, E. W. Roughton has described the case of a medical man in whom the transverse arch was reversed, there being a dorsal concavity instead of a convexity opposite the heads of the metatarsal bones. This sinking of the arch would account for increased pressure on the nerves. Packard (quoted by Morton) and L. Guthrie,* from personal observation, concluded that there was a subluxation of one of the metatarso-phalangeal joints, a condition quite compatible with a sunken transverse arch. In marked and typical cases the patient may complain of a corn which is found to be placed over the head of the 4th metatarsal. Tubby† has also made a similar observation and associates the condition with gout.

Diagnosis.—Goldthwait‡ has pointed out that in metatarsalgia the impression of the foot is altered. Dr. Goldthwait has kindly given me permission to reproduce Fig. 166 *a—f* from his article.

In the normal foot there is a sharp re-entering angle where the impression of the ball of the foot joins that made by the outer side, as is shown in Fig. 166, *a* and *b*. Both represent normal feet: Fig. 166, *a*, a foot of the long slender type; Fig. 166, *b*, the other extreme. When the transverse arch is lost, the impression presents an entirely different appearance, as is shown in Fig. 166, *c* and *d*. In place of the re-entering angle the tracing bulges at that point. In both these cases the longitudinal arch is still present.

While it is possible to obtain an impression that is characteristic when the anterior arch is obliterated, this characteristic outline is lost if at the same time the longitudinal arch is destroyed. . . . In the cases where the valgus deformity was not rigid, the impressions to determine the condition of the anterior arch could be taken with the same degree of accuracy as when the longitudinal arch was present (Fig. 166, *e* and *f*).

Treatment.—In the worst form of cases most observers are agreed that nothing short of operative measures is of use. Morton excised the 4th metatarso-phalangeal joint. He describes the operation as follows:—

* Leonard Guthrie, "A Form of Painful Foot," *Lancet*, March 19, 1889.

† Tubby, "Deformities," p. 490.

‡ Joel E. Goldthwait, *Boston Med. and Surg. Journal*, Sept. 6, 1894.

An incision two inches in length was made on the outer edge of the extensor tendon of the fourth toe; the metatarso-phalangeal articulation was then excised; at the same time a portion of the shaft of the metatarsal bone was removed, with a quarter of an inch of the shaft of its associated phalanx.

R. Jones (*loc. cit.*) recommends removal of the head of the offending metatarsal bone through a dorsal incision and division of the extensor and flexor tendons of the toe. The proceeding is thus described:—

After the part has been carefully asepticated, an incision should be made a little over an inch in length, starting above the metatarso-

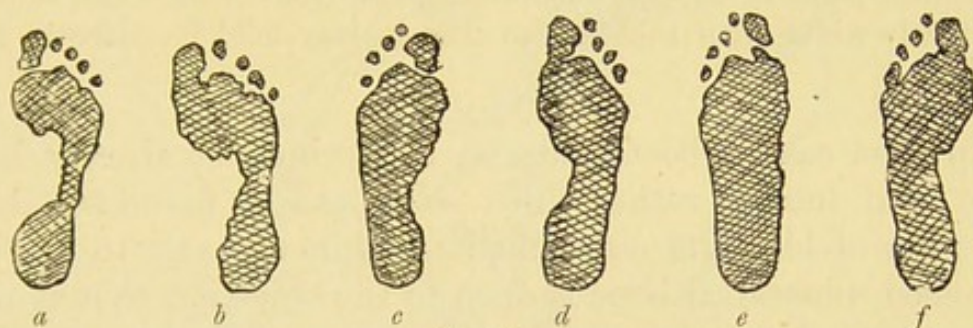


Fig. 166.

a, normal impression of a slender foot; *b*, normal impression of broad foot; *c*, *d*, impressions of feet in transverse flat-foot; *e*, impression of foot with both longitudinal and transverse flat-foot; *f*, impression of the same foot with less pressure on it. (*After Goldthwait.*)

phalangeal joint, and extending over the middle line of the toe. The extensor tendon is divided, the capsule opened, and the head of the metatarsal dissected out by a blunt instrument. With fine bone nippers the head is removed and the flexor tendon below divided. The wound is then stitched and, as a rule, no vessels need securing. The after-treatment consists in keeping the patient in bed for about ten days, with the foot elevated. Massage should then be commenced and the patient, with a bar under the boot, allowed to walk. There is usually nothing to hinder complete recovery in from five to six weeks, when boots such as I have earlier described should be prescribed.

For traumatic cases, rest, hot douching, anodyne application in the early stages, and comfortable boots in the later stages are required.

What is the best form of boot in this affection must be found for each case. If a firm bandage round the instep, *i.e.* round the bases of the metatarsals, relieves the pain, Gibney's plan may be followed.

Gibney* tried a Spanish last that raises the arch of the foot and makes considerable pressure in this region, and found that a boot "built on such a last and laced simply across the instep and left rather free across the ball of the foot, with a modified French heel, would nearly always give relief."

Jones recommends that the sole of the boot should be thickened by half an inch behind the heads of the metatarsal bones. Royal Whitman† recommends a metal support made upon a cast of the foot.

"The front of the brace should be slightly wider than the foot, the plaster being hollowed out just behind the affected joint where the highest point of support should be. The front of the brace should be slightly wider than the foot, so that it may hold its place in the shoe."

In most cases a boot made on the principles already laid down, and having rather thick soles, will be found suitable. The plan of blocking out a depression in the sole to fit the depressed metatarsal bone is open to the objection that it encourages the deformity, and in a case that came to my notice it had been tried without success.

Illustrative Cases.—A gentleman, aged thirty-four. General health good; no history of gout or rheumatism; has severe pain which radiates from the head of the third metatarsal up the outer side of the leg to the thigh. The pain is more severe at some times than at others; it persists often when the boot is removed. It prevents patient from hunting as it is brought on by bearing weight on the foot in the stirrup. The pain has remained practically unchanged for six years, and it has interfered with patient's pursuits. The condition dated from patient getting his boots wet. After the boots had been dried patient noticed a "rise" in them at the region of the ball of the foot. A corn developed at the seat of pain; the latter is not relieved by removal of the corn. I found that the corn had formed over the head of the third metatarsal bone, and that pressure upon it started the pain.

This was one of the more severe type of cases, and I explained to the patient that an operation might be required, but before having recourse to it simpler methods should first be tried. I ordered a properly-shaped pair of boots with stout soles and a thickening of five-tenths inch behind the heads of metatarsals. After giving the boots

* Gibney, "The Non-operative Treatment of Metatarsal Neuralgia," *Amer. Journ. of Nerv. and Mental Dis.*, Sep. 1894, p. 592.

† Royal Whitman, *Trans. Amer. Orthop. Assoc.*, 1898.

a good trial the patient wrote to me saying: "I have had *no discomfort* since you had the piece put on the sole."

Case 2.—A gentleman, aged 35. General health good, but has had "rheumatism"; father gouty. Two years ago when fishing in "waders" patient felt a pain which started inside the base of the little toe and radiated up the outer side of the leg and thigh. Since then the pain has come on periodically. In bicycling, etc., the pain is felt also in the arm. After standing long the patient describes the pain as "excruciating," and

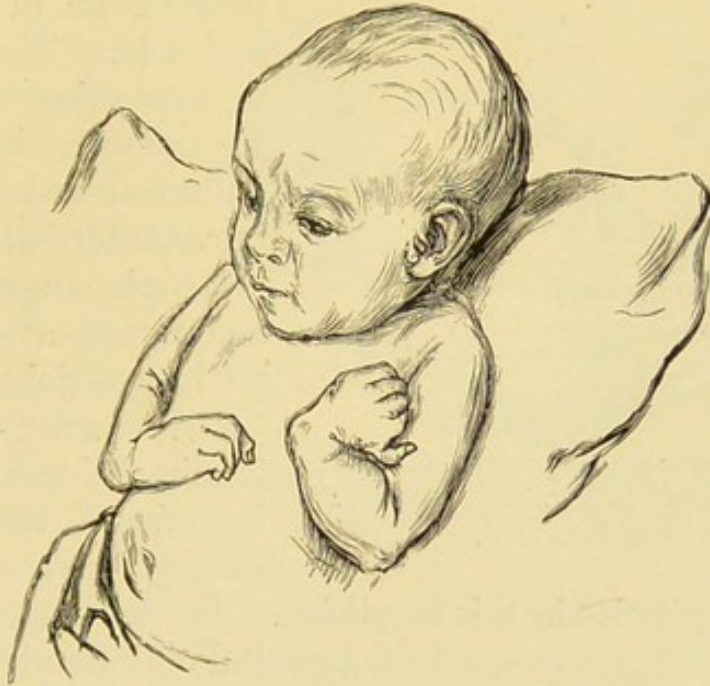


Fig. 167.—Congenital Club-hand. (*Clutton: Treves's "System of Surgery."*)

he says that in the leg it has latterly been constant. On examination I found the second, third and fourth toes were slightly hyper-extended at the metatarso-phalangeal joints, and there was great tenderness behind the head of the fourth metatarsal bone. The same measures that were successful in Case 1 failed to give relief in this instance, so an operation was decided upon, the head of the fourth metatarsal bone being excised, part of the extensor tendon removed, and the flexor tendons divided. The patient's medical man wrote four weeks after operation: "Toe easy, but no movement in it. He [the patient], however, gets about on it very well." I saw the patient four months later. He had remained absolutely free from pain, and the fourth toe had recovered both flexion and extension movements.

Deformities of the Hand.—*Congenital Club-hand.*—A condition analogous to congenital club-foot is met with in the upper extremity. As compared with congenital club-foot the condition is rare. This is accounted for by the earlier and stronger intra-uterine growth of the hand as compared with

the foot, the protection from intra-uterine pressure afforded to the hand by the space between the head and the trunk.

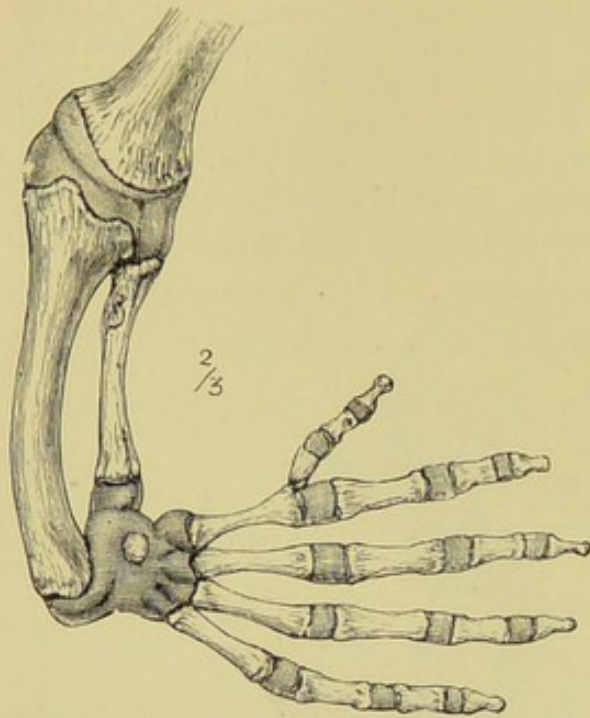


Fig. 168. — Skeleton of the Forearm and Hand in the Case shown in Fig. 167. (Clutton: Treves's "System of Surgery.")

The commonest form of club-hand, apart from grave skeletal defects, is that shown in Figs. 167 and 168. The wrist is in a position of flexion, the thumb is strongly adducted and the digits are extended at the metacarpo-phalangeal joints, and flexed at the interphalangeal joints.

Treatment. — Patient manipulation and splinting from the earliest infancy give the only

satisfactory results in this condition. In the severer cases of congenital club-hand the radius and the thumb are not infrequently suppressed, as is shown in Figs. 169 and 170.

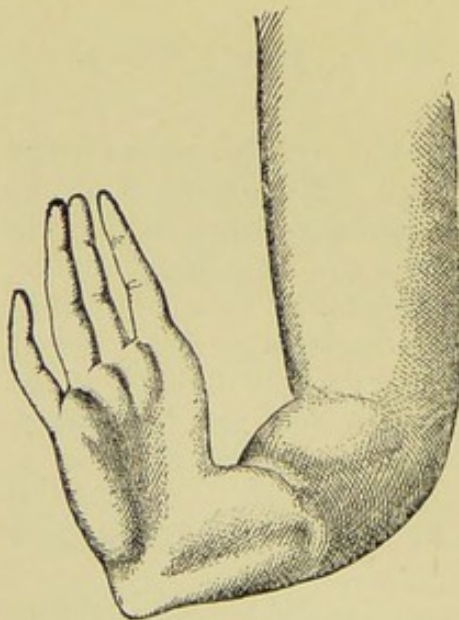


Fig. 169. — Appearance of the Limb in a Case of Congenital Club-hand, with Absence of the Radius and Thumb. (Hoffa.)

Congenital Dislocation of the Wrist.—A few cases have been described by Smith and Mayer. The hand in these cases has been displaced either forwards or backwards; in the former case the hand was placed at a right angle with the forearm, and in the dorsal dislocation at an acute angle. The forearm is shortened. The patients in such cases have been able to use their hands.

Acquired Spontaneous Subluxation of the Wrist.—In this condition the carpus is sub-

luxated forwards, causing undue prominence of the lower ends of the radius and ulna on the posterior aspect of the limb.

Anatomy.—The lower end of the radius is bent towards the palmar aspect, the ligaments of the wrist are lax and the bones are abnormally soft.

Causation.—The affection appears in young subjects between the ages of fifteen and twenty-five. It is attributable to hard, manual labour in a condition of weakness of bone and ligament.

Symptoms.—Apart from the prominence of the lower end of the bones there is some forward displacement of the

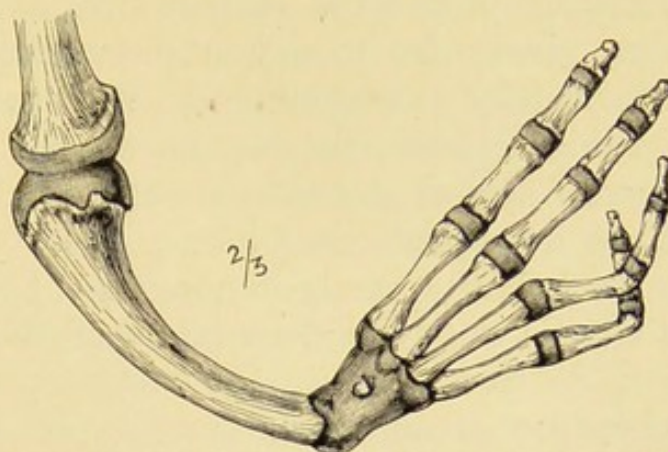


Fig. 170.—The Bones of the Right Hand (Fig. 169).
(Clutton: Treves's "System of Surgery.")

carpus, and marked prominence of the flexor tendons in front of the wrist-joint. The range of both active and passive extension in the joint is diminished, that of flexion is increased. The joint is usually somewhat painful.

Diagnosis.—The pain ceases with the growth of the bones in length, but the deformity is difficult to overcome.

Treatment.—In order to prevent increase of the deformity a support jointed at the wrist and provided with an extending spring is to be recommended.

Paralytic Deformities of the Hand.—The deformities of the hand caused by paralysis of nerves, though they show themselves chiefly by the altered position of the fingers, are really comparable to the paralytic forms of club-foot. The full discussion of the various forms assumed by the hand in different nervous affections belongs mainly to medicine. The surgical considerations apply chiefly to injury of nerve trunks, as the musculo-spiral, the ulnar, and the radial.

Musculo-spiral Paralysis.—The hands assume the position known as "wrist-drop."

When the affection is due to lead-poisoning the supinator longus retains its power. This fact is useful in diagnosis.

"Crutch palsy," from the use of crutches that are either too long or too short, is a paresis from pressure on the musculo-spiral near its commencement.

Paralysis of the ulnar nerve leads to the deformity known as claw-hand, marked by hyper-extension of the metacarpo-phalangeal and flexion at the inter-phalangeal joints giving rise to a very pronounced "clawed" condition described by Duchenne, and attributed by him to paralysis of the interossei muscles, the normal action of which is to produce flexion at the metacarpo-phalangeal and extension at the inter-phalangeal joints.

In infantile paralysis, progressive muscular atrophy, and in spastic paralysis deformities of the hand corresponding to those that occur in the lower extremity from the same causes are encountered.

Treatment.—The surgical treatment of paralytic affections varies according to the cause. Faulty crutches must be laid aside in "crutch palsy," and, if necessary, galvanism and massage employed. In traumatic cases, if all response to galvanism is lost in the muscles to which the nerve is distributed, there should be no delay in performing secondary nerve-suture. Scars, callus, or tumours causing pressure paralysis should be removed. In paralytic and spastic conditions tenotomy may be required. Massage, galvanism, and gymnastics are often of use.

Contractures and Ankylosis of the Wrist and Carpal Joints.—All forms of contracture are met with in the neighbourhood of the wrist.

Many are the results of injury: scars, injuries to tendons, stiffness after fracture at the lower end of the radius, and other injuries that require treatment by fixation. Rheumatic, osteo-arthritic, suppurative and tubercular joint-affections are also of frequent occurrence. Ischæmic contractures have already been considered. When severe disease is present in the wrist and carpal joints, forward dislocation at the wrist frequently occurs.

Treatment.—This, of course, varies with the cause. When the stiffness is the result of inflammatory adhesions, forcible

manipulation, followed by regular gymnastic exercises, is required. In breaking down adhesions, the principles already mentioned under the heading of "bone-setting" are to be observed. Hoffa recommends a preliminary stretching for a week or two on an Esmarch's splint. The method of exercise by a pendulum, introduced by Krukenberg, is particularly suited to inflammatory or traumatic stiffness of the wrist-joint. The necessary apparatus consists of sheaths of plaster of Paris or leather applied to the forearm and hand, and connected by a metal framework, which is jointed opposite the wrist, and is attached to a long pendulum at the upper end of the lower segment. By alterations in the weights attached to the pendulum, and in its length, the degree of passive force exercised by its swinging movement can be regulated, and also the force required for the patient to set the pendulum in motion.

Osseous ankylosis at the wrist seldom requires operative interference, but if there is much deformity from forward displacement at the wrist, excision of the wrist may be performed.

The treatment of deformity from ischæmic degeneration of muscle by division of all the flexor tendons above the wrist has already been mentioned (p. 49). Some years ago I had the pleasure of assisting my colleague, Mr. Chisholm Williams, in operating on a case of this kind by elongation of the flexor tendons above the wrist. The result was very satisfactory. Mr. Raymond Johnson in 1898 showed before the Harveian Society a boy in whom he had treated the deformity by resecting portions of the radius and ulna. In this case there was a failure of repair of the bones.

SECTION III.

DEFORMITIES OF THE LONG BONES OF THE LIMBS.

CONGENITAL deformities of the femur, except in gross monstrosities, are not common.

Spontaneous arrest of growth at the epiphyses of the femur and tibia, at the knee-joint.—In this condition the affected bones lag more and more behind their fellows, and by the time the patient's growth is complete there may be a difference of four inches, or more, in the length of the two limbs. Accompanying the shortening of the bones there is some flexion-contraction of the knee-joint, which appears to be due to a backward curve of the lower end of the femur. The patella stands above its normal level. The movements of the knee-joint are quite free. Nicoladoni, who has published an account of two cases of this condition, refers it to a premature ossification of the epiphyseal cartilages, beginning on the posterior aspect of the limb.

Congenital Absence of the Tibia, Partial or Complete.—Though rare, congenital defects of the tibia are met with from time to time. The condition is usually accompanied by other deformities, of which extreme equino-varus is the most frequent; absence of the astragalus, of the os calcis, of part of the fibula, and of the patella, has been observed in different cases. (Fig. 171.)

Billroth and others have made dissections and have found that in complete absence of the tibia the fibula articulates with the outer condyle of the femur, and the muscles usually attached to the upper end of the tibia are inserted into the capsule of the knee-joint.

Prognosis.—In the course of the patient's growth the deformity becomes more apparent on account of diminished length of the affected limb.

Treatment.—In the first seven or eight years of life all that can be done is to maintain the parts in a position that

approaches the normal as nearly as possible. This is best done by a padded metal splint applied to the outer aspect of the limb, and furnished with a sole-plate for the foot. This treatment must be combined with daily friction, etc.

When the child is sufficiently developed the operation described by Albert may be performed. It consists of implanting the upper end of the fibula into the femur between the two condyles.

In order to give some fixation at the ankle-joint an arthrodesis has been made between the astragalus and the fibula. Bardenhauer successfully split the fibula at its lower end, freshened the lateral surfaces of the astragalus, and implanted the latter in the cleft between the fragments of the fibula.

If the condition has been left untreated during the first years of life, amputation and the use of a prosthetic apparatus are the best resources.

Congenital Defects of the Fibula.—The lower part of, or the entire fibula may be absent at birth. In such cases the foot is in the position of marked valgus, and at the ankle the external malleolus is wanting. If the tibia is intact, the knee-joint may either be normal or the external lateral ligament, the patella, or the crucial ligaments may be wanting, and the little toe is commonly absent, or several of the outer toes, with or without the corresponding metatarsal bones, may be missing.

In many instances of congenital absence of the fibula there is at the lower part of the tibia a sharp bend, with its convexity looking forwards, and on the summit of the bend is a scar-like depression.

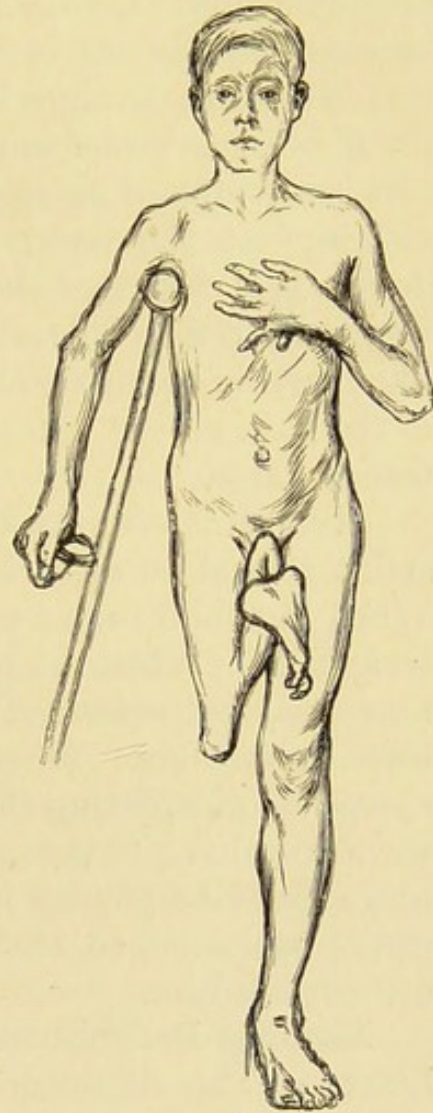

Fig. 171.—Congenital Absence of the Tibia. (Clutton: Treves's "System of Surgery.")

Causation.—Hoffa, who has excised and examined the scar in one of these cases, found its structure was only compatible with its having been caused by pressure from without. He regards it as probably the result of the pressure of an amniotic band. Comparing the marked equino-varus present in cases of absence of the lower part of the tibia with the marked calcaneo-valgus in cases of absence of the lower part of the fibula, it is probable that both defects are the result of the foot being pressed up against the inside of the leg in one case, and against the outer side in the other. In these grave defects it is clear that the deformity must be determined at a very early stage of development. The causation of the scar-like mark is in my opinion the same as that of the thinning of the skin on the outer side of the foot in severe congenital equino-varus.

Treatment.—In the early months of life an internal metal splint should be applied, and the limb rubbed twice a day. When the child begins to attempt to walk, a valgus shoe may be applied. When the patient is two or three years old, osteotomy may be performed in those cases where there is a sharp bend in the tibia. When adult life is reached, Bardenhauer's operation of splitting the lower end of the tibia and forcing the astragalus into the cleft thus made, may be adopted. The foot should be put up in the position of equinus at the end of the operation, so that the shortness of the limb may be compensated for.

Rachitic Deformities of the Long Bones of the Lower Limbs.—The diminished resistance of bone affected by rickets is most frequently evidenced by alterations in the form of the leg bones. The femur and bones of the foot are also very often affected, and no part of the skeleton is exempt. Even when no obvious deformity is produced the disease may be evidenced by diminished growth of the bones in length.

The bending is produced by two forces, acting separately or in conjunction. These are 1, Muscular traction; 2, the weight of the body. The first factor may produce a deformity even before a child has commenced to walk. The more marked curves are formed after the age of one year, and are caused by the weight of the body in walking and

standing. The commonest of these curves is due to a yielding of the whole of the shafts of the tibia and fibula in an outward direction. Not infrequently the tibia and fibula bend forwards, the summit of the curve being at the lower part of the leg, the anterior border of the tibia standing out sharply. The outward general bend of the leg bones is often combined with the forward bend.

A sharp bend convex outward about the meeting of the middle and lower thirds of these bones is also a familiar appearance. When this localised outward bend is unilateral a radiograph will probably show it to have the characters of a green-stick fracture, though no history of injury can be obtained. With the outward curve of the leg bones severe flat-foot may be present.

One of the less common rachitic deformities of the tibia is due to the formation of a backward bend between the upper epiphysis and the shaft. This condition simulates genu recurvatum.

Period of Life.—Most commonly beginning in infancy, before the age of two years, rachitic deformities may make their first appearance about puberty or even later. Genu valgum, for instance, is very frequently first developed between the ages of six and ten years.

The Seat of the Change in the Bones.—The normal physiological growth of the long bones and the changes produced by rickets in the normal structure of bones have already been discussed and only need be mentioned here in connection with the clinical varieties and admixtures of rachitic deformity. These are rendered somewhat difficult of exact definition by reason of the mixture of popular and scientific terms applied to them. Some writers give lists of synonyms for the chief varieties of rachitic deformity of the lower limbs in which popular and scientific terms are given equal prominence.

In some such categories the terms "bow-leg" and genu varum are used as synonymous in meaning. Now the term "bow-leg" is perhaps most commonly applied to a condition in which there is outward bowing of the leg bones without any genu varum in the strict sense, there being no outwardly salient angle at the knee. It will be convenient here to

attempt a definition of the commoner rachitic deformities of the lower limbs. Macewen* observes: "In the normal limb a line drawn from the head of the femur to the middle of the ankle-joint passes through the centre of the

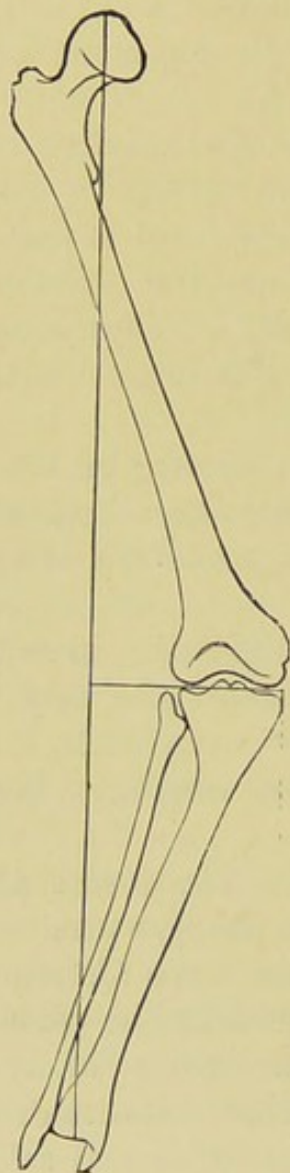


Fig. 172.—Diagram showing the Nature and Degree of Genu Valgum. (Macewen.)

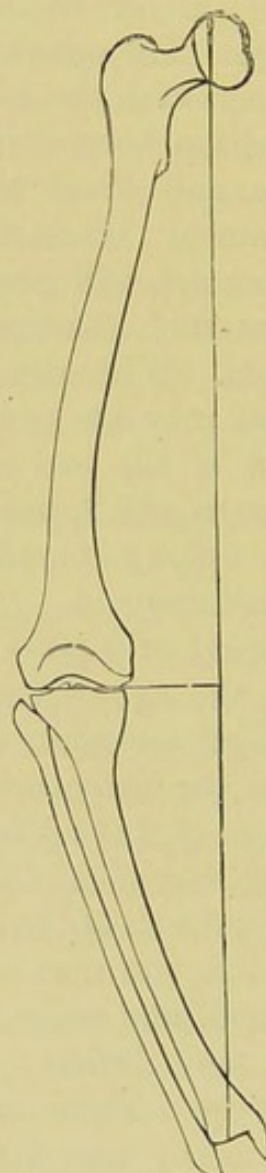


Fig. 173.—Diagram showing the Nature and Degree of Genu Varum. (Macewen.)

knee-joint; in knock-knee the middle of the knee-joint is thrown to the inner side of this line." In genu varum the converse of this holds good, and hence we arrive at the following definitions:—

Genu Valgum is the deformity in which a line drawn

* For the use of Figs. 172, 173 and 174, I have Prof. Macewen's kind permission.

from the head of the femur to the middle of the ankle-joint passes external to the centre of the knee-joint (Fig. 172).

Genu Varum is the converse of *genu valgum*, namely, the deformity in which a line drawn from the head of the femur to the middle of the ankle-joint passes internal to the centre of the knee (Fig. 173).

As an illustration of the confusion caused by the lists of

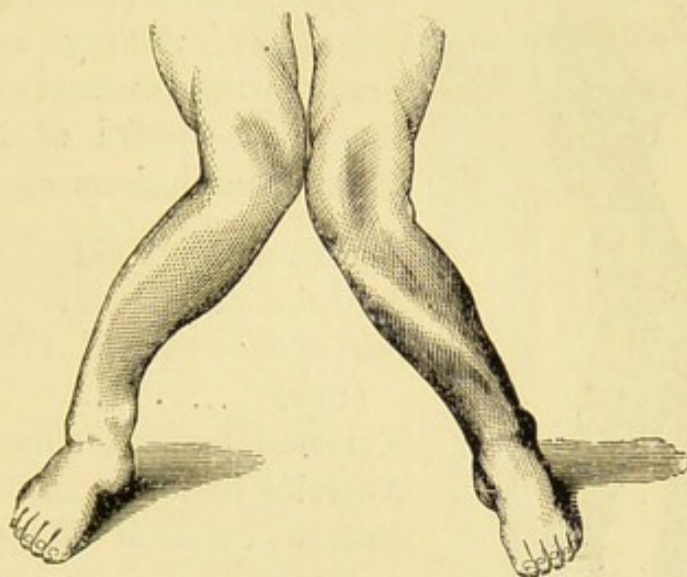


Fig. 174.—Combination of Genu Valgum and External Tibial Curves, or Tibial "Bow-leg." (*Macewen.*)

synonyms already alluded to, the common combination of *genu valgum* with outward bowing of the leg bones may be given (see Fig. 174). In this instance, if "bow-leg" be taken as the equivalent of "*genu varum*," there would be two mutually exclusive conditions, *genu varum* and *genu valgum*, present together in the same limb. Similarly, external femoral curves may be associated with *genu valgum*, as shown in Fig. 175. Both *genu valgum* and *genu varum* may be produced by different anatomical changes, as will be discussed more fully later (p. 226 *et seqq.*; p. 241 *et seqq.*). As far as instrumental treatment is concerned it does not matter whether the anatomical changes are situated at the upper end of the tibia or the lower end of the femur, or in both these situations, but in view of operative treatment which is required in some cases owing to neglect of early treatment, it is advisable to distinguish between *tibial*, *femoral*, and *tibio-femoral* *genu valgum*, or *genu varum*, as

the case may be. Among the commoner rachitic deformities of the long bones of the lower extremity are anterior curves of the femur or tibia; the latter is frequently associated with genu valgum. In severe cases of rickets S-shaped curves of the femur are common.

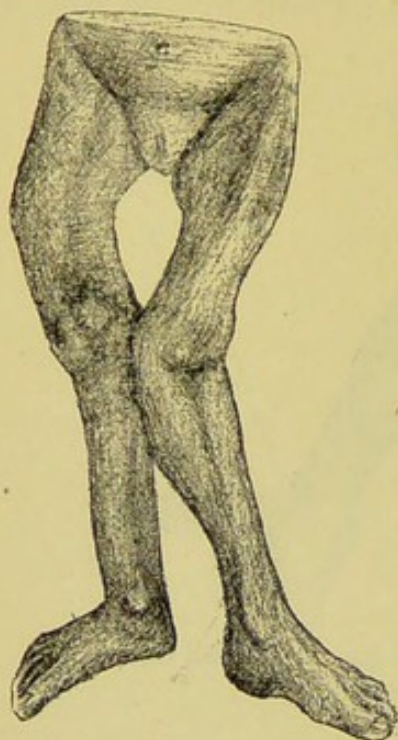


Fig. 175.—External Femoral Curves associated with Genu Valgum.

(From a cast in the Museum of the City of London Orthopaedic Hospital.)

It is necessary to use a somewhat extensive terminology in order to speak with precision of even the commoner rickety curves in the shafts of the bones of the lower limbs. The more useful of the terms and their abbreviations are:—

External tibial curve	...	E. T. C.
Anterior tibial curve	...	A. T. C.
Antero-external tibial		
curve	A.-E. T. C.
External femoral curve	...	E. F. C.
Anterior femoral curve	...	A. F. C.
Antero-external femoral		
curve	A.-E. F. C.

Coxa Vara, a not uncommon rachitic deformity, though it received its designation as late as 1889, is due to an alteration in the direction of the neck of the femur. In its mode of production it is similar to genu varum, *i.e.* it results from an

alteration in the growing bone at the junction of epiphysis and diaphysis.

Another rachitic deformity is termed "*back-knee*," and it depends on a receding angle being formed between the epiphysis and the juxta-epiphyseal parts of the shafts of the femur or tibia near the knee.

Genu Valgum.—*Anatomy.*—In a case of uncomplicated genu valgum of the femoro-tibial type our knowledge of the mode of growth of bones and of the pathological changes in rickets would lead us to look for changes in the bones in the juxta-epiphyseal areas, that is, in the shafts of the bones, rather than the epiphyses.

A most careful examination of a case of genu valgum adolescentium has been published by Prof. Johnson Symington in the Transactions of the Royal Academy of Medicine in Ireland, 1896, and by the courtesy of the author and of the Council of the Academy I am allowed to reproduce in Fig. 176 the appearance of the bones in this case. On reference to the figure it will be seen that the epiphyseal cartilage at the lower end of the femur, and in a slighter degree that at the upper end of the tibia, show the changes characteristic of rickets, changes that render easy of comprehension the deformity seen in the bones at the knee-joint, of which the clinical expression is genu valgum.

As Dr. Symington observes: "It has been frequently asserted that in cases of knock-knee the internal condyle is abnormally increased in length, but Mikulicz has endeavoured to show that this is not the case, the marked prominence of the internal condyle being due to an increased growth of the inner part of the lower end of the femoral diaphysis, so that the epiphysis is placed against a surface looking obliquely downwards and outwards. It is evident that this point can only be determined with accuracy by the examination of the femur in cases of knock-knee before the epiphyseal cartilage has become ossified, and, preferably, shortly before adult life, when the cartilage is thin."

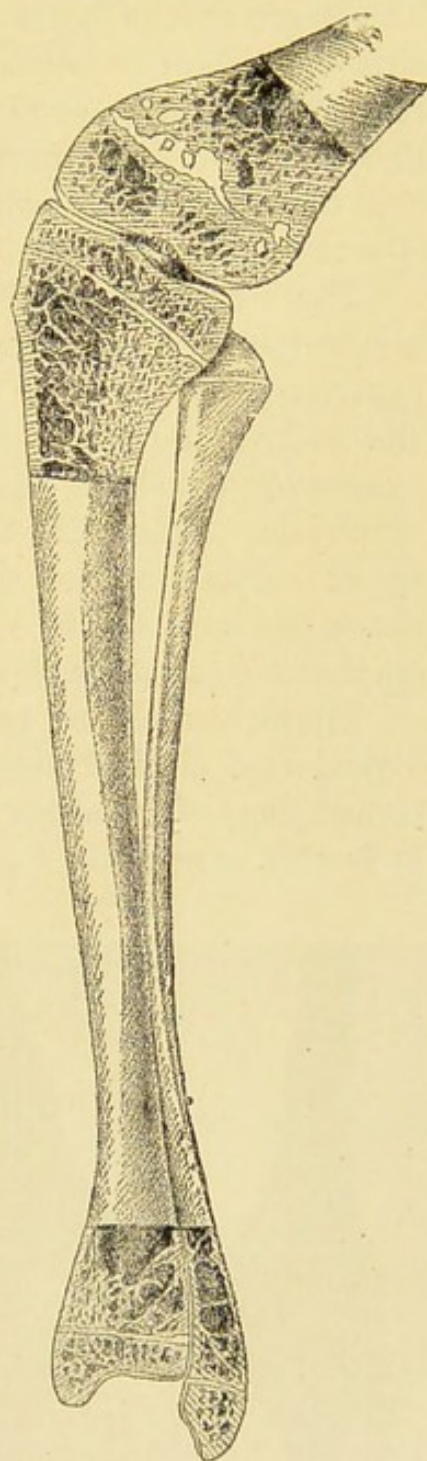


Fig. 176.—The Bones in a case of Genu Valgum that began during Adolescence. (Symington.)

Symington found that there was in this case *no elongation of the internal condyle* and no shortening of the external. The shaft of the bone was not excessively curved, so that the excessive downward projection of the inner condyle (this, when the femoral shaft was held vertical, amounted to one inch against a quarter of an inch in a normal bone) was due to an increased growth of the inner side of the diaphysis—a result in accord with the observations of Mikulicz.

The condition of the tibia as described by Symington is noteworthy: "An examination of the tibia showed that it contributed *even more than the femur* to the production of the in-knee deviation, and that this was due entirely to an excessive growth of the inner side of the upper part of its diaphysis. Thus, with the shaft vertical, the inner edge of the upper surface of the tibia projected one inch and an eighth above the level of the outer edge, and on coronal section the epiphysis was rather thinner on the inner than the outer side."

These results are entirely in accord with my own pathological and clinical observations. There is one point in the terminology of the above account which requires some definition. It is the expression "excessive growth."

The growth on the inner side of both femur and tibia in the juxta-epiphyseal regions at their knee-joint extremities is in excess of that at the outer aspect of the same parts. This, however, may be due to some arrest of growth at the outer part of the bones, and so be rather relative than absolute. Good radiographs are helpful in giving an idea of the anatomical changes present in any given case.

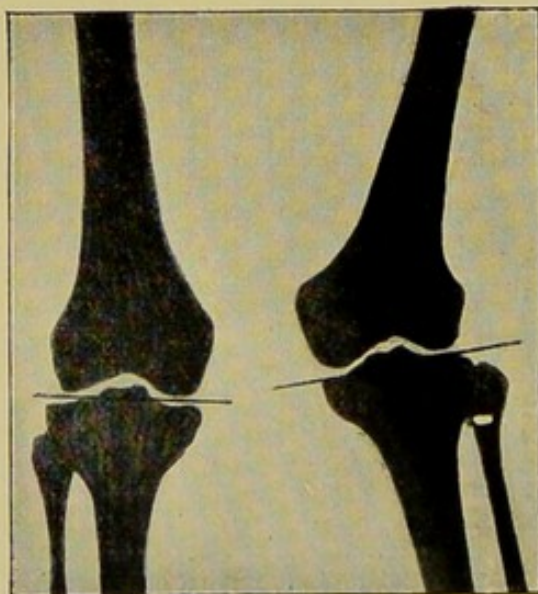


Fig. 177. — Radiograph showing Unilateral Genu Valgum. (Coxeter and Son.)

Tibial Spines. — Knob-like or pointed bony projections are not infrequently to be found at a variable distance below the internal tuberosity of the tibia. They

are rare in adolescent cases, and only arise when the patient has walked.

Cases of unilateral genu valgum serve to give at once a comparison of the normal with the condition of genu valgum. Thus, in Fig. 177, the bones at left (apparent right) knee are normal, whilst those on the other side show a marked amount of genu valgum. It will be observed that in the normal knee a line passing through the lowest parts of the condylar surfaces of the femur is fairly horizontal, whilst a similar line

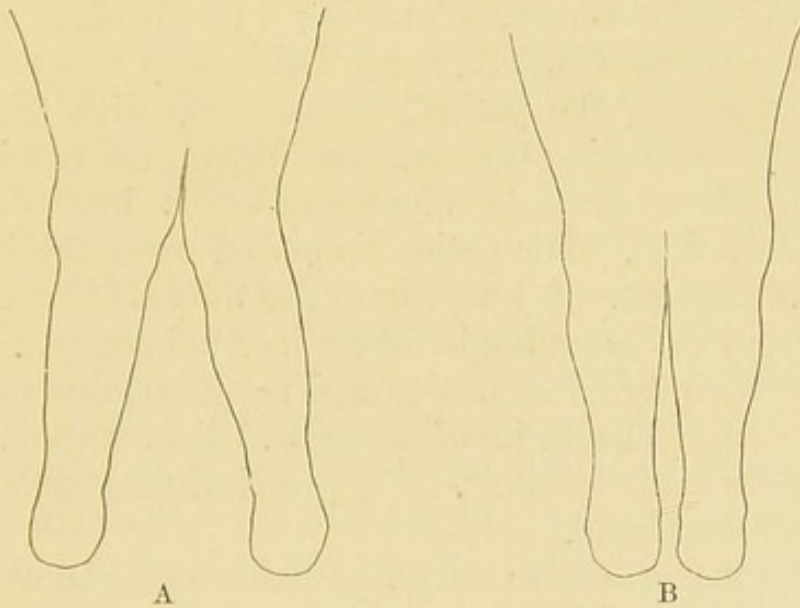


Fig. 178.—Reduced Tracings of the Limbs of a Child aged two years.

A, at the beginning of treatment by splints and, B, after two months' treatment on the ambulant plan.

on the side affected with genu valgum inclines downwards and inwards.

When the lower limbs are vertical and parallel the obliquity of the line drawn through the lowest parts of the condylar surfaces of the tibia may be taken as a measure of the femoral part of the deformity, since it shows the degree to which the internal condyle projects below the external.

In radiographs of younger patients the epiphyseal cartilages are represented, and information is afforded as to the seat of the alteration in form of the bones. Thus, in Fig. 177, on the right (apparent left) side a line skirting the shadow of the lowest part of the femoral diaphysis is slightly less oblique inwards than a line joining the lowest part of the two condyles, and in so far would point to some elongation of the inner

condyle as maintained by Macewen. Ordinary radiographs, however, afford only approximate images of the bones, and though they serve to give general information, are not to be made the basis of mathematical deductions unless complicated precautions are taken. For this reason it is preferable to study anatomical preparations before forming definite conclusions. It will be observed in Fig. 184 that the upper third or more of the tibia curves outwards.

Measurement of the amount of Genu Valgum.—In young children this is best done by drawing a rough outline of the limb, as shown in Fig. 178, A B. This rough record can be made by directing the patient to stand up with the knees together and measuring the distance between the two internal condyles. More accurate measurement is best done by Macewen's method. The patient is placed upon the back on a firm, level surface. A line, parallel to the axis of the trunk, is drawn from the lower border of the internal condyle. From the tip of the internal malleolus and perpendicular to this a line is drawn. The ratio of these two lines expresses the amount of deformity present. For practical purposes the first method is most useful.

Mode of Examination.—The patient should be examined with the knees extended, because in most cases the outward deviation of the tibiae disappears when the knee-joints are flexed. This is partly explained, as Bradford and Lovett observe, by the natural supposition that though the lower surfaces of the condyles are on different levels, yet their backward projection is unaffected: when the upper end of the tibia is altered in form and contributes to the deformity, the genu valgum persists even in the flexed position;—and partly from the fact that when the knee is bent the hip is nearly always similarly flexed, and at the same time there is some outward rotation of the femur, which naturally tends to bring the heels together.

The explanation of this phenomenon advanced by Hueter and Girard was that this was due to the form of the condyles—*i.e.* that, whilst their relative vertical depth was altered, their posterior parts were relatively unchanged. Mikulicz, having shown that there was usually practically no alteration in the form of the condyles, pointed out that

the apparent disappearance of deformity was the result of a compensatory outward rotation of the hip-joints that accompanies the flexion.

In genu valgum the knee-joint is frequently capable of hyper-extension, and the leg of abnormal external rotation at the knee. Abnormalities in the form of the bones at the knee as well as laxity of ligaments best explain these phenomena. In unilateral genu valgum there is often shortening of the limb.

Complications of Genu Valgum.—Flat-foot in rickety children is a very common accompaniment of slight genu valgum. The reasons for this association are not far to seek. The same causes tend to produce the two conditions. Muscular weakness and the posture assumed in consequence of this weakness; softness of bones and ligaments, whether from rickets or osteo-arthritis, act equally in producing the two conditions. Flat-foot, however, does not form a necessary part of genu valgum: on this point Macewen* observes: "At the outset of this affection [genu valgum] there is a tendency for flat-foot to form, and it actually does take place when the whole muscular system is lowered. In such cases, however, the patient walks with difficulty or not at all. As the patient gains strength, the knock-knee continuing, the ankle and foot assume the typical form. If flat-foot did pertain to knock-knee, the foot would have little hold on the ground; it would be liable to slip sideways. In order to prevent this slipping, the muscles of the leg and foot exert themselves, an attempt is made to grasp the floor, with the result of causing the outside of the foot to come to the ground and the instep to be made higher. The boot worn by a typical knock-kneed person is twisted inwards, the convexity corresponding to the ankle being towards the outer side; the outer aspect of the heel is always worn more than the inner."

The association of tibial bow-leg with genu valgum has already been remarked upon. In genu valgum lateral curvature of the spine from obliquity of the pelvis is not uncommon, for the deformity is usually worse on one side than upon the other. The femur likewise is frequently bowed forwards.

* Macewen, "Osteotomy," p. 35.

Ætiology.—The predisposing cause of knock-knee is in most cases rickets. A few cases of congenital genu valgum have been observed. The two or three cases that have come to my own notice have been obviously intra-uterine pressure-effects akin to congenital dislocation of the knee. Traumatism and suppurative arthritis of the knee may also cause the deformity. Numerous rickety infants who have never walked may have marked knock-knee. In such cases, either the proliferative growth at the inner side of the lower femoral and upper tibial epiphyseal planes has occurred to a greater extent than it has on the outer side, or this proliferation is diminished to a greater extent on the outer than on the inner side by the stronger action of the biceps muscle as compared with that of the inner hamstrings. In the majority of cases, however, the deformity is of less uncertain origin. It is directly produced by the weight of the body in standing or walking. In the erect posture, with the heels together, the weight of the body is transmitted through the knee-joints midway between the condyles.* A line let fall from the summit of the head of the femur to the middle of the lower articular surface of the tibia passes between the condyles, and has been termed by Mikulicz the "direction-line." In genu valgum this line falls external to its normal position, and in marked cases it falls outside the joint altogether.

In order to stand erect, with the feet close together, the muscles of the lower limbs and trunk must be in a state of activity in order to preserve the balance of the body. When the muscles are weak, as they are in rickets, a person stands with the feet far apart, so that the supporting base is widened. In this position (*see* p. 16) vertical growth of tissue is encouraged by diminished pressure on the inner aspect of the knee, whilst the converse holds good for the outer aspect. It thus follows that the growth of the upper ends of the diaphyses of the tibiæ, or the lower ends of those of the femora, or both, may be increased.

Symptoms.—On looking at a person affected with knock-knee of marked degree the straddling carriage and gait are

* Some observers consider that the line of gravity passes normally just outside the centre of the knee-joint.

striking; in slight cases a closer inspection is required. In standing, the patient's knees are unduly prominent at the inner side.

In cases of genu valgum the patient, in order to avoid the knees coming together, abducts the thighs alternately in walking, giving at each forward step of the advancing limb an outward swing which is very conspicuous. If the deformity is very severe the knees form a lozenge-shaped interval, one knee being crossed behind the other, and then walking is extremely difficult. In some cases, besides the alteration in the direction of the legs, there is an outward (more rarely an inward) rotation of the tibia.

Prognosis.—As in other rachitic affections the question of spontaneous recovery must be considered. The greater frequency with which knock-knee is seen in children as compared with adults is sometimes taken as an argument to prove that most cases of genu valgum recover spontaneously. As an answer to this proposition, Whitman counted the number of cases of knock-knee in 2,000 male adults he met consecutively in the streets of Boston. They amounted to thirty-two. Another consideration is that in almost every severe case the surgeon will hear from the mother that she had been assured that the child would "grow out of it," or she would have had the child treated for the condition. No reliance is to be placed upon a natural recovery from the deformity. In children under five or six years genu valgum is easily and certainly corrected by the simplest apparatus, and if the treatment is begun whilst the disease is still in progress there will be not the least necessity for operative measures.

Treatment.—As in all rachitic affections the general treatment must be attended to, for the local condition is but an indication of the general disease. The great majority of cases can be treated without confining the patient to bed; only when rickets is severe, as shown by great weakness, emaciation, and great enlargement of the epiphyseal regions of the bones, the patient must be confined to bed until the general condition is sufficiently improved. In the majority of cases the children are sturdy and, if the genu valgum is their only complaint, are much better treated by the ambulant method from the first.

The apparatus required is simple to a degree and has been already referred to (pp. 75-78).

The best method of applying splints for genu valgum is shown in Fig. 185. It will be noted that the upper band does not pass across the front of the body. The essential points are, that the knee-joints must be kept extended, and that the treatment must be applied night and day. Hoffa recommends Thomas's splints, shown in Fig. 179. Where the patient's circumstances allow, I usually advise the use of a steel apparatus, with ring-catches at the knee, by day, and simple splints by night, the limbs being douched and rubbed twice daily. As a

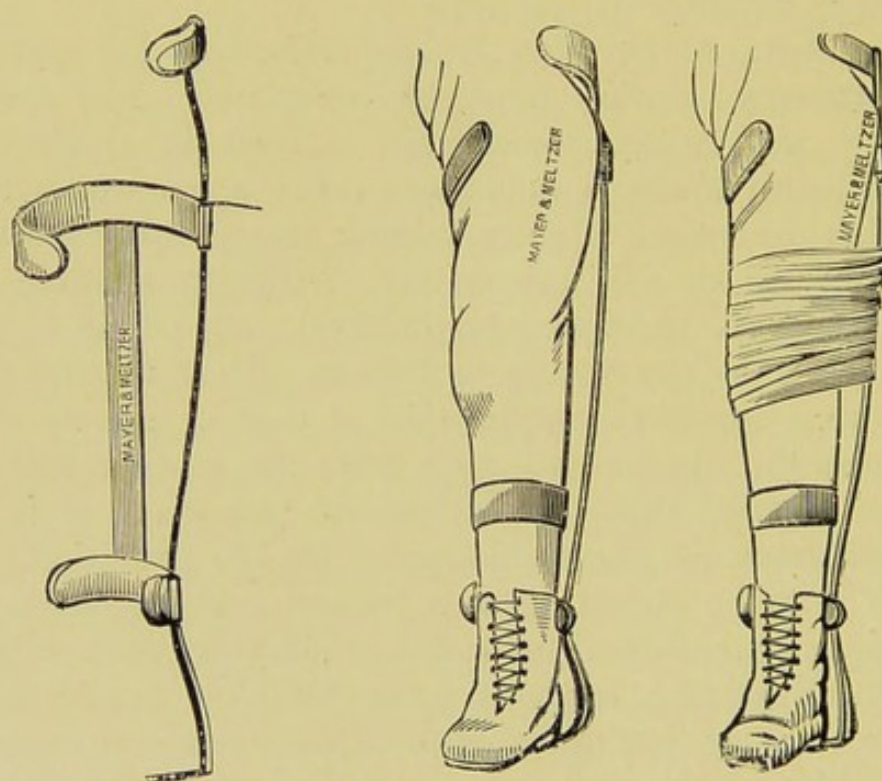


Fig. 179.—Thomas's Splints for Genu Valgum. (Hoffa.)

record of the progress of a case tracings of the limbs, made as suggested by Bradford and Lovett, are very useful. The patient sits on a sheet of paper with the legs extended, knees close together, and feet pointing upward, and then with a pencil held vertically and close to the limb, the surgeon traces the outlines of the parts. Such tracings when dates are recorded also serve to record the rate of progress (Fig. 178).

The method of treatment by recumbency is thus described by Mr. H. S. Collier:—*

* H. S. Collier, *St. Mary's Hospital Gazette*, April, 1898, p. 52.

I show you the splints which are in use in the out-patients' room at Great Ormond Street Children's Hospital, for most rachitic deformities of the lower limbs.

Each consists of a light padded board to be applied to the outside of the pelvis and lower limb. Its upper end is on a level with the crest of the ilium, and its lower end reaches three inches below the foot. A splint is applied to each lower limb. A webbing band connects the upper ends of the two splints, both in front and behind the pelvis; a second band passes from the splint round the middle of the thigh, a third round the middle of the leg, and a T-shaped strap connects the foot with the splint.

This arrangement does not absolutely oblige the child to remain supine, but as it becomes irksome in the sitting-up posture, the child is not likely to sit for long at a time.

The splints are removed twice a day so that the nutrition of the limb may be aided by friction with oil or with salt water.

For how long must the restraining treatment be continued?

In the minor degrees of deformity, six months' splinting may suffice. In the more severe cases two or even three years may be required.

The prospect of such a long process may make you hesitate to recommend such a course of treatment, but you will not err if you will bear in mind that the alternative measures are almost sure to be followed by relapse, unless the same tedious splinting be insisted upon.

Children adapt themselves very easily to circumstances, soon become reconciled to the splints, and their general health does not suffer to any great extent from interference with their normal activity.

Hueter at one time tried fixing the knee in the flexed position on the supposition that since the deformity disappears in the flexed position, it might be cured by fixation of the limb in that position. This plan, after patient trial, was found to be highly unsatisfactory.

Bradford and Lovett record that they tried Rushton Parker's plan of treating knock-knee by raising the inner

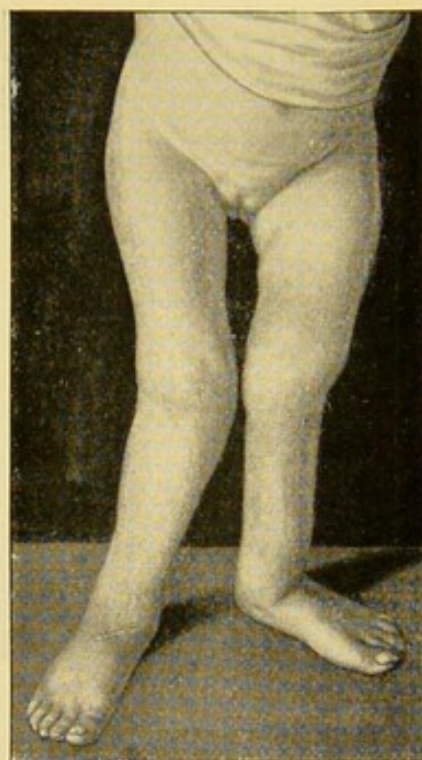

Fig. 180.—Photograph of the Legs of a Girl, aged nine years, who had severe Genu Valgum and Anterior Tibial Curves on both sides. From the position of the Limbs the Genu Valgum shows best on the right, the Anterior Tibial Curve best on the left side.

border of the boot. They found that no reliance could be placed upon the plan. In conclusion, the words of these authors may be quoted: "Mechanical treatment, it has been said, is of two kinds. The old-fashioned method was to confine the child to the bed, or to some retentive apparatus, while modern treatment allows and encourages locomotion."

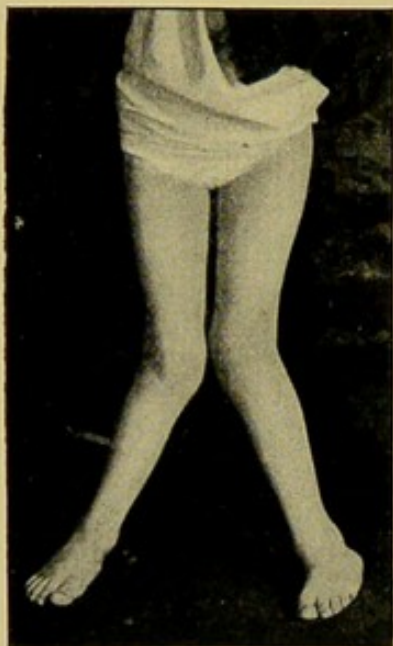

Fig. 181.—Photograph of the Legs of a Girl, aged eight years, showing severe Genu Valgum, before Macewen's Operation.

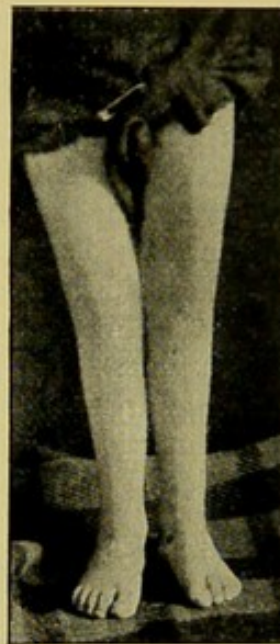


Fig. 182.—The Case illustrated is Fig. 181 three months after Macewen's Operation.

Among some hundreds of cases of genu valgum in young children I have only had occasion to recommend recumbency in two or three instances, and in these for a short time only, on account of some complication.

Operative Treatment.—This is only necessary when mechanical treatment has been neglected, *i.e.* when the deformity has been allowed to persist until the bones have become hard. In genu valgum, oftener than in any other condition, are unnecessary operations performed. It is impossible to give any age-limit for the operation, since rickets and genu valgum may not begin until a person has reached adolescence, or, on the contrary, rickets may have ceased and the bones have become hard by the age of eight or ten years. For my own part I try to avoid osteotomy

whilst rickets is in progress, and I seldom perform it on a child under eight years of age.

The only operations that need be considered are Macewen's and the Reeves-Ogston operations, and osteotomy of the tibia. Macewen's supra-condylar osteotomy has been described already (p. 110). A few fatalities and accidents have been reported. Macewen attributes most of them to faulty operating, *e.g.* (1) slipping of the chisel from its being loosely held; (2) directing the chisel too much in a backward direction when dividing the posterior layers of the bone; (3) by the use of too broad an osteotome. Fat embolism also has occurred.

Seeing that in most cases the chief deformity lies to a considerable extent in the tibia, Macewen's operation cannot rectify the deformity present, but it rather compensates for it by the addition of another deformity in the femur. Schede introduced osteotomy of the tibia and fibula just below the level of the tuberosity of the tibia. When the deformity is chiefly tibial, this operation is certainly indicated. Mr. John Ewens,* of Bristol, in 1892 advocated removal of a wedge from the inner side of the upper part of the tibia in similar cases.

Sometimes several osteotomies are necessary; thus, in the patient whose lower limbs are shown in Fig. 180 I found, after dividing the femur by Macewen's method, it was necessary to divide the tibia below the tubercle in order to correct the genu valgum, and again at the meeting of the middle and lower thirds for the anterior tibial curve.

Ogston's Operation.—Ogston recommended separation of the internal condyle of the femur and subsequent correction of the deformity. The knee is flexed and a narrow-bladed knife is entered two inches above the adductor tubercle of the femur at the middle of the inner border of the thigh, and is passed downwards and outwards across the front of the condyles, until the point reaches the groove between them in the interior of the joint. The knife is then withdrawn and a narrow-bladed saw is passed along its track. The bone is then sawn nearly through. The saw is then withdrawn and the limb forcibly corrected.

Reeves modified the operation by using a chisel instead

* John Ewens, *Provincial Med. Journ.*, Jan. 1893.

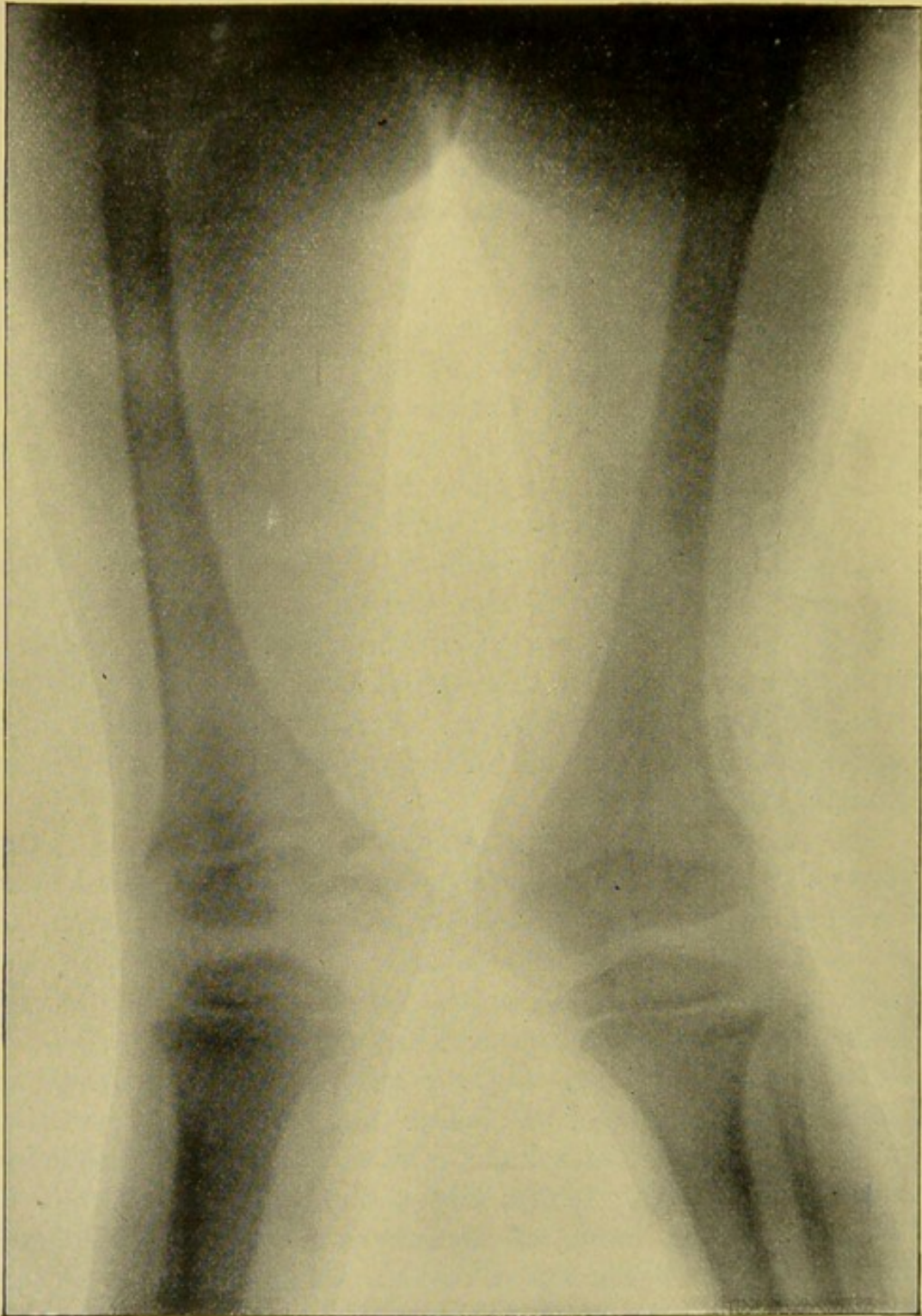


Fig. 183.—Radiograph of Genu Valgum in case shown in Fig. 181 (posterior aspect) before Macewen's Operation. (*Coxeter and Son.*)

of the saw, and making a smaller incision. Mr. Willett* recommends the Reeves-Ogston operation for severe cases of knock-knee.

* Willett, *Brit. Med. Journ.*, Dec. 11, 1897.

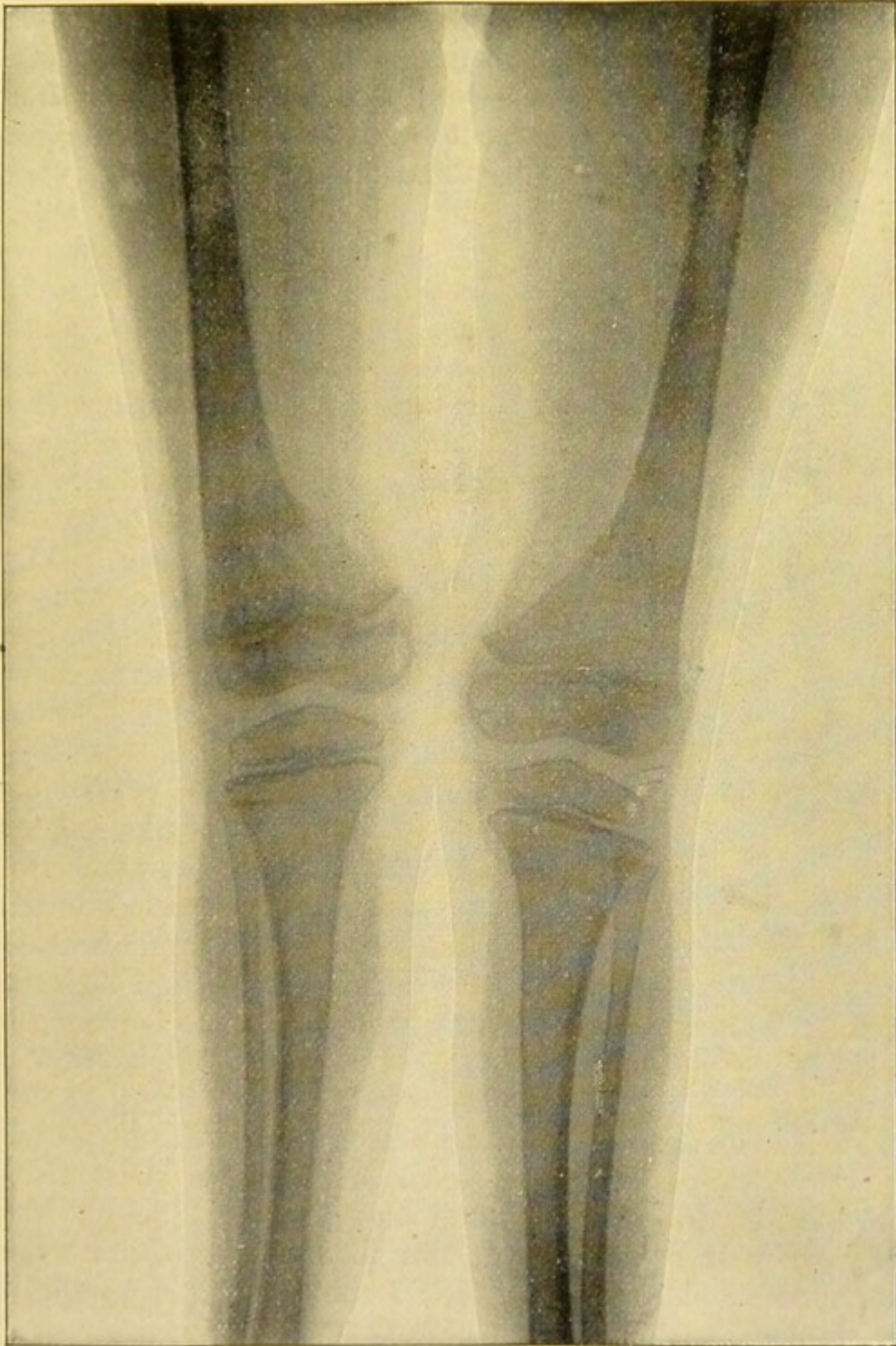


Fig. 184.—Radiograph of Genu Valgum in case shown in Fig. 181 (posterior aspect) after Macewen's Operation. (*Coxeter and Son.*)

Since this operation traverses the epiphyseal cartilage, it should be reserved for patients who have passed the period of growth.

Results of Conservative and of Operative Treatment Compared.—In a considerable number of patients ranging from five to eight years that I have discharged as cured after from two to three years' treatment by the ambulant method, the resulting form of the bones and the function of the knee-joint has appeared to me to be perfect. In the case of a




Fig. 185.—Wooden Splints for Knock-knee.

The upper bandage does not pass in front of the body.

girl aged eight years I performed Macewen's operation, not because the conservative method would not have cured the patient, but because the patient suffered from excessive shyness, which rendered frequent visits painful to her. The appearances of the legs before and after operation are shown in Figs. 181 and 182, and radiographs in Figs. 183 and 184. It will be seen that the operation leaves an alteration in the plane of the articulating surfaces of the knee-joint which is the converse of that due to the femoral part of genu valgum. I have known cases in which after osteotomy this alteration in the joint-planes made it impossible for the patient to walk, although the legs were straight. Returning to the consideration of the case of my patient aged eight, I will mention that she had still a slight degree of rickets. I therefore

ordered her to wear the splints shown in Fig. 185 for at least a year after operation. In this time the knee-joint would become moulded to its proper form and relapse would be prevented.

In my opinion, no operation, save in exceptional circumstances, should ever be done during the continuance of rickets. During the last ten years the medical journals contain illustrations of numbers of children operated on for genu valgum between the ages of two and six years. Nearly all

these have, like early operations for genu varum, coxa vara and similar conditions, been unnecessary operations. Further, in adolescent cases, so long as rickets is active, conservative treatment by ambulant methods suffices to cure. Only when, from neglect of early treatment, the bones have been allowed

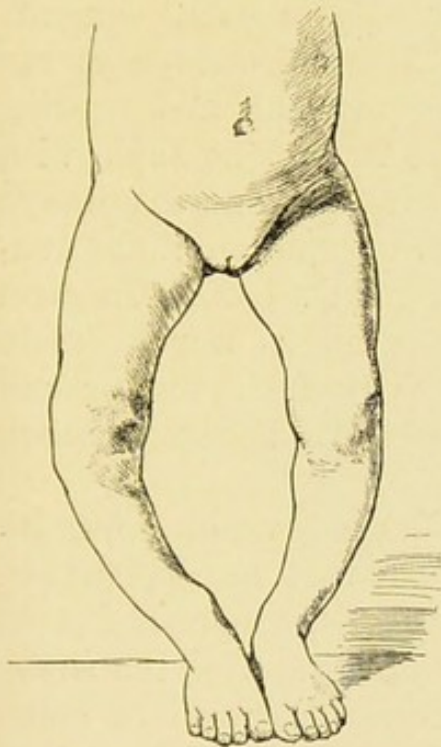


Fig. 186.—Genu Varum. The Legs of a Patient aged five years.

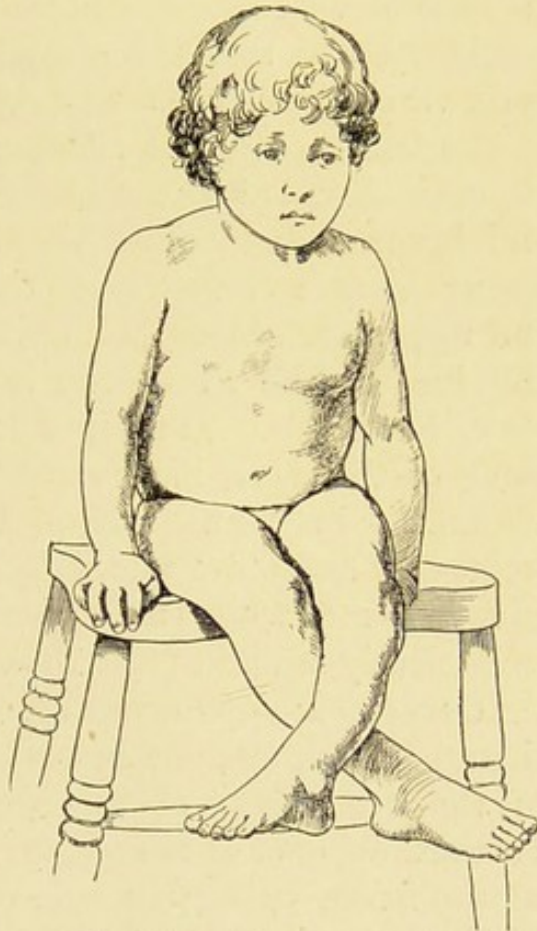

Fig. 187.—The same Patient (Fig. 186) sitting with crossed Legs.

to become hard in their deformed condition are operations required. If the deformity is chiefly of tibial origin, osteotomy of the tibia* and fibula is preferable to Macewen's operation. The latter is required when there is a femoral element in the deformity and it may need to be supplemented by a tibial osteotomy.

Genu Varum.—This deformity has already been defined (*see p. 225*).

Symptoms.—When the patient stands erect with the internal malleoli close together the knees are separated by

* *See a paper by Morton (Bristol), Brit. Med. Journ., 1898.*

a greater or less interval (Fig. 186). In extreme cases the legs describe a circle.

Anatomy.—A general outward bowing of the shafts of the tibia frequently, and a general outward bowing of the shafts of the femora sometimes, accompanies genu valgum. It follows that these deformities may exist separately or combined, and that the change in the bones that determines genu varum has its seat near the knee-joint in the extremity of the femur or of the tibia, or of both. In the radiograph shown in Fig. 188, the plane of the knee-joint slopes upwards and inwards or, in other words, the external condyle of the femur is at a lower level than the internal; and further, the upper surface of the tibia is not at a right angle with the line of the shaft, the latter being prolonged upwards on its outer side. Thus, in this case the condition is the converse of that seen in a femoro-tibial genu valgum. In genu varum, as in genu valgum, the tibia is, as a rule, more frequently and more markedly affected than the femur; and in many cases when the legs are crossed the femora are seen to be nearly straight (Fig. 187).

Causation.—Genu varum is a much less common deformity than genu valgum, and in trying to arrive at an explanation of the occurrence of this deformity as distinguished from outward or forward bowing of the middle parts of the shafts of the femur or leg-bones, two considerations must be taken into account:—first, the varying degree in which rickety changes occur in the same bone; and second, the habitual attitude of the patient in walking and standing. If the softening of the growing tissue at the epiphyseal line is greater on the inner than the outer aspect of the bones, then genu varum rather than genu valgum will be likely to occur.

In viewing such cases as that shown in Fig. 187 with the legs crossed, the suggestion arises that a habit of resting with the upper parts of the legs crossing may be the determining factor in the origin of genu varum.

Bradford and Lovett observe that in marked cases the patient stands with the lumbar spine arched forwards and the thighs flexed and slightly rotated out. In this position the line of gravity would fall internal to the knee-joint even if the

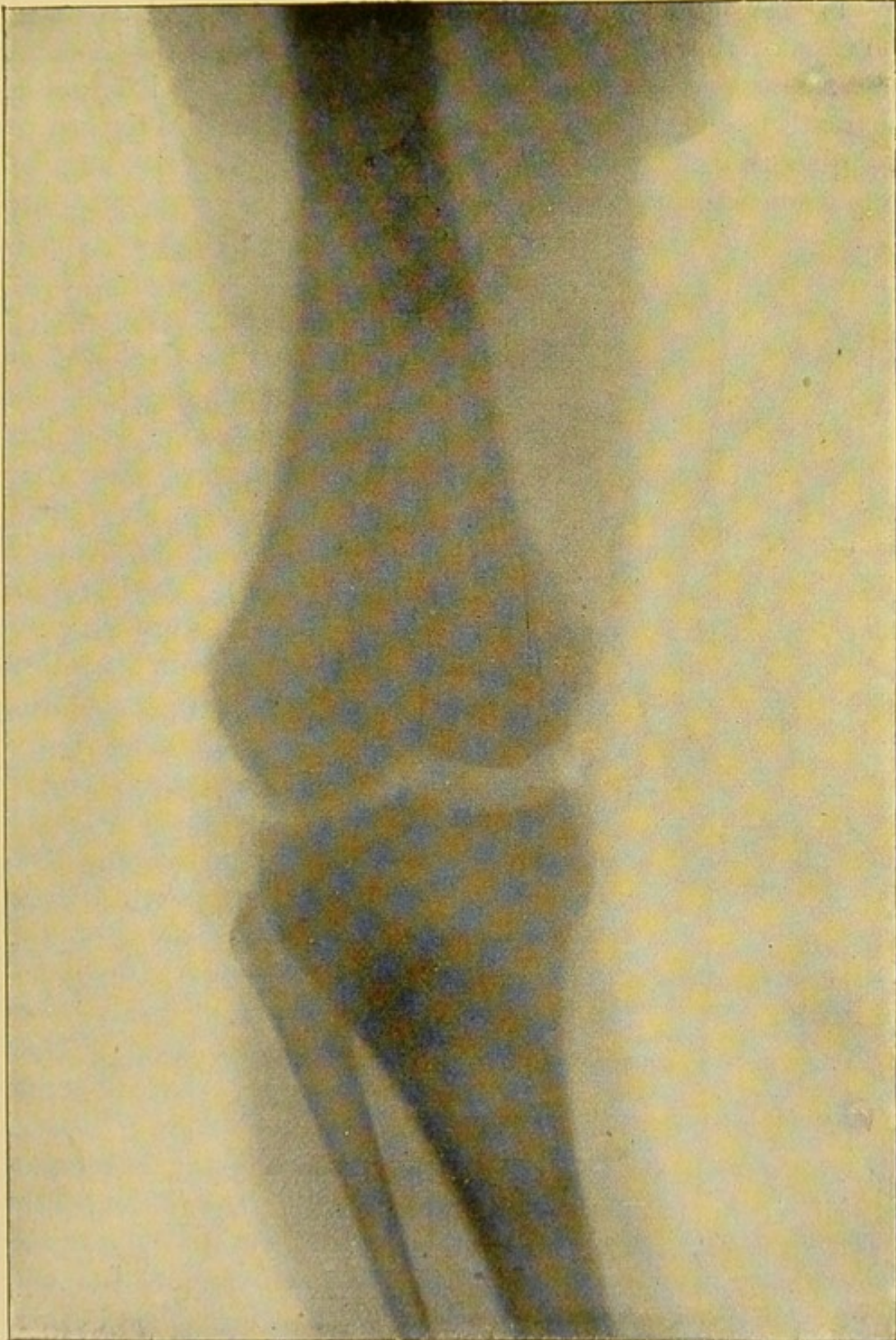


Fig. 188.—Radiograph of Case of Genu Varum (posterior aspect).
(Coxeter and Son.)

shape of the bones were normal. It seems possible that this posture is rather a consequence than a cause of genu varum.

It has already been observed that a general outward bowing of the shafts of the femur or leg-bones does not of itself cause genu varum, but when this deformity is found in marked degree such curves are usually present and they serve to give the affected limb a sinuous instead of the angular appearance presented by a simple case of genu valgum.

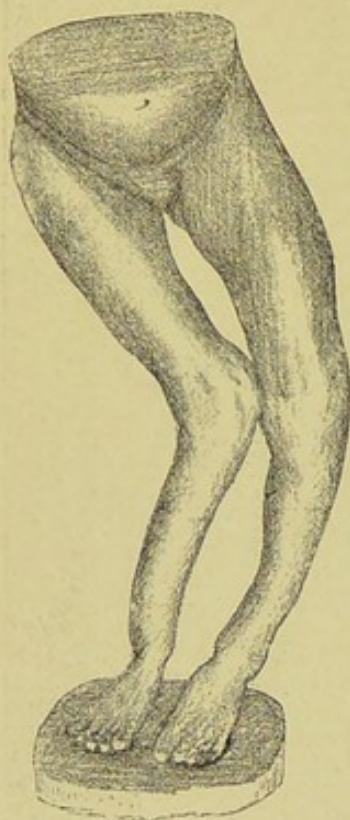


Fig. 189.—The Lower Limbs in a Case of Genu Varum and Genu Valgum occurring in the same Person.

(From a cast in the Museum of the City of London Orthopædic Hospital.)

In stating this view, I know that it is at variance with that expressed by some of the most authoritative writers. Thus Macewen writes: * “In this election of site which attended rickets was found a probable determining point between genu valgum and varum, as the latter would be associated with those cases where the shafts of the long bones were softened.” And again, Hoffa,† writing on the same subject, observes: “Its development is easily understood. Outward bending of the leg-bones first occurs. Then the heads of the tibiæ bend more and more in an outward direction, and so the lower ends of the femora by their ligamentous connection with the upper end of the leg-bones at the inner side of the knee become drawn out with them, which the freedom of movement allowed by the hip-joints permits. Thus arises the sickle-shaped, outward bending of the knee-joints.”

The fact that outward bowing of the leg-bones is not infrequently associated with genu valgum seems to me to oppose the last view. Genu varum is pretty often present on one side and genu valgum on the other (Fig. 189). Such cases usually date from a period before the child has walked, and are attributable to pressure of the legs against the body of the nurse. Thus, when an infant is carried on

* William Macewen, *loc. cit.*

† “Orthopædic Surgery,” p. 615.

the nurse's left arm, the child's right leg will tend to be displaced towards and its left away from the sagittal line of the child's body.

Diagnosis.—In marked cases the separation of the patient's knees when the feet are placed together is at once apparent and is best recorded by a tracing, as in knock-knee (Fig. 190). The gait is of a somewhat rolling character and may suggest the presence of congenital dislocation of the hip. In every case coxa vara must be looked for.

Prognosis.—Though in some cases the deformity is corrected spontaneously, and this tendency is much greater than in knock-knee, the considerable number of cases of bow-legs seen in adults,* even in well-to-do classes, is sufficient to justify treatment in every case, since in sound mechanical treatment we have a certain cure for the outward deviations of the femur and the tibia when the patients are young children in whom the bones are growing rapidly. Marked anterior tibial curves are more difficult to remedy, yet they can be corrected to some extent by mechanical treatment and they can be prevented from growing worse. In older subjects, whose bones have become hard, osteotomy may be required.

Treatment.—Mechanical treatment should be always accompanied by daily rubbing and gentle manipulation of the limb. The precise form of appliance required must be ascertained and prescribed for each case. A record of the progress of a case is best kept by tracings. Examples of the appliances most commonly required may now be given.

One of the simplest appliances for uncomplicated genu varum is that recommended by Bradford and Lovett (Fig. 191). The upper ends of the irons are joined together by a strap behind the body, and a second strap passes from

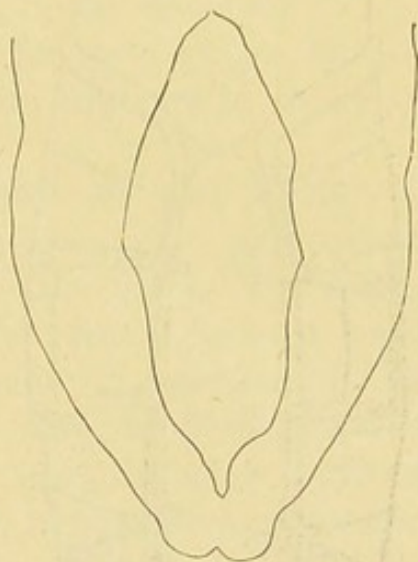


Fig. 190.—Tracing from a Case of Genu Varum.

* Royal Whitman counted in the streets of New York 400 bow-legged men out of 2,000. (*Bradford and Lovett.*)

near the upper ends of the irons to hold up the knee-cap on the external aspect of the limb.

In complicated cases the usual walking apparatus is to be preferred. The iron is carried from below the hip-joint behind the limb, and made fixable opposite the knee by a "ring-catch." By slight modification this apparatus can be made to correct curves in the shaft of the femur or the tibia.

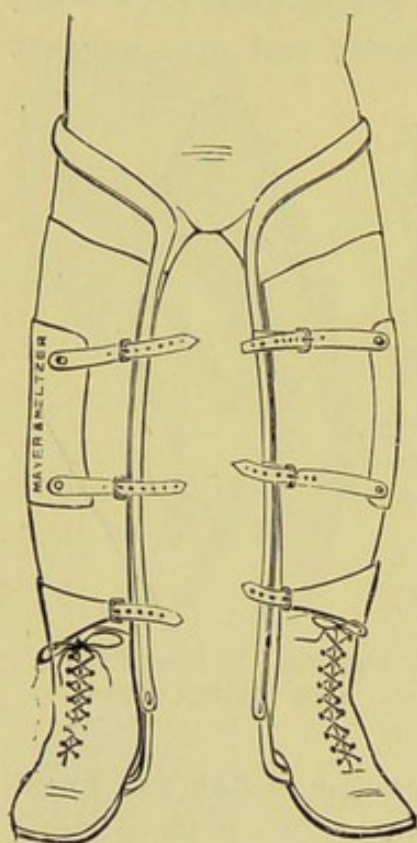


Fig. 191.—Ambulant Apparatus for Genu Varum.
(Bradford and Lovett.)

Operative Treatment. — *Osteotomy.* — Billroth (Langenbeck's "Archiv," 1874) successfully divided the tibia one inch below the spine for genu varum.

The seat of the operation is determined by the summit of the convexity in the bones involved.

The osteotomy may be transverse or oblique, or a wedge of bone may be removed. In the case of a sharp anterior tibial curve an oblique osteotomy may be done by practised surgeons (*see p. 112*).

Osteotomy for pure genu varum should be the converse of that required for genu valgum. The cases in which the operation is

required are usually complicated, and thus several osteotomies may be required in each of the bones. Macewen* writes: "The outer side of the tibia is that which, theoretically, ought to be divided, and the inner portion snapped. It is, however, easier to divide the inner superficial portion along with the outer margin of the tibia, the back part being divided partly by a horizontal movement from the inner side, guarding well against injuring the muscle. The fibula, unless when it can be bent or snapped, requires division. In operating on the fibula, an osteotome must be used less than the breadth of the bone, otherwise the soft tissues may be injured. . . . In division of the tibia at its lower third great care

* Macewen, "Osteotomy," p. 149.

must be observed not to injure the soft parts. . . . On performing osteotomy of the femur from the outside for genu varum, the manipulative precautions noticed under the criticism of division of this bone at the lower third for genu valgum, apply, and it would be well to bear them in mind. In dividing the femur higher up, such as at the middle of the shaft, the very dense layer of osseous tissue will in the adult be found to be very hard and resistant to the osteotome."

Some surgeons perform osteoclasis for genu varum, but, in my opinion, osteotomy is a more certain measure in the only cases that require operative treatment.

Rachitic Deformities of the Shaft of the Femur.—Deformities of the shaft of the femur are not of so frequent occurrence as those of the tibia, but they are by no means uncommon. A general outward and a general forward bend are the more common. These two may be combined in an antero-external bend, or the curve may be S-shaped, the femur bending outwards above and inwards below. When such mixed curves are present, there is usually found some twisting of the shaft of the bone.

Treatment.—The general indications for treatment are similar to those for curves of the leg-bones (*q. v.*).

Outward Curves of the Leg-bones.—This is the commonest of all rachitic curves in the limbs. When the tibia is very sharply bent at the junction of the third and lowest fourths of the shaft, a radiograph will generally show that the deformity has the characters of a greenstick fracture.

Treatment.—For slight outward tibial curves the wooden splints such as those used at the City of London Orthopædic Hospital (*see* Fig. 35) are all that is required; if genu valgum is present in addition to the outward tibial curve, an outside support will be needed besides.

When the curve is more pronounced, an internal iron resting on the internal condyle by a pad, fixed to the heel of the boot in the usual way, and acting on the most prominent part of the outer border of the leg by a broad padded strap, is required.

Anterior tibial curves are also readily recognised; in pronounced cases there is a sharp projection at the junction of the middle and lower thirds of the tibia, and the muscles at

the back of the limb can be seen to stretch from the ankle upward as the base of a triangle, the other two sides of which are formed by the leg-bones.

Treatment.—If taken in time, anterior tibial curves may be successfully treated by instruments. A posterior iron fixed below the knee and into the heel of the boot, and making a bearing-point for a broad, softly-padded anterior pad, is required.

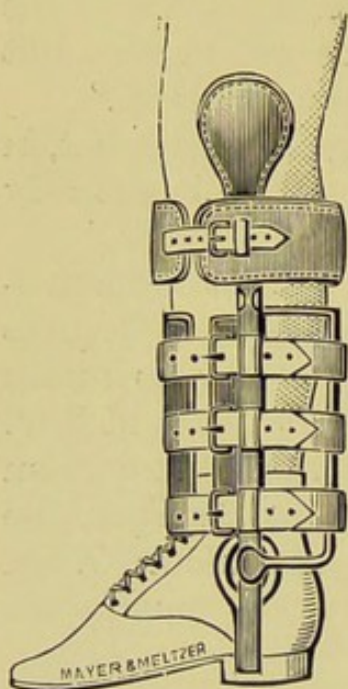


Fig. 192.—Instrument and Boot for Antero-external Tibial Curve.

When an external curve is present, the addition of a posterior splint or iron to the internal support is necessary (Fig. 192).

Barton Hopkins* has advocated an operation termed "osteotomoclasis" for tibial curves.

Thus, in a child aged three years the tibiæ were half divided by the osteotome, and eleven days later the form of the limb was corrected by means of an osteoclast. This proceeding seems to expose the patient to the risks of a second anæsthetisation and the discomfort of a second operation,

and its advantage over a single osteotomy (which, by the way, is always an osteotomoclasis) is hard to see. Certainly, at the age of three the outward tibial curve for which the operation was done could have been readily cured by instrumental treatment.

Rachitic Incurvation of the Neck of the Femur or Coxa Vara.—The term "coxa vara" was first introduced by E. Müller† in 1889, and it will help to a clear understanding of the meaning of the term if we recall this author's description of the condition to which he applied it. Müller's words, literally translated, run thus: "The course of the affection is as follows: in young individuals from fourteen to eighteen years of age, either without any special cause or following some slight injury, pain and a sense of fatigue set in in one

* Barton Hopkins, "Ann. of Surg.," July, 1898.

† *Beitrag. für Klin. Chirurg.*, vol. iv., 1889.

hip, and are followed gradually by shortening of the lower limb on the affected side." Müller's view of the pathology of the affection may also be recalled: "That it is rickets which induces this typical weakening and yielding of the neck of the femur does not allow of positive demonstration, but it appears to me to be the most plausible explanation."

Rotter, Lauenstein, Schultz, Hoffa, Whitman, and many others have contributed to the literature of the subject.

Hofmeister * divided cases into two groups :

I. With simple elevation of trochanters.

II. With elevation of trochanters with increased outward rotation.

Whilst for practical purposes I think it is best to consider coxa vara as a purely rachitic affection, it must at the same time be remembered that other conditions will produce a similar deformity. Just as syphilis and other chronic inflammatory conditions will produce curvings of the long bones, so a variety of pathological lesions may contribute to the production of incurvation of the neck of the femur. The close kinship of rachitic deformities to those resulting from greenstick fractures has been already pointed out, and it holds good for the femoral neck. Fractures of the femoral neck in young people are rare, but where coxa vara is produced suddenly by violence there need be no hesitation in making a diagnosis of greenstick fracture of the neck of the femur. In children coxa vara is practically always a rachitic affection, though Kredel has described a case of congenital coxa vara.

Symptoms : Pain.—During the initial period of the deformity this symptom is usually present and is often marked. It may simulate early hip-disease. The duration of the painful period is usually some weeks or months. It is often overlooked or passed over as "growing pains."

Lameness.—This symptom varies with the degree of the deformity, and according to whether the affection is unilateral or bilateral. In bilateral cases there is a rolling gait, somewhat akin to that seen in cases of double congenital hip-dislocation; in unilateral cases the lameness consists in a sudden dip and lurch of the body towards the affected side.

* *Ibid.*, vol. xii., 1894.

Attitude.—In unilateral cases the pelvis is tilted downwards towards the affected side. In infants a marked eversion of the limb is often the first sign of the deformity; Fig. 193 is taken from a patient of my own, a little girl aged $1\frac{1}{2}$ year. The feet could be inverted to point forwards, but not beyond

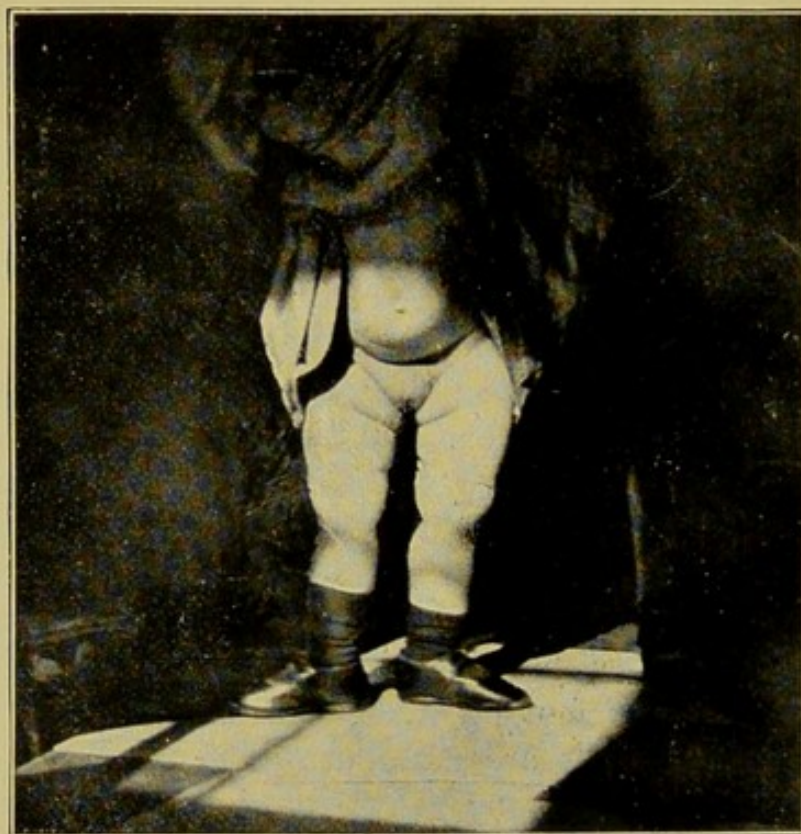


Fig. 193.—Lower Limbs of an Infant showing early Coxa Vara with Eversion.

this. In advanced cases, the adduction of the limb leads to crossing of the legs and scissor-legged progression. An instance of this has been given by J. G. Cooke* of Londonderry, and by his permission and that of the editor of the *British Medical Journal* I am able to reproduce the illustration of his case (Figs. 194, 195).

This scissor-legged posture is seen also with the patient lying down, as is shown in C. H. Frazier's case (Fig. 196).

In infants with severe rickets the curious resting posture shown in Fig. 197 is often assumed, and it may play a part in the production of eversion. The illustration is taken from the record of a case of bilateral coxa vara by Dr. G. A.

* J. G. Cooke, "A Case of Scissor-legs," *Brit. Med. Journ.*, Dec. 3, 1898.

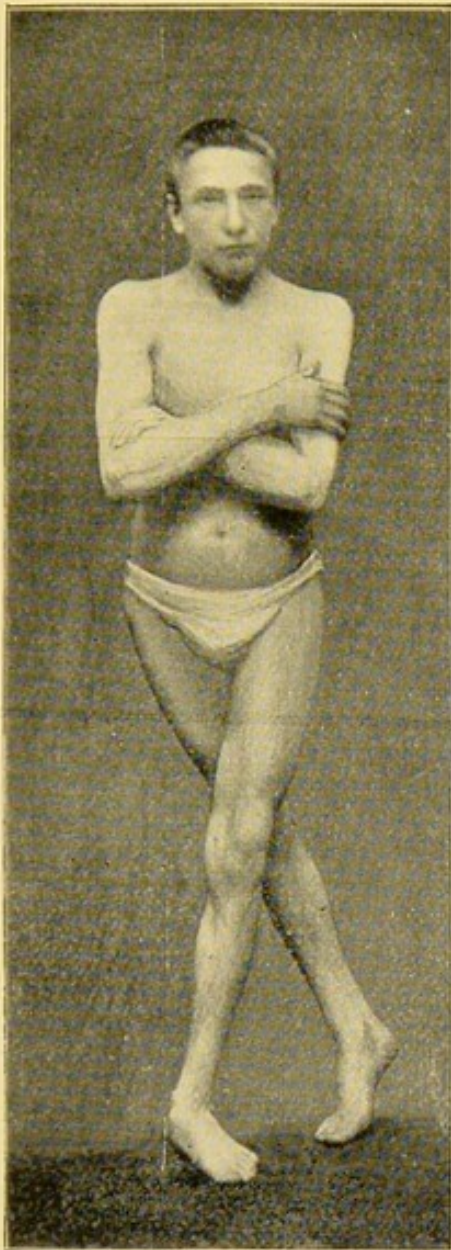

Fig. 194.—Scissor-legged Pro-
gression from Coxa Vara: front
view.




Fig. 195.—Scissor-legged Pro-
gression from Coxa Vara: from
behind.

Sutherland,* and is reproduced here by his kind consent and that of the editor of the *Clinical Journal*.

C. H. Frazier† has tabulated the variations in the attitude of the limb in sixty cases as follows:—

Outward rotation...	...	43	Inward rotation	2
Outward rotation and			Inward rotation and adduction	2
adduction	...	6	Adduction	1
Outward rotation and			Adduction and flexion	1
flexion	...	5	Normal	8

* Dr. G. A. Sutherland, *Clinical Journal*, 1899.

† C. H. Frazier, "Annals of Surgery," July, 1898.

The same author gives the displacement of the trochanter above Nélaton's line in eighty-eight cases:—

1 Centimetre...	...	11 Cases.	5 Centimetres and a		
2 Centimetres and a			fraction	...	4 Cases.
fraction	...	27 "	6	"	1 "
3	"	19 "	7	"	3 "
4	"	11 "	Not stated	...	12 "

Differential Diagnosis.—Many cases of coxa vara have been mistaken for congenital hip-dislocation. In the earlier years of the latter affection, the undue mobility of the head of the femur and the fact that traction on the limb causes the

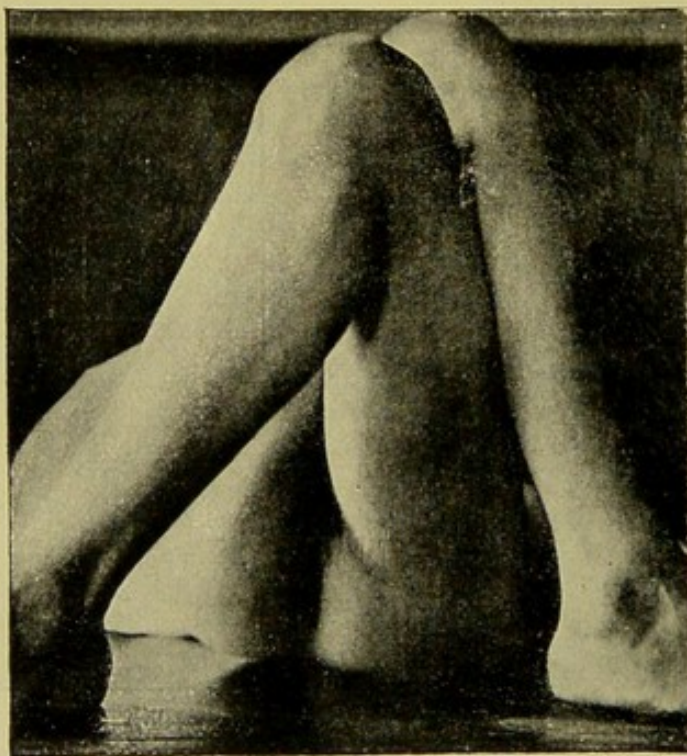


Fig. 196.—Bilateral Coxa Vara, with marked Adduction: the Patient lying down. (Frazier.)

great trochanter to descend, will enable the observer to distinguish it from coxa vara; when, on the contrary, in a case of congenital dislocation, the head of the bone has become more fixed in its abnormal position, it may be impossible to pronounce an opinion until a good radiograph has been taken. The importance of radiography in the diagnosis of coxa vara cannot be overstated. At the time when operative measures were widely practised for congenital hip-dislocation, it was not infrequently found that a mistake had been made; thus, among

Zehnder's six cases was that of a boy, aged eleven, in whom the right hip-joint was opened on the supposition that there was a congenital dislocation of the hip. The head of the femur was found to be normal, and to lie in a normal acetabulum, and the operation was desisted from. This case

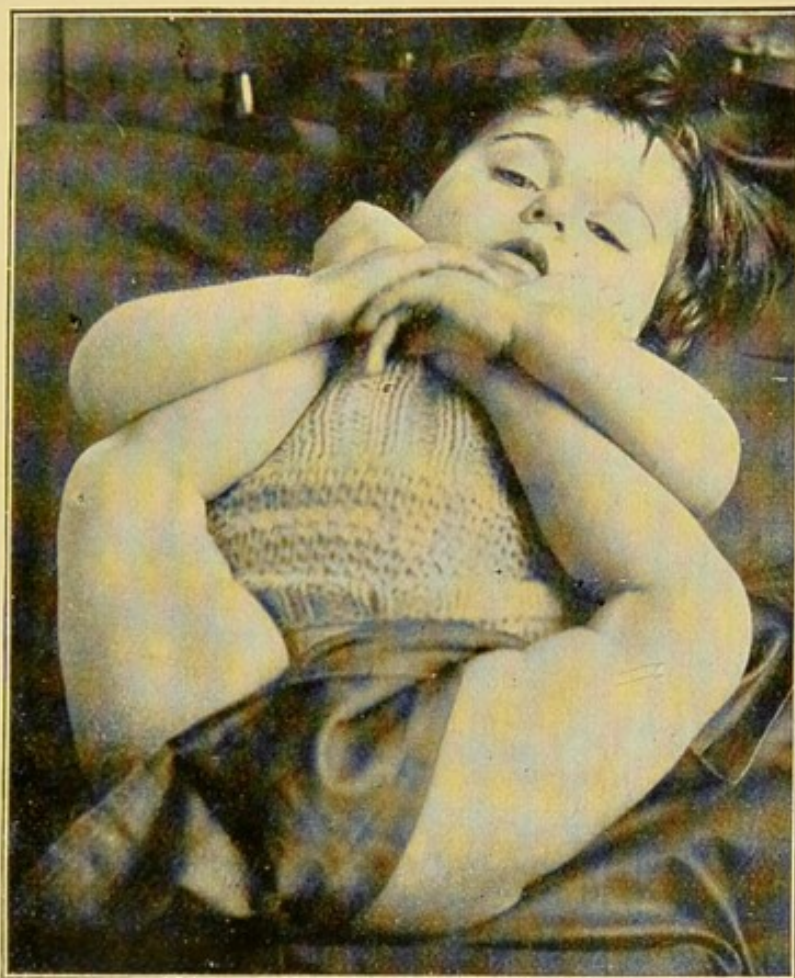

Fig. 197.—Resting Position of a Child who had Bilateral Coxa Vara with Eversion.

affords an illustration of the difficulty there may be in distinguishing between coxa vara and congenital hip-dislocation.

A radiograph of a marked case of coxa vara is shown in Fig. 198, borrowed from Frazier's above-quoted article.

As in other rachitic conditions, the deformity of the neck of the femur is frequently accompanied by other rachitic deformities; a common admixture is the combination of coxa vara with a total outward convexity of the shaft of the femur, as shown in Fig. 13, p. 24.

In estimating the upward displacement of the head of the

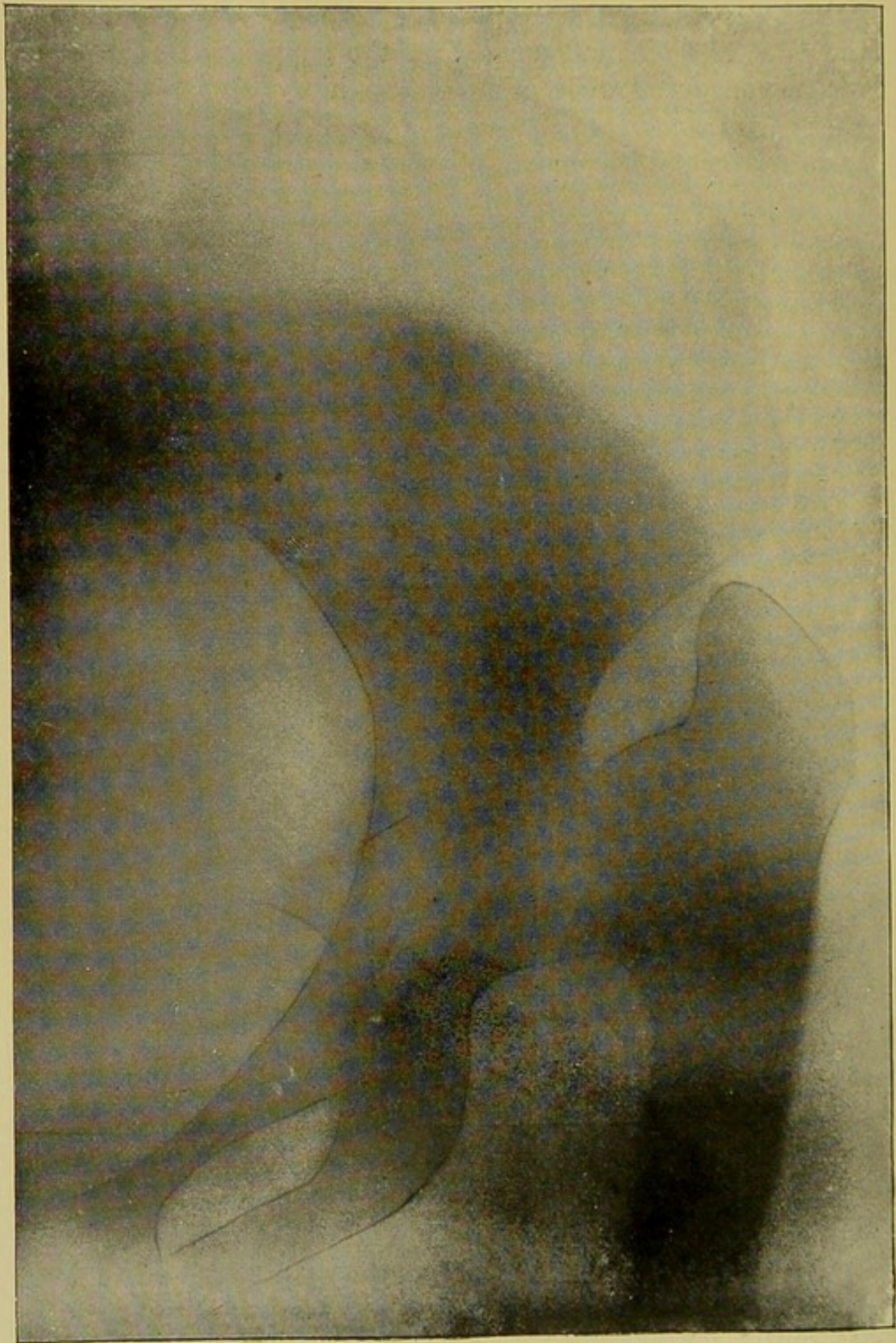


Fig. 198.—Radiograph of Coxa Vara. (*Frazier.*)

great trochanters Nélaton's line is more reliable than Bryant's triangle. The distinction of an ordinary case of congenital

hip-dislocation of old standing from a case of coxa vara is not difficult. The outward projection of the trochanters and, as a rule, their elevation are greater in the case of congenital dislocation, as also are the lordosis and projection of the buttocks. In dislocation also, on rotating the limb, the head of the bone can usually be felt to move about with a crackling sensation, which is absent in coxa vara.

Coxa vara of adolescence may be closely simulated by the results of arthritis deformans. Prof. Maydl (Prague) has described (*Wiener klinische Rundschau*) a series of seventy-four cases which he had treated by excision of the hip-joint, in which rickets and osteo-arthritis appeared to have combined in producing deformity.

I have seen two typical instances of osteo-arthritis produce deformity similar to coxa vara. Both were in elderly women. In another case which I saw recently with Dr. Napier Jones (of Plaistow), the patient, aged fifty-five, had typical osteitis deformans, with thickening and curving of the bones of the extremities, clavicles, and skull. The great trochanters were more than an inch above Nélaton's line, and the progression was of the scissor-legged type. In the case of osteo-arthritis, the deformation may be confined to the articular parts of the bones and not involve the neck of the bone. In the cases of traumatic arthritis deformans, the neck of the bone may also be unaffected. For this reason it seems to me better to describe rachitic coxa vara separately from deformity caused by arthritic, traumatic, and other causes.

Age.—Most cases of rachitic coxa vara develop probably at an earlier age than is usually supposed. Two cases have been mentioned in which the deformity occurred before the age of two years; I have observed several other cases before the age of six years. Many cases begin during the period of rapid growth that precedes puberty—*i.e.* between the ages of nine and thirteen. Many cases, again, develop at puberty. Since the epiphyseal cartilage between the head and the shaft of the femur remains until between the eighteenth and nineteenth year, marked rachitic changes may occur in the neck of the femur up to that period.

Pathology.—From the foregoing observations it may be gathered that various conditions may cause incurvation of the

neck of the femur. The most important of these is *rickets*. In infants the nature of the affection is obvious. By the kindness of Dr. W. S. Colman, I have examined a section from a wedge of bone removed by Mr. Keetley from the neck of the femur in an adolescent case. The structure of the bone shows a marked and active rachitic change, excess of fibro-vascular tissue, and diminution of bone and normal marrow.

Treatment.—During the active stage of rickets, as evidenced by local pain in the hip and general enlargement of epiphysis in young children, and by general weakness and anæmia, the condition is curable by rest and extension. In the early period the patient is to be treated in bed with a weight-extension, care being taken to maintain the lower limbs in good position, *i.e.* with the feet pointing forward. Gentle passive movements and massage should be combined with this mode of treatment.

After the acute stage has passed, the patient may be allowed to walk supported by walking-apparatus, consisting of a pelvic band and leg-irons, the former provided with perineal straps that transfer some of the weight of the body from the ischial tuberosities to the instrument. By this plan I have removed existing deformity and prevented its farther progress in three cases of infantile and one of adolescent coxa vara. If the condition is not treated until the bones have become hard, some operative measures are required. In some earlier cases the unnecessarily severe operation of sub-trochanteric excision of the head and neck of the femur was done. Hofmeister suggested sub-trochanteric osteotomy of the femur. This operation was first performed in England by Keetley,* Watson Cheyne,† and others. Kraske,‡ in a case of marked double coxa vara, cut down on the anterior inter-trochanteric line, raised the periosteum, and resected a wedge-shaped portion with its base two centimetres wide and directed antero-superiorly. Continuous extension was kept up during healing.

The operation that in my opinion is most likely to be of

* Keetley, *Illust. Med. News*, 1888.

† Watson Cheyne, *Clin. Soc. Trans.*, 1894.

‡ Kraske, *Centralblatt für Chirurg.*, 1896, No. 6.

value is that recommended by Hofmeister* in a recent article on coxa vara. This is *inter-trochanteric osteotomy*.

Division of the adductor tendons may be required when adduction is marked. In the treatment of this as in other

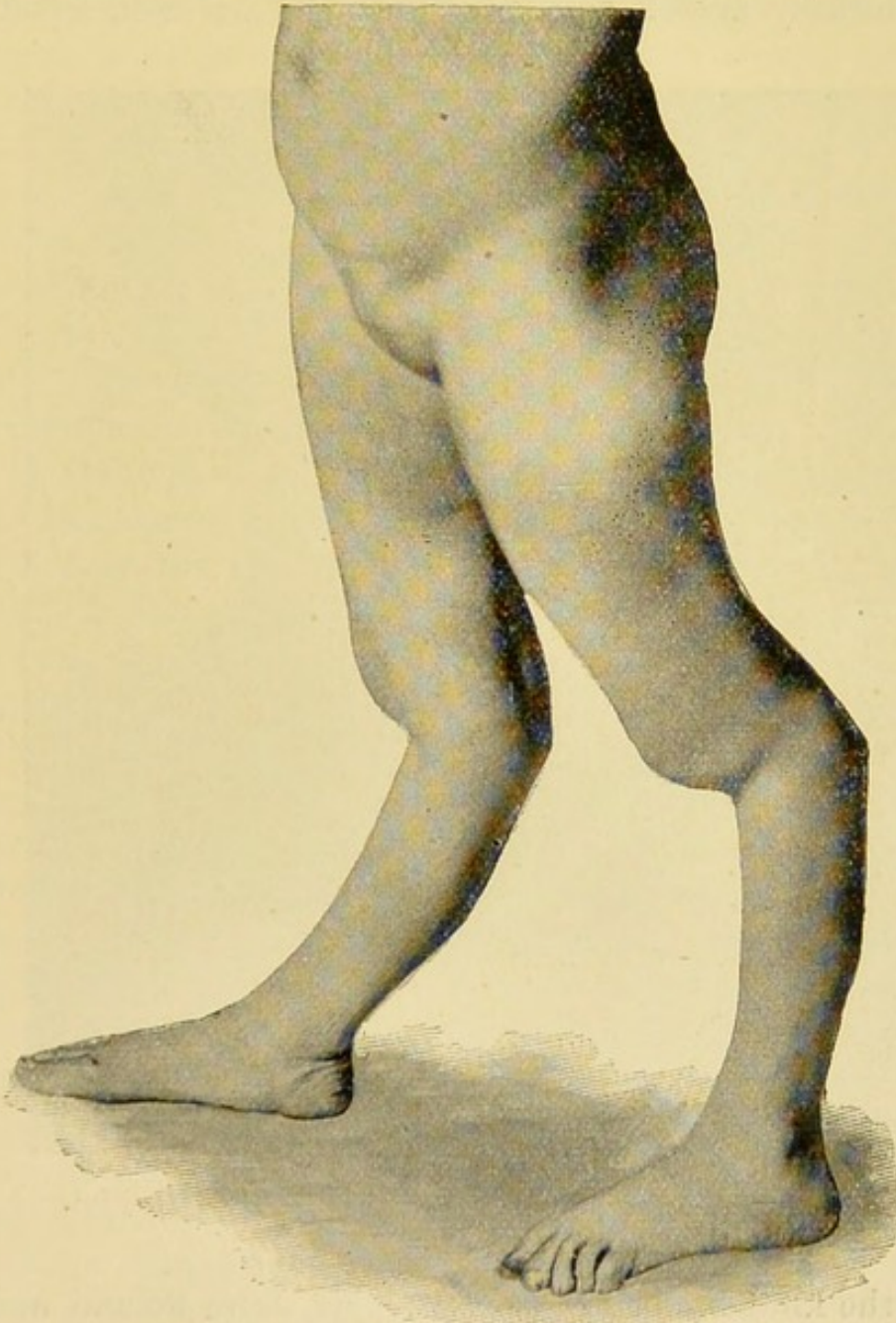

Fig. 199.—Rachitic Back-knee. (John Poland.)

rachitic affections, no operation should be performed whilst the bones are soft, or, in other words, whilst rickets continues. In unilateral cases, operation will rarely be necessary.

Before deciding to operate in any given case, it must be

* F. Hofmeister, *Beit. zur klin. Chirurg.*, 1898, vol. 21, part 2, p. 299.

remembered that in course of time the lameness and difficulty in walking tend to disappear and a reasonable time should be allowed for this natural improvement to be effected.

Rachitic Back-knee, Genu Retrorsum.—The character of this deformity is well shown in Figs. 199 and 200, which I

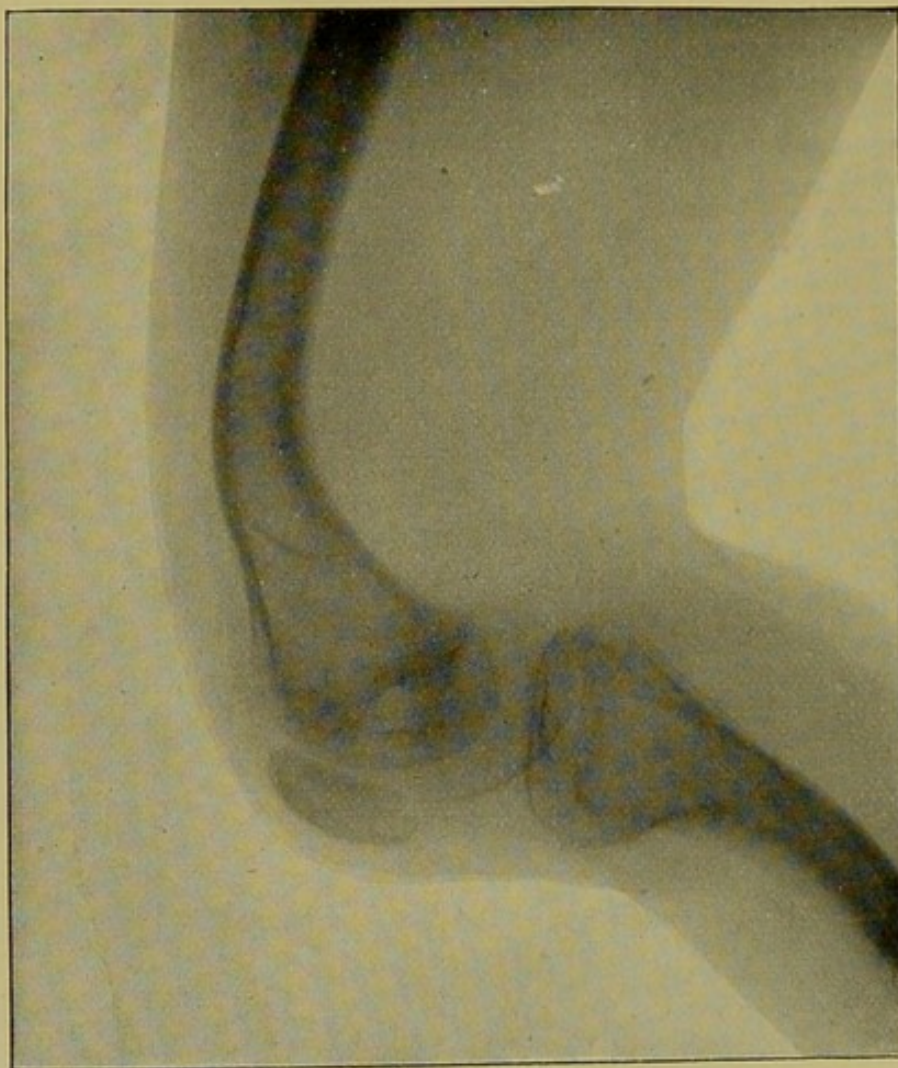


Fig. 200.—Radiograph of the Bones about the Right Knee-joint.

owe to the kindness of my colleague, Mr. John Poland, and to the editor of the *British Medical Journal*. The patient is a young woman who for a short time attended among my out-patients at the City of London Orthopædic Hospital, where she was admitted under Mr. Poland, who divided both tibiæ by Adams's saw and straightened them. Mr. Poland contemplated performing additional operations on the femora.

Anatomy.—The radiograph shows that the chief part of

the deformity consists in a sharp backward bend of the tibia immediately below its upper epiphysis. In this instance the deformity is complicated and increased by an anterior bend of the femur.

Deformities of the Long Bones of the Upper Limb.—The *humerus* is subject to arrest of growth in severe infantile paralysis, and injuries to the epiphyses. In rickets an anterior or antero-external curve is not uncommon. Out of 1,000 cases of rickets, Reeves found that the humerus was deformed in 115 instances. Other rachitic deformities of the humerus are attributable to pressure against the nurse's arm, etc.

The *radius and ulna* are sometimes the seat of congenital defects. Total absence of the ulna has been observed and, rather more frequently, absence of the olecranon.

The lower part of or the whole radius is not infrequently absent in cases of club-hand (see Fig. 170). In this example of deformity the radius and the thumb were totally absent, and the carpus articulated with the outer aspect of the lower end of the ulna (see also p. 215).

In the earlier part of this work a case of congenital curving of the bones of both forearms has been referred to (p. 13).

Arrest of growth from abnormalities of the epiphyseal cartilage at the lower end of one of the bones of the forearm causes diminished growth in length of the affected bone, and deviation of the hand towards the shorter bone. The cause of the loss of the epiphyseal cartilage may be some congenital abnormality, the result of septic inflammation or injury.

Treatment.—During the period of growth excision of the epiphyseal cartilage of the longer bone, chondrectomy, is the proper means of correcting the deformity. When the cartilages have disappeared, resection of a portion of the longer bone is required.

Rachitic Deformities of the Bones of the Forearm.—Rickety curving of the shafts of the radius and ulna is less common than it is in the corresponding bones of the leg. When it occurs, it is usually due to the action of the flexor muscles causing the bones to yield with a convexity towards the dorsal surface. Hoffa mentions a spiral twisting of radius and ulna such that a certain degree of pronation was

present. The treatment required in such cases consists in manipulation and the application of a straight splint.

Deformity of the Forearm from Fractures.—Of these, greenstick fractures at the lower end of the shaft of the radius are most common. A rickety child falls and is supposed to have sustained a sprain for which no medical treatment is sought. After a week or two the swelling of the callus and some deformity of the forearm are observed.

In such cases the bone can usually be refractured by manual force. If this is not found to be possible, osteotomy should be done and the fracture properly set.

Fractures in the middle of the shafts of either or both bones rarely cause subsequent trouble. There is, however, in the museum of St. Mary's Hospital a specimen which I have described as follows :—

140. The bones of the right forearm showing a fracture of the radius above the insertion of the pronator teres.

A mass of ossified callus unites the two bones. The upper fragment is supinated by the supinator brevis. The lower fragment has been drawn inwards and pronated by the pronators teres and quadratus. The specimen shows that the fracture was not properly treated, not having been put up in complete supination.

In such cases, besides performing osteotomy, redundant callus will need to be chiselled away.

Badly-set Collis's fractures and fractures at the upper end of the ulna, combined with dislocation of the head of the radius, may also require osteotomy and, in the latter case, removal of the head of the radius.

SECTION IV.

DEFORMITIES CAUSED BY CHANGES IN THE
LARGE JOINTS OF THE EXTREMITIES.

THE SURGICAL ASPECTS OF SPASTIC PARALYSIS, ETC.

The Ankle Joint.—Congenital deformities and paralytic contractures have already been dealt with under "Club-foot," etc. The chief remaining deformities may be briefly noticed.

Traumatic deformities, e.g., those resulting from badly-set Pott's or Dupuytren's fractures.—When the eversion of the foot is great and causes disability to the patient, the condition can be greatly improved by osteotomy of the fibula on a level with the lower surface of the tibia and suture of the detached internal malleolus to the tibia; usually section of the tendo Achillis will be required. A good radiograph should be taken as a guide of what is to be done.

Suppurative conditions that have been allowed to terminate in ankylosis in a bad position usually demand excision.

Rheumatoid arthritis is to be relieved by the use of light support.

Tubercular arthritis, unless very rapid, should be treated for a time by conservative measures, and if, after a patient trial, these fail, free excision is required.

Deformities of the Knee-joint.—All the various kinds of deformity are met with at the knee-joint: thus, congenital defects, *e.g.,* intra-uterine pressure deformities; neurogenous, myogenous, dermatogenous, and arthrogenous.

Congenital Defects of the Knee-joint and Congenital Genu Recurvatum.—Congenital dislocation of the knee-joint may be either unilateral or bilateral. No hereditary influence has been observed. The tibia in nearly every recorded case has been displaced forwards. Combined with the forward dislocation there may be an inward or outward or a rotatory

displacement of the tibia. Like other congenital deformities, congenital dislocation of the knee, especially when it is bilateral, may be accompanied by other errors of development.

Symptoms.—In congenital dislocation of the knee forwards, the joint is in a state of hyper-extension; there is also some accompanying flexion of the hip-joint. If the receding angle

between the thigh and the leg on the anterior aspect is very obtuse, the condition is termed "congenital genu recurvatum" (see Fig. 201); if it approaches a right angle, it is termed a congenital dislocation.

The hyper-extension can be increased or diminished by passive force, but the joint when released returns to its original form. Attempts to force the knee into the flexed position cause pain. The femoral condyles are prominent on the posterior aspect of the limb.

Anatomy.—On opening such joints, the articular surfaces have been found to be altered in form; the trochlear surface of the femur is prolonged upon the anterior aspect of the bone, whilst

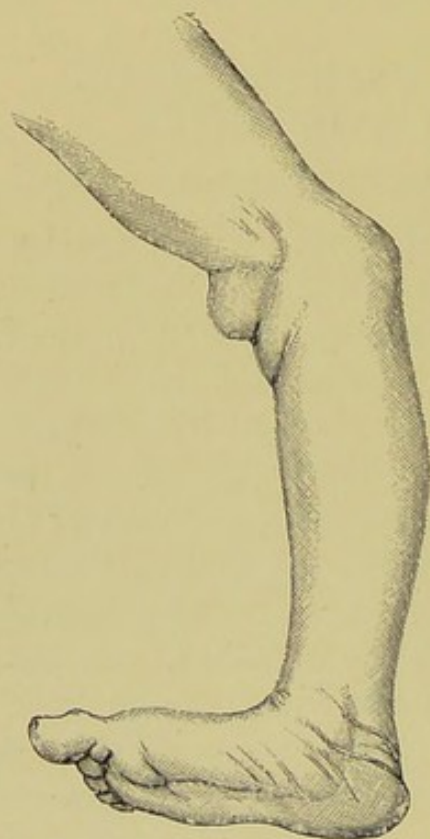


Fig. 201.—Congenital Genu Recurvatum. (*Shattock: Treves's "System of Surgery."*)

the condyles are small and malformed. In severe congenital dislocation of the knee the patella may be absent (Maas).

Treatment.—This consists in flexing the knee as nearly to a right angle as possible and fixing the knee in this position with a plaster or other apparatus. The hip- and ankle-joints must be fixed at the same time. At intervals of a week, massage and passive movements should be done. In unilateral cases, where the patella is present, a good result can be promised. In complicated cases a perfect limb is seldom obtained.

Congenital Contracture of the Knee-joint.—In some instances there is present at birth a fixation of the knee in the

flexed position. The defect consists in some cases in the presence of a web of skin joining the buttock to the heel (see Fig. 2, p. 12), in other instances only the muscles and ligaments are at fault.

This condition has been observed alone or combined with contracture of the hip-joint, spina bifida, etc. It is most often met with in monsters in its severer grades.

Treatment.—Instruments furnished with lateral steel rods and a rack-joint at the knee to produce gradual extension will suffice in slight cases. When the skin is contracted at the back of the knee, a plastic operation may be required.

Congenital Affections of the Patella.—*Absence of the patella* has been observed by Maas in severe congenital dislocation of the knee. The suppression of the bone in this condition is easily explicable as the result of intra-uterine pressure-atrophy. The importance of the condition consists in its prognostic significance; in the absence of the patella a perfect knee-joint cannot be obtained.

Incomplete Congenital Dislocation of the Patella.—This designation is applied to a condition in which, when the knee is extended, the patella lies upon the external condyle, but when the knee is flexed the patella returns to its normal position.

Intermittent Congenital Dislocation of the Patella.—The condition to which this term is applied is the converse of that last mentioned. The patella lies in its normal position in the extended state of the limb, but becomes displaced outwards when the knee is flexed.

Complete Congenital Dislocation of the Patella.—In this condition the patella rests on the outer surface of the outer condyle in all positions of the joint; its displacement is sometimes increased by flexion of the knee. There is often a concomitant outward bending of the leg on the thigh (congenital genu valgum) or an outward rotation of the leg.

Illustrative Case.—A female infant brought to me for severe congenital calcaneo-valgus (see p. 159). On examining the right leg, it was seen to be rotated out (Fig. 120). The mother had noticed the fact that a cracking sound was heard in the knee-joint at times. This I found to be due to movement of the patella upon the outer surface of the outer condyle. The displacement of the patella in this case was accompanied by marked outward rotation of the leg at the knee. By daily

manipulation the displacement of the patella was corrected, and after some months the tendency to displacement had disappeared.

In those cases of complete outward congenital luxation of the patella in which congenital genu valgum is also present,

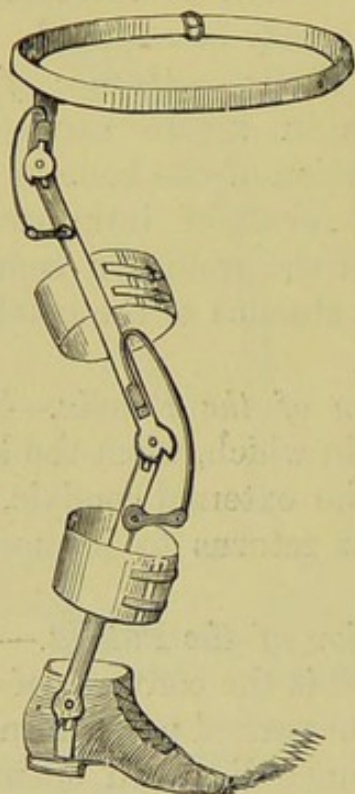


Fig. 202.—Walking Instrument with Extension Springs for Hip and Knee. (Heather Bigg.)*

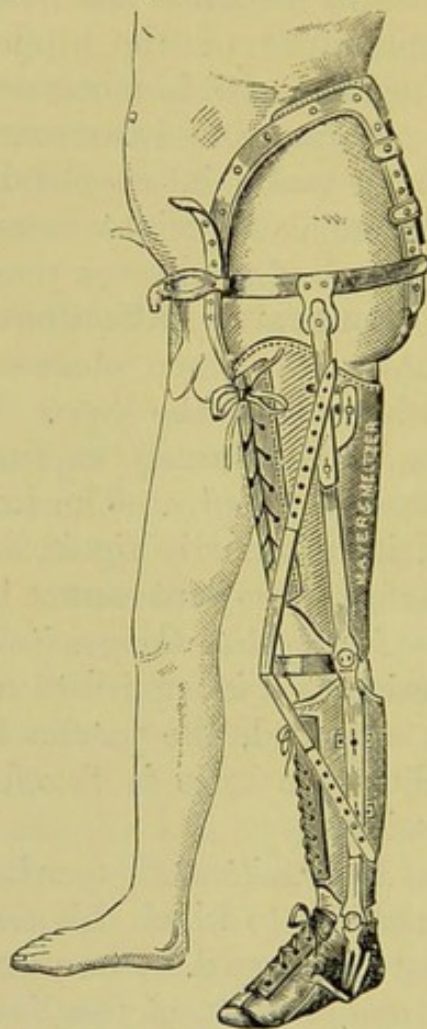


Fig. 203.—Hessing's Apparatus with Elastic Springs for Extension of the Knee. (Hoffa.)

both deformities may be corrected by manipulative and instrumental treatment combined, if such treatment is begun in early infancy.

Acquired Contracture and Ankylosis of the Knee.

Dermatogenous contractures from scars are not uncommon and require as treatment gradual extension or plastic operations, according to the duration of the condition.

Myogenous contractures from rheumatism or ischæmia

* For the use of Figs. 202, 237, 259, and 299 I am indebted to Mr. H. R. Heather Bigg.

are occasionally seen, and may require massage and mechanical treatment, with or without tenotomy.

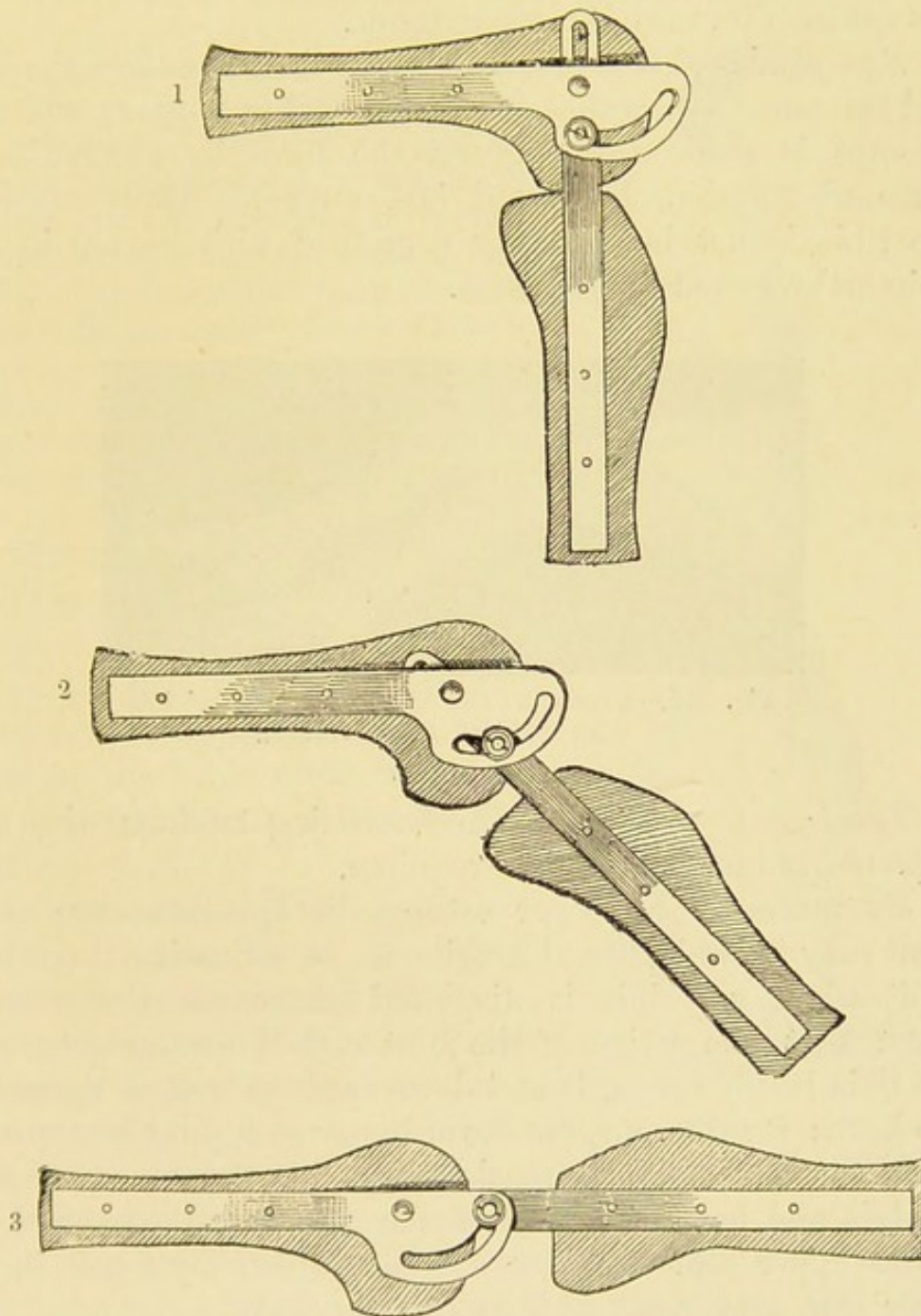


Fig. 204.—Braatz's Plan of Joint in Instruments used at the Knee in Cases of Flexion-contracture. (*Hoffa.*)

Neurogenous Contractures.—These are chiefly due to infantile and spastic paralysis. The contraction of spastic paralysis is treated separately below. The deformities of the knee-joint caused by infantile paralysis are: (1) contracture; (2) paralytic genu recurvatum.

Paralytic contracture of the knee arises when the extensors of the knee are completely paralysed and the flexors retain more or less power. In bedridden, paralysed patients the contraction may become extreme.

Symptoms.—These are, an inability fully to extend the knee and the tense appearance of the hamstring tendons when an attempt is made to straighten the limb by passive force. Outward rotation, backward and outward displacement of the tibia, is not infrequently combined with flexion in this as in arthrogenous contracture.

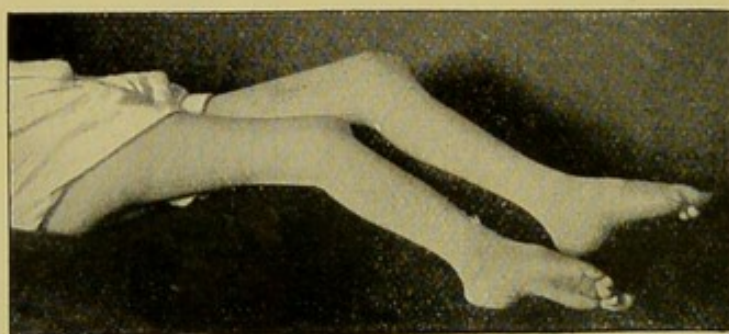


Fig. 205.—Paralytic Contracture of the Knee-joints with Paralytic Equino-valgus.

Treatment.—Section of the hamstring tendons with subsequent gradual extension is required.

By means of a proper orthopædic apparatus the treatment may be ambulant throughout. In adjusting the instrument when the tibia is displaced backwards care must be taken that the action of the joint at the knee tends to carry the tibia bodily forwards and downwards as well as extending the knee; for this purpose the ordinary rack-joint is not sufficient. A free joint is needed opposite the centre of each condyle, and below it a semicircular slot in the expanded end of the upper joint receives a screw which is fixed in the lower iron and works in the slot (Fig. 204).

To this apparatus an extending spring may be added (*see* Figs. 202, 203), or daily improvement in position may be obtained by manipulation and maintained by fixing the screw below the joint with the limb in an improved position.

When the position of the limb has been corrected, the patient may be allowed to walk with the knee fixed in the extended position.

Illustrative Case.—A girl, aged fifteen, whose lower limbs are shown in Fig. 205, had been paralysed from infancy and unable to walk without crutches. Several operations—which had not, however, been followed up by instrumental treatment, and hence proved failures—had been performed upon the feet, but no treatment had been applied to the knees. The latter were flexed to nearly 45° and extremely rigid. After I had divided the peronei tendons and the hamstrings at both knees a course of splinting and daily manipulations was adopted and the deformities were removed. In this case, though the paralysis of the extensors of the knee is complete on both sides, the patient is enabled, by walking instruments that reach to the waist, to get about without the aid of crutches.

Paralytic Genu Recurvatum.

—This is not a very common deformity; it occurs in some cases of partial paralysis of the anterior muscles of the thigh. The position of the limb when it is used in progression is as shown in Fig. 206.

Causation. — This deformity occurs where there is partial paralysis of the quadriceps extensor muscle, and it is due to the patient's using the limb so that it compensates in a measure for the muscular weakness. In taking a forward step with the paralysed limb the leg is swung forwards so that the heel comes to the ground with the limb in full extension, the patient keeps the centre of gravity of the body in front of the centre of the knee, so that when the limb at each alternate step comes to bear the weight of the body the latter tends to hyper-extend the joint, and in course of time the posterior and the crucial ligaments become stretched, so that the extension movement becomes more than physiological. Hoffa quotes Volkmann's comparison:—

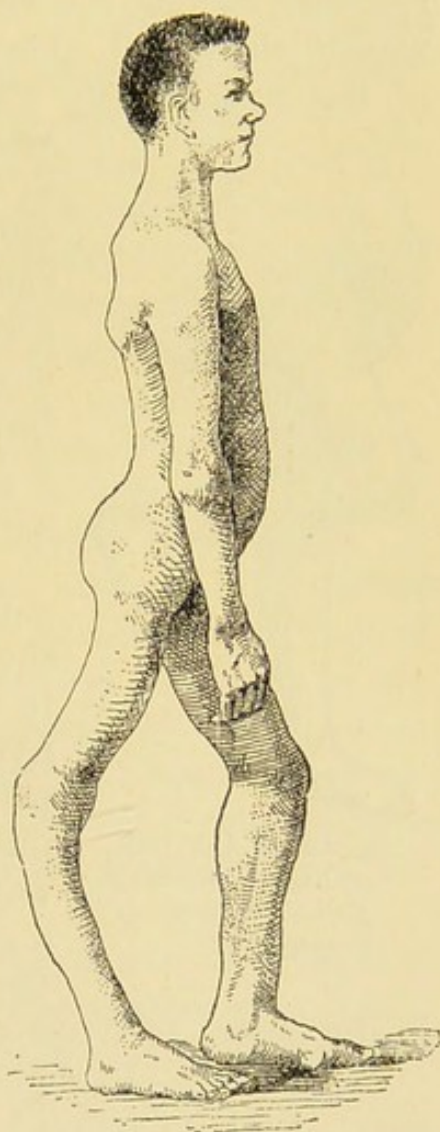


Fig. 206.—Paralytic Genu Recurvatum. (Hoffa.)

"If you take a pocket-knife in the hand and hold it by the haft with the point of the blade upon the table, with the back of the knife looking away from you, the blade will represent the leg, the haft the thigh, and the joint the knee, whilst the hand grasping the haft represents the body of the patient. By slight alterations in the direction of

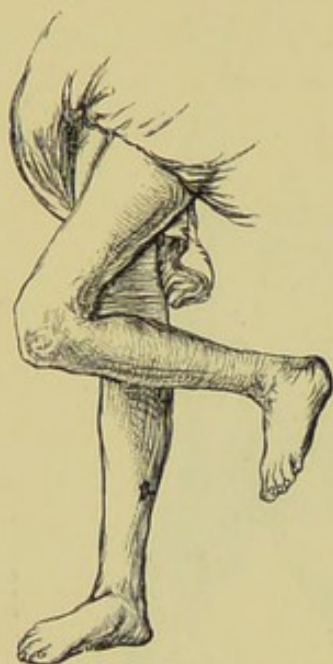

Fig. 207. — Ankylosis of Knee. (*Clutton, Treves's "System of Surgery."*)

pressure movements can be produced at the joint. . . . If the pressure falls behind the joint, that is, on the side of the edge of the knife, the blade springs back when the pressure is sufficient; if the pressure falls towards the back of the knife, the blade opens, and if it is fully opened you can exert any amount of pressure on the handle."

To recapitulate these points: the patient, in taking a step forward, swings the leg forward so that the foot comes to touch the ground with the knee in a hyper-extended position, in which the patient is able to bear his weight on the limb without the knee suddenly giving way. This mode of progression causes a gradual yielding of the ligaments at the back of the knee, and an increase

in the degree of hyper-extension allowed at the joint.

Treatment.—In slight cases an apparatus with a "front-stop" joint to prevent over-extension is needed; in more severe cases an extension-spring at the knee is required.

Paralytic Flail-joint at the Knee.—When both flexors and extensors are fully paralysed, the knee-joint moves passively in all directions.

Treatment.—In order to render progression possible, the knee-joint must be fixed by suitable apparatus, or arthrodesis must be performed in order to produce ankylosis.

Arthrogenous Contractures of the Knee.—Pyæmia, post-scarlatinal, gonorrhœal, and other infective inflammations, especially tubercle, give rise to many cases of contracture. The tubercular cases are so much more common that they may be taken first.

Deformity of the Knee from Tubercular Arthritis.

—The knee-joint is a very common site for tubercular disease. The general symptoms and management are so fully described in works on general surgery* that there is no need to go into details here. Most of the cases that require operative measures result from the want of perseverance in conservative treatment. The displacement in an ordinary case of untreated tubercular disease of the knee is threefold. The knee is flexed, the tibia is displaced backwards and rotated outwards. This applies equally to other forms of knee-joint disease and to some forms of contracture; thus, after traumatic infection, pyæmic or gonorrhœal suppuration, the knee tends to the same deformed condition.

Treatment.—Prevention of deformity is of the first importance. Plaster bandages, though they fit well when first applied, are apt to become loose from wasting of the limb. A leather splint moulded to the limb and stiffened with lateral steel bands is a much better splint. A simple appliance of this kind worn night and day, combined with rest in the horizontal position, will, in the majority of cases, secure subsidence of active symptoms. When all heat and tumefaction have been absent for some weeks, and if the patient is old enough to use crutches, a Thomas's knee-splint (Fig. 56, p. 87) may be worn.

If flexion is present, it should be corrected gradually. When any spasm or other signs of inflammation are present, an extension apparatus of adhesive plaster should be applied below the knee and arranged so that the traction is at first in the line of the deformity. This is done by supporting the leg on a box covered by a soft pillow; the height of the box will vary according to the degree of flexion at the knee.

When all active symptoms have disappeared, an apparatus allowing the patient to walk with crutches, *i.e.*, without using the displaced leg, and tending to effect gradual rectification of the bad position, is required. Thomas used his splint for this purpose by applying it so that the thigh-band comes in front and the leg-band behind the limb. Its use for this purpose is not to be recommended since it causes increased pressure between the anterior edge of the tibia and the femur,

* See, for instance, Howard Marsh, "Diseases of Joints and Spine."

and has frequently been observed to re-waken inflammatory symptoms. Any force that is applied should act on the leg in a downward as well as a forward direction or on the principle of Braatz's joint.

If backward displacement is present, it should be corrected before the correction of the flexion is begun. In the active state of the joint there should be added a weight working over a pulley and attached by a band passing round the upper end of the tibia, whilst a second band passes round the lower end of the femur and has a downward acting weight attached to it.

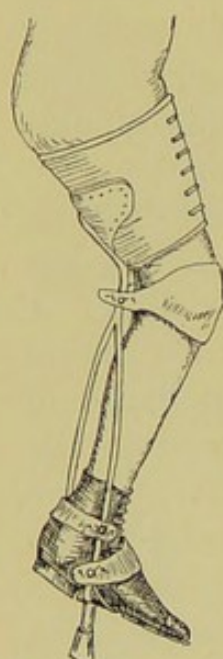

Fig. 208. — Apparatus for Palliation of Contracted Knee.

Forcible Correction under an Anæsthetic.

—This proceeding—when certain precautions against rupture of skin, arteries or nerves at the back of the joint have been taken—which is safe in cases of fibrous ankylosis after traumatic affections, must be approached with some caution in tubercular cases. In the early stages gradual correction will usually suffice to remove deformity. For manual correction the patient is placed supine on a mattress on the floor; the surgeon, standing over him, holds the knee in both hands, the fingers grasping the popliteal space. Adhesions are broken down by increasing the flexion by the weight of the surgeon's trunk.

In cases where there is backward displacement of the tibia, Bradford and Lovett use a powerful lever for correcting backward displacement of the tibia.

In cases of firm ankylosis, resection of the knee may be safely done in persons under fifteen years of age, and even in healthy young adults. After excision, a Thomas's splint should be worn for six months after the patient leaves his bed.

In cases of firm osseous ankylosis with enlargement of the condyles, a wedge of bone may be removed from the femur.

Some patients prefer to retain the limb in the bent position rather than undergo any operation. In such cases progression can be aided by apparatus (Fig. 208).

Internal Derangement of the Knee.—This condition, first

described by Hey, sometimes yields to orthopædic treatment. When an obvious loose cartilage or other free body in the knee can be felt, or is shown by a radiograph, or when the fore part of the internal semilunar cartilage can be felt to slip forwards and backwards, there should be no hesitation in performing arthrotomy. In other cases these indications are absent, and then a support that prevents lateral and rotatory movements should be tried. In several cases I have found this succeed perfectly. After the larger instrument has been discarded, the smaller "patella truss" may be worn for a time with advantage (Fig. 209).

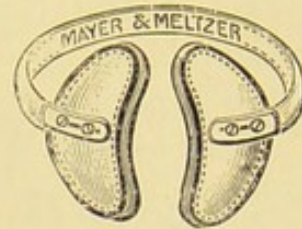


Fig. 209—Patella Truss.

Deformities, etc., of the Hip-joint.—The functional importance of the hip-joint, and the known predilection of tubercle for this joint, together give a gravity to affections of this above all other joints of the body. This joint should be carefully examined in every child that is observed to limp.

Among the many local conditions that may occasion deformity or impaired movement at the hip-joint may now be enumerated—

1. *Dermatogenous causes*, e.g., scars from burns, inguinal abscesses, etc.

2. *Desmogenous causes*, e.g., contraction of the fascia lata from long maintenance of an abnormal position of the limb, or shrinking of the periarticular structures owing to previous inflammation.

3. *Myogenous Causes*.—Notable among these is contraction of a psoas muscle from spondylitis, perityphlitis, perinephritis, etc.

Permanent contraction of muscles is common in cases of hip-disease and, after the original disease has disappeared, may remain as the sole cause of deformity.

4. *Neurogenous Causes*.—Such is the contracture of muscles observed in some cases of infantile paralysis, a condition comparable to paralytic club-foot. Under this head may be included the neurosis of the hip-joint or hysterical hip.

5. *Arthrogenous Causes*.—Of these dislocations, tubercular coxitis, arthritis deformans coxæ, and other forms of synovitis and arthritis are the commonest.

6. A number of other conditions, including the results of intra-articular fractures, coxa vara, and painful conditions of the bone—*e.g.*, epiphyseal hyperæmia, the hypothetical basis of “growing pains”—may simulate affections of the hip-joint.

Symptoms.—With a view to arriving at an exact diagnosis, each symptom must be accurately recorded. Careful consideration of the history of a case will often serve to establish a diagnosis.

Limitation of the physiological action of the hip-joint is shown by various symptoms, the chief of which are:—

1. Lameness.
2. Alterations in attitude.
3. Atrophy and, in cases of joint-disease, there may also be—
4. Pain in hip or knee.
5. Muscular spasm.
6. Swelling.

Abnormal Attitude.—The cases that come to the notice of the orthopædic surgeon are chiefly those in which there is contracture or ankylosis. In such cases the abnormal attitude, due to the altered position of the limb, whether in standing, walking, lying, or sitting, is often the most pronounced feature and, in all forms of joint-affection, requires careful study, and in none is it of greater importance than in the case of the hip. The different abnormal attitudes may be given as follows:—

1. *Fixation in Extension*.—The patient is able to advance the foot in walking only by wheeling the corresponding half of the pelvis forwards. In the course of time the sacro-iliac and intervertebral ligaments become stretched, and the increased mobility of the corresponding joints enables the patient to move forward with the aid of a stick carried in the hand of the affected side. In sitting, the pelvis rests on the front edge of the seat, and by a compensating bend of the lumbar spine (kyphosis) the patient is enabled for a time to assume a more or less upright position.

2. With one hip-joint fixed in the flexed position, the patient stands with the sound joint flexed, whilst the lumbar spine is arched backwards (lordosis) in order to bring the weight of the body over the supporting feet.

When both hip-joints are fixed in the fully-flexed position, it may be impossible for the patient to stand at all without support.

3. If one limb is fixed in abduction, the sound limb must be adducted to bring the legs parallel in standing. This necessitates a tilting of the pelvis downwards on the side of the affected limb, the latter being thus virtually or apparently elongated. The tilting of the pelvis is brought about by a lateral curving of the lumbar spine, convex towards the affected side.

Abduction affecting both sides gives rise to a frog-like attitude.

4. *Abduction with Flexion.*—This is a common condition, because it is the usual position in early tubercular coxitis. When the legs are placed together in standing, the pelvis is inclined downwards and forwards on the affected side; in other words, there is lateral curvature, combined with lordosis of the lumbar spine. There is apparent lengthening of the lower limb on the affected side.

5. *Adduction.*—The sound limb is abducted and the pelvis is tilted upwards on the affected side by a lateral curve of the lumbar spine convex to the sound side. There is apparent shortening of the affected limb (Fig. 233).

Adduction affecting both hip-joints, when marked, gives rise to the scissor-legged deformity, a condition in which the patient is severely handicapped, and is obliged, in progression, to swing the body forward on crutches. Adduction combined with flexion of the limb is one of the more frequently recurring deformities, since the limb assumes this position in the later stages of tubercular coxitis, when not prevented by suitable treatment.

Diagnosis and Method of Examination.—The patient should lie upon a firm, flat couch. The degree of flexion is estimated by placing the deformed limb in such a position that all lordosis disappears; abduction and adduction are estimated by so placing the affected limb that the anterior-

superior spines of the ilia are at the same level, and that all scoliosis and tilting of the pelvis disappear. This having been done, the sound limb is placed in full extension, so that

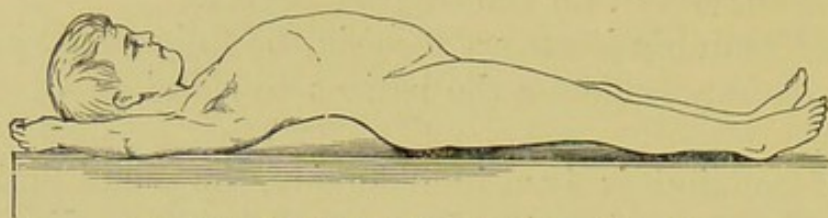


Fig. 210.—Method of Examination of the Hip.

Child with some fixed flexion of the right Hip. The lower limbs are parallel in extension; therefore the spine is lordotic.
(Owen's "*Surgical Diseases of Children*.")

the pelvis may be held at its normal inclination by the ilio-femoral ligaments (Figs. 210–212).

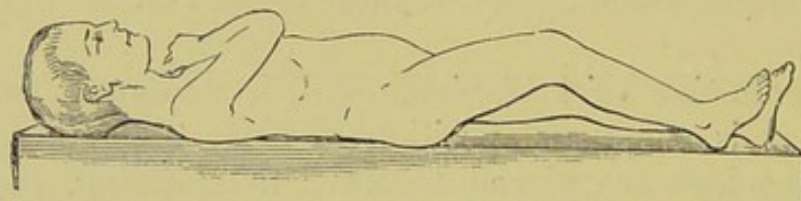

Fig. 211.—The same as in Fig. 210, with the affected Hip flexed : the Lordosis disappears.
(Owen's "*Surgical Diseases of Children*.")

The nature of the disability may, in some cases, be ascertained; for instance, if it be found that the hip-joint of

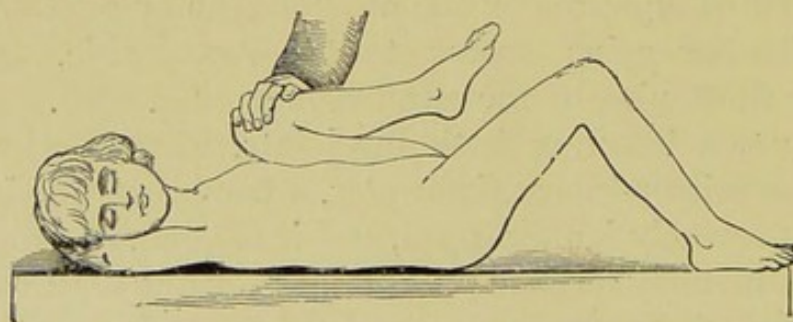


Fig. 212.—H. O. Thomas's Mode of ascertaining the Degree of Flexion.
(Owen's "*Surgical Diseases of Children*.")

the affected limb is capable of a certain degree of passive movement without any alteration in the position of the trunk, a complete ankylosis is excluded, and the condition is probably one of contracture; but in every instance the history of the case should be fully considered, and other symptoms such as wasting, pain, swelling, and muscular

spasm should be looked for, and where any doubt exists a radiograph will often give valuable help.

Muscular spasm is indicated by slight involuntary startings of the limb in the opposite direction to that in which the surgeon's hand is endeavouring to move the joint. The slightest force will elicit this symptom.

The exact estimation of angular deformity at the hip may be measured by an ankyrometer such as that of Lorenz, but a practised observer will be able to record the deformity with sufficient accuracy for practical purposes. The utmost gentleness must be used throughout the examination.

In the case of an infant in arms, the patient may be first examined on the mother's lap. In tubercular coxitis, abduction of the limb is opposed by muscular spasm, whilst in the case of psoas-contraction abduction is usually unopposed. An anæsthetic should not be given before all possible observations have been made without it. The distinction between organic psoas-contracture from tubercular spondylitis and contracture due to early hip disease is sometimes ambiguous. If there is organic shortening of the psoas the range of the extension movement at the hip-joint remains diminished when the patient is anæsthetised. By this method of examination the nature of the disability will be made clear in all but a few cases which may require to be kept under observation for some time before a decided opinion can be given. The more important morbid conditions demand separate consideration. These are: congenital dislocation of the hip, tubercular coxitis, "hysterical hip," and rheumatoid arthritis.

Congenital Dislocation of the Hip.—This deformity, which may be unilateral or bilateral, is marked at birth by an instability of the hip-joint, and subsequently by upward displacement of the head of the femur with all its consequences; shortening of the limb, lameness, and when, as is usual, the head of the femur is displaced backwards, by secondary changes in the spine, *e.g.* lordosis.

Anatomy.—In considering the anatomy of the condition a clear distinction must be made between what may be called its essential morbid anatomy, *i.e.* the state of the articulation

at birth, and its secondary anatomy, that is the changes produced in the course of time, which resemble those in old unreduced dislocations.

At birth the displacement is easily reduced and as easily returns. Mikulicz* states that at birth (1) the head and neck of the femur are nearly normal, (2) the acetabulum is

large enough to retain the head of the femur, (3) the capsule is large and roomy, (4) the ligamentum teres is either absent or is thickened and elongated. The parts are all nearly normal, and there is no obstacle in the way of reduction.

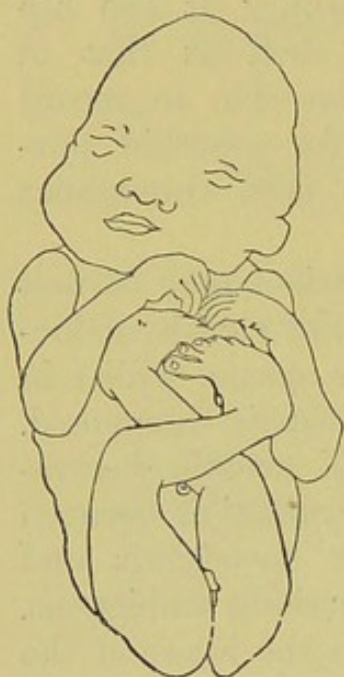

Fig. 213.—Intra-uterine attitude of a Foetus born with double Congenital Dislocation of the Hips.

Lockwood† has dissected two foetuses in which a similar condition was present, and found that the cartilaginous rim of the acetabulum was absent, and he concluded that: "The absence of the margin of the acetabulum is a prime feature, and it predisposes to displacement of the head of the femur either before or after birth." This conclusion is not supported by a case of double congenital dislocation that I examined and in which, though the acetabula were small, their rim of cartilage and the

cotyloid ligament were present and of normal structure, as shown by the microscope. The result of the dissection of my case may be given here since it affords an example of what I believe to be the usual primary anatomy in congenital dislocation of the hip. The subject was a still-born foetus which presented, besides congenital dislocation of both hips, slight hydrocephalus, spina bifida, and a deformity of the chest-wall with double talipes equino-varus. The deformity of the chest-wall and the position into which the lower limbs naturally fell, made it easy to place the foetus in the position it had held when *in utero*. (Fig. 213.)

* J. Mikulicz, *Arch. für klin. Chirurg.*, Bd. xlix., heft. 2.

† Lockwood, *Trans. Path. Soc.*, 1887.

On dissection both hip-joints had the appearance shown in Fig. 216.

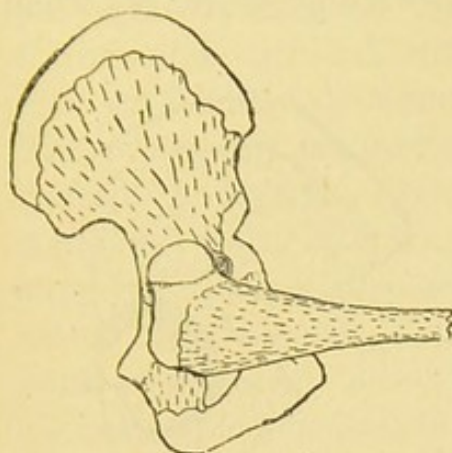


Fig. 214.—Original position of the Bones after Removal of the Capsule.

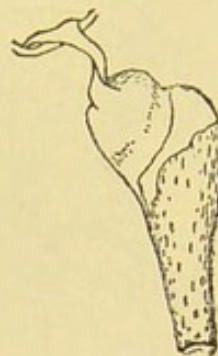

Fig. 215.—Head of Femur, seen from behind.

It is slightly flattened. The ligamentum teres is drawn out and flattened.

The femora were rotated out and their heads rested on the ilia above the acetabula. In the flexed position, inward

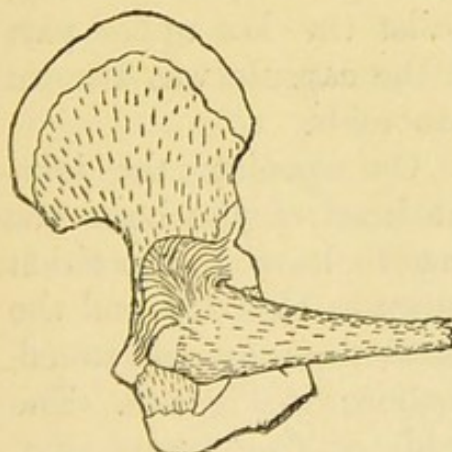


Fig. 216.—Appearance of Hip-joint after Removal of all the Soft Parts external to the Capsule.

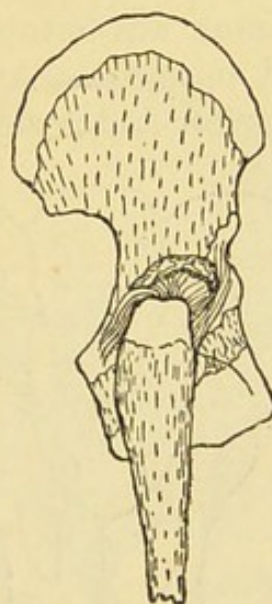

Fig. 217.—The same (Fig. 216) after reducing the Dislocation by Inward Rotation and afterwards extending the Joint.

rotation through 90° caused the head of the femur to enter the shallow socket, but the slightest upward pressure reproduced the dislocation. In the extended position, inward rotation through 90° , combined with downward traction for

a quarter of an inch, caused the head of the bone to enter the socket, and so long as the limb was kept extended and rotated in it would bear some little upward pressure; but when

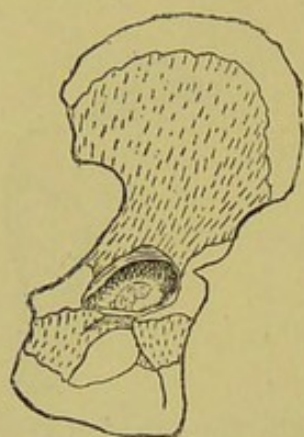


Fig. 218.

Side view of the right Os Innominatum of the Foetus shown in Fig. 213. The Acetabulum is small, shallow, and misshapen. The Cotyloid Ligament is flattened out in the upper half of the acetabular rim. The Os Pubis is not directed as much inwards as in the normal bone.

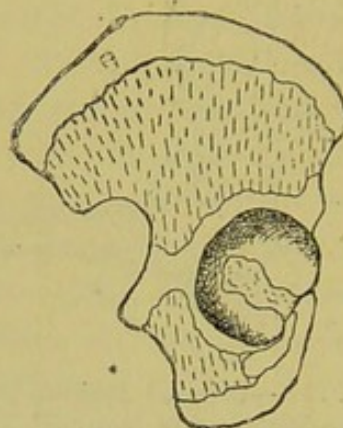


Fig. 219.—The right Os Innominatum of a Normal Foetus at Full Term for comparison with Fig. 218.

the femur was rotated out the head of the bone at once slipped upwards. After reduction in the extended position the anterior and posterior fibres of the capsule were tightened, whilst the lax upper part of the capsule was thrown into folds.

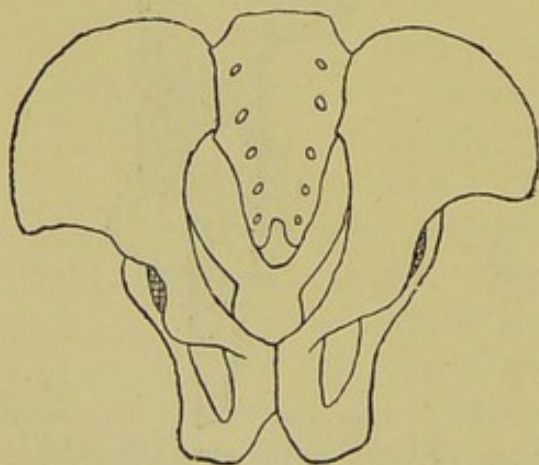


Fig. 220.—The Pelvis considerably compressed from side to side.

On opening the joint the head of the bone was seen to have the position shown in Fig. 214, and the acetabulum was narrowed, as shown in Fig. 218. The head of the femur (Fig. 215), was not much changed, being but slightly flattened on its posterior aspect. The pelvis (Fig.

220) was somewhat flattened from side to side. The round ligament was broad and elongated. The acetabulum of a normal, full-term foetus is shown in Fig. 219, for comparison.

None of the muscles as seen on dissection are at all markedly affected. The flexors and external rotators are slightly shortened. The uterus of the mother contained several fibroid tumours. It is not to be supposed that the displacement of the head of the bone is primarily alike in all cases of congenital hip-dislocation. In some cases there is rotation of the limb inwards, and hence the head of the bone rests on the ischium.

Until the child begins to walk the anatomy of congenital dislocation remains in all probability practically the same as at birth.

After the patient has begun to walk, the secondary changes begin: 1, the upward displacement of the head of the bone increases; 2, the capsule becomes stretched into an hour-glass shape (Fig. 222); 3, the head of the femur becomes flattened; 4, various sets of muscles become contracted; and 5, more or less of a new socket is formed on the innominate bone.

Lorenz has fully described the secondary

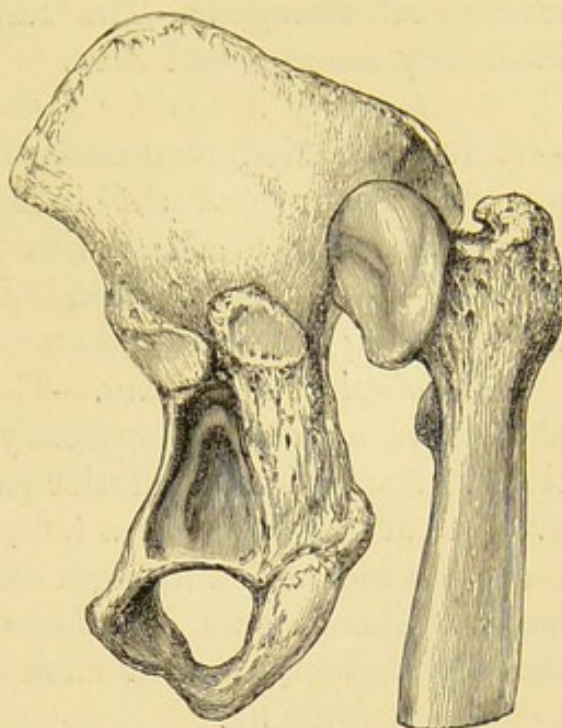


Fig. 221.—Old unreduced Congenital Dislocation of the Hip.

The shallow acetabulum has a triangular shape, and there is a shallow new socket above it. (Howard Marsh.)

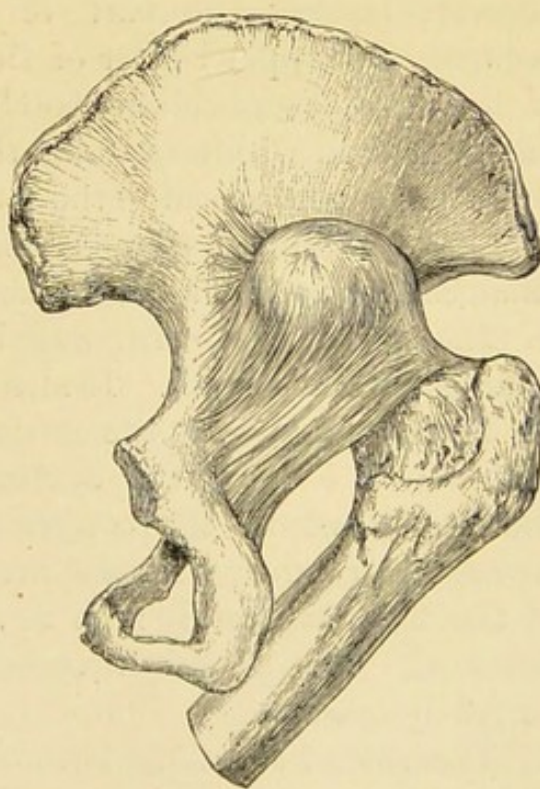


Fig. 222.—Old unreduced Congenital Dislocation of the Hip.

The capsule is elongated and of an hour-glass shape. (Howard Marsh.)

anatomical changes.* The result of his observations may be briefly summarised here.

Anatomy of the Older Cases of Congenital Dislocation.—A recent period of operative enterprise has added much to our knowledge of the anatomy of congenital hip-dislocation, and this, together with previous knowledge, has been embodied by Lorenz in an admirable monograph from which the following account is taken.

Pathological Anatomy.—The acetabulum is rudimentary, and, in some cases, completely filled up with firm fibrous tissue. As a rule the anterior part of the capsule is stretched over the acetabulum like a tent, and beneath the capsule there is a space into which a finger can be introduced. Sometimes, however, the capsule is adherent to fibrous tissue which fills the acetabulum, and in such cases the articular cavity is completely filled up.

The Head of the Femur.—The most striking change is complete atrophy. In advanced cases in adults the head may be altogether wanting. The commonest malformation of the head is a flattening of its postero-internal segment from pressure against the part of the dorsum ilii which lies between the upper border of the acetabulum and the middle of the great sacro-sciatic notch. Exceptionally the head is flattened from within out and then it assumes a buffer shape. In some cases the head of the femur is almost normal in shape. Rickets sometimes plays a part in the production of the changes in the head of the femur.

The neck of the femur may be bent forwards (anteversion) to an abnormal extent. It also tends to become horizontal.

The Capsule.—In the normal state the capsule and the acetabulum obscure the contours of the head and neck of the bone, but in the congenital dislocation the capsule is stretched so tightly over the head of the femur that the shape of the latter is readily seen as soon as the muscles have been removed. The capsule becomes greatly thickened and may be partly ossified.

The *round ligament* becomes elongated and flattened; it may subsequently undergo disintegration. So long as it

* Lorenz, "Pathol. und Therap. der angeborenen Hüftverrenkung," Wien, 1895.

persists it prevents adhesions forming between the posterior border of the acetabulum and the anterior part of the capsule which is stretched over it.

Muscles.—The upward and backward displacement of the lesser trochanter causes the ilio-psoas to rest finally over the original acetabulum, more than half-encircling the narrow part of the hour-glass-shaped capsule. The gluteus minimus may become fibrous and partly fuse with the capsule. The muscles which tend to draw the head of the bone upwards are the biceps, semi-membranosus, semi-tendinosus, sartorius, tensor fasciæ latæ, rectus, and the strong lower part of the adductor magnus.

The *direction of the displacement* is nearly always upwards and backwards; the exceptions are few. The head has been found to be displaced directly upwards, upwards and forwards, upon the pubes, and in one case downwards and forwards.

The New Joint.—The apposition and friction of the bones produce a new cavity, but it is never sufficiently deep to contain the head of the bone, and it is only formed relatively late in life. The cavity is completed by the thickened capsule which surrounds the head of the femur—in a few cases in which the head of the bone has caused absorption of the posterior part of the capsule, and so has come to lie directly against the bone.

Modifications in the Muscles.—The pelvi-trochanteric muscles are such as pass from the pelvis to the upper part of the femur; those which extend from the pelvis to the shaft of the femur are termed pelvi-femoral; the group of muscles which pass from the pelvis to the upper ends of the tibia and fibula are termed pelvi-crural.

Pelvi-trochanteric Group.—The ascent of the head of the femur causes the fibres of the gluteus maximus to become more horizontal in direction; the great trochanter may come to project above the upper border of the muscle, the lower border of which rises, and the gluteal furrow rises with it, the ischial tuberosity being left uncovered by the muscle. The anterior border of the gluteus medius passes horizontally backwards. The gluteus minimus, from having a nearly vertical position, becomes nearly horizontal. The deeper

pelvi-trochanteric muscles are also changed in direction, ascending instead of descending to their insertions. The psoas may become cartilaginous when it crosses the pelvis. The traction of this muscle aids in producing lordosis, which is thus not entirely the result of displacement of the point of support of the ilium upon the femur.

Only the anterior fibres of the glut. max. and the posterior fibres of the glut. med. and min. are parallel to the displacement, and only these fibres are shortened. The glut. max. undergoes a relaxation when the fibres of the tensor fasciæ latæ are divided. By reason of the outward displacement of the great trochanter due to the movement of the femoral head over the ilium, the middle glut. and glut. min. become elongated, and also the middle parts of these muscles are pushed upwards so that their fibres no longer take the shortest direction between origin and insertion. The deep pelvi-trochanteric muscles and the psoas also undergo elongation, whence the result that this group of muscles *cannot constitute an obstacle to reduction*. "Hence Brodhurst's plan of subcutaneous section of the muscles inserted into the great trochanter is based upon an error, and Hoffa's method, which is based upon that of Brodhurst, is likewise erroneous."

Of the *pelvi-femoral* muscles, the inner part of the adductor magnus is shortened. The horizontal fibres of the adductors become elongated.

The *pelvi-crural* muscles are greatly shortened and constitute the most important obstacle to reduction.

In old subjects of congenital dislocation, the muscles, especially the glutei, tend to become degenerated, owing to interference with their functions.

The *great sciatic nerve* undergoes shortening, which can only be safely overcome by gradual extension.

Changes in the Pelvis.—In double dislocation the ilia become smaller, there is lordosis, and the sacro-vertebral joint is unduly mobile. The ischia are everted, giving rise to increase in the transverse diameter of the pelvis and in the circumference of the pelvis.

Causation.—Hippocrates attributed congenital dislocations to injuries received by pregnant women. A great variety of opinions have been advanced, but only two deserve notice—

(1) That the condition is due to a peculiar position of the lower extremities of the fœtus *in utero*; * (2) that it is due to arrest of development, the hip-joint remaining in an early fœtal condition.

Hoffa observes that the hereditary tendency observed in certain cases of congenital hip-dislocation favours the latter view. It must be admitted, however, that this is not conclusive, since the hereditary tendency may be to the intra-uterine position of the lower limbs, *i.e.* with the hips acutely flexed, and the dislocation may follow as a consequence of the position. It is important to remember that whatever the cause the tissues of the joint and the muscles are free from disease, and hence congenital hip-dislocation is comparable with congenital club-foot.

Frequency.—The hip is the commonest site of congenital dislocation. Krönlein observed ninety cases of congenital hip-dislocation to five of the humerus, two of the radius, and one of the knee.

Hoffa, in 1,444 cases of deformity, observed seven cases of congenital hip-dislocation. The same author has collected statistics of 342 cases. Out of these less than 300 were in females, 42 in males; 134 were bilateral; 198 were unilateral; 100 on the left, 98 on the right side.

Symptoms.—If every new-born infant were carefully examined for the condition, the instability of a congenitally dislocated hip-joint would be discovered, and the condition could be treated from the beginning. As a rule, however, the condition usually attracts no attention until the child begins to walk at the age of two or even three years. "Then it is noticed to stand ordinarily with the back unduly arched and to waddle most markedly when walking is well begun When the dislocation is only unilateral, the waddle becomes an exaggerated limp; in stepping on that leg the child suddenly lurches violently to the affected side and the leg seems to have grown suddenly shorter." †

In double dislocation the waddling occurs to either side alternately. It is explicable by the mechanical conditions

* This was the view of Dupuytren, who was the first to describe the pathology of this condition.

† Bradford and Lovett, *loc. cit.*, p. 514.

present, the unstable articulation of the femoral head with the ilium causing the patient to incline to the weight-bearing side, so that the ilium may lie as nearly as possible

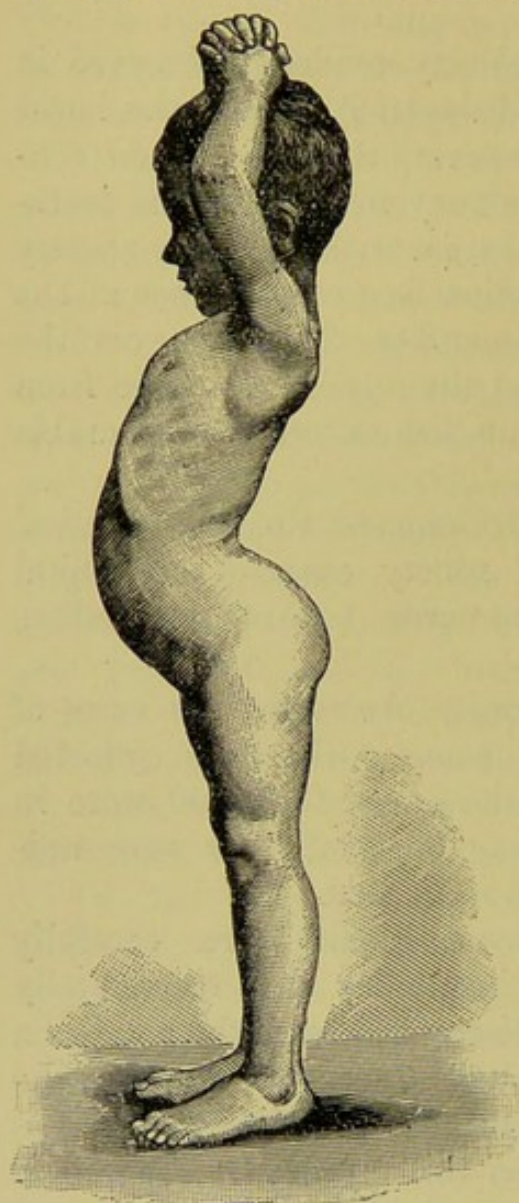


Fig. 223.—Double Congenital Dislocation of the Hip. (Lorenz.)

in a plane at right angles to the head of the femur. When the head of the femur is placed near the anterior-superior spine, the lordosis and the waddling may be but little marked. As the patient grows the trochanters and the buttocks become very prominent. (See Fig. 223.) Fatigue is readily felt and the unstable joints are very liable to sprains.

The displacement of the upper parts of the thighs outwards leaves a gap between the thighs at the perineum. The head of the femur may sometimes be felt near the anterior-superior spine, more commonly it is displaced backwards on the dorsum ilii; but whatever the position of the head of the bone, the foot usually points more or less forwards, owing to adaptive changes in the head and neck of the femur.

The lumbar spine becomes abnormally mobile in order to compensate for the restricted mobility of the hips. The thighs also become adducted from their separation above. In young subjects traction in the leg causes the great trochanter to descend, but in older patients the parts have become more rigid, and this may no longer be observed to any marked extent.

In unilateral congenital displacement we can compare the normal with the abnormal side. The latter shows a

marked flattening and the gluteal fold is straighter and deeper there. The great trochanter on the affected side is found to be displaced upwards and the affected limb is markedly shortened, and to compensate for this the patient usually holds the ankle of the affected side in the position of talipes equinus, or when the shortening is very great the knee of the sound side is flexed. The pelvis is inclined forwards on the affected to a greater extent than on the sound side, or, in other words, there is some flexion of the abnormal hip. Owing to the inequality of the limbs in length slight scoliosis may supervene; if the patient is affected with rickets the scoliosis may be considerable.

In early childhood the range of movement of the dislocated joint is exaggerated except in regard to abduction. The limb may often be adducted to a right angle with the axis of the body. In older subjects the range of movement is less and, especially in the direction of extension, may be diminished. Abduction is always limited in congenital dislocation. This is due to the contraction of the adductor muscles and is removed by subcutaneous section of the adductor longus and brevis.

In unilateral cases the lower limb on the affected side is less well nourished than the sound limb.

Sometimes the patient compensates for the shortening by allowing the limb of the sound side to assume the position of genu recurvatum.

Diagnosis.—This will be made on the examination of the hip as described already (p. 273). The trochanter will be displaced upwards above Nélaton's line from half an inch to three inches. In young subjects the trochanter can be felt to descend when traction is made upon the limb, whilst the pelvis is fixed. The affected limb may be either everted or directed normally. On moving the thigh preternatural mobility may be observed at the hip. The perineum is abnormally broad.

Differential Diagnosis.—Immediately after birth there should be little difficulty in recognising the condition. A preternatural mobility of the joint and a sensation of the head of the bone slipping over the shallow acetabular depression as the thigh is rotated in and out will afford certain proof of the condition. Traumatic conditions, *e.g.* dislocation

and *separation of the upper epiphysis*, are, however, possible. Traumatic dislocation will be distinguishable by the firmness of the articulation when reduction has been successfully performed, separation of an epiphysis by some swelling in the joint, and by the cessation of active movements and eversion of the limb, as well as by shortening. If the child was born by the breech and also if other deformities such as

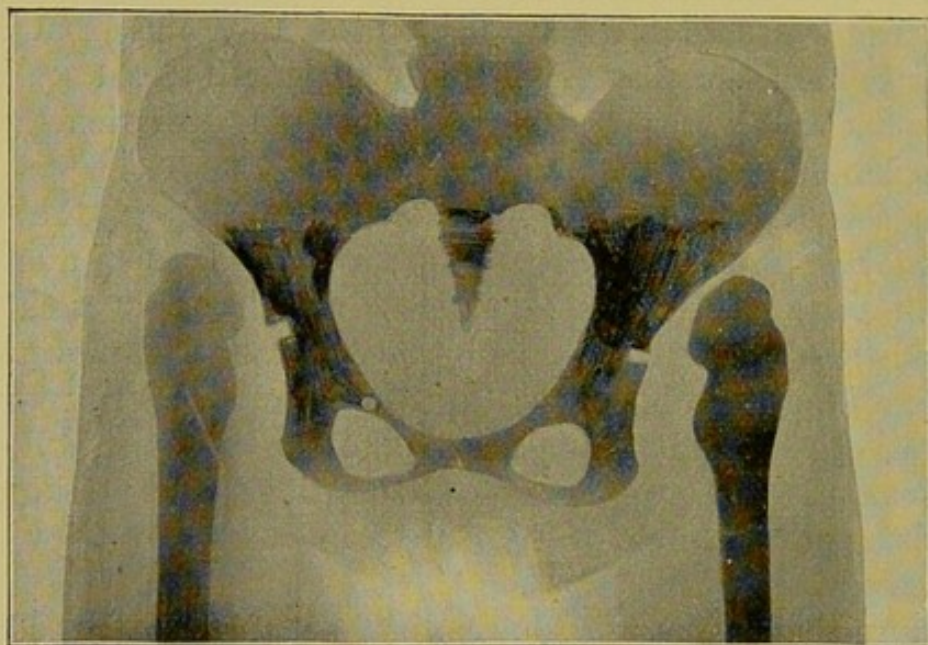


Fig. 224.—Radiograph of a case of Double Congenital Dislocation of the Hip. (Muirhead Little.)

club-foot are present, these will support a diagnosis of congenital dislocation.

If some months or a year or two have passed before the examination is made other possibilities must be considered. The chief of these are *coxa vara* and *infantile paralysis*.

Coxa vara, or incurvation of the neck of the femur, was first described in adolescents and young adults. It is now, however, known to occur also in young infants. The most certain means of identifying the condition is by a good radiograph (Fig. 224.)*

Infantile paralysis of the pelvi-femoral muscles often simulates congenital dislocation most closely. In fat children the wasting of muscles about the joint is sometimes difficult to recognise by inspection, but by palpation it can usually be

* E. Muirhead Little, *Brit. Med. Journ.*, 1898.

made out. Electrical investigation will, when necessary, give further information. When the muscles about the hip-joint are paralysed a partial or intermittent dislocation of the joint is very commonly observed. The absence of tone in the muscles and the ease with which the dislocation is reduced will serve to distinguish paralytic subluxation.

Prognosis.—Congenital dislocation of the hip within certain limits is curable. There is no doubt that in cases diagnosed soon after the patient has begun to walk and treated from the beginning, the unstable joint can be made to become a stable one, or, in other words, the condition can be cured. Thus, if efficient treatment is begun at an early period the prognosis is good. Up to the age of seven years the most recent experience has shown that there is a very fair chance of cure. In older children the chance of success diminishes with age, but a successful result has been obtained at the age of sixteen years. After the age of eight to ten palliation is all that can be certainly promised. In a few cases the head of the femur becomes arrested by a firm nearthrosis in a favourable position near the anterior-superior spine, and then no treatment beyond the wearing of a high boot is required.

Treatment.—There is absolute agreement amongst all observers that at birth congenital dislocation of the hip is easily reduced and that an acetabulum is present and is capable of receiving part of the head of the femur, though from the shallowness of the acetabulum the articulation is an unstable one.

Schede* Mikulicz† and others have found that where well-directed treatment has been begun before the child has been allowed to walk, the unstable articulation can be converted into a stable one. Schede's abduction treatment consists in the application of an apparatus by means of which abduction and inward pressure on the great trochanter are obtained by means of a screw. In young infants Schede finds that extension in an abducted position combined with slight pressure on the great trochanter is sufficient. One of Schede's patients was shown at the age of sixteen years. Treat-

* Schede, *Verhandlungen der deutsch. Gesellsch. für Chirurg. Cong.*, 1894.

† Mikulicz, *Arch. für klin. Chirurg.*, 1895, Bd. xlix., Heft 2.

ment by means of extension was begun at the age of eleven months and continued for three months. After this the abduction apparatus was worn for twelve months. A complete and lasting cure was obtained.

It would thus appear that congenital hip-dislocation, at once the commonest and most formidable of all congenital dislocations, can be cured by the simplest means if skilfully and patiently applied during the first two years of life. It becomes, then, a matter of the first importance to diagnose the condition at the earliest possible moment.

Buckminster Brown obtained a cure in the case of a little girl, aged four, affected with double congenital dislocation by applying continuous traction, the patient being confined to bed for thirteen months. After this, supported on a wheel-chair, she was allowed to move the legs as in walking, but without bearing weight upon them. By degrees she was allowed to bear more and more weight upon the lower limbs until finally she was allowed to walk without support. The treatment was completely successful. Post, of Boston, obtained a cure in a young child affected with unilateral congenital dislocation by reducing the displacement under anæsthesia and retaining the head of the bone in place by means of a plaster of Paris bandage, which enclosed the trunk and thigh.

It is a striking comment upon recent experience in the treatment of this formidable malformation, that whilst Lorenz, in his monograph dealing with the subject, which was published in 1895, recommended operative interference as the only hopeful measure, unless in certain exceptional cases, when the anatomical conditions allowed of the head of the bone being replaced in the acetabulum without operative interference, three years later the same surgeon* no longer recommended the operation, but a bloodless method of reduction and subsequent treatment which combine some original features with others previously practised, *e.g.* by Roser, Schede, Mikulicz, and Paci.

The chief points aimed at in Lorenz's method are, first, to obtain a true reduction, *i.e.* to make the head of the femur rest in the diminutive acetabulum; and, secondly, in

* Lorenz, *Wiener med. Woch.*, Sept. 3, 1896.

the after-treatment to maintain the affected limb in a position of abduction for a sufficient length of time for the original socket to enlarge and the articulation to become firm. This method has only proved successful in the case of young children; and from personal experience I can testify to its failure in the case of a patient of twelve years of age, though Kummell has recorded a successful case at the age of sixteen years, so that the method is deserving of a patient trial, even in unpromising cases. The steps of the operation are as follow:—

Reduction by Manipulation—

Stage I. To bring the head of the femur to the level of the acetabulum. In children who have never walked this is easily effected. In severe cases the adductors may be thoroughly kneaded or even cut subcutaneously, or all the resistant muscles may be forcibly stretched under anaesthesia by a screw-extension apparatus which is fixed to the end of the operating table, making traction by a fillet from above the knee; counter-extension being exerted by a perineal band. This part of the operation is rendered more easy by a preliminary course of gradual stretching by extension.

Stage II. To open up the passage of the head of the femur into the acetabulum, the thigh must be fully flexed and slightly rotated in. If the fullest abduction is now produced in the flexed position, the head of the femur clears the posterior border of the acetabulum, and reduction is effected often, but not always, with a distinct shock that can be felt and heard.

Stage III. Full abduction being kept up, the thigh is rotated out, thus forcing the head of the femur more firmly into the socket. The surgeon may now endeavour to deepen the socket by manipulations, grinding the head of the femur into the acetabulum, taking care to keep up full abduction, in which position the tendency to displacement ceases. The limb is put up in plaster, extending from the pelvis to the knee, the position being that of full abduction and slight external rotation and extension. Lorenz directs in cases of double dislocation that the treatment of one side shall be completed before that of the other is begun. Hoffa has found that both limbs may be operated on at the same time.

After ten to twelve weeks the plaster is changed and the limb is put up with less abduction. The second plaster surrounds the bathing-drawers area. The child is now encouraged to walk with flexed knees, which it does readily.

After the second plaster Tausch* uses Schede's abduction apparatus combined with a spinal support by a Hessing's hip-piece. This arrangement has the usual advantages over plaster. A screw enables pressure on the trochanter to be kept up at night. A joint opposite the hip permits of flexion movements.

Duration of Treatment.—For six months fixation must be kept up. In cases of double dislocation fixation is required for a longer time.

Re-education of muscles and abduction-gymnastics call for some months of treatment, massage, etc., after the fixation has been discontinued.

Hoffa advises that in bilateral cases both joints should be simultaneously operated on by Lorenz's bloodless method, the thighs being put up in plaster abducted to a right angle and so allowed to remain for two or three weeks, at the end of which time the plaster is renewed with a less degree of abduction.

The results of Lorenz's method are highly satisfactory. At the International Congress held at Moscow in 1897, Lorenz reported 160 cases with only five relapses. In most of the successful cases the head of the femur does not remain in the acetabulum, but forms a firm new joint beneath the anterior-superior iliac spine. In some cases, however, the head of the bone remains in the acetabulum. In either case a useful and freely movable limb remains.

The dangers of the proceeding are not encountered in young children. In older subjects paralysis from injury to the great sciatic nerve, hæmatoma from laceration of the soft parts, and in some cases subsequent suppuration have been recorded. In one case Hoffa met with a fatality from "convulsions and shock-like symptoms." For older children a Chance's spinal support, to the pelvic piece of which are attached one or two leg-irons, according as the case is unilateral

* Tausch, *Münch. med. Woch.*, July 13, 1897.

or bilateral, is used at the City of London Orthopædic Hospital, together with daily massage and gymnastics.

Illustrative Cases.—At the present time I have two patients under treatment. One, a girl, aged seven years, with unilateral dislocation, the second a girl aged two and a half years, with bilateral dislocation. In both I adopted Lorenz's method, and I am able to confirm the view that by this means a veritable reduction is obtained. The time of treatment has as yet been too short to judge of the permanent results.

Operative Treatment.—Since Guérin first applied operative measures to the treatment of congenital dislocation of the hip many different plans have been employed. Of these, excision of the head of the femur and the methods of Hoffa and Lorenz alone require mention here.

Resection of the head of the femur was first practised by Rose and Reyer in Germany, and has been adopted by Ogston and other surgeons in England. Hoffa observes that the results of dealing with the deformity by simple excision leave much to be desired. Complete cure had never been obtained, and in the cases of bilateral dislocation the patients have walked as badly as before operation. In unilateral cases, out of sixteen cases six were worse off than before operation, and only one was able to walk without undue fatigue.

The same surgeon, however, recommends excision for cases of congenital dislocation that are too old for other modes of treatment. The essential part of the plan consists in removing, as well as the head of the femur, the part of the capsule of the joint that separates the head of the femur from actual contact with the surface of the ilium.

The joint is opened by a lateral incision and the soft parts are separated subperiosteally from the great trochanter and the capsule is detached from its insertion into the neck of the femur, so that the head of the bone can be luxated and made to protrude from the wound. The head of the bone is detached by a narrow saw close to the inter-trochanteric line. The funnel-shaped capsule is then put on the stretch and its hinder part is severed by a cut which passes through its middle and reaches the periosteum of the os innominatum. The attachment of the capsule to the acetabulum is now severed, adhesions between the capsule and periosteum of the os innominatum and the two parts of the capsule are removed. Thus the sawn surface of the femur can be placed against a free periosteal surface on the os innominatum.

Hoffa's original operation consisted in exposing and opening the hip-joint by Langenbeck's posterior excision, separation of all muscular attachments from the great trochanter, and then deepening the shallow acetabulum and replacing in it the head of the bone. Hoffa* candidly admits: "The final functional results were not so good as I had expected, seeing that successful reduction had been accomplished; and Lorenz soon showed the reason of this, namely, that the pelvi-trochanteric muscles were not shortened, but, on the contrary, were elongated, and he had modified my operation by opening the joint from the front and leaving the pelvi-trochanteric muscles intact. In exchange, he recommended section of the adductors and the attachments of the hamstrings to the tuber ischii in order to neutralise the shortening of these muscles. Later he showed that these multiple tenotomies were not wholly harmless, and that retraction could be overcome by forcible stretching at the operation."

Lorenz's Operation.†—The steps of this operation are—

I. Drawing down the head of the femur by manual force or by a windlass. In very obstinate cases a preliminary course of weight-extension may be required.

II. Anterior incision in skin and fascia lata and exposure of the capsule by separating the tensor fasciæ latæ in front and internally from the gluteus medius behind and externally.

III. **T**-shaped incision in the capsule by entering the bistoury close to the anterior iliac spine and cutting along the neck of the femur to its attachment to the latter. With a probe-pointed bistoury the incision in the capsule is converted into a **T**-shape by a cut at the outer extremity of the first.

IV. The head of the bone is brought out of the incision and, if necessary, the round ligament is removed and the head of the femur trimmed so that it has a spherical shape.

V. Deepening the acetabulum by sharp spoons.

VI. Reposition by extension and abduction of the thigh.

VII. Suture and immobilisation of the limb in the abducted position by a plaster apparatus.

After-treatment.—Allowing two weeks for the healing of

* "Orthopædic Surgery," 1898, p. 584.

† Lorenz, "Congenital Dislocation of the Hip," translated by Cottet, p. 201.

the wound, daily massage and electric stimulation of the muscles around the joint, and especially of the glutei, are required. Soon active movements must be begun and persevered in until the patient has the power and the will to make them. The abduction movements must be especially cultivated. According to Lorenz, the patients may generally be allowed to walk unassisted five or, at latest, six weeks after operation. If stiffness remains, a period of weight-extension is indicated.

Anatomical Results.—Hoffa has published the results of an autopsy on a boy aged four years, who died of diphtheria one year and a half after his open operation had been performed. In this case a firm nearthrosis had been established at the site of the original acetabulum. The same author has demonstrated by radiographs the condition of the joints in three cases two years after operation. In two of these cases the operation had been performed on one side only and in the remaining one on both sides. All the radiographs show satisfactory new joints with good acetabula and a normally-directed femoral neck. Hoffa has had but one instance of redislocation among his later cases.

Physiological Results.—Lorenz considers that a very good physiological result is obtained when the patient can flex the hip to ninety degrees, and even one half this degree of mobility is satisfactory. Not infrequently a tendency to flexion-contracture has been observed, but it has always yielded to treatment. Lorenz found that in one of his cases fibrous ankylosis resulted, but in spite of this the physiological result was very good. The tendency to roll from side to side in walking remains for a time in some cases and is to be overcome by gradual education in walking.

Dangers of the Open Operation.—In 200 cases Hoffa had six fatalities. Lorenz has also recorded a fatal case. These deaths were from sepsis and other preventible causes.

Hoffa states that since he has operated without division of the muscles and with faultless asepsis, he has had no further deaths.

Indications for the Operation.—Cases suitable for bloodless reduction are to be treated by that method. Hoffa considers that the best period for operative treatment is between the

third and the eighth year, and as a general rule he would fix the age-limit for the operation at ten years, for older patients substituting the operation described at p. 292. Lorenz observes that in bilateral cases this limit should be adhered to, but in unilateral cases where the femur can be brought down readily, the open method may be used for older subjects.

In bilateral cases it is immaterial whether only one or both hips are operated upon at the same time. The condition of the patient as to shock, etc., must decide in each case.

Contra-indications.—Lorenz says that there is only one absolute contra-indication, namely, absence of the head of the femur. Absence or gross deformity of the head of the femur can be ascertained by palpation and it may occur at any age. Rickets is the main cause of these additional deformities. This amounts to the proposition that severe coxa vara is a contra-indication, and in radiography there now is a certain test of this point, and no case should be operated upon unless a good radiograph has been obtained and studied. Lorenz also states that "anteversion" of the femoral head is a contra-indication.

Palliative Treatment.—When the dislocation has been allowed to go untreated for so many years that it can no longer be treated by reposition or by open operation, the question arises as to whether anything remains to be done. In a few cases nature secures a good result by a fixation of the dislocated head of the femur near the anterior-superior spine. When the parts are in this position, the balance of the body is maintained without any lordotic arching of the spine. In the great majority of cases the head of the femur rests upon the ilium at a point posterior to and far above the acetabulum. In such a condition marked lordosis, or, if the condition be unilateral, scoliosis ensues. In many cases adductor spasm and shortening result in additional disablement of the patient's walking powers. Many patients are relieved by walking instruments that transfer some of the weight to the ischial tuberosities. In some cases there is much pain in the spine. This and the lordosis are best moderated by the use of a Chance's single-upright spinal splint. When instruments are worn daily, exercises are required to prevent loss of tone in the muscles.

Severe adductor contracture can generally be overcome by manipulation and by the patient wearing an abduction-apparatus at night.

As soon as a firm articulation has been obtained with the head of the femur directed forwards, instruments may be gradually dispensed with.

Operative treatment, namely, infra-trochanteric osteotomy, has been suggested by Kirrmisson* for severe adduction. In my experience patient manipulation and stretching, combined if necessary with subcutaneous section of the adductor longus tendons, will render such an operation unnecessary.

On some Affections that Simulate Congenital Dislocations.

—In connection with congenital dislocations certain deformities of traumatic and paralytic nature that date from birth demand mention. In the section dealing with congenital dislocations of the shoulder reference is made (p. 313)

to the relation that exists between congenital dislocation and "birth-palsy." The distinction between the classes of cases is made more difficult by reason of the fact that in congenital dislocation there is an abnormal position of the arm, and hence some difficulty in parturition is to be expected. On the other hand, in tedious or in precipitate labours, injury to the brain, brachial plexus, or the epiphyses, etc., may occur, leading to paralytic and traumatic disabilities that must be distinguished from congenital dislocations. As an example of a congenital paralytic condition (*see* Fig. 225) that had been mistaken for a double congenital dislocation of the hip, I may mention a case brought to my notice at the North-West London Hospital by my colleague, Dr. G. A. Sutherland, to whom I am indebted for the following notes:—

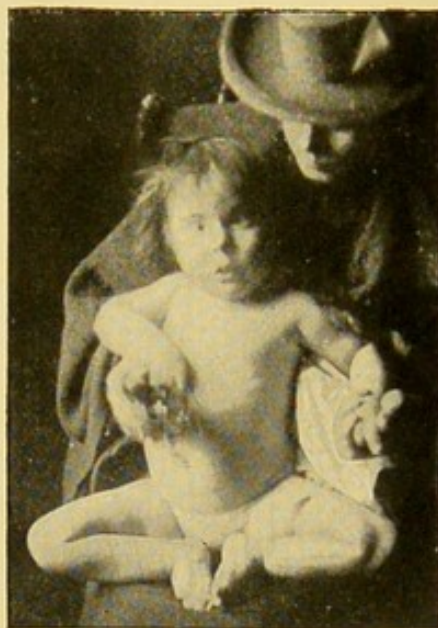

Fig. 225.—Congenital Paralysis of the Lower Extremities.

* Kirrmisson, "Revue d'Orthopédie," No. 3, 1894.

Mary E. D., aged two years. Patient has bronchitis and sweats about the head. General nutrition is good. Feet always cold.

Lower extremities lie absolutely flaccid in a semi-flexed position with complete eversion, the buttocks, knees, and outer borders of the feet being in contact with the bed in the same horizontal plane. Flexion at the knees accompanied with contraction of the hamstrings. No knee-jerk. Sensation in lower limbs very defective.

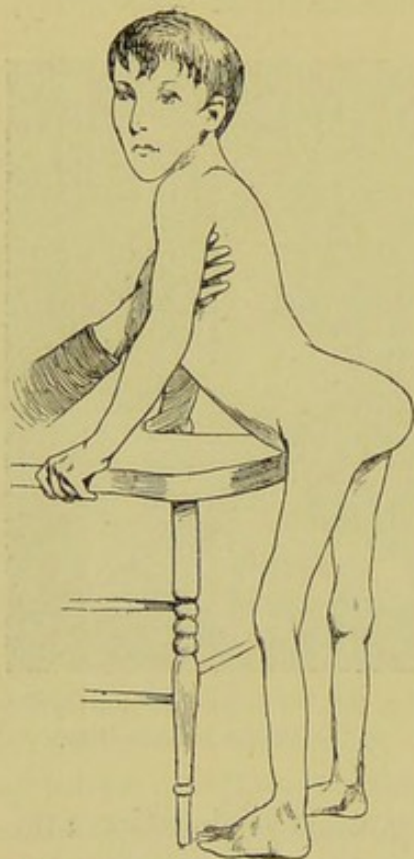

Fig. 226.—Paralytic Contracture of both Hip-joints.

Arms.—Limitation of movement in the right shoulder-joint. The right scapula farther from the spine than the left. Right elbow shows some flexion-contraction. Right arm cannot be pressed to the side.

Double internal strabismus, which was not seen until the patient began cutting teeth.

Talking defective: can say "da-da." Does not answer questions—looks intelligent. Mother has never seen any movement in the lower limb; patient can only move the toes. When she does move the trunk, the muscular action does not extend beyond the pelvis. Head small.

Family History:—

First child lived ten weeks; premature; died of bronchitis.

Second, living; aged five years; quite healthy.

Third, full time; born dead after instrument delivery.

Fourth (the patient), seven months' child; labour induced premature;

because of previous difficult labour. Delivery by podalic version; difficulty in bringing down right arm.

There has never been any movement in the lower limbs, and the movements of the right arm were always defective.

Electrical Reactions.—The abdominal muscles react well to both currents. No reaction to either faradic or galvanic currents in either thigh or calf muscles.

Contracture of the Hip from Infantile Paralysis.—This is nearly always a flexion-contraction, as shown in Fig. 226. The superficial muscles, sartorius, and tensor fasciæ femoris, and the fascia lata, are most frequently contracted, but in some cases the rectus and other deep muscles are at fault.

Treatment.—The contracted muscles require division and

the improved position must be maintained by proper instruments.

Tubercular Coxitis.—*Symptoms and Diagnosis.*—It is in the slighter degrees of hip disease alone that mistakes are likely to be made. For a full consideration of the differential diagnosis of inflammatory conditions general surgical works must be consulted.* The various symptoms: (1) lameness, which may be due to tenderness, altered position, weakened or contracted muscles; (2) pain (often referred to the knee); (3) impaired movement; (4) muscular wasting; (5) swelling, must be carefully looked for and their degree noted.

The most common error is to mistake neurotic or functional affections of joints (so-called "hysterical hip") for examples of disease or *vice versâ*. Experience alone will enable the surgeon to separate the clear from the doubtful cases. Incipient or convalescent hip disease in a neurotic girl may require repeated examinations before a definite opinion can be formed. As a rule, however, the absence of the classical signs of disease and the emotional state of the patient will enable the diagnosis to be made, but this should always be done with caution. In the functional affection, as a rule, the patient complains of severe pain in the limb, especially on an attempt to move the joint. The pain is more likely to be referred to the hip than the knee. It is important to measure the girth of the thighs, for wasting, which is seldom absent in tubercular coxitis, is usually wanting in the functional affection. In cases, however, of typical neurotic contracture that have been kept up for some years there may be distinct wasting of the affected limb. Thus, in the case of the young woman shown in Fig. 227:—

The patient was aged twenty-four. She gave out that she was "crippled with rheumatism." For five years she had been in one infirmary, and for two years more in a "home of rest." The matron of the latter institution informed me that the patient would sometimes get up and walk about of her own accord, but that she was always worse when called upon to work. She was admitted under my care at the North-West London Hospital. After careful consideration of the case with my colleague, Dr. Leonard Guthrie, the diagnosis of hysteria was made. I had the patient carried to the operation theatre,

* *E.g.* Howard Marsh, "Diseases of the Joints and Spine," p. 388.

where the photograph was taken. This done, she was sternly bidden to put the left leg out straight. This she did with ease. All the movements of the hip were normal, though the left thigh was one inch smaller in circumference than the right. The patient walked down to the ward, and by daily exercise in walking alone she completely recovered her powers.

In all doubtful cases unconscious movements of the hip in walking should be looked for, and the well-known device of pressing alternately on the trochanters, with counter-pressure on the side opposite to the one complained of, should

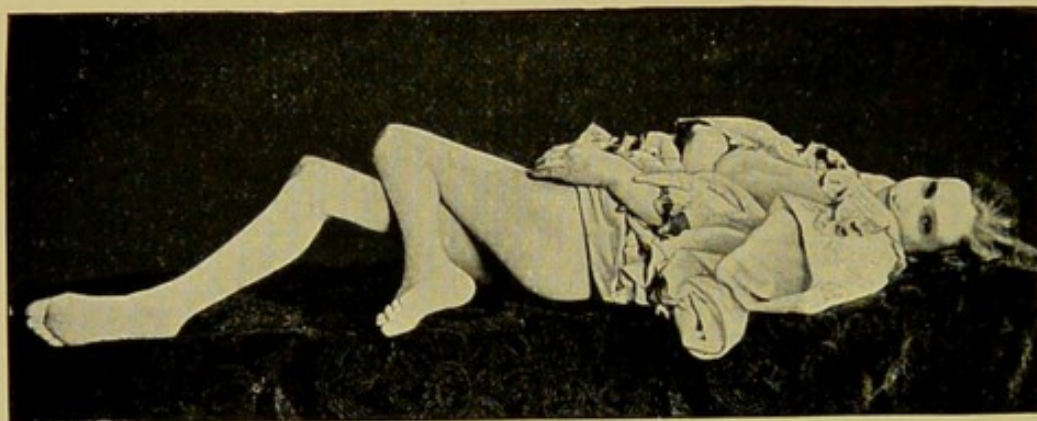


Fig. 227.—Hystercal Contracture of the Left Arm, Hip and Knee.

not be omitted. Having excluded the possibility of the case being one of functional disability, a diagnosis of tubercular coxitis must not be made until the conditions enumerated on p. 271, and incipient coxa vara, have also been excluded. A radiograph may be required.

Prognosis.—The prognosis in hip disease depends chiefly upon the completeness with which proper treatment can be carried out. If the surroundings of the patient are good, conservative treatment holds out an excellent prospect of recovery with a useful limb.

Treatment.—In the earlier period of tubercular disease of the hip, deformity is due to reflex muscular spasm. This spasm, although it results in fixation of the joint, cannot be regarded as a natural protection, for it results in increased intra-articular pressure of the bony surfaces and so increases the destructive process leading to pathological dislocation, abscess formation, etc., and the concomitant symptoms of pain, fever, etc.

In the earlier period of the affection the only point in treatment that may be termed orthopædic, as distinguished from general surgical considerations, is the effort to remove any existing deformity and to secure repair in the best possible position for the future welfare of the patient.

Experience has taught the necessity of avoiding interosseous pressure in the treatment of joint disease. When the symptoms are pronounced, rest on a firm, flat hair mattress with weight-extension is called for. The patient must be secured in the bed in such a manner that the trunk is straight, and the pelvis is square with the trunk, that is, free from tilting. This is done by applying a long splint to the sound side and, in the case of children, applying shoulder-straps. Instead of shoulder-straps the bed-frame, and instead of weight-extension the extension-splint recommended by Bradford and Lovett, may be used. In beginning treatment by extension it is important at first to make the traction in the line of the deformity,* gradually improving the position of the limb, a proceeding that is rendered easy by the relaxation of the muscles.

In suitable cases, as Phelps has observed, outward traction may be added to longitudinal traction by fixing a fillet round the uppermost part of the thigh in addition to the weight-extension. The passage in which this recommendation was originally made is worth quoting:—"To apply extension to a hip-joint we should not only make traction in the line of deformity, but also in a line at right angles to that deformity. In other words, to relieve perfectly intra-articular pressure extension must be made in a line corresponding to the axis of the neck and not to the axis of the shaft, for the following reasons: the adductors and abductors pass from the femur diagonally across the body of the pelvis. . . . the flexors act in a line corresponding to the axis of the shaft."

Phelps's bed, according to this surgeon's original description, is as follows: "A board is cut to correspond with the length and width of the child. This is carefully padded. The child is now laid on the board and enveloped with a plaster of Paris bandage from the feet to the axilla to a thickness of

* A. M. Phelps, "Treatment of Hip-joint Disease," *The N. Y. Medical Record*, May 4th, 1889.

three-eighths of an inch. When the plaster is set the front is cut away. This bed can now be lined and a front put on it and lacings put in, or the child can be held in place by means of bandages. As the plaster bandages are rolled on they should be nailed to the edges of the board, thus making

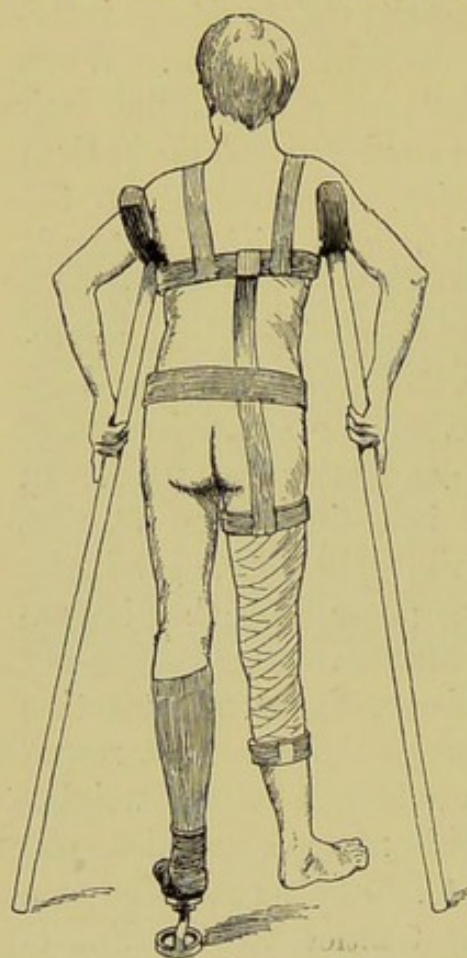


Fig. 228.—H. O. Thomas's Single Hip-splint applied.
(Mayer & Meltzer.)

board and plaster one. This bed will be found to fit better and be much lighter and more convenient to make than the iron cuirass. Extension is made to the foot-piece and lateral extension by cutting away the side a little and putting in a staple, to which the bandage is tied."

In order to save the trouble of using plaster bandages a simple box-splint* can be obtained at a reasonable charge with padded wooden sides.

The double Thomas's splint (Fig. 51, p. 83) is another and very valuable means of obtaining complete fixation of the trunk and limbs. By giving ready access to every part of the body it has the great advantage of cleanliness, and if the lateral bars are made movable and of such a temper that they can be wrenched

to assume the contour of the part of the body against which they rest there need be no fear of pressure sores. But when this splint is applied and left without proper supervision very ugly sores may form.

Ambulant Treatment of Tubercular Coxitis.—As soon as the local condition allows, it is better for the general health of the patient, and hence for the local conditions, if some apparatus that permits of the patient getting about can be applied. For this purpose the instrument most widely

* Mr. Tungate, 3, Portman Market, Lisson Grove, W., makes very satisfactory box-splints.

known in Great Britain is Thomas's hip-splint (Fig. 228). For convalescent cases, in which deformity has been almost or quite overcome, this is a very valuable as it is a simple appliance. If, however, it is wrongly made or inefficiently applied it is dangerous and ineffectual. The splint is more often than not wrongly adjusted. It should be suspended by two braces, as shown in Fig. 228, and from time to time it should be readjusted by the surgeon (not the mechanic) so as to improve the position of the limb and avoid undue pressure at any point. Thomas divided the course of treatment into four stages. In the first stage the patient wears the splint in bed (in lieu of the extension treatment already described); in the second stage the splint is worn continuously, but the patient is allowed to go about with crutches and a patten on the sound foot by day; in the third stage the patient leaves off the splint at night; in the fourth stage the splint is left off, the crutch and patten alone being used.

Among the out-patients at hospitals, unfavourable results of the plan of treatment are not uncommonly observed. Speaking of the single Thomas's splint Bradford and Lovett* remark:—"A Thomas's splint cannot be said to furnish complete fixation, nor does it prevent the occurrence of subluxation or counteract the spasmodic muscular contractions of the muscles connecting the lower extremity with the pelvis.

. . . . The appliance, however, prevents motion to any great amount, enables the patient to be lifted without jarring the hip, and prevents and corrects flexion of the thigh."

In my own experience the apparatus represented in Fig. 229 offers a more certain way of fixing the hip-joint, and one admitting of more readily effected improvement in the position of the limb. The dorsal part of the appliance shown

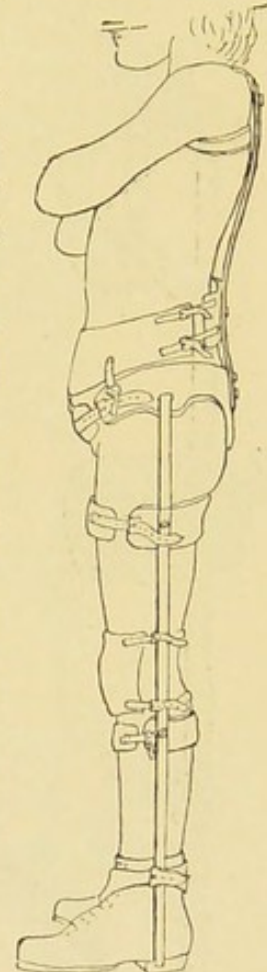


Fig. 229.—Apparatus recommended by the Author in Hip Disease.

A patten on the sound side and crutches are used in the earlier period of treatment.

* *Loc. supra cit.*, p. 304.

in Fig. 229 is a Chance's splint. It is connected with the leg-iron by means of a stout iron bar which is so tempered that it admits of alteration of form by means of wrenches.

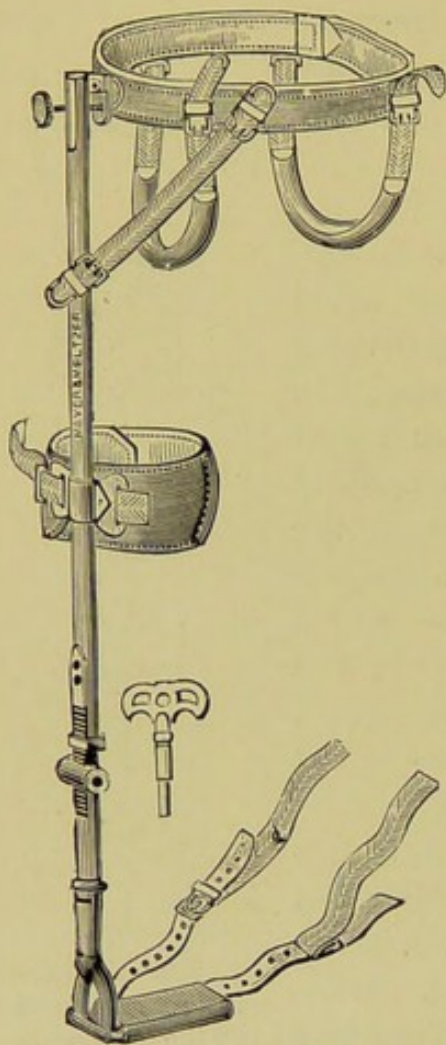


Fig. 230.—Taylor's Traction Apparatus for Hip Disease.

Thus, abduction can be obtained diminishing the outward curve, and flexion can be diminished and abnormal rotation can be eliminated by periodical slight modifications in the form of the bar; or, as is preferable in older patients, two rack-joints can be inserted in the connection between the pelvic girdle and the leg-iron, as shown in Fig. 229.

In cases where sinuses exist a dressing can readily be applied under this splint.

When the joint is sufficiently recovered, the bar may be interrupted by a movable joint. The instrument has the advantage of being adaptable to the growth of the patient, and so in the end it is cheaper than the Thomas's splint, which requires constant renewal.

Many American surgeons* employ traction splints, by means of which the weight of the body

in walking is transferred to the tuber ischii by means of perineal bands.

The essential parts of these appliances are:—"An outside steel upright reaching from the trochanter to below the foot. At the upper end is a horizontal rigid pelvic girdle in which the patient is secured by one or two perineal straps. To the bottom of the shaft is attached some appliance for exercising traction upon the limb, the latter being well held to the bottom of the splint by means of adhesive plaster gaiters,

* The treatment of hip disease by extension is largely due to the initiative of Dr. H. G. Davis, of New York (1850).

circular straps, or bandages. In the adjustment of traction to varying lengths of leg the splint is easily provided for in several ways, usually by means of a sliding rod moving within a tube, the amount of motion being controlled by means of a key and ratchet, a spring securing the rod when in the proper position."* The best known of these appliances are Taylor's (Figs. 230 and 231). Personally, I have not felt the need of such an instrument for tubercular coxitis on account of the excellent results obtained with the use of the appliance shown in Fig. 229, which, when convalescence is established, is converted into a simple hip-splint by removal of the dorsal part of the appliance, and when necessary a perineal band is added.

Hessing, according to Hoffa, carries an iron half-hoop across the front of his thigh-piece joining the lateral rods. From the front of this an elastic band is attached, which below joins a vertical iron that passes upwards to the inguinal part of the pelvic band, and is joined to the thigh sheath by a leather slip. The elastic band is stretched in flexion of the hip.

In carrying out the mechanical treatment of hip disease there is one consideration of especial importance. This is to decide on the best position for the affected limb in any given case. It has been urged that where there is shortening of the limb or a tendency to dislocation it is better for the patient to have the limb fixed in the abducted position so that when recovery takes place the tendency to dislocation and any shortening of the limb may be compensated for by the oblique position of the pelvis. The great drawback to fixation of the thigh in the abducted position is the effect it may have on the patient's spine and the awkwardness of gait. It has been my rule to aim at a slight degree of flexion and

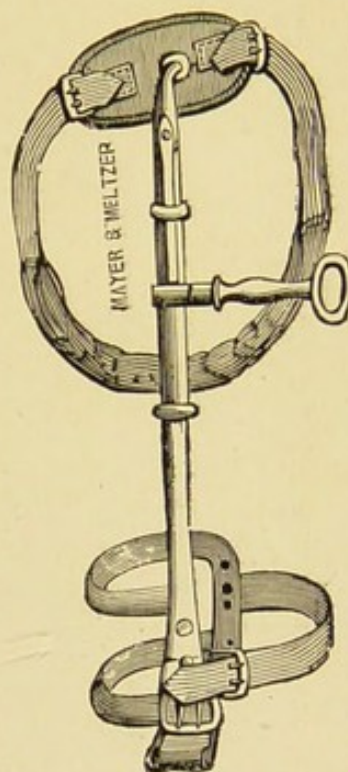


Fig. 231.—Taylor's Short Traction Splint.

* Bradford and Lovett, *loc. cit.*, p. 311.

abduction in such cases as seemed certain to lead to firm ankylosis; on the other hand, where there is prospect of obtaining some movement at the hip-joint to secure the joint in the extended position.

The Complications of Tubercular Coxitis.—Abscess and pathological dislocation are the chief local complications.

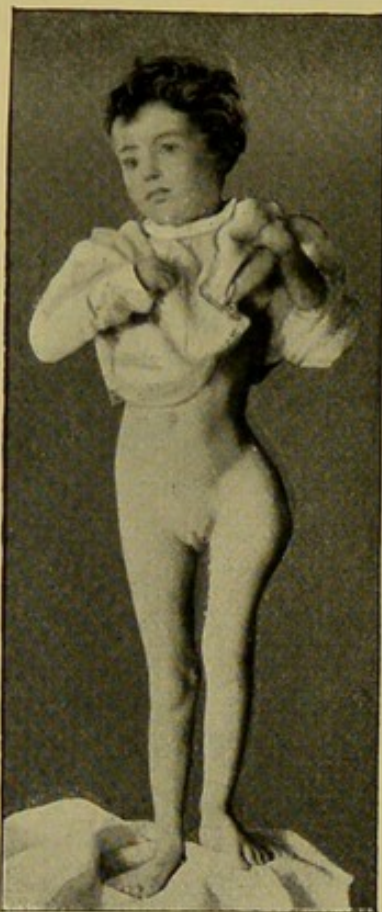


Fig. 232.—Dislocation from Tubercular Coxitis.

The occurrence of *abscess* is an indication for treatment in bed. In my opinion free opening, curetting, and washing out with hot 1—40 carbolic, with every detail of antiseptic surgery duly observed, give the best results in case of abscess. Healthy repair is often obtained. In such cases, treatment by weight-extension should be carried out whilst the abscess is under treatment.

Dislocation occurs in two distinct modes—1. Suddenly from effusion into the joint-cavity. In this condition the acetabulum is preserved, and the reduction of the dislocation by manipulation with subsequent fixation of the joint is indicated; in the second form the dislocation is produced slowly from the gradual destruction of the upper and posterior part of the margin of the acetabulum.

In such cases (Fig. 232) gradual extension by weight combined with complete fixation of the joint in a good position is called for.

Ankylosis.—This may be fibrous or osseous. In fibrous ankylosis the question of the desirability of forcible correction of any flexion, adduction, or other fixed deformity arises. In London the majority of surgeons, after gradual methods have failed to restore the parts to a good position, have recourse to a sub-trochanteric osteotomy or other operation. On this matter the experience of Mr. Robert Jones* is of interest:—

* Robert Jones, *Lancet*, Dec. 17, 1898.

In the practice of the late H. O. Thomas, in that of Mr. Rushton Parker and in my own, it has always been the custom to rectify with varying degrees of force any tubercular joint in a wrong position, so far as that phrase might be applied to the deformity known as flexion. . . .

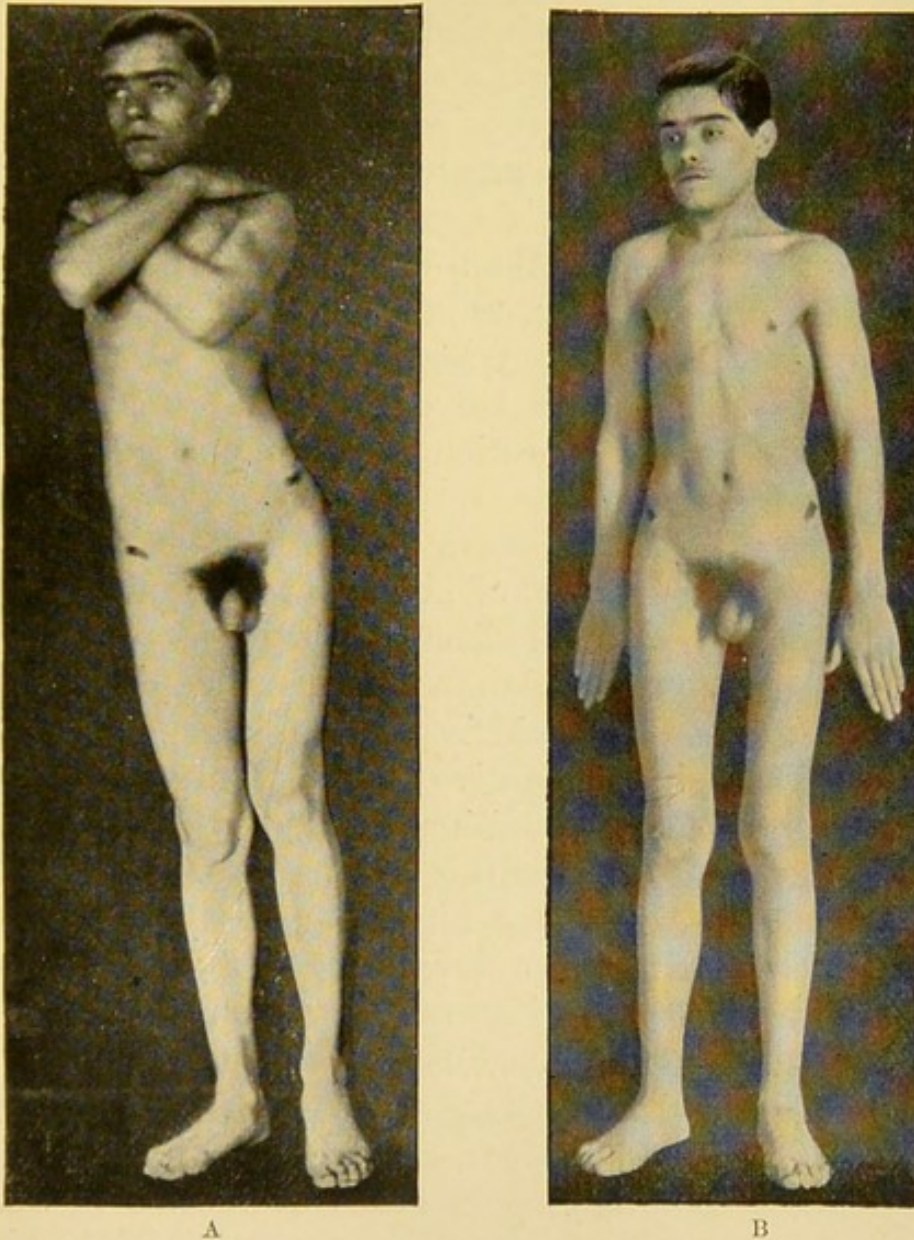


Fig. 233.—Standing Posture of a Patient before (A) and after (B) Forcible Correction of Deformity due to Tubercular Disease.

Not only have I never as a preliminary condition waited for recovery to take place from the tubercular process, but I have looked upon the active stage as that most appropriate for reduction on account of the great facility with which reduction may be effected. In the case of the knee particularly, I commonly reduce an angle of from 30° to 40° , and allow the patient to travel home the same morning, sometimes a considerable distance.

In the case of a young man who had the usual flexed adducted, and internally rotated deformity from old-standing hip disease, I forcibly corrected the position, with the result shown in Fig. 233. There was no pain immediately after the operation and no evidence of re-awakened disease for the six months that have elapsed since the operation.

When firm osseous ankylosis with deformity has occurred, osteotomy of the femur is required. The choice of operation must be made for each separate case. If the neck of the bone is long and there is no great shortening of the limb, Adams's operation will be the best. If the neck is short and there is no great shortening of the limb, sub-trochanteric osteotomy is called for. When shortening of the limb is present, inter-trochanteric osteotomy and careful fixation of the limb in abducted position during the period of healing are indicated.

After any of these operations a well-designed splint securing a certain amount of abduction is required.

The discussion of the indications for excision of the hip-joint is a subject that belongs to general surgery. In this place all that need be said is that in young patients the results of thorough conservative treatment are still far better than are those of early excision.

Non-tubercular Deformities of the Hip.—The contractions and deformities of the hip-joint other than those due to tubercular coxitis have been briefly referred to above. Their management must be conducted on principles that guide the surgeon in the conservative surgery of other parts, *e.g.* as in congenital and paralytic club-foot, ankylosis of the shoulder, etc. Two affections, however, demand more than passing notice; they are, spontaneous dislocation of the hip as a sequel to a specific fever and osteo-arthritis of the hip.

Deformities of the Hip-joint and other Joints arising after Specific Fevers, etc.—Let it be remembered that this class of affections are essentially pyæmic phenomena, and further that the manipulation of a joint that has become fixed after a suppurative process is liable to re-awaken suppuration.

As an example, a case published by Mr. John Ewens*

* I am allowed to quote this case and reproduce one of the illustrations by the courtesy of Mr. Ewens and the editor of the *Provincial Medical Journal*.

in the *Provincial Medical Journal*, July, 1892, may be quoted.

E. S—, æt. eleven years, admitted into the Bristol Hospital for Children on March 10th, 1890, with dislocation on dorsum ilii of left femur, extensive necrosis of right tibia, and consequent dislocation backwards on femoral condyles, knee being ankylosed (fibrous) at an angle of 45° . He was in a very weak state, and the skin had scarcely finished peeling after scarlatina, therefore he was placed in the scarlet fever ward, and kept there until the beginning of May, when desquamation had completed. Palliative treatment of the tibia was adopted; wound kept moist with carbolic-acid lotion, and gradual extension of knee was attempted. He was then quite unable to stand without support and Fig. 234 gives a fair representation of his appearance at that time.

History given as follows: On October 23rd, 1889, the boy complained of pain in the right knee, and began to limp. The knee swelled and was "lanced" by the local doctor. Early in November scarlet fever developed and during this illness he complained also of pain in his left lower limb, but not localised, the limb gradually getting distorted. The right knee was said not to have been painful during the illness. No other joint was affected. Two bed-sores had formed, one behind the left trochanter, and one below and behind antero-superior spinous process of the ilium. Scars only remain and there is no evidence of "morbus coxæ." The fever lasted a month and he had a very bad throat.

In June, 1890, the tibia was freely gouged and large quantities of sequestra were removed, the case progressing most favourably, new bone readily forming.

On September 2nd the notes made by Mr. Morton, surgical registrar and pathologist, are as follows: Boy seems now in fair health. Right knee flexed at 45° , with some slight lateral and backward displacement. No movement of joint possible and no pain nor tenderness. The left hip is dislocated, so that the head of the bone lies on the dorsum ilii, where it can be felt. . . .

Sept. 4th.—Under chloroform an attempt was made by manipulation and extension to reduce the left hip: some adhesions were broken down and the limb was put up in a long splint in very fair position, with a tendency to rotation inwards. The right hip was very freely manipulated and adhesions about it were broken down, but complete freedom of internal rotation and adduction was not obtained. The adhesions in the knee-joint were to a considerable extent broken down and the limb was extended, but complete extension was not obtained, nor even the patella detached from the condyles. This limb was also put up on a long splint.

Sept. 5th.—The boy does not seem to have suffered much from the manipulation, but yesterday had a good deal of pain in the left limb near the knee. Temperature normal.

Sept. 29th.—Examination under chloroform. Left limb in very good

position now; not possible to compare measurement with the right limb, but the trochanter is not raised with regard to Nélaton's line. There is only very slight movement possible at the false joint, the pelvis moving mainly as a whole. The right knee was fairly straightened with considerable difficulty, adhesions being freely broken down, and a back splint was applied. Both limbs were again put up in long splints.

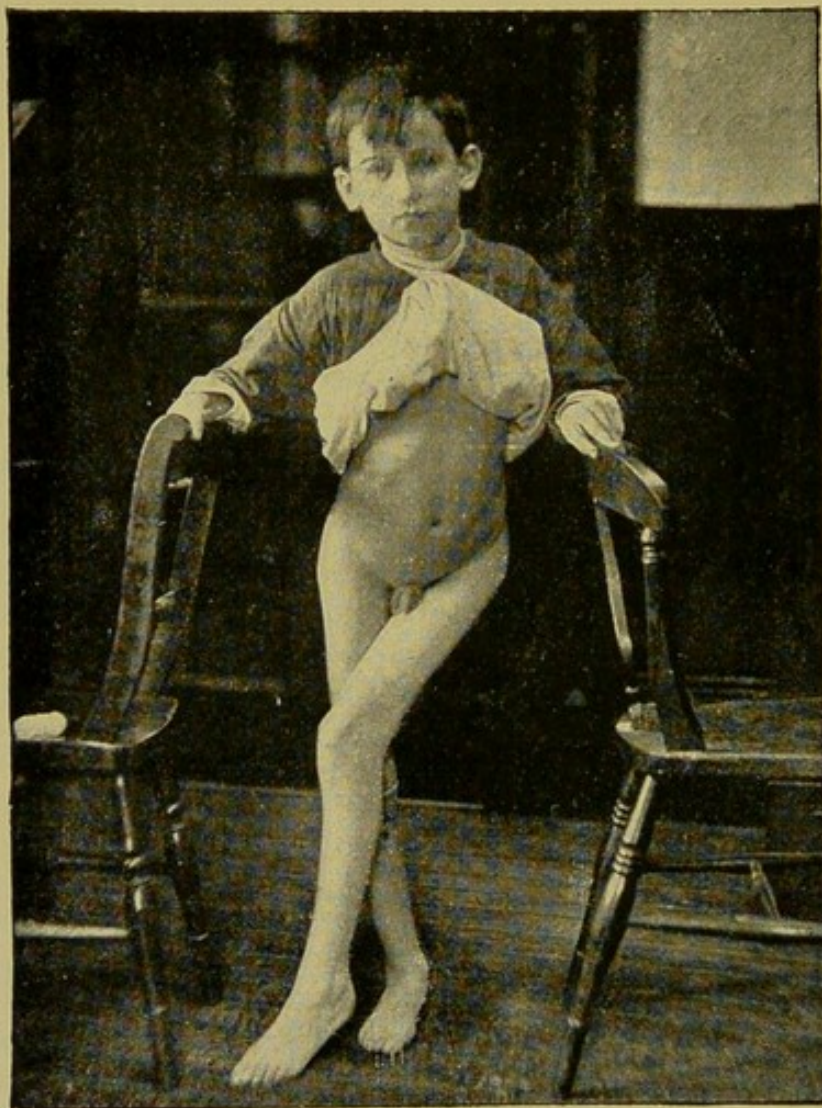


Fig. 234.—Dislocation of the Left Hip from Post-scarlatinal Arthritis.

Abduction and rotation inwards of the right hip are still very limited. Considerable pain in knee followed this last extension.

Sept. 30th.—No pain now, but knee much swollen.

Oct. 2nd.—Knee swollen, but not very tender; temp. 102° last night; ice applied.

Oct. 3rd.—Knee less swollen, no pain, but temperature 104° last night, now (11 a.m.) 101° .

Oct. 7th.—Swelling subsiding.

Oct. 13th.—Some fluctuation at sides of patella, but no pain.

Oct. 17th.—Increased swelling and rise of temperature ; free incision into joint outside patella ; considerable quantities of pus evacuated ; drainage-tube inserted.

Oct. 18th.—No pain, but the boy looks very ill and pulled down. Splints removed and limbs gradually assume old distorted position.

Oct. 20th.—Cicatrix of old necrosis on shin has broken down, discharging freely foetid pus. From this time up to Oct. 30th the boy's condition was one causing great anxiety, counter-openings having to be freely made around the knee-joint. Temperature rose every night, but less pain was experienced than might have been expected. He got very anæmic. On Oct. 30th note made as follows : Hardly any discharge from any of the openings now ; quieting down ; dressed with wet carbolised lint and iodoform ; knee getting back into old position again.

Nov. 12.—Sinuses healed ; limbs about same position as on Sept. 2nd. Temperature rises to 100° every night ; no cough ; anæmic.

It was now obvious that any further attempt at forcible extension of the knee would be attended with serious danger, therefore it was decided to send him home after Christmas, and readmit him in the spring for excision of the knee and Adams's operation on the left hip-joint, apparatus quite failing to maintain permanent good position.

April 15th, 1891.—*Readmitted*.—Health much improved, but condition of limbs exactly as before. Small sinus leading down to necrosed bone at upper part of old tibial scar. This was scraped on April 28th and parts gradually healed with exception of one small spot.

July 17th.—Knee excised under carbolic spray and dressed antiseptically ; put up on metal back splint, with foot-piece and bracketed opening around knee and swung.

Aug. 5th.—Wound healed. Temperature never rose above 100° for first few days after operation ; since then normal. No pain or inflammatory condition since operation. Firm union effected in about a month after operation.

Later, Mr. Ewens performed Adams's operation on the neck of the femur close to the trochanter and in the end obtained a truly excellent result.

Arthritis Deformans of the Hip.—The term arthritis deformans is used to designate a group of instances of disability of the hip-joint in order to include affections variously designated as traumatic arthritis, rheumatoid arthritis, or osteo-arthritis, and *malum senile coxæ*. In the section on pathology (p. 38), the general relations of these affections have been discussed as far as present knowledge enables this to be done. It remains now to indicate their practical aspects as far as the hip-joint is concerned.

Arthritis deformans of spontaneous origin is not uncommon

in patients who have reached or passed beyond middle-age, but it may, like other osteo-arthritic affections, occur in early life.

In most cases the condition is part of a widespread affection of joints, but sometimes it is non-articular, especially after injury to the joint.

Symptoms.—The affection begins with pain about the joint. Radiating neuralgic pains are common, especially along the course of the great sciatic nerve. The movements of the joint are restricted, flexion and eversion being specially painful. Atrophy of the muscles about the joint, as evidenced by flattening of the nates, ensues. In the earlier stages of the affection the limb may be flexed and abducted as in hip-joint disease. In the later stages the hip-joint tends to become fixed in a position of adduction and flexion. Eversion of the limb is sometimes marked and together with the apparent shortening due to adduction and, in some cases, real shortening from absorption of bone, a diagnosis of intra-capsular fracture is very likely to be made, especially in traumatic cases. Maydl* has drawn attention to cases in which arthritis deformans may either simulate or complicate coxa vara in adolescence.

Diagnosis.—In elderly patients, though tubercular coxitis is rare, it must be excluded before a diagnosis of arthritis deformans is arrived at. Coxa vara, sciatica, and impacted fracture are also to be considered. Good radiographs will assist in doubtful cases.

Treatment.—In every case of osteo-arthritis careful medical treatment must be secured. A month's stay at Bath, Buxton, or Harrogate, will often greatly improve what appears to be a local condition. If pain is severe, local hot-air baths and galvanism may relieve it. In some cases drilling the bone, recommended by Noble Smith, relieves the pain. Rest and weight-extension are indicated when pain is severe. When the condition has sufficiently progressed, a protective walking apparatus is of great service.

Illustrative Case.—A painter, aged fifty-eight, sent to me by Dr. Sutherland, whose notes ran: "Left leg been wasting nearly twelve months. Has not been able to walk well since rheumatism in left

* Karl Maydl, *Wiener klin. Rundschau*, March 7 and 14, 1897.

knee and ankle twelve months ago. Right leg also affected, but has recovered.

"P. has some flat-foot. Tenderness over tarsal bones on dorsum of foot. Wasting left leg. K. J. present. Some grating in left knee."

A radiograph confirmed the diagnosis of osteo-arthritis, and I had the apparatus shown in Fig. 235 made and applied. The improvement in the power of walking and diminution of pain was marked and continued.

Rheumatoid arthritis of the knee and other joints is also in many cases markedly benefited by suitable apparatus which serves to protect the joint surfaces from undue wear and tear.

Sacro-iliac Disease. — Tuberculosis of the sacro-iliac joint usually comes on in early adult life. Lameness and pain are always present and usually from the commencement of the disease. In standing and walking the patient throws the weight of the body chiefly upon the leg of the sound side by tilting the pelvis. This causes the trunk to be inclined towards the opposite side and there is apparent lengthening of the leg on the affected side. Local swelling and rise of temperature may be observed. In lying down the patient rests upon the sound side.

Pain is usually felt along the course of the sciatic nerve and it is frequently referred to the upper part of the leg. It is sometimes referred to the bladder and rectum. Intermittent at first, the pain becomes constant and it is often very severe.

Abscess occurs in the majority of cases. More commonly it forms on the inner aspect of the joint, sometimes it is superficial to the joint, and fluctuation can be obtained.

Muscular spasm is absent owing to the fixed character of the joint.

Diagnosis. — In the earlier stages diagnosis between

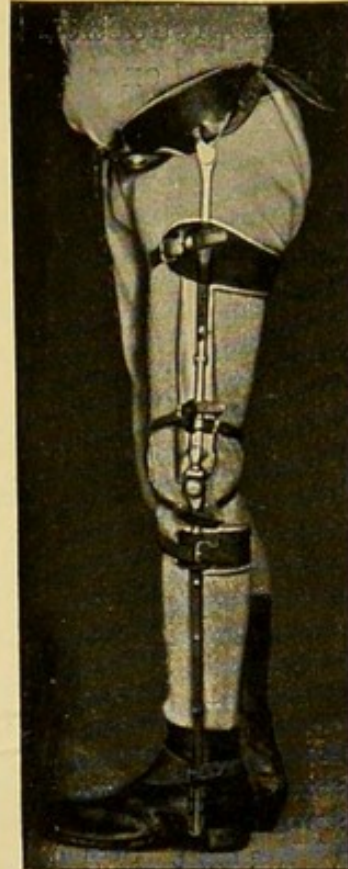


Fig. 235. — Apparatus used in a Case of severe Arthritis Deformans of the Hip.

sacro-iliac disease and disease of the lower lumbar vertebrae may be difficult. The attitude of the patient and the absence of rigidity of the spine are points to be looked for in sacro-iliac disease. Absence of deformity in the lumbar spine and of fulness at the side of the spinous processes will also serve to exclude lumbar spinal disease. A pathognomonic symptom is the production of pain referred to the joint by forcing the two iliac bones either apart from or towards each other. The affection is readily distinguished from hip-joint disease by finding that all the movements of the hip can be executed without eliciting any pain or limitation of movement. Hip disease is most closely simulated when there is an abscess forming in the iliac fossa and, in consequence, there may be flexion and eversion of the limb combined with abduction. A diagnosis of sciatica is made in most cases at first.

Prognosis is always grave, especially when abscess is present. If the disease is recognised early and proper treatment is carried out, the majority of cases recover.

Treatment.—The chief measures are such as secure rest to the joint and elimination of pressure—rest in the horizontal position on a firm mattress combined with a weight-extension apparatus applied to the lower limb on the affected side. Howard Marsh recommends blisters or the cautery applied over the joint if the pain is severe. Golding Bird,* Van Hook, and others recommend operative treatment in the early stages. A curved flap of skin and muscle is turned down from the posterior part of the iliac crest and a trephine opening is made at the root of the posterior-inferior spine. The opening in the bone is enlarged in the axis of the joint, that is, a line drawn from the upper part of the spine to the junction of the anterior and middle thirds of the iliac crests. During convalescence the patient should walk with crutches, the sole of the boot being raised on the sound side and a moulded support applied to the pelvis and affected thigh.

Congenital Defects of the Clavicle.†—Complete absence is rare and is generally accompanied by a peculiar conformation of the head, the frontal and parietal eminences

* *Lancet*, vol. i., 1895, p. 1117.

† G. Schorstein; G. Carpenter, "Cases of Absence of the Clavicles," *Lancet*, Jan. 7, 1899.

being pronounced and the former separated by a groove. The fontanelles are late to close—a fact that points to a general maldevelopment of membrane bones.

The Signs.—There is no marked deformity; but the shoulders can be made to meet in front of the patient's body by the surgeon.

The functional effect of absence of the clavicles is not serious. Dr. Carpenter, describing the case of a girl, aged thirteen, writes: "The amount of inconvenience was so small that neither the patient nor her mother was aware of anything wrong until it was pointed out to them. On examination, it was found that there was practically no ordinary movement that the child could not carry out at will. She can lift a heavy weight right above the head with ease. She can give a fairly heavy blow from the shoulder and can lift her body when suspended by the arms."

Congenital Displacement of the Scapula.—This is a rare deformity. Only one case has come to my notice.

The left scapula is more commonly at fault. The displacement consists in an elevation of the bone, which is usually increased in size and may present one or more exostoses arising from the upper border of the bone.

Pathology.—The condition was first described by Sprenghel* in 1891. He regarded the deformity as the result of the arm of the affected side having been fixed behind the back in intra-uterine life. Schlange attributed the deformity to amniotic adhesions. In one case recorded by Koelliker an apparent exostosis was found to consist of an enlargement of the angle of the scapula itself. In the case that came under my own observation the exostosis had been removed, but without any marked improvement being obtained. Associated deformities have sometimes been observed; *e.g.* cranial asymmetry and club-foot; absence of radius and maldevelopment of the soft parts on the affected side have also been observed.

Deformities of the Shoulder-joint.—*Congenital Dislocations.*—In congenital dislocation of the shoulder the head of the humerus may be displaced forwards and inwards (sub-coracoid), or backwards and inwards (sub-spinous). In one of the cases dissected by Smith, of Dublin, the head was

* Quoted by Pischinger, *Munch. med. Woch.*, 1897.

displaced backwards and lay at the back of the joint beneath the acromion (sub-acromial dislocation). Froriep has also described an upward and outward displacement.

Diagnosis.—Congenital dislocation of the shoulder is to be distinguished from the effects of infantile paralysis, about to be described. In congenital dislocation there is limitation, in paralysis excess of passive mobility.

Illustrative Cases.—Two cases of the sub-acromial variety are now under my care. In both, the position of the affected arm was the same, viz. rotated in, the elbow directed forwards and slightly downwards as well as outwards. The head of the humerus was visible behind the acromion and the movements of adduction and flexion were impaired. The patients were girls, one aged two and the other three years. In both cases the deformity was readily reduced, but as readily returned. Both patients improved considerably under a treatment by manipulation and massage. In such cases the muscular power of the dorsal scapular muscles is impaired, but electrical examination shows that there is no real paralysis. Very similar cases are, however, rightly described under the name of "birth-palsy," etc. (see p. 295).

Treatment.—In infants the deformity should be corrected and the improved position maintained by suitable apparatus. Daily manipulation and massage are also required. By these means, if treatment is undertaken early, the deformity can be cured.

Such cases of congenital dislocation of the shoulder are more common than might be inferred from the sparseness of literature on the subject. C. L. Scudder* has described two cases both of which agree with those described above as to the position of the arm. In one, a girl aged three, the bones of the upper limbs were smaller on the affected (right) than on the sound (left) side.

Length of right clavicle	2 $\frac{7}{8}$ ins.
Length of left clavicle	3 $\frac{1}{8}$ "
From acromion to external condyle of right humerus	5 $\frac{1}{2}$ "
From acromion to external condyle of left humerus	5 $\frac{7}{8}$ "
Length of right radius	5 "
Length of left radius	5 $\frac{1}{2}$ "
Length of right ulna	4 $\frac{7}{8}$ "
Length of left ulna	5 $\frac{3}{8}$ "

* *American Journal of the Medical Sciences*, Feb. 1898, p. 125.

Scudder attributed one of his cases to injury during parturition. In the three cases I have seen, the ease with which the displacement disappeared on manipulation and reappeared when left to itself, was rather that of a true congenital (*i.e.* developmental) dislocation than of a co-natal traumatic displacement. Traumatism during parturition may readily complicate a true congenital dislocation of the shoulder, owing to the diminished mobility and abnormal position of the arm. In some of the cases a certain amount of paresis or paralysis of the anterior part of the deltoid appears to be present.

Paralysis of the Shoulder-muscles.—When the deltoid and muscles that surround the capsule of the shoulder-joint are paralysed, the weight of the limb draws down the head of the humerus and causes a depression beneath the acromion which, from the accompanying wasting of the deltoid, stands out prominently. The arm hangs limp at the side of the body and is rotated inwards by the pectoralis major, the latissimus dorsi, and teres major. As a rule, the forearm is pronated, the passive range of movement at the joint may be greatly increased, so that a flail-like character of the articulation is present.

Causes.—The most common cause is infantile paralysis. When the shoulder-muscles are severely attacked by anterior poliomyelitis, there is usually at the same time some paralysis of the muscles of the lower extremities. Occasionally, however, the shoulder-muscles are singled out. Injury to the brachial plexus during birth gives rise to a similar condition.

Diagnosis.—The condition is to be distinguished from traumatic separation of the upper epiphysis of the humerus and also from syphilitic epiphysitis.

Prognosis.—In old-standing cases no improvement in the paralysed muscles is to be expected, but in most cases, under suitable treatment, the patient can be enabled to write and enjoy other uses of the hand and arm.

Treatment.—The indications are to support and steady the arm at the shoulder. This can be effected by a moulded leather apparatus made in two parts, one for the shoulder, the other for the arm. They are connected by a metal joint opposite the shoulder.

Schüssler's bandage is provided with three air-cushions. Two small ones, equilateral triangles, lie one before and one behind the shoulder. The larger air-cushion is a truncated pyramid in form and fits in the axilla, holding up the shoulder.

If it is found impossible to restore usefulness to the arm by any form of support, *arthrodesis of the shoulder-joint* has been tried with success. The joint may be opened from the outside, part of the capsule is cut away, and then the articular surfaces of the bones are denuded of cartilage. The head of the humerus may be fixed to the glenoid cavity by a silver stitch before the operation is concluded. If the operation is successful in producing firm fibrous ankylosis of the humerus and the scapula, the latissimus dorsi and pectoralis major, together with the trapezius and rhomboids, effect movements of adduction and abduction, *i.e.* of raising and lowering the arm (Hoffa).

Contracture and Ankylosis of the Shoulder-joint.—The shoulder-joint is so greatly exposed to traumata of various kinds that it is frequently crippled from intra-articular adhesions from traumatic synovitis. Dislocations, intra-capsular and extra-capsular fractures in the neighbourhood of the joint, also frequently occasion stiffness that requires patient treatment. There is no joint in the body that so often affords examples of the ill-effects of excessive immobilisation in the treatment of slight traumatic conditions. Complicated dislocations, such as subcoracoid dislocation with separation of the greater tuberosity, may leave permanent disability.

Chronic inflammation of the sub-deltoid bursa, tubercular and other forms of infective arthritis, rheumatoid arthritis, and other intra-articular conditions, as well as hysterical contracture, are to be thought of in this connection.

Symptoms and Diagnosis.—The chief effects of loss of function of the shoulder are: (1) An alteration in the conformation of the shoulder due to wasting of muscle, whereby the acromion process and the outer contour of the upper end of the humerus become more visible and more palpable than they are on the sound side; and (2) the movements at the shoulder-joint are restricted, and the mobility of the scapula compensates for the loss as far as possible.

Treatment.—In most cases the results of treatment are very satisfactory, but much patience and perseverance is required. In children it is of special importance to restore the function of this joint, since, by disuse, not only the shoulder and upper arm undergo atrophy, but the upper part of the trunk also becomes atrophied, and the equilibrium of the body is affected in such a way that lateral curvature of the spine is likely to ensue.

In cases following an injury there is synovitis, probably from some hæmorrhage into the joint, and subsequent formation of adhesions (*see also* "Bone-setting," p. 87).

A caution is needed in the case of bleeders, in whom, of course, any forcible movement of joints is inadmissible. In cases of doubt as to whether the fixation of the joint is due to fibrous or bony ankylosis, an anæsthetic should be given.

In tubercular cases the question of excision must be considered and, in this joint, should be given preference to other measures.

Fixation of the shoulder-joint from scars in the axilla and elsewhere should be treated on general principles, gradual stretching or plastic operation being resorted to according to circumstances.

Deformities of the Elbow-joint.—*Congenital Dislocations.*—Congenital dislocations of both radius and ulna, forwards or backwards, are rare as congenital affections; more common is congenital dislocation of the upper end of the radius. The latter displacement may be forwards, outwards, or backwards.

Symptoms.—The clinical symptoms are usually not observed until the child begins to use the hands. The prominent radial head can usually be seen and felt in an abnormal position. The movements of pronation and supination are, as a rule, greatly interfered with.

Causation.—The above-named deformities are due to errors of development and they show a marked hereditary character. Thus, F. C. Abbott* has related the history of a family in which he examined no fewer than seven members affected with congenital dislocation of the radius forwards.

In a certain number of cases accidental intra-uterine pressure accounts for the deformity.

* F. C. Abbott, *Trans. Path. Soc.*, 1892, p. 129.

Anatomy.—This varies according to the direction of the displacement. In one case dissected by Abbott the head of the radius articulated by a concave facet on its posterior surface with the capitellum, which also articulated with the widened coronoid process of the ulna.

Treatment.—Each case requires separate study and its own treatment. In the early years of infancy manipulations and splinting may minimise the interference with the movements of the joint. If the patient is grown up and the interference with movements of the hand is great, excision of the head of the radius will probably be the best treatment. In some cases the whole elbow-joint has been excised.

Cubitus valgus and varus are terms that have been applied to deflection of the forearm, to the radial and ulna sides respectively. These designations are based upon a superficial resemblance of the condition to genu varum and valgum. They may result from various conditions, the more common of which are, (1) congenital subluxation; (2) diminished growth at one side of the lower epiphysis of the humerus; (3) injuries, such as fracture of one of the condyles of the humerus.

The treatment in congenital cases will consist of the use of mechanical support, to give as far as possible the growth of the parts in a normal direction. In epiphyseal cases osteotomy may be done after the period of growth is passed. In traumatic cases re-fracture and correct splinting will be required.

Contractures and Ankyloses of the Elbow-joint.—*Cicatricial Contracture.*—The elbow is a common site for cicatricial contracture. After burns, etc., the treatment must be on the lines laid down on p. 92.

Gradual stretching by weight-extension is preferable to mechanical extension. Should this not succeed, a plastic operation will be needed and must be devised for each case.

Desmogenous and myogenous contractures at the elbow may limit either flexion or extension of the joint. Treatment must consist of manipulations, massage, local hot-air baths and mechanical extension. In applying apparatus it is important to see that the joints at the elbow are opposite the

axis of movement of the joint, *i.e.* slightly above and behind the epicondyles (Hoffa).

Ankylosis of the Elbow—Fibrous ankylosis must be dealt with by forcible movement of the joint. The surgeon first ascertains whether any movement remains in the joint. If so, the position of the adhesions is localised by finding the positions at which passive movement is arrested, and the points in the synovial membrane at which pain is felt. The operator supports the patient's elbow with the left hand, whilst with his right he grasps the patient's wrist and performs the required movements until every obstacle to flexion and extension, pronation and supination is overcome. If the adhesions are universal, in a non-tubercular case a movable joint is still obtainable. In tubercular cases, if repair has taken place with the elbow fixed at a right angle and the hand midway between supination and pronation, the condition may be left to itself. If the tuberculosis shows signs of activity, complete excision of the joint is the best treatment.

Bony Ankylosis of the Elbow.—If the position is a good one, no treatment is required, but if the limb is ankylosed in the extended position, excision must be performed.

THE SURGICAL ASPECTS OF SPASTIC PARALYSIS, ETC.*

This affection was first systematically described by the English orthopædic surgeon, Little,† who rightly ascribed the majority of cases to superficial lesions of the cerebral convolutions resulting from meningeal hæmorrhage arising during parturition. It is naturally commonest in first-born children and is usually congenital. Some cases, however, are not congenital, but arise in infancy from thrombosis of the superficial cerebral vessels during the course of fevers, such as measles, scarlet fever and influenza. The intellectual functions may be totally destroyed or completely intact. In the latter case, it has been supposed that the affection is of spinal origin, though there is no satisfactory proof that this invariably holds good. In some

* Much of this section is reprinted from the *Lancet*, Oct. 9, 1897.

† Little, Trans. Royal Med. Chirurg. Soc., 1862.

cases, certainly, the symptoms are such as might be produced by spinal lesions, and some authors* attribute them to syphilis, consanguineous marriages, etc. In several such cases I have detected mental irritability quite abnormal in character after chloroform has been given for operations. Doubtless a few cases are of spinal origin and some of these may be due to spinal hæmorrhage during parturition.

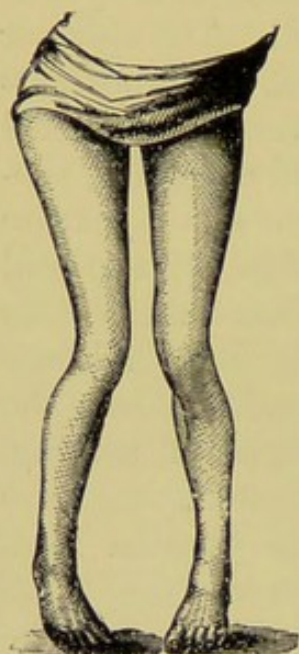

Fig. 236. — Appearance of the Lower Limbs in Spastic Paralysis. (Adams.)

Symptoms.—The exact distribution of the muscular symptoms will depend upon the site and extent of the original cerebral injury. The relative degrees in which spasm and paralysis are present vary greatly.

When the damage to the brain is on one side only, the distribution of paralysis has a *hemiplegic* character, and to a certain extent resembles the hemiplegias that occur in later life from cerebral hæmorrhage, and that are also sometimes marked by post-hemiplegic spasm or post-hemiplegic "chorea." When both sides of the brain are damaged, the condition is a *diplegia*.

In many of the cases that come to the surgeon for treatment the chief feature is tonic spasm of the muscles of the lower limbs—a spastic *paraplegia*. To this condition the term *spastic paralysis* is usually applied.

In such cases the tonic spasm of the muscles is the predominant symptom. There is a constant spasm of the muscles of the legs. The legs are rigid, with the knees semi-flexed and ankles extended. The gait, when the patient can walk at all, is characteristic; the toes scrape the ground and the thighs are pressed together, or even crossed from the adductor spasm. If the spasm is forcibly overcome, as, for instance, by flexing a knee-joint, the original position is resumed with a spring-like movement. Ankle clonus is usually present, and the tendon-reflexes are increased, though

* Seeligmüller, *Deutsch. med. Woch.*, Nos. 16 and 17, 1876.

they are often masked by the muscular rigidity. The electrical reactions are unchanged.

The limbs are cold and often atrophic.

In the slightest cases the posture of the patient in standing is often almost normal, a slight lordosis marking some increased inclination of the pelvis upon the thighs. This lordosis is sometimes mistaken for a purely spinal condition and treated accordingly; even in such slight cases the characteristic gait reveals the nature of the case.

In children the teeth are often irregular, the incisors of the second set may be notched and suggest a syphilitic taint. Strabismus is of common occurrence. The hard palate is often unduly arched.

The mental faculties are usually more or less impaired. Occasionally the patient is plainly idiotic, with saliva dribbling from the mouth, and the sense of cleanliness may be wanting. In a few cases no mental defect is to be detected, the children being bright and doing their school work as well as their fellows. The age at which symptoms appear varies. In pronounced cases they date from birth. Sometimes none are observed until the patient is two or three years old.

Diagnosis.—The symptoms sketched above can rarely be mistaken, though it is often desirable to have a thorough examination made by a competent physician, because, in rare instances, tumours of the pons and cerebellum have given rise to spastic conditions,* as in a case of glioma of the pons I remember in St. Mary's Hospital under Sir William Broadbent, which, as house physician, I watched to its end, securing the brain for the museum.

The cases of infantile cerebral degeneration, with symmetrical changes at the macula, first observed by Waren Tay and recently described by Kingdon and Risien Russell,† must be borne in mind. Such cases begin in infancy and end fatally about the end of the second year. They are marked by progressive paralysis and some rigidity.

Prognosis.—In severe cases, whether hemiplegic, diplegic,

* Sharkey, "Spasm in Chronic Nervous Disease," London, 1886.

† Kingdon and Russell, Transactions of the Royal Medical and Chirurgical Society, 1897.

or paraplegic in character, but little natural improvement is to be expected. The slighter cases of paraplegic character will improve naturally by voluntary efforts at walking if the patient has sufficient intellect. In cases that require surgical treatment benefit may safely be promised if the measures to be adopted are thoroughly carried out.

Treatment.—The first step is to alter the form and action of the stronger affected muscles by thorough tenotomy.

Lorenz,* who has published an important series of observations on this topic, attributes the good effect of thorough tenotomy in spastic cases to the shortening of the bellies of the tenotomised muscles, so that their range of action is diminished. In severe cases of spastic contraction of the knee Lorenz recommends excision of from one inch to one inch and a half of the tendons of the biceps, semi-tendinosus, and semi-membranosus muscles; and even after such tenectomies and subsequent straightening of the knee, Lorenz has never observed a failure of union in the widely-separated ends of the tendons. Thus, after an ordinary tenotomy, failure of union need not be feared. For the marked adductor spasm which, by causing the knees to press against each other, is often such a serious hindrance to progression, Lorenz has found that in mild cases forcible stretching of the adductors combined with manipulation is successful, in more severe cases subcutaneous tenotomy answers, whilst in the most pronounced cases he has successfully excised a section of the obturator nerve—an operation of some difficulty in the adducted position of the limb.

If a case of infantile paralysis is compared with one of spastic paralysis, a marked contrast may be observed. Infantile paralysis is caused by destruction of the cells of the anterior cornua of the spinal cord; spastic paralysis is attributable to partial disablement of the cells of the motor cortex or to partial blocking of the pyramidal tracts. In infantile paralysis massage and faradism in the early stages help the recovery of any muscular fibres of which the nutritive nerve cells have not been completely destroyed; in spastic

* A. Lorenz, *Wiener klinische Rundschau*, Nos. 21-26, 1897.

paraplegia massage is of no use apart from complete tenotomy. In infantile paralysis suitable apparatus prevents the occurrence of deformity; in spastic paralysis the deformity is only overcome by the use of much force and at the cost of some distress to the patient. In deformity due to infantile paralysis tenotomy, etc., are only employed to bring the limbs into workable shape and, save in the very slightest cases,

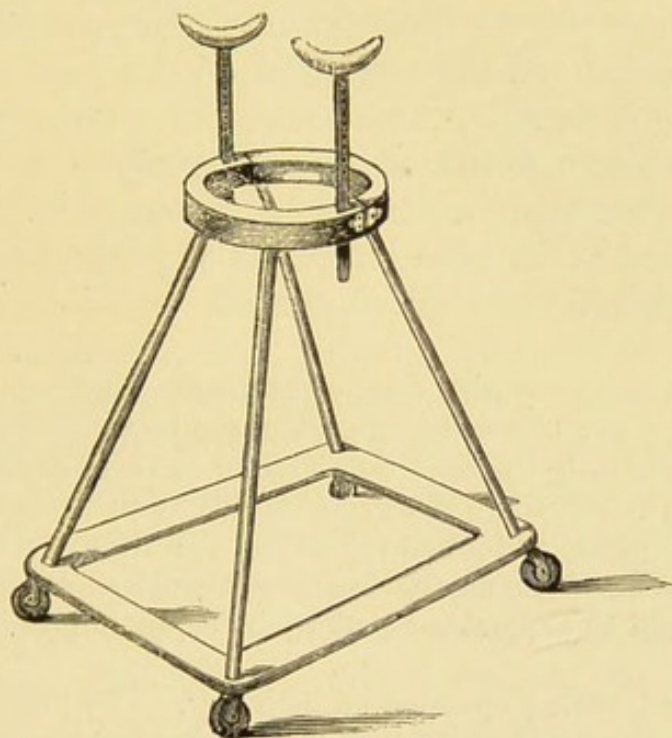


Fig 237.—Go-cart for teaching a Patient to walk after Operation for Spastic Paralysis. (*H. R. Heather Bigg.*)

the retentive apparatus must be worn for the rest of the patient's life; in spastic paralysis efficient tenotomy, by weakening the muscles, the persistent over-action of which produces the deformity, tends to restore the balance of muscular power, and in most cases this may be so far successful that retentive apparatus can be dispensed with.

After operation the use of an apparatus similar to that shown in Fig. 237 often assists the patient in learning to walk.

The failures after operation are due to half-hearted operative measures and ill-directed after-treatment

Indications for Operative Treatment.—Before deciding to undertake the operative treatment of any case various factors

have to be weighed. In the first place, the condition of the intellectual faculties must be considered. Often the mind is altogether vacant, and in such cases it is not worth while to rectify malpositions. Care must be taken not to accept the parents' estimate of a child's mental capacity. Sometimes the condition is complicated by bilateral athetosis (general chorea), and this may be taken as a distinct contra-indication. Epilepsy is a somewhat rare complication and would also be an argument for non-interference. General rigidity renders improvement of the condition of the legs of but little service to the patient.

The paraplegic forms of spastic paralysis are the more amenable to treatment, especially when the chief part of the disability consists in spastic club-foot. Such cases give complete satisfaction to all concerned.

Illustrative Case.—A girl, aged eight years. She was able to run about up to the age of three years, when she began to drag the feet in walking, and gradually the condition became more pronounced. When I first saw the patient, there was great rigidity from the buttocks downwards, with typical adduction-spasm in the thighs. Her general health was good and the mental faculties, though somewhat impaired, allowed the child to understand and wish for an improvement in her condition.

In November, 1897, I operated on both legs. The tendo Achillis on each side, at the knees the semi-tendinosus, semi-membranosus, and the biceps tendons were divided, the latter through open incisions. The adductors were forcibly stretched and manipulated without tenotomy.

The first effect of the operation was noticed and remarked on by the mother; it consisted in the patient being able to sit up and look about her, a thing she had been previously unable to do. The lower limbs, previously cold and stiff, became warm and supple. Steel walking instruments reaching to the waist, and tin night-shoes reaching to the middle of the thighs were prescribed. Two months afterwards the patient went home to the country, where the treatment was skilfully guided by the family medical man. I last saw the patient eleven months after the operation. When wearing instruments, she was able to walk easily when one hand was lightly held. She could walk round the room helping herself by occasionally resting one hand on a chair or table. The lower limbs had improved greatly in nutrition, and the calf-muscles especially had increased in size. The mental irritability had greatly diminished since the patient had been able to get about. One most important point for the future of the case is that the patient still takes much interest in herself, and steadily endeavours to improve her power of walking.

Pseudo-hypertrophic Muscular Paralysis.—This is another condition that, although its general management belongs to the sphere of the physician, not infrequently comes to the notice of the surgeon. The affection is characterised by a loss of power, accompanied by an apparent increase of bulk in certain muscles.

Causation.—Heredity is a marked feature. The disease tends to appear in certain families, and it affects males more commonly than females in about the proportion of five to one.

Pathology.—Pseudo-hypertrophic paralysis is regarded as a primary myopathy. The distinguishing feature is atrophy of the muscular fibres and increase of the interstitial cellular tissue in the form of fat.

Symptoms.—The earliest symptoms are the result of muscular weakness; the patients tire easily and find it difficult to get up or down stairs. They learn to walk late, and are perpetually falling down. In standing, the legs are kept far apart, and there is often marked lordosis. In walking, the patient throws the centre of gravity of the body over the supporting leg, and the result is a waddling gait. The weakness slowly increases so that it becomes difficult for the patient to assume the upright position, and then progression is effected on the hands and knees. In this position there is a marked "saddle-back" depression of the lumbar spine. The method in which such patients rise from the "all-fours" position is characteristic:—

1. The patient first extends the knee-joints, resting the clenched hands and the toes upon the ground.

2. One hand is taken from the ground and placed above the knee of the same side.

3. The second hand is similarly treated.

4. The patient works the hands alternately a few inches up the thighs until the centre of gravity is brought over a point between the feet, which are placed some distance apart. The muscles of the calf are usually hard and tense to the touch. In the upper extremity the muscles waste as in progressive muscular atrophy; in the later stages of the affection contractures are observed. The feet tend to

assume the position of talipes equinus, the knees and hips are fixed in flexion, and there is sometimes lateral curvature of the spine.

Diagnosis.—As far as the orthopædic aspects of the condition are concerned, diagnosis is the most important task. These cases have been mistaken for spastic and infantile paralysis, for paraplegia due to tubercular spondylitis, and even for rickets. Careful attention to symptoms and study of the history of a case will enable the surgeon

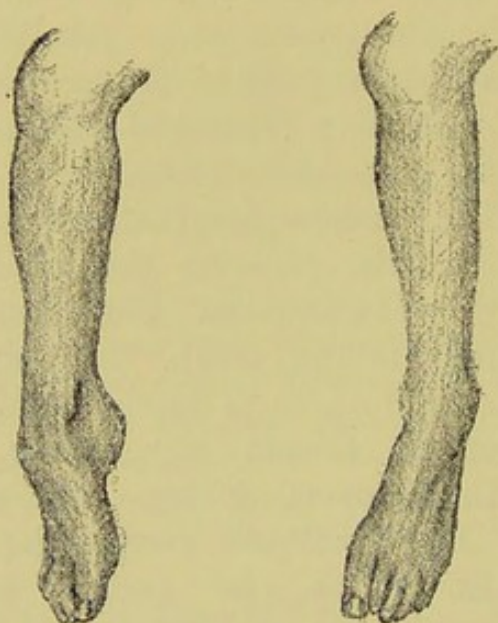


Fig. 238.—Position of the Feet in Pseudo-hypertrophic Muscular Paralysis.

to exclude spastic paralysis and paraplegia from spinal disease.

It is in the later stages of the affection, *i.e.* when deformities have arisen, that pseudo-hypertrophic paralysis may be mistaken for infantile paralysis.

The so-called paralysis of rickets is accompanied by general malnutrition and wasting rather than increase of bulk in muscles.

Course.—The disease is steadily, though slowly, progressive. Recovery is practically unknown and arrest of the disease is very exceptional. The first stage, that of muscular weakness, lasts several months and passes into the hypertrophic stage. This begins in the calves and extends upwards and in some cases affects the upper extremities.

This stage takes about eighteen months to reach its maximum. The disease then remains stationary for a variable number of years. Lastly, the atrophic stage appears in which the muscles waste, contractures appear and the patient's strength wanes. Death usually takes place between the ages of fifteen and twenty years from pneumonia or some other pulmonary affection.

Illustrative Case.—A boy, aged seven years, was brought to me with severe talipes equinus of both feet. The lower limbs were somewhat wasted (Fig. 238). In sitting the patient drooped forwards from weakness of the muscles of the spine. On examination, the ankles were found to be rigidly fixed in the deformed position, and there was some flexion-contraction of the knees. Owing to the late period of the affection, I explained to the parents that it was impossible to restore the power of walking. At their request, however, I corrected the deformities present, in order that the patient might be improved in appearance.

Treatment.—By gentle muscular exercises adapted to the weak condition of the patient the last stage may be postponed, and when contractures have appeared tenotomy of the tendo Achillis, and, if need be, of the hamstrings, may for a time restore the power of walking.

SECTION V.

DEFORMITIES OF THE SPINE.

Introductory to Deformities of the Spine.—*Preliminary Observations.*—The normal spine is almost straight at birth and during early infancy. Only when the child begins to sit up, does the desire to look around cause it to raise the head and so the cervical spine to become convex forwards.*

At first, in sitting, the child's back below the cervical region is curved with a general convexity backwards. This is owing to the inability of the dorsal muscles to hold the spine upright:—when the spine is bent forwards the strain is thrown upon the strong posterior ligaments. It is only when the child begins to stand that the lumbar curve develops. In order to balance the body on the extended lower limbs, the pelvis is tilted forwards and downwards upon the transverse axis of the hip-joints. This position of the pelvis entails a forward bend of the lumbar spine, the dorsal region of the spine retaining its original forward concavity. Not before the sixth or seventh year do these normal curves in the spine become permanent, *i.e.* cease to disappear when the patient lies down. When the development of the spine is completed, the line of gravity in the erect position of the body passes through the middle of the head, the front of the atlas, the promontory of the sacrum, and just behind the middle of the acetabulum, in front of the centre of the knee-joint, and between the feet opposite the mid-tarsal joints.

The cervical, dorsal, and lumbar curves depend chiefly upon

* Some authors describe slight normal curves as being present at birth. However this may be, it does not affect the importance of posture and muscular action in the normal development of the spine. The not inconsiderable number of cases in which as an acquired deformity the normal dorsal curve is reversed tends to show that the form of this part of the spine is not so strongly pre-determined by nature as some writers suppose.

the shape of the intervertebral discs, which together form one-fourth of the length of the movable part of the column. Owing to the compressibility of the discs, the length of the spine is from one-half to three-quarters of an inch longer in the recumbent than it is in the erect position. For the same reason a normal person's height is slightly greater in rising in the morning than it is at the end of the day.

Adams* observes: "It would probably be correct to assume that about one-fourth, or between one-fourth and one-fifth of the length of the spinal column above the sacrum is composed of elastic intervertebral cartilage, and it is important for us to bear this in mind in reference both to the production and treatment of spinal curvature."

The normal range of movement in the spine is greater in the young than in the aged. Flexion and extension are more extensive in the cervical and lumbar than in the dorsal region. The movements in other directions are determined principally by the articular processes. To quote from Quain's "Anatomy" (9th ed.), they are as follows: "In the dorsal region the articular surfaces of each vertebra lie in the arc of a circle whose centre is in front, between the bodies of the vertebræ, and round this centre a certain degree of rotation is permitted. In the lumbar region the centre of the circle in which the articular surfaces lie is placed behind so that rotation is prevented; the articular processes, however, permit of lateral flexion, and by combination of this with antero-posterior flexion, some degree of circumduction is produced. The articular surfaces of the cervical vertebræ, being oblique and placed in nearly the same transverse plane, allow neither pure rotation nor pure lateral flexion. They permit, besides forward and backward motion, only one other, which is rotary round an oblique axis—the inferior articulating process of one side gliding upwards and forwards on the opposing surface, and that of the other side gliding downwards and backwards, by which a combination of lateral flexion and rotation is obtained. The normal curves of the spine are maintained by a variety of forces, and, if any one of these forces is diminished, deformity results."

* "Lectures on Curvature of the Spine," 1st ed., p. 16.

The Chief Varieties of Deformity of the Spine.—The terms used to designate the chief deformities of the spine were introduced by Galen about the year A.D. 170. These are—*kyphosis* (Gr. *κυφός* = stooping), signifying a forward bowing of the spine, *e.g.* that commonly known as “round shoulders”; *lordosis* (Gr. *λορδός* = bent supinely), signifying a forward convexity of the spine; and *scoliosis*, (Gr. *σκολιός* = crooked), is generally used to signify a combination of lateral curvature with rotation of the spine.

Very many different causes may, singly or combined, result in the production of the same deformity.

The functions of the spinal column are not limited to those of supporting and protecting other parts of the body, and to the part it plays in locomotion; the spine has an important share in the mechanism of respiration. In full inspiration the dorsal segment is straightened, whilst in expiration it returns to the more curved expiratory position. Thus, severe scoliosis and kyphosis of the dorsal part of the spine entail an impediment to respiration, which in its turn causes a disturbance of the circulation and of the general health.

The Mode of Examination of the Patient for Spinal Deformity.—Little children, boys and men, should be entirely undressed; women and girls should be undressed to the hips, so that the top of the intergluteal cleft is just visible; the garments can be fixed round the hips by a strap or a safety-pin. The lower part of the skirts should also be pinned up so as to show the feet and ankles. A warm shawl may be thrown round the front part of the body. A firm table and a stool are required. It is necessary to have a good light and it is advisable to have true vertical and horizontal lines in the wall; in the absence of these a plumb-line may be suspended near the patient.

The natural movements of the patient should be watched, since valuable information is often to be gained in this way. Thus, a patient whose spine is the seat of early tubercular disease will often first notice a difficulty in getting up and down stairs.

In little children the mobility of the spine can be

ascertained by gentle manipulation. In older subjects the patient may be seated on a stool and made to flex, extend, and rotate the spine in turn. The rotation movement may be elicited by fixing the pelvis in the standing position and directing the patient to look in turn over the right and the left shoulders.

When disease is present, the stiffness and cautiousness in the movements may be demonstrated by asking the patient to stoop and pick up some small object from the floor.

It should be borne in mind that the physiological antero-posterior curves differ in degree in different individuals, so that the general conformation of the individual, the age, sex, and occupation, must all be considered before any antero-posterior curve is decided to be pathological.

The causes of spinal deformity include those discussed in the introductory chapter of this work, and they will be again referred to in connection with the special types of deformity.

Abnormal spinal conditions that come to the notice of the surgeon in private practice are generally attributable to some underlying cause, such as anæmia, rickets, or osteoarthritis, but in many of these cases a determining cause, such as inequality in length of the legs, is frequently to be found. The causes of spinal deformity are then in the main the same as those of other parts of the skeleton, but they are more complex owing to the greater physiological importance of the spine, and to its relation to the respiratory and circulatory systems. Habitual postures, when assumed regularly for considerable periods, modify the direction of growth of the individual vertebræ and of the soft parts, resulting in various deformities of the spine. In this manner the "round back" seen in many shoemakers, clerks, and others owes its origin to exaggeration of the dorsal curve.

In a similar manner the spines of those who have to carry heavy weights on the head or back become modified in form. Thus, the skeletons of dock-porters, coal-heavers and others show changes readily explicable by reference to the various occupations of the individuals.

Abnormalities in the point at which the weight of the body is transmitted from the pelvis to the femora also entail abnormal postures of the spine. Thus, in dislocation of the hip when, as is usual, the head of the thigh-bone rests at a point posterior to the acetabulum, the pelvis tilts forwards, necessitating an increase in the

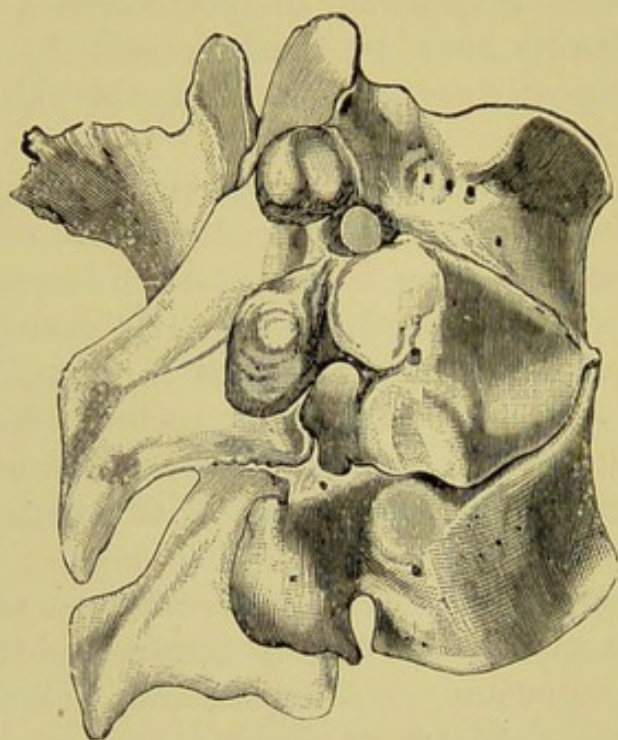


Fig. 239.—Half-vertebra. (*Shattock: Bland Sutton's "Tumours."*)

lumbar curve. Similarly, lateral tilting of the pelvis entails lateral bending of some part of the spine.

Alterations in the resisting power of the bones and ligaments entail deviations from the normal form of the spine. It is thus that in rickets, rheumatoid arthritis, and in tuberculosis of the spine, various deformities may arise. When the anterior or posterior muscles of the spine are weakened by paralysis or malnutrition deviations from the normal may occur.

Again, if the thorax is altered by cicatricial or other changes in the lungs, the dorsal curve tends to increase; if one side of the chest is affected only by cicatricial changes, *e.g.* after empyema, lateral curvature of the dorsal spine may ensue.

Congenital Deformities of the Spine.—Congenital defects

of the spinal column are present in the various kinds of spina bifida. In dissecting the body of a child, the subject of a spina bifida occulta, I found, besides the defect in the laminae, that there was an S-shaped lateral curvature affecting the whole spinal column. In some cases of congenital lateral curvature, absence of some vertebrae and associated deformities of the clavicles have been described. The presence of half-vertebrae (*see* Fig. 239) has also been observed in such cases.

I had recently under my care a lady, aged twenty-nine, who suffers from a marked kyphotic bend, of congenital origin, situated at the root of the neck. In another similar case a father and three children were affected.* Many cases of congenital wry-neck are of intra-uterine origin. They entail a lateral curve of the cervical spine; the last-named deformity is best explained as being due to abnormal intra-uterine pressure.

Thoracic Kyphosis, or Dorsal Excurvation of the Spine.—This is the commonest form of spinal deformity, and it may arise from a great variety of causes. In old age it may be regarded as, to some extent, a normal condition. The intervertebral discs in their aggregate are somewhat thicker in their anterior than in their posterior parts, and thus they maintain the dorsal segment of the spine in a less curved condition than would be the case were the bones in contact with each other. In late life the intervertebral discs undergo atrophy with the other fibrous tissues of the body, and hence a certain degree of kyphosis is common and, as stated above, may be regarded as normal in old age.

The pathological kyphoses are due to the following causes:—

1. Congenital, from intra-uterine cramping of the foetus.
2. Rickets, chiefly in infancy and childhood.
3. From nasal obstruction, *e.g.* adenoids (with which rickets is usually combined) and deviated nasal septum.
4. From pulmonary disease, *e.g.* bronchitis, emphysema, asthma.
5. From muscular weakness, anæmia, "rachitis adolescentium."

* Compare W. Adams's "Curvature of the Spine," 2nd ed., p. 64.

6. From nerve affections, *e.g.* hysteria, infantile paralysis, progressive muscular atrophy, pseudo-hypertrophic paralysis.

7. From bone affections other than rickets, *e.g.* osteoarthritis, osteitis deformans, osteomalacia.

The form of dorsal excurvation that most frequently calls for treatment is that which occurs in children and young persons, especially young women. A typical instance is shown in Fig. 240. In such cases there are often marked impairment of muscular power and some pain and tenderness in the spine.

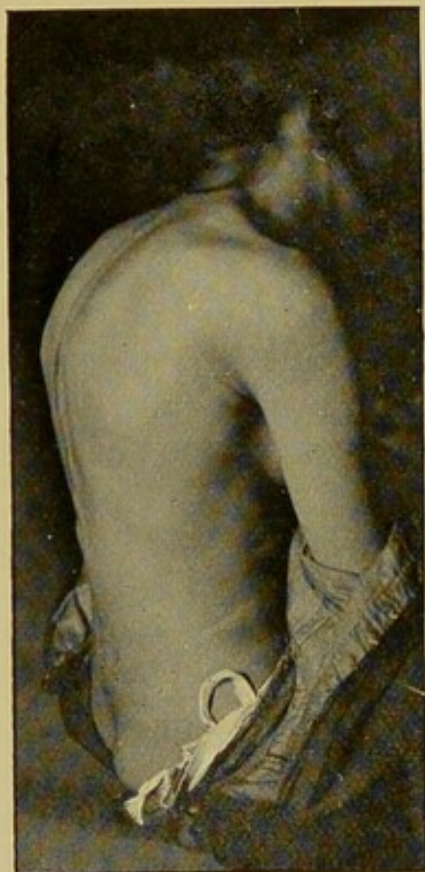


Fig 240.—Girl, aged twelve years, showing marked Thoracic Kyphosis.

Causation. — Most observant persons must have noticed that when they are fatigued, and are in the standing or sitting position, the back tends to become more arched, and the respirations to diminish in vigour. In this position, the strain of supporting the weight of the head and shoulders is thrown upon the strong ligaments at the back of the dorsal vertebræ, and so the erector and other muscles are rested. If at such times the spine is kept free from lateral inclination, the posture assumed approaches that shown in Fig. 240. If this attitude, from mental apathy or physical weakness, be assumed frequently and persisted in for considerable periods,

it will become *fixed*—that is to say, the patient cannot voluntarily correct the deformity.

Diagnosis.—The condition requires careful examination, especially in young children, so that some more serious condition shall not be mistaken for it. Early tubercular disease, and, in some cases, rickets, or paralysis of the back muscles, may give rise to the same deformity. In older subjects, rheumatoid arthritis, osteitis deformans, osteomalacia, tubercle, cancer, and other conditions must be thought of.

Treatment.—Attention to the general health and hygiene, proper intervals of rest and exercises, are all that are indicated in slight cases. The exercises should be properly directed and regulated, and the strength of the extensor muscles of the back should be tested from time to time with a dynamometer. The school chairs, desks, etc., should be examined, and care should be taken that they allow of the patient sitting in a good posture. Where the curve is pronounced, and does not readily respond to these measures, there is no doubt that a light support should be worn in addition. The best form of support for this purpose is, in my opinion, a properly-made and -fitted Chance's splint, described on p. 84. In using this or any other instrument care must be taken that there is no lateral pressure upon the ribs. The use of a support must never be taken as an excuse for omitting exercises, of which the respiratory exercises described on pp. 365 and 440 are the most important.

Lordosis.—In conditions of weakness lumbar lordosis may be combined with dorsal kyphosis as described above (p. 333). In greatly debilitated persons the body often assumes an attitude of lordosis when the patient attempts to stand. The condition is natural during the later months of pregnancy, when it is due to an adaptation of a posture that secures a balance of the body; the upper part of the trunk is thrown backwards in order that the centre of gravity may be brought over the centre of support. A similar attitude is observed in stout persons and in persons suffering from large abdominal tumours.

Rachitic Lordosis.—In rickety children both dorsal and lumbar curves are not infrequently exaggerated, or, in other words, kyphosis and lordosis are both present, giving to the spine an **S**-shaped deformity. Lordosis in rickets is attributable to the pelvis being flattened and becoming more horizontal in position.

Secondary Lordosis.—In a great variety of conditions lordosis is secondary. It will save repetition if the commoner conditions in which this occurs are examined in this place.

Flexion at the hip-joints, e.g. in hip-disease, in contraction of the psoas, in contraction of the flexor muscles due to infantile paralysis of the extensors of the hip. In such

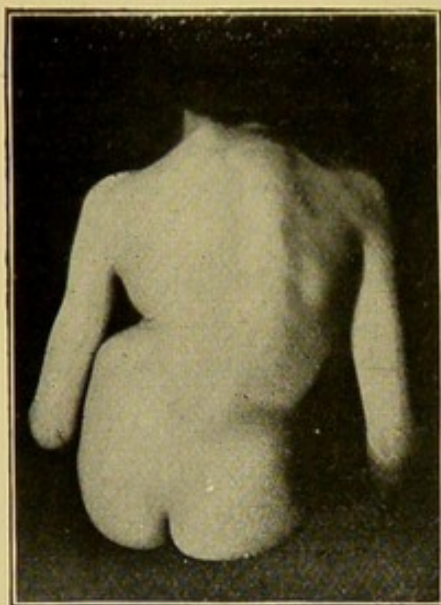


Fig. 241.—Back of a Girl, aged thirteen years, with severe total Right-Convex Scoliosis. There is marked pelvic asymmetry.

must hold the first place. Gentle exercises calculated to strengthen the anterior muscles of the spine and the

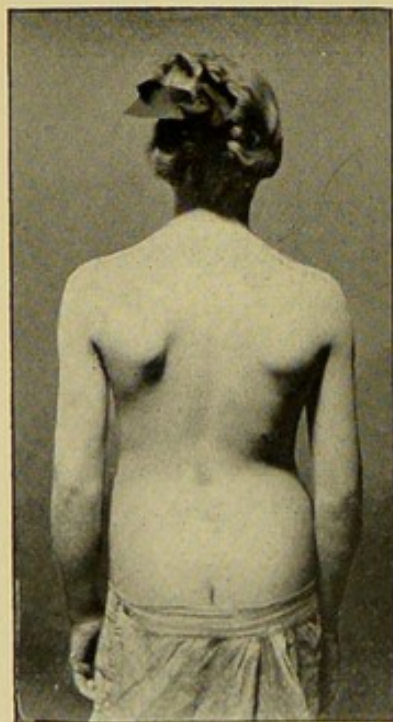


Fig. 242.—Back of a Girl, aged ten years, with a moderate degree of Right - dorsal Left-lumbar Scoliosis.

cases, when the patients stand with the lower limbs vertical, the body would project more or less horizontally forwards did not the spine arch backwards to accommodate itself to the limitation of extension at the hip-joint.

Another class of case in which lordosis occurs has already been referred to, namely, the lordosis due to a backward displacement of the point at which the head of the femur rests upon the iliac bone.

Treatment.—In slight cases due to weakness of muscles, diet, rest, and hygienic measures are all useful. In many cases a light support to the back with a broad abdominal band must be worn for a time. Where the condition is secondary, attention must be directed to removal of the original cause. Thus, in congenital hip - dislocation, if the patient is too old for the condition to be cured, the head of the femur can be made to rest near the anterior-superior spine, and kept there by suitable mechanical means until it is firmly established in its new position. The instrumental treatment of lordosis will be further discussed in dealing with scoliosis and tubercular spondylitis.

Lateral Curvature of the Spine, or Scoliosis.—By the term scoliosis is meant any lateral deviation of the spine from its normal form.

Lateral curvature is usually associated with a rotation of

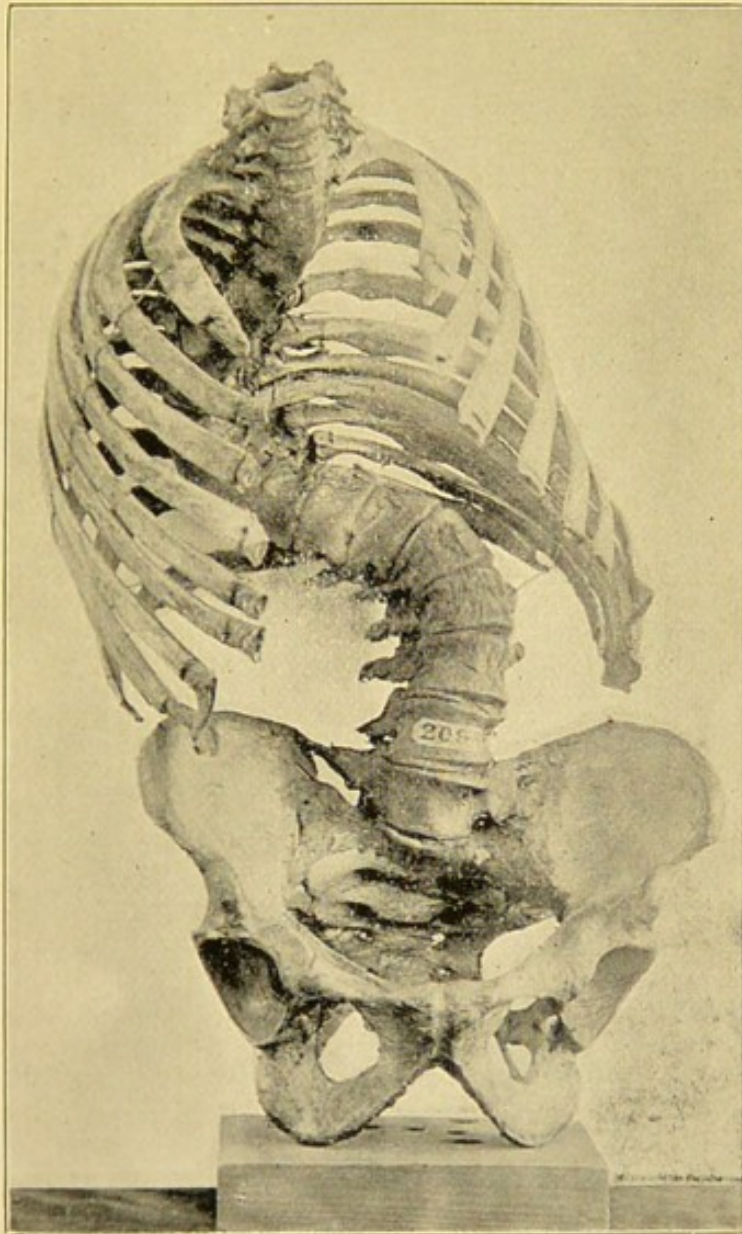


Fig. 243.—Front View of Scoliotic Skeleton in the Museum of the Royal College of Surgeons.

the vertebræ towards the convexity of the curve, but lateral curvature may exist without rotation, and *vice versa*.

Cases are either—1, simple, *i.e.* presenting but one curve, or 2, compound, when two or more curves are present. If the whole spine is involved in a simple distortion, there is said to

be total scoliosis; if only a part of the column is affected, the term partial, *e.g.* dorsal or lumbar scoliosis, is applicable.

Illustrative examples best convey a meaning of descriptive terms. Thus, in Fig. 241 is represented an instance of severe

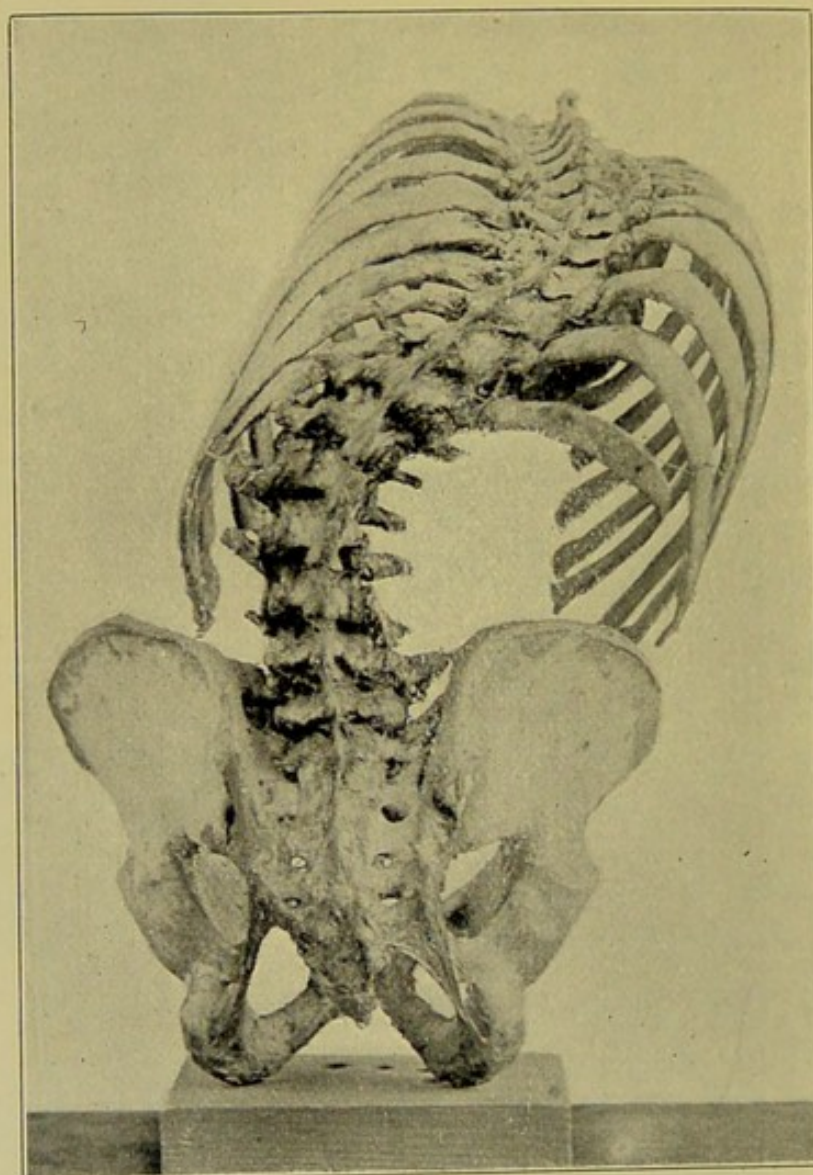


Fig. 244.—Back View of Scoliotic Skeleton in the Museum of the Royal College of Surgeons.

total right-convex scoliosis; in Fig. 242 a moderate case of right dorsal, left lumbar scoliosis. A total scoliosis convex to the left is shown in Fig. 253, and in Fig. 256 a simple cervico-dorsal scoliosis convex to the left.

A primary simple scoliosis frequently becomes compound by the formation of secondary curves.

Frequency.—Scoliosis is one of the commonest of deformities, especially in large towns. Hoffa puts it as high as 27.63 per cent. of all cases of deformity. This estimate agrees closely with the number of the cases observed at the

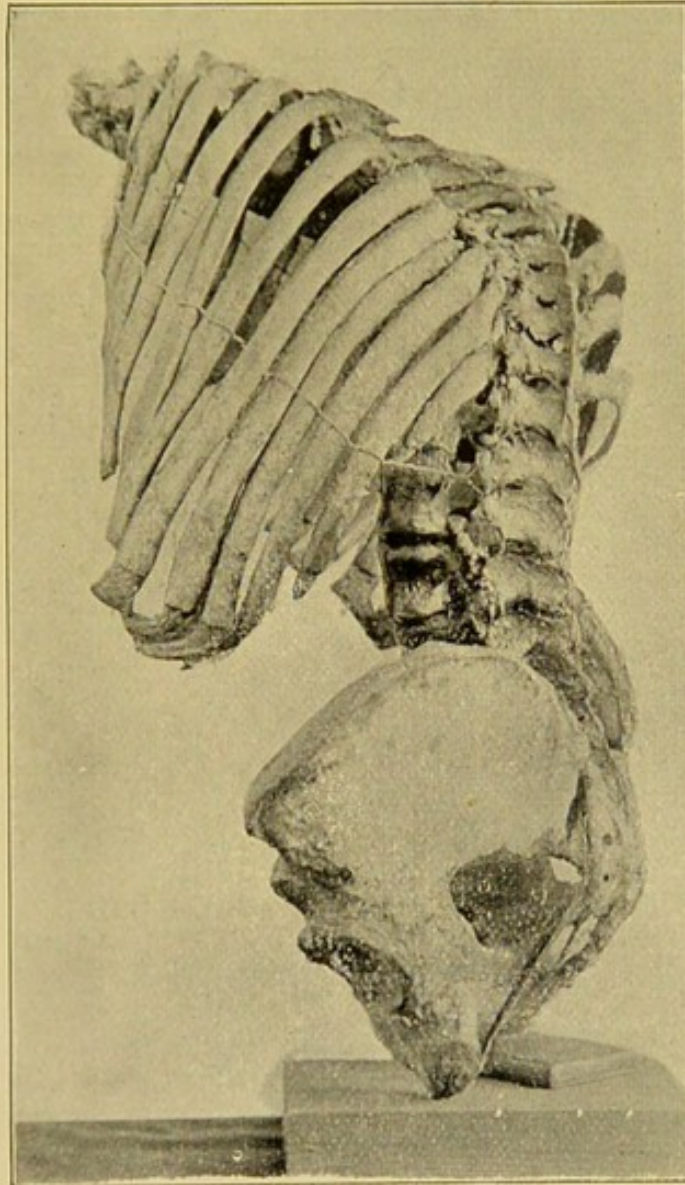


Fig. 245.—Side View of Scoliotic Skeleton in the Museum of the Royal College of Surgeons.

City of London Orthopædic Hospital. Scoliosis is more common in females than in males by five or six to one.

Pathological Anatomy.—The anatomy varies according to the peculiarities of each case, but many features are common to all cases.

The study of scoliosis is, perhaps, best begun by the

examination of a skeleton in which there is a marked degree of the more common form of scoliosis, *i.e.* right-dorsal and left-

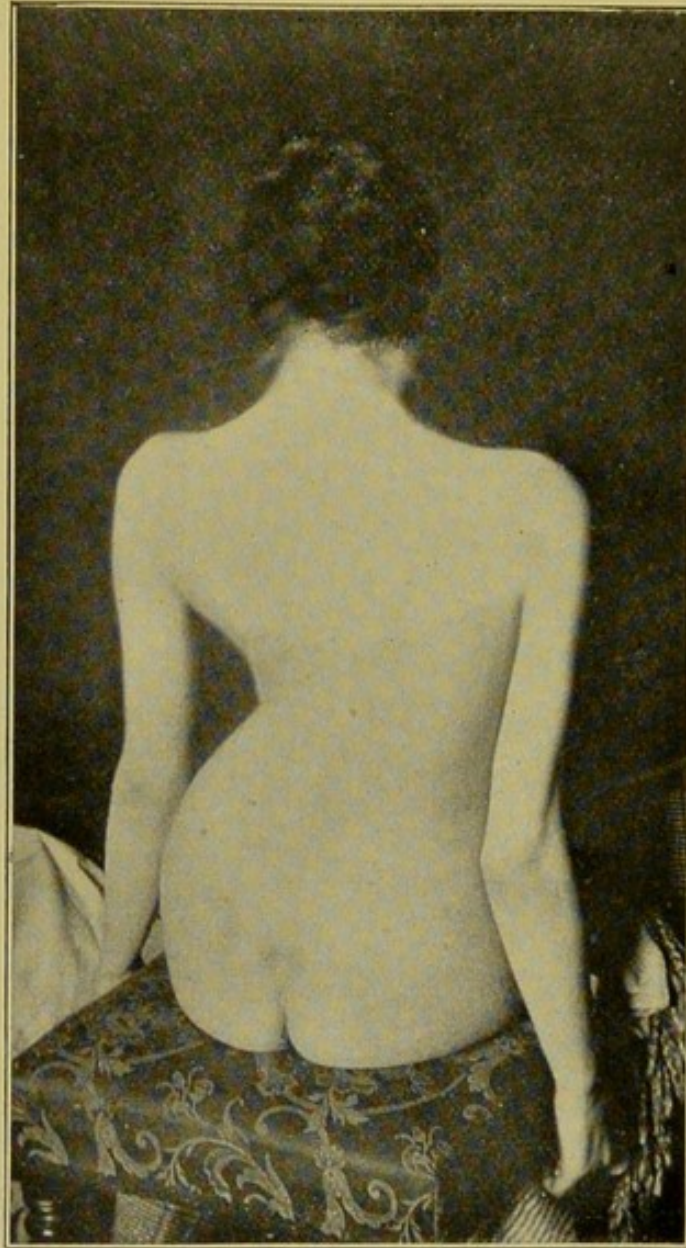


Fig. 246. —Posterior View of a fairly severe case of Scoliosis of the Flat-backed type.

lumbar curves. By the kind permission of the President and Council of the Royal College of Surgeons, I am able to reproduce three views of such a skeleton (Figs. 243, 244, 245). Seen from before (Fig. 243) the chief features observed are—1st, an **S**-shaped lateral bending of the spine, to the right in the dorsal, to the left in the lumbar region; 2nd,

a rotation of the vertebræ involved in these curves, their bodies being turned towards the convexity of the curves.

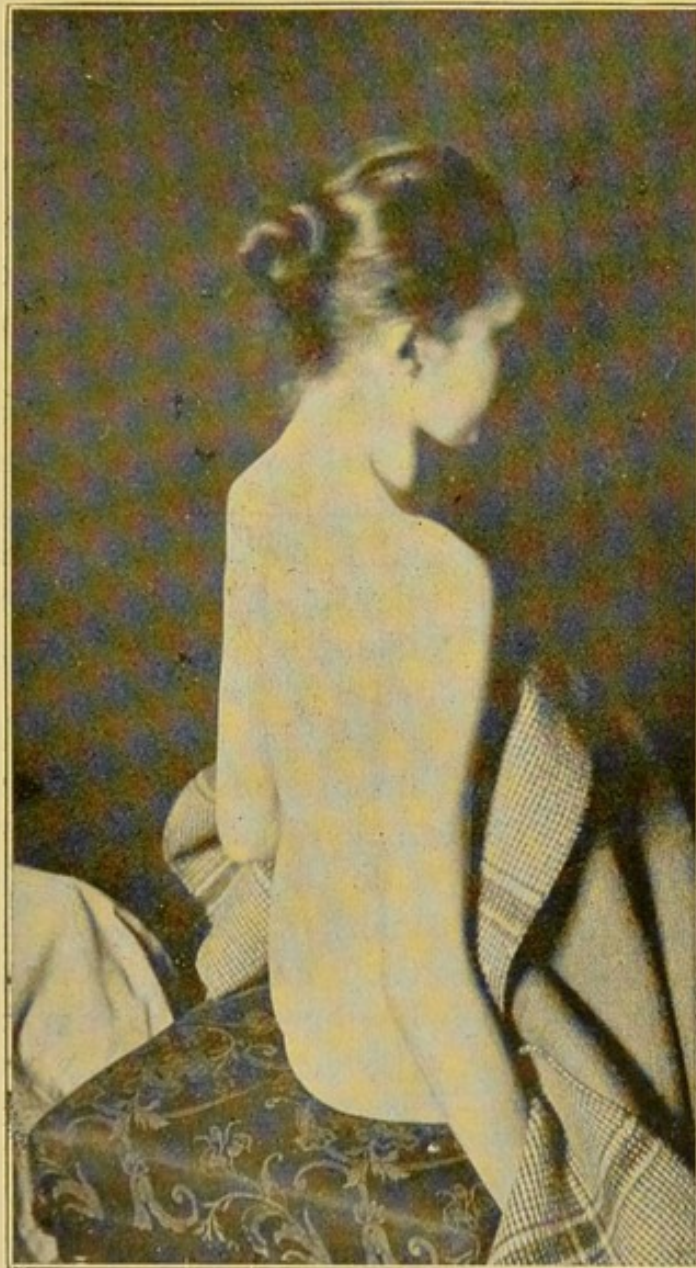


Fig. 247.—Side View of the case shown in Fig. 246.

Seen from behind (Fig. 244) the same features are observed, and, in addition, it is seen that the spinous processes are rotated towards the concavity of the curves, that is in the opposite direction to the bodies. In slight degrees of the affection this rotation may be sufficient to bring the spines into vertical line with one another. This is a matter of

practical importance in diagnosis, for there may be present a considerable amount of scoliosis without any deflection of the spines. In severe cases the rotation of the spines in

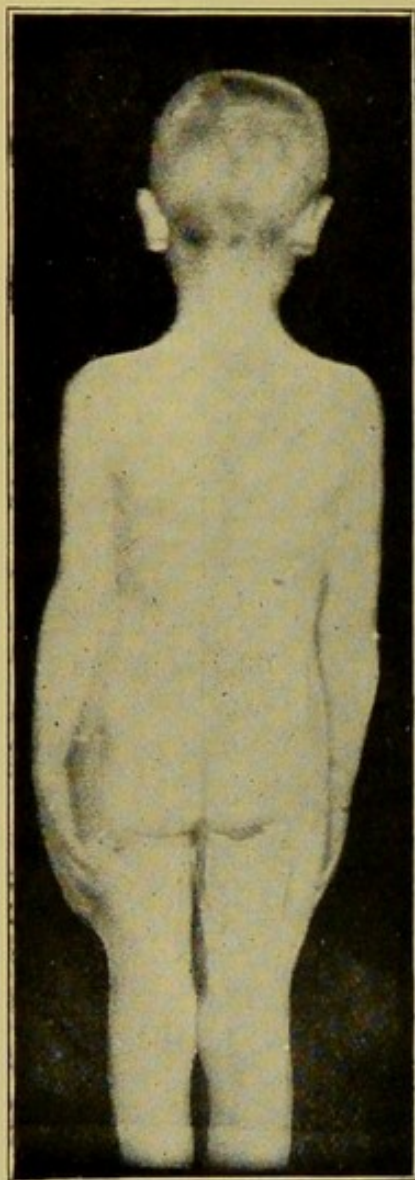


Fig. 248.—Slight case of Right-dorsal Left-lumbar Scoliosis showing Inclination of the Trunk to the Right.

the opposite direction to the bodies is not so marked as might be expected. This is due to the resistance offered to the progress of the distortion by the attachment of muscles to the spinous and other processes, which induces a structural asymmetry in the individual vertebræ. Another striking feature, seen both in the anterior and posterior views, is a general inclination of the trunk to the right. This deviation of the trunk is often seen even in slight cases of scoliosis; an instance is given in Fig. 248. It will be further observed in the dorsal region that the ribs on the convex side are separated from one another, and are sharply bent at their angles, their posterior parts having followed the rotation of the vertebræ, whilst their anterior parts have resisted this movement. On the concave side the ribs are close together and are displaced forwards by the rotation of the vertebræ.

Turning next to the side view (Fig. 245) of the skeleton, the alteration in form is not less remarkable. The most pronounced change is a sharp forward bend in the dorsal region.

This association of kyphosis with dorso-lumbar scoliosis is not uncommon, but the kyphosis is by no means a necessary part of scoliosis; some of the worst cases are of the "flat-backed" type (Fig. 246); in them the

normal antero - posterior curves are diminished or even reversed.

To recapitulate the chief features presented by this typical skeleton we recall two essential features.

1. The two principal lateral curves: the dorsal convex to the right, the lumbar convex to the left. This is termed *inflexion* of the spine.

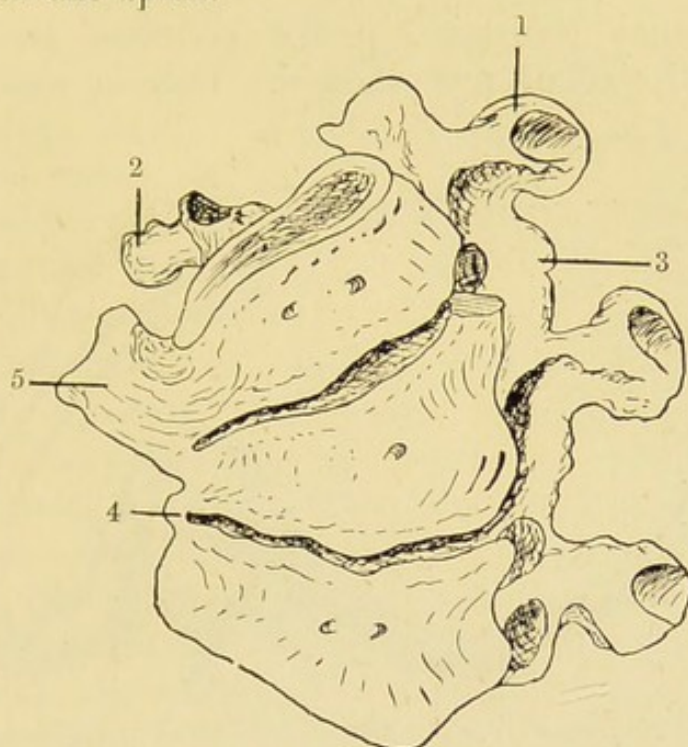


Fig. 249.

Three dorsal vertebrae from the apex of the dorsal curve. The transverse and articular processes are larger and the vertebral bodies are much deeper on the convex than on the concave side. 1, 2, transverse processes; 3, articular processes ankylosed together; 4, bridge of bone joining the vertebral bodies; 5, head of a rib ankylosed to the vertebrae. From an old person who had suffered from rheumatoid arthritis.

2. *Rotation* of such a nature that the anterior part of the vertebrae is turned towards the convexity of the curves and also, but to a less extent, their posterior parts are turned towards the concavity of the curve. This is termed *torsion* of the spine.

The points at which one curve passes into another have been named "points of interference." The vertebra that forms the apex of a curve has been termed the wedge-vertebra because it tends to assume a more marked wedge-shape, *e.g.* the middle of the three vertebrae shown in Fig. 249.

The body of the vertebra which is situated at a point

of interference is twisted spirally. The remaining vertebræ approach a wedge-shape, which is the more pronounced the nearer they are situated to the apical vertebra. Examined singly, the vertebræ are seen to present a marked asymmetry, which is not only lateral but of a complicated nature, affecting the body, arch and processes (Fig. 249).

The internal structure of the vertebræ is also disturbed, as Nicoladoni first showed. This is most evident

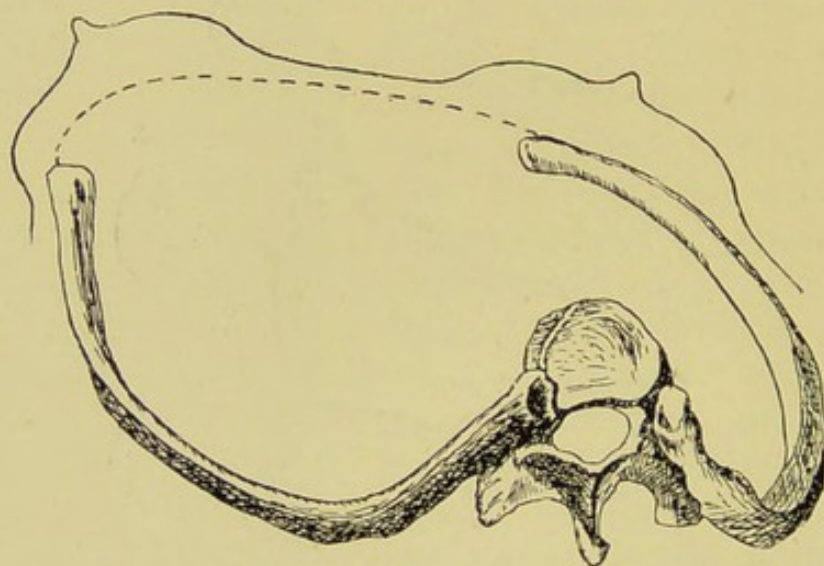


Fig. 250.—Diagram showing Section of the Thorax in Right-dorsal-convex Scoliosis.

in the cross-vertebræ, in which, instead of the strongest trabeculæ standing vertically to the upper and lower surfaces of the bodies of the vertebræ, they pass obliquely, sometimes at an angle of 45° , from one surface to the other. As in deformed long bones, the tissue is denser on the concave than on the convex side.

Not only the spine but the whole of the thoracic skeleton is deformed in dorsal scoliosis. This is shown diagrammatically in Fig. 250. The sternum is displaced towards the concavity of the dorsal curve.

In cases that date from early life, especially in rachitic cases, the pelvis becomes distorted in a manner that recalls the deformity of the vertebræ themselves. The half of the pelvis on the side of the lumbar concavity is lower than that on the opposite side, and

from the pressure of the head of the femur the pelvic cavity on the latter side is narrowed. The thoracic and, to a less extent, the abdominal viscera are disturbed in their relations. The lung on the side of the dorsal convexity is compressed and flattened, and the heart is displaced towards the concavity of the dorsal curve and sometimes shows hypertrophy of the right side.

In severe cases the intercostal nerves are subjected to more or less pressure on the concave side, giving rise to neuralgia-like pain. This, however, is more marked in rheumatoid cases.

The spinal muscles of both sides of the body have been found by Adams and others to be in an atrophic state in advanced scoliosis.

The Causation of Scoliosis.—Predisposing Causes.—The mode of origin in different cases of scoliosis is not always the same and a survey of the different theories of the ætiology of scoliosis is one of the most perplexing of pathological studies. A great part of the obscurity that exists is due to the fact that most observers have treated the problem as a purely mechanical one, whereas, in a majority of cases, there is a pathological weakening of the spine that determines the onset of deformity; the pathological aspect of the matter being the more important, it may be considered first.

Morbid curvatures of the spine may be regarded as the converse of flat-foot. In the latter condition a series of cuboidal articulated bones normally form an arch which, in conditions of muscular weakness or softening of ligament and bone, as in rickets or osteo-arthritis, becomes straightened out, yielding to pressure applied at its highest part: under similar conditions, in lateral curvature, a jointed column becomes abnormally sinuous from its yielding to the weight of the head and upper part of the body. We may recall the conditions that have been discussed in the consideration of the origin of genu valgum (p. 226).

During the period of growth any posture assumed too frequently and persisted in too long is capable of causing deformity even in healthy parts. Young and healthy

individuals are hardly likely to remain voluntarily in one position for a sufficient length of time for deformity to arise; but if the resisting power of the bones or ligaments or both is diminished, or if the strength of the muscles is impaired, then, in a long, unstable, jointed column, like the spine, deformity is easily produced. Thus, in too-rapidly growing children, and in those suffering from rickets or rheumatoid arthritis, obliquity of the pelvis in standing, and oblique and twisted postures in sitting, readily determine scoliosis.

Rickets.—In rickets, besides the abnormal softness of the bodies and arches of the vertebræ and the presence of a more or less thick layer of osteoid tissue at each epiphyseal region, there is frequently nasal obstruction from adenoids, or respiratory impediment from bronchitis, which not only help to produce pigeon breast and other deformities of the front and sides of the chest, but may also help to cause distortion of the spine, which is the main stem of the thorax.

The question naturally arises whether there is present in scoliosis of adolescence some change in the bones, similar in character to that seen in the case of genu valgum. My own opinion is that such is generally the case. Experience has led me to believe that the cases of scoliosis commencing in early childhood and directly attributable to rickets are far more numerous than most authors appear to think. Although in the more severe grades of rickets extreme distortion may ensue, and so lead the observer to conclude that rachitic scoliosis is something essentially different from the scoliosis of adolescence, yet if a large number of cases are carefully observed, it will be found that in the slighter grades of rickets the resulting scoliosis conforms to the regular type described above; and further, that the more closely the evidence of the date of the deformity is inquired into, the earlier will this be found to be, so that the cases of scoliosis first observed in infancy and those first noticed at puberty are connected together by other cases arising at any age between one and fifteen years.

Even among the children of the upper classes a case

of adolescent scoliosis, if carefully examined, will frequently show traces of rickets in infancy by the presence of slight tibial and other deformities. This, together with the general condition of the patient, has often led me to the conclusion that in many such cases there is a recrudescence of rickets during adolescence. In other words, such cases of scoliosis are due as much to the softening of bones and ligaments as to muscular weakness and inequalities in the lower limbs. In this connection the case referred to on p. 29 may be recalled.

Rheumatoid arthritis is also a frequent determining factor in the production of scoliosis. Not a few of these cases begin in childhood and adolescence, though in many cases of this kind the patient is not brought to the surgeon before middle age.

Infantile paralysis, so common a cause of deformity in the extremities, is also responsible for lateral curvature in a relatively small proportion of cases. The affected muscles may be either those of the abdomen or those of the back. In either instance the convexity of the curve is formed towards the paralysed side. V. Lesser found that in animals section of one phrenic nerve produced scoliosis.

The Hereditary Character of Scoliosis.—All who have to deal with many cases of scoliosis will have observed families in which several members are affected, and in which the deformity occurs in different generations. Excepting rare cases in which the deformity depends on some inherited peculiarity, such as a half-vertebra, it is not difficult to arrive at a conclusion as to the nature of this hereditary trait. It is experienced in families, the members of which are tall and slim, during the period of rapid growth, and sometimes there is in the family a tendency to rickets or to rheumatoid arthritis, affections which diminish the resisting power of the skeleton. Thus the hereditary character of the deformity is nothing more than a common lack of stability in the spinal column during adolescence. It will be noticed that where several sisters are affected, the direction of the deviation is often reversed in the different individuals.

It has frequently been asserted that the commonest form of scoliosis is a pathological increase of a normal physiological dorsal convexity to the right. As Lorenz has pointed out, this view does not explain the very common primary lumbar curves, nor, again, can it be said to be established on anatomical grounds; for the appearance of a right-dorsal-convex curve was observed by Lorenz* in seven out of fifty cadavera, and on investigation in these the appearance proved to be due not to any real lateral curve of the spine, but to a slight flattening of the left sides of the bodies of some of the dorsal vertebræ attributable to the pressure of the aorta. There was also slight deviation of the dorsal spines to the right, a deviation that did not form part of any general asymmetry of the vertebræ such as is seen in true scoliosis, but was attributable to the scapular muscles having been used more upon the right side than upon the left.

The Exciting Cause of Scoliosis.—It is now generally conceded that the exciting cause of scoliosis is *pressure*.

In the erect posture of the body, whether in sitting or in standing, the weight of the head and succeeding parts of the trunk as well as of the upper limbs is transmitted through the spinal column to the femora. The load upon each segment of the spine increases from above downwards. Normal individuals by instinctively changing their posture as one or other set of muscles become fatigued, and lying down when fatigue is felt in the whole of the muscles, ligaments, joints, and bones concerned in maintaining the erect position, manage unconsciously to guide the growth of the skeleton in normal directions. When, however, by reason of occupation, or of some deformity such as a short leg or a contracted hip, the patient is constrained to stand with the pelvis tilted either to one side or both, laterally and anteriorly, the spine is necessarily maintained in a bent position in standing, and in some cases also in sitting.

As instances of the latter may be adduced—(1) the vicious “writing posture” necessitated by many badly constructed school seats and desks; and (2) a case of ankylosis of the hip.

* Quoted by Hoffa.

After a time the child becomes unconscious of his twisted position, and thus remains in this position for sufficiently long periods for the posture to become fixed by structural changes in muscles, ligaments and bones.

Experimental Investigations.—Judson regards rotation as the result of the posterior parts of the vertebræ being more fixed than the anterior parts, and devised an experiment in which a spinal column is arranged in a rectangular frame, the spinous processes being attached by elastic cords to the sides of the framework. A brass rod is passed through the spinal canal, and is of such a form that when pressure is made on a knob at its upper extremity, the rod bends laterally, in a single curve when no resistance is offered, and in a double curve when the central part of the column is checked by a lateral attachment. In either case the bodies of the vertebræ rotate as in scoliosis towards the convexity of the lateral curves.

Rogers-Harrison,* in 1842, anticipated Judson's view in a work on spinal deformities.

Bradford and Lovett by a carefully planned series of experiments have shown that vertical pressure is capable of producing rotation with lateral curvature of the spine in the cadaver.

German surgeons have directed special attention to the writing postures of school-children. Schenk† by means of apparatus has studied the posture in two hundred children. He finds that the common position is that in which the paper is to the right of the writer, and the lines are directed from the left obliquely to the right and upwards. The writer's left forearm is placed on the table and his trunk is inclined to the right, so that there is a single dorso-lumbar curve to the left. One hundred and sixty out of the two hundred assumed this attitude.

A more dangerous posture is that in which the scholar inclines the upper part of the trunk to the right, but twists it to the left in order to relieve the writing arm from pressure. This posture is that of habitual scoliosis. Thirty-four assumed this attitude; in six only there was no twist of the body, and

* Quoted by Noble Smith, "Curvatures of the Spine," 3rd ed., p. 51.

† Schenk, "Zur Ätiologie der Scoliosis," Berlin, 1885.

in but thirty-four was the transverse axis of the body parallel with the edge of the desk.

It is to be remembered that in a school-room, where all the children are nearly equally badly off as regards seats, desks, and light, only a small percentage of them become scoliotic. The underlying predisposing cause is a pathological one: anæmia, rickets, etc. Hence if the general health of school-children is carefully watched, and they are kept away from school when unfit for work, scoliosis will become rare. At the same time every care should be exercised in the lighting and fitting of school-rooms.

Symptoms.—The general symptoms are those of the predisposing condition, whether weakness from rapid growth, anæmia, rickets, osteo-arthritis, rapid respirations and pulse from the altered conditions of the thoracic vertebræ. V. Lesser has described one form of respiration in scoliotics as *chorea respiratoria*.

Locally there is usually pain or a sense of weakness in the back. The pain is most frequently referred to the lower dorsal region. There is often hyperidrosis in the skin over the spinous processes, and this may be accompanied by more or less venous telangiectasis and overgrowth of hair. The onset of deformity shows itself in different ways; sometimes the elevation of a shoulder, sometimes the projection of a hip. When a normal person stands or sits with the arms hanging down, between the arm and the side is a triangle with its apex directed inwards. In normal conditions these "waist-triangles" are equal in size, in scoliosis they are unequal.

The Various Types of Scoliosis.—In some cases of lateral curvature the deformity can be observed to begin in one or other part of the spine, and hence cases have been classified as *primary dorsal* and *primary lumbar*, according to the region of the spine first affected. For instance, in a young lady aged twelve years, shown in Fig. 256, the only part of the spine rigidly affected as proved by a radiograph was the cervico-dorsal region. The determining cause in this case was the shortness of the left leg, which measured $\frac{3}{4}$ -inch less than the right. In such a case a secondary lumbar curve would be likely to develop in the opposite direction

to the primary curve. In total scoliosis the whole spine is implicated in the single primary curve.

Primary Right-convex Dorsal Scoliosis (Fig. 251).—In this



Fig. 251.—Back View of a man, aged twenty, with severe Right-dorsal Left-lumbar Scoliosis.



Fig. 252.—Front View of a Man, aged twenty, with severe Right - dorsal Left - lumbar Scoliosis (see Fig 251).

form, on inspecting the back, though the line of the spinous processes may be unchanged, the ribs are seen to be more sharply bent than normal near their angles on the right side, and those on the left slightly flattened; the right shoulder-blade is more prominent than the left. The latter is sunken, its lower angle is turned towards the spinous processes, and has a fold of the soft parts passing out from its lower angle (see

Fig. 242). The posterior border and lower angle of the right scapula are prominent, because the fore part of the shoulder is carried forwards with the bending of the ribs. The inner border of the right shoulder-blade is usually farther from the line of spines than that of the left, which gives the right half of the thorax the appearance of being wider than the left. In the later stages the deviation of the spines to the right becomes marked and the left breast and left side of the chest become prominent. At the same time the lumbar spine becomes curved with a convexity to the left, causing the left hip to project, and the rotation of the lumbar vertebræ causes the erector spinæ of that side to project as a sausage-shaped swelling. The cervical spine also becomes secondarily curved with a convexity to the left. Thus a wry-neck completes the distortion. The spine is necessarily shortened by reason of its twisted shape, and the whole of the patient's trunk assumes a shortened form. Finally, the whole trunk is inclined to the right (Fig. 252).

Primary left-convex dorsal scoliosis is the converse of the foregoing, and, as Hoffa expresses it, the "mirror-picture" of a case of primary right-convex dorsal scoliosis represents a left-dorsal case.

Primary Left-convex Lumbar Scoliosis.—The first sign is a displacement of the trunk to the left side of the pelvis. This is more marked when the patient stands up. The left waist-triangle becomes smaller, its apical angle more and more obtuse, until in marked cases it disappears. The right waist-triangle is enlarged, its apical angle becoming more acute and a shadow or a fold in the skin may prolong it towards the spinous processes of the vertebræ.

The left hip appears to have become smaller in size. When the patient stoops forward, a vertical muscular projection, the longissimus dorsi appears on the left side of the lumbar spine—pushed back by the tranverse processes.

The lumbar curve very often includes the lower dorsal vertebræ.

In the earlier stages the spine above the tenth dorsal vertebræ shows no deviation, later a secondary right-convex dorsal scoliosis develops.

Even in old cases of primary left-lumbar scoliosis, the left

waist-triangle as described above is obliterated, whilst in primary right-dorsal-convex cases it is, at most, converted to a half-moon shape.

Primary right-convex lumbar scoliosis is the converse of the foregoing.

Total Left-convex Scoliosis.—The spinal column forms a single curve to the left (see Fig. 253).

The second lumbar vertebra as a rule becomes the apex-vertebra. The trunk is pushed to the left, the arm stands a little out from the body, so that the left waist-triangle is elongated.

Total right-convex scoliosis is the converse of the foregoing.

Irregular Forms.—A localised lateral deviation united to three or more of the spines, and accompanied by more or less pain, must always be held as suspicious of tubercular disease. In osteo-arthritis localised deviations which do not conform to any of the above-mentioned types are not infrequently observed.

Diagnosis.—It is in the earlier stages of the deformity that diagnosis is of most importance, and it is certainly essential that every practitioner should be familiar with the earliest indications of this deformity.

The Method of Examination.—The general arrangements described above (p. 330) are to be observed. The patient should sit with the back to a window on a level table or stool, and the arms should hang freely from the shoulder. A vertical line of wall and a horizontal one of wainscot or dado will, as Barwell has observed, assist the eye.

A rough outline sketch will serve to show obvious

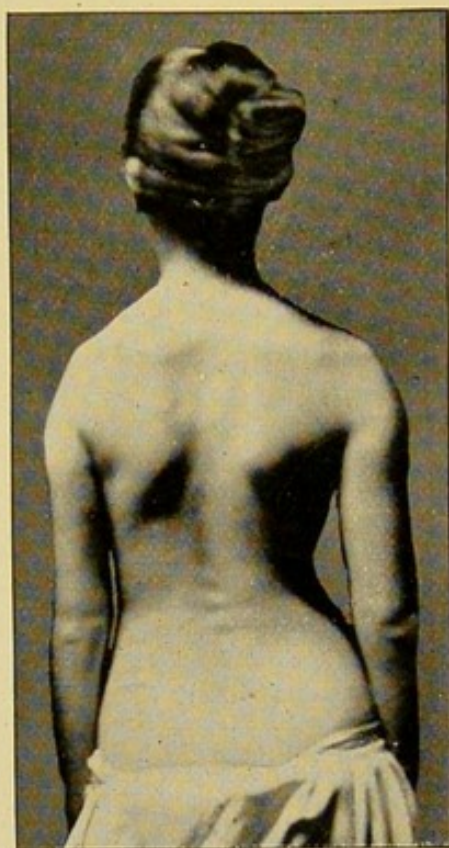


Fig. 253.—Back of a Girl, aged thirteen years, showing total Left-convex Scoliosis.

differences in the position of the scapulæ and in the form of the triangles between the arms and the sides. Only rarely, when necessary, need the front of the trunk be inspected. After examination in the sitting position the patient should be examined standing with the heels together and the weight borne equally on the two feet.

The amount of dorsal rotation is best seen when the patient stoops with the arms hanging loosely and the knees

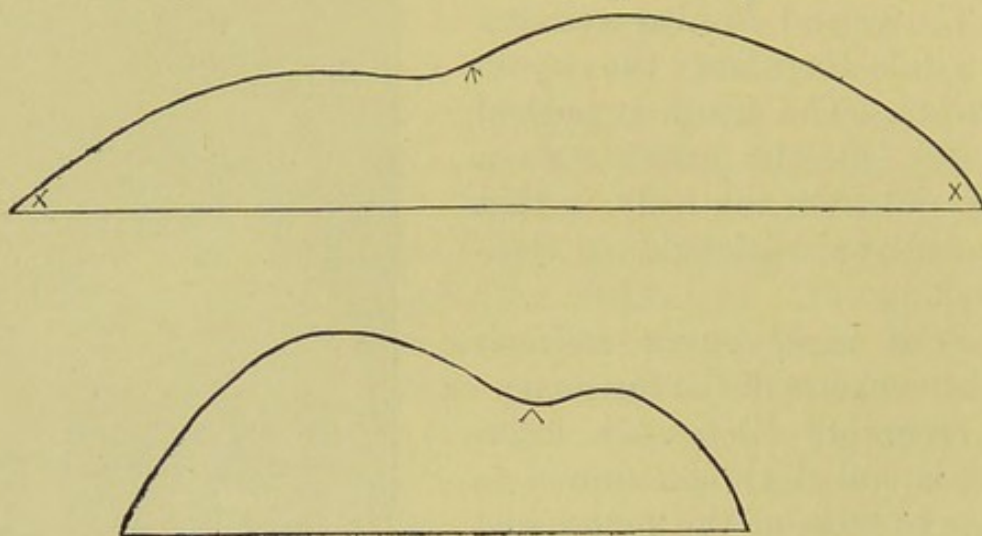


Fig. 254.—Tracings of the Contour of the Back in a case of Right-dorsal Left-lumbar Scoliosis.

The arrows mark the position of the spinous processes and the crosses that of the angles of the scapulæ.

kept extended, and may be recorded by moulding a strip of lead or tin transversely to the back at the level of the angles of the scapulæ, the position of the latter and of the spine being marked on the strip before it is removed. The curve thus obtained can be transferred to paper by tracing with a pencil along the inner surface of the upper edge of the metal. Tracings of the kind are shown in Fig. 254. A similar tracing, taken between the twelfth ribs and the iliac crests, may be used to record the lumbar rotation (Roth). Photographs alone do not give a complete record, but they serve to check the graphic notes made in the sketch. A full back view of the trunk should be photographed, first in the sitting and second in the standing position. In a case of right-dorsal curve the right side of the chest is flattened, whilst the left side is prominent, as shown in Fig. 252.

With a view to prognosis the degree of resistance to manual correction offered by the spine should be noted.

The degree of inclination of the trunk may be measured by fixing a plumb-line to the vertebra prominens by strapping,

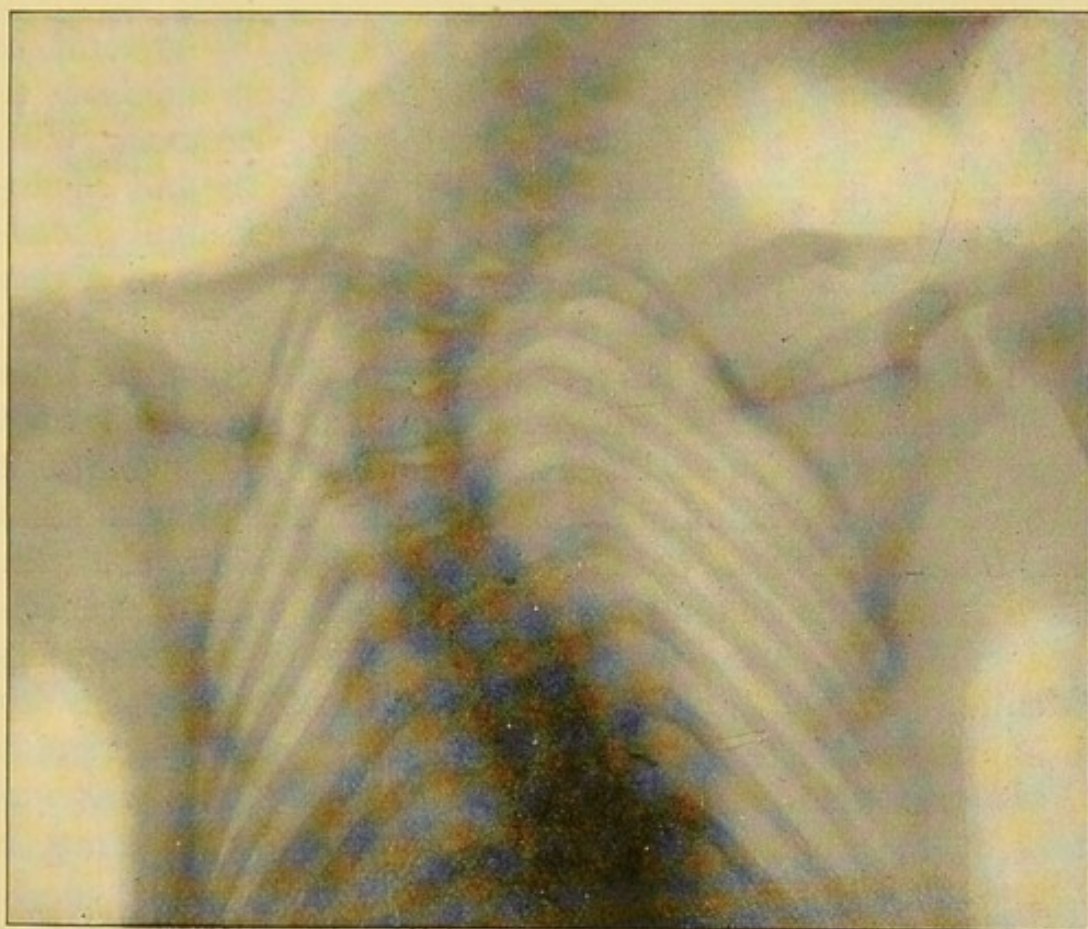


Fig. 255.—Radiograph from a case of Scoliosis. (*Coxeter and Son.*)

and noting the distance between the plummet and the top of the intergluteal cleft.

The last feature to be recorded is the line of spinous processes. These can be marked by a flesh pencil. Finally, the patient should be made to stand in order to see whether there is any increase or diminution as compared with that observed in the sitting posture. If one leg is shorter than the other, or if the pelvis is held obliquely for any reason, there will be a certain amount of additional deformity.

In addition to the photographs, I usually have a radiograph made in cases where it is of importance to make careful note of the progress of the deformity. The value of the Röntgen

method is nowhere greater than in scoliosis, and it affords us a good means of recording the exact amount of deformity that is present and hence renders unnecessary elaborate means of measurement (*see* Fig. 255, reproduced by permission from a case under the care of Dr. W. S. Colman).

Scoliosimeters. — Many attempts have been made to furnish a means of recording accurately the amount of scoliosis present at any time. The nearer these approach to correctness the more complicated they become. With sketches, the metal band, good radiographs, and photographs, taken at the same place and under similar conditions, a sufficiently correct idea of the progress of a case can be formed.

Course and Diagnosis.—Cases which in my experience offer most difficulty of diagnosis are those in which what may be termed *intermittent scoliosis* occurs. At one visit the patient may be found to present lateral deviation, rotation and inclination of the trunk; the next day, perhaps, the same patient may be carefully examined, and no trace of scoliosis be found. This condition is observed chiefly in adolescents with long weak backs. In other cases, though the deformity is always present when the patient is in the erect position, it disappears when the patient lies down or makes a voluntary effort to straighten the back; it has been termed a *lateral deviation* of the spine (Fisher).

In most cases of flat-foot and genu valgum a corresponding stage is to be recognised and is looked on as the *first stage* of these deformities. So in scoliosis it is questionable whether the use of a separate term for the first stage does more than confuse the student. The *second stage* or *stage of development* is characterised by the appearance of an increasing amount of fixed deformity that does not disappear when the patient lies down, and when the dorsal part of the spine is affected this fixed part of the deformity usually becomes more evident in the flexed position of the dorsal spine. The *last stage* or *stage of arrest* (Bradford and Lovett) is that in which the deformity ceases to increase and in which adaptive changes occur in the bones. The age of onset and the duration of the various stages vary in different cases. In an average case the first stage occurs in childhood, the second stage

extends from puberty to the cessation of growth, and the stage of arrest occurs about the age of twenty-five years. The whole three stages may, however, be confined to the space of a few months.

Tuberculosis of the spine, both in the early and late stages, may cause a localised lateral deviation of the spine; but the localised nature of the deviation and other symptoms will serve to distinguish this condition from scoliosis.

Rigidity, one of the most important signs of tubercular disease is present in the later stages of scoliosis.

If all the points in the method of examination described above are carefully studied, angular curvature, even in a slight degree, will readily be recognised. It must always be borne in mind, however, that in the lumbar region one or more prominent spines are frequently observed in scoliosis.

By the time that the mother, the nurse, or the dressmaker has noticed an "outgrowing" shoulder or hip, or some peculiarity of carriage, the deformity is generally well advanced.

In severe cases it might be thought that there would be little difficulty in recognising the condition at a glance, yet the prominent vertebræ in high dorsal curves have been mistaken for tumours in the supra-clavicular fossa; prominent lumbar curves have also been mistaken for growths. Adams* has recorded a case in which the lumbar muscular prominence was mistaken for an abscess by several experienced surgeons. I have known surgeons of experience, misled by the prominence of one hip, to ascribe the deformity to some abnormality of the hip-joint. A little clinical experience and study of scoliosis will, however, be sufficient to prevent mistakes in pronounced cases. It is in the earlier stages of the

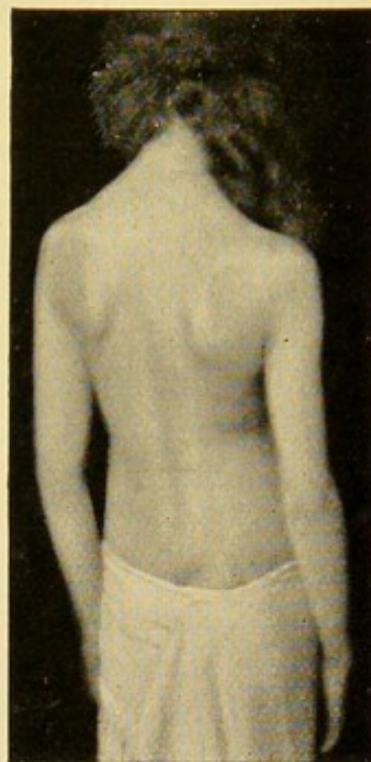


Fig. 256.—Back of a Girl, aged twelve years, showing primary Left-convex Cervico-dorsal Curve.

* William Adams, "Lectures on Curvature of the Spine," 2nd ed., p. 204.

deformity that diagnosis is of the greatest importance. The average appearance of a case of moderate degree, that most usually seen at a first visit, is shown in Fig. 242.

Prognosis.—Scoliosis, when once established, is never spontaneously cured, or even diminished. The progress of the deformity is, however, not infrequently *arrested* by improvement in the general health of the patient. If such arrest occurs before much distortion has been produced, only a slight deformity, recognised chiefly by the tailor or dressmaker, will remain and will possibly give no farther trouble. But in a certain proportion of cases, after remaining stationary for many years, the deformity again begins to increase, owing to the development of rheumatoid arthritis, or some other disturbance of nutrition.

Unfortunately we cannot rely upon an early arrest of the deformity in any given case, for in many instances the disease increases steadily until a shocking deformity is produced. Nor are the disabilities experienced by those who suffer from severe scoliosis due merely to altered personal appearance. The alteration caused in the position of the heart and lungs produces considerable dyspnœa. Neuralgic pain in the spine is not uncommonly complained of, especially where rheumatoid arthritis is present.

A slight lumbar curve in a young child, if left untreated, may increase in severity so that the patient's capacity for walking and movement is greatly diminished.

B. Roth* states that in every case of scoliosis a certain posture can be found in which the deformity is reduced to a minimum. This posture, he says, gives the "key-note" in prognosis, being an indication of the amount of correction possible. A recent writer, P. G. Lewis, says on this point, "Taking the most common key-note position, namely, that with the left arm up by the side of the head, and the right out at right angles with the body, one cannot but wonder where the key-note is. The appearance of deformity is thus removed, chiefly by putting the lower part of the trapezius and the upper part of the latissimus on the stretch on the left side." My experience is in harmony with this statement.

* B. Roth, *Brit. Med. Journ.*, Oct. 9, 1897.

A few practical points considered as elements in prognosis may be mentioned.—1. The general type and stamina of the patient and of the patient's family. 2. The degree of deformity present. 3. The duration of the deformity. 4. The character of the curves. 5. The patient's age.

Information as to the probable degree of correction possible in any given case is obtained by trying to what extent the deformity can be diminished by manual pressure. It has been recently stated that "osseous deformity of the vertebræ, even to the slightest extent, is to that extent incurable." In judging of the value to be attached to this statement it is to be remembered that up to the age of twenty-five years the vertebræ contain a considerable amount of cartilage, and that up to this age the body of a vertebra presents a structure comparable to that of a long bone. In describing the causation of scoliosis it was observed that any posture that entailed a lateral bending of the spine would, if maintained too long, produce scoliosis. This may be postulated from the known fact that the growth of a long bone is readily influenced when one side of the epiphyseal cartilage is made to bear more than its share of pressure, *e.g.* in the production and in the cure of genu valgum. It follows that if in a young subject we can reverse the forces that act on the spine in the production of a scoliotic curve we can cure bone-deformity in the spine as we can in the bones at the knee-joint. By the use of effective apparatus employed continuously the growth of the vertebræ can also be guided. If this were not so the most fundamental principles of orthopædic surgery would be violated. The statement is, then, not correct in so far as it applies to growing subjects. After the growth of the patient has ceased and in relation to certain methods of treatment, the statement holds good.

Treatment.—The question, "Does every case of scoliosis require treatment?" may be asked. For answer it is sufficient to recall the fact that there are not a few active and even athletic individuals between twenty and thirty who suffer from scoliosis, and in whom the deformity neither increases nor interferes with the activity of the person, the only symptom of the disease consisting in the deformity and a

quickened respiration. After the growth of the bones has attained its full development, and the epiphyseal cartilages have disappeared, a general supervision at long intervals is all that is required. Excessive exercise, which in the presence of impeded respiration is likely to produce cardiac dilatation or hypertrophy, is to be avoided. The onset of rheumatoid arthritis is to be watched for.

Preventive Treatment.—In the physical education of children the possibility of the occurrence of lateral curvature is to be thought of. By suitable diet and general hygiene, rickets and bone-weakness in general are to be guarded against. Attention to dress is important. It has been rightly pointed out that the dress and under-garments should be cut so that they are not tight across the chest when the wearer stands upright with the back to a wall. During the school period ample and proper food and exhilarating general exercises are to be secured. No one who has noted the effects on recruits of the physical drill as described in the official "infantry drill" can doubt the advantage of systematic drill upon the young. There is, however, a caution to be observed. Latterly in London it has become fashionable to submit young girls to fatiguing calisthenic and dancing lessons, lasting for two hours with but little intermission. Such classes are responsible for many cases of deformity. On an average half an hour of such exercise is sufficient at one time.

Threatened Scoliosis.—When a tendency to scoliosis is detected special precautions are needed, *e.g.* proper school chairs and desks are to be used; and the one-sided exercises and those which, like bicycling, tend to promote stooping, are to be discarded. Increased intervals of rest on a proper chair or couch are to be observed, and the physician is responsible for the correction of inequalities of the legs and bad postures, also for the correction of errors of vision by suitable glasses.

The chair and desk for school use recommended in some text-books are defective in several ways. Their chief fault consists in the presence of a buffer-like wooden pad for support of the lumbar region. Such a pad must tend to produce lumbar rotation and a faulty mode of sitting on the part of the child. To obviate this defect Mr. John Carter has constructed,

according to my instructions, the chair and desk shown in Fig. 257.

The Treatment of Rickety Scoliosis.—I am so constantly told by the mothers that scoliotic infants were crooked in the back when they were born, that I cannot avoid the conclusion that a certain proportion of such cases are of intra-uterine origin, and that in such cases treatment should commence

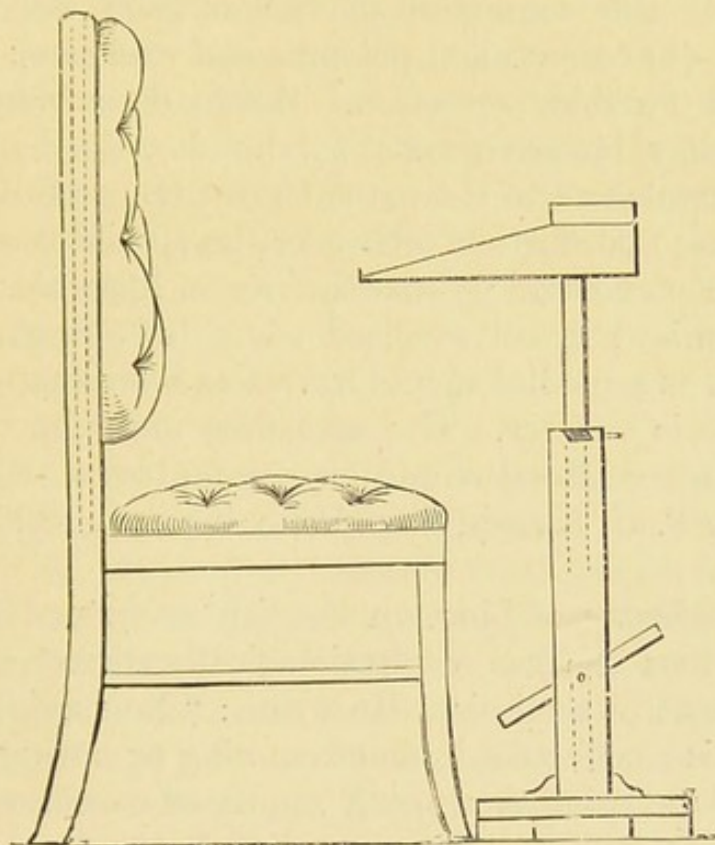


Fig. 257.—Chair and Desk for use in the School-room, etc.

The height of the desk and that of the footboard are adjustable. The chair is separate from the desk, so that both can readily be carried from one room to another.

with life. The infant should rest in Adams's padded wicker cradle and the padding may be so arranged that it tends to correct the deformity.

The method of carrying an infant on the left arm usual with mothers and nurses should be avoided.

As soon as the child begins to sit up, a moulded leather backboard should be substituted for the cradle. In rickety children of two years and over I find that the best results are obtained by the use of a Chance's splint. The splint must be removed twice a day and the back should be well rubbed and

moulded by the hands. The splint should be readjusted from time to time as the shape of the back improves. It is especially in rickety children that adenoids should be looked for and completely removed. In paralytic scoliosis the only means of diminishing deformity lies in the application of a suitable support.

The Treatment of Actual Scoliosis in Adolescence.—The measures at the command of the surgeon fall into three categories—(1) correctional postures and exercises; (2) instruments; (3) forcible correction. Before describing these at length it may be premised that the dietetic, hygienic and medicinal treatment of the patient must be carefully managed in every case and, further, whatever the special treatment the importance of general gymnastics as a hygienic factor has been recognised in all civilised countries. Special medical gymnastics as remedial agents have also been long established in orthopædic surgery. The measures most in use at the present time for lateral curvature can be traced to the system evolved by P. H. Ling in Stockholm between 1805 and 1839 (*see* p. 67).

Independently of Ling, an English surgeon, John Shaw,* fully described the use of physiologically correct exercises in the treatment of scoliosis. He wrote: "No single method of treatment is so effectual in counteracting or curing slight distortions of the spine as properly regulated exercises."

Ling's system, which was introduced into England by the late Mr. Roth, became needlessly complicated, but the principle of resisted movements remains as a valuable resource in orthopædic surgery. More recently G. Zander devised a system by which the gymnast in Ling's system is replaced by mechanical contrivances. B. Roth has applied Ling's system to the treatment of scoliosis. Of the first series of twelve exercises eight are performed with the patient lying on the back upon a firm couch, whilst the surgeon exercises in turn the upper and lower limbs; three of the twelve exercises are directed to increasing the power of the spinal muscles. During most of the exercises the patient is directed to count aloud, with a view to exercising the respiratory muscles. An

* John Shaw, "The Nature and the Treatment of Distortion of the Spine and Chest," 1823, p. 181.

interval of two or three minutes is allowed between the various exercises, and during this interval the patient rests upon a special couch, the back resting on an upholstered board fixed at an angle of 75° . Later more severe exercises are used. It will be observed that this system is really a combination of mechanical with gymnastic treatment; the couch acts as a splint to the back. In Mr. Roth's hands this mode of treatment has had a measure of success. The drawbacks are, however, considerable. The author candidly admits that it is incapable of correcting fixed deformity. This is equivalent to the view that scoliosis in the second stage is incurable. In most cases of simple deformity, such as knock-knee, the bones are affected from the beginning; and when scoliosis is not corrected spontaneously when the patient lies down, it may be inferred that alteration in the form of the bones is also a factor in producing this deformity. And in such cases the so-called "treatment by exercises alone" may result in improving the patient's health, and so in stopping the progress of the malady, but not in curing it. It is in my opinion most certain that many cases in the earlier stages continue to grow worse after the course of treatment is discontinued. In many cases the patient, in spite of diet, and medicine, and exercises, remains weakly for months or years and then, besides regular exercises, instrumental support is needed. The amount of time taken up by daily exercises requiring the personal supervision of the surgeon renders the method very costly and it interrupts schooling.

On this point John Shaw may again be quoted: "I consider it, or rather a similar but more simple instrument, to be necessary to the cure of lateral distortion."*

Anyone who for a number of years has had to treat many cases of scoliosis will be able to recognise the following groups of cases:—

(1) Congenital; (2) rachitic; (3) adolescent; (4) osteoarthritic; (5) paralytic; (6) hysterical; and (7) cases due to empyæma and other causes. Of these the rachitic and osteoarthritic are associated with marked histological changes in and softening of bone.

Cases that arise in adolescence are, according to Rupprecht,

* *Loc. cit.*, p. 171.

with whom I agree, very often due to "*rachitis adolescentium*." Some adolescent cases are also due to osteo-arthritis. And even when there is some cause, such as unilateral genu valgum or inequality of length in the legs, swellings at the epiphyseal cartilages denoting bone-changes can often be found when the deformity is developing.

We may ask how the dictum that "If there be osseous deformity of the vertebræ and ribs, the deformity is to that extent incurable," applies to the case of a rickety infant of two or three years of age? In such a case the vertebræ are changed in form in a manner similar to the bones near the knee in rachitic genu valgum, a condition which is readily curable by the proper use of instruments. The spinal deformity in such cases can only be cured by similar means, and it is by denying to the patient skilled instrumental treatment in the early period of the deformity that so many cases are allowed to become incurable. The same is also true of rapidly-growing children, of adolescent cases during the continuance of "*rachitis adolescentium*" or kindred affections.

Similarly an attempt to treat a patient suffering from progressive scoliosis due to osteo-arthritis by gymnastic exercises would prove a failure from the commencement.

There is one class of case, the paralytic, that is due to purely muscular defect and in just these cases mechanical support is imperative. By limiting the consideration of the treatment of scoliosis to the measures appropriate to cases of old standing, the importance of the recognition of the deformity during its development, when not only muscles but bones and ligaments are often, nay usually, weakened, is lost sight of, and the mind is taken away from the necessity of early diagnosis and early treatment. I agree that instruments should be dispensed with whenever it is possible. Many instruments are worse than useless and the best is useless when wrongly employed. Many patients have been injured by the misuse of instruments. I have also seen many patients who have been allowed to become permanently deformed, in spite of a costly course of treatment, for want of the use of a proper support combined with other measures.

In bad cases the special reclining couch and rest in the

horizontal position are, in my experience, far less effective than a properly-constructed and properly-managed support combined with regular exercises. It is especially in fairly muscular youths that the power of will and muscles to arrest deformity is most effective, and the use of even simple instruments is to be avoided if possible. By the use of simple exercises after a few drills under the supervision of the surgeon, the need of daily visits is avoided, though it is of course necessary for the surgeon to inspect the patient at regular intervals in order to modify details of treatment. I need not describe at length the exercises for the muscles of the limbs, but I may briefly refer to the chief of those I employ to exercise the muscles of the back and abdomen, and those for increasing respiratory power. Flat-foot, if there is any tendency to it, should also be treated.

The following exercises it must be borne in mind are only examples selected from a much more extensive series. Each case must be carefully considered before prescribing the exercises indicated. In each case the exercises require modification from time to time.

1. *Extensor Muscles of Neck*.—Patient seated in an ordinary low-backed chair, and an india-rubber tube fixed at its free end to the front of a webbing band which encircles the head. Hyper-extension of cervical and upper dorsal spine repeated ten times.

2. *Abdominal and Ilio-psoas Muscles*.—Patient lying on the back with the arms extended above the head. The body is raised to the sitting posture. Repeat five times.

3. *Erector Spinae*.—Patient lying on the face, arms out at right angles, hands prone. Patient supinates hands, throws the scapulæ well back, raises the hands from the floor, and lifts the trunk. Repeat three times. (R. H. Sayre).

4. *Dorsal Rotation and Respiration*.—Patient seated as in 1. The arm on the side of the dorsal convexity is passed in front of the body, the other behind the body, the hands holding elastic traction cords. Slow, deep respiration. (Barwell).

5. *Suspension Exercises on the Horizontal Bar*.—In right-convex dorsal cases the left hand should be higher than the right; this is effected by using a double bar, the upper round of which is higher than the lower.

The patient should be taught to breathe deeply and regularly during all exercises, a habit that can be acquired by counting aloud.

Special Resistance Exercises for the Chest.—The mother or nurse can be taught to exercise yielding resistance to inspiration with the outspread hands, whilst the patient sits with the back supported in a suitable chair, or lies down on a flat couch, and breathes deeply and regularly.

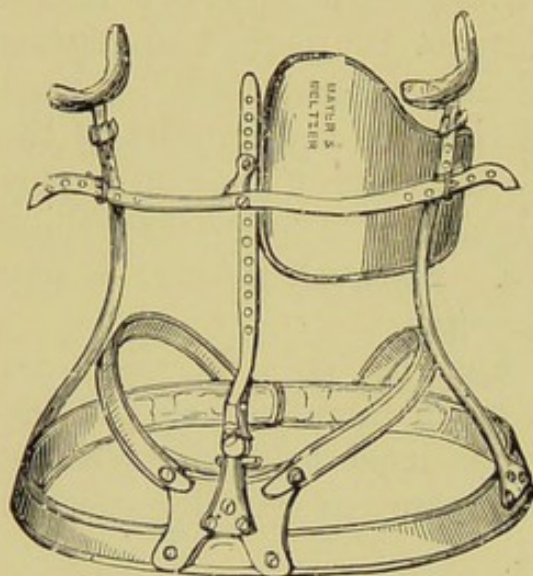


Fig. 258.—Adams's Support for Scoliosis.

mind. The instrument should be firmly fixed to the pelvis; the main upright should have the outline of the normal slight dorsal and lumbar curves; the splint should be so applied that the dorsal excurvation (kyphosis) and the lumbar incurvation (lordosis) are corrected. Pads should be placed so that they tend to correct both the lateral deviation and also the rotation. Whilst giving support to the spine, and thus resting the spinal muscles, it should leave the latter free to act within a limited range. The instrument should be arranged in such a manner that its form can be easily modified to follow up improvement in the shape of the body. It should be as light as is compatible with efficacy, and it should be easily removable by the patient or mother for the performance of exercises. Another desideratum is that it should be moderate in price. It should not interfere with the patient's wearing ordinary dress and mixing in society, going to school, and taking ordinary exercise. Such an instrument acts like a simple splint in such a condition as

Instrumental Treatment.
—Bearing in mind that a certain proportion of cases of spinal curvature are due to rickets and a still larger proportion to conditions which are closely akin to rickets, there is a clear indication for the use of instruments during the evolution of the deformity. In the choice of an instrument the objects aimed at must be kept closely in

genu valgum, but the complexity of the deformity in scoliosis demands a corresponding complexity in structure.

Among the many instruments that have been employed in the treatment of scoliosis are plaster and felt corsets. These I am convinced do nothing but harm.

Another type of instrument is that shown in Fig. 258. In this instrument the crutches for the arms do not come into action unless injurious

pressure is exerted upon the axillæ. For many years supports, consisting of a median upright bar with lateral pads, have been used in England, as shown in Fig. 259, for the use of which I am indebted to Mr. H. R. Heather Bigg. The same principle in greater perfection is embodied in the instrument that I have found of most service in scoliosis—Chance's splint as modified by Noble Smith (Fig. 260). A firm pelvic band (1) rests by a projection on the chair when the patient sits, and has at-

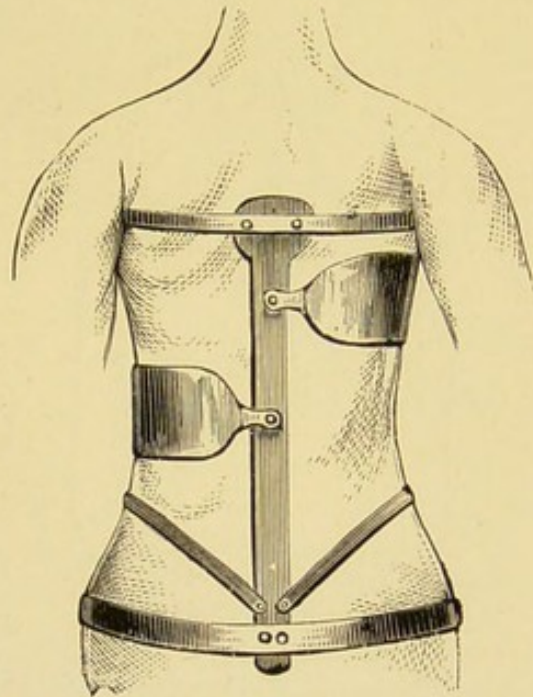


Fig. 259.—Sheldrake's Spinal Support for Lateral Curvature.

tached to it a firm steel upright which, when seen in profile, is slightly curved to the shape of the normal profile of the spinal column. The upright ends at the level of the shoulders in a pad, from which bands (2) pass round the shoulders holding back the upper part of the thorax and undoing the "stoop," which often forms an important element in scoliosis. An abdominal band (3) is fixed to the lumbar part of the instrument and tends to correct the "lordosis" which accompanies the lumbar curve. Finally, padded metal plates are adjusted when the patient is holding herself in the best position she can assume, so that she cannot fall back into it and allow further deviation to occur. The plates act also as guides to muscular self-correction on the part of the patient. This instrument is lighter than any support of poroplastic felt that I have seen; it is easily

removed for the purpose of exercising the patient, and it does not necessitate any loss of time from school or employment. It may also be remarked that in the sitting position the splint, if properly made and applied, acts in a manner similar to but more perfect than the special couch, which is

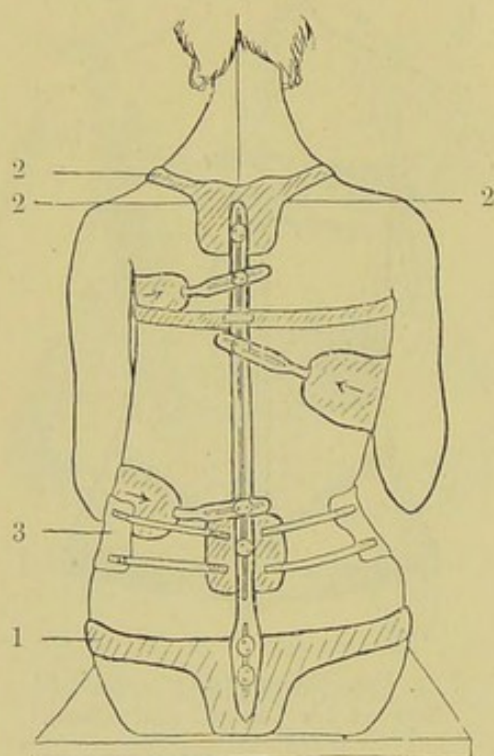


Fig. 260. — Diagram showing the action of Chance's Splint as applied to a case of Right-dorsal Left-lumbar Scoliosis.

1, pelvic band; 2, shoulder strap;
3, abdominal band.

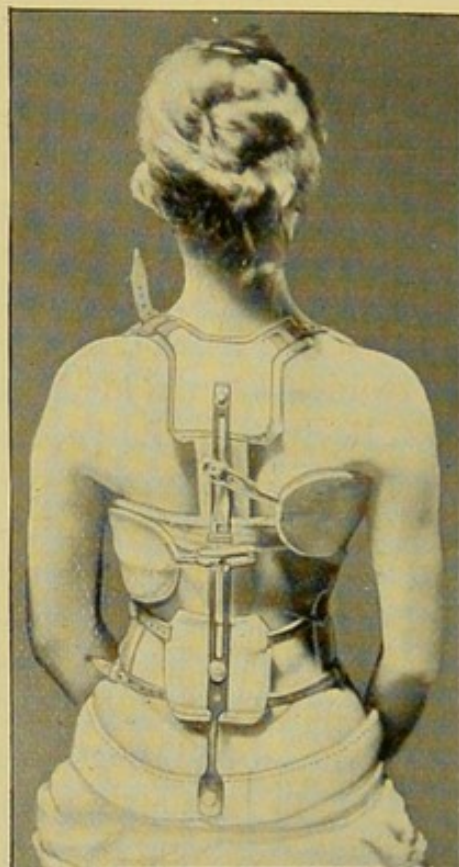


Fig. 261. — Chance's Splint as applied to a case of total Left-convex Scoliosis.

the instrument employed by some who appear to be under the impression that they treat scoliosis by exercises alone.

The action of the splint as applied in the ordinary way is shown in Fig. 260. In some cases of old standing, but needing slight support, I have found Prothero Smith's brace of use (p. 86).

Where there is severe rotation I have latterly employed Chance's splint by adding in the dorsal region on the concave side a semicircular arm which ends in a pad by which

pressure is brought to bear upon the prominence of the ribs in front. A webbing band which acts on a pad over the dorsal prominence on the convex side serves to draw the body towards the middle line whilst the pads correct the rotation. The lumbar curve is dealt with in a similar way.

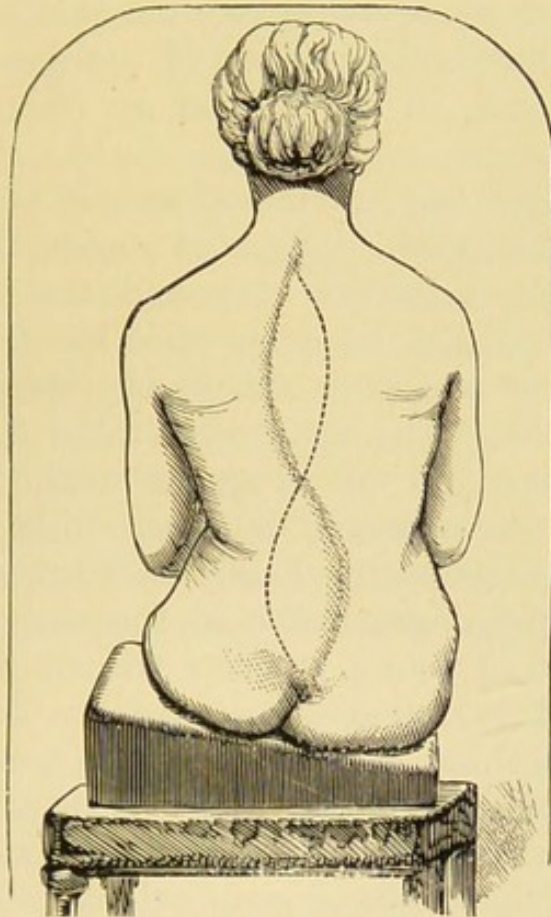


Fig. 262.—Barwell's Seat.

Barwell, deprecating the use of any rigid instruments, recommends amongst other measures the use of posture and elastic swathes. Barwell's oblique seat is a well-known and valuable device. Its structure and mode of action are shown in Fig. 262, for the loan of which I am indebted to Mr. Barwell. The swathes recommended by the same author are, in my opinion, of less certain value. For a typical case one bandage acts from the lumbar convexity to the top of the opposite trochanter, and would doubtless either abduct the corresponding thigh or tend to diminish the lumbar convexity. A second surrounds the right shoulder and joins the upper part of the loin bandage, both in front and behind. This

swathe is supposed to counteract the dorsal curve, but from its disposition the force exerted by it must have a downward as well as a horizontal action, and so tend to increase deformity at the junction of the curves, and it also would tend to increase the dorsal rotation. This last feature has evidently struck the author, who arranges the bands in a different manner when dorsal rotation is a marked feature. The imperfect mechanical effects of the dorsal part of this apparatus render it, in my opinion, an uncertain means of treatment.

If wrongly used, any instrument, simple as it may be, may do harm instead of good. It is most important that the splint should be removed twice a day, and the spinal exercises mentioned should also be done twice daily, whilst general exercises for legs and arms should be performed with the instrument applied. The instrument takes the place of the special couch used in following the method of treatment without instruments, and it is much more effective. In most cases the instrument should be worn at night. The marked and rapid improvement in the shape of the spine I have observed in young subjects treated in this manner has caused me to relinquish a credence I formerly lent to the words of those who denounce the use of any instrument in scoliosis. It is the abuse of instruments that is to be deprecated, not their use. The conditions are similar to those present in a case of genu valgum. The application of the force is more difficult, but, rightly applied in a suitable case, a similar effect is produced. Arbuthnot Lane* has observed, "in rickets . . . the epiphyseal line, which is large and irregular in outline, reacts to pressure in a much more marked manner than does the epiphyseal line of the child that is merely wanting in vigour." A close watch for the onset of scoliosis should be kept in rickety children—and rickets is by no means confined to infancy, nor to the poorer classes—and as soon as the condition is observed continuous mechanical support is required. If this were done in all cases, the severer grades of scoliosis would soon cease to be known.

Forcible Correction.—There is no doubt that in severe

* "Clinical Lectures on Surgical Subjects," 1898.

cases in growing subjects, forcible correction combined with exercises and the continuous application of an effective splint in suitable cases gives a rapid improvement in the form of the spine. Lorenz effects this end by bending the patient with the convexity of the dorsal curve resting on a padded horizontal bar; Barwell by strong and wide webbing bands acted on by pulleys. Noble Smith has lately recommended manual correction. I employ both the latter methods in suitable cases.

The Patient.—One last observation may be allowed; that is, whatever the deformity may be, in selecting the exact method of procedure the strength, age, and sex of the patient must be considered. Treatment suitable to a muscular boy would not be appropriate to a delicate girl, and any energetic gymnastic treatment would be out of place in the case of a patient suffering from advanced heart-disease or phthisis. There is no affection that requires more thought, more careful selection of methods, than lateral curvature of the spine. Moreover, in the course of the same case the treatment demands variation as the condition improves.

Results of Treatment and Prognosis.—In the past few years a considerable number of scoliotic cases has passed through my hands. In early cases of scoliosis—that is, in cases with some bony deformity—in adolescents I have found a combination of *instrumental treatment* with *exercises* invariably prevent increase in and frequently cure the deformity when faithfully carried out. Caution is necessary in giving a prognosis, because a case may be of old standing when the mother thinks it is only the matter of a few months. In severe cases in growing children and adolescents, although a complete removal of deformity is not to be expected, the deformity can be diminished and the general health greatly improved by the same means.

The chief difficulty that is encountered arises from the too long delay that so often occurs before the patient is brought to the surgeon. Old cases, in which the bones have become hard and adapted to their altered form and disposition, according to Wolff's law, only require attention to the general health and muscular power, unless osteo-arthritis

or some other bone disease should arise, in which event slight support for varying periods is required.

Rickets of the Spine.—When we reflect that genu valgum is usually due to rickets effecting changes in growth at the epiphyseal ends of the femur and tibia, and that the spine contains from the third cervical to the first sacral vertebra, inclusive, no less than forty-eight epiphyseal cartilages, the capacity for the occurrence of deformity when the spine is affected by rickets may be realised.

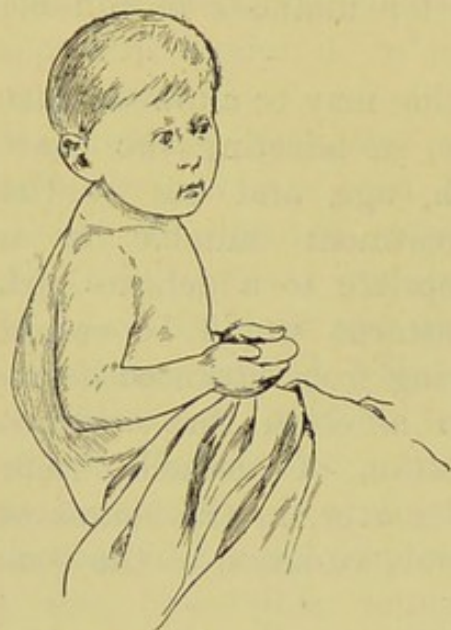

Fig. 263.—Rachitic Kyphosis.

The proportion of instances of spinal deformity in the total number of cases of severe rickets is a very large one. The spinal deformity in rickets may assume any form—kyphosis, lordosis, or scoliosis. In some cases of rickets marked lordosis may develop without the spine being seriously affected. This happens when the pelvis becomes flattened by the weight of the body

acting from the sacrum, and when at the same time it assumes a more horizontal position, necessitating a certain degree of lordosis. Hoffa suggests that the bulging abdomen in rickets also aids in drawing the lumbar spine forward into a lordotic position.

Rachitic Kyphosis.—*Pathology.*—This form of kyphosis is usually most marked from the ninth dorsal to the third lumbar vertebra. Bouland* recognises three anatomical types:—

1. The intervertebral discs are diminished, whilst the ossific nuclei of the bodies of the vertebræ and the epiphyseal cartilages are increased in vertical thickness anteriorly.

2. The ossific nuclei are deeper in front than behind, whilst the converse holds good for the epiphyseal cartilages.

3. The intervertebral discs, ossific nuclei, and the epiphyseal discs all participate, but especially the two latter.

* Quoted by Hoffa.

Symptoms.—In rachitic kyphosis the lumbar and dorsal parts of the spine present a backward convexity when the child sits. In severe cases the cervical spine also forms part of the same curve, the whole spine assuming a C-shaped curve (Fig. 263).

In moderate cases the deformity consists in the fixation of the infantile sitting position. In more severe cases a certain section of the spine may project sharply backwards,

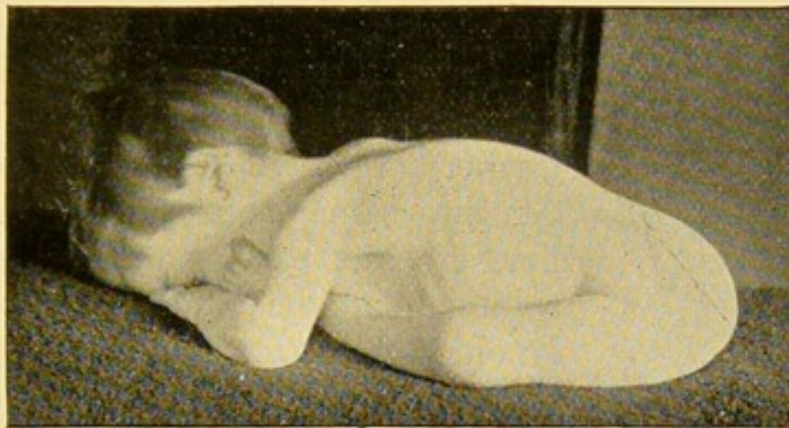


Fig. 264.—Photograph of a Boy aged three years in an Attitude assumed naturally.

The child has very severe rickets and kyphosis amongst other deformities.

forming an angle which simulates the hump in tubercular disease.

In such cases some of the deformity remains even when the child lies down (Fig. 264).

Differential Diagnosis.—It is sometimes a matter of difficulty to decide between the rachitic and tubercular kyphosis. This happens when there is a sharp local excurvation, accompanied by general rickets and some rigidity. Rigidity, though usually absent in rachitic spondylitis, is present in many cases that are purely rachitic; it is then produced by muscular spasm. If in such cases the back is examined after the patient has been at rest for some hours in the supine position, the rigidity will be found to have disappeared and the diagnosis of rickets can then be made. In some cases the patient will have to be watched for some weeks before a diagnosis can be made.

Prognosis.—The prognosis of rachitic kyphosis is favourable.

In some cases, however, where the patient has been confined for a long period in a plaster of Paris or a poroplastic jacket, I have found that the curve has become fixed from the altered form of the bones.

Treatment.—The kyphosis in young infants is the immediate result of the patient adopting the sitting posture. Therefore the little child should be placed in the supine position until the more active stage of the disease has been overcome by proper diet, which should include cod-liver oil, good air, etc.

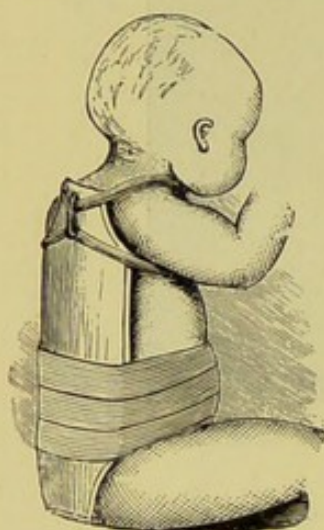

Fig. 265. — Rachitic Kyphosis.

The back-board applied.
(Noble Smith.)

In children between one and two years old a stiff back-board of padded leather (Fig. 265) should be worn. At the same time gentle douching, massage, and passive movement of the spine should be practised twice a day. In older children a light Chance's splint is, in my experience, the best form of support; in every case suitable exercise should be performed.

Rachitic Lordosis. — In rickety children lordosis develops in the standing position. This is usually due to one or two causes—(a) the lower limbs, weakened by malnutrition both of

muscle and bone, are not capable of balancing the body so well as in normal conditions, therefore what may be termed the natural lordosis is increased; (b) the pelvis, by becoming flattened from above downwards, involves some backward displacement of the acetabula and hence a compensatory lordosis.

The treatment of rachitic lordosis is that of rickets and of lordosis (p. 335). Whilst the disease is active the patient must be kept in the dorsal position, afterwards a light support must be worn, and daily gentle exercises performed until the skeleton and muscles are sufficiently strong to maintain the body in its normal form.

Rachitic Scoliosis.—The scoliosis of rickets in its anatomical character is not different from scoliosis due to other causes. Indeed, apart from cases of simple lateral

deviation of the spine secondary to deformity of the lower limbs, *e.g.* hip-joint disease, some pathologists would attribute the great majority of cases of scoliosis of infancy and adolescence to rickets. My experience is entirely in accord with this view. For this reason I have thought it desirable to combine the description of rachitic scoliosis with that of scoliosis in general. In this place I would only observe that since in scoliosis there is usually not only a lateral deviation, but also a rotation of the vertebræ, together with some dorsal kyphosis and often lumbar lordosis, the deformity is much more complex than the simple ones just described. The necessary treatment is thus more difficult and unless it is efficient and begun in good time the prognosis of rachitic scoliosis is far more grave than that of the simpler deviations.

Rheumatoid Arthritis of the Spine.—This affection, also known as spondylitis deformans, is one of the most common of spinal affections in Great Britain. Owing to its painful character as well as to the serious deformities that it occasions, it is at the same time a serious affliction. The anatomy of osteo-arthritis of the spine is peculiar in that the vertebræ tend to become joined together by bridges of bone which develop as osteophytes springing from adjacent borders of the vertebral bodies and either fuse together or interlock over the intervertebral discs (Fig. 266). The anterior common ligament and other ligaments may ossify. The atlo-axoid joint may also become stiff from changes similar to those observed in other diarthrodial joints. The bodies are usually more extensively affected than other parts of the vertebræ, but the pedicles, laminae and processes are all liable to

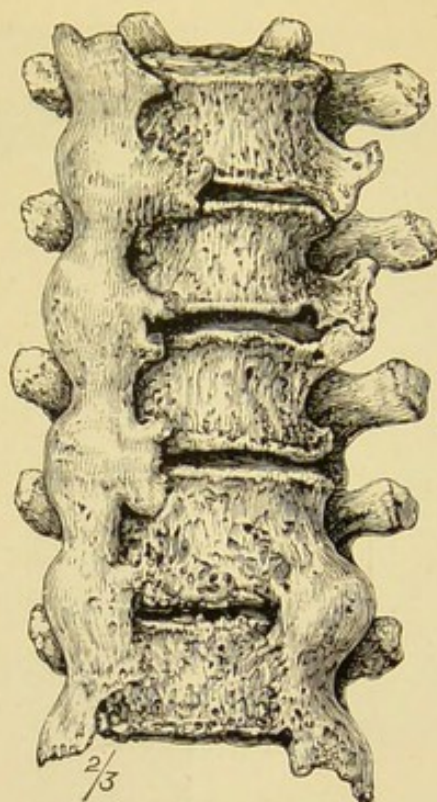


Fig. 266.—Five Dorsal Vertebrae ankylosed together from Rheumatoid Arthritis. (Treves's "System of Surgery.")

suffer. Thus the spines are frequently thickened and strands of ossified aponeurosis may form in connection with them.

The heads of the ribs become joined to the vertebræ by similar bridges of bone and thus lose their respiratory movement. Inflammatory swellings of the costal cartilages at

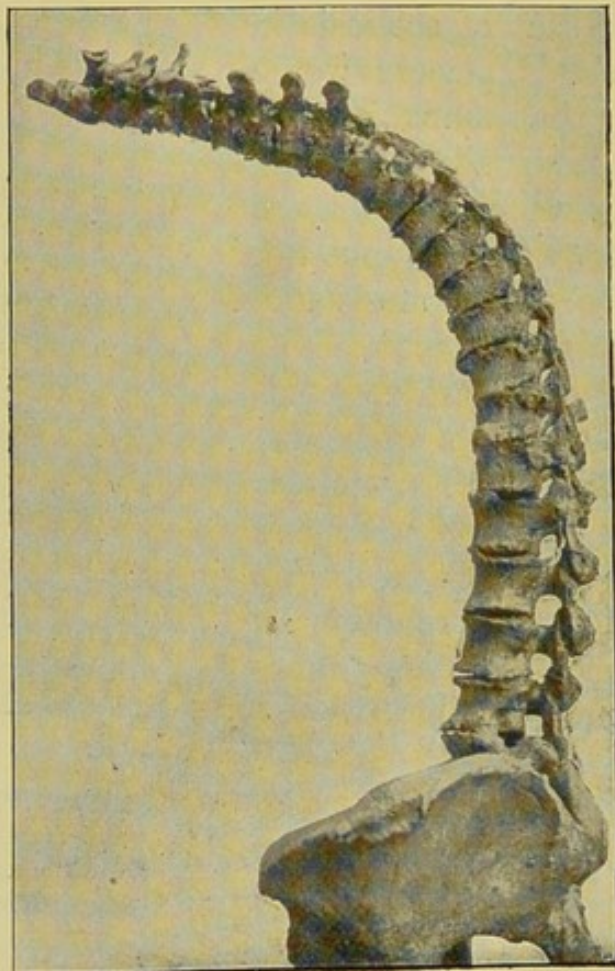


Fig. 267.—Side View of a Spinal Column affected by Rheumatoid Arthritis.
(*Museum of the Royal College of Surgeons.*)

their junction with the sternum or the ribs, I have also observed in several cases.

Previous to the stage of ankylosis of the vertebræ there is in most cases a period of inflammatory softening which leads to the production of more or less deformity of the spine. The kind of deformity that results from rheumatoid arthritis varies greatly. In many cases the well-known total kyphosis shown in Fig. 267 occurs and becomes fixed when no proper instrumental treatment is applied early in the course of the case. Kyphosis, however, is by no means the only deformity

produced by the disease. In my experience lateral curvature results nearly as commonly as kyphosis, as in the instance shown in Fig. 268. The scoliosis may conform to one or other of the types previously described or it may be irregular, here and there a few vertebræ yielding to one side or the other.

The Age of Onset.—In the spine rheumatoid arthritis may set in at any age from infancy upwards. It has already been pointed out (p. 44) that a sharp forward bend of the upper part of the dorsal spine is characteristic of infantile rheumatoid arthritis. In one typical case mentioned below (*see Case 2, next page*) the affection began at the age of four. In young women it is a relatively common complaint and it is frequent in adult life and middle age.

Symptoms.—Pain is usually the predominant symptom. So much is this the case that when a patient complains chiefly of pain in the spine the case is more likely to be one of rheumatoid arthritis than of tuberculosis. In many cases the pain radiates from a region of the spine and is accompanied by puffiness of the subcutaneous tissue, indicating a neuritis of the nerve-roots.

Local tenderness accompanied by enlargement of one or more of the spinous processes is frequently complained of. I have found that several cases diagnosed as "spinal irritation" have proved to be instances of early rheumatoid arthritis.

When ankylosis has occurred, there is marked rigidity of the spine. It might be anticipated that when ankylosis has set in the pain would be diminished. Unfortunately, this does not always follow.

Prognosis and Treatment.—The prospect of complete recovery in any case is small, but very great benefit which is

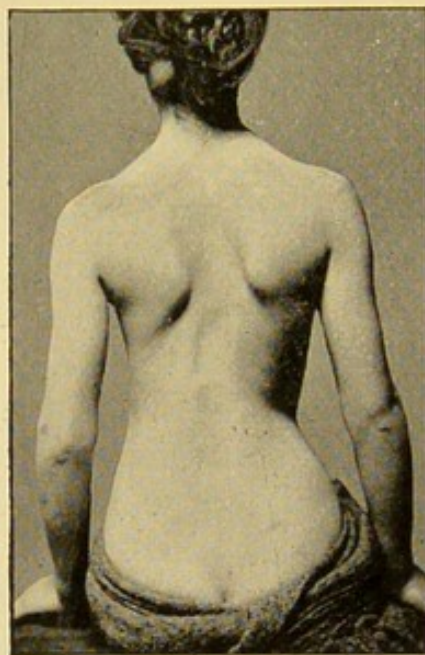


Fig. 268.—Back of a Patient aged twenty-seven, showing Lateral Curvature due to Rheumatoid Arthritis.

often lasting can be obtained in most cases. In the general measures adopted much discrimination is necessary. Some cases require a liberal, others a restricted diet.

In cases of osteo-arthritis of the spine a course of treatment at a suitable spa is often of great utility. I have found the English spas—Bath, Buxton, and Harrogate—most serviceable.

Among drugs, the iodides, colchicum, and salicylates in the active stages, and arsenic, iron, and the hypophosphites in the later stages, are most helpful.

Locally.—Dry heat and hot air, hot and electric baths, are useful. Manipulation with a view to correcting or preventing stiffness is, in the experience of those who have tried it, harmful and useless. The application of counter-irritants in the form of blisters or strong solution of iodine is frequently of service.

When lateral curvature is taking place owing to the softening of bone entailed by the rheumatoid process, or when an old lateral curvature, one that has been stationary from childhood, is increasing from the same cause, and also when pain is aggravated by movements, or is diminished by resting the arms on a chair-back or other support, mechanical help is called for. For this purpose I have found Chance's splints the lightest and most useful instruments.

Illustrative Cases.—1. A married lady, aged thirty-five, who has borne two children in the last two years. For the past twelve months patient has complained of pain in the lumbar region and the sacro-iliac joints and has had pain at times down the outside of the thighs and legs. There has been much wasting of the muscles of the back and lower limbs, with general weakness, indigestion, etc. On examination, I found a well-marked, localised, lateral curve to the left in the lumbar region, and I recommended a double upright Chance's splint, which I adjusted. I learn that the patient finds that the support relieves the pain and enables her to walk about with comfort, and she has resumed active work among the poor. The instrument is left off at night. After a few weeks the back had so far improved that exercises were begun.

2. A girl, aged sixteen, sent to me by Dr. M. M. Loudon, of Arundel, to whom and to Dr. A. Tenison I am indebted for some of the following notes. The patient was healthy until the age of four years when, during an attack of whooping cough, she was noticed to have lateral curvature. This became gradually more marked. At the age of six years she was offered a bed at a hospital, which was declined on

the advice of a medical man, who assured the patient that she would "grow out of it."

Present State.—The patient is of average height for her years, decidedly anæmic and walks with the spine rigid. In the lower cervical and upper dorsal region there is a localised lateral curve to the right, the corresponding scapula is elevated and a band of ossified aponeurosis stretches from the base of the spine of the scapula to the seventh cervical spine. A second lateral curve, also to the right, is present in the lumbar region. There are swellings in several costal cartilages at their junctions with the ribs. The patient suffers much from paroxysmal pain in the cervical and lumbar regions of the spine. Great relief is given to these spasms by leaning heavily on the right arm fully extended. The right arm below the elbow becomes painful, and from the elbow to the shoulder completely numb, with complete loss of sensation. She has "jumpings" of her right leg and they are so severe that they shake all the furniture in a room. Patient always knows when these "jumpings" are coming on, as she says she feels "as if the leg were going to burst" and it becomes intensely itchy. About half an hour after this it begins to jump and patient cannot control it; but it gradually decreases and passes off in about an hour.

A Chance's splint was adjusted, and cod-liver oil and iron ordered. The patient has been free from pain and in improved health since this treatment was adopted three months ago.

Other Forms of Non-tubercular Spondylitis.—*Syphilitic disease*, though not common, has been observed from time to time. In a man, aged fifty-six, Fournier verified the diagnosis after death. T. H. Myers (*N. Y. Acad. of Med.*, Feb. 17, 1898) records two cases in boys. In one case the disease affected the cervical region, causing wry-neck, in the other the dorsal region was affected. In both cases much relief was obtained by instrumental treatment.

Rheumatism of the spine, as distinguished from rheumatoid arthritis, is sometimes observed. It generally forms part of an attack of sub-acute rheumatism, which affects other diarthrodial joints as well as those of the spine.

Diagnosis.—Rheumatism is to be distinguished from rheumatoid arthritis of the spine. The former is a rare, the latter a common condition; both are painful. Complete recovery may be obtained in the former condition, whilst it is rare in the latter.

The differential diagnosis is most difficult in very chronic cases of true rheumatism. Rheumatic nodules under the scalp and about the tendons at the wrist and ankle and

about the elbows are to be sought for. The assistance of a physician should be obtained in such cases, especially if endocarditis, carditis, or pericarditis be suspected.

Post-scarlatinal rheumatism and *gonorrhœal rheumatism* may also affect the spine, though this occurrence is rare.

Post-typhoidal periosteal inflammation of the vertebrae is not so rare and many months may elapse between the attack of typhoid and the date at which the affection of the spine becomes troublesome. Rest in bed and the administration of iodide of potassium will usually cure this condition.

Osteitis deformans affects the spine as well as other parts of the skeleton. It produces a marked kyphosis.

Mollities ossium, *hydatids*, *aortic or other aneurysms*, *actino-mycosis* and *acute septic-osteomyelitis*, must all be excluded before any other spinal affection is diagnosed. Conditions such as tumours of the cord, myelitis, etc., must also be considered.

Neurotic Affections of the Spine.—Under this heading an indefinite group of cases must be ranged, and some of them are independent of deformity, save in that there is some weakness of the back which is liable to result in deformity: others again furnish many of the cases of "round shoulders" already referred to under "kyphosis."

The utmost caution is to be exercised in making an exhaustive examination of the patient before any case is termed neurotic. The commencement of scoliosis in young girls is frequently accompanied by the presence of points of pain and tenderness in the back. Again, in rheumatoid arthritis, which in young people is often associated with neurasthenia, very definite tender areas may be present. Not infrequently has an awful error of diagnosis been made in mistaking early tubercular disease for "hysterical" spine.

Two groups of cases only are to be classed as purely neurotic. In the first are comprised instances of young or middle-aged persons of both sexes who complain of pain in the spine, and in whom all the movements of the spine are normal. There is no rigidity and the pain is not felt on coughing, sneezing, or in going upstairs. Frequently there are patches of hyperæsthetic skin over certain of the lower dorsal or

lumbar spines, a symptom not met with in tubercular disease. Certain spines may be prominent, but on flexion of the column they cease to stand out. The psychical condition of the patients is to be taken into account. They may complain that certain movements are painful, but they move readily enough when following their own inclination

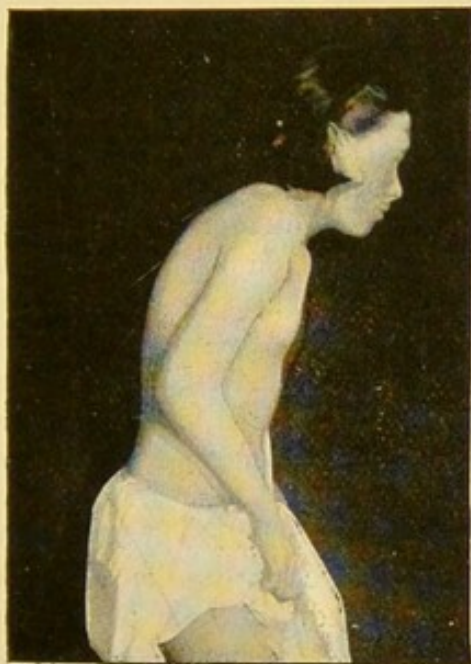


Fig. 269.—Hysteric Contracture of the Spine, Right Arm and Leg in a Girl aged thirteen years.




Fig. 270.—The simple Support found to be necessary in this Case (Fig. 269).

As Howard Marsh* observes, "The things they like are easily done."

Treatment.—General measures are the most important. The "Weir-Mitchell" treatment is often most effectual. Massage, rest, and liberal diet are always required. In some cases where there is wasting of muscle a light support worn in the day is of service.

The second group of cases is distinctly attributable to severe hysteria. This class of case may best be illustrated by a typical case.

A girl, aged thirteen, brought to my out-patient department with "dorsal excurvation" and contracture of the right elbow and knee. The right trapezius was contracted and hard. The history was that the patient

* Howard Marsh, "Diseases of the Joints and Spine," p. 516.

had had good health up to the age of eleven, when, whilst reading for an examination, she was seized with pain "at the top of the head." Spasmodic attacks followed in the face and limbs on the right side. During these attacks the eyes were firmly closed. Consciousness was not lost. She was taken to the Hospital for Paralysis, Queen's Square, where she was out-patient for five weeks, and afterwards in-patient under Sir William Gowers. There she showed complete hemianæsthesia and spastic contraction of the muscles of the right side (Fig. 269).

I found the patient was unable fully to extend the right elbow and knee. The movements of the right arm and leg were generally impaired. When the patient was asked to extend the right arm as in striking, her head and the upper part of the body nodded in a peculiar manner, showing that the spastic condition involved the trunk-muscles as well as those of the limbs.

Treatment.—Rest from school and books, liberal diet, massage, and firm moral treatment were ordered and carried out for a month. At the end of this period, although the patient had put on flesh, the condition of the spine and limbs was unaltered. The simple support shown in Fig. 270 was then applied.

The upright stem of the instrument was so arranged that when the patient's back was arched the instrument pressed slightly against the mid-dorsal spine, and the patient was instructed that when she felt this pressure she was to hold herself straighter. Gentle exercises were prescribed at the same time. The good effect of these measures was at once apparent. In a fortnight the dorsal excurvation had disappeared and the condition of the limbs had improved. A little later the child was sent to the "invalid" school, and save for one relapse, which lasted only a few days, the spine has remained normal up to the present time—*i.e.* for a year and some months.

Tuberculosis of the Spine,* or Tubercular Spondylitis.—

Tubercle may affect the spine at any point from the atlas to the coccyx, and it may be mistaken for a great number of other affections. Thus atlo-axoid tuberculosis has been mistaken for occipital neuralgia, and tubercle of the coccyx for ordinary "fistula in ano."

The affection may begin at any period of life, from the earliest infancy to advanced years. Tubercular disease of

* Since the year 1880, when R. Koch made the meaning of the term tuberculosis definite, the affection of the vertebræ caused by tubercular infection is best named "tubercular spondylitis." The term "Pott's disease" honours a great surgeon, but it is less convenient than a strictly descriptive term. "Spinal caries" is a common designation, but it is indefinite, since caries or rarefaction of bone may be due to many different agents. "Angular curvature" is a self-contradictory phrase and is best avoided.

the spine is closely simulated by other conditions, *e.g.* rickets, rheumatoid arthritis and malignant disease, hence the closest study is required to prevent error in diagnosis and in treatment.

Pathology.—The favourite starting-point of tuberculosis in the long bones is in the cancellous tissue of the diaphysis close to the epiphyseal cartilage. Similarly it is in the cancellous tissue at the juxta-epiphyseal region of the bodies of the vertebræ that tubercle is probably first formed in the vertebræ. Moreover, it is in the anterior far more frequently than the posterior parts of the bodies that early tubercular changes are found when opportunities for post-mortem examination occur in suitable cases. From this starting-point it extends in all directions, involving the neighbouring intervertebral discs and attacking the bodies of neighbouring vertebræ.

This form of the affection is by far the more common, and it has been designated "*spondylitis profunda*" in order to distinguish it from another form of the affection in which the tubercle spreads widely beneath the anterior common ligament constituting "*spondylitis superficialis*." *Spondylitis profunda* commonly spreads from a single focus, but not very rarely several foci, resulting from the same original discharge of bacilli, are formed and may be recognised clinically by the presence of two or more projections in the line of the spinous processes. An originally deep tuberculosis may become superficial by extension to the surfaces (Fig. 271).

The spread of the tubercular granuloma takes place in




Fig. 271. — Part of a Spinal Column.

The body of one of the lower dorsal vertebræ has been destroyed by a deep tuberculosis and extensive destruction of the anterior surface of the spine by superficial extension. (Museum of the Royal College of Surgeons.)

all directions; vertically, as has already been described, it tends to invade neighbouring intervertebral discs and vertebral bodies; superficially, it reaches the periosteum and the soft parts and frequently ends in the formation of abscess. If caseous material or pus accumulate in the spinal canal, pressure-paraplegia may follow.

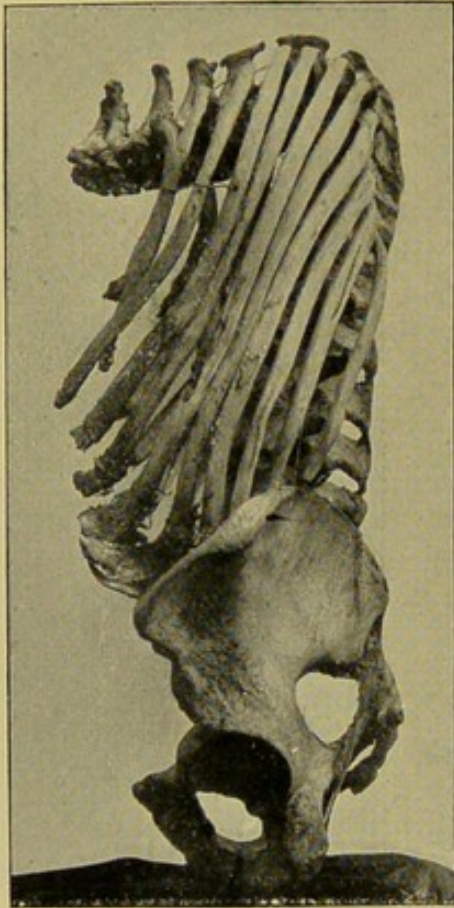


Fig. 272. — Part of a Skeleton showing the Deformity of the Spine and Thorax in Dorsal Tubercular Spondylitis. (Museum of the Royal College of Surgeons.)

The course of the affection depends upon (1) the resisting power of the individual and (2) upon the treatment. If the individual is fairly protected, the balance of power between the invading organisms and the resisting powers of the individual leads to the formation of granulation tissue around the bacilli. This "granulation-tuberculosis" is favourable to the ultimate arrest of the disease; at the same time it is accompanied by the formation of necrotic and caseous areas and sometimes of abscess.

If the progress of the disease is more rapid, there is not time for the absorption of bone *pari passu* with increase of the infected area and dead masses of bone (sequestra) are left in the midst of the tubercular area: this has been termed tubercular necrosis. The presence of sequestra is usually a token of widespread disease. Large sequestra are rare in tubercular disease of the spine.

Anatomical Effects.—The gradual destruction of one or more of the vertebral bodies causes an alteration in the form of the spine. The latter usually becomes sharply bent forwards opposite the vertebral body in which the disease began. This kinking, or "angular curvature" of the spine, produces a projection (*gibbus*) in the line of the

spines. When the tubercular granulation tissue spreads more in the lateral part of the body of a vertebra, a localised *lateral curvature* results. The sharpness of the angle varies with the extent of the destruction. When a number of vertebræ are involved the gibbus is of a rounded rather than an angular form. The rounded form of the

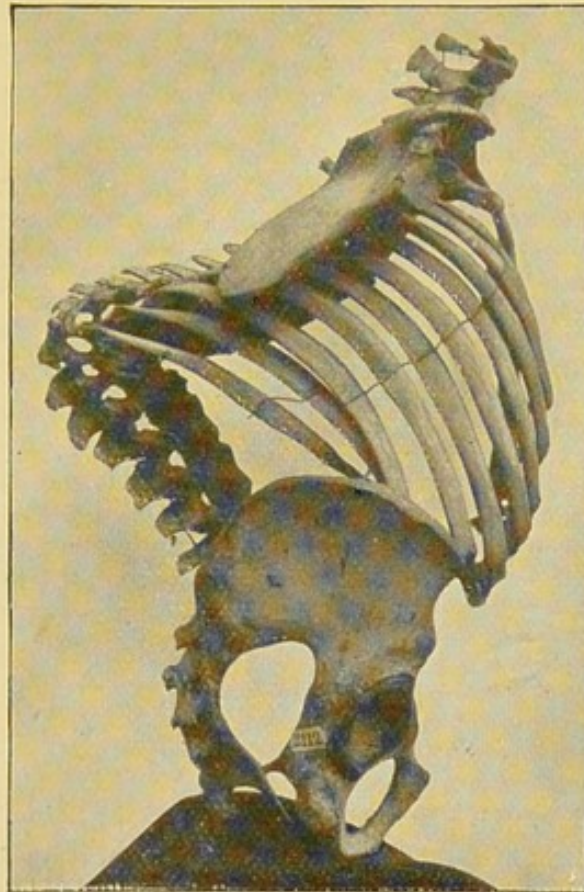


Fig. 273.—Part of a Skeleton showing Deformity arising from low Dorsal Disease. (*Museum of the Royal College of Surgeons.*)

gibbus is contributed to by an adaptive change in the spinous processes which, owing to the traction of attached ligaments, become bent in proportion to the sharpness of the curve in the spine. In the lumbar and cervical regions, where there is a normal backward concavity of the spine, the first effect is a *straightening* of the region affected.

In a few instances, whilst the destructive process is taking place in the vertebral bodies, new bone is thrown out from the deep surface of the anterior common ligament which serves also as periosteum to the front of the vertebræ.

In such cases there may be no deformity in spite of extensive bone destruction.

Tuberculosis of the Vertebral Arches.—A primary tuberculosis of the vertebral arches is very rare. This is owing to their more compact structure. Like the ribs, however, they are occasionally attacked by tubercle. A *simple* inflammatory ostitis of the vertebral arches and processes,

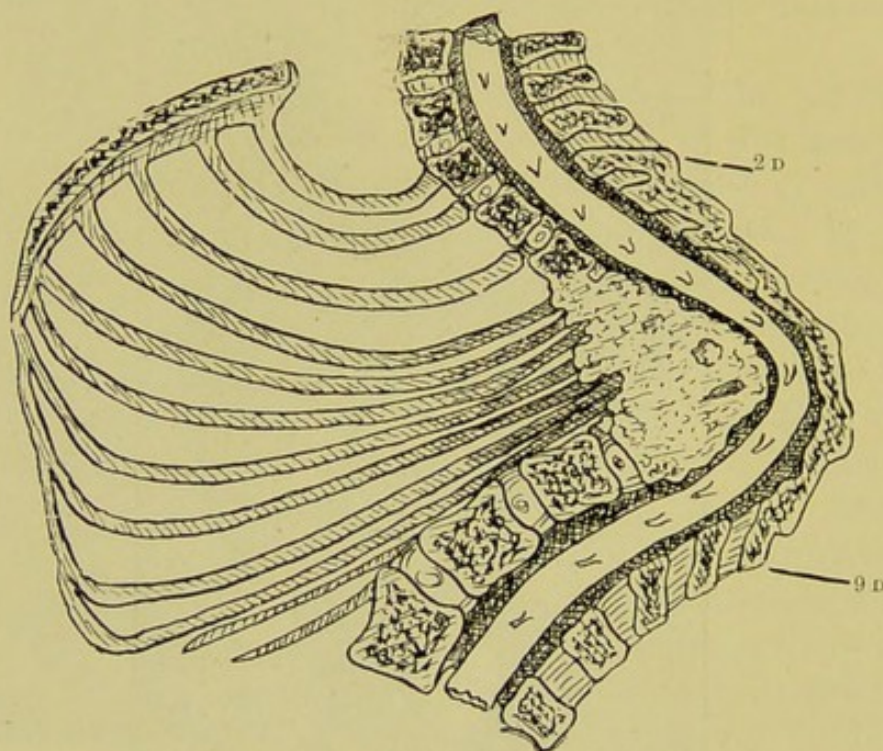


Fig. 274.—Healed Tuberculosis of the Spine.

Sketch of the right half of the thorax of a woman aged twenty-eight, who had suffered from spinal tubercle in childhood and who died of bronchitis. The vertebral bodies from the 4th to the 9th have been destroyed, and are represented by hard new bone which contained caseous foci. The spines of the vertebrae from the second to the ninth are ankylosed together.

due to absorption of irritating toxic material, is usual in advanced tuberculosis of the bodies.

Recovery.—In well-treated cases where the patient is not of the feeblest resisting power natural recovery occurs. In such cases, when the parts are examined long after active disease has ceased, the remains of the bones of the vertebrae are found to be sclerosed and ankylosed. There is usually not so much formation of new bone as is shown in the accompanying diagram (Fig. 274).

Abscess.—The pus of a tubercular abscess contains

tubercle bacilli and, unless it has become secondarily infected by staphylococci or streptococci, it will separate readily into a watery and a denser layer after evacuation. Like other abscesses, those secondary to spinal tuberculosis tend to spread in the direction of least resistance; thus in each segment of the spine the probable route of an abscess is known beforehand, as will be more fully indicated on p. 395. The frequency with which abscess-formation is observed in spinal tuberculosis is very great. Dollinger in 700 cases found abscesses in 154. Small abscesses that have not been discovered during life have frequently been met with post-mortem.

Secondary Effects on the Skeleton.—The spinal canal is usually widened rather than narrowed (see Fig. 275). Exceptions to this rule arise, however, now and then, e.g. when a traumatic fracture or dislocation occurs in a case of tuberculosis or when a loose sequestrum (see Fig. 276) is displaced backwards. The intervertebral spaces suffer no narrowing because they lie behind the axis of the disease. The nerves are thus not directly pressed upon. The pain is due to extension of inflammation to the sheaths of the nerve-roots.

The angular deformity entails a forward displacement of the centre of gravity of the body, and to compensate for this a lordosis of the part of the spine below the projection is brought about by muscular action.

In disease of the cervical or upper dorsal spine the lordosis of the part of the spine below the projection may involve nearly the whole of the dorsal vertebræ below the projection.

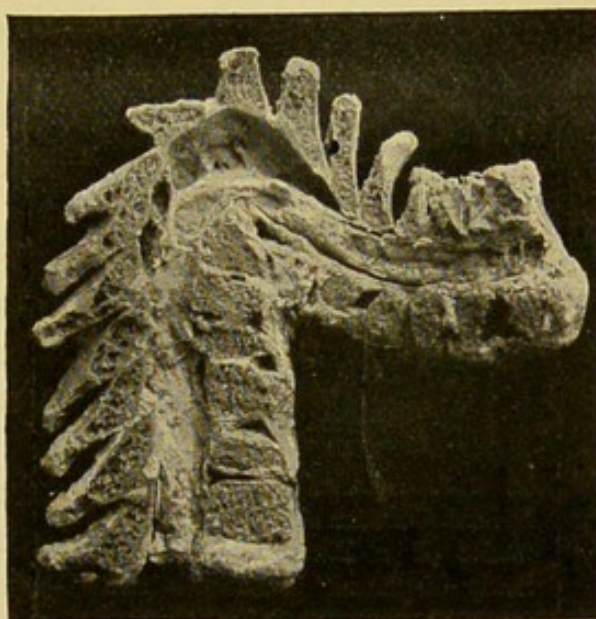

Fig. 275.—Section of part of a Spine deformed from the Tubercular Disease.

The spinal canal is enlarged opposite the seat of disease. (Museum of the Royal College of Surgeons.)

Thus the normal convexity backwards of the dorsal region may be changed to a lordotic condition which may extend to the interscapular region. For the same reason the part of the spine above the projection also becomes lordotic, so that

the head is projected backwards (Fig. 273).

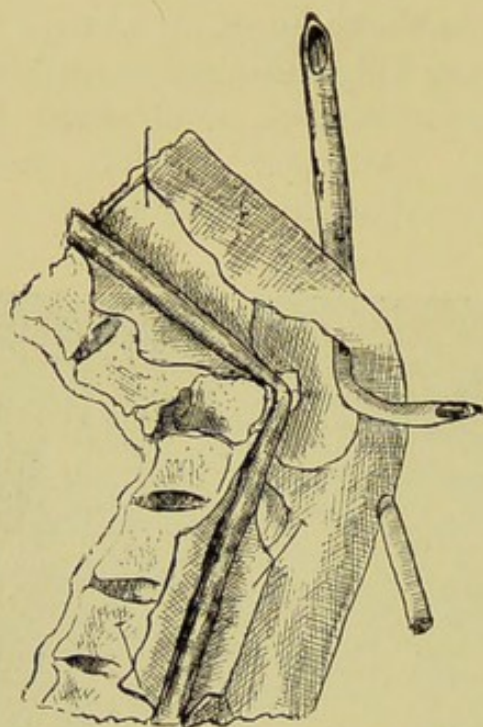


Fig. 276.—Section of part of a Spinal Column showing the remains of a Necrotic Vertebral Body displaced backwards and pressing upon the Spinal Cord.

The patient was a boy aged nine and a half years. Paraplegia developed suddenly in the space of a night; priapism, bed-sores, and involuntary jerkings of the lower limbs were present. Laminectomy was performed and the patient died of broncho-pneumonia. The entire body of a vertebra was found to be necrosed and displaced backwards, pressing on the cord. (*Vincent.*)

Lumbar kyphosis is compensated for by lordosis of the neck and slight diminution of the normal dorsal kyphosis; if the seat of the lumbar kyphosis is low the inclination of the pelvis is diminished and the extension of the hips is increased.

Most important are the effects on the respiratory and circulatory organs owing to alterations in the form of the thorax.

When the projection is in the mid-dorsal or lower dorsal part of the spine the thorax becomes greatly increased in its antero-posterior, whilst it is diminished in its vertical and transverse measurements. The upper end of the sternum becomes elevated. In this way the thorax assumes a keel-shape (Figs. 273, 274).

On the contrary, when the deformity is in the upper

dorsal region the antero-posterior measurement is diminished, the thorax becoming approximated to the pelvis and the chest flattened (Fig. 272).

When the lumbar region is the seat of the deformity the thorax may sink till the lower ribs rest on the pelvic bones. The abdomen is thus thrust downwards and forwards. The pelvis assumes the kyphotic form: its

lateral walls are approximated, the inlet is widened and the outlet narrowed.

Witzel first described the change in the skull. The mento-occipital measurement is increased and the fronto-occipital diameter is diminished.

The aorta and vena cava may be kinked with narrowing of their lamina and cardiac hypertrophy may occur, or the large blood-vessels may be softened and perforated by abscesses leading to extensive hæmorrhage.

Spinal Cord.—Save in exceptional cases there is no direct pressure, but in rare instances this takes place either from the backward displacement of a sequestrum or from rapid yielding of vertebræ. According to Kraske, this direct pressure was observed only once in fifty-two cases of paraplegia examined after death. In nearly all cases the paraplegia is due to extension of the tubercular process to the tissues of the spinal canal. The cord may then be affected in various ways: (1) by the pressure of tubercular granulations formed in the fatty tissue outside the cord; (2) by abscesses formed outside the dura mater; (3) by simple inflammatory processes (pachymeningitis externa) in the dura mater, which is highly resistant to the specific tubercular inflammation. In cases of severe paraplegia followed by a spastic condition in the lower limbs the cord itself becomes involved in the simple peri-tubercular inflammation. This has been proved by post-mortem examination. Later, even the dura may be destroyed by the specific tubercular inflammation, but this event will follow, not precede, the paraplegia, anæmia or œdema of the cord having been the direct cause. Thus, œdema is to be referred to pressure on lymph-channels in the subarachnoid space. W. G. Spiller* has published a series of observations, two of which may be briefly quoted:—

(1.) Boy, æt. twelve. Lower cervical and first dorsal vertebræ attacked; died of dyspnœa.

P.M.—Early case; no compression of cord. Intense round-cell infiltration of meninges and cord without specific tubercular inflammation internal to the dura.

(2.) Child, æt. three years. Disease of first, second, and third dorsal vertebræ. Paraplegia gradually developed.

* "Johns Hopkins Hospital Reports," June, 1893.

P.M.—The cord was found to be compressed by the bones, and microscopically it showed in the compressed part but few medullated fibres and no nerve-cells. The pia mater was thickened, and there was both ascending and descending degeneration of the motor and other tracts.

Symptoms; Pain.—In infants the first indication of the disease is a loss of liveliness. The child, previously active and in constant movement, becomes fretful and ceases to play. These are evidences of *pain*. If the patient is too young to speak, it may nevertheless indicate the seat of the pain; for example, by placing the hands on the back of the head, the side of the chest, the abdomen, or the lower limbs, according to the site of the disease. Older children and adults who can describe their sensations speak of the pain as a dull ache, sometimes increased at each pulse-wave. Though the pain is usually symmetrical, varying in the dorsal and lumbar regions from a sense of constriction to a distinct girdle pain, it is sometimes one-sided owing to the inflammatory process affecting one side more than the other.

Pain in the limbs, in the bladder and penis, and “gastric crises,” have all been noticed. The pains are worse at night and after meals. Children often scream at night, and there may be hyperæsthetic areas in the skin supplied by the affected nerves so that the pressure of the bed-clothes cannot be borne. In some early cases pain is not a marked feature and it may only be felt when the patient sits down, because in the sitting position the lumbar part of the spine becomes arched forwards. The pain is also made worse by movements, such as stooping, laughing, coughing; also by riding in a train or other vehicle, or by the jar of a false step. The apprehension of the pain caused by such movements may give the patient an anxious expression. The degree of pain present in different cases varies greatly. In some cases it is of a lancinating character. As a rule, however, the pain in a case of tuberculosis of the spine is less than that of rheumatoid arthritis. In some remarkable cases a pronounced angular curvature has developed without any pain having been present. In the rare cases in which the tubercular process begins at the back of the bodies of the vertebræ pain may be absent for a considerable time.

Thus the absence of pain must never be taken as proof of the absence of tubercular disease. Many carefully recorded cases and specimens in museums attest the fact that pain in tubercular disease of the spine may be absent, or so slight that it is overlooked. Thus, instances of extensive cervical disease have been mistaken for wry-neck, melancholia, etc. The dyspnœa dependent on pressure of a retro-pharyngeal abscess has been diagnosed as "croup." If a more complete examination had been made in such cases and *rigidity* had been looked for, these mistakes would probably never have occurred. A radiograph is often useful in doubtful cases, especially in the cervical region.

Tenderness.—It is seldom advisable in the examination of the patient to bring out this symptom, either by pressing on the head or shoulders, or locally on any prominent spine; in fact, tenderness is rather against than for tuberculosis. In rheumatoid arthritis, there is superficial tenderness to pressure on the spine, and the presence or absence of this symptom can be ascertained without using pressure sufficient to cause pain or alarm to the patient. If the patient feels pain on coughing or other sudden movement, this is the expression of tenderness of the spine.

Rigidity.—Of all the symptoms of tuberculosis of the spine this is by far the most important. Just as in joint disease, say of the hip, there is fixation of the joint from spasm of muscles, so also in disease of the spine is there a loss of natural mobility from the same cause.

In the examination of the patient this symptom must be carefully looked for. The patient's manner of holding himself in walking may betray the fact that part of the spine is kept rigid. In every case where tuberculosis of the spine is suspected, the flexibility and rotatory capacity of the spine should be systematically looked for. Thus, in the examination of the cervical part of the spinal column, the degree of flexion, extension and lateral bending that the patient is capable of must be ascertained, as well as the power of rotation effected between the atlas and axis, and finally the nodding movements between the occiput and atlas.

In young infants the flexibility of the spine can be ascertained by placing the palm of the hand under the patient's

back and gradually and gently lifting the child by raising the hand. If there is no rigidity of the spine, it will be felt to become extended as the weight of the child's body falls more and more upon it. This same feature may be demonstrated by laying the child on the ventral aspect and raising the body gently by the legs.* Impairment of flexibility of the spine is

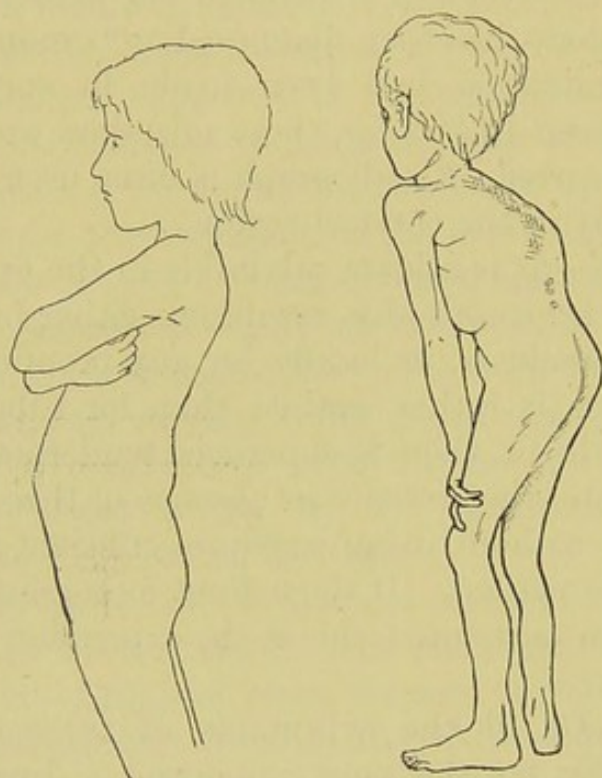


Fig. 277.—Attitudes assumed Spontaneously by Patients suffering from Lumbar and Dorsal Disease.

often well brought out by making the patient pick up some small object from the ground. If the spine is normal the patient stoops and rises without hesitation, but if tuberculosis of the spine is present, the back is held rigid whilst the patient gradually sinks on the knees in order to bring the hand sufficiently low to enable him to grasp the object. Difficulty in ascending or descending stairs is often an indication of spinal disease.

Abnormal postures are assumed in order to remove from the seat of disease the weight of the superincumbent part of the body. Thus, a child with disease of the cervical spine may support the head on the hands whilst the elbows

* Edmund Owen, *Clin. Journ.*, Aug. 3rd, 1898.

rest on a table. In high dorsal caries the head may be retracted, so that the centre of gravity is thrown farther back, and hence a greater part of the weight transmitted through the sound articular processes and less through the diseased bodies of the vertebræ. Again, a child suffering from dorsal caries often stands with the knees flexed and the hand resting on the thighs, so that some of the weight of the upper part of the body is transmitted through the arm, and in lumbar disease there may be lordosis (Fig. 277).

The Examination of the Back.

—The patient should stand with the back to a good light. The surgeon must be cautious in basing an opinion on the disposition of the series of spinous processes, first, because in normal backs the intervals between the spines vary in different individuals; second, because in well-marked tuberculosis of the spine there may be no recognisable deformity. Another point to be remembered is this, that in some cases of tuberculosis of the spine the deviation caused in the series of spines is to one or other side (lateral) and not directly backwards (angular).

Lateral deviation may be observed in still more pronounced degree in old cases of tubercular disease of the vertebræ. In one such case I have now under observation, four spinous processes form the angles of a small square, being placed side by side. This disposition of the spines represents a very sharp bend in a limited part of the spinal column. In the lumbar region, where the spinal column is naturally concave forwards, it frequently shows itself by a diminution of the natural backward concavity. The same is true of the cervical region, with the difference that the smallness of the vertebræ in this region results in the production of deformity with greater rapidity than in other regions, and it is

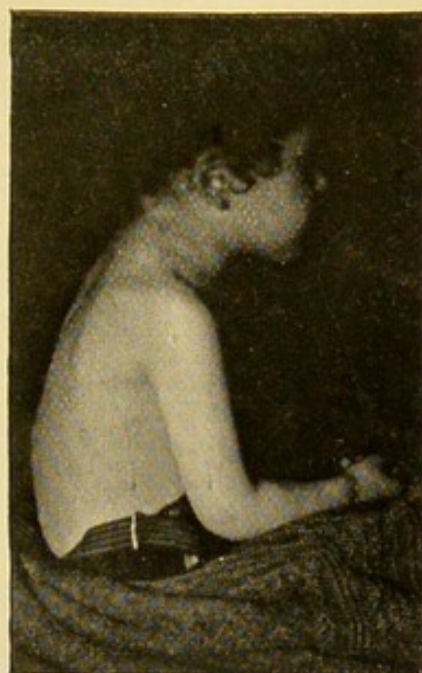


Fig. 278.—Photograph of a Boy showing a prominent Vertebra in the Neck from Tubercular Disease.

especially in the neck that lateral deviation from tuberculosis is most likely to occur. In the cervical region, however, a prominent vertebra is usually present (Fig 278). Thus, cervical tubercular disease is apt to be mistaken for some other form of wry-neck.

Method of Recording Angular Deformity of the Spine.—

When the deformity is a simple one, it can readily be recorded by placing the patient face downwards on a firm couch, or other level surface, and moulding a

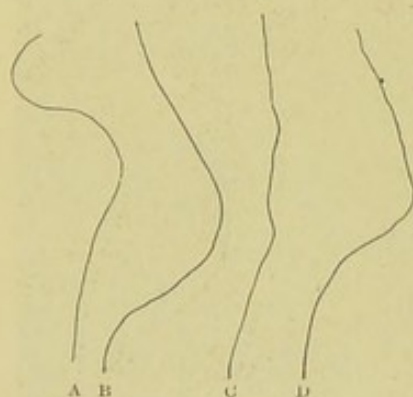


Fig. 279.—Reduced Tracings from cases of Tubercular Spondylitis.

A, high dorsal; B, extensive mid-and-lower dorsal; C, showing two separate projections in the dorsal region; D, dorsal curve with marked lordosis below the gibbosity.

strip of tin or other flexible metal over the spines, and then transferring the outline thus obtained to paper by placing the edge of the strip of metal on the paper and marking along the metal with the point of a pencil. The curves A, B, C, D, in Fig. 279, illustrate the method, which is useful as a record of progress, as tracings taken from the spine at intervals in the course of the disease serve to show whether the deformity is increasing or has been arrested or even diminished under treatment.

Differential Diagnosis.—Many

cases of tubercular disease of the spine are attributed to injury. In the majority of these, doubtless, the injury simply finds out an existent focus of disease, in some a slight traumatic lesion determines the seat of infection. This association of tubercular spondylitis with injuries imposes on us a grave responsibility in the distinction between early disease and *sprain of the spine*. In many cases it is desirable to watch the course of events for a week or two before giving an opinion. The distinction from *scoliosis* has already been drawn (p. 356). *Wry-neck* is sometimes but a symptom of tubercular disease. The absence of muscular spasm and the presence of rigidity, together with the prominence of one or more spines, will usually serve to distinguish the two conditions. In some cases of *hip disease* there is rigidity of the lumbar spine,

together with flexion of the hip as in psoas contracture from commencing psoas abscess. The absence of spasm of the adductors in disease of the spine will help to distinguish the conditions. *Rheumatoid arthritis* and *spinal hyperæsthesia* are generally associated with more superficial tenderness than is seen in tubercular disease and in these conditions the characteristic deformity is wanting. *Malignant disease of the spine* may for a time be indistinguishable from tubercular disease, but its more rapid course will soon declare its nature.

Course and Prognosis.—The course is always a chronic one, and in cases that have long been progressing favourably, a sudden increase of deformity and the supervision of some grave complication may occur. On the whole, however, in well-supervised cases, the prognosis as far as the local condition is concerned, is hopeful. When a fatal issue occurs it is more commonly due to tuberculosis of the lungs, intestines, or some other part. Death may also be due to the effects of abscess opening into the pericardium, peritoneum, pleura, lungs, or bronchus. Pyæmia and lardaceous disease, and meningitis, or myelitis, may be mentioned among other causes of a fatal issue.

The period of time occupied for the achievement of a natural cure is usually more than three years and protective apparatus must be worn for a much longer time.

The Complications of Tuberculosis of the Spine.—The chief complications are—(1) abscess, (2) sinus and (3) paraplegia.

*Abscess.**—When liquid exudation is formed in greater quantities than can be absorbed, it collects and tends to accumulate wherever the tissues offer least resistance. This is in the spaces filled by loose connective tissue, *e.g.* inter-muscular spaces along the course of arteries and nerves. Aponeurotic structures form barriers against the extension of pus, thus directing the course of abscesses.

Tubercular pus is sometimes white and thick, sometimes thin and whey-like, or it may be reddish-brown from admixture of blood. In the upper cervical region pus usually first

* The account given by Hoffa, "Orthopædic Surgery," is largely followed in this section.

collects behind the pharynx, forming a retro-pharyngeal abscess (Fig. 280); by gravitation it may pass behind the

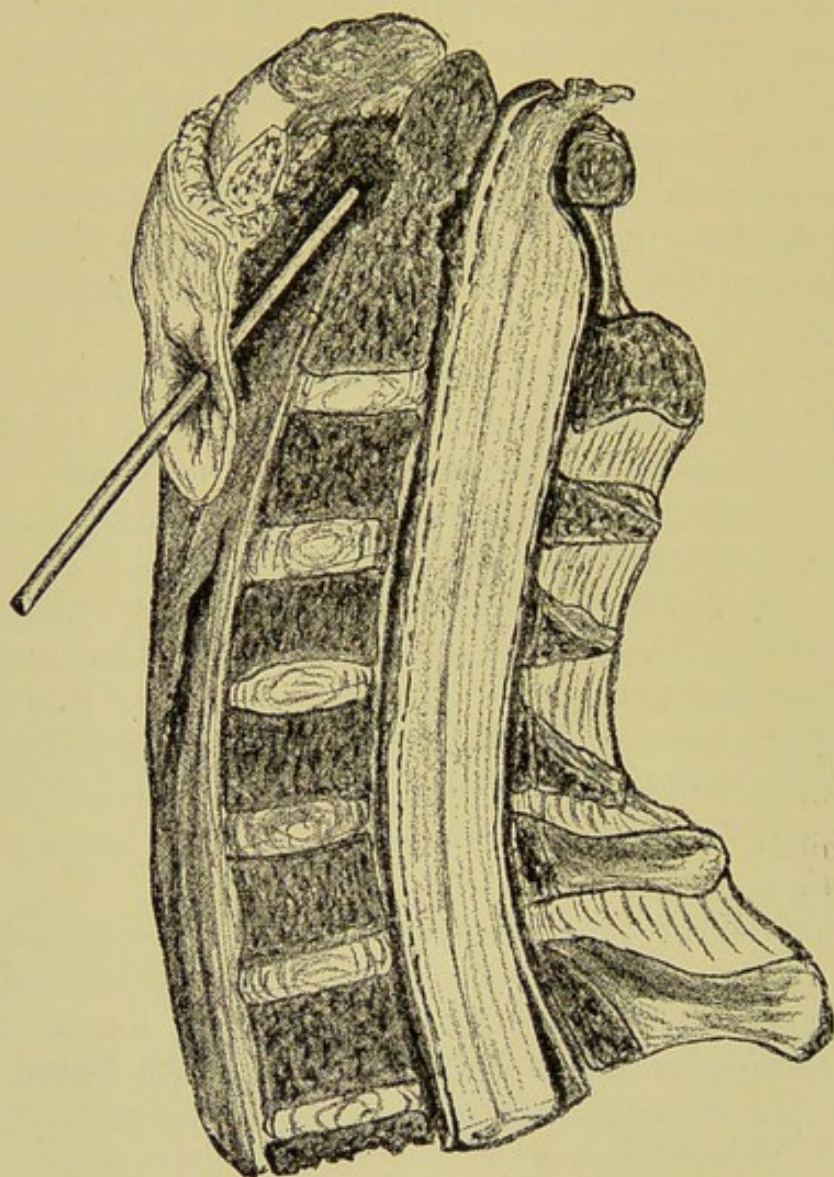


Fig. 280.—Atlo-axoid Disease.

The atlas is displaced $\frac{3}{4}$ inch forwards, and the uppermost part of the cord is compressed between the posterior arch of the atlas and the odontoid process. The glass rod marks a perforation in the posterior wall of the pharynx, where a retro-pharyngeal abscess opened. There was pus between the vertebrae and the dura mater, and the latter is adherent to the cord from meningitis. (From a girl aged nineteen who, from the age of seven, had complained of pain at the top of the head, and who had been treated for neuralgia. There was marked backward projection of the spine of the axis and a retro-pharyngeal abscess. Cheyne-Stokes respiration developed before death.)

oesophagus, the connective tissue between the pharynx and oesophagus being lax. Extension to the parotid region has been observed. From the lower cervical spine pus tends to pass into the posterior mediastinum and, reaching the aorta,

it follows its course, and may finally pass along the iliac arteries to the thigh.

Pus originating in the thoracic vertebræ tends first to collect in the posterior mediastinum and to follow the course of the aorta, pushing the œsophagus before it. Perforation into one or other pleura, or, if this had become adherent, into

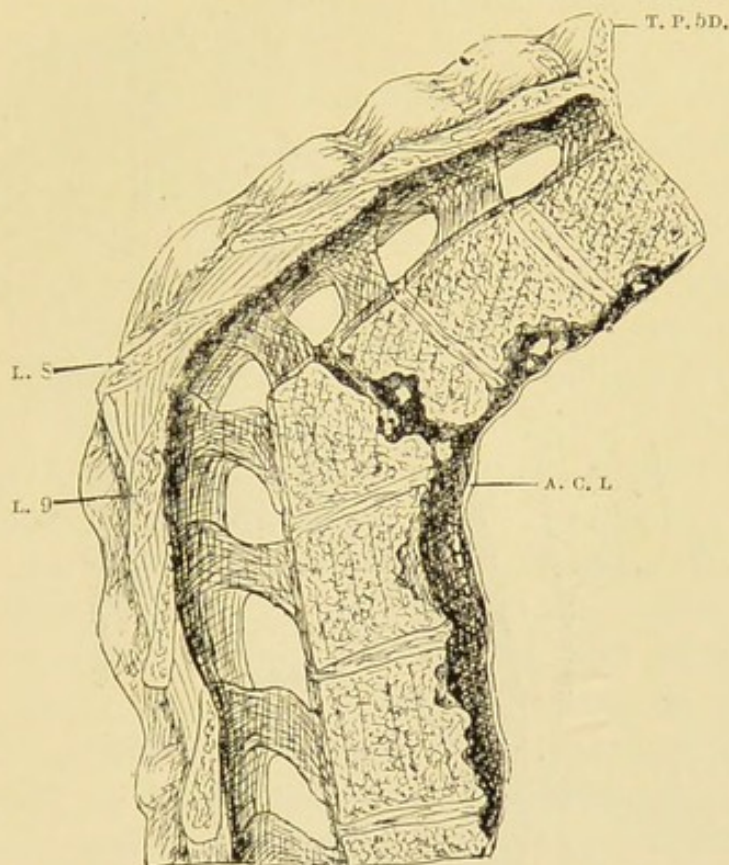


Fig. 281.—Section through part of a Spine.

The body of the 8th dorsal vertebra has been destroyed. The anterior common ligament (A.C.L.) is raised up by caseous pus. L.8, 8th lamina; L.9, 9th lamina; T.P.5D., transverse process of 5th dorsal vertebra.

the lung, sometimes occurs. The pericardium in some instances has been perforated. More frequently the matter follows the course of the aorta to the retro-peritoneal space, and when it reaches the lower part of the abdomen it may collect in the iliac fossa, forming an iliac abscess, or continuing along the iliac and femoral vessels, it may either form an ilio-femoral abscess, or pass along the internal iliac vessels into the true pelvis where it may open into the bladder or rectum, or on the surface near the anus, simulating a fistula in ano. Or again, it may leave the pelvis by following the course of the sciatic nerve, appearing as a gluteal abscess or passing

beyond into the back of the thigh. Less commonly pus from the dorsal vertebrae follows the course of one or more intercostal nerves, appearing in the back as a dorsal abscess by tracking along their posterior branches.

From the lower dorsal and the lumbar vertebrae pus usually finds its way into the sheath of a psoas muscle, constituting a

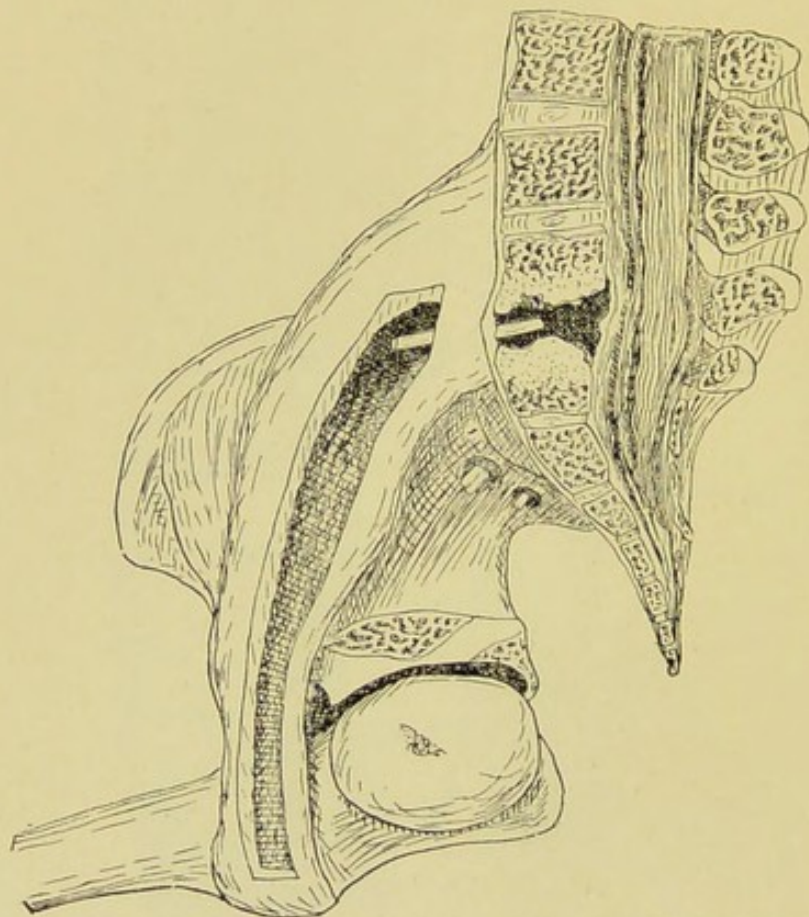


Fig. 282.—Dissection of a Psoas Abscess the Wall of which was Calcified.

psoas abscess. The iliacus muscles, as well as the psoas, may be destroyed by the suppurative process. The usual clinical appearance is a fluctuating swelling above and below Poupart's ligament. The sheath of these muscles may be perforated and the abscess may pass along the adductors and point at the inner side of the thigh, or it has been known to find its way even as far as the ankle.

A double psoas abscess may result from the same area of disease. The pus not uncommonly finds its way into the quadratus lumborum muscle and, accumulating, forms a *lumbar abscess* between the last rib and the iliac crest; from

this pus may penetrate widely between, beneath, or superficial to the layers of the abdominal wall.

The wall of a chronic abscess becomes thickened and it may undergo calcification (Fig. 282). If one pouch of a complicated abscess becomes shut off, its contents may become changed to a firm caseous mass. In some cases the anterior common ligament is widely separated from the vertebræ by collection of pus beneath it (Fig. 281).

Adherent to or near the wall of an abscess from spinal disease chains of tubercular glands may be present.

Diagnosis of Abscess.—The onset of fever of the hectic type and a rapid deterioration in the general health and strength of a patient are sometimes the first sign of abscess. In the case of psoas abscess flexion of the hip may be observed long before any fluctuating swelling is formed. An increase of pain is also usually present at the commencement of abscess formation. Retro-pharyngeal abscess is evidenced by dysphagia and dyspnœa.

The Treatment of Tubercular Spondylitis.—There is no one method of treatment applicable to all cases alike. Each case must be studied carefully before any plan of treatment is adopted, and with varying conditions variations in treatment must be introduced. Moreover, the varying ages of the patients will necessitate variations in treatment. The various measures of proved efficacy will here be described in turn and indications given for their application in cases of varying severity.

Treatment by Recumbency.—When a person lies flat upon the back on a firm hair mattress all pressure due to the weight of the superincumbent parts of the body is removed from every segment of the spinal column. For this reason the length of a normal adult is greater by an inch to an inch and a half when lying on a flat horizontal surface than when standing or sitting. This is not the case when the person lies upon a soft yielding substance such as a feather bed, in which case the curves of the spine are not diminished to the same extent as when the surface is firm; and the amount of pressure borne by the vertebræ of any segment of the column is in normal conditions proportionate to the curves of the column.

When tubercular disease is present in the spine in an actively progressive form, recumbency on a firm hair mattress is indicated. The mattress should be rather longer and wider than the patient and it should rest on a shallow wooden tray (Marsh) so that it may admit of the patient being carried into the open air and from room to room. Restless patients can be secured to the mattress by suitable straps.

In order to render the bed more portable a light bed-frame may be used in place of the tray. "If four stout steel bars, one half-inch wide and one-fourth inch in thickness, be fastened together so as to make an oblong frame of the patient's height and width, and over this stout sheeting be wound and fastened, the patient can lie on this if it be placed upon the bed, as comfortably as upon the bed; straps across the shoulders fastened to buckles secured to the frame, and others about the hips, will secure the patient in a recumbent position, while the frame and child can be carried about easily. . . . The sheeting should be cut out at the region of the buttocks so that the bed-pan can be used." *

Traction can be combined with recumbency in suitable cases.

In cases of atlo-axoid disease a small pillow should be placed under the neck and a horseshoe-shaped sandbag above and at the sides of the head (Marsh).

The advantages of recumbency combined with portability of the patient have been secured by various other contrivances such as the "gouttière de Bonnet" and Phelps's box (see p. 299). In it the patient's legs lie in separate compartments, and there is provision for defæcation and micturition being performed without disturbing the patient. Phelps's box is the same in principle as Bonnet's, but is rather simpler in construction and it forms a cheap appliance for hospital cases.

A modification of Thomas's double hip-splint, if carefully made and well padded, serves the same end as other arrangements for recumbency.

Instead of a dorsal decubitus the patient may usually be treated by rest on a prone couch (Fig. 283) combined

* Bradford and Lovett, *loc. supra cit.*, p. 55.

with the use of a good antero-posterior support. By this plan the patient is enabled to be amused by toys or to learn lessons when old enough.

The question arises, how long should a patient be kept

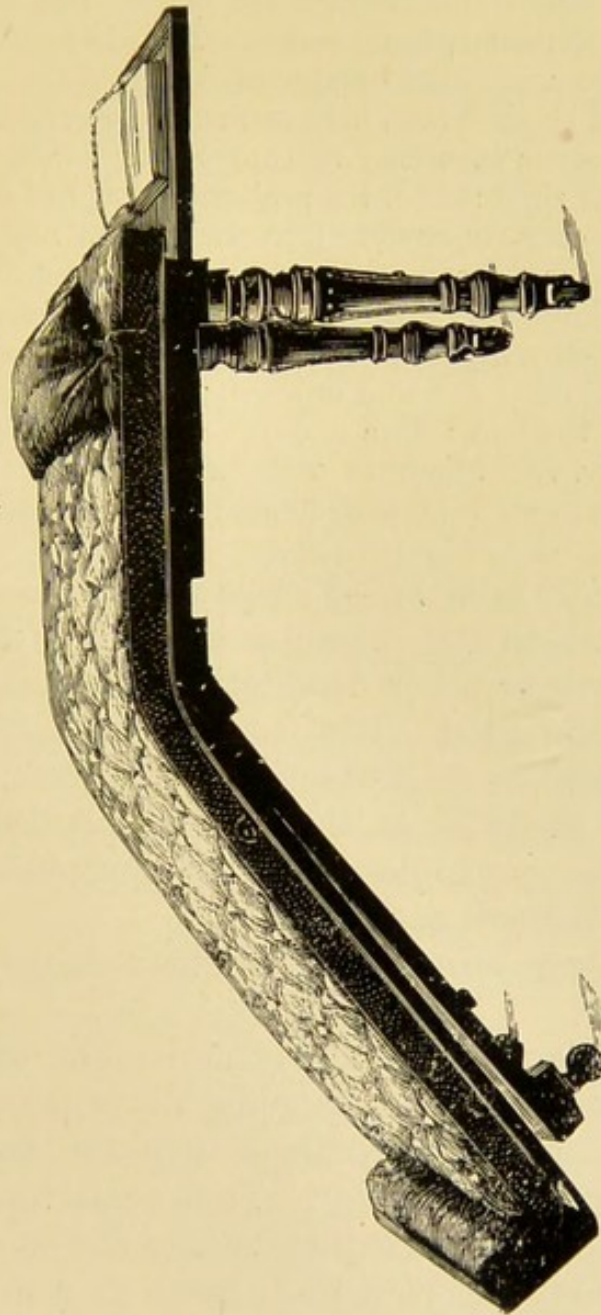


Fig. 283.—Prone Couch. (*John Carter.*)

recumbent? A minimum period for the complete healing of a tubercular focus in bone is about twelve months and in some cases it is found to be six or seven years. Now, after a certain time strict recumbency by impairing the patient's muscular power and general nutrition does more harm than

good. As one of many instances that I have observed of this I may mention the following case:—

A girl, aged six years, was brought to the out-patient department of the City of London Orthopædic Hospital on a double Thomas's spinal splint. The splint was well made and well adjusted. It had evidently been carefully watched, for although the patient had lain upon it for four years there were no pressure-sores. The disease in this case had shown itself in the upper dorsal region at the age of two years, and from that time forward she had been kept supine and motionless. The spine showed a sharp curve involving the upper four dorsal vertebræ, there was a sinus on the right side of the projection that had developed about a year after the commencement of treatment and had remained open ever since. The general condition of the patient was deplorable. The muscles of the limbs were wasted, the patient was limp and extremely anæmic. I applied a light metal support with a head-piece such as the one described on p. 410, and ordered ʒj of 1–40 carbolic lotion to be injected into the sinus once a day. The patient's general health improved rapidly, she began to walk, and the sinus closed permanently a few weeks after the commencement of the treatment.

Mechanical Treatment.—Except in the most rapid cases, and in cases where the muscular strength of the patient is reduced by fever or other debilitating condition, mechanical treatment is indicated. The form which I have found to be most effective is that which was introduced by the late E. J. Chance in 1852 at the City of London Orthopædic Hospital. The principles of this apparatus have been already described (*see* p. 84).

For very severe curves the upright rods may be adapted to suit the case.

This splint must be worn day and night, and whilst the patient is in bed it renders shoulder-straps, etc., unnecessary. In many cases it is an advantage to place the patient on a prone couch during the day. This contrivance, combined with the splint, secures adequate rest to the spine and at the same time allows the patients to read, play with toys, learn lessons, and to feed themselves in the ordinary way. The most comfortable angle for a prone couch varies in different cases.

A certain degree of muscular tone is required for a patient to derive the full advantage of a mechanical appliance, and when extreme prostration is present, or if the deformity

should be increasing, the recumbent dorsal position described above is required.

With regard to Sayre's plaster jacket I cannot do better than quote Mr. Howard Marsh* :—

“In former years . . . I used Sayre's jacket in a large number of cases of Pott's disease in patients between the ages of three and ten. In those in whom the disease was active, the jacket often produced decided improvement. It relieved pain and enabled the patients to move about with less difficulty. It steadied the spine and limited movement at the seat of disease. In other words, it secured some amount of mechanical rest. But its effect was not sufficient to exercise any very marked influence on the course of the disease. It did not prevent the further increase of deformity, or diminish the proportion of cases in which suppuration occurred ; while paraplegia was, I believe, certainly more common than it is when patients are treated in the recumbent position. . . . As to the ‘jury-mast,’ although a contrivance of considerable mechanical ingenuity, it was disappointing in practice and was given up. It is now seldom used by English surgeons.”

The Felt Corset.—This appliance has most of the disadvantages of the plaster jacket. By surrounding the chest and abdomen it impedes respiratory movement ; by its impervious nature it retains the perspiration. It is much heavier than a Chance's splint, and when strengthened by steel ribs its weight is increased without the mechanical advantages of a good steel support being obtained.

The defects of the mode of action of a felt corset are readily seen when compared with a proper antero-posterior support applied to the same case. Thus, in Figs. 284, 285 and 286 are respectively represented the patient sitting without any appliance, with the felt jacket, and with Chance's splint. It will be seen that the jacket supports the upper part of the body only by pressing on the thorax and the axillæ. The former pressure is distinctly harmful in that it adds another obstacle to respiration ; the effect of the jacket upon the part of the spine below the projection is to prevent any improvement in the lordosis. In recording my opinion of plaster

* Howard Marsh, “Diseases of the Joints and Spine,” p. 496.

and felt jackets it should be remembered that some surgeons of experience hold a different view; thus Mr. A. H. Tubby* writes: "In the plaster of Paris jackets properly applied,

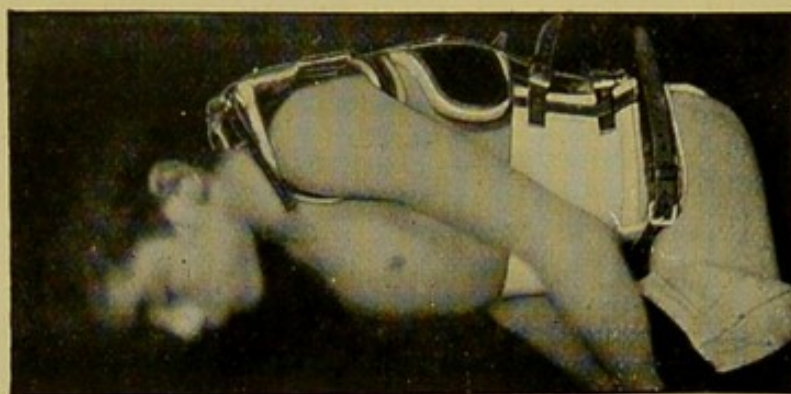


Fig. 286.—The same patient with Chance's Splint applied.




Fig. 285.—The same patient wearing a Poroplastic Jacket.

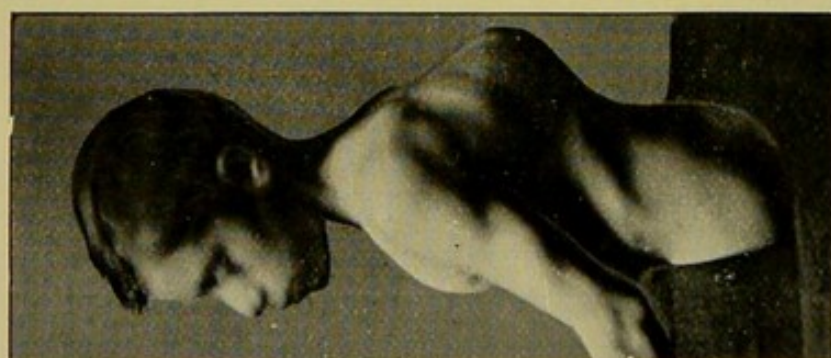


Fig. 284.—Case of severe Dorsal Deformity.

and to a considerable extent in the poroplastic jacket, all the needful requirements are fulfilled. . . . With the jackets either of plaster or felt I am content."

* A. H. Tubby, "Orthopædic Surgery," 1896, p. 55.

Forcible Correction of Deformity in Tubercular Spondylitis.—From the time of Hippocrates, about 400 B.C., up to the present time, various methods of forcible correction of spinal deformity appear in medical literature. After Hippocrates, Galen (A.D. 130–200) and Ambroise Paré, 1517–1590, employed the method of removing the deformity by extension combined with direct pressure. This method has recently been revived. This revival of an ancient mode of treatment was first advocated by Chipault of Paris in 1895, but it owes its *vogue* chiefly to the work of Calot, of Berck-sur-Mer. Calot's first paper on the subject was read in December, 1896, before the Paris Academy of Medicine, and since that time many hundreds of cases have been submitted by various operators to this method of treatment.

It is clear that the great stimulus to the adoption of this method has been the powerlessness of plaster or other corsets to restrict the deformity. Thus Calot (*Rev. de Thérap.*, September 1st, 1897) says: "If treatment is limited to the measures hitherto employed neither troughs nor corsets can prevent the return of the deformity." He quotes Lannelongue to the like effect, "In Pott's disease the deformity appears and increases in spite of rest in the horizontal position." And again: "The deformity progresses within Sayre's apparatus, as I have witnessed in my own cases and in cases of the most competent surgeons."

Again, Bilhaut et Levassort (*Jour. de Méd. de Paris*, 1897, p. 303) write concerning Sayre's jacket:—

"When the suspension ceases the patient humps himself up within the corset; the deformity, scarcely diminished by the stretching, returns not only when the patient sits up, but when he remains immobile in the horizontal position."

Pathology.—The appearance of the diseased parts after forcible correction is known from experiments on the cadaver and the results of autopsies in cases where death has occurred within a few months of the operation.

By permission of Mr. R. W. Murray and of the editor of the *British Medical Journal* I am enabled to reproduce such a specimen (Fig. 287). It will be seen that even three months after the operation there is a cavity lined with

tubercular granulations separating the remains of the diseased vertebræ. Such a cavity would tend to close by the re-appearance of angular deformity. In more favourable cases a certain amount of repair occurs. It is, however, highly improbable that in any given case the whole of the cavity will




Fig. 287.—Section of Spine showing the Cavity left after Forcible Correction of Deformity in Tubercular Spondylitis.

be replaced by firm bone, and even if this did occur in the case of a child this hypothetical new bone would be devoid of epiphyseal discs, and hence would lag behind the rest of the spinal column in longitudinal growth, with the result that unless some efficient splint were worn deformity would return.

The operation consists in applying traction which, according to Calot, should not exceed 80 kilos. in an adult and, if necessary, in applying direct pressure to the hump. In all published cases the patient has been placed face downwards on the table and anaesthetised in that position. The operation

requires three assistants besides the operator. Redard, Jones, Tubby, and others have devised mechanical arrangements to minimise the number of assistants. One drawback to the operation is the difficulty experienced by the anæsthetist. Williams (*Sem. Méd.*, July 28, 1897) has advocated doing the operation without anæsthesia. As regards this point I do not see why the object should not be attained just as certainly with the patient lying on the back. The same extension on head and shoulders in one direction, and on legs and pelvis in the other, can be made. The surgeon could meet his hands beneath the hump and by lifting upwards exert quite as much direct force. Should I have occasion to do the operation again I shall certainly use the latter method.

J. E. Goldthwait (*Boston Medical and Surgical Journal*, July 28, 1898) has devised a simple apparatus consisting of an oblong frame of gas-piping carrying extension screws at both extremities, and a movable, arched, double bridge, on which the transverse processes in the vicinity of the deformity rest. This is a great gain, since it permits of the operation being performed with the patient in the supine position and in most cases without an anæsthetic.

"At first this method was used simply to obtain the best possible position of the spine after the forcible straightening under ether, but it was soon found that the same apparatus could be used for the correction, and that in a surprisingly large number of cases no other force than the weight of the body was necessary to straighten and over-extend the spine. With the spine in this over-extended position the head was thrown so far back, and the body-weight put so much upon the spinous and transverse processes, that it was possible to discard the helmet as a part of the support except when the disease was situated above the fourth dorsal vertebra. In nearly all of the cases since the first, the after-treatment has consisted in the application of a plaster of Paris jacket carried low enough to grip the pelvis and to limit the motions of the thighs, and also high enough to prevent the shoulders from drooping forward, and the bending forward of the head.

"In the early cases ether was used for the correction, but since then the work has been done entirely without anæsthetics, except in the cases where the disease has been of

several years' duration. Cases of one and two years' duration have been easily straightened without ether, and with practically no pain or suffering to the patient.

"In this way the operation has been simplified to such an extent that the word operation is hardly necessary for its designation, and it is so simple that in the acute or early stages of the disease the patients are treated in the office or the hospital out-patient department, the correction being accomplished and the jacket applied with no more disturbance than is expected with the application of such an apparatus in the ordinary method. In some of the cases the relief of the existing acute symptoms has been very striking with the improved position of the spine."

Lange* asks how far is the redressment to be carried? Must the aim be to remove every trace of the excurvation, and thus in a severe case for an hour or more exert one's own strength? Lange thinks not. If the prominence does not give way to moderate pressure one must rest content with the improvement obtained in the position of the sound parts of the column. Many patients can be greatly improved thereby, although the prominence remains unchanged.

Wullstein† also directs his aim to a correction of the deformity of the spine on each side of the hump ("Paragibbare Korrektion"); others proceed to correction by stages; others, again, limit the scope of the operation by formulating definite indications, only adopting Calot's operation in the slighter cases, and content themselves with a partial result. Wullstein considers that the "paragibbous" correction is indicated in old cases with much deformity. In all other cases Wullstein thinks the complete removal of the deformity should be obtained not by the one brief act of Calot's operation, which entails the risks detailed above, but by a method that combines immobilisation and removal of pressure with absence from restraint of the thorax and abdomen, and a controllable stretching of the soft parts. Should complications arise, this treatment may be interrupted for a time, the amount of improvement previously gained being maintained by the application of a proper corset. For the application of this

* Lange, *Munch. med. Woch.*, April 20, 1897.

† Wullstein, *Centralbl. für Chirurg.*, July 9, 1898.

idea Wullstein has devised an apparatus which serves at once as a bed and an extension apparatus (Fig. 288). The amount of extension is regulated by a screw and indicated by a dynamometer, and is used in the first place to overcome the muscular spasm and afterwards to influence the form of the spinal column.

Calot, on the contrary, has advocated its extension to old healed cases, where not only is there quiescence of the

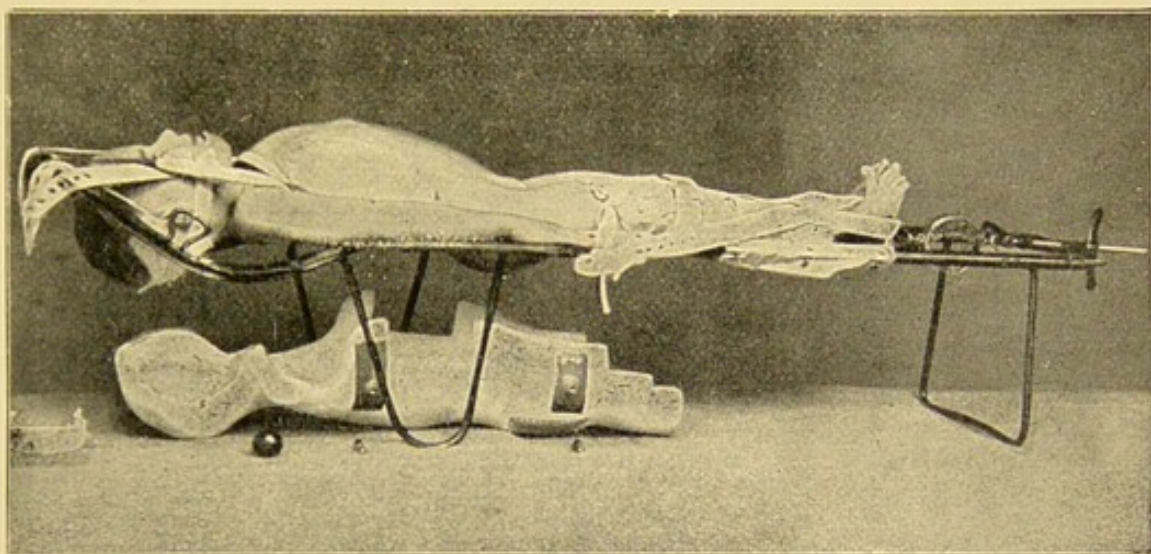


Fig. 288.—Wullstein's Apparatus for the Gradual Correction of Deformity in Spinal Disease. (*Centralblatt für Chirurgie.*)

disease in the anterior parts of the spine, but where the spines and laminae are synostosed together. In such cases he chisels the fused laminae apart before completing the operation, which in such cases results in a complete fracture of the spine.

Mortality.—The mortality traceable directly to the operation is very small. Calot lost two out of 300 cases,* and these were from chloroform.

Paraplegia occurred during the first few weeks after operation in three out of 600 cases.

In conclusion, I would put forward the following propositions:—

1. That as yet there is no evidence that immediate reduction of angular curvature will be permanent, and further experience is required before any decision can be made as to the success of the operation.

* *Brit. Med. Journal*, Nov. 20, 1897.

2. That a mechanical method of fixing the spine in the over-extended position would be better than the plaster of Paris occipito-pelvic jacket. I should not be inclined to keep a child on it longer than three months and then I would replace it by a Chance's splint.

3. That only early cases free from complications such as abscess, etc., would be suitable for the operation, even should



Fig. 289.—Patient wearing Apparatus for high Dorsal Caries after Forcible Correction of Deformity.

it prove to be successful in diminishing or removing the deformity.

4. That cases treated from the beginning by efficient mechanical means will give as good results as those treated by forcible extension.

Illustrative Case (B. M. J., Feb. 12, 1898).—Certain considerations led me to perform immediate correction on a little girl, aged two and a half years, in August last. The case was a favourable one, of two months' duration, and uncomplicated. There was an angle of about 20° opposite the sixth dorsal spine. The operation was easy, and the patient was put up in plaster strengthened by an iron framework extending from the head to the pelvis. The child seemed to be in no way disturbed by the

operation. At the end of six weeks the plaster cuirass had to be removed on account of the presence of vermin, which had appeared in spite of careful nursing. We then found that most of the deformity had recurred. The spine was again straightened, and the child put up on a metal-plaster apparatus so arranged that the spine was over-extended, and that extension could be applied to the arm-pits and the lower limbs. The patient was perfectly comfortable in this position for a month, when the spine was again examined. The deformity was certainly diminished but not removed. The part was now free from tenderness, and on giving an anæsthetic it was found that there was more resistance, pointing to some form of ankylosis having taken place, so the remaining deformity was not corrected. The patient was replaced in the apparatus. A fortnight later a Chance's splint, with an occipital piece as shown in Fig. 289, was applied.

At the present time—three and three-quarter months after the first operation—the child can sit up without discomfort and without fatigue.

The results of the operation in this case are a slight improvement in the deformity and a certain amount of repair, as shown by ankylosis; but neither the improvement in shape nor the degree of repair is greater than I should have expected from careful general treatment, combined with the use of a Chance's splint. It may be that a better mode of fixation after operation would give a greater improvement. In this connection I would refer briefly to the double Thomas's splint recommended by Messrs. Tubby and Jones. That this instrument needs careful management is evidenced by the extensive scars frequently seen in patients who have used it without proper supervision. Mr. Tubby mentioned two or three years as the period during which the patient would be likely to be required to remain in this instrument. This, to my mind, would be a very serious bar to the method. I have lately had brought to me a little girl, aged five, who had lain for four years on a double Thomas's splint for high dorsal caries. Although the splint was well-constructed and carefully watched, a dorsal abscess had formed and opened, and left a sinus (*see* p. 402).

Other Operative Measures.—Chipault, of Paris, has recommended suture of the spinous processes of the projecting part of the spine with a view to immobilising the parts. This proceeding is unnecessary when a proper mechanical support can be obtained.

Victor Horsley, in a paper read before the British Medical Association (*B. M. J.*, Oct., 15, 1898), advocated laminectomy and erosion of the diseased parts in every instance of dorsal abscess. With all deference to the opinion of so experienced a surgeon, I am of opinion that as a routine measure, if generally practised by even the most skilled surgeons, it

would increase the mortality and greatly prolong the period of recumbency and in the end give results inferior to more conservative methods.

Lambotte* has gone even further. On the 4th September, 1896, he performed this operation on a child aged four, with high dorsal disease, when, after raising the soft parts with the spines, removing four laminae after division of the right intercostal nerves, and drawing aside the cord, he exposed the diseased vertebral bodies and removed the diseased tissues with the curette. The patient was well and able to sit up three weeks after the operation.

Costo-transversectomy.—This proceeding was invented by Ménard† as a substitute for laminectomy in paraplegia from caries. He was led to it by two considerations—first, in a case in which laminectomy was done, a tubercular cavity was accidentally opened and the patient began to improve immediately; second, in another case he had done laminectomy two and a half months previously without any benefit being obtained, and he then explored the sides and front of the diseased vertebræ after removing some transverse processes; immediate and progressive improvement followed.

The operation consists in making a transverse incision over the right vertebral groove at the level of the apex of the projection. The muscles are divided in order to expose a transverse process and the posterior part of the corresponding rib. The transverse process is first cut through and removed, then the rib is divided a little external to the tip of the transverse process, and the posterior segment is removed. A second or several transverse processes and ribs may be removed in the same way until an opening is made that permits of a finger being passed to the front of the vertebræ for exploration, and with a gouge caseous material and sequestra are carefully scraped away. In one case reported by Ménard, although no liquid discharge was evacuated, the paraplegia rapidly disappeared after the operation.

The Treatment of the Complications of Tubercular Spondylitis.—Whatever the complicating factor may be, the condition of the spine itself is always to be remembered, and

* Lambotte, *Journal de Méd. de Paris*, 1897.

† Ménard, *Revue d'Orthopédie*, Nov. 1, 1894.

the treatment proper to it is not to be relaxed on account of the complicating condition.

Psoas Contraction.—Flexion of one or both hips in tubercular disease of the spine is usually a sign of commencing psoas abscess. It is a serious complication, owing to the disability it entails should recovery occur with contracture of one or both hips. Thus this complication calls for energetic treatment. The patient should be placed in bed upon a Chance's splint and weight extension applied, the limbs being gradually brought to the extended position. If abscess should develop it should be freely drained.

The Treatment of Spinal Abscesses.—An abscess due to tubercular spondylitis should be opened, thoroughly mopped out with small antiseptic sponges charged with 1–20 carbolic lotion, and, save at the most dependent part, where a drain of iodoform gauze wet with 1–20 carbolic should be left for twenty-four hours, the opening should be sutured in order to obtain primary closure of the wound. Scrupulous antisepsis must be observed at every stage of the operation. If such precautions can be fully carried out, there is not at the present time any cause for waiting for a chance of the abscess undergoing resorption. Although well-authenticated cases in which this event has occurred are on record, I may say that I have watched a great number of cases that have been treated by recumbency and every care, without the desired result being obtained. When the patient is first put to bed, the tension of the abscess diminishes for a time, but as a rule it reappears, and the abscess extends along the path of least resistance. Lumbar and iliac abscesses are the most liable to undergo spontaneous rupture, and since this is generally followed by septic infection, it should be anticipated. I have seen faecal fistula result from a neglected retro-peritoneal abscess. Cervical abscesses are often accompanied by serious symptoms due to sudden rupture and occlusion of the larynx, or laryngeal or tracheal stenosis from pressure and œdema; and, again, they are liable to extend to the mediastinum, or to become diffused in the deep tissues of the neck. For all these reasons they require speedy evacuation. Aspiration in my opinion should be avoided, since it not infrequently leads to septic contamination. E. Vincent (*Revue de*

Chirurgie, Jan. and Aug., 1898) recommends thorough and systematic drainage. When the abscess cavity extends across the front of the vertebral column an opening is made on each side, and a tube passed through (inter-somatic drainage) (see Fig. 290).

Expectant Treatment.—In many cases where abscesses have been allowed to open naturally, and septic infection and a discharging sinus have resulted, the sinus has healed in time without further serious complication. Thus, in a girl aged ten, I found six scars from sinuses that had opened at various times since the commencement of the disease eight years previously. The centre of the projection was at the eighth dorsal spine, and at least six vertebræ were involved. The scars were placed, one at the lower angle of the scapula, one above the iliac crest, one behind the

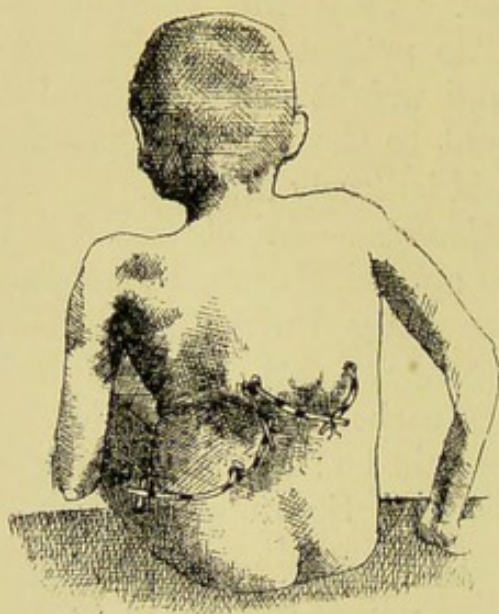

Fig. 290.—Vincent's Case of Inter-somatic Paravertebral and Lumbo-abdominal Drainage.

great trochanter, and one in Scarpa's triangle, all on the right side. Such a result cannot be relied on in many patients, when septic sinuses succumb to amyloid disease, pyæmia, meningitis, or the results of perforation of the lung, intestine, or bladder.

Operative Measures required for Special Forms of Abscess:—

Retro-pharyngeal Abscess.—An incision along the posterior border of the sterno-mastoid is the best way of attacking abscess arising in the upper cervical vertebræ; the integuments and fasciæ are divided, and a path for drainage is made as far as possible by blunt dissection, behind the carotid vessels and jugular vein, and in front of the vertebral vessels to the seat of the abscess. The cavity is carefully scraped, mopped out with sponges and drained for twenty-four hours. In the dorsal region abscesses usually point at

the outer edge of the erector spinæ. In order to deal with them more successfully, a portion of a rib may require removal, extreme care being observed to avoid wound of the pleura. If there is reason to suspect the presence of a sequestrum, *costo-transversectomy* is indicated.

Lumbar and Iliac Abscess.—A psoas abscess should be opened by an incision opposite the outer border of the erector spinæ. If the cavity extends to the thigh an additional opening should be made below.

Illustrative Cases:—

I. *Lumbar Caries with Psoas Abscess.*—Jessie C., aged ten. The patient had suffered from the disease for two years, when she was brought to me. She was thin and fretful. There was then a projection in the lumbar region and a psoas abscess. She was admitted into hospital and a Chance's splint was applied. In the evenings the temperature averaged 100° Fahr. As early as possible the abscess was operated on. An incision was made at the outer edge of the left erector spinæ, and the parts were divided until the tip of the third lumbar vertebra was reached, from which the attachments of the quadratus lumborum etc., were separated, and pus was sought for by blunt dissection in the direction of the psoas muscle. No pus being hit upon, an opening, 1½ inch long, over the fluctuating area below Poupart's ligament, was made and about ten ounces of pus were evacuated. The cavity was well mopped out with carbolised sponges and much thick false-membrane removed. The cavity was then explored with the finger and a narrow aperture leading to the upper part of the cavity was found. A stout sound was passed along this to the neighbourhood of the lumbar incision, and after a little dissection the end of the sound was protruded. The upper part of the cavity was then mopped out, and one drachm of glycerine and iodoform was injected into the upper and the same amount into the lower part of the cavity, and the wounds were closed save the lower part of the thigh wound, in which a gauze drain was placed and removed next day. On the ninth day stitches were removed, and the lumbar wound was found to have healed normally, whilst the thigh wound showed some infiltration. A fortnight later this infiltration had increased, and the patient was anæsthetised, and the thigh wound was found to lead to a cavity lined with grey tubercular tissue. This was carefully scraped away and the wound healed soundly. Three months after admission the patient left the hospital wearing a Chance's splint. She had improved greatly in general health and was free from pain. When last seen, one year and five months after operation, the patient was quite well and the deformity had disappeared.

CASE II.—*Dorsal Caries; Iliac Abscess.*—A girl aged twelve. Severe dorsal curve involving from the fourth to the tenth vertebræ. A large

abscess formed rapidly in the left iliac fossa. The abscess acquired a remarkable tension, and caused constipation and œdema by pressing on the sigmoid flexure and the iliac veins. I incised the skin a little above the fore part of the iliac crest, and immediately several pints of thin pus escaped in a jet, which at first rose to the height of a foot and fell at some distance from the patient. The same steps for cleaning out the cavity were taken as in Case I., small sponges on the holder being passed upwards and downwards along the psoas sheath. Healing took place rapidly and without any trouble. The patient was provided with a Chance's splint and left the hospital some months later.

CASE III.—*Lumbar Disease; Diffuse Abscess in the Thigh.*—A young man, aged eighteen. Had had symptoms of lumbar disease for more than six months. The lumbar concavity had disappeared, and the second, third, and fourth spines were prominent. There was a girdle pain, pain and tenderness along the crural nerves, and evidence of slight contraction of the patient's left psoas. There was an ill-defined swelling above and below the left Poupart's ligament. Under anæsthesia the usual lumbar incision was made, but on careful dissection right into the psoas muscle no pus was obtained. The patient was turned over and it was found that the anterior swelling had disappeared. It was evident that the collection of pus previously observed had become diffused in some direction. The patient was put back to bed to await events. These marched rapidly, for at the end of thirteen days the whole of the left thigh had become swollen, and fluctuating areas were found over Scarpa's triangle and at the back of the thigh. These were opened and much pus escaped. On exploring with the finger the inter-muscular spaces of the thighs were found to have been widely opened up by suppuration. The cavities communicated by the openings in the adductor magnus. They were well mopped out and syringed with 1-40 carbolic, and a little iodoform and glycerine were injected and gauze drains were introduced. The patient's temperature came down to normal and remained so for fourteen days, when it again became elevated, and pain, over the lower part of Hunter's canal, radiating beyond the knee, was complained of. An abscess was found above the knee on the inner side of the thigh and opened. After this, with daily syringing, all the large cavities closed slowly, but soundly, and three months after the last operation the patient left the country in good condition. In this case the pus had probably not entered the sheath of the psoas, but had coursed behind the peritoneum along the iliac and femoral vessels.

The accompanying photographs (Figs. 291, 292), kindly sent to me by Dr. D'Olier, of Arundel, represent the present condition of this patient, whose general health leaves nothing to be desired.

Sinus.—The treatment of this condition has already been referred to on p. 402. I have not yet met with a case that has failed to heal or to be kept in check when the injection

of small measured quantities (3j to 3iij) of 1-40 carbolic has been carried out regularly. In rare instances where relatively large sequestra are present some operative measures may be required, *e.g.* in the dorsal region, costo-transversectomy, in the lumbar, Treves's operation may be called for.*




Fig. 291.—Young Man after Operation for Lumbar Abscess with Instrument.

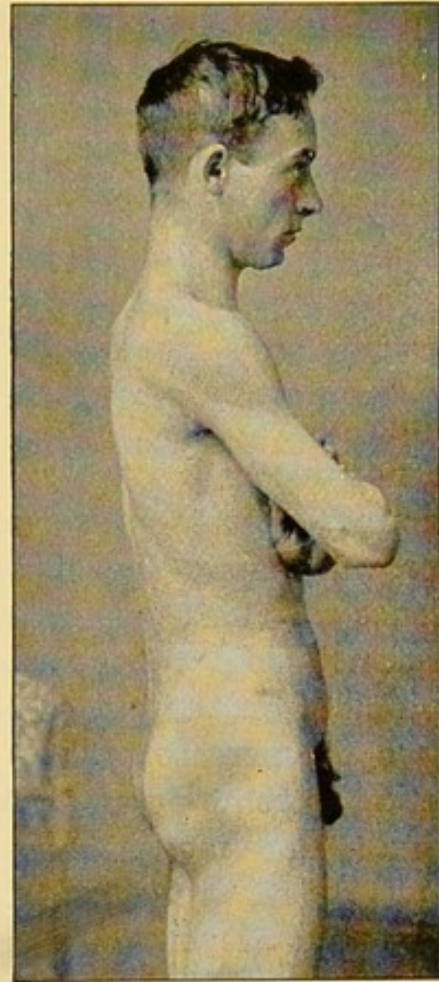


Fig. 292.—Same Patient after Operation for Lumbar Abscess without Instrument.

The latter is a systematised plan of lumbar drainage. A vertical incision is made at the outer edge of the erector spinæ. The attachment of the quadratus and psoas muscles are separated from the transverse processes and the diseased area is explored with the finger. For a full description see Treves's "Operative Surgery."

* In one instance a patient with two small sinuses that had been treated in this manner for three years was sent to a convalescent home where the carbolic injections were changed for a lotion of boracic acid; extensive suppuration and lardaceous disease rapidly developed.

Paraplegia. Symptoms of Implication of the Spinal Cord.—The commoner sensory symptoms are a girdle pain and pain at the pit of the stomach and in the limbs. Hyperæsthesia above and patchy anæsthesia below the lesion are also sometimes observed. Early motor symptoms are weakness in the limbs, clumsiness from catching of the toes in walking and difficulty in standing. In atlo-axoid disease sudden compression of the medulla and death may occur. The superficial and deep reflexes are exaggerated in the early stages and are diminished or lost in the later stages. Trophic lesions, *e.g.* wasting of muscles, herpes and bed-sores may arise. The limbs may become cold, congested and hyperidrotic. In cervical disease the phrenic nerves may be paralysed and in the dorsal region intercostal paralysis may occur. With prolonged and efficient rest there are but few cases of paraplegia from tubercular spondylitis that will not recover completely. Even when the condition is pronounced and there is evidence of its being not merely due to pressure upon the spinal cord, but to myelitis, in the presence of ankle-clonus, œdema of the legs and bed-sores, a patient course of efficient fixation of the spine will be rewarded with the practically complete recovery of power, a trace of increase of knee-jerk and of ankle-clonus alone attesting to some permanent damage to the cord.

If after two months' rest on a prone couch, combined with the use of a well-made and well-adjusted Chance's splint, no improvement is obtained, some further measures should be adopted. These measures are—1, forcible correction of the deformity; 2, laminectomy; 3, other operations, *e.g.* costo-transversectomy.

Forcible correction of the deformity, as has been shown on p. 406, results in the formation of a potential space in front of the spinal cord. At the moment of its formation a negative pressure exists in this space and that negative pressure will exert a suction action on fluid exudation outside the cord and, by diminishing pressure, will relieve paraplegia. In the rare cases where there is direct pressure of bone upon the cord forcible correction might reasonably be given a trial. Among the many cases of tubercular spondylitis in which this operation has been done paraplegia has been present in some and

has been at once relieved by the operation.* In my opinion this measure is indicated in such cases.

Laminectomy.—This, in practised hands, is an easy operation to perform, and in healthy subjects it is free from serious risks. For the condition under consideration the operation has the powerful support of V. Horsley. Remembering that the subjects of paraplegia are often weakly and likely to suffer much shock from an operation that entails a rather prolonged anæsthesia, laminectomy for tubercular spondylitis cannot be said to be free from immediate risk. Again, in this affection the laminae are sound and constitute an important factor in supporting the trunk; their removal weakens the spine, especially in cases where the articular processes are affected by inflammation. The result of this is that in some cases that I have seen the patient has required to be kept lying on the back for many years after the operation, whilst other equally severe cases treated in other ways have, with a suitable support, been happily walking about and have regained strength. In a few cases the wound has become infected by tubercular matter and a large red tubercular area has developed, and at the same time the resisting power of the spine has been greatly decreased. Laminectomy is indicated when paraplegia sets in late and is persistent: features that point to thickening of the meninges.

Operations other than Laminectomy.—Costo-transversectomy in the dorsal region and Treves's operation in the lumbar region are indicated when there is reason to suspect pus or sequestra in cases of paraplegia, and they may be applied in any such case as an alternative to forcible correction.

Malignant Disease of the Spine.—*Pathology.*—Malignant disease of the vertebræ may resemble tuberculosis in its early effects. The forms of malignant disease that I have observed in the vertebræ are lympho-sarcoma, spindle-celled and round-celled sarcoma, and secondary cancer. Lympho-sarcoma extending from deep lymphatic glands, whether in the neck, chest, or abdomen, in my experience occurs most commonly.

Symptoms.—Pain and paraplegia are the most constant

* See Clin. Soc. Trans., 1898, where the late W. Cotterell recorded two such cases.

symptoms. The latter differs from that of tubercular spondylitis in having no tendency to get well under treatment.

Diagnosis.—The importance of diagnosis depends upon the desirability of letting the patient's friends know the gravity of the case as much as upon the need of data for treatment. Cancer or sarcoma may be present in some other part of the body or may have been previously operated upon. In some cases, in the neck or abdomen a mass of growth can be felt adhering to the front or the sides of the abdomen; in other cases growth can be detected about the laminae and spinous processes. Like tuberculosis, malignant disease of the spine may occur at any age.

Treatment.—In no case that I have examined would any operation have helped the patient. Coley's fluid may be tried in cases of sarcoma, but it is just in sarcomatous growths arising in bone that this method has been found least helpful. In cases of cancer it is useless. In most cases all that can be done is to make the patient as comfortable as possible by rest in bed and careful nursing.

Wry-neck or Torticollis.—Wry-neck is an involuntary deviation or malposition of the head and neck, whether lateral, anterior, or posterior. Lateral deviation is the most common and it is generally accompanied by more or less rotation of the head. The various conditions usually grouped under the head of wry-neck are roughly separated into acute and chronic.

Acute or Rheumatic Torticollis is accompanied by pain, either in the muscles or in the articulations of the spine. The condition usually mends in a few days, but it may recur and finally become chronic. Although the consideration of this affection belongs to medicine rather than surgery, for the purpose of diagnosis and preventive treatment a few words must be devoted to it in this place.

The muscular form is marked by the sudden onset of pain and deformity, the dull and subsequently more acute pain, which is eased by immobilisation of the head and increased by attempts to correct the position of the head; the articular form by tender points over the seat of the articular, spinous, and transverse processes. The pain in this variety of torticollis is generally seated about the third or fourth cervical

vertebræ, and sometimes is greatest on the side opposite to that to which the head inclines. Even though the occipito-atloid joints are not involved the patient is unable to impart any movement to the head or neck.

The particular character of the malposition of the head will depend upon the particular muscles that are contracted. If the sterno-mastoid is chiefly concerned, the head will be drawn down to the shoulder of the side on which the muscle is acting, whilst the face will be turned to the opposite side.

When the contraction of the trapezius is the chief factor in producing the deformity, the head will be drawn back to a greater or less extent, as well as inclined to the side.

In some cases *retrocollis*, that is, inclination of the head backwards without lateral deviation, has been observed. In others the attitude of the head varies at different periods of the attack, according to the intensity of the rheumatic inflammation moving from one point to another.

Causation.—There is no doubt that the abnormal attitudes depend upon reflex painful contractions of the cervical muscles.

Secondary deviation of the spinal column is seen in this as in other forms of torticollis.

General Symptoms.—There is some fever, with chills and malaise.

Course and Terminations.—The pain disappears and the head as a rule assumes its natural appearance at the end of a few days. Occasionally, troublesome neuralgia from inflammation of the nerve-trunks as they pass through the intervertebral foramina, and skin-lesions, such as herpes, etc., are observed. In a few cases of the articular rheumatic form the affection becomes acute or chronic, and pachymeningitis of the medulla or of the base of the brain has been observed as a complication. Though seldom accompanied by general articular rheumatism, cardiac complications have been observed in children.

Treatment.—The full discussion of methods of treatment belongs to works on medicine. If the case tends to become subacute or chronic a suitable extension (Fig. 293) should be applied to the head, the patient resting on a firm mattress with the head supported upon a small air-cushion or soft

pillow. Massage and the constant current are frequently of use when suitably applied.

Other forms of wry-neck are secondary to inflammatory conditions, in the cervical lymphatic glands. Inflammation of the spinal accessory nerve from septic thrombosis of the internal jugular vein has also been observed. These and other conditions are to be distinguished from ordinary acute torticollis.

Ocular Torticollis.—Landolt and other oculists have specified the abnormal conditions that may give rise to oblique

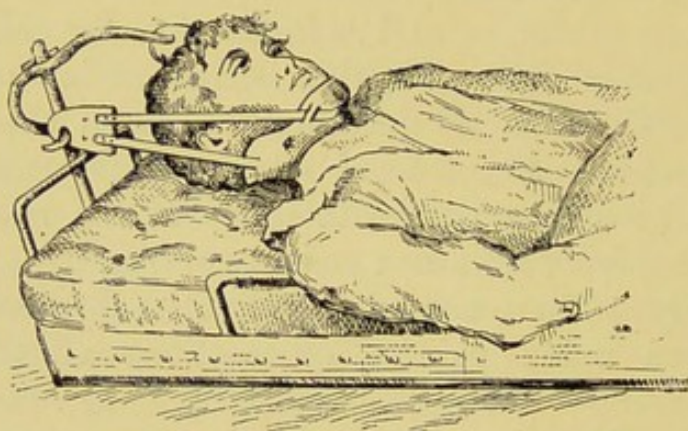

Fig. 293.—Method of Extension applicable to cases of Torticollis.
(Redard.)

positions of the head. Affections of the fourth nerve leading to paralysis of the superior oblique muscle are the chief cause of this form of torticollis, which disappears when the ocular defect is corrected.

Chronic Torticollis.—*Chronic torticollis* is made to constitute a large group of cases, which is subdivided into—

a. Congenital cases, in which the sterno-mastoid or other muscles are permanently shortened, so that chloroform anaesthesia produces no modification in the deformity. There is a varying amount of compensating scoliosis and hemiatrophy of the face may be present.

b. Acquired permanent cervical scoliosis may be due to contraction of muscle, to arthritis (usually rheumatic), to disease of bone (caries); rachitic, due to softening of bones and ligaments.

c. Chronic nervous torticollis, the clonic form of which (spasmodic wry-neck) is more familiar than the tonic form.

Brissaud's "mental" variety of this affection, is characterised by the ease with which the spasm is overcome (see figs. 301, 302).

d. Hysterical wry-neck, whether from contracture or paralysis.

e. Paralytic torticollis, distinguished from the hysterical form by the electrical reactions.

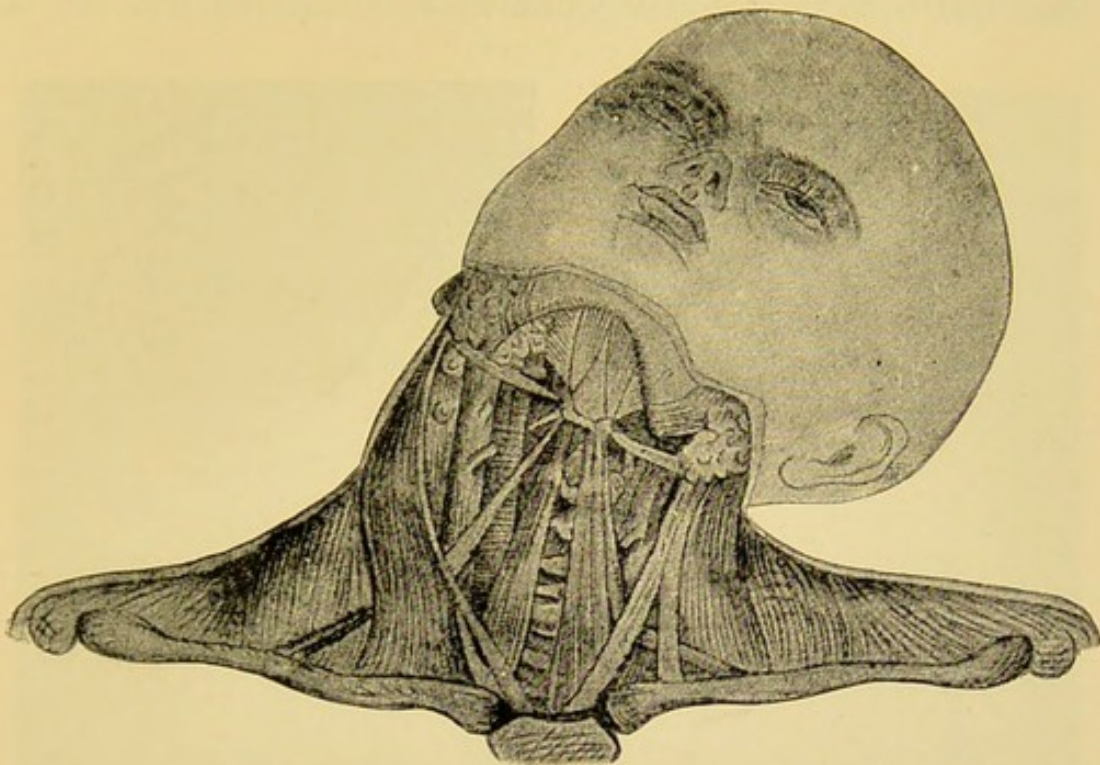


Fig. 294.—Dissection of a case of Congenital Torticollis.
The left sterno-mastoid is atrophied. (Lüning and Schultess.)

f. A group of cases secondary to various conditions, such as scars from burns, or tubercular lymphatic glands, or to chronic mastoid disease.

g. Nodding spasm in children must be distinguished from spasmodic wry-neck.

Congenital Wry-neck.—In this condition the deviation is determined by structural shortening of certain muscles and concomitant changes in form of the cervical column. The particular character of the deformity varies according to the anatomical condition present.

Anatomy.—The sterno-mastoid muscle is that most commonly at fault. The degree to which this muscle may be affected is shown by a case recorded by Lüning and Schultess (Fig. 294).

The shortened muscle in this case was fibrous in character. The attachments of the muscle in such cases are frequently abnormal. Of the two sterno-mastoid muscles the right is more frequently affected, and the sternal more extensively shortened than the clavicular fasciculus.

Post-mortem examinations made soon after birth show that the condition is developed in intra-uterine life. It is

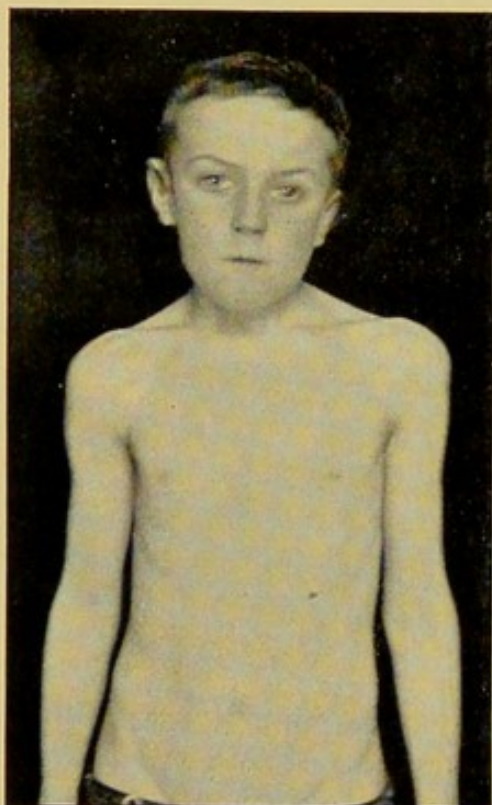


Fig. 295.—Congenital Torticollis.
Front view.

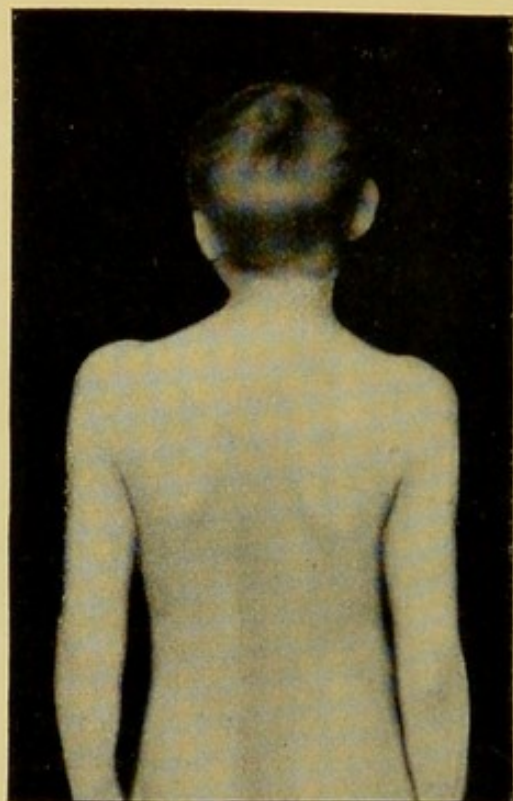


Fig. 296.—Congenital Torticollis.
Back view.

hard to explain why, in congenital cases, there should be any cicatricial contraction of the affected muscle, although we should expect it to be atrophic, as are the muscles in cases of congenital club-foot. In my opinion, in true congenital cases of muscular origin the muscle would probably be the seat of atrophy and fibrous substitution rather than of inflammatory changes. In one congenital case I have observed slight shortening of both sterno-mastoids, resulting in a cervical kyphosis. The cervical spine in these cases of congenital wry-neck must exhibit a scoliotic curve. In some cases the shape of the bones is so markedly altered that it alone accounts for the persistence of the deformity.

The *chronic wry-neck of childhood* closely resembles congenital wry-neck. The sterno-mastoid muscle is the one usually at fault. The usual explanation of this deformity is that it is the result of cicatricial contraction of a sterno-mastoid secondary to rupture during delivery, and subsequent formation of a hæmatoma.

Although cases of this kind have been recorded in which

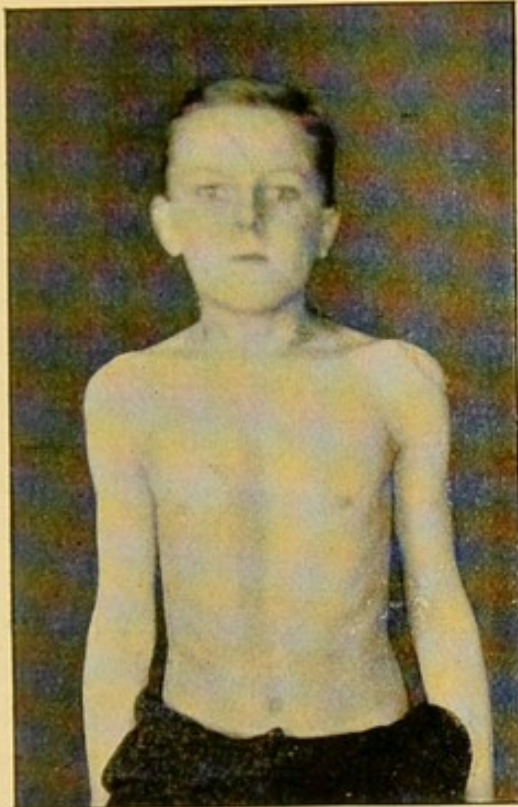


Fig. 297.—The Patient of Fig. 295
after Operation.
Front view.

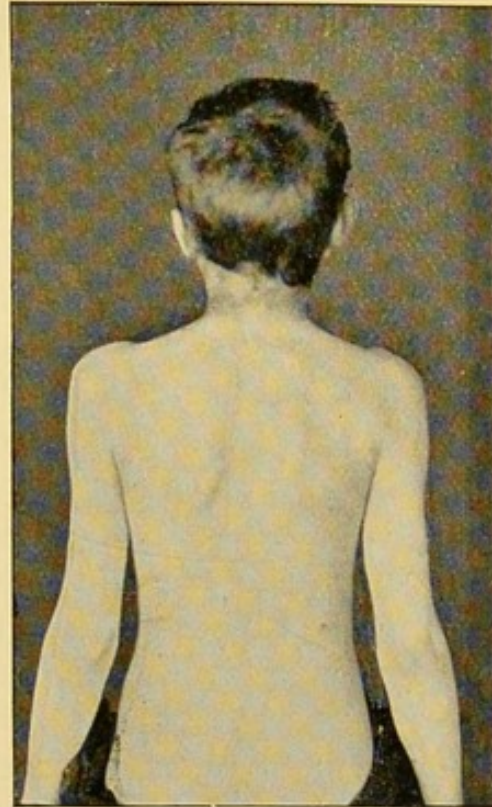


Fig. 298.—The Patient of Fig. 295
after Operation.
Back view.

no wry-neck has followed, and in spite of the fact that rupture of a muscle such as the biceps traction results not in shortening, but rather in elongation of the muscle, I am inclined to agree with those who attribute the deformity to injury. In such cases the infant, to obviate pain, instinctively holds the head in the position of the greatest relaxation of the muscle, and thus the shortening is due to adaptation as well as cicatricial changes in the muscle. In a case recently under my care the patient was sent to me at the age of two weeks. There was slight swelling and a little hardness of the left sterno-mastoid. Some of these cases of induration of the

sterno-mastoid are due to syphilis and must be treated accordingly.

Illustrative Case.—A boy, aged eleven and a half years, previously untreated. I divided the sterno-mastoid through a small vertical incision. The appearance of the patient before operation is shown in Figs. 295 and 296, and the immediate result in Figs. 297 and 298. In order to correct the associated fixed lateral curvature that had arisen in this case the apparatus shown in Fig. 300 was adapted.

Treatment.—This consists in complete section of all the contracted fibres of the sterno-mastoid, and the subsequent wearing of a support which maintains the head in good position until all farther contraction has been avoided. In cases in which the sternal portion of the muscle is chiefly at fault it can be divided subcutaneously. The patient, being fully anæsthetised, is laid on the back on the table and a firm pillow placed under the shoulders. One assistant depresses the forehead with his left and rotates the head with the right hand. Another draws down the shoulder of the affected side. The surgeon draws the skin over the tendon outwards with the thumb of the left hand, and passes a sharp-pointed tenotome under the tendon from the outer side, about three-quarters of an inch above its insertion. A blunt-pointed tenotome is then taken and the section completed, the assistants holding the head as directed by the surgeon. Some surgeons prefer to divide the tendon from its superficial aspect. The clavicular part of the muscle may be divided in the same way, but most surgeons prefer to do this through an open wound on account of the proximity of the large vessels of the neck. The open operation is best done through a transverse incision an inch or more in length, parallel to the clavicle and about one-third of an inch above it. Lorenz recommends a short transverse incision an inch long, its centre placed over the space between the two heads, so that by drawing the skin first one way, then the other, both heads can be exposed to view divided in turn. An incision along the lower part of the anterior border of the sterno-mastoid may be used instead of a transverse cut.

In children with wry-neck the muscle is usually very small, and an adequate incision for the purpose leaves a very inconspicuous scar.

The after-treatment of these cases is of as much importance as the operation. For efficient fixation of the head a Chance's back splint with a cervical piece added gives the best support in my experience. The head is held by a padded metal band to which frontal and mental straps are attached and to which a branch for the chin may also be added on the side opposite

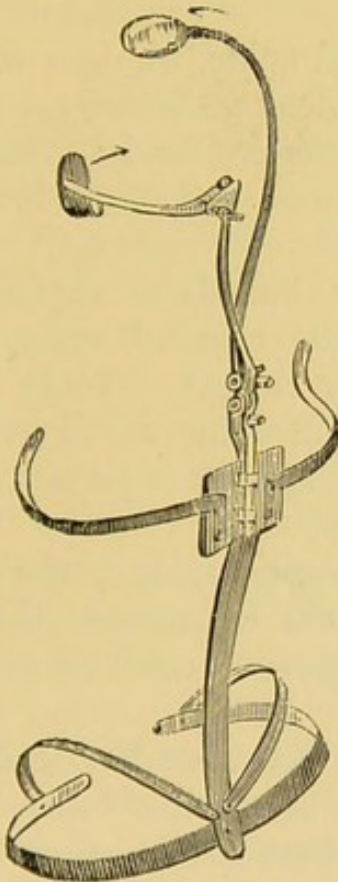


Fig. 299.—Rack and Pinion Apparatus in Gradual Correction of Wry-neck.
(H. R. Heather Bigg.)




Fig. 300.—Apparatus used by the Author for Wry-neck.

the deformity. A similar contrivance can be used for the gradual (see Fig. 299) correction of early cases. In infants, strapping and bandages may be used:

Wry-neck of Articular or Osseous Origin.—Chiefly from the point of view of diagnosis it is necessary to refer again to certain affections of the cervical spine that not infrequently cause wry-neck.

Rheumatoid Arthritis.—In certain cases of rheumatoid arthritis marked lateral or anterior torticollis is observed.

Chronic articular torticollis usually follows the acute form of rheumatoid arthritis. The attacks of pain and the deformity persist with more or less fever. The spine is tender and pain is felt at the root of the neck and along the arms. Grave deformity, followed by wasting of muscles, is apt to be produced by changes in the joint-surfaces and capsules. The cervical spine becomes extremely rigid.

Treatment.—The proper treatment is to prevent deformity by a support to the head.

Tubercular disease of the cervical spine, whether in the atlo-axoid region or in the lower cervical vertebræ, may give rise to lateral as well as antero-posterior bending and so simulate wry-neck. In rare instances the head is bent backwards in atlo-axoid disease.

Rachitic Torticollis.—This name has been applied to lateral or posterior deviation of the cervical spine, due to yielding of the bones softened by rickets. There is no muscular spasm in these cases and the deformity is at first readily corrected. Later, more or less rigidity is present from changes in the bones.

The diagnosis is arrived at by the general signs of rickets and by the ready improvement obtained by suitable diet, etc. The head requires support in a good position until all trace of rickets has disappeared.

Spasmodic Wry-neck, or Chronic Nervous Torticollis.—Spasmodic or intermittent torticollis shows itself in a great variety of forms. Two principal forms are to be distinguished, clonic and tonic. The former is the commoner and from it the name of this group is taken. The two forms are often combined in the tonico-clonic torticollis (Benedikt).

Clonic Form.—The spasm is usually unilateral and is seated in sets of muscles supplied by different nerves, *e.g.* spinal accessory, facial, cervical, hyoglossal, etc. The muscles more commonly affected are the sterno-mastoid, the trapezius, the splenius, the levator anguli scapulæ, the supra- and infra-spinatus. Before the muscles of the neck become affected spasms may have shown themselves in other regions, *e.g.* the arm, the face, the floor of the mouth.

The exact character of the deformity depends upon what muscles are affected.

1. Spasm of a single sterno-mastoid is not common. It shows itself by a series of sometimes painful contractions which bring the occiput towards the shoulder of the side on which the contracting muscle is, the face being turned in the opposite direction.

2. *Spasm of the Upper Part of one Trapezius*.—The head is drawn backwards and downwards towards the affected side and slightly rotated towards the opposite side. The scapula is drawn towards the spine and the shoulder is slightly raised.

3. *Spasm of the Splenius*.—The head is inclined backwards and slightly turned towards the contracted side. In its upper third the muscle can be felt to harden during the contractions.

4. *Spasm of the Levator Anguli Scapulae*.—The head is slightly inclined to the affected side; the shoulder is drawn up.

5. *Spasm of the Posterior Cervical Muscles of both sides* gives rise to retraction of the head or retrocollis. The posterior deep muscles seldom act singly and, indeed, combined action of muscles is commoner than isolated action in all forms of spasmodic torticollis.

6. *Spasm of one Sterno-mastoid and of the Trapezius of the same side*.—This gives rise to marked rotation of the head so that the skin of the same side of the neck is thrown into deep folds.

7. *Spasm of the Sterno-mastoid and the Splenius of the same side*.—This produces a marked inclination of the head towards the shoulder. It is not a frequent combination.

8. *Spasm of the Sterno-mastoid of one side and of the Cervical Muscles of the opposite side*.—This gives rise to marked rotation of the head—the so-called “rotatory tic.” When the splenius on one side and the sterno-mastoid of the other are affected, the rotation is extreme.

Various other combinations are observed and each case must be studied by itself. The platysma is often affected, throwing the skin of the neck into ridges. Conjugate deviation of the eyes, spasm of the muscles of the face, or floor of the mouth, are rather rare complications.

The clonic spasms may come on suddenly or be preceded by stiffness or pain. The movements occur every few minutes and the head cannot be kept still. The movements cease during sleep. They are increased by emotion, excitement, or fatigue. The muscles sometimes show hypertrophy—they never waste.

Torticollis Nutans.—In this condition the neck is flexed, the chin is bent forward in a series of nodding movements.

The Tonic Form or Spastic Torticollis.—If the sternomastoid alone or in combination with the trapezius, are the muscles affected, the head is continuously drawn to the same side, whilst the face is turned in the opposite direction. The head is sometimes drawn backwards by simultaneous contraction of the posterior cervical muscles. When clonic increase of spasm is observed in cases of spastic wry-neck the term clonico-tonic has been used.

Ætiology.—In England the affection is commoner in women than in men. It usually commences in middle age. Very rarely it has been observed in infants under a year old; in such cases it has ceased after a few months.

Pathology.—This is obscure. It is common to observe slight degrees of clonic spasm in various muscles, *e.g.* of the eyelids, floor of the mouth. Such conditions, though they do not incapacitate the individual from the ordinary vocations of life, are probably of kindred origin to spasmodic torticollis. All are probably of central origin.

Diagnosis.—The condition must be distinguished from spasmodic affections due to organic brain lesions, such as syphilitic gumma. The degree of spasm in spasmodic torticollis sometimes is so powerful that it is almost impossible to correct the deformity. At other times it is readily corrected. The latter condition (Figs. 301, 302) has been termed "torticollis mental" by Brissaud.

Prognosis.—The prognosis is always grave. Under suitable general medical treatment the local condition improves for a time and in a few instances seems to have disappeared altogether. The more severe cases require operative treatment.

Treatment—Non-Operative.—In the slighter cases rest combined with the use of a light support, liberal diet, etc.,

will serve to keep the patient comfortable. Drugs are usually of little service, but nerve tonics, *e.g.* valerianate of zinc and the use of the constant current, may be helpful.

The surgical treatment of spasmodic torticollis is practically confined to two procedures—excision of a portion of the spinal part of the spinal-accessory nerve, first done by



Fig. 301.—Mental Torticollis. (Redard.)

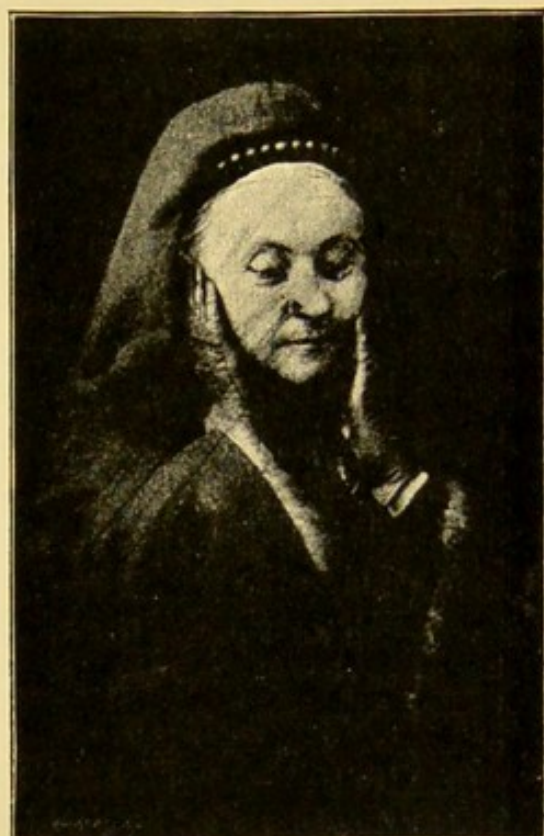

Fig. 302.—Mental Torticollis. (Redard.)

The patient is unable to prevent the spasms, but can easily replace the head by the hands.

Campbell de Morgan* in 1866, and excision of parts of the posterior primary branches of the upper cervical nerves. The latter operation, performed in America by W. W. Keen in 1889, was first performed in England by Noble Smith.† The report of a case by the latter surgeon will serve to illustrate this operation on the cervical nerves.

The operation for excision of part of the spinal accessory nerve is best done by an incision along the upper part of the anterior border of the sterno-mastoid.

* Campbell de Morgan, *Brit. and For. Medico-Chirurg. Rev.*, 1866.

† Noble Smith, "Spasmodic Torticollis," London, 1891.

The operation for the division of the posterior branches of the cervical nerves is thus described by Noble Smith :—

I made an incision from the occiput downwards for about three inches, parallel to and about an inch to the right of the spinous processes ; through the trapezius down to the edge of the splenius, some of the fibres of which muscle I had subsequently to divide to enlarge the wound, then through the complexus, and eventually exposed the posterior branches of the cervical nerves. The great occipital nerve then came into view, and this I had to separate from its attachments and draw aside. I excised a piece of the external division of this nerve, also of the third and fourth posterior branches. Considering the extensive connection of nerves in this part, I thought it well to separate the splenius from parts beneath it, and search for and excise all filaments of nerve passing into that muscle. I also acted in the same manner as regards the complexus. I had intended to try to excise a piece of the suboccipital nerve, but having already made a rather deep dissection, and found that some veins interfered with such further operation, I desisted from doing any more. This operation was recovered from as rapidly and as satisfactorily as the others, and to the great satisfaction of the patient and myself all spasmodic action was practically put an end to. The night of the operation the patient, for the first time for sixteen years, was able to rest her head on her pillow without spasmodic action. This good result has continued. There is an occasional slight twitch of the head to the right, caused doubtless by the deepest layer of the rotators supplied by the suboccipital nerve, but this action is very trifling and is thought nothing of by the patient, after her long period of severe spasm. This slight spasm subsequently ceased.

A very important point in respect to these operations is one which I had all along been anxious about, and that was the loss of power from the muscular paralysis. This loss of power has proved to be very slight indeed, and the patient expresses herself as experiencing no discomfort or disability. She cannot lift the left hand quite as high above her head as she can the right, nor quite so far backwards, but she can use it as freely to any part of the head, or in any way that she usually requires. The paralysis on the right side of the neck from the last operation appears to cause no loss of control whatever.

Upon this point it may be stated that these operations may be freely undertaken without fear as to any weakness or loss of power that might be expected. Of course there will be a wasting of the paralysed muscles ; but to counterbalance this condition, there has been in this patient so marked an improvement in her figure, including almost complete removal of the curvature of the neck, that any little differences that may remain in the size of the shoulders will be a very unimportant matter.

I saw this patient again six months after the operation, and she remained quite well. A portion of the spinal accessory nerve had previously been excised.

If there should be any clear indication for excision of part of the suboccipital nerve the venous hæmorrhage may be met by rapid operating and temporary packing.

R. H. Parry,* Glasgow, has given details of three cases, and by his courtesy and that of the editor of the *British Medical Journal*, I am able to reproduce photographs of two of Mr. Parry's patients. (Figs. 303, 304.)

CASE I.—J. McP., aged thirty-seven, was admitted into the Victoria Infirmary, Glasgow, on September 18th, 1895, suffering from spasmodic torticollis. His history is as follows: He was all right until three years previously, when he tripped and fell backwards over a block of wood, striking his neck. After this injury he felt a slight pain in the spine of the neck, which became worse, but was never very severe. He continued at his work as a riveter in a shipbuilding yard, and one day his mates ob-

served and told him that his head was constantly jerking, and was drawn to the left side—a position, however, which he assumed while at his work. Two months after the injury he consulted a doctor, who advised him to go to a hospital. He did not follow that advice till three months later, during which period the pain and spasms had increased, and the head was drawn over much more strongly, so that he could not straighten it except with the help of his hands. He had now to leave off work, as, instead of looking at his work, his vision was directed along the side of the ship. He then entered the Glasgow Royal Infirmary, where he remained for about two months. He states that a nerve was divided on the right side of his neck, and this statement was corroborated later by Dr. Barlow, who performed the resection of the right spinal accessory nerve. No improvement followed this operation.

Some months later he saw Professor Macewen, who suggested a further operation, which I am led to understand was excision of right

* R. H. Parry, *Brit. Med. Journ.*, Nov. 5th, 1898.

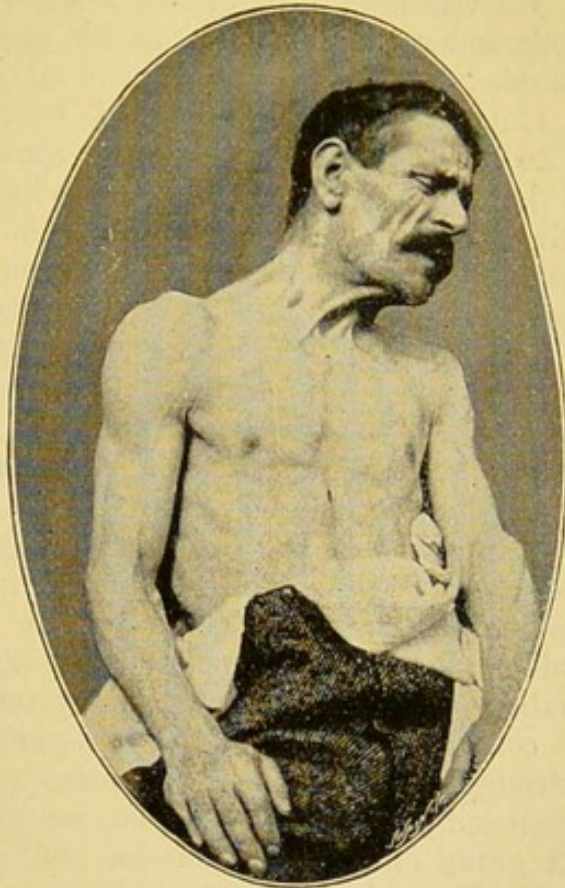


Fig. 303.—Spasmodic Torticollis.
Dr. Parry's first case.

sterno-mastoid muscle, but to this the patient objected. Fifteen months later he was admitted to the Royal Infirmary, Edinburgh, where he was first of all treated by medicines, and a subsequent proposal to open the head did not meet with his approval. He remained there fourteen weeks and was dismissed *in statu quo*.

He was now examined by a well-known surgeon on behalf of the Boilermakers' Society, and as his case was considered hopelessly incurable he received £120 in lieu of all further claims.

On admission into the Victoria Infirmary it was evident that we had to deal with a very severe case of spasmodic torticollis, the head being so drawn to the left that the face looked over the left shoulder. The chin could not be brought to the middle line without the aid of both hands, and no sooner was this movement successfully accomplished than the platysma, sterno-mastoid, trapezius, and splenius were seen to contract, and force the head back into its old position. The right sterno-mastoid remained relaxed and therefore took no part in causing or maintaining the deformity. During sleep the jerking movements ceased, but the head remained in the twisted position. Pain was very severe while the spasms lasted.

The treatment was directed during the first few weeks to allaying the spasms of the muscles. Chloroform was given and the muscles on the left side were thoroughly stretched. In anæsthesia the spasms ceased and the head was easily rotated to the right side, showing that the muscles on the left side were not permanently contracted or shortened. On return to consciousness the spasms reappeared. Massage, stretching and galvanism were then tried for many weeks, but unsuccessfully. I now concluded that the only hope left was to divide the nerve supplying the left group of occipital muscles and accordingly I explained to the patient the serious character of the operation and the prospect it held out to him. He very readily consented to have it done, but at the same time warned me that if it were unsuccessful he would commit suicide, as his life was a burden to him.

Operation.—An incision was made along the posterior border of the left sterno-mastoid, and all the structures divided down to the splenius—the latter muscle and the complexus were then divided in order to expose the suboccipital triangle. The great occipital nerve was seized with pressure forceps, and was traced to the posterior division of the second nerve. The posterior division of the first nerve was then sought, where it lies between the posterior arch of the atlas and the vertebral artery. The posterior primary division of the third and fourth nerves were then divided, but these were very difficult to find by reason of the depth of the wound and the absence of any guide, such as was provided in the case of the second nerve.

During the operation the hæmorrhage was easily controlled, the occipital artery and some veins being ligatured. Owing to the size and depth of wound and the difficulty of applying pressure by external dressing, the wound was packed with gauze for twenty-four hours. The after-treatment of the wound was unimportant.

When seen the evening of operation the head was in a normal position, the spasms had ceased, and he had no difficulty in maintaining the chin in middle line. He continued in this state for about a fortnight, when it was noticed that there was a slight tendency for the head to turn to the left side again, but I expressed a very definite opinion to the effect that it was only temporary and due to contraction of the wound. When the parts were quite healed the neck was thoroughly massaged and in the course of a few months the patient was completely cured, and able to resume his usual employment as riveter, after being nearly four years unable to work.

The second case resembled the first in several points. The occupation was the same; the history of injury the same—namely, a blow on the back of the head—and the deformity the same. He had likewise been under treatment in various hospitals before admission into the Victoria Infirmary.

It may be gathered that his condition was not very satisfactory from the fact that he was offered £80 by the Boilermakers' Society instead of a weekly payment for an indefinite period. The treatment in this case consisted in resection of a portion of the right spinal accessory nerve, this was followed by but slight improvement. Attention was then directed to the muscles on the left side. These were thoroughly massaged and in the course of a few months we were rewarded for our pains by the patient's complete recovery. He has now been working for over two years.

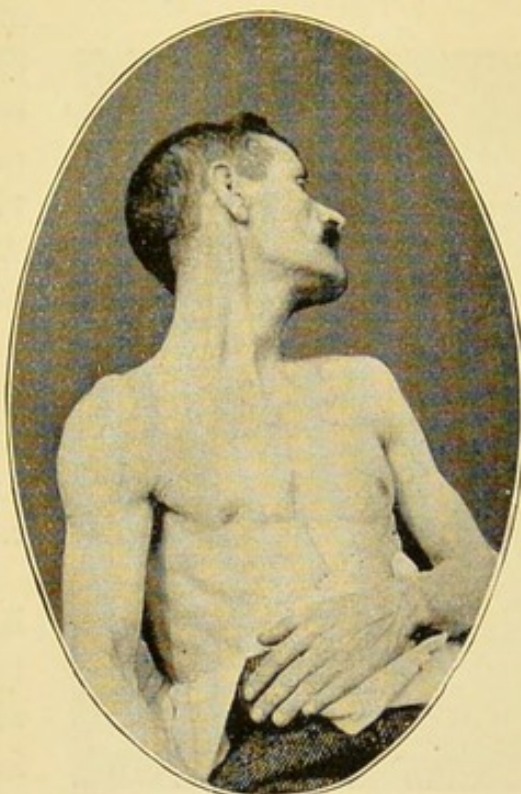


Fig. 304.—Spasmodic Torticollis.
Dr. Parry's second case.

Hysterical Wry-neck.—Two forms of this affection occur: (1) hysterical contraction; (2) hysterical paralysis. The former is the more common.

Hysterical wry-neck from contracture may begin either suddenly or gradually. Sometimes the contracture is continuous, sometimes it is intermittent. In the latter case the contraction only appears during certain actions: *e.g.* when the patient changes a lying to a sitting posture (P. Richer).

Diagnosis.—The diagnosis is confirmed by sensory or

motor signs of hysteria in other parts, as in the exceptional case in which the wry-neck is the only evidence of hysteria, patches of cutaneous anæsthesia or hyperæsthesia may be found limited to the skin covering the contracted muscle.

Hysterical Wry-neck from Paralysis.—The head inclines to one side. The head can be replaced in position without

any difficulty. The moment the head is released it falls back into its malposition. The paralysis which causes the deviation is in general of short duration and tends to reappear at intervals, ushered in by a feeling of numbness on one side of the neck. Finally, the malposture may become habitual. This form of wry-neck is rare.

Diagnosis.—The condition is distinguished from real paralytic torticollis by the fact that all the muscles react readily to faradisation.

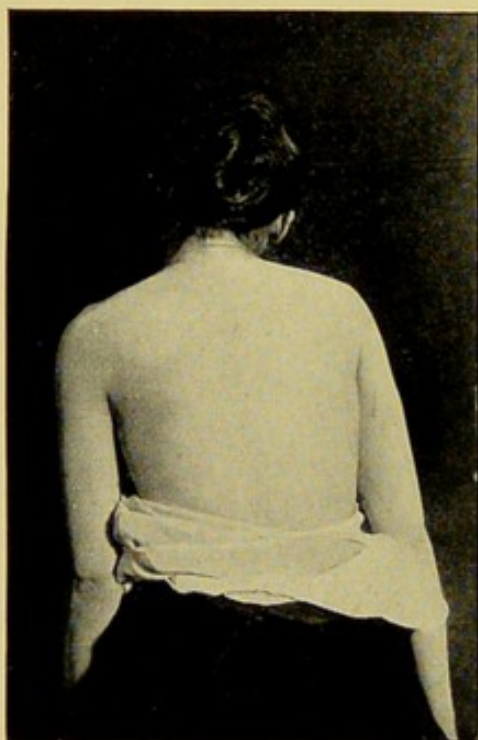

Fig. 305.—Hysterical Wry-neck.
The habitual position.

Illustrative Case.—A lady, aged thirty-two. The habitual position is shown in Fig. 305. The patient is a

distinctly neurotic subject and suffers from lichen planus. She has had slight rheumatism in wrists and ankles. The deformity first appeared nine years ago and then remained for two years. It then disappeared for about two years and returned again at the end of that time. The deformity is worse when the patient is fatigued. Her friends have noticed that it disappears when the patient becomes interested in anything. The head can readily be put in its proper position, but falls back at once on removing the supporting hand. I found also that when I corrected the position of the trunk without touching the head, the latter fell naturally into its place. All the muscles on both sides of the neck reacted readily to the faradic current. After a patient trial of general and medical treatment, combined with daily exercises, had given no good result, I recommended a light support to keep the head in its proper place.

Paralytic Torticollis.—The head inclines to the side opposite to the paralysed muscles. The deformity is easily corrected, but returns as soon as it is left to itself. If the

deformity has been present for a long time contraction of the muscles on the side to which the head inclines will occur.

Diagnosis.—This form of torticollis can be distinguished from the foregoing by the electric reactions of the muscles.

Treatment.—Massage, electricity and the use of a light support are required.

Deformities of the Thorax.—It has already been pointed out that deformities of the spine often entail alteration in the form of the thorax. In kyphosis, whether the ordinary round shoulders or that of tubercular or other disease, the alteration in the form and relations of different parts of the bony thorax, and the important deformity of the general

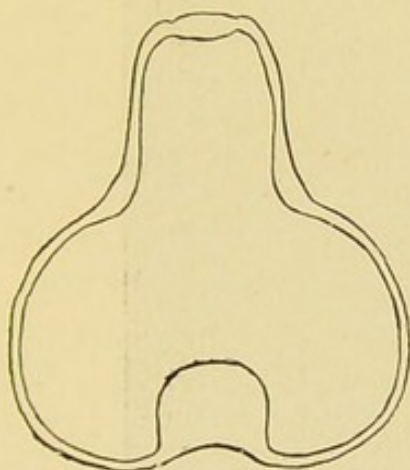


Fig. 306.—Diagrammatic Section of the Chest in Pigeon Breast.

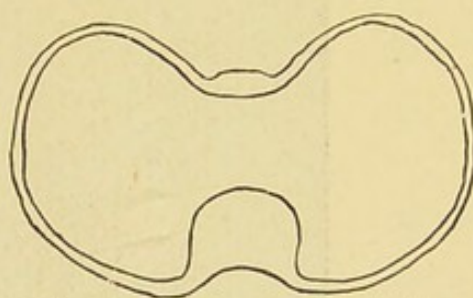


Fig. 307.—Diagrammatic Section of a Rickety Chest in which the Sternum and adjacent portions of the Ribs are depressed.

arrangement of the thorax have already been described. There remain to be mentioned some congenital and acquired deformities of the thorax.

Congenital Deformities.—The sternum is not infrequently cleft at birth. It may be altogether absent, or the failure of fusion of its two halves may take the form of membranous foramina in the bone. Congenital depression of the sternum is also occasionally met with. The condition differs from that observed in cobblers, in whom there is a pit at the lower end of the bone; in congenital cases the upper end of the bone is the seat of depression which has been attributed to pressure of the chin upon the sternum in intra-uterine life.

Congenital Affections of the Ribs.—The most important of these is the presence of a supernumerary cervical rib which may be mistaken for a growth at the root of the neck.

The cartilages of the ribs may also be defective by failing to unite with the sternum.

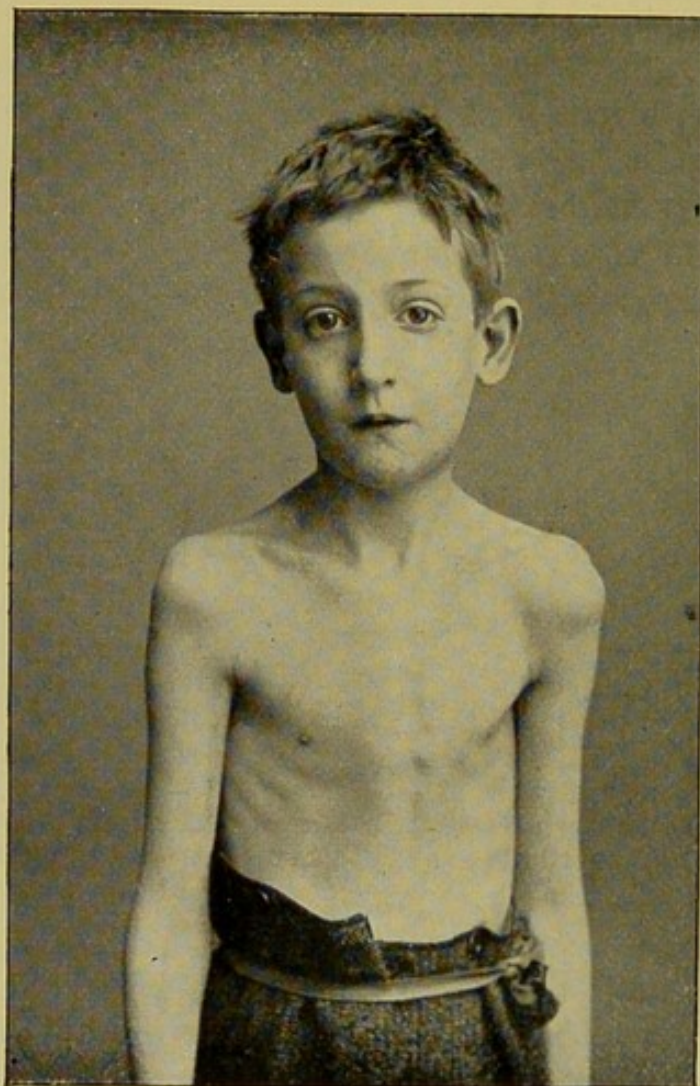


Fig. 308.—Pigeon Breast due to Rickets. Front View.

Acquired Deformities of the Thorax.—These are chiefly due to rickets, and were well described by Glisson. The two commoner deformities are shown diagrammatically in Figs. 306 and 307.

Pigeon Breast.—This is perhaps the commonest of the rachitic deformities of the chest. A typical example is shown in Figs. 308 and 309, taken from a patient under Dr. G. A. Sutherland.

The narrowing of the thorax in such cases is produced by a depression at the junction of the ribs and cartilages, and also by an increase of the natural bending of the ribs at their angles. When deformity of the thorax is produced by obstruction to entry of air, *e.g.* by adenoid bronchitis,

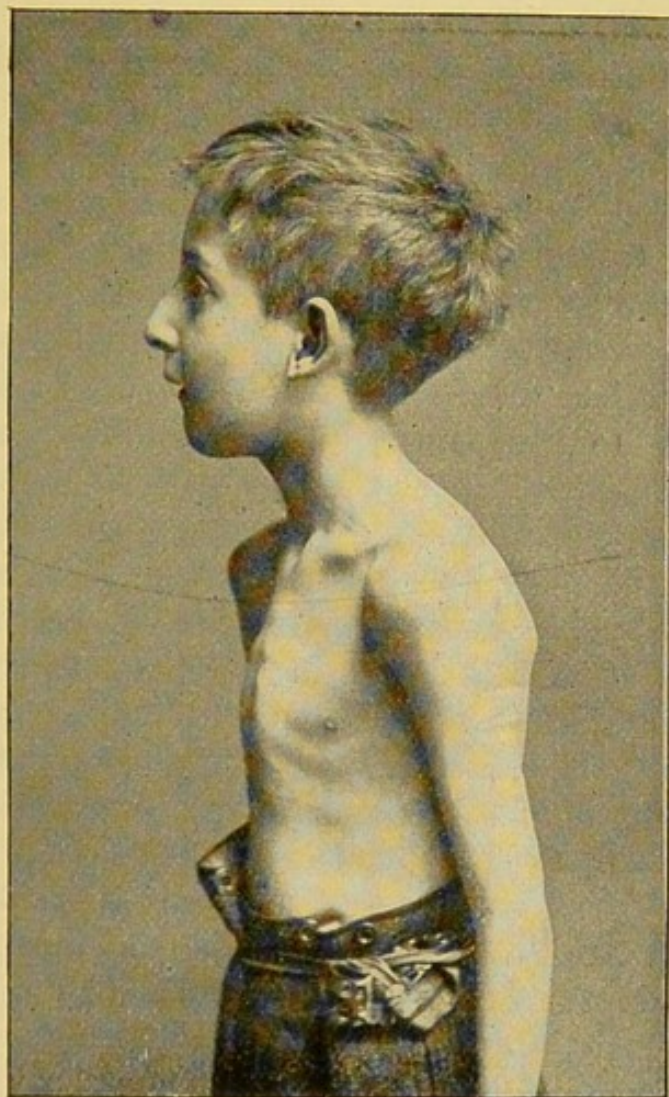


Fig. 309.—Pigeon Breast due to Rickets. Side View.

etc., rather than by great softening of the bones due to severe rickets, the shape of the thorax is altered in a different manner; the retraction chiefly showing itself at the lower part of the sternum and the lower margins of the thorax; in such cases the upper part of the thorax appears to bulge forwards. Since obstructed breathing from adenoids is often present in rachitic cases (*see* p. 28) the retraction of the lower part of the thorax is not infrequently combined

with pigeon breast. To recapitulate; the types of rachitic deformity of the thorax are—

1. Pigeon breast.
2. Depressed sternum.
3. Depression of the lower segment of the thorax.

These types may be combined in the same individual.

Acquired Thoracic Deformities from Causes other than Rickets.—Empyæma, asthma, chronic tuberculosis, emphysema, and other causes produce deformities of the chest familiar to physicians.

Treatment.—Some of the congenital deformities call for instrumental treatment, *e.g.* for the protection of the heart in cases of severe cleft sternum and for the prevention of secondary deformities of the spine (kyphosis and scoliosis) which may arise from want of strength in the thoracic skeleton due to the congenital deficiency. Cervical ribs may require excision on account of pain or deformity.

In rachitic deformities the underlying condition must be treated, and nasal or other obstruction must be removed as far as possible. The resisted respiratory exercises which have already been mentioned in the treatment of scoliosis (p. 366) are of the first importance in treating the rachitic deformities of the chest. In addition to what has been said above on this head, the following observations, kindly supplied to the author by Dr. George C. Cathcart, who has closely studied the subject, may be given:—

If the deformity be more marked on one side of the chest than on the other, it will be best to pay exclusive attention to that side till it be brought into conformity with the other.

First Exercise.—Place the hand on that part of the chest where the depression is, and endeavour to exaggerate it by compressing the ribs while the patient expires. He will thus learn to feel the part that needs attention. Now direct him to concentrate all his attention on that part of the chest, and endeavour to push the hand away by inhaling with four short inhalations, letting the breath go between each one. He will thus be enabled after a little practice to make the more depressed side equal to the larger one. Having once grasped the idea of how to obtain

the result required, he can now apply both hands, one to each side of the chest, and while exhaling as before press in the ribs on either side. Then repeat the same exercise as that given above for the one side of the chest. Though this exercise seems very simple, it is astonishing how much difficulty many people have in grasping the idea of what is required to be done. Of course, the time required to complete the cure will vary both with the mental capacity of the patient and the patience and perseverance of the teacher.

It is important to bear in mind that these exercises should always be practised in a dress which does not restrict the fullest movements of the ribs backwards, forwards, laterally, and upwards. Further, in order that the ribs may not be pulled up by the muscles connecting the upper ones and the clavicles with the head, the neck should be bent forwards so that they cannot be brought into play.

Second Exercise.—Stand sideways to a wall, and stretch out the arm with the back of the hand turned upwards till the finger can just touch the wall. Now take a slow inspiration through the nose, letting the chest expand and rise well up. It will be found that the fingers touch the wall more easily. Now step away from the wall one or two inches, and touch it again. Go on doing this till it becomes difficult to touch the wall. When this position has been reached, let the breath suddenly go and the chest fall, and at the same time try to keep the fingers touching the wall. It is only after some practice that this can be done.

Repeat with the other arm.

Third Exercise.—Stand with the back against the wall or door, and stretch the arms up above the head, keeping (if possible) the elbows and the back of the arms against the wall. At the same time take a slow inspiration through the nose. Then draw the arms slowly down till the hands are on a level with the shoulders, and then let the breath go. At first it will be found somewhat difficult to keep the arms and elbows steadily against the wall, but this can be overcome by practice.

Fourth Exercise.—Let the patient lie down on his back on the floor, and while his feet are held down either by

an assistant or by putting them under the edge of the bed or wardrobe, let him slowly raise himself into a sitting posture. When this can be done quite easily, let him try to do it without having the feet held down. Then let him practise doing it with his arms stretched out above his head, and always behind it when rising, so that their leverage acts against him and not with him.

Fifth Exercise.—Let the patient lie face downwards on the floor with his toes and chin touching it. Then let him flex his elbows and place his hands on the floor palms downwards just external to the shoulders, and endeavour to push himself up from the floor till his arms are straight and vertical six times in succession. While doing this he must be careful to keep the body straight and stiff, and the abdomen drawn well in. It is more difficult if the chin is turned slightly up.

THE END.

INDEX TO SUBJECTS.

- Achondroplasia, 32
 Acquired deformities, 14
 Ankle-joint, Deformities of, 261
 Ankylosis, 56
 —, Traumatic, 58
 Artificial limbs, 86
 Arthritis, Chronic traumatic, 38
 —, — ulcerativa, 38
 — pauperum, 46
 —, Suppurative, 58
 —, Tubercular, 59
 Arthrodesis, 114
- Back-knee, 226, 258
 "Bone-setting," 87
 Bones, Excision of, 114
 Bradford's operation, 180
 Buchanan's operation, 176
- Children, Inspection of, 4
 Chinese lady's foot, 162
 Clavicle, Congenital defects of, 312
 Club-foot, Introduction to, 153
 Club-hand, Congenital, 215
 —, Introduction to, 153
 Congenital deformities, Primary, 9
 — —, Secondary, 12
 Contracture, Arthrogenous, 55
 —, Desmogenous, 48
 —, Myogenous, 48
 —, Neurogenous, 50
 —, Paralytic, 51
 —, Spastic, 50
 Contractures, 17
 —, Dermatogenous, 47
 —, Inflammatory muscular, 48
 Costo-transversectomy, 412
 Coxa vara, 226, 248
 — —, Diagnosis of, 252
- Coxa vara, Pathology of, 255
 — —, Symptoms of, 249
 — —, Treatment of, 256
 Coxitis, Tubercular, 297
 —, —, Ambulant treatment, 300
 —, —, Ankylosis in, 304
 —, —, Complications of, 304
 —, —, Diagnosis, 297
 —, —, Dislocation in, 304
 —, —, Symptoms, 297
 —, —, Treatment, 298
 Cubitus valgus, 318
 — varus, 319
- Deformity, Symptoms of, 62
 Diagnosis, General, 62
 Didot's operation, 139
 Digits, Suppression of, 137
 Drop finger, 145
 Dupuytren's contraction, 146
 — —, Anatomy of, 147
 — —, Treatment of, 149
- Elastic traction, 85
 Elbow-joint, Ankylosis of, 319
 —, Contractures of, 318
 —, Deformities of, 317
 Electricity, 69
 Exercises, Passive, 66
 —, Resisted, 67
- Femur, Arrest of growth of, 220
 —, Incurvation of the neck of (*see*
 Coxa vara), 248
 —, Rachitic deformities of shaft of,
 247
 Fibula, Congenital defects of, 221
 Fingers, Congenital contraction of, 140
 —, — deformity of, 136
 —, — dislocation of, 140

- Fingers, Congenital hypertrophy of, 151
 —, Desmogenous contracture of (*see* Dupuytren's contraction), 140
 Fitzgerald's operation, 181
 Flat-foot, Congenital, 194
 —, Infantile, 194
 —, Rheumatic, 194
 —, Static, 196
 —, —, Anatomy of, 200
 —, —, Treatment of, 203
 —, Transverse, 210
 Fragilitas ossium, 34
- Genu recurvatum, Congenital, 261
 — —, Paralytic, 267
 — retrorsum, 258
 — valgum, Ætiology of, 232
 — —, Anatomy of, 226
 — —, Comparison of conservative, with operative treatment of, 240
 — —, Complications of, 231
 — —, Definition of, 224
 — —, Macewen's operation for, 111
 — —, Mode of examination for, 230
 — —, Ogston's operation for, 237
 — —, Prognosis of, 233
 — —, Reeves's operation for, 237
 — —, Treatment of, 233
 — varum, 241
 — —, Anatomy of, 242
 — —, Causation of, 242
 — —, Definition of, 225
 — —, Prognosis of, 245
 — —, Treatment of, 245
 Gighli's saw, 113
 Gout, 46
 Gymnastics, 65
- Hallux flexus (*see* Hallux rigidus)
 — retractus, 135
 — rigidus, 128
 — —, Treatment of, 129
 — valgus, 117
 — —, Causation of, 118
 — —, Treatment of, 120
 — varus, 127
 Hammer-toe, 130
 —, Anatomy of, 130
 Hammer-toe, Cases of, 133
 —, Pathology of, 131
 —, Treatment of, 131
 Hand, Paralytic deformities of, 217
 Hip, Arthritis deformans of, 309
 —, Congenital dislocation of, 275
 —, — —, Anatomy, 275
 —, — —, Bloodless reduction, 289
 —, — —, Diagnosis, 285
 —, — —, Operations for, 291
 —, — —, Treatment, 287
 —, Deformity of, after specific fevers, 306
 —, Hysterical, 297
 —, Non-tubercular deformities of, 306
 Hip-joint, Deformities of, 271
 — disease (*see* Coxitis, Tubercular)
 —, Method of examining, 273
 —, Symptoms, 272
 Hot-air apparatus, 41
 Hydrotherapy, 69
- Instruments, 69
- Joints, Resection of, 114
- Knee, Ankylosis of, 264
 —, Arthrogenous contracture of, 268
 —, Contracture of, 264
 —, Flail-joint at, 268
 —, Internal derangement of, 270
 —, Tubercular disease of, 269
 Knee-joint, Deformities of, 261
 Knee-splint (Thomas's), 86
 Kyphosis, Rachitic, 372
 —, Thoracic, 333
- Laminectomy for paraplegia in tubercular spondylitis, 419
 Lateral curvature of spine (*see* Scoliosis), 337
 Liquor amnii, Absence of, a cause of deformity, 12
 Lordosis, 335
 —, Rachitic, 374
- Macroductyly, 151
 Mallet finger, 145
 Manipulative treatment, 87

- Massage, 64
 Metatarsalgia, 211
 —, Treatment of, 212
 Myositis, Ischæmic, 49
 —, Ossifying, 48
 Myotomy, 107

 Nicoladoni's operation, 163
 Norton's operation, 138

 Ogston's operation, 208
 Operations, 92
 Orthopædic surgery, Scope of, 2
 Osteoclasia, 109
 Osteotomy, 110
 —, Astragaloid, 179
 —, Cuneiform, 113
 —, Curvilinear, 113
 —, Oblique, 113

 Paraplegia from tubercular spondylitis, 418
 Paralysis, Congenital, 295
 Patella, Congenital affections of, 263
 Phelps's operation, 177
 Pigeon breast, 438
 Plaster of Paris, Uses of, 70
 Pressure deformities, 15
 Prognosis, General, 63
 Progressive muscular atrophy, 55
 Prophylaxis of deformities, 60
 Pseudohypertrophic paralysis, 324

 Rachitic deformities of the long bones, 222
 Rachitis adolescentium, 29
 Rack-and-pinion, 81
 Radius, Deformities of, 259
 Retrocollis, 421
 Rickets, 25
 —, Causation of, 28
 —, Congenital, 30
 —, Distribution of deformities in, 27
 — in adolescence, 29
 Rheumatic polyarthritis (chronic), 45
 Rheumatism, 45
 Rheumatoid arthritis, 35
 — — in children, 43

 Sacro-iliac disease, 311

 Scapula, Congenital displacement of, 311
 Scoliosimeters, 356
 Scoliosis, 337
 —, Diagnosis of, 356
 —, Exciting causes of, 348
 —, Exercises for, 365
 —, Forceful correction of, 370
 —, Frequency of, 330
 —, Hereditary character of, 347
 —, Method of examination for, 353
 —, Pathological anatomy of, 339
 —, Predisposing causes of, 345
 —, Preventive treatment of, 360
 —, Prognosis of, 358
 —, Treatment of, 359
 —, Types of, 350
 Shoulder-joint, Ankylosis of, 316
 —, Contracture of, 316
 —, Deformities of, 313
 — muscles, Paralysis of, 315
 Spastic paralysis, 319
 — —, Diagnosis, 321
 — —, Operative treatment, 323
 — —, Prognosis, 323
 — —, Symptoms, 320
 — —, Treatment, 322
 Spinal splints, 83
 Spine, Angular curvature of (*see* Spondylitis), 382
 —, Deformities of, 328
 —, Dorsal excurvation of, 333
 —, Lateral curvature of (Scoliosis), 337
 —, Malignant disease of, 419
 —, Neurotic affections of, 380
 —, Post-typhoidal lesions of, 380
 —, Rheumatism of, 379
 —, Rheumatoid arthritis of, 375
 —, Rickets of, 372
 —, Syphilitic disease of, 379
 —, Tuberculosis of (*see* Spondylitis), 382
 Spondylitis deformans, 38, 375
 —, Tubercular, 382
 —, —, Complications in, 395
 —, —, Effects of, 384
 —, —, Examination of the back in, 393
 —, —, Forceful correction of deformity in, 405

- Spondylitis, Tubercular, Mechanical treatment of, 402
 —, —, Method of recording deformity in, 394
 —, —, Pathology, 383
 —, —, Postures in, 392
 —, —, Spinal cord in, 389
 —, —, Symptoms of, 390
 —, —, Treatment of, 399
 —, —, — complications, 413
 Springs, 85
 Statistics of deformities, 62
 Stokes's operation, 210
 Syndesmotomy, 108
 Syphilis, 34

 Talipes calcaneo-valgus, Congenital, 159
 —, —, Treatment of, 159
 —, —, Paralytic, 163
 — calcaneo-varus, Congenital, 164
 — calcaneus, Congenital, 156
 —, —, Paralytic, 161
 —, —, Treatment of, 162
 — cavus, 184
 —, —, Treatment of, 193
 — equino-varus, Congenital, 165
 —, —, Anatomy of, 166
 —, —, Treatment of, 168
 —, —, Paralytic, 190
 — equinus, Acquired, 181
 —, —, Anatomical changes in, 184
 —, —, Congenital, 164
 —, —, Paralytic, 183
 —, —, Treatment of, 187
 — valgus, Paralytic, 161
 —, —, Spasmodic, 195
 —, Varieties of, 155
 — varus, Congenital, 164
 —, —, Paralytic, 190
 Tendon grafting, 107
 —, Methods of lengthening, 103
 —, — of shortening, 104
 —, Repair of, 95
 —, Stages in repair of, 99
 — transplantation, 107
 Tenotomy, 93
 —, Open, 102
 Tenotomy, Subcutaneous, 94

 Thomas's hip-splint, 82
 Thorax, Deformities of, 437
 —, —, Treatment, 440
 Tibia, Arrest of growth of, 220
 —, Congenital absence of, 220
 Tibial Curves, Anterior, 247
 —, —, External, 247
 Toes, Arthritic deformity of, 134
 —, Clawing of, 184
 —, Congenital deformity of, 136
 —, Paralytic deformity of, 136
 Torticollis, 420
 —, Acute, 420
 —, Chronic, 422
 —, —, of childhood, 425
 —, Congenital, 423
 — from rheumatoid arthritis, 428
 —, Hysterical, 435
 —, Mental, 430
 —, Ocular, 422
 — of articular origin, 427
 — of osseous origin, 427
 —, Rachitic, 428
 —, Rheumatic, 420
 —, Spasmodic, 428
 —, —, Clonic form, 428
 —, —, Operations for, 431
 —, —, Tonic form, 430
 —, —, Treatment, 431
 Treatment, General, 64
 Treves's operation for lumbar spinal abscess, 417
 Trigger finger, 143

 Ulna, Deformities of, 259

 Vestimentary deformities, 17

 Webbed fingers, 10
 — and Toes, 137
 —, Treatment of, 138
 Wolff's law, 21
 Wrist, Congenital dislocation of, 216
 —, Contracture and ankylosis of, 218
 Writer's cramp, 145
 Wry-neck (*see* Torticollis), 420

 Zeller's operation, 138.

INDEX TO AUTHORS.

ADAMS, WILLIAM :	PAGE
Method of performing subcutaneous tenotomy	95
Repair of tendons	101
Osteotomy	110
Description of hammer-toe	131
Operation for hammer-toe	132
Congenital finger contraction	140
Operation for Dupuytren's contraction... ..	149
Congenital talipes equino-valgus	159
Astragalus in congenital club-foot	167
Scarpa's shoe for flat-foot	207
Normal structure of spine	329
Spinal support	366
ALBERT :	
Arthrodesis	115
ANDERSON, WILLIAM :	
Operation for hallux valgus	127
Hallux varus with macrodactyly	128
Operation for hammer-toe	132
Tendon elongation by Z-shaped section	143
Theory of Dupuytren's contraction	148
ANDRY :	
"L'Orthopédie"	1
Illustration of the principle of the rigid splint	74
BAGINSKY :	
Plantar reflex	192
BAKER, F. F. :	
Club-foot wrenches	175
BANNATYNE, G. A. (and WOHLMANN) :	
Rheumatoid arthritis	39
Rheumatoid arthritis in children	45
BARKER, A. E. :	
Operation for hallux valgus	126
BARTON, RHEA :	
Osteotomy	110
BARWELL, R. :	
Elastic traction	85
Exercise for scoliosis	365
Seat for scoliosis	369

	PAGE
BERKART, J. B. :	
Gout	47
BIGG, HEATHER :	
Orthopædic apparatus	163, 264, 323, 367, 427
BILHAUT (and LEVASSORT) :	
Spinal corsets	405
BILLROTH :	
Osteotomy for genu varum	246
BONNET :	
Apparatus for exercising ankle ..	68
BRADFORD, E. H. :	
Operation for club-foot	180
BRADFORD AND LOVETT :	
Statistics of paralytic deformity	55
Taylor's spinal support	84
Genu valgum	230
Genu varum	245
Thomas's hip splint	301
Bed-frame for cases of spinal disease	400
BRISSAUD :	
Mental torticollis	431
BROADBENT, SIR WILLIAM :	
Spasm in cerebral tumour	321
BRODHURST :	
Congenital hip dislocation	282
BUDINGE :	
Trigger finger	144
BUSCH :	
Ling's exercises	67
CALOT :	
Forcible correction of deformity of spine	405
CARPENTER, G. :	
Congenital absence of clavicles	312
CATHCART, G. C. :	
Respiratory exercises	440
CHANCE, E. J. :	
Spinal splint	84
Hallux varus	128
Talipes equinus	184
CHIPAULT :	
Forcible correction of hump-back	405
CLUTTON, H. H. :	
Excision of metatarso-phalangeal joint in hallux valgus	127
Bifurcated hand	136
Talipes cavus	193
Club-hand	215
Ankylosis of knee	268
Congenital absence of tibia ..	221
COLLIER, H. STANSFIELD :	
Congenital deformity	13

COLLIER, H. STANSFIELD (<i>continued</i>):								PAGE
Genu valgum	235
COLLIER, JAMES:								
Talipes cavus	192
COLLIER, MAYO:								
Hallux rigidus	129
COLMAN, W. S.:								
Coxa vara	256
DAVIES, COLLEY:								
Hallux valgus	127
Tarsectomy	180
DAVY:								
Tarsectomy	180
DE MORGAN, CAMPBELL:								
Spasmodic torticollis	431
DUCHENNE:								
Paralytic deformities	55
DUVAL:								
Terminology in club-foot	155
ECCLES, J. SYMONS:								
Massage	64
ELLIS:								
Exercise for flat-foot	66
EWENS, J.:								
Genu valgum	237
Pathological dislocation of hip-joint	306
FITZGERALD:								
Operation for club-foot	181
FOWLER, G. R.:								
Boots for hallux valgus	126
FRAZIER, C. H.:								
Coxa vara	251
GALEN:								
Gymnastics	66
Forcible correction of spinal deformity	405
GARDNER, WILLIAM:								
Phelps's operation	177
GARROD, ARCHIBALD:								
Achondroplasia	33
Gout and rheumatoid arthritis	47
GARROD, SIR ALFRED:								
Gout and rheumatoid arthritis	47
GOLDTHWAIT, J. E.:								
Metatarsalgia	214
Forcible correction of spinal deformity	407
GROSSE, ULHRICH:								
Plaster of Paris	71


	PAGE
GUÉRIN :	
Section of ligaments	107
GUTHRIE, LEONARD :	
Metatarsalgia	211
HEBERDEN :	
Gout and rheumatoid arthritis	47
HESSING :	
Orthopædic apparatus	72
HIPPOCRATES :	
Massage	64
Forcible correction of spinal deformity	405
HOFFA, A. :	
Wolff's law	21
Statistics of deformities	62
Paralytic genu recurvatum	267
Congenital dislocation of the hip	283
Types of scoliosis	352
HOFMEISTER :	
Coxa vara	256
HOLMES, TIMOTHY :	
Tenotomy in paralytic talipes	86
HOPKINS, BARTON :	
Osteotomoclasis	248
HUETER, C. :	
Causation of deformities	19
HUGHES, KENT :	
(See WALSHAM AND HUGHES.)	
HUTCHINSON, JONATHAN :	
Dupuytren's contraction	47
JOHNSON, RAYMOND :	
Ischæmic contracture	219
JONAS, A. F. :	
Phelps's operation	177
JONES, ROBERT :	
Metatarsalgia	213
Ankylosis of hip	305
Forcible correction of spinal deformity	411
KASSOWITZ :	
Congenital rickets	30
KEEN, W. W. :	
Dupuytren's contraction	147
Wry-neck	431
KEETLEY, C. B. :	
Coxa vara	256
KELLOCK, T. H. :	
Phelps's operation	177
KIRMISSON :	
Congenital dislocation of the hip	295


	PAGE
KÖLLIKER :	
Congenital displacement of the scapula	313
KREDEL :	
Congenital coxa vara	249
KRUKENBERG :	
Mechanical gymnastics	69
KÜSTNER :	
Congenital flat-foot	194
LAMBOTTE :	
Radical treatment of tubercular spondylitis	412
LANE, ARBUTHNOT :	
Chronic traumatic arthritis	38
Buchanan's operation	176
Phelps's operation	177
LANGE :	
Forcible correction of spinal deformity	408
LEVASSORT :	
(See BILHAUT.)	
LEWIS, P. G. :	
Scoliosis	358
LITTLE, MUIRHEAD :	
Spring for flat-foot	85, 206
Congenital dislocation of the hip	286
LING, P. H. :	
Exercises	67
LOCKWOOD, C. B. :	
Dupuytren's contraction	148
Congenital dislocation of the hip	276
LORENZ :	
Flat-foot	202
Congenital dislocation of the hip	279
LOVETT :	
(See BRADFORD AND LOVETT.)	
LUCAS, CLEMENT :	
Rachitis adolescentium	29
LUFF, A. P. :	
Hot-air apparatus	42
LUND :	
Excision of astragalus	180
LÜNING AND SCHULTESS :	
Congenital wry-neck	423
MACEWEN, WM. :	
Osteotomy	111
Rachitic deformities	224
Genu varum	246
MARSH, HOWARD :	
Ankylosis	59
Tubercular coxitis	297
Spinal supports	403

MÉNARD :		PAGE
Costo-transversectomy	...	412
MEYER, H. VON :		
Structure of bones	...	20
Boot construction	...	120
MIKULICZ :		
Genu valgum	...	227
Congenital dislocation of the hip	...	276
MURRAY, R. W. :		
Forcible correction of spinal deformity	...	405
NICOLADONI :		
Tendon transplantation	...	107
Congenital talipes calcaneus	...	157
NOTTA :		
Trigger finger	...	143
OLLIER :		
Oblique osteotomy	...	112
Chondrectomy	...	114
OPENSHAW :		
Ogston's operation	...	210
OWEN, EDMUND :		
Examination of hip	...	274
Examination of spine	...	392
PARKER, R. W. :		
Tenotomes	...	95
Syndesmotomy	...	108, 173
Congenital talipes valgus	...	158
PARRY :		
Spasmodic wry-neck	...	433
PEPPER :		
Tubercular coxitis	...	60
PHOCAS :		
Tendon shortening	...	106
POLAND, JOHN :		
Rachitic back-knee	...	258
PORAK :		
Ächondroplasia	...	33
RAILTON, T. C. :		
Congenital deformity	...	31
REDARD :		
Torticollis	...	422
REEVES L. :		
Trigger finger	...	143
Genu valgum	...	237
RICHER, P. :		
Hysterical torticollis	...	435

	PAGE
RIEDEL :	
Hallux valgus	127
ROTH, B. :	
Mode of recording rotation in scoliosis	354
SAYRE :	
Curvilinear osteotomy	113
SCARPA :	
Method of treatment of club-foot	168
SCHEDE :	
Congenital dislocation of hip	287
SCHLANGE :	
Congenital displacement of scapula	313
SCHÖRSTEIN, G. :	
Congenital absence of clavicles	313
SCUDDER, C. J. :	
Congenital deformity of shoulder	314
SEELIGMULLER :	
Statistics of paralytic deformities	55
SHAW, JOHN :	
Exercises in scoliosis	362
SIMS, PARKER :	
Construction of boots	123
SMITH, NOBLE :	
Spinal supports	84
Normal movements of ankle	154
Drilling bone for relief of pain	310
Chance's splint for scoliosis	367
Operation for spasmodic wry-neck	432
SMITH, PROTHERO :	
Spinal support	86
SOLLY :	
Tarsectomy	180
SPILLER, W. G. :	
Paraplegia in tubercular spondylitis	389
SPRENGEL :	
Congenital displacement of scapula	313
STILL, G. F. :	
Rheumatoid arthritis in children	43
STROMEYER :	
Subcutaneous tenotomy	93
SUTHERLAND, G. A. :	
Peripheral neuritis	35
Attitude in coxa vara	253
Congenital paralysis	295
SYMINGTON, JOHNSON :	
Genu valgum	227
TAYLOR, C. F. :	
Spinal support	83

THOMAS, H. O.:								PAGE
Hip-splints	82
Knee-splint	87
THOMAS, WILLIAM:								
Club-foot wrench...	175
TREVES, F.:								
Operation for lumbar abscess	417
TUBBY, A. H.:								
Repair of tendons	100
Metatarsalgia	212
Spinal supports	404
VINCENT, F.:								
Spinal abscess	413
VOLKMANN, R. von:								
Pressure deformities	19
Open operations	108
WALSHAM:								
Tendon shortening	106
WALSHAM AND HUGHES:								
Plaster bandages	71
Congenital talipes calcaneus	157
Buchanan's operation	177
Talipes equinus	185
Treatment of flat-foot	206
WHITMAN, ROYAL:								
Construction of boots	121
WILLETT:								
Tendon shortening	104
WILLIAMS, CHISHOLM:								
Ischæmic contracture	219
WINIWARTER, VON:								
Operations on fascia	93
WOLFF, JULIUS:								
Pressure deformities	20
WULLSTEIN:								
Forcible correction of spinal deformity	408
ZANDER:								
Mechanical exercises	68
ZEHNDER:								
Coxa vara	253





Important Original Work on Surgery.

Complete in Two Volumes, price 48s.

A System of Surgery.

BY

CHARLES B. BALL, M.D., T.C.D.	W. ARBUTHNOT LANE, M.S.
ARTHUR E. BARKER, F.R.C.S.	Lond.
WILLIAM H. BENNETT, F.R.C.S.	C. B. LOCKWOOD, F.R.C.S.
ANTHONY A. BOWLBY, F.R.C.S.	G. H. MAKINS, F.R.C.S.
STANLEY BOYD, F.R.C.S.	J. H. MORGAN, F.R.C.S.
W. WATSON CHEYNE, F.R.S.	HENRY MORRIS, M.B. Lond.
W. BRUCE CLARKE, M.B. Oxon.	HERBERT W. PAGE, M.C.
H. H. CLUTTON, M.B. Cantab.	Cantab.
H. PERCY DEAN, M.S. Lond.	BERNARD PITTS, M.C. Cantab.
ANDREW DUNCAN, M.D., B.S.	A. MARMADUKE SHEILD, M.B.
Lond.	Cantab.
A. PEARCE GOULD, M.S. Lond.	J. BLAND SUTTON, F.R.C.S.
FREDERICK W. HEWITT, M.D.	FREDERICK TREVES, F.R.C.S.
Cantab.	HERBERT F. WATERHOUSE,
JONATHAN HUTCHINSON, JR.,	F.R.C.S.
F.R.C.S.	G. SIMS WOODHEAD, M.D. Edin.

EDITED BY

FREDERICK TREVES, F.R.C.S.

Each Vol. contains Two Coloured Plates and Several
Hundred Original Woodcut Illustrations by
CHARLES BERJEAU, F.L.S., and others.

CASSELL & COMPANY, LIMITED, *London, Paris,*
New York & Melbourne.

Price 10s. 6d.

Medical Diseases of Infancy and Childhood.

By DAWSON WILLIAMS, M.D. Lond.,

*Fellow of the Royal College of Physicians of London, and of
University College, London; Physician to the East
London Hospital for Children, Shadwell.*

648 pages, crown 8vo, with 52 Illustrations.

"Notwithstanding the large amount of literature now existing on the diseases of children, a want has been felt for a small handy volume which would serve as a guide to the student and junior practitioner."—*Edinburgh Medical Journal*.

"We have great pleasure in recommending Dr. Dawson Williams's book to all members of the profession as a thoroughly practical and trustworthy guide to the study and practice of diseases of infancy and childhood."—*Treatment*.

"A systematic and concise treatise on medical diseases of infancy and childhood, by a physician who has gained a very extensive clinical experience by 'many years' service at the East London Hospital for Children."—*Sheffield Medical Journal*.

"This is a thoroughly good book — good as a complete and impartial presentment of the wide range of subjects with which it deals, and good also as a clinical manual for the practitioner."—*The Hospital*.

CASSELL & COMPANY, LIMITED, *London; Paris,
New York & Melbourne.*

Seventh Thousand. With 162 Illustrations. 12s. 6d.

Difficult Labour.

*A Guide to its Management. For Students
and Practitioners.*

BY

G. ERNEST HERMAN, M.B. Lond., F.R.C.P.,

*Senior Obstetric Physician to the London Hospital; Physician
to the General Lying-in Hospital, &c. &c.*

CONTENTS.

WHAT IS NATURAL LABOUR?	TREATMENT OF LABOUR WITH CONTRACTED PELVIS.
DIFFICULT OCCIPITO-POSTERIOR POSITIONS.	THE RARE FORMS OF CONTRACTED PELVIS.
FACE AND BROW PRESENTATIONS.	SLOW DILATATION OF THE SOFT PARTS.
THE MOULDING OF THE HEAD.	LABOUR COMPLICATED WITH TUMOURS.
PELVIC PRESENTATIONS.	RUPTURE OF THE UTERUS.
TRANSVERSE PRESENTATIONS.	THE INJURIES TO THE GENITAL CANAL IN CHILDBIRTH.
PROLAPSE OF EXTREMITIES.	HÆMORRHAGE BEFORE DELIVERY.
ANOMALIES OF THE UMBILICAL CORD.	HÆMORRHAGE AFTER DELIVERY.
TWINS.	THE FORCEPS.
MALFORMED CHILDREN.	TURNING.
ABNORMAL UTERINE ACTION.	OPERATIONS FOR LESSENING THE CHILD'S SIZE.
THE COMMON FORMS OF CONTRACTED PELVIS.	CÆSARIAN SECTION.
THE RESULTS OF CONTRACTED PELVIS.	SYMPHYOTOMY.
THE DIAGNOSIS OF PELVIC CONTRACTION.	THE INDUCTION OF PREMATURE LABOUR.
THE MECHANISM OF LABOUR WITH CONTRACTED PELVIS.	

"We consider that Dr. Herman has succeeded in producing an excellent, practical, and at the same time concise, guide to the management of difficult labour that cannot fail to be of much assistance to those for whom it is intended."—*The Lancet*.

"The book is well-arranged and profusely illustrated with excellent diagrams. It is a decided acquisition to the literature of midwifery, and we have pleasure in recommending it to all interested in the subject."—*Glasgow Medical Journal*.

"There are few so learned who cannot receive instruction from the perusal of this book, and we confidently predict that it will not fail in the object for which it was written."—*Dublin Journal of Medical Science*.

CASSELL & COMPANY, LIMITED, *London; Paris,
New York & Melbourne.*

NEW AND REVISED EDITION.

Price 21s.

Intestinal Obstruction:

Its Varieties with their Pathology, Diagnosis
and Treatment.

BY

FREDERICK TREVES, F.R.C.S.

WITH 118 ILLUSTRATIONS.

EXTRACT FROM THE AUTHOR'S PREFACE.

"The entire arrangement of the work has been altered. It has been found more convenient to divide the subject into three distinct parts, and to consider first, the pathology of intestinal obstruction, then its clinical manifestations, and finally, its treatment. A large number of new illustrations has been added, for which I am indebted to Mr. Berjeau."

ENTIRELY NEW EDITION.

Price 7s. 6d.

Materia Medica and Therapeutics.

BY

J. MITCHELL BRUCE, M.D., F.R.C.P.

A full account of the many important drugs contained in the Addendum to the British Pharmacopœia, recently issued, will be found in the NEW EDITION.

"We welcome its appearance with much pleasure, and feel sure that it will be received on all sides with that favour which it richly deserves."—*British Medical Journal.*

CASSELL & COMPANY, LIMITED, *London; Paris;*
New York & Melbourne.

MANUALS FOR Students and Practitioners of Medicine

Published by **CASSELL & COMPANY.**

Consisting of compact and authoritative Manuals embodying the most recent discoveries, and containing all the information required for the Medical Examinations of the various Colleges, Halls, and Universities in the United Kingdom and the Colonies.

COMPLETE IN TWO VOLUMES, price 48s.

A System of Surgery. Edited by **Frederick**

Treves, F.R.C.S. Each Vol. contains Two Coloured Plates and Several Hundred Original Woodcut Illustrations by **CHARLES BERJEAU, F.L.S.**, and others.

A List of Contributors, with Contents, will be forwarded on application.

Gout, Its Pathology and Treatment.

By **Arthur P. Luff, M.D. Lond., B.Sc., F.R.C.P.** Physician in Charge of Out-Patients and Lecturer on Forensic Medicine at St. Mary's Hospital. Crown 8vo., 256 pages, 5s.

"We have nothing but commendation for Dr. Luff's treatise . . . It is not given to many to be so well equipped for the task in hand as Dr. Luff . . . Unlike many literary efforts that have preceded it on the subject, Dr. Luff's book does not 'smell of the lamp,' but, on the contrary, it is redolent of fruit freshly gathered from the field of honest work."—*Edinburgh Medical Journal.*

Operative Surgery, A Manual of.

By **Frederick Treves, F.R.C.S.** With 422 Illustrations by **CHARLES BERJEAU, F.L.S.** Two Volumes. £2 2s.

"The feature of all others in this work which specially commends it, and in which it is in striking contrast to some manuals and text-books, is the pains Mr. Treves has taken to mention the work of other surgeons under their name . . . This is a special and very praiseworthy feature of the book, and is the strongest evidence of the care taken in its preparation."—*The Lancet.*

A Manual of Medical Treatment or

Clinical Therapeutics. By **I. Burney Yeo, M.D., F.R.C.P.** With Illustrations. *Fifth Edition.* Two Vols. 21s.

"This work, with its information always well up to date, may be warmly recommended, as its use will help to disseminate a knowledge of rational therapeutics in the strictest meaning of the term."—*British Medical Journal.*

Tropical Diseases. A Manual of the Diseases of

Warm Climates. By **Patrick Manson, M.D., LL.D. Aberd.,** Fellow of the Royal College of Physicians, London; Lecturer on Tropical Diseases at St. George's Hospital and Charing Cross Hospital Medical Schools; Medical Adviser to the Colonial Office and Crown Agents for the Colonies. With 38 Illustrations and Two Coloured Plates. 10s. 6d.

"It is a good book, conceived and written in a scientific spirit and well up to date, and—not to admit in these utilitarian days a practical view of its merits—it strikes us as sound and judicious in regard to the general dietetic and therapeutical treatment of the malarial which it describes. The volume is of a handy size and admirably illustrated."—*The Lancet.*

Medical Diseases of Infancy and

Childhood. By Dawson Williams, M.D. Lond., Fellow of the Royal College of Physicians of London, and of University College, London; Physician to the East London Hospital for Children, Shadwell. With 52 Illustrations. 10s. 6d.

"This is a thoroughly good book—good as a complete and impartial presentment of the wide range of subjects with which it deals, good also as a clinical manual for the practitioner."—*The Hospital*.

Diseases of Women.

A Clinical Guide to their Diagnosis and Treatment. By George Ernest Herman, M.B. Lond., F.R.C.P., Obstetric Physician to, and Lecturer on Midwifery at, the London Hospital; Examiner in Midwifery to the Universities of London and Oxford; and Examiner in Midwifery to the Royal College of Surgeons, etc. etc. With 252 Illustrations. 25s.

"Dr. Herman's book is unique in this field, being neither a systematic text-book nor a volume of clinical lectures, but a 'clinical guide' to the diagnosis and right treatment of the diseases of women."—*Lancet*.

Ringworm.

In the Light of Recent Research. Pathology—Treatment—Prophylaxis. By Malcolm Morris, F.R.C.S. Edin., Surgeon to the Skin Department, St. Mary's Hospital, London. With 22 Micro-photographs and a Coloured Plate. 7s. 6d.

"Mr. Malcolm Morris has now given the profession a most excellent, concise, and readable account of Ringworm, viewed from the modern standpoint; and we heartily commend his book to the attention of every practitioner."—*Dublin Medical Journal*.

Injuries and Diseases of the Genital and Urinary Organs.

By Henry Morris, M.A., M.B. Lond., F.R.C.S. Eng., Surgeon to, and Lecturer on Surgery at, the Middlesex Hospital, etc. etc. With 97 Illustrations. 21s.

"After a careful reading it will be admitted that neither the practitioner nor the student will look in vain for the satisfaction of his wants . . . Thoroughly practical and eminently readable."—*Practitioner*.

Diseases of the Joints and Spine.

By Howard Marsh, F.R.C.S., Surgeon to, and Lecturer on Surgery at, St. Bartholomew's Hospital, etc. *New and Revised Edition*. With 79 Illustrations. 12s. 6d.

"This volume is excellently planned. Mr. Marsh brings to bear upon it keen critical acumen."—*Liverpool Medico-Chirurgical Journal*.

Surgical Diseases of the Ovaries and Fallopian Tubes, including Tubal Pregnancy.

By J. Bland Sutton, F.R.C.S. With 146 Illustrations. *New and Enlarged Edition*. 21s.

"We have nothing but praise for the contents of the book."—*Edinburgh Medical Journal*.

Difficult Labour.

A Guide to its Management. For Students and Practitioners. By G. Ernest Herman, M.B. Lond., F.R.C.P. With 162 Illustrations. *Fifth Thousand*. 12s. 6d.

"The book is well arranged and profusely illustrated with excellent diagrams. It is a decided acquisition to the literature of midwifery, and we have pleasure in recommending it to all interested in the subject."—*Glasgow Medical Journal*.

On the Origin and Progress of

Renal Surgery, With Special Reference to Stone in the Kidney and Ureter; and to the Surgical Treatment of Calculous Anuria. Being the Hunterian Lectures for 1899. Together with a Critical Examination of Subparietal Injuries of the Ureter. By **Henry Morris, M.A., M.B. Lond., F.R.C.S.,** Surgeon to, and Lecturer on Surgery at, the Middlesex Hospital, etc. etc. With 23 Illustrations. *6s.*

Tumours, Innocent and Malignant: Their Clinical Characters and Appropriate Treatment. By **J. Bland Sutton, F.R.C.S.** With 250 Engravings and 9 Plates. *21s.*

"The work is one which will enhance the reputation of its author as a surgeon and pathologist. It would give a poor conception of the book if we did not refer to the wealth and beauty of its illustrations . . . a work which must have entailed on its author the expenditure of infinite labour and patience, and which there can be little question will rank high among works of its class."—*The Lancet.*

Diseases of the Skin. An Outline of the Principles and Practice of Dermatology. By **Malcolm Morris, F.R.C.S. Ed.,** Surgeon to the Skin Department, St. Mary's Hospital, London. *New and Revised Edition.* With Two New Coloured Plates and a Number of New Engravings. *10s. 6d.*

"The new edition of this book has been carefully edited and brought up to date . . . It gives within a relatively small compass an account of diseases of the skin sufficient for the needs of all but specialists; to the latter, also, it may be commended for the accuracy and conciseness with which all that is essential in the subject is summarised."—*British Medical Journal.*

On Gall-Stones and Their Treatment. By **A. W. Mayo Robson, F.R.C.S.,** Professor of Surgery in the Yorkshire College of the Victoria University, &c. &c. Illustrated. *9s.*

"There can be no question that this book well repays perusal, and will be the work to which all practitioners and students will turn for information on the surgery of the gall-bladder."—*Provincial Medical Journal.*

Surgical Diseases of Children. By **Edmund Owen, M.B., F.R.C.S.,** Senior Surgeon to the Hospital for Sick Children, Great Ormond Street; Surgeon to, and Lecturer on Surgery at, St. Mary's Hospital. With 5 Chromo Plates and 120 Engravings. *Third Edition, Revised and Enlarged.* *21s.*

"Mr. Owen's volume will rank as an invaluable *résumé* of the subject on which it treats."—*Medical Press and Circular.*

The Pulse. By **Sir W. H. Broadbent, Bart., M.D.,** Senior Physician to, and Lecturer on Clinical Medicine at, St. Mary's Hospital. Illustrated with 52 Sphygmographic Tracings. *9s.*

"There is so much that is interesting and well done, that it is hard to emphasise any."—*Hospital.*

Ophthalmic Surgery. By **R. Brudenell Carter, F.R.C.S.,** Ophthalmic Surgeon to, and Lecturer on Ophthalmic Surgery at, St. George's Hospital; and **W. Adams Frost, F.R.C.S.,** Assistant Ophthalmic Surgeon to, and Joint-Lecturer on Ophthalmic Surgery at, St. George's Hospital. With Chromo Frontispiece and 91 Engravings. *Second Edition.* *9s.*

"Its clearness and conciseness will cause it to be welcomed by students and young practitioners as an agreeable and useful guide to the modern practice of eye diseases."—*British Medical Journal.*

Diseases of the Rectum and Anus.

By Charles B. Ball, M.Ch. (Dublin), F.R.C.S.I., Surgeon and Clinical Teacher at Sir P. Dun's Hospital. With Chromo Plates and 61 Engravings. *Second Edition.* 9s.

"As a full, clear, and trustworthy description of the diseases which it deals with, it is certainly second to none in the language. The author is evidently well read in the literature of the subject, and has nowhere failed to describe what is best up to date. The model of what such a work should be."—*Bristol Medico-Chirurgical Journal*.

Diseases of the Breast.

By Thomas Bryant, F.R.C.S., Surgeon to, and Lecturer on Surgery at, Guy's Hospital. With 8 Chromo Plates and numerous Engravings. 9s.

"Mr. Bryant is so well known, both as an author and a surgeon, that we are absolved from the necessity of speaking fully or critically of his work."—*The Lancet*.

Diseases of the Tongue.

By H. T. Butlin, F.R.C.S., Assistant Surgeon to St. Bartholomew's Hospital. With 8 Chromo Plates. 9s.

"Mr. Butlin may be congratulated upon having written an excellent manual, scientific in tone, practical in aim, and elegant in literary form. The coloured plates rival, if not excel, some of the most careful specimens of art to be found in the pages of European medical publications."—*British Medical Journal*.

Syphilis.

By Jonathan Hutchinson, F.R.S., F.R.C.S., Consulting Surgeon to the London Hospital and to the Royal London Ophthalmic Hospital. With 8 Chromo Plates. *Seventh Thousand.* 9s.

"The student, no matter what may be his age, will find in this compact treatise a valuable presentation of a vastly important subject. We know of no better or more comprehensive treatise on syphilis."—*Medical News, Philadelphia*.

Surgical Diseases of the Kidney.

By Henry Morris, M.B., F.R.C.S., Surgeon to, and Lecturer on Surgery at, Middlesex Hospital. With 6 Chromo Plates and numerous Engravings. 9s.

"It would be difficult to find these subjects treated more carefully and thoroughly."—*British Medical Journal*.

Insanity and Allied Neuroses.

By George H. Savage, M.D., Medical Superintendent and Resident Physician to Bethlem Royal Hospital, and Lecturer on Mental Diseases at Guy's Hospital. With numerous Illustrations. *Seventh Thousand.* 9s.

"Dr. Savage's grouping of insanity is practical and convenient, and the observations in each group are acute, extensive, and well arranged."—*The Lancet*.

Clinical Methods:

A Guide to the Practical Study of Medicine By Robert Hutchison, M.D., M.R.C.P., Demonstrator in Physiology, London Hospital Medical College; and Harry Rainy, M.A., F.R.C.P. Ed., F.R.S.E., University Tutor in Clinical Medicine, Royal Infirmary, Edinburgh. With 137 Illustrations and 8 Coloured Plates. 9s.

"It is fresh, terse, thoroughly up to date, and obviously the result of much practical experience in teaching on the part of both authors. An abundance of good material is crowded into the volume, and the standard of accuracy maintained is very high. We have very little doubt that this book will rapidly win for itself a large measure of success."—*The Lancet*.

Diseases of the Ear.

By A. Marmaduke Sheld, M.B. Cantab., F.R.C.S. Eng. With 4 Coloured Plates and 34 Woodcut Illustrations. 10s. 6d.

"This compact and handy little work contains practically all that is required by the student or the general practitioner in the way of a guide to the diagnosis and treatment of diseases of the ear."—*British Medical Journal*.

Manuals for Students and Practitioners of Medicine (*Contd.*).

Intestinal Obstruction. By Frederick Treves,
F.R.C.S. *New and Enlarged Edition. Illustrated. 21s.*
In Preparation.

Food in Health and Disease. By I.
Burney Yeo, M.D., F.R.C.P., Professor of the Principles and
Practice of Medicine in King's College. *New and Enlarged*
Edition. 10s. 6d.

"We think that Dr. Yeo is to be congratulated on having accomplished his desire;
we became more and more favourably impressed with the work as we went through the
various chapters, and we have no doubt that it will attain, as it deserves, a great success."
—*The Lancet.*

MANUALS FOR Students of Medicine

Published by CASSELL & COMPANY.

Elements of Histology. By E. Klein, M.D.,
F.R.S., Lecturer on General Anatomy and Physiology in the
Medical School of St. Bartholomew's Hospital, London; and J. S.
Edkins, M.A., M.B., Joint Lecturer and Demonstrator of Physio-
logy in the Medical School of St. Bartholomew's Hospital, London.
Revised and Enlarged Edition, with 296 Illustrations. 7s. 6d.

"A work which must of necessity command a universal success. It is just exactly
what has long been a desideratum among students."—*Medical Press and Circular.*

Hygiene and Public Health. By B.
Arthur Whitelegge, M.D., B.Sc. Lond., D.P.H. Camb.,
Medical Officer of Health to the West Riding County Council.
With 23 Illustrations. *Sixth Edition. 7s. 6d.*

"It is in every way perfectly reliable, and in accordance with the most recently
acquired knowledge."—*British Medical Journal.*

Elements of Surgical Pathology.
By A. J. Pepper, M.S., MB., F.R.C.S., Surgeon and Teacher of
Practical Surgery at St. Mary's Hospital. Illustrated with 99 En-
gravings. *Fourth Edition, rewritten and enlarged. 8s. 6d.*

"A student engaged in surgical work will find Mr. Pepper's 'Surgical Pathology' to
be an invaluable guide, leading him on to that correct comprehension of the duties of a
practical and scientific surgeon which is the groundwork of the highest type of British
Surgery."—*British Medical Journal.*

Clinical Chemistry. By CHARLES H. RALFE,
M.D., F.R.C.P., Physician at the London Hospital. With numerous
Engravings. *5s.*

"The volume deals with a subject of great and increasing importance, which does
not generally receive so much attention from students as it deserves. The text is concise
and lucid, the chemical processes are stated in chemical formulæ, and wherever they
could aid the reader suitable illustrations have been introduced."—*The Lancet.*

Human Physiology. By HENRY POWER, M.B.,
F.R.C.S., late Examiner in Physiology, Royal College of Surgeons
of England. *Fourth and Enlarged Edition. 7s. 6d.*

"The author has brought to the elucidation of his subject the knowledge gained by
many years of teaching and examining, and has communicated his thoughts in easy, clear,
and forcible language, so that the work is entirely brought within the compass of every
student. It supplies a want that has long been felt."—*The Lancet.*

Materia Medica and Therapeutics.

By J. Mitchell Bruce, M.D., F.R.C.P., Lecturer on Materia Medica at Charing Cross Medical School, and Physician to the Hospital. A full account of the many important drugs contained in the Addendum to the British Pharmacopœia, recently issued, will be found in the NEW EDITION. 7s. 6d.

"We welcome its appearance with much pleasure, and feel sure that it will be received on all sides with that favour which it richly deserves."—*British Medical Journal*.

Surgical Applied Anatomy. By

FREDERICK TREVES, F.R.C.S. With 61 Engravings. 16th Thousand. 7s. 6d.

"The author of 'Surgical Applied Anatomy' is an able writer, and is also an authority on purely anatomical questions. There are excellent paragraphs on the anatomy of certain well-known surgical affections, such as hip-joint diseases, constituting a feature quite original in a work of this class, yet in no way beyond its proper scope."—*London Medical Recorder*.

A Manual of Chemistry : Inorganic and

Organic, with an Introduction to the Study of Chemistry. For the Use of Students of Medicine. By Arthur P. Luff, M.D., B.Sc. Lond., M.R.C.P.; Fellow of the Institute of Chemistry, etc. etc. With numerous Engravings. Third Thousand. 7s. 6d.

"The author is evidently a master of his subject, and the work is one which may be confidently recommended to the student of chemistry."—*Hospital Gazette*.

Elements of Surgical Diagnosis : A

Manual for the Wards. By A. Pearce Gould, M.S., M.B., F.R.C.S., Senior Assistant Surgeon to Middlesex Hospital. 7s. 6d.

"We do not hesitate to say that Mr. Gould's work is unique in its excellence."—*The Lancet*.

Comparative Anatomy and Physio-

logy. By F. Jeffrey Bell, M.A., Professor of Comparative Anatomy at King's College. With 229 Engravings. 7s. 6d.

"The book has evidently been prepared with very great care and accuracy, and is well up to date. The woodcuts are abundant and good."—*Athenæum*.

Physiological Physics. By J. McGregor-

Robertson, M.A., M.B., Muirhead Demonstrator of Physiology, University of Glasgow. With 219 Engravings. 7s. 6d.

"Mr. McGregor-Robertson has done the student the greatest service in collecting together in a handy volume descriptions of the experiments usually performed, and of the apparatus concerned in performing them."—*The Lancet*.

First Lines in Midwifery. A Guide to

Attendance on Natural Labour. By G. E. Herman, M.B. Lond., F.R.C.P., F.R.C.S., Obstetric Physician and Lecturer on Midwifery, London Hospital. With 81 Illustrations. Sixth Thousand. 5s.

"This manual is of considerable merit, and is likely to prove highly popular in London schools and lying-in hospitals."—*British Medical Journal*.

The Student's Handbook of Surgical

Operations. By Frederick Treves, F.R.C.S. With 94 Illustrations. Sixth Thousand. 7s. 6d.

Works by Cassell & Company.

Authoritative Work on Health by Eminent Physicians and Surgeons.

The Book of Health : A Systematic Treatise for the Professional and General Reader upon the Science and the Preservation of Health. *21s.* Roxburgh, *25s.*

"Is what it aims to be—authoritative, and must become a *standard work of reference* not only with those who are responsible for the health of schools, workshops, and other establishments where there is a large concourse of individuals, but to *every member of the community.*"—*Lancet.*

Clinical Papers on Surgical Subjects.

By **Herbert W. Page, M.A., M.C. Cantab., F.R.C.S. Eng.,** Surgeon to St Mary's Hospital and Lecturer on Surgery at its Medical School; Member of the Court of Examiners, Royal College of Surgeons. *5s.*

ENLARGED SERIES, in MONTHLY PARTS. Price 2s.

Annals of Surgery. A Monthly Review of Surgical Science and Practice. "Annals of Surgery" is the only high-class Journal published in the English language, devoted exclusively to presenting current work in the science and art of surgery. A subscription of One Guinea, paid in advance, will secure the Journal being sent post free for one year.

The Uric Acid Diathesis. By **Dr. F. Levison.**

Translated from the German and edited by **Lindley Scott, M.A., M.D.** Being a Compendium of Recent Investigations on the Pathology and Treatment of Gout, Sand, and Gravel. *3s. 6d.*

A Guide to the Instruments and Appliances Required in Various Operations.

By **A. W. Mayo Robson, F.R.C.S.** *1s. 6d.*; post free, *1s. 7d.*

Vaccination Vindicated. Being an Answer to the Leading Anti-Vaccinators. By **John C. McVail, M.D., D.P.H. Camb.**; President of the Sanitary Association of Scotland, etc. *5s.*

Medical Handbook of Life Assurance.

For the use of Medical and other Officers of Companies. By **James Edward Pollock, M.D., F.R.C.P.,** and **James Chisholm** (Fellow of the Institute of Actuaries, London, and of the Faculty of Actuaries, Scotland). *Fourth Edition. 7s. 6d.*

The Year-Book of Treatment : A Critical

Review for Practitioners of Medicine and Surgery. Issued Yearly. *7s. 6d.*

"It is a book of extreme value to all who in these busy times find it difficult to keep pace with the ever-advancing march of the science and art of medicine."—*Lancet.*

NEW SERIES.

The Practitioner. A Journal of Practical Medicine

Edited by **Malcolm Morris, F.R.C.S. Edin.** Monthly, *2s.*; Yearly Subscription, *21s.*; Half-Yearly Volume, *15s.*

"Is now one of the cheapest and best of the medical periodicals at home or abroad."—*Dublin Journal of Medical Science.*

Works by Cassell & Company.

Cookery for Common Ailments. By
A Fellow of the Royal College of Physicians, and Phyllis
Browne. Limp cloth. 1s.

"Cram-full of information, overflowing with helpful detail and invaluable advice."—*Pall Mall Gazette*.

Handbook of Nursing for the Home and for the
Hospital. By CATHERINE J. WOOD, Lady Superintendent of
the Hospital for Sick Children, Great Ormond Street. *Tenth and
Cheap Edition.* 1s. 6a.; cloth, 2s.

"A book which every mother of a family ought to have, as well as every nurse
under training."—*Guardian*.

**A Handbook for the Nursing of Sick
Children.** By CATHERINE J. WOOD. 2s. 6d.

"Miss Wood's book is succinct clearly written, and goes straight to the heart of
each detail in a thoroughly business-like fashion."—*Health*.

**Advice to Women on the Care of
their Health, Before, During and After
Confinement.** By FLORENCE STACPOOLE, Diplômée
of the London Obstetrical Society, etc. etc. Paper covers, 1s.; or
cloth, 1s. 6d.

"Is written very sensibly, and with no affectation of superior knowledge, but simply
and directly to meet obvious wants in private home nursing."—*Glasgow Herald*.

**Our Sick and How to Take Care of
Them;** or, Plain Teaching on Sick Nursing at Home. By
FLORENCE STACPOOLE. *Third Edition.* Paper covers, 1s.; or
cloth, 1s. 6d.

"Well written and very much to the point. The book will be valuable to anyone
called upon to perform the responsible and arduous duty of nursing the sick."—*British
Medical Journal*.

An Address in School Hygiene. By
CLEMENT DUKES, M.D. 1s.

CASSELL & COMPANY'S COMPLETE CATALOGUE, con-
taining particulars of upwards of One Thousand Volumes,
including Bibles and Religious Works, Illustrated and
Fine-Art Volumes, Children's Books, Dictionaries,
Educational Works, History, Natural History, Household
and Domestic Treatises, Science, Travels, &c., together
with a Synopsis of their numerous Illustrated Serial
Publications, sent post free on application.

CASSELL & COMPANY, LIMITED, Ludgate Hill, London:
Paris, New York & Melbourne.

