

A clinical, pathological, and experimental study of fracture of the lower end of the radius : with displacement of the carpal fragment toward the flexor or anterior surface of the wrist / by John B. Roberts.

Contributors

Roberts, John B. 1852-1924.
University College, London. Library Services

Publication/Creation

Philadelphia : P. Blakiston, 1897.

Persistent URL

<https://wellcomecollection.org/works/mxw2cv2c>

Provider

University College London

License and attribution


This material has been provided by This material has been provided by UCL Library Services. The original may be consulted at UCL (University College London) where the originals may be consulted.

This work has been identified as being free of known restrictions under copyright law, including all related and neighbouring rights and is being made available under the Creative Commons, Public Domain Mark.

You can copy, modify, distribute and perform the work, even for commercial purposes, without asking permission.



Wellcome Collection
183 Euston Road
London NW1 2BE UK
T +44 (0)20 7611 8722
E library@wellcomecollection.org
<https://wellcomecollection.org>



Arch.

Ortho SC
WE 820 ROB

c

WITHDRAWN


~~F2h2Ro~~


~~QUEENS COUNTY MEDICAL SOCIETY~~

~~118-25 QUEENS BLVD.,~~


~~FOREST HILLS, N. Y.~~

~~9637~~











A CONTRIBUTION
FROM THE
SURGICAL LABORATORY
OF THE
PHILADELPHIA POLYCLINIC AND COLLEGE
FOR GRADUATES IN MEDICINE.



A CLINICAL, PATHOLOGICAL, AND EXPERIMENTAL
STUDY OF FRACTURE OF THE LOWER
END OF THE RADIUS

WITH DISPLACEMENT OF THE CARPAL FRAGMENT
TOWARD THE FLEXOR OR ANTERIOR
SURFACE OF THE WRIST.

is there
BY

JOHN B. ROBERTS, A.M., M.D.,

PROFESSOR OF ANATOMY AND SURGERY IN THE PHILADELPHIA POLYCLINIC; PROFESSOR OF SURGERY IN
THE WOMAN'S MEDICAL COLLEGE OF PENNSYLVANIA; SURGEON TO THE
METHODIST AND JEWISH HOSPITALS.

WITH THIRTY-THREE ILLUSTRATIONS.

PHILADELPHIA:
P. BLAKISTON, SON & CO.

1012 Walnut Street.

1897.

3035

CONTENTS.

	PAGE
CASES AND SPECIMENS	5
EXPERIMENTAL OBSERVATIONS	42
CAUSES AND MECHANISM	47
SYMPTOMS	54
DIAGNOSIS	69
TREATMENT	73



A CLINICAL, PATHOLOGICAL, AND EXPERIMENTAL
STUDY OF FRACTURE OF THE LOWER END
OF THE RADIUS WITH DISPLACEMENT OF
THE CARPAL FRAGMENT TOWARD
THE FLEXOR OR ANTERIOR
SURFACE OF THE WRIST.

CASES AND SPECIMENS.

It is believed by many that forward displacement of the lower fragment in fractures of the base of the radius is of rarest occurrence, and that the backward or dorsal displacement is almost universal. While it is true that the latter is the common deformity, the forward displacement happens in a considerable number of instances.

The usual, or so-called classical, fracture of the radial base, to which the name of Colles has been attached by English writers, generally, if not always, occurs because the patient receives the force of a fall upon the palmar surface of the hand. The displacement is the result not of muscular action but of the vulnerating force; and the relative position of the fragments will be practically always the same, if the force has been sufficient to cause separation of the fracture surfaces.

The exact line of break will make little difference, because the muscular surroundings have little to do with the causation or continuance of the distortion. In this injury the lower fragment is driven backward toward the dorsal surface of the forearm.

Displacement of the lower fragment in the opposite direction, that is, toward the flexor aspect of the wrist, would probably be

equally common, if the force was received as frequently on the back of the hand. A falling man usually extends his hands involuntarily, so as to receive the impact of the force on the palms. This circumstance probably accounts for the excessive relative frequency of backward displacement in basal fracture of the radius.

I have seen no fracture immediately after its receipt in which forward displacement had taken place; but on three occasions I have seen old fractures which seemed to have been injuries of this kind. The literature of the subject is scanty, but I have collected a number of recorded cases, and have obtained accounts of others by personal correspondence. A limited search in museums has been rewarded by the discovery of a fairly large number of specimens, most of which, however, have come from dissecting-rooms, and have, therefore, no clinical history.

The scarcity of reported cases is, without much doubt, due to the fact that the younger members of the medical profession have, as a rule, charge of the hospital dispensaries where the great proportion of forearm fractures are treated; while the older surgeons who would be more likely to recognize the interest of an unusual deformity have comparatively little opportunity to study such injuries critically.

CASE I. *Old injury to the wrist, believed to be fracture of the lower end of the radius, with anterior displacement of the carpal fragment.*—Author's first case. A man, J. McD., aged about thirty years, received an injury to the right wrist in the early part of 1891, which was about eighteen months before I made the cast of his forearm and hand. He was unloading lumber from a car, and, by some of the lumber falling, was thrown around in such a manner that he struck his right hand against the corner of the car, and to use his own expression, "put it out." Immediately after the injury his associates "pulled it into place." I was unable to get an accurate account of the exact position of the hand at the time of injury; but the patient seemed to think that it was bent backward and not forward. He seemed quite certain that the force was not applied to the hand in such a way as to flex it.

Some time after the injury, when the swelling had largely disappeared, he was sent to me by Dr. J. P. McCleery, of Milton, Pa. I concluded that the injury had been a fracture of the lower end of the radius, with the lower fragment displaced forward, and that union had taken place with the fragments in malposition, because reduction had not been accomplished. I determined to attempt refracture of the deformed union with the object of obtaining a better apposition of the fragments. While the patient was in the city for this purpose he became intoxicated, and suddenly went home.

FIG. 1.

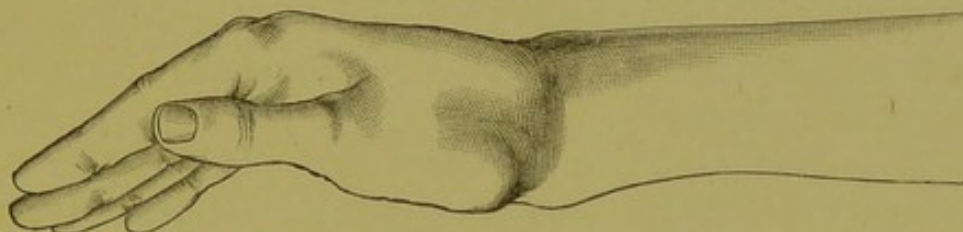
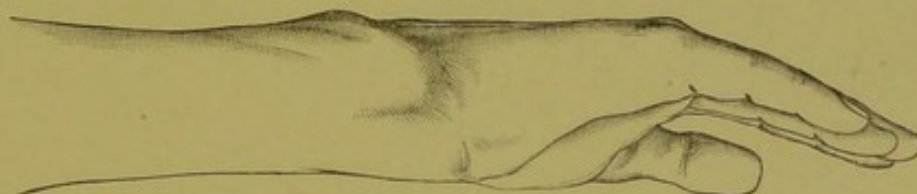


FIG. 2.



Forearm and hand of Case I. The prominence at the front of the lower end of the radius is seen in Fig. 1; the increased antero-posterior diameter in the same region is shown well in Fig. 2.

Some months afterward Dr. McCleery obtained for me the photographs of the wrist and hand, and, as stated above, I made a plaster cast of the arm and hand about eighteen months subsequent to the receipt of injury. At that time the patient had perfect use of the wrist and fingers, but experienced some pain in bad weather.

The head of the ulna seemed prominent on the dorsal surface of the wrist. There was a marked prominence on the palmar aspect of the wrist, which did not involve the lower end of the ulna. Above this prominence—that is, toward the elbow—I could push my fingers deeply inward toward the shaft of the radius; and it seemed as if there was quite a steep ledge of bone a short distance above the line of the wrist-joint, such as would be caused by a lower fragment thrust in front of the shaft of the bone. The prominence was very hard and was covered by the flexor tendons, which could be felt coming

over the edge of the supposed displaced fragment and to a certain extent concealing its outlines. The back of the wrist at the radial side presented no special change; at least none was observed by me, who had not then, it must be admitted, as much knowledge of the injury as I have now. Perhaps I would now notice slight changes then overlooked.

I examined carefully for the possible existence of dislocation, but the deformity on the palmar surface did not present the appearance of a forward displacement of the carpus. I had no opportunity for accurate measurements, but the absence of the normal hollow on the palmar surface of the wrist was very evident when the injured wrist was compared with the sound one. The bulging of a hard mass against the flexor tendons, just above the wrist-joint of the abnormal limb, was very evident.

CASE II. *Old injury of the right wrist shown by skiagraphy to have been fracture of the lower end of the radius, with forward displacement of the carpal fragment.*—Author's second case. In April, 1894, I had under my care at the Woman's Hospital a woman thirty-nine years of age, who about twenty months previously had fallen down a stairway into a cellar.

FIG. 3.

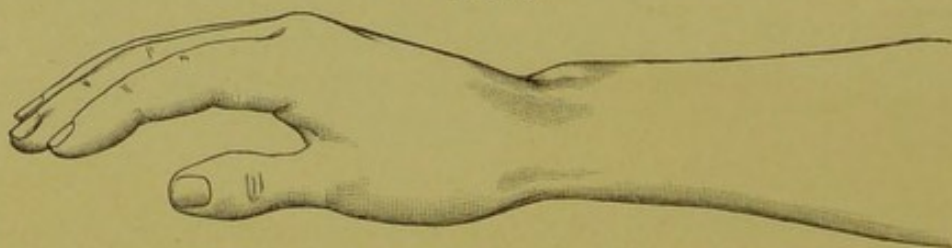
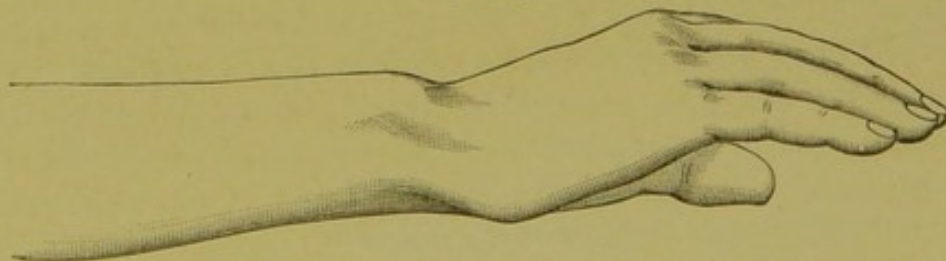


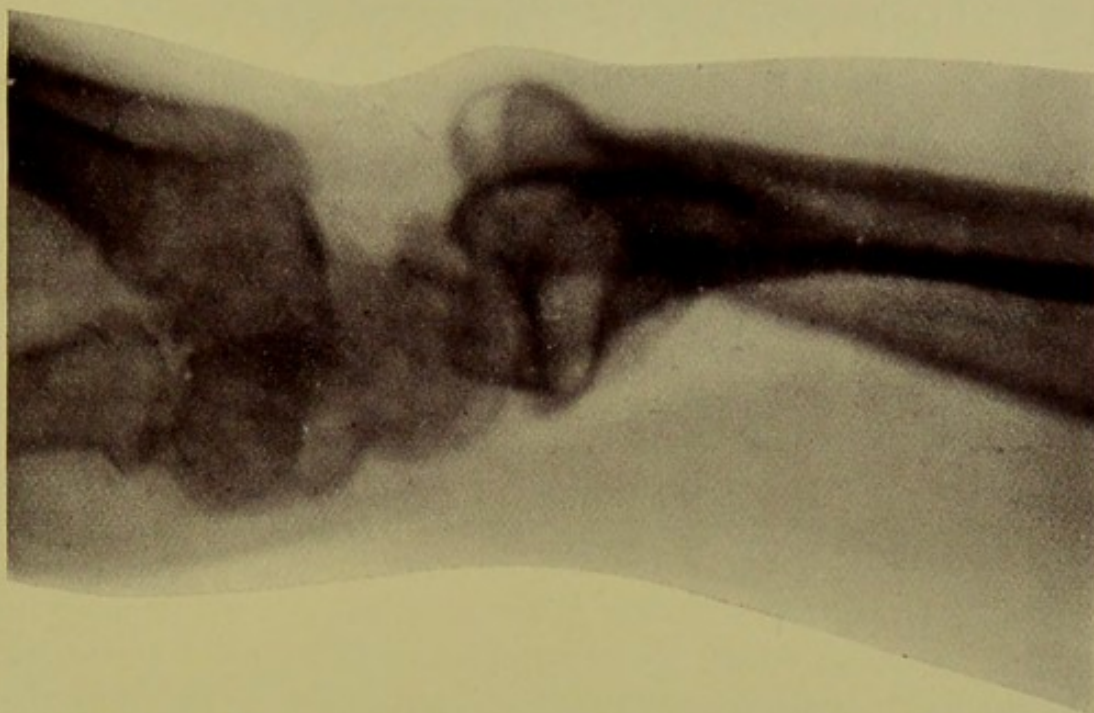FIG. 4.



Forearm and hand of Case II. The prominence of the head of the ulna is shown in Fig. 3. In Fig. 4 the forward displacement of the hand due to the fracture is very evident.

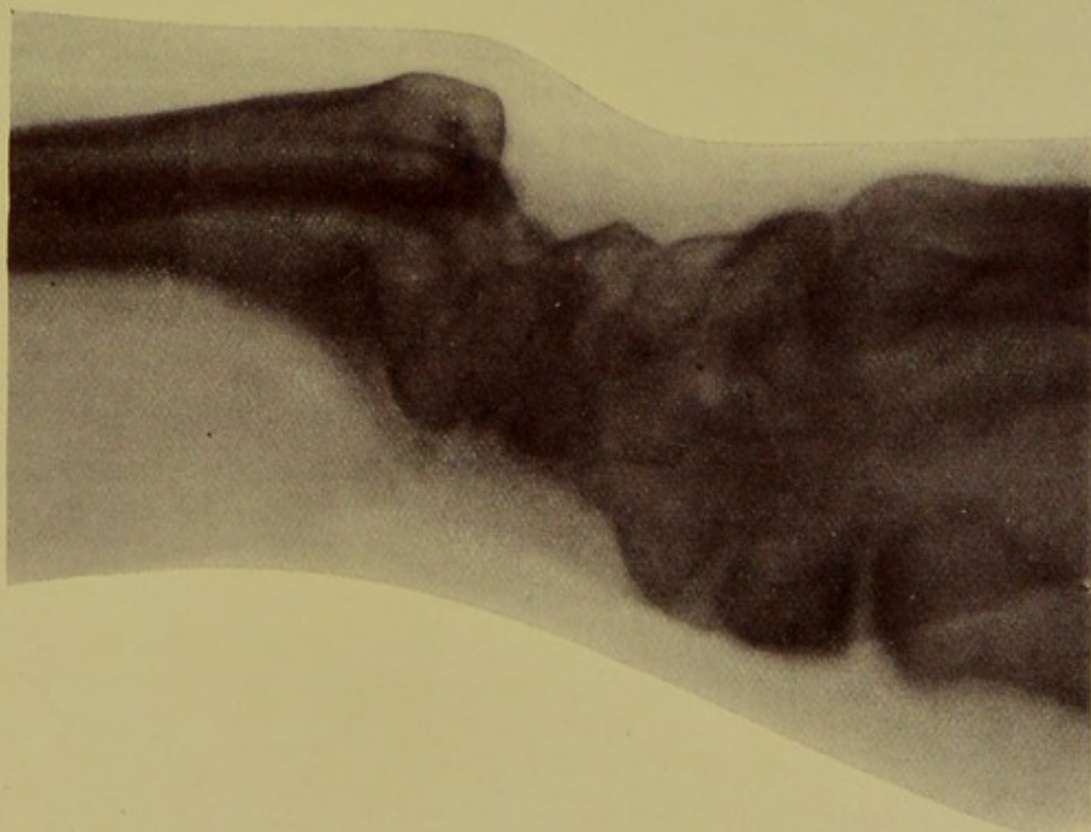Voluntary extension and flexion at the wrist were impaired, and pronation and supination almost if not entirely absent. Passive prona-

FIG. 5.



Skiagraph of Case II., showing the curve in the lower portion of the radius due to the displacement forward of the lower fragment. The prominence of the head of the ulna at the dorsum is conspicuous. [Radial border of wrist was placed next to the photographic plate.]

FIG. 6.



Skiagraph of Case II., exhibiting the manner in which the hand and carpus lose their normal relations to the ulna after fracture of the radial base with anterior displacement. [Ulnar border of wrist was placed next to the photographic plate.]



tion and supination could be made to a slight extent, but caused pain. There was an abnormal deflection of the hand to the radial side, such as is seen after the ordinary fracture of the base of the radius, and due to shortening of the bone. The ulna was abnormally prominent on the back of the wrist, and the carpus on the ulnar side seemed to be displaced forward. The outside of the head of the ulna seemed to be a little irregular, as if there might have been a line of fracture there. The tendons of the radial flexor of the wrist and of the long palmar muscle were exceedingly prominent on the palmar aspect of the forearm near the wrist-joint. At the ulnar side of these tendons was felt upon deep pressure a hard mass, apparently of bone. On the back of the wrist below the head of the ulna, and crossing over to the radial side, a distinct transverse groove was felt by deep pressure. It was either in the carpal region or at the lower end of the radius. This gave the impression that for some reason the carpal bones, with, perhaps, a detached piece of the radius, occupied a more anterior position than normal.

The patient could not close her fingers entirely. By the greatest effort she could not bring the partially flexed fingers nearer to the palm than one inch. Flexion of the little finger was less perfect than of the other fingers. Massage and frictions with liniment were prescribed, and the patient's pain was somewhat relieved thereby. The rigidity of the wrist and fingers became less marked. She can now, September, 1896, flex the fingers, except the little finger, until their tips almost touch the palm. She can pronate almost completely, but can only supinate partially. The movements are feeble.

Repeated examination led me to believe that the original injury was more probably a fracture of the lower end of the radius with displacement of the carpal fragment toward the palmar aspect than a forward dislocation of the carpal bones from the lower end of the radius. The accompanying illustrations will give some idea of the appearance of the wrist.

The discovery of the permeability of the soft parts of the human body to the Röntgen rays has recently given me opportunity to prove the correctness of my diagnosis. The skiagraphs taken for me by Prof. Goodspeed show that the fracture was similar to the specimen in the cabinet of the New York Hospital, described in a later part of this essay.

CASE III.¹ *Probable fracture of the lower end of the radius, with forward displacement, due to extreme flexion of the wrist.*—Author's third case. I recently met socially a young physician who had injured his left wrist a year and a half previously while playing foot-ball. He said that while passing the ball from his left hand to his right side he was tackled and grasped by the left thigh. His left wrist was flexed at the time. He fell with his left arm and hand under him, and felt something snap at his wrist, as the joint was forcibly flexed between his body and the ground. The deformity consisted, he says, in the hand being displaced forward. His companions pulled on the hand to overcome the deformity, believing that he had sustained a dislocation of the wrist. He says that there was no "snap" such as is heard when a dislocation is reduced. A physician who examined the limb afterward obtained no crepitus, and thought no fracture had occurred, though the patient himself was convinced by the sound at the time of injury and his sensations that fracture had taken place; he thought it involved the carpal bones.

When I met this gentleman there was a marked thickening of the lower end of the radius in the antero-posterior diameter, and a hard projection could be felt under the flexor tendons. I have little doubt that he sustained a fracture of the radial base, with forward displacement of the carpal fragment. The displacement was either not great or was partially, but not completely, reduced immediately after its occurrence by efforts to reduce a supposed luxation.

This fracture, as that with backward displacement, frequently gives no crepitus unless the impacted fragments are disentangled. This circumstance, combined with the inconsiderable deformity when it was examined, may have deceived the attendant who treated the patient.

If the injury had been a dislocation of the radio-carpal joint, there would probably either have been noticed a "snap" at the time reduction was attempted, or marked deformity would have persisted to the present time; and the moderate deformity of the palmar surface of the lower end of the radius, now present, would not have occurred. I endeavored to have a skiagraph taken of the lateral aspect of this gentleman's forearm, but failed to obtain it.

¹ During the progress of this monograph through the press I examined a fourth case in a boy of fourteen years, who fell from a tree eighteen months previously. The fracture had not been reduced, and the fragment could easily be felt under the flexor tendons. The ulnar head was prominent laterally, and the hand displaced to the radial side.

A most instructive case, of which I have knowledge through the courtesy of Dr. Addinell Hewson, Jr., is the following, in which two surgeons believed that a fracture with forward displacement existed. An examination made some months after the receipt of injury convinced me that the lesion was confined to the soft parts, and was not a fracture, though the photograph made at the time the patient was under Dr. Hewson's care certainly would lead to the belief that the fracture existed:

Injury of the wrist, resembling fracture of the lower end of the radius, with forward displacement of the carpal fragment.—Dr. A. Hewson's case of injury resembling fracture. A boy of thirteen years was hurt in October, 1891, while riding in a barrow or pushcart. While sitting in the cart, which was being pushed by a man, his right hand, which hung over the side of the vehicle, was caught either between the wheel and the side of the cart or between the spokes. The boy's account of the manner of the injury was not very clear. His right wrist was injured, but he gave it no especial attention until at the end of two or three weeks he applied for treatment at the dispensary of the Episcopal Hospital.

He was seen by Dr. Addinell Hewson, Jr., who, from the deformity, considered the patient to have sustained a fracture of the lower end of the radius, with forward displacement of the lower fragment, and had a photograph of the arm taken by Dr. Tunis. Dr. William Barton Hopkins, attending surgeon to the hospital, saw the patient at Dr. Hewson's request, and concurred in the belief that the injury was that mentioned. The two surgeons concluded, however, to make no attempt at reducing the supposed fracture, as consolidation had probably taken place if such fracture had actually occurred. The boy shortly disappeared from observation.

About five months afterward I saw the boy, after having made considerable search for him, because of my interest in the photograph which Dr. Hewson had kindly presented to me. I examined the patient carefully and had plaster-casts made of both wrists. The left wrist had never been injured. The right one seemed to me to be practically identical in its outlines with the uninjured wrist. At this time all swelling had disappeared, and no one would have suspected that any serious injury had ever been received by the radius or the soft tissues of the right arm. I made very careful study of the case because of my interest in the subject, and came to the conclusion

that there was perhaps a little thickening about the radius at its lower extremity. The movements of the fingers and of the wrist were perfect. It would seem, therefore, that this case was an instance of contusion and inflammation of the soft parts of the wrist, accompanied by great swelling and inflammatory exudation on the palmar surface of the lower arm, simulating deformity due to bony displacement after fracture.

As no treatment looking toward reduction had been instituted by Dr. Hewson, and as the patient, after omitting hospital treatment, had had no other surgeon reduce the fracture, it seems evident that the deformity could not have been the result of a bony lesion.

I shall now give the histories of a number of cases which I have collected by personal correspondence and the insertion of journal notices asking for information of such fractures. They are, I believe, in all instances published now for the first time.

CASE IV. *Fracture of the lower end of the radius, with forward displacement of the lower fragment.*—Dr. Frank N. Drake, of San Francisco, informs me that in 1889 he met with this case while practising in Nevada. A man came to him for treatment for what he called a "sprained wrist." The injury had been sustained more than two weeks previously. Dr. Drake writes me thus: "On removing the arnica-soaked dressings from his hand and wrist a fracture of the lower end of the radius, with marked displacement of the lower fragment forward, could plainly be seen, requiring no manual examination to determine the condition." He "tried to rock the carpal fragment back into its place, but could not fully succeed in overcoming the deformity." Among a number of cases of fracture of the lower end of the radius he had seen only this one with forward displacement. In the case mentioned he has an indistinct recollection that the accident occurred as the result of the man's horse falling while he was riding, and that there was some evidence of slight abrasion of the skin on the back of the hand, as if the force of the blow had been expended upon that surface during flexion of the wrist-joint.

CASE V. *Injury near the wrist-joint; possibly fracture of the radius, with anterior displacement of the lower fragment.*—Dr. T. E. Nott, Jr., of Spartanburg, South Carolina, informs me that in 1890 he treated a woman who had fractured the lower end of the radius by falling while going up some rickety steps with an armful of wood.

The fracture was near the wrist-joint, and the lower fragment was displaced toward the palmar aspect of the limb. Dr. Nott says the deformity was curious, and that he was very much at a loss to understand the exact injury. He reduced the deformity by manipulation, which consisted in pulling upon the hand and pressing the lower fragment backward. A gypsum bandage was applied, and the result was "by no means good."

In this case the report is necessarily defective, because no accurate notes were taken, and the case is only reported from memory. It is possible that it may have been a dislocation of the carpus forward.

CASE VI. *Fracture of the lower end of the radius, with displacement forward and great mobility of the carpal fragment.*—In April, 1894, Dr. J. Clark Stewart, of Minneapolis, wrote me that he had recently had a case of fracture of the lower end of the radius, in which the lower fragment was displaced forward. There was a great deal of bruising and swelling. Reduction was easy under an anæsthetic. He was struck with the peculiar anterior displacement of the lower fragment and the marked difference in the deformity from that pertaining to the commonly seen fracture at this point. The unusual mobility of the lower fragment he attributed to great laceration of the periosteum on the dorsal surface of the bone, and felt sure that no dislocation of the carpus existed. I append a report of the case given in Dr. Stewart's own words:

"The injury occurred in a rather stout woman, aged forty-five years, who slipped on an icy, sawdust-covered sidewalk, and fell heavily, striking on her back with her right arm twisted under her. I saw her in consultation two hours after the accident, and found the wrist greatly swollen. The hand was resting upon the knee and the palm downward, while the forearm was in a semi-prone position. Under an anæsthetic it was easily determined that there was a fracture of the lower end of the radius, the lower fragment being about three-quarters of an inch in length, displaced anteriorly and rotated, causing exaggerated pronation of hand. Reduction was easy, but retention required support, as the hand and lower fragment tended to fall forward. The fracture was treated by flat anterior and posterior board splints till the tenth day, when it was put up in plaster, and again eight days later. The result is good as to function but only fair cosmetically, as there is slight twisting of the hand toward the radial side. There is marked callus both anteriorly and posteriorly."

CASE VII. *Fracture at the upper part of the base of the radius, with forward displacement of the lower fragment.*—In January, 1894, Dr. W. G. Johnston, of Titusville, Pa., had the following case under his professional care:

"Mrs. R., colored, aged fifty-one years, slipped on an icy walk and fell backward, striking the back of the right arm on a fence picket, fracturing the radius about one inch from the carpal end and displacing the carpal end anteriorly. The fracture was easily reduced and treated on a Bond splint, and made an uninterrupted recovery, with perfect motion. The fracture was through the upper part of the base of the radius" "The displacement of the lower fragment was toward the flexor tendons, and the reason for this in this case was, I think, because the fracture was due to direct force applied to the bone, the bone striking on a picket of a fence when it was fractured. There was no impaction of the fragments. The lower end of the ulna was somewhat more prominent than usual, due to the lateral displacement of the hand. There is no change in the appearance of the radial side of the wrist at the present time, and motion is as perfect as it was before, and only a small layer of callus can be felt."

CASE VIII. *Transverse fracture of the left radius, with anterior displacement of the carpal fragment.*—The following case is reported to me by Dr. E. K. Sprague, of the United States Marine-Hospital Service:

"W. B., aged thirty-nine years; admitted to U. S. Marine Hospital, Cairo, Illinois, January 24, 1894. Patient stated that twenty-four hours before admission, while in a state of intoxication, he had fallen, striking upon his left hand. The exact position his hand was in at the moment of injury could not be ascertained. There was a transverse fracture of left radius about 2.5 cm. above its carpal articulation. The lower or carpal fragment was displaced anteriorly, and the end could be distinctly made out beneath the flexor tendons. The fracture was reduced by extension, and a good result followed."

CASE IX. *Compound transverse fracture of the lower end of the radius, with displacement forward of the lower fragment; coincident fracture of the ulna.*—A boy, aged twelve years, fell on October 7, 1893, from a tree, a distance of twenty feet. Dr. J. R. Lehman, of Mountville, Pa., saw him an hour afterward and says: "There was a compound transverse fracture of the radius three-fourths of an inch from the carpal extremity, with an oblique fracture of the ulna one inch higher."

There was such a marked forward displacement of the lower end that the whole fractured end was exposed to view. The wound corresponded to the site of the fracture, and was one inch in length. Under chloroform I reduced the fracture, washed the parts with a bichloride solution, and applied pasteboard as a temporary dressing. Five hours afterward I took Dr. Alexander Craig, of Columbia, with me to see the case. We removed the splints, applied chloral hydrate, three drachms to a pint of water, as an antiseptic, and used Day's posterior splint. In spite of our antiseptic, part of the carpal end became necrosed. Dr. Craig on February 10th removed all of the necrosis. At the present time the bone is solid. There are some contractions of the flexor tendons, but the deformity is only trifling, the usefulness is normal."

CASE X. *Fracture of the lower end of both radii, with forward displacement of the lower fragment in each case.*—Dr. W. M. Mastin's (Mobile) case. A boy, aged ten years, while swinging from a trapeze bar, fell from a height about eight feet, fracturing the lower end of each radius. There was marked forward displacement of the carpal fragment on the right side, while on the left the distal or carpal end of the bone was tilted forward, although to a less degree. Reduction was accomplished under ether, and the final result was admirable.

Dr. Mastin writes: "I do not now recall that there was any particular bruising of posterior surface of wrists, as if blow or force had been applied there, but do remember that there was in one arm—the right, I think—a good deal of blood extravasation on both sides of wrist. This was especially noticeable a week or ten days after the accident, and was still apparent even after splints were permanently removed."

CASE XI. *Fracture of the lower end of the radius, with forward displacement of the lower fragment and much injury to the integuments.*—Dr. C. H. Mastin's (Mobile) case. "Just at this time I recall only one case of the accident to which you refer. It happened last summer in a little girl, aged about twelve years, who climbed up a small tree, a limb broke and she fell some fifteen feet. The fracture you speak of occurred. I found it difficult to keep fragment in place owing to *injury of the integuments*; it would not bear the *least* pressure. Still she made a *good (?)* recovery. In falling caught upon palms of hands."

CASE XII. *Case of deformity of wrist due to forward displacement of lower fragment after fracture of the carpal end of radius.*—Dr. J.

McF. Gaston's (Atlanta) case. "A boy was brought to my clinic of last week with a united fracture of five weeks' standing, with anterior prominence just above the carpal end of the radius, which must have been a fracture with anterior displacement. There is considerable deformity from neglect of proper treatment, but I did not venture to interfere."

CASE XIII. *Fracture of the lower end of the radius, with forward displacement; difficulty in reduction.*—Dr. J. H. Packard's (Philadelphia) case. A woman, aged about fifty years, fell on the ice, and "had a marked displacement of the carpal fragment forward, or, at least, a deformity the reverse of that usual in Colles's fracture. I saw her at my office a few hours after the injury; great swelling had already occurred, and I never succeeded in effecting reduction. She had much inflammation of the thecæ, and when I last saw her was still suffering from stiffening of the joint and tendons, and neuralgic pain. I made one (perhaps two) efforts to break up the adhesions, but without success." The patient was under observation for three or four months, and was treated with electricity and massage.

CASE XIV. *Fracture of the lower end of the radius, with forward and outward displacement of the lower fragment.*—Dr. J. S. Wright's (Brooklyn) first case. "May 15, 1874, a girl, aged about ten years, was at play upon her father's cart, which stood on the street in front of his house. She fell to the cobble stone pavement, and struck the back of her right hand and wrist upon one of the stones. Her mother brought her to my office, and on examination I found a wound over the styloid process of the ulna; the hand bent forward and somewhat outward; posteriorly a depression at the location of the carpus and the lower end of the radius; a prominence just above this depression; a depression in front of the wrist just in front of this dorsal prominence. The lower fragment of the radius had been displaced forward and outward; the lower end of the ulna appeared prominent under the skin. There had been about five-eighths of an inch of the lower end of the radius broken off and displaced forward and somewhat outward, the angular displacement being the greater. The fragments were easily reduced by means of traction and counter-traction, aided by backward pressure upon the lower fragment and forward pressure upon the upper fragment. A trough splint made of wire-cloth and passive motion enabled me to bring about an excellent result."

CASE XV. *Fracture of the lower end of the radius, with forward displacement of the carpal fragment and fracture of the styloid process of*

the ulna.—Dr. J. S. Wright's second case. "In October, 1882, a laborer, aged about forty years, was thrown down by a runaway horse, and, as he fell he came down upon the back of his right wrist, injuring it severely. He was brought to my college clinic, where, on examination, I found a fracture of the base of the right radius, about one-half inch from the lower end. The lower fragment had been displaced forward so as to make a deformity similar to that in the previous case. The lower fragment had been displaced forward and somewhat outward, leaving the head of the ulna projecting backward and inward under the skin. The styloid process of the ulna had been broken off at its base. The soft parts on the back of the hand and the wrist had been severely bruised, but there was no wound. The treatment, reduction, retention, and passive motion, was the same as in the previous case. A good result followed."

As an appendix to this series of fifteen cases, all, or nearly all, of which are now first published, I, after an extensive search in medical literature, add the histories of the very few cases that I have been able to find recorded. The scarcity of such published clinical histories is due to the comparative rarity of the lesion, to medical men failing to print accounts of the instances seen by them, and to non-recognition of the injury.

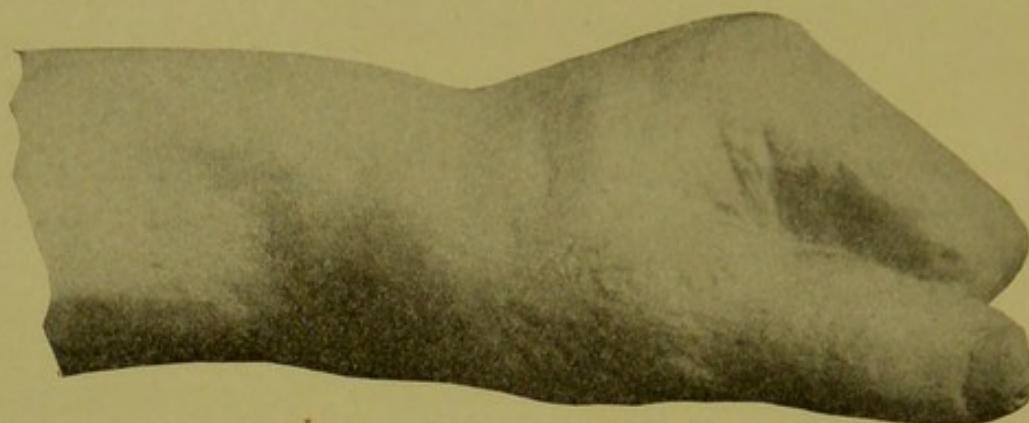
CASE XVI. *Fracture of the lower extremity of the radius, with displacement of the lower fragment forward.*—R. W. Smith,¹ of Dublin, in his classical work on *Fractures*, devotes, as is well known, considerable attention to this injury, which is, in consequence, sometimes called "Smith's fracture of the lower end of the radius." He tells of a case, which he figures in his book. He gives a very short history of its clinical details, though he writes quite an elaborate account of the fracture. I have obtained from Prof. Bennett, of Dublin, a photograph of the cast made of this patient's wrist. Bennett² says that this cast is Smith's only fact, and that it is clear from Smith's description that he had not the history of the case in his possession. Smith says: "In the case from which the preceding drawing was made, the patient, in endeavoring to save himself from being run over by a car, fell with great violence upon the back of the hand; the lower

¹ *Fractures in the Vicinity of Joints, etc.*, p. 164. Dublin, 1847.

² *Transactions of the Royal Academy of Medicine in Ireland*, 1892, vol. x. pp. 323-24.

end of the radius was broken and driven forward, along with the carpus, and the head of the ulna was displaced backward.

FIG. 7.



From photograph of plaster-cast of R. W. Smith's case. Case XVI.

CASE XVII. *Fracture of four weeks' duration, showing deformity due to want of reduction of the fragments*—Mr. George W. Callender's¹ (London) first case. "A female, aged fifty-one years, came to my out-patient room with a fracture of the carpal extremity of her right radius, of four weeks' duration. The forearm had been kept continuously at rest in the prone position on a straight splint. For the last week she had been directed to use the wrist twice daily. She complained of pain about the seat of fracture and of a considerable deformity. The bone had been broken across about three quarters of an inch from the carpus, and the distal fragment formed a well-marked projection on the palmar aspect; on the dorsal the proximal end was, of course, prominent. The wrist was fixed and half the rotation of the radius was lost—that is to say, there was no movement beyond that which placed the thumb uppermost from extreme pronation. By long-continued passive movements her condition was somewhat improved, so that flexion and extension at the wrist were slowly acquired. Whilst, however, flexion was exaggerated, extension was, in the end, less complete than natural. The bone deformity persisted.

"In this case no treatment could, I believe, have obviated the deformity or the damaged extension, although supination might perhaps have been bettered. Such bad results are sufficiently accounted for by post-mortem examination of similar fractures."

¹ St. Bartholomew's Hospital Reports, 1865, p. 281.

CASE XVIII. *Recent fracture, with such impaction that reduction was not accomplished.*—Mr. George W. Callender's¹ (London) second case. "A man employed in the General Postoffice attended my outpatient room in February, 1864. He had fallen a day or two previously with his left elbow projecting. The hand, bent at the extreme flexion, was crushed beneath his body, the full force of the blow falling upon the radius, as it was fixed between the bent hand and the ground. The nature of the injury had not been diagnosed. The wrist was the seat of great pain, and he was unable to move it. On the dorsum of the forearm was a well-marked prominence about three-quarters of an inch above the wrist-joint, toward which—the wrist—the radius inclined at an obtuse angle, with the remainder of the shaft, to the palmar surface, where it projected at the wrist. On this aspect and opposite to the dorsal prominence was a considerable depression. No crepitus could be detected, nor could I in any way reduce or lessen the deformity. The forearm and hand were fixed in partial supination by means of splints. Ten months later the deformity persisted; he had good rotation; but whilst flexion was exaggerated, he failed to extend the hand beyond a straight line with the forearm."

CASE XIX. *Green-stick fracture of both radii, produced by muscular action during galvanism.*—Mr. George W. Callender's² (London) third case. "On Whit-Monday, 1854, W. G., aged fourteen years, went to the Polytechnic, and was there galvanized. He was in good health and free from distortions of any kind. Whilst holding on to the conductor the shocks were increased in force, and he struggled violently to free himself, but for a time was unable to do so. His wrists subsequently became very painful, and the next morning he was unable to go to his work. A week later, after having been treated for a sprain, he came to the hospital. Either radius close to the carpal end was bent at a considerable angle to the shaft, so that on the dorsum there was on either forearm a well-marked prominence, greater on the right. All his other bones were natural. Mr. Stanley, who took much interest in the case, kept him under observation for some time, and by degrees he recovered good movement at the wrists, but he retained an unsightly deformity. It was presumed that either bone above its epiphysis had been bent or partially broken during the violent muscular efforts."

¹ St. Bartholomew's Hospital Reports, 1865, p. 289.

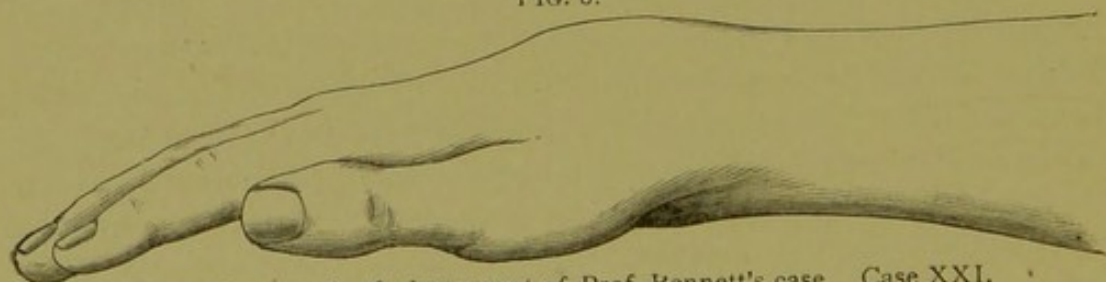
² Ibid., p. 295.

The report of this case is not very detailed; but I presume the boy took hold of a pair of handles to receive electrical shocks, with the intention of showing how strong a current he could receive without flinching. This experiment is often tried at exhibitions. It seems probable that the current produced strong contraction of the flexors of the wrists and fingers, and, bent by muscular action the soft bones of the young boy produced a partial or so-called "green-stick" fracture. Any one who has tried the experiment knows how powerful the muscular action of the flexors becomes under a strong current, and how difficult it is to let go of the metal handles or conductors through which the current is conveyed to the hands.

CASE XX. *Fracture followed by a perfect result, though wrist remained stiff at time of report.*—Dr. F. H. Hamilton's¹ (Buffalo) case. "Simple fracture; result perfect. T. B., of Buffalo, aged twenty-two years, fell, March 2, 1851, fifteen feet into the hold of a vessel. I was called about nine hours after the accident occurred. The left wrist was much swollen and the radius broken about one inch and a half above the joint. The lower fragment was displaced forward. I reduced the fragments and applied two broad, well-padded, straight splints. Three months after the bones were united without displacement, but the wrist remained stiff."

CASE XXI. *Fracture with great mobility of the fragments.*—Dr. E. H. Bennett's² (Dublin) case. "A jockey, aged nineteen years, was

FIG. 8.



From photograph of plaster cast of Prof. Bennett's case. Case XXI.

backing for the first time a three-year-old filly; she bucked, burst the girths, and sent saddle and rider into the air. The rider fell to the ground, striking first on the back of his right hand. I saw him the

¹ Transactions of the American Medical Association, 1856, vol. ix. p. 145.

² Transactions of the Royal Academy of Medicine in Ireland, 1892, vol. x. p. 325.

day following. The injury had been readily recognized by the deformity, the facility of reduction, and the distinct osseous crepitus felt on the reduction; immediately on the relaxation of the reducing force the deformity recurred. I took the patient into the hospital and verified the details, and treated him until union was obtained."

CASE XXII. *A case of fracture of both radii at the lower extremity: one with displacement of the lower fragment forward, the other with the usual displacement backward.*—Mr. James Hinshelwood's¹ case. "The deformity presented by the left forearm suggested at first sight a dislocation forward of the carpus; but, on examination, I found it was a fracture of the lower end of the radius, with displacement of the lower fragment forward. The deformity was exactly opposite to that of Colles's fracture, the relative positions of hollow and prominence on both dorsal and palmar aspects being reversed. On the dorsal aspect, instead of the prominence just above the carpus, there was a hollow, and above the hollow a marked rounded projection. On the palmar aspect opposite the annular ligament was a slight prominence, and above this a marked hollow."

CASE XXIII. *Oblique fracture of the lower end of the radius, with displacement forward.*—Poirier's² case. A coachman, aged thirty-eight years, was admitted in October, 1893, to the Lariboisière Hospital. On the day of his admission to the hospital he had been thrown by an accident from the box of his carriage to the road. His left hand, which held the reins between his flexed fingers, struck the ground rather on the dorsal surface of the fingers than of the heel of the hand, as was shown by abrasions of the skin on the dorsal surface of the second phalanges of the middle and index finger.

The swelling of the wrist did not at first permit an exact estimate to be made of the direction of the line of fracture. Two days later, however, it was easy to demonstrate on the dorsal surface of the lower extremity of the radius a marked bony edge belonging to the upper fragment carried backward and a little outward. The line of fracture, beginning at the internal surface, ran very oblique downward and outward, ran toward the base of the styloid process of the radius, where the upper fragment ended in a sharp point driven into the lower surface of the skin, which at this level showed a slight umbilicated depression. This point projecting outward simulated a second styloid

¹ British Medical Journal, November 3, 1888, p. 992.

² J. Hennequin, *Revue de Chirurgie*, 1894, xiv. p. 576.

process, situated half a centimetre above the tip of the first. There was no penetration of the fragments into each other. The upper fragment, movable in the antero-posterior direction, was directed backward and outward; the lower, which was situated at the inner side, was directed inward and forward. The deformity exhibited was caused more by the swelling than by the displacement of the fragments. The hand showed a tendency to incline toward the ulnar side in spite of a slight elevation of the styloid process of the radius. At the level of the insertions of the posterior and internal stylocarpal ligaments pressure caused quite severe pain. The fracture was reduced by the combined action of traction on the hand carried toward the ulnar side, and pressure in contrary directions on the extremities of the fragments.

The position of the hand during the fall—namely, the fist closed—the great obliquity of the line of fracture, and the displacement backward and outward of the upper fragment, whose sharp extremity pierced the deep layers of the skin, causing what looked like a second styloid process, gave this fracture a peculiar appearance very different from that seen in the ordinary so-called Colles's fracture. The mechanism, however, was the same, in the opinion of the reporter, although the hand was closed instead of being open, as is the rule in falls on the wrist. He asks whether the different effect of the injury on the lower extremity of the radius, on the extensive and peculiar obliquity of the line of fracture, and on the abnormal and rare displacement of the upper fragment should be attributed to the position of the fingers at the time of the receipt of the injury. The transmission of the resistance to the articular surface of the radius was not the same, he says, as when the thenar and hypo-thenar eminences sustain the shock first. The decomposition of forces had been more complex, passing at first through the flexed fingers forward to reach the bones of the carpus. These, without being protected from all direct pressure, were nevertheless compelled to modify their relations with the glenoid cavity, to which was transmitted the sum of the forces of resistance under a resultant of which the direction was different.

CASE XXIV. *Probable fracture of the lower end of the radius with displacement of the lower fragment forward, complicated with posterior dislocation of the ulna, occurring in childhood.*—Cruveilhier's case. Malgaigne¹ gives an extract of the notes of a case reported by

¹ Mémoire sur les Luxations du Poignet. Gazette Médicale de Paris, Nov. 24, 1832, p. 788.

Cruveilhier,¹ as a forward luxation of the wrist. He believes, however, from the notes and the illustration that the injury was a fracture of the radius with forward displacement. There was no history to the case. He believes that the injury had occurred in infancy, and consisted of a fracture or separation of the epiphysis, due to a fall on the back of the hand. The patient was an adult woman, whose forearm appeared shorter than natural. The lower extremities of the radius and ulna caused a considerable projection of the skin. The lower end of the radius was less prominent and did not come down as far as that of the ulna. The upper extremity of the carpus was situated on a plane higher and more anterior than that of the lower extremity of the bones of the forearm. The hand formed a right angle with the forearm, and was besides inclined toward the radial side. This inclination could be greatly increased. Extension of the wrist was impossible; flexion could be carried much farther than a right angle.

The patient died and the injury was dissected. Cruveilhier found atrophied muscles, the tendons altered in their relations to the bones and marked changes in the carpal bones. The ulna showed little alteration in form, but extended lower down than the lower extremity of the radius. At a position corresponding to the extremity of the radius, which was some distance above its own lower extremity, it had a deep excavation to receive an articular process of the radius. It was attached to the cuneiform bone by an extremely long ligament. This permitted the hand to be bent strongly toward the radial border of the forearm. The radius itself was shortened and deformed. The deformity pertained principally to the lower extremity, which was bulky, as if it had been crushed and deeply grooved on the back for the lodgement of the united tendons of the extensor muscles. There was a sort of transposition of the articular facet of the radius, which was situated upon the anterior surface of the end of the bone. A prominent projection at its internal side articulated with the ulna. The body of the radius was larger than in the normal state, its lines of insertion and its processes more prominent, and its superior extremity, instead of being grooved to receive the articular surface of the humerus, was convex, and its circumference somewhat lessened.

Malgaigne adds to this description some observations derived from

¹ Anatomie Pathologique avec figures, in folio. Maladies des Articulations, p. 3 (tome I, ix^e livraison).

a study of the illustration, which was the only source of information available, as the specimen had been lost. He says the lower part of the forearm appeared to have a very considerable antero-posterior diameter. The articular surface of the radius appeared to be divided into two parts by a very deep hollow. The external portion seemed to be a continuation of the body of the bone. It presented below a conical elevation which might very well pass for the styloid process, but outward and above there was another conical prominence, very regular and without analogy on the normal bone. The other portion, much larger and wider, did not pertain to the body of the bone. It was situated on an oblong and rounded process separated from the body of the bone, being a sort of neck or contraction.

Malgaigne states that he took a dry radius and supposed a transverse fracture or epiphyseal separation at a distance of six lines above the joint. By applying the fragment to the anterior surface of the radius he imitated perfectly the extraordinary aspect of Cruveilhier's specimen. The external and upper prominence would be the styloid process; the inferior represented very well the spine which separated the tendinous grooves of the radius behind.

In addition to these interesting clinical reports of special cases, I have letters from a number of surgeons, stating that they recollect seeing such fractures, but have no detailed notes of the patient at hand. They are John Ashhurst, Jr., Philadelphia; A. F. Cabot, Boston; R. F. Weir, New York; J. William White, Philadelphia; J. M. Barton, Philadelphia; Roswell Park, Buffalo; John M. Parmenter, Buffalo; Carl Gussenbauer, Vienna; W. S. Halsted, Baltimore; and Thomas Bryant, London.

On the other hand, the injury has not been seen, or, at least, the fact of seeing it is not recalled, by Sir James Paget, London; Max Schede, Bonn; Sir William MacCormac, London; Sir Joseph Lister, London; F. C. Abbott, London; Mr. Clutton, Mr. Pitts, Mr. Battles, and Mr. Stabb, London; and Dr. Fordea, Hamburg.

The opinion of Mr. Thomas Bryant, of London, founded on his personal experience, justifies the publication of a long extract from his letter. He says:

"I am convinced that fracture of the lower end of the radius, with displacement of the carpal fragment forward toward the flexor aspect of the forearm, is by no means an uncommon affection. It occurs as an imperfect fracture in the majority of cases, and is consequently overlooked, particularly when there is swelling of the parts to obscure symptoms. If surgeons would in every case of injury to the wrist compare the position of the styloid processes of the injured side with that of the sound side, they would at once recognize the existence of the injury named by the styloid process of the radius being on a higher level than normal, and with this fact before them the diagnosis would be sure. This should be a binding rule to all cases of injured wrist. I have seen a great number of cases of this kind that have been overlooked and treated as examples of sprain, when too late for treatment. If you will impress the view upon the teachers of surgery in your country you will be helping good surgery, first for diagnosis, and later for treatment."

W. H. Allport, of Chicago, believes he has seen cases with slight displacement forward. His statement is worthy of consideration on account of the evident resemblance of his cases to those instances in which the displacement backward occurs, but to a very slight degree:

"In my experience I must say I can recollect no case of pronounced flexor displacement of the distal fragment. The most I can say is that I have noticed many cases where the displacement was neither markedly forward nor backward, and in a few cases I have noticed a little prominence near the pronator quadratus, as though the distal fragment rode slightly toward the palmar surface of the forearm instead of in the usual direction."

When I began this study I believed that the injury under consideration was rare, and it was my intention to make a rather exhaustive search in the various medical museums for specimens. I have been deterred from this step, however, to a considerable extent, because I soon found that clinical cases and museum specimens illustrating the lesion were not so exceedingly uncommon as I had supposed.

I shall give descriptions of those specimens which I have

seen, and also refer to others of which I have obtained information from professional friends.

There are three specimens in the Mütter Museum of the College of Physicians of Philadelphia.

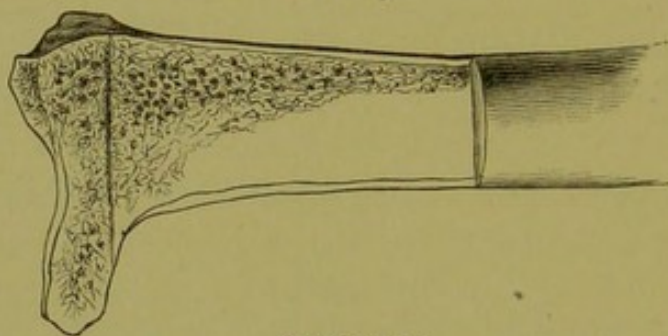
The first has the following description in the catalogue:

SPECIMEN 1. *Probable epiphyseal fracture, with moderate displacement.*—(Mütter Museum, Philadelphia.)

"No. 1277. 55 Rad. 10. Lower end of right radius and ulna. Transverse fracture of the lower end of the radius. Union.

"The fracture passed close to the joint. Measuring the fragment, which has been sawn vertically in the antero-posterior line, it is seen to vary from 5 cm. to 1 cm. in thickness, and the fracture is well defined by a distinct band of indurated spongy tissue. Dissecting-room specimen. Purchased."

FIG. 9.



Specimen 1.

The lower fragment is displaced anteriorly, causing the normal curve of the palmar surface of the radius to become almost a right angle. The radial side of the radius has been lost after the bone was sawn. There is a little dried soft tissue adherent to the bony surface in places. There is no evidence of callus or periosteal separation. The transverse line of "indurated spongy tissue" seen in the cancellated tissue looks as though it was the epiphyseal line. It seems to correspond with a groove on the external surface of the dorsum of the bone. It seem likely that the injury was an epiphyseal fracture with moderate anterior displacement.

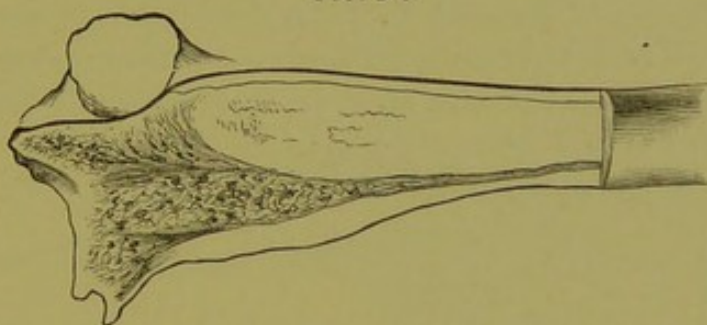
SPECIMEN 2. *Fracture, with probable stripping up of the periosteum.*—(Mütter Museum, Philadelphia.)

"No. 1277. 60. Lower end of right radius and ulna. Transverse fracture of the lower end of the radius. Union.

"The fracture passed on the posterior surface, within 1.7 cm. of the joint. Anteriorly it probably passed a little closer. Union has occurred with a slight anterior displacement of the lower fragment. Vertical section shows induration of the spongy tissue of the lower end."

The bone is sawed vertically. It looks to me as if the periosteum had been stripped up on the anterior surface in the manner that often occurs in posterior displacement, and that ossification of the exudate under the periosteum had occurred.

FIG. 10.




Specimen 2, showing head of ulna prominent at dorsum.

The lower fragment lies more anteriorly than the articular surface of the head of the ulnar, which projects upward above the posterior border of the radius. This abnormal relation is apparently due to the displacement forward of the fractured lower end of the radius. The tip of the styloid of the ulna has been broken off, but is now united.

SPECIMEN 3. *Oblique fracture, with displacement.*—(Mütter Museum, Philadelphia.)

FIG. 11.



Diagrams showing change in articular surface of specimen 3.

"No. 1277. 65. Bones of right forearm and hand. Oblique fracture of the lower end of radius, involving the joint. Union. Barton's fracture(?). The lower fragment embraces the styloid process, the outer portion of the articular surface and 1.5 cm. of the external bor-

der. Absorption and upward displacement of the lower fragment allowed the hand to be carried away from the ulna. Union has occurred, with a slight amount of callus; the bone is smooth anteriorly, but is marked by an oblique groove posteriorly. Purchased."

The displacement here is forward. The lower end of the radius is much altered by the great amount of absorption at the line of fracture. The articular surface presents obliquely toward the radial side of the forearm, so that its plane marks an angle of perhaps 40° with the normal plane. No evidence of caries exists.

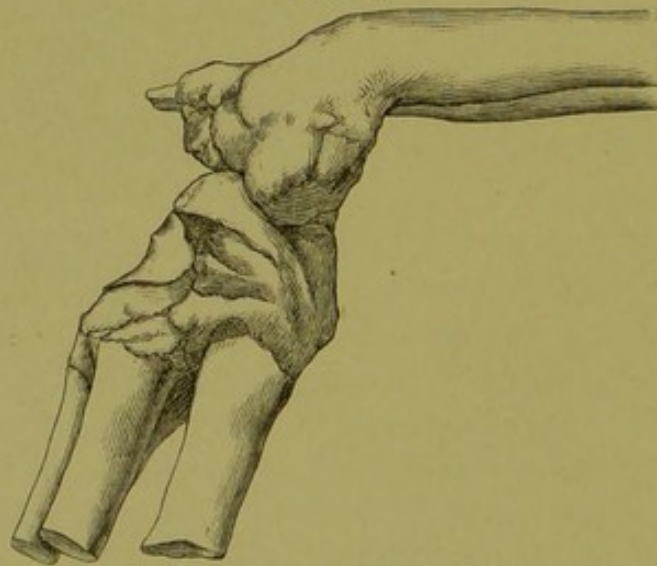
This specimen belonged to Dr. Henry H. Smith, and is figured in Dr. John H. Packard's English translation of Malgaigne on *Fractures*, page 497, and is called by him an instance of Barton's fracture.

The fracture which John Rhea Barton described¹ is, however, a breaking off of the posterior lip of the lower end of the radius.

It is unfortunate that none of these specimens have any clinical history.

SPECIMEN 4. *Fracture, with very marked deformity.*—(Museum Royal College of Surgeons, Edinburgh.)

FIG. 12.



Specimen 4. Radial side.

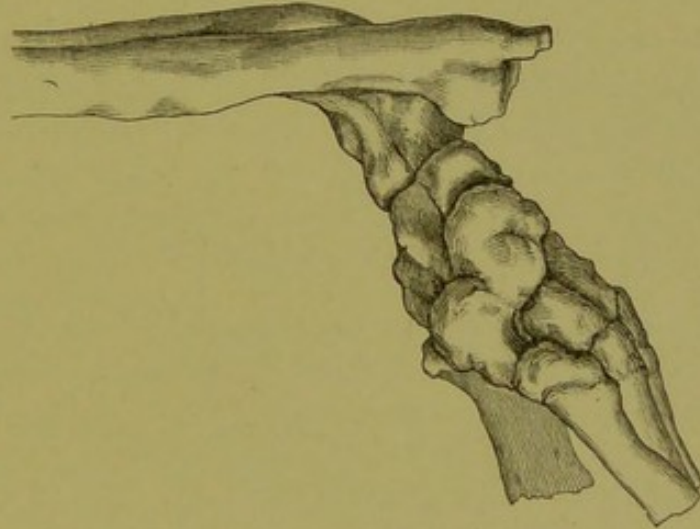
This characteristic specimen was obtained from a subject in the dissecting-room by Mr. C. W. Cathcart, to whose kindness I am indebted for the photograph from which the cuts have been made.

¹ Medical Examiner, Philadelphia, 1838, and The American Journal of the Medical Sciences, 1840, xxvi. p. 253.

The record in the catalogue of the museum is:—

“142. United ‘Smith’s’ fracture Right radius and ulna, carpus, and part of metacarpus macerated, showing the above. There has been a fracture through the lower end of the radius, just above the articular surface, with a displacement similar to that seen in Colles’ fracture, only forward instead of backward. The styloid process of radius is at a higher level than that of ulna. The articular surface of radius looks now very obliquely forward. The normal hollow, just above the articular surface in front, is increased, while there is a marked projection at a corresponding place at the back. There are deep grooves on the back of the radius for the tendons of the extensor

FIG. 13.



Specimen 4. Ulnar side.


secundi internodii pollicis and the extensor indicis. This fracture is produced by a forcible bending of the hand forward, *i. e.*, in a direction the reverse of that by which Colles’ fracture is produced. Presented by Charles W. Cathcart, F.R.C.S.E., 1893.”

SPECIMEN 5. *Fracture with angular displacement.*—(Museum of St. Thomas’s Hospital, London.)

Mr. F. C. Abbott writes that there is a dry radius with this deformity in the Museum of St. Thomas’s Hospital. Its number is 263 in Part 1 of the catalogue. This specimen is doubtless the one exhibited as a card specimen by Samuel G. Shattock at the London Pathological Society some years ago. It was then stated that the specimen had long been in the museum named, and that no history of the patient was connected with it.

"The unusual feature in regard to this specimen is the angular displacement forward of the lower fragment, such as is stated to result from falls on the back of the hand. Firm osseous union has taken place."¹ No discussion of the subject was entered into by the members of the society.

FIG. 14.



Specimen 5.

FIG. 15.



Specimen 5. Another view.

Mr. Abbott has sent me two photographs of this specimen, which are very interesting. The catalogue of the museum states: "Union has occurred with a rare displacement of the lower fragment, which is tilted forward instead of backward. The articular surface presents no trace of having been involved in the fracture." The last statement evidently refers to the lower articular surface, for Mr. Abbott writes that the articular facet for articulation with the ulna is distinctly involved in the line of fracture. Fig. 14, which represents the bone with the interosseous ridge toward the reader, shows the marked displacement forward, toward the right in the figure, and the fracture line involving the lateral articulating facet. The fracture appears to have been a comminuted one. Fig. 15 gives another view of the bone.

SPECIMEN 6. *Fracture with impaction*.—(Museum Westminster Hospital, London.)

This specimen is described by Callender,² who says:

"The carpal extremity of a radius has been fractured and the ulna is also broken at its styloid process. The distal end of the radius is

¹ Trans. Pathological Society of London 1887, xxxviii. p. 260.

² St. Bartholomew's Hospital Reports, 1865, p. 289.

displaced forward and outward, chiefly in the last named direction, but there is no rotation of the shaft on its long axis. The proximal portion is driven into the cancellous tissue of the carpal end on the palmar aspect and toward the outer side, burying itself, as is seen in the section, to a depth of a trifle more than three-tenths of an inch."

SPECIMEN 7. *Fracture with probable impaction*.—(St. Bartholomew's Hospital, London.)

Mr. Callender describes¹ this specimen in connection with Specimen 6.

"In our own museum there are portions of a radius and ulna, the radius having been fractured a little more than an inch above its carpal end. The union is firm, but there is a prominent angle on the dorsal aspect of the radius in the line of the fracture, and an elevation of new bone on the corresponding part of the palmar surface, where it is probable that the palmar margin of the upper fragment was driven into the cancellous tissue of the lower one. The triangular fibro-cartilage was almost completely separated from the radius."

SPECIMENS 8 and 9. *Fractures without comminution*.—(Queen's College Museum, Belfast.)

These specimens are described by Gordon, who gives a cut of one of them.²

"The fragment broken off in each specimen is of the same size, and the only difference between them is the displacement of the one a little higher than the other. The fracture commences internally at the junction of the carpal surface with the compact tissue behind, and passes directly outward until it arrives at the base of the styloid process; then it ascends, crosses the outer border of the radius, next descending it passes obliquely inward.

"The fragment has on it the whole of the carpal surface, the articular surface for the head of the ulna, and externally the styloid process and the entire ridge on the outer border of the radius (supinator ridge); it is displaced upward, forward, and outward, over-riding the lower end of upper fragment in front. The carpal surface is horizontal. In one of the specimens the lower overlaps the upper fragment so much that it might be styled an impacted fracture."

¹ St. Bartholomew's Hospital Reports, 1865, p. 289.

² A Treatise on Fractures of the Lower End of the Radius, by Alexander Gordon, M.D., p. 30.

SPECIMEN 10. *Fracture apparently showing impaction.*

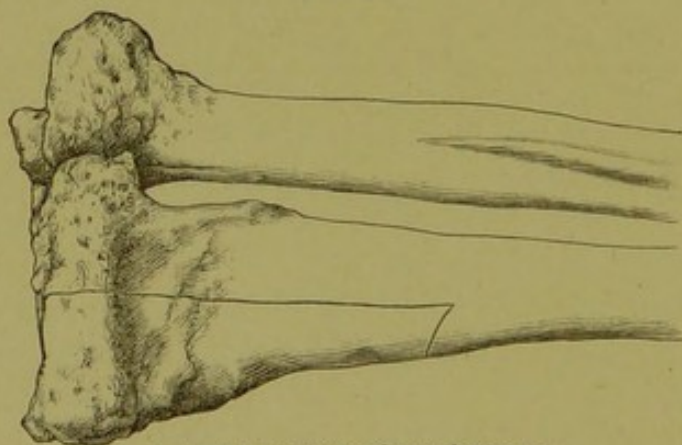
L. Voillemier gives¹ an illustration of a specimen, but I have found in his book no history of the case. He gives a short account of this lesion on p. 43, but makes no allusion to the specimen shown in the plate at the end of the volume.

SPECIMEN 11. *Transverse fissured fracture produced experimentally in cadaver.*—Dr. F. H. Hamilton² gives a cut of a transverse fissure of the lower end of the radius produced by forced palmar flexion in the cadaver.

He says fractures by forced palmar flexion are produced experimentally in the dead body, not quite so readily as in forced dorsal flexion, and that the break occurred in his experiments a little lower than is usual in the ordinary fracture with backward displacement.³

SPECIMENS 12, 13, 14, 15, 16, 17, and 18. *Seven united fractures found in the dissecting-room*—Professor E. H. Bennett, of Dublin, in a paper "On the Rarer Forms of Fracture of the Carpal Extremity of the Radius," presented to the Royal Academy of Medicine in Ireland,⁴ refers to seven specimens of the injury under discussion, which were found in subjects dissected in the School of Physic of Trinity College, and in the museum of that school. Professor Bennett had, at my request, these specimens photographed. They are all instances of forward displacement, though the line of fracture varies considerably.

FIG. 16.



Anterior surface of specimen 12.

SPECIMEN 12. *Slightly oblique fracture.*—The museum number of this specimen is 695. The preparation consists of the radius and ulna, which are exhibited in the photograph in the position of

¹ Clinique Chirurgicale, 1862, p. 67, and Pl. I. Fig. 1.

² Treatise on Fractures and Dislocations, Stephen Smith's edition (1891), p. 281.

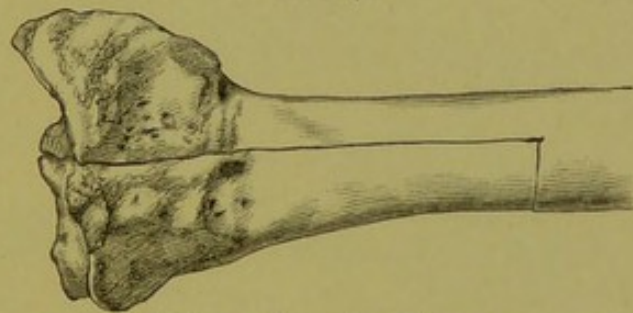
³ Idem., p. 283.

⁴ Transactions, 1892, vol. x. p. 323.

supination with the palmar surfaces in view. The line of fracture begins a little above the base of the styloid process of the radius, and runs somewhat obliquely upward and inward to the ulnar side of the bone. The fracture is nearly transverse. The styloid process of the radius is higher than normal, being about on a level with that of the ulna, instead of being below it. The forward displacement of the lower fragment is apparently not great.

SPECIMEN 13. *Transverse fracture*.—Museum number is apparently 690. The palmar surface of the radius is shown in the photograph.

FIG. 17.

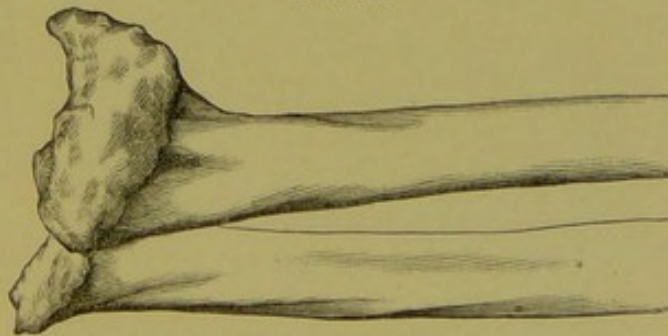


Anterior surface of specimen 13.

The fracture is transverse, and is situated perhaps three-quarters of an inch above the articular surface of the bone. The forward displacement is apparently quite marked. The styloid process appears to be in normal relation to the articular surface.

SPECIMEN 14. *Transverse fracture with tilting of the lower fragment*.—A radius and ulna in supination, showing palmar surfaces.

FIG. 18.



Anterior surface of specimen 14.

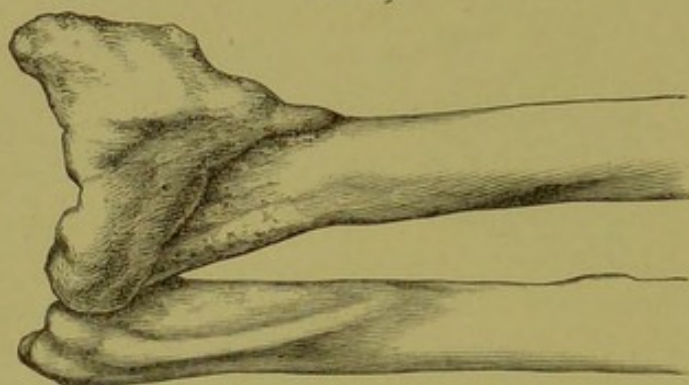
Museum number is 1618. The line of fracture is nearly parallel to the articular surface of the radius, and is, therefore, transverse. There is much tilting of the lower fragment toward the radial or outer

border of the arm, and great anterior displacement. Crushing or impaction probably occurred at the time of injury.

This causes the styloid process of the radius to be much higher or nearer the elbow than normal. It is higher instead of being lower than the styloid process of the ulna. In the living subject the osseous displacement would have caused the hand to have been deflected to the radial side and the head of the ulna to have been unusually prominent at the back of the wrist.

SPECIMEN 15. *Very oblique fracture.*—A radius and ulna, showing palmar aspect. Museum number, 2627. The fracture runs very

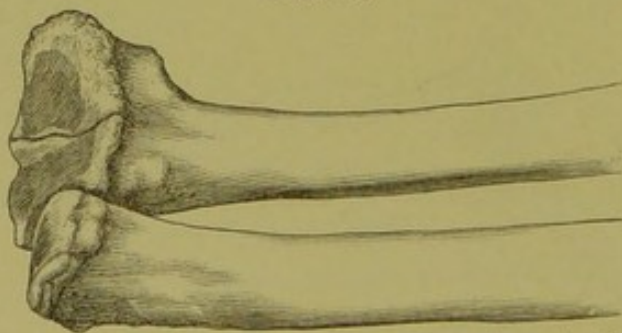
FIG. 19.



Specimen 15. Bones in mid supination, showing anterior surface of radius.

obliquely upward and outward from the upper border of the facet for articulation with the ulna to a point on the outer border of the radius, perhaps an inch and a half above the top of the styloid process. The forward displacement is marked.

FIG. 20.



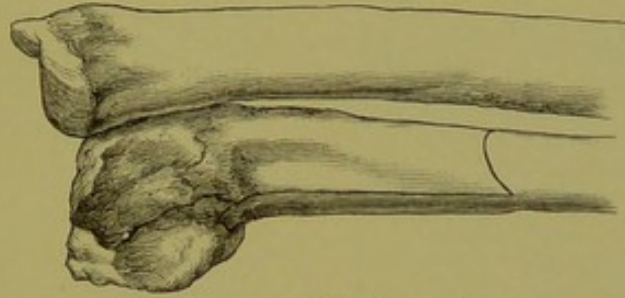
Specimen 16. Anterior surface. Bones in supination.

SPECIMEN 16. *Fracture involving the articular surface.*—A radius and ulna showing palmar surfaces. Museum number, 2281. This

fracture seems to have been transverse and near the articular surface, which surface appears to have been fissured.

SPECIMEN 17. *Great deformity with probable involvement of the joint.*—A radius and ulna, exhibiting palmar surfaces with the radius in extreme supination. Museum number, 117(?). The carpal end

FIG. 21.

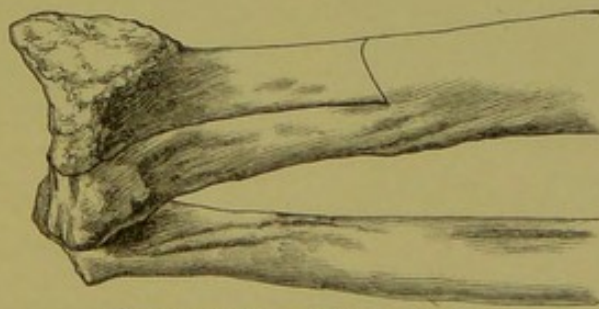


Specimen 17. Anterior surface.

of the radius is much deformed. Great anterior displacement of the lower portion of the bone, with elevation of the styloid process, has apparently occurred. The line of fracture is not to be determined with accuracy by a study of the photograph; but there seems to have been a line of fracture involving the articular surface.

SPECIMEN 18. *Articular fracture.*—Museum number, 291. The radius appears to have been obliquely fractured from its outer border downward and inward, so that the styloid portion was detached.

FIG. 22.



Specimen 18. Anterior surface.

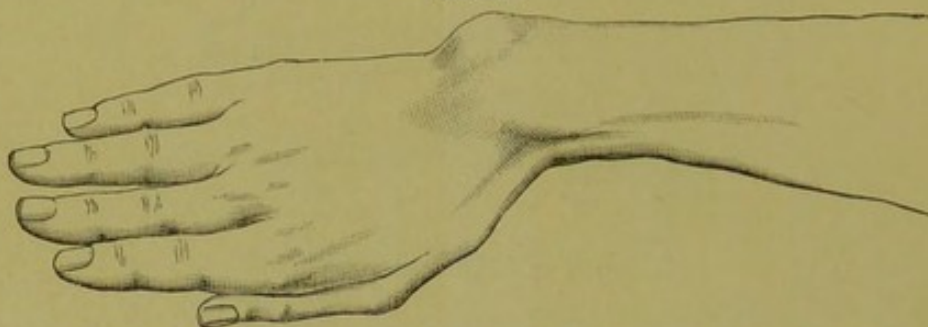
There has also been a fracture of the radius at its middle, where a bridge of bone has been developed across the interosseus space.

Professor Bennett says that this one of the series is the only one to which the term "articular fracture of the lower end of the radius," used by Gordon, of Belfast, is appropriate.

SPECIMEN 19. *Oblique fracture causing great shortening of the radius.*
—(Royal College of Surgeons in Ireland.)

Bennett refers in his paper to a similar specimen "from the museum of this college, to which it was presented by Mr. Swan in 1885." He gives no description of the specimen, and evidently means by his remark that it is in the Museum of the Royal College of Surgeons in Ireland.

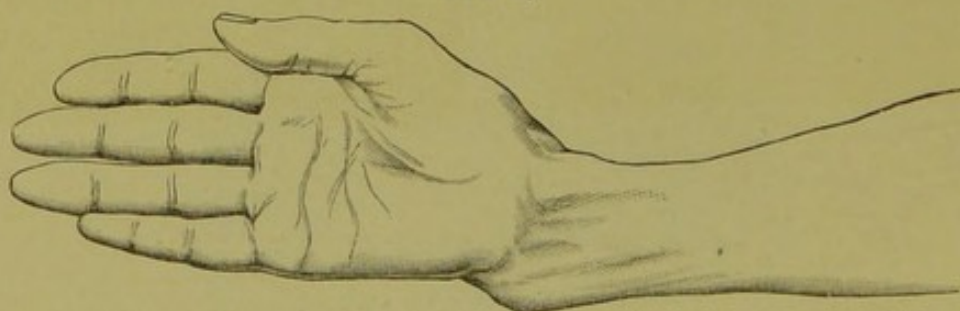
FIG. 23.



Dorsal surface of specimen 19 before dissection; taken from a cast.

I have obtained, through the courtesy of Mr. J. Alfred Scott, of Dublin, photographs of this specimen, showing the palmar and dorsal surfaces of the bones. He has also sent me photographs of the plaster cast taken of the forearm and hand before the soft parts were removed, and plaster casts of the forearm and of the lower ends of the radius and ulna. There is no clinical history of the injury. It is probably a dissecting-room specimen.

FIG. 24.

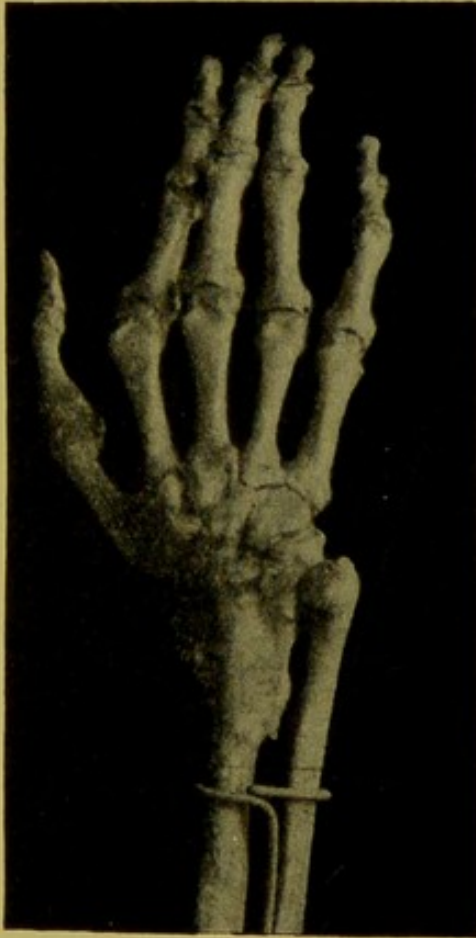

Palmar surface of specimen 19 before dissection; taken from a cast.

The fracture is situated over an inch and a half above the articular surface of the radius at its ulnar side, and appears to have extended obliquely downward and outward. The carpal fragment is not displaced much forward, but is greatly tilted to the radial side. Union

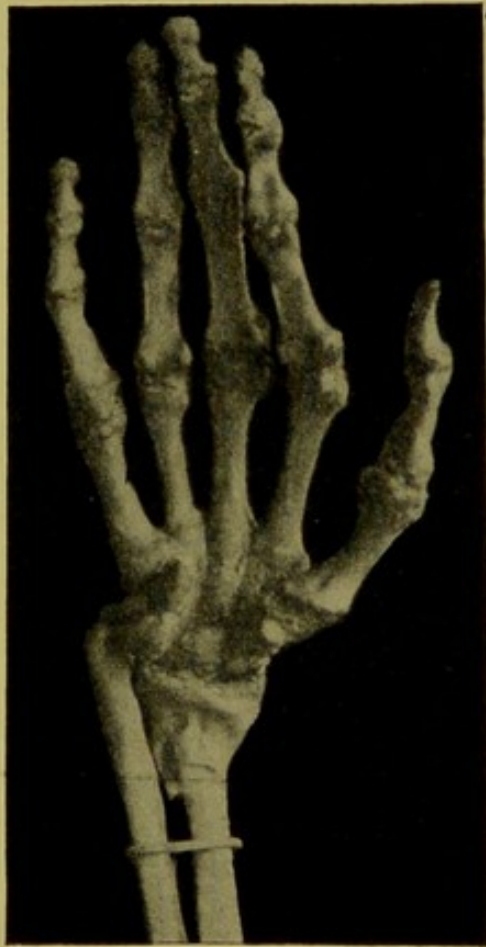has occurred in this position. The upper end of the lower fragment, or a mass of callus, projects toward the ulna so as to considerably lessen the interosseous space. The deviation of the hand to the radial side, due to the shortening of the radius, and the tilting of the lower fragment are very marked.

FIG. 25.



Dorsal surface of bones, specimen 19.

FIG. 26.



Palmar surface of bones, specimen 19.

The head of the ulna is not displaced backward. The styloid process of the radius, as well as that of the ulna, is deformed by absorption or involvement in callus. The radial styloid is nearer the elbow than normal because of the over-riding at the seat of fracture. The lower articular surface of the radius presents in about the normal direction, except that its plane is higher than normal at the radial side of the joint. This is due to the shortening of the radius and the elevation of the styloid portion of the radius.

The deformities corresponding to the bony changes are well seen in the cast made before the soft parts were removed by maceration.

In discussing this and his own seven specimens together, Bennett mentioned the fact that three of them present an unbroken carpal surface, and that five have this surface more or less fissured by fractures. He attributes this splitting to the same cause that produces comminution of the lower fragment in the fracture of the lower end of the radius with backward displacement, namely, intrusion of the inferior end of the upper fragment into the spongy tissue of the lower fragment. He calls attention to the fact that in three of the specimens, as well as that figured by Voillemier,¹ the bone is broken transversely. This circumstance causes him to reject the term "the articular fracture" used by Alexander Gordon,² of Belfast, in connection with this lesion.

SPECIMENS 20 and 21. *Two specimens of impacted fracture*—Adolf Bardeleben states³ that mutual impaction has been observed in fracture of the lower end of the radius, with displacement of the lower fragment forward, as well as in the ordinary fracture with displacement backward. He gives two cuts of fracture with forward displacement, but does not furnish any details of the cases from which the specimens were obtained.

In both instances the bones which are shown in the illustrations have been sawed longitudinally, so that the impaction which occurred is evident. In one there is a marked angular projection on the palmar surface of the seat of fracture. The other specimen is interesting because of the marked amount of compact tissue in the anterior portion of the bone in the neighborhood of the line of fracture. The illustration does not make it clear whether or not this is the result of the stripping up of the periosteum on the palmar surface at the time of the injury.

SPECIMEN 22. *Green-stick fracture, with dislocation from the lower end of the ulna.*—(Pathological Cabinet of New York Hospital.)

In the New York Hospital is preserved a specimen of the fracture under consideration, donated by Dr. Markoe, and a drawing made from it by Dr. M. Morris. Of this case the catalogue says:—

"No. 139. United Fracture of the lower End of the Radius," taken from an adult. The fracture originally existed through the radius, a

¹ Clinique Chirurgicale, pl. I., Fig. 1.

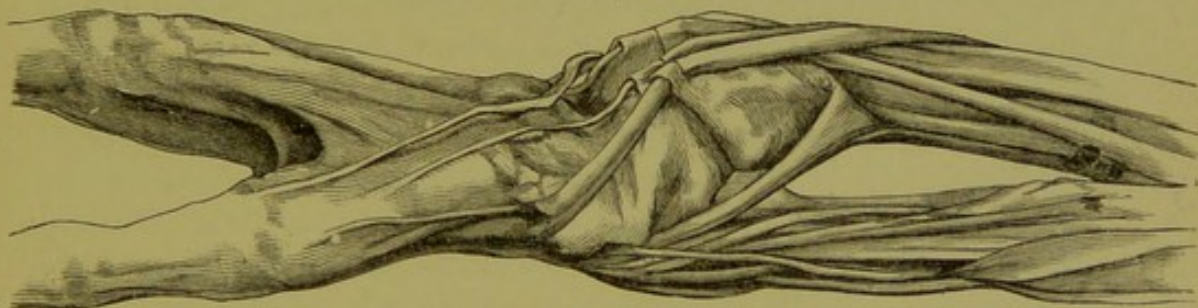
² Fracture of the Radius, p. 30.

³ Lehrbuch der Chirurgie und Operationslehre, ii. 440.

little above the carpus. The lower fragment has been tilted downward toward the palmar aspect of the forearm, and has, at the same time, been drawn upward. In this position the fracture has firmly united; the carpal bones and hand have been carried along with the lower fragment, giving the case the appearance of a dislocation forward of the wrist, the ulna resting upon the dorsal aspect of the carpal bones. The muscles, tendons, and ligaments are preserved."

I have personally examined this specimen with much interest. The hand looks as if the patient had been a woman or a man of delicate build. The patient evidently was young, for the line of the lower ulnar epiphysis is not completely ossified. No epiphyseal line is detectable at the lower end of the radius or at the upper end of the ulna. The upper end of the radius is too much covered with the dried soft parts to permit examination of this quarter. The bones are in a position about midway between pronation and supination, but a little more prone.

FIG. 27.



Specimen 22. Radial side, showing the dissected and dried muscles, and the bent condition of the lower end of the radius.

The radius is curved forward at its lower end, as though it had been bent, and its articular surface looks almost directly toward the palmar surface of the limb. The carpus is held by the ligaments in its proper relation to the articular surface of the radius, and has not been dislocated from it. There is a marked bending between the first and second rows of carpal bone, which enables the hand to have the same axis as the forearm. The posterior surface of the radius is exposed, except for a covering of dried periosteum. No line of fracture is to be seen. There exists no callus and no ridge indicating fracture. The anterior surface of the radius is not so easily examined, because the square pronator muscle and long flexor of the thumb cover it. The appearance is that which would result from a green-stick fracture occurring long before death or, perhaps, from a rachitic bending.

There is no corroborative evidence of rachitis elsewhere in the specimen.

The fracture or bending occurred, as is easily seen by the change in the direction of the bone, about an inch above the articular surface. The hollow between the radius and volar eminence on the anterior surface of the forearm, due to the forward displacement of the carpus and hand, is very great, as is shown by the flexor tendons spanning the arch.

On the ulnar side the head of the ulna lies on the posterior surface of the carpus, which has been dislocated forward. The upper surface of the carpal bones is more than half an inch higher (toward elbow) than the styloid process of the ulna. The ulna lies on the back of the carpus with its radial facet dislocated backward from the radius, whose lower end has been bent forward by the fracture. It looks as if the posterior ligaments had been torn and the ulna head uncovered. The ligaments between the lower end of the ulna and the carpus are seen curving forward to accommodate themselves to the new positions of the bone. A diagram of the ulnar side of this specimen is shown in Fig. 32 on p. 66.

Extension of the patient's hand must have been restricted. Flexion would apparently have been possible to a greater extent than normal.

SPECIMEN 23. *Case of fracture, with displacement forward.*—(Pathological Cabinet of the New York Hospital.) In the same hospital is preserved a cast of this form of fracture. The description in the catalogue, p. 81, is: "No. 137. Fracture of the Lower End of the Radius. (Cast.) The hand is carried toward the palmar aspect of the forearm, and the antero-posterior deformity is, therefore, the reverse of that in the previous casts. There is still present the abnormal prominence of the ulna and slight adduction of the hand."

Six specimens are preserved in the Warren Anatomical Museum, Boston. I describe them from photographs received from Dr. W. F. Whitney.

SPECIMEN No. 24. Catalogue number, 3693. "Old Comminuted Fracture with Suppuration. Amputation." This is a comminuted fracture of the base and of the lower third of the shaft of the radius, which scarcely belongs to the class of fractures under consideration.

SPECIMEN No. 25. Catalogue number, 5194. "Old Fracture, healed. Marked Deformity. No History." The fracture is situated about

one half inch above the joint, and is transverse, except that it runs upward at the base of the styloid process. The lower fragment does not seem to be fissured. The displacement is forward and to the radial side. The latter is marked, though the line of fracture is not oblique but transverse. The dorsal surface of the bone is shown in the photograph.

SPECIMEN No. 26. Catalogue number, 6212. "Recent Fracture. Separation of Epiphysis(?). No History." Dorsal surface shown in photograph. No union. The separation seems to have occurred at the epiphyseal junction. Rotation has apparently occurred in such a way that the radial border of the carpal fragment is displaced further forward than the ulnar. There appears to be a line of fracture running into the joint.

SPECIMEN No. 27. Catalogue number, 8281. "Old Fracture, Healed. Also Fracture of Both Bones higher up. No History." Radius and ulna showing palmar surface. The fracture of the lower end of the radius is oblique and extends upward and outward from a little above the articular facet for the ulna. The displacement forward is considerable, and the elevation of the radial styloid process toward the elbow is evident. At the upper third of the forearm the two bones are united by a bridge of callus.

SPECIMEN No. 28. Catalogue number, 8302. "Old Fracture, Healed with Deformity; also Fracture of the Leg. No History." The fracture is about two inches above the joint and runs obliquely upward and forward. The lower fragment is displaced forward at the line of fracture, and the articular surface, therefore, presents less forward than normal.

SPECIMEN No. 29. Catalogue number, 8117. Radius, ulna, and carpus. The base of the radius is much comminuted by several lines of fracture. The articular portion is thrown forward and to the radial side. The elevation of the radial styloid process toward the elbow and the deflection of the carpus to the radial side of the limb are marked. The head of the ulna is left behind, as it were, by the carpus being displaced forward and outward.

SPECIMENS 30 and 31. In the Catalogue¹ of the Musée Dupuytren, at Paris, there are described two specimens, apparently obtained by Jobert de Lamballe. From the account given, there seems to be only slight forward displacement of the carpal fragment in these fractures.

¹ Published in 1877, p. 121, Nos. 108e, 108f.

EXPERIMENTAL OBSERVATIONS.

I believe that the classical fracture of the lower end of the radius, which results in backward displacement of the lower fragment, is often produced by falls, causing extreme extension of the wrist. The fracture in the same region, with anterior displacement, is probably frequently due to extreme flexion of the wrist.

I have made some experiments on the cadaver to throw light on the causation of this injury.

EXPERIMENT 1. *Epiphyseal separation with anterior displacement produced by extreme flexion of the wrist.*—The forearm of a boy of fourteen years, amputated at the elbow for railroad injury, was used while fresh for this experiment. Eighteen hours after the accident the forearm and hand were laid on the dorsal surface horizontally upon the floor. The hand was then seized by both hands of the experimenter, and the wrist flexed forcibly and extremely by the operator while kneeling, suddenly throwing his body forward, so that his weight was brought to bear upon the flexed wrist of the limb.

The bone gave way at the epiphysis and caused slight anterior displacement of the lower fragment.

EXPERIMENT 2. *Fracture of os magnum and unciform by extreme flexion of the wrist.*—Right hand and forearm of male cadaver, not young, previously injected with zinc and afterward kept in alcohol and water. Arteries not injected with plaster. Radius and ulna sawed off a short distance below the elbow joint. I placed the back of the hand on the floor, seized the forearm with both hands and flexed the wrist strongly. My assistant then put both hands on top of mine and suddenly threw his weight forward so as to make extreme flexion of the forearm on the hand. A loud crack was heard, as though fracture had occurred, but no fracture or dislocation could be diagnosed on examination. Dissection showed no damage to radius or ulna or to the wrist joint. On dissecting the deep tissues away from the carpus posteriorly a fracture was seen running transversely across the distal ends of the os magnum and the unciform. The fragment separated from the os magnum was about three-sixteenths of an inch long at the dorsal surface, with the line of fracture running obliquely downward and forward, so that the lower edge of the frag-

ment was sharp. The entire articulating surface of the os magnum was not involved, as the line of fracture entered the joint. The piece broken from the front of the unciform bone was similar in shape but smaller.

EXPERIMENT 3. *Fracture of the os magnum and unciform in an experimental attempt to break the radius by extreme flexion of the wrist.*—Left hand of same subject as Experiment No. 2. Subject preserved with chloride of zinc. Amputated at elbow, and in alcohol for about six months. Back of hand was placed upon the floor. The upper ends of radius and ulna were grasped by the operator, who suddenly threw the weight of his body upon the upper end of the specimen so as to make flexion of the forearm upon the hand. A loud snap was heard.

At the base of the metacarpal bone of the middle finger where it articulates with the carpus it seemed as if there were an abnormal degree of motion, and a transverse linear depression could be felt with the tip of the finger as a distinct groove. A longitudinal incision over the base of the metacarpal bone of the middle finger showed that there had been a rupture of the ligaments joining the second row of carpal bones with the metacarpus on the posterior surface. Further investigation showed that there was a fracture of the posterior lip of the dorsal portion of the os magnum, and that a small piece had been separated from it at the ulnar side. This fragment measured five-sixteenths of an inch in length and three-sixteenths at its greatest width. The fragment remained attached by ligaments to the ulnar side of the base of the metacarpal bone of the middle finger. A very small fragment, not more than one-third the size of that broken from the os magnum, had been torn from the corner of the unciform bone joining the point of fracture of the os magnum. This little fragment remained attached by ligaments to the base of the metacarpal bone of the ring finger. The rupture of ligaments extended from about the middle of the base of the metacarpal bone of the ring finger across to the radial side of the base of the metacarpal bone of the index finger. A small fragment was broken off the dorsal edge of the base of the index finger at its radial side. This remained attached to the trapezium. The fragment was about midway in size between that broken from the os magnum and that broken from the unciform bone. There was no fracture of the radius.

The injury may therefore be described as a rupture of ligaments and a fracture extending across the back of the hand from the radial

side of the base of the metacarpal bone of the index finger to the middle of the base of the metacarpal bone of the ring finger, with three portions of bone torn obliquely from the articular and dorsal surfaces of the unciform, os magnum, and index.

EXPERIMENT 4. *Fracture of a carpal bone by extreme flexion of the wrist.*—The amputated forearm and hand of a cadaver were laid upon their dorsal surface on the floor and the hand grasped by two men, who forcibly flexed the wrist by throwing their weight forward. A fracture occurred in one of the carpal bones. Examination made without dissecting the tissues thoroughly seemed to show that the broken bone was the os magnum.

EXPERIMENT 5. *Fracture caused by extreme flexion of wrist after partial osteotomy.*—The dorsal wall of the radius in a cadaver was weakened by being cut transversely a short distance above the lower end by an osteotome directed a little upward. The forearm of the cadaver was then placed vertically, with the elbow resting on the table, the wrist flexed, and a heavy blow struck on the back of the hand so as to suddenly cause extreme flexion. Fracture occurred at the line of osteotomy. Previous attempts to fracture the carpal bones or radius by similar blows had failed.

EXPERIMENT 6. *Fracture of styloid process due to extreme flexion after partial osteotomy.*—The right radius of an adult female cadaver was subjected to osteotomy of the dorsal wall at the base of the styloid process. The plane of the osseous incision was directed upward and forward. A blow on the back of the flexed hand while the forearm was held vertically with the elbow on the table completed the fracture through the styloid process, though previous blows similarly applied failed to break either radius or carpal bones. The soft tissues were disturbed as little as possible before the experiment.

EXPERIMENT 7. *Transverse fracture due to extreme flexion after partial cuneiform osteotomy on palmar surface.*—The left radius of the subject used in Experiment 6 was carefully uncovered and weakened by cutting a transverse wedge-shaped groove in the compact wall of the palmar surface at the most prominent part of its concavity. The base of the wedge of the bone removed was about one-eighth of an inch in width, and extended across the radius. A moderate blow upon the back of the flexed hand while the forearm was held vertically easily fractured the radius at the point where the compact tissue had been removed.

EXPERIMENT 8. *Oblique fracture caused by extreme flexion after partial cuneiform osteotomy.*—The lower end of the right radius of an aged and obese female cadaver was uncovered carefully without disturbing the tendons, and an oblique gutter cut through the dorsal wall from above the base of the styloid process to the upper part of the facet for articulation with the ulna. The wedge-shaped groove was about one-eighth of an inch in depth and about one-eighth of an inch wide at the surface of the bone. It did not involve the sides of the bone, but was limited to the dorsum. The limb was then placed, as in the other experiments, with the elbow on the table, the forearm vertical, and the wrist flexed. A heavy blow on the back of the flexed hand caused fracture of the radius along the oblique groove, with a V-shaped extension downward on the radial border. The interior of the bone was very fatty. No impaction occurred. Forward displacement of the carpal fragment was easily produced by pressure on the hand and wrist.

EXPERIMENT 9. *Forward displacement produced by extreme flexion after extreme extension had fractured the radius previously weakened by partial osteotomy.*—The right forearm of an aged woman, preserved with zinc chloride, was used for this experiment. The front and back of the lower end of the radius were exposed by cutting flaps of skin and carefully displacing the tendons. An osteotome was then applied to the dorsum of the bone about a half inch above the articular surface, and the posterior wall of compact bone transversely divided. The osteotome was directed slightly upward. A similar transverse cut was then made on the palmar surface a little higher up than the dorsal osteotomy, with the plane of the incision in the bone directed downward. These incisions were made in the bone in order to weaken it and more readily permit me to fracture its base. I then seized the hand of the cadaver in both my hands, and, while the forearm was vertical with the elbow on the table, made extreme extension of the wrist. The radius readily broke at the point where its wall of compact tissue had been divided with the osteotome. I then made extreme flexion and found that the carpal fragment was at once displaced forward, and remained in that position.

This experiment seems to me to prove that the forward displacement in some fractures of the lower end of the radius may be due to a secondary force causing extreme flexion of the wrist after extreme extension has broken the bone.

EXPERIMENT 10. *Fracture of the anterior lip of the base of the radius by impact of the carpal bones against its articular surface.*—Using the

same subject as in Experiment 9, I cut off the hand by a transverse incision with knife and saw through the middle of the carpus. The line of amputation ran between the trapezium and scaphoid, but sawed through the trapezoid, magnum, and unciform. This gave me a level surface at the end of the limb with the wedge-like upper row of carpal bones still in normal relation with the articular surface of the radius. The forearm was then held vertical, with the elbow supported on the table, and a heavy blow given upon the end of the stump—that is, upon the carpal bones—so as to drive them against the articular end of the radius without causing flexion or extension of the wrist. The intention was to obviate entirely, if possible, the factor of either extension or flexion at the radio-carpal joint.

The first blow apparently caused no injury. A second and heavier one was given. The carpal bones, the lower end of the radius, and the ulna at its upper third were then found to be broken. The scaphoid, semilunar, and cuneiform bones were split by various lines of comminution. The cuneiform sustained the greatest amount of damage.

The interesting injury, however, was that of the radius, which showed the fracture of the anterior edge of the base described as of occasional occurrence by Barton when he wrote his classical essay¹ on fractures of the wrist. The piece broken from the lower end of the bone consisted of a portion of the articular and palmar surfaces. The line of fracture ran obliquely upward from the joint surface for about a half-inch and chipped off part of the anterior edge of the base. The base of the piece broken off was formed by the articular surface, and measured about a third of an inch antero-posteriorly and about half an inch laterally. The line of fracture seemed to involve the lateral facet for the ulna. The fragment may be said to have consisted practically of the anterior portion of the surface with which the semilunar bone articulates. Inspection of a radius will show that there exists here a well-marked projecting edge or lip.

The dorsum of the radius and the radial side of the radial base were uninjured, as was the ulnar styloid process.

The fragment broken from the lower end of the radius with the attached semilunar and cuneiform bones was displaced forward, making a prominence under the muscles.

¹ Medical Examiner, Philadelphia, 1838, and the American Journal of the Medical Sciences, 1840, xxvi. p. 253.

This experiment affords reasonable proof that fracture of the lower end of the radius may occur as a result of the wedge-like action of the carpal bones when driven against the lower surface of the radial base. It is not probable that there was any action of flexion or extension exerted in this experiment.

CAUSES AND MECHANISM OF THE INJURY.

John Rhea Barton, in his classical article¹ on the ordinary fracture of the lower end of the radius with backward displacement, details what he considers to be the character of the lesion in the usual injury; and he continues: "It sometimes happens, also, though rarely, that fracture of a similar character to the one just described occurs *on the palmar side* of the radius, from the application of force against the back of the hand whilst it is bent forward to its ultimate degree. This usually happens in awkward attempts to parry the blow of a fist, from pressure in dense crowds, and from falling on the back of the hand whilst it is bent forward."

The injury is apparently attributed by R. W. Smith also to extreme flexion, for he says² that "it generally occurs in consequence of a fall upon the back of the hand."

Contrary to these authors, Onésime Lecomte declines to recognize the action of falls on the back of the hand in the production of this fracture. He says³ that he will gladly admit that, when fracture has taken place as a result of a fall on the palm, a secondary pressure on the dorsal surface may be capable of pushing the lower fragment forward. He believes that neither experiment nor observation has shown that fractures through the entire thickness of the bone occur by forced flexion. He attributes the occurrence of fracture with the displacement of the lower fragment forward to falls on the palm producing the fracture, and forward displacement being subsequently pro-

¹ Medical Examiner, Philadelphia, 1838, and The American Journal of the Medical Sciences, 1840, xxvi. p. 253.

² Fractures and Dislocations, p. 164.

³ Archives générales de Médecine, 1861, i. 79, 80, 196.

duced by the hand, after having received the shock of the fall on its palmar surface, being turned on its dorsal surface and submitted to a secondary pressure. The patient, in his opinion, falls with the forearm under him in these cases and sustains a vulnerating force on the palm which breaks the bone, and a secondary force received on the dorsal aspect pushes the lower fragment forward. Patients, according to Lecomte, may think that the injury has been received on the back of the hand, when really the closed fist has received the blow against the ground on the palm of the hand and the back of the second and third phalanges of the closed fingers. The fingers may show signs of injury on the back, but the force of the blow was really in these cases received on the *front* of the closed fist.

My experiment No. 9 proves the possibility of this method of causation.

According to Gordon,¹ the force causing forward displacement "must have been applied from behind, forward, and upward, carrying the carpal surface with a considerable portion of the anterior and outer part of the lower end of the radius before it, leaving all the compact tissue internal to the interval between the first and second extensors of the thumb uninjured, whilst that external is attached to the broken fragment."

This description seems to indicate that he believes the line of fracture to be always oblique, and considers that the injury is caused by force applied to the back of the hand or wrist. The former opinion is upset by a study of the specimens; the latter corresponds with that held by several other authors quoted.

That the fracture occurs from falls on the back of the hand has been asserted by Linhart, who, according to Franz Koenig,² has confirmed his assertion experimentally and clinically. The lesion is produced, these observers think, by the dorsal ligaments maintaining their integrity during the violence, so that a piece of the radius is torn off.

¹ Fractures of the Lower End of the Radius, 30.

² Lehrbuch der Speciellen Chirurgie, 149.

Koenig adds, however, that Honigschmied was unable to produce radial fracture by overflexing of the wrist in the cadaver.

My experiments above detailed prove that overflexion is capable of causing the fracture.

A study of the 24 clinical histories incorporated in this essay will show that in 11 cases the reporters attributed the injury to violence applied to the back of the hand or to flexion of the wrist. The cases are Nos. 3, 4, 7, 14, 15, 16, 18, 19, 21, 23, 24. In four of these the opinion of the reporter was founded upon or confirmed by the occurrence of abrasions or bruises on the dorsal surface of the limb.

In 10 cases (Nos. 2, 5, 8, 9, 10, 12, 13, 17, 20, 22) no satisfactory account is given of the manner in which the force was applied.

In two instances (Nos. 1, 11) it seems as if the violence may have been received on the palmar surface of the hand and wrist, though in neither of them is the evidence very convincing.

In one case (No. 6) it seems as if the injury was the result of extreme flexion very much as in No. 18, which I have included in the list of those which the reporters believed to have been fractures due to the violence received on the back of the limb.

I believe that one cause at least of this fracture with forward displacement is extreme flexion of the radio-carpal joint, by which a portion of the base of the radius is torn off by a sort of cross-breaking strain, due to the fact that the dorsal ligaments retain their integrity. The continuation of the vulnerating force, after the fracture occurs, gives rise to varying degrees of forward displacement of the carpal fragment. This was well shown in Experiment No. 1, where I produced an epiphyseal fracture by forced flexion, in which there was little forward displacement at first. By applying more power in a similar direction I was enabled to considerably increase the amount of displacement.

It is quite possible that fracture and anterior displacement may occur, without flexion of the joint, by direct violence applied to the posterior surface of the lower end of the radius. Perhaps the injury occurred in this manner in the patient (case

No. 7) who "fell backward, striking the back of the right arm on a fence picket."

Extreme flexion is probably more often concerned in the usual mechanism of injury, as in Case 18. Here the account says that the man fell with his left arm under him, the elbow projecting. "The hand bent at the extreme flexion, was crushed beneath his body, the full force of the blow falling upon the radius, as it was fixed between the bent hand and the ground." My third case sustains this view.

The affirmative evidence as to the causation of injury furnished by the statements contained in the cases which I have collected is, I admit, not very strong. Reporters would be very apt to say, without making a very thorough investigation, that the violence was received on the back of the hand, because the statement of many text-books is to this effect.

Strong corroborative evidence is found, however, in the frequent occurrence of the opposite displacement by over-extension of the joint, due to violence applied to the palmar surface of the hand. This common and classical fracture of the base of the radius is nearly always due to falls on the palm, and shows displacement of the carpal fragment of the radius backward, with frequent penetration and impaction of the fragments.

One would expect the reverse displacement to be due to a reverse application of force.

It is intelligible that the injury under discussion might be occasioned by the hand and wrist being held in machinery or caught in a hole while the arm of the patient was forcibly thrown in a dorsal direction. Such a mechanism is evidently not the usual one.

Lecomte's belief that the radius is broken in this injury by falls upon the palm, and that the anterior displacement is due to a secondary force applied on the posterior surface, will scarcely be accepted at the present day. It requires a more complicated mechanism than the opinion that the fracture and displacement are produced by one and the same force applied upon the dorsum.

The careful studies of the fracture with backward displace-

ment made by Moore, Pilcher, Levis, Packard, and others, since Lecomte's paper was written, would probably have influenced his views if they had been known to him.

Pilcher¹ says that comminution of the lower fragment in the classical fracture of the base of the radius occurs by the wedge-like action of the carpus, which is driven up against the articular surface of the radius and fissures it, after which the lower portion of the radius may be torn off by avulsion through tension exerted through the anterior carpal ligaments. This he thinks the most common method of production. Comparatively rarely the lower fragment is split by descent into it of the upper fragment.

D'Arcy Power² contends that in the fracture with backward displacement the comminution of the lower fragment is very frequent, and is often unnoticeable except by most careful examination. In some cases the splitting is only made evident by dissection. He found splitting of the carpal fragment in 31 out of the 59 specimens examined.

He suggests that abrasions on the back of the second and third phalanges of the fingers do not prove that the vulnerating force was received dorsally, since the first may have been closed at the time of the fall, and the backs of these phalanges, therefore, be brought in contact with the ground when the palmar aspect of the hand strikes.

This is indeed true; I do not doubt that these phalanges may show abrasions on their dorsum when the fall has been upon the palm of the closed fist. A fracture of the radial base with backward displacement may doubtless be produced by such a fall, causing *over-extension* of the radio-carpal articulation; but on the other hand, the fall may occur in such a way that, although the closed fist strikes the ground on its palm and on the back of these phalanges, the wrist may be *over-flexed*. The character of the surface of the ground, the direction in which the falling man is propelled, and the exact point of first contact of the

¹ Annals of Anatomy and Surgery, 1881, iii. p. 133.

² Trans. Path. Soc., London, 1887, xxxviii. p. 250.

closed fist determine whether the wrist-joint be flexed or extended.

The mere fact of the situation of these abrasions on the back of the phalanges would not, in my opinion, determine the mechanism of the fracture.

Analogy with the manner in which the backward displacement is often produced and the histories of the cases are the chief factors which have led me to accept the belief of those who oppose Lecomte's views.

From analogy, it seems quite possible that occasionally force applied to the palm might cause fracture with anterior displacement, for it is asserted that force received upon the back of the hand has resulted in the fracture with posterior displacement. Hamilton, for instance, reports¹ this occurrence in a woman who fell, striking on the back of the hand while the hand was shut. Cameron records² a similar injury in a woman who fell with the fist closed and struck on the back of the wrist, producing fracture with posterior displacement of the lower fragment.

My experiments on the cadaver just detailed and analogy with the causation of fractures of the radial base with the usual backward displacement seem to show that the fracture with anterior displacement is caused in three ways: 1. Tearing off of the lower end by a cross-breaking strain exerted through the posterior ligaments during extreme flexion, when the force is applied to the back of the hand in front of the anterior surface of the radius. 2. Crushing of the anterior portion of the bone between the wrist-bones and the shaft, or mutual penetration of the diaphyseal and epiphyseal portions. 3. Rupture of the bony tissue of the weakest point by decomposition of the force to which the limb is subjected.

My experiment, No. 9, shows that fracture may be produced by extreme extension of the wrist, and anterior displacement of the lower fragment occur from a secondary force causing extreme flexion of the wrist.

¹ Fractures and Dislocations, edition 1891, p. 280.

² Glasgow Medical Journal, March, 1878, p. 97.

It must be remembered that specimens which seem to show marked penetration of the compact outer shell of one fragment into the spongy tissue of the other fragment may give false evidence, because the periosteum may be stripped up on the palmar surface of the bone, above and below the fracture, and give rise to additional development of compact bone at that point. Condensing osteitis during repair of a broken bone is perhaps capable of giving the specimen the appearance of penetration or impaction.

Crushing may cause comminution of one or other fragment, or may, perhaps, compress the cancellated bone as an ordinary sponge is squeezed in the hand, and thus give rise to angular displacement forward without impaction.

It is probable that the fracture may be caused by any one of the three methods mentioned; but fracture at the weakest point of the radius and carpus by decomposition of forces seems to me to be probably the most common mechanism. The osseous injury is in some cases due, perhaps, to a combination of more than one method.

It is interesting to note that in one of Callender's cases, No. XIX., fracture occurred from muscular contraction due to galvanic stimulation of the muscles. This was without doubt produced by the strong flexor muscles being too powerful to be successfully resisted by the relatively weak extensors, and the bone gave way at the epiphyseal line.

The muscles have indirectly some indefinite agency in the production of the lesion in the living subject, for by their normal tonic tension they keep the elbow-joint and wrist-joint fixed. They have also, I believe, some effect in limiting anterior displacement, for the extensor muscles are drawn tensely over the dorsal surface of the lower end of the radius as soon as the lower fragment attempts to move forward. This was shown well in my experiments on the cadaver. This restrictive influence would seem to be less operative in backward displacements, because the concavity of the anterior surface of the radial base does not afford the flexor muscles the same opportunity as that given the weaker extensors by the almost flat dorsal surface.

The fracture of the os magnum in some of my experimental attempts to produce radial fracture by extreme flexion of the wrist (Experiments Nos. 2 and 3) apparently indicates that the strain occurs at the articulation between the first and second row of carpal bones, and not at the radio carpal joint. On the other hand, the occurrence, under extreme flexion, of fracture at the epiphyseal junction in Experiment No. 1, and of the radial base, when weakened by a previous division of the compact bone on either the anterior or posterior surface in Experiments Nos. 5, 7, and 8, seems to show that a weak radius will break more readily than the carpal bones.

If any deduction can be drawn from these observations it is apparently this: that, although in extreme flexion of the wrist the strain comes first upon the intercarpal joint, it is also felt by the radius, and will cause a fracture in one or other region in accordance with the exact direction of the force and the relative fragility of the bones.

It is well known that fractures occur at the wrist more readily than dislocations, because of the great strength of the ligamentous surroundings. The exact situation of the fracture evidently depends on the decomposed forces finding a relatively weak bony tissue.

These various considerations have led me to the opinion that no one of the three methods of fracture detailed is exclusively responsible for all the cases.

Fracture with anterior displacement can occur from a splitting force exerted on the articular surface of the radius by the first row of carpal bones being driven up against it. This is beautifully shown in my Experiment No. 10.

SYMPTOMS OF THE INJURY.

It will be interesting to quote at once the description of the symptoms of this fracture given¹ by R. W. Smith, who seems to have been the earliest author to study the condition. He says:

¹ Fractures and Dislocations, p. 164.

"The situation of the fracture is from half an inch to an inch above the articulation; it is accompanied by great deformity, the principal features of which are a dorsal and a palmar tumor, and a striking projection of the head of the ulna at the posterior and inner part of the forearm; the dorsal tumor occupies the entire breadth of the forearm, but is most conspicuous internally, where it is constituted by the lower extremity of the ulna displaced backward; from this point the inferior outline of the tumor passes obliquely upward and outward, corresponding in the latter direction to the lower end of the superior fragment of the radius. Immediately below the dorsal swelling there is a well-marked sulcus, deepest internally below the head of the ulna, directed nearly transversely, but ascending a little as it approaches the radial border of the forearm.

"The palmar is less remarkable than the dorsal tumor; formed principally by the lower fragment of the radius, it is obscured by the thick mass of flexor tendons which cross the front of the carpus, but toward the ulnar border of the limb there is a considerable projection, which marks the situation of the pisiform bone, passing down to its attachment into which can be seen the tendon of the flexor carpi ulnaris thrown forward in strong relief. The transverse diameter of the forearm is not much altered, but the antero-posterior is considerably increased, and the radial border of the limb becomes concave at its lower part."

The cast of the case from which Smith was led to make these deductions has already been shown (Fig. 7). He had apparently never seen a specimen of the injury, and the pathology and symptomatology were at that time, to a certain extent, theoretical.

Gordon's description of the symptoms is not altogether satisfactory. He says:

"Radio-carpal articulation well defined; carpus seemingly shortened. Ulna very prominent, especially behind and internally; lower end of radius behind prominent; carpus displaced outward and forward. Styloid process displaced forward and outward, and on the same plane as the anterior surface of the shaft of the radius.

Concavity of radius much increased. The displacement of the lower fragment forward and externally is so marked that the accident might be easily diagnosed by this sign alone."¹

Voillemier² lays stress on the change in contour of the limb, and mentions the backward projection of the ulna in the following words :

"The fracture, with forward displacement of the lower fragment, scarcely differs from that which I have just described, except by the more marked projection inward and backward of the head of the ulna and by a different arrangement of the antero-posterior break of the axis of the limb. A first plane extends on the posterior face of the forearm as far as the level of the fracture; a second runs forward on the lower fragment; a third belongs to that fragment, to the carpus, to the metacarpus and to the extended fingers. The inclination of the second plane is not as great as one would expect from the normal direction forward of the articular surface of the radius; which position is increased still more by the displacement which the inferior fragment has undergone. The carpus, always movable on this surface, does not follow it entirely in its displacement; but, dragged by the extensor muscles, it rolls from behind forward, and, by a slight movement of extension, corrects a little the deviation of the articular surface. It is for this reason that the second plane presents an inclination less marked than in fractures of the other variety."

Koenig³ calls attention to the change in shape of the forearm, which, he says, consists in a hollow on the back of the wrist and a flat arching forward on the palmar surface, which has a slight hollow above it. He mentions also the fact that in some cases there may be no displacement, though signs of effusion of blood into the joint are evident as a symptom of injury.

The prominence at the back of the limb is placed by Callender⁴ at about an inch above the wrist. A projection on the

¹ Fractures of the Lower End of the Radius, p. 30.

² Clinique Chirurgicale, p. 43.

³ Lehrbuch der Speciellen Chirurgie, p. 149.

⁴ St. Bartholomew's Hospital Reports, 1865.

palmar surface, close to the carpus, and a depression opposite the dorsal elevation are other symptoms mentioned by the same writer.

A study of the herein reported cases and specimens gives considerable light on the symptomatology of this fracture.

The injury appears to occur more frequently on the right side, a circumstance probably due to the fact that most persons, when falling, involuntarily use the right hand and arm for protection. I find that among the cases and specimens described in this essay the fracture is stated to have occurred in the right radius 22 times, and in the left 9 times. In 2 cases both radii had sustained this unusual fracture. In 19 cases the side is not mentioned. In one of the patients who had met with the injury on the left side, the right radius had been broken simultaneously, but the lower fragment on the right side presented the usual backward displacement.

The line of fracture may be transverse, as in Specimen No. 13, or oblique. If oblique, it may run upward and inward, as in Specimen No. 12, or upward and outward, as in Specimen No. 15. It may be so oblique downward and outward as to give to the upper fragment of the radius a sharp end which will resemble the normal styloid process. This point, situated higher up the limb than the styloid process, may be driven into the lower layers of the skin, as in Porrier's case (No. XXIII.), and cause a dimpling of the integument. It is conceivable that a greater vulnerating force would cause an open fracture by driving the sharp fragment through the skin.

It is quite probable that the plane of the fracture runs obliquely upward from the dorsal to the palmar surface of the bone, since this direction would be rather more apt to permit sliding of the carpal fragment forward. The argument is, however, not very strong, because the displacement is principally due to the vulnerating force and not to muscular traction causing overriding.

The break seems to occur generally at a distance from the articular surface of from one-half inch to one and a half inches. In the specimen in the Museum of the Royal College of Sur-

geons in Ireland (No. 19), the line of fracture on the ulnar side of the radius is, however, one and three-quarter inches above the joint, and runs obliquely downward and outward until at the radial side of the radius it was apparently about one and a quarter inches from the joint surface. Specimen No. 1 seems to prove that the solution of continuity may be even nearer the joint than a half inch; and there is no reason known to me why the line might not be very near. I have produced in the cadaver, fracture with backward displacement in which the line was only about one-quarter of an inch from the joint. It is presumable that the same thing might occur with forward displacement.

It is admitted, I think, that occasionally only the anterior edge of the lower end of the bone may be chipped off, as was suggested by Barton, when he erroneously asserted that this chipping off occurred at the posterior lip of the articular surface in the ordinary injury in this situation. Such injuries must, however, be excessively rare at the anterior margin of the radius, since they are almost unknown even in the fracture with posterior displacement.

Involvement of the articular surface with lines of comminution apparently occurs somewhat rarely. It is probable that it requires unusual force to cause such comminution of the lower fragment, and that the mechanism of its production is often an intrusion or impaction of the upper fragment into the lower.

In Specimen No. 5, the facet on the radius for articulation with the ulna is implicated in the line of fracture.

The displacement of the lower fragment varies greatly. Koenig says there may be none. Bryant says, in his letter, that the injury is "an imperfect fracture in the majority of cases, and is, consequently, overlooked." Allport writes in a similar strain. They probably mean that there is little displacement of the fragments.

In some cases the displacement forward is comparatively slight while the tilting or displacement laterally toward the radial or outer border of the arm is very marked. This is the condition, for example, in Specimen No. 19 and in Case No. XIV.

In Case No. XXIII. the upper fragment was displaced backward and outward—toward the radial border of the limb—but the lower fragment forward and inward—toward the ulnar border. This is, I think, a very unusual deformity.

The bending forward seen in the skiagraph of Case No. II. and in Specimen No. 22 would seem likely to occur in young bones only; but the age of the patient described as Case No. II. was between thirty-five and forty years at the time of the injury. It is possible that this condition occurs in adult bones by the anterior edge of one fragment being driven into the cancellated tissue of the other fragment, so that there is little separation of the fragments on the dorsal surface. Union occurring without reduction of the fracture might then give the appearance of the bone having been bent when soft.

It is possible for the carpal fragment to be thrust forward bodily without crushing occurring or angular displacement taking place. In this instance the fractured surfaces would seldom entirely pass each other. This form of displacement would be expected to give to the examiner's fingers the impression of a distinct mass of bone under the flexor tendons. Perhaps the upper edge of the carpal fragment might be distinctly felt. In my first patient I thought I detected this condition with my fingers.

The side of the lower fragment toward the ulna may sometimes remain in something like its normal relation to the shaft of the radius by reason of the radio-ulnar, the internal lateral and the triangular ligaments being more or less uninjured.

Angular displacement may, perhaps, occur by the bone bending at the posterior surface, as on a hinge, and the anterior portion being crushed or undergoing penetration or impaction. This would cause the articular surface to present abnormally downward and forward, and give the appearance seen in several of the specimens.

It is also possible that the hinge-like motion between the fragments may occur at the anterior face of the radius, and the line of fracture be thereby opened on the dorsal aspect of the bone. It is possible that the opened fissure would become

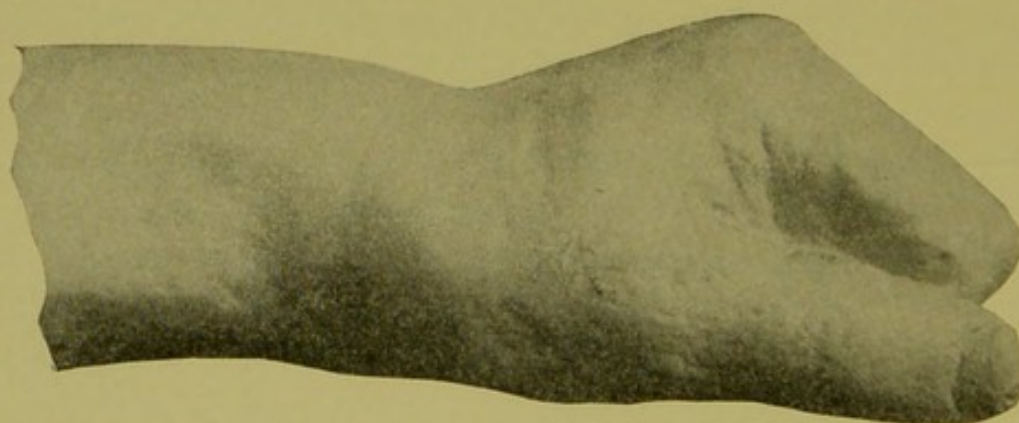
filled and obliterated by callus if the fragments were left unreduced.

I have seen this opening of the fracture on the dorsum produced in my experimental fractures by rocking the fragments in endeavors to increase the deformity.

Whether the carpal fragment is displaced directly forward in a plane at a right angle to the horizontal plane of the radius, is tilted forward as upon a hinge at the flexor surface of the shaft, or is displaced laterally, with or without much forward distortion, seemingly depends upon the line in which the osseous fibres give way and the manner of application of the vulnerating force.

The deformity of the forearm and wrist is characteristic in instances where the carpal fragment is much displaced forward. An elevation is seen across the back of the forearm, running obliquely upward from the ulnar to the radial side. The ulnar portion of this elevation is the more prominent, and is made by the head of the ulna, which was left behind when the carpal fragment of the radius with the attached hand was carried forward by the injury. This is well shown in Specimens Nos. 2, 4, and 22, and in Cases I. and II. On the radial side of the limb the elevation is further from the hand and is less prominent. It is due to the lower end of the upper fragment of the radius.

FIG. 28.

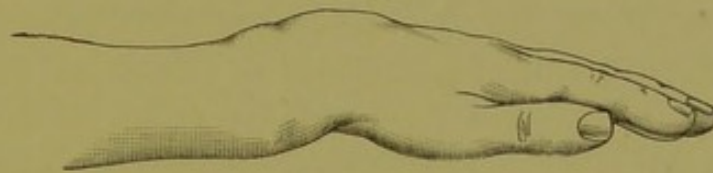

Cast of Smith's case of fracture (Case XVI.), showing character of deformity.
Contrast this figure with Figs. 29 and 30.

This dorsal prominence is quite different in appearance from the hump on the radial side of the dorsum seen in the fracture

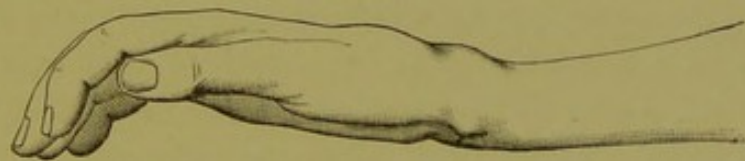of the lower end of the radius with backward displacement of the carpal piece. In the latter case the elevation is great on the radial half of the limb, and the surgeon's finger carried along the back of the shaft of the radius can readily feel the ledge of bone corresponding to the dorsal surface of the lower fragment. The ulna makes little or no prominence on the back of the forearm in the classic fracture, though in both forms it is apt to be prominent on the ulnar edge of the limb, because the outward displacement, common in both instances, carries the hand away from the head of the ulna.

FIG. 29.



Showing deformity in fracture, with backward displacement of lower fragment. Taken from cast of case made before reduction and treatment.

FIG. 30.



Showing deformity in fracture, with backward displacement. Taken from cast of experimental fracture in cadaver. The elevation on dorsum due to lower fragment, and the prominence on palmar surface due to upper fragment, are well shown. There is no swelling because the fracture is in a cadaver.

In the fracture under consideration the surface slants downward from the dorsal elevation toward the back of the hand, whose plane is at a lower level than that of the forearm, but more or less parallel to it. The occurrence of these three planes in the fracture with forward displacement is due to the movement normally allowed between the displaced articular surface of the radius and the first row of carpal bones, and between the first and second rows of carpal bones. The articular surface of the radius is displaced so that it looks forward. Therefore the extensor muscles cause rolling between it and the first row of carpal bones and between the two carpal rows.

This slant in the surface below the dorsal elevation causes somewhat the appearance of a furrow across the forearm, which is deeper just below the head of the ulna. Pressure with the fingers will make this hollow more evident, and show that the lower end or base of the radius occupies a position more anterior than normal. This sulcus is, as the elevation, a little further from the hand on the radial side.

FIG. 31.

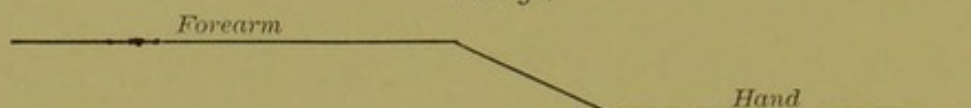


Diagram of Deformity in Fracture with Forward Displacement



Diagram of Deformity in Fracture with Backward Displacement

On the palmar surface there is some prominence, due chiefly to the lower fragment, but is less marked than the elevation seen on the dorsum. This is probably due to the fact that when the hand is carried forward with the base of the radius the flexor tendons must span the arch made by the broken radius and the carpus. They thus obscure the deformity in the bony outlines, which would be made conspicuous if the palmar surface of the radius was normally flat like the dorsal surface. In the fracture with dorsal displacement the overlying tendons are pushed up and increase the elevation; in the fracture with palmar displacement the tendons are stretched across an abnormally great arch, and therefore conceal to a certain extent the change in the contour of the bone.

The pisiform bone makes, however, it is said, a more pronounced elevation than normal. This is intelligible when it is remembered that the ulna and the hand have parted company, as it were. The lower fragment may, perhaps, be felt as a hard mass under the flexor tendons. It seemed as if this was pretty clearly established in my case (Case I.). The prominence and

hard mass will clearly be disconnected with the lower end of the ulna. This point aids in distinguishing the injury from fracture of the lower end of both radius and ulna. In my patient (Case II.) the normal hollow on the palmar surface just above the base of the thenar eminence is absent, and bone can be felt there. This obliteration of the hollow is probably due to the rotated scaphoid and trapezium.

The great deepening of the normal curve of the palmar surface of the lower end of the radius would seem to be a necessary feature of cases in which the lower fragment was simply tilted forward, or the bone bent as in Specimens No. 22 and No. 28. It is conceivable that the base of the radius might be broken from the shaft and displaced forward, but so rotated on its transverse axis that its articular surface for the carpus would present slightly dorsally instead of being made to look more toward the flexor surface than normal. Such a displacement would probably obliterate instead of increase the normal arch of the palmar surface of the radius. Comminuted fractures would be likely to cause irregular distortions and increased masses of callus.

The lateral deformity which is usual is deviation of the hand toward the outer or radial side of the forearm. This sometimes causes a concavity of the lower part of the radial border, and is due to the shortening of the radius from the crushing of the bony tissue, or to the outward tilting of the lower fragment in oblique fractures. In Poirier's case (Case XXIII.) the hand had a tendency to deviate to the ulnar or inner side of the arm, because the line of fracture ran obliquely downward from the ulnar to the radial edge of the bone. This is apparently very rare. The specimen in the Museum of the Royal College of Surgeons in Ireland (Specimen 19) shows deviation to the radial side, which is the common form, in an excessive degree. In fact, there is very little forward displacement in this specimen.

In Dr. Stewart's case (Case VI.) such rotation of the lower fragment was present that the hand was in a condition of exaggerated pronation. The case seems to have required special attention during the treatment to overcome this tendency.

The tendon of the ulnar flexor of the carpus, which is inserted into the pisiform bone, becomes prominent in the fracture under consideration, as would be supposed from the statement made previously that the pisiform bone becomes more projecting than in the normal hand. In one of my cases (Case II.) the tendons of the radial flexor of the carpus and the long palmar muscle stand out quite prominently at the wrist; but they do so in the normal wrist also.

Careful observation of patients with this fracture will, I think, show that there is a tendency for the base or upper border of the thenar eminence to ascend toward the elbow, because of the relative shortening of the radius. The upper margin of the hypothenar eminence is usually, I think, in uninjured limbs the nearer the elbow. Hence, a line drawn across from the upper margin of these eminences, when the axis of the hand corresponds with the axis of the forearm, will generally be oblique, with the ulnar end nearer the elbow. In this fracture the line will be more or less transverse or, perhaps, have its radial end nearer the elbow. This displacement, of course, depends on the change in length of the radius and the outward deviation of the lower fragment.

The same change, perhaps, occurs in fractures with dorsal displacement of the lower fragment, though it does not seem to be present in several casts of the injury before me.

The deflection of the hand radially causes, necessarily, the head of the ulna to become very prominent on the inner or ulnar border of the lower part of the forearm. It is also a marked feature on the back of the arm. If the lower fragment is displaced very much both inward and forward, the ulnar head becomes prominent, both dorsally and at the ulnar border of the arm. If the forward displacement alone is great, the projection of the ulnar head is chiefly backward. If the displacement of the carpal fragment is mainly outward, the projection of the end of the ulna is noticeable chiefly on the ulnar side of the limb. Variations from these extremes occur with the varying directions of displacement of the carpal portion of the radius.

The transverse diameter of the forearm at the region of the

fracture is not likely to be increased in this fracture. The antero-posterior diameter, however, may be a good deal greater in the injured than in the normal arm. This would be expected particularly in patients in whom the lower fragment was displaced forward as a whole, and not simply tilted. In great comminution of the lower fragment the increased thickness of the forearm in the antero-posterior diameter would probably be quite marked if the fracture were not properly reduced and the smaller pieces of bone were welded together by a mass of callus.

A careful examination of the styloid process of the radius will show in all cases, except those in which there is no displacement of the lower fragment, that this process has been displaced forward. It very often will also be displaced outward. The abnormal position of the process will be either marked or scarcely noticeable in accordance with the degree of alteration in the relation of the lower fragment to the shaft of the bone. Its most readily observed change in position, however, is the elevation toward the elbow, due to the bending, to the impaction, or to the crushing of bony tissue. This higher position of the radial styloid is claimed by Bryant to be a diagnostic point of great value.

It must be recollected that in a normal condition of the bones the radial styloid is lower—that is, further from the elbow than the ulnar styloid. After fracture of the lower end the radial process is carried upward toward the elbow. In the classic fracture, with dorsal displacement, it may be displaced backward and outward as well as upward, so in the fracture under consideration it may be carried forward and outward as well as upward. A point of bone on the outer side of the radius belonging to the upper fragment, due to an oblique fracture might, by a careless observer, be mistaken for the styloid process itself. Examination, however, would soon show the fallacy of such an observation.

The styloid process of the ulna may be broken off at the time of injury, as occurred in case No. XV. Specimen No. 2 is an illustration of this complication, for the styloid process of the

ulna is seen to have been the seat of a fracture, though it is now united to the head of the bone.

The force which carries the hand at the time of fracture away from the ulna may cause the styloid process of that bone to tear through the skin. This was probably the causation of the wound mentioned in the report of Case XIV. In Case IX. there was, in addition to the fracture of the base of the radius, which was transverse and open, an oblique fracture of the ulna an inch higher than the radial fracture. The latter was situated about three-quarters of an inch from the carpal end of the bone.

The articulating surface of the radius cannot be made out by palpation in fracture with forward displacement, as in dislocation forward of the carpal bones. Its plane in fractures is carried forward. This would cause the hand to assume the appearance of flexion of the wrist-joint if it were not that the extensor muscles have a tendency to cause extension between it and the first row of carpal bones and between the two rows of carpal bones, and thus bring the hand into a plane corresponding approximately with that of the forearm. This condition is particularly noticeable in the specimen belonging to the New York Hospital (No. 22). The way in which the articular surface looks obliquely forward is beautifully shown in the specimen from the Royal College of Surgeons of Edinburgh (No. 4).

FIG. 32.

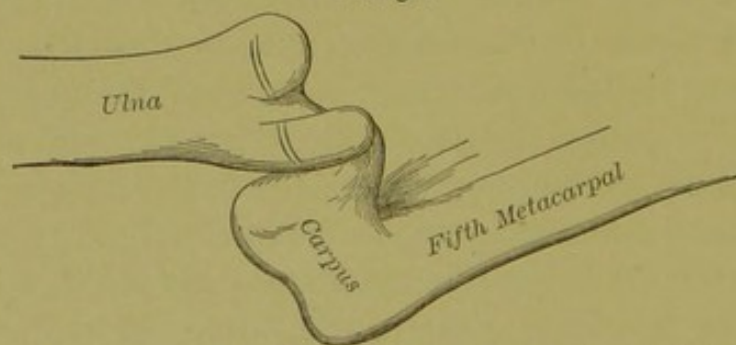


Diagram of displacement on ulnar side. Specimen 22 [New York Hospital].

No lateral motion is to be expected between the carpal bones and the lower end of the radius, since the lateral ligaments,

which prevent lateral mobility in the normal joint, are not disturbed by the lesion. The abnormal direction of the articulating surface permits exaggerated flexion of the wrist and diminished extension in old and unreduced fractures. Attention is called to this in two of the cases reported by Callender (XVII. and XVIII.). In one of these cases (XVII.), which was an old case with unreduced fragments, there was diminution of supination as well as the changes in flexion and extension.

The carpus in these fractures seems to be shortened. This is probably due to the fact that the head of the ulna overrides the carpus, and that the lower fragment of the radius is displaced somewhat upward as well as forward. The carpus, of course, follows the radial fragment, and is displaced forward and usually outward. These two circumstances make the space occupied by the carpus seem shorter than usual. The manner in which the carpal bones roll upon each other and upon the radius, in order to overcome the displacement of the articular surface of the radius, has already been mentioned.

In recent fractures voluntary movement is more or less restricted because of pain or fear of pain. In old cases in which reduction has been neglected, stiffness in flexion, extension, and rotation is to be expected.

Preternatural mobility would be obtainable in comminution of the lower fragment in fractures where the periosteum was greatly lacerated, and, indeed, in most fractures where there was no impaction. In incomplete or green-stick fractures it would, of course, be unobtainable until the fracture was made complete.

To obtain crepitus the surgeon should grasp the lower fragment with the thumb and fingers of one hand, and endeavor to get mobility in the antero-posterior direction while steadying the shaft of the bone with the other hand.

The point of mobility and the point of pain on pressure will be in the neighborhood of from a half to one inch above the joint. Firm pressure at this point will aid in the diagnosis where there is no special deformity or great mobility. In sprains the point of intense pain, on making pressure with the finger, will be over the joint which is lower down than the point

at which pain is experienced when a fracture exists. I have often used this test with great advantage in fractures of the lower end of the radius with no displacement either forward or backward. The injury in such cases is probably associated with little or no laceration of the periosteum.

Crepitus will be obtained in fractures in which mobility is present, but will not be demonstrable, or demonstrable only with difficulty, in cases where there is little periosteal laceration.

In cases of impaction the force applied to reduce the deformity and readjust the fragments will give a coarse, grating crepitus when the lower fragment is pushed backward into place. It should be remembered that this fracture, as in fractures with backward displacement, differs from ordinary fractures in other regions in that crepitus and mobility are quite often absent, because impaction is frequently present.

The fracture is easily reduced if sufficient force be used, but it requires a good deal of pressure applied directly over the flexor surface of the lower fragment, accompanied by extension and counter-extension, and sudden extreme extension in a dorsal direction. At least this is my belief from my experience in reducing the fracture with backward displacement. Many surgeons speak of the difficulty of reducing the latter fracture. I have, however, never found it so if I have put sufficient force directly upon the lower fragment. Ether is sometimes necessary, but extension and counter-extension, with pressure of one of the thumbs upon the back of the lower fragment at the time sudden flexion of the wrist-joint is made, will nearly always accomplish the desired object. I have occasionally, in unreduced fractures of several weeks' duration, been obliged to bend the limb across my knee, in order to loosen and coapt properly the fracture surfaces.

Similar manœuvres would doubtless succeed in reducing the deformity in all cases of forward displacement. Etherization is desirable if pain is to be avoided. The suddenness with which the manipulation is completed makes an anæsthetic often unnecessary. There would be, I should think, little tendency for the deformity to recur after proper readjustment of the fracture.

It may be thought that in this respect the injury would resemble a dislocation of the carpus with displacement in the same direction; but the reduction of the fracture is not accompanied by the sudden snapping-noise which is heard when a dislocated carpus is reduced.

The fracture may be accompanied by such laceration of soft parts as to convert the injury into an open or compound one. This complication was present in case No. 9. Necrosis indeed occurred as a sequel, and required operative removal.

Fracture of the radial base, with forward displacement, may be mistaken for sprain of the wrist or contusion. The resemblance to fracture caused by inflammatory thickening of the soft parts after contusion may be great. Dr. Hewson's case of injury (p. 11), which resembled this fracture, is an instance in point. The boy, however, was not seen by Dr. Hewson until two or three weeks after the receipt of the injury. An examination made immediately after the accident would probably have made the diagnosis more clear, as the inflammatory exudate would then have been less indurated.

DIAGNOSIS.

The diagnosis between contusion or sprain and fracture will largely rest on a careful study of the relation of the bony outlines. The position of the head of the ulna and of the radial styloid process will be normal in the former injuries, but abnormal in fracture if any displacement of the fragments has taken place.

The swelling in sprains or contusions will be soft and will be compressible by the fingers. The prominences due to altered osseous relations will be hard. The pain on pressure in sprain will be over the joint, because of the consecutive synovitis immediately arising. The ecchymosis under and in the integument will appear later in fractures, because the blood flowing from the bones requires time to reach the superficial tissues. The appearance, after a few days, of a hard swelling along the suspected line of fracture will confirm the diagnosis of fracture.

This callus is not deposited in sprain or contusion. Tonic muscular spasm is a more frequent accompaniment of sprains than of fractures in other regions, and may be a diagnostic sign of value here.

The swelling in sprain would be conspicuous over the back of the wrist-joint, and hence nearer the hand; at least on the radial side of the dorsum. Crepitus and abnormal mobility would be absent in sprain or contusion. Unfortunately, these symptoms are often absent in the fracture, since it is at times impacted.

Fractures with little displacement are difficult to distinguish from the other lesions under consideration. The limited area, about half an inch above the radio-carpal joint, in which pain is produced by pressure of the surgeon's finger-tip, may be the only symptom to point to a fracture. A diagnosis of the fracture can at times be made by this single symptom. The ridge of callus occurring later will confirm the truthfulness of the diagnosis. I believe such fracture has often been mistaken for a sprain.

The usual fracture with backward displacement can hardly be confused with fracture with anterior displacement, if the surgeon makes a careful examination and remembers the possibility of the less frequent injury. The deformity is quite different, as has been shown in discussing the symptoms of the latter lesion. The prominence on the back of the forearm near the wrist in the anterior displacement is so evidently due to the carpus and end of the radius leaving the forearm behind, that it cannot easily be mistaken for the elevation which rises up *above* the normal level of the back of the forearm in the backward displacement. The plane of the back of the forearm is undisturbed in the former injury until there is a drop downward at the seat of fracture. The deep groove on the palmar aspect of the limb opposite the dorsal hump and behind the ball of the thumb is also characteristic of posterior displacement of the lower fragment.

When fracture of the radius takes place without displacement these distinguishing features of the two forms of displacement are necessarily absent.

Backward dislocation of the carpus resembles fracture with backward displacement of the inferior fragment, and is not likely to be mistaken for fracture with forward displacement. The elevation, due to the carpus, extending across the whole width of the dorsum, the convex upper border of the carpus felt by palpation, and at times even seen, the commonly observed tilting forward of the hand, as in a state of flexion of the wrist, the projection of the ends of the radius and ulna forward, and the relations of the two styloid processes to each other and to the bones of the hand, will usually make the existence of dislocation obvious. The snap heard on reduction and the rapid return of normal movements and usefulness to the limb will confirm the diagnosis of luxation.

When only the scaphoid and semilunar bones are dislocated backward and the ulnar side of the carpus remains attached to the ulna the differential diagnosis of luxation and fracture is more difficult. Careful examination will, however, usually render the true condition clear.

Forward dislocation will produce a deformity resembling in some respects that resulting from fracture with displacement forward. It may be argued that mistaking one injury for the other is unlikely, but it is not to be forgotten that the surgical world believed the usual fracture in this region to be a backward dislocation of the carpus, until Dupuytren proved it to be a fracture of the radius with posterior displacement of the carpal fragment.

In forward luxations it seems to be not unusual to have the anterior margin of the articular surface of the radius chipped off. A similar chipping of the posterior margin occurs not infrequently in the posterior luxations, causing as a complication of the luxation the form of fracture which Barton described as being the usual lesion in the common fracture of the base of the radius.

The breaking off of the anterior edge of the radial articulating surface may, by causing easy reproduction of deformity after reduction and by giving rise to crepitus, make the diagnosis between luxation and fracture more difficult than in ordinary cases.

In most cases, however, the surgeon will probably have little trouble in distinguishing between fracture with forward displacement and forward luxation of the carpus. In the former the lower border of the dorsal prominence runs obliquely upward across the back of the lower part of the forearm from the ulnar to the radial side, being constituted by the head of the ulna and the lower end of the upper radial fragment. In the dislocation the elevation is either transverse or runs obliquely downward from the ulnar to the radial side, and is constituted by the articular ends of the radius and ulna.

In dislocation forward of the carpus the hand, according to Stimson,¹ may occupy any position between moderate dorsal and palmar flexion, the latter being more common, and the fingers are slightly flexed.

I have never seen the injury, but would have expected slight dorsal flexion to be more common, especially if the carpus was displaced upward to any great degree. The greater strength of the flexor muscles as compared with the extensors is, I presume, the explanation of the tendency to flexion of the wrist.

In this dislocation there is a marked hollow at the back of the wrist below the lower ends of the radius and ulna, which forms an abrupt ending of the plane of the back of the forearm, running nearly transversely across the limb.

There is a prominence at the front of the wrist under the flexor tendons. Perhaps the upper border of this prominence may be felt as a convex mass extending entirely across the forearm. The hand has the appearance of being shortened, and the distance from the styloid process of either side to the corresponding metacarpal knuckle will be found to be less than normal. The wrist will be decidedly increased in its antero-posterior diameter. The injury is probably rarer than fracture with anterior displacement of the lower fragment, but must be remembered as a possibility. A still rarer injury is incomplete dislocation forward of the carpus, in which the scaphoid and semilunar bones leave the radius, but the cuneiform bone main-

¹ Fractures and Dislocations, vol. ii. p. 361.

tains its normal relation with the triangular cartilage and head of the ulna.

Attention to the variations in the deformity and a careful examination of the bony landmarks and of the relations of the two styloid processes to each other and to the bones of the hand will probably enable the surgeon to determine whether the injury in a given case is a forward dislocation or a fracture with anterior displacement. The snap with which the dislocation is reduced and the rapid acquirement of normal voluntary movement will point to dislocation. The grating crepitus felt when the fracture is reduced, the subsequent thickening from callus, and the delay in regaining motion will point to fracture.

TREATMENT OF THE INJURY.

The treatment consists in immediate and complete reduction of the fracture, followed by a retentive dressing which will not interfere with the free use of the fingers.

The deformity must be overcome even if great force is necessary to put the fragments in normal position. The impaction that is probably often present may prevent a timid surgeon from obtaining the object sought, but one who understands the injury and the impaired function liable to result if the displaced bone is allowed to remain displaced will not be deterred, even if he has to give a general anæsthetic and bend the forearm at its lower end across his knee.

He should grasp the metacarpus of the patient with one hand and the lower part of the forearm with the other. This should be done with the patient's hand in the supine position. The thumb of the surgeon's hand which holds the metacarpus should be placed on the palmar surface of the carpal fragment of the radius as it lies just behind the thenar eminence. Extension and counter-extension are to be made for a moment; the hand should then be suddenly bent backward in strong dorsal flexion, and at the same instant the surgeon's thumb should push the lower fragment backward into place. This can be done in a moment and will not require anæsthesia. It

will be exceedingly painful, but is so quickly done that, as a rule, etherization is unnecessary. If sufficient force is applied the fragments will be driven into place at once with a coarse grating sensation. Occasionally a repetition of the manipulation may be needed to obtain perfect restoration of the bony contour.

This manipulation is the same that I use in reducing the fracture with dorsal displacement, but is applied to the palmar surface instead of to the dorsal.

In fractures which have been left un'duced for several weeks more power will be required because the reduction then becomes a refracture. Here it may be necessary to bend the united bone across the surgeon's knee, which is applied to the front of the forearm at the level of the fracture. After the fragments have been broken apart by extension and counter-extension, and a cross-breaking strain over the knee, applied to the palmar surface so as to tend to increase the displacement, coaptation is to be accomplished by the manipulation just given for the reduction of recent fractures.

As in the ordinary fracture of the base of the radius, immediate and complete reduction is the essential of treatment. If reduction is perfect there will be little trouble in most cases, and restoration of function will be prompt and perfect. Stiffness, pain, and other discomforts are due to imperfect reduction, which interferes with the movement of the tendons and probably causes injurious nerve pressure.

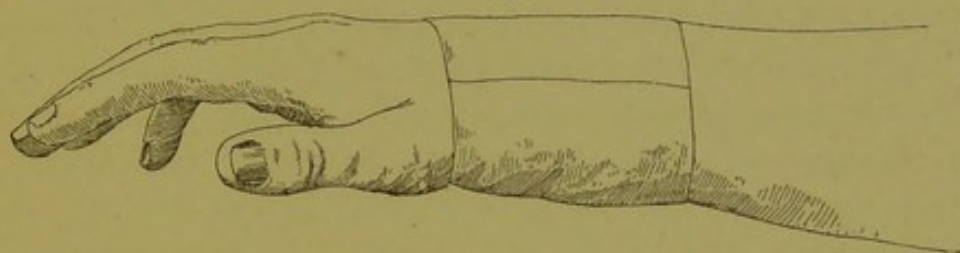
Most cases will probably show little tendency to reproduction of deformity, for the broad serrated surfaces of the fragments will hold them in apposition, and there is little tendency to displacement from muscular action.

In cases with little or no comminution and with a transverse line of fracture, a cuff or wristlet of superimposed layers of adhesive plaster three inches wide, extending an inch and a half below and an inch and a half above the wrist-joint, and made sufficiently thick to prevent motion of the wrist, will be all that is necessary in the way of splint.

If the lower fragment is comminuted or easily displaced be-

cause of the obliquity of the fracture-line, or if the patient is a boy liable to engage in boisterous games, a more rigid and elaborate splint may be demanded. Then a circular bandage of gypsum applied from the metacarpo-phalangeal joints to the upper third of the forearm is a perfect splint that exactly fits the irregularities of the patient's limb.

FIG. 33.



Fracture of the lower end of radius dressed with a wristlet of adhesive plaster.

If there is danger of swelling causing either of these two forms of dressing to become too tight, the plaster-of-Paris splint or the adhesive plaster one should be split up the middle of the dorsum and held in place by a roller bandage.

Instead of these dressings, the surgeon can readily construct and apply a dorsal or palmar splint made of strips of gauze dipped in wet gypsum and moulded to the surfaces of the hand and forearm. In some cases it may be wise to use both a dorsal and a palmar moulded splint of this kind; but, usually, either one, if made very rigid, will be sufficient.

A padded strip of wood six inches long, one inch wide, and an eighth of an inch thick applied to the dorsal surface of the forearm and metacarpus makes a good splint for these fractures. The dorsum of this region is straight, and a flat splint can, therefore, be properly used on the back of the limb.

If the attendant decides to apply a splint to the front of the limb, instead of to the back, he must use a moulded splint which will conform to the curve of the palmar surface of the radius. Hence plaster-of-Paris, or a moulded metal or gutta-percha splint should be adopted. In all cases the fingers should be unrestrained during the entire period of treatment.

The results in fractures of the lower end of the radius with forward displacement will nearly always be good if reduction is immediate and complete. If the fragment is permitted to remain unreduced, restricted movement, pain, and deformity will persist.

Old cases with unreduced fragments should be treated by refracture, if the deformity or disability is marked. My experience in treating old unreduced fractures with backward displacement leads me to believe that four to six months are not too late to attend remedial refracture. Osteotomy can be adopted if refracture is believed to be difficult. It is a more certain method of obtaining separation of the fragments at the exact spot desired. I would only use it, as a rule, in cases over six weeks or two months old.

Massage, hot fomentations, and electricity will do much good in neglected or unrecognized cases in restoring motion and relieving pain. The benefit derived by these means in Case II. was very great, though not begun until nearly two years after the receipt of injury.

