

Surgical operations / by William Mac Cormac.

Contributors

Mac Cormac, William.
Ramsay, Winson
Royal Postgraduate Medical School.
University College, London. Library Services

Publication/Creation

London : Smith, Elder, and Co., 1889.

Persistent URL

<https://wellcomecollection.org/works/u7rwa7j8>

Provider

University College London

License and attribution

This material has been provided by UCL Library Services. The original may be consulted at UCL (University College London) where the originals may be consulted.

This work has been identified as being free of known restrictions under copyright law, including all related and neighbouring rights and is being made available under the Creative Commons, Public Domain Mark.

You can copy, modify, distribute and perform the work, even for commercial purposes, without asking permission.

**wellcome
collection**

Wellcome Collection
183 Euston Road
London NW1 2BE UK
T +44 (0)20 7611 8722
E library@wellcomecollection.org
<https://wellcomecollection.org>

SURGICAL OPERATIONS


PART II.

AMPUTATIONS, EXCISION OF JOINTS

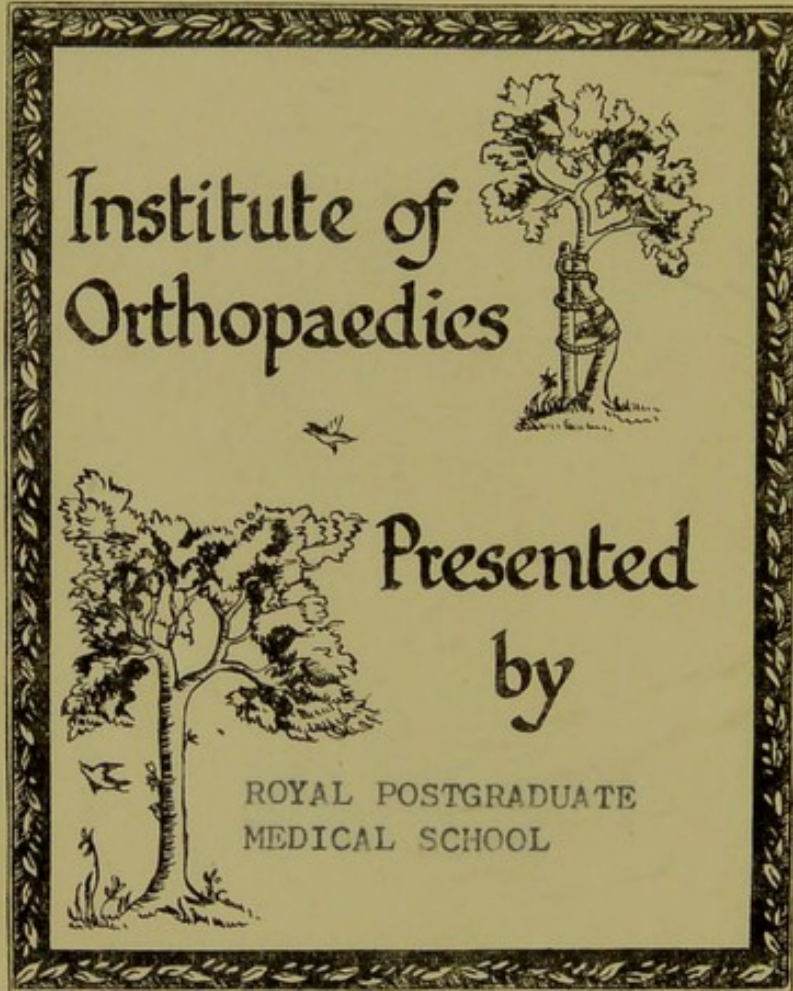
OPERATIONS ON NERVES



*Presented
by Roy Bond
Med. Sch.
Stack*








Arch.

C

617-089 ru

~~STACK~~

~~MACCORMAC~~



SURGICAL OPERATIONS

PART II.

Ballantyne Press
BALLANTYNE, HANSON AND CO.
EDINBURGH AND LONDON

SURGICAL OPERATIONS

PART II.

AMPUTATIONS, EXCISION OF JOINTS
OPERATIONS ON NERVES

BY

SIR WILLIAM MAC CORMAC

SURGEON, AND LECTURER ON SURGERY
ST. THOMAS'S HOSPITAL



LONDON

SMITH, ELDER & CO., 15 WATERLOO PLACE

1889

4977

965162

PREFACE.

IN continuation of Part I. of "Surgical Operations" I now publish Part II., containing an account of the ordinary methods of Amputation and Excision. The operations practised upon Nerves are also included in this Part.

For many of the Illustrations I have again to thank my colleague, Mr. William Anderson: several have been copied from photographs, and a few have been selected from other sources.

WILLIAM MAC CORMAC.

13 HARLEY STREET,

January 1889



CONTENTS.

AMPUTATIONS.

- General Remarks.—Historical introduction—Indications for amputations—
Lesions which require amputation—Contra-indications—Time for am-
putating—Place in which to amputate Pp. 135-143
- Preparation to be made for Amputation.—Instruments—Tourniquets—Digital
compression—Esmarch's apparatus—Position of operator—Immediate
objects to be secured by amputation Pp. 144-157
- Circular amputation—Flap amputation—Oval amputation . . . Pp. 157-170
- Disarticulation.—Circular method—Oval method—Osteo-plastic amputation—
Arrest of hæmorrhage—Circumstances and results unfavourable after
amputation—Statistics Pp. 170-195
- Special Forms of Amputation.—In lower extremity—Amputation of toes—Dis-
articulation of ungual phalanges—At joint between first and second
phalanx—At metatarso-phalangeal joint of great toe—At metatarso-
phalangeal joint of toes—Of great toe at internal cuneiform bone—Of
fifth toe and its metatarsal bone—Of all the toes at the metatarsal joints—
Partial amputation of foot—Amputation through metatarsus—Lisfranc's
amputation—Chopart's amputation—Malgaigne's sub-astragaloid ampu-
tation—Syme's amputation—Roux's amputation—Parry's modification—
Pirogoff's amputation—Gunther's modification—Lefort's modification—
Amputation of leg—Supra-malleolar amputation—Sédillot's method—
Disarticulation at the knee-joint—Smith's method—Amputation of thigh
—Gritti's osteo-plastic amputation—Stokes' modification—Carden's
amputation—Teale's amputation—Vermale's amputation—Disarticulation
of the hip-joint—By modified oval method Pp. 196-271
- Amputations and disarticulations in upper extremity of all the fingers at the
phalangeal and metacarpo-phalangeal joints—Amputation of thumb—

Of thumb and first metacarpal bone—Excision of metacarpal bone of thumb—Disarticulation of little finger—Amputation of the four metacarpal bones—Disarticulation of wrist—Amputation of forearm—Disarticulation of elbow—Oval or racquet-shaped disarticulation of elbow—Amputation of arm—Disarticulation of shoulder-joint . Pp. 272-308

EXCISION OF JOINTS.

General Remarks.—Resection—Indications—Contra-indications—Mortality
Pp. 309-315

Osteo-plastic resection of foot—Wladimiroff—Mikulicz—Excision of metatarsophalangeal joint of great toe—Excision of os calcis—Of ankle-joint—Langenbeck's method—Excision of knee-joint—Excision of hip-joint—Osteotomy of femur—Excision of the phalangeal and metacarpophalangeal joints—Excision of wrist—Langenbeck's method—Excision of elbow—Excision of elbow for ankylosis of joint—Splints—Excision of shoulder—Excision of scapula—Excision of clavicle—Excision of upper jaw—Resection of the lower jaw—Resection of temporo-maxillary articulation Pp. 316-426

OPERATIONS ON NERVES.

Neurotomy—Neuroraphy—Neurotony—Neurectomy—Operations of the nerves of the lower extremity—Operations on the nerves of the arm and forearm—Operations on the nevers of head and neck Pp. 427-482

LIST OF ILLUSTRATIONS.

FIG.	PAGE
94. Amputating knives of three sizes	144
95. Method of holding knife for circular amputation	144
96. Method of holding knife for flap amputation	145
97. The scalpel	145
98. Method of holding scalpel	145
99. Straight bistoury or finger knife	145
100. Elevator	146
101. Bow saw	146
102. Bone forceps	146
103. Single retractor	147
104. Double retractor	147
105. Pressure artery forceps	147
106. Stump of thigh, with artery forceps applied	148
107. Petit's tourniquet	149
108. Digital compression of the brachial artery	150
109. Digital compression of the femoral artery	151
110. Compression of femoral artery by tourniquet	152
111. Esmarch's apparatus, prior to Teale's amputation	152
112. Broad elastic band, prior to a circular amputation of arm	153
113. Compression of brachial artery by Petit's tourniquet	154
114. Compressors for the abdominal aorta	154
115. Signoroni's tourniquet	155
116. Manner of holding knife in a circular amputation	158
117. Manner of forming a manchette of skin	159
118. Manner of completing the division of soft parts in a circular amputation of the arm	160
119. Amputation by skin flaps and circular division of muscles	161
120. Application of single retractor in amputation of thigh	161
121. Application of double retractor	162
122. Manner of transfixing limb in a flap amputation	164
123. Flap amputation of arm with digital compression of brachial	166
124. Mixed method of amputation of arm	169

FIG.		PAGE
125.	Oval method, as applied to amputation of finger	172
126.	Oval-shaped incision for removal of little toe	173
127.	Oval method of disarticulation at shoulder-joint	174
128.	Application of force-pressure forceps.	177
129.	Tenaculum	178
130.	Stump after amputation of thigh	178
131.	Plastic periostitis of divided ends of bone	181
132.	Stump of femur, showing thickening of sawn end	182
133.	Appearances of ends of bone after amputation	183
134.	Sequestra separated after osteo-myelitis	184
135.	Large formation of new bone, in chronic osteo-myelitis	184
136.	Necrosis following osteo-myelitis in bone of a stump	184
137.	Conical stump with protrusion of bone and neuromata	186
138.	Conical stump with neuromata after amputation	186
139.	Conical stump after amputation, due to atrophy of soft parts	188
140.	Disarticulation of unguis phalanx of great toe	197
141.	Removal of little toe by oval method at metatarso-phalangeal joint	198
142.	Lines of incision for amputation of great toe at metatarso-phalangeal joint and of great toe together with its metatarsal bone	200
143.	Disarticulation of little toe with its metatarsal bone	201
144.	Method of holding foot in amputation of all the toes	202
145.	Formation of dorsal incision in amputation of all the toes	202
146.	Synovial membranes of the foot	203
147.	Sagittal section through the foot	205
148.	Showing intervals between bones of foot, where operations are performed	206
149.	Direction of tarso-metatarsal joint of right foot	207
150.	Median transverse section of the foot	208
151.	Tarso-metatarsal joint, Lisfranc's operation	208
152.	Hey's and Lisfranc's amputations	209
153.	Lisfranc's operation, line of incision	210
154.	Method of disarticulating the second metatarsal bone	211
155.	Formation of the plantar flap in Lisfranc's operation	211
156.	Formation of the plantar flap in Lisfranc's operation by cutting from within outwards	212
157.	Stump resulting from Lisfranc's operation	213
158.	Mid-tarsal joint, the position for Chopart's amputation	214
159.	Line of the base of the plantar flap in Chopart's amputation	214
160.	Plantar incision in Chopart's amputation	214
161.	Dorsal and external incisions in Chopart's amputation	215
162.	Dorsal incision in Chopart's amputation	215
163.	Lines of dorsal and internal incisions in Chopart's amputation	215
164.	Lines of dorsal and internal incisions in Chopart's amputation	216

FIG.		PAGE
165.	Three views of a stump after Chopart's amputation	217
166.	Stump dissected after Chopart's amputation	218
167.	Stumps after Chopart's amputation	218
168.	<i>a</i> , Incision for Malgaigne's sub-astragaloid amputation	221
168.	<i>b</i> , Stump after Malgaigne's amputation	222
169.	Vertical section through the malleoli, ankle-joint, and heel-pad	223
170.	Dorsal incision in Syme's amputation	224
171.	Incisions on outside of foot in Syme's amputation	224
172.	Incisions on inside of foot in Syme's amputation	225
173.	Plantar incision in Syme's amputation	225
174.	Plantar incision in Syme's amputation	226
175.	Transverse section of the right ankle from below	226
176.	Stumps after Syme's amputation	227
177.	Roux's method of amputation at ankle-joint	228
178.	Roux's method of amputation at ankle-joint	228
179.	Lines of incision on external surface of foot in Parry's amputation	229
180.	Incisions on inner side of foot in Parry's amputation	230
181.	Position in which bones are cut in Pirogoff's amputation	232
182.	<i>a</i> , Stump after Pirogoff's operation, lateral aspect	233
182.	<i>b</i> , Stump of left limb after Pirogoff's amputation	233
183.	Gunther's modification of Pirogoff's amputation	234
184.	Gunther's modification of Pirogoff's amputation	234
185.	Direction in which bones are sawn in Gunther's amputation	235
186.	Direction in which bones are sawn in Lefort's amputation	236
187.	Incision on outside of foot for Lefort's amputation	237
188.	Incision on inside of foot for Lefort's amputation	237
189.	Line of plantar incision in Lefort's amputation	238
190.	Stump after Lefort's modification of Pirogoff	239
191.	Section through middle of left leg	240
192.	Section through left leg close to knee	240
193.	Amputation just above ankle	241
194.	Amputation of leg in lower third	242
195.	Amputation in upper third of leg	242
196.	Sédillot's amputation of the leg	243
197.	Sédillot's amputation of the leg	244
198.	Lateral flap method of amputation of leg	244
199.	Transverse section through the condyles of femur	246
200.	Vertical antero-posterior section through knee	247
201.	Disarticulation at knee by anterior and posterior flaps	248
202.	Disarticulation of the knee by antero-posterior flaps	249
203.	The external flap in Smith's amputation	250
204.	Appearance of the parts in Smith's amputation	250
205.	Stump after Stephen Smith's amputation	251

FIG.		PAGE
206.	Amputation of thigh by double flaps formed by transfixion	252
207.	Amputation of thigh by double flaps	253
208.	Gritti's amputation	254
209.	Incision for Stokes' supra-condyloid amputation	255
210.	Section through lower third of left thigh	256
211.	Amputation through lower third of the thigh	257
212.	Transverse section of thigh at apex of Scarpa's triangle	258
213.	Teale's amputation in the middle of the thigh	259
214.	Contrast between Teale's and antero-posterior flap operations	260
215.	Application of knife in a circular amputation of thigh	261
216.	A conical stump after circular amputation of thigh	261
217.	Section of neck of femur and capsule close to acetabulum	263
218.	Incisions on outside of thigh for disarticulation of hip-joint	264
219.	Method of transfixing anterior flap in disarticulation of hip-joint	265
220.	Formation of anterior flap in disarticulation of hip-joint	266
221.	Completion of anterior and posterior flaps	267
222.	Result of the flap operation at the hip-joint	268
223.	A patient after removal of the limb at hip-joint	268
224.	Disarticulation of the hip-joint by the modified oval method	269
225.	Stump after disarticulation at the hip-joint	271
226.	Skeleton of finger, showing relations of the knuckles to the joints	273
227.	Creases of the palm of hand and fingers and position of the joints	274
228.	Dorsal incision in amputation of the ungual phalanx	275
229.	Amputation of the last phalanx of the finger	275
230.	Palmar flap by cutting from within outwards	276
231.	Disarticulation subsequent to formation of palmar flap	276
232.	Amputation of a phalanx by long dorsal flap	276
233.	Amputation at the metacarpo-phalangeal joint	277
234.	Amputation at the metacarpo-phalangeal joint	278
235.	Incision for amputation of thumb and its metacarpal bone	279
236.	Amputation of thumb and first metacarpal bone by flap method	280
237.	Appearance of parts after amputation of thumb and first metacarpal	280
238.	Method of transfixing and position of palmar flap in amputation of all the fingers with their metacarpal bones	282
239.	Line of the dorsal incision and stump in amputation of all the fingers.	283
240.	Transverse section through the second row of carpal bones	284
241.	Synovial cavities of the wrist-joint	285
242.	Amputation at wrist-joint by double flaps	287
243.	Amputation at wrist-joint by flap from thenar eminence	288
244.	Transverse section through middle of right forearm	290
245.	Amputation of forearm by circular method	290
246.	Formation of skin flap in circular amputation through lower end of forearm	291

FIG.		PAGE
247.	Completion of the manchette in amputation of the forearm	291
248.	Amputation of forearm by means of a manchette and circular division of muscles	292
249.	Section of forearm opposite the bicipital tubercle	293
250.	Incisions in Teale's amputation in lower part of forearm	293
251.	Transverse section through elbow-joint	294
252.	Formation of anterior flap prior to disarticulation of the elbow-joint	295
253.	Flaps after disarticulation at elbow-joint	296
254.	Amputation through elbow-joint by oval method	297
255.	Transverse section through middle of the arm	298
256.	Completion of the circular method of amputation of arm	299
257.	Teale's method of amputation in lower third of arm	300
258.	Ravaton's incision in amputation of the arm	300
259.	Teale's incisions in amputation at middle of arm	300
260.	Flap amputation of the arm, formation of anterior flap	301
261.	Flap amputation of the arm, formation of posterior flap	301
262.	Incisions for disarticulation of shoulder by oval method	303
263.	Disarticulation of shoulder-joint with digital compression of subclavian artery	305
264.	Oval method of disarticulation of shoulder-joint	306
265.	Appearance after disarticulation through shoulder-joint	307
266.	Sagittal section of the foot	316
267.	Incisions in Mikulicz's operation	317
268.	Mikulicz's osteo-plastic resection	318
269.	Stump after osteo-plastic resection of Mikulicz	319
270.	Vertical section of left ankle-joint	325
271.	Horizontal section through right ankle-joint	325
272.	Tarsal joints	326
273.	Langenbeck's fibular incision for removal of ankle-joint	328
274.	Langenbeck's tibial incision for removal of ankle-joint	329
275.	Splint for treatment of excision of ankle-joint	330
276.	Transverse section through condyles of femur and knee-joint	338
277.	Vertical section through knee-joint	339
278.	Curved anterior incision for resection of knee-joint	341
279.	Splint for excision of the knee	343
280.	Langenbeck's method of excising the knee	345
281.	Bones removed from left limb after excision of knee	347
282.	Vertical section of hip-joint, showing muscles	353
283.	T-shaped form of incision	354
284.	Langenbeck's incision for resection of hip-joint	355
285.	Large retractor for holding aside the surfaces of the wound	357
286.	Lücke's anterior straight incision for resection of hip	359
287.	Osteotomy of femur, a possible substitute for excision	360

FIG.		PAGE
288.	Transverse section through wrist-joint	367
289.	Bones concerned in excision of wrist	368
290.	Synovial cavities of wrist	369
291.	Carpal tendons and line of incision recommended by Lister for excision of wrist	371
292.	<i>a</i> , Lister's splint for excision of wrist	373
292.	<i>b</i> , Lister's splint applied	373
293.	Dorsal incision in Langenbeck's excision of wrist	375
294.	Transverse section through elbow-joint	382
295.	Dorsal incision for resection of elbow-joint	383
296.	Incision in \perp form	385
297.	Moreau's H-shaped incision	386
298.	Method applicable to cases of synostosis which cannot be broken down	389
299.	Bayonet-shaped incision for excision of elbow-joint	391
300.	Result after partial excision of elbow	392
301.	Result after partial excision of elbow	393
302.	Flexion of elbow after excision in case of strumous arthritis	394
303.	Extension after excision of elbow in case of strumous arthritis	395
304.	Mason's resection splint	395
305.	Suspension apparatus after excision of elbow	396
306.	Elbow resection splint	396
307.	Wire splint for excision of left elbow	396
308.	Suspension apparatus with interrupted splint	397
309.	Horizontal section through shoulder-joint	402
310.	Method of excising shoulder-joint, by Moreau	404
311.	Method of resection by single anterior incision	405
312.	Position of posterior incision made for resection of shoulder	407
313.	Stromeyer's cushion	408
314.	Result after excision of the shoulder for gunshot injury	409
315.	Incisions for removal of the scapula	412
316.	<i>a</i> , Incisions for removal of the upper jaw	418
316.	<i>b</i> , Removal of the upper jaw	421
316.	<i>c</i> , Line of incision for the resection of the inferior maxilla	424
316.	<i>d</i> , Transverse section of the median nerve	431
317.	Cutaneous nerve supply of front of the thigh and dorsum of foot	438
318.	Cutaneous nerve supply of back of leg and sole of foot	439
319.	Incision to expose the external peroneal nerve	440
320.	Incision for exposure of anterior crural nerve	441
321.	Manner of exposing the great sciatic nerve in upper part of thigh	444
322.	Cutaneous nerve supply of back of arm, forearm, and hand	6
323.	Cutaneous nerve supply of front of arm, forearm and palm of hand	447
324.	Ulnar nerve and its branches	448

LIST OF ILLUSTRATIONS.

XV

FIG.		PAGE
325.	Incisions to expose ulnar and median nerves near the wrist	450
326.	Incisions to expose ulnar nerve in arm and median at wrist	451
327.	Incision to expose musculo-spiral nerve	453
328.	Musculo-spiral, radial and posterior interosseous nerves	454
329.	Incision to expose brachial plexus in neck	456
330.	Incision to expose branches of cervical plexus	458
331.	Distribution of the spinal accessory nerve	459
332.	Dissection to expose spinal accessory nerve	460
333.	Distribution of nerves on head and face	462
334.	Terminal branches of nerves on face	463
335.	Incision to expose the supra-orbital nerve	466
336.	Incision to expose the infra-orbital nerve	466
337.	Distribution of superior-maxillary division of the trifacial nerve	468
338.	Incision to expose supra-orbital nerve	469
339.	Incision to expose infra-orbital nerve	469
340.	Inferior maxillary division of the trifacial nerve	472
341.	Incision to expose the inferior dental nerve	474
342.	Inferior dental nerve as it enters the foramen	474
343.	Relations of the inferior dental and lingual nerves	475
344.	Portion of bone to be removed to expose inferior dental nerve	476
345.	Method of exposing the mental branch of inferior dental nerve	477
346.	Point at which gustatory nerve may be divided	478
347.	Position of the foramen ovale	480
348.	Relations of the third division of the fifth nerve with the internal maxillary artery	482
349.	Dissection to expose the facial nerve	485



SURGICAL OPERATIONS.

PART II.

“ Il est si difficile de mettre clairement et entièrement par escrit la chirurgie manuelle.”

AMBROISE PARÉ.

AMPUTATIONS.

General Remarks.—Amputation, derived from *amputare*, to cut, signifies the removal by operation of a part of the body. Thus, one may speak with propriety of the amputation of a limb, the tongue, the penis, or the breast. The term, if not qualified, is commonly applied to the removal of a portion or the whole of one of the four extremities. The necessity for amputation has been urged as a reproach to surgery, but, on the contrary, the operation, so long as men are subject to incurable disease and severe forms of injury, must be looked upon as beneficial and scientific.

How great is the relief experienced by a patient after the removal of a limb smashed by cannon-shot, or machinery, thus substituting a comparatively small for a large wound, or of a limb which has become gangrenous after the ligature of a large vessel, or dangerous because of some malignant growth which has invaded it! Is surgery to be reproached for possessing the power to rid the sufferer of disease whose presence is a source of pain and danger, thereby prolonging the patient's life, and very often restoring him to usefulness? The great improvements introduced of late years in the manner of treating wounds have now rendered it practicable to save many cases, even of the most severe injury—cases of compound fracture, for example, and wounds of joints—from the mutila-

tion which amputation of necessity entails. In other instances, the modern accuracy of diagnosis and a clearer discrimination of the nature and tendency of disease enable us to save parts which previously might have been sacrificed.

Amputation has been practised from the earliest times, but it was not until the time of Celsus—who lived in the first century of our era—that any surgeon dared to cut through the living tissues. Celsus also mentions the process of cutting between the gangrened and sound parts, somewhat nearer the latter, dividing the bone a little higher up. Before his day, and even as late as the Middle Ages, gangrene was almost the only condition for which amputation was permissible, and even then the surgeon merely completed the severment of the living parts from the dead.

Before the introduction of the tourniquet in the sixteenth and seventeenth centuries, amputation was indeed but little practised. The older surgeons used the hot iron, or even a red-hot knife, in order to prevent or arrest the so greatly dreaded hæmorrhage.

In the latter half of the sixteenth century, Botalli proposed to amputate with an instrument not unlike a guillotine, and this was actually accomplished in respect of the fingers and toes down to a comparatively recent period. Sickle-shaped and other curved knives continued to be employed until far into the eighteenth century, when the straight blade was first introduced.

Ambroise Paré, at the beginning of the sixteenth century, was one of the first to amputate through quite sound parts, and to secure the vessels one by one by ligature.

Great improvements in the manner of amputation took place towards the middle of the seventeenth century. More attention was then paid to methods of covering the stump with skin. Lowdham, in 1679, made in the leg a large lateral flap, formed by cutting from without inwards. Petit introduced the double incision, first dividing and retracting the skin, then the muscles, and, lastly, sawing the bone. Ravaton, in 1750, and Vermale, a little later, recommended two flaps in place of one; the former choosing lateral flaps, the latter antero-posterior ones. Alanson, in 1779, modified the circular method so that the bone should be divided at a much higher level, thus forming the apex of an inverted cone of soft parts. Sédillot, in 1841,

commended flaps of skin, containing a moderate portion of muscular tissue. It is here only needful to mention, in order to condemn them, the elastic ligature of Silvestre in 1874, the *écraseur* of Chassaignac—first suggested, indeed, as a method of amputation by Guy de Chauliac in the beginning of the fourteenth century—amputation by caustics, and lastly, the diaclastic procedure of Maisonneuve, in which the bone was first broken by a machine, and the soft parts afterwards divided by a wire loop, or the galvano-cautery.

Indications.—The indications for amputation have proved the text of numberless discussions, and even yet are by no means finally settled for all cases.

Speaking generally, amputation may be performed on account of deformity, of disease, or of injury severally.

Deformity may be congenital or acquired, but in neither case will it necessitate amputation, unless there be in addition much suffering, or such interference with the usefulness of a limb as to interfere with the patient earning a livelihood.

An ankylosed knee may render the limb useless. In many cases resection, or subcutaneous division of the bone will restore a sufficient amount of desirable function. One toe overriding another, or bent beneath the sole, may render progression so difficult and painful as to necessitate its removal. A supernumerary finger or toe should, as a rule, be amputated. Operations of expediency, however, those styled by the French *de complaisance*, must not be lightly undertaken. They have, in the opinion of most surgeons, been hitherto attended by a larger ratio of mortality than others of greater apparent necessity.

The various organic and traumatic lesions do not so often necessitate amputation as formerly. Excision, erosion, or drainage of diseased or injured joints, for example, has in very many instances successfully replaced the total removal of the limb. In other cases, conservative treatment may be crowned with an amount of success almost altogether unknown prior to the more general adoption of antiseptic procedures. The lesions which require amputation are commonly divided into two classes:

(a) Those which are perfectly incurable, or are otherwise likely to entail mortal consequences.

(*b*) Those which are not absolutely incurable or fatal, but only partially curable after a long interval, and are meanwhile productive of great deformity, compromise the health and usefulness of the patient, and offer a better chance of recovery after amputation than by any other form of treatment.

In the first division may be included :

1. Sarcoma, or carcinoma, affecting the bone or the soft parts of a limb.
2. Acute osteitis, osteo-myelitis, and caries or necrosis, when too extensive to be treated by resection of the diseased parts.
3. A joint which has become thoroughly disorganized by acute or chronic inflammation and which it is undesirable to resect.
4. A rapidly increasing diffused aneurism threatening to induce gangrene.
5. Large aneurisms involving the bone or penetrating an articulation.
6. The complete, or nearly complete, avulsion of a limb by a large projectile in war, or by machinery.
7. Extensive destruction of the soft parts or of the bone.
8. Comminuted and compound fractures with injury of the great nervous or vascular trunks.
9. Wounds penetrating large articulations when the condition of the soft parts or bone forbids resection or conservative treatment.
10. Compound dislocations with extensive injury to the soft parts and great vessels.
11. Severe burn, with great destruction of tissue.
12. Traumatic and some other forms of gangrene.
13. Cases in which a wound becomes a local infecting centre, and symptoms of pyæmia or septicæmia are imminent or declared.

In the second division the more chronic cases are included. They comprehend those in which the surgeon decides upon amputation as being the best means at his disposal in the present and future interest of the patient.

1. Cases, generally, where conservative treatment after an injury, or for disease, has failed to preserve a useful limb, or by its further prolongation endangers life.

2. Certain chronic affections of the bones, due to syphilis and tubercle, producing necrosis or caries, not yielding to treatment and wasting the patient's strength.
3. Very extensive ulcers which will not heal, and destroy the utility of the limb.
4. Cases of long-continued suppuration after extensive laceration and irreparable loss of substance.
5. Certain forms of secondary hæmorrhage not infrequently due to septic causes in overcrowded hospitals.
6. An ulcerated, conical, or neuralgic stump may possibly require re-amputation.

These indications are subject to revision according to the position and extent of the lesions, the age, constitution, and habits of patients, and the conditions, material and hygienic, in which they are placed.

Contra-indications.—Before performing an amputation the surgeon should be assured of his ability to remove the whole of the disease. Thus in a case of cancer, amputation of a limb will not materially benefit the patient if the disease have already invaded the lymphatic glands, unless indeed these also can be extirpated.

In cases of multiple joint disease it may be expedient, on account of severe suppuration and to afford relief from suffering, to remove the part most affected; but, generally speaking, such cases are not suited for operation. Where a patient has sustained many injuries, one of which is calculated to prove mortal, a needless amputation should be avoided. The extreme shock which follows certain extensive injuries contra-indicates amputation while it continues.

Visceral organic disease is also a contra-indication. Pyæmia and tetanus, except in the early stages, forbid the performance of amputation, as in such cases this treatment would rather hasten than retard the course of the secondary disease.

AT WHAT TIME SHOULD AMPUTATION BE PERFORMED?

Amputation, it may be said in a general way, ought to be undertaken as soon as the necessity for it becomes apparent.

Operations for disease afford a certain latitude of choice which does not exist in operations performed for injury.

Amputations for injury are classified into primary, intermediate, and secondary, according to the period at which they are performed, either immediately or shortly after the accident, during the subsequent period of inflammatory reaction, or when suppuration is established. It is convenient to make this distinction, as the results to the patient may differ materially according to the time chosen for operating, but since the use of antiseptic precautions, this classification has not the same intrinsic importance as formerly.

Primary amputations are those performed during the first twenty-four or thirty hours, and before the occurrence of inflammatory symptoms.

Intermediate amputations are those performed during the active inflammatory period, which may last four or five days.

Secondary or consecutive amputations are those performed after the acute inflammatory symptoms have subsided and suppuration has been fully established, but this is a period of uncertain duration.

In comparing the mortality after amputation during the secondary and primary periods, the number of those who die before reaching the time when secondary amputation becomes possible has to be taken into account. The determination of the period at which we should amputate must often rest wholly upon the question of diagnosis. If on examination of the wound the surgeon consider the condition entails immediate danger to life, amputation, when practicable, is to be performed at once. If the condition afford hope that limb and life may be saved without amputation, and the circumstances of the case otherwise justify it, expectant treatment should be decided upon.

It may, however, be difficult or impossible to control subsequent inflammation, and in this event intermediate amputation may have to be performed at a more unfavourable time for the patient.

When the inflammatory period has passed over, the surgeon may find it difficult to decide whether it shall be necessary to perform a secondary amputation, inasmuch as the patient may still have strength sufficient to recover, or, again, his condition and surroundings may be such as to render amputation more expedient. In such cases the nature of the decision will

depend very largely on the surgeon's sagacity and experience. These considerations, however, are now materially influenced by the antiseptic treatment of wounds, since it lessens risk as well as largely removes many of the dangers of the intermediate and secondary periods.

The question is of yet greater surgical significance in time of war than during civil practice. In field surgery the great numbers of wounded may render exact or even approximative diagnosis impossible. The means of treatment are often wholly inadequate. After great battles, many cases (which might have been better treated, had it been at all practicable, by primary amputation) first come under observation after severe inflammation has set in, the risk to life and limb being thus materially increased.

All the weight of experience establishes primary amputation as the better and preferable method, when the injury is sufficiently severe to require the removal of the limb. The necessity for early amputation in certain forms of gunshot wound, was well known to Wiseman more than two hundred years ago. He advises that in the heat of the fight, whether on sea or on land, the surgeon must consider at the first dressing what possibility there is of preserving the wounded member, and if there be no means of saving it to make his amputation at that instant while the patient is free of fever. Larrey has gone so far as to say that if in a hundred patients, the subjects of severe injury received in battle, we were to amputate immediately in all, the number of deaths would not amount to one-fourth or one-third of those that must otherwise ensue.

On the other hand, Bilguer, in 1761, strongly protested against the then dreadful frequency of amputation.

Opinion has of late been greatly altered in respect of the cases which appear to demand amputation. Many gunshot fractures of the femur and penetrating wounds of joints, are treated conservatively and with success, which would once have been unconditionally submitted to amputation.

Statistics throw comparatively small light on the difficulties of each individual case. No account is kept by them of the great mortality amongst cases not submitted to amputation. They merely state, for instance, that primary amputations for injury, those of the thigh excepted, succeed better than secondary. The real point of difficulty, whether it were better to perform amputation or to abstain from it, or whether efforts to

preserve the limb be more or less dangerous than amputation, receives no elucidation.

Occasionally a double amputation is required. Double amputations for injury should be performed simultaneously or in immediate succession, while in cases of disease they had better be performed at different periods.

In the former case, the chief danger is the shock following the operation being superadded to that produced by the original injury; but if the patient be able to withstand this, there can be little doubt it is preferable to remove all the injured parts at one and the same time. I have on more than one occasion amputated one limb while my assistant, then or immediately afterwards, in fact while the vessels of the first amputation were being secured, amputated the other. This was done in order to shorten, as much as possible, the duration of the operative procedures and the time the patient had to be kept under the anæsthetic.

In chronic disease there is no such emergency, and when it is requisite to sacrifice two limbs, it is more advantageous to submit the already debilitated patient to the shock of the removal of one only at a time. The condition of the other limb will not materially change during the period needed for treating the wound accruing from the first amputation.

SELECTION OF THE PLACE IN WHICH TO AMPUTATE.

No surgical principle is better established than that the smallest possible portion of diseased or injured parts should be sacrificed, consistent of course with an effective result. The nearer to the trunk the operation has to be performed, the greater is the risk which the patient has to run. The practice, once common, of amputating at what is called the seat of election, should be definitively abandoned. A leg, for instance, should not be amputated in the upper third, if the nature of the case be such as to permit of removal in the lower. Neither the convenience of the instrument-maker, nor any other reason, is sufficient in my opinion to counterbalance increased risk to life. The seat induced by necessity, and not the seat of election, should decide the point at which to amputate.

In general, amputation performed immediately below an articulation is

less serious than if carried through the joint, and this again is not so serious as amputation just above the joint.

In cases of injury it is usually the position and extent of the damage to the soft parts and bone that must determine the place of amputation.

In machine and street accidents the skin, in virtue of its elasticity, is often detached for a long way above the injury apparent externally, and although showing but little outward sign of damage, may be so greatly devitalized as to prove quite unfit to form a proper covering for the stump.

After injuries of a more localized character, more especially gunshot fractures, a portion or even the whole of the injured soft parts may be preserved, and in that case we can amputate much lower down, taking care, however, to divide the bone, if fractured, above the seat of injury.

Amputation is more easily performed than disarticulation. The place at which to divide the bone is chosen by the operator, and the wound is more regular and less extensive. The bone, however, being cut and its interior exposed, entails an increased liability to necrosis, osteo-myelitis, and pyæmia, the hæmorrhage from the cut surface of the bone is sometimes troublesome, its sharp edges not infrequently cause irritation of the soft parts, and in some cases, where they are thin, a subsequent perforation of the flap.

In disarticulation, on the other hand, there is greater difficulty of execution; larger flaps are required to cover the end of the bone, and the soft parts are often thin and liable to gangrene. The quantity required has to be estimated with great exactitude, as the bone cannot be cut shorter should the soft coverings prove scanty.

The articular end of the bone is smooth and rounded, unirritating to the neighbouring parts, there is lesser liability to necrosis and pyæmia, the stump is broader, and as a rule better capable of bearing pressure. These operations, however, may prove inconvenient on account of the large synovial surface exposed, the irregular shape of the end of the bone, and possible necrosis of the encrusting cartilage. Instrument-makers also complain that it is less easy to adapt satisfactorily an artificial limb to the stump.

PREPARATION TO BE MADE FOR AN AMPUTATION.

The instruments necessary for an amputation should be arranged beforehand. A tourniquet or Esmarch's elastic compressor must be ready at

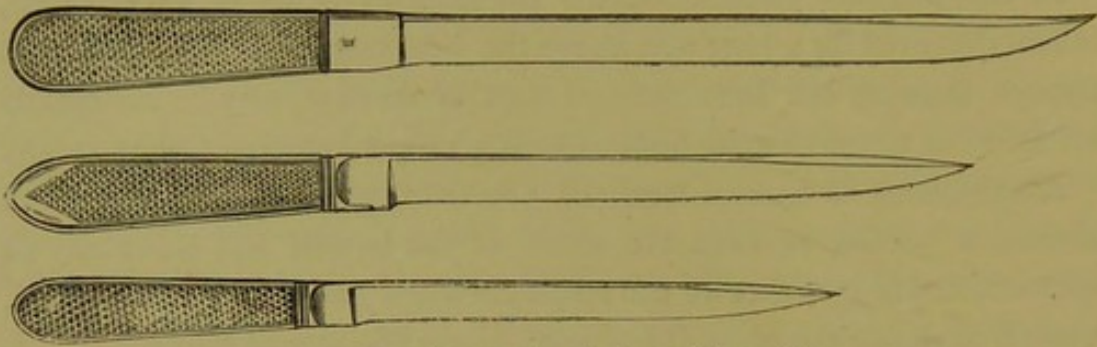


FIG. 94.—Amputating knives of three sizes.

hand, unless in certain cases where these are to be replaced by digital compression. Amputating knives of various lengths will be requisite, the

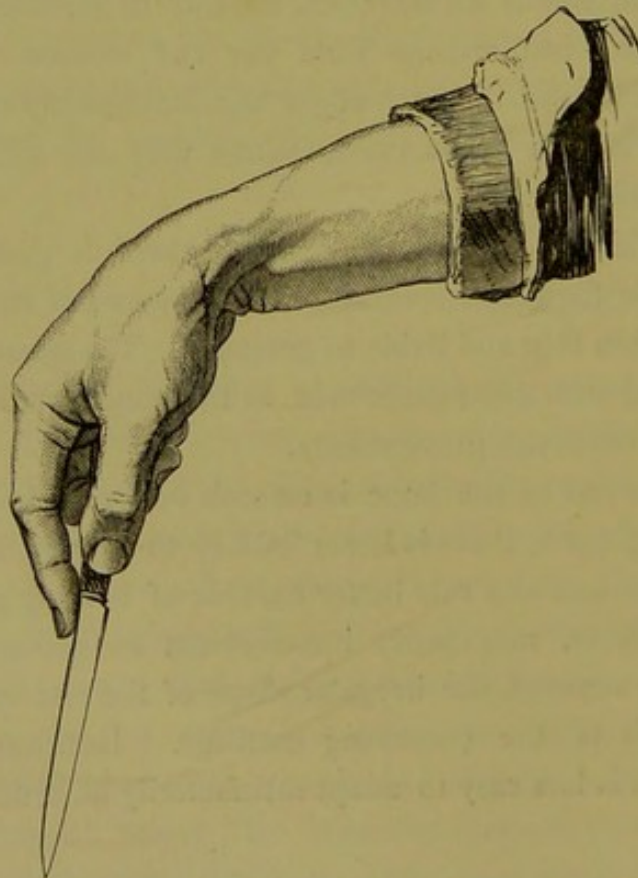


FIG. 95.—Manner of holding the knife when completing the circular incision, or forming a flap by cutting from without inwards.

knife selected being long in proportion to the thickness of the limb to be removed. The knives are narrow-bladed, with an almost straight cutting

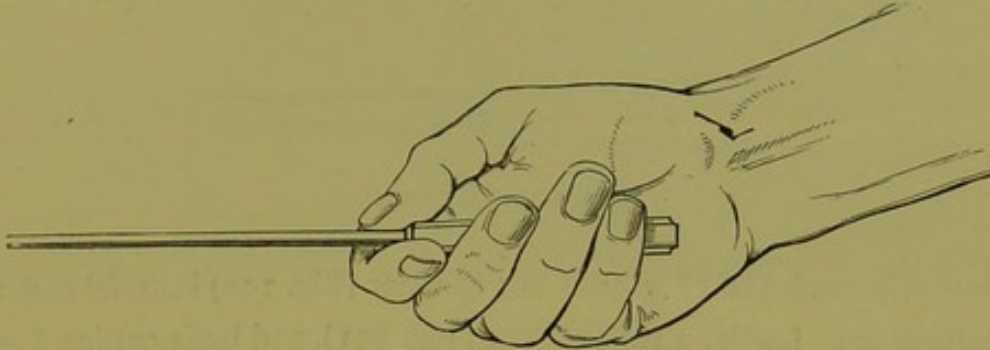


FIG. 96.—Amputating-knife, as held in the hand during the act of transfixing a limb prior to cutting a flap from within outwards.

edge (Fig. 94). Double-edged knives—with the exception of the narrow two-edged knife, called a Catlin, for dividing the soft parts between the




FIG. 97.—The scalpel.

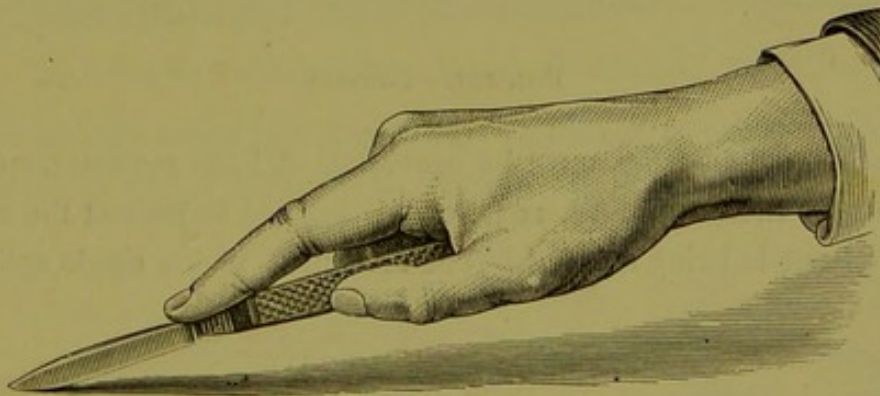


FIG. 98.—Scalpel, as used for dividing muscular fibres attached to the bone, or in forming a periosteal flap.




FIG. 99.—Straight bistoury, or finger-knife.

bones of the forearm and leg—are no longer employed; and the Catlin may be well replaced by a narrow single-edged knife, and is therefore, in

fact, unnecessary. A scalpel (Fig. 97) is used to separate the deep muscles and periosteum from their attachments to the bone. For amputations of the fingers, a long narrow-bladed knife, in shape like a straight bistoury,

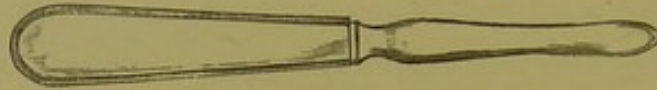

FIG. 100.—Elevator.

is commonly employed (Fig. 99). An elevator (Fig. 100) is useful to detach the periosteum. Lastly, a suitable saw (Fig. 101), and bone-cutting forceps (Fig. 102) are required. All needful accessories, such as antiseptic solu-

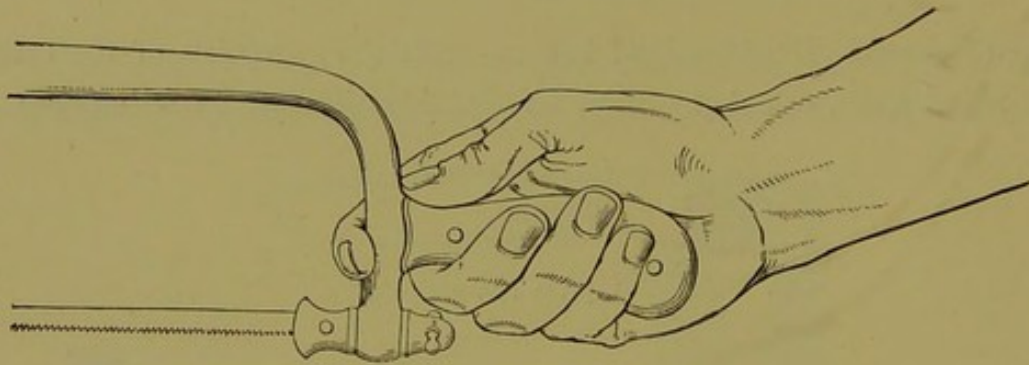

FIG. 101.—Bow-saw.

tions, basins and sponges, must be provided. A linen retractor, split either in one or two divisions (Figs. 103, 104), is applied to protect the soft parts while the bone is being divided. The retractors, with a single split for the

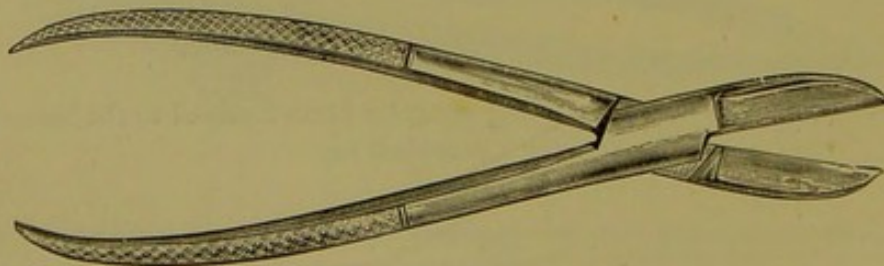


FIG. 102.—Bone forceps.

arm and thigh, and doubly split for the forearm and leg, are very useful in the absence of ample assistance, and in the circular method of amputation.

When the flap method is adopted a retractor is hardly necessary; the assistant's hands answer better to hold the soft parts back. The usual




FIG. 103.—Single retractor.




FIG. 104.—Double retractor, for use in amputating the leg and the forearm.

apparatus for the arrest of hæmorrhage, consisting of numerous artery forceps and silk or catgut ligatures, an irrigator filled with iced carbolic lotion,

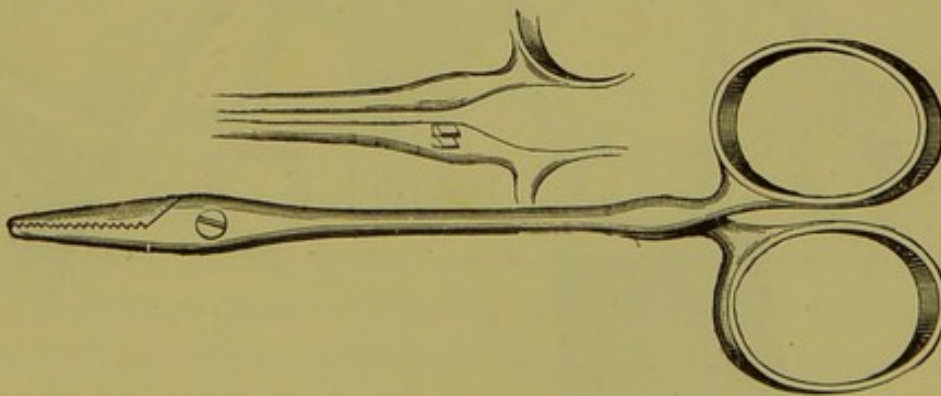


FIG. 105.—Pressure artery forceps (Koeberlé, Wells, Péan).

sutures, and dressings, complete the preparations. The artery forceps should be sufficiently numerous to secure all the bleeding points before

proceeding to apply the ligatures (Figs. 105, 106). Carbolized silk and chromicized catgut are the best materials for ligatures and sutures. The needles may be straight or curved. A Higginson's syringe will also be found

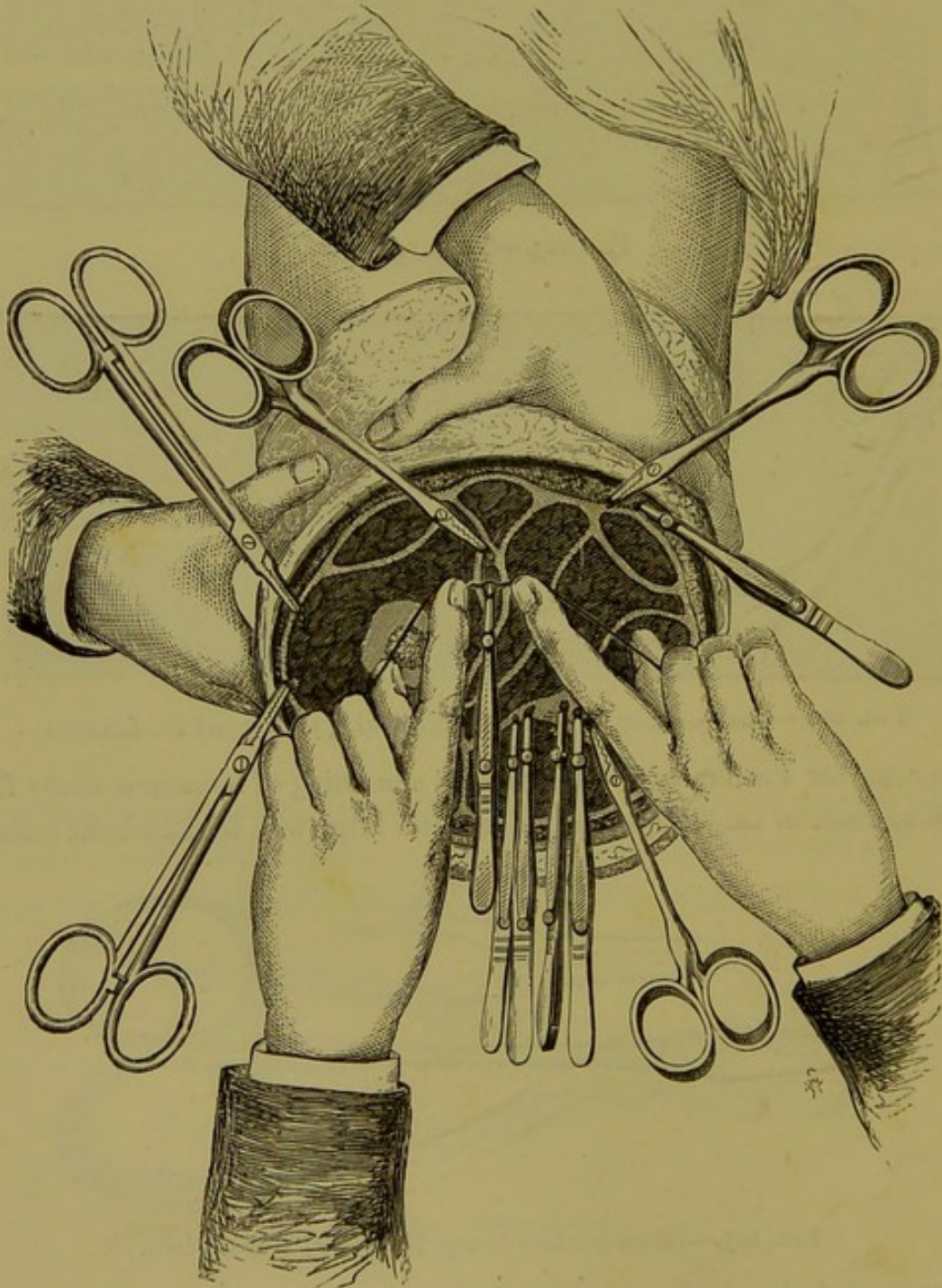


FIG. 106.—Cut surface of a stump after amputation of the thigh, with numerous artery forceps applied to the bleeding points. Diagrammatic.

useful. Everything used during the operation should be carefully disinfected beforehand. The sponges must be carbolized and in sufficient number; basins of hot and cold carbolized water should be in readiness, with carbolized or sublimate aseptic gauze, boracic lint, gauze bandages, and salicylic or iodoform cotton-wool. Plaster-of-Paris or gutta-percha, to form an external splint to support the stump, will be further requisite. The patient should be placed in a good light, on a firm table, with the limb

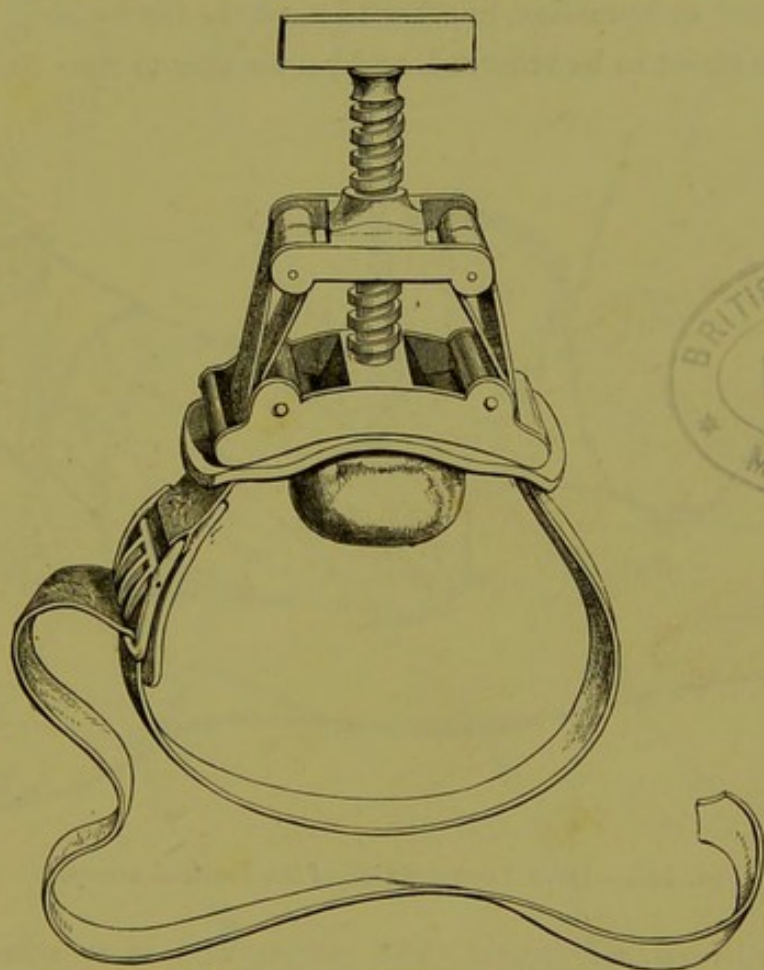


FIG. 107.—Petit's tourniquet.

to be operated on projecting over it, and the opposite one held out of the way by an assistant, or fastened to the leg of the table. The limb should be shaved and afterwards purified with soap and carbolic lotion. The spray may be used throughout the operation, or only during the period of dressing. When an operation is performed on the upper extremity the shoulder should be well raised, the body projected from the table, and the arm abducted from the side. If it be the lower extremity, the limb



should project sufficiently beyond the lower end of the table to allow of space for the assistant's hands above the seat of amputation. The operator should always stand on the right-hand side of the limb to be removed—that is, on the outer side of the right upper and lower extremity and on the inner side of the left.

The duties of the assistants at an amputation are only second in importance to those of the operator himself. An assistant is required to superintend the compression, another to hand the instruments, another to hold the limb about to be removed, and yet another to take charge of and

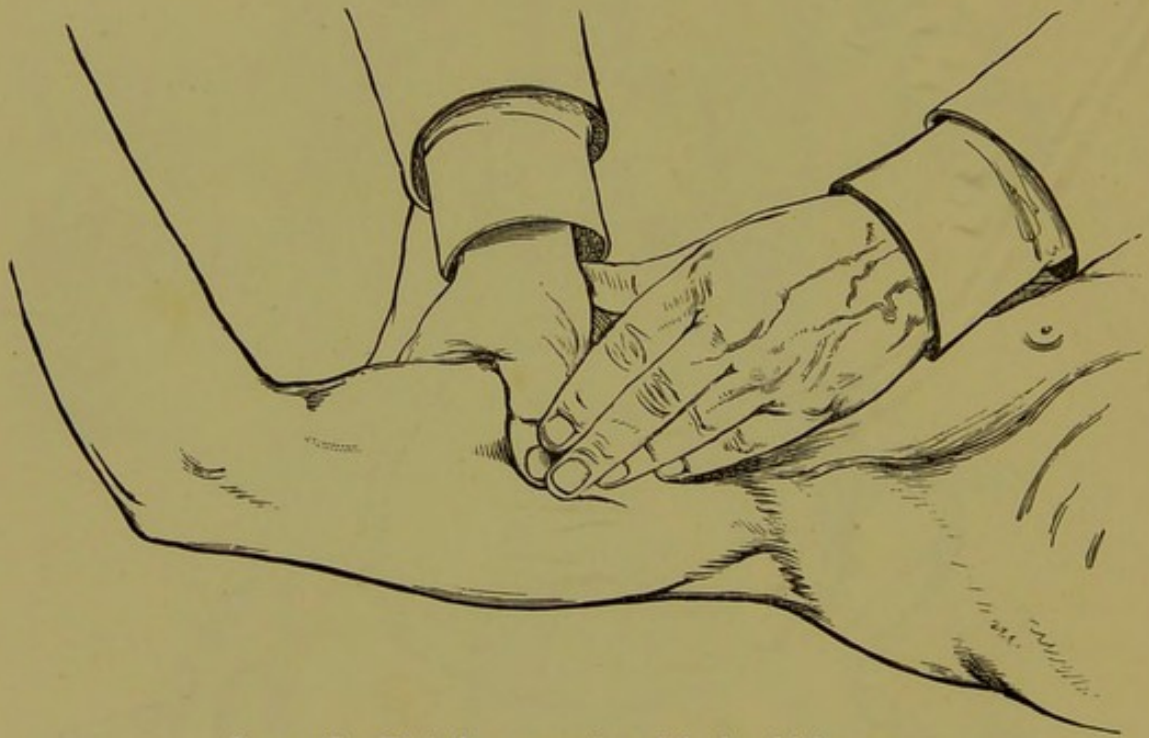


FIG. 108.—Digital compression of the brachial artery.

retract the divided soft parts. The person who is to administer the anæsthetic should devote himself exclusively to the task, and be competent to perform it without giving anxiety to the operator.

Where the tourniquet (Fig. 107) is not applied, an assistant should control the circulation through the main vessel of the limb by digital pressure, which is often the best method (Figs. 108, 109). It can be applied and removed in a moment, and there is no risk of injuring the adjacent vein. The assistant charged with this important duty must recollect that a comparatively small degree of pressure, if accurately applied, suffices to

arrest the flow through the largest arteries. The corresponding vein should not at the same time be compressed. This is easy enough to avoid in the case of the larger trunks.

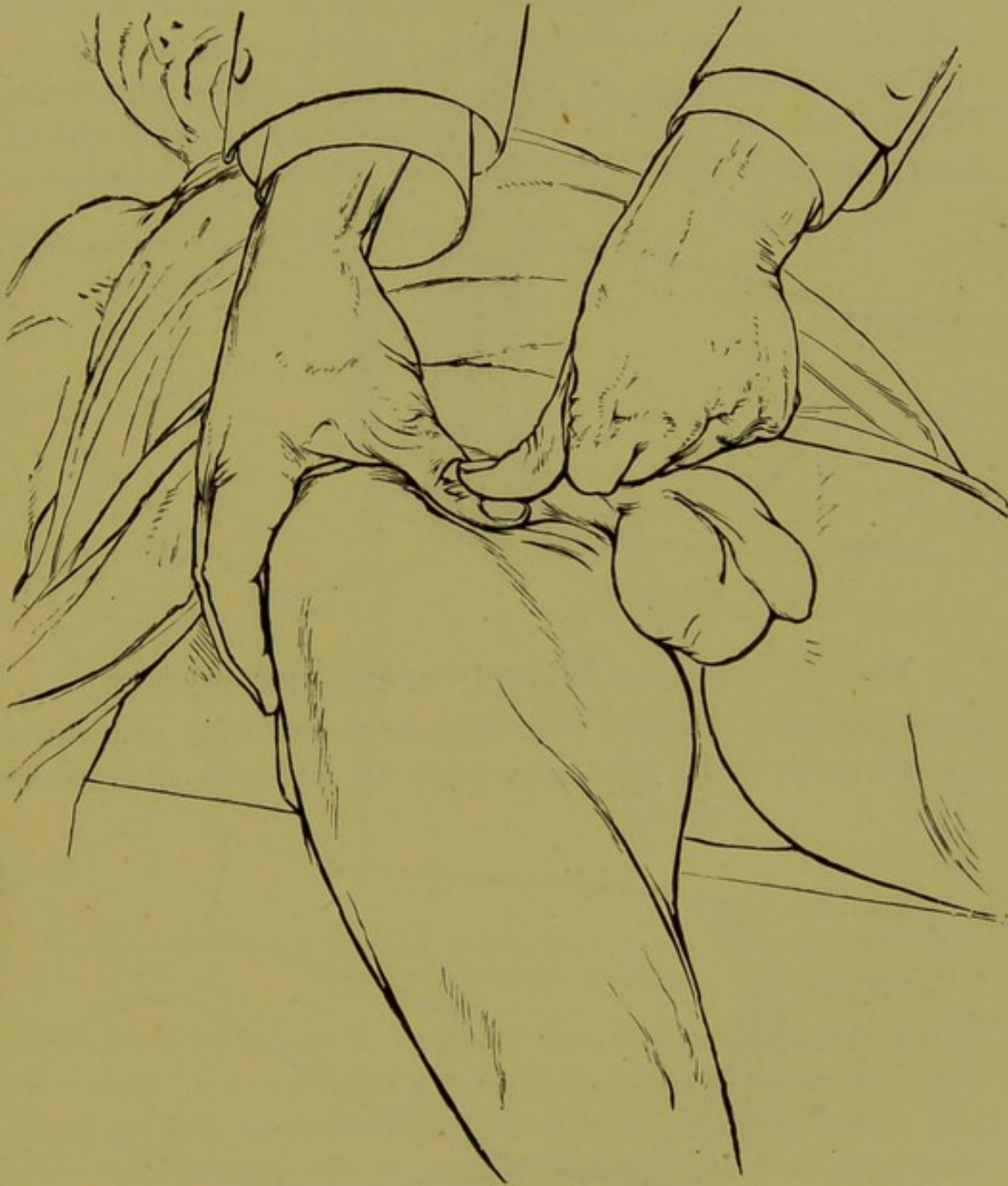

FIG. 109.—Digital compression of the femoral artery.

In some cases an improvised tourniquet may be used, as in Fig. 110. When digital pressure is adopted the brachial artery should be com-

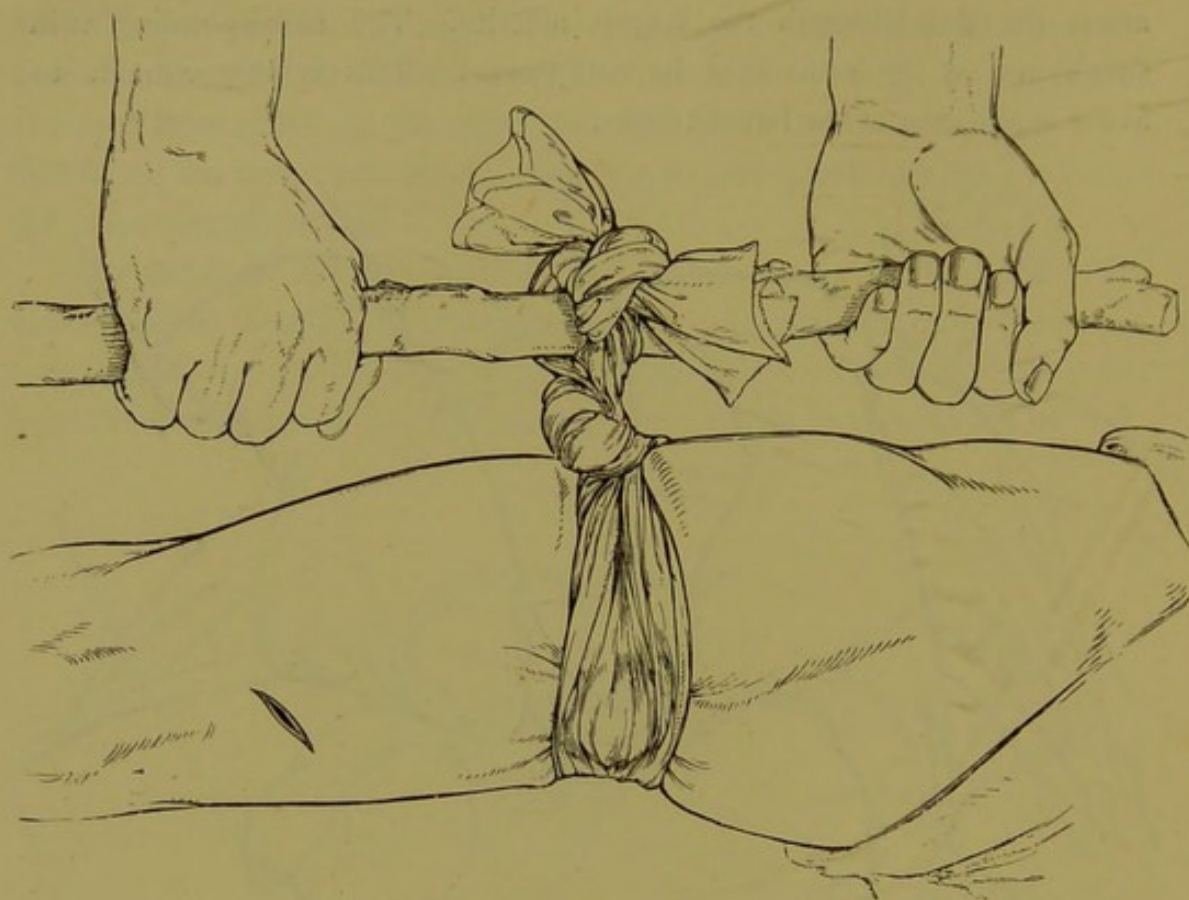


FIG. 110.—Compression of the femoral artery by an improvised tourniquet.

pressed against the humerus (Fig. 108); the femoral artery as it passes over the ramus of the pubes (Fig. 109); the subclavian artery, where

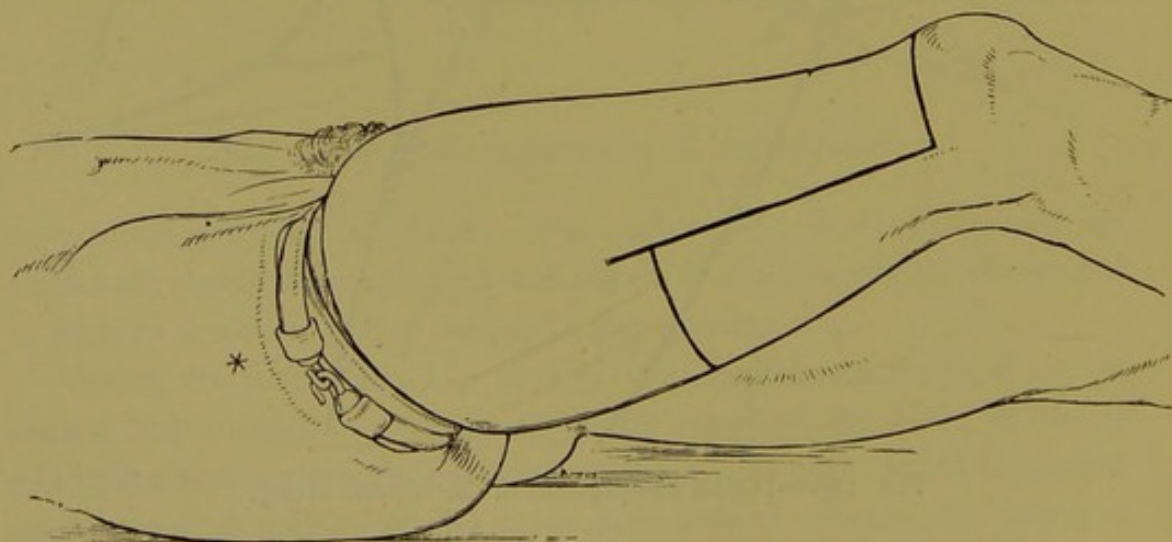


FIG. 111.—Esmarch's apparatus, as applied to the thigh prior to performing, say, a Teale's" amputation; the indicating lines are marked.

it crosses the first rib in front of the scalenus medius, the abdominal aorta against the third lumbar vertebra. Before any form of tourniquet is applied the extremity should be elevated to empty it of blood. If Esmarch's apparatus be employed, the elastic bandage is first applied to the limb to empty the parts of blood, or the limb may be simply vertically raised as when the tourniquet is to be used. The elastic bandage must not be applied in cases of malignant tumour or where the soft parts are infiltrated by inflammatory products. The elastic compressing tube

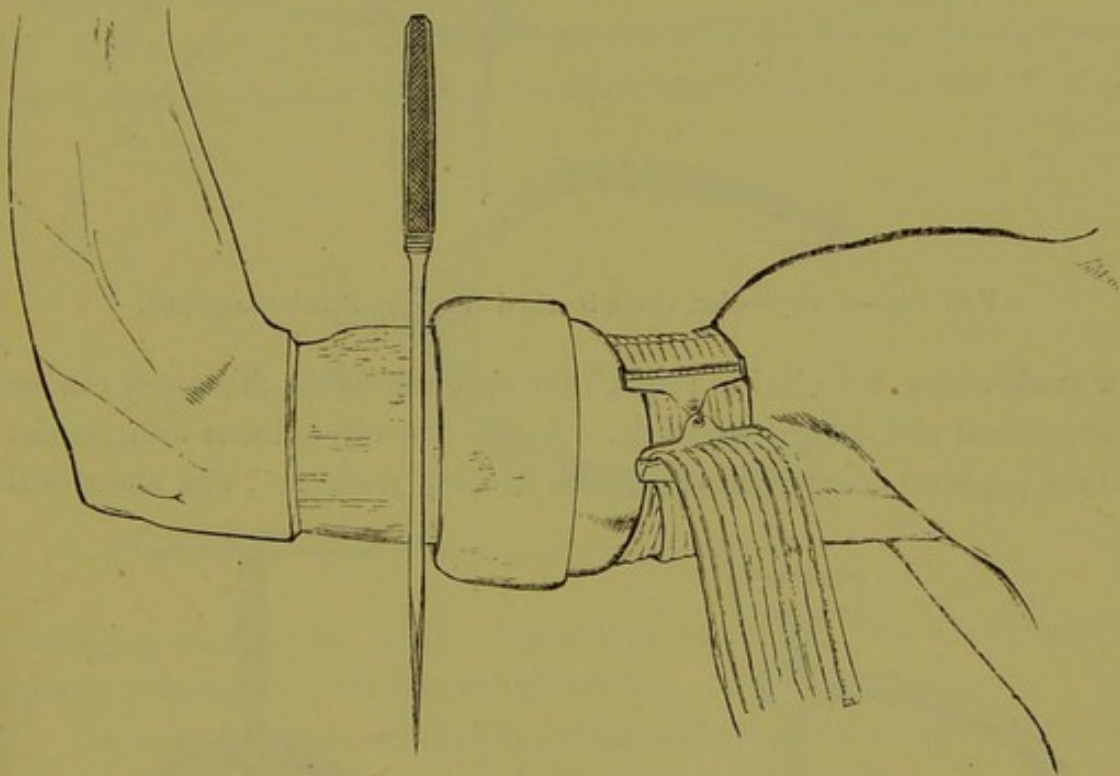


FIG. 112.—Broad elastic band applied to the arm prior to a circular amputation of the limb with a manchette of skin.

should never be applied to the upper arm, as it presses unduly on the nerve-trunks; a broad elastic band (Fig. 112) is to be substituted. It is difficult to apply digital pressure efficiently to the subclavian artery. The place where pressure can be most successfully applied is immediately external to the outer edge of the sterno-mastoid and just above the clavicle. The direction of the force must be downwards and slightly backwards, so as to compress the vessel against the upper surface of the first rib and anterior border of the scalenus medius muscle. If an incision

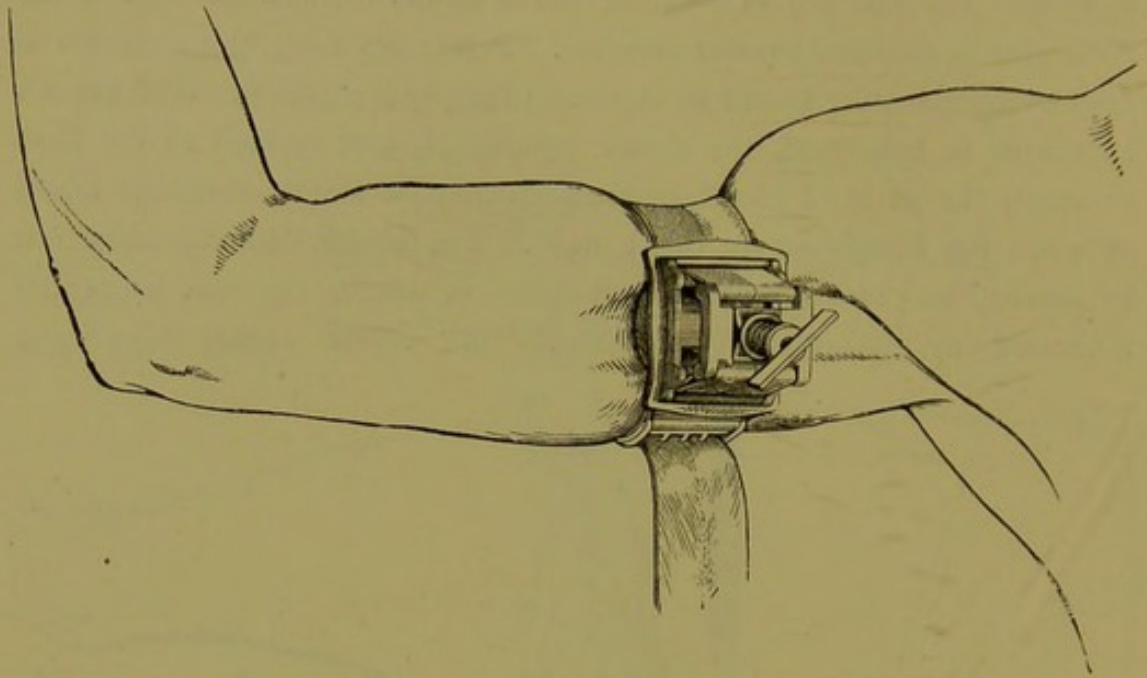


FIG. 113.—Compression of the brachial artery by Petit's tourniquet.

be made above the clavicle through the skin and fascia, the artery can be compressed with greater certainty. A like difficulty subsists with respect to the popliteal artery in the ham from its deep position. The abdominal

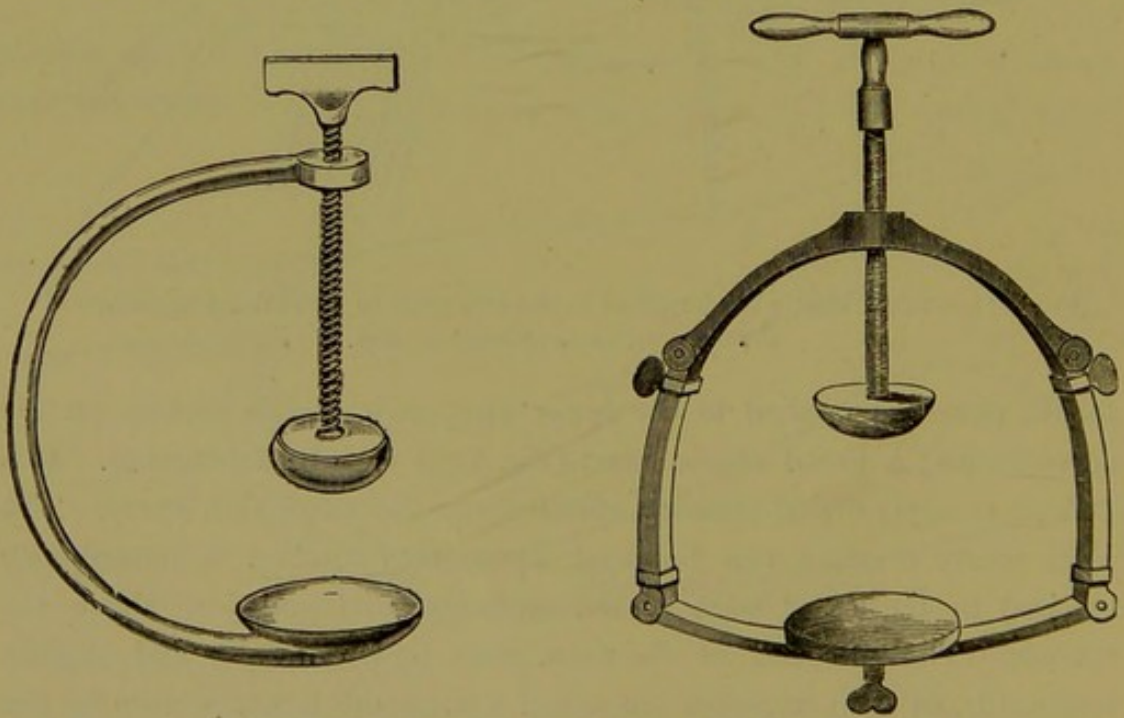


FIG. 114.—Compressors for the abdominal aorta.

aorta may be compressed by instruments designed for the purpose (Fig. 114), and in thin or young subjects by digital pressure.

In applying Esmarch's elastic compressor too much traction is often exercised on the rubber cord or tube, and ill consequences result, more especially in the arm, such as temporary paralysis from pressure on the nerves. In all cases its prolonged use materially increases the subsequent bleeding from the smaller vessels in the stump, and often necessitates the application of double or triple the number of ligatures commonly employed.

If the ordinary tourniquet be resorted to, it should not be tightened until the last moment, so as not to arrest unnecessarily the flow of blood

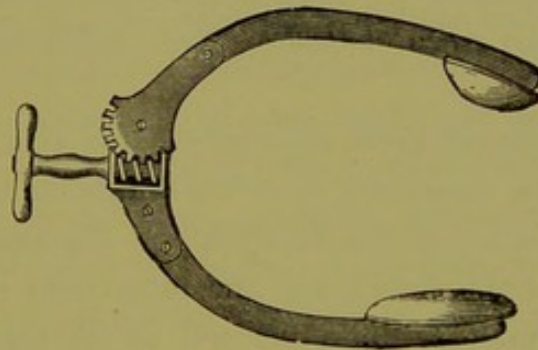


FIG. 115.—Signoroni's tourniquet.

returning through the veins. Signoroni's tourniquet (Fig. 115) may be found convenient to obviate this drawback.

In some instances of disarticulation at the hip and shoulder the main artery has been previously tied, but this is rarely requisite.

An assistant should hold the limb about to be removed, taking care neither to elevate nor depress it during the section of the bone. If the first be done the saw becomes locked, or if the second the bone will break and splinter before it is completely divided. The same assistant may afterwards aid in securing the vessels.

Position of the Operator.—As a general rule, it is best to stand on the right-hand side of the limb to be removed; that is, for the right upper or lower extremity the operator will stand on the outer side, and for the left on the inner side, so that the limb to be amputated shall be always on his right hand. This position affords greater facility for forming the flaps and

sawing the bones, while the surgeon's left hand is free to retract and protect the soft parts as they are divided, to hold the limb above the point of division of the bone, or to control a bleeding vessel with the finger.

Sometimes the operator prefers holding the part to be removed. In cases of disarticulation he then possesses the advantage of being able to move the limb in such wise as most easily to divide the ligamentous connections and muscles about the joint. When this is done an assistant must be employed to retract the skin and muscles as they are divided.

IMMEDIATE OBJECTS TO BE SECURED BY AMPUTATION.

The operation consists of three stages:—Division of the soft parts; sawing the bone; and arrest of hæmorrhage—followed by the application of suitable dressings.

The section of the soft parts, especially of the skin, is to be made in such a way that these shall easily cover the end of the bone without strain, that the line of junction of the flaps shall be dependent so that efficient drainage may be accomplished, and the subsequent cicatrix placed well out of the way of pressure upon the end of the stump. The principal bloodvessels and nerves should also be cut short so as to be out of reach of subsequent pressure. It is important to preserve the skin as much as possible, as by so doing the subsequent formation of a conical stump is to a great extent prevented. It is important to remember that this occurrence is most frequent in the upper arm, and especially in young persons, where the growth at the epiphysis does not cease till about the twentieth year.

In all cases where it is practicable a circular or flap-shaped portion of periosteum should be separated from the bone with an elevator, without, however, unnecessarily disturbing its connection with the surrounding soft parts. It should be sufficient in extent to fully cover the divided extremity of the bone. A periosteal flap protects the exposed medulla, diminishes the risk of necrosis and of septic absorption. The cicatrix in the bone is more perfectly and more quickly formed, and the resulting stump is sooner and better able to bear pressure on its extremity.

There are three principal modes of operating:—(1) The circular

method ; (2) the flap method ; and (3) the oval manner of incision ; but of these there are many modifications in detail.

The circular and flap methods of incision are the two principal. The oval incision is in fact a modification of the circular.

CIRCULAR AMPUTATION.

The circular method requires less manual dexterity, and produces a smaller extent of wound surface, than that by flaps. It provides a good covering for the end of the stump.

Circular amputations were originally performed after the simplest fashion :—a ligature was first applied around the limb above the point of section to raise and steady the flesh, and then with one sweep the whole of the soft parts were divided to the bone, which was afterwards cut through at the same level. The method of Celsus was to divide the soft parts with one incision down to the bone, separating them afterwards to the higher point at which the bone was sawn. Cheselden and J. L. Petit were among the first to point out the necessity for dividing the operation into stages and sawing the bone at a much higher level.

The method of J. L. Petit, which entirely superseded earlier plans, consists, in the first instance, in dividing the skin and subcutaneous tissues, and when these are sufficiently retracted the muscles are cut at a sufficiently higher level right down to the bone, or preferably in layers by successive sweeps of the knife, as advised by Alanson, so that the sawn end of the bone should form the apex of a hollow cone.

In the present method of amputating the superficial incision through the skin and fascia is usually made in the following way :—Having decided at what point to divide the bone, the operator or his assistant draws the skin upwards. A circular incision is made through the skin at a point below that where the bone is to be sawn, equal to about three-fourths of the diameter of the limb ; or if the subject be a muscular one, at a level equal to the full diameter of the limb. The operator, with his right foot forwards, passes his arm and the hand holding the knife beneath the limb to be removed, encompassing it as completely as possible in order to

begin the incision with the heel of the knife on the side towards himself, and then drawing the full length of the cutting edge gradually around the limb (Fig. 116), he terminates the incision with the point of the knife at the place where he began. If he cannot completely encircle the limb with one sweep of the knife, he must reapply the heel of the instrument to the termination of the incision first made, which probably includes considerably more than half the circumference, and thus bring it to the point where it was commenced. The assistant who holds the limb may materially assist

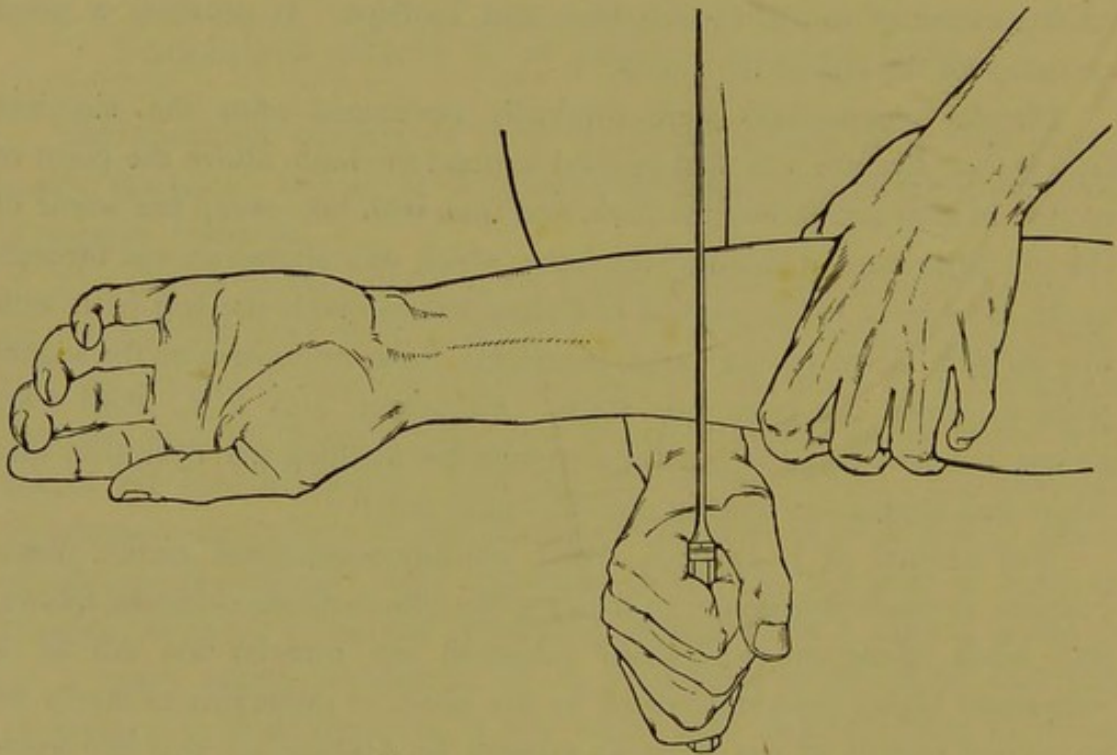


FIG. 116.—Manner of holding the knife when performing a circular amputation of the forearm.

the operator at this stage by rotating the limb in the opposite direction to that in which the knife is travelling. During the whole time the cutting edge of the knife must be kept vertical to the surface, and as it comes round the surgeon's hand and wrist ought to be so turned as to keep it vertical. If this has been done with equable pressure the skin and fascia will be uniformly divided all round down to the aponeurosis, any strands remaining being touched with the point of the knife.

A cuff or collar of skin and subcutaneous tissue may now be dissected

upwards (Fig. 117). In thin individuals, especially in amputations of the thigh and upper arm, the skin may often be retracted sufficiently to avoid actual dissection. In the leg and forearm this is scarcely possible. The formation of a so-called manchette, however, is generally undesirable, because of the parts forming it being thin and the dissection interfering materially with its vascularity. In many cases, therefore, the formal dissection of the skin to make the manchette may be better avoided.

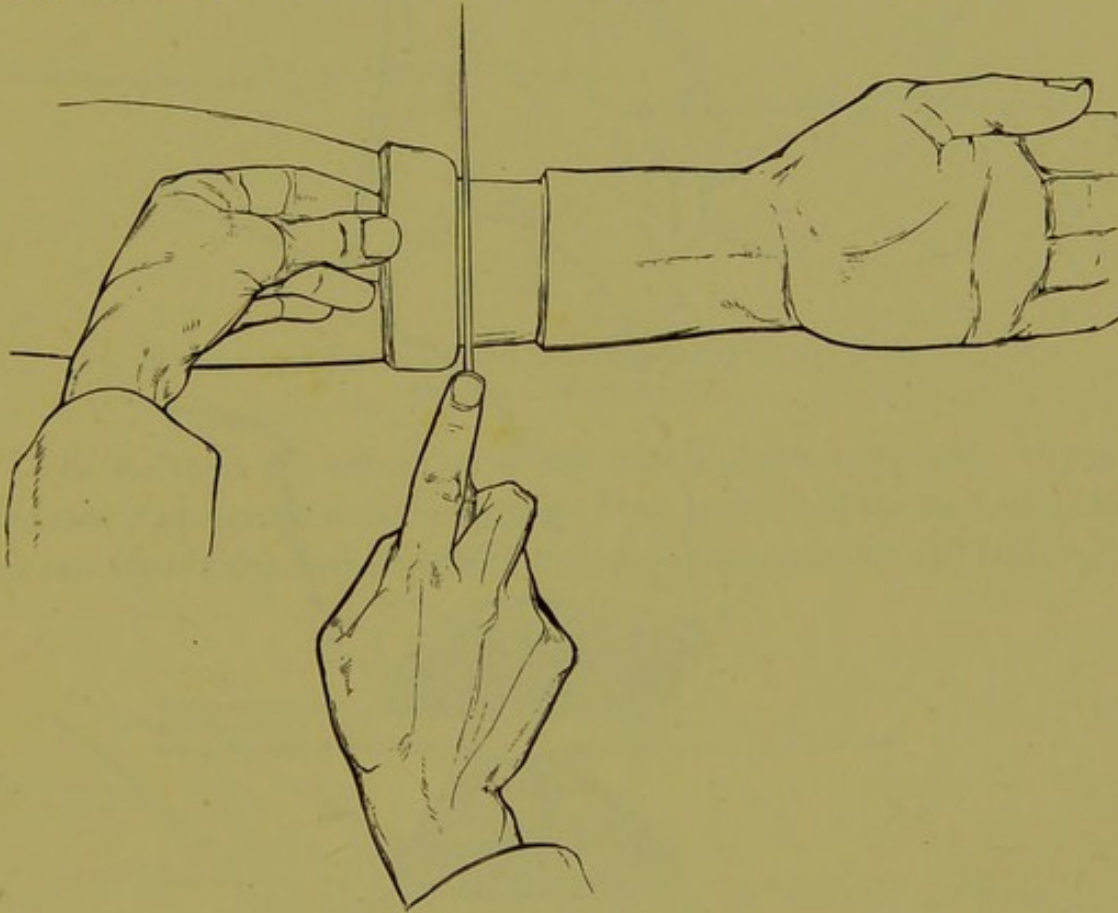


FIG. 117.—Manner of holding the knife and dissecting up a cuff or manchette of skin and subcutaneous tissue in circular amputation of the forearm.

* The surgeon having divided the skin and subcutaneous cellular tissue with the first sweep of the knife, the parts cut through are pulled upwards by an assistant, who should continue to retract them during the whole of the operation. With the next sweep the superficial layers of muscle are incised at the level to which the skin has been retracted. This allows the soft parts to be drawn still further upwards, and with the third sweep the deeper muscles are divided at a yet higher level (Fig. 118). Any muscular

fibres adherent to the bone may now be separated with a scalpel, and then at the highest level the exposed bone is sawn through, a periosteal flap, sufficient to cover its extremity, having been first detached.

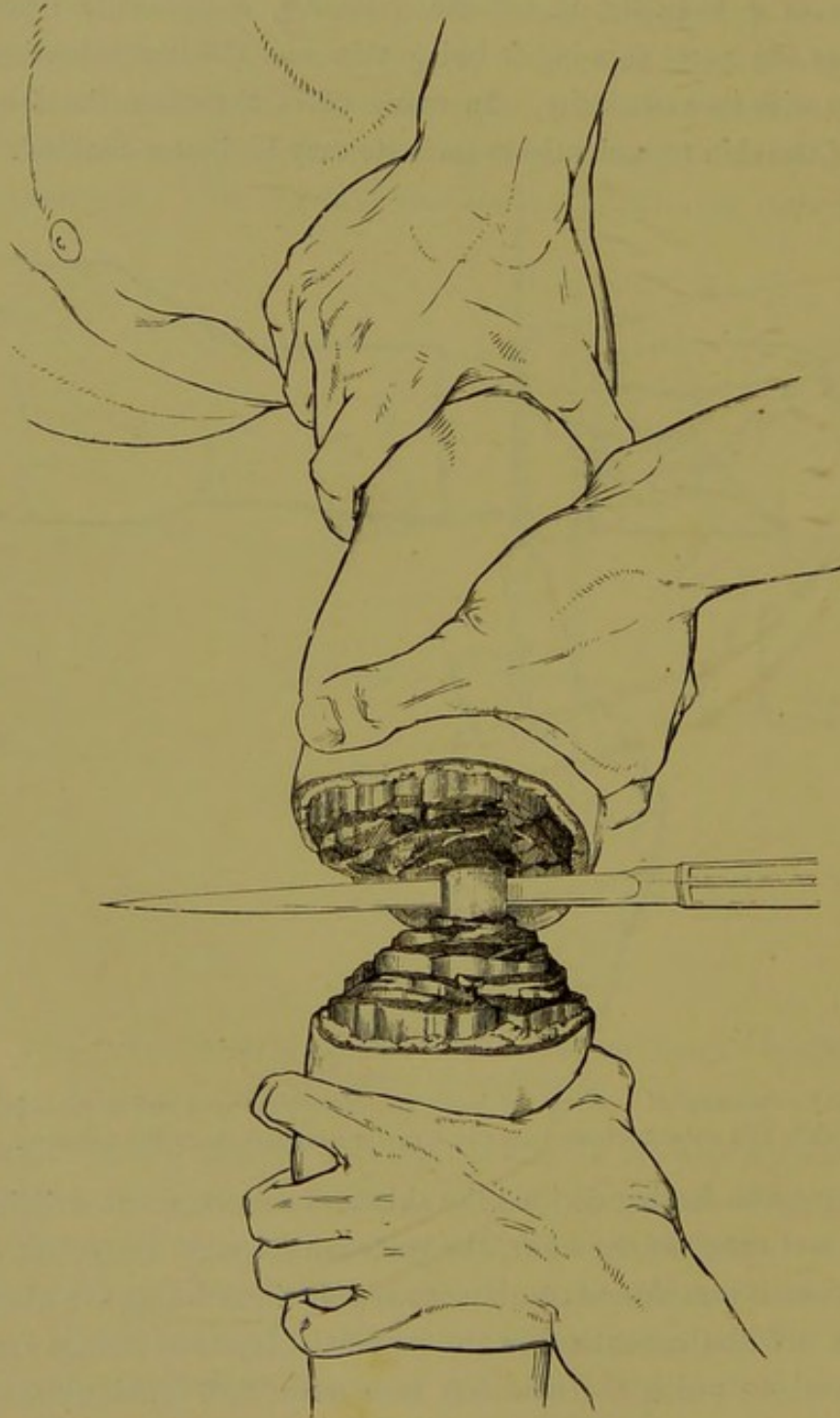


FIG. 118.—Manner of completing the division of the soft parts in a circular amputation of the arm.

In this way, when the parts are relaxed the bone will be found at the apex of a cone of which the divided skin forms a base.

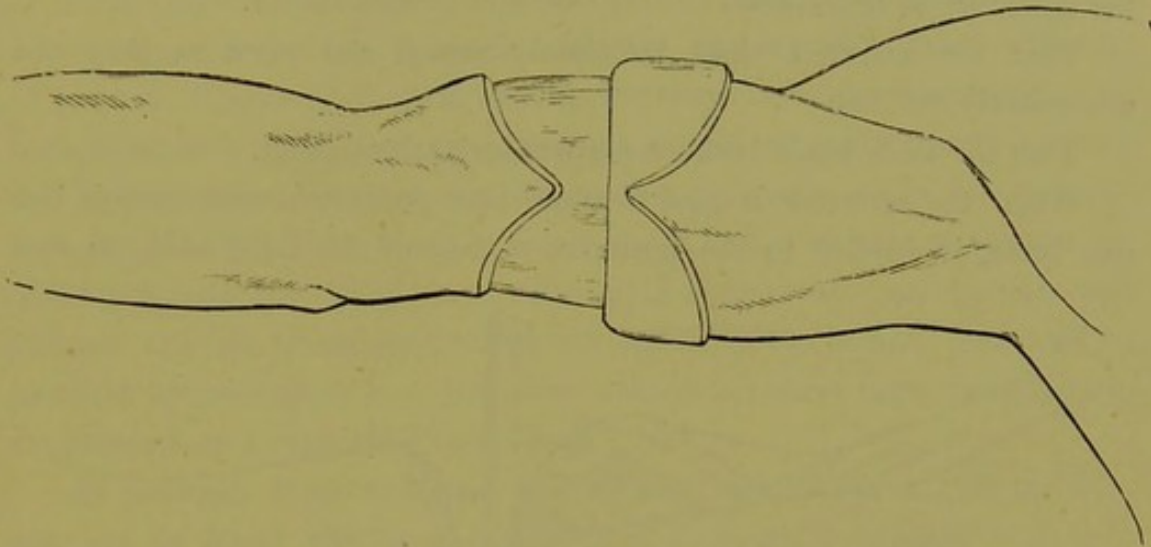


FIG. 119.—Amputation of the arm by skin flaps and circular division of the muscles. Diagrammatic.

To facilitate the separation of the skin a single or double lateral incision is sometimes made on opposite sides of the limb in its long axis, or two flaps of skin may be formed and afterwards dissected up (Fig. 119).

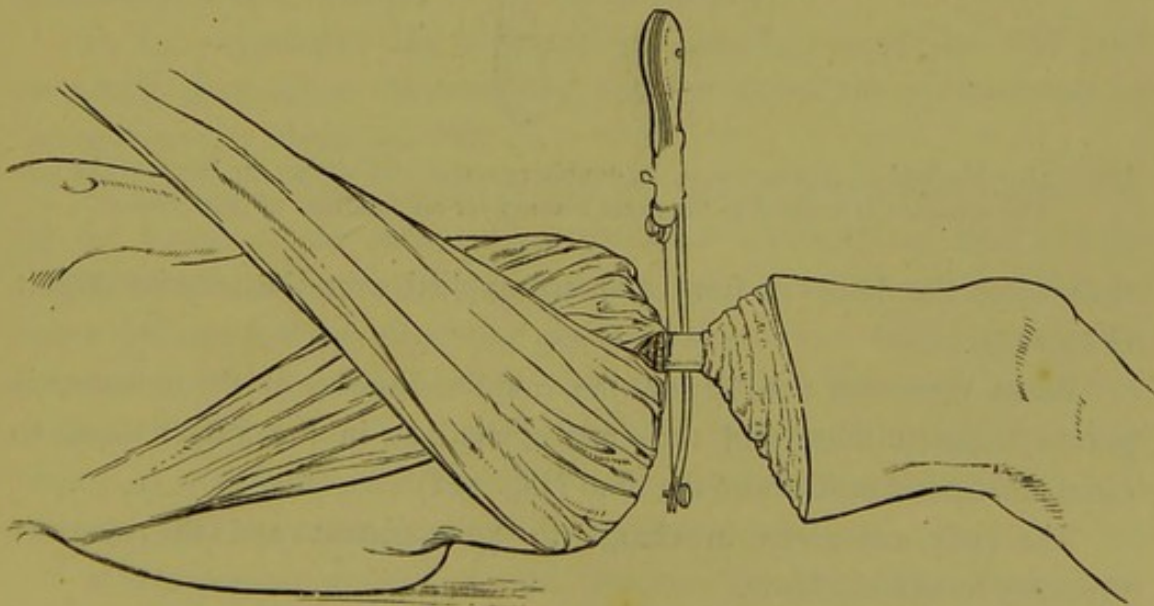


FIG. 120.—Application of the single retractor in amputation of the thigh, and method of sawing the bone. The retractor is applied in a similar fashion in amputations of the arm.

The important points to attend to in the successive sections of the muscles, which may be numerous if the limb be very thick, and in sawing the bone, are as follows :—

That the assistant shall sufficiently retract the parts as they are successively divided.

That the knife-blade be kept perpendicular throughout.

When the retractor is used the undivided portion, in case there is but one bone, is applied to the posterior surface of the limb, while its two

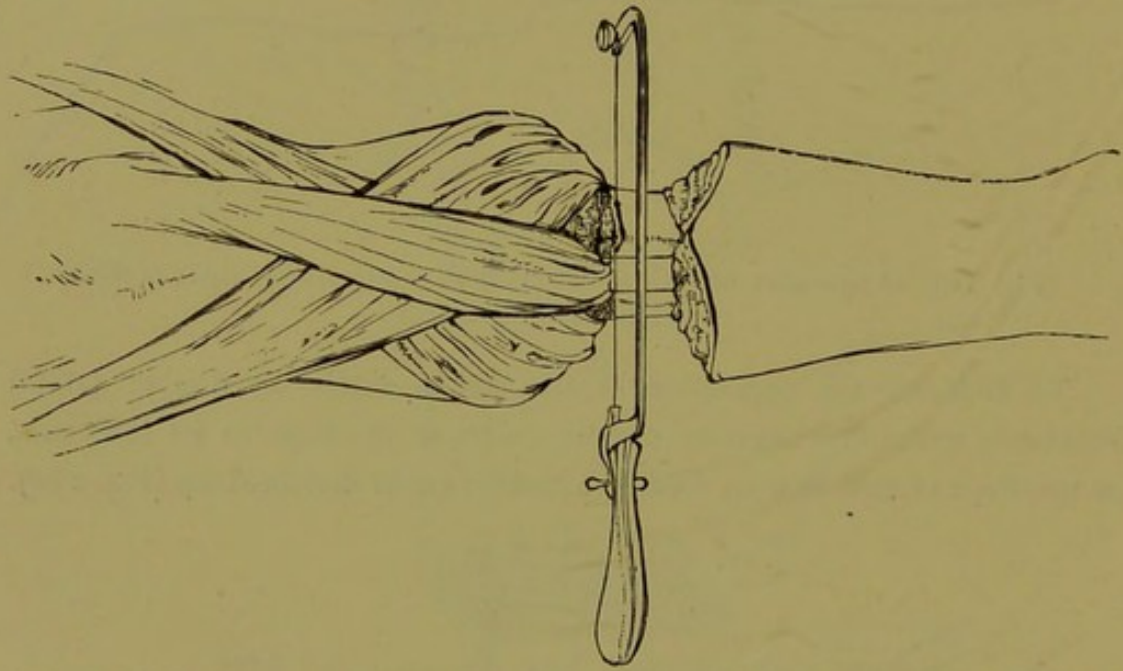


FIG. 121.—Method of application of the double retractor and sawing the bones of the leg. The retractor is applied in the same manner for amputations of the forearm.

ends cross the bone in front and are applied over the anterior aspect (Fig. 120).

When there are two bones, the middle division of the retractor is passed between them, and the ends applied, as in the former case, to cover the lateral portions of the limb (Fig. 121).

The ends are given in charge to an assistant and the operator proceeds to saw the bone.

The first object should be to make a groove in which the saw shall run smoothly without danger of slipping out and lacerating adjacent parts.

This may be done by making short and very light cuts, or, better

still, by placing the heel of the saw on the bone and drawing it lightly back through its full length.

When two bones require division a groove should first be made in the larger one, and then the saw will catch on the second without difficulty (Fig. 121). The division of the smaller and more movable bone ought to be completed first. The sawing of the bone should be executed with a steady but light hand, in long and not too rapid movements while its thickness is being divided, with shorter, more rapid, and very light strokes as the division approaches completion. Too rapid movements heat the saw and increase the risk of necrosis of the cut surface of the bone. This may be avoided by pouring on it a stream of carbolized water from the nozzle of an irrigator, or a moistened compress.

An assistant must hold the limb in such wise as not to lock the saw, nor yet to break the bone before it is completely divided. If this, however, should happen, the splinter must be afterwards removed with the bone forceps. In the leg it is further desirable to remove the anterior sharp corner of the tibia. During the division of the bones of the forearm the limb is to be held completely supinated, while in sawing the tibia and fibula the leg should be rotated inwards. In this way the bones in both cases may be sawn through nearly simultaneously.

In flap operations the assistant can readily retract the soft parts and keep them out of the saw's way, and the use of the retractor may be advantageously dispensed with.

It may prove requisite to modify the operative procedure according to the nature of the case. When the limb is of ordinary size, and the cellular tissue loose, the circular operation is easy to execute and may be done without formally dissecting up the skin. In a subject wasted by disease the circular amputation is also easy, and the bone can be covered with facility, but in a muscular subject, as in amputation performed for injury on persons in good health, or when the tissues are infiltrated, it is less easy and the stump is more likely to become conical.

It is important, as before stated, to cover the sawn surface of the bone with a periosteal flap. This may be done without difficulty after the periosteum has been cut through with the scalpel by detaching and pushing it upwards with the elevator, leaving it as much as possible in undisturbed

connection with the tissues outside. The periosteum separates very readily in young persons, and in cases of operation performed for disease. In adults, and in operations undertaken for injury, it is more difficult to detach.

FLAP AMPUTATION.

This mode of operating seems to be of ancient date, but it was not largely practised until the beginning of the last century. It is more

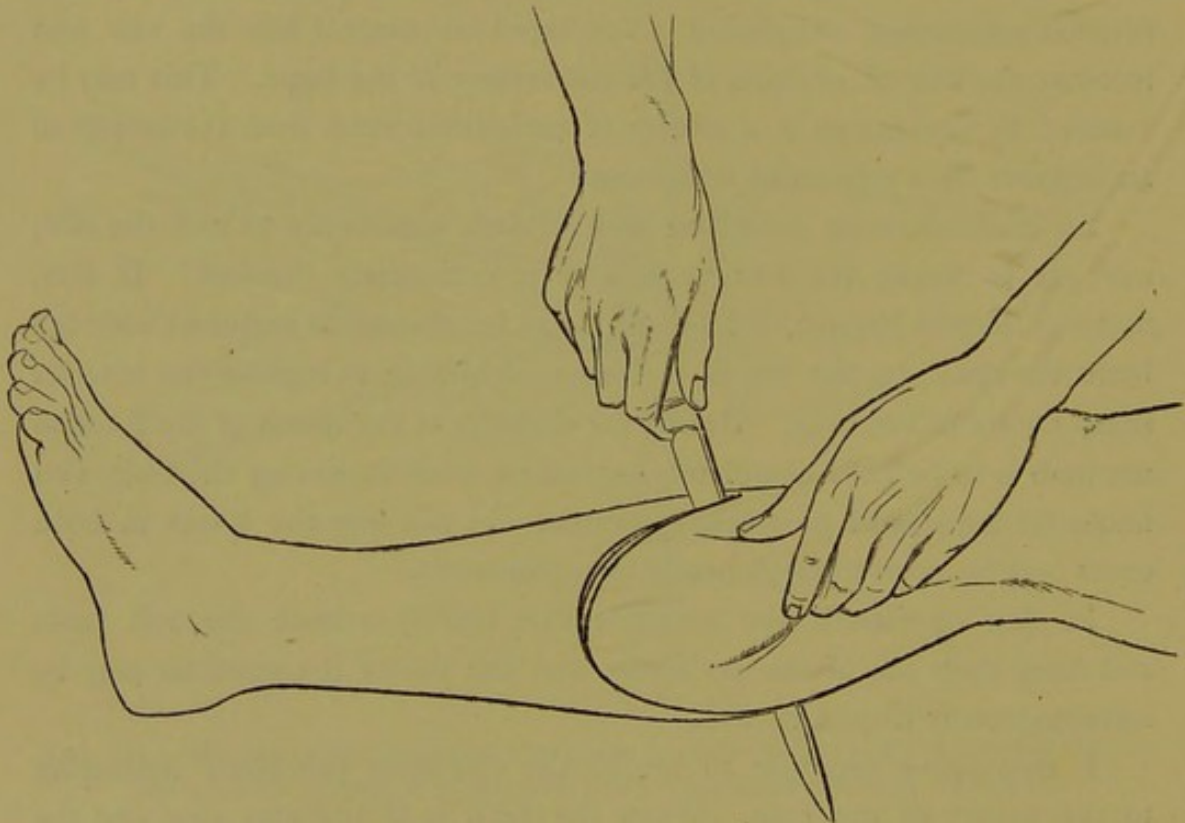


FIG. 122. —Manner of grasping the soft parts and transfixing the limb in a flap amputation.

quickly performed, accompanied by less loss of blood, and demands fewer assistants, than any other. The flaps may consist of skin and subcutaneous tissue only, or may include a greater or less thickness of muscle. The latter is much the preferable method, as the flaps are better nourished and form a more substantial covering for the end of the bone. They may be single or double, anterior, posterior, or lateral, according to the part of the limb operated upon and the extent to which the soft parts are involved by disease or injury.

The flap amputation is a better procedure than the circular in amputations through most joints, near the trunk, or when the tissues are more extensively diseased or damaged on one side of the limb than the other.

The flaps may be formed either (1) by transfixion, (2) by cutting from without inwards, or (3) a combination of both measures. By the method of cutting from without inwards the exact shape as well as thickness of the flap can be more accurately determined, while by the transfixion method increased rapidity of execution is possible. It is often advantageous to make one flap by cutting from without, the other by transfixion. In a very muscular subject the method by transfixion is less desirable, as the flap will almost certainly be too thick, and the cut ends of the muscles are apt to project beyond the edges of the divided skin, disadvantages that are avoided when the flap is raised up by cutting from without inwards.

In the method by transfixion (Fig. 122) the knife is passed from one side of the limb to the other close to the bones, emerging at a point exactly opposite to that of entrance, the soft parts being grasped and held up by the left hand, the thumb and forefinger of which mark respectively the points of entrance and exit of the knife. Then with a to-and-fro movement, first parallel to the long axis of the limb and then gradually directed outwards, the flap is completed. In all cases the edge of the knife should be finally brought out at right angles to the surface, the skin being at the same time drawn upwards. The knife is now introduced behind the bone, and a similar but usually shorter flap made in the same way (Fig. 123). Both flaps having been drawn upwards, and any remaining tissue circularly divided, the periosteum is separated and the bone sawn through. Flaps made in this way, however, in a muscular limb are thick and may prove unmanageable. The great vessels and nerves may be cut too long, or very obliquely, or even slit along their length. An oblique section of the veins renders them more liable to bleed.

The proper length and shape of the flaps must depend on the judgment of the operator; as a rule they should be **U** shaped. When brought together the line of union should be in such wise that drainage is facilitated, and a cicatrix over the end of the bone avoided. A long anterior and a short posterior flap fulfil most requirements. The anterior flap had better be made from without inwards, because its form can usually be thus

more accurately mapped out, and it should consist not only of skin and subcutaneous tissue, but of a certain thickness of muscle also. It should

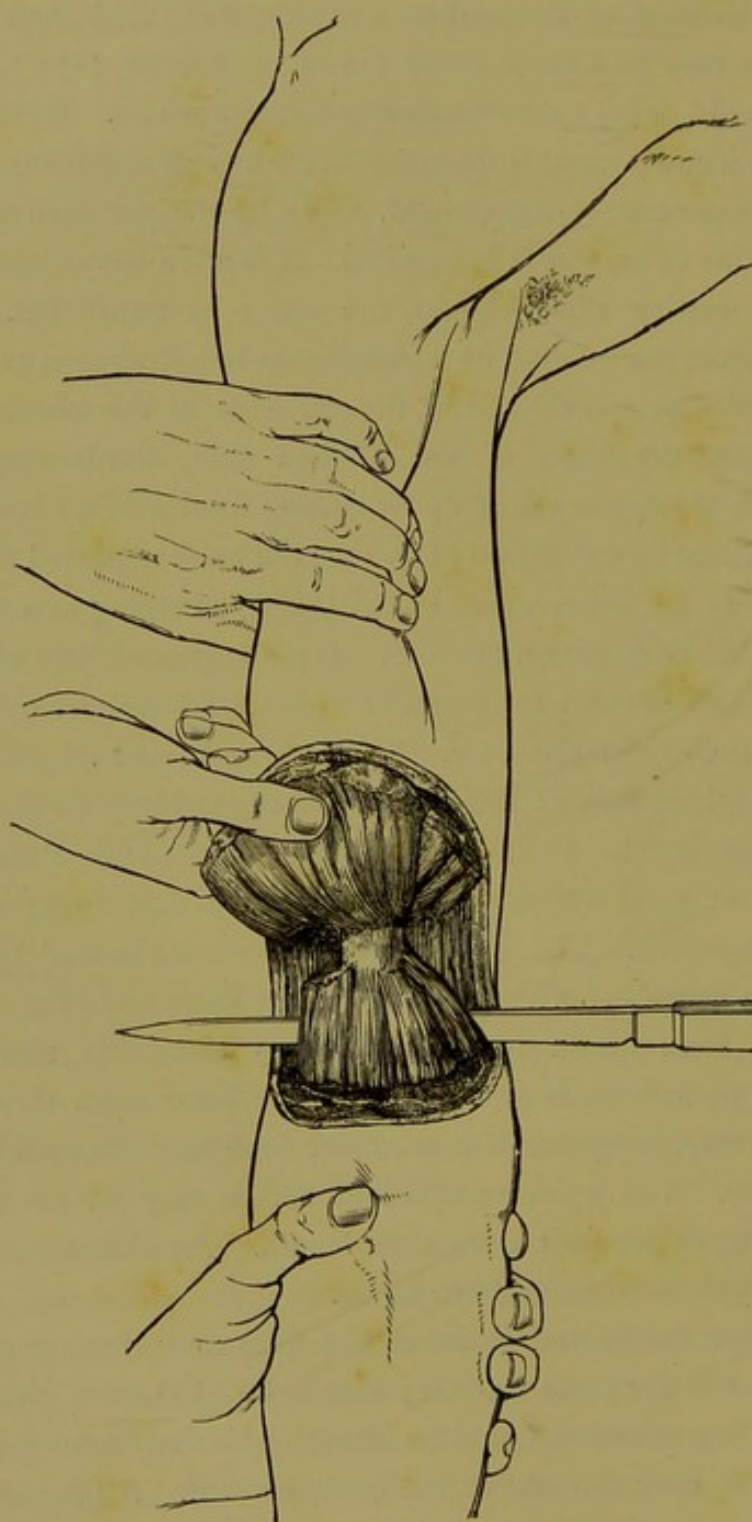


FIG. 123.—Manner of transfixing the limb in a flap amputation of the arm with digital compression of the brachial artery.

have a rounded extremity nearly as wide as its base, which should equal at least half the circumference of the limb where the bone is to be divided, and be one and a half times as long as its diameter. It should always be large enough to cover without tension the entire surface of the stump. The posterior flap may be made one-third the length of the anterior one, usually by transfixion. When the anterior flap is fully detached and the posterior flap made, any remaining muscular tissue is to be cut through by a circular sweep of the knife. After the section of the deep layer of muscular fibres, the periosteum should be divided at a lower point and detached to a sufficient extent to cover the cut extremity of the bone as already described. As modifications of this method, some prefer to make the longer flap of skin only, while others again, after Teale, would include the whole thickness of the muscles in both flaps.

The quantity of muscle to be included in the anterior or long flap may be largely determined by the depth of the first incision. The more muscular the limb, the less ought the proportional thickness to be. A muscular flap is preferable to one composed only of skin, especially when the latter is infiltrated or œdematous. In commencing and terminating the incision on the lateral aspects of the limb, it should be for a short distance parallel to the long axis. In making the first incision, we have to divide the skin and subcutaneous tissue. A certain amount of retraction will follow; the superficial layer of muscles may then be divided at the level to which the skin has retracted. The flap should now be strongly retracted, and the knife carried with a full sweep across the limb from side to side, the knife edge being kept nearly vertical to the surface. In this way slicing of the flap is avoided, and the thickness of the muscular layer can be determined at the will of the operator.

When one flap only is made, a procedure which has been ascribed to Lowdham, it must of course be sufficiently long to cover the whole face of the stump. It should be made from the anterior surface of the limb, so that it may afterwards hang downwards by its own weight.

The preferable method is, however, to have in addition to the long anterior a shorter posterior flap, and this should always, when practicable, be so placed that the principal bloodvessels and nerves are left in the shorter flap.

In some cases the outline of the flap may first be mapped out by a deep groove with the knife, and the section then completed by transfixion, the knife emerging in the incision. The blade readily finds its way out through the groove which has been made for it. This plan precisely determines the form of the flap and also the thickness of its edges. Thus they will not prove too thick, and the surface cannot be scored. In parts of the body where the flaps must be taken from somewhat irregular surfaces, as for instance the sole of the foot or the palm, this modification will be found advantageous.

Vermale and Ravaton appear to have originated the double flap amputation. Ravaton first divided all the tissues circularly down to the bone, and then by means of two deep lateral cuts on opposite sides of the limb raised two square blocks of muscle, the bone was then sawn at the point predetermined upon.

Legouest mentions that during the Crimean war the Russian surgeons exclusively employed Ravaton's procedure in amputating the thigh. This operation is evidently the precursor of the plan of the late Mr. Teale, who suggested, as Ravaton did, that the flaps should include the whole thickness of the soft parts. Teale recommended, however, that one flap should be made much longer than the other—long enough, in fact, to encircle the end of the bone. He also advised certain preliminary measurements. The circumference of the limb is first to be taken, opposite the point selected for dividing the bone. The longer flap is then marked in pen or pencil on the limb, square in outline, and equal in length and breadth to half the circumference of the limb. If possible, it should be so placed as to be anterior, and to contain no important vessels or nerves. The shorter flap is of the same width as the anterior, but only one-eighth of the circumference of the limb in length, and should contain the principal vessels and nerves. These measurements having been first marked on the limb (Fig. 111), the flaps are formed by making longitudinal and transverse incisions right down to the bone. The long anterior flap is then dissected up, and subsequently the shorter posterior one. Both flaps are rectangular, and after the bone has been sawn through, their cut extremities being exactly equal in width, can be accurately brought into contact throughout.

This operation may be modified by not extending the lateral incisions quite down to the bone; the anterior long flap will then contain when dissected up only a partial thickness of the soft parts, a necessary modification in a muscular subject.

Another modification is to commence the lateral incisions at the level of what would otherwise be the extremity of the posterior flap, and to divide the bone flush with this. In other words, a single square anterior flap is made, without any posterior one, the muscles behind being cut straight down to the bone by a circular sweep of the knife.

Teale's amputation provides a good thick cover to the end of the bone, and the discharges drain off readily. But the surface of the divided soft parts is, I consider, very needlessly large, as is also the amount of bone sacrificed. Indeed, I fail to see the advantage of this mode of operating over that

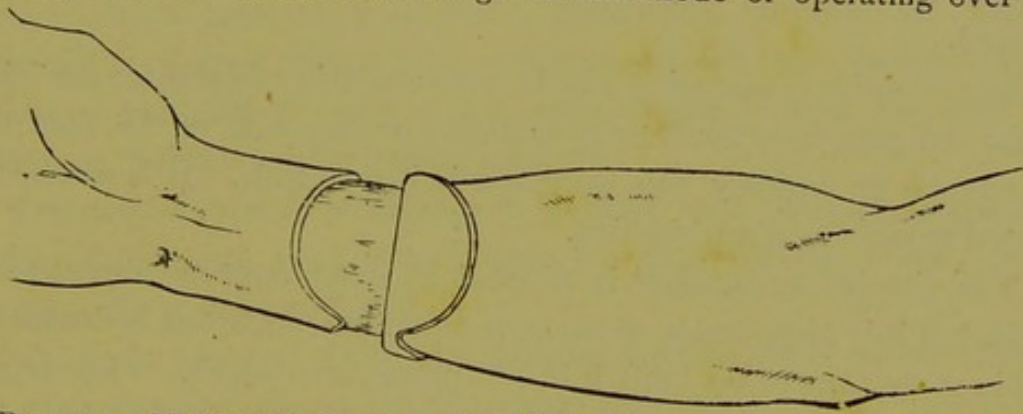


FIG. 124.—Mixed method of amputation in the forearm by skin flaps and circular division of the muscles. Diagrammatic.

in which a long anterior oval flap (Fig. 211), made to include part of the muscles, is combined with a shorter posterior one. The inordinately high division of the bone which Teale's operation entails, can be seen by any one who marks out, say upon the thigh (Fig. 214), the measurements given by the author. A skilful surgeon will always be able to fashion his flaps so as to utilize the soft parts to the greatest advantage, make the longest stump possible, give ample covering to the bone, and ensure that the line of union shall hold a dependent position, and all this can be done without having recourse to rectangular flaps.

A mixed or modified circular method is sometimes selected. Two flaps are made to include merely the skin and subcutaneous cellular tissue (Fig. 124).

When detached sufficiently, the muscular tissue is divided circularly at the level of the base of the flaps, and the operation completed as in the other cases.

OVAL AMPUTATION.

The elliptic or oval method of incision is but little practised except at the joints, and more especially those of the fingers and toes (Fig. 125).

The operation may be commenced with a semi-elliptical incision, the concavity downward, around the sides and posterior aspect of the limb, and finished with a second semi-ellipse having a downward convexity around the other half, dividing in the first instance only the skin and subcutaneous tissue, which are then dissected up; or the flaps may be formed to include a layer of muscle as well, the preferable procedure. The racquet-shaped incision is another variety of oval method, and is the one generally adopted.

Such a mode of operating may be very useful in cases where the injury to the soft parts is so much more extensive on one side of the limb that the circular or ordinary flap operation is inapplicable. It is usually restricted to cases of disarticulation.

The circular amputation is adopted by some surgeons almost exclusively, but it is inapplicable when amputation near the trunk is demanded, and in some parts of the body it is difficult of performance. Flap amputation, as a rule, is more easy of execution; there is less likelihood of subsequent protrusion of the bone, and there is less tendency for blood and discharge to fill the wound. Conical stumps, too, are less frequent than after the circular method. Lastly, in cases of injury more of the limb may often be saved by cutting a long flap from the less injured side than by the employment of the circular procedure.

DISARTICULATION.

Disarticulation, or amputation through a joint, was rarely practised until re-introduced by Brasdor. It is, of course, inapplicable where the joint surfaces are diseased.

The serious consequences often following a wounded joint doubtless acted in preventing surgeons from having resort to this operation. In the

fingers it is the usual method, but too frequently the undesirable practice of removing the articular head of the proximal phalanx, or the head of the metacarpal bone, has been adopted. The encrusting cartilage was thought almost certain to perish, or to act as a foreign body and keep up suppuration—a fear experience has dissipated. In a large articulation a very copious discharge of sero-synovial bloody fluid is likely to occur at first, and should be provided for. Even this may be avoided by dissecting out the synovial membrane. In any case the discharge soon ceases, and as for the cartilage, if the wound be kept aseptic there is no danger of it causing trouble, and union will probably ensue without exfoliation of cartilage, which may subsist for months with scarcely appreciable change.

Should suppuration or septic changes occur in the wound the cartilage may necrose and exfoliate, or it may gradually disintegrate and become replaced by a granulating surface. Meanwhile, however, the bone is protected to a great extent from septic absorption; and there is, in consequence, less risk of pyæmia and osteo-myelitis than if the shaft had been sawn through and its interior exposed.

Disarticulation is more difficult to perform than ordinary amputation. Similar instruments are required, with the exception of a saw; but a shorter knife is to be preferred.

The exact position of the joint must be carefully made out beforehand, but when swelling subsists this may prove difficult.

The *lignes de locomotion*, given as guides to an articulation, are often obscured when the joint has been enlarged by disease, or when it is partially, or, completely, ankylosed. Adjacent bony prominences and the movement of the joint, however, form after all the best guides to its precise position.

The flaps must be accurately made of the proper length and shape: oftentimes skin alone can be utilized. The flaps are proportionately larger than in ordinary amputation in order to cover the expanded articular extremity of the bone. One cannot, as in ordinary amputation, afterwards saw the bone higher up than was originally intended in order to compensate for an insufficient provision of soft covering.

The mode of operating most applicable in each individual joint will be considered farther on. A preliminary compression of the blood stream is

in some cases unnecessary—as, for example, at the shoulder, where the main artery need not be divided till the last moment.

The circular method is usually inapplicable for disarticulation, but if selected, may be conducted as elsewhere. After the manchette has been

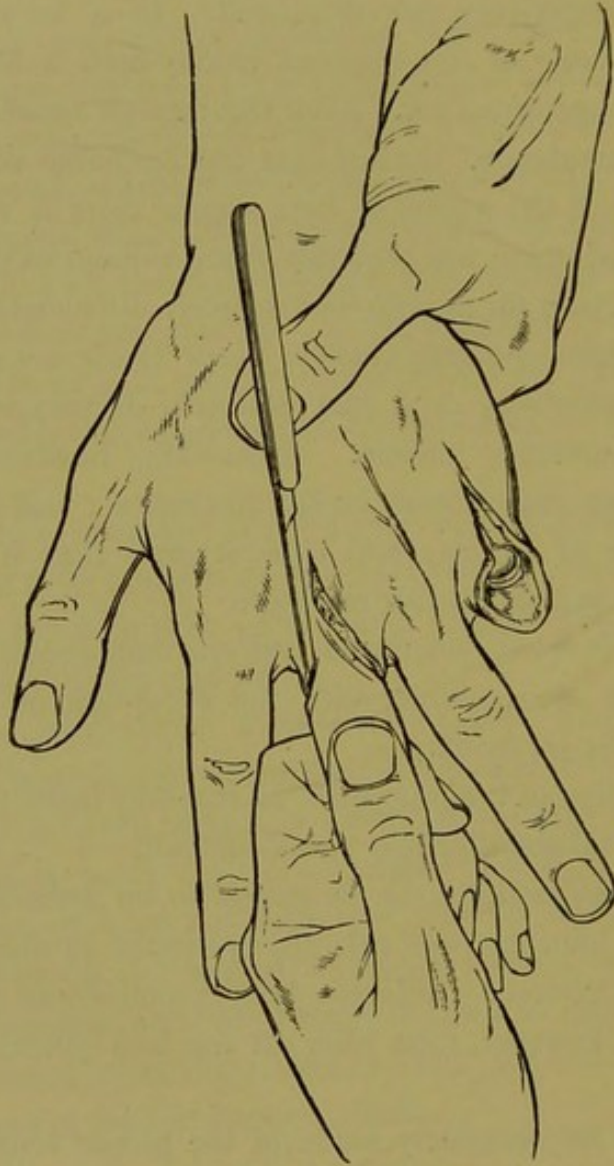


FIG. 125.—Oval method as applied to amputation of a finger. Disarticulation of other joints may be practised in a similar manner.

dissected up and the muscles divided, the joint is opened, its ligaments and capsule are cut through, and the disarticulation completed.

These operations are frequently performed with a single flap, or by means of a long flap and a short one, so arranged that the longer is

anterior and falls into place as if by its own weight. In other cases lateral flaps may be preferable.

The flaps are usually of skin only, or in others a proportion of muscle is included as well. Around some joints there are only tendons and fascia, and little or no muscular tissue.

The flaps had better be formed, in most cases, by cutting from without, and the longer or principal flap should always be so made.

In the oval, or racquet method, the portion corresponding to the handle

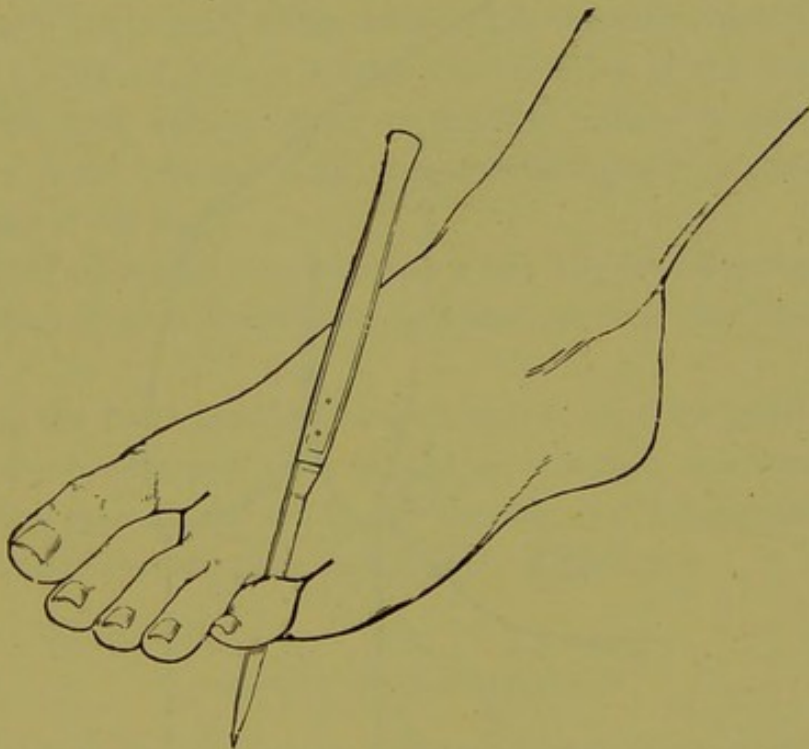


FIG. 126.—Oval-shaped incision for the removal of the little toe.

should be above and in front, while the rounded extremity remains inferior and behind.

This method is the one generally employed in disarticulating the fingers and toes. It was adopted by Guthrie for the shoulder-joint, and even for the hip. Scoutetten proposed its adoption in all amputations.

A good idea of the shape of the oval incision for amputation or disarticulation may be obtained by saying that it represents a triangle to whose base has been applied a semicircle (Fig. 125).

This form of amputation is not very generally applicable. To perform it, two incisions, divergent downwards like an inverted Λ , are to be made in

succession on each side of the joint. They ought to begin a little above the line of the articulation, and the knife is then to be carried round the joint, sufficiently below the line of articulation, in a semicircular manner. The result is a racquet or pegtop shaped elliptical wound. The margins of the incision are dissected up, the joint capsule exposed and divided, the tendinous insertions and ligaments cut through, and disarticulation com-

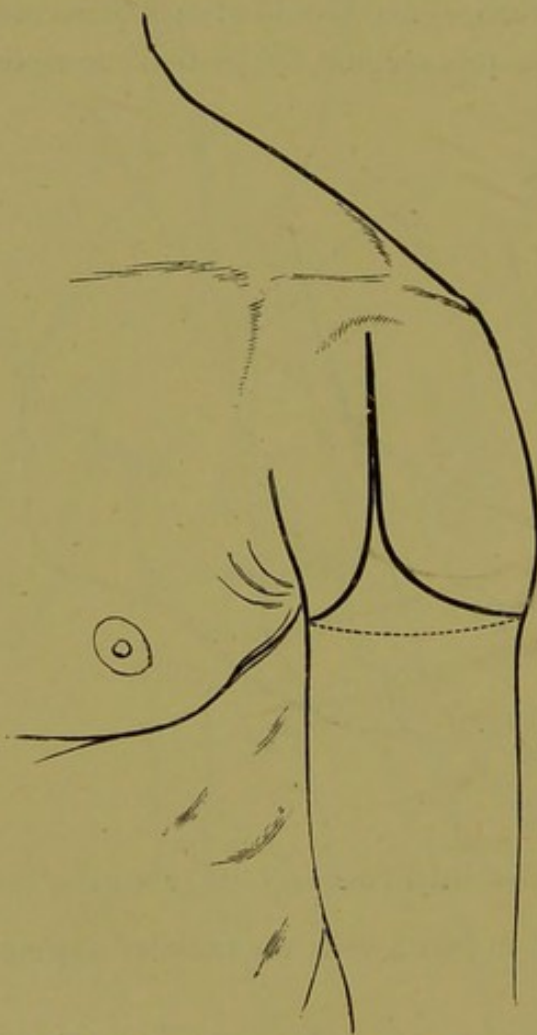


FIG. 127.—Oval method of disarticulation at the shoulder-joint. The woodcut further suggests how an operation for excision may be converted into an amputation of the shoulder-joint.

pleted. When the hæmorrhage is arrested and the wound purified, the edges of the incision are brought together in a vertical line, which permits very effective drainage. Except at the shoulder, the flap method is the better one.

After either amputation or disarticulation any irregularity of the parts

divided must be corrected, projecting tendons and nerves should be cut short, and all diseased or doubtful tissue carefully removed before closing the wound.

OSTEO-PLASTIC AMPUTATION.

This name is given to operations in which to the sawn surface of the bone in the stump another sawn surface is applied and made to unite. Operations of this kind are often called after the name of the author, as in Pirogoff's amputation at the ankle, Lefort's modification of the operation, and Gritti's amputation through the condyles of the femur. In the first two the sawn surface of the os calcis is applied to the cut end of the tibia; in the last, the sawn surface of the patella is attached to the divided end of the femur.

The chief advantage in osteo-plasty is found in the solid character of the stump, which is usually extremely well fitted to bear firm pressure on the end.

Among the disadvantages, however, may be cited the general inapplicability of the operation to cases of disease, increased risk from the larger bone surface exposed, the occasional necessity for longer after-treatment, and the chance that the bone surfaces may fail to unite.

ARREST OF HÆMORRHAGE.

The first thing to attend to after completing the cutting part of the operation is to secure the divided vessels. Any considerable loss of blood during the progress of the operation is effectively prevented when instrumental or digital compression is resorted to. Considerable hæmorrhage from any cause enhances the shock, and probably retards healing, especially in persons suffering from exhausting disease, and it also predisposes to septic infection. In strong plethoric subjects, however, the loss of a little blood will do no harm.

Bleeding, called *intermediary*, occurs within a few hours after the patient has begun to show signs of reaction and a renewed activity of circulation. This accident renders fresh dressing necessary, or perhaps the reopening of the stump, if it be distended by blood or clot. To avoid so undesirable

a complication, the greatest care should therefore be taken to secure every bleeding-point at the time of operation.

The bleeding may be *secondary*—that is, occurring ten days or a fortnight after, or perhaps later, from ulcerative changes invading the blood-vessels in the stump. This occurrence is now comparatively rare. Rapid healing of the wound has become the rule. Ligatures no longer require to be detached one by one by ulceration. The wound is kept free from septic change, and the septicæmic conditions so frequently productive of secondary hæmorrhage are now commonly prevented.

Ligature or torsion are the means generally employed to arrest hæmorrhage. The former is now the more general, and is certainly easier and probably more secure, at all events for smaller vessels. The great argument in favour of torsion, or such methods as acupressure, has fallen to the ground since the introduction of aseptic ligatures, with the practice of cutting off both ends. When the wound has been rendered aseptic, no ill results attend the presence of buried ligatures. Formerly, when all the ligatures (twenty, thirty, or even more in number) were each represented by an end of thread hanging out between the edges of the flaps, the case was very different.

In resorting to torsion it is needful to isolate the artery or vein from the surrounding tissues so that nothing shall be included in the torsion forceps except the vessel itself, which should then be twisted until the coats rupture, when resistance and all tendency to untwist will cease. The number of turns required varies with the size of the vessel. Three or four suffice for the smaller arteries, five or six for the larger.

The best procedure is to apply artery forceps rapidly to as many vessels as can be distinguished on the face of the stump (Fig. 128), and then to ligature them in succession with carbolized silk or catgut, first the principal artery of the limb, and then the muscular branches. The surgical knot (Fig. 24) is preferable, and both ends should be cut short. When all the vessels visible are tied, the compression should be relaxed, and any remaining bleeding-points seized. Warm, not cold, carbolic lotion ought first to be used to irrigate the stump, in order to encourage the smaller vessels to bleed. When the bleeding is thoroughly arrested, cold applications may be substituted, and all coagula carefully removed. Finally deep and super-

facial sutures are introduced, and drainage-tubes passed to the deepest parts of the wound and made to emerge at each angle, where they can be secured

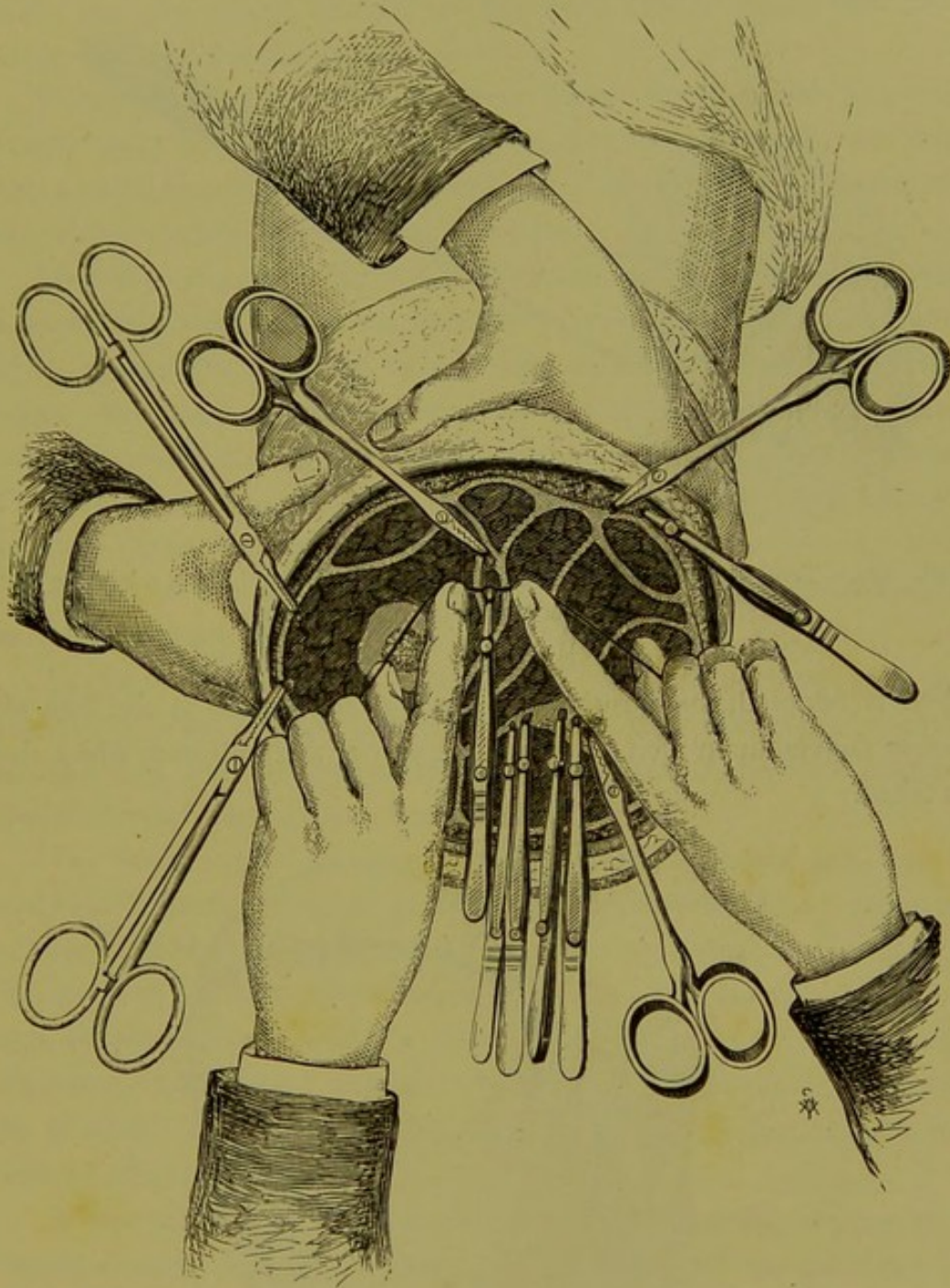


FIG. 128.—Application of force-pressure forceps to the divided ends of the vessels. Diagrammatic.

by a point of suture, or a safety-pin. Two or more tubes (Fig. 130) are better than a single one running from side to side.

After a circular amputation, the edges of the incision may be approximated, either vertically, horizontally, or obliquely. When the flap

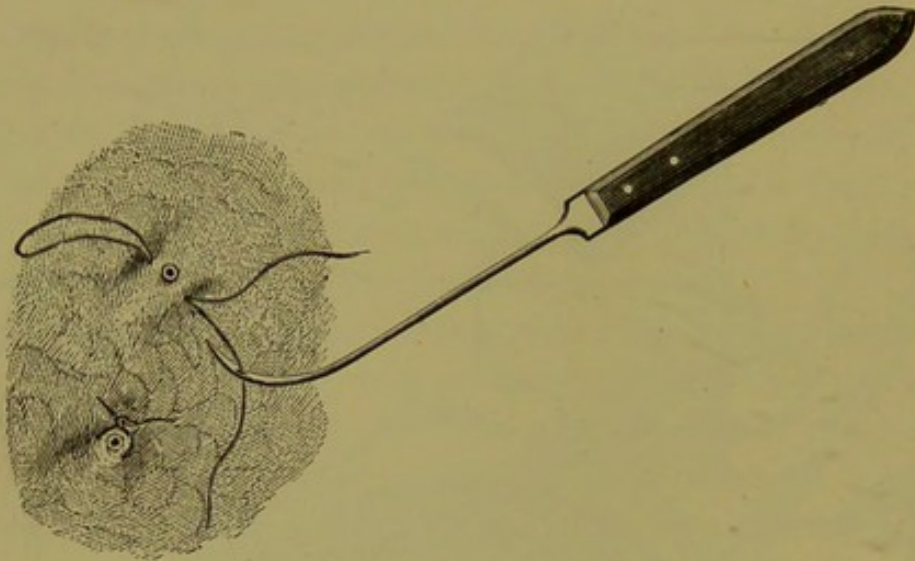


FIG. 129.—Tenaculum, occasionally employed to pick up and apply a ligature to bleeding points.

method is adopted, the position of the line of junction of the flaps will of course depend upon their shape and the part of the limb from which they were taken.

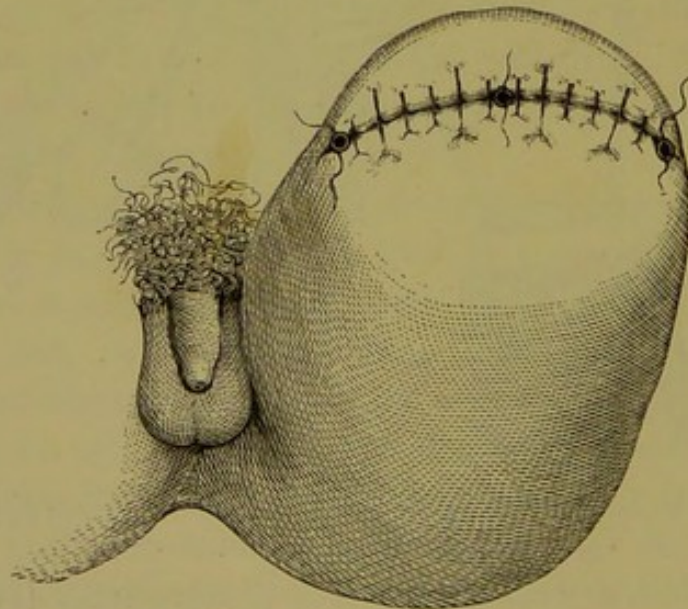


FIG. 130.—Stump after amputation of the thigh, sutured and drained.

If on bringing the soft parts together there be any tension, it is better at once to divide the bone at a higher level. After detaching the periosteum to the requisite extent, the end of the bone may be seized with the lion forceps and the needful amount removed.

When the cut surface of the bone bleeds freely, gentle pressure will usually arrest it. Should an artery in the bone bleed it may be stopped with a pellet of wax, a piece of catgut, or, if these fail, the sharpened end of a wooden match may be used as a plug.

Bleeding veins are to be tied in the same way as arteries. The practice is unobjectionable, and, as has been already said, much of the after-success of the operation will depend on the pains taken to secure every bleeding-point. Too much time and trouble can scarcely be devoted to accomplish this, nor should the flaps be drawn together until it has been well assured. The sutures can meanwhile be introduced, but should not be drawn tight until the hæmorrhage is arrested, otherwise clot will distend the interior of the wound, which has then to be reopened, entailing needless suffering and risk upon the patient.

In cases of chronic and inflammatory disease, the number of vessels requiring ligature is much greater than when the operation is performed for recent injury, and the long-continued application of Esmarch's apparatus materially increases the number of bleeding-points.

The deep sutures introduced should preferably be of silk, and must embrace a good thickness of the substance of the flaps; afterwards a sufficient number of superficial ones, commonly catgut, are used to bring the edges of the skin into accurate approximation. Sometimes very deep sutures are employed with the view of bringing the entire surface of the flaps into close contact, but this is not essential, since the desired end may be obtained by external compression with pads and bandages, combined with efficient drainage.

A serous bloody discharge, often copious, exudes during the first twenty-four or forty-eight hours, and, if means be not provided for its escape, becomes pent up in the interior of the wound, to the distress and damage of the patient.

The drainage tubes should be of sufficient number to permit its ready escape; they are inserted at dependent parts of the line of junction of the

flaps, and left in place during from four to seven days or until the discharge has mainly ceased.

The drainage-tube is commonly made from india-rubber tubing of various sizes in which lateral openings have been pierced. Absorbable drains of decalcified bone are also sometimes employed, as well as tubes of glass or metal.

Dressing.—Some form of antiseptic dressing should be applied, and outside this a moulded splint of plaster-of-Paris or gutta-percha so as to support the stump and prevent painful startings. When the patient is put to bed, the dressed stump may rest on a cushion or pillow, slightly elevated, and exposed to the air, or only covered for the first few days with the sheet or one blanket, which should be supported by a wire cradle. In case of emergency an improvised cradle such as a split bandbox answers the purpose fairly well. The dressing may remain for two, three, or more days, according to the amount of discharge. In some cases one dressing only is required.

As a general rule, it is better for the patient's comfort to renew the dressings on the fourth or fifth day, when they will be found soaked with more or less bloody discharge. The sutures and often the drainage-tubes may then be removed. The fresh dressings applied will usually not require to be disturbed for a week or ten days, when union will in most cases be sufficiently advanced to permit the application of some simpler form of dressing; such, for example, as boracic lint. When the sutures are taken out, and there is a tendency to gape, the soft parts may require the support of strips of sticking-plaster.

Should parenchymatous or intermediary bleeding occur, the stump should be elevated and gently pressed with a large soft sponge, or an iced douche may be applied. If the hæmorrhage continue, the stump must be reopened and the bleeding-points sought for and secured. In cases of secondary hæmorrhage, if local measures fail, the main trunk may require ligature, and this is sometimes preferable to any interference with the flaps.

In the matter of dressing there is considerable diversity in the material employed, but it always involves some form of antiseptic agency. Carbolic acid, corrosive sublimate, iodoform, salicylic acid, boracic acid, are used in combination with gauze, jute, cotton-wool, sand, turf moss, wood-wool, and other mediums. If thorough asepsis be realized, the patient generally

progresses uninterruptedly to recovery without febrile reaction, and the stump rapidly heals; often without suppuration, or otherwise with very little. The patient sleeps and eats well, and feels little or no pain. The bowels should be kept open, simple and nourishing food given, and both mind and body kept at ease.

The open-wound treatment is still occasionally resorted to. In this case no sutures are introduced, and no dressings, compresses, or bandages are applied. The stump rests on a cushion, completely exposed to the surrounding atmosphere. There is suppuration, of course, and the wound heals by second intention or granulation. The discharges, however, flow away as soon as formed, and the part can be irrigated and cleansed as often as need be without much, if any, disturbance.

Results —The collateral circulation is soon established in the stump after

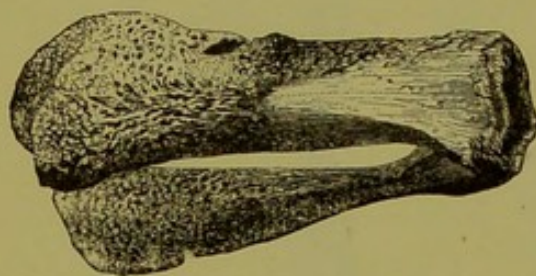


FIG. 131. — Plastic periostitis of the divided ends of the bone.

the main vessel is divided and the vascular supply to all parts becomes abundant. The divided skin, muscles, bloodvessels, nerves, and bone are invaded by the leucocytes, which become transformed into fibrous material, and the parts are finally blended together by intervening areolar tissue. After disarticulation, the cartilage is eventually transformed into fibrous tissue, and thus blends with the parts superficial to it. The muscular tissue for the most part wastes, becomes fatty, and disappears. Changes also occur in the elements of the nerve trunks in an amputated limb. The fibres atrophy, the lymph spaces enlarge, and the connective tissue increases. These changes may be traced in some instances as far as the spinal cord, principally through the posterior nerve roots, the number and structure of the cells in the postero-lateral and central groups being chiefly affected. The divided extremity of the nerves assume a bulbous form, becoming two or three times as thick as the nerve trunk itself. This

bulb is mainly composed of fibrous material, which forms a matrix, in which young nerve fibres have been demonstrated. The end of the bone may become closed by cicatricial tissue, which is finally converted into bone. Sometimes it expands into a mushroom-like form (Fig. 132) or may be surrounded by osteoplastic growth (Fig. 131), but generally it becomes more or less pointed (Fig. 133), and atrophic. Six to twelve months at least are required before these changes are completed in a large bone, and the stump becomes well adapted to accommodate an artificial limb.

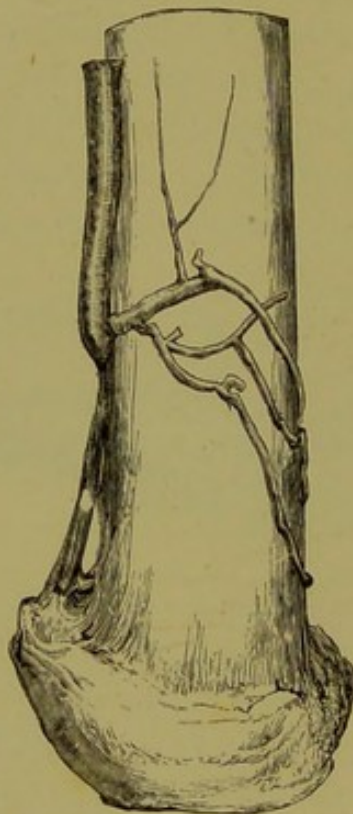


FIG. 132.—Stump of femur, seen from behind, showing a considerable thickening of the sawn extremity of the bone. The lower two inches of the femoral artery are obliterated, being represented by a fibrous cord, and from the pervious portion above branches run down to the extremity of the stump, anastomosing with ramifications of a large branch coming from a higher portion of the femoral artery.

When amputation has been practised in the adult limb, in the thigh, for example, the whole of the remaining portion of the bone usually becomes atrophic (Fig. 133), the obliquity of the neck of the femur increases, and, as has been pointed out by Pollock, the atrophic changes may extend to the pelvic bones on the side of the amputated limb,

probably because of the impaired function of that side of the body, while the increase of work imposed on the opposite limb induces hypertrophic changes in it.

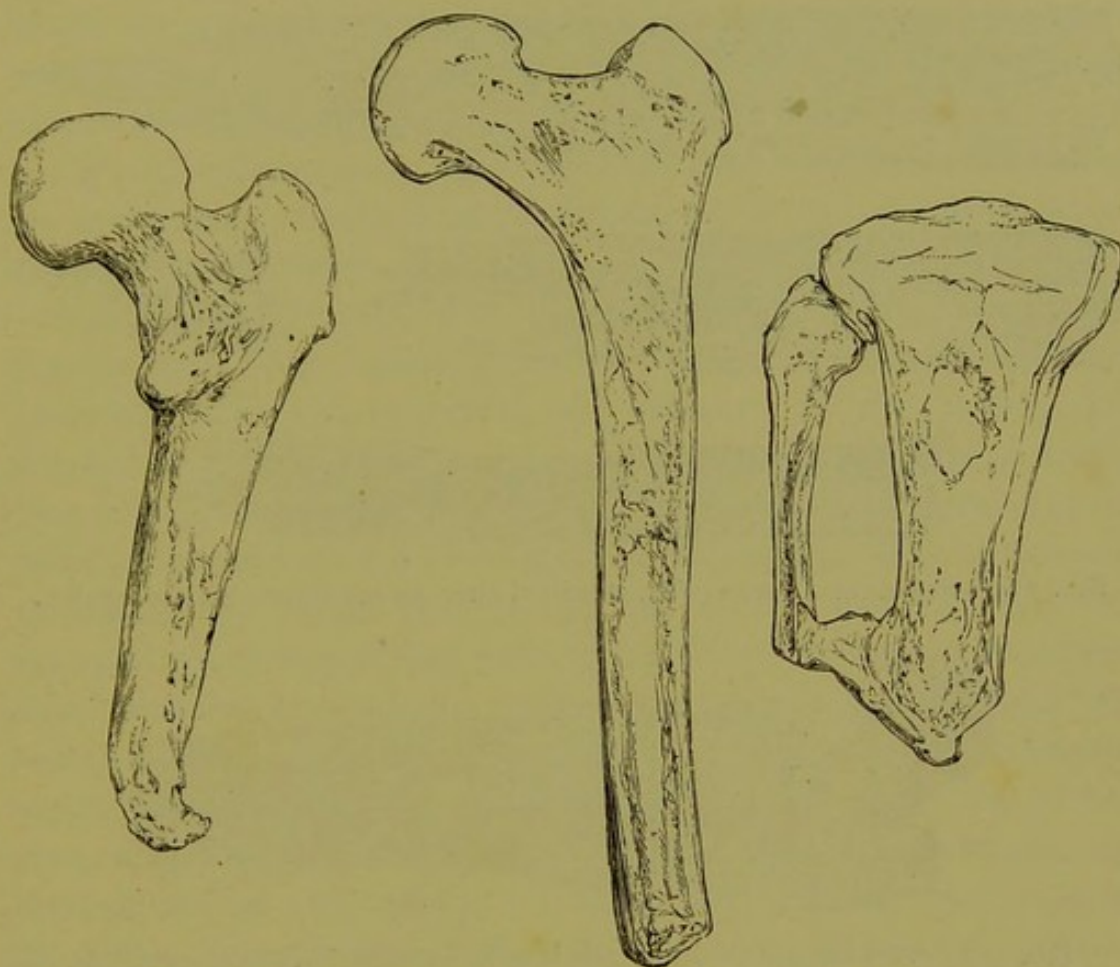


FIG. 133.—Appearances of the ends of the bone after amputation.

UNFAVOURABLE CIRCUMSTANCES AND RESULTS AFTER AMPUTATION.

Necrosis of the cut surface of the bone may occur, or of a larger portion of the shaft, but usually only a thin lamina separates from the cut surface. The sequestrum takes some time to exfoliate, and sinuses persist. The necrosed portion may be large or small. In cases of osteo-myelitis, it involves a considerable length of bone (Fig. 134). Overheating, caused by a too rapid action of the saw, may perhaps, in some cases, account for a limited necrosis. The formation of a periosteal flap, however, greatly diminishes the tendency to this complication.

Osteo-myelitis.—Both acute and chronic osteo-myelitis may occur after amputation. In the acute form it sets in with high fever, preceded by rigors and followed by sweating; the wound becomes unhealthy,

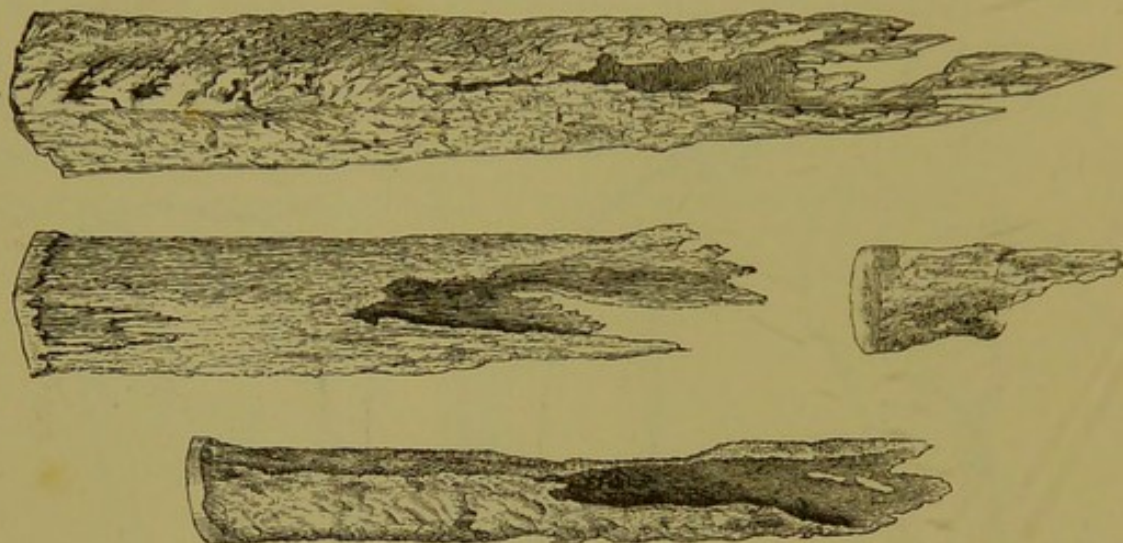


FIG. 134.—Sequestra of various sizes separated after the occurrence of osteo-myelitis.

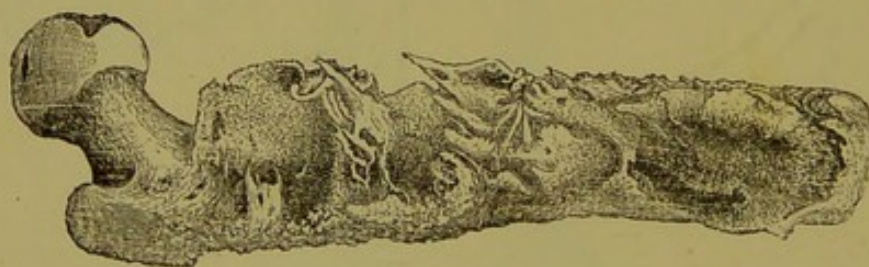

FIG. 135.—Very large formation of new bone in a case of chronic osteo-myelitis. Re-amputation was successfully performed at the hip-joint by Otis.

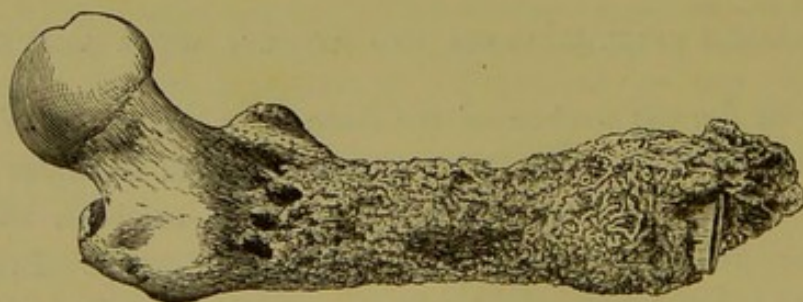


FIG. 136.—Necrosis following osteo-myelitis of the bone of a stump, for which coxo-femoral disarticulation was successfully performed by Packard five months after amputation of the thigh in the lower third. A large amount of new periosteal bone had formed.

the periosteum separates, the discharges are thin and scanty, and the soft parts retract, leaving the bone exposed, and from this the medulla projects as a grey protruding mass, which may persist or become disintegrated by suppuration, leaving the end of the bone hollowed out, and the cortical tissue dry and necrosed. Acute osteo-myelitis, being generally associated with a severe form of septic poisoning, is very fatal.

When the disease assumes the more acute form, with rigors and high temperature, it may extend as far as the articular end of the bone, and is accompanied by intense fever. The complexion becomes earthy, the skin dry, sweating fits and diarrhœa occur, the wound shows no tendency to heal, but discharges much unhealthy pus; the tissues become more and more infiltrated, fresh abscesses ensue, the extremity of the bone is surrounded by a sheath of thickened periosteum, and, if the patient survive long enough, by new bone, the shaft may project through the retracted soft parts, and sanious pus flows from the medullary cavity. Even at this stage the disease may become arrested and the necrosed portion of the shaft separated and thrown off, but more frequently a fatal result follows from blood-poisoning or exhaustion. Sometimes re-amputation has been performed to relieve the patient from the consequences of the exhausting suppuration or septicæmia. Osteo-myelitis is comparatively rare of late, since operations have been performed with antiseptic protection, and thorough surgical purity assured. It is less likely to occur after disarticulation than when the bone is divided through its cancellated extremity or shaft.

In the chronic form it may be either limited or diffused. In the first case the patient does well for a time, but the stump does not heal. It becomes fistulous, is always ready to inflame, the parts around are doughy, abscesses frequently form, and openings persist. After a time pieces of necrosed bone separate, and the patient may get well.

Adherent cicatrix.—When the cicatrix is placed over the end of the bone, the latter usually adheres to it, the skin may then become tender and prone to ulcerate. This occurrence is not uncommon if the mode of amputation be badly chosen. It is, on the whole, more frequent when the circular method is adopted.

Neuroma of stump.—In the event of neuromata forming in a stump,

the cut extremities of the nerves become bulbous—three or four times their natural size—and exquisitely sensitive. Often, great suffering, with

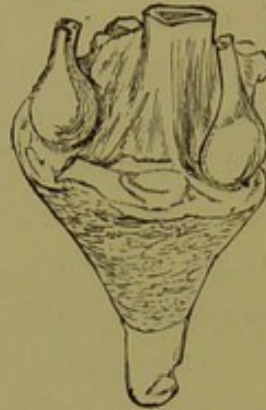

FIG. 137.—Conical stump after amputation of the arm, protrusion of the bone, and formation of neuromata on the ends of the divided nerves.

subjective sensations of pain referred to the amputated part, is thus occasioned. The diseased end of the nerve may be excised, or re-amputa-

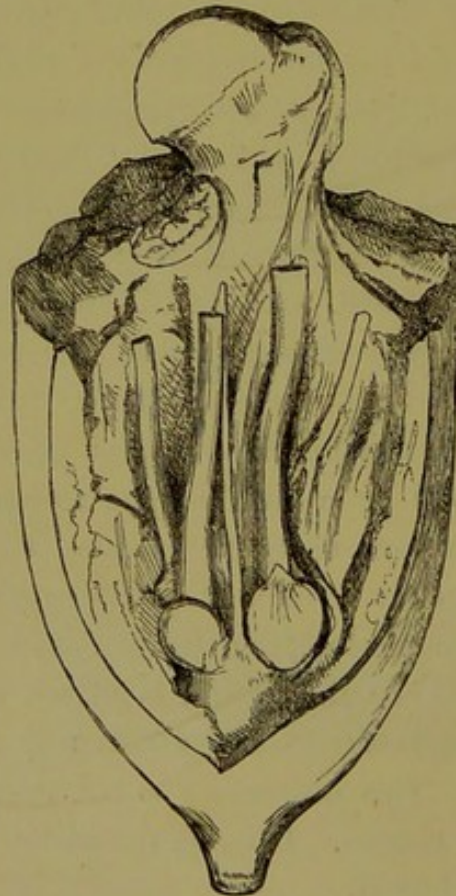


FIG. 138.—Conical stump with neuromata after amputation of the arm.

tion performed. Even then the disease is apt to recur in the cut extremities of the nerves. Neuromata have been most frequently observed in cases of amputation of the arm (Figs. 137, 138).

The influence of the weather upon a stump is always more or less observable. Some stumps become very sensitive and painful under unfavourable atmospheric conditions.

Ulceration of stump.—The stump again may ulcerate, usually from misdirected or too great pressure from without, as from an ill-fitting artificial limb, or by reason of its low vitality.

Conical stump.—A conical stump is sugar-loaf in form; the end of the bone, instead of being deeply buried in the soft parts, is at the apex of the cone, and covered either with a tense thin scar or by granulations. In some cases the bone actually protrudes. This condition may be due to excessive contraction of the soft parts, and in certain cases, as in the arm, a conical stump will be associated with the presence of neuromata. Sometimes the bone is not sawn sufficiently high, or the flaps are cut too short, which comes to much the same thing. In either case there may be great tension, with gangrene of the flaps, and the bone protrudes. Protracted healing apparently may also give rise to a cone-shaped stump.

In the lower extremity the ossifying process and growth of the limb in length are most active at the lower end of the femur and the upper end of the tibia. In the upper limb these conditions are in some respects reversed, growth is most active at the upper part of the humerus and the lower part of the forearm. The growth in a stump after amputation performed in young persons, does not keep pace with the development of the rest of the body. The bone is deprived of the stimulus which the use of the limb affords, and of the means of growth at one end, and does not, therefore, elongate in proportion to the corresponding bone in the opposite limb.

As an exception, especially after amputation of the arm, the bone sometimes appears to elongate unduly, and may even require partial removal some years after the amputation. Prolonged irritation at the end of the stump, or a want of proportion between the development of the soft parts and the growth of the bone, may account for this after amputation of the forearm and leg. The undue growth of the humerus or femur,

combined with the natural wasting of the soft parts (Fig. 139), may push the end of the divided bone against the cicatrix and by degrees produce a conical stump. Conical stump is most frequently observed after the circular method of amputation, probably because the tissues covering the bone are thinner than after the flap incision.

Much may be done, by proper dressings and extension applied to the flaps, to hinder the formation of so undesirable a kind of stump. When the condition is fully developed, a fresh portion of bone ought to be removed. To do this, make a circular incision around the end of the

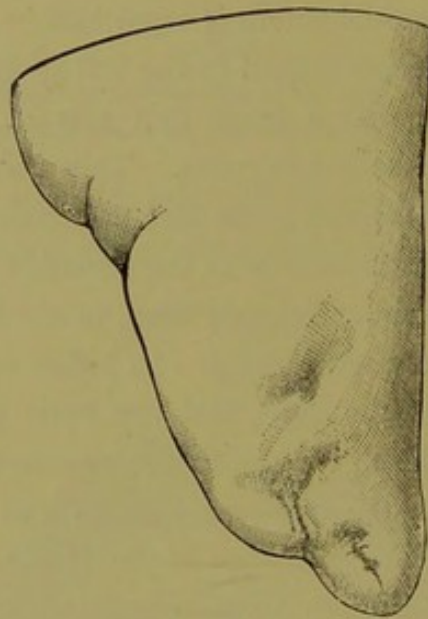


FIG. 139.—Conical stump after amputation of the thigh, due chiefly to atrophy of the soft parts.

bone, separate the soft parts with the periosteum up to the point at which the bone is to be divided. To facilitate the operation, a longitudinal incision can, if needful, be made on the side of the limb opposite the vessels, and by this means ample space will be secured. The preservation of the periosteum in connection with the surrounding soft parts abates the severity of the operation, increases the solidity of the stump, and restricts the tendency to further retraction.

Shock and collapse.—The amount of shock after amputation will vary with the cause and the magnitude of the operation. The patient suffers much more in this respect when amputation is performed for a traumatic

cause, than when the operation has been undertaken for the removal of disease, perhaps because, in the former case, the system has already been subjected to severe shock by the damage to the tissues and by the loss of blood occasioned by the original lesion. In the latter condition an operation may afford immediate relief by the removal of the diseased structures, and by substituting for them a healthy wound comparatively limited in extent.

Children and old persons suffer more from shock than adults, and women more than men. The amount of shock will also depend upon the bulk of the portion of the body which has been removed. After amputation at the hip, it is always very great, and sometimes even causes death.

The question of the best time for performing an operation is influenced by the occurrence of shock. In cases of severe railway or machinery accidents, the shock may be so great that the patient never rallies. Should sufficient reaction take place and amputation be performed, the additional shock thus sustained may occasion a fatal termination. If a limb be much mangled and the bleeding is continuing, it is better to amputate so soon as any reaction appears. Under these circumstances an anæsthetic must be cautiously and sparingly administered, especially where there has been great loss of blood. In other cases, a more complete reaction has to be awaited.

Pyæmia.—Pyæmia was formerly a common result of amputation. It has now become infrequent. It is only under very exceptional circumstances that it is likely to happen. Loss of blood, either before or after operation, overcrowding, privation, and fatigue, all predispose to the disease. In time of war, where the excessive number of the wounded may preclude antiseptic treatment being effectively carried out, and where also there are overcrowding, bad ventilation, with want of food and proper attention, an outbreak may take place at any time. It is less frequent after disarticulation than after an amputation through the continuity of the bone. During the Crimean War, in the hospital of Dolmabatche at Constantinople, out of 639 cases of amputation, 224, or more than 35 per cent., were lost through pyæmia. Amongst these the amputations in continuity gave one death in every two and a half cases, while after disarticulation only one died in four and three-quarters. Pyæmia occurs from time to time

in all hospitals, but amongst the wounded in war it has been until quite recently the principal cause of the mortality. After Sedan nearly all the fatal cases of amputation died from this cause.

Tetanus.—Tetanus is a rare complication after amputation. It seems more likely to ensue in traumatic cases which have been exposed to previous suffering and hardship, or those in which the nerves have been much torn; otherwise there is no known cause for its occurrence in one case more than another; the view that it is of bacterial origin, has of late gained considerable support.

Gangrene.—This accident may occur in the flaps as the result of the method of operation employed or because of the antecedent injury. Gangrene of a portion of the flaps may occur if they be too long, or insufficiently nourished, or if too much pressure is exerted by improperly applied dressing. It is most likely to occur in the case of the long single-flap operation, and has been unusually frequent in the long anterior flap after amputation through the knee-joint. It may occur in traumatic cases, where the skin and subcutaneous fat are often separated for a long distance from the aponeurosis and deeper structures, and, although these appear sound externally, they are in reality robbed of their vitality and unfit to employ as a covering for the stump.

Acute traumatic gangrene of a limb may occur independently of the operation from injury to the main vessels, or occasionally as the result of an acute infective process.

Lastly, epidemic gangrene may ensue in hospitals crowded with the wounded, and where sanitary precautions are inadequately attended to.

The rule for the treatment of spreading traumatic gangrene, as laid down by Larrey, has been to perform immediate amputation without waiting for a line of demarcation. It is very doubtful, however, if this be a perfectly wise or judicious practice. Gangrene, the consequence of vascular damage, generally becomes arrested, but in certain cases, as the result probably of constitutional infection, it shows no tendency to limit itself, and after amputation the disease will reappear in the stump. Should a line of demarcation show itself, amputation may be performed at once, but if the operation be carried out in the absence of this indication, gangrene will very probably invade the flaps afterwards. As a general

rule, however, it will be safe to operate, if the cause of the gangrene be purely local, but if the gangrene and its spread be due to the deteriorated state of the tissues generally, and the local injury is merely the spark which has caused the flame, an operation will scarcely improve the patient's condition. In cases of disease radiating from some septic focus, however, the only chance remaining, if matters have not gone too far, is to amputate. In gangrene of the more acute type, the propriety or otherwise of operation is always a difficult question to determine.

Contrast.—The advantage of amputation as contrasted with disarticulation is that the limb may be removed at any point, the disadvantage being that the section made through the bone may occasion hæmorrhage or necrosis, and under certain circumstances will favour the occurrence of osteo-myelitis and pyæmia. By disarticulation we may remove a limb higher up than is otherwise possible, as in the case of the shoulder- and hip-joints. On the other hand, a much longer stump may be preserved by this method, as, for instance, in disarticulation at the knee-joint compared with amputation in the lower third of the thigh. Disarticulation requires, however, larger as well as less regular flaps, often only to be formed of skin. Many tendinous sheaths have to be opened, and suppuration, followed by necrosis of the tendons, may take place. As a rule, in such cases much broader surfaces remain to sustain pressure afterwards, and the weight of the body may be more easily borne by the end of the stump.

Artificial limbs.—Various kinds of apparatus have been more or less successfully designed to take the place of the lost limb. They should, as far as possible, replace it in form and function. Pressure upon the scar must be avoided, as also interference with the circulation in the stump.

In the upper extremity an artificial hand can be constructed in which the fingers close with a spring, while they are extended by catgut cords fastened to the upper arm and shoulder. Various instruments, such as a fork, a hammer and other tools, may be fastened to the apparatus. After amputation of the forearm, the movements at the elbow-joint should be turned to account, while after amputation in the upper arm the shoulder-blade of the opposite side may be utilised for fixing the artificial limb.

In the lower extremity cases of partial amputation of the foot can be provided with an ordinary boot suitably cushioned. In the lower part of

the leg a bearing can be taken from the head of the tibia, while two lateral supports jointed at the knee extend up the thigh, the external one being attached to a pelvic girdle. In the upper third of the leg, the weight of the body is best borne on the flexed knee, and the patient can walk very firmly on a peg leg. After amputation of the thigh, the body has to be supported from the pelvis, principally by the tuberosity of the ischium. The patient sits as it were upon the apparatus. When the stump is long, the instrument can have a movable knee-joint, and further be provided with a foot, which is articulated at the ankle. As a rule, however, the simplest form of artificial limb is the most useful.

Mortality.—It is well ascertained that amputations performed for disease are much less fatal to life than those performed on account of injury.

In cases of injury, the superadded amputation causes an additional shock to the system. In cases of disease, the source of the exhaustion and irritation is often removed by amputation, and a lesser evil substituted for a much greater one. The extent of wounded surface in a limb amputated for disease where the muscles and other tissues are wasted is comparatively small, and the amount of suppuration and traumatic fever will usually be less than where the parts are in a state of full muscular development, and abundantly provided with cellular tissue and fat.

Fenwick has collected the following statistics :—

Amputations for Disease.

	CASES.	DEATHS.	MORTALITY PER CENT.
Of the Thigh	313	124	39·61
Of the Leg	193	75	38·86

Amputations for Injury.

	CASES.	DEATHS.	MORTALITY PER CENT.
Of the Thigh	174	117	67·24
Of the Leg	193	100	50·18

Age has an important influence on the results of amputation. The comparatively young, say from five to fifteen, bear it best. At an age below that, amputation is not so well borne. From fifteen to twenty the mortality increases, as also from twenty to thirty-five ; but between twenty and fifty the variation is small. From fifty to sixty-five the mortality notably increases. Statistics appear to show that amputation is less fatal in women than men.

The nearer the trunk, the greater, *cæteris paribus*, becomes the danger. "Zollweise stiegt die Gefahr." Legouest has prepared the following table as giving an approximate scale of the comparative gravity of the different forms of amputation :—

	PER CENT.
Fingers and Metacarpals	13
Toes	18'9
Tibio-tarsal Disarticulation	23'2
Wrist	35
Metatarsus and Partial Foot Operations	38
Forearm	41'1
Arm	47'7
Disarticulation of Shoulder	59'5
Disarticulation of the Elbow	48
Leg	49'9
Thigh	74
Disarticulation of the Knee	87
Hip-joint	87'7

This scale shows a very high death-rate. It is interesting and instructive as showing the results obtained by a former generation of surgeons. It is constructed from data afforded by older and much less successful practice than we are now accustomed to, and the general range of mortality is also much higher, I think, than that which ever obtained in this country. But the comparative rate of mortality probably holds good. Disarticulation of the elbow and of the knee form two exceptions to the regularity of the scale. Operations in the upper limb are less fatal than those in a corresponding part of the lower, one reason, doubtless, being the smaller size of the parts.

In the upper limb the comparative mortality is pretty nearly in the following order:—

Amputations of the Hand 1	Amputations of the Arm 4
" " Forearm 3	" " Shoulder 7

In the lower it may be stated thus:—

Partial Amputation of the Foot 1	Amputations at the Knee 5
Amputations at the Ankle-joint 2	" of the Thigh 5
" of the Leg 3	" at the Hip 10

Fischer has calculated the mortality after amputations in time of war, from the statistics of the more recent European campaigns, as follows:—

	PER CENT.
Thigh	82·6
Knee	68·0
Leg	61·3
Foot	46·7
Shoulder	62·8
Arm	37·4
Elbow	24·0
Forearm	21·2
Wrist	42·0

Schede has compiled a table of 321 cases occurring in civil practice of amputations performed antiseptically, attended by a mortality of only 4·4 per cent; while in 387 cases of amputation of equal importance treated during the pre-antiseptic period, the mortality, which was due chiefly to pyæmia, was 29·18 per cent.

The following results are taken from the Reports of St. Thomas's Hospital for the ten years 1876–1885 inclusive.

Primary Amputations for Injury.

	CASES.	DEATHS.	PERCENTAGE.
Upper Extremity	142	3	2·11
Lower Extremity	132	32	24·24
Totals	274	35	12·77

Secondary Amputations for Injury.

	CASES.	DEATHS.	PERCENTAGE.
Upper Extremity . . .	22	5	22'72
Lower Extremity . . .	44	11	25'00
Totals	66	16	24'24

Amputations for Disease.

	CASES.	DEATHS.	PERCENTAGE.
Upper Extremity . . .	83	2	2'4
Lower Extremity . . .	255	34	13'33
Totals	338	36	10'65

Total for all kinds of
amputation 678 ... 87 ... 12'8

These last tables probably represent a fair average of the results attained in the London Hospitals.

SPECIAL FORMS OF AMPUTATION.

AMPUTATIONS AND DISARTICULATIONS IN THE LOWER EXTREMITY.

AMPUTATION OF THE TOES.

Indications.—Frequent sources for these operations are contused and lacerated wounds, strumous disease of the bone, and frost-bite.

A toe may be the subject of whitlow, and so damaged as to require amputation. The bursa over the great toe sometimes inflames, and as it often communicates with the metatarso-phalangeal joint, serious mischief may be set up therein, leading to excision or amputation.

A number of cases occur in which the second toe projects very much upwards, with extreme flexion of the second joint and complete extension of the first, or so called hammer toe. In some others the toe is drawn under the sole of the foot. Either condition renders walking painful and difficult, and may require for its relief amputation of the affected toe.

Surgical Anatomy.—The metatarso-phalangeal articulations are placed somewhat behind the line of the webs of the toes. There are two small digital arteries for each toe. The plantar fascia is partially attached to the thick pad beneath the line of the articulations, and should not be interfered with if possible.

Instruments.—The best instrument is the so-called finger-knife, a straight narrow-bladed bistoury (Fig. 140), or a scalpel. If the head of the metatarsal bone be removed, a cutting forceps will be also needed.

Assistants.—An assistant will be required to compress the tibial arteries behind the internal malleolus and in front of the ankle-joint with the fingers of one hand, the other hand being free ; or Esmarch's apparatus may be applied. Adjacent toes must be held aside so as to be out of the operator's way, while he himself grasps the part to be removed with the fingers of his left hand.

In performing the disarticulation of a toe, the covering for the end of

the bone should always be obtained if possible from the plantar surface of the foot.

DISARTICULATION OF THE UNGUAL PHALANGES.

The operator stands facing the patient, and seeks the line of the joint between the two phalanges, which usually corresponds to the deepest furrow on the dorsal surface. The phalanx being completely extended, the knife is held like a violin bow (Fig. 140), and an incision should be made to cut right down to the bone, immediately below the dorsal line of the joint. This

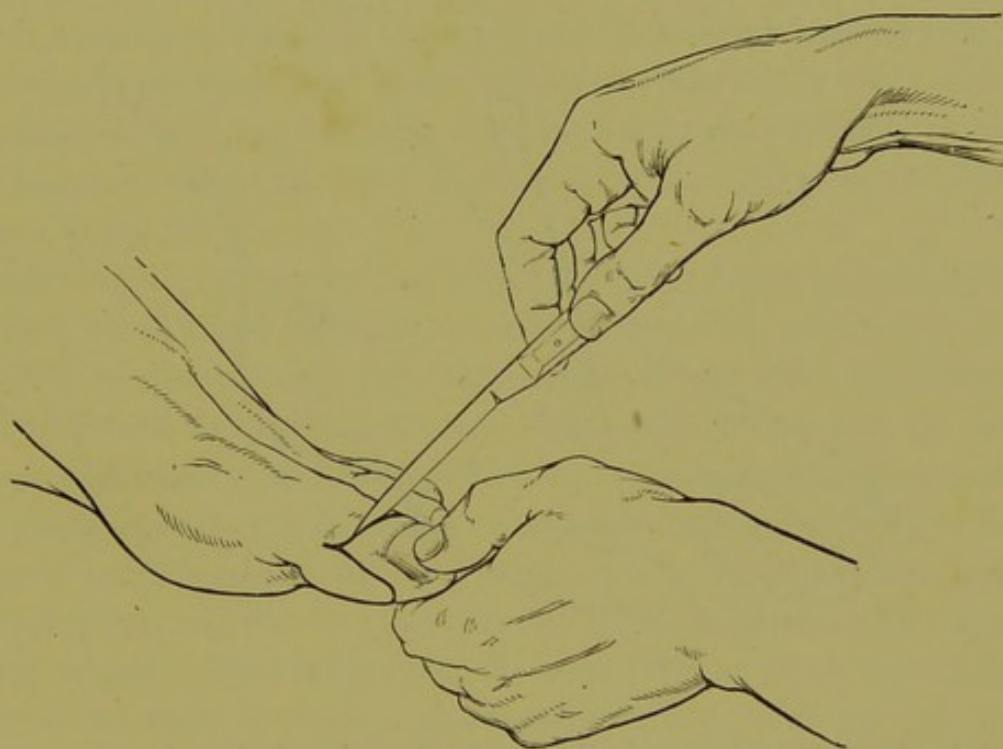

FIG. 140.—Disarticulation of the unguis phalanx of the great toe. Lines of incision and method of forming the dorsal flap in amputation of the unguis phalanx.

incision ought to be slightly curvilinear, the convexity being downwards. If the toe be bent the wound will gape, and in the return movement of the knife the lateral ligaments and capsule of the joint should be divided and the articulation fully laid open. The knife is now placed horizontally behind the joint, the phalanx again extended, and a flap formed from the plantar surface three-quarters of an inch long, cutting from within outwards with a to-and-fro movement of the knife. Care should be taken to round the end of the flap when terminating the incision, the knife being held

horizontally when making the central portion of the flap, and cutting vertically downwards when completing it, otherwise the thickened epidermis will be divided obliquely. To avoid this, in the case of the great toe, it will be better to mark out the form of the plantar flap by a preliminary incision. The digital arteries may now be secured, although this is not always necessary, and the flaps brought together; the line of junction will be on the dorsal aspect, and well removed from pressure. As a rule it is much better not to remove the articular surface of the bone

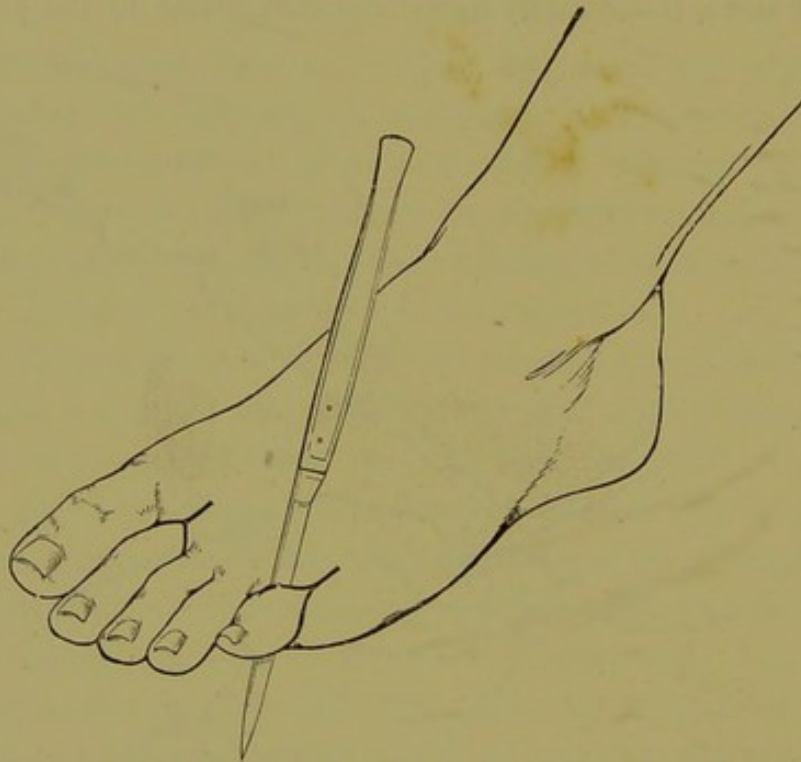


FIG. 141.—Manner of removing the little toe by the oval method, at the metatarso-phalangeal joint. Any of the other toes may be amputated after a similar fashion.

unless it be diseased or have received injury. Healing takes place just as rapidly, and an increased length of stump is preserved—matters of the greatest moment both in the hand and foot.

DISARTICULATION AT THE JOINT BETWEEN THE FIRST AND SECOND
PHALANX OF THE FOUR OUTER TOES.

Disarticulation at this joint is performed with a plantar flap, in exactly the same manner as at the unguis phalanx of the great toe. In cases where the injury or disease requires it, one or two lateral flaps may be made, but this is not so good a method.

DISARTICULATION OF THE TOES AT THE METATARSO-PHALANGEAL JOINT.

For the four lesser toes the oval incision is the one commonly employed, the pointed extremity being on the dorsal surface (Fig. 141). With the finger and thumb of the left hand the position of the joint ought to be distinctly made out. The knife, held in the manner before described, should be introduced over the centre of the dorsal aspect of the joint, then carried round to the plantar aspect of the toe, about three lines below the plantar fold, and then upwards upon the other side to the point of commencement. The lateral branches of the incision should be slightly convex downwards, otherwise there will not be sufficient soft covering for the comparatively large head of the metatarsal bone, and in the case of the great and little toes, the flap away from the contiguous toe should be somewhat longer, to ensure the position of the cicatrix as far from the line of pressure as possible.

In making the plantar incision round the toe it should be held forcibly extended, which brings the web between the toes into prominence ; this must on no account be cut into, the incision being made well below it. The lateral ligaments and capsule may now be divided, as also the flexor and extensor tendons, and the toe removed. Care should be taken to keep close to the bone, as otherwise the contiguous joint on either side is in danger of being opened. After the arteries are secured the parts can be sufficiently held together by approximating the adjacent toes with a strip of sticking plaster. This being done, the wound will assume a vertical form, the lower extremity of which is well beyond the margin of the sole. The subsequent contraction of the cicatrix removes it from the line of pressure.

It is very important when practicable not to remove the head of the metatarsal bone, for by so doing the transverse arch of the foot is weakened and the subsequent power of progression impaired.

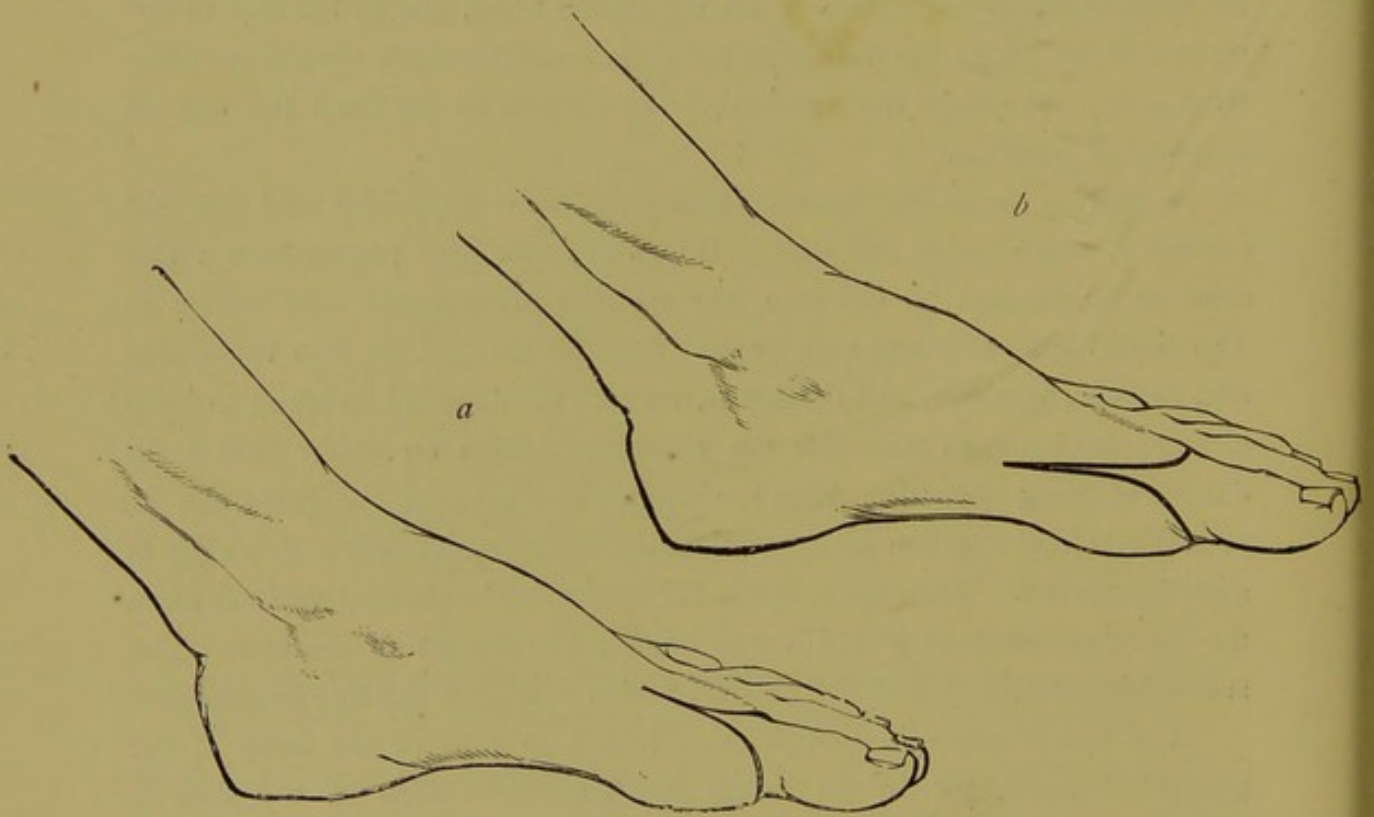DISARTICULATION OF THE GREAT TOE AT THE METATARSO-PHALANGEAL JOINT.

The incision in this case is commenced on either the dorsal or lateral aspect, and the flap must be made proportionately large, as the head of the first metatarsal bone is of great size. The incision is to be brought round about a quarter of an inch below the ball of the toe, and the operation is completed by carrying the knife around the inner side of the base of the toe,

till it joins the first incision, and then disarticulating. We must avoid, if possible, removing the large articular head of the metatarsal bone, as its removal seriously impairs the capacity of the foot to bear the weight of the body (Fig. 142 *a*).

DISARTICULATION OF THE GREAT TOE AND METATARSAL BONE AT THE JOINT BETWEEN THE LATTER AND THE INTERNAL CUNEIFORM BONE.

The position of the operator is the same. An assistant draws the other toes outwards, and the operator holds the great toe in his left hand. The position of the joint must be carefully discriminated, the guide being the tuberosity on the first metatarsal bone. An incision should be



FIGS. 142 *a* & *b*.—Lines of incision for amputation of the great toe at the metatarsophalangeal joint, and of the toe together with its metatarsal bone.

made downwards from the joint on the centre of the dorsal surface of the metatarsal bone, or on its internal surface. Passing underneath along the margin of the sole of the foot, it is then carried upwards to join the first made incision at a very acute angle (Fig. 142 *b*). The toe being now held forcibly up, the soft parts are to be detached from the lateral and plantar aspects of the metatarsal bone, leaving the sesamoid bones behind, if not diseased. The shaft of the bone must now be cleared, the origin of the

first dorsal interosseous muscle separated and the bone drawn forcibly inwards, and then a few touches of the knife will readily sever the attachments of the peroneus longus, tibialis anticus, and ligaments from the base of the bone. In cases where the sesamoid bones are removed, it is necessary to cut the tendons of the flexor brevis, abductor and adductor hallucis muscles as well. The first dorsal interosseous artery will require ligature, and the wound, when drawn together, should assume a linear form. The objects aimed at in this operation should be to avoid having the cicatrix in the sole of the foot, and to preserve as far as possible the thick pad of the great toe.

DISARTICULATION OF THE FIFTH TOE TOGETHER WITH ITS METATARSAL BONE.

This operation is performed in a similar manner to that on the great toe

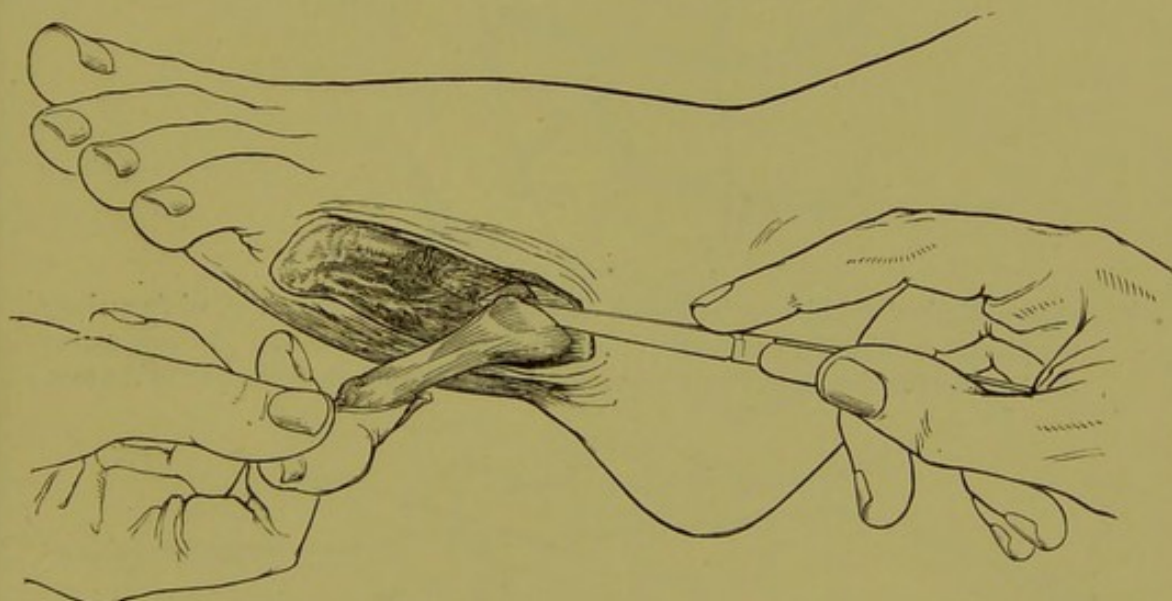


FIG. 143.—Disarticulation of the little toe together with its metatarsal bone.

the soft parts being somewhat more difficult to detach, especially around the projecting portion of the base of the metatarsal bone.

DISARTICULATION OF ALL THE TOES AT THE METATARSO-PHALANGEAL JOINTS.

This operation has been frequently performed on account of frost-bite. In order to obtain sufficient covering for the heads of the metatarsal bones, a dorsal as well as plantar covering will be required. The plantar incision should be first made while the toes are forcibly dorsally flexed with the left hand (Fig. 144), beginning in the left foot at the base of the great toe,

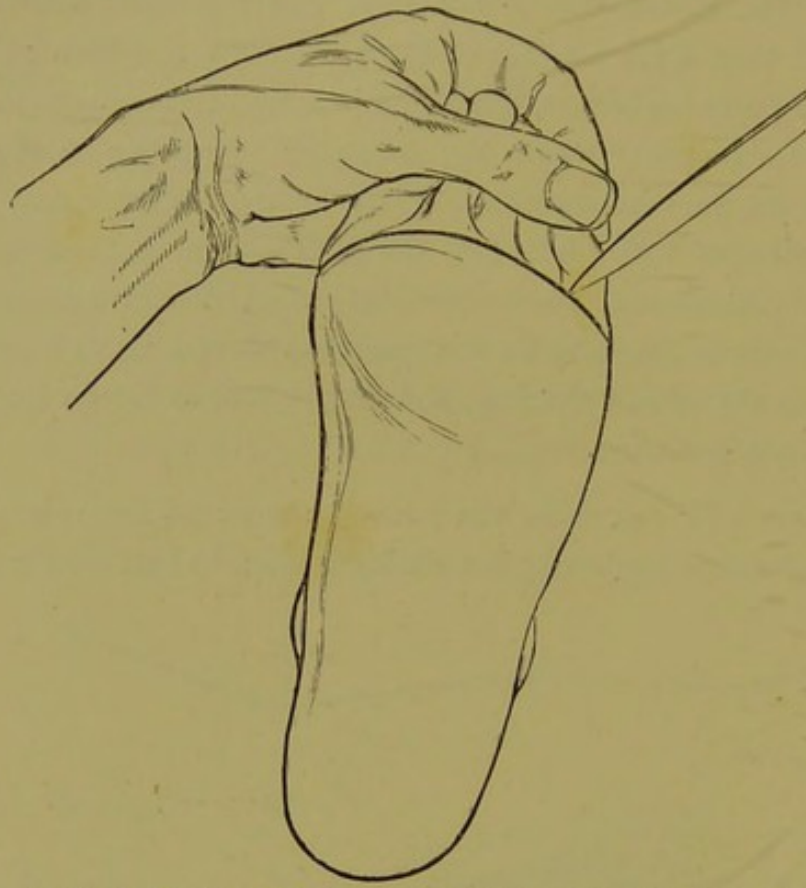


FIG. 144.—Method of holding the foot in amputation of all the toes, or while making the plantar incision for amputation through the metatarsal bones. In amputating the toes the incision should pass lower down along the centre of the web of the toes.

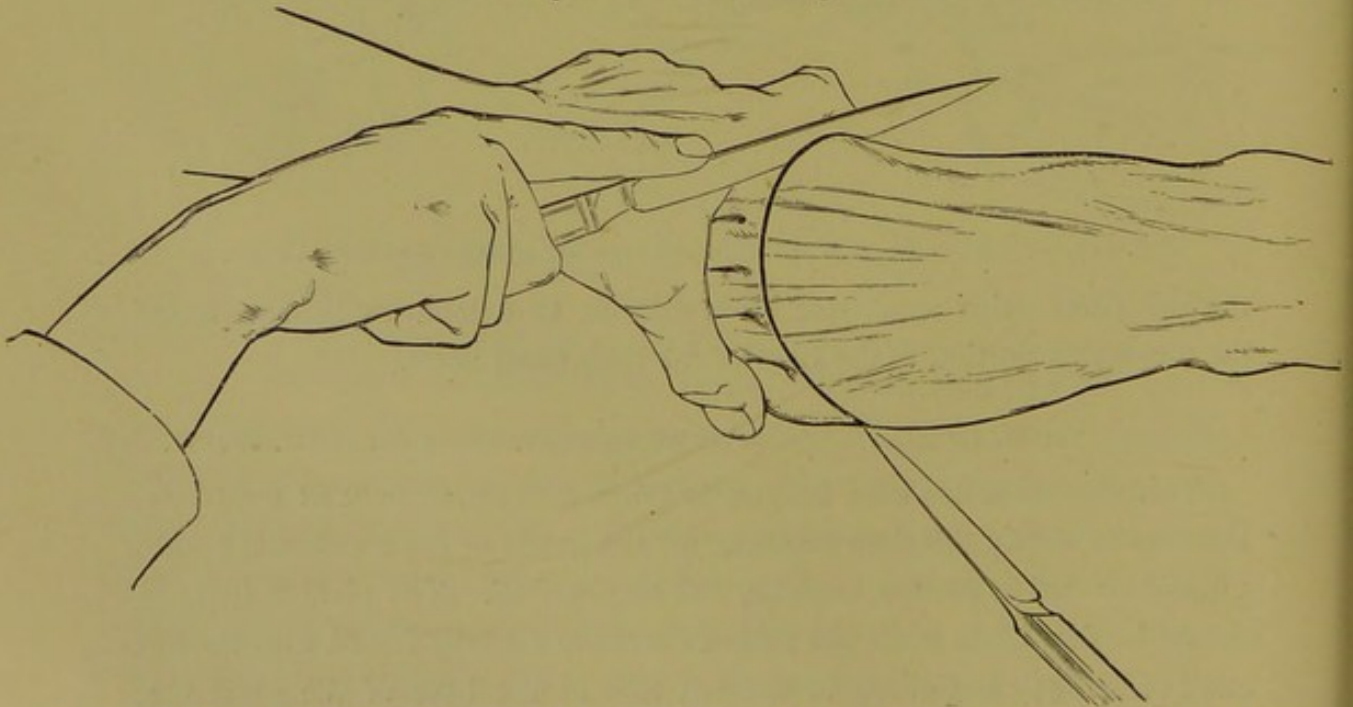


FIG. 145.—Formation of dorsal incision in amputation of all the toes, or in the continuity of the metatarsal bone. For the first-named operation the incision must be made a little lower down.

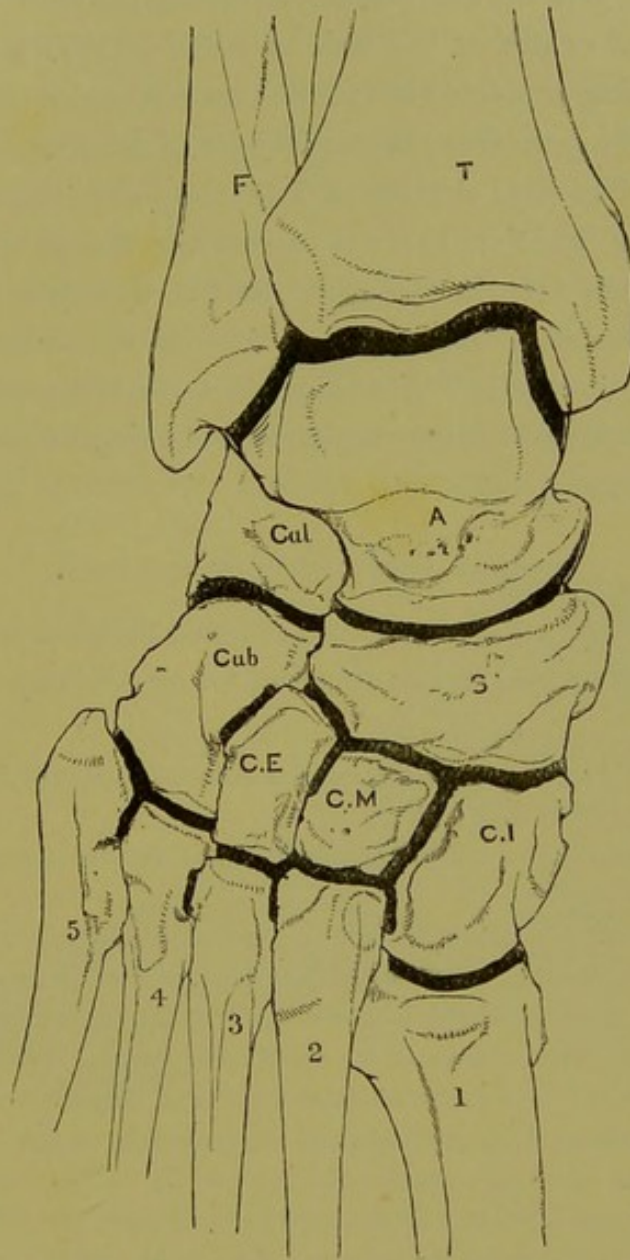


FIG. 146.—Synovial membranes of the foot.

The synovial cavities of the ankle and tarsal joints are eight in number.

The *first* lines the under surface of the inferior extremity of the tibia and the articular surfaces of the malleoli of both tibia and fibula above, and the corresponding articular surfaces of the astragalus below.

The *second* (not shown in the sketch) lines the posterior articular surfaces of the astragalus and calcis behind the interosseous ligament.

The *third* lines the contiguous surfaces of the anterior part of the astragalus and its head, the posterior concave surface of the scaphoid, as well as the upper surface of the

and on the right side at the metatarso-phalangeal joint of the little toe, cutting along the centre of the web so as to include it in the flap—the adjacent toes being separated in order to do this—and terminating the incision opposite the metatarso-phalangeal joint of the great or little toe. The dorsal incision (Fig. 145) consists of little more than the act of uniting the incisions, already made in the web, across the dorsal surface of each of the toes, which may then, in succession, be disarticulated. The margins of the flaps are somewhat irregular, but will be found fairly sufficient to cover the articular surfaces. If at any point the soft covering be scanty, the head of the corresponding metatarsal bone may be removed with the cutting bone-forceps.

PARTIAL AMPUTATIONS OF THE FOOT.

Instruments.—A very strong scalpel-shaped knife, four to five inches long, a saw, and the other instruments required for an ordinary amputation.

calcaneo-scaphoid ligament and the anterior articular surface of the calcis, in front of the interosseous ligament.

The *fourth* lines the anterior surface of the os calcis and the posterior surface of the cuboid bone.

The *fifth* lines the front part of the scaphoid bone, and the posterior surfaces of the three cuneiform bones, sending two prolongations forwards: of these one passes between the contiguous surfaces of the external and middle cuneiforms, the other passes between the contiguous surfaces of the middle and internal cuneiforms, and expands in front so as to line the anterior articular surfaces of the middle and external cuneiform bones, sending short prolongations on each side of the base of the second metatarsal bone.

The *sixth* synovial space intervenes between the external cuneiform and the cuboid.

The *seventh* lies between the anterior surface of the cuboid and the posterior surfaces of the fourth and fifth metatarsal bones, sending a prolongation between the latter bones.

The *eighth* lines the anterior surface of the internal cuneiform and posterior surface of the first metatarsal bone.

From this it will be apparent that disease affecting the bones on the outer side of the foot is much more likely to remain limited than when it occurs on the inner side. Disease, in point of fact, is often confined for a long period to the cuboid or os calcis and the treatment will have to be modified accordingly. Disease affecting the scaphoid bone or one of the cuneiform bones or the bases of the second or third metatarsal bones, will not remain limited, but spread to the whole of the anterior and inner portions of the tarsus, and in a short time destroy the integrity of the foot.

Indications.—In all amputations of the foot, the covering of the stump should mainly consist of the soft parts taken from the sole of the foot. They are thicker, better adapted for the purposes of progression, while the subsequent cicatrix is removed from the line of pressure. In order to define precisely the margins of the large plantar flap it is preferable, as a preliminary step, to map it out by a deep incision, made from without inwards, the flap being completed at a subsequent stage of the operation by cutting from within outwards, when the edge of the knife will thus readily emerge through the previously made groove. The plantar flap may also be dissected up throughout. The greater thickness of the internal margin of the foot should always be allowed for, and the flap made proportionately longer on this side.

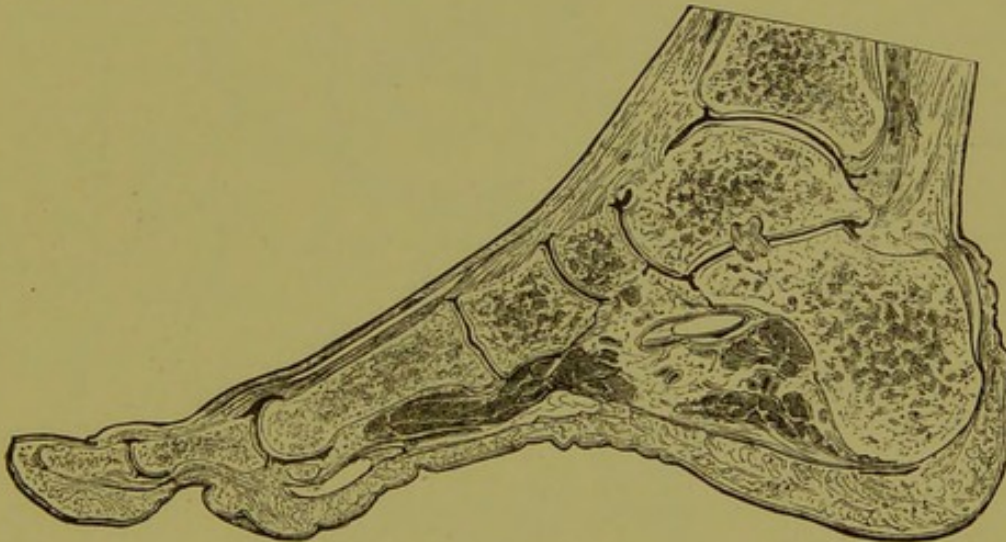


FIG. 147.—Sagittal section through the foot. The section runs through the os calcis, astragalus, scaphoid, and the internal cuneiform bones, the first metatarsal bone and its phalanges.

AMPUTATION THROUGH THE METATARSUS.

Occasionally, amputation may be practised through the continuity of the metatarsal bones. After extending the toes, make an incision, across the sole, sufficiently convex downwards, and terminating on each side at the point where the bones are to be divided. When the plantar flap is dissected up to the needful distance, a transverse incision should be made across the dorsum, half an inch lower than the point of section of the bones, to allow for the retractility of the skin (Figs. 144, 145). The tendons and

muscular tissue are now divided, as also the interosseous muscles, with a narrow-bladed knife; and, finally, the bones—one metatarsal bone after another—are cut through at the same distance from their extremities, so that

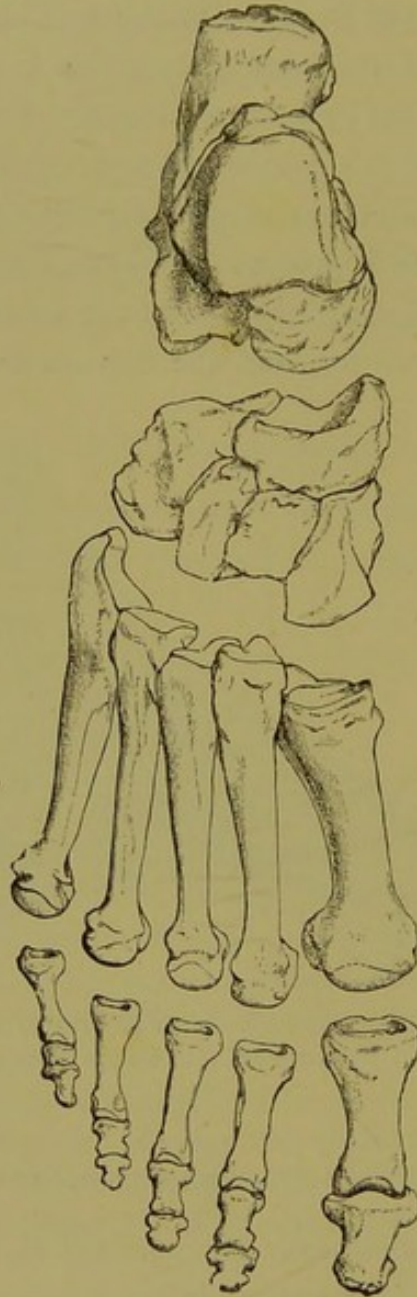


FIG. 148.—Showing the intervals between the bones where the chief operations on the foot are performed—viz., amputation of all the toes, the tarso-metatarsal or Lisfranc's amputation, and the medio-tarsal amputation or that of Chopart.

the stump will be longer on the inner than the outer side, and assume in this respect somewhat the same form as the normal foot.

DISARTICULATION BETWEEN THE TARSUS AND METATARSUS—LISFRANC'S
AMPUTATION.

Indications.—Injury or disease of the metatarsal bones. The operation has been objected to as being likely to be followed by a condition resembling pes-equinus, but this may be prevented by supporting the stump during healing with a posterior splint.

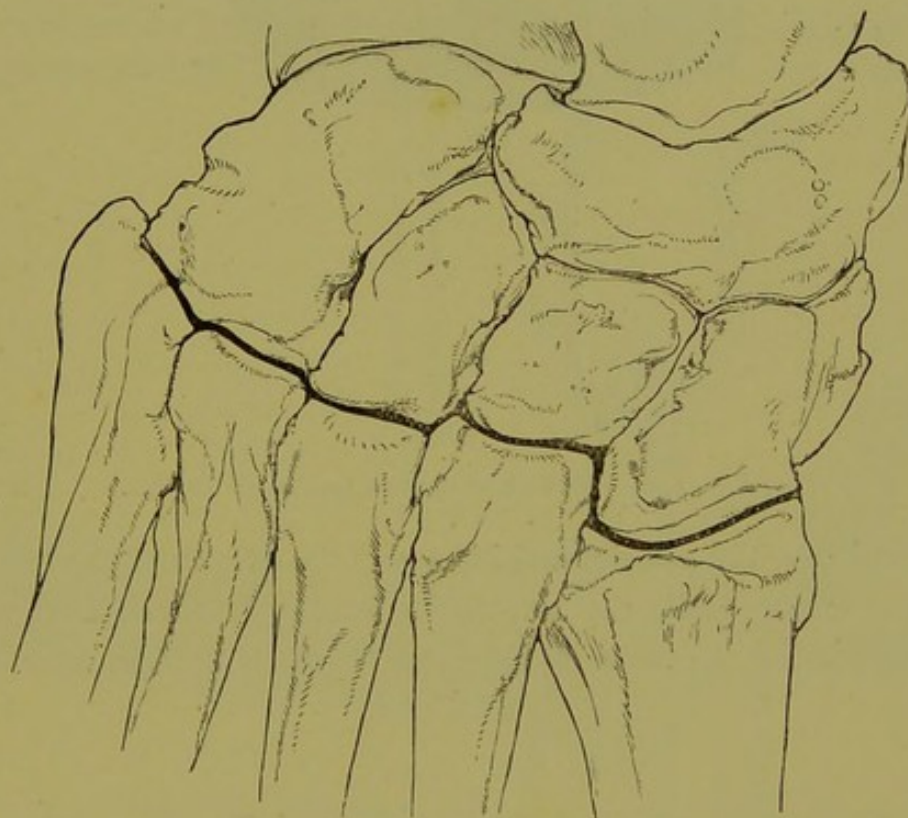


FIG. 149.—Drawing to show the direction of the tarso-metatarsal joint of the right foot.

Surgical anatomy and guides.—In general direction the tarso-metatarsal joint runs obliquely across the foot from just behind the tuberosity of the first metatarsal bone to the prominent tip of the base of the fifth metatarsal. There is one notable irregularity in the otherwise uniform line of the joint. This consists in the manner in which the second metatarsal bone projects backwards between the cuneiform bones (Fig. 149). After opening these joints the disarticulation may be completed with comparative ease.

In Fig. 150 the relation of the various structures divided, and the position of the vessels requiring ligature, is clearly indicated.

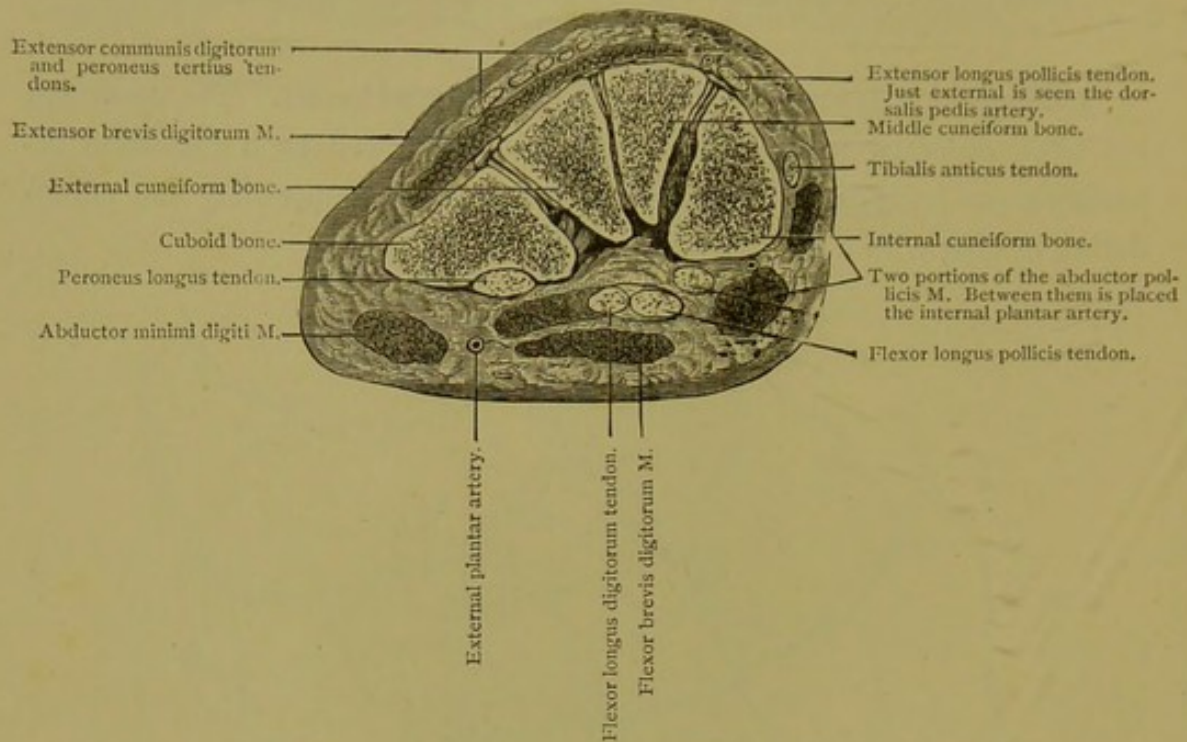


FIG. 150.—Median transverse section of the foot.

Operation.—The anterior incision across the dorsum of the foot should begin and end opposite the articulation of the first metatarsal with the internal cuneiform on the inner side, and the tip of the fifth metatarsal on

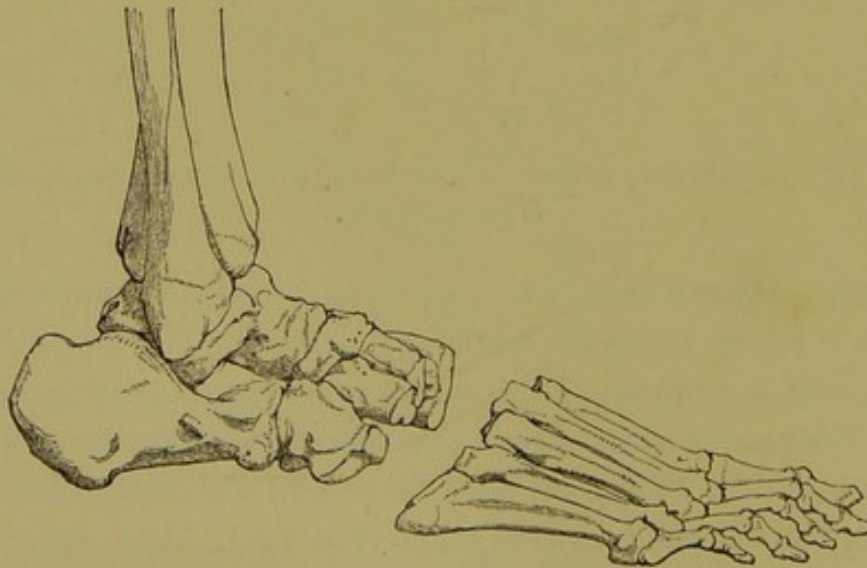


FIG. 151.—Diagram showing the tarso-metatarsal joint (Lisfranc's operation).

the outer side. These two points should be carefully determined beforehand. The foot to be amputated should be firmly held on its plantar surface with the left hand of the operator, the tip of the forefinger and thumb being used to indicate the commencement and ending of the joint (Fig. 152). The knife should be carried obliquely across the dorsum of the foot about a quarter of an inch below the line of the articulation, to allow for retraction. The skin, with the subcutaneous tissue, being cut through in the first sweep of the knife, an assistant should draw them upwards, and then the tendons and ligamentous structures are divided in a position precisely corresponding with the articular line. These incisions are commenced

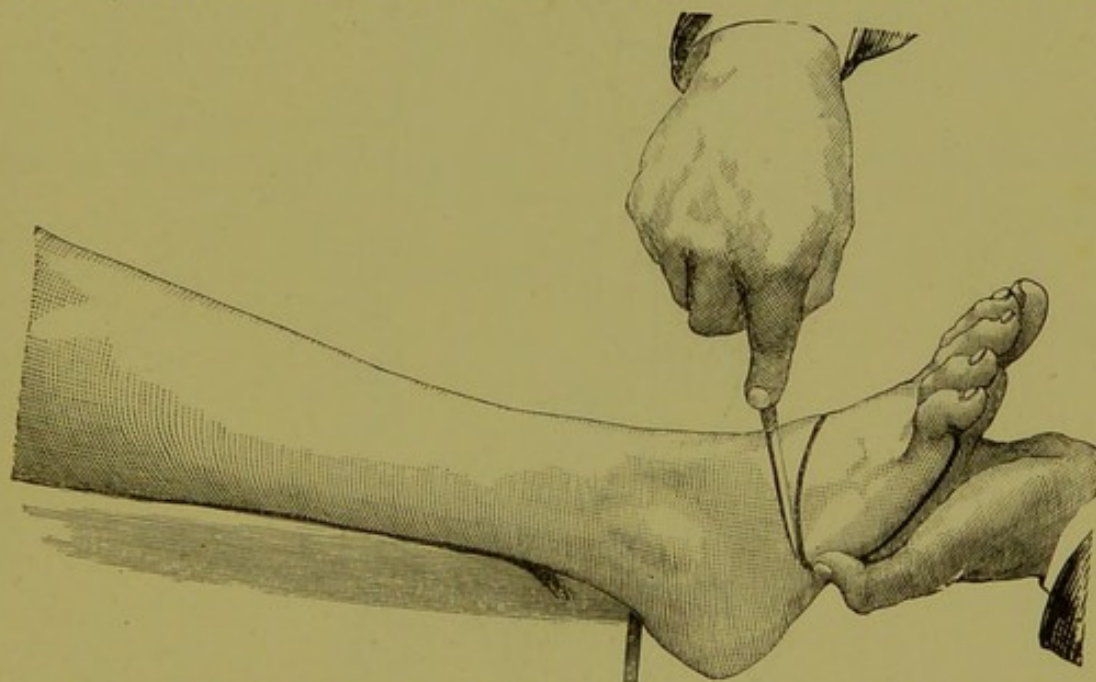


FIG. 152.—Manner of holding the foot and line of incision made in Hey's and Lisfranc's amputations.

at the inner border of the left foot, and the outer of the right foot (Fig. 152). The joints are now opened in succession, commencing in the left foot with that of the first metatarsal and internal cuneiform, then by introducing the knife on each side with the edge towards the ankle, nearly vertically, but inclining the point towards the centre of the sole, the projecting extremity of the second metatarsal is separated from its lateral connections (Fig. 154). A transverse cut, a quarter of an inch higher than the other joints, will divide the dorsal ligament connecting the second metatarsal with the middle cuneiform, and then the three remaining metatarsal bones

may be separated from the cuboid by dividing the ligamentous connections along the oblique line of the articulation. On the right foot the operation is easier, the three outer metatarsals being first readily separated, and the

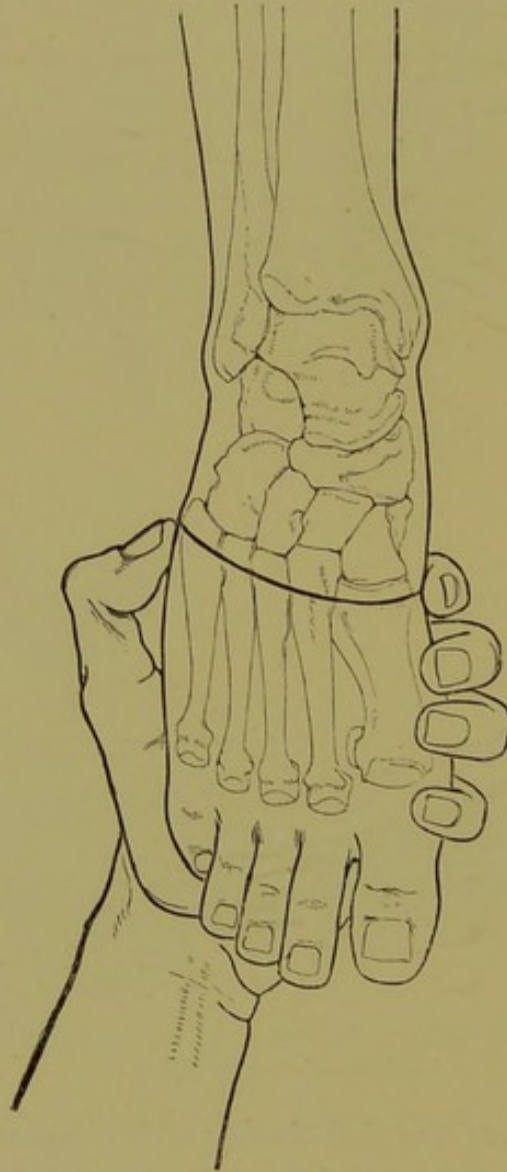


FIG. 153.—Method of holding the foot, and line of the dorsal incision, in Lisfranc's operation.

joints of the second metatarsal are afterwards more easily found. During this part of the operation the anterior portion of the foot should be depressed.

It is best as a first step to make a longitudinal incision about an inch long on the inner and outer side of the joint. This will better define the terminations of the flaps, and considerably facilitate the opening of the joint between the first metatarsal bone and internal

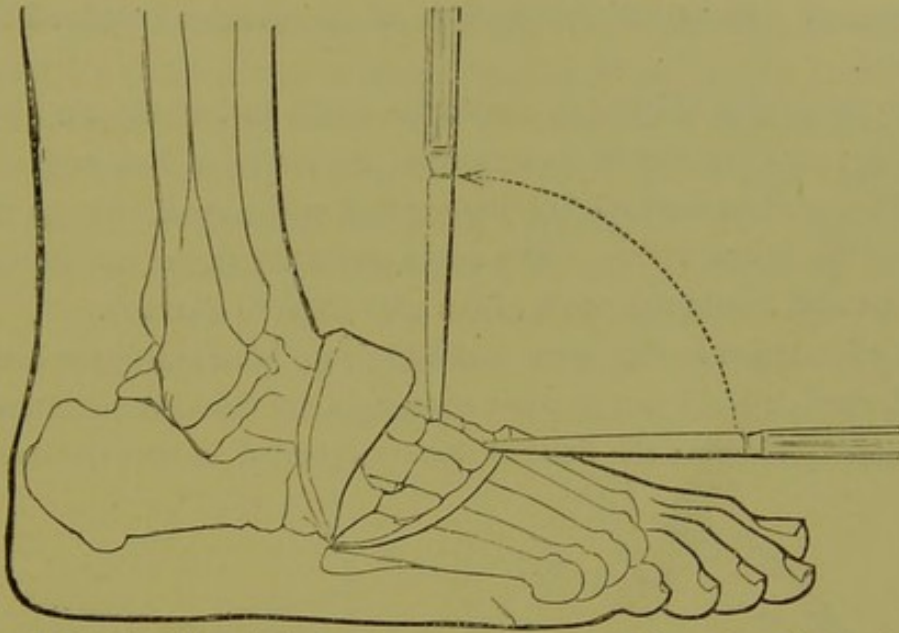


FIG. 154.—Method of disarticulating the second metatarsal bone from its attachments to the internal and external cuneiform bones. Diagrammatic.

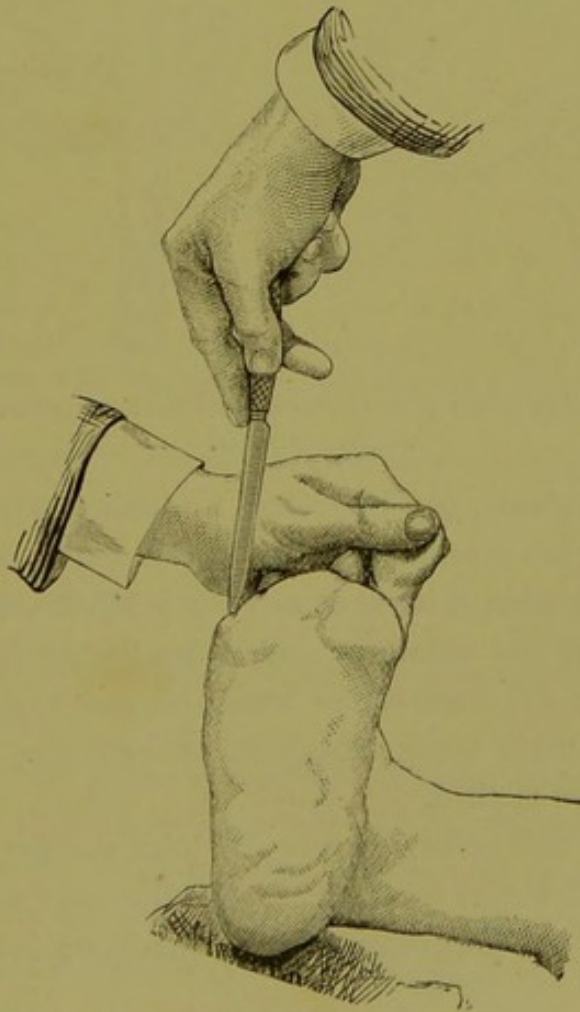


FIG. 155.—Formation of the plantar flap in Lisfranc's amputation.

cuneiform, as well as the enucleation of the proximal end of the fifth metatarsal.

The plantar flap (Fig. 155) should be made to include the whole sole of the foot; and in order to do this more accurately, a deep groove should be cut from without inwards, holding the foot well upwards by the toes and extending the lateral incisions first made along the inner and outer margins of the foot and across the bases of the toes close to the web.

The articulation having been now laid open, seize the upper part of the foot with the left hand and depress it strongly, cut through the interosseous and plantar ligaments; the knife is then introduced behind the metatarsus

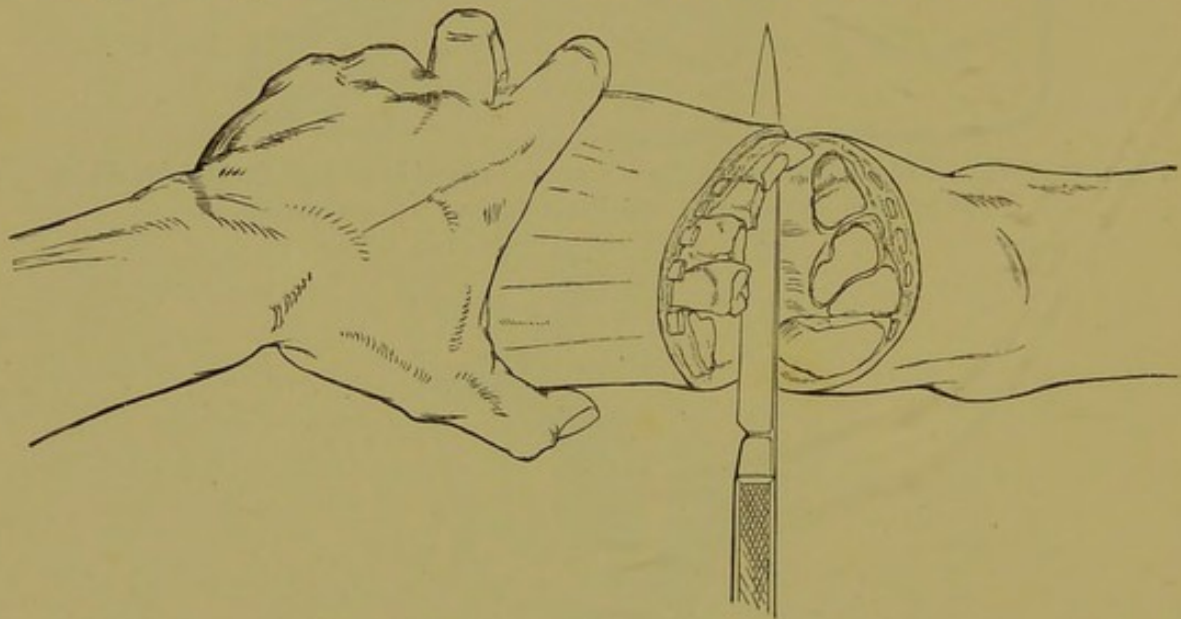


FIG. 156.—Formation of the plantar flap in Lisfranc's operation by cutting from within outwards.

(Fig. 156), and the plantar flap completed by cutting from within outwards. If it be preferred, however, the flap, as before stated, may be formed by cutting wholly from without inwards, and this is much the better plan.

After the plantar and metatarsal arteries are ligatured, the long plantar flap is turned over the ends of the bones, sutured to the short anterior flap, and drainage tubes being introduced at the angles, the dressings and a posterior splint are applied.

A flap made in this manner covers the joint surfaces without tension. It is at least an inch longer on the inner than the outer side, which is quite necessary to cover the projecting internal cuneiform bone. Hey advises

that this should be sawn off, an unnecessary and undesirable procedure, as it has the great disadvantage of shortening by so much the inner side of the foot and interfering somewhat with the insertion of the tibial tendons.

This operation has been seriously objected to, because the unrestrained action of the tendo-Achillis, constantly drawing the heel upwards, may bring the cicatrix into the line of pressure, and render the stump painful or useless. This, however, can be obviated during the after treatment by the use of a posterior splint. The division of the tendo-Achillis is sometimes recommended; but this I regard of little use, as it speedily reunites

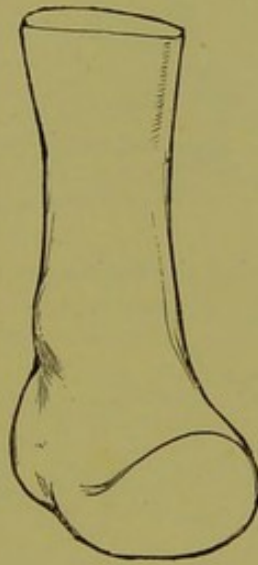

FIG. 157.—Stump resulting from Lisfranc's amputation. From a cast. The patient could walk long distances with ease and comfort.

again. In my experience, the stump, after this operation, is at once well formed and useful (Fig. 157).

AMPUTATION THROUGH THE MEDIO-TARSAL JOINT—CHOPART'S AMPUTATION.

Indications.—The indications for this operation are similar to those for the one last described.

Surgical anatomy.—The disarticulation is made between the scaphoid and cuboid bones in front, and the head of the astragalus and os calcis behind (Fig. 148). On the inner side the joint is situated immediately behind the tuberosity of the scaphoid; on the outer side it lies rather less than an inch behind the tuberosity of the fifth metatarsal bone.

Operation.—The foot is held and the flaps are made in a similar way to those for Lisfranc's amputation. The plantar flap, however, must be

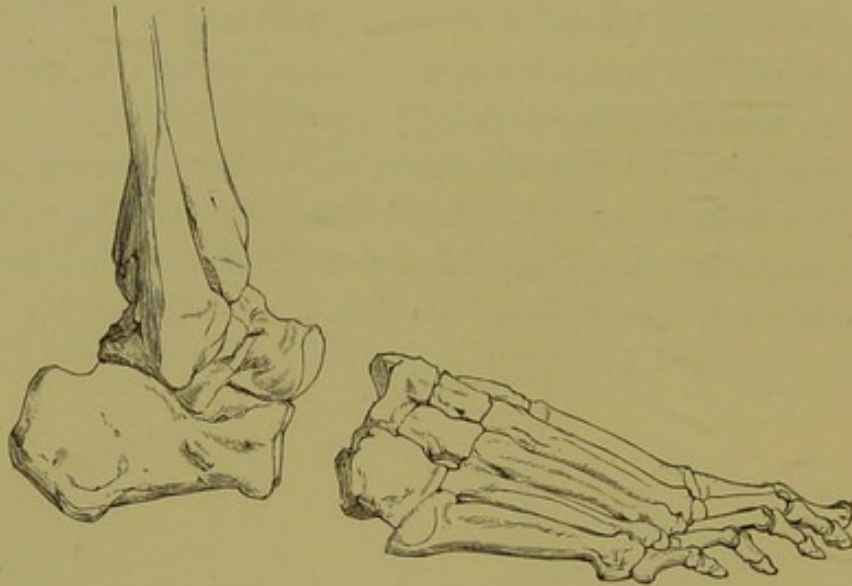


FIG. 158.—The mid-tarsal joint, the position at which Chopart's amputation is performed.

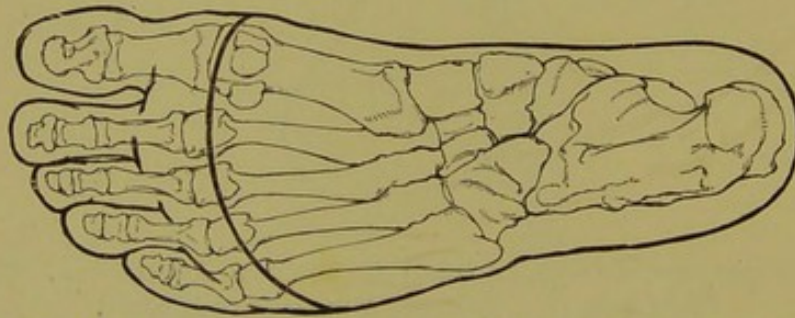


FIG. 159.—The line of the base of the plantar flap in Chopart's amputation

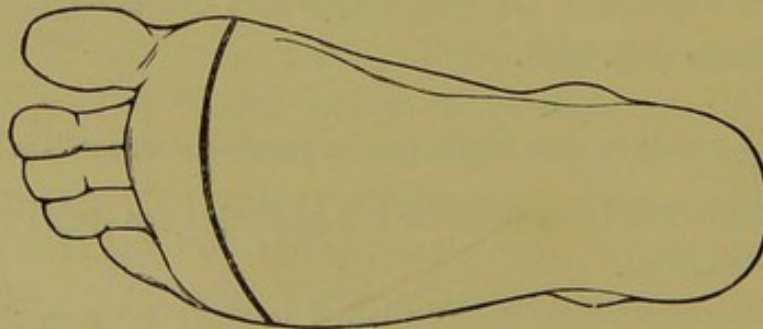


FIG. 160.—Plantar incision in Chopart's amputation.

one inch shorter, taking care that its inner margin shall be nearly an inch longer than the outer. In other words, make the incision parallel to the bases of the toes, thus crossing the sole obliquely and not transversely.

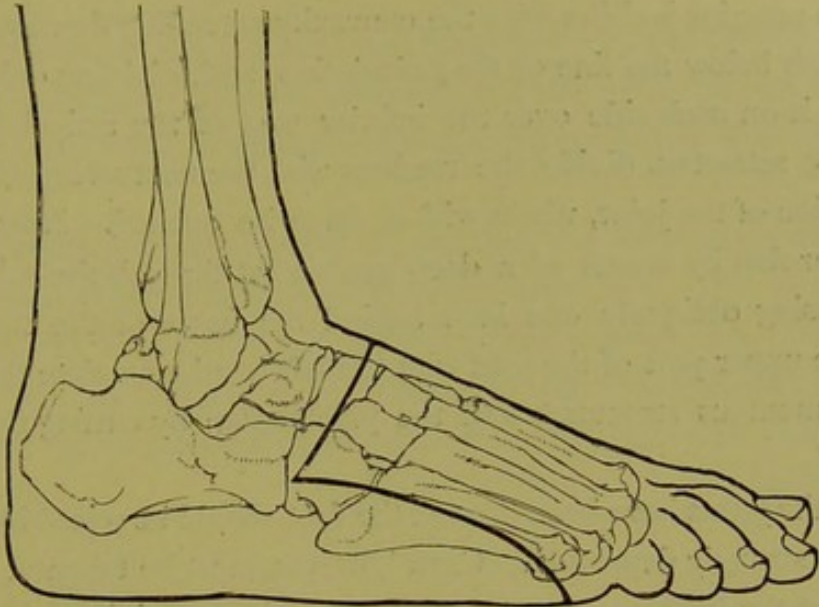


FIG. 161.—Lines of the dorsal and external incisions in Chopart's amputation.

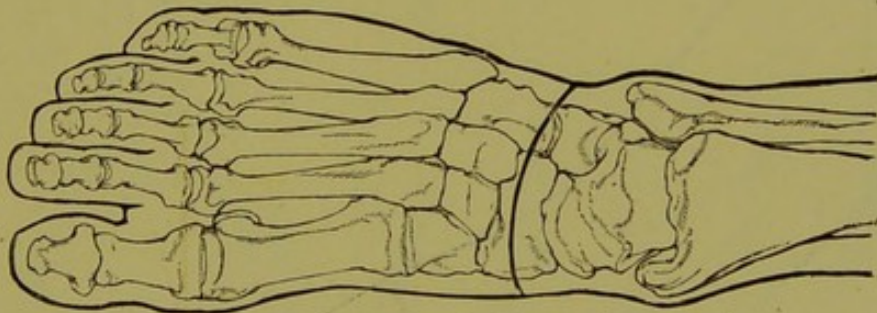


FIG. 162.—Dorsal incision in Chopart's amputation.

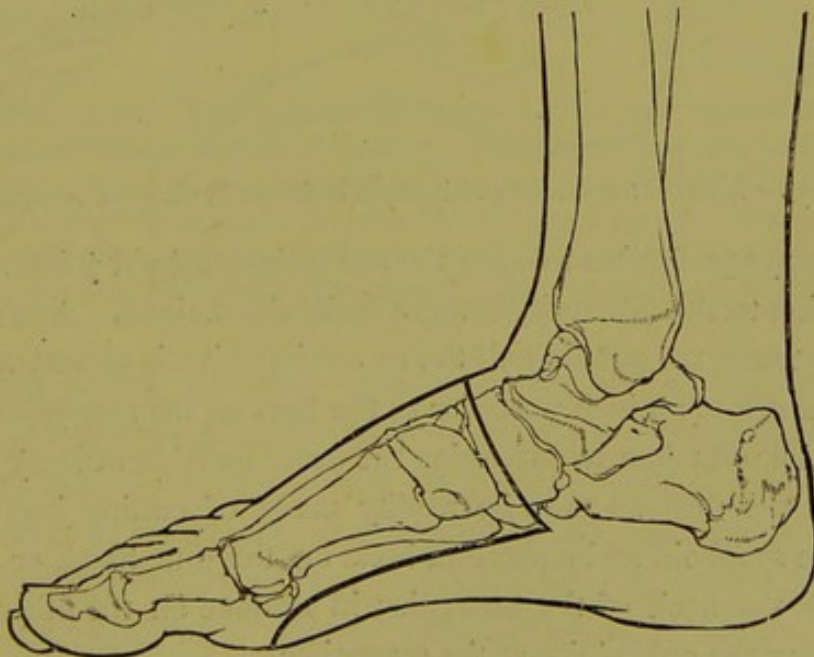


FIG. 163.—Lines of the dorsal and internal incisions in Chopart's amputation.

Make the anterior incision with the convexity extending downwards nearly half an inch below the line of the articulation, and, dividing only the skin, terminate it on each side over the inferior part of the articulation. The skin being retracted, divide the tendons with the next sweep of the knife over the line of the joint, which will at once be opened. Now mark out the plantar flap by means of a deep groove cut through the sole with the knife, crossing obliquely one inch behind the bases of the toes. Then seizing the upper part of the foot with the left hand, complete the division of the ligamentous structures and the plantar flap by cutting from within outwards.

When the joints have been opened the foot should be seized by its dorsal aspect and strongly depressed. Care, however, must be taken at this point not to allow the knife to enter the astragalo-calcanean joint.

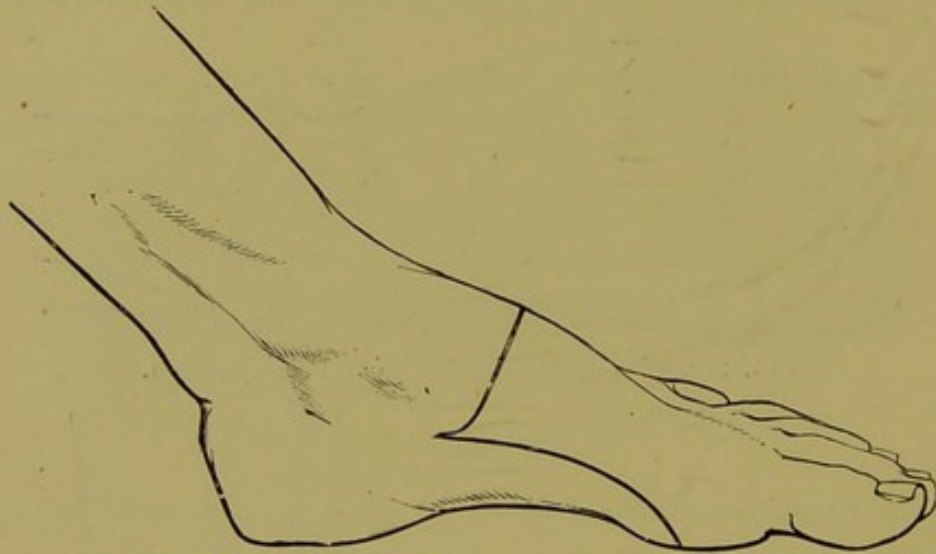


FIG. 164.—Lines of the dorsal and internal incisions in Chopart's amputation.

It is always preferable to open the astragalo-scaphoid joint first, as its exact relation to the tuberosity is more easily determined. And afterwards the joint between the cuboid and the os calcis, which is almost vertical and nearly a quarter of an inch posterior to the head of the astragalus.

If care be not taken to determine the exact position of the joint on the inner side, the mistake may be readily made of cutting into the joint between the scaphoid and cuneiform bone on the one hand, or trying to cut through the neck of the astragalus in mistake on the other, and probably opening the ankle-joint at the same time.

When the disarticulation has been completed the joint surfaces of the os calcis and astragalus, if found diseased, may be sawn off, caution being exercised to saw close to the articular surfaces so as to avoid opening the ankle-joint.

The dorsalis pedis artery, and the internal and external plantar arteries, are the vessels of importance which require ligature.

Langenbeck considered Chopart's method a good one. He divided the tendo-Achillis at the time of amputation with Dieffenbach's tenotome, to anticipate the occurrence of pes equinus. He regarded it as important

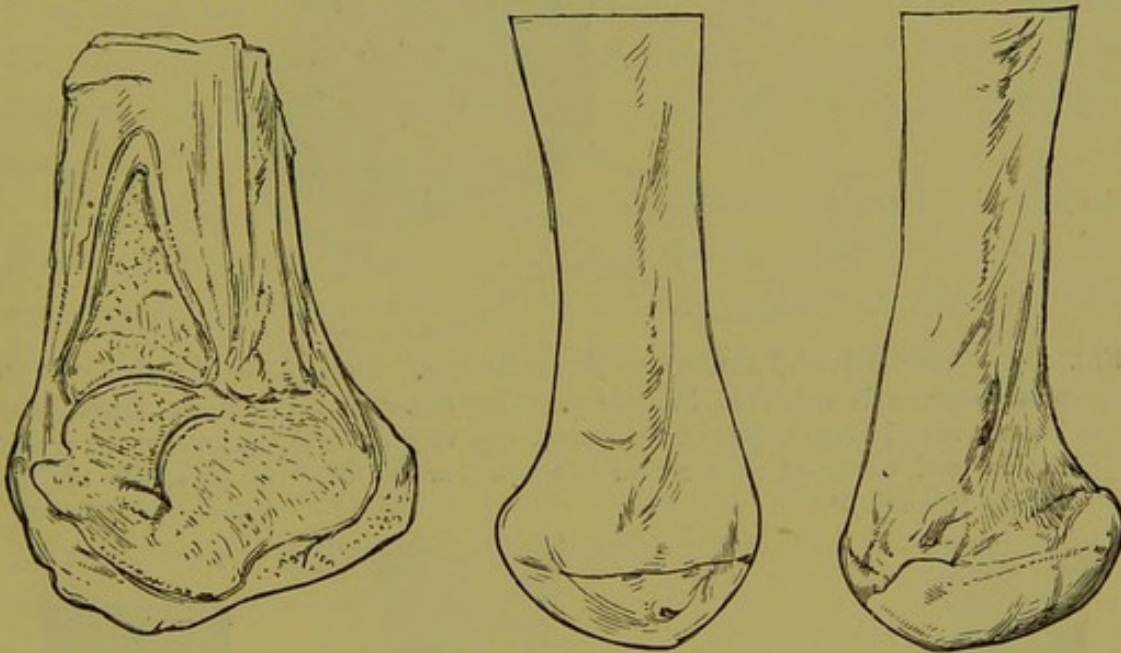


FIG. 165.—Three views of a stump after Chopart's amputation. The operation in this case was performed on account of frostbite. The patient died two years later from tuberculosis. The heel is considerably retracted, and the weight borne on the anterior portion of the stump. In the section the displacement of the astragalus and calcis is evident. Although the cicatrix is out of the direct line of pressure, the patient was not in this instance able to walk without assistance.—Schneider, *Lang. Archiv.*

to divide the tissues anteriorly well below the line of the articulation, especially on the inner side, in order to allow for retraction of the skin, thus to avoid tension when the flaps are sutured together, and lastly, and most important, to ensure sufficient covering for the head of the astragalus, which would otherwise project and render the healing process tedious and difficult. It is necessary to procure union by the first intention to ensure a good stump. The dorsal incision should therefore reach as far forward as

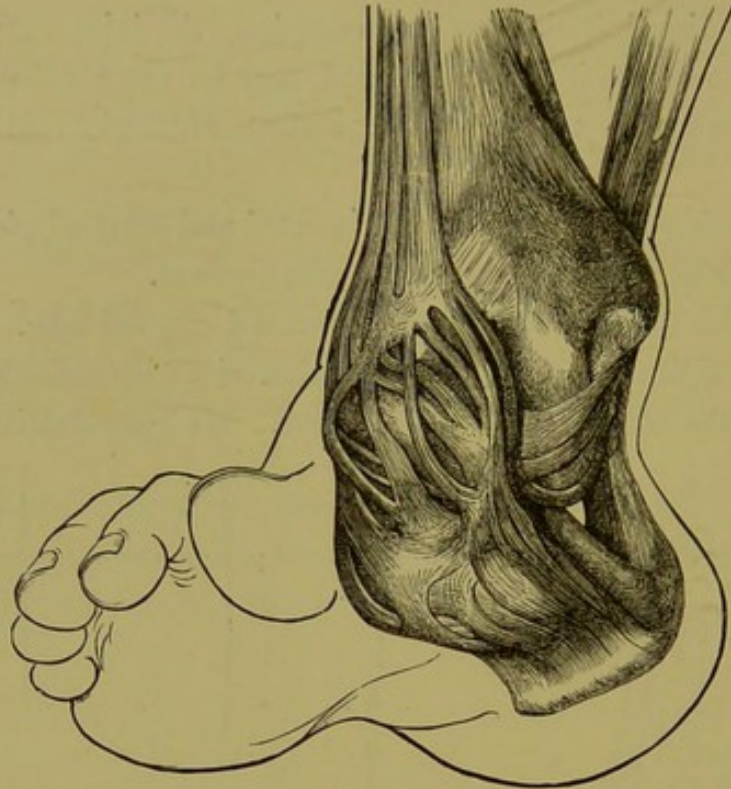


FIG. 166.—Stump dissected after Chopart's amputation. The portion of the foot which was removed is indicated in outline. The flexor and extensor tendons have become united over the face of the stump, and very complete and active power of flexion and extension of the remaining portion of foot was possessed by the patient (Blandin).

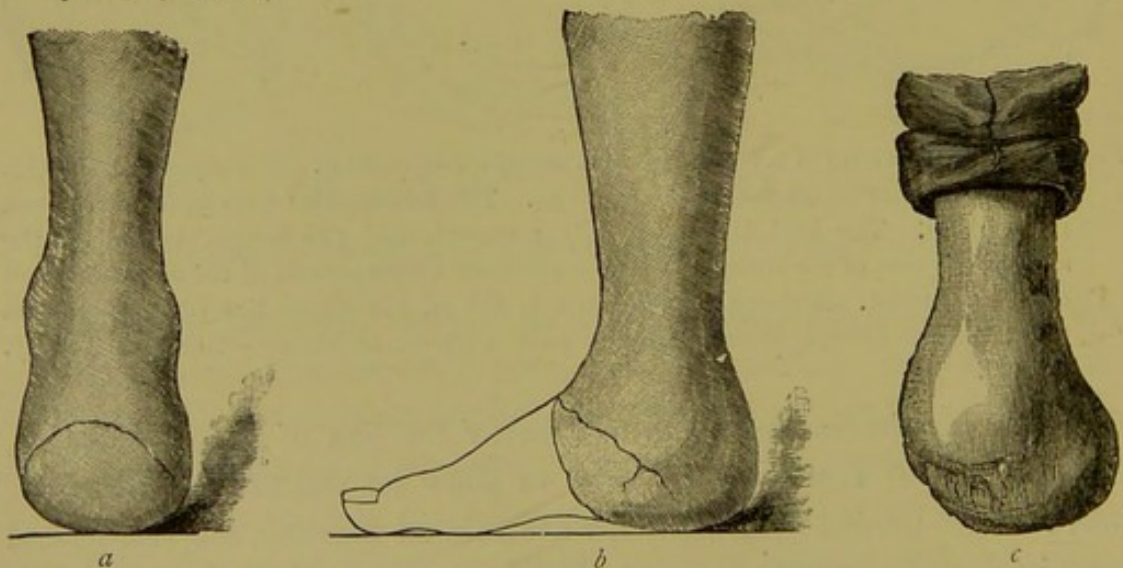


FIG. 167.—(a) Stump after Chopart's amputation. Anterior view. The cicatrix has not been drawn down, and is well out of the line of pressure.
 (b) Stump after Chopart's amputation. Lateral view. The outline of the portion of foot removed has been indicated. There is no displacement or drawing up of the heel.
 (c) Stump after Chopart's amputation of the left foot; the heel is somewhat displaced.

the *anterior* border of the scaphoid on the inner side. This mode of operation is more troublesome, as the joints have to be opened with the point of the knife. Langenbeck forms the plantar flap by cutting from within outwards with long sweeps of the knife, taking care that the flap shall not be too thick. The flap must be always thinner towards its extremity. By making preliminary lateral incisions more room is obtained, and disarticulation rendered much easier.

In cases where the scaphoid bone is not diseased it will be a perfectly proper procedure to leave it, making the disarticulation between it and the cuneiform bones. An insertion will thus be preserved for the anterior and posterior tibial tendons and a very useful stump prove the result. The dorsal and plantar flaps, however, must in this case be made proportionately longer on the inner side.

The operation is often followed by an indifferent result, so far as function is concerned, because of the drawing up of the heel, and the cicatrix consequently coming into the line of pressure. The structures behind the ankle-joint, and especially the loose posterior ligament, become permanently shortened, and when this takes place the division of the tendo-Achillis does not suffice to remedy the equinus position of the stump. The retraction of the heel must be prevented during the after-treatment of the stump by the application of a posterior splint, and if need be by the division of the tendo-Achillis as well.

DISARTICULATION OF THE FOOT BETWEEN THE OS CALCIS AND ASTRAGALUS.
MALGAIGNE'S SUB-ASTRAGALOID AMPUTATION.

Indications.—This operation may be occasionally required on account of injury; it will rarely be possible to perform it on account of disease. For injury, when practicable, it is admirable and preferable to Pirogoff's or Syme's amputation.

The astragalus is left undisturbed in its connections with the tibia and fibula, its head being disarticulated from the scaphoid bone and its lower surface from the os calcis.

Surgical anatomy.—It is necessary accurately to make out the position of the joints. The articulation between the astragalus and os calcis is just

on a level with the tip of the external malleolus. On the inner side the sustentaculum tali is generally easy to make out, about one inch below the tip of the internal malleolus. Immediately above this point, is the joint between the os calcis and astragalus. These indications and the tubercle of the scaphoid are the anatomical guides.

Operation.—In this as in all the other operations on the foot the surgeon should stand facing the patient, who is placed on a table of convenient height, with the foot projecting a little beyond its end.

One method of operation is similar to that of Syme's amputation. Care must be taken, however, to terminate the plantar incision at least three-quarters of an inch below both the internal and the external malleolus, otherwise the ankle-joint would probably be opened, rendering the completion of the operation impossible.

The incision across the sole ought to be quite vertical, as in that of Syme, but rather farther forward. The anterior incision should extend on the inner-side of the dorsum of the foot quite as far forward as the joint between the scaphoid and cuneiform bones. The flap will thus be sufficiently long and broad to cover the large rounded head of the astragalus without any strain. In cases where the flap must be made shorter than this, the head of the astragalus may be subsequently cut off. The tuberosity of the scaphoid must always be well determined before forming this anterior flap. On the external aspect the incision must terminate three-quarters of an inch below the tip of the external malleolus, and on the inner, over the sustentaculum tali, or about the same distance below the internal malleolus.

After raising the tissues from the heel in the same way as it is done in Syme's operation, which is always a little difficult and tedious, the anterior flap is formed by making an incision convex downwards across the front of the ankle three-quarters of an inch below the line of Chopart's joint, uniting the extremities of the flap first made. The articulation between the scaphoid and head of the astragalus should first be opened, the foot is then depressed, and great care must be taken at this stage to avoid opening the joint between the cuboid and calcis. It is difficult to avoid entering the articulation between the cuboid and the os calcis, and this will inevitably be done if the knife be carried too far outwards. If this happen the purchase upon the foot is lost, and the operation can only be

completed with difficulty. The strong interosseous ligament between the os calcis and the astragalus is cut through from the outside in front, backwards and inwards, commencing on the outer side of the head of the astragalus, the knife being held horizontally. The insertion of the lateral ligaments to the scaphoid and os calcis respectively and the tendo-Achillis are one by one to be divided, taking care to cut close to the bone, and the operation will then be completed, the entire foot with the exception of the astragalus being removed.

Another perhaps preferable method of operating is by means of an oval

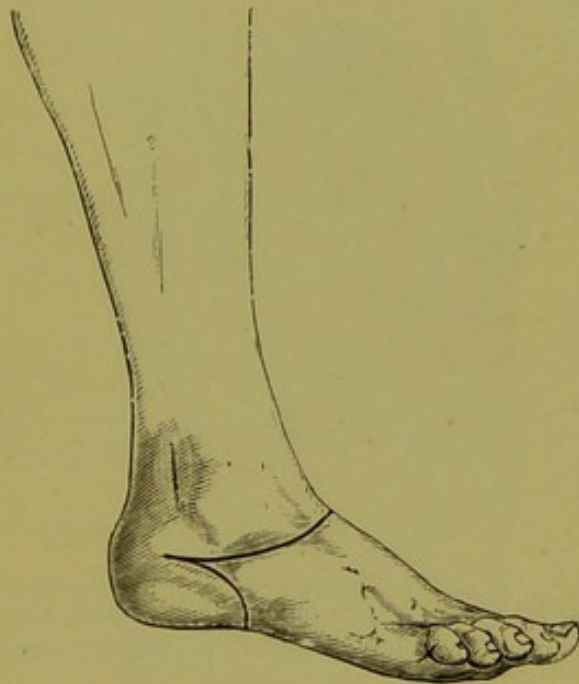


FIG. 168 *a*.—Incision for Malgaigne's sub-astragaloid amputation of the foot.

incision, the tail of which should commence three-quarters of an inch below and behind the external malleolus. First carry the knife from this point across the dorsum of the foot, three-quarters of an inch below the head of the astragalus, continue vertically downwards, then transversely across the sole, and pass obliquely upwards to the point of commencement (Fig. 168 *a*).

This line of incision permits the soft parts to be readily separated from the heel, while the disarticulation of the scaphoid and calcis from the astragalus is more easily performed in a manner similar to that already described. An ample amount of soft covering is provided for the head of

the astragalus, together with effective drainage. The subsequent stump is excellent (Fig. 168 *b*). It contains all the weight-bearing portion of the heel,

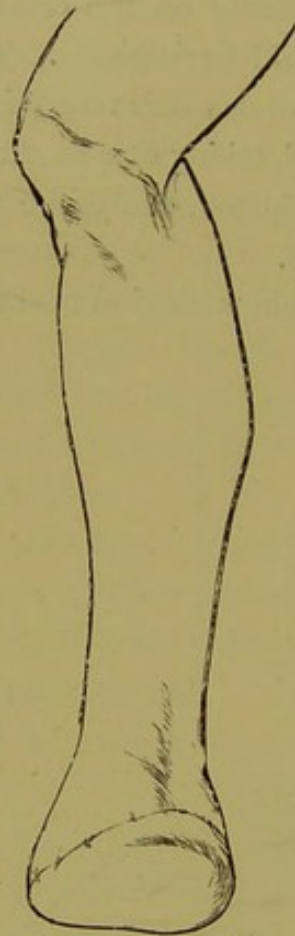


FIG. 168 *b*.—Stump after Malgaigne's amputation. The patient, from whom this drawing was made, could walk long distances without inconvenience.

is very broad, and well calculated to sustain the weight of the body. A considerable amount of movement at the ankle-joint is also preserved.

DISARTICULATION OF THE FOOT AT THE ANKLE-JOINT, WITH REMOVAL
OF THE MALLEOLI.—SYME'S AMPUTATION.

Indications.—This operation was first introduced for cases of disease of the tarsal bones by the surgeon whose name it bears, because of the frequency with which a number of these bones are at once affected, and the liability to recurrence of disease in the remaining portion of the tarsus after partial amputation has been performed.

It is also indicated in cases where the injury is too extensive to admit of any of the previously named operations being practised.

Surgical anatomy.—The anatomical facts to be remembered in performing this operation are these:—The posterior borders of the two malleoli correspond in level. The tip of the internal malleolus is three-quarters of an inch above the level of the external, and slightly anterior to it. The joint is consequently more easily opened from the inner side. The posterior tibial artery and its terminal branches, the plantar arteries, lie close to the deltoid ligament of the ankle-joint, and care must be taken in clearing the heel-flap not to injure these vessels by slicing them, and thereby endanger the subsequent vitality of the heel-flap.

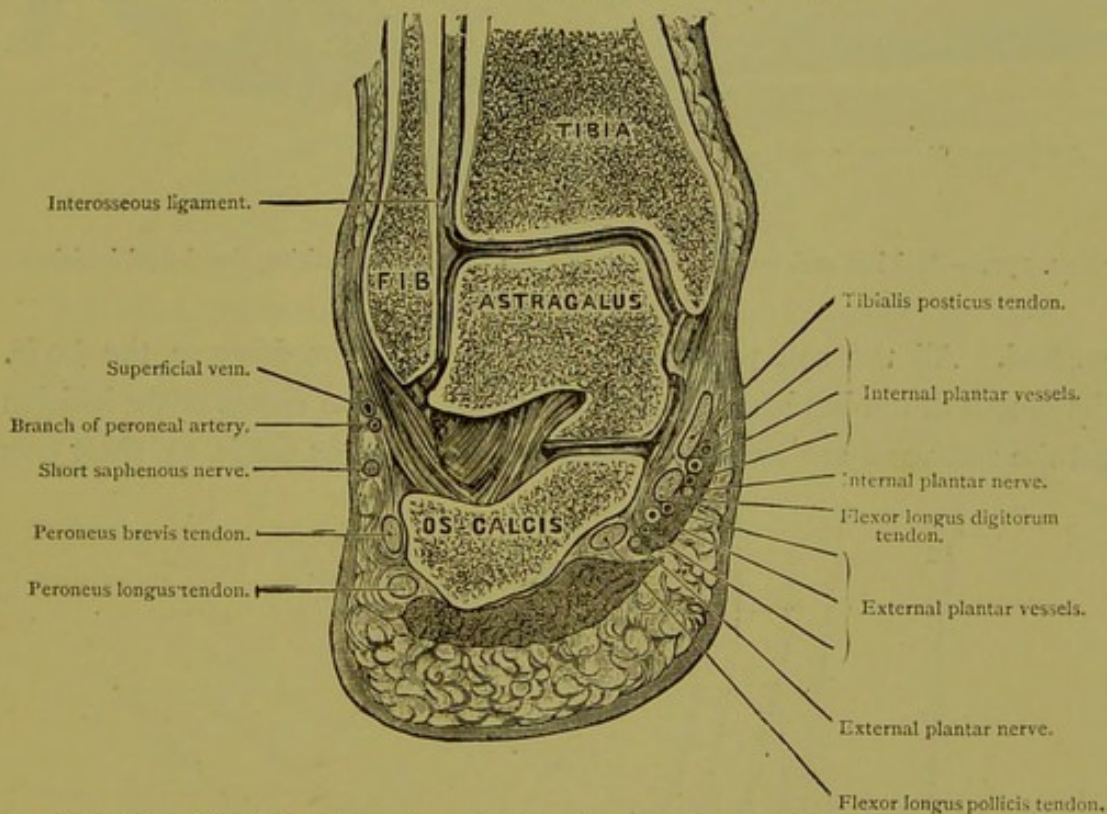


FIG. 169.—Vertical section through the malleoli, the ankle-joint, and heel-pad.

Operation.—The patient must be placed in the position already described, the surgeon standing before the foot, the front part of which should be held in the left hand. In the right foot a vertical incision is first made round the sole from the tip of the external malleolus, which will be a point rather nearer its posterior than its anterior edge, to a point precisely opposite to it on the inner side of the foot, that is to say, terminating three-quarters of an inch below and a little behind the tip of the internal malleolus. For the left foot the direction of the incision must be

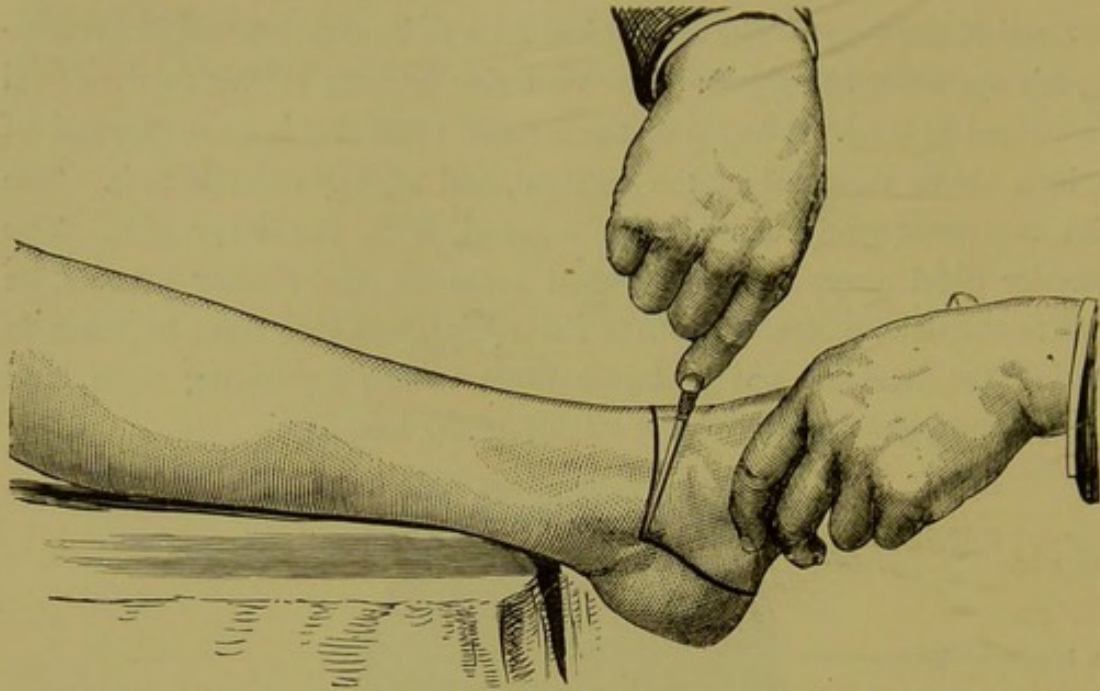


FIG. 170.—Position and manner of holding the foot when making the dorsal incision in Syme's amputation.

reversed. All the soft parts are to be divided right down to the bone. The thumb of the left hand is now introduced into the centre of the incision and the soft parts are gradually detached from the os calcis, by short cuts

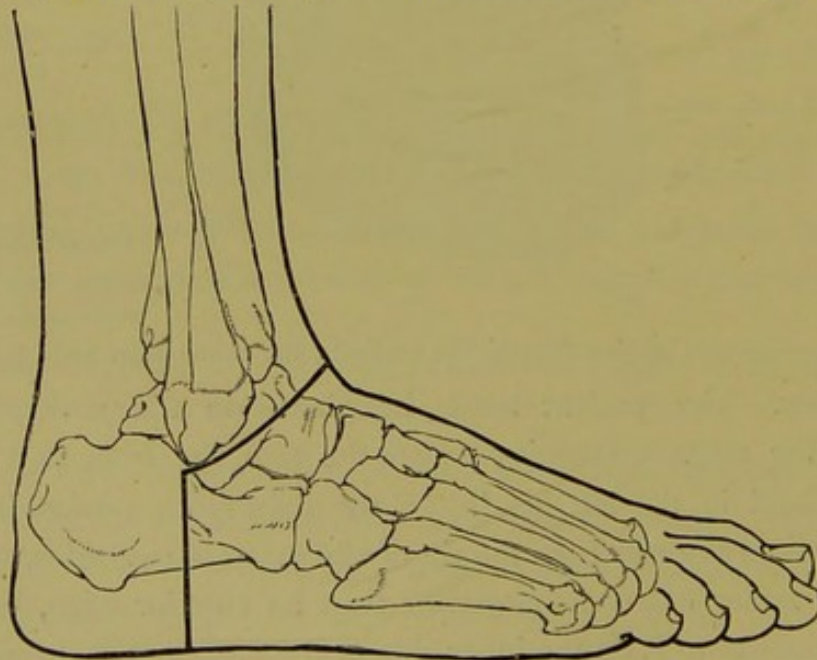


FIG. 171.—The incisions on the outside of the foot in Syme's amputation. "The plantar incision should be made vertically around the heel, sloping neither forward nor backward" (Syme).

of the knife made quite close to the bone until the insertion of the tendo-Achillis be reached. This portion of the operation is fatiguing and difficult,

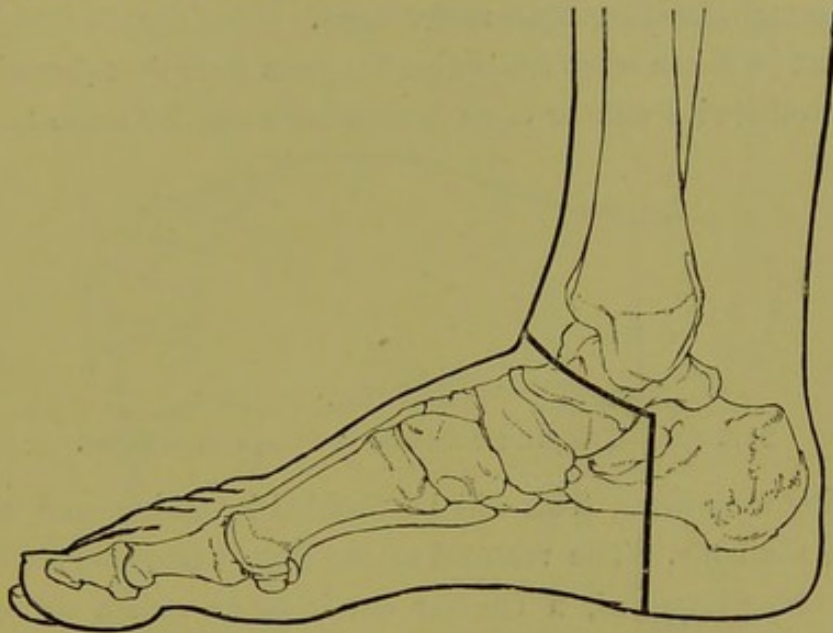


FIG. 172.—The incisions as seen on the inside of the foot in Syme's amputation.

especially if the parts prove infiltrated by inflammation products. Then the upper surface of the foot is to be taken firmly in the left hand (Fig. 170),

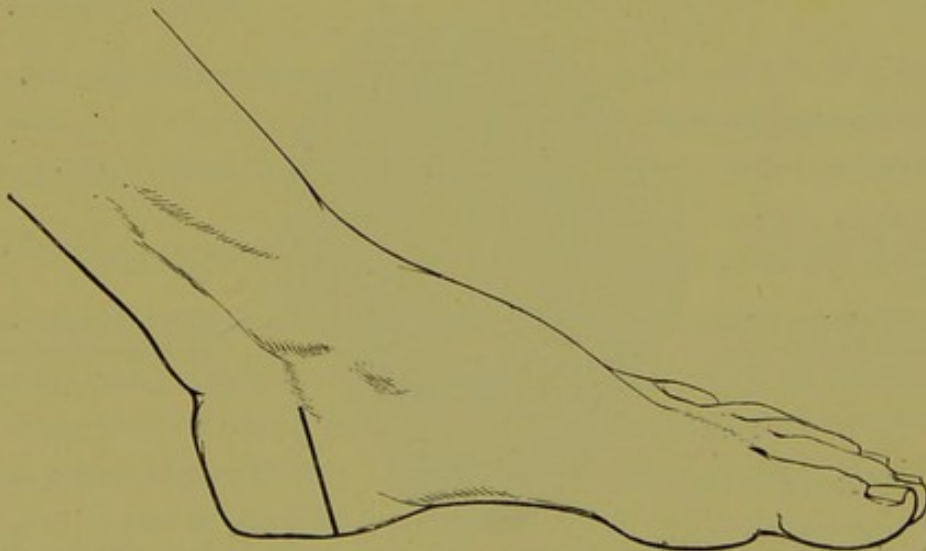

FIG. 173.—Plantar incision in Syme's amputation, commencing three-quarters of an inch below and a little behind the tip of the internal malleolus. Position of the foot when about to make the dorsal incision.

and the extremities of the incision first made united by one made directly across the ankle-joint. The foot being forcibly depressed, the extensor

tendons are readily divided and the joint opened. The soft parts and ligaments on the lateral aspects and the insertion of the tendo-Achillis are now to be cut through, keeping close to the bone.

Care must be taken when separating the parts from the tuberosity of the os calcis, as otherwise one or more button-holes will be made in the flap,

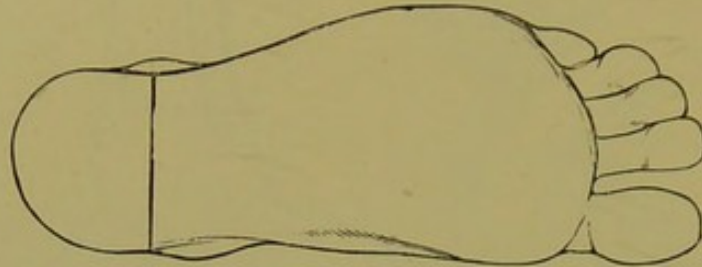

FIG. 174.—The plantar incision in Syme's amputation.

the skin being very thin. This will be avoided by taking care always to cut close to the bone. The removal of the foot is now completed. The soft parts being retracted, a circular cut is made with a strong scalpel round the lower end of the tibia and fibula immediately above the level of the articular surface of the tibia, and the malleoli and joint surfaces removed with the saw; the thinnest possible layer being cut off the tibia.

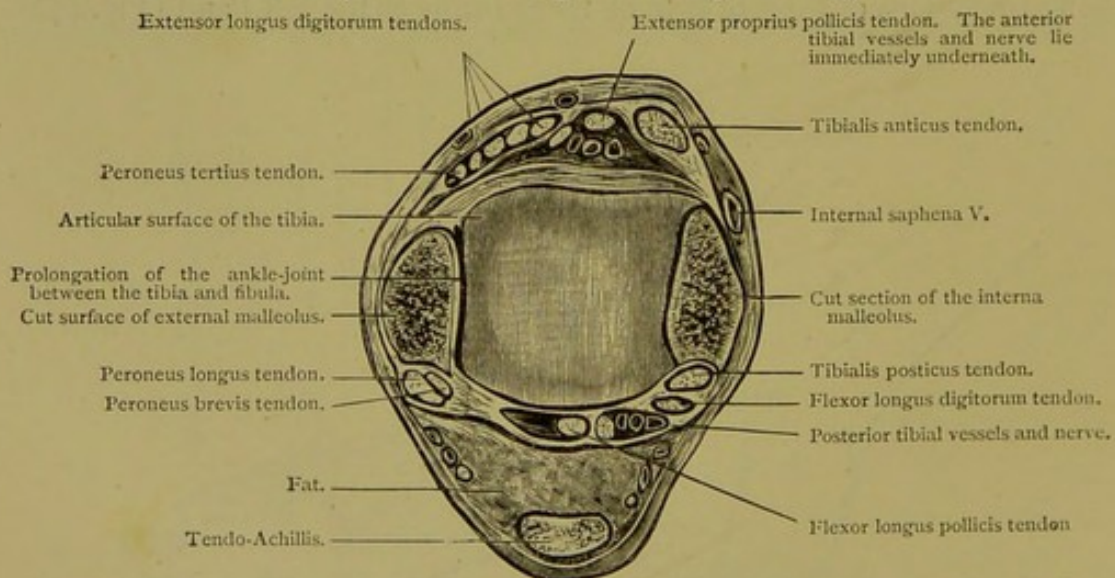


FIG. 175.—Transverse section of the right ankle through the malleoli seen from below.

The posterior flap is now to be carefully sutured to the anterior margin of the wound and a drainage tube inserted. In Fig. 175 the relative position of the principal parts concerned in Syme's operation is very clearly seen.

The anterior tibial artery and the posterior tibial, or rather the internal

and external plantar near their origin, are the principal vessels which require ligature. The division of the two plantars rather than the posterior tibial preserves the internal calcanean branches for the flap.

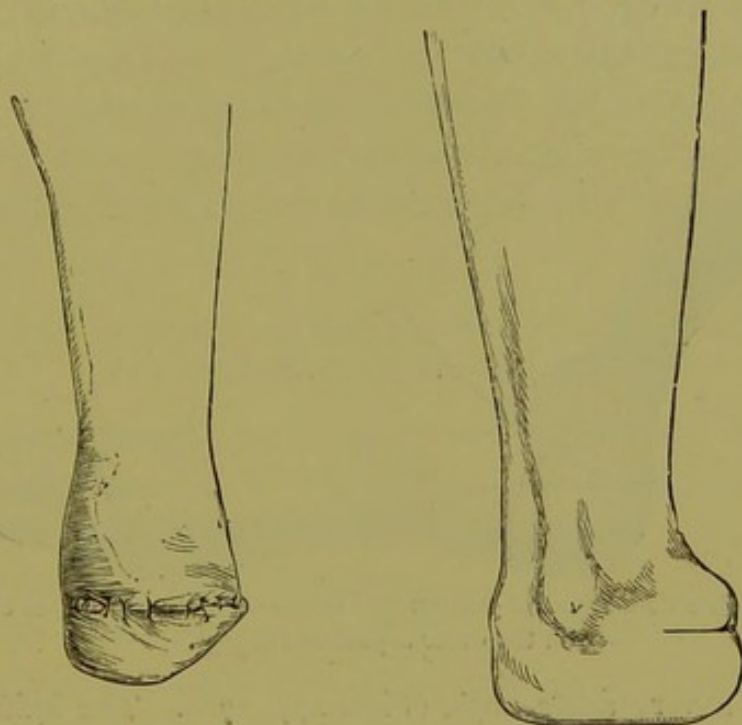

FIG. 176.—Stumps after Syme's amputation—one recent, the other after an interval of use.

The stump is an excellent one for sustaining pressure, as it is formed of the extremity of the heel (Fig. 176). With suitable apparatus the individual should be able to walk very well.

ROUX'S METHOD OF AMPUTATION AT THE ANKLE-JOINT.

The advantages claimed for this method are the more perfect preservation of the soft parts forming the pad of the heel, and, by reason of the external incisions reaching far back, greater facility in separating the foot from its connections with the leg and disarticulating at the ankle-joint.

The front part of the foot is to be held firmly in the operator's left hand, with which its position may be altered so as to assist the progress of the knife.

Commence the incision at the outer border of the tendo-Achillis, continue it half an inch below the external malleolus, and cross the front of the ankle-joint at the same distance below the line of the articulation as far

as a point a little in front of the internal malleolus. The knife should then be carried directly downwards and across the sole of the foot, and finally made to slope obliquely upwards and backwards, to join the incision

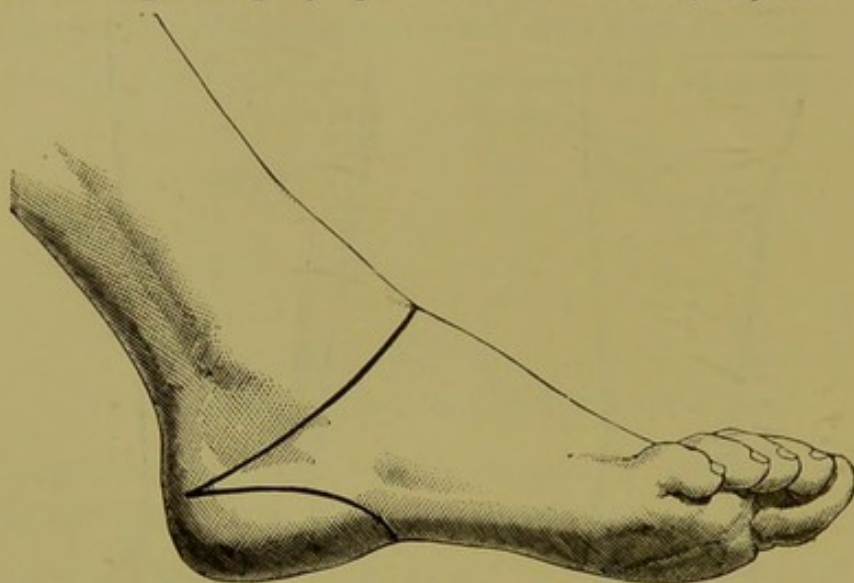


FIG. 177.—Roux's method of amputation at the ankle-joint. Lines of incision on the outer aspect of the foot.

first made at a very acute angle (Figs. 177, 178). The knife should be made to divide all the soft parts down to the bone in the first incision.

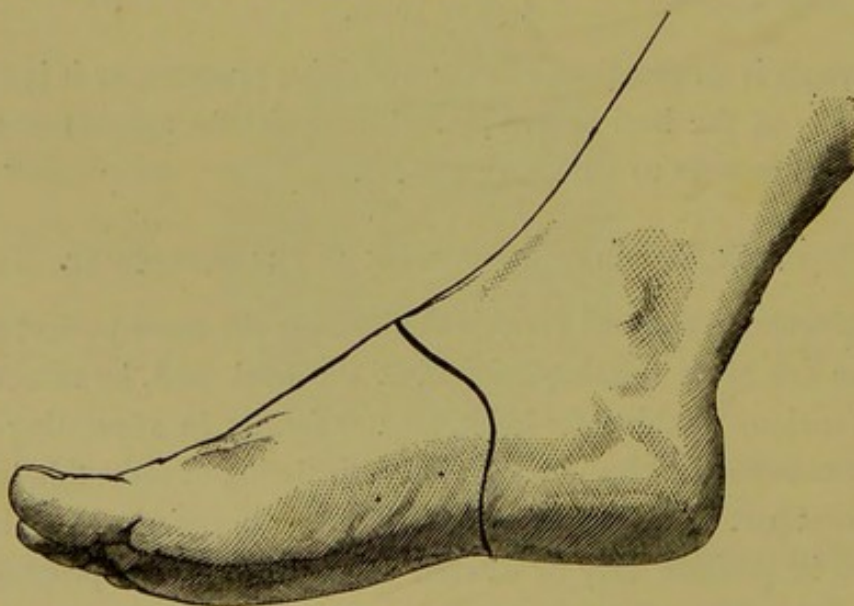


FIG. 178.—Roux's method of amputation at the ankle joint. Incision on the inner aspect of the foot

The edge of the anterior flap is now dissected up and the ankle-joint opened.

It will be needful to make vigorous use of the left thumb in detaching the heel-pad from the os calcis from without inwards as far as its inner border.

The disarticulation should now be completed from the front, the soft parts being well held back by a retractor. The remaining structures on the inner side of the joint can be easily cut through, the tendo-Achillis divided and the disarticulation completed. As in other amputations at the ankle-joint, the malleoli should be sawn off flush with the articular surface of the tibia.

MODIFICATION OF SYME'S OR ROUX'S AMPUTATION OF THE FOOT—
BY DEPUTY-INSPECTOR-GENERAL PARRY.

This operation has the advantage of ensuring division of the plantar arteries only; of removing indeed, all risk of puncturing or dividing the posterior tibial artery if the commonest care is taken. It is speedy and easy both on the dead and living subject.

Right Foot.—The leg is to be held by an assistant so that the foot is on a level with the operator's chest, and at first *inverted* (Fig. 179).

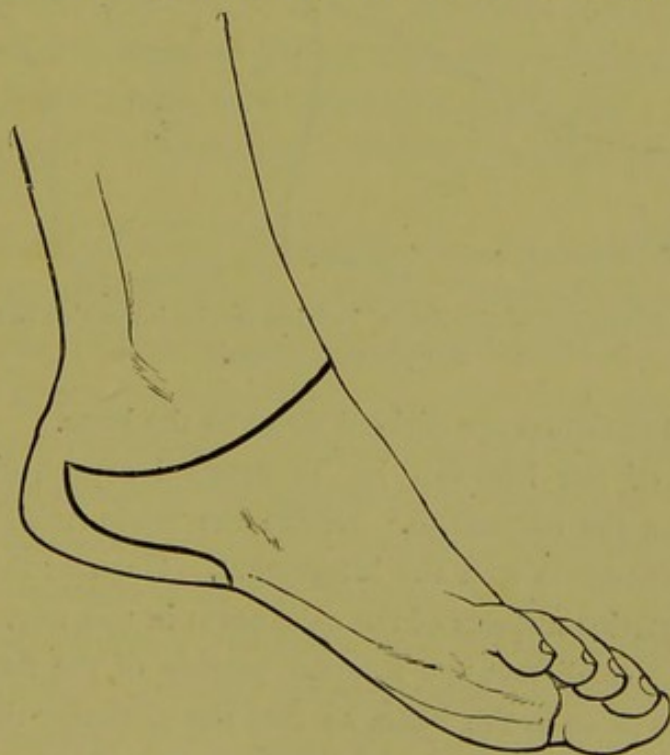

FIG. 179.—Position and direction of the lines of incision on the external surface of the foot in Parry's amputation.

Insert the point of the knife in front of the outer border of the tendo-Achillis about a quarter of an inch above the insertion of the tendon into the calcaneum, carry the incision around the outer malleolus about half an inch below its extremity, and across the instep till it reaches the upper and inner border of the protuberance of the navicular bone which will be readily felt by the finger. Then continue it somewhat obliquely across the plantar aspect of the foot (down to the bone) immediately in front of the pad of the heel as far as its outer border, and connect it with the original point of entrance of the knife by an incision following the general curve of the outline of the heel, and not more than one inch above the outer border of the foot, otherwise it is more difficult to dissect the heel-flap from the calcaneum.

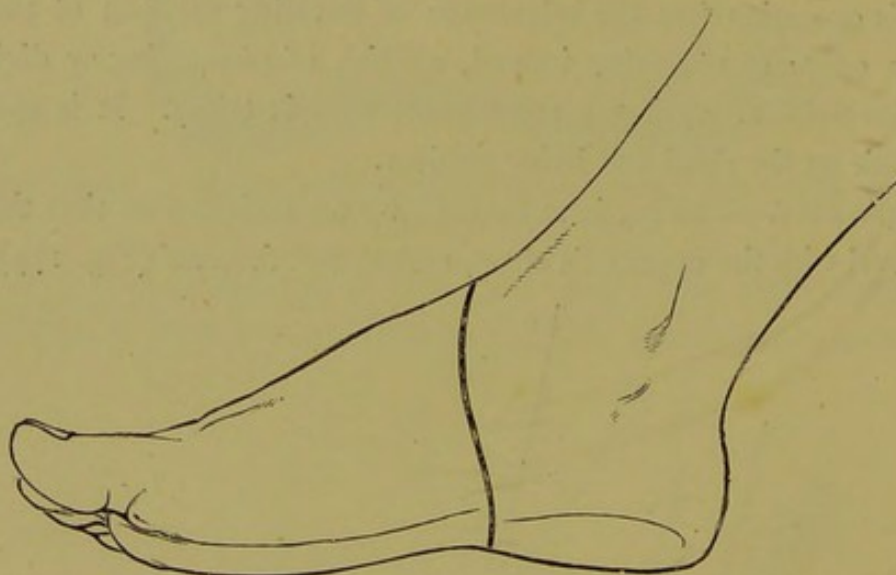


FIG. 180.—Direction of the line of incision on the inner side of the foot in Parry's amputation.

See that all the tissues are divided down to the bone.

Take hold of the heel-flap by its external aspect, dissect it back, detaching it from the calcaneum. Divide the tendo-Achillis so as not to derange its connections with the integument. Uncover the whole of the external and posterior surfaces of the calcaneum in this way.

Now proceed to dissect the internal portion of the flap, keeping the edge of the knife close to the bone, so that the posterior tibial artery may remain intact in the soft tissues of the flap. Do this by repeated short incisions, the edge of the knife being turned towards the bone, while the

operator takes charge of the flap and draws it back with the left hand. The anterior edge of the internal malleolus being reached, the ankle-joint is now opened, the foot separated, and the malleolar extremities of the tibia and fibula subsequently removed.

Left Foot.—Reverse the order of incision. Begin at the protuberance of the scaphoid, and proceed to the edge of the tendo-Achillis in making the first incision, and from the scaphoid beneath the plantar surface of the foot to the same point for the second incision.

The rest as with the right foot.

The resulting stump is an excellent one.

The cicatrix does not come so much to the front of the stump after healing, and has thus an advantage over Syme's operation, in which the position of the cicatrix is occasionally an inconvenience in fitting a shoe or boot.

DISARTICULATION OF THE ANKLE-JOINT, THE MALLEOLI BEING SUBSEQUENTLY
SAWN OFF AND THE OS CALCIS DIVIDED VERTICALLY JUST IN FRONT
OF THE TUBEROSITY.—PIROGOFF'S AMPUTATION.

Indications.—This amputation is a modification of Syme's operation. It may be performed in cases of disease when the os calcis is healthy, and is available in cases of injury to the front part of the foot. The stump is somewhat longer, and it is capable of bearing pressure better than after Syme's operation.

Surgical anatomy.—The anatomical points of interest are much the same as for the preceding operation (Syme's). The operator will do well to bear in mind that the insertion of the tendo-Achillis is low down on the posterior surface of the tuberosity of the os calcis, and that between the tendon and the posterior surface of the calcaneum is a bursal sac, which closely connects the tendon to this surface of the bone, and which should consequently not be encroached upon. As soon as the articular surface of the astragalus is separated from the tibia and fibula, the saw should be applied to the upper surface of the calcis, and the vertical section of this bone completed without dissecting the soft parts further backwards, as is done in Syme's operation.

Operation.—The incisions made through the soft parts are similar to those adopted for Syme's amputation. After the plantar incision is com-

plete, the soft parts are not to be detached from the heel, but the foot is at once disarticulated after making the dorsal incision. Holding it in the left hand and sufficiently depressed, the saw is applied to the upper surface of the os calcis just behind the sustentaculum tali, and the bone divided vertically downwards, that is, in a direction corresponding to the margins of the plantar flap, any undivided soft parts being first separated by a circular sweep of the knife, so that the incisions through the bone and soft parts shall be in one plane. The extremities of the tibia and fibula are now to be removed in the same manner as in Syme's amputation, and after the bleeding has been arrested the posterior flap and cut surface of the

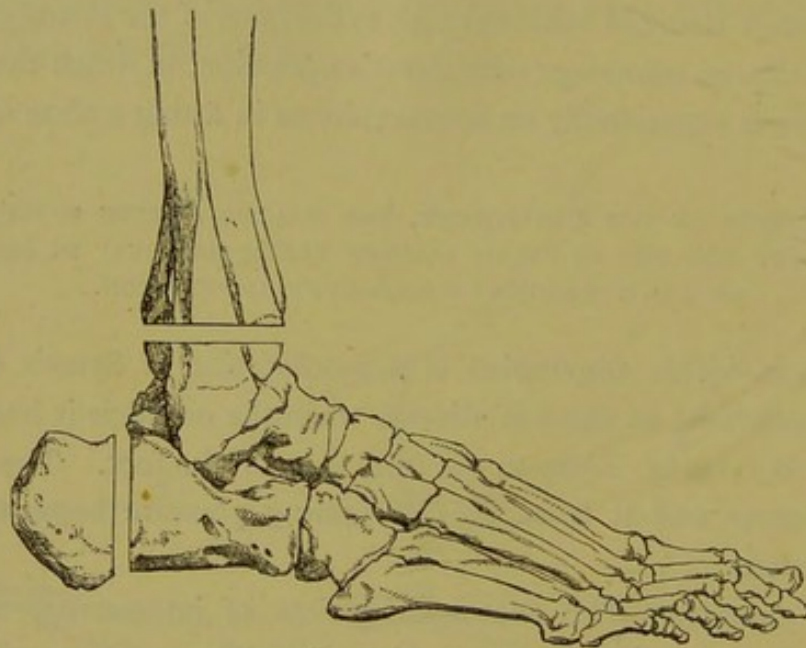


FIG. 181.—The position in which the bones are cut in Pirogoff's amputation.

os calcis can be exactly applied to the cut surface of the tibia, and the soft parts sutured together. After union has taken place, the posterior part of the os calcis is directed downwards and the surface of the stump will be found well calculated to sustain pressure.

Pirogoff's amputation is not a good operation in time of war. It is only desirable when we can calculate on primary union. Langenbeck always divides the tendo-Achillis. The plantar incision should be made quite vertically round the sole, from just behind the tip of the external malleolus to a corresponding point on the inner side of the foot. One must take care, in sawing through the bone, that its cut surface shall exactly correspond

with the section of the skin. Half an inch of the tibia with the malleoli is to be removed. The cut surfaces of the bones must now be accurately adjusted together, and then the tibia and os calcis pressed hard and fast against each other, so that their irregularities may as it were inosculate. The parts must then be provided with a suitable dressing, so that they shall be firmly sustained *in situ*.

If any difficulty should be experienced in bringing the cut surfaces of the bone into exact apposition, the tendo-Achillis ought to be divided. It has also been recommended to connect the bones with one or two silver

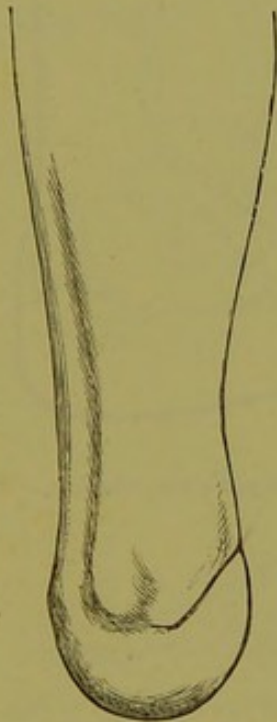

FIG. 182a.—Stump after Pirogoff's amputation, lateral aspect.

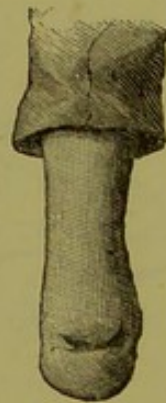

FIG. 182b.—Stump of the left leg after Pirogoff's amputation, front view.

sutures. This would prevent retraction and consequent separation of the cut surface of the os calcis from the extremity of the tibia.

Pirogoff's aim in the procedure which bears his name, was to realize as nearly as possible the normal length of the limb; and Neudorfer, to secure this result even more fully, has proposed in cases where one is obliged for any reason to cut away a considerable length of the tibia, to preserve the calcaneum entire. A little shortening, however, is often useful, because it permits the use of a cushion beneath the stump, the contact of which is softer than that of sole leather.

GUNTHER'S MODIFICATION OF PIROGOFF'S OPERATION.

The plantar incision begins and terminates close to the tip of the malleoli, and is carried transversely across the sole along the posterior

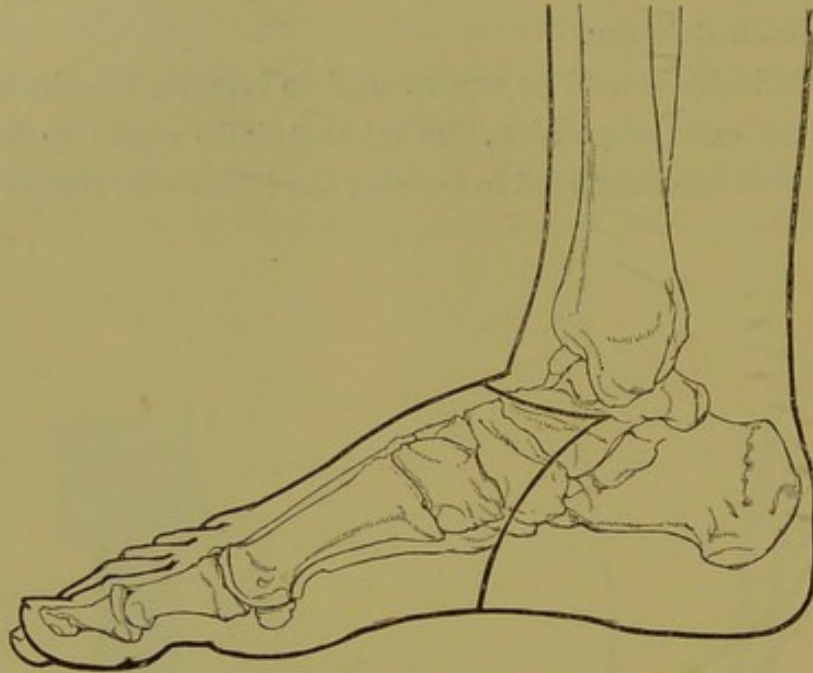


FIG. 183.—Gunther's modification of Pirogoff's amputation.

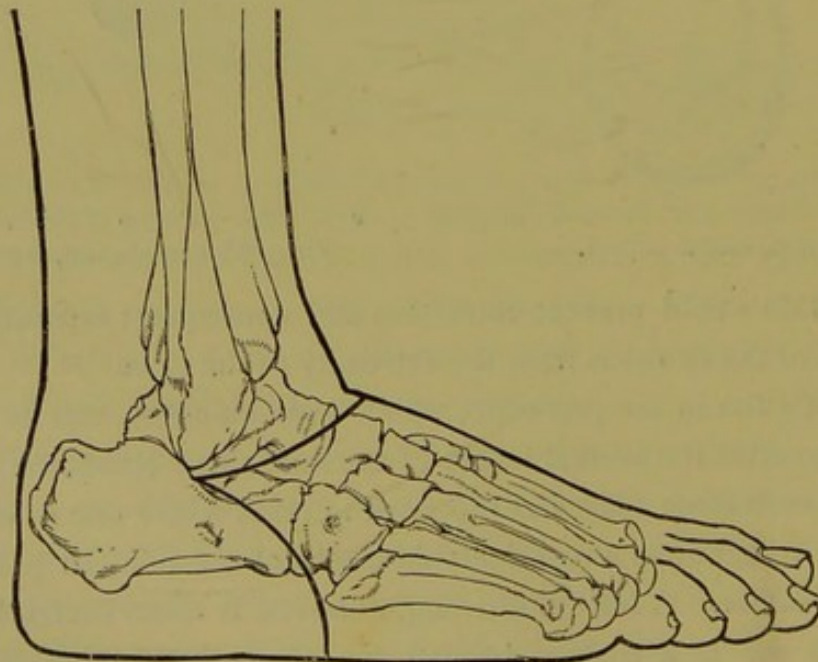


FIG. 184.—Gunther's modification of Pirogoff's operation.

border of the scaphoid bone. The dorsal incision is convex downwards, and should extend as far as the scaphoid (Figs. 183, 184).

When the ankle-joint is opened, the soft parts on each side of the calcaneum are separated obliquely from above downwards and backwards as far as the insertion of the tendo-Achillis, and care must be taken to avoid injury to the posterior tibial artery. The saw is now applied to the upper surface of the os calcis, close in front of the insertion of the tendo-Achillis, and the bone sawn through obliquely from above downwards and forwards. The tibia and fibula are then sawn through in the same direction (Fig. 185).

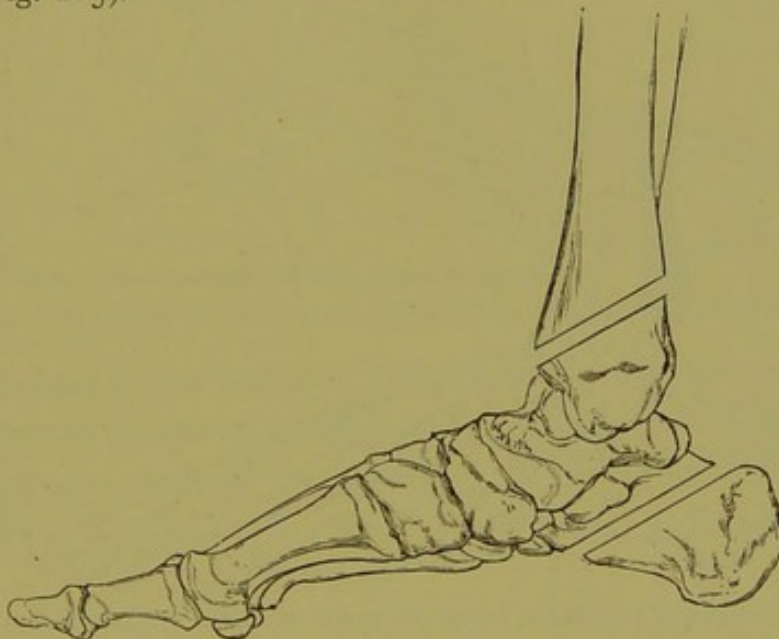

FIG. 185.—Direction in which the bones are sawn in Gunther's modification of Pirogoff's amputation.

The cut surfaces of bone may now be brought into close contact without tension, and there is no necessity to divide the tendo-Achillis. The cut surfaces may, however, be fastened together with one or two catgut sutures with advantage.

LEFORT'S MODIFICATION OF PIROGOFF'S OPERATION.

Lefort has thus modified Pirogoff: In place of cutting vertically behind the trochlear surface of the astragalus, the saw is inserted posterior to the tuberosity of the os calcis, and the bone divided either horizontally (Fig. 186), or very obliquely forwards and downwards. The incision through the soft parts of the heel is made to slope forwards, and then the

flaps will come admirably together, and the portions of the heel accustomed to pressure form the end of the stump.

Sédillot has also recommended to make the plantar incision through the soft parts to slope obliquely forwards in order to prevent tension, and to divide the os calcis and tibia in a similar way to Gunther (Fig. 185).

Lefort gives the following description of the objects he has in view in his proposed modification, and the manner of performing the operation.

It is of importance not to change the natural surface of support. The structure of the skin does not readily permit the weight of the body to be borne by parts other than those naturally destined to sustain it. It is

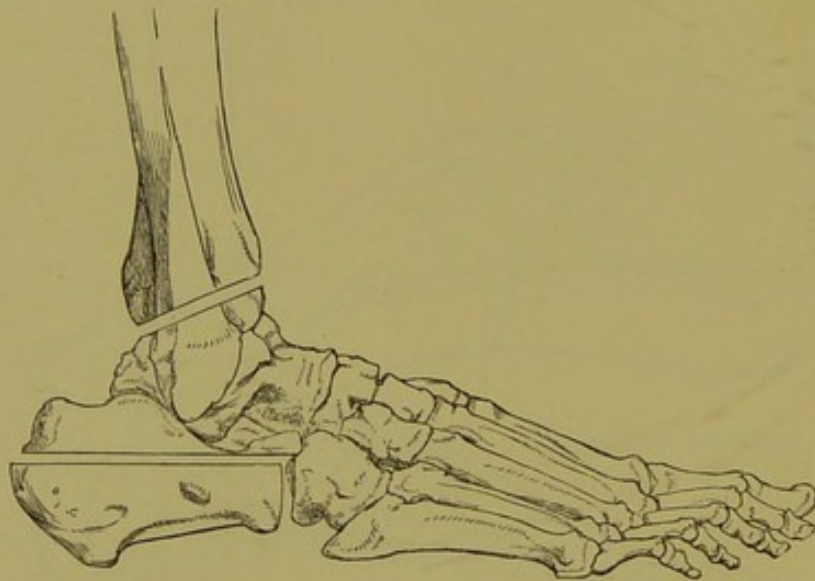


FIG. 186.—Direction in which the bones are sawn in Lefort's modification of Pirogoff. The tibia and fibula are usually divided as in Fig. 181, the slight obliquity of the section forwards and upwards diminishes the tendency to displacement of the calcis backwards.

therefore desirable that in amputations of the foot at or near the ankle-joint, the under surface of the heel should form the support. In Syme's and Pirogoff's amputations the posterior surface of the heel becomes the plane of support, and this detracts from the value of these operations. The same objection, but to a lesser extent, also exists in Sédillot's mode of procedure. Lefort's idea is to devise an operation free from the inconveniences attending the other tibio-tarsal amputations, one which would yield the normal support furnished by the heel with its skin covering intact, avoiding strain on the tendo-Achillis and the possible displacement of the posterior flap. To secure these results, the soft parts covering the heel

are to be left *in situ*. The calcaneum is divided horizontally parallel to its articular surface, and the articular surface of the tibia removed on the

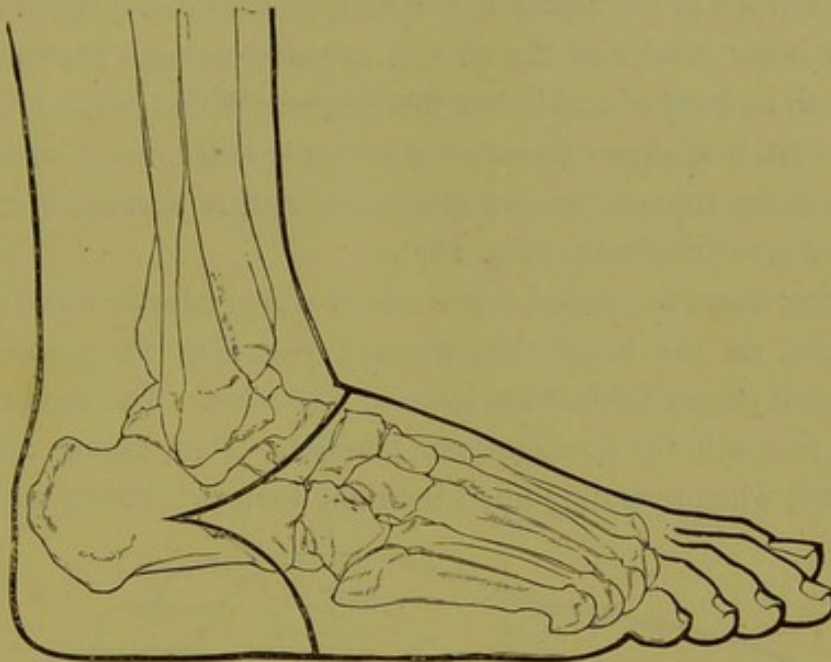


FIG. 187.—Incision on the outside of the foot in Lefort's amputation.

level of the base of the malleoli. The incision in the soft parts is made after the manner suggested by Roux, being commenced three-quarters of an inch below the external malleolus (Fig. 187), and continued forwards a

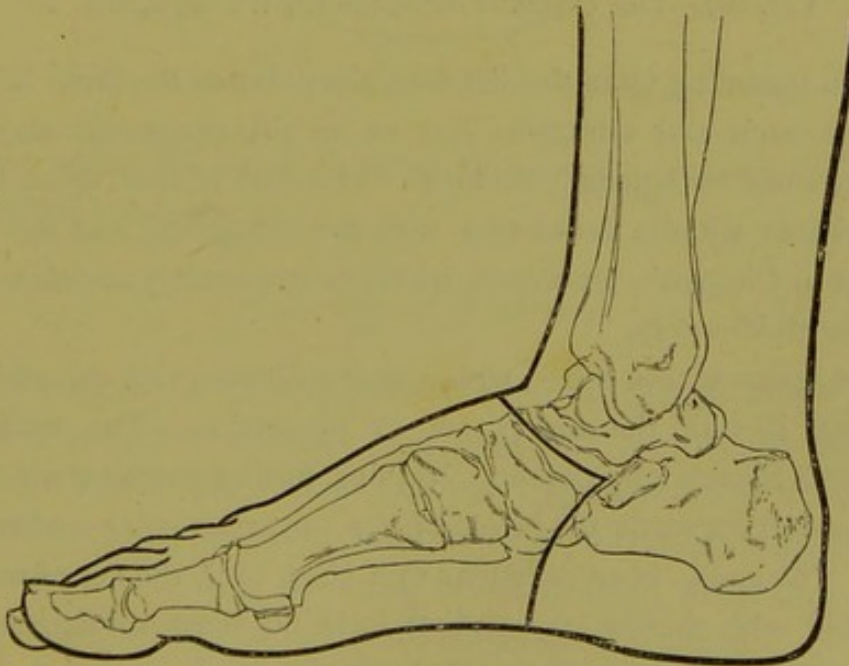


FIG. 188.—Incision on the inside of the foot in Lefort's amputation

far as the anterior third of the calcaneum. Having reached this point, the knife describes a curve across the dorsum of the foot, whose anterior convexity corresponds to the astragalo-scaploid articulation. When the knife reaches the inner border of the foot, it is made to pass backwards, and stops one inch in front of and below the inner malleolus (Fig. 188). Then raising the foot, a slightly convex plantar flap is made, which passes transversely across the sole of the foot (Fig. 189), and rejoins the first incision below the external malleolus (Fig. 187).

This being done, the dorsal flap is raised and great care taken to detach the soft parts, on the inner side, without wounding the posterior tibial artery, where it passes behind the internal malleolus. The ligaments connecting the foot with the fibula are not divided. Then taking the foot in the left hand, when operating upon the right foot, or making an assistant

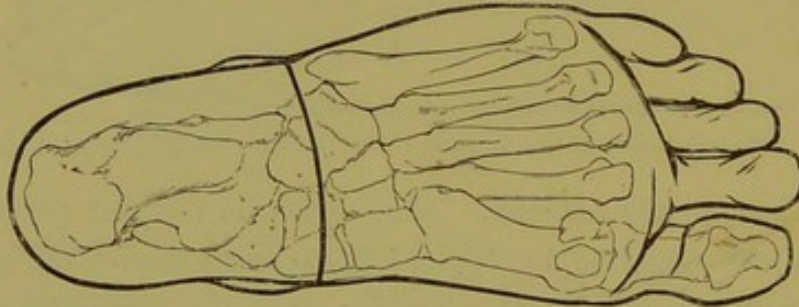


FIG. 189.—Line of plantar incision in Lefort's amputation.

hold it when operating upon the left foot, the point of the knife is entered between the calcis and astragalus just as in sub-astragaloid amputation, and the interosseous ligament divided. The foot is now separated and luxated inwards without interfering with the astragalus, and the foot is removed as in Chopart's procedure, which more certainly avoids wounding the posterior tibial artery.

The astragalus is now seized with a strong forceps, and everything that still connects it with the leg is cut in succession. The malleoli are removed as in Syme's amputation. Nothing further remains save to saw off from behind forwards the whole of the upper articular surface of the os calcis. The stump is an excellent one (Fig. 190), the act of walking is accomplished with facility, the patient feels no sense of fatigue, and a simple boot with a circular sole is all that is afterwards needed.

This operation may be more easily and rapidly performed after making the same incision in the soft parts by first opening the tibio-tarsal articulation, disengaging the upper margin of the tuberosity of the calcaneum, and making the saw traverse the bone horizontally forwards. There will then be no need to invade the astragalo-calcanean articulation, the upper articular surface of the calcaneum being removed with the rest of the foot. There is the great advantage of having a good solid purchase on the rest

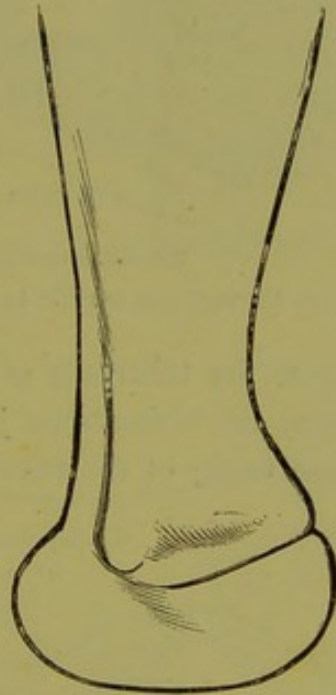


FIG. 190.—Stump after Lefort's modification of Pirogoff.

of the foot, whilst the calcis is being divided, the remaining connections being divided subsequently.

AMPUTATION OF THE LEG.

Indications.—The leg may require to be amputated either low down close to the ankle, in the middle portion, or high up, near the knee. Both the flap method of amputation and the circular method are applicable. The chief reasons for operation are compound fractures, destruction of the foot by injury or disease involving the ankle-joint, frost-bite, gangrene, malignant tumours of either the bones or of the soft parts.

The bones of the leg may be sawn through at any point, either close to

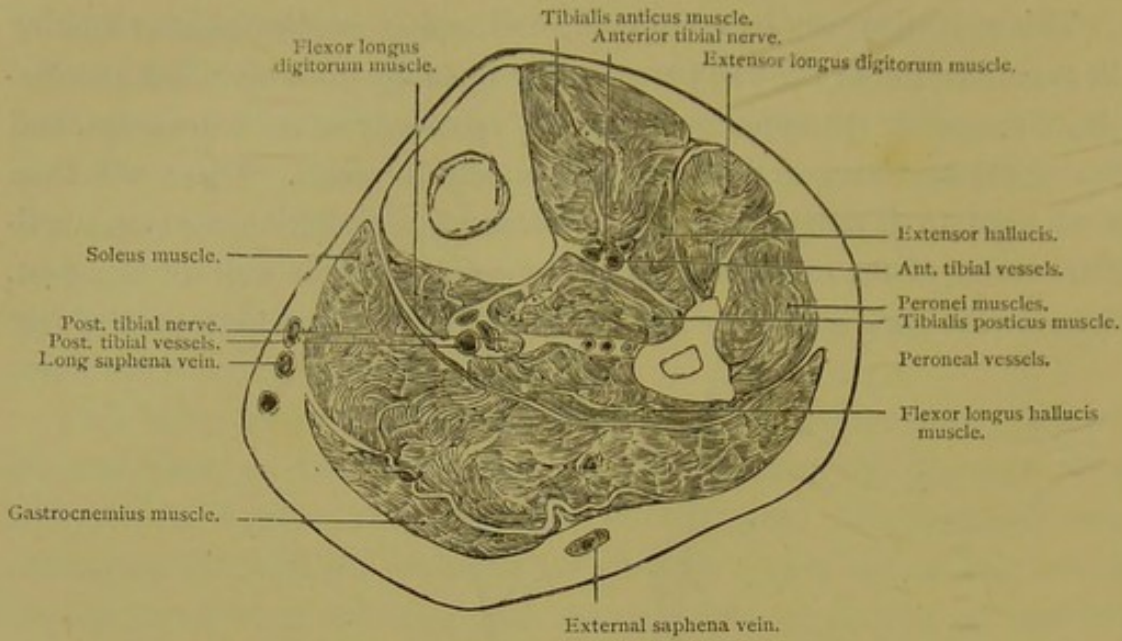


FIG. 191.—Section through the middle of the left leg.

the lower end or as high up as the tuberosity of the tibia. Above this is undesirable, as one may open the tibio-fibular joint, and this frequently communicates with the general cavity of the knee-joint. I have, however,

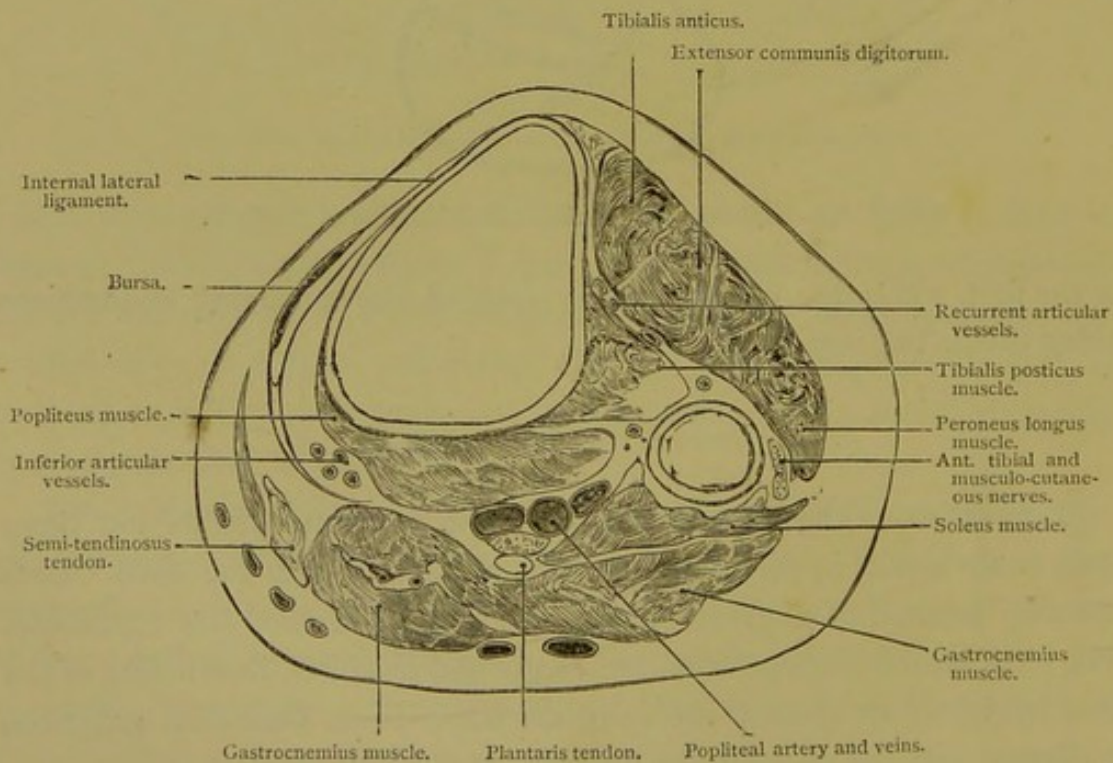


FIG. 192.—Section through left leg close to the knee.

in some cases of high amputation removed the head of the fibula with advantage.

SUPRA-MALLEOLAR AMPUTATION.

Indications.—Frost-bite, gangrene, or injury of the foot.

Surgical anatomy.—The deep structures in this position are largely composed of the various tendons passing around the ankle-joint. The anterior tibial vessels lie deeply on the interosseous membrane and anterior surface of the tibia, between the extensor longus digitorum and extensor proprius hallucis tendons. The posterior tibial vessels lie close along the posterior border of the tibia just external to the tendon of the flexor longus digitorum, and the peroneal vessels lie along the posterior border of the fibula covered by the flexor longus pollicis muscle.

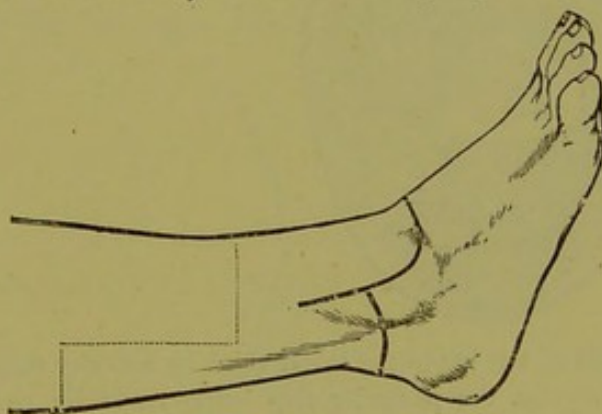


FIG. 193.—Amputation just above the ankle by an anterior flap, and a little higher by a square flap. Modified scale.

Operation.—The circular method may be practised, or two skin flaps made, the anterior one being the longer (Fig. 193). The latter is the preferable plan in this situation. The position and shape of the flaps, will here as elsewhere require frequent modification. The skin in the lower fourth of the leg is very fixed, not easily retracted, and is not well suited to form a manchette. On the inner surface of the tibia the skin is very thin and closely connected with the periosteum, which, if practicable, should be raised together with it.

A small amputation knife or long scalpel may be employed. With this the skin may be divided circularly, and if a manchette be dissected up, this procedure will be facilitated by a vertical incision, an inch long, at opposite sides of the limb; then the deeper parts are divided circularly

and the bones sawn through, taking care that the fibula shall be sawn through before the tibia is completely divided.

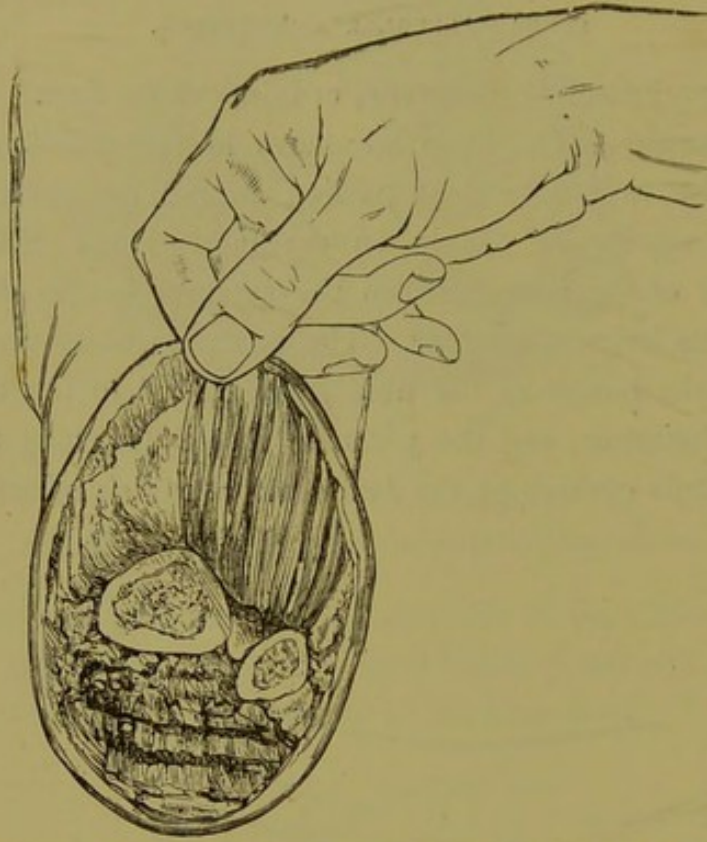


FIG. 194.—Amputation of the leg in the lower third by anterior flaps formed by cutting from without inwardly, the posterior flap being made by transfixion. The same method can be adopted in any other part of the leg.

Amputation may be performed in any part of the leg by a long rounded anterior flap composed of skin and subcutaneous tissue equal at its base to half the diameter of the limb, and terminating on the outer side opposite

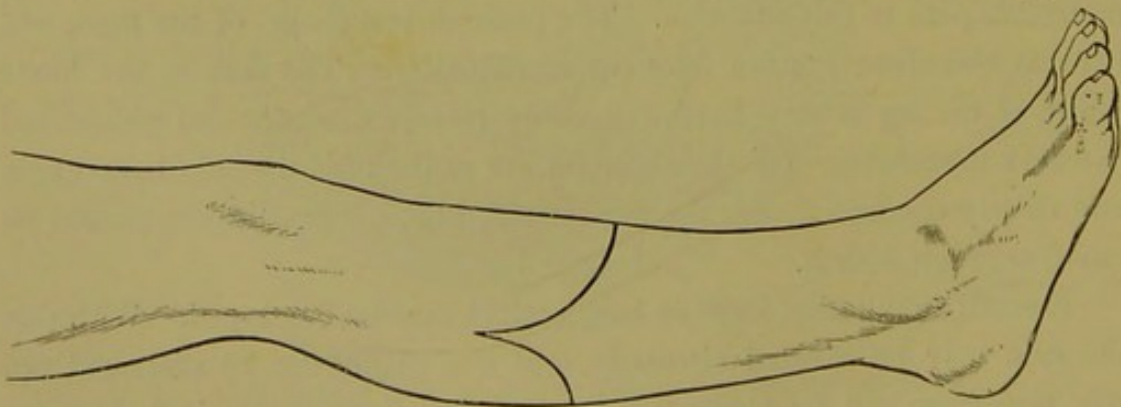

FIG. 195.—Amputation in the upper third of the leg by means of anterior and posterior flaps, the anterior being the longer.

the fibula. When the knife is introduced to form the posterior shorter flap by cutting outwards, the risk of passing it between the bones is avoided.

The anterior and posterior tibial vessels, the peroneal artery and a few muscular branches require ligature (Fig. 191).

Teale's method is adopted by some in amputating the leg, and is carried out in a manner similar to that in other parts. The long anterior flap must be somewhat irregular, being thin when it is taken from the inner surface of the tibia, and thick where it includes the muscles lying between the bones.

SÉDILLOT'S METHOD OF AMPUTATING THE LEG.

An operation devised and practised by Sédillot, and thus described by him, will in some cases be found an excellent proceeding in the upper part of the limb. In the left leg: The surgeon, standing in front of the limb

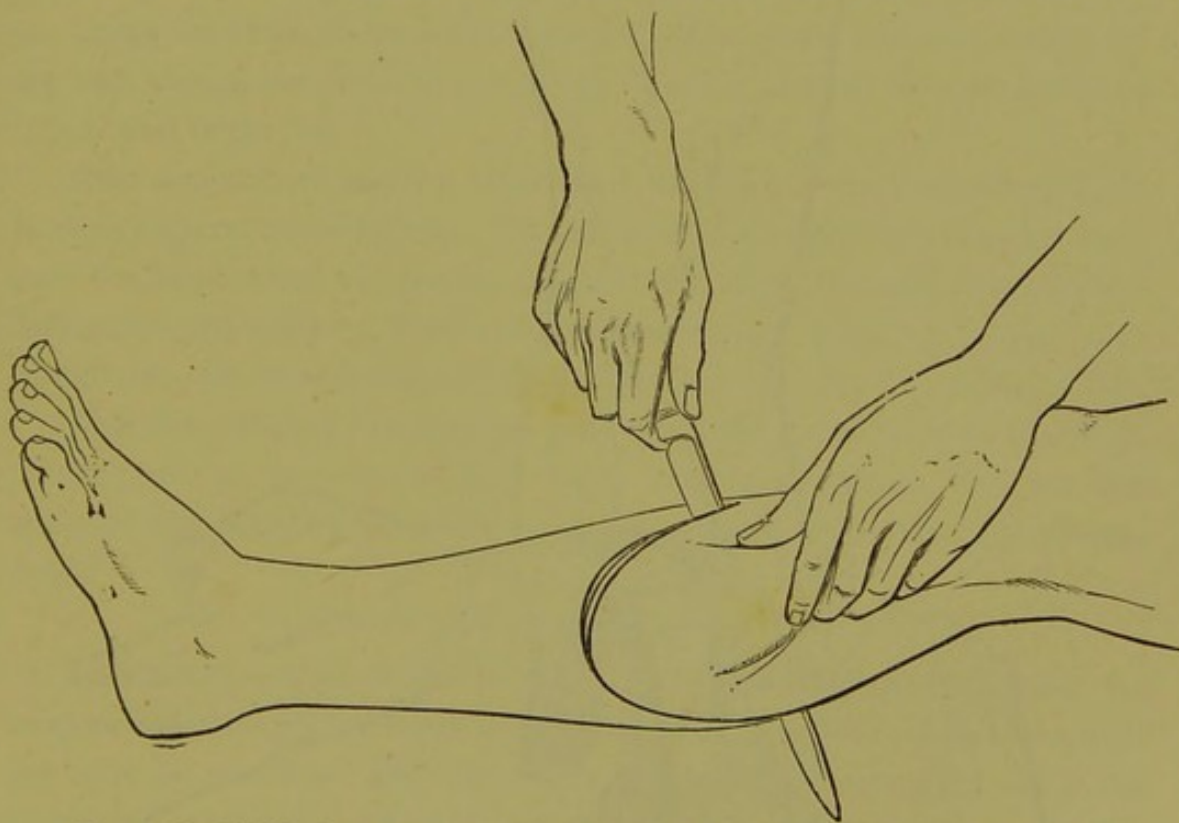


FIG. 196.—Sédillot's amputation of the leg method of forming the long external flap.

and having its external surface held upwards, seizes the skin and muscles over the upper outer part of the leg in his left hand, and lifts them off the fibula (Fig. 196). He then enters the point of a transfixion knife about

two fingers' breadth below the tubercle of the tibia, and one finger's breadth external to the crest. He transfixes the limb from before backwards towards

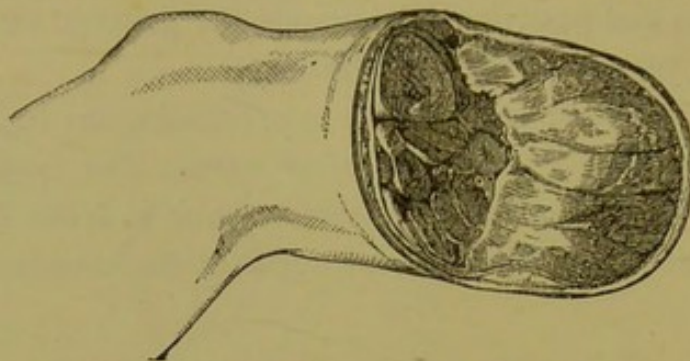


FIG. 197.—Sédillot's amputation of the leg.

the fibula, touching this latter bone and bringing the point out about two fingers' breadth above the level of the point of entrance. He then cuts

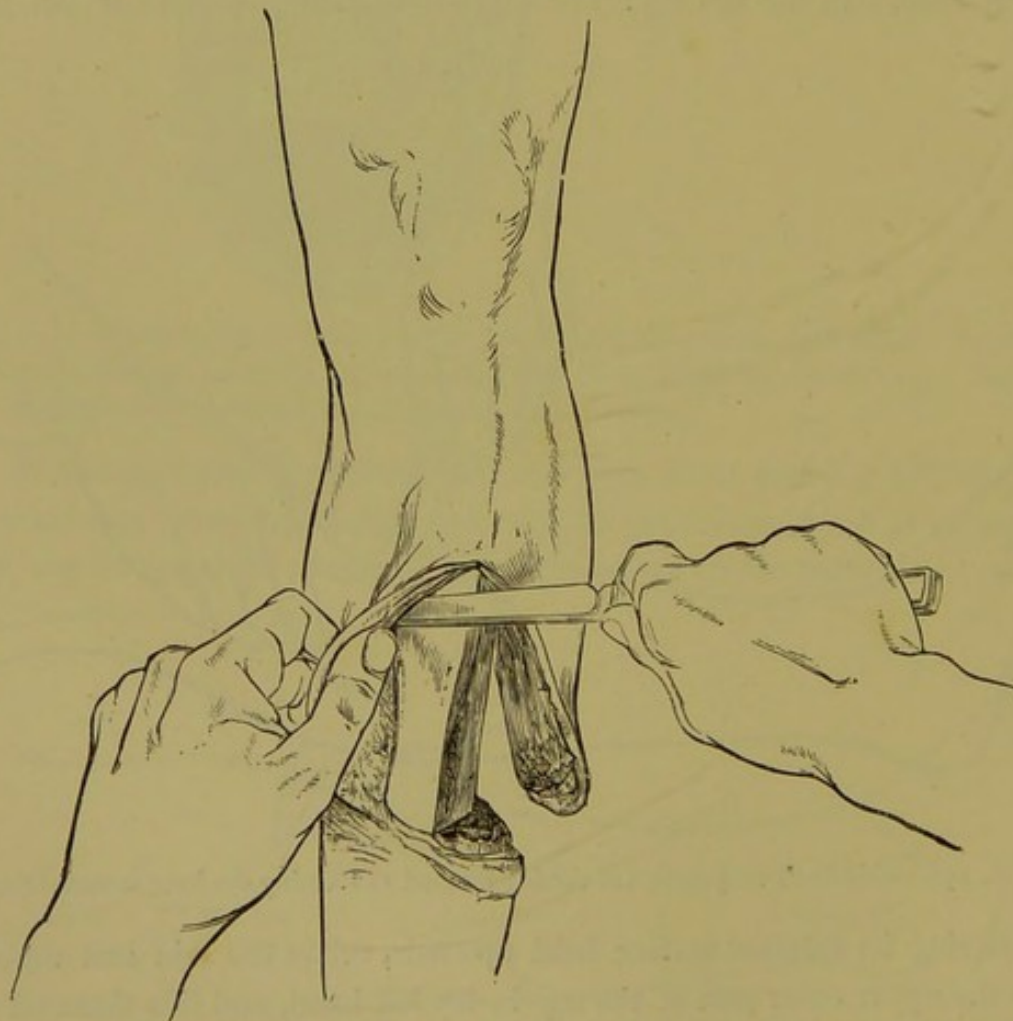


FIG. 198.—Lateral flap method of amputation of the leg.

downwards and forms a flap about four inches in length, formed of the peroneal and part of the gastrocnemius muscles. An assistant retracts the flap, and the operator then divides the soft parts on the inner side by an incision from one end of the flap to the other in a circular manner, with a slight convexity directed downwards. The internal incision can also be begun and ended a little below the base of the flap, and so preserve more skin. The operator then clears the remainder of the muscles from the bones, so as to allow the application of the saw close below the tubercle of the tibia (Fig. 197).

Lateral flaps of equal length may also be formed (Fig. 198), either chiefly muscular or of skin only. Ordinarily antero-posterior flaps are made (Fig. 195), which may be either cutaneous or muscular, the anterior being the longer. The anterior flap had better be made by cutting from without inwards, the posterior by transfixion, and then the tissues around the bones are to be divided with a Catlin. The sharp anterior portion of the tibia should always be rounded off. Teale's method is also practised in any part of the leg.

After amputation near the tubercle of the tibia, it is sometimes difficult to detect the retracted arteries. The anterior tibial artery is generally found near the interosseous membrane, where it lies deep between the muscles. Behind are the posterior tibial and peroneal arteries, lying on a deep layer of muscles—the former near the tibia, the latter near the fibula (Fig. 195).

It is inexpedient in amputation high up in the leg to remove the head of the fibula as has been advised. In a certain proportion of cases the superior tibio-fibular articulation communicates with the cavity of the knee-joint.

DISARTICULATION AT THE KNEE-JOINT.

Indications.—This operation may be performed, as a substitute for amputation through the lower third of the femur, in cases where the whole leg must be sacrificed, and the femur is intact. In successful cases the stump is a large broad one, well fitted to sustain pressure on its extremity, and patients can walk better with an artificial limb than when amputation is performed through the thigh.

It was strongly recommended by Baudens, Markoe, and Velpeau, and in this country by Lane, Pollock, and others.

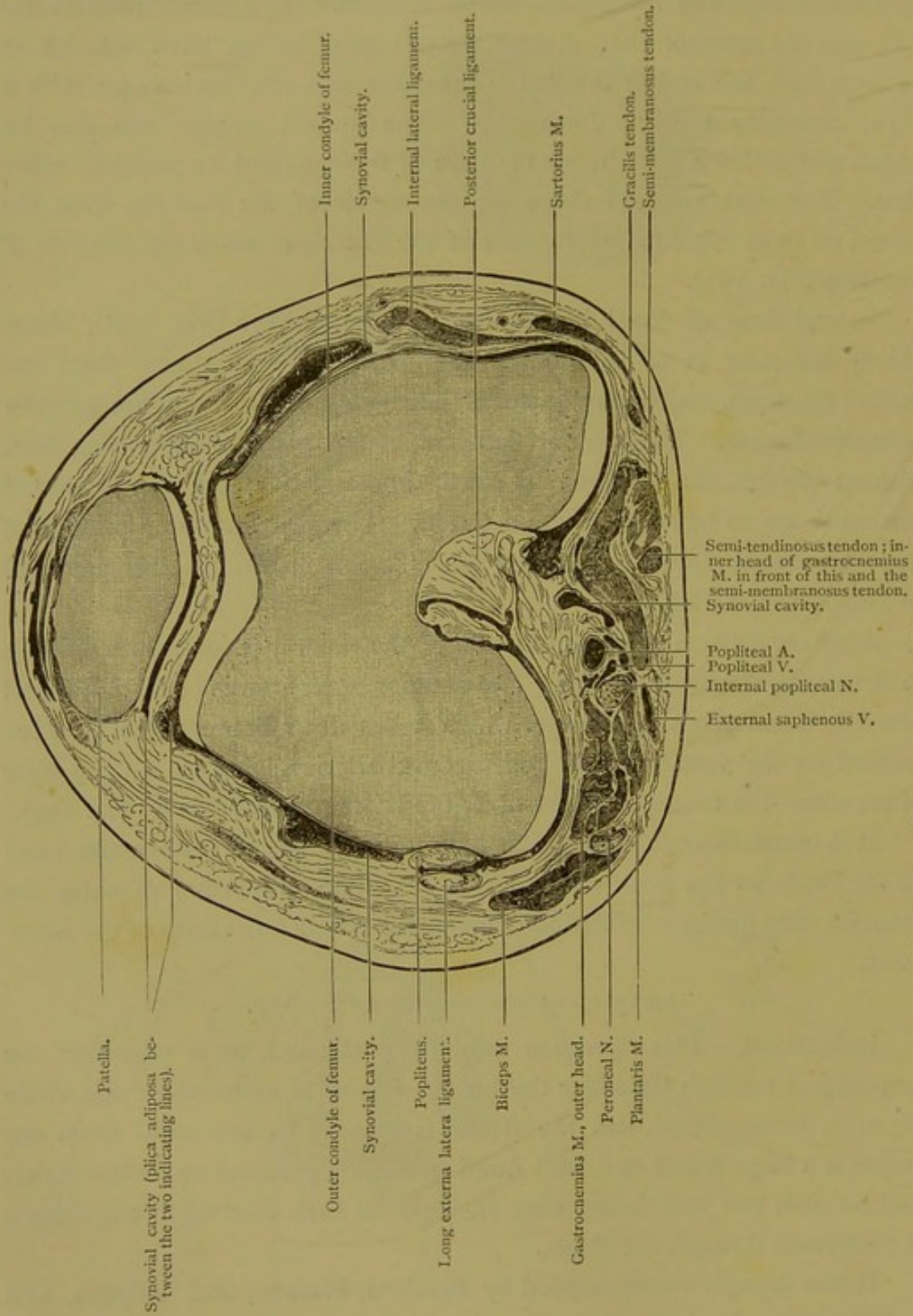


FIG. 199.—Transverse section through the condyles of the femur.

The operation has been objected to on account of the great length of the flaps requisite to cover the large rounded extremity of the femur, and of the alleged difficulty of fitting an artificial limb to the large extremity of the stump. The flaps are made chiefly of skin, the anterior one entirely so. This is of great length, by no means vascular, and not infrequently its margin has become gangrenous to a greater or less extent.

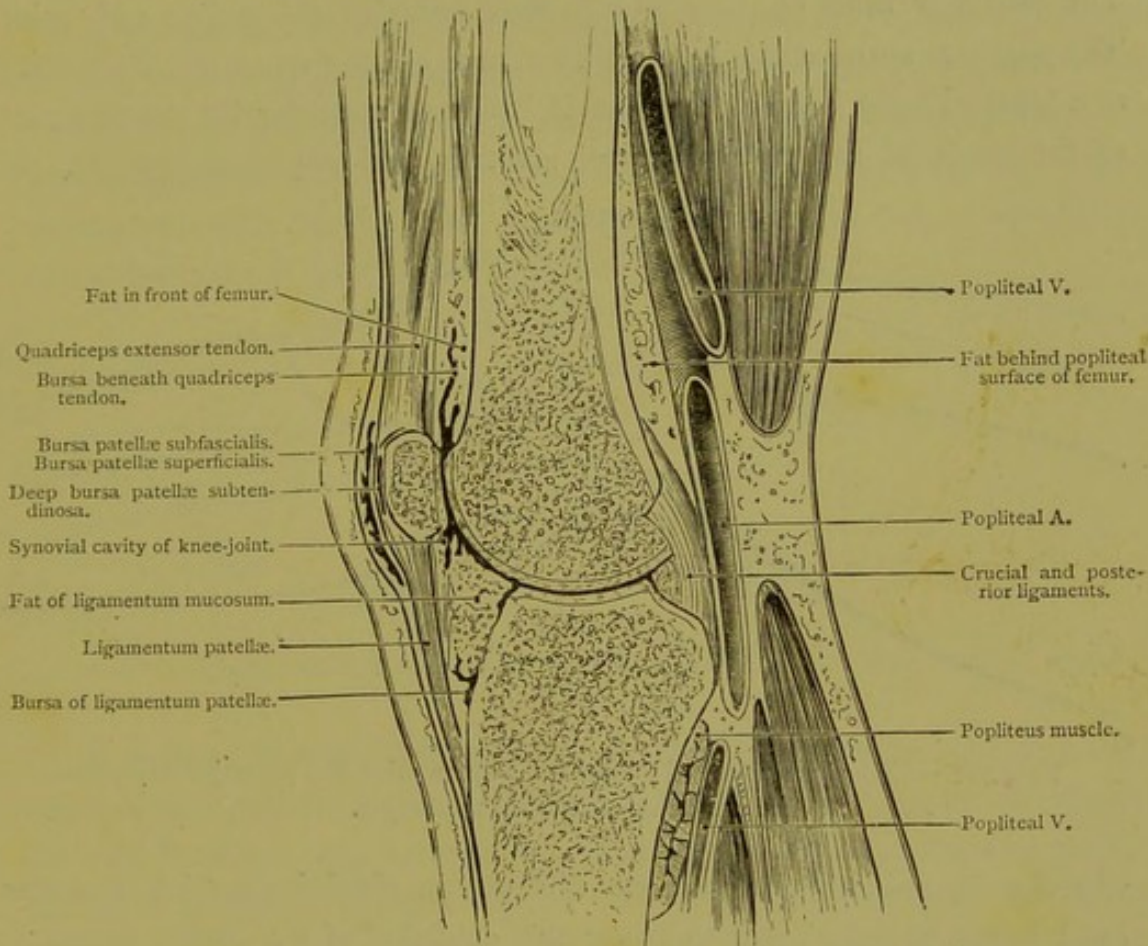


FIG. 200.—Vertical antero-posterior section through knee. The popliteal artery is almost in contact with the posterior margin of the tibia, but is separated by a considerable interval filled with fatty tissue from the femur (Figs. 199, 200), a fact to be borne in mind during resection of the joint.

Surgical anatomy.—Considered with reference to amputation, the anatomy of the parts surrounding the knee is peculiar. For nearly two-thirds of the circumference of the limb, anteriorly and extending upwards and downwards for about six inches, the investing structures of the bones comprising the articulating surfaces of the joint are composed of fibrous

tissues and tendons, complicated in parts with bursal sacs, and closely bound together by a fascial envelope (Fig. 199). In front is the large quadriceps extensor tendon (containing the patella) terminating below in the ligamentum patellæ. On the inner and outer sides, the lateral ligaments and internal and external hamstring tendons are all invested by processes of the fascia lata, and only covered by the skin and subcutaneous tissue. The posterior third of the circumference contains the artery and vein. The popliteal space above is in reality a large cellular space like the axilla; at a level with the head of the tibia it becomes muscular by the presence of the heads of the gastrocnemius, plantaris and popliteus muscles. It

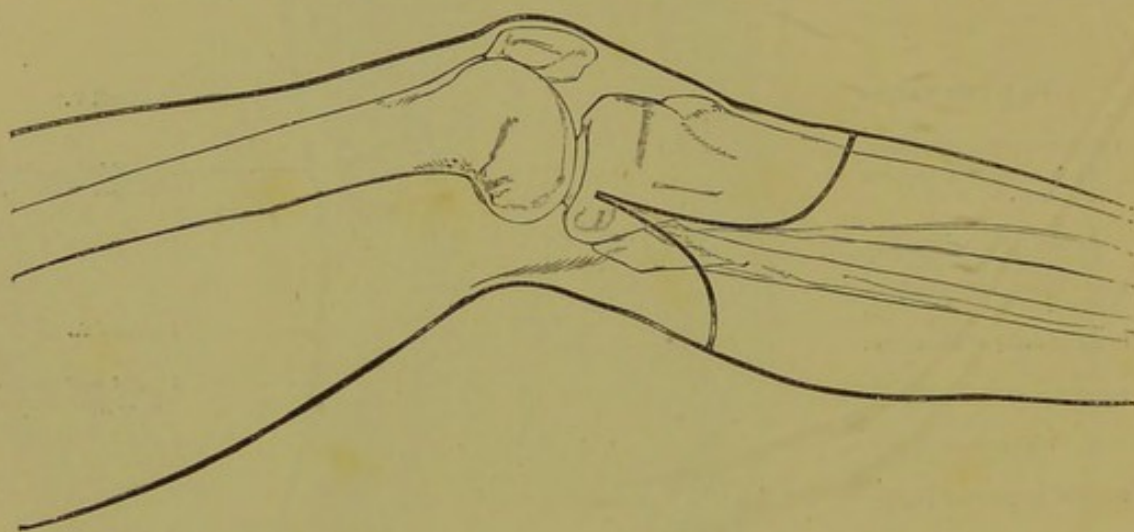


FIG. 201.—Disarticulation at the knee-joint by anterior and posterior flaps, the former being somewhat the longer.

will thus be seen there is a great difficulty in obtaining a thick muscular (and hence vascular) flap to cover the condyles of the femur, except it be taken from the calf of the leg and turned upwards over the condyles, a former method of performing the operation which is now abandoned.

Operation.—The two common methods of disarticulation at the knee-joint have been by means of a long anterior or a long posterior flap, the great disadvantage in the former case being that the end of the flap frequently mortifies. While if a long posterior flap be made, especially if it include the muscles of the calf, its weight is very great, and the constant tendency to fall down and retract terminates frequently in protrusion of the bone. After a considerable experience, I think that the best stump

may be formed by making the anterior and posterior flaps of nearly equal length, or from about five to six inches (Figs. 201, 202), neither will be so long as a single flap must be, and gangrene will not occur. The retraction of the soft parts on the back of the limb is often excessive, and the skin and tissues divided several inches below the line of the articulation on the posterior aspect of the limb will very soon retract, so as to be on a level with the end of the bone, and eventually the line of junction of the flaps will be considerably drawn up above and behind it. This excessive tendency to retraction will be to a large extent obviated by preserving the semilunar cartilages, and leaving them undisturbed in their connections with the femur as advocated by Brinton, in 1872. But this is not always easy of accomplishment.

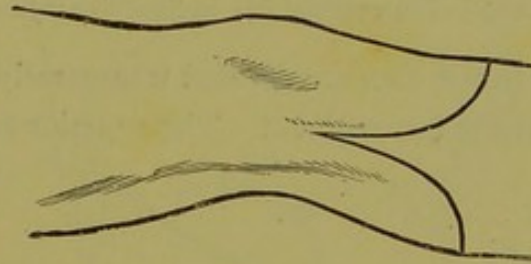


FIG. 202.—Disarticulation of the knee by antero-posterior flaps made of equal length.

It is best to make both flaps by cutting from without inwards; they will embrace half the circumference of the limb at their bases, and should be quite broad at their extremities. The anterior flap may be first made; the knife is usually entered on one side of the joint an inch below the line of the articulation and carried vertically downward for four inches, then across the front of the tibia, with a broad convexity downwards, and finally brought upwards to a point exactly corresponding to the commencement of the incision on the opposite side of the limb. The anterior flap extending about five inches below the lower margin of the patella, is dissected upwards, the ligamentum patellæ divided, and the joint laid open. The posterior flap, consisting like the anterior of skin and subcutaneous tissue, or in some cases a thin slice of the muscular tissue, is mapped out by an incision on the back of the limb and then dissected up, or it may be completed by cutting outwards after the ligaments have been divided.

Both flaps being now held upwards by an assistant, the remaining soft parts are divided by a circular sweep of the knife, and the limb separated. In

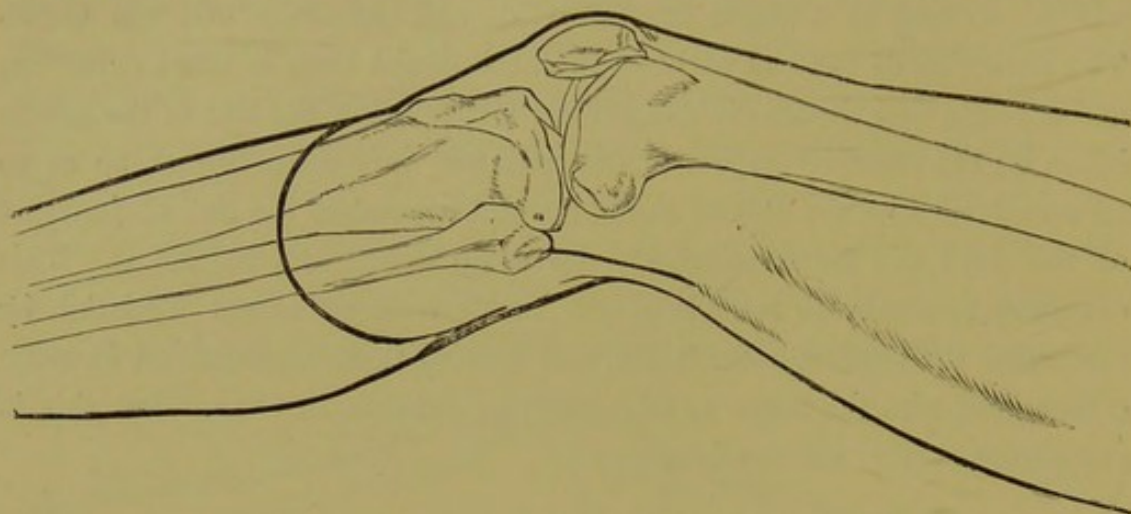


FIG. 203.—The external flap in Smith's amputation.

this way the tissues in the ham are divided transversely, the popliteal artery and vein being cut at the last moment. The superior pouch of the synovial

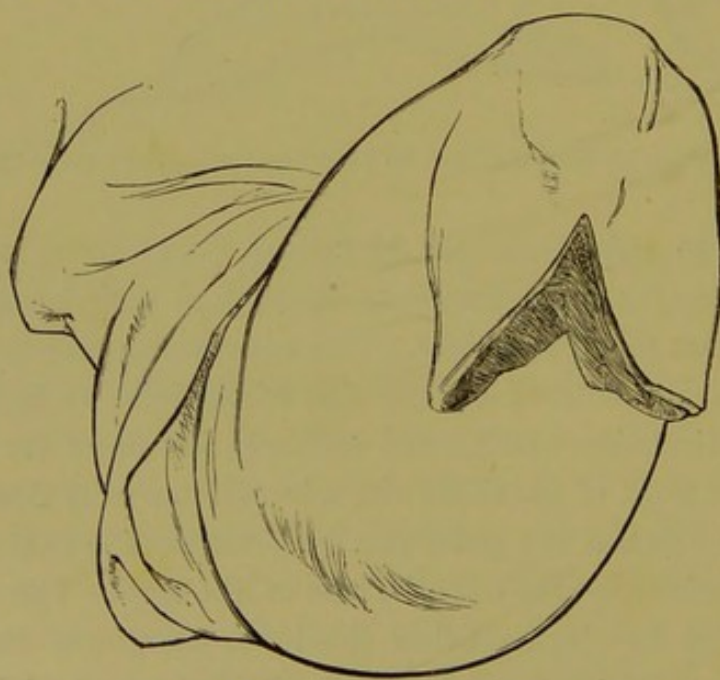


FIG. 204.—Appearance of the parts, showing the formation of the flaps in Smith's amputation.

membrane and the lateral connections of the patella are not disturbed or interfered with ; the semilunar cartilages are either left covering the end of

the femur, or, if necessary, may be dissected out. It is better, however, to leave them. By this mode of operating there is much less chance of gangrene in the flaps (Figs. 201, 202).

Stephen Smith advised the following method of disarticulating the knee by two lateral flaps (Figs. 203, 204).

Commence the incisions in front one inch below the tubercle of the tibia, and carry them downwards and forwards over the front of the leg; laterally the incisions should curve moderately downwards on each side of the leg till they reach the posterior surface, when they curve upwards and

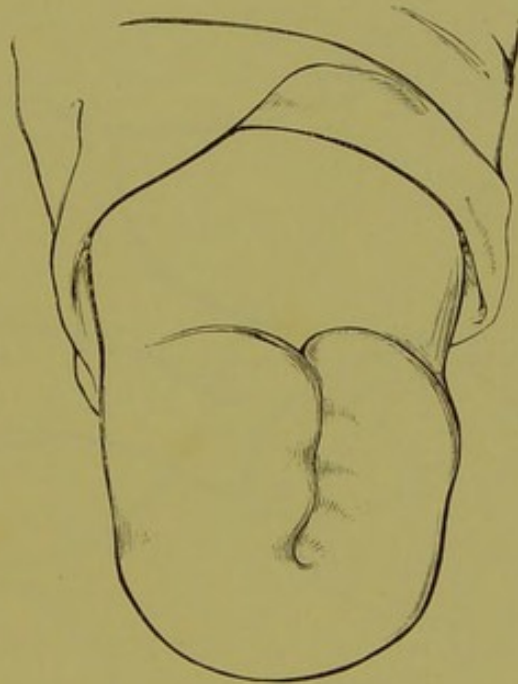


FIG. 205.—Stump after Stephen Smith's amputation, seen from behind.

meet in the ham in the median line (Fig. 203), being continued directly upwards as far as the line of the articulation. The skin, fascia and cellular tissue are now reflected, the ligamentum patella divided, and the joint structures severed. The patella is left. The inner flap should be somewhat longer to ensure sufficient cover for the larger internal condyle.

The appearance of the flaps directly after the disarticulation are seen in Fig. 204. The end of the femur is well covered, and the stump subsequently presents the form seen in Fig. 205; after cicatrization is complete the scar will lie over the notch between the condyles out of the way of pressure.

The operation may be also performed by means of two lateral flaps of equal length formed by cutting from without inwards, or one may be somewhat longer than the other if the circumstances demand it, or the circular method strongly advocated by Velpeau, in 1829, may be adopted, but these are not such good operations as those first described. When the

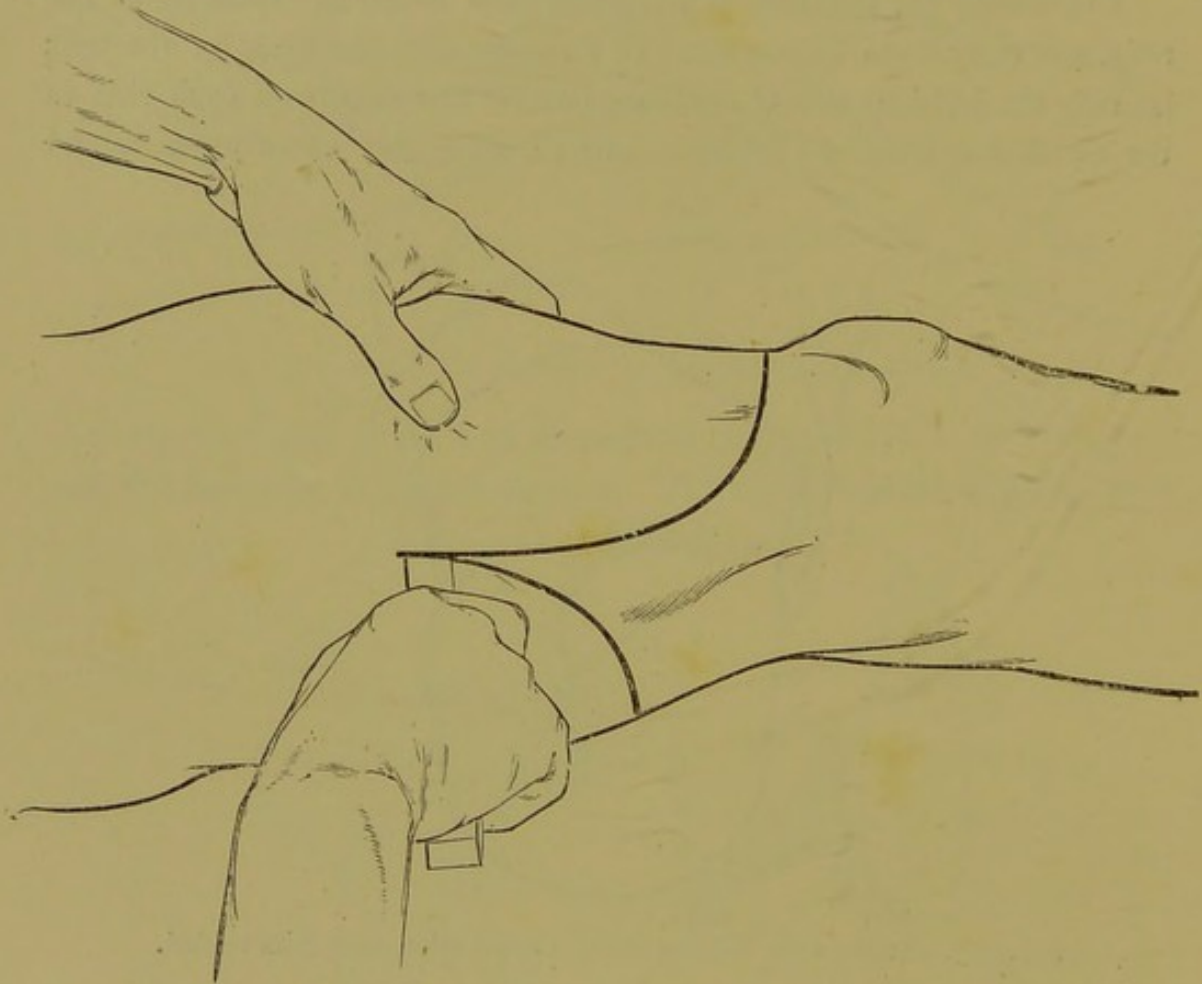


FIG. 206.—Method of amputating the thigh by means of double flaps formed by transfixion.

operation is done with antiseptic precautions, suppuration, particularly in the synovial pouch, is not likely to take place. A drainage tube had better, however, be inserted into it from each angle of the wound.

AMPUTATION OF THE THIGH.

Indications.—Amputations of the thigh are very frequently performed on account of disease or injury affecting the knee-joint and leg, for tumours

in the upper part of the leg, lower part of the thigh, or for gangrene of the leg. The operation may be performed by means of the circular method or some form of flap amputation.

The best method is probably by a longer anterior flap and a shorter posterior one, in which the principal vessels and nerves should always be

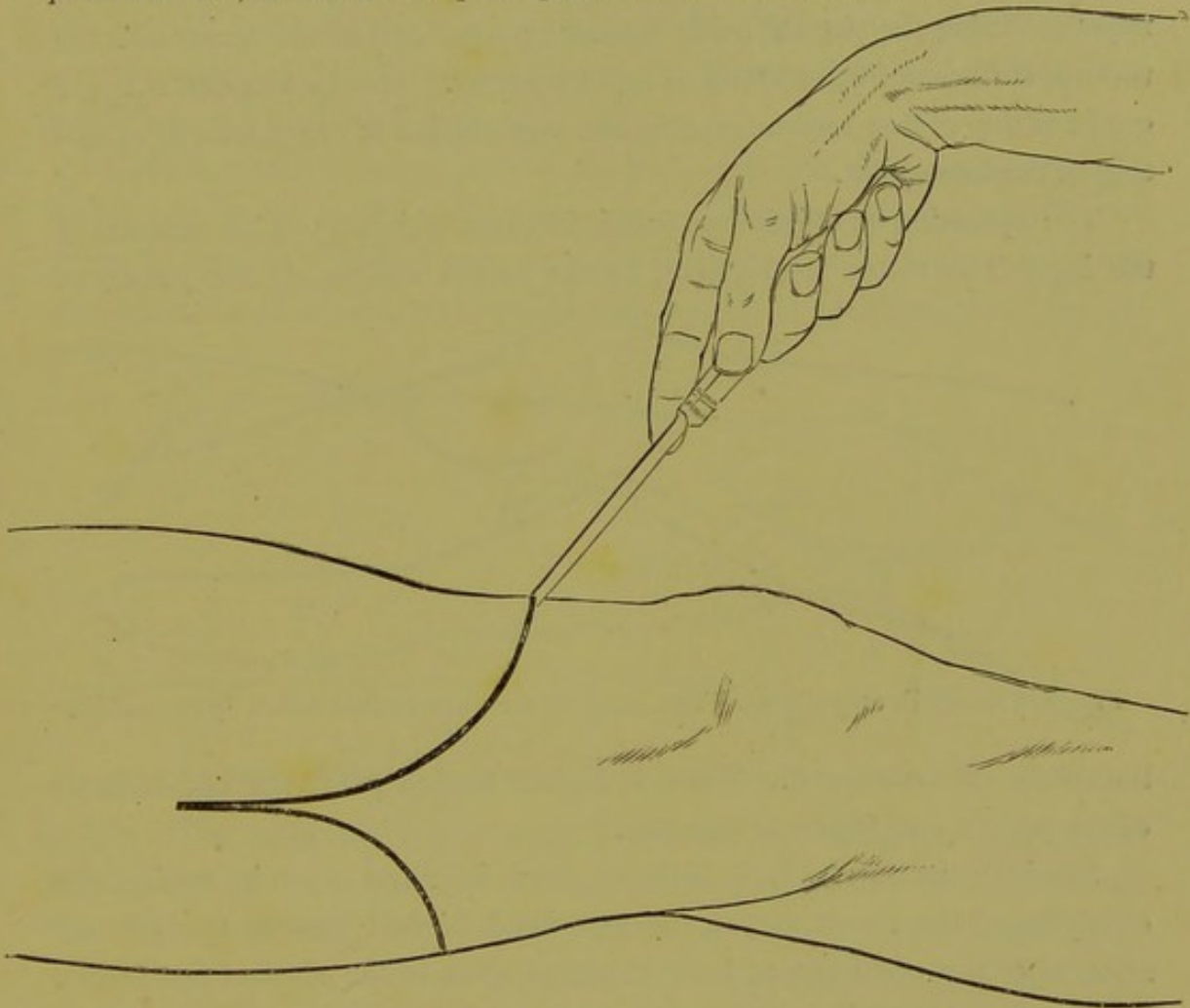


FIG. 207.—Method of amputating the thigh by means of double flaps the anterior being formed by cutting from without inwards. In most cases the surgeon will fashion the anterior flap in this way, and complete the operation by forming the posterior flap by transfixion, or both flaps may be formed by transfixion.

contained. The flap may be made by transfixion or by cutting from without inwards (Fig. 207).

GRITTI'S OSTEO-PLASTIC AMPUTATION THROUGH THE CONDYLES OF THE FEMUR.

In cases where disarticulation at the knee-joint cannot be performed, or is inadvisable, the supra-condyloid amputation introduced by Carden

of Worcester, or the operation advised by Gritti of Milan, may be substituted.

Indications.—In suitable cases the method of amputation introduced by Gritti of Milan may be performed. In this, the condyloid surface of the femur is sawn off, and also the articular surface of the patella, the anterior flap containing the patella being turned over the end of the femur and the two cut surfaces of bone made to unite together. It is to Velpeau that the credit is due of first recommending the preservation of the patella in operating at the knee-joint.

The operation is chiefly applicable in cases of injury, or for tumours of the leg. The result is excellent, so far as the weight-bearing powers of

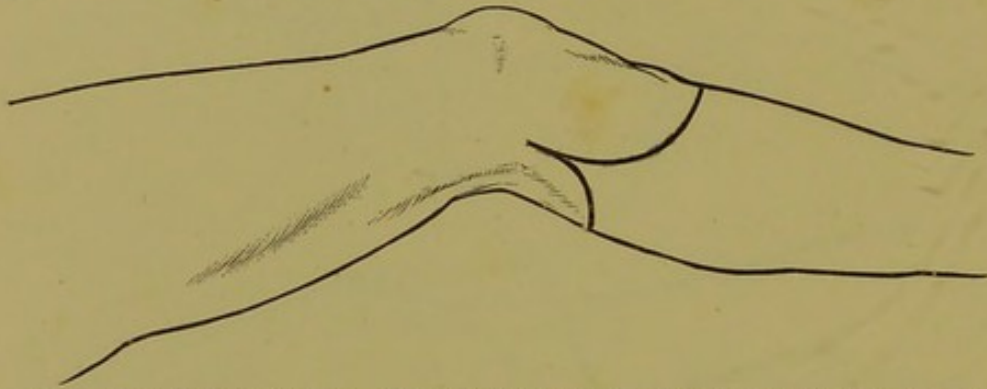

FIG. 208.—Gritti's amputation. The incisions are those recommended by the author.

the stump are concerned. There is a great tendency for the cut surfaces of the patella and femur to separate.

Surgical anatomy.—It is well to bear in mind that in sawing the condyles of the femur across, the saw must be laid parallel to the lower surfaces of the condyles, and not at right angles to the shaft of the femur. The surface that will subsequently sustain the pressure will thus more nearly resemble the natural direction of the condyles.

Operation.—The operation can be performed by making an incision commencing on the inner or outer side of the joint opposite the line of the articulation, and passing across the front of the limb a little below the tubercle of the tibia so as to form a somewhat square-shaped flap. The base of the anterior flap is equal to half the circumference of the limb. The convexity should extend about one inch below the insertion of the ligamentum patellæ. This flap, containing the patella and surrounding

structures, is now reflected, the articulation opened, and the short posterior flap made by cutting from within outwards. The shape of the posterior flap may be first mapped out with advantage. The condyloid extremity of the femur is then sawn off, and the articular surface of the patella. After the bleeding points are carefully secured, the anterior flap is turned down and the patella fastened to the cut surface of the femur by one or two silver sutures, which are twisted and cut short, the flaps being united and drainage tubes inserted in the ordinary way.

Stokes' modification of Gritti's amputation largely obviates a difficulty which sometimes occurs, in keeping the cut surfaces of the patella and femur in contact. Stokes saws through the femur at a point one-half to three-quarters of an inch above the upper margin of the cartilage of encrus-

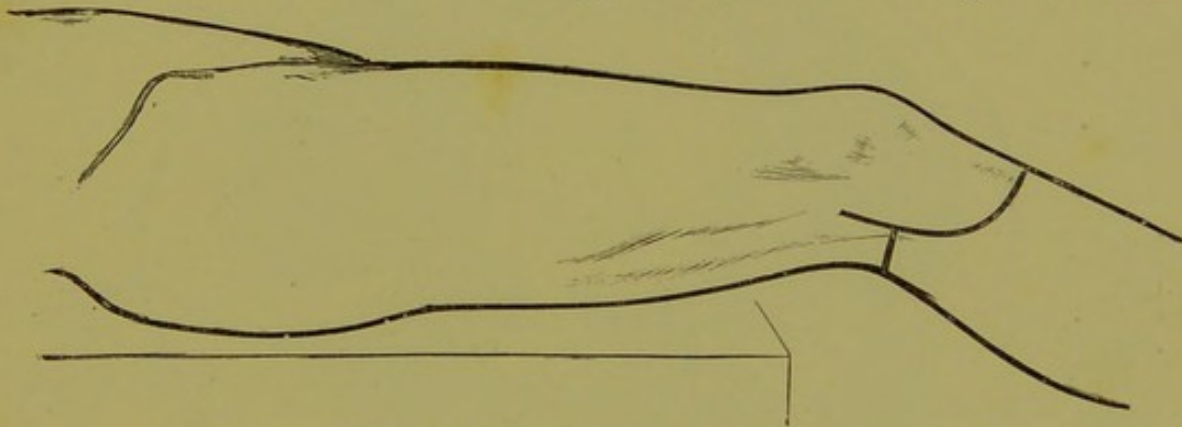


FIG. 209.—Incisions for Stokes' supra-condyloid amputation of the thigh.

tation. The medullary cavity of the femur will not be opened, and tilting forward the patella is avoided. The anterior flap should be oval, extend from a point one inch above either condyle to the other, and reach downwards as far as the tubercle of the tibia. A posterior flap, at least one-third the length of the anterior, is then made by cutting from without inwards. After the bones have been sawn through, the patella should be fastened to the cut extremity of the femur by buried sutures of wire or chromicised catgut.

CARDEN'S AMPUTATION.

Indications.—This operation is performed when it is possible to divide the femur very low down: it has been called trans-condyloid, because the bone is sawn through the condyles, and of course the medullary canal of the bone is not opened.

Operation.—The operation is best performed by a long anterior flap made by cutting from without inwards, and a shorter posterior flap formed by transfixion, similar but slightly higher up than the flap lines in Fig. 208. Carden did not advise a posterior flap, but it is certainly necessary to make one, as the soft covering will otherwise be insufficient. The anterior flap, made in a manner similar to that in Gritti's amputation, should extend as far as the insertion of the ligamentum patellæ and have a

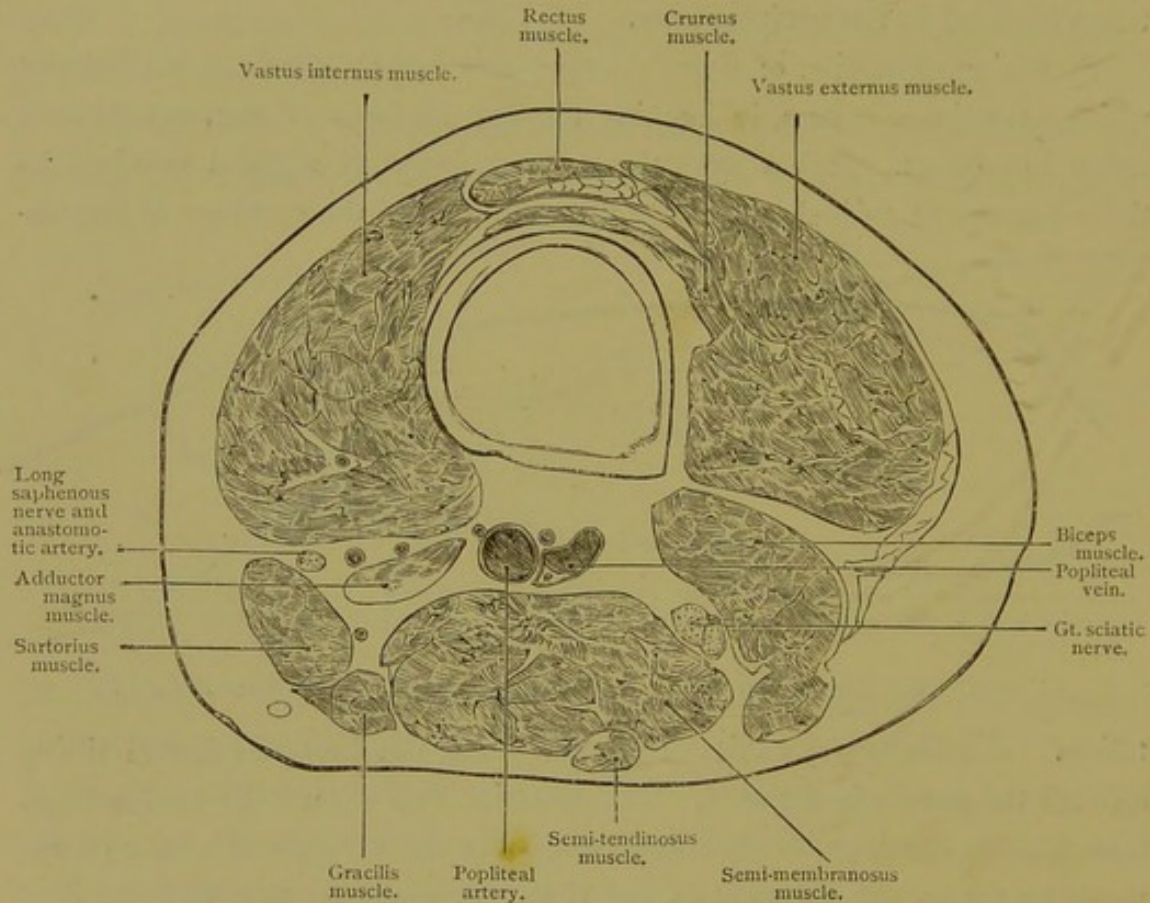


FIG. 210.—Section through the lower third of the left thigh.

broad extremity. It should be turned upwards after the knee-joint is laid open. The patella is dissected carefully out, keeping as close as possible to the bone. The remaining ligaments of the joint are divided and the posterior flap is formed. The soft parts are now to be retracted and the condyles sawn off, the stump being treated as before described. In cases of disease the synovial pouch may be dissected out, and a more speedy union accomplished. Where the amputation is performed for injury this proceeding is unnecessary.

FLAP AMPUTATION IN THE MIDDLE OR LOWER THIRDS OF THE THIGH.

Indications.—Injury and disease of the knee-joint, extensively involving the soft parts, and the lower end of the femur or the upper part of the leg.

Surgical anatomy.—In this position the main vessels lie to the inner and posterior side of the femur, and slightly separated from it by the vastus internus muscle. The termination of the profunda lies still further posterior, separated in the middle third of the femur from the femoral vessels by the insertion of the adductor longus, and the only other artery of importance is the descending branch of the external circumflex artery which lies beneath the vastus externus muscle. The bone approximately occupies the centre of the mass of muscles.

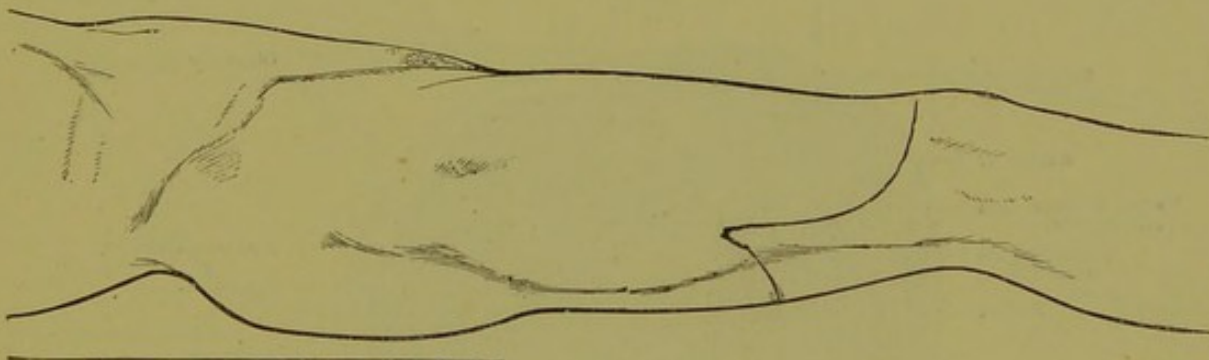


FIG. 211.—Amputation through the lower third of the thigh.

Operation.—The thigh may require to be amputated at any level, according to the necessities of the case, and the circular or flap method may be adopted according to the predilection of the operator. The surgeon should stand on the outer side of the right limb and inner side of the left. The patient is placed on the operating-table with the whole length of the thigh projecting beyond the end of it, the sound limb being fastened out of the way. An anterior flap, sufficiently long and broad to cover the face of the stump, and equal at its base to half the circumference of the limb, should be made by cutting from without inwards. The ends of the incision on the inner and outer side of the limb should be about an inch below the point selected for the division of the bone. In the first sweep of the knife the skin and subcutaneous tissue are to be cut through from end to end of the incision; then grasping the soft parts with the left hand and raising them up, the flap can be rapidly detached with one or two sweeps of the knife from side

to side, raising a layer of muscular tissue at the same time. The flap should be rather to the outer side of the limb, so that the femoral vessels shall not be included in it. The knife is then introduced from side to side behind the femur, at the upper extremity of the wound, and, after passing downwards a short way, it is made to cut almost directly outwards, thus forming a short posterior flap in which are placed the principal vessels.

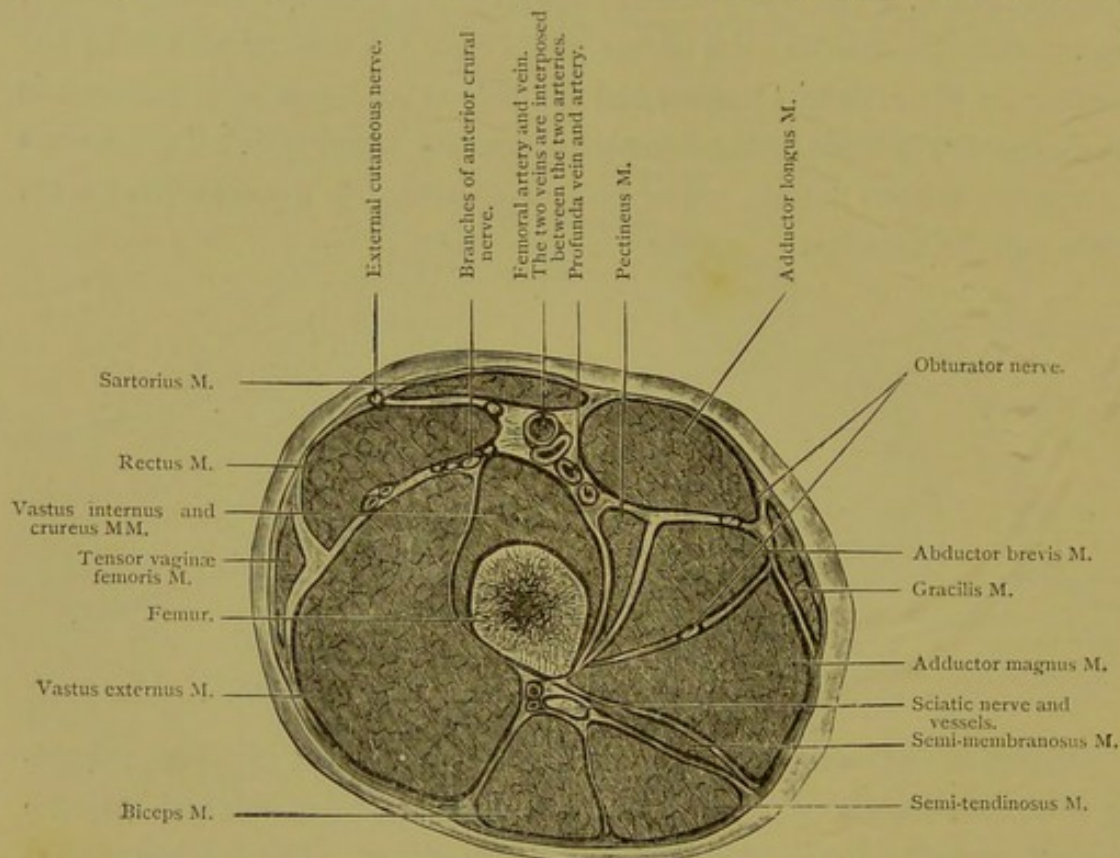


FIG. 212.—Transverse section of the right thigh at the apex of Scarpa's triangle. In this plate the position of the principal vessels requiring ligature is indicated.

The flaps must now be retracted. The periosteum is cut by a circular sweep of the scalpel, one inch below the point selected for sawing the bone, and separated up to this level with an elevator; along the linea aspera, a touch or two of the knife may be required. Then the bone is sawn through slowly and steadily, the linea aspera being cut through before section is completed, an assistant taking care to hold the limb in such a way as not to lock the saw and interfere with the free to-and-fro movement of the instrument, nor by depressing the limb unduly towards the termination of the sawing to cause splintering of the bone.

When all the bleeding points have been secured, and the flaps are brought together, the line of junction will be posterior to the bone. The subsequent greater retractility of the long muscles on the posterior aspect of the limb tends to draw the cicatrix considerably upwards out of the line of pressure. A tube a quarter of an inch in diameter should be passed from side to side across the base of the flaps, antiseptic dressings applied, then a posterior plaster-of-Paris splint to keep the parts steady and prevent the painful startings otherwise so liable to occur.

TEALE'S AMPUTATION.

The rules for this method of amputation, invented by Mr. Teale in 1853, are the same in all parts of the body.

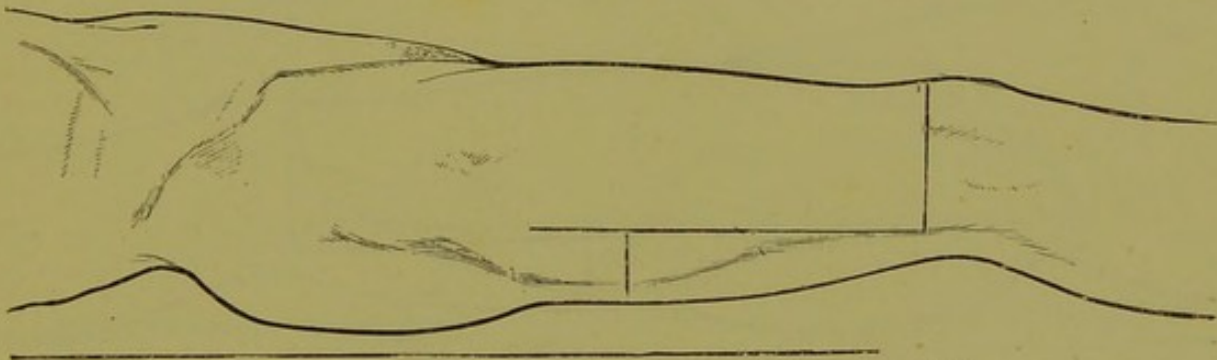


FIG. 213.—Teale's amputation in the middle of the thigh.

A long anterior square flap is formed containing all the muscular structures. This flap equals in length and breadth half the circumference of the limb at the point selected for sawing the bone. The posterior flap is arranged so as to contain the principal vessels and nerves, and is of the same width as the anterior, but only one-fourth the length.

If, for example, the circumference of the thigh be taken as twelve inches, the long anterior flap will be six inches long and six inches wide both at its base and at its extremity. The shorter posterior flap will also be six inches wide, but only one inch and a half in length.

It is first needful to mark the outline of the flaps on the limb after careful measurements have been taken. The incisions are then made exactly in the line of the markings, down to the bone, so that when the flaps are dissected up they include the entire thickness of the muscular tissue. When, however, the operation is undertaken for injury, and the limb is

well developed, it will be better to modify Mr. Teale's original direction and make the incisions less deeply, as in this way the cushion of muscular tissue will be less cumbrous. It should be remembered that, as the limb is more or less cone-shaped, and the flap a square one, the lateral incisions in the leg or thigh will not be parallel to the long axis of the limb but slope backwards.

After the bone is sawn through, the long flap is turned over its extremity, and can thus be exactly fitted and sutured to the posterior short flap. The chief advantages claimed for the method are an abundant covering for the end of the bone, and a more solid stump, capable of bearing pressure on its extremity. The great disadvantage is the necessity for dividing the bone at a much higher level than the necessity of the case

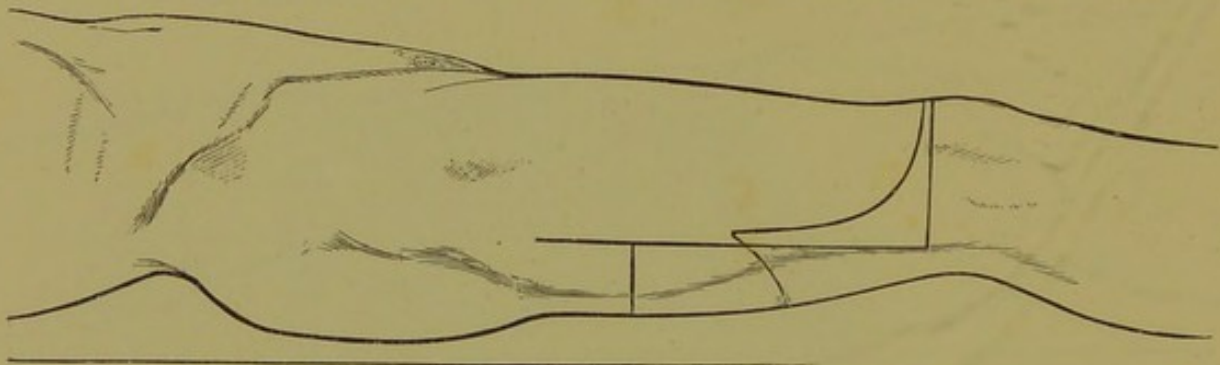


FIG. 214.—Contrast between the lines of incision required in Teale's amputation and those of the usual antero-posterior flap operation.

otherwise demands. In the thigh this is very apparent from the markings seen in Fig. 214, where the outline of Teale's flaps are contrasted with those of the ordinary antero-posterior method. By the latter, in a similar case, either of disease or injury, the bone may be sawn through at a much lower level, and with diminished risk to the patient.

Vermale's operation in the middle of the thigh is thus performed :—The operator seizes the fleshy mass external to the femur in his left hand and draws it outwards from the bone. He then enters the transfixion knife in the middle line, passes it down to the femur, around which the knife is made to pass until the point emerges as near the middle line behind as possible. A large flap is thus cut from within outwards from the external muscles of the thigh. Having entrusted this to an assistant, the surgeon again enters the point of the knife in the same

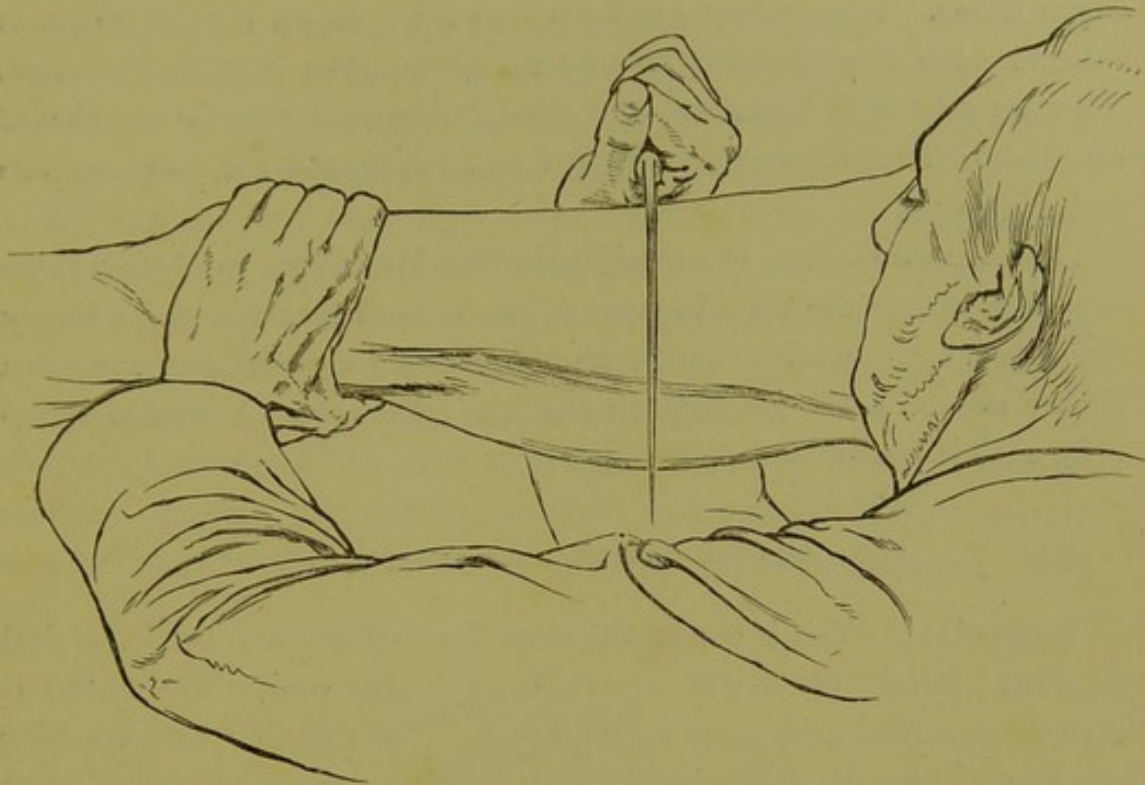


FIG. 215.—Application of the knife in performing a circular amputation of the left thigh.

place as before, and causes it to pass close to the internal side of the femur and brings it out at the same point behind. He then cuts a flap from within outwards on the inner side, making it somewhat shorter than the

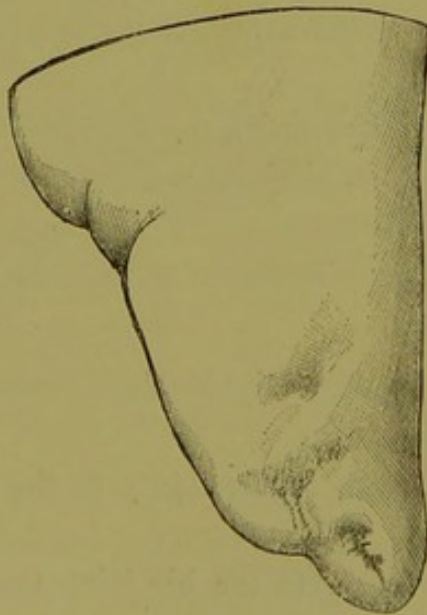


Fig. 216. A conical stump after circular amputation of the thigh.

external one. It is necessary to keep near the bone on the inner side, as otherwise the femoral artery may be cut higher than is advisable. Both flaps are now held back, and any remaining muscular fibres are divided circularly. The periosteum is incised and raised, and the bone sawn an inch higher up.

The circular method, or one with skin flaps, is often preferred through the central portion of the thigh in cases of injury, as the muscles are so largely developed. Amputation by the circular method may be performed in a similar manner at all positions in the limb (Fig. 215). A conical stump (Fig. 216) is not unlikely to result.

DISARTICULATION AT THE HIP-JOINT.

Indications.—This is one of the most formidable operations in surgical practice. Nearly one-fourth of the body is removed. The wound is a very large one, and close to the trunk. The difficulty of controlling bleeding during the operation is great, and the shock afterwards most serious. The disarticulation may be performed by means of a long anterior flap, which is the method generally preferred, or by a long posterior one, which is very undesirable. In other cases the method by lateral flaps or by circular or oval incisions, has occasionally been adopted. The operation is required for injury, tumours, gangrene of the limb after aneurism, or for disease not otherwise remediable—for instance, after a resection of the joint which has failed.

Lücke, from his experience during the Franco-German war, says, that in cases of gunshot injury of the hip-joint, expectant treatment, resection and disarticulation are alike disastrous.

He gives the following indications as respects the necessity of performing disarticulation :—

1. Tearing off of the extremity high up, or extreme laceration of the soft parts.
2. When, together with severe injury to the bone, the vessels are torn.
3. When, besides injury to the hip-joint, the femur is extensively shattered or the knee-joint of the same limb opened.

In civil practice disarticulation is only performed in cases not amenable to resection, as, for instance, tumours of the femur extending high up, and severe smashing; also where after excision the caries continues, suppuration and fistulæ persist, and the patient's strength is failing.

Heyfelder collected sixty-three cases which are statistically valuable; of these thirty-three recovered, and thirty died. Fifty-five of these operations were performed for coxitis and caries, with twenty-three deaths or 41.8 per cent. and nine for gunshot injury with eight deaths, in which there was therefore the large mortality of 88.8 per cent.

Surgical anatomy.—The position of the hip-joint in front of the thigh is midway between the anterior superior spine and the spine of the pubes, and about one inch below the level of Poupart's ligament. The

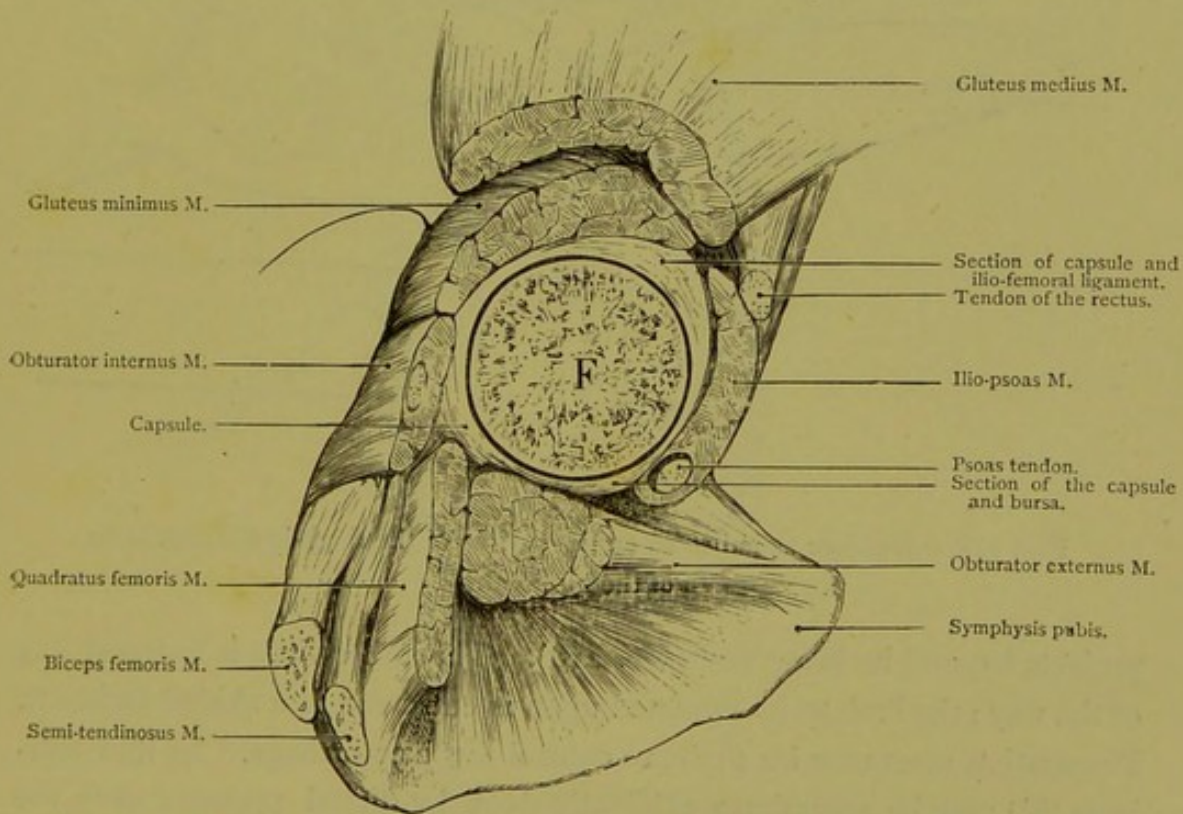


FIG. 217.—Section of the neck of the femur and capsule parallel and close to the border of the acetabulum.

centre of the anterior surface of the joint would be indicated by the extremity of a line an inch and a-half long drawn downwards and outwards at a right angle from the centre of Poupart's ligament. The femoral artery passes directly across the anterior part of the capsule, and is only separated

from it by the psoas tendon. The flap method is the one usually practised. In cutting the anterior flap, the knife must keep close to the femur until it begins to cut out, otherwise there is a risk of slicing the profunda artery, or even the femoral itself. In introducing the knife the direction of a line parallel to Poupart's ligament must be rigorously maintained. Its point must be first directed to strike the neck of the femur, over which it will glide, and in so doing will open the capsule (Fig. 219).

Operation.—The patient must be placed on a table so that the pelvis

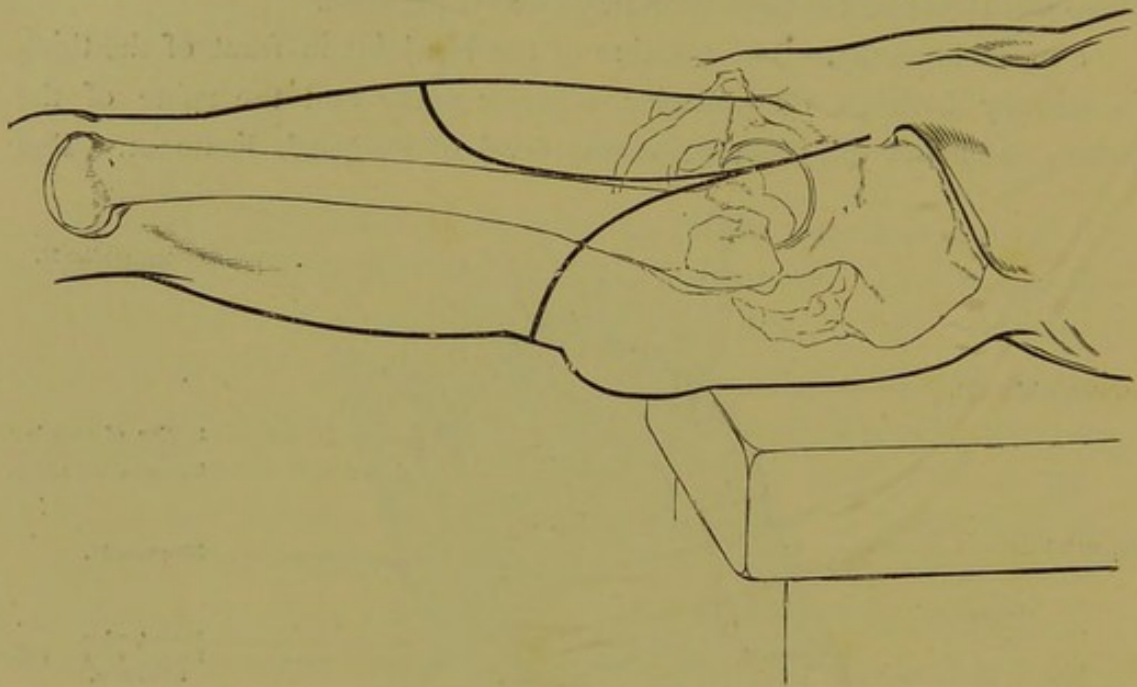


FIG. 218.—Incisions as indicated on the outside of the thigh in disarticulation of the hip-joint.

projects beyond its lower end (Fig. 218). The other limb is fastened out of the way; the limb to be operated upon is entrusted to a skilled assistant. Preparation must now be made to control the hæmorrhage. In thin subjects this may be sometimes efficiently done by digital pressure over the bifurcation of the aorta. In some cases, Lister's or Esmarch's tourniquet is used, but risk in the case of the former is thereby run of damaging the intestine. By means of Davy's lever introduced into the rectum the common iliac artery may be compressed and the hæmorrhage effectively controlled. During the operation itself the femoral artery may be seized between the fingers and thumb of an assistant, by his immediately following the knife

while the anterior flap is being made (Fig. 220). In this way all bleeding from this vessel can be arrested. But there will still remain uncontrolled the severe hæmorrhage from the posterior flap.

The exact position of the joint should first be carefully determined.

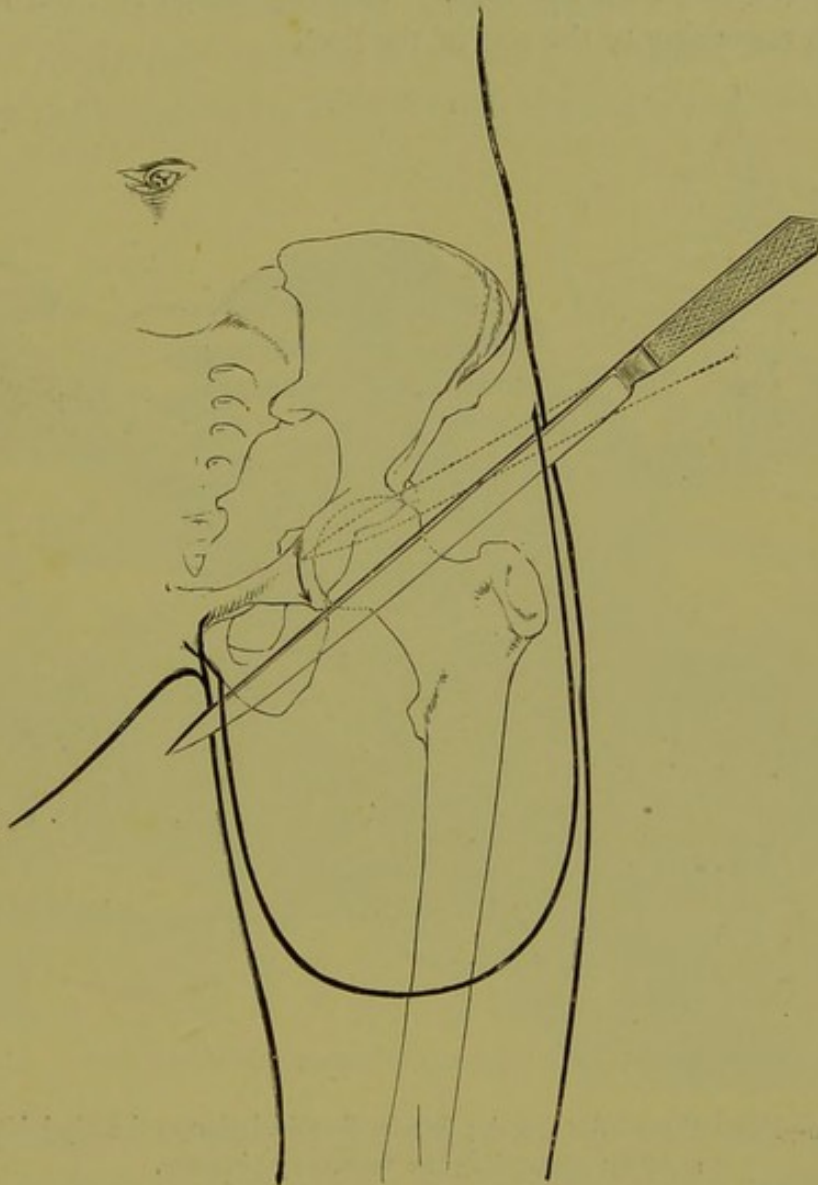


FIG. 219.—Showing the method of transfixing the anterior flap in disarticulation at the hip-joint.

The operator must stand on the outer side of the limb to be removed. The thigh being slightly flexed and rotated outwards at the hip-joint, a long knife is introduced immediately below the anterior superior spine. The point of the knife is made to travel in a direction parallel to Poupart's

ligament and through the anterior portion of the capsule of the hip-joint, which it should open, and is then made to emerge at the junction of the thigh, with the perineum as low down as possible in the direction of the ischial tuberosity. The knife is made to cut downwards for about four or more inches, and then outwards. This flap should be from six to ten inches long, according to the size of the limb.

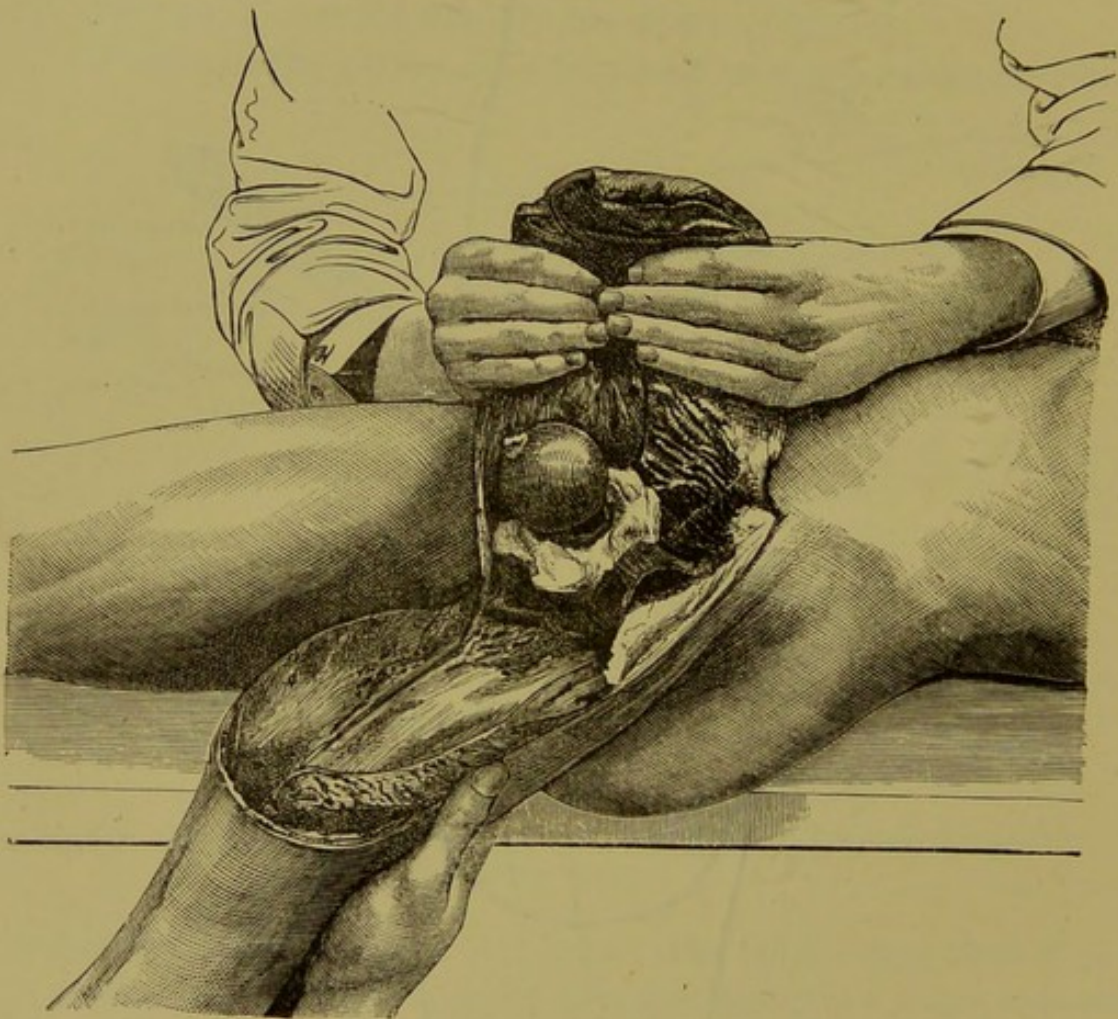


FIG. 220.—Formation of the anterior flap in disarticulation at the hip-joint, the assistant controlling the vessels by pressure.

The next step of the operation consists in disarticulating the joint. The limb is forcibly extended and rotated outwards, and the knife drawn transversely across the capsule and the muscles on both sides. The head will start forward, and the ligamentum teres can be divided, if present, from the inner side. To do so the point of the knife should be introduced at the notch of the acetabulum, the head of the femur being rotated outwards, and

the limb abducted. The operator having seized the head with his left hand and pulled it forward, divides the posterior part of the capsule, and the limb being rotated inwards slightly, the muscles inserted into the great trochanter are severed by transverse incisions cutting close to the bone. The head and great trochanter are in this way completely freed, and the limb being held straight, the operation is completed by cutting downwards and outwards with the amputating knife, the skin being divided about two inches

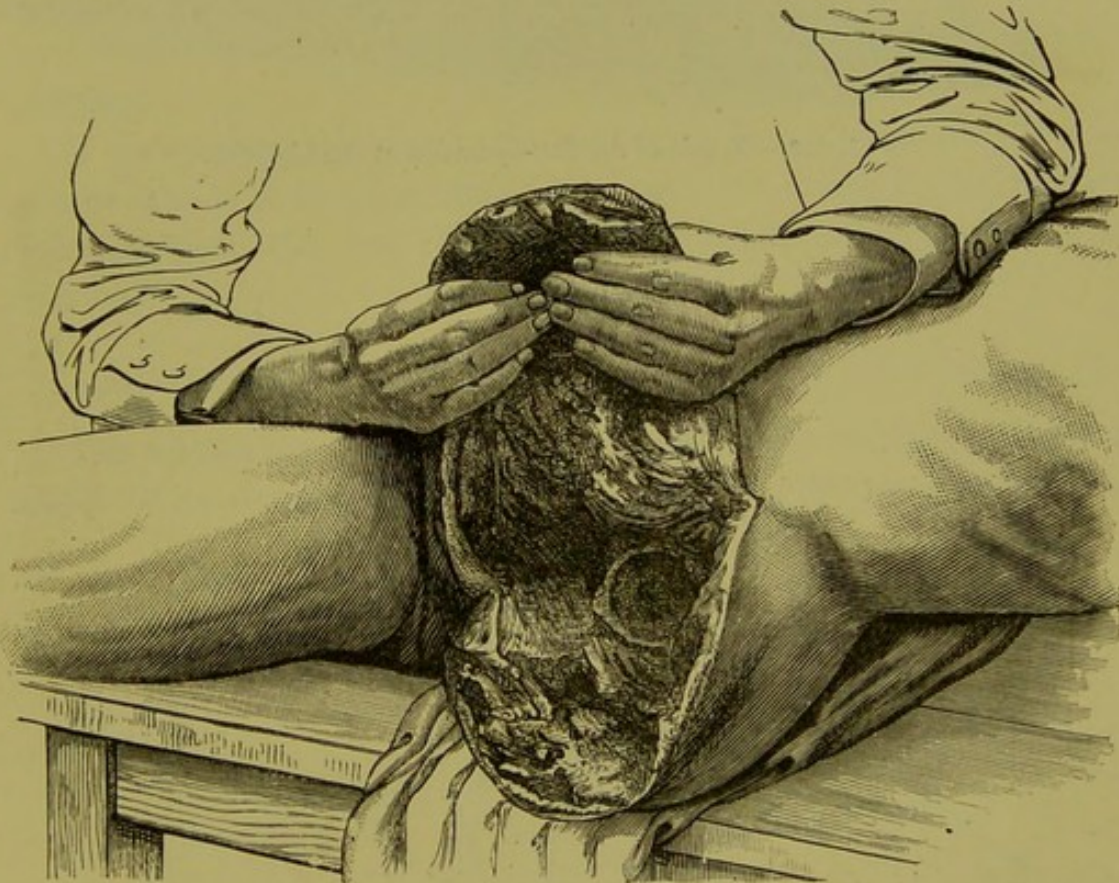


FIG. 221.—Completion of anterior and posterior flaps.

below the fold of the buttock. Langenbeck considers this step of the operation may be more accurately and rapidly performed by a circular sweep of the knife cutting from without inwards. The bleeding vessels must now be seized as rapidly as possible and ligatured, attention being first given to those in the posterior flap, as the bleeding from the anterior flap can be completely controlled by the fingers of the assistant (Fig. 221). Anteriorly, the femoral and profunda arteries require to be tied. In the posterior flap the ischiatic and gluteal arteries and their branches, and the obturator

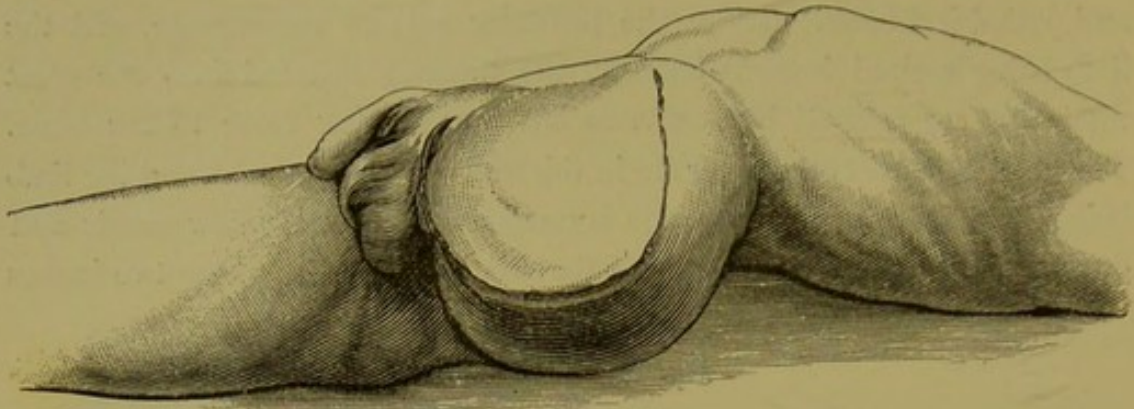


FIG. 222.—Result of the flap-operation at the hip-joint.

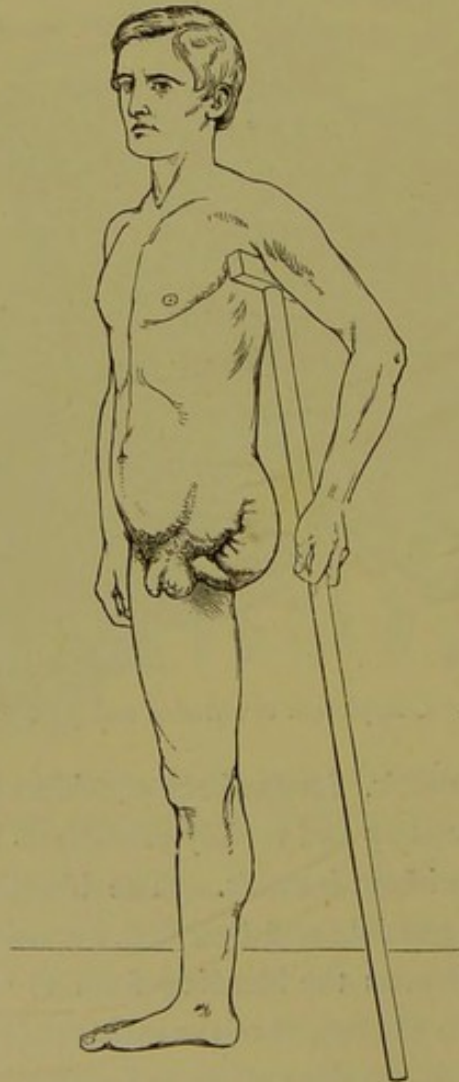

FIG. 223.—Appearance of a patient after removal of the limb at the hip-joint.

artery on the inner side of the posterior flap, are the chief vessels requiring ligature.

Many surgeons prefer to stand between the patient's legs when the right limb is to be amputated. The knife is entered just below and anterior to the ischial tuberosity, passed across the joint and made to emerge below the anterior superior spine. Although contrary to the usual rule of standing to the right of the limb to be removed, this arrangement allows the knife to be more readily handled in cutting the long anterior flap. The remainder of the procedure is identical with that already described.

In thin persons, the anterior flap may be made by cutting from without inwards with a short amputating knife, and the vessels in the flap immediately tied; the rest of the operation being completed as before described.

DISARTICULATION AT THE HIP-JOINT BY THE MODIFIED OVAL METHOD.

This amputation, originally suggested by Furneaux Jordan, is extremely useful. It has frequently been made in old hip-joint disease, especially after

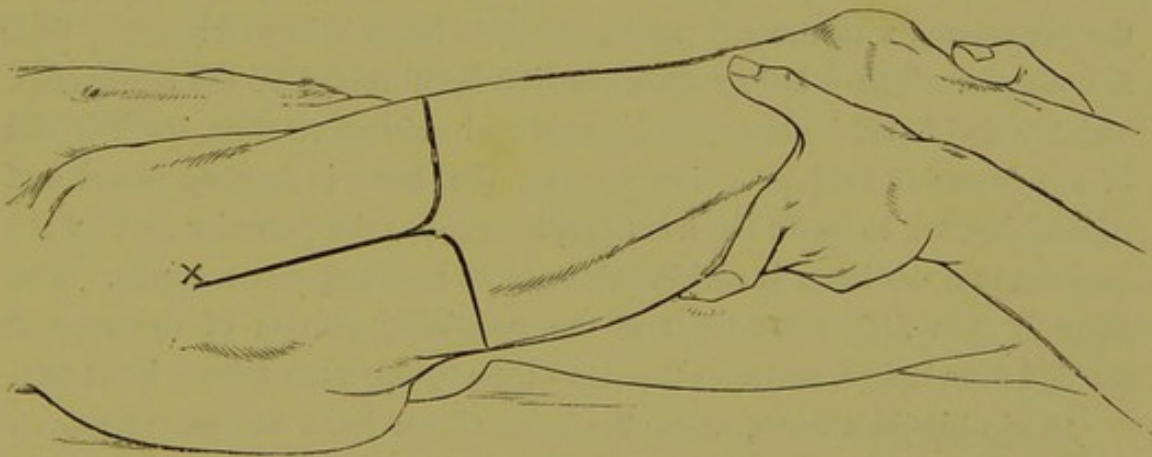


FIG. 224.—Disarticulation of the hip-joint by the modified oval method.

excision has been performed, also in cases of removal of the lower limb high up for malignant disease of the femur.

The advantages claimed for the method are that, the wound being smaller, less shock follows, the hæmorrhage is more easily controlled, and in suitable cases the removal of the upper end of the femur may be per-

formed sub-periosteally, so that a new stump of bone may subsequently be formed.

Either the external or the circular portion of the incision may be made first, but the latter plan is in most cases preferable, as the main vessels can at once be seized and the operation more conveniently proceeded with. If the external incision be commenced with, although no large vessels are divided, yet free hæmorrhage ensues, leading either to considerable loss of blood, or expenditure of time in applying clamp forceps, which, for the sake of convenience, need to be tied off at once.

The body being drawn to the end of the table and the limb held extended (Fig. 224), a circular incision is made through the skin and subcutaneous tissues, and the muscles are then divided in successive sweeps as in an ordinary circular amputation. The bone is sawn through and the large vessels seized and ligatured.

A second incision is now made from two inches above the tip of the great trochanter downward for six to eight inches to meet the circular wound, this is carried at once to the bone, which is rapidly freed as high as the hip-joint around its whole circumference, the knife being kept close to its surface ; (or the periosteal raspatory may be employed to separate the periosteum with the soft parts), the flaps being held well apart by their free angles. The rotator muscles having been freed from the trochanters, which is facilitated by alternate internal and external rotation, the cut end of the femur is held in a lion forceps, the bone is forcibly flexed and rotated inward, to make the head project against the posterior part of the capsule, and the latter is divided close to its acetabular attachment. The bone is then fully extended and the remaining portion of the capsule divided from before, and after division of the ligamentum teres it is set free.

In old hip-joint cases, where the head of the bone has been removed by excision or by long-standing disease, this operation is much easier than where it is performed for injury or new growth. In the former class of cases the lightness of the limb, and consequent ease of manipulation, render the preliminary division of the bone unnecessary.

Verneuil and Rose have recommended the thigh to be disarticulated much in the same fashion as a big tumour would be removed. A large scalpel is used, flaps of the ordinary size are marked out, and the tissues

divided *seriatim* with small strokes of the knife, each bleeding vessel being taken up and secured at the moment of its division. A double ligature

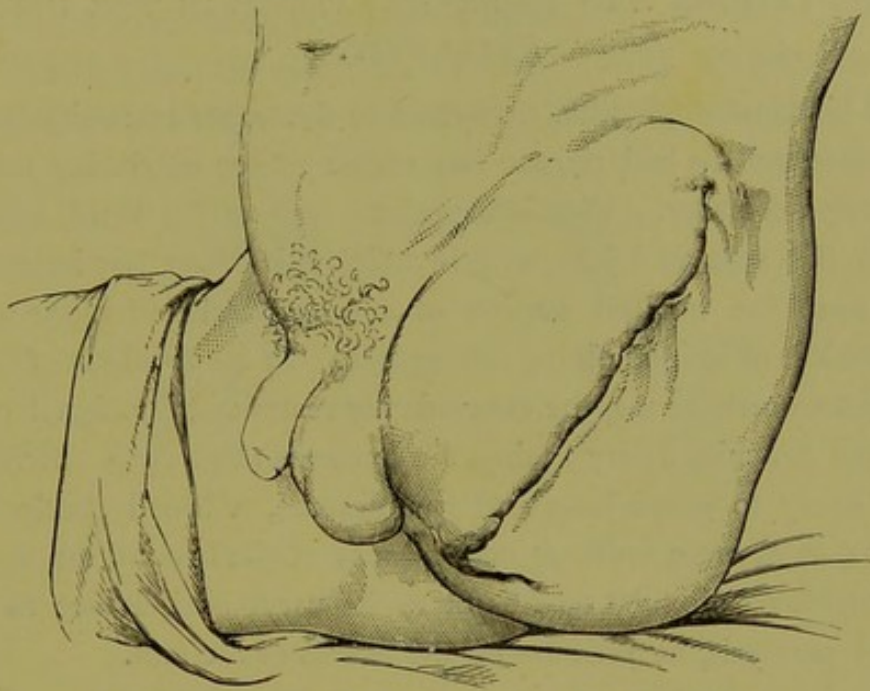

FIG. 225.—Stump after disarticulation at the hip-joint.

must in most instances be applied, one to secure the proximal and the other the distal end of the divided vessel. An operation conducted after this style takes a very long time, but any notable loss of blood is prevented.

AMPUTATIONS AND DISARTICULATIONS IN THE UPPER
EXTREMITY.

In all kinds of amputation performed in the upper extremity too much stress cannot well be laid on the importance of not sacrificing more than is absolutely necessary. This is especially true of the hand, which is so frequently the seat of injury, and in which it is of the last importance to preserve even the smallest portion of a finger, and still more so of the thumb, the loss of which nothing can replace. In amputations of the upper extremity hæmorrhage may be conveniently restrained by digital compression of the brachial artery against the humerus (Fig. 108). If the operation be likely to prove long and troublesome, a broad elastic bandage (Fig. 112), or even an ordinary one, may be applied round the upper arm, but Esmarch's elastic tube ought not to be used, as it is apt to produce temporary paralysis, by pressure on the nerves of the arm.

AMPUTATION AND DISARTICULATION OF THE FINGERS AT THE PHALANGEAL
AND METACARPO-PHALANGEAL JOINTS.

Indications.—Injury by machinery and other accidental causes, tumours and destructive inflammation, such as whitlow. The phalanx in whitlow is generally necrosed, and it may be sufficient merely to extract the dead bone.

Surgical anatomy.—To the bases of the unguis phalanges on their anterior and posterior surfaces are attached respectively the long flexor and the extensor tendons. On the dorsal surface of the first phalanx of the index and little fingers the special extensor tendons of these digits join the common extensor expansions. Into the ridge at the middle of each lateral border of the second phalanx is attached on either side the split tendon of the flexor perforatus. On the posterior surfaces of the bases of the second phalanges are inserted the central slips of the tendons of the extensor communis digitorum. The sides of the bases of the proximal phalanges receive part of the insertions of the interosseous muscles whilst the other portions of the tendons pass (with those of the lumbricals to join the expansion of the extensor communis on the posterior surface of the first phalanx.

To the base of the first phalanx of the thumb on its radial border is

attached the tendon of the abductor pollicis and the tendon of the outer head of the flexor brevis pollicis ; on its ulnar aspect is inserted the abductor pollicis and the inner head of the flexor brevis.

The abductor and the flexor brevis minimi digiti are attached to the ulnar border of the base of the first phalanx of the little finger.

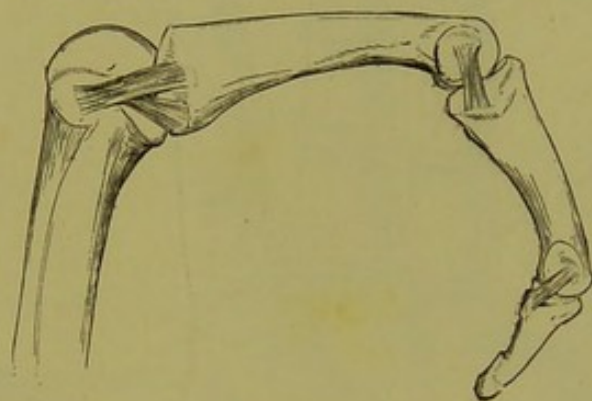


FIG. 226.—Sketch of skeleton of the finger, showing the relation of the knuckles to the joints.

The ligaments of the metacarpo-phalangeal and inter-phalangeal articulations are alike. Each joint has two strong cord-like lateral bands, and an anterior fibrous plate of a very thick and dense structure, sometimes called the glenoid ligament.

The principal creases in the palm, form in most hands a tolerably well shaped Σ . The lowest crease is the best marked, and is produced by the bending of the three inner fingers. It begins opposite the interval between the index and middle fingers, crosses the palm transversely and corresponds pretty closely to the necks of the three inner metacarpal bones. A little lower, about midway between this fold and the webs of the fingers, lie the metacarpo-phalangeal joints. The third fold, formed mainly by the flexion of the first and second metacarpo-phalangeal joints, begins near the base of the index finger, at a point opposite to the termination of the lowest fold on the ulnar border of the hand. It runs obliquely across the palm, inclining upwards to the wrist and opposite the third metacarpal bone, it nearly corresponds in position to the superficial palmar arch. The uppermost fold begins in common with the second at the radial border of palm and runs in a curvilinear direction to the centre of the wrist, roughly corresponding to the thenar eminence. The proximal folds, in front of the fingers, are from half an inch to three-quarters of an

inch below the corresponding metacarpo-phalangeal joint. These folds are double for the middle and ring fingers, but single for the index and little fingers. The next folds are double, and the uppermost corresponds

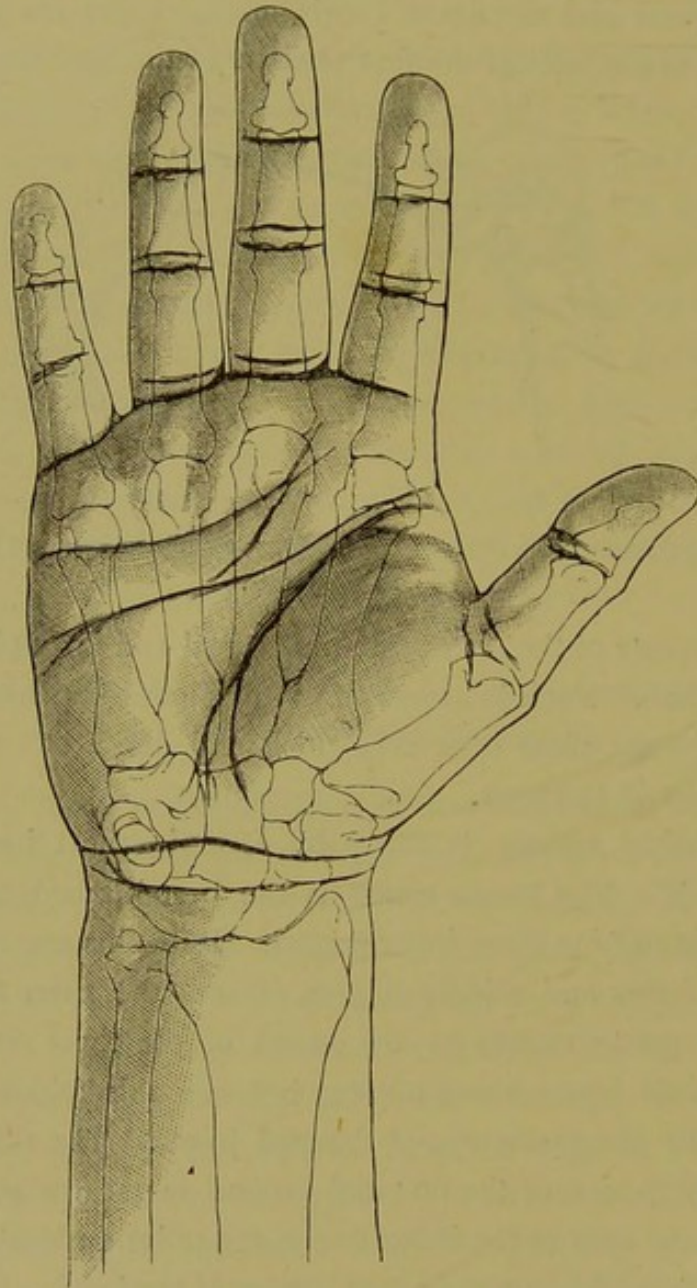


FIG. 227.—Diagram to show the folds or creases of the palm and fingers and the position of the metacarpo-phalangeal and inter-phalangeal joints in reference to the surface-markings.

exactly with the joint between the first and second phalanges. The lowest folds are single, and about an eighth of an inch higher than the corresponding joints.

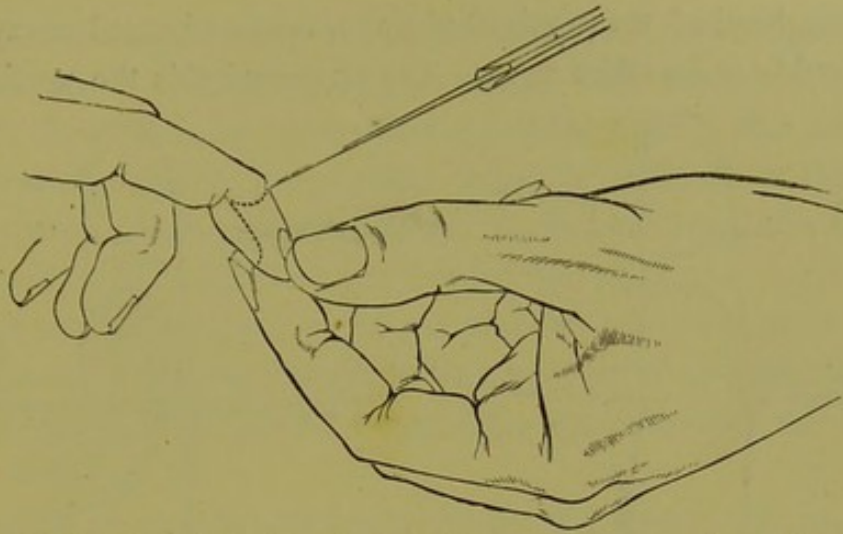


FIG. 228.—Method of forming the dorsal incision in amputation of the ungual phalanx of the finger.

Operation.—Disarticulation of the phalanx at the first or second joint is performed in a manner similar to that adopted in the toes; a long flap is made from the palmar surface of the phalanx, and a shorter one on the dorsal

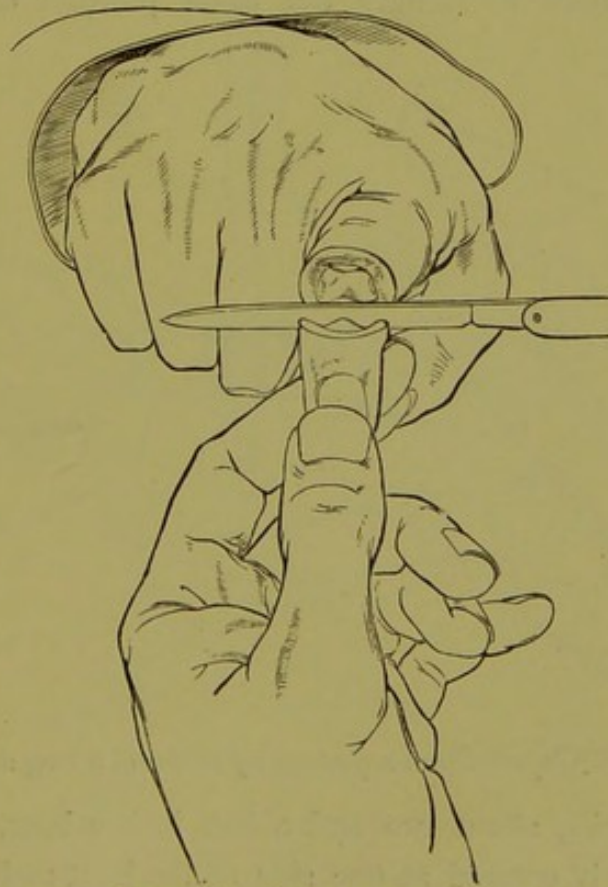


FIG. 229.—Amputation of the last phalanx of the finger.

aspect. The head of the proximal phalanx, unless diseased or extensively injured, should not be taken away. The operator holds the portion to be

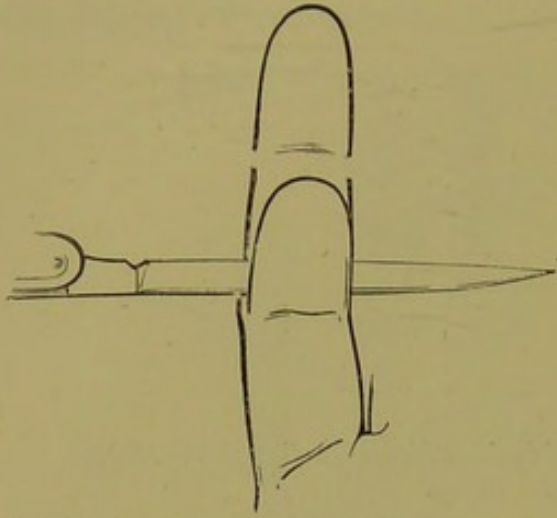


FIG. 230.—Formation of a palmar flap by cutting from within outwards.

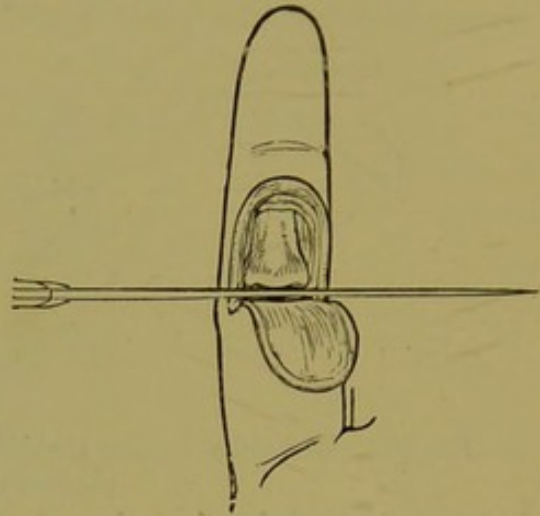


FIG. 231.—Disarticulation subsequent to the formation of a palmar flap.

removed (Figs. 228 and 229) between his left finger and thumb, the thumb-nail being first used to identify the exact position of the joint. A

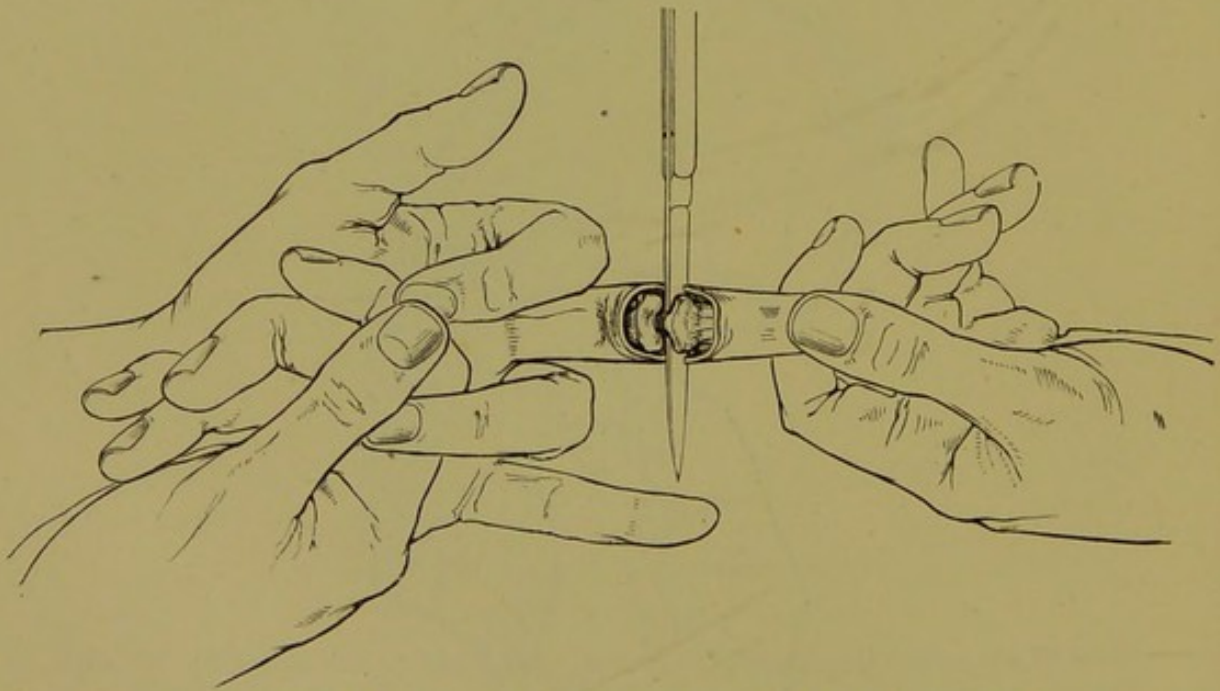


FIG. 232.—Amputation of a phalanx by means of a long dorsal flap.

narrow-bladed knife, about two and a half inches long, called a finger-knife (Fig. 228), is entered at one side of the joint and swept across the back of the phalanx to the other, a line's breadth below the position of the

joint. In the return movement of the knife the lateral ligaments and capsule should be divided, and the joint laid fully open, the digit being sufficiently flexed in order to facilitate this being done. The knife is now laid horizontally behind the phalanx, which is replaced in the extended position, and an adequately long palmar flap formed by cutting downwards and outwards with a to-and-fro movement (Fig. 229).

In this way any of the phalanges may be removed at the first and second joints. It is very important to preserve, if possible, the base of the second phalanx, on account of the insertions into it of the flexor and extensor tendons.

The state of the soft parts may render it necessary to take the soft coverings for the end of the bone from the dorsal aspect of the finger. In that case the long flap is formed in the manner seen in (Fig. 232).

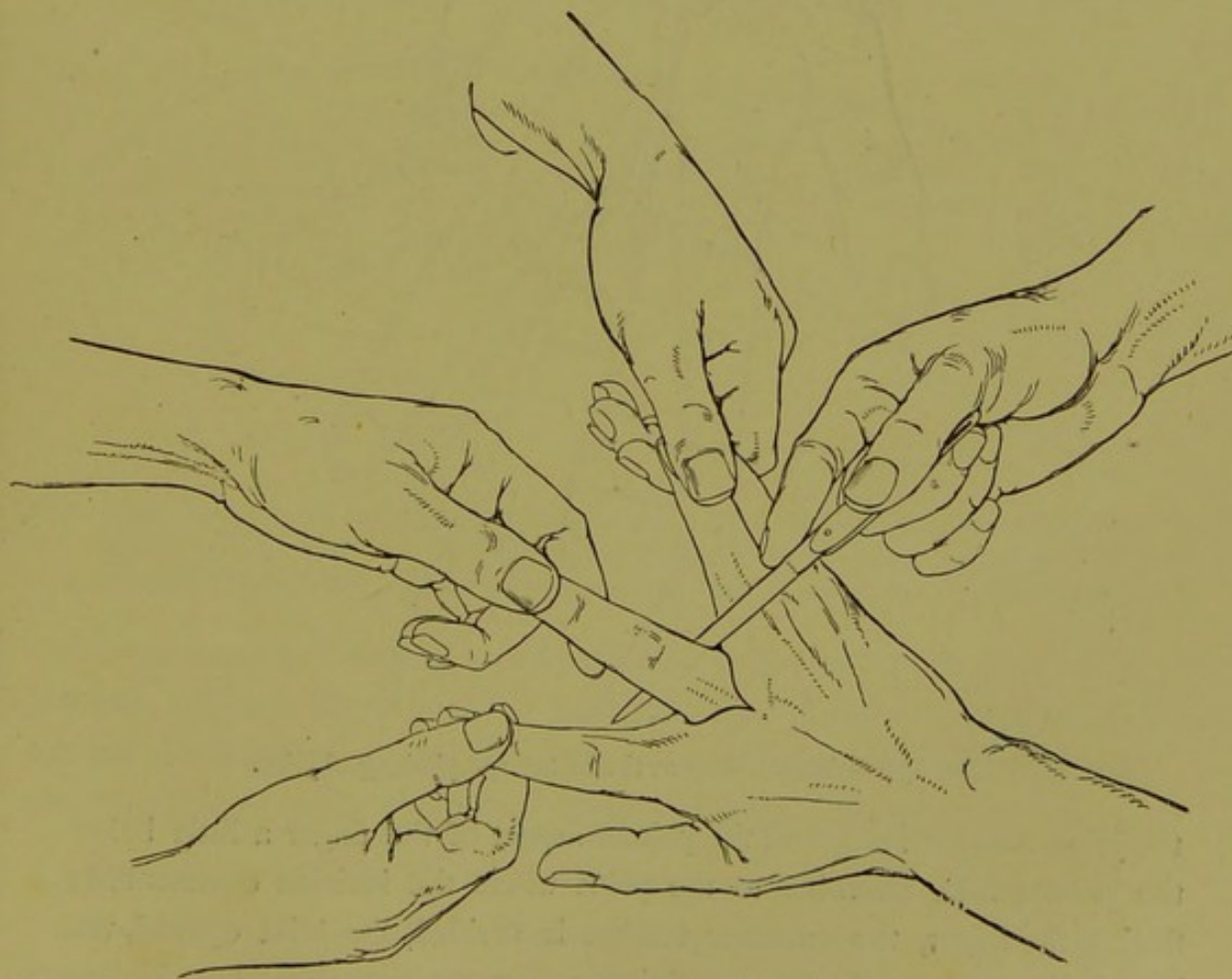

FIG. 233.—Amputation at the metacarpo-phalangeal joint. Method of holding aside the other fingers, and shape and position of the incision.

At the metacarpo-phalangeal joint the oval method of operation is to be preferred. The finger to be amputated is held in the left hand by the operator, and an assistant should hold the adjacent fingers aside (Fig. 233). The knife is then to be introduced over the centre of the dorsal aspect of

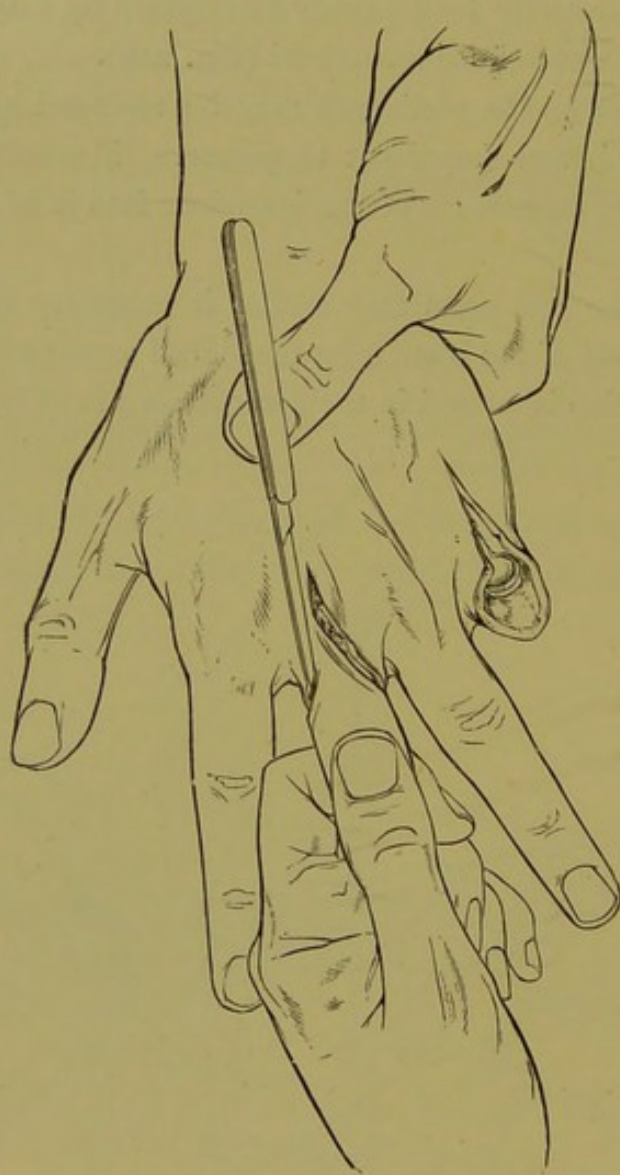


FIG. 234.—Amputations at the metacarpo-phalangeal joint.

the joint, and carried round the palmar aspect of the finger a little below the palmar fold, returning to the point where the incision commenced; flexing the finger, the extensor tendon is divided, the joint opened, the lateral ligaments and the remaining soft parts cut through. Unless diseased or injured, the head of the metacarpal bone should not be

removed, as the power of the hand in grasping will be thereby seriously diminished. After the vessels have been secured, one or two points of suture and a drainage-tube are introduced, the dressings applied, and the two adjacent fingers drawn together. The wound assumes a linear form, and sutures may often be dispensed with.

When a portion of the metacarpal bone requires to be removed along with the finger, the dorsal incision must be commenced higher up, and the palmar incision should be made in the groove at the base of the finger. After the soft tissues have been divided the metacarpal bone can be cut through with a bone forceps and the operation completed.

AMPUTATION OF THE THUMB.

The thumb is the most important member of the hand, and every possible portion of it should be preserved, however small. The phalanges

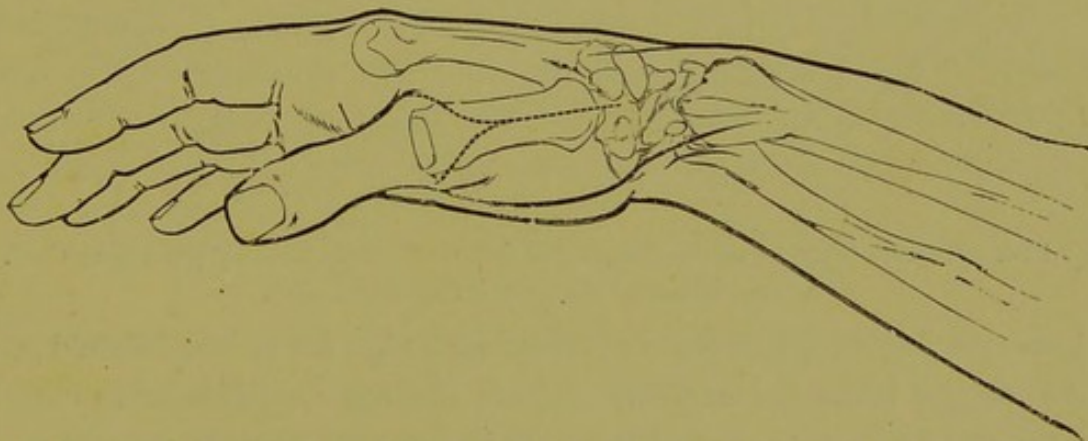


FIG. 235.—Incision for amputation of the thumb and its metacarpal bone by the oval method, cutting from without inwards. The thumb alone can be amputated by a somewhat similar oval incision commenced lower down, just as in one of the fingers.

may be removed in a manner precisely similar to that for the fingers. It is, however, of great importance to leave the base of the first phalanx, as thereby the insertions of the small muscles of the thumb are preserved, and the stump is more useful for grasping and other purposes.

AMPUTATION OF THE THUMB, AND OF THUMB AND FIRST METACARPAL BONE.

Amputation at the carpo-metacarpal joint can easily be performed by the oval method by means of an incision commencing near the base of the metacarpal bone, and extended downwards on the bone, then passing

transversely across the web, and continued on the opposite side to the commencement (Fig. 235). The tissues and thenar muscles must be divided from below upwards; the abductor, adductor, flexor brevis, and opponens pollicis, as well as the tendon of the flexor longus pollicis muscles; and on the dorsal aspect, the tendons of the extensores primi internodii, secundi internodii, and ossis metacarpi pollicis and the origin of the first dorsal interosseous muscle will be cut.

When it is necessary to amputate the thumb, together with the metacarpal

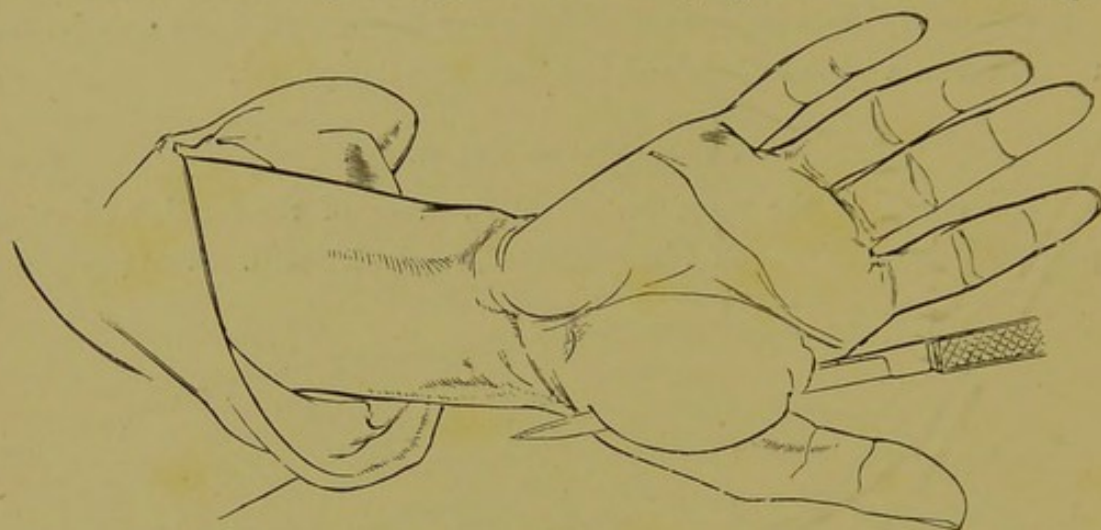


FIG. 236.—Amputation of the thumb and first metacarpal bone by the flap method. Transfixion of the palmar flap (right side).

bone, the following is also a convenient method. An assistant should grasp the fingers while the surgeon abducts the thumb. The knife may be introduced into the centre of the web, and passed towards the trapezium, beneath the muscles of the thumb (Fig. 236), made to emerge at the base of

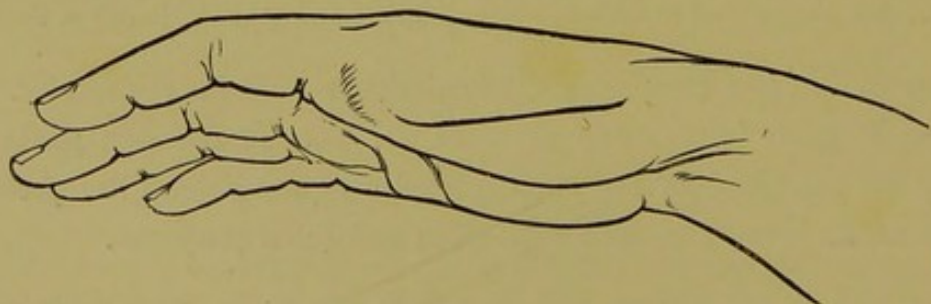

FIG. 237.—Amputation of the thumb and first metacarpal bone. Subsequent appearance of parts.

the metacarpal bone, and then by cutting outwards a rounded flap is formed, comprising the whole of the tissues of the ball of the thumb. The ex-

tremities of this flap are now united by a straight incision across the dorsal aspect, and the thumb being still held strongly abducted, the remaining soft tissues are divided, the joint opened on the inner side, and the disarticulation completed. The flap may be formed by introducing the knife at the base of the metacarpal bone, and bringing it out at the centre of the web; this is preferable on the left side. The parts will now be found to be easily adjustable, the edges may be united by three or four sutures, a drainage tube inserted, and the dressings applied.

EXCISION OF THE METACARPAL BONE OF THE THUMB.

In some cases the metacarpal bone may be excised, and the rest of the thumb preserved. This operation is indicated in cases of caries, or tumour of the bone. In order to remove the bone, make an incision along its radial border, and free first the joint at the digital extremity, then that at the proximal end. The operation, in suitable cases, may be performed subperiosteally, and thus a sufficient amount of new bone may be formed to usefully support the thumb and ensure a good functional result. In any case this will be better practice than wholly to sacrifice the thumb.

DISARTICULATION OF THE LITTLE FINGER, EITHER ALONE OR TOGETHER WITH ITS METACARPAL BONE.

Indication:—Injury or disease of the bones and soft parts.

Surgical anatomy.—In the former operation the following tendons are severed near the metacarpo-phalangeal joint:—Those of the extensor communis, extensor proprius minimi digiti, and internal lumbrical, as well as those of the abductor, flexor brevis minimi digiti, and the third palmar interosseous muscle. In the latter operation, as well as those mentioned, the insertion of the opponens minimi digiti and the origins of the fourth dorsal and third palmar interosseous muscles need separation from the shaft of the metacarpal bone. To the base of the bone are attached the insertions of the extensor and part of the flexor carpi ulnaris.

Operation.—The amputation of the finger may be accomplished by the usual oval incision. Including the metacarpal bone the operation may be best done in the manner described by Walther for amputation of the fifth toe with its metatarsal bone. For the right hand the operator faces the

patient, and for the left hand he turns in the opposite direction. The finger being drawn well aside by an assistant, the point of the knife is introduced at the border of the web in the interval between the two fingers and an incision made close around the base of the fifth; the tail of the oval incision is prolonged on the dorsal surface of the metacarpal bone as far as its base.

The whole metacarpal bone may be removed, or it may be divided in its continuity, in which case the wrist-joint escapes the risk of being implicated, and the insertions of the flexor and extensor of the ulnar side of the carpus are preserved.

AMPUTATION OF THE FOUR METACARPAL BONES WITH THE CORRESPONDING FINGERS.

This may be done in the same way as in the foot, the covering being chiefly taken from the palmar surface, in order that the line of the cicatrix

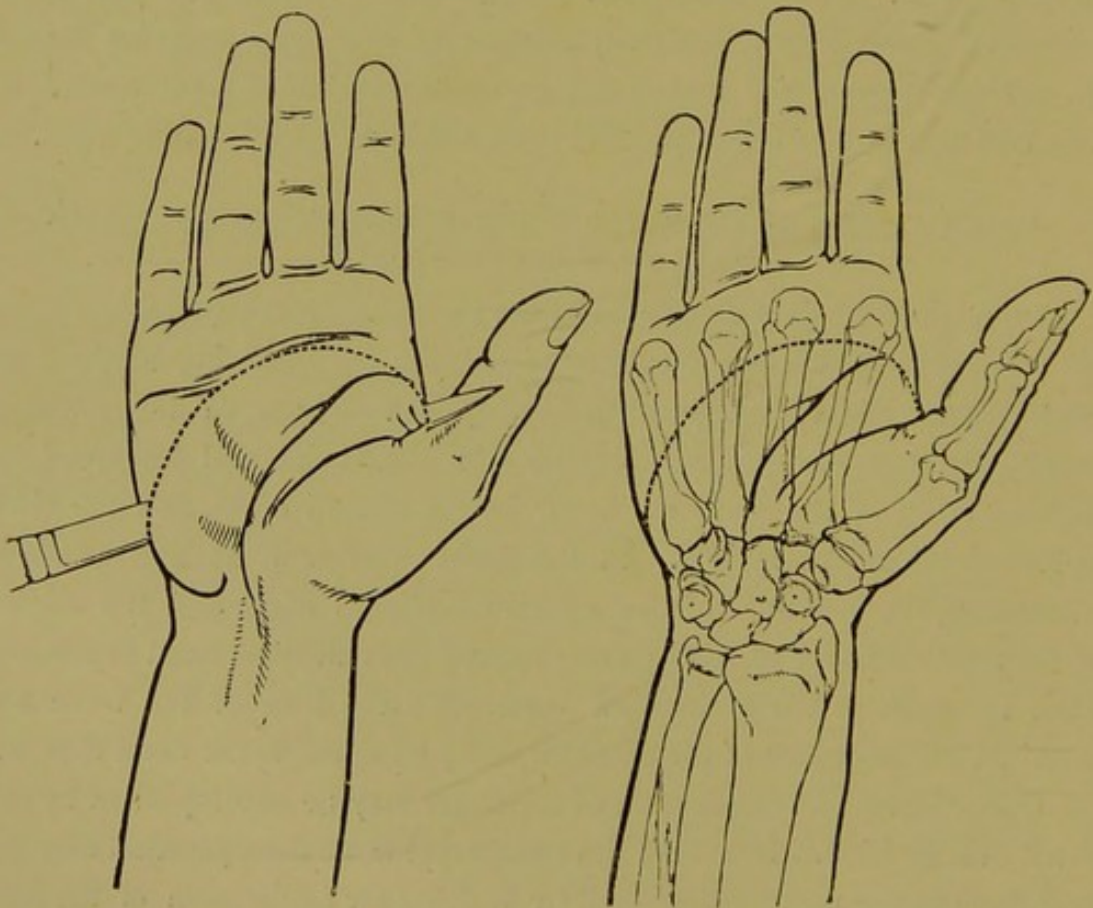


FIG. 238.—Method of transfixing and position of palmar flap in amputation of all the fingers with their metacarpal bones.

may be on the dorsal aspect, and by sawing the bones, so as to leave the carpal articulations intact if practicable.

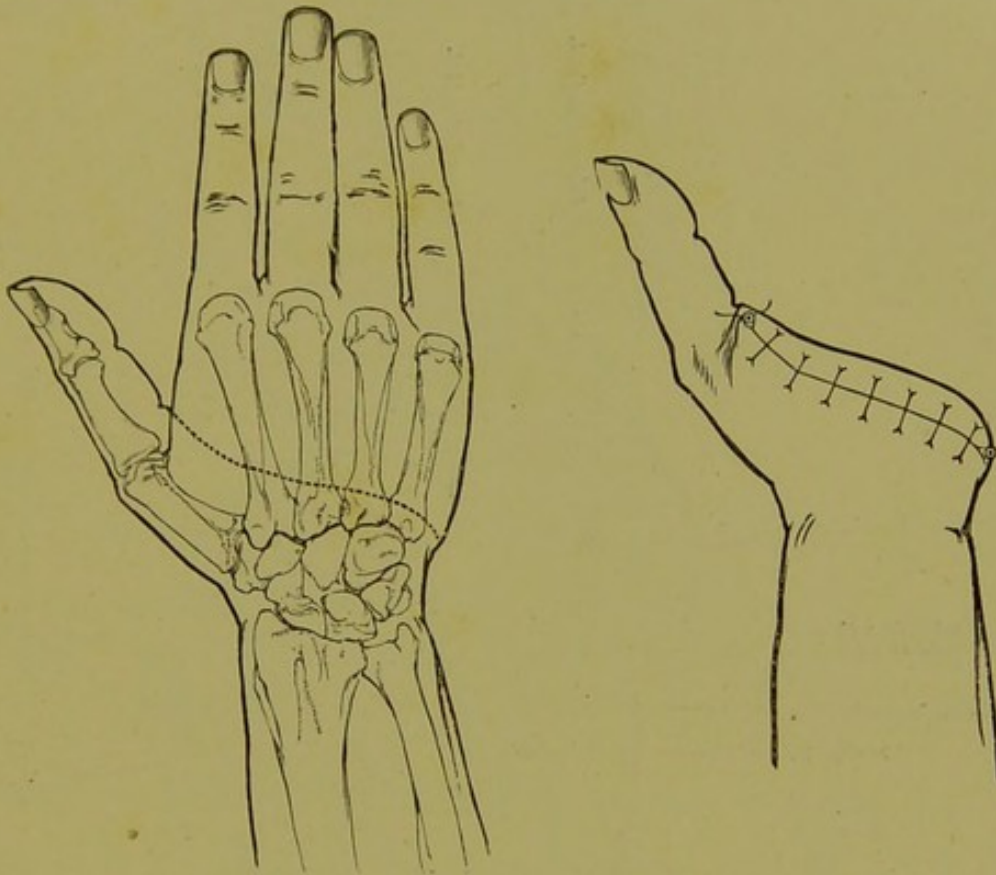


FIG. 239.—Line of the dorsal incision, and resulting stump in amputation of all the fingers with their metacarpal bones.

In some cases it may be necessary to remove the bones at the carpo-metacarpal joints; and, in some, a part of the carpus also may have to be removed.

DISARTICULATION OF THE WRIST-JOINT.

Indications.—Extensive disease or injury of the carpus and hand.

Surgical anatomy.—This joint is very complex, surrounded by tendons, and the skin covering it is thin and mobile. The styloid process of the radius, which is crossed by the extensor tendons of the thumb, projects half an inch further downwards than that of the ulna. The palmaris longus, when present, is very prominent, exactly in the centre of the anterior surface when the wrist is flexed, and to its outer side is the tendon of the flexor carpi-radialis muscle, the median nerve lying beneath and between them. The

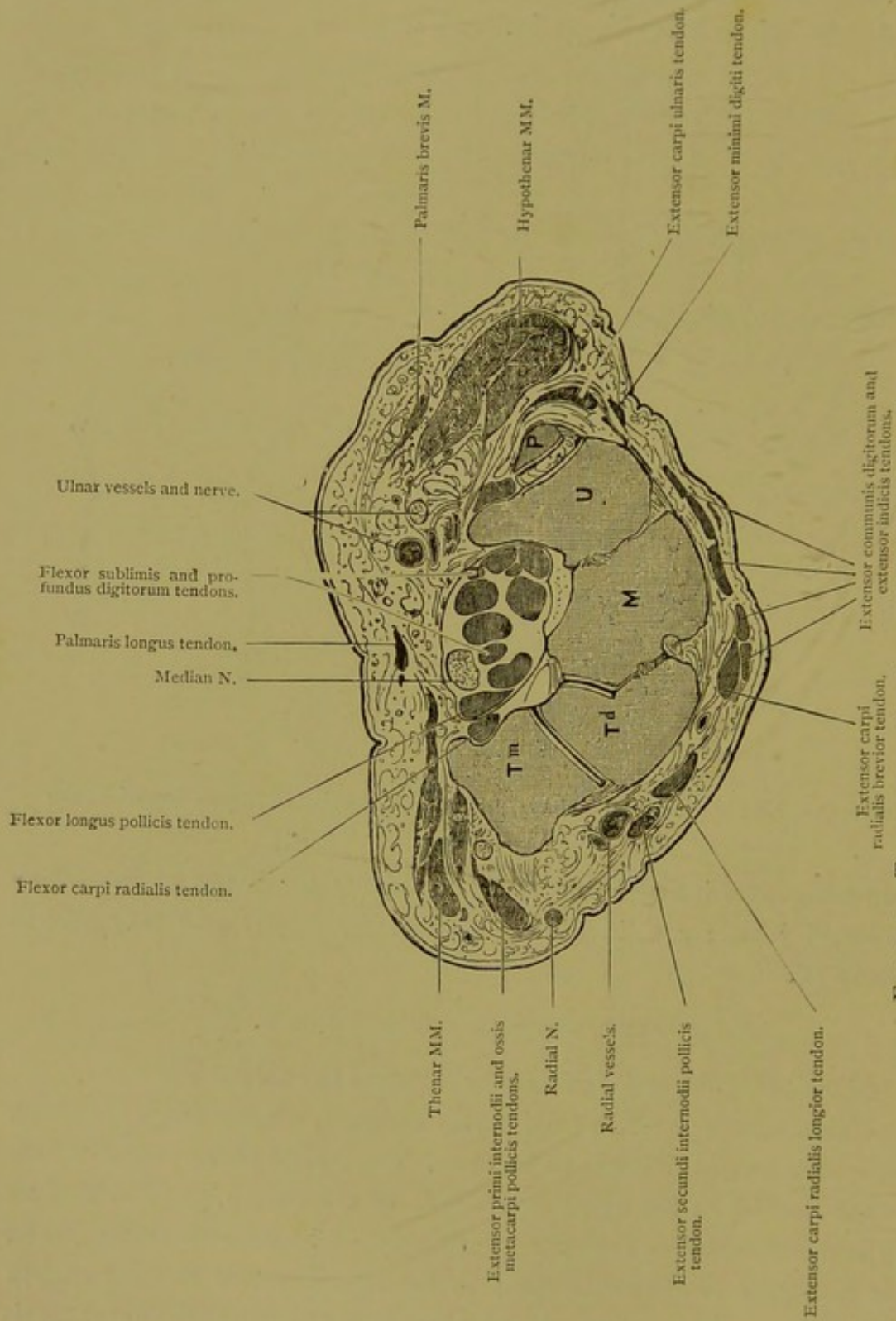


FIG. 240.—Transverse section through the second row of carpal bones.

tip of the ulna corresponds to the line of the radio-carpal joint on the inner side, the extremity of the radius indicating it on the outer, the line joining these points being about half an inch below the concave articular surface

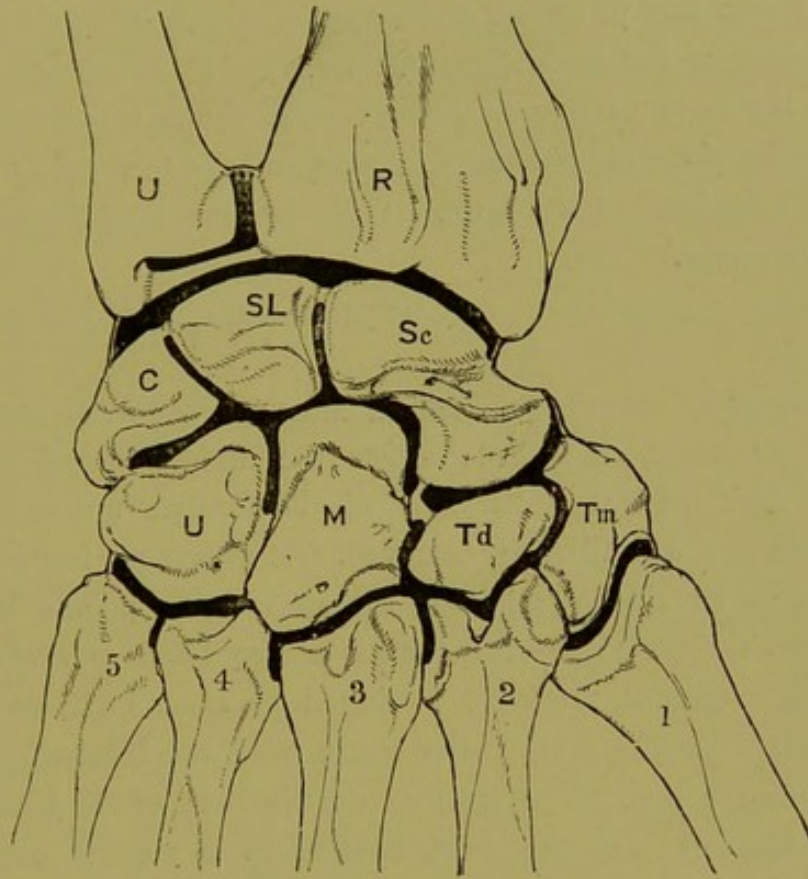


FIG. 241.—Diagram illustrating the synovial cavities of the wrist-joint.

The synovial sacs lining the articulating surfaces composing the wrist-joint are seven in number.

The *first* lines the sigmoid cavity of the radius, the head of the ulna, and the superior surface of the inter-articular fibro-cartilage.

The *second* covers the inferior extremity of the radius, inferior surface of the inter-articular fibro-cartilage, and the superior articular surfaces of the scaphoid, semilunar and cuneiform bones.

The *third* covers the contiguous articular surfaces of the scaphoid, semilunar and cuneiform bones above, and the unciform and os magnum below, sending upwards two prolongations, one between the cuneiform and semilunar, and one between the semilunar and scaphoid, and downwards one on each side of the os magnum, between it and the unciform and scaphoid respectively.

The *fourth* covers the contiguous surfaces of the scaphoid above and the trapezium and trapezoid below, sending a prolongation between the trapezium and trapezoid, which is often continuous with that lining the contiguous surfaces of the trapezoid, os magnum, and the second and third metacarpal bones; from this there is a short

of the radius. The well-marked fold of skin in front of the joint just above the thenar and hypothenar eminences, corresponds to the upper border of the anterior annular ligament, and is about half an inch higher than the carpo-metacarpal line of joints, and opposite the third metacarpal bone crosses the neck of the os magnum (Fig. 227). It is one inch above the position of the deep palmar arch which corresponds very exactly to the upper extremity of the clefts between the adjacent metacarpal bones readily to be felt on the back of the hand. The superficial arch is an inch lower down than the deep.

Operation.—The operation may be performed either by the circular or flap method.

If the former be chosen, the incision must be made two inches below the styloid processes, or a little above the middle of the metacarpal bones. An assistant draws the skin of the forearm upwards, and the surgeon, holding the hand to be removed, first makes an incision on the back from side to side, completing the circle by a palmar incision at the same level. The skin on the back of the hand is now retracted forcibly by the assistant, the knife freeing it by short incisions (the edge being directed vertically towards the bone) until the level of the radio-carpal joint is reached. The tendons on the back of the hand are cut through transversely, and the joint opened by a slightly curved incision, convex upwards, made from one styloid process to the other, whilst the hand is forcibly flexed. Then the lateral ligaments are divided, and

diverticulum extending upwards between the trapezoid and os magnum, and a prolongation downwards between the second and third metacarpal bones.

The *fifth* lines the inferior surface of the unciform and superior surfaces of the fourth and fifth metacarpals, sending a prolongation between the latter bones.

The *sixth* intervenes between the articulating surfaces of the trapezium and first metacarpal bone.

The *seventh* is a small sac between the contiguous surfaces of the pisiform and cuneiform bones (not shown in the diagram).

In general disease of the carpus the joints of the trapezium and pisiform are very frequently exempt. The radio-carpal articulation and the radio-ulnar may be separately involved in disease. Disease, however, attacking any of the bones of the second row will speedily become general. It may be observed that the unciform articulates with the fourth and fifth metacarpal bones, and possesses a distinct synovial sac, just as the cuboid in the foot possesses one in common with the fourth and fifth metatarsal bones.

the flexor tendons and the remaining soft parts, cut through from above downwards. The palmar portion is not to be dissected up. Care should be taken not to leave the pisiform bone behind. In this manner an excellent covering is provided for the ends of the bones. The dorsal and volar branches of the radial, the ulnar artery and its deep branch, are the vessels which require ligature.

If the flap method be adopted, the longer one may be formed either from the palmar or the dorsal aspect, according to the necessities of the case.

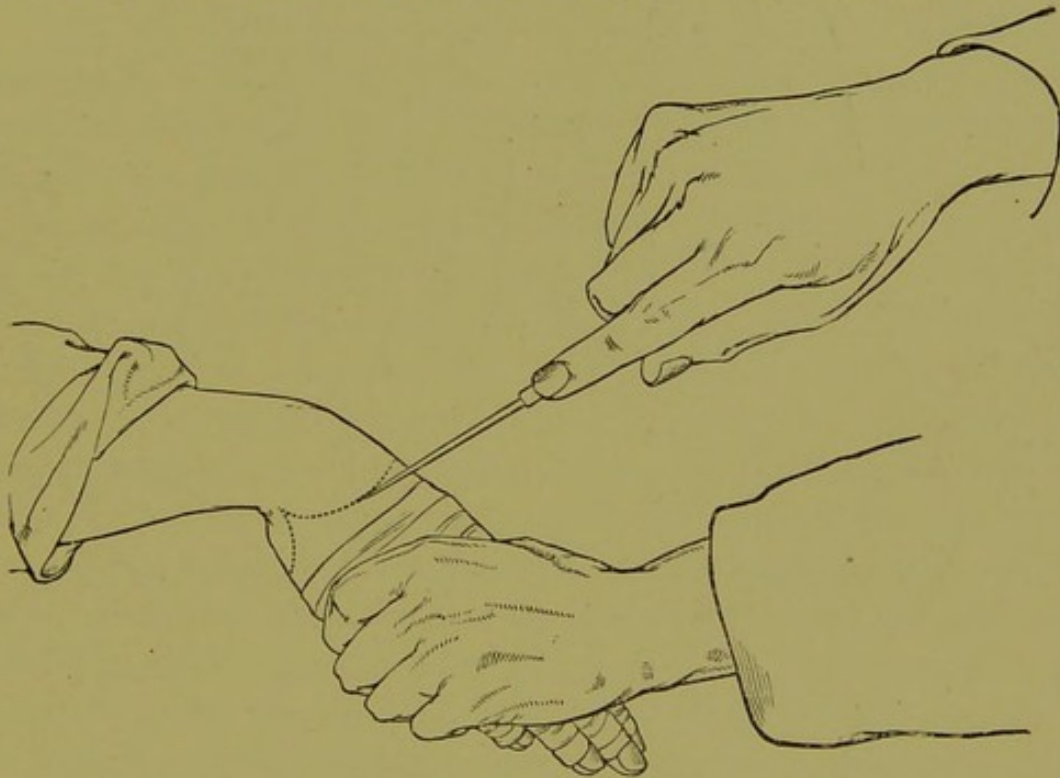


FIG. 242.—Amputation at the wrist-joint by means of double flaps.

The former realizes a better stump, while the latter is easier to perform, the surface being regular and the soft parts easily dissected up. When the method by dorsal flap is adopted, the hand, being completely pronated, is held by the surgeon with his finger and thumb grasping the lateral aspects of the joint, so as to render the skin tense, while his assistant pulls the soft parts upwards. The incision should now begin opposite one of the styloid processes, pass vertically downwards as far as the middle of the metacarpal bones, across which it should run transversely, and then extend upwards to the opposite styloid process (Fig. 242). The extremities of this incision are united by a transverse palmar cut slightly convex

downwards from one styloid process to the other; the dorsal flap is now dissected up, the joint opened, and the remaining soft parts divided precisely as in the former operation.

When the long flap is taken from the palm it should be marked out by cutting from without inwards. The incision proceeds in a similar way, from one styloid process to the other, first passing vertically downwards, then transversely across the centre of the palm. It should include the

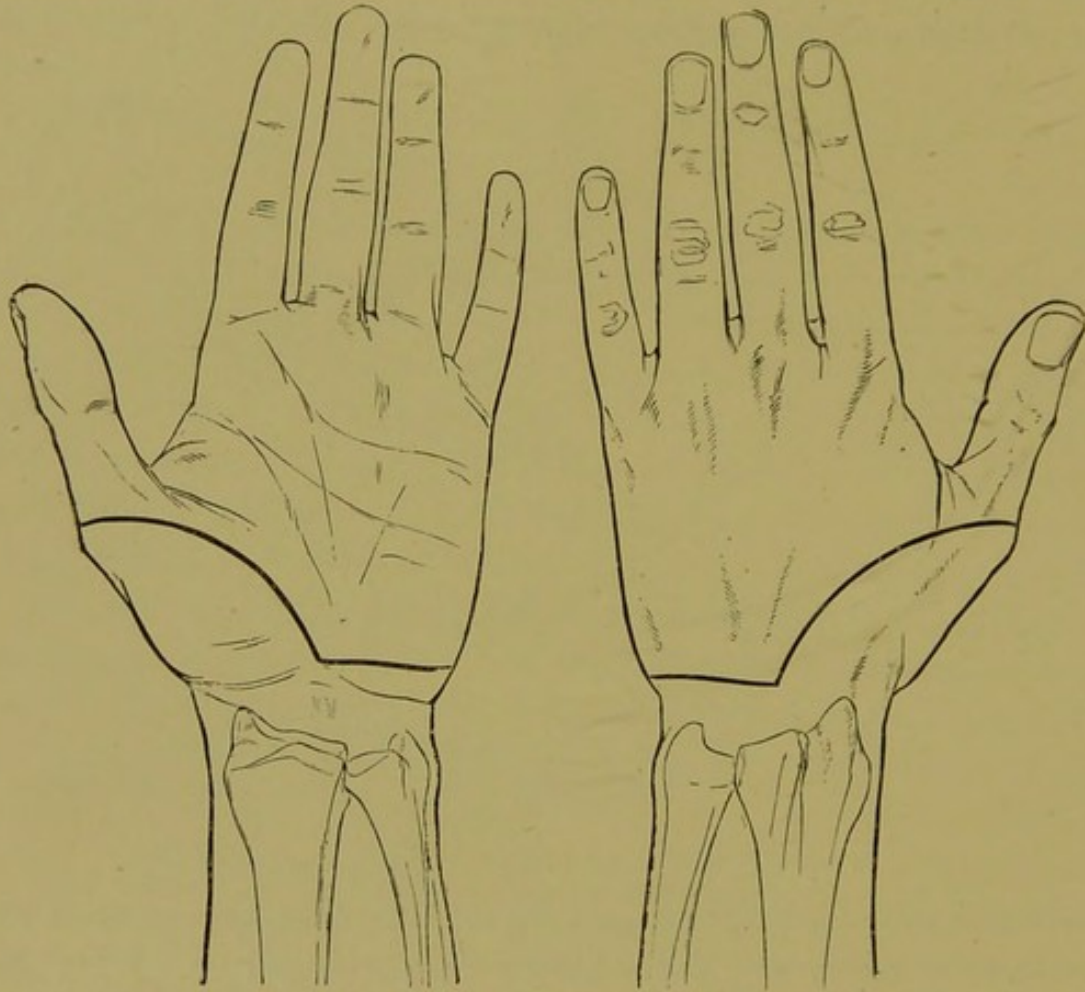


FIG. 243.—Amputation at the wrist-joint by means of a flap taken chiefly from the thenar eminence.

muscles of the ball of the thumb as well as those of the hypothenar eminence. On the back of the wrist, a very short posterior flap is to be made, the skin retracted, the joint opened, and the separation of the palmar flap completed by cutting from within outwards, or it may be wholly dissected up.

On account of the quantity of fat contained in the palmar flap and its somewhat irregular shape, union takes place more slowly than after the

other method, but the stump is firm and solid, and the cicatrix better protected from pressure.

In cases of gunshot wounds, machinery accidents, or other injury of a similar nature affecting the hand, it sometimes occurs that one or other side has escaped extensive laceration, though amputation through the wrist is called for. In these cases the flap may be taken from the thenar or hypothenar eminences, and corresponding parts at the back of the thumb or little finger respectively (Fig. 243).

The operations are thus performed:—If a sufficiency of soft parts exist on the radial side of the hand, an incision is begun opposite the centre of the carpal bones in front, and carried downwards round the inside of the thenar eminence, and across the back of the hand to a corresponding point on the middle of the wrist. A second incision is then commenced where the first began, and is carried along the palmar margin of the hypothenar eminence, across the metacarpo-phalangeal articulation of the little finger, and running round the back of the wrist as far as the termination of the first incision. The flap first mapped out is then dissected backwards from the front and dorsum of the thumb, and the skin and other structures separated from the front and back of the outer side of the carpus. Lastly, the wrist-joint is disarticulated, and the articular surface of the radius and head of the ulna removed with the saw. The vessels having been treated in the usual manner, the thenar flap is carried across the face of the stump, and attached by several points of suture.

When the flap is taken from the ulnar border of the hand the lines of incision are reversed and the flap formed from the hypothenar eminence and skin covering the dorsal surface of the fifth metacarpal bone as far as its head. The operation is completed by a straight incision coursing around the radial side.

AMPUTATION OF THE FOREARM.

Indications.—This operation is most frequently required for injury to the hand or wrist, or for extensive disease of the carpus with a useless hand.

Surgical Anatomy.—The limb is much wider in its transverse axis, the bones are placed nearer the posterior than the anterior aspect, and they are nearest together in the middle of the forearm. In a well-developed subject the prominences due to the supinator longus and radial extensors

are visible on the outer side, and, lower down, those of the extensors of the thumb. Along the middle of the posterior surface the extensor communis

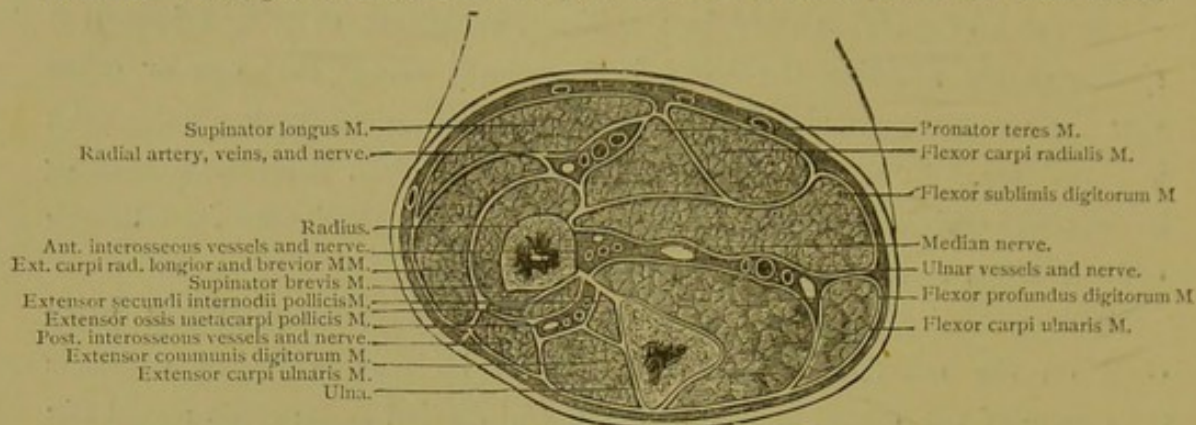


FIG. 244.—Transverse section through the middle of the right forearm.

forms a prominence. Very few vessels or nerves of importance are to be found in the back of the forearm (Fig. 244).

Operation.—Either the flap or circular method may be adopted, but the

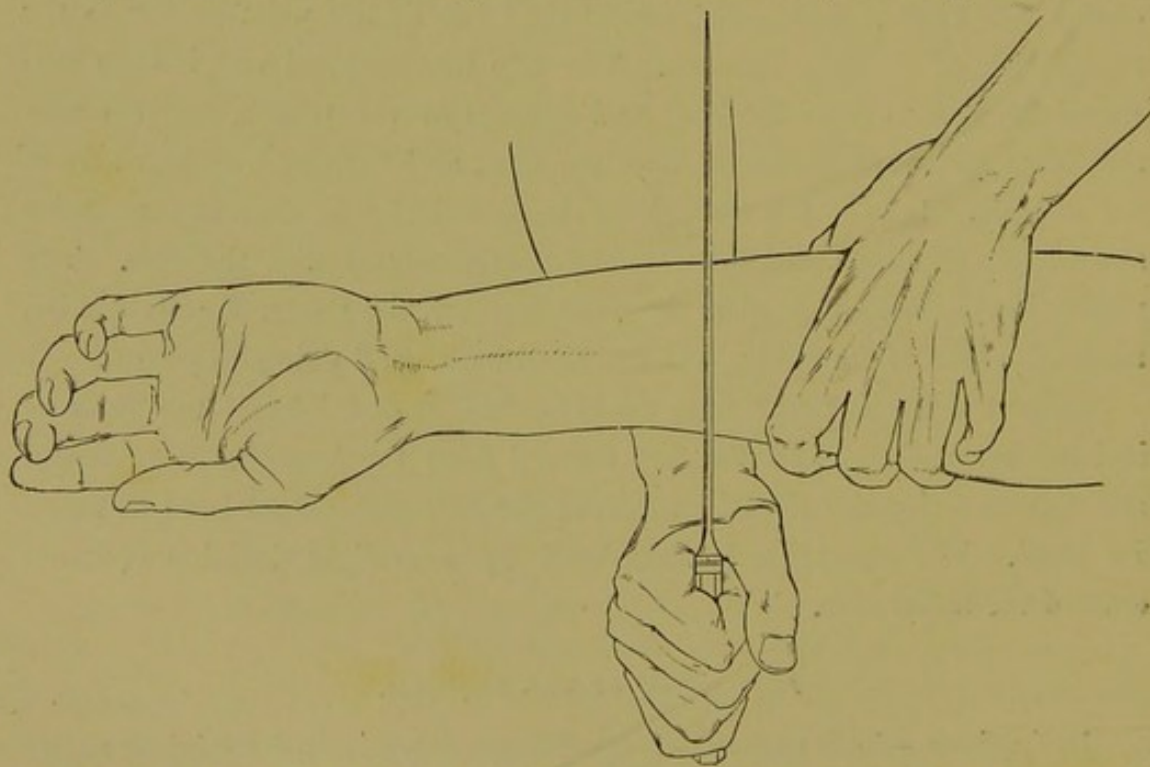


FIG. 245.—Amputation of the forearm by the circular method. Manner of making the first incision through the skin and subcutaneous tissue.

latter is somewhat difficult on account of the shape of the forearm, and there is a tendency afterwards for the cicatrix to adhere to the bone.

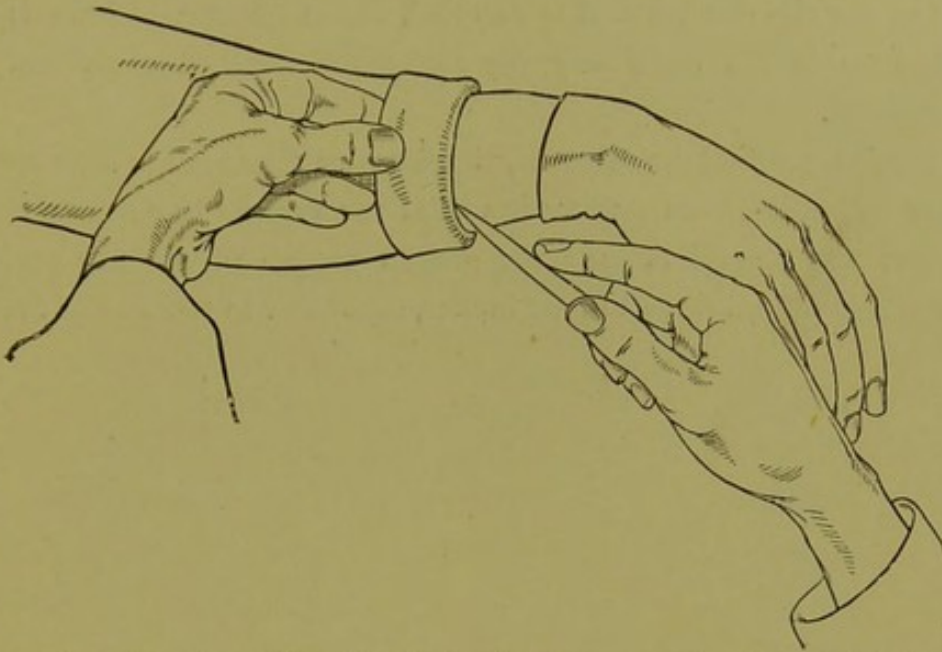


FIG. 246.—Formation of the skin-flap in circular amputation through the lower end of the forearm.

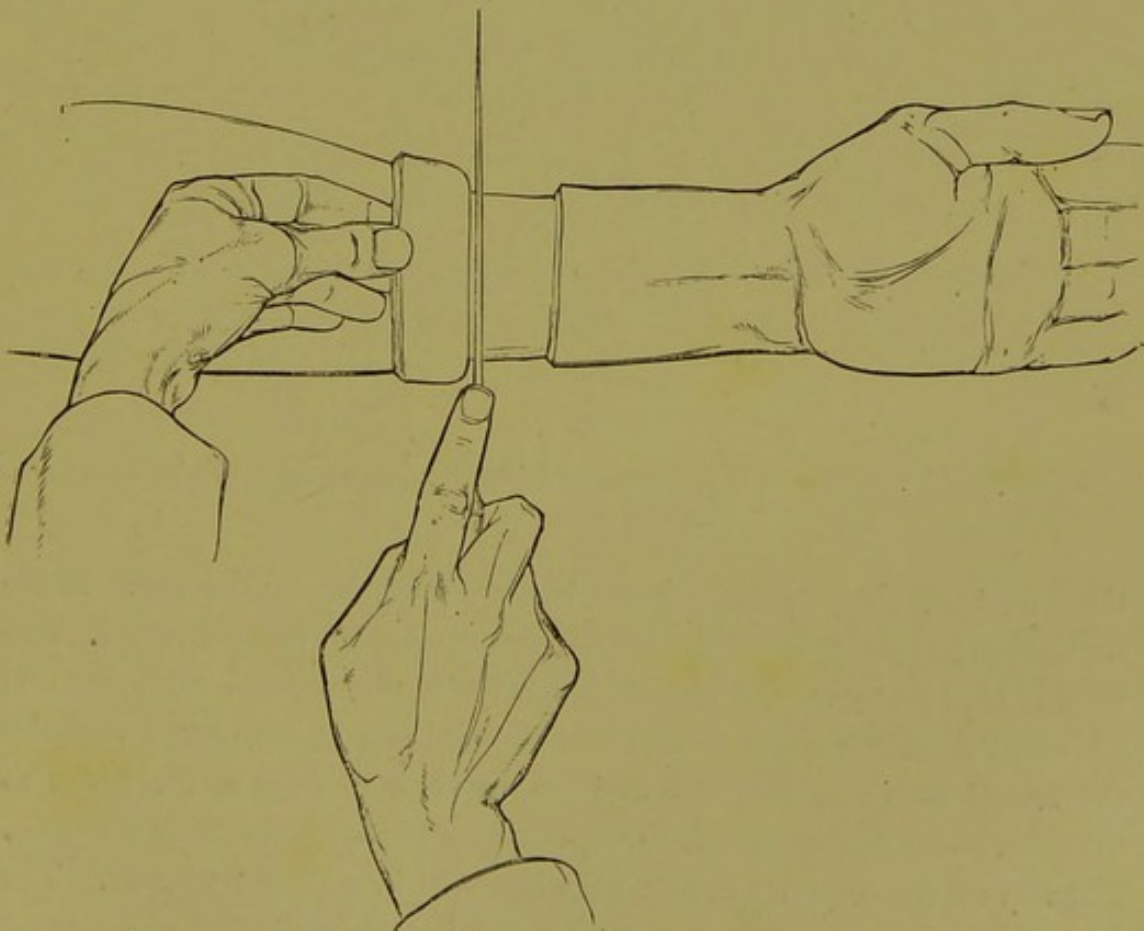


FIG. 247.—Completion of the manchette in amputation of the forearm.

When the circular method is adopted, the manchette of skin is to be dissected up in the usual way, the muscles divided circularly and bones sawn through.

If the flap method be selected, the flaps may be made either by transfixion or by cutting from without inwards; the anterior one should be made the longer and should include the greater portion of the soft parts. Its length will vary from three to four inches, according to the size of the limb;

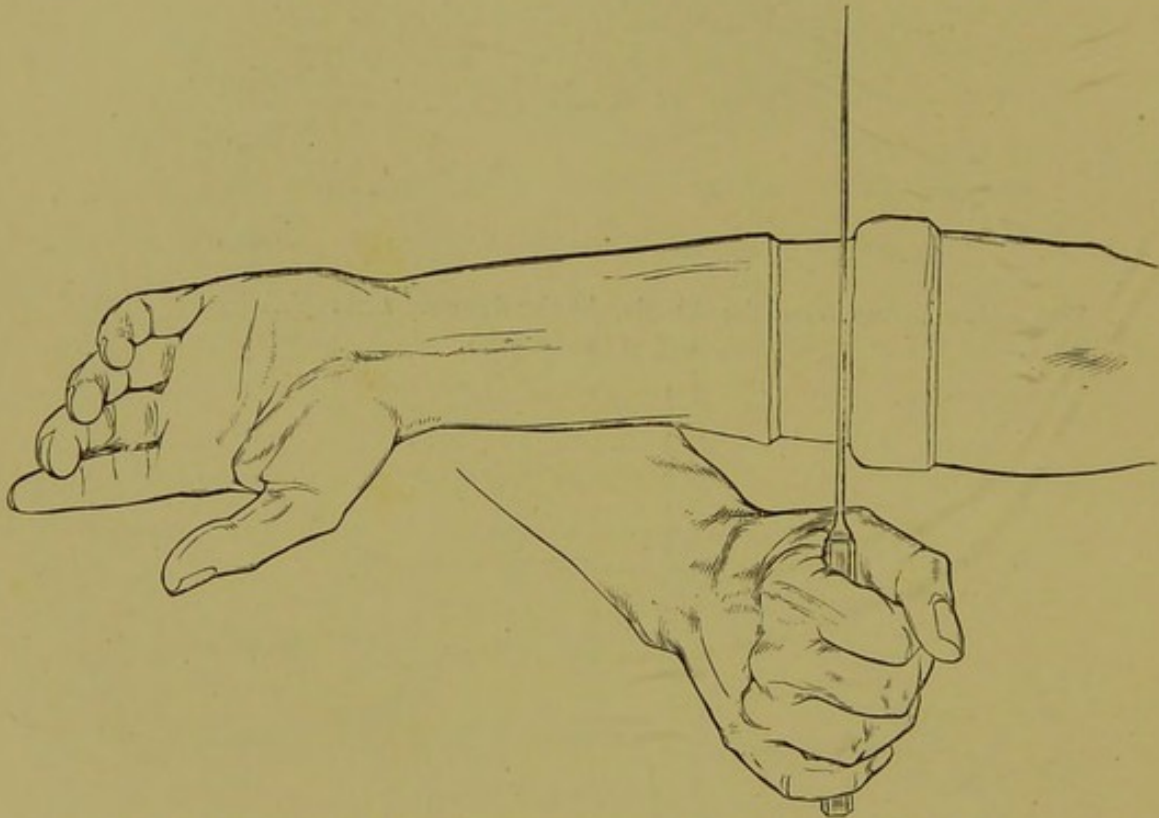


FIG. 248.—Amputation of the forearm by means of a manchette of skin and circular division of the muscles.

the dorsal flap should be about half the length of the anterior one. If the transfixion method be adopted, the anterior flap should be formed first. The wrist is held firmly by the surgeon's left hand, the forearm supinated and abducted from the side; a short amputating knife is introduced opposite the lateral border of the limb and passed close in front of the bones to the other side; first cutting vertically downwards and then sharply outwards. The flap on the posterior aspect may be made in a similar manner. The flaps should now be retracted and the remaining tissue divided with a small Catlin, both around and between the bones, which may then be sawn

through. The radial, ulnar, anterior and posterior interosseous arteries require to be secured. In the lower part of the forearm it is better to cut the flaps from without inwards. Their shape can thus be more

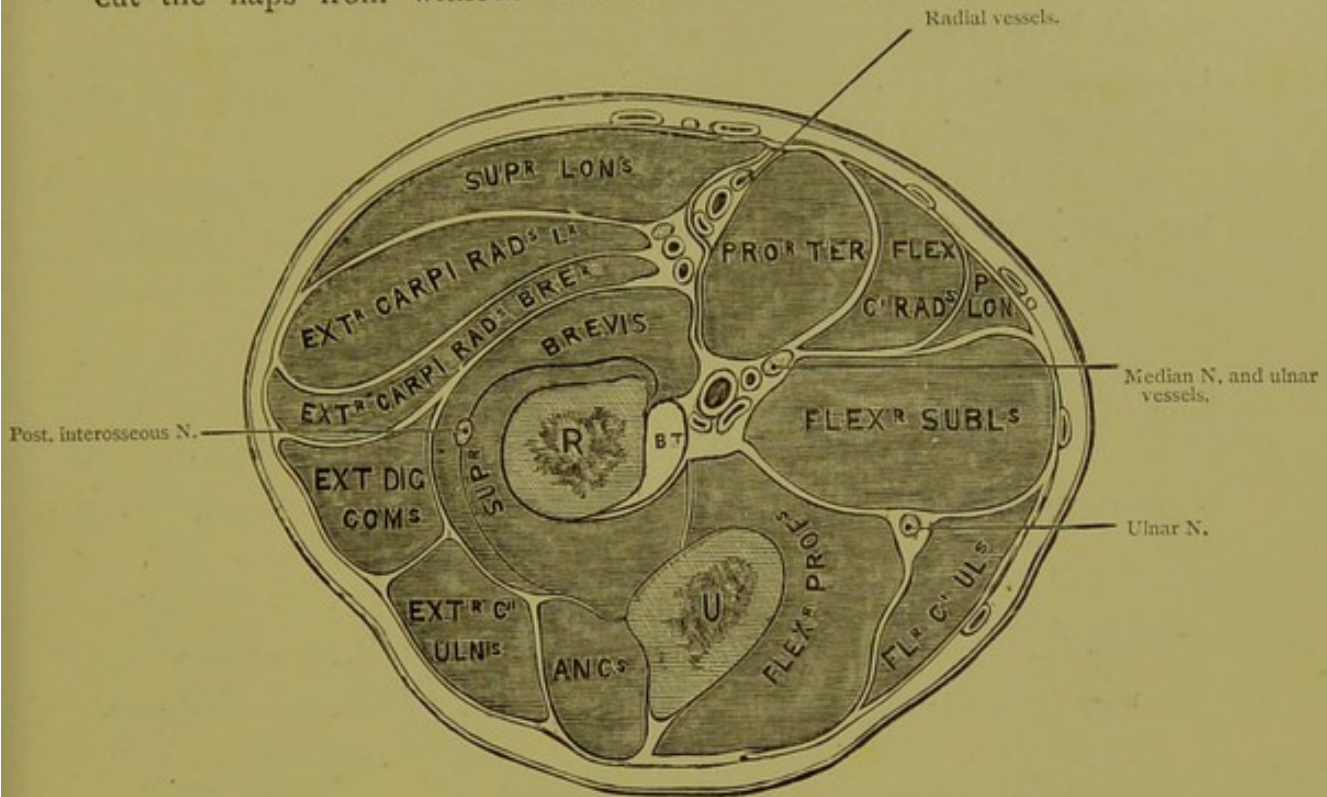


FIG. 249.—Section of the forearm opposite the bicipital tubercle.

accurately determined and the tendons will not be cut too long, as they are apt to be in the method of transfixion. In some cases Teale's method may be adopted (Fig. 250).

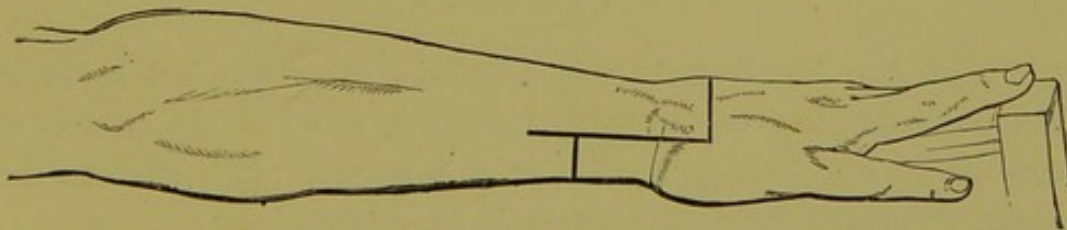


FIG. 250.—The lines of incision for Teale's amputation in the lower part of the forearm.

DISARTICULATION AT THE ELBOW-JOINT.

Indications.—The operation is rarely performed, but it may be advantageously practised where the condition of the soft parts and bone, either consequent on disease or injury, admits of it.

Surgical anatomy.—The line of the articulation is mainly oblique from the outer side inwards—that is to say, the humero-radial articulation is horizontal, while the humero-ulnar slopes downwards and inwards, the internal condyle is more than an inch above the articulation, the external condyle three-quarters. The internal condyle projects downward nearly half an inch below the outer and is the more prominent.

When the forearm is extended, the top of the olecranon corresponds to a line joining the tips of the two condyles, and when the forearm is at a right angle it is vertically below this line. The olecranon is nearer to

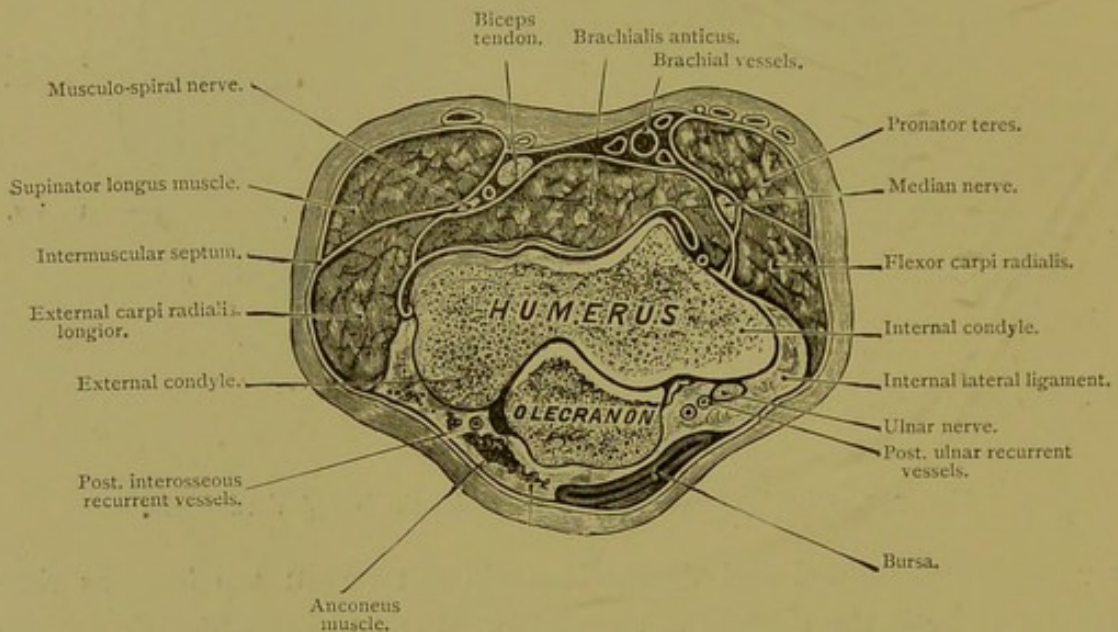


FIG. 251.—Transverse section through the elbow-joint at the level of the condyles of the humerus.

the internal than the external condyle. To its outer side, just below the external condyle, is a well-marked depression, in which the head of the radius can be felt rotating when the wrist is moved. It is almost subcutaneous, and easily distinguished even in fat persons.

The brachial artery bifurcates a finger's breadth below the bend of the elbow.

Operation.—According to the circumstances of the case, the flap method or the circular may be adopted. When the former is selected, the flaps may be antero-posterior, lateral, a long anterior single flap, long posterior flap, or Teale's method may be practised. A single lateral flap,

taken either from the inner or the outer aspect of the limb, will also be found to afford an excellent result. The long anterior flap is the method usually selected (Fig. 252), and this may be formed either by transfixion, the forearm being flexed, or by cutting from without inwards. It should

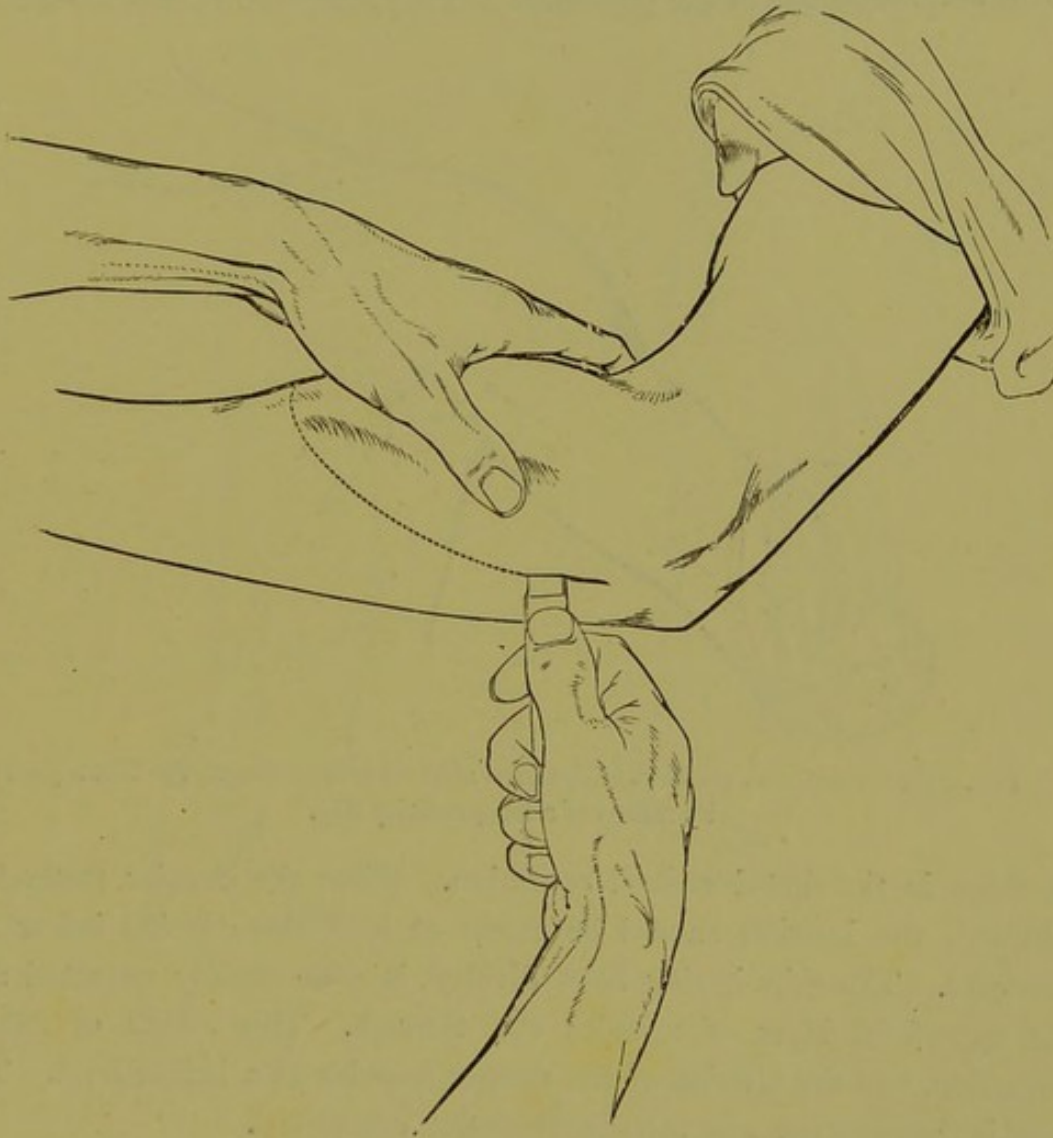


FIG. 252.—Formation of the longer anterior flap by transfixion prior to disarticulation of the elbow-joint.

be from three to four inches in length, and its base made to correspond with a line a half to three-quarters of an inch below the condyles. After the flap is dissected up to the joint, the capsule and lateral ligaments are cut through, and a short posterior flap formed. This is best accomplished by cutting from without inward, so as to detach the soft parts from the ole-

cranon. In some cases the olecranon has been sawn through at its base and its connections with the triceps extensor muscle left undisturbed. This diminishes the otherwise considerable tendency of the posterior flap to retract. When the long flap is made from either of the lateral aspects of the limb, the steps of the procedure and the subsequent result are similar

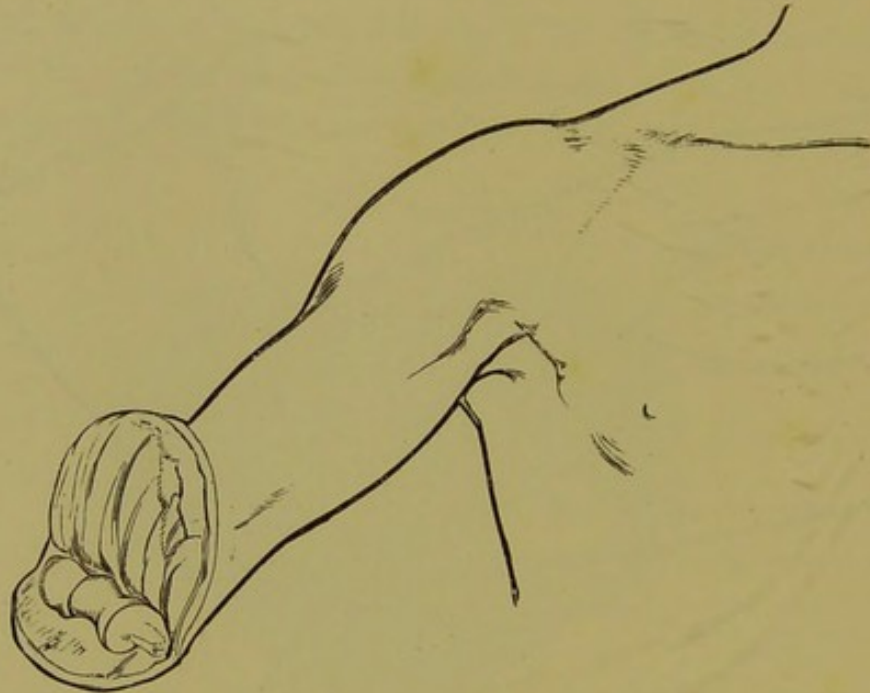

FIG. 253.—Form and position of the flaps after disarticulation at the elbow-joint by means of a long anterior flap.

to those in the first-described operation. When the circular method is adopted, the incision should be made at least three inches below the condyles. The skin, having been divided, is then forcibly retracted and the superficial layer of muscles cut through. This allows of further retraction, and the division of the deeper muscles at a higher level. The joint is then opened, and the disarticulation completed.

OVAL OR RACQUET-SHAPED AMPUTATION AT THE ELBOW-JOINT.

The operator takes the limb in his left hand, placing his index-finger on the olecranon process of the ulna, and his thumb in the ante-cubital fossa, his three other fingers grasping the posterior edge of the ulna. With a scalpel or other small knife an incision is begun opposite the coronoid process of the ulna, and carried downwards and outwards in an elliptical

direction through the supinator muscles. A similar one is then carried downwards and inwards through the flexor muscles as in the diagram. That through the supinator muscles must be a little the longer. The ends of the two incisions are then joined by one, running across the back of the forearm. The two lateral flaps are dissected

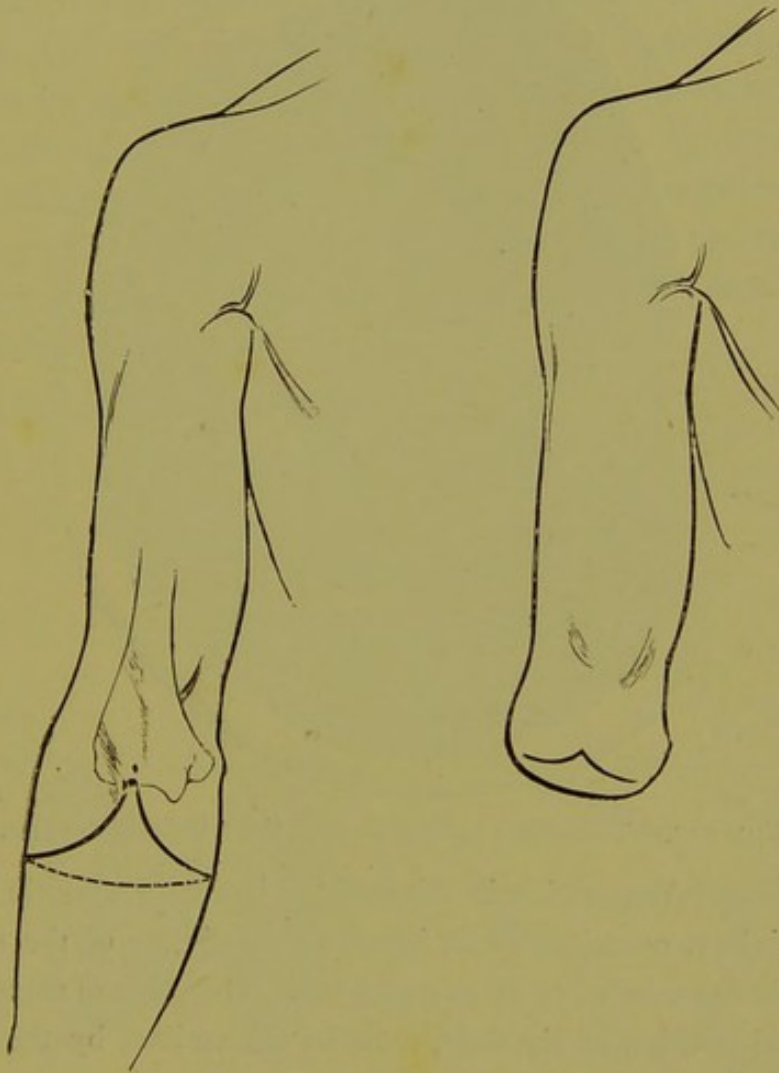


FIG. 254.—Amputation through the elbow-joint by the oval method.

away from the elbow-joint, and the articulation opened from the radial side, and, keeping the edge of the knife near the bone, the radius and ulna are to be separated behind from the posterior flap. Care must be taken lest a "button-hole" be made in the flap opposite the olecranon process. Any synovial membrane and loose capsule may then be dissected away and the parts brought together.

AMPUTATION OF THE ARM.

The circular method is well adapted to this part of the body, and so also is the flap method, either with antero-posterior or lateral flaps.

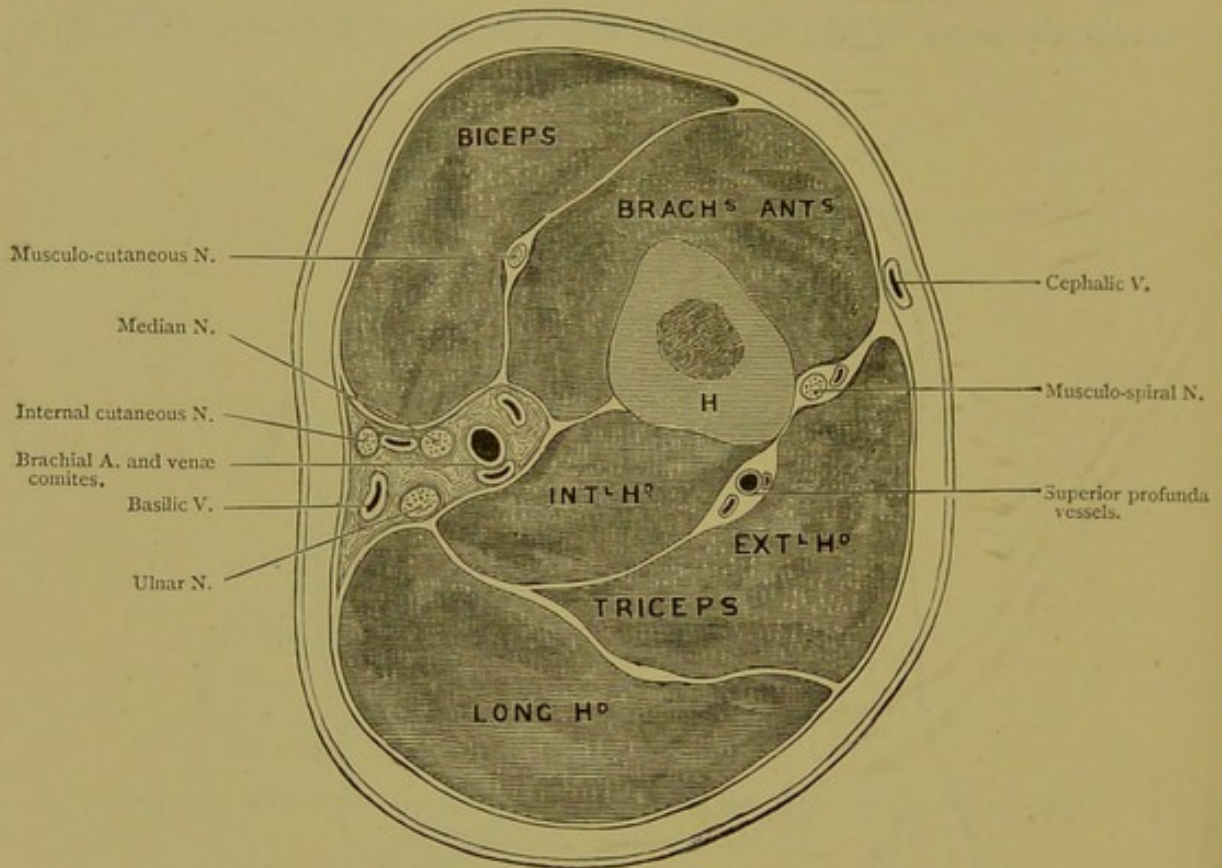


FIG. 255.—Transverse section through the middle of the arm.

Indications.—Amputation in this position is most frequently required on account of injury, occasionally for irremediable disease of the elbow-joint, not amenable to excision, or for new growths. The place of amputation, and the form and position of the flaps, must be determined by the nature and extent of the damage or disease.

Surgical anatomy.—In the middle portion the arm is flattened from side to side. There is a groove on each side of the prominent biceps muscle, the inner, in which the principal vessels run, being the better marked.

The insertion of the deltoid muscle corresponds to the middle of the shaft of the bone, and is on the same level as the insertion of the coracobrachialis and origin of the brachialis anticus muscles; the musculospiral

nerve and inferior profunda artery cross the back of the humerus, and the nutrient artery also enters the inner aspect of the shaft at this level.

In front of the lower end of the humerus, we find the biceps and brachialis anticus muscle in the centre. The supinator longus muscle on the outer side, and the flexor muscles on the inside, form a somewhat Y-shaped space, in which lie the main vessels and nerves. The inner limb of the Y transmits the brachial artery, the anterior branch of the inferior profunda vessels and the median and internal cutaneous nerves; the outer limb transmits the anterior branch of the superior profunda vessels and the musculo-spiral nerve. The leg of the Y is generally spoken of as the ante-cubital fossa. Behind in this position the humerus is somewhat evenly covered by the tendinous expansion of the triceps muscle and the sub-anconeus muscle.

Operation.—The circular method is very easy to perform. At the point

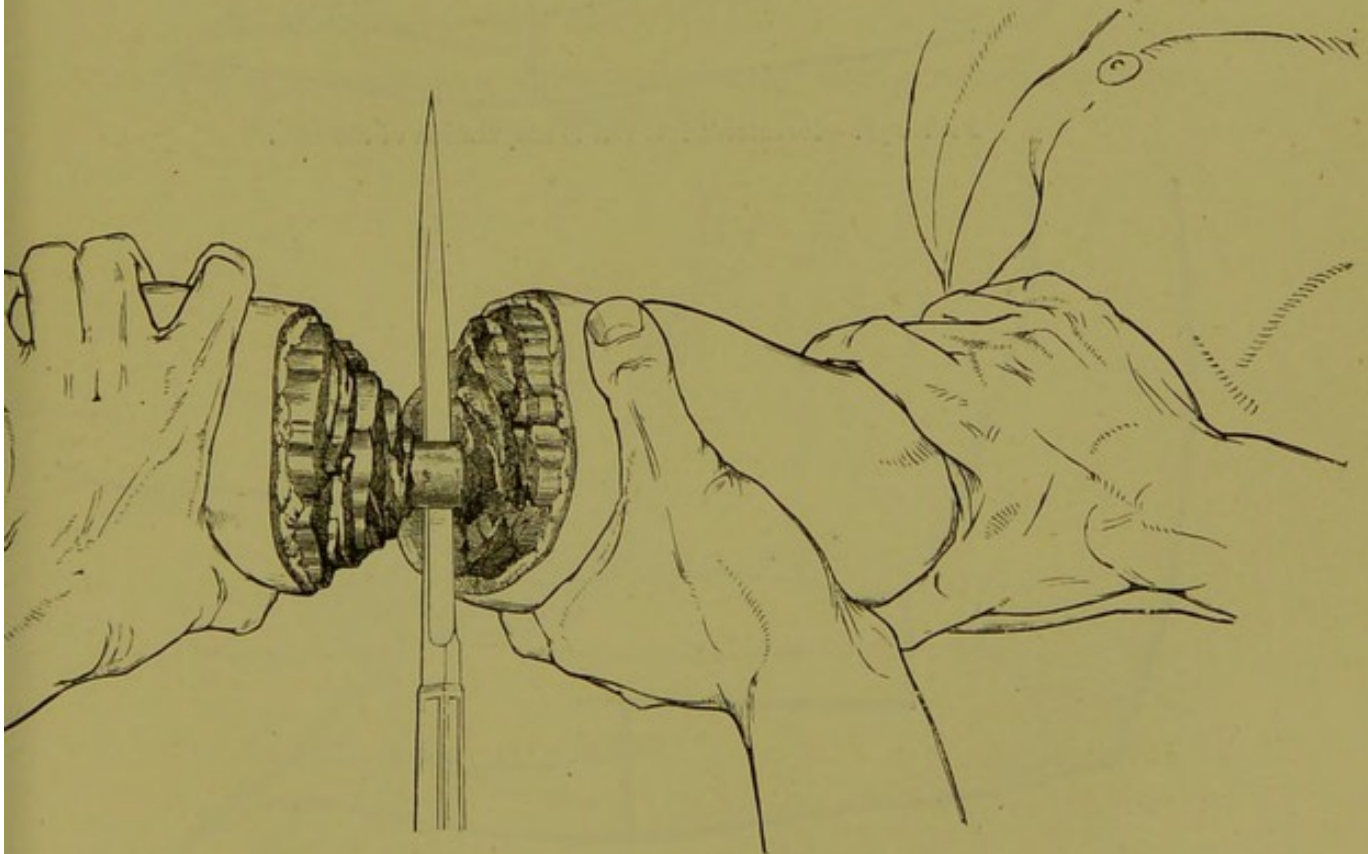


FIG. 256.—Completion of the circular method of amputation of the left arm. The right hand of the assistant compresses the axillary artery. Many operators prefer to stand on the inner side of the left limb.

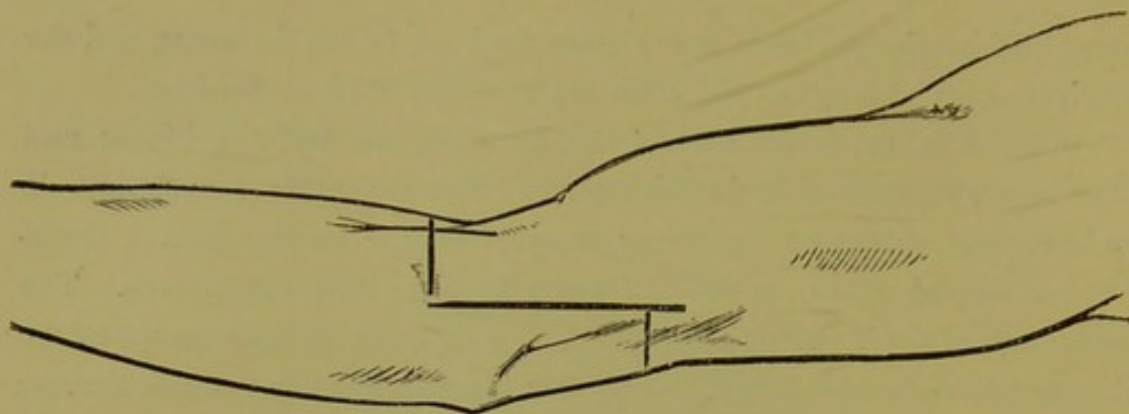


FIG. 257.—Teale's method of amputation in the lower third of the arm.

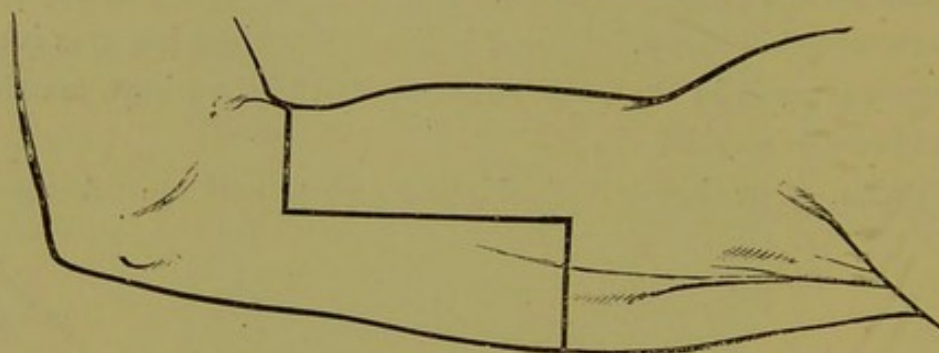


FIG. 258.—Ravaton's incision in amputation of the arm.

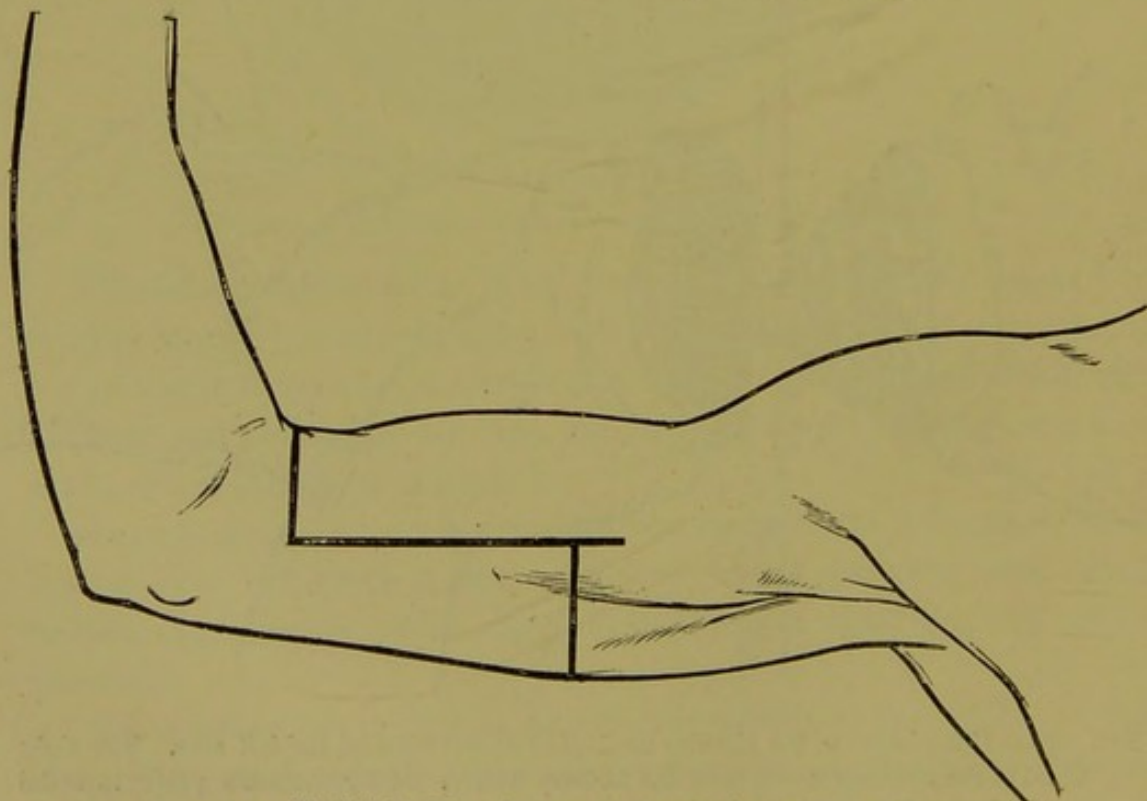


FIG. 259.—Teale's incisions in amputation at the middle of the arm.

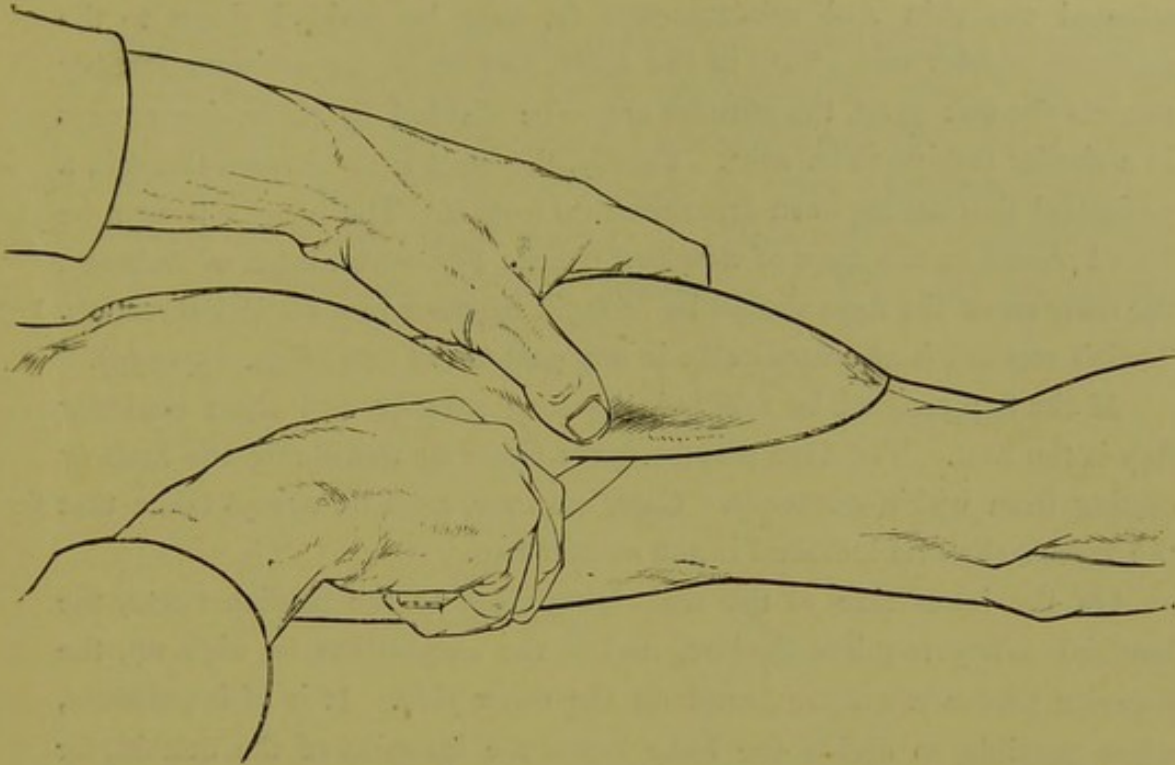


FIG. 260.—Flap amputation of the arm. Method of transfixing the limb to form the anterior flap.

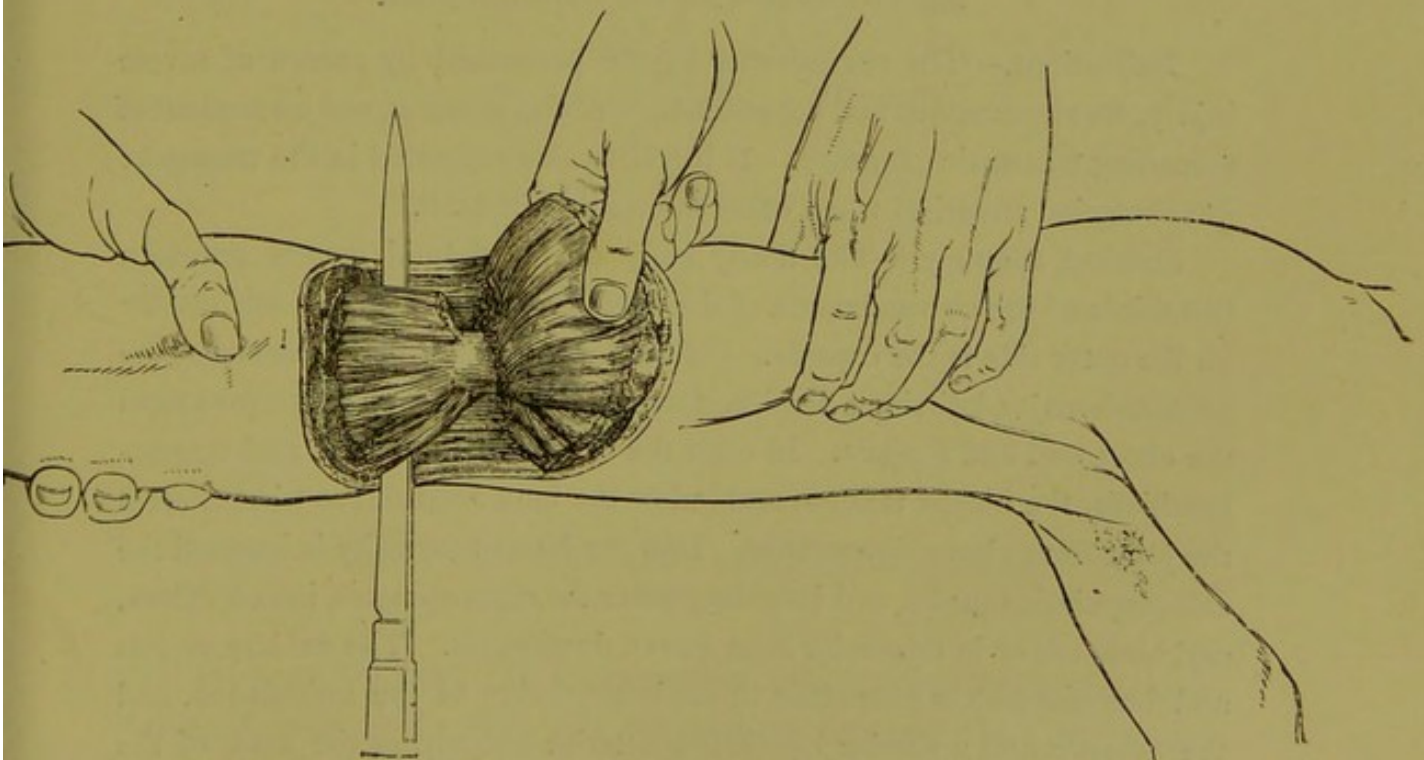


FIG. 261.—Flap amputation of the arm. Manner of forming the posterior flap, and of applying digital compression to the brachial artery.

selected the skin and subcutaneous fat may be divided down to the aponeurosis with one sweep of the knife, and whilst the assistant forcibly retracts the soft parts, the muscles are to be divided by successive sweeps in a similar fashion (Fig. 256). Finally, the bone is to be sawn through, a periosteal flap having been first raised up from it. The bone will now be found placed at the apex of a hollow cone. For convenience of drainage, the margins of the flaps should be brought together in a vertical direction. Teale's method is also applicable in any part of the arm (Figs. 257-259).

If the flap method be selected, the long anterior and short posterior flap is the best. The flaps may be made either by transfixing the limb or cutting from within outwards. Care, however, must be always taken that the vessels shall be included in the shorter flap.

On the inner side of the arm, lying close to the median nerve, the brachial artery requires ligature, and if the amputation be high up, the superior profunda will be found on the outer side. It is of importance, when possible, to divide the bone below the insertion of the deltoid, for the sake of the increased power thus given to the stump.

DISARTICULATION AT THE SHOULDER-JOINT.

Indications.—The operation is chiefly performed by reason of severe injury, for sarcomatous and other tumours of the humerus, and on account of spreading traumatic gangrene. It has been also suggested in the treatment of subclavian aneurism when other means do not avail.

Surgical anatomy.—The fleshy belly of the deltoid muscle envelops two-thirds of the circumference of the shoulder-joint. Beneath this muscle on the outer side is the capsule. On the inner side are the insertions of the pectoralis major, latissimus dorsi, and teres major muscles, passing across from the chest wall and scapula. In front the origins of the biceps and coracobrachialis, the biceps tendon, and below the long head of the triceps, cross the joint from above downwards. Into the lesser tuberosity is inserted the sub-scapularis muscle, and into the greater the supra-spinatus, infra-spinatus, and teres minor in this order from above downwards. The axillary vessels and brachial plexus pass close to the internal side of the articulation, and the anterior and posterior circumflex arteries encompass the neck of the bone just below its tuberosities.

Operation.—The point of first importance in performing this operation is to be able thoroughly to control the hæmorrhage. In cases of thin, long-necked persons, this may be done by compressing the subclavian artery downwards and backwards against the first rib above the clavicle with the fingers or a key-handle shaped compressor. Both methods of compression are, however, uncertain, especially because of the necessary movements

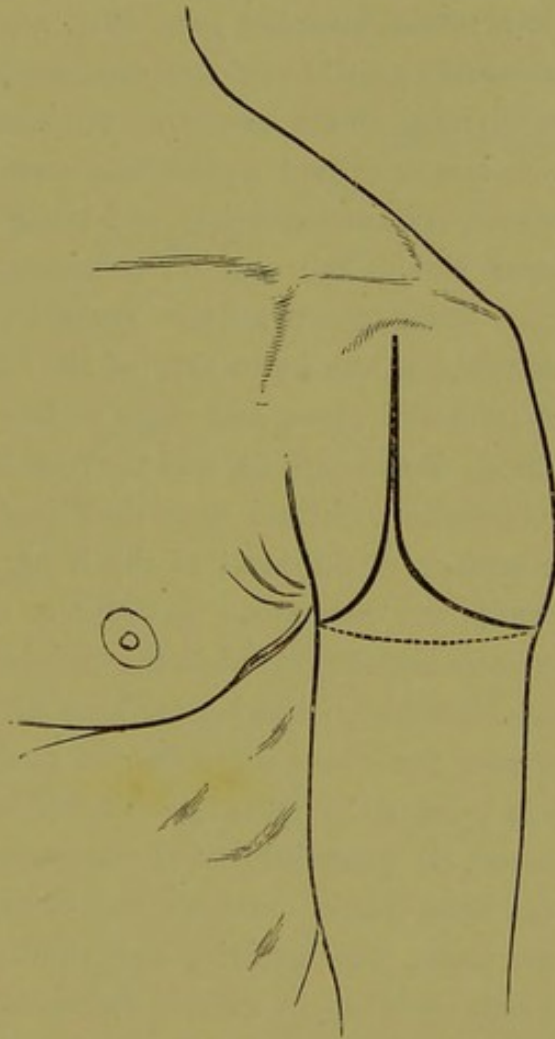


FIG. 262.—Position of the incisions for the disarticulation of the shoulder by the oval method.

imposed upon the arm. In short-necked and fat individuals if a small incision be made in the skin over the clavicle, through which the thumb may be introduced, it will render the application of the compression, either digital or instrumental, more easy and efficient during the operation.

A safer plan is so to form the flaps that the vessels need not be divided until the last moment, and before this is done it becomes possible to compress them in the flap by the fingers of an assistant.

The patient should be placed in a position with the shoulder well elevated. The surgeon stands on the outer side of the right arm and the inner side of the left, which should be well abducted from the side.

A good method of operation is by means of a modified oval incision, with the apex over the acromio-clavicular joint (Fig. 262). Entering the knife here, an incision should be made vertically downwards in the direction of the bicipital groove, dividing all the tissues to the bone for a space of four inches. The knife is now carried transversely outwards, close above the insertion of the deltoid, still cutting deeply, and brought round the back of the arm to the inner side. The incision terminates by joining the wound first made, care being taken at this stage to divide only the skin and subcutaneous tissue on the inner side of the arm. The external flap is to be detached from the upper and outer surface of the joint; a transverse incision is made in the capsule, and the muscles inserted in the greater and lesser tuberosities, divided near their insertions by cutting at right angles to the surface of the head of the bone, while the arm is alternately rotated inwards and outwards. In order to open the articulation most readily, the knife may be placed in the bicipital groove and run up along it into the shoulder-joint, following the long tendon of the biceps. The assistant now presses the elbow upwards and pushes the head out of the wound, which is grasped by the surgeon's left hand, and the external flap being retracted, the posterior part of the capsule is divided, and the knife made to cut from within outwards and downwards, keeping it first quite close to the bone, thus avoiding the trunk of the posterior circumflex artery and only dividing the axillary vessels at the last moment, the assistant meanwhile grasping them in the posterior flap before their division. The knife is thus made to emerge from the wound previously marked out, and the parts come together very accurately, and in a position well suited for effective drainage (Fig. 264). This is the method to adopt when an excision has possibly to be converted into an amputation.

If the method of double flaps be adopted, the tip of the coracoid process is felt for in front, and the spine of the scapula at the base of the acromion

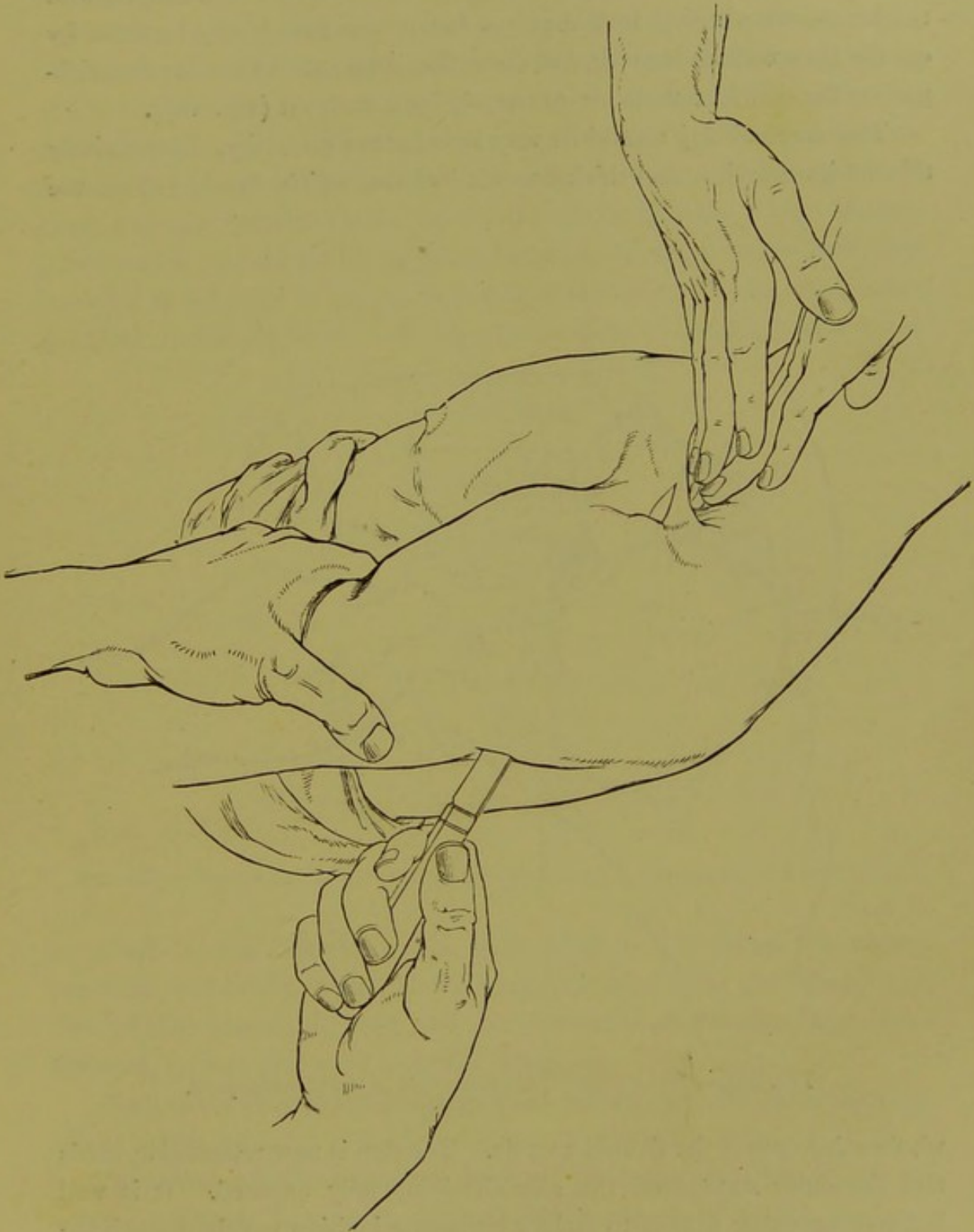

FIG. 263.—Disarticulation at the shoulder-joint, with preliminary digital compression of the subclavian artery upon the first rib.

process behind. A long flap reaching to the insertion of the deltoid, with the base corresponding to the points before mentioned, may be made by cutting from without inwards, and dissecting it up so as to include the thickness of the deltoid muscle, or conversely by transfixion (Fig. 263).

The external flap should be very broad at the extremity, comparatively thin at its margins, and thick towards its base, which should include the

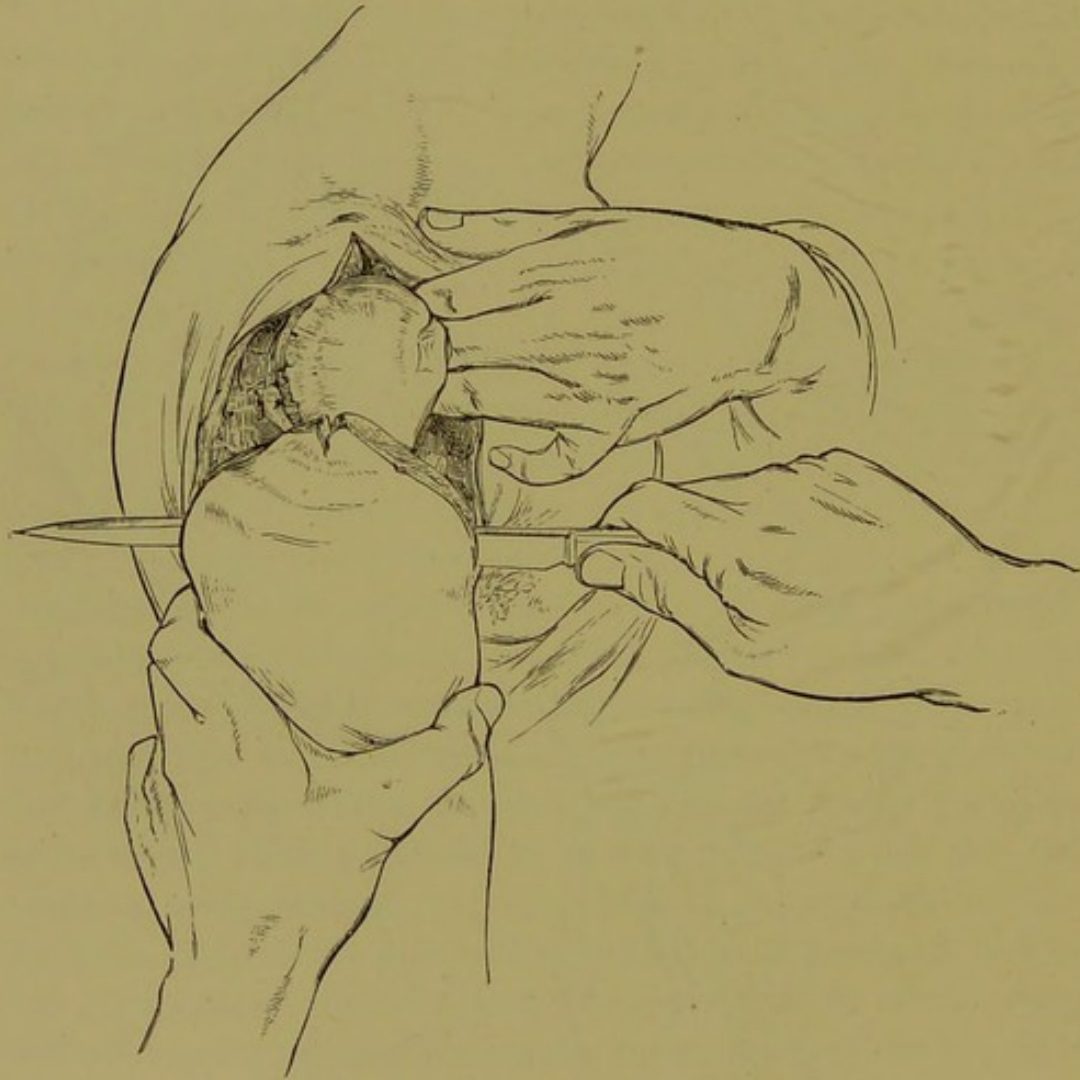


FIG. 264.—Oval method of disarticulation at the shoulder-joint.

whole substance of the deltoid muscle. The flap is now retracted upwards and the outer surface of the shoulder-joint fully exposed. It is well before proceeding further to make a transverse incision merely through the skin and subcutaneous tissue across the inner side of the arm two or three inches below the axilla, joining the flap first formed two inches below its

upper extremity. The joint is now cut down upon, the capsular muscles and capsule itself divided, as well as the long tendon of the biceps, as in the operation before described; the head of the bone is made to project, and the operation completed by forming the short internal flap by cutting outwards. The knife should always pass downwards for some distance close to the bone, cutting through the insertions of the pectoralis major in front, and the latissimus dorsi and teres major behind. The brachial plexus, axillary artery and vein lying between them, are undisturbed until the edge of the knife is turned outwards and caused to emerge through the incision already made. Before this is done the axillary artery can

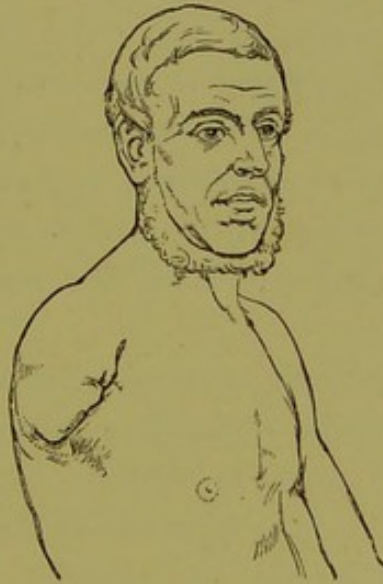

FIG. 265.—Appearance of the parts after disarticulation through the shoulder-joint.

be seized by the assistant. The short head of the biceps, the coracobrachialis, and the long head of the triceps are divided in the internal flap. The axillary artery and vein, and the circumflex arteries, are now to be ligatured, as well as several muscular branches.

The oval or racquet-shaped incision of Larrey may also be adopted as shown in Fig. 264.

First make a vertical incision down to the bone from the tip of the acromion process to a point one inch below the head of the humerus. From the lower extremity of this two oblique incisions are made, one on the posterior, the other on the anterior, aspect of the joint, as far as the

anterior and posterior axillary folds including the muscles, and dividing their attachments to the humerus, keeping very close to the bone. The edges of these incisions are now separated and the capsular muscles and capsule divided, the head of the bone can then be luxated upwards, the knife passed behind it, and the operation completed by cutting outwards and slightly downwards through the tissues of the axilla which remain undivided between the extremities of the oblique incisions. The artery can meanwhile be effectively compressed by an assistant before its division in the substance of the internal flap.

EXCISION OF JOINTS.

General remarks.—Excision or resection is a name given to operations in which one or more bones, or portions of bone, are removed, whilst preserving the soft parts and the limb. It is practised more frequently now than formerly as a means of retaining parts which would otherwise fall to the amputating knife. The operation was indicated in the writings of many of the old authors. Galen once successfully removed a portion of the sternum for caries; but although resection of portions of bone, and probably even of joints, has been practised from very early times, it is only within a century that the excision of joints has become established as a regular surgical procedure, and fixed rules have been formulated for its performance.

Until Park's letters and Jeffrey's translation of Moreau's book appeared in 1806, followed by Syme's work in 1831, we possessed in English no treatise on the excision of joints, and yet so early as 1803 Moreau had excised nearly all the larger joints.

Park, of Liverpool, published in 1782 a letter to Percivall Pott, advocating excision of the knee, and giving the account of a successful case in a sailor, who subsequently exercised his profession; but until Sir William Fergusson revived the operation it had been rarely resorted to.

To the Edinburgh surgeons the merit undoubtedly belongs of making excision of the elbow-joint one of the most successful procedures in modern surgery.

Anthony White, of London, first successfully excised the hip-joint in this country. The patient, a boy, lived for five years afterwards, and subsequently died of phthisis.

The elder Moreau had excised the ankle-joint in 1782, yet Hancock performed the first operation of the kind in this country in 1851.

Excision of the wrist was also first performed by Moreau.

One of the first instances of what we may term sub-periosteal resection was that related by Charles White in 1768. It is erroneously cited by many authors as the earliest case of excision of the shoulder-joint. If, however, White's own account be read, it becomes evident that the patient, a young subject of fifteen, had suffered from acute periosteal abscess, originating probably in epiphysitis. The superior epiphysis of the humerus had become separated, and was extracted. Subsequently, four inches of the shaft of the humerus, quite bare of periosteum, were removed. A very complete reproduction of bone followed, and the restored motion of the joint was all but perfect. White gives a plate of the portions of bone removed, and by comparing these with a humerus in which the superior epiphysis is not united to the shaft, the correctness of this view will readily be verified. The periosteum had evidently been separated from the bone by disease. What in this case was the sequence of an accident is now systematically practised in suitable cases with great advantage. It has resulted in a most important surgical advance: in sub-periosteal resection the wound is more simple, there is but little bleeding, the injury to the surrounding parts is less great, and the tendency to suppuration or septic poisoning becomes probably much diminished.

The several methods of operation recommended for the various joints of the body will be described in detail hereafter.

Excisions or resections may be divided into articular, and resections in continuity of a bone, as in cases of fracture, necrosis, false joint, or badly united fracture.

Resection of a joint is meant as a substitute for amputation. Caries and necrosis, often the result of tubercle, in the articular extremities of the bones forming the joints, and disease of the synovial membranes, are the most frequent indications for its performance. In cases of injury excision may be either primary, intermediary, or secondary. For diseased conditions it is usually undertaken after suppuration has set in.

In recent years much attention has been devoted to the question of the preservation of the periosteum of resected portions of bone. Heine and Flourens demonstrated the osteo-genetic power of periosteum, and Ollier showed how periosteal grafts might be transplanted and new bone produced in different parts of the body, although the new bone thus formed

seldom seems to be very permanent. Sédillot attributes great osteo-genetic power to the thin layer of bone next the periosteum, and advocates its preservation by means of the so-called *évidement de l'os*. When the periosteum is preserved, along with its attachments to surrounding parts intact, new bone is rapidly formed, and being deposited in a sort of mould, it sometimes closely reproduces the primary aspect and dimensions of the part removed. As the muscular insertions are raised at the same time as the periosteum, the muscles remain undivided from their attachments, and the subsequent movement of the limb is more completely recovered. Another considerable advantage possessed by sub-periosteal resection is the much smaller loss of blood, no important vessels being divided. The lesser amount of bleeding, relative absence of intermuscular suppuration, and more perfect bone reproduction, are all well-recognised advantages.

In primary excisions it is difficult to detach the periosteum. It often cannot be completely separated, but at the same time this ought to be done as perfectly as is possible. In secondary resections it becomes much easier, although here also it often proves troublesome, and in some diseases is altogether contra-indicated.

As little bone as possible should be removed, and as much periosteum as possible preserved in order to reproduce the excised bone. This is more especially true when the operation is performed for injury; when for disease, the removal of the diseased parts should be more extensive.

The more the bone is taken away, the more the muscular attachments are interfered with, and the more seriously will subsequent function be impaired.

Where ankylosis is sought for, the cut surfaces of the bones should always be placed in strictly accurate apposition, and the limb immobilized for a sufficient time in suitable apparatus. Absolute rest must be maintained for a protracted period, about as long, say, as that which is required for the union of a compound fracture. But in cases where restoration of mobility is the object, passive action of the joint should begin as soon as inflammatory reaction has subsided, and the new material thrown out is sufficiently organized. Probably this will be, on an average, within two or three weeks.

Various forms of incision have been recommended for the purpose of gaining ready access to a diseased or injured joint.

Crucial **X**-, **H**-, **T**-, and **L**-shaped incisions are commonly employed. The simple straight incision originally recommended by Park for the elbow and knee, has again come into favour in respect of different joints. Langenbeck employed it for the excision of the shoulder, elbow, wrist, hip, and knee joints, and also devised lateral incisions for the ankle-joint. Whatever be the method of incision employed, the soft parts must, as much as possible, be respected, and the large vessels and nerves protected from injury.

As a rule, Esmarch's apparatus ought not to be employed, as the subsequent capillary bleeding is thereby much increased. It is especially inapplicable in the upper limb, because temporary paralysis of the extremity is frequently produced by the pressure exerted on the comparatively unprotected nerve trunks. Digital pressure on the vessel above is here sufficient, inasmuch as the amount of hæmorrhage is never very serious, especially in sub-periosteal operations. Infrequent dressing is most desirable after excision, and reactionary hæmorrhage necessitates several changes of the dressings and considerable disturbance of the parts.

Indications.—In the present place it is only intended to discuss the various methods of performing excision, and their principal indications, in cases of injury and in articular disease. In the upper extremity the operation is in many respects more successful and less serious than in the lower. Mobility is the chief object to be compassed, and this may be realized to a relatively greater degree in excisions of the shoulder, elbow, and wrist. In the lower extremity, ankylosis is generally to be expected after excision of the knee-joint; but in the hip and ankle a limited amount of movement is often to be obtained.

Gunshot fractures have frequently given occasion for successful excisions in the upper extremities; whilst in the lower, except at the ankle, excisions have hitherto proved notably unsuccessful in military surgery.

Compound, also old unreduced dislocations, and anchyloses of joints, especially if in a faulty position, furnish reasons for performing resection.

Excision is in general more difficult to perform than amputation of the corresponding part, whilst it is certainly not much less serious, both

immediately and afterwards, in consequence of being a more extensive operation, and because of the protracted confinement and tedious convalescence which may follow it. But, whenever it may properly be chosen, it is infinitely preferable to amputation, inasmuch as the limb is preserved, as are often also the functions of the joint.

Resection may be partial or complete. The latter is generally the more satisfactory in its results.

In articular resections in the upper extremity, and also in the hip and ankle, the divided ends of the bones have a tendency to adapt themselves to each other, and to assume to some extent their original form, whilst at the same time the surrounding muscles are in time more or less able to resume their arrested functions. In the knee bony ankylosis should always be sought for.

The first question in all cases of resection is not so much as to the probable result as regards function, as whether the contemplated operation be more dangerous to life than the alternatives of conservancy or amputation.

The indications laid down by Hueter are, suppurative synovitis, osteitis, synovitis granulosa hyperplastica, compound luxation, suppuration after joint injury, deformity, ankylosis, and irreducible luxation with pressure symptoms on adjacent vessels or nerves.

In cases of joint suppuration the acute symptoms due to retention of the secretion are, as a rule, dispelled by resection, which therefore proves a valuable antiphlogistic.

This holds especially good in acute epiphysitis, as of neck of femur, where excision offers a better chance of drainage than any incision; but in joints capable of efficient drainage it is often better to incise, and await a more satisfactory state of the surrounding tissues.

It were just as unreasonable to delay operation in such cases as it would be to wait to open an abscess until fever disappears.

If septic suppuration and severe general symptoms have set in, the operation has been decided upon too late, and will not prove successful in arresting evil results.

Stromeyer says of resection after gunshot injury, that in case it has to be performed, the earlier it is done the better. Where resection, however, is not immediately demanded, conservative treatment is to be preferred. But

should suppuration follow, then if the joint be one in which excision promises better results than union by ankylosis, it should at once be performed, unless indeed amputation appear to be necessary.

In traumatic cases Langenbeck preferred to operate in the later period when possible, because of the probably better functional results. The periosteum is then thick and vascular, easily detached, and it reproduces bone better.

The comparative safety and value of primary and secondary excision in war surgery is not yet quite settled. It is often impossible to perform a primary resection on or near a field of battle, and, were it possible, the after-treatment would probably be defective.

Czerny decides in favour of primary resection in cases of extensive splintering of the bones of a joint, as these can only separate after a long process of suppuration and necrosis.

The presence of bullets or foreign bodies in the joint usually necessitates primary resection. The aseptic removal of the foreign body and of the bony fragments may, however, materially modify this conclusion.

As a rule, life is less endangered by excision than by amputation or disarticulation at a higher point of the limb. The danger after resection, just as in amputation, is relatively less the further the operation is removed from the centre, and it is also less in the upper than in the lower extremity.

The result may be perfect, only partially successful, or it may be wholly unsuccessful.

Except in the knee, a greater or less degree of mobility is the result which may generally be calculated upon.

Stumps, the result of amputation, are as a rule liable to become painful more often than are excised joints: and joints which become ankylosed are frequently the subject of recurrent inflammation. Even the flail joint, which sometimes follows after excision, may oftentimes be improved by treatment and suitable apparatus.

Contra-indications.—Extensive disease of the bones, necessitating so free removal as to render the limb useless or less satisfactory than an artificial one.

Extensive disease of the soft parts unlikely to be greatly bettered by the removal of the diseased joints.

Acute inflammation of the soft parts around the joint.

Enfeebled constitution from any cause, especially visceral disease.

Extreme youth; in very young persons the check to growth of the limb and tendency to gradual deformity render excision less satisfactory than arthroectomy.

Advanced age. Forty years is, as a rule, the extreme limit.

Another point to be borne in mind is that excision in cases of joint disease, accompanying general constitutional conditions, occasionally leads to the lighting up of fresh mischief in other joints or parts of the body; this is especially to be remembered in cases of more or less acute tuberculosis, and in so called rheumatoid arthritis.

Excision of an ankylosed joint should not be performed where an equally good functional result may be obtained by osteotomy in its neighbourhood, a less serious operation, and one not interfering with any residual products of prior inflammation.

MORTALITY AFTER EXCISIONS.

Referring to the Reports of St. Thomas's Hospital for the years 1876-1885 inclusive, the following statistics of the mortality are given after excision of the joints:—

JOINT.	NO. OF CASES.	DEATHS.	PER CENT.
Shoulder . . .	20	2	10'00
Elbow	47	1	2'40
Wrist	11	0	0'00
Hip	146	26	7'80
Knee	88	8	9'00
Ankle	14	1	7'14
Toes	12	1	8'30

EXCISION OF SPECIAL JOINTS.

OSTEO-PLASTIC RESECTION OF THE FOOT.

WLADIMIROFF, MIKULICZ.

This operation appears to have been first performed by Wladimiroff of Kasan, in 1872, but Mikulicz of Prag published an account independently (Langenbeck's *Archiv*, 1881), and from his description it became known and practised. The heel portion of the foot is altogether removed, the operation being exactly the converse of a Syme, after division the cut surfaces of the tarsal bones being made to form a synostosis with the sawn surface of the tibia. The functional result obtained is admirable, being in fact an artificial pes equinus. The operation is intended to apply to those cases in which the posterior part of the foot is either much injured or diseased, the anterior being healthy. The principal object is to preserve the toes and metatarsal bones for purposes of progression, which are sacrificed in other forms of amputation of the foot. These are brought into

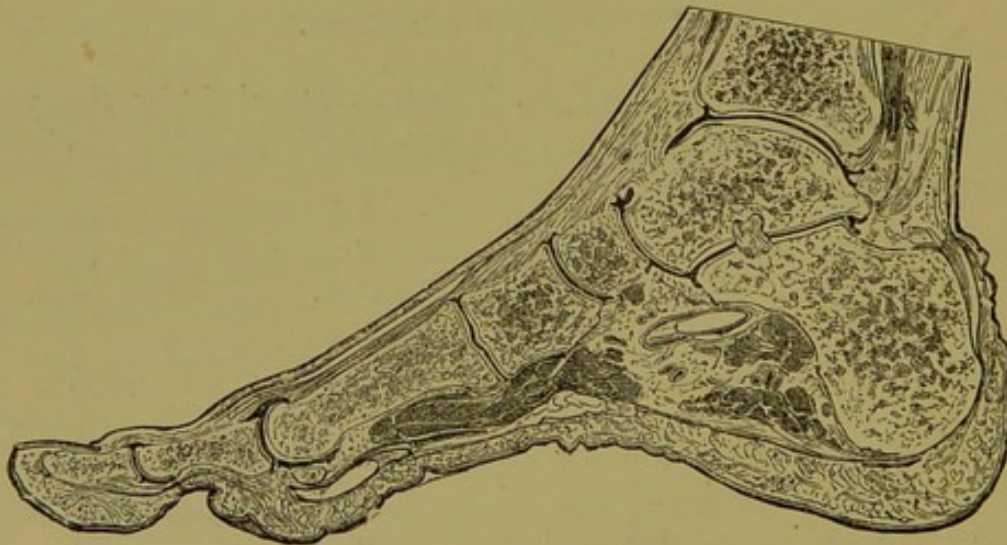


FIG. 266.—Sagittal section of the foot. The arch of the foot is longitudinal, it is tied by the inferior calcaneo-scapoid ligament, and has for keystone the astragalus. Its piers are the posterior extremity of the os calcis behind, and in front the sesamoid bones on the inner side, and the metatarsophalangeal articulation of the little toe on the outer side.

a position of complete extension in a straight line with the leg, the toes extended to a right angle with the foot, are placed in a position of extreme dorsal flexion, and the weight of the body falls more especially on

the ball of the great and little toes and the heads of the metatarsal bones. The support thus given is broader than after Syme's or Pirogoff's amputations, and possesses some elasticity. In ordinary cases the limb will be lengthened about an inch, the difference being readily compensated for by increasing the thickness of the heel and sole of the boot on the sound foot.

Indications.—The os calcis, as is well known, is often the subject of caries or tubercular osteitis, and the diseased process after a time may spread from it to the adjacent bones and the ankle-joint.

When the calcis is diseased, Pirogoff's operation is inapplicable, and the number and position of the fistulous tracks may forbid the performance of Syme's amputation.

Traumatic cases are those best fitted for this method; cases of gunshot wound and injury by machinery, in which the calcis and soft parts covering the heel are extensively injured; also cases of caries, when the disease is limited to the calcis, astragalus, and ankle-joint.

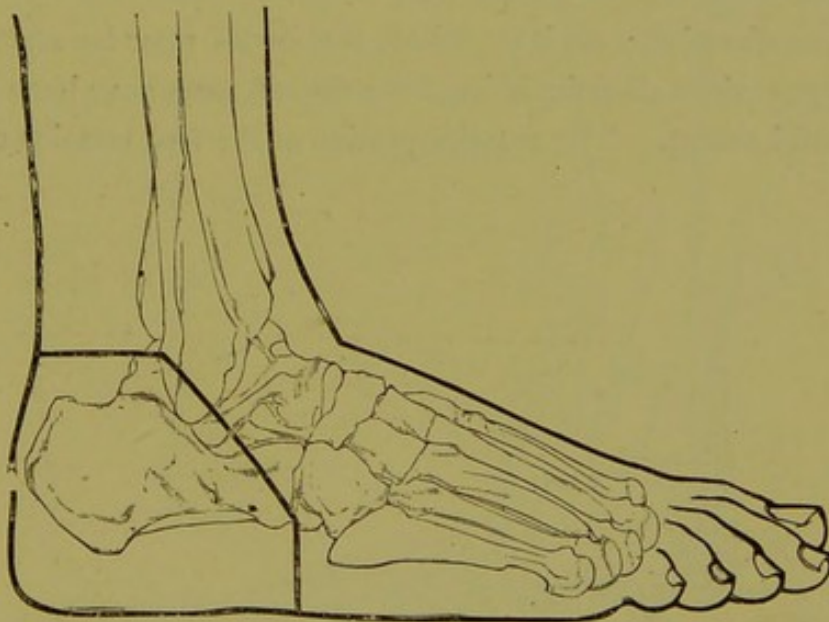


FIG. 267.—Line of incision in soft parts, made in performing Mikulicz' operation.

Operation.—The patient must be placed in the prone position. If it be the right foot the knife is introduced on the inner border of the foot; just in front of the scaphoid tubercle, and a transverse incision extending to the bone is made across the sole of the foot to a point a little behind

the tuberosity of the fifth metatarsal bone. For the left foot the direction of this incision will be reversed.

From the inner and outer extremities of the wound, an incision is to be prolonged obliquely upwards and backwards over the corresponding malleolus, and the extremities of these incisions united by a transverse cut across the back of the leg (Fig. 267), made down to the bone at the level at which it is to be sawn, which will usually be just above the line of the joint surface of the tibia. In some cases a larger removal of the bones of the leg has been practised, and then, of course, the lateral incisions will be more oblique and the posterior transverse cut made at a higher level. The ankle-joint is now opened from behind, and disarticulation effected. The foot being dorsally flexed the soft parts are carefully separated in front until the medio-tarsal joint is reached, at which disarticulation is accomplished as in Chopart's operation. The posterior portion of the foot, consisting of the astragalus, calcis, and soft parts covering the heel, is then removed; and the malleoli and articular surface of the tibia sawn off from behind forwards. The joint surfaces of the cuboid and scaphoid bones are then removed in the same direction; or, if preferred, the bones may be sawn through without any previous disarticulation, after the soft parts have been separated to the needful extent. The anterior portion of the foot remains connected

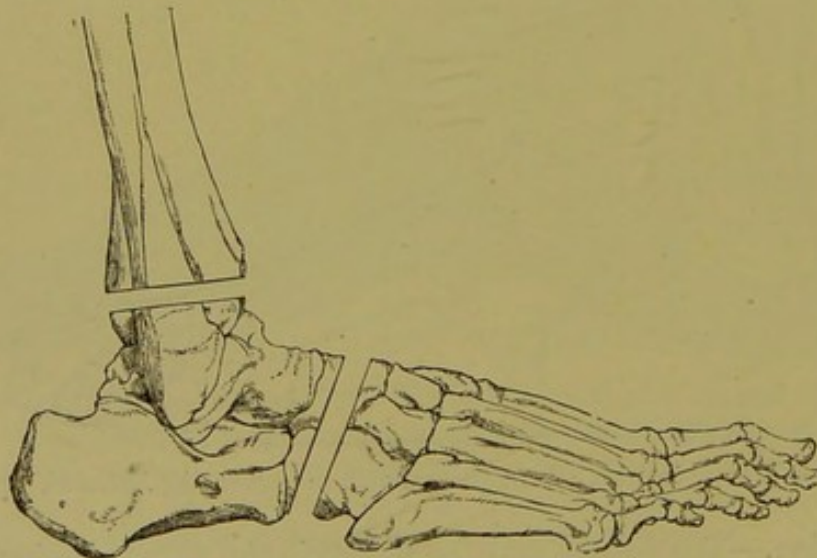

FIG. 268.—Line of section of the bones. Mikulicz' osteo-plastic section.

with the leg by a bridge of skin three to four inches wide, together with the extensor tendons in front of the ankle-joint. It derives its blood-

supply from the anterior tibial artery, which appears to be ample, for very shortly after the amputation the blood issues freely in jets from the distal extremities of the divided internal and external plantar arteries. As soon as the hæmorrhage is arrested, the cut surfaces of the scaphoid and cuboid bones are applied to those of the tibia and fibula, and should be sutured

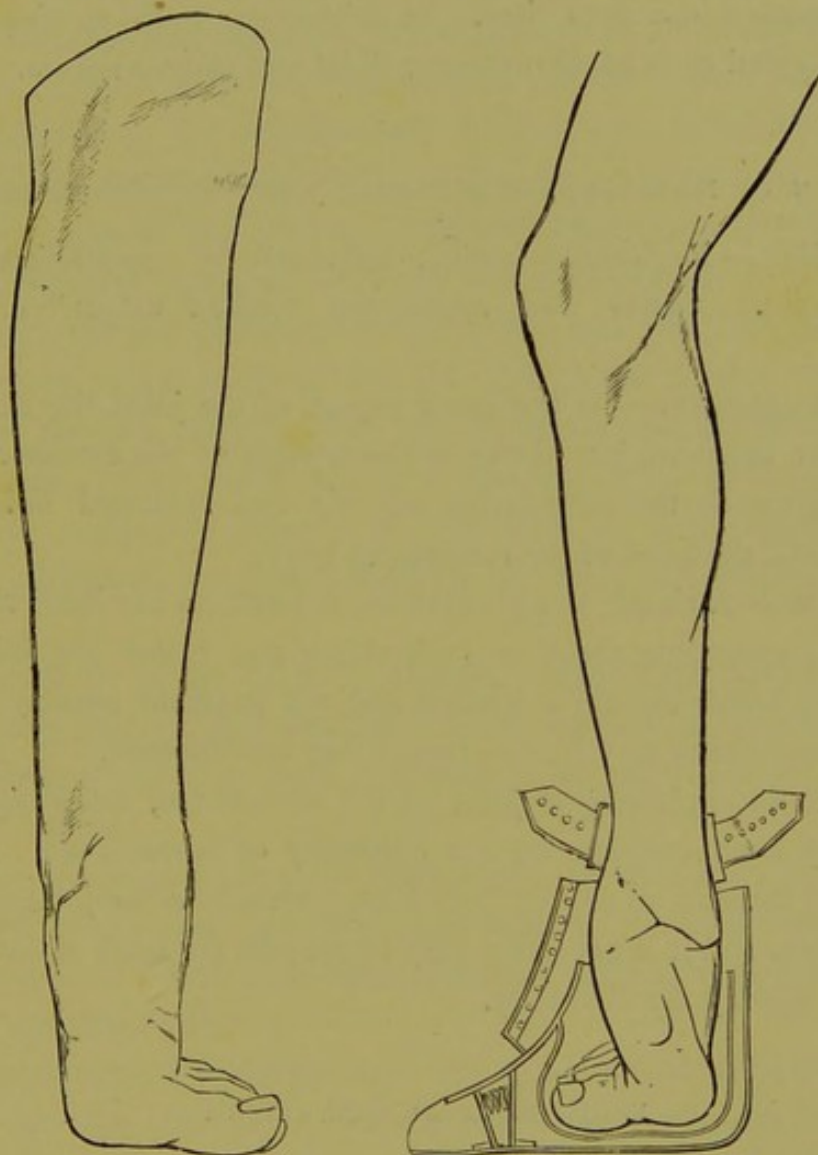


FIG. 269.—Stump after the osteo-plastic resection of Mikulicz. In the second figure a suitable boot is seen applied.

there to prevent shifting. The remainder of the foot is thus brought into a straight line with the leg, and bony union, with an excellent useful stump, is the final result. A posterior as well as an anterior splint should be applied to secure the parts in good apposition, and in order to maintain

the toes in a state of complete dorsal flexion, or at right angles with the foot.

In successful cases an admirable result is procured, and the patient can walk long distances with ease and comfort. In two instances in which I performed this operation the sensation in the anterior part of the foot was perfectly restored in a short time. In neither was I able to dissect out or unite the divided ends of the posterior tibial and plantar nerves.

EXCISION OF METATARSO-PHALANGEAL JOINT OF THE GREAT TOE.

Indications.—Neglected bunion, followed by suppuration opening into the joint. Caries and aggravated "hallux valgus," or "hallux flexus."

Surgical anatomy.—On the inner aspect of the joint the skin covers the capsular ligament, but above is the tendon of the extensor proprius hallucis. Beneath the articulation are the two sesamoid bones which articulate with the head of the metacarpal bone.

Operation.—A simple straight incision is made on the inner side of the articulation, extending about an inch above and below the joint. The ends of the bones are then everted and the requisite portion removed. The sesamoid bones may be left, unless they are diseased.

The first inter-phalangeal joint of the second toe, more rarely of the others, may need excision for the deformity of hammer-toe. A simple longitudinal incision on one or both lateral aspects of the joint suffices for this operation, and it is necessary only to remove the head of the proximal phalanx to remedy the deformity.

EXCISION OF THE OS CALCIS.

Indications.—Caries, gunshot wounds. The arrangement of the synovial cavities of the foot allows localized disease to be more common in the calcaneum, than is the case with any other of the tarsal bones, so that it has been excised with some frequency.

Operation.—In cases of caries or gunshot injury, existing fistula or wounds often serve as the basis of the incision, enlargement being

effected on the outer aspect of the bone, the principal points to bear in mind being the avoidance of injury to the vessels on the inner side, and the opening of tendon sheaths.

For complete removal of the bone in disease a large U-shaped sole flap was formerly raised, but since the operation should always be performed sub-periosteally, the less extensive incision proposed by Ollier is much to be preferred. The incision is commenced at the lower outer border of the bone, just anterior to the calcaneo-cuboid joint, and carried backward to the outer border of the tendo-Achillis, along which it then courses vertically upward for about two inches. The periosteum is divided below and behind the peroneal tendons, and then with the elevator it is displaced upwards; with the same instrument the under and posterior surfaces are likewise cleared, a few touches with the knife being needed to separate the origin of the sole muscles from the tubercles, and the tendo-Achillis from the back. The joints are now opened, and the inner surface of the bone completely freed; if the limit of the periosteum be throughout observed, the tendo-Achillis is the only one divided or injured.

In the majority of the cases of disease, however, the cancellous tissue being primarily affected, it is possible to remove this with the sharp spoon, leaving a compact shell to form a mould, as an important step towards future regeneration.

Results.—When performed sub-periosteally, an excellent result is often attained, the bone being very fairly reproduced. Vincent has collected sixty-nine cases, of which forty-nine produced good results, while twenty turned out unsatisfactorily.

Of the remaining tarsal bones none are so favourably situated for local treatment, but the astragalus and cuboid have both been successfully removed for caries, the astragalus also in cases of old unreduced dislocation, and the cuboid in extreme talipes varus.

The astragalus, when excised for disease, may be best enucleated by an incision on its outer aspect so arranged as to avoid injury to the peroneal or extensor tendons, and making use of any existing sinuses. The other bones, as also a displaced astragalus, may be most readily exposed and enucleated by \perp -shaped incisions.

EXCISION OF THE ANKLE-JOINT.

Excision of the ankle was first performed by the elder Moreau in 1782, for chronic disease of the joint the consequence of injury: the result was perfectly successful. Hey of Leeds had removed the lower ends of the tibia and fibula for compound dislocation in 1766; but Hancock was the first to perform complete excision in this country, in 1851. He adopted Moreau's method. Amputation of the foot had been until then the usual operation both in tarsal and ankle-joint disease. Hancock very properly protested against the indiscriminate sacrifice of so useful a member of the body, or that a solitary exception should be made in the case of the ankle-joint, while all the other joints were freely excised. He contrasted the operation with Syme's amputation, urging that besides the loss of the foot there may be sloughing of the flap, suppuration in the stump or along the sheaths of the divided tendons; while in excision at the ankle no important structure need be divided, there is but little deformity or shortening, and the patient is afterwards able to walk and even run with ease.

Indications.—The usual indications are acute and chronic disease, both with and without suppuration in the joint; gunshot wound of the ankle, and compound fracture implicating it.

The operation has proved much less successful when performed for disease than when undertaken for injury. In cases of disease the best results are observed where the operation has been done at an early stage.

The most favourable cases for operation, and those which afford the best results, are those of articular wounds and their consequences.

Many wounds implicating the ankle-joint are capable of cure without operation, and an attempt should undoubtedly be made, by immobilization in a splint, and free incisions and drainage, combined with other measures, to secure so desirable a result; excision is indicated where severe symptoms or septic suppuration set in after a wound implicating the joint, as in compound fractures and dislocations, and in cases of gunshot injury with extensive splintering, where amputation does not appear imperative in the first instance.

Primary excision may properly be performed for severe compound

injury of the ankle-joint, and under these circumstances the operation increases the chances of saving both life and limb; but the operation affords better functional results when performed at a later date, at what is called the secondary period.

Primary excision for injury has, however, been but rarely practised.

Few, if any, primary excisions have been put on record in war surgery, either a diagnosis cannot be made early enough, or the patient comes too late under treatment.

Where the joint has been extensively opened, the soft parts much damaged, the bone fissured or comminuted into the articulation, the astragalus fractured, or when pyæmia or gangrene threatens, amputation must probably be performed.

Delay is advisable in doubtful cases, as where a conservative method of treatment fails, the results of secondary excision are much better than those following a primary one.

A gunshot wound of the ankle with slight injury to the bone, involving only the external or the internal malleolus, may be safely treated expectantly. Contusions and grooving wounds of the joint surfaces will often do well under conservative treatment.

French military surgeons generally amputate at once in cases of injury to the ankle-joint, but it could only be proper to adopt this rule if the injury appears so extensive that even after resection a satisfactory result does not seem probable. Extensive comminution or fissure of the bone indicates primary amputation.

Primary resection is in general unsatisfactory as regards active function and a useful strong limb, but it should nevertheless be performed where conservative treatment affords no good prospect of success, and amputation does not appear needful.

In cases of injury by heavy projectiles the damage done to the bone is often very extensive, and primary excision, even if practicable, would expose the patient to the probability of subsequent necrosis; cases of this kind generally require amputation, otherwise a secondary excision is preferable; a surer knowledge of the extent of the bone damage is thus acquired, and the final result is better. Even in cases of extensive comminution it may be sometimes proper to immobilize the limb in gypsum, and

await the definition of the necrosis. There is always a risk that intense suppuration or pyæmia may supervene and destroy all chance of success.

In cases where moderate suppuration has set in, and the parts are not hopelessly damaged, free incisions with drainage may be resorted to, and the conservative treatment prolonged.

The comparative danger to life incurred in dealing with an injury to the ankle, either by conservative means, by resection or amputation, is the proper guide in cases of gunshot injury. The risk of impaired function is of smaller account in comparison.

The operation is indicated in cases of disease so soon as other approved methods of treatment fail to cause any amelioration in joints chronically inflamed, useless for progression, affected by synovitis granulosa, or already suppurating.

In cases of chronic caries of the joint the results of the operation are very doubtful. Of course the operation is inapplicable in cases in which the other joints and bones of the foot are implicated by disease, and this condition of affairs is unhappily common. Disease of one or more of the tarsal joints is commonly associated with that in the ankle, as may be seen after a Syme's amputation has been completed, even when there have been few or no previous symptoms to point it out.

The reproduction of bone is imperfect in cases of operation for strumous disease, and the morbid action is apt to reappear in some of the tarsal joints, or in the operation wound itself.

It is rarely necessary to excise the ankle, or to perform amputation of the foot from chronic disease of the ankle in children. Conservative treatment is often followed by recovery, while in adults this condition commonly requires either a Syme's or Pirogoff's amputation for its relief. In young children the disease in the foot is usually very limited, and formal excision contra-indicated: the carious parts may be gouged out, and excellent results have been obtained in this way.

When the diseased condition is consequent on an acute attack, better results may be achieved in the adult by excision than are usually accomplished in more chronic cases.

Where ankylosis has taken place in a useless position of the foot,

either pes equinus or calcaneus, an operation may be performed for the purpose of improving the function of the limb.

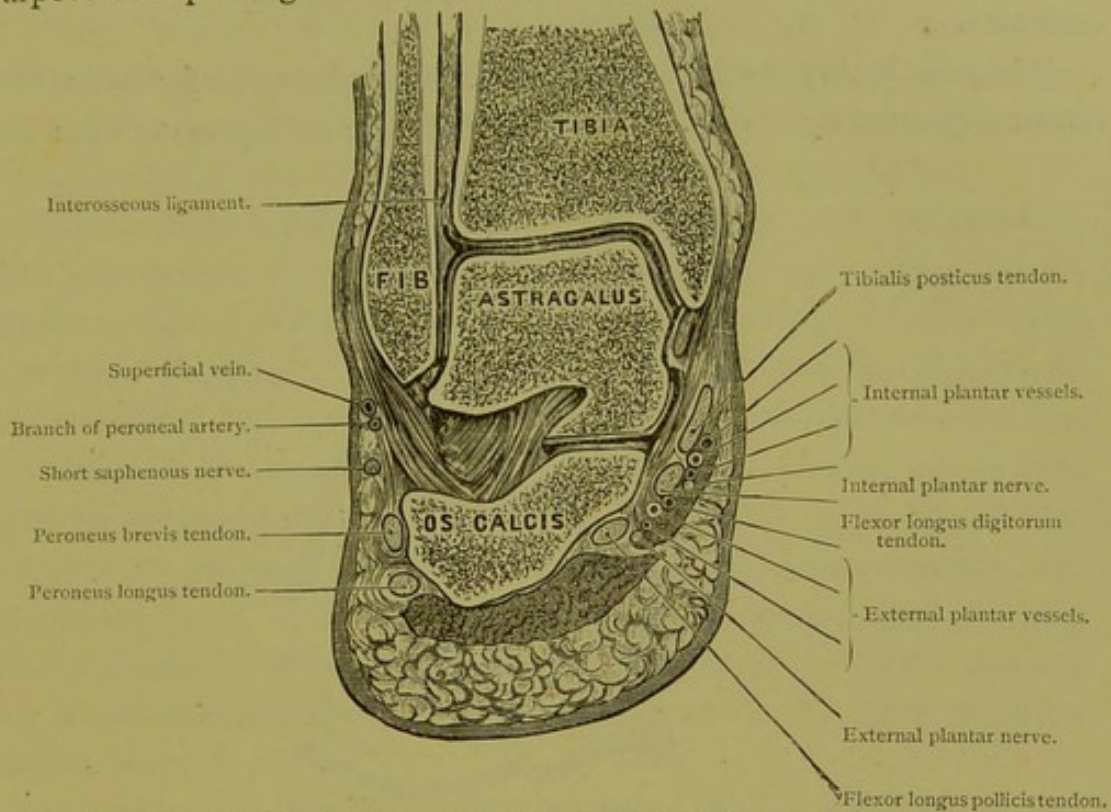


FIG. 270.—Vertical section of the left ankle-joint immediately covering the anterior tibial vessels and nerves.

Deformity may also occur after fractures through the malleoli which have been badly treated ; but osteotomy will often sufficiently overcome this.

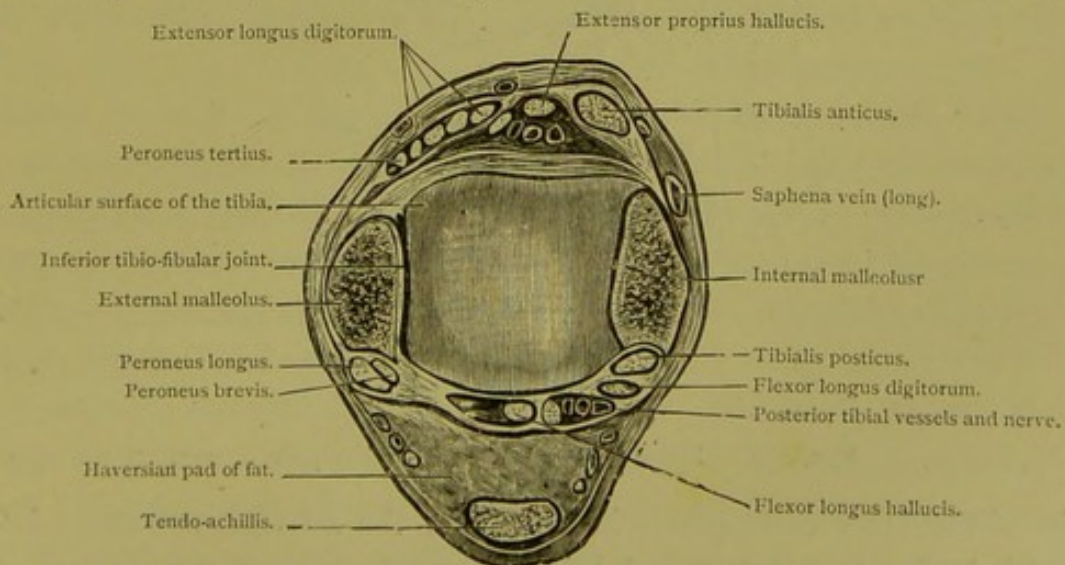


FIG. 271.—Horizontal section through the right ankle-joint at the level of the superior articular surface of the astragalus (seen from below).

Surgical anatomy.—The ankle is a hinge-joint; the astragalus projects upwards between the tibia and fibula, and is protected by the malleoli on each side.

The joint is very superficial, surrounded by tendons and ligaments, and nowhere covered by muscle. The malleoli can be readily made out: the

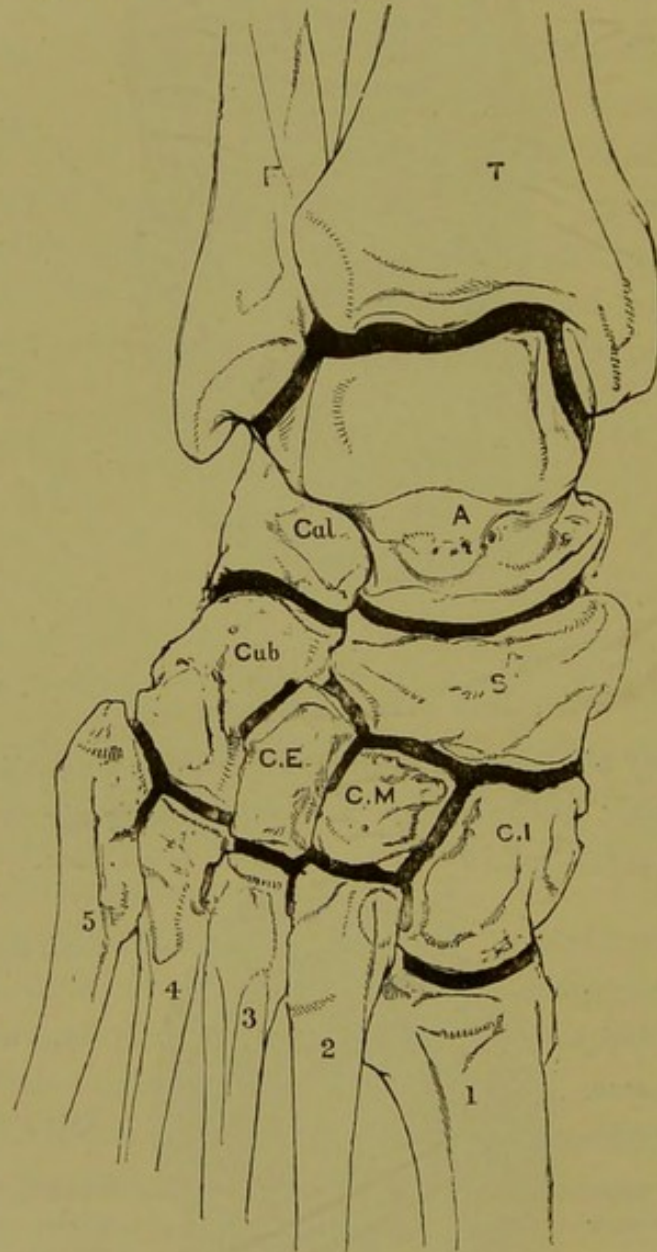


FIG. 272.—Tarsal joints. For description, see p. 203.

tip of the outer corresponds in level with the astragalo-calcanean joint, and is half an inch below and behind the extremity of the internal one. The sustentaculum tali is placed an inch vertically below the inner

malleolus, and the tubercle of the scaphoid an inch in front of it; between them lies the tendon of the tibialis posticus muscle. On the outer side the external surface of the calcis is subcutaneous; an inch below and slightly in front of the malleolus is the peroneal tubercle. The upper surface of the astragalus is about half an inch above the extremity of the internal malleolus; the head lies just behind the scaphoid tubercle.

Methods of operation.—Moreau made a vertical incision on each side of the joint behind the malleoli, and continued it around each malleolus to meet a short horizontal incision below the processes. He first made the external longitudinal incision, commencing below at the tip of the outer malleolus, and continued upwards for three or four inches close along the posterior margin of the fibula. From the lower end of this wound he made a second incision directly forwards as far as the edge of the tendon of the peroneus brevis. Another longitudinal incision was then effected on the inner side from the internal malleolus upwards along the inner margin of the tibia for three or four inches, a further incision being made forwards from its lower extremity, as far as the tibialis anticus tendon.

The peroneal tendons having been dislodged, and the external lateral ligament divided, the lower end of the fibula was cut away. Then the soft parts being sufficiently cleared from the tibia before and behind, a keyhole-saw was introduced, and the bones divided *in situ* from before backwards, the soft parts being protected by the handle of a scalpel introduced behind the tibia. The upper surface of the astragalus was afterwards sawn off.

Andrew Buchanan, of Glasgow, recommended a single incision, which began externally two inches above the end of the fibula, coursed downwards on the posterior margin of this bone to its tip, round which it passed, and then across the front of the joint. Free access to the articulation on its outer side is thus given, but the internal structures are difficult to separate, and some of the extensor tendons have to be divided.

Langenbeck's manner of excising the ankle is admirable. It may be described as follows:—Turn the foot on its inner side, and rest it on a firm cushion. Make a vertical incision three inches in length along the anterior border of the fibula to the tip of the malleolus. This may with advantage be continued so as to return for an inch upwards along the posterior border

of the bone, and it may be continued for one-third of an inch beyond the tip of the malleolus if care be taken to avoid injury to the peroneal tendons (Fig. 273). The periosteum and soft parts are now detached from the bone, often a difficult and tedious business, and the fibula may then be removed by sawing it through somewhat obliquely from above downwards an inch above its extremity; the divided end is seized in the lion forceps, or held outwards by a sharp hook inserted in the bone, while the deeper connections, especially the interosseous tibio-fibular ligament, are detached by the

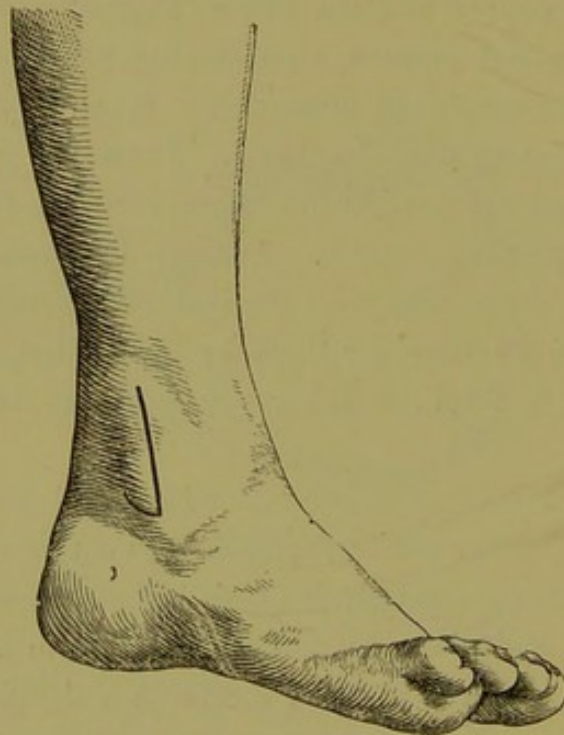


FIG. 273.—Langenbeck's fibular incision for the removal of the ankle-joint.

elevator and knife, the most tedious part of the operation. The latter structure should be preserved in traumatic cases on account of its active osteo-genetic power. The ligaments are thus preserved in connection with the periosteum, and the sheaths of the tendons are not opened. Next, the upper surface of the astragalus is to be removed with a keyhole-saw. This is most easily done at this stage of the operation, before the parts are rendered loose and movable by further dissection; if required, even the whole bone can be removed. Many, however, prefer to make the internal incision before removing the astragalus or sawing off its upper surface. The foot in that case is to be placed on its outer side, and an incision made, two to

three inches in length, along the centre of the inner surface of the tibia terminating at the tip of the internal malleolus. All the tissues should be at once divided down to the bone, the periosteum inclusive. It is advantageous, in order to give greater space, to make a semicircular incision close around the end of the malleolus, but dividing only the skin and subcutaneous tissue (Fig. 274). The periosteum and soft parts are now to be detached from the bone, which is more easily done than in the case of the fibula, and when laid bare by division of any still uncut portions of tissue, especially the ligaments attached to the malleolus (the knife being made to cut close to and perpendicular to the bone), the end of the tibia may be

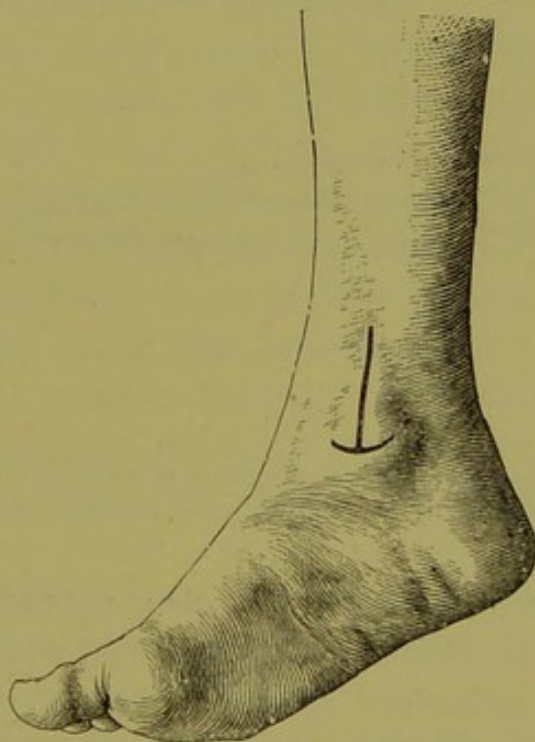


FIG. 274.—Langenbeck's tibial incision for the removal of the ankle-joint.

projected through the incision, and the determined amount of the bone sawn off. In traumatic cases this will be limited, and on a level with the insertion of the capsule. The articular surface of the astragalus can be now removed with the keyhole-saw. Although difficult it is important not to open the sheath and expose the tendon of the *tibialis posticus* muscle, nor indeed any of the tendons.

Operations which consist in the removal of one joint surface or of portions of bone are incomplete or partial excisions, and chiefly applicable to

traumatic cases, especially gunshot injuries. These have the disadvantage of being associated with less effective drainage, and there is often delay in procuring sound ankylosis. There is also a greater chance of subsequent deformity, but admirable results have followed such operations.

The after-treatment is matter of extreme importance. The foot and leg must be immobilized in a suitable splint (Fig. 275) and so fixed that the wounds may be readily uncovered and dressings applied. Some form of plaster-of-Paris splint can be adopted. To steady the foot adequately the point of the heel should be included in the plaster bandage. The empty space left by the removal of the bone should be preserved by means of

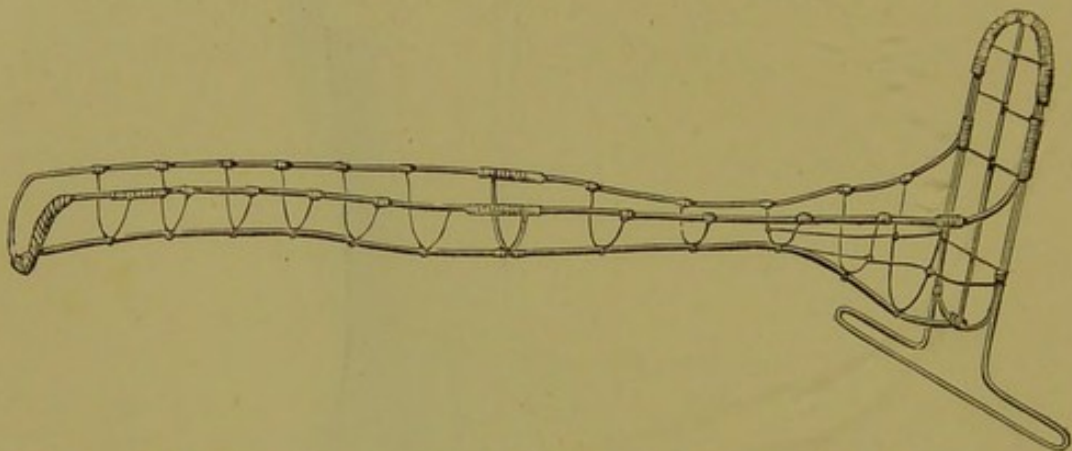


FIG. 275.—A convenient splint for the treatment of excision of the ankle. The shape can easily be modified by bending the wire and the limb immobilized in it by plaster of Paris.

extension. The foot must be placed exactly at right angles to the leg, and so fixed that it shall be neither inverted nor everted, adducted nor abducted, and should be so maintained throughout. Any acquired malposition would, if permanent, most materially impair the subsequent power of walking. If motion be sought for, passive movements ought to be commenced very early; but sound ankylosis is the most common and most desirable result.

It is afterwards necessary to wear an instrument with lateral cross supports for a considerable time, in order to prevent any giving way of the new joint. A support behind, in the form of an artificial gastrocnemius, is often useful; this is effected by means of a rubber cord attached to the heel of the shoe and to a strap at the knee. The os calcis is prevented slipping forward by this means.

Results.—Langenbeck has done much to popularize this operation and make it more successful. Many of the results which he obtained in cases of gunshot injury are surprising. He mentions the case of one officer who was, after an extensive removal of bone, able to ascend Monte Rosa, and had an apparently perfect ankle. The shortening, in these cases, has been, as a rule, rather less than one inch—an unimportant amount, and easily compensated for by a thick-soled boot. Shortening may be wholly absent, or amount merely to a fraction of an inch. Large portions of the tibia and fibula have been excised without compromising the subsequent result; that is, very considerable shortening may occur, but the foot and leg prove thoroughly serviceable.

Many remarkably successful cases are recorded by Langenbeck. As much as $2\frac{1}{2}$ inches of the tibia and $4\frac{3}{4}$ inches of the fibula have been removed by him in one instance with but little subsequent alteration of the form of the parts. The patient walked without difficulty with a heel $1\frac{1}{2}$ inches thick. A patient, after removal of the lower end of the tibia and fibula during the war of 1870-71, could follow game on foot for hours, or go upstairs with ease: there were two inches shortening, but the joint was actively mobile. In favourable cases usefulness and mobility in the parts go on increasing *pari passu*, and a good result once obtained is not afterwards lost, as may be the case after excision in the upper extremity.

It is necessary to see the thin, slender cylinder of soft parts holding the foot to the body after excision of the ankle to appreciate the great regenerative power of the human frame.

Volkman mentions the case of an Austrian captain wounded at Trautenau in 1866. The ankle was smashed by a ball; the upper surface of the astragalus and $3\frac{1}{2}$ inches of the tibia and fibula were removed by secondary resection. The ankle afterwards is stated to have become normal in shape, firm, actively movable, and the shortening amounted only to $1\frac{1}{2}$ inches. The patient could walk about all day long without inconvenience.

The so-called flail-joint is unknown after excision of the ankle.

Langenbeck states that in 75 per cent. of the cases recently under his notice the patients recovered with an useful limb, and Volkman

mentions having operated twenty-one times with three deaths, one case only requiring subsequent amputation.

The mortality is comparatively small—less certainly than that after amputation in the lower part of the leg—and the result is often very perfect in cases performed for injury. When successful, the operation of excision of the ankle-joint affords excellent functional results; and the foot appears to be almost equally useful, whether a movable joint be the final result or not. When the ankle is ankylosed, compensatory movements take place, to a large extent, in the other tarsal joints, especially the medio-tarsal.

No form of sub-periosteal excision can be performed more thoroughly than that at the ankle, and to this circumstance the occurrence of such excellent results in traumatic cases is mainly due. The regeneration of the excised bone proceeds with great activity, especially in the tibia, the periosteum of the lower epiphysis having very considerable osteo-genetic power. Even after extensive removal of bone, a massive, broad tibial extremity, with thick malleoli, may result; indeed the reproduction is often excessive; the newly formed malleoli present a greatly increased width, and only after months of shrinking do they assume a more normal appearance. The reproduction of the external malleolus proceeds with less vigour than the internal. It is questionable if any regeneration of the astragalus ever occurs after excision. It is no doubt possible to obtain a movable joint after sub-periosteal resection of the ankle, but it is generally wiser to strive for solid bony ankylosis with the foot at right angles to the leg. This end is certainly easier to accomplish, and the very complete compensatory movement which occurs in the remaining tarsal joints secures a first-rate result as regards function.

The operation is not very frequently performed, and the number of cases is not sufficient to enable us to appreciate sufficiently the comparative efficiency of one or the other method.

Resection of the ankle was first introduced into military surgical practice in 1866. The mortality is greater than what obtains in civil practice, as it depends largely on external circumstances as well as on the extent of the injury. It is not so great, however, as that after amputation of the leg.

Probably in one-fourth of the cases an unsuccessful result follows complete excision.

Langenbeck reckons that ill consequences follow after operation for traumatic causes in nearly one-half the cases. In some, however, the result has been so satisfactory that an examination of the joint makes one doubt the fact of its previous resection.

The results of resection for caries are very discouraging, and one may well feel disposed to recommend amputation instead. When performed for caries, the operation should be resorted to much earlier than it has hitherto been, and good results would much more generally follow an excision performed before abscess and fistulæ have long persisted: the patient's strength becomes undermined, and the periosteum destroyed.

EXCISION OF THE KNEE-JOINT.

The merit of originating the operation in this country is due to Park of Liverpool, who performed it in 1781, published the first recorded case in 1783, and described this in a famous letter to Percivall Pott. The subject of the operation was a sailor, who made so good a recovery that he afterwards followed his profession, and could climb the rigging of his ship. Ten years later, Moreau successfully performed excision of the knee in France. But with the exception of a few isolated cases, the operation remained in abeyance till revived by Fergusson in 1850.

Indications.—Excision of the knee should be performed, as a rule, in persons under twenty-five years, whose general health is not seriously impaired, and in whom the amount of articular disease is comparatively limited. Under these circumstances it may prove very successful; but where the local disease is extensive or the general health seriously impaired—where, in short, amputation is indicated—the method of excision is no longer applicable.

For injury the operation has been comparatively rarely performed, and in cases of gunshot injury with so little success that it would seem, for the present at least, to be wholly contra-indicated.

Excision of the knee is intended as a substitute for amputation in the sense of averting its necessity. It cannot be properly regarded merely as an alternative to amputation. It should not be performed, as formerly it used to be, as a last resort when other means of treatment have been exhausted. It cannot be contended that it is a less serious operation than

amputation, but the advantage of preserving the limb may be held to counter-balance the somewhat increased risk. Statistics hitherto show a mortality after amputation of thigh for disease of about 20 per cent., but this is of late years much diminished. The results after excision for disease show a mortality of from 20 to 30 per cent., while after conservative treatment the mortality is about the same.

The after-treatment of cases of excision is longer and makes a greater demand on the resources of the patient than does amputation. If a successful result therefore would be obtained, the operation must be performed before the patient's strength is too much diminished.

Strumous arthritis in the knee runs a slower course, and is of longer duration than in the hip. The question arises as to the propriety of excision before the suppurative stage is reached in those cases which go on for a long time and do not yield to treatment. Volkmann, writing of excision of the knee-joint,* states that in Germany up to that date the operation was followed by a mortality of 50 per cent., and he recommends its performance only in those cases where the disease endangers life, where suppuration has taken place in the joint, accompanied by hectic fever and emaciation. He has since greatly modified this opinion. In this country such cases would be usually deemed unfitted for excision.

The prospects of a successful result in cases of atonic caries are not good; in these there is abundant cheesy matter in the joint ends, associated with destruction of the ligaments and synovial membrane, and but little active inflammation, a state of matters not uncommon, and unsuitable for excision. Recovery in such cases is rare, and subsequent amputation frequently necessary.

Where the joint is filled with red fungous granulations the condition is more favourable. The subsequent reaction is less severe; indeed, the antecedent fever may abate immediately after the operation.

The most favourable cases are those where the disease is rather of local than constitutional character. Cases where an antecedent inflammation in the cancellated end of the bones, sometimes due it may be to trifling injury, results in a quiet necrosis, and from thence, as from a focus, inflammatory changes subsequently extend.

* "Klinische Vorträge," No. 51.

Sub-articular necrosis and caries may exist for a long time without materially interfering with the joint function. Periodical exacerbations of symptoms occur with intervals of relief and comparatively free movement. These inflammatory attacks are induced by slight causes, and each attack leaves the joint more damaged and more prone to a fresh recurrence.

When the necrosis ceases to be a quiet one and suppuration takes place, it generally spreads to the joint, and destructive inflammation may rapidly follow; but the course the disease takes depends on whether the abscess points towards and enters the joint through the articular cartilage, as is too often the case, or passes into a peri-articular space.

Excision may be performed in cases of long duration unyielding to treatment and subject to repeated attacks of fresh inflammation, even before the occurrence of suppuration or caries of the articular surfaces.

In children the results of excision are better than in adults as regards immediate recovery, but the subsequent growth of the limb is often most seriously impaired.

In children under ten, where the disease is extensive enough to necessitate removal of the whole of the lower epiphysis of the femur, the subsequent growth of the limb is practically arrested, and amputation is generally preferable. The growth of bone at the upper epiphysis of the tibia is at least equal to that of the lower epiphysis of the femur, and this would likewise be sacrificed.

Excision, or else amputation, must be performed when hectic sets in, the patient loses flesh, and other treatment has proved unavailing.

Abscesses or fistulæ, if not on the posterior aspect of the joint, are of comparatively little importance.

In white swelling of the knee, peri-articular abscesses are not unfrequent, and may exist without grave implication of the joint. In children many cases may be cured by arthrectomy, that is, by carefully clearing out the fistulæ and the interior of the joint from every particle of disease by dissection or with the sharp spoon.

In traumatic inflammation of the knee-joint excision has not proved successful. If conservative treatment fail—and fortunately it very frequently does not—amputation will probably be the better course.

In the Franco-German war most of the patients died on whom excision,

whether as a primary or secondary operation, was performed. The operation proved to be much more dangerous than amputation of the thigh.

A large number of perforating gunshot wounds of the knee, both with and without injury to the bone, have recovered after conservative treatment.

But although excision in cases of gunshot injury of the knee has been for the present abandoned in favour of conservative treatment, the question must not be considered as settled for all cases. Military experience has hitherto been against it, though most surgeons hope that, with better means of after-treatment and selection of suitable cases of injury, the operation may in the future be more successful.

The great difficulty is to form an exact diagnosis ; many cases of injury to the knee cannot be accurately made out.

The nature of the individual case, the surrounding circumstances, added to the surgeon's individual experience, are of great importance.

In cases of limited fracture, either of the condyles or the patella, or a simple perforation of the joint produced by gunshot, conservative treatment offers the best prospect of success. During the Franco-German war more than twenty cases of perforating gunshot wound of the knee, both with and without injury of the bone, recovered after conservative treatment under Volkmann's observation : and Langenbeck informed me he had seen at least one hundred such cases during the same campaign. These would be the cases most likely to be treated by primary excision, but the results would certainly be very much less favourable. When excision was performed after conservative treatment had been tried and failed, the results likewise proved most unsatisfactory. Here also amputation is the preferable course.

In traumatic suppuration of the joint, the result of a wound, immobilization and free antiseptic incisions, with drainage or irrigation, combined with extension by weight, may be adopted in the earlier stages.

When the suppuration extends and abscesses burrow, it may be wiser to persevere, as the patient, who cannot recover from the traumatic inflammation of the knee, is scarcely fitted to bear a high amputation of the thigh. But this must be decided in regard to the special circumstances of each case.

If symptoms of pyæmia set in, amputation should be at once performed, though the prospect of recovery be but slight.

Excision has been frequently undertaken to remove the deformity in bent and ankylosed joints.

This may be done by the removal of a wedge-shaped piece of bone, but the operation is somewhat severe, and an almost equal gain, with a far less amount of risk, may be in most cases accomplished when subcutaneous supra-condyloid osteotomy is adopted instead.

Surgical Anatomy.—The knee is the largest joint in the body, and of a complex nature. It may be divided into three parts, composed of the articular surface of the patella and the condyloid surface of the femur, and of each condyle with the corresponding portion of the tibia; the two latter portions being partially separated from one another by the ligamentum patellæ and crucial ligaments. The joint is a slightly modified ginglymoid, has a capsule and lateral ligaments, and semilunar cartilages deepening the articular facets on the tibia.

The axis of the limb changes in direction at the knee, the line of the femur being inclined inward as it approaches the joint, while the axis of the tibia is vertical; the internal condyle is longer than the external, and the knee presents therefore a re-entrant angle, which is greater in women than men. The articular line is not always easy to make out if there be swelling or the knee cannot be flexed; on the outer side it is a finger's-breadth above the head of the fibula, and on the inner side a little below this level. The bursa in front of the patella is constant, and is generally multilocular (Fig. 277). In extension the patella rests mainly upon the external condyle; in flexion it lies in the inter-condyloid space.

The synovial pouches in relation to the knee are of much surgical interest. The sub-crural bursa lies beneath the extensor tendon. It communicates with the general synovial cavity in about eight cases out of ten; in some instances it is shut off close above the patella; on its superficial surface it is closely adherent to the tendon, but its deep surface is loosely connected with the surrounding tissue, and it can therefore be enucleated without difficulty during excision (Fig. 277). The popliteus bursa usually communicates with the interior of the articulation at the posterior and outer margin of the external semilunar cartilage.

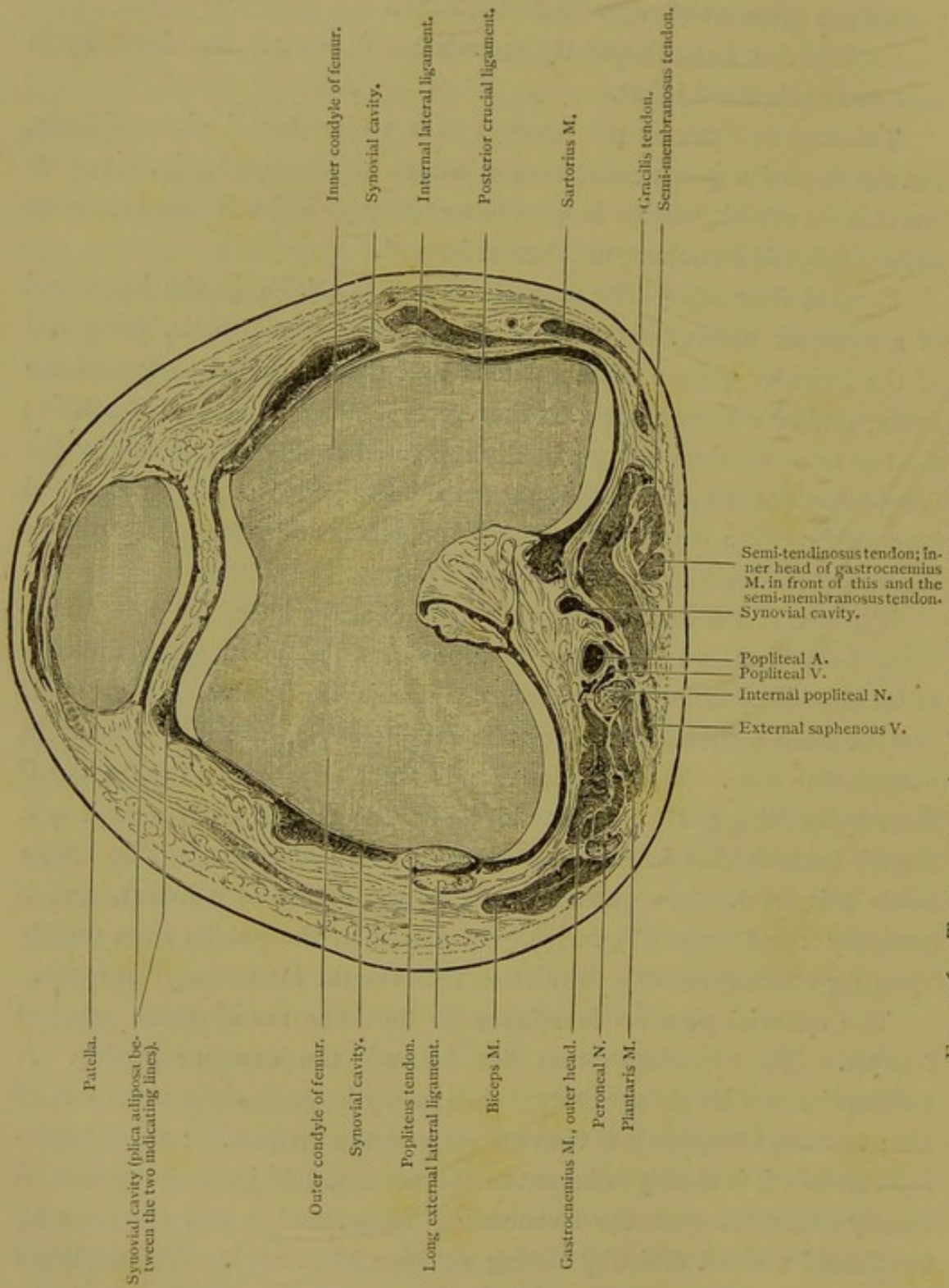


FIG. 276.—Transverse section through the condyles of the femur and knee-joint.

The large bursa of the semi-membranosus tendon communicates with the joint in about half the number of cases.

The bursa beneath the tendo-patellæ is of varying size ; it is surrounded by sub-patellar fat, and often becomes enlarged.

The capsule is inserted in front at some distance from the joint surfaces, and extends, when there is a communication with the sub-crural

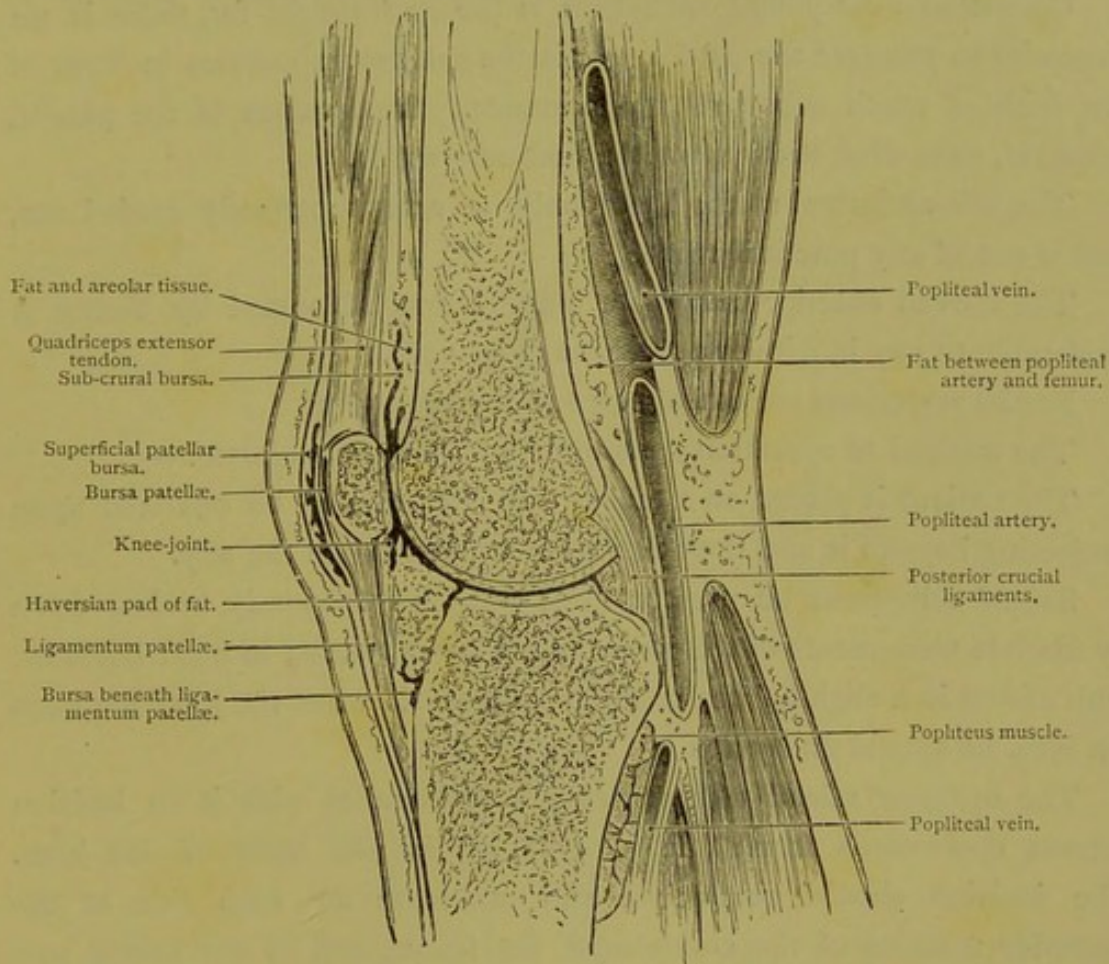


FIG. 277.—Vertical section through the knee-joint. From a preparation in St. Thomas's Hospital Museum.

synovial pouch, one inch to four inches above the patella. From the highest point the insertion passes obliquely downwards to the epi-condyles, rather more posteriorly on the inner side, to be inserted along the margins of the cartilages. The capsule passes over the lateral ligaments and beneath the fascial expansion of the extensor tendon, to be inserted along the margins of the tibia in front. The crucial ligaments are covered with the synovial membrane, and connected by loose connective tissue with

the posterior part of the capsule. The synovial membrane is attached to the margins of the cartilages, and extends upwards for an inch or more over the condyles and front of the femur, being generally continuous with the membrane lining the sub-crural bursa. In chronic synovial disease the membrane becomes much thickened, and its area is very clearly defined.

Operation.—As sound ankylosis is the end sought for, there is no necessity to preserve the patella, nor is the extensor apparatus in front of the limb of much subsequent importance. Preservation of the patella, however, somewhat strengthens the limb afterwards.

The sub-periosteal method can only be very imperfectly carried out, and is not of any practical value.

The curved anterior transverse incision first advocated by Textor is preferable to any longitudinal incision (Fig. 278).

Partial resections are out of place in the knee-joint.

The method of operation commonly adopted is as follows:—

The patient is placed on a table, with the limb to be operated upon projecting beyond it and the other limb secured out of the way.

Should adhesions be present these must be previously broken down by forcible movements of the joint. An assistant sitting in front holds the limb at first in a slightly bent position; afterwards, when the joint has been cut into, he should firmly flex it.

The operator selects a large scalpel, and makes with it an incision convex downwards from side to side across the front of the joint. The incision should commence and terminate on each side at the posterior margins of the condyles of the femur, and at the lowest part in front correspond to the insertion of the tendo-patellæ. After the skin and subcutaneous tissues are divided the knee should be bent a little, and a second sweep of the knife will divide the tendinous insertions of the patella, and the capsule, fully exposing the joint. The anterior flap can then be detached and thrown back, exposing the deep surface of the patella. The articulation should now be completely flexed by the assistant while the operator divides in succession first the lateral, then the crucial, and the attachments of the posterior ligaments.

The condyles of the femur which should be first removed will now

readily project from the wound, and the knife is drawn around them along the line of application of the saw to detach any still adhering soft parts; the articular surface is sawn off in a direction at right angles to the long axis of the shaft, keeping strictly parallel to the plane of the free surface of the condyles. It is a matter of indifference from which side the bone is sawn, as the femoral artery is separated from the posterior surface of the femur by a considerable interval filled with fat (Fig. 276).

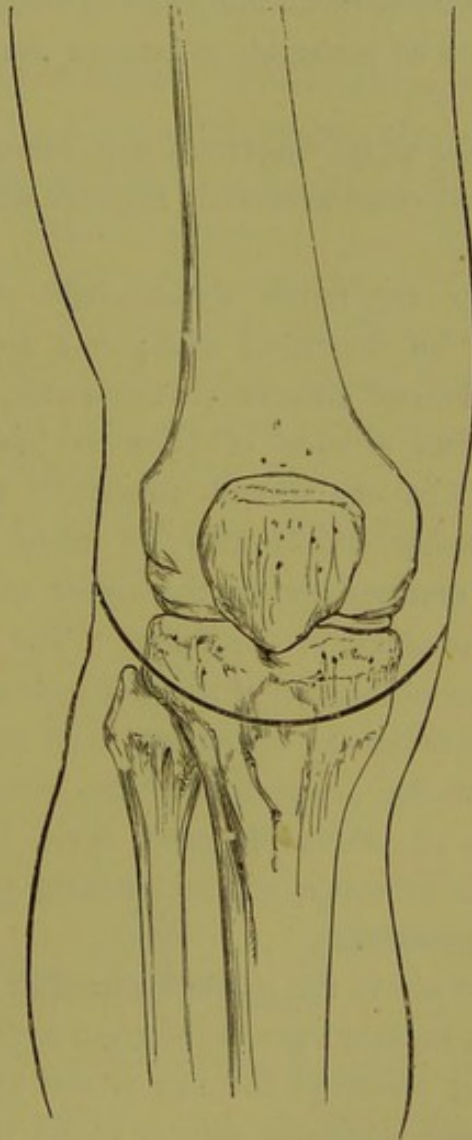


FIG. 278.—Curved anterior incision for resection of the knee-joint.

The tibia being now pushed vertically up and held forward by the assistant placing his left hand high up behind the leg and supporting the foot with his right, the knife is passed close round the articular margin

of the bone to make a groove for the application of the saw, and a thin slice of the tibia removed by sawing from before backwards, taking care that the cut section shall be exactly parallel with the plane of the articular surface of the bone and that the soft parts behind are protected from injury. To make the latter quite certain, the bone may be divided from behind forwards, for at this level the popliteal artery is in the closest relation with it (Fig. 277). Should any diseased bone be left behind, it may be subsequently removed with the gouge or sharp spoon.

In some cases it may be preferable to remove the tibial portion of the joint surface first.

When the extremities of the bones are thus removed the two cut surfaces will be parallel, and come accurately together when the limb is placed in the straight position.

It is essential for the future development of the limb that the epiphyses should not be interfered with; only so much bone should be removed as the disease absolutely necessitates, hence it is imperative to remove as thin a layer of bone as possible from the joint surfaces, and a very thin one should always be taken from the tibia. The section of the femur should also be made below the epiphysial line whose position corresponds to the upper margin of the encrusting cartilage of the trochlea of the femur. The cut surfaces of the bone must then be examined, and if found diseased can be spooned out afterwards. It is erroneous to think one must needs operate through perfectly healthy structures, *quoad* bone: bone simply inflamed may be left. Even in cases in which diseased bone has been extensively gouged out, the cortical substance and its investing periosteum only being left, a good result may follow.

The most convenient saw to use is a bow-saw (Fig. 101). The less simple modification known as Butcher's saw is preferred by many.

If the patella is to be preserved the flap is now everted and the surface fully exposed, and after cutting a groove round it for the saw to rest in, a thin slice may be removed. Many surgeons prefer to excise the whole bone, as its subsequent presence can be of little functional importance, since the sawn surface becomes ankylosed to the anterior aspect of the femur; unless, however, it be extensively diseased, this step is scarcely

necessary. By leaving the patella in the flap, a stronger and more solid covering is left for the front of the knee.

Lastly, every portion of diseased synovial tissue should be carefully removed with the knife and scissors, including that lining the synovial pouch above the patella. This is the most tedious, but certainly a most necessary part of the operation, and one on whose proper performance much of the subsequent success will depend, especially in cases of tuberculous disease.

This form of operation facilitates effective drainage; one drainage-tube should be introduced from side to side, straight across, behind the bones; two others should be inserted from each angle of the wound as far as the superior extremity of the synovial pouch.

After the bleeding has been arrested and the cut surfaces accurately adjusted together, it may be well to suture the femur and tibia together by silver wire inserted at two points, passed through holes drilled obliquely through the margins of the bone, the ends being afterwards twisted or tied together. Catgut or kangaroo tendon may be employed, or the bones can be fastened securely by ivory or metal pegs. The edges of the

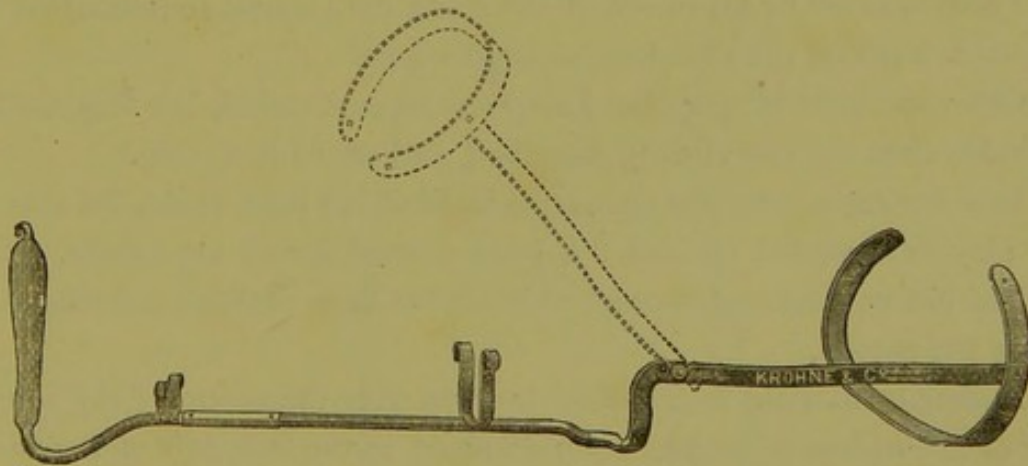


FIG. 279.—A convenient form of splint for excision of the knee.

external wound are then sutured, and the limb placed on a posterior interrupted splint, with a foot-piece and pelvic girdle (Fig. 279).

To this it may be fastened with strips of flannel dipped in plaster-of-Paris, circular bandages being applied over all. Some modification of the plaster-of-Paris splint is the best apparatus to adopt during the after-treatment, the front and sides of the joint being left uncovered by the splint. The

apparatus should remain, if possible, without change until complete consolidation has taken place. In all cases the axis of the limb should be kept absolutely straight; the recommendation to put it up with a slight amount of flexion at the knee is decidedly improper. It is unnecessary in progression, as the excised limb is always the shorter, and the flexion is liable to increase to an inconvenient degree. This undesirable bending is much more likely to take place when the limb has been originally put up in a flexed position; an absolutely straight one is therefore very much to be preferred. In young subjects more especially, even after sound bony ankylosis has apparently taken place, the limb often yields at the line of junction, and a gradually increasing amount of flexion takes place at the knee. The subsequent employment of a leather splint prevents this to some extent, but not altogether, and the bending is often so considerable as to render the limb comparatively useless, and make a subsequent osteotomy necessary for its relief.

The bandages employed to fasten the leg to the splint must always be so applied as to leave an ample interval for the easy application of dressings. These are to be renewed as often as may be necessary; but, if possible, the limb should never be taken out of the splint until sound consolidation has occurred, a period of at least six or eight weeks.

Other methods of operation have been recommended, but they are less desirable than the one already described, and afford less room.

In a few cases, after the transverse incision has been made, the anterior flap may be dissected up and the joint opened above the patella. This method has no advantage except where it has been decided beforehand to excise the patella.

A straight anterior longitudinal incision over the centre of the patella, four or five inches in length, has been made in the long axis of the limb; the patella must now be removed after cutting its tendinous connections above and below; the knee is bent, and the subsequent steps of operation are similar to those already described. The wound in this case does not give sufficient space, and is badly placed for subsequent effective drainage.

Still less to be commended is the vertical splitting of the patella. The patella has in some cases been thus divided across its middle after a transverse incision of the soft parts and the two halves separated, being subse-

quently united by sutures. But the alleged advantages of these modifications scarcely compensate for the diminished amount of space and the serious inconvenience thereby entailed.

Volkman has suggested a modification, which consists in cutting transversely across the joint over the centre of the patella, then cutting through

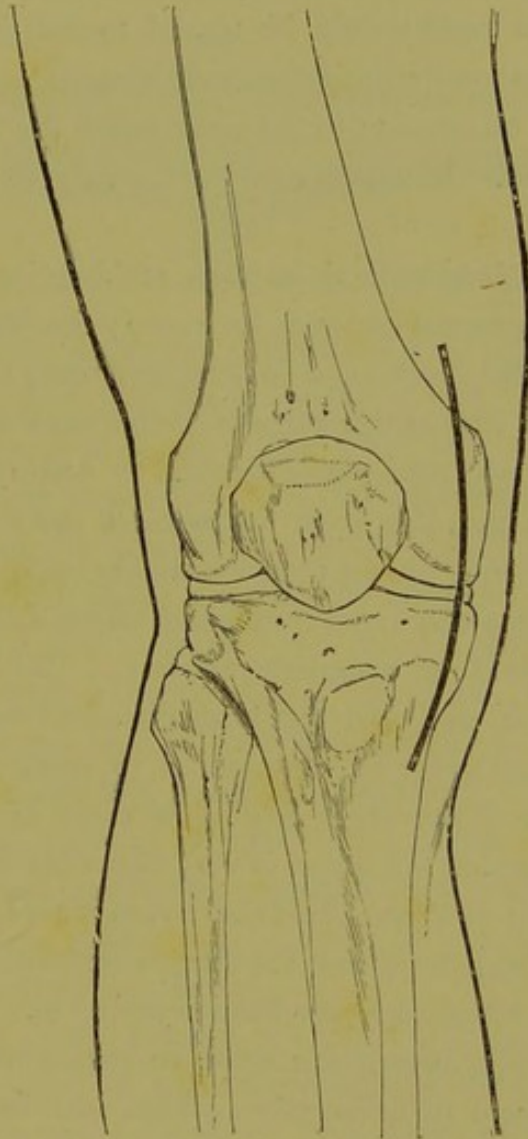


FIG. 280.—Langenbeck's method of excising the knee.

this bone transversely with the saw ; the subsequent steps of the operation being conducted as previously described. When the ends of the femur and tibia have been removed, the edges of the patella are united by suture. This method, however, does not afford easy access to the joint. The chief

advantage claimed for it is, that the parts are well supported afterwards by the sutured patella, and that a stronger limb is the result.

Langenbeck recommends an incision of the inner side of the joint with a backward convexity (Fig. 280). The incision is four or five inches long, divides the vastus internus half-way between the inner margin of the patella and the internal condyle, and terminates over the tuberosity of the tibia. The flap thus made should be turned to the outer side; the ends of the bone are successively dislocated inwards and removed. The operation is difficult on account of the small space the incision affords, and drainage is imperfect. It would scarcely be feasible except in cases of excision for injury.

All the forms of longitudinal incision are inferior to the curvilinear transverse one. They must be made very long; the difficulty of protruding the bones is great; the discharges do not gain a ready exit; and the preservation of the patella and its ligamentous connections is only of temporary importance, as the ultimate result desired is one of ankylosis. The attempt to obtain a movable joint has once or twice succeeded, but it is very rare, and experience proves that it is highly undesirable to seek for it.

Results.—In successful cases firm bony union follows. From two to six months are required for complete recovery. The limb is very useful, the patient can walk well and for long distances with a thick sole to his boot, which should never be so thick as to make the extremity quite equal to the length of the other limb. In cases of failure suppuration continues, sinuses persist, the union is very imperfect or altogether absent, and the parts remain swollen. In some cases where sinuses persist the diseased bone may be gouged out, the sinuses scraped, and recovery ensue. In a few instances re-excision has been resorted to. Where the general health begins to suffer, amputation must be performed. In children, as before stated, the bond of union often yields, and the knee must be supported by a stiff leather splint to prevent angular curvature or displacement. The mortality has greatly diminished of late years, and is smallest in those cases operated on early; it is greater where the disease is of old standing and when a large quantity of bone has to be removed. Removal of the patella seems in some slight degree to increase the risk. In children under five years of age disease may often be cured by conservative

treatment; where it does not yield, erosion—that is, scraping out of all diseased tissue—may be performed, but the joint should seldom be formally excised, as the subsequent development of the limb is so much interfered with.

In no part of the skeleton is the longitudinal growth of the body so active as near the knee-joint; the femur and tibia owe their increase

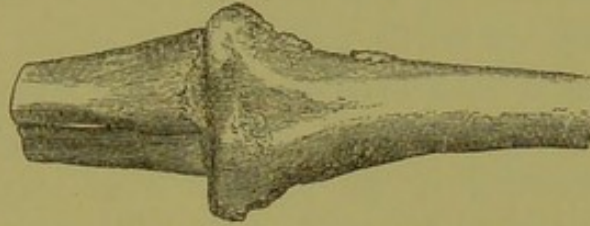


FIG. 281.—Bones removed from the left limb after excision of the knee.

in length chiefly to the epiphyses at the knee, and if they be sacrificed, the development of the limb is seriously interfered with: this is the great objection to the operation in children. The epiphysial cartilages are so near the articular surfaces that they will be necessarily sacrificed in any extensive excision of the joint in very young subjects. In the latter the saw need not always be used: the diseased parts can be removed with the knife. Only a very thin slice of bone can be properly removed, any further diseased osseous tissue being afterwards scraped out. The epiphysial cartilage may be often laid bare in this way on the side next the joint, and in some cases will be found perforated; if so, the sharp spoon may with advantage be used to remove any diseased bone on the further side, no more of the epiphysial cartilage itself being removed than is absolutely required, as even if only a portion be preserved, it will prove the means of future growth in the bone.

In patients over thirty years of age amputation is generally the preferable procedure; as also in all cases where any organic visceral disease exists.

König gives 122 cases performed in children of different nationality: 62 per cent. were cured.

EXCISION OF THE HIP-JOINT.

The operation was suggested, but not actually performed, by Charles White of Manchester, in 1769. It seems to have been practised for the first time in this country by Anthony White, of the Westminster Hospital,

who excised the hip-joint of a boy in 1818. The lad was much exhausted by suppurative coxitis, from which he had suffered for three years. The head of the bone was displaced upon the dorsum of the ilium, and there were numerous fistulæ about the joint. White removed the diseased bone by sawing through the femur just below the trochanter minor. The boy recovered by the end of a year, and could walk about well with a thick-soled boot. The operation was also performed in Dublin, in 1836, by Sir Benjamin Brodie, but its revival in this country seems to be chiefly due to Sir William Fergusson. On the Continent the operation has of late years been more largely practised than in England.

Indications.—Excision of the hip-joint is an operation almost exclusively performed in young persons and for disease. It is very seldom required in the adult, and then usually for gunshot injury. For this the mortality has proved so great that practically it has been almost abandoned. In excision for gunshot fractures secondary resection is to be preferred to primary, since the diagnosis of the nature and extent of the injury is so difficult in the first instance, and also because of the great fatality of the primary operation. In such cases total resection is preferable to a partial one.

Acute suppurative inflammation of the hip-joint in the adult is a rare and most fatal disease, seldom affording any opportunity for effective operative interference. In children it is often of an infective type.

In very young children excision of the hip is inapplicable—first because the risk entailed by the operation itself is not inconsiderable; and secondly, the results of expectant treatment are on the whole quite as favourable to life and the preservation of a useful limb. In cases where excision has been performed in the very young, the more frequent result has been to leave a useless, greatly shortened, and atrophied member of little or no use in progression.

It is difficult to fix a limit of age for effective interference, but one may very safely say that the operation of excision of the hip in children under ten years is likely to prove unsatisfactory. Many of these cases recover without operation, and it should therefore only be done if recovery otherwise appears impossible. If the abscesses which form be opened, the sinuses scraped out, and carious portions of bone removed, the patient will often be placed in a more favourable position for recovery than if a more formal operation had been resorted to.

In children hip-joint disease is often very chronic ; in many cases it assumes the features of *caries sicca* ; no abscesses form, or at least none open externally, and recovery ensues sooner or later, with a shortened limb and generally an ankylosed joint. If proper treatment has been adopted, the adduction and flexion which would otherwise occur may be prevented, and the patient can afterwards walk very well. In such cases excision would clearly be improper ; what is needful is to maintain the limb in a right position, to give the joint rest, and in order to effect this Thomas's splint is one of the best means. Again, in other cases the suppuration will be limited ; the joint becomes filled with granulation tissue, afterwards becoming fibrous ; and a more or less complete ankylosis may eventually follow. This may take place even where the peri-articular suppuration has been abundant. Here also excision is contra-indicated.

In cases of peri-articular abscess, which, however, is rarely found in connection with this articulation, excision should not be performed.

On the other hand, when excision is considered the proper course to adopt, it ought not to be delayed until the abscesses burst, numerous sinuses form, and the continuance of the suppuration produces hectic or exhaustion—then an operation will be performed at great disadvantage.

As a rule, excision becomes proper when suppuration has taken place in the joint, and not till then. The occurrence of suppuration is the main indication for excision in coxitis. An early operation, before the occurrence of fistulæ and whilst the patient is still relatively strong, is indicated. Operative interference, if too long deferred, seldom exercises a curative effect.

It is proper to excise where an acute condition has supervened on a more chronic state of suppuration, where the purulent discharge becomes abundant, and where marked fever and increasing weakness supervene.

Excision is proper in chronic cases of granulation synovitis which have quickly filled the acetabulum and invaded the articular surface of the head, with few or no acute symptoms, so soon as this tissue begins to break down, and acute suppuration sets in with elevated temperature.

In some cases of multiple sinuses formal excision may be replaced by scraping out the diseased tissue with a sharp spoon ; but whether this be practicable or not must usually be decided under chloroform upon the operating table. When fistulæ open below Poupart's ligament, the joint



may be spooned out from that side, and loose pieces of bone in this way are often fished out. Only the diseased and softened tissue will be removed by the spoon; no danger is incurred of injuring healthy parts. In favourable cases the scraping out will be followed by immediate lowering of temperature, as also by contraction and healing of the fistulæ.

The ultimate result will resemble that of excision, but the method is less severe.

The spooning process often requires repetition so soon as the process of healing comes to a standstill, else the granulations become flabby and the suppuration again increases.

Volkman mentions two cases in which all the symptoms of suppurative coxitis were present. In one he was able to remove a sequestrum with the sharp spoon out of substance of the great trochanter, and in the other a sequestrum from the excavated neck of femur, the joint itself appearing to be but little involved.

Where the disease can be localized in the head and neck, relief may be given and a cure often effected by trephining the trochanter and neck, affording in this way free drainage and removing any sequestrum there placed.

In cases where acute or sub-acute symptoms supervene upon a hitherto "quiet" course of things, attended by but little disturbance of the general health, the disease has probably been originally a caries sicca, which frequently occurs in a highly developed form in the hip-joint. Dry granulations, at first few in number, take their origin from the periosteum of the neck and from the line of reflection of the synovial membrane. They gradually increase, eat their way into the bone, and thus invade the neck, head, and acetabulum. The entire head and neck may disappear in the process. Even in cases of extensive disease the pain is perhaps trifling. The joint becomes early fixed and motionless, the surrounding parts are not much swollen, the muscles atrophy, and render the bony prominences more marked. Children so affected limp, but can often walk long distances, and are not confined to bed, although the destructive process is continually going on. In well-marked examples an examination will reveal shortening and deformity of the limb, with evident disorganization of the joint, and yet neither suppuration, abscess, nor fistula has ensued. Under such circumstances some over-exertion, a chill, or the like, may excite suppuration;

the granulations occupying the place of the former joint are transformed into pus, and excision becomes urgently called for. The results, however, are not very satisfactory, nor is a final cure frequent. A notable symptom in these cases is presented when the hitherto stiff and ankylosed joint becomes freely movable, and grating may then be sometimes felt when the patient is under chloroform.

In other cases, the head is separated from the neck at the epiphysial line. It remains in the acetabulum to which it becomes more or less united by granulation tissue, while the great trochanter with the limb is displaced upwards and backwards.

Excision should at once be performed if the evidence be such as to show that an articular abscess has perforated the acetabulum and entered the pelvic cavity. At one time acetabular disease was regarded as a positive contra-indication. French surgeons consider that when the acetabulum is involved one should not operate; but the converse is more true—viz., that it justifies operative interference, as affording the only possible means for effective drainage, removal of the diseased parts, and closing of the cavity of the abscess. The results of disease of the acetabulum are even more disastrous than those in which the mischief is chiefly confined to the femur, and it therefore more urgently demands operative interference, although the results are often by no means satisfactory. Intra-pelvic suppuration separates the soft parts from the bone, and caries of the inner surfaces of the ilium and ischium often takes place.

Perforation of the acetabulum may occur from the constant pressure of the head of the femur against the inflamed and softened bone, thus producing a rounded hole, which constantly tends to increase in size. Necrosis may ensue in the floor of the cavity, or suppuration in the joint cause separation of the Y-shaped cartilaginous synostosis in younger subjects. After excision in such cases it is often necessary to enlarge the opening in the acetabulum, to provide more free means of exit for the purulent discharge.

Excision should be performed if the head of the femur has left the acetabulum during acute suppuration, and is lying dislocated amidst the gluteal muscles. The occurrence of dislocation of the head in cases of suppurating coxitis indicates therefore immediate operation.

In this case the operation is easy of performance, as it often resolves itself into mere opening of the abscess cavity, and sawing off the displaced head. The adducted, inverted, and flexed position of the femur caused by the displacement is at once removed. The injury done to the patient is but slight and the result promises a more useful limb than if no operation were performed.

Dislocation occurring apart from serious pathological changes in the joint is unusual and difficult to diagnose, as a similar deformity occurs from the displacement produced by the gradual enlargement upwards of the acetabulum, with absorption of the head and neck; as also in those instances in which severment of the head from the neck at the epiphysial line has resulted from suppurative epiphysitis. Its sudden occurrence, accompanied by the characteristic deformity, are the most prominent symptoms. Spontaneous dislocation of the hip-joint most frequently occurs where the inflammation is not of a destructive character. The etiology is in many cases quite obscure.

An acute serous or purulent effusion may cause displacement of the head when it is only slightly or not at all diseased. Such effusions are generally quickly absorbed, and the inflammation subsides as quickly. Dislocation has been observed in cases of typhoid, and after exanthematous fevers. Reduction should be attempted, and I have accomplished this in some cases with success. Occasionally the joint suppurates acutely after the reduction and then excision must be performed.

The question of excision in cases accompanied by diffuse osteomyelitis of the upper end of femur is difficult to determine. When suppuration has extended from the diaphysis to the joint the result is almost certainly fatal. The suppuration in the shaft of the bone may merely extend as far as the great trochanter, or a little way into the neck, producing by its proximity an acute catarrhal suppuration in the cavity of the joint. If the femur be extensively implicated excision is contra-indicated.

Surgical Anatomy.—The position of the joint may be localized by drawing a line, the thigh being semi-flexed, from the anterior superior spine of the ilium to the most prominent part of the tuberosity of the ischium. This will cross the tip of the trochanter. A line passing transversely inwards from the tip of one trochanter towards the opposite

trochanter will pass through the centre of the head of the femur and acetabulum. In the extended position of the body, the upper margin of the acetabulum corresponds with a point half-way between the anterior superior spine and the tip of the great trochanter. The anterior portion of the joint is immediately beneath a point half an inch vertically below and internal to the anterior inferior spine, and it is also indicated by the extremity of a line drawn for one inch downwards and outwards at right angles to the centre of Poupert's ligament. The capsule is weakest at this point, and here the communication takes place between the ilio-psoas bursa and the synovial cavity. Where it exists there will be marked fulness in the groin at a very early period in hip disease. The anterior inferior spine of the ilium can usually be made out in front, an inch below and somewhat internal to the anterior superior spine.

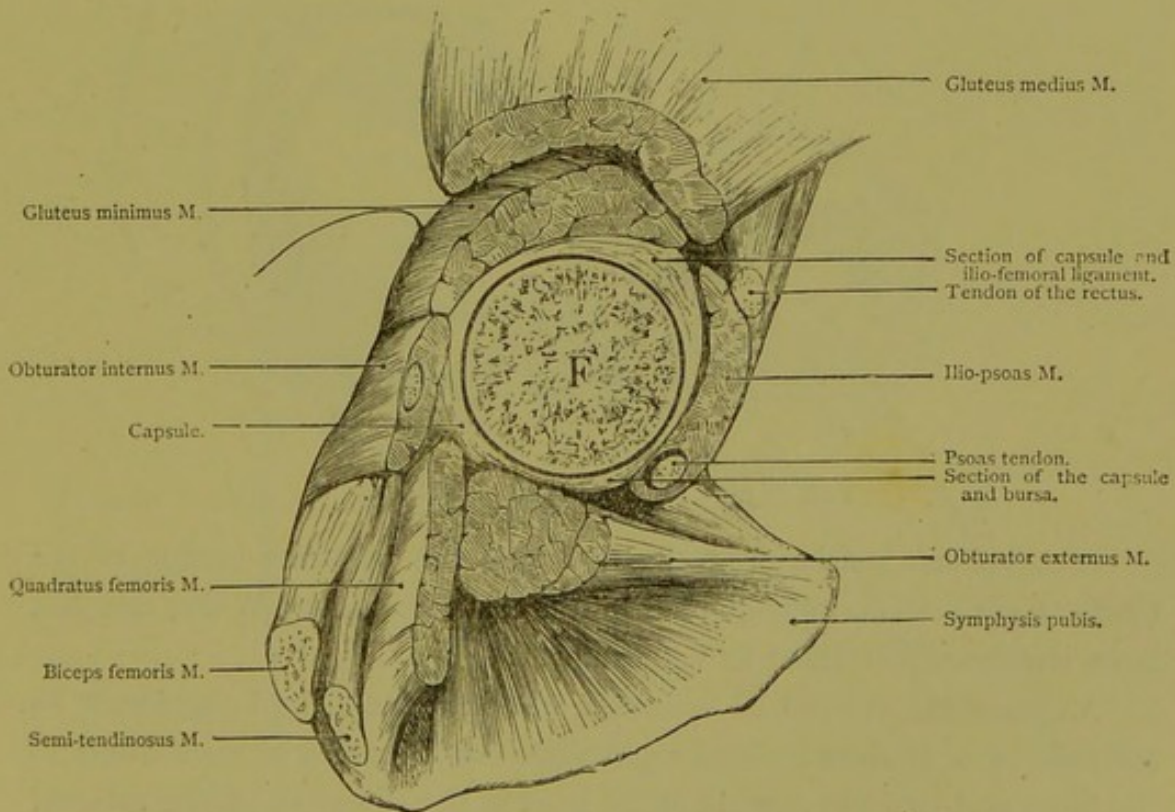


FIG. 282.—Vertical section showing the muscles immediately surrounding the hip-joint.

The hip-joint is surrounded by muscles. In front are the psoas and iliacus, separated by a bursa from the capsular ligament. This bursa often

communicates with the interior of the joint. Above are the short head of the rectus and the gluteus minimus muscles; internally the obturator externus and the pectineus are in immediate proximity; while behind are the pyriformis, the gemelli, and obturator internus muscles, as also the obturator externus and the quadratus femoris as they pass to their insertions.

The posterior surface of the joint is comparatively superficial, and effusion in the capsule may be readily detected there.

Operation.—A great many forms of procedure have been recommended for excising the hip-joint.

The head alone, or the head and neck of the femur, may be removed, or the head and trochanter major together with the neck. The acetabulum may also require to be in part removed. A T-shaped wound, as in Fig. 283, is often adopted.

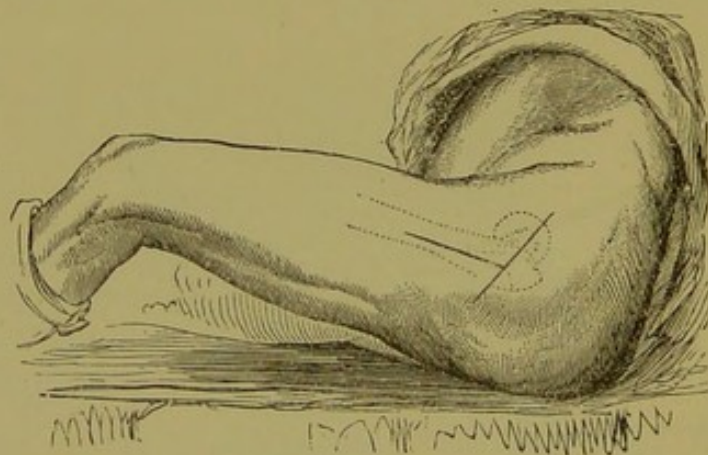


FIG. 283.— T-shaped form of incision.

A curvilinear incision from the tip round the posterior border of the trochanter is a favourite method. It was that of Anthony White, and has been erroneously ascribed to Velpeau.

An excellent method of operation was introduced by Langenbeck in the form of a straight incision on the outer side, cutting at once down to the bone and into the capsule of the joint in the direction of the external wound.

The patient is placed on the opposite or sound side, the limb flexed nearly to an angle of 45° , and slightly rotated inwards. An incision is then made in the long axis of the femur over the outer side of the trochanter

major, similar to the incision made over the olecranon for excision of the elbow. It should run a little behind the middle of the great trochanter, and correspond with a line directed towards the posterior superior iliac spine (Fig. 284).

Two-thirds, or nearly, of the length of the wound, which is about four and a half inches long, lies over the ilium above the trochanter, and the

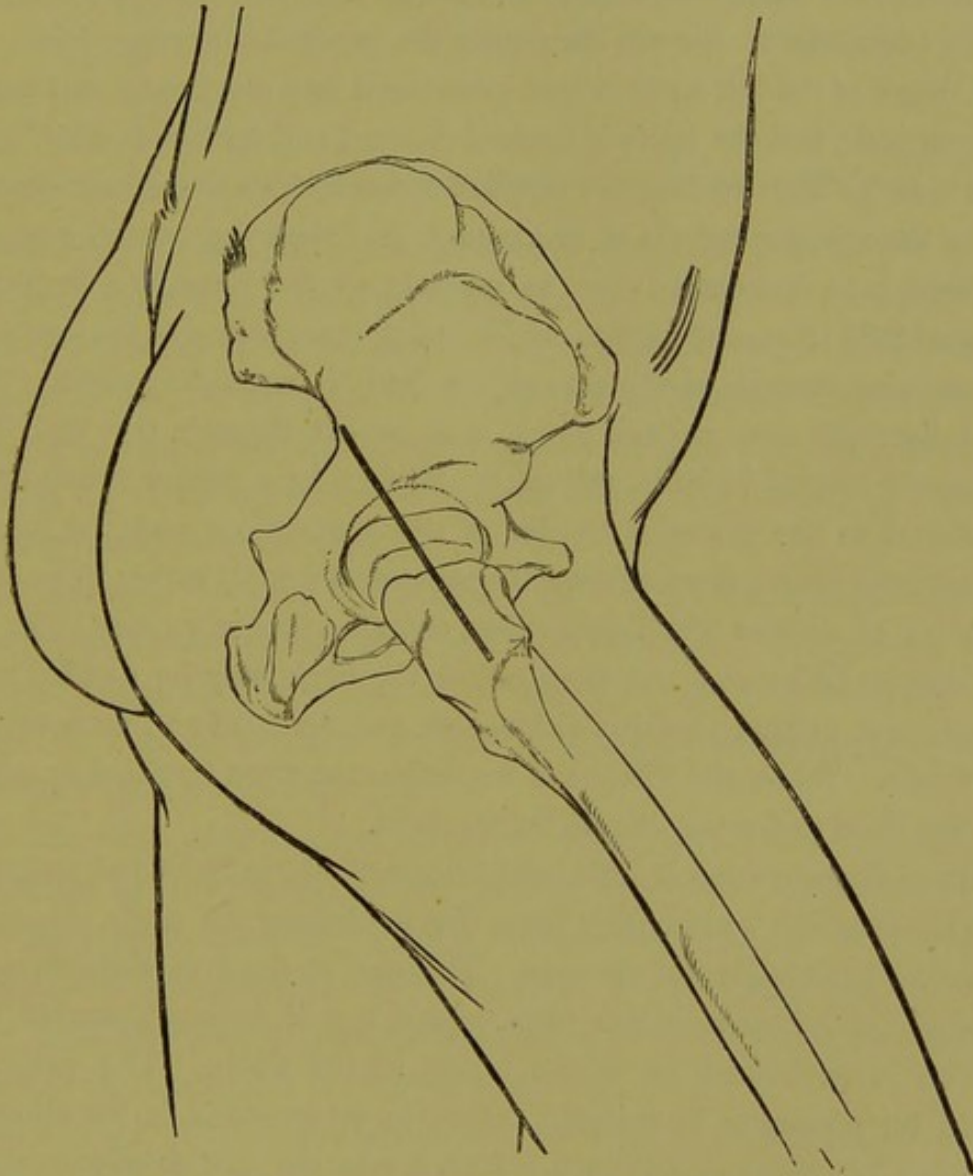


FIG. 284.—Langenbeck's incision for resection of the hip-joint.

remaining third upon the trochanter and femur. The situation of the great sciatic notch must be carefully made out beforehand, so that the incision, which runs near to its upper margin, may not implicate it.

It is important to go at once down to the bone and capsule of the joint with one cut. The wound, if necessary, may subsequently be enlarged by cutting from within outwards and upwards with a probe-pointed knife. The gluteal muscles are thus evenly divided, and the capsule and upper external margin of the acetabulum laid bare.

The capsule is now opened in the direction of the external wound, and the ligamentous tissue transversely divided on each side close to its insertion into the acetabulum. Air will then enter the previously air-tight joint. The index finger of the left hand is now introduced into the wound and incision in the capsule, and the latter is hooked forward and further divided, as well as the muscles inserted into the trochanter major close to their attachments, first on the anterior margin of the wound, and then the posterior margin. The knife is to be kept as close as possible to the bone, the limb being first gradually rotated outwards, while during the division of the muscles on the posterior margin of the wound the limb is rotated inwards. If the round ligament still exist, it must now be cut through, the limb being moderately rotated inwards, abducted, and flexed; a narrow strong knife is introduced at the posterior border of the acetabulum and the ligament divided from above downwards. These remarks apply rather to traumatic cases, as in disease the ligamentum teres no longer exists. The head may now be dislocated and sawn off, or the neck may be divided with a keyhole-saw, without previous dislocation, and the head and neck removed afterwards. When the disease is extensive the great trochanter, together with the head and neck, should be removed.

When the operation is done sub-periosteally the muscles and periosteum must be detached successively from the trochanter on each side of the wound with the knife and elevator. This can be done in children and in cases of secondary resection after injury, but it is impracticable where excision is performed for recent injury in the adult. The periosteum should be preserved in suitable cases—in other words, in the absence of tubercle; but these of course will form a minority, not merely on account of its osteo-genetic properties, but because the tendinous insertions into it are thus preserved and the result is better. The insertions of the gluteal muscles remain connected with the periosteum and with each other, while the insertions of the small rotators are also preserved.

Deep retractors (Fig. 285) should be inserted on each side after the first incision has been made, and the margins of the wound held apart; the division of the capsule and the rotator muscles is thereby much facilitated.

There is much difference of opinion as to whether it is desirable in all cases to remove the trochanter. Contrary to expectation, the removal of

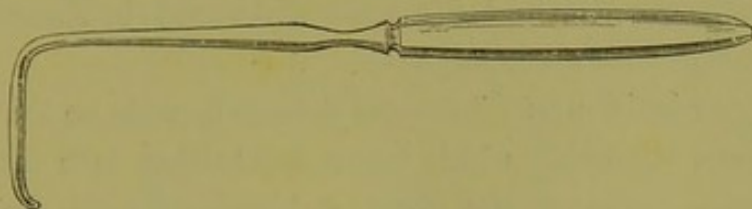


FIG. 285.—Large retractor for holding aside the surfaces of the wound.

the parts by cutting below the trochanter does not seem to give a worse functional result than simple decapitation. A new head, or a head-shaped excrescence, which takes the place of the amputated one, is usually formed.

Sayre urges that the great trochanter should always be removed because it interferes with effective drainage from the deep part of the wound, and locks up the secretions like a cork in the mouth of a bottle; and statistics appear to verify this assertion.

In Germany, the neck is generally sawn through first, and the trochanter subsequently removed, only if it be found diseased. Langenbeck thinks that where the condition admits of it, only the head and neck of the femur should be excised, and that as good a result is obtained as when the great trochanter is also removed.

If the head only requires excision, the periosteum and capsule may be elevated from the neck, and the bone divided with a keyhole-saw.

When a more extensive operation than mere removal of the head is required, the periosteum is to be further elevated from the trochanter major, together with the muscles inserted into it, first in front, and then behind the trochanter as previously described.

Among the advantages claimed for the straight incision are that the head and neck are at once largely exposed, and no more bone than what is actually diseased or injured need be cut away.

Ollier's method of removing a diseased hip-joint is but slightly modified from that of White. The thigh being a little flexed, an incision is made over the ilium downwards towards the trochanter tip, beginning four

fingers' breadth beneath the iliac crest, and equidistant between the anterior and posterior superior iliac spines. When the trochanter is reached the direction of the knife is changed somewhat, so as to complete the incision in a direction parallel to the shaft of the slightly bent femur. The neck is thus exposed, the periosteum raised from it, the capsule and round ligament divided, and the head dislocated backwards, the neck being cut through with a keyhole-saw.

The anterior incision of Lücke and Schede is made on the outer side of the crural nerve, beginning a little below and half an inch internal to the anterior superior spine of the ilium, and passing vertically downwards for four or five inches. (Fig. 286). The internal border of the sartorius is first exposed, then the rectus and the outer border of the ilio-psoas muscle. The limb is now flexed, abducted, and rotated outwards, the sartorius and rectus muscles are drawn to the outer side, the psoas and iliacus muscle to the inner, and the capsule thus exposed is incised; the subsequent steps being similar to those in other operations.

In cases of spontaneous cure properly treated, recovery may ensue with the limb in a straight line with the body, or with only a slight degree of deformity; but there is a class of frequently occurring cases where ankylosis has taken place in a more or less faulty position. In the most common form, the position of the limb is one of considerable flexion, adduction, and inversion, and in those cases of spontaneous cure which have not been adequately attended to the limb becomes firmly ankylosed in this inconvenient attitude. The patient, while in the erect posture, cannot touch the ground with the sole of the foot, but is obliged to support himself on the toes, the pelvis being much inclined to the affected side, and an excessive spinal compensating curve necessarily ensues.

Various operations have been devised to remedy this condition of things. Rhea Barton sawed through the neck of the femur, and excised a wedge-shaped piece of bone so as to permit of extension of the limb. The operation, however, proved fatal in nearly half the cases. Sayre, with the expectation of creating in some cases a new and movable joint, cut out an oval-shaped portion from the femur just below the lesser trochanter. Adams advocates an operation which has now been performed many times with excellent results. The neck of the bone is sawn through from above

downwards with a saw which he specially devised, or it may be divided by a chisel. In many cases of disease the neck has been removed by absorption, and a simpler and easier method is to divide the femur from

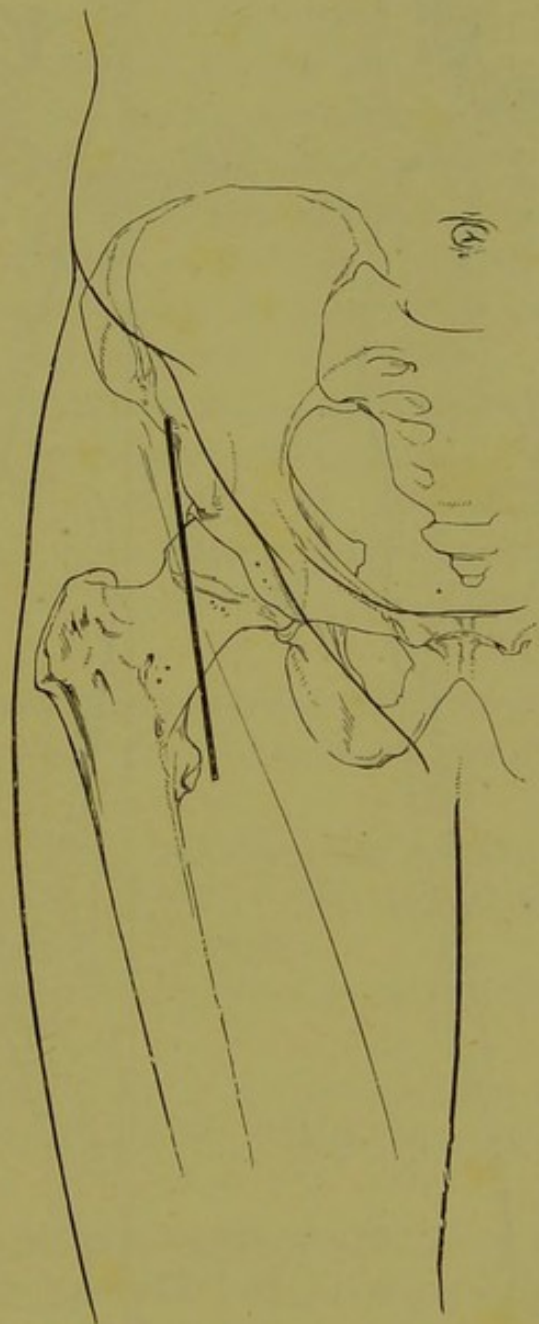

FIG. 286.—Lücke's anterior straight incision for resection of the hip-joint.

the outer side, immediately below the lesser trochanter, with the chisel, the limb can then be straightened and kept in splints until union has taken place. This method gives excellent results, and has the advantage of being

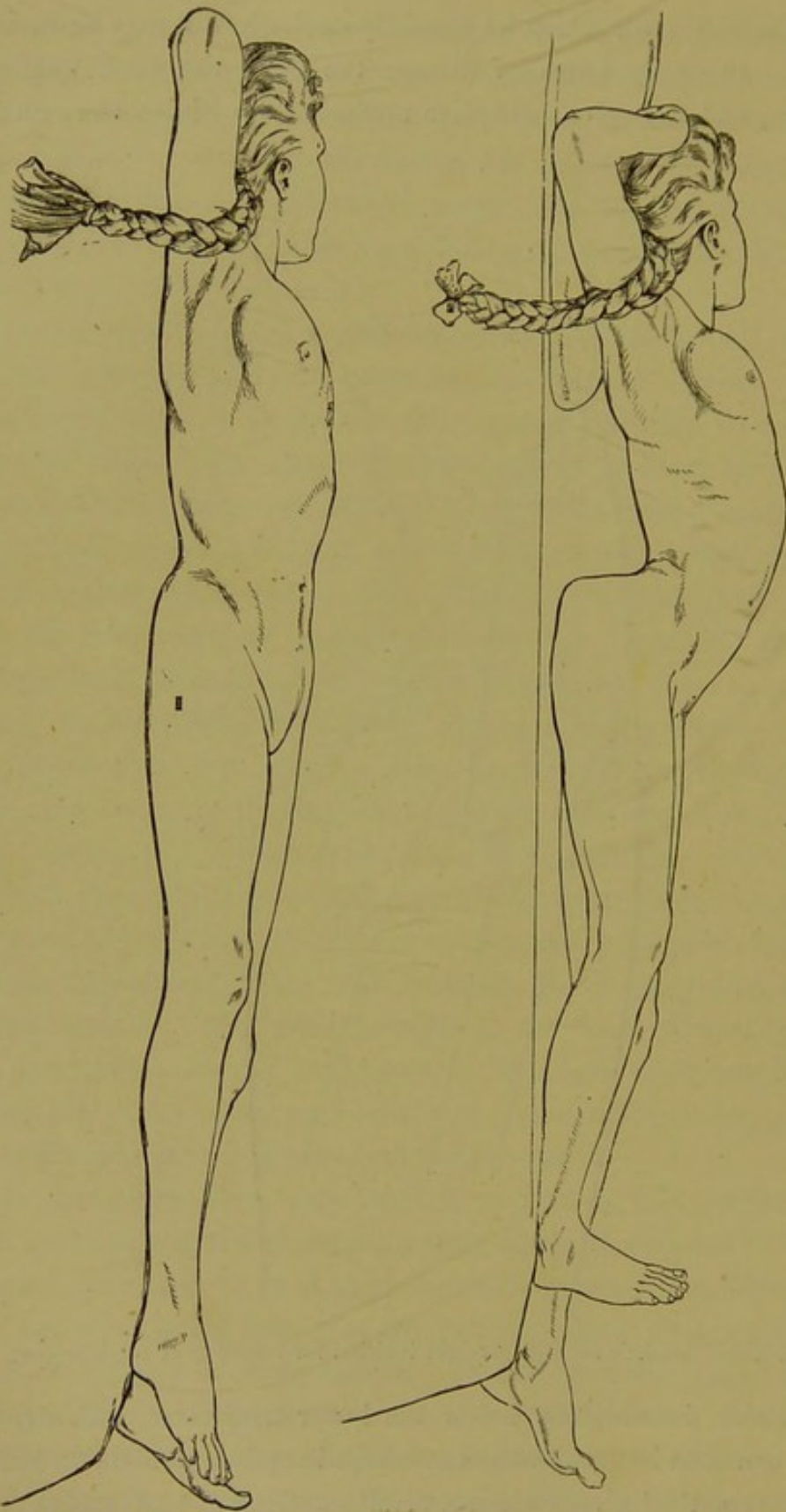


FIG. 287.—Osteotomy of femur. Illustrating a possible substitute for excision in cases of deformity.

subcutaneous, as the external wound needful to introduce the chisel is very small (Fig. 287).

After-treatment of cases of excision.—The wound is drawn together by sutures, more especially at the femoral extremity. A drainage-tube introduced near the other end will pass straight into the deepest part of the acetabulum, and then after a suitable dressing a bracketed splint, with extension, or a modified Thomas's splint, is applied.

The single or double Thomas's splint, modified to pass along the outside instead of the back of the limb, is a good appliance. A long outside splint, bracketed opposite the joint, with a weight attached to the limb by a cord running over a pulley, answers well.

A mattress with a hollow space opposite the wound and continuous on the opposite side, facilitates the after-treatment; a horseshoe cushion under the buttocks is often a great relief. In all cases the apparatus should be such as to permit the discharge to pass freely away, and the wound itself to be dressed and cleansed without much moving either of the joint or the patient.

The treatment after excision requires much patience. It is apt to be protracted. The excised joint is to be kept at rest, and the wound must not be pressed upon.

During the first two or three weeks the acetabulum and extremity of the femur should be kept well apart. The tendency to adduction must be sedulously guarded against throughout.

Results.—The results of excision in military practice and in civil hospitals differ extremely.

Leisrink's tables show that of 56 removals below the trochanter 51·7 per cent. were cured, and out of 72 simple decapitations 33·3 per cent. recovered.

Langenbeck's statistics of military practice tell us that in 49 cases of resection there were 44 deaths and 5 cases of recovery, or say 89·79 per cent.; in 157 cases of disarticulation there were 141 deaths and 16 recoveries, or 89·8 per cent.; a mortality practically alike for both.

Otis finds that in 85 cases the mortality after resection for gunshot injury was 90·6 per cent., and after disarticulation 90·0 per cent.; which is pretty much the same.

Leisrink collected 176 cases of hip excision for caries up to 1871, with a mortality of 63·6.

Of 105 deaths, 24 died of accidental wound diseases, 23 of exhaustion, 12 of phthisis, 3 from diarrhoea, 8 from amyloid disease, and 4 from the continuance of caries.

Hueter believed that no case of gunshot injury of hip had recovered after expectant treatment; and Lücke asserts that in only a single instance did recovery follow a gunshot injury of this joint during the war of 1870-71. So that although it is quite exceptional for a patient to recover after either excision or disarticulation of the hip-joint performed for gunshot injury, a purely conservative treatment appears to have been hitherto followed by results quite as disastrous.

The experience, however, obtained in the Austro-Prussian and Franco-German wars shows that some cases of hip-joint injury might benefit by excision. Portions of the head or neck of the femur have been found in such cases lying loose in the joint, the ball itself embedded in the head or neck, or lying amidst fragments which could only have been removed by excision.

In future campaigns, excision of the hip will probably be practised more frequently, but it is essential that the operation should be performed early, and that suitable means for the proper after-treatment of the patient should subsist.

The functional results after excision for injury can scarcely be known, so rarely has the operation been successfully performed.

For caries, excision of hip is a life-saving operation; it generally improves the patient's condition. Should it fail, amputation may be performed at a later period. The patient seldom dies in consequence of the operation itself, but usually from the associated conditions of disease.

Jacobsen, in his tables of cases of suppurative coxitis, 1874, tabulates 63 cases where conservative treatment was adopted, with 46 deaths, or 73 per cent.; while in 167 cases of excision there were 81 deaths, or 48·51 per cent. The age of the patient has a great influence on the rate of mortality, the younger bearing operation better than older persons.

The result after a successful excision for caries is generally fairly satisfactory as regards function; ankylosis rarely occurs, but the limb is

frequently atrophic. Half perhaps of the successful cases can walk without the assistance of a stick ; the other half require one. Crutches are seldom needed. A thick sole to the boot is requisite in order to allow for the shortening which is always present.

When the femur dangles, and the limb is weak and useless, a good deal may be accomplished by a properly fitting apparatus, consisting of a pelvic girdle with a side support attached to the boot, jointed at the knee and foot.

An important question to consider in operations on the young is how far the subsequent growth of the limb is likely to be interfered with by excision, and the probability of a successful conservative treatment.

The long bones principally increase in length at their extremities, and there is in addition a certain amount of interstitial growth. In the femur the principal increase takes place at the lower epiphysis ; there is comparatively little at the upper. Hence excision of the hip does not so greatly influence the after-growth as in the shoulder or knee-joints, where the growth takes place chiefly at the epiphyses concerned in the operation. Observation would indeed show that shortening after hip excision is not very considerable and not more than what follows after recovery under conservative treatment ; but in either case the muscles are often wasted and the entire limb in a badly developed condition. The amount of shortening therefore depends mainly on the arrested growth of the whole limb. The interstitial growth of the bone is also interfered with, the tibia on the affected side will often be much shorter than the other, and the foot is smaller than that of the sound limb.

The defective function after the operation may be therefore regarded as to a large extent the consequence of defective development, and if by excision we convert a useless into a useful limb, we really favour rather than impede its growth, although in doing so we have to excise the superior epiphysis of the bone.

The period necessary for recovery varies from two months to two years. In some cases the patient may be able to get about in two months with a support, and to walk in one year. In favourable cases he may get about fairly well in six months

The results under antiseptic dressings are much better than those

formerly obtained, the wound often closing in about four or five weeks, and the patient soon after able to get about, supported by a sort of go-cart, or on crutches.

EXCISION OF THE PHALANGEAL AND METACARPO-PHALANGEAL JOINTS.

Indications.—These operations are rarely performed, and do not receive much notice in surgical literature. They are indicated in recent injury to the joint of a compound nature where the bone is damaged, or where after conservative treatment suppuration threatens to occur in and around the joint. I have also excised the phalangeal joints for stiff or ankylosed fingers and for unreduced dislocations with satisfactory results. After a rightly conducted operation and careful subsequent treatment very complete restoration of function may be often expected. Should ankylosis occur it may be made to take place in a useful and convenient position. For caries the operation is not promising.

A wound of a finger-joint is to be treated for the most part in the first instance conservatively. A compound dislocation, after reduction has been effected, will, as a rule, be managed in the same way, but ankylosis is a common result.

In some cases where the bone has been injured it is well to cut off the damaged portion and try to procure a movable joint.

Operation.—A lateral incision may be made one side of the joint so as to avoid injury to the flexor and extensor tendons, as also the blood-vessels and nerves. After the soft parts have been detached, one or both joint surfaces may be excised. Generally, only the head of the proximal phalanx or metacarpal bone needs removal. It can be readily caused to protrude through the wound. The bone may then be severed with the cutting bone forceps. The adjacent finger may generally be used as a support during the healing of the wound, or a small palmar splint can be applied. The operation of excision of the metacarpo-phalangeal articulation will most frequently be required in the case of the thumb and index finger.

Passive movements should be begun early in these cases. If mobility is not sought for the finger should be kept slightly flexed, as that is the most favourable position for ankylosis to occur in, but a movable joint can ordinarily be obtained.

EXCISION OF THE WRIST.

The first operation for the excision of this joint was performed by Moreau. The results are much less satisfactory than in other articulations. The stiffened condition of the fingers and ankylosed wrist-joint which often follow in many of the cases which recover, seriously detract from the value of the operation. When performed for caries, the operation fails in a large proportion to arrest the disease; sinuses continue to discharge; unhealthy granulation tissue accumulates in fungating masses, and amputation must be performed.

If recovery ensue, however, the functions of the part may be more or less perfectly re-established, and, of course, a hand, however imperfect, even although it may be embarrassed by a stiff wrist, is preferable to no hand at all, and is better than any artificial substitute.

Many varieties of incision have been employed: a single incision on the ulnar side about six inches long, the straight dorso-radial wound, double lateral incisions, a horseshoe-shaped dorsal flap, or an anterior and posterior median incision as performed by Simon.

Lister has described a somewhat complicated method, one of whose main objects is to preserve the tendons. In this country it superseded the older plans; but abroad, the straight dorso-radial incision, as practised by Langenbeck, finds general acceptance, and is, in my opinion, the best method of operation.

Indications.—The operation is generally undertaken on account of carpal caries, and for such cases it must be as complete and thorough as possible. When performed for chronic disease, the operation is not dangerous to life, but the functional results are often very imperfect. It may also be required on account of acute traumatic inflammation of the joint, and for ankylosis. Apart from injury, acute suppuration of the wrist is very rare. After suppuration of the carpal joints, ankylosis always follows recovery. The tendons become adherent to their sheaths, and there is a very limited mobility in the fingers; hence the propriety of excision in these cases. A good result, however, can only be obtained where passive movements are afterwards persistently carried out.

Excision of the wrist-joint may be required for injury—chiefly gunshot

wounds or compound fracture. The latter is of rare occurrence. In time of war it has been frequently required both as a primary and secondary measure. The latter is preferable, as it is more easy and followed by better results. When the radius or ulna, as well as the carpus is injured, a primary operation must be performed. When one part of the wrist is wounded, even the base of the fifth metacarpal bone, inflammation is very apt to spread throughout the whole articulation. Pyæmia has been of frequent occurrence after gunshot injury of this joint. A good many cases of wound of the wrist may be treated conservatively, and a partial excision may be possible in some traumatic cases. For caries the operation should always be very complete.

Secondary resection is usually indicated because of a diffusion of traumatic inflammation accompanied by necrosis. When performed in such cases the operation is generally followed by satisfactory results.

Of the results of excision for gunshot injury there is not a sufficient experience. With the advantages accruing from antiseptic treatment, amputation of the hand should certainly only be performed in cases of very extensive disease not amenable to excision, or in those cases where excision has failed, or where life is in danger.

When performed for disease, the functional activity of the fingers is often lost to a large extent before the operation is undertaken, and great stiffness or complete loss of movement is very apt to follow. Early excision has therefore been advised in order to secure better functional results. The tendons are in close proximity to the diseased bones, inflammatory changes take place in them by extension, they not only adhere to their sheaths, but in some cases necrose, and to this is largely owing the frequent uselessness of the hand after excision of the wrist-joint. Antiseptic precautions, however, render the occurrence of suppurative tendovaginitis after operation less frequent.

As the entire carpus is generally concerned, it is rare for a single bone to be affected by disease. Occasionally, an injury may involve the radio-carpal joint, and the subsequent inflammation remain limited to this articulation, the intercarpal joints escaping. On two occasions I have excised the os magnum, the rest of the carpus appearing to be healthy and completely isolated from the diseased area.

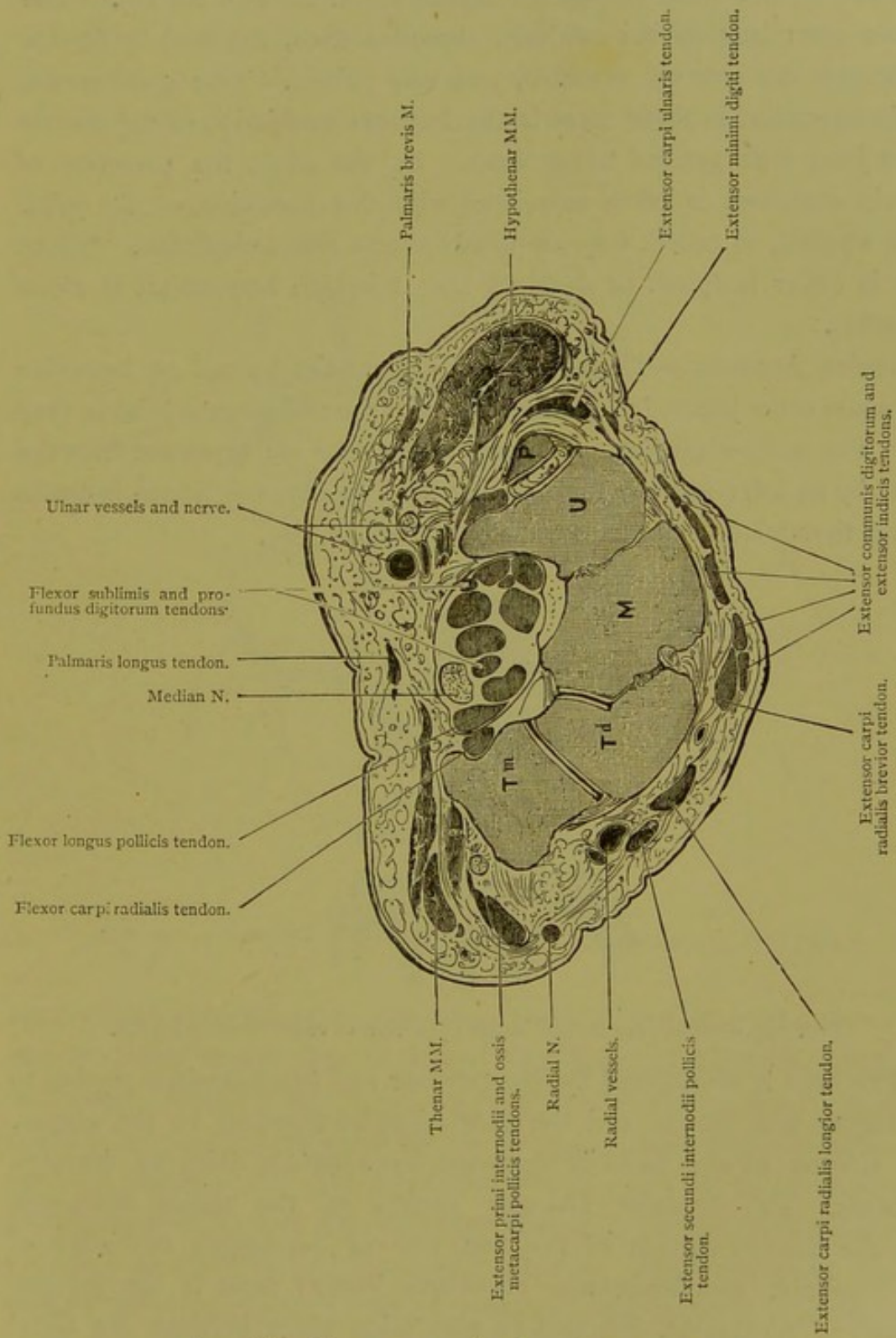


FIG. 288.—Transverse section through the wrist-joint.

In white swelling or granulation synovitis, the synovial membrane is first affected, and subsequently the bones, which become carious. The tendons are raised by the swelling, abscesses form, followed by fistulæ. The fingers are scarcely movable, and very painful. One great reason against operation in these cases is the frequent association of the disease in the joint with general tuberculosis. In the adult, the presence of tubercle elsewhere is often associated with this condition of the joint. Senile scrofula, so called, very frequently affects this articulation. Where there is either incipient or declared lung mischief, amputation is alone admissible.

Surgical Anatomy.—The movements of the wrist are not so extensive as in some other joints, but the movement of the radio-carpal joint is very free. The radio-ulnar joint and end of the ulna are separated from the carpus by an inter-articular fibro-cartilage. The internal lateral ligament uniting the ulna and carpus is somewhat slack.

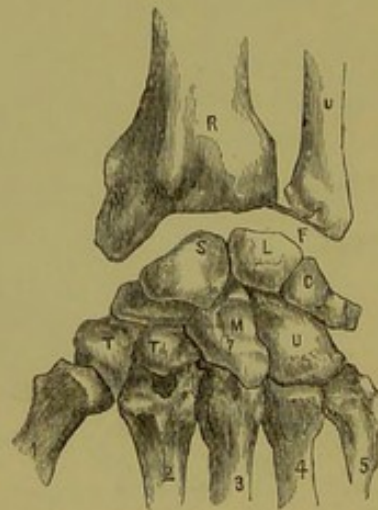


FIG. 289.—Bones concerned in the operation of excision of the wrist.

The wrist is surrounded by the extensor and flexor tendons passing to the fingers and thumb, and the short muscles attached to the carpus. The motion of the hand is regulated by a double joint of complex character. The concave articular surface of the radius articulates with the convex surface of the first row of the carpus, consisting of the scaphoid, semilunar, and cuneiform bones; here is the greatest amount of movement, but motion also takes place between the distal surfaces of these bones, which articulate with the head of the os magnum

and with the unciform, while the scaphoid presents two articulating facets for the trapezium and trapezoid. There is no movement between the carpal and metacarpal bones. The free communication between the different carpal joints has an important bearing on the spread of inflammation in the wrist-joint (Fig. 290). The synovial membrane

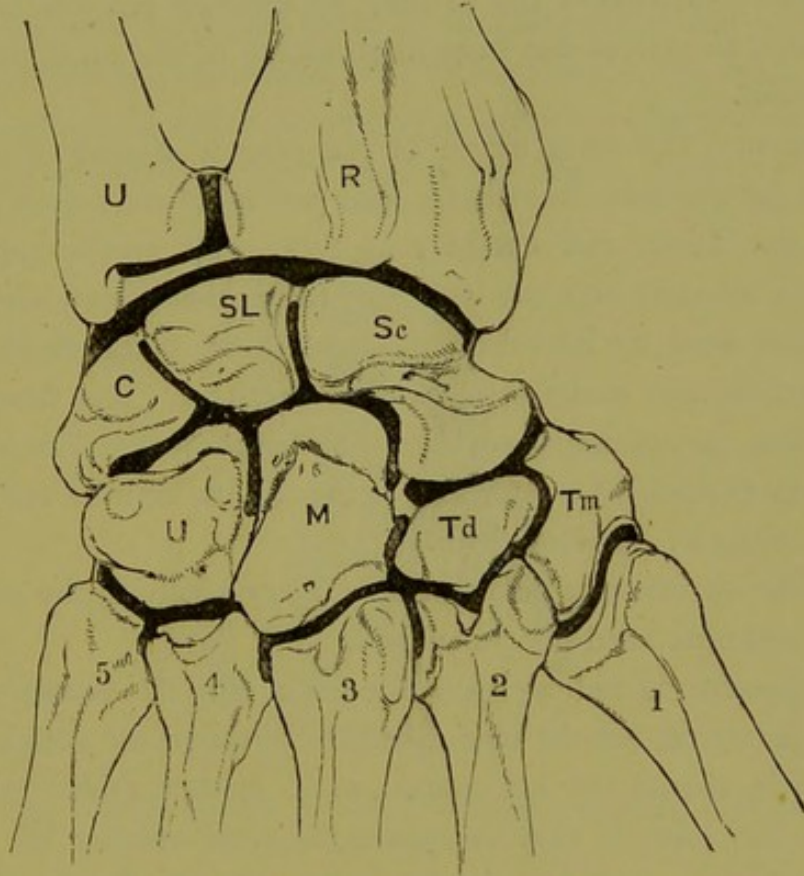


FIG. 290.—Synovial cavities of the wrist. (For description, *see* p. 285.)

between the scaphoid, semilunar and cuneiform bones on the one part, and the radius on the other, is shut off from the second row of joints, but the latter communicates with the carpo-metacarpal joint through a channel between the trapezoid and os magnum. The pisiform bone has usually a separate joint with the cuneiform, although in some cases this joint communicates with the carpal articulation. The articulation between the trapezium and the thumb is always distinct. The flexor carpi ulnaris, with the pisiform (which is really a sesamoid bone), should, if possible, be preserved. The trapezium also is generally free from disease and may be

left; it is difficult to excise on account of its position and saddle-shaped articulation with the thumb. The abductor pollicis, part of the flexor brevis pollicis and flexor ossis-metacarpi pollicis, arise from it and have a distinct synovial sac; it should therefore, if possible, be preserved. The functional result of the operation is better when these bones are not removed. In many cases of excision of the carpus, the articular surfaces of the metacarpal bones, as well as the hook-like process of the unciform, may also be left behind.

Operation.—The main object of the present method of operating is so to plan the incisions that the tendons passing to the fingers and thumb, both on the flexor and extensor aspects, shall escape injury. Only the tendons inserted into the bases of the second, third, and fifth metacarpal bones need be interfered with, and these, being divided close to their insertions, can easily form new connections. The flexor tendons, ulnar, median, and radial nerves lie out of harm's way. The radial artery, where it passes round the outer side of the carpus, may be readily injured if the trapezium be interfered with.

When the operation is performed for injury involving the carpus alone, the radius and ulna need not be excised.

The operation is not an easy one; not only the vessels and nerves must be protected, but the tendons which surround the wrist on all sides. Their sheaths should not be opened, as it renders them very liable to necrose. The joint is very composite, a great number of bones and synovial capsules enter into its formation, and in no other is there so great a tendency to subsequent ankylosis; the bones, therefore, may be very freely excised.

Lister's operation for excision of this joint is at once complicated and difficult. So good a view of the diseased parts is not obtained, and it is not easy to separate the parts on the ulnar side of the wound.

Langenbeck's dorso-radial incision is very superior.

The use of Esmarch's bandage applied to the forearm renders the operation easier. If abscesses or fistulæ be present it is better to simply raise the arm before applying the constriction, the free bleeding afterwards is, however, a great objection to the prolonged elastic constriction.

LISTER'S METHOD OF EXCISING THE WRIST.

Elastic constriction having been first applied to the forearm, any adhesions present are forcibly broken down to facilitate the subsequent steps of the operation.

An incision is now made downwards and outwards from the middle of the dorsal aspect of the radius as far as the inner side of the joint between the trapezium and the metacarpal bone of the thumb (Fig. 291). Then at an obtuse angle the incision is prolonged vertically downwards along the radial border of the metacarpal bone of the index finger as far as its middle.

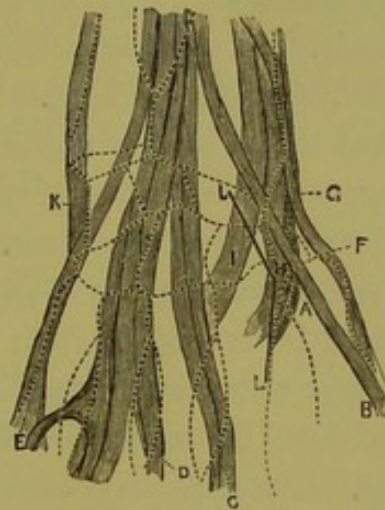


FIG. 291.—Carpal tendons, and line of incision recommended by Lister for excision of the wrist-joint.

- | | |
|--|--|
| A. Radial artery. | F. Extensor primi internodii tendon. |
| B. Extensor secundi internodii tendon. | G. Extensor ossis metacarpi tendon. |
| C. Extensor indicis tendon. | H. Extensor carpi radialis longior tendon. |
| D. Extensor communis tendon. | I. Extensor carpi radialis brevior tendon. |
| E. Extensor minimi digiti tendon. | K. Extensor carpi ulnaris tendon. |

This incision commences in the angle formed between the extensor communis digitorum and the extensor secundi internodii pollicis (Fig. 291). The first portion runs parallel to these tendons and directly across the insertion of the extensor carpi radialis brevior, which will be divided. The angle of the two branches of the incision is close to the insertion of the extensor carpi radialis longior. If the first portion of the incision be carried too far downwards the radial artery may be divided where it

passes over the back of the trapezium and head of metacarpal bone of the thumb.

The soft parts are first detached from the bone on the radial side of the incision, cutting the extensor carpi radialis longior tendon close to its insertion.

Now fully extend the hand and detach the soft parts from the bones on the ulnar side of the incision as far as is practicable, the remaining portion being afterwards separated from the ulnar incision, which should now be made. This should commence rather near the palmar aspect of the ulnar border of the wrist, two inches above the styloid process of the ulna, pass about four inches vertically downwards between the ulna and the tendon of the flexor carpi ulnaris, and terminate over the middle of the palmar aspect of the fifth metacarpal bone. The tendons and soft parts on the dorsal aspect of the wrist may now be completely separated, the tendon of the extensor carpi ulnaris being cut close to its insertion, as also the dorsal and internal lateral ligaments. The pisiform bone is left connected with the tendon of the flexor carpi ulnaris. The hand being flexed the knife should be carried close to the ulna so as to avoid injury to the ulnar artery, and through the ulnar incision the flexor tendons are to be separated from the carpus, and the unciform process cut with the bone forceps. The soft parts having been now detached, disarticulate the carpus from the radius, and then, by means of the cutting bone forceps, the carpus from the metacarpus. Retract the soft parts on the radial border of the first incision, and with them withdraw the tendon of the secundi internodii and the radial artery out of the way. Detach the trapezium from the trapezoid and scaphoid bones by cutting with the bone forceps in the vertical portion of the incision. No attempt should at this stage be made to remove the former bone, as in doing so the radial artery would probably be divided. The whole carpus is now detached with the exception of the trapezium and pisiform bones, and may be extracted *en bloc*, any remaining connections with the soft parts being separated by a touch of the knife.

The ends of the radius and ulna are readily protruded through the ulnar wound, and a thin slice removed from their articular surfaces with the saw. Saw the ulna obliquely, if possible, so as to preserve the styloid

process. This will counteract the after-tendency to displacement of the hand toward the ulnar side. The gouge, or sharp spoon, may be used if the disease be more extensive.

The extremities of the metacarpal bones must be exposed and their articular surfaces sawn off with a narrow-bladed saw; the fourth and fifth are most easily reached from the ulnar wound, and the second and third from the radial side. Lastly, if thought advisable to remove it, the trapezium is to be seized in a lion forceps and dissected out, cutting quite close to the bone to avoid wounding the radial artery lying directly on its outer side, or injuring the tendon of the flexor carpi radialis which is imbedded in a groove on its anterior aspect. If diseased, the articular surface of the first metacarpal bone may also be removed, and the pisiform, if implicated, may be dissected out, or at least its cartilaginous surface removed.

The tendons which require division are the ulnar and radial extensors of the carpus. These tendons should be cut as long as possible, so that they may form new attachments.

After-treatment.—Drainage-tubes are inserted, and the wound is closed by suture.

Lister advises a simple wooden anterior splint with an obtuse-angled piece of cork fastened to it (Fig. 292 *a*), the thumb being supported by a projecting piece of cork fastened to the anterior surface of the splint. The wrist will thus be slightly extended and the fingers bent.

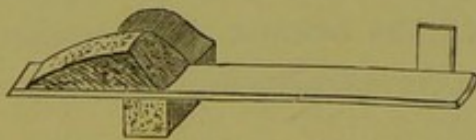


FIG. 292 *a*.—Lister's splint for excision of wrist.

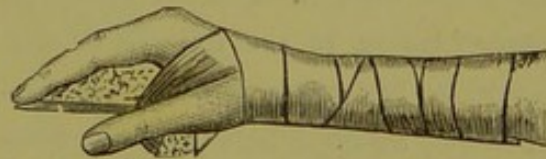

FIG. 292 *b*.—Lister's splint applied.

The main object after the operation is to obtain mobility in the fingers. The amount of movement in the wrist is of less importance.

Passive movements should therefore be begun in the fingers at the earliest possible date—in fact, as early as the second or third day after the operation. They should, if possible, be fully flexed and extended every day, the wrist being held firmly and disturbed as little as possible during the manipulation.

The metacarpo-phalangeal articulations are especially liable to get stiff, and care has to be taken to move them thoroughly.

The thumb is apt to be drawn inwards to the index finger. This must be prevented by a suitable pad. As the wound consolidates the splint may be shortened and the fingers allowed to project further. Passive movements must be continued so long as there is a tendency on the part of the tendons to contract adhesions with their sheaths. The wrist must be supported so long as there is any weakness and disposition to become adducted, which must be effectively guarded against.

LANGENBECK'S METHOD OF EXCISING THE WRIST-JOINT.

In Langenbeck's method of excision of the wrist, it is convenient to place the hand of the etherised patient on a small table beside the one on which the patient lies. The surgeon sits on a stool in front. An Esmarch's bandage is to be employed in order to prevent the troublesome oozing which otherwise ensues.

In this method a straight incision is made near the middle of the posterior aspect of the wrist, the guide to it being the radial border of the extensor indicis tendon, which can be readily caused to become salient by extending the finger.

The hand being slightly abducted, the incision should begin close to the ulnar margin of the metacarpal bone of the index finger, at a point corresponding to the middle of the bone. The extensor indicis tendon should be first pushed to the ulnar side, and the soft parts incised down to the bone, which is here subcutaneous.

The incision is prolonged upwards for four and a half inches until it terminates on the dorsal surface of the lower end of the radius at the angle of junction of the extensor indicis and extensor secundi internodii tendons (Fig. 293). Its centre thus corresponds to the carpus. Over the metacarpal bone it lies along the radial side of the extensor indicis tendon, and a little higher up on the ulnar border of the tendon of the extensor carpi radialis brevis, close to its insertion into the base of the metacarpal bone of the middle finger.

The dorsal ligaments of the wrist are divided in the deeper portion of

the wound, but the radio-ulnar joint should not be opened, as this makes it afterwards difficult to expose the end of the ulna.

It is a matter of much importance to avoid opening the sheaths of the various tendons. The extensor indicis is exposed in the lower part of the

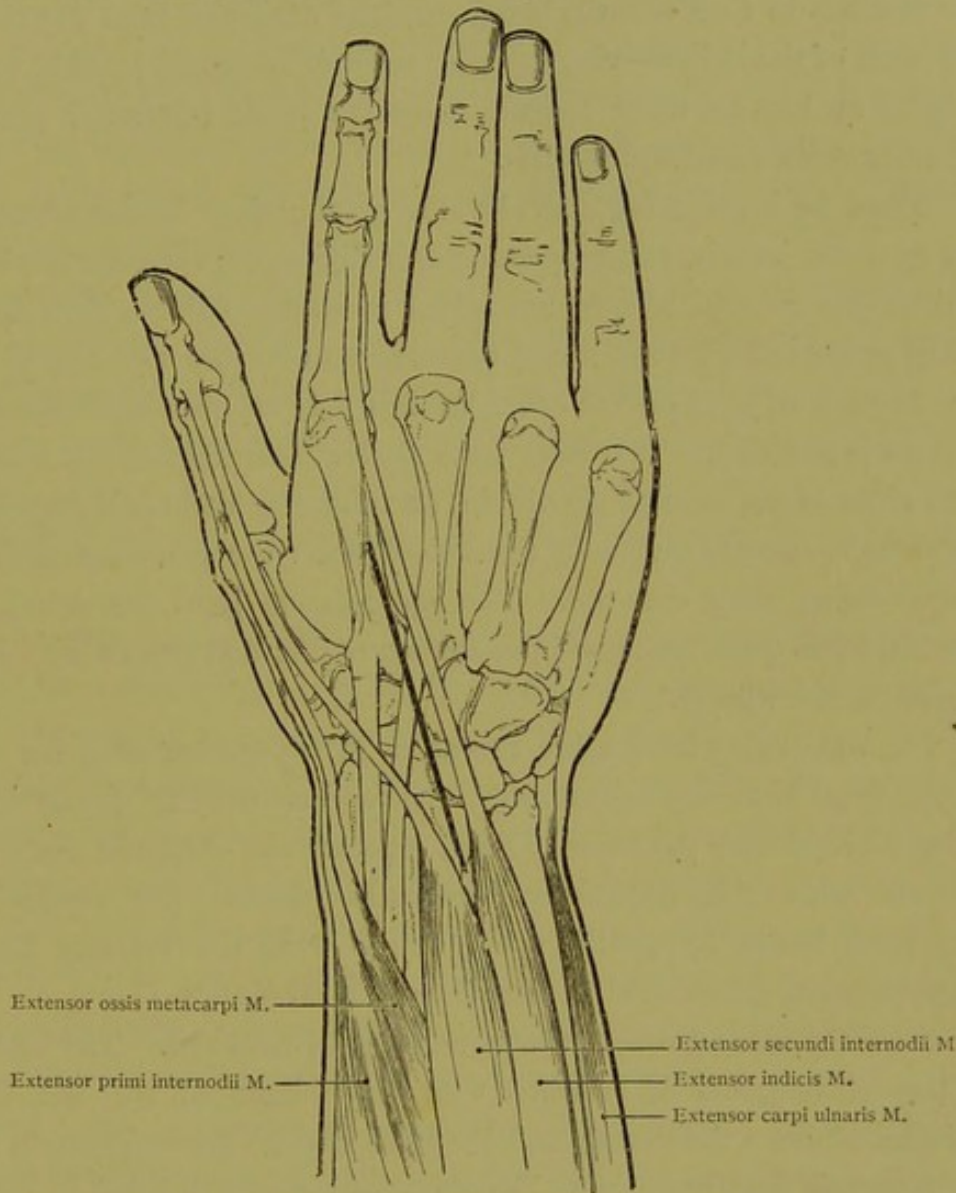


FIG. 293.—Dorsal incision in Langenbeck's excision of the wrist.

wound. Near the centre the extensor carpi radialis brevis is seen at its insertion into the base of the metacarpal bone of the middle finger, and may be divided close to its insertion or raised from the bone with the elevator. In either case it will soon form new adhesions. The tendon of the extensor carpi radialis longior may be subsequently treated in a similar fashion.

A little patience is now required to detach the extensor tendons from the back of the radius, especially the extensors of the thumb.

The soft parts are first drawn by a retractor towards the radial side, and the capsule being split longitudinally, they are raised by the elevator, the tendons in their sheaths being carefully detached from the grooves on the back of the radius—viz., extensor secundi internodii pollicis, extensores longior et brevior carpi radialis, extensor primi internodii pollicis and extensor ossis metacarpi pollicis.

Then, by introducing the elevator on the ulnar border of the wound, the extensor indicis, extensor communis digitorum, extensor minimi digiti, and extensor carpi ulnaris are raised in similar fashion, their connection being preserved with the dorsal ligament on one side and the periosteum and capsule of joint on the other, in this way all chance of injury to their sheaths is avoided. The soft parts being now thoroughly elevated on both sides of the wound, we obtain, on retracting them and slightly flexing the wrist, a complete view of the articulation: the posterior surface of the carpus being fully exposed. The radio-carpal joint lies open, and on the hand being further flexed the surface of the first row of the carpus will project in the wound.

The bones may be readily removed in succession with the elevator, at the same time any ligamentous connections which impede extraction being divided with the knife. First, separate the scaphoid from its connection with the trapezium; secondly, detach the semilunar and cuneiform bones by gently raising them with the elevator whilst the corresponding intercarpal ligaments are cut through.

Now the second row of the carpus can be removed. The round head of the os magnum is steadied with the fingers of the left hand, an assistant abducts the thumb, and the knife divides the articulation between the trapezoid and trapezium. The carpo-metacarpal joint is entered in a direction towards the ulna, whilst the dorsal ligaments at the proximal ends of the metacarpal bones are divided as the assistant flexes the hand. The three bones of the distal row, the trapezoid, os magnum, and unciform can now be removed *en bloc*. The hook-like process of the unciform requires some care during its enucleation. It may be snipped off in some cases to facilitate removal of the bone, but with a little trouble

it can be cut out. The pisiform should for the present be left. It is rarely implicated in the general disease, and at most its cartilaginous surface may require to be cut off. If necessary it can be dissected out.

As a rule, however, the pisiform bone need not be interfered with; it is generally healthy. It is, moreover, a sesamoid bone, through which the flexor carpi ulnaris finds an insertion into the base of the fifth metacarpal bone, and thus forms an important connection with the abductor minimi digiti. If preserved it will have a considerable influence in counteracting subsequent deformity.

The trapezium remains to be dealt with. It is better not to remove it, as it forms a separate joint with the thumb, and is usually exempt from disease. The abductor pollicis and flexor ossis metacarpi arise from it, as does also the flexor brevis pollicis. Its extraction besides is not easy, the tendon of the flexor carpi radialis runs in a groove on its upper anterior surface, while the radial artery is in dangerous proximity on the outer side.

It now remains to cut off the articular surfaces of the radius and ulna. Still flexing the hand the ulna and radius project from the wound, and with a bow or metacarpal saw the ends can be quite readily removed. The external lateral ligament with the periosteum must be carefully detached with the elevator, otherwise the princeps pollicis artery may be divided as it runs over the trapezium to penetrate the first interosseous space. It facilitates this step of the operation not to have previously opened the radio-ulnar joint. The resection of the radius should be as limited as possible. Finally, the cartilages, or what remains of them, are cut off the ends of the metacarpal bones. If the extremities of the metacarpals require removal the incision must be prolonged somewhat downward. All gelatinous granulations should be scrupulously removed and the wound disinfected.

If the operation be conducted in this way the joint is most completely exposed, without any of the bruising and pulling about of the soft parts incidental to other methods. The carpal bones may be removed with comparative ease; the sheaths of the tendons, and the lateral ligaments, are preserved intact, and the arteries and nerves run little risk of injury. The wound is a comparatively limited one. The soft parts of the forearm are but little disturbed, and the only tendons which need to be divided are

those of the extensors carpi radialis longior and brevior close to their insertions.

The limb is to be adjusted on a splint, leaving the thumb and fingers free. A good form of splint is still a desideratum. Langenbeck fixes the hand and forearm midway between pronation and supination in a plaster-of-Paris splint.

After-treatment.—The after-treatment is of the utmost importance, and should be begun as early as possible.

The finger movements may be begun almost immediately after the operation, and those in the wrist after eight or ten days, or as soon as the condition of the parts admits of it.

Besides passive movements the induction current may be used after the wound is healed.

The patient must lend untiring aid in the after-treatment for at least two or four months or even longer.

Carrying a weight in the hand which has been operated upon for several hours daily is of great service; and writing, piano-playing, and drawing are useful exercises.

There is a great tendency for the tendons to adhere to their sheaths. This is to be overcome by assiduous movement, and in bad cases by forcible bending under chloroform from time to time.

The subsequent tendency for the hand to assume a position of adduction is to some extent prevented by preserving the styloid process of the ulna.

EXCISION OF THE ELBOW-JOINT.

Excision of the elbow seems to have been first performed by Shrimpton in 1758 for compound dislocation. In 1782, Park, of Liverpool, detailed the steps of the operation as performed on the dead body. In the same year Moreau performed the operation for disease. In more recent times, Roux, Crampton, and Syme revived the procedure, and made it an established method of dealing with instances of disease and injury of this articulation, which otherwise might possibly have called for amputation of the arm. Syme did more than any modern surgeon to make the operation, so to say, popular. He adopted the **H**-form of incision recommended by Moreau, which he

regarded as best calculated to secure a perfect result ; a method, however, now for the most part abandoned in favour of a single straight incision.

Indications.—This joint is very frequently excised both on account of injury and for disease.

Acute suppuration or septic synovitis of the joint may indicate excision when free drainage fails to arrest disease. The incisions for washing out and draining the joint should be made between the radius and olecranon on the outer side, and on the inner side of the triceps near the olecranon on the inner side.

Chronic synovial disease is a frequent cause for operating. In the elbow its occurrence is about one-fourth in point of frequency among the larger articulations. In children, free incisions into the joint, with removal of the granulation tissue and diseased surfaces of the bone with a sharp spoon, will often suffice ; in the adult, however, excision is preferable, and is indicated in those chronic cases of disease which resist other modes of treatment, whether there be suppuration and fistulæ or not. In the non-suppurating cases extensive bone changes may occur, the cartilages are removed, and ankylosis or a more or less stiff joint must follow. Loose bodies in the articulation, from the changes they set up, and the condition called papillomatous synovitis, may require the performance of the operation on account of the swollen, useless condition of the joint. Next the knee, so-called "loose cartilages" most frequently occur in the elbow. In many cases they may be successfully removed by an incision between the head of the radius and the olecranon.

Excision of this joint, however insuflcing may prove the result, appears in many cases to merit the preference in traumatic cases over expectant treatment, and it is less dangerous to life than amputation of the arm.

The formation of a new joint with good movement is the aim sought for. The occurrence of ankylosis is *pro tanto* a failure, although in some cases its occurrence will not materially damage the working power of the individual. Flail-joint is not uncommon when an operation has been performed for injury, or there has been an extensive removal of the bones. In cases of flail-joint one may cut down on the part, freshen the surfaces of the bone and suture them together with silver wire. In one case in which I performed this operation, after an unsuccessful excision for injury, the

result was a strong actively mobile joint. If ankylosis should follow, which is unlikely, a good useful position may be ensured.

Excision has been successfully practised for the relief of fibrous or bony ankylosis in a straight position, for stiff joint the result of acute inflammation or connected with an articular fracture, and after old unreduced dislocations.

Gunshot and other compound fractures may require excision. Where there is a possibility of choice, the secondary period should be selected. In military surgery most authorities agree that the danger to life is less after a primary resection, but the functional results are not so good, and primary resection is as a rule impracticable on the field.

Billroth indeed ascribes better functional results to primary resection, as he believes the periosteum loses its osteo-genetic power after long-continued suppuration. But in cases of primary excision the reparative power of the periosteum is, in truth, very small, and flail-joint frequently follows the operation. This is the great objection, for as regards risk to life resection is less formidable, and is not so dangerous as amputation of the arm in its lower part in the proportion of 20 to 30. Excision, moreover, is not only less dangerous than amputation, but also than conservative treatment, after severe injury of the elbow-joint.

With the advantages of aseptic treatment amputation in cases of gunshot injury is only necessary in very extensive injury to the bone, or if the brachial vessels have been injured or gangrene makes its appearance.

In most cases where the injury is not severe enough to lead to immediate amputation an attempt should be made to preserve the limb, and only in those instances where conservative measures fail should excision be resorted to.

A commencing phlegmon around the joint or between the muscles is no contra-indication to excision, as good drainage is thus provided.

The experiences of the Franco-German war have shown that intermediate resection performed with aseptic precautions is not more formidable than primary.

An intermediate operation may be performed for incised and punctured wounds when the conservative plan has failed and suppuration and fever run high.

Hueter during the Franco-German war performed most of his elbow excisions between the fourth day and third week.

The former fatal character of intermediate resection and this recent change in military surgical practice are mainly due to the disinfection of the wound surfaces, the introduction of the sub-periosteal method, a better plan of operating, and more effective drainage.

When, however, extensive comminution of the joint surfaces has taken place, primary excision will be the better course to adopt. Where this has not been possible an intermediate resection may probably become necessary.

The question of the treatment of gunshot fracture of the elbow is still in some uncertainty. If a condyle be simply knocked off, the olecranon broken, or the capsule simply opened, we may elect to treat conservatively.

Our practice, however, must be largely guided by the circumstances of the individual case.

Hannover's tables of the final results after elbow resection have made some military surgeons doubt its propriety altogether, seeing that so many cases had afterwards to be amputated in which bad results or a flail-joint had followed.

The operation may be required for other kinds of injury, such as compound dislocation, or an extensive wound associated with severe fracture. Again, the injury may be such as to justify conservative treatment, as in compound fracture of the olecranon, fracture above the condyles with a limited wound in the skin, or, lastly, compound dislocation in which the reduction is readily accomplished and there is no concomitant severe injury. Of course, in all these cases a very strict disinfection of the wound and subsequent antiseptic treatment will have to be carried out.

Surgical Anatomy.—The ligaments and capsule are tense; the joint is closed by the olecranon behind. In front the arteries and nerves render it inaccessible, and it is, moreover, surrounded by muscles for the greater part of its circumference. Its interior is irregular and complex, and in consequence it is extremely difficult to wash out and thoroughly disinfect.

It is essential, in order to secure the active power of extension to

preserve the continuity of the triceps muscle and tendon and its connection with the extensor muscles and fascia of the forearm.

It is also of the greatest moment not to divide the external lateral ligament, and preserve its important connection with the orbicular ligament

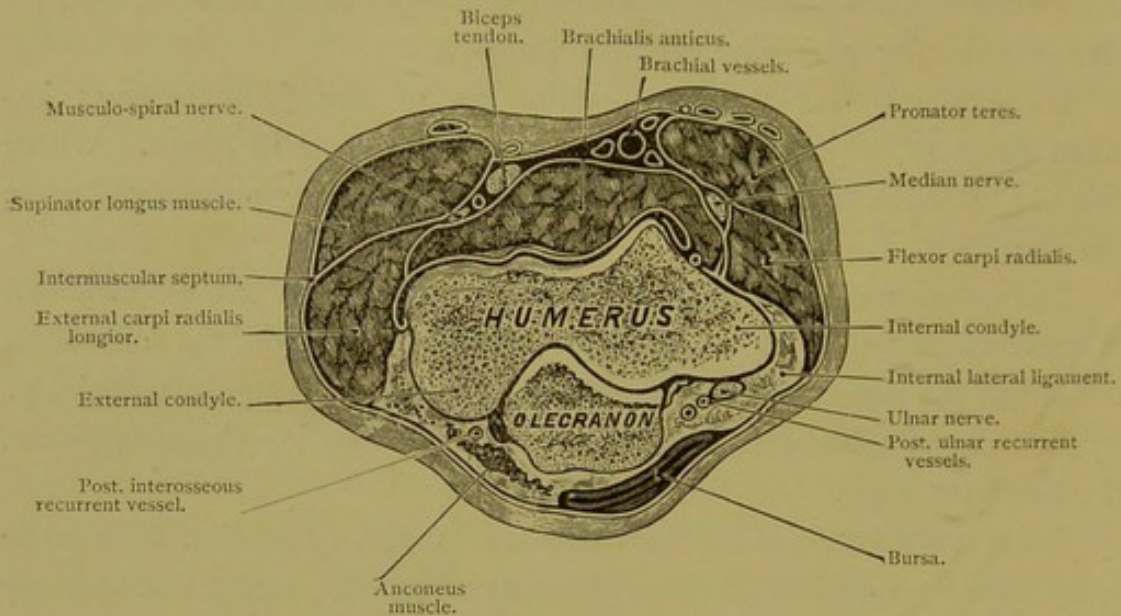


FIG. 294.—Transverse section through the elbow-joint at the level of the condyles of the humerus.

of the radius. When these are preserved the future usefulness of the limb is materially enhanced.

There is seldom any bleeding of importance. Only one nerve, the ulnar, as it passes behind the internal condyle, is in danger of injury.

Operation.—A median incision on the back of the joint (Fig. 295), about four inches long, with sub-periosteal raising of the parts, preserves the ulnar nerve and all essential parts from injury. The patient should be placed on the sound side, and the operator can hold the limb conveniently by drawing it across the body.

The longitudinal incision may be made with advantage rather nearer the internal than the external border of the olecranon. It is by far the best form of incision, as it allows of almost perfect preservation of the triceps extensor tendon and its insertion. The ulnar nerve is protected from injury, and the sub-periosteal method can be readily carried out. The wound may be made at once down to the bone for its

entire length. The centre corresponds with the base of the olecranon, above which it should extend for two inches. The triceps tendon is split longitudinally, and the capsule opened posteriorly in a vertical direction. The left forefinger is now introduced in the wound, its inner margin raised, the inner half of the tendon of the triceps is separated from the olecranon, then the flexor carpi ulnaris and fascia covering it

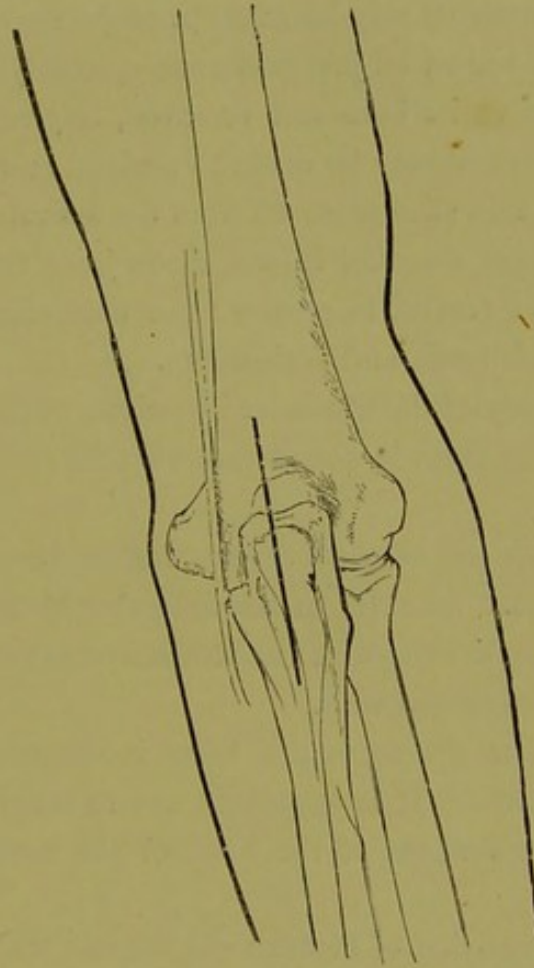


FIG. 295.—Straight dorsal incision for resection of the elbow-joint, the position of the ulnar nerve is indicated.

detached from the ulna, the whole bulk of the soft parts being thus gradually detached from the olecranon, and as far as the internal condyle, by means of the elevator and a strong scalpel, with which short cuts are to be made, the edge being always directed towards the bone; the ulnar nerve should not be exposed, and is in this way safe from injury. When the epicondyle is reached, the muscles inserted into it and the internal lateral ligament are to be detached by cutting close to the bone. Then

the soft parts on the outer side of the incision are to be separated from their connections with the olecranon and ulna, partly raising the anconeus where it is inserted on the outer side of the ulna, and detaching the external lateral ligament together with the periosteum. The knife must always cut with short strokes close to the bone, while the soft parts are held well back with retractors and the elevator. If there be no considerable swelling the humerus may be made to project on strongly flexing the joint, and the surface sawn off just below the epicondyles, or the olecranon may be first divided at its base and removed, to give more space. Then the bones of the forearm may be made to project, and if the olecranon be already removed, a thin slice removed from the articular surfaces.

It is perhaps more essential in the elbow-joint than in any other, in order to secure good results, to preserve the muscular insertions intact in their connection with fascia and periosteum.

From the epicondyles the muscular insertions must be cut off close to the bone, thus leaving them in connection with the periosteum and internal lateral ligaments.

Only the articular end of the humerus should be cut off, just below or through the condyles. As little as possible should be removed from the bones of the forearm, as otherwise the movement of pronation and supination are materially interfered with.

In traumatic cases the more the bone is removed, the less likely is a good result to follow. It is important not to remove more than a thin slice of the articular surfaces of the head of the radius and the base of the olecranon.

Formerly the **H**-incision of Moreau was the one most generally adopted. The **T**-incision of Liston and a curved transverse incision across the back of the joint were also employed. All of these, however, interfere with the triceps, and have been abandoned in favour of a single long incision over the centre of the olecranon. If the parts be swollen and more room is required, this may be gained by an incision from the middle of the longitudinal wound transversely outwards over the base of the olecranon to the head of the radius (Fig. 296), and in this case the longitudinal incision had better be made more internal over the position of the ulnar nerve.

Moreau's method was strongly advocated by Syme, who regarded it as the only one by which a perfect result could be obtained. It doubtless affords ample space for the removal of the bones without bruising of the soft parts, but the value of the operation is greatly diminished by the

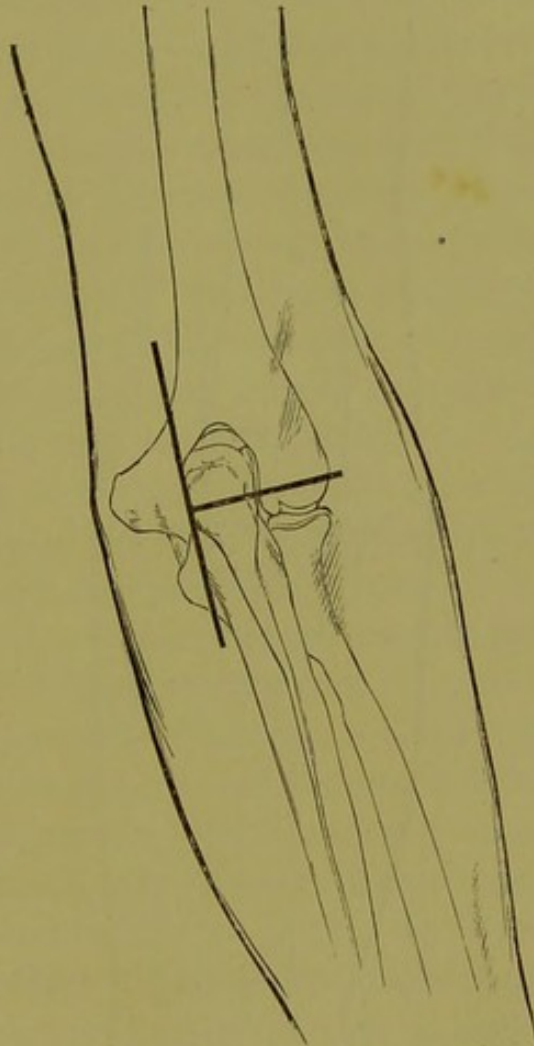


FIG. 296.—Incision in **┣** form which may be made when the parts are much swollen and additional space is required.

transverse wound through the triceps tendon. Two longitudinal incisions are first made on the back of the joint at each side, and these are joined by a transverse one immediately above the tip of the olecranon (Fig. 297). Dissect up the flaps, and cut off the olecranon; then divide the internal lateral ligament. Push the ulnar nerve over the internal condyle, free the end of the humerus, and saw it off on a level with the condyles. Lastly, remove the radius and ulna opposite the base of the coronoid process.

To take away a greater extent of bone than what is thus defined is at once, Syme urges, unnecessary and injurious, while less will hardly suffice to get rid of the disease, or even if it did, there would be the risk of ankylosis or impaired mobility.

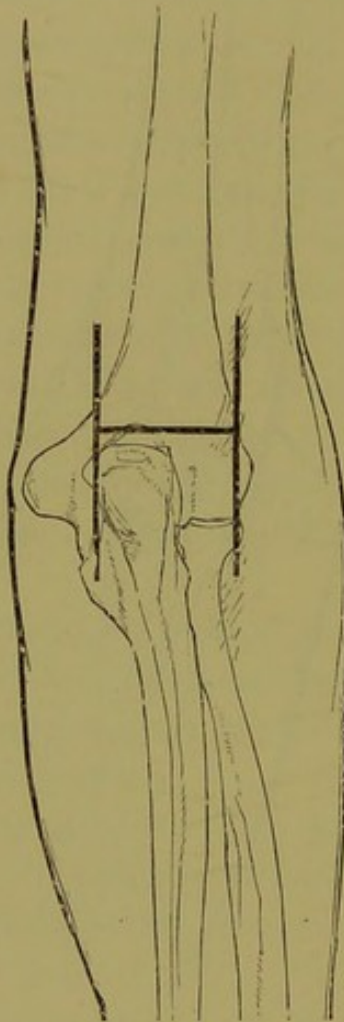


FIG. 297.—Moreau's H-shaped incision.

In cases of disease a larger amount of bone may be removed without running the risk of a loose joint than can be safely attempted in traumatic ones. In the former the sub-periosteal method is not applicable, as the synovial membrane is diseased, and must be removed. When the operation is undertaken on account of ankylosis or imperfect mobility, the consequence, for example, of an old unreduced dislocation, much difficulty may be experienced in freeing the end of the humerus, which is buried in the depth of the wound. In these cases it is sometimes

unnecessary to do more than remove the end of the humerus, leaving the bones of the forearm intact. In cases of bony ankylosis, the soft parts must be separated as before from the back of the joint, the ulna sawn through on a level with the coronoid process, and the humerus subsequently divided on a level with the condyles of the humerus—a matter of considerable difficulty from the depth at which they are placed.

Some operators—as Ollier (whose plan of operation for cases of synostosis is indicated in Fig. 298), Hueter, and Von Bruns—prefer a double lateral incision, especially in cases of ankylosis. Hueter, whose operation is a modification of that of Ollier, first makes an incision one inch long, a little to the anterior surface of the internal epicondyle. Through this he separates the internal lateral ligament, and the origins of the pronator teres, flexor carpi radialis, palmaris longus, flexor sublimis, and flexor carpi ulnaris muscles. He then makes an incision on the radial border of the joint four inches in length, whose centre is over the external condyle, and divides the external and orbicular ligaments in the long axis of the wound. The soft parts are then detached from the bones, and the head of the radius is thus at once exposed; and after the soft parts are separated from it with the knife and elevator, the neck is cut through with a keyhole-saw, and the head removed. The finger is now introduced into the joint from the ulnar side, beneath the capsule, which is thus made tense, and then divided at its attachments to the humerus in front. More room is now obtained, and the capsule is to be further divided close to its insertion into the back of the humerus from the external towards the internal condyle. The forearm being adducted, the end of the humerus projects from the wound on the radial side, and may then be sawn off. In the large gap thus left the triceps tendon may be readily separated from the olecranon, and the ulna sawn through on a level with the coronoid process. The ulnar nerve does not come into view. Hueter claimed for this method that the lateral ligaments are at once reached and divided, the triceps extension apparatus is preserved intact, and the ulnar nerve is placed beyond the reach of injury. The results as regards function are very good.

When excision of the elbow is undertaken for chronic granulation synovitis, all the granulations must be removed with a sharp spoon. Iodoform is the best after-dressing for these cases.

The after-treatment must be commenced as early as the condition of the wound permits. Usually, slight movements may be imposed in a week.

EXCISION OF THE ELBOW FOR ANCHYLOSIS OF THE JOINT.

Indications.—The indications for resection in cases of ankylosis have not been much studied. The operation was not performed till long after its adoption for disease.

An operation is admissible for ankylosis in the straight position, but whether it should be performed in cases of obtuse or right angled ankylosis cannot be so decisively answered. Much must depend on the occupation of the patient.

Many cases of ankylosis follow suppurative arthritis or acute synovitis. Fracture, unreduced luxation, acute traumatic arthritis, compound fracture, and gunshot wounds also prove causes of stiff-joint.

The ankylosis may be fibrous, inter-cartilaginous, or osseous.

The lower end of the humerus in cases of ankylosis is narrowed transversely; the condyles are less prominent. Excision may be performed in imminent as well as accomplished ankylosis.

Resection of an ankylosed elbow is especially indicated in young subjects. Below thirty years of age sub-periosteal excision of the elbow is a valuable and successful operation.

After thirty, or at all events thirty-five, the regeneration of the excised bone is less complete, and a flail-joint more likely to follow; therefore it is important in such cases to remove as little bone as possible.

Excision is considered by some as not advisable in ankylosis. Those who object to excision employ forcible flexion (*brisement forcée*), mainly to procure a more useful position. The olecranon is usually fractured. An amendment may take place in this way in the amount of usefulness, but mobility is very rarely acquired, especially if the ankylosis be the consequence of suppuration. The fibrous or osseous adhesions become reproduced with wonderful pertinacity, and the operation only succeeds in altering the position of the limb.

If the ankylosis dates from eight to ten years, the muscles will be atrophied and have lost most of their power.

Cases of unreduced luxation or of articular fracture give the best chance of mobility being regained after excision.

Anchylosis in a straight line is rare nowadays. It is more frequent at an angle of 130 to 150—the angle at which spontaneous cure usually takes place.

Operation.—In anchylosis there is either osseous union or else some mobility which may be discovered under chloroform. In the latter case the adhesions can be first broken down, and the excision afterwards performed in the ordinary way.

In the former condition the operation is much more difficult. An osteotomy with the saw or chisel must be practised to divide the bone, and this exposes the neighbouring parts to great risk of injury.

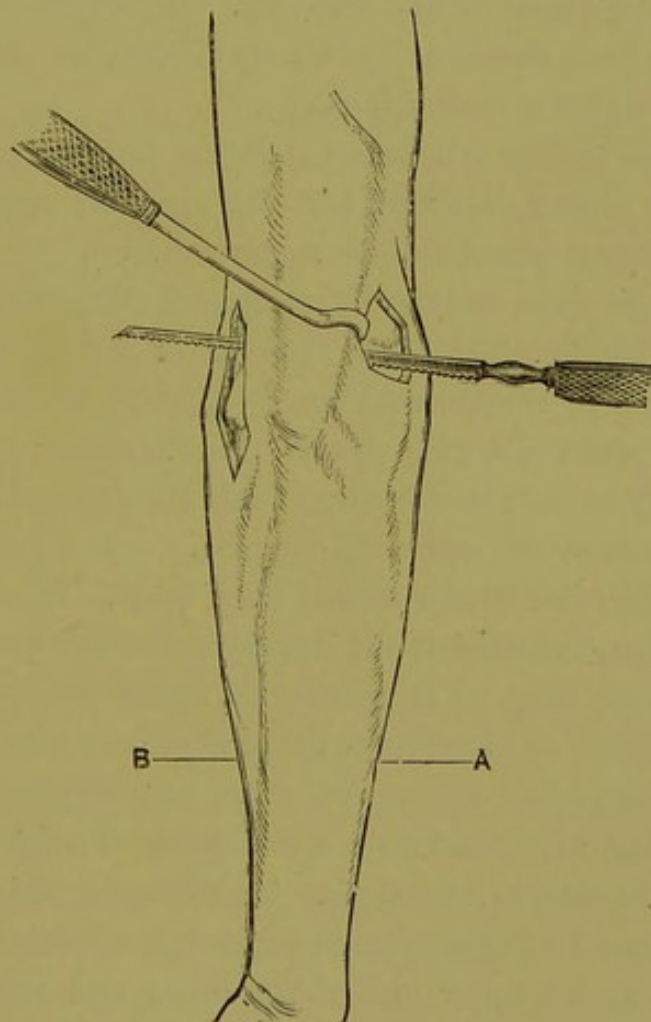


FIG. 298.—Method applicable to cases of synostosis which cannot be broken down. A. Ulnar border of the forearm. B. Radial border.

In 1867 Ollier described a method of operation for gunshot wounds of the elbow, which he also adopts for cases of ankylosis in an extended position, which cannot be broken down.

An incision is first made three inches long on the outer and back part of the joint (Fig. 298), through which the soft parts can be detached from the bone on both sides of the wound. He then makes a vertical incision on the inner side of the joint, two inches long, just inside the ulnar nerve and parallel with the inner border of the humerus.

The ulnar nerve is exposed as soon as the aponeurosis is divided, is readily retracted along with the surrounding tissues, and thus runs no further risk. After the soft parts have been fully separated on the back of the joint, a narrow-bladed saw is passed beneath the triceps, and the humerus cut through from behind forwards. In order not to injure the parts in front the bone should not be wholly divided, but only so far as the anterior lamella, which is broken through.

As soon as the section is accomplished the parts become mobile, the soft parts can be further detached, and the operation completed by the removal of a sufficient quantity of the radius and ulna.

In cases where some mobility is preserved, Ollier always prefers the bayonet-shaped incision (Fig. 299). The upper part of the bayonet incision corresponds to the external condyloid ridge of the humerus; the middle portion passes obliquely across the olecranon; the lower part runs vertically along the inner border of this process, and descends upon the posterior subcutaneous surface of the ulna.

Ollier considers this wound affords most room. It sacrifices neither muscle nor tendon, and renders the denudation of the extremities of the bones comparatively easy. The subsequent facility for drainage is good, a tube being inserted, so as to rest at the level of the epitrochlea.

Mere osteotomy of an ankylosed elbow can only serve to alter the position of the limb; it cannot make a new joint. Partial excisions must also be rejected in cases of ankylosis. To excise the end of the humerus alone will not permit of pronation or supination movements being afterwards acquired, as the upper end of the radius and ulna are soldered together. In adults about two inches in vertical depth of the bone require to be removed. The operation should not be sub-periosteal. Bony

anhylosis, affords proof of a tendency to ossific union, and there is great proneness to its repetition in the newly made joint. In children and young persons especially a fresh anhylosis is to be feared. In adults and older persons a return of the anhylosis is not to be apprehended, a

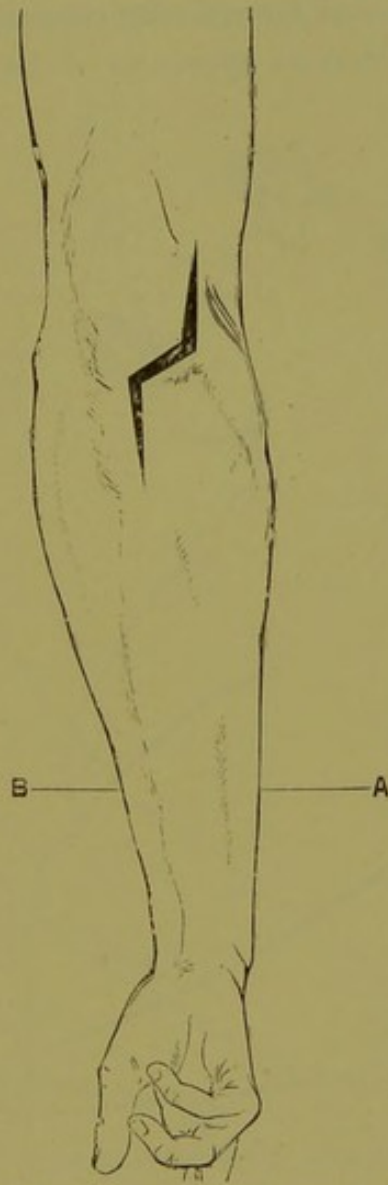


FIG. 299.—Bayonet-shaped incision for the excision of the elbow-joint where the articulation is mobile. A. Dorsal surface of the forearm. B. Palmar aspect.

flail-joint is more likely to follow. The muscles, besides, are atrophied, and the periosteum has lost its osteo-genetic properties.

Partial resections.—A great variety of opinion obtains as to whether in partial injury affecting one bone the others should be also resected. For instance, when the radius alone is injured, the difficulty occurs whether

removal of its head shall prove sufficient. Should this be deemed the case, asepsis should be secured; and, furthermore, good drainage must be provided; but, nevertheless, if great pains be not taken ankylosis will very probably ensue.

For gunshot injuries, and therefore for traumatic cases, as occurring in civil practice, partial resections appear to be desirable. One is not com-

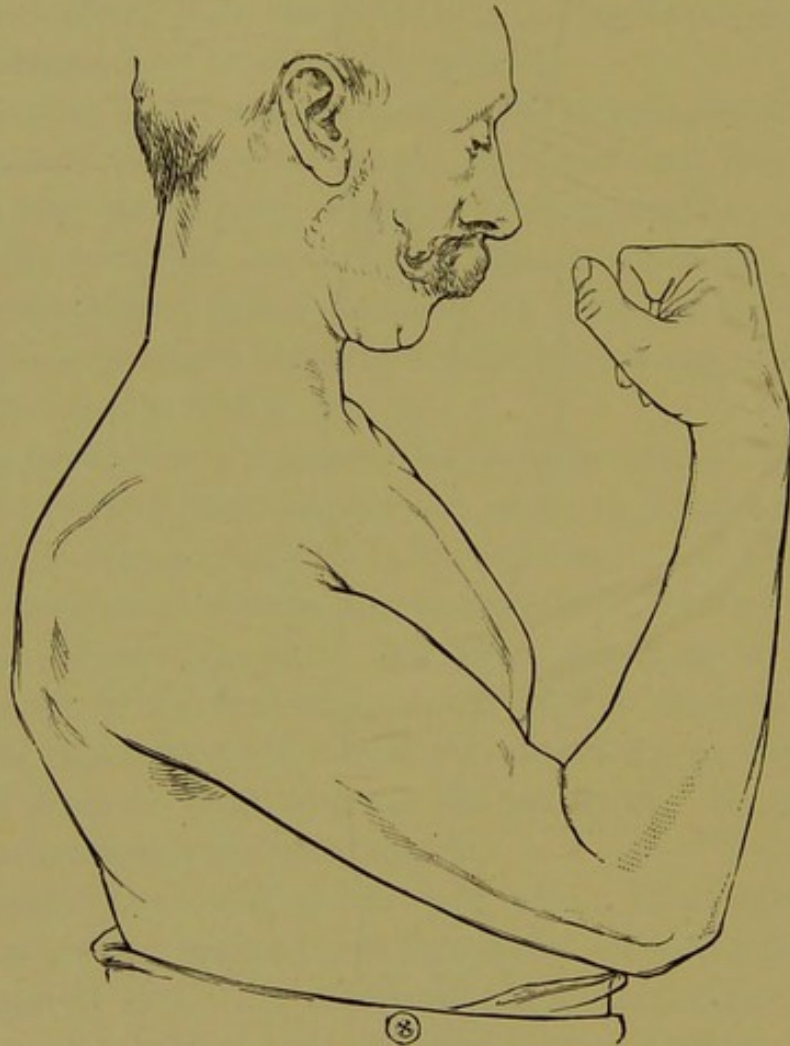


FIG. 300—Result obtained after a partial excision of the elbow for injury. The elbow is flexed to rather more than a right angle, and the forearm completely supinated. (From a photograph.)

pelled to remove all fractured pieces, and fissuring of the bone is not an indication to excise the shaft. When the humerus only is injured it may be dealt with, and the radius and ulna left alone; or, *vice versa*. I have obtained perfect movement, after partial resection of the joint, in a man who had been injured by a circular saw, which caused a vertical wound

four inches long on the back of the elbow, almost in the situation of incision made in Langenbeck's method of operation. The elbow was bent at the time, and the saw cut through the olecranon process and the condyles of the humerus. The injured portions of bone were removed, the joint carefully disinfected, and the patient, a healthy man of about

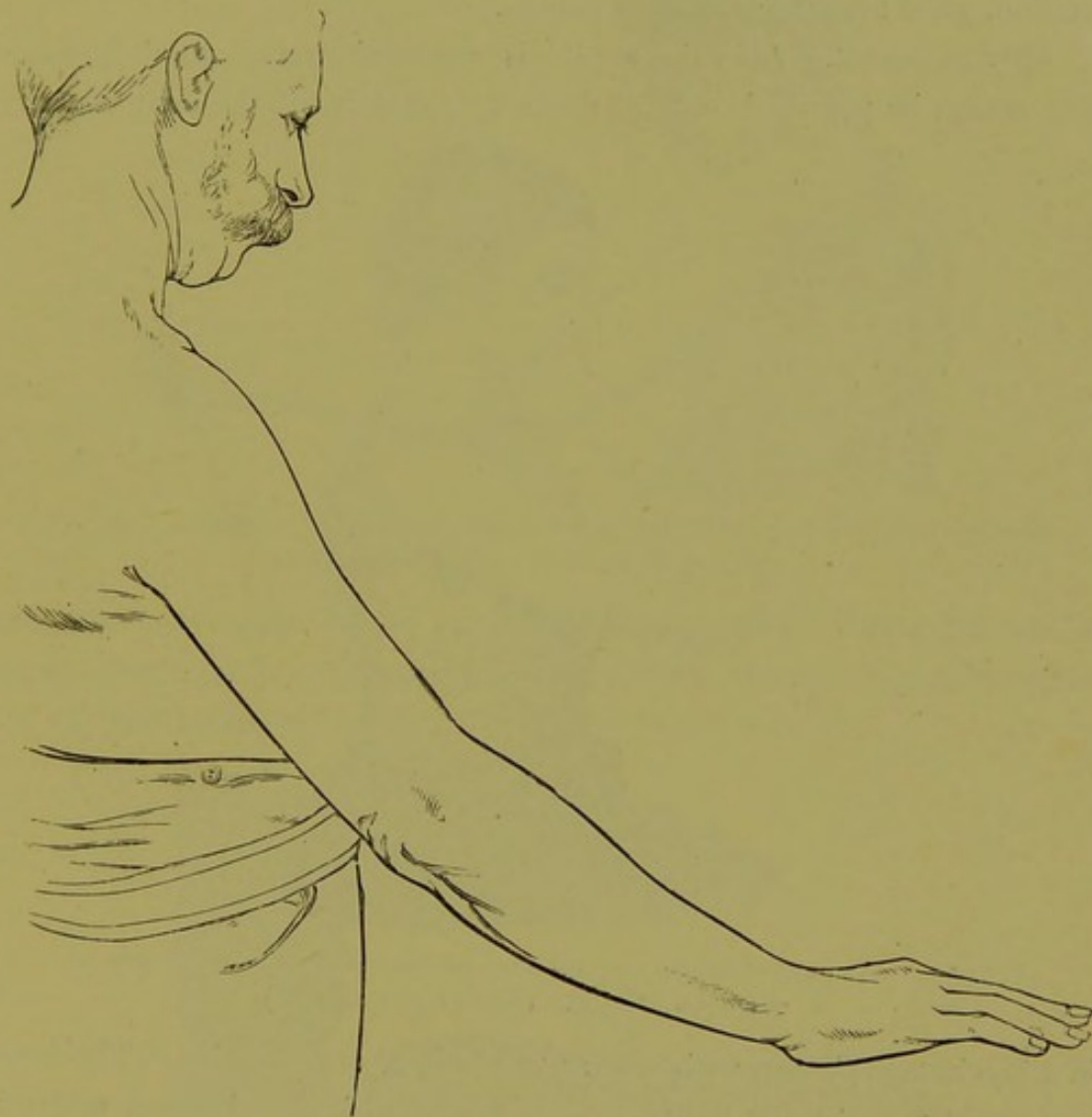

FIG. 301.—Result obtained after a partial excision of the elbow-joint, the arm is almost completely extended at the elbow, and the forearm is pronated. (From a photograph.)

thirty years of age, made a speedy recovery. The power of pronation and supination was complete, and the range of flexion and extension very nearly so, as the Figs. 300, 301 show.

It is not necessary in all cases of excision for fracture to have a smooth-

sawn surface. Loose fragments of course are to be removed, but the presence of fissures may be disregarded.

Dominick's large table of resections (1876) proves that total excision is a more dangerous operation than partial, in the proportion of 25 to 20, and that although ankylosis is of frequent occurrence after partial excision, good function also often follows.

After-treatment.—After the wound is rendered aseptic, good drainage must always be provided, suitable dressings applied, and the limb fastened

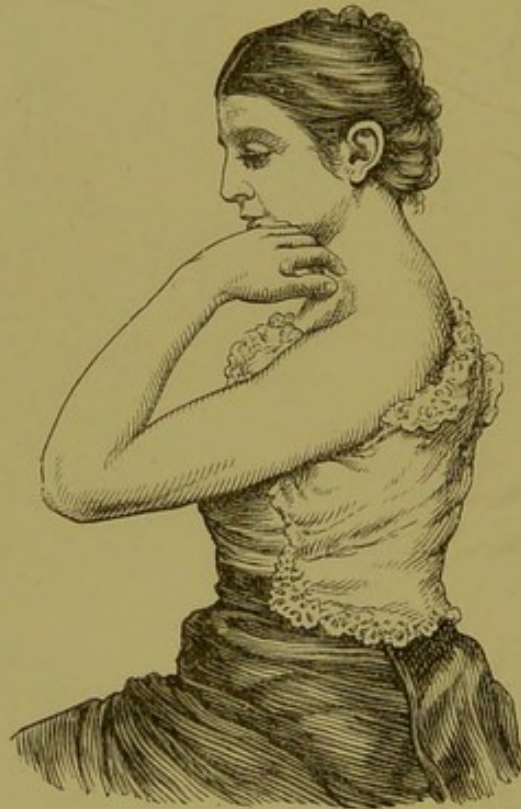

FIG. 302.—Amount of flexion realized after excision of the elbow in a case of strumous arthritis. (From a photograph.)

in a bracketed splint in such wise as to admit of easy dressing. The forearm ought at first to be but very slightly bent, and placed about midway between pronation and supination. The apparatus should be slung, to admit of movement of the patient without disturbing the limb. Esmarch has contrived a very suitable splint (see Fig. 307). In many cases it is sufficient to lay the arm on a cushion, or between sand-bags. After eight or ten days, when the wound has begun to heal, the joint should be gradually flexed and extended, as well as daily pronated and supinated. Mason's

splint permits these movements without disturbance of the dressing (Fig. 304). Care must be taken, on the one hand, to avoid ankylosis by employing a sufficient amount of movement; while, on the other hand

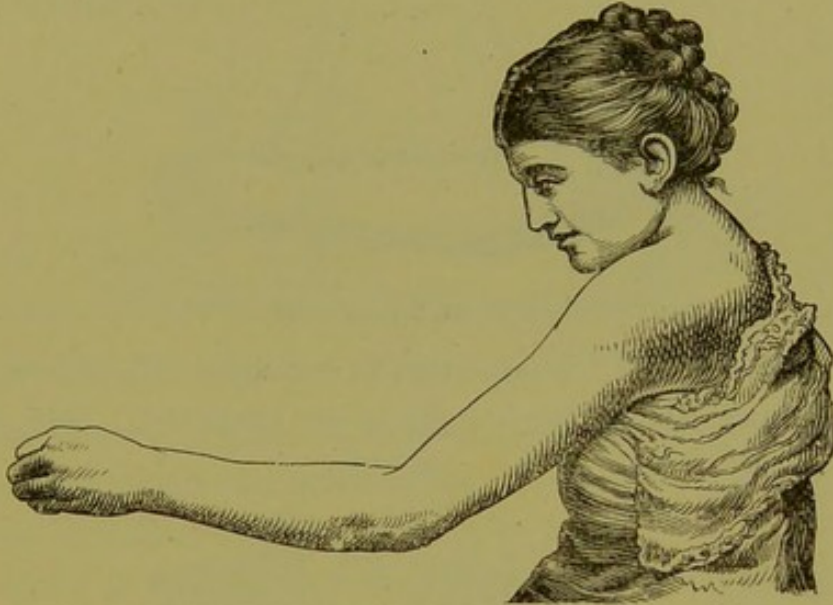


FIG. 303.—Degree of extension realized after excision of the elbow in a case of strumous arthritis. (From a photograph.)

too free movement might produce a loose joint. Later on, active movements must be encouraged. Shampooing, electricity, and douches are valuable means of restoring function in wasted muscles.

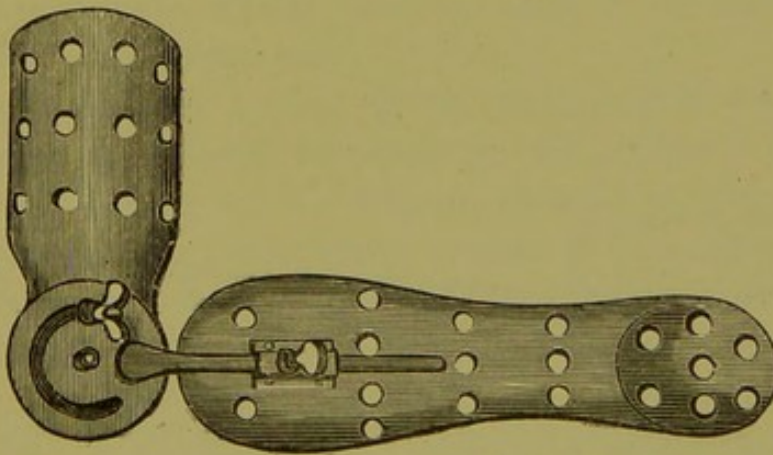


FIG. 304.—Mason's resection splint is useful during the after-treatment, as it admits of altering the degree of flexion and extension, and also the amount of pronation and supination, without removing the splint or disturbing the dressings.

Limited passive movement, controlled by the patient's sensations, may usually be commenced as soon as on the tenth day; its early employment

during the after-treatment is of great value, but it must not be begun too soon, as the healing process is interfered with, and fresh inflammation and swelling are liable to occur. Gentle, slight, and repeated movements

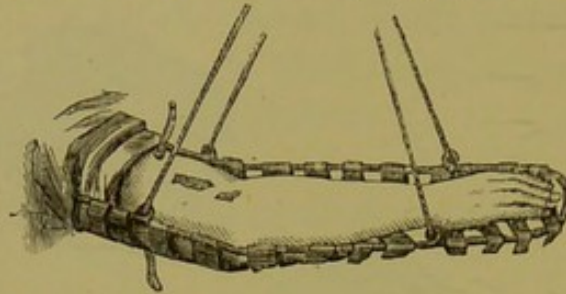


FIG. 305.—Suspension apparatus for use after excision of the elbow.

are much the best; and it is important to encourage the patient to move the elbow himself, else no force ought to be employed. Pain on move-

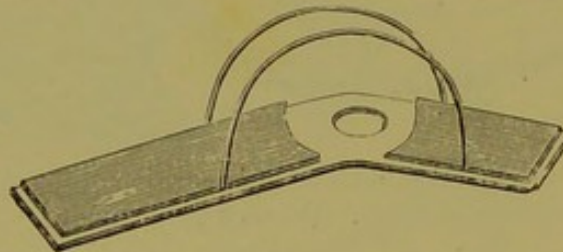


FIG. 306.—Elbow resection splint.

ment, or protracted inflammation following it, contra-indicate passive motion. In some instances osteophytic growths have been ascribed to this

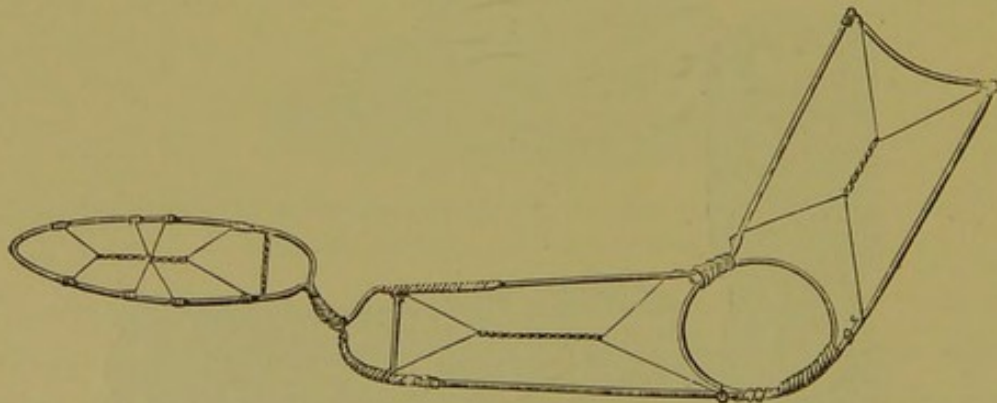


FIG. 307.—Wire splint for excision of left elbow. The supine position of the hand, which it is important to preserve, is well maintained in this splint, which is suitable for use with plaster-of-Paris bandages. (Esmarch.)

cause; and again, premature movement may be the means of producing a flail-joint.

The position during the after-treatment is important.

Place the limb at first in an apparatus in which it is bent but slightly, about an angle of 100 or 130, and by degrees alter it to a right angle, but only after four or five weeks. This will avoid the risk of displacement of the forearm backwards.

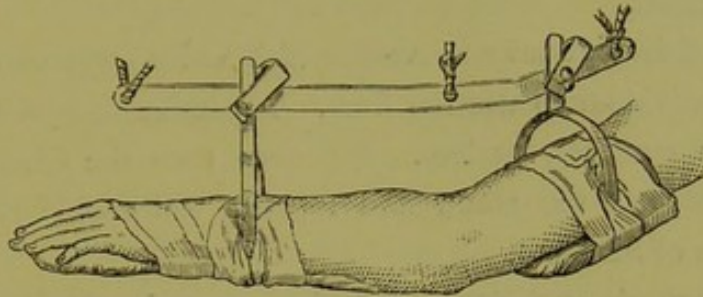


FIG. 308.—Suspension apparatus with interrupted splint.

Results of the operation.—The difficulty of obtaining trustworthy data as to the value of the results following excision of the elbow applies to civil as well as military practice.

The results in favourable cases are exceedingly good, and in some the restored function is all but perfect, in others more or less perfect mobility may be attained. In others, again, ankylosis will follow. Even in these a re-excision may sometimes be done, and a good result take place; or the limb can be fixed in the position most useful afterwards to the patient. If ankylosis be the object in view, almost at a right angle will generally be the best position. Finally, there are cases of complete failure, in which it is necessary to amputate.

After gunshot injury in time of war, excision gives less favourable results than when performed for trauma in civil practice. The very insufficient after-treatment, and the frequent presence of additional injury either to the muscles or nerves, mainly account for the difference. It is difficult to compare the results obtained during war and in civil practice, since in the statistics of the latter all kinds of resection, both for trauma and disease, are grouped together, and of the former there are comparatively few. The mortality varies from 10 to 20 per cent., according to circumstances. It has been generally greatest in the French armies.

After primary excision for injury, a flail-joint—that is, a weak joint with excessive mobility—may follow, and the limb be comparatively useless.

There are two kinds of flail-joints: an active flail-joint, one in which

the muscles are strong and exercise control; and a passive flail-joint, where the muscles are wasted and the hand only can be used. When there has been an injury of the ulnar nerve, long-continued disease, or some obscure interference with nutrition, the latter condition may readily come about.

An active flail-joint may be very useful, and a support to the elbow enables the individual to use the limb. A passive flail-joint with wasted muscles is comparatively useless. But even then the employment of a fixation apparatus to the elbow and forearm will enable the patient to make good use of his hand.

To such a result ankylosis at a right angle is of course far preferable.

Ankylosis is most frequent, and a flail-joint least so, after partial excisions of the elbow.

Most of the flail-joints follow the extensive removal of the lower end of the humerus, in cases of injury more especially. It is of much importance, in respect of future power of movement, to interfere as little as practicable with the condyles of the humerus and the muscular attachments connected with them. In operations performed for traumatic trouble we cannot, as a rule, be too conservative; but, on the other hand, we commit a fault by being very conservative when the operation is necessitated by disease.

According to Hannover, out of 15 gunshot resections, 14 were weak and useless joints; and Löffler states that 71 per cent. of those performed during the campaign of 1864 were flails.

Dominick relates that in 263 cases where the results were accurately observed after the Franco-German war—in 28 cases (10·6 per cent.) there was good active motion and a more or less useful hand; in 129 cases (49 per cent.) ankylosis took place, and in 31 of these cases with a useless hand; in 24 cases there was an active flail, with a more or less useful hand; in 41 cases passive flail-joint, with a useless extremity.

The total number of flail-joints was 65, or 24·4 per cent.; and in six cases there was incomplete ankylosis with a useless hand.

Faulty after-treatment, imperfect reproduction of the bone after extensive loss of substance, an unfavourable position of the bones,

or the muscles losing their points of attachment, are amongst the principal causes.

Paralysis from injury to the ulnar or median nerves by the bullet or surgeon's knife, or by their implication in the cicatrix, with long-continued inactivity of limb, are perhaps the most common of all causes.

The sub-periosteal method affords the safest means of guarding against the occurrence of a flail-joint; and a careful after-treatment is also imperative.

Anchylolysis, if inevitable, had perhaps best take place at an angle of 80 degrees. It is the position most generally useful. Some occupations demand special exception; as in some the rectangular, in others the fully extended position, suits best.

In successful cases the future function and usefulness of the limb, after resection of the elbow, is superior to that obtained in any other joint.

Preservation of both form and function are possible; but in other instances the result varies from this to a most useless condition of the joint and limb.

We may classify the degree of usefulness:

1. Good active movement.
2. Restricted movement.
3. Anchylolysis, fibrous or bony.
4. Flail-joint.
5. Useless limb with or without nerve injury.

Billroth considers that the best average result obtained is when the range of joint motion amounts to one-third the normal power of flexion and extension. The result present six or eight months after operation will remain permanent. In my experience the tendency is rather to anchylolysis than to an increased mobility—at least after cases excised for disease. The converse may be true in traumatic cases.

EXCISION OF THE SHOULDER-JOINT.

Some of the earlier operations recorded as excisions of the shoulder-joint were in reality performed for epiphysitis, the head of the bone being found loose in an abscess cavity, with more or less necrosis of the upper end of the shaft. Of this nature was Thomas's case in 1740, and that of

C. White, of Manchester, in 1769. At a later period the joint was more often excised for compound dislocation and fracture, as also for ankylosis, than it was for disease.

The operation is frequently incomplete in this joint, even more so than in the hip; the glenoid surface of the scapula not being removed. Moreau in 1786 appears to have performed the first complete excision: he removed the glenoid cavity as well as the head.

A prolonged discussion at one time took place as to the comparative safety of disarticulation as contrasted with resection of the shoulder-joint. Velpeau thought the latter as dangerous, and Marjolin yet more so than disarticulation at the shoulder-joint. Sédillot, on the other hand, places disarticulation first in respect of danger to life in the treatment of injuries of the shoulder; conservative treatment comes second, and resection third. Resection, however, in itself, and especially for cases of disease, is an operation attended with comparatively little risk. Primary excision for injury is a serious operation, and entails greater danger to life than does secondary.

Indications.—Excision of the upper end of the humerus is very seldom required for tumours. Possibly a myeloid sarcoma might indicate the operation, but disarticulation is usually demanded in such cases.

For chronic inflammation, suppuration, and tubercular caries resection is perhaps most frequently performed. For caries the results of the operation are not so satisfactory as for injury. Sinuses generally persist, and the disease often relapses.

In caries the diseased process is often shortened by resection, and a movable joint obtained where otherwise ankylosis would have taken place, even if a cure had ensued. A suspicion of tubercle should hasten the operation.

For simple punctured or incised wounds of the joint excision is not indicated until conservative treatment has failed. After severer injury, or when extensive suppuration occurs, the removal of the head facilitates drainage. Conservative treatment followed by secondary excision will often preserve a useful limb in cases of seriously injured joints, even after extensive suppuration has occurred.

For gunshot wounds, resection should be generally performed as a

secondary operation. We can seldom tell the extent of the bone injury at the first examination, and many cases do quite well under conservative treatment.

Extensive injury to the shoulder by gunshot fracture, however, usually indicates primary resection in every instance. The results in military surgery have been very good.

Smashing of the bone and carrying away of the soft parts do not necessarily indicate disarticulation, but rather an expectant treatment and recourse to operation when necessary.

Stromeyer considered that injury to the bone, with an opening into the joint, indicates resection, and is a chief means of preventing septic suppuration. He therefore advised primary excision.

Langenbeck believed that in the slighter cases of gunshot injury of the shoulder conservative treatment is justifiable in the first instance, although secondary resection may often be needed; this he also preferred to primary, on account of the better functional results obtained.

Compound dislocation, suppuration, arthritis deformans, ankylosis, old-standing unreduced dislocations, may indicate a necessity for excision of the shoulder-joint.

It is proper to excise in cases of old dislocation where the limb is comparatively useless, and as soon as serious symptoms of pressure on the nerves appear. Pressure of the displaced head on the cords of the brachial plexus may occasion great suffering, and the arm becomes atrophic and useless. Excision may also be resorted to in ankylosis of the bones. The object in all cases is to realize if possible a useful joint.

It is often difficult to decide the question as to the propriety of the excision of an ankylosed joint. It depends on the circumstances of the particular case, the degree of usefulness of the limb which the patient already enjoys, and his occupation. The operation is of necessity difficult, and should not be lightly undertaken, the more so as the increased mobility of the scapula largely compensates for the absent movement of the shoulder-joint.

The prospect of obtaining a mobile joint is always an important question to determine in deciding on the propriety of resection of the shoulder.

Surgical anatomy.—The shoulder possesses most extensive mobility, dependent on its loose capsule and the numerous muscles which surround it.

The coracoid and acromion processes with the coraco-acromial ligament, control the upward movement of the head. When the arm rests at the side only one-third of the head of the bone is in contact with the glenoid cavity, and three-fourths of its thickness are in front of a vertical line drawn downwards from the tip of the acromion process.

The large sub-acromial bursa is often distended, and this may simulate joint disease.

In the supine position of the forearm, with the arm hanging by the side, the lesser tuberosity and the bicipital groove present directly in front of the joint.

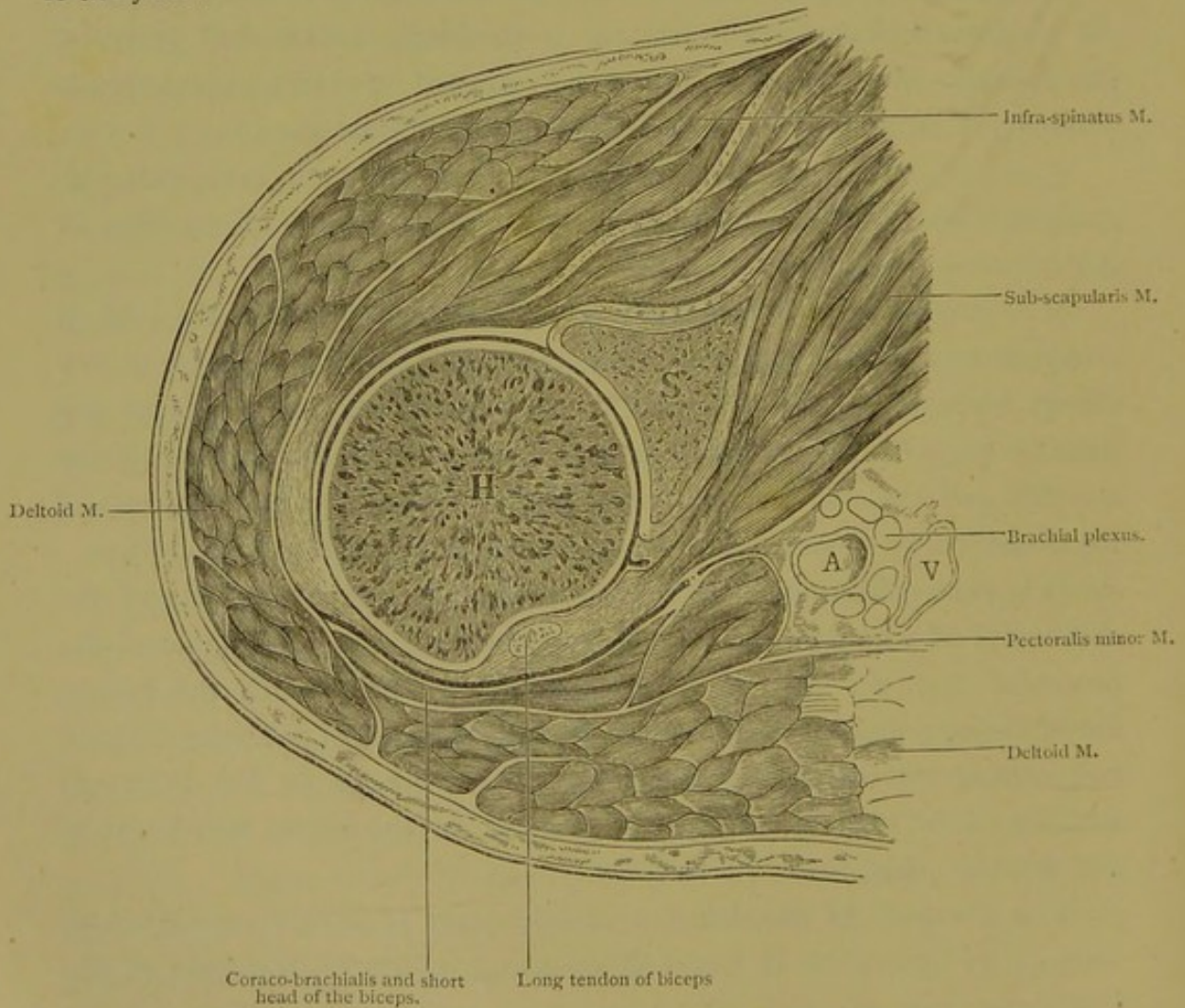


FIG. 309.—Horizontal section through the shoulder-joint at the level of the greater tuberosity.

The capsular muscles (supra-spinatus, infra-spinatus, teres minor and sub-scapularis) are inserted into the tuberosities close to the attachment of the capsular ligament to the anatomical neck of the humerus, and beneath the sub-scapularis tendon is a bursa that very frequently communicates with the cavity of the joint. The infra-spinatus also has a bursa beneath its tendon, but in this case the communication with the joint is less constant. The long tendon of the biceps is surrounded by a sheath of synovial membrane as it passes through the joint, and the synovial membrane lining the articulation is prolonged down for a short distance along the floor of the bicipital groove. Through one or more of these diverticula fluid or pus in the joint is liable to point. Also at the position where each of the other two capsular muscles cross the capsule its fibres are thin, and in advanced cases of suppuration pus sometimes makes its way along one of the muscles into the supra-spinous fossa, infra-spinous fossa, or axilla.

Pus may extend to the termination of the bicipital groove and there find an exit, or find its way from the sub-scapular cul-de-sac into the venter of the scapula and point at the lower and posterior part of the axilla.

Suppuration beneath the deltoid usually points anteriorly.

Operation.—In performing the operation White made a single longitudinal incision similar to that now generally adopted (Fig. 311). Moreau preferred a square-shaped flap (Fig. 310), formed by one incision in front of the articulation, and the other behind, united above by one transversely dividing the deltoid muscle a few lines below the acromion. Other methods have been also carried out: a **V**, **T**, or **L**-shaped wound has been recommended, or a large external flap turned up, as it is in amputation.

The operation may best be performed by a long anterior incision (Fig. 311), but in some few instances a posterior one may be preferable (Fig. 312), especially if the scapula be diseased. In no articulation is the preservation of the joint muscles, and their attachments so important. The operation must, if possible, be sub-periosteal and sub-capsular, so that after the removal of the head the empty capsule shall retain its connections with the surrounding structures.

Where it is not so important to preserve the muscular insertions and capsule, as in some cases of ankylosis, Moreau's plan of operation may be adopted. The two vertical incisions are first made right down to the

bone, as shown in Fig. 310, and their upper extremities afterwards united by an incision made transversely just below the tip of the

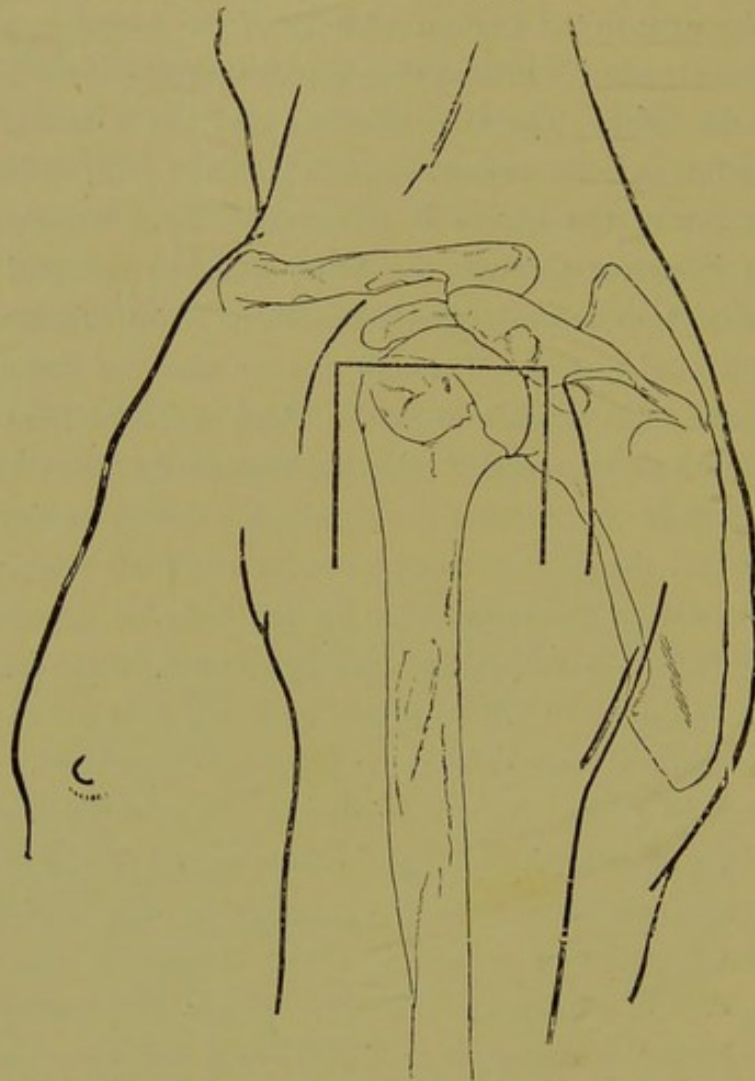


FIG. 310.—Method of excising the shoulder-joint, adopted by Moreau.

acromion. The first vertical cut is to be made from the mid-point between the acromion and the coracoid process downwards for two and a half or three inches, the arm, if possible, being rotated outwards. The second is made behind the joint while the arm is rotated inwards. The third joins the upper extremities of the incision first made as before stated. In cases where mobility exists, thoroughly divide the remains of the capsule, and then the head may be dislocated and the posterior part of the capsule divided afterwards. If the ankylosis be bony, there is ample space for the use of a small saw, or the bone may be divided by a chisel.

The sub-periosteal method of excision may be regarded as the normal one in all traumatic cases. When disease chiefly or entirely affects the bone it is also applicable, but the method cannot be carried out in chronic caries with fungoid granulations.

Operation by anterior incision.—The patient having been placed on the operating table, and an anæsthetic administered, the arm should rest in the ordinary supine position, with the external condyle pointing directly outwards. In this position the bicipital groove will be directly anterior and just beneath the line of the wound. Make a vertical incision about four inches long, which should begin above, immediately over the acromio-

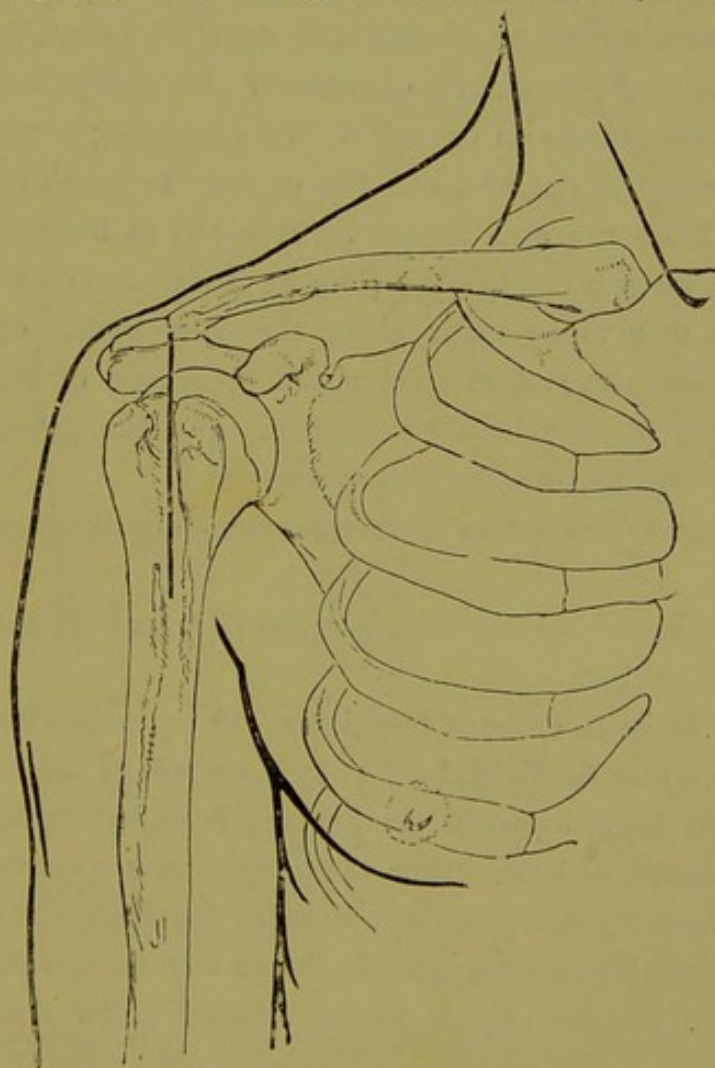


FIG. 311.—Method of resection by a single straight anterior incision.

clavicular joint (Fig. 311) ; divide the skin, subcutaneous tissue, and fibres of the deltoid muscle down to the capsule of the joint. This incision will

expose the biceps tendon in the bicipital groove, which will at once be recognized when the margins of the wound are drawn asunder.

When the head, together with the tuberosities, as is usually the case, require removal, cut down to the bone, along the internal margin of the bicipital groove, and divide the periosteum vertically; continue this incision upwards into the joint, and divide the capsule thoroughly with a probe-pointed knife, cutting from within upwards and outwards, then elevate the periosteum and soft parts on the inner side by pressing the elevator inwards below the lesser tuberosity, while the arm is being gradually rotated outwards by an assistant. From the tuberosity itself the attachment of the muscle must be divided with a scalpel by cutting close to the bone, so that it may preserve its connection with the periosteum on one side and the joint capsule on the other. By continuing to rotate outwards the axillary surface is reached, and the capsule thoroughly separated on this aspect. Then the arm should be replaced in the first position, the biceps tendon, when present, lifted from its groove and displaced inwards. An incision is now to be made along the outer border of the bicipital groove, the periosteum and muscles raised by means of the scalpel and elevator, in the manner before described, from the greater tuberosity. The head may now be turned out and sawn off.

This method of operation possesses some disadvantages as well as advantages.

The deltoid is divided where its integrity in regard of subsequent function may be important.

When the incision extends low down, the cutaneous branches of the circumflex nerve may be divided where they are still of large size.

The incision being anterior, the drainage is imperfect, but a drainage-tube may be passed out behind from the deepest part of the wound through a button-hole opening made at the border of the latissimus dorsi muscle. Indeed, it is advisable in most cases to have a counter-opening.

If the bone do not require to be divided below the tuberosities, these disadvantages may be avoided by having the incision for its removal on the posterior aspect of joint (Fig. 312). The patient must be placed on the sound side, the arm flexed at the elbow, somewhat abducted and rotated outwards, so that the external condyle looks backwards. This brings the

middle of the great tuberosity into the line of the wound. A vertical incision is then made downwards for about four inches from the prominent angular projection so plainly felt on the inferior margin of the acromion.

The posterior part of the deltoid is divided, and the knife sunk at once into the capsule beneath the acromion.

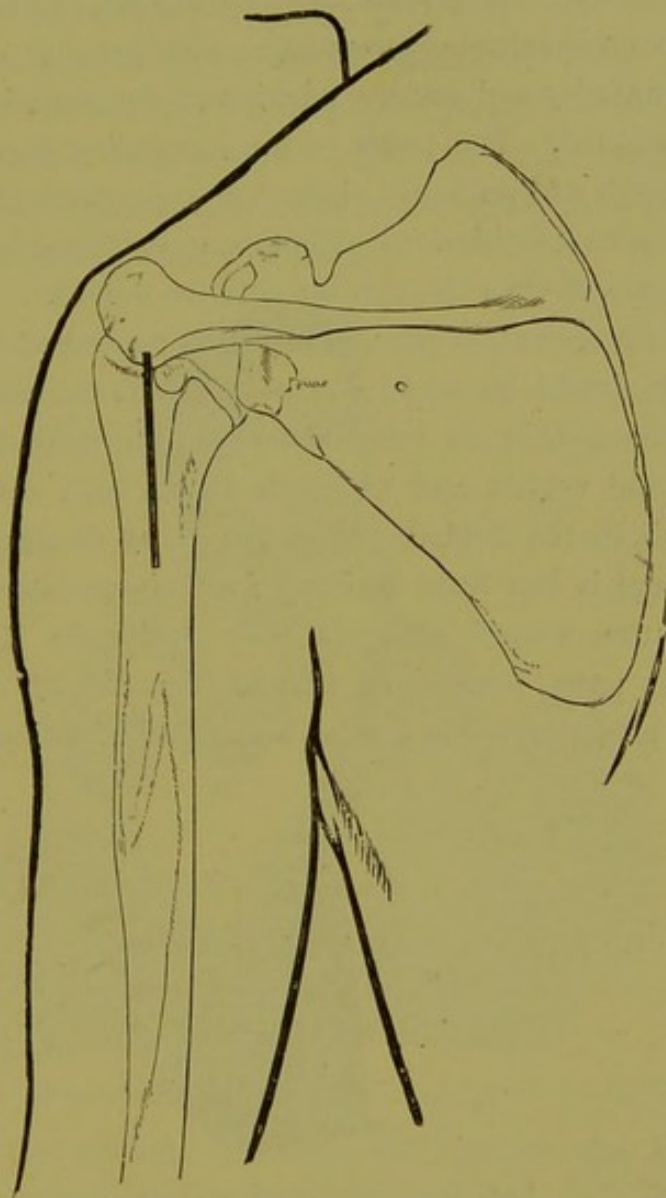


FIG. 312.—Position of the posterior incision made for resection of the shoulder.

The great tuberosity and the bicipital groove just in front of it may now be brought within the area of the wound, and the muscles attached to the tuberosity can be separated.

The rotation outwards of the arm being continued, the elevator is used to raise the periosteum and capsule till the bicapital groove is reached, when the biceps tendon is dislodged. Then the arm must be strongly rotated inwards, and the subscapularis muscle at its insertion will come into view. This is separated in a similar manner from the lesser tuberosity. The head may now be made to project from the wound, and by rotating alternately outwards or inwards any remaining soft parts or capsule may be divided on the anterior and axillary margins of the wound, the head fully luxated and removed. The trunk of the circumflex nerve will in this case be cut through and no active abduction can afterwards be expected. Through the posterior incision the glenoid cavity, if need be, can be much more readily removed than through the anterior wound.

Maisonneuve proposed, in cases of resection performed for old luxation, that the incision should be made downwards from the external margin of the coracoid process or in the interval between the deltoid and pectoralis major muscles, the vessels and nerves, being in such cases pushed considerably inwards by the displaced head, are out of danger.

As a rule there is but little bleeding: a drainage-tube is inserted, and the edges of the wound sutured. The antiseptic dressing usually immobilizes the parts sufficiently without the aid of a splint. The forearm should be supported in a sling, and a pad of salicylic wool placed in the axilla.

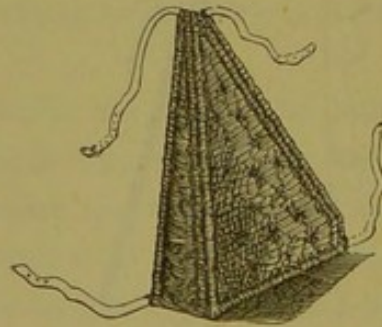


FIG. 313.—Stromeier's cushion.

Stromeier's cushion (Fig. 313) also forms a very comfortable and adequate support for the arm, and in a short time the patient will be able to get about with the forearm supported in a sling. The after-treatment should be begun as early as the condition of the wound shall permit. It

consists in passive movements, and subsequently, so soon as possible, active motion should be encouraged. Electricity and massage are of great service when the wound is healed sufficiently to admit of their application.

Results.—The method of operating has much influence in producing bad or good results, and also the care with which the after-treatment is carried out by massage, douches, electricity, and otherwise.

The sub-periosteal method is of great advantage in this operation. The periosteum presents a barrier which shuts off the intermuscular septa of cellular tissue, and diffuse suppuration is less likely to occur. The bone also is reproduced much more completely.

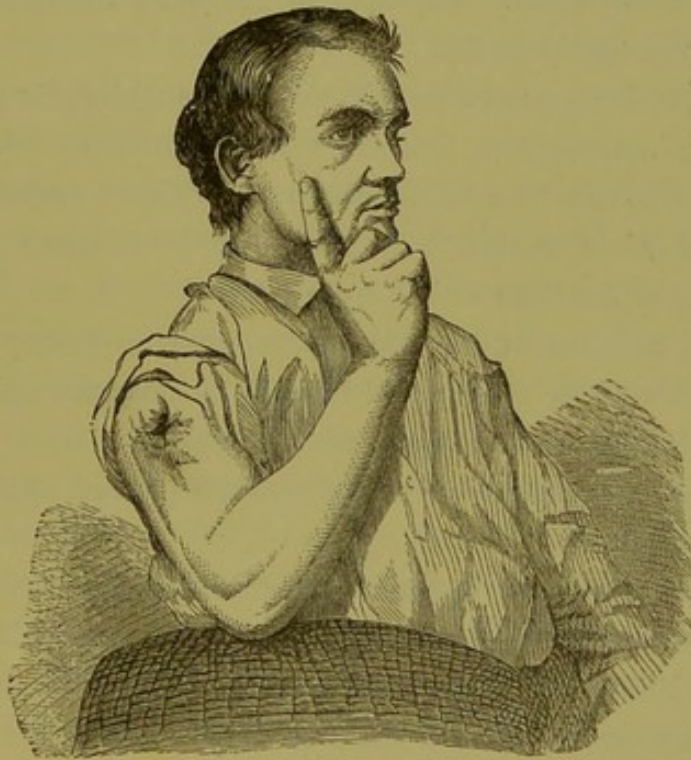

FIG. 314.—Result after excision of the shoulder for gunshot injury.

As regards the amount of subsequent function, the single anterior incision and the subperiosteal method favour the realization of best results.

The capsular muscles are not divided, and their integrity exercises a material influence on the amount of future function. After the bone has been removed a cylinder of periosteum remains, connected everywhere with the capsule, as also with the glenoid cavity and the insertion of the capsular muscles. The latter, therefore, do not retract, and the cut

extremity of the bone is less likely to be drawn inwards by the thoracic muscles to a position beneath the coracoid process.

In other methods the extremity of the resected humerus is apt to take up the position occupied by the head in a sub-coracoid dislocation ; the supra- and infra-spinatus and teres minor muscles being cut across, allowing the great pectoral and latissimus dorsi muscles to pull the humerus inwards.

Von Bergmann thinks that after resection of the shoulder the neck of the scapula glides forwards and outwards, and that its inferior angle approaches the spine.

Anchylolysis, or stiff joint, more frequently results after excision of the shoulder than a flail-joint. In cases of flail-joint the forearm and hand may be made thoroughly useful.

It has not yet been ascertained in cases of excision for gunshot injury what amount of subsequent function can be realized. We do not know how often the arm can be actively abducted without scapular movement, how often anchylolysis occurs, how often flail-joint, much less how often general atrophy of the limb with a useless arm.

Hannover's account of the subsequent results is very unfavourable. Out of fifteen cases only three could be said to have any use of the arm. In the remainder there was atrophy of the limb.

The highest degree of success is where the patient can raise his arm to the horizontal level.

Langenbeck relates an instance of excision of the shoulder in which subsequent necrosis of the humerus occurred ; the diaphysis was extracted, and finally excision of the elbow performed, with a residuary useful arm. In a somewhat similar case I performed excision of the shoulder- and elbow-joints in the right arm for gunshot injury. The shaft of the humerus here also became necrosed and was subsequently removed. But the reproduction of new bone was so complete that a wonderfully good and most useful arm was the result.—*Med.-Chir. Trans.*, vol. lv.

EXCISION OF THE SCAPULA.

This operation appears to have been first performed by Cumming in 1808 ; he was followed by Liston, who removed nearly the entire bone in

1819. Luke, in 1828, removed all the vertebral portion, preserving the glenoid cavity and acromion process. Since that date the operation has been frequently performed, and has become an established operation in surgery.

Indications.—Caries, necrosis and tumours of the bone.

Surgical anatomy.—The scapula articulates with the humerus and clavicle, and also with the side and back of the thorax. The articulation with the clavicle practically exists in the conoid and trapezoid ligaments, the acromio-clavicular articulation being a subsidiary connection. By means of the coraco-clavicular ligaments, the scapula receives support and is capable of performing certain movements, as, for instance, those belonging to animals provided with a bony communication between the shoulder girdle and the hæmal spines. The preservation of the coracoid process and glenoid cavity, where it is practicable, materially adds therefore to the future utility of the limb.

The articulation between the bone and the chest walls consists of two distinct inter-muscular spaces. That between the surface of the subscapularis and the serratus magnus is well marked, very extensive, and permits of the rotatory movement of the scapula. The antero-posterior movements are performed in the space between the serratus magnus and the ribs and external intercostal muscles. This kind of joint is known as a *syssarcosis*, and is (as its name implies) formed entirely of muscles. The scapula is connected with the following muscles, which will all require to be divided when the entire scapula is removed—at its vertebral border with the levator anguli scapulæ, rhomboidei major and minor, and serratus magnus. To the spine is attached the trapezius and deltoid, and on the superior border is the omohyoid, on the anterior surface is the subscapularis, and behind the spinati and teres muscles; to its axillary border the teres muscles and the long head of the triceps, and to the margin of the glenoid cavity the long head of the biceps are attached. Finally, in front, to the coracoid process are attached the pectoralis minor, coraco-brachialis, and biceps muscles. The latissimus dorsi is occasionally attached to the inferior angle.

The bone is surrounded by a complete vascular network. At its upper border is the supra-scapular artery, and close to its coracoid process

runs the subclavian artery, about to become axillary. Along the axillary border runs the sub-scapular artery, and the posterior scapular vessels follow the line of its vertebral border or base. The branches of these four vessels form numerous inosculations in the fossæ and at the angles.

Operation.—The operation for removal of the entire bone may be thus described. The incisions necessary are one carried along the vertebral

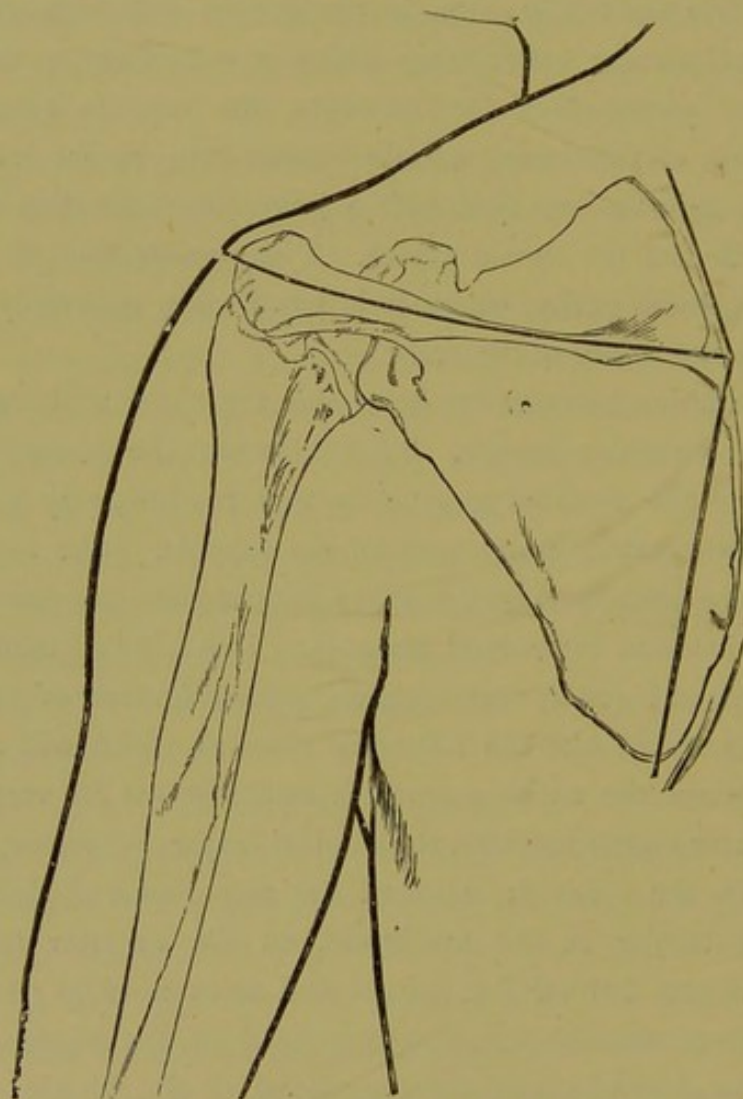


FIG. 315.—Incisions for removal of the scapula.

border from the superior to the inferior angle of the bone, and another carried along the spine from the tip of the acromion process till it meets the first (see Fig. 315). The upper flap is now dissected up, having first separated the insertion of the trapezius from the upper border of the spine.

Then the lower flap is likewise separated, cutting away the deltoid from the acromion and spine. The acromio-clavicular articulation is now opened, and the conoid and trapezoid ligaments divided from behind, taking care to keep the edge of the knife closely applied to the under surface of the clavicle. One of two courses is now open to the surgeon, either to dissect the muscles from the axillary border and find the subscapular artery with the object of tying it, or, preferably, to detach the muscles from the vertebral border; draw the scapula away from the ribs, turn its inferior angle forwards, and then detach the biceps, coraco-brachialis and pectoralis minor from the coracoid process. Finally, divide the capsular muscles and capsule of the shoulder-joint and dissect out the axillary border, when, by keeping close to the bone, we may divide the subscapular and dorsalis scapulæ arteries in the final step of the operation, just before the bone is removed. The subscapular artery should always be divided last, and can usually be compressed in the soft parts by the fingers of an assistant before it is cut through. The hæmorrhage is usually profuse. The vertical incision may be extended to the clavicle, and so give space for an assistant to control the subclavian artery by direct pressure with his fingers. When the large vessels are cut last, and the others picked up with clamp forceps as they are divided, much of the alarming hæmorrhage may be avoided.

Division of the clavicle with a small saw just internal to the conoid ligament increases the facility with which the later steps of the operation may be completed, for then time is not lost in detaching the outer extremity of the clavicle from its connections with the scapula.

The superior branch of incision may be extended so as to expose the clavicle where it can be conveniently sawn through.

In the case of removal for tumours, many of the muscles are spread out over the surface of the growth and should be taken away with it.

EXCISION OF CLAVICLE.

Indications.—Necrosis, caries, and tumour.

Surgical anatomy.—The clavicle is that portion of the shoulder girdle that articulates with the hæmal spines and is not a true bone, inasmuch as it is developed entirely distinct from the skeleton proper. It gives attach-

ment to the following muscles: in front, the pectoralis major and deltoid; behind and above the trapezius, sterno-cleido-mastoid, sterno-hyoid, and sometimes sterno-thyroid, and passing beneath it in its long axis is the subclavius muscle.

The ligaments attached to it are: to the sternal end, the inter-clavicular, anterior and posterior sterno-clavicular, the inter-articular fibro-cartilage, and the rhomboid. To the shaft: costo-coraco-clavicular membrane, conoid and trapezoid ligaments, and to the acromial end a capsular ligament uniting it to the acromion process, and sometimes spoken of as anterior, posterior, superior, and inferior acromio-clavicular ligaments.

Beneath its centre pass the subclavian vessels, and along its posterior border lies the transversalis humeri artery and vein. On the right side its sternal end is in close apposition with the innominate artery, where it divides into common carotid and subclavian, and the pleura is near to the sternal ends of both bones.

It is connected with the scapula by means of the conoid and trapezoid ligaments, which attach it to the coracoid process, and by means of a weak set of fibres its extremity articulates with the acromion process. This latter joint has sometimes a double synovial sac, with a more or less perfect inter-articular cartilage.

Its articulation with the manubrium sterni is more complicated, and is the centre for all the movements of the shoulder girdle. It consists of two separate joints, divided by an inter-articular fibro-cartilage. That between the manubrium sterni, together with a portion of the cartilage of the first rib and the inter-articular cartilage, allows of antero-posterior movements of the shoulder girdle and clavicle, and that between the clavicle and inter-articular cartilage allows of vertical movements of the shoulder girdle and clavicle, and the combination of the two permits of rotatory movements.

Operation.—The first complete excision was performed by McCreary, of Kentucky, in 1811. Similar operations have been since frequently followed by success. An incision is carried along the bone from the acromial end to the manubrium sterni. In cases of tumour, this incision may have to be increased in length, or by others suitably placed. When the bone is sufficiently cleared to pass a chain-saw around, it should be divided in the middle or at one end, as this facilitates the further steps of

the operation. The sternal portion is seized by a strong-forceps and carefully dissected out, taking care to keep the knife close to the bone, especially at its articular extremity, where it dips deeply backwards and downwards in close proximity to the pleura. The bleeding vessels must be tied as they are cut. The acromial end is now dissected out in a similar manner, after dividing the coraco-clavicular ligaments.

The hæmorrhage in this operation is frequently severe, and may require the application of a large number of ligatures to control it, and the operation is often a prolonged one, especially in the case of tumours, for which as a rule it may become necessary.

In cases of necrosis of the bone, the removal of the sequestrum is a comparatively simple matter, but when the bone is excised for tumours, it may have to be removed in one piece, and this necessitates a prolonged and careful dissection.

STERNO-CLAVICULAR JOINT.

Indications.—Necrosis of the sternal end of the clavicle, and joint disease. A portion of the sternal end of the bone has also been excised in a case of pathological dislocation backwards, due to spinal curvature, where troublesome pressure-symptoms existed.

Operation.—The joint may be exposed by an incision in the line of the clavicle, extra room being gained, if necessary, by an upward or downward incision from the centre of the joint. The proximity of the great vessels and pleura must be borne in mind in enucleating the end of the clavicle.

EXCISION OF THE UPPER JAW.

The upper jaw, first resected by Gensoul in 1827, has since been very frequently removed with, considering the serious nature of the operation, remarkable immediate success. Few such operations are technically complete, since in many cases portions of the jaw are left, while in others the growth is found to extend beyond the limits of the individual bone, necessitating the removal of parts of others or even its fellow.

The principal dangers in this formidable operation are, hæmorrhage at the time, the entrance of blood into the air-passages, and, during the after-

treatment, the passage of the wound discharges or food into the bronchi and lungs, leading to bronchitis or pneumonia.

Hæmorrhage during the operation must be combated by careful arrest of all bleeding points as the soft parts are successively divided, and prompt removal of the bone when exposed. For the prevention of the entrance of blood into the air-passages various plans have been devised. The simplest of these, that of Rose, is to arrange the patient with the head hanging over the end of the operating table; but this is open to the objection of causing considerable venous congestion, and hence extra trouble with hæmorrhage, and it has been little adopted in this country.

Other methods consist in plugging the posterior nares—a valuable aid in partial removals where the growth principally invades the nasal cavities (Gosselin and Verneuil)—and in performing a preliminary tracheotomy. The latter method is of great value in very extensive cases, the trachea either being fitted with Trendelenburg's cannula, or the top of the larynx fully plugged with a pad. The pad is perhaps to be preferred to Trendelenburg's cannula, as it is more easily arranged, and may be large enough to close the pharynx also; and the danger, moreover, of the apparatus getting out of order and allowing the slow passage of blood into the trachea by the side of the tampon bag is avoided. It must be borne in mind, however, that such preliminary operations somewhat increase the danger of the whole procedure, and they should be adopted in exceptional cases only.

The operations may be partial or complete, certain growths specially affecting the alveolus, others being more or less limited to one portion of the jaw and allowing certain parts of it to be preserved. It need scarcely be said that in all possible cases a partial operation when the growth can be freely removed is eminently preferable.

The various incisions which have been devised for the removal of the entire bone have been planned with two objects—avoidance of unnecessary disfigurement and the gaining of sufficient room with the least possible injury to the soft parts.

The bone consists of a body containing a large irregularly conical cavity, and four processes—malar, nasal, alveolar, and palate. It enters into the formation of the orbit, mouth, and nose, also of the sphenomaxillary and zygomatic fossæ, and the sphenomaxillary and pterygo-

maxillary fissures. The enumeration of these cavities and spaces sufficiently indicates the magnitude of an operation for its complete removal. It articulates with the frontal, ethmoid, nasal, malar, lachrymal, inferior turbinated, palate, vomer, and the opposite upper jaw bones. Few of these articulations, however, are precisely disjoined in excision; those between it and the lachrymal, ethmoid, and sphenoid are irregularly separated more or less in the line of junction, but the palate bone in great part and the inferior turbinated in entirety are removed with the jaw, while in the case of the remaining sutures a saw-cut is usually made in their immediate vicinity.

The best incision is an extension upward of the lip incision of Fergusson, but a short description of that of Langenbeck will be given, as it is still much in vogue on the Continent. The principal objection to the latter is that, as in Liston's, the nerves and vessels are cut farther from the periphery, and the division of Stenon's duct renders the formation of a subsequent salivary fistula possible; an advantage, however, exists in the preservation of the upper lip entire.

Indications.—New growth, simple or malignant; necrosis.

Operation.—The patient is arranged at a convenient height, with the head and shoulders raised, the surgeon standing on the same side as the jaw to be removed, and his chief assistant opposite. The central incisor tooth of the corresponding side is drawn, and the incision is then commenced by splitting the upper lip into the nostril; the vessels in this, especially the superior coronary and the artery to the columella, are clamped, and the upper lip is then separated from the bone by division of the mucous membrane and central attachment of the orbicularis oris. The incision is now prolonged around the ala of the nose up its side to half an inch below the inner canthus, and carried, with a slight curve following the line of the lower margin of the orbit, to the outer limit of the eye, or, if necessary, onwards to the zygoma. The large flap (Fig. 316*a*) thus marked out is then raised from the bone as rapidly as possible, all bleeding points being taken up as the vessels are divided, an assistant meanwhile compressing the facial artery so as to minimize the loss of blood. In the dissection of this flap the origins of the following muscles need to be separated:—Orbicularis oris, depressor alæ nasi, compressor naris, levator anguli oris, levatores labii superioris proprius, et alæque nasi, orbicularis

palpebrarum, masseter, external and the small head of the internal pterygoids. The trunk of the facial artery and a number of small branches are divided, also the terminations of the infra-orbital and transverse facial vessels. The infra-orbital nerve at its exit from the foramen and numerous small branches of the fifth and seventh nerves are cut.

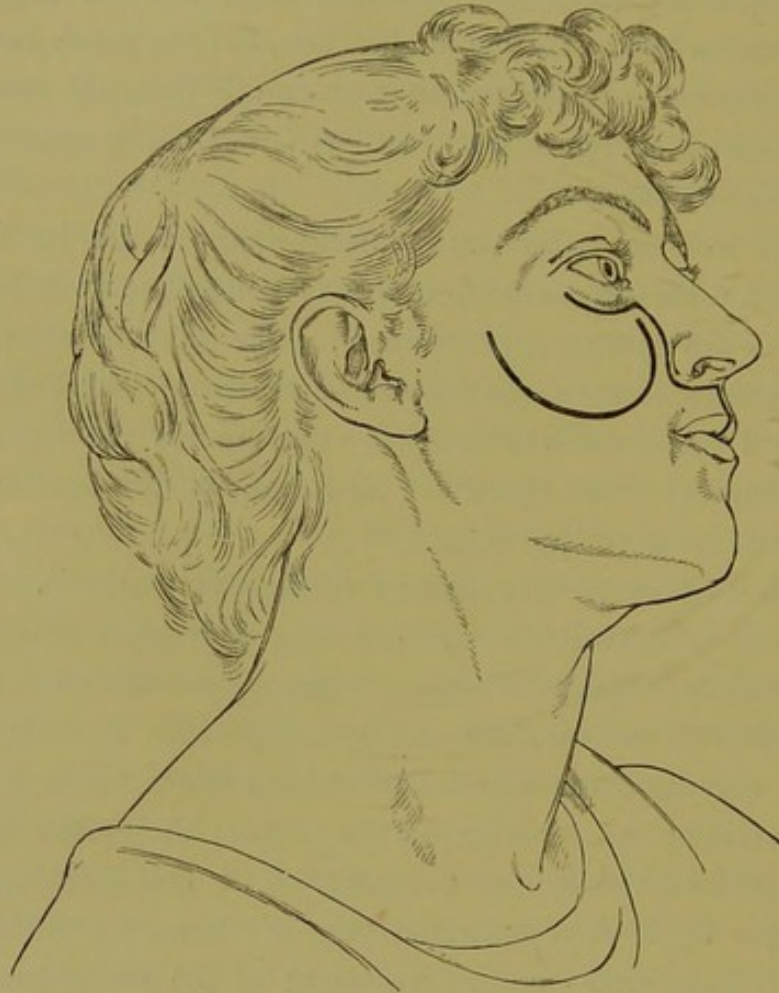


FIG. 316*a*.—Incisions for removal of the upper jaw. The semi-circular curved flap, convex downwards, is Langenbeck's; the other, through the upper lip and following the outline of the nose and orbit, Fergusson's.

When the flap is sufficiently reflected, and all hæmorrhage from its deep surface controlled, the nose is separated from the margin of the anterior nares, and the periosteum is divided along the margin of the orbit so as to allow the elevation of the eye and orbital muscles with as little disarrangement as possible. In this latter procedure the inferior oblique muscle of the eye is separated from its origin. In cases of extensive

malignant disease the periosteum must be sacrificed—a considerable disadvantage. A pair of bone-forceps or the keyhole saw is now made to cut through the nasal process from the anterior nares, and the malar bone is in like manner sawn through, the cut extending into the spheno-maxillary fissure. Prior to sawing the palate process, the mucous membrane of the mouth is divided longitudinally, and, the saw being introduced by the nostril, the section is rapidly made. The bone, now freed from all but its posterior and upper lateral connection, is seized with a lion-forceps and twisted out. If the soft palate be not implicated, a preliminary incision along the posterior margin of the hard palate should be made, as the horizontal plate of the palate usually comes away with the jaw-bone.

After removal of the bone, hæmorrhage from the branches of the third portion of the internal maxillary artery divided close to the trunk is free,

needs to be at once controlled. It is derived principally from the posterior dental, infra-orbital, and posterior palatine arteries; the latter, being often partially enclosed in its canal, may need a plug, or the application of the thermo-cautère or a piece of solid ferric perchloride. Firm compression with a sponge immediately after the removal of the bone arrests bleeding from the smaller vessels, and allows the others to be more readily taken up. The nasal duct is removed with the bone. The wound surface is dusted over with iodoform or, if it be preferred, painted with Whitehead's varnish, and the cavity is then plugged with iodoform gauze, each plug or strip having a silk string attached to it, which is brought out of the mouth and fastened to the cheek so as to allow of ready removal. No drainage-tubes are necessary. The cheek is carefully sutured, and the lip usually united by the use of hare-lip pins. The external wound may be strewn over with iodoform, or painted with Whitehead's varnish, and covered with salicylic wool.

The patient for the first week will be entirely restricted to fluid nourishment, and it may be advisable during the first day or two to feed him with a Nélaton's tube should there be any difficulty in getting enough food taken. Nutrient suppositories or enemata may also be used.

The plugs may often be allowed to remain untouched two days or even more after the operation, but they should always be removed before they become offensive, those introduced later will need changing daily, as

they are necessarily arranged much more loosely, and readily soak up food.

The above operation may be modified to meet almost any case. When the alveolus only requires removal, no external incision is often needed; when the alveolus and a part of the body is affected, Fergusson's lip incision carried just round the ala nasi answers admirably. When possible, the palate process and alveolus should of course be saved; and, even when it is impossible to save the bone, the periosteum and mucous membrane, having been previously separated, may be sutured across to the remaining jaw and a diaphragm thus preserved by Langenbeck's method. The floor of the orbit may with more frequency be left intact, and, avoiding as this does the possibility of subsequent downward displacement of the eye, with consequent double vision, it should always be attempted where safe.

It is sometimes necessary to remove both upper jaws; when this is the case, the same incision may be employed on each side of the face, and the bones are sawn in the same lines, the only exception being the palate process; the omission of the latter section renders the removal of both bones a more speedy operation than would be expected.

Langenbeck's incision commences at the junction of the lateral cartilage with the nasal bone, and, passing with a downward convexity to the junction of the upper lip and cheek, it again courses upward to the malar bone (Fig. 316*a*). As already mentioned, this divides the parotid salivary duct and the middle branches of the facial nerve, but the form of the mouth is preserved, as also the nerve supply of the orbicular muscles of the mouth and eye. The flap is raised upwards, and gives plenty of room for partial excisions, but for complete ones the outer margins of the wound need some separation. It certainly has no advantages over the first incision, the preservation of the form of the mouth being counterbalanced by the division of the parotid duct, and the more unsightly cicatrix remaining.

By Liston's incision a flap is raised in an exactly opposite direction to the one recommended; this again divides the arteries and nerves freely much farther from their periphery, and wounds the parotid duct. Starting from the angle of the mouth, it describes a wide curve through the cheek to about the centre of the malar bone. It should only be employed in

cases where a portion of the cheek is involved on the outer aspect of the bone, and needs removal (Fig. 316*b*).

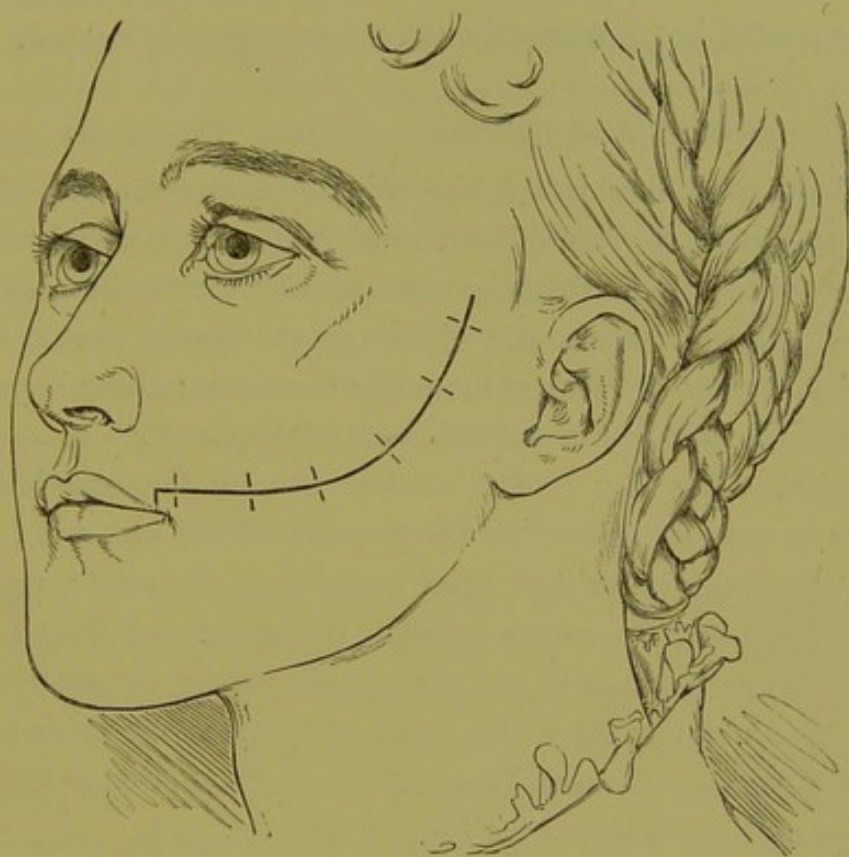


FIG. 316*b*.—Removal of the upper jaw. Oblique curved incision from the angle of the mouth to the malar bone (Lizars, Liston, Velpeau). It is best to begin or terminate the incision a short way from the angle.

Results.—As already mentioned, the immediate result, for so serious an operation, is usually good. Of 606 cases collected by Rabe, 494 recovered, a death percentage of 33·3. This number, however, included many partial resections. Rabe gives 25 per cent. as the mortality after complete removal. In cases of simple tumour a permanent cure may be looked for, but in malignant disease a recurrence is unfortunately the rule. In both, free removal of the growth offers the best chance. In cases of necrosis, especially the form due to phosphorus poisoning, sub-periosteal resection is followed by the formation of a wonderfully good new jaw; in these the resection is usually partial. If the periosteum be sacrificed, the cavity shrinks and is in part filled up by connective tissue. Removal of the

alveolar process for simple or myeloid growths is a very successful procedure if sufficiently freely carried out.

Removal of both upper jaws has been followed by equally good immediate results, but it is happily much less frequently needed.

OSTEO-PLASTIC RESECTION OF THE UPPER JAW.

This bold procedure is another which we owe to the superlative ingenuity and operative skill of von Langenbeck. It is designed to allow of the removal of retro-maxillary growths without the sacrifice of the upper jaw, and without any interference with its palate process, the upper part of the superior maxilla and part of the malar bone being raised in connection with a tongue-shaped flap of the soft parts of the cheek.

Operation.—The flap is first marked out by the following incision. The knife is entered below the inner angle of the eye, and is directed outwards along the lower and outer margins of the orbit; reaching externally to just below the suture between the malar and frontal bones, it crosses the frontal process of the malar, and, curving downwards, reaches the lower border of the zygomatic arch; and finally it is carried from this point with a downward convexity across the cheek, ending at the junction of the bony and cartilaginous portions of the nose.

The periosteum is divided in the same line, being stripped from the floor of the orbit as far back as the speno-maxillary fissure, especial care also being taken to detach with it the origin of the masseter from the lower border of the malar bone.

No portion of the flap thus marked out is separated from the bones.

A pointed elevator is now passed immediately below the zygomatic arch, and made to travel horizontally, and parallel to the surface of the frontal bone, through the pterygo-maxillary fissure to the inner wall of the nose; it is then made to pierce the latter, the point being recognized by a finger passed behind the soft palate. The elevator is removed and the keyhole saw, with its cutting edge upwards, is introduced in its track and made to cut through the zygomatic arch and the frontal process of the malar into the speno-maxillary fissure, whence it crosses the floor of the orbit to the lachrymal bone. The saw is removed, re-introduced at the point where the elevator was originally passed, this time with the cutting edge down-

wards, and lastly made to cut through the walls of the antrum into the anterior nares at the internal extremity of the incision forming the lower boundary of the flap.

The elevator is again introduced into the pterygo-maxillary fissure, and the wedge of jaw set free by the incisions made is levered upwards, the nasal process turning on its connections with the nasal and frontal bones as on a hinge. The orbit, nose, fauces, and zygomatic fossa are now laid open, and ample space is given for the removal of growths springing from any of these situations. The growth having been removed, the bone is replaced, and the cheek sutured so as to hold it in position. If thought necessary, correct replacement may be ensured by a suture passed through holes drilled in the two parts of the malar bone.

RESECTION OF THE LOWER JAW.

A portion or the whole of the lower jaw bone may need resection. New growths, as a rule, more commonly affect the horizontal ramus, and this to the right and left of the median line, but they may extend to the vertical portion of the bone, and more rarely they may be situated in the median line. As in the case of the upper jaw, the alveolus is a frequent seat of tumours, either simple or malignant, which may necessitate free removal of bone surrounding the point of attachment.

Indications.—New growth ; necrosis.

Operation.—The central incisor tooth on the side to be removed needs to be extracted. An incision is commenced just beyond the most prominent part of the chin, and, carried backward to the angle, the knife is carried at once down to the bone dividing the skin fascia and platysma muscle, and the trunk of the facial artery, which is at once ligatured. The latter may, if preferred, be bared only by the incision and doubly ligatured before division. The incision is further prolonged around the angle and upwards along the posterior border of the vertical portion of the bone as high as the lower border of the external auditory meatus. The incision should never rise above this point, lest the transverse facial artery and the branches of the seventh nerve supplying the muscles around the eye and the cheek should be injured (Fig. 316*c*).

The soft parts are now separated from the outer surface of the bone ;

the levator menti, depressor labii inferioris, depressor anguli oris, buccinator, and masseter muscles need to be raised, and in the case of simple growth or necrosis they should be lifted with the periosteum. This being done, an elevator is insinuated behind the bone at the point where the incisor tooth has been previously extracted, and held there as a guard while the bone is sawn through. The distal end of the opposite inferior dental artery sometimes needs plugging. The cut end of the part to be removed is now best grasped with a sharp hook, and held outwards while the soft parts are rapidly separated from the inner aspect of the bone. The mucous membrane needs division, the sub-maxillary and sub-lingual glands must be pushed away, and the following muscles are freed from their attachments:—Genio-hyo-glossus, genio-hyoid, digastric, mylo-hyoid,

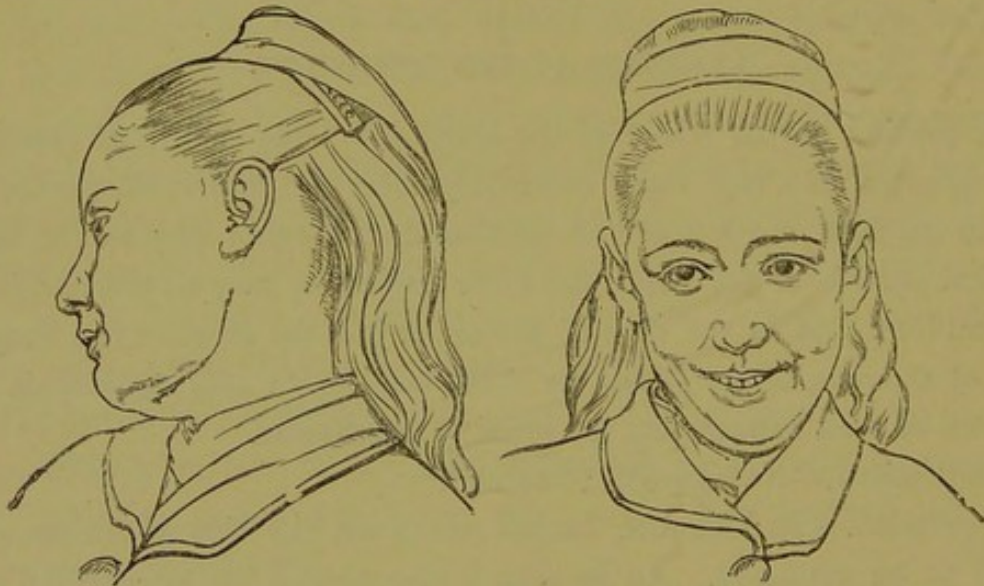

FIG. 316 c.—Line of incision for the resection of the inferior maxilla. It runs parallel to and under the ramus of the jaw, and its length corresponds to the extent of bone which requires removal. The resulting deformity is comparatively small, as the second cut indicates.

superior constrictor, and internal pterygoid. As in the case of the outer surface, the periosteum should be saved if possible. The inferior dental artery and nerve are divided; also the pterygo-maxillary, stylo-maxillary, and internal lateral ligaments.

The cut end of the bone is now forcibly depressed, and the insertion of the temporal muscle separated from the anterior border of the vertical ramus and from the coronoid process; if this part of the operation be difficult, it may be simplified by cutting the coronoid process off, which if needful can be removed later.

The jaw is now free except for its condyloid attachments; these are divided on their outer aspect, and the bone is forcibly twisted, while, with light touches of the knife, the insertions of the external pterygoid muscle and the circumference of the joint capsule are successively divided, care being taken not to pass the knife behind the condyle and endanger the internal maxillary artery.

The wound may now be dusted with iodoform, and the mucous membrane of the floor of the mouth may be united to that of the cheek by fine sutures; lastly, the external incision is sutured, and two or three points of drainage arranged for. The after-treatment will not differ materially from that after removal of the upper jaw.

If the disease be bilateral, the same operation is repeated on the other side. If a portion of the horizontal ramus only be affected, it may be removed by a modified operation, the incision along the border of the jaw only being needed; in sawing the bone, it should not be completely divided in either cut, but the division should be finished with the cutting-forceps, so as to ensure steadiness and avoid locking of the ends. If the centre of the bone have been removed, a stitch should always be passed through the tip of the tongue, brought out of the mouth, and fastened with strapping, for with the separation of the attachments of the genio-glossi great risk of suffocation from falling back of the tongue exists. In unilateral excision also this is a good rule to observe. The removal of the central portion of the jaw leads to considerable functional trouble later from the difficulty of keeping the ends apart and preserving the parallelism of the teeth; this must be striven for by the use of suitable apparatus, but the result is usually unsatisfactory. Portions of the alveolus may usually be removed from the mouth, but, should more room be needed, the rule of not splitting the lip should be rigidly adhered to,⁷ and sufficient space sought by an incision along the lower border like that used for resection.

Results.—The results after excision of the lower jaw are good, the operation being less immediately dangerous than that for removal of the upper jaw, and the position of the bone allowing greater certainty of free removal. After sub-periosteal resection, especially in cases of phosphorus necrosis, an excellent bony jaw is reproduced in young people.

RESECTION OF THE TEMPORO-MAXILLARY ARTICULATION.

This joint is rarely diseased, and has, therefore, not been very frequently resected, but the operation may be readily performed, and gives good results.

Indications. — Suppurative arthritis; chronic rheumatoid arthritis; ankylosis.

Operation.—An incision is made over the outer aspect of the articulation anterior to the position of the temporal artery, and reaching from the zygoma to the level of the transverse facial artery below. The position of the temporal artery is readily ascertained by palpation; it is usually about a finger's breadth anterior to the tragus. To avoid the transverse facial branch the lower end should not extend below the base of the lobule of the ear. Additional room may be gained by a transverse incision coursing along the lower border of the zygoma. The external lateral ligament being divided, the neck of the jaw is freed with an elevator and its base divided with a chisel. The condyle is now seized with a strong forceps and twisted out of its bed, any remaining connections being divided with a knife, care being taken to keep the edge directed towards the bone, and thus to avoid injury to the internal maxillary artery, which lies close to the internal aspect of the joint capsule. A small drain is inserted and the wound sutured. Movements of the jaw should be commenced after the first few days.

OPERATIONS ON THE NERVES.

NEUROTOMY OR NERVE-SECTION, NEURECTOMY OR NERVE-RESECTION, NEUROTOMY
OR NERVE-STRETCHING, NEURORAPHY OR NERVE-SUTURE.

Neurotomy and Neurectomy.—Section of a nerve-trunk, without or with excision of a portion of its length (Neurectomy), is practised chiefly for the relief of neuralgia of peripheral origin in connection with purely sensory nerves, but it has also been employed in the treatment of certain cases of muscular spasm, epilepsy, and tetanus. For neuralgia it is usually contra-indicated when the pain is due to a central lesion, or to a disease nearer to the centre than the part accessible to the surgeon, and where the nerve-trunk includes motor fibres. It is called for most frequently in neuralgia of the branches of the trifacial, and in cases of lingual cancer involving the distribution of the gustatory nerve. The results are usually satisfactory— or a time at least ; but the restoration of the functions of the nerve may take place after a very short interval ; or the operation may be partially or wholly ineffective from the first, owing either to the existence of secondary changes in the centre, or to a free inter-communication between the fibres of the divided nerve and those of an adjacent trunk.

The procedure should not be undertaken until all the obvious or probable causes have been as far as possible removed, and the ordinary means of treatment have been fairly tested. In the majority of cases, moreover, it will be well to try the effect of nerve-stretching before resorting to section, or the two measures may be combined, the trunk being first stretched and then divided.

NERVE-STRETCHING.

Nerve-stretching has a much wider range of utility than neurotomy or neurectomy. It may be employed to supplement or replace section in cases for which that operation is eligible, and it is, moreover, beneficial in

various affections of mixed and motor nerves, and in certain neuroses of central origin, for which a division of the nerve might prove useless or injurious.

The operation of nerve-stretching as a remedy for irregular muscular action appears to have been suggested by the effects of an unintentional experiment. Nussbaum, who first proposed the measure, accidentally observed that in a case in which he had excised the elbow-joint, the muscular contractions in the forearm ceased after the ulnar nerve had been very forcibly drawn aside by a blunt hook; but before this (in 1869) Billroth obtained a similar result after the exposure and manipulation of the sciatic nerve, in a case of muscular contraction of the lower extremity; he found no lesion, but during the inspection the nerve was stretched, and the spasm almost directly abated and finally disappeared.

Indications.—Up till 1877, when P. Vogt's monograph appeared on the subject of nerve-stretching, only eleven cases had been published; but since then the operation has become frequent, especially for the relief of neuralgia of peripheral origin. The proceeding may also be of advantage in certain affections due to central lesion, as in locomotor ataxy and tabes dorsalis; in these however, the effects of the operation are uncertain, although great improvement is said to have followed the treatment in several cases.

Nerve-stretching has been substituted to a large extent for nerve section in the treatment of many forms of neuralgia due to peripheral causes; and has even been tried in cases where the pain is occasioned by central lesions, but its efficacy in these is very uncertain.

The success of the operation in conditions due to central causes depends in a large measure on the height at which the disease is placed in the spinal cord, apart altogether from the nature of the lesion: the higher the lesion, the less successful is operative interference likely to be. The operation is useless for nervous symptoms resulting from cerebral disease, except perhaps in muscular contractions. In motor paralyses it can be of little use. In sciatica, brachial and intercostal neuralgia, tic, affections of the spinal accessory nerve, painful ulcer of the skin, nerve contusion, and in chronic thickening of neurilemma produced by continued irritation, nerve-stretching affords a good chance of success.

Nerves have been stretched for the relief of impaired sensation; or for hyperæsthesia of a part; for inco-ordinate or clonic muscular movements in cases of painful stump after amputation; for tonic spasm, as in torticollis; and in tetanus.

The operation is of course contra-indicated if the pain be dependent on disease of the vertebræ; and nerves implicated in tumour growths are unsuitable for stretching.

The extensibility of nerves is not very great, but it is greater in the peripheral than the central portions; the nerves are more extensile near to the spinal cord than at a distance, probably owing to their greater size in this situation, and the relatively lesser thickness of the sheath. The nerves of the upper limb are more extensile than those of the lower, as the sheath, which bears the chief strain during the process of stretching, is less resistant in the former than in the latter case. In the living animal the elasticity of the nerves is considerable, and after moderate stretching they quickly resume very nearly their original length. The median nerve of an adult man requires a weight of 3 kilogrammes to draw it out two centimetres, and only after this weight has been applied for many hours will the nerve fail to return to its normal length on removing the extending force. There is great variety in the limit of extensibility, elasticity, and breaking strain of various nerves, and even of the same nerve in different subjects; thus, in the case of the sciatic nerve the breaking strain varies from 82 to 280 pounds, the branches of the trigeminus bear from 6 to 12 pounds, the cords of the brachial plexus 50 to 64 pounds, the ulnar nerve 58 pounds, the musculo-spiral 61 pounds, the median 84 pounds, the crural 83 pounds, and the internal popliteal 114 pounds. According to Stintzing, the normal function of the healthy sciatic nerve was completely restored even after the nerve had been stretched with a force somewhat greater than half the body weight; more than about 60 pounds cannot, however, be safely imposed on the healthy sciatic nerve of a man, while for a diseased sciatic nerve the strain should probably not exceed half this amount, or about 30 pounds; this Mr. Marshall has shown (Bradshaw lecture, 1883) is about equivalent to the traction that a man can effect by an ordinary exertion of strength while holding the nerve-trunk between his fingers and thumb. If this be regarded as the limit for the

great sciatic nerve, the amount would diminish *gradatim* for the smaller nerves. A dynamometer has been invented to test the amount of traction force used, but its practical application has proved unsatisfactory, and the resistance offered to the fingers will perhaps be found the safer and better guide. After a few experiments on the dead subject the amount of force necessary to overcome the resistance and to produce an adequate amount of extension will not be difficult to gauge. The traction must always be gentle and steady, and presently the nerve sensibly yields to it; the pull must not be sudden nor in a series of jerks, but should consist of a continuous stretch or strain of three or four minutes' duration. As a rule, it is best to stretch both centripetally and centrifugally, especially for cases of neuralgia.

Pathology.—All the constituents of the nerve seem to be modified by force thus applied; the sheath is rendered very tense, the nerve within is compressed, and its fasciculi and fibres elongated. Mr. Horsley finds in the unstretched nerve the sheath composed of wavy fibres, with the nerve tubules more or less loose in the sheath. After stretching, the fibres, instead of being wavy, are perfectly straight, and the tubules are stretched to an extraordinary degree. In the transverse section of a healthy nerve the fasciculi are separated by interspaces, and the perineurium is loose around them; but after stretching, the sheath becomes tightened, the fasciculi become pressed together, and the spaces between the nerve-bundles are obliterated. Changes also occur in the tubules; the natural segmentation is replaced by an abnormal irregular breaking-up of the medullary sheath. Sometimes the tubuli break; more rarely the axis cylinder gives way; and larger or smaller extravasations of blood take place within the sheath.

Both the motor and sensory functions of the nerve are diminished by the process of stretching, and generally in proportion to the amount of force employed; but comparatively the motor functions are affected to a slighter degree.

Experiments on the sciatic nerve in animals show that when a nerve is slightly stretched its irritability or power of conducting impressions is often increased; but as the extension goes on, this diminishes gradually, and is finally abolished; the reflex properties are also lowered in the

same way. After an interval of about six weeks the nerve tissue has resumed its normal appearance and function.

Great difference of opinion has been expressed as to whether the mechanical effects of nerve-pulling are transmitted to the spinal cord. The latest experiments show that the cord itself is not directly acted upon through the roots of the nerves; the dura-mater may be disturbed a little, and the cord shaken through the ligamentum denticulatum on each side,

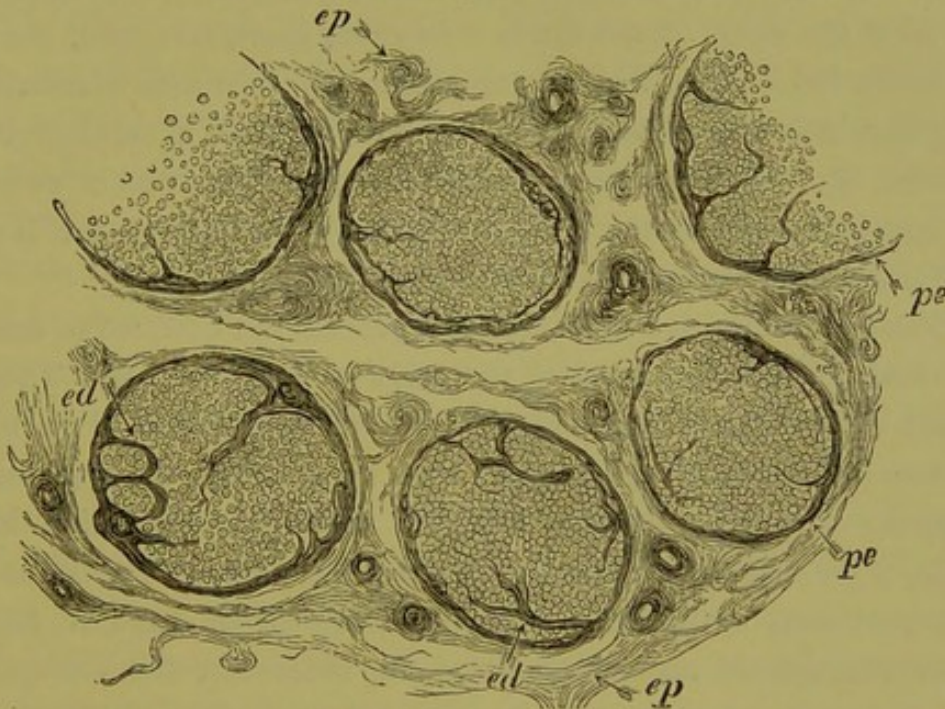


FIG. 316*d*.—Transverse section of the median nerve of an adult woman. Enlarged 70 diameters. *ep*. Epineurium; *pe*. Perineurium; *ed*. Endoneurium. The bundles of nerve fibres are united together by connective tissue, or neurilemma. According to Axel Key, the outer and looser portion is properly called the Epineurium; the denser layer in immediate contact with the nerve is the Perineurium; while the septum of connective tissue which penetrates the bundles is the Endoneurium.

but there is no change in the intra-spinal tension, and no movement imposed upon the cord as a whole.

The explanation of the influence of nerve-stretching when the cause is peripheral seems more easy than when the lesion is central. The nerve becomes isolated by the process, and thus in some cases may be freed from inflammatory adhesions contracted with surrounding tissues—a condition which is, however, very rare; its relations to the sheath are altered, and its nutrition is improved.

In neuralgia the pain is concentrated in the area of distribution of a particular nerve, often at one point in that area; it is usually unilateral, and increased by movement or pressure; and is more severe where the nerve passes close to or around some bony point against which it is liable to be compressed. In sciatica the most painful spot is where the nerve passes over the lesser sacro-sciatic ligament and spine of the ischium; neuralgia of the external popliteal is most painful where the trunk passes over the neck of the fibula. In many cases, no doubt, the pain is due to the influence of the *nervi nervorum*, which Messrs. Marshall and Horsley have discovered in the sheath of the nerves, and in nerve-stretching these small filaments must be elongated or broken, but in other cases the effect may be caused by the temporary arrest of function of the internal tubules and the indirect effects produced on the nerve centres.

In locomotor ataxy the pains are more general, not confined to one side of the body, and often involve the areas of many nerves. They are produced by changes in the posterior roots and in the cord itself. In such cases nerve-stretching probably acts by affecting the ganglia and exciting the vaso-motor centres, and the consequent alteration in the nutrition of the nerve elements, may account for the benefit obtained.

A nerve when stretched is notably diminished in diameter, and the primitive nerve-fibres are lengthened. In order that this change may produce a permanent effect it is necessary that the strain be sufficiently great and sufficiently prolonged. The amount will vary with the size of the nerve, and should be in proportion to, but of course far short of, its breaking weight.

For the extension of large nerves the bent forefinger is probably the best instrument to employ: the nerve should be held between this and the thumb, and pulled in succession upwards and downwards with the necessary amount of force. For smaller nerves a blunt aneurism needle or small elevator may be employed, but great care must be taken when using such instruments to avoid crushing or tearing the fasciculi. A small india-rubber tube is also a good means to employ. After the operation the nerve must be gently replaced; a sufficient number of sutures and a drain are inserted into the wound, and the dressings applied. Where a favourable progress ensues, no inflammatory reaction should result, either local or

general. After the operation the part of the body or limb should be supported in a convenient position so as to keep the adjacent parts relaxed. As a rule, the proceeding is without danger, and in properly selected cases the good effects speedily appear; but in some cases abscesses have formed, and recovery was in consequence very slow.

NERVE SUTURE—NEURORAPHY.

Daniel Würz is said to have been the first to suture a nerve, but Laugier and Nélaton first described the operation, which was performed by them in Paris in the year 1864. The results in Laugier's first case were so remarkable—sensation having returned after so short an interval—that doubts were even cast upon the accuracy of the report.

Indications.—Nerves may require suture after division in wounds either inflicted by accident or caused unavoidably in the course of an operation. The conducting power of a nerve may also be destroyed by severe contusion, for which resection and suture of the damaged portion may be needful.

Nerves which have been accidentally divided—such as the musculo-spiral on the outer side of the arm, the median, ulnar and radial nerves, and even so large a nerve as the sciatic itself—have been successfully sutured, and the lost functions completely restored to the supplied parts.

The ends of nerves accidentally divided may sometimes unite by natural processes, and their function become restored; but usually the ends retract, and if there be union, it is by means of a fibrous, non-conducting tissue.

In contused injury of nerves, as of the musculo-spiral, from a blow, or of the cords of the brachial plexus in dislocations of the shoulder, or from the inclusion of a nerve in a ligature, the nerve function, if restored at all, is reproduced more slowly than after complete division; and in many cases it does not return at all. Excision of the bruised portion, and union of the cut surfaces by suture, is hence a desirable practice under these circumstances.

The nerve-trunks in the extremities are in many places comparatively superficial, and very liable to division in cases of accidental injury; they may be also unwittingly cut through during the performance of opera-

tions. The ulnar nerve has frequently been divided during the excision of the elbow-joint; the external popliteal nerve has been cut through in tenotomy of the biceps tendon; the musculo-spiral is frequently implicated in wounds near the external condyle of the humerus, and the median nerve in injuries of the forearm and arm.

Pathology.—The fear of irritating the nerve and of inducing tetanus by the introduction of sutures, and the impossibility of securing union in suppurating wounds, doubtless interfered with the adoption of the practice of nerve suture in former days. The manner in which the divided ends reunite is not thoroughly made out. After simple division, if the extremities be kept in accurate contact, the axis cylinders and nerve-fibres may join by a process of immediate union; but of course the corresponding fibres and portions of nerve cannot be brought into apposition. Union probably occurs most frequently by means of granulation cells which invade the divided ends and the intervening space, and into this material grow a new set of nerve-fibres, probably derived from the cells of the sheath of Schwann. According to Wagner, a limited portion of the excised nerve-tissue may thus be reproduced. The time required for regeneration of the nerve conductivity varies. It is shortest after simple transverse division of the nerve, in which there has been no loss of substance; longer, if the injury be of the nature of a contusion, or if there be loss of substance. Sensation always returns before movement, and generally more perfectly. In favourable cases sensation generally returns in from eight to fourteen days, while the power of movement is restored at a considerably later date. The rapidity with which the nerve function may be reproduced in some of these cases, even where it may have been in abeyance for months or years, is surprising. In more than one case I have seen distinct sensation return to the part in less than twelve hours. Richet points out that after division of a great nerve, and more especially in the case of the median, more or less sensibility may remain in the area of distribution, or, if lost, may gradually return after a brief interval, even without any union taking place in the nerve. This has been explained by the numerous inter-communications which exist on the periphery, and later, perhaps, by the formation of new nerve-fibres in the material interposed between the cut ends.

Operation.—The operation of suturing a divided nerve may be either

primary or secondary ; that is, performed immediately after the injury, or not until cicatricial changes have taken place in the wound. Nerve suture is rendered more successful than heretofore by the maintenance of aseptic conditions in the wound.

When a nerve-trunk has been divided, either in an accidental or surgical wound, the ends should be immediately united by means of a sufficient number of points of interrupted suture, preferably of very fine silk, introduced through the corresponding margins of the sheath so as to bring the cut surfaces into accurate apposition. If the suturing of the edges of the sheath do not alone suffice, it will be better to pass the needle deeply enough to include a portion of the nerve-tissue as well, a practice which does not entail unfavourable consequences. If the divided surfaces be irregular, they should be cut transversely with a sharp knife. A deficiency of half an inch or more thus occasioned may be readily compensated for by gentle traction of the nerve from the adjacent parts. According to Dr. Assaky (*Thèse de Paris*: "*La Suture des Nerfs à Distance*") : "Whenever there is loss of substance in the nerve, it is advisable to attach the central to the peripheral extremity by means of catgut sutures ; even though the extremities of the nerve cannot be absolutely united, the presence of sutures produces excellent results, and favours the formation of new nerve fibres. Experiments on animals show that sutures thus applied prevent further retraction of the nerve ends, lessen the space which divides the extremities, and hasten regeneration of nerve tissue. The cicatrix along the track of the catgut is richer in newly formed nerve fibres than when no sutures are used."

When a considerable period has elapsed after the division of the nerve, and cicatricial changes have occurred in the wound, the operation is more difficult. The divided ends have retracted, and an inch or even a greater interval may be found between them. They are involved in the cicatricial tissue, and difficult to discover. It is usually much more easy to find the upper end than the lower, as the former is commonly enlarged and bulbous, and, like the bulbous nerves of a stump, very painful and sensitive to pressure. The distal extremity, on the other hand, is atrophied, and often indistinguishable from the cicatricial mass surrounding it, or may not correspond in position with the course of the upper end. These are

difficulties, however, which may be overcome by patient dissection and an accurate knowledge of the anatomical relations of the parts.

When the ends have been fully exposed, they may be drawn out sufficiently to meet without tension, by stretching the nerve; then cut square off and sutured accurately together. The operation should be conducted antiseptically; antiseptic dressings are subsequently applied, and the limb fixed by plaster-of-Paris or other splints, in such a manner as to place the parts concerned in a complete state of rest and relaxation.

The operation for exposing a nerve is the same, whether undertaken for the purpose of division, resection, suture, or stretching. Its position and anatomical relations having been recalled, an incision of sufficient length is made directly over it, and the dissection must be carried on until it is exposed lying in its sheath.

The intergrafting of a portion of a nerve taken from an inferior animal, to replace an extensive loss of nerve structure, will probably be found too uncertain in its results to constitute a standard operation; but the experiments of Kawa indicate that the grafting of the distal end of a divided nerve, upon the side or into the trunk of an adjacent nerve, may restore the lost function. Experiments on dogs, however, are valueless on this point, on account of the free nervous intercommunications found in these animals, and for a solution of the question we must rely upon the rare opportunities met with in the course of our surgical practice. A case in point has been reported by Després. In this there was such extensive destruction of the median nerve as to preclude the possibility of approximating its ends, and he therefore engrafted the distal end of the injured nerve on the trunk of the ulnar nerve. Fifty-four days after the operation the functions of the parts supplied by the median nerve were partially restored. In another case, in which it was necessary to resect the right ulnar nerve during the removal of a neuroma in a male patient, aged thirty-six years, the distal portion of the divided nerve was grafted on the trunk of the median. The sheath of the median was removed, and the broadly chamfered end of the ulnar nerve laid in contact with it and secured by three fine catgut sutures. The operation was followed by immediate paralysis of the parts supplied by the ulnar; but on the eighteenth day slight sensation returned along the ulnar side of the ring finger, and there seemed to

be some contractile power in the flexor carpi ulnaris muscle. Four months after the operation the patient could feel a slight touch on the ring finger, and there was an increased warmth in the little finger, although no tactile sense was restored to it; the hand could be abducted with considerable vigour, but there was no power over the terminal phalanges.

The evidence furnished by these two cases certainly warrants further efforts in this direction.

It has been also proposed to excise part of the shaft of a long bone to enable the separated ends of the nerve to be approximated.

OPERATIONS ON SPECIAL NERVES.

When the object of the operation is nerve-stretching or nerve-division, the place of election—that is, the most accessible position for the exposure of the nerve on the proximal side of the lesion—is more particularly to be considered; but in cases of injury the damaged nerve must be sought for in the wound or cicatrix, as in the case of divided arteries, and the place of operation in cases of tumour is also determined by the seat of the disease.

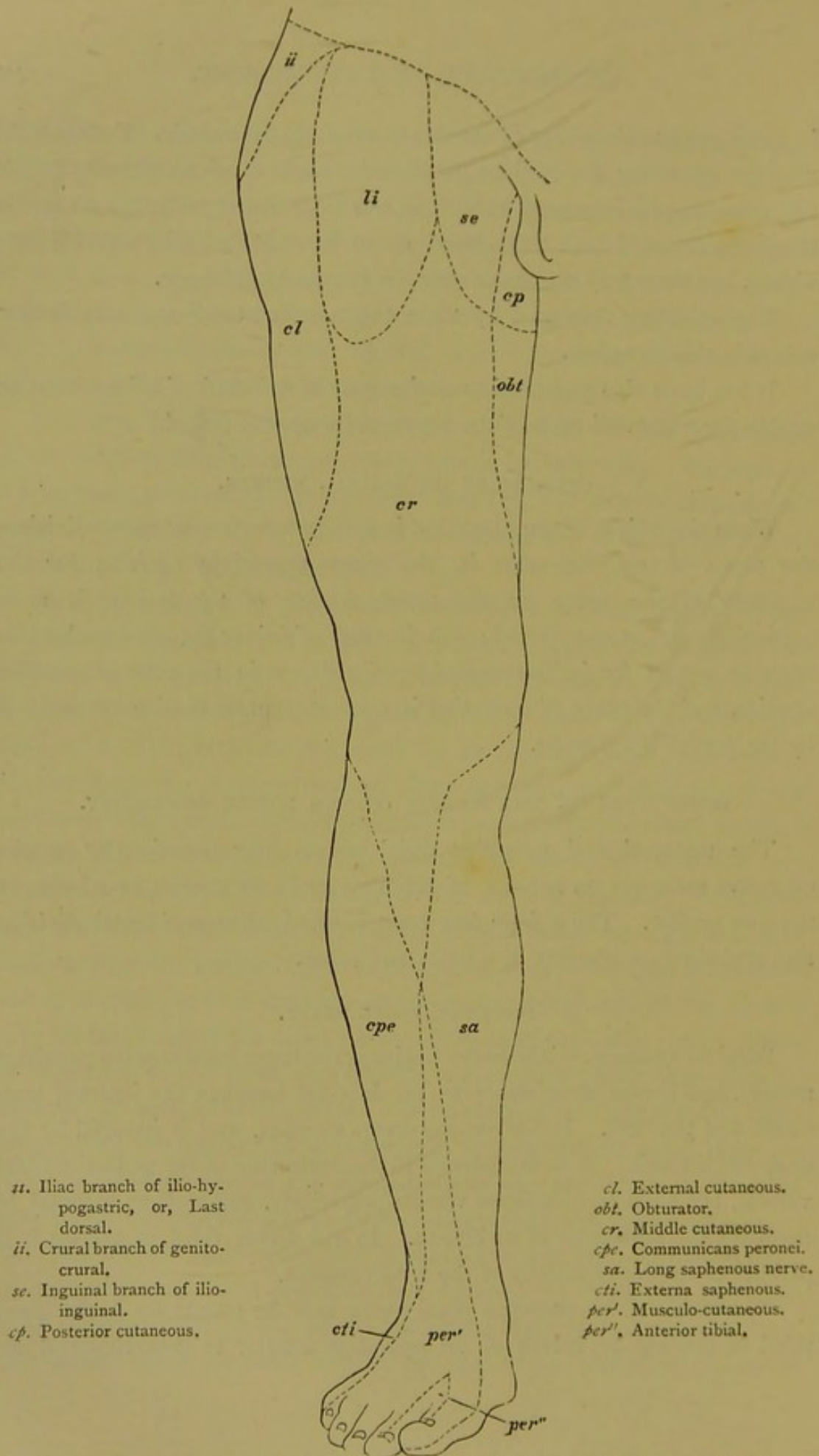
OPERATIONS ON THE NERVES OF THE LOWER EXTREMITY.

The peroneal and posterior tibial nerves may occasionally require operative measures on account of direct injury to the trunks, or a lesion of the toes or foot. The sciatic has been sutured after accidental division and stretched on account of sciatica and tabes.

POSTERIOR TIBIAL NERVE.

Surgical anatomy.—The nerve begins at the lower border of the popliteus muscle, and passes downwards to the interval between the internal malleolus and the heel. It lies on the deep muscles, and is covered by the deep tibial fascia. It is first placed to the inner side of the posterior tibial vessels, but soon crosses those vessels posteriorly, and is then external to them for the remainder of its course. In the lower third of the leg it is parallel to the inner margin of the tendo-achillis.

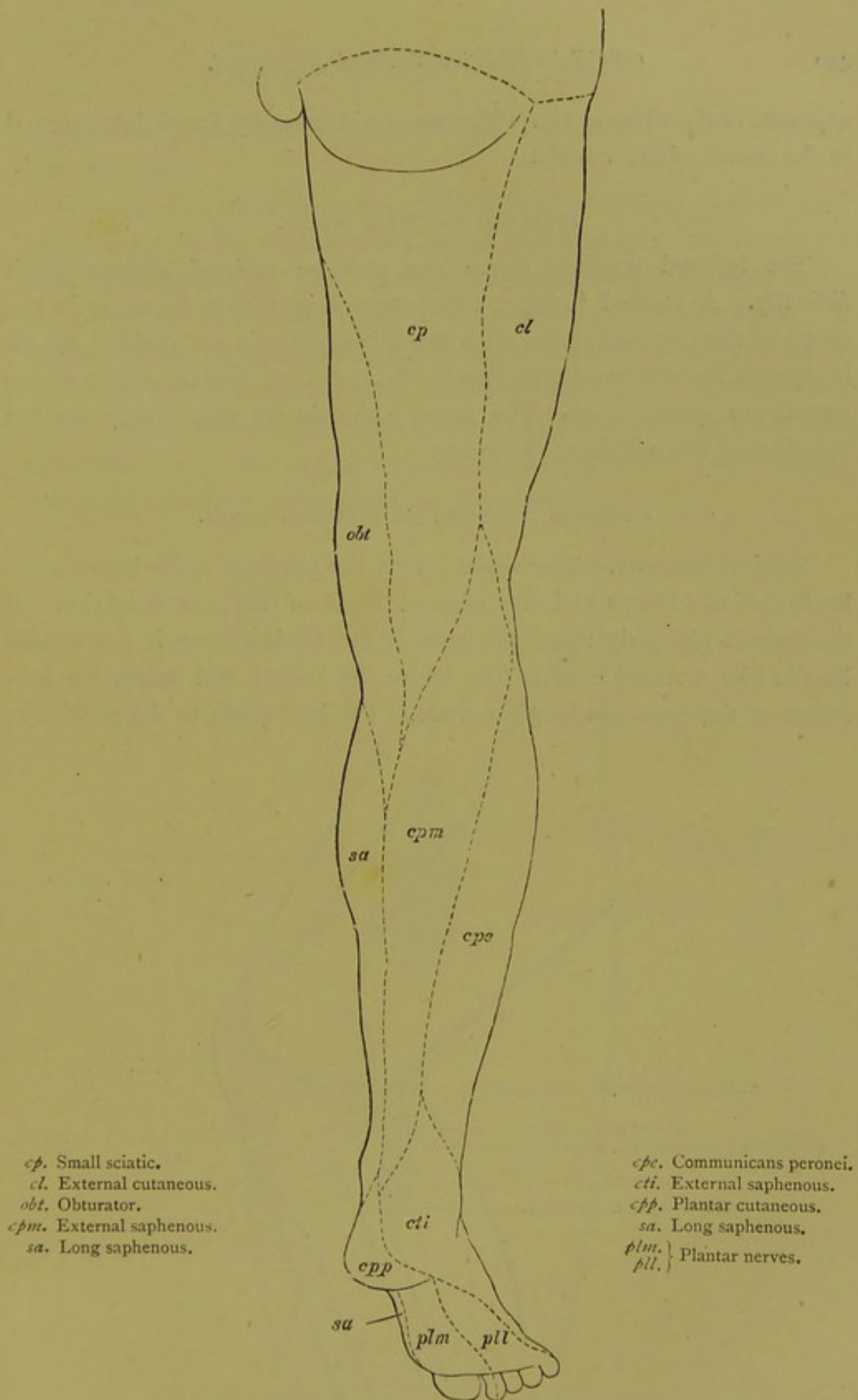
Operation.—The posterior tibial nerve may be sought for in the lower third of the leg by means of an operation similar to that required for



ii. Iliac branch of ilio-hy-
 pogastric, or, Last
 dorsal.
ii. Crural branch of genito-
 crural.
se. Inguinal branch of ilio-
 inguinal.
cp. Posterior cutaneous,

cl. External cutaneous.
obt. Obturator.
cr. Middle cutaneous.
cpe. Communicans peronei.
sa. Long saphenous nerve.
cti. Externa saphenous.
per''. Musculo-cutaneous.
per'''. Anterior tibial,

FIG. 317. —Cutaneous nerve supply of the front of the thigh and the dorsum of the foot.



ep. Small sciatic.
cl. External cutaneous.
obt. Obturator.
epm. External saphenous.
sa. Long saphenous.

cpe. Communicans peronei.
cti. External saphenous.
cpp. Plantar cutaneous.
sa. Long saphenous.
plm. } Plantar nerves.
pll. }

FIG. 318.—Cutaneous nerve supply of the back of the thigh, leg, and the sole of the foot.

exposure of the tibial artery. The nerve will be easily found, just external to the sheath of the vessels.

INTERNAL POPLITEAL NERVE.

The internal popliteal nerve can also be exposed without much difficulty. A vertical incision, two inches long, should be made in the centre of the popliteal space, after the skin and fascia are divided, the fat is separated carefully with the handle of the scalpel, and the edges of the wound are drawn apart. The nerve will then be seen lying over the vessels near the middle of the space.

EXTERNAL POPLITEAL OR PEROENAL NERVE.

Surgical anatomy.—The nerve leaves the popliteal space between the tendon of the biceps and the external head of the gastrocnemius. It then winds obliquely round the neck of the fibula (where it can usually be felt like a round cord rolling under the finger) and enters the substance of the peroneus longus muscle. The best guide to the position of

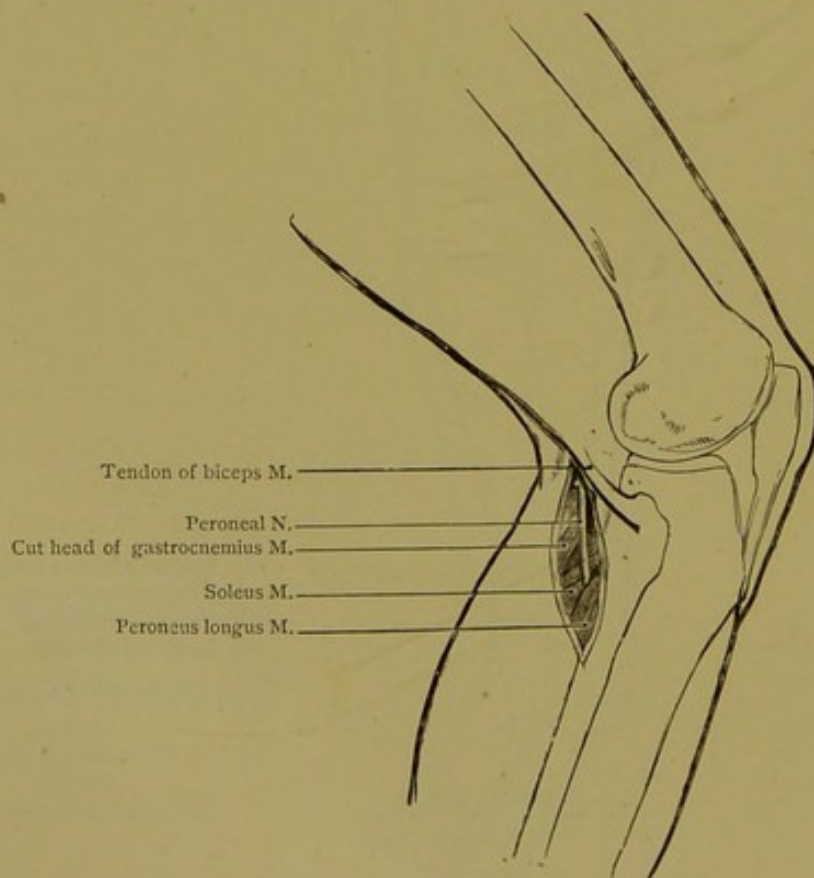


FIG. 319.—Incision to expose the external popliteal nerve.

the external popliteal nerve is the tendon of the biceps, near its insertion into the fibula.

Operation.—Make an incision, an inch and a half long, close to the internal margin of the tendon of the biceps, terminating below, opposite the neck of the fibula (Fig. 319). After the skin and fascia have been divided, the nerve may be seen and dealt with according to circumstances. The incision should be made during the extended position of the limb, and the search made for the nerve with the knee semi-flexed. Or the incision may be made lower down and carried a short distance along the fibula, and thus the nerve may be exposed as it crosses the bone before it enters the substance of the peroneus longus muscle.

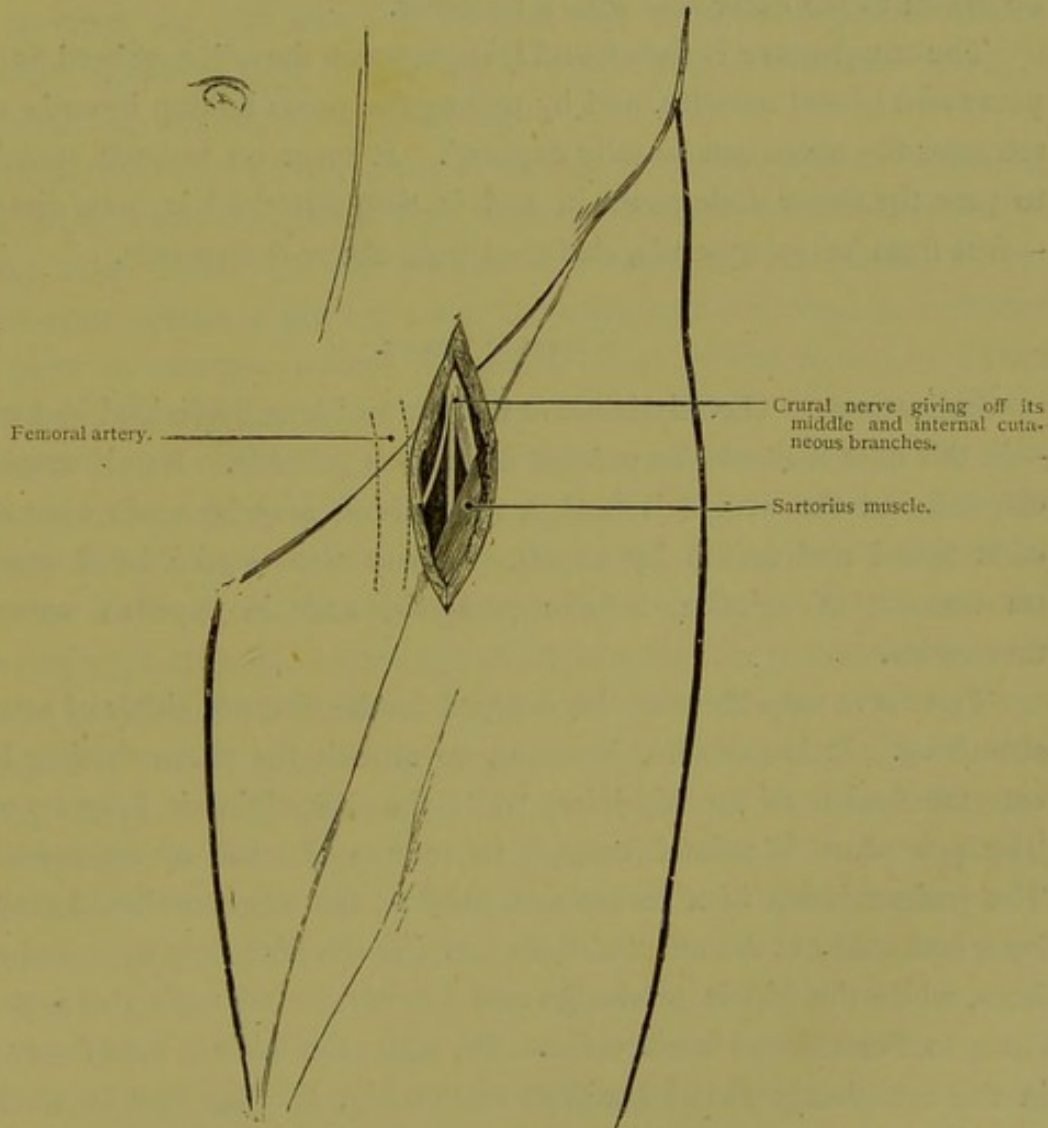


FIG. 320.—Incision for the exposure of the anterior crural nerve.

THE ANTERIOR CRURAL NERVE.

Indications.—Wounds, neuralgia, or tetanus.

Surgical anatomy.—The nerve passes beneath Poupart's ligament, in the interval between the psoas and iliacus muscles, lying close to the bone, and separated from the femoral vessels by the psoas muscle.

Operation.—Make a vertical incision, two inches long, half an inch external to the position of the femoral artery, commencing a little above Poupart's ligament. After the skin and superficial fascia are divided, cut through the deep fascia on a director.

The edge of the sartorius muscle will be exposed, and, if necessary, can be drawn to the outer side with a retractor.

The crural nerve is then found lying between the adjacent borders of the psoas and iliacus muscles, and by pulling the psoas tendon inwards with a retractor the nerve can be fully exposed. It must be isolated sufficiently to pass the finger underneath it, and is then stretched in both directions—first from below upwards, and then from above downwards.

SCIATIC NERVE.

Indications.—The sciatic nerve may be accidentally divided in a wound—in this case it should be sutured as soon as possible. If an interval have elapsed, and the wound is healed, an incision may be made over it, the ends found and united by suture. It may also require local treatment on account of sciatica, tabetic paralysis, and in myelitis ascendens traumatica.

This nerve may therefore be exposed for the purpose either of suture or stretching. It is possible, however, to stretch the nerve forcibly by an extreme flexion of the hip-joint, while the knee-joint is fully extended. The procedure is painful enough to require the use of an anæsthetic. The patient being in a recumbent posture, the surgeon should grasp the knee and ankle of the affected limb, keeping the limb fully extended at the knee, while the hip is gradually and forcibly flexed until the foot is as close to the chin as it will come. Or, while the thigh is held firmly fixed in the completely flexed position at the hip, the leg may be gradually straightened upon the thigh, and finally the foot dorsally flexed upon the

leg; in this way a great amount of strain can be brought to bear upon the sciatic nerve as it passes out of the pelvis. This method has in many cases proved successful in abating the pain of sciatica, but a permanent cure seldom follows.

Surgical anatomy.—The nerve passes out of the pelvis through the great sacro-sciatic foramen below the pyriformis muscle. It descends between the great trochanter and the tuberosity of the ischium, and passes down the back of the thigh for a distance of about two-thirds of its length, approximately following a line drawn from a point midway between the tuber ischii and trochanter major femoris, but rather nearer the former, and another point midway between the condyles of the femur. It is well to bear in mind the fact that the internal and external popliteal nerves sometimes have a high origin, and in this case the sciatic nerve is represented by two cords instead of one.

Operation.—The nerve is most accessible for the purpose of stretching immediately below the gluteal fold, midway between the trochanter major and the tuber ischii. In this position it is relatively superficial; no important vessel comes in the way; and the trunk can, if necessary, be traced to its point of emergence from the pelvis. The patient should be turned on his face; the position of the posterior superior angle of the trochanter major and the prominence of the tuber ischii are first marked on the skin, and an incision exactly midway between them is made downwards in the direction of the long axis of the limb (Fig. 321). The wound should be about four inches in length, varying somewhat according to the muscularity of the subject, and should commence above just over the gluteal fold; divide the skin, fascia, and a thick layer of fat; the lower border of the gluteus maximus will then be exposed, running obliquely downwards and outwards, crossing the gluteal fold obliquely. If the border of the muscle be now drawn upwards with an elevator, the biceps femoris will be seen passing downwards on the outer side. This muscle, with the semi-membranosus and semi-tendinosus, should be drawn inwards. After some intervening cellular tissue has been divided, the large trunk of the nerve will be exposed. Some further separation enables the finger to be passed around, it and the necessary amount of traction can then be exercised both upwards and downwards. Careful drainage is necessary after this operation, as

in some cases troublesome suppuration has taken place beneath the gluteus muscle and downwards along the nerve into the thigh.

Trombetta and Billroth strongly advocate stretching the sciatic nerve in this way for cases of sciatica. The former found that in the dead body the sciatic nerve could be thus elongated one inch.

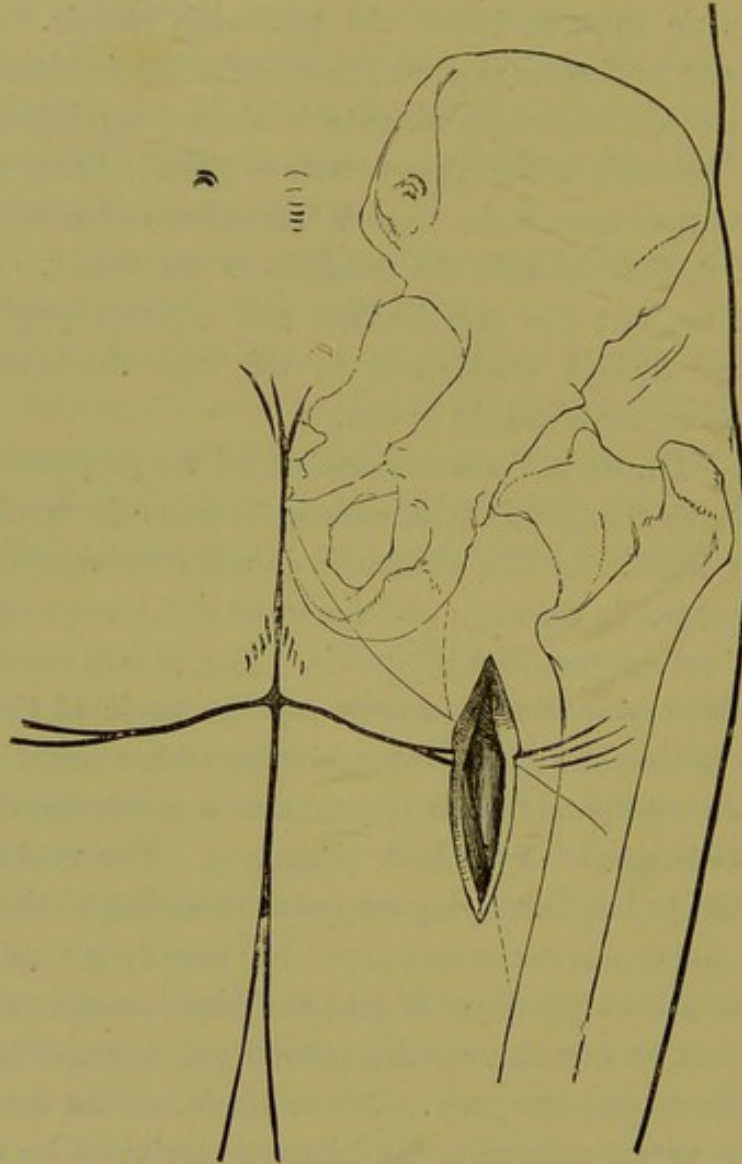


FIG. 321.—Manner of exposing the great sciatic nerve in the upper part of the thigh. The faint oblique line corresponds to the lower border of the gluteus maximus muscle.

THE ANTERIOR TIBIAL NERVE.

Indications.—Wounds, lacerations in fracture of the leg, painful ulcer of the foot, tetanus.

Surgical anatomy.—From the bifurcation of the peroneal nerve in the substance of the peroneus longus muscle, the nerve runs obliquely across

the interosseous membrane and joins the anterior tibial vessels at the junction of the upper with the middle third of the leg. At first it lies external, then anterior, and near the ankle-joint external to the anterior tibial vessels. The inner tendon of the extensor longus digitorum forms the best guide to its position.

Operation.—Make an incision two and a half inches long parallel to the tendon of the extensor communis digitorum just above the anterior annular ligament, and close to its tibial or inner edge. The nerve will be found lying close to the outside of the artery and its veins.

THE LONG SAPHENOUS NERVE.

Indications.—Neuralgia, painful ulcer, tetanus.

Surgical anatomy.—It passes from its origin towards the inside of the knee-joint in close connection with the femoral artery and lying to its outer side. It leaves the femoral artery at the opening in the adductor magnus, and accompanying the superficial branch of the anastomotica magna artery it first becomes subcutaneous at the insertion of the sartorius tendon, where it joins the long saphena vein. It then passes with the vein close behind the internal edge of the tibia to the antero-internal aspect of the ankle-joint, where it divides into its two terminal branches.

Operation.—The nerve can most easily be found as it crosses the internal lateral ligament of the knee beneath the tendon of the sartorius muscle by a curvilinear incision along the posterior edge of the sartorius tendon. The saphena vein and the nerve will be found lying in close proximity, and the latter can be drawn up on a hook or the finger quite easily, more especially if the leg be meanwhile flexed.

OPERATIONS ON THE NERVES OF THE ARM AND FOREARM.

Indications.—The exposed position of the nerves of the upper extremity accounts for their liability to injury. They are frequently implicated in gunshot wounds: the musculo-spiral nerve may be damaged in fracture of the humerus; the ulnar has frequently been divided in the neighbourhood of the elbow, especially during excision of the joint. The median, ulnar, and radial nerves may be involved in wounds near the wrist.

Surgical anatomy.—A knowledge of the manner in which the nerves are

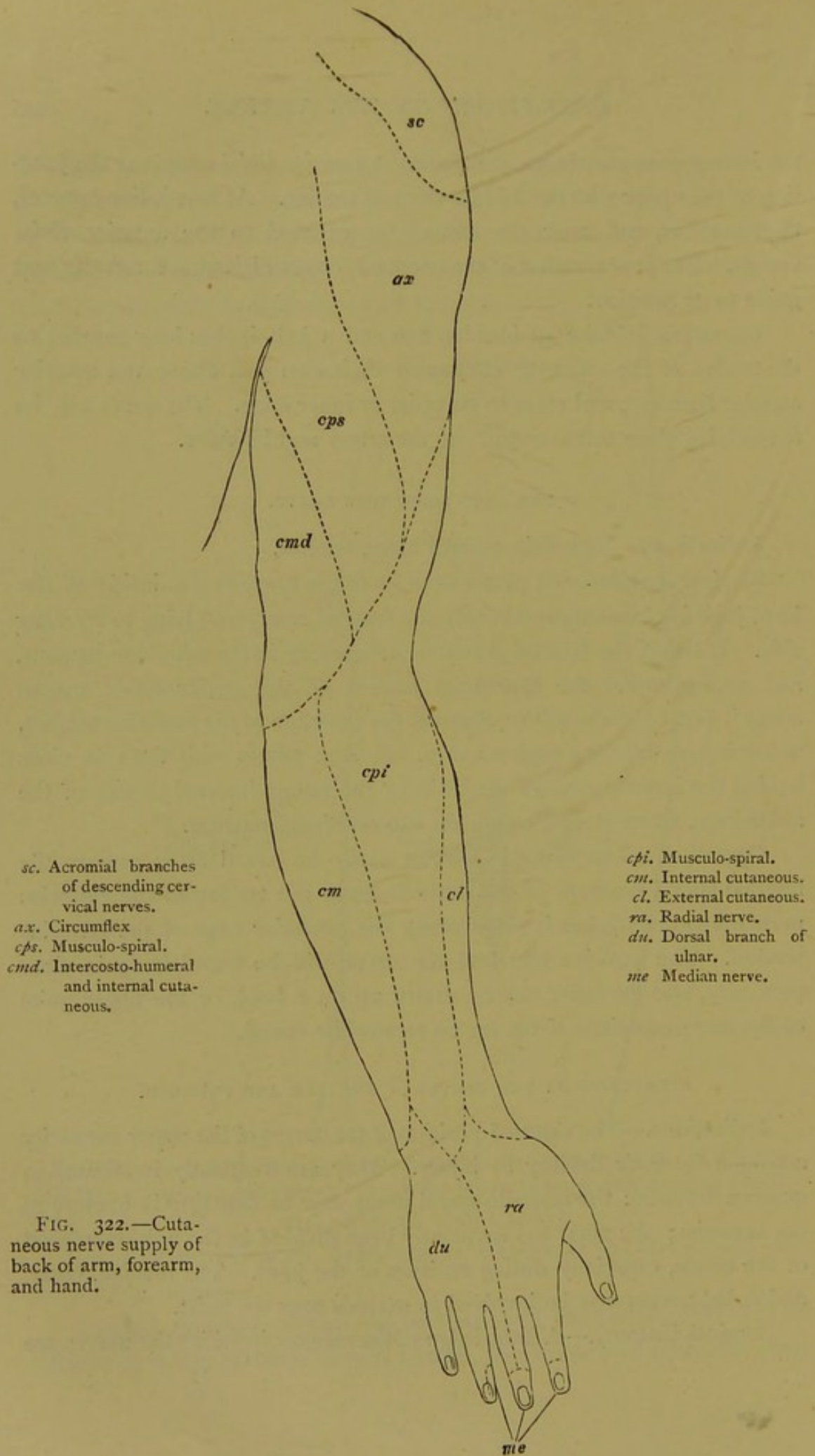


FIG. 322.—Cutaneous nerve supply of back of arm, forearm, and hand.

sc. Acromial branches
of cervical nerves.
ax. Circumflex nerve.
cmd. Intercosto-humeral
and nerve of Wris-
berg.

cm. Internal cutaneous.
cl. External cutaneous.
cp. Radial.
pu. Ulnar.
me. Median.
u. Ulnar.

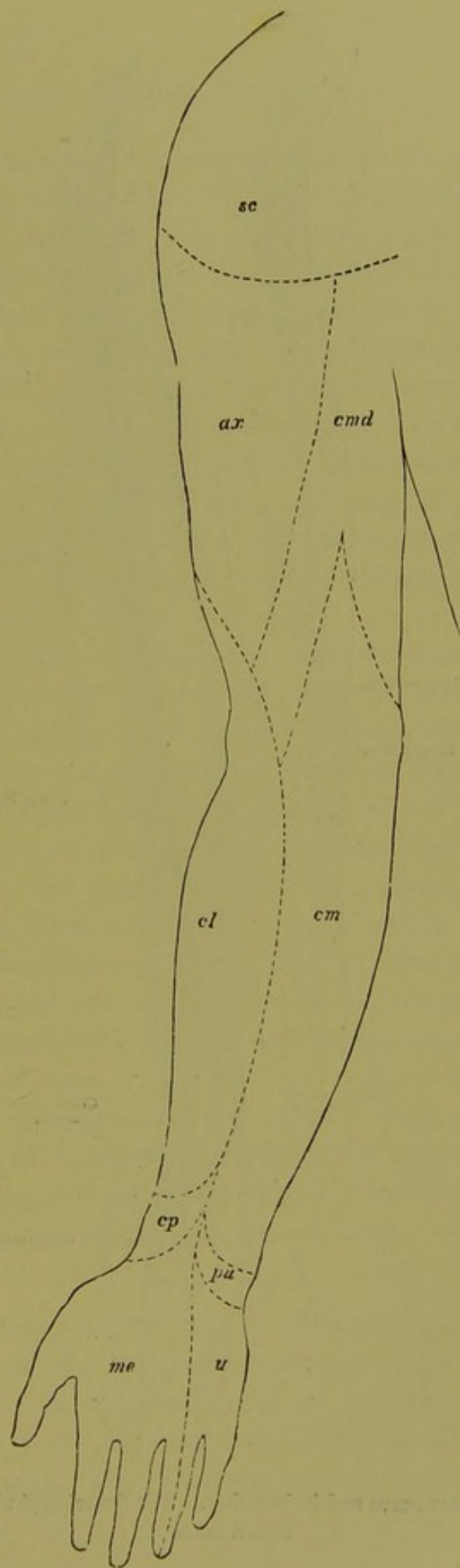


FIG. 323.—Cuta-
neous nerve supply of
the front of the arm,
forearm, and palmar
aspect of the hand.

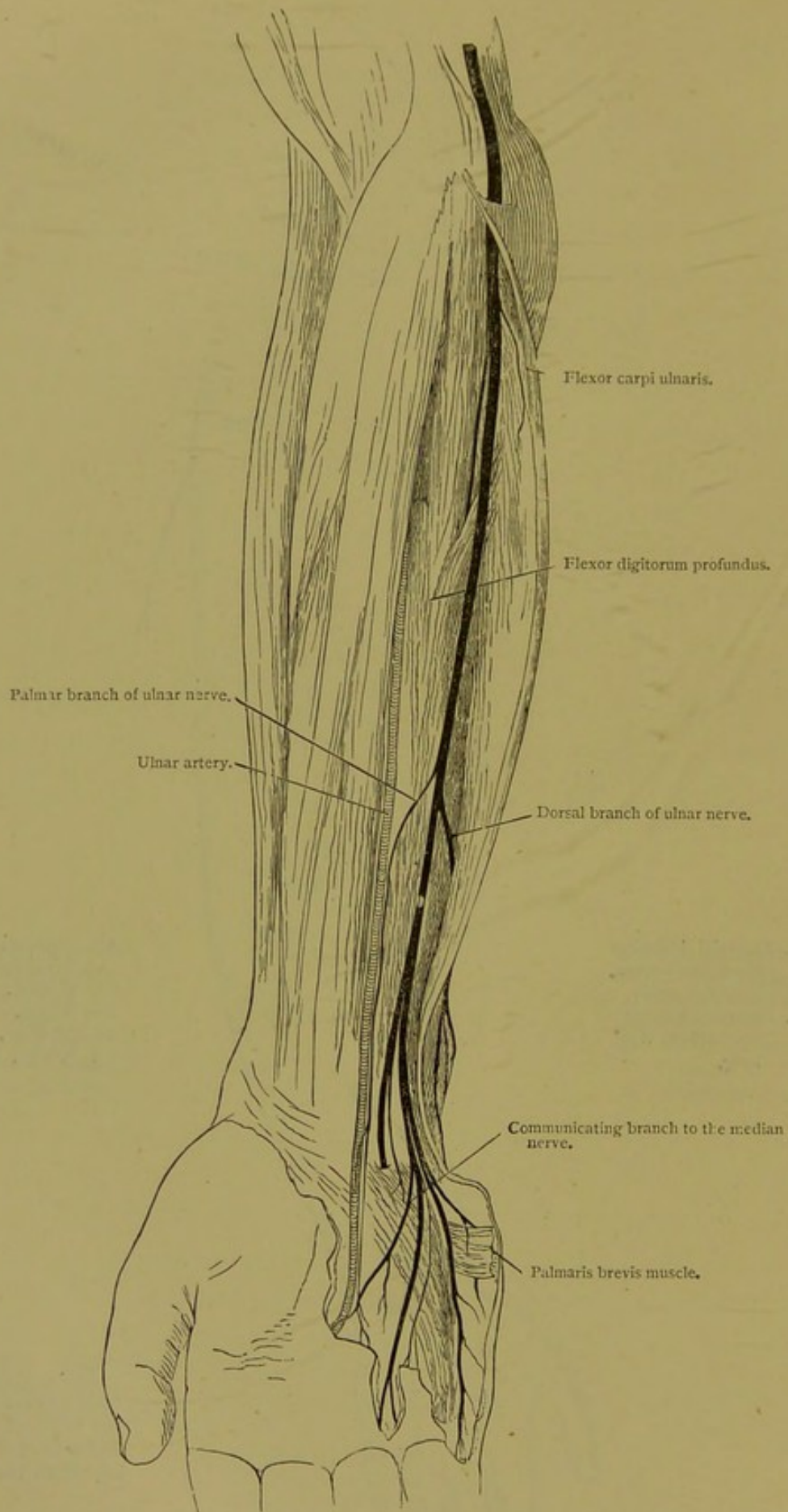


FIG. 324.—Ulnar nerve and its branches. The flexor carpi ulnaris muscle is turned aside

distributed in the hand and fingers is necessary for the purpose of arriving at a diagnosis as to which nerve is implicated (Figs. 322, 323, 324).

The skin of the palm and front of the wrist is partly supplied by the median, partly by the ulnar; that of the ball of the thumb by the superficial branch of the radial; the median supplies sensation to the flexor surfaces of the thumb, index, middle, and radial side of ring finger; while the other side of the ring and both sides of the little finger are supplied by the ulnar nerve. On the dorsal aspect the little finger is supplied by the ulnar nerve, and the thumb by the radial; the proximal phalanx of the ring finger, and the ulnar border of the middle finger, are supplied by the ulnar; the proximal phalanx of the index finger and the radial side of the middle finger are supplied by the radial nerve; the remaining phalanges being supplied by the median.

The median supplies motor filaments to the flexor muscles, with the exception of the flexor carpi ulnaris and the ulnar half of the flexor digitorum profundus; to the muscles of the ball of the thumb, with the exception of the adductor pollicis and inner head of the flexor brevis pollicis; and to the two outer lumbricales. The ulnar supplies all the other muscles, the flexor carpi ulnaris and the inner half of the deep flexor of the fingers, the palmaris brevis and two inner lumbricales, the adductor pollicis, the deep head of the flexor brevis pollicis, the abductor minimi digiti, flexor brevis and flexor ossis metacarpi, and the interossei. The musculo-spiral supplies the supinator longus, and extensor carpi radialis longior; the supinator brevis, and the remaining extensor muscles being supplied by its branch the posterior interosseous.

When the nerve supplying any one group of these muscles is divided they lose power and rapidly atrophy; the skin of the area supplied by the nerve is insensitve, cold, bluish-coloured, and easily ulcerates, and other indications of defective nutrition are soon apparent.

ULNAR NERVE.

Surgical anatomy.—In the forearm (Fig. 324), the ulnar nerve can scarcely be injured without extensive damage being done to adjacent structures as well. In the lower third of the forearm, the ulnar nerve lies between the artery and the flexor carpi ulnaris tendon, covered by skin and fascia (Fig. 324). The tendon may be easily traced to its insertion into

the pisiform bone ; the dorsal branch of the nerve is given off at a variable distance above the wrist, and it will be therefore better, in cases of nerve stretching, to seek the trunk a short distance above the elbow (Fig. 326).

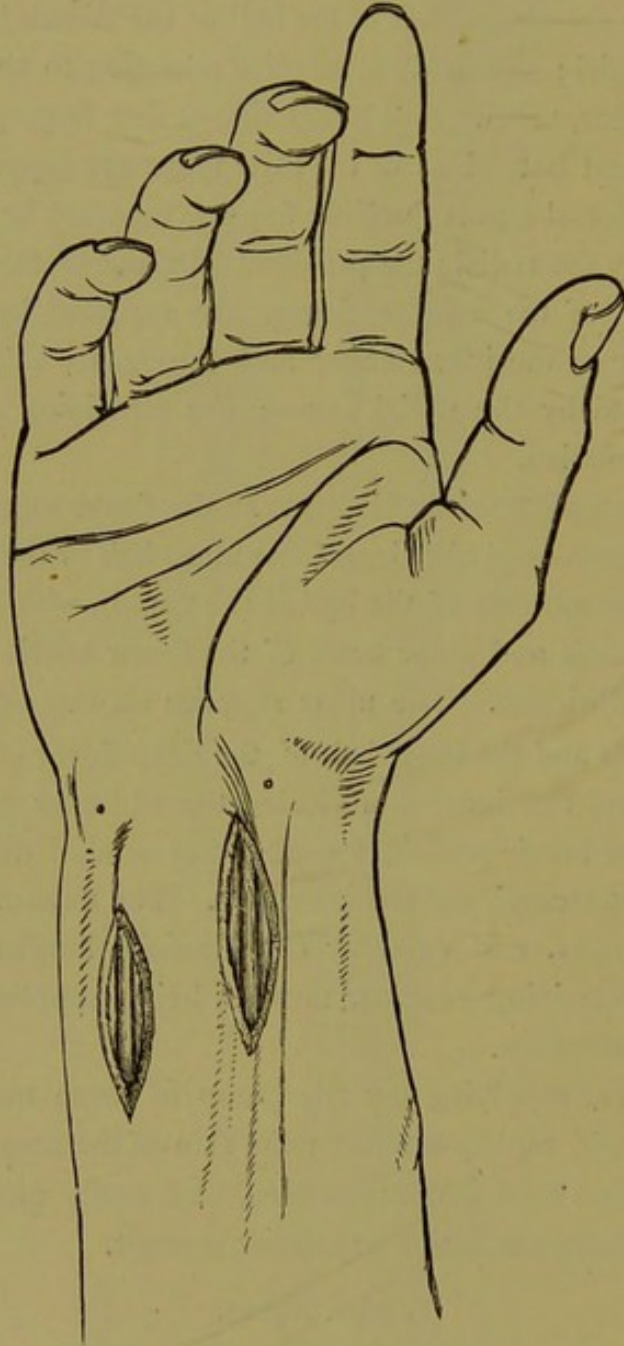


FIG. 325.—Position of the incisions necessary to expose the ulnar and median nerves near the wrist.

In the lower half of the arm the direction of the ulnar nerve is best indicated by a line drawn from the centre of the brachial artery, that is, about the level of the insertion of the coraco-brachialis muscle, to the mid

point between the internal condyle and olecranon. Above, the nerve closely follows the course of the artery.

Operation.—In the lower half of the forearm the nerve may be exposed by an incision, two inches long, made through the skin, parallel to the tendon of the flexor carpi ulnaris and on its radial side (Fig. 325). When the fascia

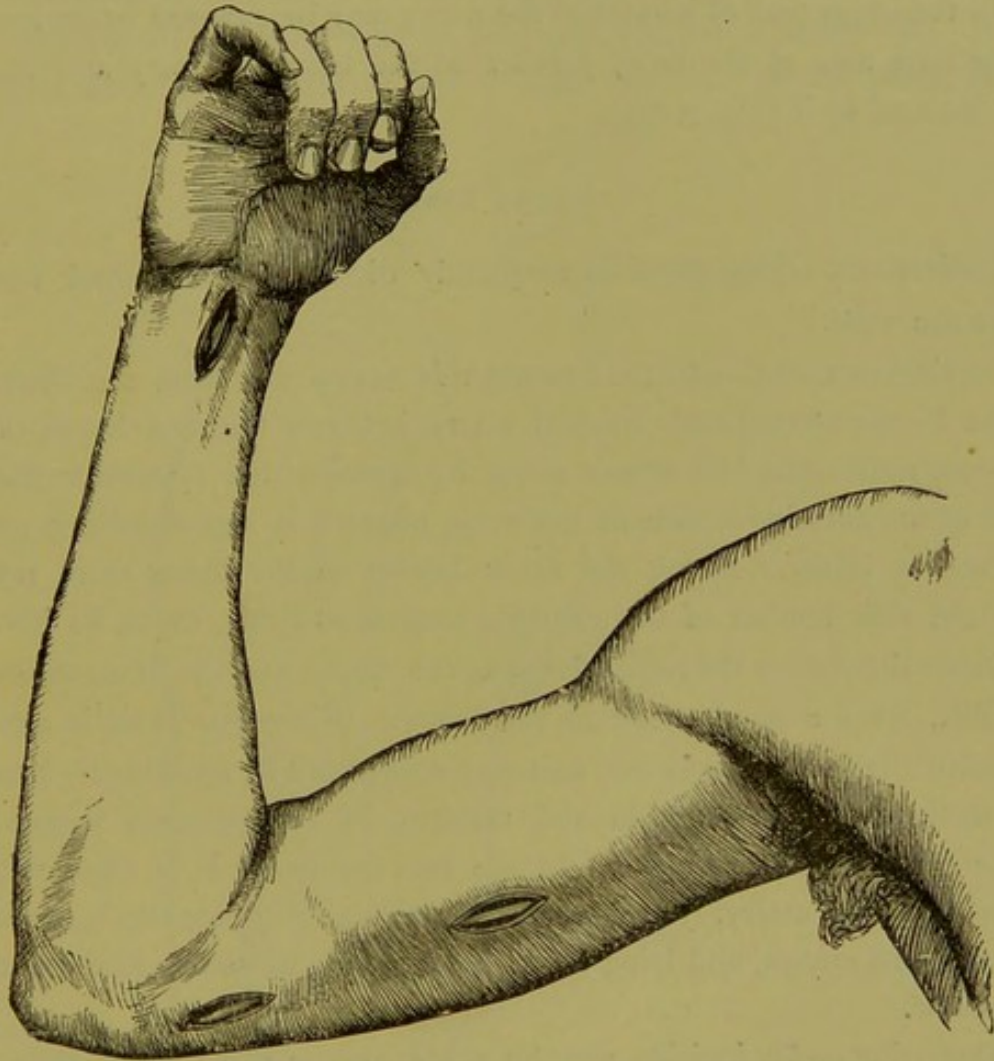


FIG. 326.—Position of the incisions which may be made to expose the ulnar nerve in the arm, and the median near the wrist.

is divided the ulnar nerve will be readily found, with the artery in close proximity. If it be necessary to expose the nerve in the lower part of the arm, the forearm should be first flexed to a right angle, and laid on its outer side as in Fig. 326. A vertical incision two to three inches long should then be made in the direction above indicated, terminating below at a point not less than two inches above the internal condyle of the

humerus; any injury to the joint is thus obviated. When the fascia has been divided the nerve may be readily exposed. It may then be treated, according to the circumstances of the case, either by neurotomy, neurectomy, nerve-stretching, or nerve suture, as laid down in the pages preceding.

In the upper part of its course the nerve may be exposed by an incision in the long axis of the limb, parallel to the brachial artery and half an inch internal to it (Fig. 326).

MEDIAN NERVE.

Indications.—The nerve is frequently divided by accidental wounds above the wrist.

Surgical anatomy.—In the forearm this nerve runs from the ulnar side of the biceps tendon and brachial artery between the two heads of the pronator radii teres, and thence along the centre of the forearm to the mid point of the anterior surface of the wrist, where it is superficial and greatly exposed to injury. Along the ulnar border of the flexor carpi radialis runs the thin tendon of the palmaris longus, and this, or in its absence the interval between the radial flexor of the carpus and the flexor digitorum sublimis, form a good guide to the nerve. When the hand is strongly extended the nerve stands out, and may sometimes be felt directly beneath the fascia and skin between the tendons of the palmaris longus and flexor carpi radialis muscles. In the arm the nerve is in close relation to the brachial artery, lying to its outer side above, crossing it about the middle of its course, and lying on its inner side in its course to the bend of the elbow.

Operation.—An incision may be made, two or three inches above the wrist, two inches long, and close to the radial border of the palmaris longus, or near the ulnar border of the flexor carpi radialis, if the palmaris be absent. After the fascia has been divided the nerve may be exposed and isolated (Fig. 325); and raised from its sheath with an elevator if stretching be required, or its extremities dissected out and united, if the case require suture.

In the arm the nerve may be most conveniently exposed by an incision, from two to three inches in length, along the inner border of the biceps,

about the middle of the limb (Fig. 326). At this point the nerve is very superficial, and can be felt as it crosses over the artery.

MUSCULO-SPIRAL NERVE.

The position in which this nerve is most accessible for the purpose of stretching is on the outer side of the arm, midway between the external condyle and the insertion of the deltoid muscle. In this situation it is

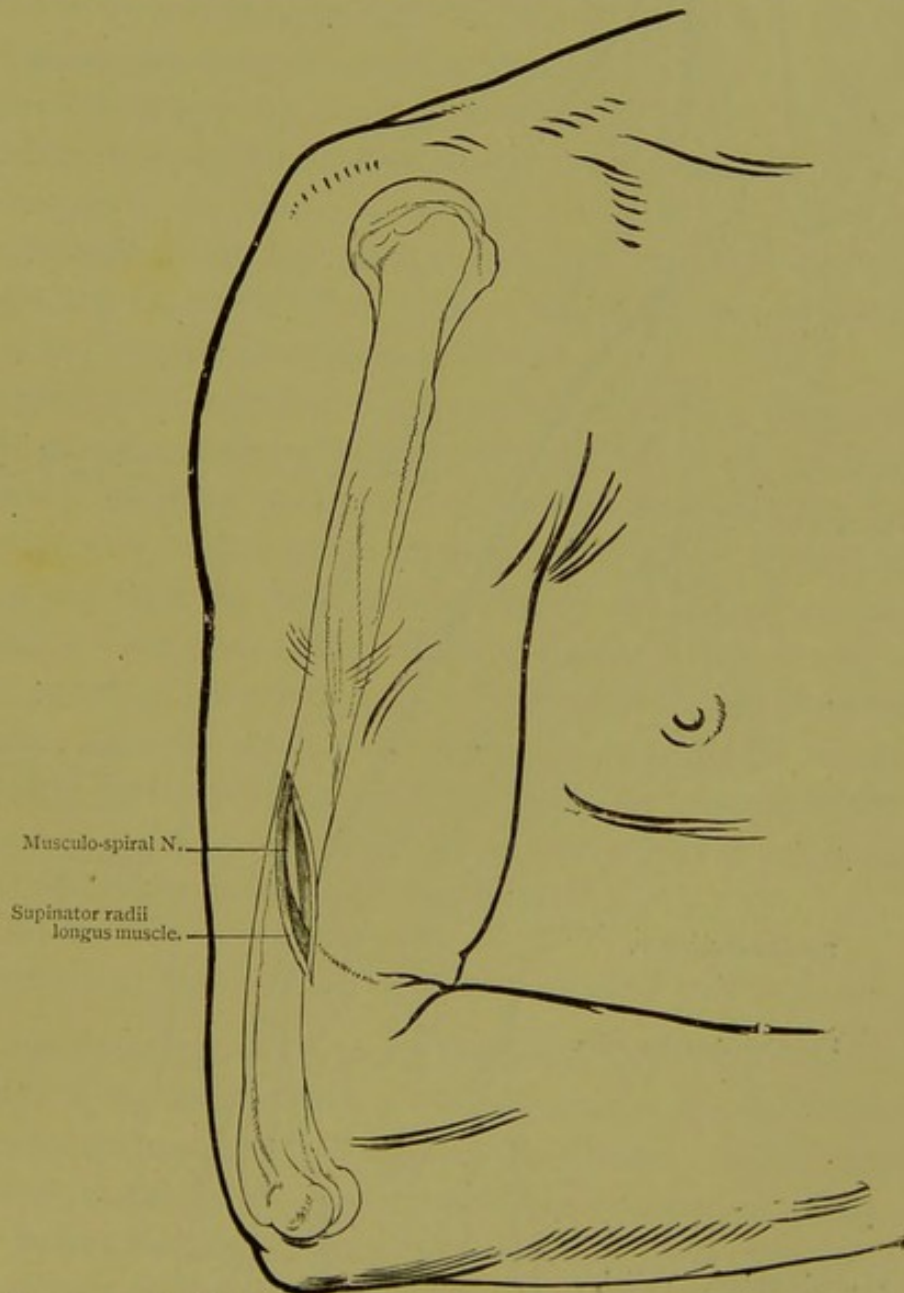


FIG. 327.—Position of the incision to expose the musculo-spiral nerve on the outer side of the arm as it lies between the supinator longus and brachialis anticus muscles.

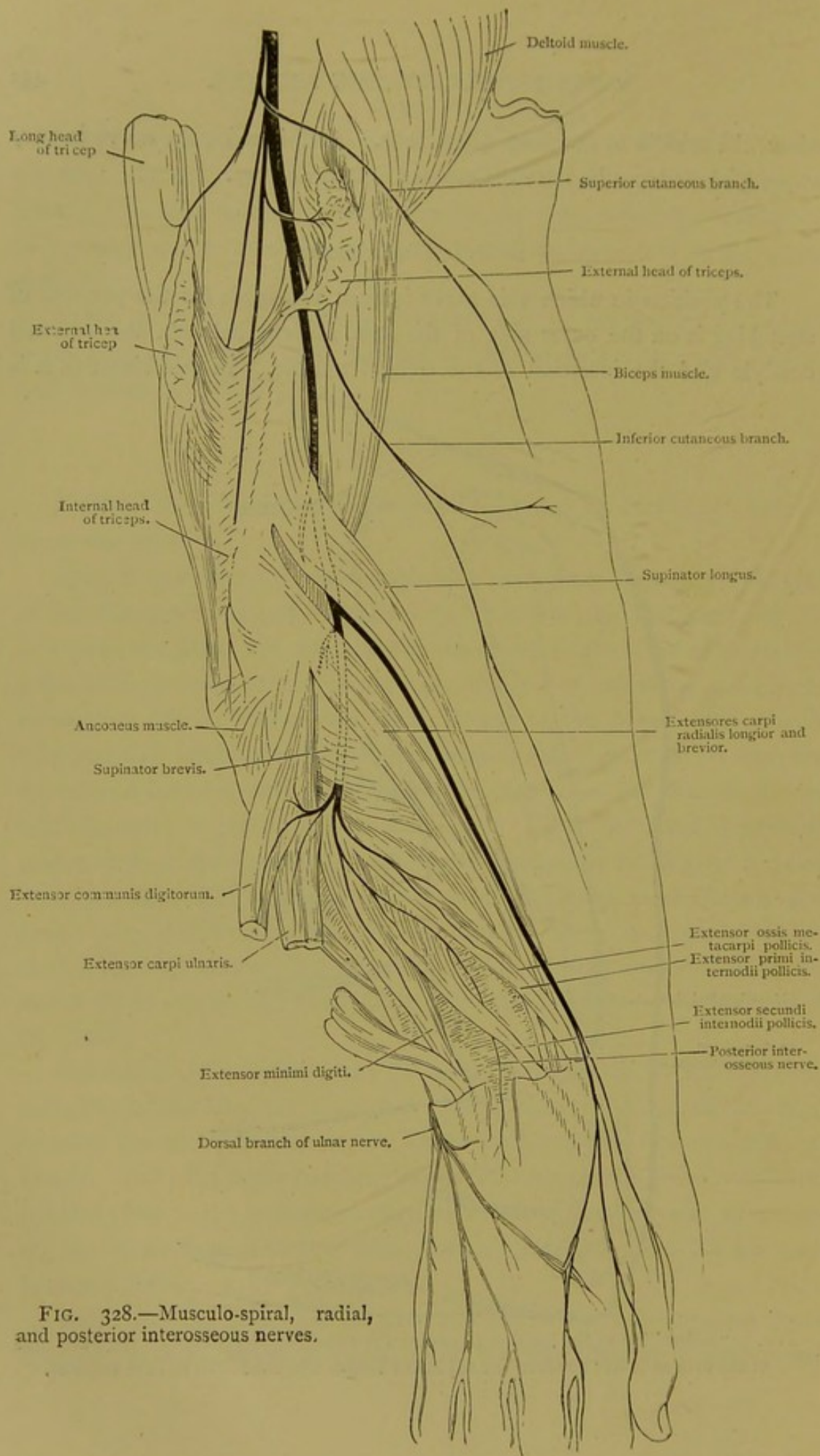


FIG. 328.—Musculo-spiral, radial, and posterior interosseous nerves.

often subject to injury which may necessitate surgical interference. It has been often damaged by blows on the arm, fracture of the humerus, or pressure from a crutch handle.

Surgical anatomy.—The nerve arises from the posterior root of the brachial plexus in common with the circumflex nerve. At its commencement it is placed behind the axillary and upper part of the brachial arteries. It then winds round the posterior part of the humerus, which it crosses opposite the deltoid insertion, lying close to the bone in the spiral groove, and accompanied by the superior profunda vessels. After piercing the external intermuscular septum, where it gives off its two cutaneous branches, one supplying the outside of the arm and elbow, and the other the outside of the forearm as far as the wrist, it passes downwards to the anterior surface of the external condyle lying between the supinator longus and brachialis anticus muscles, and terminates by dividing into the radial and posterior interosseous nerves.

Operation.—A vertical or slightly oblique incision through the skin and fascia, of two to three inches long, may be made in the lower third of the arm along the outer border of the biceps muscle; the anterior border of the supinator longus, which forms a good guide, should be retracted, and if the finger be now introduced into the wound the nerve will be felt like a tense cord rolling over the humerus. Care should be taken to avoid wounding the posterior articular and the terminal branches of the superior profunda artery (Fig. 327). Higher up, the triceps must be divided to reach the nerve, which lies upon the humerus, where it often is exposed to injury by reason of fracture of the bone or by being enclosed in the callus subsequently formed.

HEAD AND NECK.—EXPOSURE OF THE BRACHIAL PLEXUS IN THE NECK.

Surgical anatomy.—The plexus lies comparatively superficial in the space bounded by the anterior border of the trapezius, the posterior border of the sterno-cleido-mastoid muscle, and the clavicle. In thin persons, when the face is turned to the opposite side, the boundaries of this space are easily traced, the plexus can be felt, and its outline is often visible.

Operation.—The cords of the plexus may be exposed by an incision similar to that adopted for the ligature of the subclavian artery, but half an

inch higher in the neck, or by a vertical incision above the centre of the clavicle. If the latter be chosen, the shoulder should be depressed, and the head turned to the opposite side. An incision, of about three inches in length, should be made nearly parallel to and about an inch in front of the anterior border of the trapezius muscle, and terminating below half an

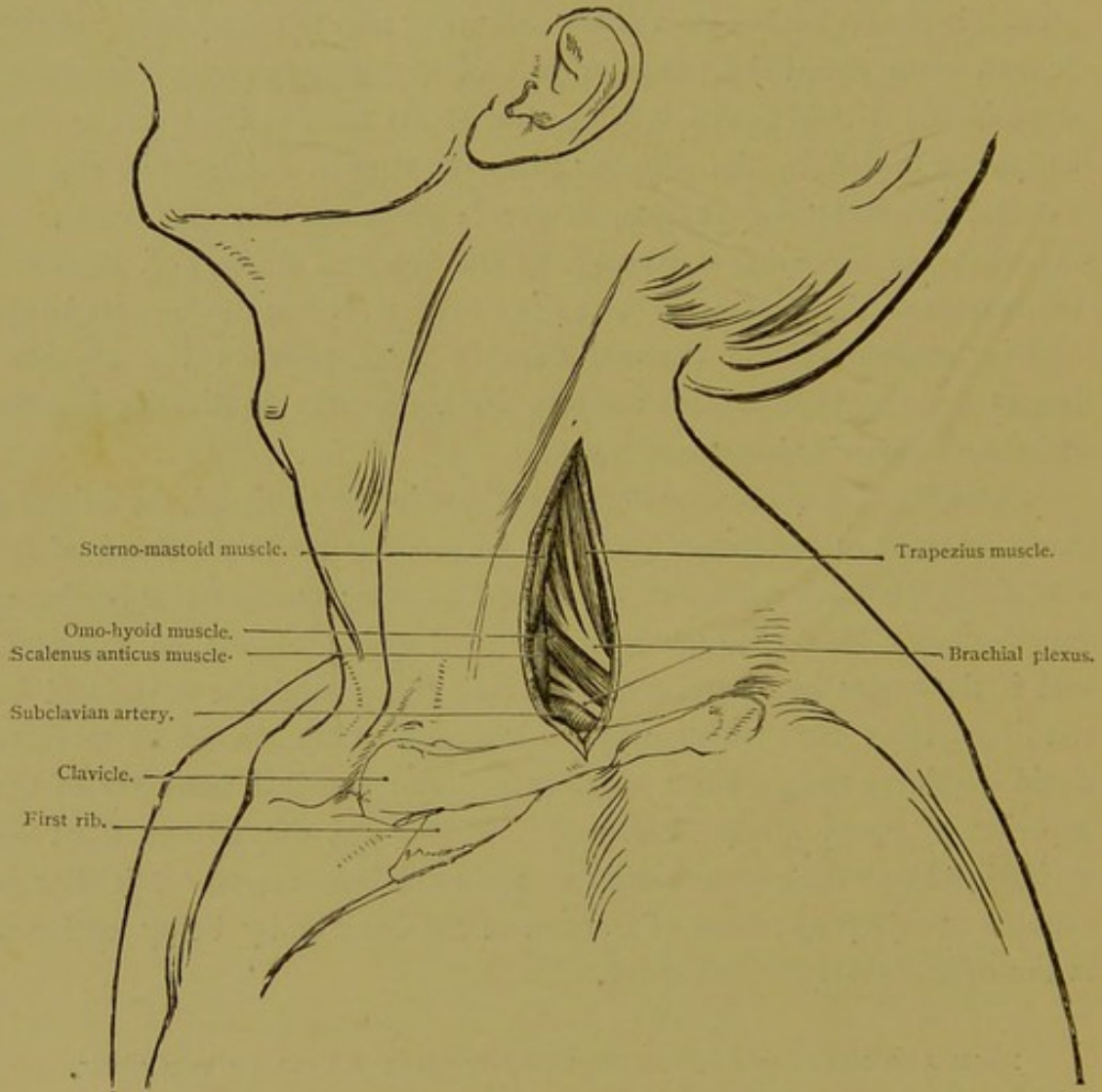


FIG. 329.—Incision to expose the brachial plexus in the neck. It has been prolonged downwards to show the position of the third stage of the subclavian.

inch or an inch above the clavicle. After the skin, platysma, and cervical fascia have been divided, the margins of the wound must be widely separated (Fig. 329), and the tissue covering the plexus torn through with a director or the handle of a scalpel. The omo-hyoid muscle, which crosses the lower portion of the wound, should be sought for and drawn upwards or down-

wards; and the tense external border of the scalenus anticus muscle will be discovered behind the sterno-cleido-mastoid. If the deeper layer of fascia be now divided, the cords of the brachial plexus will be exposed as they emerge from behind the anterior scalenus. They must be carefully isolated, so that the bent finger may be introduced behind them. By this method of operation no vessel is divided, except, perhaps, the superficial cervical, which can be easily secured. The transversalis colli artery crosses the lower part of the wound, and need run no risk of injury. The subclavian artery should not be exposed. As soon as the plexus has been bodily hooked up on the finger, its sheath should be opened, and the individual cords may be then separated as far as the transverse processes of the vertebræ (the lowest passing behind the third part of the subclavian artery). The necessary amount of stretching in both the centrifugal and centripetal directions may then be practised, and the cords are afterwards replaced; a drainage tube is inserted at the lower end of the wound, and antiseptic dressings are applied.

EXPOSURE OF THE CERVICAL PLEXUS.

Indications.—Neuralgia in the area of distribution of the nerves; spasmodic affections of certain muscles.

Surgical anatomy.—The plexus is placed high in the neck opposite the four upper cervical vertebræ, and is formed by the anterior branches of the four upper cervical nerves. It rests upon the scalenus medius and levator anguli scapulæ muscles, and is covered by the sterno-mastoid muscle. The superficial nerves of the neck emerge from behind the centre of the posterior border of the sterno-mastoid muscle. A line from this point crossing the sterno-mastoid at right angles corresponds to the superficial cervical nerve. The great auricular nerve corresponds in direction to the external jugular vein, and is indicated by a line drawn across the muscle to the back of the pinna, while the small occipital nerve runs upwards along the posterior border of the sterno-mastoid muscle to the scalp.

The great occipital nerve pierces the complexus and trapezius, then it emerges on the back part of the head with the occipital artery, and is distributed to the scalp as far as the vertex (Fig. 334).

Operation.—Turn the head completely to the opposite side, make an

incision two and a half inches in length along the posterior border of the sterno-cleido-mastoid muscle, beginning at a point about two inches below the tip of the mastoid process. When the skin and fascia have been divided the borders of the trapezius and sterno-mastoid muscles will be seen lying close together; the latter must be carefully isolated and drawn forwards. A little careful dissection will now lay bare the great auricular nerve, passing upwards across the sterno-mastoid (Fig. 330). A little lower down,

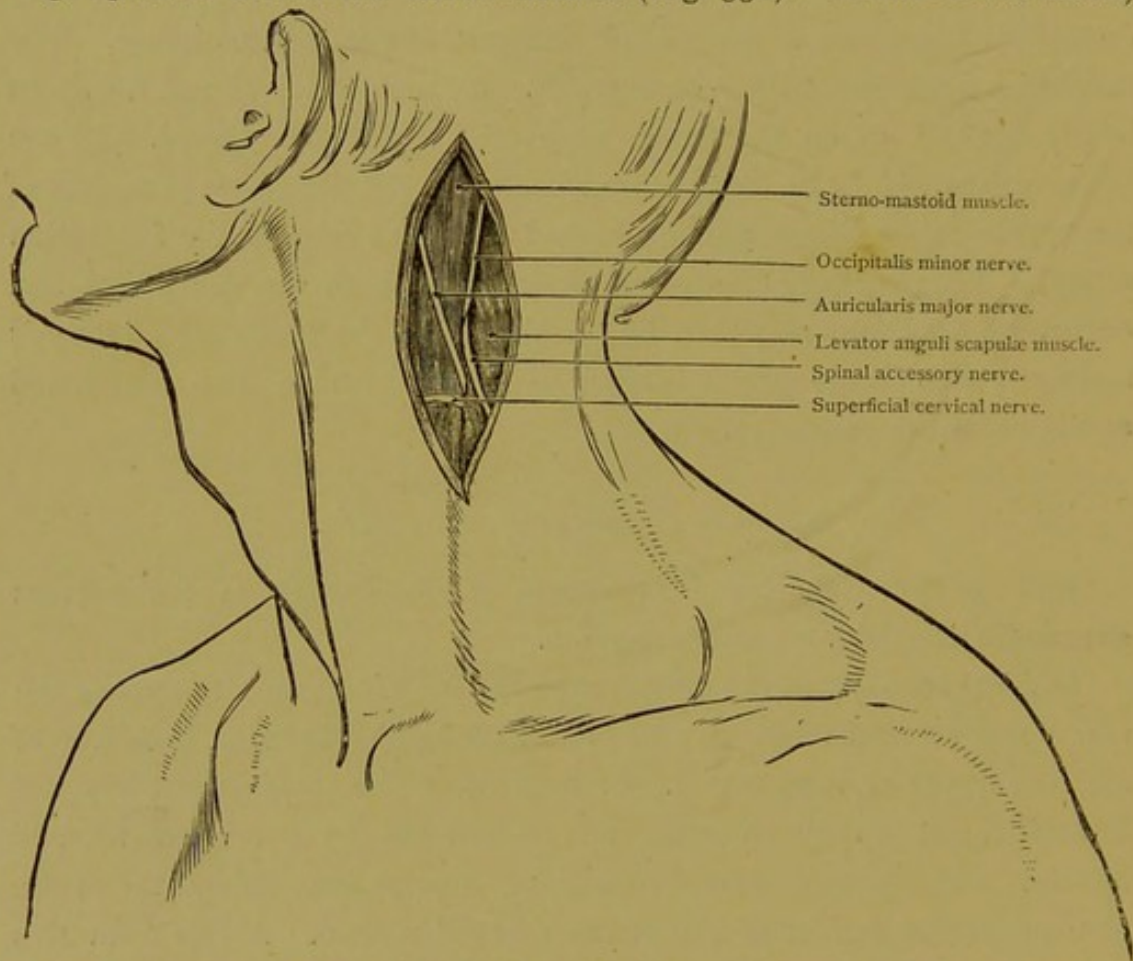


FIG. 330.—Incision to expose the branches of the cervical plexus.

crossing the muscle transversely, will be found the trunk of the superficial cervical nerve, which may be traced in the space between the scalenus and the levator anguli scapulae muscles to its point of exit from the spinal column. The fourth cervical nerve, giving off the superficial descending branches (supra-sternal, supra-clavicular, and supra-acromial), must be looked for lower down, behind the posterior border of the sterno-mastoid. If there be occasion to stretch this cord, its connection with the phrenic nerve must be remembered.

THE SPINAL ACCESSORY NERVE.

Indications.—Uncontrollable spasmodic action of the trapezius and sterno-mastoid muscles.

Surgical anatomy.—The spinal accessory leaves the skull through the foramen lacerum posterius in close connection with the pneumogastric

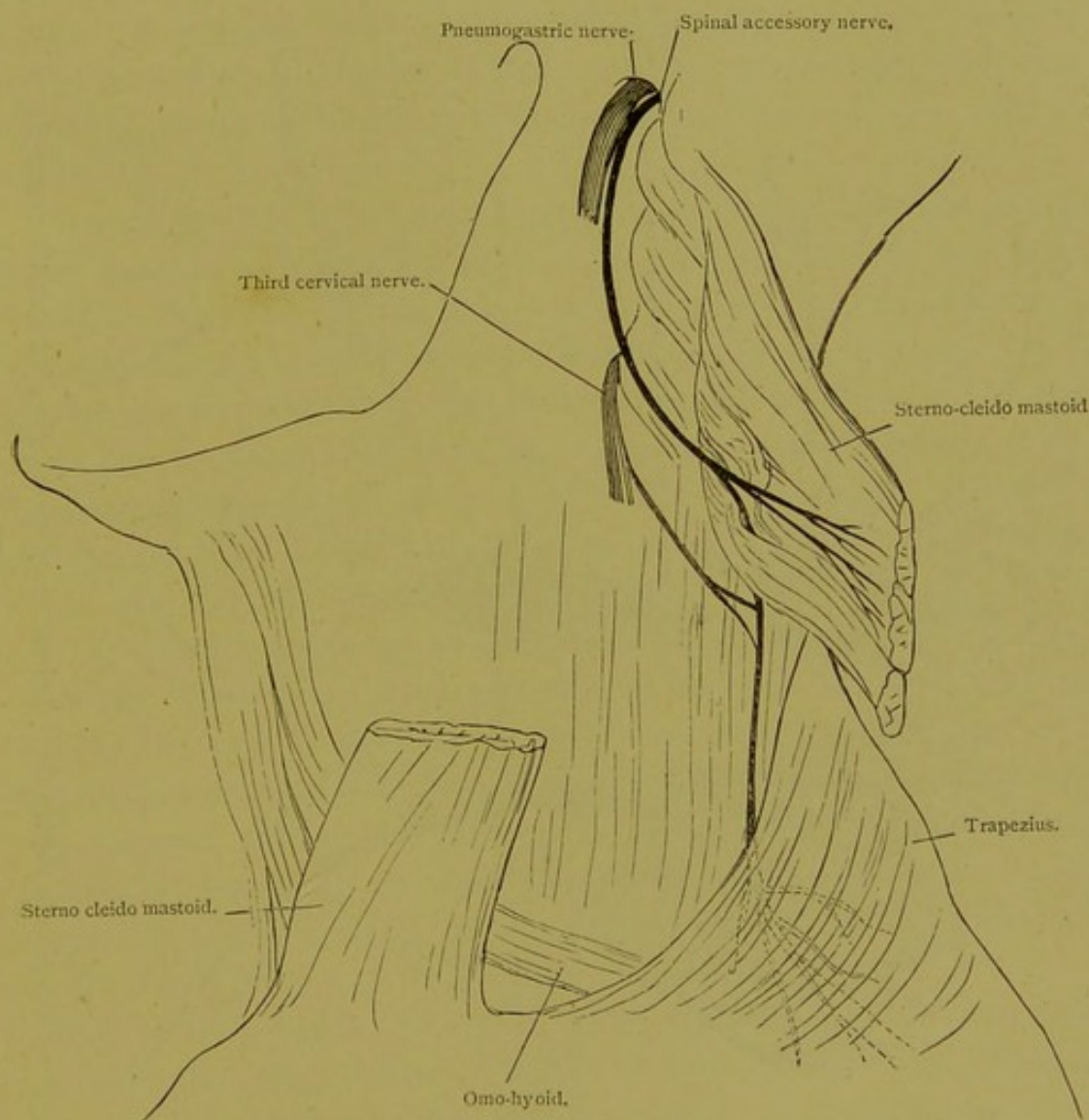


FIG. 331.—Distribution of the spinal-accessory nerve.

being enclosed in the same sheath. At its exit it passes backwards between the internal jugular vein and the occipital artery, either internal or external to the vein, descends obliquely behind the digastric and stylo-hyoid muscles, and immediately enters the upper part of the sterno-mastoid

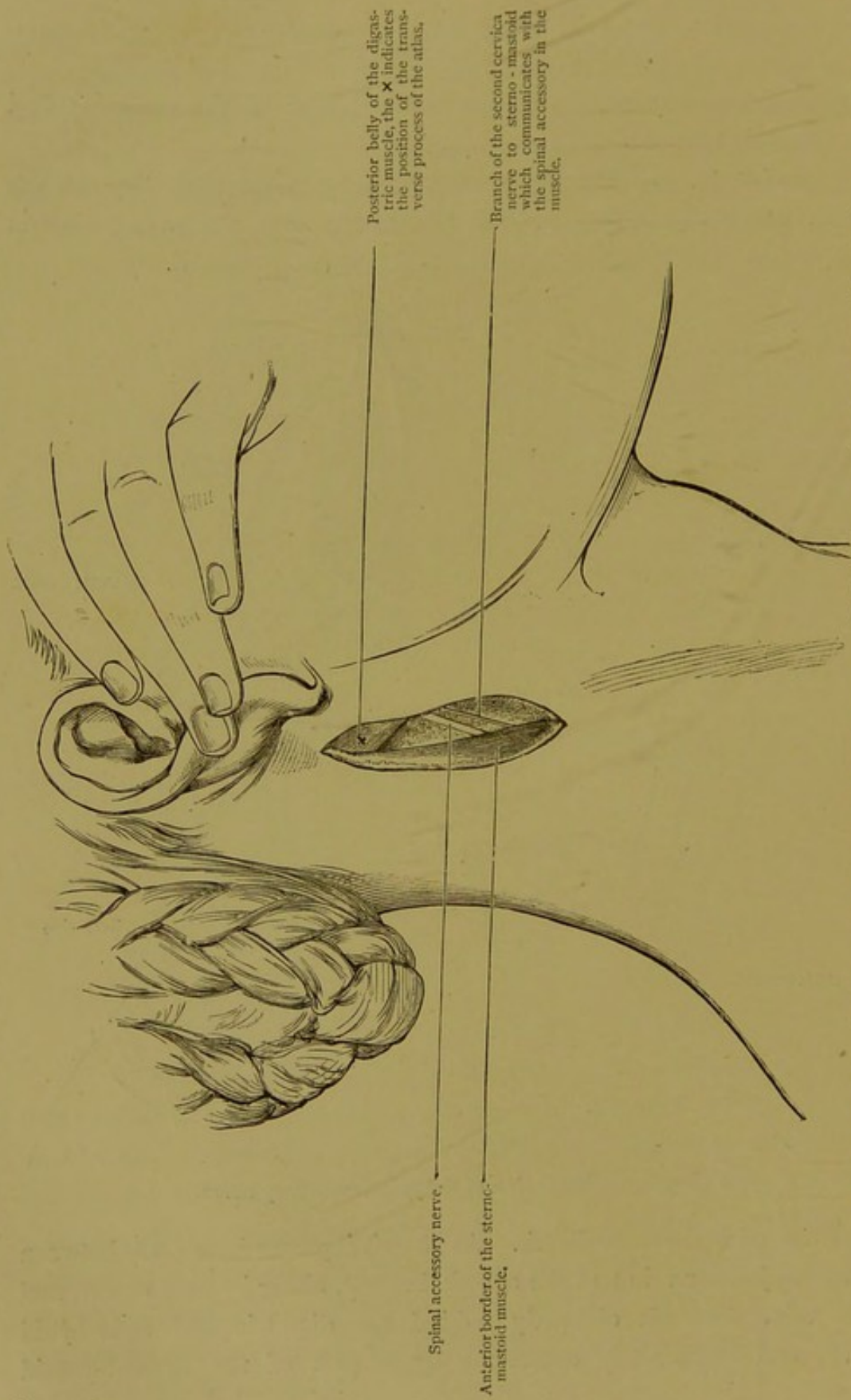


FIG. 332.—Dissection to expose the spinal accessory nerve before it enters the sterno-mastoid muscle.

muscle, at a point two inches below the mastoid process. In this course it lies very deep, and the best guide is the transverse process of the atlas, which can readily be made out, or its direction is indicated by an imaginary line drawn downwards at right angles from the centre of a line joining the angle of the inferior maxilla and the apex of the mastoid process. After passing through the sterno-mastoid muscle it makes its exit about the centre of its posterior border. It crosses the posterior triangle of the neck and dips beneath the border of the trapezius, where it joins with the third and fourth cervical nerves opposite the spine of the vertebra prominens.

Operation.—The nerve may be exposed as it passes into the sterno-mastoid and divided, or a portion excised. Make an incision two and a half inches long from the tip of the mastoid process on a level with the lobule of the ear downwards along the anterior margin of the sterno-mastoid muscle, this will reach a point corresponding to the angle of the jaw, divide the integuments and fascia and expose the anterior border of the muscle, retracting the soft parts to each side. The edge of the muscle must be pulled back, and in doing so the nerve is put on the stretch and it can thus be seen or felt beneath the fascia. The best guide to its position is the transverse process of the atlas, which can be distinctly felt in the wound, the nerve lies immediately in front of and then below it. The fat and areolar tissue are carefully cut through, and the posterior auricular nerve may require to be divided, the edge of the posterior belly of the digastric will be seen crossing the upper part of the incision and immediately below this the spinal accessory will be exposed as it runs downwards and backwards to the deep surface of the sterno-mastoid muscle (Fig. 332).

Mr. Ballance has performed this operation in one case with very satisfactory results. Mr. Wheeler of Dublin has also twice operated on this nerve for spasmodic torticollis. On one occasion he stretched the nerve, and on the other cut a portion of it out. Both operations were followed by marked improvement, but the benefit derived from the excision of a portion of the nerve was permanent.

FIFTH OR TRIGEMINAL NERVE.

Indications.—Division of the branches of the fifth nerve appears to have been first performed by Maréchal, in the last century. The operation

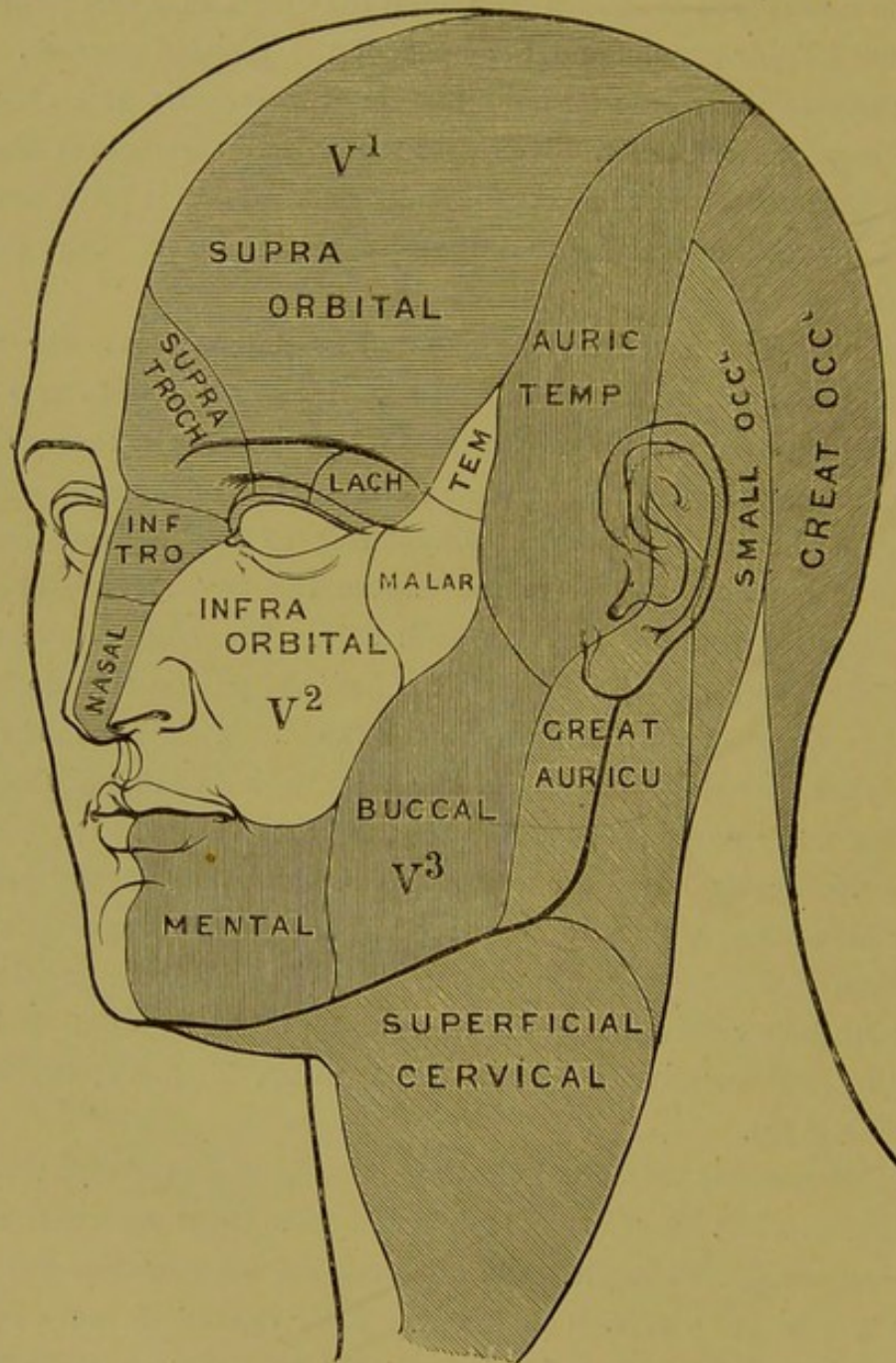


FIG. 333.—Areas of distribution of the branches of the fifth nerve and of the cervical plexus upon the head and face.

is undertaken for the relief of severe pain in the area of distribution of the nerve and in some cases proves very successful; in others not at all. The

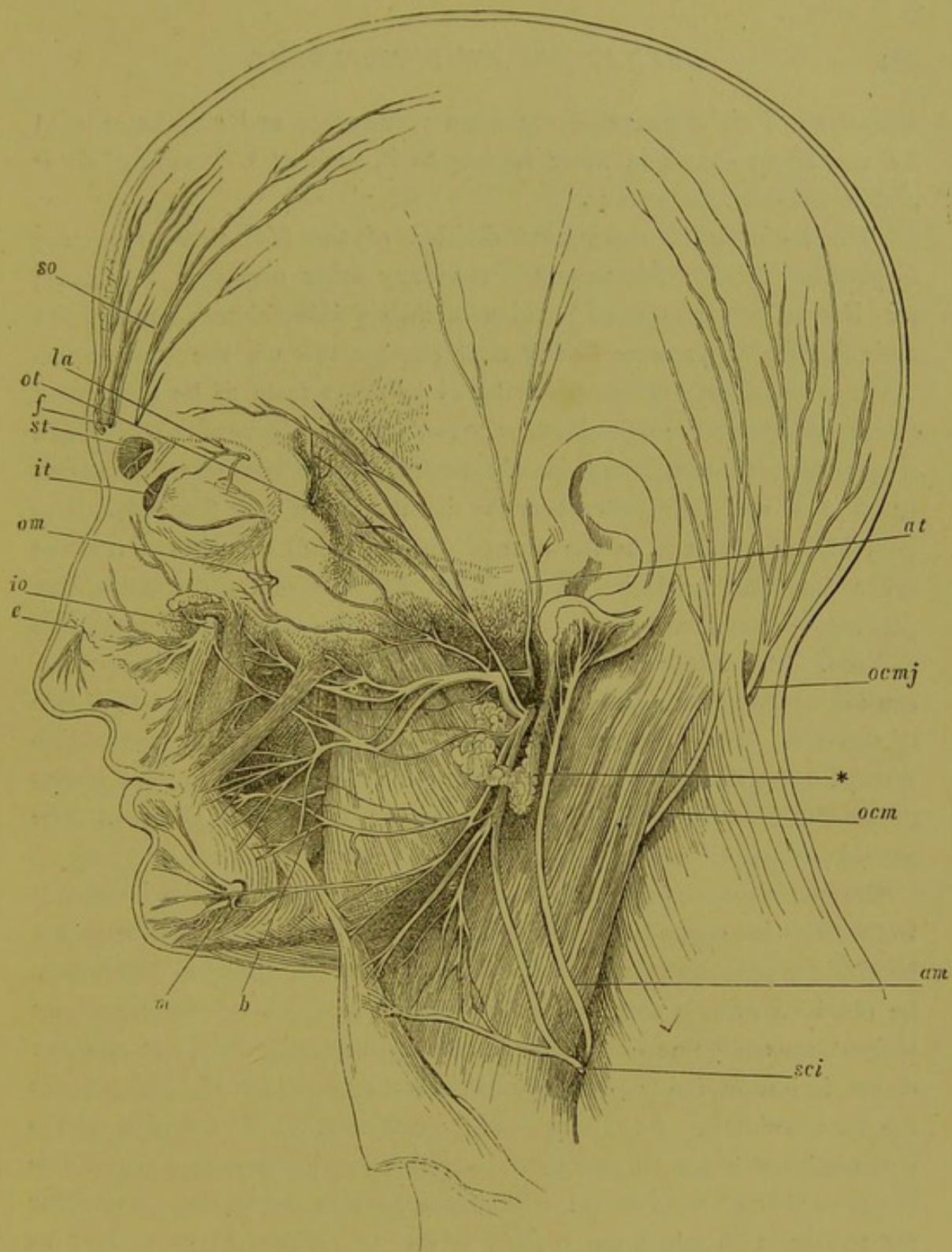


FIG. 334.—Terminal branches of the facial and sensory nerves of the face ; the parotid gland * is almost completely removed.

so. Supra-orbital.
la. Lachrymal.
ot. Temporal.
f. Frontal.
st. Supra-trochlear.
it. Infra-trochlear.
om. Malar.
io. Infra-orbital.

e. Nasal branch of ophthalmic.
m. Mental.
b. Buccal.
sci. Superficial cervical.
am. Great auricular.
ocm. Small occipital.
ocmj. Great occipital.
at. Auriculo-temporal.

symptoms of facial neuralgia are often very severe, and may be aroused by very slight causes in those subject to it, such as a draught of air or a mere touch on the surface.

The branches of the second division of the fifth nerve are more frequently affected with neuralgia than any other nerves in the body; this is due to the exposed position of their peripheral terminations, and their liability to pressure during their passage through the bony canals that transmit them; the posterior dental branches seem to be a common starting-point for the lightning-like pains, which are generally centrifugal, frequently starting from the point of emergence of the nerves from their bony canals, and radiating thence over the distribution of their filaments. The pain may also extend to the area of distribution of branches of a nerve other than that primarily involved, but the seat of the disease will be generally determined by the greater severity of the attack in the nerve first affected. The motor nerves also are often concerned, their implication causing spasm and impaired nutrition of the muscles on the affected side of the face. There may be in addition sudden flushing of the face, lachrymation, salivation, and various anomalies of sensation, and in the intervals of the attacks there may be altered sensation of the part affected. The paroxysms may be caused by direct or reflex irritation.

Neuralgia due to peripheral causes, where the seat of irritation is external to the skull, is amenable to surgical interference. If the cause of irritation be within the cranium, the condition is less favourable, but improvement may be obtained, even in these cases, by resection of the nerve concerned, by which means the line of communication between the periphery and the centre is interrupted; and many of the exciting causes of neuralgic attacks are thus removed. As a result of frequent attacks, the nutrition of the nerve is interfered with, and in the severest forms the patient's existence becomes almost unendurable. Those cases are of course most favourable for treatment in which the malady is due to peripheral causes, such as tumours in or pressing upon the nerve, fractures of the jaw badly united, diseases of the teeth, and inflammation of the periosteal lining of the canal through which the nerve passes. Neuralgia may also result from intracranial syphilis, tumour, or hæmorrhage; or it may be due to malarial or hysterical influences.

Diagnosis.—It is often difficult to distinguish radiating from primary nerve pain, more especially in old-standing cases. At the beginning the pain may be confined to the area of a single nerve, but afterwards it is prone to radiate. A diagnosis must then be made as to its causation, whether peripheral or central. Some of the peripheral causes have been already mentioned. If the pain be of central origin, there may be evidence of brain implication, and no peripheral cause will be made out. In peripheral neuralgia, the pain will be usually limited to one nerve; while, if there be a central lesion, the peripheral manifestation will probably be distributed over the areas of two or more nerves, and other grave symptoms will probably be present. Relapse after operative interference is very frequent. In some of these cases the nerve appears to be regenerated, but in most instances collateral branches seem to transmit the painful sensations afresh.

Treatment.—Wherever a peripheral cause of irritation is detected it should be removed, if possible. In other cases the nerve may be divided between the source of irritation and the centre, and even in cases of neuralgia of undoubted central origin the section or stretching of the nerve may do some good by interrupting the communication. Excision of a portion of a nerve in neuralgic cases is preferable, as a rule, to simple division; and in many instances the nerve may, with advantage, be stretched before it is divided or excised. Relapses occur in perhaps one-third of the cases, either due to the restoration of the conducting medium, or the continuance of the source of irritation.

As a rule, if section be decided upon, a large portion of the nerve should be removed at a point as near the centre as possible. In cases where nerve-stretching is practised the traction should be made both in the centrifugal and centripetal directions. This proceeding often seems to alter for the better the nutrition of the nerve.

FIRST DIVISION OF THE TRIFACIAL.

The frontal branch of the ophthalmic nerve divides into two branches—supra-orbital and supra-trochlear while in the orbit; the operation of neurotomy may be practised upon either of these.

SUPRA-ORBITAL NERVE.

Indications.—Neuralgia.

Surgical anatomy.—The supra-orbital notch, or foramen, through which the nerve passes, can often be distinctly felt through the skin, at the junction of the middle with the inner third of the superior orbital margin.

Operation.—This point being determined, and its position marked by the left forefinger, a vertical incision (Fig. 335), an inch long, should be made through the eyebrow and upper part of the eyelid, exactly over the

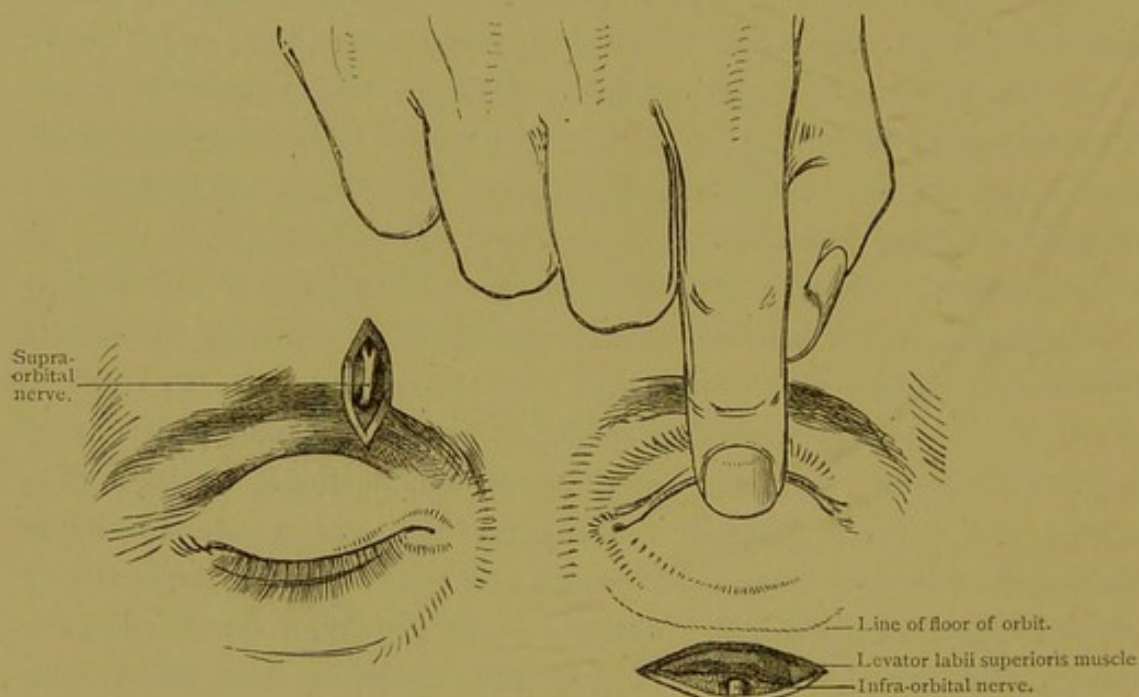


FIG. 335.—Incision to expose the supra-orbital nerve.

FIG. 336.—Incision to expose the infra-orbital nerve.

notch; the edges of the wound are then drawn asunder, and after division of some fibres of the orbicularis muscle the nerve will be exposed. An aneurism needle may now be passed beneath it to draw it farther out of the orbit, when it will be possible to stretch it in two directions, to divide it, or to resect a portion.

The nerve may also be divided subcutaneously. Stretch the eyebrow and skin of the forehead upwards with the left hand, and enter a tenotome just above the notch; cut first downwards, and then towards the bone: the vessels are divided at the same time, and the bleeding must be stopped by pressure. When neurectomy is practised, the incision may be made parallel

to the orbital margin, an inch long, dividing the orbicularis muscle and fascia; the bulb and orbital fat are pressed downwards, and the nerve having been exposed as far back as possible, is drawn out with a blunt hook and divided as near to its origin as safety will permit. If it be necessary to remove a longer portion, the supra-trochlear nerve should be excised at the same time; it is a small branch and may be difficult to find.

SUPRA-TROCHLEAR NERVE.

Surgical anatomy.—The anatomical position of the supra-trochlear nerve is indicated by an imaginary line drawn from the outer angle of the mouth through the inner canthus of the eye to the orbital margin, at this point the nerve will be found as a single branch, or in two or three slender filaments, escaping from the orbit above the pulley of the superior oblique. It may here be reached, as it lies deeply on the periosteum, by a curved incision, about half an inch long, crossing the track of the nerve. Though it appears a very small nerve to the anatomist, there is less difficulty in finding and isolating it than might be expected.

Operation.—To reach this nerve, make a convex incision at the superior internal angle of the orbit, immediately below the eyebrow; and search for the pulley of the superior oblique muscle, above which the nerve runs.

The operation of stretching the supra-trochlear nerve was brought forward in 1882 by Badal of Bordeaux. He suggested that it might be effective in ciliary neuralgia, in certain forms of glaucoma, and in sympathetic ophthalmia.

Abadie practised stretching of the nerve in a case of glaucoma where sclerotomy followed by iridectomy had failed to give relief. He stretched the nerve almost to rupture, and then removed about a centimetre of its proximal extremity; the tension of the globe afterwards slowly sank to normal, the vision improved, and the pain disappeared.

SECOND DIVISION OF THE TRIFACIAL OR SUPERIOR MAXILLARY NERVE.

Surgical anatomy.—This nerve passes through the foramen rotundum into the sphenomaxillary fossa, and then traversing the infra-orbital canal, escapes by the infra-orbital foramen on to the cheek. It gives off temporo-

malar, spheno-palatine, and two or three dental branches before appearing upon the face.

The infra-orbital nerve emerges from the infra-orbital canal at a point immediately above the canine fossa. The foramen corresponds with the

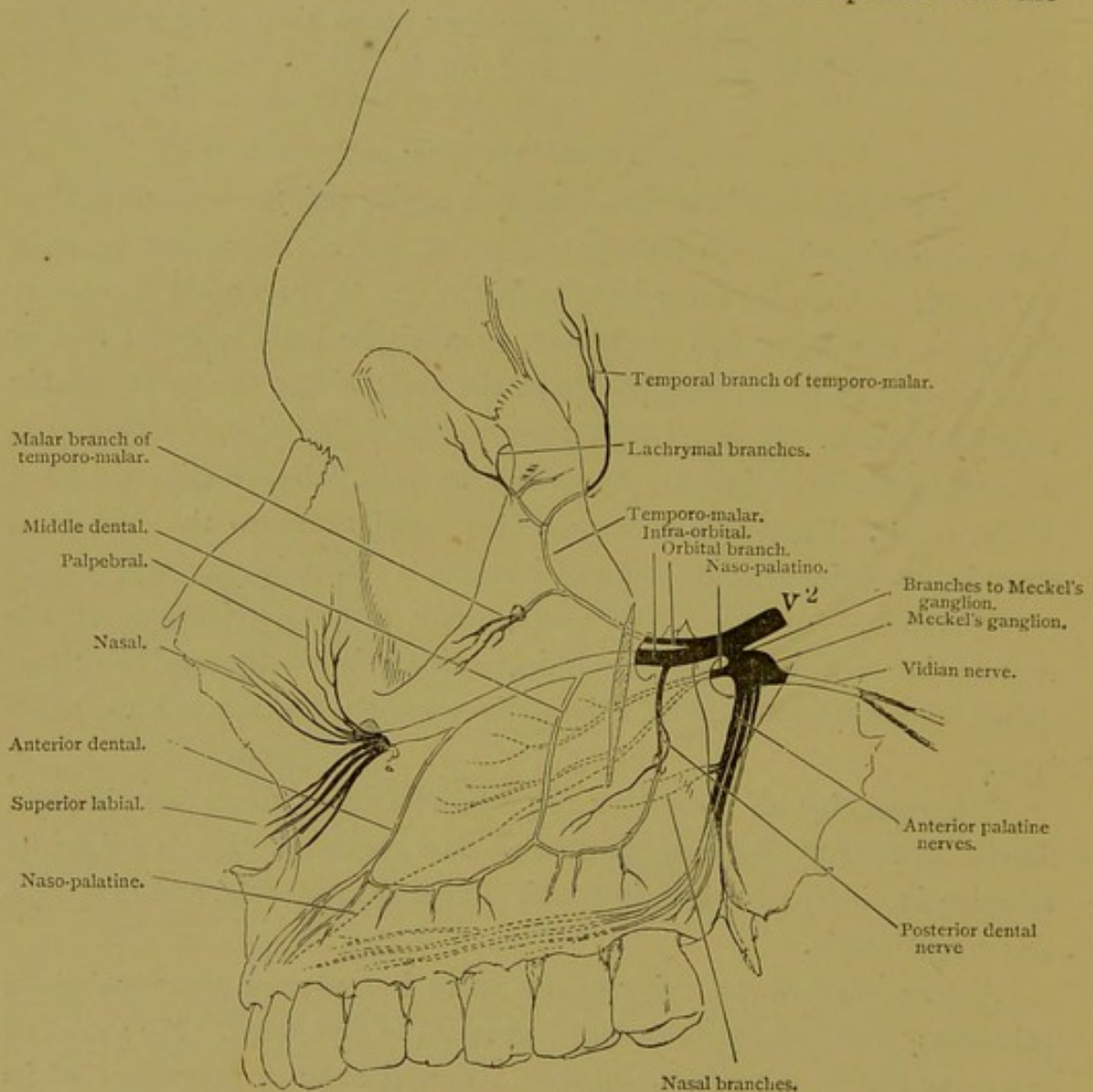


FIG. 337.—Distribution of the superior maxillary division of the trifacial nerve.

junction of the inner with the middle third of the orbital margin, and lie rather deeply about a third of an inch below it.

Operation.—The infra-orbital nerve may be divided subcutaneously either from the mouth or from the cheek, but resection or stretching is much to be preferred, and for this its exposure by dissection is necessary. A transverse incision may be made along the inferior margin of the orbit,

dividing the skin, orbicularis muscle, and fat, and exposing the foramen just below the origin of the levator labii superioris muscle ; about half an inch of

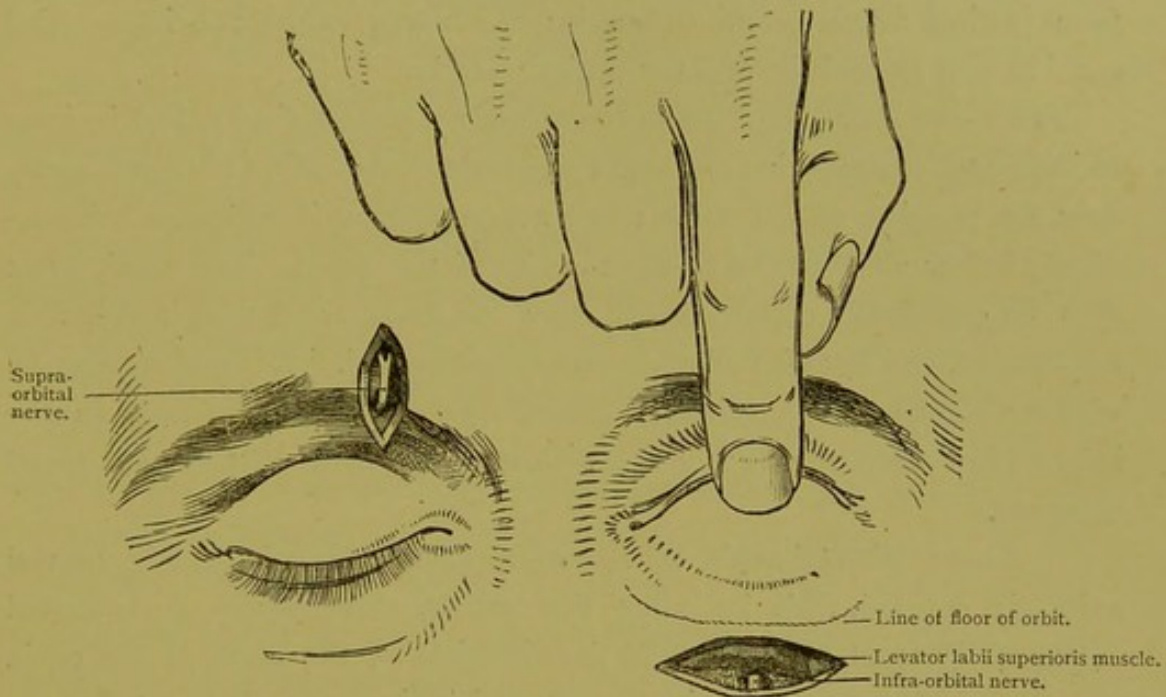


FIG. 338.—Incision which may be made to expose the supra-orbital nerve.

FIG. 339.—Incision to expose the infra-orbital nerve as it emerges from the infra-orbital canal.

the nerve may thus be excised (Fig. 339). This operation, however, is generally insufficient, on account of the alveolar and other branches given off nearer to the origin, and it may be necessary to remove the portion of the nerve contained in the canal.

For this purpose, after the nerve has been exposed at its point of exit, the orbital fascia is divided along the lower margin of the orbit, and the eyeball with its muscles and fat are raised up by a spatula. After the bleeding has been arrested, the nerve may be divided with a tenotome as it enters the canal, and the distal portion may be then drawn out through the foramen, the anterior dental branch being broken by the traction.

This method does not with certainty dispose of the posterior dental branches, and in many cases of severe neuralgia, involving the branches of this nerve, Langenbeck found it necessary to remove the whole length of the infra-orbital nerve lying in the infra-orbital canal.

In this operation the nerve is divided subcutaneously as it enters the orbit, and is afterwards drawn out from the infra-orbital canal.

The inferior orbital or speno-maxillary fissure, between the orbital process of the superior maxillary and the great wing of the sphenoid, runs from behind forwards and outwards; the nerve enters the infra-orbital canal almost an inch behind the orbital margin.

The nerve is first exposed in the cheek by means of a vertical incision an inch long, commencing above at the margin of the orbit, and made exactly over the position of the nerve; or by a curvilinear incision made immediately below and parallel to the margin of the orbit. The trunk must then be completely dissected out from the granular fat with which it is surrounded, and its point of emergence fully exposed. Its close connection with the bone, and the resistance offered by the branches given off in the infra-orbital canal, render it difficult to stretch it efficiently in the central direction.

A strong Dieffenbach's tenotome, a narrow-bladed slightly curved knife, is entered, with its edge downwards, close below the external palpebral ligament, and passed in the direction of the apex of the orbit, at an angle of about 60° , along the external orbital wall, till it reaches the posterior part of the speno-maxillary fissure. If the point be not allowed to enter the speno-maxillary fossa too deeply, and its edge be kept close to the bone, no injury can occur to the contents of the orbit. The point of the knife having entered the posterior part of the speno-maxillary fissure near the apex of the orbit, it is then made to cut forwards and outwards till the anterior extremity of the fissure is nearly reached, its edge being kept throughout closely applied to the inferior or maxillary border of the fissure. In this way the nerve must be necessarily divided before it enters the infra-orbital canal. When this has been accomplished the nerve may be seized with a stout pair of forceps and pulled out of the canal by twisting it around the points of the instrument, caution being exercised to avoid its breaking. There is often some hæmorrhage and exophthalmos after the operation, because of the simultaneous division of the infra-orbital artery. Both Wagner and Langenbeck have in some cases found that after a time the pain returns, and state that the nerve can be regenerated even after this very extensive removal.

Wagner also recommends, in order to ensure the removal of a sufficient length of the infra-orbital nerve, that the canal should be freely laid open.

by means of a chisel, while the eyeball is held upwards by a spatula: the nerve can then be raised up, separated from the artery with an aneurism needle having a lateral curve, and removed, or the necessary amount of stretching may be accomplished with forceps, the points of which are protected by india-rubber tubing. This plan, however, is very severe, and difficult of execution.

Chavasse has performed neurectomy of the second division of the fifth nerve in two cases—for neuralgia arising from irritation of the posterior dental nerves, and removed an inch and a half or an inch and three-quarters of the nerve in front of the foramen rotundum, together with Meckel's ganglion. He thus describes the operation: "An incision is made from the inner to the outer canthus on the affected side along the lower margin of the orbit. A vertical one is made from the centre of this through the substance of the cheek, curved at its lower extremity, and terminating at the angle of the mouth. The flaps thus marked out are reflected, and a dissection made to expose the infra-orbital nerve as it emerges from its foramen. This having been laid bare, a half-inch trephine is applied to the antrum, and its anterior wall partly removed. The posterior wall of the cavity is next partially removed by a quarter-inch trephine, and the speno-maxillary fossa thus opened. At this period of the operation the hæmorrhage is profuse. The bony canal containing the infra-orbital nerve is next broken up by means of a small chisel and a pair of scissor-pliers. The nerve can then be traced back, but with considerable difficulty, to the speno-maxillary fossa, the posterior dental branches divided, Meckel's ganglion exposed, and the nerve divided at its point of emergence."¹

In a second similar operation Meckel's ganglion was not identified. The hæmorrhage also is stated to have been severe, especially on opening the speno-maxillary fossa. Both operations were successful.

Carnochan, who was the first to advocate the resection of this nerve, considered it best performed by making a V-shaped incision through the cheek, the angle of which lay beneath the infra-orbital foramen. Chavasse regards Langenbeck's plan as imperfect, as he questions whether it will allow division of the nerve-trunk behind the posterior dental branches. Professor

¹ *Med.-Chir. Trans.*, vol. xlix. Second Series.

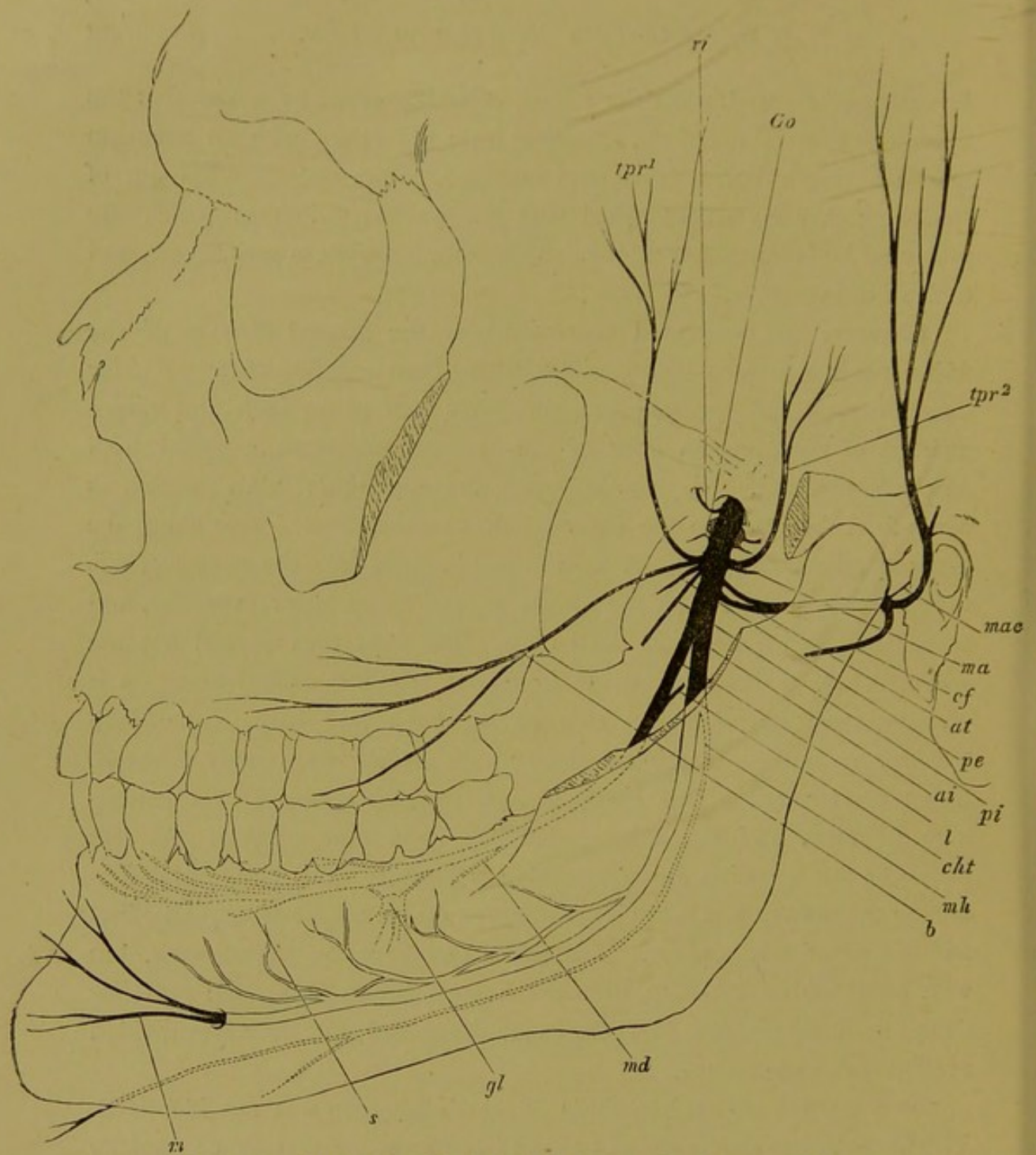


FIG. 340.—Inferior maxillary division of the trifacial nerve.—*Henle.*

- | | |
|--|--|
| <i>tpr</i> ¹ . Anterior temporal branch. | <i>ai</i> . Inferior dental. |
| <i>ri</i> . Recurrent branch. | <i>l</i> . Lingual. |
| <i>Go</i> . Otic ganglion. | <i>cht</i> . Chorda tympani. |
| <i>tpr</i> ² . Posterior temporal branch. | <i>mh</i> . Mylo-hyoid branch. |
| <i>mae</i> . Branch to meatus auditorius externus. | <i>b</i> . Buccal branch. |
| <i>ma</i> . Masseteric branch. | <i>md</i> . Branches to the mucous membrane. |
| <i>cf</i> . Communicating branch to facial nerve | <i>gl</i> . Submaxillary ganglion. |
| <i>at</i> . Auriculo-temporal. | <i>s</i> . Branches to the submaxillary gland. |
| <i>pe</i> . Nerve to external pterygoid. | <i>m</i> . Mental branch. |
| <i>pi</i> . Nerve to internal pterygoid. | |

Lücke, in performing neurectomy of the superior maxillary nerve, makes an oval incision from the outer canthus, first backwards, then downwards and forwards ; the masseter muscle is divided, the zygomatic arch sawn through in front and fractured behind, and the piece of bone, with the temporal fascia attached, turned upwards ; the speno-maxillary fossa is then exposed, and the nerve divided as it emerges from the skull : this effected, the bone is replaced, and the masseter muscle united to it by sutures. The bone shortly unites, but the muscle does not—at least in some instances. To obviate this difficulty Professor Lossen divides the temporal fascia along the upper edge of the zygoma, and after fracturing the bone turns it back with the masseter muscle intact ; in this way the full movement of the inferior maxilla is preserved, and the cicatricial deformity is very small.

THIRD DIVISION OF THE TRIFACIAL NERVE.

Surgical anatomy.—Operative interference is limited to the sensory branches of this nerve—the auriculo-temporal, the inferior dental, and the lingual or gustatory. The two last run on the inner side of the internal maxillary artery, beneath the internal and external pterygoid muscles, towards the inferior dental canal, where they lie side by side (Fig. 343) ; while the auriculo-temporal turns upwards between the ear and the temporo-maxillary articulation to join the superficial temporal artery. The inferior maxillary gives off a mylo-hyoid branch before entering the canal, and at this point the lingual leaves it to pass along the side of the tongue immediately beneath the mucous membrane.

INFERIOR DENTAL NERVE.

In the dental canal the inferior maxillary gives off branches to the teeth and a mental branch, which emerges through the mental foramen.

To obtain a successful result in cases of neuralgia of this nerve, the nerve must generally be attacked before its entrance into the canal. It may be exposed at this point either from the mouth or by an incision through the cheek.

The division of the nerve from the mouth, without interfering with the bone, is the older operation, and has been revived by Billroth. It may be accomplished in the following manner. The jaws must be kept widely open by a suitable speculum, and the angle of the mouth must be drawn

well outwards, or, if need be, the cheek divided; the mucous membrane is then incised down to the bone for at least an inch along the anterior border of the ascending ramus of the lower jaw (Fig. 341). An elevator is inserted, and the periosteum and soft parts detached from the inner surface of the jaw until the dental foramen is exposed; the gustatory nerve crosses the lower extremity of the wound, somewhat internally, as it passes to the

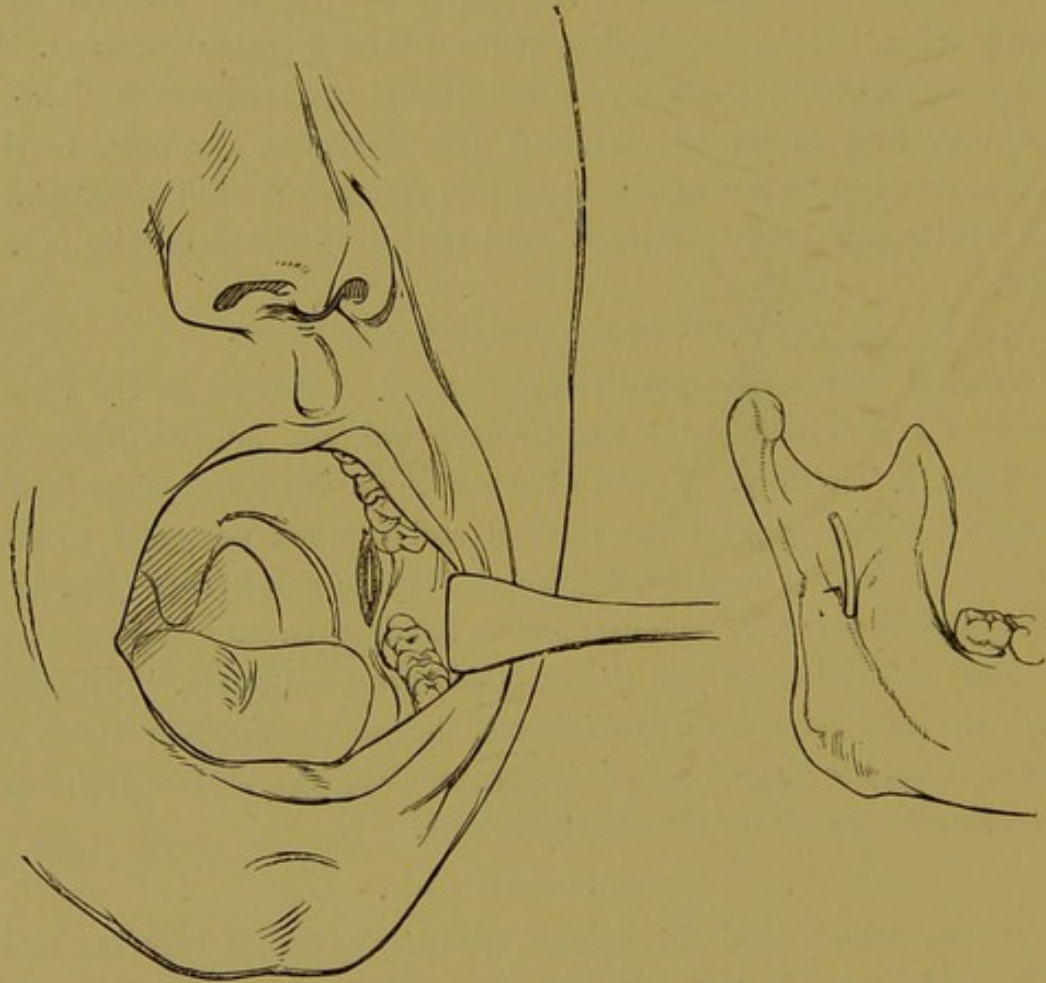


FIG. 341.—Incision within the mouth to expose the inferior dental nerve.

FIG. 342.—Inferior dental nerve as it enters the foramen.

side of the tongue. Before dividing the inferior dental nerve the relation of the gustatory nerve to it must be recollected; one blade of the scissors must, therefore, be introduced between the two nerves. Both the dental nerve and artery will be divided; nearly an inch of nerve can be removed by this method. The operation is difficult owing to the limited space available within the mouth, the proximity of the inferior dental artery and

gustatory nerve. It is therefore decidedly open to some objection, although it has been successfully accomplished on several occasions.

Velpeau reached the nerve from an opening made through the ascending ramus of the jaw, while Kühn exposed it from below after resecting a portion of the angle of the jaw. Lücke has lately modified Kühn's operation. He makes an incision around the angle of the jaw corresponding to the insertion of the masseter muscle, raises the soft parts from the internal surface with an elevator, until the inferior dental nerve, and in front of it the lingual, can be felt with the finger; a hook is then passed round the nerve just as it enters the canal.

If the nerve is to be reached directly through the inferior maxilla (which

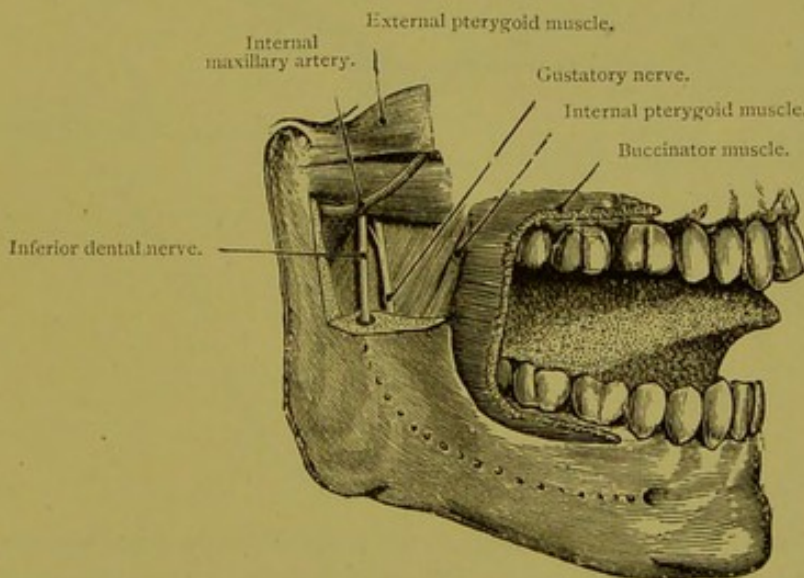


FIG. 343.—Relations of the inferior dental and lingual nerves.

is an easy and direct method), a curved incision, convex downwards, about two inches long, must be made through the masseter muscle down to the bone. When this is exposed the periosteum must be raised so that the central portion of the ascending ramus is laid bare, and the detached soft parts are then drawn upwards. In this way the parotid gland, Stenson's duct, and the facial nerve are preserved from injury. According to Velpeau's procedure, the bone over the opening of the canal is removed with a trephine. We must remember in using this instrument that the jaw is much thicker below than above; and hence the trephine should be laid aside when the upper part of the jaw has been divided, and the rest of the

circle of bone must be detached by means of the elevator and chisel. If care be not taken, the artery as well as the nerve may be cut through during the operation, and the bleeding is sometimes very severe. Linhart makes a vertical incision through the masseter for its whole length, and detaches it on each side from the bone, together with the periosteum; he then cuts away the external table of the bone with a chisel, and thus exposes the canal for the space of half an inch, and resects the nerve.

The nerve may be likewise exposed by cutting out a **V**- or **U**-shaped

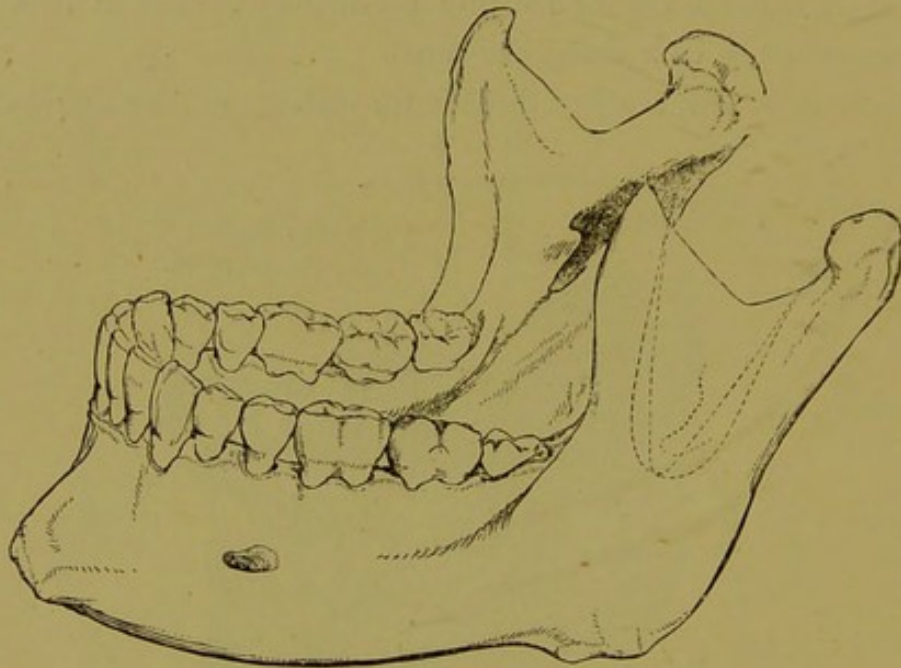


FIG. 344.—Portion of bone, **U**- or **V**-shaped, to be removed when the inferior dental nerve is exposed from without. The positions of the mental foramen and the point of exit of the mental nerve opposite the second bicuspid tooth, and midway between the alveolus and the lower border of the jaw, are indicated.

piece of the ascending ramus of the maxillary bone (Fig. 344), the base of the excised portion of the bone being at the coronoid notch, and the apex a little below the opening of the inferior dental canal. The coronoid process can be easily felt from within the mouth when the jaw is depressed. Its position determined, a vertical incision, two inches long, must be made through the integuments over the middle of the ascending ramus of the jaw, the masseter is sufficiently dissected from its attachment to the ramus, and the periosteum is detached with it. The necessary amount of bone may then be removed with the chisel, or by means of a cylindrical

drill, half an inch in length and the same in diameter, inserted into the mandril of a powerful surgical engine. By it, in revolutions to the extent of 5000 times in a minute, the nerve is quickly laid bare at its place of entrance in the inferior dental foramen. Next, the opening is enlarged until the internal pterygoid muscle is fairly exposed to view; the nerve is cut below, lifted from its bed, and, while held on the stretch, may be isolated up to the point of emergence at the base of the

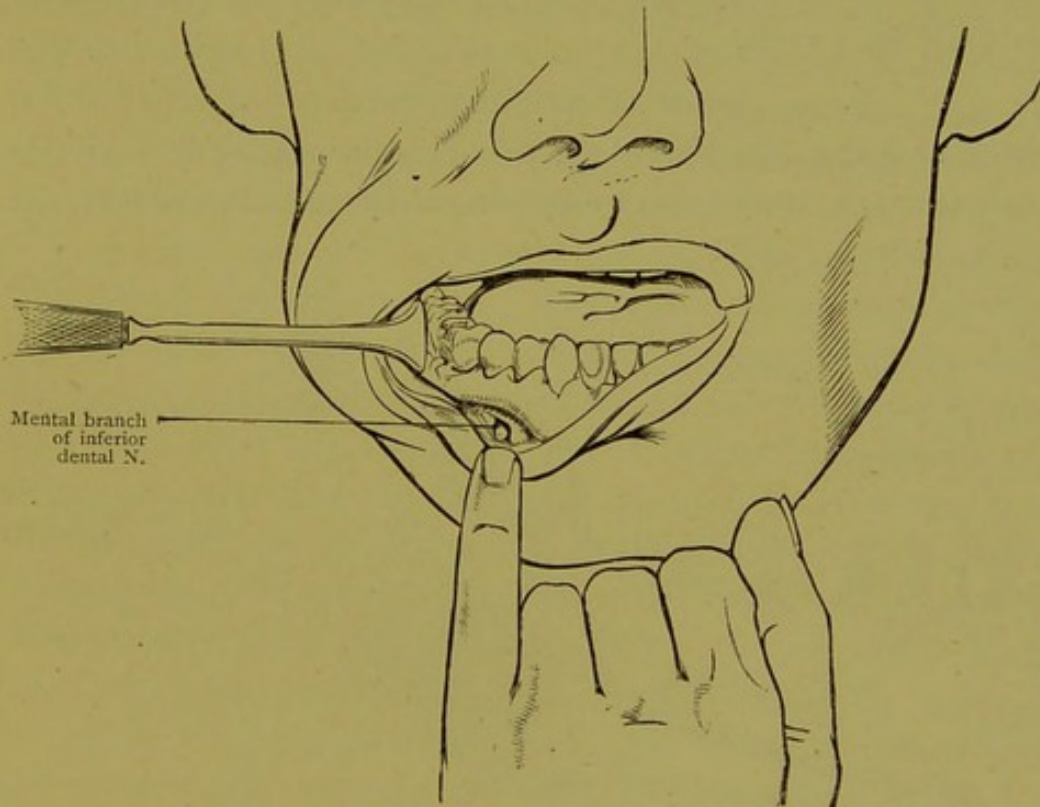


FIG. 345.—Method of exposing the mental branch of the inferior dental nerve.

skull by the handle of a scalpel. Finally it is excised with a pair of delicate iris-scissors.

It is possible from the same opening to reach the gustatory nerve, which lies slightly anterior to the inferior dental.

The mental nerve can scarcely ever require division; it may be easily reached, however, and divided or stretched at its point of exit from the foramen by an incision through the mucous membrane, close to the gum and opposite the second pre-molar tooth (Fig. 345). The corresponding angle of the mouth should be drawn downwards and outwards as in Fig. 345, a horizontal incision one inch long is made opposite the second

lower bicuspid tooth. The mucous membrane and periosteum are divided down to the bone, and raised sufficiently with an elevator to expose the nerve as it emerges from the foramen at the middle of the vertical thickness of the jaw. It should now be detached by dividing its dense investing sheath with the point of the knife at the borders of the canal; an aneurism needle can then be passed below it. If the mental artery be cut through, pressure will suffice to arrest the bleeding. The trunk can also be reached, and a portion of the nerve resected by trephining the outer table of the maxilla.

LINGUAL OR GUSTATORY NERVE.

Surgical anatomy.—In front of the palato-glossus muscle near the side of the tongue the gustatory nerve is only covered by mucous membrane, and

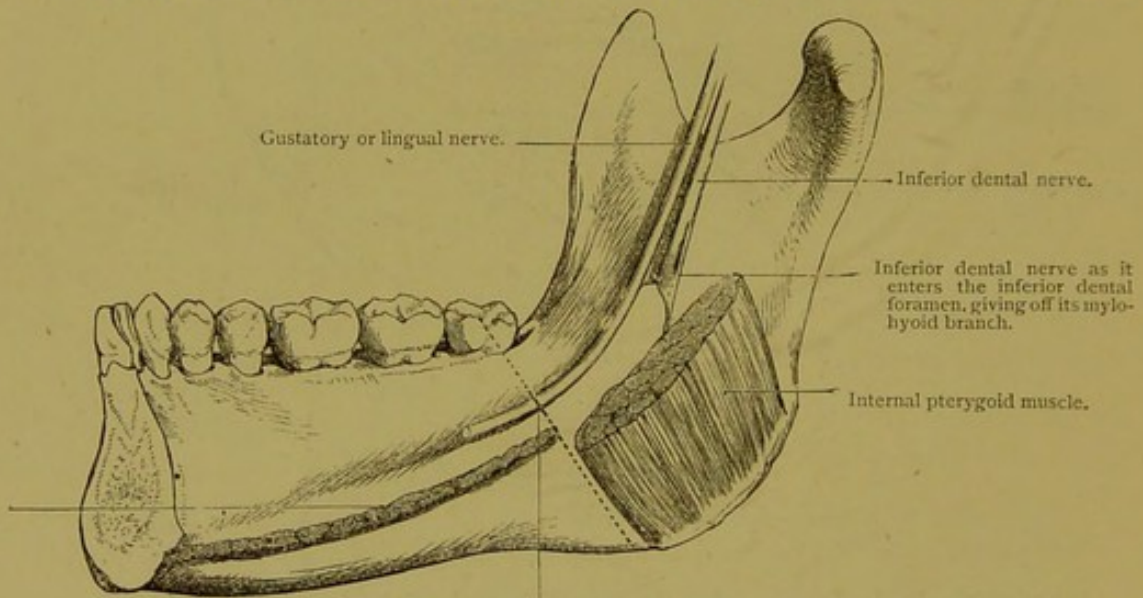


FIG. 346.—Point at which the gustatory nerve may be divided—namely, the junction of the upper with the middle third of an imaginary line drawn from the last molar to the angle of the jaw. The nerve is here immediately beneath the mucous membrane.

is quite accessible if the organ be drawn forwards, upwards, and to the opposite side. The nerve may be most easily reached opposite the last molar tooth in the lower jaw (Fig. 346). A good guide to its position is afforded by the pterygo-maxillary ligament, which can readily be felt, when the mouth is widely opened, stretching obliquely beneath the mucous membrane behind the last molar tooth; the nerve can be felt a little below and in front of the attachment of the ligament to the lower jaw, half an inch below and behind the last molar tooth.

Operation.—A longitudinal incision one inch in length may be made through the mucous membrane forwards from the ascending ramus of the jaw. If the cheek be first divided, the operation is facilitated. Through this incision the nerve can be readily exposed midway between the jaw and the side of the tongue. It may also be divided by entering a knife three-quarters of an inch behind and below the last molar in an imaginary line drawn from it to the angle of the jaw (Fig. 346), and cutting outwards towards the jaw, in a direction forward and upward for half an inch from the direction of the tooth, but it must be remembered that when the tongue is drawn over to the opposite side the nerve accompanies it, leaving the bone. It may be reached in the digastric triangle by an incision along the inferior margin of the jaw from the anterior border of the masseter almost to the chin. The skin and platysma are divided, but the facial artery should be avoided; the cervical fascia covering the submaxillary gland is then cut through, and the gland drawn forwards and downwards, exposing the mylo-hyoid muscle covered by fascia, with the mylo-hyoid nerve and artery lying upon it; more deeply is seen the hyoglossus muscle, with the hypoglossal nerve upon its outer surface, and if the mylo-hyoid muscle be now drawn forwards and the lingual artery depressed, the gustatory nerve will be exposed above the hypoglossal and close beneath the mucous membrane, near the last molar tooth; it may be seized by a hook and stretched, or traced as far back as the margin of the internal pterygoid muscle, where it can be divided, and a considerable portion excised. The operation from within the mouth, even though it entail the division of the cheek, is very much preferable to this complicated procedure.

BUCCAL AND AURICULO-TEMPORAL NERVES.

The buccal and auriculo-temporal branches of the inferior maxillary nerve may require division on account of severe neuralgia.

The buccal nerve may be found from within the mouth opposite the middle of the anterior margin of the ascending ramus of the lower jaw. If the mucous membrane and fibres of the buccinator be here vertically divided, and the tissues separated with a director, the nerve will be exposed.

The auriculo-temporal may be most readily exposed where it crosses the zygoma between the temporal artery and the pinna.

SECTION OF THE THIRD DIVISION OF THE FIFTH NERVE AT ITS EXIT FROM THE SKULL.

It is now over eighteen years since the first operation was performed for the relief of persistent neuralgia of the inferior maxillary division of the trifacial nerve. The credit of this bold undertaking is due to Professor Pancoast of Philadelphia, whose patient, a man of advanced age, made a good recovery and was permanently relieved from his suffering. Since this time the experiment has been repeated with various modifications

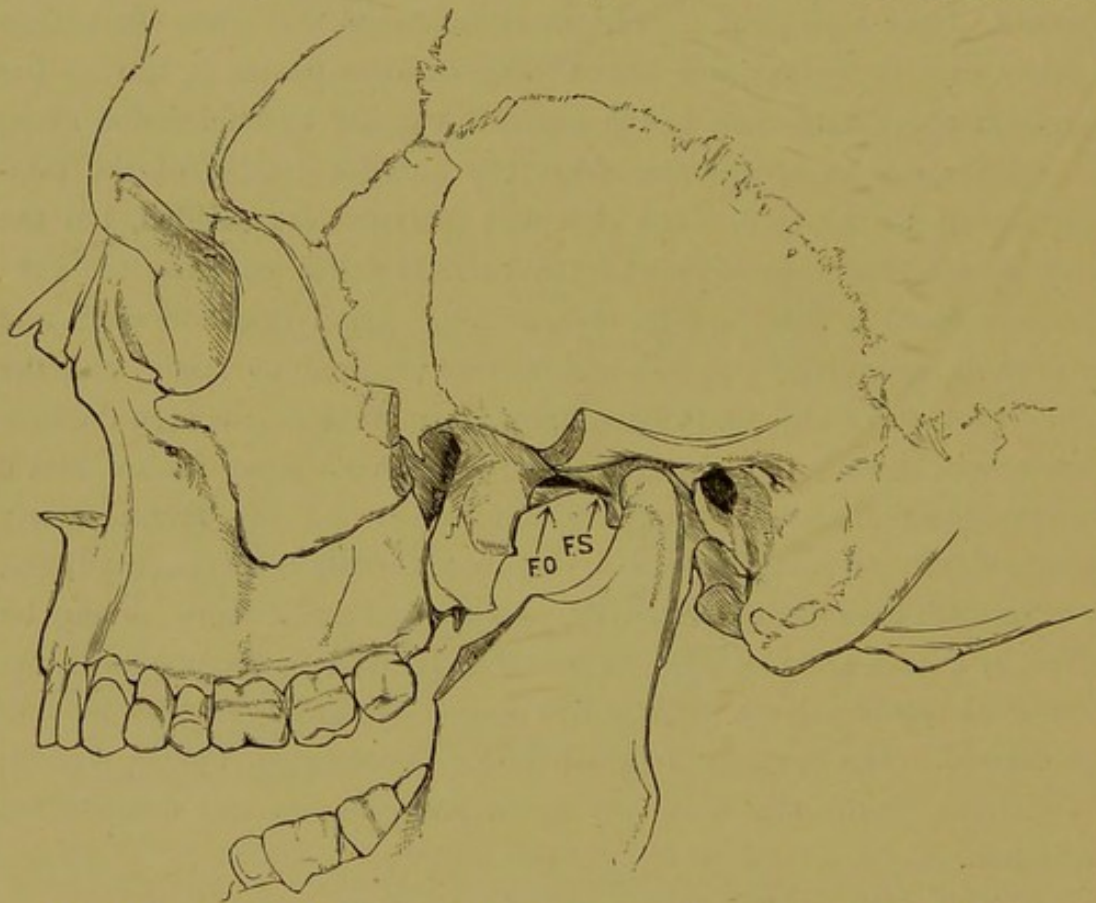

FIG. 347.—Diagram to illustrate the position of the foramen ovale with reference to the eminentia articularis, and the spinous process of the sphenoid. F.O., foramen ovale; F.S., foramen spinosum.

of detail by Credé, Israel, Krönlein, Madelung, Rydygier, Stelzner, Bergmann, Mikulicz, Sutton and Horsley, and the results have justified its establishment as a recognized surgical procedure.

Surgical Anatomy.—The feasibility of the operation may be easily demonstrated by a study of the relations of the foramen ovale at the base of the skull (Fig. 340). It will be seen that the aperture lies at a depth

of about one inch and a quarter from the zygomatic arch, in the transverse axis of the cranium opposite the eminentia articularis. It is placed behind the root of the external pterygoid plate; sometimes immediately posterior to the sharp curved ridge of bone bounding the process in this position, sometimes one, two, or three lines farther back; and is a little anterior and external to the foramen spinosum—the distance between the two apertures varying from about half a line to one-quarter of an inch. If, then, the finger be introduced into the zygomatic fossa opposite to the articular tubercle, the root of the third division of the fifth nerve should be found between two bony landmarks—the posterior border of the root of the external pterygoid plate, and the spine of the sphenoid, both of which can be readily distinguished by the touch. It will be noticed, moreover, that the great vessels with the 9th, 10th, 11th, and 12th nerves lie at some distance behind the foramen ovale, and hence, if a knife be passed along the under surface of the great wing of the sphenoid, and between the middle meningeal artery and the nerve trunk, the latter may be divided from behind forward with perfect safety. The only source of danger is the middle meningeal artery, which sometimes runs so close to the nerve that it would be difficult to insert the knife between the two structures.

The section would in all probability involve the small meningeal artery as it passes through the foramen ovale, and the lesser superficial petrosal nerve in its course to the otic ganglion through the same aperture. The result of the operation in the living subject would be paralysis of the masseter, temporal, external and internal pterygoids, mylo-hyoid and anterior belly of the digastricus, as well as of the muscles supplied by the otic ganglion—the tensor tympani and tensor palati; and loss of sensation over the distribution of the auriculo-temporal, gustatory, inferior dental, and buccal nerves (Fig. 333). Pain in the sensory areas would be relieved at the same time, provided of course that the cause of the neuralgia lay upon the distal side of the foramen ovale. The depression of the lower jaw would be associated with a slight rotation of the chin towards the side of operation, the oblique grinding movements would take place only from the opposite side, while the direct antero-posterior movements would be lost. Theoretically, some impairment

of the power of deglutition should follow the paralysis of the mylohyoid and tensor palati, and the hearing should be affected by the loss of

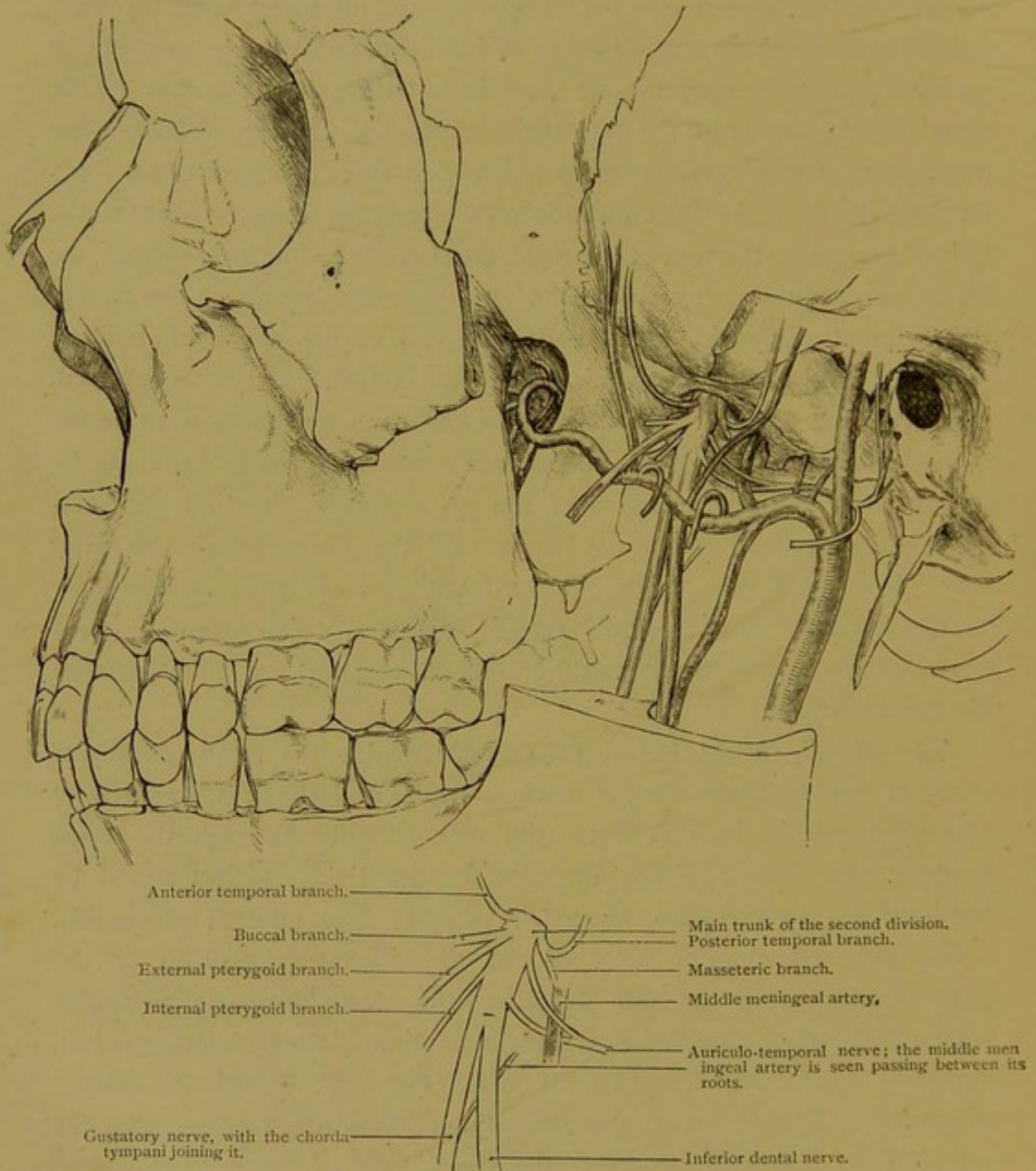


FIG. 348.—Scheme of the relations of the third division of the fifth nerve and its branches to the internal maxillary artery.

tension of the tympanic membrane; but it does not appear that these symptoms have been observed in any of the cases under treatment.

Operation.—It now remains to be seen in what manner the nerve may

be most conveniently and safely approached, and, thanks to the recent careful investigations of Salzer, we are furnished with all the data necessary to guide us in our selection of a suitable method.

The plans hitherto adopted are as follows :—

(1.) In the parent operation, that of Pancoast, a flap was made from below upwards commencing over the ascending ramus of the jaw above the level of Stenson's duct, terminating at the level of the zygoma, and including all the soft parts down to the inferior maxilla. This being turned up and the bone laid bare, the coronoid process was sawn through at its base, and removed, together with the insertion of the temporal muscle. The internal maxillary artery was tied in two places and divided between the ligatures, the upper head of the external pterygoid was separated from the under surface of the great wing of the sphenoid, and the nerve branches thus exposed at the bottom of the wound were resected with scissors and forceps.

(2.) Credé's method is in some respects an inversion of the last, as the flap, which is made to include the zygoma, is turned downwards after the two ends of the zygomatic arch have been sawn through. The nerve is then reached through the sigmoid notch while the temporal muscle is drawn backwards with a blunt hook. The internal maxillary artery is not exposed.

(3.) Krönlein's operation resembles that of Credé in the principle of its flap, but differs from it in comprising the division of the coronoid process. The bone is not removed, as in Pancoast's method, but is turned upwards with the attached temporal muscle. Like Pancoast, however, Krönlein ties and divides the internal maxillary artery.

(4.) Bergmann's plan differs from Krönlein's mainly in the fact that the flap does not include the zygoma.

(5.) Lastly, Salzer has devised an operation which is on the whole the most eligible, but may, perhaps, be profitably combined with that part of Krönlein's method which consists in division of the coronoid process, and turning it up with the temporal muscle attached. Not only may increased space be gained by resection of the coronoid process, but this step would allow the internal maxillary artery to be more quickly secured in the event of hæmorrhage. Like Krönlein and Credé, Salzer makes his flap from above downwards, and includes the zygoma, but additional space is secured by carrying the upper incision (corresponding to the free extremity

of the flap) a finger's-breadth or more above the zygomatic arch, and through the temporal muscle down to the bone. The divided temporal vessels are ligatured, the zygomatic arch is sawn through at its two extremities, and the flap containing the zygoma, the lower portion of the temporal muscle, and the zygomatic origin of the masseter, together with the integuments and fasciæ, is drawn downwards in such a manner as to expose the roof of the zygomatic fossa. The origin of the upper head of the external pterygoid muscle is then detached from the bone and the nerve trunk exposed.

Should the middle meningeal vessels unfortunately be wounded, it would be advisable to try to secure the artery near its origin close to the anterior border of the neck of the jaw, or to tie the internal maxillary trunk on either side of the branch. In this way the danger of recurrent hæmorrhage would be almost entirely removed, since the intra-cranial anastomoses of the middle meningeal artery are of small size.

If the knife be not kept in close contact with the bone during the section of the nerve, it is possible that the higher branches, such as the auriculo-temporal, temporal, external pterygoid, and buccal nerves might escape, and in certain cases it may be desirable to seek this result.

It is probable that in many cases stretching would be preferable to section as a primary operation. It would not only be less open to the risk of hæmorrhage, but its effects might extend to the Gasserian ganglion, or even to the root of the trifacial.

Where section or stretching of the second division of the fifth nerve is also indicated, the Salzer-Krönlein operation might be extended in such a manner as to effect the object. For this purpose the separation of the upper head of the external pterygoid muscle should be carried forward as far as the anterior border of the root of the pterygoid process, and the superior maxillary nerve would then be found crossing the speno-maxillary fossa at the level of the floor of the orbit. The infra-orbital branch of the internal maxillary artery would usually escape injury, especially if the nerve were attacked close to the posterior wall of the fossa, but the Vidian nerve and Meckel's ganglion would be endangered.

FACIAL NERVE.

Indication.—Facial tic, a clonic mimetic spasm of the facial muscles depending probably on some lesion of the facial centre in the pons, has been treated both by stretching and division of the facial nerve.

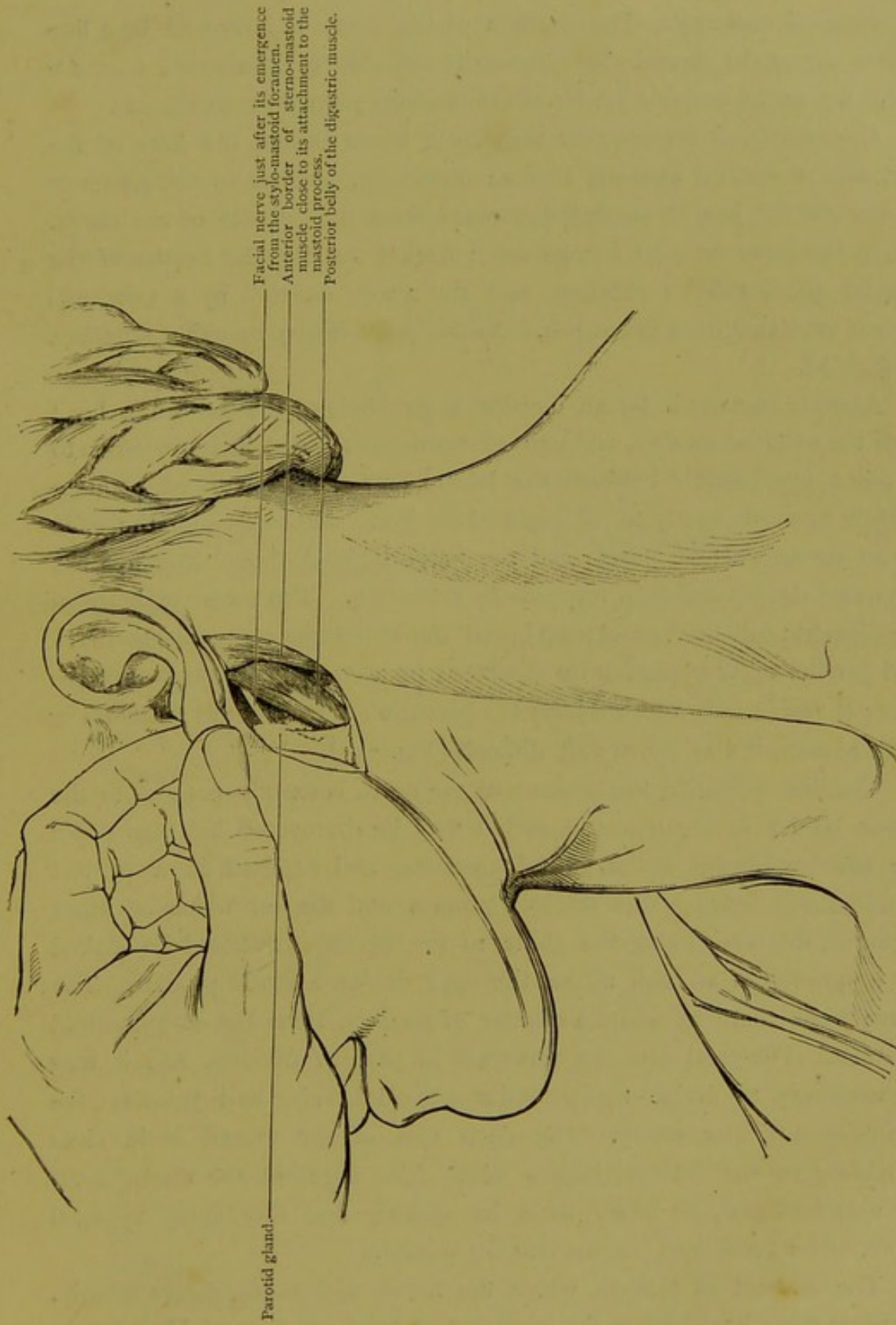


FIG. 349.—Dissection to expose the facial nerve at the anterior border of the mastoid process, close to its point of emergence from the stylo-mastoid foramen.

Surgical anatomy.—The position of the nerve is indicated by a line drawn across the parotid gland, forwards and slightly downwards, from the point where the anterior border of the mastoid process meets the ear.

Operation.—A semicircular incision is made around the lobe of the ear, and a vertical incision, half an inch long, parallel to the posterior border of the jaw, is carried downward from the middle of the curve. When the three flaps so formed are reflected the anterior border of the parotid gland will be exposed, and the nerve, covered by a vein, will appear emerging from beneath it. At this point it may be either stretched or divided.

Another method is by an incision begun behind the ear on a level with the external meatus, and carried downwards and a little forwards to a point immediately beneath the lobule and then prolonged, slanting slightly forwards nearly to the angle of the jaw. After exposing the edge of the sterno-mastoid muscle and the parotid gland, these structures are separated deeply and held forwards by retractors. The posterior belly of the digastric will now be exposed, and the structures immediately above and parallel to its upper border separated by a blunt instrument until the nerve is visible. In thin subjects the operation is easy, but in muscular or stout persons it may prove very difficult (Fig. 349).

The line indicating the position of the nerve is exactly parallel to the upper border of the digastric, and it may be discovered half-way down the anterior border of the mastoid process, and exposed in a vertical wound made between the mastoid process and the ear which is drawn forwards, the bone being the guide to the nerve. It should be looked for a quarter of an inch above the apex of the mastoid process. The nerve would here be about a quarter of an inch from the stylo-mastoid foramen. The great auricular nerve will in part be divided, and it may be necessary to divide the posterior auricular vein, and possibly the posterior auricular artery. The deep part of the wound is in close proximity to the internal jugular vein. The edges of the wound must be well retracted, all blood must be quickly and thoroughly sponged away, and a good light thrown into the wound.

The amount of tension which the nerve withstands, differs greatly. In some cases it will resist the strongest pull for an appreciable time, in others it yields with great ease.

INDEX.

A

- Amputations—
Choice of time for, 139
Comparison with disarticulation, 143,
191
Contra-indications, 139
Control of hæmorrhage, 150
Disarticulation, 170
Double amputations, 142
General remarks, 135
Hæmorrhage, arrest of, 175
History, 136
Indications for, 137
Instruments for, 144
Intermediary amputations, 140
Ligature of arteries, 176
Methods—
Circular, 157
Flap, 164
Oval, 170
Teale, 169
Mode of dressing, 180
Mortality, 192
Objects of, 156
Osteo-plastic, 175
Point of selection, 142
Primary, 140

Amputations—(*continued.*)

- Results, 181
Secondary, 140
Suture, 178
Statistics, 192
Unfavourable circumstances after,
183

Amputations, special—

- Ankle-joint, 222
Lefort, 235
Gunther, 234
Parry, 229
Pirogoff, 231
Roux, 227
Sédillot, 236
Syme, 222
Arm, 298
Circular, 299
Flap, 301
Ravaton, 300
Teale, 300
Carpo-metacarpal, 282
Elbow-joint, 293
Flap, 294
Oval, 296
Fingers, 272
Forearm, 289

Amputations, special—(*continued.*)

- Hip-joint, 264
 - Flap operation, 264
 - Modified oval, 269
 - Rose, 270
 - Verneuil, 270
- Knee-joint, 245
 - Stephen Smith, 251
- Leg, 239
 - Sédillot, 243
 - Supra-malleolar, 241
 - Teale, 245
- Medio-tarsal, 213
 - Chopart, 214
- Metatarso-phalangeal joints, 201
- Metatarsus, through, 205
- Shoulder, 302
 - Flap, 304
 - Larrey, 307
 - Oval, 304
- Sub-astragaloid, 219
- Tarso-metatarsal, 207
 - Hey, 212
 - Lisfranc, 207
- Thigh, 252
 - Carden, 255
 - Flap, 257
 - Gritti, 253
 - Stokes, 255
 - Teale, 259
 - Vermale, 260
- Thumb, 279
- Toes, 196
- Wrist-joint, 283
- Artificial limbs, 191

D

- Davy's lever, 264
- Digital compression—
 - Brachial artery, 150
 - Femoral artery, 151

Disarticulation, 170

See Amputations

E

Excisions—

- Contra-indications, 314
- Esmarch's tourniquet, 312
- Forms of incision, 312
- General remarks, 309
- History, 309
- Indications, 312
- Mortality, 315
- Sub-periosteal, 310

Excisions, special—

- Ankle-joint, 322
 - Buchanan, 327
 - Indications for, 322
 - Langenbeck, 327
 - Moreau, 327
 - Results, 331
- Astragalus, 321
- Clavicle, 413
- Cuboid, 321
- Elbow—
 - Bayonet-shape, 391
 - H form, 386
 - Hueter, 387
 - Indications, 379
 - Ollier, 389
 - Partial, 391
 - Results, 409
 - Straight dorsal incision, 383
 - T form, 385

Hip, 347

- Indications, 348
- Langenbeck, 355
- Lücke and Schede, 358
- Ollier, 357
- Results, 361
- White, 354

Excisions, special—(*continued.*)

- Jaw, lower, 423
 - Bilateral, 425
 - Results, 425
- Jaw, upper, 415
 - Fergusson, 417
 - Langenbeck, 420
 - Liston, 420
 - Osteo-plastic, 422
 - Results, 421
- Knee-joint, 333
 - Indications, 333
 - Modes, 340
 - Results, 346
- Metacarpal bone of thumb, 281
- Metacarpo-phalangeal, 364
- Metatarso-phalangeal, 320
- Os calcis, 320
- Osteo-plastic, of foot, 316
- Scapula, 410
- Shoulder-joint, 399
 - Indications, 400
 - Moreau, 403
 - Posterior incision, 406
 - Results, 409
 - White, 405
- Sterno-clavicular, 415
- Temporo-maxillary, 426
- Wrist, 365
 - Indications, 365
 - Langenbeck, 374
 - Lister, 371

F

Flail joint after resection of elbow, 397

G

Gunshot injuries—

- Ankle, 323, 331
- Elbow, 380, 398

Gunshot injuries—(*continued.*)

- Excision for, 312
- Hip-joint, 262, 361
- Knee, 333
- Shoulder, 400, 410
- Wrist, 366

L

Ligature of arteries, 176

N

Nerves, operations on—

- Neurectomy, 427
- Neurotomy, 427
- Neurotony, 428
 - Indications, 428
 - Pathology, 430
- Neuroraphy, 433
 - Indications, 433
 - Intergrafting, 436
 - Pathology, 434

Nerves, special—

- Anterior crural, 442
- Anterior tibial, 444
- Brachial plexus, 455
- Cervical plexus, 457
- External popliteal, 440
- Facial, 480
- Fifth nerve, 462
 - First division, 465
 - Meckel's ganglion, 471
 - Second division, 467
 - Third division, 473
- Internal popliteal, 440
- Long saphenous, 445
- Median, 452
- Musculo-spiral, 453
- Posterior tibial, 437
- Sciatic, 442
- Spinal accessory, 459
- Neuroma in amputation stumps, 185

O

- Osteo-plastic amputation, 175
 Foot, 316
 Upper jaw, 422
 Osteotomy of femur, 358

S

- Stromeyer's cushion, 408

T

- Torsion of arteries, 176
 Tourniquets—
 Esmarch, 153
 Ill-effects of, 155, 272
 For abdominal aorta, 154
 Petit, 154

Tourniquets—(*continued.*)

- Signoroni, 155
 Trendelenburg's cannula, 416

U

- Unfavourable circumstances after amputation, 183
 Adherent cicatrix, 185
 Artificial limbs, 191
 Conical stump, 185
 Gangrene, 190
 Necrosis, 183
 Neuroma, 185
 Osteo-myelitis, 184
 Pyæmia, 189
 Shock and collapse, 188
 Tetanus, 190
 Ulceration of stump, 187

