

**A report on amputations at the hip-joint in military surgery / [by George A. Otis].**

**Contributors**

United States. Surgeon-General's Office.  
Otis, George Alexander.  
University College, London. Library Services

**Publication/Creation**

Washington : Government Printing Office, 1867.

**Persistent URL**

<https://wellcomecollection.org/works/zexgrmyx>

**Provider**

University College London

**License and attribution**

This material has been provided by This material has been provided by UCL Library Services. The original may be consulted at UCL (University College London) where the originals may be consulted.

This work has been identified as being free of known restrictions under copyright law, including all related and neighbouring rights and is being made available under the Creative Commons, Public Domain Mark.

You can copy, modify, distribute and perform the work, even for commercial purposes, without asking permission.



Wellcome Collection  
183 Euston Road  
London NW1 2BE UK  
T +44 (0)20 7611 8722  
E [library@wellcomecollection.org](mailto:library@wellcomecollection.org)  
<https://wellcomecollection.org>







15-5-

Anch.

Orth SC Quent.  
WB UNI

C



Digitized by the Internet Archive  
in 2015

<https://archive.org/details/b21289475>





WAR DEPARTMENT,  
SURGEON GENERAL'S OFFICE,

WASHINGTON, JULY 1, 1867.

---

CIRCULAR No. 7.





CIRCULAR No. 7.

---

WAR DEPARTMENT,  
SURGEON GENERAL'S OFFICE,  
WASHINGTON, JULY 1, 1867.

---

A REPORT

ON

AMPUTATIONS AT THE HIP-JOINT

IN

MILITARY SURGERY.

[George Alexander Otis]

---

WASHINGTON:  
GOVERNMENT PRINTING OFFICE.  
1867.



2384

959982

## CIRCULAR No. 7.

---

WAR DEPARTMENT,

SURGEON GENERAL'S OFFICE,

*Washington, July 1, 1867.*

The following Report, embodying the experience of the War of the Rebellion in relation to Amputations at the Hip-Joint, is published for the information of the Medical Officers of the Army.

JOSEPH K. BARNES,

*Surgeon General.*





A REPORT  
ON  
AMPUTATIONS AT THE HIP-JOINT  
IN  
MILITARY SURGERY.

BY GEORGE A. OTIS,  
ASSISTANT SURGEON AND BREVET LIEUTENANT COLONEL, U. S. ARMY.

SURGEON GENERAL'S OFFICE,  
WASHINGTON, D. C.,  
June 30, 1867.

BREVET MAJOR GENERAL J. K. BARNES,  
SURGEON GENERAL, U. S. ARMY.

GENERAL:—

In accordance with your instructions, I have examined how far the experience acquired in the war of the rebellion has augmented our data for estimating the value of the operation of amputation at the hip-joint as a resource in military surgery, and have embodied the results of that inquiry in the following report:

Compared with the immense aggregate of major amputations, the number of amputations at the hip-joint during the war was not large; but considered with reference to the previously recorded examples of this amputation as performed for gunshot injury,\* they constitute a great accession to the statistics of the operation.

---

\*In Mr. Cox's table, (*A Memoir on Amputations of the Thigh at the Hip-joint*, London, folio, 1845,) thirty-two amputations at the hip-joint are recorded as having been performed on account of gunshot injury; but several of them were of doubtful authenticity. Of the ninety-eight cases enumerated in Dr. Stephen Smith's well-known statistical paper, published in 1852, (*New York Journal of Medicine*, Vol. IX, p. 184,) but twenty-three followed gunshot fractures. M. Legouest, in 1863, (*Traité de Chirurgie d'Armée*, p. 699,) gave a carefully studied tabular statement of forty-four such cases as are in question. In 1864, Dr. Demme (*Militär Chirurgische Studien*, Würzburg, 1864, Vol. II, p. 351) added eighteen cases to M. Legouest's list, and made a table of sixty-two coxo-femoral amputations for gunshot fractures. He erroneously includes a successful operation by M. Sédillot, which was done for a compound fracture caused by a fall from a window. His total should be sixty-one cases.



It would be difficult, indeed, to find in the annals of military surgery a hundred and twenty authentic instances of amputation at the hip-joint for injuries inflicted by weapons, or to produce half that number in which even meagre histories of the cases have been preserved. With a few interesting exceptions, the operations of this character done during the Crimean, Italian, and Schleswig-Holstein wars are known to us only through numerical returns. It is, therefore, the greater matter of satisfaction that in more than fifty instances in which this operation was performed during the war of the rebellion, the more important facts in relation to each case have been ascertained.

At the present day surgical statistics commonly encounter severe criticism, and the results of the numerical method of medical and surgical investigation are viewed with distrust. "Excellent in the hands of M. Louis," M. Velpeau says of this method, "it is detestable as manipulated by many of his followers." A recent writer\* on the special point in surgery under consideration has well discussed the causes that have led to this scepticism. These are the magnitude and frequency of the errors propounded after a faulty application of the statistical method; which are the more pernicious because a long period often elapses before evidence can be collected to refute conclusions derived from a large number of defective observations presented with a great parade of rigid analysis; and when such results are finally disproved, the greater discredit is thrown upon the numerical method, which, when properly employed, is one of the most potent engines for the attainment of truth and the elimination of error.

In the collection of surgical statistics there are several special sources of fallacy. The desire for distinction of ambitious operators sometimes tempts them to report successful results prematurely, and to fail to record unfortunate cases. Feverish partizans of particular operative procedures, in accumulating statistics, not unfrequently evince an unpardonable disregard for the fundamental rules of evidence, and admit testimony abounding in transparent fallacies. Some writers, in their zeal to gather together numerous observations, group those that are very dissimilar, and deduce inferences from the collection that are pertinent only to particular cases. In the bibliography of the operation under consideration, for example, we find a primary amputation at the hip-joint performed for traumatic lesions in a vigorous man collated with a case where the necrosed head and trochanters of the femur were enucleated from the thigh stump of a strumous child.

When these and other sources of error are avoided, it may reasonably be hoped that the analysis of large numbers of surgical cases, due attention being paid to essential particulars, must result in the establishment of rules for the performance of operations more nearly approaching scientific method and accuracy than those that now prevail, and in the selection of proper cases for operation at the stages and under the circumstances most conducive to success. And when compilers of surgical statistics first carefully inquire into the reliability of individual cases, and then into the soundness of the method of arranging them and reasoning on them, Morgagni's aphorism, *Observationes perpendendæ non numerandæ*, must be modified to express the proper order of inquiry, and to read: Observations of fact must be well weighed AND then counted,† and confidence in the numerical method as a powerful aid to surgical investigation will be restored.

\* Mr. J. Samson Gamgee, of Birmingham, England, in his excellent monograph, entitled "*A History of a Successful Case of Amputation at the Hip-joint.*" Quarto. London, 1866.

† GAMGEE, *loc. cit.*



An endeavor has been made, in the examination of the statistics of amputation at the hip-joint in the war of the rebellion, to conform to the principles above indicated. In the histories of the operations recorded farther on in this report, errors may be detected hereafter, and some of the histories are, of necessity, very incomplete. But their authenticity has been scrutinized, and doubtful cases have been rigidly excluded; the cases have been arranged in separate categories according to their clinical relations; and all the material facts that have been ascertained in regard to the individual cases are set forth, to enable the reader to judge of the correctness of the statistical conclusions.

The list of operations includes not only those that were performed in the army of the United States, but those done in the Rebel army. In collecting the histories of the latter, the most cordial and intelligent co-operation has been received from the distinguished professor of surgery at Nashville, Tennessee, Dr. Paul F. Eve.

In addition to the collection of cases in which amputation at the hip-joint was performed during the war, an account will be given of a few cases in which conservative measures were adopted under circumstances commonly believed to justify, or even demand, exarticulation of the femur—cases illustrating, so to speak, the natural history of gunshot injuries of the upper portion of the thigh.\* And the matured opinions of several military surgeons, who had large experience of the graver gunshot injuries of the upper portion of the femur, treated either by amputation at the joint, or by excision, or by attempts at conservation, will be recorded.

In order to show how far these contributions increase our means of judging of the value of amputation at the hip-joint as a resource in military surgery, it is necessary to review the history of the operation, and to determine the state of the question prior to the war. This report will consequently be divided into an historical summary, an account of individual cases, a citation of the opinions of surgeons, and a discussion of results.

---

\* A full report on this most interesting class of injuries must be deferred until the completion of the analysis of the immense statistical material on gunshot fractures of the femur recorded in this office.

## HISTORICAL SUMMARY.

Sauveur François Morand, who studied surgery in England in 1729, under the celebrated Cheselden, and subsequently became surgeon of the Hotel des Invalides, and a professor at the Parisian hospital of La Charité, was the first practitioner who directed his attention in a particular manner to amputations at the coxo-femoral articulation and proclaimed the practicability of this formidable operation. He studied different methods for this disarticulation upon the cadaver, and reported instances of its successful performance upon dogs and cats; and learned societies and academies were compelled by his great authority to consider the subject.

In March, 1739, two of Morand's pupils—Volher, surgeon to the horse-guards of the King of Denmark, and Puthod, a practitioner at Nyon, in Switzerland—communicated memoirs to the Royal Academy of Surgery at Paris, in which the propriety of this operation was formally advocated, and the various injuries and diseases for which it might be regarded as the only resource were pointed out. These papers were written with much ability, and they were subsequently published by Morand in his works.<sup>1</sup> MM. Le Dran and Guérin were appointed by the Academy to consider these memoirs, and, after many dissections and long investigation, they made, July 26, 1740, a favorable report.

In 1743, Ravaton desired to perform the operation in the case of a gendarme of Louis XV, with a complicated fracture through the trochanters, but was prevented by the opposition of his colleagues.<sup>2</sup>

In 1748, Lalouette published a thesis strongly recommending a trial of the operation,<sup>3</sup> and the same year, Lacroix, of Orleans, completed an amputation which nature had nearly effected, in the case of a child of fourteen with sphacelus of the lower extremities induced by ergotism. Lacroix, in the presence of Le Blanc, divided with scissors the round ligament and sciatic nerve and shreds of tissue that connected the left thigh with the trunk; and four days afterwards he repeated this procedure and disarticulated the right femur. The boy survived the second operation eleven days.<sup>4</sup> Many writers, among others Mr. W. Sands Cox<sup>5</sup> and Dr. Stephen Smith,<sup>6</sup> cite this case as the first recorded example of amputation at the hip-joint on the living human subject; but it assuredly cannot justly be considered an operation of amputation.

<sup>1</sup> *Opusculs de Chirurgie*, par M. MORAND. Paris, 1768, pp. 189 and 199.

<sup>2</sup> RAVATON, *Chirurgie d'Armée ou Traité des Plaies d'armes à feu*, Paris, 1768, p. 331; and *Pratique Moderne de la Chirurgie*, Paris, 1776, Tome III, p. 458.

<sup>3</sup> ALBERTUS HALLER. *Disputationes Chirurgicæ Selectæ*. Lausanne, 1775, T. V, p. 265.

<sup>4</sup> RICHERAND, *Nosographie et Thérapeutique Chirurgicales*, T. IV, p. 545, Paris, 1821; and VELPEAU, *Nouveaux Eléments de Médecine Opératoire*, Paris, 1832, T. I, p. 513. M. Velpeau says the right thigh was removed first.

<sup>5</sup> WILLIAM SANDS COX, F. R. S. *A Memoir on Amputation of the Thigh at the Hip-joint, with a successful case*. London, 1845, folio, p. 46.

<sup>6</sup> STEPHEN SMITH, M. D. *Statistics of the Operation of Amputation at the Hip-joint*. *New York Journal of Medicine*, September, 1852, p. 93.



In 1756, Morand succeeded in having this subject made the prize question for that year by the Academy of Surgery;<sup>1</sup> but the twelve memoirs presented were adjudged unsatisfactory, and the subject was again proposed in 1759, when thirty-four essays were offered, and the academy appears to have given its sanction to the proposal by according the prize to the essay of Barbet.

With eighteen others of the essayists, Barbet defended the propriety of amputating at the hip-joint under certain conditions, and he specified some of the circumstances under which he considered the operation justifiable. Thus, if the thigh was crushed by a cannon ball in the neighborhood of the joint, and only a small portion of the soft tissues remained to be divided by the knife, or if gangrene involved the circumference of the joint and had destroyed the greater portion of the flesh, he thought the disarticulation should be undertaken; and he dwelt very much on Lacroix's case as an illustration. He gave general rules for the performance of the operation, but wisely observed that the particular plan must be varied according to the nature of the cases in which it was required.<sup>2</sup>

In 1758, Goursaud, surgeon to the College of Paris, proposed a new operative procedure for amputation at the hip-joint. The following year Moublet,<sup>3</sup> surgeon of the hospital at Tarascon, in Provence, published a good essay in advocacy of the operation. Shortly afterwards Puy, of the Hotel-Dieu of Lyons, and Lecompte, announced the successful results of their disarticulations of the femur in the lower animals, and Lefebure published an essay in which the operation was considered in all its relations, and first suggested the propriety of the ligation of the femoral artery as a preliminary step.

On the other side, Callisen,<sup>4</sup> Richerand,<sup>5</sup> Bilguer,<sup>6</sup> and Pott<sup>7</sup> condemned the operation.

In 1773, Perault, a surgeon at Sainte-Maure, in the department of Indre-et-Loire, imitated Lacroix, in the case of a man twenty-one years of age, named Gois, whose right thigh was crushed between the pole of a wagon and a wall and was almost totally disorganized by the progress of gangrene.<sup>8</sup> The patient recovered and lived for many years as a cook at an inn in Sainte-Maure, where M. Velpeau saw his son and heard his history in 1815.<sup>9</sup> In Perault's case, as in that of Lacroix, the separation of all the parts which it

<sup>1</sup> The question was propounded in the following form: "Dans le cas où l'amputation de la cuisse dans l'article paroitroit l'unique ressource pour sauver la vie à un malade, déterminer si l'on doit pratiquer cette opération, et quelle seroit la méthode la plus avantageuse de la faire?" *Mémoires sur les Prix de l'Académie Royale de Chirurgie*. T. IV, p. 41.

<sup>2</sup> Barbet's memoir is published in full in the *Mémoires sur les Sujets proposés pour les Prix de l'Académie Royale de Chirurgie*. Nouvelle Édition avec Notes. Paris, 1819. Tome IV, p. 41.

<sup>3</sup> *Journal de Médecine de Paris*, 1759. Tome IX, p. 40.

<sup>4</sup> *Systema Chirurgiæ Hodiernæ in usum publicum atque privatum adornatum*. Hafnizæ, 1815-1817. Vol. II, p. 418.

<sup>5</sup> *Nosographie et Thérapeutique Chirurgicales*. Tome IV, p. 545. 5th ed. "Un chirurgien prudent doit s'abstenir de l'amputation de la cuisse dans l'articulation de la hanche, lorsque la nature ou l'accident ne l'ont point commencée."

<sup>6</sup> *Disertatio inauguralis Medico-Chirurgica de membrorum amputatione rarissime administrandâ aut quasi abrogandâ, quam pro gradu Doctoris Medicinæ et præcipuè Chirurgiæ ritè consequendo, die vigesima unâ Martii 1761, in alimâ Regiâ Fridericianâ, speciminis loco, publicâ eruditorum censura submisit JOHANNES ULRICUS BILGUER, Curia-Rhætus, generalis præfectus Chirurgorum exercitus Regii Borussiae*. Traduite en François et augmentée de quelques remarques, par M. Tissot, Docteur en Médecine, 1764.

<sup>7</sup> *The Surgical Works of PERCIVALL POTT, F. R. S.* Vol. II, p. 317. 1st Am. Ed. Strangely enough Pott quotes the Prussian surgeon Bilguer and his French annotator Tissot as advocates of the operation, though Bilguer's entire dissertation is a plea for the abandonment of amputations, except in the rarest cases, and his strictures on this particular operation are so severe that Morand (*Opuscules de Chir.*, p. 232) felt compelled to reply to them in an elaborate memoir.

<sup>8</sup> SABATIER. *De la Médecine Opératoire*. Nouvelle ed., 1832. T. IV, p. 673.

<sup>9</sup> M. VELPEAU. *Élém. de Méd. Opératoire*. Tome I, p. 513.



is dangerous to divide had been accomplished without the aid of the surgeon; and these cases are justly styled by Hénoc<sup>1</sup> mere simulacra of amputations at the hip.

In December, 1774, Kerr, of Northampton, in England, amputated at the right hip-joint in the case of a consumptive girl of eleven or twelve years, who had coxalgia with lumbar abscess and extensive caries of the acetabulum and of the adjacent parts of the os innominatum. The subject of this unjustifiable operation survived it seventeen days.<sup>2</sup> This is the first authentic instance of a true amputation at the hip-joint, and the result of the case was, in one respect, of great value, since it dispelled the exaggerated fears that had been entertained of the immediate danger of the operation, and proved that in more favorable cases an expectation of recovery after this mutilation might reasonably be entertained.

About this period, according to tradition, another amputation at the hip-joint was performed in England by Henry Thomson, surgeon of the London Hospital.<sup>3</sup> It is not recorded, Mr. Curling states, on the books of the hospital.<sup>4</sup> It is supposed to have been a speedily fatal case, and the one probably witnessed by Pott, and which led to his emphatic condemnation of this operation.

For the next twenty years amputation at the hip-joint was commonly described in systematic books of surgery, and demonstrated on the dead subject by surgical lecturers; but we find no instances of its performance on the living. The next example of the operation on record, and the first instance of its performance for gunshot injury of the higher part of the femur, occurred in the French army of the Rhine, in 1793. The operator was the illustrious Larrey, then and thenceforward a zealous advocate of the operation. The patient bore the operation well,<sup>5</sup> and several hours afterwards his condition was most satisfactory; but it was then necessary that he should follow the army in a precipitate march of more than twenty-four hours duration, in the depths of winter, and he died probably from the exposure and fatigue. It would be superfluous to recapitulate the earnest arguments appended to his report of this case by Larrey, with which he insisted upon the introduction of this operation into military surgery. They are referred to in most modern surgical treatises, and are given in full in Cooper's Surgical Dictionary, and other readily accessible works. On their publication amputation at the hip-joint became a recognized resource in military surgery.

It has been alleged that, in 1794, A. Blandin amputated at the hip-joint three or four times for gunshot fracture of the upper part of the femur.<sup>6</sup> M. Velpeau states that Blandin operated three times, and saved two of his patients, while the third survived fifty-eight days; and adds that another military surgeon, Perret, in the same year, did a successful

<sup>1</sup> *Recueil de Mém. de Méd. de Chir. et de Phar. Mil.* Deuxième Série. Tome VI, p. 94.

<sup>2</sup> DUNCAN'S *Medical Commentaries*. Edinburgh, 1799. Vol. VI, p. 337.

<sup>3</sup> JOHN THOMSON, *Report of Observations made in the British Military Hospitals in Belgium after the Battle of Waterloo*. Edinburgh, 1816, p. 264.

<sup>4</sup> J. F. SOUTH'S *Notes to Chelius's System of Surgery*. Am. ed. Vol. III, p. 189.

<sup>5</sup> *Mémoires de Chirurgie Militaire et Campagnes de DOMINIQUE JEAN LARREY*, Premier Chirurgien de la Garde, Baron de l'Empire, etc. Paris, 1812. Tome II, p. 180.

<sup>6</sup> M. VELPEAU, *Nouveaux Élém. de Méd. Opér.*, Tome I, p. 514, ed. 1832; and BOURGERY, *Iconographie d'Anatomie Chirurgicale et de Médecine Opératoire*, Premier Division, p. 270. These statements are quoted by the successive writers on the subject, each citing his predecessor. Alexandre Blandin was "aide-major" to Larrey. He wrote a thesis on amputations, which I have not been able to procure. S. e. MALGAIGNE. *Bulletin de l'Académie de Méd.*, Aout. 8, 1848.



amputation at the hip-joint for gunshot injury. Bourguery says that but one of Blandin's patients recovered. Neither author gives any authority for his statement.<sup>1</sup>

Dr. Wendelstaedt, of Emerichof, near Limburg, on the Lahn, relates<sup>2</sup> that he had examined an English sailor whose thigh was carried away by a cannon ball at the naval battle of Abouqyr, August 1, 1798, and who subsequently underwent amputation at the hip, and who was in good health years after the operation. It is very singular that there is no other record of the case.

In 1799, Larrey performed the operation twice at the siege of Saint-Jean d'Acre.<sup>3</sup> One of his patients, an officer, M. Bonhomme, was in excellent condition on the seventh day, when he was suddenly carried off by the plague. The other, a drummer boy, died in an ambulance during the retreat of the army.

About this period it is alleged that Krimer amputated at the hip-joint for gunshot fracture. The patient is said to have died of tetanus on the tenth day.<sup>4</sup>

At Wagram, July 6, 1809, Larrey operated at the hip-joint on two soldiers of the imperial guard. These were intermediate amputations, and resulted fatally in a few hours.<sup>5</sup>

In 1811, Brownrigg amputated at the hip-joint unsuccessfully, at Elvas, in Spain.<sup>6</sup> But he was more fortunate the following year, in a similar operation on a private of the 13th British Dragoons. This man recovered and lived for many years afterwards at Spalding, in Lincolnshire.<sup>7</sup> This was a secondary operation, performed December 12, 1812, for complications resulting from a gunshot fracture of the femur received at Merida, in Spain,<sup>8</sup> on December 29, 1811. It is the first successful amputation at the hip-joint recorded in military surgery. Brownrigg also performed the operation in two other cases during the Peninsular war; these terminated fatally.<sup>9</sup> In this year also Guthrie performed the operation unsuccessfully at the siege of Ciudad Rodrigo.<sup>10</sup>

In 1812, Larrey also operated twice: first, on July 29th, at Witepsk, on a Russian soldier, whose left thigh had been carried away by a cannon ball.<sup>11</sup> Ribes assisted at this operation. Larrey believed that the patient would have recovered had it been possible to provide suitable nourishment for him. He died from dysentery on the twenty-fifth day, the wound having nearly cicatrized. The other case was that of a French subaltern of dragoons, whose thigh was terribly injured by a cannon ball at the battle of Borodino, on September 7th. He was removed to the abbey of Kolloskoï, and thence to Witepsk,

<sup>1</sup> I agree with M. LEGUEST (*Mém. de la Soc. de Chirurgie*, T. V, p. 157) that the proof that these operations were performed is insufficient. And the same remark applies to the case ascribed to Perret. They are not mentioned in any of the systematic surgical treatises of the period, nor in P. F. Blandin's elaborate Essay on Amputations, (*Dict. de Méd. et de Chir. Pratiques*, Tome II, p. 274.)

<sup>2</sup> *Journal der Prakt. Heilkund.* VON HUFELAND und HIMLY, 1811. Band VI, p. 110.

<sup>3</sup> *Rélation Historique et Chirurgicale de l'Expédition de l'Armée d'Orient en Egypte et en Syrie*, par D. J. LARREY. Paris, 1803, pp. 329, 332.

<sup>4</sup> GRAEFKE UND WALTHER. *Zeitschrift für Chir.* B. XII, p. 121.

<sup>5</sup> *Mém. de Chir. Mil.* T. III, p. 349. Larrey says these patients were "victims of the delay in performing the operation."

<sup>6</sup> *Commentaries on the Surgery of the War in Portugal, Spain, France, and the Netherlands.* By G. J. GUTHRIE, F. R. S. 6th Am. ed., p. 77.

<sup>7</sup> AVERILL'S *Operative Surgery*. 2d ed., p. 217.

<sup>8</sup> *Dict. Pract. Surg.* By SAMUEL COOPER. Am. ed., p. 77.

<sup>9</sup> AVERILL. *Loc. cit.*

<sup>10</sup> *A Treatise on Gunshot Wounds.* By G. J. GUTHRIE, F. R. S. 3d Lond. ed., p. 332.

<sup>11</sup> *Mém de Chir. Mil.* T. IV, p. 26.



where he remained, under the care of Surgeon-Major Bachelet, until he was nearly well. He was then sent to Orcha, and the surgeon-major in charge there reported to Larrey, three months after the operation, that he had entirely recovered.<sup>1</sup> This case is cited as the second successful amputation at the hip-joint in military surgery, and the first successful primary amputation; but, as the patient never reached France, and his death is not accounted for, the adversaries of the operation will not admit the case as a success.

In the war of 1812, between the United States and Great Britain, no examples occurred of the performance of this operation.<sup>2</sup>

In April, 1814, after the unsuccessful assault on Bergen-op-Zoom, Cole performed this operation by the circular method. A few days subsequently Samuel Cooper operated at Oudenbosch on a soldier who had received at the same assault a dreadful fracture of the upper part of the femur by a grape-shot. Both cases resulted fatally.<sup>3</sup>

Dr. Emery operated, July 2, 1814, on a corporal whose left thigh had been fractured by a musket ball a year previously in Spain. The patient died thirty days afterwards from secondary hæmorrhage.<sup>4</sup>

The third successful amputation at the hip-joint in military surgery was that performed by Guthrie, on July 7, 1815, at Brussels, on the French soldier, François Duguet, wounded at the battle of Waterloo.<sup>5</sup> This man was living at the Hotel des Invalides in 1836.

On August 15, 1815, Mr. Blicke performed the operation at Antwerp, on a soldier with osteomyelitis of the femur produced by a contusion from a musket ball received at Waterloo. The patient survived eight days.<sup>6</sup>

Alcock relates<sup>7</sup> that he was informed by Dr. Belmont that an accomplished Spanish surgeon, educated at Barcelona, had twice amputated at the hip-joint during the Peninsular war, and once with success.

For the next twelve years peace was maintained in Europe, and no instances are recorded of amputation at the hip-joint for gunshot injury.

In May, 1827, during the siege of Athens by the Turks, Dr. Bryce, who accompanied Lord Cochrane to Greece, reports that he amputated at the hip-joint in the case of a soldier whose femur was badly shattered by a six-pound cannon ball. There had been copious hæmorrhage, yet the patient is said to have recovered rapidly, and to have been seen six weeks subsequently at Paros, by the operator, perfectly cured.<sup>8</sup> The history of this case

<sup>1</sup> LARREY, *Mém. de Chir. Mil.*, Tome IV, p. 50; and BRIOT, *Histoire de l'État et des Progrès de la Chirurgie Militaire en France*, Besançon, 1817, p. 182.

<sup>2</sup> *Medical Sketches of the Campaigns of 1812*. By JAMES MANN, M.D., Surgeon of the Army, &c., 1816. Octavo, p. 318.

<sup>3</sup> COOPER'S *Surgical Dictionary*, 8th English ed., p. 116. DR. STEPHEN SMITH (*New York Jour. of Med.*, Vol. IX, p. 204) rather unreasonably excludes Cooper's case from his statistics, because the patient died before the operation was completed.

<sup>4</sup> GUTHRIE, *A Treatise on Gunshot Wounds*, 3d London ed., p. 334.

<sup>5</sup> GUTHRIE, *A Treatise on Gunshot Wounds*, 3d London ed., p. 342; LARREY, *Clinique Chirurgicale*, Tome V, p. 427; and HENNEN, *Principles of Military Surgery*, 3d London ed., p. 265.

<sup>6</sup> THOMSON, *Report of Observations made in the Military Hospitals in Belgium after the battle of Waterloo*, Edinburgh, 1816, p. 270; and GUTHRIE, *Op. cit.*, p. 351.

<sup>7</sup> *Notes on the Medical History and Statistics of the British Legion in Spain, comprising the Results of Gunshot Wounds in Relation to important Questions in Surgery*. By RUTHERFORD ALCOCK, Deputy Inspector General of Hospitals. London, 1838, p. 78.

<sup>8</sup> *Glasgow Medical Journal*, 1831, p. 262; *Brit. and Foreign Med. Chir. Review*, Vol. XV, p. 512; COSTELLO, *Cyclopædia of Pract. Surg.*, Vol. I, p. 182; M. VELPEAU, *Op. cit.*, Tome I, p. 514; COX, *Op. cit.*, p. 11, etc., etc. But all the successive authors take their account from Dr. Bryce's report in the *Glasgow Journal*.



is traced for so short a period that it cannot be regarded as an authenticated example of recovery.

On July 29, 1830, P. J. Roux, performed the operation without success on a Swiss subaltern<sup>1</sup> wounded in the revolution in Paris. On November 10th, of the same year, Dr. Clot Bey had an unsuccessful secondary operation at Marseilles.<sup>2</sup>

In 1831, Demme, the elder, performed the operation three times during the campaign in Poland. These were all unsuccessful intermediate amputations for gunshot fracture of the femur.<sup>3</sup> In the same campaign, M. Sédillot had an unsuccessful primary operation.<sup>4</sup>

In 1832, at the siege of the citadel of Antwerp, Letulle performed the operation primarily on an artilleryman whose left thigh was badly shattered by a cannon ball. The patient survived nine days.<sup>5</sup>

Amputation at the hip-joint for gunshot injury was performed at least eight times in the campaigns of the French in Algeria, from 1836 to 1840. Twice by Hutin<sup>6</sup> unsuccessfully. Five times, primarily and unsuccessfully, by Guyon, Bertherand, and others.<sup>7</sup> Once successfully by Baudens,<sup>8</sup> being the fourth authentic instance of the successful performance of the operation in military surgery.

About this time Wedemeyer had a successful intermediate operation, and a primary operation, which resulted fatally.<sup>9</sup> Three fatal primary operations were recorded by Jubiot;<sup>10</sup> and Sir Benjamin Brodie operated unsuccessfully in a case of accidental gunshot fracture of the femur.<sup>11</sup>

In the war between the United States and Mexico, in 1846 and 1847, there were no amputations at the hip-joint.<sup>12</sup>

In the insurrection in Paris, in June, 1848, amputation at the hip-joint was performed for gunshot injury five times by Richet,<sup>13</sup> Baudens,<sup>14</sup> Vidal,<sup>15</sup> Robert,<sup>16</sup> and M. P. Guersant.<sup>17</sup> Richet's was a primary, the others were intermediate cases; all terminated fatally.

<sup>1</sup> *Gazette des Hôpitaux*, 1830, p. 392.

<sup>2</sup> *Gazette des Hôpitaux*. Tome IV, p. 96.

<sup>3</sup> Dr. HEIMANN DEMME, *Militär-Chirurgische Studien, Zweite Abtheilung*, p. 352. Würzburg, 1864.

<sup>4</sup> *Traité de Médecine Opératoire*, par le docteur CH. SÉDILLOT, 3d ed., Paris, 1865, T. I, p. 455; and *Annales de Chirurgie Française et Étrangère*, T. II, p. 279. LEGUEST (*Chirurgie d'Armée*, p. 699) credits Sédillot with five cases; but the other four were operations done in Algiers by Bertherand and others, and are simply referred to by Sédillot.

<sup>5</sup> *Histoire Chirurgicale du Siège de la Citadelle d'Anvers*, par HIPPOLYTE LARREY. Paris, 1833, p. 367.

<sup>6</sup> *Mém. de Chirurgie Mil.* 1<sup>re</sup> Série. Tome XLIV, p. 219. Both were primary operations. One patient lived ten days; the other died on the day of the operation.

<sup>7</sup> M. SÉDILLOT, *Ann. de Chir. Franc. et Étrang.*, Tome II, p. 279; LEGUEST, *Loco citato*; GUYON, *Expédition de Cherche*!; *Gazette Médicale de Paris*, 1838; *Medico-Chirurgical Review*, Vol. XXXV, p. 214.

<sup>8</sup> *Clinique des Plaies d'Armes à Feu*, par M. J. BAUDENS. Paris, 1836, p. 513. The patient, a soldier, twenty-four years old, was wounded at the Atlas, April 1, 1836, and was amputated at the hospital at Algiers on April 7. He recovered rapidly, and was for a long time afterwards an inmate of the Invalides. His stump is figured in Bourgery's Plates. T. VI, Pl. 91, Fig. 9.

<sup>9</sup> *Bulletin de M. le Baron FÉRUSAC*. Tome III, p. 161.

<sup>10</sup> *Thèses de la Faculté de Montpellier*, 1840. I have not been able to refer to or to verify these cases.

<sup>11</sup> COSTELLO, *Cyclopædia of Practical Surgery*. Vol. I, p. 182. There is no question as to the authenticity of these cases, but I cannot find recorded any particulars in regard to them.

<sup>12</sup> *Hand-book for the Military Surgeon*, by CHARLES S. TRIPLER, A. M., M. D., Surgeon, U. S. Army, Cincinnati, 1864, p. 52; and *Medical and Surgical Notes of Campaigns in the War with Mexico, during the years 1845, 1846, 1847, and 1848*, by JOHN B. PORTER, M. D., Surgeon, U. S. Army.

<sup>13</sup> M. L. LEGUEST. *Chirurgie d'Armée*, p. 699.

<sup>14</sup> *Recueil de Mém. de Méd. et de Chir. Mil.* 2<sup>e</sup> série. Tome X, p. 139.

<sup>15</sup> VIDAL. *Traité de Pathologie Externe et de Méd. Opér.* Tome V, p. 703. Troisième ed.

<sup>16</sup> M. L. LEGUEST. *Loco citato*.

<sup>17</sup> *Idem*.



During the war in Schleswig-Holstein, in 1848 and 1849, this operation was performed seven times: five times in 1848 and twice in 1849.<sup>1</sup> Five of the operations were done by Dr. B. Langenbeck, and one of his patients, a youth of seventeen, recovered.<sup>2</sup>

In 1849, after the riot in Astor Place, New York, an amputation at the hip-joint was performed at the New York Hospital for a gunshot fracture of the neck of the femur by a musket ball,<sup>3</sup> the patient surviving the operation two days. This was the first instance in which the operation was practiced in this country for gunshot injury.

In the war in the Punjaub, in 1848 and 1849, three primary amputations at the hip-joint were performed for cannon-shot wounds, involving extensive lacerations of the thigh, with comminuted fracture of the femur. Dr. James McRae states that the patients died—one in six, one in twelve, and one in thirty-six hours, from shock.<sup>4</sup>

In 1853, two amputations at the hip-joint for gunshot injury were performed at Rangoon, in India. One, a primary operation, was done on February 16th by Dr. J. Fayrer; the patient survived one month.<sup>5</sup> The other was done by Dr. Beatson, six days after the reception of the injury; the patient, a man of sixty-one years, died from the shock of the operation.<sup>6</sup>

In 1854 and the following year, in the war in the Crimea, this operation was performed not less than forty-four times; twice in the Sardinian, eight times in the Russian, fourteen in the British, and twenty in the French army. Porta mentions that the operations in the Piedmontese army resulted fatally. Pirogoff operated in the eight cases in the Russian army. He describes his patients as in almost every instance anæmic and unfit to undergo so grave a mutilation. Two survived five days; the others perished within two or three days.<sup>7</sup> All of the operations in the English army were primary. Five were performed after Alma, Balaclava, and Inkermann. The director general, Thomas Alexander, did two of these operations. His patients lived to reach Scutari; one, a man of the thirty-third regiment, survived three weeks, and the other, a Russian prisoner, lived a month.<sup>8</sup> Dr. Richard McKenzie operated in another of these cases,<sup>9</sup> and Assistant Surgeon Wyatt in a fourth.<sup>10</sup> Nine operations were performed during the siege of Sebastopol. Two of the patients were officers and seven enlisted men.<sup>11</sup> All of these cases ended fatally. Of the twenty amputations at the hip-joint in the French army, twelve were done in the Crimea and eight at the hospitals on the Bosphorus. Five primary and eight intermediate or early secondary amputations were reported by the operators, MM. Paulet, Lustreman, Thomas,

<sup>1</sup> *Maximen der Kriegsheilkunst* von Dr. L. STROMEYER. Hanover, 1861, p. 532.

<sup>2</sup> *Ueber Reactionen nach Schusswunden* von Dr. FRIEDRICH ESMARCH, Kiel, 1851, p. 124; LONGMORE, in *Holmes's System of Surgery*, Vol. II, p. 82; and DEMME, *Op. cit.*

<sup>3</sup> *The Transactions of the American Medical Association*. Vol. IV, p. 316.

<sup>4</sup> MCRÆ, *Indian Annals of Medical Science*, April, 1857, p. 663; and *Military Surgery*, by GEORGE WILLIAMSON, Surgeon-major, 64th regiment, London, 1863, p. 202.

<sup>5</sup> *Clinical Surgery in India*. By J. FAYRER, M. D., p. 630.

<sup>6</sup> *Indian Annals of Medical Science*. October, 1854.

<sup>7</sup> *Grundzüge der Allgemeinen Kriegschirurgie* von N. PIROGOFF. Leipzig, 1864, p. 1136.

<sup>8</sup> LONGMORE. *Loco citato*.

<sup>9</sup> *Notes on the Surgery of the War in the Crimea*. By GEORGE H. B. MACLEOD, M. D., F. R. C. S., etc., etc. London, 1858, p. 369.

<sup>10</sup> *Medical and Surgical History of the British Army in the Crimea*. Vol. I, p. 3.

<sup>11</sup> Staff-Surgeon T. P. MATTHEW, in the *Medical and Surgical History of the British Army in the Crimea*. Vol. II, p. 374.



Perrin, Mounier, Legouest, Larivière, Mauger, and Salleron.<sup>1</sup> Such particulars of these thirteen operations as could be collected are presented in the tables in another part of this report. Besides them, seven primary coxo-femoral amputations were done by the French surgeons in the Crimea of which no memoranda were preserved. Three of these were performed during or after the battle of the Alma, September 20, 1854, and three at Inkermann, November 5, 1854. None of these patients survived the operation twenty-four hours, and, consequently, says M. Chenu, their names were not inscribed on the registers of the field hospitals, and it is not known whether they were French soldiers or Russian prisoners.<sup>2</sup>

The Italian war of 1859 was the occasion of at least nine amputations at the hip-joint for gunshot injury, or the complications consequent thereon. A primary operation after the battle of Palestro, by the French surgeon Bertherand, on an Austrian soldier, whose left thigh was shattered by a shell, terminated fatally in three hours.<sup>3</sup> In two primary operations reported by Demme,<sup>4</sup> death resulted from hæmorrhage during the operation. In two other cases the patients survived the shock of the operation but a short time. A secondary operation by Isnard, at a hospital at Brescia, succeeded, and the patient was able to get about on an artificial limb. Neudörfer also had a successful secondary operation at the Santo Spirito Hospital at Verona.<sup>5</sup> Two patients who were sent to Toulon were operated on by M. Jules Roux and M. Arlaud about six months after the reception of the injury in each case, and both recovered.<sup>6</sup>

Two unsuccessful primary amputations at the hip-joint were performed on account of gunshot fractures in the French naval service during the Crimean or Italian wars. The exact dates of these operations are not recorded.<sup>7</sup>

Setting aside the doubtful or unauthenticated cases of Blandin, Perret, Wendelstaedt, Krimer, Alcock, and Bryce, there have been enumerated in the foregoing summary one hundred and eight amputations at the hip-joint performed on account of gunshot injuries or their consecutive lesions. Admitting Larrey's case at Borodino to have been successful,<sup>8</sup>

<sup>1</sup> *Rapport au Conseil de Santé des Armées sur les Résultats du Service Médico-Chirurgical aux Ambulances de Crimée et aux Hôpitaux Militaires Français en Turquie, pendant la Campagne d'Orient, en 1854, 1855, 1856.* Par J. C. CHENU, Médecin Principal, etc. Paris, 1865, p. 660.

<sup>2</sup> CHENU, *Op. cit.*, p. 658; and SCRIVE, *Relation Médico-Chirurgicale de la Campagne d'Orient*, Paris, 1857, pp. 106, 125.

<sup>3</sup> A. BERTHERAND. *Campagne d'Italie de 1859*, p. 37.

<sup>4</sup> *Allgemeine Chirurgie der Kriegswunden nach Erfahrungen in den Norditalienischen Hospitälern von 1859.* Von Dr. HERMANN DEMME, Würzburg, 1861, p. 254.

<sup>5</sup> Dr. DEMME. *Loc. cit.*

<sup>6</sup> *De l'Ostéomyélite et des Amputations Secondaires à la suite des Coups de Feu d'Après des Observations recueillies à l'Hôpital de la Marine de Saint-Mandrier sur des Blessés de l'Armée de l'Italie.* Par le Docteur JULES ROUX, Premier Chirurgien en Chef de la Marine, etc. Paris. Quarto, 1860, pp. 98, 99. From the title of M. Roux's Memoir, and from the numerous abstracts of it that have been published, it would be inferred that the six operations and four successes which Roux reported were all instances of amputation at the hip-joint for gunshot injury. This is only true, however, of the two cases of the series noted above, in one of which M. Arlaud, the colleague of M. Roux, operated. The other operations were done on account of lesions resulting from falls or other traumatic causes.

<sup>7</sup> *Désarticulation de la Cuisse, d'après les Observations recueillies en 1859 sur des Marins de la Flotte et des Blessés de l'Armée de l'Italie.* Par le Docteur JULES ROUX, Premier Chirurgien en Chef de la Marine. *Comptes Rendus Hebdomadaires des Séances de l'Académie des Sciences*, Tome L, p. 752.

<sup>8</sup> M. Legouest in his tables (*Chirurgie d'Armée*, p. 699) accredits Larrey with one successful case, and places it in the category of intermediate operations. He counts six of Larrey's seven operations as primary. Now it is certain that Larrey's two operations after the battle of Wagram were intermediate, for he ascribed the fatal results to the delay in operating. It is equally clear that the operation at the battle of Borodino or Mosaisk, which is claimed as a success, was a primary one, for Larrey said he performed it "sur le champ de bataille." (*Mém. de Chir. Mil.*, T. IV, p. 51.) M. Legouest must either refuse to admit that any of Larrey's operations were successful, or he must amend the proposition enunciated in his *Mémoire sur la désarticulation coxo-fémorale au point de vue de la Chirurgie d'Armée*, that primary amputations at the hip-joint have hitherto been invariably fatal.



the recoveries were ten in number—one after a primary, four after intermediate, and five after secondary operations—a percentage of mortality of 91.66.

Except in the references to the cases of Kerr, and the alleged cases of Lacroix, Perault, and Thomson, introduced in tracing the early history of this operation, notice has only been taken, in the preceding retrospect, of examples of the operation occurring in the domain of military surgery. Yet the results of the amputations at the hip-joint done in civil practice, especially for such as were performed on account of injury, unquestionably exerted much influence upon the minds of military surgeons in their estimate of the operation. The cases recorded in civil surgery are as numerous as those occasioned by the accidents of war. The French boast of eight successes in civil practice, by Mulder,<sup>1</sup> Delpech,<sup>2</sup> M. Sédillot,<sup>3</sup> Hénot,<sup>4</sup> M. Guersant,<sup>5</sup> Foullyoy,<sup>6</sup> and M. Jules Roux,<sup>7</sup> and lament fifteen failures, by Baffos,<sup>8</sup> Pelletan,<sup>9</sup> Dupuytren,<sup>10</sup> Blandin,<sup>11</sup> Gensoul,<sup>12</sup> Delpech,<sup>13</sup> Gerdy,<sup>14</sup> M. Velpeau,<sup>15</sup> and M. Jules Roux.<sup>16</sup>

The German surgeons, if all their unsuccessful cases are reported, have been more fortunate. The successes outnumber the reverses. In thirteen operations, Jaeger,<sup>17</sup> Hysern,<sup>18</sup> Textor,<sup>19</sup> and B. Langenbeck,<sup>20</sup> each claim one success, and Heyfelder<sup>21</sup> three; while Von Walther,<sup>22</sup> Graefe,<sup>23</sup> Dieffenbach,<sup>24</sup> in two cases, and Heyfelder, also in two, endured the mortification of failure.

Four amputations at the hip-joint for disease, by the Polish surgeons Peliken, Korseniewski, and Porcienko, resulted fatally.<sup>25</sup>

<sup>1</sup> In 1798, on a girl named Wiertz, aged eighteen. VELPEAU, *Op. cit.*, p. 514.

<sup>2</sup> *Revue Médicale*, 1825, and *Ann. de Chir. Franç. et Étrang.* T. II, p. 277.

<sup>3</sup> *Recueil de Mém. de Méd. et de Chir. Mil.* 1 série. Tome XLIX. p. 277.

<sup>4</sup> *Idem.* 2d série. Tome VI, p. 93.

<sup>5</sup> *Jour. de Méd. et de Chir. Prat.* 1848.

<sup>6</sup> VIDAL. *Traité de Path. Ext. et de Méd. Op.* 3d ed. Tome V, p. 760.

<sup>7</sup> Two secondary operations, for chronic osteomyelitis following injuries. *Comptes Rendus Hebdomadaires des Séances de l'Académie des Sciences.* T. L, p. 753.

<sup>8</sup> In 1812, in a child of seven years with coxalgia. The cotyloid cavity was diseased and the child died in a few months after the operation. *Bulletin de la Faculté de Médecine.* Tome VIII, p. 112.

<sup>9</sup> S. COOPER'S *Surgical Dictionary.* 8th Lond. ed., p. 117.

<sup>10</sup> Six operations, six deaths. *Leçons Orales de Clin. Chir.* 2d ed. T. II, p. 370.

<sup>11</sup> *Transactions Médicales.* Tome X, p. 353.

<sup>12</sup> *Lancette Française.* Tome II, p. 220.

<sup>13</sup> *Idem.* Tome XIII, p. 301.

<sup>14</sup> *Bulletin de la Thérap. Médico. Chir.* Tome VIII, p. 318.

<sup>15</sup> *Op. cit.* Tome I, p. 515.

<sup>16</sup> *Comptes Rendus de l'Acad. des Sciences.* Tome L, p. 753.

<sup>17</sup> *Hamburger Zeitschrift für die gesammte Med.* Band III, Heft. 1.

<sup>18</sup> *Opérations Générales par BOURGERY.* Tome VI, p. 271.

<sup>19</sup> METZ. *Ueber de Lösung des Oberschenkels aus dem Hüftgelenke.* Würzburg. 1841.

<sup>20</sup> STROMEYER. *Max. der Kriegsheilkunst*, p. 277.

<sup>21</sup> *Deutsche Klinik.* March, 1853.

<sup>22</sup> In 1824, for complicated fracture. The patient lived eleven days. GRAEFE UND WALTHER, *Zeitschrift für Chir.* Band VI, p. 1.

<sup>23</sup> *Normen für die Ablösung grösserer Gliedmassen*, p. 117.

<sup>24</sup> *Jour. Univ. des Sci. Méd.*, Tome XLVIII, p. 381; and *London Lancet*, 1834, p. 908. One patient was a child with osteosarcoma; the other was an adult with fracture through the trochanters. A secondary amputation was performed, which he survived ten hours.

<sup>25</sup> *Acts of the Imperial Academy at Wilna*, quoted by M. Velpeau, Mr. Cox, and others. Pelikan's operation was on a man of twenty-five, with fungus hematodes. Korseniewski operated on account of neuroma. Porcienko had two operations: one in 1821, on a woman of fifty; one in 1834, on a Jewess.



In the annals of British civil surgery not less than forty-seven of these operations are recorded, with sixteen recoveries. The successful operators were A. Cooper,<sup>1</sup> Orton,<sup>2</sup> Mayo,<sup>3</sup> Macfarlane,<sup>4</sup> Mr. Syme,<sup>5</sup> Mr. Cox,<sup>6</sup> Mr. Wigstrom,<sup>7</sup> Mr. Whipple,<sup>8</sup> Mr. Humphrey,<sup>9</sup> Mr. Tatum,<sup>10</sup> Mr. Gamgee,<sup>11</sup> Mr. Hancock,<sup>12</sup> Mr. Holmes,<sup>13</sup> Mr. Lee,<sup>14</sup> and Mr. Godfray.<sup>15</sup> In four of the cases the thigh had previously been amputated in the continuity. In one case, in a child of two years, the operation was done on account of injuries; in the remainder for disease.

In the thirty-one unsuccessful operations, the operators were Kerr, A. Cooper,<sup>16</sup> Brownlow, Bromfield,<sup>17</sup> Carmichael,<sup>18</sup> Mr. Syme, Liston,<sup>19</sup> Smith,<sup>20</sup> Handyside,<sup>21</sup> Mr. Jones,<sup>22</sup> Mr. Hancock,<sup>23</sup> Dr. R. J. Mackenzie,<sup>24</sup> Mr. C. Guthrie,<sup>25</sup> Mr. Wheateroft,<sup>26</sup> Mr. Adams,<sup>27</sup> Mr. Erichsen,<sup>28</sup> Stanley,<sup>29</sup> Mr. Lane,<sup>30</sup> Badley,<sup>31</sup> Mr. Butcher,<sup>32</sup> Mr. Young,<sup>33</sup> Mr. Wells,<sup>34</sup> Mr. Swain,<sup>35</sup> and Mr. Curling.<sup>36</sup>

<sup>1</sup> *London Lancet*. Vol. II, 1824, p. 96.

<sup>2</sup> In 1824, for caries. *Medico-Chirurgical Transactions*. Vol. XIII, Part I, p. 605.

<sup>3</sup> A reamputation for neuroma. *Cooper's Surg. Dictionary*. 8th Lond. ed., p. 117.

<sup>4</sup> For compound fracture in a child of two years. *Clin. Report of Glasgow Royal Infirmary*, 1832, p. 182.

<sup>5</sup> A reamputation, the first successful case in Scotland. *Edin. and Lond. Monthly Jour.*, 1848.

<sup>6</sup> A reamputation. See memoir already cited.

<sup>7</sup> At Lahore, India, for disease of the femur. *London Lancet*. Vol. I, 1850, p. 411.

<sup>8</sup> At Plymouth, for disease of the femur. *London Lancet*. Vol. II, 1846, p. 883.

<sup>9</sup> Two cases: one of compound fracture, the other of chronic disease resulting from injury. *EVE's Remarkable Surgical Cases*, p. 565. From *Provin. Ass. Med. Jour.*, 1855.

<sup>10</sup> In 1855, at St. George's Hospital, for malignant disease. *London Lancet*. Vol. II, 1855, p. 77.

<sup>11</sup> For malignant disease. See monograph already cited.

<sup>12</sup> For necrosis, at Charing Cross Hospital. *Med. Times and Gazette*, January, 1857, p. 114.

<sup>13</sup> For fibroid disease of thigh. *London Lancet*. Vol. I, 1866, p. 367.

<sup>14</sup> For coxalgia. *London Lancet*. Vol. I, 1866, p. 386.

<sup>15</sup> For extensive necrosis. *Dublin Quarterly Jour. Med. Sci.*, November, 1866, p. 302.

<sup>16</sup> COSTELLO'S *Cyclopaedia of Surgery*. Vol. I, p. 183.

<sup>17</sup> In Sir Astley Cooper's fiftieth lecture the cases of Brownlow and Bromfield are mentioned. *London Lancet*, 1824.

<sup>18</sup> On a girl of nineteen, with osteosarcoma. *Trans. of Coll. of Physicians of Ireland*. Vol. III, p. 8.

<sup>19</sup> "During my residence in Edinburgh the operation was done twice by Mr. Liston and twice by Mr. Syme. All the patients died." Mr. W. FERGUSSON. *A System of Practical Surgery*. 4th Lond. ed., 1867, p. 506.

<sup>20</sup> On account of compound fracture. *London Med. Gazette*. Vol. XVI, p. 551.

<sup>21</sup> On a boy with medullary sarcoma. *Lond. and Edin. Monthly Jour.*, April, 1845, p. 254.

<sup>22</sup> For hæmorrhage from a lacerated wound of the thigh. *Medical Times*, March, 1854, p. 434.

<sup>23</sup> Two cases: one a reamputation, the other for compound fracture. *London Lancet*. Vol. I, 1860, p. 319; *Idem*, Vol. I, 1857, p. 31.

<sup>24</sup> For necrosis. *Edinburgh Medical and Surgical Journal*, 1854, p. 117.

<sup>25</sup> For malignant disease. *London Lancet*. Vol. I, 1853, p. 405.

<sup>26</sup> For coxalgia; fatal in four hours. *London Lancet*. Vol. I, 1853, p. 470.

<sup>27</sup> For malignant disease. *Medical Times*, April, 1854, p. 349.

<sup>28</sup> Two cases: one of compound fracture, the other of encephaloid. *London Lancet*. Vol. I, p. 363, 1855, and Vol. I, 1866, p. 222.

<sup>29</sup> For medullary cancer. *London Lancet*. Vol. I, 1857, pp. 343 and 380.

<sup>30</sup> Three cases: two of malignant disease, one of injury. *London Lancet*. Vol. II, 1857, p. 443; *Idem*, Vol. I, 1865, p. 651; *Idem*, Vol. I, 1865, p. 566.

<sup>31</sup> In 1814, the patient, a boy, had his thigh crushed by machinery. Mr. W. S. COX. *Op. cit.*, p. 12.

<sup>32</sup> For osteosarcoma. *Dublin Quarterly Journal of Medical Science*. No. LXXXIV, p. 305, Nov., 1866.

<sup>33</sup> For a bad fracture. *London Lancet*. Vol. I, 1865, p. 652.

<sup>34</sup> For malignant disease; the patient lived nearly a year. *London Lancet*. Vol. I, 1865, p. 652.

<sup>35</sup> For encephaloid. *Dublin Quarterly Journal of Medical Science*, November, 1866, p. 302.

<sup>36</sup> Two cases: one of medullary cancer, the patient survived ten months; one of necrosis, ending fatally in five weeks. *London Lancet*. Vol. I, 1856, p. 6, and Vol. I, 1865, p. 566.



In American civil practice, twenty-four examples of amputation at the hip-joint are recorded. Fifteen successful cases are reported; so large a preponderance as to lead to the suspicion that all the unfortunate cases have not been published. The operators in the successful cases were Brashear,<sup>1</sup> Mott,<sup>2</sup> Duffee,<sup>3</sup> Dr. Van Buren,<sup>4</sup> Dr. May,<sup>5</sup> Dr. Bradbury,<sup>6</sup> Dr. Potter,<sup>7</sup> Dr. Blackman,<sup>8</sup> Dr. J. Mason Warren,<sup>9</sup> Dr. Buchanan,<sup>10</sup> Dr. Pancoast,<sup>11</sup> and Dr. Gross.<sup>12</sup>

In the nine unsuccessful cases, the operators were Brainard,<sup>13</sup> Buel,<sup>14</sup> Clark,<sup>15</sup> Dr. Van Buren,<sup>16</sup> Dr. J. Mason Warren,<sup>17</sup> Dr. Hachenburg,<sup>18</sup> and Dr. Hewson.<sup>19\*</sup>

Of the one hundred and eleven amputations at the hip-joint in civil practice here recorded, forty-six succeeded and sixty-five ended fatally: a mortality rate of 58.56.

All of the facts here recapitulated were not known to our surgeons at the commencement of the war of the rebellion. Some of them, indeed, have transpired during its progress, or since its termination. But a large proportion of them were well known, and the conclusions deduced from these were not materially modified by the additional cases. It was considered well established, that in amputation at the hip-joint for chronic disease, the mortality was less than in several other major operations in surgery; that the mortality had lessened since the introduction of anæsthetics had furnished the means of diminishing

<sup>1</sup> In 1806. *Mott's Velpeau's Surgery*. Vol. III. *Exc's Remarkable Cases in Surgery*, p. 362.

<sup>2</sup> In 1824, for caries following fracture. *Philadelphia Journal of Medical and Physical Sciences*, 1827. Vol. V, p. 101.

<sup>3</sup> In 1840, for coxalgia. *Institutes and Practice of Surgery*. By WILLIAM GIBSON. 7th ed. Vol. II, p. 464.

<sup>4</sup> In 1850, a reamputation for osteochondroma. *Contributions to Practical Surgery*. By W. H. VAN BUREN, M. D. Philadelphia, 1865, p. 10.

<sup>5</sup> In 1850, for scrofulous degeneration. *Am. Jour. of the Med. Sci.*, October, 1851, p. 313.

<sup>6</sup> In 1851, a reamputation of a thigh stump of a strumous child. *Boston Medical and Surgical Journal*. Vol. XLVI, p. 349.

<sup>7</sup> Two cases: one in 1853, for caries, *N. Y. Jour. of Med.*, 1854; and another in 1860, for disease of the femur resulting from the kick of a horse, *Am. Med. Times*, Vol. I, p. 369.

<sup>8</sup> In 1855, for osteocephaloma. *Western Lancet*, 1857. Vol. XVIII, p. 7.

<sup>9</sup> In 1859, for osteosarcoma. *Boston Med. and Surg. Jour.*, 1859. Vol. LX, p. 329.

<sup>10</sup> In 1859, on a boy of fourteen years, for necrosis. *Boston Med. and Surg. Jour.* Vol. LXI, p. 227.

<sup>11</sup> Two cases. One in 1860, for medullary sarcoma; the patient died two years subsequently from recurrence of the disease in the trunk. *Am. Jour. Med. Sci.* Vol. LII, p. 23. The other in 1865, for osteochondroma. *Op. cit.* Vol. LII, p. 28.

<sup>12</sup> Two cases. One in 1862, on a child of nine years, for deformity following a burn. *Am. Jour. Med. Sci.* Vol. XLVIII, p. 105. The other in 1865, for encephaloid. *Op. cit.* Vol. LII, p. 31.

<sup>13</sup> In 1837, for a tumor involving the femur. *Am. Jour. Med. Sci.* Vol. XXII, 1838, p. 372.

<sup>14</sup> In 1847, for a railroad accident. *Am. Jour. Med. Sci.* N. S. Vol. XVI, p. 34.

<sup>15</sup> In 1853, for medullary cancer. *Peninsular Journal of Med.* Vol. I, p. 59.

<sup>16</sup> Two cases: one in 1853, one in 1855; both for railroad accidents. *N. Y. Jour. of Med.*, Vol. XII, p. 151, and *Contributions to Prac. Surg.*, p. 33.

<sup>17</sup> In 1858, for compound fracture in a boy of six years. *Boston Med. and Surg. Jour.* Vol. LIX, p. 284.

<sup>18</sup> In 1861. *Boston Medical and Surgical Journal*. Vol. LXVI, p. 150.

<sup>19</sup> Two cases: one in 1864, for a railroad accident; another in 1865, for enchondroma. *Am. Jour. Med. Sci.* Vol. LII, pp. 28-31.

\* I have omitted the sixth, ninth, and eleventh cases of Dr. Stephen Smith's tabular statement of eleven amputations at the hip-joint in American practice. The sixth case has already been enumerated among the amputations for gunshot fracture. In the ninth case the operation is said to have been done successfully by Drs. Richards and Claggett, in Washington county, Maryland. (*Transactions of the Am. Med. Assoc.*, Vol. IV, p. 269.) The eleventh case consists of a statement of Dr. Willard Parker, that he had heard that the operation had been successfully performed by Dr. Fuller, of Norwich, Connecticut. These two cases, reported on the basis of the merest rumors, are unfit for statistical purposes. It is questionable if the first case, also, should not be set aside, since the operator, Brashear, did not report the operation until forty years after its performance, and then declined to state the causes that necessitated it. (*New Orleans Med. and Surg. Jour.*, Vol. II., and *Mott's Velpeau*, Vol. III.) I have also discarded from the lists of European cases the operations of Lacroix and Perault, the two pretended successes of Millingen, (*Jour. de Méd. de Vartermonde*, T. II, p. 240.) the cases ascribed to Thomson, Brooke, Ravaton, Goursault, Delauney, Kerst, Rossi, and Cherubini, being unable to find evidence of their authenticity.



the shock of the operation; and it was hoped that the methods recently proposed for controlling the circulation in the thigh by compressing the aorta might remove another of the great dangers of the operation. It was admitted that, in cases of injury, the results of the operation were very unsatisfactory, and the experience reported from the Crimean war had led to the conviction that, in military surgery, the results were especially discouraging and deplorable.

With such impressions, few of the practitioners who engaged in the surgery of the war looked forward to such exigencies as might require amputations at the hip-joint with hopeful anticipations. Many believed that as patients with terrible gunshot injuries of the upper part of the thigh often lingered for a long period, it was more humane to abandon them to inevitable death than to subject them to a mutilation which was so rarely successful, and such practitioners were willing that the operation should be discarded altogether from military practice. The majority contended that the results had not been so hopeless as to lead us to abandon the operation. Dr. Chisolm, who prepared a manual of military surgery for the use of the Southern medical officers, observed "an unfortunate ambition—we might even use a stronger term for it—a criminal desire, to have an amputation at the hip-joint in the list of operations performed, which misleads many surgeons to perform this disarticulation, when their better judgment teaches them that it must be a useless mutilation."<sup>1</sup> But manifestations of this criminal spirit were certainly uncommon, for the great body of surgeons were earnestly and conscientiously seeking for the best solution of the grave problem of how to deal with the severer gunshot injuries of the upper part of the thigh. There was a disposition on the part of the leading surgeons to give conservative surgery a very fair trial, and the operation of excision of the upper extremity of the femur in such cases as had formerly been treated by extirpation of the thigh was advocated by many.

---

<sup>1</sup> *A Manual of Military Surgery, for the use of Surgeons in the Confederate States Army.* By J. JULIAN CHISOLM, M. D., Professor of Surgery in the Medical College of South Carolina, etc., etc. Third ed., p. 483.



## HIP-JOINT AMPUTATIONS IN THE WAR OF THE REBELLION.

---

There occurred, in the war of the rebellion, fifty-three authenticated instances of amputations at the hip-joint, performed on account of injuries inflicted by weapons or of lesions consecutive thereto. Thirty-four of these operations were performed in the armies of the United States, and nineteen in the rebel armies. There have been reports or rumors of a number of other examples of the operation. Some of these, upon investigation, have been proved to be altogether unfounded, and others too uncertain and indefinite to be admissible for statistical purposes.

Surgeon H. Z. Gill, U. S. Volunteers, has communicated to this office a statement that, in the autumn of 1861, Surgeon J. Frank Gabriel, 11th Ohio Volunteers, in charge of the hospital at Gallipolis, Ohio, amputated at the hip-joint in the case of a soldier whose thigh had been frightfully crushed by a cannon shot. Dr. Gabriel, however, states that although he considered the case to be one in which the operation would have been indicated had it come under his care in season, he did not operate, because the patient was nearly moribund when he reached the hospital.

A successful secondary amputation at the left hip-joint was reported from Armory Square Hospital in the autumn of 1862, and an intermediate amputation at the right hip-joint, in the case of Corporal R. A. Whitworth, Co. E, 64th Georgia (Rebel) Regiment, was mentioned in the surgical report of the hospital at Fort Monroe, for the third quarter of 1864. But it was ascertained by inquiries addressed to Surgeon D. W. Bliss, U. S. Volunteers, and Assistant Surgeon E. McClellan, U. S. Army, in charge, respectively, of these hospitals, that these cases were both instances of amputation in the upper part of the continuity of the thigh, and that the mistakes arose from clerical inaccuracies in making up the returns from these very large establishments.

A statement that he had performed during the war an unsuccessful amputation at the hip-joint for gunshot injury has been received from Surgeon C. C. Cox, U. S. Volunteers, with an assurance that he would forward the details of the case; but as yet no account of it has reached this office.

Surgeon T. H. Squire, 89th New York Volunteers, and Surgeon J. A. Bigelow, 11th Connecticut Volunteers, report that Acting Staff Surgeon M. Storrs amputated at the hip-joint after the battle of Antietam. Dr. Storrs declares that this report is an error, arising probably from the fact that he performed an excision of the head of the femur on that occasion.

Surgeon Bigelow also reports that a primary exarticulation at the hip was performed, in September, 1864, at the 18th Corps Hospital, before Petersburg, by Surgeon F. J. D'Avignon, 96th New York Volunteers, on a soldier whose thigh was carried away by a



shell, who died during the night succeeding the operation. The case is not mentioned in the casualty lists of the 18th Corps, and it has been impracticable to obtain any confirmation of the report.

In the register of the Convalescent Camp Hospital, near Vicksburg, Mississippi, there is an entry of the case of "Private Andrew M. Jackson, Co. C, 41st Illinois Volunteers, wounded July 23, 1863, in the left hip, amputated and died July 29, 1863." There are no quarterly reports from this hospital, and all attempts to obtain further information respecting this case have been unsuccessful.

It has been alleged that Surgeon Charles J. Nordquist, 83d New York Volunteers, amputated at the hip-joint, in May, 1864, during the battle of Spottsylvania, in the case of private J. W. Dadds, Co. B, 4th Maryland Volunteers. The facts of this case are still under investigation; but it is believed that the operation was an excision of the head of the femur.

From the difficulty of collecting information from the rebel armies, vague and unreliable reports from that source are still more numerous.

Mr. W. L. Henderson, a medical student under Professor F. H. Hamilton, reported to his preceptor that he had witnessed an amputation at the hip-joint, performed in March, 1862, at Memphis, Tennessee, by Dr. E. S. Fenner, and that he subsequently saw the patient in perfect health as late as four months after the operation.<sup>1</sup> There can be but little doubt that this statement is entirely erroneous,<sup>2</sup> and it is much to be regretted that it has been widely disseminated.

Dr. J. W. Clift, of Savannah, Georgia, reports that Dr. Cullen, a surgeon of General Longstreet's Corps, performed an amputation at the hip-joint for gunshot injury, and the editors of the *Richmond Medical Journal* record that Dr. Cullen mentioned to one of them two successful coxo-femoral amputations within his knowledge.<sup>3</sup>

Professor Paul F. Eve, has communicated the fact that a case-book of the late Dr. Hargrove Hinkley, surgeon of a rebel regiment, contained entries of three amputations at the hip alleged to have been performed at Jackson, Mississippi, in the summer of 1863. But Dr. John Pugh, of Pinecourt, writes that he was intimately associated with Dr. Hinkley throughout the war, and that he can positively assert that Dr. Hinkley never exarticulated the thigh.

Professor Eve also mentioned that he had been informed, and believed, that Surgeon Cowan, of the staff of the rebel General Forrest, twice amputated at the hip-joint during the war.

<sup>1</sup> See Circular No. 6, S. G. O., 1865, p. 49, and *A Treatise on Military Surgery*, by F. H. HAMILTON, pp. 423 and 482.

<sup>2</sup> Dr. C. H. Mastin, of Mobile, Alabama, who was inspector of the rebel hospitals at Memphis in 1862, is positive that Dr. Fenner performed no such operation there. Dr. Fenner, of Memphis, called at this office in the summer of 1865, with Dr. Nott, of Mobile, and denied any knowledge of such a case. He suggested that the operation might have been done by Professor E. D. Fenner. That eminent practitioner is dead; but his colleague, Professor D. W. Brickell, states positively that he never attempted the operation of amputation at the hip-joint. Assistant Surgeon W. S. Tremaine, U. S. Army, stationed at Memphis, Professor J. J. Chisolm, of Charleston, and Professor Paul F. Eve, of Nashville, have made diligent inquiries in relation to this alleged operation, and have arrived at the conclusion that the report of it is altogether apocryphal.

<sup>3</sup> *The Richmond Medical Journal*, Vol. I, p. 11, January, 1866. Dr. Gilmore writes that Dr. Cullen excised the head of the femur, in November, 1863, in the case of a prisoner, a Michigan cavalry soldier, who survived the operation a few days. This exarticulation may probably have been confounded with an extirpation of the thigh.



Professor J. J. Chisolm, of the Medical College of South Carolina, has communicated a report that Surgeon Myddleton Michel had amputated at the hip-joint several times, and that Professor P. F. Eve had performed the operation once at least. Dr. Eve has contradicted this report, so far as it relates to himself. It is unnecessary to recapitulate more of these indefinite statements.

The fifty-three authenticated operations now to be described are divided into four categories: primary, intermediate, and secondary amputations, and reamputations. Practical surgeons are very generally agreed at the present day that amputations for injury should be classified in at least three categories, according to the period at which they are performed, and that the old division into primary and secondary operations is insufficient.<sup>1</sup> Beyond question there are three distinct, successive, and easily appreciated periods in which amputations are performed: the period between the reception of the injury and the appearance of the inflammatory symptoms; when inflammatory action has commenced and is more or less capable of disturbing the animal economy; and when the violence of the inflammatory symptoms and symptomatic fever have abated and the suppurative stage is fully established. Operations done in either of these periods differ widely in their attendant circumstances and in their results. It is important therefore that they should be grouped in separate classes.

Some authors subdivide still further, and separate the first class into immediate amputations, or amputations *sur le champ*, performed, without awaiting reaction, at the earliest possible moment after the reception of the injury, so that the shock to the system from the operation may be confounded, so to speak, with that from the injury, and primary operations performed after reaction and previous to the accession of the inflammatory stage.<sup>2</sup> M. Legouest would separate the third class into consecutive amputations, done during the suppurative period after the acute inflammatory symptoms have subsided, and ulterior amputations, performed when the traumatic phenomena have entirely disappeared and the case has become assimilated to a case of chronic disease.<sup>3</sup> These refinements could hardly be adopted in dealing with extended statistics.

It is greatly to be desired that a uniform system of classification of amputations and of their nomenclature should be adopted by surgeons, in order that the results of operations performed at different periods should be compared with precision. At present, authors refer to the first class as immediate or primary; to the operations done in the middle period as delayed, tardy, mediate, intermediate, intermediary; to those of the third period as consecutive, ulterior or secondary amputations. And there is great confusion in the definition of these epithets.<sup>4</sup> Some surgeons mean by primary amputations those done

<sup>1</sup> BÉRAUD, DENONVILLIERS, and GOSSELIN, in *Compendium de Chirurgie Pratique*, T. II, p. 504. BARON HIPPOLYTE LARREY, *Bulletin de l'Académie Impériale de Médecine*, Tome XXV, p. 647. DR. HAMILTON, *A Treatise on Military Surgery*, p. 428. MR. FERGUSSON, *A System of Practical Surgery*, 4th London ed., p. 197. ALCOCK, *Notes on the Medical History and Statistics of the British Legion in Spain*, p. 67. M. J. ROUX, *De l'Ostéomyélite*, etc., p. 169. BALLINGALL, *Outlines of Military Surgery*, 5th ed., p. 424. MR. ERICHSEN, however, (*Science and Art of Surgery*, 2d Lond. ed. p. 22,) declares that "this distinction is a somewhat trivial one." M. LEGOUEST (*Dict. Encyclopéd. des Sciences Méd.*, 1865, T. III, ART., Amputation) advises five divisions.

<sup>2</sup> BOYER, *Traité des Maladies Chirurgicales et des Opérations qui leur conviennent*, 5th ed., Tome IV. HUTCHISON, *Some Practical Observations in Surgery*, p. 6. DR. HAMILTON, *Loco citato*. GUTHRIE, *Commentaries*, &c.

<sup>3</sup> M. LEGOUEST. *Dict. Encyclopéd. des Sciences Méd.* Paris, 1865. Tome III. ART., Amputations.

<sup>4</sup> "L'exactitude dans la dénomination des amputations suivant le moment où elles sont pratiquées est un des desiderata importants de la science; c'est un élément capital à la détermination de l'époque où il convient d'opérer dans le cas de lésions traumatiques." M. LEGOUEST. *Loco citato*.



within a few hours after the reception of the injury; others extend the primary period to several days. Of late, many designate as secondary amputations only those in which a previous amputation has been performed on the same limb. Baron H. Larrey is a strenuous advocate of this discrimination.

I have placed in the class of *primary* amputations those performed in the interval between the reception of the injury and the commencement of inflammatory symptoms, and I believe that, in cases of gunshot injury, the duration of this period will very rarely be found to exceed twenty hours. I have selected the epithet *intermediate* for the operations of the second class as being more conformable to our idiom than *mediate* or *intermediary*, and I have included in this category those amputations performed during the persistence of the inflammatory stage, a variable period, usually included between the day after the reception of the injury and some time in the second or third month. The *secondary* amputations comprise those performed at a period when the inflammation had abated and the lesions had become, in a measure, local and analogous to chronic disease, excluding the cases in which amputation had been previously performed in the continuity. I have placed those cases in which an amputation in the continuity has preceded the amputation in the contiguity in a fourth category, and have designated such operations *reamputations*. It appears to me impracticable, even were it desirable, to restrict the term *secondary*, which has been so long used in a more general sense, to these operations. And yet it is important that they should be separated into a distinct class, because they are quite numerous and widely differ in the risk attendant upon them from other secondary operations. The term *reamputations*, if awkward, is not likely to be misunderstood.

The histories of the cases in each category are arranged in chronological order.

#### PRIMARY AMPUTATIONS.

In each of the nineteen cases included in this category, amputation was performed within twenty hours of the infliction of the injury. Several of the operations were immediate amputations in the strictest construction of that term. The average interval between the reception of the wound and the operation was seven hours. Eleven of the patients succumbed to the direct shock of the operation, surviving from a half hour to ten hours. Three lingered for two days, and two for eight or ten days. One has survived the operation over four years, and is now in excellent health. Two so far recovered that they were known to be in good condition, in one case two months, and in the other six months from the dates at which the operations were performed. It is to be hoped that the subsequent histories of these men may be traced, and that it may be proved that the operations had permanently successful results. At present, these cases cannot be regarded as recoveries authenticated beyond all question. Excluding these cases, the percentage of mortality in the primary amputations at the hip-joint was 94.73. Including them, the mortality rate is reduced to 84.21. Eight of the operations were performed by surgeons in the armies of the United States, one was done by a medical officer of the U. S. Navy, and ten were performed by surgeons in the rebel armies.

The imperfect abstract of the first case is compiled from letters from Surgeon G. C. Harlan, 11th Pennsylvania Cavalry, Surgeon R. B. Bontecou, U. S. Volunteers, Dr. R. K.



Browne, and Dr. L. McLean, the operator. Dr. McLean's memoranda of the case, together with the pathological specimen, were unfortunately destroyed, August 30, 1862, at the second battle of Bull Run, by the burning of an hospital train.

**CASE I.**—On March 9, 1862, in the engagement between the U. S. frigate Congress and the rebel iron-clad Merrimac, a private of the 99th New York Volunteers, or Union Coast Guard, detailed as a seaman on the Congress, was wounded by a piece of shell, which tore away the muscles on the outer side of the left thigh, so as to expose the bone, and comminuted the neck and trochanters of the femur. He was immediately conveyed to the military post hospital at Newport News, Virginia, which was distant but a few hundred yards from the anchorage of the Congress, and restoratives and stimulants were administered. Eight hours after the reception of the injury, reaction having taken place to a considerable degree, the patient was placed under the influence of chloroform by Surgeon R. K. Browne, U. S. Volunteers, and Surgeon Leroy McLean, 2d New York Volunteers, amputated the injured limb at the hip-joint by the lateral double-flap method of Baron Larrey the elder. His principal assistants were Dr. Evarts, Dr. R. K. Browne, and Brigade Surgeon J. Curtis, U. S. Volunteers. The operation was rapidly accomplished, with the loss of but little blood. Six arteries required ligature. The patient did not rally from the shock of the operation, and died in less than two hours after its completion.

Memoranda of the next seven cases, all of which occurred in the rebel armies, were communicated to this office by Professor Paul F. Eve, of Nashville. It is believed that none of these cases have been published hitherto. In a few instances the operators or surgeons who witnessed the operations have reported some additional details; yet the histories of several of the cases are still very incomplete.

**CASE II.**—A private in General A. S. Johnston's army was wounded on the morning of Sunday, April 7, 1862, at the battle of Shiloh, by a fragment of shell, which shattered the upper extremity of the left femur. The comminution extended to the neck and head of the bone, and the soft parts at the upper third of the thigh were torn into shreds. Notwithstanding the terrible nature of the injury, the patient reacted, and it was thought, in the evening, that his condition justified amputation. At seven in the evening disarticulation at the hip-joint was performed by Dr. D. W. Yandell, Medical Director. The operation was well borne; but about three hours after its completion symptoms of exhaustion were manifested, and the case terminated fatally seven hours after the operation, at two o'clock of the morning of April 8, 1862.

Dr. J. T. Gilmore, of Mobile, Alabama, has courteously furnished such particulars of the three following cases as his memory retained. Full notes of the cases, which he had preserved with a view to publication, were unhappily lost at the battle of Cedar Creek, October 19, 1864. The case of Williamson, in all probability a successful one, is of great interest, and it is to be hoped that its ulterior history may be hereafter traced:

**CASE III.**—Private Williamson, 13th Mississippi (Rebel) Regiment, was wounded at an advanced picket station near Seven Pines, on June 4, 1862. A conoidal musket-ball entered the posterior part of the right thigh about two inches below the trochanter major, and, passing forwards and downwards, made its exit at the middle third of the thigh in front, having badly shattered the femur in its course. The wounded man was carried to the field hospital in charge of Surgeon J. T. Gilmore, located in a church building on the "Nine-mile Road" to Richmond, and was there placed under the influence of chloroform about two hours after the reception of the injury. After an exploration of the wound, it was decided that amputation should be performed. Dr. Gilmore began the operation with the belief that the comminution of the femur was mainly below the entrance wound, and that by making a long anterior flap the bone might be sawn at least through the trochanters; but when the anterior flap was reflected, and the fracture was exposed, it was found that fissures extended upward into the neck quite within the capsular ligament, and that disarticulation must be resorted to. A ligature was first placed upon the femoral artery, and the incisions were then extended upwards, the joint opened, the round ligament divided, and a short posterior flap formed by cutting downwards and outwards. Assistants compressed the bleeding orifices of the arteries, which were then rapidly picked up and tied. The amount of blood lost was small. The wound was dressed, and the patient was comfortably in bed within three hours after the reception of the injury. He was put upon a very nutritious regimen, a messenger being sent daily to Richmond for eggs, milk, and other delicacies which could not be procured in camp. Dr. Gilmore attended him for two weeks, during which suppuration was not excessive, and the healing of the wound progressed favorably. He was then placed under the charge of Acting Assistant Surgeon Spinks. Early in July he was carried to Richmond upon a hand-litter to a private house, at which he received every attention. In the middle of July, six weeks subsequent to the amputation, the wound had entirely healed, and he was allowed to start for his home in Mississippi. Dr. Gilmore learned that he arrived there in safety; but no intelligence was subsequently received from him.

In explanation of the omission of this and the two following cases in the published official return of wounds and operations in the Army of Northern Virginia for 1862,\* Dr.

\* Published in the *Confederate States Medical and Surgical Journal*. Vol. I, p. 155.



Gilmore writes that, "until General Lee took command of the army, battle-field reports of casualties were not required. During and after the battles about Richmond, in consequence of the scarcity of hospital accommodations, the men were transferred or furloughed with no other requirement than a wound to exhibit to the provost-guard. The almost total absence of organization in the medical department at that period sufficiently explains why no mention is made in the official reports of many important operations performed in the early part of the war."

CASE IV.—A private of the 18th Mississippi (Rebel) Regiment, of Barksdale's Brigade, a robust man, under thirty years of age, received a gunshot fracture of the upper extremity of the left femur, at the battle of Malvern Hill, on the afternoon of July 1, 1862. The injury was probably caused by a conoidal musket ball, and there was great splintering of bone, extending to the neck. Early on the morning of July 2d the patient inhaled chloroform, and amputation at the hip-joint was performed by Surgeon J. T. Gilmore, P. A. C. S., by forming anterior and posterior flaps by transfixion. There was no reaction, and the patient died from the shock of the operation an hour or two after its completion.

Dr. Gilmore, formerly Surgeon-in-chief of McLaws' Division of Longstreet's Corps, reports the fifth case also:

CASE V.—A private of the 21st Mississippi (Rebel) Regiment, a young, healthy man, was wounded at the battle of Malvern Hill, July 1, 1862, by a conoidal musket ball, which fractured the left femur through the trochanters and neck. Twelve hours after the reception of the injury he underwent amputation at the hip-joint. The operation was performed under chloroform by Surgeon J. T. Gilmore, by the antero-posterior flap method, the flaps being formed by transfixion. The patient only partially reacted after the operation, and though he lingered until the morning of July 4th, he died apparently from the shock of the operation.

Dr. William M. Compton, of Holly Springs, Mississippi, has communicated the particulars of the sixth case and of two others in which he amputated at the hip-joint:

CASE VI.—A lieutenant in an Arkansas (Rebel) Regiment in Cabell's Brigade, aged twenty-eight years, was wounded at the attack on Corinth, Mississippi, October 3, 1862. A solid cannon-shot struck the right hip and made a formidable wound, tearing up the soft parts of the buttock and shattering the upper extremity of the femur. The trochanters and about five inches of the shaft of the femur were comminuted; the head of the femur was exposed and was split across. It was decided that amputation at the hip presented the only possible surgical resource, and the operation was undertaken, two hours after the reception of the injury, by Surgeon W. M. Compton, 2d Texas (Rebel) Regiment. The operation consisted in paring into shape the lacerated soft parts at the posterior part of the thigh, completing the disarticulation already partly effected by the projectile, and forming a large and long antero-internal flap. The patient was under the influence of chloroform. There was but little hemorrhage. The flap covered the immense wound and was adjusted with tolerable accuracy to meet the incision at the gluteal region. The combined shock of the injury and operation was very great, and the patient reacted slowly and with difficulty. But he rallied finally, and progressed very favorably for several days. The inflammation was not intense, appetite returned, and strong hopes of the patient's recovery were entertained. But, on the seventh day, erysipelas invaded the stump and extended rapidly, in spite of the use of tincture of iron and such other treatment as it was thought proper to institute. The case terminated fatally on October 12, 1862, thirty-six hours after the invasion of erysipelas.

A report from Professor Paul F. Eve, with a copy of a letter from Dr. J. Grant, of Pulaski, Tennessee, furnishes the scanty details of the next case:

CASE VII.—A private soldier of Major Douglass's (Rebel) Cavalry was accidentally wounded by a comrade near Laverne, Tennessee, on October 19, 1862. The injury was inflicted by a round ball, with buckshot, fired from a fowling-piece, the muzzle being within a few inches of the person of the man who was wounded. The charge passed directly through the thigh, just below the trochanters, comminuted the femur and extensively lacerated the soft parts. The operation was performed eight hours after the reception of the injury. Chloroform was administered until anesthesia was complete. Then an assistant controlled the femoral at the groin, and the operator, Dr. J. F. Grant, entered the point of a knife twelve inches long an inch below the anterior superior spinous process of the ilium and transfixed, according to Lisfranc's method, on the outer side of the femur, bringing the point out near the tuberosity of the ischium, and cutting an external and posterior flap five inches long. The gluteal and sciatic arteries were then tied; then an antero-internal flap was cut and the head of the bone was disarticulated. The patient bore the operation satisfactorily. He was taken to the neighboring house of a widowed lady on the Murfreesboro' pike, between Laverne and Nashville. Here he was seen by Dr. Grant on October 22d, and seemed in every respect to be doing well. On this day that locality was occupied by United States troops, and Dr. Grant did not see his patient again. He received a message from him on October 30th, but no subsequent information. It is altogether probable therefore that the patient died.



The authorities for the following very remarkable case are Professor Paul F. Eve, Dr. G. M. B. Maughs, of St. Louis, Missouri, formerly a surgeon in the Rebel Army, the operator, Dr. William M. Compton, of Holly Springs, Mississippi, and Dr. J. M. Green, who directed the after-treatment. It can hardly be doubted that the case had a successful issue; but like one of Dr. Gilmore's cases, (CASE III,) its later history is involved in obscurity, and it is greatly to be desired that it may be hereafter traced and authenticated beyond cavil:

**CASE VIII.**—Private Robinson, of a Louisiana (Rebel) Regiment, aged thirty-five years, was wounded at Battery Pemberton, at the confluence of the Tallahatchie and Yalabusha Rivers, on March 13, 1863, by a fragment of a twenty-four pounder shell, fired from one of the United States gunboats attacking the work. Surgeon William M. Compton, 2d Texas (Rebel) Regiment, was standing near the wounded man when he fell, and ran to his assistance. Hastily exposing the wound, Dr. Compton found that the immense projectile, consisting of nearly half of an elongated shell, had buried itself in the upper part of the left thigh, smashing the trochanters and neck of the femur and wounding the femoral artery. An assistant compressed the artery at the crural arch, while the necessary preparations for an amputation were made on the spot. Chloroform was administered, and then Dr. Compton made an irregular circular incision through the integuments just above the margin of the huge lacerated wound, dissected up and retracted the skin, trimmed away the lacerated muscles and divided those that were intact, and exarticulated the head of the femur, making, as Dr. Compton described it, an awkward circular amputation. The arteries were now rapidly secured and the wound dressed. Strange to say, the patient reacted with scarcely a symptom of shock. When the influence of the anæsthetic passed away, he was cheerful and even jocular. He was moved to a field hospital and was treated under Dr. Compton's immediate supervision until March 17th. The febrile reaction was very slight; the appetite never failed; the wound had as healthy an appearance as could be desired. On the fifth day the patient was sent on a steamer to the large general hospital at Yazoo City. The surgeon in charge of that hospital, Dr. J. M. Green, writes that the case presented a most extraordinary example of union by the first intention throughout almost the entire extent of the vast wound. The patient left the hospital on April 20, 1863, in fine health and excellent spirits. Dr. Green received direct intelligence from him near the close of the ensuing September, more than six months subsequent to the operation, and he then reported himself in good condition.

The next case is already well known to surgeons.\* It is satisfactory to record that the patient still lives and enjoys comfortable health. Letters are frequently received from him at this office complaining of the insufficiency of his pension, but rejoicing in his physical condition:

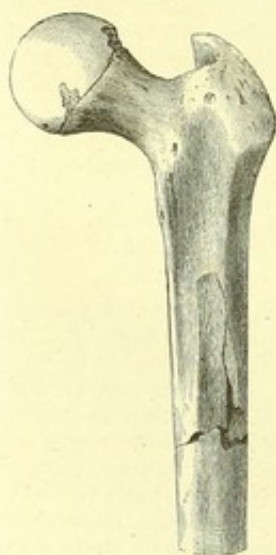


FIG. I. Fracture of the femur by a musket ball. Spec. 1148, A. M. M.

**CASE IX.**—Private James E. Kelly, Co. B, 56th Pennsylvania Volunteers, aged twenty-eight years, was wounded at about nine o'clock of the morning of April 29, 1863, in a skirmish of the First Division, First Corps, on the Rappahannock, nearly opposite Pratt's house, two miles below Fredericksburg. A conoidal musket ball, fired from a distance of about three hundred yards, entered the upper part of his left thigh in front, fractured the femur, and passed out at the posterior part of the thigh. The ball struck the femur four inches below the great trochanter and fractured it somewhat obliquely, but with less comminution than is usual. A long fissure extended however to the level of the trochanter minor. (See Figure II.) The important vessels and nerves were uninjured. Surgeon Edward Shippen, U. S. Volunteers, Surgeon-in-chief of the First Division, consulted the senior medical officers of the brigades attached to the division, and it was decided that in order to give the man a chance for his life amputation at the hip-joint should be performed. At four o'clock, seven hours after the reception of the injury, the patient was placed fully under the influence of chloroform, and Surgeon Shippen commenced the operation, assisted by Surgeons G. W. New, A. W. Preston, Browne, and Murdock. The patient's nates were brought well over the edge of the operating table, and the femoral artery was compressed at the

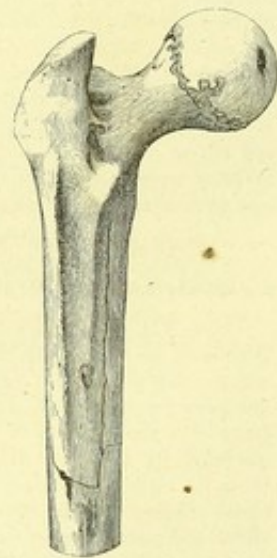


FIG. II. Posterior view of the same specimen, exhibiting a fissure running to the trochanter minor.

\* See Circular No. 6, S. G. O., 1865, p. 48. *A Treatise on Military Surgery*, by F. H. Hamilton, M. D., New York, 1865, p. 482. *Confederate States Medical and Surgical Journal*, Vol. I, p. 153. *The Dublin Quarterly Journal of Medical Science*, No. LXXXIV, p. 301. *Annales d'Hygiène Publique*, Deuxième Série, T. XXVI, p. 270.



groin. A ten-inch catling was then introduced about midway between the trochanter major and the anterior superior spinous process of the ilium, the point at first directed slightly upwards in order to open the capsule of the joint; then the handle was raised and the point made to come out about an inch in advance of the tuberosity of the ischium. A large flap was then cut from the anterior and inner side of the thigh, about six inches in length; the hemorrhage being controlled by Surgeon James B. Murdock, 24th New York Volunteers, who grasped the flap and compressed the femoral artery before it was cut. The heel of the knife was then placed where the point came out, and the points of entrance and exit were connected by an incision cutting to the bone. Part of the capsule being opened by the first incision, the remainder of it was divided, the round ligament cut, and the head of the femur removed from the acetabulum. The hemorrhage was then arrested, the femoral artery being tied last. The loss of blood was very slight, less even than in an ordinary amputation of the thigh. The stump having been dressed, the patient was placed in an hospital tent, and remained under Dr. Shippen's charge for three days. The operation was admirably borne, and the case was progressing most favorably on May 2d, when the patient was transferred to the Corps Hospital at the Fitzhugh House, under charge of Surgeon A. W. Whitney, 15th Massachusetts Volunteers, in consequence of the movement of the First Division to the battlefield of Chancellorsville. No unfavorable symptoms occurred. The patient improved daily, the stump granulating finely. He had an excellent appetite, and was quite content with the soldier's ration. But Dr. B. A. Clements, Assistant Medical Director and Dr. Taylor, Medical Inspector, visited him and provided that he should be furnished with such delicacies as the resources of the hospital could not supply. In the latter part of May, Surgeon Shippen having returned from Chancellorsville, saw the patient frequently and removed the ligatures until, on May 28th, the last had come away. The case continued to progress favorably until June 15th, when the greater portion of the Army of the Potomac having moved northward, the wounded and sick at the Fitzhugh House were captured by the rebels. Kelly was taken to Fredericksburg in a wagon, and thence to Richmond by rail, and was incarcerated in Libby Prison. The extraordinary nature of his case appears not to have procured for him any modification of the amenities of that place of confinement. According to his report, he lay upon the floor on his blanket, and received a diet of diluted tea and corn bread, and twice a week a bowl of soup. He was not subjected to any surgical attendance. After a week of the prison regimen, the wound became gangrenous and a troublesome diarrhoea supervened. On July 14th, the prisoner was exchanged. He was sent to Annapolis, and entered the hospital there in an exhausted state. His normal weight before the removal of the limb was one hundred and fifty-five pounds; he now weighed sixty-three pounds. There was a sloughing sore extending from the upper outer angle of the wound downwards over a space larger than the hand. There was profuse diarrhoea. He was ordered to take pills of opium and bismuth, with tincture of sesquichloride of iron, and beef essence and rice jelly for nourishment. Bromine was applied to the sloughing parts on three successive days, but without apparent benefit. A dilute lotion of chlorinated soda was then substituted. On July 24th the slough separated, leaving a clean, healthy, granulating surface. On August 19th, Acting Assistant Surgeon Stovell, who had immediate charge of the case, reported that the patient had steadily improved since his admission and might be considered out of danger. On September 17th, Surgeon T. A. McParlin, U. S. A., reported that Kelly was rapidly improving; that the wound was healed, except at a point where there was a slight purulent discharge and over an ulcerated space as large as a walnut, which was granulating kindly. The patient had been removed to the tent colony or camp of convalescents. On December 23, 1863, the wound had entirely healed, and Kelly visited Washington and obtained his discharge from service and a pension of one hundred and eighty dollars a year. He then went to his home at Blairsville, near Black Lick post office, Indiana county, Pennsylvania. His general health was then good and his weight had increased to one hundred and twenty-four pounds. In the autumn of 1863, before the wound had completely cicatrized, an excellent picture of Kelly, in water color, was made by Mr. Stauch, under the direction of Surgeon J. H. Brinton, Curator of the Army Medical Museum. In December, 1864, Lieutenant Colonel G. K. Johnson, Medical Inspector U. S. A., procured a very satisfactory photograph of Kelly's stump. From these two pictures the plate which accompanies this history was prepared. Kelly still resides at Blairsville, and his general health continues good.

The next is one of the three cases reported by Dr. W. M. Compton:

CASE X.—Private Cooper, of an Alabama (Rebel) Regiment, aged twenty years, was wounded at the siege of Vicksburg, on May 22, 1863, by a fragment of shell, which inflicted a terrible laceration of the upper exterior part of the right thigh, comminuted the upper third of the femur, and fractured the tuberosity of the ischium. There was profuse hemorrhage. Surgeon W. M. Compton, 2d Texas (Rebel) Regiment, decided to operate, because the wounded man most earnestly begged that an attempt should be made by amputation to save his life. A few hours after the reception of the injury, he was placed under chloroform, and amputation at the right hip-joint was rapidly performed by making a large anterior flap and dividing the soft parts posteriorly by a circular sweep of the knife. The stump was dressed and the patient actively stimulated, but he never rallied from the shock of the operation, and died in less than an hour after its accomplishment.

Professor P. F. Eve and Dr. S. L. Nidelet, of Mobile, Alabama, formerly Surgeon-in-chief of General Maury's (Rebel) Division, communicated the facts of the following case. While this report was in the printer's hands a letter was received from the operator, Dr. Benjamin D. Lay, now of Paducah, Kentucky, giving some additional particulars respecting the operation:

CASE XI.—A private of the 3d Missouri (Rebel) Regiment was wounded at the siege of Vicksburg, in June, 1863, by a large fragment of shell. The projectile produced a frightful laceration of the tissues on the inner and posterior parts of the



right thigh, completely divided the femoral artery, and comminuted the femur through an extent of eight or nine inches. A surgeon in the trenches put a ligature on the femoral artery, and the wounded man was conveyed to the City Hospital, and was plied with cordials. The sufferer had but recently recovered from an attack of illness; the primary hæmorrhage had been copious, and reaction was very imperfect. A consultation of surgeons decided that amputation at the hip-joint should be practised, and the wounded man expressed a desire to have the benefit of this forlorn chance. Surgeon B. D. Lay undertook the operation with great reluctance, fearing that the patient might die under the knife, he was so very feeble. Stimulants were freely administered and morphia; but it was decided that the operation should be done without anæsthetics. The nature of the wound determined the direction of the incisions. There was a rent in the soft parts laying bare the tuberosity of the ischium, and another extending nearly to Poupart's ligament, in which the ligated femoral artery was hanging. Dr. Lay commenced the operation, in the presence of Surgeons Britts, McDowell, Nidelet, and others, by making a clean circular cut through the inner and posterior parts of the thigh, dividing all the soft parts down to the articulation; a semilunar flap was then obtained from the outer and anterior part by cutting from without inwards; the head of the femur was then disarticulated. Eight ligatures were required. The flap fitted well. The operation was well supported, and the patient said that he felt more comfortable after than before it. However, reaction was never fully established. Dr. Nidelet relates that the patient died upon the table within an hour and a half after the completion of the dressing. Dr. Lay's recollection is that he survived the operation some fourteen or sixteen hours.

Special reports from the operator, Assistant Surgeon Benjamin Howard, U. S. Army, and Surgeon Thomas M. Flandreau, 146th New York Volunteers, have furnished the particulars of the next case.<sup>1</sup>

CASE XII.—Private James Martin, Co. I, 146th New York Volunteers, aged twenty years, was wounded on the afternoon of July 13, 1863, in one of the reconnaissances of General Lee's position near Williamsport. He was carried to the rear and placed in a barn by the roadside not far from Williamsport. On the following morning a consultation was held in the case, at which Assistant Surgeons Howard, C. Wagner, and Colton, U. S. A., and Drs. Stearns, Lord, Dean, and others assisted. It was

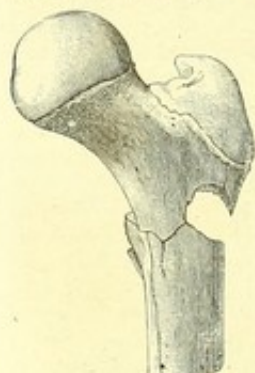

FIG. III. Comminuted gunshot fracture of the femur in a young subject. Spec. 1379, A. M. M.

found that a conoidal musket ball had passed through the upper part of the left thigh from before backwards, and had struck the femur a little below the great trochanter and produced a comminuted fracture. It was believed that the fracture extended into the coxo-femoral articulation, and it was decided that no operative procedure could be advantageously practised except an amputation at the hip-joint. Dr. Howard was invited to operate. Chloroform having been administered, he removed the limb by a double-flap operation. He describes the operation as performed by "entering the knife about four or five inches below the anterior superior spinous process of the ilium, and causing it to emerge by transfixion an inch and a half to the inside of the course of the femoral vessels. The operation was completed in the ordinary manner of flap amputations. By transfixing at the points described, the mouths of the divided vessels were so near the margin of the anterior flap as to be readily seized immediately after division, and by the external obliquity of the plane of incision, drainage of pus was facilitated more than by the ordinary horizontal antero-posterior flaps." It appears that the disarticulation was rapidly accomplished,

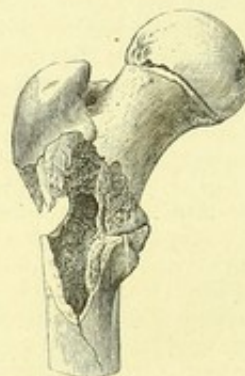

FIG. IV. Posterior view of Specimen 1379, A. M. M.

and that very little blood was lost. The shock was great, but the patient is reported to have rallied so far that it was considered safe to move him. On July 11, 1863, he died on the road to Sharpsburg, about forty-eight hours subsequent to the operation. An examination of the pathological specimen from this case, which was forwarded by Assistant Surgeon Howard to the Army Medical Museum, where it is numbered Specimen 1379, justified the opinion formed before the operation, that an excision of the head of the femur was impracticable; for besides the comminution about the lesser trochanter and the fissures towards the neck, fissures ran down the shaft of the bone for a long distance.

A letter from the operator, Surgeon Albert C. Gorgas, U. S. Navy, and a memorandum from Surgeon P. J. Horwitz, Chief of the Bureau of Medicine and Surgery of the Navy Department, have furnished the data from which the abstract of the following case is compiled.<sup>2</sup>

CASE XIII.—Seaman George Cook, aged twenty-one years, an Englishman by birth, was wounded on February 1, 1864, in an engagement of a gunboat with a battery supported by sharpshooters, at Smithfield, Virginia. A rifle ball grazed his

<sup>1</sup> See Circular No. 6, S. G. O., 1865, p. 50, Case 5.

<sup>2</sup> See Circular No. 6, S. G. O., 1865, p. 50, Case 13.



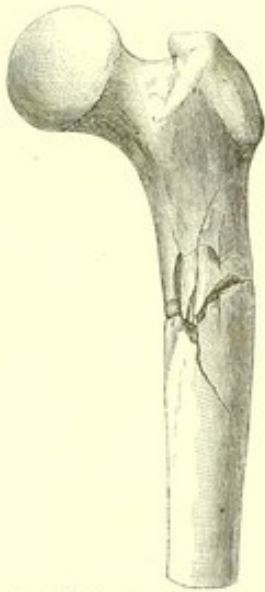

FIG. V. Comminution of femur by a rifle ball. Spec. 2273, A. M. M.

right thigh, passed through both testicles and entered the left thigh, fractured the femur, and passed out at the posterior and outer portion of the limb. The wounded man was taken to the Naval Hospital, at Portsmouth, Virginia, not many miles distant, and Surgeons Solomon Sharp, A. C. Gorgas, John Paul Quinn, and Assistant Surgeon G. S. Franklin, U. S. Navy, held a consultation, at which it was decided that the femur was extensively shattered, and that an amputation at the hip-joint presented the only chance of saving the patient's life. On the morning of February 2d, the patient was placed under the influence of chloroform, the femoral artery was compressed at the groin, and Surgeon Gorgas, assisted by his colleague, proceeded to remove the limb. The operation was performed by transfixing and forming an anterior flap, disarticulating, and then making a posterior flap by cutting from within outwards. Very little blood was lost; yet the patient never reacted, but succumbed about two hours after the completion of the operation. The pathological preparation from the case was forwarded by Surgeon Gorgas to the Army Medical Museum. It is numbered *Specimen 2273*. It is a very strong and compact bone. The ball has separated five large fragments, and has produced fissures extending from above the level of the trochanter minor a little over four inches down the shaft.

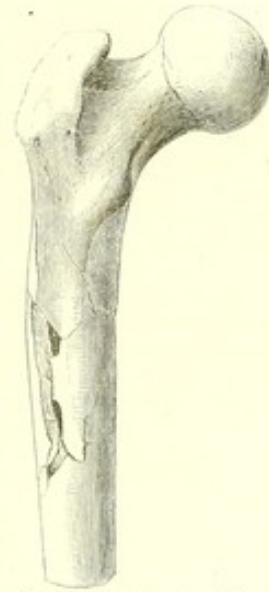


FIG. VI. Posterior view of *Specimen 2273*, A. M. M.

A brief memorandum of the following case appeared in Circular No. 6, Surgeon General's Office, 1865, at page 50, whereupon Dr. James Chapman, of Medina, New York, formerly surgeon of the 123d New York Volunteers, wrote and contended that the record was erroneous, and that no such operation had been performed. Dr. Chapman argued that as he was the chief operator of the field hospital of the First Division of the Twentieth Corps, and was present at the Division Hospital at every battle and skirmish in which the corps was engaged, from its organization to its disbandment, and that an operation of the magnitude of an amputation at the hip-joint could not have been performed at the hospital without his knowledge. But it appears from the reports to this office that the patient was not treated at the First Division Hospital, but at that of the Second Division, where Dr. Chapman was not employed. The surgeons-in-chief of the two divisions, Surgeon A. L. Cox, U. S. Volunteers, and Surgeon A. Ball, 5th Ohio Volunteers, report the facts of the case in terms which accord entirely. The medical director of the corps, Surgeon H. E. Goodman, U. S. Volunteers, writes, in a letter dated April 30, 1867, that the case was described to him at the time, and that he was told that it was one very unfavorable for an operation. Other evidence is available; but sufficient has been adduced to show that there is no reason to question the authenticity of the case:

**CASE XIV.**—Private William Waters, Co. K, 123d New York Volunteers, was wounded at the battle of Resaca, Georgia, on May 15, 1864, by a large fragment of shell, which completely carried away his left thigh and fractured both the tibia and fibula of the right leg. He was carried to the Field Hospital of the Second Division of the Twentieth Corps, and as soon as he had partially rallied from the shock of his frightful injuries chloroform was administered, and Surgeon J. W. Brock, 6th Ohio Volunteers, amputated at the left hip-joint; and then removed the right leg at the place of election. The patient survived the double operation but a short period. The exact length of time is not stated; but he died in the afternoon of the day on which he was wounded, May 15, 1864.

The history of the next case has been published by the operator,\* to whom, however, the patient's name was unknown. By the casualty list of the Third Division of the Ninth Corps for Spottsylvania, the patient has been identified beyond a doubt, and Surgeon

\* *A Treatise on Military Surgery*, by F. H. HAMILTON, M. D., etc. pp. 485, 627. See also Circular No. 6, S. G. O., 1865, p. 50, Case 7.



Henry Wheaton Rivers and Assistant Surgeon A. G. Sprague, of Rhode Island, and Surgeon M. K. Hogan, U. S. Volunteers, have furnished some additional particulars relative to the case:

CASE XV.—Private Richard Gordon, Co. H, 7th Rhode Island Volunteers, a stout and apparently healthy man, of about twenty-eight years of age, was wounded at about eight in the morning of the 18th of May, 1864, in one of the assaults on the lines at Spottsylvania, and was carried on a stretcher, two or three miles to the rear, to the Field Hospital of the Third Division of the Ninth Army Corps. A fragment of shell had completely shattered the left thigh, leaving the lower part of the limb attached to the upper by shreds of integument and muscles only. There had been but slight primary hæmorrhage. He was conscious and his pulse was perceptible; but he was in extreme collapse. A consultation was held, at which the Surgeon-in-chief of the division, Surgeon P. A. O'Connell, Surgeon James Harris, 7th Rhode Island Volunteers, and others, assisted, and it was determined to give the man the chance of an operation rather than to allow him to die without an effort to save him, and Dr. J. M. Carnochan, a civil surgeon, who had volunteered his services at the hospital, was selected to operate. Chloroform was carefully administered by Surgeon Harris, and Dr. Carnochan, as a preliminary step, tied the femoral artery three-quarters of an inch below Poupart's ligament, and then proceeded to amputate at the hip-joint by a modification of the oblique method of Guthrie. A vertical incision three inches long, commencing an inch above the great trochanter was made, the soft parts being divided down to the bone. From the lower third of this incision, two oblique incisions, one before and one behind, were made to diverge and then to reunite about two and a half inches below the level of the ischiatic tuberosity. The head of the femur was then disarticulated, and the knife being carried to the inner side of the neck the operation was finished by dividing the soft parts on that side by a single sweep of the instrument. The operation, including the ligation of the femoral, was completed in two minutes. The patient recovered kindly from the influence of the anæsthetic. He was placed in a shelter tent and took a dose of opium. He died ten hours after the operation, no reaction having taken place.

The operator, Surgeon C. C. Jewett, 16th Massachusetts Volunteers, has transmitted a very full account of the following case, and Surgeon Henry F. Lyster, 5th Michigan Volunteers, and Assistant Surgeon J. D. Stewart, 74th New York Volunteers, have communicated facts regarding it:

CASE XVI.—Private Jacob Barger, Co. B, 26th Pennsylvania Volunteers, aged twenty-two years, of robust constitution and sanguine temperament, was wounded on the morning of May 18, 1864, in the attack of Birney's Division of the Second

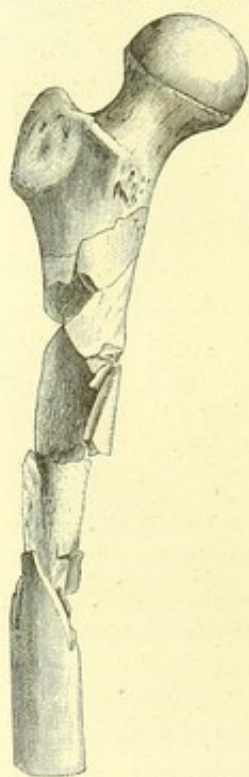

FIG. VII. Communion of femur by a shell. Spec. 3080, A. M. M.

Army Corps upon the intrenchments before Spottsylvania Court House. He was struck by a fragment of shell, which shattered the femur from a little above the trochanter minor for nine inches downwards, and tore and mangled the soft parts on the anterior and lateral aspects of the thigh, leaving uninjured a V-shaped portion of integument and subjacent tissue on the antero-internal femoral region, seven inches wide at the base and ten inches in vertical length. He was carried to the Field Hospital of the Third Division of the Second Corps and was examined about two hours after the reception of the injury. There was no apparent shock, and there had been very little hæmorrhage. The pulse was full and calm, and the surface of the body was of a natural temperature. The senior surgeons of the division concurred in the opinion that this was one of the few cases of extensive gunshot injury of the femur in which a successful result might reasonably be anticipated from an amputation at the hip-joint. The patient was desirous that an operation should be practised. He was of a hopeful, buoyant nature, and was sanguine of a favorable issue. Amputation having been decided upon, chloroform was administered by Surgeon John Wiley, 6th New Jersey Volunteers, a medical officer of great experience and caution in this duty. Only two drachms of the anæsthetic was used, given from a napkin, with great regard to a due admixture of atmospheric air. Surgeon C. C. Jewett, 16th Massachusetts, performed the amputation, by making a single antero-internal flap. Assistant Surgeon J. T. Calhoun, U. S. Army, and others present on the occasion, have described the admirable dexterity and skill manifested in the operative procedure. The disarticulation was completed in less than forty seconds. Surgeon C. H. Irvine, 72d New York Volunteers, compressed the crural artery at the groin; Surgeon F. Prentice, 73d New York Volunteers, grasped the flap and secured the cut end of the femoral; Surgeon James Ashe, 76th New York Volunteers, had charge of the limb; Surgeon Evarts, 26th Indiana Volunteers, Surgeon E. A. Whiston, 1st Massachusetts Volunteers, and Assistant Surgeon J. T. Calhoun, U. S. Army, also aided in the operation. The flap, the form and location of which were determined by the wound, was made by cutting from without inwards. Immediately after the head of the bone was freed from the acetabulum a spasmodic catch was heard in the patient's respiration, and an assistant exclaimed: "Stop the chloroform!" Surgeon Wiley promptly responded: "He is not taking any." The next instant an assistant at the wrist reported that the pulse was failing. The arteries were now rapidly secured. The loss of blood was estimated not to exceed a single ounce. But the patient was insensible, the respiration labored, the pulse very slow and feeble. The usual restoratives were employed without effect. The patient did not rally; he lingered for about two hours, and died a little after noon, May 18,



1864. At this juncture, in consequence of an advance of Rhodes's Division of Ewell's Corps, the Field Hospital was hastily broken up. Surgeon Jewett was under the impression that the specimen was lost. This, however, was not the case. Some one fastened a label with the names of the patient and operator to the mangled limb, and it was forwarded, with other pathological specimens, from Spottsylvania to the Army Medical Museum, where it arrived safely, and furnished the preparation numbered 3080, which is figured on the preceding page.

The casualty list of the Third Division of the Twenty-third Army Corps, and the reports of Surgeon A. M. Wilder, U. S. Volunteers, Acting Medical Inspector of the Army of Ohio, and of Surgeon C. S. Frink, U. S. Volunteers, Surgeon-in-chief of the Third Division, Twenty-third Corps, have furnished the facts of the next case.\*

CASE XVII.—Private Jeremiah M. Brown, Co. H, 63d Indiana Volunteers, was wounded on June 16, 1864, in the attack of the 23d Corps upon the earthworks at Lost Mountain, near Marietta, Georgia. A conoidal musket ball struck his right thigh and shattered the upper extremity of the femur, fissures extending through the trochanter major. He was conveyed to the Field Hospital of the Third Division, Twenty-third Corps, and early on the morning of June 17th, about fourteen hours after the reception of the injury, he was placed under the influence of chloroform, and after a careful examination of the injury, it was decided to amputate at the hip-joint. The operation was performed by the Medical Director of the Corps, Surgeon Edward Shippen, U. S. Volunteers. The operative method was similar to that adopted by Dr. Shippen in his successful operation, (CASE IX.) Comparatively little blood was lost, but the patient succumbed to the shock of the operation and died upon the operating table very soon after the completion of the disarticulation.

Professor Paul F. Eve and the operator, Dr. J. R. Buist, of Nashville, Tennessee, have furnished the facts of the following case:

CASE XVIII.—A private of the 27th Tennessee (Rebel) Regiment was wounded at the battle of Jonesboro', Georgia, August 31, 1864, by a cannon-shot, which frightfully lacerated the soft parts on the upper and outer part of the thigh, and shattered the femur, the splintering extending quite to the neck of the bone. Six hours after the injury, Surgeon J. R. Buist, 1st Tennessee (Rebel) Regiment, Chief Surgeon of Maury's Brigade of Cheatham's Division, removed the limb at the hip-joint by the antero-posterior flap method by transfixion. The patient was rendered insensible by chloroform. He rallied promptly from the anæsthetic and from the shock of the operation. Cold water dressings were applied to the stump, and stimulants and concentrated nourishment were administered. After about eight hours the patient began to sink, and he died thirty-six hours after the operation, September 2, 1864.

The abstract of the nineteenth case is compiled from the reports of the First Division, Twentieth Army Corps, and from two letters from the operator, Dr. H. Z. Gill, of Richboro', Pennsylvania:

CASE XIX.—Private James A. Alling, Co. D, 3d Wisconsin Volunteers, was wounded on March 16, 1865, at the battle of Averysboro', North Carolina, by a conoidal musket ball, which entered the upper part of the left thigh in front, and produced a comminuted fracture of the femur through the trochanters, with longitudinal splintering extending a short distance down the shaft and upwards within the capsular ligament. The wounded man was conveyed to the Field Hospital of the First Division of the Twentieth Corps. Chloroform was administered and the wound was thoroughly explored, and it was determined to amputate at the hip-joint, because it was imperative to move the wounded on the following day over rough roads, and either an excision of the head of the femur, or an attempt at conservation of the limb, offered, under the circumstances, less chance of a favorable result than the removal of the limb. Five hours after the reception of the injury, Surgeon H. Z. Gill, U. S. Volunteers, performed the amputation by the double flap method. The patient reacted well after the operation, but the amendment was of brief duration. He died seven hours after the completion of the amputation, March 17, 1865.

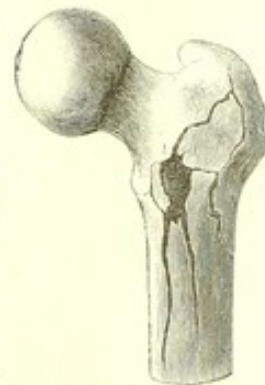


FIG. VIII. Gunshot fracture through the trochanters of the left femur. From a drawing by Surgeon H. Z. Gill, U. S. V.

Reviewing the foregoing nineteen cases of primary amputation at the hip-joint, it appears that the operation was one of absolute urgency in CASES VIII and XI, in which, together with great injury to the head and neck of the femur and the contiguous soft parts, the femoral artery was wounded, and amputation or the abandonment of the patients to certain death were the only alternatives. As much may be said, perhaps, of CASE XV, in which, if the account of the lesions is not exaggerated, the entire thigh was nearly torn away by cannon-shot. In CASE XVI the operation was obligatory almost, on account of the extraordinary extent of the injury to the femur, and because an attempt at conservation

\* See Report of the Adjutant General of the State of Indiana, Vol. VI, p. 31, and Circular No. 6, S. G. O., 1865, p. 50, Case 8.



involved the transportation of the wounded man to the depots at Fredericksburg or Belle Plain, a three days' ambulance journey, in which it is almost certain he would have succumbed. In CASE XIX also the consideration of transportation had decisive influence. Surgeon Gill, the operator, observes that he would have excised the upper extremity of the femur in this case in preference to amputation, had he possessed any means of securing subsequent immobility of the limb, had he been able even to procure plaster of Paris for an immovable dressing. CASES I, II, VI, X, and XVIII, in which Drs. McLean, Yandell, Compton, and Buist operated, were examples of extensive lacerations by shells or other large projectiles; cases in which but faint hope of success under any treatment could be entertained, in which the operation at least mitigated the patient's sufferings. CASE XIV, in which a double amputation of the lower extremities was performed, was plainly a hopeless one, and the operation must be condemned. In regard to the eight remaining cases in which amputation was done for injuries to the upper extremity of the femur by musket balls, notwithstanding the one or two successful results, surgeons will not fail to discuss whether an equal or greater saving of life might not have been attained by an expectant or temporizing plan. Dr. Gilmore, who operated in three of these cases, and subsequently twice excised the head of the femur, and also treated a comparatively large number of similar injuries by the conservative method, declares, as the result of his unusually extended observation, that recovery ensues in a far larger proportion of gunshot injuries of the upper extremity of the femur left to the efforts of nature than in such injuries treated by primary amputation or excision.

#### INTERMEDIATE AMPUTATIONS.

The eighteen operations included in this category resulted fatally. They were all done, of course, during the inflammatory period, and without exception upon patients who from unavoidable neglect and exposure were ill fitted to undergo operations. The interval from the reception of the injury to the date of the operation in these cases varied from twenty-four hours to one month; its mean length was a little over ten days. Though all the patients died, the one who survived longest living but eight days, yet a far less proportion succumbed to the immediate shock of the operation than in the series of primary cases. Of the sixteen fatal primary cases, eleven died from shock; and the average duration of life after the completion of the operation was but thirty-eight hours. Of the eighteen intermediate cases but five died from shock; and the patients of this series survived the operation on an average fifty-two hours. One died of pyæmia; two from rapidly spreading gangrene; two, probably, from the effects of hæmorrhage at the time of the operation; and eight from the exhaustion consequent upon the surgical fever, suppuration, and other disorders attendant upon so grave a mutilation. Ten of the operations were performed by medical officers of the U. S. Army; eight were done by surgeons of the Rebel Army—four upon their own men, four upon prisoners.

The first intermediate amputation at the hip-joint of the war was performed at a hospital in Richmond, upon a prisoner taken at the battle of Bull Run. The fact that this operation was performed was communicated by Professor Paul F. Eve, of Nashville, and the scanty details of the case recorded here were supplied by Professor T. G. Richardson, of New Orleans, who was present at the operation:



CASE XX.—A private soldier of the U. S. Army was wounded at the first battle of Bull Run, July 21, 1861, by a musket ball, which fractured the lower third of the right femur. He fell into the hands of the enemy, and, on the following day, was conveyed in an army wagon to Manassas Junction, and thence by rail to Richmond, where he was admitted to the Alms House Hospital. One week after the reception of the injury there was extensive purulent infiltration in the muscles of the thigh and incipient gangrene of the leg. Under these circumstances Drs. St. George Peachy and Charles Bell Gibson decided to amputate at the hip-joint. On July 29th, the operation was performed by Dr. Peachy, in the presence of Drs. Gibson, A. E. Peticolas, Richardson, and others. A preliminary ligature was placed upon the femoral artery at the beginning of the operation, which was probably done according to Larrey's method. The patient is believed to have survived the operation two or three days.

It appears that this case was neither published nor reported, as it is not included in the statistics of the southern hospitals for the first year of the war, as recorded in the "Confederate States Medical and Surgical Journal." Both Dr. Peachy and his principal assistant, Dr. Gibson, died before the conclusion of the war. In view of the meagre history of the case that is accessible, criticism may be omitted.

The next case is alluded to by Dr. A. M. Fauntleroy in his paper on amputation at the hip-joint.\* The particulars related were communicated by Professors J. S. Davis and J. L. Cabell, of the University of Virginia, to Professor Paul F. Eve, by whom they were transmitted to this office:

CASE XXI.—Private J. H. Wolf, Co. D, 4th Virginia (Rebel) Regiment, had his femur fractured at the battle of Bull Run, July, 21, 1861, by a musket ball, which traversed the upper part of the thigh in an antero-posterior direction, and striking the femur four inches below the trochanters, shattered it quite up to the neck. The patient was removed to Charlottesville, Virginia, and was received in the General Hospital at that place on July 24th. The fracture was treated by Smith's anterior suspensory splint, and this mode of dressing proved very serviceable for a time. The inflammatory phenomena did not abate however, and after four weeks it was decided that removal of the limb at the coxo-femoral articulation alone afforded a hope of preserving the patient's life. On August 21st, the operation was performed by Brigadier General Edward Warren, Surgeon General of North Carolina, and was rapidly executed by the double-flap method, with inconsiderable hæmorrhage. On the following day there was slight hæmorrhage. Death from exhaustion ensued on August 23, 1861, thirty hours after the operation. The constitutional condition of the patient was unfavorable, and he was suffering from colliquative diarrhœa.

The particulars of the next case were also communicated by Professor Paul F. Eve, to whom they were furnished by Dr. Charles H. Mastin, of Mobile, formerly medical inspector of General A. S. Johnston's army, and by Dr. D. D. Saunders, of Memphis:

CASE XXII.—Private Jackson, aged twenty-one years, of Colonel Tappan's (Rebel) Brigade, was wounded at the battle of Belmont, Missouri, November 7, 1861, and was conveyed on a steamer to Memphis, and admitted to the Marine Hospital. He had a badly comminuted fracture of the upper extremity of the femur. On November 15th, Dr. Richard Potts proceeded to amputate at the hip-joint by the antero-posterior flap method. The patient succumbed promptly to the shock of the operation; dying, indeed, before its completion, according to Dr. Mastin, or, according to Dr. Saunders, ten hours after its completion.

The next three operations were performed upon men wounded at the battle of Shiloh. The condition of all three of these patients was probably very unfavorable, on account of their long exposure on the battle-field. The particulars of Dr. D. P. Smith's case were reported by Brevet Colonel Thomas W. Fry, late Surgeon U. S. Volunteers, and Assistant Surgeon M. C. Tolman, 2d Minnesota Volunteers, who assisted at the operation.†

\* *The Richmond Medical Journal*, January, 1866. Vol. I, p. 9.

† The case is described by Surgeon D. P. Smith in the *American Medical Times*, Vol. IV, p. 332, June, 1862, as a possibly successful one. It is also alluded to in his "Narrative of Services," in response to a circular from the Surgeon General's Office, of May 1, 1863. On receiving an application for the details of the case, Surgeon Smith replied that he had kept no notes of it.



CASE XXIII.—Private Henry H. Hale, Co. G, 14th Illinois Volunteers, twenty-one years of age, was wounded at the battle of Shiloh, April 6, 1862. A fragment of shell\* shattered the upper portion of his left femur, so that fissures extended to the neck and far down the shaft. The soft parts on the outer aspect of the thigh were extensively lacerated and contused; the femoral vessels and nerves were uninjured. On April 9th, with four hundred and sixty other wounded brought from the field, he was placed on the hospital transport steamer *Crescent City*, to be conveyed to St. Louis. On April 12th, Brigade Surgeon D. P. Smith, U. S. Volunteers, assisted by Brigade Surgeons Thomas W. Fry and H. P. Stearns, U. S. Volunteers, and Assistant Surgeon M. C. Tolman, 2d Minnesota Volunteers, performed amputation at the hip-joint. The patient being made insensible by chloroform, a long anterior flap was made by transfixion. Surgeon Stearns, following the knife with his fingers, compressed the vessels in the flap, and completely controlled the hæmorrhage. The head of the femur was rapidly disarticulated and the soft parts posteriorly were divided by a straight incision. The arteries of the posterior portion of the wound were first secured, and then those of the anterior flap. It was estimated by the operator that the bleeding did not exceed six ounces. The shock was slight and the patient reacted fairly, and for a short period after the operation the case wore an hopeful aspect. On April 14th, the hospital transport arrived at St. Louis, and the wounded were transferred to hospitals in that city. Shortly after Hale's admission to hospital his stump began to look badly, the vast wound suppurated profusely, gangrene supervened, and he sank and died, on April 20, 1862.

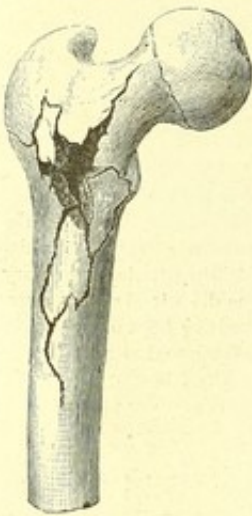

FIG. IX. Comminuted gunshot fracture of the femur. From a drawing furnished by Dr. Blackman.

A memorandum of the next case was published in *Circular No. 6, S. G. O.*, 1865, p. 50. Additional details respecting it have since been communicated by the operator, Professor George C. Blackman, of Cincinnati:†

CASE XXIV.—A private soldier of an Ohio regiment, about thirty-five years of age, was wounded on the first day of the battle of Shiloh, April 6, 1862, by a fragment of shell, which extensively comminuted the shaft, trochanters, and neck of the right femur, as illustrated in the accompanying wood-cut. The patient was left on the battle-field during the tempestuous night of April 6th, and until late on the following day. He was then removed to a temporary hospital, and thence to the steamer *Lancaster*, to be transported to Cincinnati. On April 16th it was decided to remove the limb, and the patient being rendered insensible by chloroform, amputation at the hip-joint was performed by Brigade Surgeon G. C. Blackman, U. S. Volunteers, by the antero-posterior flap method. The shock and hæmorrhage were inconsiderable, and the patient rallied satisfactorily from the operation. On April 18th, the hospital transport arrived at Cincinnati, and the patient was transferred to St. John's Hospital in that city. Dr. C. D. Palmer, house-surgeon at St. John's, who was placed in charge of the case, reports that soon after the patient's admission to hospital the flaps began to slough badly, and that symptoms of pyæmia then supervened. Death ensued on April 22, 1862, six days from the date of operation.

The abstract of the next case was furnished by the operator, Dr. J. P. De Bruler, a highly esteemed practitioner of Evansville, Indiana, who, at the time, was an acting assistant surgeon in charge of the military hospital at that place:

CASE XXV.—Private Peter Pausbeck, Co. K, 43d Illinois Volunteers, was admitted on April 20, 1862, with nearly three hundred other wounded men from the battle-field of Shiloh, to Hospital No. 2, at Evansville. He had been wounded on April 7th, probably by a conoidal musket ball. The projectile had entered the front of the left thigh, about an inch below the level of the trochanter major, and ranging a little upwards had emerged from the gluteal region opposite. The upper portion of the femur was crushed and almost powdered, and so extensive was the injury to the soft parts that some doubt was entertained as to the nature of the missile, several surgeons suggesting that it might have been a grape-shot. A consultation, at which the entire surgical staff of the hospital assisted, was held on the morning of April 21st, and every surgeon present concurred in the

\* In *Circular No. 6, S. G. O.*, 1865, p. 50, it is stated that the wound was caused by canister-shot, on the authority of Surgeon John H. Brinton's careful report of the wounded at Shiloh. Dr. Smith states (*Am. Med. Times, loc. cit.*) that a Minié ball inflicted the injury. Dr. Fry's account, copied from the original entry made at the time in his note-book, is most probably correct.

† In the *Cincinnati Journal of Medicine*, Vol. I, p. 101, February, 1866, Dr. Blackman has indulged in some acrimonious reflections upon the value of the statistics of *Circular No. 6*, 1865, on the ground that the date of the fatal result in his amputation at the hip-joint after Shiloh is erroneously reported in that circular. It is, therefore proper to state that Dr. Blackman omitted to make a report of his operations after Shiloh, and that before the statement in *Circular No. 6*, the authority for which is there given, was published, three distinct applications were made to him for the particulars of his case, which applications were disregarded.



opinion that amputation at the hip-joint afforded the only possible chance of preserving the patient's life. Accordingly no time was lost. Chloroform was administered by a careful assistant, who habitually discharged this duty at the hospital. The anæsthetic acted kindly, and an unusual amount was not required. Dr. DeBruler operated, assisted by Dr. T. N. Myers and others. In consequence of the position of the wounds of entrance and exit the amputation was executed by making external and internal flaps after Lisfranc's method. The loss of blood was very trifling. After the completion of the operation the pulse, which had been carefully watched, was observed to fail rapidly. Unavailing attempts were made to give brandy and other restoratives. In a few moments the man was dead. There was no reason to believe that the use of chloroform had any connection with the fatal result, which was apparently due solely to the shock of the operation. Such was the opinion of the eminent professor of surgery of Jefferson College, Dr. S. D. Gross, who happened to visit the hospital half an hour after the operation. Professor Gross expressed his approbation of the course that had been adopted, since, although it had resulted unfortunately, it afforded the only hope of saving the patient's life.

The next case was first reported to this office by Professor Paul F. Eve, of Nashville, and additional particulars in relation to it were communicated by Dr. James D. Wallis, of Franklin, Tennessee, formerly surgeon of the 1st Missouri (Rebel) Regiment, who witnessed the operation. The operator, Dr. Felton, died in the summer of 1863:

CASE XXVI.—A private of Colonel Dockery's Arkansas (Rebel) Regiment of Cabell's Brigade was wounded at the battle of Corinth, Mississippi, October 3, 1862, by a conoidal musket ball, which shattered the neck of his right femur. He was conveyed to an hospital at Iuka, where, on November 3d, his thigh was amputated at the hip-joint by his regimental surgeon, Dr. R. A. Felton. The patient died upon the table before the dressing of the stump was completed. The operation was done under chloroform, and it was the general impression of the surgeons present that the anæsthetic was administered too freely.

The abstract of the twenty-seventh case is compiled from a letter from Lieut. Colonel Pineo, Medical Inspector, U. S. Army, of December 26, 1864, and a memorandum accompanying *Specimen* No. 710 of the Army Medical Museum. The case is briefly noted in the register of Douglas Hospital:\*

CASE XXVII.—Private P. Johnson, Co. C, 2d Delaware Volunteers, was wounded at the battle of Fredericksburg, December 14, 1862, by a conoidal musket ball, which entered the upper part of the right thigh in front and passed out at the nates, having, in its course, divided the femoral artery and perforated the great trochanter. Except that the primary hæmorrhage was slight, little is known of the early history of the case. On December 25th, the wounded man was conveyed to Washington, and placed in the Douglas Hospital. On admission, nearly the entire injured limb was gangrenous, and it was believed that the fracture extended into the hip-joint. Brigade Surgeon P. Pineo, U. S. Volunteers, in charge of the hospital, decided to amputate at the hip-joint, "with no hope of a favorable result, but to mitigate patient's distress in the last moments of life." On December 27th, anæsthesia being induced by ether, the operation was performed. The patient survived it only a few hours. The pathological specimen was sent to the Army Medical Museum, and exhibits a perforation of the great trochanter, with radiating fissures, which separate the trochanter and neck into four fragments, and run obliquely down the shaft. Traces of the results of periostitis are visible along the shaft.

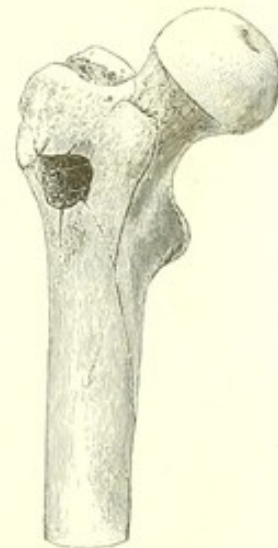


FIG. X. Perforation of the right femur by a musket ball. *Spec.* 710, A. M. M.

The four following cases were reported to this office by Professor Paul F. Eve. Additional particulars regarding cases XXVIII and XXIX were communicated by the operators, Drs. Crymes and Kinloch:

CASE XXVIII.—A private of General Bragg's army, whose name and military description are not recorded, a large man, six feet high, of fair complexion, about twenty-six years of age, was wounded on December 28, 1862, in a skirmish prior to the battle of Murfreesboro'. A conoidal musket ball produced a fracture of the trochanter major and neck of the femur, with fissures extending within the capsular ligament. The wounded man was placed in a field hospital, and his injured limb was supported in a proper position; but the local inflammation and constitutional disturbance that ensued were intense, and, on January 5, 1863, it was determined to amputate at the hip-joint. The patient being placed under chloroform, the operation was performed

\* See Circular No. 6, S. G. O., 1865, p. 50, Case 10.



by the antero-posterior flap method by Assistant Surgeon A. C. Crymes, 39th Alabama (Rebel) Regiment. On being removed to his bed, the patient manifested extreme prostration, and stimulants were freely administered. After a few hours he was able to take nutriment in a concentrated form, and a supporting and stimulating treatment was perseveringly pursued. In a very few hours after the operation, however, the stump evinced a tendency to unhealthy action, and the patient sank into an adynamic condition, and died on the morning of January 8th, three days after the operation.

Details of the foregoing case were communicated to Dr. Eve by Dr. Caleb Tosey, formerly surgeon of the 19th Alabama (Rebel) Regiment, and to this office by the operator, Dr. Crymes, of Fort Browder, Alabama. In his letter relative to the case, Dr. Crymes observes that the mortality among the wounded of General Bragg's army after Murfreesboro' was fearfully great, in consequence of the unavoidable confusion in the hospital arrangements, the overcrowding of patients, the inevitable omission of adequate hygienic regulations, the mental depression resulting from defeat, the want of suitable medical supplies, and hasty and rough transportation. All of these causes operated to the disadvantage of the patient whose history has been related.

CASE XXIX.—A private of Co. C, 54th Massachusetts Volunteers, a colored man, was wounded and made a prisoner in the assault on Morris Island on the morning of July 11, 1863. A fragment of a shell from Fort Wagner struck the upper and outer part of his right thigh, and fractured the neck and head of the femur and the rim of the acetabulum, and extensively lacerated the soft parts in its exit through the posterior part of the thigh. The patient was conveyed to Charleston on the afternoon of July 12th, and was placed in an hospital hastily prepared for the reception of wounded colored prisoners. The contract surgeon in charge of the hospital reports that the patient's condition, in view of the terrible wound he had suffered, was remarkably good, and that the symptoms of shock were unusually slight. On July 13th, the third day after the reception of the injury, Surgeon R. A. Kinloch, P. A. C. S., saw the case, and amputated at the hip-joint by Manec's method. The knife, being entered midway between the anterior superior spinous process of the ilium and the great trochanter, and carried downwards and inwards until its point emerged just in front of the ischium, was made to form a large antero-internal flap; the soft parts on the outer and posterior part of the thigh were then divided by a semi-circular incision from without inwards, and the head of the femur was then disarticulated. The patient bore the operation well, but a few hours subsequently there was extreme depression, and the case terminated fatally on the following morning, July 14th, twenty hours after the operation.

It is probable that the fracture of the pelvis was not recognized in this case until the disarticulation was effected, else an operation would hardly have been undertaken. In his narrative of the case, Dr. Kinloch mentions that a surgeon of the U. S. Navy, a prisoner, was present at the operation, and subsequently requested him to operate upon several United States officers who required amputation. No pathological preparation was preserved from the case of amputation at the hip-joint.

CASE XXX.—Private John Chamberlain, of one of the United States regiments engaged at the battle of Chickamauga, was wounded on the morning of the second day of that battle, September 20, 1863. A conoidal musket ball passed through the upper part of the thigh, and produced great comminution of the upper extremity of the femur, the fissures extending to the neck of the bone. The wounded man was left upon the field when the United States forces were driven back, and fell into the hands of the enemy. On September 21st, he underwent amputation at the hip-joint, the operation being performed by Surgeon R. P. Bateman, P. A. C. S., now a practitioner of Memphis, Tennessee. The man survived the operation thirty-six hours, and died September 23, 1863.

CASE XXXI.—Private James Carden, of the army of Major General Rosecrans, was wounded at the battle of Chickamauga, in the second day's fight, September 20, 1863, by a fragment of shell, which caused great laceration of the soft parts at the upper part of the thigh, with comminuted fracture of the femur. He was left upon the field, and was made a prisoner. On the evening of September 21st, Surgeon R. P. Bateman amputated his thigh at the hip-joint. He died on September 27, 1863, six days after the operation.

A letter addressed to Dr. Bateman requesting him to supply further details of the two preceding cases has received no response.



CASE XXXII.—Private Sullivan Gaines, Co. M, 2d Michigan Cavalry, was wounded on January 31, 1864, near Knoxville, Tennessee, by a conoidal musket ball, which shattered the neck and head of the right femur. On the following day the patient was admitted to Hospital No. 4, at Knoxville. He was greatly prostrated, and his constitutional condition was considered unfavorable. On February 3d, Surgeon Edward Shippen, U. S. Volunteers, amputated at the hip-joint in the presence of Surgeon Henry S. Hewit, Medical Director, and others. The patient being placed under the influence of chloroform, a long double-edged knife was introduced about an inch above the trochanter major; the point was first directed inwards and slightly upwards, so as to divide the capsule freely, and was then depressed and brought out near the tuberosity of the ischium; a large antero-internal flap was then formed, an assistant having passed his hands into the incision and compressed the femoral artery in the flap before it was cut. The flap was now raised, and the heel of the knife was placed at the inner angle of the wound, and a straight incision was made connecting this point with that at which the knife first entered, and dividing the tissues on the back of the thigh down to the bone. Disarticulation was then effected. The gluteal, sciatic, obturator, and other arteries in the posterior portion of the wound were secured first; the femoral was the last vessel tied. The patient never rallied from the shock of the operation. He died in about one hour.

This account of the case of Gaines is compiled from the register of Knoxville Military Hospital No. 4, and from a letter from Dr. Shippen of February 10, 1867.\* Though the injury to the thigh bone appears to have been limited to the epiphysis, neither report discusses the reasons for preferring the operation of amputation at the hip-joint to that of excision of the head and neck of the bone.

CASE XXXIII.—Private Charles Lackey, Co. E, 7th Wisconsin Volunteers, thirty years of age, was struck, at the battle of Spottsylvania, May 12, 1864, by a conoidal musket ball, which entered in front at the upper part of the right thigh and produced a comminuted fracture of the femur through the trochanters and extending downwards nearly half the length of the shaft of the bone, and then lodged in the muscles at the posterior part of the thigh. After the fatiguing journey to Belle Plain, to which most of the wounded from Spottsylvania were unavoidably subjected, Lackey was conveyed on a hospital steamer to Washington, and was received at Judiciary Square Hospital on May 18th. The wounded limb was much swollen. The sharp extremity of the lower fragment of the femur had lacerated the muscles, and there was profuse suppuration with burrowing of pus throughout the thigh. The fracture was believed to extend into the joint. The patient earnestly demanded that an operation should be performed for his relief. His condition was unpromising, for he was suffering from surgical fever of an intense character. A consultation of surgeons decided however that, without operative interference, the case would prove inevitably and speedily fatal; and as the extensive fracture of the shaft of the femur and the purulent infiltration of the thigh precluded excision, amputation at the hip-joint was determined on. On May 21st, anesthesia was induced by sulphuric ether, and Assistant Surgeon Alexander Ingram, U. S. Army, performed the operation by the antero-posterior flap method. After the operation the patient reacted but partially. After removal to the ward he was plied with beef-teen and stimulants and restoratives; but he continued to sink, and died on the following day, May 22, 1864, twenty hours after the operation.

The history of the foregoing case is compiled from the register of Judiciary Square Hospital, and that which follows from the register of Chesapeake Hospital, and from letters from Assistant Surgeon E. McLellan, U. S. Army, and Acting Assistant Surgeon George Bayles. Both cases are reported in brief at page 50 of Circular No. 6, S. G. O., 1865.

CASE XXXIV.—Private Levi Eckley, Co. A, 67th Ohio Volunteers, was wounded May 20, 1864, in the assault upon Major General Butler's entrenchments near Bermuda Hundred. A conoidal musket ball passed through the left thigh, shattering the upper extremity of the femur and wounding the sciatic nerve. The patient was conveyed on an hospital transport to Fort Monroe, and was admitted to Chesapeake Hospital on May 22d. A consultation was held, at which it was decided that amputation at the hip-joint presented the only chance of preserving life. The patient's condition was unfavorable; he was greatly prostrated. On May 24th, the operation was performed by Assistant Surgeon H. C. Roberts, U. S. Volunteers, by forming antero-posterior flaps by transfixion. The femoral artery was compressed at the groin by Surgeon D. G. Rush, 101st Pennsylvania Volunteers, and Acting Assistant Surgeons Bayles, Frick, and others aided in the operation. The hæmorrhage was excessive. Notwithstanding, the patient reacted fairly, and when removed to his bed, he partook of nutritious food and stimulants. He died from exhaustion four days after the operation, May 24, 1864.

The facts given in regard to the next case are derived from letters from Dr. Samuel J.

\* See also *Report of Adjutant General of Michigan*, for 1864, p. 38, and *Hamilton's Treatise on Military Surgery*, p. 485, and *Circular No. 6, S. G. O.*, 1865, p. 50, Case No. 9.



Allen, formerly Surgeon-in-chief of the Second Division of the Sixth Corps, and Dr. David M. Goodwin, late Surgeon 3d Vermont Volunteers. The operation is briefly noted in the register of the Field Hospital of the Second Division, Sixth Corps:

CASE XXXV.—Private Joseph Minott, Co. A, 4th Vermont Volunteers, was wounded early on June 23, 1864. He was on duty on the advanced picket line before our fortifications in front of Petersburg, when an assault was made on the works, and a large number of the skirmishers were killed, wounded, captured, or driven from the ground, which was not re-occupied for several days. Minott had his right femur fractured in the upper portion of the shaft by a conoidal musket ball at the outset of the attack, and he lay where he fell, beyond the reach of succor, the ground being commanded by the sharpshooters of the enemy. On the morning of the third day, June 25th, having been without food or drink for forty-eight hours, he crawled into our lines, a distance of over half a mile. He was carried to the Field Hospital of the Second Division of the Sixth Corps, greatly exhausted, of course, by the privation, exposure, and suffering to which he had been subjected. After he had received nourishment and cordials, his injuries were examined, and it was found that besides the extensive comminution of the femur, rapidly spreading gangrene had supervened. In front, mortification already extended to within a few inches of Poupert's ligament. A consultation of the senior surgeons of the division decided that coxo-femoral amputation offered the only chance of recovery, and that the operation could not be delayed. On the afternoon of June 25th, therefore, the patient was rendered insensible by chloroform, and the amputation was performed by Surgeon Goodwin. A short anterior flap was made by transfixion, and the femoral artery was then tied. The edge of the knife was then directed downwards, and made to divide the capsular ligament; the head of the femur was then disarticulated, and a long posterior flap was formed, gangrene not having progressed so high up on the posterior portion of the thigh. But little blood was lost. The patient rallied promptly from the effects of the chloroform and from the shock of the operation. But this reaction was of brief duration. He soon began to sink, and expired in the evening of June 25th, two hours after the completion of the operation.

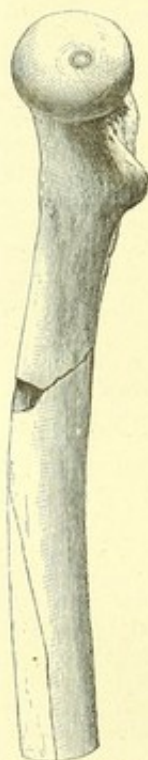

FIG. XI.—Femur with longitudinal and oblique fissures, produced by a musket ball. Spec. 1020, A. M. M.

The history of the next case is taken from the reports of the Third Division Hospital at Alexandria, by Surgeon Edwin Bentley, U. S. Volunteers: \*

CASE XXXVI.—Sergeant Lewis Carroll, Co. H, 1st Delaware Volunteers, aged twenty-three years, was wounded on October 22, 1864, in one of the engagements attending Major General Warren's movement upon the Weldon Railroad. A conoidal musket ball entered the right thigh in front, and, striking the femur at the junction of the upper thirds, produced a remarkable longitudinal splintering of the bone, extending from an inch below the lesser trochanter downwards for ten inches, together with several oblique fissures. The wounded man was conveyed in an ambulance to one of the field hospitals of the Fifth Corps, where the ball was extracted, and the sharp extremity of the upper fragment of the femur was sawn off. The fractured limb was then dressed, and the patient was sent to City Point, and thence on a hospital steamer to Alexandria, where he was admitted to the Third Division Hospital on November 2d. The thigh was swollen to three times the size of its fellow. An incision six inches long on the outer side presented inflamed everted edges, between which fasciculi of muscles protruded. There was much febrile irritation, but the patient's strength was maintained to a remarkable degree. On November 11th, there was quite free hæmorrhage from a small artery, and the patient was etherized and the vessel secured, and afterwards a thorough exploration of the wound was made. The very extensive longitudinal splintering was recognized; the bone was found denuded in several places; the soft tissues of the thigh were infiltrated with pus of a very offensive character. In view of this condition of things, it was determined to remove the limb at the hip-joint. The patient was placed under the influence of chloroform, and the operation was performed by Surgeon Edwin Bentley, U. S. Volunteers. An external flap was made by cutting from without inwards; then the head of the femur was disarticulated, and an internal flap was cut from within outwards. The loss of blood was slight, and the patient reacted promptly. The progress of the case for two or three days after the operation was very favorable. Then a chill occurred, followed by a cold clammy sweat. The wound looked badly, and the discharge was unhealthy; the stump was kept covered with yeast poultices. Beef essence, stimulants, and anodynes were administered. Six days after the operation there was yellowness of the surface and of the conjunctival membranes; then delirium and coma, and death on November 19th, eight days from the date of the operation. At the autopsy, pus was found in the external iliac vein, metastatic foci in the lungs, and a gangrenous abscess in the enlarged spleen. The preparation of the femur was sent to the Army Medical Museum. It is numbered *Specimen 1020*, and is figured in the adjacent wood-cut.

\* See Circular No. 6, S. G. O., 1865, p. 50, Case 18.



The registers of Judiciary Square Hospital, and a report of a board of medical officers appointed to investigate the case, furnish the data from which the following abstract is prepared:\*

**CASE XXXVII.**—Private George M. Spencer, Co. B, 2d New York Mounted Rifles, seventeen years of age,† was wounded on March 31, 1865, at Dinwiddie Court House, Virginia, by a conoidal musket ball, which entered the right gluteal region, and striking the great trochanter, produced a fracture through the trochanters, with very remarkable longitudinal splintering, extending nine inches down the shaft. (See *Figure XII*.) The projectile then lodged. The wounded man was sent to City Point, and thence by steamer to Washington, and entered Judiciary Square Hospital on April 4th. There was already a good deal of inflammatory swelling and suppuration, but the constitutional condition was encouraging. Upon examination of the wound, it was thought that the fracture did not extend below the trochanter and that the joint was probably involved, and it was determined to excise the head of the femur. The patient having stated that he was anxious to avail of the benefit of any operation that was deemed necessary, he was placed under the influence of chloroform on April 12th, and Surgeon Elisha Griswold, U. S. Volunteers, proceeded to disarticulate the head of the femur through a long vertical incision on the outside of the thigh, and to remove the head with an obliquely fractured fragment of the shaft attached to it. The splintering of the shaft was now discovered, and after a hasty consultation with the surgical staff, it was decided that amputation at the hip-joint was the only procedure which afforded the patient any prospect of recovery. This operation was rapidly executed by Surgeon Griswold, aided by Acting Assistant Surgeons Hill, McCalla, Colton, and Abern, by the double-flap method. There was but little hæmorrhage; but the shock of the operation was too great. The usual means to promote reaction were diligently employed, but the patient never rallied, and survived the operation less than an hour.

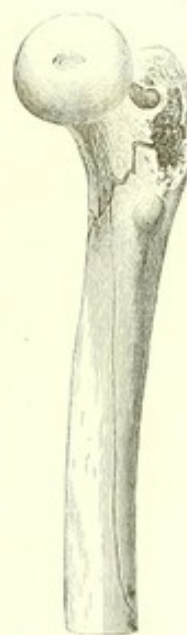

FIG. XII. Longitudinal fissuring of right femur. Spec. 4257, A. M. M.

#### SECONDARY AMPUTATIONS.

Of the nine cases included in this series two recovered and seven died, a percentage of mortality of 77.78. Three patients sank from the shock of the operation. One with a shattered constitution, with phthisis and lithiasis, died seventeen weeks after the operation, his stump nearly healed. One had secondary hæmorrhage and phlebitis subsequently, and succumbed in twenty-three days. One died on the tenth day from the giving way of the femoral at the point of ligation. One died on the third day with surgical fever and erysipelatous inflammation of the stump. Excluding the case in which death resulted from profuse secondary hæmorrhage, those patients survived longest in whom the operation was longest deferred. The average period the patients survived the operation in the seven fatal cases was twenty-two days. The shortest interval between the injury and operation was forty-three days; the longest was two years, nine months and twenty-one days. The average interval in the nine cases was four hundred and twenty-nine days.

The details of the first case are taken from a careful report from the operator, Surgeon Edwin Bentley, U. S. Volunteers:

**CASE XXXVIII.**—Private Michael O'Neil, Co. E, 58th Massachusetts Volunteers, aged nineteen years, was wounded at the battle of Cold Harbor, June 3, 1864, by a conoidal musket ball, which entered the upper anterior part of the right thigh and passed backwards and slightly upwards through the limb, comminuting the upper extremity of the femur. The fissures extended about three inches down the shaft, and through the trochanters half-way up the neck. The wounded man was sent in

\* See Circular No. 6, S. G. O., 1865, p. 50, Case 21.

† The preparation of the fractured femur would indicate that the patient was much older. \* Ossification is complete, and the epiphyses are perfectly united to the shaft.



an ambulance to the White House, on the York river, and thence by an hospital steamer to Alexandria, where he was received at the Third Division Hospital on June 7th. On admission, his limb was much swollen, yet there was but little pain, and this was not increased by moving the limb. His general condition was satisfactory, though he reported that he was subject to attacks of intermittent fever. His limb was arranged in a straight position, supported by cushions and pillows; evaporating lotions were applied to the wound, and a nutritious diet was ordered. On June 10th, several fragments of bone were extracted. On June 12th, the patient had a chill, and was ordered to take four grains of sulphate of quinia every four hours. The injured limb was now suspended by means of Smith's anterior splint. On June 24th there was another chill. The wound was now suppurating freely,

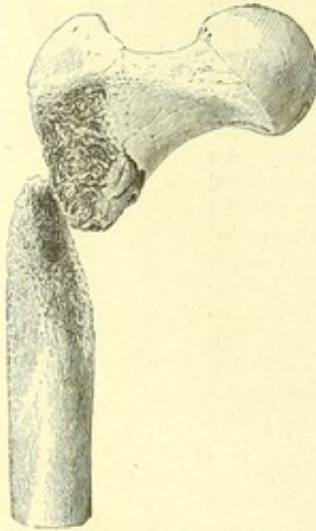

FIG. XIII. Gunshot fracture of the upper extremity of the right femur. *Spec. No. 3288, A. M. M.*

and the limb was very sensitive when handled. On June 31st, there was a slight chill. From this date to August 1st there was little change in the symptoms. It was now decided that there was little hope of consolidation of the fracture. The suppuration was profuse, and it was believed that the patient would inevitably succumb ultimately to the constitutional irritation and the drain upon the system. It was determined, therefore, that amputation should be performed, and the character of the fracture admitted only of amputation at the hip-joint. On August 10th, the patient was anesthetised by sulphuric ether, and amputation at the hip-joint was performed by the lateral flap method by Surgeon Edwin Bentley, U. S. Volunteers. There was but little hæmorrhage, and the operation was borne well. The patient had an anodyne, and was freely stimulated. For forty-eight hours after the operation there was some febrile excitement, with complete anorexia. The fever then subsided, and the appetite returned. The wound looked well, and the amount of suppuration was trifling. The case progressed very favorably until August 20th, when secondary hæmorrhage supervened, from ulceration of the femoral near the ligature. About six ounces of blood were lost. A ligature was promptly placed upon the external iliac, just above Poupart's ligament. After the operation the patient was very weak and faint, and stimulants were freely administered. On August 22d, there was an excess of febrile excitement, but this abated on the following day, and the appetite again became moderately good. On August 28th, there was nausea and vomiting, which persisted for forty-eight hours. The wound at this time had assumed a very unhealthy appearance, and the patient had become much emaciated. On the night of September 1st, there was delirium. The case terminated fatally on the morning of September 3d, twenty-three days after the operation. At the autopsy, the viscera were found to be healthy, except that there was an old cicatrix with cretaceous deposit at the apex of the left lung. The lips of the wound were united in nearly their entire extent. There was a large accumulation of pus within the flap, bathing the acetabulum and the gaping mouth of the femoral artery. The wound left by the incision above Poupart's ligament, through which the external iliac was tied, communicated with an abscess between the iliacus externus muscle and the iliac fascia, filled with fetid pus. The ligature on the external iliac was found to be placed about half an inch below the origin of the epigastric; the circumflex iliac was given off a little below the epigastric. There was a firm conical plug in the external iliac, ending at the origin of the epigastric. Through this plug ran a canal communicating with the mouth of the circumflexa ilii; this canal was closed by a clot colored by included red corpuscles, and of more recent formation than the plugging clot. Ulceration of the external iliac just above the ligature had commenced. The femoral vein was collapsed and contracted; the external iliac vein was distended by a dirty fluid, which, when placed under the microscope, was found to abound in pus globules. Higher up, the contents of the vein consisted of a granular detritus. The branches of the external iliac vein was blocked up by dense coagula. The deep-seated abdominal lymphatic glands were enlarged and deeply injected. An examination of the fractured femur showed that it was shattered, with much loss of substance, just below the trochanters; the fissures ran up within the capsule, and the fractured extremities of the bone were carious, and had lost tissue by absorption.

The quarterly surgical report from Lincoln Hospital, a medical descriptive list from Acting Assistant Surgeon John Morris, and a record of the autopsy by Acting Assistant Surgeon H. M. Dean, have furnished the data for the history of the following case.\* The fractured bone is deposited in the Army Medical Museum, and is numbered *Specimen No. 2288*. The ends of the fragments are carious, and there is no trace of any reparative action.†

\* See Circular No. 6, S. G. O., 1865, p. 50, Case 15.

† See Catalogue of the Surgical Section of the United States Army Medical Museum, Washington, 1866, p. 247.



**CASE XXXIX.**—Private Daniel H. Bowman, Co. C, 110th Pennsylvania Volunteers, twenty-four years of age, was wounded on July 27, 1864, at Deep Bottom, on the left bank of James River. A conoidal musket ball entered at the upper posterior part of the right thigh, comminuted the femur from the trochanters downward for several inches and lodged. The wounded man was transported to Washington on an hospital steamer, and was received at Lincoln Hospital on July 30th. The injured limb was shortened two and a half inches; the soft parts were badly lacerated. On August 7th, the position of the ball at the anterior part of the thigh was detected. An incision was made and the ball and several detached fragments of bone were removed. On August 17th, the wound looked badly, and there was slight sloughing. For the next few weeks the patient lost ground steadily. There was profuse suppuration, with great constitutional irritation. There appeared to be no attempt at union at the seat of the fracture. The patient had become much emaciated, and his powers of resistance were failing daily. After due consultation it was determined to amputate at the hip-joint. On September 15th, the operation was performed by Assistant Surgeon J. C. McKee, U. S. Army. The patient was rendered insensible by sulphuric ether. The method by antero-posterior flaps formed by transfixion was adopted. The amputation was rapidly completed and very little blood was lost. The patient did not rally, but died one hour after the operation, September 15, 1864. At the autopsy, the lungs were found to be attached to the thoracic walls by firm fibrinous adhesions. In the upper lobe of the right lung there were two small isolated abscesses. Otherwise the lungs were normal. The right weighed 13 and the left 11 ounces. The abdominal viscera were normal, save that the liver and kidneys were unusually small, the former weighing 44½ and the latter 9½ ounces. At the seat of the fracture of the femur there was no attempt at repair; the fragments were carious: a large one, consisting of nearly half of the cylinder of the shaft, was four inches long and was quite detached. Fissures penetrated the trochanters, and extended posteriorly half-way up the neck of the bone.

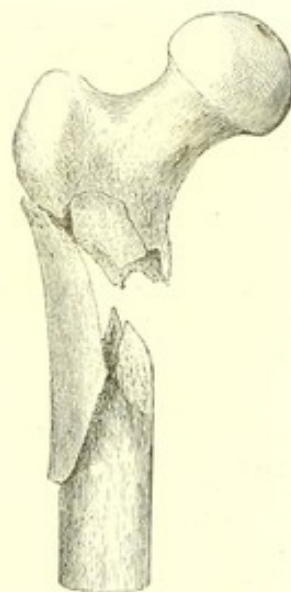

FIG. XIV. Gunshot fracture of the femur. Spec. 2288, A. M. M.

The facts relating to the next case are taken from the casualty lists of the Ninth Army Corps, and from the reports of the Beverly Hospital:\*

**CASE XL.**—Private John Williams, Co. F, 13th Ohio Cavalry, forty-four years of age, was wounded at Peebles' Farm, near Petersburg, September 30, 1864, by a conoidal musket ball, which passed through the left thigh and contused or partially fractured the femur. He was conveyed in an ambulance to the Field Hospital of the First Division of the Ninth Corps, and his wounds were dressed, and he was then sent by rail to City Point, and thence to the North in an hospital transport steamer. On October 7th, he was received at the General Hospital at Beverly, New Jersey. For over three months the case progressed very favorably under the simplest treatment; but early in February, abscesses formed in the thigh; and, when they were incised, they discharged copiously an offensive pus. About the same time the patient was attacked by an obstinate diarrhoea. On February 17, 1865, an exploratory incision was made, and a careful examination with the finger and the probe indicated that the femur was necrosed as high as the trochanters. It was then considered that amputation at the hip-joint presented the only chance for preserving life. The operation was performed by Assistant Surgeon Clinton Wagner, U. S. A. The patient inhaled chloroform; anterior and posterior semilunar flaps were made by transfixion; the femoral artery was tied as soon as divided; disarticulation was then effected, and the operation completed by securing the minor vessels. Very little blood was lost. The patient reacted satisfactorily, but sank and died, apparently from shock, twenty-nine hours after the operation. An autopsy revealed a healthy condition of the viscera and no lesion worthy of special mention. The femur displayed an interesting example of necrosis of the entire diaphysis. It is numbered *Specimen 84* in the collection of the Army Medical Museum.

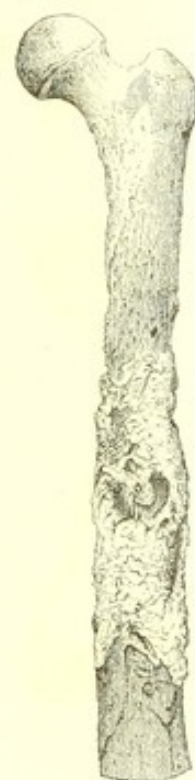

FIG. XV. Necrosis of the femur following gunshot injury. Spec. 84, A. M. M.

The abstract of the next case is compiled from the registers of the various military hospitals in which the patient was treated, and from a letter from Dr. R. F. Weir, surgeon of the civil hospital at which the operation was performed:†

**CASE XLI.**—Corporal Frederick Kelb, Co. G, 7th New York Volunteers, was wounded at the battle of Fredericksburg, December 14, 1862, by a conoidal musket ball, which fractured the right femur

\* See *Circular No. 6, S. G. O., 1865, p. 50, Case 20, and A Report of Interesting Surgical Operations performed at the U. S. A. General Hospital, Beverly, New Jersey, by C. WAGNER, Assistant Surgeon, U. S. A. 8vo, pp. 16.* [Printed but not published.]

† See *Circular No. 6, S. G. O., 1865, p. 52.*



at the junction of the upper and middle thirds. After remaining for a fortnight in the Field Hospital of the First Division of the Second Corps he was conveyed to Washington and placed, on December 25th, in the Patent Office Hospital, where the injured limb was placed in a fracture box and the wound was dressed with oakum. The case progressed favorably, and on April 2, 1863, the patient was transferred to Judiciary Square Hospital. He continued to improve, and, on May 9th, was sent to De Camp Hospital, at David's Island, New York. On July 10th, he was removed to McDougall Hospital, at Fort Schuyler; and on January 19, 1864, he was readmitted to De Camp Hospital. On June 8, 1864, he was discharged from the service of the United States. The fracture had consolidated, but there was evidence of disease of the femur. On June 7, 1865, Kelb was admitted to St. Luke's Hospital, in New York city. There had been a series of recurring abscesses in the thigh, and it was believed that nearly the entire femur was necrosed. It was determined to amputate at the hip-joint, and, on June 7th, the patient being anesthetized by sulphuric ether, and the aorta being compressed by Signoroni's clamp tourniquet, the amputation was performed by the attending surgeon, Dr. R. F. Weir, by the method recommended by Dr. Van Buren,\* an anterior flap being formed by transfixion and a posterior one by section from without inwards.† The hæmorrhage was slight and the shock was moderate. The case at first progressed very favorably. Three weeks after the operation the healing of the stump was far advanced and the patient was able to leave his bed. After this he began to lose ground very gradually. He died on October 4, 1865, nearly four months after the operation. At the autopsy, the pelvis of the right kidney was found to be blocked up with numerous calculi; there was an abscess in the left kidney, and there was tuberculosis of both lungs at an advanced stage. The stump was still open and the horizontal portion of the os pubis was necrosed. A section of the exarticulated femur presented the characteristic lesions of chronic osteomyelitis.

The history of the following successful case of amputation at the hip is derived from the registers of the Third Division Hospital at Alexandria, and of the Harewood Hospital, and from letters from the operator and the patient.‡

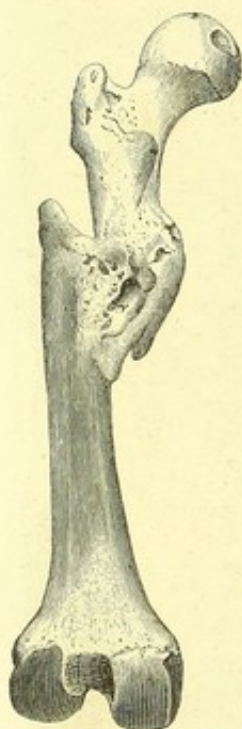

FIG. XVI. Consolidated gunshot fracture of the left femur. Spec. 4326, A. M.M.

CASE XLII.—Private George W. Lemon, Co. C, 6th Maryland Volunteers, aged thirty years, had his left femur fractured, at the junction of the middle and upper thirds, by a conoidal musket ball, at the battle of the Wilderness, May 5, 1864. He was left in a shelter tent on field, and fell into the hands of the enemy. On May 13th he was recaptured, and was sent to Fredericksburg, and thence to Alexandria, where he was received at the Third Division Hospital, on June 14th. When admitted he had diarrhœa, and was greatly emaciated. There was a bed-sore, four inches in diameter, over the sacrum, and smaller sores over the prominences on the spine and scapula. The lower end of the upper fragment of the femur protruded from the wound, from which there was a profuse offensive ash-colored discharge. To check the diarrhœa, to administer suitable nourishment, and to take pressure from the bed-sores by supporting the body on air cushions, were the first matters attended to. Then moderate extension was applied to the injured limb, and a tolerably good position was maintained by means of pillows and cushions. In three weeks the bed-sores were healed, and there was a slight improvement in the general constitutional condition. Extension of the limb causing pain, it was discontinued. For the next ten or twelve months the patient clung to life by the slenderest thread. Detached fragments of bone frequently gave rise to inflammatory swelling, abscesses in the thigh, and profuse suppuration. Yet the appetite and digestion continued to be good, and the great drain upon the system was supported unusually well. In May, 1865, it was found that the fracture was quite firmly consolidated. The patient now occasionally sat up in a chair, but every attempt of the sort was followed by acute inflammation of the thigh, with increased suppuration. It was now decided that the patient must ultimately sink under the profuse suppuration, and that an operation should be performed as soon as it was opportune, and that every effort should be made to put the patient in a condition to support this shock. On October 12, 1865, Surgeon Edwin Bentley, U. S. Volunteers, proceeded to amputate at the hip-joint. Chloroform was administered; the external iliac artery was compressed at the pubis; anterior and posterior semilunar flaps were formed by transfixion, and the femur was disarticulated. The hæmorrhage was inconsiderable, and the patient reacted soon and satisfactorily. From the day of the operation he steadily improved, with scarcely an untoward symptom. On November 15th, Dr. Bentley reported that the ligatures had all come away, and that the wound was granulating kindly. In December, the stump was healed, and the patient began to get about on crutches. The fracture of the exarticulated femur was found to be imperfectly but quite firmly united, with great antero-posterior angular deformity and shortening. The bone was sent to the

\* *Transactions of New York Academy of Medicine*, Vol. I, and *Contributions to Practical Surgery*, by W. H. VAN BUREN, 8vo, Phila., 1865, p. 9.

† M. A. Guérin has suggested the same plan. *Médecine Opératoire*. Tome I, p. 273.

‡ See *Circular No. 6, S. G. O.*, 1865, p. 52.



Army Medical Museum, where it is preserved as *Specimen 4386*. A posterior view of it is given by the wood-cut, and a lateral view in Plate III. On January 31, 1866, a photograph of the man was taken, from which the accompanying plate is copied. Lennon was then transferred to the Harewood Hospital, at Washington. He was then quite well, and able to go where he chose on crutches. The cicatrix was firm and healthy. On February 3, 1866, he was discharged from the hospital, and from the service of the United States, at his own request. He went to his home at Bird Hill, Carroll county, Maryland, and resumed his trade of shoemaking. He was granted a pension of fifteen dollars a month. On April 26, 1867, a letter was received from him, in which he stated that his health was excellent; that he weighed ninety-nine and a half pounds, an increase of twelve and a half pounds from the date at which he left the hospital; and that he had been able to walk to the village of Westminster, a distance of seven miles, without fatigue.

The facts from which the history of the following example of a successful secondary amputation at the hip-joint was compiled, were contributed by the operator, Dr. George C. Blackman, Professor of Surgery in the Medical College of Ohio. Dr. Blackman also transmitted a sketch of the patient five months after his recovery, prepared in water-color, carefully rendering the appearance of the stump at that period. The accompanying chromolithograph is copied from this sketch:\*

CASE XLIII.—Private Woodford Longmore, a rebel soldier, twenty-five years of age, a robust, healthy man, was wounded at a skirmish at Cynthiana, Kentucky, on June 11, 1864. A ball from a Belgian rifle, at short range, passed through his right thigh, shattering the shaft of the femur. There was profuse hemorrhage and the shock was alarming. He remained almost insensible for three or four days, and for a fortnight there was extreme prostration. He was placed in a rebel field hospital, and the injured limb was put in a fracture box, with which was connected a crutch piece extending to the axilla. On the evening of the reception of the wound numerous detached bony splinters, a handful almost, were extracted. For six weeks, extension and counter-extension were maintained, but so much suffering arose from this treatment that it was discontinued, and the limb was simply supported in a comfortable position. The patient was confined to his bed for eight and a half months. In the middle of March, 1865, he was removed to Florence, Kentucky, seven miles from Cincinnati, and Dr. George C. Blackman, professor of surgery in the Medical College of Ohio, was consulted in the case. There was a profuse discharge of offensive pus, and the patient's strength seemed to be failing under the protracted irritation and spoliation. There had been frequent recurrences of abscesses in the thigh, attended with excessive pain and swelling, and followed by the elimination of fragments of necrosed bone. Ever since the reception of his injury the patient had taken morphia very freely. Evidently there were still loose sequestra and diseased bone with which sinuses communicated, and Dr. Blackman proposed to remove these sources of irritation. On April 23d, the patient consented to an operation, and a number of necrosed fragments were extracted with much relief to the local irritation and benefit to the general health. During the autumn, however, evidences of extensive destructive inflammation of the shaft of the femur became unmistakable, and, in December, a second operation for the removal of fragments was performed without advantage. The discharge became more offensive and sanious, and the strength of the patient rapidly gave way. In January, 1866, his condition became almost hopeless, and the removal of the diseased limb was determined on. The operation was performed on January 18th. Ether was administered and the lower extremities were kept elevated for a few minutes before the incisions were made. Then the right femoral was compressed at the groin, and the disarticulation was rapidly effected by Lacauchie's method.† A circular cut through the skin was made at the junction of the upper third of the thigh; then the integuments were retracted and the muscles were divided circularly down to the bone. A vertical incision was now made on the outer side of the limb, commencing a little above the trochanter and joining the first incision. The head of the bone was then exarticulated. There was but little hemorrhage, and the patient rallied from the operation remarkably well. The following day he suffered greatly from nausea, which he ascribed to the use of the ether. This distressing complication soon subsided, however, and thenceforward there was no unpleasant symptom, and the patient progressed rapidly towards recovery. In February, 1867, Longmore reported himself to Dr. Blackman as in excellent health, and as having recently married. In the latter part of June, 1867, seventeen months after the operation, Dr. Blackman again saw him, and found that his general health was good, and that his stump was sound, though subject to occasional attacks of neuralgia of extreme severity. He was accustomed, in these attacks, to alleviate his suffering by taking large doses of morphia. An examination of the limb after its removal showed that the entire shaft of the femur had been affected by osteomyelitis. The specimen, with its delicately encased sequestra and fragile deposits of new bone, was destroyed by an unskilful preparator.

The history of the forty-fourth case is compiled from the registers of the Gettysburg and Chambersburg hospitals, and from the careful report by Dr. William Pepper, resident

\* The case is briefly referred to in the *Cincinnati Journal of Medicine*, Vol. I, p. 101. February, 1866.

† M. A. E. Lacauchie, chirurgien principal, and chief medical officer of the French army of occupation in Rome, gives a description, with illustrations, of his procedure for amputating at the hip-joint, in the *Gazette Médicale de Paris*, Nos. 19, 20, 25, and 26, 1850.



surgeon at the Pennsylvania Hospital, contained in Dr. Thomas G. Morton's excellent paper on amputations at the hip-joint.\* The pathological preparation from this case is in the collection of the Museum of the Pennsylvania Hospital; but, through the courtesy of Dr. Morton, photographs of the preparation, from which the wood-cuts accompanying the history are copied, have been sent to the Army Medical Museum.

CASE XLIV.—Private James McGeehen, Co. K, 107th Pennsylvania Volunteers, aged forty-eight years, was wounded at the battle of Gettysburg, Pennsylvania, on July 1, 1863, by a conoidal musket ball, which entered at the inner aspect of the middle of the right thigh, and traversed the entire thickness of the limb, badly comminuting the shaft of the femur in its progress. He lay upon the field for about five hours, and lost a good deal of blood, although none of the larger vessels appeared to have been wounded. He was then conveyed to a temporary field hospital, and his wounds were dressed. On July 6th, he was removed to the Seminary Hospital at Gettysburg, where he remained until September 4th, at which date there was profuse suppuration and some sloughing at the wound of entrance, and it was deemed expedient to put the patient under canvas in the Camp Letterman Hospital. On October 11th, he was moved to the Town Hall Hospital at Chambersburg. Here he was able to move about on crutches, but the injured limb was greatly enlarged and deformed, and numerous fistulous openings successively formed, through which pus was freely discharged, and bits of necrosed bone were occasionally eliminated. On April 23, 1864, by order of the Medical Director at Harrisburg, he was discharged from the military service of the United States on account of "permanent lameness resulting from gunshot fracture of the right femur." Nearly two years subsequently, April 9, 1866, McGeehen entered the Pennsylvania Hospital, at Philadelphia. His general condition was satisfactory; his spirits were excellent; a careful examination failed to detect organic disease of any viscus. His injured thigh remained greatly deformed and enlarged; the original wounds had long since closed, but there were numerous fistulous sinuses, discharging on an average a gill of pus daily, and, at intervals, scales or nodules of necrosed bone; three tracks seemed to ascend to within an inch and a half of the trochanter major. It was thought probable that above this point the femur was healthy. After a careful consultation, it was determined to remove the limb at the hip-joint. The patient was placed upon tonic treatment, with nourishing diet; his bowels were also carefully regulated. He complained of nothing excepting his cough, arising from a slight bronchitis, which, however, gave him very little trouble. On April 21, 1866, Dr. D. H. Agnew, Surgeon to the Pennsylvania Hospital, removed the limb. The abdominal tourniquet was employed, and by this means the circulation of the abdominal aorta was completely controlled. The method of operating was by antero-posterior skin flaps, with circular division of the muscles. The femoral artery was ligated after the anterior flap was dissected up. The femoral vein was not included in the ligature. Twenty-one of the smaller arteries required deligation. The disarticulation was accomplished in a minute and a half. Pressure was maintained by the abdominal tourniquet for twenty-seven minutes while the minor vessels were secured. The hemorrhage during the entire operation did not exceed three ounces, scarcely more than an ounce and a half of which was arterial blood. Ether alone was employed in inducing anesthesia, and about three ounces sufficed, as he inhaled it without effort, and soon came under its influence. The stump was packed with lint. The leg, when drained entirely of blood, weighed twenty-two pounds, the entire weight of the body at that time being about one hundred and forty-five pounds. Immediately after his removal to the ward, an enema of half a drachm of tincture of opium was administered, and this was repeated at eight in the evening, when the stump was closed by lead sutures, and dressed with cerate. On the following day the patient had entirely reacted from the slight amount of shock following the operation. Pulse, which, under agitation from the approaching operation, had been averaging from 100 to 115, had fallen to 96; respiration 20; skin moist and pleasantly warm. No stimulus; moderate diet, and a drachm of laudanum by enema. On April 23d, he was more comfortable. Had passed a quiet night; had a good appetite. A considerable part of the stump had united by first intention, and there was only a little greasy, watery discharge from the inner angle. Dry dressing continued. On April 24th, he was doing well. Discharge thin and small, and flaps were rapidly uniting. He was ordered four ounces of whiskey daily, and half an ounce of Basham's mixture. Dry dressing continued. April 25th, no unpleasant symptom, save a rather frequent bronchitic cough. The flaps are united at the middle of the stump; the discharge comes from the angles, and is evidently due to the breaking down of the subcutaneous fat. Laudanum enemata were now given twice daily; warm-water dressings were substituted for the dry applications. April 26th, he ate and slept well, but was troubled by his cough, which was severe, accompanied by tenacious mucous sputa. The opiate enemata were suspended, and from two to four drachms of solution of sulphate of morphine were given every night; during the day, a sedative expectorant mixture every three hours. The stimulus was not increased. April 27th and 28th, steady improvement; cough less troublesome, discharge more purulent, and increased in quantity; warm-water dressing still applied. April 29th, discharge purulent and quite abundant, amounting, probably, to three or four ounces daily. April 30th, much the same, excepting that the cough was again more troublesome. The union of the flaps was daily becoming more secure, and the discharge now consisted of laudable pus. Four ligatures came away. May 1st, seemed brighter and better than any day heretofore; ate heartily, stump looked perfectly healthy, discharge moderate; two more ligatures came away. May 2d, condition excellent; the stump was rapidly healing; the skin remained as soft and healthy as on the day of operation. Most of the stitches had been cut away. The pulsation of the external iliac artery, which for several days was very marked, had diminished greatly, and seemed as though propagated through a firm clot. He had been troubled considerably with cough for two days. At midnight, in the absence of the watchman, hæmorrhage occurred, and on the return of the latter the patient was found dead. Upon removing

\* *The American Journal of the Medical Sciences*, Vol. LII, p. 17, July, 1866.



the dressing, it was seen that a secondary hæmorrhage had taken place. Most of the blood was retained either in the stump or inside the dressing; the little that had escaped had flowed from the inner angle of the stump back under the body. The hæmorrhage was found to have proceeded from the femoral artery. The most powerful restorative measures were employed for a long time, but without producing the slightest effect. Upon dissecting the stump, the union was found to be complete over one-half of the entire surface of the flaps, whilst the deeper portions of the stump were covered with healthy granulations. The femoral vein, which was not ligated, was entirely occluded; the femoral artery was patulous, its inner coat projecting somewhat beyond the other two; the inner coat of the artery was deeply stained and roughened for at least one and a quarter inches above the extremity; higher up it appeared perfectly healthy; the ligature which had secured the vessel was still attached to a shred of the outer fibrous coat. It had evidently very recently cut its way through, and still retained in its loop the end of the vessel which had sloughed off. Lying immediately in front of the femoral vessels, imbedded in a recent clot, was found the plug which had been driven out of the artery. This was a firm, flesh-colored clot, of the calibre of the vessel, and long enough to reach up to the origin of the deep epigastric and circumflex iliac arteries. No positive testimony could be obtained that the patient had suffered from one of his violent spells of coughing immediately before the accident, as all in the ward were asleep excepting the watchman; but all the appearances render it highly probable that directly after the ligature of the femoral became detached, the violent succussion of the diaphragm incident to a paroxysm of coughing had expelled the clot from that vessel. All the other vessels appeared completely obliterated. Only the thoracic and abdominal cavities were examined. The lungs were large, and free from pleuritic adhesions. They were somewhat emphysematous, and showed a large amount of pigment over their surface. The anterior portions were anæmic, but posteriorly there was marked congestion of the lower lobes. The heart was quite flabby, and moderately dilated. There was no valvular disease or apparent insufficiency, but microscopic examination showed advanced fatty degeneration of the muscular fibres. The liver was also very soft and fatty. Kidneys anæmic and pale. Other viscera healthy. The large vessels and heart contained very little blood. There was a small collection of unhealthy purulent matter in the manubrium of the sternum. The limb, upon dissection, showed very great disease of all the soft parts between the trochanters of the femur and the knee-joint. The muscles had undergone fatty degeneration; their sheaths were very much hypertrophied, and of almost cartilaginous density. Toward the bone there was a thick layer of tenacious colloid bone cartilage, apparently resulting from periosteal disease. Through the dense and morbid mass, fistulous tracks radiated in every direction, many of them containing small spiculae of bone. The bone itself was diseased from the condyles to within one and a half inches of the lesser trochanter. The shaft had been fractured obliquely, with considerable comminution, and union had taken place by formation of a very large amount of dense bony structure, which projected in spurs and ridges in all directions. The original track of the ball was marked by a deep groove, and one or two small fragments of lead were found imbedded in the bone. There was a large anfractuous cavity bridged over in places by newly formed bone, which still contained several quite large sequestra. There was incipient periosteal disease along the linea aspera up to the trochanters. A section of the bone showed that if osteomyelitis had existed, it had not extended within several inches of the trochanters.

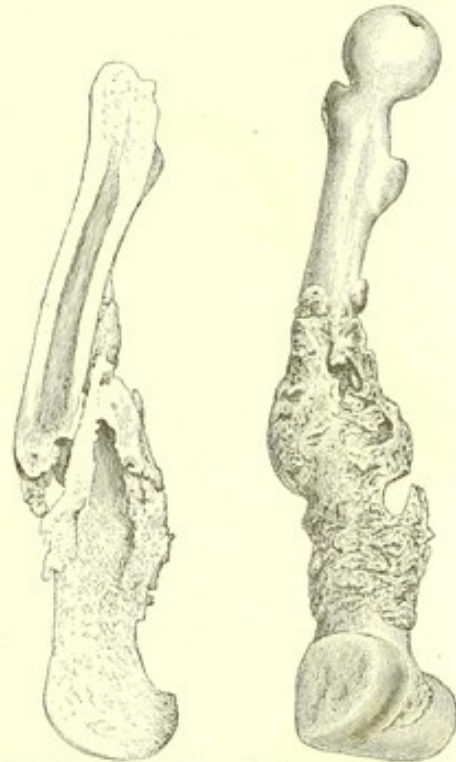


FIG. XVII. Consolidated gunshot fracture of the femur, with secondary lesions. From a photograph by Willard.

The particulars of the next case were obtained from the records of the different military hospitals in which the patient was treated, and from a report obligingly furnished by the operator, Dr William S. Forbes, Surgeon to the Episcopal Hospital of Philadelphia, who also contributed to the Army Medical Museum photographs of the patient and of the pathological specimen.\*

\* The case is concisely referred to in Dr. Morton's paper, *American Journal of the Medical Sciences*. Vol. LII, p. 36.



**CASE XLV.**—Sergeant Hiram H. Davis, Co. B, 156th New York Volunteers, aged twenty-six years, was wounded at the battle of Opequan, Virginia, on September 19, 1864, by a conoidal musket ball, which passed through the fleshy part of the left thigh, and, entering the other thigh, fractured the upper third of the right femur. He was sent by his regimental surgeon, Dr. G. C. Smith, to the Sheridan Field Hospital, near Winchester, where the fracture was adjusted upon a double inclined plane. Thence he was transferred, on March 6, 1865, to the General Hospital at Frederick, Maryland, which reports the flesh wound in the left thigh healed, great deformity and shortening of the fractured limb, and copious suppuration from fistulous sinuses communicating with necrosed bone. On April 25th, he was transferred, in a somewhat improved condition, to the Cuyler General Hospital, at Germantown, Pennsylvania, where no special alteration in his symptoms or treatment is noted. On May 10th, he was moved from Cuyler to Mower Hospital, and thence, on October 18th, to the Post Hospital at Philadelphia. The register of the Post

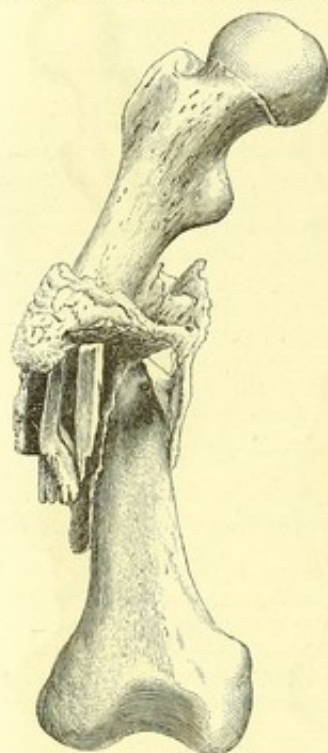


FIG. XIX.—Partial union of gunshot fracture of the femur. From a photograph by Rhoads.

Hospital states that the fracture of the femur was consolidated at the date of his admission, and that he was discharged from service on November 8, 1865. In the spring of 1866, Davis was received at the Episcopal (civil) Hospital, in Philadelphia. The appearance of the injured limb at the date of his admission is indicated in the accompanying wood-cut. The right lower extremity was shortened six and a half inches; there was false ankylosis of the knee and ankle joints on this side; extensive cicatrices on the thigh indicated the location of former sloughing; there were five fistulous canals communicating with diseased bone; apparently the entire upper portion of the femur was necrosed. On May 5, 1866, Dr. William S. Forbes, Surgeon to the Hospital, amputated the limb at the hip-joint. Ether was employed as an anæsthetic, but it did not act satisfactorily. The vessels were controlled by the abdominal aortic compressor. An anterior flap was made by cutting from without inwards, the integument being dissected up to form the longer portion of the flap. Then the femoral artery was tied; and then the bone was disarticulated and the posterior flap was completed. The hæmorrhage was estimated at less than eight ounces. The patient rallied bravely from the shock of the operation. On the following day his condition was promising, and the probabilities of his recovery were regarded as very encouraging. Forty-eight hours after the operation the pulse fell, and for about five hours there was great depression. This was followed by a febrile reaction, accompanied by an erysipelatous blush, which, commencing at the outer angle of the wound, gradually involved its entire extent. After this the patient sank rapidly, and expired sixty-four hours after the operation, May 8, 1866. On examining the injured femur it was found to be imperfectly united by fragile masses of callus, which enclosed large fragments of dead or diseased bone.

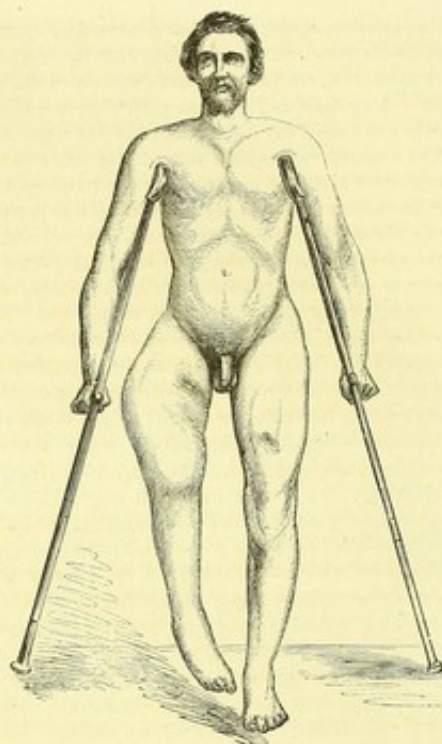


FIG. XVIII.—Gunshot fracture of the right femur with great shortening and deformity. From a photograph by Newell.

The details of the following case have been communicated by the operator, Brevet Major Henry A. DuBois, Assistant Surgeon, U. S. Army. The pathological preparation in this case has been forwarded from New Mexico to the Army Medical Museum, but has not yet been received:

**CASE XLVI.**—Antonio Mutieres, a Mexican, thirty years of age, employed by the depot quartermaster at Fort Union, New Mexico, was wounded in an altercation with another Mexican, on May 10, 1867, by a conoidal pistol ball, which entered two inches below the anterior superior spinous process of the left ilium, and passed downwards and lodged in the neck of the left femur at its junction with the head. He was admitted to the Post Hospital at Fort Union on May 11th, when Assistant Surgeon DuBois, Post Surgeon, enlarged the wound and extracted the ball and wadding with a pair of Tiemann's bullet forceps. After the removal of the ball, the finger could be passed half an inch or more into the substance of the cervix, in which the ball had been imbedded. The patient suffered but little pain, but he gradually lost flesh and strength from the surgical fever, suppuration, etc. On June 14th, he began to have severe pain, running up the side of the trunk and downwards to the



knee, which became more continuous and distressing on the succeeding day. Surgeon J. C. McKee, U. S. Army, Chief Medical Officer of the District of New Mexico, now saw the patient in consultation, and advised that amputation should be performed in preference to an excision. At noon, on June 22d, Assistant Surgeon DuBois operated, assisted by Dr. Short, of Los Vegas, and Dr. Simpson, of Moro. A rude clamp abdominal compressor had been made at the post under the direction of Dr. DuBois, and this instrument applied a little above and to the left of the umbilicus efficiently controlled the aorta. A long anterior and short posterior flap were made. The disarticulation was completed in fifteen seconds. Eighteen arteries were ligated. The soft parts were much diseased, and there was a large amount of venous hæmorrhage. A mixture of chloroform and ether was used as an anæsthetic. The patient breathed well notwithstanding the compression of the abdomen. The flaps were left open, a cerate cloth being interposed. In the evening the patient was free from pain and had slept a little; but he had not reacted satisfactorily, and talked and laughed excitedly. His pulse was at 160 and feeble. It was fuller and less frequent immediately after the operation. Milk punch had been given in small quantities every fifteen minutes. Hypodermic injections of tincture of opium, in doses of from ten to thirty drops, repeated every twenty minutes or at longer intervals, were now administered. This remedy appeared to bring the pulse up, and to act as a stimulant and not as a narcotic—a therapeutic result observed by Dr. DuBois in other cases of shock in using laudanum by this method. The patient died at twenty minutes before six, on the afternoon of June 23, 1867, about thirty hours after the operation. At the autopsy the acetabulum was found to be extensively diseased.

#### REAMPUTATIONS.

This category comprises seven cases, with the low mortality rate of 42.85—four patients having recovered. Of the three fatal cases, one died from pyæmia, eight days after the operation, and two, worn out by protracted suffering, were unable to support the shock of the operation, and sank in a few hours. In six of the cases the antecedent amputation was done on account of gunshot injuries; in one, for a bayonet stab of the knee. The latter is placed in this section for convenience sake; yet not in its chronological order, but at the close of the entire series of histories of coxo-femoral disarticulations. In six of the cases the previous amputations were done at the lower third of the thigh on account of injuries of the knee-joint. In one the exarticulation was subsequent to an amputation at the upper third for comminuted fracture of the shaft of the femur. In five cases resections of the necrosed extremity of the femur, or extractions of cylindrical sequestra, were practised in the intervals between the amputations in the continuity and the disarticulations. The shortest interval between the original injury and the disarticulation was nine weeks, and the longest three years and seven months; the average was nineteen months. In the four successful cases the average interval was fifteen months; in the three fatal cases it was two years. In the fatal cases the prior amputations had been primary in two instances; secondary, and at the upper third, in the remaining case. The successful disarticulations followed primary amputation in the continuity in one instance, intermediate amputations in two, and secondary in one.

The details of the first case are derived from reports from the Camden Street, Baltimore, and Ladies' Home, New York, Hospitals, by Acting Assistant Surgeons John Neff, E. G. Waters, and J. W. Rolin, and from letters from Dr. Gurdon Buck, and his house-surgeon at St. Luke's, Dr. C. H. Packard.\*

**CASE XLVII.**—Charles H. Hawkins, a second lieutenant in Co. C, 4th New York Cavalry, aged twenty-three years, was wounded in a reconnoissance a short distance beyond Strasburg, Virginia, on the night of June 1, 1862. A conoidal ball, from a Colt's cavalry pistol, entered the posterior surface of the right thigh, and, passing downwards and forwards, fractured the femur at the lower part of the middle third, and lodged under the skin about five inches above the knee. The wounded man lay out all night in the rain and in the sun next day until three in the afternoon, when he was brought into camp, and had the ball removed by his regimental surgeon. He was then conveyed in an ambulance to an hospital in Strasburg, where his limb was dressed with a straight splint, moderate extension and counter-extension being maintained. After ten days he was carried on a stretcher to a private house, where he remained seventeen days. Two fragments of bone were extracted during this

\* See Circular No. 6, S. G. O., 1865, p. 50, Case 17, and *American Medical Times*, Vol. VI. p. 185, and Vol. VIII. p. 1.



period. He was next transferred to a tent hospital, five miles distant, near Middletown, and after a sojourn of nine days, was again transferred to an hospital at Winchester, fourteen miles distant. Here the splints were removed, and the limb was bandaged. On July 19th, he was put upon the cars and was conveyed to Baltimore, and admitted to the Camden Street Hospital on July 20th. His general condition at this time was very unpromising; there was much irritative fever, a copious suppuration, and partial union of the fracture, with three inches shortening and much angular deformity. No apparatus was applied; but the limb was maintained in an easy position by pillows, and attention was mainly directed to improving the general condition by wholesome diet and a supporting regimen. Two months subsequently the patient had decidedly gained ground, and it was determined to undertake an operation to remove the diseased bone and to break up the faulty union of the fragments. On October 1st, the posterior orifice or wound of entrance was enlarged and a number of denuded fragments of bone were removed by forceps, and the deformed callus was chiseled and gouged away. There was a temporary improvement after this. The limb was put in a proper position and the wound was daily syringed out by iodine injections. After a time, however, it became manifest that the broken extremities of the femur were still diseased. On April 5, 1863, the patient was transferred to the Ladies' Home Hospital, in Fifty-first street, New York city, where he was received on April 8th. He was greatly reduced in strength; the wounds discharged profusely, and he complained of much pain. On April 29th, Surgeon A. B. Mott, U. S. Volunteers, amputated the limb at mid-thigh. The results of the operation were not satisfactory. Evidence that the femur was diseased above the point at which it was sawn soon became apparent, and after a protracted effort to induce healthy action, the flaps were freely laid open and the femur was resected, four inches of the shaft being removed. After this, the patient was put upon a full diet, with an allowance of brandy and of porter daily. The stump still failed to assume a healthy action, but became much enlarged, undergoing apparently a fatty degeneration. On April 4, 1864, Lieut. Hawkins was mustered out of the military service, and was transferred to St. Luke's, a civil hospital, and came under the care of Dr. Gurdon Buck. The patient was anæmic, his appetite capricious; he was compelled to keep his bed continually, on account of the pain he suffered when the stump was in a dependent position. For over five months every means were used to bring the patient up to a condition in which an operation for the removal of the diseased femur stump, the great cause of irritation, might be safely undertaken. At last it was decided that it could not reasonably be anticipated that he should attain a better condition, and, on September 21st, he was placed under the influence of sulphuric ether, and Dr. Buck proceeded to disarticulate. The tissues of the stump were indurated and inelastic, and it was found necessary to bisect the stump, uncovering the neck of the bone on the inner as well as the outer aspect, by an incision which commenced above the great trochanter and ran around the extremity of the bone to near the tuberosity of the ischium. During the operation the administration of ether was suspended on account of the extreme feebleness of the circulation, and brandy was freely given, and warm applications were made to the trunk. The loss of blood was not great, but every possible means had to be called into requisition to bring about a partial reaction after the operation, so great was the prostration and so feeble the recuperative powers. After twenty-four hours of great apparent suffering, the patient died in a syncope, September 22, 1864. The portion of the femur removed consisted of the head, neck, and trochanters, with four inches of the shaft. The head and neck were much softened and the shaft was atrophied and fatty.

The details of the next case are derived from the quarterly surgical reports from University Hospital, New Orleans.\*

CASE XLVIII.—Private Lewis Larry, Co. A, 1st New Orleans Volunteers, aged twenty-three years, was shot through the left knee by a sentry, July 17, 1864, while attempting to avoid arrest. He was carried to the University Hospital. It was found that the condyles of the femur were badly comminuted. Synovial fluid was dribbling from the wound, with but little hæmorrhage. Amputation at the middle of the thigh was promptly performed, under chloroform, by double flaps. The patient did well for about three weeks, when he was attacked with persistent diarrhœa, to which he had been subject. Erysipelas now attacked the stump. Sloughing phagedæna of the flaps ensued, and purulent sinuses extended upwards along the femur, the necrosed extremity of which protruded from the stump. It was decided that amputation at the hip-joint afforded the only chance of safety, and, on September 21, 1864, the operation was performed by Acting Assistant Surgeon F. Hassenburg. The patient being brought under the influence of chloroform, and put in the usual position for the operation, and the artery being controlled at the groin, an anterior flap was formed by transfixion, the capsule divided and disarticulation effected, and a posterior flap cut from within outwards. The hæmorrhage was inconsiderable, and the patient promptly rallied from the shock of the operation. For a few days afterwards his appetite and general health improved; then the wound assumed an unhealthy aspect, and finally sloughed. Symptoms of pyæmic infection set in, and death ensued on September 30, 1864, a week subsequently to the disarticulation. On dissecting the portion of the thigh that was removed, it was found riddled with abscesses. The periosteum was enormously thickened and contained flaky ossific deposits. The shaft of the femur was necrosed quite up to the trochanters, the dead bone being included in a redundant friable involucrum. The preparation was forwarded to the Army Medical Museum by Surgeon Samuel Kneeland, U. S. Volunteers, in charge of University Hospital, and is numbered *Specimen 3738*.

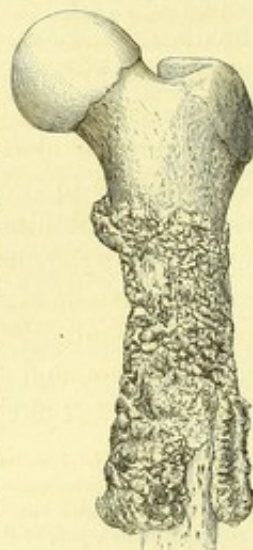


FIG. XX.—Diseased stump of femur from a case of coxo-femoral disarticulation. *Spec. 3738, A. M. M.*

\* See Circular No. 6, S. G. O., 1865, p. 50, Case 16.



The following remarkable case of successful reamputation at the hip-joint has already been brought repeatedly to the notice of the profession.\* Some additional details relative to the ulterior history of the case are here given:

**CASE XLIX.**—Private Eben E. Smith, Co. A, 11th Maine Volunteers, aged nineteen years, was wounded on August 16, 1864, in one of the engagements following Major General Hancock's movement upon Deep Bottom, on the left bank of James River. A musket ball passed through the right leg from within outwards, fracturing the head of the tibia. The wounded man was conveyed to the Field Hospital of the First Division of the Tenth Corps, where it was determined that an attempt should be made to preserve the limb. Constant cold applications were made to the wounds. After a few days the patient was sent to the North on an hospital steamer, and, on August 22d, he was received at the U. S. General Hospital at Beverly, New Jersey. On admission, he suffered but little pain though the knee-joint was considerably swollen. On September 14th, secondary hemorrhage occurred, and it was deemed advisable to remove the limb. The amputation was performed by Acting Assistant Surgeon J. C. Morton, at the lower third of the thigh, by the circular method, the patient being anesthetised by chloroform. On examining the seat of the injury, it was found that a fissure ran through the external tuberosity of the tibia and the external articular surface, and that the bone was carious in the vicinity of the fracture. The preparation was forwarded to the Army Medical Museum by Assistant Surgeon C. Wagner, U. S. A., and is numbered *Specimen 3709*. The case progressed favorably until October 17th, when there was hemorrhage from the stump to the amount of twelve ounces. The stump was in a sloughing condition, and it was therefore determined to tie the femoral artery in Scarpa's space, which was done by Dr. Morton. The ligature came away on November 1st. The wound remained in an unhealthy condition, with a copious fetid suppuration, and the necrosed extremity of the femur protruded from the upper angle of the wound. On November 5th, the soft parts were retracted, and four inches of the shaft of the femur were resected by the chain saw. After this the stump became much swollen, frequent abscesses formed, and it was finally decided that necrosis involved the femur quite up to the trochanters. This conclusion was verified by an exploratory incision made on January 19, 1865, when it was determined to proceed at once to amputate at the coxo-femoral articulation. The operation was performed by Acting Assistant Surgeon John H. Packard. The patient being already under the influence of chloroform, the femoral artery was exposed and tied just below Poupart's ligament. Anterior and posterior flaps were then formed and disarticulation effected. Some difficulty was experienced in securing an artery supposed to be the *comes nervi ischiadici*; but the quantity of blood lost in the operation was not considered large. There was extreme depression after the operation, and the patient was kept on the amputating table for two or three days, lest an attempt at removal should prove fatal. Large quantities of stimulants and concentrated food were administered, and artificial warmth was applied to the surface of the body. Eight days after the operation, hemorrhage to the extent of six ounces occurred, and a ligature was placed upon the external iliac artery by Dr. J. C. Morton. The ligature separated on February 17th. On the 19th, there was profuse bleeding from the point of ligation, which was controlled by pressure. Direct compression was maintained for fourteen days. After this the patient rapidly improved, and by the end of March he was quite well. In April, Mr. Baumgras, one of the artists of the Army Medical Museum, was sent to Beverly, and made a sketch of the patient. From his drawing, revised by Mr. Faber, the accompanying plate has been prepared. On April 12th, Smith was transferred to the White Hall Hospital, near Bristol, Pennsylvania. On May 27, 1865, Assistant Surgeon W. H. Forwood, U. S. Army, reported his discharge from service with a sound stump and robust health. After his discharge, Smith went to his home at Eastbrook, in Maine, and was granted a pension of fifteen dollars a month. On February 27, 1867, and again on March 9th, he wrote to this office that his general health was excellent, but that the cicatrix of his stump was painful. In May, 1867, he was admitted to the eastern branch of the U. S. Military Asylum for disabled volunteer soldiers, at Togus Springs, near Augusta, Maine. On May 12th, the surgeon of the asylum, Dr. B. B. Breed, wrote that he "was apparently in perfect health, and complained only of congestion of the stump after standing for some time." An attempt was proposed to adapt an artificial limb to the stump. A preparation of the exarticulated portion of the femur was forwarded to the Army Medical Museum by Assistant Surgeon C. Wagner. It is numbered *Specimen 81* of the Surgical Series, and is very well represented in the first figure of Plate VI. The remaining portion of the shaft has become necrosed quite up to the trochanters, and is included in a fragile honeycombed deposit of new bone.

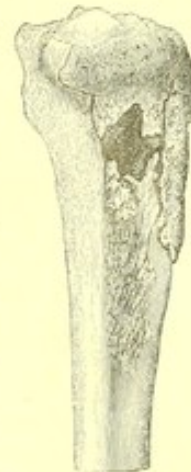

FIG. XXI. Orifice of exit of a musket ball through the external tuberosity of the tibia. Spec. 3709, A. M. M.

The abstract of the following successful case is abridged from the history published by the operator,† Dr. A. M. Fauntleroy, who has courteously transmitted to this office a photograph of the pathological preparation taken from the case, and also a photograph taken in July, 1866, representing the appearance of the patient and of his stump sixteen months after the operation, when the stump had completely healed. The accompanying plate is copied from this photograph:

\* See Circular No. 6, S. G. O., 1865, p. 49; *Report of Interesting Surgical Operations*, by C. Wagner, p. 15; Morton, in *American Journal of the Medical Sciences*, Vol. LII, p. 32; Packard, in *New York Medical Journal*, Vol. II, p. 161, etc., etc.

† *The Richmond Medical Journal*. Vol. I, p. 7. January, 1865.



CASE L.—Private R. A. Vick, Co. E, 43d North Carolina (Rebel) Infantry, aged thirty-seven years, received a gunshot wound of the knee-joint at the battle of Cedar Creek, October 19, 1864, and underwent primary amputation at the lower third of the right thigh. On December 19th he was sent to the General Hospital at Staunton. On January 1, 1865, the stump had almost cicatrized, but there were two small apertures through which fetid pus issued, amounting daily to four or five ounces. On February 15, 1865, the daily discharge from the openings had considerably increased in quantity. An exploration with a silver probe revealed bone denuded of periosteum and much roughened. Another aperture led to a somewhat superficial fistulous track of six or eight inches. It was evident that something must be done for the relief of the patient, and it was determined to open the face of the stump, with a view to the removal of the diseased bone. The operation was performed on March 11, 1865, by the surgeon in charge of the hospital, Dr. A. M. Fauntleroy, assisted by Drs. T. W. Glocker and R. K. Carter. The patient took a stimulant, and chloroform was administered. A transverse incision was then made over the face of the stump. At the exposed extremity of the femur was a redundant mass of new bone, which was sawn off. It was then found that the carious shaft of the bone was encircled by a soft porous osseous deposit. About six inches of this formation was stripped off by the gouge, yet the limits of morbid action had not been reached. The carious condition of the shaft was evidently peripheral in origin, as the periosteum was in a state of fatty degeneration, whereas the medullary membrane was comparatively healthy. It was determined to extend the exploration until sound bone was reached. With this view, an incision on the outer



FIG. XXII. Diseased stump of femur. From a photograph sent by Dr. Fauntleroy.

side of the thigh, between the vastus externus and biceps, was gradually extended upwards to a point between the great trochanter and the anterior iliac spine, and revealed the fact that the entire femur was diseased. It was now decided to disarticulate at the hip-joint. The femoral artery was compressed upon the pubic bone, and anterior and posterior flaps were formed, the arteries being secured as they were cut. The loss of blood was trifling. The cotyloid cavity was healthy. The flaps were brought together by silver sutures, and the stump was dressed with dry lint. As soon as consciousness was restored, the patient was freely stimulated by whiskey, and warm bricks were applied to the surface of the body; the patient rallied completely in a few hours, and drank, during the day, nearly a pint of cream, and ate two soft-boiled eggs. The whiskey was exhibited every half hour during the evening, and every hour during the night. At bed-time his pulse numbered 120 beats. He stated that, normally, his pulse was very frequent and quick. On the following morning the patient was doing very well; he ate three soft-boiled eggs for breakfast, and batter cakes, and drank nearly half a pint of cream. Pulse still the same in quickness and frequency. He was ordered to take half an ounce of whiskey every hour during the day. On March 13th, in the evening, his condition was satisfactory; his appetite was remarkably good; he ate during the day seven soft-boiled eggs, batter cakes, and drank largely of rich milk. Suppuration having commenced, cold water was directed to be constantly applied to the stump to lessen the secretion of pus. Whiskey was continued in same amount, and at like intervals as on the previous day, and he was ordered twenty drops of the tincture of the sesquichloride of iron thrice daily, and ten grains of Dover's powder at bed-time. Whiskey was only to be given in the event of his waking during the night. Suppuration amounted to half a pint during the day. On March 20, 1865, he was still doing well. Suppuration was diminished in quantity and was laudable. Sutures were removed, and adhesive strips used to support the flaps and maintain them in apposition. The patient's bowels had been regular since the operation. His tongue had at no time been furred. On March 26th, the patient had three dejections, caused, probably, by imprudence in eating cabbage, for which he had a craving desire. This diarrhoea was checked by a pill containing two grains of acetate of lead and half a grain of opium, given at bed-time, and repeated on the 27th. The stump was doing well. The discharge had abated to three or four ounces. The patient was very cheerful. March 28th, the progress of patient was highly favorable. In addition to the iron, an ounce and a half of cod liver oil, with an ounce of whiskey, was ordered to be taken an hour after each meal. March 29th, the patient's condition was comfortable and favorable; the cod liver oil agreed with his stomach; his appetite continued remarkably good; he ate seven eggs daily. The stump along the lower surface seemed to have united firmly; on the side, granulations were healthy; the pus discharged was laudable.

From this time forward the patient steadily improved. Not a single untoward symptom arose to retard recovery. On April 24th, the face of the stump had entirely healed. There was still a granulating sore at the outer angle. On July 18th, 1865, the patient started for his home, near Tarborough, in Edgecomb, North Carolina. He was in excellent health, and walked about on crutches with facility. A year subsequently he was in Lynchburg, Virginia. Since that date no intelligence has been received from him, and it is not known whether he still survives.

The history of the next case is compiled from the registers of the military hospitals in which the patient was treated, from the published report\* of the operator, Dr. Thomas G. Morton, and from letters from the patient. Dr. Morton has kindly contributed to the Army Medical Museum a photograph of the preparation of the upper extremity of the diseased femur, deposited in the pathological collection of the Pennsylvania Hospital; and the patient, Mr. Ulmer, has furnished a photograph of himself, taken in September, 1866, seven months subsequently to the operation, in which the condition of the stump is well exhibited:

\* *The American Journal of the Medical Sciences*. Vol. LII, p. 27, July, 1866. A few trifling errors relative to the military description of the patient, etc., in Dr. Morton's report, are corrected in the text.



**CASE LI.**—First Sergeant Edwin D. Ulmer, Co. G, 15th New Jersey Volunteers, aged twenty-one years, was wounded at the battle of Cedar Creek, October 19, 1864, by a conoidal musket ball, which entered the inner face of the left thigh, fractured the bone, and lodged under the skin on the outer side of the limb. The femur was badly comminuted, fissures extending into the knee-joint and upwards for seven inches. (See Figure XXIII.) There was but little hæmorrhage at the time of the injury. The ball was readily extracted at the Field Hospital of the First Division of the Sixth Corps, and it was determined to attempt to save the limb. The wounded man was conveyed to Baltimore, and received at Jarvis Hospital on October 24th. The train of symptoms consequent upon gunshot injuries implicating the knee were soon developed. Intense arthritis supervened, with deep dissecting abscesses in the thigh. On November 14th, twenty-six days after the injury, hæmorrhage to the extent of twenty-five ounces took place from both orifices, which were in a sloughing condition. The patient was put under ether, and amputation at the middle of the thigh was performed by Acting Assistant Surgeon Edward G. Waters, anterior and posterior flaps of integument being formed, and the muscles being divided circularly. The patient was very weak and nervous at the time, but he rallied promptly after the operation and convalesced rapidly, and in a few weeks was able to get about on crutches. Yet the stump continued open and painful, and the extremity of the femur was found to be necrosed. In March, 1865, it was found that a cylindrical sequestrum was loose. This was removed on March 8th, by Acting Assistant Surgeon B. B. Miles, with forceps. The patient's general condition rapidly improved after this operation. On May 29, 1865, he was discharged from the service of the United States, the stump still discharging slightly. On the following day, he started for Philadelphia, and, unfortunately, on the journey he fell with violence upon the stump. After this, there was increased suppuration, with deep-seated pain in the stump. On the 22d of January, 1866, fifteen months after the original injury, while dressing the part as usual, a hæmorrhage occurred from one of the fistulous openings at the end of the stump, amounting, according to his statement, to at least a pint. On account of this hæmorrhage,



FIG. XXIV.  
Cylindrical  
sequestrum  
from femur  
stump. Spec.  
107, A. M. M.

he was admitted into the Pennsylvania Hospital. The usual local remedies were applied to guard against its return; he was put upon a stimulating treatment, with the best diet. The stump presented the following appearances: The edges of the flaps were ulcerated, inverted, and covered with fungous granulations, which were red, painful, and disposed to bleed on the slightest probing. No examination of the bone was made for fear of exciting hæmorrhage. On the outside of the stump, which was swollen, sinuses were found, the mouth of each being surrounded by puffy, pale, granulating tissue. The femur seemed much thickened, could be felt through the integument, and was very painful to pressure; but no examination of the bone was made through the fistulous tracks. The head of the femur seemed also involved on account of the pain about the region of the socket, and his inability to allow much motion in the joint. He was greatly prostrated from the long continued drain, and lastly from the hæmorrhage. The history of the case, and the present appearances of the stump, clearly indicated the existence of osteomyelitis, with necrosis of the neck, and probably ulceration of the head of the bone. The risk of recurrence of dangerous hæmorrhage, and the extensive disease of the femur, obviously demanded operative treatment; the removal of the stump at the coxo-femoral articulation offered the only chance for recovery. The patient's general health improved, and there was no further hæmorrhage until about the 15th of February, when the discharge again became mixed with blood. On the 17th, in the hospital amphitheatre, before the clinical class, the patient being etherised, an exploratory operation was made. An incision upon the outer side of the thigh revealed a diseased condition of the bone as high as the neck. Amputation was decided upon in consultation with Drs. Hunt and Agnew. The abdominal tourniquet having been applied, antero-posterior integumentary flaps were dissected up; the femoral artery, which was exposed with some difficulty on account of the hardened and altered condition of the tissues, consequent upon the previous inflammation of the soft parts, was then tied. The muscles having then been cut, circularly, close to the pelvis, the head of the bone was readily disarticulated. The aorta was so completely controlled by the tourniquet of Mr. Syme, that no arterial jet was observed during the operation; the loss of blood being very trifling, hardly amounting to three ounces. About sixteen ligatures were applied. The flaps were approximated with adhesive plaster, no sutures being deemed necessary. The subsequent dressings consisted of lint soaked in pure laudanum, until the parts had almost healed, when simple cerate dressing was substituted. The patient was much prostrated by the operation, but reacted well. The discharge was very profuse; and during the first week the edges of the flaps appeared a little sloughy. Under vigorous stimulating treatment and the local application of permanganate of potash in solution he rapidly recovered. No other unfavorable symptoms having occurred, and the ligatures being all away by the end of the second week, two small openings in the stump alone remaining, he left the hospital March 27th, thirty-eight days after the operation, for his home in

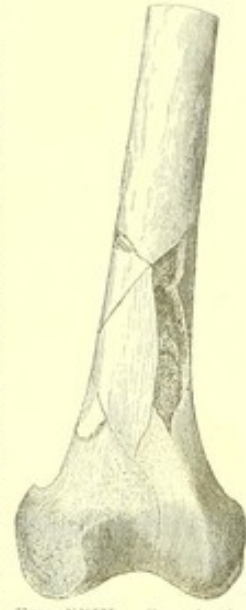


FIG. XXIII. Comminution  
of the lower extremity of  
the femur by a musket ball.  
Spec. 5734, A. M. M.

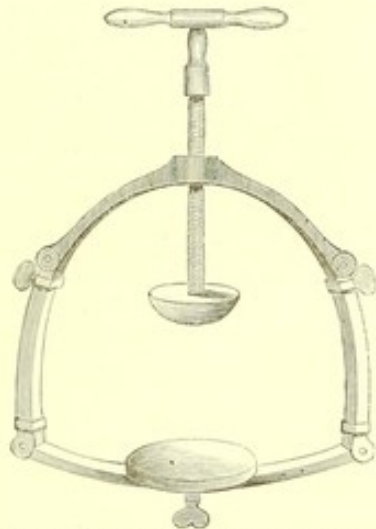


FIG. XXV. Mr. Syme's Abdominal Compressor, as made by Kolbe.



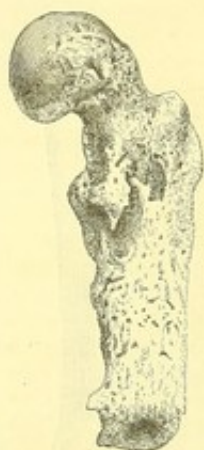

FIG. XXVI. Necrosis of the femur following osteomyelitis. From a photograph by Willard.

the northern section of the city. The exarticulated portion of the femur presented a characteristic example of necrosis following osteomyelitis. A long, loose sequestrum was found encased in a new deposit of porous bone, and was not limited to the diaphysis, but extended quite into the neck, and then projected through the ulcerated capsular ligament. The head of the femur was ulcerated. The acetabulum was healthy. On May 10th, the patient was able to get about town on crutches. On the 20th, he left for New Jersey to fill a situation as telegraph operator. On July 24th, he sent a letter to this office from Milford, New Jersey, announcing that his health was excellent, and a few weeks subsequently he corroborated this statement by transmitting his photograph. On October 27, 1866, he was supplied with an artificial limb by Clement, of Philadelphia. On June 28, 1867, Mr. Ulmer wrote to this office that he had never had a day's illness since the hip-joint amputation was performed, and had never been in better health than then. He was stouter than ever before, weighing one hundred and seventy-five pounds, or twenty-five more than his average weight when he had both lower extremities. His stump was firm and solid and gave him no pain or inconvenience. He considered his artificial limb an excellent one, and could walk on it "right well," but found it inconvenient at his work, which required him to sit all day on a high stool.

The following history, communicated by the operator, Dr. James B. Whitcomb, of Brooklyn, Connecticut, formerly Surgeon 11th Connecticut Volunteers, relates to the case of a camp follower, a sutler's clerk:

**CASE LIH.**—Henry Campbell, aged twenty-three years, received, in March, 1863, at New Orleans, a pistol shot in the left knee. Primary amputation at the junction of the middle and lower thirds of the thigh was performed by Acting Assistant Surgeon Avery. The stump did not do well. Osteomyelitis supervened and resulted in necrosis. After a few months the patient was removed to his home in Connecticut. In October, 1864, eighteen months subsequent to the injury, he was visited by Dr. Bauer, of New York, who laid open the cicatrix, crowded with fistulous openings, and removed a cylindrical sequestrum five inches in length. For a few months after the removal of this sequestrum the general health of the patient improved, and hope was entertained of his recovery without further operative interference; but persistent pain and constitutional disturbance then recurred with augmented intensity. The lower part of the stump was riddled with sinuses and the tissues were much indurated. The probe detected dead bone, or morbid bone formation, in every direction. This state of things became gradually worse, and, after a protracted reliance upon the reparative powers of nature, in October, 1866, the medical attendants resolved that an operation should be performed for the radical removal of the diseased bone. It was hoped that it would be only necessary to remove a portion of the shaft of the femur. On October 22d, the patient was placed under the influence of chloroform, and Dr. James B. Whitcomb, assisted by Dr. Charles Bliss, of Willimantic, and others, proceeded with the operation. An exploratory incision was made on the outside of the thigh, extending quite up to the trochanter. On exposing the new osseous formation at the end of the stump, it was found to be more than twice the normal diameter of the shaft of the femur, rough, porous, and fragile. The immensely thickened periosteum was studded with plates and spines of new bone, and in many cases there were foliaceous masses of callus unconnected with the shaft. Towards the upper extremity of the femur the periosteum appeared less diseased, but the bone was found to be softened and disorganized quite up to the great trochanter. Taking the previous history into consideration, it was thought unreasonable to anticipate recovery, or even temporary improvement, without the removal of the diseased bone, and it was therefore decided to amputate at the hip-joint. The patient had thus far inhaled chloroform. Ether was now substituted. Pressure with the thumb on the femoral artery served to control the hemorrhage. A large antero-internal flap was formed and disarticulation effected. There was very little loss of blood, but the patient was greatly prostrated by the shock of the operation, which, from the beginning of the exploration to the completion of the amputation, lasted fifty minutes. The free administration of ammonia and brandy brought about reaction; but it was temporary, and the case terminated fatally, five hours after the operation, October 22, 1866.

The last case to be recorded is distinguished from all that have preceded, by the fact that it was not a case of gunshot injury. The first amputation was performed on account of a bayonet wound of the knee. The history of the case has already been published several times.\*

**CASE LIIL.**—Private Lewis Francis, Co. I, 14th New York Militia, aged forty-two years, was wounded July 21, 1861, at the first battle of Bull Run, by a bayonet thrust, which opened the right knee-joint. He received not less than fourteen other stabs in different parts of the body, none of them implicating the great cavities. He was taken prisoner, and conveyed to

\* See Circular No. 6, S. G. O., 1835, p. 49, and HAMILTON'S *Treatise on Military Surgery*, p. 629.



Richmond and placed in hospital. One of his wounds involved the left testis, which was removed on July 24th. On October 28, 1861, his right thigh was amputated at the middle, on account of disease of the knee with abscesses in the thigh. The double-flap method was employed. The stump became inflamed, and the femur protruded. An inch of the bone was resected, and the flaps were again brought together. In the spring of 1862, the patient was exchanged and sent to Fort Monroe. Thence he was transferred to a Washington hospital, and thence, in March, 1862, to his home in Brooklyn. There was necrosis of the femur, and in May, 1862, its extremity was again resected by a civil surgeon. On October 28, 1863, Francis was admitted to the Ladies' Home Hospital, New York. Necrosis had apparently involved the remaining portion of the femur. On May 21, 1864, Surgeon A. B. Mott, U. S. Volunteers, laid open the flaps and exarticulated the bone. The patient recovered rapidly and had a sound stump. He was discharged August 12, 1864. On October 1, 1865, the photograph from which the accompanying\* plate is copied was taken, and forwarded by Surgeon Mott to the Army Medical Museum. Dr. Mott reported that the pathological specimen of the exarticulated femur was stolen from his hospital. For some months after his discharge Francis enjoyed good health; but then the cicatrix became unhealthy, pus was discharged through several sinuses, and there was bleeding from the slightest irritation. In March, 1867, a messenger was sent to his residence, 54 Hamilton Street, Brooklyn, and found him in very poor health. He had been unable to leave the house since November, 1866. On April 12, 1867, he was visited by Dr. E. D. Hudson, who reported him as then confined to his bed. There was a large ulcer at the upper outer angle of the cicatrix, which communicated with extensive sinuses; there was a fistula-in-ano also. The pus from the different fistulous orifices was thin, oily, and ichorous. There could be little doubt that there was disease of some portion of the innominatum. The patient was much emaciated, and had a cough with muco-purulent expectoration. His pulse, however, was not frequent, and he had a good appetite. In May, 1867, it was reported that his general condition had somewhat improved.

The seven foregoing cases, and Guthrie's Ciudad Rodrigo case,† are the only recorded examples, it is believed, in military surgery, of amputations at the hip-joint succeeding previous amputations in the continuity of the thigh. But in the records of the surgery of civil life a number of similar cases are found, and it seems very proper to compare these with the cases in military surgery. For amputation at the hip-joint, where the thigh has been already amputated in the continuity for gunshot injury of the knee-joint or lower portion of the femur, is required by such complications as osteomyelitis, or necrosis, or uncontrollable hæmorrhage, or gangrene; and these are precisely the causes which demand disarticulation in civil practice, where the thigh has been already amputated for disease or injury. It is probable that there is a greater liability to osteomyelitis in amputations for gunshot fractures; but this is balanced by the fact that in civil practice the operation is sometimes necessitated by the recurrence of the malignant disease for which the first operation was performed.

Samuel Cooper adverts to the successful amputation at the hip-joint by Sir Astley Cooper‡ for disease of the higher part of the femur, with the remark that, as this patient had formerly suffered amputation at the thigh, the operation was certainly unlike "the sudden removal of nearly a quarter of him;" but he "cannot presume to say what difference in the chances of success, and whether any, would be connected with this circumstance." He adds that "the same remark applies to a case lately under Mr. Mayo when the patient, a young woman, recovered. The proceeding was adopted on account of the agony experienced by the patient from a neuralgic affection of her stump." But at the present day it is possible to say, without presumption, that the circumstance to which S. Cooper alluded makes a very great difference in the chances of success; and,

\* Several of the cases illustrated by plates come together so closely in the text that it has been decided to bind all the plates at the end of the report.

† The patient, Private Mason, 23d British Infantry, or Welch Fusileers, had his thigh amputated at the middle at the siege of Ciudad Rodrigo, and was sent to the divisional hospital at Aldea del Obispo. Here the stump sloughed, and there was uncontrollable secondary hæmorrhage. Guthrie amputated at the hip-joint, with the assistance of Dr. Cartan and Mr. Loane. The patient survived the operation seven hours. *A Treatise on Gunshot Wounds*, by G. J. GUTHRIE, F. R. S. Third London edition, p. 332.

‡ *Dictionary of Practical Surgery*. 8th London edition. Vol. I, p. 117.



latterly, Dr. S. D. Gross,<sup>1</sup> Dr. W. H. Van Buren,<sup>2</sup> and Dr. J. H. Packard<sup>3</sup> have emphatically insisted on the less danger of amputations at the hip-joint effected after the previous removal of a portion of the limb below. Professor Gross enumerates eight cases, including that of Guthrie. Dr. Packard recapitulates these cases, cites his own operation, and quotes Fayrer's successful, but not his unsuccessful case, and makes out a very favorable exhibit for this class of operations.<sup>4</sup>

Ten cases are on record of disarticulations at the hip-joint after previous amputation of the thigh in its continuity for disease or for injuries received in the accidents of civil life. The operators were Astley Cooper,<sup>5</sup> Mayo,<sup>6</sup> Cajetan Textor,<sup>7</sup> Mr. W. S. Cox,<sup>8</sup> Mr. Syme,<sup>9</sup> Dr. W. H. Van Buren,<sup>10</sup> J. C. Bradbury,<sup>11</sup> Dr. J. Fayrer,<sup>12</sup> Mr. Hancock,<sup>13</sup> Dr. J. Fayrer.<sup>14</sup> Eight of these patients recovered and two died, a mortality rate of 20. only. Grouping these ten cases with the seven reamputations at the hip-joint of the war of the rebellion and with Guthrie's Ciudad Rodrigo case, a series of eighteen examples of removal of thigh stumps by amputation at the hip-joint is obtained, with twelve recoveries and six deaths.

For convenience in reference, I here insert a tabular statement of the fifty-three amputations at the hip-joint described in this report, together with those of the one hundred and eight previously recorded hip-joint amputations in military surgery of which some details have been published.

<sup>1</sup> *A System of Surgery*. 3d edition. Philadelphia, 1864. Vol. II, p. 1046.

<sup>2</sup> *Contributions to Practical Surgery*. Philadelphia, 1865, p. 10.

<sup>3</sup> *New York Medical Journal*. Vol. II, p. 161.

<sup>4</sup> PACKARD, *loc. cit.* Dr. Packard observes that he knows of Guthrie's case only through Professor Gross's quotation.

<sup>5</sup> In 1824. See *Lancet*. Vol. II, 1824, p. 96.

<sup>6</sup> In 1835, for neuroma. COSTELLO, *Cyclopaedia of Practical Surgery*, Vol. I, p. 182, and S. COOPER, *loc. cit.*, p. 117; and DRUITT'S *Surgeon's Vade Mecum*, 9th London ed., p. 777.

<sup>7</sup> In 1841, for gangrene. *Gazette Médicale de Paris*, Sept. 4, 1841.

<sup>8</sup> In 1844, in the case of a woman aged 23 years with carcinoma. *Memoir on Amputations of the Thigh at the Hip-Joint*. London, 1845.

<sup>9</sup> In 1848. *London and Edinburgh Monthly Journal*, 1848, and *Medical Times*, 1849, p. 252. This was the first successful amputation at the hip-joint in Scotland.

<sup>10</sup> In 1850. *Contributions to Practical Surgery*. Philadelphia, 1865, p. 10.

<sup>11</sup> In 1851, on a scrofulous boy 10 years of age. *Boston Medical and Surgical Journal*. Vol. XLVI, 1852, p. 349.

<sup>12</sup> In 1853. FAYRER'S *Clinical Surgery in India*, p. 669, London, 1865. Case of Ishmael Hadji, aged 36 years.

<sup>13</sup> In 1860. *London Lancet*, 1860. Vol. I, p. 319.

<sup>14</sup> In 1864. FAYRER, *op. cit.*, p. 699. Case of Shaikh Asghur, aged 16 years.



## PRIMARY AMPUTATIONS AT THE HIP-JOINT IN MILITARY SURGERY.

NO.	DATE.	OPERATOR.	PATIENT.	INJURY.	OPERATION.	RESULT.	REMARKS.
1	1793	D. J. Larrey...	A soldier of the French Army of the Rhine.	Gunshot fracture of the femur.	Larrey's method. External and internal flaps.	Died within a week.	He did well for several hours, and Larrey thought that a forced march of twenty-four hours in inclement weather induced the fatal termination. <i>Mémoires de Chirurgie Militaires et Campagnes</i> , par D. J. LARREY. Paris, 1812. Tome II, p. 180.
2	1799	D. J. Larrey...	Bonhomme, officer of the 18th Demi-Brigade, Army of Egypt.	Fracture of the trochanter of the right femur by a fragment of a bomb-shell, with division of the femoral artery and great laceration of the soft parts, at St. Jean D'Acre, Syria, April or May, 1799.	Larrey's method. Preliminary ligation of the femoral.	Died of the plague on the eighth day.	Union by first intention nearly complete on the sixth day. <i>Relation Chirurgicale de l'Armée d'Orient</i> , par D. J. LARREY. Paris, 1803, p. 329.
3	1799	D. J. Larrey...	Drummer of Second Light Demi-Brigade, Army of Egypt. Age 20 years.	Right thigh torn off by a shell. Femur fractured quite into coxo-femoral articulation. Great prostration from hæmorrhage. May 19, 1799. St. Jean D'Acre.	Larrey's method.	Died in the retreat a few days after the operation.	<i>Relation Chirurgicale de l'Armée d'Orient</i> , par D. J. LARREY. Paris, 1803, p. 332.
4	1812	D. J. Larrey...	A Russian soldier.	Left femur shattered by a cannon ball. Two-thirds of the thickness of the soft parts of the thigh were torn away. Witepsk, July 29, 1812.	Larrey's method.	Died on the twenty-ninth day from dysentery.	<i>Mémoires de Chirurgie Militaire et Campagnes</i> . Paris, 1817. Tome IV, p. 36.
5	1812	D. J. Larrey...	Lieutenant of Dragoons, of the French Army of invasion of Russia.	A five-pound cannon ball shattered the great trochanter and neck of the femur; femoral artery uninjured, muscles terribly torn. Borodino, September 7, 1812.	Larrey's method.	Never reached France.	Was moved to Kolloskoi and then to Witepsk and Orcha, and said to have been seen at Witepsk by M. Bachelet three months after the operation; also said to have been seen at Orcha perfectly cured. <i>Mém. de Chir. Mil. et Camp.</i> Paris, 1817. Tome IV, p. 50.
6	1830	P. J. Roux.....	A Swiss subaltern.	Gunshot wound of the thigh with fracture of the trochanter major. July 29, 1830.	Lateral flaps.....	Died on the day of the operation.	<i>Gazette des Hôpitaux</i> . 1830, p. 392.
7	1831	C. Sédillot.....	A Russian prisoner.	Gunshot fracture of the neck of the right femur. Poland, 1831.	Oval method of Cornuau.	Died very soon after the operation.	<i>Annales de la Chirurgie Française et Étrangère</i> . Tome II, 1841, p. 279. SÉDILLOT, <i>Traité de Médecine Opératoire</i> . Tome I, p. 455.



## PRIMARY AMPUTATIONS AT THE HIP-JOINT IN MILITARY SURGERY—Continued.

No.	DATE.	OPERATOR.	PATIENT.	INJURY.	OPERATION.	RESULT.	REMARKS
8	1832	Letulle.....	A French cannonier of the 11th Regiment of Artillery.	Comminuted fracture, extending to within an inch of the great trochanter of the left femur, by a cannon ball, accompanied by great laceration of the integuments and muscles on the outer aspect of the thigh. Antwerp, Dec. 13, 1832.	Internal flap and short posterior flap. Preliminary ligation of the femoral.	Died Dec. 22, 1832.	The patient did well till the 20th of December, when he was moved in an ambulance to Boom. The next day the wound looked badly and the patient rapidly sank. H. LARREY, <i>Hist. Chir. du Siège de la Citadelle d'Anvers. Paris</i> , 1833, p. 307.
9	1836	F. Hutin.....	M....., a soldier of the 1st Light Battalion.	Fracture of the neck of the left femur by a musket ball. Constantine, Africa, December 3, 1836.	Manec's method.	Died Dec. 13, 1836.	<i>Recueil de Mém. de Méd. de Chir. et de Phar. Mil.</i> 1e série. Tome XLIV, p. 219.
10	1836	F. Hutin.....	L....., 3d Regiment of Engineers.	Fracture of the upper extremity of the left femur by a musket ball. Constantine, Dec. 4, 1836.	Manec's method.	Died Dec. 4, 1836.	<i>Recueil de Mém. de Méd. de Chir. et de Phar. Mil.</i> Tome XLIV, p. 220.
11	1848	L. Baudens....	X....., a soldier of the 18th French Light Infantry.	Wound of the upper third of the thigh by a musket ball comminuting the great trochanter and upper portion of the femur. June 27, 1848.	Single anterior flap.	Died June 28, 1848.	BAUDENS. <i>Des Plaies d'Armes à feu, dans Rec. de Mém. de Méd. de Chir. et de Phar. Mil.</i> 2e série. Tome X, p. 130.
12	1849	Dr. Lente.....	John Dalzell, aged 23 years.	Compound fracture of cervix femoris by a musket ball. Astor Place Riot, N. Y. May 10, 1849.	Lateral flaps.....	Died May 12, 1849.	<i>Transactions American Medical Association.</i> Vol. IV, 1848, p. 316.
13	1853	J. Payrer.....	Moung Schwé-Mo, a Burman, aged 30 years.	Fracture of the left femur through the neck and trochanters, by a slug from a musket. Rangoon, Bengal, February 15, 1853.	Antero-posterior flaps.	Died March 17, 1853.	FAYRER'S <i>Clinical Surgery in India.</i> London, 1866, p. 630.
14	1854	Thomas Alexander.	A Russian prisoner.	Gunshot fracture of the femur. Alma, September 20, 1854.	.....	Died October 20, 1854.	LONGMORE, in <i>Holmes's System of Surgery.</i> London, 1861. Vol. II, p. 82.
15	1854	Thomas Alexander.	A private of the 33d British Infantry.	Gunshot fracture of the femur. Alma, September 20, 1854.	.....	Died October 11, 1854.	LONGMORE. <i>Loco citato.</i>
16	1854	Dr. Richard McKenzie.	Soldier.....	Gunshot fracture of the femur. Alma, September 20, 1854.	.....	Died within twenty-four hours.	MACLEOD. <i>Notes on the Surgery of the War in the Crimea,</i> p. 369.
17	1854	Asst. Surgeon Wyatt.	An officer of the Coldstream Guards.	Gunshot fracture of the thigh, together with several bayonet wounds. Inkerman, Nov. 5, 1854.	.....	Died immediately after the operation.	<i>Military Med. Hist. of Coldstream Guards, in Med. and Surg. Hist. of British Army in the Crimea.</i> Vol. I, p. 111.
18	1855	Paulet.....	Soldier.....	Gunshot fracture of the femur.	.....	Died in one hour after the operation.	CHENU. <i>Rapport Méd. Chir. sur la Camp. d'Orient,</i> p. 661.
19	1855	Lustreman.....	Soldier.....	Gunshot fracture of the femur, the patient in <i>extremis.</i>	.....	Died five hours after the operation.	CHENU. <i>Rapport Méd. Chir. sur la Camp. d'Orient,</i> p. 661.



## PRIMARY AMPUTATIONS AT THE HIP-JOINT IN MILITARY SURGERY—Continued.

No.	DATE.	OPERATOR.	PATIENT.	INJURY.	OPERATION.	RESULT.	REMARKS.
20	1855	Thomas.....	Soldier .....	Gunshot fracture of the femur.	.....	Died five hours after the operation.	CHENU. <i>Rapport Med. Chir. sur la Camp. d'Orient</i> , p. 661.
21	1855	Thomas.....	Soldier .....	Gunshot fracture of the femur.	.....	Died eleven hours after the operation.	CHENU. <i>Rapport Med. Chir. sur la Camp. d'Orient</i> , p. 661.
22	1855	Perrin .....	A private of the 32d French Infantry.	Comminuted fracture of the left femur through the trochanters by a portion of the percussion cap of a shell, which was found embedded in the bone. Wound of left leg with fracture of the fibula. July 4, 1855.	July 4, 1855, at the Curénage ambulance station.	Died in one or two days.	CHENU. <i>Rapport Med. Chir. sur la Camp. d'Orient</i> , p. 660.
23	1855	Franklyn .....	A private of the 77th British Infantry.	Comminuted fracture of the femur, extending nearly the whole length of the shaft and into the capsule of the hip-joint. Sevastopol, August, 1855.	.....	Died twenty-two hours after the operation from exhaustion.	<i>Military Medical Hist. of 77th Regt., in Med. and Surg. Hist. of the British Army in the Crimea.</i> Vol. I, p. 377.
24	1855	Dr. Dunlop ....	A soldier of the 88th Regiment, Connaught Rangers.	Fracture of the femur by a splinter of shell.	Double-flap operation.	Died soon after the operation.	<i>Military Medical Hist. of 88th Regt., in Med. and Surg. Hist. of the British Army in the Crimea.</i> Vol. I, p. 403.
25	1855	Surgeon Major Trousfield.	Private of 50th British Regiment.	Comminution of the upper third of the thigh to the neck, with great laceration of soft parts, by a round cannon-shot. Sevastopol, 1855.	Double-flap method.	Died the day of the operation.	<i>The Surgeon's Vade Mecum: a Manual of Modern Surgery.</i> By ROBERT DRUITT. 9th London ed., 1865, p. 160.
26	1862	Dr. McLean....	Private of 99th New York Volunteers.	Comminution of neck and trochanters of left femur by a piece of shell. Naval battle at Newport News, March 9, 1862.	Lateral double-flap method.	Died in two hours.	Circular No. 7, War Department, Surg. General's Office, Washington, July 1, 1867, p. 24.
27	1862	Dr. Yandell....	Rebel soldier.....	Gunshot fracture of the upper extremity of the left femur. Shiloh, April 7, 1862.	.....	Died in seven hours.	Circular No. 7, War Department, S. G. O., Washington, July 1, 1867, p. 24.
28	1862	Dr. Gilmore....	Private Williamson, 13th Mississippi Regiment.	Gunshot fracture of the right femur by a conoidal musket ball. Near Seven Pines, June 4, 1862.	Antero-posterior flaps.	Was sent to Mississippi in six weeks, his stump healed.	Circular No. 7, War Department, S. G. O., Washington, July 1, 1867, p. 24.
29	1862	Dr. Gilmore....	Private of 18th Mississippi Regiment.	Gunshot fracture of the left femur. Malvern Hill, July 1, 1862.	Antero-posterior flaps.	Died in one hour.	Circular No. 7, War Department, S. G. O., Washington, July 1, 1867, p. 25.



## PRIMARY AMPUTATIONS AT THE HIP-JOINT IN MILITARY SURGERY—Continued.

No.	DATE.	OPERATOR.	PATIENT.	INJURY.	OPERATION.	RESULT.	REMARKS.
30	1862	Dr. Gilmore....	Private of 21st Mississippi Regiment.	Gunshot fracture of the trochanters and neck of the left femur by a conoidal musket ball. Malvern Hill, July 1, 1862.	Antero-posterior flaps.	Died in two days.	Circular No. 7, War Department, S. G. O., Washington, July 1, 1867, p. 25.
31	1862	Dr. Compton...	A Lieutenant of an Arkansas Regiment.	A cannon ball struck the right hip and shattered the upper extremity of the femur. Corinth, October 3, 1862.	Single flap.....	Died in eight days.	Circular No. 7, War Department, S. G. O., Washington, July 1, 1867, p. 25.
32	1862	Dr. Grant.....	Rebel soldier .....	Gunshot fracture of the femur by round ball and backshot passing directly through the thigh. October 19, 1862.	Lisfranc's method.	Probably died..	Circular No. 7, War Department, S. G. O., Washington, July 1, 1867, p. 25.
33	1863	Dr. Compton...	Private Robinson, Louisiana (Rebel) Regiment, age 35.	A fragment of a 24-pounder shell buried itself in the upper part of the left thigh, smashing the trochanters and neck of the femur. Battery Pemberton, Mar. 13, 1863.	Antero-internal flap.	Was in good health six months afterwards, and probably ultimately recovered.	Circular No. 7, War Department, S. G. O., Washington, July 1, 1867, p. 26.
34	1863	Dr. Shippen...	Private Jas. Kelly, 56th Pennsylvania Vols., age 28.	Gunshot fracture of the upper portion of left femur. April 29, 1863.	Single anterior flap.	Recovered. Still living, July 1, 1867.	Circular No. 6, War Department, S. G. O., Washington, Nov. 1, 1865, p. 48.
35	1863	Dr. Compton...	Private Cooper, Alabama (Rebel) Regiment, age 20.	A fragment of shell comminuted the upper extremity of the femur and fractured the tuberosity of the ischium. Vicksburg, May 22, 1863.	Large anterior flap.	Died in one hour.	Circular No. 7, War Department, S. G. O., Washington, July 1, 1867, p. 27.
36	1863	Dr. Lay.....	Rebel soldier.....	Gunshot fracture of the upper third of femur by a fragment of shell. Vicksburg, Miss., June, 1863.	Single anterior flap.	Died in one hour.	Circular No. 7, War Department, S. G. O., Washington, July 1, 1867, p. 28.
37	1863	Dr. Howard....	Private James Martin, 146th New York Volunteers, age 20.	A conoidal musket ball comminuted the left femur, the fracture extending into the coxo-femoral articulation. July 13, 1863.	Antero-posterior flaps.	Died in forty-eight hours.	Circular No. 7, War Department, S. G. O., Washington, July 1, 1867, p. 28.
38	1864	Dr. Gorgas....	George Cook, a seaman, age 21.	Gunshot fracture of the upper part of the left femur. Smithfield, Va., February 1, 1864.	Antero-posterior flaps.	Died in two hours.	Circular No. 7, War Department, S. G. O., Washington, July 1, 1867, p. 29.
39	1864	Dr. Brock.....	Private Wm. Waters, 123d New York Volunteers.	A fragment of shell completely carried away his left thigh. Resaca, Ga., May 15, 1864.	.....	Died in half an hour.	Circular No. 7, War Department, S. G. O., Washington, July 1, 1867, p. 29.



## PRIMARY AMPUTATIONS AT THE HIP-JOINT IN MILITARY SURGERY—Continued.

No.	DATE.	OPERATOR.	PATIENT.	INJURY.	OPERATION.	RESULT.	REMARKS.
40	1864	Dr. Carnochan.	Private Rich'd Gordon, 7th Rhode Island Volunteers, age 28.	The left thigh was completely shattered by a fragment of shell. Spottsylvania, May 18, 1864.	Modification of Guthrie's method.	Died in ten hours.	Circular No. 7, War Department, S. G. O., Washington, July 1, 1867, p. 30.
41	1864	Dr. Jewett....	Private Jacob Bar-ger, 26th Penna. Vols., age 22.	A fragment of shell shattered the trochanter minor and nine inches of the shaft of femur. Spottsylvania, May 18, 1864.	Single antero-in-ternal flap.	Died in two hours.	Circular No. 7, War Department, S. G. O., Washington, July 1, 1867, p. 30.
42	1864	Dr. Shippen ...	Private J.M. Brown, 63d Indiana Vols.	A conoidal musket ball shattered the right femur, the fissures extending through the trochanter major. Lost Mountain, Ga., June 16, 1864.	Single anterior flap.	Died in one hour.	Circular No. 6, War Department, S. G. O., Washington, Nov. 1, 1865, p. 50.
43	1864	Dr. Baist.....	A private of 27th Tennessee (Rebel) Regiment.	A cannon ball shattered the femur quite to the neck of the bone. Jonesboro', Ga., Aug. 31, 1864.	Antero-posterior flap method.	Died in thirty-six hours.	Circular No. 7, War Department, S. G. O., Washington, July 1, 1867, p. 31.
44	1865	Dr. Gill.....	Private James A. Ailing, 3d Wisconsin Vols.	Gunshot fracture of the left femur through the trochanters. Averysboro', N. C., March 16, 1865.	Double-flap method.	Died in seven hours.	Circular No. 7, War Department, S. G. O., Washington, July 1, 1867, p. 31.

## INTERMEDIATE AMPUTATIONS AT THE HIP-JOINT IN MILITARY SURGERY.

No.	DATE.	OPERATOR.	PATIENT.	INJURY.	OPERATION.	RESULT.	REMARKS.
1	1809	D. J. Larrey...	A French soldier at Wagram.	Thigh frightfully shattered by a cannon ball. Wagram, July 6, 1809.	Larrey's method.	Died in three hours.	In this and the following case the injuries were so appalling and the prostration so great that Larrey operated with little or no hope of saving the patients, and mainly to mitigate their sufferings. <i>Mémoires de Chirurgie Militaires et Campagnes</i> , par D. J. LARREY. Paris, 1812. Tome III, p. 350.
2	1809	D. J. Larrey...	A French soldier at Wagram.	Thigh frightfully shattered by a cannon ball. Wagram, July 6, 1809.	Larrey's method.	Died within twenty-four hours.	<i>Mém. de Chir. Mil. et Camp.</i> Tome III, p. 351. Larrey ascribes the fatal event in this and the preceding case to the delay in operating.
3	1814	Samuel Cooper.	A British soldier...	Fracture of the upper part of the femur by a grape-shot. Profuse suppuration. Bergen-op-Zoom, March 8, 1814.	Circular operation. Abernethy's method. "A few days" after the injury.	Died in a few minutes.	The exarticulation was not completed. S. COOPER. <i>Dict. Pract. Surg.</i> 8th London ed., p. 116.



## INTERMEDIATE AMPUTATIONS AT THE HIP-JOINT IN MILITARY SURGERY—Continued.

NO.	DATE.	OPERATOR.	PATIENT.	INJURY.	OPERATION.	RESULT.	REMARKS.
4	1815	G. J. Guthrie ..	François Duguet, 45th French Regiment; age 25 yrs; a prisoner after Waterloo.	The upper extremity of the right femur was shattered and the soft parts on the external aspect of the thigh were extensively torn by a cannon ball. Waterloo, June 18, 1815.	Guthrie's oblique method. July 7, 1815.	Recovered.....	This soldier was exhibited to surgeons in London in 1816, and in 1830 was living at the Hotel des Invalides in Paris. He was able to walk with the aid of a very ingenious artificial limb. LARREY: <i>Clin. Chir.</i> , Tome V, p. 248. GUTHRIE: <i>Treatise on Gunshot Wounds</i> , 3d London ed., p. 342. GUTHRIE: <i>Commentaries</i> , 6th American ed., p. 77. Guthrie calls him Francis De Gay.
5	1836	L. Baudens ....	C....., a soldier in the Battalion d'Afrique, 24 y's old.	Comminuted fracture of the lower third of the shaft of the femur by a musket ball, followed by purulent sinuses extending around the trochanter major. Battle of the Atlas, Algiers, April 1, 1836.	Anterior flap. April 14, 1836.	Entirely recovered in six weeks after the operation.	<i>Lancette Française</i> , July, 1836, and <i>Clinique des Plaies d'Armes à Feu</i> , par M. L. BAUDENS, 8vo., Paris, 1836, p. 517.
6	1848	Aug. Vidal, (de Cassis.)	A French student of medicine.	Fracture of the upper extremity of the right femur by a musket ball. Profuse suppuration and great constitutional irritation. Paris, 1848.	Single anterior flap.	Died .....	Velpeau and Guersant assisted. Less than two ounces of blood lost. VIDAL: <i>Traité de Pathologie Externe et de Médecine Opératoire</i> , 3d ed. Tome V, p. 700.
7	1853	Dr. Beatson....	Thomas Lisbey, age 61. Conductor in the Ordnance department.	Comminution of the neck of the left femur by a musket ball. Donabaw, March 19, 1853.	Antero-posterior flaps. March 25, 1853.	Died March 25, 1853.	RANKING'S <i>Abstract</i> , No. 21, 1853, p. 158.
8	1854	Mounier.....	Garassimoff, a Russian prisoner.	Comminuted gunshot fracture of the upper extremity of the femur. Alma, Sept. 20, 1854.	At Dolma-Batg-tché Hospital, Constantinople.	Died September 29, 1854, two days after the operation.	CHENU: <i>Rapport Méd. Chir. sur la Camp. d'Orient</i> , p. 660. The ligature on the femoral gave way.
9	1854	L. Legouest....	Ignatius Woloken-ski, of the 5th Russian Infantry, 30 years of age.	The upper part of the left femur was completely smashed by a conoidal musket ball. Alma, Sept. 20, 1854.	Single antero-in-ternal flap. October 5, 1854.	Died February 9, 1855.	The flaps had adhered to a point by the middle of December, at which date the patient was able to walk about on crutches. Shortly after he fell and hurt his stump so that it bled. Inflammation was set up, renewed hæmorrhage followed, and, on January 30, an uncontrollable diarrhœa. LEGUEST: <i>De la Désarticulation coxo-femorale au Point du Vue de la Chirurgie d'Armée</i> . CHENU: <i>Op. cit.</i> MACLEOD: <i>Surgery of the War in the Crimea</i> . 1st Lond. ed., p. 369.
10	1854	Mounier.....	Chiftzoff, a Russian prisoner.	Fracture of the femur through the trochanters by a musket ball. Inker-mann, Nov. 5, 1854.	At Dolma-Batg-tché Hospital, Constantinople, Nov. 25, 1854.	Died December 2, 1854, one week after the operation.	Profuse secondary hæmorrhage. CHENU: <i>Rapport Méd. Chir. sur la Camp d'Orient</i> , p. 660.



## INTERMEDIATE AMPUTATIONS AT THE HIP-JOINT IN MILITARY SURGERY—Continued.

NO.	DATE.	OPERATOR.	PATIENT.	INJURY.	OPERATION.	RESULT.	REMARKS.
11	1855	Mounier.....	Pietron, a Russian prisoner.	Gunshot fracture of the femur. Inkermann, November 5, 1854.	At Dolma-Batg-tché, December 19, 1854.	Died December 29, 1854.	Purulent absorption and choleric form diarrhoea. CHENU: <i>Rapport Med. Chir. sur la Camp. d'Orient.</i> , p. 660.
12	1855	Larivière.....	Kerigla, a Russian prisoner.	Gunshot fracture of the femur. Traktir Bridge, Aug. 16, 1855.	At Gulhané.....	Died Aug. 23, 1865, during the operation.	CHENU. <i>Rapport Med. Chir. sur la Camp. d'Orient.</i> , p. 660.
13	1855	Mauger.....	A Russian prisoner.	Gunshot fracture of the femur. Traktir Bridge, Aug. 16, 1855.	On the <i>Jean Bart</i> , war steamer, Aug. 18, 1855.	Died soon after the operation.	CHENU. <i>Rapport Med. Chir. sur la Camp. d'Orient.</i> , p. 661.
14	1855	Salleron.....	Soldier.....	Gunshot fracture of the femur. Sevastopol, 1855.	Oval method.....	Died twenty hours after the operation.	SALLERON. <i>Compte-rendu des amput. prim. et des amput. consécutives, &amp;c.</i> , in <i>Mém. de Chir. Mil.</i> Tome 21, p. 317, 2e série.
15	1855	Salleron.....	Soldier.....	Gunshot fracture of the femur. Sevastopol, 1855.	Oval method.....	Died sixty hours after the operation.	Idem.
16	1859	A. Betherand...	An Austrian soldier, a prisoner after the battle of Palestro.	Comminuted fracture of the upper fourth of the left femur by a fragment of shell, laceration of the muscles on the posterior aspect of the thigh. Palestro, June 4, 1859.	Single anterior flap.	Died three hours after the operation. June 6, 1859.	BETHERAND. <i>Camp. d'Italie de 1859</i> . Paris, 1860, p. 37.
17	1861	Dr. Peachy.....	U. S. Soldier.....	A musket ball fractured the right femur in the lower third, followed by gangrene. Bull Run, July 21, 1861.	Larrey's method. July 29, 1861.	Died two days after.	Circular No. 7, War Department, S. G. O., Washington, July 1, 1867, p. 33.
18	1861	Dr. Warren.....	Private J. H. Wolf, 4th Virginia (Rebel) Regiment.	A musket ball shattered the femur quite into the neck. Bull Run, July 21, 1861.	Double-flap method. August 21, 1861.	Died in thirty hours.	Circular No. 7, War Department, S. G. O., Washington, July 1, 1867, p. 33.
19	1861	Dr. Potts.....	Private Jackson, a Rebel soldier.	A badly comminuted fracture of the upper extremity of the femur. Belmont, Missouri, Nov. 7, 1861.	Antero-posterior flaps. November 15, 1861.	Died in ten hours.	Circular No. 7, War Department, S. G. O., Washington, July 1, 1867, p. 33.
20	1862	Dr. D. P. Smith.	Private Henry H. Hale, 14th Illinois Vols., age 21.	Fracture of the upper portion of the left femur by a fragment of shell. Shiloh, April 6, 1862.	Long anterior flap. April 12, 1862.	Died in eight days.	Circular No. 7, War Department, S. G. O., Washington, July 1, 1867, p. 34.
21	1862	Dr. Blackman...	A soldier of an Ohio Regiment.	A fragment of shell comminuted the shaft, trochanters, and neck of the right femur. Shiloh, April 6, 1862.	Antero-posterior flaps. April 16, 1862.	Died in six days.	Circular No. 7, War Department, S. G. O., Washington, July 1, 1867, p. 34.
22	1862	Dr. De Bruler.	Private Peter Pausbeck, 43d Illinois Volunteers.	The upper portion of the femur was crushed and almost powdered by a conoidal musket ball. Shiloh, April 6, 1862.	Lisfranc's method. April 21, 1862.	Died in one hour.	Circular No. 7, War Department, S. G. O., Washington, July 1, 1867, p. 34.



## INTERMEDIATE AMPUTATIONS AT THE HIP-JOINT IN MILITARY SURGERY—Continued.

NO.	DATE.	OPERATOR.	PATIENT.	INJURY.	OPERATION.	RESULT.	REMARKS.
23	1862	Dr. Felton . . . .	Private of Docke- ray's Arkansas (Rebel) regiment.	A conoidal musket ball shat- tered the neck of the right femur. Corinth, October 3, 1862.	November 3, 1862.	Died in one hour.	Circular No. 7, War Department, S. G. O., Washington, July 1, 1867, p. 35.
24	1862	Dr. Pinceo . . . . .	Private P. Johnson, 2d Delaware Vol- unteers.	A conoidal musket ball perforated the great tro- chanter of the right femur. Fredericksburg, Decem- ber 14, 1862.	Dec. 27, 1862. . . .	Died in three hours.	Circular No. 7, War Department, S. G. O., Washington, July 1, 1867, p. 35.
25	1862	Dr. Crymes. . . .	A private of Bragg's (Rebel) Army. Aged 26 years.	Gunshot fracture of the tro- chanter major and neck of the femur. Dec. 28, 1862.	Antero-posterior flap method. Jan. 5, 1863.	Died in three days.	Circular No. 7, War Department, S. G. O., Washington, July 1, 1867, p. 35.
26	1863	Dr. Kinloch. . . .	A private of 54th Massachusetts Volunteers (col- ored).	A fragment of shell fractured the head and neck of the femur. Fort Wagner, July 11, 1863.	Manec's method. July 13, 1863.	Died in twenty- four hours.	Circular No. 7, War Department, S. G. O., Washington, July 1, 1867, p. 36.
27	1863	Dr. Bateman. . . .	John Chamberlain, a U. S. soldier.	Gunshot fracture of the up- per extremity of the femur. Chickamauga, September 20, 1863.	Sept. 21, 1863. . . .	Died in thirty- six hours.	Circular No. 7, War Department, S. G. O., Washington, July 1, 1867, p. 36.
28	1863	Dr. Bateman. . . .	James Carden, a U. S. soldier.	Comminuted fracture of the femur by a piece of shell. Chickamauga, September 20, 1863.	Sept. 21, 1863. . . .	Died in six days.	Circular No. 7, War Department, S. G. O., Washington, July 1, 1867, p. 36.
29	1864	Dr. Shippen. . . .	Private Sullivan Gaines, 2d Michi- gan Cavalry.	Gunshot fracture of the neck and head of the right femur. Knoxville, Tenn., Jan. 31, 1864.	Single antero-in- ternal flap. Feb. 3, 1864.	Died in one hour.	Circular No. 7, War Department, S. G. O., Washington, July 1, 1867, p. 37.
30	1864	Dr. Ingram . . . .	Private Charles Lackey, 7th Wis- consin Vols.	Gunshot fracture through the trochanters of the right femur. Spotsylvania, May 12, 1864.	Antero-posterior flaps. May 21, 1864.	Died in twenty- four hours.	Circular No. 7, War Department, S. G. O., Washington, July 1, 1867, p. 37.
31	1864	Dr. Roberts. . . .	Private Levi Eckley, 67th Ohio Vols.	Gunshot fracture of the up- per extremity of the left femur. Bermuda Hundred, May 20, 1864.	Antero-posterior flaps. May 24, 1864.	Died in four days.	Circular No. 7, War Department, S. G. O., Washington, July 1, 1867, p. 37.
32	1864	Dr. Goodwin. . . .	Private Joseph Mi- nott, 4th Vermont Volunteers.	Gunshot fracture of the right femur in the upper third. Petersburg, June 23, 1864.	Antero-posterior flaps, the poste- rior made long. June 25, 1864.	Died in two hours.	Circular No. 7, War Department, S. G. O., Washington, July 1, 1867, p. 38.
33	1864	Dr. Bentley. . . .	Sergeant Lewis Car- roll, 1st Delaware Volunteers.	Gunshot fracture of the right femur; great longitudinal splintering. Weldon Rail- road, October 22, 1864.	External and in- ternal flaps. Nov. 11, 1864.	Died in eight days.	Circular No. 7, War Department, S. G. O., Washington, July 1, 1867, p. 38.
34	1865	Dr. Griswold. . . .	Private George M. Spencer, 2d N. Y. Mounted Rifles.	Gunshot fracture through the trochanters of the right femur. Dinwiddie C. H., Va., March 31, 1865.	Double-flap meth- od. April 12, 1865.	Died in one hour.	Circular No. 7, War Department, S. G. O., Washington, July 1, 1867, p. 39.



## SECONDARY AMPUTATIONS AT THE HIP-JOINT IN MILITARY SURGERY.

No.	DATE.	OPERATOR.	PATIENT.	INJURY.	OPERATION.	RESULT.	REMARKS.
1	1811	Brownrigg.....	Soldier .....	Gunshot fracture of the femur. Elvas, 1811.	Antero-posterior flaps.	Died in eight days.	GUTHRIE. <i>Commentaries</i> , 6th Am. ed., p. 77.
2	1812	Brownrigg.....	A private of the 13th Light Dragoons, British Army.	Gunshot fracture of the upper part of the femur. Merida, Spain, December 29, 1811.	Antero-posterior flaps. At Plymouth, England, December 12, 1812.	Recovered .....	This man was living many years afterward at Spalding, in Lincolnshire, in perfect health. S. COOPER: <i>Dict. Pract. Surg.</i> , 8th Lond. ed., p. 117. WM. SANDS COX: <i>Memo. on Amput. of the Thigh at the Hip-Joint</i> , Lond., quarto, 1845, p. 10. AVERILL'S <i>Operative Surgery</i> , London, 1825, 2d ed., p. 217.
3	1814	Dr. Cole.....	Soldier .....	Gunshot fracture of the upper extremity of the femur. Bergen-op-Zoom, March 8, 1814.	Circular operation. Abernethy's method.	Died in twenty hours.	S. Cooper assisted in this operation. S. COOPER: <i>Dict. Pract. Surg.</i> , 8th Lond. ed., p. 117. GUTHRIE: <i>Treatise on Gunshot Wounds</i> , 3d Lond. ed., p. 351.
4	1814	Dr. Emery.....	Sebastian de L'Amour, Corporal Chasseurs Britanniques.	Fracture of the middle of the left femur by a musket ball. Caries of the femur. Profuse suppuration. Near St. Sebastian, Spain, August, 1813.	Lateral flaps. Larrey's method. July 21, 1814.	Died Aug. 20, 1814.	Preliminary ligation of femoral. GUTHRIE: <i>Treatise on Gunshot Wounds</i> , 3d Lond. ed., p. 334.
5	1815	Mr. Blicke.....	A British soldier ...	Contusion of the femur by a musket ball, producing inflammation of the marrow and abscesses along the thigh. Waterloo, June 18, 1815.	.....	Died in eight days.	GUTHRIE: <i>Treatise on Gunshot Wounds</i> , 3d Lond. ed., p. 351. DR. JOHN THOMSON'S <i>Report of Observations after the Battle of Waterloo</i> , octavo, Edinburgh, 1816, p. 270.
6	1830	Clot Bey.....	Ali Homer, an Arab, aged 26 years.	Gunshot fracture of the femur.	Single internal flap.	Died November 17, 1830.	LEGOUEST. <i>Chirurgie d'Armée</i> , p. 700. <i>Gazette des Hôpitaux</i> , Tome IV, p. 96.
7	1859	Arnaud.....	Louis Legalan, Fusilier, 84th French Regiment, age 25 years.	Fracture of the middle of the shaft of the right femur by a musket ball. Montebello, May 29, 1859.	.....	Recovered .....	JULES ROUX. <i>De l'Ostomyélite et des Amputations Secondaires</i> . Paris, 1860, p. 99.
8	1859	Isnard.....	A French captain...	Gunshot fracture of the femur, involving the trochanters, with extensive injury to the soft parts. Solferino, June 24, 1859.	.....	Recovered .....	DEMME. <i>Allgemeine Chirurgie der Schwerverwunden in der Norditalienischen Hospitälern</i> , von 1859. Würzburg, 1861, p. 254.
9	1859	Jules Roux, (de Toulon.)	Lt. Joseph Vitarel, 65th French Infantry, age 24 years.	Comminuted fracture of the upper third of the left femur by a musket ball, at Magenta, June 4, 1859. Conservative treatment at the hospital Maggiore at Milan. At the end of four months there was incomplete union with evidence of the presence of necrosed fragments and secondary sequestræ. At this date the patient was transferred to Toulon.	Antero-posterior flap operation. Nov. 26, 1859.	Recovered; re-joined his regiment in June, 1860.	This officer was exhibited by Baron H. Larrey to the French Academy of Medicine at the meeting of April 24, 1866. His general health was good, and the cicatrix firm and solid. JULES ROUX, <i>De l'Ostomyélite et des Amput. Sec.</i> , Paris, 1860, p. 98. <i>Bulletin de l'Académie Impériale de Médecine</i> , T. 31, p. 582.



## SECONDARY AMPUTATIONS AT THE HIP-JOINT IN MILITARY SURGERY—Continued.

No.	DATE.	OPERATOR.	PATIENT.	INJURY.	OPERATION.	RESULT.	REMARKS.
10	1859	Neudörfer.....	Soldier.....	Gunshot fracture of the femur.	.....	Recovered.....	DEMME. <i>Speciale Chirurgie der Schusswunden in den Norditalienischen Hospitälern</i> , 1859, Würzburg, 1861, p. 351.
11	1864	Dr. Bentley....	Private Michael O'Neil, 58th Massachusetts Vols.	Gunshot fracture of the upper extremity of the femur. Cold Harbor, June 3, 1864.	Lateral flaps. August 10, 1864.	Died in twenty-three days.	Circular No. 7, War Department, S. G. O., Washington, July 1, 1867, p. 39.
12	1864	Dr. McKee.....	Private Daniel H. Bowman, 110th Penna. Vols.	The right femur was comminuted from the trochanters downward by a conoidal musket ball. Deep Bottom, July 27, 1864.	Antero-posterior flaps. September 15, 1864.	Died in one hour.	Circular No. 7, War Department, S. G. O., Washington, July 1, 1867, p. 41.
13	1864	Dr. Wagner....	Private Williams, 13th Ohio Cavalry.	Partial fracture of the femur by a conoidal musket ball. Peeble's Farm, September 30, 1864.	Antero-posterior flaps. February 17, 1865.	Died in twenty-nine hours.	Circular No. 7, War Department, S. G. O., Washington, July 1, 1867, p. 41.
14	1864	Dr. Weir.....	Corporal Frederick Kelb, 7th New Volunteers.	Gunshot fracture of the right femur at the junction of the upper and middle thirds. Fredericksburg, December 14, 1862.	Antero-posterior flaps. June 7, 1865.	Died four months after the operation.	Circular No. 7, War Department, S. G. O., Washington, July 1, 1867, p. 42.
15	1865	Dr. Bentley....	Private George Lemon, 6th Maryland Volunteers.	Gunshot fracture of the left femur. Wilderness, May 5, 1864.	Antero-posterior semi-lunar flaps. October 12, 1865.	Recovered.....	Circular No. 7, War Department, S. G. O., Washington, July 1, 1867, p. 42.
16	1866	Dr. Blackman..	Private Woodford Longmore.	Gunshot fracture of the shaft of the right femur. Cynthiana, Ky., June 11, 1864.	Lacouchie's method. January 18, 1866.	Recovered.....	Circular No. 7, War Department, S. G. O., Washington, July 1, 1867, p. 43.
17	1866	Dr. Agnew....	Private James McGeehen, 107th Penna. Vols.	Gunshot fracture of the shaft of the right femur. Gettysburg, July 1, 1863.	Antero-posterior skin flaps, with circular division of the muscles. April 21, 1866.	Died in ten days.	Circular No. 7, War Department, S. G. O., Washington, July 1, 1867, p. 44.
18	1866	Dr. Forbes.....	Sergeant Hiram H. Davis, 156th New York Volunteers.	Gunshot fracture of the upper third of the right femur. Cedar Creek, September 19, 1864.	Antero-posterior skin flaps. May 5, 1866.	Died in sixty-four hours.	Circular No. 7, War Department, S. G. O., Washington, July 1, 1867, p. 46.
19	1867	Dr. Dubois.....	Antonio Mutieres...	A conoidal pistol ball lodged in the neck of the left femur. Fort Union, N. M., May 10, 1867.	Antero-posterior flaps. June 22, 1867.	Died in thirty hours.	Circular No. 7, War Department, S. G. O., Washington, July 1, 1867, p. 47.



## REAMPUTATIONS AT THE HIP-JOINT IN MILITARY SURGERY.

No.	DATE.	OPERATOR.	PATIENT.	INJURY.	OPERATION.	RESULT.	REMARKS.
1	1812	G. J. Guthrie...	Private Mason, 23d Infantry, Welch Fusiliers.	Sloughing stump, after amputation at mid-thigh for gunshot injury, with secondary hæmorrhage. Ciudad Rodrigo, 1812.	Oblique method...	Died seven hours after the operation.	GUTHRIE, <i>Treatise on Gunshot Wounds</i> . 3d Lond. ed., p. 332.
2	1864	Dr. Buck.....	Lieutenant Charles H. Hawkins, 4th N. York Cavalry.	Diseased stump after amputation at mid-thigh for gunshot fracture of the femur. June 1, 1862.	Antero-posterior flaps. Sept. 21, 1864.	Died in twenty-four hours.	Circular No. 7, War Department, S. G. O., Washington, July 1, 1867, p. 47.
3	1864	Dr. Hassenburg.	Private Lewis Larrey, 1st New Orleans Volunteers.	Diseased stump after amputation at mid-thigh for gunshot fracture of knee-joint. New Orleans, July 17, 1864.	Antero-posterior flaps. Sept. 21, 1864.	Died in seven days.	Circular No. 7, War Department, S. G. O., Washington, July 1, 1867, p. 48.
4	1865	Dr. Packard....	Private Eben E. Smith, 11th Maine Volunteers.	Necrosis of femur following amputation at lower third of the thigh for gunshot fracture of the head of the tibia. Deep Bottom, Aug. 16, 1864.	Antero-posterior flaps. January 19, 1865.	Recovered.....	Circular No. 7, War Department, S. G. O., Washington, July 1, 1867, p. 49.
5	1865	Dr. Pauntleroy.	Private R. A. Vick, 43d North Carolina (Rebel) Regiment.	Caries of the femur after amputation at the lower third of the thigh for gunshot wound of knee-joint. Cedar Creek, Oct. 19, 1864.	Antero-posterior flaps. March 11, 1865.	Recovered.....	Circular No. 7, War Department, S. G. O., Washington, July 1, 1867, p. 50.
6	1866	Dr. Morton.....	Sergeant Edwin D. Ulmer, 15th New Jersey Vols.	Osteomyelitis, after amputation at mid-thigh for gunshot fracture of femur and knee-joint. Cedar Creek, October 19, 1864.	Antero-posterior flaps. February 17, 1866.	Recovered.....	Circular No. 7, War Department, S. G. O., Washington, July 1, 1867, p. 51.
7	1866	Dr. Whitcomb..	Henry Campbell...	Disease of the femur after amputation of the thigh for gunshot wound of knee-joint. New Orleans, March, 1863.	Antero-internal flap. October 22, 1866.	Died in five hours.	Circular No. 7, War Department, S. G. O., Washington, July 1, 1867, p. 52.
8	1864	Dr. Mott.....	Private Lewis Francis, 14th N. York Militia.	Necrosis of femur, following amputation of the thigh at the middle for a bayonet wound of the right knee-joint. Bull Run, July 21, 1861.	Antero-posterior flaps. May 21, 1864.	Recovered.....	Circular No. 7, War Department, S. G. O., Washington, July 1, 1867, p. 52.

In the historical summary, 108 authenticated amputations at the hip-joint in military surgery were referred to, and, in the next chapter, 53 additional cases were described. The tables include these 53 cases and 52 of the first series—105 cases altogether. I have been unable to obtain sufficient details of the 56 remaining cases to place them in the tables. The results of the whole number of 161 cases may be summed up as follows:

	Died.	Recovered.	Doubtful.
105 tabulated cases .....	88	14	3
2 Sardinian, 8 Russian, 7 French, 7 English cases in the Crimea .....	24	..	..
7 Schleswig-Holstein, 3 Punjab, 5 Algerian, 4 Italian cases .....	18	1	..
Cases of Brownrigg, Demme, Wedemeyer, Brodie, Richet, Robert, Guersant, and French Naval Surgeons .....	12	1	..
Total.....	142	16	3







## OPINIONS OF SURGEONS ON AMPUTATIONS AT THE HIP-JOINT.

In estimating the value of amputation at the hip-joint as a resource in military surgery, an examination confined to the results of the operation is not altogether sufficient. The results should be compared with those of the two other expedients to which the surgeon may resort in severe gunshot injuries of the higher part of the thigh: the excision of the head of the femur, and the attempt at conservation of the limb. An exact comparison is impracticable at the present time. In addition to the histories of thirty-two excisions of the head of the femur for gunshot fracture, recorded in the surgical report in Circular No. 6, S. G. O., 1865, pp. 62-74, there have been transmitted to this office memoranda of over thirty such operations, which are yet under investigation. The compilation of the voluminous statistics of gunshot fracture of the upper part of the femur in possession of the office is still incomplete. It is believed that a full discussion of the results of both classes of cases will be in readiness for publication before the conclusion of the present year. Meanwhile, it is of interest to know what were the matured opinions on this subject of surgeons who had the largest opportunities of observing grave gunshot injuries of the higher portion of the thigh, treated by these three methods.

Surgeon E. Shippen, U. S. Volunteers, Surgeon E. Bentley, U. S. Volunteers, Surgeon J. T. Gilmore, P. A. C. S., and Surgeon W. M. Compton, 2d Texas (Rebel) Regiment, each amputated at the hip-joint in three instances. Both Dr. Shippen and Dr. Bentley have the satisfaction of knowing that one out of three of their patients recovered and is still living. Both Dr. Gilmore and Dr. Compton may boast that, in three primary amputations, each had one patient who survived for weeks, and, in all probability, ultimately recovered. Yet none of these surgeons are warm advocates of primary amputation at the hip. Dr. Shippen declares that the operation "should never be attempted, except when no other means present themselves of saving the patient's life. It should always be considered a last resort."<sup>1</sup> Dr. Compton would apparently attach little value to the operation, since he closes his report by the exclamation: "Thus ended my third, and I trust my last amputation at the hip!" Dr. Bentley expresses his view as follows:

"My opinion of amputation at the hip-joint is, that it will scarcely if ever be admissible as a primary operation in military surgery," for the accident requiring so formidable an operation necessarily produces so severe a shock as to make the operation unjustifiable, in my judgment, if performed before reaction comes on, for the result will be almost certainly fatal. If it is delayed until reaction comes on, it will be rare to find a man with sufficient stamina to undergo so extensive a mutilation with a reasonable prospect of a second favorable reaction. But as a secondary operation, the system has become educated to endurance and suffering, and the brain and nervous system have been brought in sympathy with the general condition; comfortable quarters, favorable surround-

---

<sup>1</sup> Letter from Dr. Shippen, April 9, 1867.



ings, and a mind composed and hopeful, have been secured. With all these conditions, I believe the operation to be perfectly justifiable, and when properly executed, it may be placed in point of success with amputations in the upper third of the thigh, at the knee, or the shoulder joint. I should consider the method of amputation important, and would always advise, when practicable, a long anterior and short posterior flap. Care should be taken to remove completely the cotyloid ligament around the acetabulum. When the operation is completed, the anterior flap should be allowed to carefully drop over the posterior one, and left without sutures or plasters, covered only by a light layer of muslin. I believe secondary amputation at the hip-joint will continue to grow in the confidence of all prudent and judicious operators until it shall receive, if it does not already, general sanction."<sup>1</sup>

Dr. Gilmore regards his case in which the patient survived the operation and went to his home as altogether exceptional, and attributes the result to the very favorable conditions in which the patient was placed as regarded nursing and after-treatment. After noticing three unsuccessful excisions of the head of the femur of which he was cognizant, he writes:

"I was in the field during the entire war, and my experience is mostly in the operative part of surgery. But this teaches me that amputation at the hip-joint is not a good operation in gunshot wounds. I recall six cases that would usually be thought to require amputation at the hip, which ended in recovery without operation; one, a Mississippian, wounded at Fredericksburg; two Georgians, wounded at Chancellorsville; and three men wounded at Gettysburg, belonging to North and South Carolinian and Georgian regiments, respectively. I believe that one-third of the cases of gunshot fracture of the femur, supposed to demand amputation at the hip, would recover if left entirely to the efforts of nature; while a much smaller proportion will recover if subjected to either amputation or resection."<sup>2</sup>

Surgeon Samuel Kneeland, U. S. Volunteers, is almost alone in regarding primary amputations at the hip as preferable to secondary operations:

"My opinion on the value of the operation is, that it is justifiable, and that it has a fair prospect of success as a primary operation and in a properly arranged field hospital; but that as a secondary operation, and in a crowded general hospital, the chance of recovery is very small."<sup>3</sup>

Surgeon George Derby, U. S. Volunteers, views the operation favorably, and writes:

"I have no doubt of the propriety of doing the operation under certain contingencies in military surgery, and regret that I did not do it myself in one case which was under my care."<sup>4</sup>

Surgeon R. B. Bontecou, U. S. Volunteers, says of amputation at the hip:

"Although the statistics are discouraging, I should advise and practise it where resection was inadmissible. I should, however, make the operation by circular incision of the upper third, soft parts permitting, and enucleate the bone by incision carried up the outside of the limb to the trochanters, believing that the hæmorrhage and shock to the system would be less than by the usual methods."<sup>5</sup>

<sup>1</sup> Letter from Dr. Bentley, May 20, 1867.

<sup>2</sup> Letter from Dr. Gilmore, March 28, 1867.

<sup>3</sup> Letter from Dr. Kneeland, March 18, 1867.

<sup>4</sup> Letter from Dr. Derby, March 19, 1867.

<sup>5</sup> Letter from Dr. Bontecou, April 18, 1867.



Surgeon H. E. Goodman, U. S. Volunteers, Medical Director of the Twentieth Army Corps, has also a favorable opinion of this procedure:

"I believe the operation of disarticulation at the hip-joint in military surgery useful, and often necessary to save life. The cases operated on were frequently unfavorable from the great amount of injury, as uncomplicated compound fractures were generally, in my experience, left to nature. If I should have a case of compound fracture of upper third of femur, with injury of artery or nerve, or both, I should not hesitate a moment in regard to the operation of amputation at the joint, feeling assured that if I neglected such an operation, I failed to perform my duty; provided, however, there was strength sufficient to carry my patient through the operation. With a skilful surgeon to operate and look after the after-treatment, good assistants, a first class nurse, and favorable circumstances, I cannot see why a hip-joint operation should necessarily be so much more unfavorable than one through the great trochanter or two inches below."<sup>1</sup>

Acting Staff Surgeon S. A. Green remarks of the operation, that:

"No surgeon would perform it with any sanguine hope of success. It would not be undertaken except in extreme cases, where there would be otherwise no chance of recovery. Yet, in such cases, one case in seven during the late war recovered. This chance must be given to the patient. Still, with this percentage of mortality, we should hardly consider the operation as one of value. Under certain circumstances, clearly stated on page 52 of Circular No. 6, S. G. O., 1865, it is admissible in military surgery."<sup>2</sup>

Surgeon A. N. Dougherty, Medical Director of the 2d Army Corps, sums up his opinion as follows:

"My opinion of the operation is, that it is justifiable but not desirable, and not imperative. I should never undertake it except at the urgent request of the patient, after he had had the perils and probable issue laid fully before him."<sup>3</sup>

Surgeon T. H. Squire, 89th New York Volunteers, whose observation of field surgery was particularly extensive and protracted, observes:

"I am not willing to say that I think the operation unjustifiable; but I do say that the operation ought not to be performed, except in cases where death is positively certain without it. I think we cannot make a general rule of action, which, on the battle-field, will apply to all cases that might come under this head. In weighing the probabilities of each case, we must put two weights into the scale against the probabilities of recovery. One weight, which may be said to be nearly uniform in all cases, is the great violence of the operation itself; and the other weight, which may be very different in different cases, is the anterior violence of the gunshot injury."<sup>4</sup>

Surgeon O. A. Judson, U. S. Volunteers, remarks of primary coxo-femoral amputation:

"I can only say that I have never seen a case in which it seemed to me indicated, and that its performance should be discountenanced under ordinary circumstances. I can readily imagine, however, circumstances where it might be proper to resort to it, but they are very exceptional."<sup>5</sup>

<sup>1</sup> Letter from Dr. Goodman, April 30, 1867.

<sup>2</sup> Letter from Dr. Green, April 10, 1867.

<sup>3</sup> Letter from Dr. Dougherty, March 18, 1867.

<sup>4</sup> Letter from Dr. Squire, March 28, 1867.

<sup>5</sup> Letter from Dr. Judson, April 1, 1867.



Surgeon C. N. Chamberlain, U. S. Volunteers, declares:

"I do not believe amputation at the hip-joint should ever be resorted to when amputation below the joint, even through the trochanters, or when resection, partial or complete, affords a promise of success. I might also add, when free incisions into the joint, with or without the removal of spiculæ, can hopefully be made, the operation is inadmissible. The necessity of transportation of the patient should be allowed its due weight in deciding the question. In my opinion, the operation should never be performed where any other operation or treatment can be substituted. In fracture of the head and neck of the femur, together with extensive comminution of the shaft of the bone, or with destruction of the principal vessels or nerves of the limb, death is the only alternative and the operation is justifiable."<sup>1</sup>

Surgeon E. Andrews, 1st Illinois Battery, would also restrict the operation as a primary procedure to a very limited class of cases:

"I should not advise this operation except in the most desperate emergency, such as the tearing away of the whole limb by a cannon shot, followed by such a reaction from the shock as gave reasonable hope of being able to stand the operation. I think it is entirely inadmissible for mere bullet or shell fractures involving the hip-joint. My present opinion is this: that no fracture of this region, of itself, justifies amputation at the hip. The operation should never be performed at that point unless there is such a destruction of tissue as leaves no lower point of election, and then only when the patient shows reactive power enough to give hope of escaping death from the shock."<sup>2</sup>

Surgeon J. F. Galloupe, 17th Massachusetts Volunteers, expresses similar views:

"When the greater portion of the diameter of the limb is destroyed, I would complete the division of the soft parts, in the most favorable manner for covering the stump, with the knife, and disarticulate the bone as best I could. By this procedure, nature would be relieved of the task of separating the injured limb, and the shock to the system would be but little compared to that which follows complete amputation with the knife. Under all other conditions, I would decline to do the primary operation, believing that the undisturbed efforts of nature would give the patient a better prospect of recovery than would follow amputation. I cannot resist the conviction that some of the cases which have died after the operation, would have recovered if no operation had been done. In my opinion, the secondary operation is demanded under a variety of circumstances, and the necessity for it must be determined by grouping the symptoms and circumstances in each case. In my opinion, the operation should not be discarded, but the utmost care and skill should be used in deciding what cases demand this terrible interference, and in what cases the indications are to avoid the operation."<sup>3</sup>

Surgeon A. H. Hoff, U. S. Volunteers, says of primary amputation at the hip-joint for gunshot injury:

"Out of more than a hundred thousand sick and wounded soldiers transferred under my direction while connected with the hospital transportation department, no case of the kind came under my observation; and of the seventeen thousand transported on the hospital steamer D. A. January, under my direct supervision, I saw no case of the kind. As regards an opinion, I am somewhat embarrassed, but a comparison with the result of operations in the vicinity of the hip-joint may lead to some fair conclusions in reference to the value of

<sup>1</sup> Letter from Dr. Chamberlain, March 18, 1867.

<sup>2</sup> Letter from Dr. Andrews, March 31, 1867.

<sup>3</sup> Letter from Dr. Galloupe, March 20, 1867.



this operation. Circular No. 6, S. G. O., 1865, gives us reliable data in reference to primary and secondary excisions of the head of the bone, with a sufficient number of cases to show the almost hopelessness of this operation. Upper third amputation of the thigh, although a less formidable operation than amputation at the hip-joint, does not offer much encouragement to the surgeon. The day after the battle of Shiloh I had occasion to make several amputations at the upper third of the thigh, most of them just below the trochanter. These cases were all transported to the general hospitals at Saint Louis, and were apparently doing well four days after the operation, but I think they all ultimately died. I received very few patients on board the hospital transports that had undergone amputation very high up in the thigh, and among the large number of applicants for artificial limbs that came under my observation while stationed in New York city, upper third stumps were great rarities. I am inclined to think that not more than ten in a hundred, if as many, survive amputation in the upper third. In this operation I fear statistics will not afford us very reliable data, as the division of the thigh into lower, middle, and upper third has not been sufficiently well defined in reporting cases. You may feel inclined to dissent from my statement in reference to the mortality of upper third amputations of the thigh, with the statistics you have in your possession. I am speaking from observation, you have the figures. But I am inclined to think there has been a large number of mistakes made in measurement. I have made quite a number of these upper third operations, and, with one or two exceptions, all primary, and have not yet had the pleasure of shaking the hand of a single survivor. Taking the result of these two operations, one involving the joint and the other in close proximity, average the chances for recovery, and what conclusions would you arrive at in reference to the value of amputation at the hip-joint, a much more formidable operation than either?

"The enumeration of the necessities for an amputation at the hip-joint, in my estimation, is a more troublesome question to settle, and the real value of the operation will hinge almost entirely on it, viz: what parts must be involved to make a resort to this operation necessary? If the head of the bone is involved, then I should think its excision would offer the best chance. If the neck of the bone was shattered outside of the capsular-ligament, this would offer no reason for the removal of the limb. If the large blood vessels were involved so high up, you would scarcely reach the case in time to be of any service; and if the whole limb was carried away up to the joint and a surgeon saw the case in time to arrest the hæmorrhage, his work as an operator would be accomplished. It would seem, then, when you come carefully to canvass the matter, that the conditions requiring an amputation at the hip-joint, if I am right in my premises, would depend on the destruction of the vessels. If this be so, then the operation is of no value as a primary operation in military surgery, and as a secondary one, I am free to confess, I have but little confidence, yet I should be very far from agreeing to be deprived of the right of doing the operation should a case occur that demanded it."

Surgeon S. W. Gross, U. S. Volunteers, who has studied the subject with much attention, expresses his conclusions as follows:

"I have never seen a case of gunshot injury in which I thought that the procedure was at all necessary; nor would I operate immediately after the reception of the injury, except in the following cases: comminution of the head and neck of the bone with injury to the great vessels; and in those cases in which the limb had been entirely, or almost entirely, carried away by a round shot so high up that flaps cannot be formed in the upper part of the thigh. The latter class of injuries, however, would be very apt to terminate fatally from the shock sustained by the system at the time of reception of the wound. In

<sup>1</sup> Letter from Dr. Hoff, March 30, 1867.



cases of gunshot fracture of the head and neck of the bone, I would never amputate immediately, but wait, at any rate, until suppurative action had declared itself. For osteomyelitis of the shaft of the thigh bone, whether the bone be primarily affected on account of fracture or other gunshot injury, or be attacked secondarily after previous amputation at some part of the thigh, disarticulation at the hip-joint is the only remedy, and I should not hesitate to resort to it. J. Roux's operations at the hip-joint and shoulder joint for this affection have been remarkably successful and are very favorable to the operation. Such, in my opinion, are the only conditions which demand hip-joint amputation. I have taken some pains to collect all the cases of the operation for gunshot injury, and have succeeded in tabulating one hundred and thirty cases, of which nineteen recovered and one hundred and eleven died, the mortality of the operation being a little over eighty-five per cent. Fifty-four operations were primary, with but two recoveries; thirty-seven were secondary, with eleven cures; and six were intermediate, with two recoveries. Of the remaining thirty-three cases, the time of performance of the operation is uncertain. From the above statistics, the great advantage of deferring the operation is obvious, since secondary exarticulation gives one recovery in every three and one-third cases, whereas primary operation shows but one recovery in every twenty-seven cases. The great mortality of the latter should not, however, deter us from operating when the procedure offers the only chance for life; but it should at the same time caution us to exercise the greatest judgment in our diagnosis. I have no idea that primary amputation will prove as fatal at the present day as formerly. The great sources of danger are shock and hæmorrhage. In regard to shock, we must take into consideration that the majority of the primary operations belong to campaigns antecedent to the use of anæsthetics. The ratio of mortality in all hip-joint amputations has certainly diminished since the introduction of chloroform, and I think that we possess in it a powerful agent against shock, which, in former days, was so fruitful a source of mortality. These considerations are entitled to great respect, since the only successful primary operations—i. e., those of our late war—were performed under chloroform. Hæmorrhage as a source of danger is now robbed of its terrors by the employment of the abdominal tourniquet for compressing the aorta. This instrument is used in Philadelphia, and by Mr. Lister, of London, with the best results. I have thus seen a hip-joint amputation with a loss of not more than five or six ounces of blood. The employment of the abdominal tourniquet and anæsthetic agents, I therefore hold, should make the operation more successful; and I should not be surprised if the mortality would hereafter exceed but little, if any, that of amputation in the upper third of the thigh. Of the consecutive dangers, as the formation of secondary abscesses, exhaustion from profuse suppuration, and pyæmia, I have nothing to say, as each case will have to be met according to its peculiar merits."<sup>1</sup>

A reference to six cases of recovery from gunshot fractures of the higher portion of the femur, in which the propriety of ablation of the thigh had been canvassed, has already been cited from a letter from Dr. Gilmore. It would be easy to multiply such instances. One of the earliest casualties of the war furnishes an interesting example.<sup>2</sup> A soldier had the neck and trochanters of the right femur shattered by a musket ball at the affair of Big Bethel. On his removal to Fort Monroe, a consultation was held, at which Surgeons Cuyler, Hoff, McKay, Gilbert, and Assistant Surgeons J. S. Smith and White assisted. The majority of voices favored amputation at the hip-joint; but Dr. Cuyler, the medical director, decided that an attempt at conservation of the limb should be made. This man

<sup>1</sup> Letter from Dr. Gross, April 14, 1867.

<sup>2</sup> A notice of the case was early published by Assistant Surgeon C. B. White, U. S. A., in the *American Medical Times*, p. 48, July 27, 1861.



is now a stalwart laborer, and suffers little or no inconvenience from his injury. The following history of his case, together with an excellent photograph, was lately transmitted by Surgeon R. B. Bontecou, U. S. Volunteers, who had charge of the case for a long time:

Private Philip Sweeney, Co. C, 3d New York Volunteers, was wounded in the affair at Big Bethel, June 10, 1861, by a conoidal musket ball, which shattered the neck and trochanters of the right femur. He was admitted to Hygeia Hospital, Fort Monroe, on June 13th, and was treated by moderate extension and dilatation of the wound by sponge tents, in order to facilitate the extraction of primary sequestra, of which many were removed. Suppuration and exfoliation persisted until March, 1862. In April, there were two severe attacks of erysipelas involving the entire limb. These greatly reduced the patient, but he quickly rallied, and in May was able to run a race on crutches with his wounded companions. He was transferred to Albany in June, 1862, but his name does not appear upon the hospital reports until March, 1863, when he was admitted to the Ladies' Home Hospital in New York city, where a number of necrosed fragments were removed. On May 25, 1863, he was discharged from service, being able to walk without a crutch, the limb being but slightly shortened. He soon afterwards engaged himself as a laborer at an iron foundry in Troy, New York, where he has since worked without intermission. On July 20, 1866, he was examined by Dr. R. B. Bontecou, who found him in perfect health, the injured limb a trifle shortened and the knee rather stiff, owing to the destruction of connective tissue about the extensor muscles of the thigh during the suppuration following the erysipelatous attacks, and doubtless the formation of adhesions. The knee-joint was in good condition and had sufficient motion to allow a firm, good gait.

Brevet Lieutenant Colonel Charles K. Winne, Assistant Surgeon, U. S. Army, has transmitted the following history of a case of gunshot fracture of the *cervix femoris*, in which he desired to perform excision, but refrained on account of the opposition of the patient. Dr. Winne now believes that had the patient consented to the operation the result would, perhaps, have been less favorable:

C. F. Beyland, a German, aged 26 years, a clerk in the Quartermaster department, was wounded by an Enfield rifle ball late in the evening of December 8, 1861. The ball entered behind, ranging downward and forward, emerging in front, completely fracturing the neck of the right femur, and producing a longitudinal fissure of the great trochanter. The wound was dressed by Surgeon Caphart, 1st West Virginia Cavalry, who transferred the case to Assistant Surgeon Winne, U. S. A., December 9th. The shock having subsided, the soiled dressings were removed and the wound thoroughly examined, the patient being under the influence of chloroform. As the neck of the femur was extensively comminuted, Dr. Winne proposed excision, but all operative interference being resolutely opposed, he was placed in Hagadorn's splint, no extension being used, the wound constantly wet with evaporating lotions, and anodynes administered as often as necessary. On December 10th, the skin was hot and dry; pulse 107 in the morning, 130 in the evening. As he had not had a passage from the bowels for several days, a draught of citrate of magnesia followed by an enema was ordered. On December 11th, the bowels were moved four times with relief to the patient. There was excessive thirst, the tongue was dry, the pulse 130. There was no great pain in the limb, though it was swelling rapidly. Hagadorn's splint was changed for a box extending from the foot to the axilla, and on the inside to the middle of the thigh, the limb being kept motionless by pads. December 12th, rested well during the night, sweating considerably; outer aspect of thigh and groin much swollen and dark color; no difference in temperature, no pain; pulse 120 and feeble; nourishing diet, with wine in addition. December 13th, slight chilliness followed by fever. On December 29th, Dr. Winne returned from leave. During his absence the case had been treated by Dr. Caphart. Two large abscesses had formed in the upper and outer part of the thigh, and discharged through opening made by entrance of ball. Appetite good, and rested well at night, though he is much less cheerful and suffers constant pain. January 13, 1862, appetite and sleep natural, pain lessened, as an abscess which had formed in the gluteal muscles, burrowing along the outer and posterior surface of the thigh, was now discharging pus mingled with blood. The exit wound has healed, pulse 100. The limb is kept perfectly motionless as he lies on a stretcher placed above the mattress; the lower wound is dressed, and his bowels moved through an opening cut in the stretcher, which is raised at these times. January 26th, has been doing well, has very little pain, and that only occasionally; no swelling on anterior part of thigh; discharge perfectly healthy in character; appetite excellent, and sleeps nearly all night; complained to-day of inability to pass urine, which was relieved by fomentations applied to the perineum and over the bladder. January 29th, pain for the last two days severe and constant, discharge increasing in quantity; greater swelling on posterior part of thigh; no change in other respects. March 1st, the discharge from the wound for the last week has been profuse, exceedingly fetid and mingled with blood, another abscess having formed, which is the fifth since the injury was received. The outer aspect of the thigh extending to the anterior superior spinous process of the ilium is much swollen, skin discolored, and slight pressure in the groin or on the hip produces intense pain. Patient's body is very much emaciated, pulse 100 and feeble; is taking wine or whiskey daily. March 16th, suppuration decreasing and more healthy than it had been; swelling in thigh diminishing; he also feels better. March 24th, suppuration still decreasing, general condition favorable. April 5th, he was removed from Clarksburg to Parkersburg, a distance of eighty miles. As the bed on which he lay was not changed, he bore the transportation by rail very well. A few days afterwards another large abscess formed, which, on being opened, discharged a large quantity of exceedingly fetid pus. May 8th, the lower gunshot opening has entirely closed, all pus now issuing from opening made in abscess; the discharge is still very fetid, though decreasing in quantity. Removed the fracture box and applied Smith's anterior splint. May 20th, the patient is doing admirably, not more than one drachm of pus is



daily discharged, and it is now assuming more of a serous character. No pain exists even when pressure is made on the fracture. He can raise the pelvis several inches from the bed, and can move the limb as much as the splint will permit; has been sitting up in bed several days. May 25th, the splint was removed; a few drops of serous discharge occasionally exudes from the opening in the side. June 29th, has been walking on crutches more or less every day since June 15th. The limb is shortened two inches; can be adducted and abducted, but can be rotated to only a very slight degree; extension can be performed and the limb can be semi-flexed. An extensive deposit of new bone, which can be distinctly felt through the muscular tissues, has taken place at the seat of fracture, and extending downward over and below the trochanter, confirming Dr. Winne's diagnosis that the fracture implicated the trochanter, which was considered probable, from the character of the missile and the history of other cases. July, 1862, the patient was discharged from treatment and returned home. Dr. Winne heard from him directly a year afterwards, and at that time he had dispensed with crutches and could walk perfectly well with the aid of a cane.

The two following cases are good examples of recoveries from gunshot fractures of the neck or trochanters of the femur without operative interference. It is not known, however, that amputation at the hip-joint was proposed in either case:

Private James McCabe, Co. A, 12th Massachusetts Volunteers, was wounded on September 17, 1862, at the battle of Antietam, by a musket ball which entered just below the right groin and made its exit at the buttock, fracturing the neck of the femur in its passage. He was conveyed to Hospital No. 5, at Frederick, Maryland, and was treated with the limb in an extended position. On November 9th, he was transferred to Frederick Hospital No. 1. In December, a large metastatic abscess formed about the right shoulder, which was incised by Assistant Surgeon R. F. Weir, U. S. A., a large quantity of pus escaping. After the healing of the abscess there was much weakness of the muscles of the acromial and humeral regions, and the patient could not raise his hand above his chin. On June 16th, he was sent in good condition to the Jarvis Hospital, at Baltimore, and thence to Point Lookout Hospital, where he remained until July 3, 1863, when, the wound being healed, he was discharged from the service of the United States. On June 10, 1867, he was examined at the office of Surgeon General Dale, of Massachusetts. The fracture was firmly consolidated. There was but a slight limp in walking. His general health was excellent. He received a pension from the U. S. Government, and was employed in the "Soldiers' Messenger Corps." He experienced no pain, except on change of weather, or when his walk was extended beyond two miles. He considered his injury but a slight disability in his business, since he had free passes on all the lines of horse cars in Boston.

In the next case, the recovery was equally satisfactory and permanent:

Private Andrew F. Dinsmore, Co. E, 3d Michigan Volunteers, aged nineteen years, was wounded at the battle of Fair Oaks, May 31, 1862, by a musket ball which fractured the trochanters of the left femur and lodged. His wound was dressed on the field by Surgeon D. W. Bliss, U. S. Volunteers, and he was then removed to the Hygeia Hospital, at Fort Monroe. In the middle of June he was transferred to the De Camp Hospital, at David's Island, and was there treated by moderate extension and counter-extension, and by the removal of numerous detached fragments of bone. By the end of 1862, firm union had taken place, and on April 19, 1863, the wound having healed, Dinsmore was discharged from the service of the United States, having a strong and useful limb, with trivial shortening and deformity. On July 11, 1863, he enlisted in the 2d Battalion, Veteran Reserve Corps, and served three years. From time to time a fistulous orifice would appear in the cicatrix and discharge a small quantity of pus. On December 21, 1866, Mr. Dinsmore was in good health, suffering little or no inconvenience from his injury, though the ball remained in the limb. He was then employed as a clerk in the General Land Office. At that date he was photographed at the Army Medical Museum. The picture is numbered 157 in the surgical series of the photographs of the Museum.

Even when the head of the femur has been fractured by a musket ball, recoveries have taken place under conservative treatment. The following case is an example:

Lieutenant Colonel James C. Strong, 38th New York Volunteers, was wounded at the battle of Williamsburg, Virginia, May 5, 1862, by a conoidal musket ball which entered over the right sartorius muscle about four inches below its origin, and made its exit near the right margin of the lower portion of the sacrum. Surgeon A. J. Berry, 38th New York Volunteers, examined the wound and found that the ball had deeply grooved the head of the femur, and had fractured the upper rim of the acetabulum. A detached fragment of the rim nearly an inch and a half in length, a part of it covered with articular cartilage, together with portions of clothing, were extracted from the wound. On the 8th of May the patient was transferred by a steamer from Queen's Creek Landing to the Hygeia Hospital at Fort Monroe. Here he remained until the 13th, when he undertook a painful journey of five days on a litter, and reached his home in Buffalo, New York. The injured limb was semi-flexed and rotated inwards, the head of the femur being dislocated upon the dorsum of the ilium. Any attempt to place the limb in position produced such acute suffering that the effort was abandoned. For ten weeks there was profuse suppuration with burrowing of pus in the thigh and intense pain, with chills, profuse perspiration and great prostration, after which a very gradual amendment took place. On December 12, 1862, the patient was removed to Philadelphia, and entered at the Officers' Hospital at Cammack's Woods, where he was able to bear treatment by Buck's method of extension by weights. Here a number of spiculae of bone were extracted or washed from the wound. On January 6, 1863, the patient was discharged from the hospital. On June 1st the wounds were nearly closed, and he rejoined his regiment on crutches and was mustered out with the regiment on June 22, 1863. On September 29th he was appointed Colonel in the Veteran Reserve Corps. He was subsequently brevetted Brigadier



General. In July, 1861, he visited the Army Medical Museum and was examined by Assistant Surgeon G. A. Otis, U. S. Army, and his photograph was taken. General Strong was then in good health. His limb was shortened nearly five inches, but, by the inclination of the pelvis and extension of the toes, he was enabled to walk with surprising ease and activity, with or without a cane. The head of the femur was firmly ankylosed on the dorsum of the ilium. The cicatrices appeared sound. His picture is numbered 156 in the surgical series of the photographs of the Museum.

That the neck of the femur should be fractured by a musket ball without fissures extending into the articulation, appears almost impossible. Yet it was thought that such a condition existed in the following case:

Captain William A. Bugh, Company G, 5th Wisconsin Volunteers, aged thirty-five years, was wounded at the engagement at Williamsburg, Virginia, on May 5, 1862, and after lying a few hours on the field, he was removed to a temporary hospital, and thence to an hospital transport in the York river and sent to Baltimore, where he was received at the Camden Street U. S. A. General Hospital, on May 10, 1862. A conoidal musket ball had entered the right groin, passed slightly downward, traversed the line of union between the thigh and trunk, fractured the neck of the femur in its transit, and emerged posteriorly at the fold of the buttock. On flexing or rotating the thigh, crepitus was plainly distinguished. His limb was suspended by Smith's anterior splint, and this treatment was continued for two months. The case progressed without a single untoward symptom, and in the middle of July, 1862, consolidation of the fracture was sufficiently firm to permit the patient's removal to the house of a friend. The limb was shortened one and a half inches. In October, Captain Bugh was able to move about on crutches and the wounds were entirely healed. About this time he took a journey to Washington, and was promoted to a Lieutenant Colonelcy in the 32d Wisconsin Volunteers and placed on recruiting service. He served until April 25, 1863. His recovery was so rapid and uninterrupted that he reluctantly assented to the assurance of his surgeon, Dr. Edward G. Waters, that he would be incapable of active duty in the field. A letter was received at this office from Lieutenant Colonel Bugh, dated June 12, 1867, more than five years subsequent to his injury, in which he stated that he had partial ankylosis of the hip-joint, and was unable to perform any labor in a stooping posture. Otherwise his condition was satisfactory, though he was more readily fatigued and debilitated than before he was wounded. He suffered no inconvenience from the slight shortening of the femur.

Brevet Major W. M. Notson, Assistant Surgeon, U. S. Army, made the autopsy in the case of Captain J. M. L——, related in Circular No. 6, S. G. O., 1865, p. 33, and he is confident that the fracture was extra-capsular in that instance.<sup>1</sup> It is barely possible that the lesion may have been of a similar character in the following case:

Private James Vanderbeck, Co. F, 145th New York Volunteers, aged 21 years, was wounded at the battle of Chancellorsville, May 3, 1863, by a conoidal musket ball which entered the left thigh above and behind the trochanter major, passed forwards and inwards, fractured the neck of the femur, and made its exit at the groin. He was made a prisoner and remained in the hands of the enemy eleven days. He was then exchanged, and conveyed to the 12th Corps Hospital at Aquia Creek. The injured limb was simply placed in a comfortable position, without any attempt at extension. On June 14, the patient was removed on an hospital transport to Alexandria and placed in the First Division Hospital. He was in good condition. The suppuration was comparatively slight, and no bone splinters were found loose, and none had come away. Three days subsequently, he was transferred to Philadelphia, and thence, on October 12, to New York, where he was admitted at the Ladies' Home Hospital. The wounds were closed at this date. The patient was discharged from the hospital and from the service of the United States on November 19, 1863. At that date he walked with crutches. His limb was shortened two inches, with eversion. He was allowed a pension of fifteen dollars a month. On August 2, 1866, Dr. E. Bradley, examining surgeon of the Pension Bureau, reported that Vanderbeck's general health was good, but that there was much lameness. The fracture was firmly consolidated.

The records of this office include numerous histories of patients who have recovered with tolerably useful limbs after gunshot fractures of the upper third of the femur. In several of these the trochanteric region was implicated. The surgical series of photographs of the Army Medical Museum includes illustrations of fifteen such cases.

---

<sup>1</sup> See Catalogue of the Surgical Section of the Army Medical Museum, p. 235.



## CONCLUDING OBSERVATIONS.

In 1861, Stromeyer declared that it was "not yet proved that amputation at the hip-joint was deserving of a place among the resources of military surgery," Loeffler denied that we were yet assured that an adult could bear this operation, and Rochard formally protested against it as a primary procedure.<sup>1</sup> For some years previously M. Sédillot had taught that primary amputation at the hip was always fatal. Jubiote and Baudens had insisted that hip-joint amputation was an exception to the general rule requiring all amputations deemed indispensable to be performed immediately, and M. Legouest had sought to establish the rule that the operation should never be performed primarily unless the thigh was almost entirely torn away from the trunk, which opinion, after a favorable report from Baron H. Larrey, was formally adopted by the Surgical Society of Paris.<sup>2</sup>

The experience acquired in the war of the rebellion indicates that these maxims and rules are too unqualified and absolute. A soldier who underwent primary amputation at the hip for gunshot injury more than four years ago (see Dr. Shippen's case, *ante*, p. 26) is still alive and well, so that the possibility of such a result cannot in future be questioned. In two other instances, (see Case III and Case VIII, of Drs. Gilmore and Compton, *ante*, pp. 24 and 26,) patients sufficiently recovered from the operation to bear transportation to their homes; and though their subsequent history has not been traced, because they lived in very remote localities, it is quite probable that they recovered completely.<sup>3</sup> I have classified these cases in the tables with that of the lieutenant of dragoons on whom Baron Larrey operated in 1812—who survived three months, but failed to return to France, conceding that the ultimate results were doubtful. I have appealed to Larrey's report of his case<sup>4</sup> to prove that it was a primary one, and that the French surgeons could not fairly claim it as a success and yet classify it among intermediate amputations. This case must be admitted to give what weight it has, with those of Dr. Gilmore and Dr. Compton, in favor of primary amputation at the hip for injury. On the other hand, the list of failures is discouragingly long. Taking the forty-four primary operations enumerated in the tables and adding to them twenty-eight similar cases which are only reported

<sup>1</sup> STROMEYER, *Maximen der Kriegsheilkunst*. LOEFFLER, *Grundsätze und Regeln für die Behandlung der Schusswunden im Kriege*. ROCHARD, *Du Service Chirurgicale de la Flotte*, appended to Saurel's *Traité de Chirurgie Navale*.

<sup>2</sup> SÉDILLOT, *Traité de Méd. Opér.* JUBIOTE, *Thèses de Montpellier*, 1840. BAUDENS, *La Guerre de Crimée*. LEGOUEST, *De la Désarticulation Coxo-fémorale au Point de Vue de la Chirurgie d'Armée*. H. LARREY, *Mém. de la Société de Chirurgie*, Tome V.

<sup>3</sup> Once misled by the erroneous report of an alleged successful primary amputation at the hip at Memphis in the early part of the war, (see *ante*, p. 21,) I am unwilling to cite any case as successful in which the permanency of the cure is not incontrovertibly established, and I have not quoted an example of successful primary amputation at the hip for gunshot injury published by Dr. W. A. East, of San Antonio, Texas, in the *Southern Journal of the Medical Sciences*, vol. 1, p. 232, August, 1866. Dr. East states that in the latter part of the year 1864, in Lavacca County, Texas, he amputated at the hip-joint, ten hours after the reception of the injury, in the case of a negro refugee, aged twenty-five years, who had the head of the right femur shattered by a rifle ball. He states that he employed Larrey's method, and that "the man's recovery was rapid; indeed, at the end of six weeks he was hobbling about on crutches." After a few weeks an abscess formed in the lumbar region, from which a flattened ball was extracted. In the winter of 1865-66, Dr. East heard from Dr. Douglas, who had assisted at the operation, that the man continued well.

<sup>4</sup> *Mémoires de chirurgie militaire et campagnes*, Paris, 1817, Tome iv, p. 50. See *ante*, p. 15, note 8.



numerically, we obtain a total of seventy-two primary amputations at the hip for gunshot injury, of which sixty-eight were fatal and one was successful, while the issue in three cases was involved in uncertainty.

Appalling as they are, these figures do not teach that the operation is to be abandoned. Few will deny that when the thigh is torn away by a large projectile so high up that amputation in the continuity is impracticable, it is incumbent upon the surgeon to regulate the wound by suitable incisions, and to disarticulate the head of the femur. This is the first condition under which primary coxo-femoral amputation is admissible in military surgery. But one instance (Case XIV, *ante*, p. 29) was reported in the late war in which the operation was practised under such circumstances.

In the next place, it may be safely asserted that when the upper portion of the femur is very extensively comminuted by solid shot or fragments of shell, and the soft parts are greatly lacerated in such proximity to the trunk as to forbid amputation in the continuity, the limb should be at once removed at the hip. There is no recorded instance of recovery from such a condition under conservative treatment, or after excision of the upper portion of the femur, while Dr. Compton's patient thus injured (Case VIII, p. 26) survived immediate amputation at the hip for six months certainly, and perhaps recovered completely. Of the nineteen primary coxo-femoral amputations described in this report, two were performed for injuries by solid shot (Cases VI and XVIII) and eight (Cases I, II, VIII, X, XI, XIV, XV, XVI) for injuries inflicted by fragments of shells. Four intermediate amputations (Cases XXIII, XXIV, XXIX, XXXI) were performed for similar injuries and all resulted fatally. Thus, the delayed operations were less successful than the primary. It may be added, that in such injuries as are described in Dr. Carnochan's case (*ante*, p. 30) and illustrated in *Figure VII*, delay is out of the question, for clearly the patient would not survive it. The operation must be done immediately in such instances or not at all.

The third condition under which primary coxo-femoral amputation appears to be admissible in military surgery, is when, with fracture of the upper extremity of the femur, the femoral vessels are wounded. This condition existed in four of the cases described in this report. (Cases VIII, XI, XIV, and XXVII.) It is erroneous, therefore, to allege, as some surgeons have done, that all patients with such wounds will perish from hæmorrhage before surgical assistance can be afforded them. In Dr. Lay's case, (*ante*, p. 28,) the femoral was immediately ligated, and the wounded man was then conveyed to the hospital where the amputation was performed. In Dr. Compton's case, (Case VIII,) so often cited, the femoral was compressed, and the amputation was done *sur le champ*, and the patient went to his home with his stump healed. In Dr. Pineo's case, (Case XXVII,) in which the operation was delayed for a fortnight, and until gangrene had supervened, there had been little primary hæmorrhage. The result was promptly fatal. The advantages are again with the primary operations.

The observations of the late war afford but little data for the determination of the question propounded by M. Legouest:<sup>1</sup> whether, in the event of the simultaneous division

<sup>1</sup> *De la Désarticulation Coxo-fémorale au Point de Vue de la Chirurgie d'Armée. Dans Rec. de Mém. de Méd. de Chir. et de Phar. Mil. Tome XV, p. 240, Deuxième Série.*



of the femoral artery and vein near the crural arch without fracture of the femur, if the surgeon has had the good fortune to master the hæmorrhage, it would be better to immediately disarticulate at the hip, or to temporize and await the invasion of gangrene?

Another question admitting of argument is: whether in those cases of fracture of the trochanters by conoidal musket balls accompanied by such extended longitudinal fissuring as precludes excision, the surgeon should not advise immediate ablation of the thigh? The experience acquired in the late war tends to determine this question affirmatively. This form of injury is illustrated in *Figures XI and XII*, representing specimens taken from patients who underwent intermediate amputations which resulted fatally. An examination of the histories of ten or twelve similar specimens in the collection of the Army Medical Museum, taken from patients who were treated without operations, show that they survived their injuries, on an average, about one month. It is probable that these patients would have had a better chance for their lives if they had been amputated primarily.

In short, the observations detailed in this report do not sanction the conclusion that ablation of the thigh is an exception to the general rule requiring amputations that are indispensable to be done immediately, and that even a brief delay is desirable in hip-joint amputations. On the contrary, they tend to show that unless the nature of the injury is such that the operation can be delayed until the secondary period, it is better that it should be done at once.

It must be admitted, however, that this view conflicts with very weighty evidence heretofore accumulated. Though the eighteen intermediate amputations of the late war resulted fatally, yet we find among the sixteen other intermediate cases recorded in the tables two recoveries, and to these must be added the well attested successful operation of Wedemeyer and probably that of Langenbeck, these being excluded from the tables because they are not reported in detail. Since this report was sent to press a letter has been received from Dr. B. F. Lay, of Paducah, Kentucky, giving information of two additional fatal coxo-femoral amputations which he performed during the war, and Dr. J. Heyfelder's report on the wounded after the battle of Sadowa,<sup>1</sup> which records three unsuccessful amputations at the hip, has come to hand. It is believed that these five were intermediate operations. Adding them to the thirty-four intermediate amputations enumerated in the tables, and adding also Demme's three cases and those of Wedemeyer, Robert, Guersant, and Langenbeck, we make the statistics of intermediate amputations at the hip-joint for gunshot injury forty-six cases, with four successes and forty-two deaths, a more favorable exhibit than can yet be claimed for the primary operation.

To the statistics of secondary hip-joint amputations, the surgery of the late war brings its contribution of two successes, (Cases XLII and XLIII,) or, if the reamputations are included, of six successes. Leaving the latter out of consideration for the present, and adding only the successful secondary operations of Drs. Bentley and Blackman to those of Brownrigg, Arlaud, Isnard; Roux, and Neudörfer, we find that in nineteen secondary amputations at the hip-joint thus far recorded in military surgery there were

<sup>1</sup> *Gazette Médicale de Paris*, Nos. 32, 33, 35, 1867. Two operations were done at the Château of Hradeck; both patients succumbed within forty-eight hours. One was performed at Negolisch, with a fatal result.



twelve deaths, a mortality rate of 63.15, or less than the average mortality in amputations in the continuity of the thigh. It must be remarked also of one of the seven unsuccessful secondary operations (Case XLI) described in this report, that the patient succumbed four months subsequent to the operation, which had in reality succeeded, from an internal disease unconnected with the operation; and of another, (Case XLIV,) that the favorable prospect of recovery which existed was lost through the negligence of the nurse, who was absent when a fit of coughing detached the ligature from the femoral artery and led to a fatal hemorrhage that might readily have been controlled.

A number of surgeons have expressed the opinion that an amputation in the continuity might have been substituted for the successful secondary disarticulation described in Case XLII, since the upper portion of the femur, which is well depicted in plate III, presented externally a normal appearance. Dr. Bentley preferred to exarticulate in this case because of his conviction that disease of the superior fragment of the bone was the principal source of irritation. The specimen (No. 4386 of the Surgical Series) was sent to the Museum after maceration, and the opportunity of examining it in the recent state was lost; but, upon subsequently making a longitudinal section of the superior portion of the bone, I found the compact tissue diminished in thickness and very porous, the spongy tissue obliterated up to the level of the lesser trochanter, and above that point rarified, presenting reticulations of extreme tenuity. There was a general discoloration of the internal structure, which I have observed in all long bones that have been affected with osteomyelitis when prepared according to the process employed at the Museum. A transverse section of the upper fragment was prepared for the microscope by Mr. Schaeffer, (Specimen 2121, Microscopical Section A. M. M.,) and was pronounced by Dr. Woodward to present the characteristic microscopical alterations of osteomyelitis.<sup>1</sup> Dr. Bentley's

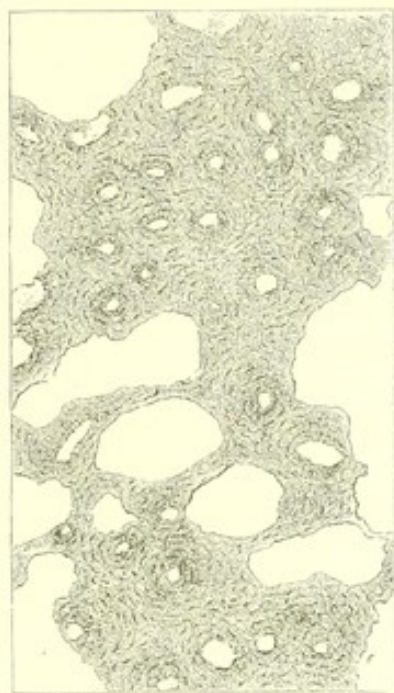


FIG. XXVII. Microscopical appearances of bone in chronic osteomyelitis, magnified 38 diameters. Spec. 1673, Microsc. Sect. A. M. M.

<sup>1</sup> Brevet Lieutenant Colonel J. J. Woodward, Assistant Surgeon, U. S. Army, has kindly furnished me with the following account of the structural alterations of bone in osteomyelitis, and I am indebted to Brevet Major Edward Curtis, Assistant Surgeon, U. S. Army, for the photomicrograph from which the illustrative wood-cut is copied:

"The first anatomical alterations in osteomyelitis beyond mere hyperemia of the involved blood-vessels, appears to be cell multiplication affecting the connective tissue corpuscles of the marrow, and of the connective tissue surrounding the blood-vessels in the canals of Havers. As a consequence, the true osseous tissue is encroached upon, and the portions of it which immediately adjoin the multiplying connective tissue disappear. In sections of the macerated long bones, therefore, the compact substance appears preternaturally porous to the naked eye, and in microscopical sections it is observed, as in *Figure XXVII*, that many of the canals of Havers are somewhat larger than natural, while others have extended into irregular channels often of considerable size. Similar changes render the areolae of any involved cancellated structure larger than normal, while the narrow cavity of the shaft is somewhat enlarged, the compact substance appearing unusually thin as well as porous. The precise steps by which the true osseous tissue thus disappears are not thoroughly made out, and observers dispute as to their details. It appears probable, however, that the bone cells which occupy the lacunae next to the multiplying connective tissue themselves enlarge and multiply, the matrix between them being absorbed, and that thus the bone cells themselves contribute to the resulting granulation tissue. The fat in the adipose tissue cells of the marrow is also absorbed, and these cells appear to contribute by their multiplication to the granulation tissue formed, as is the case in inflammation of the subcutaneous adipose tissue."

"The subsequent alterations of suppuration or gangrene need not be here described."



decision is therefore vindicated by the pathological condition as well as by the successful issue of his case.

The large number of reamputations at the hip-joint constitutes an interesting and novel feature in the surgery of the late war. Had these been included, as has commonly been done, with the secondary amputations, the statistics of the latter would appear in a still more favorable light. The successful reamputations augment to the number of seven the total of recoveries during the war after amputation at the hip-joint, apart from the probably successful cases of Drs. Gilmore and Compton (Cases III and VIII). The appearances of the stumps of these seven survivors, long after their recovery, are presented in the plates appended to this report. Of these plates, it may be remarked in passing, that several of them were unavoidably copied from very inferior photographs, and that the prints of the first of the series are inferior to the proofs.

It is probable that anæsthetics were administered in each of the fifty-three operations described in this report, except in that of Dr. Lay (Case XI). But in the reports of six of the cases this point is not mentioned. In thirty-two of the forty-six remaining cases chloroform was used; in eleven, ether; and in three cases a mixture of the two was employed. Although, in case XVI, the supposed effects of the chloroform excited some anxiety, and in case XXVI, in which the patient died upon the operating table, the surgeons thought that chloroform had been too freely administered, there is not sufficient evidence that anæsthesia tended to promote the fatal result in any instance. On the contrary, there is reason to believe that anæsthesia, in addition to its beneficent influence upon the *morale* of the patients, diminishes the shock both of injuries and operations. But it would be expecting too much of anæsthesia to anticipate that it should remove this great source of danger altogether, and it has been pointed out in the prefatory remarks to the different categories of cases, that in the primary operations more than one-half of the patients succumbed to the direct shock of the mutilation, while less than one-third of those operated on at a period remote from the injury perished from this cause.

In twenty-seven of the operations, the right thigh was extirpated; in twenty, the left; in the reports of six cases, it is not specified which limb was removed.

It has been already mentioned that fourteen of the operations were done for injuries produced by cannon shot. Thirty-eight operations were performed on account of wounds caused by small-arm projectiles, or for lesions consequent upon such injuries. In thirty cases the missiles were conoidal musket balls; in four, musket balls of undescribed shapes; in one case, the large round ball with buckshot; in three, conoidal pistol balls. Lastly, one operation was rendered necessary by complications following a bayonet wound of the knee-joint.

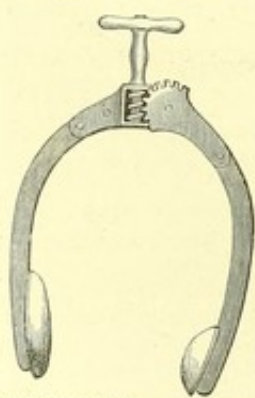


FIG. XXVIII. Signoroni's horse-shoe compressor.

Next to the shock to the system, hæmorrhage during the operation has been esteemed the principal immediate source of danger in amputations at the hip-joint. Since the beginning of the war some progress has been made in our means of averting this peril. In 1845, Mr. W. S. Cox advised that the arterial compressor invented by Signoroni, of Padua, should be employed in amputations at the hip-joint to control the arterial circulation at the groin without impeding the return of blood by the veins. This suggestion apparently met



with but little favor, and surgeons continued to rely in this operation upon digital compression of the crural artery upon the ramus of the pubes, or else upon preliminary ligation of the femoral artery. After all, the bleeding from the branches of the internal iliac was chiefly feared; for, in most of the methods of operating, the femoral could be readily commanded, either by preliminary ligation, or by compression in the flap prior to its division. But, by lengthening the blades of Signoroni's tourniquet, it may readily be made available for compression of the abdominal aorta, and thus the bleeding from the gluteal, obturator, sciatic, pudic, and other arteries at the back of the thigh, may be controlled as perfectly as that from the branches of the femoral. When this is accomplished, amputation at the hip-joint may be done with great security as regards hæmorrhage, as has now been demonstrated in many instances. Compression of the aorta has been resorted to without any injurious effect upon the general circulation or the respiration in most of the hip-joint amputations recently done in England; and since 1860, when it was introduced in Philadelphia by Professor Joseph Pancoast, it has been employed in several such operations in that city. It was successfully adopted in five of the fifty-three cases detailed in this report by Drs. Weir, Morton, Agnew, Forbes, and DuBois. As Signoroni's instrument is liable to slip, one of the circular arterial compressors may be advantageously used. A modification suggested by Skey or Syme and employed in Philadelphia is figured on page 51. Other forms have been recommended by Carte, Lister, and Pipilet. The circular tourniquet made for the U. S. Army by Tiemann, of New York, is represented in *Figure XXX*.

In twenty-three of the fifty-three amputations at the hip described in this report, the hæmorrhage, during the operation, is described as "slight," "inconsiderable," "trifling," or "trivial;" in five, it is said to have been moderate; and in three cases it is admitted that it was excessive. In twenty-two cases this point is not alluded to. On an average, fourteen or sixteen ligatures were required. In six cases the femoral was ligated as a preliminary measure. One or two surgeons preferred to include the femoral vein in the ligature of the artery. Acupressure was not employed in any of the cases. It was applied in an hip-joint amputation for disease, by Dr. A. Hewson, in 1865,<sup>1</sup> but there was much loss of blood before all the needles were placed, and the patient died without reaction.

The hæmorrhage, at the time of injury, is described as profuse in one of the fifty-three cases, and as copious in another. In a third, there was free bleeding from a small vessel twenty days after the injury.

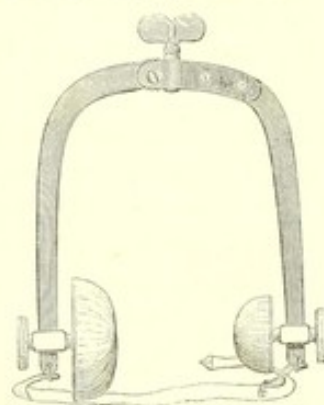


FIG. XXIX. Signoroni's tourniquet modified for compression of the aorta.

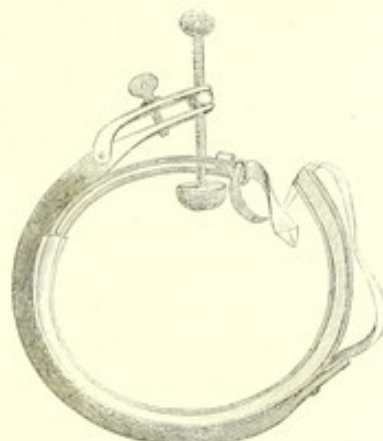

FIG. XXX. Aortic compressor made by Tiemann.

<sup>1</sup> *American Journal of the Medical Sciences*. Vol. LII, p. 32. July, 1866.



There was secondary hæmorrhage in five of the fifty-three operations. In one case it was *foudroyante* and promptly fatal. In two others it was copious, and necessitated the ligation of the external iliac. In one of these cases, (Case XLIX,) the bleeding recurred on the separation of the ligature and was controlled by digital compression, persevered in for a fortnight.

Of the forty-two cases in which the cause of death is stated, the patients succumbed to the direct shock of the operation in twenty-one cases, three died of pyæmia, one from sudden secondary hæmorrhage, and eighteen from causes grouped under the general head of exhaustion, in three of whom there had been much hæmorrhage during the operation, in two of whom erysipelas involved the stumps, and in four, gangrene. In two of the operations gangrene had invaded the limbs before the operation was performed.

Of the different modes of operating little need be said. Fourteen or more have attained the distinction of being generally known by the names of the surgeons who proposed them. Several of them have been practised only on the dead subject. In military surgery, especially, there must be much variation in the mode of operating, according to the location of the injury. I shall briefly recapitulate the different methods with which the medical officers of the army are familiar, in order to point out which were employed in the operations done during the war.

#### CIRCULAR METHOD.

Abernethy proposed this method for amputating at the hip-joint, and demonstrated it at his lectures for many years. He made a circular division of the integuments, about three inches below Poupert's ligament, retracted the skin as much as possible, divided the muscles by a second circular incision, and then disarticulated. His precepts were followed by Cole and S. Cooper.<sup>1</sup> It would appear that Kerr had already employed this method in his operation in 1774.<sup>2</sup> Graefe<sup>3</sup> operated by this plan, using a knife of his invention, enlarged and rounded off at the end, to divide the muscles obliquely after the manner of Alanson. The circular operation was practised also by Krimer<sup>4</sup> and Jaeger.<sup>5</sup> Veitch<sup>6</sup> advocated it and proposed a trivial modification. Larrey finally advised a modification of the circular method,<sup>7</sup> although his own operations were done by forming double lateral flaps. Lacauchie has likewise recommended the circular method, modified by a vertical incision over the trochanter major to facilitate disarticulation.<sup>8</sup> Surgeon R. B. Bontecou approves of this plan, because it enables the operator, upon definitely ascertaining the extent of the injury in the femur, to disarticulate or to saw the bone below the trochanters, at his option (*ante*, p. 68). In the operations performed during the late war, this method was successfully adopted by Dr. Blackman, (see *ante*, p. 43, Case XLIII,) and was employed also by Dr. Compton in the case of his patient who survived the operation for six months or more (see *ante*, p. 26, Case VIII).

<sup>1</sup> COOPER'S *Dictionary of Practical Surgery*, 8th London ed., p. 115.

<sup>2</sup> *An Account of the Operation of Amputation of the Thigh at the Upper Articulation, lately performed*, in *Edinburgh Medical and Philosophical Commentaries*, vol. vi, p. 337. See also *South's Chelms*, Am. ed., vol. iii, p. 690.

<sup>3</sup> *Normen für die Ablösung grösserer Gliedmassen*, p. 117.

<sup>4</sup> VON GRAEFE and VON WALTHER'S *Journal*, vol. xii, p. 121.

<sup>5</sup> *Hamburger Zeitschrift*, vol. iii, part i.

<sup>6</sup> *Edinburgh Medical Journal*, vol. iii, p. 131, 1807.

<sup>7</sup> *Clinique Chirurgicale*, par le Baron D. J. LARREY, Tome iii, p. 613. The operation is figured and described in Bourguery's *Plates*, Tome vi, Pl. 88, Fig. 3.

<sup>8</sup> *Gazette Médicale de Paris*. Numéros 19, 20, 25, 26. 1850. And *Ann. de la Chir. Franç. et Étrang.* T. II, p. 44.



## MIXED METHOD.

This method, which was first recommended by Le Dran,<sup>1</sup> consists in making flaps of integument and dividing the soft parts by circular incisions. It was largely and advantageously employed in the war of the rebellion in amputations in the continuity. It was described as the most suitable operation for the hip-joint by Skey,<sup>2</sup> and was adopted by Dr. J. Mason Warren in his successful hip-joint amputation in 1859.<sup>3</sup> Professor Joseph Pancoast operated successfully by this method in 1860, and again in 1865, and Professor S. D. Gross employed it in his successful amputation at the hip in 1865.<sup>4</sup> It was employed by Drs. Agnew, Forbes, and Morton in three of the cases detailed in this report: Case XLIV, Case XLV, and Case LI, the last being a successful operation.

## OVAL METHOD.

The V-shaped incision for disarticulating at the hip-joint was proposed by Belmas in 1824, and frequently demonstrated by him on the dead subject at the medical school at Strasbourg. Entering the knife an inch above the great trochanter, he made an oblique incision downwards, outwards, and backwards to a point four fingers' breadth below the ischial tuberosity; then placing the knife in the superior angle of this wound he made another incision forwards, downwards, and inwards till it joined the first; then the muscles on the outside were deeply divided; the knife reached the articulation externally and opened it. An assistant introduced his fingers into the wound and compressed the femoral, and the division of the soft parts was then completed and disarticulation effected. In 1827, Scoutetten<sup>5</sup> published a minute description of this operation and of the surgical anatomy of the region, illustrated by excellent plates. Sundry modifications, such as dissecting up the skin before dividing the muscles, disarticulating the femur before dividing the internal mass of soft parts, making a vertical cut over the trochanter and letting the oblique incisions diverge lower down so as to preserve more integument, putting the apex of the V-shaped incision near the superior iliac spine instead of above the trochanter, making a preliminary ligation of the femoral artery, etc., constitute the procedures of Sanson,<sup>6</sup> Cornuau,<sup>7</sup> Malgaigne,<sup>8</sup> and Foullyoy.<sup>9</sup> It is admitted that the thigh may be removed at the hip by the oval method, in a brilliant, expeditious manner; but M. Velpeau sneers at it as a dissecting room operation, and Mr. Cox, S. Cooper, Costello, and others, also object that it has not been tested on the living subject. These objections are unfounded. M. Sédillot operated by this method in the campaign in Poland in 1831,<sup>10</sup> and Sir Astley Cooper's operation in 1824 was certainly performed according to this plan,<sup>11</sup> though the epithet "oval" had not then come into use. Although Guthrie

<sup>1</sup> *Traité des Opérations de Chirurgie*, Paris, 1742.

<sup>2</sup> *Operative Surgery*, by F. C. SKEY, F. R. S., Am. ed., 1851, p. 336.

<sup>3</sup> *Boston Medical and Surgical Journal*, vol. 60, 1859, p. 329, and *Surgical Observations, with Cases and Operations*, by J. MASON WARREN, 1867, p. 402.

<sup>4</sup> *The American Journal of the Medical Sciences*, vol. lii, p. 58.

<sup>5</sup> *La Méthode Oculaire, ou Nouvelle Méthode pour amputer dans les Articulations*, par H. SCOUTETTEN, quarto, Paris, 1827, p. 31.

<sup>6</sup> SABATIER, *Méd. Opér.* Édition de MM. SANSON et BEGIN, Paris, 1832. Tome iv, p. 682.

<sup>7</sup> M. VELPEAU, *Nouv. Élém de Méd. Opér.* Tome 1, p. 525.

<sup>8</sup> BOURGERY, *Iconographie d'Anat. Chir. et de Méd. Op.* Tome vi, p. 274, et Planche 88, Figs. 1, 2, et 3.

<sup>9</sup> VIDAL, *Traité de Path. Ext. et de Méd. Opér.* Troisième éd. Tome v, p. 701.

<sup>10</sup> SÉDILLOT, *Traité de Méd. Opér.* Troisième éd. Tome i, p. 465.

<sup>11</sup> S. COOPER'S *Surgical Dictionary*, 8th ed., p. 115.



styled his plan of amputating at the hip a double flap operation, it is essentially identical with the oval method, and is so described by many authors (Sanson, Chelius, Malgaigne, etc.) Professor Heyfelder, of Erlangen, adopted this method some years since in five successive amputations at the hip-joint, three of which resulted favorably, and he attributed his success in a great measure to the advantages for the apposition and cicatrization of the wound afforded by this plan of operating. In the cases detailed in this report, the oval method was adopted once only, in Case XV, by Dr. Carnochan.

#### FLAP METHOD.

1. SINGLE FLAP.—Puthod proposed this procedure,<sup>1</sup> recommending that a single flap should be cut from within outwards, from the gluteal region and posterior part of the thigh. Bryce (*ante*, p. 12) is said to have operated by this plan. It is commended by Hunczorsky.<sup>2</sup> It is perhaps the most objectionable of the modes of amputating by single flap.

Lalouette originated the plan of amputating at the hip by a single antero-internal flap.<sup>3</sup> He directed the operator to make a semi-circular cut from the trochanter to the ischial tuberosity and to carry it at once down to the joint, to divide the capsular and round ligaments, and then, grazing the neck of the bone, to cut downwards and inwards a flap of adequate dimensions. Delpech modified this plan by first tying the crural artery, forming the flap by transfixion and making it more internal, disarticulating, and then dividing the soft parts posteriorly.<sup>4</sup> Lenoir revived Lalouette's plan, in which the prompt disarticulation of the head of the femur is easier than in Delpech's procedure.

Plantade was one of the first to propose, in 1806, to put the single flap altogether in front. He advised that it should be cut from without inwards, and rectangularly, after the manner of Ravaton.<sup>5</sup> In 1831, Dr. Ashmead, of Philadelphia, who was then in Paris, demonstrated a modification of Plantade's procedure,<sup>6</sup> consisting in cutting an anterior semi-lunar flap from without inwards, reflecting it and securing the arteries, disarticulating and dividing the remaining soft parts by an horizontal incision. M. Velpeau commended this plan and adopted it in his case of amputation at the hip. In 1831, also, Manec<sup>7</sup> demonstrated on the cadaver a modification closely resembling Ashmead's, except that the single anterior flap was made by transfixion. The plan of amputating at the hip by a single anterior or antero-internal flap was preferred and practised by Langenbeck, Baudens, Vidal, M. Sédillot, and M. Velpeau. Surgeon E. Shippen, U. S. Volunteers, gave it a decided preference, and employed it in three operations. It was also adopted during the late war by Surgeons Jewett, D. P. Smith, Whitcomb, Lay, and Kinloch, and by Surgeon Compton in two operations.

2. TWO LATERAL FLAPS.—Larrey<sup>8</sup> proposed a plan of amputating at the hip by two lateral flaps, which has been often practised. After the preliminary ligation of the crural

<sup>1</sup> MORAND. *Op. cit.*, p. 207.

<sup>2</sup> *Anweisung zu Chirurgischen Operationen*, p. 256.

<sup>3</sup> M. VELPEAU. *Nouv. Éléments de Méd. Opér.* Tome i, p. 519.

<sup>4</sup> *Journal général de Médecine*. Tome ciii, p. 429, 1828.

<sup>5</sup> BOURGERY. *Opérations générales*. Tome vi, p. 272.

<sup>6</sup> M. VELPEAU. *Op. cit.*, p. 521.

<sup>7</sup> *Précis Iconographique de Méd. Opér. et d'Anat. Chir.* par BERNARD et HUETTE, p. 85.

<sup>8</sup> *Mém. de Chir. Mil.* Tome ii, p. 186. *Clinique Chir.* Atlas, pl. 13.



artery and vein, on which he always insisted, standing on the inner side of the limb, he thrust a straight knife perpendicularly between the muscles attached to the little trochanter and brought out the point diametrically opposite; then turning the edge obliquely inwards, he cut a rather small inner flap. He tied all bleeding branches of the obturator and pudic arteries, and then, taking a bistoury, laid open the capsular ligament, and, abducting the thigh, divided the inter-articular ligament. He then resumed the amputating knife, and formed an external flap. Lisfranc<sup>1</sup> is said to have amputated at the hip on the dead subject in ten seconds by his modification of the lateral flap method. He entered a narrow, long catling one inch below and half an inch to the inner side of the anterior superior iliac spine and thrust it downwards until it struck the head of the femur, when it was carried to the outer side of the bone and pushed on, the handle being carried outwards so that the point should emerge just below the sciatic tuberosity. The knife was then carried around the great trochanter and an external flap three or four inches long was cut. Then the knife was made to enter and emerge at the points at which the limb was first transfixed, but the blade was this time carried to the inner side of the femur and cut an internal flap. An assistant followed this incision with his fingers, and compressed the femoral artery in the flap before it was divided. Disarticulation was then accomplished. Dupuytren<sup>2</sup> operated in nearly the same manner, but he cut the flap from without inwards, which made the operation more tedious. Of the operations detailed in this report, those by Surgeons McLean, Gill, De Bruler, Grant, Peachy, and Warren, and one of the operations by Surgeon Bentley (Case XXXVI) were performed by the lateral flap method.

3. ANTERO-POSTERIOR FLAPS.—Amputation at the hip by forming anterior and posterior flaps by transfixion, sometimes described as Bécclard's<sup>3</sup> operation, is the plan recommended by Liston,<sup>4</sup> and that most commonly selected at the present day. It was employed in twenty-seven of the fifty-three operations described in this report. Some surgeons prefer, after forming and reflecting the anterior flap, to secure the arteries before disarticulating. Others regard it as an improvement to cut the posterior flap from without inwards. The majority advise that the posterior flap should be made very short. When this is done the result of the operation differs very little from that of the single anterior flap procedure. Dr. Bentley, whose experience in this operation entitles his opinion to much weight, recommends that care should be taken to remove completely the round and capsular ligaments and all the fibrous and fatty tissue about the cotyloid cavity.

In primary amputations, the procedure of a single anterior flap has been most successful. In secondary amputations, the condition of the tissues is frequently such that the mixed method of integumentary flaps with circular division of the muscles presents many advantages.

Of the general condition of those who recover after amputations at the hip-joint, as illustrated by the seven survivors of this operation during the war, it may be observed that the progress of those who underwent secondary operations was similar to what is

<sup>1</sup> *Précis de Médecine Opératoire*, par J. LISFRANC, Paris, 1846.

<sup>2</sup> *Leçons Orales de Clin. Chir.* par M. le Baron DUPUYTREN, Tome iii, p. 369.

<sup>3</sup> BOURGIER, *Opérations Générales*, Tome vi, p. 273, pl. 89, fig. 1.

<sup>4</sup> *Elements of Surgery*, by ROBERT LISTON, p. 787.



observed in patients who recover after amputations for disease. The functions of nutrition were promptly recuperated. Such a subject has been compared to a tree in which one of the principal branches has been lopped off, and it has been supposed that the reparative material destined for the member that has been removed continues to be prepared by the digestive organs and gives greater vigor to the remaining portions of the organism. On those persons who have lost a lower limb a comparatively sedentary life is imposed, and hence another cause of a tendency to obesity. It has been stated, at page 52, that Mr. Ulmer, now employed in a publishing house in Philadelphia, weighs at this time twenty-five pounds more than his average weight before he lost his limb. His photograph, sent to this office within a few weeks, would hardly be recognized as the picture of the same person represented in plate VIII, copied from a photograph taken ten months ago, except from the identity in the appearance of the stump. Lemon, Longmore, and Smith have also largely gained in weight.

The rule is reversed in primary amputations for traumatic causes, after which patients commonly became emaciated rapidly, and long remain in a state of feebleness, from which they recover very gradually. Such has been the experience of Kelly. Though more than four years have elapsed since his recovery from a primary coxo-femoral amputation, he still writes that his health is delicate, and that he can do but little towards earning a maintenance.

Of the condition of the stumps of the seven survivors, it is known that in the case of Francis there are sinuses and other indications of disease of the innominatum. Longmore has neuralgia in the stump, and Smith suffers from a sense of congestion of the stump after being long in an erect posture. In the others the stumps are healthy. Ulmer alone wears, with comfort, an artificial limb.

Of the changes that take place in the pelvis after amputation at the hip, our information is limited to the single case of the soldier whose thigh was exarticulated by M. Sédillot, on account of disease of the femur after a fracture by a fall from a window, who survived the operation twenty-two years. In this instance the acetabulum was obliterated, and its location was covered by a fibro-fatty substance. The articulations of the sacrum and coccyx were ankylosed and deviated to the right. The internal iliac fossa was abnormally hollowed. The anterior superior spine of the ilium was nearer than is natural to the sacro-vertebral angle, and the external wall of the os innominatum had become almost vertical.

The accessions to our means of estimating the value of the operation of amputation at the hip-joint as a resource in military surgery afforded by the war of the rebellion, may be summed up as follows:

1. We have learned that the primary operation for traumatic causes is not uniformly fatal, as has latterly been taught, and are enabled to define three conditions under which it should be undertaken, while two other conditions in which it may be justifiable are left *sub judice*.

2. Much evidence has been brought to controvert the prevailing doctrine that disarticulation at the hip is an exception to the general rule requiring all amputations deemed indispensable to be performed immediately, the eighteen intermediate amputations performed during the war having all resulted fatally.



3. We have proved that secondary amputations at the hip for necrosis of the whole of the femur or for chronic osteomyelitis following gunshot injury, may be performed with as successful results as hip-joint amputations for other pathological causes.

4. It has been shown that when, after amputations in the continuity of the thigh, the stump has become diseased, reamputations at the hip may be done with comparative safety.

I am, General,

Very respectfully,

Your obedient servant,

GEORGE A. OTIS,

*Assistant Surgeon and Brevet Lieutenant Colonel, U. S. Army.*

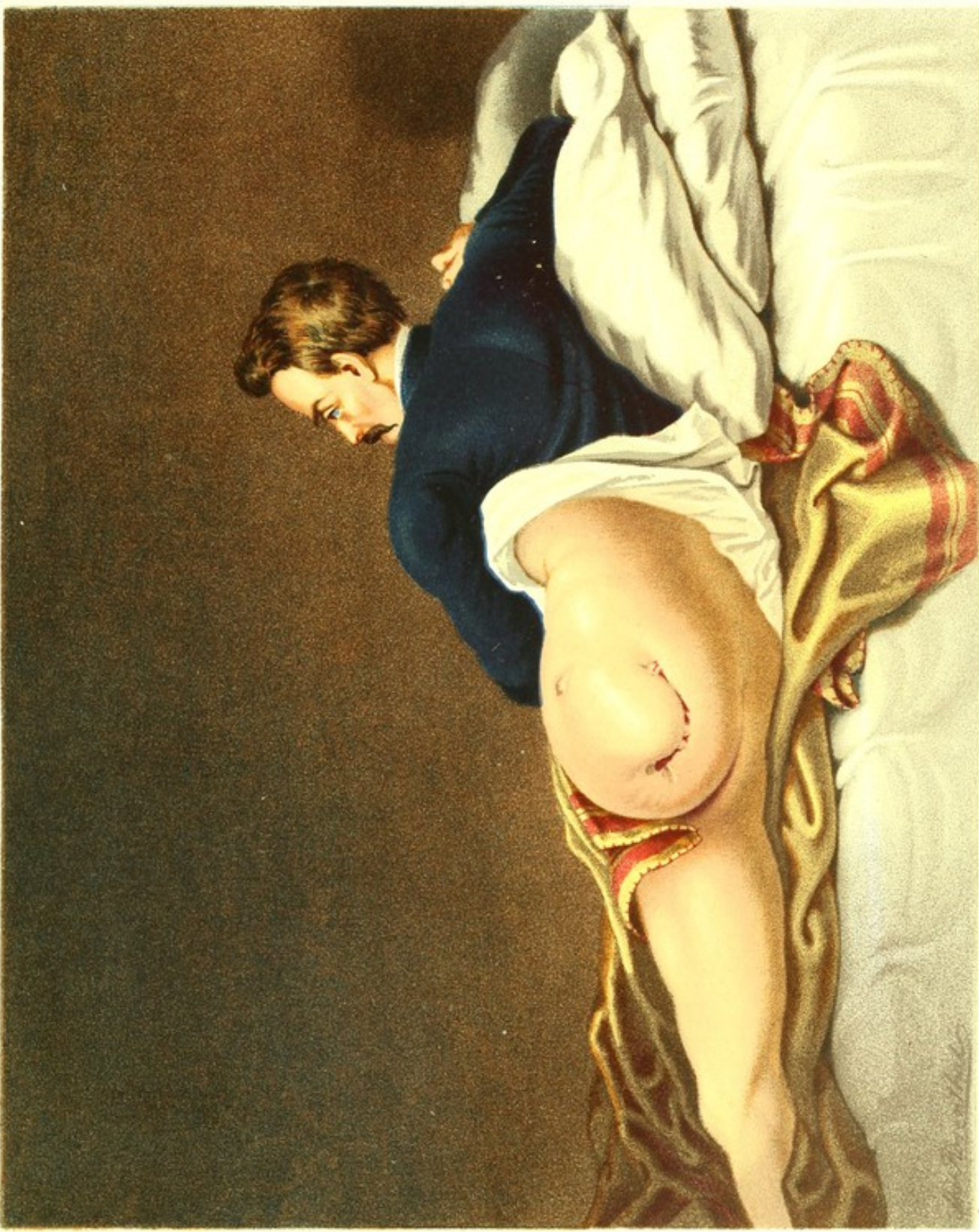*Curator of the Army Medical Museum.*



## ERRATA ET CORRIGENDA.

- On page 11, 28th line, for twenty-fifth, read twenty-ninth.  
On page 14, 7th line, for practiced, read *practised*.  
On page 15, 11th line, for primary, read *intermediate*.  
On page 18, last line but one in notes, for Vartermonde, read *Fantermonde*.  
On page 29, 28th line, omit the words *and that* after the word disbandment.  
On page 35, Case XXVII, 10th line, for anaesthesia read *anæsthesia*.  
On page 37, 36th line, for McLellan, read *McClellan*.



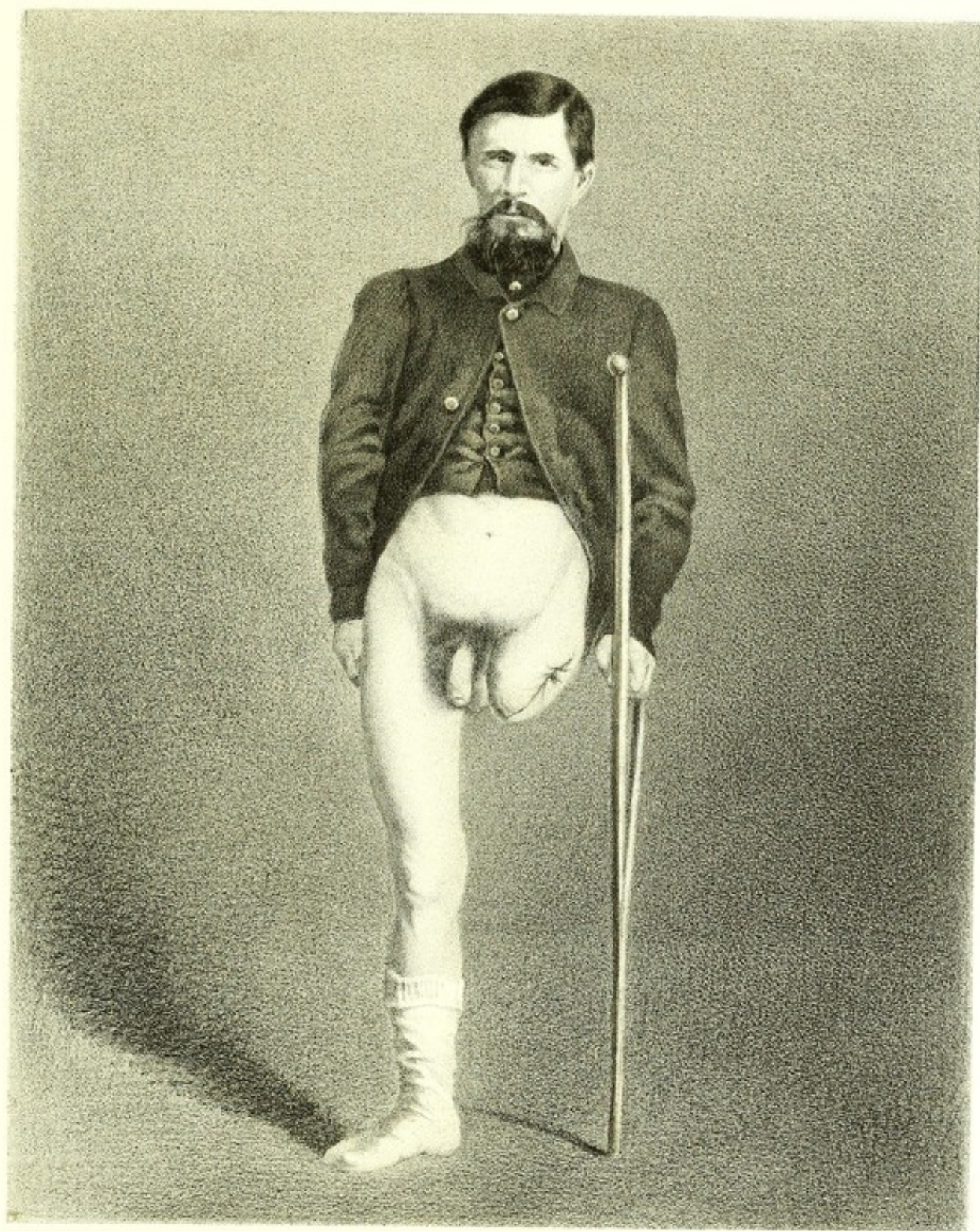


Fisher del.

SHIPPEN'S SUCCESSFUL PRIMARY AMPUTATION AT THE HIP-JOINT.

L. N. Rosenthal chromo-lith.





E. M. Wells del.

Julius H. Thompson lith.

BENTLEY'S SUCCESSFUL SECONDARY AMPUTATION AT THE HIP JOINT



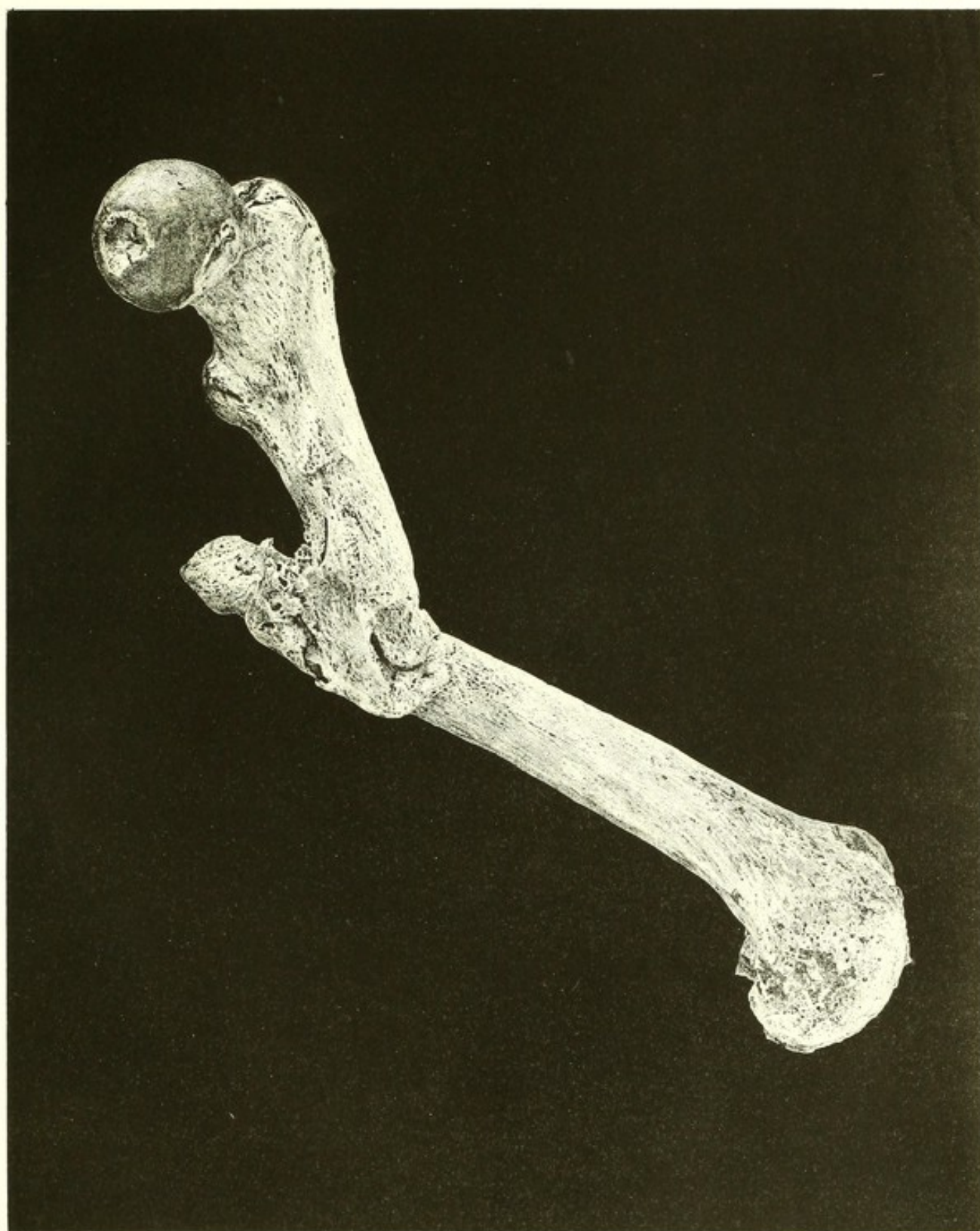
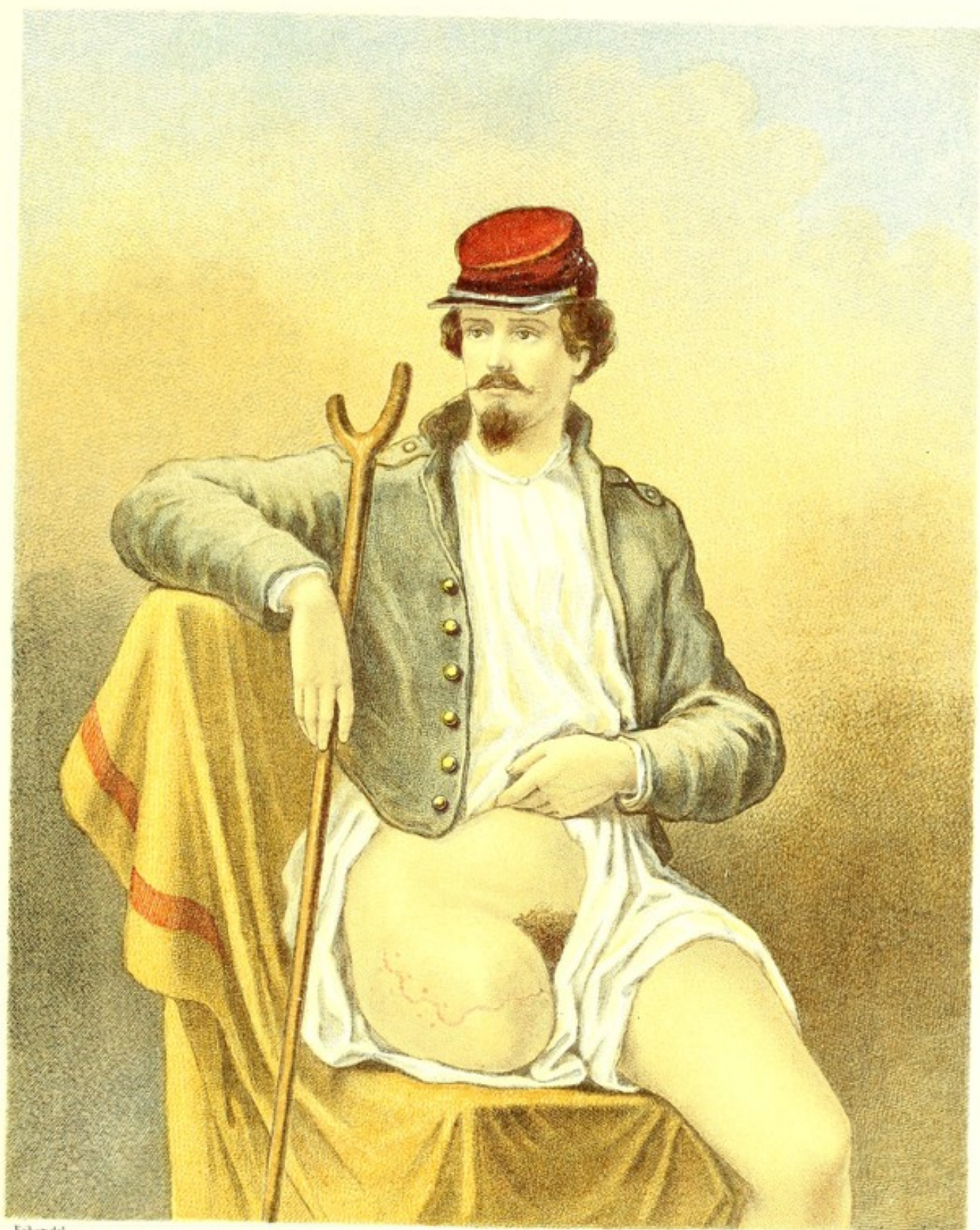
Fig. 1016

DISEASED FEMUR PARTIALLY UNITED AFTER GUNSHOT FRACTURE. See Case and John Martin Hewitt  
*From Dr. Bentley's Successful Secondary Amputation at the Hip Joint.*



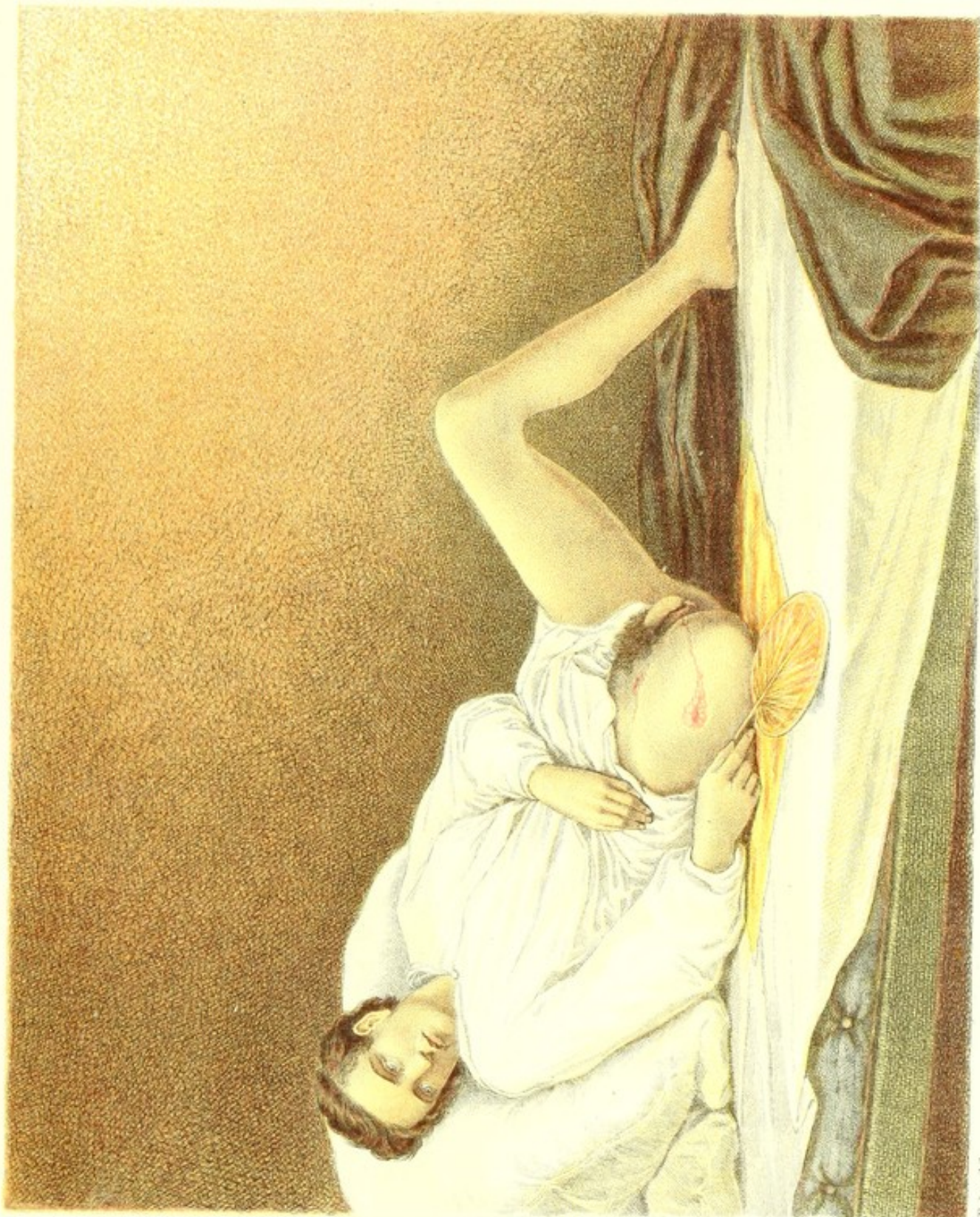

Faber del.

F. Moras chromolith.

BLACKMAN'S SUCCESSFUL AMPUTATION AT THE HIP-JOINT.  
SECONDARY AMPUTATION.



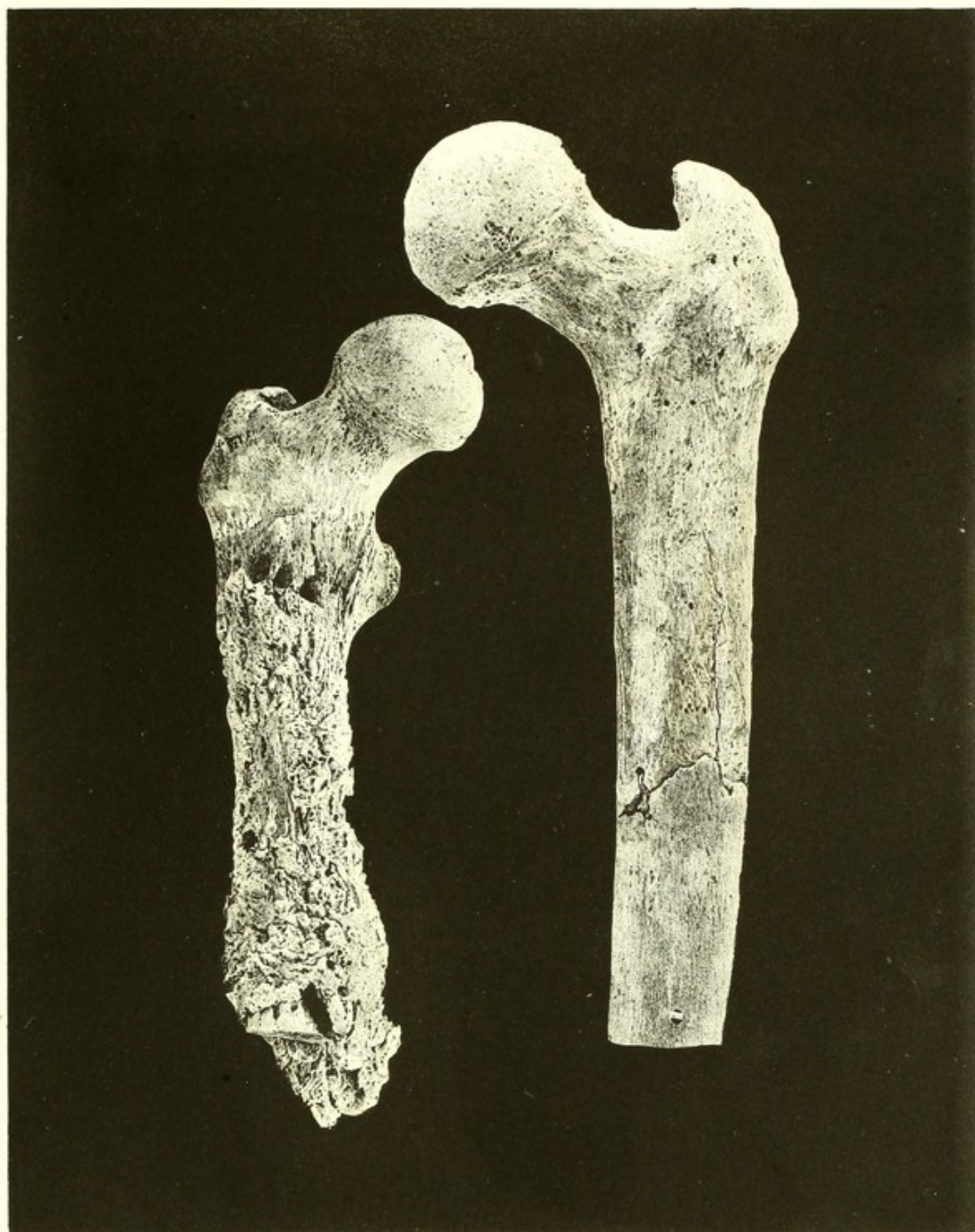


Faber del.

F. Morris chromolith.

PACKARD'S SUCCESSFUL RE-AMPUTATION AT THE HIP-JOINT.






Win. Bell, phot.

J. Allen lith.

FIG. I. DISEASED STUMP OF RIGHT FEMUR. *Specimen in John Warren's Museum.  
From Dr. Richardson's case of Successful Re-Amputation at the Hip Joint.*

FIG. II. UPPER HALF OF LEFT FEMUR, FRACTURED BY A CONOIDAL MUSKET BALL. *Specimen in John Warren's Museum.  
From Dr. Shippen's Successful Primary Amputation at the Hip Joint.*






Morgan photo

Wm. F. Felt, 1861

FAUTLERDY'S SUCCESSFUL RE-AMPUTATION AT THE HIP-JOINT.





Schultze del.

F. Moras chromolith.

MORTON'S SUCCESSFUL RE-AMPUTATION AT THE HIP-JOINT.





Schulze & Jones del

J. Ben chromo-lith

MOTT'S SUCCESSFUL RE-AMPUTATION AT THE HIP-JOINT.



P/M















