

**A study of the ocular manifestations of systemic gonorrhoea [sic] with reports of cases of this nature / by W. Gordon M. Byers.**

**Contributors**

Byers, W. Gordon M.  
University College, London. Library Services

**Publication/Creation**

[Montreal] : [Royal Victoria Hospital], 1908.

**Persistent URL**

<https://wellcomecollection.org/works/rpyedj7u>

**Provider**

University College London

**License and attribution**

This material has been provided by This material has been provided by UCL Library Services. The original may be consulted at UCL (University College London) where the originals may be consulted.

Conditions of use: it is possible this item is protected by copyright and/or related rights. You are free to use this item in any way that is permitted by the copyright and related rights legislation that applies to your use. For other uses you need to obtain permission from the rights-holder(s).



Wellcome Collection  
183 Euston Road  
London NW1 2BE UK  
T +44 (0)20 7611 8722  
E [library@wellcomecollection.org](mailto:library@wellcomecollection.org)  
<https://wellcomecollection.org>

# GONORRHŒAL OCULAR METASTASES

---

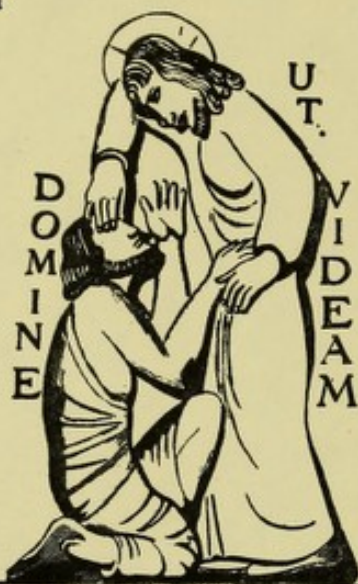W. GORDON M. BYERS, M.D.,



No. 141 / H

J.62


360



THE INSTITUTE  
OF  
OPHTHALMOLOGY  
LONDON

EX LIBRIS







B/L 2809390875

✓  
III

E. 25.

OPHTHALMOLOGIST HCF BYERS

B. 1. 4  
25

STUDIES FROM THE ROYAL VICTORIA HOSPITAL  
MONTREAL. VOL. 2, No. 2. (OPHTHALMOLOGY 2).



---

A STUDY OF THE OCULAR MANIFESTATIONS OF SYSTEMIC GONORRHŒA  
WITH REPORTS OF CASES OF THIS NATURE,

BY

W. GORDON M. BYERS, M.D.,

ASSISTANT OCULIST, ROYAL VICTORIA HOSPITAL,  
LECTURER IN OPHTHALMOLOGY, MCGILL UNIVERSITY.

FEBRUARY, 1908.



STUDIES FROM THE ROYAL VICTORIA HOSPITAL  
ONTARIO VOL. 2, No. 2. OPHTHALMOLOGY 21.



A STUDY OF THE Ocular Manifestations of Systemic Gonorrhea  
WITH REPORTS OF CASES OF THIS NATURE

W. GORDON M. BYERS, M.D.

Assistant Surgeon, Royal Victoria Hospital,  
London, Ontario

Published by the Royal Victoria Hospital,  
London, Ontario

1671717

# FOREWORD

## CONTENTS

TO  
THE MEMORY  
OF  
FRANK BULLER, M.D., M.R.C.S.,  
IN  
GRATITUDE, RESPECT, AND AFFECTION.



## CONTENTS

---

	Page
Preface .....	5
History of the Subject .....	7
General Considerations .....	13
Pathological .....	13
Clinical .....	18
Therapeutical .....	21
Affections of the Conjunctiva .....	23
Metastatic Conjunctivitis .....	23
Phlyctenular Conjunctivitis .....	34
Affections of the Cornea .....	35
Affections of the Sclerotic .....	58
Affections of the Uveal Tract .....	61
The Author's Case of Iridocyclitis .....	62
Affections of the Optic Nerve and Retina .....	91
Tenonitis .....	103
Dacryoadenitis .....	105
Conclusions .....	117
Bibliography .....	121



## PREFACE

---

In the following pages, something more than a compilation has been attempted. The writer has striven, during the past few years, to gather all that has been written on the subject of gonorrhœal ocular metastases, and to sift that which was good in the collected material from that which was valueless; to understand the often conflicting opinions expressed in regard to these conditions, and to compare them with data obtained by fresh analyses of the cases in the literature as originally recorded.

It must be confessed, however, at the end of this study that the degree of finality hoped for has not been attained. So many of the reports, especially those which had to do with inflammations of the uveal tract, were lacking in essential details, that, in numerous instances, facts, altogether satisfying for criteria, could not be elicited. Still, errors which have crept in during the long development of the subject, have been pointed out; and conclusions have been reached which, though now provisionally advanced, will, it is thought, eventually prove to be correct. In any case, it is hoped that the field has been to some extent cleared and the way to much needed work made more apparent.

The unusually large number of reports throughout the study have been placed there for two reasons: first, and principally, because it is only by bringing together the material in this way that one can, at the present time, properly appreciate the extent and variety of the affections that have been attributed to systemic gonorrhœal infection; and, secondly, because it is hoped that these abstracts, which had in any case to be prepared for the purposes of this study, will temporarily lighten the work of others, especially among English-speaking colleagues who may come to labor in this field.

Some cases which have come under the writer's observation will be found in the appropriate sections, but attention is especially called to the case of iridocyclitis, of probable gonorrhœal origin, on page 62.

I cannot allow this opportunity to pass without recording my deep appreciation of Professor Adami's stimulating interest in the preparation of this study, and my indebtedness to him for criticism and advice. My warm thanks are also due to Professor Stirling, and my colleague in the eye department, Dr. Fred. Tooke, for their care and trouble in reading over my manuscript; and to them, again, and to Dr. Oskar Klotz for valuable suggestions.



## PREFACE

In the following pages something more than a compilation has been attempted. The writer has written during the past few years to gather all that has been written on the subject of gonorrheal ophthalmia, and to all that which was given in the collected material from that which was valuable, to understand the often conflicting opinions expressed in regard to these conditions, and to compare them with the opinions of the writer, and to present the literature as originally recorded.

It must be confessed, however, at the end of this study that the literature of gonorrheal ophthalmia has not been so much as it should be. Especially those which had to do with the treatment of the disease were lacking in essential details, and in many instances the literature was so scattered and so widely different that it was difficult to gather together what was of value. Still, errors which have crept in during the preparation of the subject have been pointed out, and corrections have been made which, though now provisionally made, will be corrected as soon as they are found. In any case, it is hoped that the field has been to some extent cleared and the way is made for further study.

Digitized by the Internet Archive  
in 2014

One of the greatest difficulties in the preparation of this work was the scarcity of the literature that has been referred to in the various chapters. In many instances, the literature was so scattered and so widely different that it was difficult to gather together what was of value. Still, errors which have crept in during the preparation of the subject have been pointed out, and corrections have been made which, though now provisionally made, will be corrected as soon as they are found. In any case, it is hoped that the field has been to some extent cleared and the way is made for further study.

I cannot allow this opportunity to pass without recording my deep appreciation of Professor Adams's assistance in the preparation of this study, and my indebtedness to him for criticism and advice. My warm thanks are also due to Professor Schilling and my colleagues in the eye department, Dr. Fred Toole, for their care and trouble in reading over my manuscript, and to them again, and to Dr. Oscar Klotz for valuable suggestions.



## I.—HISTORY OF THE SUBJECT.

---

The old writers on Ophthalmology, influenced probably in the first place by the teaching of St. Yves‡ (1722), described a form of metastasis in connection with certain ocular affections of gonorrhœal origin; but their views on this subject differ widely from those which we hold to-day. They imagined that a gonorrhœal inflammation could appear in the eyes of an individual affected with specific urethritis as the result of a suppression of his urethral discharge. Their conception was, in fact, more that of a transposition of inflammation; and it is clearly expressed in the term "retropulsion," which they commonly employed.§ As an outcome of this supposition, the oculists of the time viewed with apprehension any undue cessation of the urethral discharge; and employed in the event of its disappearance, means, such as the passage of catheters or fresh inoculation of the urethra with gonorrhœal pus, to re-establish the condition.† It is noteworthy how greatly and for how long a time the profession was influenced by this theory.

Professor Adami points out that this conception that the disease rendered quiescent in one region tends to become active in another is not antagonistic to that of systemic infection; on the contrary. Retropulsion demands that the causative agent of the disease gain entrance to the tissues in general in order that it may affect some susceptible tissue more particularly. The conception of the old writers was faulty in that it demanded that the flaring up in one area be constantly associated with the dying down of the local manifestation in another. We recognize now that this is not essential. Nevertheless "retropulsion" is a definite phenomenon of more frequent occurrence, it may be, than is generally imagined. Phthisiologists, for example, have frequently observed that the active extension of laryngeal tuberculosis is accompanied by a lulling of the previously active extension of the pulmonary disease.

Recently von Eberts and Hill (*Amer. Journ. Med. Scs.*, July, 1907, p.

---

‡Mackenzie, *Diseases of the Eye*. American reprint, 4th Eng. ed., p. 471, Phil., 1855.

§For example: Robertson, Robert. History of a case of Retropulsed Gonorrhœa, succeeded by a severe affection of the eyes, terminating favorably. *Annals of Medicine*, Vol. IV., p. 455-458, 1800.

†See Yvan. *Ann. Soc. de Méd. Prat.* Montpellier, T. VII., p. 119, 1806; and Lawrence, *Treatise on the Diseases of the Eye*, American Ed., 1854, p. 301-302.



35,) have drawn attention to the striking evidence of auto-inoculation uniformly manifested during the early stages of gonorrhœal epididymo-orchitis in the sudden cessation of the urethral discharge. With the backward extension of the disease, and the attendant inflammation, there takes place an absorption of gonococcus toxines—in some cases of the organisms themselves—leading to a marked rise in the immunity index, which latter feature is responsible in their opinion, for the marked decrease or complete disappearance of the urethral discharge; an attenuated discharge reappearing, in the majority of cases, with the decline of the complicating inflammation and the concomitant ebb of the immunity. In three cases at the Montreal General Hospital, following inoculation for gonorrhœal rheumatism, the effect in every instance upon the urethral discharge was identical with the phenomenon observed in involvement of the epididymis and testicle. The same scientific explanation is applicable to the phenomena correctly observed but misinterpreted by the older oculists.

The development of our knowledge of the systemic phases of gonorrhœa began with the work of Selle and Swediaur, who independently described in 1781 the condition commonly known as "gonorrhœal rheumatism." The discoveries of these two men were not long in being confirmed by John Hunter (1786) and a large number of observers†; and very gradually, in the following century, numerous other affections were described as occurring in association with gonorrhœa. The interpretation of these manifestations was the subject of many a controversy which need not be here discussed; but the theory of systemic infection by some virus was very generally accepted before the work of Neisser (1879) and others, quickly following him, placed the matter on a basis of solid fact.

In 1818 Sir Benjamin Brodie<sup>2</sup> cited in his well known work "On the Diseases of the Joints," a number of instances of metastatic conjunctivitis and iritis occurring in association with gonorrhœal rheumatism, and stated that he had had the opportunity of seeing many patients in whom a similar train of symptoms took place. The reports of this celebrated English worker are clear and convincing, and constitute our first accurately recorded cases of metastatic eye affections of gonorrhœal origin. In 1820 Vetch<sup>3</sup> reported a case of systemic gonorrhœa with iritic symptoms of which he more or less clearly recognized the constitutional nature; and Abernethy<sup>4</sup> in his lectures at St. Bartholomew's Hospital (1825) cited a case of metastatic inflammation of the eye, and stated that he had known many men in his time, and a medical man in particular, who were liable to rheumatism, to puriform discharges from

---

†Fournier, A. *Nouv. Dict. de Méd. et de Chir. Prat.*, Vol. V., p. 224, 1866.



the urethra, and an "irritable" ophthalmia which used to alternate the one with the other. Sir Astley Cooper<sup>5</sup> (1830) expressed himself as certain that "whether by the absorption of the poison or the constant irritation produced by the inflammation of the urethra, gonorrhœa produced ophthalmia and rheumatism, and that, when not a single drop of matter had been applied to the eye"; and cited the following case which is sufficiently quaint and true to merit reproduction:

Case 1. (Cooper<sup>5</sup>)—Gonorrhœa—Metastatic Ophthalmia—Arthritis.

"An American gentleman came to me with a gonorrhœa, and after he told me his story, I smiled and said—do so and so—(particularizing the treatment), and that he would soon be better; but the gentleman stopped me, and said, 'Not so fast, sir; a gonorrhœa with me is not to be made so light of—it is no trifle; for in a short time you will find me with inflammation in the eyes, and in a few days after I shall have rheumatism in the joints. I do not say this from the experience of one gonorrhœa only, but from that of two, and on each occasion I was affected in the same manner.' I begged him to be careful to prevent any gonorrhœal matter coming in contact with the eye, which he said he would. Three days after this I called on him, and he said, 'Now you may observe what I told you a day or two ago is true.' He had a green shade on, and there was ophthalmia in each eye. I desired him to keep in a dark room, to take active aperients, and apply leeches to the temples in order to reduce the inflammation. In three days more he sent for me rather earlier than usual for a pain in one of his knees (the left); it was stiff and inflamed. I ordered some applications, and soon after the other knee became affected in a similar manner. The ophthalmia was with great difficulty cured, and the rheumatism continued many weeks afterwards."

In a study of the development of our knowledge concerning the gonorrhœal affections of the eye prominence must be given to the work of Sir William Lawrence. "This distinguished surgeon and physiologist," said Professor Graves<sup>8</sup> to his students at the Meath Hospital, Dublin, 1837-8, "has done more than all who preceded him to illustrate his subject. . . . In fact, gentlemen, nothing satisfactory was published on gonorrhœal ophthalmia until Mr. Lawrence's Treatise on the 'Venereal Diseases of the Eye' appeared in 1830." In the classic work just mentioned Lawrence<sup>6</sup> sharply separated the gonorrhœal from the syphilitic affections of the eyes; and described (p. 10) three distinct forms of ophthalmic inflammation as occurring in conjunction with, or dependent upon gonorrhœa, namely:

- (1.) Acute inflammation of the conjunctiva.
- (2.) Mild inflammation of the conjunctiva.



(3.) Inflammation of the sclerotic coat sometimes extending to the iris—gonorrhœal iritis.\*

Under the first heading Sir William described contagious gonorrhœal ophthalmia in a masterly way and largely determined—so far at any rate as English-speaking workers were concerned—the purely local character of this disease.† He undoubtedly pictured under the second term the condition we to-day designate metastatic conjunctivitis; and gave, under the third heading, the first general description of gonorrhœal iritis that is at all clear. Sir William pointed out the tendency of the iritic inflammation to recur, and its association and alternation with metastatic conjunctivitis; but he did not regard gonorrhœa as the direct cause of the inflammation. He only looked upon it as one exciting agent—perhaps the most frequent—of many that could set up rheumatism in subjects of a "peculiar constitution."

Mackenzie<sup>10</sup> in the third edition of his classic work§ gave a very full description of gonorrhœal iritis which even yet largely influences our ideas in regard to this form of inflammation; and in France, Ricord more than any other worker defined the characters of gonorrhœal eye affections of metastatic origin and differentiated them from contagious gonorrhœal ophthalmia.†

A study of the literature from this time on shows that a good deal of vagueness and confusion existed in regard to gonorrhœal iritis. Numerous authors of text-books and writers on iritis omit any mention of a gonorrhœal form; while others, making no sharp distinction between gonorrhœal rheumatism and "irregular gout" and rheumatism proper, describe as "rheumatic" or "arthritic" or "gouty" cases which were no doubt of this character. The venereologists, especially of the French school, had the condition always in mind; but one comes to Fournier<sup>21</sup> (1866) before gonorrhœal iritis is again clearly treated in a general way. This writer described under the term "ophthalmie rhumatismale" three separate conditions, namely, aquo-capsulitis, iritis, and metastatic conjunctivitis. He placed iritis as regards frequency second in the list; stated that it scarcely differed in its manifestations from simple iritis; and mentioned the plastic exudations in the anterior chamber,

\*See also Lawrence, Sir William. *Treatises on the Diseases of the Eye*. First ed., p. 233-236, 1833.

†The question was finally settled by the splendid work of Piringer, whose classic article, "Die Blennorrhœ am Menschenauge," was published at Graz in 1841.

§1840, p. 475-478.

†Fournier. *Nouv. Dict. de Méd. et Chir.*, p. 245.



which were, according to Mackenzie,<sup>10</sup> more common in this than in any other variety of iritis. In the following year (1867) Galezowski<sup>23</sup> made the strong statement "that rheumatic iritis non-gonorrhœal in nature was a rare thing," and described what he considered to be the special features of gonorrhœal iritis in a very succinct manner.

In the first edition of the monumental work of Graefe and Saemisch both De Wecker<sup>32</sup> (1876) and Færster<sup>33</sup> (1877) wrote strongly in support of a gonorrhœal iritis. The latter urged the necessity of examining the urethra as a routine procedure in cases of iritis. "Whoever," he said, "does this in every case of iritis, and especially elicits an exact anamnesis in every frequently recurring iritis, will soon find a number of cases in which no trace of syphilis, but a connection with gonorrhœa is present." Since the work of these writers, and as a result of the better understanding of the systemic phases of gonorrhœa, made possible by the discoveries of Neisser (1879), Petrone, Kammerer, Souplet, and many others, gonorrhœal iritis has received more recognition; though the views of the profession still differ in regard to its frequency and characters. The statistical analyses of personal cases by Nettleship<sup>41</sup> and by Collins<sup>112</sup> along these lines are worthy of special comment; and the paper of Griffith,<sup>120</sup> regarding the possibility of an iritis being a late and sole expression of a systemic gonorrhœal infection, created fresh interest in this field.

But, while gonorrhœal iritis was uninterruptedly recognized by all branches of the profession, the case was somewhat different with metastatic conjunctivitis. Once the contagiousness of gonorrhœal ophthalmia had been firmly established as a result of the prolonged discussion which followed the fresh importation of trachoma into Europe from Egypt by Napoleon's troops and the memorable experiments of Piriniger,† ophthalmologists went to the other extreme in their views regarding metastasis. After 1850 the followers of the new school of ophthalmology believed only in direct infection in cases of inflammation of the conjunctiva.\* The general practitioners of medicine and surgery never ceased to recognize metastatic conjunctivitis as a clinical entity; but the cases of this character which they reported were looked upon by the specialists as examples of a mild ophthalmia due to an attenuated gonorrhœal

---

†See Friedenwald, "Joseph Friedrich Piringer; His Methods and Investigations." *Johns Hopkins Bull.* Nos. 77-78, Aug.-Sept., 1897.

\*See Haltenhoff.<sup>80</sup>



infection. The classic article of Fournier<sup>21</sup> (1866), and the masterly paper of Haltenhoff<sup>60</sup> on this subject in 1885 commanded a great deal of attention, but made no deep impression. Ophthalmologists have been slowly forced into believing again in this form of gonorrhœal metastasis only as the result of a gradual accumulation of bacteriological data. These began with Rückert<sup>60</sup> and Trousseau,<sup>57</sup> both of whom described in 1886 a case of metastatic gonorrhœal conjunctivitis in which an examination of the conjunctival discharge for gonococci was entirely negative. Five years previously (1881) Haab,<sup>39</sup> and Hirschberg and Krause,<sup>40</sup> had reported cases of this kind with an absence of bacteria in the conjunctival secretion; but they did not fully appreciate the metastatic nature of the inflammation. They recognized that the condition was aberrant; but Hirschberg and Krause<sup>40</sup> without committing themselves stated merely that the von Græfe school would have looked upon their case as an "abortive" gonorrhœal ophthalmia, while Haab<sup>39</sup> regarded his case as one of simple acute conjunctivitis accidentally occurring during the course of a gonorrhœa. Since 1886 reports with bacteriological findings have been published by Liebrecht,<sup>71</sup> Vanderstraeten,<sup>72</sup> Morax,<sup>81</sup> Burchardt,<sup>86</sup> Gielen,<sup>101</sup> Lichtenstern,<sup>105</sup> Becker,<sup>106</sup> Van Moll,<sup>115</sup> Knapp,<sup>116</sup> Fage,<sup>128</sup> Kurka,<sup>138</sup> Apetz,<sup>144</sup> Thorner,<sup>149</sup> Sym,<sup>152</sup> Burnett,<sup>165</sup> Posey,<sup>174</sup> McEttles,<sup>171</sup> and Carroll.<sup>176</sup> Van Moll's paper<sup>115</sup> at the International Ophthalmological Congress in 1899, and Lawford's introductory remarks,<sup>132</sup> at Cheltenham, 1901, and the discussions which followed these addresses caused the profession very generally to realize that metastatic gonorrhœal conjunctivitis was no longer a fancy, but a distinct clinical entity.

Other conditions which have been attributed to systemic gonorrhœal infection are, in chronological sequence, as follows:

- 1872—Iridochoroiditis, by Koeniger.<sup>28</sup>
- 1882—Keratitis, by Colsmann.<sup>41</sup>
- 1882—Panophthalmitis, by Martin.<sup>45</sup>
- 1890—Optic Neuritis, by Panas.<sup>67</sup>
- 1894—Dacryoadenitis, by Panas.<sup>85</sup>
- 1894—Retinitis, by Burchardt.<sup>86</sup>
- 1895—Tenonitis, by Puech.<sup>92</sup>
- 1900—Thromboses of Retinal Vessels, by Galezowski.<sup>126 130</sup>



## II.—GENERAL CONSIDERATIONS.

(1.) **Pathological.**—The gonococcus, described first by Neisser in 1879, has been proven beyond all question to be the specific organism in gonorrhœa. Coming in contact with the urethra it enters the mucous membrane of this structure mainly through the cellular interstices; and rapidly produces a very positive chemiotaxis. A struggle then begins between the multiplying gonococci on the one hand, and the cellular elements of the body, largely here polynuclear leucocytes, on the other. Generally the gonococcus is overcome and the inflammation subsides; but often the tissues are only sufficiently strong to hold it in check; the organism adapts itself to its altered surroundings, becomes attenuated in fact; and lurks in the recesses of a chronically inflamed urethra—"gleet." That the gonococcus can exist for a very long period in the urethra has been demonstrated by Wertheim, who made cultures from a case of urethritis of two years' standing. Under these circumstances if the local conditions are rendered again favorable, through, say, excess in wine or coitus, the organism can resume its old virulency and cause a temporary flaring up of the smouldering inflammation. Numerous well authenticated cases are on record where an apparently healed specific urethritis has relapsed after some excess, and been accompanied by ocular or other general manifestations of systemic infection.\* The older writers were misled no doubt by these cases into believing in a non-specific urethritis, which was as much an expression of some rheumatic diathesis as were the articular manifestations. A case, cited by Fœrster, is illustrative of this point:

Case 2. (Fœrster<sup>33</sup>)—Gonorrhœa — Gonorrhœal Rheumatism — Recurring and Relapsing Iritis—Relapsing Urethritis.

A wealthy tenant farmer, aged 54, who had formerly suffered a great deal from gonorrhœa, but had had no further infection for twenty years, acquired iritis for the first time twenty-five years previously. From this date on, suffering almost every year for months at a time from rheumatism in the muscles or joints, he experienced also, about every four or five years, a recurrence of the iritis, now on the right side, now on the left. In

\*The most remarkable instance of this phenomenon is found in the report of Apetz, for which see p. 50. Read also Haltenhoff's case, p. 41.



1868 he was iridectomied by von Græfe; but he was again in the von Græfe clinic for three months in 1869 for a recurrence of the iritis. The attacks of iritis did not always coincide with the rheumatic affection. At times they preceded, at times followed it; but always a thin, yellowish discharge from the urethra appeared with the recurring rheumatism.

In the great majority of instances gonorrhœa remains a purely local affection; but in a small percentage of the cases it gains entrance into the general circulation. Here it may give rise to a definite septicaemia, some thirty-two cases of this kind having been described by Thayer and others; or, what is much commoner, to disseminated infections, "gonorrhœal metastases." Among the latter the commonest and best known are the joint affections known as gonorrhœal "rheumatism," which occur, according to Warren,\* in from two to three per cent. of all cases of specific urethritis. After the arthropathies the ocular lesions have received most general recognition; but of late years a very large number of conditions have been definitely laid at the door of the gonococcus.

Exactly what conditions favor the entrance of the gonococcus into the system are not known. Certain individuals are undoubtedly very prone to systemic infection by the gonococcus, and are liable to develop systemic manifestations with the acquisition of each fresh urethritis; but a previous lowering of the bodily strength from accident or sickness seems to play little or no part in the causation of their more widespread disorder. Lemierre and Faure-Beaulieu<sup>100</sup> after studying the literature could only point to the observation of Barbiani,† where the system was invaded in a diabetic, who recovered, and that of Doleris,‡ where a mortal infection occurred in a woman six months pregnant. Numerous writers have described a special type of person as liable to systemic infection; but there is little or no consonance between the different descriptions. The rheumatic diathesis has been frequently put forward as a predisposing cause, and it has been claimed that women are less susceptible to the disease than men. There are, however no definite figures at hand to prove this latter statement, and we must remember that men are more often affected with gonorrhœa than women; that in the male urethra the gonococcus has a larger surface upon which to grow than in the female organ; and that the male urethra and the associated prostate and vesiculæ

\*Int. Text-Book of Surgery, Vol. II., p. 756.

†Giom. Ital. della Mal. ven e della pelle, 1902, p. 9.

‡Presse Méd., July 11, 1900.



seminales, present greater opportunities for retention and increased tension than are present in the female genito-urinary parts. In any case it is now generally held that systemic infection usually occurs in those cases in males in which the posterior urethra and the contiguous structures are involved. In this connection the observations which seem to show that certain gonococci are more virulent and more prone to enter the system than others, are of interest. Several individuals, contaminated at the same source, have all been observed to develop systemic manifestations; and an experimental fact of Ahmann\* is still more suggestive. This investigator having inoculated the urethra of a healthy subject with gonococci isolated from the blood of a man affected with generalized gonorrhœal infection saw not only a urethritis develop but a septicæmia with secondary localizations in the synovial sheaths and the lung. Exposure to cold and, perhaps with more reason, laceration of the urethra by sounds and catheters have been put forward as causes which favor the entrance of the gonococcus into the system.

While the urethra is almost invariably the starting point of systemic gonorrhœa, it is well known that this condition may occur from an inflamed conjunctiva. A large number of cases of arthritis have now been observed to follow ophthalmia neonatorum; and in exceptional instances in adults the generalized infection may possibly have had its origin in a gonorrhœal conjunctivitis.

Case 3. (*Gonella*<sup>95a</sup>)—Gonorrhœa—Gonorrhœal Conjunctivitis—Double-sided Dacryoadenitis—Gonorrhœal Rheumatism.

*Gonella* saw a blenorrhœal inflammation of the conjunctiva of the right eye with gonococci in the discharge, develop in a young woman, aged 20, who suffered from vaginal gonorrhœa. After the inflammation had subsided and gonococci were no longer demonstrable in the conjunctiva there developed an acute, total, and bilateral dacryoadenitis. Subsequently the patient suffered from arthritis for more than a year; and this only subsided after the vaginal inflammation, which had been neglected up to this time, was healed. *Gonella* was inclined to believe that the dacryoadenitis in his case was of a toxic nature and was directly connected with the gonorrhœal infection of the conjunctiva as well as that of the vagina.

Case 4. (*Mengin*<sup>95</sup>)—Gonorrhœa—Double-sided Gonorrhœal Conjunctivitis—Polyarthritis—Metastatic Iritis.

A farmer, aged 28, was brought to *Mengin* in a helpless condition on January 9th, 1880. Examination showed an intense double-sided gonorrhœal conjunctivitis. About the beginning of October the patient had contracted gonorrhœa which he had allowed to go untreated and was still

---

\*Archiv. für Derm. u. Syph., Vol. XXXIX., p. 323-334, 1897.



present as a moderate discharge. On December 20th the left eye became affected with gonorrhœal ophthalmia and four days later the same condition made its appearance in the right eye. Between December 28th and January 4th a severe polyarthritis developed. The fever was intense and the patient was completely exhausted. The left eye went on to suppuration. Six weeks later (Feb. 24th), a large corneal staphyloma was present on that side; but in the right eye the cornea was clear and the vision normal. The arthritis improved, but the gonorrhœa became chronic.

On August 16th the patient returned with a very painful plastic iritis of the right eye of five days' standing. The left eye was perfectly quiet. After fifteen days of energetic treatment, though slight pericorneal injection remained, all the adhesions had been broken down, the fundus was well seen, and vision, which equalled hand-movements on admission, had risen to fingers at twelve feet. In this case it is to be noted that the arthritis appeared only after the outbreak of the conjunctivitis.

The pathology of systemic gonorrhœa is still in the making; but the accumulating facts seem more and more to show that the gonococcus itself is responsible for the metastases.† As our bacteriological technique improves, the role of the mixed and secondary infections becomes an ever less important one. Contaminations more seldom occur; and in the secondary lesions the gonococcus is being more often found in association with the staphylococcus, streptococcus, and pneumococcus, the organisms which, it is thought, can at times be solely responsible for the metastases. The existence of a gonotoxin has been placed beyond question by the work of numerous observers; but the action of this substance in the system is poorly understood. We do not yet know for certain if the poison is capable alone of setting up metastases, or what parts of the body it tends especially to pick out; if it can diffuse itself throughout the system from the initial point of infection, or if its action is a purely local one intimately associated with the presence of the gonococcus itself. On the other hand, a mass of evidence has now been collected which enables us to clearly follow the invasions of the gonococcus from the initial point of infection to the most remote metastases. They have several times been observed in abundance in thrombotic capillaries near the site of the primary inflammation; have been repeatedly grown in pure cultures from the blood; and have been isolated from lesions in practically every part of the body. The chain of evidence is indeed complete, and it remains more to establish the relative frequency with which the organism is at work.

---

†In the preparation of this section the writer owes special acknowledgment to the recent excellent paper of Lemierre and Faure-Beaulieu.<sup>166</sup>



The meagre bacteriological evidence, collected from cases of ocular metastases, is rather in favor of a gonococcal origin for the inflammations. Morax,<sup>81</sup> Burchardt,<sup>98</sup> Van Moll,<sup>115</sup> Knapp,<sup>116</sup> Kurka,<sup>138</sup> and Sym<sup>152</sup> (doubtfully) have described the organism in the secretion of cases of metastatic conjunctivitis, and Etievant<sup>142</sup> in the discharge from a case of suppurative dacryoadenitis.

To solve the question, which Axenfeld raised at the ninth International Ophthalmological Congress, as to whether the gonococci could possibly remain in the conjunctiva and from there produce the inflammation without passing into the secretion, Kurka<sup>138</sup> examined sections of a bit of the bulbar conjunctiva excised from one of his patients. He found the blood as well as the lymph vessels filled to bursting, while the epithelium of the conjunctiva was tolerably normal. In the stroma of the conjunctiva there existed a moderate accumulation of leucocytes, principally along the blood vessels, but without any suggestion of follicle-formation. Pathogenic organisms were nowhere to be found in the tissue. More recently Gendron<sup>161</sup> has examined with entirely negative results the hypopion removed by paracentesis from two cases of iritis which appeared for the first time as a complication of gonorrhœa and recurred without being accompanied by any fresh urethral symptoms. To explain these cases one must attribute the inflammation to the action of a toxine, or believe that the gonococci had already died out or were present in such scanty numbers as to escape detection. Similar reasoning applies to the negative findings in the case of iridocyclitis described in this paper, special cognizance being taken of the local conditions which prevented a complete inspection of the inflamed tissues.

One can surmise in a general way only in regard to the changes in the eye in gonorrhœal metastases, as no pathological material has been obtainable from cases of this nature. The gonococci are probably carried as emboli to the minute vessels of the eye; and through their growth and production of toxines excite the cellular proliferation. Judging from clinical features this is generally of a plastic nature; but in numerous instances the leucocytes are called forth so numerously that the exudation has a distinctly purulent character. It is worthy of note that in some of the reported cases of suppurative irido-choroiditis the pyogenic features followed a plastic phase, and this fact points rather to the presence of the gonococcus, whose pyogenic action is known to be somewhat evanescent, than to the pyogenic organisms proper, which would almost



certainly have produced an inflammation purulent from the onset. To explain the cases in which relapses occur, say, in the iris, repeatedly and long after the organisms have ceased to enter the system from the inflamed urethra, one must conjecture that the gonococci become encapsuled or dormant, as they often do in cases of urethritis, and break into fresh activity as the result of conditions which we do not at all understand.

The work of Stock\* teaches us how it may be that an organism, virulent as is the gonococcus when applied directly to the tissues of the eye, can yet produce comparatively mild results when acting in a metastatic way. This author injected into the general circulation through the veins of rabbits' ears cultures of bacillus pyocyaneus B. Ocular metastases were frequently produced, especially, as would be expected, in the iris and choroid; but these often created only slight inflammatory reaction and frequently ended in resolution. Cultures of the same organism, made from the deposits in the uveal tract, produced, however, when injected directly into the globe virulent panophthalmitis and destruction of the eyeball. The explanation is that in the one case the organisms were able to spread directly in the tissues; while in the other they found themselves within the capillaries, the walls and surrounding lymph spaces of which acted as a barrier to their progress.

(2.) **Clinical.**—There are certain features which characterize in a general way the various manifestations of systemic gonorrhœa; and these form especially in the eye a strong back-ground for the various local clinical pictures. One is struck at the outset by the uncertainty and irregularity which the ocular inflammations exhibit as regards the time of occurrence, the extent to which the parts are involved, the severity of their symptoms, and their course and behavior. These features are the outcome of several different factors.

The invasions of the gonococci depending upon the resisting powers of the tissues are indefinite both as regards time and number. They may occur at the height of an acute inflammation, or during the course of a chronic urethritis; and they may take place on one or several occasions. Nor can we, except in a very general way, premise the distribution of the cocci within the eye. Several parts of the globe may be simultaneously or successively affected; or the cocci may confine themselves to an isolated area. Clinically the profession has heretofore been generally willing to

\*Beilageheft. Festschrift zur Manz, Klin. Monats-Bl., 1902.



accept as gonorrhœal the ocular conditions occurring in association with other systemic manifestations; but it has shown much greater hesitancy in regard to the isolated inflammations in the eye. There have been good grounds for this because, in the present state of our knowledge, the diagnosis of these cases must necessarily be based upon clinical evidence. Still, since it has been definitely proven that a systemic gonorrhœa can confine itself solely to the valves of the heart or to a single joint, there is every reason to believe that it can find its sole site in one of the coats of the eye; that for instance an iritis may be the sole expression of a systemic gonorrhœa.† Nor is there any reason why the eye should not show the first manifestation of a general infection. As a matter of fact, as has been shown elsewhere in this study, it frequently does; and I only mention this point because the old idea of Ricord, passed on to us by DeWecker, to the effect that some joint mischief must always precede the development of the eye trouble, still finds expression in certain of our text-books.‡ A variation in the number and virulence of the gonococci themselves is another factor which undoubtedly adds to the protean character of the infections.

The tendency of gonorrhœal ocular metastases to relapse and to recur with each fresh urethritis are well known clinical features which have been already spoken of. The close association of changes in the eye with changes in other parts of the body is easily understood and should be always borne in mind. In any obscure affection of the eye in which gonorrhœa is suspected of being the cause, additional light might be obtained from a thorough examination of the internal organs, a bacteriological examination of the blood, and, if permissible, of the aqueous humor.

The varying phases of systemic gonorrhœa, especially as it affects the eyes, are well illustrated in the following well known case of Rückert<sup>60</sup>, which is here given in somewhat full abstract.

Case 5. (Rückert<sup>60</sup>)—Gonorrhœa—Ocular Inflammation and Rheumatism—Repeated Attacks of Inflammation of the Eyes—Second Gonorrhœa, Arthritis, Iritis—Third Gonorrhœa, Polyarthritis, Metastatic Conjunctivitis, Iritis, Iridocyclitis, Relapse of Urethritis, Iridocyclitis—Relapse of Urethritis, Iridocyclitis—Iritis and Arthritis Without Urethritis—Double Iridocyclitis, Herpes of Cornea, Arthritis—Iritis, Polyarthritis, Urethritis, Iridocyclitis, Conjunctivitis, Iritis, Polyarthritis.

A book-keeper, aged 29, acquired a gonorrhœa in 1882. He was there-

†According to Rollet,<sup>20</sup> Ricord long ago (*Leçons Cliniques*, *Gaz. des Hôp.* 1835-1853) clearly recognized this fact.

‡E.g.: Swanzy and Werner, *Diseases of the Eye*, 9th edit., p. 356, 1907.



upon seized by slight double-sided ocular inflammation, and shortly after this by articular rheumatism. Repeated attacks of inflammation of the eyes occurred between the years 1882-1884. In 1884 a second gonorrhœa was acquired and with it were almost immediately associated pains and swelling of the knee joint. In November of the same year he was received into the Erlangen Clinic for a right-sided iritis. Cloudiness of the aqueous and swelling and greenish discolorization of the iris were noted at that time; but there were no synechiæ or only those easily overcome by atropine. The patient was discharged, fully healed, after eight days' treatment. V=6/6 with -2.50.

On January 12th, 1885, the patient again presented himself for admission with the alarming diagnosis, made by physicians, of a beginning double-sided gonorrhœal conjunctivitis. A third gonorrhœa had been acquired on January 4th, and six days later signs of inflammation appeared simultaneously in both eyes and the right foot. On admission one made out a fresh gonorrhœal urethritis with moderate muco-purulent secretion. Both eyelids were slightly swollen, reddened, and somewhat stuck together with dried secretion; the conjunctiva was everywhere moderately thickened and markedly hyperæmic. The affection was more especially pronounced in the fornix and conjunctiva bulbi; but there was no noticeable chemosis, and the cornea and deeper structures on both sides were intact. By the second day the manifestations on both sides had subsided under appropriate treatment, and at the end of a week the process in the left eye was altogether extinguished. In the right eye, however, an iritis with pain and reduction of vision occurred on the fourth day. The iris was hyperæmic and swollen with indistinct tracery and a narrow pupil. At the end of six days, though the pupil had become well dilated and a temporary dulness of the cornea and marked cloudiness of the aqueous had largely cleared, an unfavorable extension of the inflammation to the ciliary body occurred. This showed itself through increased tension of the eye, pains in its vicinity, ciliary tenderness, and an exudation into the vitreous. This last mentioned became more apparent from the fact that in the following days the diffuse exudate in the anterior chamber which had existed until then now rolled itself back, like a cloud, and left a part of the pupil free. The absorption of the exudate in the anterior chamber proceeded quickly; but the vitreous exudate cleared slowly and finally remained so incomplete that on the discharge of the patient on the 13th of March, i.e., eight weeks after the commencement of the iritis or seven weeks after the obvious involvement of the ciliary body diffuse opacities could still be made out in the vitreous and the vision totalled scarcely 6/36 as against 6/6 at his previous discharge. The primary outbreak of inflammation in the eyes and foot was but the forerunner of a very widespread systemic infection. In the interval just covered, at least twelve large and small joints were involved; and the poly-arthritis was constantly accompanied by a considerable degree of fever of a remittent character.

On March 15th, the patient returned on account of diminution of sight and pain caused by a recurrence of the urethral discharge. No new gonorrhœa had occurred. There existed an iridocyclitis of the left eye which subsided at the end of three weeks with fully normal vision. Shortly after



this presentation in order prevent a recurrence an iridectomy was done on the right side the vision of which 6/60. The uncomplicated operation did not, however, have the desired result; for, fourteen days later, with simultaneous recurrence of the urethral discharge without new infection, a fresh inflammation occurred under the picture of a mild and quickly-coursing iridocyclitis with moderately-rich, fibrinous exudation. Six weeks after the last recurrence the patient was visited by a left-sided iritis which was unassociated with the urethral involvement but with a slight and localized joint affection in its later course. It differed from the former illness through the great persistence of the pains in the eye. This time also there was moderately rich exudation in the aqueous, diffuse at first, but later cloudy in appearance through rolling together of the opacity. The tendency to the formation of synechiæ was particularly marked, and the reaction to atropine somewhat imperfect, so that at the patient's discharge, five weeks later, the adhesions were not entirely overcome and the vision equalled 5-9th only, though one month later it reached the normal degree. From his exit on July 22nd, the patient remained well until the middle of September when there occurred without other manifestations, and with severe pain first a left and four days later a right-sided iridocyclitis which was marked by rapidly passing exudation in the anterior chamber and by rich synechiæ-formation. The last mentioned was accompanied on the right side by pains of the severest character, by a small herpetic eruption on the cornea, and by a slight affection of the joints of the left thumb. After a month's treatment the patient was discharged with vision equal respectively to 6/9 and 2/60; and he now rejoiced during a period of three and a half months in an uninterrupted state of good health.

From the end of January, 1886, to the middle of April, the patient was again visited by the whole connected series of protean affections above mentioned. First there occurred a slight recurrence of the iritis of the right eye, the course of which was perhaps hastened or rendered more mild through the continued use of atropine up to this time; and soon after a spreading polyarthritis of increasing severity made its appearance. During the continuance of this a fresh urethral discharge suddenly occurred without any new infection. At the beginning of March a right-sided iridocyclitis developed. All the characteristic signs were present and the vision was reduced to counting fingers at 1 ft. At the same time one had the impression that there existed an affection of the conjunctiva though the iridocyclitis stood out more prominently. Though under treatment all these manifestations quickly subsided, the left eye was again seized by a conjunctivitis of a catarrhal nature with swelling and hyperæmia of all parts of the membrane and rich secretion.

On the 7th day this had almost entirely disappeared and given place to an iritis, accompanied by a slight exudation. On the right side also the iritic process recurred for a short time in moderate intensity and then slowly subsided. An arthritic inflammation, present also at the beginning of March, became much more widespread with febrile manifestations.

(3.) **Therapeutical.**—The profession has not heretofore accorded to the metastatic gonorrhœal lesions of the eye that measure of



consideration which they deserve. Cases of this nature should not be treated as ambulatory patients. They ought, on the contrary, to be confined to bed as they carry within them the seeds of grave and even fatal disorders. The urethritis should receive serious attention; and the patients should be treated as those actually suffering from an infectious disease.

It seems well established that the metastatic localizations readily pick out points of lessened resistance.† Arthritis appears at times in articulations previously affected by other infections. Hochman has noted a metastatic phlegmon of gonorrhœal origin develop at a point contused a short time previously; and Busquet and Bicholenne have reported suppuration in a hæmatoma of some standing. The process is particularly frequent in endocarditis, where one sees the gonococcus become localized on valves which have been previously damaged. In certain cases, as first pointed out by Mackenzie,<sup>10</sup> the ocular inflammation seems to have followed upon excessive use of the eyes. For this reason the writer would lay stress upon the necessity of carefully protecting the eyes from exposure to strong light and of avoiding anything approaching eye strain, so long, at least, as one feels that systemic infection is in progress. It is not too fanciful to think that the extremely trying light of some of our rooms and public wards, and an overtaking of the ciliary muscle might bring about a state of lowered resistance favorable to the development of the disorder. As another prophylactic measure patients should be specially impressed with the serious danger they run in acquiring a fresh urethritis.

Quite recently efforts have been made to treat cases of this kind by a vaccine, according to opsonic principles, as laid down by Sir A. E. Wright. Successful results have been reported and the matter deserves serious consideration. The treatment of the special conditions is discussed in the various sections.

---

†De Lapersonne reports in his recent paper two cases in which a gonorrhœa had apparently started up fresh trouble in eyes previously affected by iritis and iridocyclitis of a purely rheumatic nature. Greff also publishes a report of this kind, but the evidence is insufficient.



### III.—AFFECTIONS OF THE CONJUNCTIVA.

#### A.—METASTATIC CONJUNCTIVITIS.†

**Definition.**—Metastatic gonorrhœal conjunctivitis is, as the term implies, an inflammation of the mucous membrane of the eye, due to the gonococcus which is carried from the urethra to the conjunctiva through the medium of the general circulation. It stands in the same relationship to the primary urethritis as does the so-called gonorrhœal rheumatism; and it is the opposite of the conjunctivitis due to direct gonorrhœal infection which is analogous to the primary urethral inflammation and may, like it, give rise to metastases.

**Frequency.**—There are no figures at hand to show exactly what percentage of cases of specific urethritis develop metastatic conjunctivitis. Almost every subsequent writer has copied Haltenhoff's<sup>50</sup> misunderstanding in regard to the statements of Fournier and White on this point. Fournier<sup>21</sup> has been frequently quoted as saying that metastatic conjunctivitis was fourteen times more common than gonorrhœal conjunctivitis from contagion; but this is incorrect. Fournier made this statement of rheumatic (metastatic gonorrhœal) "ophthalmia"; but, as he embraced under the term "ophthalmie rhumatismale" three separate conditions, namely, aquo-capsulitis, iritis, and metastatic conjunctivitis, and placed these conditions as regards frequency in the sequence mentioned, it can be easily seen how erroneous his estimate has been made to appear. What Fournier actually did state in regard to the inflammation under discussion was that, while metastatic conjunctivitis was rarer than the other two conditions (serous cyclitis, and iritis), it had several times come under his observation. In a similar way White<sup>47</sup> embraced under his "ophthalmie blennorrhagique" inflammations of the sclerotic, the iris, and the oculo-palpebral con-

†Of the various synonyms which have been put forward for this condition the terms "catarrho-rheumatic gonorrhœal ophthalmia" and "rheumatic ophthalmia" should be discarded. They imply a relationship with rheumatism which one knows in the light of present knowledge does not exist. "Gonorrhœal conjunctivitis without inoculation" is circumlocutory and indefinite. The term "metastatic" implies as clearly as "endogenous" an origin from within, and in addition gives the idea of infection from a distance. For these reasons the name "conjunctivitis gonorrhœica metastatica" or "metastatic gonorrhœal conjunctivitis" seems to the writer to be the one most applicable to this condition. The idea expressed in "conjunctivite blennorrhagique spontanée" cannot now be even considered.



junctiva. He did not make any assertion in regard to the frequency of metastatic conjunctivitis as compared with contagious gonorrhœal ophthalmia; but noted merely that one saw one case of blennorrhœal "ophthalmia" in every fifty to sixty cases of specific urethritis as compared with only one to seven hundred or eight hundred in the case of conjunctivitis from contagion.

Kurka<sup>138</sup> reporting two cases in 1902, stated that they were the first to be noted in the Vienna Clinic, notwithstanding that the material had risen to over twenty thousand new patients a year. I believe, however, that the condition is one of comparative rarity only, and that it will be oftener met with now that it has gained for itself a wider recognition. During the past nine years five instances of this affection have come under my notice in a material of about ten thousand patients, i.e., one in every eighteen hundred cases.

#### THE DISEASE AS PICTURED BY PREVIOUS WRITERS.

Before discussing the symptomatology of metastatic conjunctivitis, I shall first quote the general description of the condition given by the more prominent writers on the subject; and later criticize these in the light of a personal analysis of the cases recorded in the literature.

Fournier<sup>21</sup> in his classic article on gonorrhœa (1866) wrote as follows: "It is a simple conjunctivitis without association with iritis or aquo-capsulitis. All that we know about it is simply this: Injection of the conjunctiva either general and uniform or more pronounced at certain points, forming, as it were, islets of vascularization; slight secretion of catarrhal mucous, which collects at the inner angle of the eye or in the cul-de-sac of the lower lid; little or no lachrymation; slight ocular pruritis and sometimes even, in the most simple cases, absolute indolence: no photophobia: no alteration of vision. As negative phenomena note further; the absence of the radiate pericorneal circle: the integrity of the cornea, of the iris, and of the anterior chamber: the conservation of the movements of the pupil, etc. In a word, all the symptoms are limited to the conjunctiva. I have even observed certain cases in which the injection, slightly marked on the conjunctiva bulbi, was concentrated on the palpebral conjunctiva and the caruncle, forming thus at these points a very high degree of intensity. From this there resulted an odd appearance of the eye, the opening of which seemed framed in a reddish or purplish fringe, formed by the somewhat projecting border of the conjunctiva of the lids."

Fournier<sup>53</sup> in a lecture delivered at the Hôpital Saint-Louis in 1885 had this further to say of the condition: "An ophthalmia visible at a distance, absolutely typical, and characteristic: a variety of ophthalmia, to speak directly, called sero-vascular conjunctivitis. This conjunctivitis, when well marked, is so peculiar that it points to gonorrhœa of which it constitutes,



par excellence, a revealing sign, and by which one can almost positively diagnose a gonorrhœa before examining the urethra."

LeRoy<sup>61</sup> summarized thus the findings in the three cases reported by him in 1887: "The affection commenced by a slight smarting, and by an agglutination in the morning of the free margin of the lids. From this moment one could make out a very marked congestion of the ocular conjunctiva, which diminished in proportion as one approached the cornea. This redness took on presently an almost uniform tint so that there appeared to be a slight sanguineous extravasation in the sub-conjunctival cellular tissues. Little or no chemosis; whitish, thickened exudate, slightly abundant on the surface of the conjunctiva; integrity of the iris, and of the interior of the eye."

Fragne<sup>62</sup> in his *Thèse de Paris* (1888, p. vi.) gives the following sketch of metastatic conjunctivitis: "Without appreciable cause the bulbar conjunctiva becomes injected; and upon the background of vivid red further vascular sinuities stand out in brighter tint. Here and there an ecchymotic stippling. With the redness there is more or less intense swelling; and this, lying especially in the inferior and external angle, borders the cornea with a crescent-like chemosis. The tumefaction and the congestion are but slightly accentuated on the palpebral portions of the mucous membrane. Of secretion little or none; and yet, this eye, so inflamed, remains open, does not shun the glare of light, causes no pain, and scarcely any annoyance. The contrast between the actual tranquility of the patient and the apparent violence of the inflammation is a characteristic feature of this infection. Two further points are still to be noticed. The migrations of this conjunctivitis which, at the onset, attacking but one eye, quits this to invade the other, without, nevertheless, excluding an aggressive return to the first: and in the second place the coincidence, the correlation with gonorrhœa."

Lipski<sup>63</sup> in his *Parisian Thèse* (of 1895, p. 15) gives the following picture. "The conjunctivitis from internal cause commences insidiously; develops rapidly after the fashion of an acute infection; attains in a few days its apogee; and finally resolves. It coincides frequently with different manifestations of gonorrhœal rheumatism, and recurs with fresh gonorrhœas. It affects most often both eyes, but rarely confines itself to one. Both eyes can be simultaneously seized from the onset, or one eye is first affected and the other only invaded some days later. It is always a sero-vascular conjunctivitis, formed by a vascular injection and a serous sub-conjunctival chemosis. The eye is red and vascularized especially about the cornea; the conjunctiva bulbi is thickened by an œdematous infiltration; the functional disturbances are slight and altogether disproportionate to the intensity of the objective lesions; pain exists hardly at all—at most slight smarting or a little ocular pruritis. The same applies to photophobia; and the lacrimal secretion is exaggerated but in slight degree. It is precisely this singular contrast between this form of conjunctivitis and the common catarrhal conjunctivitis which becomes in this variety a suggestive diagnostic element and denotes its special origin."

Kurka<sup>138</sup> (1902) summarized the findings as follows: "It has to do always with an inflammation, which affects simultaneously or almost sim-



ultaneously both eyes, and whose principal seat is the conjunctiva of the globe. Generally the fornices are more and the tarsal-portion of the conjunctiva less affected. Clinically, metastatic conjunctivitis is characterized by great injection of the conjunctiva palpebrarum with slight swelling; by great swelling and deep episcleral injection of the conjunctiva bulbi; and by mucoid, thread-like secretion. The inflammation is accompanied by reflex manifestations such as pains, lachrimation and photophobia. These stand generally in the fore-ground of the disease-picture."

#### SYNOPSIS.

In studying these descriptions one sees that the writers agree in describing metastatic conjunctivitis as a benign inflammation of the conjunctiva in which the injection is most pronounced in the conjunctiva bulbi; and the discharge, mucoid or catarrhal in nature, is scanty or even, occasionally, absent. Its frequent coincidence with other gonorrhœal manifestations, its recurrence with repeated gonorrhœas, and its double-sided character are mentioned as expressive of its systemic nature. Lipski,<sup>88</sup> Fragne,<sup>63</sup> and Kurka<sup>138</sup> speak of the presence of swelling or chemosis, but there is an entire absence of any reference to roughening from papillary enlargement such as one sees in contagious gonorrhœal ophthalmia. Only Kurka diverges radically from the other writers on the question of the subjective symptoms; and slightly in regard to the character of the injection. Lipski and Fragne, following the description of Fournier,<sup>21 53</sup> emphasize the slightness of the subjective symptoms in comparison with the objective signs; and set forth this lack of relationship as a differential point between metastatic conjunctivitis and the other forms of inflammation of the conjunctiva. Kurka found, on the other hand, that the inflammation was accompanied by reflex manifestations, such as pains, lachrimation, and photophobia, which stood generally in the foreground of the disease picture; and, while the other writers confine the injection to the posterior conjunctival system of vessels, he brings forward deep episcleral injection of the conjunctiva bulbi as an accompaniment too of metastatic conjunctivitis. We shall see below how these divergent views stand in the light of a fresh analysis of the clinical data.

#### SYMPTOMATOLOGY.

The essential relationship which exists between metastatic conjunctivitis and gonorrhœa has of course been recognized by every writer believing in its existence; but the breadth of the tie has not been so generally realized. With the pathology of the condition



in mind, one can see no reason why metastatic conjunctivitis should not occur at any moment during the presence of the gonococcus in the blood, or be at times the sole expression of the systemic infection; and a digest of the reports yields fully what one would be led to expect. In a series of fifty cases in which these points are noted metastatic conjunctivitis occurred as the initial symptom of a generalized infection eighteen times; appeared simultaneously with other manifestations eleven times; and followed the outbreak of inflammatory phenomena elsewhere eleven times. In the remaining ten cases the conjunctivitis occurred as the sole expression of the systemic gonorrhœa. It is quite possible that many of the above cases, which include all that have heretofore found their way into the literature, were reported because of their unusual features; but it would appear that when metastatic conjunctivitis does occur it is often as an early expression of the systemic infection.

**Sex and Age.**—Of the thirty-eight cases in the literature in which the sex is given all were males. In thirty-two cases the age is stated; and the analysis only confirms the rule in regard to gonorrhœal affections, namely, that the period of greatest sexual activity yields the largest number of cases.

Arranged in half decades the figures are as follows:

15-19 inclusive.....	2 cases
20-24 " .....	9 "
25-29 " .....	11 "
30-34 " .....	2 "
35-39 " .....	3 "
40-44 " .....	1 "
45-49 " .....	1 "
50-54 " .....	1 "
55-59 " .....	2 "

**Simultaneous Onset.**—When both eyes are affected they very generally become involved at the same time. Of forty-three cases of binocular metastatic conjunctivitis the eyes were simultaneously invaded in twenty-one instances; were probably affected at the same time—though the fact is not definitely stated—in fifteen cases; and were involved in only seven patients, at an interval which varied from twenty-four hours (Haab,<sup>39</sup> Haltenhoff,<sup>50</sup> Becker<sup>65</sup>) to nine days (Trousseau<sup>57</sup>), and eleven and sixteen days (Fragne<sup>63</sup>). In the seventh case (Vanderstraeten's<sup>62</sup>) the length of the interval is not stated.



**Symmetrical Character.**—Metastatic conjunctivitis is almost invariably double-sided. In an analysis of forty-four cases I find that both eyes were affected in forty-two instances, while in two cases only was the inflammation unilateral. In its symmetrical appearance metastatic conjunctivitis follows, therefore, the rule of systemic infections. To the case of Thorner and the doubtful case of Fragne, which constitute the sole instances of monolateral metastatic conjunctivitis in the literature, the writer is able to add another. The cases are as follows:

**Case 6. (Fragne<sup>63</sup>)**—Gonorrhœa—Conjunctivitis—Arthritis—Second Gonorrhœa, Monolateral Metastatic Conjunctivitis.

Victor V—, aged 36, a "rheumatic," with plaques of eczema breaking out on the legs. Thirty months ago a blennorrhœa and conjunctivitis of uncertain duration. Since six months pain and swelling of the left elbow and lately pains in the left knee. Gonorrhœa for one month and since some days swelling of the conjunctiva of the left eye. This showed moderate redness of the conjunctiva bulbi and œdema downwards and outwards; but no pain or secretion. Observation interrupted by non-reappearance of the patient.

**Case 7. (Thorner<sup>149</sup>)**—Gonorrhœa—Polyarthritis—Monolateral—Conjunctivitis.

A waiter, aged 32, had a hard chancre in 1896; and received treatment for the same at intervals during 1897-98. He was infected with gonorrhœa in 1900, and about July 11th, 1903, he again noticed a discharge from the urethra; but whether this was the result of a fresh infection or a flaring up of the old inflammation is not stated. Nine days later a polyarthritis made its appearance; and to this was added at a further interval of ten days an inflammation of the right eye.

The patient was a well-nourished man, with a profuse urethral discharge, which contained numerous gonococci. There was a gonorrhœal arthritis affecting four joints. The left eye was normal; but on the right side there was great injection of both the bulbar and palpebral conjunctiva with moderate swelling of the latter portion of the mucous membrane. The injection occupied especially the periphery of the globe, leaving a zone around the cornea, about three mm. broad, almost entirely clear. The secretion, aquo-mucoid in character, contained no gonococci; the cornea was intact; and the interior of the eye normal.

The conjunctivitis began to mend about the fourth day; and had entirely subsided at the end of a week. The urethritis disappeared about three weeks after the ocular trouble; but the rheumatism persisted for a few months.

**Case 8. (Author's)**—Gonorrhœa—Monolateral, Metastatic Conjunctivitis.

A young man, aged 23, the subject of a gonorrhœa of five months' standing, was referred to me by Doctor J. G. McCarthy, on November 25th,



1901, for an ocular inflammation which had existed for six days. I found on examining the right eye, slight œdema of the lid, very marked congestion of the conjunctival vessels, and slight chemosis. The inflammation was more pronounced below than above, and was especially severe in the vicinity of the caruncle and plica semilunaris which were swollen and greatly reddened. There was no involvement of the anterior conjunctival vessels, and the cornea and iris were perfectly intact. The patient complained of itchiness and of a moderate amount of pain. Cover slip preparations of the discharge, which was very scanty, contained no gonococci; and inoculated tubes of specially-prepared agar and blood-serum were likewise negative. The left eye, which was bandaged as a precautionary measure, never became involved; and at the end of three days, during which a two per cent. solution of nitrate of silver was applied once every twenty-four hours, the right eye was practically well and the patient was discharged.

**Ocular Appearances.**—The literature affords thirty-two cases in which the character of the injection is fully enough described to enable one to more or less clearly appreciate the conditions present. In twenty-six of the thirty-two cases both the ocular and the bulbar conjunctiva were involved apparently as in any acute catarrhal inflammation. Occasionally the injection was largely or entirely confined to the palpebral conjunctiva (Haltenhoff,<sup>50</sup> Nobel<sup>80</sup>); or to the bulbar conjunctiva (Fragne,<sup>63</sup> Rückert,<sup>60</sup> Trousseau<sup>57</sup>); or to the fornix (Sym<sup>162</sup>); and not uncommonly the palpebral conjunctiva of the upper lid was entirely spared or less affected than that of the lower (Fragne,<sup>63</sup> Liebrecht,<sup>71</sup> Lichenstern,<sup>105</sup> Trousseau<sup>57</sup>).

In a few cases deep-seated congestion was observed in addition to congestion of the vessels of the posterior conjunctival system. Morax<sup>81</sup> notes in two of his cases "a very active congestion of the bulbar as well as the palpebral conjunctiva which is at the same time both superficial and deep-seated"; and in a third case describes "a deep-seated and superficial congestion of the conjunctiva bulbi of both eyes as in scleritis; not uniform but more marked at certain points, and without chemosis." In two cases cited by Scheffels<sup>114</sup> the coloration was of a peculiar rose-red, deep-seated character, and was especially marked in the conjunctiva bulbi; while, finally, Liebrecht<sup>71</sup> noted marked ciliary congestion in addition to pronounced swelling of the conjunctiva of both sides.

Œdema of the conjunctiva, often expressing itself as chemosis of the bulbar portion, is present in nearly fifty per cent. of the cases; but in three instances only (Haltenhoff,<sup>50</sup> Thorner<sup>149</sup>) was there any reference to a sand-like character or papillary enlargement in the mucous membrane. Swelling of the lids, accompanied at times by reddening, is present in about ten per cent. of the cases. It is



almost invariably slight. Only in Boquin's<sup>48</sup> case, one in which the disease ran its course as a pure inflammation of the conjunctiva, was the swelling "very" marked.

After carefully weighing the facts above enumerated one gets the impression that the clinical picture in metastatic conjunctivitis differs little if at all from that of any catarrhal inflammation of the conjunctiva. There is certainly nothing so special about the condition that one could say, as certain of the French writers have claimed, that the individual with the conjunctivitis was suffering also from a specific urethritis. Thorner's<sup>149</sup> statement that "peculiar and even characteristic for this form of inflammation is the pronounced reddening in the periphery of the conjunctiva bulbi while the parts bordering on the cornea maintain an almost normal appearance" is beside the mark. This is only a description of congestion of the posterior conjunctival system of vessels as one would expect to find it in any mild inflammation of the conjunctiva. Nor can the writer agree with Kurka<sup>138</sup> in placing "deep episcleral congestion" among the characteristic features of the disease. In a series of forty-six cases it was present in only six instances; and in some of these it may have been merely expressive of a developing inflammation of the deeper structures. Thus, for instance, in Liebrecht's<sup>71</sup> case iritis appeared on the fifth day of the disease; and in one of Scheffel's<sup>114</sup> patients the trouble went on to a chorio-retinitis. The condition, however, was present in three of Morax's<sup>81</sup> cases which ran their course without any involvement of the structures of the interior of the globe; but it would perhaps be better to regard these as aberrant types or classify them as instances of sclero-conjunctivitis. The writer observed a case of this character some years ago; and believes that in time a sufficient number of cases will collect to form a sub-group by themselves. (See also scleritis, page 58.)

**Amount and Character of the Secretion.**—In nineteen out of twenty-eight cases the discharge was slight; in four moderate only; and in five considerable in amount. As regards its character in a series of twenty-four cases it was:

Watery (? Serous) .....	in 1 case
Sero-mucous .....	in 4 cases
Mucoid (including catarrhal) .....	in 9 "
Muco-purulent .....	in 8 "
Purulent .....	in 2 "
<hr/>	
24 cases	



The opinions of former writers in regard to the scantiness of the discharge in metastatic conjunctivitis are substantiated by the facts; and with the secretion of a mucoid character in eighty-seven per cent. of the cases, one must surely place the condition among the catarrhal inflammations of the conjunctiva.

**Subjective Symptoms.**—When one comes to analyze the subjective symptoms one finds that the resulting data are at variance with the statements of former writers, particularly of the French school. In an analysis of twenty-three cases in which the point is noted, the writer finds only one case in which the subjective symptoms were entirely absent. Of the remaining twenty-two cases, the subjective symptoms, which consisted of burning, pricking, smarting, a feeling of grittiness, lachrimation, and photophobia, were slight or mild in thirteen cases, and marked or severe in nine cases. With these facts before one it is impossible to say that the subjective symptoms are, as Fournier<sup>21 53</sup> and his followers, Lipski<sup>88</sup> and Fragne,<sup>63</sup> have stated them to be, characteristically mild in comparison with the severity of the objective signs. Indeed, in some of the cases in which the objective appearances were least pronounced, the patients suffered most. On the other hand, while one cannot go so far as to say with Kurka<sup>138</sup> that the reflex symptoms stand in the foreground of the clinical picture, one must admit that he is nearer the truth than the French writers. Frankly, the figures are too few to justify any hard and fast conclusions; but it would not perhaps be far astray to say that the subjective symptoms of metastatic conjunctivitis are much the same as those of the group of inflammations of the conjunctiva to which it belongs; or, if anything, somewhat more severe.

**Course, Termination, and Complications.**—Gonorrhœal metastatic conjunctivitis runs its course as a pure inflammation of the conjunctiva in only about sixty-five per cent. of the cases; in the remaining thirty-five per cent. it becomes complicated by affections in other coats of the eye, some of which at least are also of the nature of metastatic inflammations. These latter when situated in the deeper structures of the globe constitute a clinical feature which ought to suggest the special character of the conjunctivitis as they are present in no other inflammation of the conjunctiva. As one would expect, the complications which involve the cornea are the most numerous; but, since these are liable to occur in any conjunctivitis, there is nothing necessarily striking in their appearance in the



metastatic variety. Nevertheless, as pointed out elsewhere (p. 56), the keratitis, which, whatever its mode of origin, accompanies systemic gonorrhœa and often stands in close relationship to the conjunctival inflammation, seems commonly to conform to a well-defined picture.

The manner in which the complications appear, as well as the time of their occurrence and their character, is very irregular. Both eyes may be affected at the same time and by the same condition, as in the cases of Legrand,<sup>142</sup> and Van Moll,<sup>115</sup> where both sides were simultaneously affected by a more or less symmetrical keratitis. On the other hand, the conjunctivitis may complete its course uncomplicated in one eye, and pass into some other condition in the other. This happened in Liebrecht's<sup>71</sup> case where the left eye, remaining normal, the right eye was suddenly affected on the fifth day by an iritis which later developed into a kerato-conjunctivitis; in Lichtenstern's<sup>105</sup> case where the left eye developed an irido-keratitis, the right remaining quiet; and in Rückert's<sup>60</sup> case where only right-sided irido-cyclitis made its appearance. As a third variation one eye may develop one condition, and the other another, as in the case of Froidbise,<sup>55</sup> where the conjunctivitis was followed almost immediately upon its subsidence by kerato-iritis in the left eye and a keratitis only in the right. There are not enough data at hand to speak positively, but it would appear from the available figures that the complications are as often symmetrical as unilateral in their appearance. The time of the appearance of the complications varies from "almost immediately" to six weeks, with an average of two weeks for nine cases in which the period is stated. As regards their character, the following conditions are noted in a series of twenty cases:

Keratitis .....	5 Times
Kerato-conjunctivitis .....	1 Time
Kerato-iritis .....	7 Times
Kerato-irido-cyclitis .....	1 Time
Herpes Corneæ .....	1 "
Iritis .....	1 "
Iritis with glaucoma .....	1 "
Irido-cyclitis .....	1 "
Scleritis .....	1 "
Uveitis .....	1 "



**Relapses.**—Relapses in metastatic conjunctivitis do occur. They are noted by Basset,<sup>56</sup> Becker,<sup>108</sup> and Thorner.<sup>149</sup> In two of these cases the return was symmetrical; in one (Thorner) unilateral. More often one gets a relapse of the conjunctivitis in association with some other condition as, for instance, keratitis (Liebrecht,<sup>71</sup> Legrand,<sup>142</sup> Sym,<sup>152</sup> Vanderstræten,<sup>72</sup> Paul<sup>163</sup>) or chorio-retinitis (Scheffels<sup>114</sup>). I have not been able to find any case in the literature marked by migrations from one eye to the other, as described by Fragne.<sup>63</sup>

**Duration.**—The duration of the cases which run a pure course varies from five days (Gielen,<sup>101</sup> Haab,<sup>39</sup> Liebrecht<sup>71</sup>) to forty-six days (Fragne<sup>63</sup>). The average duration of twenty-nine cases was approximately two weeks. The different periods, tabulated, are as follows:

5-10 days (inclusive).....	16 cases
11-15 " " .....	4 "
16-20 " " .....	4 "
21-25 " " .....	0 "
26-30 " " .....	3 "
38 " " .....	1 "
56 " " .....	1 "

**Diagnosis.**—The diagnosis has to be made between acute catarrhal conjunctivitis on the one hand, and contagious gonorrhœal conjunctivitis on the other. A microscopical examination by methods which are too well known to require description here, in revealing an entire absence of gonococci and of the bacterial excitors of catarrhal inflammation of the conjunctiva would readily differentiate metastatic conjunctivitis from these conditions. The problem in regard to contagious ophthalmia might be difficult if one found as Morax,<sup>81</sup> Knapp,<sup>116</sup> Van Moll,<sup>115</sup> Sym<sup>152</sup> (?), Burchardt<sup>98</sup>, and Kurka<sup>138</sup> have done, gonococci in the secretion of the metastatic inflammation; and the cases were, as rarely happens, unilateral in character. Here the scarcity of the organisms, the mildness of the subjective and objective symptoms, the absence of any history of gonorrhœal material having come in contact with the eye, and the presence of other manifestations of systemic gonorrhœa would excite suspicion; and time would soon reveal the true nature of the case if it were really one of contagious conjunctivitis.



**Prognosis.**—The prognosis in pure cases of metastatic conjunctivitis is entirely good; but one must be guarded in view of the frequency with which, as previously pointed out, the condition is complicated by inflammations in other coats of the eye.

**Treatment.**—The treatment is of the mildest character. Simple bathings of boracic acid with the daily application of a mild solution of nitrate of silver where the secretion is at all marked, or, in the absence of secretion, simple cleansing drops of boracic acid and biborate of soda are sufficient. In unilateral cases the other eye will, as a matter of routine, be protected until the true nature of the inflammation is apparent. (See also p. 22.)

#### B.—PHLYCTENULAR CONJUNCTIVITIS.

In two cases observed by Kipp<sup>36</sup> phlyctenules appeared in the course of ocular inflammations which were thought to be of gonorrhœal origin. Their occurrence may have been merely a coincidence; but it is worthy of special note, in view of the frequency with which, as pointed out elsewhere, keratitis of a superficial character occurs in these conditions. Brief extracts of Kipp's cases, which are fully reported in the section on inflammation of the uveal tract, are as follows:

Case 9.—Two and a half months after the entire subsidence of the congestion in a case of exudative gonorrhœal iritis there was a recurrence of pain with injection of the vessels near the other margin of the cornea caused by the development of a phlyctenule in the limbus which, however, speedily disappeared.

Case 10.—Four months after the subsidence of the pericorneal congestion in a case of double-sided iridochoroiditis, with which was associated a certain amount of mucous secretion from the conjunctiva, K. noted fresh ciliary congestion and a few phlyctenules on the margin of the cornea of both eyes. These, however, disappeared under dustings of calomel in a few days.



#### IV.—AFFECTIONS OF THE CORNEA.

---

Although isolated cases of keratitis have been described in association with systemic gonorrhœa the metastatic affections of the cornea of gonorrhœal origin have never been treated in a general way. Even yet an attempt in this direction may be premature, because the material available for study is small in amount and rests entirely on clinical evidence which is often of a superficial character. The writer fully realizes that to build up a subject of this nature at this time without bacteriological data is comparable to building a house upon the sands: nevertheless the present effort may be of value in presenting what has been already noted in this direction, in clearing the ground, and in drawing attention to clinical possibilities which have not as yet found general recognition.

In his recent excellent work Axenfeld† points out that it is impossible for the pus-producing organisms to settle in a part of the transparent tissue of the cornea which is entirely separated from the margin and there set up an isolated abscess; because these germs do not lead to abscess formation at some distance after spreading in the avascular tissue, but immediately act as excitants at the point where they leave the vessel wall. This reasoning while sound does not, however, necessarily bar the possibility of gonorrhœal metastases. It has been proven of late years that the gonococcus gains entrance to the body, largely if not chiefly, through being carried into the general circulation by the attacking leucocytes; and that with the death of the white cells in distant parts of the body the germs are set free to produce local changes. As the leucocytes are free to enter the lymph spaces of the cornea, gonorrhœal metastases of this structure cannot at least be regarded as an impossibility. To the bacteriologist, who has so far done nothing in this direction, the metastatic affections of the cornea of gonorrhœal origin offer a promising field for development. The difficulties are great and perhaps not as yet entirely surmountable; but a few exact investigations in cases of this nature would be of the greatest interest and scientific value.

---

†Die Bakteriologie in der Augenheilkunde. Jena, 1907, p. 322.



A thorough search of the literature yields 28 cases\* in which a keratitis existed in association with other manifestations of systemic gonorrhœa. A few of these are of little value; but, as they occupy little additional space, the whole series is given in chronological order below, the better to obtain a complete idea of the work done in this field.

One has to decide at the onset in these cases, first, whether the corneal complications were really symptomatic of a systemic gonorrhœa, or merely instances of a keratitis accidentally occurring in the course of a gonorrhœal rheumatism; and, in the second place, granting that the corneal affections were part of a generalized infection, if they were true metastases or merely secondary inflammations resulting from a pre-existing metastatic conjunctivitis. The decision in regard to the first point seems clear. As a rule throughout the whole series the relationship of the corneal to the other general disturbances is so close that one is forced to believe that, whether directly or indirectly produced, keratitis occasionally occurs as an accompaniment of systemic gonorrhœal infection; but the determination of the second question is not so simple. As stated above, the whole evidence for these cases is of a clinical nature, and one can therefore make only general inferences in regard to their mode of origin. It will, however, be probably admitted that, generally speaking, an absence of any previous conjunctivitis, multiple foci, a central situation, a symmetrical arrangement, and a simultaneous onset or close association of the keratitis with other ocular or general manifestations of systemic infection speak for a primary origin; while a history of a preceding conjunctivitis, a single focus, a marginal situation, and an asymmetrical (monocular) arrangement, and an absence of other general manifestations are in favor of a secondary inflammation of the cornea. It is not necessary that all these characters be present before we can decide that a case is metastatic.

---

\*The case of Lichtenstern,<sup>105</sup> which makes twenty-nine, was overlooked in the working up of this section; but the figures given are not essentially altered by its omission. The case was that of a male, aged nineteen, who developed a double-sided, metastatic conjunctivitis seventeen to eighteen days after the acquisition of a specific urethritis. Gonococci were found in the urethra, but not in the conjunctival discharge; and blood cultures were negative. The conjunctival inflammation on the right side subsided without any complication; but in the left eye a hyperæmia of the iris, going on to actual inflammation of this structure, developed slightly in advance of an arthritis, and was associated in about ten days with a moderately-large, circumscribed infiltration in the centre of the cornea. The keratitis was very probably an expression of the systemic infection, but is not fully enough described to admit of exact classification. It entirely disappeared in thirty-eight days. See also the doubtful case of Eliasberg,<sup>79a</sup> and the recent case of Carroll.<sup>176</sup>



Our determination must be based upon the sum of the conditions found. Thus, for example, the bilateral nature of a keratitis might be due to coincident infection of both eyes; but, in general, the greater probability lies in favor of metastasis. Conversely, one eye only being affected is by no means proof positive of the non-metastatic nature of the affection. We have abundant examples in other diseases where metastases may involve one only of a pair of organs. In pyæmia, for instance, we may encounter multiple minute abscesses in one kidney and none in the other. Briefly stated then, an asymmetrical arrangement by no means militates against the theory of systemic infection, while the contrary heightens its probability. At any rate, working from these premises I have tried to form an idea of the probable nature of the inflammation in every case found in the literature, and to succinctly state this at the end of each report as follows:

Case 11. (Lawrence<sup>6</sup>)—Gonorrhœa—Rheumatism—Iritis or Episcleritis—Keratitis.

Mr. F. had a mild attack of gonorrhœa (his second) at the age of 29. It was followed after seven weeks by rheumatism of the feet and hip and by an inflammation which was of the nature of an iritis or episcleritis. In four days the eyes regained an almost normal appearance. Six weeks later they were free from pain, but weak when the inflammation returned. There was ciliary congestion on both sides and a small white speck near the centre of the left cornea. There was considerable pain, profuse lacrimation, and dimness of vision particularly on the left side. Nine days later the eyes were quite well and the patient returned to his occupation at the end of a month.

Though the meagre details of this case render it of little value it is rather clear that the keratitis followed in the train of an ocular disturbance which was apparently produced by systemic gonorrhœal infection.

Case 12. (Brandes<sup>12</sup>)—Repeated Gonorrhœas—Facial Paralysis—Rheumatism—Recurrence of Urethral Discharge without Fresh Infection—Ophthalmia and Rheumatism—Kerato-Iritis.

From 1838-1840 the patient had three attacks of gonorrhœa, the last being followed by facial paralysis after exposure to cold. In 1841, a fourth gonorrhœa was complicated in eight days by rheumatism which recurred in 1842, 15 days after the commencement of a urethral discharge not due to fresh infection. 1844, discharge, followed by slight ophthalmia and arthritis; 1845, discharge and rheumatism; 1846, discharge, after an excess, with ocular inflammation and arthritis; 1847, attacked in the same manner; but the ocular inflammation was not on this, as on the first occasions, a simple con-



junctivitis. Injected vessels extended from the margin of the cornea which became slightly opaque and infiltrated. There was a tiny spot in its inferior portion and the iris was also a little affected.

One had to do here with a monolateral, marginal ulcer the nature of which is altogether doubtful.

Case 13. (**Legrand<sup>14a</sup>**)—Gonorrhœa—Metastatic Conjunctivitis—Polyarthritis—Relapse of Conjunctivitis—Keratitis.

A man, aged 22, of habitual good health, was attacked about fifteen days after acquiring a gonorrhœa by an inflammation of the conjunctiva which simultaneously affected both eyes. At the end of about two weeks when, notwithstanding an intervening outbreak of polyarthritis, the injection of the mucous membrane had practically disappeared, a relapse of the conjunctivitis occurred. The inflammation affected especially the right eye and was followed in six days by a double-sided keratitis. The corneæ were lustreless and showed very slight ulceration when viewed from the side. There was pericorneal congestion and very marked photophobia and blepharospasm. The corneæ re-acquired their lustre in three days, and at the end of a month all signs of the ocular inflammation had disappeared.

An example of a relapse in metastatic conjunctivitis. The origin of the keratitis is doubtful as one had here a preceding conjunctivitis to speak for a local contamination and a symmetrical arrangement for metastasis. That the keratitis was here a part of the systemic trouble and not an accidental infection is scarcely to be doubted.

Case 14. (**Hutchinson<sup>29</sup>**)—Several Attacks of Gonorrhœa, followed by Liability to Severe Facial Rheumatism, and to Relapsing Balanitis in Association with Rheumatism—Recurrent Iritis of Both Eyes, with Secondary Cataract of One—Corneal Ulceration with Disorganization of the Cataractous Eye and Almost Complete Blindness of the Other.

Joseph K., aged 35, with a doubtful history of remote syphilis, had gonorrhœa on several occasions and rheumatism for the first time after one of these attacks. Following the first seizure he had had many attacks of rheumatism, often being laid up for two or three months at a time. It affected the muscles and his joints did not swell. On several occasions he had attacks of profuse balanitis and his impression was that they came on spontaneously in association with his rheumatism.

He was first sent to Mr. Hutchinson in the spring of 1870 on account of iritis of both eyes. He was also suffering severely from rheumatism and there was a cataract in the right eye which had been forming for several months before the pain and inflammation set in. He was seen again in March, 1871, for a relapse of iritis in the left eye and a perforated cornea in the right. His right eye had been inflamed for three months and his left for six weeks on this occasion. He had had rheumatism with this



attack of iritis; and at this time, as well as on his first visit a year earlier, he had profuse balanitis. The iritis in the left eye became worse; the whole iris grew muddy, and the pupil obscured; there were no nodules of lymph and the whole attack was not accompanied by much pain. The right eye was quite lost, when he came for the second time; its tension diminished, iris in contact with cornea, anterior chamber leaking through a fistula left by the perforating ulcer, and the eye a possible source of irritation to its fellow. The iritis continued in a slow chronic form, and the artificial pupil became almost gradually blocked, so that three weeks later another iridectomy was made. Vision remained about as before the operations, and was extremely defective. There was never any increase of tension.

The right eye, which was quite disorganized, was excised. The choroid was widely separated from the sclerotic and the retina from the choroid. The spaces between these tunics were filled by bloody fluid, and there was much cholesterine lying loose on the choroid. The epithelium of the choroid was disturbed in places and accumulated into dense heaps of black. The lens was opaque.

In this case a keratitis leading to perforation developed six weeks before rheumatism, left-sided iritis, and balanitis broke out; but whether the corneal condition was the first outbreak of a new systemic infection or occurred quite independently of the other manifestations it is impossible to say. It is certainly not to be regarded as secondary as there was no conjunctivitis immediately preceding.

**Case 15. (Kipp<sup>30</sup>) — Gonorrhœa — Arthritis — Conjunctivitis — Suppurative Keratitis—Iridochoroiditis.**

Two months after the subsidence of a right-sided conjunctivitis, possibly metastatic in character, there developed a small ulcer of the cornea which healed rapidly under treatment. The same eye was affected some fourteen weeks later by an iridochoroiditis.

This case is more fully reported in the section on plastic as one of metastatic iridochoroiditis. The details concerning the cornea are too few to make the report of any value in this section.

**Case 16. (Hirschberg and Krause<sup>40</sup>)—Gonorrhœa—Inflammation of the Conjunctiva—Keratitis.**

A forty-four year old laborer had had ten years previously a gonorrhœa followed by an ocular inflammation which ran a course similar to the one described, but milder. The gonorrhœa returned May 19th, 1881, and was again followed by an affection of the eyes. The lids were swollen and reddened, but could be spontaneously opened. There was moderate chemosis and intense redness of the palpebral conjunctiva and fornix with moderate swelling of the same. The discharge at first profuse was slight



in amount at the time of examination. The bacteriological examination was negative. At the end of sixteen days, when the conjunctival inflammation was almost allayed, a slight marginal infiltration of the cornea occurred. A second, small infiltration appeared about two weeks later, but rapidly healed.

Though the conjunctivitis in this case followed close upon a fresh urethral infection its metastatic nature is rendered somewhat doubtful in a clinical way through the absence of other manifestations. The bacteriological findings come too early to exclude the other organisms which were later recognized as producers of conjunctivitis. If one allows any connection with systemic gonorrhœa in this case the two attacks of keratitis were probably secondary in nature as the inflammation was preceded by a conjunctivitis and affected the margin of the cornea.

**Case 17. (Haltenhoff and Martin<sup>45</sup>)—Gonorrhœa—Prostatic Abscess—Pyæmia—Metastatic Panophthalmitis.**

A clerk, aged 24, previously treated for ciliary blepharitis, entered the hospital November the 27th, 1879, with high fever, cough, thoracic pain, pain in the shoulder joint, enlargement of the spleen and some blood and albumen in the urine. The disease had commenced with chilly sensations followed by rigors. On December 1st, injection of the left eye was first observed and some days later double-sided parotitis. While the symptoms of a right-sided pleuro-pneumonia continued with high fever and several joints became swollen and painful, there developed during the following days a progressive annular abscess of the cornea with hypopion, slight œdema of the lid, and severe iritis with pupillary exudate. T + 2; V, only hand movements. A diagnosis of metastatic iridochoroiditis was made. On December 9th, the whole cornea was yellowish infiltrated, and the following day endo—and pericardial symptoms were added. Consciousness was always clouded and there was severe dyspnœa and fever of high grade. The cornea perforated downwards and the patient died on the 13th.

It was subsequently learned that the patient had recently suffered from a gonorrhœa and the post mortem examination revealed a most extensive pyæmia secondary to a prostatic abscess which had been caused by the gonorrhœa. No histological examination of the eye was made because of its having been lost.

Here the ocular condition, which from its obvious relationship to the other pyæmic lesions was clearly metastatic in nature, took the form of a suppurative keratitis and iridochoroiditis with secondary glaucoma. One is not told if the gonococcus itself was responsible for the infection but, as the pyæmia did result from a prostatic abscess set up by the urethritis, one must consider that the gonorrhœa was primarily responsible for the metastases and that the corneal affection was a metastatic keratitis of gonorrhœal origin.





## AFFECTIONS OF THE CORNEA

41

Case 18. (Colsman<sup>41</sup>)—Gonorrhœa—Polyarthrititis—Superficial Keratitis with Hyperæmia of the Iris—Relapse of Keratitis—Kerato-Iritis.

The patient, aged 38, when seen by Colsman was suffering, in addition to an inflammation of several joints which had come on during the course of a gonorrhœa acquired six weeks previously, from an inflammation of both eyes of several days standing.

On both sides, without any involvement of the conjunctiva but with intense injection of the episcleral vessels and severe ciliary neuralgia, there was a peculiar disease of the corneal epithelium. This was completely wanting over moderately large parts of the cornea, while on the other hand this structure was clouded at other spots. The substantia propria was not materially altered. The iris was markedly hyperaemic since it dilated slowly under atropine. Synechiae were not present and otherwise no morbid processes were observable in the eyes. The treatment, which consisted of atropine and ice compresses, produced a rapid subsidence of the pain; and after some days the cornea regained their normal appearance. After a pause of scarcely two weeks a second attack of ocular inflammation appeared; but this subsided more quickly than the first under the same treatment.

A third, more severe attack, which occurred at the end of two months was reported to Colsman by Doctor Stachelhausen. This time the inflammation lasted three weeks, was characterized by more marked involvement of the iris, and led to the formation of adhesions between the iris and lens capsule. The inflammatory manifestations subsided first after sodium salicylate had been regularly taken for four or five days. Many years previously Colsman had treated the same patient for an ocular affection which might have been of a similar nature.

This was apparently a case of vesicular keratitis, almost certainly metastatic in nature since there was no pre-existing conjunctivitis and the affection occurred symmetrically and in association with an outbreak of arthritis. The third attack which took the form of an iritis with synechia-formation strengthens this view.

Case 19. (Haltenhoff<sup>50</sup>)—Gonorrhœa—Recurrence of Urethritis without Fresh Infection—Metastatic Conjunctivitis—Arthritis—Vesicular Keratitis—Second Gonorrhœa, Metastatic Conjunctivitis, Lumbago, Arthritis.

The patient, a bank clerk, aged 26, consulted Haltenhoff on January 27th, 1879, for a very painful inflammation of the right eye. There was no history of previous rheumatism or ocular affection. In 1874 the patient, previously quite healthy, acquired a gonorrhœa which became chronic and lasted eighteen months. In 1878 he was taken ill with a gastro-enteritis which he attributed to change of climate and indiscretions in diet. This was soon followed by a mild urethritis with slight mucoid secretion. Opportunity for coitus had not occurred. The patient was well aware of the danger of the urethral secretion, and denied the possibility of having soiled the eyes, "since he took pains never to touch his sexual organs with uncovered



hands." On the second day following the urethral manifestation one eye, and on the third day the other eye, became affected with catarrhal conjunctivitis with moderately profuse discharge. On the fourth day severe arthritis broke out which confined the patient to bed for one month.

About two weeks after the beginning of the ocular catarrh new symptoms were added which the attending physician designated herpes of the cornea. When Haltenhoff saw the patient he had just returned from his trip, in consequence of which the ocular affection of the right side had grown worse. There were found in the cornea of this eye, which was markedly injected and photophobic, several epithelial vesicles and a pair of light-grey spots, evidently resulting from former vesicles. There was still scarcely a trace of conjunctivitis present, no fever, and only traces of clear mucous from the urethra. The eye healed rapidly; the arthritis only slowly under treatment.

In March, 1882, the patient again contracted a slight gonorrhœa which was immediately followed by a double-sided conjunctivitis. The urethritis soon got well; but the conjunctiva became more inflamed and secreted some muco-pus. A lumbago set in and confined the patient to bed. The eyes were cured in two weeks; but an arthritis, similar to that of three years previous, now broke out; and from this the patient did not recover for nearly six weeks.

One had to do here with a vesicular keratitis; but it is impossible to say whether this was of the nature of a primary manifestation of the scarcely-questionable systemic infection or of a corneal inflammation secondary to the pre-existing conjunctivitis.

Case 20. (Haslund<sup>51</sup>)—Gonorrhœa, followed by Ocular Inflammation and Arthritis—Recurrence of Urethritis with Double-Sided Conjunctivitis and Arthritis—Relapse of Conjunctivitis with Keratitis.

A tinker, aged 21, acquired a gonorrhœa which was treated ambulatorily. At the same time there was slight redness and irritation of the right eye, and swelling and sensitiveness of the left knee which disappeared without treatment. Half a year later purulent discharge again appeared from the urethra, and this was followed by a double-sided conjunctivitis and an arthritis of the left knee in four and two days respectively. The ocular condition and the joint, which was aspirated, gradually improved for two weeks, when the conjunctiva again flared up and an infiltration appeared in the right cornea. On the following day a similar condition appeared in the left cornea and in both places superficial ulceration developed. The conjunctivitis disappeared and the corneal ulcerations healed within a month without leaving any opacities behind.

Though a conjunctivitis here preceded the superficial affection of the cornea the symmetrical character of the latter speaks for metastasis.



Case 21. (Rückert<sup>60</sup>)—Repeated Attacks of Urethritis and Ocular Inflammation—Fresh Relapse of Urethritis and Cyclitis—Iritis—Iridocyclitis—Vesicular Keratitis with Arthritis, Etc.

In Rückert's case, after an immunity from symptoms of nearly two months duration, there occurred without other manifestations, but with severe pain, first a left-sided, and four days later a right-sided iridocyclitis, which was marked by rapidly-transitory exudation into the anterior chamber and by rich synechia-formation. The last mentioned was accompanied on the right side by pains of the severest character, by small herpetic eruptions on the cornea, and by a slight affection of the joints of the left thumb.

In this case, which is fully reported on page 19, the absence of any pre-existing conjunctivitis and the simultaneous outbreak of the iridocyclitis, herpes corneæ, and arthritis speak for a metastatic keratitis.

Case 22. (Froidbise<sup>55</sup>)—Gonorrhœa—Arthritis—Metastatic Conjunctivitis—Relapse of Conjunctivitis with Kerato-Iritis—Superficial Keratitis.

A soldier was admitted November 18th, 1884. Coitus had occurred on November 9th. On the 14th, the left knee become painful and swollen; on the 15th, urethral discharge was noticed; and on the 17th, redness of the eyes appeared.

Examined on the 18th, one found acute arthritis of the left knee. Intense injection of the conjunctiva without papillary enlargement and large vessels, starting from the fornices, extending on to the conjunctiva bulbi. No deep-seated congestion; cornea and iris negative. A little mucous concretion along the margins of the lids. Urethritis, with comparatively little discharge. Two days later improvement set in.

On the 26th, the eyes, which had resumed their normal aspect, again showed a very marked conjunctival hyperaemia; and on the left side there was, in addition, slight, deep-seated, pericorneal congestion with discolorization of the iris, diminution in size of the pupil, and slowness in reaction. The cornea showed small points of superficial desquamation and its inferior portion was clouded. The patient complained of dryness of the eyes and of a sensation of sand beneath the lids. There was photophobia, but no periorbital pain or purulent secretion. On the right side, where the injection was less marked and the iris intact, the cornea showed on the following day a condition similar to that of the left. By December 5th, the eyes had returned to their normal condition; but towards the end of the month a fresh outbreak of superficial keratitis occurred. This, however, promptly recovered.

Here, too, though there was a pre-existent conjunctivitis the symmetrical and multiple character of the keratitis would speak for a systemic origin.



Case 23. (**Friedenberg**<sup>69</sup>)—Gonorrhœa—Arthritis—Iritis—Keratitis.

In Friedenbergs case, two weeks after the acquisition of a gonorrhœa and one week before the outbreak of a spreading polyarthritis, the right eye became affected by a violent uveitis and keratitis. The cornea, at first steamy throughout, became more and more affected until eleven days later it was noted to be "densely infiltrated with flocculent yellow exudation in the anterior chamber." Under treatment a rapid clarification of the cornea preceded a more gradual resolution of the uveal inflammation.

The concomitant outbreak of the keratitis with the uveitis, and the subsequent occurrence of polyarthritis would seem to indicate that the keratitis was of a metastatic nature. The case is more fully reported on page 83.

Case 24. (**Vanderstræten**<sup>72</sup>)—Gonorrhœa—Metastatic Conjunctivitis—Subsidence—Arthritis and Fresh Outbreak of Conjunctivitis with Keratitis and Hyperæmia of the Iris.

A male, aged 20, had had gonorrhœa for fifteen days. Following the urethritis, at a period not stated, the right eye and then the left became affected without pain and only slight subjective symptoms. There was slight swelling of the lids, especially the lower one. The palpebral conjunctivæ were markedly hyperæmic, of a vivid, uniformly red color, and smooth. The redness extended to the conjunctiva of the cul-de-sac and globe, but did not reach the cornea except at very circumscribed points. In certain areas it had the appearance of ecchymotic taches. Slight serous chemosis on the right side. The discharge was muco-purulent and slight. It contained no gonococci on microscopical examination.

At the end of eight days, when the conjunctivitis was plainly resolving, an arthritis made its appearance; and twenty days later a fresh conjunctivitis occurred. The conjunctival discharge this time also was free from gonococci; but there was photophobia, spasm, and pain on moving the eyes on both sides. The cornea had lost its lustre and transparency, and was the seat of an epithelial exfoliation which occupied especially its centre. There was moderate pericorneal injection, deep anterior chamber, and transparent aqueous. Pupil a little contracted and slightly mobile. Iris swollen and hyperæmic. Complaints of slight periorbital pains and sensations of burning and a foreign body.

The symptoms mended insensibly, and at the end of twelve days the affection had almost resolved without leaving any trace of the previous inflammation.

The association with arthritis, and the concomitant outbreak of the keratitis with the second attack of conjunctivitis would seem to show strongly that the corneal affection was metastatic in origin.



Case 25. (Nobl<sup>76</sup>)—Gonorrhœa—Polyarthrititis and Conjunctivitis—Symmetrical Keratitis—Endocarditis and Tonsillitis.

A laborer, aged 27, acquired a gonorrhœa which was followed in three weeks by inflammatory mischief developing in several joints in rapid succession and simultaneously affecting the eyes. The primary ocular trouble was of the nature of a metastatic conjunctivitis, the right eye being first affected and then the left. There existed in both eyes profuse lacrimation and photophobia. The conjunctivæ were markedly reddened, but only slightly swollen. The corneæ were normal and the globes only slightly injected. No cultures were taken.

A new phase in the ocular condition, the course of which is not noted, occurred six days after its onset. The patient complained of headache and the conjunctiva bulbi became more markedly congested with distinct pericorneal injection. In the right upper quadrant of both corneæ one found superficial, sickle-shaped losses of substance, with slightly-clouded bases, placed parallel to the limbus and about four mm. distant from this structure (catarrhal ulcers). In the right eye the aqueous slightly clouded; the iris moderately discolored, with its tracery maintained; but the pupil middle wide only and reacting sluggishly. The affection showed a marked improvement in five days and was entirely well in twenty.

Five days later a fresh outbreak of arthritis and of iritis of the left eye followed an exacerbation of the urethritis, but the ocular condition entirely recovered in a further period of five days.

Though a preceding conjunctivitis was present in this case the highly symmetrical character of the keratitis speaks for metastasis.

Case 26. (Jahn<sup>79</sup>)—Iritis—Uveitis and Secondary Glaucoma—Keratitis.

Three weeks after the acquisition of a gonorrhœa, which was complicated by phimosis and cystitis, an artilleryman developed an affection of the eyes. For about a week the ocular inflammation presented the features of a left-sided iritis with secondary conjunctivitis, as well as slight transitory sympathetic participation of the other eye; but at the end of this time the disease passed into a purulent uveitis with secondary glaucoma and diminution of vision to perception of light only. As the left eye gradually improved, the right developed a small ulcer on the inner margin of the cornea, fifteen days after the onset of the ocular trouble; and six days later the retinal vessels were noted to be full and tortuous. The inflammation of the right eye subsided in thirty-six days; that of the left gradually disappeared up to the time of his discharge on the hundred and eleventh day of the disease and later.

Here the systemic infection, if it really existed, found its sole expression in the eye. As the corneal ulcer was marginal and followed a slight preceding conjunctivitis, one must look upon the keratitis as probably secondary in character. For fuller report of this case, see page 84.



Case 27. (Nobel<sup>80</sup>)—Gonorrhœa—Arthritis—Conjunctivitis—Kerato-Iritis—Iritis.

Nobel presented a man who ten weeks previously had contracted a gonorrhœa. Thereupon followed a gonitis on both sides, and then an ocular affection which the ophthalmologist declared to be a blenorrhœal conjunctivitis. More joints were affected and staphylococci were grown from the joint of the left knee. The eye affection ran a favorable course in fourteen days; but later iritis and ulcers of the cornea developed. The rapid disappearance of the eye affection gave ground for the suspicion that it might not be primary. Two days previous to the presentation of the case iritis occurred in the until then healthy eye and as cause only the urethral affection could be found. The iritis differed in no respect from the usual picture.

Here, too, the description of the case is too brief to make the report of value.

Case 28. (Burchardt<sup>98</sup>)—Gonorrhœa—Metastatic Conjunctivitis—Arthritis—Multiple Keratitis and Plastic Iritis—Iritic Hæmorrhages—Kerato-Iritis—Keratitis Striata—Iridocyclitis.

A mechanic, aged twenty-six, was admitted to the Charité October 23, 1895. He stated that he had suffered from gonorrhœa for fourteen days, and that both his eyes had been red since the 20th of October, and his left knee painful since the 22nd.

Examination of the purulent urethral discharge showed gonococci. Right vision=3|5; left vision=3|6. The conjunctiva of both globes was actively congested so far as it was in contact with the lids, and the palpebral conjunctiva was also greatly reddened. Gonococci could not be found in the conjunctival discharge and the eyes were negative in every other respect. There was also an inflammation of the left knee without swelling.

On October 31st the patient was transferred to the department of internal medicine; because, while the conjunctival inflammation had almost completely disappeared, the inflammation of the left knee was increasing. But on November 11th he returned to the ophthalmological department, where the following conditions were made out: Gonorrhœal arthritis still present but essentially better. L. eye (V=3|6) is not inflamed; but right, V=3|60 only, and the eye is distinctly congested. In the lower outer quadrant of the cornea three inflammatory deposits from one half to two millimetres in diameter; epithelium absent over two of them. Pupil irregularly triangular in shape, between five and six millimetres wide and entirely closed by a film except for an aperture upwards. On trans-illumination it appears studded with fine granules. Tn.

Under treatment a rather rapid improvement occurred. By November 15th the pupillary film had greatly shrunk and the corneal infiltrations had cleared up. On November 21st an increase in the inflammation of the right eye occurred; and a hæmorrhage which remained in the a.c. for twenty-four hours was noted on November 22nd. Inflammation of the sterno-clavicular joint appeared November 25th, but improvement in the eye was noted from



then until December 13th when there appeared, without known external cause, intense reddening of the conjunctiva, multiple inflammatory deposits in the cornea, and a cloud in the anterior chamber in front of the pupil of the right eye. On December 16th some blood was again noticed at the lower margin of the pupil; the cloud in front of the pupil had thickened to a film; and the cornea was diffusely clouded and traversed by fine, light-grey, inflammatory stripes, lying immediately in front of Descemet's Membrane.

From December 20th onwards the severity of the manifestations diminished. A week later the vision of right eye had risen to  $\frac{3}{6}$ , and the eye was pale; but the cornea was occupied, downwards and outwards, by opacities as large as one millimetre, and in the obliquely-oval pupil, six to eight millimetres large, lay a delicate membrane which had separated itself outwards from the iris. In the pupillary area apart from coarser deposits, numberless dust-like granules were visible by reflected light. The polyarthritis being also better the patient was discharged though there still existed slight urethral discharge.

On March 2nd the patient was re-admitted for an iritis of the left eye which, in spite of treatment, went on to a painful iridocyclitis with obscuration of the fundus and reduction of vision to  $\frac{3}{30}$ . On March 17th a slight cloudiness of the whole of the left cornea was noted, as well as a small inflammatory mass below. From March 21st onwards diminution in the severity of the symptoms occurred; and the patient was discharged on May 2nd with vision in both eyes equal to  $\frac{3}{5}$ . Apart from a light red and black mottling of the macular area which had previously been of a uniform red tint the right eye showed no change from the last note.

In this case, if a preceding conjunctivitis speaks for a secondary keratitis, the simultaneous outbreak of a multiple corneal affection, accompanied on one occasion by an iritis and on another by both metastatic conjunctivitis and iritis, favors strongly a primary keratitis.

**Case 29. (Burchardt<sup>98</sup>)—Gonorrhœa—Polyarthritis—Metastatic Iritis—Recurring Iritis and Iridocyclitis—Second Gonorrhœa, Metastatic Conjunctivitis, Kerato-Iritis, Polyarthritis, Iritis and Keratitis.**

A merchant, aged 34, was admitted to the Charité May 12th, 1894. A gonorrhœa acquired in September, 1893, had been followed after fourteen days by gonorrhœal rheumatism; and in the following October he had had a double-sided conjunctival inflammation which was cured in a few days. An inflammation of the iris began in the right eye at the end of October, 1893, and in the left at the end of January, 1894. The attacks lasted respectively four and seven weeks. On May 11th, 1894, the right eye was again affected by a plastic exudative inflammation of the iris. This time complete closure of the pupil occurred and an iridectomy was performed on June 11th. A similar operation had been performed on the left eye on June 4th for glaucoma secondary to the former iritis. On September 6th, the left eye was again visited by an iridocyclitis which was associated with a fresh inflammation of the joints and lasted until October 13th. Six days later



a fresh iridocyclitis occurred on the same side, but this had completely subsided by December 17th, when the patient was discharged with vision on left and right sides equal respectively to  $3/5$  and  $3/1.5$ . The patient now remained healthy for seven months; but returned to the Charité on July 29th, with a history of probable fresh gonorrhœal infection, of urethral discharge, and of purulent discharge from the eye for eight, five and two days respectively. Gonococci were found in the pus cells from the conjunctiva as well as those from the urethra. An outbreak of polyarthrititis occurred on August 2nd, but the conjunctivitis quickly disappeared and the patient was discharged August 14th, with the urethritis unhealed. Exactly a week later the patient returned to the Charité on account of a right-sided iritis and an ulcer 3 mm. large which had developed along with several inflammatory infiltrations in the lower outer quadrant of the cornea. Mercurial inunctions, as well as local treatment, were at once instituted, but in the following days further small infiltrations appeared in the upper half and in the lower inner fourth of the right cornea; and in addition deposits of fine granules were made out on the posterior surface of the cornea (iritis serosa). In the further course of the disease a polyarthrititis broke out and almost simultaneously from September 2nd onwards left-sided iritis. On September 6th, ulcers were noticed in the left cornea, but these were allayed by the galvano-cautery. Under treatment the corneal and iritic inflammation subsided and at the patient's exit on October 12th, 1895, the vision of the left eye equalled  $3/3$  to  $3/2.5$ , and that of the right  $3/1.75$ .

In this case although the occurrence of a preceding conjunctivitis with gonococci in the conjunctival discharge favors the view of a secondary inflammation of the cornea, and the concomitant iritis may very well have been merely an accompaniment of the other affection, the subsequent occurrence of rheumatism and of inflammation of the iris in the other eye and the multiple character of the keratitis speak for metastasis.

Case 30. (Burchardt<sup>104</sup>)—Gonorrhœa—Plastic Iritis—Keratitis—Arthritis—Papillo-Retinitis.

In an eye, affected for about a month by gonorrhœal iritis and for some time by papillo-retinitis, three opacities, separated from one another by narrow light streaks and observable only by strong lateral illumination, were made out in the pupillary area of the cornea. They were so transparent as to be invisible by trans-illumination and cleared up within six days.

Arthritis was present also in this case as further proof of systemic infection. The central position of the infiltrations and the absence of a preceding conjunctivitis would favor rather a primary origin for the keratitis which may, however, on the other hand have been merely of the nature of a keratitis striata such as one often observes in cases of iritis.



Case 31. (Burchardt<sup>104</sup>)—Gonorrhœa—Iridocyclitis—Polyarthrititis—Neuro-Retinitis—Multiple Keratitis.

About three weeks after a fresh outbreak of iridocyclitis in an eye affected only a short time previously with this condition, three dense circumscribed opacities formed to the size of 4.5 mm. in the outer half of the right cornea with slight cloudiness of the rest of this structure. Two weeks later the right eye was outwardly quiet, but a small transparent corneal opacity was present in front of the lower outer margin of the pupil, and above this were two still more minute opacities which were scarcely visible by focal illumination.

An extensive polyarthrititis in association with the ocular changes would seem to justify a diagnosis of systemic infection; and, in the absence of a preceding conjunctivitis, one might with equal right look upon the keratitis as metastatic in character. For fuller report of this case see page 98.

Case 32. (Van Moll<sup>115</sup>)—Gonorrhœa—Arthritis—Conjunctivitis—Keratitis.

The patient, a male, affected for two days by a double-sided conjunctivitis which was complicated by gonorrhœa and arthritis of the right knee. The inflammation, under appropriate treatment, subsided quickly at first and then more slowly; but the secretion disappeared after some days. The inflammation of the joints extended, and on the twelfth day of treatment the eyes became again affected and small corneal "phlyctænen" developed on both sides. The patient was cured at the end of seven weeks. Cultures gave several non-pathogenic organisms. The "phlyctænen" contained staphylococci.

The preceding conjunctivitis, which was very likely metastatic would favor the view of a secondary keratitis; but the symmetrical character of the corneal affection would point rather to a systemic origin.

Case 33. (Knapp<sup>116</sup>)—Chronic Urethritis—Gonitis—Metastatic Conjunctivitis—Ulcers of the Cornea.

Knapp's case was presented as one of metastatic conjunctivitis before the New York Academy of Medicine. The patient had suffered from a mild form of gleet and had developed a gonitis one week previously. There was no swelling of the lids at any time and at first the secretion in the eye was scant and mucoid. There were superficial ulcers of the cornea. Repeated examinations of the secretion showed gonococci distinct and characteristic.

The details of this case are too few to permit of any definite conclusions, though the keratitis appears directly or indirectly to have been associated with a systemic gonorrhœa.



**Case 34. (Kurka<sup>138</sup>)—Gonorrhœa—Metastatic Conjunctivitis—Polyarthritidis—Iridocyclitis—Keratitis—Neuro-Retinitis.**

E. H., aged 22, asserted that he had suffered from acute gonorrhœa for two weeks, and from severe inflammation of both eyes for three days. The conjunctiva of the lids on both sides was intensely reddened and covered with mucous secretion. The conjunctiva bulbi was also injected, but the corneæ were normal. Bacteriological examination of the conjunctival secretion revealed no gonococci, very few leucocytes, and isolated cocci.

At the end of five days there suddenly appeared a polyarthritidis which lasted until the patient's exit two months later. The conjunctival inflammation visibly improved and was limited on the 12th day of treatment to the folds of the lower fornix; but at the end of four weeks right-sided iridocyclitis suddenly broke out, and soon afterwards there developed in the centre of the cornea of the left eye a small epithelial defect which was surrounded by a greyish cloudy ring.

At the patient's exit, about two months later, the polyarthritidis was still present. The palpebral conjunctiva in both eyes was still moderately injected, but the conjunctiva bulbi was pale. Right cornea bright, somewhat less transparent than normal and studded in its lower part with fine deposits. Anterior chamber deep. Iris greenish discolored. Pupil jagged, and the pigment border of the iris adherent to the anterior lens capsule. In the centre of the cornea of the left eye a greyish but not sharply defined opacity, the size of a head of a pin. The fundus on the right side was blurred and indistinctly visible. On the left side the retina was slightly cloudy, the boundaries of the disc indistinct, and the veins markedly filled and tortuous. R. V.=6/60; L. V.=6/12.

The metastatic nature of the conjunctivitis in this case is established by the bacteriological examination and its association with polyarthritidis. The preceding inflammation of the conjunctiva, makes it impossible to exclude a secondary infection of the cornea; but the central position of the epithelial defect and the fact that it occurred after subsidence of the conjunctivitis and followed close upon the iridocyclitis would somewhat point to a primary origin.

**Case 35. (Apetz<sup>144</sup>)—Gonorrhœa—Recurrence after Six Years without Fresh Infection but with Concomitant Outbreak of Polyarthritidis, and Metastatic Conjunctivitis—Relapse of Urethritis, Conjunctivitis and Arthritis—Subacute Conjunctivitis, Suppurative Kerato-Iritis—Fresh Outbreak of Urethritis, Arthritis, Keratitis, and Conjunctivo-Iritis—Renewed Double-Sided Conjunctivitis, Hyperæmia of Iris, and Arthritis—Vitreous Opacities—Secondary Glaucoma.**

The case was that of a medical "candidat," who, of his own desire, communicated the most exact statements regarding his affection. In July, 1893, he acquired a gonorrhœa which confined itself to the urethra and, under appropriate treatment, was looked upon as fully healed after the beginning of the following October. The patient had not the slightest idea that the



urethritis was not fully arrested, because, though the urine was not examined for gonorrhœal shreds, no symptoms whatever of a chronic gonorrhœa made themselves manifest. Suddenly, one morning, in the beginning of November, 1899, i.e., more than six years later, after an excess in Baccho, and not, as Apetz was assured in the most positive manner by the colleagues of the man who had recently started practice as a physician, after a preceding coitus, profuse purulent discharge appeared from the urethra, and the patient experienced on the same day a feeling of "sand in the eyes." The next day a pronounced conjunctivitis with scanty muco-purulent secretion as well as a spreading polyarthritis broke out. According to the statement of the physician who treated the patient at this time, it had to do, apart from an affection of practically all the joints, with a gonorrhœal tendovaginitis of the dorsum of the right foot. While the conjunctivitis completely subsided after about eight days' treatment, the urethral discharge disappeared only in the middle of December and the joint affection in May, 1900. Yet the patient still complained periodically in the beginning of June of joint-pains especially during changes of weather.

About the middle of July, 1900, sudden discharge again appeared, without preceding excess in Venere or Baccho, and, simultaeously, renewed, acute, double-sided conjunctivitis, this time with somewhat more profuse muco-purulent secretion and rapid involvement of the joints previously affected. The conjunctivitis again rapidly subsided under treatment; but recurred before the end of July. At the commencement of August ulcers appeared in the cornea. These rapidly spread so that the patient consulted Apetz August 23rd, in the following condition:

The patient's skin was of a pale color and his nutrition had noticeably fallen off. Both eyes, but the right more than the left, presented the appearance of a subacute conjunctivitis. While on the left side the cornea, iris, etc., appeared intact, and the visual acuity with correction of a 3.5 D. myopia equalled the normal, the right cornea presented the following picture: On the temporal, lower, and nasal margins there was a deep ulcer which took in about two-thirds of the whole circumference and was about one and a half to two mms. broad. This passed without interruption into an infiltration almost as broad, which was situated in the upper margin of the cornea and embraced, in an annular manner with the lower marginal ulcer, the whole cornea. In the centre, and encroaching more on the lower half of the cornea, a superficial ulcer of about two and a half mms. diameter was visible with purulently infiltrated margins. The parts of the cornea still intact were clouded a slight greyish-yellow, so that one still saw the iris shine through faintly. It appeared hyperæmic and discolored; while there was present in the bottom of the anterior chamber a lens-shaped exudate which occupied more than a half of the cavity. Pupil scarcely recognizable; some indistinct precipitations on the posterior surface of the cornea, to a certain extent still transparent. Intraocular tension slightly increased; ocular tenderness; vision, fingers at nearest distance; no ophthalmoscopic view.

In the following eight days, while the peripheral ulcer and the iritis showed no change and the central ulcer and hypopion diminished somewhat in size, the whole cornea became so clouded that its entire destruction was



feared. The conjunctival discharge, slight on both sides, disappeared entirely on the left side in from eight to ten days. From the tenth day on, the peripheral ulcer became markedly vascularized, especially along its lower temporal border, and the cornea slowly cleared; but on September 10th, concomitantly with a fresh outbreak of arthritis and of the urethral discharge which had been absent since the end of August, two small, new infiltrations were observed in the cornea, nasalwards from the centre. The cornea became again somewhat more clouded in its entirety and at the same time a subacute conjunctivitis again appeared in the completely cured left eye together with hyperæmia of the iris and resistance of this structure to atropine.

As the result of hot baths and appropriate local treatment an improvement in the arthritic troubles and a quite striking diminution in the inflammatory appearances could be made out after a few days. In particular, the iris was again normal and dilatable, and the discharge had diminished to the smallest amount.

The vascularization of the ulcerated marginal portions of the cornea now progressed more rapidly while the ring of infiltration at the upper corneal margin only slowly clarified. Both of the newly arisen infiltrations also became smaller and the central, cauterized ulcer had healed by the end of fourteen days. On the 12th of October the ulcerative process in the right eye had almost spent itself: the whole lower half of the cornea was clouded an intense greyish-white, while the upper infiltrations appeared smaller. The iris showed some jagged posterior synechiæ and dilated half ways. There was no secretion of any sort from the conjunctiva.

On October 15th, double-sided subacute conjunctivitis again suddenly appeared with pericorneal congestion, and in association on both sides with hyperæmia of the iris and resistance of this structure to atropine, and increased pains and swelling in the knee joints.

On October 18th, there were numerous small epithelial defects and infiltrations in the left upper corneal margin, but the iritis was less. Under appropriate treatment this time also rapid subsidence of the conjunctival inflammation and of the infiltrations in the left cornea together with abatement of the arthritic manifestations.

On October 21st, the patient complained for the first time of *muscæ volantes*. There was still no ophthalmoscopic view on the right side and the intraocular tension remained heightened from time to time. R. V.: fingers at one meter; field of vision normal for large objects.

Under the administration of eserine, mild astringents, and massage with yellow ointment, the vision on the right side slowly rose, so that on April 16th, 1901, fingers could be counted at four to five metres with—2 D. After medium dilatation one succeeded in seeing a normal fundus and making out a large, formed vitreous opacity. On another occasion in 1902, the vision of the right eye equalled 1/10 with + 3.5 D; and that of the left, 1 with—4 D. The right cornea, of normal curvature, was clouded grey-white in its lower half as well as in the centre. A linear opacity ran parallel to the upper corneal margin while between this and the limbus a peripheral seam of still transparent cornea traversed by fine isolated vessels, visible in the deeper layers with the corneal loupe, was preserved. Conjunctiva and intraocular tension normal; *muscæ volantes* still present. The joint troubles



had disappeared since 1901 and the patient had been completely well during nine months. No microscopical examination of the urethral or ocular secretion was made in this case.

The first keratitis followed a conjunctivitis; but the second outbreak of keratitis was the only manifestation in the right eye, and was concomitant with a renewed arthritis and a conjunctivo-iritis of the other side. The corneal lesion in this instance at least was probably primary. On the third occasion the three days which supervened between the conjunctivo-iritis and the corneal affection is perhaps a little brief for a secondary infection.

Case 36. (Sym<sup>152</sup>)—Gonorrhœa—Relapse of Urethritis with Concomitant Outbreak of Inflammation in Joints and the Eyes—Conjunctivitis and Keratitis.

A young man had three months previously acquired a gonorrhœa from which he had almost completely recovered under treatment. About three weeks before Sym saw the patient urethral discharge had spontaneously begun again and concomitantly several joints and the eyes became affected. Improvement which was rapid was followed by relapse and then Sym was asked to see the patient. He found a well-marked conjunctivitis with fairly abundant discharge and some slight swelling of the lid margin. The conjunctiva was moderately injected. The discharge was for the most part watery with an admixture of a little muco-pus. At the margin of each cornea there was a very small clean ulcer. The irises were injected a little, but no more than one usually finds in a corneal ulcer in an adult. Several joints were affected. The patient rapidly improved and went to his home in England to recover from his rheumatism.

It is impossible to argue anything from this case. The marginal situation of the ulcer and the fact that it followed a conjunctivitis, speak for a secondary infection; but the symmetrical character of the lesion would point rather to metastasis.

Case 37. (Greff<sup>154</sup>)—Gonorrhœa—Polyarthritis—Iritis, Cyclitis, Keratitis.

The patient had become infected with gonorrhœa in 1881; but apart from this he had always been healthy and there was no personal or family history of syphilis. For three years he had suffered from polyarthritis. At the time of his reception into the hospital, January 20th, 1897, the joint between the first and second phalanx of the right middle finger and the right knee were swollen. He had never before suffered from sore eyes. A left-sided iritis with complete occlusion of the pupil, almost complete seclusion of the pupil, cyclitis and keratitis were made out. The joint and ocular affection were thought to be secondary to gonorrhœa because gonococci were demonstrated in the urethral discharge.

This case is too superficially reported to be of any value.



Case 38. (Paul<sup>163</sup>)—Gonorrhœa—Metastatic Conjunctivitis—Arthritis—  
Relapse of Conjunctivitis with Keratitis.

The patient, aged 21, had infected himself with gonorrhœa eight weeks previously. Eight days after the infection an acute double-sided conjunctivitis occurred with very marked involvement of the conjunctiva bulbi. The subjective symptoms especially the photophobia were intense; but there was only a very slight purulent secretion from the conjunctiva. With a moderately bad state of the general health a painful swelling simultaneously appeared in both knee joints. The ocular affection resolved after an existence of eight days, but at the end of a further period of eight days a severe recurrence set in with the same conjunctival manifestations. With it a double-sided corneal affection simultaneously associated itself without external cause. This began first in the left eye as a flat ulcer in the centre of the cornea and a few days later appeared in a similar manner in the right eye. After a short time the conjunctival and corneal inflammation began concomitantly to resolve, so that at the time of reporting there was present on the left side only a delicate macula corneæ and on the right side a moderate central corneal infiltration. Gonococci could not be found either in the conjunctival discharge or in the blood of the patient.

The simultaneous outbreak in this case of the keratitis with the relapse of the metastatic conjunctivitis, speaks for a primary corneal inflammation.

#### SUMMARY.

In summarizing, one must exclude from the above series the cases of Lawrence, Brandes, Kipp, Knapp, Nobel, Sym and Greff, which are too meagerly reported to be of value; those of Hutchinson and Hirschberg and Krause, which doubtfully belong in this place; and that of Burchardt, (case 30), which may not have been a real inflammation. While freely admitting that any estimate of the remaining eighteen cases is opened to criticism, I would yet attempt to classify them for the sake of order and discussion as follows:—

- |   |   |
|---|---|
| (A). Cases probably metastatic in origin .....  | 9 |
| (Martin, Colsman, Rückert, Friedenberg, Vanderstræten, Burchardt, Burchardt, Apetz, Paul).  |   |
| (B). Case probably due to secondary contamination from the conjunctival sac....   | 1 |
| (Jahn).   |   |
| (C). Cases doubtful in regard to origin; either primarily metastatic or else secondary to some preceding metastatic conjunctivitis..... | 8 |
| (Legrand, Haslund, Froidbise, Nobel, Burchardt, Van Moll, Kurka, Haltenhoff).   |   |

Total..... 18



Studying the nine cases which were probably metastatic in nature, we have two (Martin, Friedenbergl), in which the substantia propria of the cornea, was clearly affected; and five (Colsman, Rückert, Vanderstræten, Burchardt, Paul), in which the inflammation was superficial in character, confined certainly in four instances to the epithelial structures. In Apetz's case the picture was of a varying character. One had to do in the first instance with a deep marginal ulcer which may have been primary or secondary; but in the second and third outbreaks, which were very probably metastatic manifestations, the inflammation was respectively of the nature of a parenchymatous and of a superficial (epithelial) keratitis.

In estimating more carefully the character of the cases in which the inflammation was confined to the substantia propria of the cornea one has to think of the possibility of their being metastatic only in an indirect way. It is recognized that in cases of panophthalmitis the toxins, acting through the aqueous humor, are capable alone of producing an annular abscess of the cornea; and that in cases of suppurative iridochoroiditis the organisms, early present in the aqueous, can attack the cornea from behind. The case of Martin-Haltenhoff appears clearly to have been of this nature, and one would not perhaps be far wrong in explaining also the changes in Friedenberg's case in this way. The difference in the degree of intensity of the intraocular inflammation in the two cases would explain the difference in the behavior of the inflammation, which in one instance led to the perforation of the cornea, but in the other ended in complete resolution.

Eliminating these cases one has seven instances of a keratitis which was probably due to gonorrhœal metastasis. In a series of six of these cases in which the fact is noted, two were double-sided and four unilateral; and, in a further series of six cases, the corneal deposits were multiple in five instances and single in one. Four of the cases at least were, as already stated, of a distinctly epithelial type, and in all seven instances the ulceration seems to have affected the central rather than the peripheral portions of the cornea.

An analysis of the cases of class C shows that in a series of six cases the deposits were multiple in character in five, and single in one instance; while in every one of seven cases in which the extent of the corneal involvement is noted the keratitis was of a superficial nature. Finally, of the eight cases, three showed a unilateral and five a bilateral arrangement; and here, too, the central portions of the corneæ appear to have been most often involved.



On comparing the figures of class A with those of class C, one finds that the picture was practically the same, with this exception; that while in class A the keratitis was more often asymmetrical, the opposite was true of class C. Though one would naturally expect to meet with a bilateral arrangement more often in class A than in class B, this finding, for reasons already given at the beginning of this section, does not necessarily militate against the preliminary supposition that symmetry speaks for infection from within. It may equally well be said to heighten the probability of the cases of class C being of this nature.

But while one must admit, after arranging and analyzing the cases in this way, that the data obtained are not altogether convincing, interesting and satisfying facts are yielded by a study of the combined cases of A and C. Grouping the seventeen cases in this way one finds that the keratitis was symmetrical in seven and asymmetrical in six of a series of thirteen cases: multiple in ten and single in two in a series of twelve cases: superficial in twelve in a series of twelve cases: and eight roughly central as opposed to peripheral in a series of eight cases in which the fact is stated. From these figures one is justified in inferring that the keratitis associated directly or indirectly with systemic gonorrhœa is typically of a multiple and superficial nature, commonly symmetrical in character, and central in situation.

The following two cases are instances of a keratitis, occurring in association with systemic gonorrhœa, which have come under the observation of the writer. It is worthy of note that here also, uncertain though the cases are, the keratitis was superficial and multiple in character in harmony with the results of the analysis given above.

**Case 39. (Author's)—Gonorrhœa—Metastatic Conjunctivitis—Arthritis—Keratitis.**

A bank clerk, aged about 30, who gave a history of previous gonorrhœas followed by ocular and other symptoms of systemic gonorrhœa, was attacked two weeks after the outbreak of a fourth urethritis by a conjunctivitis which appeared first in the right eye and exactly two days later in the left. When seen twenty-four hours after the outbreak of inflammation in the eye last affected the patient presented the appearance of a typical, double-sided, catarrhal conjunctivitis. There was swelling of the right upper lid with narrowing of the palpebral fissure on that side; injection of the palpebral and bulbar conjunctivæ less marked on the left side than on the right, and practically absent beneath the upper lids; some swelling of the fornices but no chemosis; slight loss of lustre without any suggestion of papillary



enlargement; and a small amount of thick, stringy muco-pus, seen especially at the inner angles and in the fornices. Subjective symptoms, present at first as a slight feeling of dust in the eyes, were entirely absent on admission. Microscopical examination of the discharge was entirely negative.

On the following day the degree of inflammation on the left side equalled that on the right and the palpebral conjunctiva of the upper lids was also involved; but from this time on the conjunctivitis subsided. The discharge entirely stopped seven and five days respectively after the onset of the inflammation in the eyes; and three days later only slight redness remained in the fornices.

About six weeks later I saw the patient at his home where he had ever since been confined by a severe arthritis which developed shortly after his first visit to my office. His right eye had become very sore five days previously (i.e., thirty-nine days after the disappearance of the conjunctivitis) with darting and needle-like feelings, always worse during the day. On examination I found slight discoloration of the iris with slight contraction of the pupil; and four small, roundish spots of infiltration, which were situated in the lower half of the cornea, suggested vesicular formation, and stained with flourescein.

The keratitis entirely subsided in fifteen days; but left behind a couple of small opacities at the site of the infiltrations. The arthritis persisted and entirely crippled the patient for many months.

**Case 40. (Author's)—Gonorrhœa—Polyarthritis—Metastatic Conjunctivitis and Conjunctivo-Iritis—Keratitis.**

A man, aged 21, acquired a gonorrhœa which was complicated by cystitis, and followed in about six weeks by an inflammation of the knees and ankles of both sides. A few days after the outbreak of the urethritis, the left eye became sore and sensitive to light with some purulent discharge; and twenty-four hours later the right eye was similarly affected.

On admission and later on gonococci were found in abundance in the urethral discharge, but several smears made from the conjunctival secretion gave entirely negative findings.

The inflammation in the left eye remained confined to the conjunctiva; though all signs of hyperæmia only entirely disappeared at the end of three months. On the right side the iritis was marked by severe pain and rich gelatinous exudation in the anterior chamber; but it ran its course in a month less than the inflammation of the other side. It was complicated about five weeks after its onset by two small, irregular-shaped patches of exudation which appeared in the temporal quadrant of the cornea but rapidly cleared up.



## V.—AFFECTIONS OF THE SCLEROTIC.

In a certain percentage of the cases of metastatic conjunctivitis one gets, in addition to dilatation of the posterior conjunctival vessels, pericorneal congestion and congestion of the episcleral vessels for a varying distance over the surface of the globe. Kurka<sup>138</sup> among others looks upon this associated bulbar injection as characteristic of metastatic conjunctivitis; but the writer believes, as previously pointed out,<sup>‡</sup> that this deep-seated congestion is often only an expression of an inflammation of the interior structures of the globe, actually present or in process of development. Apparently, though, cases of this character do occur; but they are perhaps better classified as instances of sclero-conjunctivitis. Wordsworth<sup>17</sup> describes them somewhat indefinitely; and Ferry's case was one of sclero-conjunctivitis in association with iritis and dacryo-adenitis.\* The following cases reported by Morax<sup>81</sup> are apparently pure examples of this kind of inflammation:

Case 41. (Morax<sup>81</sup>)—Gonorrhœa—Sclero-Conjunctivitis and Polyarthritides—Relapse of Sclero-Conjunctivitis.

N. Le., aged 23, entered the St. Louis Hospital, September 27, 1892. There was nothing special to note in the previous personal or family history of the patient. A month previously he had contracted his first gonorrhœa. The purulent discharge was very abundant at the onset and accompanied by severe pains on micturating. On the morning of September 3, 1892, he found on awakening that the lids of both eyes were adherent, that the two eyeballs were slightly injected, and that there was slight lacrimation. He experienced, in addition, slight general malaise and moderately severe pain in several joints; and he was unable to go to work. During the following days the conjunctival discharge slightly increased and the general symptoms became aggravated. The patient had noticed a marked diminution in the urethral discharge with the appearance of the constitutional disturbances. On examination, on September 27th, the following conditions were made out: Robust constitution, slight redness of the urethral meatus, but no purulent discharge on pressure. In addition to a rather extensive polyarthritides, very active congestion of the bulbar and palpebral conjunctiva of both eyes. This injection was at the same time superficial and profound; but it was unaccompanied by chemosis. Secretion not very abundant; but it formed nevertheless greyish accumulations at the inner angle and small

<sup>‡</sup>See page 30.

\*See page III.



flakes in the inferior cul-de-sac. No corneal lesions; lids scarcely swollen; preauricular gland not palpable; slight smarting only as subject phenomena; slight temperature; profuse sweats; nothing pathological in respiratory or circulatory systems.

The secretion completely disappeared within a few days; but the injection persisted. It was deep-seated and more particularly limited to the peripheral portion of the globes, while the parts in the neighborhood of the corneæ were almost normal. One had to do especially with an injection of the sclerotic. On November 3, the patient had, after some days of amelioration, a fresh polyarticular outbreak accompanied by very marked injection of the conjunctiva and sclerotic. The lids were not adherent and there was hardly any secretion. The attack subsided in five days. Microscopical examination of the conjunctival secretion was undertaken on the day of the patient's admission, the following day, and on November 3, at the onset of the second outbreak of sclero-conjunctivitis. On the first day one made out numerous, more or less altered leucocytes. Some of these contained in their protoplasm diplococci which had the aspect and characteristic disposition of gonococci. They did not take Gram and did not exist outside the cells. On November 2, one again found certain cells containing gonococci; but they were less numerous than on the previous day. On November 3, one found on five slides only occasional leucocytes and no micro organisms.

**Case 42. (Morax<sup>81</sup>)—Gonorrhœa—Double-Sided Sclero-Conjunctivitis.**

M. D., aged 28, contracted a gonorrhœa about November 19th, 1893. On December 15th, on wakening he found that his lids were stuck together and the two eyeballs strongly injected; and he noticed that the urethral discharge had disappeared from this day on. On December 19th, one made out a superficial and deep-seated injection of the conjunctiva bulbi of both eyes as in scleritis. This congestion was not uniform, but was more marked at certain points. There was no chemosis; only very slight secretion; and a slight sensation of pricking. No urethral discharge even on pressure. Complete recovery recurred in nineteen days. Microscopical examination failed to reveal gonococci.

**Case 43. (Morax<sup>81</sup>)—Gonorrhœa—Sclero-Conjunctivitis—Previous History of Gonorrhœa and Conjunctivitis.**

The patient, who gave a history of gonorrhœa followed by arthritis and conjunctivitis two years previously, had acquired a second urethritis about a month prior to consultation. Fifteen days after the onset of the gonorrhœa he found on awakening that the lids on both sides were adherent and that the eyes were injected without any secretion. There had been very marked photophobia, and one made out pronounced injection of both the bulbar and palpebral conjunctiva which was at the same time both superficial and deep-seated. The corneæ were clear and the conjunctival secretion very slight. Recovery of the conjunctivitis took place without complication in about twenty-five days. No gonococci were found on microscopical examination.



In a case reported by Kipp (see page 75) injection of the subconjunctival vessels on the temporal half of the sclerotic was the precursor of a severe inflammation of the uveal tract in that eye. A peculiar case of severe, double-sided purulent ophthalmia which presented in its initial stages the appearances of a scleritis is reported by Parinaud. He was sure it was metastatic in nature because of its characters at the onset of the infection, of its simultaneous development in both eyes, of its alternation with articular pains, and, finally, because of the disappearance of the urethral discharge when the conjunctivitis declared itself.

Case 44. (Parinaud<sup>68</sup>)—Gonorrhœa—Arthritis—Double-Sided Scleritis followed by Purulent Ophthalmia—Involvement of Corneæ.

A patient presented himself at Parinaud's clinic for an affection having the appearances of a double-scleritis. In the left eye, in particular, on the outer half of the globe there was a patch of deep-seated, well-localized injection, without chemosis and without secretion. In the right eye there was a little secretion and chemosis of the conjunctiva which appeared suspicious. Of special significance was the fact that the ocular affection had succeeded rheumatic pains of the two shoulders which disappeared when the eyes were involved. This affection was not long in assuming in both eyes the characters of a grave purulent ophthalmia with infiltration of the cornea. Parinaud looked for gonorrhœa but could find no urethral discharge. The patient related to him, however, that fifteen days previously he had had a discharge for some days which spontaneously disappeared when the rheumatic pains manifested themselves. The patient was not long afterwards again seized by articular pains in all his limbs, and he was received into the hospital with both eyes already greatly damaged. The right had, in fact, been lost. The urethral discharge had reappeared as the rheumatism and conjunctivitis had diminished.



## VI.—AFFECTIONS OF THE UVEAL TRACT.

---

As stated elsewhere, it would seem from recent investigations and pathological observations that in metastatic ocular affections the various micro-organisms differ in their affinities for the several coats of the eye; that, while the pyogenic cocci most often lodge in the retina, the gonococcus like the tubercle bacillus finds its most favorable environment in the uveal tract. Gonorrhœal metastases of the vascular coat of the eye were, with metastatic conjunctivitis, the first to be accurately recorded after the connection between gonorrhœa and gonorrhœal arthritis had been pointed out; and they have been more numerous reported than those of any other part. The exact relative frequency with which the various structures of the eye are visited by gonorrhœal metastases remains, however, to be determined; for, on the one hand, a very large number of cases of inflammation of the uveal tract, particularly the less serious ones, have been undoubtedly looked upon as too trivial to report, while, on the other hand, affections of the other parts, much more recently observed, have, because of their rarity, been very generally placed on record.

**Etiology.**—There are no figures to show what part the gonococcus plays in the production of the inflammations of the uveal tract viewed collectively, and the figures for iritis which might be taken as a fairly accurate index for the whole vascular coat, are not in entire agreement. In fourteen of his one hundred patients suffering from primary non-traumatic inflammation of the iris, Collins<sup>112</sup> could trace the ocular inflammation to a specific urethritis; and Kipp<sup>36</sup> found gonorrhœa or gonorrhœal rheumatism present at the onset in something less than seventeen per cent. of his cases of inflammation of the uveal tract. Yeld<sup>134a</sup> analyzed 159 cases of primary iritis, and eight per cent. of these was attributed to gonorrhœa; and in another series of 150 cases by Gutmann<sup>164</sup> in which the general examinations were made by Litten and Lassar, five were thought to have been caused by systemic gonorrhœa. Hennart's<sup>118</sup> figures give syphilis as the etiological factor in 50 to 60 per cent. and rheumatism in 30 to 40 per cent. of all cases of primary iritis. The remaining 10 per cent. are due to acute infections of the organism including gonorrhœa; constitutional dyscrasias such as scrofula, diabetes, albuminuria; or to uterine catamenal manifestations. Some-



what opposed to these statistics are the findings of von Michel,<sup>125</sup> who does not mention gonorrhœa as the etiological factor in a single one of his series of eighty-four cases of primary iritis which were submitted to a most searching general examination. These figures, too, were said to be in accord with those of Haas,<sup>113a</sup> who analyzed all the cases of this nature which had attended the Wuerzburg clinic during a period of ten years. It will be seen then, from the foregoing figures, that the estimates in regard to the part played by systemic gonorrhœa in the production of inflammations of the uveal tract vary not a little, and that it is impossible to assign any exact proportion to gonorrhœal infection. It is probably better, therefore, to read the figures as they stand, and infer that the percentage varies within the limits mentioned largely as the result of differences in the social and hygienic conditions of the places in which the statistics are collected.

**Pathology.**—The general pathological features of systemic gonorrhœa have been discussed elsewhere. The local changes probably differ in no essential particular form from those which characterize inflammations of the uveal tract in general, and are too well known to call for special mention here. In this connection, however, the following case of mild "iritis," very probably of gonorrhœal origin, in which I was able to obtain the eyeball for examination, is interesting and instructive.


Case 45.—Gonorrhœa, Cystitis, Pyelo-Nephritis—Gonorrhœal Septicæmia, Polyarthritides, Iritis—Death from Acute Dilatation of the Stomach.

Charles ———, aged 29, entered the Royal Victoria Hospital, Montreal, on April 25th, 1900, complaining of pains in the back, pains in the great toe, and a discharge from the urethra.

The young man, a clerk by calling, and moderate in his habits, stated that there was no personal or family disposition to rheumatism and gave the following account of his illness: About a month previous to his admission, he noticed, a day or so after exposure, a purulent discharge from the urethra, but paid little attention to the matter during the following three weeks. At the end of this time frequency of micturition accompanied by pains of a burning character, induced him to seek medical advice; but in spite of treatment of the urethral condition, general weakness and pain in the back and ankle supervened during the following week and he was referred to the hospital by his physician.

On admission, the case was diagnosed as clearly one of "gonorrhœal rheumatism," syphilitic infection being carefully excluded; and during the patient's illness the great toe of the right foot, the right and left knee-joints, the spinal column, especially the lumbar region, and the (? right)







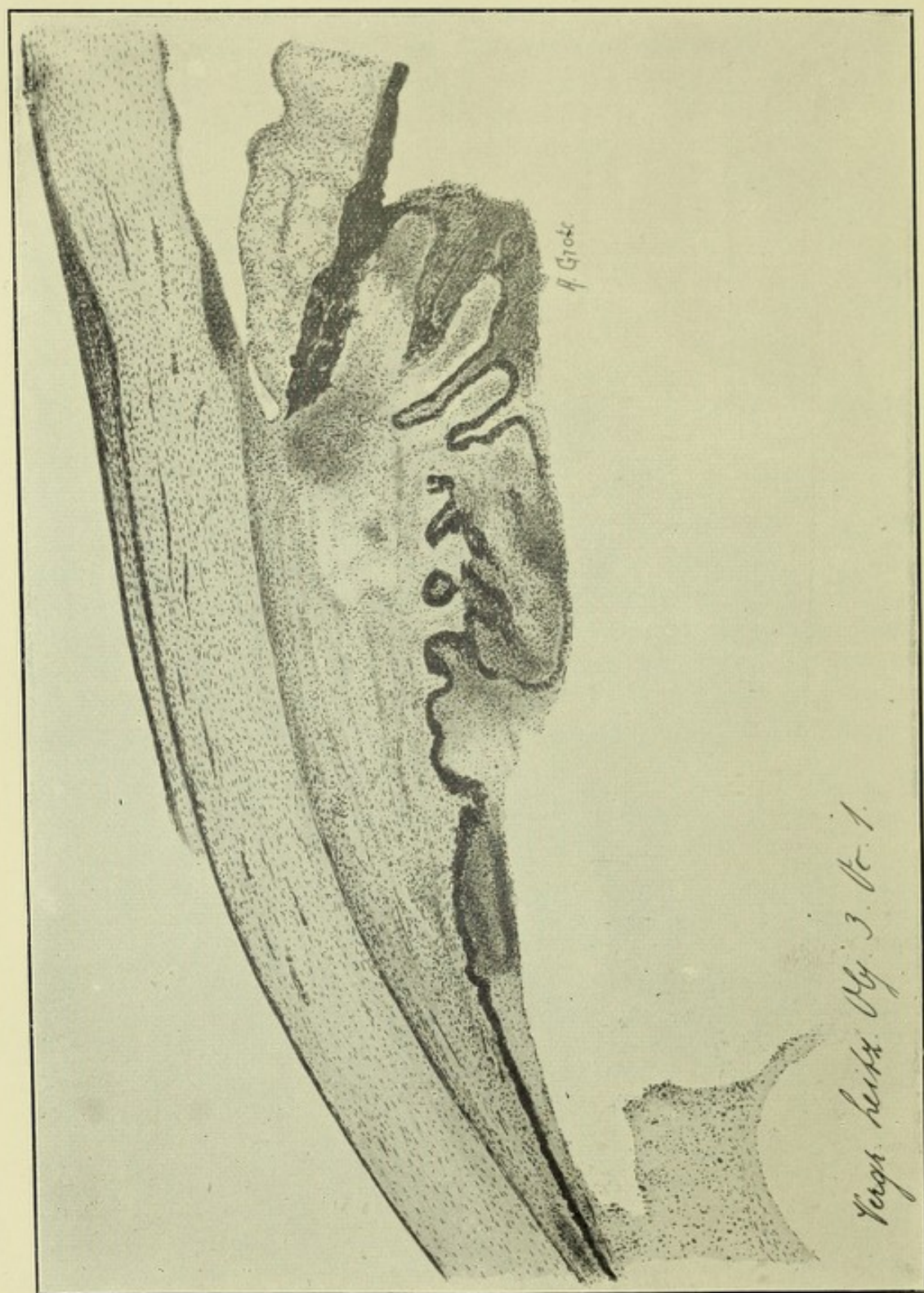


Illustration of a microscopical section from the author's case of iridocyclitis of probable gonorrhoeal origin.



wrist were the sites of inflammatory changes more or less marked. The joint manifestations were accompanied by a temperature which, while not high, was of a distinctly septic type.

On March 11th, i.e., about six weeks after the onset of the illness, I examined, at the request of the late Prof. Stewart, the patient's left eye, and found pericorneal injection, and the usual evidences of a well-defined inflammation of the iris. While not thinking at the time to inspect the cornea with high magnification for cyclitic dots, there was nothing in the routine examination to make one think of looking for them; and, as there was no special pain or tenderness, severe reflex disturbances or marked diminution of vision, there was no clinical reason for supposing that the ciliary body participated in the inflammation. The case was, therefore, looked upon as one of pure metastatic iritis with no special features except perhaps, that the conjunctival vessels showed more injection than is usually present in an ordinary case of inflammation of the iris.

Two days later severe, obscure gastro-intestinal symptoms made their appearance, and the patient died on March 22nd. The eye condition, under treatment, had been rapidly progressing towards recovery.

The post-mortem examination, five hours after death, showed that the direct cause of death was acute dilatation of the stomach. It will suffice to mention only this fact as the condition was quite independent of the gonorrhœal disorder and will be described more fully elsewhere by Prof. Adami. The left eyeball, still showing a pupil, fully dilated to atropine, and an iris, greenish discolored from inflammation of its tissue, was removed and placed for hardening in formaline.

As regards the other organs, there was marked urethritis, moderate cystitis, slight inflammation of the left ureter, and of the left kidney with involvement of its pelvis. Gonococci were found in abundance in the urethra, and in slight numbers in the bladder and kidney pelvis; but cultures from the fluid of the affected joints, the heart blood, and other parts were sterile.

On examining the eyeball microscopically, the corneal epithelium showed no change; but the conjunctival and ciliary vessels corresponding to the injection present during life, were dilated and lined externally by small, round-cells which had invaded the loose episcleral tissue, especially in the immediate vicinity of the limbus. This dilatation of the vessels could be noted for some distance backwards over the surface of the sclerotic.

The substantia propria of the cornea was normal; no increase in its cellular elements could be made out. The endothelial cells on Descemet's membrane appeared likewise to be unaltered; but the posterior surface of the cornea, along its whole extent, was lined by numerous cells, which in places formed small clumps or aggregations, i.e., cyclitic "dots." The spaces of Fontana, and Schlemm's canal were crowded with cellular elements; but the angle of the anterior chamber was everywhere open.

The iris as a whole showed swelling, and a small-round-cell infiltration, which was especially marked along its anterior border. But more striking were the changes in the ciliary body. The substance of this structure was likewise swollen; in certain sections its anterior border was seen to be pressed forward against the posterior surface of the iris, though apparently



without any adhesion formation having taken place. The ciliary body proper was densely invaded by cells, while along the whole extent of the ciliary processes, external to the retinal-pigment layer, was seen a fibro-cellular exudate, of a rather massive character. In the iris and ciliary body, the proliferated cells showed a marked tendency to form areas of denser infiltration. This appearance was one of the most striking in the sections.

Studying the cellular elements in the exudate along the ciliary body and the pars ciliaris retinae one saw (1.) Cells entirely filled by pigment granules and of relatively large size. Some of these were round, some more or less oval, and others pear-shaped in character. At times their single large nucleus could be indistinctly made out. (2.) Cells no doubt of the same nature which were only partially filled by pigment granules and showed a single deeply-staining nucleus. (3.) Mono-nuclear cells of different sizes and shapes having eccentric nuclei and all the characters of plasma cells; and (4.) Polyneuclear cells, also differing in size and shape, in some of which the nucleus was seen to be in the process of breaking up (pycnosis). These four groups of cells were so indistinguishable from those in the clumps on Descemet's membrane that one inferred that they all had a common origin in the ciliary body. The various cellular forms in the ciliary exudate decreased in number from before backwards and finally entirely disappeared. Along the retina one saw a few cells of relatively large size with a large palely staining nucleus; but these did not appear in the cyclitic dots. A differential count of the cells in the exudate showed that the small mono-nuclear cells were slightly in excess of the poly-nuclear form. Sections (paraffin as well as celloidin) carefully stained in different ways for gonococci and other possible organism gave entirely negative results.

Summarizing this report, one had to do clinically with a case of systemic infection almost certainly of gonorrhoeal origin which had given rise among other manifestations to an inflammation of the iris. As previously remarked, there was nothing in the state of the eye to suggest involvement of the ciliary body, and I wish particularly to emphasize that the clinical picture was that of a mild and simple iritis which had already undergone a considerable degree of resolution when the death of the patient occurred.

In view of the slight ante-mortem changes, the extensive microscopical findings in the ciliary body, which were largely unexpected, are highly instructive. They prove conclusively that in every case of so-called iritis the pathological process is by no means limited to the iris but extends at least to the adjacent portion of the uveal tract. It is particularly interesting in this case to note how closely the changes are limited to the parts supplied by the anterior ciliary vessels. In the light then of this fact, and what pathology has already taught us, we are compelled, even though we retain the old nomenclature, to broaden our conception of these inflamma-



tions; and it would be justifiable and perhaps even advisable to discard the word *iritis* and substitute therefor the terms mild or severe *iridocyclitis*, the better to express the character and extent of the changes which we know to be present in these cases.

The finding microscopically of cyclitic dots so extensively on Descemet's membrane fully bears out the statement so clearly expressed by Friedenwald in 1896\* that they are present in every case of *iritis*, if only one looks for them with sufficiently high magnification. As stated above, it was possible to show with certainty that the cells composing the clumps on Descemet's membrane were identical with those in the cyclitic exudate; that both were the outcome of the inflammation of the ciliary body. Friedenwald's findings are therefore additional proof of a constant and concomitant ciliary involvement in cases where clinically the inflammatory process seems to be entirely confined to the iris.

In other respects, the pathological findings are what one would expect to find in a case of mild and resolving *iridocyclitis*. The exudate is everywhere highly cellular in character, and at no place is there any attempt at formation of adhesions.

One might say with justification that the negative bacteriological findings favor the purely toxic theory of inflammation; but the fact that microorganisms were not found lessens very little the probability of their presence. The difficulties in the way of detecting bacteria in the eye are great; indeed for certain parts of the organ insurmountable at the present time. Moreover, the germs may very well have died out, have been present in too scant numbers to detect, have undergone post-mortem autolysis or have been situated in portions of the globe which did not come under inspection. On the other hand, in a positive way, the numerous areas of denser infiltration which one finds in inflammation of the iris and ciliary body, were particularly well marked in this instance, and strongly suggest an underlying embolic process or the focal growth of gonococci or other bacteria in the affected tissues.

**Symptomatology.**—In discussing the symptomatology of the inflammations of the uveal tract, I shall first present, as I did in the case of metastatic conjunctivitis, a review of the observations of previous writers in regard to these affections; and later criticise these views in the light of an analysis of the reports of cases of this nature gleaned from the literature. I shall not attempt to quote all

---

\*Archives of Oph. Vol. XXV., p. 191, 1896.



that has been written on the subject; but will give only the extracts which are important and in reality cover all that we know in this field. One begins then with Lawrence (1830) who, as stated in the introduction, gave us our first general description of gonorrhœal iritis. Under the title "Gonorrhœal inflammation of the external tunics and iris," Sir William wrote as follows :

Lawrence<sup>7</sup>: "The vascular trunks lying between the conjunctiva and sclerotica are distended, and the anterior portion of the latter membrane becomes pink or purplish red. As the conjunctiva participates but slightly in the affection, these changes are distinctly seen through it. There is increased lachrymal secretion, severe pain in the eye, with sense of tension, intolerance of light, with discharge of tears on slightest exposure. The pain and intolerance are sometimes excessive, so that the smallest access of light cannot be borne.

"The inflammation soon extends to the iris, which loses its brilliancy, assuming a dull and deeper hue. The pupil contracts, and lymph is effused from its margin. The external redness is increased, the vessels of the conjunctiva being more distended. The cornea, at the same time becomes hazy, and vision is more or less impaired. Nebulous opacity and speck of the cornea are sometimes produced. As the inflammation subsides, the iris recovers its natural color, and vision is restored.

"If the inflammation becomes considerable, it may cause adhesion of the pupil, with contraction of the aperture; and the adhesions thus formed are sometimes white, as in arthritic iritis. Even permanent dimness of sight may be produced. Sometimes repeated attacks of the disease occur, each of which causes fresh adhesions, so that at last the pupils are fixed in their whole circumference, and considerably contracted."

Mackenzie<sup>10</sup>: "The iritis which owes its origin to gonorrhœa, may or may not be preceded by synovitis. In general, the inflammation of the eye is very severe. It often commences with redness of the conjunctiva and sclerotica, and a striking haziness of the lining membrane of the cornea. The inflammation speedily affects the anterior surface of the iris, which loses its natural color. The disease for some days appears to be an aquo-capsulitis. It then merges into an iritis serosa. The pupil becomes contracted and the vision dim. A profuse effusion of coagulable lymph now takes place, speedily filling the pupil, and sometimes falling down, in a curd-like form, and in considerable masses, into the anterior chamber. In some cases, the anterior surface of the iris covered with lymph, as if coated with white paint. The anterior chamber is sometimes almost filled with the effused lymph. In fact, no other variety of iritis presents this symptom in the same degree. There is, in general, violent pain in and round the eye, with epiphora and intolerance of light. I have seen considerable chemosis, or conjunctival œdema attend gonorrhœal iritis; but there is no purulent discharge from the conjunctiva. There are no tubercles or abscesses on the surface of the iris, as in syphilitic iritis. The pupil, if the case is left to itself, remains contracted, and adherent to an opaque capsule, with the retina much more sensible, the iris less changed in structure, and the eye-



ball altogether less thoroughly disorganized, than in syphilitic iritis, but with a great disposition left for relapse.

"The patients who have been observed to suffer from gonorrhœal synovitis and iritis, have generally been young men of scrofulous constitutions, who lived hard, and were careless of exposure to cold. Each time the patient catches gonorrhœa he is liable to an attack of synovitis or iritis, or suffers first from the one and afterwards from the other. In some cases, however, there has been no new gonorrhœa, although a second or third attack of inflammation has affected the joints or the eye. Over-exertion of sight has sometimes produced a new attack of severe gonorrhœal iritis. Generally one eye only is affected; sometimes the same eye suffers repeatedly. In other instances, first one eye is attacked, the next time the other is inflamed. Rarely are both eyes affected at once.

"The patient is generally troubled with gleet, when the iritis occurs. In some cases, the iritis alternates with synovitis and gonorrhœa, so that when one of them is present, the others are gone. It rarely happens that all three are present at once. In many instances, the patients are harassed for years by a succession of the three, and at last are left in a state of great debility, their sight much impaired, and several of their joints incapable of motion. An eruption (ecthyma cachecticum ?) covers in some the scalp and the extremities, and the nails of the fingers and toes are destroyed.

"The gonorrhœal is generally more rapid in its progress than any of the other varieties of iritis, and is one of the most severe and formidable while it lasts; but it yields more promptly to decided treatment than any of the rest, and affords examples of perfect recovery, even when the aqueous chambers are filled with lymph. In no other variety of iritis is the recovery so striking and complete. A first or second attack, energetically treated, gives way readily, and absorption proceeds rapidly so that it is rarely the case that, under such circumstances, tags are left between the iris and the capsule. The patient often suffers several severe attacks, and yet vision is preserved entire. It is only from very numerous relapses, and when the treatment has been originally mismanaged, that the pupil is left irregular and contracted, and vision permanently deteriorated.

"After the lymph in the anterior chamber and within the verge of the pupil is absorbed, a cake of it is sometimes seen lying on the centre of the capsule. This is also absorbed. Although the disposition, then, to an effusion of lymph is greater than in any other iritis, the tendency to organization of the effused lymph is less than in the other varieties."

Wordsworth<sup>17</sup>, in a paper published in 1862, quotes Lawrence's description as covering all that he had observed of this disease; but remarks specially that the subjective symptoms were severe out of proportion to the objective signs. Five years later Galezowski<sup>23</sup> wrote strongly in favor of gonorrhœal iritis and described the condition under seven headings as follows:—

1. Gonorrhœal iritis can manifest itself in the course of a gonorrhœal arthritis. It can nevertheless appear independently of the articular affection.
2. The recurrences of the iritis are not due to an accidental cause such as fatigue of the eyes, cold, etc.; but are consecutive to the evolution of a gonorrhœal virus imprisoned in the organism which breaks out afresh



under the influence of a new irritation of the urethra. 3. The first attacks of iritis are most commonly of a serous nature; in the successive recurrences the iritis takes on a graver form and is accompanied by plastic exudations. 4. All the flakes that fill the anterior chamber, as well as the capsular exudations reabsorb. 5. The disease commences most often in one eye, but in the successive recurrences passes from one eye to the other. 6. The deep membranes of the eye ordinarily conserve their normal condition. The vision is blurred only during the inflammation or when one has not been able to prevent the formation of posterior synechiæ. 7. Sometimes the iritis is accompanied by a periscleritis.

In the first edition of the *Handbuch* of Græfe and Sæmisch contributions to the subject were made by DeWecker (1876) and Fœrster (1877). These exerted a very wide influence.

DeWecker<sup>32</sup>: "A mixed form of plastic and serous iritis occurs in such a characteristic manner in those affected with gonorrhœa that it must necessarily be brought into relationship with the inflammation of the urethra. Contrary to many observers (Ricord) we have never seen the iritis follow immediately upon a gonorrhœa: a rheumatic joint affection, especially of the knee, constantly precedes it (Fournier).

"What justifies us in separating this form from the one described in the previous paragraph (rheumatic iritis) is that here the characteristics of the rheumatic iritis\* are not pronounced; that it has much more to do with a mixed form which generally rapidly disappears under appropriate treatment without leaving behind any trace. Further, that an iritis of this character easily recurs, even when no trace of posterior synechiæ is present so soon as the individual in question is attacked by a fresh gonorrhœa."

Fœrster<sup>33</sup>: "If the existence of gonorrhœal iritis is still questioned in many quarters, the reason is to be found in the fact that one is still too little accustomed to examine the urethra in the presence of iritis. Whoever does this in every case of iritis, and especially elicits an exact anamnesis in every frequently recurring iritis, will soon discover a number of cases in which no traces of syphilis but a connection with gonorrhœa is present. That this connection is not an accidental one is evident from the fact that in the same individual repeatedly recurring gonorrhœas are accompanied by repeatedly recurring iritis. Generally posterior synechiæ are present in both eyes, and the patient suffers simultaneously on ever-recurring joint inflammations, which as a rule are designated rheumatic or even gouty. Both eyes are constantly involved, though not always at the same

---

\*A. Pronounced participation of the episcleral tissue in the inflammation of the iris. B. Great density and adhesiveness of synechiæ. C. Relatively slow subsidence of the swelling and injection of the pericorneal tissue as compared with other forms of iritis. D. Longer duration of inflammation of the episcleral tissue as compared with that of the iris. E. Extraordinary tendency to recurrences as the result of injurious circumstances, particularly damp cold; and, F. When, after repeated relapses, the characteristic picture of the rheumatic iritis has become blurred, and the case presents more the features of an irido-choroiditis with complete posterior synechiæ by (1.) episcleral areas of inflammation, (2.) discoloration of the sclera about the cornea, and (3.) a peripherally sclerosed portion of cornea.



time. I have never seen in these protracted forms one eye remain entirely unaffected. Extensive adhesions of the posterior surface of the iris with the lens capsule always arise under these circumstances. Especially characteristic feature by which one could recognize the gonorrhœal nature of this iritis do not exist. Nevertheless, according to my experience, it stamps itself in this way: that plastic exudations are not so quickly or so richly precipitated as in the syphilitic variety. Vitreous opacities are frequently present."

Kipp<sup>36</sup>: "Proceeding now to describe the eye affection, I may state that in only a very few of my cases was the inflammation limited to the iris and of a mild type. In all the others the disease presented itself under the form of an intense inflammation of the entire uveal tract with an abundant fibrinous exudation in the anterior chamber and an effusion into the vitreous body. In these cases there was found about the fourth day from the beginning of the disease, instead of the ciliary injection seen in simple iritis, marked chemosis and an intense congestion of the vessels of the whole ocular conjunctiva. The aqueous was usually from the beginning of the disease more or less turbid, and about the third or fourth day a yellowish-grey exudation, not unlike a layer of wax, was found to cover the pupillary area of the anterior capsule of the lens. In several cases I found at the same time the lower half of the lower two-thirds of the surface of the iris covered with a whitish granular deposit. During the following days there was usually a marked increase in the turbidity of the aqueous, so that the iris was only indistinctly visible, and this was followed soon by the appearance of yellowish-white flakes in the aqueous or by the coagulation of the exudation into a gelatinous or spongy mass which sometimes nearly filled the anterior chamber. The iris was in all cases, much swollen, and the pupil could not be kept in a state of dilatation by the frequent instillations of strong solution of atropine and cocaine, even in cases in which these drugs were used from the very commencement of the disease. No ophthalmoscopic examination could of course be made at this stage. The sight was always greatly impaired. Intense pain in and around the eye was a marked feature in these cases from the beginning, and it usually continued till coagulation of the exudation in the anterior chamber had taken place. In some of the cases the coagula looked at first like an opaque lens suspended in the aqueous in front of the pupil; subsequently it was changed by absorption into a greyish disc which was either attached to the surface of the anterior capsule of the lens or rested in the lower part of the anterior chamber. In a number of my cases the absorption of the coagulum progressed steadily till it had entirely disappeared, but in others it was interrupted by an increase in the inflammatory action, manifested by a new exudation of fibrinous matter. This was always accompanied by an increase or a return of the pain in the eye and a diminution of the size of the pupil. In several of my cases such relapses occurred, and two or three weeks elapsed before the fibrinous exudation was entirely absorbed. With the beginning of the absorption of the fibrinous substance in the anterior chamber there was always associated a marked decrease in the congestion of the vessels of the ocular conjunctiva, and by the time the exudation had disappeared only a moderate ciliary injection remained, which usually continued for some



weeks more. Posterior synechiæ remained in most cases; and even in those cases in which the pupil had been kept moderately dilated throughout the course of the disease adhesions between the pupillary margin and the lens capsule could not be entirely prevented. The ophthalmoscopic examination which was always made, as soon as the pupil was free, showed in every case some diffuse opacity of the vitreous body, and in many cases there were also present membranous opacities of varying density. In some cases the outline of the disc was obliterated, and the retinal veins were as a rule found congested and tortuous. Changes in the choroid could not be seen in any of the cases. The period required for the complete clearing up of the vitreous body varied from two to six months, and in a few of the cases some fleeting opacities, remained as long as the patient was under observation. In most of the cases the sight was completely restored, while in a few it remained somewhat impaired.

"In only a few of the cases were both eyes attacked simultaneously, but in several the second eye became affected before the first had entirely recovered. In other cases, the second eye was attacked by the same disease a year or two after the first, while in still others the unaffected eye remained healthy as long as the patient was under observation. Relapses were quite frequent, and in some of my cases one or the other eye would be attacked almost every year. The relapses were, however, always of a milder type than the initial attack and yielded more speedily to treatment.

"From the above it will be seen that the great majority of my cases of gonorrhœic irido-choroiditis presented the features not infrequently seen in cases of irido-choroiditis following idiopathic, chronic, articular rheumatism, and that the gonorrhœic form has no symptoms peculiar to it."

Nettleship<sup>141</sup>: "Gonorrhœal rheumatism is not unfrequently the starting-point of relapsing iritis and the other conditions named above, as well as of chronic relapsing rheumatism. Rheumatic iritis occurring for the first time with gonorrhœal rheumatism is, in my experience, more often symmetrical than other forms of arthritic iritis, or than the later attacks of iritis in the same patient; a fact which sometimes makes the distinction between rheumatic and syphilitic iritis difficult.

"This statement is based on records of 104 cases of iritis with well-marked rheumatic symptoms, and 6 with gonorrhœa but no rheumatism, in all of which syphilis was, so far as possible, excluded. (a) In 34 of this series the first attack of iritis came on during, or very soon after, gonorrhœal rheumatism; and in exactly one-half of these the iritis was double. In 6 others (making 40 in all) there were iritis and gonorrhœa, but no rheumatism ("gonorrhœal iritis"), and here the proportions were the same. (b) In the remaining 70 cases the first iritis had no relation to gonorrhœa; and in the subseries the attack was single in 56 and double in, at the most, 13 (two or three being doubtful), or about one-fifth. No corresponding difference obtained in regard to relapses, the vast majority of the recurrent attacks in both subgroups (a and b) affecting only one eye at a time."

Studying these descriptions more minutely one sees that Lawrence describes an iritis with rather severe reflex symptoms and a tendency at times to repeatedly recur: or perhaps more accurately



stated an iridocyclitis, especially if one interprets the corneal changes to be those which occur in this condition. Mackenzie pictures an intense iritis, or more properly an iridocyclitis, exhibiting a marked tendency to relapse and to recur with each fresh gonorrhœa; an inflammation which may or may not be preceded by a synovitis and affects generally only one eye; which is characterized by an absence of abscesses or tubercles; and which, finally, though showing a greater disposition to lymph-effusion than any other iritis, is less liable than the other varieties to have this substance undergo organization and tends generally to run a favorable course. Wordsworth entirely agrees with Lawrence; but remarks specially that the subjective symptoms are severe out of proportion to the objective signs. Galezowski clearly recognizes the connection between iritis and gonorrhœa but adds little to the clinical picture. He describes an inflammation, generally monocular and limited to the iris, which is usually serous in character in the first attacks and more plastic in recurrences. He points out an occasional association with periscleritis. From DeWecker's description one gets simply the impression of a mild iritis, always preceded by a synovitis, which tends easily to relapse and to recur with successive urethral inflammations. Færster emphasizes a double-sided nature of the affection but recognizes no specially characteristic features. He states only that plastic exudations are not so quickly or so richly precipitated as in the syphilitic variety, and that vitreous opacities are frequently present. Kipp's description is very similar to that of Mackenzie: severe local reflex symptoms with a marked tendency to exudations into the anterior chamber, to the formation of posterior synechiæ, and to recurrences, exacerbations and relapses; vitreous opacities with great impairment of sight; in a word, as he says, nearly always the picture of an intense inflammation of the entire uveal tract, and in a few cases only that of a mild iritis. Nettleship's contribution is a well grounded statement to the effect that rheumatic iritis occurring for the first time with gonorrhœal rheumatism is more often symmetrical than other forms of arthritic iritis or than the later attacks of iritis in the same patient.

While many other references to gonorrhœal iritis and inflammations of the uveal tract are to be found in the literature virtually all that is now taught by the profession in regard to these affections is embodied in the abstracts presented above. From them it will be seen that while the connection between gonorrhœa and uveal



inflammations and the recurring and relapsing character of these conditions are very generally recognized, much difference of opinion exists in regard to the many other phases of the diseases under discussion. The numerous points which arise will be dealt with more minutely in the sections which follow.

I have collected for study from the literature 112 cases of inflammation of the uveal tract; but the figures obtained from a classification of this material according to diagnoses gives one neither a precise idea of the relative frequency with which the different parts of the vascular coat are affected—of the extent of the inflammation if one likes better so to express it—nor of the usual character and severity of the gonorrhœal uveal inflammations. The reasons for this are obvious. On the one hand, innumerable mild cases have been undoubtedly looked upon as too unimportant for publication, and only the peculiar or severe cases have been placed on record. On the other hand, the conception of the various clinical entities has varied widely with the observer. What one writer calls a severe iritis, another designates an iridocyclitis or even iridochoroiditis. Much depends on the thoroughness with which the routine examination has been made and the pathological knowledge of the reporter, though the effect of tradition has also to be taken into account. To the early writers the term iritis covered at least all the changes which occurred in inflammations of the ciliary body as well as the iris but one feels that later ophthalmologists have, with more accurate pathological knowledge, followed the older ones too closely in applying this term to inflammations which were obviously more widespread.

In view of these facts it is impossible, with sufficient accuracy, to arrange the cases according to the common classification based upon the anatomical subdivisions of the uveal coat; and granting it possible to so satisfactorily treat the material the paucity of cases, even when one includes all that are to be found in the literature, is too great to permit of satisfying generalizations. Compelled, therefore, to depart from the customary lines, I shall first, taking for granted that they are practically the same, no matter what portion is affected, consider the general features of these affections as a class, and afterwards present examples of the various types of inflammation of the uveal tract to which systemic gonorrhœa is supposed to give rise. One can do no more at the present time, with the material at hand; but this field offers splendid opportunities for clinical research.



## GENERAL FEATURES.

**Sex and Age.**—A predominance of the male sex is well shown in the following figures, as is also the occurrence of systemic gonorrhœa at the period of greatest sexual activity. Of one hundred and nine cases of inflammation of the uveal tract one hundred and five were males and only four were females. These latter were reported by Burchardt,<sup>86</sup> Cheatham,<sup>96</sup> Panas<sup>100</sup> and Reyling.<sup>111</sup> The ages of ninety-one patients, arranged according to half decades, are as follows :

	Cases
15-19.....	6
20-24.....	19
25-29.....	22
30-35.....	15
36-39.....	15
40-44.....	2
45-49.....	5
50-54.....	4
55-59.....	2
60-65.....	1
	—
Total.....	91

**Symmetrical Arrangement.**—The symmetrical character of these affections is a question upon which writers are at variance. To add something further to our knowledge of this matter I have analysed the cases which give information upon this point. From accurate comparison with previous statistics all inflammations supposedly involving the choroid—plastic and suppurative iridochoroiditis—have in this case been excluded. An analysis of the ninety-five cases of iritis and iridocyclitis, which pathologically considered are one and the same thing, yields the following facts:

(1). In seventy-six cases in which the eyes were involved for the first time the affection was monocular in forty-eight cases and binocular in twenty-three.

(2). In nineteen cases in which the eyes were attacked on the second or subsequent occasions the inflammation was single in sixteen instances and double in three.

From this it will be seen that generally speaking gonorrhœal iritis or iridocyclitis is much oftener asymmetrical than symmetrical; but if one compares the cases in which the eyes were affected for



the first time with those in which they were involved in later attacks, the findings of Nettleship, namely, that rheumatic iritis occurring for the first time with gonorrhœal rheumatism is more often symmetrical than the later attacks of iritis of this nature in the same patient is largely borne out. In the first class of this series over one-third of the cases were symmetrical; while in the second class, only about one-sixth were of this character.

**Relationship to other Manifestations.**—The chronological relationship of the ocular to the other manifestations of systemic gonorrhœa—by which is meant in particular the joint inflammations—is the same as in metastatic conjunctivitis. In a series of eighty-one cases the ocular (1) preceded other manifestations in ten cases, (2) appeared concomitantly with other manifestations in nine cases, (3) followed other manifestations in sixty-two cases.

These figures entirely disprove the view that a joint inflammation must necessarily precede the outbreak in the uveal tract; and if, as shown above, the ocular trouble can even for a time be the sole expression of the systemic gonorrhœa, it is only reasonable to suppose that it can be the only manifestation of the condition. Quite a number of cases of this character have been reported; but none has as yet been accompanied by pathological corroboration.

#### TYPES OF INFLAMMATION.

In classifying the affections of the uveal tract which have been attributed to systemic gonorrhœal infection one finds practically all the commoner types of acute inflammation of this nature represented.\* To describe these is to describe much of what is commonly accepted in regard to uveal inflammations in general. Still, for purposes of comparison with those resulting from other etiological factors, it is advisable to sketch all the various clinical pictures to which systemic gonorrhœa is supposed to give rise. In the after study of these, however, one must not take for granted that the various entities are as fixed in their character as the classification might lead one to suppose. The boundaries of the inflammations are never sharply defined, and they exhibit a tendency to spread and to vary greatly in their degree of intensity. The recurrences and the relapses are commonly different from the primary attack, and altogether the picture is protean in character. Finally, some of the

\*To this statement one striking exception has to be noted. Burchardt is the only writer I can find who describes serous cyclitis (aquo-capsulitis) though this was looked upon by Fournier as a commoner expression of systemic gonorrhœa than either iritis or metastatic conjunctivitis.



paragraphs do not describe types in the strict sense of the term, but rather phases which conditions of this kind often present. With these points in mind one can distinguish the following groups of cases :

1. **Mild Iridocyclitis (Iritis).**—The case reported on page 62 of this study may be taken as a type of this class. The well-known signs of iritis are present, but the subjective symptoms are of the mildest character or even entirely absent. There is little exudation into the chambers and vision is but slightly interfered with. The tendency to synechia formation is slight, and the inflammation shortly ends in resolution never to recur. One has to do here, as previously shown, with an inflammation of the ciliary body as well as of the iris; and one ought really to employ the term iridocyclitis to denote the extent of the inflammation present.

2. **Severe Iridocyclitis.**—Here one has exaggerated all the signs and symptoms of iritis, with a few additional features. The local congestion is greater and there is chemosis and œdema of the lids to a varying extent. Ciliary pain and tenderness, a tendency to increased or diminished tension, greater cloudiness of the media, more marked diminution of vision, and coarser deposits on Descemet's membrane fill out the picture. This symptom group is commonly met with in gonorrhœal metastases; but the cases in the literature have often been loosely described under the term iritis.

3. **Plastic Iridochoroiditis.**—These cases, judging from published descriptions, are often indistinguishable from those of the preceding class. The differentiation is arbitrarily based upon the amount of exudation into the vitreous and the diminution of vision; but just why this should be so it is a little difficult to see. Undoubtedly the term iridochoroiditis describes more accurately than iridocyclitis, the extent of the inflammation in these cases, as the whole uveal tract is involved when the process is at all severe. Still, one knows this from pathological rather than clinical findings. No choroidal changes have been made out ophthalmoscopically in these cases; and the iris and ciliary body and not the choroid are responsible for the exudations which are visible and cloud the sight. The following five cases of Kipp and Bull will illustrate the conception of this group by the profession :

Case 46. (Kipp<sup>36</sup>)—Gonorrhœa — Arthritis—Iritis — Rheumatism — Second Gonorrhœa—Arthritis—Iridochoroiditis.

A gonorrhœa, contracted some years previously by a gentleman, aged about 20, was followed by an inflammation of the right knee joint and an



iritis of the right eye; and after this repeated attacks of rheumatism occurred. A second gonorrhœa, acquired some months previously, was again followed by inflammation of the knee joint; and two days previous to consultation pain was noted in the left eye.

On examination one found slight urethral discharge, and injection of the sub-conjunctival vessels on the temporal half of the sclerotic of the left eye. There were no visible changes in the cornea or iris and vision was perfect. The right eye was quiet, but its pupil was bound down by numerous, broad posterior-synechiæ and obstructed by a dense pigment deposit as the result of the previous attack of iritis. V.=5|30.

Two days later the whole ocular conjunctiva of the left eye was intensely injected; but the aqueous was clear, and the pupil widely dilated from the instillation of atropine. The iris was neither swollen nor discolored, and examination showed the interior of the eye healthy. On the following day there was great œdema of the ocular conjunctiva; the aqueous was cloudy; the iris swollen and discolored; the pupil much smaller than the day before, and blocked by a greyish exudation. The eye was very painful and sensitive; but there was no purulent discharge whatever. During the next three days the aqueous became more turbid, and on the fourth day the lower two-thirds of the anterior chamber was filled by a grayish gelatinous (fibrinous) exudation. Vision was greatly impaired and the pain was exceedingly severe. On the following day, while the left eye showed no change, considerable circumcorneal injection was noticed in the right eye, which, up to this time, had been free from pain. The anterior chamber contained an exudation similar to that in the other eye, and the iris was swollen and discolored. The patient was now nearly blind in both eyes. During the next two days the eyes underwent but little change, except that the exudation seemed to contract. On the following day there was increased pain in the left eye, the chemosis was more marked, and the aqueous was again quite muddy. The right eye was decidedly better. During the following week there was a steady improvement in both eyes. In the left the chemosis gradually diminished, the aqueous became clear, the gelatinous exudation assumed first the shape of a lens, then that of a disc and then after remaining suspended in front of the dilated pupil for several days gradually disappeared. About this time a filmy exudation was noticed to cover the lower portion of Descemet's membrane, and a mass of pigment made its appearance on the outer pupillary margin. The vitreous was so hazy that the details of the fundus could not be made out with the ophthalmoscope. Two weeks later there was still injection of the sub-conjunctival vessels for some distance around the limbus of the left eye, but the cornea and aqueous were perfectly clear. On the anterior capsule of the lens were several concentric grayish rings (the remains of the exudation) and the vitreous was still hazy. The tension of the eye was somewhat below the normal. V.=5|21. About six weeks later all injection of the ocular conjunctiva of the left eye had disappeared. The iris was still somewhat discolored but not swollen; the vitreous was clear and the fundus apparently normal; and tension and vision were normal. The eye remained in this condition for about two and a half months, when there was again some pain with injection of the vessels near the outer margin of the cornea, caused by the development



of a phlyctenule in the limbus which, however, speedily disappeared. After that the eye gave no trouble and vision remained perfect. The urethral discharge stopped shortly after the disappearance of the iritis.

**Case 47. (Kipp<sup>36</sup>)—Rheumatism—Gonorrhœal Arthritis—Conjunctivitis—Keratitis—Iridochoroiditis.**

A young man, about 20 years of age, presented himself for treatment of his inflamed right eye. Some five years before he had had a severe attack of acute rheumatism, and about six months previously had contracted a gonorrhœa. This was soon followed by arthritis and an inflammation of the right eye which the physician looked upon as gonorrhœal conjunctivitis and successfully treated.

About two months later he again presented himself with a small ulcer of the cornea which healed speedily under the usual treatment. After that he was entirely free from eye trouble until ten days previous to consultation when his right eye became again painful. He still had some gleet, and on examining his eye one found great congestion and œdema of the whole ocular conjunctiva. The cornea was clear, but the aqueous was cloudy, and in front of the lower half of the iris and pupil was a thin membranous exudation with sharply defined upper margin. The entire iris was discolored but not much swollen. The vitreous was hazy and the details of the fundus could not be made out. Three days later the aqueous was clear and the membranous exudation had entirely disappeared. All evidence of the eye affection had disappeared four weeks later.

**Case 48. (Kipp<sup>36</sup>)—Gonorrhœa—Double-sided Iridochoroiditis—Phlyctenular Conjunctivitis.**

A rather thin but healthy man, forty-three years of age, who had never had syphilis or rheumatism and had always enjoyed excellent vision, contracted gonorrhœa about three weeks before the disease began. Kipp saw the patient for the first time on the 16th November. The right eye had then been inflamed five days, and the left three days. There was still some discharge from the urethra, but the patient had no rheumatism. The condition of the eyes was as follows: Right: both lids puffy; palpebral conjunctiva congested but not swollen; ocular conjunctiva intensely injected and œdematous; no disease of the cornea, but aqueous turbid; iris discolored, but not much swollen in its upper half; in its lower half covered by a whitish, granular deposit; pupil dilated, and its centre occupied by a grayish disc-like exudation (atropine had been used for several days); in the vitreous numerous floating opacities preventing an examination of the background of the eye; vision reduced to fingers at two feet; T=n; visual field intact; very great pain; no purulent discharge. Left: lids, conjunctiva and cornea, same as right; lower two-thirds of anterior chamber filled with a grayish, gelatinous exudation, the upper margin of which is convex; pupil contracted; fundus not illuminable; V.—p.l. only; tension and field normal; excessive pain; no purulent discharge.

Two days later some mucous discharge was noticed from both eyes, but by December 13th injection of the conjunctiva of both sides had disap-



peared. A month later the sight had so far improved that the patient was able to walk around with safety and the vitreous had cleared to such an extent that one could indistinctly see the optic discs and retinal vessels.

The eyes remained pale until March 19th, when pericorneal injection and a few phlyctenulæ were seen on the margin of the cornea in both eyes. These disappeared in a few days under dustings of calomel. At the last note June 5th, an abrasion of the epithelium was found almost in the centre of the cornea of the right eye. The vitreous still contained grayish opacities and the vision=6/60. Although the patient did not return again for consultation, his vision must have still further improved as he was able to keep his account books and read large print.

Case 49. (Bull<sup>77</sup>)—Gonorrhœa—Orchitis—Polyarthrititis—Monocular Iridochoroiditis.

A gentleman aged 32, contracted a gonorrhœa, which was treated by his family physician. For a week there was no complication except a mild orchitis; but on the 8th day the left shoulder and right knee became painful, and there soon developed an acute arthritic inflammation in both joints with great swelling and high fever. On the 14th day, after a violent attack of pain in the right side of the head and right eye, the eye became inflamed and vision was rapidly impaired. When seen by Bull on the 15th day there was considerable swelling of the lids; some chemosis of the conjunctiva; marked conjunctival and ciliary injection; a hazy aqueous humor; discolored iris; posterior synechiæ; and a diffuse infiltration in the vitreous, with scarcely any reflex from the fundus. Vision was reduced to perception of light; but the tension was normal.

The same line of treatment was pursued in this case as was employed in the first case (leeches, fomentations, atropine and cocaine, salicylate, etc.) For the first three days no visible effect was produced upon the intraocular inflammation, though the pain in the head, shoulder, and knee-joints was decidedly relieved. The pain in the eye subsided about the 5th day, and from the 9th day on, rapid recovery took place. All acute inflammatory symptoms in the joints disappeared; the urethral discharge ceased; the aqueous and vitreous cleared rapidly; and the ocular injection gradually diminished. Three weeks after the patient's first visit to Bull all signs of irido-choroiditis had disappeared; the media were perfectly clear and vision had risen to 20/30. The other eye remained intact throughout.

Case 50. (Bull<sup>77</sup>)—Gonorrhœa—Polyarthrititis—Double-sided Iridochoroiditis.

A gentleman aged 25, had a severe attack of gonorrhœa in April 1892, which lasted nearly three months. This was accompanied by an acute arthritis of the right knee and left shoulder joints; but at this time the eyes were not affected. He recovered from the urethritis and the arthritis completely; but in the second part of September contracted a second gonorrhœa, which resisted treatment as obstinately as the first. On the fourth day after the appearance of the urethral discharge he was attacked by severe arthritis of both knee-joints, and on the 6th day by an acute inflammation of the left ankle and wrist joints. On the 8th day after the appearance of



the urethral discharge, the right eye became inflamed with severe pain, photophobia, and lachrimation of a scalding character. When seen two days later by Bull all the symptoms of a severe irido-choroiditis of the right eye were present: excessive ciliary and conjunctival injection, chemosis of the ocular conjunctiva, cloudy aqueous humor, discolored and immovable iris, posterior synechiæ, extensive exudation into the vitreous humor masking all details of the fundus, vision only 10/200, tension decidedly increased, and excessive pain in the eye and head. At that time the left eye was intact, but on the next day signs of iritis appeared in the right eye and a severe irido-choroiditis developed. Energetic treatment (leeches, cocaine and atropine, hot fomentations and salicylates) was at once instituted and after twenty-four hours the patient was almost entirely relieved from pain. On October 11th, the left eye was markedly improved with a widely dilated iris, hazy vitreous, and vision of 20/100; but in the right eye the ciliary injection was still quite marked, and there was considerable chemosis of the conjunctiva. The iris, however, was widely dilated; all the adhesions were broken; the vitreous was much clearer; and the details of the fundus were visible. By the 16th November, vision was 20/20 in each eye, and the tension was normal; there was no pain, and the ciliary injected had nearly subsided. The knee joints were nearly, and the wrist and ankle joints entirely well. The urethral discharge had also ceased.

4. **Exudative Iritis.**—Exudations into the anterior chamber have been very generally regarded as characteristic of gonorrhœal inflammation since Mackenzie stated that they were more common in this than in other forms of iritis. There are no figures for other inflammations with which one can compare the frequency of occurrence of this condition in gonorrhœal iritis. Woods,<sup>155</sup> only, in his small series of recurrent iritis, found that the phenomenon was commoner in the rheumatic cases proper than in those due to other causes, gonorrhœa included. Exudations of a gelatinous character were present in thirteen of the 112 cases of uveal inflammation collected by me from the literature. They are very generally expressive of a severe type of inflammation. In only three of the cases does the trouble seem to have been of the nature of a moderately intense iritis. In the rest of the cases the diagnosis was that of iridocyclitis or severe iritis in seven, and of an iridochoroiditis in three cases. Woods, too, found that the exudations bore some relationship to the severity of the inflammation; and after all, an excessive formation of inflammatory products is simply what one would expect in the intense as compared with the milder infections.

5. **Hæmorrhagic Iritis.**—Hæmorrhages into the anterior chamber in cases of uveal inflammation of supposed gonorrhœal origin are mentioned in only three cases; by Dunn,<sup>87</sup> Burchardt,<sup>98</sup> and Lipski.<sup>88</sup> In all three cases the inflammation appears to have been



of a rather sharp character. In the patient of Burchardt the hæmorrhages were associated with a gelatinous exudation into the anterior chamber.

6. **Recurrent and Relapsing Iritis.**—These terms sometimes used synonymously, express in reality two different but well recognized phases of these conditions.

The special liability of those once affected with systemic gonorrhœa to further generalized infections with the acquisition of each fresh urethritis has been very generally admitted since the fact was first pointed out by Ricord in 1848. To the new inflammations occurring in this way the term "recurrent" should be employed in contradistinction to "relapsing," which ought to be reserved for the disturbances that follow the primary ocular inflammation, and are entirely the outcome of the primary urethreal infection. What factors underlie recurrences we do not know; but that there is a special liability thereto seems to be borne out by abundant clinical evidence.

The tendency of these affections to relapse has been widely recognized since the time of Mackenzie. One cannot say what percentage of cases presents this feature, but many convincing illustrations are to be found in the literature. One or more relapses are noted in twenty-two, or practically one-fifth, of the hundred and twelve cases collected for this study. As cause, one is led to think of fresh inroads of cocci when the primary bacteria have spent their virulence; or of a disposition on the part of the gonococci to lie dormant in the tissues of the eye, as they do in those of the urethra, for a variable period, and then break into fresh activities for reasons for which we do not as yet understand. Neither of these explanations, however, is sufficient to account for those relapses which apparently take place long after the longest period the present state of our knowledge will permit us to believe the gonococcus can continue to exist in the system. The primary disturbances apparently leave behind here some susceptibility to inflammation which has not as yet been satisfactorily explained.

The following case, the gonorrhœal nature of which seems clinically well-grounded, is illustrative of the marked tendency to relapses that is held to be so characteristic of gonorrhœal iritis.

**Case 51. (Hutchinson<sup>55</sup>)—Gonorrhœa—Gonorrhœal Rheumatism—Relapsing Iritis—Twenty Attacks—Great Damage to the Eyes.**

William Webb, aged 45, came under the care of Mr. Hutchinson at Moorfields in 1861. He was of sanguine temperament, but pale and sallow.



Excepting his liability to rheumatism and to iritis, he considered that he had enjoyed good health. He had never had syphilis. In early life he had contracted two attacks of gonorrhœa, and nine months after the second, both his eyes inflamed. He was suffering at the time from rheumatism which had begun within a few weeks of the attack of gonorrhœa. Neither of his attacks of gonorrhœa lasted more than a week or two, and both were uncomplicated. He was treated for his first attack of iritis by Mr. Babbington, in St. George's Hospital, who considered it rheumatic. After the first attack of iritis he remained well only three or four months when a relapse occurred. He had had on the whole twenty attacks, and had usually suffered most during the month of March. Until 1846, he did not experience any material injury to his sight, but an attack during that year was treated without belladonna, and on recovery from it he found his sight much impaired. An attack in the following year damaged his sight still more. Three or four years ago he was obliged to give up his occupation as a draper on account of his defective sight.

The state of his eyes when he first came under Mr. Hutchison's observation was as follows: With the right eye he could see shadows, but nothing more; the pupil was not larger than a pin's head, and was closed by a false membrane; the iris was bulged forward by effusions behind it, and its structure was much altered by stretching. The left pupil was excluded and occupied by a false membrane, through the centre of which was an aperture sufficient to allow him, under favorable conditions, just to manage to read.

It seemed very probable to Mr. Hutchinson that in this case the rheumatism was gonorrhœal as the patient was not aware of rheumatism or gout in his family.

One would expect that, as a result of lessened virulence on the part of the germs, relapses would be less severe and of shorter duration than the primary attacks; but a study of the cases fails to bear out this supposition. An equal number can be found to speak for and against the theory. Nor does it invariably follow in cases, where in the first instance only one eye was inflamed, that the affected side is more liable to be visited by the recurrences than the other. Apparently the sound eye is as often involved as the one previously inflamed.

Great variations in the severity of the symptoms are frequently a marked feature of these inflammations. To-day an eye is comparatively well; to-morrow in a painful and critical condition. Often an exacerbation is indicative of a fresh outbreak of trouble elsewhere: in the cornea, conjunctiva, or adjacent portions of the uveal tract. An improvement in the eye with a concomitant back-set in the joints or urethra or other eye and vice versa has been often noted.

(7.) **Suppurative Iridochoroiditis.**—The nine cases of this sort that have been reported and are given below form a very interest-



ing group. In some of them the corroborative clinical evidence is of the slightest description, but in several others it is sufficiently strong to make their connection with systemic gonorrhœa highly probable. This latter statement applies especially to the cases of Koeniger, Friedenbergs, Morax, Zimmerman, and Galezowski. It is to be regretted that in Professor Panas's report no mention is made of a bacteriological examination of either the vaginal discharge or the evacuated hypopion.

The clinical features of suppurative uveal inflammations in general, which are too well known to call for detailed description, form the backgrounds of the disease pictures in these cases; but certain points call for special attention as being perhaps somewhat characteristic of the gonorrhœal disorders of this nature. Foremost among these is the excellent recovery which often occurs even in apparently hopeless cases. Thus, for instance, in Koeniger's case the vision rose in seven weeks from faulty p. l. to 1/6; in Jahn's case in ninety days from questionable p. l. to 6/12; in Coppez's case in three months from p. l. to 2/3; and in Zimmerman's case in seven weeks from hand movements to 15/15. Perhaps no other suppurative iridochoroiditis presents this feature to a like extent; and the results should be encouraging from the standpoint of prognosis.

In the second place, certain of these cases go to show that there is no sharp line of demarcation between the purulent and the non-purulent forms of intra-ocular inflammation occurring in association with systemic gonorrhœa. In Koeniger's case, for instance, steel-gray vitreous opacities were observed to take on a yellowish tint suggestive of purulent changes: in Friedenbergs's patient, who was suffering from an intense plastic iridochoroiditis, a flocculent yellow exudation appeared in the anterior chamber simultaneously with the outbreak of an articular inflammation: and in Jahn's case a marked purulent infiltration of the iris was grafted upon a plastic iritis, associated with a secondary inflammation of the conjunctiva. In all three cases the suppurative inflammation passed again into a plastic phase, and one would infer that this evanescent purulency speaks rather for the work of the gonococcus, the pyogenic powers of which are slight, than for the pus-germs proper, which one would expect to produce an inflammation, purulent from the outset.

Finally, there is perhaps a less marked tendency to relapses in the suppurative than in the plastic inflammations produced by systemic gonorrhœal infection. In the purulent conditions the inten-



sity of the inflammation seems to destroy that power of the organism to break out afresh which is so marked a feature of the plastic forms. The data are as yet insufficient, however, to enable one to dogmatize on this point; and that the rule is not without exception is proven by the case of Despagent cited below.

Case 52. (Koeniger<sup>28</sup>)—Gonorrhœa, Polyarthrititis—Second Gonorrhœa, Polyarthrititis, Iritis, Iridochoroiditis.

A book-binder's apprentice, aged 29, who gave a history of two previous gonorrhœas followed on the first occasion by polyarthrititis and on the second by iritis as well as joint manifestations, acquired a third (fresh) urethritis about the middle of September, 1872. This attack, which was immediately treated by injections, was complicated at the end of six weeks by an outbreak of rheumatism and at a further period of eight days by a fresh inflammation of the left eye.

At consultation two weeks later (Nov. 18) the following ocular conditions were made out: Marked cloudiness of the aqueous rendering ophthalmoscopic examination impossible; very extensive synechiæ not yielding to atropine; intense pericorneal injection and reflex symptoms; ciliary tenderness; L. V.=fingers 12'; f. of v. free.

Five days later there was little improvement and slight defects were made out in the field of vision up and out and down; but in the following twenty-four hours (Nov. 24th) the pupil and anterior chamber had cleared to such an extent that one could make out that the region behind the lens was occupied as far as one could see by homogeneous, steel-grey, vitreous opacities which were entirely without movement. On November 26th fingers could no longer be centrally counted; the projection was faulty to diminished light; and an ophthalmoscopic examination showed that the exudation behind the pupil had become more distinct and had taken on a yellowish tint which suggested purulent changes in the vitreous. By December 2nd, the vitreous opacities had lost their ominous yellow tint and resumed their previous steel-grey color; and from now on gradual clearing occurred. The optic discs and vessels could be indistinctly seen on December 22nd through the greyish clouds in the lower part of the vitreous; V=1|9; and the f. of v. was free. Two days later (roughly seven weeks after the onset) V=1|6, and signs of irritation had almost entirely disappeared.

Case 53. (Friedenberg<sup>69</sup>)—Gonorrhœa—Arthritis—Second Gonorrhœa—Kerato-Iridochoroiditis—Polyarthrititis.

The patient, a young man of 19, had always enjoyed good health until he contracted gonorrhœa in February, 1890. Two weeks later the left ankle joint became swollen and painful, and soon after this the right knee joint was similarly affected. The urethral discharge ceased about April the 1st; but the arthritis was not cured until the middle of May.

On December 7th, 1890, the patient consulted Friedenberg complaining of redness, pain, and rapid diminution of vision in the right eye. A se-



cond gonorrhœa had been contracted two weeks previously. On examination the right eye showed marked ciliary injection without chemosis; cornea steamy throughout; iris discolored and covered with a shining greyish membrane; pupil of medium size (atropine) and pupillary margin everywhere adherent to lens capsule; no r. r.; ciliary region hardly at all tender; V=hand movements at six feet; O. S. normal.

On December 11th, while the cornea was more infiltrated a reddish-brown reflex was obtainable from the fundus and V=20/200. Three days later inflammation was noted in the tibio-tarsal articulation, and on the eighteenth, the arthritis persisting, dense infiltration of the cornea was observed with flocculent, yellow exudation in the a. c. There was great blurring of the iris, and V = 0.

Under repeated mercurial injections into the right temple the cornea rapidly cleared and the exudation in the a. c. disappeared; but the vitreous was now seen to be infiltrated with a similar yellowish exudation which disappeared very slowly, leaving permanent floating opacities. An extensive polyarthritis which had developed concomitantly with the ocular inflammation gradually subsided.

Case 54. (Jahn<sup>79</sup>)—Gonorrhœa—Phimosis—Cystitis—Iritis with Secondary Conjunctivitis—Kerato-Iridochoroiditis—Keratitis.

Three weeks after the acquisition of a gonorrhœa which was complicated by a phimosis and a hæmorrhagic cystitis, both of short duration, an artilleryman developed an affection of the eyes. For about a week the ocular inflammation presented the features of a left-sided iritis with secondary conjunctivitis, as well as slight transitory participation of the other eye: but, at the end of this time, the disease, which up to this moment had shown a tendency to heal, exacerbated concomitantly with the outbreak of a severe affection of the uveal tract. The whole cornea became markedly cloudy and the iris purulently infiltrated, with deposits on the anterior lens capsule. Vision was reduced to questionable p. l. and the intra-ocular tension raised. But the eye thus seriously affected slowly improved from two days later on. The secondary glaucoma passed into hypotonia; and, as the exudation in the a. c. and on the lens capsule grew less, a greyish reflex from vitreous opacities behind the lens could be made out on focal illumination.

Six days after the relapse of the inflammation in the left eye the right eye showed slight irritation and injection. On the following day along with congestion of the bulbar and palpebral conjunctiva dilatation and tortuosity of the retinal veins were made out, and twenty-four hours later a small ulcer had developed on the inner margin of the cornea. In this eye all trouble had apparently subsided at the end of a month. On the ninetyeth day of the ocular disease the conjunctiva and iris as well as the tension of both eyes were normal; there was a good reflex from the fundi and no vitreous opacities or subjective symptoms; and the gonorrhœa was cured. R. V.=n; L. V.=6/12. According to a later report the patient's eye had still further improved.



**Case 55. (Despagnet<sup>82</sup>)—Gonorrhœa, Hypopion Iritis—Relapse of Iritis as a Plastic Inflammation—Second Gonorrhœa, Recurrence of Plastic Iritis.**

The case was that of a young man, aged 19, who presented himself in October, 1884, with a severe iritis of the left eye complicated by hypopion. The globe was intensely injected; the cornea transparent; the aqueous flakily clouded; and the anterior chamber showed a small, whitish mass below. The pupil was contracted and clouded, and a small posterior synechia was present downwards. The eye was weeping and sensitive to light, and the periorbital region was the site of very severe pains. No history of traumatism or syphilis was obtainable, but the patient had been under treatment for six days for a gonorrhœa acquired fifteen days previously. Examination of the urine for sugar and albumin was negative, and the joints and other organs were normal. In the left submaxillary region there were two scars the result of an old suppurative adenitis. The patient was subject to bronchitis, and a brother of his father had died of tuberculosis. Nevertheless, the general appearance of the patient was tolerably good.

Under treatment the iritis continued without much change during some days; but from the twelfth to the seventeenth day it recovered with extraordinary rapidity. The pus was re-absorbed, the anterior chamber regained its transparency, the vision improved every day, and there remained only the posterior synechia previously made out. In time the gonorrhœa itself mended. The discharge without being dried up had changed its character, and everything pointed to a speedy recovery.

About the middle of 1886 the patient again presented himself with an intense iritis of the same eye, but this time without hypopion. He had not acquired a fresh gonorrhœa, but had, using his expression, been caught (pincé) twelve days previously. The same treatment as before brought about recovery in twelve days.

Finally, in November, 1887, the patient came for the third time with a history of a fresh gonorrhœa of twenty, and of a fresh iritis of the left side of two days' duration. This time the iritic inflammation was much more slight, because, at the first manifestation and on his own authority, he had applied leeches and put drops of atropine into his eye. On this, as on the previous occasions, no articular manifestations had occurred, and recovery took place seven days later without the formation of any new synechiæ.

**Case 56. (Morax<sup>90</sup>)—Gonorrhœa, Urethral Stricture, Gleet—Polyarthritides—Suppurative Iridochoroiditis.**

A man, aged 43, presented himself on March 13th, 1895, with the complaint of loss of vision in the left eye. There was moderately pronounced swelling of the lids which the patient opened with difficulty. The cornea was a little cloudy, and the conjunctiva presented an extreme degree of chemosis. The iris was slightly discolored and thickened; the pupil contracted; and there was a small hypopion. The vitreous was entirely clouded so that illumination of the fundus was impossible. Pressure on the globe was painful, but the tension normal. The condition of the eye gradually improved from the following day forward. All pain and tenderness had disappeared by March 23rd. And on April 6th, the visual acuity=5/15. The patient was afterwards lost sight of.



The patient had suffered from gonorrhœa on two occasions. The last attack acquired at the age of forty-one had been followed a month after its onset by polyarthritis, and had left behind a stricture and a gleet. During the last two years the patient had had no fresh, acute articular outbreaks, but had experienced transient pains in the phalanges and noticed a slight morning purulent discharge from time to time. The ocular trouble commenced on the 2nd of March, 1895. On wakening the eye was injected and the vision became considerably clouded during the day. The trouble appeared to have commenced without any provocation, though the patient attributed it to a blow on the left temporo-parietal region eight days previously. Along with the loss of vision the patient had experienced violent pains in the eye, the forehead, and the temples, which had kept him awake for five nights.

Case 57. (Coppez<sup>91</sup>)—Gonorrhœa and Double-sided Purulent Ophthalmia—Suppurative Iridocyclitis.

A telegraph operator, aged 31, had had a gonorrhœa accompanied by double-sided purulent ophthalmia three years previous to consulting Coppez. The ophthalmia lasted more than one month and was accompanied by an intense fever; but since that time the patient had enjoyed excellent health and had never experienced any further ill effect from his gonorrhœa. About April 18th, 1895, redness and later intraocular pain appeared in the right eye; and on April 27th, the following conditions were made out:

Right eye: lids greatly tumefied and reddened; considerable chemosis protruding hernia-like from the palpebral fissure; mucous membrane dark red, but no secretion; cornea slightly opalescent in its deep layers; corneal epithelium perfectly intact; transparency of aqueous lost; small crescentic hypopion; iris hazy and of a dirty-brown, rusty tint; yellowish exudate in the pupillary area; no fundus reflex; T. +; v = p. l.

Suppurative iridochoroiditis was diagnosed, and injections, atropine, compresses, etc., instituted. On April 29th, very considerable improvement was noted; the anorexia persisted, but the pain had entirely disappeared. The next day fingers were counted at two metres, and the following conditions were made out by focal illumination: (1). A slight opacity on the posterior surface of the cornea which, starting 2 mm. from the external part of the limbus of the cornea, extended inwards in the form of a tongue and ended at a point near the internal portion of the pupillary orifice. (2). An exudative opacity, more pronounced than the first, which occupied the p. a. and left a circular space of 1 mm. between the inner margin of the iris and periphery of the exudate. Through this slight rift one got a red reflex ophthalmoscopically. The iris showed some synechiæ.

Two days later it was noted that the papilla was coming into view and that the tension was returning to normal; and four days after this that the p. a. was entirely free. Gradual clearing of the vitreous occurred, but more quickly on the temporal than on the nasal side as was especially apparent from the perimetric tracings. About three months after the onset of the inflammation (July 12th) there was no longer any appreciable ophthalmoscopic lesion and the patient was allowed to resume his work with his vision = 2/3.



Case 58. (Zimmerman<sup>95</sup>)—Chronic Urethritis with Stricture—Suppurative Iridochoroiditis—Recovery and Complete Restoration of Visual Acuity—Previous Attacks of Gonorrhœa and Polyarthrititis.

A Canadian sailor, aged 29, who still suffered from stricture of the urethra, had had gonorrhœa twelve, five, and three years previously; and following the second and third gonorrhœas attacks of polyarthrititis which lasted eighteen and eight weeks respectively. While reading on the evening of October 10th, 1894, the patient had experienced pain in the right eye which also looked inflamed. Five days later Zimmerman observed the following conditions:

Left eye: normal. Right eye: lids greatly swollen; intense chemosis of the whole of the conjunctiva bulbi with bloody suffusion; cornea somewhat clouded; iris veiled and discolored; pupil contracted and covered by greyish-yellow exudate; hypopion; T: not essentially increased; no red reflex with the ophthalmoscope; V = hand-movements close before the eye.

Noticeable improvement followed treatment until October 18th, when marked deterioration in the condition of the eye occurred, probably, it was thought, in consequence of cold. The chemosis was increased; the iris blurred and the pupillary-area filled with abundant, fresh, opaque exudate. The patient experienced pain and general malaise and could not count fingers even at the closest distance. But from this time on recovery gradually occurred. On October 14th, a small remnant only of the exudate remained in the centre of the pupil and one could make out vitreous opacities which had been previously hidden by the opaque contents of the anterior chamber. By December 8th, 1894, the vision had risen to 15/15 and the vitreous opacities had entirely cleared. There remained, however, numerous posterior synechiæ (the upper part of the iris only re-acted well to light), pigment deposits on the anterior capsule of the lens, and at certain points in the pupil membranous-like remains of the exudate.

Zimmerman looked upon the condition as an endogenous infection by the gonococcus of Neisser, and believed the satisfactory outcome of the case spoke strongly in favor of the subconjunctival injections of mercury which had been employed in addition to the usual mydriatic treatment.

Case 59. (Panas<sup>110</sup>)—Gonorrhœa—Metastatic Intraocular Suppuration—Keratitis Profunda.

A robust woman, aged 26, had never before had any serious illness apart from a vaginal discharge which dated back "some months." Her eyes had always been perfectly sound until May, 1898, when, without any appreciable cause, blurring of vision, injection, dull pains, and a spot appeared in the left eye. Some days later on presenting herself at the Hotel Dieu, the following conditions were made out:

Hypopion of the lower third of the anterior chamber; and synechiæ and yellowish discoloration of the iris. The hypopion instead of having its superior margin concave, as is the rule, formed a sort of tiny hillock at the level of the lower part of the pupil, and this portion appeared to extend along the posterior surface of the cornea and to be adherent there to a certain height. The cornea was cloudy about this prolongation which



appeared by focal illumination as well as by corneal magnification to have a sort of tiny focus in the deep layers of the cornea in direct communication with the adhesion of the hypopion of which it appeared to be a prolongation. The corneal epithelium was everywhere intact.

In spite of vaginal and ocular treatment the hypopion increased up to the middle of the cornea and was treated by an inferior paracentesis. The cornea regained for the most part its transparency; but there remained a sort of deep-seated opacity as if one had in reality a point of infiltration. The situation grew worse with the anterior chamber absent and the iris adherent to the cornea. There was no longer any visible hypopion nor was the eye very painful on pressure; but the tension was greatly diminished and the vision reduced to feeble perception of light.

The eye so desperate in appearance changed, however, for the better. The anterior chamber gradually reformed and the iris took on a less yellow color. The cornea carried on its inferior third a sort of deep greyish track and the pupil was in part clouded; but the eye regained its normal-consistency and the patient counted fingers at 50 c. m.

**Case 60. (Galezowski<sup>147</sup>)—Gonorrhœa, Polyarthrititis—Polyarthrititis, Irido-choroiditis.**

M. C., aged 39, enjoyed habitual good health until February, 1902, when he contracted a gonorrhœa. This was followed by a severe polyarthrititis which kept him in bed for three months. The gonorrhœa was said to have been treated in a clinic and the discharge to have disappeared. In February, 1903, a new rheumatic outbreak occurred, but much milder than that of the preceding year. In revenge the left eye was affected and some days later Galezowski made out the following conditions: Injection and pus in the a. c.; iris moderately inflamed and posterior synechiæ present.

As the result of treatment very rapid improvement occurred. The pains presently disappeared and during the last days of February every trace of pus was effaced from the anterior chamber. One small posterior synechia and a slight exudate on the anterior surface of the lens remained as signs of the previous inflammation. The fundus was negative; but there was slight cloudiness of the vitreous.

#### **(8.) Inflammations of the uveal tract in association with other conditions.**

(a) Irido-conjunctivitis. In numerous instances cases have been reported where one had, in addition to the symptoms of an iritis or iridocyclitis, a well marked metastatic inflammation of the conjunctiva. Kurka's case (see page 100) is illustrative of this suggestive type of irido-conjunctivitis. In other instances, which have been noted in the section on metastatic conjunctivitis, the uveal inflammation has been observed to follow close upon the subsidence of the inflammation of the conjunctiva, or to occur as a complication of this condition.



(b) Keratitis. The possibility of indirect involvement of the cornea as the result of toxines acting through the aqueous has been discussed elsewhere; but in a few instances a keratitis has been observed to break out simultaneously or almost simultaneously with the inflammation in the uveal tract. An example of this occurrence is afforded by the other case of Kurka (p. 50), in which a right-sided iridocyclitis broke out four weeks after the subsidence of a metastatic conjunctivitis, and was in turn soon complicated by a keratitis.

(c) Retinitis and neuro-retinitis. In seven of the cases collected for this section, a neuritis, retinitis, or neuro-retinitis was associated with an inflammation of some part of the uveal tract. These are fully given and discussed in the section on affections of the optic nerve and retina.

(d) Dacryoadenitis. In the case reported by Ferry (see p. III) an iritis was associated with a double-sided inflammation of the palpebral portion of the lacrimal gland as well as with a metastatic conjunctivitis.

#### DIAGNOSIS, PROGNOSIS, AND TREATMENT.

The points of value in the diagnosis of these conditions will have been gathered from what has preceded. Of the first importance is the determination of the presence of a specific urethritis and of other lesions attributable to a systemic gonorrhœal infection. The examination should not be confined to the genito-urinary organs and urine, but include the whole body; and every modern method of clinical and bacteriological research may be brought to the solution of difficult cases. A history of previous gonorrhœas and of systemic gonorrhœal infections should be carefully inquired for and every other possible cause for the local condition ought, it is needless to say, to be carefully excluded. There are no local features which are entirely characteristic of these conditions, but in the plastic forms, nodular swellings of any kind in the iris tissue, speak absolutely in a negative way against a gonococcal infection, while in a positive way gelatinous exudations into the anterior chamber and a marked involvement of the conjunctiva (associated metastatic conjunctivitis) are suggestive. Though I was unable to obtain sufficient data from the literature to permit of generalizations on this point, my impression is that the synechiæ in these cases do not differ in appearance or adhesiveness (as expressed in their resistance to the action of mydriatics) from those produced by



other inflammations. The frequent bilateral character of these infections in the first attacks should be borne in mind in comparing them with syphilitic conditions. In the suppurative forms a preceding plastic phase and a well marked tendency to recovery can perhaps be looked upon as indicative of gonococcal infection.

In the purulent forms the prognosis is apparently relatively good as compared with similar conditions due to other infections. In the plastic forms one must bear in mind the undoubted tendency to recurrences, and to relapses.

The remedies of value here are those commonly employed in inflammations of the uveal tract in general, and are too well known to require special mention at this point.



## VII.—AFFECTIONS OF THE OPTIC NERVE AND RETINA.

---

Thirteen cases of neuritis, neuro-retinitis, or retinitis, attributable to gonorrhœal metastasis, have been placed on record since Professor Panas published his first report in 1890. The clinical evidence in the series, taken as a whole, is rather strong, and justifies the belief that systemic gonorrhœa does at times produce metastatic inflammations of the optic nerve and retina. In eleven of the thirteen cases the ocular inflammation was associated with changes in the joints and other parts of the body which are more generally looked upon as characteristic of gonorrhœal systemic infection. In the remaining two cases (Highet, Eperon) the diagnosis was arrived at by carefully excluding every other etiological factor; and this seems to have been carefully done.

In comparison, though, with the uveal tract, the retina and optic nerve are probably relatively seldom affected in systemic gonorrhœa. It would seem from the work that has been done in connection with ocular metastases that bacteria vary in their predilection for the different coats of the eye.† The pyogenic organisms apparently exhibit a tendency to lodge in the retina, particularly when the inflammation is of a double-sided character; but, judging from clinical statistics, the gonococcus, like the tubercle bacillus, finds its most favorable environment in the vascular coat of the eye.

There are, as Antonelli\* points out, two ways by which bacteria or toxic substances can be conveyed to the optic nerve; first, the blood-vessels of this structure, and, second, the lymph spaces which are in direct continuity with the lymph spaces of the great cerebro-spinal cavity. The latter anatomical arrangement has been looked upon as extremely favorable to the spread of intracranial inflammations. Professor Panas believed his second case of metastatic neuritis was due to an outbreak of basal meningitis with serous exudation which had surrounded especially the right optic nerve without doubt because its sheath was more permeable than that of

---

†The writer has freely consulted the recent excellent work of Axenfeld, "Die Bakteriologie in der Augenheilkunde," in connection with several points in this section.

\*Antonelli. *Les Nevrites Optiques dans le cours des infections aiguës*. Paris, 1903. Also *Arch. d'Oph.*, 1903, p. 454.



the left side. The most recent pathological work tends, however, to minimize the part played by the lymph spaces. In cases of intra-ocular metastasis occurring in the course of cerebro-spinal meningitis, Rudnew, Celler, and Uhthoff found the optic sheaths normal while the retina or choroid were purulently destroyed. In a case of metastatic ophthalmia following pneumococcus meningitis, Axenfeld discovered the bacteria in abundance in the retina, but perfectly normal conditions in the lymph spaces of the nerve. Further, De Lieto-Vollaro, and Axenfeld have shown that generally in cases of this nature early blocking of the optic foramen occurs to stop the passage of the organisms; and, finally, Lieto-Vollaro found streptococci in the sheath-spaces in a case of purulent, traumatic meningitis, but no evidence of the organisms having entered the globe. The evidence, therefore, seems to favor the blood-vessels as being the principal route for the infection.

If a gonotoxin, coursing free in the general circulation, be ever responsible for gonorrhœal metastases it ought, arguing from what is generally known in regard to the etiology of neuritis, to play a part in the production of the conditions under discussion. One can only say that satisfactory proof of this is wanting; and that the recent experimental and pathological findings are more in favor of a local toxic action inseparably connected with the presence of the organism in the affected tissues.

As with the affections of the other structures of the globe, the inflammation of the optic nerve and retina can be the first manifestation of the systemic infection, as in the case of Fromaget; or follow inflammatory troubles elsewhere, as with Hilbert's patient; or form the sole expression of the metastatic process, as (supposedly) in Highet's and Eperon's cases.

The neuritis, or neuro-retinitis occurs as the sole ocular change, or forms part of a more widespread metastatic inflammation of the eye. Of the thirteen cases, six fall in the former class, and seven in the latter. In two cases of the second series the nerve alone was affected in one eye, while in the other it was involved along with the uveal tract.

The ophthalmoscopic picture, with one exception, was that of a neuro-retinitis. Occasionally the swelling of the disc is marked, as in the case of Highet where the prominence reached 3.0D; but generally one has to do with a scarcely measurable blurring of the margins of the disc. The inflammatory changes extend from the papilla well into the retina; and some-



times the retinal œdema is pronounced, as in the patient of Hilbert, who applied the term *retinitis serosa* to his case. In Burchardt's third patient the changes were entirely confined to the retina. This structure was noted to be somewhat yellow in a sickle-shaped area below the lower circumference of the papilla, and later indefinite discoloration of the macular area and retinal pigmentation were observed.

Of eleven cases in which the fact is noted, the retinal affection was double-sided in six and one-sided in five. The inflammations follow the rule that has been noted in connection with other metastatic affections of the retina, namely, that when this structure is involved alone the inflammation is generally double-sided, but when it is concomitantly inflamed with the uveal tract the retinitis is unilateral. The condition when double-sided is commonly more marked on one side than on the other.

The scanty records of the field of vision give only peripheral limitations and no central scotomata as in axial neuritis. Too few figures are at hand to say anything positive in regard to the central vision. It seems to correspond to what one observes in inflammations of a similar nature due to syphilis.

In the cases of Burchardt (second case), Highet, Fromaget, Hilbert, and Burchardt (first case), the neuritis followed the gonorrhœa in two, three, four, six, and seven weeks respectively. In the patient of Eperon the inflammation apparently occurred some months after the urethritis, and in the case of Galezowski it was attributed to a gleet of many years standing. The inflammation ran a favorable course in from three to four weeks (Hilbert), five weeks (Burchardt), fourteen weeks (Highet), to a year or more (Burchardt). On the other hand, atrophy was noted at the end of a month in Fromaget's case, and, according to the statement of Panas's patient, vision was entirely gone at the end of twelve days.

The prognosis must be guarded, though generally speaking the outlook is good. Of nine cases in which the ultimate result is given six recovered: the remaining three ended in atrophy.

Worthy of special note is the typical relapse which occurred in the case of Hilbert. It is very suggestive of a relationship to other gonorrhœal inflammations.

The treatment is the same as in other affections of a similar nature; but regard should be had to the general principles laid down on page 22, for systemic gonorrhœal infection in general.



Case 61. (Panas<sup>87</sup>)—Gonorrhœa — Rheumatism — Second Gonorrhœa—Arthritis—? Meningitis — Double Neuro-Retinitis.

A butcher, aged 25, of sturdy build but anæmic, consulted Professor Panas for visual disturbances. The family history was negative. The patient had never before been ill; and he never used tobacco or alcohol in excess. Four years previously he had had a severe gonorrhœa and generalized gonorrhœal rheumatism. In the course of 1889 a fresh gonorrhœa was contracted, and, during the acute period of this, there occurred a second very painful and extensive polyarthritis which confined the patient to his bed for nearly three months.

In October 1889 the patient was seized immediately after exposure to cold by very violent pains in the head which necessitated a sojourn in bed of ten days. Twelve days after the commencement of these troubles he discovered that the vision on the right side was completely lost; and some days later he presented himself at the *Quinze-Vingt* where a diagnosis of optic atrophy from cold was made.

When seen by Professor Panas the articular and sciatic manifestations had completely disappeared; there remained only some pains in the right superciliary region and the nervous system appeared to be in good condition. The right eye was completely amaurotic; the pupil was noticeably enlarged and the reflexes for light and accommodation abolished. Ophthalmoscopically the optic disc was manifestly atrophic; nevertheless, this atrophy was not yet complete because the nerve tissue was not of that dull white chalkiness and had not that aspect of a wafer that one finds in old ataxics. It was of a whitish-roseate tint, and Panas could but admit a nerve in process of degeneration and not a completed atrophy. The veins were normal in distribution, but dilated and tortuous; the arteries on the other hand were small and almost filiform. And not only was the papilla not white but it was clouded and its confines were less distinct; its borders were hidden and one passed without transition from nerve into retinal tissue. By the direct method one found protrusion of the papilla into the interior of the eye; and on the temporal side, between the papilla and the macula, there existed a fine lace-work, indicating that the nerve fibres of the retina were the site of an analagous œdema. One had manifestly to do with a neuroretinitis.

While the left eye had remained normal to all appearances, the patient did not complain of any modification on this side, the visual acuity=1, and the field of vision was not restricted or at most showed a very slight band at the superior and interior part. Yet the ophthalmoscope demonstrated that the left papilla was the site of a lesion, analagous to that of the opposite side, though of a less degree.

Case 62. (Burchardt<sup>86</sup>)—Gonorrhœa — Arthritis — Iridocyclitis — Neuroretinitis—Retinitis.

A painter's daughter, aged 15, was admitted to the *Charité*, November 6th, 1893, for eczematous inflammation of the conjunctiva and cornea of both sides. The patient was weak and poorly-nourished, with insect-marks on the body, and urethral and vaginal gonorrhœa. On the day following admission she developed an acute inflammation of the left and right hip



joints with fever. Under treatment, the eye condition, which was not thought to have any connection with the gonorrhœa, cleared up; and, the joint mischief persisting, the patient was transferred on November 11th to the Department for Women.

From here she returned on December 18th to the eye ward where the following conditions were made out: Patient pale and thin; vaginal and urethral gonorrhœa still present. Left eye, V=fingers at 35 cm.; lids swollen; marked photophobia; lively inflammation of the palpebral and bulbar conjunctiva; cornea very lightly and diffusely clouded; pupil=2-1/2 mm. broad; pupillary margin of the iris retracted; anterior chamber deep; ophthalmoscopically red reflex only; T=n. Right eye: V=3/12; T=n; trace only of injection at the corneal margin downwards; margins of the optic disc less sharp than normal.

On December 22nd, a filmy mass covering the pupillary area was made out in the anterior chamber of the left eye; but this disappeared two days later. On December 28th, pains were still present in the right hip joint, but only after long standing. The left eye still showed intense pericorneal injection with very fine granules thickly covering the anterior surface of the lens; obscuration of the margins of the optic disc; swelling of the surrounding retina; and abnormal tortuosity of the individual retinal veins.

Gradual improvement was noted on January 13th, 1894. The left eye was pale; there were dust-like opacities on the anterior surface of the lens and in the vitreous; the margins of the optic disc were still covered, and the retinal veins tortuous. On the right side, below the lower circumference of the papilla, the retina was noted to be somewhat yellow in a sickle-shaped area.

On February 1st the left pupil was 8 mm. wide and regular. On February 6th, the retina was noted to be irregularly discolored at the macula lutea in an area the size of the optic disc. There were some black spots about 1/15 mm. in diameter and the retina was still slightly swollen in the vicinity of the papilla. The patient presented herself again on March 30th, 1894. The left vision=3/25; the margins of the optic disc were distinct. Right vision=3/3.

Case 63. (Panas<sup>93</sup>)—Gonorrhœa—Sciatica—Neuro-Retinitis.

A waiter, 26 years old, tall and sturdy but pale and anæmic, consulted Professor Panas for serious disturbances in the left eye. The family history was negative. A year previous he had belonged to a society of Free-shooters so that his sight at that time must have been excellent. He had not had syphilis, rheumatism, or eruptive fevers; but for many years had been affected by a chronic gonorrhœa which recrudesced from time to time for a variable period. For about a year he had found himself obliged to keep his bed during some days of every month because of violent pains which woke him up several times during the night. These pains, deep-seated and constrictive, were situated principally in the lumbar-region, whence they radiated as "lightning" pains towards the pelvis and the lower limbs along the course of the sciatic and crural nerves. They were associated with pelvic pains of a vesical character—frequent and imperative desires to urinate, painful micturition, accompanied by spasms of the neck of



the bladder, and the passage of thick, cloudy, ammoniacal urine. Between the attacks the urine was clear and micturition regular. There was very marked genital depression.

On examination no motor, sensory or trophic disturbances could be made out. The patellar reflex was slightly exaggerated on the right side. In spite of the preservation of the nutrition and of the motility of the lower limbs, the double sciatic neuralgia, recurring periodically and accompanied by vesical troubles and lumbar pains, compelled Panas to localize the origin of all these disorders in the lower part of the spinal cord.

The left eye was functionally intact; but with the right eye the patient could only count fingers with difficulty at one and one-half metres. The field of vision was concentrically narrowed and a scotoma was present downwards and inwards. The chromatic sense was as perfect as the feeble acuity of vision would permit, the patient being able to distinguish all the principal colors.

The ophthalmoscopic examination showed by the inverted image a simple, well-marked papillo-neuritis. The optic disc was clouded; its margins were slightly soft, poorly defined, and invaded by numerous capillary vessels. The veins were normal in distribution, but tortuous; the arteries, on the other hand, were small and filiform. With the direct image the papilla appeared slightly prominent, and in the vitreous one could distinguish a fine cloudiness which Professor Panas attributed to inflammatory trouble in the retina. In the left eye there was also found a lesion similar to that of the opposite side, but of less degree. It consisted of a slight cloudiness of the papilla with turgescence of the veins.

Case 64. (Hilbert<sup>94</sup>)—Gonorrhœa—Arthritis—Retinitis Serosa—Relapse of Gonorrhœa—Arthritis—Papillo-Retinitis.

A man, aged 29, acquired a gonorrhœa in December, 1893, which was followed in two or three weeks by arthritis of both knees lasting four and a half weeks. The patient remained entirely well until January 8th, 1895, when he acquired a second gonorrhœa. This was followed 2½ weeks later by polyarthritis, and 6½ weeks later by sparkling and fogginess before the eyes and noticeable diminution of vision.

On February 25th, the eyes were externally normal; and the pupils, of medium size, reacted sluggishly to light. V=6/18. The field of vision could not be taken on account of the patient being in bed, but it was certainly restricted. Ophthalmoscopically the retina was greyishly-clouded, and the borders of the optic disc were blurred. The papilla itself was reddened, and the retinal vessels were thickened and tortuous and disappeared in places in the cloudy retina. One could notice about the papilla a delicate radiate striation. The picture in both eyes was that of a retinitis serosa.

The conditions remained much the same until April 2nd, when rapid improvement set in. On April 18th, vision was normal and scarcely any change could be made out.

On September 16th, a third gonorrhœa or, according to the statement of the patient, an outbreak of the old urethritis occurred. Ten days later the arthritis reappeared, and simultaneously the vision was reduced to 6/9. The same subjective retinal symptoms were present. Corresponding to the



lighter functional disturbances only slight papillo-retinitis and slight cloudiness of the retina with fine radiate striation about the papilla were made out. At the end of four weeks the urethritis, arthritis and retinitis had completely disappeared.

**Case 65. (Highet<sup>97</sup>)—Gonorrhœa—Inguinal Adenitis—Neuro-Retinitis.**

A male, aged 20, consulted Highet, February 22nd, 1894, for a visual disturbance of the left eye of three weeks' standing. Three weeks before the appearance of the ocular trouble he had contracted a gonorrhœa followed by swelling of the inguinal glands on both sides; but both these conditions became rapidly better.

On the right side visual acuity = 20/20; on the left side 20/80. Both sides H = 1.0D. The fields of vision for colors, especially those for red and green, were much retracted on the left side, but normal on the right. Ophthalmoscopically the right fundus was normal; but on the left side a typical neuro-retinitis was seen. The papilla was red and swollen (3.0D) and its outlines were concealed by an exudation diffused also over the parts of the retina adjacent to the optic disc. The vessels were hidden in places, swollen, and tortuous. The macular area was likewise veiled; but the peripheral parts of the fundus were very distinct.

Three weeks later the vision of the left eye = 20/60; the macular region was transparent, and the confines of the optic disc were commencing to reappear. A month later acuity = 20/30; limits of the disc more distinct, and certain vessels only still veiled by the exudation.

Three months and a half after the commencement of the ocular affection the papilla was normal; and all the details, including a well-developed physiological excavation, were distinctly visible. The retinal vessels were still veiled in places; but the visual acuity = 20/20. There was no tendency to atrophy, and the color fields were normal in extent.

**Case 66. (Burchardt<sup>104</sup>)—Gonorrhœa—Iridocyclitis—Polyarthritides—? Endocarditis—Neuro-Retinitis—Multiple Keratitis.**

A merchant, aged 29, was admitted April 3rd, 1896, with a history of three previous attacks of gonorrhœa accompanied by gout and an inflamed eye. He stated that he had been again suffering from gonorrhœa for ten days and that his right eye had become inflamed two days after the onset of the urethritis.

On April 4th, 1896, the condition was as follows: Profuse discharge from the urethra. Left eye normal; V = 15/7. Right eye = hand movements at 1¼ metres; conjunctiva actively reddened; cornea diffusely clouded; ciliary tenderness; pupil 2½ mm. wide and closed; iris somewhat bulging, especially in its upper circumference; T +; extensive polyarthritides.

The following day gonococci were demonstrated in the urethral discharge; and on April 8th the iritic adhesions had been everywhere overcome except for a fine posterior synechia downwards and outwards. Signs of cardiac dilatation with impaired sounds were present on April 16th, but disappeared on May 10th under treatment. They were again noticed during the following month. By May 14th the gonorrhœa had entirely disappeared.



On June 3rd it was noted that, in spite of the neuro-retinitis, then only demonstrable but supposedly of two weeks' standing, and of cloudiness in the vitreous and on the lens, the vision =  $3/3$  with correction. Three days later swelling of the optic disc to the extent of one diopter, swelling of the surrounding retina, and abnormal tortuosity of the veins were made out.

On June 20th, a fresh, painful irido-cyclitis occurred, and on July 12th, three dense, circumscribed opacities formed to the size of 4.5 mm. in the outer half of the right cornea with slight cloudiness of the rest of this structure. The cloudiness of the refractive media, as a whole, was now so great that the existence of the optic disc could only be guessed at from the lighter color of the corresponding part of the fundus; and the vision was reduced to  $3/30$ .

The patient was discharged on July 25th. The affected joints were no longer painful, but in part greatly limited in movement. The left eye was normal. The right eye was pale and somewhat soft with three circumscribed opacities in the outer half of the cornea. Pupil, 7 mm. wide and somewhat irregular. There were dust-like deposits on the lens capsule and extensive, cloudy, vitreous opacities, beginning close behind the lens. The fundus was greatly obscured, but nevertheless the poorly-defined optic disc and morbidly tortuous veins, were definitely recognizable.

On June 26th, 1897, the left eye was still normal in every respect. The right eye was outwardly quiet and vision =  $1/5$ . A small transparent corneal opacity was present in front of the lower outer margin of the pupil; and above this were two, still more minute, opacities scarcely visible by focal illumination. The iris showed two detached posterior synechiæ downwards and outwards, and a fine hair-like adhesion inwards. Fine dust-like opacities existed on the anterior lens surface and in the vitreous. The individual arteries of the optic disc protruded over the surface of this structure; and the retinal veins in the vicinity still showed tortuosity in part.

Case 67. (Burchardt<sup>104</sup>)—Gonorrhœa—Plastic Iritis—Keratitis, Keratitis—Arthritis—Papillo-Retinitis.

A barber's assistant, aged 19, was admitted to the Charité June 4th, 1896. He had had an operation on the left eye for squint in 1892; and had been infected with gonorrhœa for the first time one year before and for the second time five weeks previous to admission. His right eye had been inflamed for eight days.

One June 5th, 1896, the following conditions were made out: Left eye V = with + 1.0D  $3/8$ . Vertical cicatrix in front of the insertion of the external rectus but otherwise normal. Right eye V =  $3/10$ , not improved; palpebral conjunctiva and that of the globe (especially in the vicinity of cornea) actively congested; sensitiveness to pressure over the ciliary region upwards; centre and outer half of cornea clouded; contraction of pupil to light slow; fundus thickly veiled.

Two days later the whole of the right cornea as well as the contents of the anterior chamber were lightly clouded; and in front of the pupil lay a delicate film which projected with ill-defined boundaries into the anterior chamber, and contained in its lower part a remnant of the pupillary membrane. The opacity of the refractive media was so great that the position



of the optic disc was only recognizable by its lighter color; yet, in spite of this, the vision had not diminished. On June 9th, inflammation of the joints between the os calcis and cuboid appeared. Two days later the right pupil had dilated to eight mm., and the cloud in the anterior chamber had disappeared. Papillo-retinitis was diagnosed and numerous joints were newly affected. On June 16th, the swelling of the optic disc equalled almost 1.0 D. On June 27th, three opacities, separated from one another by narrow light streaks and observable only by strong lateral illumination, were made out in the pupillary area of the right cornea. They were so transparent as to be invisible by trans-illumination. The margin of the optic disc was quite hidden.

The patient left the hospital on June 29th, with the left eye as on admission; but the right eye still showed lively peri-corneal congestion, and the corneal opacity was still present. The pupil = 8 mm.; and posterior synechiæ were present downwards and inwards. The fundus, though veiled by the opacity on the anterior lens surface and in the vitreous, was distinguishable in its finest details. The margins of the optic disc were swollen only 0.5D, but appeared greatly hidden.

A final note on July 3rd, 1897, states that the left eye was as before, and right vision with + 1.25 = 3/4. There was no trace of the previous corneal opacity; the pupillary margin was quite free and the pupil mobile; and the opacities and papillo-retinitis had entirely disappeared.

Case 68. (Fromaget<sup>121</sup>)—Gonorrhœa—Iritis—Optic Neuritis—Arthritis.

A young man, aged 20, who had been affected with gonorrhœa for a month, presented himself for consultation in January, 1898. There was slight pericorneal congestion and the pupil reacted badly to light. Oblique illumination demonstrated the presence of a moderate number of synechiæ. On dilating the pupil no trouble was found either in the lens or vitreous; nevertheless the vision equalled only 1/10. Examination of the fundus revealed a marked neuritis. The papilla was red, and its borders lost themselves in the retinal tissue. The arteries had almost disappeared; but the veins were tortuous and dilated. Exploration of all the other parts showed nothing abnormal. Presently the patient was obliged to lie up because of an inflammation of the knee of the right side which was thought to be of the same nature as the eye affection. A month later the patient had recovered from his urethritis, arthritis, and iritis; but the papilla was then in process of atrophy.

Case 69. (Kurka<sup>138</sup>)—Gonorrhœa—Metastatic Conjunctivitis—Polyarthritis—Iridocyclitis—Neuro-Retinitis.

E. H., aged 22, asserted that he had suffered from acute gonorrhœa for two weeks, and from severe inflammation of both eyes for three days. The conjunctiva of the lids on both sides was intensely reddened and covered with mucous secretion. The conjunctiva bulbi was also injected, but the corneæ were normal. Bacteriological examination of the conjunctival secretion revealed no gonococci, very few leucocytes, and isolated cocci.

At the end of five days there suddenly appeared a polyarthritis which lasted until the patient's exit about two months later. The conjunctival



inflammation visibly improved and was limited on the 12th day of treatment to the folds of the lower fornix; but at the end of four weeks right-sided iridocyclitis suddenly broke out, and soon afterwards there developed in the centre of the cornea of the left eye a small epithelial defect which was surrounded by a greyish, cloudy ring.

At the patient's exit about two months later the polyarthritis was still present. The palpebral conjunctiva in both eyes was still moderately injected, but the conjunctiva bulbi was pale. Right cornea bright, somewhat less transparent than normal, and studded in its lower part with fine deposits. Anterior chamber deep. Iris greenish discolored. Pupil jagged, and the pigment-border of the iris adherent to the anterior lens capsule. In the centre of the cornea of the left eye a greyish but not sharply defined opacity, the size of the head of a pin. The fundus on the right side was blurred and indistinctly visible. On the left side the retina was slightly cloudy, the boundaries of the disc indistinct, and the veins markedly filled and tortuous. R. V. = 6/60; L. V. = 6/12.

**Case 70. (Kurka<sup>188</sup>)—Gonorrhœa—Metastatic Conjunctivitis—Iridocyclitis—Hyperæmia of the Retina.**

A draughtsman, aged 26, had suffered for three weeks from his first attack of gonorrhœa. Two weeks after the onset of the gonorrhœa, pains, lacrimation, and photophobia appeared in both eyes without known cause, and grew visibly worse.

The patient was a man of medium strength with profuse purulent discharge from the urethra. In both eyes the lids were reddened and slightly swollen with a mild eczema on the lower ones. Palpebral conjunctiva reddened, but otherwise soft and without infiltration. Conjunctiva of the globe intensely injected, slightly chemotic. Profuse, mucoid, stringy secretion. Cornea on both sides slightly dull and clouded; anterior chamber deep; iris greenish discolored and blurred in its structure; pupil very narrow and reactionless. In the right pupil a thick, in the left a delicate membrane. R. V. = fingers at 1 m. L. V. = 6/18. (?) No red reflex from the right eye, and the left fundus indistinctly visible.

On the second day the manifestations increased in intensity on both sides. The deterioration manifested itself especially through great chemosis and intense pains in both eyes. The aqueous was clouded by numerous, swimming, fibrinous threads. Iris greatly swollen and only partly dilated after solid atropine. Left pupil clouded by a thick membrane which left free the uppermost third. On the left side the membrane had shrivelled and covered the pupillary margin of the iris in its lower-inner quadrant.

On the 19th day of the ocular inflammation marked improvement was noted; but on the 22nd day a recurrence took place in the right eye, and on the 28th day in the left eye which led to a great exudate in the anterior chamber. On the 50th day of the ocular trouble, the condition was as follows: Conjunctiva, apart from insignificant hyperæmia, normal; iris on both sides greenish discolored; blackish precipitates on the lower part of the cornea; numerous synechiæ, and a pupillary membrane, especially thick on the right side. The fundus shows a tolerably severe hyperæmia of the retina, recognizable in veiling of the papillary margins and greater fulness



of the retinal veins. The final vision on the 70th day of the condition was R. 6/60, L. 6/36, and the deterioration was in part attributed to vitreous opacities.

Case 71. (Eperon<sup>140</sup>)—Gonorrhœa—Orchitis—Neuro-Retinitis.

The case was that of a young man who presented a neuro-retinitis of the right eye analagous to that which results at times from syphilitic infection. He had never shown either primary or secondary symptoms. On the other hand, he had suffered for several months from an urethral blenorrhœa complicated by orchitis. A mixed antisiphilitic treatment followed for six weeks produced no amelioration. Nevertheless, recovery slowly recurred at the end of eight months under the influence of simple hygienic precautions.

Case 72. (Galezowski<sup>147</sup>)—Gonorrhœa—Rheumatism—Meningo-Encephalitis—Paralysis of the Sixth Nerve—Hemorrhagic Neuro-Retinitis.

Mr. P. R., aged 44, was brought to Galezowski on October 27th, 1899, for a very serious amblyopia of both eyes caused by some meningo-encephalic disturbances with diplopia and a slight "buphthalmia" of the left eye. G. recognized a paralysis of the left sixth nerve; and a hemorrhagic neuro-retinitis following venous stasis as one could judge by the accompanying illustrations. The patient had had a serious attack of measles at the age of thirteen. This had been complicated by abscesses in the groins, but albumen had not been found in the urine. The affection of the optic nerve was thought to be due to this rheumatism, very probably of gonorrhœal origin, since there was still traces of the urethritis. Energetic treatment was persevered in for a consecutive year, and at the end of this time three-fourths of the hemorrhages had disappeared, and the patient was able to read number 3 with a + 4.0D lens.

Case 73. (Galezowski<sup>159</sup>)—Chronic Gonorrhœa—Sciatica—Neuro-Retinitis and Bilateral Iritis.

A man, aged 63, consulted Galezowski for the first time on July 22nd, 1901, for a grave inflammation with profound disturbance of vision of both eyes. A neuro-retinitis of the right eye, posterior synechiæ and iritis in both eyes, and spots of choroidal exudation and atrophy towards the ora serrata were made out. The patient had been the subject of a rheumatic sciatica, which followed a severe gonorrhœa, for more than seven or eight years. The disturbances were sometimes accompanied by very violent and prolonged pains in the head with vertigo and fever. The rheumatism, located in several articulations, subsided; and, on November 24th, 1902, the patient was completely cured of every trace of inflammation of the irises and of the deeper structures of the right eye.

B.—THROMBOSIS AND PHLEBITIS OF THE RETINAL VESSELS.

In 1900 Galezowski<sup>126</sup> asserted, after a careful study of ocular thromboses extending over several years, that often the sudden and



spontaneous loss of vision which one attributed to a morbid coagulum, fibrinous or otherwise, coming from the heart or aorta, was not in reality due to this cause but to an obliterating inflammation of the vessels of the optic nerve and retina of a gonococcal nature. He held that his views were borne out by numerous analagous conditions reported in the general literature, particularly by Koenig, and cited the following case in illustration of his theory:

**Case 74. (Galezowski)—Gonorrhœa—Sciatica—Gonorrhœal Rheumatism—Retinal Thrombosis.**

N. T., aged 49, consulted Galezowski for loss of vision which suddenly supervened toward the end of the month of January, 1900, with all the signs of a retinal thrombosis. The patient had never had syphilis, but had suffered for more than six years from a gonorrhœal urethral discharge of which he was never able to entirely rid himself. Five years previously he had suffered for a year from sciatica, and recently from rheumatism, supposedly of a gonorrhœal nature. The heart was normal, and the eyes had been otherwise unaffected. Treatment for the rheumatism was instituted with good results. Vision returned in great part; but a peripheral scotoma, corresponding to the thrombosed vessel, persisted.



## VIII.—TENONITIS.

---

One would expect from the close similarity which the eyeball and its capsule of Tenon present to a ball-and-socket joint that tenonitis would be often met with in gonorrhœal systemic infection; but so far Peuch has been the only one to attribute the inflammation in a case of this nature to gonorrhœal metastasis. In the absence of any bacteriological findings and other metastatic manifestations it must be admitted that the clinical evidence in this instance was slight; but the possibility of endogenous gonorrhœal infection is so probable that one should always bear it in mind in dealing with obscure cases of this sort. Fuchs, Gasparrini, and Schwartz, in growing pneumococci in cases of suppurative tenonitis, have given a bacteriological basis to the disease\*; but it remains to be shown whether the mild cases of this nature, especially those of supposed gonorrhœal origin, are due to the bacteria themselves or to their products. Apart from its one-sidedness, the case of Peuch, which follows, presented all the characteristic features of this somewhat rare condition as it occurs secondary to systemic infections.

### Case 75. (Peuch<sup>92</sup>)—Gonorrhœa—Metastatic, Unilateral Tenonitis.

A carter, who was a chronic alcoholic and the victim of an acute gonorrhœa of three weeks standing, suddenly experienced moderately intense pain in the left side of the face, and in the eye of the same side, while returning from the country in a strong wind. On entering the house, he observed that his eye was red; and during the whole of the night the pain increased in intensity and disturbed his sleep. In the morning the lids (but especially the upper) were slightly swollen, and he opened his eyes with great difficulty. During the whole of the day the pains recurred by fits and starts, often very painful, as well in the forehead as deep in the orbit; and the patient could not any longer separate his lids. Two days after the commencement of the affection the following conditions were made out:

Complete ptosis of the upper lid with slight œdema, especially marked in the vicinity of the ciliary border, and almost complete loss of the power of elevation; very apparent exophthalmos; moderate chemosis; and almost complete immobility of the eyeball in all directions; pupil, pupillary reactions, vision, and optic disc, normal; retinal veins perhaps slightly increased in size; moderately severe pain on pressing the eyeball back into

---

\*Axenfeld; Die Bakteriologie in der Augenheilkunde, p. 328.



the orbit. On the 16th or 17th day the patient could almost completely open his lids and the muscles of the eye had regained in great part the amplitude of their movements, but they were slow and accompanied by dull pain. The patient complained for more than eight hours after the examination of discomfort which obliged him to lie down. On the 28th day the ocular movements had completely returned; the patient could keep his eye open without great fatigue and could follow his work; but even after two months the pains recurred by fits and starts.



## IX.—DACRYOADENITIS.

---

Inflammation of the lacrimal gland, first described and designated "Dacryoadenitis" by Adam Schmidt in 1803, is now thought to be produced certainly in two, and probably in three, different ways: First, by the direct extension along the lacrimal ducts of inflammations of the conjunctiva such as trachoma, gonorrhœal conjunctivitis, and membranous conjunctivitis; second, by endogenous infection, occurring in the course of systemic conditions, such as influenza, scarlet fever, measles, syphilis, and mumps; and third, by the action of certain inorganic substances, such as potassium iodide and calomel.

To the second, well-founded class belong the seventeen cases of inflammation of the lacrimal gland that have been attributed to systemic gonorrhœal infection. These begin chronologically with the case of Miller who first definitely attributed an inflammation of the lacrimal gland to this cause. In the series, generally speaking, the diagnosis is based upon scant grounds. In ten of the seventeen cases it rests solely upon the presence of a urethritis, with or without bacteriological corroboration, and the exclusion of all other etiological factors. In Seeligsohn's two cases a gonorrhœa, which had been acquired some months previously but had entirely run its course, was the only possible cause that could be found for the dacryoadenitis. The evidence is stronger in the remaining five cases. In Professor Panas's patient the association of the lacrimal inflammation with gleet, gonorrhœal arthritis, iritis, and sero-vascular conjunctivitis speaks strongly in favor of the gonorrhœal nature of the trouble; while in the case of Etievant, though the bacteriological examination was not as comprehensive as one could wish, the presence of gonococci in the pus discharged from the suppurating gland is proof not only of the gonorrhœal character of the dacryoadenitis but of the occurrence of gonorrhœal metastases in general. In Ferry's case Morax found gonococci in the conjunctival secretion on the evening of the patient's admission; but unfortunately cultures were not made at this time, and he was afterwards unable to obtain them in this way, on slides, or by inoculating culture tubes with a piece of the lacrimal gland. In this case, and in the patients of Causé and Pes, sclero-conjunctivitis, metastatic con-



conjunctivitis, and œdema of the glottis, were respectively present to heighten the probability of the diagnosis.

The clinical picture of dacryoadenitis is well defined and the diagnosis easily made. There is redness and œdema of the upper lid in varying degree, especially toward the upper-outer angle of the orbit. In extreme cases the outer palpebral surface may be level with that of the forehead. The lid droops and is fixed, and the patient throws back the head and uses the occipito-frontalis as in congenital ptosis. Commonly the palpebral fissure becomes triangular in shape with the apex outwards (Pes), but it may be entirely closed when the swelling is great. In these cases the appearance strongly suggests that seen in gonorrhœal ophthalmia (Ayres).

On palpation the swollen lacrimal gland is felt protruding below the supraorbital margin to an extent which varies with the intensity of the inflammation. Its surface is irregular owing to its lobulated structure. Occasionally, as in Grimaldi's case, only the palpebral portion of the gland is involved; or both parts may be concomitantly inflamed as in three of Pes's cases. There is apparently little or no difficulty in determining what portions are affected. The feeling to touch is described as "tense," "elastic," "hard," or "extremely hard," but softening can be made out in cases going on to suppuration. The parts may be more or less insensitive to pressure, or prove exquisitely tender, especially just below the outer end of the eye-brow, as in the cases of Panas, Ferry, Terson, and Miller.

The outer portion of the upper fornix is more or less obliterated; and, in extreme cases, the bulbar conjunctiva, inflamed and chemotic, protrudes through the lids and covers the outer margin of the cornea. There is little or no secretion except in cases like those of Ferry, Panas, and Causé where an actual metastatic conjunctivitis probably co-existed. As previously mentioned, gonococci were found by Morax in the conjunctival secretion from Ferry's case, but Pes and Giani made repeated examinations with negative results. The lacrimal secretion is commonly scanty or arrested, but may sometimes be increased in amount and acrid.

Marked swelling of the gland gives rise to displacement of the globe downwards and inwards, and to limitation of its outward excursion. Diplopia is sometimes complained of as in Etievant's, and Cosali's cases.

The subjective symptoms vary from a sense of heat and heaviness in the eyes, and a sense of fulness in the forehead, to severe



orbital pain radiating to the brow and temples. Chilly sensations and general malaise are not uncommonly present, and in the acute cases the temperature may reach 38.5 to 38.8 C. (Etievant and Causé).

In fourteen of the seventeen cases the dacryoadenitis was bilateral; in three (Sgrosso, Etievant, Pes) unilateral in character. With one exception (Grimaldi's case) the patients were all males ranging from twenty to fifty-seven years of age. In a series of thirteen cases in which the fact is noted, resolution occurred in eleven instances and suppuration in two (Sgrosso, Etievant). In Etievant's patient while the inflammation resolved on the left side a discharge of pus occurred from the right gland on the fifth day of the disease. These figures are in keeping, therefore, with what is known of dacryoadenitis in general, namely, that while the cases caused by direct extension are generally unilateral and go on to suppuration those produced by metastasis are usually bilateral in character and end in resolution.

The inflammation runs its course in from three to thirty days or even more (one hundred and two days) if Seeligsohn's cases be accepted. The average duration of twelve cases was about nineteen days.

Attention to the underlying cause, hot fomentations, and drainage into the conjunctival sac in case of suppuration, constitute the necessary treatment.

Case 76. (Miller<sup>52a</sup>)—Gonorrhœa—Acute, Bilateral, Non-Suppurative Dacryoadenitis.

In a discussion following the presentation of a case of acute dacryoadenitis at the meeting of the American Ophthalmological Society in 1884, Miller stated that he had seen one case of acute bilateral inflammation of the lacrimal gland. It had been sent to him by the family physician, who supposed it to be a case of gonorrhœal ophthalmia. There was great swelling and exquisite tenderness. The diagnosis was not difficult. The patient had gonorrhœa at the time. The inflammation subsided in three days without suppuration under hot-water dressings.

Case 77. (Seeligsohn<sup>70</sup>)—Gonorrhœa—Double-sided, Non-Suppurative, (? Gonorrhœal) Dacryoadenitis.

A goldsmith, aged 21 years, came for consultation April 9th, 1890. On both sides there was œdema and redness of the lids; the upper one drooped and covered, even when the palpebral fissure was opened to its maximum, the upper two-thirds of the cornea. The conjunctiva bulbi protruded from the palpebral fissure as a tense, elastic tumor of yellowish-red color, and



overlapped the cornea, particularly outwards. The uneven tumor could be followed in both eyes up to the margo supraorbitalis. On palpation one distinctly felt the individual lobules of the swollen lacrimal gland. The palpebral conjunctiva was hyperæmic, but, like that of the inferior cul-de-sac, not swollen. Pressure on the external part of the upper lid was very painful; no discharge; cornea clear; vision and ophthalmoscopic appearances normal.

The patient stated that on the afternoon of April 7th he had experienced sudden lacrimation of the right eye. Thereto was added on the following day lacrimation of the left eye, slight feeling of pressure in the forehead, and febrile manifestations. In the afternoon and during the night the eyes swelled so that the patient could only come with difficulty alone to the clinic. He had always been healthy as a child, showed no traces of scrofula or syphilis, but had acquired gonorrhœa half a year previously. Examination of the urethra showed a very slight narrowing of the pars membranacea, and a fold in the mucous membrane close behind the external orifice, which was probably congenital and somewhat constricted the lumen. Through both a very slight secretion was maintained. Gonococci were not present. The glands, especially the preauricular, were not swollen, and examination of the nose and adjacent cavities showed them to be entirely normal.

On the following day the patient was brought into the clinic and ice compresses applied. The eyelids were completely closed by the swelling; the lacrimal glands were still more enlarged, and the lobules distinctly palpable; but there was no discharge. On April 12th the swelling of the lids had subsided in great part, and on April 18th nothing more could be felt of the gland lobules; the lids and conjunctivæ bulborum were normal; and there remained only a slight conjunctival discharge which disappeared after eight days' treatment with drops of zinc sulphate.

Case 78. (Seeligsohn<sup>70</sup>)—Gonorrhœa—Relapsing, Double-sided, Non-Suppurative, (? Gonorrhœal) Dacryoadenitis.

A laborer, aged 33, came to the clinic on July 2nd, 1890. At the outer portion of both upper lids, in the region of the lacrimal gland, one noticed slight swelling of the skin without reddening; and on palpation one felt, on the left side, a tense tumor, about  $1\frac{1}{2}$  centimetres long, which protruded two millimetres below the margo supraorbitalis, and extended from the middle of the upper lid upwards and outwards. The individual lobules of the tumor, which ended mesially in an uneven swelling the size of a hemp-seed, could be distinctly made out. Outwards and upwards on the right side one felt further a band one centimetre long, which, with its vertex margin protruding ? beneath the margo supraorbitalis, was divided by transversely placed constrictions into several smaller humps and a larger one about the size of a pea. The palpebral fissure was narrowed on both sides. On opening this and everting the lids swelling of the palpebral conjunctiva was seen at the site of the tumor, which was not movable and slightly sensitive only to pressure. The preauricular glands were not infiltrated.

The swelling, which had been noticed by the patient for fourteen days, had caused him only a slight feeling of pressure above the eyelids. He



gave a history of soft ulcers fifteen years ago, and of gonorrhœa at Christmas, 1889. On examination there were no manifestations of lues. In the urethra an area of stricture was found a few centimetres from the external orifice; and purulent filaments in the urine, but no gonococci.

In the following days, after the patient had been taken into the clinic, the tumor increased so in size that he could only open the lids with difficulty; but from July 8th onwards a gradual diminution of the swellings was noticed. On the 16th they protruded only one millimetre below the margo-supraorbitalis, and the feeling of pressure over the eyes had disappeared. On the 19th of July there suddenly developed an inflammatory œdema of both lids which were red and swollen. The enlarged lacrimal gland protruded on the left side about five millimetres, and on the right side about three millimetres below the supraorbital margin. The tumor had attained a length on the left side of  $2\frac{1}{2}$  centimetres, and on forcibly opening the palpebral fissure one saw the eyeball pressed inwards and downwards. Two days later the œdema of the lids had disappeared, and the swelling itself gradually diminished in the following days to its condition before the œdema. On July 3rd acute œdema of the lids occurred for the second time; but on this occasion with only slight enlargement of the lacrimal glands. The œdema lasted this time also only two days and the tumor then visibly diminished. On September 28th, the enlargement was the size of a pea only and felt noticeably softer. It was expected, therefore, that the swelling would entirely disappear in the following months.

Case 79. (Panas <sup>85</sup>)—Gonorrhœa—Gonorrhœal Arthritis, Metastatic Irido-Conjunctivitis, and Acute, Bilateral, Non-Suppurative Dacryoadenitis.

A young joiner, who worked regularly in a dark basement, presented himself for consultation at the beginning of 1894. His father had been tormented for a long time with chronic eczema, but he himself did not present any previous manifestations of rheumatism.

On examination there was a swelling of the lids and photophobia; moderately abundant conjunctival secretion of a purely serous character, discharging every time one attempted to open the contracted lids; and copious tears mixed with insignificant filaments of mucus. The patient suffered scarcely any with his eyes but walked with difficulty, using a cane and dragging the left leg; and he stated that the ankle and knee of the affected limb had been swollen and painful.

The cause of these ailments was thought to be a gonorrhœa, which he had acquired in the first days of November, 1893; for this urethritis, his first, had left him a slight urethral oozing, clouded urines, and uncomfortable micturition. About six weeks after the commencement of the discharge, simultaneously with the onset of moderately intense pains in the situation of the left instep, which had reddened and swelled greatly, his eyes had also reddened at the same time that his lids became œdematous. The upper lid of the right side had always been more voluminous than that of the left side, and the right eye more photophobic than its fellow.

On examining the eyes more closely one made out on the left side diffuse reddening of the conjunctiva, tortuous vessels, but very mobile pupil. On the right side the same general redness, still more pronounced about the



cornea, and forming a veritable circle of pericorneal, vascular injection, corresponding to a lesion of the internal membranes of the eye. The iris was discolored, the aqueous humor slightly turbid, the pupil irregular, and there were numerous small synechiæ, but no plastic exudation. There was present in fact an iritis of moderate intensity, along with a state of hyperæmia of the conjunctiva with serous secretion—a true sero-vascular conjunctivitis. On asking the patient to direct his right eye downwards and inwards, one saw a reddened, lobulated protrusion, the size of a French bean, which occupied the whole of the external portion of the superior cul-de-sac. At the same time palpation revealed a kind of hardened mass occupying the region of the lacrimal fossa of the orbit. This was the lacrimal gland itself, inflamed and increased in volume, but not producing exophthalmos because of its mediocre dimensions.

A foot-note adds that in less than a week after the delivery of the clinical lecture, the dacryoadenitis had become bilateral and had developed to an equal degree of intensity on both sides.

Case 80. **Sgrosso**<sup>108</sup> made mention at the annual meeting of the Italian Ophthalmological Society, 1898, of a case of right-sided dacryoadenitis in a student, previously suffering from gonorrhœa, which broke out after 'an excess in venere and suppurated, but quickly and completely recovered under appropriate treatment.

Case 81. (**Terson**<sup>131</sup>)—Gonorrhœa—Acute, Non-Suppurative, Bilateral Dacryoadenitis.

The case was that of a cook, aged 38, who presented himself on February 5th, for a violent, bilateral inflammation of the upper lid of three days' duration. The facies of the patient was so characteristic that one could make a diagnosis from a distance. The palpebral fissure was almost normal inwards, but outwards it was hidden by a bulging which overhung it. The bulging, which was more marked on the right and had commenced some hours before that of the left side, occupied the outer fourth of the upper lid. On the right side it was considerable; as large as a small nut. On palpation one felt on each side, flattened against the bone, a mass, which was extremely hard and knotty and evidently constituted by the orbital lacrimal gland. The glands of Rosenmueller, though so visible, did not present any abnormal size; and, apart from a slight œdema of the lids, the weeping eyes (not relatively dry as has been noted in some cases of dacryoadenitis) were normal. There was no chemosis, and the mobility of the eye was perfect without exophthalmos. No glandular inflammation. The patient had had the month preceding a gonorrhœa treated by baths and emollient drinks, and without active measures which could have provoked metastasis. There still remained a discharge moderately profuse in the morning. He had never had any general disturbance, or articular manifestations, or orchitis. Nor had he been exposed to cold, though the weather was chilly during the week the adenitis appeared. The gland of the right side was hard and so tumefied that one could have feared a tendency to suppuration; nevertheless it did not occur and resolution was complete in about a month.



**Case 82. (Grimaldi<sup>137</sup>)—Gonorrhœa—Acute, Double-sided, Non-Suppurative Inflammation of the Palpebral Portion of the Lacrimal Gland.**

The writer observed a well-defined swelling of the palpebral portion of of the lacrimal gland of both eyes in a woman twenty-three years of age. There existed slight ptosis, and swelling of the upper lid, as well as injection of the chemotic conjunctiva of the upper fornix. The affection completely resolved at the end of a week under hot fomentations and antiseptic bathings. The author looked upon the case as one of double-sided, circumscribed, dacryoadenitis which occurred acutely, did not come to suppuration, and was attributable to gonorrhœal endogenous infection, since the patient suffered a short time before the outbreak of the eye affection from a vaginal discharge.

**Case 83. (Ferry<sup>136</sup>)—Gonorrhœa—Gonorrhœal Rheumatism—Acute, Non-Suppurative, Bilateral Inflammation of the Palpebral Portion of the Lacrimal Gland—Sclero-Conjunctivitis and Iritis.**

The patient was a young man, aged 25, who had contracted gonorrhœa a month previous. During the course of this condition generalized articular manifestations broke out; and these were still present when the patient presented himself for treatment. About three weeks after the onset of the urethritis, and apparently at some unstated period after the occurrence of the joint troubles, pain, redness of the conjunctiva, and diminution of vision made their appearance. Some days afterwards the upper lids swelled. The patient presented a bilateral dacryoadenitis, affecting the palpebral lobe of the glands, and more marked on the right side; and further a sclero-conjunctivitis, with scarcely noticeable secretion, and iritis with posterior synechiæ.

**Case 84. (Etievant<sup>142</sup>)—Gonorrhœa—Double-sided, Gonorrhœal Dacryoadenitis going on to Suppuration on one side.**

X., aged 22, while suffering from gonorrhœa, was suddenly seized, without appreciable cause, by orbital pains on both sides radiating to the forehead, and at the same time there appeared all the signs of a violent inflammation in the region of the right lacrimal gland.

The patient presented himself with a lid so very much swollen that it was impossible to raise it far enough to see if anything were protruding beneath; slight chemosis in the external part of the bulbar conjunctiva; deviation of the eye inwards without protrusion; movements of abduction limited and painful; and homonymous diplopia. Palpation of the lacrimal region revealed under the infiltrated skin a deep-seated tumefaction at the site of the lacrimal fossa. There was severe pain on pressure and the temperature was 38.5° C. The left eye was affected twenty-four hours later, and on this side one could see underneath the upper lid the lacrimal gland swollen to the size of an almond.

Treatment—resolvent and antiphlogistic. At the end of the fifth day a sudden cessation of the painful phenomena occurred with a discharge of pus which, when examined, showed very clearly the presence of the gonococcus.



Following this marked amelioration there was subsidence of the temperature and of the pain on the right side with discharge of a certain amount of pus during the night. On the sixth day there still existed boggiess on the right side and tumefaction on the left. At the end of the tenth day the phenomena on the left side disappeared without suppuration; but eight days later one could still make out induration formed by the hypertrophied lacrimal gland. The patient was seen, however, at a later date when the swelling was noted to have entirely disappeared.

Case 85. (Etievant<sup>142</sup>)—Gonorrhœa—Unilateral, Non-Suppurative Dacryadenitis of supposed Gonorrhœal origin.

The second case, followed less carefully on account of its occurring at a distance, was that of a young man, aged 28, who had been affected with urethritis for two months. Ocular symptoms seemed to follow a sudden arrest of the discharge, the exact date of which, however, was not precisely stated.

The left lid and the external oculo-orbital region were the site of an œdematous swelling which turned outwards around the supero-external angle of the orbit to finish without transition on the temple. Over this œdema the skin was red and pressure painful. The conjunctiva was injected in the external angle and the superior cul-de-sac absent outwards, being completely filled by the tumefaction of the lacrimal gland. The upward movement of the lid was much restricted and the eye was half closed. Cephalgia; temperature 38° C. The patient was able, nevertheless, to attend to his business.

It was at least twenty-five days before the inflammatory phenomena almost completely disappeared under resolvent applications. At a later date the swelling was noted to have entirely subsided.

Case 86. (Causé<sup>148</sup>)—Gonorrhœa—Acute, Bilateral, Non-Suppurative Dacryadenitis in Association with Metastatic Conjunctivitis.

K. F., a twenty-five year old cabman, was brought for examination November 13th, on account of great swelling of both upper lids and inflammation of the eyes of three days' standing. The patient had been taken into the hospital two days previously for a recurring gonorrhœa with hæmorrhagic urethral discharge. The œdema of the lids as well as the inflammation of the conjunctiva were already present at that time. Up to the fourth day of the disease there existed temperature elevations which, with slight malaise, reached 38.8° C. Gonococci were easily demonstrable in the urethral secretion, but not in the moderately profuse discharge of the conjunctiva, though repeated examinations were made. The whole appearance spoke from the very onset against a specific gonorrhœal inflammation of the conjunctiva. There existed in both eyes to about the same extent an intense œdematous swelling of the upper lids with slight reddening of the skin; and a moderate injection of the conjunctiva bulbi with œdematous infiltration to the margin of the cornea. The swelling became ever greater toward the fold of the upper fornix; but downwards it and the injection gradually diminished. On palpating the upper lid, which was slightly painful, it was



possible to feel with great distinctness through the œdema a hard, ragged tumor, larger than a bean; and to follow this to the bony orbital wall behind which it disappeared. The tumor had its greatest palpable diameter in the transverse direction; the œdematous lid was freely movable over it in every direction. On everting the lid the lower border of the lacrimal gland, corresponding to the tumor, appeared as a thick blueish-red swelling with uneven surface. Otherwise there was nothing special: slight myopia: normal ophthalmoscopic findings. The gonorrhœa evinced a benign character: the conjunctivitis, accompanied by moderate secretion, caused little trouble and became rapidly better. The inflammation of the glands persisted in the same degree for eight days; then gradually declined; and had completely disappeared at the end of fourteen days. Regarding the lacrimal secretion the patient made no complaint until the last day when he stated that a rich flow of tears followed a state of morning dryness.

Case 87. (Pes<sup>153a</sup>)—Gonorrhœa—Acute, Double-sided, Non-Suppurative Dacryoadenitis.

A laborer, aged 20, after a night of carousal, was urgently admitted to the hospital on January 20th, 1898, for a very acute, bilateral dacryoadenitis. Severe constitutional disease, or ocular disturbances proper, were not present. The patient was robust and strong; but there existed an acute blenorrhœal inflammation of the urethra with profuse purulent secretion.

The upper lid of both eyes was greatly swollen and reddened, especially towards the outer angle; and there was very considerable limitation of movement. The conjunctiva was chemotic, especially in the outer angle, where it projected beyond the half closed palpebral margin. There was no catarrhal secretion and the corneæ were clear. On palpating along the upper outer orbital margin one could make out that the lacrimal glands projected beyond this structure; that the gland capsule was greatly stretched and very sensitive to pressure; and that the upper lid was swollen in its upper two-thirds and thickened with a peculiar elastic resistance. The lacrimal secretion was slight. The excursion of both eyes was interfered with on looking outwards and upwards; while (?) the globes were displaced slightly downwards and inwards. Diplopia could not be elicited because of the inflammatory ptosis. The patient complained of a feeling of heaviness, of inability to open the lids, and of intermittent, sticking pains. Gonococci were found in abundance in the urethral secretion; but most carefully made cultures failed to procure them from the lacrimal discharge. Under cold compresses and treatment of the urethritis the temperature sank to normal in three days and complete resolution of the dacryoadenitis had occurred twenty-four hours later.

Case 88. (Pes<sup>153a</sup>)—Chronic Gonorrhœa—Acute, Unilateral, Non-Suppurative Dacryoadenitis in Association with œdema of the Glottis, Sublingual Adenitis, and Hyperæmia of the Retina.

A male, 23½ years old, had suffered from chronic gonorrhœa since October, 1900. Following an intercourse on the night of October 14th, 1903, the patient experienced a feeling of oppression, of contraction about



the throat, dyspnœa, headache and lachrimation. On the 15th a complete dacryoadenitis appeared on the right side. It presented the usual symptoms and was very severe. The patient was received into the hospital on the 16th, and on the following day œdema of the glottis appeared with severe disturbance of the general health and fever. On the 21st a regression of all the inflammatory manifestations in the lacrimal apparatus could be made out; but a swelling of the sublingual salivary glands occurred with intense hyperæmia and tenderness, and the œdema of the glottis persisted though to a slighter degree. Repeated examination of the fundus showed a distinct hyperæmia of the retinal vessels, but without any manifestations whatever of a neuro-retinitis. In the first days slight photophobia was noted, but no joint pains or cardiac disturbance were present. By the 24th all inflammatory symptoms had disappeared. There remained only a hyperæmia of the conjunctiva especially in the upper fornix on both sides. The patient left the hospital almost healed on October 16th, 1903. Repeated examination of the lacrimal secretion gave no micro-organisms; but moderately large numbers of gonococci were present in the urethral discharge.

Case 89. (Pes<sup>153a</sup>)—Acute Gonorrhœa—Acute Total Bilateral and Non-Suppurative Dacryoadenitis.

G. M., 21 years old, appeared on February 2nd, 1904, with an intensely acute bilateral and total dacryoadenitis. There was also present an acute gonorrhœa with profuse purulent discharge of twenty days' standing. The inflammation of the lacrimal glands began three days previously with local pain, fatigue in the ocular movements, constitutional disturbance and fever. Later a swelling appeared which reached its maximum on the day of admission to the clinic. Photophobia was not present and the examination of the fundus gave nothing positive. Morbid conjunctival secretion and cardiac and arthritic manifestations were absent. The patient left the hospital improved at the end of three days. Numerous gonococci were found in the urethral discharge, but none were obtained from the conjunctiva of either eye.

Case 90. (Pes<sup>153a</sup>)—Gonorrhœa—Acute, Double-sided, Non-Suppurative Inflammation of both the Palpebral and Orbital Divisions of the Lacrimal Gland.

A notary, 57 years old, experienced on the evening of October 25th, transitory chills with elevation of temperature and marked general debility; tenderness of the globe, and a feeling of heat and heaviness in the lids of both eyes. In the following days the symptoms increased in severity and on October 27th, 1900, the patient was admitted with a considerable inflammation of the orbital and palpebral portions of the lacrimal gland on both sides. The conjunctivæ were hyperæmic and œdematously swollen; the lacrimal secretion slight; photophobia and morbid discharge were absent; and the fundus was normal on both sides. The patient suffered from a urethral blennorrhœa of three years' standing, which had become acute probably in consequence of the new infection. No cardiac or arthritic manifes-



tations were present. Gonococci were found in abundance in the urethral discharge; but were constantly absent from the lacrimal secretion.

Resolution suddenly began on November 13th and on November (?) 21st the patient left the hospital completely cured.

Case 91. (Giani<sup>167</sup>) — Gonorrhœa — Acute, Bilateral, Non-Suppurative Dacryoadenitis.

A junior officer, in the School of Musketry, came to the military surgeon complaining of double dacryoadenitis. He stated that he was also suffering from gonorrhœa of ten days' duration; and that this was under treatment by internal remedies and injections of protargol. There was a very considerable degree of swelling and redness in and about the two upper lids, with œdema locally and pain radiating through the temple, loss of appetite and a raised temperature. In the next few days the swelling rather increased, especially at the upper part of the orbit, and there was some impairment of movement of the globe laterally. There was lachrymation and a good deal of catarrhal secretion from the eye; the conjunctiva was red and œdematous, especially at the outer side; the eye could hardly be opened, and the patient had slight photophobia. The point of greatest tenderness was on each side precisely in the region overlying the lacrimal gland, just below the outer end of the eyebrow, which could be felt tense and somewhat swollen. At the same time fundus and media were quite normal. No visceral lesion could be discovered, the heart and joints being examined with particular care, but with a negative result. Gonococci were found in abundance in the urethral secretion; but repeated examination of the conjunctiva and even of the punctured lacrimal gland gave a negative result.

Apparently the patient was of a somewhat neurotic temperament, for in spite of being assured that the malady was not very important and that the swelling would clear up without leaving any trace, he had several convulsive seizures with loss of consciousness, and with some mental dulness remaining afterwards. However, the local condition, under cold compresses, &c., recovered gradually and completely.

Case 92. (Casali<sup>168</sup>) — Gonorrhœa — Double-sided, Non-Suppurative Inflammation of the Lacrimal Gland (Palpebral Portion).

The patient was an actor of Florence, age 26. There was nothing in the family or personal history apart from a gonorrhœa which had been contracted in 1896 and had since broken out from time to time for brief periods. Six days previous to consultation he had imprudently exposed himself to the cold on leaving the theatre; and the following morning, on urinating, had experienced a burning sensation in the urethra and noticed a drop of sero-pus precede the urine. In the afternoon he was seized with slight febrile-symptoms which lasted until midnight, and a sensation as of a foreign body beneath the eye-lid. Looking at himself in the mirror he saw that his eyes had become reddened. The general phenomena completely disappeared in four or five days but the ocular manifestations continued. The next day the fever returned about five o'clock to terminate towards one a.m. though



concominately the ocular symptoms increased in severity. It was also noticed that up to the second day of the illness the upper eyelids had become red and tumefied with profuse lacrimation and slight catarrhal secretion. After a few days, not noticing any mitigation, the patient decided to enter the clinic on December 14th, 1900, when the following conditions were made out:

The upper lids were slightly swollen and reddened especially outwards where they seemed somewhat displaced from the globes and the orbito-palpebral sulci were less manifest. The excursions of the eyeballs were only slightly restricted; there were slight hyperæmia of the conjunctiva, with chemosis of its external part; lacrimation, and scanty catarrhal secretions. Fixed beneath the most external portion of the upper lid and the bulbar conjunctiva was a small tumor which protuded beneath the margin of the lid. It was about the size of a small bean and of hard consistency. There was no displacement of the globes, but the movements upwards and outwards were difficult and accompanied by homonymous diplopia. Recovery was complete at the end of eight days.



## CONCLUSIONS AND PRINCIPAL POINTS OF THE STUDY.

---

I. The early British and French writers were the pioneers in the development of our knowledge of gonorrhœal ocular metastases. From the first, gonorrhœal iritis has been uninterruptedly recognized by the profession; but after 1850 the general practitioners alone continue to believe in a metastatic conjunctivitis. The specialists, influenced especially by the work of Piringer, went to the opposite extreme and accepted only the theory of direct infection; but they have been again forced into recognizing metastatic conjunctivitis through the bacteriological investigations which have followed Neisser's discovery. The occurrence of numerous other conditions in the eye, and the phenomena which gave rise to the old theory of "retropulsion," have been made easier to understand through the better appreciation of the systemic phases of gonorrhœa of recent years.

II. Systemic gonorrhœa most commonly occurs in males, in those cases in which the posterior urethra and the contiguous structures are involved; but nothing definite is known in regard to the factors which underlie the undoubted predisposition of certain individuals to this disease.

The accumulating pathological evidence seems more and more to show that the gonococci themselves, and not their free toxins or the secondary or mixed infections, are responsible for the local manifestations.

Metastatic inflammations of the eye, of gonorrhœal origin, are marked, in general, by uncertainty and irregularity as regards the time of their occurrence, the extent to which the parts are involved, the severity of their symptoms, and their course and behaviour; by their close association with metastases of like origin in other parts of the body; and by a marked tendency to relapse, and to recur with fresh gonorrhœas.

Ocular inflammations are often the first manifestation of systemic gonorrhœa, and there is every reason to believe that they frequently form the sole expression of this condition.

Patients with systemic gonorrhœa should be treated as those actually suffering from an infectious disease; and, as there are grounds for thinking that gonorrhœal metastases pick out points of



lessened resistance, excessive use of the eyes, while the systemic infection is in progress, is to be deprecated.

III. Metastatic gonorrhœal conjunctivitis is a well established clinical entity. The figures of Fournier and of White in regard to its frequency have been often misquoted; but it will probably be oftener met with now that it has gained for itself a wider recognition. It occurs at any time during the course of a systemic gonorrhœa, but apparently more often than the other eye conditions as an initial manifestation. The infection is almost invariably bilateral, and both eyes are usually simultaneously involved. The objective appearances, and the subjective symptoms differ little, if at all, from those of any of the so-called acute "catarrhal" inflammations of the conjunctiva. The discharge is typically slight in amount, and almost always mucoid in character. Pure cases run their course in two weeks; but in thirty per cent. of the patients the inflammation is complicated by affections in other coats of the eye. Some of these, at least, are of the nature of deep-seated metastatic inflammations which throw light on the true nature of the conjunctivitis. Relapses occur either alone, or, more often, in association with affections of other parts of the globe.

IV. Though it is impossible at the present time to determine its exact mode of development, a keratitis occurs in association with systemic gonorrhœa which is typically of a multiple and superficial nature, and commonly symmetrical in character, and central in situation.

V. The deep-seated congestion sometimes observed in metastatic conjunctivitis is often only an expression of an inflammation of the interior structures of the globe, actually present or in process of development. The cases of pure sclero-conjunctivitis, which apparently do occur, ought to be differentiated from metastatic conjunctivitis, and classed by themselves.

VI. In every so-called iritis the pathological process is by no means limited to the iris, but extends at least to the adjacent division of the uveal tract. It is justifiable, and perhaps even advisable, to discard the word iritis, and substitute the terms mild or severe iridocyclitis, the better to express the character and extent of the changes known to be present in these cases.

VII. There are no figures to show what part the gonococcus plays in the production of the inflammations of the uveal tract, viewed collectively; but, taking the statistics for iritis as an index,



it would seem that the percentage of cases, attributable to this organism, varies as the result of differences in the social and hygienic conditions of the places in which the statistics are collected.

While the gonococcus apparently finds its most favorable environment in the vascular coat of the eye, the exact relative frequency with which the various structures of the globe are visited by gonorrhœal metastases remains to be determined. Likewise, no definite idea can, at the present time, be formed of the usual extent, duration, and severity of the inflammations of the uveal tract, or of numerous special features of these conditions. Writers, generally, have been too loose in their nomenclature, and too many reports are lacking in essential details and exact description, to allow of a determination of these points.

Arranged according to types, one finds that all the common forms of uveal inflammation have been attributed to systemic gonorrhœa, though the statements of Fournier in regard to the frequency of serous cyclitis (aquo-capsulitis) are not borne out by a study of the literature.

Generally speaking, metastatic gonorrhœal affections of the uveal tract show a tendency to be double-sided in the first as compared with the second and later attacks, and to relapse, and to recur with fresh gonorrhœas. They precede, or follow, or break out simultaneously with other manifestations, or form the sole expression of the systemic infection; but they are marked by no special features, except that swellings of any kind in the iris tissue are never observed. Gelatinous exudations are more indicative of the severity of these inflammations than of their origin. An associated metastatic conjunctivitis is suggestive. The purulent forms, which often show no sharp line of demarcation from the plastic, are marked by an extraordinary tendency to recovery.

VIII. The metastatic gonorrhœal inflammations of the optic nerve and retina commonly take the form of a diffuse, and scarcely-measurable neuro-retinitis, associated, at times, with considerable retinal œdema. The cases follow the rule, that when the nervous apparatus of the eye is solely involved the affection is bilateral, but when it is implicated along with the uveal tract the neuro-retinitis is unilateral in character. The pathological evidence favors the blood-vessels rather than the lymph spaces as being the principal route for the infection in these conditions. The prognosis must be guarded though, generally speaking, the outlook is good.



IX. The cases of dacryoadenitis, which have been attributed to systemic gonorrhoeal infection, conform to what is known of inflammation of the lacrimal gland in general, namely, that while the cases caused by direct extension are generally unilateral and go on to suppuration, those produced by metastasis are usually bilateral in character and end in resolution.



## X.—BIBLIOGRAPHY.

1800. (1). Robertson, Robert. History of a case of retropulsed gonorrhœa, succeeded by a severe affection of the eyes, terminating favourably. *Annals of Med.*, Vol. IV., p. 455-458, 1800.
1818. (2). Brodie, Sir Benj. C., Bart. *Pathological and Surgical Observations on Diseases of the Joints.* London, 1818, p. 55-63. (5th edition, p. 46-49, for sequel and other cases.)
1820. (3). Vetch, John. *A practical Treatise on the Diseases of the Eye.* London, 1820, p. 243-246.
1825. (4). Abernethy, John. Pseudo-syphilitic Ophthalmia, *Lancet*, Vol. VII., p. 5-7.
1830. (5). Cooper, Sir Astley, Bart. *Lectures on the Principles and Practice of Surgery*, p. 499-500, London, 2nd edition, 1830 (not in the first edition).
- (6). Lawrence, Sir William. *Treatise on the Venereal Diseases of the Eye*, (Cases XVI. to XXIV.), p. 109-129, 1830. For abstracts, see Hutchinson, R. O. H. *Repts.*, Vol. VII., 1873.
1833. (7). Lawrence, Sir William. *Treatise on the Diseases of the Eye*, (first edition, 1833), p. 232-236.
1838. (8). Graves, R. J. Clinical Lecture VI., on Gonorrhœa, Gonorrhœal Rheumatism and Ophthalmia, etc. *London Med. Gazette*, Vol. XXIII., p. 438-443.
1839. (9). Lawrence, Sir William. Clinical Lecture on Variculous Ophthalmia, Gonorrhœal Ophthalmia, and Gonorrhœal Rheumatism. *London Med. Gazette*, Vol. XXIII., p. 506-514.
1840. (10). Mackenzie, W. "Gonorrhœal Iritis." *A Practical Treatise on the Diseases of the Eye*, 3rd edition, p. 475-478.
1850. (11). Lippert. *Canstatt's Jahresbericht.* Vol. II., p. 176.
1854. (12). Brandes. Du rhumatisme blennorrhagique. *Arch. Gén. de Méd.*, T. IV., p. 257-272, 1854. (Observations, 2, 3, 5, 6, 8, 9, 10).
1858. (13). Rollet, J. Du rhumatisme symptomatique de la blennorrhagie, (synovite et iritis blennorrhagique). *Gaz. Méd. de Lyon.*, T. X., ps. 138, 170, 215. These papers published in 1858 as one volume entitled, "Nouvelles Recherches sur le Rhumatisme blennorrhagique."
1860. (14). Ellitson, John. Reasons for regarding as simply Urethral Rheumatism and Ophthalmia what are generally termed Gonorrhœal Rheumatism and Ophthalmia, with suggestions for their cure and prevention. *B. M. J.*, p. 642-644, 1860.



1860. (14a). Legrand. *La France Méd. et Pharm.*, Vol. VII., p. 179-181, 1860.
- (15). Bergh, Rud. *Bidrag til kundskrab om Gonorrhœ hos Mandfolk*, Kjöbenhavn, C. A. Reitzel, 1860. (Ref. Canstatt's *Jahresbericht der Med.*, Vol. II., p. 342).
1861. (16). Cullerier. *Des affections blennorrhagiques*. Paris, 1861, p. 165.
1862. (17). Wordsworth, J. C. *Gonorrhœal Inflammation of the Eyeball or Gonorrhœal Iritis*. *R. O. H. Repts.*, Vol. III., p. 301-310.
1863. (18). Ricord, Ph. *Lettres sur la Syphilis*. 3rd edition, p. 30, (Galezowski), 1863.
1864. (19). Icard. *Blennorrhagie; arthrite; ophthalmie purulente*. *Mem. et Compt., Rendus Soc. des Sc. Méd. de Lyon*, T. IV., Part II., p. 6-9, 1864-1865.
1865. (20). Rollet, J. *Traité des Maladies veneriennes*, Paris, 1865, p. 350-352.
1866. (21). Fournier, Alfred. *Ophthalmie rhumatismale*. *Nouv. Dict. de Méd. et de Chir. Prat.*, Vol. V., p. 245-251, 1866.
- (22). Tixier, H. *Considérations sur les accidents a forme rhumatismale de la blennorrhagie*. *Thèse de Paris*, p. 41-56 and 75-79, 1866. (Observation 5.)
1867. (23). Galezowski. *Iritis rhumatismale blennorrhagique*. *Gaz. des Hôp.* T. XL., p. 17-18, 1867.
- (24). Fournier, Alfred. *Note sur le rhumatisme urethral, etc.* *Union Méd.*, p. 132 and 149.
1869. (25). Wells, J. S. *A Treatise on the Diseases of the Eye*. 1st edition, p. 163.
- 1870-71(26). Thiry. *Des Ophthalmies blennorrhagique simples*. *La Presse Méd. Belge*. Vol. XXII., p. 413-416 and Vol. XXIII., p. 22-23.
1872. (27). Galezowski. X. *Iritis blennorrhagique*. *Traité des Maladies des Yeux*, ps. 346-347.
- (28). Königer, K. *Ueber die sogenannten metastatischen Complicationen der Gonorrhœ; insbesondere über einen Fall von Iridochoroiditis gonorrhœica*. *Inaug. Diss. Berlin*, 31 pages.
1873. (29). Hutchinson, Jonathan. *A Report on the Form of Eye Diseases which occur in Connection with Rheumatism and Gout*. *R. O. H. Repts.*, Vol. VII., p. 287-332 and p. 453-494, 1873; also Vol. VIII., p. 191.
1874. (30). Gosselin. *Iritis blennorrhagique coïncidant avec une nevralgie faciale—Difficulté de diagnostic etiologique*. *Gaz. Hebdom. de Méd. et de Chir.*, T. XI., p. 269-270, 1874. See also Bergeron, *La France Méd.*, T. XXI., p. 291.
- 1874-75(31). Grima. *A Case of double Gonorrhœal Ophthalmia which presented peculiar Features*. *New Orleans Med. Jour.*, Vol. II., p. 925.



1876. (32). Von Wecker, L. Die blennorrhagische Iritis. Handbuch der ges. Augenheil. First edition, Vol. IV., part II., p. 497-498.
1877. (33). Færster, R. Iritis Gonorrhoea. Handbuch der gesammten Augenheilkunde, Graefe-Sæmisch, 1st ed., Vol. VII., p. 86-87.
1879. (34). De Wecker, L. Ocular Therapeutics, Eng. Ed. by Forbes, p. 176.
1880. (35). Mengin. Note sur un cas d'iritis blennorrhagique. Rec. d'Oph., T. II., p. 679-685, 1880.
- (36). Kipp, Charles J. On Gonorrhoeic Irido-choroiditis. Med. Record, Vol. XVII., p. 717-719.
1881. (37). Noyes, H. D. Diseases of the Eye, 1st edition, p. 206.
- (38). Horstmann. Ueber recedivierende iritis. Centralbl. f. prak. Augenheil., p. 297-302.
- (39). Haab, O. Kleinere ophthalmologische Mittheilungen. Correspondenz-Bl. für Schw. Aertze, Bd. II., p. 105.
- (40). Hirschberg, J. and Krause, F. Zur Pathologie des Ansteckenden Augenkrankheiten. Centralbl. f. prak. Augenheilk. Bd. V., p. 271.
1882. (41). Colsmann. Ein Fall recidivierender Hornhauterankung bei gonorrhoeischer Gelenkentzündung. Ber. Klin. Woch. Bd. XIX., p. 243-244.
- (42). Perrin, M. De la Conjonctivite purulente rhumatismale, Bull. de l'Acad. de Méd., T. XL., p. 48-60 (1882), T. XII., p. 514 and suite, 1883.
- (43). Parizot, L. Des formes atténuées de l'Ophthalmie blennorrhagique. Lyon Méd., T. XLI., p. 333-340.
- (44). Clemens. Ueber iritis gonorrhoea. Inaugural Dissertation, Berlin.
- (45). Martin, H. Recherches anatomo-pathologiques sur les inflammations metastatiques à la suite de la gonorrhoe. Thèse Genève, 1882. Abstract Arch. für Augen., Bd. XIV., p. 116-117. (By Haltenhoff.)
1883. (46). Nolen, W. Ueber den sogenannten Rheumatismus gonorrhoeicus. Deutsch. Archiv. für Klin. Med., Bd. XXXII., p. 120-148, 1882-1883. Oph. (141-142).
- (47). White, J. W. Ophthalmie et conjonctivite blennorrhagique. Encyc. Internat. de Chir. (Ashurst), fasc. IV., p. 560-561.
1884. (48). Boquin, Albert. Du rhumatisme oculaire et de ses principales manifestations. Thèse de Paris, p. 43-46, p. 64-70.
- (49). Galezowski, X. Le affezione oculari de reuma e da blennorrhagia. Ann. di Ottalm., Vol. XIII., p. 558. (Del reumatismo blennorragico). 1884.
- (50). Haltenhoff, G. Ueber Conjunctivitis gonorrhoea ohne Inoculation. (a). Archiv. für Augen., Bd. XIV., p. 103-120. 1884-1885. (b). Translation of above by A. Backan, Archives



- of Oph., Vol. XV., p. 169-179, 1886. (References more fully given in German text.)
- (51). Haslund. Beitrag zur Pathogenese des Gonorrhöischen Rheumatismus, Vierteljahresschrift für Derm. U. Syphilis, Vol. XI. (Case 366-367.) P. 359-373, 1884.
- (52). Swanzy, H. R. Diseases of the Eye. 1st edition, p. 195.
- (52a). Miller, H. G. Tr. Am. Oph. Soc., Vol. III., p. 735.
1885. (53). Fournier, Alfred. Conjunctivite blennorrhagique spontanée. Gaz. des Hôp., T. LVIII., p. 1201-1203, 1885; and (same title), Gaz. des Hôp., T. LIX., p. 12-13, 1886, (continuation).
- (54). Schweigger, G. Handbuch der Augenheilkunde, p. 323, 1885.
- (55). Froidbise. Urethrite compliquée de synovite de genou gauche et d'irido-conjunctivite. Arch. Med. Belges, T. XXVIII., p. 100-107.
1886. (56). Basset, H. Rhumatisme Blennorrhagique. Ann. de Derm. et de Syph., T. VII., p. 334-349.
- (57). Troussseau, A. La Conjunctivite blennorrhagique Spontanée sans inoculatoir. Rev. Clin. d'Oc., T. VI., p. 61-63.
- (58). Armaignac, H. Note sur un cas de conjunctivite blennorrhagique séro-vasculaire bénigne spontanée. Rev. Clin. d'Oc., T. VI., p. 1-5.
- (59). Loeb, M. Die Rheumatoiderkrankung der Gonorrhöiker. Deutsch. Archiv. für klin. Med., Bd., XXXVIII., p. 166-168, 1885-1886.
- (60). Rückert, Fr. Ueber Iritis, Conjunctivitis, und Polyarthritis gonorrhöica. Klin. Monats-Bl. für Augen., Bd. XXIV., p. 339-358.
1887. (61). Le Roy. La Conjunctivite rhumatismale blennorrhagique. Bull. de la Soc. de Méd. prat. de Paris, 1887, p. 396-399. (Discussion.)
- (62). Froidbise. De la conjunctivite blennorrhagique spontanée. Ann. de la Soc. Méd.-Chir. de Liege, p. 149-157, April, 1887.
1888. (63). Frange, Charles. De la conjunctivite blennorrhagique séro-vasculaire sans inoculation. Thèse de Paris, 1888. 55 pages. (Observations, I, II, III.)
- (64). Despagnet, F. (a). De l'iritis blennorrhagique. Bull. et mem. de la Soc. Franc. d'Oph., T. VI., p. 172-176, 1888. (b). Same title and paper. Rec. d'Oph., T. X., p. 260-265, 1888. Abstract, Rev. Gén. d'Oph., T. VII., p. 241.
1889. (65). Becker, H. Metastatic Gonorrhœal Conjunctivitis. (Discussion.) Compte rendu IX., Cong. Int. D'Oph., Utrecht, p. 192.
- (66). Berry, George A. Diseases of the Eye, p. 132.
1890. (67). Panas, Ph. Nevrite Optique d'origine blennorrhagique. La Semaine Méd., T. X., p. 477-478, 1890.



1891. (68). Parinaud. Bull. et Mem. Soc. Franc. D'Oph., T. IX., p. 270.
- (69). Friedenbergh, E. Gonorrhœal Irido-choroiditis. Brooklyn, M. J., Vol. V., p. 576-577.
- (70). Seeligsohn, W. Zwei Fälle von Dacryoadenitis Spontanea. Klin. Monats.-Bl., Bd. XXIX., p. 25-30, 1891.
- (71). Liebrecht. Conjunctivitis bei constitutioneller gonorrhöischer Erkrankung. Klin. Monats.-Bl. für Augen., Bd. XXIX., p. 176-179.
- (72). Vanderstraeten. Des affections oculaires de la nature blennorrhagique. Arch. Méd. Belges, T. XL., p. 5-29.
- (73). Legros, E. Les Complications oculaires de la blennorrhagie (urethrite gonococcique). Presse Méd. Belge, Vol. XLIII., p. 721-725.
1893. (74). Alt, Adolf. Two cases of Gonorrhœal Iritis. Am. Jour. Oph., Vol. X., p. 3-4.
- (75). Nobl, G. Ueber Seltenere Complicationen der Blennorrhœ. Jahrbuch der Wien. Krankenanstalten. Bd. II., p. 408-423, 1893. (Case II., p. 413-414.)
- (76). Morax, V. Formes rares d'iritis. Ann. d'Oc., T. 109, p. 368-372, 1903. (Case II., Iritis recidivante blennorrhagique, p. 370.)
- (77). Bull, C. S. Gonorrhœal Iridocyclitis. Annal. Oph. and Otol., Vol. II., p. 109-112.
- (78). Cary, Chas. Gonorrhœal Iritis. Int. Clinics, 3. s., Vol. II., p. 258-260.
- (79). Jahn, Fred. Ueber die Complicationen der gonorrhœ, insbesondere ueber einen Fall von geheilter, akuter, eitriger, metastatischer Irido-choroiditis. Inaug. Diss., Berlin, 1893. (30 pages.)
- (79a). Eliasberg. A case of bilateral, parenchymatous keratitis, of gonorrhœal? origin. Recovery in three months. Wjestnik oftalmol, 1893. Ref. Centralbl. f. prakt. Augenheil., 1893, p. 183. Archiv. für Derm. u. Syph., Vol. XXVII., p. 278, 1894.
1894. (80). Nobel. Gonorrhœal Metastatic iritis with arthritis. Arch. für Derm. und Syph., Bd. XXVI., p. 147, 1894. See also Ann. de Derm. et de Syph., T. V., p. 344, 1894.
- (81). Morax, V. Recherches bactériologiques sur l'étiologie des conjonctivites aiguës, et sur l'asepsie dans la chirurgie oculaire. Thèse de Paris, 1894, p. 69-75.
- (82). Despagne. (Discussion, meeting Soc. D'Oph. de Paris, Feb. 13, 1894.) Rec. d'Oph., Vol. XVI., p. 99-101, 1894.
- (83). De Schweinitz, George E. Gonorrhœal Iritis, treated with sub-conjunctival injections of bi-chloride of mercury. Phil. Polyclin., Vol. III., p. 391-392.
- (84). Kucharzewski. A Case of Gonorrhœa complicated by Polyarthritis, Disturbances in the Nervous System, Iritis, and Cyclitis. Kron. Lekarska, Vol. XV., p. 9, 1894 (not



- verified). Abstract: Nagel's Jahresbericht, Vol. XXVI., p. 511.
- (85). Panas, P. Dacryoadenite, Iritis, et conjonctivite séro-vasculaire d'origine blennorrhagique. Rev. Gén. Méd. et de Therap., T. VIII., p. 169-171, 1894.
- (86). Burchardt, M. Entzündung der iris und des Strahlen-Körpers des liken Auges, Netzhautentzündung beider Augen und mehrfache Gelenkentzündung nach Gonorrhoe. Charité-Annalen, Bd. XIX., p. 246-248, 1894.
1895. (87). Dunn, H. Percy. Remarks on Gonorrhœal Iritis, B. M. J., p. 1489-1490.
- (88). Lipski, H. Des Complications oculaires metastatiques de la blennorrhagie. Thèse de Paris, 1895. (70 pages.)
- (89). Knies, Max. Relation of Diseases of the Eye to General Diseases. English edition edited by Noyes. P. 312.
- (90). Morax, V. A propos d'un cas d'irido-choroidite suppurative terminée par la guérison. Ann. d'Oc., T. CXIV, p. 241-246.
- (91). Coppez, H., fils. Un Cas d'irido-choroidite suppurative avec guérison et restitution complète de l'acuité visuelle. Rev. Gén. d'Oph., T. XIV., p. 385-390.
- (92). Peuch. Observation sur un cas de Ténonite. La Clin. Oph., Vol. I., p. 8-9.
- (93). Panas, P. Nevrite optique d'origine blennorrhagique. La Presse Méd., Vol. III., p. 65-66.
- (94). Hilbert, R. Retinitis in Folge von gonorrhöischer infection. Memorabilien. Zeitsch. für ration. praktische Aerzte, Bd. XL. (New series, Bd. XV.), p. 385-388.
- (95). Zimmerman, C. Ein Fall von Irido-choroiditis suppurativa mit Heilung und vollständiger Wiederherstellung der Sehschärfe. Klin., Mon.-Bl., f. Augenheil., Bd. XXXIII., p. 45-50, 1895.
- (95a). Gonella. Soc. dei Cultori delle Sc. Med., Cagliari, Luglio, 1895; Rendiconto riassuntivo del XV. Cong., dell' Assoc. oft. ital., p. 55, 1898 (Pes).
1896. (96). Cheatham, W. Gonorrhœal Iritis and Non-Suppurative Gonorrhœal Conjunctivitis and their Pathology. Arch. of Oph., Vol. XXV., p. 510-518.
- (97). Highet, H. Campbell. Gonorrhœa as a cause of Neuro-retinitis. Annal. d'Oculistique, T. CXV., p. 49-50. (English edition); T. CXV., p. 47-48. (French edition).
- (98). Burchardt, Max. Iritis und Polyarthritus gonorrhœica. Charité-Annalen, Bd. XXI., p. 356-361.
1897. (99). Frischmann, J. Consekutive Organerkrankungen der gonorrhœ. Pester Med. u. Chir. Presse, Bd. XXXIII., p. 1162-1169.
- (100). Karsnitski, A. V. Sluchaï Gonorroïnavo irita (iritis gonorrhœica). Voyenno-med., J. St. Petersburg, CXC., med.-spec. pt., 824-829 1897, (not verified).



- (101). Gielen. Ueber gutartige doppelseitige Conjunctivitis nach Affectionen der Urethra. Inaug. Dissertation, Bonn.
- (102). Scholtz, K. Az iritis gonorrhœicáról. Szemeszet, Budapest, p. 63, 1897. Abstract, Cent. Bl. für prak. Augen., Bd. XXI., p. 578.
- (103). Costello, D. R. (a). Iritis blenorragica. Rev. de Méd. y Cirug. pract., Vol. XL., p. 161-164, 1897. (b). Iritis blenorragique. La Clin. Oph., T. VI., 112-113, (Translation).
- (104). Burchardt, M. Entzündung der Iris, der Hornhaut, der Schnervenscheibe, und der Netzhaut in Folge von Gonorrhœ. Charité-Annalen, Bd. XXII., p. 345-353.
1898. (105). Lichtenstern, E. Zwei Fälle von gonorrhöischer Allgemeinfektion. Prag. Med. Woch., Bd. XXIII., p. 550-552.
- (106). Becker. Die Metastatische gonorrhöische Augenbindehauterkrankung. Jahresbericht der Gesellschaft für Natur und Heilkunde in Dresden, p. 85-89, 1897-1898.
- (107). Pes, O. Doppelseitige acute Dacryoadenitis im Verlaufe einer acuten Gonorrhœ. Oph. Klinik, Bd. III., p. 241, 1899. (Report of annual meeting of Italian Ophthalmological Society, Turin, 1898.) See also Ann. di Ottamol., Vol. XXVIII., p. 77, 1899.
- (108). Sgrosso, P. Case of Dacryoadenitis attributed to Systemic Gonorrhœal infection. Cited in discussion following Report of Pes.
- (109). Milbury, Frank S. Gonorrhœal Conjunctivitis and Iritis. Jour. Am. Med. Assoc., Vol. XXXI., p. 715-716.
- (110). Panas, P. Suppuration intraoculaire metastatique d'origine blennorrhagique. Rev. Gén. de Clin. et de Therap., Paris, T. XII., p. 721-722.
- (111). Reyling. Gonorrhœal Iritis. Langsdale's Lancet, Vol. III., p. 4-6, 1898.
- (112). Collins, Treacher. The Constitutional Causes of Iritis. Int. Clinics, 8th series, Vol. III., p. 297.
- (113). Norris and Oliver. Syst. of Diseases of the Eye. (Brailey and Stephenson), Vol. III., p. 292-293.
- (113a). Haas. Inaugural Dissertation, Würzburg, 1898.
1899. (114). Scheffels. Metastatic Gonorrhœal Conjunctivitis. (Discussion.) Compte-rendu IX. Cong. Int. d'Oph., Utrecht, p. 192.
- (115). Van Moll. Gibt es eine Metastatische Conjunctivitis?. Compte-rendu IX. Cong. Int. d'Oph., Utrecht, 1899, p. 183.
- (116). Knapp, H. Metastatic Gonorrhœal Conjunctivitis. Arch. of Oph., Vol. XXIX., p. 108.
- (117). Morax-Elmassian. Du rôle des toxines dans la production des inflammations de la conjonctive. 9th Internat. Cong. for Oph., p. 465-505.



- (118). Hennart, E. Sur un cas d'iritis blennorrhagique chez un syphilitique. T. VIII., p. 169-174, 1899. Abstract, Rec. d'Oph., T. XXII., p. 58, 1900.
- (119). Boettcher. Ein Fall von gonorrhöischer Allogenmeininfektion. Pet. Med. Woch., Vol. XVI., p. 69.
- (120). Griffith, J. Iritis a sequel to Gonorrhœa. Tr. Oph. Soc. U. K., Vol. XX., p. 83-92, 1900. See also Abstract Oph. Rev., p. 344, 1899.
- 1899-1900(121). Fromaget. Fautes Cliniques. Ann. de la Policlinique de Bordeaux, T. XI-XII., p. 6.
1900. (122). Kaldrovitis, A. Fälle von Endogener Gonokokken-Infektion. Nagel's Jahresbericht, p. 376.
- (123). Santamaria, A. Metastasi oculari del gonococco. Subdivision 5 of paper entitled, Sul metabolismo patogenetico del Gonococco di Neisser. Arch. Internaz. di Med. et Chir. Vol. XVI., p. 123.
- (124). Usemblo. Über Einen Fall Von Gonorrhöischer Iritis. Wrasch, 1900, No. 47, (Abstract of von Hoffmann used).
- (125). Michel, J. Zur Kenntniss der Ursachen einer primären Iritis auf Grund einer statistischer Zusammenstellung. Münch. Med. Woch., Bd. XLVII., p. 853-855.
- (126). Galezowski, X. Des Thromboses arterielles du Nerf optique. Rec. d'Oph., T. XXII., p. 264-265. (See Remarks by Koenig, p. 265.)
- (127). Lechner, C. S. Ophthalmia Gonorrhöica Metastatica. Ref. Nagel's Jahresbericht für Oph., Bd. XXXI., p. 258.
- (128). Fage. Conjunctivite blennorrhagique Métastatique. Recueil d'Ophthal., T. XXII., p. 193-195.
- (129). Kucharzewski, H. Un cas de blennorrhagie compliquée de rhumatisme, de troubles nerveux, et irido-cyclite. Progrès Méd., T. XI-XII., p. 52-54.
- (130). Galezowski, X. Thromboses et phlébites gonococciques de la rétine. Rec. d'Oph., T. XXII., p. 206-208, 1900. Abstracts: Oph. Klin., Bd. IV., p. 153-, 1900. Ann. d'Oc., p. 301.
- (131). Terson, A. Dacryoadenite blennorrhagique. Rec. d'Oph., T. XXII., p. 162-163, 1900. See also Oph. Klinik., p. 152-153, 1900; and Ann. d'Oc., p. 205.
- (131a). Morton, H. McI. Upon the relation of certain catarrhal and purulent inflammations of the conjunctiva to urethritis and arthritis. Oph. Rec., Vol. IX., p. 293-295.
1901. (132). Lawford, J. B. A Discussion on the Relation of Gonorrhœa to Diseases of the Eye (excluding purulent ophthalmia), Rept. of Proceedings of Sect. of Oph. B. Med. Assoc., Cheltenham, 1901. B. M. J., p. 1330-1332, Nov. 2.
- (133). Groenouw, A. Beziehungen der Allgemeinerkrankungen und Organerkrankungen zu Veränderungen und Krankheiten des Sehorganes. Græfe-Sæmisch Handbuch der gesam. Augenheilk. 2nd ed., Bd. XI., p. 143-147.



- (134). Greef, R. Ueber gonorrhoeische Augenerkrankungen. Berl. Klin. Wochenschr., Vol. XXXVIII., p. 181-184.
- (134a). Yeld, R. A. B. M. J., 1901, pt. 2, p. 1331.
1902. (135). Lesser. Conjunctivitis duplex rheumatica nach gonorrhoe. (Notice of presentation of case.) Münch. med. Woch., Vol. XLIX., p. 1238.
- (136). Ferry, M. Dacryoadenite bilaterale au cours de l'infection blennorrhagique. Rec. d'Oph., T. XXIV., p. 585, 1902. See also Ann. d'Oc., T. CXXVIII., p. 375, 1902.
- (137). Grimaldi, E. Contributo alla casuistica della dacrioadenite acuta. Giornali Int. delle Sci. Med., Vol. XXIV., p. 344-348, 1902. Abstract Jahresbericht für Oph., Bd. XXXIII., p. 510.
- (138). Kurka, A. Ueber metastatische Bindehautentzündung bei Gonorrhoe. Wiener Klin. Woch., Bd. XV., p. 1032-1035.
- (138a). Morax. Remarks concerning the pathological examination of Ferry's (136) case of dacryoadenitis. Ann. d'Oc., Vol. CXXVIII., p. 448.
- (138b). Byers, W. G. M. On the Ocular Manifestations of Systemic Gonorrhoea. Montreal M. J., Vol. XXXI., p. 863-866.
1903. (139). von Hoffmann, Karl. Gonorrhoeische Allgemeininfektion und Metastasen (Mit Ausschluss der Gelenks-, Knochen-, Sehnen-, und Schleimbeutel-, sowie der Nervösen Erkrankungen). Sammelbericht über die Literatur vom Jahre, 1890, an, Centralblatt für die Grenzgebiete der Medizin und Chirurgie, Bd. VI., p. 241, 308, 347, 375.
- (139a). Malherbe, H. Blennorrhagie aigue compliquée d'arthropathie et d'iritis. Jour. des Mal. Cut. et. Syph., Vol. XV., p. 728-732.
- (140). Eperon. See Dind, "La blennorrhagie et ses Complications," F. Rouge, Lausanne, 1903, p. 190-254.
- (141). Nettleship, E. Diseases of the Eye. See 5th Am. Ed., p. 446.
- (142). Etiévant. Dacryoadenite Blennorrhagique. Lyon Méd., T. C., p. 509-512, 1903. See also p. 485: report of meeting of Société des Médecins-Praticiens de Lyon, February 27th.
- (143). Poynton, F. J. and Paine, A. A Contribution to the Study of rheumatic iritis, Tr. Oph. Soc., U. K., Vol. XXIII., p. 39-45.
- (144). Apetz, W. Ueber gonorrhoeisch-metastatische Entzündung am Auge Erwachsener. Mün. Med. Woch., Bd. L., p. 1340-1341.
- (145). Meighan. Two cases of Iritis with History of Gonorrhoea two years previously. Glasgow M. J., Vol. LX., p. 366.
- (146). Collins, Treacher. Recurrent Iritis in Connection with Gonorrhoeal Arthritis. Polyclinic, London, Vol. VII., p. 41.



- (147). Galezowski, X. Irido-choroidite avec nevrite optique et panophthalmite dans une meningite cerebro-spinale gonococcoque. *Rec. d'Oph.*, T. XXV., p. 309, 311, 312, 313, 379. (Observations: 2, 3, 4, 6, 7.)
1904. (148). Causé, Fritz. Metastatische Tränendrüseneentzündung bei Gonorrhoe. *Zeitschrift für Augen.*, Bd. XI., p. 399-405.
- (149). Thorner, W. Ueber metastatische Conjunctivitis gonorrhoeica. *Char. Annalen*, Berlin, Bd. XXVIII., p. 340-347.
- (150). Saemisch, Th. *Gräfe-Saemisch Handbuch der gesam. Augenheilk.*, 2nd ed., Bd. V., p. 273-278.
- (151). Sonder. De l'iritis blennorrhagique. *La Clin. Oph.*, T. X., p. 373-376.
- (152). Sym, W. G. Metastatic gonorrhoeal ophthalmia. *Tr. Méd.-Chir. Soc. Ed.*, Vol. XXIII., p. 245-249, 1903-1904. Also (same title), *Ed. Med. Jour.*, Vol. XVI., p. 126-129.
- (153). Roosa, D. B., St. John. *Diseases of the Eye*, p. 313.
- (153a). Pes, O. Die acute bilaterale Entzündung der Tränendrüse bei Blennorrhagie der Urethra, etc. *Archiv. für Augen.*, Vol. LI., p. 144-171.
1905. (154). Greff, R. Ueber Metastasen im Auge bei Gonorrhoe. *Charité-Annal.*, Bd. XXIX., p. 620-643.
- (155). Woods, H. Recurrent Iritis: A Study of nine Cases. *Oph. Rec.*, Vol. XIV., p. 320-332.
- (156). Baylac. Iritis double dans un cas d'infection blennorrhagique. *La Clin. Oph.*, T. XI., 84-85. See also, *Oph. Klin.*, Bd. XI., p. 115.
- (157). De Lapersonne. De l'iritis blennorrhagique. *Jour. de Méd et Chir.*, T. LXXVI., p. 330-334.
- (158). Greff, R. Ueber Metastasen im Auge bei Gonorrhoe. *Med. Klinik.*, Bd. I., p. 949-953.
- (159). Galezowski, X. Des Irido-Choroidites Gonococciques. *Rec. d'Oph.*, T. XXVII., p. 321-333. See also *La Clin. Oc.*, Jan., 1905. Full translation and same title, *La Progrès Méd.*, T. XXI., p. 1-5.
- (160). De Lapersonne, F. Existe-t-il une iritis blennorrhagique? *Arch. d'Oph.*, T. XXV., p. 137-144.
- (161). Gendron. L'iritis blennorrhagique à rechutes. *L'Oph. Prov.*, T. I., p. 4, 1905.
- (162). Lehmann, J. Ueber Gonorrhoeische Metastatische Iritis. *Inaug. Diss.*, Berlin. 28 ps.
- (163). Paul. Metastatische-Gonorrhoeische Augenaffectio. *Ber. Klin. Woch.* Bd. XLII., p. 250.
- (164). Gutmann, A. Beitrag zur Aetiologie und Statistik der primären Iritis. *Deut. Med. Woch.*, Vol. XXXI., p. 1671-1673.
- (165). Burnett, S. M. Inflammations of the Eye due to the Toxins of the Gonococcus. *Jour. A. M. A.*, Vol. XLV., p. 1926-1928.



1906. (166). Lemierre-Faure-Beaulieu. Septicemie et pyohemie gonococcique. *Gaz. des Hôp.*, Vol. LXXIX., p. 231-237, and p. 267-271, 1906.
- (167). Giani, P. Dacryoadenitis from Gonorrhœa. *Rev. Ital. di Ottal.* Aug., 1906. Abstract of Sym., *Oph. Rev.*, Vol. XXV., p. 312, used in this paper.
- (168). Darier, A. Double iritis blennorrhagique, etc. *La Clin. Oph.*, Vol. XII., p. 212-213.
- (169). Casali, A. Due casi di dacrioadenite acuta. *Ann. di Ottal.*, Vol. XXXV., p. 191-206.
- (170). Roosa, D. B. St. J. A case of metastatic gonorrhœal choroiditis. Enucleation of the eye. *The Post-graduate*, Vol. XXI., p. 692-693.
1907. (171). McEttles, W. J. An Address on the Pathology and Treatment of Gonorrhœal Infection. *Lancet*, p. 69.
- (172). Ullmann, K. Ueber Konjunktivitis, Iridozyklitis, and andere entzündliche Augenerkrankungen als Teilerscheinungen eines Gonorrhœismus. *Wien. Klin. Rundschau*, Vol. XXI., p. 229, 281, 299, 315. Translation by Alt, *Am. J. Oph.*, Vol. XXIV., p. 139, 185, 201.
- (173). George, Edgar G. Removal of a piece of iron from an eye followed later by gonorrhœal iritis. *The Clinique*, Vol. XXVIII., p. 196-198.
- (174). Posey, W. C. Some unusual ocular manifestations of gonorrhœa. *Annals of Oph.*, Vol. XVI., p. 71-80.
- (175). Demaria, E. B. Conjunctivitis blenorragica metastásica ó endogena; (esclero-conjunctivitis blenorragica metastasica). *Arch. de oftal. Hispano-Am.*, Vol. VII., p. 757-762.
- (176). Carroll, J. J. Metastatic Conjunctivitis in Gonorrhœa. *Jour. Am. Med. Assoc.*, Vol. XLIX., p. 110-114. (For discussion by Woods, Posey, Green, Rothrock, see p. 170-172).



1919  
The American Medical Association is a non-profit corporation organized for the purpose of promoting the interests of the medical profession and the public. It was organized in 1847 and has since that time been the leading organization of the medical profession in the United States. The Association is composed of more than 50,000 members, who are organized into local, state, and national societies. The Association's principal activities are the publication of the Journal of the American Medical Association, the holding of annual meetings, and the promotion of medical education and research. The Association also maintains a large library and a museum of medical history. The Association's headquarters are located in Chicago, Illinois.

The Journal of the American Medical Association is a weekly publication that contains a wide variety of articles on medical topics. The articles are written by leading medical experts and are intended to provide medical professionals with the latest information on medical practice, research, and education. The Journal is also a valuable resource for the general public, as it contains articles on a wide range of medical topics that are of interest to all people.

The Journal of the American Medical Association is published by the American Medical Association, which is a non-profit corporation organized for the purpose of promoting the interests of the medical profession and the public. The Association was organized in 1847 and has since that time been the leading organization of the medical profession in the United States. The Association is composed of more than 50,000 members, who are organized into local, state, and national societies. The Association's principal activities are the publication of the Journal of the American Medical Association, the holding of annual meetings, and the promotion of medical education and research. The Association also maintains a large library and a museum of medical history. The Association's headquarters are located in Chicago, Illinois.



