

The Erasmus Wilson lectures on the anatomy and pathology of the eye : delivered at the Royal College of Surgeons on Feb. 12th, 14th, and 16th, 1900 / by E. Treacher Collins.

Contributors

Collins, E. Treacher 1862-1937.
Royal College of Surgeons of England.
University College, London. Library Services

Publication/Creation

[London] : [publisher not identified], [1900]

Persistent URL

<https://wellcomecollection.org/works/c8ve7sjf>

Provider

University College London


License and attribution

This material has been provided by This material has been provided by UCL Library Services. The original may be consulted at UCL (University College London) where the originals may be consulted.

Conditions of use: it is possible this item is protected by copyright and/or related rights. You are free to use this item in any way that is permitted by the copyright and related rights legislation that applies to your use. For other uses you need to obtain permission from the rights-holder(s).



Wellcome Collection
183 Euston Road
London NW1 2BE UK
T +44 (0)20 7611 8722
E library@wellcomecollection.org
<https://wellcomecollection.org>



BC 2811014910

✓
~~14~~
~~B. 21~~



110



THE INSTITUTE
OF
OPHTHALMOLOGY
LONDON

EX LIBRIS

S/3814

OPHTHALMOLOGY HC COLLINS

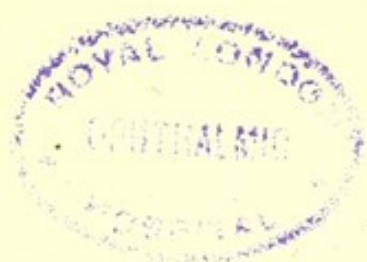H. K. LEWIS & Co. LTD.,
135, GOWER STREET,
LONDON, W.C. 1.

B2 1

25a



Apr. 1921





Digitized by the Internet Archive
in 2014

<https://archive.org/details/b21286292>



SYSTEM OF
OPHTHALMIC PRACTICE
P Y L E

PATHOLOGY AND BACTERIOLOGY
COLLINS AND MAYOU

AN INTERNATIONAL SYSTEM
OF
OPHTHALMIC PRACTICE

Edited by WALTER L. PYLE, A. M., M. D.
*Member of the American Ophthalmological Society,
Ophthalmologist to the Mt. Sinai Hospital,
Philadelphia, formerly Assistant Surgeon
to Wills Eye Hospital, etc.*

Compact Well Illustrated Octavo Volumes.

DARIER. *Ophthalmic Therapeutics.* According to the most Recent Discoveries. By DR. A. DARIER, of Paris. Translated by SYDNEY STEPHENSON, M. B., F. R. C. S., London. *Late Hon. Sect. Ophthalmological Society.* Illustrated.

KNAPP. *Medical Ophthalmology.* By ARNOLD KNAPP, M. D., Professor of Ophthalmology, College of Physicians and Surgeons, New York City. Illustrated.

BEARD. *Ophthalmic Diagnosis.* By CHARLES H. BEARD, M. D., Surgeon to the Illinois Charitable Eye and Ear Infirmary, Chicago. Illustrated.

COLLINS and MAYOU. *Pathology and Bacteriology of the Eye.* By EDWARD TREACHER COLLINS, F. R. C. S., Surgeon to the Royal London Ophthalmic Hospital; and M. S. MAYOU, F. R. C. S., Surgeon and Pathologist, Central London Ophthalmic Hospital, etc. Illustrated.

HOLMES. *Affections of the Orbit and Accessory Cavities.* By CHRISTIAN R. HOLMES, M. D., Cincinnati. Illus.

PYLE. *Examination and Refraction of the Eye and Eyestrain.* By the Editor, DR. WALTER L. PYLE. Illustrated.

OPHTHALMIC SURGERY. This volume, completing the series, will be announced later.

AN INTERNATIONAL SYSTEM
OF
OPHTHALMIC PRACTICE

EDITED BY

WALTER L. PYLE, A. M., M. D., Philadelphia
MEMBER OF THE AMERICAN OPHTHALMOLOGICAL SOCIETY

PATHOLOGY AND BACTERIOLOGY

BY

E. TREACHER COLLINS, F. R. C. S.

SURGEON TO THE ROYAL LONDON OPHTHALMIC HOSPITAL AND OPHTHALMIC SURGEON TO THE
CHARING CROSS HOSPITAL, ETC.

AND

M. STEPHEN MAYOU, F. R. C. S.

SURGEON AND PATHOLOGIST TO THE CENTRAL LONDON OPHTHALMIC HOSPITAL, ETC.

WITH THREE COLORED PLATES AND TWO HUNDRED
AND THIRTY-SEVEN FIGURES IN THE TEXT



LONDON
WILLIAM HEINEMANN
(REBMAN LTD.)

1911

COPYRIGHT, 1911, BY P. BLAKISTON'S SON & CO.

Printed in America

0062

PREFACE.

IN text-books dealing with diseases of the eye the method usually employed is to treat separately of the affections met with in each of its different anatomical divisions. As diseases are frequently not limited by anatomical landmarks such a classification necessarily results in much overlapping.

It is possible to give an inclusive description of the various diseases which occur in an organism, or in one part of an organism such as the eye, by dividing them into the several processes which occur in its life history; this is the method which we have adopted.

The life of all organisms consists of a process of evolution or development to a state of maturity, which is reached and maintained by the absorption of nutrient material together with a capacity for resisting pernicious influences in the environment. Finally there comes a process of involution or degeneration.

The first chapter in this book deals with various aberrations which occur in the eye in its process of evolution.

Tissues after having arrived at a state of maturity may reassume some of their embryonic characteristics, such a condition is spoken of as an atavism of tissue or teleplasia, and the resulting new formations as teleplasms. These teleplasms are described in the second chapter on new growths.

The nutrition of the eye is maintained by various fluids, the changes which result from derangements in their circulation forms the subject of Chapter III.

Chapters IV, V and VI are devoted to disturbances resulting from pernicious influences in the environment.

Chapter IV treats of injuries mechanical, chemical,

thermal, electrical and radial. Chapter V of the reaction of the tissues to irritation, or inflammation; and Chapter VI of various parasites which invade the eye and the specific reactions to which they give rise. There are some affections that are presumably parasitic in origin but in connection with which up to the present no specific organism has been definitely demonstrated, these also are included in this chapter.

The process of involution or degeneration of the various tissues of the organ is described in the last chapter.

An appendix at the end of the book treats of the different laboratory methods employed in the pathological examination of the tissues of the eye and of the bacteria found in association with it.

The facts and theories of which our knowledge of the pathology of the eye is made up are the outcome of the work of an immense number of different observers. Anyone who writes a treatise on the subject must necessarily be indebted for much of his material to the writers who have preceded him.

About some matters there is much difference of opinion, but we have not thought it necessary in a book of this character to discuss at length the rival merits of all the different theories which have been advanced, or even to mention some that have been found definitely untenable. We have preferred to dwell chiefly on those which accord best with our own observations, adapting or modifying them in such ways as we have found desirable.

We have not thought it advisable to insert any names of authors in the text of this book or to give anything like a complete list of references in the foot-notes. First, because we think the insertion of names in the text tends to distract the attention of the reader from the subject which is being dealt with. Second, because to have done so with anything like adequate justice would have invested the book with a bibliographical character which it is not desired that it should possess.

We have both enjoyed exceptional opportunities for the practical study of pathology of the eye and it is the outcome of the experience we have thus gained which we have endeavoured to record. We have already written numerous separate articles bearing on the subject and references have been given to these in footnotes in appropriate places to enable the reader, who so desires, to find further evidence for the views expressed than it has been possible to include here. A few references to the articles by other writers which it has been thought would prove useful for a similar reason have also been given.

E. TREACHER COLLINS.
M. S. MAYOU.

CONTENTS.

CHAPTER I.

Aberration in Development.

	PAGE
I. ABERRATIONS CONNECTED WITH THE FORMATION OF THE PRIMARY AND SECONDARY OPTIC VESICLES	3
Anophthalmia; cyclopia or synophthalmia; congenitally cystic eyeball; shot-silk or watered-silk retina; coloboma of the retina and optic nerve; microphthalmia with cysts; congenital pigmentation of the retina; congenital ectro- pion of the uveal pigment of the iris; absence of nerve fibres; opaque nerve fibres; crater-like hole of the optic disc; physiological cup of the optic disc; pseudo-neuritis; congenital day-blindness with colour-blindness; congenital night-blindness (Mooren's retinitis punctata albescens); congenital amblyopia.	
II. ABERRATIONS CONNECTED WITH THE INVAGINATING SURFACE EPIBLAST	30
Congenital aphakia; congenital nuclear cataract; defect- ive development of the posterior capsule; opaque mem- brane behind the lens; shrunken fibrous tissue cataract; posterior lenticonus; disc-shaped cataract; congenital Morganian cataract; axial fusiform cataract; backward or forward displacement of the nucleus of the lens; tri- radiate opacities; coralliform axial cataract; congenital punctate cataract.	
III. ABERRATIONS CONNECTED WITH THE INVAGINATING MESOBLAST	43
Persistence of the central hyaloid artery or its sheath; abnormalities in the arteria centralis retinae; cilio-retinal arteries; atypical development of the vitreous humour; muscae volitantes; congenital defects in the suspensory ligament of the lens; ectopia lentis; coloboma lentis; lenticonus anterior; adhesions of ciliary processes to the back of the lens.	

	PAGE
IV. ABERRATIONS CONNECTED WITH THE ENCIRCLING MESO-BLAST	62
Congenital opacities and vascularity of the cornea; congenital anterior synechiæ of the iris, pupillary membrane or lens; congenital anterior staphyloma; congenital glaucoma or buphthalmos; persistent pupillary membrane; aniridia; coloboma of the iris; polycoria; corectopia, microcoria and discoria; coloboma of the choroid, typical or atypical; congenital crescent; albinism; melanosis of the eye.	
V. ABERRATIONS CONNECTED WITH STRUCTURES IN THE LINE OF THE ORBITO-NASAL FISSURE AND THE FORMATION OF THE EYELIDS	90
Coloboma of the eyelid; absence of the lacrimal canal; congenital shallowness of the orbits and exophthalmos; orbital meningo-encephalocele; dermoid cysts along the line of the orbito-nasal fissure; abnormalities of the lacrimal canaliculi; congenital obstruction in the lacrimal duct; fistula of the lacrimal sac; cryptophtalmia; dermoid growths; fibro-fatty growths of the conjunctiva; microblepharon and lagophthalmos; congenital notches in the lower lids at the outer canthus; abnormally large plica semilunaris; ankyloblepharon; trichiasis; districhiasis.	

CHAPTER II.

Neoplasms.

I. TELEPLASMS ARISING IN PARTS DERIVED FROM CUTICULAR EPIBLAST	106
Squamous carcinoma or epithelioma; papilloma; horns; epithelial plaques; glandular cancer of the skin or rodent ulcer; carcinoma of the Meibomian glands; adenoma; carcinoma and adenoma of the lacrimal gland; moles or nevi of the conjunctiva and the malignant growths arising from them.	
II. TELEPLASMS ARISING IN NEURAL EPIBLAST	114
Glioma or neuro-epithelioma of the retina; innocent tumours of the pars ciliaris retinae (adenoma); innocent pigmented growths in uveal tract (melanoma); malignant melanotic growths of the pigment epithelium of the uveal tract (melanotic carcinoma).	

	PAGE
III. TELEPLASMS ARISING IN TISSUES DERIVED FROM MESO-BLAST	126
Intraocular sarcoma; epibulbar sarcoma; sarcoma of the orbit; neuro-fibroma and neuro-fibromatosis; heman- gioma; lymphangioma; myoma; lymphoma.	
IV. METASTATIC GROWTHS	155
Intraocular metastatic carcinoma; orbital metastatic lymphosarcoma.	
V. CYSTS	156
i. Cuticular epiblastic. Dermoid cysts; implantation cysts; cysts of the lacrimal gland; cysts of Zeiss' glands; cysts of Moll's glands; cysts of Meibomian glands; cysts of Krause's glands; cysts of Henlé's glands.	
ii. Neural epiblastic. Congenital; cysts at the back of iris; cysts on the inner surface of ciliary body; simple detachment of retina; cysts in the retina.	
iii. Mesoblastic. Extraocular lymphatic cysts; intra- ocular endothelial lined cysts.	

CHAPTER III.

**Derangements in the Circulating Fluids of the Eye and of
the Vessels in which They are Contained.**

I. DISEASES DUE TO CHANGES IN THE VESSEL WALL	172
i. The blood supply to the interior of the eye.	
ii. Vascular sclerosis: a, Obstruction to the central reti- nal artery; b, thrombosis of the central retinal vein; c, choroidal vascular sclerosis.	
iii. Diseases dependent on vascular sclerosis. Local: Retinitis pigmentosa; retinitis pigmentosa without pig- ment. General: Albuminuric retinitis; diabetic retinitis.	
iv. Intraocular hemorrhage. Retinitis proliferans; mass- ive retinitis; retinitis circinata.	
v. Dilatation of the orbital vessels. Pulsating exophthal- mos; exophthalmic goitre.	
II. DISEASES DUE TO CHANGES IN THE BLOOD	194
Hemorrhage; chlorosis; pernicious anemia; leukemia; blood coagulability; embolism; cavernous sinus throm- bosis.	

	PAGE
III. TOXIC AMBLYOPIA	197
i. Endogenous. Diabetes, uremia and puerperal states.	
ii. Exogenous.	
a. Poisons acting on the nerve elements of the retina—tobacco; alcohol; carbon disulphide.	
b. Poisons acting by causing retinal ischemia—quinine, ergot, nitrobenzol, filix mas, aniline, aryol-arsenates.	
c. Poisons affecting the kidneys and producing secondary retinal changes—lead.	
d. Poisons which affect the cerebral centres for vision—salicylic acid; santonin.	
IV. GLAUCOMA	204
i. The mechanism for the maintenance of normal intra-ocular tension.	
ii. The effects of increased intraocular tension.	
iii. The rationale of the treatment of primary glaucoma.	

CHAPTER IV.

Injuries.

I. RUPTURE OF THE EYEBALL	236
II. CONCUSSION INJURIES	239
Iridodialysis; rupture of the ligamentum pectinatum and ciliary muscle; dislocation of the lens; retroflexion of the iris; rupture of the sphincter pupillæ; mydriasis and cycloplegia; concussion cataract; rupture of the choroid; rupture of the retina and commotio retinæ; hole in the retina at the macula; intraocular hemorrhage; gunshot injuries of the orbit; birth injuries.	
III. WOUNDS OF THE EYE AND OPTIC NERVE	255
Wounds of the cornea; simple abrasion of the epithelium; uninfected wound of the anterior part of the globe; simple perforating wounds; complicated wounds; adhesions of iris; cystoid cicatrix; adhesion of lens capsule, entanglement of the vitreous; operation and perforating wounds which pass into the periphery of the anterior chamber; wounds of the conjunctiva; perforating wounds of the globe behind the limbus; wounds of the iris; wounds of the lens; wounds of the optic nerve.	

	PAGE
IV. FOREIGN BODIES IN THE EYE	274
Foreign bodies in the cornea, conjunctiva, or sclerotic; ophthalmia nodosa; foreign bodies in the interior of the eye; siderosis bulbi.	
V. BURNS AND INJURIES WITH CAUSTICS	280
VI. INJURIES FROM EXPOSURE TO BRIGHT LIGHT, ELECTRIC SHOCKS, LIGHTNING AND THE X-RAYS	281
Eclipse-blindness; night-blindness; erythropsia; glass- workers' cataract; injuries from lightning; injuries from the X-rays.	

CHAPTER V.

Inflammation.

I. THE CHANGES COMMON TO ALL INFLAMMATORY PROCESSES.	285
Inflammation; definition; cause; the changes in the tissue; the part played by the blood-serum; the part played by the cells.	
II. THE MODIFICATIONS OF THE GENERAL PROCESSES OF INFLAMMATION IN THE VARIOUS STRUCTURES OF THE EYE	304
Conjunctiva: new gland formation; cysts; xerosis; phlec- tenulæ; follicular formation.	
Cornea: ulceration; leukoma; keratocele; anterior staphy- loma; edema; vesicular keratitis; herpes cornea; bullous keratitis; superficial punctate keratitis; dendritic keratitis; filamentary keratitis; annular infiltration; ring abscess; kerectasia.	
Sclerotic: episcleritis; scleritis; sclerosing keratitis.	
Uveal tract. Choroiditis; suppurative; non-suppurative; supra-choroiditis. Irido-cyclitis; serous; plastic; suppu- rative; sequelæ.	
Retina: edema; retinitis—non-suppurative and suppu- rative.	
Optic nerve: retrobulbar; interstitial; perineuritis; papil- litis.	
Lacrimal gland: dacroadenitis—acute, chronic.	
Lacrimal canals: dacrocystitis.	
Eyelids: blepharitis; trichiasis; madarosis; tylosis.	
Tenon's capsule: inflammation—acute; chronic.	
Orbit: cellulitis.	

	PAGE
III. THE METHOD OF INFECTION OF THE OCULAR TISSUES. . .	346
Infection—definition; Koch's postulates; dissemination of infection in eye diseases; stages of the infective process; ectogenous and endogenous infection. Pyemia, acute and chronic. Wound infection.	

CHAPTER VI.

Parasitic Diseases Affecting the Eye.

I. BACTERIA	355
i. Cocci. Staphylococcus; streptococcus.	
Diplococci (Gram positive).	
Pneumococcus.	
Diplococci (Gram negative).	
Gonococcus.	
Diplococcus intracellular meningitidis.	
ii. Bacilli.	
a. Influenza group.	
B. of Koch-Weeks.	
B. of Müller.	
B. of influenza.	
b. Diphtheroid group.	
B. of Klebs-Loeffler.	
B. Xerosis.	
c. Diplobacillary group.	
B. of Morax-Axenfeld.	
B. of Petit.	
d. Capsulate bacilli group.	
B. of Friedlander (pneumobacillus).	
B. nucocus capsulatus.	
B. of ozena.	
e. Coli group.	
B. coli communis.	
B. of typhoid.	
f. The acid fast bacilli.	
B. of tubercle.	
B. of leprosy.	
g. Unclassified bacilli.	
B. Mallei.	
B. of Ducrey (soft sore).	
B. of Zur Nedden.	
B. Aerogenes.	
B. subtilis.	
B. pyocyanus.	

	PAGE
II. FUNGI	409
Streptothricæ; aspergillus; penicillium; botryomycosis; hefæ; favus; ringworm.	
III. ANIMAL PARASITES	413
i. Unicellular organisms.	
Protozoon. Spirocheta pallida.	
Malarial parasites. Trypanosomiasis.	
ii. Multicellular organism.	
Entozoon. Cysticercus; hydatid; filaria.	
Insectivora.	
IV. THE DISEASES WHICH ARE PROBABLY DUE TO MICRO- ORGANISMS	426
Trachoma; vernal catarrh; Sympathetic ophthalmitis.	

CHAPTER VII.

Degenerations.

I. CUTICULAR EPIBLASTIC	441
Atrophy of epithelium; edema, vesiculation, des- quamation; keratinisation and hyperkeratosis; mucoid, fatty and hyaline changes.	
II. LENTICULAR EPIBLASTIC	447
Capsular cataract; anterior polar cataract; subcapsular cataract; diabetic cataract; naphthalin cataract; second- ary cataract; senile degeneration of capsular epithelium; equatorial cataract; senile cataract; nuclear and perinu- clear cataract; presbyopia; lenticular myopic degenera- tion or sclerosis of the nucleus of the lens; black cataract; zonular or perinuclear cataract; tetany cataract.	
III. NEURAL EPIBLASTIC	470
<i>a.</i> Degeneration of the ganglion cells of the retina; amaurotic family idiocy; <i>b.</i> Degeneration of the nerve- fibre layer of the retina and of the optic nerve; ascend- ing atrophy of the optic nerve; trunk atrophy of the optic nerve; hereditary optic atrophy or neuritis; de- scending atrophy of the optic nerve; <i>c.</i> Degeneration of the outer layers of the retina and its neuroglia; <i>d.</i> Degen- eration of the retinal pigment epithelium; <i>e.</i> Degeneration of the pars ciliaris retinae and pars iridis retinae.	

	PAGE
IV. MESOBLASTIC	483
<i>a.</i> Hyaline degeneration; nodular opacity of the cornea; reticular opacity of the cornea; pingueculæ; pterygium; hyaline nodules in the optic disc; <i>b.</i> Amyloid degeneration of the conjunctiva; corpora amylacea in the optic nerve; <i>c.</i> Fatty degeneration; arcus senilis; cholesterine; synchysis scintillans; <i>d.</i> Calcareous degeneration and bone formation; transverse calcareous films of the cornea; ossification of the choroid; <i>e.</i> Staphyloma.	

APPENDIX.

Practical Methods.

Methods of obtaining material for examination	511
Post-mortem methods. Injection of the eye	514
Methods of fixing and hardening	516
Methodical examination of the eye	519
Method of mounting macroscopic specimens	523
Method of preparing microscopic specimens	525
Cutting; stains; tables	527
Method of examination of fluids	540
Collecting blood; film making	542
Preparation of vaccines	542
Wassermann reaction	544
Agglutination test	549
INDEX	551

LIST OF ILLUSTRATIONS.

PLATE		FACE PAGE
I.	The cells found in the conjunctiva	299
II.	Follicular formation in the conjunctiva	310
III.	Trachoma	430
FIG.		PAGE
1.	Contents of the orbit of a chick the subject of congenital anophthalmia	6
2.	Human cyclops with extreme degree of microphthalmia	7
3.	Human cyclops, showing absence of proboscis and notching of the upper lids	8
4.	Human cyclops (twin)	8
5.	Human cyclops, showing two secondary optic vesicles and two lenses in one globe	9
6.	Human cyclops, showing optic disc with two retinal and two central hyaloid arteries	9
7.	Human cyclops showing base of skull and cranial nerves	10
8.	Human cyclops showing absence of convolutions and fissures in the brain	10
9.	Diagram showing normal involution of secondary optic vesicle	11
10.	Diagram showing normal upgrowth of mesoblastic tissue into the cavity of the secondary optic vesicle, etc.	12
11.	Diagram of a coloboma of retina and choroid	14
12.	Microscopical appearances of posterior half of a microphthalmic eye	15
13.	Diagram of a congenitally microphthalmic eye with a cyst attached to it	16
14.	Diagram of a congenitally microphthalmic eye with a cyst attached to it	16
15.	Diagram of a congenitally microphthalmic eye with a cyst attached to it	17
16.	Diagram of a congenitally microphthalmic eye with a cyst attached to it	17
17.	Shows portion of eye represented in Fig. 16 highly magnified	18
18.	The iris in a case of congenital partial aniridia	21
19.	Section of a horse's iris showing the corpus nigrum	21

FIG.	PAGE
20. Lateral view of head of anencephalic fetus	22
21. View of skull from above of the fetus of Fig. 20	23
22. Transverse section of optic nerve of anencephalic fetus.	23
23. Horizontal section through posterior part of the eye anencephalic fetus.	24
24. Section through head of the optic nerve in a case of opaque nerve fibres	25
25. Section through a lens with a congenital gap in the pos- terior capsule	34
26. Section through a lens from a microphthalmic eye with a congenital gap in the posterior capsule	35
27. Section through the front part of a microphthalmic eye in which there was posterior lenticonus.	36
28. Antero-posterior section through a congenitally disc- shaped cataract	38
29. Diagrammatic section through a microphthalmic eye in which the whole fetal vascular system of the lens had persisted	39
30. Section through a lens with congenital punctate cataract	42
31. Transverse section of the central artery of the vitreous in a human fetal eye	44
32. Transverse section of the same artery shown in Fig. 31 further forward in the vitreous	44
33. Diagram of section of eye with persistent and patent hyaloid artery	47
34. The same condition as Fig. 33 with the ciliary process lying behind the lens	47
35. An eyeball with sight destroyed by ulceration of the cornea showing persistent remains of a hyaloid artery	48
36. Semi-diagrammatic section of microphthalmic eye with coloboma of iris and choroid	51
37. Portion of retina and atypically developed vitreous from a microphthalmic eye	53
38. Branching fibres with granules on them from the vitreous humour of a normal human fetal eye	54
39, 40. Show suspensory ligament of the lens in sections of a normal human eye.	55
41. Congenital coloboma and displacement of the lens	57
42. Section through front half of an eye lost from glaucoma, with congenital coloboma of iris and lens.	58
43. Section of anterior half of eye of an infant with congenital anterior staphyloma and anterior lenticonus	60

FIG.	PAGE
44. Section through the ciliary body in an eye which had atypical development of the vitreous and suspensory ligament of the lens	61
45. Section through another part of ciliary body from same eye as Fig. 44.	62
46. Congenital anterior synechia of a persistent pupillary membrane and of the iris.	66
47. Lateral half of a cat's eye with a congenital anterior synechia of pupillary membrane.	67
48. Microscopical appearances of the pupillary membrane in the cat's eye depicted in Fig. 47.	67
49. Pigmented pupillary membrane adherent to the substantia propria of the cornea from the cat's eye depicted in Fig. 47.	68
50. Microphthalmic eye of a chick with lens adherent to the cornea	69
51. Section through an eye the subject of congenital glaucoma or buphthalmia	71
52. The angle of the anterior chamber in an eye affected with congenital glaucoma	72
53. Congenital microphthalmia and persistent pupillary membrane	74
54. Anterior half of right eye of a patient with apparent aniridia	75
55. Section of eye showing a rudimentary iris in which clinically no iris was visible.	76
56. A congenital abnormality at the angle of anterior chamber in a case of partial "aniridia".	77
57. Section of the eye of a woman who had congenital aniridia and, after a perforating ulcer of the cornea, developed glaucoma	78
58. Section showing mode of termination of ciliary body at the seat of a congenital coloboma of the iris.	78
59. Microphthalmic eye with coloboma of the iris.	79
60. Congenital coloboma of iris with a bridge.	81
61. Section through head of optic nerve in case in which there was a congenital crescent at the lower border of the optic disc	87
62. Outer wall of the nose in a new-born child	
63. Horizontal section through lacrimal region of a new-born child	91
64. Congenital coloboma of upper eyelid	92
65. Small congenital indentation in border of upper eyelid	94

FIG.	PAGE
66. Symmetrical congenital notches in lower lids	102
67. Section of commencing epithelioma of ocular conjunctiva	108
68. Section through a hard papilloma from the margin of an eyelid	110
69. Glioma of the retina	116
70. Section through an eye containing glioma of retina	118
71. Section through a glioma of the retina showing rosette-like formation of cells	119
72. Gliomatous growths in two eyes, one much shrunken	121
73. Innocent pigmented growth of the iris	123
74. Congenital pigmented tumour of ciliary body	124
75. Melanotic carcinoma of the ciliary body	125
76. Bleached section of the melanotic carcinoma depicted in Fig. 75	125
77. Melanotic sarcoma of ciliary body	128
78. Lateral half of an eyeball containing a melanotic sarcoma of the ciliary body	129
79. Shows an eye with sarcoma growing from the choroid	130
80. Melanotic sarcoma growing from the choroid at the margin of optic disc	131
81. Lateral half of an eyeball containing an angiosarcoma of the choroid	134
82. Section through an angiosarcoma of the choroid	135
83. Epibulbar, melanotic sarcoma of the conjunctiva	138
84. Sarcoma which started at the limbus and involved the cornea	139
85. Microscopical appearances of a tumour of the lacrimal gland	142
86. Microscopical appearances of the skin of the eyelid in a case of neuro-fibromatosis	144
87. Microscopical appearances of a buphthalmic eye in a case of neuro-fibromatosis	145
88. Section through the choroid of an eye affected by neuro-fibromatosis	146
89. Shows the hypertrophied nerve-end organs in the choroid in Fig. 88 under a higher power	146
90. Intradural tumour of optic nerve	147
91. Longitudinal section through tumour of optic nerve	148
92. Transverse section through intradural tumour of optic nerve	149
93. Microscopical appearances of a vascular growth of the retina	152

FIG.	PAGE
94. Epithelial lined cyst in the anterior chamber	157
95. Lining epithelium of cyst shown in Fig. 94	157
96. Cyst in the iris following on the implantation of an eyelash	158
97. Part of the wall of the cyst shown in Fig. 96.	159
98. Epithelial implantation cysts in the cornea	159
99. Epithelial implantation cyst in the cornea	160
100. Laminated epithelium lining cyst in the cornea depicted in Fig. 99	160
101. Large epithelial lined cyst in a shrunken globe.	161
102. Plastic iritis after a perforating wound producing cyst between the two pigment-epithelial layers on the back of the iris	164
103. Cyst formed by the separation of the two layers of the pars ciliaris retinae.	165
104. Section through the iris with a cyst on its posterior surface	166
105. Pigmented cyst of the iris	166
106. Detached retina with cysts	170
107. Section through the retina with a sclerosed artery cut transversely	176
108. Section through the retina with a thrombosed retinal vein cut transversely.	178
109. Section through the coats of the eye with sclerosed cho- roidal and retinal vessels cut transversely.	180
110. Section through the coats of the eye in case of albumin- uric retinitis	183
111. Section through the macula lutea in case of albuminuric retinitis	184
112. Mass of retained and degenerate blood clot at the angle of the anterior chamber	186
113. Section through the coats of the eye in a case of sub- hyaloid hemorrhage	189
114. Section through the coats of the eye in a case of albu- minuric retinitis	190
115. "Massive retinitis"	191
116. Bleached section of the ciliary body of a normal eye showing processes of cells dipping down from the pigment-epithelium	206
117. Processes of cells depicted in Fig. 116 more highly magni- fied	206
118. Bleached section of ciliary body with some of the down- growths from the pigment epithelial layer cut trans- versely	207

FIG.	PAGE
119. The normal angle of the anterior chamber	208
120. Angle of anterior chamber in recent glaucoma.	210
121. A condition of iris bombé resulting in secondary glaucoma	211
122. Lateral half of an eye with wound of cornea through which lens and iris escaped. It subsequently developed glaucoma	212
123. Section through angle of anterior chamber of the eye depicted in Fig. 122	212
124. Lateral half of an eye from which a cataract was extracted and which afterwards developed glaucoma.	213
125. Glaucoma secondary to dislocation of the lens.	214
126. Section through the cornea in case of congenital glaucoma showing rupture in Descemet's membrane.	220
127. Ectropion of the uveal pigment at pupillary margin of the iris	222
128. Angle of anterior chamber in case of glaucoma of long standing	222
129. Section through the optic nerve in case of glaucoma	228
130. Section through angle of anterior chamber of an eye upon which iridectomy had been performed	229
131. Section of an eye with a cystoid cicatrix	231
132. Section of an eye in which iridectomy failed to relieve tension in glaucoma	232
133. Iridectomy performed for absolute glaucoma; lens adherent to iridectomy cicatrix	233
134. Lateral half of an eye ruptured by blow from fist	236
135. Rupture of globe showing a prolapse of the iris	237
136. Rupture in the sclerotic and subconjunctival dislocation of the lens	238
137. Eye injured by blow from stick of a catapult, producing iridodialysis and rupture of the ligamentum pectinatum	240
138. Partial rupture of the ligamentum pectinatum.	241
139. Complete rupture of the ligamentum pectinatum	242
140. Concussion injury to eye and rupture of ligamentum pectinatum	243
141. Lateral dislocation of the lens.	244
142. Lens dislocated into anterior chamber	245
143. Rupture of the posterior capsule of lens	247
144. Rupture of the choroid (late stage)	248
145. Blood staining of the cornea	251

FIG.	PAGE
146. Microscopical appearances of stained area in cornea depicted in Fig. 145	252
147. New formation of hyaline membrane on posterior surface of a scar in the cornea.	258
148. Anterior synechia of the iris.	259
149. Prolapse of a knuckle of iris into a wound at the sclero-corneal margin	260
150. Cystoid cicatrix in an eye lost from glaucoma	261
151. Entanglement of lens capsule in wound, after extraction of cataract	262
152. Adhesion of lens capsule to posterior surface of an extraction scar	263
153. Wound of the cornea and suspensory ligament of lens with prolapse of vitreous humour	264
154. Cicatrix left after incision through the cornea with a keratome for iridectomy for glaucoma	265
155. Gaping wound at the sclero-corneal margin with prolapse of ciliary body.	265
156. Perforating wound of cornea and lens	270
157. Two layers of the lens capsule after extraction with laminated tissue lying between them.	272
158. Two layers of lens capsule after extraction of cataract with bladder-like cells between them.	272
159. Section through a phlyctenule of the conjunctiva	308
160. Same as Fig. 159 in a later stage.	309
161. Extensive suppurating ulcer of the cornea	311
162. Section through cornea showing inflammatory cells infiltrating the anterior layers of the substantia propria	312
163. Anterior synechia of the iris following perforating corneal ulcer	314
164. Perforating ulcer of the cornea and incarceration of the iris	315
165. Cornea destroyed by ulceration and replaced by mass of fibrous tissue	316
166. Lens capsule adherent to posterior surface of a staphylomatous cornea.	317
167. Vesicles in the epithelium on the anterior surface of a staphylomatous cornea.	318
168. Organising edematous exudate on the surface of the cornea in case of hereditary syphilitic kerato-iritis.	319
169. Anterior part of the cornea in an eye with "filamentary keratitis"	320

FIG.	PAGE
170. Mooren's ulcer involving whole cornea	322
171. New formation of connective tissue between the sclerotic and choroid in a shrunken eyeball	326
172. Ciliary body and angle of anterior chamber in a case of cyclitis	328
173. Posterior surface of cornea in an eye with keratitis punctata	329
174. Plastic iritis as a result of a perforating wound of the cornea and lens	331
175. The iris drawn back into the angle of anterior chamber the result of iritis following a perforating wound.	332
176. Section of an eye which had had plastic cyclitis	333
177. Tubular processes of epithelial cells in cyclitis.	334
178. "Pseudo-glioma"	335
179. Optic neuritis secondary to a tuberculous mass at margin of optic nerve	341
180. Microorganisms found in smear preparations of the con- junctival secretion in different forms of ophthalmia	362
181. A smear preparation from discharge from the conjunc- tiva containing Klebs-Loeffler bacilli.	378
182. Tubercular nodules involving root of iris.	395
183. Iris with tubercular nodules at pupillary margin.	396
184. Tubercle of the iris	396
185. Iris thickened with tubercular nodules.	397
186. Tuberculous mass in choroid causing intense neuritis	400
187. Tuberculous mass in choroid	401
188. Conglomerate mass of tubercle starting in choroid	402
189. Streptothrix fosterii removed from the canaliculus.	409
190. Aspergillus growing in the cornea	411
191. Penicillium glaucum	412
192. Gumma in the root of the iris.	416
193. Cornea affected with interstitial keratitis.	418
194. Cornea which had become vascularised as the result of interstitial keratitis	419
195. Gumma of the ciliary body	420
196. Papillary formation in early trachoma	427
197. Cornea affected with trachomatous pannus	434
198. Discharge from a case of vernal catarrh.	435
199. Papilla from a case of vernal catarrh.	436
200. Section through choroid in case of sympathetic oph- thalmitis.	438
201. Conjunctiva in a case of xerosis.	444
202. Shrunken dry conjunctiva and keratinisation.	445

FIG.	PAGE
203. Anterior polar cataract of less than six weeks' formation.	449
204. Anterior polar cataract of seven months' formation.	450
205. Anterior polar cataract of eleven years' formation.	451
206. Anterior polar cataract of twenty-one years' formation.	452
207. Anterior polar cataract of eleven years' formation.	453
208. Melanotic sarcoma of ciliary body giving rise to capsular cataract	454
209. Subcapsular cataract	456
210. Shrunk eyeball with Morgagnian cataract.	462
211. Section through a cataractous lens from an eye with a melanotic sarcoma of the choroid	465
212. Zonular cataract	460
213. Section through head of optic nerve in case of simple optic atrophy	474
214. Hyaline formations on inner surface of the elastic lamina of choroid	482
215. Hyaline formations in head of optic nerve	483
216. Hyaline excrescences on inner surface of Descemet's membrane	485
217. Nodular opacity of the cornea	486
218. Reticular opacity of the cornea	487
219. Section through a transverse calcareous film of the cornea	496
220. Section through band of bone formed in a mass of organised inflammatory exudate from the choroid.	498
221. Intercalary staphyloma	500
222. Ciliary staphyloma	501
223. Equatorial staphyloma	501
224. Antero-posterior section through a highly myopic eye .	503
225. Section through head of optic nerve in an eye in which there was a myopic crescent	505
226. Method of making a smear preparation with a platinum loop	512
227. Glass tube for centrifugalisation.	513
228. Museum jar for mounting macroscopic eye specimens .	524
229. Opal glass plate to fit in above jar to hold eye in position	524
230. Globe-Wernicke book case for macroscopic specimens. .	525
231. Leitz "Base sledge" microtome	527
232. Leitz "Base sledge" microtome for cutting paraffin sections	528
233. Method of drawing up fluid into pipettes.	540
234. Wright's blood capsule.	541
235. Ehrlich eye-piece dividing the field into squares.	542
236. Sealed glass capsules for vaccine, serum, etc	543
237. Small glass capsules for holding blood organisms, etc.	544

CHAPTER I.

ABERRATIONS IN DEVELOPMENT.

Aberrations occurring in the development of the eye are necessarily most of them congenital defects, but not all, *e.g.*, the medullary substance around the fibres of the optic nerve is not formed until after birth and the abnormality due to formation of medullary substance around the nerve fibres in the retina, though an aberration in development, is not a congenital defect.

On the other hand it is necessary to remember that all congenital defects are not aberrations in development; some of them may be changes due to intrauterine inflammation and others due to injuries at birth. These will be described under inflammations and injuries, respectively.

At present we are unable to say what causes the usual orderly cycle of transformations which ensue after the fertilization of the ovum, and consequently frequently unable to account for disorderly occurrences in that cycle. It is perhaps more surprising that such a complicated structure as the eye should so often develop in a uniform way than that occasional irregularities should occur.

All we can do in many abnormal conditions is to describe them as arrests of development probably attributable to some nutritional, chemical, or mechanical influence brought to bear on the developing embryo. The eye commences to develop very early and soon becomes a prominent feature; it is, therefore, exposed to disturbing influences occurring over a considerable period of embryonic life. The earlier the dystrophic influence arises the greater the deformity likely to be produced and the more difficulty there is in ascertaining its nature

Variations in the distribution and arrangement of blood-vessels are so frequent that they may be regarded as natural individual peculiarities. Variations in the arrangements of comparatively small vessels will, in the structures of the eye, sometimes lead to gross changes.

The pressure caused by bands in the amnion play a conspicuous part in the production of malformations in connection with the fissures about the face, doubtless some of the aberrations in connection with the development of the eyelids and front of the eye may be accounted for in a similar way.

Heredity in the causation of some conditions exerts a potent influence, congenital aniridia, corectopia and some forms of congenital cataract have been met with in several members of different generations of the same family. Microphthalmia and albinism, though not directly inherited, often occur in several members of the same childship.

The evolution of the fetus is a modified recapitulation of the evolution of the race or in the words of Haeckel "ontogeny is a recapitulation of phylogeny," hence in arrests of development we find aberrations which suggest conditions that are normal in animals. Some abnormalities also suggest the reappearance of structures which have become rudimentary or suppressed altogether in the evolutionary process, such are true examples of atavism.

The development of the eye is here divided for purposes of description into several separate stages: 1. The formation of the primary and secondary optic vesicles. 2. The ingrowth of invaginating surface epiblast. 3. The upgrowth of invaginating mesoblast. 4. The elaboration of surrounding mesoblast. 5. The formation of the eyelids and structures in the line of the orbito-nasal fissure. After a brief description of each of these stages the various conditions which arise from aberrations in connection with them will receive detailed consideration.

I. Aberrations Connected with the Formation of the Primary and Secondary Optic Vesicles.

The first stage in the development of the eye consists in the outgrowth of a hollow process from the anterior cerebral vesicle, which is termed the primary optic vesicle. It expands anteriorly but remains connected with the brain by a stalk in the track of which the optic nerve is afterward developed.

The second stage is the invagination of this primary optic vesicle anteriorly and inferiorly resulting in the formation of a cup composed of two layers, the secondary optic vesicle. From the outer of these two layers is formed the retinal pigment epithelium and from the inner the retina proper.

Into the anterior part of the cup of the secondary optic vesicle passes a downgrowth of surface epiblast to form the lens vesicle, and from below an upgrowth of mesoblast from which is developed the vitreous humour. The space through which the upgrowing mesoblast passes to enter the cup of the secondary optic vesicle is termed the fetal ocular cleft; it ultimately becomes closed by the union of the layers of the secondary optic vesicle on its two sides.

The stalk which is left connecting the brain with the secondary optic vesicle does not take any part in the formation of nerve fibres. The tissue composing it probably becomes part of the supporting framework of the optic nerve. Its distal part becomes invaginated below like the primary optic vesicle and in the invaginating mesoblast is developed the central artery of the retina.

The axis-cylinders composing the optic nerve and the nerve-fibre layer of the retina are usually considered to be in part formed from outgrowths of the ganglion cells of the retina which extend up into the brain, and in part from outgrowths of the ganglion cells in the brain which extend down to the retina. The axis-cylinders in the optic nerve are at first devoid of medullary sheaths. The formation

of these sheaths begins at the cerebral end and extends downward. They do not reach the posterior surface of the lamina cribrosa, where they end, until after birth.

The aberrations which may arise in connection with the formation of the primary and secondary optic vesicles are as follows:

Failure of the primary optic vesicles to bud out—**anophthalmia**.

Undue approximation or fusion of the primary optic vesicles on the two sides—**cyclopia or synophthalmia**.

Failure in the invagination of the primary optic vesicle—**congenitally cystic eyeball**.

Imperfect coaptation of the two layers of the secondary optic vesicle—**shot-silk or watered-silk retina**.

Failure in the closure of the cleft in the secondary optic vesicle—**coloboma of retina and optic nerve; microphthalmia with cyst**.

Union of the two layers of the secondary optic vesicle—**congenital pigmentation of retina**.

Unusual extension forward of the secondary optic vesicles—**ectropion of the uveal pigment of iris**.

Defective downgrowth or upgrowth of axis-cylinders from ganglion cells—**absence of nerve fibres in optic nerve and retina**.

Abnormal medullation around axis-cylinders in retina—**opaque nerve fibres**.

Atypical development of neural portion of secondary optic vesicle—**crater-like hole in optic disc**.

Excessive space for passage of nerve fibres into the eye—**physiological cupping of optic disc**.

Restricted space for passage of nerve fibres into the eye—**pseudo-neuritis**.

Defective formation of light-percipient elements in retina—**congenital day-blindness with colour-blindness; congenital night-blindness (Mooren's retinitis punctata albescens)**.

Failure in differentiation of macula—**congenital amblyopia**.

Defective deposition of pigment in the outer layer of the secondary optic vesicle—**Albinism** (see page 88).

Anophthalmia.—One or both eyes may be congenitally absent. The abnormality is met with in healthy well formed children, but not uncommonly other malformations, such as hare-lip and supernumerary digits, occur in association with it.

The eyelids though small are usually well formed; they may be adherent at their margins. The orbit, smaller than normal, is lined throughout by conjunctiva. Digital examination of it frequently reveals a small hard, mobile, nodule near the extreme apex. The lacrimal puncta may be absent in one or both lids but the lacrimal gland is usually present.

In these cases the optic nerve has never been found to enter the orbit; it either ends as a cone or fibrous filament at the optic foramen, or it is entirely absent together with the chiasma. The olfactory lobes and cerebral hemispheres have also been found deficient, which is of interest in that they, like the primary optic vesicles, are outgrowths of the anterior cerebral vesicle. It is a failure of the primary optic vesicles to bud off from the anterior cerebral vesicle which seems to be the usual cause of anophthalmia.

Microscopical examination of the nodules met with in the orbits has shown¹ them to be composed of subsidiary parts of the eye, of mesoblastic origin. A capsule of fibrous tissue like the sclerotic containing pigmented choroidal tissue but not any retina (Fig. 1), *i.e.*, there is complete absence of the essential nervous elements constituting an eye. It is to these cases that the term anophthalmia should, strictly speaking, be limited. Unfortunately the presence or absence of the essential nervous elements in a nodule in the orbit can only with certainty be determined by microscopical examination. So that clinically it becomes very difficult to distin-

¹ Treacher Collins and J. H. Parsons. Trans. Ophth. Soc. of the U. K. XXIII, 1903, 244.

guish between true anophthalmia and very high degrees of microphthalmia.

Cyclopia or Synophthalmia.—Cyclopia or synophthalmia is a condition in which there is a blending of eyes or orbits of the two sides; it is always associated with other extensive malformations, especially of the face and brain, so that the subjects of it do not long survive birth.

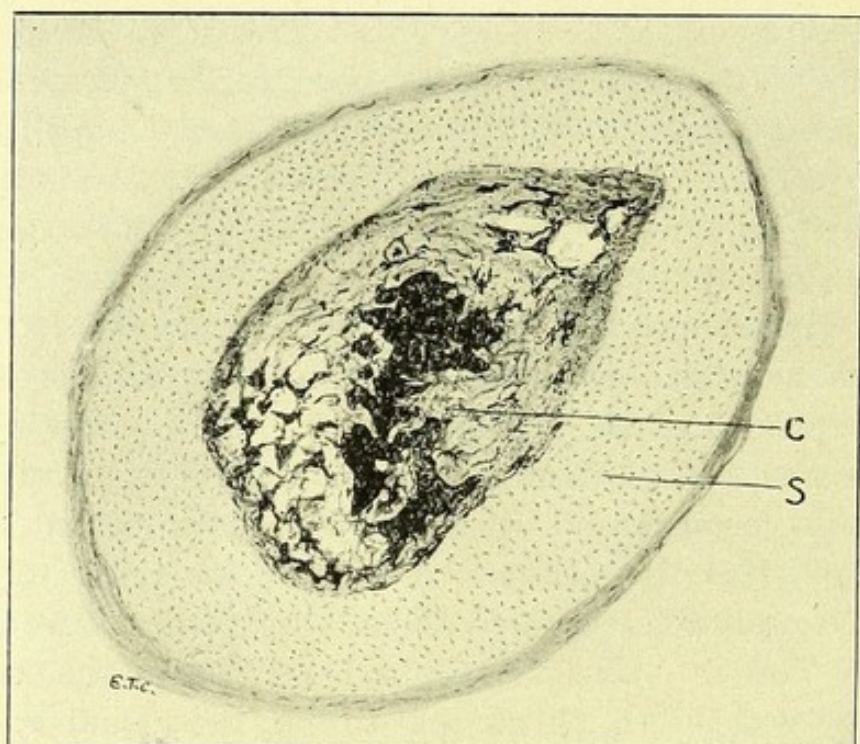


FIG. 1.—The mesoblastic constituents of an eyeball from the orbit of a chick the subject of congenital anophthalmia. *S* points to a ring of hyaline cartilage representing that normally found in the sclerotic; *C* points to tissue like that of the uveal tract contained within this ring. There was no optic nerve or any tissue representing that formed from the secondary optic vesicle present.

Many gradations in the degree to which the two orbits are approximated or the two eyes blended are met with.¹ In the least marked cases there are two orbits, each with a normally formed eyeball, which however are only separated from one another by a single very small nasal aperture. In the most marked cases there is a single orbit with a single eyeball having one optic nerve and not any duplication of its parts.

¹ M. S. Mayou. Trans. Ophth. Soc. of the U. K., XXVI, 1906, 267.

The fusion of the two orbits results in the fronto-nasal process, from which the nose should have developed being pushed forward and formed into a proboscis which hangs down from above the orbit (Fig. 2).

When one central orbit is formed it is surrounded by four eyelids, the palpebral aperture between which is roughly diamond-shaped (Figs. 3, 4). The upper canaliculi become suppressed; the lower are present but terminate in a blind canal.

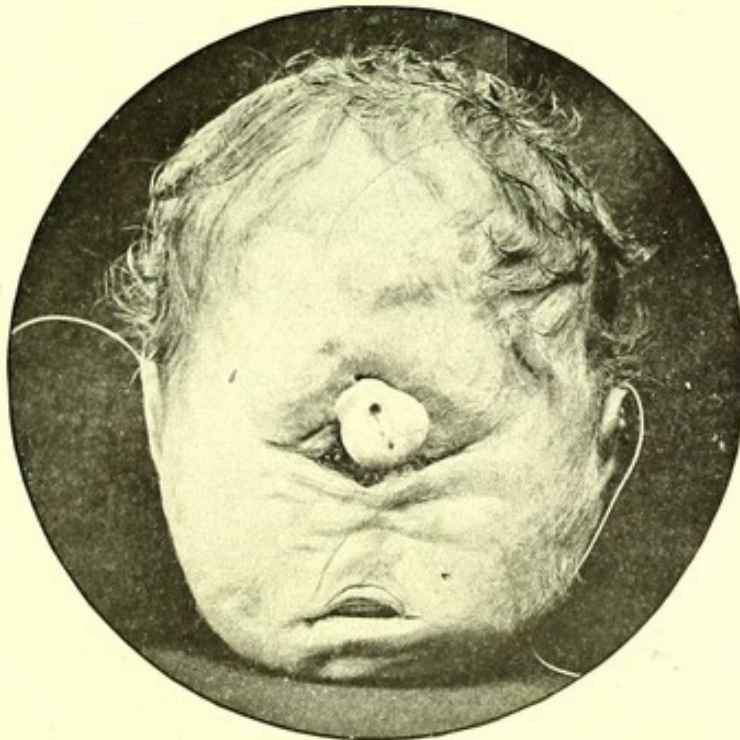


FIG. 2.—Human cyclops with extreme degree of microphthalmia. Note proboscis with opening at the end (the upper hole is due to a pin mark).

The degree of fusion of the two eyes is very various; often besides the changes resulting from the mere fusion there are other maldevelopments. The fused eyes may be microphthalmic or abnormally large.

When one eye is present without any duplication of its structures, the cornea is generally of an oval shape with the long axis horizontal.

All the structures in the eye may be single and the lenses alone show signs of fusion. The cornea and sclerotic may be single, but the iris, choroid, retina, lens and vitreous

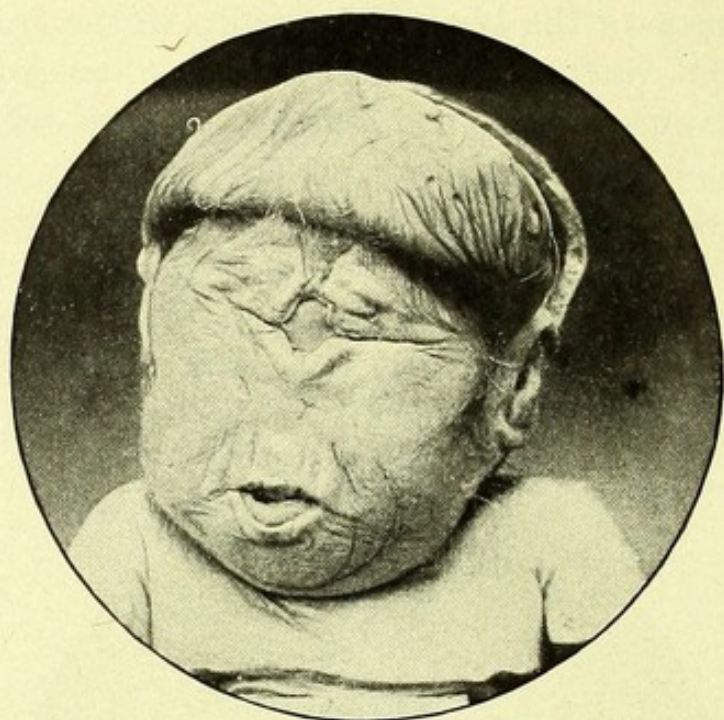

FIG. 3.—A human cyclops, showing the absence of a proboscis and notching of the upper lids.

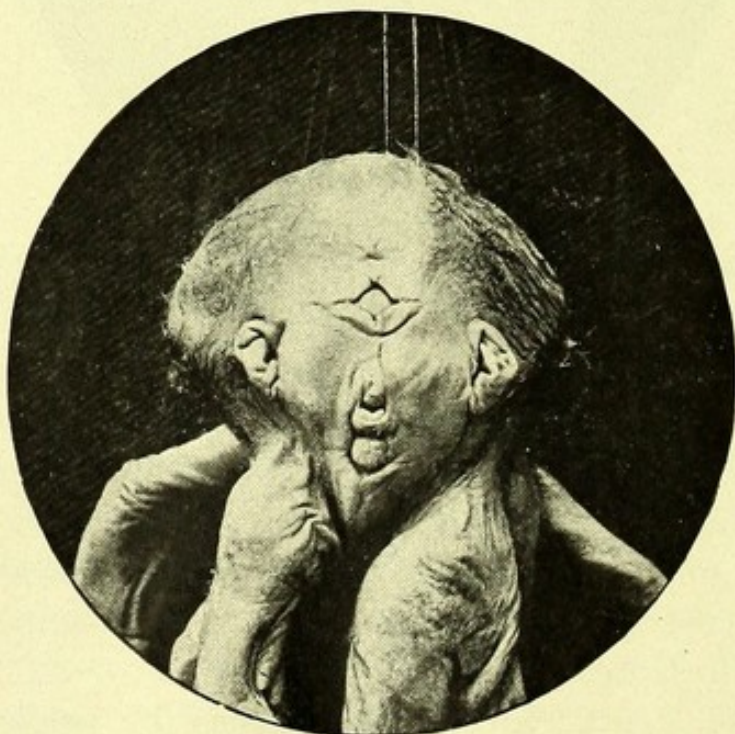


FIG. 4.—Human cyclops (twin). There is an exactly similar face on the other side of the specimen. The eye, although practically fully formed except for a coloboma of the optic nerve, is derived half from each fetus.

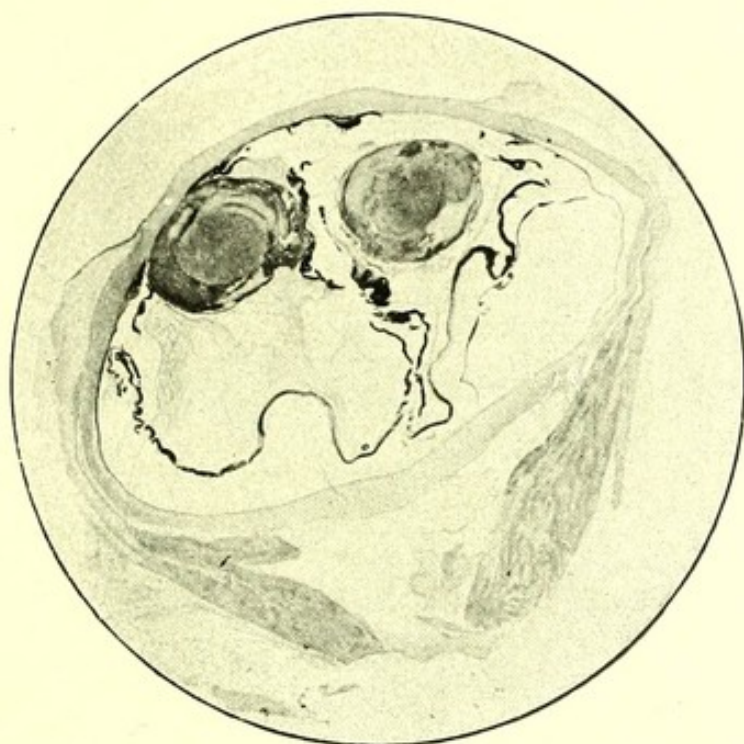

FIG. 5.—A human cyclops, showing two secondary optic vesicles and two lenses in one globe.

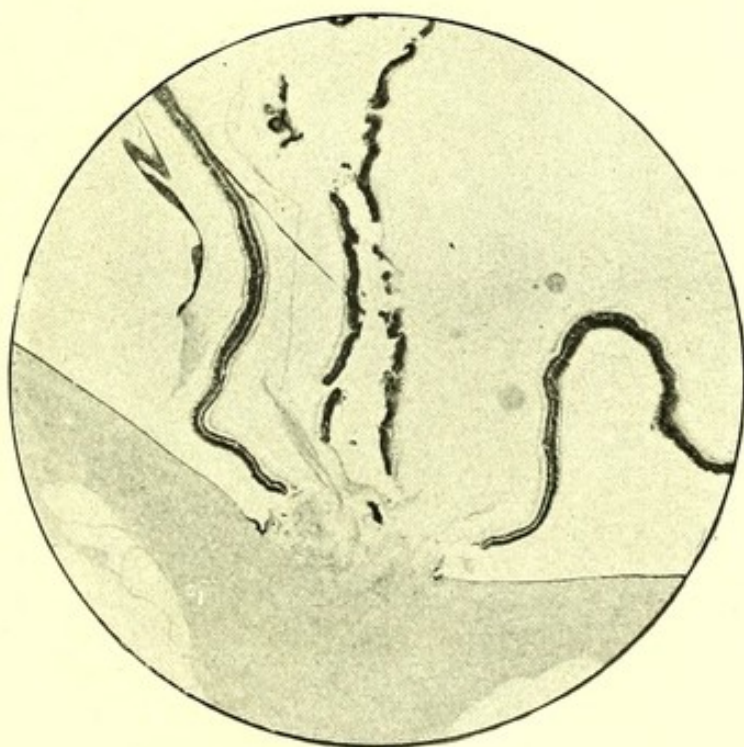


FIG. 6.—A human cyclops, showing the optic disc with two retinal and two central hyaloid arteries.

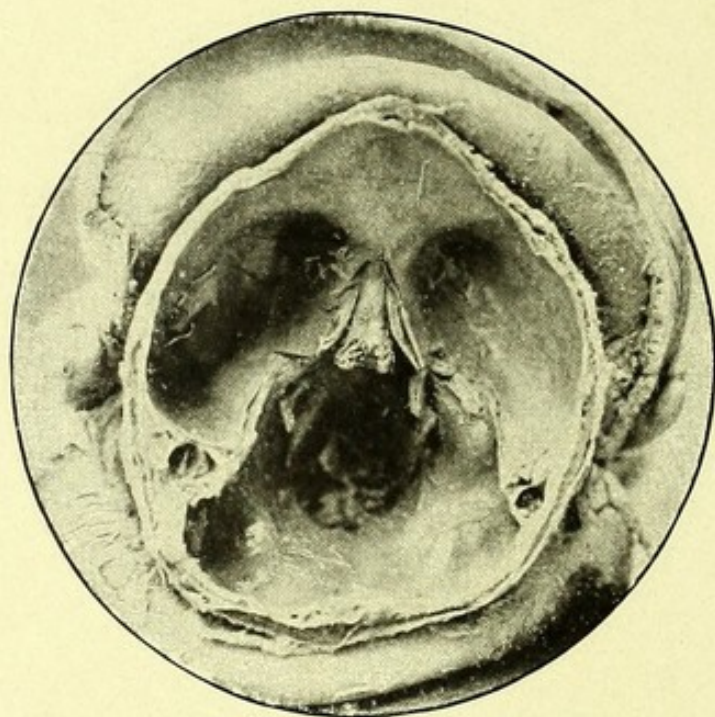


FIG. 7.—Human cyclops showing the base of the skull and cranial nerves (note the single optic nerve).

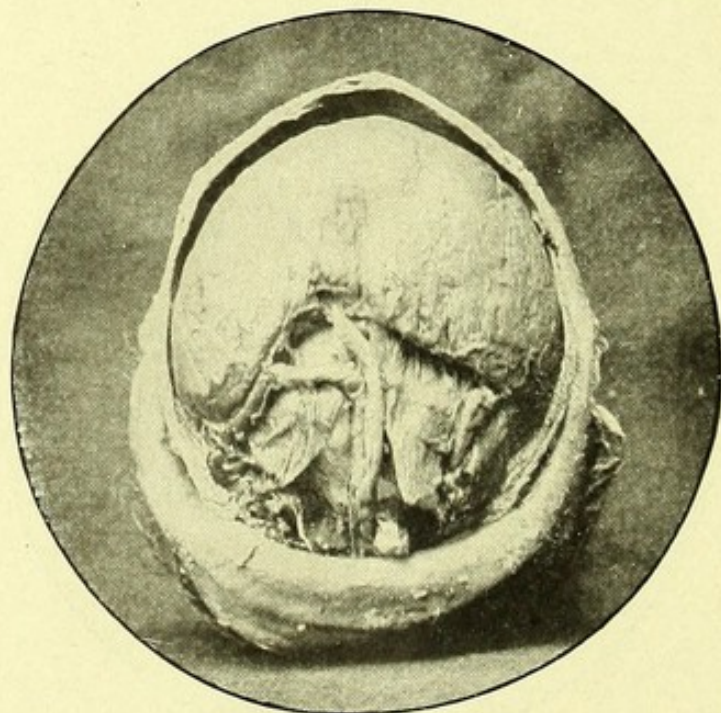


FIG. 8.—Human cyclops, showing the absence of convolutions and fissures in the brain, the posterior part of the cerebrum is occupied by a large cyst (local hydrocephalus).

contained within them double (Figs. 5, 6). The sclerotics on the inner side of each eye may be the only parts fused. Two entirely separate eyes may lie side by side in the same orbit.

The condition is due to some maldevelopment of the anterior part of the neural tube. This has been attributed¹ to pressure of the amnion resulting in early closure of its vertical cleft, so that the optic vesicles instead of budding

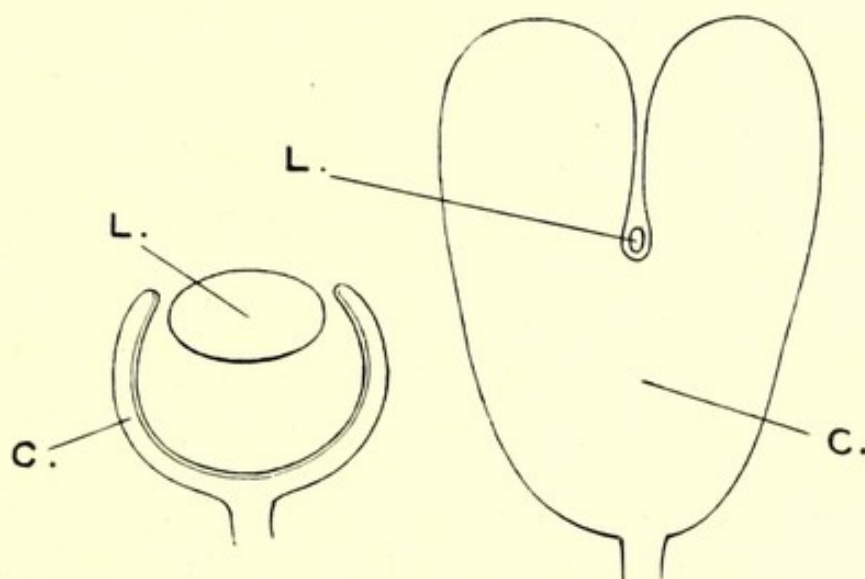


FIG. 9.—Diagram showing the normal involution of the secondary optic vesicle, and how a failure in its involution may result in the formation of a cystic eye. C, Cavity of cyst; L, lens.

out one on each side become unduly approximated or blended. It is in keeping with this that the ventricles are found undifferentiated, forming a single cavity which sometimes distends the posterior part of the hemispheres into a cerebral cyst (Fig. 8).

Congenitally Cystic Eyeball.—A few cases have been recorded in which an infant at birth has been found to have a cyst in the orbit replacing the eyeball, of which clinically none of the normal structures can be detected.

Pathological examination of two such cysts² has shown

¹ Dareste. *Annals d'oculist*, CVI, 1891, 171.

² M. S. Mayou. *Trans. Ophth. Soc. of the U. K.*, XXIV, 1904, 340. Treacher Collins and Johnson Taylor. *Trans. Ophth. Soc. of the U. K.*, XXVI., 1906, 177.

the outer wall to be composed of fibrous tissue with the tendons of the orbital muscles inserted into it. The lining membrane was composed of retinal tissue; posteriorly of a single row of cells, partly pigment like the pigment epithelium, representing the outer layer of the secondary optic vesicle; anteriorly of ill-formed retina representing the inner layer of the secondary optic vesicle. Apparently, the normal involution of the primary optic vesicle had failed to take place and the two layers of the secondary optic vesicle had

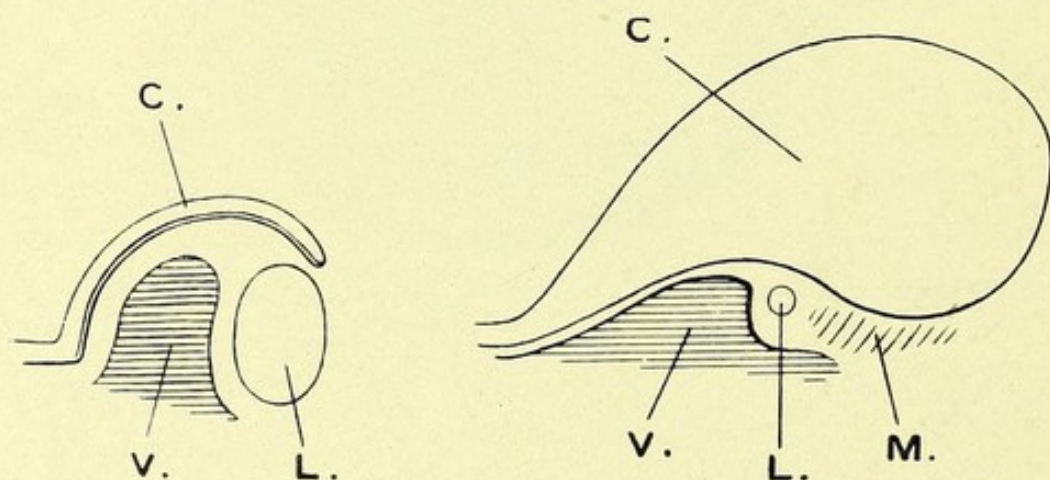


FIG. 10.—Diagram showing the normal upgrowth of mesoblastic tissue into the cavity of the secondary optic vesicle, and the upgrowth of this tissue when involution of the primary optic vesicle has failed to take place and a cystic eye is developed. V, Vitreous; L, lens; M, mesoblastic tissue anterior to lens; C, cavity of cyst.

never come in contact, the cavity of the cyst being the cavity of the primary optic vesicle (Figs. 9, 10).

Shot-silk or Watered-silk Retina.—The condition which is described by one or other of the above names is very common in the eyes of young people, and tends to disappear on the growth of the eye to its full dimensions. It often remains permanent in hypermetropic eyes and is not met with in myopia. A dark background to the retina from a deeply pigmented choroid renders it most conspicuous.

With the ophthalmoscope a number of light reflexes are seen which shimmer and shift with every movement of the mirror. They are most marked along the line of the retinal vessels and around the macula.

The inner layer of the secondary optic vesicle during fetal life grows quicker than the outer layer, or the surrounding mesoblast. It becomes, therefore, thrown into folds which project inward toward the vitreous chamber. As the eyeball approaches its full dimensions these folds gradually become flattened out so that the two layers of the secondary optic vesicle lie everywhere in close contact.

In the eyes of young people and in small hypermetropic eyes the inner surface of the retina is imperfectly flattened out; slight inequalities in the level of its inner surface are present, especially in the position of the retinal vessels, and it is these inequalities which catch the light and reflect it so as to give rise to the watered-silk appearance.

Coloboma of the Retina and Optic Nerve. Microphthalmia with Cysts.—The fetal ocular cleft normally closes early in fetal life, cutting off the mesoblastic structures external to the secondary optic vesicle from those internal to it.

In some animals a permanent union between the mesoblastic structures inside and outside the eyeball exists, the ocular cleft never becoming entirely closed. In fish the falciform process projects upward through the cleft and in birds the pecten.

Occasionally in man a union is found to have persisted between the tissues external to the retina and the vitreous humour, which is usually atypically developed, in the region of the cleft. Such a union must necessarily prevent the edges of the secondary optic vesicle coming together and a gap or coloboma in the retina results. Eyes with this form of coloboma and atypically developed vitreous usually do not expand to the full extent and are microphthalmic.

A delay in separation of the external and internal mesoblast, without permanent union, may also result in failure in the closure of the cleft in the secondary optic vesicle and the formation of a coloboma. When this occurs the changes are not limited to the structures derived from the secondary optic vesicle, but involve also those immediately external to it. If the defective closure is in the

extreme posterior part of the cleft, there is a coloboma of the optic nerve sheath; if somewhat further forward, a coloboma of the choroid; if near the anterior lip of the cup, a coloboma of the ciliary body and of the iris which normally grows forward from it. Colobomata of these structures will be described more fully under the aberrations connected with the formation of the enveloping mesoblast (see page 83). coloboma of the optic nerve and retina being dealt with here.

The region in which a coloboma occurs is frequently a weak spot in the walls of the globe, there being a defective closure in the cleft in the retina or optic nerve and a faulty formation of the structures derived from the mesoblast immediately external to it. On the expansion of the globe the colobomatous area is very liable to become ectatic as the result of the intraocular pressure, sometimes to such an extent as to produce considerable cystic protrusions.

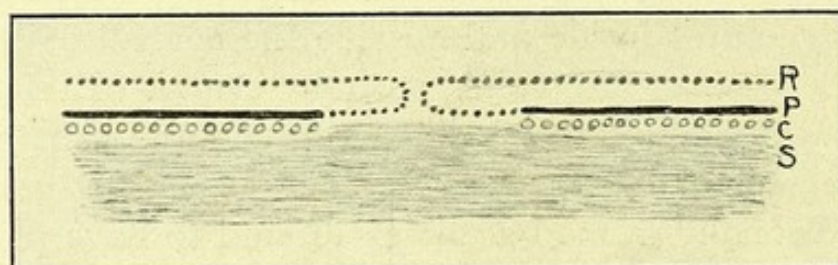


FIG. 11.—Diagram of a coloboma of the retina and choroid showing how folds of the retina may extend across the area in which the choroid is deficient. *R*, Retina; *P*, pigment epithelium; *C*, choroid; *S*, sclerotic.

Microscopical examination of eyes with colobomata of the choroid have shown varying conditions of the retina in the region of the defect. In most specimens vertical antero-posterior sections have alone been made and no gap in the retina has been demonstrated. The absence of such a gap can only be definitely determined by equatorial sections.

The pigment epithelium representing the outer layer of the secondary optic vesicle has usually been found absent over a part of the defect. It frequently exists as an unpigmented row of cells before it finally ceases altogether.

The retina proper representing the inner layer of the secondary optic vesicle has been found in various degrees of attenuation and maldevelopment. Two layers of fairly well formed retina have been met with in the colobomatous area, situated with their normally outer, rod and cone surfaces in contact with one another. Such an arrangement suggests that across a gap in the region of the cleft, between the outer layers of the secondary optic vesicle, folds of the inner layer of the secondary optic vesicle had extended. It has already been pointed out that the inner layer of the

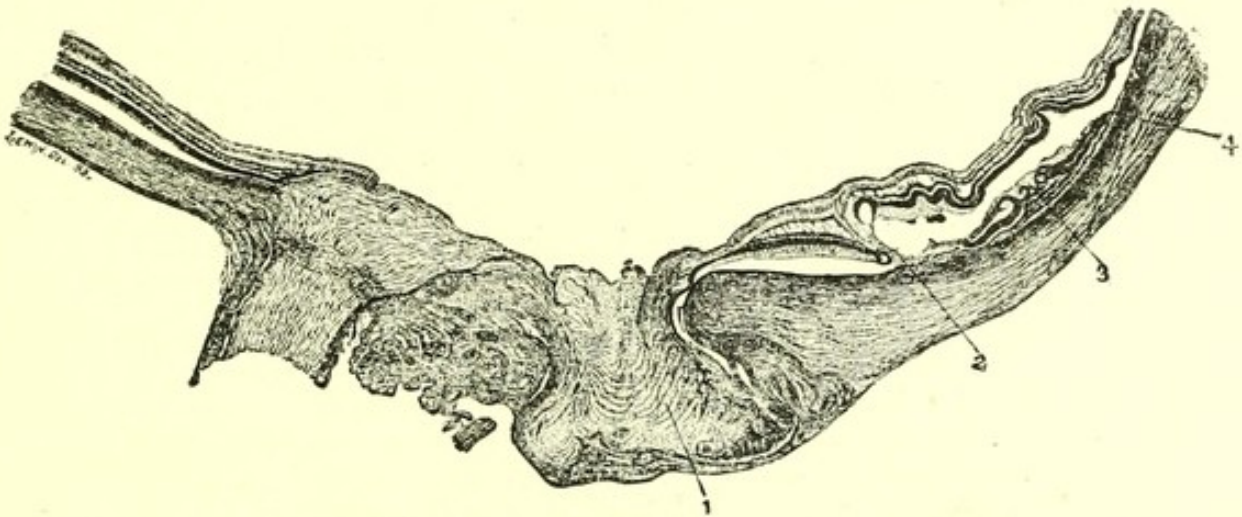


FIG. 12.—Microscopical appearances of the posterior half of a microphthalmic eye, showing a break in the continuity of the sclerotic and choroid through which knuckle of retina (1) tissue is protruding. A coloboma of the choroid commences at (2) in front of which the pigment epithelial layer is replaced by tissue like retina (3) but so placed that its nerve fibre layer faces the sclerotic. At (4) the pigment epithelium is again present and the coloboma of the choroid ceases.

secondary optic vesicle grows much faster than the outer and in the fetal eye is thrown into numerous folds; an extension of a fold from the margins of the cleft would seem to be a very probable explanation of the retinal lining found over colobomatous areas (Fig. 11). When the coloboma becomes ectatic, and when from absence of the choroid its nutrition is defective, the retinal tissue becomes atrophied.

In some eyes a portion of retinal tissue is found protruding through the fetal cleft into or through a gap in the choroid and sclerotic (Fig. 12). The size and extent of such a protrusion varies very considerably. It may be only

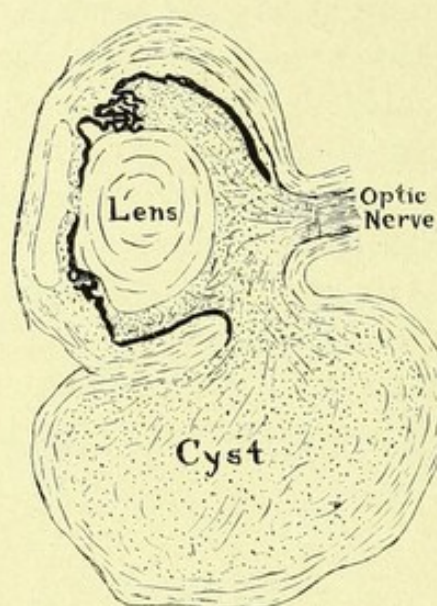


FIG. 13.—Diagram of a congenitally microphthalmic eye with a cyst attached to it. Retinal tissue protrudes through a gap in the sclerotic and choroid at the lower and posterior part and fills the cavity of the cyst.

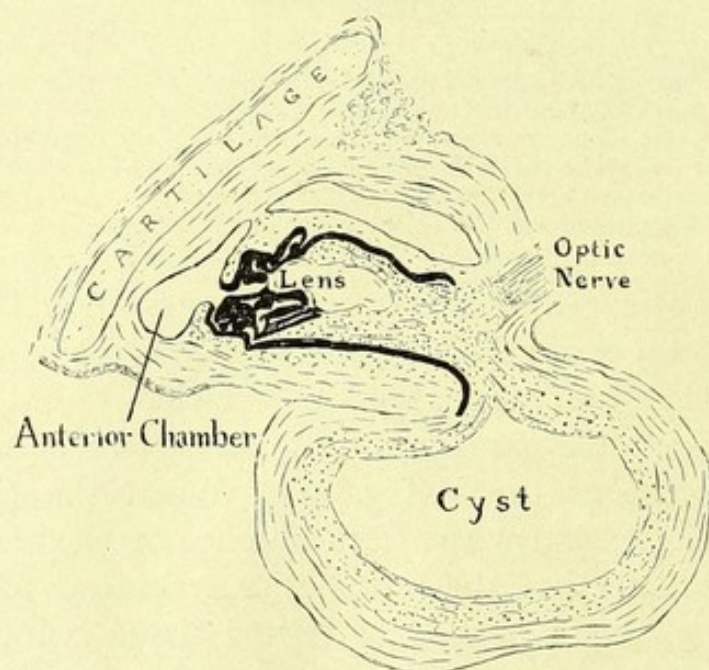


FIG. 14.—Diagram of a congenitally microphthalmic eye with a cyst attached. The cyst is connected with the eye at its lower and posterior part, and is lined by retinal tissue. There is an abnormal development of hyaline cartilage in the sclerotic.

a small knuckle of retinal tissue or consist of quite two-thirds of the membrane.¹ Sometimes it forms a solid mass with an external fibrous tissue covering, at others folds of

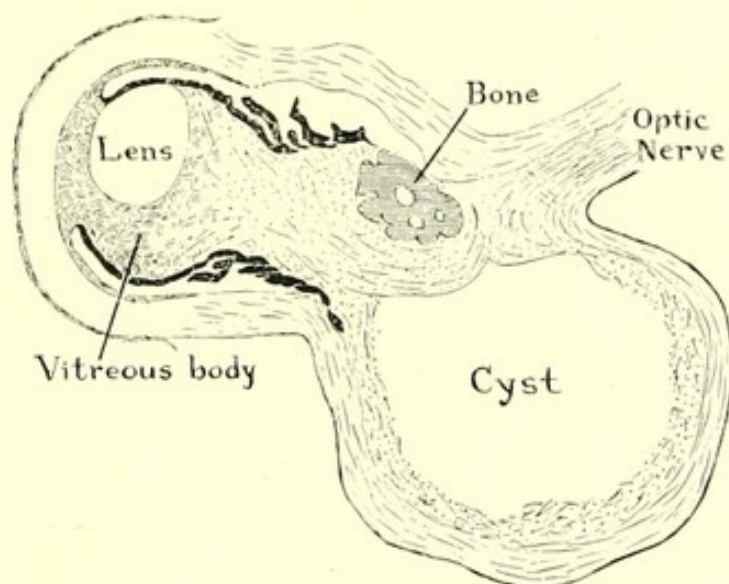


FIG. 15.—Diagram of a congenitally microphthalmic eye with a cyst attached. There is a wide opening of communication between the interior of the eye and the cavity of the cyst which protrudes from its lower and posterior part. The optic disc faces downwards towards the cavity of the cyst and the lining of the latter is composed of retinal tissue.

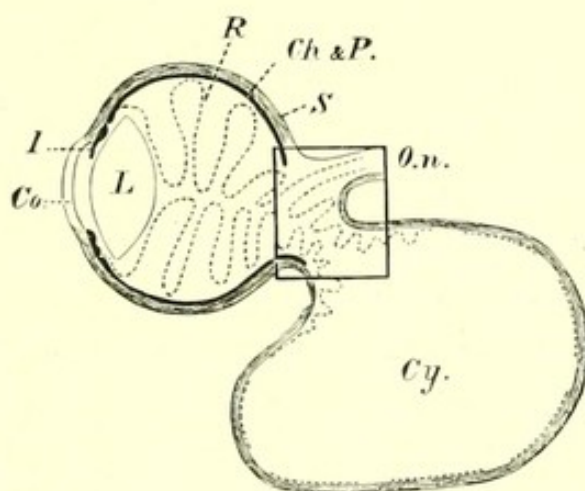


FIG. 16.—Diagrammatic representation of a microphthalmic eye with a cyst attached. *Co*, Cornea; *L*, lens; *I*, iris; *R*, retina much folded; *Ch* and *P*, choroid and pigment epithelium; *S*, sclerotic; *On*, optic nerve; *Cy*, cyst lined by atrophied retina. The part marked off by straight lines is shown magnified in Fig. 17. Case recorded R. Lond. Ophth. Hosp. Rep., XII, 1889, 289.

retinal tissue become distended by fluid into cysts with an outer fibrous tissue coat (Figs. 14, 15, 16). The protuberant

¹ Treacher Collins. Trans. Ophth. Soc. of the U. K., XII, 1892, 289 and XVII, 1897, 254.

retina may consist merely of nuclear bodies and a little retiform tissue, or be so well formed that several of its layers can be easily differentiated. When well-formed retina is

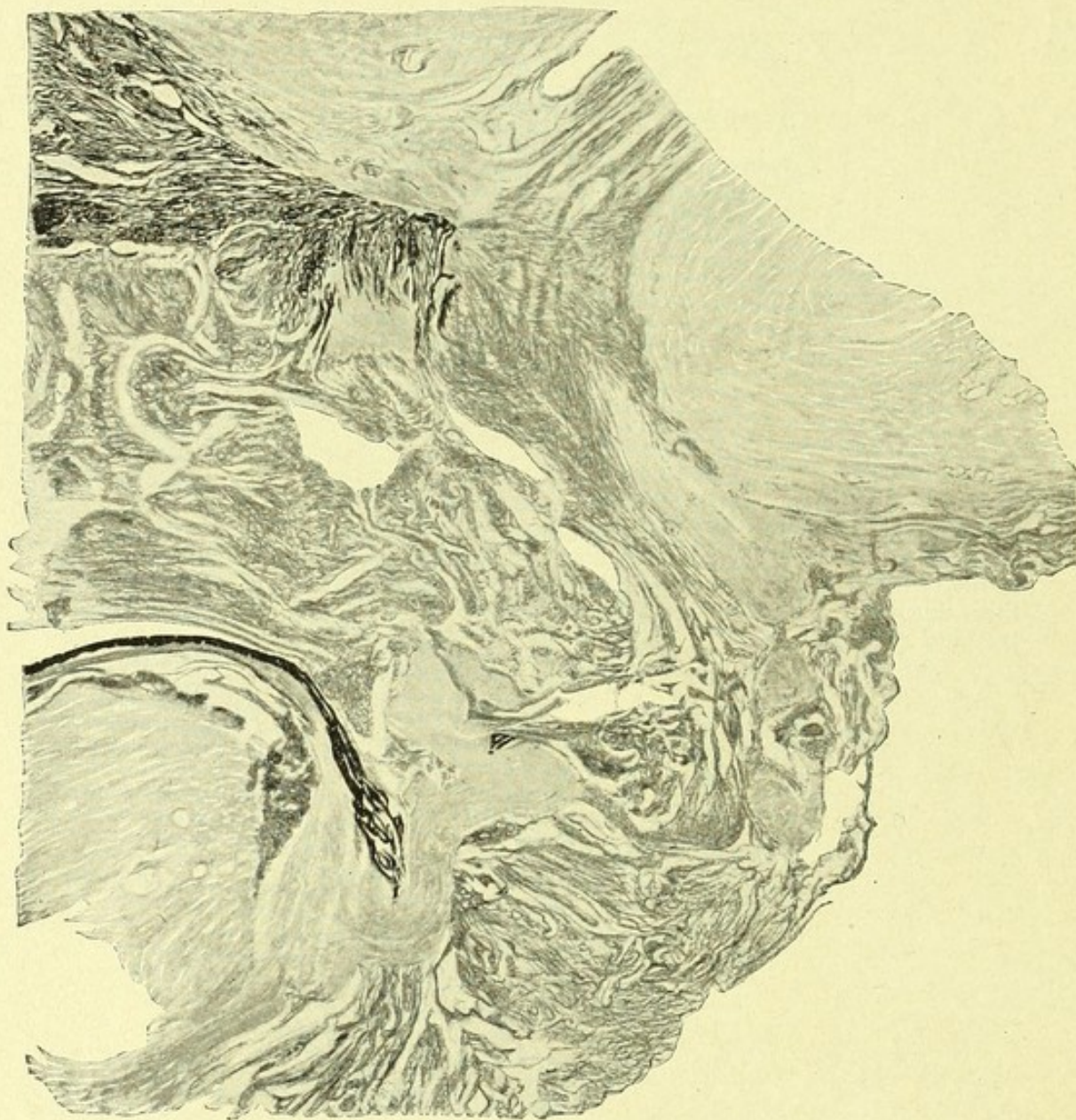


FIG. 17.—Shows the portion of the eye represented in Fig. 16, in the square, highly magnified. The neck of the cysts is seen with retinal tissue passing through it from the eyeball into the cyst.

present in a cyst its inner surface is directed outward to the fibrous tissue covering, and the rod and cone layer toward its cavity.

Where a cyst is present the eyeball is always microph-

thalmic, the degree of microphthalmia depending on the amount of protuberant retina.

The cyst projecting from the lower surface of the globe usually forms a marked translucent prominence in the lower lid of a bluish colour. It may be so extensive as to hide the small eyeball from view in the orbit.

The most probable explanation of these protuberant nodules and cysts, which are evidently only degrees of the same defect, is: that due to some non-expansion of the globe, from defective development of the vitreous humor, one or more folds of the inner layer of the secondary optic vesicle grew outward round the edge of the cleft in the outer layer of the secondary optic vesicle into the mesoblastic tissue beneath. If a fold of this sort became distended with fluid the position of the retina would be such as has been described as occurring in these cysts.

If the coloboma involves the optic nerve, as the result of expansion of the gap before the intraocular pressure, marked changes are produced in the region of the optic disc. It is usually enlarged and depressed, sometimes only in its lower part, at other times over its whole area and to different degrees in different parts. The colour of the depressed area is white with greyish markings. The retinal vessels which are formed from the upgrowing mesoblast may or may not have attained their normal position in the centre of the disc. Where they have not done so, those going to the lower part of the fundus curve with a sharp bend round the lower border of the colobomatous opening, while those going upward have a straight course. In other cases the whole retinal blood supply seems to be derived from cilio-retinal vessels which arise from the margins of the area corresponding to the optic disc.

Conditions which are termed colobomata of the optic nerve are often colobomata of the choroid, reaching up to the nerve, which have become ectatic; so that the lower border of the nerve is displaced upward and backward, the surface of the papilla facing downward.

In such cases the sheath of the nerve is not involved in the coloboma.

Small folds of retinal tissue are also met with at the margin of the optic disc projecting into the underlying sclerotic, nerve sheaths, or nerve.

A coloboma of the nerve alone, the adjacent choroid being quite normal, is of rare occurrence.¹ Pathologically it would be differentiated from one involving both choroid and nerve by the relation which the excavation bore to the intervaginal space in the sheath of the nerve. If on its inner surface, it would be a coloboma of the nerve; if on the outer surface, a coloboma of the choroid.

In a coloboma of the nerve alone the nerve entrance is practically of normal dimensions and all the abnormalities are within its boundaries. A fold of retina is then found passing through the lamina cribrosa and hollowing out the nerve.

Congenital Pigmentation of the Retina.—Congenital pigment spots of a chocolate-brown colour are met with in the retina, they are angular in outline, and situated in groups somewhat suggestive of the arrangement of collections of sarcinæ. They are usually restricted to a wedge-shaped area of the fundus and do not give rise to any symptoms.

Microscopically² they have been found due to aggregations of deeply pigmented epithelial cells in the retina, some of them surrounding nodules of hyaline material. This hyaline material, which is similar to that composing the membrane of Bruch, is doubtless secreted by the abnormally placed pigment epithelial cells. The condition is the result of an abnormal union of the two layers of the secondary optic vesicle.

Congenital Ectropion of the Uveal Pigment of the Iris.—When the secondary optic vesicle is first formed the point of junction of the two layers anteriorly corresponds to what in the fully developed eye is the termination of the retina

¹ George Coats. R. Lond. Ophth. Hosp. Rep., XVII, 1908, 178.

² J. H. Parsons. X Congres Internat. D'Ophth., 1904, 152.

proper, or pars optica retinae at the ora serrata. The pigmented and unpigmented layers of cells lining the ciliary body, or pars ciliaris retinae, and the two pigmented layers of cells on the back of the iris, or pars iridis retinae, are extensions forward from the secondary optic vesicle and

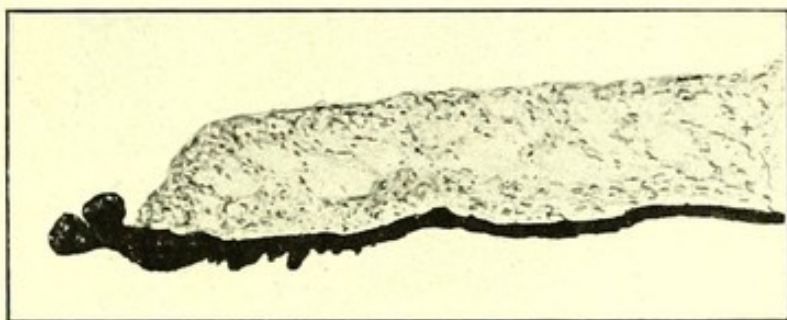


FIG. 18.—The iris in a case of congenital partial "aniridia" showing well marked ectropion of the uveal pigment. The sphincter pupillae muscle is absent.

develop later. In the fully formed eye the anterior termination of the secondary optic vesicle may be regarded as the point of junction of the two pigmented layers situated just at the pupillary margin. Ectropion of the uvea is the abnormal extension forward of these two layers to the anterior surface of the iris. It is occasionally met with as a

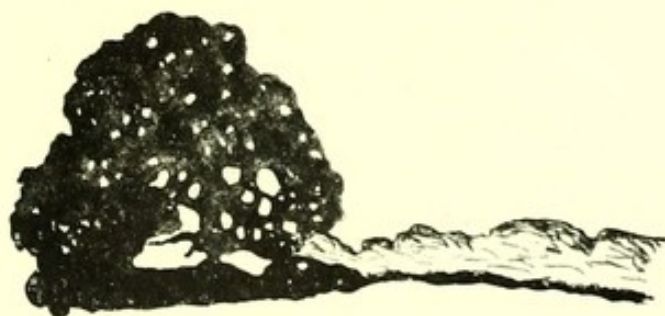


FIG. 19.—Section of a horse's iris, showing the prominent mass of pigmented epithelial tissue at its pupillary border, the corpus nigrum.

congenital defect in the form of one or more deeply pigmented little nodules at the pupillary margin.

It occurs in connection with coloboma of the iris and incomplete "aniridia," where it is the outcome of defective development of the mesoblastic portion of the iris and not overgrowth of pigment epithelium (Fig. 18).

In many of the Ungulata, which have oval pupils with the long axis horizontal, there is an extension forward of the pigment epithelium of the iris round the pupillary margin; this at the upper part forms a black mass termed the **corpus nigrum** (Fig. 19).

Absence of Nerve Fibres.—In cases of anencephaly (Figs. 20, 21) and in some cases of defective development

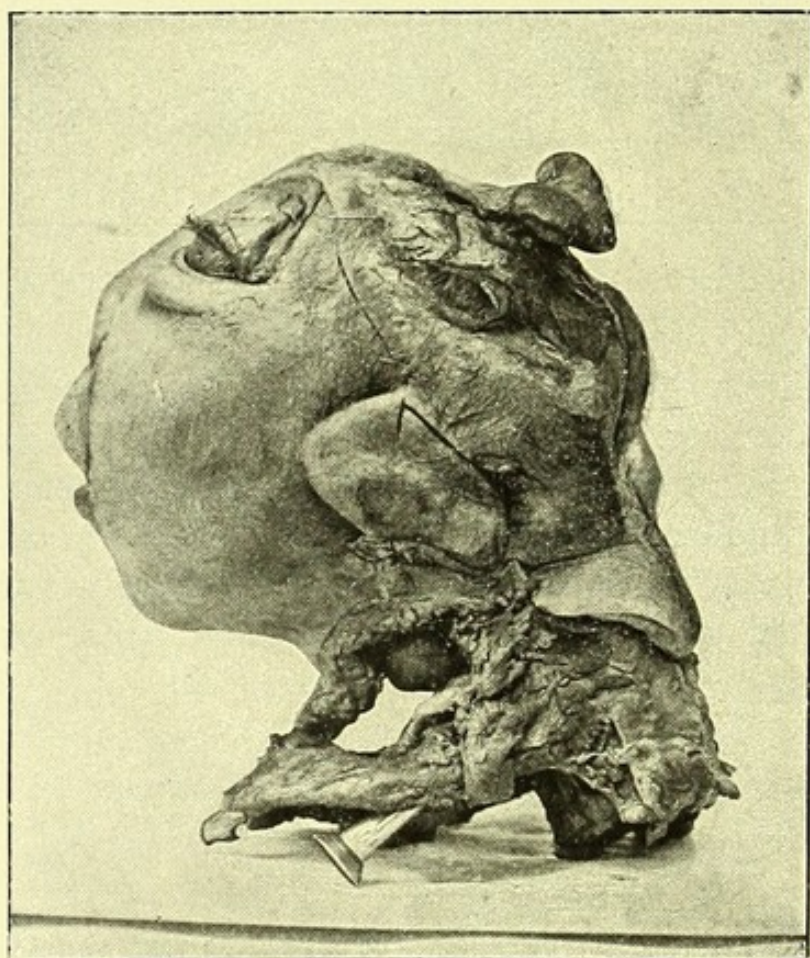


FIG. 20.—Lateral view of the head of an anencephalic fetus, showing the deficient frontal eminences and proboscis.

of the occipital lobes, the result of congenital cystic distension of the lateral ventricles, there is a complete absence of all the axis-cylinders in the optic nerve and retina. The fibrous tissue elements of the nerve, *i.e.*, its sheath and trabeculæ, are formed but the spaces in the trabeculæ contain no nerve fibres (Fig. 22). The optic disc is deeply cupped, due in part to the absence of the nerve fibres and in part to the

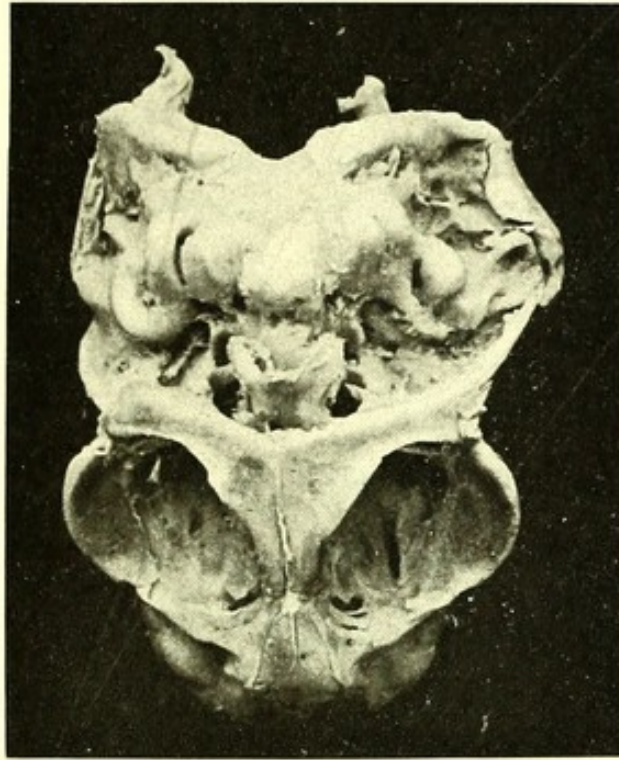


FIG. 21.—View of the skull from above of the anencephalic fetus depicted in Fig. 20. The absence of the vault of the skull is shown, deficient foramen magnum, large semicircular canals, and the opening of the optic foramen.

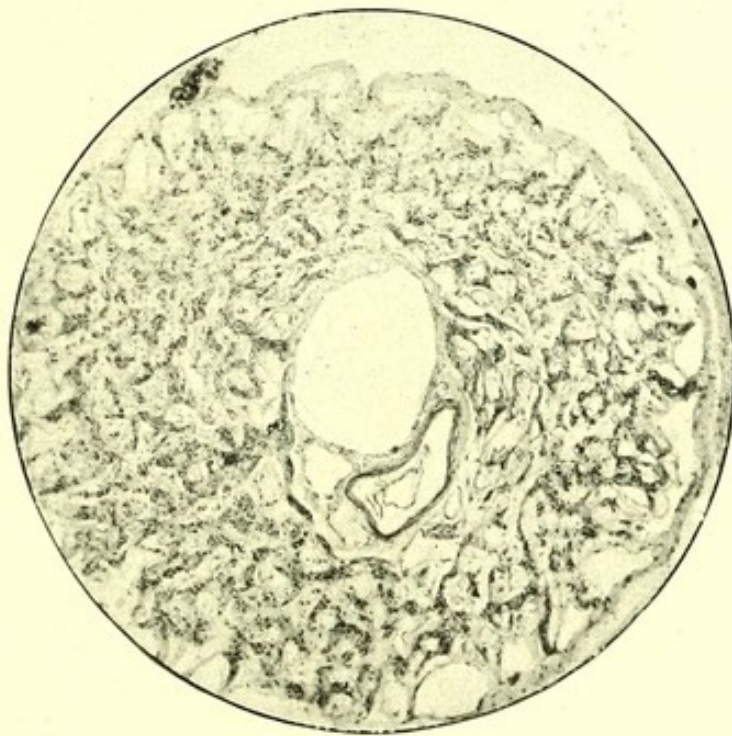


FIG. 22.—Transverse section of the optic nerve of an anencephalic fetus, showing empty trabeculae and a large central artery and vein.

weak lamina cribrosa yielding to the normal intraocular pressure (Fig. 23). The retina shows much of its usual arrangement, even ganglion cells are sometimes present. The nerve-fibre layer, however, is absent, and the blood-vessels of the retina lie in direct contact with the hyaloid membrane of the vitreous.

These cases¹ suggest that the axis-cylinders of the optic nerve and retina are largely cerebral in origin and that

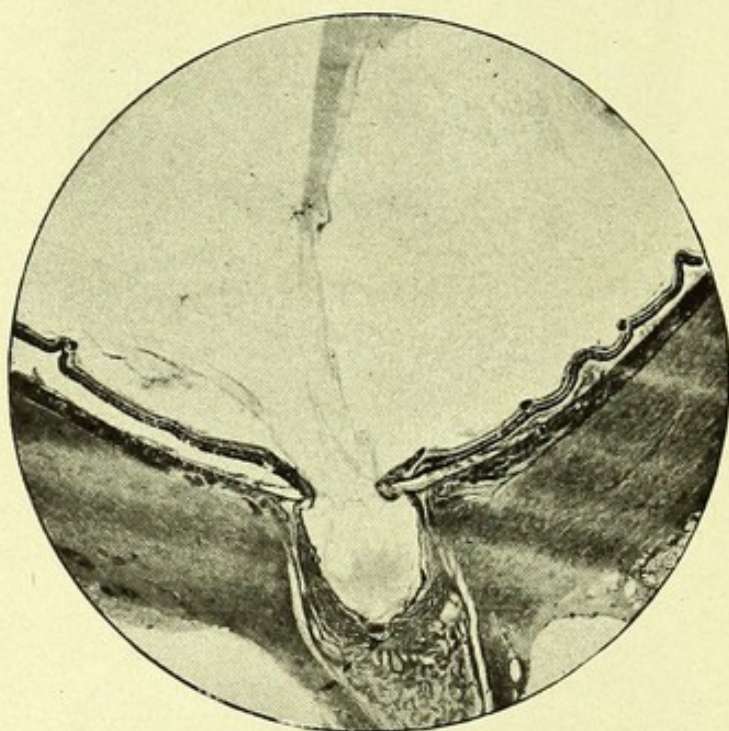


FIG. 23.—Horizontal section through the posterior part of an eye of an anencephalic fetus, showing deep cupping of the optic disc.

the integrity of the cerebral centres is necessary for their formation.

Opaque Nerve Fibres in the Retina.—In some animals nerve fibres in the retina are found normally surrounded by medullary sheaths and when viewed ophthalmoscopically appear as white striated areas obscuring the red reflex of the choroid. In the rabbit bundles of such opaque fibres spread out horizontally from each side of the optic disc and all the

¹ M. S. Mayou. Trans. Ophth. Soc. of the U. K., XXIV, 1904, 150.

retinal blood-vessels are grouped in the positions occupied by these patches.

In man normally only axis-cylinders are met with in the nerve-fibre layer of the retina which is a transparent membrane. Occasionally, as an abnormality, areas are found in which medullary sheaths have developed and the retina is white and opaque. In most cases such patches of opaque nerve fibres are situated at the margin of the optic disc, but they may occur in the periphery of the fundus quite unconnected with it.

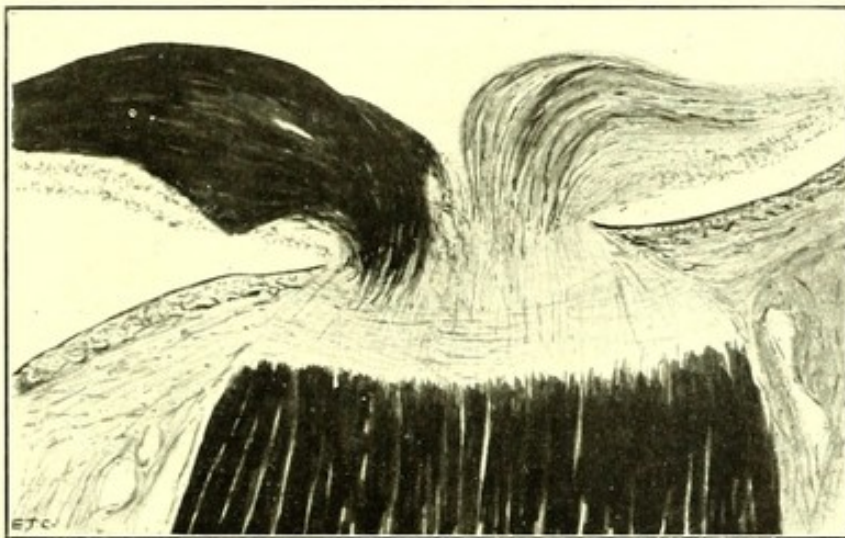


FIG. 24.—Section through the head of the optic nerve in a case of opaque nerve fibres. The medullary substance is stained black by Weigert's method.

The striation at the margin of these patches is a characteristic feature of the condition. The retinal blood-vessels lie in the nerve-fibre layer of the retina; where they pass through an opaque patch they are generally entirely or in part obscured from view.

*Microscopical sections of eyes stained either by Weigert's or Pal's method with patches of opaque nerve fibres at the margins of the disc show well the arrangement of the medullary substance.¹ The medullary sheaths around the fibres in the optic nerve are seen to end in the usual way at the

¹ C. H. Usher. *Ophthalmic Review*. XV, 1896, 1.

posterior surface of the lamina cribrosa. Axis-cylinders alone are present in the lamina cribrosa, and it is not until they emerge from that structure that they again become invested with the darkly staining medullary substance (Fig. 24).

This abnormality of medullation of the nerve fibres in the retina is one which is developed after birth, for as already pointed out the medullation of the fibres in the optic nerve itself is not completed until then.

Crater-like Hole of the Optic Disc.—The condition which has been described under the above name differs from a coloboma of the optic disc; it is rarely situated in the line of ocular cleft and two holes may be present in different parts of the same disc. It consists of a deep pit situated at the margin of the papilla and varying in size from $1/6$ to $1/3$ of the diameter of the disc. Its depth may be an amount which is just appreciable by the observation of a parallax ophthalmoscopically, or as much as 8 to 9 mm. The walls and floor of the pit are usually pigmented but to a different degree in different cases.

The microscopical examination of specimens¹ in which this condition was apparently present showed a deep pocket in the nerve which passed backward at its lower border, cutting off the junction of the lamina cribrosa with the scleral promontory and causing a defect in the former. The pit was entirely in the nerve, filled with altered retinal elements, and lined by pigment epithelium. The retinal tissue would probably be almost transparent ophthalmoscopically and so not hide the pigment in the floor of the depression.

It has been suggested² that in certain cases the neural portion of the secondary optic vesicle, instead of being transformed into an epiblastic framework for the support of the nerve fibres, develops in an atypical way, becoming differentiated into tissue such as is normally only met with in the eyeball itself. A layer of pigment epithelium (correspond-

¹ G. Coats. R. Lond. Ophth. Hosp. Rep., XVII, 1908, 215.

² Monthus and Opin. *Archiv D'Ophth.*, XXIII, 32.

ing to the outer layer of the secondary optic vesicle) is then met with on the inner surface of the pial sheath, and malformed retina (corresponding to the inner layer of the secondary optic vesicle) deeper in the nerve. Such an explanation would, it is considered, adequately account for the presence of the retinal tissue and pigment epithelium in these crater-like holes in the optic disc.

Physiological Cup of the Optic Disc.—A much commoner form of depression in the optic disc than that last described is the “physiological cup.” It varies in size, does not extend to the margin of the disc, and is usually situated a little external to the middle line. The floor of the cup is of a lighter colour than the rest of the disc, and on it some grey markings are often to be seen due to the fibres of the lamina cribrosa which are exposed to view. The retinal vessels on emerging from the nerve curl round the inner margin of the cup.

The fibres of the optic nerve in passing into the eye to reach the retina traverse an opening in the sclerotic and choroid. They are always grouped about the sides of the opening; if its size is excessive they do not entirely fill it, and a vacant space, which appears ophthalmoscopically as a depression, is left in the centre of the disc.

Pseudoneuritis.—In eyes which are abnormally small, *i.e.*, in cases of high hypermetropia, an appearance of the optic disc is met with which closely resembles that brought about by inflammation, for which it is very liable to be mistaken. Ophthalmoscopically, the disc is seen to have no central depression, to be unusually protuberant, of a greyer colour than normal with a striated and somewhat ill-defined margin.¹

This condition may be regarded as just the reverse of the physiological cup. The small eye has a small opening in the choroid for the passage of the optic nerve fibres; consequently they become unusually closely packed together,

¹ W. T. Holmes Spicer. Trans. Ophth. Soc. of the U. K., XVI, 1896, 134.

no space is left at the point from which they radiate outward, and a central depression is not formed.

Congenital Day-blindness with Colour-blindness, and Congenital Night-blindness (Mooren's Retinitis Punctata Albescens).—These two rare conditions will be described together, because they are probably both due to some defective development of the percipient end organs in the retina, and because it is interesting to contrast the symptoms which they present.

The affection which has been termed¹ congenital day-blindness with colour-blindness always affects both eyes, the patients have nystagmus, and are amblyopic and colour-blind. Usually they are totally colour-blind, but gradations in the severity of the affection occur, some having less defect of vision and only a central scotoma for colours. The ophthalmoscopic changes are very slight, some pallor of the disc may be present and frequently some small white dots at the macula, or a little stippling, has been noted. The condition is hereditary, members of the same childship being affected and also of successive generations. Some of the patients are mentally defective.

The name "retinitis punctata albescens" has been applied to several different conditions but should² be restricted to an affection with stationary night-blindness and numerous minute white spots at the fundus.

The night-blindness is doubtless congenital, dating from infancy and showing no tendency to increase. Both eyes are involved. The acuteness of vision in bright light is normal or very slightly defective; there may, however, be marked amblyopia. In dull lights it is always reduced. The field of vision is in some cases restricted in bright light, in others only in dim lights. Ophthalmoscopically, a multitude of tiny dull white dots are seen disseminated over the fundus. They are never present at the macula and become usually smaller and less numerous near the periphery.

¹ E. Nettleship. St. Thomas's Hosp. Rep., X, 1880. Grunert. *Arch für Ophth.*, LVI, 1903, i, 132.

² E. Nettleship. Trans. Ophth. Soc. of the U. K., VII, 1887, 301.

The dots are round or oval in shape, some seem to be joined together and look like dumb-bells. They are entirely free from any pigmentation and are situated at a deeper level than the retinal blood-vessels. Their average width is about half that of a medium-sized retinal artery. They remain indefinitely without undergoing any alteration in appearance. The condition has been met with several times in members of the same childship but not so far in successive generations. Consanguinity in the parents of those affected is not uncommon. No pathological examination of the retina in these cases has yet been made and the exact nature and position of the white dots can only be conjectured.

It has been pointed out¹ that the retina has a dual function, one associated chiefly with the cones and the other with the rods. The one form of vision has the power of distinguishing colours, requires high intensity of light, and gives great definition and clearness. It is most marked in the centre of the field and is associated with the cones. The other form is characterized by an inability to appreciate colours, has its greatest sensibility in weak illuminations and a marked preference for rays of medium or short wave-lengths. It is wanting in definition, absent at the macula, and is associated with the rods.

Congenital day-blindness has been described as cone-blindness, and it will be seen that the visual functions just described as associated with the cones are those which are found to be absent or weakened in that affection.

In congenital night-blindness, on the other hand, the symptoms which are usually present seem to indicate defective rod vision. It is true that in some cases there has been defective form sense, which is not what would have been expected, but this may have been due to some other cause superadded. The absence of the white dots at the macula in all the cases shows that the region in which cones only exist was unaffected.

¹ Von. Kries. *Arch. für Ophth.*, XLIII, 1896, iii, 95.

Congenital Amblyopia.—That congenital amblyopia or congenitally defective form-sense at the macula is due to a defect in its development seems highly probable. The macula is absent in all mammals below the simiæ and is developed in association with the higher forms of binocular vision, when the production of one highly sensitive spot in the retina for form sense becomes essential.

Some eyes with congenital amblyopia and nystagmus have been examined microscopically, in which the condition occurred in association with aniridia and albinism.¹ In these cases there was an absence of the fovea and of the usual distinctive characteristics of the retina at the macula.

II. Aberrations Connected with the Invaginating Surface Epiblast.

The development of the lens from the surface epiblast may be divided into the three following stages:

1. The downgrowth of a fold of cuticular epiblast which is separated in the form of a hollow vesicle from the rest of the surface epiblast and becomes surrounded by a hyaline capsule. This hyaline capsule was at one time regarded as a structure of mesoblastic origin and the product of the fibrovascular sheath which surrounds the lens during fetal life. There is, however, considerable evidence to show that it is really epiblastic in origin, being developed as a kind of secretion from the epithelial cells lining it and beginning to make its appearance before the fibro-vascular sheath is formed.

2. The lengthening out of the cells composing the posterior layer of the vesicle until they fill its entire cavity. These are the first formed lens fibres and persist as the most central part of the fully developed lens.

3. The proliferation of the cells lining the anterior capsule and transformation of them at the periphery of the lens into lens fibres. A transformation which is effected by

¹ Seefelder. *Arch. für Ophth.*, LXX, 1909, i, 39.

their lengthening out anteriorly and posteriorly, so as to encircle the fibres previously developed from the posterior layer, lines of suture resulting where their ends come into contact. This laying on of fresh fibres laterally continues throughout life, but its rapidity is lessened as age advances through the increasing intracapsular tension tending to check the proliferative activity of the cells.

The lens during its most active period of development receives its nutrient supply from a special set of blood-vessels which are arranged in a plexus around it, constituting what is called the fibro-vascular sheath. The blood-vessels in this sheath are derived from the central hyaloid artery posteriorly and the anterior ciliary arteries anteriorly. Before birth, when the anterior chamber is formed, this sheath disappears, the lens for the rest of life receiving its nutrition by osmosis through its capsule.

The aberrations which may arise in connection with the invaginating surface epiblast are as follows:

A failure in the downgrowth of the surface epiblast—**congenital aphakia**.

Delayed closure of the anterior wall of the lens vesicle—**congenital nuclear cataract**.

Defective development of the posterior capsule resulting in:

1. **Opaque membrane behind the lens.**
2. **Shrunk fibrous tissue cataract.**
3. **Posterior lenticonus.**

A failure in development of the nucleus from the cells of the posterior layer of the lens vesicle—**disc-shaped cataract**.

A failure in development of cortical fibres from the proliferating cells of the capsule—**congenital Morganian cataract**.

Defective extension of the laterally formed lens fibres around the front or back of the nucleus—**axial fusiform cataract**; **backward or forward displacement of the nucleus**.

Defects in the line of sutures between the lens fibres—**triradiate opacities**; **coralliform axial cataract**.

Abortive development of some of the lens fibres laid on at the sides—**congenital punctate cataract.**

Congenital Aphakia.—It would seem improbable that a functional eye could be produced if the downgrowth of cuticular epiblast which results in the formation of the lens failed to take place. Pathological examination of an eye could alone determine whether or not a lens had been formed. Cases of microphthalmic eyes in which, after careful examination, the lens appeared to be completely absent have been recorded.

Congenital Nuclear Cataract.—Sections of the lens of an embryo fowl, 150 hours old, have been described¹ in which the lens vesicle had not separated from the surface epithelium, its anterior wall being also unclosed. Through the gap in the anterior wall, lens fibres derived from the posterior wall and undergoing degeneration on the surface, protruded.

It is suggested that if in this case development had continued, the vesicle would ultimately have separated and closure of the anterior wall have taken place. A central defect in the lens would then have been left, causing opacity around which clear cortical fibres would have been laid on.

Defective Development of the Posterior Capsule.—As the lens capsule is the product of its lining epithelial cells, it is obvious that the posterior part of the capsule has only a very short time in which it can be formed, for the cells which compose the posterior layer of the lens vesicle soon lengthen out into lens fibres, and then become separated from the lens capsule by the growth around them of the new lens fibres laid on laterally; the posterior capsule for the remainder of life being devoid of any cellular lining. Under these circumstances it is not surprising that defects in the development of the central part of the posterior capsule should occasionally be met with, causing it to be unduly thin or absent altogether.

The cases in which there is a congenital defect in the

¹C. Hess. Handbuch der gesamten Augenheilkunde, VI, 1905, 202.

posterior capsule of the lens may be divided into three classes¹:

1. Where the gap in the capsule is filled by fibrous tissue from the anterior part of the vitreous (atypically developed vitreous). This gives rise to opacity at the back of the lens.

2. Where there has been considerable extension forward through the gap in the capsule of atypically developed vitreous. This gives rise to shrunken, fibrous tissue, cataract.

3. Where there has been a protrusion backward of lens substance through the capsule into the vitreous; or if the capsule is only abnormally thin and not actually deficient a bulging backward of the lens substance at the posterior pole. A protrusion backward of the lens in either of these ways is known as posterior lenticonus.

1. **Opaque Membrane behind the Lens.**—The eyes which have been examined microscopically in which the first of the above conditions are found have usually been removed from infants on the suspicion that they contained a gliomatous growth of the retina.

A grey reflex was seen at the back of the lens, and sometimes in the tissue which gave rise to the grey reflex blood-vessels were detected or a hemorrhage was present. In most of the cases at the time the eye was removed the remainder of the lens was clear. It has, however, been found to gradually become completely opaque.

Usually the eyes are smaller than normal. The central hyaloid artery of the vitreous is found to have remained persistent and sometimes to continue to carry blood. Tags of pupillary membrane may also be present.

The gap in the capsule of the lens is at its posterior pole and is filled by tissue composed of elongated cells and fibres which is continuous with the vitreous humour (Figs. 25, 26). It is into this tissue that the central hyaloid artery when present passes and breaks up, the lens capsule

¹ Treacher Collins. *The Ophthalmoscope*, VI, 1906, 577, 663.

around the gap being usually corrugated and thicker than normal.

The lens substance even in cases in which it appeared quite clear before removal of the eye has shown changes microscopically which cannot be attributed wholly to hardening reagents. In some the nucleus has been displaced

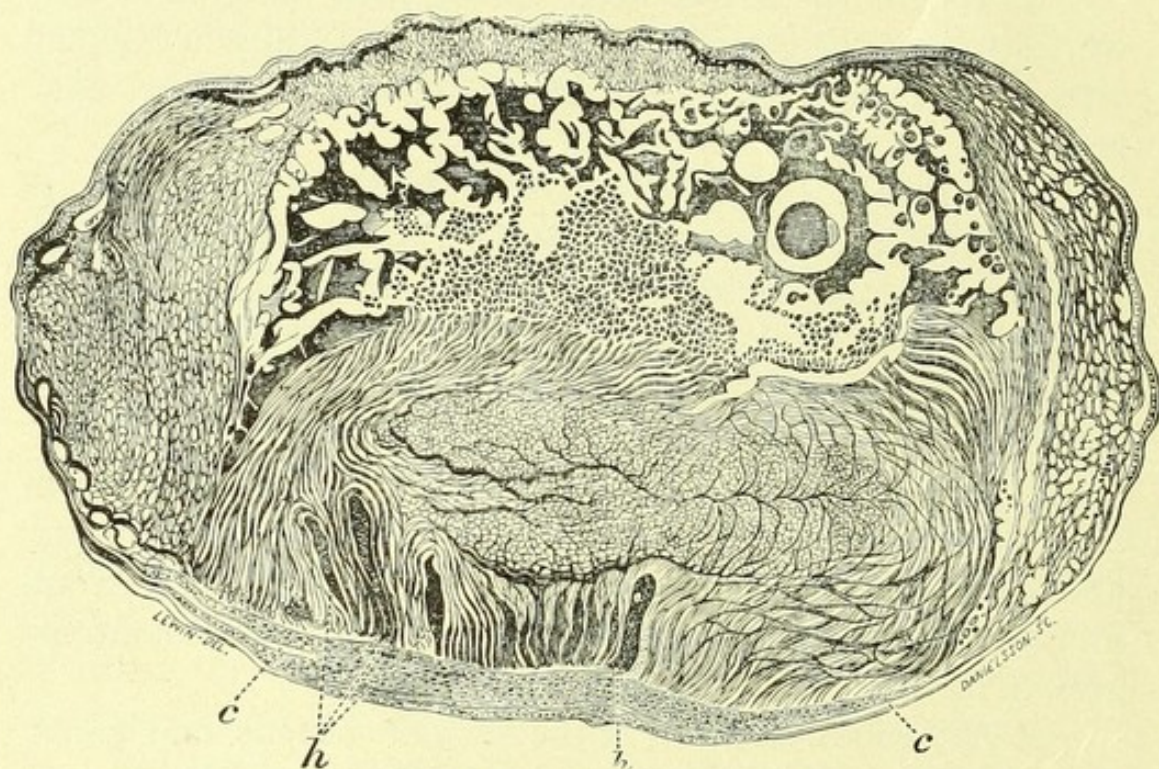


FIG. 25.—Section through the lens from the eye of a child aged 9 months. Clinically a gray reflex was seen from its posterior surface with a hemorrhage apparently in the lens itself. The lens fibres have become much broken up as the result of the hardening reagent. There is a mass of fibrous tissue shown at the posterior surface of the lens filling a gap in the posterior capsule (*c*). In front of this fibrous tissue in the lens substance are hemorrhages (*h*) which doubtless came from the central hyaloid artery. Case recorded in R. Lond. Ophth. Hosp. Reps., XIII, 363.

backward. Probably in many of the cases the lens would in time have become completely opaque if the eye had not been removed.

If in a case of this sort, in which the lens has become completely opaque, if the operation of discission of the anterior capsule is performed, the lens matter in front of the fibrous membrane will become absorbed by the action of the aqueous humour on it, but the membrane itself will

remain unchanged. To tear it with a needle will be difficult owing to its tough consistency, and an attempt to draw it out with forceps will almost certainly be followed by loss of vitreous, seeing that it is continuous with the vitreous and really part of it.

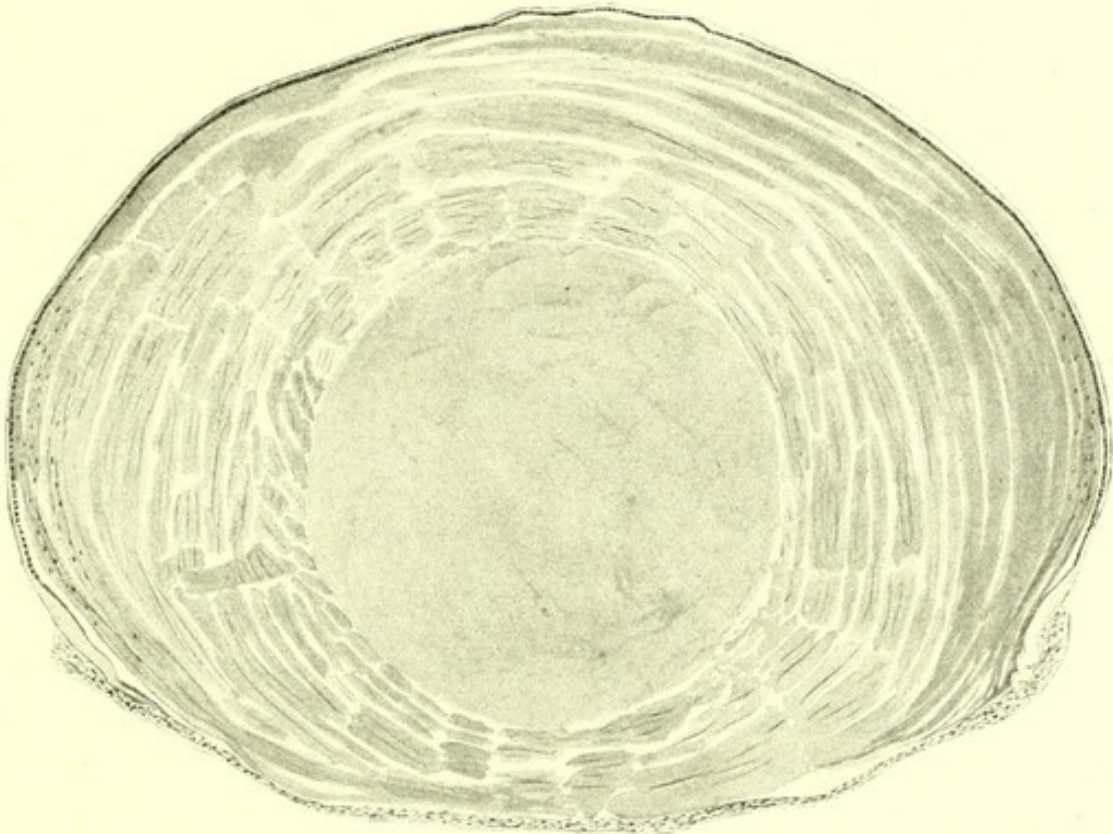


FIG. 26.—Section through the lens from the microphthalmic eye of a child aged 10 weeks, which had atypical development of the anterior part of the vitreous, a persistent hyaloid artery, and a congenital gap in the posterior capsule of the lens. Fibro-cellular tissue fills the space where the capsule is absent. The nucleus of the lens is sharply differentiated off from the cortex. Case recorded by J. H. Parsons, *Trans. Oph. Soc. of the U. K.*, XXII, 1902, 258.

2. **Shrunken Fibrous Tissue Cataract.**—This condition resembles the former, but in it instead of the fibrous tissue, or atypically developed vitreous, merely bridging across the gap in the posterior capsule of the lens it extends through the gap into the lens. This invasion of lens substance by mesoblastic tissue causes considerable absorption of it and shrinking of the lens.

3. **Posterior Lenticonus.**—In the large majority of cases of posterior lenticonus in which an anatomical examina-

tion has been made¹ a gap has been found in the posterior capsule. In the few in which its continuity was unbroken it was abnormally thin (Fig. 27). Where the gap existed the lens fibres were either in direct contact with the vitreous humour or separated from it by a connective-tissue membrane similar to that mentioned in the first class of cases.

In some of the cases the only changes in the lens itself were in the fibres projecting backward into the vitreous, or in

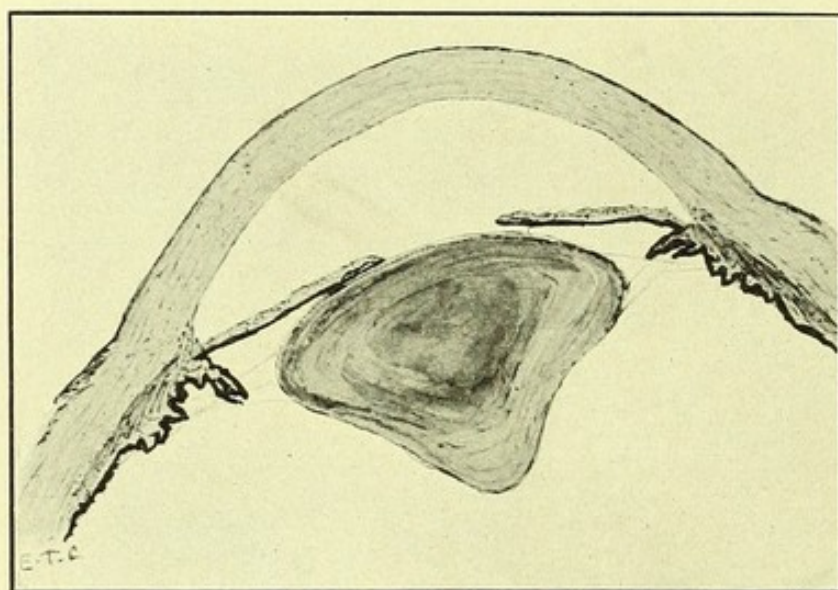


FIG. 27.—Section through the front part of a microphthalmic eye in which there was posterior lenticonus. The capsule is intact throughout, but thinner than normal posteriorly. Case recorded Trans. Ophth. Soc. of the U K., XXVIII, 1908, 107.

those in their immediate neighbourhood. In others there were anterior cortical changes or the nucleus of the lens was displaced backward.

It has been suggested that the gap in the capsule is due to rupture of it either from increase in size of the lens, or traction produced by a persistent hyaloid artery. There is, however, nothing to account for any increase in the size of the lens in such cases, and in a large proportion of them no trace of a hyaloid artery is present. The condition has, moreover, been met with in a chicken embryo 150 hours old.²

¹ A. Patry. *Sur l'histologie et l'etiologie du Lenticone Postérieur*. Genève, 1906.

² Hess. *Handbuch der gesamten Augenheilk.* VI, 201.

It seems more probable that the thinness of the capsule at the posterior pole, or the gap in it, are developmental defects. That on the growth of the lens, the thin capsule has bulged outward, or when deficient, the lens fibres have protruded through the opening into the vitreous.

Disc-shaped Cataract.¹—The form of cataract which has been termed disc-shaped cataract is one which, owing to absence of the nucleus, the lens is much flattened from before backward. It is always associated with an anterior polar cataract. This is seen clinically as a dense white central opacity which, while extending to the anterior surface of the capsule, is at a distinctly deeper level than the surface of the iris at its pupillary margin. Around the central white patch there is usually some irregular greyish opacity in which it seems to be set. With an undilated pupil the central opacity may fill the whole of its area and appear to be a much shrunk opaque lens. If, however, a sufficient dilatation of the pupil can be obtained a peripheral clear area will be discovered. If an iridectomy is performed so that the edge of the lens becomes visible it will be seen not to present its normal rotundity but to be too thin from before backward.

When a discission operation is performed on these cataracts, the central white densely opaque part can with a little maneuvering be separated from the rest of the lens. It will then often drop down into the lower part of the anterior chamber, where it may remain for an indefinite time showing no tendency to become absorbed or to give rise to irritation. After the dense white central plaque has been picked off a central black opening is left through which the patient can see.

The anatomical appearances found in these cataracts are as follows:² Flattening antero-posteriorly, most marked in the centre, so that in a section two lateral rounded masses

¹ For the difference between this form of cataract and Doyne's cataract see page 42.

² Treacher Collins. *Trans. Ophth. Soc. of the U. K.*, XVIII, 1898, 124; and *The Ophthalmoscope*, VI, 1908, 669.

are seen connected by a band, an appearance in section comparable to that of a dumb-bell (Fig. 28). In the central flattest part of the lens, a laminated mass of tissue is situated similar to that met with in anterior polar cataracts. It extends backward from the anterior to the posterior capsule, no lens substance intervening. In the rounded parts on either side of the central laminated mass, there is lens substance, showing a variable amount of disturbance in the vicinity of the central part, and becoming more normal and regular in its arrangement toward the periphery.

The explanation of the condition seems to be a failure in the development of the nucleus; *i.e.*, a failure of the cells

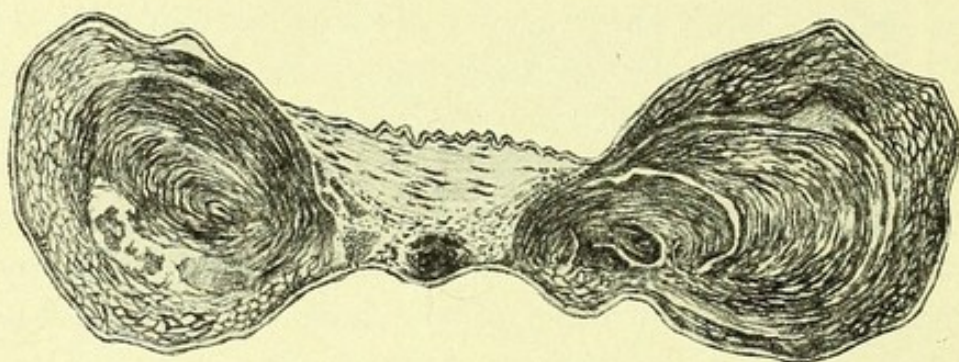


FIG. 28.—Antero-posterior section through a congenitally disc-shaped cataract. The nucleus of the lens has failed to develop and there is a dense laminated mass at the anterior pole.

which compose the posterior layer of the lens vesicle to lengthen out into lens fibres. This failure in the development of the nucleus does not seem to check the activity of the cells lining the anterior and lateral parts of the lens capsule. The laminated mass in the centre, which resembles in structure an anterior polar cataract, is probably produced in the same way as anterior polar cataracts in other conditions. That is by the proliferation of the cells lining the anterior capsule as the outcome of low intracapsular tension in their vicinity (see page 453). In these lenses in which the nucleus fails to form there would be abnormally low intracapsular pressure in the neighbourhood of the anterior pole of the lens, hence the formation of an anterior polar cataract.

The activity of the cells lining the sides of the capsule not being interfered with, lateral lens fibres develop. These having no nucleus around which to group themselves form accumulations of fibres at the sides of the anterior polar mass, with irregularities and vacuolations of varying distribution.

Congenital Morganian Cataract.—This is a complete cataract which presents a characteristic uniform milky

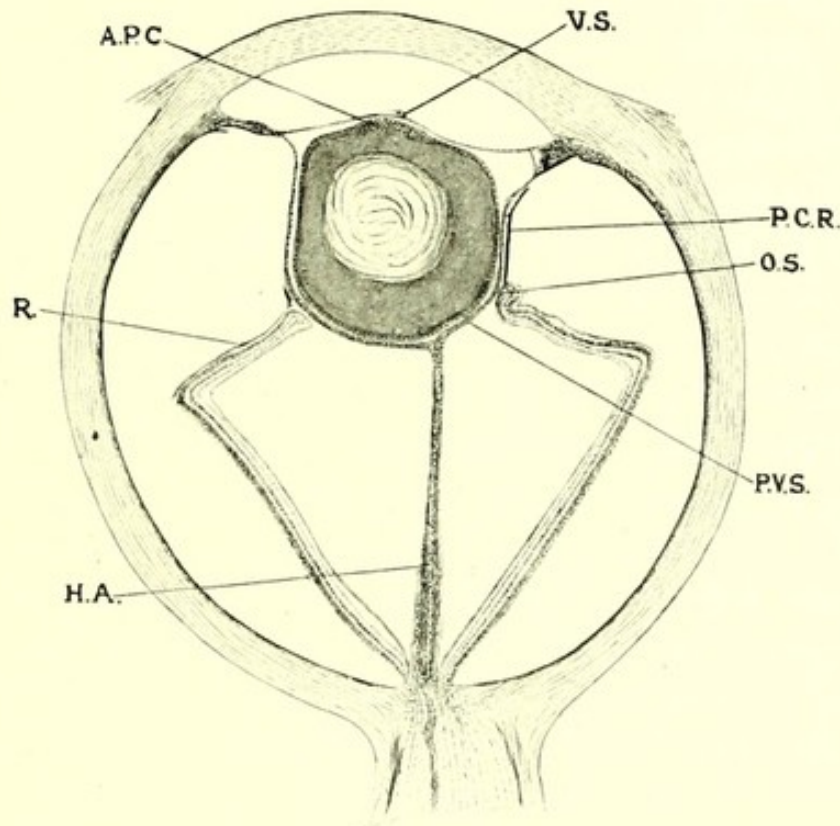


FIG. 29.—Diagrammatic section through a microphthalmic eye in which the whole fetal vascular system of the lens had persisted; the central hyaloid artery of the vitreous *H.A.*; and fibro-vascular sheath, *P.V.S.* and *V.S.* There was arrested development of the iris, "partial aniridia"; failure in separation of the pars ciliaris retinae *P.C.R.*, and retina *R.* at the ora serrata, *O.S.* from the sides of the lens; and a congenital Morganian cataract, with an anterior polar opacity *A.P.O.*

white colour, sometimes with a few dense white specks on the surface. When the capsule is pricked with a needle opaque fluid containing flocculent material escapes into the anterior chamber. If left there and not evacuated, increased tension often ensues.

On anatomical examination of such cataracts the cortex is found almost entirely composed of a homogeneous ma-

terial (Fig. 29), while the nucleus consists of lens fibres concentrically arranged, sometimes with vacuoles in them like those seen in the affected area in lamellar cataract.¹

In the disc-shaped cataract some dystrophic influence exceedingly early in fetal life arrests the development of the lens fibres which should form from the cells of posterior layer of the lens vesicle, but does not interfere with the later development of the fibres from the cells at the sides of the capsule. In congenital Morganian cataract the lens fibres derived from the cells forming the posterior layer of the vesicle develop in a normal, or comparatively normal, manner; and the occurrence of some dystrophic influence later interferes with the development of the laterally-formed lens fibres from the cells at the sides of the capsule. The one condition therefore appears to be the reverse of the other.

Axial Fusiform Cataract. Backward or Forward Displacement of the Nucleus of the Lens.—Under the name congenital axial fusiform cataract a condition has been described in which a spindle-shaped opacity extends from the anterior to the posterior pole of the lens. It has been suggested that it is due to adhesion of the nucleus to the anterior and posterior capsule so that on growth and expansion of the lens it becomes drawn out into a fusiform shape.

A backward displacement of the nucleus of the lens is frequently met with where there has been a defect in development of the posterior capsule. It has been several times recorded in specimens with posterior lenticonus. It can be recognised clinically when the nucleus is opaque and the cortex clear.

Adhesion of the nucleus to the anterior capsule has also been described.

The lens fibres which are developed laterally, in order to encircle those which are formed from the posterior layer of the lens vesicle, have to lengthen out anteriorly and posteriorly. Some extend more forward and others more backward. Adhesions of the nucleus to the anterior or

¹ Treacher Collins. *The Ophthalmoscope*, VI, 1908, 671.

posterior capsule would prevent the forward or backward growth of the fibres.

An adhesion to the anterior capsule might be due to defective closure of the anterior surface of the lens vesicle. An adhesion posteriorly to defect of development in the posterior capsule.

Triradiate Opacities. Coralliform Axial Cataract.—At the place of meeting of the fibres of the lens at its anterior and posterior poles lines of suture exist which vary in their arrangement, at different stages of its development and at different depths in the fully formed lens.

The fibres which are developed from the posterior layer of the lens vesicle have their extremities all meeting at a point at the anterior and at the posterior pole. The lens when composed of these fibres only is globular in shape. As new lens fibres are laid on at the sides it alters in shape, the lateral diameters increasing more than the antero-posterior, then instead of the lens fibres all meeting in a point they meet in a line; the line at the anterior pole being placed at right angles to that at the posterior. This allows of some shortening of the lens fibres, those which have to extend furthest anteriorly not having to extend so far posteriorly and *vice versa*. A further and later modification, effecting the same purpose, is for the line of junction of the fibres to have a triradiate arrangement, the three arms of the triradiate figure at the anterior pole being situated in the reverse direction to those at the posterior. This is the arrangement of the sutures on the surface of the lens at birth.

In the layers of fibres laid on after birth the lines of suture assume a still more elaborate arrangement, a star-shaped figure with primary and secondary radiations being produced, along which the ends of the fibres come into contact with one another.

Congenital triradiate opacities of the lens are met with in front or behind its nucleus. They are sometimes seen on the anterior surface of a zonular cataract. They are met

with behind the nucleus in the disc-shaped opacities which are often hereditary and which have been termed "Doyne's cataract." These cataracts must be distinguished from the discoid cataracts already described in which the whole lens has the shape of a disc. In Doyne's cataract it is the area of opacity in a normally shaped lens which is discoid.

At birth the triradiate opacities, which are doubtless due to disturbance along the line of sutures, are probably situated close to the poles of the lens. As age advances,

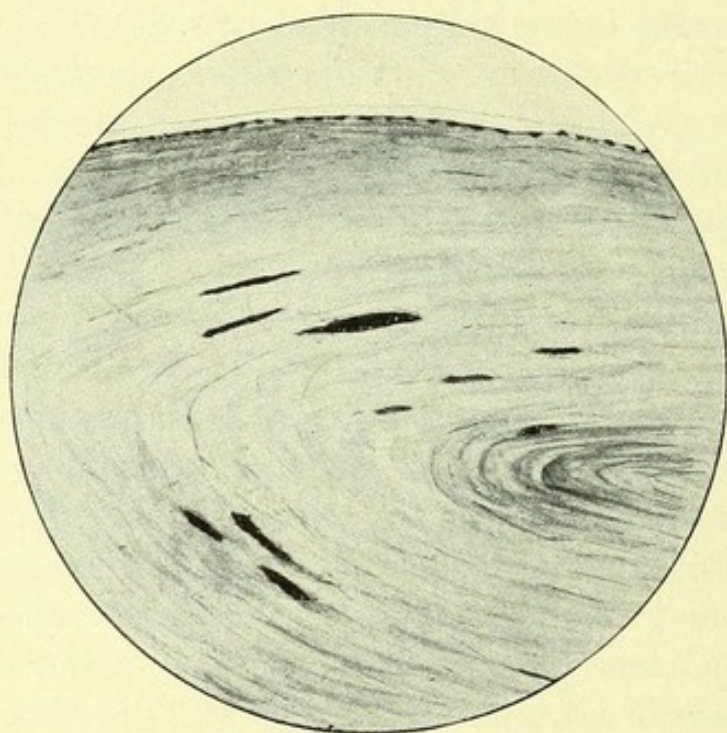


FIG. 30.—Section through a lens with congenital punctate cataract showing spindle-shaped spaces between the lens fibres filled with deeply staining granular material.

unaffected cortical lens fibres are laid on in front of them so that they are then found some distance away from the surface.

In the form of axial cataract which is termed coralliform cataract¹ opacities having a tube-like appearance are met with radiating forward and outward from the centre. They terminate just short of the capsule in an ampulliform man-

¹ R. Marcus Gunn. Trans. Ophth. Soc. of the U. K., XV, 1895, 119.

ner. So far no anatomical examination has been made of this form of cataract. The position occupied by the opacities is that of the lines of the sutures in the antero-posterior plane and it is probable that they are due to some disturbance situated in them.

Congenital Punctate Cataract.—In congenital punctate cataract small circumscribed grey or white opacities are seen in the cortical layers of the peripheral parts of the lens. They vary in number in different cases and may be exceedingly numerous. They are stationary and owing to their peripheral distribution do not usually give rise to disturbance of vision. Both eyes are generally involved and frequently several members of the same childship.

Microscopically spindle-shaped spaces are found between the lens fibres filled with a granular material which stains more deeply than the surrounding parts with nuclear stains (Fig. 30).

From the position and distribution of these opacities it would seem probable that they are laterally formed lens fibres which have failed to develop in the normal way, breaking up instead into granular substance and remaining as such surrounded by other healthy fibres.

III. Aberrations Connected with the Invaginating Mesoblast.

From the mesoblast which invaginates the primary optic vesicle from below are developed the central blood-vessels of the optic nerve, the blood-vessels of the retina the central hyaloid artery, the vitreous humour and probably the fibres of the suspensory ligament.

Blood-vessels have been detected in the invaginating mesoblast in sections of a human fetal eye of the sixth week. At first they are evenly distributed throughout the rudimentary vitreous body, but as it grows they become differentiated into one central vessel and several peripheral ones. The former becomes the central hyaloid artery and the latter become incorporated in the nerve-fibre layer of the

retina, constituting the vascular system of that structure. The hindmost part of the invaginating mesoblast grows up into what subsequently becomes the optic nerve, and from it the central vessels are developed.

The central hyaloid artery in its fully formed condition arises from the central retinal artery on the optic disc and passing forward divides dichotomously. The branches thus formed spread out on the posterior surface of the lens in what is called the posterior fibro-vascular sheath, and extend round its sides anastomosing when they reach its anterior surface with branches of the anterior ciliary vessels.

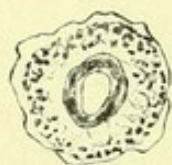

FIG. 31.

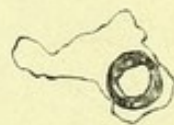


FIG. 32.

FIG. 31.—Transverse section of the central artery of the vitreous, showing the cellular sheath and hyaloid membrane surrounding it. From a human fetal eye of between the 5th and 6th months.

FIG. 32.—Transverse section of the same artery shown in Fig. 31 further forward in the vitreous. The cellular sheath has ceased, but the artery is still surrounded by a hyaloid membrane.

These branches of the anterior ciliary vessels extend inward in the form of loops on the anterior surface of the lens in what is called the anterior fibro-vascular sheath.

All the blood from the plexus of vessels around the lens is carried into the anterior ciliary veins, there being no central hyaloid vein running with the artery.

The central hyaloid artery lies in a canal in the vitreous lined by a hyaline membrane, the canal of Cloquet. At the posterior part the artery is encircled by a cellular sheath (Fig. 31), but as it passes forward this cellular sheath ceases and the artery then lies devoid of any covering in the canal (Fig. 32). The hyaline canal broadens out as the artery divides up and approaches the back of the lens.

The system of blood-vessels in the vitreous and around the lens reaches its greatest development at the seventh

month of fetal life, after that it begins to degenerate and usually has completely disappeared at birth.

The external hyaloid membrane of the vitreous humour can be seen as early as the tenth week in the human fetus.

During part of fetal life the whole of the vitreous is permeated by a close network of delicate fibres, which have little granules lying on them at the points where the fibrils intersect with one another. These granules, which are about one-eighth the size of the nucleus of a cell in the sheath of the hyaloid artery, stain densely with hematoxylin. As the vitreous humour increases in size these granules and fibres stain fainter, become more spaced out, and far less conspicuous.

When the fibro-vascular sheath first encircles the lens that portion of the eye in which the ciliary body subsequently develops lies in contact with it at the side of the lens. While so situated cellular adhesions form between it and the lens capsule, which subsequently develop into the fibres of the suspensory ligament.

As the eyeball grows it does so at a greater rate than the lens; so that the ciliary body, at first in contact with the lens, gradually becomes separated further and further from it. The adhesions between the two structures, originally cellular, become stretched out into fibres, to which for some time the nuclei adhere and then gradually disappear.

With regard to the origin of the cells which thus become transformed into the suspensory ligament there is still some uncertainty. While some regard them as coming from the fibro-vascular sheath and, therefore, of mesoblastic origin, others consider them to be derived from the pars ciliaris retinae and analogous to the fibres of Müller in the retina, which are epiblastic.

The aberrations which may arise in connection with the invaginating mesoblast are as follows:

Failure in the disappearance of the fetal vascular system of the vitreous—**persistent central hyaloid artery**—**persistent sheath of central hyaloid artery**.

Defective or irregular formation of the retinal blood-vessels—**abnormalities in the arteria centralis retinae—cilio-retinal arteries.**

Formation of the mesoblast into connective tissue instead of normal vitreous—**atypical development of the vitreous.** Persistence of portions of the framework of the fetal vitreous. **Muscae volitantes.**

Failure in the formation of adhesions between the ciliary processes and the lens capsule in a portion of its circumference—**ectopia lentis, coloboma lentis, lenticonus anterior.**

Persistence in the cellular character of a portion of the developing suspensory ligament—**adhesion of ciliary processes to the back of the lens.**

Persistence of the Central Hyaloid Artery or its Sheath.—

In all vertebrates except mammals a permanent vascular system is met with in the vitreous. It presents many variations in different species. There may be either a plexus of vessels in the centre of the vitreous such as the pecten in birds and the processus falciformis in fish and reptiles; or a network of vessels spread out on its surface lying in contact with the retina but not in it.

In many mammals a vestigial pecten or remains of a central hyaloid artery is present. It is met with in all ruminants and in a large number of rodents and marsupials.¹

The different conditions which may arise from the abnormal persistence of the central hyaloid artery or its sheath in the human eye may be summarized as follows:

1. The central artery persisting throughout its whole length and continuing to carry blood. When such an abnormality is present the anterior part of the vitreous develops into fibrous tissue (Figs. 33, 34) (see atypical development of the vitreous).²

2. The persistence of the central artery throughout its whole length as a slender cord without any blood circulating

¹ Lindsay Johnson. Philosoph. Trans. of the Royal Society of London, 1901, 53.

² Treacher Collins. R. Lond. Ophth. Hosp. Rep., XIII, 1890, 81.

through it. Such a cord is usually thinnest in the centre expanding where it is attached to the optic disc and the back of the lens. The anterior extremity is often situated not quite in the centre of the posterior surface of the lens but a little below it or to one side. In a few rare cases the posterior extremity has been seen not to start from the optic disc but from a part of the fundus below it. In one case it was found to start in the centre of a coloboma of the choroid at the macula.

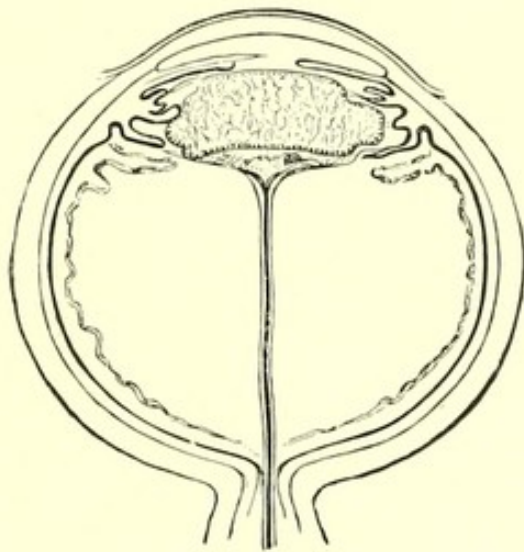


FIG. 33.

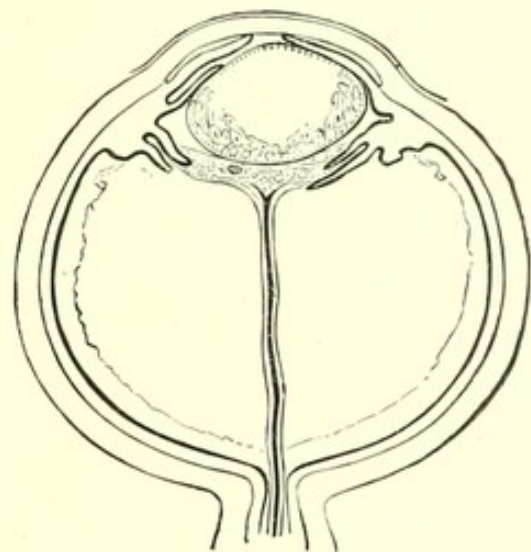


FIG. 34.

FIG. 33.—Diagrammatic representation of a section of an eye with a persistent and patent hyaloid artery which terminated in a thick fibrous tissue membrane at the back of the lens.

FIG. 34.—Diagrammatic representation of a section of an eye presenting much the same form of malformation as in Fig. 33. The ciliary processes nearly all lie behind the lens, being attached to the mass of fibrous tissue in the anterior part of the vitreous in which the central hyaloid artery terminates.

Microscopically these cords are composed of rather dense fibrous tissue lying in a persistent canal of Cloquet.

3. The persistence of a cord, representing the posterior part of the central artery, attached to the optic disc but ending in a free extremity in the vitreous (Fig. 35), with or without an opacity on the posterior surface of the lens. The length of the cord varies considerably in different cases. It may be of a dark colour and easily seen, or light grey and semi-transparent when the recognition of its presence calls

for careful observation. The free extremity of the cord is sometimes rounded and knob-like, at others fine and tapering. It may bifurcate once or oftener. Ophthalmoscopically the cord on movements of the eye often oscillates with an undulating motion and might easily be mistaken for a filaria in the vitreous. The opacity at the posterior surface of the lens, when present, may be flat and have a tag protruding back from it with a free extremity in the vitreous.

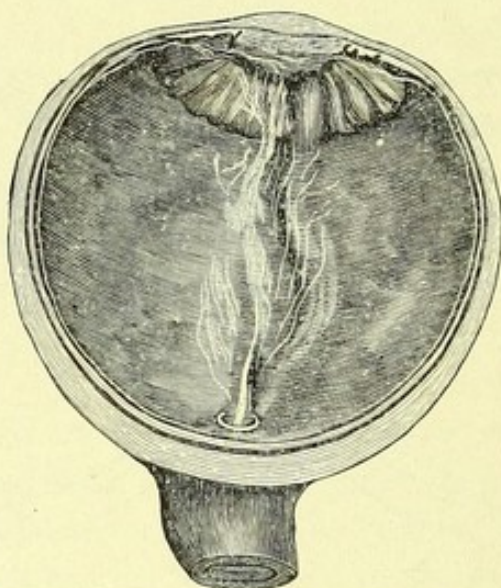


FIG. 35.—An eyeball the sight of which had been destroyed by ulceration of the cornea. Prolonged forward into the vitreous from the optic nerve is a tag of white membrane, which is due to a persistence of the central hyaloid artery.

4. The persistence only of the anterior extremity of the artery in the form of an opaque patch at or near the posterior pole of the lens. As in the last class the opaque patch may have a free and mobile tag attached to it.

5. The persistence of the cellular sheath which surrounds the posterior part of the artery inside the canal of Cloquet; the artery itself having entirely disappeared.

This persistent sheath is seen ophthalmoscopically as a grey membrane filling up the depression in the head of the nerve, or covering over one or more of the retinal vessels on the optic disc.

Little rounded bodies of steel grey colour presenting a yst-like appearance are sometimes seen ophthalmoscopically

in front of and attached to the optic disc. They are probably cystic distentions of the sheath of the artery.

Abnormalities in the Arteria Centralis Retinæ. Cilio-retinal Arteries.—It is only in mammals that blood-vessels are present in the retina and in the different species there are striking variations in their arrangement.

In some mammals the retina is devoid of blood-vessels. In some they come entirely from the ciliary blood-vessels in the sclerotic and gain access to the retina at the margin of the optic disc around which they curl. In others there is a mixed supply of blood-vessels, some coming as just mentioned from the ciliary vessels and some from the central retinal vessels.

In all primates the chief supply is the central retinal artery. In all the Leporidæ¹ what are called the retinal vessels are internal to the membrana limitans interna.

The congenital abnormalities which are met with in the retinal blood-vessels in man are comparable in many instances to these different arrangements which are met with in the mammalia.

1. A case has been recorded² of a boy who was born blind and who had a complete absence of all retinal blood-vessels.

2. As already mentioned in some cases of coloboma involving the optic disc, the whole of the retinal blood supply has been seen to come from vessels which have emerged from the margin of the optic disc at different portions of its circumference (cilio-retinal vessels). A similar abnormal blood supply to the retina has also been met with when no coloboma was present.

3. A mixed blood supply to the retina from the central vessels and one or more cilioretinal vessels is by no means infrequent.

Cilioretinal vessels have been estimated as present³

¹ Lindsay Johnson. Philosoph. Trans. of the Royal Society of London, 1901, 42.

² V. Graefe. Arch. f. Ophth., I., 1854, 1.

³ Lang and Barrett. R. Lond. Ophth. Hosp. Rep. XII., 1888, 59.

in 17 per cent. of a series of cases examined ophthalmoscopically. They are recognized by emerging from the margin of the optic disc with a sharp bend not in the direction of the central vessels but of the sclerotic. Cilio-retinal veins are less common than cilio-retinal arteries. The connection of these vessels with the ciliary vessels in the sclerotic has been anatomically demonstrated.¹

Retinal vessels are sometimes found to arch forward for a portion of their extent away from the retina. Whether they penetrate the hyaloid membrane and pass actually into the vitreous humour has not been determined. Their abnormal position can be explained as a failure of the outer vessels of the fetal vitreous humour to become incorporated in the nerve-fibre layer of the retina.

Atypical Development of the Vitreous Humour.—As a congenital malformation a portion of the vitreous humour is sometimes found composed of fibrous tissue, a condition which is usually associated with a persistence of its vascular supply.

This atypically developed vitreous may be met with in different situations. One of the commonest is at the back of the lens where it forms a thick membrane into which the central hyaloid artery passes and breaks up (Fig. 25). Such a condition, as already mentioned, is frequently associated with a defect in development of the posterior capsule of the lens.

If the lens substance is clear, the symptoms to which it gives rise closely resemble those of a glioma of the retina, and several eyes in which it was present have been excised under the supposition that they contained such a growth.

In a new-born child there is seen immediately behind the lens the glistening, greyish-yellow reflex to which the fibrous tissue gives rise, and the branches of the central hyaloid artery which course through it resemble very closely the branches of the retinal vessels seen on the surface of a gliomatous growth.

¹ E. Nettleship. R. Lond. Ophth. Hosp. Rep., IX, 1877, 161.

The way in which the blood in the central hyaloid artery in these cases escapes from the eye has been the source of much speculation. There is no central vein running with the artery. The exit of the blood by the anterior ciliary veins, which takes place in the fetal state, though present in some cases, has been excluded in others. It is possible that a communication with the retinal veins may

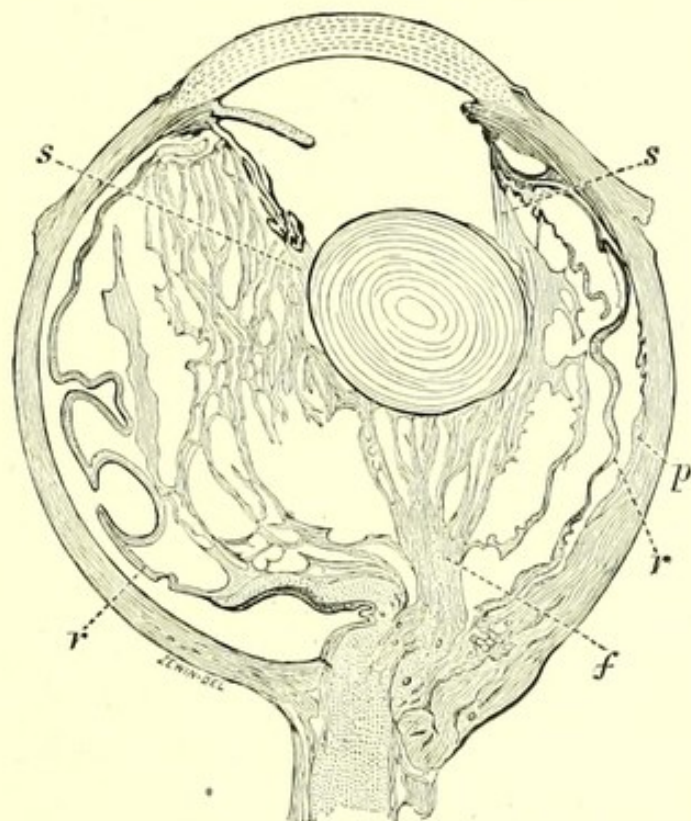


FIG. 36.—Semi-diagrammatic section of a microphthalmic eye with a coloboma of iris and choroid and a band of fibrous tissue in the vitreous, stretching from the posterior pole below the optic disc to back of the lens, which latter has been held back by it, the anterior parts of the eye having grown forwards, the ciliary processes being much elongated. *s*, Suspensory ligament; *r*, retina; *f*, fibrous tissue in vitreous; *p*, coloboma of choroid.

sometimes exist, for in a primitive condition of the vitreous humour such a communication does occur; it has not yet, however, been demonstrated anatomically in these cases.

Eyes with atypically developed vitreous humour frequently do not expand to their normal dimensions, being microphthalmic.

The fibrous tissue, unlike the normal vitreous, is very tough and inelastic so that on the growth and expansion of

the globe the structures to which it is attached often become distorted or displaced.

The ciliary processes may be held attached to the membrane behind the lens, becoming much stretched and attenuated. A fold of retina in the region of the ora serrata may become drawn forward by an adhesion to the membrane.

A band of atypically developed vitreous adherent to the back of the lens and to the walls of the globe may hold the former down so that on expansion of the globe it becomes displaced backward and downward, possibly also causing some distortion in its shape (Fig. 36).¹

Adhesion of bands of non-expansile, atypically developed vitreous may also lead, on growth of the eye, to separation of the retina from the pigment epithelial layer; *i.e.*, separation of the two layers of the secondary optic vesicle. Sometimes the separation extends into the region of the ciliary body, the non-pigmented layer of cells of the pars ciliaris retina being drawn away from the pigmented layer (Fig. 29).

Cases have also been described in which tissue similar to this atypically developed vitreous had extended from the back of the lens round its lower border to the anterior part of the ciliary body with which it had become blended. Its union to the walls of the globe in that situation had checked the forward growth of the iris and so caused a coloboma of that structure.

Atypically developed vitreous is sometimes met with in the lower part of the eye and found to be continuous with the sclerotic through the ocular cleft, the adhesion of the structures having obstructed its closure.

Many of the above changes described as resulting from atypical development, of the vitreous are only to be discovered on pathological examination. There are cases, however, in which ophthalmoscopically white bands or masses of fibrous-looking tissue are seen with blood-vessels in them, where the presumption is that the defect is of a similar nature. Support being afforded to such a view from the de-

¹ Treacher Collins. Trans. Ophth. Soc. of the U. K., XIII, 1893, 117.

fect of vision having been noted since birth, and from the location of the fibrous tissue either in the track of the central hyaloid artery or in the position of the ocular cleft.

Why the mesoblastic tissue which invaginates the primary optic vesicle, and usually develops into the delicate reticulum of the vitreous, should sometimes be transformed into dense connective tissue is not definitely known. The frequent association of the condition with a persistent vascular supply suggests that it is the presence of blood-vessels

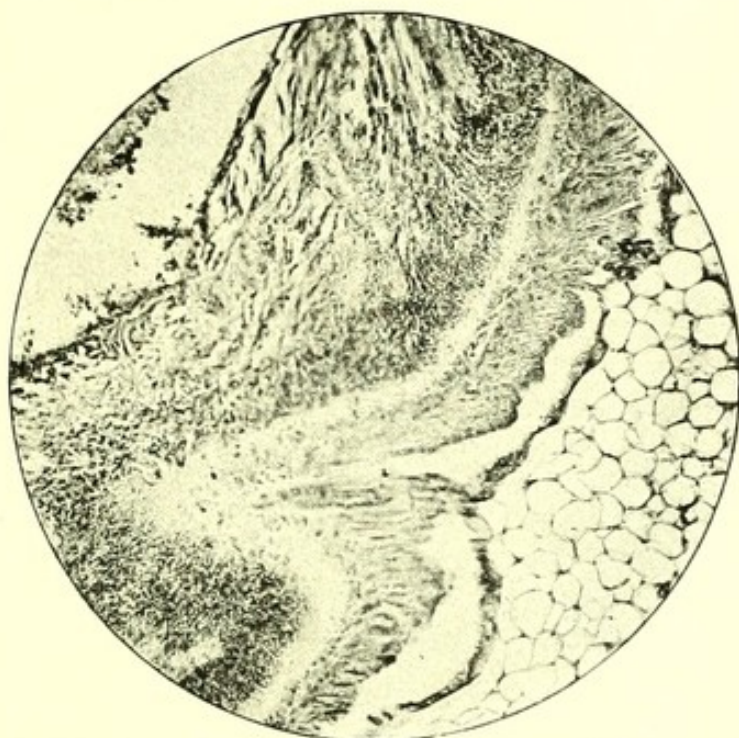


FIG. 37.—A portion of the retina and atypically developed vitreous from a microphthalmic eye. The atypically developed vitreous shown on the right-hand side of the figure is transformed into adipose tissue.

which causes the tissue to become more highly developed. In some cases the fibrous tissue has been found to have undergone fatty changes, adipose tissue then takes the place of the vitreous (Fig. 37).¹

The frequent association of a membrane of atypically developed vitreous at the back of the lens with a defect in development of its posterior capsule suggests, that the former is a compensatory change to make good the defect caused by the latter.

¹ M. S. Mayou. Trans. Ophth. Soc. of the U. K., XXIV, 1904, 355.

Muscae Volitantes.—Most people can perceive entoptically when looking at a white surface opacities which slowly float in front of them. They present various shapes, usually resembling threads or portions of a net with beads on them.

These so-called "*muscae volitantes*" are due to opacities in the vitreous humour and must be regarded as a physiological peculiarity. They consist of portions of the network

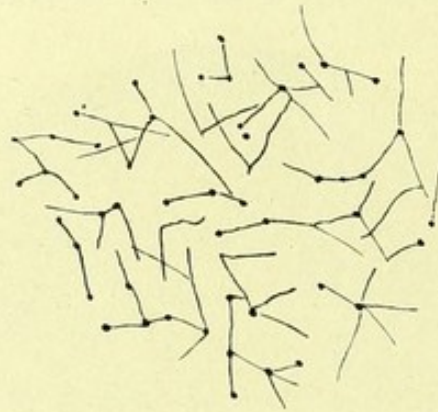


FIG. 38.—Branching fibres with granules on them from the vitreous humour of a normal human fetal eye. $\times 300$.

of fibres and granules which, as already mentioned, extends throughout the developing vitreous in the fetal eye (Fig. 38).

Congenital Defects in the Suspensory Ligament of the Lens.—Defect in the development of the suspensory ligament of the lens may result in absence of some of its fibres, or in a persistence in the cellular character of the adhesions between the ciliary body and the lens capsule from which its fibres are formed.¹

The absence of a portion of the suspensory ligament is most frequently met with in the lower part of its circumference; *i.e.*, in the position in which a coloboma of the iris and ciliary body usually occurs. The probable explanation of its failure in development in such cases is, that imperfect or delayed closure of the fetal ocular cleft prevented the ciliary body from coming in contact with the side of the lens

¹ Treacher Collins. Royal London Ophth. Hosp. Rep., XIII, 1890, 81.

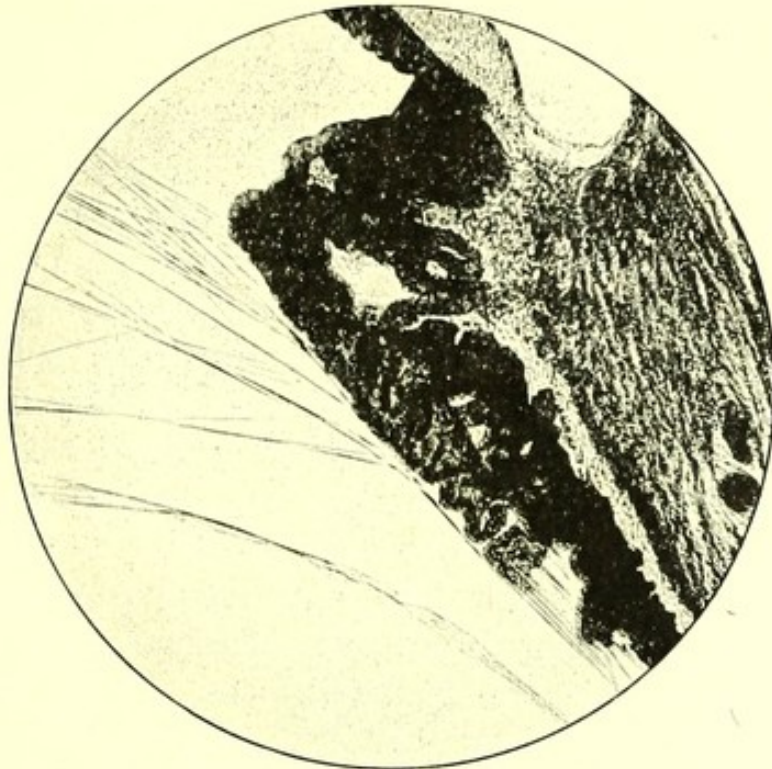


FIG. 39.

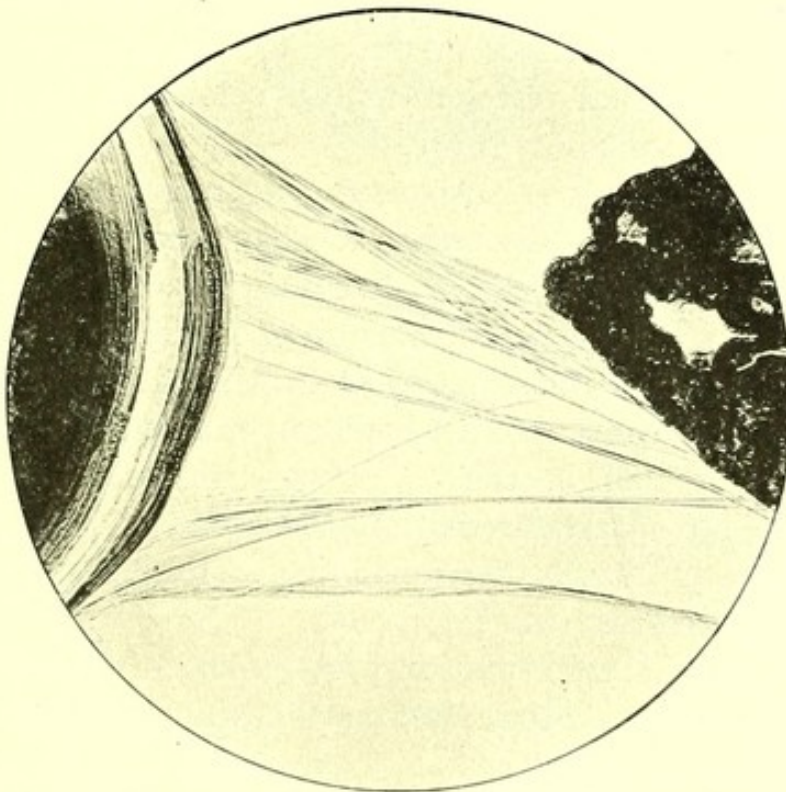


FIG. 40.

FIGS. 39, 40.—Show the suspensory ligament of the lens in sections of a normal human eye. The foremost fibres shown in Fig. 40, are the orbiculo-antero-capsular fibres, the prolongation of which backwards to the non-plicated part of the ciliary body is shown in Fig. 39. The hindermost fibres shown in both figures are the orbiculo-postero-capsular fibres. The cilio-equatorial fibres can be seen in Fig. 40 crossing the orbiculo-antero-capsular fibres, and passing direct from between the ciliary processes to the equator of the lens. The cilio-postero-capsular fibres are shown in Fig. 40, and at their commencement in Fig. 39. They cross the cilio-equatorial and orbiculo-antero-capsular fibres, and pass to the back of the lens. From photomicrographs by E. Collier Green.

at the time when the adhesions between those structures are usually formed.

There must, however, be other causes for the defect as it is occasionally met with in other positions, and in eyes without any sign of coloboma of the uveal tract.

Owing to the absence of the fibres of the suspensory ligament there may be a complete gap involving its whole thickness, or only certain sets of its fibres may have failed to form, thus: the orbiculo-antero-capsular fibres, which pass from the non-plicated part of the ciliary body to the anterior capsule, may be absent, and the cilio-postero-capsular, passing from the ciliary processes to the posterior capsule, and the orbiculo-posterio-capsular, passing from the non-plicated part of the ciliary body to the posterior capsule, present (Figs. 39, 40).

An absence of a portion of the suspensory ligament necessarily has some effect on the shape and position of the lens, and **congenital ectopia lentis**, **coloboma lentis** and **lenticonus anterior** result from it.

In cases where the suspensory ligament has retained its cellular character distortion or displacement of ciliary processes often occurs. A persistence of the cellular character of the cilio-postero-capsular fibres leads to the permanent attachment of a ciliary process to the back of the lens.

Ectopia Lentis.—Lateral displacement of the lens from a congenital defect in the suspensory ligament must be differentiated from backward displacement due to fibrous tissue bands of atypically developed vitreous which has already been referred to.

It is a rare malformation, but markedly hereditary, usually bilateral with the direction in which the lenses are displaced symmetrically.

In the large majority of cases the lens is displaced upward with a slight inclination either inward or outward. It has been met with displaced horizontally (Fig. 41), also downward and outward and downward and inward, but not directly downward.

Very frequently there is myopia, and monocular diplopia may be complained of.

The iris is tremulous and the anterior chamber generally deeper on the side the lens is absent than elsewhere. On oblique illumination with a dilated pupil and sometimes without, the curved edge of the lens can be seen, the lens appearing grey and the aphakic area outside its margin black.

By reflected light the curved edge of the lens is seen as a dark line in the area of red reflex. In some of the cases,

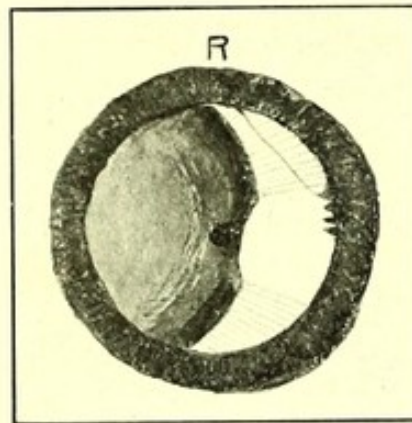


FIG. 41.—Congenital coloboma and displacement of the lens. Opposite the coloboma is a complete gap in the suspensory ligament. There are some persistent remnants of the pupillary membrane.

due to the prismatic action of the edge of the displaced lens, a reduplicated picture of the optic disc can be seen ophthalmoscopically.

The lens often appears smaller and more globular than normal; though usually quite clear it may have opacities in it.

Varying conditions of the suspensory ligament in the aphakic area have been met with clinically. In some cases it is entirely absent and the lens is mobile; in others there are a few fibres only present or gaps in it are visible; in a few cases no break in its continuity could be detected.

Congenital displacement of the lens is brought about by unequal traction on its sides as the ciliary body grows away from contact with it. This unequal traction may be due to:

1. Absence of the whole thickness of the ligament over a large area.
2. Weakness of it over a large area from absence of some of its bundles of fibres.
3. Abnormal toughness of the ligament on one side, it having developed there in an atypical manner and become composed of fibrous tissue.

Coloboma lentis is also a rare form of abnormality; it consists in a congenital defect in the border of the lens pre-

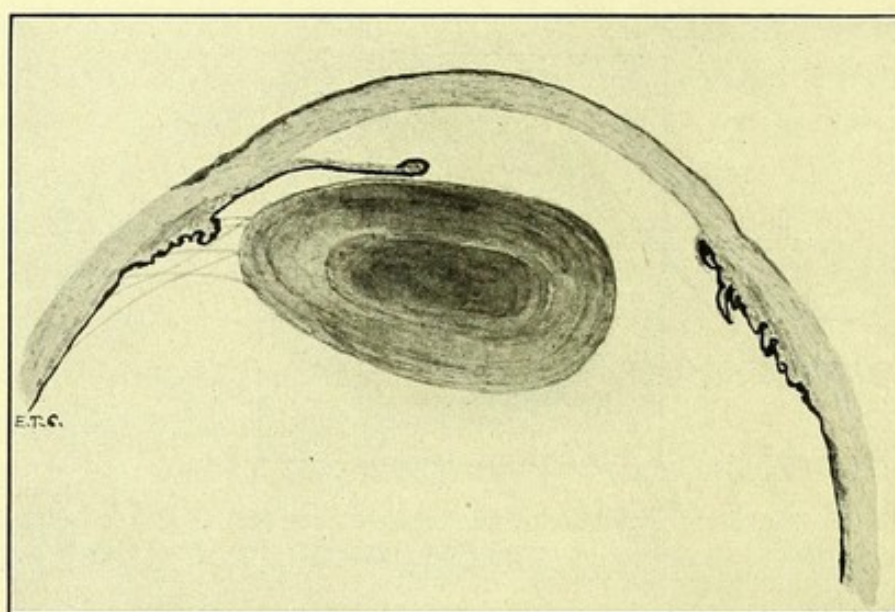


FIG. 42.—Section through the front half of an eye lost from glaucoma, which had a congenital coloboma of the iris and lens. The section passes through the seat of the coloboma in both structures. The suspensory ligament is absent opposite the coloboma of the lens and the latter is broader in that situation antero-posterior than in the rest of its circumference. The angle of the anterior chamber is closed on the opposite side by the root of the iris and there is ectropion of the uveal pigment.

senting the appearance of a loss of substance. It varies in shape, extent, and position. It may be a triangular, crescentic (Fig. 42), or saddle-shaped notch; or the margin of the lens may, instead of presenting its usual curve, at the seat of the defect appear as a straight line, sometimes with little projecting bosses on it. The depth of the defect varies from the slightest indentation to one-fourth of the diameter of the lens. The commonest position for a coloboma of the

lens is its lower border. It has been met with in other positions and two separate defects have been seen in the same lens.

The suspensory ligment is usually absent in the position of the coloboma, though cases have been recorded in which no break in it was observed clinically.

Myopia is frequent in these cases. In patients who have had the defect in one eye only it has been observed that the defective eye is myopic and the unaffected eye emmetropic.

In eyes which have been examined pathologically with coloboma of the lens an absence of the suspensory ligament at the site of the defect has been found, and the lens in that region was broader antero-posteriorly than in other parts of its circumference (Fig. 42).

The size of the defect in the suspensory ligament which occasions a coloboma of the lens is a less extensive one than that which causes its congenital displacement.

On the growth of the ciliary body away from the sides of the lens the part of it opposite the gap in the suspensory ligament is not drawn upon in the same way as elsewhere. The absence of traction on the anterior and posterior surfaces of the lens capsule prevents the lens fibres from becoming compressed and bent in that position. The defect in the transverse diameter is compensated for by an increase in the antero-posterior. The lens is there rounder than normal, as in accommodation when the suspensory ligament is relaxed; hence the frequency with which myopia is met with in these cases.

The variations in the shape of the defect in the lens margin in these cases is attributable to varying degrees of defect in the suspensory ligament. The bosses projecting from a straight margin are accounted for by the presence of a few strands in an area where it is otherwise defective. The presence of fibres in the colobomatous area when viewed clinically does not prove the absence of a defect in the suspensory ligament. One set of fibres may be present such as

those going to the front or sides of the lens while those going to the back are absent. It is necessary for fibres of the suspensory ligament to go to both surfaces of the lens to produce the compression which keeps the lens fibres bent in a state of tension.

Lenticonus anterior has only been seen clinically in a few cases, it has been found pathologically in eyes with congenital buphthalmos and other gross malformations.¹ A conical projection is seen from the surface of the lens at the

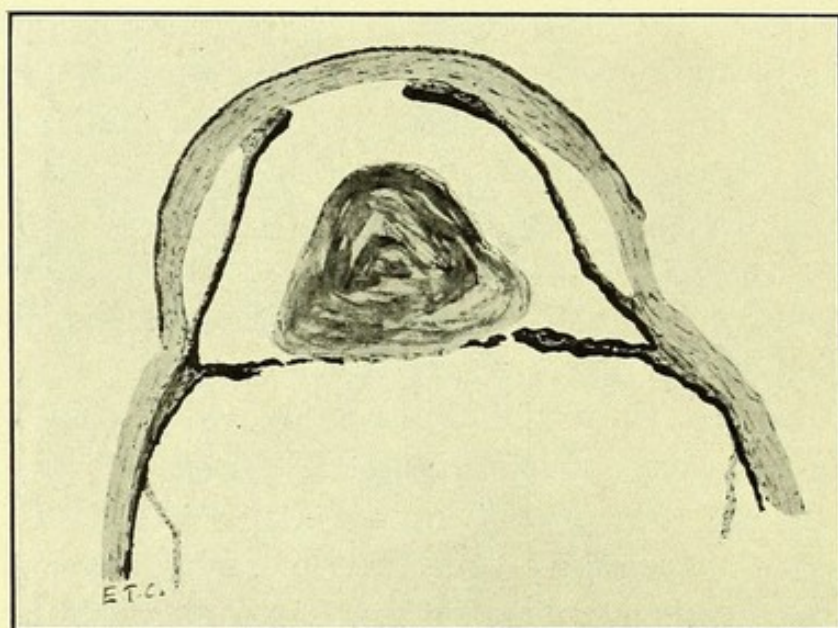


FIG. 43.—Section of the anterior half of the eye of an infant æt. 7 weeks. It shows a congenital anterior staphyloma with anterior synechiæ of the iris. Also lenticonus anterior. The ciliary processes are adherent to the posterior surface of the lens. The fibres of the suspensory ligament which should go to its anterior surface have failed to develop.

anterior pole usually unassociated with any opacity (Fig. 43). Its occurrence may be attributed to a failure in development of the orbiculo-antero-capsular fibres of the suspensory ligament, which stretch from the anterior capsule to the hindermost part of the ciliary body. By the growth of the ora serrata and non-plicated part of the ciliary body outward and backward from the side of the lens, these fibres come to exert considerable traction on its anterior

¹ M. S. Mayou. Trans. Ophth. Soc. of the U. K., XXX, 1910, 120.

capsule and flatten out its anterior surface. When they become relaxed in the act of accommodation the anterior surface of the lens becomes more convex, the most marked alteration taking place at the anterior pole; *i.e.*, there is an approach to the condition of anterior lenticonus which defect is probably due to their complete absence.

Adhesion of the Ciliary Processes to the Back of the Lens.—With the formation of fibrous tissue at the back of

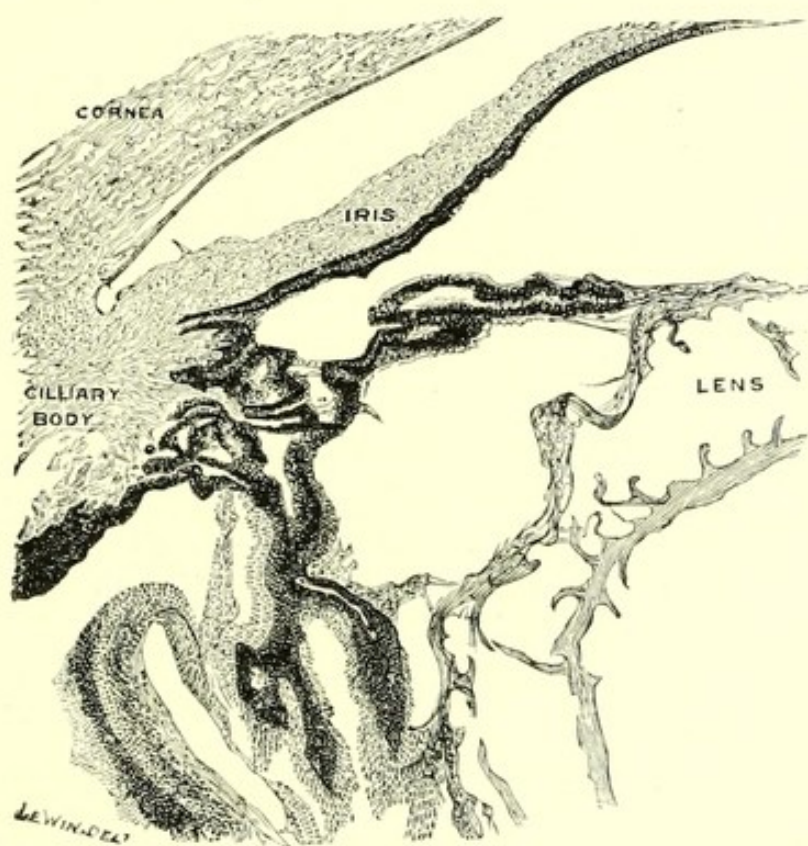


FIG. 44.—Section through the ciliary body in an eye which had atypical development of the vitreous at the posterior surface of the lens with a persistent hyaloid artery. The fibres of the suspensory ligament are represented by cellular adhesions passing from the ciliary body to the lens capsule. The lens fibres have become much disorganised as the result of the hardening reagent. Case recorded in the R. Lond. Ophth. Hosp. Reps., XIII, 1890, 81.

the lens due to atypical development of the vitreous humour, defects in the suspensory ligament are frequently associated (Figs. 44, 45).

The cilio-posterior-capsular fibres of the ligament, instead of becoming elongated on expansion of the globe, into delicate strands of tissue, may persist as fibrous tissue.

Some of the ciliary processes then remain in direct contact with the lens capsule and being much stretched become considerably attenuated. When the lens remains clear these elongated ciliary processes can be seen clinically on its posterior surface. Pigmented patches on the back of the lens sometimes occur, which are probably the seat of adhesions which have subsequently given way with the growth of the eyeball.

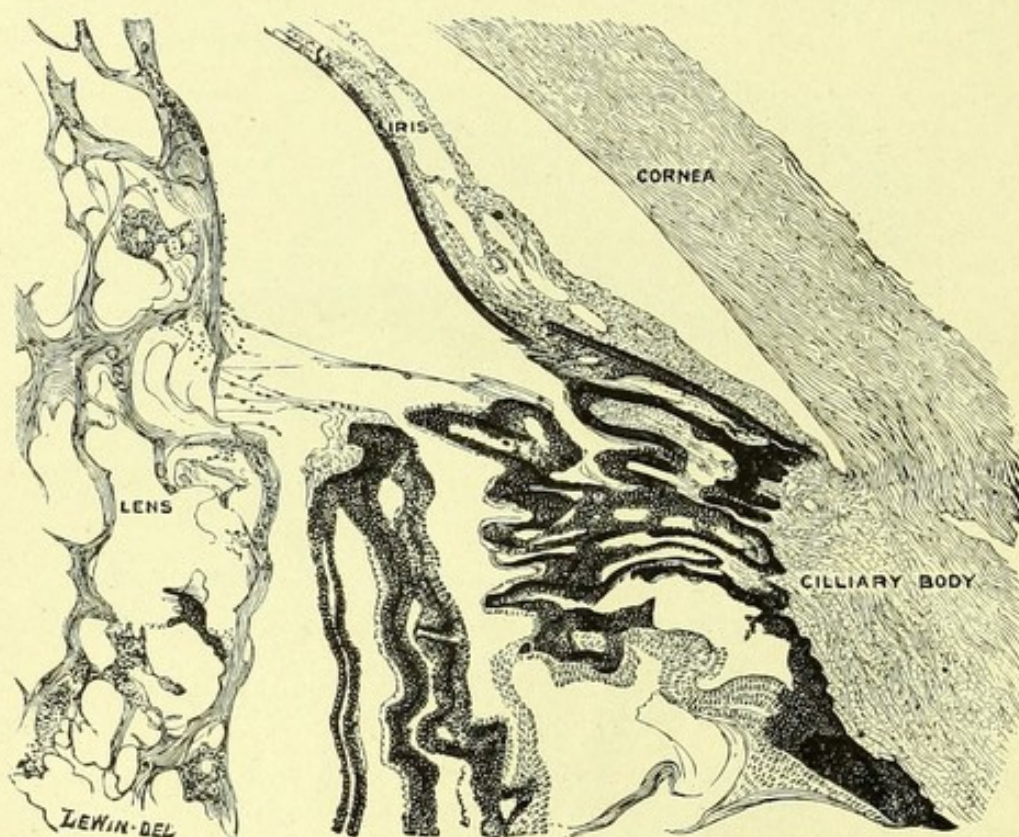


FIG. 45.—Section through another part of the ciliary body from the same eye as Fig. 44. The fibres of the suspensory ligament of the lens are shown with nuclei on them.

IV. Aberrations Connected with the Encircling Mesoblast.

The lens vesicle becomes separated from the surface epiblast by the growth in between them of mesoblastic cells from the sides. From this mesoblast are gradually differentiated the substantia propria of the cornea; Descemet's membrane and its lining endothelium; the ligamentum pectinatum; and the antero-fibro-vascular sheath of the lens.

The hyaline layer of Descemet's membrane can be seen as a thin delicate membrane in the human fetus of the sixth week. It increases in thickness with the growth of the eye and is probably the product of the endothelial cells on its inner surface.

The cells of the mesoblastic tissue anterior to it multiply rapidly and become elongated out into fibres. From them is formed the substantia propria of the cornea. The cells posterior to it become arranged into two rows, from the anterior of which is developed the endothelium of Descemet's membrane, whilst in the posterior, blood-vessels are formed converting it into the anterior fibro-vascular sheath of the lens.

The site of the ligamentum pectinatum in the fetal eye is at first occupied by a collection of round cells radiating from a single row lining the back of the cornea. These blend with others which form the basis of the ciliary muscle. The fibres of the ligamentum pectinatum stain and react in precisely the same way as the hyaline layer of Descemet's membrane and, like it, are probably the product of the cells which ultimately line them. Schlemm's canal can be distinguished as a ring of cells before the development of the ligamentum pectinatum is complete.

The blood-vessels which pass into the anterior fibro-vascular sheath of the lens from the anterior ciliary arteries are formed later than the vessels in the posterior fibro-vascular sheath, which are derived from the invaginating mesoblasts. They are arranged in loops which give off fine branches which anastomose. The main loops come close together at the anterior pole of the lens but do not join.

The iris is formed by a prolongation forward of the two layers of the secondary optic vesicle beneath the anterior fibro-vascular sheath, and the deposition of mesoblastic tissue external to them to constitute its stroma. In its extension forward the secondary optic vesicle insinuates itself between the lens capsule and the anterior fibro-vascular

sheath, pushing the prolongation of the posterior fibro-vascular sheath which joins the latter before it. That portion of the anterior fibro-vascular sheath which extends across the pupil has been termed the pupillary membrane.

It has been suggested that the muscular tissue of the iris is not mesoblastic in origin but the product of its pigment epithelial layers.¹

The mesoblastic tissue immediately surrounding the secondary optic vesicle when it is first formed consists of a mass of undifferentiated cells. The first indication of the formation of the choroid is the development of blood-vessels in larger numbers in the inner part of this tissue than in the outer. The cells composing the outer part, or future sclerotic, become lengthened and transformed into fibrous tissue. The average time at which pigment first makes its appearance in the branched cells of the choroid is the seventh month; the pigmentation of the stroma cells of the iris occurs much later, not commencing until after birth.

The aberrations which may arise in connection with the formation of the encircling mesoblast are:

Atypical development of the mesoblast intruding between the surface epithelium and lens vesicle—**congenital opacities and vascularity of the cornea—congenital anterior synechiæ of iris, pupillary membrane and lens—congenital anterior staphyloma.**

Defective development of the ligamentum pectinatum and canal of Schlemm—**congenital glaucoma or buphthalmos.**

Failure in disappearance of the pupillary membrane—**persistent pupillary membrane.**

Failure in the growth forward of the secondary optic vesicle and in the deposition of mesoblastic tissue external to it—**aniridia—coloboma of the iris—pseudo-coloboma of the iris—polycoria.**

Defective development in the stroma of the iris—**corectopia—microcoria—discoria.**

¹ Forsmark. "The Muscular Tissue of the Human Iris; its Structures and Development." Jena, 1905. See *Ophth. Review*, XXIV, 1905, 134.

Failure in differentiation of mesoblast immediately external to the hinder part of the secondary optic vesicle—**coloboma of the choroid**.

Failure in deposition of pigment in mesoblastic tissue encircling the secondary optic vesicle and in the outer layer of the secondary optic vesicle—**albinism**.

Excessive deposition of pigment in the above structures—**melanosis**.

Congenital Opacities and Vascularity of the Cornea.—Congenital opacities of the cornea are often the outcome of injuries at birth (see page 254), some may be due to keratitis, but others are undoubtedly developmental defects.

Congenital opacity and vascularity are often associated but not always. In the form of congenital opacity termed **arcus juvenilis**, there is a complete ring of opacity at the margin of the cornea without abnormal vascularity. It resembles somewhat an arcus senilis, but differs from it in not having a diaphanous zone between the margin of the cornea and the opacity.

In the congenital opacity spoken of as **sclerophthalmos** there is usually also some vascularity. In this condition the margin of the cornea cannot be defined; it looks as though a portion of the sclerotic was prolonged on into the cornea. The opacity is of a dense white colour and may occupy the whole or a portion only of the circumference of the cornea.

Congenital opacity of the cornea is frequently associated with microphthalmia or congenital anterior staphyloma. Microscopical examination of corneæ presenting this condition has shown an absence of the anterior limiting membrane, some irregularity of the fibrous-tissue lamellæ of the substantia propria, and the permeation of them with blood-vessels (Fig. 59).

At what period of fetal life the cornea becomes a transparent tissue is not known. It is never a vascular structure. The abnormal extension of blood-vessels into it is the probable cause of the formation of opacity in some cases.

Congenital Anterior Synechiæ of Iris, Pupillary Membrane or Lens.—Imperfect differentiation of the mesoblast, which intrudes between the surface epithelium and the lens vesicle, into the several structures which are derived from it may result in the formation of congenital synechiæ of the tissues bounding the anterior chamber.

The anterior layers of the iris which are formed from the anterior fibro-vascular sheath of the lens may fail to become differentiated from the endothelial cells lining

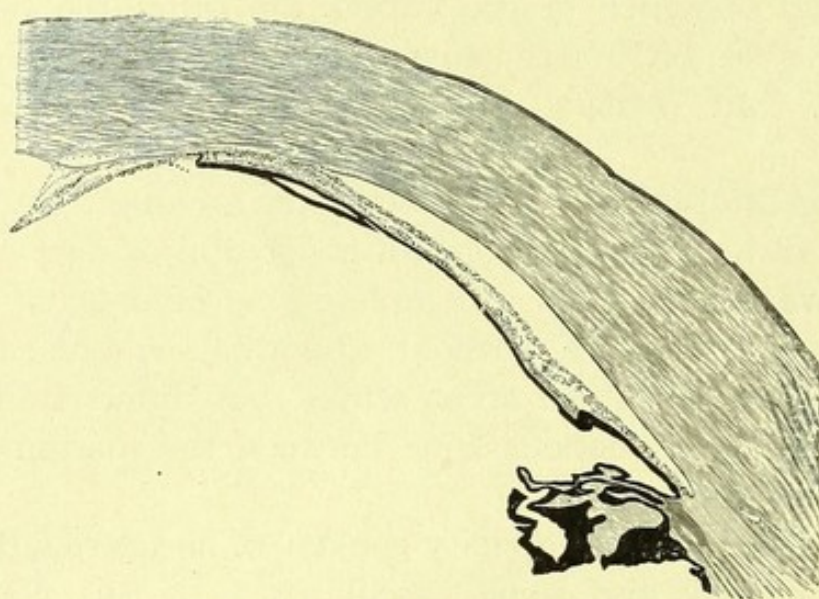


FIG. 46.—Congenital anterior synechia of a persistent pupillary membrane and of the iris.

Descemet's membrane and an anterior synechia of the iris results (Fig. 46). A portion of the pupillary membrane which has failed to disappear may in a similar way remain attached to the back of the cornea (Figs. 47, 48, 49).¹

In some cases where a congenital anterior synechia of these structures occurs, at the seat of the adhesion there is an absence of the hyaline layer of Descemet's membrane, the stroma of the iris or pupillary membrane being continuous with the substantia propria of the cornea; these structures apparently having failed to become differentiated off from one another.²

¹ Treacher Collins. Trans. Ophth. Soc. of the U. K., XXVII, 1907, 203.

² M. S. Mayou. Trans. Ophth. Soc. of the U. K., XXX, 1910, 120.

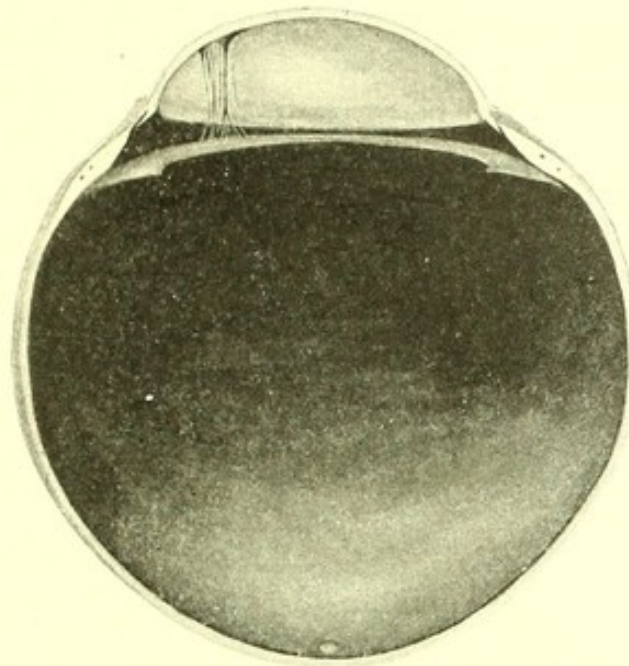


FIG. 47.—Shows the lateral half of a cat's eye from which the lens has been removed. Persistent tags of the pupillary membrane stretch from the anterior surface of the iris to the back of the cornea. Case recorded in the *Trans. Ophth. Soc. of the U. K.*, XXVII, 1907, 203.

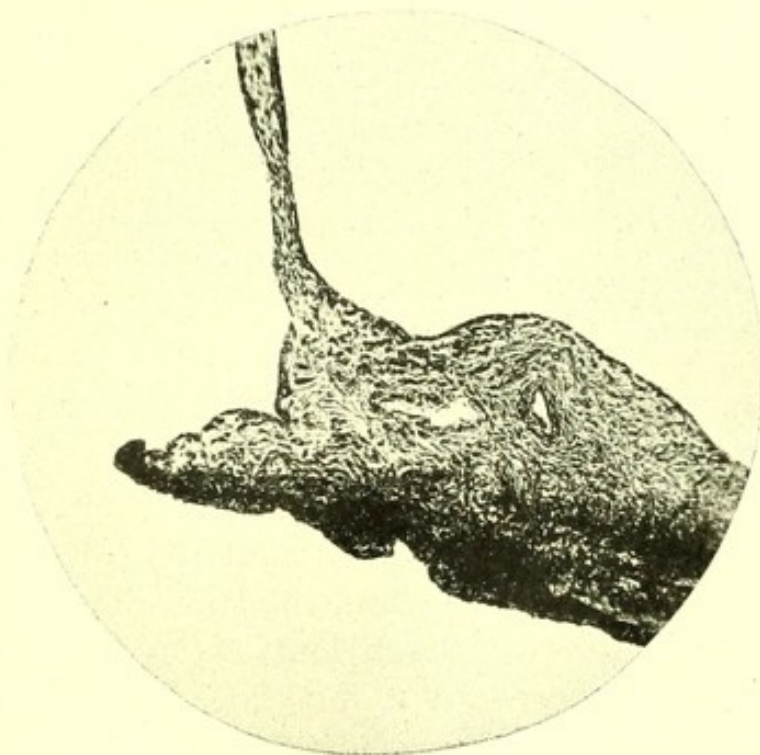


FIG. 48.—Shows the microscopical appearances of the pupillary membrane where it starts from the iris present in the cat's eye depicted in Fig. 47. From a photo-micrograph by E. Collier Green.

When there is a very extensive congenital adhesion of the iris to the cornea the channels for exit of fluid from the eye at the angle of the anterior chamber become blocked, the tension of the eye is increased, and an anterior staphyloma is formed.

The case of a microphthalmic eye in a chick has been recorded¹ in which Descemet's membrane had failed to

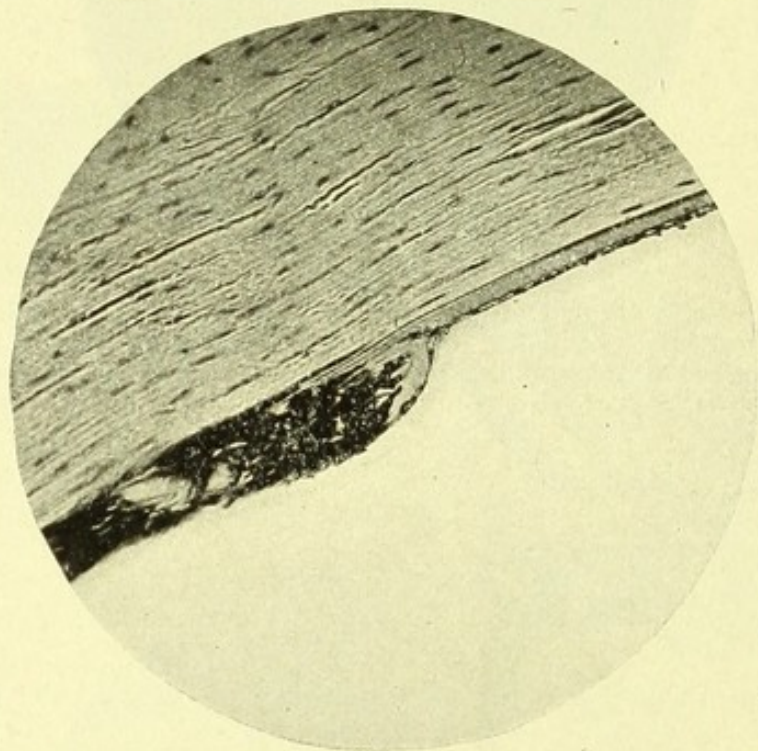


FIG. 49.—Shows a piece of pigmented pupillary membrane adherent to the substantia propria of the cornea, Descemet's membrane being there absent. From the cat's eye depicted in Fig. 47. From a photomicrograph by E. Collier Green.

develop and the anterior capsule of the lens was adherent to the substantia propria of the cornea. The adhesion of these structures obstructed the growth inward of the iris between them. In part of its circumference it was absent and in part had extended behind the lens (Fig. 50).

Congenital Anterior Staphyloma.—Congenital anterior staphyloma of the cornea is a very rare condition. It presents both clinically and pathologically appearances very

¹ Treacher Collins and J. H. Parsons. Trans. Ophth. Soc. of the U. K., XXIII, 1903, 241.

similar to those of anterior staphyloma which occurs in infancy as the result of a perforating ulcer.

There is a variable amount of corneal opacity and often vascularity. The iris is in contact, or adherent, to the posterior surface of the cornea so that there is no anterior chamber and no means of escape of the aqueous humour

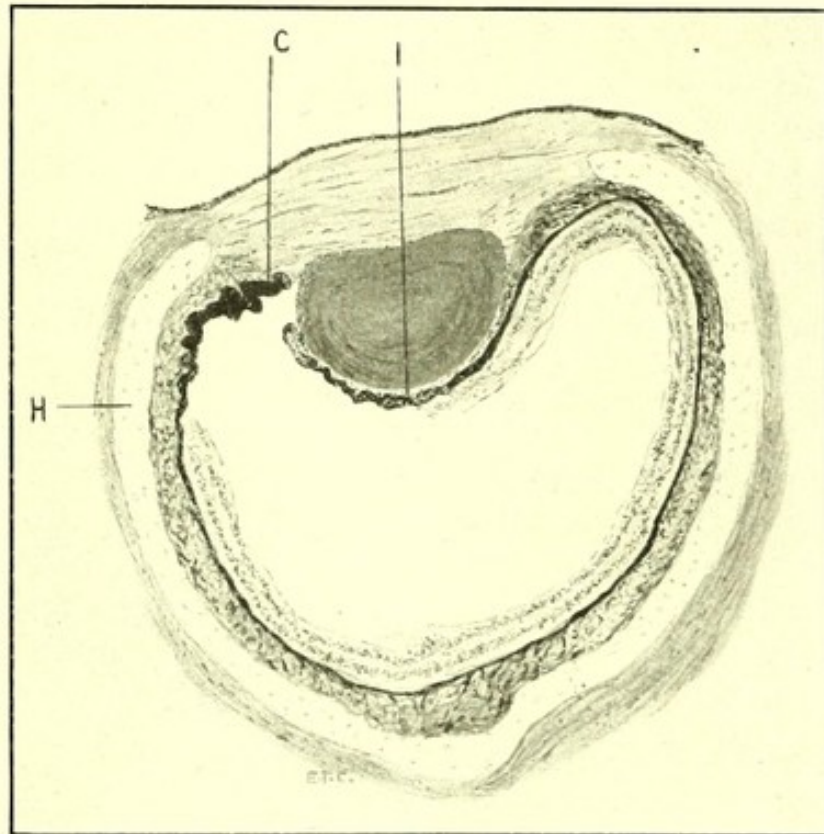


FIG. 50.—The microphthalmic eye of a chick in which the lens has remained adherent to the cornea. The iris at *C* has been arrested in its growth inward. At *I* it has extended round the posterior surface of the lens instead of between it and the cornea. *H* points to the hyaline cartilage in the sclerotic.

from the eye, the increase of intraocular tension thereby occasioned causing the expansion of the anterior part of the globe.

Several observers¹ have been led to infer that the change in these cases must have resulted from intrauterine ulceration. It is, however, very difficult to believe that a perforating ulcer of the cornea could occur *in utero*, heal, and result in a fully developed anterior staphyloma before birth. In

¹ G. Coats. *Ophthalmoscope*, VIII, 1910, 248.

one recorded case of congenital anterior staphyloma the whole of Descemet's membrane and the ligamentum pectinatum were found absent.¹ The complete absence of these structures never results from ulceration of the cornea.

It would seem in the cases which have been examined pathologically that the mesoblast which grows in between the surface epithelium and the lens, over the whole or a portion of its extent, failed to become in any way differentiated. Over the affected area the anterior fibro-vascular sheath and Descemet's membrane were not formed, the mesoblast being there entirely converted into a vascularized mass of fibrous tissue.² The two layers of the secondary optic vesicle which form the pigment epithelium of the iris had spread beneath it, but as there was no anterior fibro-vascular sheath no stroma of the iris developed. The blood vessels which should have supplied it passed instead into the mass of undifferentiated fibrous tissue.

Congenital Glaucoma or Buphthalmia.—Congenital glaucoma can usually be accounted for by some defect in the development of the ligamentum pectinatum or canal of Schlemm, the main channels through which the intra-ocular fluid escapes from the eye. The cornea and sclerotic in an infant's eye are very expansile structures and increase of tension occurring at that stage of life causes them to stretch, the whole globe becoming enlarged. An enlargement of the cornea and deepening of the anterior chamber produces the appearance of a bullock's eye hence the term "buphthalmia" (Fig. 51).

Various defects of development have been met with in connection with the filtration area at the angle of the anterior chamber in cases of buphthalmia.³ The ligamentum pectinatum and canal of Schlemm have both been found absent, Descemet's membrane instead of splitting up into

¹ Treacher Collins. Trans. Ophth. Soc. of the U. K., XXIX, 1909, 169.

² M. S. Mayou. Trans. Ophth. Soc. U. K., XXX, 1910, 120.

³ F. Richardson Cross. Trans. Ophth. Soc. of the U. K., XVI, 1896, 340.

a number of fibres at the angle of the chamber being continued round on to the anterior surface of the iris, the ciliary muscle taking origin from the sclerotic to which also the root of the iris has been found attached.

2) The ligamentum pectinatum has been found normal but the canal of Schlemm absent.

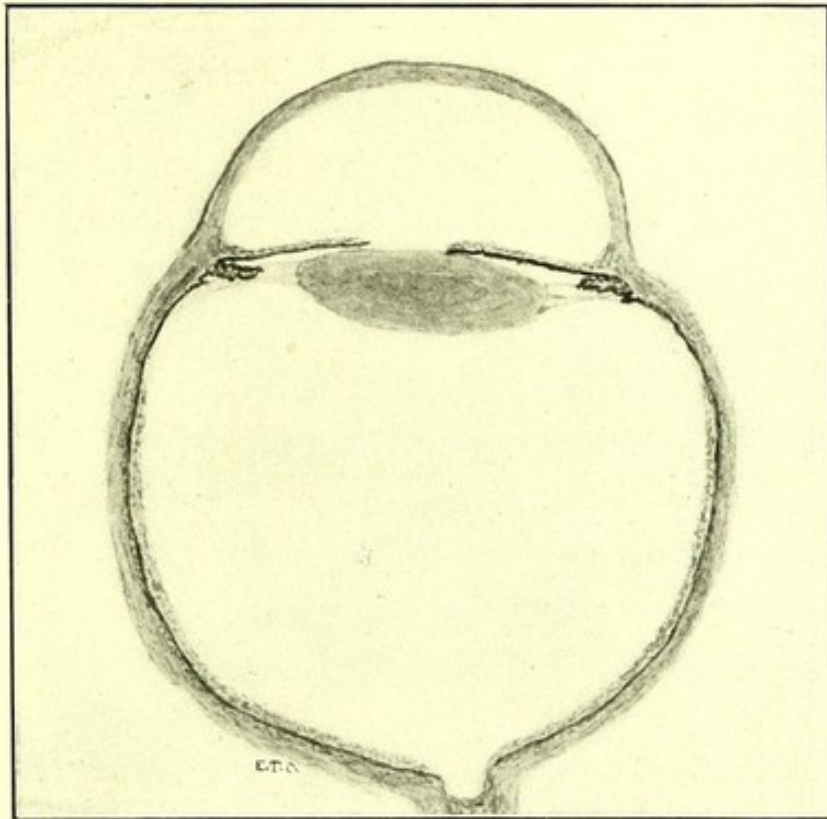


FIG. 51.—Section through an eye the subject of congenital glaucoma or buphthalmia. There is an enlargement of the globe in all its diameters. Both cornea and sclerotic are stretched and thinned. The effect of the stretching on the lens has been to flatten it antero-posteriorly. The optic disc is cupped.

In nearly all mammals the fibres of the ligamentum pectinatum are more numerous and fill up more of the angle of the anterior chamber than in man.

The size of the cornea compared with the size of the globe is much less in the human eye than in those of other mammals. Its diameter in the human eye is considerably less than half the antero-posterior diameter of the globe, in all other mammals it is more than half except in the higher apes.

The reduction in the size of the cornea, as compared with that of the globe, seems to be associated with a prolongation outward of the angle of the anterior chamber and a simplification of the structure of the ligamentum pectinatum. In the human fetus the relative size of the cornea to the globe and the condition of the angle of the anterior

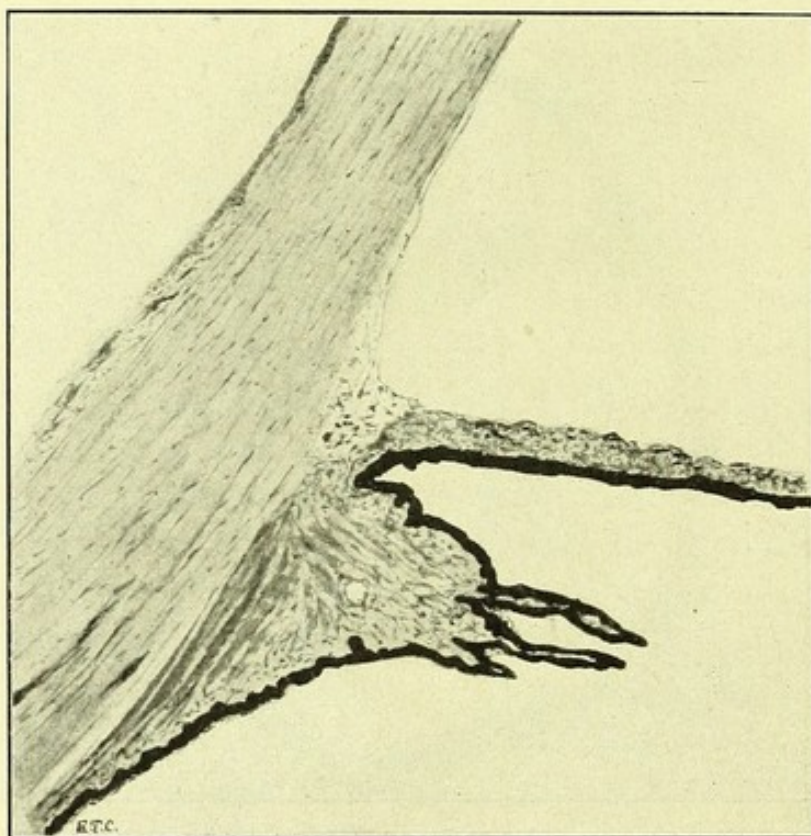


FIG. 52.—The angle of the anterior chamber in an eye affected with congenital glaucoma, or buphthalmia. It shows an imperfect separation of the root of the iris from the back of the cornea.

chamber and ligamentum pectinatum resembles that which is met with in the lower animals.

In some cases of buphthalmia the prenatal condition of the ligamentum pectinatum is found; a network of fibres filling up a space at the angle of the anterior chamber, which in the normal fully developed eye is part of the anterior chamber (Fig. 52). It seems probable that the persistence of this prenatal state of the ligamentum pectinatum is re-

sponsible for obstructed exit of fluid from the eye and the occurrence of increase of tension.¹

The adhesions which are met with stretching across the angle of the chamber in these cases vary in density. They may be broad and compact or only a few fibres or strands extending across a widely open angle. Doubtless these adhesions with the increase in the size of the globe and deepening of the anterior chamber, become considerably stretched and attenuated, some even giving way.

Cases of buphthalmia are occasionally met with in which the progress of the affection after a certain time seems to become spontaneously arrested, the tension becoming normal and the globe ceasing to enlarge. The breaking through and stretching of congenital adhesions such as those above referred to may be the explanation of this arrest.

Persistent Pupillary Membrane.—The pupillary membrane, which consists of that portion of the antero-fibro-vascular sheath which stretches across the pupil, exists until between the seventh and eighth month of fetal life and then disappears. It consists of some delicate fibres and a plexus of small blood-vessels whose walls are constituted of endothelial tubes with spindle cells external to them.

When portions of it persist permanently they are usually of stouter consistency and more cellular structure than that of the membrane in the fetal state. Like the stroma of the iris before birth the fetal membrane is unpigmented, but portions of it which persist may also, like the stroma of the iris, become pigmented.

The frequency of the persistence of portions of the pupillary membrane has been estimated by two different observers as follows: Out of 3508² people it was present in thirty-two, or 0.9 per cent.; in eighteen there were filaments only, in fourteen a membrane; three cases had remnants present in both eyes.

¹ Treacher Collins. *Compte.-Rendu*, IX, Congrès Internat. D'Ophtal., 88.

² Franke. *Archiv. f. Ophth.*, XXX, 1884, 4.

Out of 3414 people¹ it was found in 68 or 1.7 per cent.; in thirteen, remnants were present in both eyes.

The appearances presented by the persistence of a portion of the pupillary membrane vary considerably; but whatever the arrangement it is always seen to start from the anterior surface of the iris. Not immediately from the pupillary margin but a little distance external to it, usually from one or more of the teeth of the small circle of the iris.

The various forms of persistent pupillary membrane may be classified as follows:

1. Fibres arising from the small circle of the iris and uniting into a membrane in the centre of the pupil.

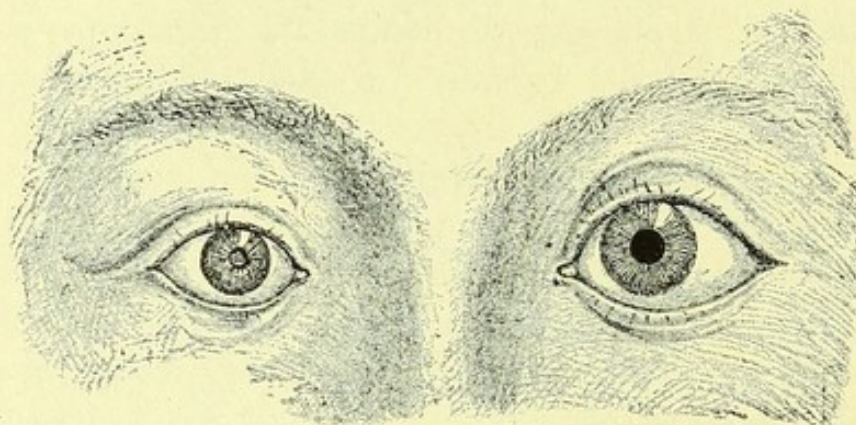


FIG. 53.—Congenital microphthalmia and cataract with persistence of numerous tags of pupillary membrane in the right eye of a girl aged 8 months.

2. Fibres arising at different points in the circumference of the small circle of the iris and stretching across the pupil to form a delicate network in front of it.

3. Fibres running tangentially between two points in the small circle of the iris (Fig. 41).

4. All the toothed projections of the small circle prolonged inward and projecting beyond the pupillary margin (Fig. 53).

5. One or more fibres attached to the small circle of the iris floating free at the other extremity.

6. A loop formed in front of the pupil (Fig. 54).

¹S. Stephenson. Trans. Ophth. Soc. of the U. K., XIII, 1893, 139.

7. One or more fibres arising from the iris attached to the capsule of the lens. Sometimes spoken of as capsulo-pupillary membrane.

8. One or more fibres arising from the iris attached to the posterior surface of the cornea. A condition already referred to on page 66.

9. A piece of membrane, pigmented or unpigmented, adherent to the anterior capsule of the lens without any attachment to the iris.

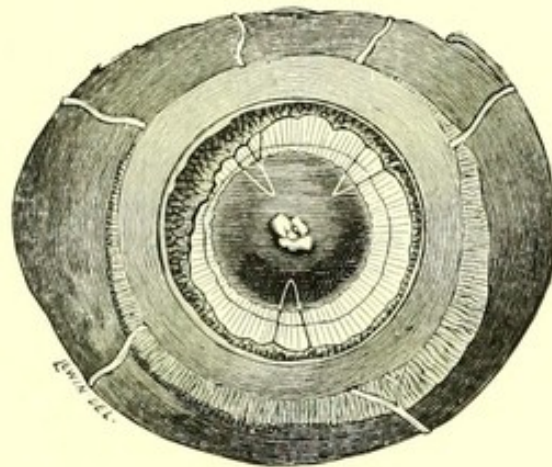


FIG. 54.—Anterior half of the right eye of a patient with apparent aniridia, from which the cornea and sclerotic have been removed, exposing a rudimentary iris, tags of pupillary membrane, lens with an anterior polar opacity, and fibres of the suspensory ligament.

A persistent pupillary membrane may be met with in association with other abnormalities of the iris such as coloboma and aniridia; also with anterior polar cataract or an atypical development of vitreous behind the lens.

Aniridia.—Apparent entire absence of the iris is always a bilateral affection. The sight is defective and the patient acquires the habit of screwing up the lids to shut off the excess of light which enters the eye. It is frequently hereditary.

On looking into the eye the part where the iris should be is black like the pupil. In some cases no iris whatever is visible, in others a small crescentic piece, or little nodules, at the periphery of the anterior chamber can be made out (partial aniridia). By reflected light the margin of the lens

and fibres of the suspensory ligament are clearly visible, sometimes also the ciliary processes.

Opacity of the periphery of the cornea (*arcus juvenilis*), anterior polar cataract, the absence of anterior chamber, and persistence of tags of pupillary membrane are occasional concomitants.

Though clinically no iris may be seen in these eyes, when they are examined anatomically a small rudimentary iris is always found to be present, the length of which varies in different cases and in different parts of its circumference

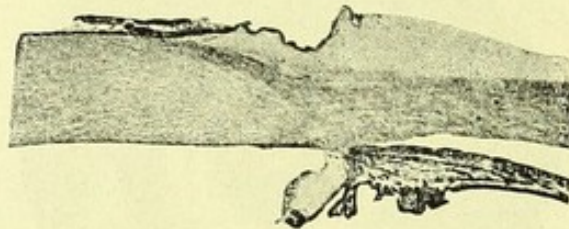


FIG. 55.—Section of an eye, showing a rudimentary iris in which clinically no iris was visible. A persistent tag of pupillary membrane is attached to the tip of iris, and an adhesion stretches between its root and the ligamentum pectinatum.

in the same case. The way in which the sclerotic overlaps the cornea at its periphery serves to hide it from view clinically (Figs. 54, 55).¹

In the rudimentary iris no sphincter muscle is developed and the pigment epithelium at its free border may be plicated or extend further than the stroma, producing so-called ectropion of the uvea (Fig. 18) (see page 21).

An ill-developed ligamentum pectinatum is a not uncommon accompaniment such as has been described on page 72. The angle of the anterior chamber appears imperfectly opened up, adhesions stretching across it between the dwarfed iris and the cornea (Fig. 56). This probably accounts for the predisposition to glaucoma of eyes with aniridia (Fig. 57). The secondary optic vesicle when the iris commences to grow has to insinuate itself between the cornea and anterior fibro-vascular sheath anteriorly.

Treacher Collins. *Ophthalmic Review*, X, 1891, 101 and *Trans. of the Ophth. Soc. of the U. K.*, XIII, 1893, 128.

only and the lens posteriorly, all of which are at that time lying in apposition. Further it has to push in front of it the prolongation* forward of the posterior fibro-vascular sheath which joins the periphery of the anterior fibro-vascular sheath. It is conceivable that an obstruction might arise to an extension inward of the two layers of the secondary optic vesicle in the following three different ways:

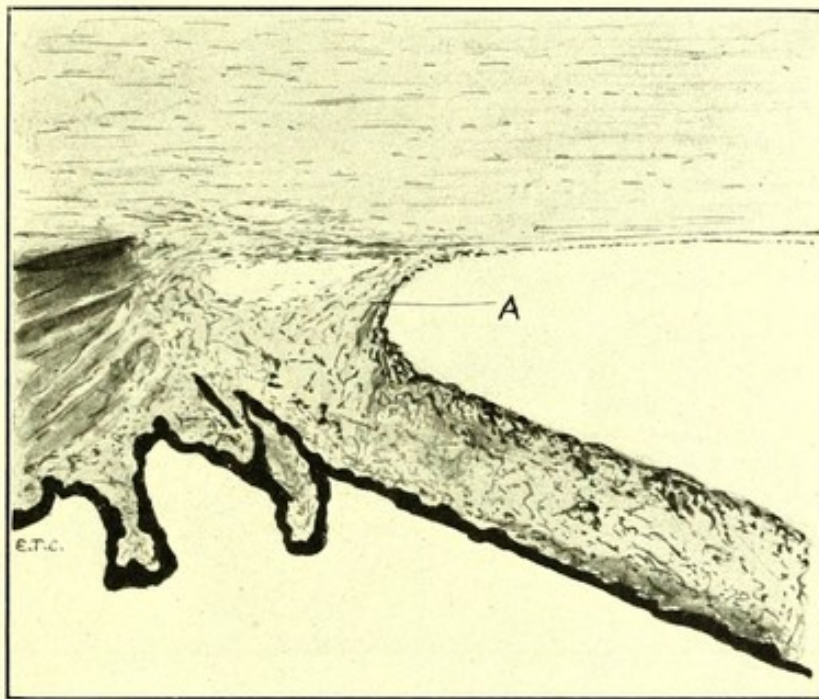


FIG. 56.—A congenital abnormality at the angle of the anterior chamber in a case of "partial aniridia." An adhesion (*A*) exists between the rudimentary iris near its root and the posterior surface of the cornea in the region of the ligamentum pectinatum, the two structures have failed to become completely separated from one another.

1. Prolonged, or abnormally firm adhesion of cornea and lens.
2. Adhesion of the anterior fibro-vascular sheath to the lens capsule.
3. Adhesion of the posterior fibro-vascular sheath to the periphery of the cornea.

As already mentioned a permanent adhesion of cornea and lens has been met with in the microphthalmic eye of a chick which arrested development of the iris (Fig. 50). Adhesions of the pupillary membrane to the lens capsule

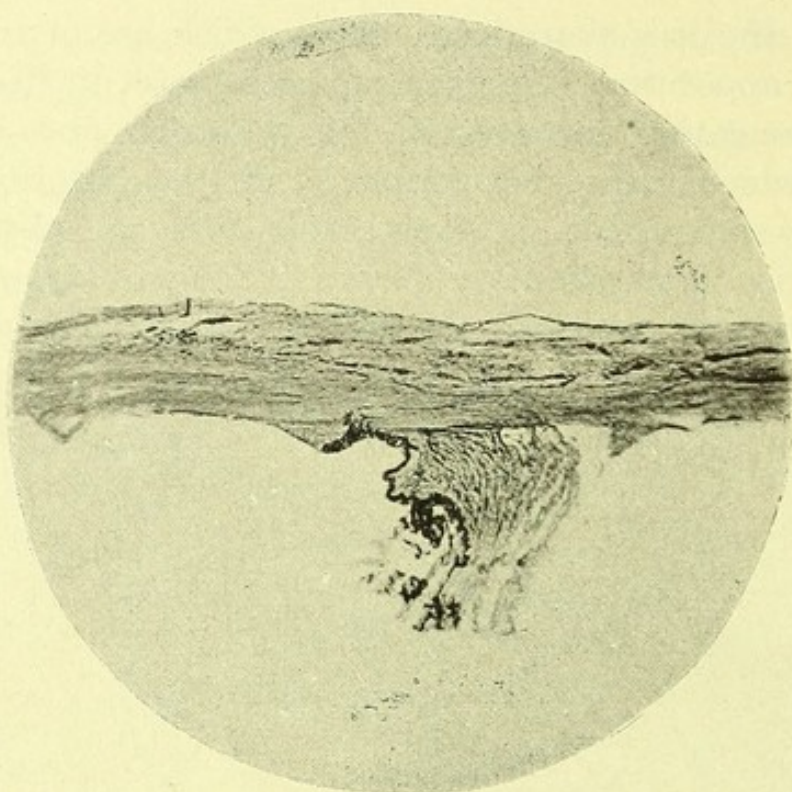


FIG. 57.—Section of the eye of a woman who had congenital aniridia and after a perforating ulcer of the cornea developed glaucoma. A rudimentary stump of iris is shown in contact with the back of the cornea in the region of the ligamentum pectinatum. Case recorded in the *Ophthalmic Review*, X., 1891, 101.

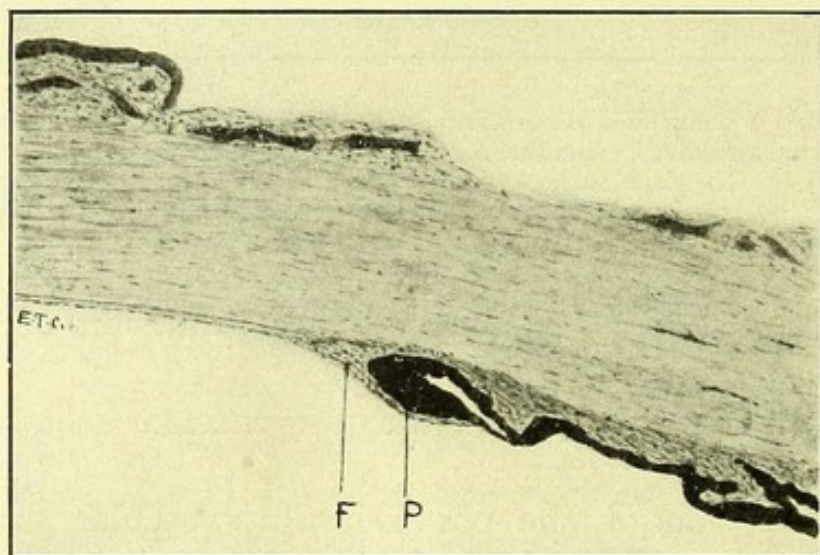


FIG. 58.—Section showing the mode of termination of the ciliary body at the seat of a congenital coloboma of the iris. *P* points to the pigment epithelium on the posterior surface of the ciliary body where the uveal tract terminates; *F* points to some tissue adherent to the ligamentum pectinatum in front of the pigment epithelium and continuous with a layer of cells posterior to it which probably represents a portion of the fibro-vascular sheath.

frequently occurs. A thickened prolongation forward of the posterior fibro-vascular sheath adherent to the periphery of the cornea has been found anatomically in eyes with coloboma of the iris (Fig. 58).

That aniridia is due to some mechanical obstruction to the growth inward of the secondary optic vesicle which forms its posterior layers seems probable, because, as already mentioned, the pigment epithelium has been found in excess and plicated on the small nodule of the iris which is present in these cases. Its frequent association with anterior polar cataract points to prolonged contact of lens and cornea.

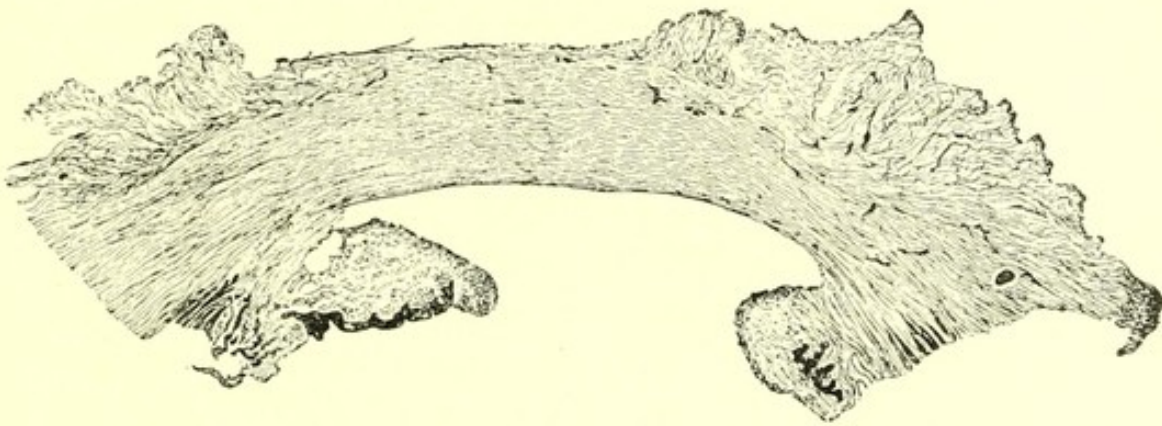


FIG. 59.—Shows the microscopical appearances of the front part of a microphthalmic eye with coloboma of the iris. Note the presence of blood-vessels in the anterior layers of the cornea. Case recorded R. Lond. Ophth. Hosp. Rep., XII, 1889, 289.

Coloboma of the Iris.—A coloboma of the iris is a deficiency in the tissue of the iris causing the pupil to be altered in shape (Fig. 59). It is one of the commonest malformations of the eye. The term **pseudo-coloboma of the iris** is applied to cases in which a portion only of the stroma of the iris is deficient, the deeper layers being present and left exposed.

In the large majority of cases of coloboma of the iris the defect is situated in its lower half, either directly downward, or downward with a slight inclination inward or outward; *i.e.*, in the position of the fetal cleft. It has, however, been met with in exceptional cases upward, inward, and outward.

Two colobomata of the iris may in rare cases occur in the same eye, and in some cases more than half the iris has been found absent, these latter merge into those of partial aniridia already referred to.

The extent and shape of the defect is even more variable than the direction. It may consist of only a slight notch in the pupillary border or the whole thickness of a sector of the iris may be absent from the margin of the pupil up to the ciliary body. Usually the edges of the gap converge to a point at the ciliary margin, the coloboma then, together with the normal pupil, forming a pear-shaped opening. In other cases the margins of the gap run parallel to one another and occasionally in rare instances diverge as they proceed outward so that the widest part is at the ciliary border.

A coloboma of the iris is frequently associated with a coloboma of the other structures of the eye, *viz.*, coloboma of the ciliary body, choroid, suspensory ligament of the lens; but may occur without any other malformation.

Its frequent association with abnormalities of the fetal ocular cleft, and its common occurrence downward, suggest that it is in some way connected with defective closure of the cleft.

The iris is formed by an extension forward of the two layers of the secondary optic vesicles beneath the antero-fibro-vascular sheath; if the cleft in the secondary optic vesicle failed to close, then necessarily in that region there would be a defect in development of the iris. If the closure of the cleft was delayed until after the usual period at which the iris commenced to grow then the time for its development would be shortened.

There are cases of coloboma of the iris which cannot be explained by defective closure of the fetal cleft; *e.g.*, cases where it is situated upward or laterally, or where two gaps are present in the same iris. Such cases can be accounted for in the same way as aniridia (see page 77). Any cause which will arrest the growth of the whole iris acting less extensively will account for a partial absence of the iris.

The iris is composed partly of mesoblast and partly of neural epiblast. In the cases of "pseudo-coloboma" the parts developed from the latter, *viz.*, the pigment epithelial layers, have apparently developed in the normal way, but there has been a defective deposition external to them of mesoblast. This defective deposition of stroma is most likely due to an absence of some of the anterior ciliary blood-vessels.

Polycoria.—The term polycoria is applied to the rare condition in which there is more than one opening in the iris. These openings are not strictly analogous to the normal pupil, for a case has never been met with in which a sphincter muscle surrounded more than one opening in the iris.

The cases of polycoria may be divided into three classes:

1. Cases in which a normally situated pupil is divided into two by a band passing across it, so that it presents the appearance of a figure 8. The band in most cases would seem to be a thickened piece of the pupillary membrane which has remained persistent.

2. Cases in which a coloboma of the iris has a band of tissue passing across it similar in appearance to the stroma of the iris; these cases are sometimes spoken of as "coloboma with a bridge." The position of the bridge is situated a little below the level of the pupillary border and is continuous with the tissue forming the toothed margin of the small circle of the iris. The opening above it is usually pear-shaped and that below it crescentic (Fig. 60).

In such cases there is evidently a defect in the colobomatous area of the part of the iris developed from the secondary optic vesicle, and a formation of a band of mesoblastic tissue from the anterior fibro-vascular sheath which constitutes the bridge.

3. Cases in which there are a number of openings variously situated, often associated with an absence of a



FIG. 60.—Congenital coloboma of the iris with a bridge.

large portion of the iris in one direction. In these cases there has probably been failure of the growth forward of the secondary optic vesicle in a large portion of its circumference and so an absence of the posterior pigment epithelial layers. The mesoblastic stroma derived from the anterior fibro-vascular sheath has been deposited in the form of bands with gaps between them instead of being formed as a continuous structure.

Corectopia, Microcoria, Discoria.—Eccentricity, undue smallness, and a want of rotundity in shape, of the pupil are sometimes associated congenital malformations or may occur independently of one another.

Normally the pupil is not exactly in the centre of the iris, being usually situated slightly downward and inward.

In cases of congenital corectopia it is generally displaced upward and outward. Very frequently displacement of the pupil in one direction is found associated with displacement of the lens in the opposite.

The condition is usually bilateral and symmetrical, and several members of the same family may be similarly affected. This renders it probable that the condition is due to some defect of development and not the outcome of fetal iritis. The association of the affection with ectopia lentis points to some defective budding out of the ciliary processes, as well as of the iris, so that the adhesions between them and the lens capsule which become the suspensory ligament failed to form. The cause of this defective growth of the iris in one part of its circumference has not yet been satisfactorily explained.

In cases which have been examined microscopically, where the iris was short it was found to be thicker from before backward than where it was long.

Pupils are sometimes found abnormally small apart from any signs of iritis, and also less responsive to light than usual. In cases of congenital cataract it is quite common to find that the pupil will not dilate well on the application of atropine, this is probably due to some defective formation of its muscular fibres.

A pupil may present congenital irregularities in its shape due to persistence of portions of the pupillary membrane. It may be congenitally pear-shaped from the presence of a small coloboma, and otherwise altered in shape from defective development of the sphincter or the small circle.

Coloboma of the Choroid.—**Typical coloboma** of the choroid is situated downward or downward and inward, in the position of the fetal ocular cleft; it is frequently bilateral.

The absence of the choroid in the affected area exposes to view the sclerotic, so that in looking into the eye with the ophthalmoscope instead of the red reflex from the vascular choroid a yellowish-white reflex from the fibrous sclerotic is seen.

Typical coloboma of choroid is usually oval in shape with the long axis from before backward. Its posterior extremity may extend up to, or even encircle, the optic disc. Its anterior extremity may be situated so far forward as to be invisible ophthalmoscopically. It may be continuous with a coloboma of the ciliary body and iris. The edges of the colobomatous area are usually bordered by pigment. Sometimes a band of healthy choroid may extend across a coloboma dividing it into two. The floor of the coloboma is always at a deeper level than that of the surrounding fundus; sometimes, due to its having become ectatic, at a considerably deeper level, or deeper in some parts than in others.

Retinal blood-vessels are frequently met with crossing a coloboma showing that some retina is present over the defective part. Occasionally a few large ciliary blood-vessels are present situated at a deeper level than the retinal vessels which cross over them.

In an eye with coloboma of the choroid there is generally a defect of the field of vision though not so extensive as to correspond to the whole of the affected area. The retina covering a coloboma may be capable of perceiving light and even of distinguishing some colours.

The microscopical appearances of the retina overlying a coloboma of the choroid have been already referred to (page 14). The vascular layers of the choroid usually end abruptly at the edge of the coloboma, the retina, choroid, and sclerotic being there frequently adherent. A thin fibrous membrane may bridge across the gap in the choroid. In the ectatic areas the sclerotic becomes abnormally thin.

In connection with **atypical coloboma of the choroid**, a rare form of defect may first be mentioned in which the whole choroid except a small area in the region of the macula appears to be absent. It has been termed **choroid-eremia**; seven cases¹ have been published all presenting similar characteristics. The patients were night-blind, had exceedingly small fields and a variable amount of central vision. In all the cases both eyes were affected. On ophthalmoscopic examination the fundus was found to present everywhere except at the macula, a glistening white appearance similar to that seen in typical coloboma. In some there were, as in typical coloboma, patches of pigment with a few large choroidal vessels visible. At the macula was a patch presenting the red reflex of the normal choroid. The retinal vessels coursed over the fundus in the usual way, the arteries sometimes being smaller than normal.

The similarity of the condition in all the recorded cases, its bilateral character, the fact that the defect of the vision remains stationary and seems to date from birth, all point to its being due to a developmental abnormality.

It is interesting to compare this congenital condition of the choroid with another which seems to be the exact reverse, namely **macular coloboma**. In it a round or oval patch with its long axis horizontal, presenting all the characteristics of a typical coloboma, is found situated at the macula, the rest of the fundus being usually normal in appearance.

The size of the patch varies in different cases from that of the optic disc to about five times its dimensions. The

¹ E. Nettleship, Royal London Ophth. Hosp. Rep., XVII, 1908, 373.

passage of retinal vessels across, and the absence in some cases of any central scotoma, shows the presence of the retina over it. The presence of imperfectly developed retina has also in several cases been proved by microscopical examination, its pigment epithelial layer and the choroid being absent.

Atypical coloboma of the choroid may occur in other parts of the fundus besides the macula. It has been found situated upward, inward, and outward. Indeed it seems that a congenital absence of any part of the choroid may occur.

A failure in the development of the choroid is due to a failure in the formation of blood-vessels in the inner part of the mesoblast which surrounds the secondary optic vesicle.

The region of the cleft in the secondary optic vesicle, through which mesoblast grows up to form the vitreous humour, and where for a time there is a connection between the encircling mesoblast and the intruding mesoblast, is the position in which this failure in vascularisation most frequently occurs, giving rise to typical coloboma. A delayed separation of the intruding mesoblast from the encircling mesoblast is the probable cause of the defective vascular formation.

The choroid receives its chief blood supply from the short ciliary arteries. These are about twenty in number and perforate the sclerotic in the vicinity of the optic nerve. They proceed from two main trunks which arise from the ophthalmic artery. A failure in the formation of all these vessels, except those which supply the region of the macula, would account for the condition described as choroideremia. The ciliary body and iris which receive their blood supply from the long posterior ciliary arteries and the anterior ciliary arteries are not affected.

The large ciliary vessels which are sometimes seen in cases of coloboma of the choroid coursing over the affected area are most likely branches of the long posterior ciliary arteries, which perforate the posterior part of the sclerotic

further forward than the short ciliary arteries, and pass to the ciliary body before breaking up. Some of them may also be veins proceeding from the ciliary body to the vortex veins which perforate the sclerotic at the equator.

In macular coloboma there seems to be a normal development of all the blood-vessels which are absent in choroid-eremia, but a failure in formation of those supplying the macular region which are present in that condition.

The other forms of atypical coloboma of the choroid may be attributed to the absence of the short ciliary arteries supplying the particular region affected.

Where coloboma of the choroid is associated with coloboma of the ciliary body there has been, not only a failure of development of short ciliary arteries in the defective area, but also of a long posterior ciliary artery.

The retina receives a considerable amount of nutrient supply from the capillary blood-vessels of the choroid; it is only natural, therefore, that where the choroid has failed to form, the outer layers of the retina should be defectively developed. It appears, however, that the vascular supply of the retinal vessels alone suffices for the formation of some light percipient elements.

Congenital Crescent.—In this condition there is at the lower margin of the optic disc a crescentic white area due to absence of the choroid and exposure of the sclerotic. The disc itself has an oval shape with the long axis horizontal, the physiological cup points downward, the retinal blood-vessels emerging in a downward direction.

The condition except for its position resembles a myopic crescent. It is frequently met with in hypermetropic eyes, often associated with astigmatism and sometimes amblyopia.

It has been described as a minimal form of congenital coloboma at the nerve entrance, and there can be no doubt that small colobomata are occasionally met with in this position.

The microscopical appearances of some of these con-

genital crescents,¹ however, resemble closely those of a temporal myopic crescent. The scleral promontory in the region of the crescent is rounded off instead of projecting as a sharp spur. The choroid, its elastic lamina, and the nuclear layers of the retina end some distance from the nerve entrance (Fig. 61). It would seem likely that both forms

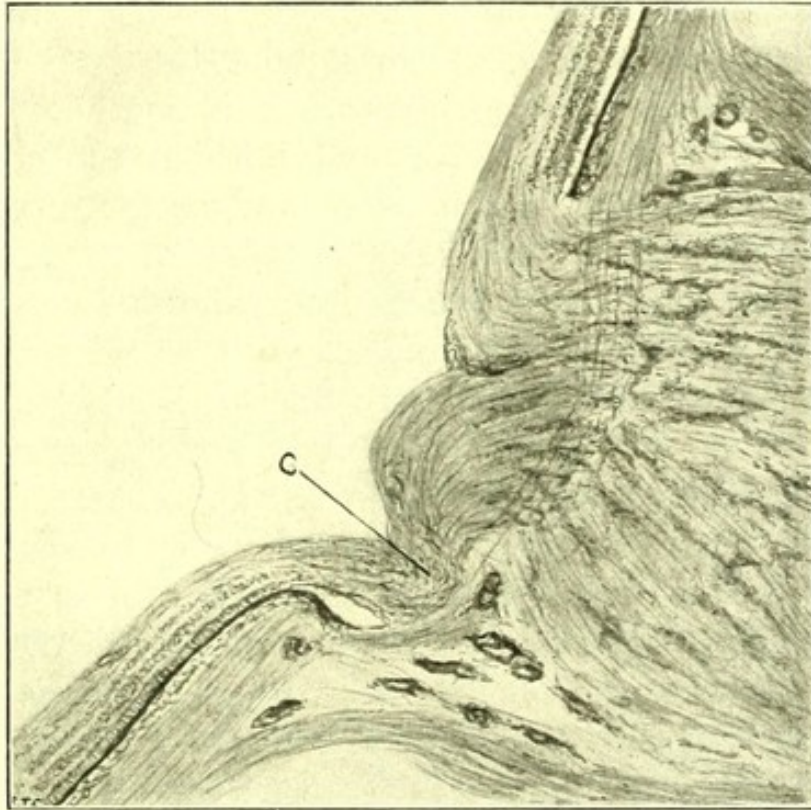


FIG. 61.—Section through the head of the optic nerve in a case in which there was a congenital crescent at the lower border of the optic disc. C points to the site of crescent. The choroid and nuclear layers of the retina are seen to end at some distance from the margin of the disc and there is a depression backwards of the retina between these two points.

of crescent are produced in the same way by stretching. In the myopic crescent the stretching is due to ectasia of the sclerotic on the outer side of the disc. In the congenital inferior crescent the ectasia is in the inferior part of the globe due probably to some congenital weakness in the region of the fetal cleft. The shape and appearances of the disc in these cases are quite in keeping with this hypothesis.

¹ Elschmig. Arch. f. Ophth., LVI, 1, 49.

In myopia, where the stretching is on the outer side, the disc is oval vertically and the retinal vessels directed temporally. In the congenital crescent the stretching is below and the disc is oval horizontally with a downward direction of the retinal vessels. The astigmatism so frequently met with is attributable to irregularities in the level of the fundus.

Albinism.—Albinism may be defined as a general defect in development of pigment throughout the body in both mesoblastic and epiblastic tissues. Thus in the eye there is defective deposition of pigment both in the epiblastic outer epithelial layer of the retina and in the mesoblastic stroma of the uveal tract.

Varying degrees of albinism occur, and in the same case different degrees of defect are met with in different parts. Sometimes the hair and skin are chiefly affected and sometimes the eyes. Within the eye itself the degree of defect may vary in its different divisions. The choroid may be found more affected than would have been expected from the appearance of the iris. In albinotic rabbits' eyes, examined microscopically, complete absence of pigment from all the tissues of the eye has been found. In the human albinotic eyes which have been so examined, some pigment, though less than normal, was present in the retinal epithelium but was entirely absent from the stroma of the uveal tract.

Infants who at birth appear not to have any pigment in either eyes or hair may attain some in both structures as they grow older. Normally at birth pigmentation of the stroma of the choroid has commenced, but pigmentation of the iris stroma does not begin until after birth.

The acuity of vision in albinotic eyes is defective, but there is no limitation of the field of vision or difficulty in the perception of colors. The defective form-sense results in the development of nystagmus and very frequently myopia. There is always marked photophobia which the patients try to lessen by keeping the eyes screwed up. A red reflex

is seen from the pupil and also through the iris. Ophthalmoscopically the network of the choroidal vessels can be seen most distinctly, especially toward the periphery of the fundus where the yellow reflex from the sclerotic shows between them. It is the presence of pigment in the branching cells of the choroid which gives rise to a uniform red reflex of the fundus, and also to the dark streaks between the vessels which are seen in people of dark complexion.

Melanosis of the Eye.—A very deeply pigmented condition of the tissue of the eye which is normal in the negro is to be regarded as an aberration in development when it appears in the white race and is termed melanosis. The patches of deeply pigmented embryonic tissue termed "nevi" or "moles," which are met with in the conjunctiva and uveal tract are different from the condition which is described here. So also are the congenital pigment patches which have been dealt with on page 20, and which are due to the adhesion of the two layers of the secondary optic vesicle.

Melanosis of the eye consists of excess of pigment in those parts in which it is found normally situated in small quantities.

In the conjunctiva a little pigment is always present at the limbus, when this is increased in amount it gives rise to a black ring surrounding the cornea. In melanosis, patches of pigment are seen in the sclerotic, especially at the points where it is perforated by the anterior ciliary arteries. Microscopically the pigment is found in the episcleral tissue and the lymphatic sheaths around the blood-vessels.

The iris is of a dark brown colour. When the condition is unilateral, as it frequently is, the contrast between the colour of the two irides forms a striking feature—**hetra-chromia iridis**.

Microscopically the excess of pigment in the stroma of the uveal tract may be so great as to obscure the arrangement of its structure. The reflex from the fundus seen ophthalmoscopically is of a chocolate brown colour instead

of a rose red, and the shimmering light reflexes of the retina are very numerous.

Some of the inner fibres of the lamina cribrosa represent the stroma of the choroid; it is asserted that pigment cells are normally met with amongst them. It is in keeping with this that in melanosis pigment patches may be present in the optic disc.

V. Aberrations Connected with Structures in the Line of the Orbito-nasal Fissure and the Formation of the Eyelids.

In the centre of the face of the human embryo at the fourth week there is a cavity called the oral cavity out of which five fissures radiate. An upper pair, the orbitonasal, a lower pair, the mandibular, and a vertical one, the intermandibular.

The upper pair radiate upward and outward between a central fold which grows down from above, the fronto-nasal plate, and processes which extend in from either side, the maxillary processes. The outer parts of these fissures ultimately remain as the orbits, the inner parts become closed by fusion of the maxillary processes with the fronto-nasal plate, which takes place about the sixth or seventh week.

The lacrimal canals are developed from the epithelium lining the inner parts of the fronto-nasal fissure. The canaliculi are formed shortly before the tenth week, probably by an infolding of the epithelium of the lid margin. They for a time consist of solid columns of cells opening into the lacrimal sac, at first about twice the diameter of the nasal end of the lacrimal duct, and remaining relatively larger until shortly before birth. The epithelial cells lining the canaliculi can from the first be differentiated from those of the lacrimal duct, being larger and having a characteristic cuboidal shape. The difference becomes more accentuated as the fetus grows. The canaliculi of the fetus differ from those of the adult in being lined by epithelium two or three

cells in thickness. The lumen is formed about the twelfth week, but at birth is almost occluded by degenerate desquamating cells.¹

The lacrimal sacs and ducts which form a portion of the facial clefts at about the sixth month are situated further forward than the eyes, owing to the lateral position of the latter. They resemble at that stage of their development the condition found in lower animals. The lower end of the

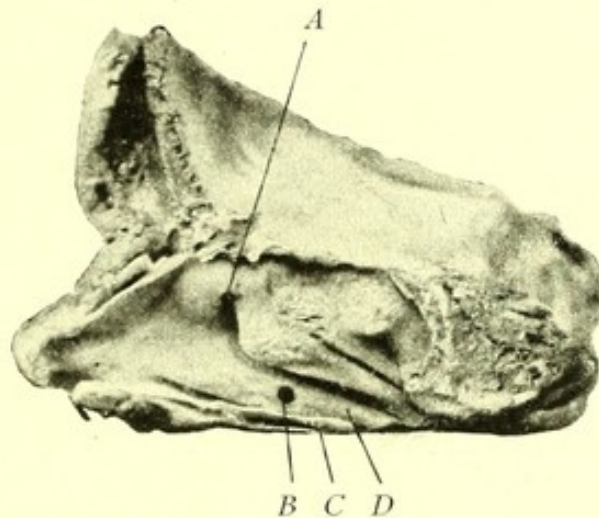


FIG. 62.—The outer wall of the nose in the new-born child. *A* is placed over the situation of the upper end of the duct; *B*, over the lower end; *C*, the inferior turbinate bone which presses both on the floor of the nose and the lower end of the lacrimal duct; *D*, the floor of the nasal cavity.

duct is the first part to be differentiated; it does not, however, acquire a lumen until about the fourth month of fetal life. The region of the lacrimal sac is the last in which the facial cleft closes. There is always a lumen to the sac after it becomes closed off from the surface, which gradually tapers down to the lower end of the duct. Bone is first deposited around the lower end of the duct commencing on its inner surface (Figs. 62, 63).

In the human fetus the formation of the eyelids commences about the eighth week, previous to that time the surface of the eye is directly continuous with the surface of the head. They appear first as ridges of mesoblastic tissue

¹ M. S. Mayou. Royal Lond. Ophth. Hosp. Rep., XVII, 1908, 246.

covered with epiblast which bud out above and below the cornea. Two weeks after their first appearance they have grown to such an extent that their margins meet over the front of the globe; the epithelium along their borders then becomes united and the conjunctiva is for a time a closed sac, which is lined by a single layer of cells. At the inner surface of the eyeball a vertical fold forms inside the other two, which in man becomes the plica semilunaris.

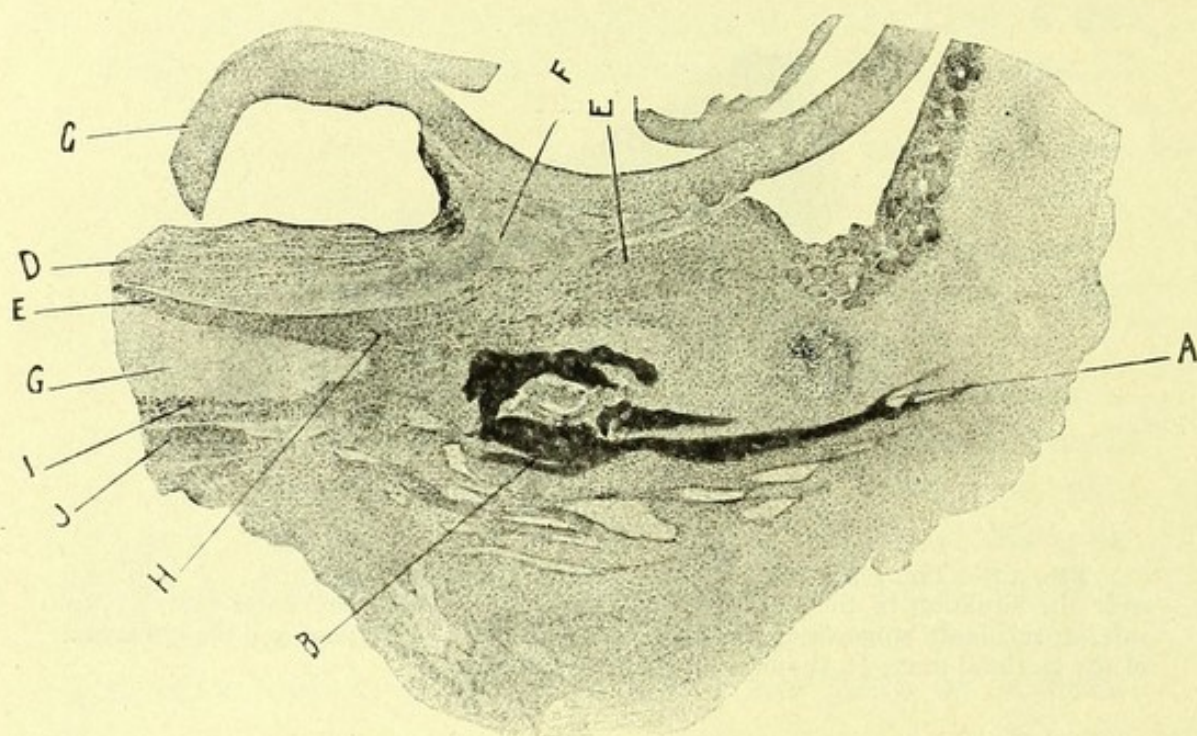


FIG. 63.—Horizontal section through the lacrimal region of a new-born child at the extreme upper limit of the lacrimal sac, which has been injected with coloured jelly. *A*, The eyelid; *B*, extravasated coloured jelly around the lacrimal sac; *C*, the sclerotic; *D*, internal rectus muscle; *E*, the fascia covering the internal rectus muscle attached to the wall of the lacrimal groove *H*; *F*, Tenon's capsule; *G*, orbital fat; *I*, periosteum; *J*, bone of the inner wall of the orbit.

While the epithelial bond of union at the margin of the lids exists processes of cells grow down from it into the mesoblast beneath, from which are formed the hair follicles of the eyelashes and the Meibomian glands. In the human fetus the epithelial union breaks through and the lids become separate again before birth. This separation commences anteriorly on the growth of the eyelashes about the fifth month. The uniform curve which the lashes acquire out-

ward is caused by their impinging, in their growth, forward on the edge of the opposing eyelid.

The aberrations met with in connection with structures in the line of the orbito-nasal fissure and the formation of the eyelids are:

Failure in union of the maxillary processes with the nasal portion of the fronto-nasal process—**coloboma of the eyelid—absence of the lacrimal canal.**

Imperfect development of orbit—**congenital exophthalmos.**

Protrusion of contents of cranial cavity into the orbital portion of the fissure—**orbito-meningo-encephalocele.**

Sequestration of the portion of the surface epithelium along the line of the fissure—**dermoid cyst.**

Defective infolding of the epithelium at the margins of the inner part of the eyelids to form the canaliculi—**absence of canaliculus—formation of a groove instead of a canal—supernumerary lacrimal puncta.**

Imperfect canalisation of the epithelium lining the lower end of the lacrimal duct—**congenital lacrimal obstruction.**

Imperfect separation of the epithelium of the lacrimal sac from the surface epithelium—**congenital lacrimal fistula.**

Failure of the eyelids to bud out in the whole or a portion of their extent—**cryptophthalmia—coloboma of the eyelid—dermoid growths of the eye.**

Failure of the eyelids to unite over the front of the eye—**microblepharon—congenital lagophthalmia—dermoid growths of the eye.**

Undue development of the third eyelid—**abnormally large plica semilunaris.**

Formation of a persistent band uniting the two eyelids—**congenital ankyloblepharon.**

Perversion in the direction of the eyelashes—**congenital trichiasis.**

Formation of eyelashes in the place of Meibomian glands—**congenital districhiasis.**

Coloboma of the Eyelid.—A coloboma is more often met with in the upper than the lower eyelid. Whether in the upper or the lower lid, it is always situated to the inner side

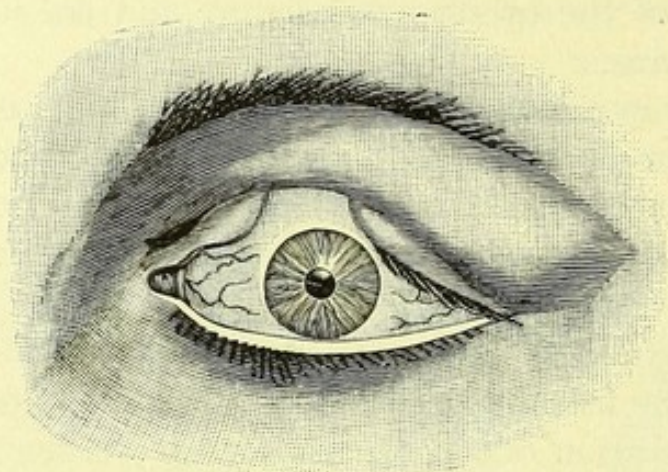


FIG. 64.—Congenital coloboma of the upper eyelid in a boy aged two years.

of the middle line. Both lids of the same eye may be affected. The inner third of one lid may be entirely absent; there may be a quadrate or triangular gap extending from the palpebral to the orbital margin (Fig. 64); or only a

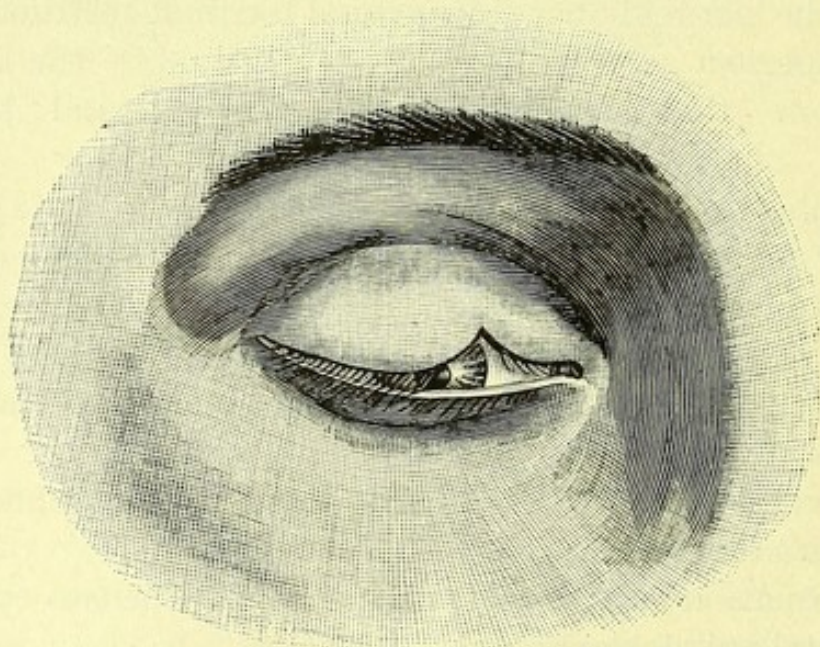


FIG. 65.—Small congenital indentation in the border of the upper eyelid.

small indentation of the free border of the lid (Fig. 65). The part of the eyeball left uncovered by the defective eyelid is often the seat of a dermoid growth (see page 100).

The abnormality is frequently associated with other congenital defects about the face attributable to defective development in the line of the facial fissures such as hare-lip, cleft-palate, macroglossia, supernumerary auricles, etc. Many of such defects are due to pressure caused by bands in the amnion. It seems probable that some cases of coloboma of the eyelid may be best accounted for by the pressure of such amniotic bands along the line of the orbitonasal fissure interfering with its closure. There may, however, be other causes leading to defective or delayed closure of this fissure which will give rise to the same condition.

Absence of the Lacrimal Canal.—In sharks there is an open skin area between the nose and the eye. The nasal duct appears first amongst the amphibia.

In some very malformed fetuses the nasal duct has been found represented by a wide groove lined by mucous membrane shelving off from the inner angle of the eye into the nasal cavity, a condition comparable to that met with in sharks, and attributable to failure in the union of a maxillary process with the nasal part of the frontal-nasal process.

Congenital Shallowness of the Orbits and Exophthalmos.—An imperfect development of the orbits causing them to be abnormally shallow is met with in connection with what is termed **oxycephaly** or "**tower skull**" an affection in which the skull is unusually high; the average height of four such skulls in the Heidelberg Museum was found¹ to be 143 mm. while that of 100 normal skulls was 131.6 mm. The average depth of these orbits was 28.4 mm. as against the normal depth of 39.05 mm. The superciliary ridges are flattened, and in some cases there is a marked protrusion in the temporal regions with bowing outward of the zygomatic arches. Males are much oftener affected than females. The condition has been attributed to premature ossification of the coronal sutures.²

¹ Velhagan, Munich, *medizin, Wochensch.*, 1904.

² W. M. Beaumont. *Trans. Ophth. Soc. of the U. K.*, XXX, 1910, 44.

As the result of the shallowness of the orbits exophthalmos is produced, which is sometimes so extreme that the eyelids fail to close over the eyes and keratitis ensues. The roof of the orbit may form an angle of 45° with the floor. From deformity about the optic foramen affections of the optic nerve are liable to occur, such as optic atrophy, and optic neuritis with ensuing atrophy.

Orbital Meningo-Encephalocele.—Orbital meningo-encephaloceles are of exceedingly rare occurrence. They form fluctuating cysts which may pulsate with respiration. Beneath the skin is found ~~the~~ fibrous tissue continuous with the dura mater. The arachnoid and pia mater are generally too much stretched and atrophied to be recognised. In most cases submitted to anatomical examination portions of the brain have been found protruding as well as the meninges. It is doubtful if a pure meningocele ever occurs. The cyst contains cerebro-spinal fluid as well as brain matter. When, through some mistake in diagnosis, they have been operated on and opened, cerebro-spinal fluid has continued to drain away until convulsions and death have ensued.

The commonest site in the orbit for the protrusion is the upper and inner angle, it passes out from the cranial cavity at the fronto-ethmoidal suture. It has also been found to gain exit through an enlarged sphenoidal fissure or optic foramen. The increase in contents of the orbit, occasioned by the protrusion into it, presses on the globe causing exophthalmos and defects in ocular development.

A hernia of the cranial contents may be attributable to some arrested development of the bony walls of the orbit along the line of the orbitonasal fissure, or to some increased intracranial pressure during their formation.

Dermoid Cysts along the line of the Orbito-Nasal Fissure.—Dermoid cysts form smooth rounded tumours beneath the skin which is freely movable over them. They may be of various sizes, usually about that of an acorn; they often grow rapidly at puberty and thereby cause the patient's attention to become attracted to them then, though they

are always congenital. There is often a depression in the bone beneath them, sometimes a complete absence of the bone, in which case the cyst lies in direct contact with the dura mater.

They may be situated in various parts of the orbito-nasal fissure. The commonest position is near the upper and outer angle of the orbit overlying the fronto-malar or fronto-temporal suture. They are also frequently found at the upper and inner angle of the orbit overlying the fronto-ethmoidal suture. They have been discovered lying at some depth in the orbit external to the cone of muscles, also in rare instances on the side of the nose in the line of the lacrimal canal.

The characteristic histological feature of these cysts is a lining of laminated epithelium with hair follicles, sebaceous glands, and sometimes sweat glands in connection with it. The surface of the epithelial lining like that of the skin is usually papillated, but when the cyst is much distended it may become much flattened out and thinned.

The contents of these cysts is generally composed of sebaceous material, epithelial debris, and hairs. In rare cases a tooth has been found. In the outer fibrous tissue wall muscle fibres and sometimes plates of cartilage may be present.

Though dermoid cysts are often met with in the course of the fetal clefts about the face they are also found in other positions, for instance they occur on the vertex of the scalp. A more comprehensive statement would be to say that they occur opposite the lines of suture of the cranial bones during fetal life.

Early in embryonic life the skin covering the head and the dura mater are in contact, on the formation of the cranial bones the two become separated remaining, however, longest in contact along the lines of the sutures. Should a piece of the skin adhere to the dura mater it might become cut off, with some of its epithelium, and sequestered, so forming the starting point of a cystic growth. Where the cyst was situ-

ated the formation of bone would be interfered with, hence the occurrence of a depression in that structure beneath it.

Abnormalities in the Lacrimal Canaliculi.—Defects of development of the upper end of the lacrimal canals are less common than those of the nasal extremity.

Complete absence of a canaliculus and of the lacrimal puncta associated with it is of exceedingly rare occurrence, it is attributable to a failure in the downgrowth of the epithelium at the inner part of the lid margin from which it is developed.

A more frequent abnormality is for the downgrowth to have occurred but to have failed to become shut off from the surface epithelium. The canaliculus is then found to exist as an open groove instead of a canal, or there may be a groove with a bridge across it so that there appears to be two puncta in one lid.

Congenital Obstruction in the Lacrimal Duct.—A congenital obstruction in the lacrimal duct is usually situated at its nasal extremity. It may manifest itself soon after birth by epiphora, or by the onset of secondary dacryo-cystitis with regurgitation of muco-purulent discharge through the puncta on pressure over the sac. The nose together with the lacrimal duct before birth are filled with epithelial debris, which normally becomes cleared away by aspiration, when the child commences to breathe. When this plug remains impacted in the lower end of the duct congenital obstruction exists.¹ One passage of a probe down the duct into the nose is generally sufficient to cure the affection.

Fistula of the Lacrimal Sac.—A congenital fistula of the lacrimal sac presents the appearance of a small dimple in the skin on the side of the nose a little below the level of the inner canthus. From the bottom of the dimple a pin-point aperture leads into the sac.² The condition is frequently bilateral. It is due to incomplete closure of the facial cleft,

¹ M. S. Mayou. Royal Lond. Ophth. Hosp. Rep., XVII, 1908, 446.

² N. Bishop Harman. Trans. Ophth. Soc. of the U. K., XXIII, 1903, 256.

the situation in which the fistula occurs, being the last part of the cleft to be shut off from the surface epithelium.

Cryptophthalmia.—Cryptophthalmia is an exceedingly rare condition in which there is complete absence of the eyelids and their appendages together with the lacrimal gland and lacrimal duct. The eyeball is entirely covered and hidden by a membrane like skin beneath which it is seen to move about, and to which it is connected by a subcutaneous cellular membrane. On dissection the orbicularis muscle has been found to be present; a wrinkling of the skin about the eye due to its action may be noticed on exposure to bright light. The condition is generally bilateral, but unilateral cases have been met with. The eyeball itself is always malformed and other gross malformations are frequently present.

In these cases the eyelids have failed to bud out and no conjunctival sac has been formed. The conjunctiva is a portion of the surface-covering of the body, which becomes modified in structure by seclusion from external influences through the union of the lids on the front of the eye. When the lids fail to grow out the external covering of the eye is exposed to the same influences as other parts of the surface of the body and assumes the same characteristics, *viz.*, those of skin. There is an alteration in both the character of the epithelium and of the sub-epithelial mesoblastic tissues; the latter simulates the corium of the skin and is very different from the fibro-adenoid tissue of the conjunctiva.

An absence of the eyelids is the normal condition in some fish but the surface of their eyes is kept moist by the fluid media in which they live.

Dermoid Growths.—In the last condition described, "cryptophthalmia," there is a dermoid or skin-like growth covering the whole of the surface of the eye. It is interesting to pass from it, an exceedingly rare condition, to the much commoner one in which the dermoid growth forms a small isolated patch, covering only a part of the surface of the globe.

Under coloboma of the eyelid it has been already mentioned that the surface of the globe opposite the defect in the lid frequently has a skin-like covering. The dermoid growths most frequently met with occur unassociated with any malformation of the lids. They consist of oval or circular isolated patches of skin on the surface of the globe situated at the margin of the cornea, a little below its horizontal meridian, more often on the outer than the inner side. There may be two growths on the same eye on opposite sides of the cornea. Usually only one eye is affected but sometimes symmetrical growths are met with in the two eyes. In size, colour, and appearance, the growths often resemble a split pea, but may be much bigger and protrude through the palpebral fissure. Should they get nipped between the lids they become pedunculated. They often show a tendency to enlarge about puberty, at which time also hairs may start to grow from them.

Dermoid growths have been met with in the eyes of dogs, horses, sheep, oxen, and pigs as well as in man. In a sheep's eye, wool has been seen springing from the tumour.

Histologically, these dermoid growths present the characteristics of skin. Beneath a covering of laminated epithelium is dense fibrous tissue as in the corium, often mixed in the deeper parts with adipose tissue. In the corium are found yellow elastic fibres, hair-follicles, sebaceous glands, sweat glands and occasionally also glands of an acinous type like Krause's glands. Blood-vessels course through the growth and medullated nerve fibres have been demonstrated in them. The surface cells of the laminated epithelium are keratinised.

When the eyelids fail to bud out and the whole surface of the eye is left exposed as in cryptophthalmia, it becomes covered with skin. When a portion of the surface of the eye is left exposed as in coloboma of the upper lid, skin forms on the uncovered part. It seems probable, therefore, that when patches of skin form on the surface of the eye opposite the palpebral aperture, there has been some failure of union

of the lids over the front of the eye in a portion of their extent which has left the affected part exposed.

A few rare cases of congenital staphyloma have been recorded in which the whole surface of the cornea was covered by a dermoid growth. In such cases the enlarged bulging cornea probably protruded through the palpebral aperture and prevented the union of the lid margins in front of it, the result being that skin was formed over the exposed area.

Fibro-fatty Growths of the Conjunctiva.—It is well to describe here another developmental defect of the conjunctiva which is often associated with dermoid growths and colobomata of the eyelids, but may occur independently of those conditions. It consists in the abnormal formation of fibrous and fatty tissue beneath the epithelium.

These fibro-fatty growths are yellowish in colour and are nearly always situated upward and outward on the surface of the globe between the superior and external recti muscles. They are usually hidden from view beneath the upper lid but when large may extend below it. Like dermoid growths they are covered by laminated epithelium and sometimes have hairs growing from them. The surface cells of the epithelium are, however, never keratinised.

The defect is essentially an aberrant development of the corium, in some cases it results in the formation of plates of hyaline cartilage or of bone with well formed Haversian systems. These congenital enchondromata and osteomata have been classed as teratomata, it is probably better to regard them as an atavism of tissue; in support of which view is the fact that the corium of the skin in some animals is capable of producing cartilage and bone in the form of an exoskeleton.

Microblepharon and Lagophthalmos.—The union of the lids at their margins for a time during fetal life seems essential for the eyelids to attain their normal length. When this union is not affected or separation takes place unusually early, either from the pressure of amniotic bands or some other cause, an undue shortness of the lids or microblepharon

is liable to occur. In this condition there is an incomplete closure of the palpebral fissure when the eyes are shut, which is termed lagophthalmos. The lid margins can usually be brought together by a strong contraction of the orbicularis, but they remain open during sleep.




FIG. 66.—Symmetrical congenital notches in the lower lids near the outer canthus and flattening of both cheek bones.

Congenital Notches in the Lower Lid at the Outer Canthus.—There are cases where a congenital notch in the lower lid is met with close to the outer canthus, which is entirely different from the colobomata of the eyelids already referred to, and for the occurrence of which no very adequate explanation has so far been offered.¹

¹ Treacher Collins. Trans. Ophth. Soc. of the U. K., XX, 1900, 190, and 191.

The notch is always small though in some cases deeper than others. It often suggests from its appearance a duplication of the outer canthus (Fig. 66). The defect in the lid is associated with a flattening or want of prominence of the malar bone. This flattening of the cheek bones, when the condition is bilateral, as it usually is, gives the patient a very characteristic physiognomy, and causes all those affected to resemble one another so that they might readily be taken for members of the same family. This defect of the eyelid may be accompanied by dermoid growths of the cornea, fibro-fatty growths of the conjunctiva and trichiasis of the lashes of the lower eyelid.

Abnormally Large Plica Semilunaris.—The plica semilunaris of the human eye is a vestigial structure representing the membrana nictitans in other animals. The membrana nictitans reaches its most perfect development in birds and consists of a plate of fibro-cartilage covered by conjunctiva. Its posterior deeper border is continuous with a cushion of fat in the orbit; the pushing of which forward on retraction of the eye in the orbit causes the membrane with its anterior thin smooth border to pass in front of the cornea.

In the ophidia and some lacertilia, the third eyelid forms a permanent transparent covering to the eye,¹ the conjunctiva being a closed sac and the animal seeing through the lid.

Among mammals, a nictitating membrane sufficient to sweep the whole cornea is only present in some of the ungulata.

An abnormally large plica semilunaris is sometimes met with as a congenital defect. It may extend as far as the cornea and sometimes be capable of slight movement.² Such cases would appear to be examples of atavism.

Ankyloblepharon.—The edges of the eyelids are united during several months of fetal life, in some animals (carnivora) the epithelial band of union persists until after

¹ M. S. Mayou. Hunterian Lectures, 1905, 8.

² Lindsay Johnson. The comparative anatomy of the mammalian eye, 1901, p. 50.

birth, but ankyloblepharon, or union of the lid margins, is an uncommon congenital defect. It only occurs in the rare cases of anophthalmia. A few cases of congenital ankyloblepharon have been recorded in which the lid margins were united by tracts or bands of a skin-like structure.

Trichiasis.—Congenital trichiasis is only met with in the lower lid. It is a simple faulty direction of the lashes not a bending in of the lid margin which is shown by the inter-marginal zones, retaining their normal positions.

An irregular union of the margins of the eyelids probably prevents the lashes of the lower lid, when first formed, from impinging on the border of the upper lid in such a way as to assume their normal outward curves. They consequently grow straight out or acquire an inward tilt.¹

Districhiasis.—In congenital districhiasis both upper and lower lids may be affected. There are two rows of eyelashes instead of one, the inner row composed of very fine hairs turning inward toward the eye.

Histological examination² of a lid in one case has shown complete absence of the Meibomian glands, their place being taken by the second row of hair follicles. There was also an over development of Moll's glands.

When the eyelids have their margins united two rows of epithelial downgrowths form; the outer developing into the hair follicles of the cilia, and the inner into the Meibomian glands. In districhiasis both rows develop into hair follicles and no Meibomian glands are formed. It has been suggested that the hypertrophy of Moll's glands is due to an attempt on their part to supply the missing secretion.

¹ M. S. Mayou. Hunterian Lectures, 1905, 15.

² Kuhnt. Zeitsch. f. Augenheilk., 1889, II., 46. A. R. Brailey. Trans. Ophth. Soc. of the U. K., 1906, XXVI, 16.

CHAPTER II.

NEOPLASMS.

Neoplasms of the eyeball and its appendages are here divided into (i) teleplasms, (ii) metastatic growths, and (iii) cysts.

By a **teleplasm** is meant a growth formed by a tissue which has reassumed some of its embryonic characteristics, *i.e.*, an atavism of tissue. The power of rapid reproduction is one of the characteristics of cells during embryonic life. As a tissue reaches maturity this proliferating activity of its cells becomes reduced to that which is required for its repair and maintenance. In all teleplasms there is reassumption of the embryonic proliferative activity; sometimes resulting in a mass of cells simulating those from which the tissue is primarily developed; at others in the formation of tissue of a more highly organised character. Like the normal tissue the more highly specialized the structure of which a tumor is composed the slower the power it has of reproducing itself; whilst the more embryonic its character the greater the rapidity of its growth, and of its liability to dissemination through the blood-vessels and lymphatics, *i.e.*, the greater its malignancy.

In malignant tumors some of the cells when undergoing mitosis show a deficiency in the number of chromatophores in the nucleus, a condition simulating that which is found in the ovum before fertilization.

In the eye there are tissues developed from different divisions of the blastoderm, from cuticular epiblast, from neural epiblast, and from mesoblast. The teleplasms are here divided into those starting in each of these three divisions.

I. TELEPLASMS ARISING IN PARTS DERIVED FROM CUTICULAR EPIBLAST.

The parts of the eye and its appendages derived from cuticular epiblast are: the crystalline lens, the surface epithelium of the skin of the lids, conjunctiva, cornea, and the lining membrane of various glands.

No new growths are met with in connection with the lens. The teleplasms to be dealt with here arising from cuticular epiblastic structures may be divided into those starting in (a) surface epithelium, (b) glandular epithelium, (c) congenitally sequestered epidermic masses, moles or nevi.

a. In the embryonic condition extensions downward of the surface epithelial cells occur into the subjacent mesoblast preliminary to the formation of hair follicles, glands, etc. After embryonic life the surface epithelium ceases to send prolongations downward and only grows outward. When a reversion to the embryonic condition occurs and prolongations downward of the surface epithelium into the tissues beneath again develop, a malignant teleplasm is formed which is termed **squamous carcinoma** or **epithelioma**.

In extending down through the basement membrane into the subepithelial tissue, cells of the growth gain access to lymphatic channels along which they grow, to the lymphatic glands, where fresh nodules of the new growth develop.

A thickening of the epithelium on the surface without any extension of it downward gives rise to innocent new formations termed **papillomata, horns, and epithelial plaques**.

b. The cells which line glands lose their primitive tendency to rapid proliferation and become specialized to produce a secretion. If their secreting function ceases and they regain their proliferative activity a teleplasm is formed. If it remains located in the region in which it started it is innocent and is termed **adenoma**. If it tends to invade surrounding structures it is malignant and termed **glandular carcinoma**.

c. Much difference of opinion exists as to the nature of

moles or nevi. Some authorities hold that the cells composing them are mesoblastic in origin and derived from the endothelium lining lymphatic channels; others regard them as epiblastic, the cells of the growth having become snared off from the surface epithelium and sequestered in the sub-epithelial tissue. Neither view can be said yet to have been definitely substantiated. Those in favour¹ of the latter, claim that in sections of moles in an early state the snaring-off process can be actually observed in its different stages. The fact that moles are only met with in close proximity to an epithelial lined surface is in favour of an epithelial origin. The cells composing them, however, differ from epithelial cells elsewhere which either proliferate throughout life or break down to form a secretion. The majority of nevi or moles are pigmented and if the cells forming them resume their proliferative activity and invade surrounding tissues, a malignant melanotic growth is produced, the name applied to which depends upon the view taken as to the origin of the primary formations. If mesoblastic they are melanotic sarcomata, if epiblastic melanotic carcinomata.

Squamous Carcinoma or Epithelioma.—An epithelioma arising in the skin of the eyelids may extend to and involve the conjunctiva. Epithelioma arising primarily on the surface of the eye usually starts at the limbus. The epithelium of the cornea and of the conjunctiva presents a very regular base line, except just at the limbus where there are down-dipping processes of cells. It is in this locality that the pathological downgrowths, which are the characteristic feature of an epithelioma, make their appearance.

At first an epithelioma of the surface of the eye forms a small, opaque, whitish, raised patch; it then becomes a warty growth which after a time ulcerates and may protrude through the palpebral fissure as a bleeding mass. Its growth forward is at first in excess of its invasion of the tissues beneath; more so than in growths of a similar character in other localities. The firm fibrous cornea and sclerotic

¹ A. Whitefield. *The British Jour. of Dermatology*, 1900, XII, 207.

are not easily infiltrated by the growth which tends to spread in the line of least resistance. When the tumour gains an entrance to Tenon's capsule it extends rapidly around the surface of the sclerotic, often covering a considerable extent without perforating it. The lymphatic sheaths of the blood-vessels in the neighbourhood of the growth become invaded and along them it may gain entrance to the interior of the globe. This most frequently occurs at the sclero-corneal

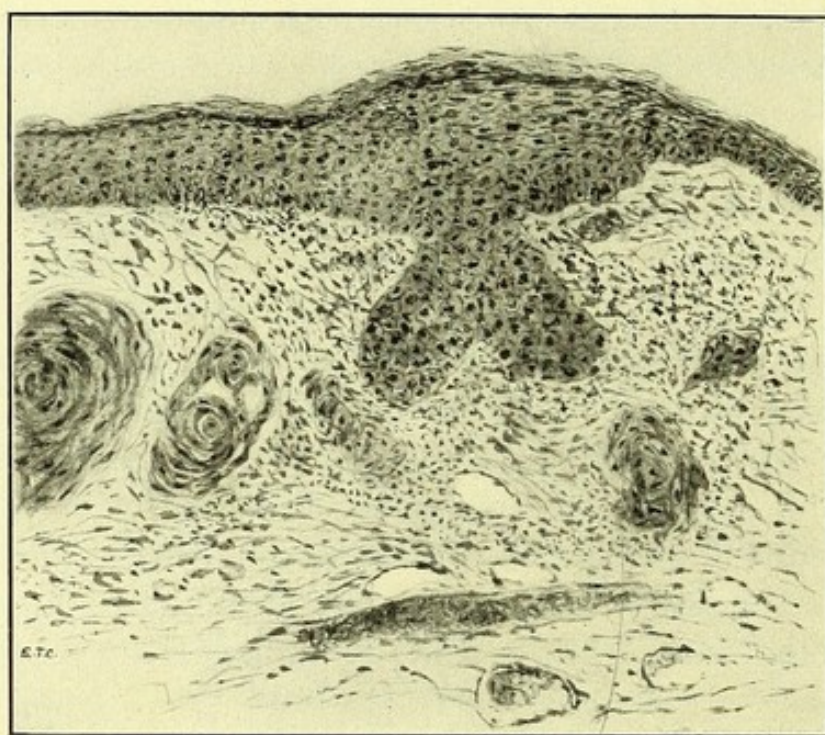


FIG. 67.—Section of commencing epithelioma of the ocular conjunctiva.

margin in the track of the canal of Schlemm. In course of time secondary growths may form in the preauricular and submaxillary glands.

The microscopical characters of an epithelioma arising on the surface of the globe are similar to those starting in other situations. There are down-growths of branching columns of cells from the surface epithelium which break through the basement membrane (Fig. 67).

Proliferation goes on in these columns of cells, and as none of the cells can be thrown off, the central ones become

compressed and flattened. In this way laminated nests of cells are formed, the central layers of which undergo keratinisation. Extensive keratinisation also occurs in the cells on the surface of the growth; other cells show vacuolation and signs of degeneration in their cytoplasm. There are always numerous polygonal prickly cells. In the peripheral parts active karyokinesis takes place.

In an epithelioma besides the cells of epiblastic origin polymorphonuclear, mononuclear leucocytes and endothelial cells are met with. The leucocytosis is doubtless excited by pyogenic organisms from the surface, and is most marked when ulceration has taken place. The proliferating endothelial cells around the growth resemble closely the cells of the growth itself for which they are liable to be mistaken. When organisation takes place bands of fibrous tissue with blood-vessels become formed between the groups of epithelial cells.

Papilloma.—Papillomata arise either from the skin of the lids or conjunctiva. Those starting in the skin form small, hard, nodulated, sessile protuberances which are termed warts. They often occur at the margins of the lids and may be multiple.

Those starting in the conjunctiva are soft, red, or pink pedunculated growths with numerous delicate finger-like processes; springing most frequently from the fornix or plica semilunaris.

Though the preponderating tissue in these growths is the epithelium there is also hyperplasia of the sub-epithelial fibrous and vascular tissue; *i. e.*, a new growth of tissue of mesoblastic origin. It is the thickening of the sub-epithelial tissue which gives rise to the papillated character of the tumour.

The relative amount of fibrous tissue, blood-vessels, and overlying epithelium varies in different growths, and for purposes of classification they are named fibromata, fibro-angiomata or papillomata according to which element preponderates. Often growths are met with presenting the

appearance of a papilloma in one part and of a fibroma or fibro-angioma in another.

In the soft papillomata of the conjunctiva the fibrous tissue consists of only a few strands lying outside loops of thin-walled blood-vessels and covered by stratified epithelium. In the harder papillomata of the skin the fibrous tissue forming the papillæ is dense and compact, and there

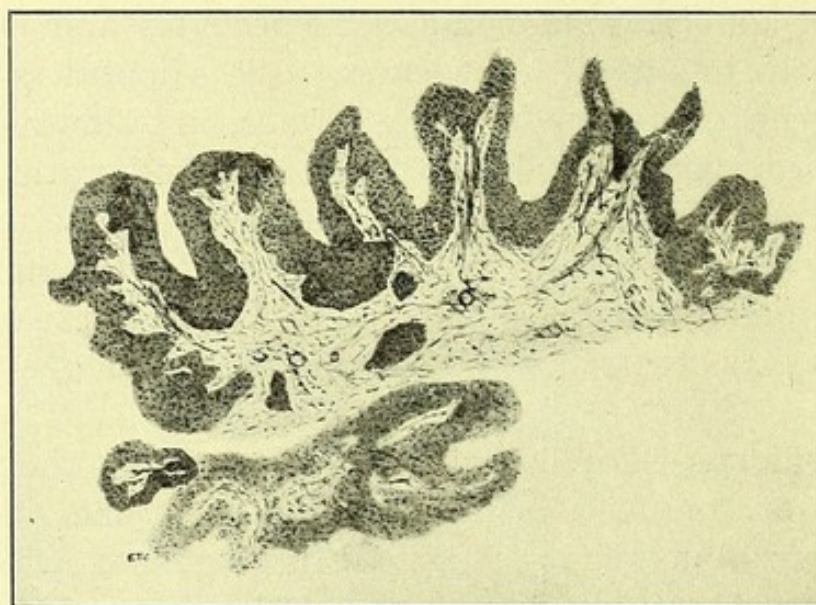


FIG. 68.—Section through a hard papilloma from the margin of an eyelid.

are fewer blood-vessels (Fig. 68). The epithelium covering them is much thicker than the normal epithelium, the surface layers frequently undergoing hyperkeratosis.

Horns.—Horns composed of desiccated surface epithelial cells, which have failed to be cast off in the usual way, are met with on the surface of warts growing at the margins of the eyelids. They are of a brown or greyish colour, hard in consistency, usually a few millimetres in diameter, and not longer than the eyelashes. They may, however, attain much larger dimensions. A specimen of one in the Moorfields Hospital Museum measures 28 mm. in length with a diameter of 26 mm. at its base.

If an anterior staphyloma protrudes between the eyelids so that it is not covered by them, the epithelium becomes

dry and undergoes a process of keratinisation, these cells not being rubbed off sometimes become converted into horn-like incrustations.

Epithelial Plaques.—A purely epithelial innocent new growth of the surface of the eye is a condition which has been described as an epithelial plaque.¹ It is essentially a localised hyperplasia of the surface epithelium appearing clinically as a sharply defined white or yellowish patch, a few millimetres in diameter, with a dull granular surface. These plaques resemble closely the patches formed in xerosis of the conjunctiva but occur in parts of the eye in which there has been no undue exposure; they are not accompanied by night-blindness or other general symptoms and, do not disappear with general treatment.

The epithelium of the cornea and conjunctiva differs from the epithelium of the skin in being considerably thinner; the superficial keratinised layer, stratum corneum and prickle cells, are absent. In epithelial plaques the epithelium is found to have assumed the characters of the skin and to possess surface layers containing keratin, keratohyalin, and prickle cells.

Glandular Cancer of the Skin or Rodent Ulcer.—Rodent ulcer is a form of new growth accompanied by ulceration which begins most frequently on the side of the nose near the inner canthus, or on the eyelids.

It commences as a small raised nodule in the skin which may remain as such for several years before any ulceration takes place. The extension of the new growth is always associated with ulceration, the edges of the ulcer being raised and thickened, as it spreads the eyelids may become destroyed and the surface of the eyeball invaded. From the ocular conjunctiva the growth often involves Tenon's capsule leading to compression and loss of mobility of the globe. Near the limbus it is liable to involve the sclerotic and may lead to perforation. The progress of the growth and de-

¹ W. T. Lister and W. I. Hancock. R. Lond. Ophth. Hosp. Rep., XV, 1903, 346.

structive process is not checked when it has extended down to bone which will also become infiltrated and eroded.

Men¹ are more often affected than women. It commences usually between the ages of thirty and fifty but has been known to begin as early as fourteen.

Microscopical examination of the nodules in an early stage shows that the growth begins sub-epidermally, apparently in the sebaceous or sweat glands of the skin, presenting the characteristics of a glandular carcinoma. It is at first distinct from the covering epithelium which only becomes involved later in the ulcerative stage.

The cells composing the growth, which are smaller and more pear-shaped than those of the surface epithelium, are grouped in columns or irregular masses and are contained in alveoli bounded by newly formed connective tissue. Sometimes the alveolar arrangement is so marked that the appearance of the growth simulates the gland tissue from which it takes origin. The outermost cells of an alveoli are usually cylindrical, and the central ones round, oval, or polyhedral. They have a tendency to undergo vacuolation and degeneration so that spaces become formed in the growth.

As the growth is derived from granular epithelium there is an absence of keratinisation, of prickle cells or of nests of flattened cells, thus differing markedly from carcinoma starting from the surface epithelium (epithelioma).

The inflammatory changes around the growth are more extensive in a rodent ulcer than in an epithelioma and there is consequently a greater development of fibrous tissue.

Carcinoma of the Meibomian Glands.—A few cases of carcinoma which appeared to originate in the Meibomian glands have been recorded. A tumour forms in the eyelid which as it extends may result in ulceration, on either or both, the skin and conjunctival surfaces. Microscopically these growths have the characters of a typical alveolar carcinoma, they are different from those of a rodent ulcer, the cells usually being larger and more of the type of sebaceous epithelium.

¹ A. Bowlby. Trans. Path. Soc. of London, 1894, XIV, 152.

Adenoma.—Adenomata met with in connection with the conjunctiva or skin of the eyelids may be of a racemose or acino-tubular type. The former arise in either the Meibomian or sebaceous glands of the skin, the latter from either the modified sweat glands of Moll or the glands of Krause.

An adenoma of a Meibomian gland is not of very rare occurrence; it is very likely to be mistaken for a chalazion. It sometimes develops chiefly on the conjunctival surface of the tarsus and at others on the skin surface. Microscopically lobules are found resembling large normal alveoli distended with polygonal cells, the more central of which show a tendency to degenerative changes.

The distinctive features of an adenoma of a gland of Moll are its location at the margin of the lid, a tendency to cystic formation, and the presence of a double row of cells lining its tubules, an inner of cylindrical epithelium and an outer of endothelium—a similar arrangement to that which is found in the normal gland.¹

In an adenoma of the gland of Krause the lining of the acini and ducts is composed of a single layer of epithelium.

Adenomata of an acino-tubular character have also been found starting in the *plica semilunaris*, probably from rudimentary glands representing those connected with the nictitating membrane in animals.

Carcinoma and Adenoma of the Lacrimal Gland.—Tumors arising in the lacrimal gland have been described as carcinomata or adenomata. A more careful study of new growths of this structure of recent years has, however, shown that the large majority of them originate in its mesoblastic constituents (see page 142).

Moles or Nevi of the Conjunctiva and the Malignant Growths Arising from Them.—Moles or nevi are met with in the ocular conjunctive presenting the same characteristics as those occurring in the skin. They form flat or slightly raised spots, usually deeply pigmented, standing out very conspicuously in contrast with the surrounding white of the

¹ M. Salzmann. Arch. of Ophth., 1891, XX, 380.

sclerotic. They may, however, be unpigmented and of a pinkish yellow colour.

The surface epithelium overlying them, instead of presenting its usual regular base line, frequently shows some down-dipping extensions of its deeper cells. The cells of the growth itself, though in close proximity to the surface epithelium, are separated from it by strands of fibrous tissue. They are of an epithelial or endothelial type of various sizes, but always smaller than the surface epithelial cells. They are arranged in spaces bound by fibrous tissue and are mostly polygonal in shape with a round nucleus. The pigment when present is located in the cells of the growth itself, in the connective-tissue cells, and in those of the overlying epithelium. Cystic space may form amongst the cells of the growth due probably to their disintegration; some of them swell up to resemble goblet cells.

In rare cases a mole may spread over the whole conjunctiva without showing any tendency to invade the deeper tissues.

A malignant growth starting in a mole of the conjunctiva presents symptoms similar to those described under epibulbar sarcoma (page 137). The history of the growth having commenced in a small pigmented patch, the existence of which had been recognised for many years previously, would suggest its real nature. Microscopically such a growth presents an alveolar structure, its cells resembling those met with in a mole, but showing a more active karyokinesis.

II. TELEPLASMS ARISING IN NEURAL EPIBLAST.

The teleplasms arising in neural epiblast are either unpigmented or pigmented. The former are by far the more frequent; they are usually termed **gliomata** and start either in the *pars optica* or *pars ciliaris retinae*.

The name glioma was given to these malignant growths of the retina on the assumption that they commence like the gliomata of the brain in cells of the neuroglia. More

extended observations have, however, not supported this view. The new growths of the retina present very marked differences, both clinically and histologically, from gliomata of the brain; *e.g.*, they occur only in early life, are more highly malignant, and are composed of an altogether different type of cell. It seems, therefore, unfortunate that they should have received the same name.

The cells composing malignant growths of the retina are of the same character as the cells present in the retina during fetal life. The name **neuro-epithelioma** has therefore been suggested as a substitute for that of glioma for these tumours, and regarding them as teleplasms it would seem more appropriate.

An innocent form of new growth arises occasionally in the pars ciliaris retinae, it has been described by different observers as an **adenoma** and an **epithelial hyperplasia**.

Congenital pigmented patches comparable to moles or nevi of the skin and conjunctiva are met with in the uveal tract; they are termed **melanomata**. Their mesoblastic or epiblastic origin, as in the case of nevi of the skin, is a matter about which there is considerable difference of opinion. Sometimes they become malignant.

A few undoubted cases of **melanotic carcinoma** arising in the pigment epithelial layer have been recorded.

Glioma or Neuro-epithelioma of the Retina.—A glioma of the retina usually first attracts attention in the second year of life and has never been known to manifest itself later than the age of eleven years. Sometimes it is undoubtedly congenital, but not always, since eyes which have been subjected to the most careful ophthalmoscopic examination, and in which no changes could be detected, have subsequently developed a gliomatous growth.

In about one-fourth of the cases the growth is bilateral, appearing either simultaneously in the two eyes or with an interval of only a few months. An interval of as much as three years has, however, been recorded.¹ The growths in

¹ Treacher Collins. Trans. Ophth. Soc. of the U. K., XVI, 1896, 142.

the two eyes arise independently; one is not metastatic to the other, and there is no extension of growth along the optic chiasma from one eye to the other. This is shown by patients' living for years after the removal of the two affected eyes, without any fresh manifestations of the disease.

The right eye is affected with the same frequency as the left and the two sexes equally. Members of the same childhood have in rare instances been the subjects of glioma

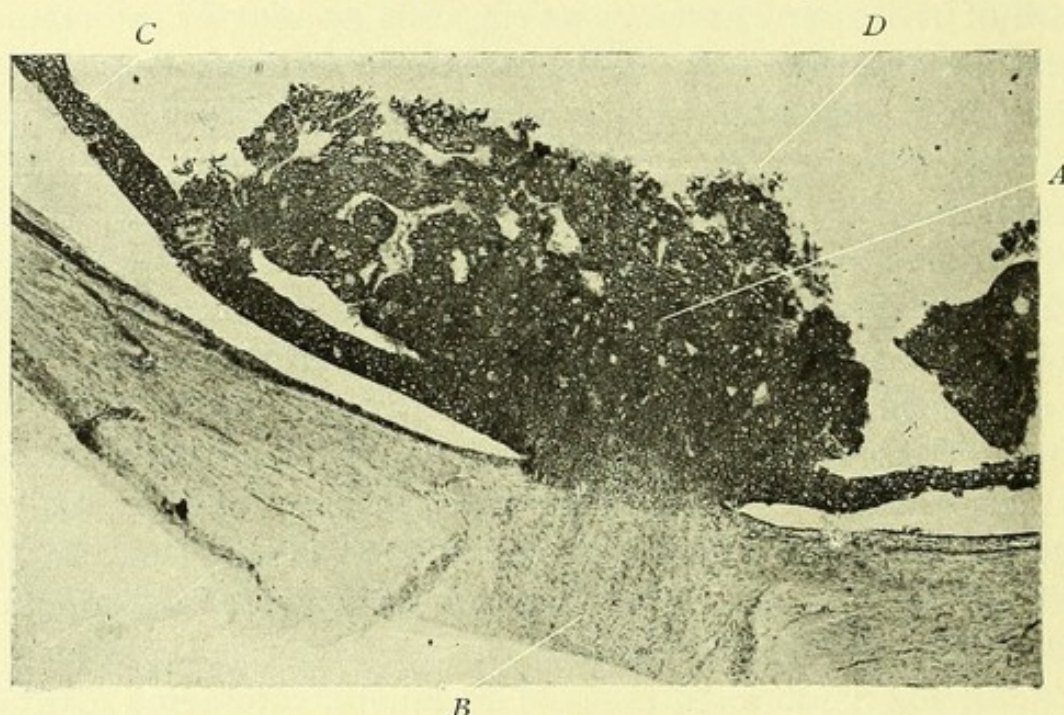


FIG. 69.—Glioma of the retina *A* commencing to involve the optic nerve; *B*. The glioma growing from the nuclear layers of the retina *C* has converted it into a mass of new growth. The portion of the growth *A* is fungating into the vitreous *D*.

of the retina, but it has not been met with in more than one generation in a family.

The symptoms of the commencement of the disease vary according to the situation of the growth. If it protrudes from the outer surface of the retina it is termed **glioma exophytum**, if from the inner surface **glioma endophytum**. In the former, which is the more frequent, the retina is displaced inward and seen clinically behind the lens with the opaque white growth beneath it. In the latter the retina remains in position, the tumour extending inward to the

vitreous chamber (Fig. 69), detached flocculent nodules often forming in the vitreous humour.

In the rare cases where it starts from the pars ciliaris retinae it grows at first superficially over the ciliary body, posterior surface of the iris, and anterior surface of the lens.

In course of time glioma of the retina gives rise to increased tension, the effect of which in a child's eye is to cause expansion of the elastic cornea and sclerotic as in buphthalmos. It tends to spread along the lymphatic sheaths of the blood-vessels and after invading the choroid will extend out of the eye into the orbit along the perforating vessels. It may also after having reached the anterior chamber extend over the iris or perforate the globe in the region of the canal of Schlemm.

When a glioma escapes from the eye its rate of growth becomes accelerated and it fungates outward, forming on the anterior surface of the eye a nodulated bleeding mass which was termed by older writers "fungus hematoides."

Glioma of the retina frequently extends backward along the optic nerve to the brain. Metastatic growths may form in the eye itself from cells of the primary growth which become detached and carried to some fresh situation, either in the vitreous chamber, anterior chamber, or sub-retinal space. Extraocular metastatic growth may form in the preauricular gland, in the periosteum of the cranial and facial bones, and occasionally in the liver.

Local recurrence after enucleation is exceedingly common and a frequent cause of death. If a patient lives three years after the removal of the eye for glioma and during that time no fresh growth has arisen all possibility of any recurrence may be considered at an end.¹

An early gliomatous growth is gelatinous in character and of a greyish colour; on division its blood-vessels show plainly as red points. When the growth has existed for some time degenerated areas form giving it a patchy appear-

¹ J. B. Lawford and Treacher Collins. R. Lond. Ophth. Hosp. Rep., 1890, XIII, 12.

ance. They are of an opaque white or yellowish colour and have sometimes particles of a dead white colour and gritty consistency in them, due to calcareous changes.

Microscopical sections of glioma of the retina stained with hematoxylin show clearly the difference between the degenerate and undegenerate parts of the growth. The

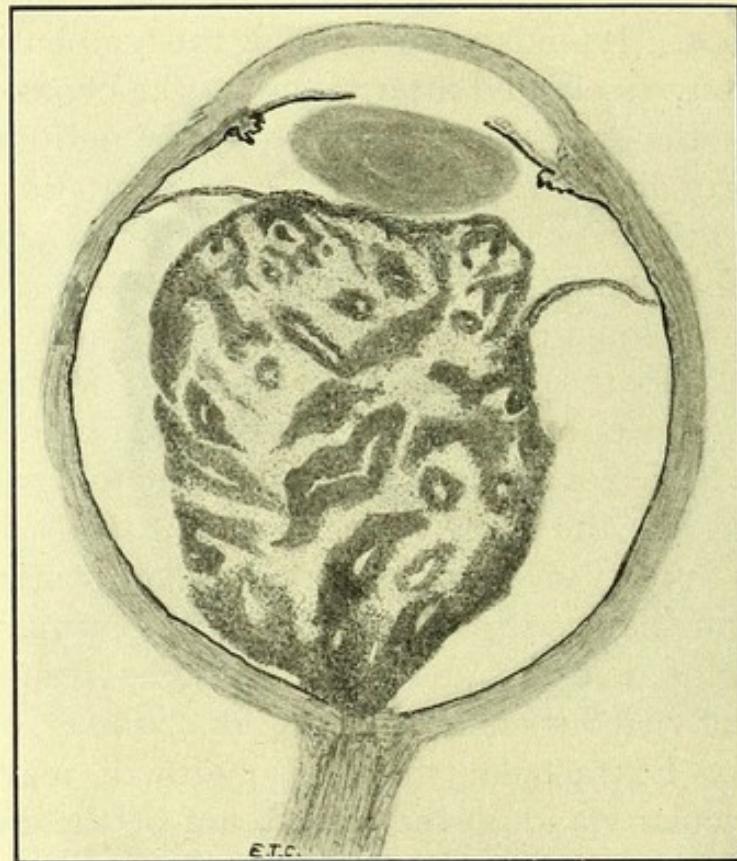


FIG. 70.—Section through an eye containing glioma of the retina. The growth is mainly from the outer surface of the membrane "glioma exophytum." The characteristic patchy way in which it stains, due to areas of degeneration, is shown.

nuclei of the cells in the latter staining deeply and those of the former very slightly or not at all (Fig. 70).

The proliferation of the cells of the growth appears to proceed at a rate which is out of proportion to the rapidity of increase of its vascular channels; so that areas in it become badly nourished and undergo degeneration. The best formed cells and those where the most active karyokinesis

is going on are found in the proximity of the blood-vessels and the most degenerate furthest from them.

A glioma does not usually start from one point only in the retina, there may be several separate foci. In sections of early foci the layer of the retina in which the growth commenced can be detected. It is usually the outer or inner nuclear layer, but occasionally the ganglion-cell layer.

The cells of which a glioma of the retina is composed are peculiar to it. They are not met with in growths arising in other parts of the body except as metastases secondary to

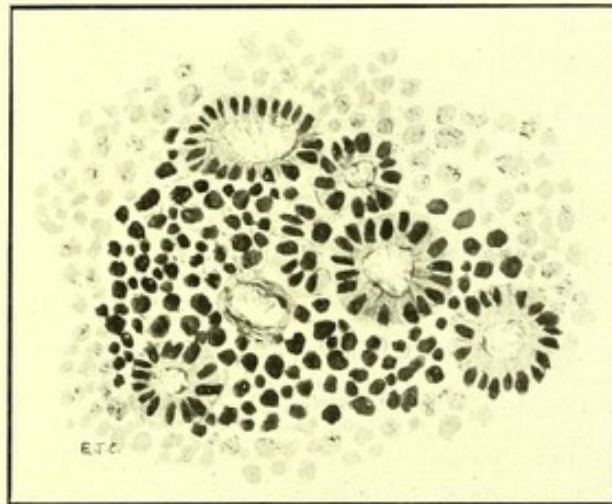


FIG. 71.—Section through a glioma of the retina showing the rosette-like formations of cells, which appear to be rudimentary rods and cones.

glioma of the retina. They have large round or oval nuclei with very little cytoplasm. In teased-out specimens little delicate processes can often be seen projecting from them. They closely resemble the cells of which the whole of the retina is composed at the third month of fetal life, before any of its several layers have become differentiated. They are also very similar to the cells forming the nuclear layers of the retina. In some gliomata of the retina all the cells are of this type, in others, cells which may be regarded as rudimentary rod and cone cells and rudimentary ganglion cells are also found.

The rudimentary rod and cone cells occur grouped

around a space which may be circular like the lumen of a tubular gland, or of an irregular shape. The circular groups of cells have been described as "rosettes" (Fig. 71).

The most highly developed cells in the rosettes are cylindrical in shape and have round or oval nuclei. The ends toward the open space taper somewhat and rod-like projections protrude from them into it. The ends of the cells nearest the lumen rest on a basement membrane comparable to the *membrana limitans externa*. Similar rosette-like formations of cells are sometimes seen in maldeveloped retina of congenitally deformed eyes.

Columnar-shaped cells bounding round or irregular spaces are met with, which may be regarded as a still more elementary stage of a rod or cone cell; and cells can be found in the various stages of transition from them to those which form the chief mass of the growth.

The rudimentary ganglion cells are more angular than the ordinary glioma cells, have more cytoplasm and a projection from them which may be regarded as a rudimentary axis cylinder. There is but little intercellular substance in gliomata,* no true stroma.

In gliomata commencing in the *pars ciliaris retinae*, single rows of cells, like those composing that structure, and cellular membranes like embryonic retina are found. Sudden transitions in the same growth from one of these conditions to the other occur, resembling the transition from the *pars optica* into the *pars ciliaris retinae*.¹

In a single section of a glioma of the retina various stages in the disintegration of its cells are often to be seen. At first the chromatin granules of the nucleus disappear so that it no longer takes up the hematoxylin but stains with eosin as a uniform pink circle. Fatty globules will next appear in this circle, then the cell breaks down, forming with others similarly affected a granular material in which lime salts may become deposited and cholesterin crystals formed.

In rare cases an eye affected with glioma of the retina

¹ F. H. Verhoeff. Trans. Am. Ophth. Soc., 1904, VIII, 351.

instead of becoming glaucomatous and enlarged, shrinks and atrophies, the progress of the growth in it becoming checked or arrested. In the majority of such cases both eyes are affected but only one becomes atrophied (Fig. 72). The cause of the atrophic process and cessation of growth cannot be said yet to be definitely determined. It seems probable that it is due to the occurrence of some intercurrent inflammation starting in the uveal tract, the toxin exciting which acts on the cells of the growth besides

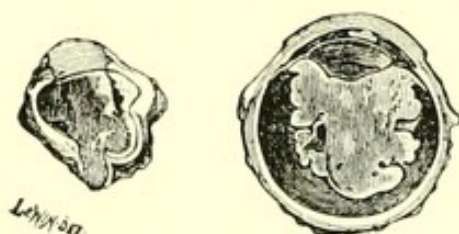


FIG. 72.—The lateral halves of the two eyes of a boy aged sixteen months. The left which is much shrunken is full of gliomatous growth, the lens is absent. The right is of normal size, a gliomatous growth involves the whole retina. Case recorded in the R. Lond. Ophth. Hosp. Rep., XIII, 1892, 393.

causing the other destructive changes in the eye. The fact that several shrunken eyes containing gliomatous growths which have been examined histologically showed inflammatory infiltration of the choroid lends support to this view.

The blood-vessels in the glioma of the retina have thin walls composed of a lining endothelium with connective tissue external to it. This latter is liable to undergo hyalin and calcareous degeneration. Hemorrhages into the growth are of frequent occurrence and sometimes extensive.

Innocent Tumours of the Pars Ciliaris Retinæ ("Adenomata").—Small innocent growths arising from the inner unpigmented layer of cells lining the ciliary process have been met with in the eyes of elderly people. As a rule they are not more than 1 mm. in diameter and do not give rise to any clinical symptoms, their presence only being discovered on pathological examination. In one case,¹ however, the growth was unusually large from the formation of a cyst, and it

¹ G. Coats. R. Lond. Ophth. Hosp. Rep., 1907, XVII, 143.

pushed forward the periphery of the iris in its locality, so leading to the recognition of its presence clinically.

These growths start at the summit of a ciliary process and usually extend outward into it; they may sometimes also give rise to thickening on the inner surface of the ciliary body.

Springing from the unpigmented layer of cells the growth itself is entirely without pigment but carries the pigmented layer in front of it as it extends outward. Both layers become invaginated, the lumen of the space so formed communicating with the interior of the eye. If the communication becomes closed and secretion from the lining cells continues, a cyst is developed.

The growth consists essentially of an increased proliferative activity of the epithelial lining of the ciliary body. This lining epithelium has been described as glandular in character; it is situated in that part of the eye in which the aqueous humour and nutrient fluid of the vitreous is poured out and has been regarded as concerned in their elaboration. Tumours arising in it have therefore been termed **adenomata**. They¹ differ, however, from adenomata arising elsewhere in not possessing any fibrous-tissue stroma, so that some prefer to speak of them as **epithelial hyperplasia**² or **innocent tumours of the ciliary epithelium**.

Melanoma. Innocent Pigmented Growth in the Uveal Tract.—Innocent pigmented growths comparable to the moles or nevi of the skin and conjunctiva are met with in the iris. They are usually situated near the pupillary border and appear clinically as small, dark, raised patches in the iris which do not increase in size. Microscopically they have been found composed of polygonal, pigmented cells, arranged usually in an alveolar fashion in the deep layers of the iris (Fig. 73).

As already pointed out there is some evidence suggesting that the cells of which a nevus of the skin is composed

¹ A. Alt. Am. J. of Ophth., 1898, XV, 321.

² J. H. Parsons. R. Lond. Ophth. Hosp. Rep., 1903, XV, 375.

are snared off from the surface epithelium. In the same way a melanoma of the iris may be composed of cells which have extended forward into its stroma from the pigment epithelium lining its posterior surface.

A pigmented new growth derived principally from the cells of the outer layer of the optic vesicle covering the ciliary →

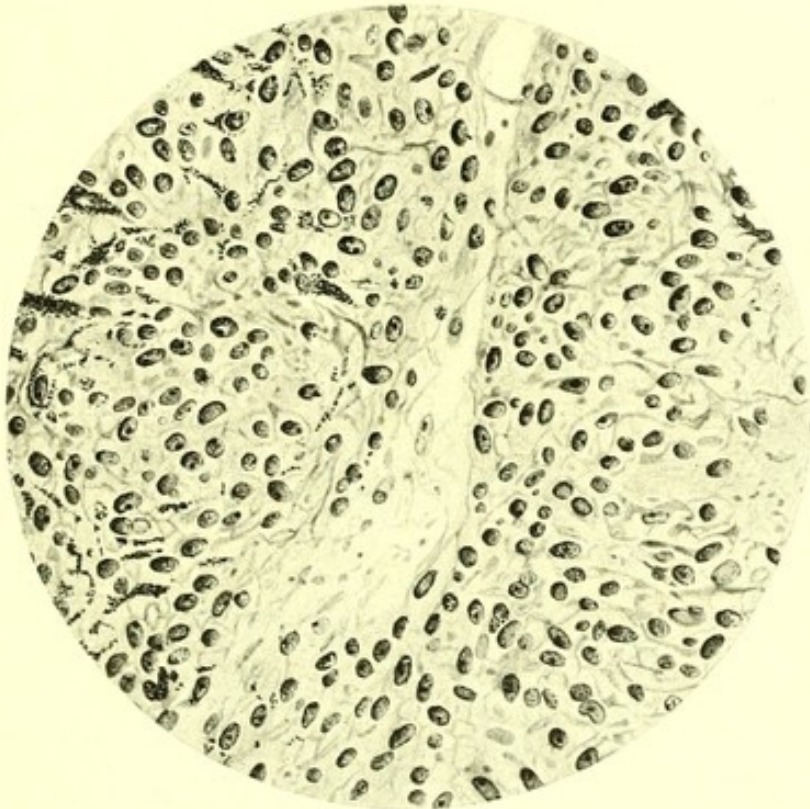


FIG. 73.—Section showing the microscopical characters of an innocent pigmented growth of the iris. $\times 300$. Case recorded in the Trans. Ophth. Soc. of the U. K., XIX, 1899, 53.

body has been found in a congenitally malformed eye (Fig. 74); the cells for the most part were arranged in contact with each other, but toward its outer part there was an attempt at alveolar¹ formation.

Oval dark patches with a sharply defined margin are seen ophthalmoscopically in the choroid. They do not increase in size or alter in appearance. It seems likely that such patches are innocent melanomata of the choroid like those seen in the iris. Patches have been discovered by

¹ M. S. Mayou. Trans. Ophth. Soc. of the U. K., XXVIII, 1908, 107.

accident during pathological examinations, which are possibly of this nature and were found to be composed of densely packed and deeply pigmented chromatophores.¹

Malignant Melanotic Growths of the Pigment Epithelium of the Uveal Tract. Melanotic Carcinoma.—Malignant

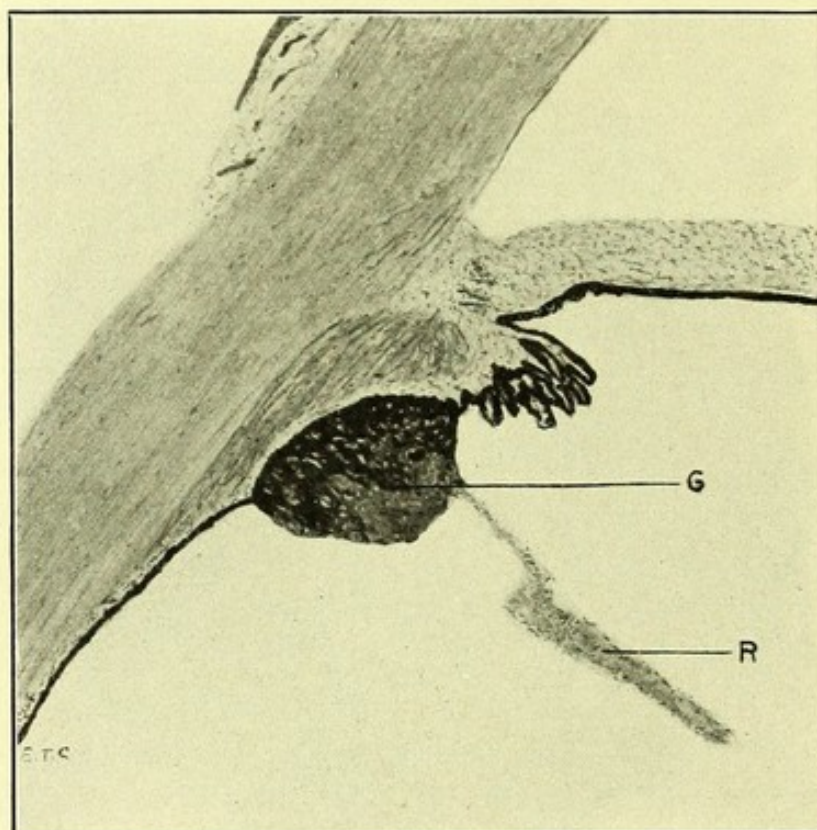


FIG. 74.—Congenital pigmented tumour of the ciliary body *G*, in a microphthalmic eye. Note the fetal condition of the angle of the anterior chamber and the separation of the two layers of the optic vesicle; the retina *R* has never been in contact with the pigment cell layer.

growths arising from the pigment epithelium of the uveal tract are exceedingly rare. Cases are described starting in its three different divisions, the iris, the ciliary body, and the choroid. They may arise directly from the epithelial layer covering its inner surface or from a melanoma. In the iris the history of a melanotic nodule for many years before the onset of a melanotic growth in it has several times been obtained.

¹ Purtscher. Arch. f. Ophth., 1900, L, 81.

Those who consider nevi to be of mesoblastic origin from the appearance of their cells regard the malignant

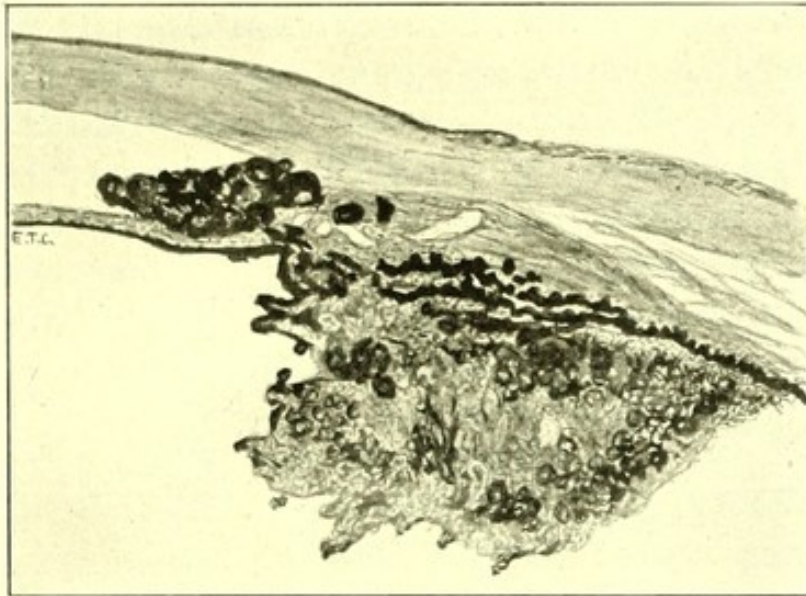


FIG. 75.—Melanotic carcinoma of the ciliary body starting as a primary growth from the pigment epithelium of the ciliary body in a woman aged 63 years. The root of the iris has become invaded.

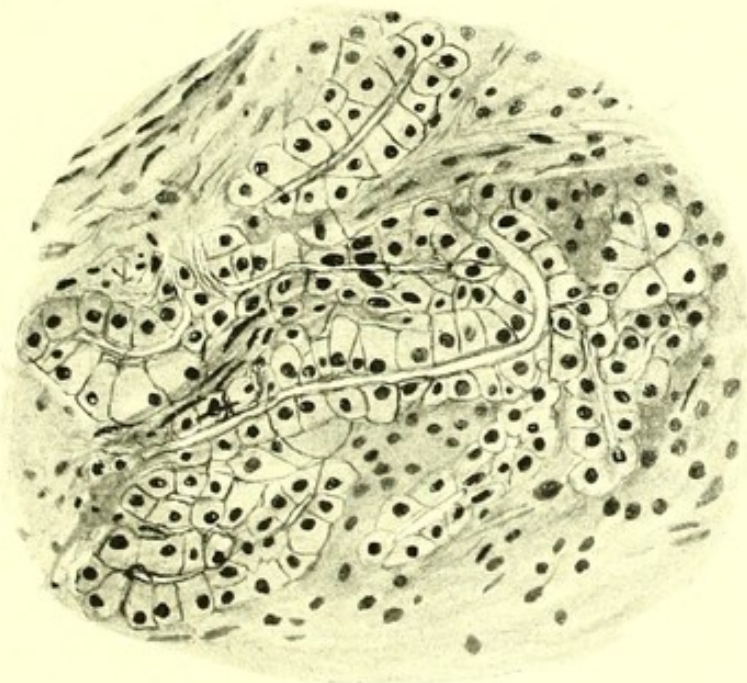


FIG. 76.—Bleached section of the melanotic carcinoma of the ciliary body depicted in Fig. 75. $\times 300$.

growths which originate in them as endotheliomata; whilst those who hold that the nevi are of epiblastic origin consider

them carcinomata. It is possible that some of the cases reported as alveolar sarcoma of the uveal tract may have arisen in innocent melanomata.

There seems to be no doubt about the epithelial origin of some of the melanotic malignant growths originating in the ciliary body.¹ Melanotic carcinoma has been found growing from the surface and involving the substance of the ciliary body and iris (Figs. 75, 76); also forming a raised annular mass on the inner surface of the ciliary body with local metastases. In some cases this form of new growth was found in eyes which had previously been the seat of plastic endophthalmitis.

III. TELEPLASMS ARISING IN TISSUES DERIVED FROM MESOBLAST.

A teleplasm arising in a tissue derived from mesoblast in which an early embryonic condition of that tissue is reproduced is termed a **sarcoma**. Such a growth is malignant. It is mainly composed of cells which are constantly proliferating, hence it rapidly increases in size. Its cells are liable to penetrate into the blood channels where becoming detached they form emboli; the transference of these cells to other parts of the body accounts for the occurrence of metastatic growths.

Sarcomata have usually been subdivided into classes according to the shape of the cells of which they are composed: hence the terms round, spindle, and mixed, cell sarcoma. A more satisfactory classification has, however, been formed, based on the type of mesoblastic tissue which the growth simulates and hence the terms endothelioma, perithelioma, cylindroma, and lympho, fibro and myeloid sarcoma; the nomenclature describing the shape of the cells being reserved for the growths of a more rudimentary type.

The **sarcomata** here described are divided into **intra-ocular**, **epibulbar**, and **orbital**.

¹ Treacher Collins. Trans. Ophth. Soc. of the U. K., XI, 1891, 61. E. Fuchs. Arch. f. Ophth. LXVIII, 1908, 3, 534.

A teleplasm composed of mesoblast more highly organised than a sarcoma is less cellular and less malignant. Any of the tissues into which the mesoblast becomes differentiated may form the predominant constituent of a growth; hence the terms, **fibroma, angioma, myoma, and lymphoma.**

Intraocular Sarcoma.—Sarcoma of the uveal tract, although the most common form of new growth arising within the eye, is a comparatively rare disease. The anterior parts of the tract are much less frequently affected than the posterior. The ciliary body is more often the primary seat of sarcoma than the iris, the choroid than the ciliary body, and the posterior half of the choroid than the anterior.

Sarcoma of the uveal tract may occur at any age, it has been met with in a child two years old and a man of eighty-four; it is most frequent between the ages of forty and sixty. The two eyes and both sexes are affected almost equally. No hereditary tendency to it has been traced, except in one case where a mother and two daughters were similarly affected.¹ Some general tendency to tumour formations in near relatives is, however, not infrequent.

The symptoms produced vary according to which of the three divisions of the uveal tract, iris, ciliary body, or choroid, is primarily involved. Whichever it may be, glaucoma and the formation of extrabulbar and metastatic growths subsequently ensue.

Sarcoma commencing in the iris manifests itself as a pigmented or unpigmented nodular swelling which steadily increases in size, is very vascular, and not uncommonly accompanied by hemorrhage into the anterior chamber. The ciliary body and ligamentum pectinatum become invaded early in the disease. The involvement of the latter causes increase of tension by preventing filtration from the eye. Extension of growth along the walls of the canal of Schlemm, or the anterior perforating vessels, gives rise to the formation of extraocular nodules.

Sarcoma commencing in the ciliary body soon invades

¹ J. H. Parsons. Trans. Ophth. Soc. of the U. K., XXV, 1905, 205.

the root of the iris and makes its appearance at the extreme periphery of the anterior chamber where it simulates clinically an iridodialysis (Fig. 77).

The interference which in its early stages it causes with the secreting function of the ciliary body may give rise to decrease in the intraocular tension. Later owing to the iris becoming pushed forward, lateral displacement of the lens, or invasion of the ligamentum pectinatum, the exit of the intraocular fluid becomes obstructed and glaucoma ensues.

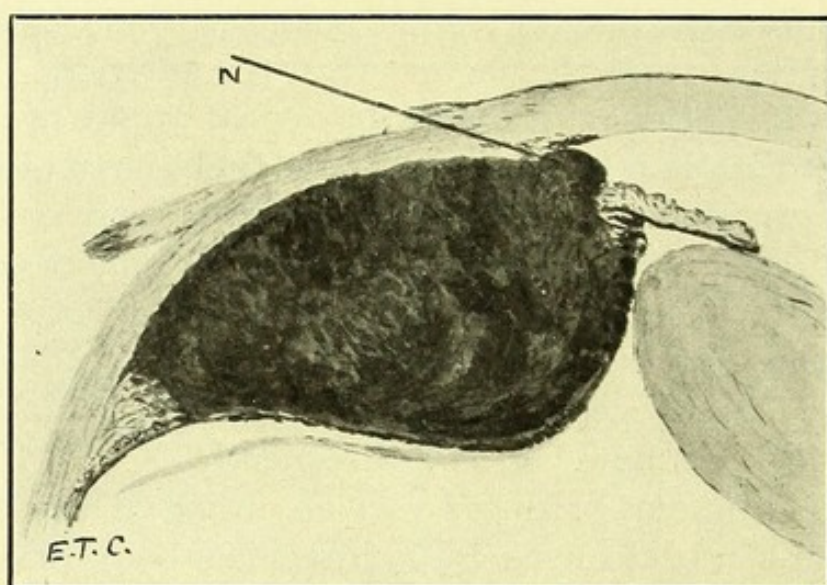


FIG. 77.—Melanotic sarcoma of the ciliary body extending forward through the root of the iris and appearing in the anterior chamber at *N*; also infiltrating the spaces of Fontana.

The growth which spreads forward through the base of the iris extends into the anterior chamber and may eventually fill it. Enlargement of the growth directly inward raises and ruptures the elastica lamina and later presses on the side of the lens, distorting it in shape and displacing it laterally. An invasion of the lens substance by a sarcomatous growth through a rupture in its capsule has been described.

From extension backward of the growth the choroid becomes implicated and in the later stages of the affection the retina may become detached. On its outer surface the

growth has the tough sclerotic which resists invasion, the channels through it of the anterior perforating vessels are, however, early implicated. The formation of nodules of pigmented growth on the surface of the globe at the site of one of these vessels being sometimes one of the first symptoms to attract attention (Fig. 78).

In some rare cases of sarcoma of the ciliary body, the growth infiltrates the whole circle of that structure instead

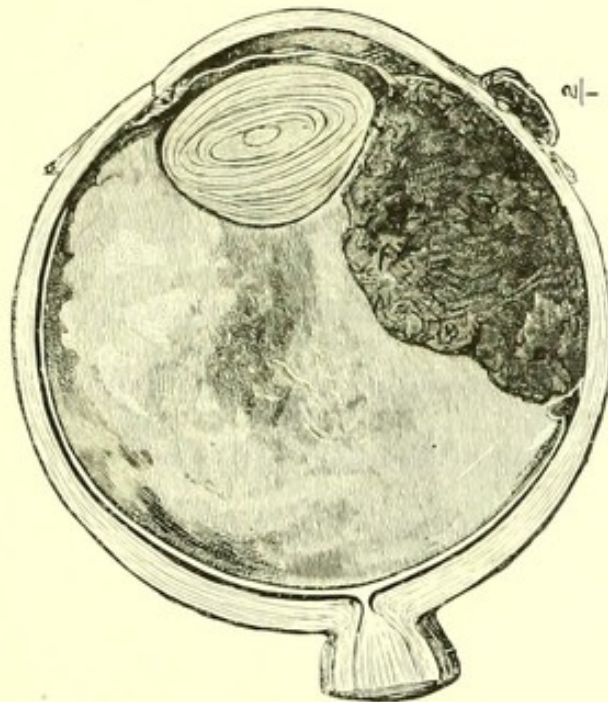


FIG. 78.—Lateral half of an eyeball containing a melanotic sarcoma of the ciliary body. There is a small extraocular nodule over the seat of one of the anterior perforating vessels, a short distance from the sclero-corneal margin. Specimen in the R. Lond. Ophth. Hosp. Museum.

of forming a protuberant mass in one part of it. Such cases are known as **ring or annular sarcomata** and are comparable to the diffuse or flat sarcomata of the choroid.¹

Sarcoma commencing in the choroid begins by spreading laterally and forming an elliptically shaped thickening. The resistance to its extension is greater on the outer surface where it has the firm sclerotic than on the inner surface where there is only the elastic lamina and retina. The elastic lamina becomes, therefore, raised up by the growth

¹ J. H. Parsons. Arch. f. Ophth., 1902, LV, 2, 350.

until the tension of it is so great that it ruptures. The resistance to its extension inward being removed, the growth fungates through the rupture in the form of a rounded knob, the whole growth thus assuming a mushroom-like shape (Fig. 79).

In rare cases, a sarcoma of the choroid instead of growing inward spreads laterally, infiltrating and thickening the membrane instead of forming a protuberant mass on its

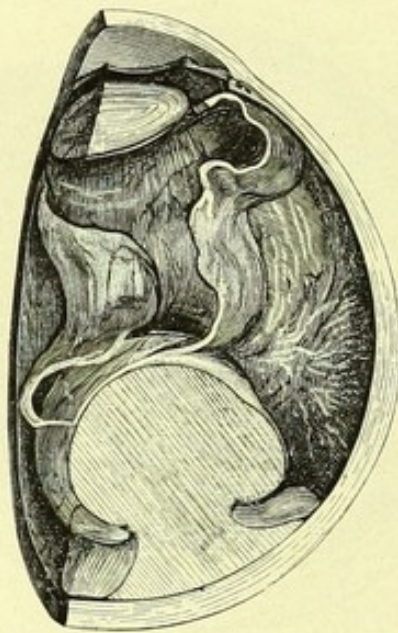


FIG. 79.—Shows an eye with a sarcoma growing from the choroid. The growth has extended inward through a rupture in the elastic lamina and then expanded into a rounded knob. Specimen in the R. Lond. Ophth. Hosp. Museum.

inner surface. Such sarcomata are termed **diffuse or flat** in contrast to the commoner variety which are **circumscribed or nodular**.

In sarcoma of the choroid the retina very soon becomes detached. The detachment extends over a wider area than that occupied by the growth; albuminous fluid which becomes coagulated by hardening reagents into a jelly-like material filling the sub-retinal space. Besides the detachment in the vicinity of the growth there is often a second independent detachment in the lower part of the globe,¹ due to gravitation of the fluid. The extent of the detach-

¹ J. H. Parsons. Ophthalmic Review, XXIV, 1905, 161.

ment tends to increase until it becomes complete, the retina assuming an umbrella shape. Frequently the retina retains an adhesion to the apex of the rounded knob of the growth, where there may be hemorrhages into it.

The detachment of the retina is caused by an out-pouring of serous fluid from the choroidal vessel due to obstruction to the venous circulation from pressure by the growth.

In the first stage of a sarcoma of the choroid there is no increase of tension. The space in the eye occupied by the

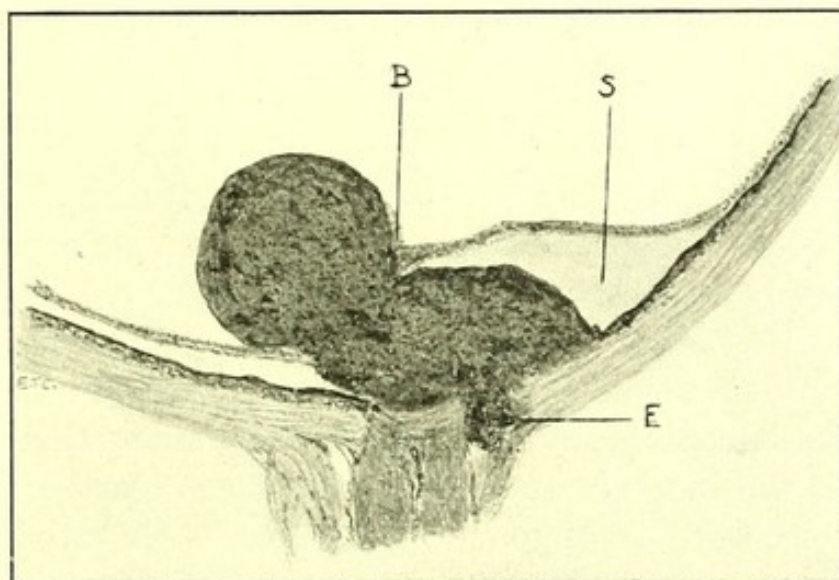


FIG. 80.—Melanotic sarcoma growing from the choroid at the margin of the optic disc; breaking through the elastic lamina at *B*, and forming a round protuberance overlying the disc. Also extending through the sclerotic into the sheath of the optic nerve at *E*; the retina is partly detached and *S* points to the subretinal albuminous exudate.

growth and sub-retinal exudate is compensated for by fluid being squeezed out of the vitreous humour. Ultimately the vitreous becomes so compressed and shrunken that the lens and iris are pressed forward and the angle of the anterior chamber becomes closed, glaucoma then ensuing.

Extension of the growth outside the eye may occur along any of the channels in the sclerotic penetrated by vessels or nerves (Fig. 80), commonly along the sheaths of the perforating vessels in the vicinity of the base of the growth. An

extrabulbar growth behind the globe increases rapidly and gives rise to proptosis.

Metastatic growths occurring in connection with sarcoma of any part of the uveal tract are the result of transference of emboli of cells of the growth by the blood. That such emboli should occur is not surprising seeing that the new-formed blood channels in the growth consists only of endothelial tubes or even sometimes seem to be bounded by the cells of the growth itself. Metastases are mostly found in the viscera, the liver and lungs being the commonest sites. The lymphatic glands connected with the eye do not become affected.

Patients who have had an eye removed for sarcoma of the uveal tract more often die of metastatic growths than of a recurrence in the orbit. In the majority of cases a patient with metastases succumbs to their effects within three years from the date of excision of the eye. Much longer intervals may, however, elapse.¹

Sarcomata of the uveal tract are sometimes divided into **melanotic sarcomata** and **leucomata sarcomata**, the former being far the more frequent. Such a classification cannot be very accurate or of much importance. Growths which appear to be quite white macroscopically are often found to contain pigment granules when examined microscopically. They may sometimes be densely pigmented in one part and devoid of pigment in another. A growth which is deeply pigmented in the eye is frequently unpigmented when it becomes extraocular. The primary growth in the eye may be pigmented and the metastatic growths unpigmented. The pigmentation of sarcomata in the uveal tract is generally due to melanin; in some, however, the pigment is derived directly from the blood usually as the outcome of hemorrhages into it; such pigmentation is termed *hematogenous*.

The character of the cells met with in sarcomata of the uveal tract vary considerably in different cases and also

¹J. B. Lawford and Treacher Collins. R., Lond. Ophth. Hosp. Rep., XIII, 1892, 104.

sometimes in the same growth. The cells are derived either from connective-tissue cells or endothelial cells.

~~Connective-tissue~~ cells of the uveal tract in their development are first round, then spindle-shaped, and afterward branching, melanin granules being deposited when they are fully formed. Endothelial cells are first small, round cells and then increase in size and become polygonal.

A malignant new growth of the uveal tract may be composed of cells of any of the above types. When two different types of cells are met with in the same growth it probably represents either a reversion to different stages of development in the cells, or to proliferative activity excited in cells of different types, such as the connective tissue and endothelial cells.

In spindle-celled sarcomata the cells have oval nuclei and are arranged in groups. In a microscopical section of the growth some of these groups may be cut transversely so that both the cells and their nuclei appear round. This might lead to the mistaken diagnosis of the growth as a mixed round and spindle-celled sarcoma, a mistake which can be prevented by the examination of a teased out specimen of the tumour.

In what are termed round-celled sarcomata it is the nucleus of the cell which is round, the cytoplasm in teased out specimens often showing projecting processes.

Endothelium in the normal uveal tract is found lining blood-vessels and lymph spaces; the latter are inter-fascicular and perivascular. Enhanced proliferative activity of any of these three different sets of cells is a possible source of a sarcomatous growth. The endothelium lining the blood channels does not often give rise to new growths.

What are termed **angiosarcomata** or **peritheliomata** of the uveal tract are growths arising in the perivascular lymphatic sheaths. Some angiosarcomata present on section macroscopically a foliated appearance simulating the convolutions of the brain (Fig. 81). Microscopically blood-vessels with thin walls are seen surrounded by zones of cell

which may be large and typically endothelial in origin (Fig. 82) or small with round nuclei and of irregular shape. The cells which are furthest from the blood-vessels in this form of growth show a marked tendency to degeneration, their nuclei staining badly and the cytoplasm undergoing fatty changes. Hyalin and myxomatous degeneration may also be present. Angiosarcomata are frequently found without any melanin but are often the seat of hematogenous pigmentation.

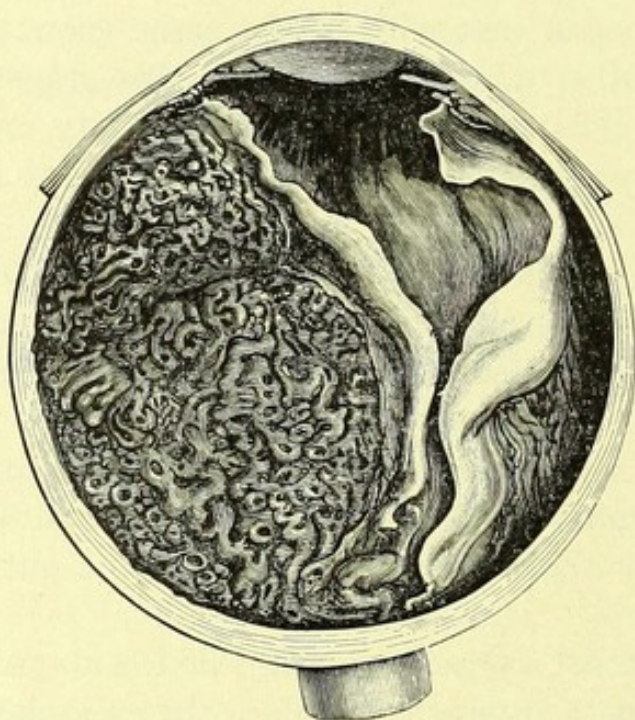


FIG. 81.—The lateral half of an eyeball containing an angiosarcoma of the choroid. Note the foliated arrangement of the tumour at the seat of section. Specimen in the R. Lond. Ophth. Hosp. Museum.

tion, hemorrhages into them being exceedingly common. In some cases the hemorrhage is so extensive that on section of the globe the presence of a growth is easily overlooked, the interior of the globe appearing to be entirely filled with degenerate blood clot.¹ In these cases degenerative changes are found not only in the growth itself, but also in the other tissues in the interior of the eye. There seems to be a general necrosis of most of the intraocular contents the cause of which has not yet been determined. It is suggested

¹ J. H. Parsons. Trans. Ophth. Soc. of the U. K., XXV, 1905, 193.

that it is the result of some toxin due to endogenous microbial infection.

There are rare cases of sarcoma of the uveal tract which, instead of going on to the glaucomatous stage, develop a plastic uveitis causing a shrinking of the globe; it may be that these cases are a later stage of degenerating angiosarcomata.

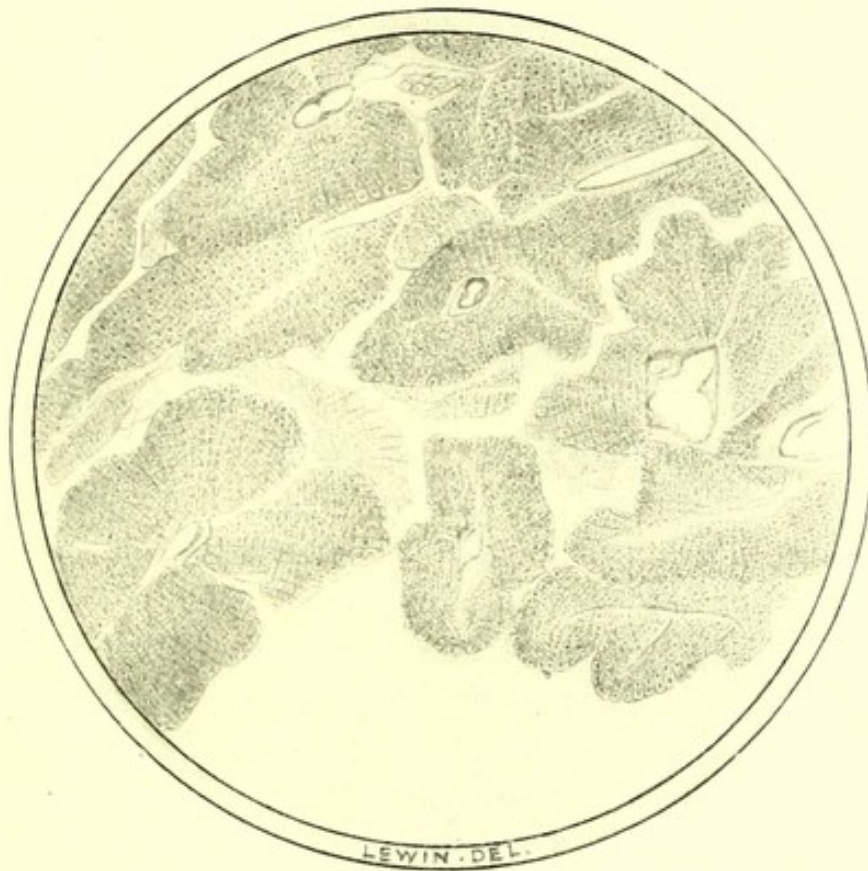

FIG. 82.—Section through an angiosarcoma of the choroid. Showing thin-walled blood-vessels surrounded by zones of cells of an endothelial type.

A malignant growth commencing in the endothelium of the lymph spaces of the uveal tract is termed **interfascicular endothelioma**.¹ It presents an alveolar formation, and when its cells are large and polygonal simulates a carcinoma from which, however, it may be differentiated by the intimate connection of the tumour cells with the connective tissue. In the early stage of carcinoma no such intimate

¹ H. Coppez. Arch. d'ophtalmol. XXI, 1901, 141.

connection exists, the cells of the growth being separated from the connective tissue by the layer of endothelial cells lining the lymphatic spaces along which it spreads.

Ring, diffuse, or flat sarcomata already referred to are mostly interfascicular endotheliomata,¹ their tendency to extend laterally along the neighbouring lymph spaces as being the line of least resistance accounting for their mode of growth. In this particular they resemble "metastatic" carcinoma of the uveal tract (see page 155).

Interfascicular endotheliomata grow slowly and are liable to degenerative changes both in the cells of the growth itself and in its connective tissue.

In the oldest parts of the growth these degenerative changes may be so extensive as to destroy its characteristic features. The cells undergo hyalin or colloid degeneration which may result in cystic formation. The connective tissue undergoes hyalin or mucoid degeneration and in some rare instances there has been a formation of cartilage. It is always necessary to examine the spreading edges and more recently formed portions of the growth to ascertain its real nature.

Tumours of pigmented endothelium arising primarily in the ligamentum pectinatum have been described.² The endothelial cells lining the spaces of Fontana are usually pigmented, so that a new growth starting from them might be expected to be of a similar character. The growths which were composed of polygonal cells arranged in an alveolar manner, besides filling the angle of the anterior chamber, invaded the cornea, iris, and ciliary body.

The pigment in melanotic sarcomata of the uveal tract is mostly located in the cells of the growth, sometimes also in the intercellular fibrous tissue.

In the normal choroid pigment is found in the large flattened cells of the lamina suprachoroidæ and in the branching cells of the outer vascular layers.

¹ M. S. Mayou. Trans. Ophth. Soc. of the U. K., XXVII, 1907, 149

² Hanke. Arch. f. Ophth., 1899, XLVII, 3, 463.

The chromatophores in sarcomata of the uveal tract are either of an embryonic type, or similar to the fully formed cells. Some are met with which appear swollen and distorted in shape from degenerative changes. The melanin in them as in the normal cells of the choroid is in the form of granules.

Some observers have thought that some of the pigmented cells in a sarcoma of the choroid which has ruptured the elastic lamina are retinal pigment epithelial cells which have proliferated into the growth, their shape and the appearance of the pigment granules in the form of short rods favouring such a view. It is difficult, however, to see how they could make their way through the capsule surrounding the growth.

Hematogenous pigmentation following hemorrhage into a sarcomatous growth may be differentiated from melanotic pigmentation by its lighter colour, being golden or brown, never black, and by giving an iron reaction.

Epibulbar Sarcoma.—Epibulbar sarcoma starts usually in the conjunctiva at the margin of the cornea (Fig. 83). The connective-tissue cells of the conjunctiva in this region contain pigment granules. In the dark races the amount of pigment is such as to produce a brown ring around the cornea. As epibulbar sarcomata are generally pigmented, and the pigment in them is melanin and not hematogenous it is probable that many of them originate in these cells.

Though the limbus is the commonest site for a sarcoma of the conjunctiva, it may occasionally begin in other parts and has been seen to start from the plica semilunaris.

The malignant epibulbar growths which arise from congenital nevi of the conjunctiva clinically resemble sarcomata. Some authorities regard such growths as endotheliomata, but for reasons already stated it has been thought best to group them with the carcinomata (see p. 107).

True endotheliomata may arise in the conjunctiva from the lining cells of the blood or lymphatic vessels, and in rare

cases extend into the cornea where they present an alveolar arrangement of cells of an endotheliomatous type.

Epibulbar sarcoma may occur at almost any age; it has been met with at the age of eight, but usually appears between forty and fifty.

It commences as a small patch which generally develops into a nodular pedunculated mass but may form a flattened

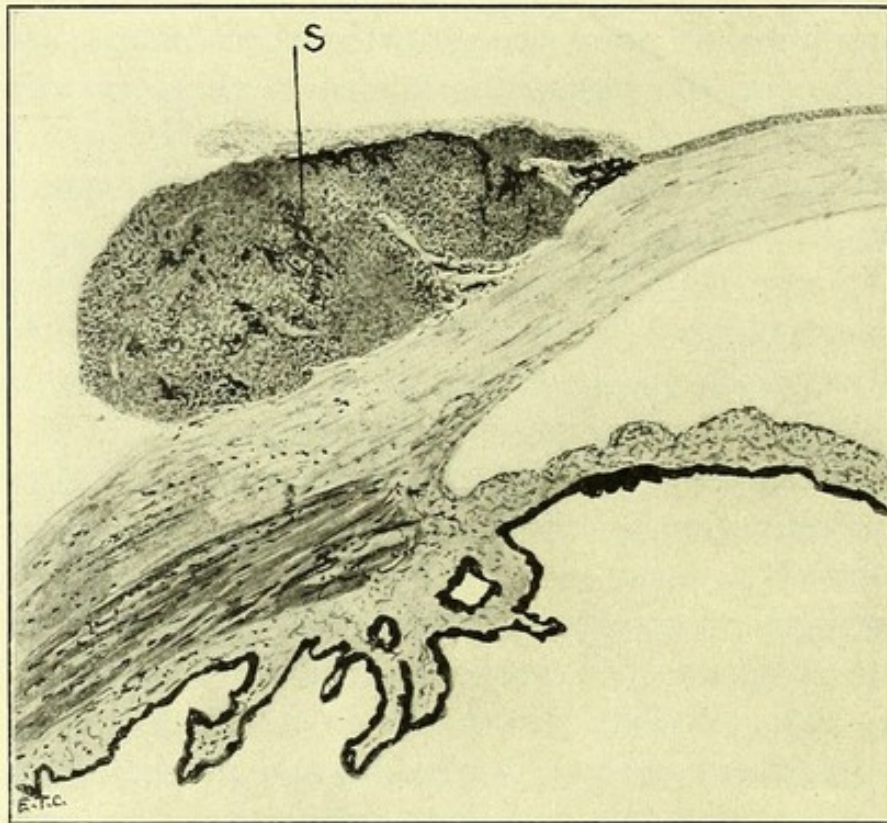


FIG. 83.—An epibulbar, melanotic, sarcoma of the conjunctiva, *S*, starting at the limbus.

sessile growth. When pigmented, as it usually is, the pigment may not be confined to the new growth but become disseminated in the tissue around especially along the margin of the cornea.

The tough fibrous tissue of the sclerotic and cornea does not readily become invaded (Fig. 84), and until it does the growth will be found to move with the conjunctiva on its surface. Intraocular invasion is rare but has been met with,

the extension backward taking place along the track of the anterior perforating vessels or the canal of Schlemm.

The difficulty which the growth has in penetrating the sclerotic allows, when a case comes under observation early, of the entire growth being removed from the surface of the eye so that no local recurrence takes place. When, however, any doubt as to the invasion of the sclerotic exists,

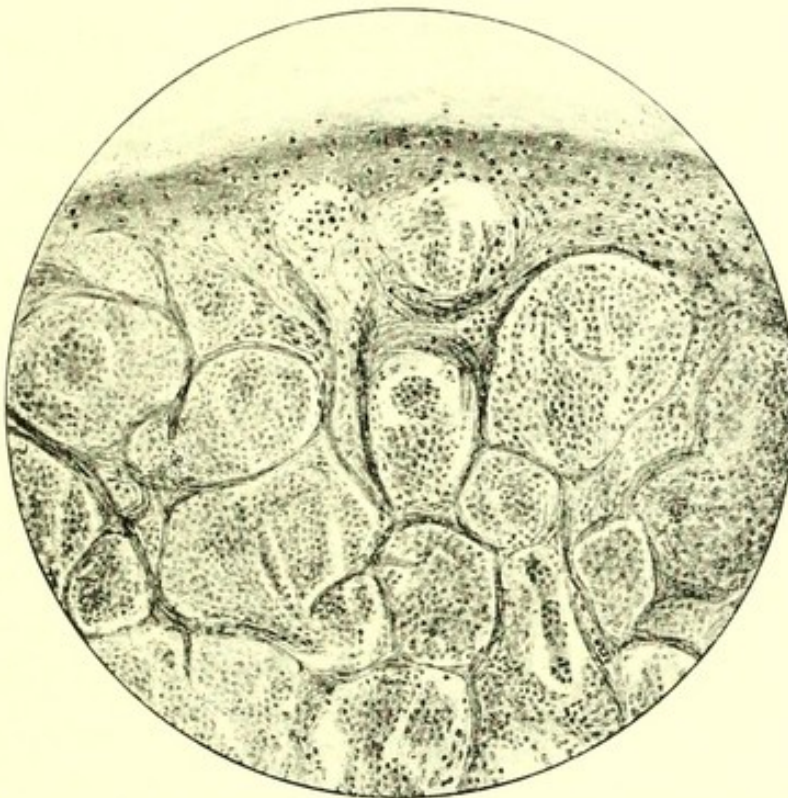


FIG. 84.—Shows the microscopical appearances of a growth which, starting near the limbus, involved the cornea. It is composed of collections of round cells grouped together in spaces bounded by bundles of fibrous tissue. Case recorded in *Trans. Ophth. Soc. of the U. K.*, XV, 1895, 90.

enucleation must be performed. Metastatic growths from an epibulbar sarcoma occur with considerable frequency.

The shape of the cells in an epibulbar sarcoma may be round or spindle-shaped, but as in most sarcomata multinucleated cells are occasionally met with. The granules of melanin are found located both in the cells of the growth itself and in the intercellular tissue.

Sarcoma of the Orbit.—The orbit contains a variety of tissues from which a sarcoma may originate. The perios-

teum, the intermuscular septa, the endothelium of the blood and lymph channels, the sheath of the optic nerve and the lacrimal gland have all been located as the primary seat of this form of growth.

Sarcoma of the orbit may also arise from extensions into it either of a growth originating in the eyeball or in one of the neighbouring sinuses. The former have already been referred to in treating of intraocular sarcoma, the latter are outside the scope of this work.

Primary sarcoma of the orbit is a rare affection. It may arise before birth and at all ages, most frequently it occurs before the age of ten. Cases having growths in the two orbits have been recorded, it would seem unlikely that these were two primary independent tumours, but were probably either lymphomata (see Metastatic Growths) or growths originating in an ethmoidal or sphenoidal sinus which extended laterally into each orbit.

All sarcomata arising in the orbit give rise to proptosis and usually to a sense of resistance on pressure of the eyeball backward. The direction of the proptosis and the possibility of recognising the presence of a tumour on palpation depends on its seat of origin.

The degree of malignancy varies with the character of the growth. Small, round-celled sarcomata extend rapidly and are very liable to cause metastases.

A tumour consisting of a large amount of fibrous tissue with round or spindle shaped cells is termed a **fibro-sarcoma**, and is the commonest form of sarcoma found in the orbit. It represents a reversion to varying degrees of development in the tissue from which it starts and has a low degree of malignancy.

The endotheliomata, though they extend rapidly locally do not give rise to metastasis with the same frequency as the small, round-celled growths.

Histologically it is often difficult to differentiate the small, round-celled sarcomata from gummata and lymphomata. The appearance of the blood-vessels may be of some

assistance; in a sarcoma their walls are frequently composed almost entirely of the tumour cells. In a gumma, on the other hand, thickened walls well differentiated from the small, round cells by which they are surrounded can be made out.

The commonest seat of origin of a round-celled sarcoma is probably the periosteum. Some sarcomata, which are undoubtedly periosteal in origin, contain osteoblasts and have fragments of bone formed in them; these are termed **osteosarcomata**.

The endotheliomata which grow from the perivascular endothelium form columns of cells and are termed **cylindromata** or **angiosarcomata**. The endotheliomatous character of the cells can usually be made out in some parts of the growth, in others they may be less fully formed and of a small round or spindle-shape, while in others again degenerative changes may obscure their characteristics.

The endotheliomata originating in lymphatics show well marked endothelial cells grouped in spaces bounded by fibrous tissue, **alveolar sarcomata**, an appearance which closely simulates carcinoma.

Sarcomata may arise from the dural sheath of the optic nerve, the nerve with its pial sheath lying surrounded by the new formation but uninvolved. Such growths are termed **extradural tumours** to distinguish them from those starting from the pial sheath or fibrous tissue trabeculae of the nerve which are **intradural tumours**. In growths originating in the optic nerve there is usually an extensive hyperplasia of connective tissue and it is frequently difficult to draw a line histologically between fibromatosis of the nerve sheath and sarcoma. Those which are most cellular and malignant are classed as sarcomata. The clinical and other characteristics of growths arising in the optic nerve and its sheaths are described under neuro-fibromatosis (page 147).

Lympho-sarcomata originate in the lacrimal gland from the lymphoid cells situated in the stroma between the gland tubules. Spreading in the stroma the alveoli become

widely separated, and extensive degeneration takes place in their lining epithelium. The progress of this form of growth is at first comparatively slow, it may remain confined within the gland's capsule for as long as a year. Ultimately it breaks through and invades the orbit. It is a form of growth which is met with usually in people over thirty-eight

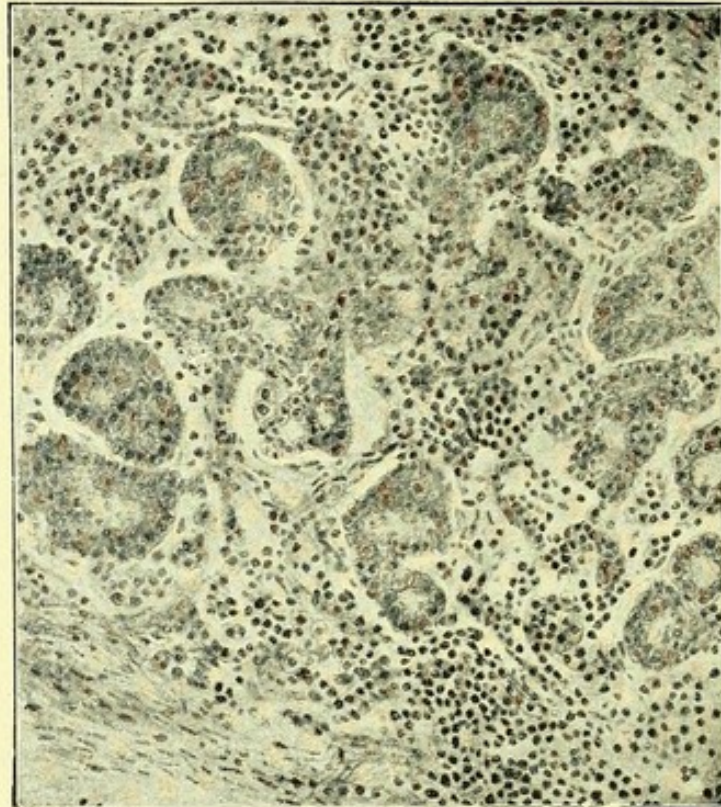


FIG. 85.—Shows the microscopical appearances of a tumour of the lacrimal gland of mixed mesoblastic tissue. The tubes of the gland are shown separated from one another by new growth of a fibrous and cellular character. Case recorded R. Lond. Ophth. Hosp. Reps., XIII, 1893, 398.

years of age and appears at first as a freely movable semi-fluctuating swelling at the upper and outer angle of the orbit.¹

Another form of tumour which starts from the lacrimal gland² is composed of mixed mesoblastic tissues. It is exceedingly rare, occurs mostly in early life and forms a painless growth which is usually encapsuled. Occasionally

¹ A. P. L. Wells and M. S. Mayou. Trans. Ophth. Soc., XXX, 1910, 97.

² A. S. Warthin. Arch. of Ophth., XXX, 1901, 601.

it assumes malignant characteristics and sometimes arises simultaneously with new growths of a similar character in the parotid and submaxillary glands.

The structure of the growth is made up of the following tissues in various combinations, columns of endothelial cells, spindle-shaped cells, fibrous tissue, myxomatous tissue, and hyalin cartilage, *i.e.*, of a mixture of the various tissues into which mesoblast may become differentiated (Fig. 85). The parotid gland tumours have been described as endotheliomata as they arise chiefly from the flattened cells lining the lymph spaces. Endotheliomata starting in other parts of the body are, however, very different in that they are more cellular and more malignant. It seems unsatisfactory to employ the same name for the two classes of growth and therefore those of the lacrimal glands are here termed **tumours of mixed mesoblastic tissue.**

Neuro-fibroma and Neuro-fibromatosis.—Neuro-fibromata occurring in connection with the eyeball or its appendages may be (1) diffuse, or (2) localised.

1. A diffuse neuro-fibroma, or neuro-fibromatosis, is a form of new growth of the fibrous tissue of the affected area associated with a marked increase of the fibrous tissue elements of the nerves. When affecting the skin it was formerly known as the **molluscum fibrosum of von Recklinghausen.** The extreme hypertrophy of the part involved led to the use of the clinical term **congenital elephantiasis.** The thickening of the nerves in some cases is so extensive that they become converted into a mass of convoluted cords with nodular and fusiform thickenings on them; hence the term **plexiform neuroma.**

Though not a malignant form of growth it often shows a tendency to continuous, slow, local increase.

Microscopically the affected nerves show an increase of both the peri- and endoneurium, the nerve fibres themselves being unaffected. When the eyelids are involved they become considerably enlarged from a general hypertrophy of their connective tissue (Fig. 86). In some cases the upper

lids form a large pendulous mass, which the patient is unable to raise sufficiently to see beneath¹. The palpebral conjunctiva becomes involved in the general hyperplasia. When the ocular conjunctiva is affected worm-like tortuous bodies due

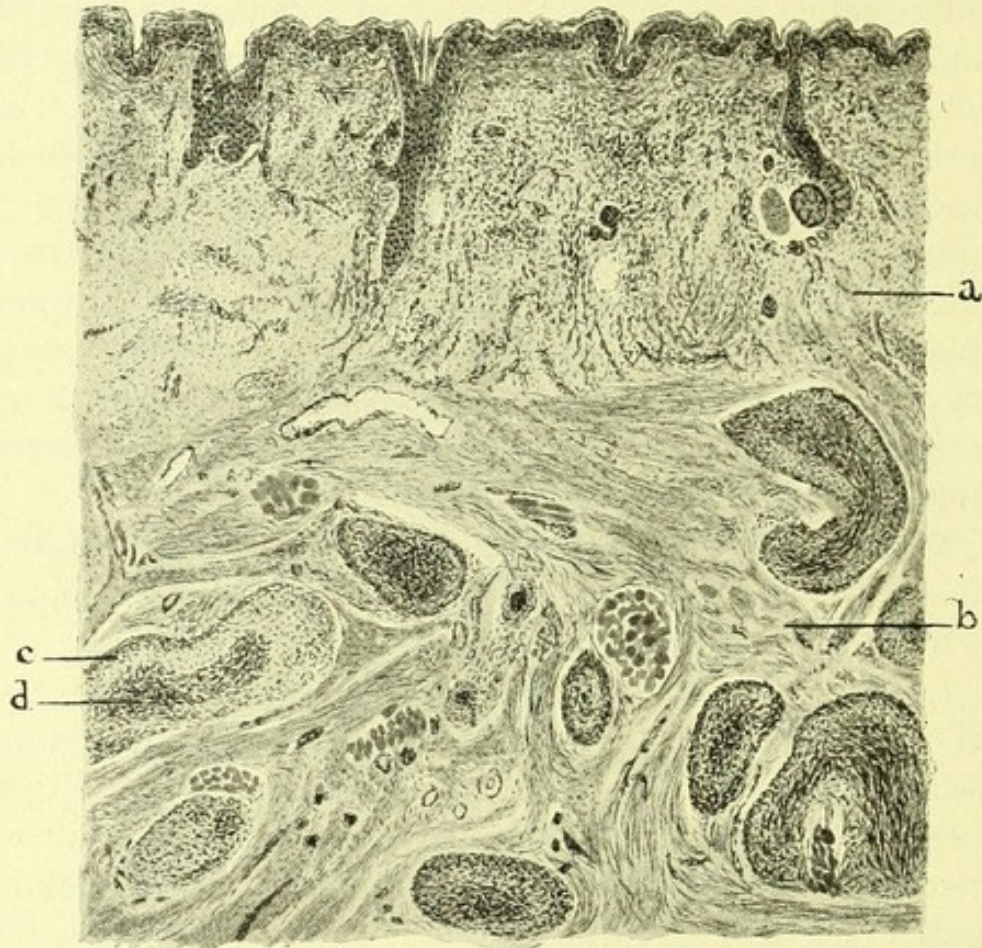


FIG. 86.—Shows the microscopical appearances of a section through the skin of the eyelid in a case of neuro-fibromatosis. *a*, Thickened corium; *b*, subcutaneous tissue with thickened nerves in it cut in various directions; *c*, the thickened perineurium of one of the nerves; *d*, nerve-fibres in the centre of the mass of thickened fibrous tissue.

to the thickened nerves are found in it on the surface of the globe. In the orbit the nerves may become converted into a convoluted mass which gives rise to proptosis and on palpation feels like a bag of worms.

In some of the cases in which the eyelids or orbit have

¹ S. Snell and Treacher Collins. Trans. Ophth. Soc. of the U. K., 1903, XXIII, 157. M. S. Mayou and G. Sutherland. Trans. Ophth. Soc. of the U. K., 1907, XXVII, 179.

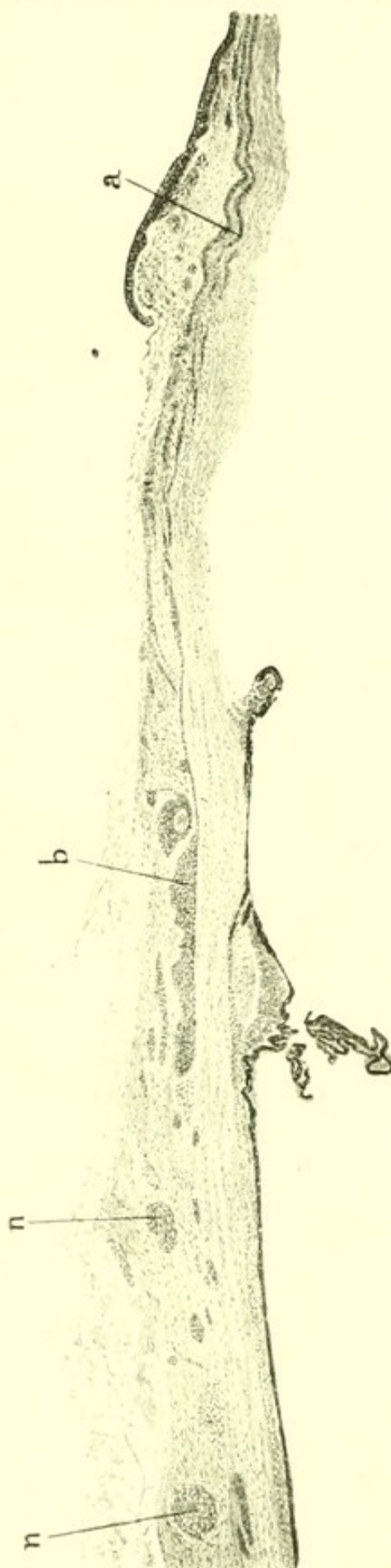
been affected, the eyeball has been found enlarged as in buphthalmos. At first it might seem natural to assume that the enlargement of the eyeball was part of the elephantiasis.

Histological examination of such eyes has, however, shown a congenital malformation about the angle of the anterior chamber sufficient to account for the obstruction of the exit of fluid from the eye (Fig. 87), the resulting increase of tension evidently being the cause of the expansion of the eyeball.

Intraocular changes of the nature of neuro-fibromatosis do, however, occur.¹ The ciliary nerves external to the sclerotic at the posterior pole of the globe may be thickened and plexiform. After entering the eye an increase of their peri- and endoneurium has also been found where they

¹ Treacher Collins and Rayner D. Batten. Trans. Ophth. Soc. of the U. K., 1905, XXV, 248.

FIG. 87.—Shows the microscopical appearances of the ciliary region and sclerocorneal margin in a buphthalmic eye occurring in connection with neuro-fibromatosis of the eyelids. The root of an ill-developed iris is seen to be very thin and adherent to the cornea. In the small piece of iris left free, a wavy line is just indicated, showing the way in which Descemet's membrane terminated. *a*, Thickened nerves in the cornea; *b*, thickened perineurium around the anterior ciliary nerves in the sclerotic cut longitudinally; *n*, nerves thickened in the sclerotic.



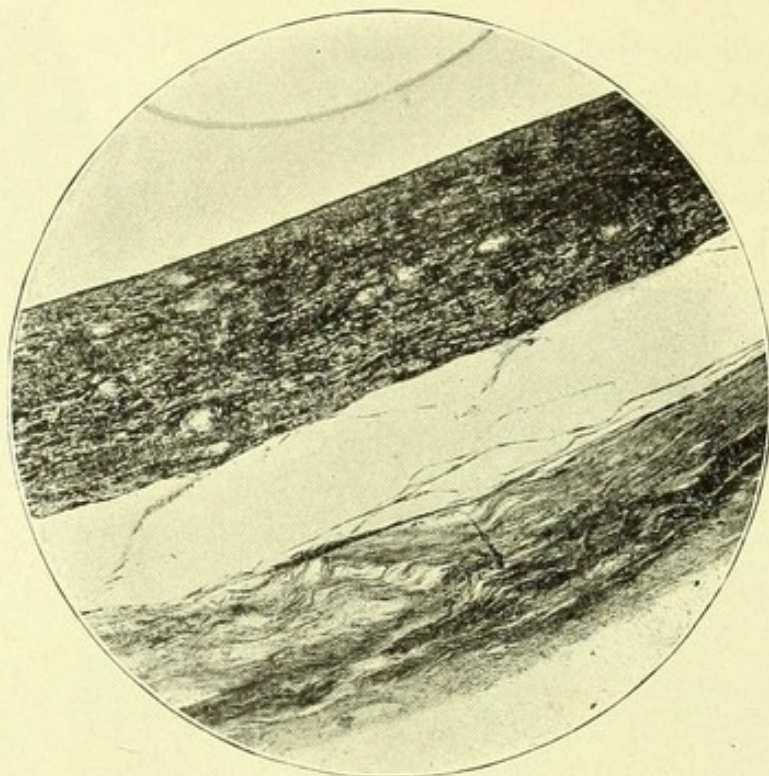


FIG. 88.—Section through the choroid of an eye affected by neuro-fibromatosis. It is much thicker, denser in structure, and more highly pigmented than normal. Scattered throughout it are shown numerous small, oval, light-coloured bodies; they are the hypertrophied nerve-end organs. From a photomicrograph by E. Collier Green.

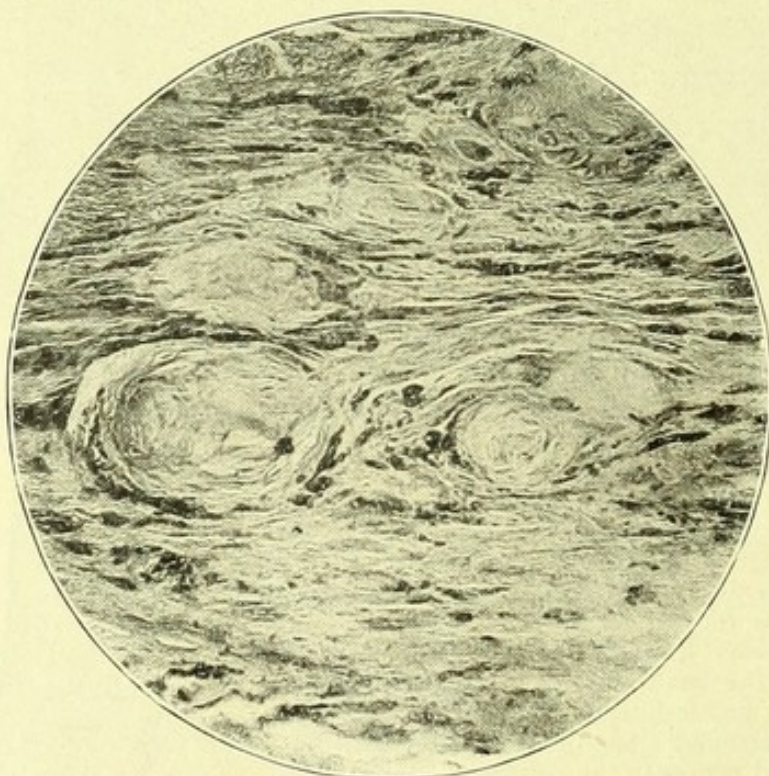


FIG. 89.—Shows the hypertrophied nerve-end organs shown in the choroid in Fig. 88 under a higher power. A convoluted delicate fibre is faintly shown in the centre of each of them. An enlarged nerve is seen to be attached like a stalk to the largest of the bodies. From a photomicrograph by E. Collier Green.

lie in the uveal tract, sclerotic, and cornea. The choroid may, moreover, become much thickened from hyperplasia of its fibrous tissue, the blood-vessels in it forming a much less conspicuous element than usual. In a thickened choroid of this character enlarged nerves and end organs have been discovered; these latter were small oval bodies with nucleated cellular capsules and a central core composed of convoluted nerve fibres (Figs. 88, 89). Bodies of a similar character have been found in the orbital tissues in cases of neuro-fibromatosis.

New growths of the optic nerve are most frequently neuro-fibromata; they do not form well defined localised

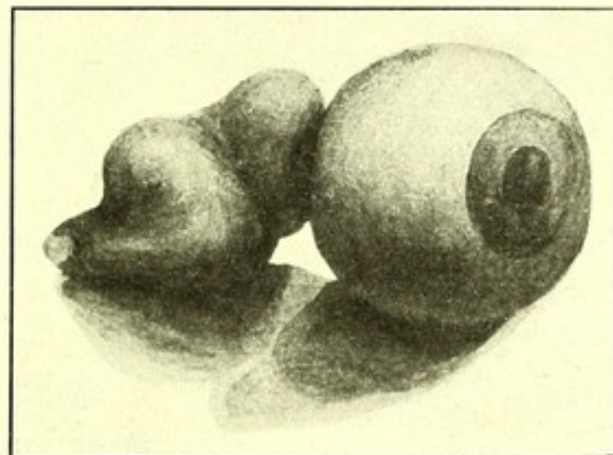


FIG. 90.—Intradural tumour of the optic nerve removed together with the eyeball from a boy aged twelve years. Case recorded by G. Lawson, R. Lond. Ophth. Hosp. Reps. vol. XII, 1888, 1.

tumours, but diffuse thickenings frequently involving not only the orbital but also the intercranial portion of the nerves, sometimes extending right up to the chiasma. Occasionally a new growth in the optic nerve is only an extension of a widely spreading intercranial neuro-fibroma.

These tumours of the optic nerve usually attract attention in early life, the large majority manifest themselves before the age of twenty.

A new growth in the cone-shaped area behind the globe bounded by the recti muscles (Fig. 90) causes proptosis usu-

ally in the line of the orbital axis, without any lateral or vertical displacement. Should, however, the growth extend from one side of the nerve more than another displacement of the globe in a direction away from the side of the tumour may also occur.

Neuro-fibromata of the optic nerve do not invade the eyeball, but steadily and slowly enlarging behind it causing a gradually increasing amount of proptosis. An edema

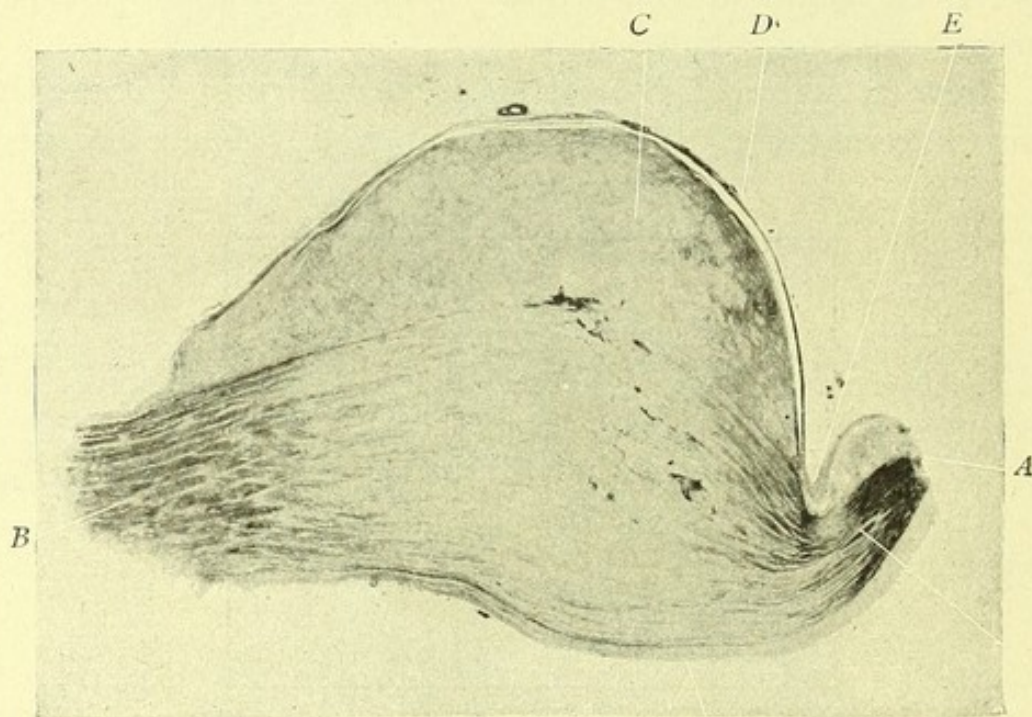


FIG. 91.—Shows a longitudinal section through a tumour of the optic nerve. *A*, The nerve divided close to the globe; *B*, the thickened nerve at the optic foramen; *C*, overgrowth of the supporting structure of the nerve; *D*, dural sheath of the nerve; *E*, kinking of the nerve which caused pressure on the vessels and thus produced edema of the optic papilla

of the head of the optic nerve, from pressure on the central retinal vein, resulting in atrophy occurs in some cases, giving rise to the signs known clinically as optic neuritis followed by secondary atrophy. In others there is atrophy without edema and the clinical appearances of simple atrophy.

Another characteristic symptom is the outcome of pressure on the back of the globe by the growth, which if the eye was originally emmetropic causes it to become hypermetropic, the amount of the hypermetropia slowly increasing.

The connective-tissue constituents of the optic nerve consists of the dural and pial sheaths, fibrous-tissue prolongations from the latter forming trabeculæ in its substance and a delicate network of fibres (the so-called neuroglia) supporting the nerve fibres in the spaces between the trabeculæ.

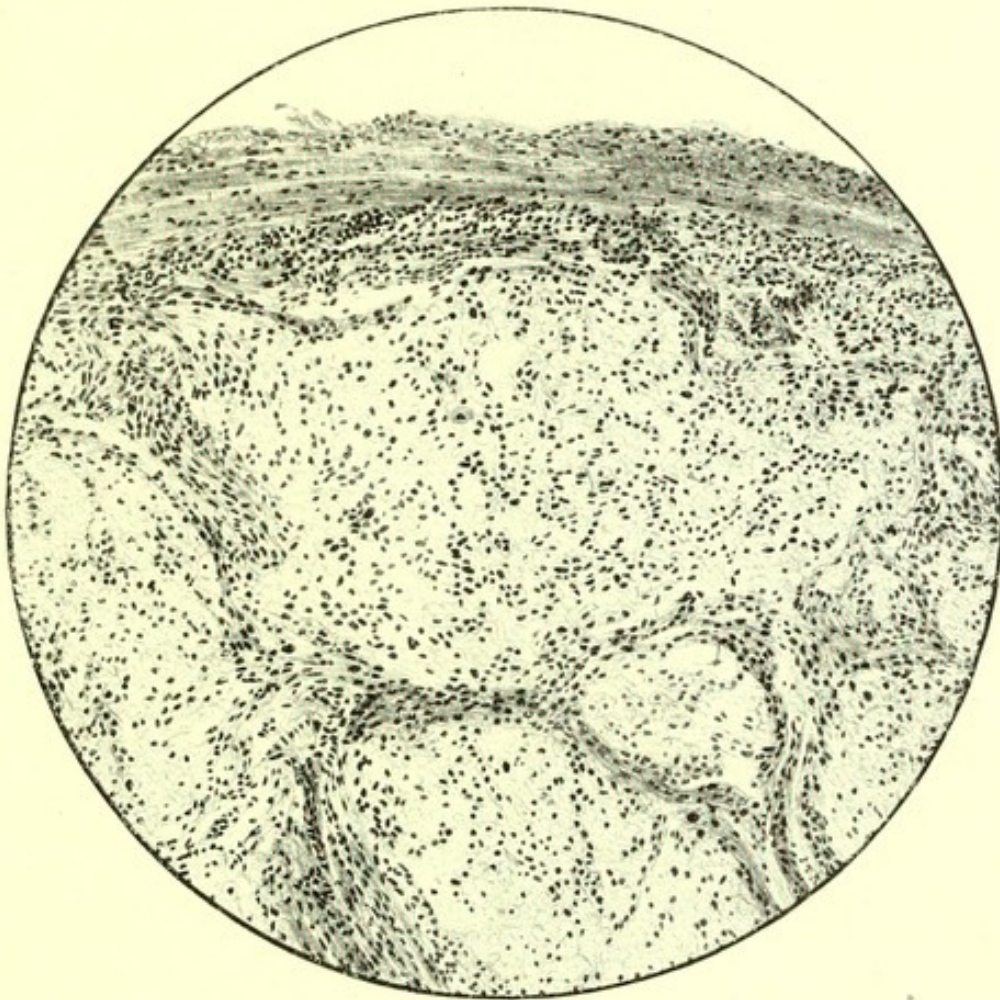


FIG. 92.—Transverse section through an intradural tumour of the optic nerve, $\times 100$. The pial sheath and fibrous trabeculæ in the substance of the nerve are considerably thickened; the spaces between the trabeculæ are occupied by a network of irregular branching cells, no healthy nerve-fibres being left. Case recorded by Treacher Collins and C. D. Marshall, *Trans. Ophth. Soc. of the U. K.*, XX, 1900, 159.

In some tumours of the optic nerve there is an overgrowth of all these connective-tissue constituents, a general fibromatosis. In others some parts are exclusively affected. The dural sheath may be alone affected or the growth may be entirely in the nerve itself starting from the neuroglia

and fibrous trabeculae, its two sheaths being uninvolved. Not uncommonly the pial sheath and the fibrous tissue in the nerve are the seats of growth, the dural sheath escaping (Fig. 91).

The new growth in these cases is composed of fibrous tissue either fully formed or of an embryonic type (Fig. 92). The degree of its development may vary in different parts of the same growth. The cellular constituents may be either spindle-shaped, irregular, polygonal, or round. Cystic spaces containing fluid may form in the growth probably as the result of lymphatic obstruction. The fluid has not been found to contain mucin and there does not appear to be any real evidence of myxomatous degeneration.

2. Localised neuro-fibromata may occur in connection with the branches of the fifth nerve supplying the skin of the eyelids. They form small, hard, freely movable, and well defined nodules in the subcutaneous tissue. Microscopically they are found to be due to thickening of the perineurium and endoneurium of the nerve fibre with which they are connected.

Hemangioma.—The blood channels in hemangiomata may consist of (a) a network of endothelial-lined spaces, **cavernous angioma**; (b) a collection of thin-walled capillary tubes, **capillary angioma**; (c) a plexus of moderately sized blood-vessels, arteries, or veins, or both, **plexiform angioma**.

The tissue between the blood channels varies in amount and character. It may consist of many of the different structures into which mesoblast becomes elaborated; *e.g.*, fibrous tissue, adipose tissue, striated muscle fibre and bone. When the intervacular tissue is small in amount the growth is termed a simple angioma, when considerable a double name is employed. If the tissue between the vessels is very embryonic and cellular in character the growth is spoken of as an **angiosarcoma**, if it is mainly fibrous tissue **angiofibroma**, or if fatty **angiolipoma**.

Most of the hemangiomata are met with in early life, a large number are certainly congenital; and it is very prob-

able that in nearly all there is some congenital rudiment which for a time escapes detection and only becomes manifest as it increases in dimensions.

The hemangiomata dealt with here may be divided into the (1) extraocular and (2) intraocular.

1. The **extraocular hemangiomata** occur in the skin of the lids, the conjunctiva, and orbit.

Hemangiomata of the skin of the lids and conjunctiva are either cavernous or capillary. In the latter situation they form either flat or polypoid growths, hemorrhages from them may occur causing the patient to shed "bloody tears." They may arise from any part of the conjunctiva but most commonly occur in connection with the plica semilunaris, the caruncle, and the fornices.

A hemangioma of the orbit, like any other new growth similarly situated usually gives rise to proptosis. A distinctive feature, however, of the proptosis due to vascular growths is the variability of its amount. Obstruction to the outflow of venous blood from the orbit, as by compression of the jugular vein, causes it to increase. Rest in the recumbent position and pressure backward of the globe will often cause it to decrease.

There are cases in which a patient is found to have, while in the erect position, one eyeball somewhat sunken in the orbit (enophthalmos), but where after hanging the head down it becomes abnormally prominent (exophthalmos). It has been suggested that in such cases there is a varicose condition of the orbital veins, or vascular growth, which has caused absorption of orbital fat so accounting for the enophthalmos. On stooping, or compression of the jugular vein, the blood-vessels in the orbit become turgid and then exophthalmos results.

Hemangiomata of the orbit, unless of the very rare plexiform variety, do not pulsate or give rise to any bruit.

Capillary angiomata involving the eyelids may extend backward into the orbit. The hemangiomata confined to

the orbit are usually cavernous and are surrounded by a fibrous capsule.

2. **Intraocular hemangiomas** are exceedingly rare but occur in connection with both the ciliary and retinal blood vessels.

An angiomatous mass in the form of a rete mirabilis is a normal part of the choroid in some of the teleostean fish and is termed the choroidal gland.

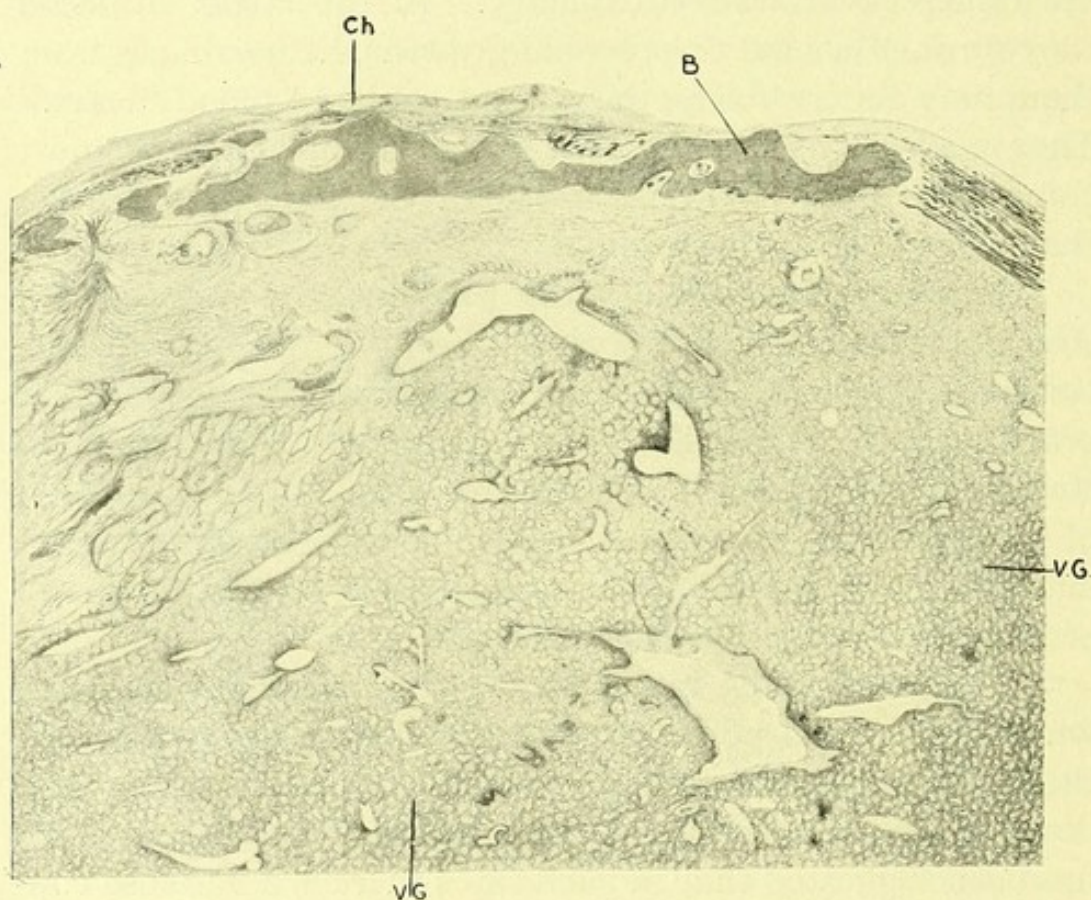


FIG. 93.—Shows the microscopical appearances of a vascular growth of the retina. Case described by Treacher Collins, Trans. Ophth. Soc. of the U. K., XIV, 1894, 141. V.G., Vascular growths; Ch, choroid; B, bone in choroid.

Cavernous angiomas of the choroid are met with usually at the posterior pole. They cause a thickening of the membrane and gradually merge into the normal choroid without any limiting capsule. A formation of bone may arise in connection with them. In some cases they have been associated with a capillary nevus of the skin of the lids, and large tortuous retinal vessels.

Angioma of the retinal vessels is often bilateral, is usually met with in young people, and has twice been observed in two members of the same childhood. Ophthalmoscopically an enormous enlargement of some of the retinal vessels, both arteries and veins, is seen. The enlargement so changes the appearance of the vessels that it is difficult or impossible to differentiate arteries from veins. The enlarged vessels terminate in a raised reddish or yellowish area. As the disease progresses vitreous hemorrhages occur and the retina becomes detached; in the course of years the surrounding parts may become invaded and secondary glaucoma with staphylomatous bulging occur. Pathological examination of eyes affected in this way has shown the presence of a capillary angioma in the tissue of the retina (Fig. 93).

Lymphangioma.—Lymphangiomata like the hemangiomata may be cavernous and consist of a network of endothelial-lined spaces, or capillary and composed of thin-walled tubes. Cysts often arise in connection with them.

The intra-ocular lymphatics consist of perivascular channels or endothelial-lined spaces and no new growths which can be classified as lymphangiomata occur in connection with them.

Extraocular lymphangiomata arise in the skin of the lids, the conjunctiva, and orbit.

A small dilatation of the lymphatics of the ocular conjunctiva, or **lymphangiectasis**, is frequently met with. True lymphangiomata of the conjunctiva are rare, they are usually congenital and slowly increase in size. The growth has the appearance of a collection of small vesicles. If cut into, clear fluid escapes, the spaces afterward becoming filled with blood; the growth then looks like a hemangioma. In course of time the blood absorbs and its original characteristics are restored. An angioid condition of the blood-vessels is sometimes associated with a lymphangioma.

Lymphangiomata of the orbit, unless they extend forward into the eyelids, are difficult to diagnose from other forms of new growth which produce proptosis. When

cystic formation occurs in them a marked increase in the proptosis takes place.

Myoma.—Unstriated muscular tissue is present in the iris and ciliary body and it is highly probable that cells similar to those composing it, or which are met with in its embryonic condition, should be found in neoplasms arising from those structures.

There is no known method of staining which will enable us to differentiate with certainty the cells of unstriated muscular tissue from those of connective tissue. In their embryonic condition they are very similar in appearance. It must, therefore, at present remain an open question whether tumours arising in the ciliary body or iris composed of spindle-shaped cells with rod-like nuclei should be classed as myomata, or as spindle-celled sarcomata of the same character as such growths occurring where no muscular tissue exists.

Lymphoma.—The conjunctiva and the lacrimal gland are the only structures in connection with the eye which normally contain lymphoid tissue; they are, therefore, the only structures in which primary lymphomata originate. The lymphomata which are met with in the orbit and eyelids are described with the metastatic growths.

Lymphomata of the conjunctiva arises usually either in the fornix or the plica semilunaris. They have been met with starting at the limbus. Clinically they present the appearance of very large follicles and give rise to no inconvenience to the patient, their presence usually being discovered accidentally, or from the presence of some slight conjunctivitis. In rare instances a lymphoma has been known to assume malignant characters, **lympho-sarcoma**.

Histologically a lymphoma presents the structural characters of a lymphatic gland. There is a delicate stroma composed of fibres, endothelial cells, and small blood-vessels which are closely packed with mononuclear leukocytes and plasma cells.

IV. METASTATIC GROWTHS.

Until recently metastatic growths, whether carcinomatous or sarcomatous were thought to be due to emboli of cells from the parent growth. Though this is undoubtedly the way in which sarcomatous growths become disseminated, it has recently been shown that secondary carcinoma is usually due to a process of permeation. The cancer cells at the seat of the primary growth extending into the lymphatics, then infiltrating, and growing along them to surrounding parts.

Intraocular Metastatic Carcinoma.¹—It has been suggested that sarcoma in the uveal tract may sometimes be metastatic, the only metastatic growths, however, occurring in the eye of which we have definite evidence are carcinomata. The condition is an exceedingly rare one and only arises in association with a widespread dissemination. So that patients when the eye is affected do not usually live longer than a few months.

Both eyes are often involved simultaneously or within a short time of one another. If only one eye is implicated it is more often the left than the right. In the large majority of cases the primary growth is an atrophic schirrhous of the breast.

The posterior part of the uveal tract is usually the region first involved, the growth extending to it presumably along the lymphatic sheath of one of the posterior ciliary arteries. A case of metastatic carcinoma beginning in the ciliary body has been recorded in which the sheath of one of the anterior ciliary arteries must probably have been the track along which the growth entered the eye.

The carcinomatous cells having reached the lymphatic spaces of the choroid proliferate in them, thickening the choroid without forming any marked localised prominence, in this respect they resemble flat or diffuse sarcomata (see page 130).

¹ C. D. Marshall. R. Lond. Ophth. Hosp. Rep., XIV, 1897, 415.

The thickest part of the growth in the choroid is always at the posterior pole of the eye, and it tapers off as it approaches the ciliary body. It rarely breaks through the elastic lamina. The interference which the growth causes to the circulation in the choroid gives rise to an effusion from its vessels resulting in detachment of the retina in an early stage of the disease and may be followed by glaucoma.

The histological characters of a metastatic carcinoma of the uveal tract depend upon those of the primary growth which it closely simulates. There are alveoli containing groups of glandular epithelial cells without any intercellular substance between them. The richness of the growth in cells and the amount of fibrous tissue bounding the alveoli varies in different cases. Scirrhus cancer originating in the breast is most frequently met with. Widespread degenerative changes in the cells are of common occurrence, they become vacuolated and break down into a hyalin or granular material.

Orbital Metastatic Lympho-Sarcoma.—Secondary growths of a lymphoid character are met with in the orbit. They are composed of closely packed, small, round cells with a very delicate, scarcely discernible reticulum. Often there are symmetrical tumours in the two orbits, and the condition is frequently, though not always, associated with chloroma or leukemia. In these cases it has usually been found impossible to locate the seat of the primary growth. In cases which have ended fatally the autopsy has revealed a wide dissemination of growth, involving most of the viscera. The absence of any lymphoid tissue normally in the orbit would seem definitely to exclude it as the possible seat of the primary growth. Moreover, where the two orbits have been found affected the independence of the growths in them has been demonstrated.

V. CYSTS.

Cysts arising in or about the eyeball may be parasitic or non-parasitic, the former are described with the para-

sites (see page 423). Non-parasitic cysts vary in the nature of their lining membrane and may be divided according to whether they are derived from (1) cuticular epiblast, (2) neural epiblast, or (3) mesoblast.

1. **Cuticular Epiblastic Cysts.**—The cysts lined with cuticular epithelium arise in different ways, and may be either (a) congenital, (b) traumatic, or (c) retention cysts.

(a) Congenital cysts lined by laminated epithelium are **dermoid cysts** (see page 96).

(b) Traumatic cysts lined by laminated epithelium may be produced by implantation of detached pieces of surface

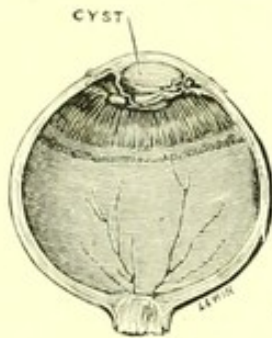


FIG. 94.

FIG. 94.—Epithelial lined cyst which formed in the anterior chamber after extraction of cataract and gave rise to glaucoma.

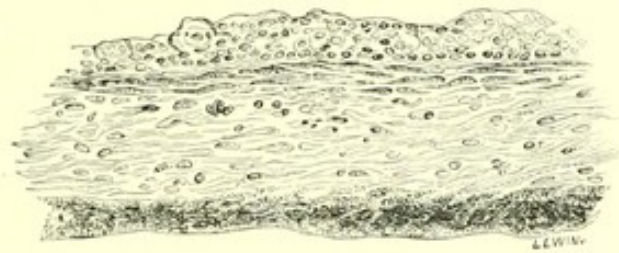


FIG. 95.

FIG. 95.—Microscopical section showing the lining epithelium on the surface of the iris of the cyst shown in Fig. 94.

epithelium into subcutaneous parts, or by the extension of epithelium downward around the lips of an unhealed wound.

The cells of implanted detached epithelium when well nourished continue to proliferate. The result is that either a solid pearl-like tumour is formed composed of concentric layers of flattened cells, or, from degeneration of the central cells, a cystic growth lined by epithelium is produced, an **implantation cyst**.

A column of epithelium forming between the lips of a slowly healing wound may produce a cyst, either by the degeneration and liquefaction of the cells in the center of it, or by its extension round a cavity, such as the anterior chamber (Figs. 94, 95).

The contents of traumatic cysts produced in any of the above ways vary according to the character of the lining epithelium. It may be fatty epithelial debris containing cholesterin crystals, or a clear or slightly turbid fluid.

Implantation cysts have been produced experimentally in rabbits' eyes by the introduction into the anterior chamber of small pieces of skin, conjunctiva, or corneal epithelium.¹ They usually occur in man as the result of punctured wounds.

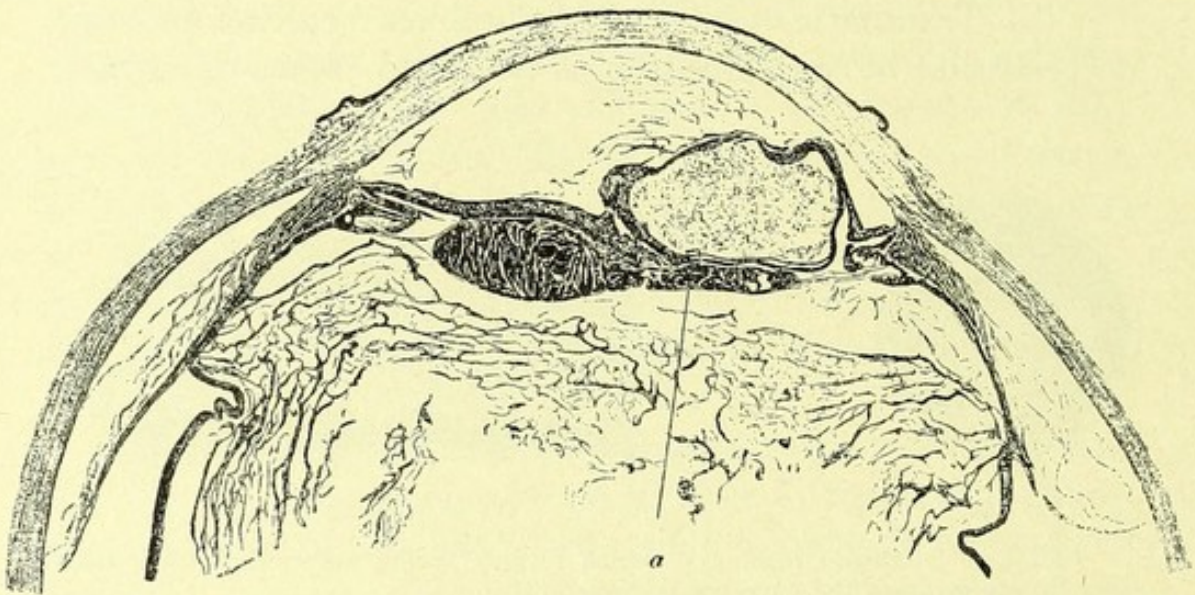


FIG. 96.—Section of the anterior half of an eye with a cyst in the iris, following on the implantation of an eyelash into the eye. The square to which *a* points is the part shown in Fig. 97 more highly magnified. $\times 10$. Recorded in Trans. Ophth. Soc. of the U. K., XIII, 1893, 199.

Epithelial pearl tumours may form around an eyelash when it becomes implanted in the interior of the eye, they arise from the cells of its root sheath (Figs. 96, 97).

Traumatic cysts lined by epithelium have been met with in the orbit, conjunctiva, cornea, anterior chamber, iris, and vitreous chamber.

In the conjunctiva they form small blister-like elevations. In the cornea they are usually only discovered on pathological examination (Fig. 98), but may give rise to a protuberance resembling a staphyloma anticum (Fig. 99).

¹ E. Masse. Kystes, tumeurs perleés et tumeurs dermoïdes de l'iris, 1885.

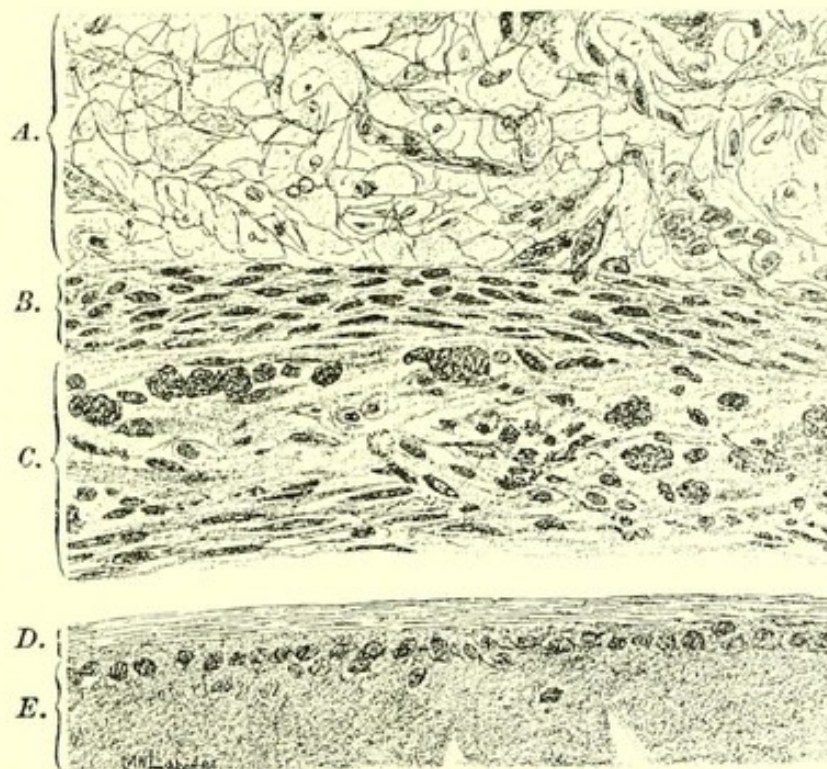

FIG. 97.—Shows part of the wall of the cyst shown in Fig. 96, and included in the square marked A. $\times 300$. A, Contents of cyst; B, epithelial lining of cyst; C, iris; D, lens capsule; E, lens.

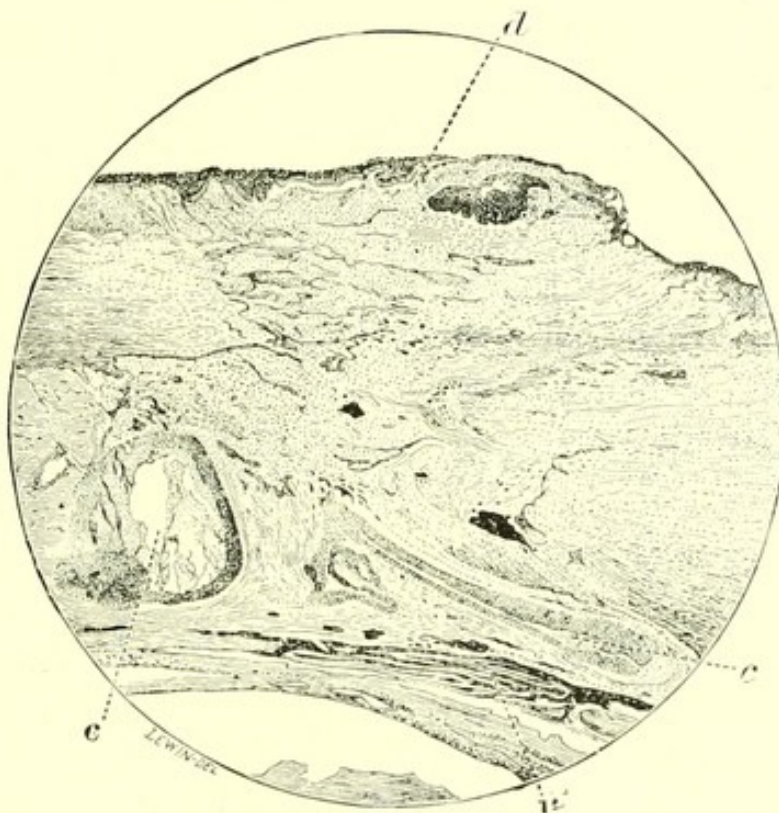


FIG. 98.—Epithelial implantation cysts in the cornea following a perforating wound with a shot. c, Cysts; d, Bowman's membrane; u, uveal pigment of iris.

In the iris they form translucent round bodies resembling white currants. If the anterior chamber becomes completely lined with epithelium it obstructs the exit of intra-ocular fluid and produces glaucoma. If left to itself a cyst

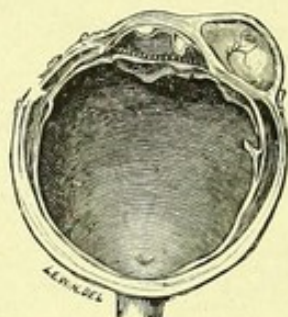


FIG. 99.—Lateral half of an eyeball, showing an epithelial implantation cyst in the cornea, following a wound with a piece of wood. Recorded in *Trans. Ophth. Soc. of the U. K.*, XII, 1892, 64.

lined by epithelium slowly expands causing by its pressure atrophy and destruction of surrounding parts. Thus in a shrunken globe which had been wounded with a tip-cat twenty-eight years previously, a cyst lined by laminated

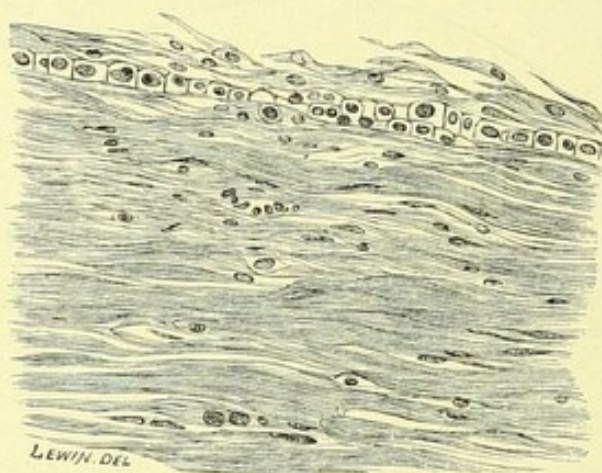


FIG. 100.—Shows the laminated epithelium lining the cyst in the cornea depicted in Fig. 99.

epithelium was discovered measuring 12 mm. by 11.5 mm. and occupying the whole of the interior of the eye¹ (Fig. 101).

The implantation cysts can be differentiated pathologically from those due to extension downward of the

¹ Treacher Collins. *Trans. Ophth. Soc. of the U. K.*, 1891, XI, 133.

epithelium along a slowly healing wound, by the absence in the former of any continuity of the lining cells of the cyst with the surface epithelium, a condition which can only be determined with certainty by the examination of serial sections.¹

(c) Retention cysts are met with in connection with the lacrimal gland and with the various glands of the eyelids and conjunctiva.

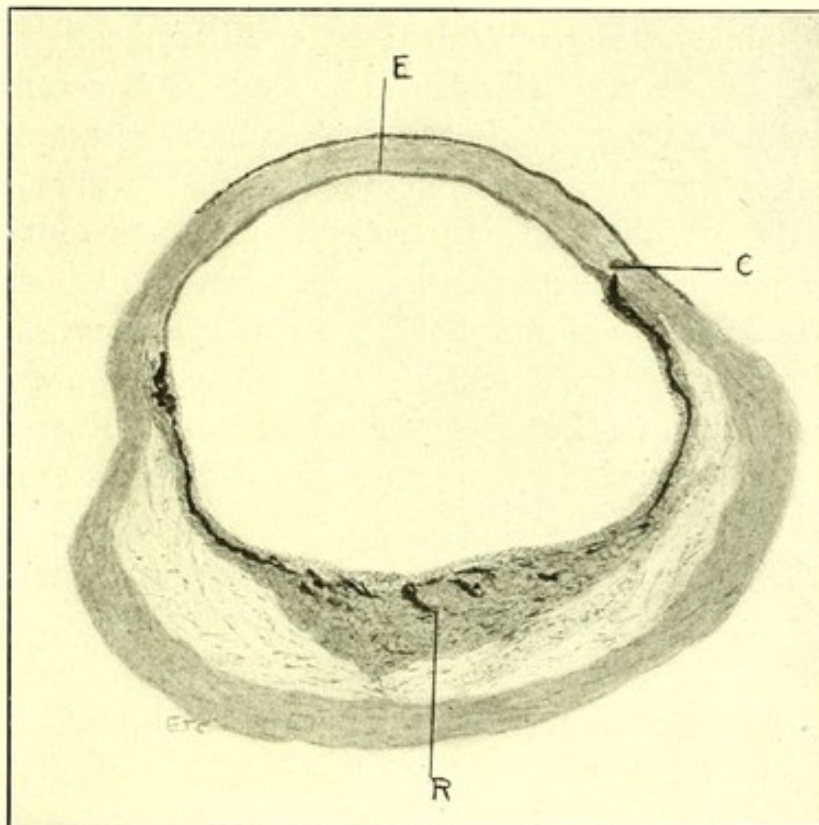


FIG. 101.—Large epithelial lined cyst in a shrunken globe removed 28 years after a wound with a "tip-cut." *C* points to the cicatrix of the wound in the cornea; *E*, to the lining epithelium of the cyst on the back of the cornea; *R*, to the retina displaced by the expansion of the cyst.

Cysts of the Lacrimal Gland.—Cysts of the lacrimal gland, to which the name **dacryops** has been given are rare. They are probably caused by an inflammation ascending from the excretory ducts of the conjunctiva which produces obstruction to their orifices either by pericanicular sclerosis or proliferation of their lining epithelium. A translucent,

¹ M. S. Mayou. R. Lond. Ophth. Hosp. Rep., XVI, 1905, 318.

fluctuating swelling is formed beneath the conjunctiva at the upper part of the outer fornix, which may reach the dimensions of a pigeon's egg.¹ It is stated that such tumours have been observed to suddenly enlarge when the patient cries.

Retention cysts of the lacrimal gland may be uni- or multilocular, the lining membrane is usually composed of cylindrical epithelium like that within the ducts of the gland; it may, however, consist of several layers of flattened cells. The fluid contents resembles the lacrimal secretion.

Cysts of Zeiss's Glands.—The large sebaceous glands connected with the eyelashes (Zeiss's glands) sometimes have the orifices of their ducts occluded from a hyperkeratosis in the hair follicle into which they open, a retention cyst is the result. Clinically such cysts form little rounded yellow coloured swellings in the skin at the margin of the eyelid, having much the size and appearance of millet seeds.

Cysts of Moll's Glands.—The glands of Moll which open into the follicles of the eyelashes are modified sweat glands; if their orifices become occluded cystic distention of them may take place. Little blister-like swellings are then formed along the free border of the eyelid internal to the roots of the eyelashes. Those which are formed from distention of the duct are unilocular and lined by a double row of cells, whilst those formed from the tubules are multilocular and lined by a single row of cells with unstriated muscle fibres external to them. The contents is a clear fluid having much the same constituents as normal sweat.

Cysts of Meibomian Glands.—The Meibomian glands resemble in structure the sebaceous glands of the skin. Their orifices frequently become occluded either from a hyperkeratosis in the duct, or from the formation of fibrous tissue in the conjunctiva, as in trachoma, or after Burrow's operation for entropion when all the ducts of the glands are divided. The blockage of their ducts seldom, however, leads

¹ Arnold Lawson. Trans. Ophth. Soc. of the U. K., XVII, 1897, 233.

to the formation of cysts. This is probably accounted for by the density of the fibrous tissue of the tarsus in which they lie embedded; which must offer much greater resistance to their expansion than the comparatively loose tissue of the corium does to that of the sebaceous glands of the skin.

For the description of **chalazion** which is often inaccurately spoken of as a cyst of the Meibomian gland (see page 358).

Cysts of Krause's Glands.—Cysts formed from obstruction of the excretory ducts of the glands of Krause are usually caused by the formation of fibrous tissue bands in the conjunctiva, and arise as sequelæ of trachoma or pemphigus of that membrane.

These cysts are situated in the retrotarsal fold and protrude on eversion of the lid. They contain a clear fluid similar to the lacrimal secretion, and have translucent walls lined by a single layer of epithelium which in some instances protrudes inward as tuft-like projections.

Cysts of Henle's Glands.—The false glands of Henle may become the seat of retained epithelial contents, which disintegrates forming a yellowish fatty material. They form small, yellowish, slightly raised areas in the conjunctiva along the attached margin of the upper tarsus. One of these glands larger than the others situated on the inner side is very frequently affected.

The small epithelial retention cysts formed in the palpebral conjunctiva which has undergone papillary formation as the result of chronic inflammation are described on page 306.

2. **Neural Epiblastic Cysts.**—Cysts lined by tissue derived from neural epiblast may be produced by a separation of the structures formed by the two layers of the secondary optic vesicle, or be located entirely in one of its layers. The former are met with on the inner surface of the iris, ciliary body, and choroid, and may result from (a) congenitally defective involution of the secondary optic vesicle, (b) the contraction of organising exudate adherent to the inner

surface of the inner layer, (c) the exudation of fluid between the two layers from the blood-vessels of the uveal tract.

a. Cysts due to congenital defect in involution of the secondary optic vesicle are described under congenital aberrations (see page 18).

b. In inflammation of the iris, adhesion of the posterior layer of pigment epithelium to the lens capsule and the

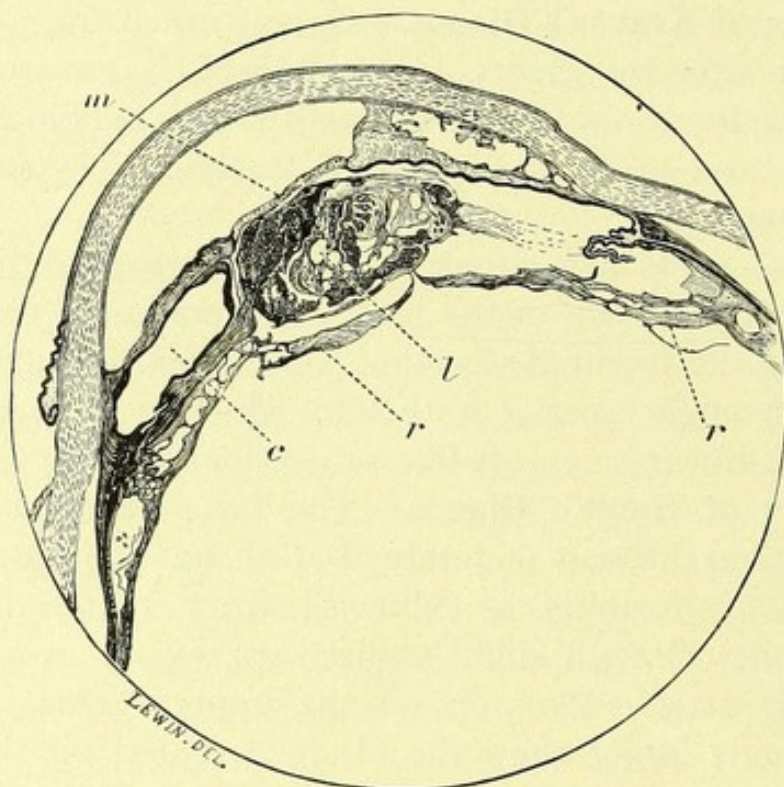


FIG. 102.—Section through the anterior half of an eye which had had plastic iritis after a perforating wound. A cyst has formed between the two layers of pigment epithelium on the back of the iris. The posterior being adherent to inflammatory exudate. *c*, Cyst; *m*, inflammatory membrane in pupil; *l*, lens; *r*, detached retina.

collection of serous fluid between it and the anterior layer over a portion of its extent is of common occurrence. Clinically the appearance produced is that of a localised condition of iris bombé (Fig. 102). If an iridectomy be performed in such a case, the stroma and anterior layer of pigment epithelium will be removed, but the posterior layer will be left adherent to the lens capsule, filling up the coloboma.

The contraction of a cyclitic membrane produced by

the organisation of inflammatory exudate in the anterior part of the vitreous is very liable to drag the non-pigment layer of cells in the region of the pars plana of the ciliary body away from pigmented layer causing the formation of a cystic space between them which becomes filled with albuminous fluid (Fig. 103).

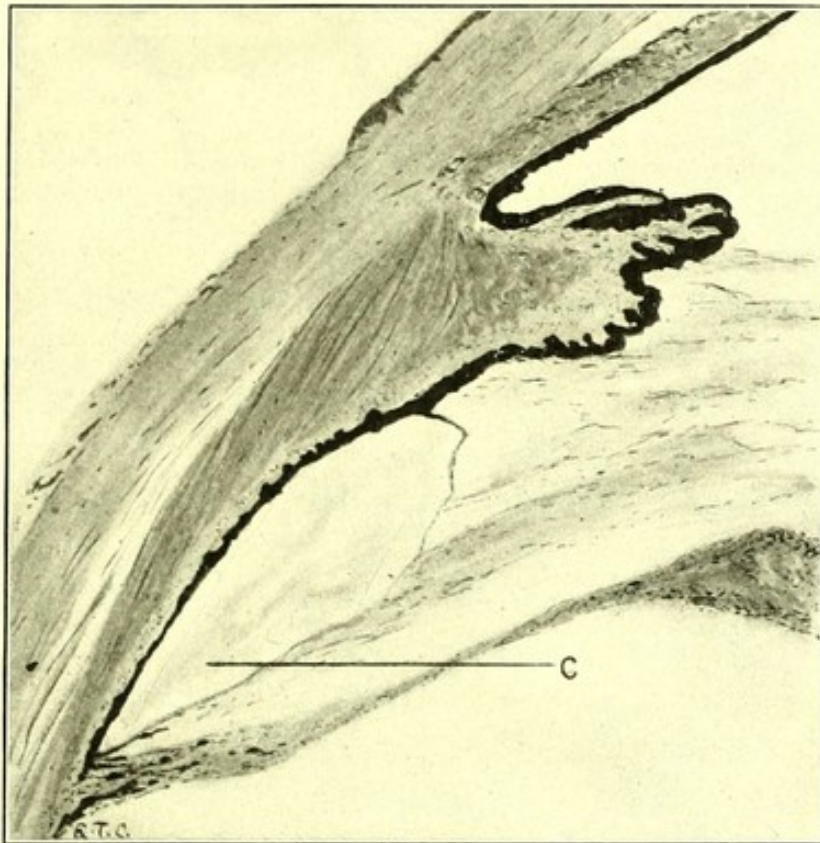


FIG. 103.—Cyst formed by the separation of the two layers of the pars ciliaris retinae, the inner unpigmented layer from the outer pigmented one. C points to the cavity of the cyst.

In a similar way the organisation of exudates further back in the vitreous which have become adherent to the inner surface of the retina drag it away from the pigment epithelial layer giving rise to one form of detachment of the retina (see page 334).

c. Edema of the iris, apart from inflammation, may result in localised accumulations of serum between the two pigment layers on its posterior surface. A cyst so formed has been found in a case where there was pressure on the

root of the iris from a sarcoma of the ciliary body, which also produced swelling of the stroma of the iris (Fig. 104). A few cases have been recorded of cysts of the iris due to separation of its pigment epithelial layers where a pigmented

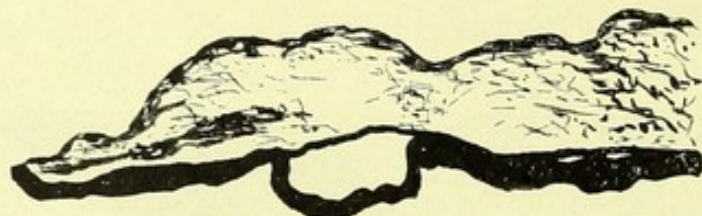

FIG. 104.—Shows a section through the iris from an eye which had a sarcoma of the ciliary body. Pressure on the root of the iris caused it to become edematous, and a small cyst formed between the two layers of pigment epithelium on its posterior surface.

protuberance has been seen clinically at the pupillary margin (Fig. 105). Such pigmented cysts are very liable to be mistaken for malignant melanotic growths.

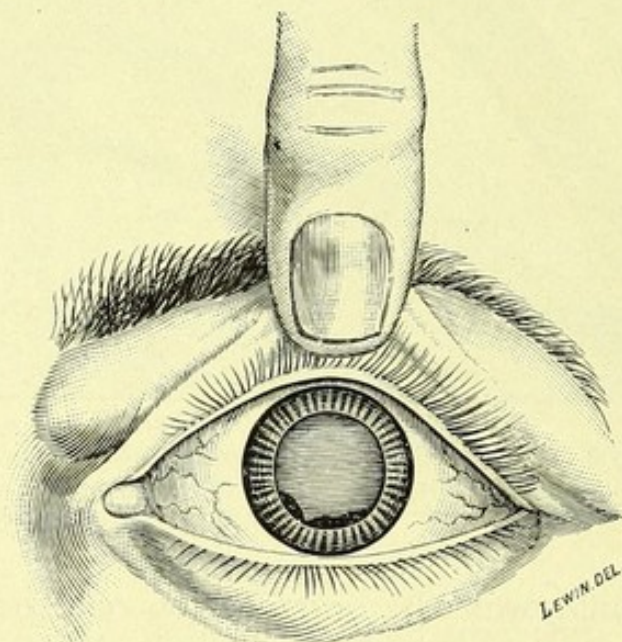


FIG. 105.—Pigmented cyst of the iris due to separation of the two layers of pigment epithelium on its posterior surface. Recorded R. Lond. Ophth. Hosp. Reps., XIII, 1890, 58.

The ciliary body being the source of the aqueous humour it is not surprising that occasionally a separation should occur of the two layers of cells lining it, which have to be permeated by the aqueous fluid in its transit from the ciliary

blood-vessels to the interior of the eye. A sudden evacuation of the aqueous humour from trauma is the most usual cause of such a separation, it may give rise to a return of increased tension after an iridectomy for glaucoma. A cyst thus formed has been mistaken clinically for a solid growth of the ciliary body.

These cysts have an outer wall of pigmented cells and an inner wall of unpigmented cells. This characteristic serves to differentiate them from two other forms of cysts lined by neural epiblast occurring in the same locality. Small cysts are sometimes found bounded entirely by pigmented epithelial cells, they are probably due to cystic distention of the tubular processes of cells which project outward from the pigment epithelial layer in the pars plana of the ciliary body and are usually the sequela of cyclitis.

② Another form of cyst of the ciliary body is lined entirely by unpigmented epithelial cells.¹ It arises by multiplication and union of the cells on the inner surface of the ciliary processes, so that a portion of the posterior chamber becomes shut off and distended by secretion. The nature of such a cyst can only be definitely determined by the microscopical examination of serial sections.

Separation of the retina from the pigment epithelial layer due to effusion of serum from the choroidal vessels may take place. It has been met with in association with general dropsy due to nephritis. In the detachment of retina which occurs in association with choroidal sarcoma, the albuminous sub-retinal fluid is undoubtedly an exudate. These detachments occur in the lower part of the globe, owing to the gravitation of the fluid beneath, whatever may be the site of growth; they are frequently entirely isolated from the tumour the intervening retina being *in situ*.² It is the first stage of the total detachment which eventually supervenes. The fluid beneath the retina is unlike the normal intraocular fluid, being highly albuminous, and exudes from

¹ A. R. Brailey. Trans. Ophth. Soc. of the U. K., XXVII, 1907, 95.

² J. H. Parsons. *Ophthalmic Review*, XXIV, 1905, 166.

the choroidal vessels as the result of the engorgement of them from the presence of the growth.

Whether or not **simple detachment of the retina** (*i.e.*, detachment occurring without any obvious cause, or in myopic eyes) is due to exudate from the choroid is a matter which has given rise to much discussion.

The two theories put forward as to the causation of a simple detachment of the retina are described as "**the exudative theory**" and "**the traction theory.**"

The objection which has been raised to simple detachment of the retina being due to choroidal effusion is that, as the tension of the eye is not raised, it necessitates the disappearance of a corresponding quantity of the contents of the vitreous chamber. A sufficiently rapid disappearance of normal vitreous humour is exceedingly difficult to account for. The vitreous humour before a detachment takes place is, however, frequently either shrunken or liquefied, when the former, serous fluid fills the space between the hyaloid membrane and the retina.

The traction theory regards a rupture of the retina as a necessary precursor to the occurrence of detachment; such ruptures are supposed to be due to traction on it from bands which have formed in a shrinking vitreous. When the rupture takes place, fluid which has accumulated between the shrunken vitreous and the retina passes out through it and raises the retina away from the choroid. The cause of the adhesion of the hyaloid of the vitreous to the retina, of sufficient firmness to tear the retina when the former shrinks is, however, left unexplained.

The occurrence of ruptures in detached retinae was noted in the early days of ophthalmoscopic research. The frequency with which they can be seen clinically has been estimated by one observer at 20 per cent. of the eyes examined with detachment of the retina, and by another at 38 per cent.

These ruptures present different appearances, some are slit-like spaces in the membrane and others punched-out holes.

The latter are doubtless produced in eyes where choroido-retinitis has preceded the occurrence of the detachment. The retina and choroid acquire firm adhesion at the seat of inflammation and remain adherent when the former becomes detached elsewhere, a piece being torn out from the surrounding retina. In eyes with detached retinae which have been examined pathologically isolated pieces of atrophied retina have been found adherent to the choroid.

Those in favour of the exudation theory attribute the slit-like spaces to rupture of the retina from the tension of the sub-retinal fluid.

A modification of the exudation theory of detachment of the retina is what is known as "the diffusion theory." It suggests that serous fluid exuded from the choroidal vessels becomes mixed with an abnormally fluid vitreous by a process of diffusion through the retina and hyaloid. The diffusion occurring according to the ordinary physical law, that is to say, a larger quantity of less albuminous liquefied vitreous humour passes outward into the subretinal space, than of more albuminous choroidal exudate passes inward into the vitreous chamber. In this way a detachment once started would tend to extend.

Small cystic spaces in the retina itself are of common occurrence; they are frequently met with immediately behind the ora serrata in the apparently otherwise healthy eyes of old people, and are probably the result of arteriosclerosis affecting the retinal capillaries.

They are also produced in various situations, not uncommonly at the macula, as the result of edema from inflammation or trauma.

In blind eyes with detached retinae quite large cysts may be formed, producing protuberances on its outer surface, sometimes as big as currants and usually multiple (Fig. 106). The fluid contained in these cysts is, as a rule, highly albuminous. It may form a coagulated gelatinous material in hardened specimens.

The primary condition seems to be always a disturbance

in the vascular supply of the retina resulting in either atrophy of its nerve elements, or edema, or both. The spaces formed by the disappearance of the nerve cells or by the effused fluid open into one another, usually at first to the greatest extent in the internuclear layer, where oval or round cavities are formed bounded by the elongated fibres of Müller.

Attenuation from stretching of the fibres of Müller leads to a further running together of small cystic spaces

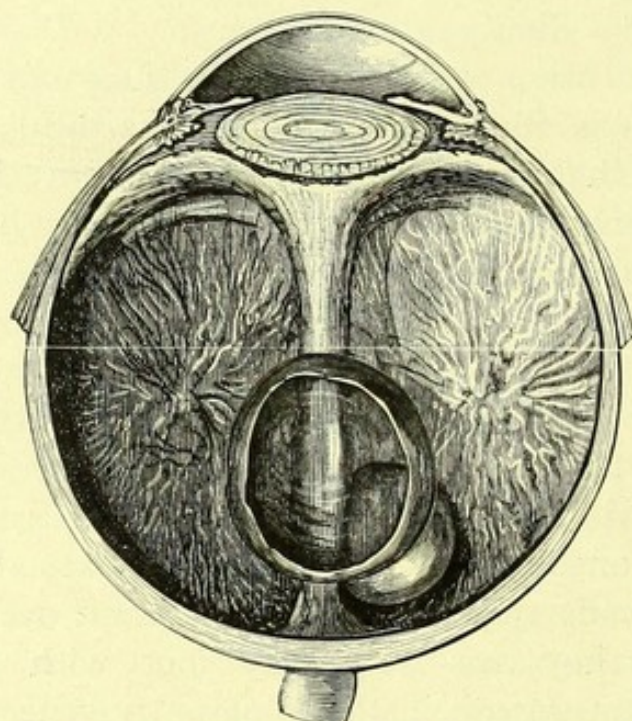


FIG. 106.—The lateral half of an eyeball showing a detached retina with cysts protruding from its outer surface. Specimen in the R. Lond. Ophth. Hosp. Museum.

and the formation of larger ones. In association with some of them there seems to be an hypertrophy of the supporting structures of the retina.

3. **Mesoblastic Cysts.**—The mesoblastic cysts are lined by a single layer of endothelial cells and arise in connection with lymphatics either in or outside the eyeball.

Extraocular lymphatic cysts occur in the conjunctiva and orbit. In both these situations, as already mentioned, they are met with in connection with lymphangiomata.

On the ocular conjunctiva a lymphangiectasis may become converted into a cyst by the complete occlusion of the channel leading from it. Multilocular cysts may arise from the fusion of several dilated lymphatic channels. Such cysts have a clear fluid contents and transparent walls; when nipped between the eyelids they tend to become pedunculated.

Orbital cysts from the distention of Tenon's capsule or portions of it forming the sheaths of the extraocular muscles are of rare occurrence. Distention of Tenon's capsule causes proptosis and the formation of a fluctuating swelling overlying the sclerotic.

Intraocular cysts with an endothelial lining are met with in the iris and in the lamina suprachoroidea. In the iris they are due to blocking of the mouths of the crypts on the surface of the iris. The result probably of thickening and fusion of the strands which are often seen crossing them, or the formation of an endothelial membrane overlying them. They have a clear fluid contents and thin transparent walls. Clinically they have much the same appearance as the epithelial implantation cysts of the iris, and they may, like them, form after an injury, though not necessarily a perforating injury.

Cysts from a dilatation and fusion of the lymphatic spaces of the lamina suprachoroidea are occasionally met within shrunken eyes where the uveal tract has become drawn away from the sclerotic by contracting fibrous tissue in the vitreous chamber. The lamina suprachoroidea may then become hypertrophied forming a network of fibres of considerable thickness between the two outer coats. In this network cystic spaces sometimes develop with an endothelial lining.

CHAPTER III.

DERANGEMENTS IN THE CIRCULATING FLUIDS OF THE EYE AND OF THE VESSELS IN WHICH THEY ARE CONTAINED.

The circulating fluids which supply nutrition to the tissues of the eye are three in number—the blood in the blood-vessels, the lymph in the lymphatics, and the intraocular fluid in the anterior, posterior and vitreous chambers.

Often no very definite division can be made between diseases due to changes in the walls of the blood-vessels and those dependent on toxic bodies circulating in the blood, the former being so frequently a sequela of the latter; one or other, however, may be the predominant factor in producing clinical manifestations in the eye.

For purposes of description this chapter will be divided up into:

- I. Diseases due to changes in the vessel walls.
- II. Diseases due to changes in the blood.
- III. Toxic amblyopia.
- IV. Glaucoma.

I. Diseases Due to Changes in the Vessel Walls.

(i) **The blood supply to the interior of the eye** is derived from the ophthalmic artery which is a branch of the internal carotid. This vessel gives off two sets of branches to the globe—the retinal, which supply the inner layers of the retina, and the ciliary, which supply the uveal tract.

The central artery of the retina enters the optic nerve some 15 mm. behind the globe. On its way forward it supplies small twigs to the nerve trunk, these communicate

with the vessels derived from its pial sheath which entirely supply the optic nerve behind the entrance of the retinal vessels. As the artery passes through the lamina cribrosa it breaks up into superior and inferior temporal, superior and inferior nasal, and macula branches. In the neighbourhood of the lamina cribrosa the vessels of the sclerotic communicate with the retinal vessels to form the circle of Zinn. The choroidal vessels, especially the veins, anastomose with the retinal vessels in the papilla. This anastomosis is of importance in that it is the only situation in which the choroidal and retinal circulation usually communicate. Occasionally a ciliary vessel may supply the retina (cilio-retinal artery or vein), (see page 49). In pathological conditions, such as embolism and thrombosis, such a vessel may be of importance in carrying on the nutrition of part of the retina (see page 177). The capillary anastomosis between the vessels of the choroid and those in the optic disc is a favourite site for the lodgment of emboli of microorganisms. The branches of the central artery in the retina resemble those in the brain in that they do not anastomose freely with each other; they are what are known as end arteries. The venous return is similar but the communication with other retinal veins and with the veins of the choroid near the disc is freer than the arterial anastomosis. The vessels within the retina run in the nerve-fibre layer and do not penetrate deeper than the inner nuclear layer, the outer layers of the retina deriving their nutrition from the choroidal vessels, especially in the anterior part of the globe. In many animals the retinal vessels are absent and the whole retina is nourished by the choroidal circulation.

The capillaries in the retina form loops. These are absent from the macular region which derives its nutrition from lymph—a fact which is probably of importance in the production of central scotoma in toxic amblyopia (see page 199). They are also absent from the perivascular lymph spaces around the main retinal vessels.

The blood-vessels of the uveal tract are the long and

short posterior ciliary arteries which penetrate the sclerotic around the nerve, and the anterior ciliary arteries which penetrate the sclerotic in the neighbourhood of the insertion of the ocular muscles. The choroid is supplied by the short posterior ciliary arteries, and the ciliary body and iris by the anterior ciliary arteries and long posterior ciliary arteries, the latter pass forward in the choroid without division and then break up and anastomose with the former. From this anastomosis recurrent branches are given off which run backward to the anterior part of the choroid and are of importance in the nutrition of the anterior part of the retina (see *Retinitis Pigmentosa*, page 182). It also gives rise to the *circulus arteriosus iridis major* and *minor* which supply the iris, forming anastomosing capillary loops in two main situations—the latter near the pupillary margin, the former at the root of the iris.

The capillary anastomosis in the other parts of the uveal tract is extraordinarily free. Indeed, the whole uveal tract consists mainly of a spongy network of blood-vessels. In the choroid the *chorio-capillaris* is closely allied to cavernous tissue and in some fishes there is a *retemirabile*. In the ciliary body around the so-called glands the ciliary processes are mainly composed of capillary networks. This enormous blood supply not only gives nutrition to the uveal tract and overlying retina but also supplies the aqueous humour and nutrient fluids of the vitreous and lens.

The major part of the blood derived from the uveal tract is returned through the *venæ vorticosæ*, some from the anterior part of the eye is returned by the anterior ciliary veins. From these vessels the blood passes into the ophthalmic vein and thence into the cavernous sinus. The orbital veins have a communication with the angular vein and with the pterygoid plexus.

(ii) **Vascular Sclerosis.**¹—The structure of the intraocular blood-vessels is similar to that of vessels in other parts. The central artery of the retina shows a well-marked elastic

¹ Marcus Gunn. Trans. Ophth. Soc. of the U. K., XII, 1892, 124.

tissue coat (membrane of Henlé) which is lined by endothelium on its inner surface, a middle coat composed of unstriped muscular fibres, and an outer coat, or adventitia, of connective tissues with a few fine elastic fibres in it. The veins consist of similar but thinner coats except that they have no definite membrane of Henlé, and that the amount of elastic tissue in the adventitia and middle coat is not so great. Within the globe the retinal veins have no elastic tissue in their walls.

Vascular sclerosis affecting the ocular vessels may be either primary or secondary. By primary vascular sclerosis is meant sclerosis which takes place apart from local inflammation, and which is probably due, as in chronic alcoholic poisoning, syphilis and albuminuria to some toxic substance circulating in the blood.

Secondary vascular sclerosis occurs as the result of a local inflammation in the eye in which the vessels participate, their coats becoming thickened and their lumen narrowed. In some diseases, such as syphilis, either primary or secondary sclerosis may occur. Thus during the secondary stage, when the syphilitic infection is general, it causes a wide spread endarteritis followed by primary vascular sclerosis; but when the disease is localized, as in disseminated choroiditis, it causes an intense local secondary vascular sclerosis.

The effect of vascular sclerosis is to lessen the lumen of the vessel and so to inhibit the nutrition of the part by diminishing or completely cutting off the blood supply to it. If the constriction of the vessels is general throughout the system the blood pressure is raised, and this, together with the disease in the capillaries, produces changes in the walls of the latter which allows of a transudation of their contents (see page 184). The secondary effects of vascular sclerosis will be discussed under degeneration (see page 440).

The actual change found in the larger vessels when sclerosed is an increase of the connective and elastic tissue in their walls (Fig. 107). This is especially marked in the

intima which may be either uniformly thickened or have knob-like prominences formed in it which project into the lumen. The effects of such constriction on a vessel are various: 1. The vessel behind the obstruction may become dilated so that milliary aneurisms are produced. This dilatation is especially liable to take place on small thin-walled venous radicals which in some instances may give way, causing intraocular hemorrhage. 2. Partly on account of the

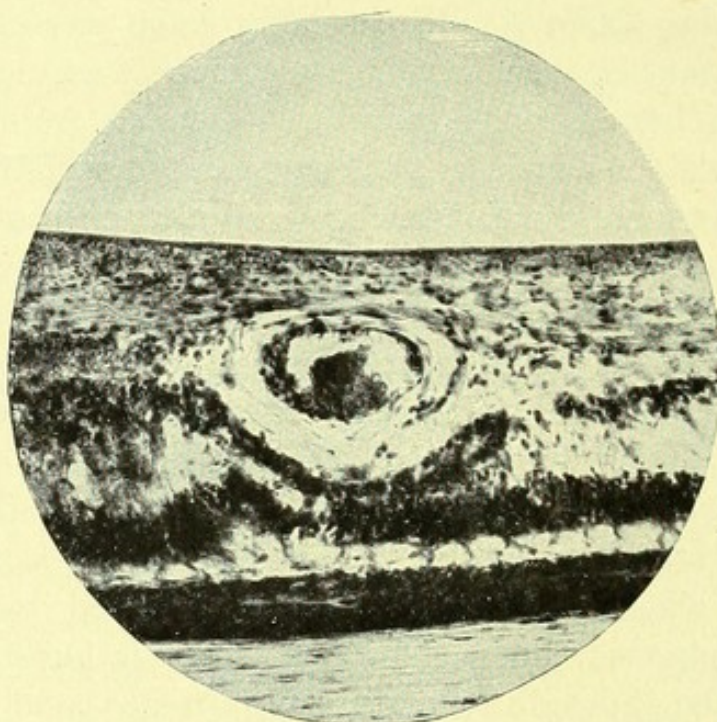


FIG. 107.—Shows a section through the retina, with a sclerosed artery cut transversely. Note the thickening of the vessel's coats.

stasis produced by the "constriction and partly on account of the irregularity and roughness of the inner surface of the vessel, thrombosis may occur. This may happen in either an artery or a vein. The results of the obstruction to the retinal circulation from sclerosis differs enormously according to whether it affects the artery or the vein.

If a branch of the **central artery¹ of the retina** be the site of complete obstruction, there is a sudden loss of sight corresponding to the area supplied by the vessel. If it be

¹ G. Coats. R. London Ophth. Hosp. Rep., XVI, 1905, 262.

the main artery that is affected, total blindness results. When, however, a cilio-retinal artery is present the retina supplied by it remains functional. A portion of the temporal field may also retain perception of light for a short time, when the periphery of the nasal part of the retina derives its nutrition from the choroidal blood vessels. The obstruction to the circulation most commonly occurs behind the lamina cribrosa, partly because the vessel becomes constricted in passing through it, and partly on account of the vessel bifurcating in that region. The immediate effect of the block in the artery is an intense anemia of the retina.

Ophthalmoscopically the retina has a white appearance which is due to its becoming non-translucent, either from coagulation necrosis or edematous changes (see page 471). The macula appears as a cherry-red spot, owing to the red choroid being seen through the retina which is much thinner in this situation than elsewhere. In a few hours after obstruction the artery begins to refill with blood as the anastomosis around the nerve head becomes opened up. At first the blood in the artery does not fill its lumen entirely. Drops of blood appear in the vessels with intervals between giving it a "railway truck" appearance. This is probably due to a drop of blood being pumped in with each systole of the heart and then the vessel collapsing under the intraocular pressure during the heart's diastole. After about forty-eight hours the artery becomes entirely filled, but it is always too late to restore the function of the retina which becomes atrophic and is followed by secondary atrophy of the optic nerve. Finally, the artery as a result of endarteritis becomes reduced to a mere thread and an ascending atrophy of the nerve takes place, owing to death of the retinal ganglion cells.

Although during the early stages the central artery contains little or no blood, the central vein is always full. This is due either to regurgitant blood from the ophthalmic vein, or, more probably, to the blood being unable to leave the eye, owing to intraocular pressure producing a collapse

of the central vein at the disc in the absence of the *vis a tergo* of the blood pressure.

It is probable that the clot may sometimes shrink to one side of the artery and its lumen again become pervious. More frequently organisation with the formation of fibrous tissue completely obliterates the lumen of the vessel.

Thrombosis of the Central Vein.¹—This may occur in either the main vein or one of its branches (Fig. 108). If it

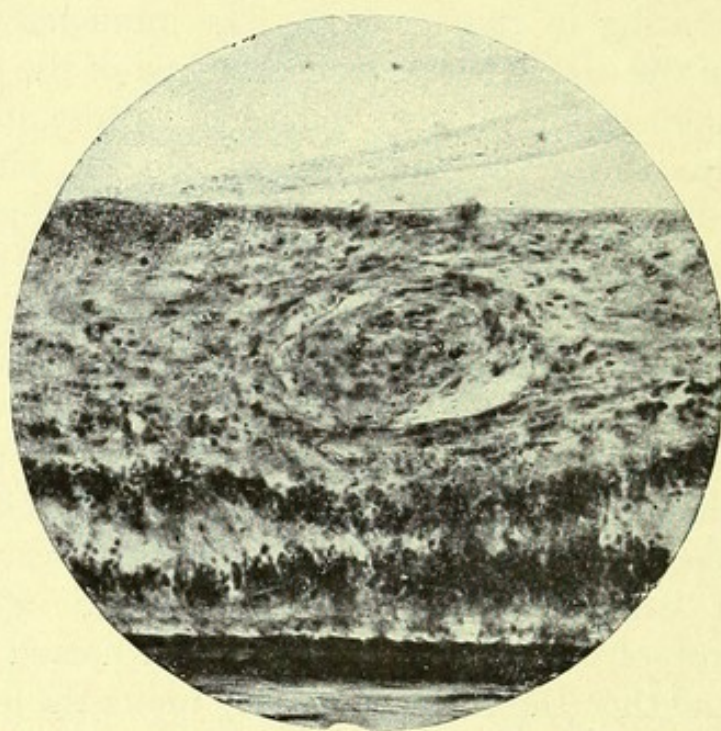


FIG. 108.—Shows a section through the retina with a thrombosed retinal vein cut transversely.

affects the main vein the block usually occurs at the lamina cribrosa where it is constricted and bent in passing out from the eye, and where it lies in close proximity to the artery which when thickened may exert pressure on its walls. Occasionally it occurs in front of the lamina cribrosa or the clot may extend so that it can be seen ophthalmoscopically as a reddish-black point on the disc. As the result of venous obstruction, blood brought by the central artery can only leave the eye by the anastomosis around the nerve head.

¹ G. Coats. R. London Ophth. Hosp. Rep., XVI, 1904, 62.

This leads to intense engorgement of the retinal veins the increased pressure in which either causes rupture of the capillaries or the transudation of their contents, so that the retina becomes covered with multiple hemorrhages. The fluid exuded also produces an intense edema of the retina and papilla, giving rise to the appearance of optic neuritis. The edema is especially marked in the papilla, owing to the engorgement caused by the opening up of the choroidal retinal anastomosis. The immediate effect of thrombosis is loss of vision; this is not usually complete and it may subsequently be to a great extent restored, either from canalization of the clot or from a fresh anastomosis around the site of the thrombosis being established. Another sequela of thrombosis which may occur results from the stagnation produced in the already diseased artery, leading to thrombosis in that vessel also; the sight is then entirely destroyed and the clinical condition previously described under obstruction to the central artery will be superimposed on the clinical appearance of thrombosis. On looking at such a fundus an intense neuritis with hemorrhages and engorged veins is seen, while the arteries are reduced to mere threads and the retina appears whitish in colour. Finally there may be complete obliteration of all the retinal vessels.

The occurrence of thrombosis of the retinal vein causes the exudate of highly albuminous fluid and this, together with the sclerosis which is usually present in the pectinate ligament and other ocular vessels, not infrequently leads, in the course of some weeks, to acute glaucoma with or without blocking of the angle of the anterior chamber by the root of the iris (see page 212). When the glaucoma has existed for some time new vessels appear on the surface of the iris—a point which is of diagnostic importance. They are probably produced by dilatation of the capillaries in a thin endothelial membrane on the anterior surface of the iris which is formed in such cases.

The highly albuminous nature of the exudate into the

retina, together with the extravasated blood, may produce a condition which is described as massive retinitis (see page 191). Subretinal exudate may cause detachment of the retina. Hemorrhage may also take place into the vitreous and produce a condition termed retinitis proliferans (see page 338).

Choroidal Vascular Sclerosis.—Both the choroidal arteries and veins may be sclerosed (Fig. 109), but as a rule the

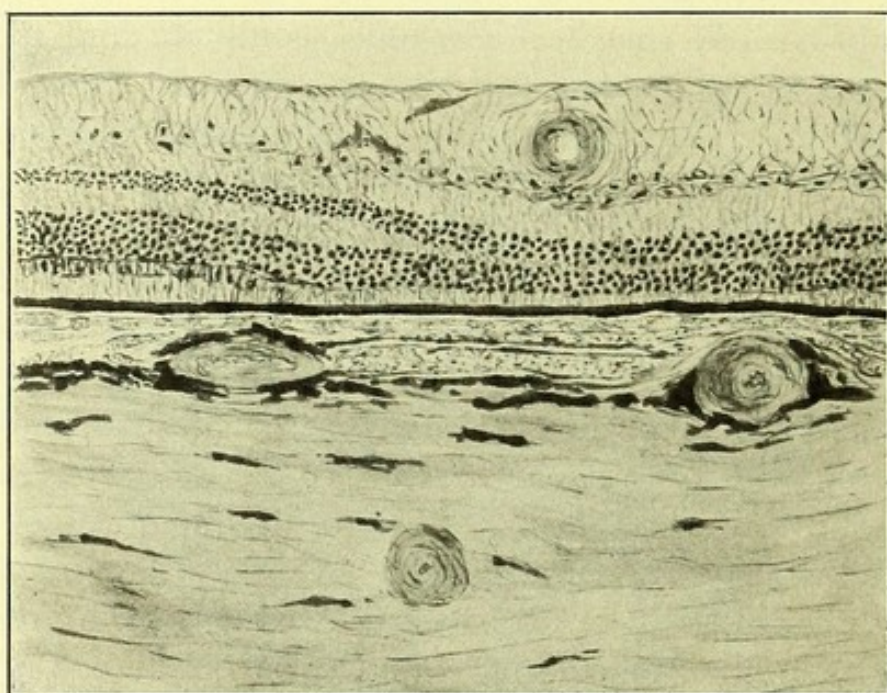


FIG. 109.—Shows a section through the coats of the eye with sclerosed choroidal and retinal vessels cut transversely.

main arteries are chiefly affected and changes are produced over areas of the choroid supplied by them. The chorio-capillaris becomes atrophied and the larger vessels are seen with the ophthalmoscope as white worm-like bodies in the fundus, occasionally with thin columns of blood within them. The atrophy of the chorio-capillaris has a marked effect on the pigment cells of the retina which proliferate and migrate. Other secondary degenerative processes, such as the formation of colloid nodules on the membrane of Bruch, follow (see page 482). In extreme cases the nutrition of the overlying retina is cut off and it loses its function in that locality.

(iii) **Diseases Dependent on Vascular Sclerosis.**

Under the old nomenclature there was a tendency to ascribe all diseases of which the pathology was not known to inflammation. Hence the terms applied to the following diseases, which are not strictly speaking of inflammatory origin at all, but dependent on vascular sclerosis.

The condition which gives rise to vascular sclerosis acts on all the ocular vessels, but one set of vessels may be more affected than others; thus in albuminuric retinitis the retinal vessels are chiefly involved and in syphilis the choroidal. In retinitis pigmentosa, on the other hand, both sets are often affected. Even when one set of vessels is the chief seat of the disease some branches may be more extensively sclerosed than others.

The diseases may be divided into

- a. Diseases dependent on vascular sclerosis confined to the ocular vessels.
- b. Diseases dependent on general sclerosis affecting the ocular vessels.

a. **Local.**—**Retinitis pigmentosa**¹ and **retinitis pigmentosa sine pigmento** are diseases due to a primary local vascular sclerosis (hyaline) entirely limited to the ocular vessels, choroidal and retinal. The pigmentation in the former is purely a secondary change following on the cutting off of the blood supply. It is absent in the latter. Why pigmentation should take place in one case and not in another is not known, as the form without pigmentation has never been examined microscopically; it is possible that pigmentation does not take place, owing to the fundus being albinotic. Slowly progressing primary syphilitic vascular sclerosis occasionally produces changes within the eye very similar to retinitis pigmentosa so that it may be a matter of difficulty both clinically or histologically to differentiate between them. Clinically retinitis pigmentosa begins as a complete or partial ring scotoma in the visual fields which is followed by a gradually

¹ W. T. Lister. R. Lond. Ophth. Hosp. Reports, XV, 1903, 254.

progressive contraction of them toward the macula. The retention of vision in the peripheral parts of the field is probably due to the anastomosis of the recurrent branches of the long posterior ciliary arteries with the short ciliary arteries supplying the anterior part of the choroid, the retina in the anterior part of the globe being mainly dependent for its nutrition upon the choroidal circulation.

The patients are unable to see at night, probably owing to the alteration in the pigment epithelium checking the formation of the visual purple upon which the light adaptation of the eye is largely dependent. The histological change found is one of extreme vascular sclerosis both of the retinal and choroidal vessels. In the choroid the occlusion of the vessels leads to atrophy of the chorio-capillaris. This condition is followed by atrophy of the outer layers of the retina and a migration of the retinal pigment cells into the retina which becomes atrophic losing its nervous elements and so causing secondary atrophy in the optic nerve. The pigment is deposited in the perivascular lymph spaces and also throughout the atrophic retina in branch-shaped masses. These changes at first are most marked about the equator and gradually approach the disc as the main retinal vessels become occluded. Other secondary degenerative changes, such as colloid bodies on the membrane of Bruch, or hyaline formations at the disc may also occur.

The disease is frequently hereditary. It may be met with in several different generations of the same family and of the same childship. Consanguinity is often present and the patients are sometimes deaf mutes.

b. General.—**Albuminuric retinitis**¹ is a condition which shows that renal disease is affecting the ocular vessels. It is most commonly associated with a contracted interstitial nephritis and more rarely with a large white or amyloid kidney. It occurs rarely in acute nephritis associated with specific fevers, and is sometimes associated with the albuminuria of pregnancy. In both the latter instances the changes

¹ E. Nettleship. R. Lond. Ophth. Hosp. Reports, XV, 1903, 320.

are probably largely due to toxic elements rather than vascular sclerosis and therefore the prognosis in these cases is not so serious provided the patient gets over the initial attack. It generally occurs in patients over the age of forty but has been known to commence as early as the age of five years. The prognosis to life in those affected is usually bad, the patient dying within two years of the onset of the ocular symptoms. This is not the case, however, when

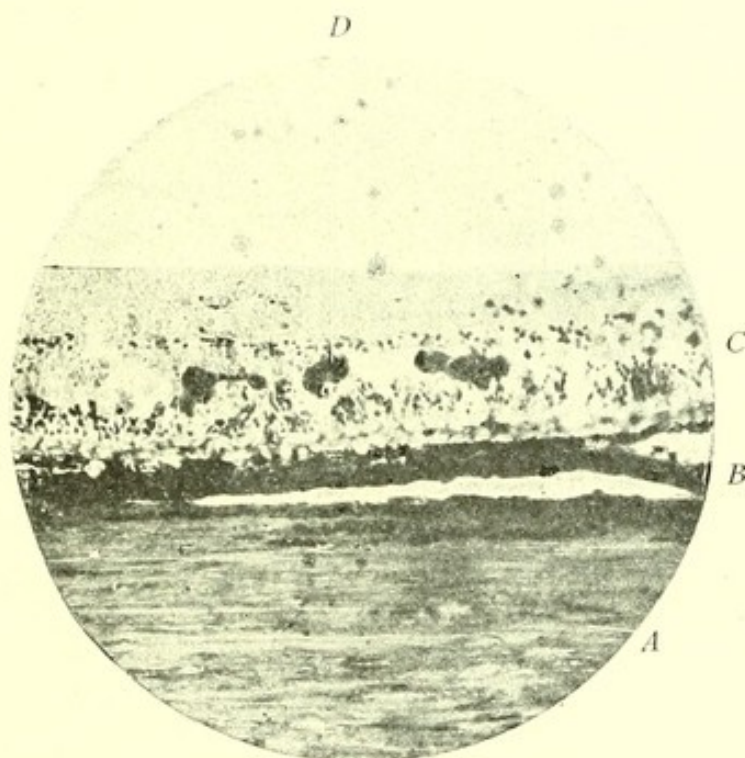


FIG. 110.—Shows a section through the coats of the eye in a case of albuminuric retinitis. In the retina there are albuminous coagula which produce the white patches seen clinically. *A*, Sclerotic; *B*, choroid; *C*, retina; *D*, albuminous coagulum.

the retinitis is associated with the albuminuria of pregnancy or in the rare cases when it occurs in connection with acute nephritis which clears up entirely.

The changes in the vessels in cases associated with chronic nephritis are those of sclerosis. Seen clinically these appear as white lines along the course of the arteries; kinking and diminution in calibre, or partial obliteration of the veins wherever they are crossed by the arteries from the direct pressure of their thickened coats; sometimes also

tortuosity of the veins and thrombosis of the artery or vein. The histological changes in the vessel walls have already been described (see page 175).

The exudate which occurs is highly albuminous and may be subretinal or intraretinal. When the exudate is subretinal it may be so extensive as to cause retinal detachment.

If intraretinal it may occur in the nerve fibre layer. Ophthalmoscopically in the early stages this gives rise to grey patches with ill-defined margins. More usually it is

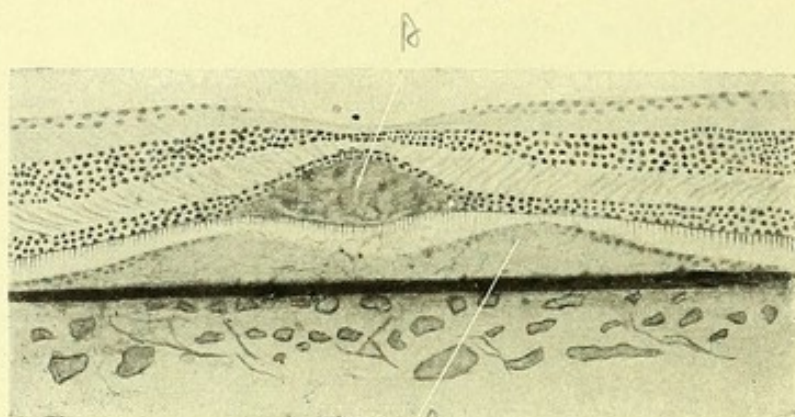


FIG. 111.—Shows a section through the macula lutea in a case of albuminuric retinitis in which a star-shaped figure was present. *A* points to intraretinal exudate and *B*, to sub-retinal exudate.

situated in the internuclear layers in the form of discreet globules which may run together and form large masses of exudation (Fig. 110).

In the macula region the exudate takes a peculiar star-shaped arrangement of sharply defined white patches. This is due to the lines of tension in the retina produced from the peculiar attachment of it to the pigment cell layer in that region. The exudate is both sub- and intraretinal (Fig. 111). For retinal hemorrhage see page 189.

Diabetic retinitis¹ is characterised by a number of punctate hemorrhages and minute white patches in the macula region. The patches of hemorrhage and exudation are very much smaller than in albuminuric retinitis and are probably derived from the giving way of capillaries in the deeper

¹ E. Nettleship. R. Lond. Ophth. Hosp. Reports, XV, 1903, 320; XVI, 1904, 11. L. Heine. Klinisch. Monats. f. Augen., XLIV, 1906, 451.

layers of the retina. Other complications due to vascular sclerosis may supervene. The disease is usually bilateral. The prognosis with regard to life is on the whole better than in albuminuria, as half the patients live over two years. Albuminuria may accompany the diabetes, but diabetes alone can cause the ocular changes.

The rare condition of lipemia which is met with in diabetes gives rise to a peculiar yellow colour of the blood-vessels. It has been attributed to the fatty constituents present in the blood becoming adherent to the vessel wall.¹

(iv) Intraocular Hemorrhage.

Hemorrhage from the uveal tract or retina may occur as the result of (A) rupture of the vessel wall; (B) diapedesis.

A. The causes of rupture of the vessels are

1. Increased intra-vascular pressure, local or general.
 - a. Local, *e.g.*, contusion of the eye, venous thrombosis, optic neuritis, and all forms of retinitis.
 - b. General, *e.g.*, hypertrophy of the left ventricle, straining, coughing, cessation of menstruation, and high arterial tension.
2. Diminished support from sudden lowering of the intraocular tension; *e.g.*, sub-choroidal hemorrhage after glaucoma iridectomy.

3. Degeneration in the vessel walls.

B. Diapedesis, as the result of

1. Increased intravascular pressure.
2. Alteration in the constituency of the blood.

The damage done by an extravasation of blood depends first on the nature and density of the tissue affected; thus delicate tissue, such as the retina, when torn up by a hemorrhage, is destroyed; second, by the amount of subsequent organisation that takes place in the clot leading to fibro-cicatricial tissue which by its contraction may press or pull on surrounding structures. The extent of the contraction probably depends on the rapidity with which blood coagu-

¹ Hale White. *Lancet*, Oct. 10, 1903.

lates, the hemolytic properties of the serum, and the absorbing power of the lymphatics in the tissues into which the hemorrhage takes place.

Hemorrhage from the iris may be extravasated into the anterior chamber (**hyphemia**). It is usually the result of injury (see page 251) but may occur when the iris is engorged with blood, as in acute iritis; also where there is much vascular degeneration, such as follows long standing cyclitis or glaucoma. If the angle of the anterior chamber

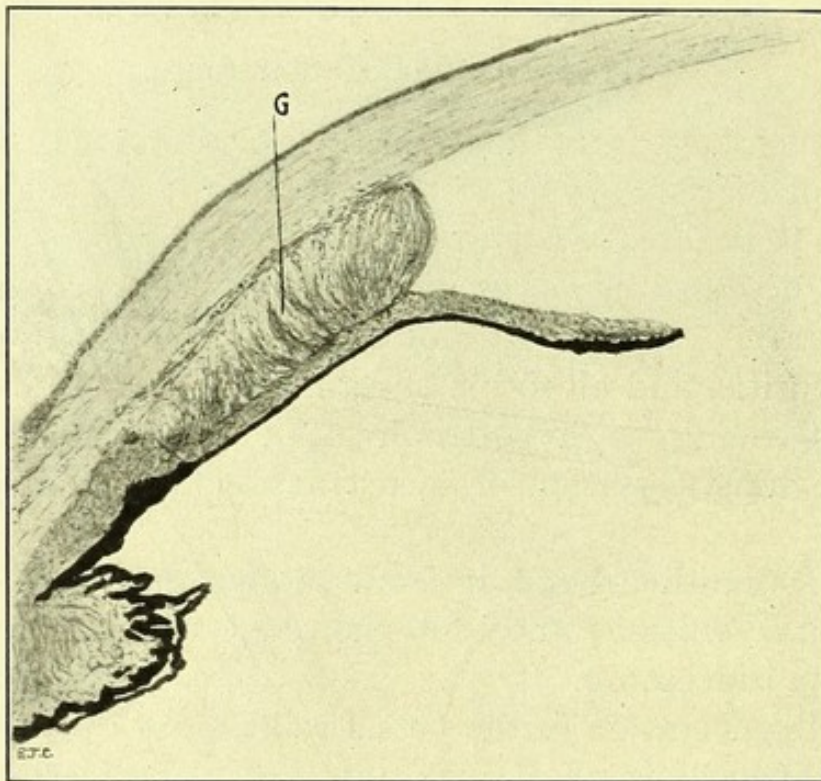


FIG. 112.—Shows a mass of retained and degenerate blood clot, G, at the angle of the anterior chamber. The slit-like spaces in it contained cholesterin crystals.

is not blocked it is readily absorbed, but if retained a long time it may organise into a large pinkish-grey coloured mass at the bottom of the anterior chamber. These masses microscopically consist of endothelial cells enclosing spaces filled with cholesterin crystals and other dèbris of degenerated blood clot (Fig. 112).

From blood long retained in the anterior chamber the hemoglobin may pass into the substantia propria of the

cornea by diffusion producing **blood staining of the cornea**;¹ the condition frequently occurs in eyes in which the tension is increased. It gives rise to a brown or green appearance of the cornea depending on the time it has existed. The condition at first sight is liable to be mistaken for a dislocation of the lens into the anterior chamber because a narrow band at the periphery of the cornea in the entire circumference remains clear. Histologically granules are found between the fibres of the substantia propria; these are of the nature of hematin (containing no iron) or hemosiderin (containing iron). The pigment is slowly absorbed from the periphery toward the centre of the cornea often taking from eighteen months to two years to clear up completely.

Hemorrhage into the vitreous may arise from the ciliary body or retinal vessels. Apart from injury the condition occurs spontaneously. In young people, more especially men, recurrent attacks take place, sometimes alternating with nose bleeding. In these cases the blood coagulability has been found to be raised, and it is probable that the hemorrhage is due to thrombosis occurring in a small vessel which subsequently gives way, owing to the *vis a tergo*. The blood may be derived from either the ciliary or retinal vessels; if from the retinal vessels, rupture of the hyaloid membrane must occur. In older patients vitreous hemorrhage is usually associated with disease in the vessel wall. The extent of the hemorrhage varies with the size of the vessel which gives way. Sometimes the whole vitreous is filled with blood which can be seen behind the lens; in other cases it merely constitutes a haze in the vitreous; between these two conditions varying amounts have been observed.

The subsequent change produced by the hemorrhage varies with the constituents of the blood extravasated and the absorbing power of the intraocular lymphatic system. The blood being in contact with living tissues takes a long

¹ Treacher Collins. Trans. Ophth. Soc. of the U. K., XV, 1895, 69.

time to coagulate; if the blood coagulability of the patient be high, due to the blood containing an excess of calcium salts, it will coagulate more rapidly than normal, and then will not undergo absorption so readily. The corpuscles discharge their hemoglobin which is absorbed by the lymphatics, the stroma is broken up, and in the degenerative process cholesterol crystals are frequently formed. The fibrin in the vitreous, which sometimes can be seen on the posterior surface of the lens, either becomes absorbed or organised. The endothelial cells from the blood-vessels of the retina or ciliary body spread into it and bands of fibrous tissue develop—a condition known as retinitis proliferans (see page 338). These bands of fibrous tissue by their contraction may cause shrinking of the vitreous, detachment of the hyaloid, and, if the latter be adherent to the retina, detachment of that structure also. Hemorrhage may occur from a ciliary or choroidal vessel during excision of the eye; in which case the recent character of the blood clot is usually sufficient to distinguish it.

Hemorrhage from the choroid occurs most frequently from the giving way of a vessel due either to injury, to the sudden lowering of intraocular tension, or to thrombosis of a choroidal vein. In the two latter cases disease in the vessel walls plays an important predisposing part. The sudden reduction of intraocular tension, as after an iridectomy for glaucoma, may cause a rupture in a choroidal vessel. If this be a large artery in the outer layers of the choroid the blood is extravasated between the choroid and sclerotic pushing the former inward. As a result the lens may be pushed forward and, if the bleeding continues, the lens, retina, and choroid escape through the wound. If a small vessel in the chorio-capillaris of the choroid gives way the blood may rupture through Bruch's membrane and hemorrhage take place into the subretinal space. Smaller extravasations of blood, such as occur at the macula in myopic eyes, may remain localised in the choroid. Such hemorrhages are followed by intense secondary pigmentation,

the pigment being partly derived from the blood and partly from the proliferation of the retinal and choroidal pigment cells.

Hemorrhage from the Retina.—The amount of blood extravasated into the retina and the damage done to it thereby depends on the size and situation of the vessel which gives way. If the vessel be superficial the bleeding takes place beneath the hyaloid membrane of the vitreous in

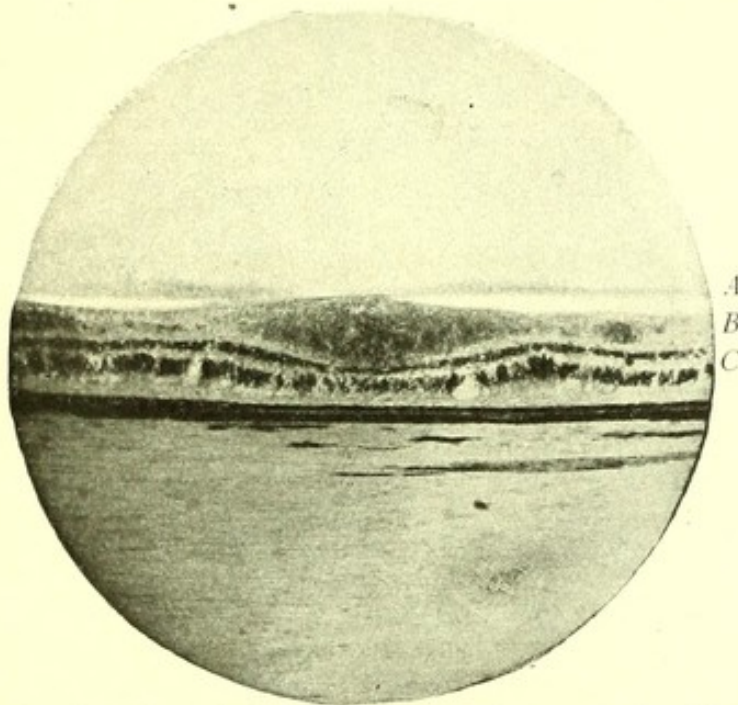


FIG. 113.—Section through the coats of the eye in a case of sub-hyaloid hemorrhage. It shows the comparatively slight change caused in the retina thereby. *A*, Hyaloid membrane; *B*, hemorrhage; the blood has accumulated at the most dependent part; *C*, retina.

which case it is usually extensive. The blood sinking downward separates the hyaloid from the retina and usually takes the form of a boat-shaped red area which is darker in colour toward the bottom, owing to the greater mass of blood being present in that situation. This form of hemorrhage does not give rise to much destruction of the retinal elements, and hence good vision may be restored (Fig. 113). Occasionally the hemorrhage may be so extensive as to cause rupture of the hyaloid and give rise to a condition of retinitis proliferans, as has already been described.

Hemorrhages into the nerve-fibre layer usually have a flame-shaped appearance and they are often striated owing to the anatomical arrangement of the nerve fibres. Hemorrhages into the deeper layers of the retina cause immense destruction of tissue, the retinal elements being torn up with the result that a permanent scotoma remains in the field (Fig. 114).

Retinal hemorrhages will persist for months without showing appreciable change. The subsequent changes

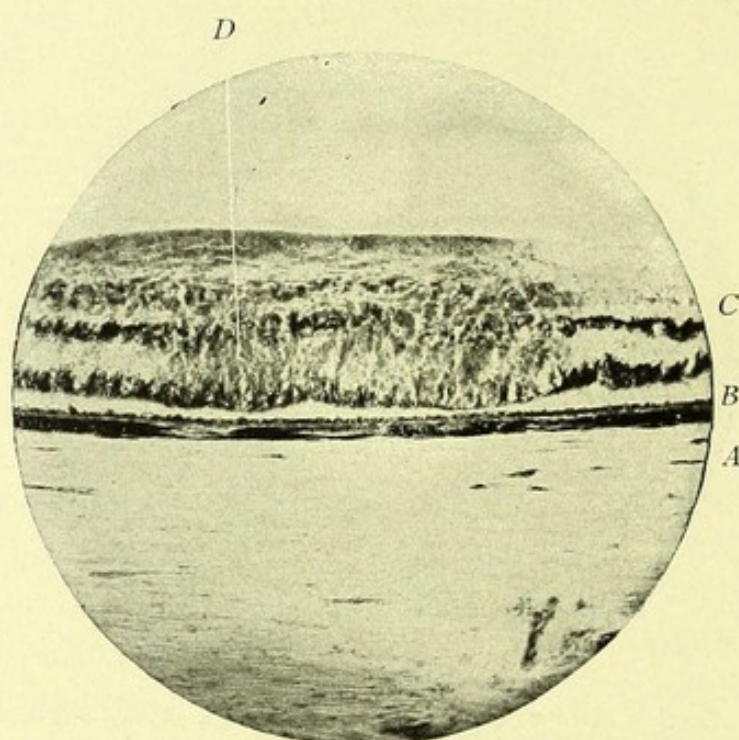


FIG. 114.—Shows a section through the coats of the eye in a case of albuminuric retinitis. The destruction to the retina caused by hemorrhage into it is seen. A, Sclerotic; B, choroid; C, retina; D, hemorrhage.

depend largely on the absorbing power of the perivascular lymphatics. As the blood in the retina disintegrates it gradually becomes darker in colour and finally black so that clinically it cannot be distinguished from the retinal pigment. Microscopically it can be distinguished by the fact that the pigment derived from the hemoglobin contains iron and for some considerable time after its occurrence it will yield the test for this substance. The breaking up of the stroma of the corpuscles may give rise to crystals of cholesterin which appear as glistening points in the fundus.

The diseases known as **massive retinitis** (Fig. 115) and **retinitis circinata** are due to retinal hemorrhage and are

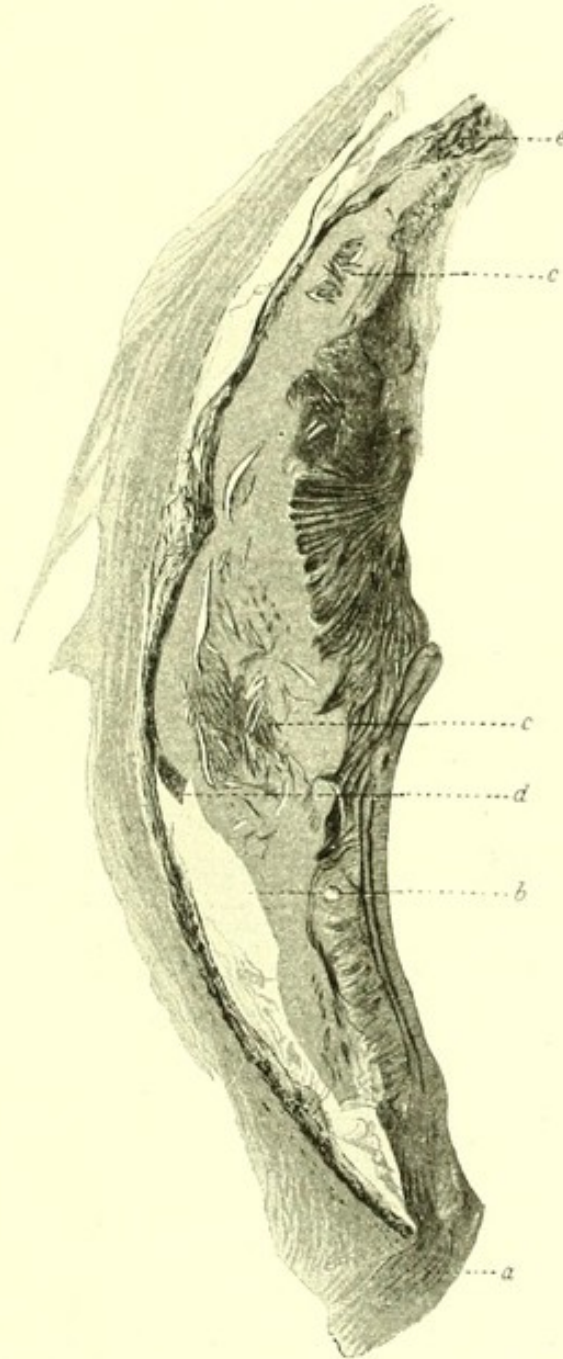


FIG. 115.—Section through the coats of the eye showing a mass of organising blood clot beneath the retina, so-called "massive retinitis." *a*, optic nerve; *b*, mass of fibrillated structure with fusiform cells in it; *c*, spaces which contained cholesterol crystals; *d*, mass of red blood corpuscles; *e*, hyalin excrescences from elastic lamina. Case recorded Trans. Ophth. Soc. of the U. K., IX, 1889, 198.

probably nearly allied to one another, the latter being a less severe form of the former, but up to the present time retinitis

circinata has only once been submitted to microscopical examination. There are two main groups of cases—(a) those associated with marked vascular degeneration of the intra-ocular vessels and therefore occurring principally in old people, although in rare instances young people may be affected; chronic nephritis being frequently present in these cases; and (b) those associated with nose bleeding, menstruation, etc., and are probably due to a high blood coagulability; these patients are usually young persons. In each instance it is probable that the determining factor in the production of the hemorrhages is thrombosis of some small venous radical. Histologically the changes are situated principally around the macula region where large raised white areas may appear; the exudate is in the internuclear layers, the supporting structures of the retina being pushed to one side to form the walls of pseudocystic spaces which contain blood clot, albuminous fluid, or hyaline material with a certain amount of organising fibrous tissue. Occasionally the walls of these spaces can be found ruptured into the sub-retinal space.

Hemorrhage into the optic nerve and its sheath may occur spontaneously or as the result of injury. The condition leads to a sudden loss of vision, owing to pressure on the nerve. If the extravasation be into the nerve sheath an edema of the papilla may be caused by pressure on the central vein. The recovery of sight depends on the amount of destruction caused by the primary extravasation or subsequently by the amount of organisation which takes place in the blood clot.

(v) ^{dilatation} **Dilation of the Orbital Vessels May be Local or General.**

Localised Dilatation of the Vessels Connected with the Orbit.—Either arteries or veins alone may be affected or a communication between the two may be established. If merely the vein is dilated as the result of the communication with the artery the condition is known as an aneurismal varix, but if an aneurism forms between the artery and the

vein the condition is known as a varicose aneurism. Dilatation of the intraocular vessels as the result of vascular degeneration has already been described (see page 176). A communication between a retinal artery and vein has been recorded; it leads to enormous distention of the vein.

In the orbit dilatation of the vessels gives rise to exophthalmos, and if a main artery takes part in the dilatation it causes **pulsating exophthalmos**, it arises as the result of trauma or spontaneously as the result of vascular degeneration which is frequently syphilitic in origin. The conditions found postmortem in the order of their frequency are: communication of the internal carotid artery with the cavernous sinus, aneurism of the ophthalmic artery in the orbit, aneurism of the ophthalmic artery outside the orbit, aneurism of the intracranial portion of the internal carotid. It is probable that a communication between the veins and artery in the orbit also occurs.

For description of the various angiomas see page 151.

General dilatation of the orbital vessels may occur as the result of local inflammation or obstruction to the venous return as has already been described. It may also occur as the result of stimulation of the sympathetic.

Exophthalmic Goitre.—The ocular features of the disease only require mention here. They are: retraction of the lid (Dalrymple sign); the upper lid does not move downward in unison with the eye (von Graefe sign); imperfect closure of the lids (Stellwags sign); defective convergence (Moebius sign); pigmentation of the lids. The proptosis is usually bilateral but may be unilateral. There have been many explanations as to its cause but the most satisfactory is, that it is due to a dilatation of the vessels of the orbit, possibly as the result of the action of the increased thyroid secretion on the sympathetic. This is borne out by the fact that the exophthalmos disappears after death except in cases of long standing. It is probable in these cases that some new tissue has been formed in the orbit as the result of the engorgement of the vessels.

II. Diseases due to Changes in the Blood.

Hemorrhage¹.—Loss of blood in large quantities may cause failure of vision, due to ischemia of either the retinal or the cerebral blood vessels. Retinal ischemia may produce secondary degenerative changes in the retina, such as edema of the retina and papilla, punctate hemorrhages, and secondary degenerative changes in the ganglion cells which may lead to a permanent defect of vision.

The source of the hemorrhage is not infrequently the stomach or intestines, but the condition may follow hemorrhage from uterus, wounds, respiratory or urinary tracts. It is possible also that the eye changes in purpura and hemophilia are due to this cause.

Chlorosis.—Beyond the light colour of the blood-vessels of the conjunctiva and occasional pulsation of the central artery of the retina it is doubtful if chlorosis produces any primary ocular changes. Optic neuritis and retinal hemorrhages have been ascribed to this disease but they are probably due to some secondary condition.

Pernicious Anemia.²—Retinal hemorrhages, edema, and optic neuritis are common in the later stages of the disease. They produce secondary degenerative changes in the nerve elements of the retina.

Leukemia³—Lymphatic leukemia may affect any of the orbital tissues. In the lids and orbit it may give rise to lymphomata (see page 136). The interior of the eye may be the seat of lymphomata; the choroid and even the retina may become involved. In the retina the condition is known as leukemic retinitis and papillitis, while the infiltration of the choroid gives rise to the yellow colour of the fundus which is sometimes associated with the disease.

Alterations in the coagulability of the blood may give rise to thrombosis, especially if the ocular vessels are

¹ W. A. Holden. Arch. of Ophth. XXVIII, 1899, 125. Snell. Trans. Ophth. Soc. of the U. K., XXIV, 1904, 186.

² G. De Schweinitz. Trans. Am. Ophth. Soc. VII, 1896, 654.

³ W. Stock. Klinisch. Mon. f. Aug., XLIV, 1906, 35.

already diseased (see page 178). It is probable also that **recurrent spontaneous vitreous hemorrhages** which occur in young people, especially men, are due to this cause (see page 187).

It is possible that the hemorrhage which occasionally occurs in the macula region associated with menstruation may be due to raising of the blood coagulability.

Embolism.—A portion of a blood clot from a thrombus, or another embolism, fibrin from the surface of the cardiac valves, atheromatous plates from the inner surface of large vessels may be carried by the blood stream and impacted in the vessels of the eye. When the material contains pyogenic microorganisms it is followed by an inflammation which is known as pyemia (see page 349). When an embolism occurs in the central artery of the retina the clot usually lodges in the vessel as it passes through the lamina cribrosa, possibly because of the narrowing of the lumen of the vessel in that situation, and possibly also because it is the common position in which bifurcation of the vessel occurs, the embolism straddling the bifurcation. Occasionally only one branch of the retinal artery is occluded. The clinical signs and subsequent changes have been described under obliteration of the central artery (see page 176). The onset is sudden and without the premonitory symptoms of temporary loss of vision as is present in some cases where the obstruction of the artery is due to vascular sclerosis.

Embolism in the Uveal Tract.—The uveal tract is a common site for the lodgment of septic emboli in the eye as will be pointed out in connection with pyemia (see page 349). There is no doubt also that aseptic thrombi, etc., lodge in the choroid, although the condition is not recognised clinically as such, probably because the anastomosis in the choroid is very free and the area affected therefore very localised. A case has been described pathologically, showing a patch of obliterated choroidal vessels with fibrosis and hematogenous pigmentation which was probably of this nature, but more evidence is wanting as to its occurrence.

Embolism in the ophthalmic artery may give rise to occlusion of both retinal and choroidal vessels. Such cases are usually associated with embolism of the common carotid artery. In this case the clot in the common carotid may extend by thrombosis to the ocular vessels, or, as is more probably the case, a portion of this clot becomes detached and carried into the ophthalmic artery.¹ Cases have been recorded which seem to show that both these conditions can occur. Thus a hemiplegia with embolism of the central artery and complete obliteration of the common carotid on the same side as the retinal artery, the choroid being normal, seems to point to a detachment of a portion of the embolism from the carotid vessel; while hemiplegia with complete obliteration of the common carotid, retinal and choroidal vessels point rather to an extension of the clot from the carotid by thrombosis completely blocking the ophthalmic artery.

Cavernous sinus thrombosis may arise from the spread of thrombosis from one of its communicating veins. These are the ophthalmic veins through which it communicates with the angular vein, the petrosal sinus through which it communicates with the veins of the ear; indirectly it also communicates with the pterygoid plexus and with the veins from the cerebrum. The two sinuses also communicate freely with each other. The cause of the thrombosis may therefore arise in the orbit, nose, ear or tonsil. The signs are enlargement of the mastoid emissary vein from venous obstruction, paralysis of the sixth nerve from pressure, and proptosis. When both sinuses are affected these signs are bilateral. The proptosis is due to engorgement and edema of the orbital tissue. Frequently there is no enlargement of the retinal veins unless the ophthalmic vein be thrombosed since the latter vessel communicates freely with the angular vein and the pterygoid plexus. In other cases papillitis and retinal hemorrhage from obstruction of the

¹ Guthrie and Mayou. Trans. Ophth. Soc. of the U. K., XXVIII, 1908, 104.

central vein may be present. If the clot be septic death usually follows, but in aseptic cases the patient may live, the exophthalmos continues, optic neuritis with atrophy following. In septic cases the staphylococcus aureus, streptococcus and pneumococcus have been found in the clot.

III. Toxic Amblyopia.

A poison circulating in the blood may produce temporary or permanent blindness by its action on the nerve elements of the retina or cerebral centres for vision.

Poisons affecting the retina do so either by their direct action on the ganglion cells or their synapsis, or by the production of ischemia which interferes with their nutrition. The ischemia is produced either by the action of the poison on the sympathetic nerves causing constriction of the retinal blood vessels, or by dilatation of the vessels in the splanchnic area causing constriction of vessels elsewhere including those of the retina.

Following the retinal degeneration atrophy of the whole or part of the optic nerve takes place, associated with which there is a leukocytosis into the nerve to remove the débris of the broken up medullary sheaths; this leukocytosis has been considered by some observers to be of the nature of a retrobulbar neuritis which they regard as the actual cause of the defect of vision, the changes in the ganglion cells being secondary.

The poisons which may affect vision in the above ways are either endogenous, *i.e.*, generated in the body itself from faulty metabolism, or exogenous.

The endogenous toxins producing amblyopia are found in connection with diabetes, uremia and the puerperal state.

The exogenous toxins which produce amblyopia are tobacco, methyl and ethyl alcohol, carbon disulphide, iodoform, quinine, ergot, nitrobenzol, anilin and aryolar-senates, filix mas, lead and salicylic acid.

(i) **Endogenous Toxic Amblyopia.**

Diabetic Amblyopia.—The toxin which produces amblyopia in diabetes is not known. The symptoms to which it gives rise are similar to those found in tobacco-alcohol amblyopia; namely, failure of vision, a central scotoma for colours and in long-standing cases pallor of the temporal side of the optic disc. From the similarity of the symptoms it may be supposed that the action of the poison is as in tobacco amblyopia mainly on the ganglion cells or their synapsis possibly assisted by defective nutrition due to changes in the vessel walls. Some authorities attribute it to a retrobulbar neuritis.¹

Uremia occurring in connection with acute or chronic nephritis may be associated with transient amaurosis without ophthalmoscopic signs, the pupil reacting freely to light. The onset of the blindness is rapid and usually complete. Recovery may also be rapid and complete but sometimes hemianopia is present for a short while. The activity of the pupils, the rapid recovery from the attack and sometimes the presence of hemianopia suggests that the amaurosis is due to the action of a toxic agent on the higher centres for vision. The view has been advanced that it is due to cerebral anemia following increased intracranial tension, but against this hypothesis is the fact that usually no optic neuritis is present. The poison which causes uremia has not so far been isolated.

The Puerperal State.—Amblyopia arising during pregnancy may be the result of uremia associated with kidney disease. There seems also to be another form of temporary amblyopia unassociated with uremia which may come on before, during, or after labour;² albumin may or may not be present in the urine, but headache, convulsions, and edema of the face are frequently present. The amblyopia

¹ Nettleship and Edmunds. Trans. Ophth. Soc. of the U. K. III, 1883, 165.

² W. P. Herringham and S. Stephenson. *Ophthalmoscope*, VIII, 1910, 168.

may last for some time, but gradual recovery, after the birth of the child, takes place. There are usually no ophthalmoscopic signs. The amblyopia is supposed to be due to some toxic product connected with the puerperal state.

(ii) Exogenous Toxic Amblyopia.

a. Poisons which Probably have their Action on the Nerve-elements in the Retina.

Tobacco Amblyopia.—In man chronic poisoning with tobacco is usually associated with the abuse of alcohol and vascular sclerosis, probably for this reason tobacco amblyopia is rarely met with before the age of thirty-five years.

The tobacco used by such patients is usually a strong form, such as shag, smoked in a pipe. It produces failure of vision consisting of defective form-sense, light-sense and a central scotoma for colours (green and red). In severe cases there may be an actual central scotoma for white. It always affects both eyes and patients state they are able to see better in dull than in bright lights. The poison is probably not nicotine but some derivative such as pyridine.

Histological examination has revealed chromolytic changes in the ganglion cells of the macula region. It is suggested that the macula region is attacked in preference to other parts of the retina because it is poorly supplied by blood, partly as the result of vascular sclerosis from the alcohol, and partly because the retinal vessels are normally absent from that region; the nutrition of the nerve-elements at the macula are therefore less able to resist the deleterious influence of the toxins. In cases in which there is much vascular sclerosis the recovery, which usually takes place on discontinuing the use of tobacco, may be delayed or not occur at all. The fact that improvement of vision is caused by dilatation of vessels following the use of nitrate of amyl is in support of the theory that the vascular supply is an important factor in the causation of the condition.

Another theory attributes the affection of the macula region to the selective action of the poison on the cone ganglion cells or, as is more probable, on the synapsis between them and the bipolar cells. The cones in the macula region have only one synapsis with their ganglion cells; while the rods, have several paths of conduction connecting them with several cells, so that if one is destroyed others will remain open. In support of the cones or their connections being at fault is the fact that patients with tobacco amblyopia see best in dull lights, the cones being particularly associated with form-sense, the rods with the light-sense.

Degenerative changes in the papillo-macula bundle of the optic nerve have been demonstrated as far backward as the basal ganglia; these changes are probably secondary to the changes in the retina although some authorities regard the condition as a primary retrobulbar neuritis and have demonstrated leukocytosis in the nerve. This latter fact has been denied and if present is probably phagocytic in nature, owing to the presence of the degenerating fibres.

Alcohol amblyopia from acute alcohol poisoning is usually due to the methyl variety, commonly known as **wood alcohol**. The blindness is generally for a time complete. As recovery takes place a central or paracentral scotoma may be present in the field. Experimental investigations on animals have shown that the primary change is in the ganglion cells of the retina, principally in the neighbourhood of the macula, followed by corresponding secondary degenerative changes in the optic nerve.¹ Previous to this the changes were thought to be due to a retrobulbar neuritis.²

The part played by **chronic ethyl alcohol** poisoning has already been referred to under tobacco amblyopia.

Carbon disulphide is used in rubber works and inhaled by the employés. **Iodoform** is used for surgical purposes. Both these substances may cause amblyopia with a central

¹ Birch-Hirschfeld. *Archiv. für Ophth.*, L, 1900.; LI, 1901; LII, 1902.

² Uhthoft. *Archiv. für Ophth.*, XXXIII, 1887, i, 257.

scotoma for colours. Probably similar changes in the retinal ganglion cells and their synapsis are produced as are found in alcohol-tobacco amblyopia. Experimental investigations on animals have shown changes in the cells of the central nervous system, but these have not as yet been demonstrated in the retina.

b. Poisons which Probably have their Action by Producing Retinal Ischemia.

Quinine amblyopia occurs mostly in those suffering from malaria for which affection enormous doses of the drug are frequently administered. The smallest dose recorded as causing defect of sight is 5 grams given in thirty-eight hours.

The symptoms produced are deafness and blindness, of rapid onset and a very marked character. The former precedes the latter and is of only temporary duration.

The blindness affects both eyes and is more complete than in any other condition from which recovery takes place. In one recorded case the deafness and blindness were so marked that the patient could only be communicated with by the sense of touch. Ophthalmoscopically the appearances at first resemble those of embolism of the central artery of the retina. There is marked ischemia of the optic disc and retina, with a white haze of the latter around the macula and disc, and a cherry-red spot at the macula. The pupils become widely dilated and are insensible to light. The duration of the complete blindness may be for several days. Some cases entirely recover; in others the only permanent defect is a contraction of the field for colours; more frequently the field for white is also permanently contracted, the patient being reduced to what is known as telescopic vision; *i.e.*, sees well in the centre of the field but not in the peripheral parts. The pupils recover their mobility with the return of vision and the ophthalmoscopic appearances in the late stages of the disease resemble optic atrophy, the disc

remaining very white and retinal vessels narrow with white lines coursing along them.

Examinations of the retina and optic nerves of dogs at periods ranging from two days to seven weeks after the administration¹ of toxic doses of quinine have been made and the changes found have been constriction of the retinal blood-vessels, degeneration of the ganglion cells, and an ascending atrophy of the optic nerve.

It will be seen that the way in which vision is affected is just the reverse of what occurs in tobacco amblyopia; in the latter there is loss of central vision, the peripheral parts of the field being unaffected; in quinine amblyopia peripheral vision may be lost and central vision retained.

Ergot may cause transient amaurosis from constriction of the retinal vessels, but no case has been recorded which has gone on to optic atrophy.

Nitrobenzol has a similar action to quinine but the ischemia is not so severe or prolonged and hence recovery is more complete.

Anilin.—Amblyopia due to poisoning by anilin oil has frequently been recorded.² The clinical changes are chiefly in the retinal blood-vessels; retinal hemorrhages are sometimes present; poisoning by this substance is of interest in view of the extensive use of the arylarsenates.

Arylarsenates.—The chief of these are atoxyl, soamin, and arsacetin. These substances are compounds of anilin and arsenic. They are administered subcutaneously in large doses in cases of spirocheta infection (syphilis, sleeping sickness, etc.). A number of these cases have been followed by optic atrophy.³ During the acute stage of the poisoning the fundus has seldom been observed. In one case there was intense retinal ischemia, the condition of the fundus resembling that found in embolism of the central artery; this was subsequently followed by optic atrophy. This case

¹ W. A. Holden. *Am. Ophth. Soc.*, VIII, 1898, 405. Birch-Hirschfeld. *Achiv. für Ophth. L.*, 1900, 166.

² Mellinghoff. *Klinisch. Mon. f. Aug.*, XLIV, 1906, 35.

³ E. Clarke. *Trans. Ophth. Soc. of the U. K.*, XXX, 1910, 240.

suggests that the action of the poison is mainly on the blood-vessels.

Although numbers of cases of arsenical poisoning have been recorded no loss of sight or similar changes in the fundus have been found associated with it. The administration of arsenic in large doses in the form of **dioxydiamidoarsenobenzol** ("606") and other compounds has not yet been followed by primary optic atrophy; presumably therefore the harmful action is due to the anilin part of the compound in the case of the aryolarsenates.

Filix mas amblyopia is probably somewhat similar to that due to quinine amblyopia. There is a limitation of the peripheral field of vision associated in the early stages with constriction of the retinal vessels. Secondary changes in the ganglion cells and optic atrophy follow. It may affect the eyes unequally; thus one eye may be blind while the other may recover nearly normal vision. *Filix mas* may also cause acute nephritis and, in a few recorded cases, optic neuritis and retinal changes similar to those associated with this disease have been found associated with the amblyopia.

c. Poisons which Affect the Kidneys and may so Produce Secondary Retinal Changes.

Lead poisoning produces two forms of optic neuritis.

a. The first in people who have often only worked for a short time in a lead factory. This comes on with headache and vomiting and optic neuritis which may be followed by optic atrophy. Albumin may be absent from the urine. It is often associated with acute encephalitis which may or may not precede it. The optic neuritis is probably due to increased intracranial tension caused by the rapid effusion of fluid into the basal cisterns of the meninges causing a condition of choked disc (see page 342).

b. The second form is met with in old standing cases of lead poisoning where the kidneys have become affected and there is albumin in the urine. The clinical appearance of

the fundus is the same as that found in albuminuria (see page 182). Uremia may be associated with this condition and give rise to coma which must be differentiated from the coma caused by encephalitis associated with the more acute forms of poisoning.

d. Poisons which Probably have their Action by Affecting the Cerebral Centres for Vision.

Salicylic acid in doses over 15 gr. may cause temporary amaurosis. It is usually accompanied by tinnitus; recovery is rapid and complete and no ophthalmoscopic signs are present. The drug probably acts on the cerebral centres for vision.

Santonin administered for worms may cause yellow vision; this passes off without producing amblyopia.

IV. Glaucoma.

Glaucoma is a disease characterised by increase in the intraocular tension. When no antecedent disease is known to be present, it is called primary glaucoma; when there has been previous disease, secondary glaucoma.

The symptoms in **primary glaucoma** vary considerably according to their mode of onset. When the rise of tension is considerable and comes on rapidly there is much congestion, great pain, and rapid loss of sight—**acute congestive glaucoma**.

When the rise of tension is slight or comes on very gradually there is no congestion, no pain, and the loss of sight proceeds very slowly—**chronic or non-congestive glaucoma**.

Various grades of severity may be met with between these two extremes. They merge into one another. An eye may be affected with one type at one time and a different one at another; or the same individual may have one type in one eye and a different one in its fellow.

(i) **The Mechanism for the Maintenance of the Normal Intraocular Tension.**—The hardness of an eyeball depends on

the pressure within it, and the elasticity of its walls. These conditions are subject to many variations, and slight differences in what may be regarded as the average normal tension are constantly occurring. The extraocular muscles, when they contract, exert pressure on the globe, thereby slightly altering its tension but not to such an extent that it can be appreciated by the finger test. The alterations which the constantly varying quantity of blood in the intraocular vessels tends to produce is compensated for by the amount of the other two fluids in the eye which are derived from it, viz., the lymph and the intraocular fluid.

The lymph which is an albuminous fluid of the same character as lymph elsewhere is formed by a transudation of the fluid constituents of the blood from the capillaries and is drained away by the lymphatics, which accompany the vessels as they leave the eye. Under ordinary circumstances it is of little importance in the maintenance of the intraocular tension.

The formation of the intraocular fluid which fills the aqueous and vitreous chambers and its mode of escape from the eye has been the subject of an immense amount of experimental research. Though many important facts have been ascertained relating to it, the whole matter cannot yet be considered as definitely worked out.

The intraocular fluid contained under normal conditions in the aqueous and vitreous chambers is practically of the same consistency but differs from lymph in being exceedingly poor in proteids, richer in salts, and containing no lymphocytes.

It has been proved by the injection of fluorescein into the circulation that the intraocular fluid is secreted by the ciliary body. It has also been shown that its rate of formation is largely regulated by the blood pressure in the intraocular vessels.¹ The intraocular fluid is not, however, solely a transudation from the vessels like the lymph, but a secretion modified by the lining epithelium of the ciliary

¹J. H. Parsons. "The Ocular Circulation, 1903."

body. The folding of the lining membrane of the ciliary body produced by the ciliary process provides a large epithelial covered surface overlying a dense plexus of blood-

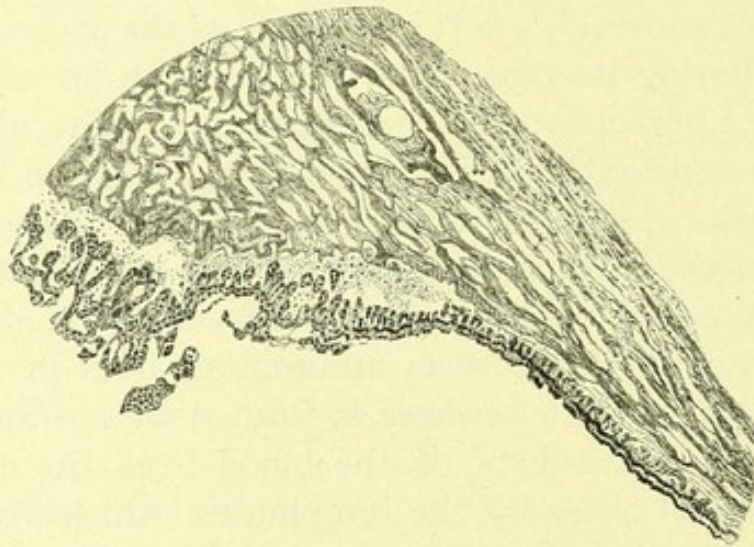


FIG. 116.—Shows a bleached section of the ciliary body of a normal eye. $\times 120$. Numerous cellular processes are seen projecting downward toward the ciliary muscle from the pigment epithelial layer which has been deprived of its pigment.

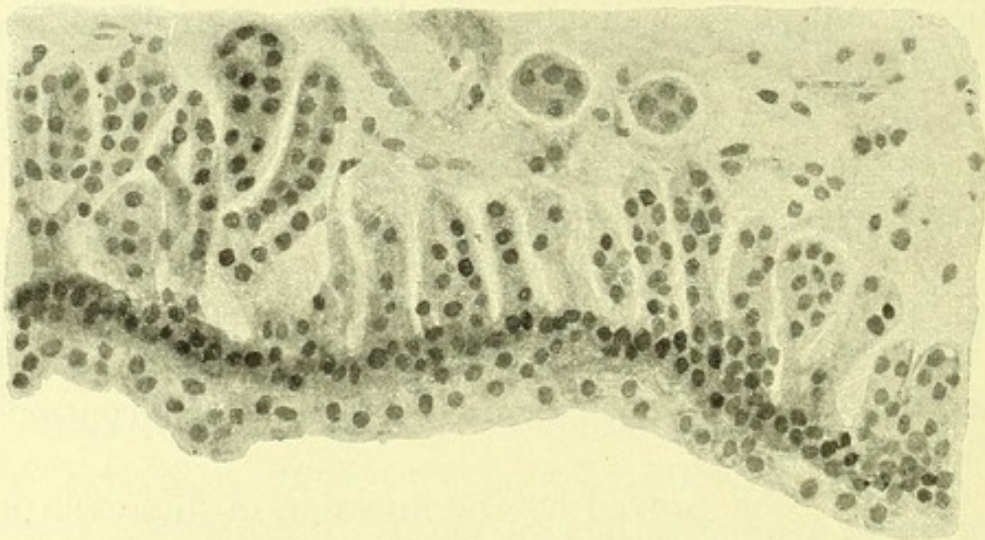


FIG. 117.—Shows the processes of cells which project downward from the pigment epithelial layer depicted in Fig. 116, more highly magnified. $\times 300$.

vessels. There are also numerous tubular downgrowths of the pigment epithelial layer apparently of a glandular character (Figs. 116, 117, 118).

If the intraocular fluid were a transudation it would be

produced not only from the ciliary body but also from the choroid and iris, and in composition it would resemble the lymph. Under certain conditions, as after paracentesis, when the ciliary epithelium is damaged, a transudation from the blood-vessel of the ciliary body does take place into the anterior chamber and the aqueous humour becomes rich in proteids (see page 257).

As the intraocular fluid is a secretion, it can be formed at a higher pressure than the blood in the intraocular veins. If, however, the intraocular tension from any cause reaches

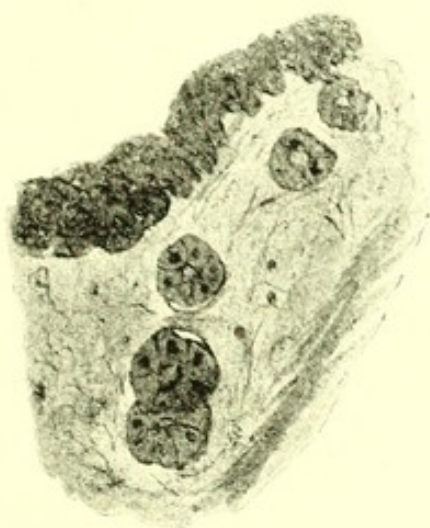


FIG. 118.—Shows a bleached section of the ciliary body in which some of the downgrowths from the pigment epithelial layer have been cut transversely. These transverse sections are seen to have a central lumen, so that the downgrowths are evidently tubular in character, and presumably glandular.

a higher pressure than is present in the capillaries they tend to become obliterated, less blood enters the eye, and secretion is diminished or arrested, both of which conditions tend to reduce the tension. On the other hand, if, either from a rise in general blood pressure or local dilatation of the vessels supplying the eye, such as is produced by inhibition of the sympathetic nerve, the capillaries of the ciliary body become dilated, increase of secretion takes place, and the intraocular tension is raised.

There is as yet no proof that there is any mechanism controlling the secretion of the intraocular fluid beyond the

vasomotor mechanism effecting the vessels which supply the interior of the eye with blood.¹

The intraocular fluid secreted by the ciliary body into the circumlental space passes backward into the vitreous by diffusion through its hyaloid membrane and forward between the iris and lens into the anterior chamber.

The mechanism by which the fluid leaves the eye is somewhat complicated. From the vitreous a certain amount

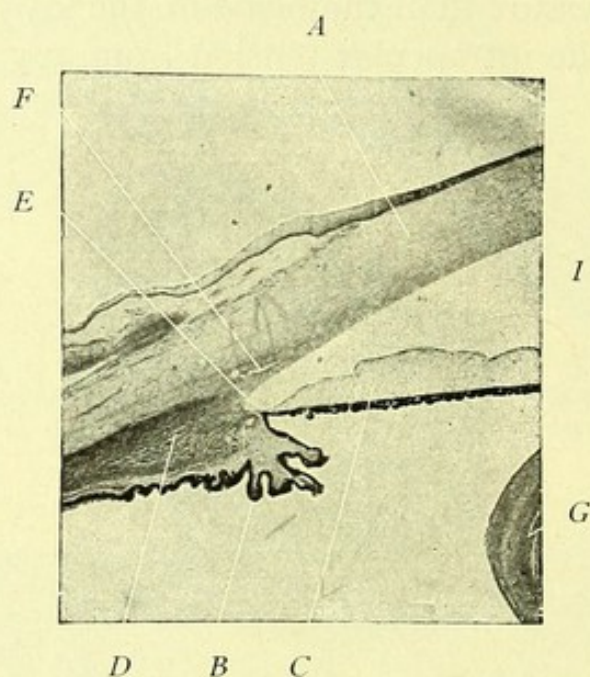


FIG. 119.—Shows the normal angle of the anterior chamber. *A*, Cornea; *B*, ciliary processes; *C*, iris; *D*, ciliary muscle; *E*, pectinate ligament, to the right of which is the angle of the chamber; *F*, canal of Schlemm; *G*, lens; *I*, anterior chamber.

of fluid is drained away by the lymphatics surrounding the arteria centralis retinae. In the anterior chamber a certain amount is absorbed through the crypts of the iris into its veins. But the largest amount of fluid leaves the eye at the angle of the anterior chamber by the vein known as the canal of Schlemm and its connections. Before the fluid reaches these vessels to be absorbed it has to filter through the channels in the ligamentum pectinatum, which are known as the spaces of Fontana, and diffuse through the vessel walls (Fig 119). It has been pointed out that the

¹ Henderson and Starling. *Trans. of Physiology*, XXXI, 1904, 305.

amount of lymph carried away by the lymphatics is small and does not influence much the intraocular tension. If the intraocular fluid were able to leave the eye freely at the angle of the chamber as the lymph by the lymphatics the tension of the eye would be extremely soft, being merely of the consistency of the ocular tissues. The intraocular fluid has to pass through the ligamentum pectinatum into the veins, and the pressure of the fluid in the anterior chamber must be higher than that in the veins before it will pass into the blood stream. The excretion from the eye is therefore inhibited by the fall of the intraocular tension, by a rise of blood pressure in the absorbing veins, or by the spaces of Fontana becoming occluded. Under normal circumstances the balance between the blood pressure and the pressure in the intraocular fluid is thus very evenly maintained.

(ii) The Cause of Increased Intraocular Tension.

The common cause of increased intraocular tension is the obstruction to the entrance of fluid into the canal of Schlemm at the angle of the anterior chamber. This may arise (a) from blocking of the angle of the chamber by the root of the iris being applied against it; (b) structural alterations in the channels of filtration, congenital or acquired; (c) the alteration in the consistency of the aqueous. (More than one of these factors may in some cases contribute to the production of glaucoma.)

a. The Blocking of the Angle of the Chamber by the Root of the Iris.—Histologically the commonest change to find in glaucoma is occlusion of the angle of the chamber by the root of the iris (Fig. 120). For this to take place, provided the angle of the chamber be originally normal, there must be some inequality in pressure within the globe so that the root of the iris is pushed up against the back of the cornea. Once the occlusion of the angle has taken place the filtration from the anterior chamber is inhibited or arrested and the tension of the eye is raised.

In primary glaucoma a shallowing of the anterior chamber frequently precedes the onset of the increase of tension. It would seem probable that it is caused by an abnormal accumulation of fluid in the vitreous body the swelling of which forces forward the lens and iris.

In the normal eye it has been shown experimentally that the pressure in the aqueous and vitreous chambers is equal. An increase of pressure in the latter might possibly

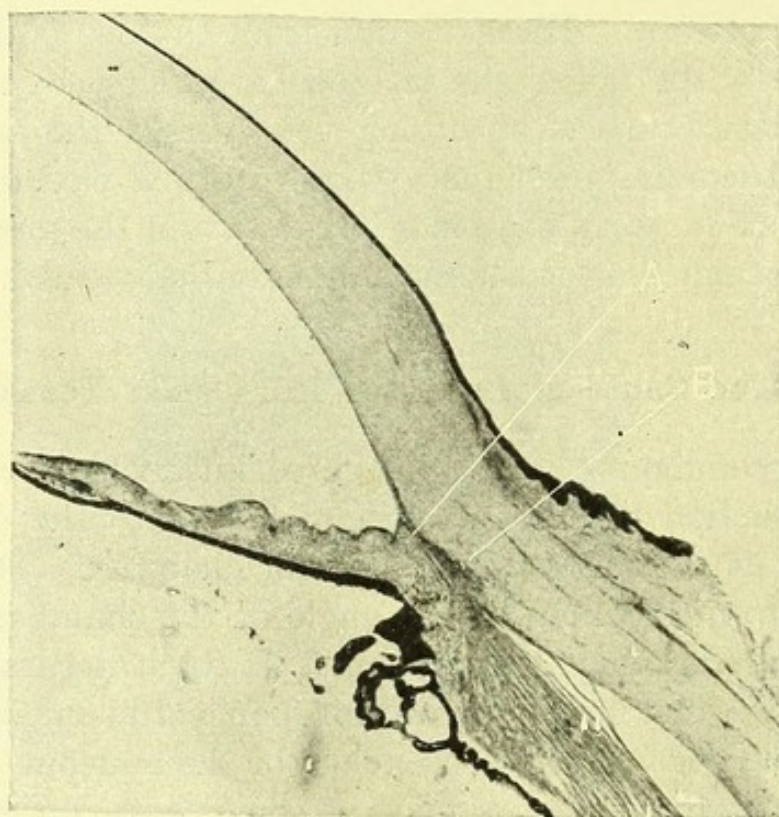


FIG. 120.—Shows the angle of the anterior chamber from a case of recent glaucoma, it is occluded by the base of the iris, *A*, which is adherent to the posterior surface of the cornea. *B* points to the canal of Schlemm.

be due to some alteration in the hyaloid membrane surrounding the vitreous disturbing its osmotic properties and inhibiting the escape of fluid through it. Some increase in the size of the vitreous might also arise from an alteration in it which increased its water-absorbing power as by the increase of proteids after vitreous hemorrhage or albuminous exudate into it. It has been suggested by some observers that some obstruction to the passage of fluid forward into the posterior

and anterior chambers is occasioned by apposition of swollen ciliary processes with one another, and the sides of a large lens, obliterating the circumlental space.

In glaucoma secondary to sarcoma of the choroid the increase of tension is often produced, not by any direct pressure on the lens by the growth, but by the increase in

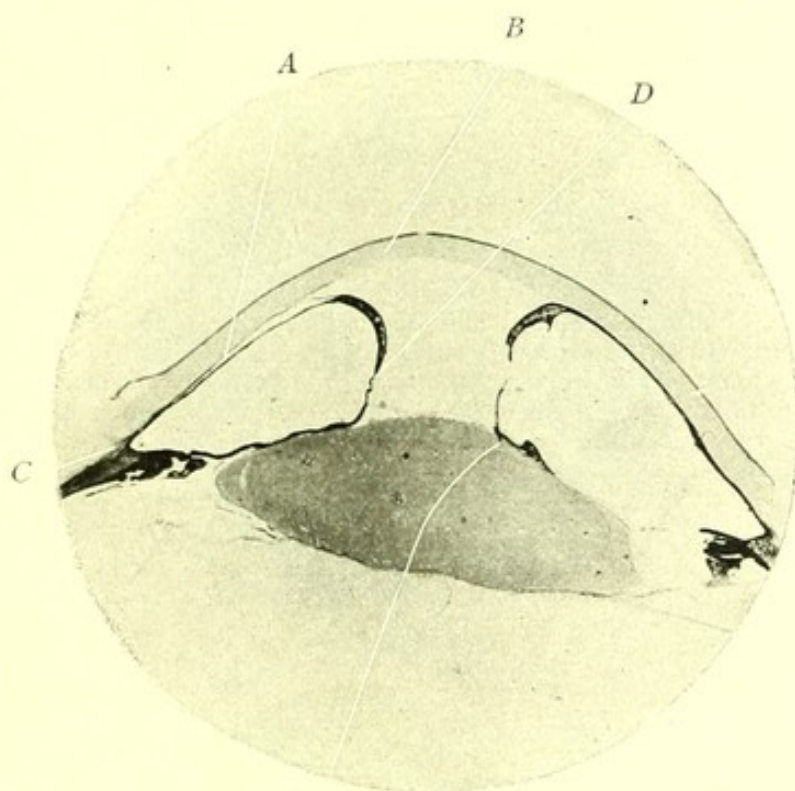


FIG. 121.—Section through the anterior part of an eye with a condition of iris bombé, which resulted in secondary glaucoma. *A*, The iris closely applied to the back of the cornea, *B*, obcluding the angle of the anterior chamber, *C*. The pupillary margin of the iris, *D*, together with some of the pigment from the posterior surface of the iris, are united by inflammatory exudate to the anterior capsule of the lens.

the contents of the globe behind the lens forcing it and the iris forward so leading to a closure of the angle of the anterior chamber. A similar condition results from hemorrhage or serous exudate beneath a detached retina.

In the causation of the glaucoma which follows thrombosis of the central retinal vein there are probably several factors. It is not necessarily an accompaniment of that affection. Vascular sclerosis is usually present and a sclero-

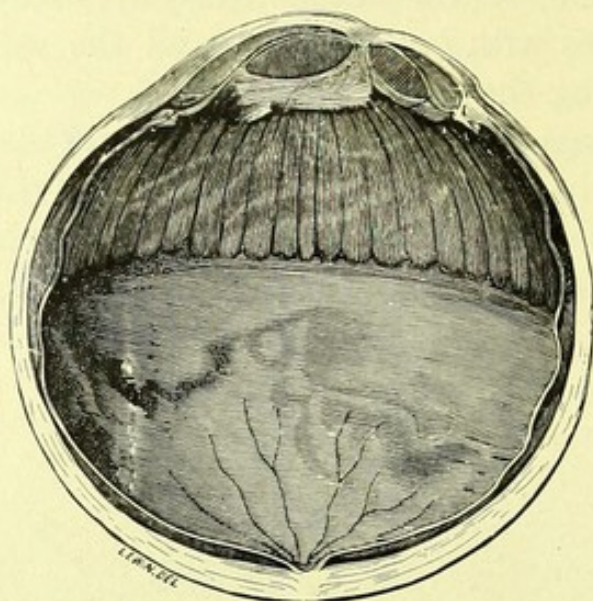


FIG. 122.—Shows the lateral half of an eye, the cornea of which had been wounded with a chisel. The whole of the iris and a large part of the lens escaped through the wound. The lens capsule, with some remains of lens substance in it, is adherent to the cicatrix in the cornea. The tension of the eye at the time of its removal, 12 years after the injury was + 2. Specimen in the R. Lond. Ophth. Hosp. Museum.

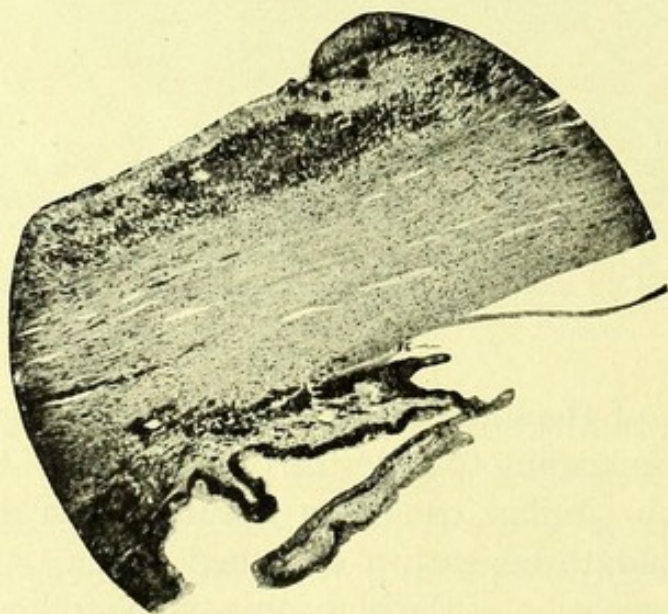


FIG. 123.—Shows a section through the angle of the anterior chamber of the eye depicted in Fig. 122. The iris has torn away at its root from the ciliary body. The most anterior of the ciliary processes is drawn forward by the adherent lens capsule into contact with the back of the cornea in the filtration area, thus blocking the exit of fluid through it, and accounting for the onset of glaucoma.

sis of the channels of filtration may have some influence in its production. The chief factor, however, is probably albuminous exudate into the vitreous from the retinal vessels due to the obstructed circulation in the veins. An increase of albumen in the vitreous would cause more of the less albuminous secretion of the ciliary body to diffuse through the anterior hyaloid membrane into it and so make it enlarge.

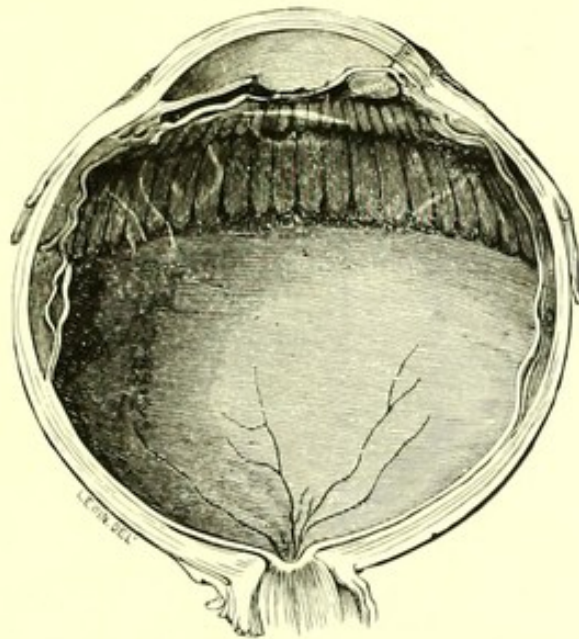


FIG. 124.—The lateral half of an eye which has had a cataract extracted from it with iridectomy one year and eight months previous to its removal. A discission of the capsule was performed a year later. The sight became destroyed as the result of secondary glaucoma. The lens capsule is shown adherent to the extraction cicatrix at the sclero-corneal margin. Its advance in position has dragged forward the iris and occluded the angle of the anterior chamber. There is a large hole in the centre of the capsule as the result of the discission operation. From the Museum R. Lond. Ophth. Hosp.

Enlargement of the vitreous would push forward the lens, shallow the anterior chamber, and approximate the root of the iris to the cornea. Occlusion of the angle of the chamber is not found in every case, the angle may be widely open and filled with an albuminous coagulum, which no doubt accounts for the increase of tension in such cases.¹

Alteration in the pressure of the aqueous in the anterior

¹ G. Coates. R. Lond. Ophth. Hosp. Reports, XVI, 1904-6, 62-516. Tatsuji Inouye. R. Lond. Ophth. Hosp. Reports, XVIII, 1910, 24.

and posterior chamber may arise in cases of occluded and secluded pupils (secondary glaucoma). The aqueous, secreted by the ciliary body, then collects behind the iris and being unable to pass through the pupil, balloons forward the iris against the back of the cornea so that the angle of the anterior chamber becomes blocked by its root and a rise of intraocular tension ensues (Fig. 121).

Blocking of the angle of the anterior chamber by the root of the iris may also result from forward displacement of

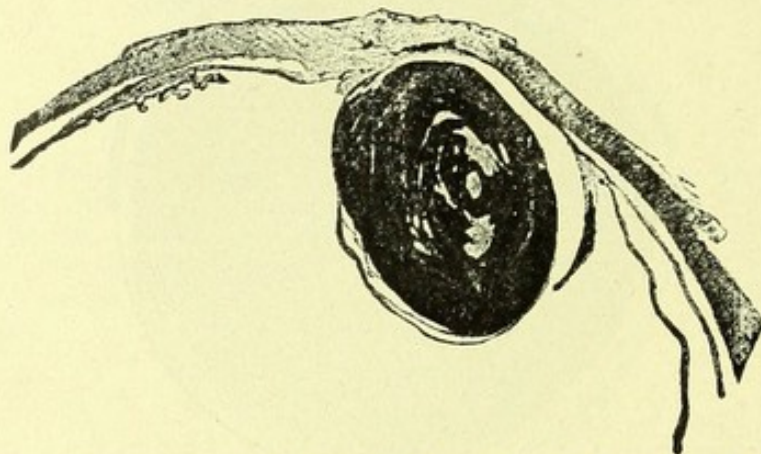


FIG. 125.—Shows a section through the front half of an eye in which the sight had been destroyed by glaucoma secondary to dislocation of the lens. The angle of the anterior chamber is markedly narrowed in its entire circumference. The lens presses forward the iris and lies with its long axis antero-posteriorly. Case recorded in R. Lond. Ophth. Hosp. Reps., XIII, 1890, 58.

the iris produced by an adhesion of it to the cornea after a perforating wound or ulcer; by adhesion of the lens capsule or vitreous to the cornea as occurs sometimes after extraction of cataract¹ (Fig. 124; or by pressure on the iris of a displaced lens (Fig. 125).

A congenital imperfect separation of the iris from the back of the cornea has been found in cases of congenital glaucoma or buphthalmos (see page 70).

b. Structural alterations in the channels of filtration may be congenital or acquired. A congenital absence of the canal of Schlemm is one of the causes to which congenital glaucoma or buphthalmos has been attributed.

¹ Treacher Collins. Trans. Ophth. Soc. of the U. K., X, 1890, 108.

The exact part played by vascular sclerosis in preventing absorption of the intraocular fluid through the walls of the blood-vessels is not known but it probably has the effect of diminishing the absorption. Sclerosis of the pectinate ligament offers resistance to the filtration into the region of the absorbing vessels.¹

c. The aqueous humour may be so altered as to contain a large amount of albumen or more cellular constituents than normal. The amount of albumen is increased in intraocular inflammation, hemorrhage, or serous exudates due to the obstruction of the venous return. Its exit from the eye is then very slow, probably owing to the difficulty the fluid finds in passing through the walls of the venous radicals. Glaucoma from this cause, without blocking of the angle by the root of the iris, may occur. The accumulation of the fluid and increase of pressure in the anterior chamber tends to push backward the iris and lens, making it abnormally deep. At the same time the vitreous becomes compressed and some fluid is squeezed out of it. The increased tension associated with serous cyclitis and following thrombosis of the central retinal vein, where the angle is found widely open, may be thus explained (see page 179).

The alteration in the aqueous may depend upon it containing cellular elements. The angle of the chamber may be blocked as the result of the exudation of leukocytes following cyclitis. The cells of a new growth may grow in the meshes of the pectinate ligament and cause occlusion of the angle.

Occasionally epithelium carried through a wound in the cornea may grow in the anterior chamber and line it. When the angle becomes covered by these cells the tension of the eye is increased.

In traumatic cataract the aqueous becomes highly albuminous, owing to the globulin of the lens becoming dissolved in the aqueous; fragments of undissolved lens matter

¹ T. Henderson. Trans. Ophth. Soc. of the U. K., XXVIII, 1908, 47.

may also be entangled in the mesh of the pectinate ligament.

In **primary glaucoma** there are many **predisposing factors** which help to bring about some of the changes above described. These may be divided into physiological and pathological conditions. Primary glaucoma is most common between the ages of sixty and seventy. It occurs extremely rarely before the age of thirty, and then it is usually due to some congenital defect such as is described under buphthalmos. The association between old age and glaucoma is probably due to general vascular sclerosis causing a rise in the general blood pressure, or localised sclerosis producing changes in the ligamentum pectinatum and the canal of Schlemm.

The size of the lens, like the tendency to glaucoma, increases with age, and it is held by some authorities that diminution of the circumlental space obstructs the passage of fluid through it so that the lens becomes pushed forward and the angle of the chamber occluded.¹ An increase in the antero-posterior diameter of the lens shallows the anterior chamber. An anterior chamber thus rendered shallow may be looked upon as one of the accompaniments of old age, and as a predisposing cause of glaucoma.

Small eyes, especially those with a small cornea, are predisposed to glaucoma to such an extent that some authorities assert that an eye with a cornea that measures less than 10 mm. will surely become affected. The fact that 50 per cent. of patients suffering from primary glaucoma are hypermetropic may be thus accounted for. In these eyes there is, moreover, generally hypertrophy of the ciliary muscle as a result of accommodative effort, which further favours blocking the angle of the anterior chamber. Glaucoma in cases of high myopia is exceedingly uncommon and acute glaucoma is practically unknown.

Occasionally glaucoma shows a marked hereditary tendency; it is probable that the tendency is to a congenit-

¹ Priestly Smith. Glaucoma, 1891.

ally small eye rather than a glaucomatous one. For the same reason some races seem more affected than others, Jews, Egyptians, and Brazilian negroes being frequently the subjects of the disease.

The exciting causes of primary glaucoma are divided into two groups; namely, 1. those which produce inequality in the pressure in the aqueous and vitreous chambers, and 2. those which tend to block directly the angle of the anterior chamber.

1. The exciting causes which produce alteration in the blood pressure and so variation in the intraocular tension are the emotions; thus grief, anxiety and worry play an important part. Females being emotional are more frequently affected. The disease commonly occurs in widows. It is possible that the alteration of the blood pressure connected with the menopause may sometimes be an exciting cause. The shock of an operation on one eye may bring on an attack in the other. Congestion of the eye as the result of injury may sometimes be a determining factor.

2. The exciting cause tending to block the angle of the anterior chamber is dilatation of the pupil, owing to the iris being retracted into the angle of the anterior chamber. This may be produced by the indiscreet use of mydriatics or by bandaging the other eye after operation.

(iii) **The Effects of Increased Tension on the Various Structures of the Eye and their Respective Functions.**

The maintenance of the normal amount of intraocular tension is most essential for the regular performance of the functions of the different structures composing the eyeball. The changes which are produced in an eye as a result of a disturbance in the intraocular tension are as follows:

Sclerotic and Conjunctiva.—A sudden onset of increased tension so disturbs the intraocular circulation of the blood

as to cause for a time a general congestion of the ciliary vessels in the sclerotic, and often also those of the conjunctiva. In the most acute cases this congestion is accompanied by edema of the conjunctiva (chemosis), and sometimes of the eyelids. The vessels being mostly engorged with venous blood, the injection has a characteristic dusky hue. The main exit of blood from the uveal tract is by the *venæ vorticosæ*; the channels in the sclerotic through which these pass run very obliquely, and when the sclerotic is stretched, as it is in glaucoma, they easily become closed. The result of such obstruction is to cause considerable enlargement of the anterior ciliary veins, which normally give exit to only a small portion of the venous blood from the ciliary body, and which perforate the sclerotic more at a right angle than the *venæ vorticosæ*.

When the onset of increased tension comes on gradually instead of suddenly, an adaptation of the intraocular blood circulation to the altered conditions is rendered possible, and the violent disturbance resulting in congestion and edema does not take place. Indeed, some cases of primary glaucoma develop so slowly that scarcely any alteration in the state of the ciliary blood-vessels is to be observed, or at most slight enlargement of the anterior perforating vessels.

The effects of increased tension on the sclerotic vary very much with the age of the patient. In early life the sclerotic is an elastic structure; as life advances, it becomes tougher and less expansible. Consequently, if increase of tension is met with in infancy or early childhood, the sclerotic will give and the whole globe become enlarged. After adolescence, the sclerotic being hard and unyielding, little alteration in the shape of the globe is met with as the result of glaucoma; usually there is slight distention in the spaces between the recti muscles, so that the globe becomes somewhat square in shape.

Should there have been, previously to the onset of the glaucoma, some weakening or thinning of the walls of the globe, as from a patch of choroiditis, then, when the tension

is increased, that spot is likely to give and to become staphylomatous.

Cornea.—As the result of increase of tension, some interference in the circulation of the lymph streams in the cornea may occur. This is especially liable to take place where the onset of tension is sudden. Its effect is to cause edema of the anterior layers; the spaces between the anterior lamellæ of fibrous tissue are found enlarged and filled with albuminous fluid. Spaces are also met with between the surface epithelium and the anterior limiting membrane, between the epithelial cells themselves, and in the channels of the anterior limiting membrane through which the nerve fibres pass to the epithelium. Clinically, this edema gives rise in the later stages of the disease to a haze of the cornea, and in cases where it has been present for a long time small vesicles form on the surface. There is another form of corneal haze met with in glaucoma which comes on rapidly when the tension is increased and disappears at once when it is decreased and which cannot therefore be attributed to edema. It is probably due to an increase in the double refractive index of the corneal fibrillæ.

Anesthesia of the cornea is a common accompaniment of glaucoma, and has been attributed to compression of the nerve fibres going to the epithelium by the fluid in the lymph spaces around them, as they pass forward through channels in the anterior limiting membrane. It is more likely to be due to compression of the long ciliary nerve, from which the corneal nerves are derived, against the hard, unyielding sclerotic, as they pass forward on the outer surface of the choroid.

The haziness of the cornea when present, apart from other causes, tends to make vision misty. It is also the cause of another very characteristic symptom of glaucoma, viz., the appearance in the dark of halos of rainbow colours around lights, the red colour always being the outermost.

A precisely similar appearance of halos of rainbow colours around lights is produced by dropping a solution of the

alkaloid erythrophleine, obtained from an African arrow poison, into the eye.¹ This drug causes also a slight steaminess of the surface of the cornea, slight anesthesia, and some blurring of vision, but does not increase the tension. Some specimens of it cause dilatation of the pupil and others contraction; with both the halos are seen. The effect can be produced in the eye of a patient who has undergone extraction of cataract. We are therefore led irresistibly to con-

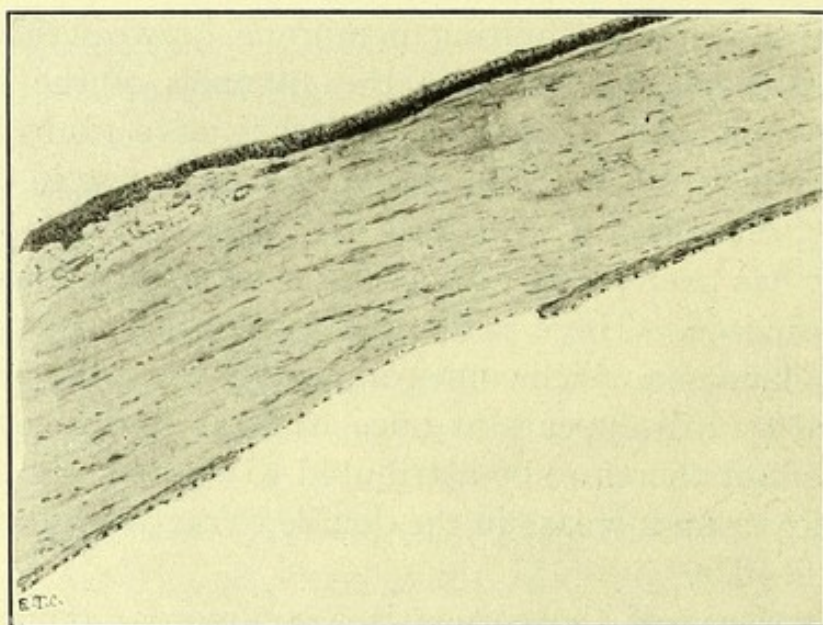


FIG. 126.—Section through the cornea near the periphery in a case of congenital glaucoma or buphthalmia. It shows a rupture which has taken place in Descemet's membrane.

clude that the halos are the result of the slight haze in the cornea and not the effect of the dilatation of the pupil, change in the lens, or pressure on the retina.

In primary glaucoma which occurs late in life no appreciable alteration in the shape or size of the cornea occurs. When, however, increase of tension is met with in infancy or early life, the cornea, like the sclerotic, being still very elastic, enlarges and becomes globular in shape (buphthalmos). The stretching of the cornea thus produced frequently results in the formation of fissures in Descemet's membrane²

¹ Treacher Collins. *Ophth. Review.*, IX, 1890, 196.

² G. Coats. *Trans. Ophth. Soc. of the U. K.*, XXVII, 1907, 48.

which can be seen clinically as fine lines, sometimes branching dichotomously. Microscopically at the seat of the fissures a gap is found in the elastic lamina but the endothelium on its posterior surface is nearly always intact (Fig. 126). It is probable that when the rupture occurs the endothelium also gives way but that proliferation of the cells soon fills up any opening in it. In some cases there has been a slight cloudy opacity of the cornea seen in the neighbourhood of the fissures, which is probably accounted for by deficiencies in the endothelium allowing of filtration of the aqueous humour into it.

Anterior Chamber.—The condition of the anterior chamber in glaucoma varies with the position at which the primary obstruction in the circulation of the intraocular fluid takes place. In primary glaucoma it is shallow; this is due to an increase of tension occurring first in the vitreous chamber, the lens with its suspensory ligament being forced forward. A continued shallowing of the anterior chamber and pressure of the ciliary processes against the root of the iris result in contact of the latter with the back of the cornea and a narrowing of the angle of the chamber.

In some cases of secondary glaucoma and in cases of congenital glaucoma the primary obstruction to the circulation of the intraocular fluid is at the angle of the anterior chamber, where it gains exit from the eye; the anterior chamber then becomes deepened.

Iris.—Pressure of the root of the iris against the back of the cornea leads to compression of both its blood-vessels and nerves. If the increased tension is sudden in onset, the compression at first causes edema and venous engorgement, which makes the iris appear altered in colour. Later on its vessels become empty and its stroma atrophies and shrinks. The pigment epithelium on the posterior surface of the iris is unaffected by the atrophy. It normally ends at the pupillary margin; but in cases of glaucoma of long standing, by the shrinking of the stroma, the pigment epithelium becomes drawn around on to the anterior surface, a condition known

as "ectropion of the pigment epithelium" (Fig. 127). Clinically it is seen as a dark pigmented area on the surface of the iris at the pupillary margin, usually extending more in one direction than another. It is most marked where the

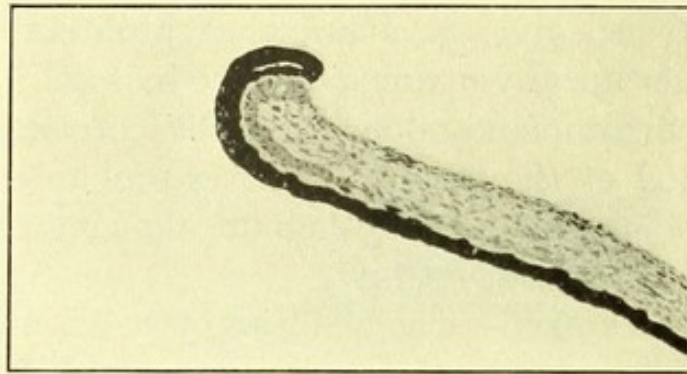


FIG. 127.—Ectropion of the uveal pigment at the pupillary margin of the iris.

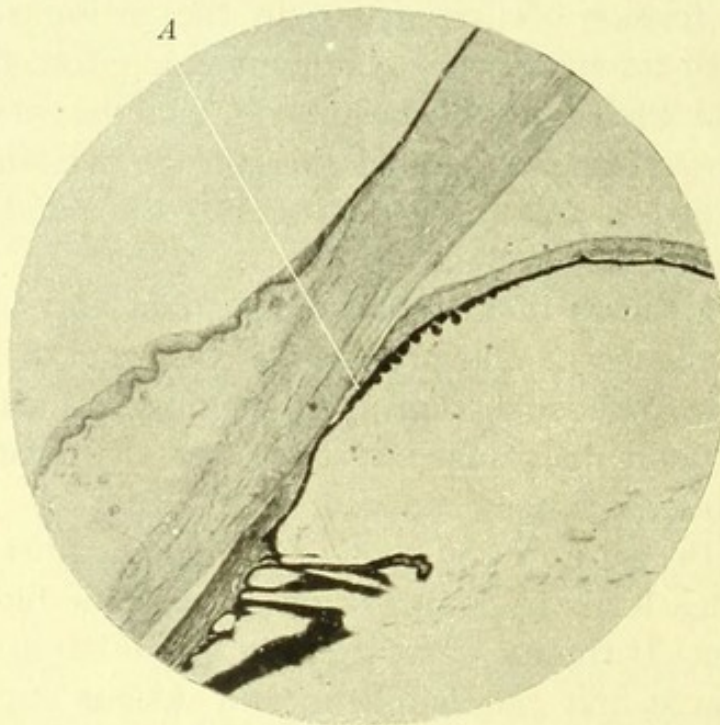


FIG. 128.—Shows the angle of the anterior chamber in a case of glaucoma of long standing. The root of iris *A* is firmly adherent to the cornea and much atrophied.

iris has become most atrophied and where the dilatation of the pupil is widest.

The pressure of the ciliary nerves against the sclerotic in acute cases of glaucoma paralyses the iritic muscles, and

the pupil becomes inactive and semi-dilated. If the tension is relieved before atrophy has set in, its activity returns. In long standing cases of glaucoma permanent dilatation of the pupil may be brought about through atrophy of the sphincter muscle and shrinking of the stroma. The amount of dilatation is sometimes not equal in all directions, so that the pupil is often oval or irregularly circular, and it may be displaced away from the centre.

When the cornea and root of the iris have been in apposition for only a short while, their separation is easily effected. After a time, however, cell exudation takes place and they become adherent, and in long standing cases of glaucoma most intimately adherent (Fig. 128).

In chronic cases of glaucoma, when the onset of tension is gradual, and there has been time for compensatory changes to take place in vessels and nerves, the dilatation of the pupil and atrophy of the iris may be absent.

Ciliary Body.—Increase of tension early causes disturbance in the accommodative action of the ciliary muscle, due probably to compression of the ciliary nerves against the sclerotic. It manifests itself by the apparent rapid advance of presbyopia, the patient requiring stronger and stronger glasses for near work. In the early stages of primary glaucoma, more especially in acute cases, the ciliary processes are swollen and edematous, the veins are engorged, and the processes are pressed forward against the root of the iris. After increase of tension has been present for some time, the ciliary muscle and processes become atrophied and shrink, so that in cases of glaucoma of long standing the latter are no longer in contact with the back of the iris, and a considerable interval is left between them and the margin of the lens. The ciliary body receives an extensive nerve supply, from both the long and short ciliary nerves, which perforate the sclerotic posteriorly and pass forward in the lamina suprachoroidea, until they break up into a network of fine branches, which is known as the ciliary plexus. It is the sudden onset of pressure on this plexus against the unyielding sclerotic

which is the cause of the excessive pain of acute glaucoma—pain which is not confined to the eye, but referred also to other parts supplied by the fifth nerve, especially those receiving branches from its first division. Reflex disturbances, such as vomiting, may also be set up.

When increased tension comes on gradually and is not very intense, the nerves, like the blood-vessels, have the power of adapting themselves to the changed conditions, and in the majority of cases of chronic glaucoma no pain is experienced by the patient.

Choroid.—The effect of increased tension on the choroid in acute cases of glaucoma, as on the other portions of the uveal tract, the iris and ciliary body, is first to produce a condition of venous congestion and edema; later on, emptying of its vessels and atrophy. In chronic glaucoma, on the other hand, no sudden disturbance of the circulation is set up, but the compression of the choroid against the sclerotic tends to empty the blood out of the capillaries. The fundus ophthalmoscopically in such cases is seen to lose its uniform red hue, and to present a tessellated appearance, due to exposure of the network of larger vessels in its outer layers.

Atrophy of the choroid, the result of increased tension, is most marked at the parts where it has the firmest attachments with the structures external to it, viz., around the optic disc and at the seats of exit of the vortex veins. When increase of tension has existed for some time, the optic disc is usually seen to be encircled by a yellowish-white ring, which is due to the atrophied choroid allowing the sclerotic to be exposed to view.

Lens.—The displacement forward of the lens in primary glaucoma tends, if the eye is emmetropic, to make it myopic, as does also expansion of the globe in the antero-posterior axis. A drag on the suspensory ligament from displacement forward of the lens or expansion of the globe in the ciliary region would, on the other hand, lessen its refractive power and tend to make an emmetropic eye hypermetropic.

In glaucoma in the adult hardly any expansion of the

globe takes place, but it is stated that during attacks of glaucoma the refraction is usually increased.

In glaucoma in early life, where considerable enlargement of the globe in all its meridians is met with, the lengthening of the globe is compensated for in part by the flattening of the lens, and the amount of myopia met with is not as much as might otherwise have been expected.

In glaucoma of long-standing the nutrition of the lens sometimes suffers, and it becomes cataractous. The opacity of the lens occasioned by glaucoma usually presents a bluish metallic lustre.

Retina.—The immediate effect of increased tension on the retinal blood-vessels is to obstruct both the entrance of blood by the arteries and its exit by the veins. Consequently the latter become enlarged and the former smaller than normal. The intraocular pressure and the pressure of the blood in the retinal vessels are so balanced, under normal conditions, that no pulsation is to be observed in the retinal arteries. When the intraocular pressure is much increased, or the arterial pressure much diminished, this balance is disturbed; blood then can force its way into the retinal arteries only during contraction of the heart, and pulsation in them becomes visible in the vicinity of the optic disc. If the increased tension in a case of glaucoma is not sufficient to give rise to pulsation of the retinal arteries, it may readily be elicited by slight pressure on the globe with the finger. Under normal conditions a considerable amount of pressure on the globe is required to produce pulsation.

Pulsation of the retinal arteries has been observed in cases of aortic regurgitation and of syncope, without increased tension of the eye due to a sudden fall in the blood pressure during the heart's diastole.

A disturbance of the function of the retina, as the result of increased tension, may be due either to diminished blood supply or to atrophy of its nerve elements. Loss of vision due solely to the first cause is recoverable; that due to the second is permanent.

If the tension of a healthy eye be increased by pressure from without, as with the finger upon the eyelid, vision may be completely abolished, it disappearing last in the region of the macula. This may be attributed to arrest of the circulation in the retinal vessels, and in the choroidal capillaries from which the outer layers of the retina receive their nutrient supply. Directly the pressure is removed, the circulation is re-established and vision returns.

In the same way in acute glaucoma, vision may, in the course of a few hours, be reduced to mere perception of light or completely abolished. If normal tension is re-established before sufficient time has elapsed for organic changes in the nervous tissue to set in, vision will be restored.

The branches of the retinal artery which go to the periphery of the retina on the temporal side have a longer course to pursue than those distributed to other parts, because the point of entrance of the optic nerve into the eye is situated to the nasal side of the middle lines. It is the capillaries, therefore, from the temporal branch which are affected first by any increase of tension.

The nerve fibres destined for the periphery of the retina, which lie in the outer portions of the optic nerve, are more liable to be exposed to pressure against the sclerotic as they enter the eye than those destined for the central regions.

These two anatomical facts serve to explain the manner in which vision fails in cases of glaucoma. The process begins at the periphery, producing a contraction of the field of vision. This contraction usually is noted first on the nasal side. As the case progresses, the field gradually becomes reduced to a more or less oval-shaped area, extending chiefly to the outer side of the fixation point. Ultimately the fixation point becomes involved, a small area in the field to its outer side being left until the last. In some chronic cases of glaucoma perfect central vision may be retained with extreme contraction of the field. In other cases, in association with a contracted field, some loss in the acuity of central vision is met with.

Though the above is the most typical way for the field vision to become affected in glaucoma, cases occur where it is contracted concentrically, or where there is a central or paracental scotoma.

When the field is tested by an object which subtends a smaller visual angle than employed with the ordinary perimeters (as in the method suggested by Bjerrum), it is found that in glaucoma, whatever be the situation of the defect in the field, it always starts from the blind spot.

The fields for colour usually fail proportionately to the field for white and to one another.

In eyes blinded by glaucoma atrophy of the nerve elements of the retina occurs, the ganglion cells become vacuolated and after a time disappear; the outer limbs of the rods and cones become bent and tend to be flattened by the intra-ocular tension against the pigment cell layer and after a time become very atrophic. Small cystic spaces in the anterior portion of the retina, in the vicinity of the ora serrata, are met with very commonly.

The position where the nerve fibres enter the globe is a weak spot in its walls. Instead of there being three coats—sclerotic, choroid, and retina—there are only the fibres of the optic nerve and the lamina cribrosa. The latter does not represent more than half the thickness of the sclerotic, and is composed mainly of yellow elastic tissue.

When the tension of the eye becomes increased, this weak spot soon begins to give way and bulge outward.

The sclerotic surrounding the optic disc is very thick and unyielding, so that, as the lamina cribrosa becomes curved backward, the nerve fibres become compressed against the tough resistant edge of the sclerotic at its margin, and consequently atrophy. When they become atrophied, instead of there being an elevation in the region of the optic disc (the optic papilla), a depression is formed.

The cupping of the optic disc in glaucoma is then the result of two causes: depression backward of the lamina cribrosa and atrophy of the nerve fibres down to it.

As the depression backward of the lamina cribrosa increases the sides of the cup tend to become quite steep; they may become expanded laterally at the posterior part, so that on section it presents a flask-shaped outline which gives rise to the broken appearance of the vessels on ophthalmoscopic examination (Fig. 129).

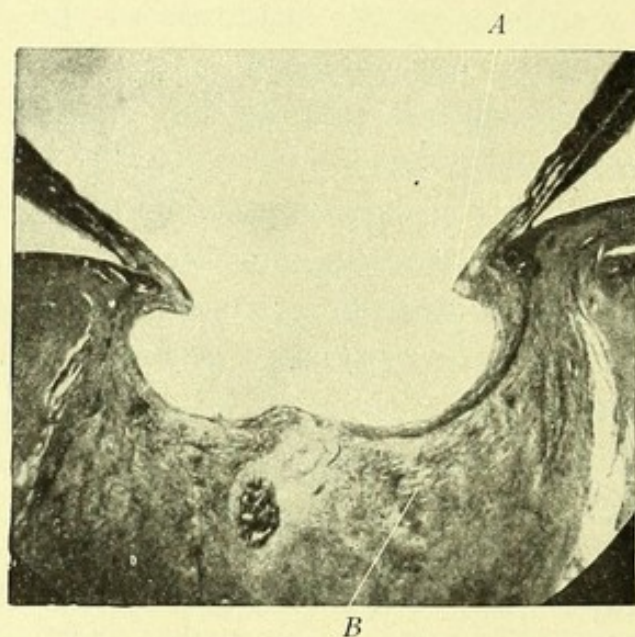


FIG. 129.—Shows a section through the optic nerve at its point of entrance into the eye in a case of long-standing glaucoma. There is deep cupping of the optic disc. The overhanging edge to the cup, *A*, is what causes the broken appearance of the retinal vessels, which is seen ophthalmoscopically at the margin of the disc. The lamina cribrosa, *B*, is displaced backward.

(iv) The Rationale of Treatment of Primary Glaucoma.

—The aim and object in the treatment of glaucoma is: 1. the opening up of the normal channels of excretion of fluid from the eye; 2. the making of fresh channels of excretion.

1. The simplest method, although usually only temporary, of opening up the angle of the anterior chamber is by the use of eserine. This drug produces contraction of the pupil as the result of which the iris becomes drawn away from the angle. For the permanent opening up of the angle of the chamber some operative measure is usually required. The means we have of opening up the canal of Schlemm is by the removal of a portion of the iris at its root where the latter

is attached to the ciliary body (iridectomydialysis), or detaching the ciliary body from the sclerotic so as to allow the ciliary muscle by its contraction to pull the ciliary body, and with it the iris, backward, leaving the canal of Schlemm open (cyclodialysis).

2. The means we have for establishing fresh channels for the filtration of the aqueous are the formation of a fistulous opening in the sclerotic beneath the conjunctiva (sclerotomy) or the establishing of a communication between the anterior chamber and the suprachoroidal lymph space.

Iridectomy or Iridectomydialysis.—The way in which iridectomy relieves tension in primary glaucoma has been

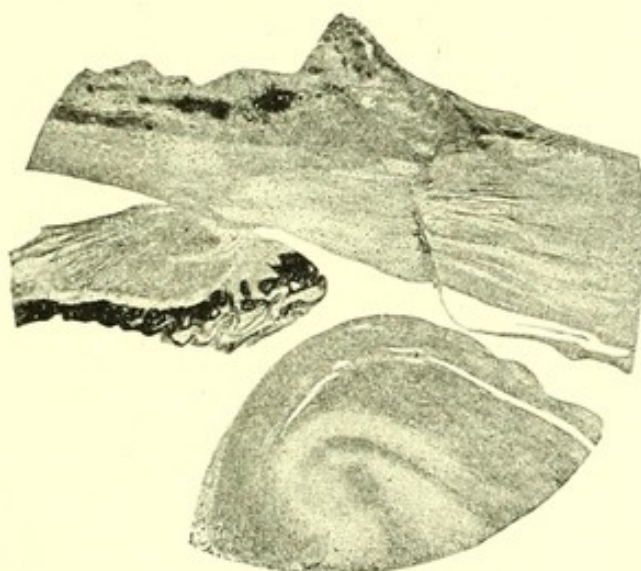


FIG. 130.—Shows a section through the angle of the anterior chamber of an eye upon which an iridectomy had been performed for the primary glaucoma of two months' duration. The tension was relieved by the operation, but the eye had to be excised five weeks later on account of ulceration of the cornea. The iris has been removed right up to the ciliary body and the angle of anterior chamber opened up.

the source of much discussion. The pathological examination and comparison of eyes in which it has proved successful with those in which it has failed have thrown much light on this matter.

Several eyes have been examined in which an iridectomy successfully relieved the tension in glaucoma and subsequently had to be removed for some intercurrent malady.¹

¹ Treacher Collins. R. Lond. Ophth. Rep., XIII, 1891, 166.

In these eyes either the obstructed passage for the exit of fluid at the angle of the anterior chamber was found opened up, or a new channel of exit had been established by the formation of what is termed a cystoid cicatrix.

The opening up of the filtration area at the angle of the anterior chamber had in some of the cases been effected by removal of the obstructing iris up to its point of junction with the ciliary body, in the vicinity of the wound (Fig. 130.) In others, although a portion of the root had been left, it became dislodged from its faulty position. Evidently in such cases sufficient time had not elapsed for it to become adherent to the cornea. The drag on the iris, escape of aqueous, and consequent relief of pressure in the vitreous chamber, together with the local escape of blood, had sufficed to restore the normal channels for the circulation of fluid.

When a **cystoid cicatrix** is present, a fistula is established in the fibrous tissue at the sclero-corneal margin, through which fluid may pass from the anterior chamber into the subconjunctival tissue and be absorbed there by the conjunctival vessels. The tissue around the fistula is found usually in a boggy condition.

The fistula results from prolapse of a fold of iris, which prevents the two sides of the wound in the fibrous tissue of the sclerotic and cornea from uniting, but over which the conjunctiva heals. At first the iris tissue lining such tract offers an impediment to the passage of fluid out of the eye; but, being a weak spot in the globe, it tends to bulge, and the iris lining it atrophies, until ultimately a fistula is established (Fig. 131).

A cystoid condition of a cicatrix after iridectomy appears most often at the angle of the coloboma—*i.e.*, the position where the prolapse of a fold of iris is most likely to occur.

Although the production of such a condition may prove beneficial in relieving tension, it is one which is attended with a certain amount of risk. What is practically an adhesion between the conjunctiva and iris, being formed,

any inflammation of the former readily spreads to the latter and is liable to start a general uveitis.

Recent observations show that it is possible to obtain a fistulous opening in the sclerotic without any entanglement of the iris, from nonunion of the edges of an opening made in it. Various new operations have been introduced which have the effect of producing such a permanent gap in the

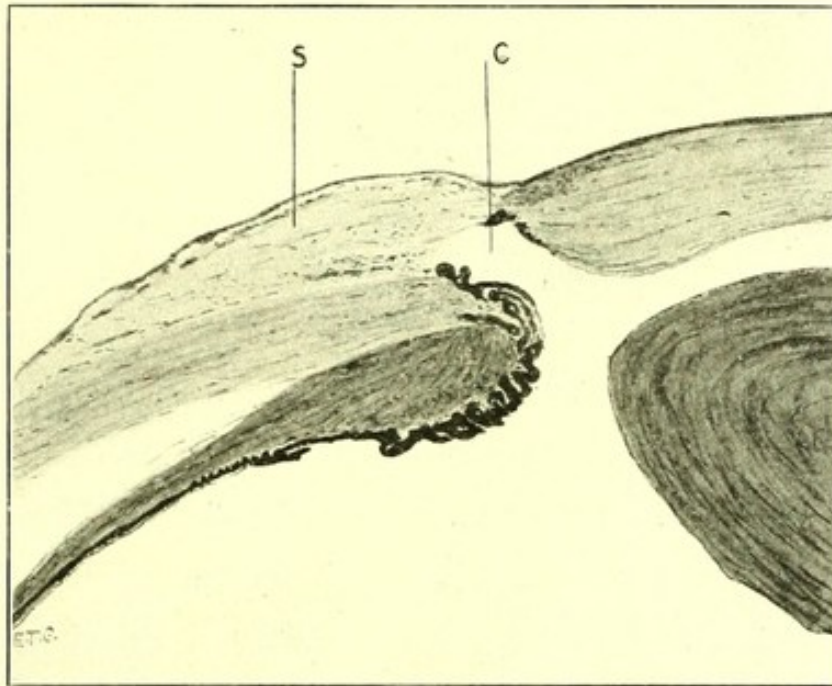


FIG. 131.—Section of an eye in which a cystoid cicatrix formed after an iridectomy operation for chronic glaucoma. Eight months later severe iritis set in, and the eye was ultimately removed for the relief of pain. *C* points to the fistula formed in the sclero-corneal tissue at the seat of the operation; it is partly lined by the ciliary processes and partly by atrophied iris; *S* points to the edematous conjunctiva due to escape of aqueous into it.

sclerotic and prove most effectual in the relief of increased tension.

An iridectomy fails to relieve tension in primary glaucoma when the normal passages for the exit of fluid from the eye remain unopened, and no new channel is formed.

The normal passages for the exit of fluid at the angle of the anterior chamber are not opened up when :

1. The root of the iris has become so intimately adherent to the back of the cornea that on being drawn upon,

instead of tearing at its extreme root it tears through at the point where it ceases to be adherent, and the portion causing obstruction is left behind.

2. By the way in which the iridectomy has been performed, a portion of its root is left behind, which, though not adherent to the cornea, has failed to become dislodged from its faulty position (Fig. 132).

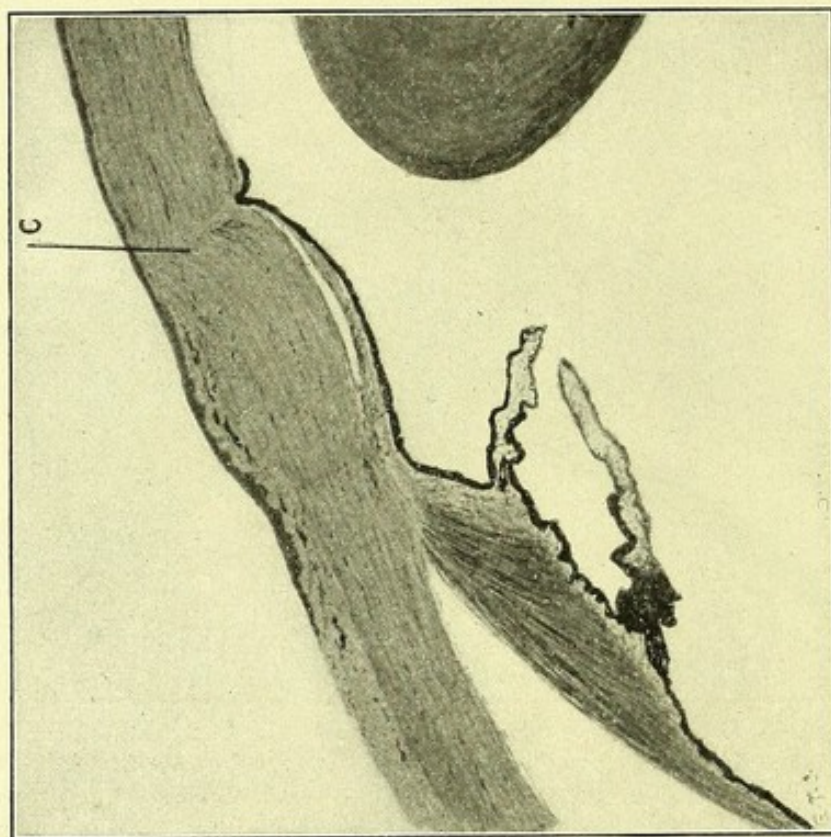


FIG. 132.—Section of an eye in which an iridectomy failed to relieve the tension in glaucoma. The iris has been cut off level with the line of cicatrix in the cornea to which *C* points. If dragged upon it would doubtless have torn away more peripherally at its junction with the ciliary body. A large piece of it would not then have been left blocking up the angle of the anterior chamber and securely fixed there by adhesion of its cut end to the corneal cicatrix.

3. By delayed reformation of the anterior chamber, the lens becomes united to the posterior surface of the wound by plastic exudation thrown out from the latter. On the anterior chamber reforming, the lens becomes drawn forward, its adherent margin pressing the anterior of the ciliary processes into contact with the filtration area in the region of the coloboma (Fig. 133).

It is obviously desirable in performing an iridectomy for glaucoma to try and remove the extreme periphery of the iris at its junction with the ciliary body. Fortunately it is at this spot that the iris is thinnest, and it is here that it is most likely to tear through when drawn upon, unless abnormally adherent or atrophic.

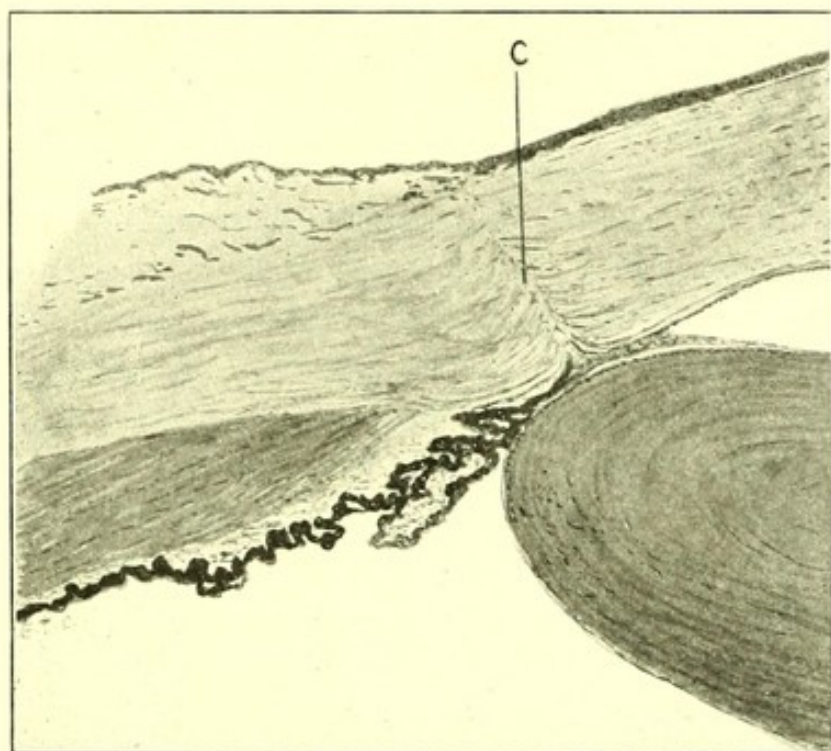


FIG. 133.—Section of an eye in which an iridectomy was performed for absolute glaucoma; the increased tension returned after the operation and the eye was subsequently removed for relief of pain. *C* points to the iridectomy cicatrix in the cornea. The lens is united by organised exudate to its posterior surface. The filtration area is blocked by the anterior part of the ciliary body and root of the iris, held forward by the adherent lens.

Cyclodialysis.—This operation has for its object the separation of the ligamentum pectinatum from its attachment to the sclerotic with the probable result that the ciliary body and iris root become retracted by the ciliary muscle, so that the canal of Schlemm is opened up and again communicates with the anterior chamber. It also opens up a communication between the anterior chamber and the supra-choroidal lymph space. It has been estimated that in 30 per cent. of the cases in which this operation is performed

a permanent relief of tension was obtained. The operation fails in some cases because the ciliary body gains a fresh attachment to the sclerotic, so shutting off the suprachoroidal lymph space from the anterior chamber, and the iris again closes the canal of Schlemm.

If a piece of the iris were removed at the time of the cyclodialysis or before new adhesions were formed, a more satisfactory result would probably follow since the canal of Schlemm would then be permanently opened up.

One of the most serious dangers of operating on a primary glaucoma in an acute or subacute stage is the possibility of **subsequent intraocular hemorrhage** from the sudden relief of the intraocular tension causing an intraocular vessel to give way. Every means, therefore, should be taken to lower the intraocular tension and also the general blood pressure before the operation. For the relief of the intraocular pressure eserine should be used, and in cases of very acute glaucoma posterior scleral puncture may be resorted to as a preliminary measure. The blood pressure is best lowered by the use of a watery purgative before operation. Leeching and venesection may also be employed with advantage.

Intraocular hemorrhage may take place from a choroidal or retinal vessel. When it takes place from a choroidal vessel the hemorrhage occurs between the sclerotic and choroid and may give rise to a temporary defect of vision after the operation, or may be so extensive as to cause active propulsion of the intraocular contents from the wound. Retinal hemorrhages are usually small and, unless occupying the macula region, do not interfere much with vision. Occasional hemorrhage may take place into the vitreous giving rise to a defective vision which tends usually to improve.

CHAPTER IV.

INJURIES.

The injuries of the eye are here described under the following headings: 1. Ruptures. 2. Concussion. 3. Wounds. 4. Foreign Bodies. 5. Heat and Chemicals. 6. Light Electricity and X-rays.

A rupture is the result of a blow from a blunt object which, compressing the globe, suddenly increases its tension, so causing the outer fibrous tissue wall to give way.

The changes which take place in the intraocular contents from blows by blunt objects in which no rupture of the outer fibrous tissue coat occurs are dealt with under the heading of concussion. The blow may be received on the front of the eye, or in other situations in gun-shot injuries of the orbit. Birth injuries produced by the pressure of forceps are included under this heading.

Wounds of the eye may be surface injuries, or produce perforation of the globe. In the latter the changes which result vary according to the position, depth, and size of the wound, and for purposes of description have to be divided up under a variety of sub-headings.

Foreign bodies may become lodged in the external coats of the eye, or penetrate them and become located in its interior, or pass through the globe into the orbit. The changes which ensue vary considerably according to the nature of the foreign body. Under the sub-heading *SIDEROSIS BULBI* the changes are described which follow when a piece of iron is left embedded in the eye some length of time.

Burns of the eye may be produced by heat or the caustic effects of chemical substances.

Under the injurious effects of excess of light are included eclipse-blindness, night-blindness, erythropsia, snow-blind-

ness and glass blowers' cataract. Electrical injuries proceed from either lightning or industrial electricity. The effects on the tissues of the eye from exposure to X-rays are also described under the last heading.

I. Ruptures.

The sudden compression of the eyeball between the bony wall of the orbit and a blunt object may so increase the tension in it as to cause its fibrous tissue outer wall to rupture. This compression of the eye is most frequently occa-

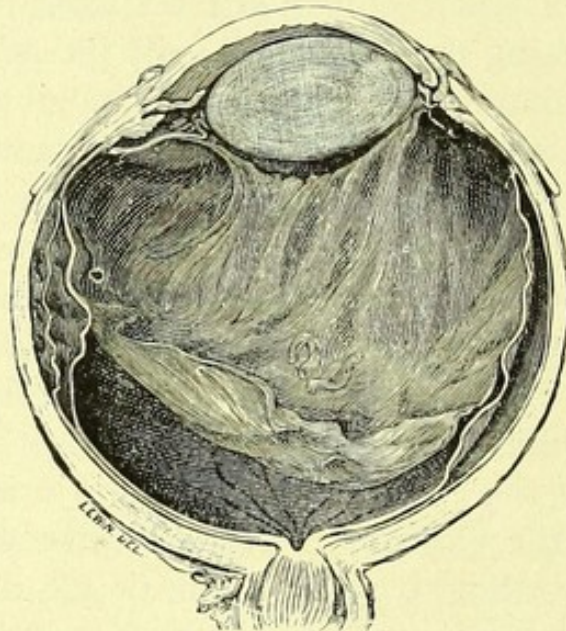


FIG. 134.—The lateral half of an eye ruptured by a blow from a fist. It is situated in the usual position and extends into the extreme periphery of the anterior chamber. The iris has prolapsed and the lens become displaced forward and upward. Specimen in the R. Lond. Ophth. Hosp. Museum.

sioned by something forced into the orbit from one side, as for example a prog with a cow's horn. A blow forcing the eye straight back in the orbit against the pad of fat behind it does not cause it to rupture.

A rupture of the fibrous tissue outer wall is always in the anterior part of the eye, usually 2 to 3 mm. from the corneal margin, passing through the canal of Schlemm and ligamentum pectinatum into the extreme periphery of the anterior chamber (Fig. 134). This is not the thinnest part

of the sclerotic, which is situated at the equator just behind the insertion of the recti muscles. It is, however, the thinnest part unsupported externally by the orbital muscles and internally by the other coats of the eye. It is also weakened by the presence of the loose tissue composing the filtration area.

Ruptures of the cornea are exceedingly rare; occasionally in an eye with the scar of an old perforating wound of

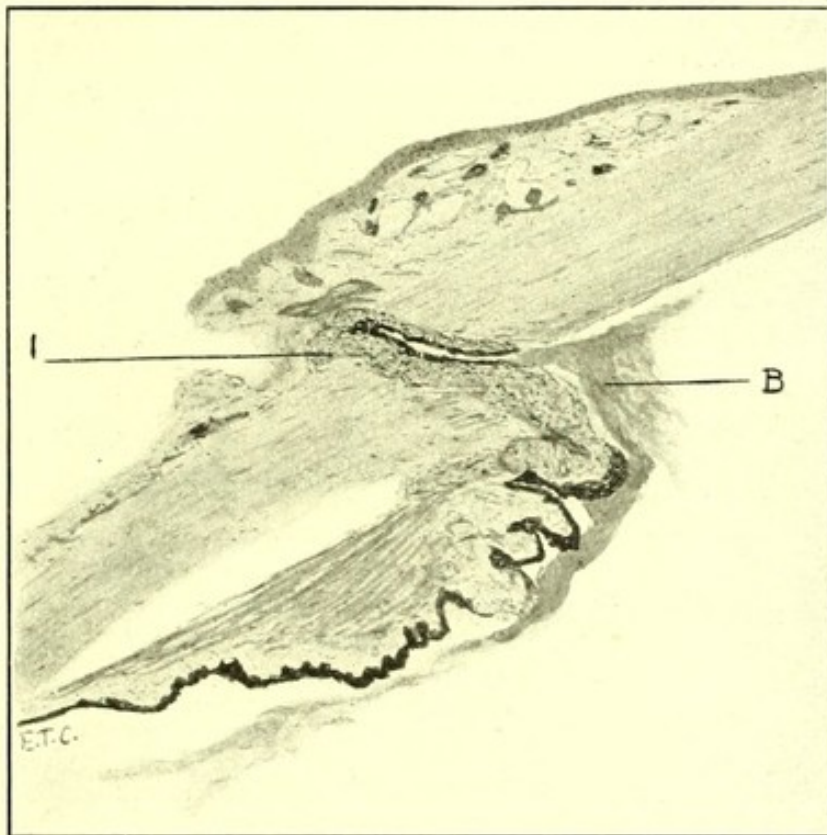


FIG. 135.—Rupture of the globe showing a prolapse of the iris, *I*, into the wound. The lens has been extruded and the anterior chamber is filled with blood, *B*.

the cornea, instead of the sclerotic rupturing, the cicatrix gives way. A rupture of the fibrous tissue outer coat of the eye occurs on the side of the globe which is brought into contact with the wall of the orbit, and on the opposite side to which the blow is inflicted. As the eye is protected on the inner side by the nose and above by the brow injuries are most often received from the outer side or below, hence ruptures

of the sclerotic most often occur upward or inward, rarely downward or outward.

The rupture through the fibrous tissue coat takes place from within outward. Incomplete ruptures occur in which the inner fibres, those in the vicinity of Schlemm's canal, alone are torn, the outer ones remaining intact. Sometimes the whole thickness of the sclerotic becomes torn through but the conjunctiva overlying it remains unlacerated.

In recent ruptures the lips of the wound are always everted; as the wound heals the cicatrization which takes

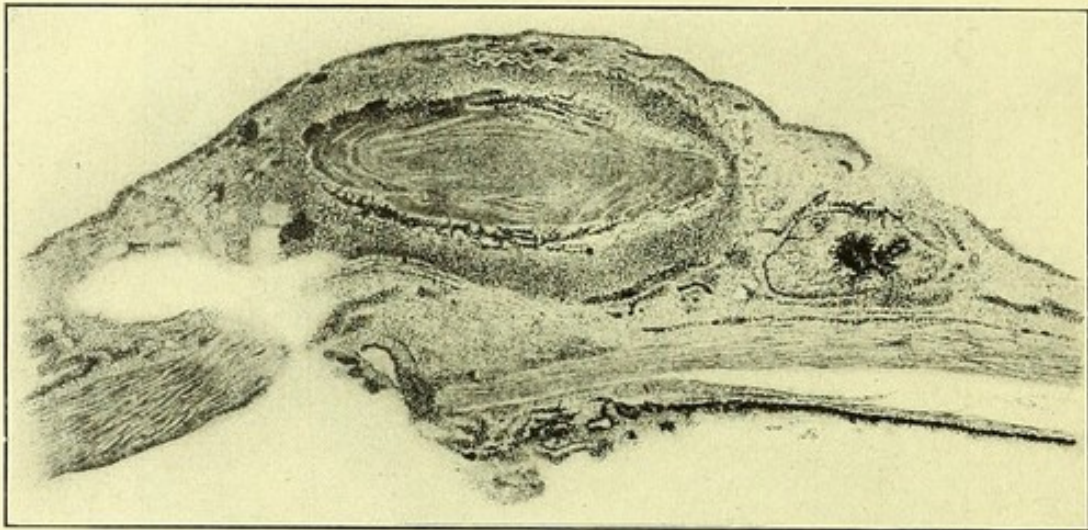


FIG. 136.—Section through a rupture in the sclerotic produced by a blow with a fist. The rupture extends into the extreme periphery of the anterior chamber, and the iris and lens have escaped through it. They are shown lying beneath the conjunctiva external to the sclerotic. The pigmented tissue on the right-hand side of the figure is the iris. Around the lens there is much cellular exudation.

place causes them to become inverted, sometimes to such an extent that a puckered depression is formed at the seat of the lesion.

The force of a blow sufficient to give rise to rupture of the sclerotic is nearly sure to cause derangement of some of the other structures of the eye. Various portions of its contents may escape either partly or entirely through the opening. If the conjunctiva remains intact, these escaping structures come to lie beneath it. The iris in the neighbourhood of the rupture frequently becomes folded and prolapses

(Fig. 135). Sometimes it becomes torn away from the ciliary body in its entire circumference and escapes from the eye with the aqueous, or lies entangled in the wound. The suspensory ligament of the lens rarely escapes being torn through, the lens becoming displaced forward toward the rupture or escaping through it in its capsule. Occasionally the capsule bursts and remains in position while its contents is extruded. When the lens escapes through the rupture and lies beneath an intact conjunctiva, a large disc-shaped prominence is seen on the surface of the globe just behind the wound, a condition spoken of as **sub-conjunctival dislocation of the lens** (Fig. 136).

A tear in the suspensory ligament of the lens allows the vitreous humour to protrude forward, prolapsing or escaping to a greater or less extent. Following displacement of the vitreous comes detachment of the retina, which may in some cases also prolapse through the opening in the sclerotic.

Hemorrhage in cases of rupture of the sclerotic is met with in all parts of the globe, subconjunctivally, in the anterior chamber, in the vitreous chamber, beneath the retina, and beneath the choroid.

The ultimate outcome of a rupture of the sclerotic varies with the amount of the contents of the globe which escapes. Some ruptured eyes regain useful vision, even after the lens has become extruded. A subconjunctivally dislocated lens if not removed becomes surrounded by phagocytes and slowly absorbed; traces of it may remain years after the injury. Where the vitreous has prolapsed, shrinking of the eye generally ensues. Infective organism from the conjunctival sac may gain entrance through the wound and excite an intraocular inflammation. Cases of sympathetic ophthalmitis following ruptures of the eye have been recorded.

II. Concussion.

As the result of a blow on the front of the eye from a blunt object various lesions of the intraocular contents may

occur without any rupture of the sclerotic being produced; these may be conveniently classed as concussion injuries.

The tendency of a blow from a blunt object on the front of the eye is to flatten out the cornea, which has a greater curvature than that of the sclerotic and projects from its surface. Flattening out of the cornea forces the aqueous humour backward and laterally. Backward displacement of the aqueous humour presses on the iris and lens, and its lateral displacement widens out the angle of the anterior

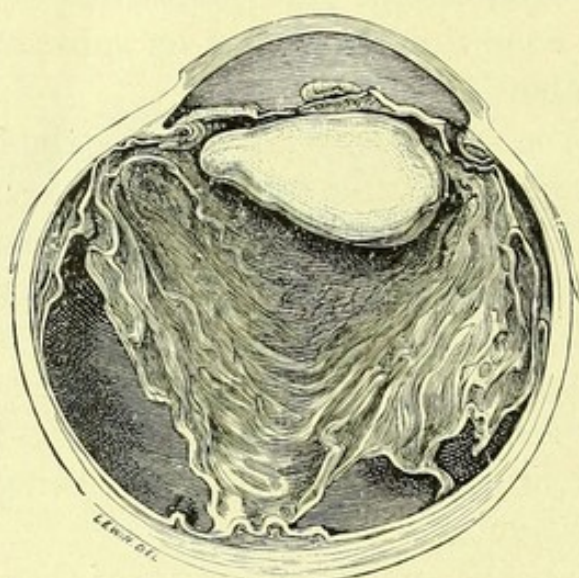


FIG. 137.—The lateral half of an eye injured by a blow from the stick of a catapult. On the right side iridodialysis has occurred, and the suspensory ligament has ruptured, the vitreous extending forward between the lens and the ciliary body. On the left side there has been a partial rupture of the ligamentum pectinatum and of the ciliary muscle, prolonging the angle of the anterior chamber outward. The lens is misshapen, due to rupture of its capsule. Specimen in the R. Lond. Ophth. Hosp. Museum.

chamber. The receding iris finds more support centrally from the lens than peripherally from the suspensory ligament. The strain produced, therefore, by such an injury is felt chiefly at the periphery of the iris, the angle of the anterior chamber, and the suspensory ligament of the lens.

Iridodialysis.—The thinnest part of the iris is at its junction with the ciliary body. One of the commonest results of a concussion injury of the eye is for it to be torn through in this situation in a portion of its circumference, a condition termed iridodialysis being produced (Fig. 137).

The gap left where the iris becomes separated from the ciliary body may be seen clinically as a black area, like the pupil. The contraction of the sphincter muscle draws the two apart and in so doing alters the shape of the pupil, destroying its normal rotundity.

The extent of an iridodialysis varies considerably in different cases. Two separate gaps may be present in the same eye. The iris never becomes reunited to the ciliary

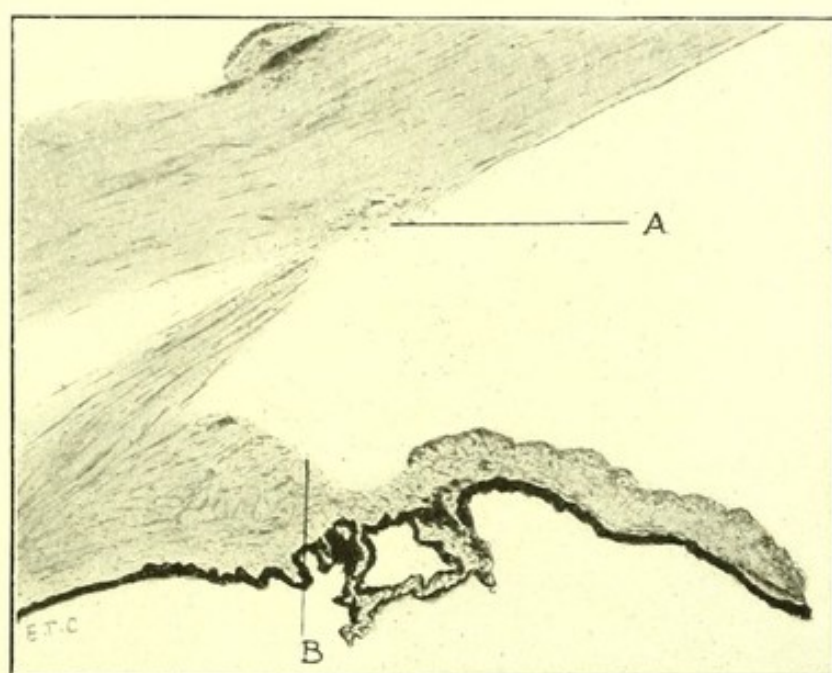


FIG. 138.—Partial rupture of the ligamentum pectinatum and ciliary muscle in the eye of a boy aged six, who was struck with a stone shot from a catapult. *A* points to the ruptured fibres of the ligamentum pectinatum which were formerly united at *B*, forming the angle of the anterior chamber.

body, though a band of fibrous tissue probably formed from organised blood clot has been found to bridge across the gap.

Rupture of the Ligamentum Pectinatum and Ciliary Muscle.—From the lateral dispersion of the aqueous humour a partial or complete rupture of the ligamentum pectinatum may result.¹ In a partial rupture of the ligamentum pectinatum it is those fibres which curve around the angle of the anterior chamber to go to the root of the iris, the so-called pillars of the iris, which become torn. The rupture may also

¹Treacher Collins. Trans. Ophth. Soc. of the U. K., XII, 1892, 180.

extend into the ciliary muscle for a short distance separating its circular fibres away from the longitudinal (Fig. 138). Partial rupture of the ligamentum pectinatum and ciliary muscle is a difficult condition to recognise clinically, the only symptom it gives rise to being deepening of the anterior chamber, most marked at the periphery in the locality of the lesion.

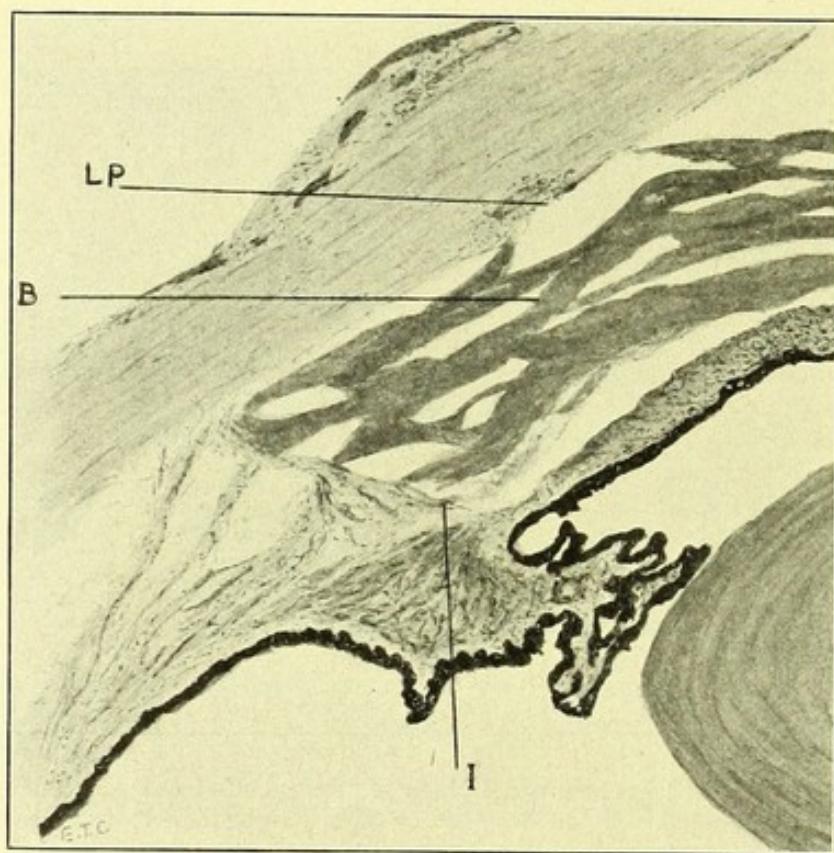


FIG. 139.—Complete rupture of the ligamentum pectinatum. *LP* points to its torn fibres which were formerly united to the ciliary body at *I*, forming the angle to the anterior chamber; *B* is blood clot in the anterior chamber.

When the ligamentum pectinatum is completely ruptured, not only are the pillars of the iris torn through, but also those fibres which give origin to the ciliary muscle (Fig. 139); that structure then loses its most fixed point of attachment, and by its contraction the ciliary body and iris become displaced outward and backward. This lesion is nearly always accompanied by considerable hemorrhage into the anterior chamber from tearing through of some of the blood-

vessels which pass between the ciliary body and sclerotic. When the blood becomes absorbed a portion of the iris may clinically have disappeared from view, or its pupillary border be alone visible in a portion of its circumference, the pupil being displaced and altered in shape. This disappearance of the iris is mainly due to its retraction by the ciliary muscle. The depth of the anterior chamber becomes altered often to varying degrees in different parts.

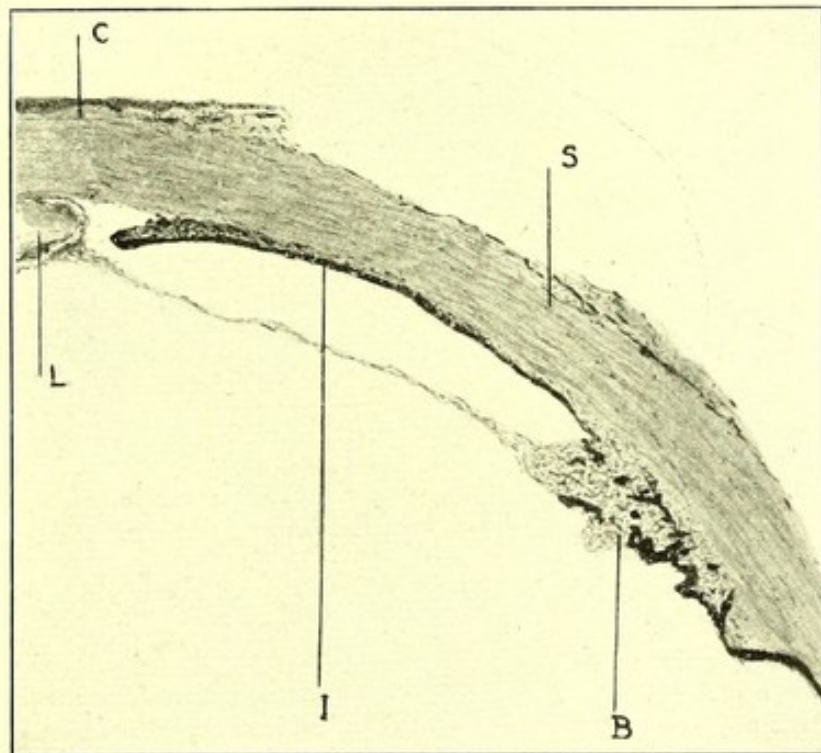


FIG. 140.—Concussion injury to eye 30 years previous to removal. Complete rupture of the ligamentum pectinatum with retraction of the ciliary body and iris, *I*, which have become readherent to sclerotic *S*. *C*, Limbus; *L*, lens; *B*, ciliary body with a mass of fibrous tissue on its surface extending to the lens.

When the ciliary body has been simply retracted along the sclerotic and has remained in contact with it, fibrous adhesion may form and reunite them¹ (Fig. 140).

Dislocation of the Lens.—A rupture of the suspensory ligament of the lens occurs in concussion injuries, either from pressure of the iris backward against it or from undue

¹ L. Buchanan. Trans. Ophth. Soc. of the U. K., XXIII, 1903, 283. M. S. Mayou. Trans. Ophth. Soc. of the U. K., XXIX, 1909, 254.

strain occasioned by a tilting forward of one edge of the lens.

If only a part of the suspensory ligament is torn the lens becomes drawn away from the injured side producing lateral dislocation. On the side toward which the lens is displaced the iris becomes pressed forward and the anterior chamber shallowed, its root sometimes being brought into contact with the back of the cornea, so as to block the filtration area.

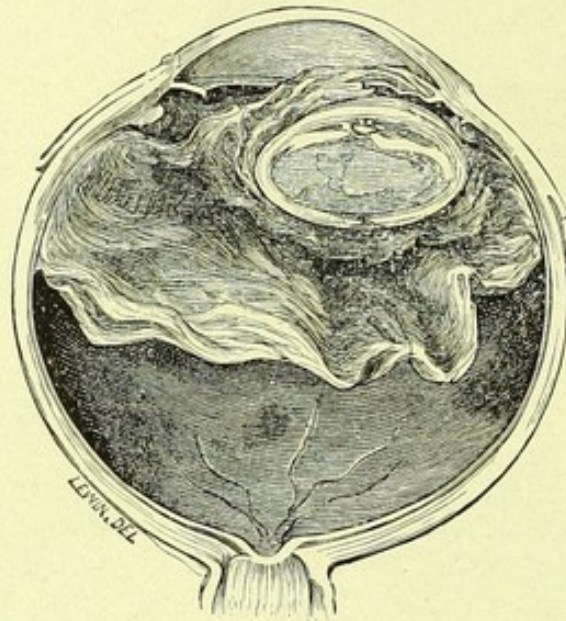


FIG. 141.—The lateral half of an eye with lateral dislocation of the lens, due to a blow from a piece of wood. The vitreous humour passes forward between the side of the lens and the ciliary body into the anterior chamber. The optic disc is cupped as the result of secondary glaucoma. The angle of anterior chamber is closed by the root of the iris which is pressed forward into contact with the cornea. Specimen in the R. Lond. Ophth. Hosp. Museum.

On the side away from which the lens is drawn the iris falls back and the anterior chamber is deepened. The withdrawal of support from behind the iris in this position causes it to be tremulous on movements of the eye, a condition termed **iridodonesis**.

The vitreous humour at the site of the rupture in the suspensory ligament may protrude forward to the back of the iris, and even pass through the pupil into the anterior chamber (Fig. 141).

Occasionally when the lens is much drawn over to one

side, and the iris much pushed back on the other, its pupillary margin will there slip round the edge of the lens to the posterior surface, a partial dislocation of the lens through the pupil being the result. In some cases the backward displacement of the iris round the side of the lens is so extensive that part of it disappears from view clinically; this is called **retroflexion of the iris**.

When, as the result of the pressure backward of the iris against the suspensory ligament, that structure becomes torn through in its entire circumference the lens may be

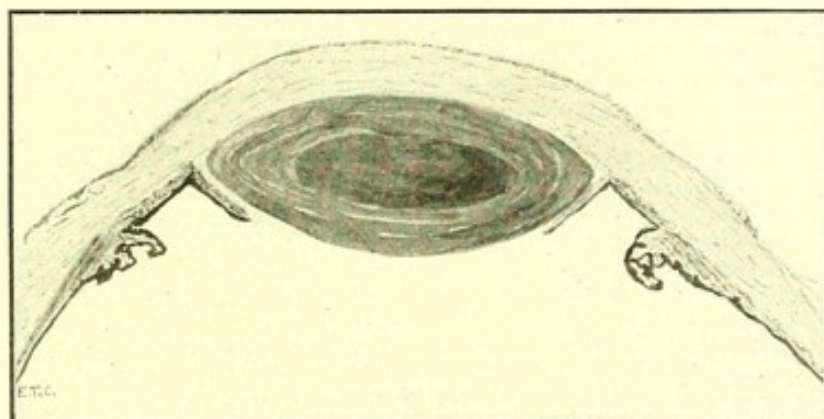


FIG. 142.—Section through the anterior part of an eye in which the lens has become dislocated into the anterior chamber as the result of blow on it. Secondary glaucoma ensued.

dislocated forward into the anterior chamber (Fig. 142) or backward into the vitreous chamber. The former is brought about by the displacement of the periphery of the iris backward, causing such a wide dilatation of the pupil that its margin slips round the border of the lens in all directions. A lens dislocated into the anterior chamber may remain clear for a time, but will ultimately become opaque.

When a lens becomes displaced into the vitreous chamber it need not necessarily have all its attachments to the suspensory ligament torn through. A lens displaced backward may be forced either between the anterior hyaloid of the vitreous and the retina or through a rupture in the anterior hyaloid membrane into the vitreous. In the old

operation for displacement of cataract (**couching**) the lens was either "depressed" into the former position or "reclinated" into the latter. If the capsule of a clear lens dislocated into the vitreous remains intact it may retain its transparency for many years. On movements of the eye a lens dislocated into the vitreous usually floats up so as to allow of its crescentic edge being seen ophthalmoscopically. All forms of dislocation of the lens are liable to be followed by secondary glaucoma, especially lateral dislocation and dislocation into the anterior chamber.

Rupture of the Sphincter Pupillæ, Mydriasis and Cycloplegia.—The sudden dilatation of the pupil which occurs in concussion injuries, from the displacement backward of the periphery of the iris may cause rupture of its sphincter muscle. One or more notches are then seen in the pupillary border of the iris and the pupil itself remains semi-dilated, failing to react normally to the usual stimuli.

Mydriasis and immobility of the pupil is also met with after concussion injuries without any apparent lesion of the sphincter, probably the result of bruising of filaments of the third nerve. Cycloplegia without any obvious injury to the ciliary muscle occurring under similar circumstance may be attributed to a like cause.

Concussion Cataract.—The flattening of the eyeball from before backward, when struck anteriorly by a blunt object, increases its transverse diameter, putting suddenly into a state of extreme tension the suspensory ligament and lens capsule; rupture not only of the suspensory ligament, but of the lens capsule also, may follow.¹

The commonest position at which the lens capsule ruptures is its equator; occasionally it bursts at the posterior pole² (Fig. 143). The margins of the capsule at the seat of rupture roll outward; if it is situated at the equator, the lens substance is exposed to the action of the aqueous humour and rapidly becomes opaque. The whole of the lens

¹ J. B. Lawford. *Ophthalmic Review*, VI, 1887, 281.

² Treacher Collins. *Trans. Ophth. Soc. of the U. K.*, XI, 1891, 126.

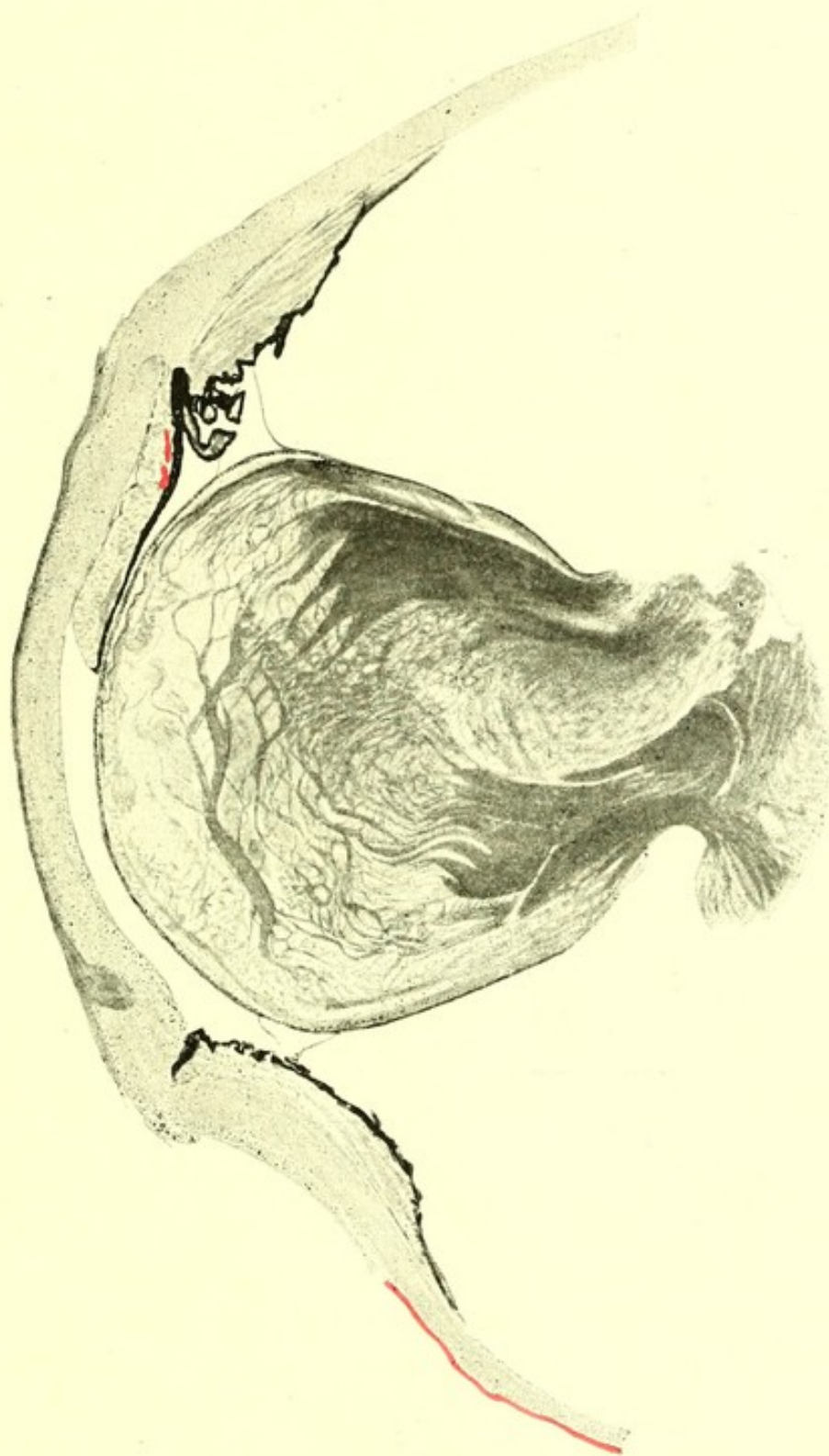


FIG. 143.—Section through the anterior half of an eye in which there has been a rupture of the posterior capsule of the lens as the result of a blow from a stone.

substance may become dissolved by the aqueous and be removed from the eye after a rupture of the capsule, leaving a clear black pupil. The lens matter which protrudes through a rupture in the posterior capsule is exposed to the vitreous humour and the formation of cataract is then a much slower process.

Rupture of the Choroid.—Another effect of flattening the globe from before backward and increasing its transverse diameter in concussion injuries is to suddenly put on the stretch its two internal coats, the choroid and retina, either or both of which may rupture.

Rupture of the choroid is more frequent than rupture of the retina, probably from the presence in it of the comparatively brittle elastic membrane of Burch. It is not, however, only this elastic lamina which tears, but also the pigment

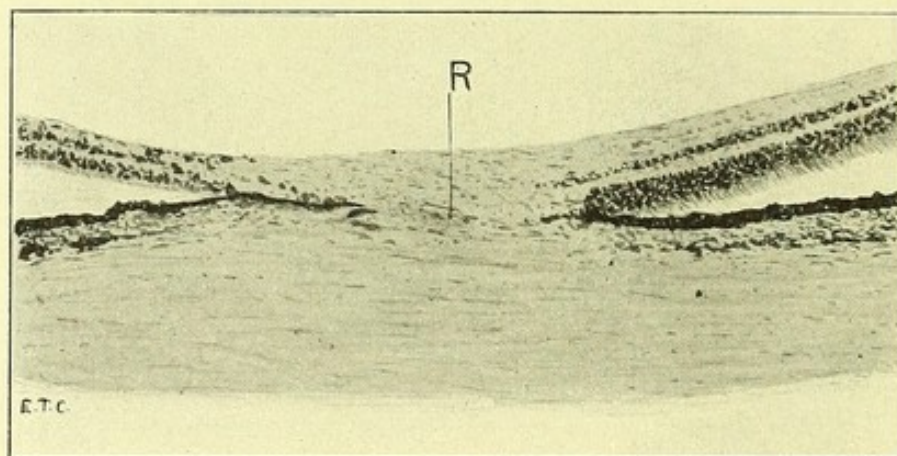


FIG. 144.—Section through the coats of an eye at the seat of a rupture of the choroid. *R*, points to fibrous tissue filling the gap in the choroid to which the retina has become firmly united.

epithelium attached to it internally and the vascular layers externally. The usual position for such a rupture is in the centre of the membrane, midway between the optic disc and yellow spot, and in a vertical direction. Multiple ruptures may occur more or less concentric to one another. Immediately after the occurrence of a rupture in the choroid there is so much hemorrhage from its vessels that the characteristics of the lesion are obscured from view. As the blood

becomes absorbed the gap in the choroid filled with newly formed fibrous tissue becomes visible ophthalmoscopically as a yellowish-white crescentic slit. The concavity of the crescent is turned toward the optic disc and its extremities are tapering or forked. Its borders are at first usually free from pigmentation, becoming blackened later from proliferation of the pigment epithelium. In course of time the retina itself at the seat of rupture atrophies, becoming adherent and incorporated in the fibrous tissue filling the gap (Fig. 144).

Rupture of the Retina and Commotio Retinæ.—As a rule, the retinal vessels as they cross a rupture in the choroid have no break in their continuity, showing that the retina remains intact. Exceptionally a rupture of the retina occurs in the same position as a rupture of the choroid and its vessels are seen torn across. In other cases a rupture of the retina may be met with independent of any rupture of the choroid. Slit-like openings are frequently seen in detached retina. When the detachment has followed a concussion injury, and shows such a slit-like opening, it is probable that a rupture of the retina has occurred through which fluid from beneath the hyaloid membrane of a shrunken vitreous passed, separating the retina from the choroid.

Another retinal condition which follows concussion of the eye is **commotio retinæ**, it may or may not be associated with either rupture of the retina or choroid. It is characterised by a milky-white opacity of the retina which after a few days' duration entirely disappears. The distribution of the opacity varies; there may be two separate patches, one at the place where the eye was struck and the other in the region of the macula lutea.¹ If it follows a blow received on the cornea the opaque area is most marked around the optic disc and macula, the latter appearing abnormally red in contrast to the surrounding pallor. The vision is usually for a time markedly affected, more especially the central vision, though the field may also become restricted. In the course of a few days it is completely restored.

¹ Haab's Atlas of Ophthalmoscopy (Figs. 49 and 50).

The immediate effect of a blow on the eyeball is constriction of the retinal vessels, and the opacity has been attributed to edema which it is assumed is the outcome of their subsequent dilatation.

Generally the condition of *commotio retinae* clears up and the vision returns, but cases occur where the sight remains permanently defective and a diffuse pigmentation of the retina makes its appearance.¹

Hole in the Retina at the Macula.—There are cases in which after a concussion injury of the eye a central permanent defect of vision is met with and where ophthalmoscopically an appearance suggesting a hole in the retina at the macula is found.² A circular or slightly oval patch of deep red colour is seen surrounded by a grey area. It varies in size in different cases, but is usually about half that of the optic disc. The grey edge appears slightly raised above the level of the red area and frequently has some irregularities in it. In many of the cases the defect is associated with an absolute central scotoma, but not in all.

A condition apparently quite similar is seen sometimes in association with iridocyclitis or retinal vascular disease where there has been no injury to the eye.

In many of the cases where it has been met with after an injury, some considerable time has elapsed before its presence was recognised.

It has been suggested that the primary condition is probably one of edema of the retina³ (*commotio retinae* in the traumatic cases) and that the inner wall of some of the cystic spaces so produced subsequently rupture. Pathological specimens showing that this may occur have been described. In cases where no absolute scotoma is present it would seem difficult to believe that there is a hole involving the whole thickness of the retina.

¹ Jon. Hutchinson (Jun). Trans. Ophth. Soc. of the U. K., IX, 1889, 116.
² R. E. Bickerton. Trans. Ophth. Soc. of the U. K., XXIV, 1904, 258.

³ F. M. Ogilvie. Trans. Ophth. Soc. of the U. K., XX, 1900, 202.

³ G. Coats. R. Lond. Oph. Hosp. Rep., XVII, 1907, 69.

A case has recently been recorded¹ in which "the hole" was seen ophthalmoscopically in an eye which had been contused the day previously in a shooting accident. It was removed four days later and examined pathologically. A hole was found in the retina at the macula, its edges were bent away from the choroid and toward the vitreous, the tissue around was swollen. In this case the hole was the direct result of the injury and not a sequelæ of the edema.

Intraocular Hemorrhage.—In concussion injuries of the eye intraocular hemorrhage may occur from different sets of vessels and in different positions. Hemorrhage may

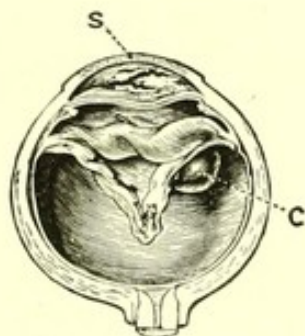

FIG. 145.—The lateral half of an eye which became blind from detachment of the retina. Four months previous to removal it received a blow from an open hand, which resulted in extensive hemorrhage into the anterior chamber and the staining of the whole cornea, with the exception of a narrow rim at its periphery, a reddish brown colour. S, Stained part of the cornea; C, cyst in detached retina. Recorded in Trans. Ophth. Soc. of the U. K., XI, 1891, 43.

take place into the anterior chamber; from the circulus arteriosus iridis major, which is not infrequently opened up in association with iridodialysis; from the small vessels of the iris; or, if the ciliary body be stripped from the sclerotic, from the anterior ciliary vessels which perforate the sclerotic.

An accumulation of blood in the lower part of the anterior chamber constitutes a **hyphema**. When the whole anterior chamber is filled with blood and remains so for some time, the hemoglobin may escape from the blood corpuscles and diffuse through Descemet's membrane, crystals of blood pigment (hematoidin and hemosiderin)

¹ C. J. Kipp and A. Alt. *Am. J. of Ophth.*, XXV, 1908, 225.

becoming deposited in the substantia propria of the cornea staining it a brown colour¹ (Figs. 145, 146).

Hemorrhage into the vitreous chamber may proceed from three different sources:

- a. From the blood-vessels of the ciliary body.
- b. From the retinal blood-vessels.
- c. From the choroidal blood-vessels provided there has been a rupture of that membrane and of the retina.

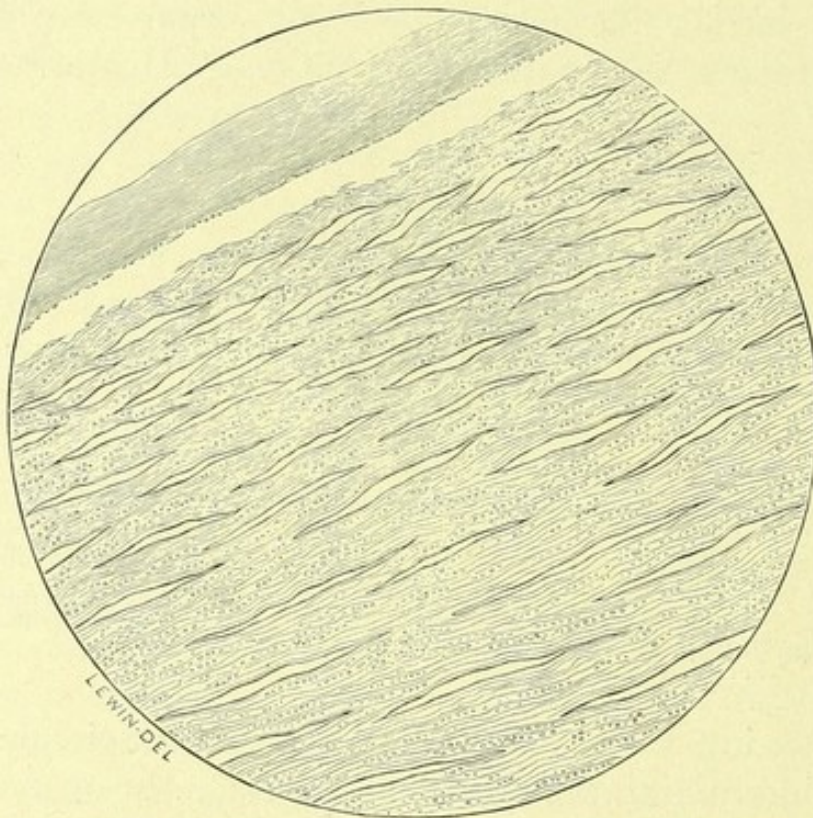


FIG. 146.—Shows the microscopical appearances of the blood-stained area in the cornea depicted in Fig. 145. There are numerous granules of blood pigment scattered throughout the substantia propria.

Hemorrhage from the retinal vessels may be located in the tissue of the retina; between the retina and the hyaloid membrane of the vitreous (**sub-hyaloid hemorrhage**); or in the vitreous humour its hyaloid membrane having become ruptured.

A sub-hyaloid hemorrhage which occurs after concussion injuries, as well as from other causes, first separates the

¹Treacher Collins. Trans. Ophth. Soc. of the U. K., XV, 1893, 69.

hyaloid membrane away from the retina over a circular area, usually in the region of the macula. Soon the blood gravitates from the upper part so that a patch is formed having a straight upper edge and curved lower one.

Traumatic hemorrhages into the vitreous may become completely absorbed, usually they leave some strands of opacity behind. Sometimes they may become organised into fibrous tissue which has new blood-vessels developed in it continuous with the retinal vessels.

Hemorrhage from the choroidal vessels, if not very extensive, may remain confined to the tissue of the choroid. Sometimes it may extend through a rupture in the elastic lamina, accumulating beneath the retina and causing detachment of it. Blood may accumulate in the lymph spaces between the choroid and sclerotic, separating the two coats from one another. Hemorrhage in these two latter positions in non-perforating injuries of the eye is limited in amount by reason of the intraocular tension to which it gives rise.

Blood accumulating between the ciliary body and the sclerotic will sometimes extend along the sheaths of the anterior perforating vessels and appear as small patches beneath the conjunctiva.

Gunshot Injuries of the Orbit.—A shot or other projectile may strike the outer surface of the sclerotic and without perforating it produce changes in the interior of the eye. In gunshot wounds of the orbit the vibration caused in the soft tissues around the globe by the passage of the projectile through them may affect the intraocular contents without it coming in contact with the sclerotic.¹

In gunshot wounds of the orbit the ciliary arteries and the optic nerve may be divided and it is often difficult to differentiate changes in the eye produced by such lesions from those the result of concussion.

Rupture of the choroid or retina, detachment of the retina and extensive intraocular hemorrhage may certainly result from concussion in these cases. The following changes

¹ E. Nettleship. Trans. Ophth. Soc. of the U. K., XX, 1900, 201.

have been shown experimentally and clinically to result from section of the optic nerve and the surrounding ciliary vessels: swelling of the head of the nerve and atrophy; white opacity of the retina; atrophy of retina and the choroid with intimate adhesions between the two membranes.

Birth Injuries.—Injuries to the eyes from compression during parturition are of more frequent occurrence than is generally supposed. Several conditions which have been regarded as developmental defects are probably attributable to them.

One observer¹ has noted the following lesions as due to pressure by forceps: excoriation, ecchymoses, edema, exophthalmos, fracture of the orbit, paralysis of the lid muscle, corneal troubles, retinal hemorrhages, optic atrophy, (strabismus with hypermetropic astigmatism.)

Intraocular hemorrhage, most frequently retinal, may occur in cases of normal labour where no instruments have been used. Probably in some cases it is due to increased blood pressure apart from any direct pressure on the eye.

The corneal lesions² may result in temporary or permanent opacity. The temporary opacities which are of comparatively frequent occurrence are due to edema. In the cases with permanent opacity there is a rupture of Descemet's membrane and sometimes of the fibrous lamellæ adjoining it. The rupture is generally linear and vertical; it is undoubtedly caused by the direct pressure on the eyeball of the instrument. Following on the rupture there is edema of the cornea and often inflammatory reaction.

Paralysis of the sympathetic nerve on one side with failure in the development of pigment in the stroma of the iris of the eye supplied by it, causing heterochromia iridis, has also been attributed to injury at birth.³

¹ H. Truc. *Ann. d'oculist.*, CXIX, 1898, 161.

² W. E. Thomson and Leslie Buchanan. *Trans. Oph. Soc. U. K.*, XXIII, 1903, 312.

³ M. S. Mayou. *Trans. Ophth. Soc. of the U. K.*, XXX, 1910.

III. Wounds.

Wounds of the Cornea.—A wound of the cornea may vary in extent from an abrasion of its epithelium to a perforation of its whole thickness.

Perforating wounds may be simple or compound, the former only involving an escape of the aqueous humour, the latter being associated with some entanglement or adhesion of the intraocular contents.

In a case of **simple abrasion of the epithelium** repair is soon affected without any nebula being left behind. Karyokinesis in the surrounding cells commences about twenty-four hours after the receipt of injury, the newly formed cells spreading laterally over the denuded area.

The value of the surface epithelium as a protection to the substance of the cornea from the deleterious action of external influences is shown by the risks to which it is exposed when an abrasion has taken place.

When a drop of a solution of fluoresceine is instilled into a healthy eye with the epithelium intact no staining of the cornea takes place. When, however, there is an abrasion of the epithelium present the fluoresceine is able to penetrate to the fibrous tissue of the cornea and stain it green. This staining only lasts a short time, not producing any deleterious effect. If a solution of subacetate of lead (lead lotion) is dropped into an eye with abraded corneal epithelium, the white carbonate of lead becomes deposited in the substantia propria at the denuded area, producing a permanent white porcelin-like opacity.

In cases of obstruction of the lacrimal duct the lacrimal sac may be inflamed and distended with discharge containing pneumococci. This germ-laden fluid will from time to time regurgitate from the distended sac over the surface of the cornea; as long as its epithelium is intact it remains unharmed. Should, however, an abrasion of the epithelium occur the pneumococci will attack the substantia propria and give rise to an infective ulcer.

In rare cases the new epithelium which forms over an abraded area fails to acquire its necessary firm attachment to Bowman's membrane. In the course of a few weeks it will become raised in the form of a vesicle which on rupturing leaves a fresh abrasion, a condition which has been termed **bullous keratitis**. In the formation of the vesicle the filaments of the corneal nerves which break up and terminate in the epithelium become stretched and the patient complains of much pain, which is relieved as soon as the vesicle ruptures and the tension on the nerve filaments lowered. This formation of vesicles is liable to recur, causing relapsing attacks of pain.

The formation of vesicles in the corneal epithelium, whether as a sequela of an abrasion or some other cause, is liable to lead to the development of filamentary processes projecting from the surface of the cornea. The condition has been termed **filamentary keratitis**, but as it may be unassociated with any inflammatory condition it is well to avoid the use of the term keratitis in connection with it (see page 321).

In an uninfected **wound of the anterior surface of the cornea**, the gap formed by the retraction of the anterior elastic lamina and anterior laminae of the substantia propria at first becomes filled with polymorphonuclear leucocytes and proliferated epithelium, so that the normal level of its surface is soon restored. Beneath this primary plug of cells others, derived from proliferating corneal corpuscles, subsequently form from which new fibrous tissue is gradually developed. In peripheral wounds there is an extension into the affected area of the marginal blood-vessels which aid in the development of the granulation tissue. The primary plug of epithelium gradually becomes forced up and reduced in thickness by the newly forming fibrous tissue, until ultimately it reaches the dimensions of that normally covering the cornea. No new formation of the anterior elastic lamina takes place, and the newly formed fibrous tissue has not the regular laminated arrangement of the normal lamellæ

of the cornea. Consequently a permanent opacity results, termed a **nebulæ** or **leukoma** according to its density.

After **simple perforating wounds of the cornea** the anterior and posterior elastic laminae, with the fibrous layers immediately adjoining them retract more than the central parts of the substantia propria. When, therefore, the lips of the wound first come together again there is contact of the central layers, and wedge-shaped gaping spaces left anteriorly and posteriorly.

The newly secreted aqueous humour replacing that which escapes is much richer in albumen than normal aqueous; this together with lymph exuded from the edges of the wound form a fibrinous coagula resulting in their agglutination. The lamellæ of the substantia propria on each side of the wound become permeated with aqueous humour and swollen, the amount of this imbibition and swelling varying with its character. In a clean incised wound such as that produced by a keratome it is but slight. In a jagged wound it is more extensive, giving rise to a greyish uniform opacity about the margins. In a wound producing a V-shaped flap the amount of haze and swelling may be very considerable. Sometimes when the flap has been fitted into its proper position it is found to rise some distance above the level of the surrounding cornea. Another form of opacity caused by imbibition is that met with sometimes after extraction of cataract, in which a greyish haze is seen mapped out into a number of squares by fine dark lines.

The vertical streaks of opacity which are not unfrequently seen extending downward from the wound after an extraction of cataract are due to rucking of Descemet's membrane as the result of a relaxation of its usual state of tension.¹ It is often inaccurately spoken of as striated keratitis; it should be termed **striated opacity**.

The triangular gap left by the retraction of the anterior lips of a perforating wound soon becomes filled by a plug of epithelium as in a non-perforating wound. Should for some

¹ Hess. *Archiv. f. Ophth.*, XXXVIII, 1892, 4, 1.

reason the sealing of the edges of the wound by the fibrinous coagula be delayed, the surface epithelium will extend backward along them, and in some cases may pass right through the wound into the anterior chamber, producing there a cystic growth (see page 157).

The two margins of the posterior elastic lamina after a perforating wound become not only retracted, but also slightly everted forward. The amount of retraction of the posterior elastic lamina is greater than that of the anterior. Endothelial cells from the two sides proliferate and extend over the gap. When it has become completely covered over

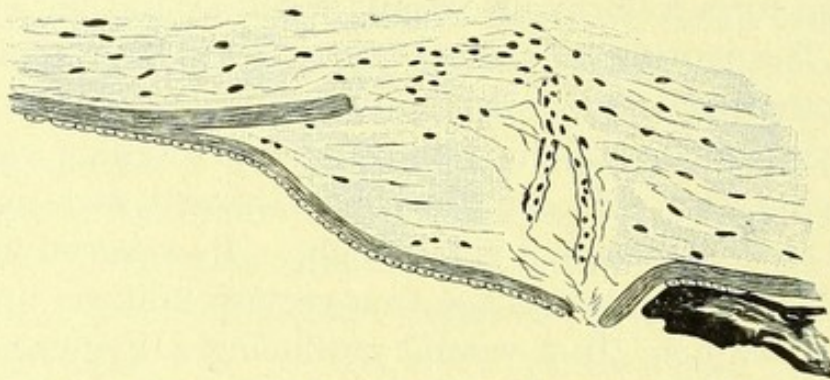


FIG. 147.—Shows a new formation of hyaline membrane lined by endothelial cells on the posterior surface of the scar in the cornea of an incision made $2\frac{1}{2}$ years previously for iridectomy. The divided ends of Descemet's membrane are separated by cicatricial tissue, that on the left side turning forward and that on the right backward. Case recorded in R. Lond. Ophth. Hosp. Reps., XIV, 1896, 310.

any further filtration of the aqueous humour into the substantia propria is arrested. Although the two margins of the divided hyaline membrane never come together again, the endothelial cells extending between them slowly form, by a kind of secretion, a fresh hyaline membrane which bridges across the gap. In the course of years this may attain the thickness of the normal Descemet's membrane (Fig. 147).

The fibrinous coagula and cellular exudate which at first agglutinates the edges of the wound in the substantia propria, forms a matrix in which cicatricial fibrous tissue subsequently develops from cells formed by proliferation of the corneal corpuscles. This cicatricial tissue as it re-

places the temporary coagula presses up the wedge-shaped plug of epithelium, gradually reducing its thickness as described under non-perforating wounds.

In **complicated wounds of the cornea** there may be adhesion or entanglement of the iris, lens capsule, vitreous humour, or retina.

If the iris lies in contact for a short time with the back of the cornea at the seat of a wound a fibrinous exudate is

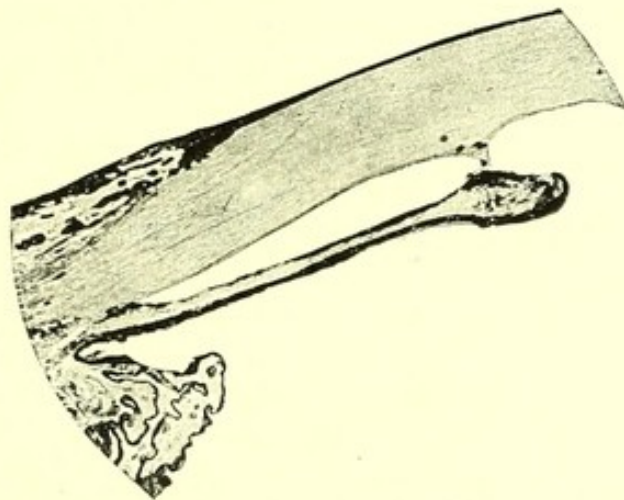


FIG. 148.—Section showing an anterior synechia of the iris near its pupillary border, which resulted from a wound of the back of the cornea with the point of a keratome in the performance of an iridectomy of glaucoma on an eye with a shallow anterior chamber. Case recorded R. Lond. Ophth. Reps., XIII, 1891, 193.

thrown out which brings about adhesion of the two structures, an **anterior synechia** (Fig. 148). This at first simple agglutination becomes in time transformed into a cicatricial adhesion with atrophy of the iris stroma.

The presence of the adherent iris arrests the extension inward of the endothelium on the back of the cornea across the gap in Descemet's membrane. Often it extends at the margins of the wound on to the anterior surface of the iris and may there secrete a hyaline layer like the posterior elastic lamina.¹

Entanglements of the iris in a corneal wound may be divided into three classes:

¹ Treacher Collins. Erasmus Wilson Lectures. *Lancet*, Feb. 17, 1900.

1. Where the cut end of a piece of iris lies in a gap in the cornea.

2. Where a fold of iris prolapses through the whole thickness of the cornea.

3. Where a fold of iris prolapses between the posterior layers of the cornea only.

1. The cut end of a piece of iris lying between the lips of a corneal wound causes more cell exudation and formation of granulation tissue than in an uncomplicated wound.

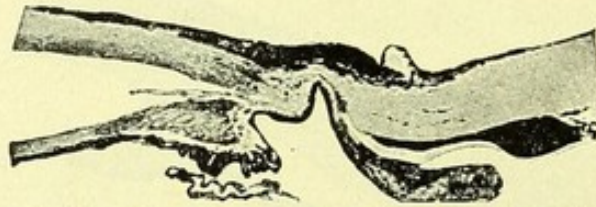

FIG. 149.—Section showing the prolapse of a knuckle of iris into a wound at the sclero-corneal margin. The eye had had an iridectomy performed for glaucoma a fortnight previous to its removal. The prolapse was at one margin of the coloboma. It represents the first stage in the formation of a cystoid cicatrix.

Ultimately the stroma of the entangled iris atrophies, its pigment epithelium remaining incorporated in the cicatricial tissue.

2. When a fold of iris prolapses through the whole thickness of the cornea an obstruction is imposed to the reunion of the fibrous tissue on the two sides (Fig. 149). A fibrinous exudate, which is afterward transformed into fibrous tissue, first agglutinates it to the sides of the wound, the stroma of the iris atrophies and its pigment epithelium alone remains. A piece of iris left protruding through a wound develops granulation tissue on its surface. Over this granulation tissue the epithelium from the sides of the wound spreads, and it itself becomes transformed into fibrous tissue. If the wound is at the periphery of the cornea the prolapsed iris may be covered by conjunctiva to which it will become adherent. A permanent gap will then be left in the outer wall of the eyeball covered by conjunctiva and lined by the pigment epithelium of the iris; this as the result of intra-ocular tension will tend to stretch and expand, forming what

is termed a **cystoid cicatrix**. As the scar stretches, gaps form in the continuity of the pigment epithelium lining it, and the aqueous humour is then able to filter into the subconjunctival tissue, giving to it an edematous appearance (Fig. 150).¹

3. Where a fold of iris prolapses between the posterior layers of the cornea only, a bulging scar, not a cystoid scar, is produced. The anterior layers of the cornea unite in the usual way and a permanent gap in the posterior layers lined

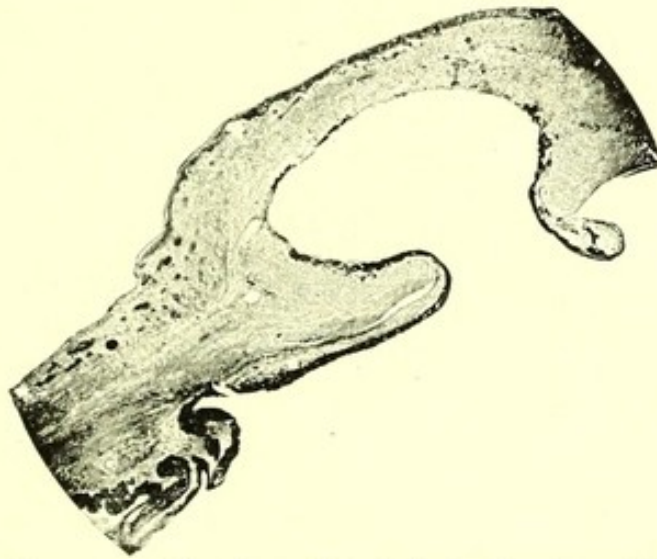


FIG. 150.—Shows a section through a full developed cystoid cicatrix, which occurred in an eye lost from glaucoma following extraction of cataract. The gap in the fibrous tissue at the corneal margin is lined by the iris, much stretched and atrophied, and with many breaks in the pigment epithelium on its posterior surface. The subconjunctival tissue around the gap is much swollen due to the filtration of aqueous humour into it.

by iris is formed. As the stroma of the iris atrophies this lining of iris comes to consist only of pigment epithelium. A scar of this description like the one previously described is a weak spot in the walls of the globe and may expand before the intraocular tension, especially if it becomes abnormally high. It, however, never expands to such an extent as to become translucent like a cystoid scar. Nor does it allow of filtration through it of the aqueous humour. It tends in bulging to considerably alter the curvature of the cornea in one of its meridians and so gives rise to marked astigmatism.

¹ Treacher Collins. Royal Lond. Ophth. Hosp. Rep., XIII, 1891, 171.

An adhesion of the lens capsule to a wound of the cornea may occur while the capsule remains intact or after it has been opened. An entanglement of the lens capsule in a corneal wound can only take place after it has been perforated.

Anterior synechiæ of the lens capsule besides occurring after accidental injuries are sometimes met with after opera-

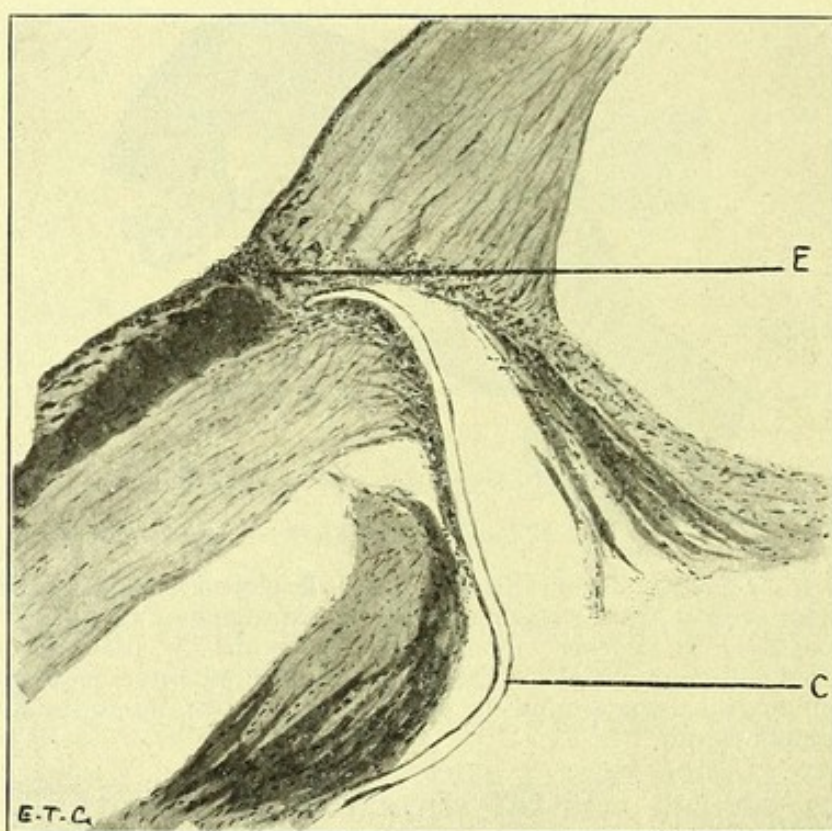


FIG. 151.—Eye removed five months after extraction of cataract on account of serous iritis and increased tension. Drawing shows a section through the extraction wound, the external part of which has alone united. *E* points to a down-growth of surface epithelium. The peripheral portion of the anterior capsule of the lens *C* lies in the widely gaping posterior portion of the wound, the lips of which show much cell infiltration.

tions. The delay which not infrequently occurs in the reformation of the anterior chamber after iridectomy for glaucoma may leave the lens lying in contact with the cornea at the seat of the incision for some time. The coagula which unites the edges of the wound may then unite the lens capsule to the cornea at the gap formed by the retraction

of Descemet's membrane. Later a permanent cicatricial adhesion between the two structures becomes established.

An adhesion of the lens capsule to the back of the cornea causes a considerable advance in the position which it normally occupies in the interior of the eye. This advance in its position draws forward the iris, shallowing the anterior chamber and narrowing its angle. Adhesion of the lens capsule to the back of the cornea after extraction of cataract gives rise sometimes to glaucoma (Fig. 152).

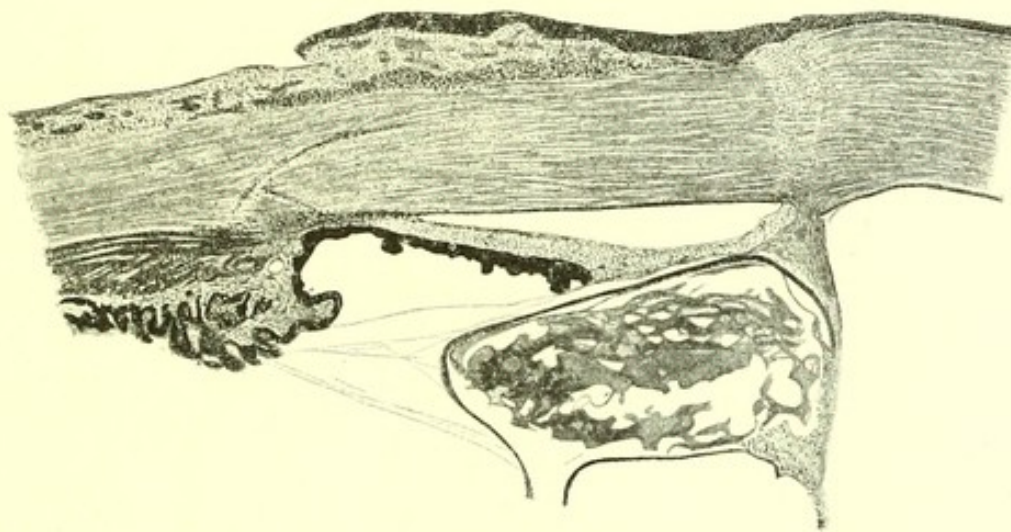


FIG. 152.—Section showing an adhesion of the lens capsule to the posterior surface of an extraction scar. Increased tension ensued, and ultimately destroyed the sight of the eye. Case recorded *Trans. Ophth. Soc. of the U. K.*, X, 1890, 124.

A piece of lens capsule entangled in a corneal wound acts very similarly to a foreign body. It delays healing sometimes for months and excites in the tissue around considerable cell accumulation (Fig. 151). Close to the capsule giant cells are found of the Langhan's type, also epithelioid cells and outside them a zone of lymphocytes. The delay in the healing of the wound renders it very prone to infection. The drag which the entangled capsule keeps up on the ciliary processes causes congestion of them. Hence eyes with wounds of the cornea complicated with an entanglement of the lens capsule often become affected with iridocyclitis.

An entanglement of the vitreous in a corneal wound may take place when after a perforation of the cornea, the lens has escaped in its capsule, or been displaced (Fig. 153). An adhesion of the vitreous to the cornea, even more than an adhesion of the lens capsule, advances the position of the iris, shallowing the anterior chamber and restricting its angle. An adhesion of the anterior hyaloid of the vitreous to the cornea after an extraction of cataract in its capsule has been found to cause glaucoma.

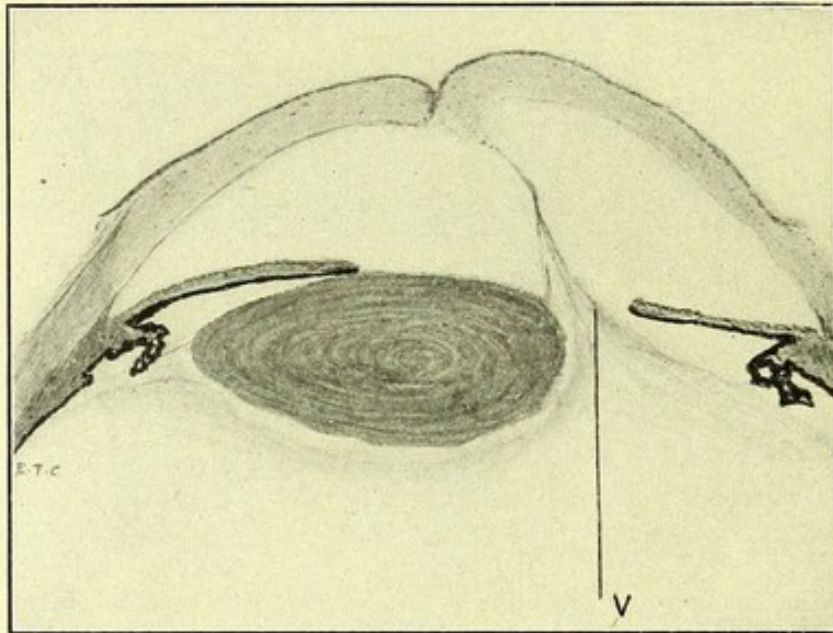


FIG. 153.—Wound of the cornea and suspensory ligament of the lens. Imperfect union owing to the vitreous, *V*, having prolapsed and become adherent to the wound. The eye was removed one month after the injury for chronic cyclitis.

An anterior synechia of the vitreous may also occur when after removal of the lens an opening has been made through the two layers of its capsule. Such entanglements have occurred after operations of needling of the lens capsule, a tag of vitreous being carried into the needle puncture in the cornea on the withdrawal of the instrument. If it protrudes through the puncture it forms a filamentary tag on the surface of the cornea which will stain with fluorescein. It may remain and delay healing for a considerable time, forming a track along which infective organisms can gain entrance to the eye.

In eyes where through a corneal wound there has been an extensive escape of vitreous; and where the lens has escaped or been displaced the retina may be detached and forced forward so as to prolapse or become adherent to the wound.

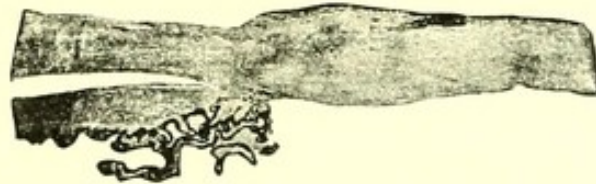


FIG. 154.—Section showing the cicatrix left after an incision through the cornea with a keratome for iridectomy for glaucoma. The increase of tension had not been of long standing and the iris was removed right up to the ciliary body.

Operation wounds and perforating wounds which pass into the periphery of the anterior chamber, owing to the obliquity of the line of junction between the cornea and sclerotic, are wounds of both those structures and also of conjunctiva. In the operation of **anterior sclerotomy** the incision passes partly through the cornea and partly through

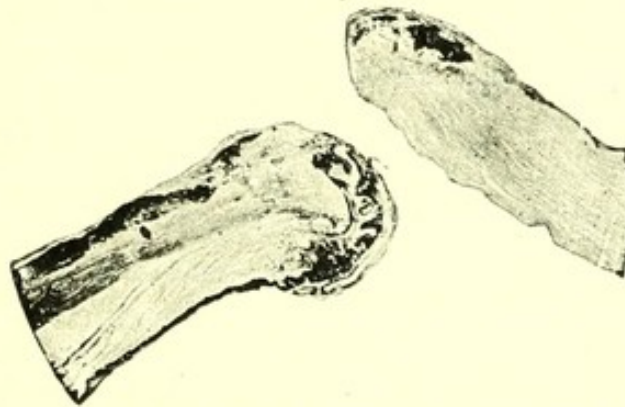

FIG. 155.—Shows a gaping wound at the sclero-corneal margin. The cornea is on the right and the sclerotic on the left. The ciliary body is prolapsing into the wound round the edge of the latter. A very peripheral incision had been made in performing an iridectomy for glaucoma and the lens escaped from the eye the day after the operation.

the sclerotic. It is very exceptional to meet with any sclerotomy or iridectomy incisions which divide the ligamentum pectinatum; they nearly always divide Descemet's membrane internal to it.¹ A Graefe's knife if introduced 1.6 mm. ex-

¹ Treacher Collins. Royal Lond. Ophth. Hosp. Reps., XIII, 1891, 166.

ternal to the apparent sclero-corneal margin penetrates the tissues obliquely and enters the anterior chamber through Descemet's membrane. An incision with a keratome passes even more obliquely through the fibrous tissue external coat of the eye than that made with a Graefe's knife (Fig. 154). The obliquity of the incision facilitates its early closing. The danger of making an incision for an iridectomy so peripherally as to pass through the ligamentum pectinatum is that prolapse of the ciliary body may occur. If the anterior part of the ciliary body prolapses into a wound, through drag on fibres of the suspensory ligament which are attached to it, the edge of the lens becomes tilted forward, resulting sometimes in the escape of that structure from the eye (Fig. 155).

A wound passing through the limbus differs from one passing through the cornea in having the vascular conjunctiva external to it. The presence of the overlying conjunctiva in such wounds prevents any preliminary downgrowth of a plug of epithelium between the gaping anterior lips of the fibrous tissue. Its place is taken by vascular subconjunctival tissue which is later replaced by newly developed fibres.

It is in wounds through the limbus where most frequently folds of iris prolapse beneath the conjunctiva and where cystoid scars make their appearance.

Wounds of the Conjunctiva.—Superficial wounds of the eyeball behind the limbus involving the conjunctiva and anterior layers of the sclerotic are often followed by much subconjunctival hemorrhage. The blood effused will readily permeate the loose subconjunctival tissue and extend up to the attachment of the conjunctiva to the corneal margin. Sometimes blood pigment will diffuse from a subconjunctival hemorrhage into the substance of the cornea, staining its margin a straw-colour.

Sections of a series of wounds made experimentally in the ocular conjunctiva at varying intervals from 6 to 170

hours have been examined microscopically.¹ They show that the edges of the wound retract and expose the episcleral tissue. The epithelium at its margins turns in, some cells swelling up and degenerating. Usually hemorrhage occurs, and in the blood clot organisms from the conjunctiva may grow. In the first twenty-four hours the blood-vessels around dilate and there is an exudation of polynuclear leukocytes brought by the blood. These have marked phagocytic powers and destroy the organisms lying in the wound. At the end of twenty-four hours proliferation of the epithelium commences; it gradually spreads and fills up all the irregularities in the surface of the wound, and in so doing produces several papilla-like processes. If the wound remains aseptic, at the end of twenty-four hours the exudate consists of mononuclear leukocytes and plasma cells only, both of which make their appearance in the vicinity of the blood-vessels and are probably derived from the endothelium and perithelium. At the end of forty-eight hours new blood-vessels begin to appear and there is active proliferation of the deep connective-tissue cells which continues for some time. These cells lengthen out and develop into new connective tissue and the plasma cells disappear, undergoing degeneration. At the end of 170 hours the new formation of connective tissue is well advanced and giant cells derived from the endothelial cells are present.

Wounds of the conjunctiva rarely become septic, but occasionally considerable polypoid-like nodules of granulation tissue make their appearance in connection with them. A little nodule of granulation tissue of this sort is not infrequently seen after the operation of excision of the eye at the apex of the orbit where the edges of the conjunctiva have not come into good apposition.

Masses of granulation tissue used to be met with in former days in connection with operation for strabismus,

¹ M. S. Mayou. *Changes Produced by Inflammation in the Conjunctiva*, 1905, 47.

when a director was passed beneath the rectus muscle which was divided by a bistoury run along its groove.

Perforating Wounds of the Globe Behind the Limbus.—

A perforating wound of the globe behind the limbus and anterior to the insertion of the recti muscles penetrates conjunctiva, sclerotic and ciliary body. One situated behind the insertion of the recti muscles, in addition to the conjunctiva, Tenon's capsule, and sclerotic, may go through one of the extraocular muscles, and will also penetrate the retina and choroid.

The amount of gaping of such wounds, and the amount of intraocular hemorrhage to which they give rise, depends on whether they run parallel to the corneal margin or at right angles to it. The edges of a wound through the sclerotic at right angles to the fibres of a rectus muscle may by the contraction of the latter be made to ride one above the other. In a wound which runs parallel to the fibres of a rectus muscle the edges fall more evenly into position.

The blood-vessels of the choroid and retina run mostly antero-posteriorly and a wound running in that direction divides fewer of them than one crossing them at right angles.

The phagocytic exudation met with about the margins of a perforating wound through the sclerotic varies in amount according to the character of the wound and the presence or absence of any irritant in connection with it. In a clean cut aseptic wound, such as that made in the operation of posterior sclerotomy, it is very slight.

The cicatricial tissue which forms after a perforating wound of the sclerotic is largely produced by proliferation of the cells of the vascular episcleral tissue, aided to some extent by the fixed cells of the sclerotic itself and the vascular tissue of the choroid.

The cicatricial tissue which forms in the opening left by a perforation of the ciliary body or of the choroid and retina is mainly produced by the proliferation of the cells about the blood-vessels of those structures. In the retina the nerve elements in the region of a perforating wound are destroyed

and never restored. It is unlikely that the epiblastic portions of that structure take any part in the reparative process. The fibrous tissue formed in the opening and on the inner surface of the membrane is probably entirely derived from mesoblastic tissue composing the retinal and choroidal blood-vessels.

Through a perforating wound of the globe into the vitreous humour some escape of fluid from that structure usually occurs. Occasionally a portion of its framework may prolapse through the wound and lying in the conjunctival sac form a channel along which infective organisms travel into the eye, there setting up intraocular inflammation.

Wounds of the Iris.—Aseptic wounds of the iris, such as are made in a surgical iridectomy, show no tendency to the formation of granulation tissue or to cicatrisation. The appearances of a wound of the iris years after its infliction, except for the absorption of the blood, may be precisely the same as when it was first made.¹ The ragged edge left remains a ragged edge, there being no new formation of fibrous tissue to fill it in, and no extension around it of the endothelium from the anterior surface or of pigment epithelium from the posterior surface. This is probably accounted for by its suspension in the aqueous humour preserving it free from all irritation. There is ample evidence that the iris is capable of producing granulation tissue and of becoming sclerosed when irritated by toxic substances. When the iris becomes prolapsed either through a wound or a perforating ulcer a granulation grows from it which subsequently develops into fibrous tissue.

After some wounds of the iris a large extravasation of blood takes place into its tissue constituting a hematoma.

Wounds of the Lens.—After a wound of the lens capsule the divided ends retract and roll outward. In small experimental aseptic wounds a layer of fibrin has first been found to cover the gap, then the epithelial cells lining the capsule proliferate and extend across it. These first formed cells

¹ T. Henderson. *Ophthalmic Review*, XXVI, 1907, 191.

lengthen out into fibres similar to those met with in anterior polar cataracts. Later, underneath these fibres a single row of cubical cells form, continuous with and similar to those lining the normal capsule. From this single row of cells a new hyaline layer, like the capsule, is slowly secreted.¹

After a wound of the lens, the aqueous or vitreous humour extends into its substance rendering it opaque. The fluid causes the lens fibres to separate, become swollen,

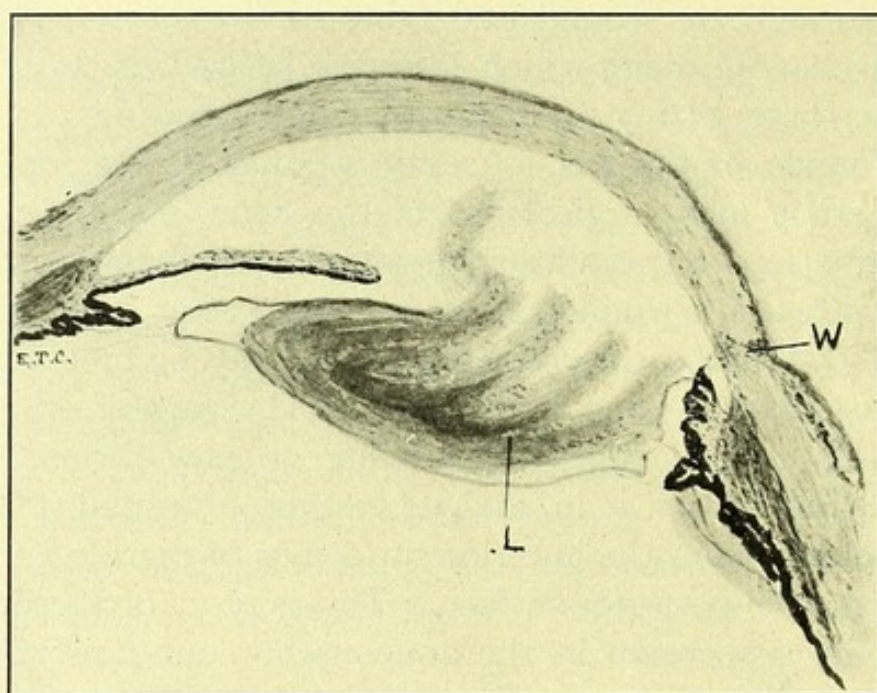


FIG. 156.—Perforating wound of cornea *W* and lens *L*. The iris prolapsed and has been cut off. The swollen lens fibres are shown breaking up and protruding through a gap in the anterior capsule into the anterior chamber.

and break up into globules or irregular shaped masses. Through a wound in the anterior capsule the lens substance will usually protrude forward into the anterior chamber. The lens fibres are mainly composed of an albuminous substance called globulin. The aqueous humour consists of a weak solution of chloride of sodium in which it is soluble. Lens matter, therefore, projecting into the anterior chamber and exposed to the action of the aqueous humour gradually

¹ O. Schirmer. *Archiv. f. Ophth.*, XXXV, 1899, 1, 220.

becomes dissolved in it. The aqueous humour is constantly filtering out of the eye and being secreted, so that as long as a wound in the lens capsule remains open fresh lens matter will become dissolved and be carried away in solution. In this way the whole lens may become absorbed and removed from the eye.

The lens substance forms an excellent nutrient media for the growth of microorganisms. After septic wounds of it polymorphonuclear leukocytes are rapidly thrown out, pass through the opening in the capsule and penetrate between the lens fibres.

In wounds of the lens with less violent inflammation of the surrounding parts, mononuclear leukocytes and fibroblasts from the iris pass into the capsule, forming fibrous tissue which unites the two structures.

When the lens is removed through an opening in its capsule, as in the operation of extraction of cataract, some of the cortex is nearly always left behind. The amount varies in different cases; usually in complete cataracts the whole of the lens substance opposite the pupillary area is removed, the anterior and posterior capsule being left there lying in contact with one another. Very commonly a ring of lens substance in the extreme periphery of the capsule remains. In incomplete cataracts some cortical matter may be left in the pupillary area, its presence owing to its transparency being unrecognised at the conclusion of the operation. Later, as the result of the action of the aqueous humour this cortical substance becomes opaque. The opening in the capsule through which the nucleus was removed, in time, becomes closed by a proliferation of the capsule cells and the opaque cortex is then shut off from the solvent action of the aqueous. It may remain in the capsule indefinitely and sometimes become the seat of calcareous deposit. A secondary opacity appearing soon after an extraction of cataract is accounted for in this way.

A secondary opacity appearing later, causing vision which for a time has been good to slowly deteriorate is due

to proliferation of the epithelial cells lining the anterior capsule. They, like the epithelial cells on the surface of the body from which they are derived, have a tendency to proliferate throughout life. When the lens is present the cap-

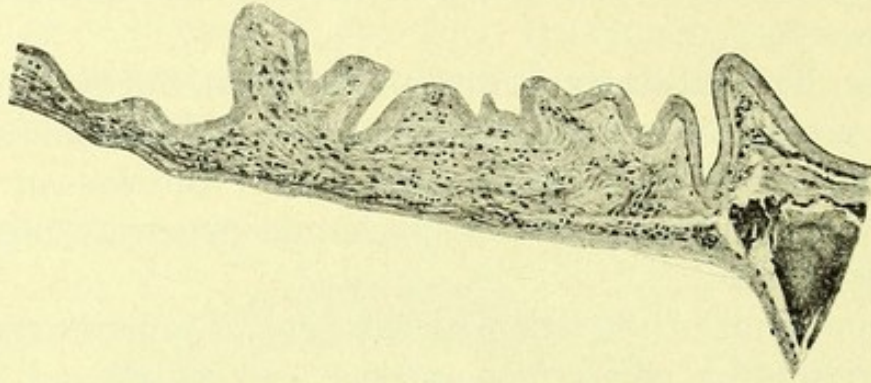


FIG. 157.—Shows the two layers of the lens capsule after extraction, with laminated tissue lying between them, formed by proliferation of the lining epithelium subsequent to the operation.

sule cells are transformed laterally into lens fibres. The proliferative activity of the cells is kept in check as years advance by the intracapsular tension to which they become exposed. After extraction of the lens this tension is relieved and the rate of multiplication of the cells increases. The

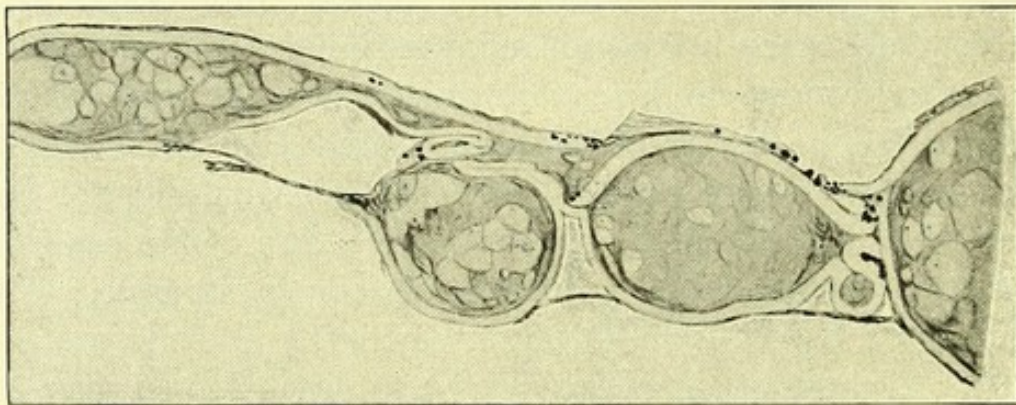


FIG. 158.—Shows the two layers of lens capsule after extraction of cataract, with large bladder-like cells, of subsequent formation, lying between them.

newly developed cells accumulate in several layers on the inner surface of the capsule and either lengthen out forming a kind of fibrous tissue (Fig. 157), as in anterior polar cataracts, or swell up into large globular cells (Fig. 158). The

opacity which such new formations give rise to is often not very dense, but the globules and irregularities in it break up the rays of light as they pass through and cause considerable disturbance of vision.

✓ A third form of secondary opacity is due to the development of true fibrous tissue inside or outside the lens capsule in the way already mentioned, such opacity is always the outcome of iritis.

Wounds of the Optic Nerve.—Accidental wounds of the optic nerve may be the result of direct or indirect injury. Direct accidental wounds are produced by stabs into the orbit with long sharp-pointed instruments or by gunshot injuries. Indirect accidental wounds are caused by blows resulting in a fracture of the base of the skull which passes through the optic foramen. The sharp edge of the fractured bone may then completely sever the nerve, or wound it, so as to give rise to hemorrhage into its sheath.

The optic nerve is sometimes intentionally divided in surgical procedures, such as optico-ciliary neurotomy, excision of the eyeball, and in Kronlein's operation for removal of a tumour of the nerve.

The symptoms of a wound of the optic nerve vary considerably according to whether it is situated in front or behind the position at which the central artery enters it, which is generally 15 to 20 mm. behind the eyeball.

A wound completely severing the nerve behind the point of entrance of the central artery gives rise at once to complete loss of sight without at first any ophthalmoscopic changes. An atrophy of the nerve fibres sets in from the point of division which manifests itself as pallor of the optic disc from three to four weeks after the receipt of injury.

Incomplete severance of the nerve behind the entrance of the central retinal artery or a hemorrhage into the nerve sheath may produce a partial loss of sight only. Hemorrhage into the nerve sheath may impair sight by direct pressure on the nerve fibres or by obstruction to the circulation in the central vessels. The blood in the sheath has been

known to extend forward and make its appearance in the eye at the margin of the optic disc. Pigmentation of the edge of the optic disc has been recorded as one of its sequelæ.

A division of the optic nerve between the back of the eyeball and the point of entrance of the central retinal artery is frequently associated with division of some of the ciliary arteries around it.

Besides the complete loss of sight there are produced ophthalmoscopic changes which are quite characteristic and which resemble those occurring in connection with embolism of the central artery.¹

There is opacity of the retina around the optic disc and macula; sometimes a white mass of exudate at the disc, either blurring its margins or completely concealing it;² a red spot at the macula; diminution in size of the retinal arteries, and diminution of intraocular tension. In course of time the opacity of retina clears up, small hemorrhages or patches of pigmentation make their appearance and the disc becomes white and atrophied.

The opacity of the retina has been attributed to edema from an alteration in osmotic pressures, as a result of the anemia. There seems, however, some reason to regard it as mainly due to coagulative necrosis of the ganglion cell layer, this matter is further discussed on page 471.

The retinal vessels refill when the cut ends become closed through the cilioretinal anastomoses about the optic disc, new capillaries being formed. The obstructed circulation due to the circuitous route the blood has to take to reach the choroidal veins probably accounts for the retinal hemorrhages.

IV. Foreign Bodies.

Cases in which a foreign body is implanted in the eye may be divided into (a) those in which it has lodged in the cornea, conjunctiva or sclerotic, and (b) those in which it has

¹ J. H. Parsons. R. Lond. Ophth. Hosp. Reps., XV, 1903, 362.

² M. S. Mayou. R. Lond. Ophth. Hosp. Reps. XVI, 1905, 157.

penetrated the outer wall of the globe and become located in the interior.

a. Foreign Bodies in the Cornea, Conjunctiva or Sclerotic.—The foreign bodies which have been met with implanted in the cornea, conjunctiva or sclerotic are fragments of iron, stone, coal, glass, porcelain, wood, copper, grains of gunpowder, particles of lime or sand, eyelashes, and hairs of caterpillars. Foreign bodies are more often found in the cornea than in the conjunctiva or sclerotic. A foreign body implanted in any of these structures usually causes considerable irritation and pain, though cases are met with in which the amount of reaction has been exceedingly slight. A foreign body in the sclerotic beneath the conjunctiva is more readily tolerated than in the cornea. If septic organisms are implanted with the foreign body a suppuration around it ensues. Some foreign substances, *e.g.*, pieces of copper, are capable of exciting inflammation by the chemical action to which they give rise. Fragments of iron rapidly cause a rust staining of the tissue around them due to oxidation.

Ophthalmia Nodosa.—The hairs of caterpillars implanted in the front of the eye may give rise to an affection which has been termed ophthalmia nodosa. It is the hairs of the caterpillar of the fox moth, the *Bombyx rubi*, popularly known as the woolly bear, to which most cases of this affection have been due, though in some the hairs from other species of caterpillars have been the exciting cause.

There is always an interval of some weeks between the receipt of the injury with the caterpillar and the formation of the nodules. An examination of the hairs shows them to be sharp-pointed with an imbricated arrangement of cells on their surface; this probably accounts for their remarkable capacity of penetrating the tissue, which is doubtless assisted by the patient's rubbing the eye on account of irritation experienced, and by the friction of the eyelids in winking.

It seems probable that the pernicious effect produced

by the hairs is to some extent the result of some specific poison contained in them, though it may be in part due to mechanical irritation caused by its toothed edge.

Around the implanted hairs semi-transparent, round or oval nodules form, about 1 to 2 mm. in diameter, grey or yellowish in colour; when in the conjunctiva they feel firm to the touch. In the cornea the hairs give rise to infiltration and vascularity. They have been known to penetrate as deep as the iris, causing inflammation and the formation of nodules in it. The nodules in the conjunctiva if left to themselves ultimately shrink and leave scars behind; they never break down and ulcerate.

Microscopically the nodules show in the centre the caterpillar's hair with a grouping of cells around it very similar to that met with in a tubercular nodule. There are giant cells with peripherally arranged nuclei, epithelioid cells, and dense round cell infiltration.

b. Foreign Bodies in the Interior of the Eye.—Any hard substance provided it is propelled with sufficient force may penetrate the coats of the eye and become lodged in its interior. Sometimes foreign bodies, such as an eyelash, may be carried into the eye with the wounding instrument and be left there after its withdrawal.

In the Moorfields Hospital Museum there are specimens showing the following foreign substances in eyes. Chips and scales of steel and iron, fragments of stone, a piece of wood, a piece of lead, a piece of coal, a piece of glass, a shot, eyelashes, and a tin tack.

A foreign body which has penetrated to the interior of the eye may lie in the anterior chamber, be entangled in the iris or embedded in the lens, float free in the vitreous chamber, pass through the vitreous and become entangled in the retina and choroid, or pass through them and be embedded in the sclerotic. Sometimes a foreign body after passing through the vitreous chamber to its posterior wall has not sufficient force to penetrate the coats of the eye a second time, but after striking them rebounds falling down

to its lowest part. In such an eye the aperture of entrance is seen and the track can be followed to the point of impact with the retina, where there will be either a bruised spot or an area of atrophy, while the foreign body will be found in the lowest part of the vitreous chamber.

Foreign bodies located in some structures of the eye are more readily tolerated than in others. Several cases in which foreign bodies have remained embedded in the lens for more than twenty years without exciting irritation have been recorded. Foreign bodies embedded in the sclerotic after passing through the eye have also frequently remained for many years without causing any disturbance. It has been shown experimentally that pieces of sterilised copper which rest on the iris or inner surface of the ciliary body always excite suppuration around them. A similar piece introduced into the lens produces no purulent exudation; it becomes enveloped by a thick coating of albumen which prevents it from exciting an irritating chemical action.

The amount of reaction excited by an implanted foreign body depends not only on its situation, but very largely on the organisms which may be carried in with it and its chemical nature.

Where virulent septic organisms are introduced with a foreign body, suppuration rapidly ensues. Not uncommonly the chips of metal which enter the eye accidentally have become sterilised by heat from being hammered before striking the eye. Experiments on animals have shown that different substances introduced into the eye produce very different effects according to the chemical reactions to which they give rise.¹ Thus pieces of sterilised gold or glass introduced into a rabbit's eye excite no inflammation, but slowly become encapsuled by a delicate covering of connective tissue or giant cells. A drop of sterilised quicksilver or a piece of sterilised copper introduced in the same way gives rise to a localised suppuration, while croton oil or cantharides

¹ T. Leber. Bowman Lecture, Trans. Ophth. Soc. of the U. K., XII, 1892, 4.

introduced aseptically cause no formation of pus but a fibrinous exudation with necrosis of tissue.

Accidents in which pieces of copper enter the eye are common owing to the explosion of percussion caps; the pieces are frequently sterile but give rise to suppuration around them. This suppuration is unlike that due to microbic infection in that it does not tend to spread. If the piece of copper is in the anterior chamber, the suppuration does not extend to the vitreous. If it is in the vitreous the suppurative inflammation excited may result in phthisis bulbi, the cornea remaining transparent and the anterior chamber unaltered.

Siderosis Bulbi.—Eyes in which pieces of iron have remained embedded for a long time undergo certain degenerative and pigmentary changes which have been termed siderosis bulbi. Night-blindness and contraction of the field of vision are observed and sometimes detachment of the retina. Various tissues become stained a rusty brown colour. Minute brown granules are found in the cornea. A ring of reddish-brown patches forms in the anterior part of the lens at the margin of the pupil. The iris if blue or grey changes to a brown or greenish-brown colour. The retina becomes pigmented. The condition is due to a solution of the iron being formed in the intraocular fluid, its diffusion throughout the eye, and redeposition in some of its tissues.

The soluble bicarbonate is probably formed by the action of the carbonic acid in the tissues. The cause of the redeposition of the iron is doubtful; it has been suggested that it is brought about by its oxidation by the blood, and the way in which it is found in the vicinity of the retinal vessels favours this view. Its deposition in the capsular epithelium of an avascular structure like the lens, is against it. Another theory, and one which has much in its favour, is that the deposition is due to a special affinity which some cells have for iron.

In sections of eyes with siderosis, which have been

hardened in alcohol or formalin, the deposited iron may be stained a blue colour by placing them first in 2 per cent. aqueous solution of ferrocyanide of potassium for a few minutes and then into a 1 per cent. solution of hydrochloric acid.

The deposition is found chiefly in the following situations: the tissue immediately around the foreign body; the unpigmented epithelial cells of the ciliary body; the retina; the cells lining the lens capsule; the iris and cornea, particularly at the angle of the anterior chamber about the fibres of the ligamentum pectinatum.

A brown discolouration of the cornea and lens may sometimes be due to their impregnation with pigments containing iron derived from the blood. After an intraocular hemorrhage the retinal pigment epithelium will also sometimes take up iron derived from it. The staining of the tissues with iron containing pigments derived from the blood has been termed **hematogenous siderosis** to distinguish it from that derived from a foreign body which is spoken of as **xemogenous siderosis**.

Leaden shot implanted in the eye are usually aseptic and set up very little irritation; they soon become encapsuled with a covering of connective tissue.

Around some foreign bodies which are lodged in the eye, giant cells, very similar to those met with in tubercular systems, make their appearance. They are most probably derived from the endothelium of the blood and lymphatic vessels and have a phagocytic function. They are usually to be seen about foreign bodies of an absorbable nature and less often around pieces of metal. The formation of nodules with giant cells around the hairs of caterpillars when they penetrate to the iris has already been referred to (see page 276). Giant cells are also met with around cilia implanted in the eye.

Cilia have been met with lying in a corneal wound, in the anterior, posterior, and vitreous chambers. They have been introduced into the anterior chamber of a rabbit's eye

experimentally. If the root sheath of the hair is carried in with it, the cells composing it proliferate and form a pearl-like epithelial tumour or a cystic growth lined by laminated epithelium (see page 158).

V. Heat and Chemicals.

Heat injuries of the eye usually arise from splashes of hot metal, from accidents with curling tongs, or from explosions of either gunpowder, dynamite, or match heads.

Injuries with chemicals are produced by splashes of strong acids or alkalies, and by lime, either unslaked in the form of calcium oxide or as mortar, that is, slaked lime mixed with sand.

The effects produced by **burns and the corrosive action of caustics** are so similar that they may be dealt with together.

The most superficial injuries only involve the epithelium of the cornea rendering it dry, opaque, and white. The abraided area formed soon becomes covered by proliferation of the cells around and no permanent opacity results. If the deeper parts are involved a slough forms which separates by a process of suppuration leaving a granulating surface. The cicatrization which takes place at the site of this granulating area leads to considerable contraction. When both cornea and conjunctiva are involved the latter, owing to its loose attachments, becomes drawn over part of the former, giving rise to a condition which simulates a pterygium and which is termed **false pterygium**.

If the opposing surfaces of the eyeball and eyelid become burnt, the two granulating surfaces readily unite. A cicatricial band joining these two structures is termed **symblepharon**.

In the most severe cases of burn perforation of the cornea or sclerotic may take place with escape of some of the contents of the globe and the other sequelæ of a perforating lesion.

After lime burns of the conjunctiva or cornea particles

of lime may remain in the tissue, as calcium chloride, and give rise to a permanent dense porcelain-like opacity, a condition which is termed **calcareous incrustation**.

Another change in the tissues of the eye which may be produced by chemicals is that of staining. This most commonly takes place in the conjunctiva either from prolonged local application of silver salts, organic or inorganic, in the treatment of ophthalmia, or as part of a general staining of cutaneous structures from the prolonged internal administration of nitrate of silver. The condition produced is brownish discolouration of the membrane, both ocular and palpebral, which, microscopically, is found to be due to the deposition of granules of black pigment chiefly around the fibres of elastic tissue, but also in the cement substance of the endothelial cells of the capillaries and smaller blood-vessels. The surface epithelium, is unaffected, its constant renewal not allowing time for any deposition to take place.

A reddish-brown or rusty colour of the upper and lower limbus of the cornea has also been described¹ as resulting from the prolonged use of copper sulphate in cases of trachoma.

VI. Light, Electricity, and X-rays.

Various affections of the eye may be produced by undue exposure to bright light. A central scotoma, positive or negative, may be produced from looking for a long time at the sun, as in watching an eclipse without the precaution of using a tinted glass.

In some cases the scotoma in course of time completely disappears, in others it remains permanent. The condition has been termed **eclipse-blindness**.

The ophthalmoscopic changes which accompany it are usually very slight and appear disproportionate to the defect in vision. A few small white dots or a little pigmentary

¹ Sydney Stephenson. Trans. Ophth. Soc. of the U. K., XXIII, 1903, 25.

disturbance is usually all that is to be seen. Edema of the head of the optic nerve, of the retina in the macular region, and retinal hemorrhages have been met with. A pallor of the macular fibres in the optic disc has been noted where the central scotoma has remained permanent.

The change is probably of a chemical nature brought about by a too prolonged concentration of the ultra-violet, chemical active rays on the retinal elements at the macula. Any damage from a concentration of the heat rays is probably prevented from a reduction in their potency by passage through the media.

A prolonged exposure to reflected light from the sea or desert plains, etc., may in badly nourished individuals cause **night-blindness**. This affection is more commonly met with in the tropics than in temperate regions. It is unaccompanied by any ophthalmoscopic changes and recovery soon takes place by protection of the eyes from bright light and an improvement of the nutrition of the patient. It is probably due to some failure in the reformation of the visual purple after it has been destroyed by bright light, the condition being a prolongation of the normal temporary failure of sight which is experienced on passing from a strongly lighted place to a dark one.

Bright reflected light, like that from snow, in persons who have undergone the operation of extraction of cataract may excite a condition called **erythropsia or red vision**. The crystalline lens probably absorbs rays of light which when it is absent are able to pass into the eye and cause this affection. It has been known, however, to occur in normal eyes with a widely dilated pupil, which have been purposely exposed to glare from snow in the mountains. The red vision is not observed until the affected person passes into a dark place, then all objects assume a roseate hue. It may last for only a few minutes or for several days. Its cause cannot yet be said to be certainly determined. Various explanations have been suggested, the most probable seems to be that it is due to entoptic vision of blood in the retinal

vessels,¹ an abnormal hyperemia of the retina being excited by the exposure to bright light in the same way as a hyperemia of the skin is produced.

Experiments on animals have shown that exposure to the ultra-violet rays produces a chromolytic action in the retinal cells which if prolonged results in injurious effects.

Besides affections of the retina, undue exposure to ultra-violet rays may produce changes in the front of the eye, conditions which are termed clinically **snow-blindness** and **ophthalmia electrica**. The symptoms occur suddenly after a latent period of some hours and consist of great photophobia, lacrimation, edema of the eyelids, conjunctival hyperemia, slight erosions of the surface of the cornea, and contraction of the pupil. A considerable number of ultra-violet rays are reflected by the snow and emanate from electric lamps, especially arc lamps and mercurial vapour lamps.

Experimentally the above symptoms together with some cloudiness of the cornea and iritis have been produced in rabbits by exposure to ultra-violet rays.

The possibility of exposure to bright light producing cataract is a matter which has been much discussed. Experimentally² it has been shown that by prolonged exposure to ultra-violet rays changes can be produced in the capsular epithelium of the lens, resulting in its degeneration and ultimate destruction. No changes were observed in the lens fibres, but the rapid clouding of the cornea which came on may have served to protect them.

Glass-workers who in their trade are exposed to incandescent molten glass are very prone to develop cataract. The appearances of **glass-worker's cataract** in its early stages are very characteristic. It commences as a circular central opacity in the posterior cortical layers of the lens, lying entirely in the pupillary area. It may remain in this condition for several years or extend to other parts of the cortex, ultimately becoming a complete cataract. It is then indis-

¹ W. H. R. Rivers. Trans. Ophth. Soc. of the U. K., XXI, 1901, 296.

² C. Hess. Arch. f. Augenheilk., LVII., 1907, 3, 298.

tinguishable from a cataract from any other cause. In glass-blowers owing to the position in which they work the left eye is usually affected first and the skin of the face on the left side acquires a peculiar reddish-brown colour.

No changes have been discovered in the eyes affected apart from the cataract. It seems improbable that the cataract can be attributed to the constant sweating of the men while at work. Men employed in other kinds of work perspire just as freely and do not suffer from lenticular changes of the same nature.

The fact that the opacity commences at the nodal point in the lens, *i.e.*, where all the principal rays passing into the eye cross, suggests that condition is set up by some of the rays radiating from the molten glass. Whether it is due to heat rays or ultra-violet rays cannot yet be said to be definitely decided, though it would seem probable that any thermic action of the former would be largely reduced by passage through the aqueous humour.

Injuries from Lightning.—Lightning may injure the eye in three different ways:

1. Through its ultra-violet rays. 2. Through its heat rays. 3. By electrolytic action or concussion.

①. Through its ultra-violet rays it produces symptoms similar to those just enumerated in connection with snow-blindness and ophthalmia electrica. In some cases these may be the only result of a lightning injury.

②. Through its heat rays burns of the skin of the lids, eyelashes or front of the eye may occasionally occur.

③. The injuries resulting from electrolytic action are very various. Most of them have been produced experimentally in animals by electric explosions from a Leyden jar made in close proximity to their heads.¹

The commonest changes are circulatory disturbances resulting in intraocular hemorrhages or opacities of the transparent media, cornea, lens, or vitreous. Nerve lesions may

¹ C. Hess. Bericht d. VII. Internat. Ophth. Kongress, Heidelberg, 1888. K. Kiribuchi. Arch. f. Ophth. L., 1900, 1, 1.

occur causing paralysis of the extra- or intraocular muscles, also atrophy of the optic nerve. Detachment of the retina has also been recorded.

Injuries from the X-rays.—Experiments have shown that the x-rays have no power of bleaching the visual purple. Little is known yet as to the injurious effects which they may produce on the eyes. On healthy living tissue they are known to cause a superficial irritation with dilatation of capillaries and, according to the amount of exposure, anything from a mild leukocytosis to an actual gangrene. They have been largely used in treatment of cases of trachoma, the leukocytosis which is set up tending to cause an absorption of the lymphoid follicles characteristic of that disease. A case of a woman has been recorded¹ who was treated with X-rays for lupus of both cheeks, having twenty exposures on the right side and eighteen on the left, the eyes being protected with rubber. Nine months afterward her sight had considerably failed. When examined some years later with dilated pupils there was found to be in each eye a dense greyish-white granular plaque at the posterior pole of the lens and also some granular opacity in the cortex. The appearances of the opacities were very similar to those met with in glass-worker's cataract.

¹ Lesile Paton. Trans. Ophth. Soc. of U. K., XXIX, 1909, 37.

CHAPTER V.

INFLAMMATION.

The inflammatory changes in the eye will in this chapter be discussed under the following headings:

I. The changes which are common to all inflammatory processes.

II. The modifications they undergo in the various structures of the eye.

III. The method of infection of the ocular tissues.

In the next chapter the specific microörganisms and the changes they give rise to in the eye will be dealt with.

I. The Changes in the Tissue which are Common to all Inflammatory Processes.

The tissues of the eye, being capable of accurate clinical and pathological examination, have largely been used as the field of experimental and histological investigations of the many problems which have arisen in connection with inflammation.

The cornea, being free from blood-vessels and not very cellular, allows, in the early stages of an inflammation, a study to be made of the manner in which the cellular exudate from the blood-vessels of the limbus make their way in the tissue toward the site of inflammation. The transparency of the cornea allows of the effect of the introduction of various substances into the anterior chamber being observed.

The aqueous, especially that freshly formed, after evacuation of the anterior chamber, contains the protective and toxic bodies found in the blood and is a means of obtaining fluid for examination of these substances and the di-

agnosis of disease by the Bordet-Gengou reaction. In inflammation of the uveal tract the aqueous contains organisms and toxins which may be obtained therefrom and examined. Cultivations may also be made for the preparation of vaccines.

In the conjunctiva the development of lymphoid tissue can be examined and the formation of the cellular elements found therein, which are so important as a protective agent against infection and in the process of repair after inflammation. The accessibility of its position allows it to be employed for testing the effects on the tissues of various toxins.

The fundus allows the examination of blood-vessels under magnification and the changes they undergo when the retina, optic nerve, or choroid becomes inflamed. The blood-vessels being the only mesoblast contained in the retina it affords a position in which to study the part played by the endothelium in the process of repair and formation of fibrous tissue.

Without going deeply into the controversies which surround the various theories put forward to explain the phenomena connected with inflammation, it is not out of place to give here a bare outline of the changes which take place and the theories which are supposed to govern them, also to show to some extent the part played by the ocular tissues in solving some of these problems.

Inflammation may be defined as the first of a series of changes which occur in the tissues as the result of an injury provided the injury is not of sufficient violence to cause instant death of the part. The injury may be either chemical, bacterial, or mechanical in its nature. The severity of the change depends on the intensity of the injury, its duration and on the length of time the cause is active.

Bacteria are by far the commonest cause of inflammation. Microorganisms growing in the tissues set up a local reaction of varying severity. They themselves or the poison they produce enter the blood stream and thereby set up profound alteration in the serous and cellular elements of

the body, which give rise to general symptoms known collectively as fever.

It may be possible **to recognise the cause of the inflammation** by one of the following means:

a. The clinical change set up by the organism may be characteristic and distinctive; *e.g.*, angular conjunctivitis, due to the diplobacillus of Morax Axenfeld.

b. The organisms may be found on microscopical examination of the secretion; *e.g.*, gonorrheal conjunctivitis.

c. The histological appearances of the affected tissues may be so characteristic as to reveal its nature, *e.g.*, tubercle.

d. Biochemical examination of the changes produced in the blood-serum as the result of inflammation, as in Widal reaction for typhoid and the Wassermann sero-diagnosis of syphilis.

e. The reaction produced by the introduction into the blood stream of small doses of the dead organisms (vaccine) similar to that causing the lesion; this may be seen locally at the site of the lesion; in the blood it may be gauged by the opsonic index or other biochemical reaction; in the whole organism by the production of fever.

f. Local reaction of the tissues to vaccine by surface inoculation, as in the ophthalmo-tuberculin reaction antiphorexis.

g. The inoculation of the diseased tissue into animals will reproduce the disease in a more typical form if the animal be susceptible to it; *e.g.*, the inoculation of tubercle into guinea-pigs.

The earliest changes which occur in the tissue of the affected area as the result of inflammation are dependent upon the blood, the changes in the blood being again dependent on the general reaction of the whole body to the infection, the blood stream merely conveying to the inflamed part the products of the tissues. The later changes, more especially those associated with the reparative processes which follow the inflammation, are dependent on the local tissues of the part.

The first change which takes place in an acute inflamma-

tion is dilatation of the vessels and an increased flow of blood to the part, as is well demonstrated in any acute inflammation of the conjunctiva; the increased flow of blood associated with increased chemical activity raises the local temperature, as has been shown by introducing specially devised thermometers into the conjunctival sac in acute conjunctivitis. After a time the blood stream is slowed, and complete stasis may occur which, in severe cases, may go on to coagulation of the blood and exudate, frequently causing necrosis of the affected area (coagulation necrosis).

The slowing of the blood stream in the capillaries allows an exudation of their contents. This consists of the plasma, which passes through their walls by a process of osmosis, and cellular elements. Leukocytes make their way through the walls by their ameboid movement, a process known as diapedesis. Certain influences (such as the toxin of the Koch-Weeks bacillus) cause the red cells also to pass out into the tissues.

This exudation of the fluid and cellular elements of the blood gives rise to swelling in the tissue which, in the conjunctiva, owing to its laxity, may be very extensive, causing the condition known as chemosis.

In addition to the local pain, redness and swelling, there is a loss of function of the part, as for example the inactivity of the pupil in iritis and the failure of vision in retinitis and inflammation of the optic nerve.

The plasma exuded from the blood-vessels, by virtue of certain bodies it contains, acts on the bacteria and either destroys them or renders them inert, while the leukocytes, especially the polymorphonuclear variety, by their ameboid movement, or more probably by some alteration in the surface tension of the organism, surround and then digest them.

The blood-serum plays a most important part in inflammation, and as the future diagnosis and therapy of many diseases of the eye will be based on its examination and use, it is necessary to give a brief outline of some of the general

principles upon which our present knowledge of **humoral pathology** is based.

Antigens is a generic term used to indicate any agents of an organic composition which, when introduced into the body, form substances in the blood-serum which may be so poisonous to the animal as to produce molecular or total death. The host into which they are introduced in sub-lethal doses reacts by producing antibodies which tend to neutralise their harmful effect.

Belonging to this group are the pathogenic bacteria. The effect they produce on the body is due to an antigen, which may be contained within the organism itself—endotoxin—as in the case of the typhoid bacillus, or which may be secreted by the organism and absorbed into the blood, as is the case with the bacillus of diphtheria.

Pathogenic bacteria when introduced into the body, produce substances which gaining access to the circulation may have a harmful effect on the animal; the host reacts by producing specific bodies which tend to neutralise their effect. The following antigens derived from bacteria and their resulting antibodies have been described:

Toxinogens (toxins) induce the production of anti-toxins which neutralise the toxin.

Agglutinogens induce the production of agglutins, which cause agglutination of the antigens.

Precipitinogens induce the production of precipitins, which in their turn cause precipitation of the antigens.

Lysinogens induce the production of lysins, which dissolve the antigens which in some instances are bacteria.

Opsoninogens induce the production of opsonins; these substances act on the body of the antigens and so alter their external surface as to allow them to be taken up by the leukocytes.

Aggressinogens give rise to aggressins. The latter neutralise those products of bacteria which paralyse the leukocytes.

When antigens are introduced into the body in sub-lethal

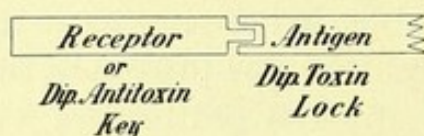
doses they produce in the serum the antibodies already mentioned; namely, antioxins, agglutins, precipitins, lysins, opsonins, and aggressins respectively. In the case of antitoxins, opsonins, and lysins, it is definitely proved that these substances are defensive in their action. It is probable also that the other substances play a part in immunity, but their exact function has not yet been demonstrated.

Antitoxin appears in the blood-serum of an animal after the injection of a sub-lethal dose of toxin and is produced by the cells of the body; this was proved in the case of the toxin of jequirity (abrin), by the grafting of a piece of conjunctiva, from a rabbit the subject of jequirity conjunctivitis, into another rabbit, which was thereby rendered immune to the action of the jequirity on its conjunctiva.

If an antitoxin is present in an animal's serum, and a dose of toxin be administered, the antitoxin enters into a biochemical combination with the toxin and renders it inert. This action is specific. If a toxin be injected into an animal and at some interval the antitoxin be administered the animal may or may not recover, the result depending on the length of time the antitoxin is administered after the toxin. The toxin enters into union with cells of the animal; the antitoxin, if administered late in the course of the disease, is unable to dissociate this compound; the action of the toxin continues and death ensues. Hence the importance of the early administration of antitoxin in diphtheria.

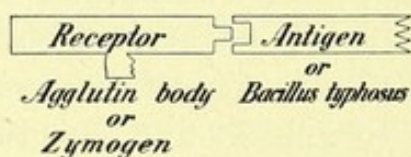
To explain the formation and reaction of the various antibodies Ehrlich propounded his "**side-chain**" theory on the principle analogous to the benzene ring in chemistry. He supposed that every cell had figurative arms by which they attach to themselves nutrition, toxins, etc. These arms he called receptors. The ultimate effect on the cell of the injection of a sub-lethal dose of the poison is an overproduction of these receptors which are thrown off into the blood and there confer on the animal an immunity (antitoxin). Thus if a sub-lethal dose of diphtheria toxin be administered there would be an overproduction of receptors or antitoxin

formed in the blood; the serum from this animal would contain receptors and when serum containing these be administered to a patient with diphtheria they would combine with the toxin (antigen) and so render the latter inert. The action of the antitoxin is specific; that is to say, the receptor must belong to the same group as that of the antigen. The



receptor has been compared to a key and the antigen to a lock. Before the lock can be opened the wards of the key must fit the lock.


Precipitins and **agglutins** have a receptor of a different order which has attached to it a special substance (zymogen), the specific action of which is so to alter the antigen as to produce agglutination or precipitation. Thus in the case of the *Bacillus typhosus*, the presence of the zymogen attached to the receptor in the serum of the ty-



phoid patient causes the bacilli in suspension to run together (agglutination, Widal reaction).

Lysins (Bacteriolysin, Cytolysin).—Bacteriolysin is a substance present in an "immunised serum" which dissolves bacteria. This immunised serum is produced by the injection into an animal of sub-lethal doses of the organism. Immunised serum, on heating to 56.5° C. for half an hour, loses its power of dissolving bacteria, but if a little fresh

serum which may come from an unimmunised animal be added this power is regained. Therefore two bodies are present in this serum: 1. a heat-resisting substance, and 2. a substance destroyed by heat which is known as the **complement** or **alexin**. The receptor which resists the action of heat in this instance is double ended and is therefore known as the **amboceptor**. By the one end it is capable of attaching to itself the antigen or bacteria and to the other the complement or substance which is destroyed by heat. The amboceptor combines first with the antigen and afterward with the complement. Immunised serum, which has been treated by heating it to 56.5°C . for half an hour, is known as "inactivated," because the serum cannot exert its lytic power, but can be "activated" again by the addition of a small quantity of serum from any unimmunised animal as it contains the complement.

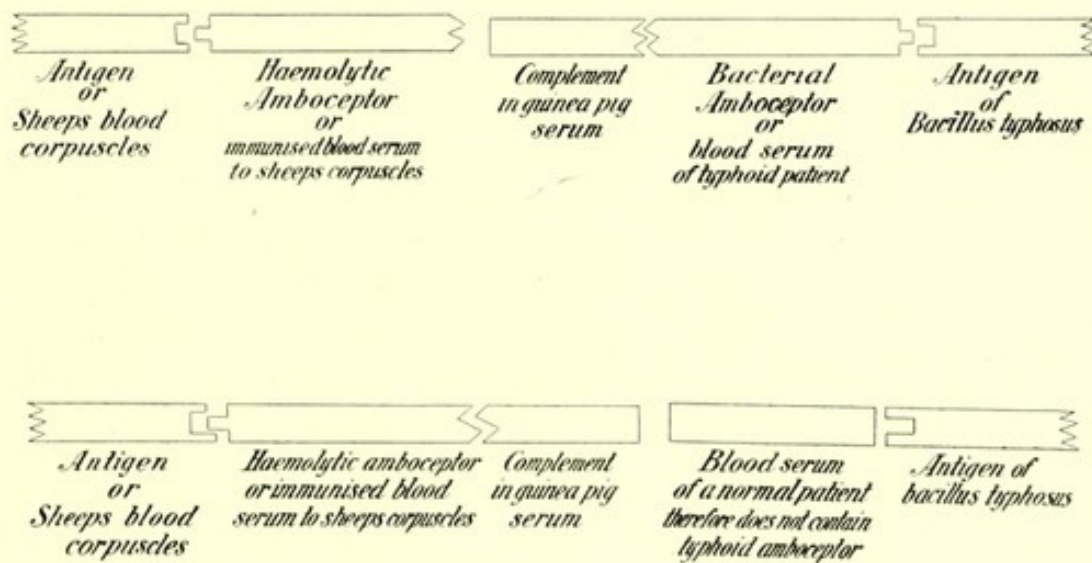


The union of the amboceptor with the antigen is specific, but the complement is not specific; from whatever serum derived it will act on any form of amboceptor so as to produce union with the specific antigen. To apply the simile again, the key can be turned in the lock by any hand, the hand representing the complement.

Antigens are not always bacteria. Emulsions of cells, provided they be of an animal of another species; animal and vegetable fluids, such as abrin; when injected into animals, produce antibodies in the serum termed collectively **cytoly-sins**. Thus, if the red blood-corpuscles of a pigeon be injected into the peritoneal cavity of a guinea-pig a lysin (**Hemolysin**) is produced in the guinea-pig's blood-serum which will dissolve the red blood-corpuscles of a pigeon. This latter reaction may be carried out in a test-tube, the

disintegration of the blood-corpuscles being shown by the discharge of their hemoglobin—a condition known as hemolysis or laking. If the immunised guinea-pig's blood-serum be heated to 56.5° C. for half an hour before it is added to the red blood-corpuscles hemolysis does not take place because the complement has been destroyed by heat, but hemolysis will take place if fresh serum from another animal, such as a guinea-pig, which has not been immunised to a rabbit, is added to it. The biochemical union which takes place between the amboceptor and the complement on the one hand and the antigen on the other is a very firm one. Upon it Bordet and Gengou have introduced a reaction which has gone far to revolutionise clinical medicine and probably may help very considerably in the diagnosis of many diseases of the eye. If the complement is engaged with its complementophile affinity of an amboceptor, developed as the result of bacterial infection, it cannot be dissociated and therefore cannot act upon the complementophile affinity of hemolytic amboceptor, such as is developed as the result of immunising one animal against the red blood-corpuscles of another. The complement being "fixed" to the bacterial amboceptor cannot act on the hemolytic amboceptor and so no hemolysis is produced. Thus, if we take an emulsion of typhoid organisms and "inactivated" serum (the complement being destroyed by heat) obtained from a typhoid patient (and therefore containing the typhoid amboceptor) and the serum of a normal guinea-pig which is rich in complement and mix them together, the complement will combine with the typhoid amboceptor. If, then, to this be added a mixture containing the "inactivated" serum of a rabbit immunised to sheep's blood-corpuscles (which therefore contains a hemolytic amboceptor) and sheep's blood-corpuscles in suspension, no hemolysis takes place because the complement in the guinea-pig's blood-serum has been already "fixed" to the typhoid amboceptor and is no longer free to act upon the hemolytic amboceptor attached to the sheep's blood-corpuscles; therefore no hemolysis takes place. If,

on the other hand (the experiment be repeated, substituting the serum of a normal person for that of the typhoid patient, no typhoid amboceptor being present), hemolysis will take place, because the normal serum contains no typhoid amboceptor, the complement will not be "fixed" to it, but will be free to combine with the hemolytic amboceptor. Hemolysis will therefore result.



The test in this form is only applicable to organisms which can be cultivated outside the body and it has been already successfully applied to tubercle, cerebro-spinal meningitis, and gonorrhoeal infections. Upon these principles depends the sero-diagnosis of syphilis introduced by Wassermann; that is to say, the diagnosis of syphilis by the fixation of the complement. It is carried out as in the previous experiment except that instead of using the *Bacillus Typhosus*, the liver or spleen of the syphilitic fetus is ground up so as to get at the *spirocheta pallida* and employ it as the antigen. The supposed syphilitic serum (containing the specific amboceptor) is obtained from the blood-serum of the suspected patient, while the other ingredients are the same

as in the previous experiment. If the syphilitic amboceptor be present in the serum no hemolysis takes place, but if it be not present hemolysis takes place owing to the complement not being "fixed" but free to combine with the hemolytic amboceptor.

Although the method given above was the original way the test was carried out, it has since been found out that the syphilitic antigen may be replaced by alcoholic extracts of syphilitic and even normal liver or heart muscle, and although this might render the reader skeptical as to its value, as a matter of practical experience the test is reliable (for method see page 544). In undoubted syphilitic lesions of the eye, a positive reaction has been obtained in 92.2 per cent., in interstitial keratitis 83.3 per cent., in iritis 33.3 per cent., in choroiditis and retinitis 28.0 per cent.

Using the aqueous as the amboceptor instead of the blood-serum the same results were obtained, as the antibody is found in it.

Opsonin is a substance which when present in the serum acts upon the organisms making them more readily taken up and digested by the phagocytes. Recent research suggests that this is dependent on the action of the opsonin on the antigen which alters the surface tension of the latter and allows the organism to be attracted by the phagocyte. The substance, although present to a certain extent in all blood sera, may be considerably increased by the injections of cultures of dead organisms in suitable doses. The opsonin contents of the serum may be above or below the normal according to the time it is estimated after inoculation. Immediately after the injection of the organisms there is a slight decrease in this substance (negative phase) which is soon followed by a considerable increase in its production (positive phase).

Vaccine therapy depends largely upon this principle. Opsonin, like lysin, is specific in its action; *e.g.*, the injection of dead staphylococci will only produce an opsonin that will act on staphylococci and will have no effect on other

organisms. So specific is it indeed that frequently only the same strain of staphylococci as that obtained from the patient will act satisfactorily. It is therefore important in most cases, whenever possible, to obtain a cultivation of the organisms for the preparation of the vaccine from the actual lesion to be treated.

The vaccine is prepared by taking a cultivation of the organism and removing it from the media by washing with saline solution. In this emulsion the organisms are then killed by heating at 60° C. for an hour on each of two successive days. It is subsequently standardised so that the dose can be calculated. This is usually performed by mixing volumes of blood and the emulsion and counting under a microscope the relative number of the red blood corpuscles with the organisms. As there are 5,000,000 red corpuscles to the cubic millimetre of the blood it is easy then to calculate the number of organisms in the vaccine (see page 543).

The treatment is most frequently employed in diseases of the eye due to staphylococcal infection. It has been used successfully in pustular blepharitis, multiple chalazion, styes, corneal ulceration, iridocyclitis following operation, and iridocyclitis of metastatic origin, such as is associated with boils, pyorrhea alveolaris and gonorrheal infection.

The preparation of the vaccine in iridocyclitis is somewhat difficult owing to the frequent absence of a satisfactory focus apart from the eye from which a culture can be obtained. It may be obtained from the aqueous by performing paracentesis, when it is desirable to use a sterile hollow needle to avoid contamination from the conjunctiva.

The dose of staphylococcus vaccine is usually 500,000,000 which may be increased to 2,000,000,000 or more, given in gradually increasing doses.

In gonorrheal infections the first dose should not exceed 20,000,000 as the organism is more toxic in its effect.

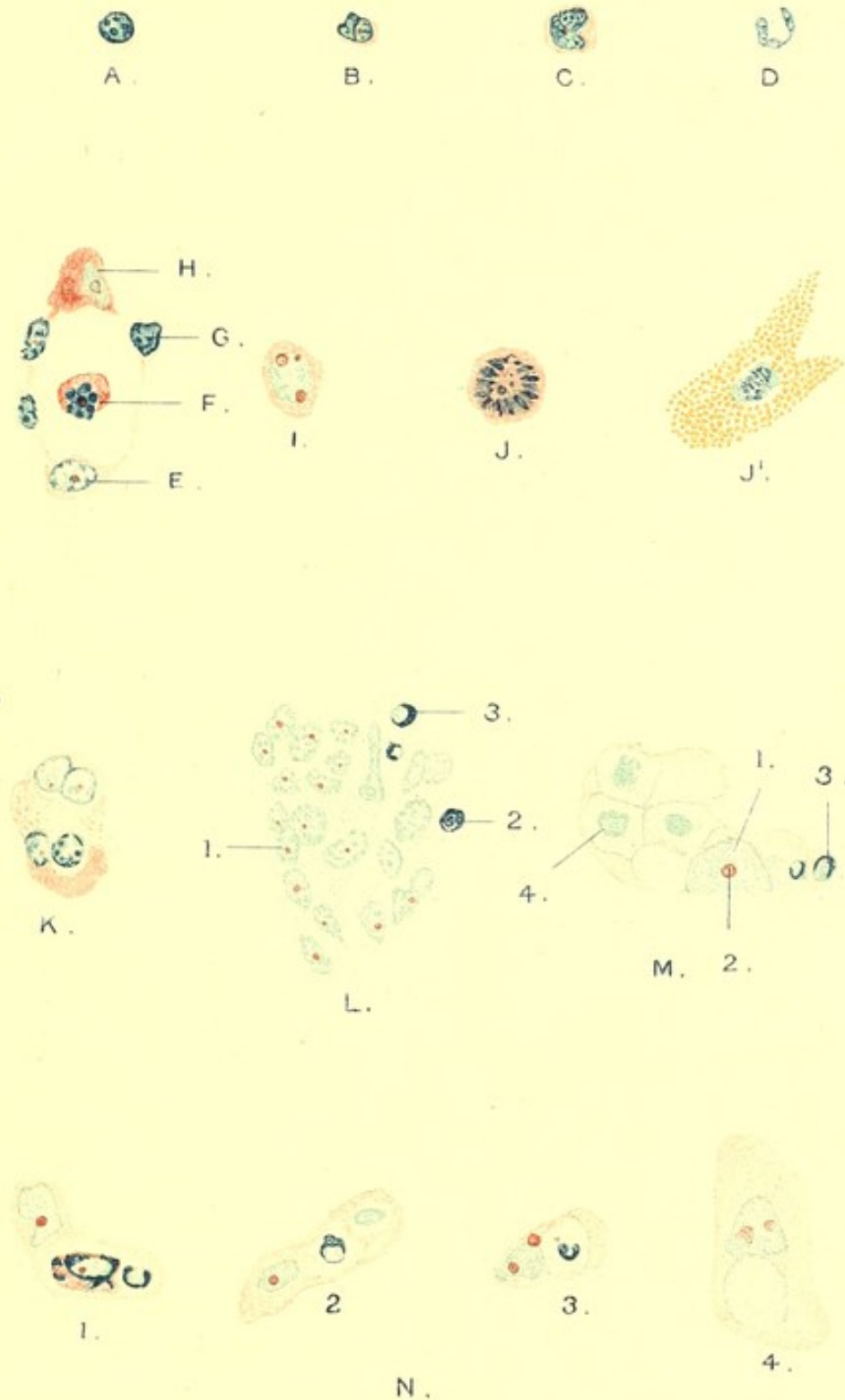In the cases of tubercle as the inoculation of dead tu-

bercle bacilli causes far too much reaction and even supuration, tuberculin T. R. (Tuberculin R chstand) is most frequently used for inoculation. It consists of an aqueous extract of the ground up tubercle bacillus killed by heating at 60  C. for an hour. The first dose should not exceed 1/2000 of a milligram of this substance. It may be gradually increased up to 1/250 or more. Inoculation should not be performed more than once in two weeks, otherwise the negative phase may be unduly prolonged.


In ophthalmic diseases the effect of the vaccine can be estimated so accurately by observing the local reaction in the eye that no other control is necessary, but where other large lesions, such as phthisis, are present, from which the patient may be making his own opsonin by autoinoculation, it is necessary to control it by the opsonic index.

The opsonic index is obtained by mixing in a capillary tube blood-serum from the patient (which contains the opsonin), polymorphonuclear leukocytes taken from a normal person, and the organism for which the index is being taken. A control experiment is made, substituting the blood-serum of a normal person for that of the patient. The capillary tubes are put into an incubator for twenty minutes and then spread out on separate slides and stained. The number of organisms in a given number of leukocytes is counted in each case. The number found in the specimen with the normal blood-serum is taken as the index and is divided into the number contained in the leukocytes of the second specimen with the patient's blood-serum in it. This gives the opsonic index. Thus, if in forty leukocytes in the preparation with normal serum there are 100 bacteria and in forty leukocytes of the preparation with the patient's serum there are fifty bacteria the opsonic index will be $50/100 = .5$.

Aggressins.—At present little is known of the constitution of these bodies beyond the fact that they stop the paralyzing action of aggressinogen on the leukocytes. It is



Cells found in inflammation: A, Lymphocyte; B, transitional; C, large mononuclear leucocyte; D, polymorphonuclear neutrophile; E, F, G, H, showing the origin of the cells from a small vessel within a follicle; E, endothelial cell which has recently proliferated; F, plasma cell; G, ? Lymphocyte, ? endothelial cell; H, clasmatocyte; I, clasmatocyte; J, mitosis in a clasmatocyte, or large plasma cell; J', mast cell; K, chorioplake (giant cell, plasma cell type); L, giant cell, endothelial type—(1) nucleus-like endothelial cell, (2) inclusion (nucleus of lymphocyte), (3) coccoid body of Leber (disintegrating cell inclusion); M, large phagocytic endothelial cell—(1) nucleus, (2) nucleolus, (3) Leber's coccoid body, (4) disintegrating lymphocyte; N, showing the various stages of digestion of a plasma cell by an endothelial phagocytic cell—(1) an inclusion of a plasma cell, (2) plasma cell breaking up, (3) coccoid body formed of nucleus, (4) vacuolisation. (Pappenheim's stain.)



probable that aggressinogen is the cause of the condition known as negative chemotaxis.

Having described the principal changes which take place in the serum during inflammation, it is necessary to describe some of the cells which are found in the inflamed area and the source from which they are derived.¹ The manner and order in which they appear in an uncomplicated wound is given under Wounds of the Conjunctiva, page 267.

Polymorphonuclear leukocytes are cells having a bi-lobed or horseshoe-shaped single nucleus with a fair amount of cytoplasm (Plate 1, D). This cytoplasm contains fine granules, the intersections of the reticulum. In some cells these do not stain strongly with either acid or basic dyes and are known as **neutrophile cells**, while some have large granules which stain strongly with acid dyes and are known as **eosinophiles**; others stain strongly with basic dyes and are known as **basophile or mast cells**. (Plate 1, J¹).

Their shape varies very considerably owing to their ameboid movements. When they are killed by the process of "fixing" for microscopical examination they are usually rounded in outline, but when imprisoned in the layers of a dense tissue like the cornea they are irregular in shape, assuming that of the intercellular space along which they are making their way and then are sometimes known as "spider" cells.

The irregularity in shape of the nuclei is also due to their ameboid movements, the denser protoplasm of the nucleus on death not assuming so rapidly the rotund form of the cytoplasm. These cells form 70 per cent. of the white cells in normal blood and are derived from the bone marrow. In inflammatory affections the percentage in the blood becomes considerably increased owing to the increased call for their production, due probably to the effect of the toxin circulating in the blood stream acting on the bone marrow. They appear at the site of injury almost immediately after

¹ M. S. Mayou. Hunterian Lecture, 1905.

its infliction and rapidly increase in number. In most inflammatory infections the toxin produces an exudation of the neutrophile cell, but in rare instances an exudate of the eosinophile cell occurs; this may be a great help in diagnosis as, for example, in differentiating between vernal catarrh and trachoma.

The attraction of the cell toward the site of inflammation is known as **positive chemiotaxis**. Occasionally bacteria with strong toxic properties produce aggressinogen which paralyses the cells so that they cannot approach the site of inflammation—a condition which is known as **negative chemotaxis**. This is sometimes seen clinically in early infective processes in the cornea, where the site of the infection is surrounded by an area of clear cornea outside which is a ring of infiltration due to the presence of these cells, which have made their way from the blood-vessels of the limbus, but cannot approach close to the site of inoculation owing to the presence of the aggressinogen.

The cellular elements of pus consist nearly entirely of these polymorphonuclear leukocytes, either alive, or in the process of disintegration caused by the bacterial toxins. At one time it was thought that pus was only produced by microbial irritation. It has, however, been shown that a hypopyon is formed when aseptic pieces of copper are introduced into the anterior chamber. This and other experiments prove that a purulent exudate can be excited by chemical agents alone.

Large mononuclear leukocytes are found in small numbers round inflammatory foci (Plate 1, C). Like the polymorphonuclear leukocytes the cytoplasm may contain neutrophile, eosinophile, or basophile granules; those containing the latter are frequently present in the conjunctiva, especially around resolving phlyctenulæ. They are also met with in chronic inflammation of the iris.

They are probably a less highly developed form of the polymorphonuclear leukocytes and are found in large num-

bers in the bone marrow, in which structure they are seen developing into the latter cell.

Large and Small Lymphocyte and Plasma Cells.—The remaining cells which are found round the site of inflammation appear at a later date and are the product of the local activity of the tissue. The derivation of the large and small lymphocyte (Plate 1, A and B) and plasma cells (Plate 1, F and J) from the local endothelium of the part can be well seen in the conjunctiva. Before birth, when the conjunctiva is free from irritation, no lymphoid tissue is present, and the rate at which it develops after birth is proportionate to the amount of irritation to which the membrane is exposed. When continued irritation is present, follicles are formed. In the conjunctiva the cells within these follicles are derived from proliferation of endothelium. They thus resemble newly formed lymphatic glands.

Although these cells are slightly ameboid and phagocytic, their presence is usually connected, in an open wound, with the process of repair or granulation. Hence when they make their appearance in a wound the inflammation is usually becoming chronic, the system having been shut off from general septic infection.

The appearance of the plasma cell in large numbers is usually associated with local immunity, since the cytoplasm of this cell becomes easily broken up in the presence of a toxin.

The relation of these cells to each other is very close. The large lymphocyte is evidently a small one which has increased in size by growth of cytoplasm. The plasma cell is probably the result of the division of the endothelial cell, which is the parent cell of them all.

The relationship of this group of cells to the large mononuclear and polymorphonuclear leukocytes is still somewhat doubtful. During early fetal life all the white cells found in the fetal blood are lymphocytes, which somewhat suggests that the one group may develop into the other.

The endothelial cells (Plate 1, E, H and G) occurring in

an inflamed area are almost entirely connected with the reparative process. They are derived from the endothelium of the blood-vessels, serous membrane, etc. Their proliferation becomes most marked as the appearance of the lymphocytes subsides. They are strongly phagocytic (Plate 1, M and N) and are found including portions of other cells, organisms, etc. They probably finally organise into fibrous tissue, which is always the outcome of any inflammation that has gone on to necrosis and yet does not lead to the total destruction of the part.

A number of other cells of less importance appear round the site of inflammation, especially when chronic. These cells are modifications of the cells already described and are probably of the nature of monstrosities produced by the action of the toxins upon them.

Giant cells (Plate 1, L) are large cells having multiple nuclei. They are derived from endothelial cells by division of the nucleus without division of the cytoplasm. Like endothelial cells they are strongly phagocytic and in tubercular foci often contain the bacillus of that disease. In this case the nuclei of the cells frequently have a peripheral arrangement or are grouped together at one side of the cell.

Chorioplaques (Plate 1, K) are giant cells formed from plasma cells by division of the nucleus without division of the cytoplasm.

Epithelioid cells are large cells found around foci of chronic inflammation, more especially of a tubercular nature. They probably have their origin in the surrounding lymphocytic exudation.

Degeneration in all varieties of cells takes place in one of two ways, depending on the osmotic properties of the cell wall. The cell may lose fluid and shrink and the granules in the cytoplasm become more marked (pyknosis); these have been mistaken by some observers for organisms in the cells.

The cell may imbibe fluid as a result of which it becomes

vacuolated, swells up, and finally bursts distributing its contents (hyperchromatosis).

Inflammation is usually divided into Acute and Chronic.—

This is only an arbitrary division as the degree varies with the nature of the injury. The acuteness of the inflammation depends on the severity of the infection, while its chronicity depends on the length of time for which it lasts. If the inflammation is very acute death results before the tissues can react. If less acute there is a cellular reaction on the part of the whole body to the infection, as is shown by the exudation of plasma and polymorphonuclear leukocytes; while if the inflammation is chronic the cellular reaction is local, as shown by the lymphocytic exudation. The disappearance of the leukocytes when the inflammation subsides is probably carried out in many ways; undoubtedly large numbers degenerate and the fragments are taken up by the endothelial and other phagocytic cells. Partly in this manner and partly by being cast off from the surface of the body the disappearance of the polymorphonuclear leukocytes is accounted for. The disappearance of the lymphocytes and plasma cells, apart from degeneration, is largely due to them being carried away by the lymphatics and small veins, as vessels packed with these cells can be found in the neighbourhood of all chronic inflammatory processes.

The process of repair, which follows the appearance of the lymphocytes and granulation tissue, is probably due to the endothelial cells which become lengthened out and converted into fibrous tissue. New blood-vessels are formed in enormous numbers by the budding out of endothelium. These subsequently largely disappear owing to the contraction occurring in the newly formed fibrous tissue.

Intrauterine Inflammation.—Infection of the fetus by microorganisms can undoubtedly occur. This may take place through the maternal blood *via* the placenta, as in syphilis, or through a minute aperture in the membranes *via* the liquor amnii, as in children born with fully developed ophthalmia neonatorum.

Before the possibility of arrests in development were recognised congenital defects were attributed to intrauterine inflammation. Without doubt defects in development are frequently the cause of congenital anomalies, but intrauterine inflammation does occur and may produce lesions which sometimes can only be distinguished with difficulty, or not at all, from faulty development. It is easier to recognise, both clinically and histologically, that intrauterine inflammation was the cause of an abnormality the nearer to the time of birth of the fetus the inflammation occurred.

The infection of the fetus through the maternal blood may take place at any time while the fetus is attached to the placenta. Undoubted evidence in the eye of its early occurrence is that there are children born with occluded pupils and iris bombé together with other signs of congenital syphilis corresponding to the late secondary stage.

Infection of the eye through the membranes can only take place while the lids are ununited; they close at the seventh week and separate at the end of the fifth month of fetal life. Children have been born with gonorrheal ophthalmia fully developed.

II. Modifications of the General Processes of Inflammation in the Various Structures of the Eye.

The conjunctiva¹ is the mucous membrane lining the eyelids and is reflected on to the globe. For purposes of description it is divided into the palpebral conjunctiva, which is firmly attached to the posterior surface of the eyelids; the bulbar conjunctiva, which is attached to the globe, firmly at the limbus and more loosely elsewhere; and the conjunctival fornices which are two folds upper and lower, where the membrane is reflected from the lid on to the globe.

The epithelium of the normal conjunctiva differs from

¹ M. S. Mayou. Hunterian Lecture, 1905.

that of the skin in that it is thinner and shows no keratinisation except under unusual conditions (see Xerosis). As the basal cells proliferate some of the superficial cells are thrown off from the surface (desquamation) while others undergo mucoid changes. These latter cells are known as goblet cells and they supply the mucus. The presence of mucin and its predecessor mucinogen in a cell causes it to swell up and the nuclei to be pressed to one side. The granules present in the degenerating epithelial cells have been mistaken by various observers for microorganisms, and it is possible that the bodies recently found in connection with trachoma may be of this type. The normal conjunctiva is smooth and contains no papillæ except at the limbus, where also there are a few pigment cells.

The epithelium of the conjunctiva in the new born infant differs considerably from that of the adult conjunctiva—a point which is of importance in connection with ophthalmia neonatorum. The epithelium, with the exception of that near the lid margins, is thinner and not so flattened as in the adult. In the fornices it undergoes considerable mucoid and desquamative changes, laying bare the basement membrane and so affording a passage through which microorganisms can easily gain entrance.

The changes in the epithelium produced by inflammation depend on whether it be kept moist or dry. If moist, the cells proliferate and undergo greatly increased mucoid changes. The passage between them of enormous numbers of polymorphonuclear leukocytes, together with the softening action of the serous exudate, cause them to be cast off in large numbers in the discharge. The exudation into the subconjunctival tissue causes the formation of papillæ from rucking of the surface epithelium; if two epithelial surfaces lie in contact with each other, it is the cells of these surfaces which show the most extensive mucoid change, commencing at the bottom of the folds, causing some irregularity of the basement membrane, and giving the appearance of a new gland formation. The glands of Henlé are of this type,

the regularity of their formation along the upper margin of the tarsus being due to this being the situation in which folding is most likely to take place, because the fixed palpebral conjunctiva there joins the loose conjunctiva of the fornix. A large gland of this type is often seen at the inner end of the tarsus and is the one which most frequently becomes cystic.

Although this is perhaps the commonest way in which these false glands of the conjunctiva are formed, they may be observed, arising in a somewhat different manner, near the junction of the moist and dry epithelium occurring in conditions due to exposure and to chronic inflammation, such as ectropion, secondary xerosis, and papillomata of the conjunctiva which have been exposed in the palpebral fissure. As the result of this exposure the epithelium becomes thickened and dips down into the subepithelial tissue in the form of papillæ. Mucoid degeneration of the epithelial cells in the centre of these papillæ takes place, with the formation of flask-shaped mucous glands. The openings of these false glands are often occluded with epithelial débris, with the result that the lower end becomes distended to form a **cyst**. These cysts on the palpebral conjunctiva are extremely common, and one conjunctiva may contain thousands of them. They are lined by flattened cells, three or four deep, and contain epithelial débris, which is sometimes calcified. In acute inflammatory conditions of the conjunctiva these cysts, if present, often become filled with pus, appearing as brilliant yellow points, which subsequently rupture. Cysts of the same nature in the bulbar conjunctiva are comparatively rare but when they occur are usually single, and transparent, containing clear fluid; they are lined by epithelium having many tuft-like processes, the cells of which undergoing mucoid change, supply the fluid contents.

If the conjunctival epithelium becomes dry, as in cases of ectropion, a process of keratinisation takes place, the surface cells remaining longer attached and the formation of keratin, keratohyaline, and prickly cells takes place. The

basement membrane becomes irregular, and processes of epithelium dip down into the subconjunctival tissue, forming papillæ. In fact, the epithelium of the conjunctiva which is exposed resembles very closely in structure the true skin with the exception of the absence of glands, hair follicles etc.

If the keratinised epithelium be again moistened, as after ectropion operations, it tends to resume its former state, in consequence of the softening of the superficial layers, with subsequent mucoid change in the deeper layers. From this it seems that the presence of lacrimal fluid is necessary to the formation of mucin by the epithelial cells.

The condition known as **xerosis**¹ is due to drying of the epithelium (see page 443).

The subepithelial tissue consists of a loose reticulum of connective tissue with fine elastic fibres in it. In the fornices it is filled with lymphocytes, thus producing a layer of lymphoid tissue. This layer of lymphoid tissue is absent in the child at birth. It develops in about four weeks, its rate of formation depending on the amount of irritation applied. If nitrate of silver be applied to the conjunctiva at the time of birth this layer of lymphoid tissue is fully produced by the end of the first week. Its presence no doubt plays a most important part in the prevention of infection.

Acute inflammation of the conjunctiva involving the whole membrane is due to organisms, growing principally in the deeper layers of the epithelium and probably also in the superficial layers of the subepithelial tissue. They give rise to toxins which are absorbed, causing changes in the subepithelial tissue. As a result of their absorption the vessels become enormously dilated and the exudation produces intense swelling of the conjunctiva which is known as chemosis. The histological character of the changes will be described under the headings of the various forms of infection.

A localised acute inflammation gives rise to the con-

¹ M. S. Mayou. Trans. Ophth. Soc. of the U. K., XXIV, 1904, 9 and 39.

dition known as a **phlyctenule**. In its simple form a phlyctenule is a small red eminence about the size of a millet seed, usually seen in the ocular conjunctiva in the region of the limbus with a leash of dilated vessels leading up to it. As a rule, as it increases in size the epithelium on the surface of the eminence gives way with the formation of a greyish ulcer but without extrusion of its contents. Occasionally these nodules of exudation disappear without the formation

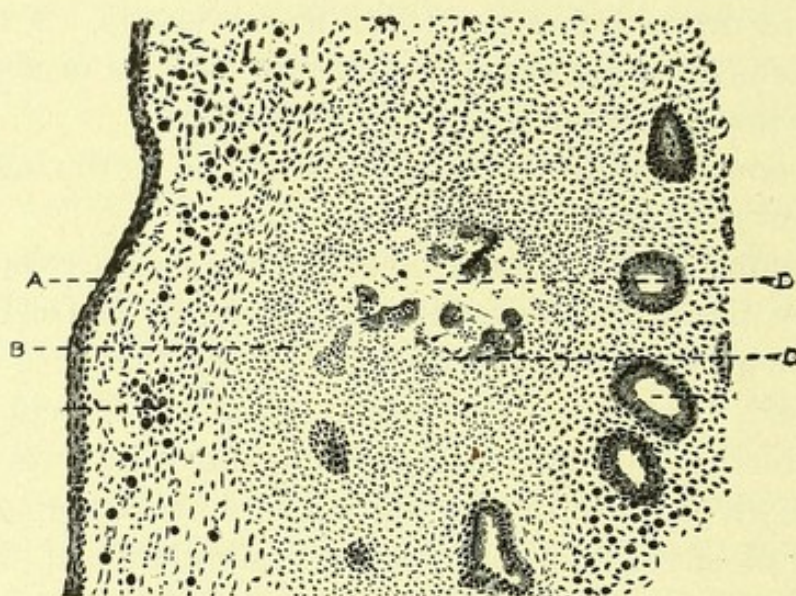


FIG. 159.—Shows a section through a phlyctenule of the conjunctiva in an early stage of its formation, before it has ruptured. *A*, Epithelium; *B* and *C*, cellular exudation; *D*, cavity containing pus.

of an ulcer. The disease is often preceded by some other form of conjunctivitis of a muco-purulent character which may be very slight.

The position of a phlyctenule is by no means limited to the limbus; it is found in other parts of the bulbar and occasionally on the palpebral conjunctiva. The frequency of its occurrence at the limbus is probably due to the conjunctiva being fixed in that position, the friction of the lid causing the organism to penetrate deeply into the tissues. Occasionally a phlyctenule on the ocular conjunctiva is accompanied by another on the palpebral conjunctiva exactly opposite to it showing its infective nature.

An ulcer produced by the phlyctenules may spread to the cornea from the limbus, and when lasting for some time, becomes vascularised by the budding out of the vessels of the limbus.

¹In the early stages a phlyctenule consists of an exudation of leukocytes in the deeper layers of the conjunctiva in the centre of which is found an area of necrosis (Fig. 159). The leukocytes toward the centre are principally polymorphonuclear, while those around are chiefly of the mono-

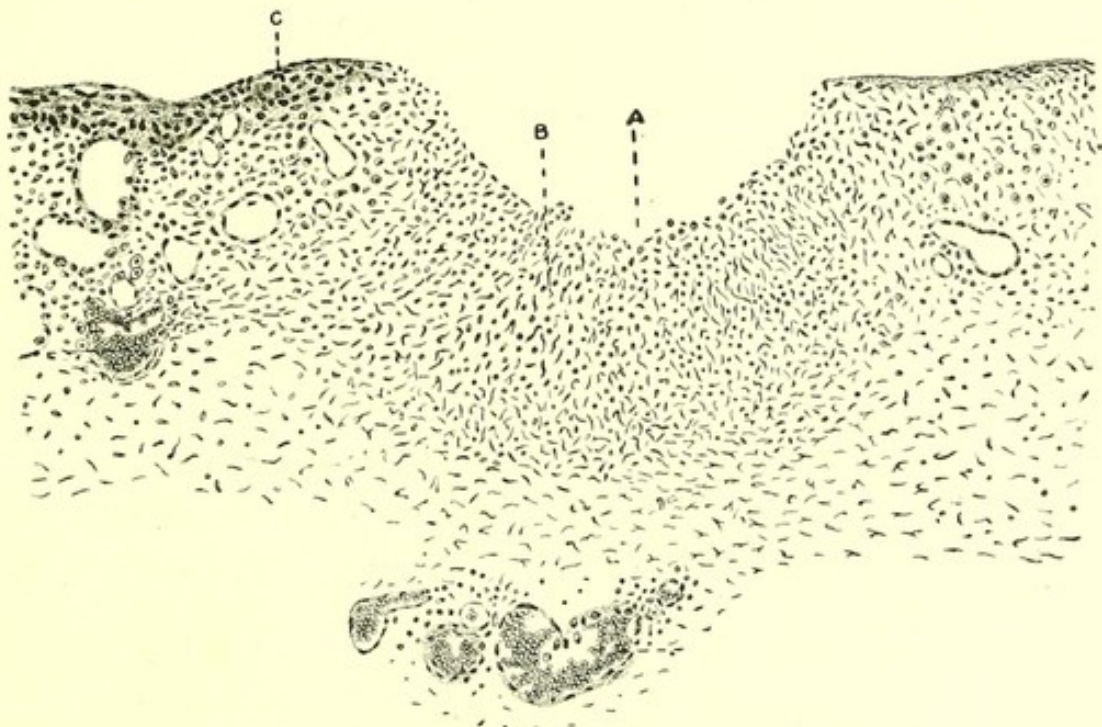


FIG. 160.—Shows a section through a phlyctenule of the conjunctiva in a later stage than in Fig. 159, after rupture has taken place. *A*, Base of the ulcer; *B*, cellular exudation; *C*, epithelium.

nuclear type. The blood-vessels in the neighbourhood are dilated and the endothelium is proliferating; in fact the condition is a minute abscess in the deeper layers of the conjunctiva. Resolution or rupture of the phlyctenule may take place. If rupture takes place the exudation, making its way along the paths of least resistance, breaks through the epithelium and an ulcer is formed.

At this stage the polymorphonuclear leukocytes have

¹ M. S. Mayou. Hunterian Lecture, 1905.

enormously increased in number, infiltrating the walls of the recently evacuated phlyctenule (Fig. 160). The vessels have become greatly dilated, their endothelium has proliferated, and a large number of plasma and mast cells made their appearance.

When the ulcer begins to heal the epithelium spreads over its surface and numbers of fine new vessels with proliferating endothelium make their appearance in the subepithelial tissue. Scattered among these are large numbers of mast cells with remains of the mononuclear and polynuclear exudation.

Occasionally, instead of an ulcer forming, the cavity becomes lined by epithelium growing down over its surface and a cyst results.

In primary **chronic inflammation of the conjunctiva** and acute processes which are subsiding, lymphoid cells make their appearance. These at first are evenly spread beneath the epithelium, but if the inflammation continue and become very chronic these cells increase in number and form aggregations which are known as follicles. They resemble in structure and function those found in the lymphatic glands in which the cells are similarly produced. The formation of these follicles is mainly limited to the fornices where there is already an existing lymphoid layer, but they may occur elsewhere; on the tarsus and at the limbus, as in trachoma. Before the classification of the inflammatory diseases of the conjunctiva, according to the nature of the infection, this follicular formation was known as **follicular conjunctivitis** (Plate 2, Figs. 1 and 2).

In the **cornea** the process of inflammation is considerably modified by its structure. The substantia propria is enclosed between two membranes, the anterior being known as Bowman's membrane which is covered by about ten layers of epithelial cells, while the posterior is known as Descemet's membrane which is covered on its posterior surface by a single layer of endothelial cells. Both these membranes are impervious to microorganisms and cellular exudations, but

Fig. 1.

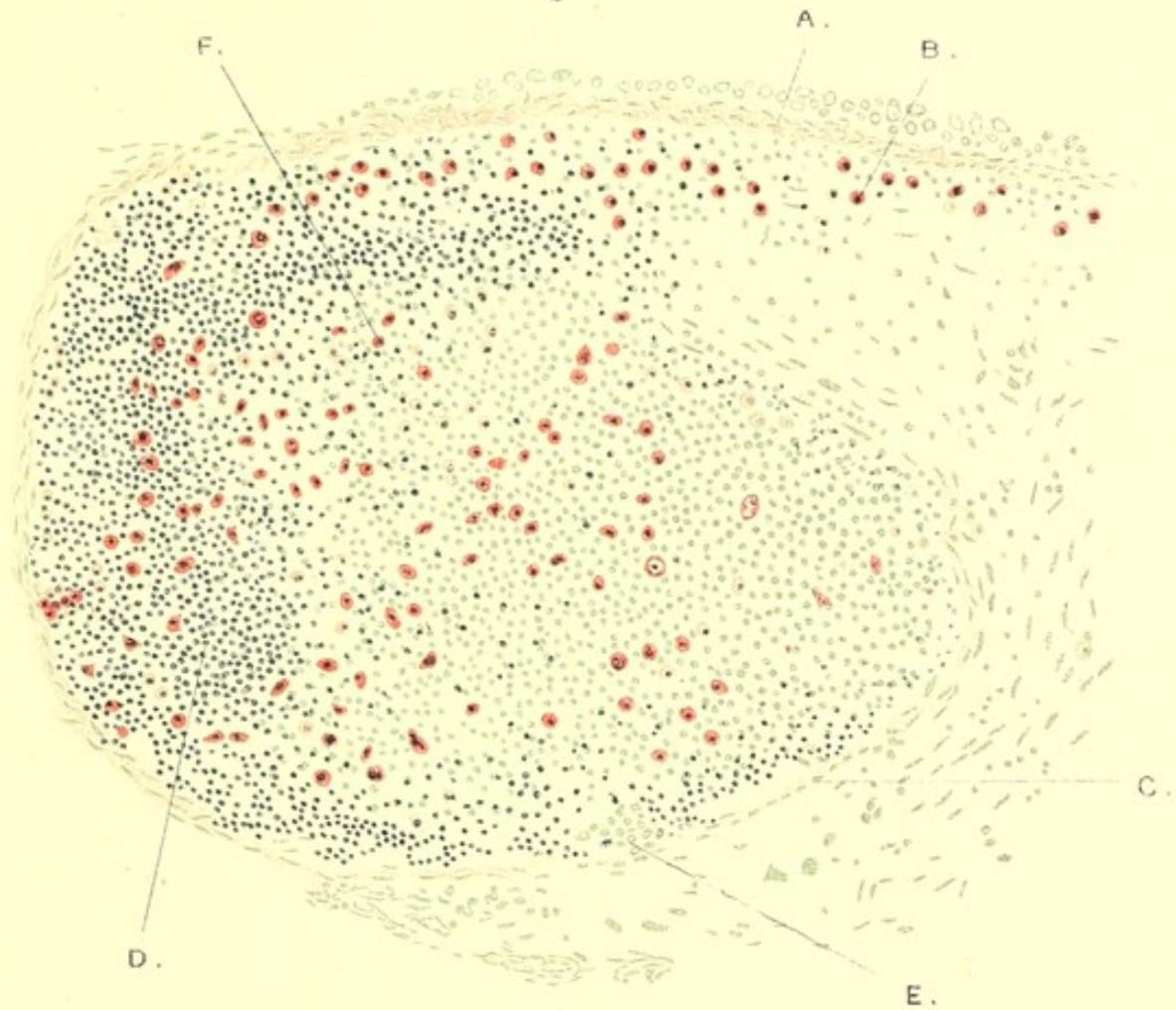


Fig. 2.

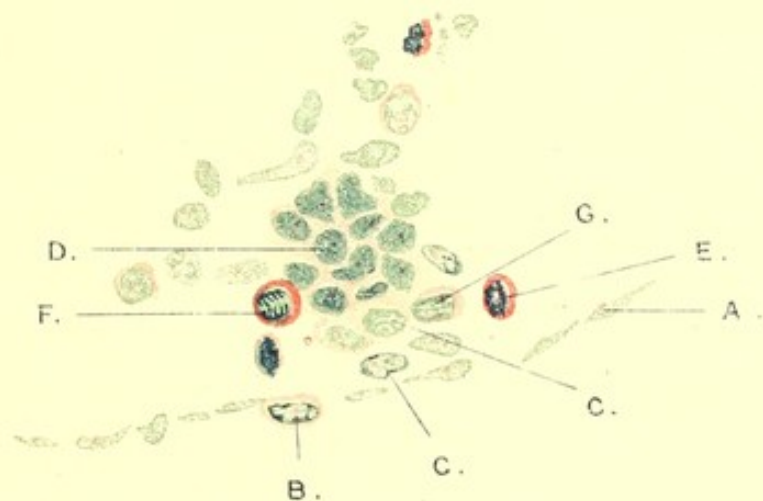


FIG. 1.—This section was made from a patient suffering from so-called follicular conjunctivitis. A, Epithelium which is undergoing proliferation and mucoid change; B, plasma cells beneath the epithelium; C, endothelium of the follicle, which is deficient towards the surface; D, an endofollicle well developed; E, an early follicle, more highly magnified in fig. 2; F, plasma cells within the follicle, numbers of which are undergoing mitosis. (Pappenheim staining.) $\frac{1}{2}$ obj. No. 4 eyepiece.

FIG. 2.—An early endofollicle. This figure also shows the probable origin of the cells within the follicle (E, fig. 1). A, Endothelial lining; B, proliferating endothelial cell; C, transition cell between endothelial cell and mononuclear leucocyte; D, mononuclear leucocyte; E, plasma cell; F, plasma cell undergoing mitosis; G, transition cells between mononuclear leucocytes and plasma cells, or between endothelial cells and plasma cells. (Pappenheim staining.) $\frac{1}{2}$ obj. No. 4 eyepiece. Long tube.

allow of the diffusion of fluids through them. Bowman's membrane with the epithelium affords protection against infection of the substantia propria, while Descemet's membrane prevents the passage of microorganisms into the eye from the cornea. Fluids containing some toxins are able to pass through both these membranes. As an instance of this the toxin produced by pneumococcal infection of the cornea and even of the conjunctiva may pass into the anterior chamber setting up an inflammation of the iris and

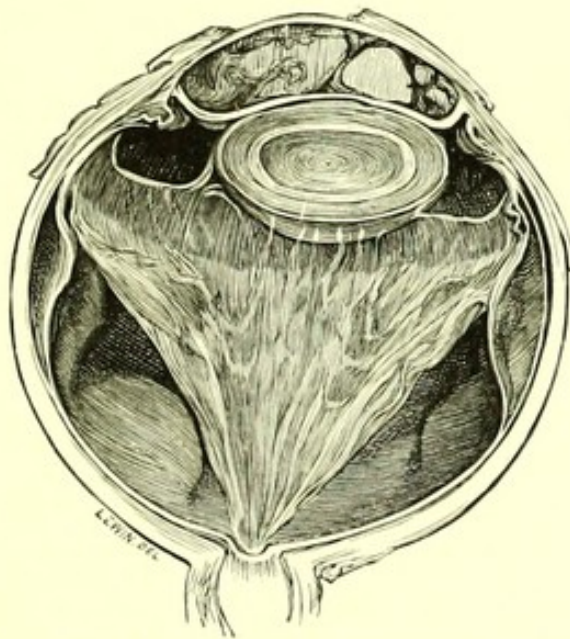


FIG. 161.—Shows the lateral half of an eye with an extensive suppurating ulcer of the cornea. There is mass of purulent exudate, which has coagulated in the hardening of the specimen, in the anterior chamber. The vitreous humour is shrunken and detached antero-laterally and posteriorly. Specimen in R. Lond. Ophth. Hosp. Museum.

ciliary body. The presence of the toxin in the anterior chamber causes an exudation of polymorphonuclear leukocytes into it (**hypopyon**, Fig. 161). These cells, being unable to make their way forward to the site of infection, owing to Descemet's membrane being impervious to their passage, fall to the bottom of the anterior chamber where they form a layer of pus which contains no organisms.

Infection of the cornea by microorganisms arises from without, as in corneal ulceration, through the blood stream, or by spread from the conjunctiva or ciliary body.

In acute inflammation due to infection from without the organisms must gain entrance through a wound of the epithelium and probably Bowman's membrane. Prolonged contact with discharge containing the gonococcus and Klebs-Loeffer bacillus is supposed by some authorities to produce ulceration without an abrasion. In rare instances microorganisms implanted in the cornea produce an abscess or onyx between its layers. If the surface of an infective corneal ulcer be scraped and the débris examined microscopically it will usually be

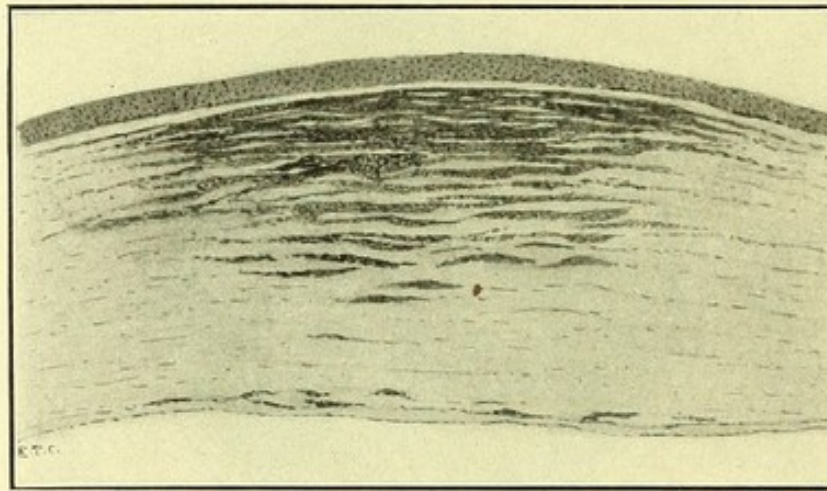


FIG. 162.—Section through the cornea showing inflammatory cells infiltrating the anterior layers of the substantia propria.

found to consist of an almost pure colony of microorganisms together with a few leukocytes and epithelial débris. Histological examination shows that the organisms do not spread deeply into the tissue but laterally along the lamellæ; hence the importance of applying the cautery to the spreading margin.

The cornea being free from blood-vessels, lymph containing protective bodies and cells, must in the early stages be derived from the blood-vessels of the limbus in inflammation of the superficial layers, and from the blood-vessels of the ciliary body in inflammation of the deeper layers. The polymorphonuclear leukocytes appear at the limbus within fifteen minutes of the injury; they make their way between the layers of the substantia propria, of which there are about sixty, along potential spaces between its fibres (Fig. 162).

The exudation may appear as a circular grey area round the site of inflammation and may reach right up to it (positive chemotaxis), or there may be a ring of clear cornea round the site of inflammation (negative chemotaxis), and outside that again a "**ring infiltration.**" The latter condition must be distinguished from "**peripheral annular infiltration**" (see page 321).

As the ulcer progresses masses of polymorphonuclear leukocytes collect between the lamellæ just beyond the spreading margin this gives rise to the yellowish infiltration which is seen clinically in **serpiginous ulceration.**

As the deeper layers of the cornea become involved the exudation from the ciliary vessels may cause Descemet's membrane to bulge inward toward the anterior chamber, become softened, split up, and even rupture before the ulceration from the surface has reached it, a condition which is known as an **internal ulcer.**

If the ulcer perforate the cornea the aqueous is lost and the tension of the eye is lowered. This allows a freer circulation of lymph and cells between the corneal lamellæ as a result of which the healing of the ulcer usually takes place. This, in some instances, may be forestalled by the surgeon performing paracentesis or cutting through the base of the ulcer (Sæmish section).

The process of repair in the cornea, owing to its non-vascularity, is slow as compared to most connective tissue. New vessels bud out from the limbus which vascularise the base of the ulcer and lymphocytes appear at the end of the fourth day.

Granulation tissue is formed slowly in the base of the ulcer which is finally filled in by fibrous tissue; this causes an opacity in the cornea which is known as **nebula, macula, leukoma,** depending on its density. The new connective tissue is very opaque at first, but as it becomes less cellular and the fibres are stretched out by cicatricial contraction the opacity becomes less marked.

In place of the ordinary connective-tissue cell there are

in the cornea large cells which are known as corneal corpuscles; these are both fixed and wander cells. They are easily distinguished from the leukocytes, being larger, having a different type of nucleus, and cytoplasm free from granules. To all intents and purposes they fulfil the same function as the large endothelial cell. In the child the cornea is thicker and softer in consistency than in the adult and therefore allows of much freer circulation of lymph and more rapid cellular changes; hence opacities in quite young children clear more thoroughly than in the adult.

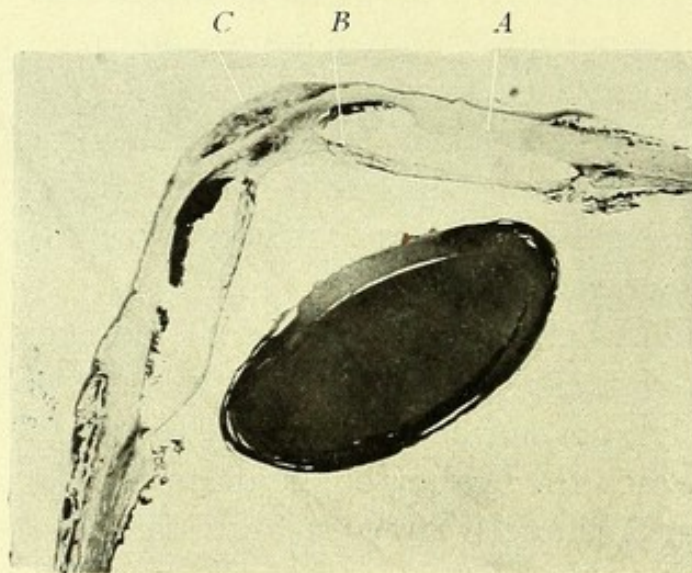


FIG. 163.—Section through the anterior part of an eye showing an anterior synechia of the iris following perforation of a corneal ulcer. *A*, cornea; *B*, iris adherent to the base of the old ulcer; *C*, leucoma.

The epithelium grows down over the sides of a healing ulcer into all its irregularities, and then thickening helps to fill in the gap in the cornea until it is on the same level as the surrounding cornea. The repair of Descemet's and Bowman's membrane is similar to that in wounds of the cornea (see page 258).

If the ulcer stops just short of perforation Descemet's membrane may bulge into its base producing a **keratocele**. This prevents the proper filling in of the base of the ulcer with fibrous tissue, so that a weak place in the cornea is left which under the normal intraocular tension may continue to expand.

If the ulcer perforates, the organism may spread into the interior of the eye and produce **panophthalmitis**. When the anterior chamber is evacuated the lens may be extruded; if the perforation be large, the vitreous and even the retina may prolapse. The lens may come in contact with the back of the cornea and the exudate adhere to the anterior capsule. The contact of the lens with the base of the ulcer causes the proliferation of the cells lining the anterior capsule and a

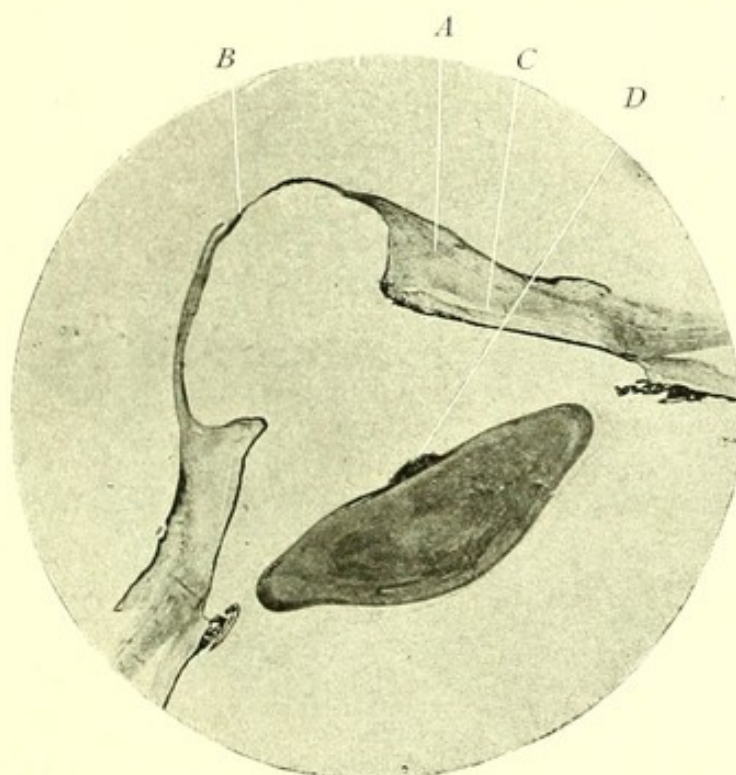


FIG. 164.—Section of the anterior part of an eye which had a perforating ulcer of the cornea and incarceration of the iris. Glaucoma ensued, and the cornea in the region of the cicatrised ulcer stretched and became staphylomatous. *A*, substantia propria of the cornea; *B*, staphyloma; *C*, iris, which is adherent to the base of the old ulcer; *D*, anterior polar opacity in lens.

subcapsular opacity of the lens is the result (**acquired anterior polar cataract**) (see page 448). When the ulcer heals the anterior chamber is re-formed and a band of fibrous tissue is sometimes to be seen passing from the surface of the cataract to the back of the cornea beneath the nebula, thus showing the origin of the cataract.

The iris may become incarcerated in the base of the ulcer and adherent thereto. After healing is completed

the condition is known as a **leucoma adherens** (Fig. 164). The iris may also prevent the proper filling in of the ulcer with fibrous tissue by bulging into the gap. The result of this is that under the normal intraocular tension the scar bulges and an anterior staphyloma is produced.

Anterior Staphyloma.—When the perforation is small the iris becoming incarcerated gives rise to the formation of granulation tissue on its anterior surface where it lies in

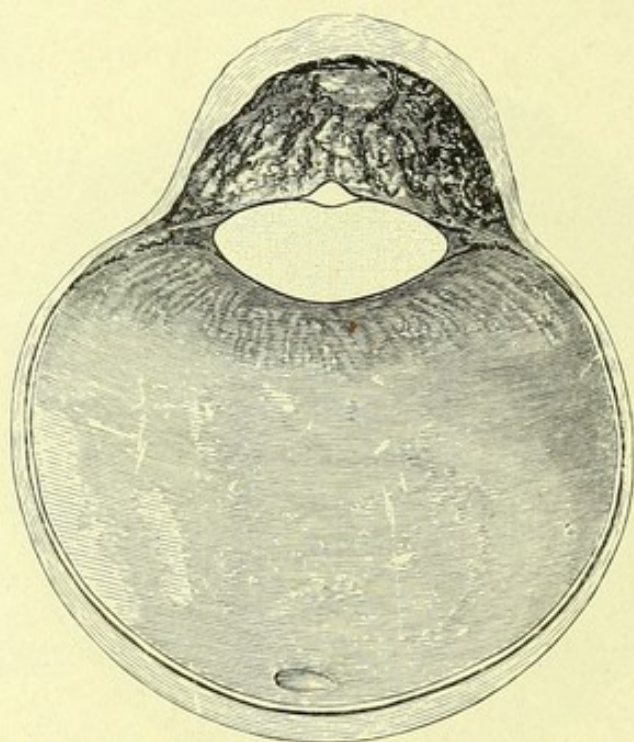


FIG. 165.—Shows the lateral half of an eye in which the whole cornea has been destroyed by ulceration and replaced by a mass of fibrous tissue, which is lined by a network of the uveal pigment. This pseudo-cornea has developed from granulation tissue on the surface of the iris. The tension of the eye was increased; the pseudo-cornea has become staphylomatous and the optic disc is cupped. There is a pyramidal-shaped opacity at the anterior pole of the lens. Specimen in the R. Lond. Ophth. Hosp. Museum.

the base of the ulcer. This granulation tissue fills in the gap in the cornea, becomes covered with epithelium and converted into fibrous tissue. This scar tissue yielding under the normal intraocular tension gives rise to a local bulging of the cicatrix which is known as a **partial staphyloma**.

When the perforation is extensive a greater surface of the iris is exposed, and as the ulcer does not heal so rapidly a much larger granuloma is formed on its surface; this may

protrude above the level of the cornea. When the anterior chamber re-forms and the scar yields, an irregularly bulging cicatrix is the result. In some situations this may be very thin, being little more than the thickness of the normal iris, while in others it may be thicker than the normal cornea. When the whole cornea is destroyed the tissue replacing it, or pseudocornea, bulging forward constitutes a **total anterior staphyloma** (Fig. 165).

The epithelium which covers the surface of the staphyloma is irregular, thickened and much papillated, due to its

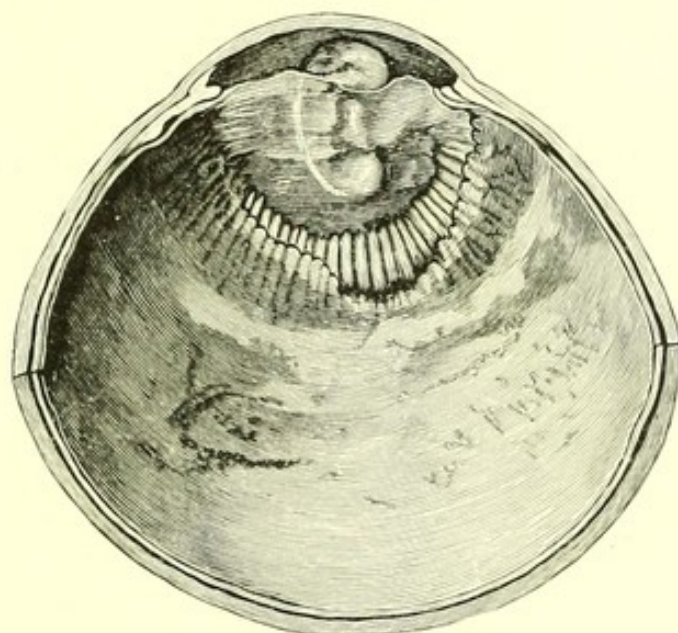


FIG. 166.—Shows the front part of an eye in which the lens capsule is adherent to the posterior surface of a staphylomatous cornea. A fold of retina is seen to have been drawn forward from the region of the ora serrata over the inner surface of the ciliary body. Specimen in the R. Lond. Ophth. Hosp. Museum.

tendency to fill up all inequalities of the surface. If the staphyloma protrude between the lids the epithelial cells on the surface become keratinised, due to their drying.

The iris, which is always incarcerated in the perforation, becomes converted into fibrous tissue, the pigment cells becoming distributed throughout the newly formed cicatricial tissue in the neighbourhood. In the early stages the scar tissue is very vascular, but in time the blood-vessels disappear and secondary degenerative changes are liable to

make their appearance. Hyalin and calcareous changes may take place beneath the epithelium and in the scar tissue. Erosions of the epithelium and atheromatous ulceration may follow.

The lens sometimes escapes through a perforating ulcer of the cornea, the lens capsule being left adherent to it; then, if the cornea becomes staphylomatous, the traction produced on the fibres of the suspensory ligament elongates the ciliary processes and draws forward a fold of retina from the region of the ora serrata over the inner surface of the ciliary body (Fig. 166).

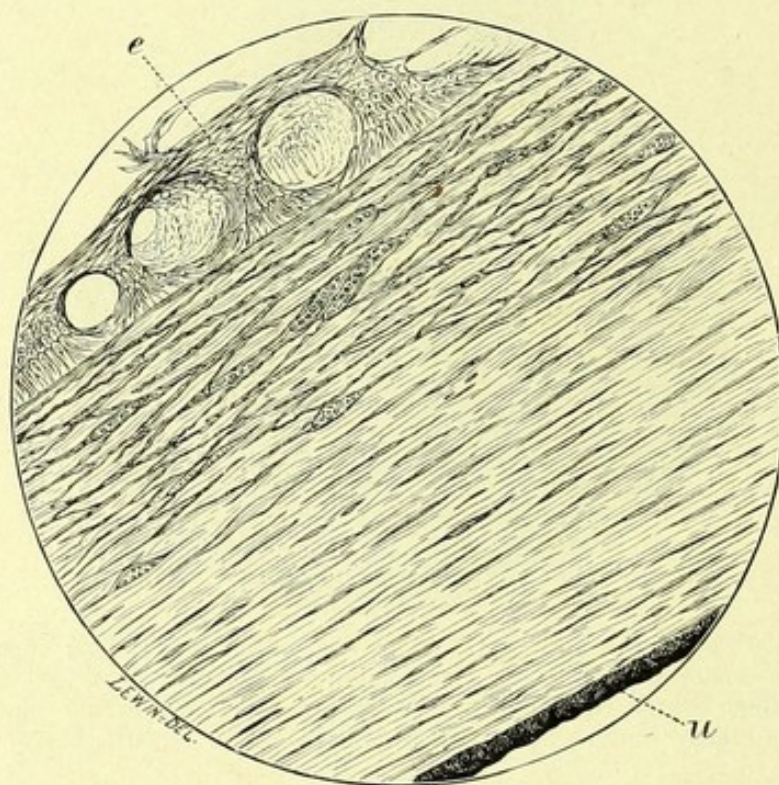


FIG. 167.—Section through a staphylomatous cornea with increased tension, showing vesicles in the epithelium on its anterior surface. *e*, Epithelium; *u*, uveal pigment adherent to the back of the cornea. Case recorded in R. Lond. Ophth. Hosp. Reps., XIII, 1890, 48.

The iris being pulled forward by the incarceration in the base of the ulcer the angle of the anterior chamber may be blocked and increased intraocular tension produced.

“Vesicular Keratitis”.—**Edema of the corneal epithelium**¹ is frequently associated with increased intraocular

¹ E. Fuchs. Trans. Ophth. Soc., XXII, of the U. K., 1902, 15.

tension, but it is also associated with deep inflammatory affections of the cornea and iridocyclitis. The change found on histological examination is a separation of the basal cells of the epithelium from each other with fluid, which causes a desquamation of the superficial cells of the epithelium, so that the surface of the cornea is irregular and presents a roughened appearance clinically. The fluid, as it increases,

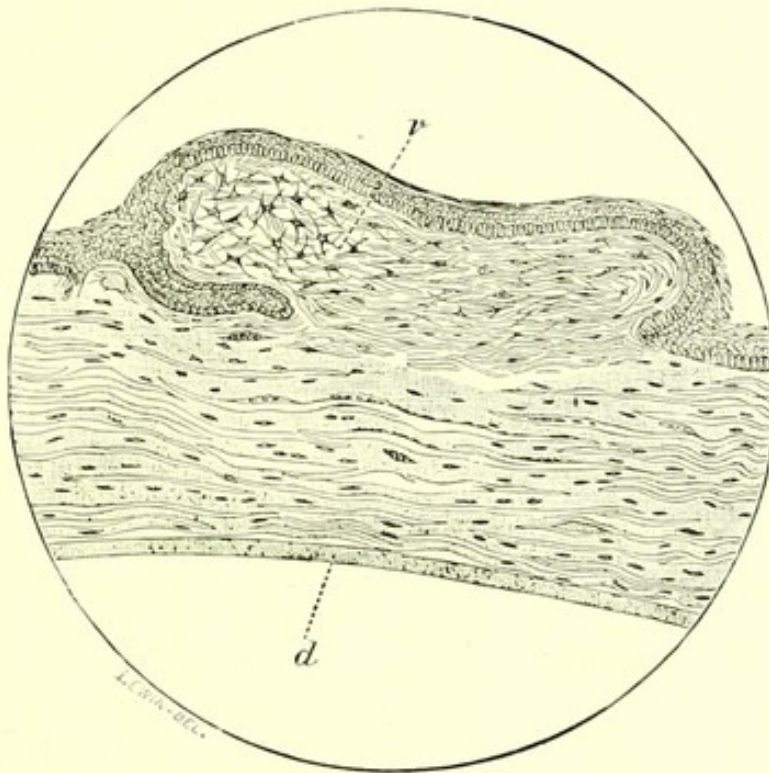


FIG. 168.—Section of the cornea from a case of hereditary syphilitic kerato-iritis, showing collection of organising edematous exudate, *v*, beneath the surface epithelium; *d*, Descemet's membrane. Case recorded in R. Lond. Ophth. Hosp. Reps., XIII, 1890, 50.

lifts up the cells from Bowman's membrane and droplets of it running together form vesicles or bullæ (Fig. 167). In the early stages the basal cells occasionally show signs of vacuolation.

In cases where vesicular keratitis is associated with plastic cyclitis the fluid gives rise to a deposit of fibrin between the epithelial cells and Bowman's membrane, into which vessels springing from the limbus may extend causing it to become organised into a thick fibro-vascular membrane (Fig. 168).

A **recurrent single bulla** occasionally occurs at the site of an old wound in the cornea. Their recurrence seems to be due to an imperfect adhesion between the epithelium and the underlying scar tissue. The process of their formation is similar to that already described, the change being limited to the area affected. (The vesicles connected with **herpes zoster** and **herpes febrilis** present the same histological characters).

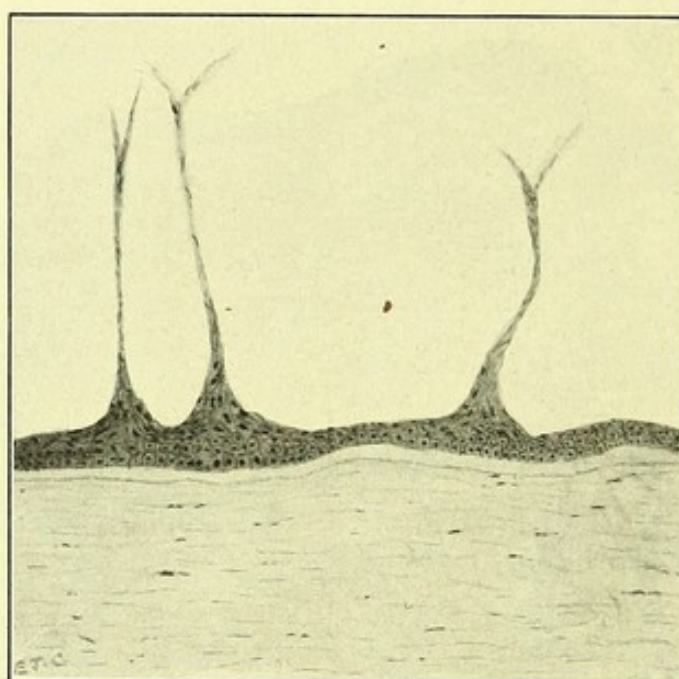


FIG. 169.—Section of the anterior part of the cornea in an eye which had had vesicles form in its surface epithelium, the vesicles have burst and given rise to the formation of filamentary processes.

Herpes zoster has been attributed to some atrophic change in the cells of the Gasserian ganglion.

The vesicles formed in herpes febrilis rupture. If these minute abrasions remain discreet a condition known as **superficial punctata keratitis** is produced, while if they run together a branch-shaped ulcer is formed (**dendritic keratitis**).

In either of these conditions the corneal abrasion may result in infection of the substantia propria with pyogenic organisms and the formation of a purulent ulcer.

Occasionally in vesicular keratitis, when two vesicles

lie in contact with each other and both rupture, the partition of epithelium lying between them remains adherent to the cornea as an epithelial filament (Fig. 169). By the movements of the eye this becomes twisted and mucus collects around it. The epithelial cells at its base proliferating cause its elongation into a cord—a condition which is known as **filamentary keratitis**.¹

Infection of the cornea by means of the blood stream must take place from the limbus so that diseases which have their origin in this way must start in that position. For the changes which take place (see page 418).

Inflammation of the substantia propria can occur also as the result of inflammation in the interior of the eye due to diffusion of the toxins through Descemet's membrane. In non-suppurative iridocyclitis, such as is associated with some septic trouble, *e.g.*, pyorrhea alveolaris, the toxin in the aqueous diffuses through Descemet's membrane and then sets up an inflammation in the deeper layers of the cornea—a condition known clinically as **keratitis profunda**, which is frequently associated with a wrinkled condition of the membrane giving rise to striation, one form of what is called **striate keratitis**.²

A more severe interstitial inflammation occurs in tubercle of the iris from the same cause. It is also possible that some cases of interstitial keratitis of syphilitic origin in the early stages may be due to the toxin in the aqueous. In severe intraocular infections leading to suppuration, such as occurs in metastatic panophthalmitis and occasionally with punctured wounds, an "**annular infiltration**" occurs which may go on to the formation of a "**ring abscess**"³ or ulcer situated usually about 4 mm. from the limbus; it is due to the toxins causing death of the central portion of the cornea, the "annular infiltration" or "ring abscess" being the line of demarcation along which the slough would subsequently separate.

¹ Treacher Collins. Erasmus Wilson Lectures, *Lancet*, Feb., 1900.

² W. T. Holmes Spicer. R. Lond. Ophth. Hosp. Rep., XIV, 1896, 33.

³ E. Fuchs. Archiv. für. Ophth., LVI, 1903.

Kerectasia is the yielding of the cornea without incarceration of the iris. The pathogenesis of a keratocele has already been explained. Occasionally after interstitial keratitis, especially in those cases which have been associated with increased tension, the whole cornea which is softened by the inflammatory process may yield with the result that the anterior chamber is deepened. Occasionally in cases where the inflammation is mainly limited to the centre of the cornea a condition of conical cornea may be produced. This yielding of the cornea may give rise to splits or ruptures in Descemet's membrane (see Buphthalmos).

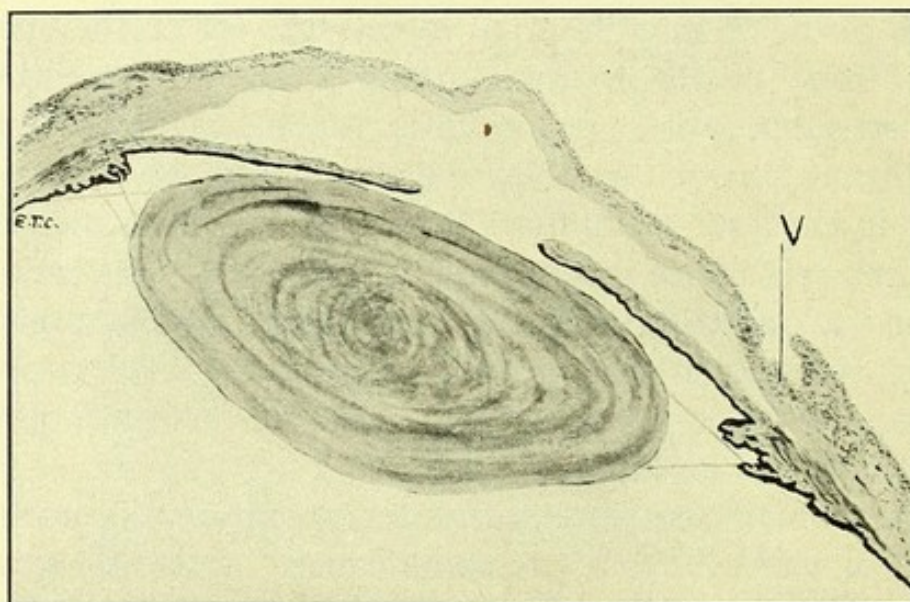


FIG. 170.—Section through the anterior half of an eye in which a Mooren's ulcer has involved the whole cornea and reduced its thickness by about half. At V a small secondary ulcer has formed.

Mooren's Corneal Ulcer.—This disease is characterised by a slow necrosis of the cornea involving about half its thickness. It is frequently bilateral and when comparatively aseptic there is little or no ciliary injection. It usually starts at the corneal margin, frequently in the upper segment, and always involves the whole cornea. It is greyish in colour, the spreading margin is deeply undermined, and has an overhanging edge of proliferating epithelium; there is no discharge unless pyogenic organisms are present. As

the disease spreads the portion which has been involved heals, the epithelium growing over its surface. There is little or no formation of new fibrous tissue, as after the healing of an ordinary corneal ulcer, so that when the ulcer has entirely healed there is a loss of half the thickness of the substantia propria of the cornea. Cicatricial tissue not being present, the opacity which follows is comparatively slight, so that fair vision may be restored. In rare cases, after the whole cornea has been involved and has healed, it may again break down. The slow character of the necrosis; the fact that it always involves the whole cornea and never perforates; together with the absence of inflammation, when free from pyogenic organisms, suggest that the disease is due to a slow necrotic process in the superficial layers of the substantia propria of the cornea—probably due to defective nutrition by the lymph or blood. This is further borne out by the fact that there is little or no attempt at reformation of fibrous tissue to replace the loss. Organisms have been found in the ulcer but none have been identified as the cause of the disease and they are probably only saprophytic in nature.

The sclerotic, being composed of interlacing fibrils of dense connective tissue which run antero-posteriorly and concentrically, offers a strong resistance to the spread of infection, either from without inward or from within outward. It is poorly supplied with blood-vessels derived from the branches of the ciliary vessels and from vessels that run along the tendons of the ocular muscles which are inserted into it. In the neighbourhood of the entrance of the optic nerve it derives further blood supply from the circle of Zinn. Due to this scanty blood supply the changes produced by inflammation are slow to form and to resolve. Infections of the sclerotic apart from wounds are always metastatic in origin, the anterior part being most commonly affected.

When the superficial portion of the sclerotic is involved it is known as **episcleritis**. This consists of a bright red patch of injection with lymphocytic infiltration but comparatively little swelling. It is usually attributed to rheumatism.

When the deeper layers are affected the term **scleritis** is used. The latter disease may start either at the outer or inner surface of the sclerotic. Upon the outer a definite vascular swelling is formed which in tubercular cases may undergo caseation, giving its centre a yellowish appearance. In this stage the disease is comparatively superficial and can be removed by excision; as it progresses it may spread anteriorly, involving the conjunctiva, but ulceration is extremely rare. It usually extends laterally around the cornea (**annular scleritis**).

Inflammation in the inner surface of the sclerotic (**deep scleritis**) usually starts either in the deep layers of the sclerotic or more commonly in the suprachoroidal lymph space. From this situation the disease may spread into the sclerotic and appear on the outside of the globe, or it may make its way forward in the mesh of the ligamentum pectinatum and involve the cornea producing a condition known as **sclerosing keratitis**. It may also involve the ciliary body and choroid, giving rise to vitreous opacities.

— **The uveal tract** consists of the iris, ciliary body, and choroid, which are continuous with each other and hence inflammation starting in one portion of the tract is liable to spread to the others. The primary source of infection may be exogenous or endogenous. Apart from wounds endogenous infection is usually the cause but inflammation may spread to it from the cornea, sclerotic, and retina. Inflammation of the uveal tract is generally divided into suppurative, plastic, and serous. At the same time there is no true line of demarcation between the processes. Taken as a general rule the more virulent the infection the more acute the inflammation, the greater the amount of exudation and the larger the area of the tract involved.

Suppurative uveitis may be produced by the infection of any portion of the tract with virulent pyogenic organisms, which leads to acute inflammatory changes rapidly spreading to all the other portions and thence to the retina, producing a condition of panophthalmitis. Less virulent pyogenic

infections may give rise to local suppuration which may resolve and not lead to panophthalmitis. If the choroid is primarily affected, it is called suppurative choroiditis (abscess in the choroid); if the ciliary body, suppurative cyclitis; if the iris, suppurative iritis.

Non-suppurative uveitis is produced by infections of a less virulent character giving rise to a plastic or serous inflammation. In the former there is an exudate of fibrin and lymphocytes together with a marked tendency to the formation of connective-tissue membranes; in the latter the exudate consists of albuminous fluid in which the cellular elements are reduced to a minimum.

The uveal tract being extremely rich in blood-vessels inflammatory changes usually occur in it with great rapidity. The amount of blood passing through these vessels, and therefore the amount of tissue change, depends very largely on the state of the intraocular tension in its relation to the blood pressure. If the intraocular tension is high the vessels are in a state of collapse and little tissue change goes on; while, on the other hand, if the tension be low, the vessels are capable of undergoing enormous distention, more especially in the choroid which varies greatly in thickness depending on the amount of blood passing through it. The increased exudation, as the result of lowering* the tension of the eye, is sometimes seen very markedly after performing paracentesis in cases of increased tension associated with plastic iridocyclitis, masses of exudate appearing on the surface of the iris twenty-four to forty-eight hours after the operation.

— **Chroiditis.**—The inner surface of the uveal tract is lined by the membrane of Bruch. This membrane, which is thickest at the posterior part of the globe, allows the diffusion of fluid containing toxins through it in the early stages of an inflammation but presents considerable resistance to the passage of cellular exudation and microorganisms. It follows that inflammation occurring in the choroid, unless very acute or prolonged, will not cause destruction of the

overlying retina, only producing an edema, by which its function may be temporarily inhibited. The exudate may be beneath or within the retinal substance. The subretinal exudate may contain granules from the pigment cells or even the pigment cells themselves which are loosened from their underlying membrane by the exudation; the proliferation and migration of these cells, and of the pigment cells of the choroid, gives rise to the pigmentation which is seen in the fundus after the inflammation subsides.

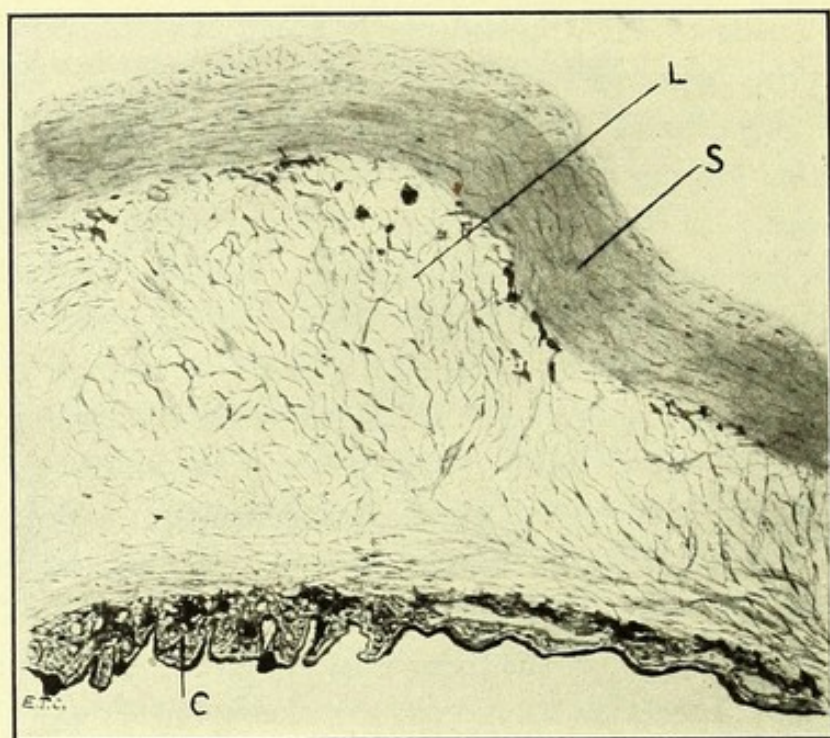


FIG. 171.—Section showing new formation of connective tissue *L* between the sclerotic *S* and choroid *C* in a shrunken eyeball which has been the subject of suprachoroiditis.

A softening of the membrane of Bruch with destruction of it may occur in long standing or very acute inflammation in much the same way as Descemet's membrane is affected in corneal ulceration; the overlying retina then becomes involved in the inflammatory process and it is deprived of its functional activity, being converted ultimately into fibrous tissue. In cases of subretinal exudation in which Bruch's membrane has given way, the exudate may become organised

by the extension of endothelial cells into it from the choroid. As the result of the cicatricial contraction which follows the formation of the fibrous tissue the retina may become rucked and folded upon itself so as to form a prominent white mass with some pigmentation. Such eyes have been excised under the idea that the surgeon was dealing with a new growth. As this scar tissue becomes less vascular secondary degeneration occurs. Fatty, hyaline, calcareous and bony changes may take place in it. The formation of colloid nodules in the membrane of Bruch will be discussed under degenerative processes (see page 432). Occasionally in shrinking eyes or in eyes that have been the subject of subchoroidal exudation or hemorrhage the subchoroidal exudation may organise into a laminated fibrous tissue membrane lying between the choroid and sclerotic (Fig. 171); this membrane is firmly attached to the choroid but not to the sclerotic. Pigmented cells from the choroid may migrate into it but secondary calcification and ossification does not take place in the same way as it does in the membranes on the inner surface of the choroid. The condition is known as **suprachoroiditis**.

Iridocyclitis.—Although Bruch's membrane can be traced forward covering the ciliary body and iris, it is extremely thin in these situations and does not offer much resistance to the passage through it of either fluid or cellular exudate.

In the anterior part of the globe the epiblastic covering of the uveal tract consists of two layers of cells—in the ciliary body an external or pigmented layer, and an internal or non-pigmented layer. The pigmented epithelium over the ciliary body dips down into the underlying tissue in processes which resemble short tubular glands¹ (Figs. 116, 117). There is little doubt that under normal conditions the epithelium covering the ciliary processes plays an important part in the formation of the aqueous humour from the blood. Although not in its strictest sense a true secretion of the cells, in that

¹ Treacher Collins. Trans. Ophth. Soc. of the U. K., XI, 1891, 55.

there are no precursory granules in them and that the amount of aqueous secreted is dependent on the blood pressure in relation to the intraocular pressure, the epithelium under normal conditions has the power of keeping back the albuminous portion of the serum. Directly the epithelium becomes damaged by inflammation or the reduction of the intra-

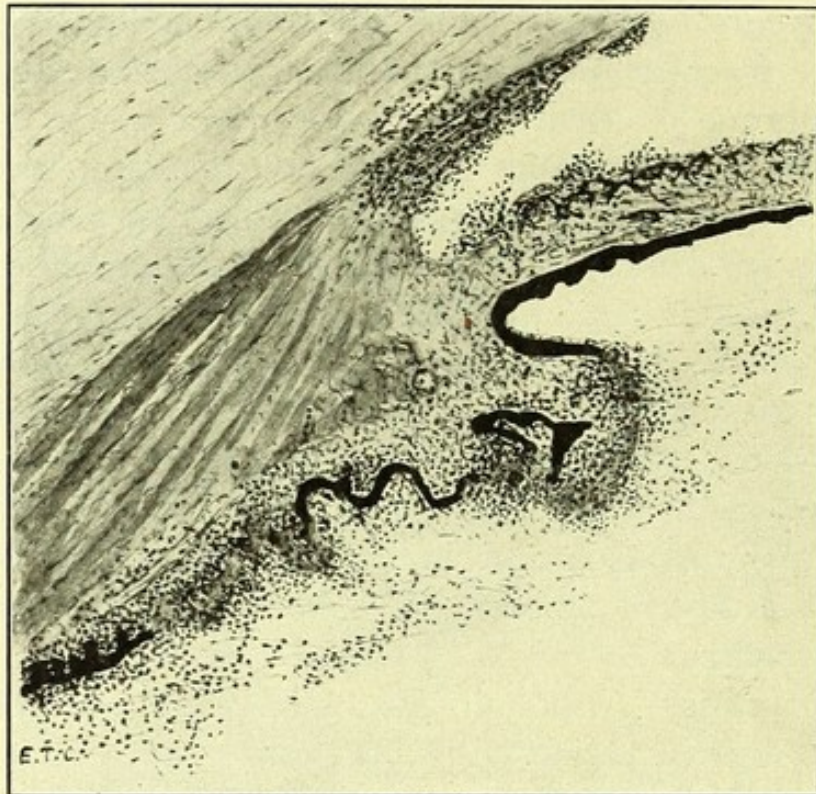


FIG. 172.—Section showing the ciliary body and angle of the anterior chamber in a case of serous cyclitis. The vascular tissue on the inner surface of the ciliary muscle is much infiltrated with inflammatory cells. The pigment epithelium lining the ciliary body shows areas of degeneration. Cellular inflammatory exudate is shown on the inner surface of the ciliary body and about the angle of the anterior chamber. The mesh of the ligamentum pectinatum is filled with cells and accumulations of them have formed on the back of Descemet's membrane and on the anterior surface of the iris.

ocular tension it allows of the transudation of the albuminous portion of the blood-serum. This process has its analogy in the epithelial cells lining the kidney glomeruli which exert the same function on the blood circulating through it, the secretion also being dependent on the local blood pressure. In inflammation of the ciliary body the cells become swollen and proliferate, the tubular processes becoming more

marked. Increase in tension of the eye during the early stages of iridocyclitis is due to the secretion being of a more albuminous character and to an accumulation of cellular elements in the mesh of the ligamentum pectinatum (Fig. 172).

It is probable that the beneficial results of paracentesis in cyclitis with increased tension is due, first, to the evacuation of some of the toxic products of the inflammation, and

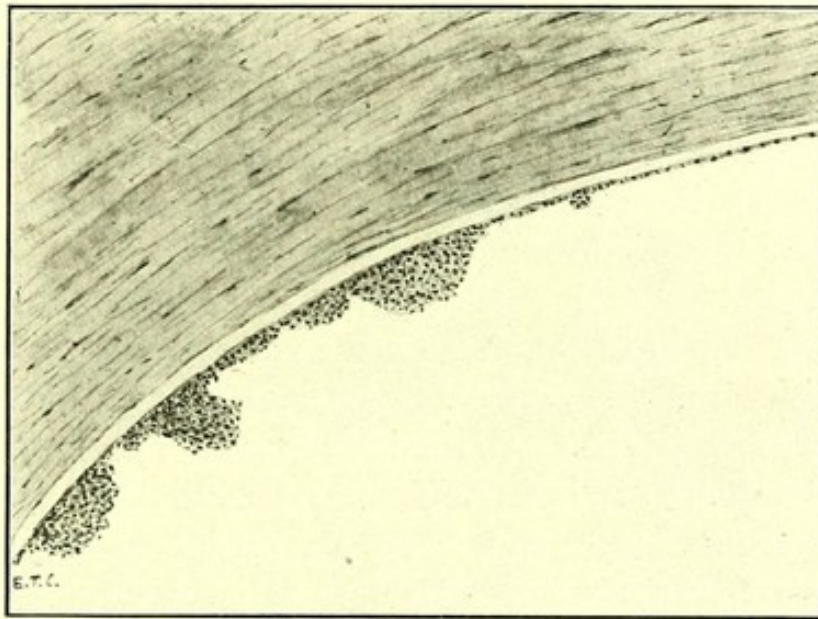


FIG. 173.—The posterior surface of the cornea in an eye with "Keratitis Punctata." The groups of cells which have become precipitated on the back of Descemet's membrane are shown.

second, to the diminution of the intraocular tension allowing a fresh filtration of fluid containing protective bodies to come from the blood-vessels.

Iridocyclitis is divided into serous, plastic, and suppurative. In **serous iridocyclitis**¹ the fibrinous exudate is reduced to a minimum while the cellular exudate consists entirely of lymphocytes and plasma cells. These cells which are derived from the iris, ciliary body, or the retina in choroidal retinitis pass in the circulation of the intraocular fluid forward through the circumlental space into the anterior chamber where they are deposited on the lower part of the

¹ M. S. Mayou. *Brit. Med. Journ.*, Oct. 28, 1910.

posterior surface of the cornea. They form collections of cells which give rise to dotted opacities on the back of the cornea arranged in a triangular form base downward. These precipitates are known as **keratitis punctata** (Fig. 173). The size of the dots varies in different cases, they may be so small that they can only be discovered on high magnification, or large and easily seen with the naked eye when they frequently resemble drops of mutton fat. This variation in size is probably due to the character of the agglutin body present in the aqueous. Their origin is often evident by the fact that they are found to contain granules of pigment from the pigment epithelium. These precipitates disappear by degeneration of the cells; sometimes the pigment granules remain marking their former position.

Prolonged chronic cyclitis may produce other changes in the eye. The exudation from the ciliary body may appear as opacities in the vitreous. Round-celled infiltration, with secondary pigmentation, is frequently present in the anterior parts of the choroid from the disease, spreading from the ciliary body to it. As the result of the osmosis of the toxic bodies the lens after a time may become opaque. The iris may become thin, blanched and atrophic, and occasionally, if the disease begin in a subacute attack of iritis, an atrophic patch has been known to occur in the iris due to its being the site of the septic embolism which gave rise to the cyclitis.

Plastic Iridocyclitis.¹—This form of iridocyclitis, when accompanying wounds in the globe, may give rise to sympathetic cyclitis.

The feature of this disease is the strong tendency that the exudate shows to the deposit of fibrin with the formation of inflammatory connective tissue membranes. The cellular exudation consists of nodules of lymphocytes and plasma cells. These are present in the iris, ciliary body, and choroid. Occasionally giant cells and large endothelial cells may be present in these follicles.

¹ L. Buchanan. Trans. Opth. Soc. of the U. K., XXI, 1901, 208.

The exudation into the vitreous causes the formation of fibrous tissue which may subsequently contract and detach the retina. The exudation from the iris causes occlusion of the pupil, total posterior synechiæ and its sequelæ.

Thick fibrinous membranes may occur on the surface of the iris, ciliary body, and choroid. Keratitis punctata occurs in all cases and occasionally a thick fibrous membrane may be found on the posterior surface of Descemet's membrane. If bullæ occur on the cornea the fluid they contain is rich in fibrin and a fibrous deposit takes place which may

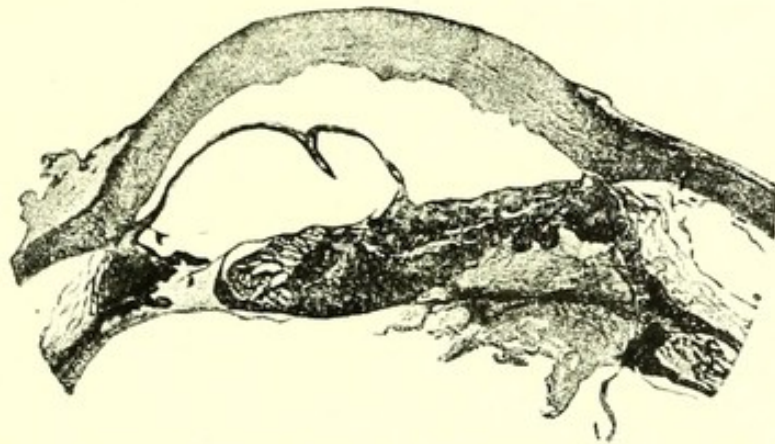


FIG. 174.—Shows a section through the front part of an eye which had plastic iritis as a result of a perforating wound of the cornea and lens. The iris on the right side is adherent in its whole length to the lens capsule. On the left side it is adherent at the pupillary margin but bowed forward, by fluid unable to pass through the pupil, elsewhere. Case recorded R. Lond. Ophth. Hosp. Rep., XIII, 1890, 55. From a photograph by E. Collier Green.

organise into a thick, fibro-vascular membrane lying between Bowman's membrane and the epithelium. Finally shrinking of the eye may result.

In sympathetic cyclitis the microscopical changes in the sympathising eye are similar to those in the exciting eye except in the region of the injury.

In iritis, the stroma of the iris is infiltrated and the exudate appears principally on its anterior surface. The swelling of the stroma and fibrinous exudate tends to obliterate the crypts on the surface of the iris causing obscuration of its pattern and discolouration. Fibrinous coagula may also form and collect at the bottom of the anterior chamber. As

the inflammatory process subsides the exudate gradually becomes absorbed, but the iris, especially after many attacks, becomes thin and atrophic and in some instances permanently discoloured.

The exudation may cause adhesions between the posterior surface of the iris and the anterior capsule of the lens (**posterior synechiæ**). If this occurs at the margins of the pupil in its entire circumference it is known as a **secluded pupil**, while if the lymph cover also the anterior capsule of

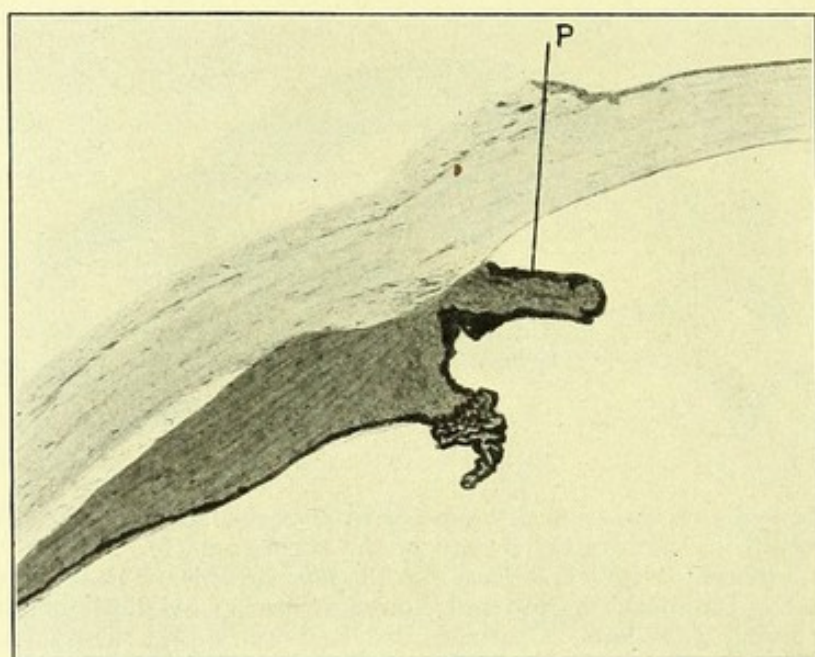


FIG. 175.—Shows the iris drawn back into the angle of the anterior chamber, from the organisation of fibrous tissue on its anterior surface, the result of iritis following a perforating wound. *P* points to the pigment epithelium which has become drawn round the pupillary margin, and covers the whole of what there is left free of the anterior surface of the iris.

the lens in the pupillary area it is known as an **occluded pupil**. The latter two conditions may lead to secondary glaucoma (see page 214). Cysts between the two pigment epithelial layers on the posterior surface of the iris are of frequent occurrence producing a condition resembling iris bombé. After very severe plastic or suppurative inflammation the whole posterior surface of the iris may be stuck down to the anterior capsule of the lens—a condition known as **total posterior synechiæ** (Fig. 174).

The exudate on the surface of the iris may organise into a membrane of varying thickness: it may be so thin that it can only be distinguished microscopically as a single layer of cells, or so thick as to conceal the iris. In both forms new vessels may be present. In cases where the iris is not bound down to the anterior capsule of the lens the cicatricial contraction of this connective tissue on the surface of the iris may cause retraction of the iris and ectropion of the pig-

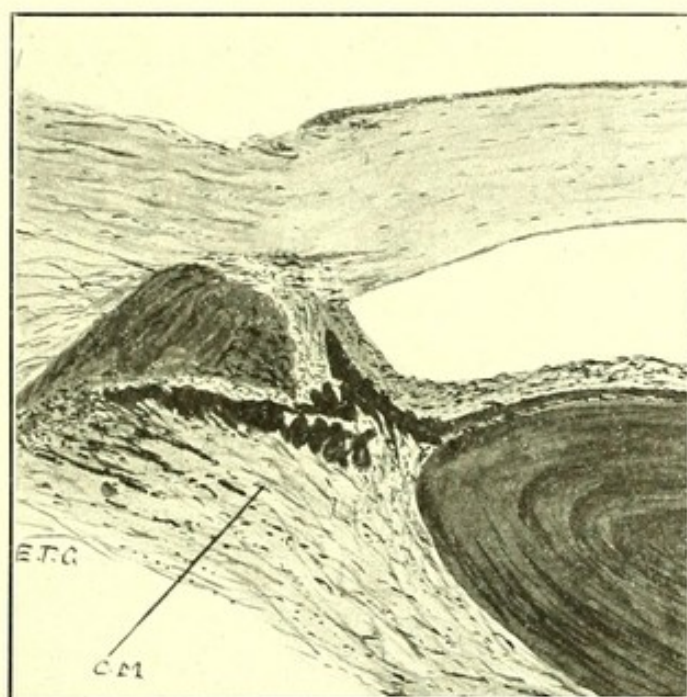


FIG. 176.—Section of an eye which had had plastic cyclitis. A cyclitic membrane, *C.M.*, has formed, the organisation and contraction of which has drawn the ciliary body away from the sclerotic and retracted the root of the iris, so deepening the periphery of the anterior chamber.

ment epithelium round the pupillary margin. The retraction in rare cases may be so great that the iris becomes drawn up into the angle of the anterior chamber and clinically an appearance of aniridia is produced (Fig. 175).

In suppurative iridocyclitis, in addition to hypopyon being present due to the polymorphonuclear leukocytes falling to the bottom of the anterior chamber, exudation of these cells takes place into the ciliary body and from its inner surface into the vitreous behind the lens. In the early stages this is seen clinically as greyish streaks or dust-like

particles in the anterior part of the vitreous. As the inflammation progresses pus forms in the vitreous and a condition of panophthalmitis may result. If this takes place, the blood-vessels of the retina and choroid participate in the formation of the exudate. Occasionally, although pus is formed in the vitreous, the inflammation may subside with the result that organisation in the exudate takes place and a

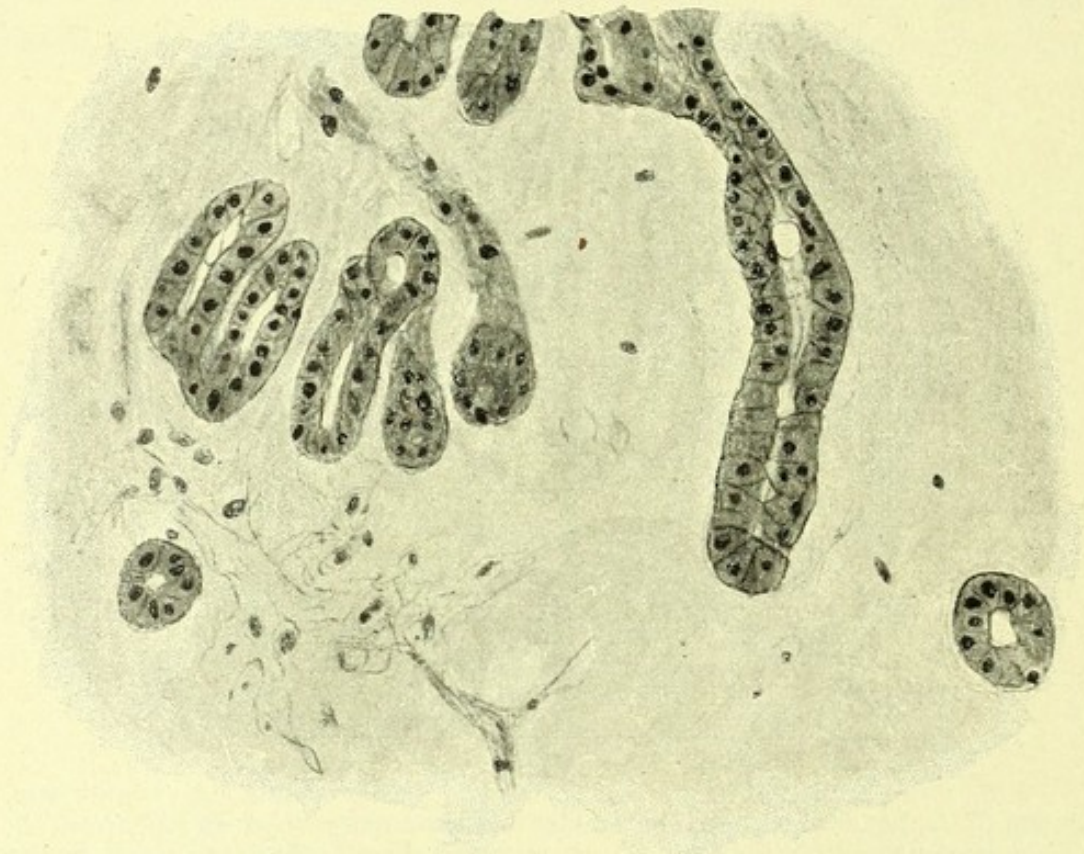

FIG. 177.—Shows a bleached section of tubular processes of epithelial cells which have extended into a cyclitic membrane, the result of plastic cyclitis. $\times 300$.

fibrous tissue membrane (**cyclitic membrane**) forms behind the lens giving rise to a yellowish reflex—a condition which may clinically resemble glioma of the retina and hence has received the name of **pseudo-glioma**.

The formation of fibrous tissue in the vitreous causes secondary changes in the eye. The vitreous may shrink and if adherent to the retina cause detachment of that membrane. In pseudoglioma the retina becomes matted up with the exudate from the ciliary body to form a large mass in which

the pigment cells proliferate and migrate. The choroid, ciliary body, and ciliary processes are pulled inward, opening up the suprachoroidal lymph space, and the root of the iris backward into the circumlental space, deepening the periphery of the anterior chamber (Fig. 176). The epithelium covering the inner surface of the ciliary body often extends into the cyclitic membrane in the form of pigmented, or partially pigmented, tubular processes (Fig. 177).

Atrophy of the ciliary body causes the eye to become soft and a buckling inward of the sclerotic takes place. This general shrinking of the whole globe is known as **phthisis bulbi** (Fig. 210). Fatty degeneration takes place and lime salts may become deposited, principally around the vessels in

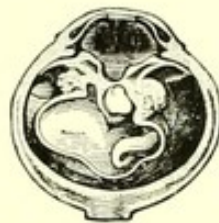

FIG. 178.—Shows the lateral half of an eye which has a mass of organised inflammatory exudate in the anterior part of the vitreous humour, "pseudo-glioma." By its contraction it has detached the retina, retracted the root of the iris, and produced a projection backward at the posterior pole of the lens. Case recorded in R. Lond. Ophth. Hosp. Reps., XIII, 1892, 391.

the choroid and to a less extent in the posterior part of the ciliary body and in the cyclitic membrane. Large cells of the nature of osteoblast, probably derived from the endothelial cells, make their appearance and true bone is deposited. This may go on to such an extent that the entire circumference of the choroid may be converted into bone which is usually thicker posteriorly than anteriorly toward the ciliary region; a round hole in the bone is present in the situation of the optic disc. Bony changes never take place in the tissue of the iris.

The lens, the posterior surface of which is embedded in the cyclitic exudation, is at first clear but after a time becomes opaque, the posterior capsule being wrinkled up and vacuolation taking place in the lens fibres. (Fig. 178). The

pressure of the exudate may produce a molding of the lens into a posterior lenticonus. Secondary calcareous changes may take place in it, but it is never followed by ossification as long as the capsule is intact.

Inflammation of the Retina.—Before the pathology of the diseases affecting the retina were properly understood many of them, such as albuminuric retinitis and retinitis pigmentosa, were ascribed to inflammation, but they are in reality degenerative processes secondary to changes in the retinal vessels.

The epiblastic constituents of the retina do not undergo any active changes in inflammation of it. In what is termed retinitis it is the blood-vessels and their contents in which the primary changes occur, the other parts of the retina undergoing merely secondary degeneration. Of these changes perhaps the commonest is edema which may be either associated with the inflammatory process or secondary to vascular sclerosis, a sequela of the inflammation. The edema may be diffuse or localised. Diffuse edema occurs in the early stages of retinitis. The exudate being highly albuminous and opalescent, it gives rise to a general retinal haze when seen with the ophthalmoscope. In localised edema the exudate may collect in any of the layers of the retina or beneath the hyaloid membrane of the vitreous. Most commonly it is situated in the internuclear layer where it forms cystic spaces which displace the nuclear layers and may burst through the membrana limitans externa into the subretinal space, a collection of fluid in the latter situation giving rise to detachment of the retina.

As a result of these changes the retina tends to become disorganised, the ganglion cells lose their Nissel's granules, become vacuolated, and after a time disappear; the rods and cones become swollen and break down into a finely granular débris. The fluid which has accumulated in the cystic spaces gives rise to sharply defined white areas, it becomes changed into the hyalin material which is so frequently found on histological examination. After a severe inflam-

mation nothing is left of the retina but the remains of the supporting elements together with fibrous tissue.

Ophthalmoscopically the situation of a retinal exudation can only be told by its relation to the retinal vessels which do not penetrate deeper than the external molecular layer. Exudation lying over the vessels must be situated in the nerve-fibre layers of the retina or beneath the hyaloid membrane, while exudation in the deeper layers will lie beneath the vessels. The retinal vessels themselves are surrounded by perivascular lymph spaces into which the exudate makes its way, producing the white lines that are so often seen with the ophthalmoscope along the vessels after inflammation. Organisation of the exudate is more liable to take place in the region of the optic disc than elsewhere as that is the most vascular portion of the retina. After the inflammation has subsided the retinal blood vessels may undergo secondary sclerosis and degenerative changes, may occur in the retina similar to those found in primary vascular sclerosis (see page 184).

It is not uncommon after inflammation of the retina to find a thin membrane composed of endothelial cells lying between its inner surface and the hyaloid membrane of the vitreous. The contraction caused by the organisation of these cells into connective tissue may produce folds in the hyaloid membrane. The white bands sometimes seen on the surface of the retina are probably accounted for by such changes. When a similar condition occurs over the optic disc the cicatricial contraction may pull a fold of retina inward over the papilla.

The part played by the membrane of Bruch in inflammatory processes has already been discussed under inflammations of the uveal tract, and it has been shown how its continuity prevents the spread of endothelial cells and subsequent organisation from the choroid to the retina. The continuity of the hyaloid membrane of the vitreous plays a part similar to the membrane of Bruch in preventing the spread of endothelial cells from the retinal vessels to the

vitreous. Leuckocytes and toxins can, however, pass through it, the former constituting the vitreous opacities which usually accompany retinitis. When gaps in the continuity of the hyaloid membrane occur, which is usually the result of hemorrhage into the vitreous, endothelial cells may spread into it causing the formation of bands of fibrous tissue—a condition which is known as **retinitis proliferans**.¹ The subsequent contraction of these bands often causes detachment of the retina from its pigment cell layer.

The part played in retinal inflammation by the pigment cells, although very prominent from an ophthalmoscopic point of view, is in reality purely a secondary one and is no direct evidence of the extent or severity of the inflammation. They receive their nutrition principally from the choroid. The changes in the pigment cells are most prominent as the inflammation begins to subside; at first they are loosened from the membrane of Bruch and degenerate; the granules of pigment are taken up by the leukocytes or lie free in the exudation. Granules of pigment which are thus set free by the breaking up of the cells may be carried into the lymphatics where they become deposited and form pigment streaks in the retina. As organisation of the inflammatory exudate begins to take place the pigment cells proliferate, the new ones migrating, either by their ameboid movements or by multiplying in continuity, into the retina and any newly formed connective tissue which may be present. The sharply defined masses of pigment which are seen with the ophthalmoscope are thus produced. Hemorrhages are a usual accompaniment of retinal inflammation due to changes in the vessel walls. For the changes they undergo (see page 190).

Purulent retinitis may arise from the direct infection through wounds, secondary to traumatic or metastatic infection of the uveal tract, and from septic embolism in the retinal vessels. The retina becomes infiltrated with polymorphonuclear leukocytes which make their way inward

¹ P. Flemming. Trans. Ophth. Soc. of the U. K., XVIII, 1898, 154.

collecting in large numbers between the retina and the hyaloid membrane and in the neighbouring vitreous. The disease progressing may end in panophthalmitis or a condition of pseudo-glioma which has already been described (see page 334). Septic emboli probably also give rise to a non-suppurative form of retinitis, which is known as **retinitis septica**, in the same way as septic emboli may produce non-suppurative forms of inflammation of the uveal tract. In retinitis septica white areas appear in the neighbourhood of the disc usually associated with retinal hemorrhage and occasionally optic neuritis. In the early stage of the disease the patches consisted of round-celled infiltration, in which organisms are found.

Inflammation in the Optic Nerve.—Inflammation may take place in the optic nerve in any part of its course, but the ophthalmoscopic appearances of optic neuritis are only present when the inflammation affects the nerve below the position of the entrance of the retinal vessels into it; that is to say, about 12 mm. behind the globe. Inflammation behind this area (**retro-bulbar neuritis**) produces subjective symptoms, such as loss of vision and tenderness on pushing the globe back into the orbit, but no changes are present in the optic disc in the early stages, although a descending atrophy may appear later.

In inflammation of the nerve the nerve fibres, and the medullary and neuroglial sheaths take no active part, but secondary degenerative changes occur in them. The inflammation may affect the connective tissue between the nerve bundles (**interstitial neuritis**) or it may affect the nerve sheath (**perineuritis**).

In **interstitial neuritis** the leukocytosis and exudate is into the connective tissue between the nerve bundles where it presses on the nerve fibres and may lead to a temporary or even permanent loss of vision. The cicatricial contraction following the inflammation causes compression of the nerve fibrils and may give rise to a shrinking atrophy of the whole nerve. More frequently, islands of inflammation may occur,

so that bundles of nerve fibres are affected; thus the macular bundle is not infrequently implicated. The nerve fibres undergo degeneration, their medullary sheaths becoming broken up into fatty globules; these are taken up by the leukocytes and endothelial cells, which may become enormously distended. The axis-cylinders become varicose and swollen and finally disintegrate.

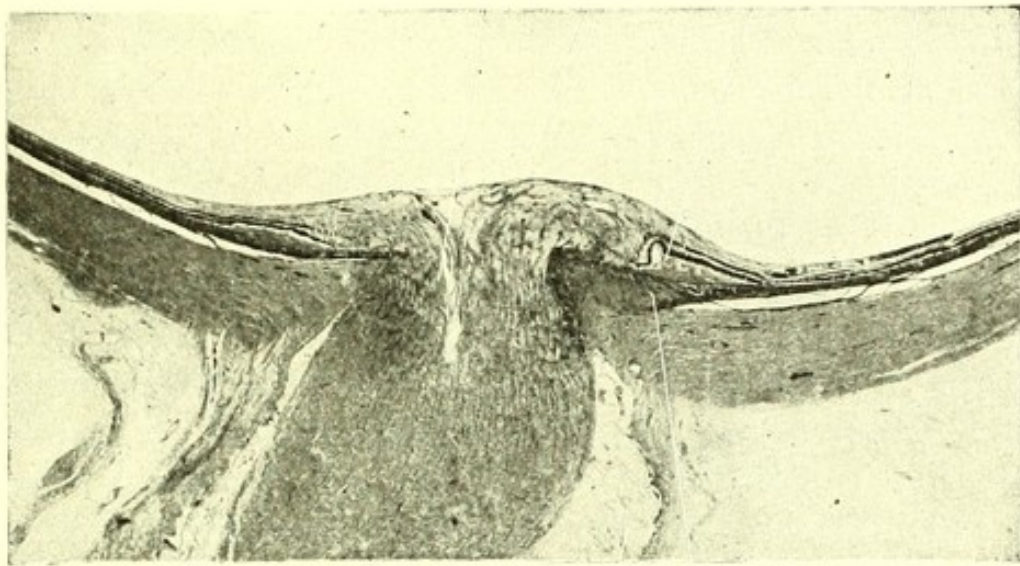
In **perineuritis** exudation takes place into the nerve sheath. The optic nerve is covered by membranes which are continuous with the membranes covering the brain, namely, the dura mater, the pia mater, and the arachnoid. Perineuritis may therefore be divided into pachymeningitis and leptomeningitis, according to the membranes most affected; both forms are usually the result of inflammation spreading from the meninges which may be of a purulent or non-purulent variety.

The purulent cases usually end in death before organisation can take place. In the non-purulent variety, or in the cases which recover, cicatricial contraction with secondary degenerative changes ensue (optic atrophy). Although perineuritis does occur associated with meningitis, the changes at the disc in cases of meningitis are more frequently due to the increased intracranial pressure distending the nerve sheath, causing venous obstructions and edema of the nerve at its entrance into the globe.

Inflammation in the nerve below the entrance of the retinal vessels causes pressure on the retinal vein where it lies in the scleral foramen, and so produces engorgement and tortuosity of it which is followed by edema of the nerve head and surrounding retina, a condition known as **papillitis** (Fig. 179). This is frequently accompanied by hemorrhages into the retina. The exudation causes the margins of the disc to become obscured; its expansion laterally pushes outward the margins of the retina so that ophthalmoscopically it appears to be enlarged. The fluid collects between the nerve fibres in cystic spaces which on section contain granular debris with a few lymphocytes. These spaces may reach

a considerable size and the exudates after a time undergoing hyaline change may give rise to a permanent swelling of the optic disc. The neuroglia stands out prominently owing to the surrounding fluid separating its fibres, but it does not seem to undergo proliferation. As the disease progresses the axis-cylinders in the neighbourhood of the papilla become broken up into finely granular material and disappear. A physiological cup when present becomes filled in by the inflam-

F A D C



B E

FIG. 179.—Section through the optic nerve at its point of entrance into the eye, showing optic neuritis secondary to a tuberculous mass at its margin. *A*, Swollen edematous nerve head; *B*, distended nerve sheath; *C*, retinal hemorrhage; *D*, sub-retinal edema; *E*, mass of tubercle involving the nerve pressing on the retinal vessels *F*.

matory exudate, and a fine endothelial membrane may form over the optic disc derived from the endothelium of the retinal vessels. The organisation over the disc helps to conceal the lamina cribrosa when viewed with the ophthalmoscope which, when the inflammation subsides, is an important point in the diagnosis between postneuritic and simple atrophy. The exudate may spread over the surrounding retina and also spread along the perivascular lymph spaces leading to white lines along the vessels. Secondary sclerosis in the retinal

vessels may result and retinal degeneration follow (see page 175).

Apart from the pressure from inflammatory exudation, obstruction to the venous return by pressure on the nerve at its entrance into the globe may take place from fluid collecting in the nerve sheath, which is first distended on its dorsal surface near the globe. This causes intense edema of the papilla commencing at the upper margin of the disc—a condition which is usually associated with intracranial tension, the state of the disc being known as “**choked disc.**”¹ In this condition, although there is very marked ophthalmoscopic change, in the early stages there is comparatively little disturbance of vision, which is in striking contrast to what occurs in the interstitial form of neuritis where there is rapid loss of sight.

Degeneration of the fibres of the optic nerve takes place in both an upward and a downward direction from the site of a lesion. This is unlike the degeneration which takes place in the peripheral nerves which only occurs in the downward direction, the upper end being left in connection with the ganglion cells from which they derive their nutrition. The optic nerve in reality is an intercentral nerve. The nerve fibres in it are derived both from the retina and the brain. Although the medullary sheaths are developed from the brain toward the eye, degeneration of these sheaths takes place both upward and downward. After division there is never any tendency to regeneration of the nerve fibres.

Inflammation of the lacrimal gland (dacryoadenitis) is the result of infection either through the ducts of the gland which open on to the upper and outer fornix of the conjunctiva, or of endogenous infection. The disease starts in the interstitial connective tissue of the gland and may be acute or chronic. **The acute form** may be suppurative or non-suppurative, the latter is more frequent, especially in children.²

¹ Victor Horsley. *Brit. Med. Jour.*, March 5, 1910.

² W. Inman. *R. Lond. Ophth. Hosp. Reps.*, XV, 1903, 379.

The palpebral portion of the gland is the part usually affected. The interstitial tissue in the gland becomes swollen and infiltrated, the normal number of lymphocytes becomes considerably increased, and polymorphonuclear leukocytes make their appearance. The swelling is communicated to the surrounding ocular and palpebral conjunctiva from which there is usually some discharge. If suppuration takes place, which is more common in inflammation of the orbital than the palpebral portion of the gland, the abscess may burst into the conjunctival sac or open through the skin of the eyelid.

In **chronic dacryoadenitis** there is an inflammation with the formation of cicatricial tissue in the substance of the gland as a result of which degenerative processes occur in the secreting epithelium. As yet only a few cases have been examined pathologically. Such changes in the glandular epithelium would lead to diminution in the secretion. It is probable a similar change may be found in connection with essential shrinking of the conjunctiva and secondary xerosis following trachoma as in both these diseases the lacrimal secretion is absent or very deficient.

Inflammation in the Course of the Lacrimal Canals.—

In the normal state the cilia of the ciliated epithelium work toward the nose and play an important part in removing organisms, débris, etc., which may gain entrance to the lacrimal sac and duct. They also prevent the spread of organisms upward from the nose on the surface of the mucous membrane.

Inflammation of the lacrimal sac (**dacryocystitis**) is always accompanied by obstruction of the duct which may be situated: (a) in the duct, due to epithelial débris and foreign bodies; (b) in the wall, to inflammatory affections in the mucous lining and surrounding bone walls; and (c) outside, to inflammation of the nasal sinuses or new growths in the nose which either fungate into the duct or involve its walls.

The common causes of lacrimal obstruction at the vari-

ous times of life are: in infants, epithelial débris blocking the lower end of the duct—**congenital lacrimal obstructions**;¹ in older children, periostitis produced by the snuffles in congenital syphilis; in adults, inflammatory affections of the mucous lining spreading from the nose. Lacrimal obstruction leads to distention of the lacrimal sac with tears and mucus (**mucocoele**). This forms a suitable pabulum for the growth of organisms which are found in large numbers in the fluid, more especially the pneumococcus. The epithelium lining the mucocoele loses its cilia and desquamates, thus leaving the subepithelial tissue open to infection. If this takes place an **acute peridacryocystitis** is the result with the formation of an abscess around the lacrimal sac which may rupture externally with the formation of a fistula. If this does not heal the epithelium growing downward from the skin lines the tract, so that a permanent opening is formed.

A more chronic inflammation also occurs around the sac in which there is a lymphocytosis and occasionally the formation of actual follicles in the subepithelial tissue. The subsequent organisation following this chronic inflammation leads to permanent fibrous thickening of the sac wall. The epithelium lining the sac in these cases is often several layers in thickness and is devoid of cilia—indeed it tends to resemble epithelium of the squamous variety.

Inflammation of the Skin of the Eyelid.—The pathology of inflammation of the skin of the eyelid, such as eczema, impetigo, etc., is not within the scope of this book.

Inflammation affecting the margins of the lids (**blepharitis**) is of either a seborrheic or pustular type. Seborrheic blepharitis merely affects the glands at the margins of the lids. Pustular blepharitis is an infective process of the glandular structures and hair follicles of the skin of the lid margins (see page 357). As a result of marginal blepharitis the hair follicles may become distorted so that the lashes turn inward (trichiasis) or they become so in-

¹ M. S. Mayou. R. Lond. Ophth. Hosp. Reps., XVII, 1908, 246.

volved in the cicatricial tissue as to be destroyed (madarosis). Thickening of the lid margin may occur (tylosis), the puncta become everted and epiphora result. This, together with the fact that the patient wipes away the tears downward, tends to produce permanent ectropion of the lid.

Tenon's capsule is a closed serous sac wrapped around the posterior part of the globe to allow of its free movements on the orbital tissues. Inflammation in the capsule may follow injury or the spread of inflammation from the interior of the globe, as in panophthalmitis. In very acute cases suppuration may take place, and if the inflammation is primarily in the capsule the abscess may burst either into the globe or externally. Usually in secondary cases, such as those following panophthalmitis, the two layers become adherent to each other by plastic exudation—a point which is very manifest when enucleation is performed on a globe which has suppurated. A serous inflammation of the capsule gives rise to proptosis owing to its distention by fluid.

Inflammation of the Orbit.—Inflammation affecting the orbit may occur as the result of infection from punctured wounds, or from inflammation spreading from the surrounding nasal sinuses, more especially the ethmoidal sinus as its bony orbital wall is very thin.¹ Inflammation in the sphenoidal sinus may affect the optic nerve at the apex of the orbit either by pressure or by the direct spread of the inflammation to it. Suppuration in the orbit may be associated with necrosis in the upper jaw, especially in children. Endogenous infection may occur associated with pyemia.

Orbital cellulitis may or may not be accompanied with suppuration. The infiltration of the orbital tissue gives rise to proptosis, the eye being pushed away from the main site of inflammation. Thrombosis of the cavernous sinus may follow. Vision may be interfered with at the time either by pressure on the optic nerve, or subsequently by the cicatricial contraction around it. An abscess may form and point either along the upper or lower orbital margin.

¹ St. Clair Thompson. *Practitioner*, 1909.

III. The Method of Infection of the Ocular Tissue.

An infectious disease is one that is transmitted by the multiplication of organisms.

The term infectious includes contagious since the difference between the two is only one of degree of contact with infective material.

Before an organism can be definitely recognised as the cause of a disease the following points must be demonstrated:

The organism must be found in the tissues.

It must be isolated and cultivated.

Inoculation into animals or man must produce the same disease in which the organism is again found.

Similar chemical products should be found on cultivation of the organism on media as in the body.

A specific serum reaction, agglutination, or bacteriolytic reaction should be obtained if the blood of an infected person be allowed to act on the specific organism producing the disease.

The dissemination of infectious diseases of the eye depends on many factors which may be divided into those which are connected with the microorganism and those connected with the individual affected.

Those connected with the microorganism are:

1. The quantity of discharge from the eye together with the number of organisms it contains:

2. The number of organisms gaining entrance to the eye.

3. The resistance of the infective material to the deleterious effects of drying, light, heat and oxygen; thus in gonococcal infections of the conjunctiva the activity of the gonococcus is destroyed or much inhibited by drying.

4. The ability or inability of the organism causing the disease to grow outside the infective tissues either in other hosts or inanimate material (facultative saprophyte).

5. The ability of the organism to grow in the skin or mucous membrane before the onset of the disease, a lowered

resistance, either local or general, on the part of the patient being required before the organism can gain a foothold in the tissues; thus the staphylococcus and pneumococcus can grow in the conjunctiva without causing infection, while the diplobacillus of Morax Axenfeld is often present in the nose and occasionally in the conjunctiva without causing symptoms. The Klebs-Loeffler may be present in the throat and nose and probably also in the conjunctiva without causing diphtheria.

Those in connection with the individual affected depend on prophylactic precautions taken with regard to its spread. Most of the infective diseases of the eye are affections of the conjunctiva. The manner in which they spread is by the discharge from the site of infection being conveyed to the eye by the fingers, handkerchiefs, towels, etc., or by washing water. The latter method of conveying the disease is not so frequent as the former since most of the organisms with the exception perhaps of the Klebs-Loeffler bacillus are killed by exposure to the influence of cold water. Most of the organisms which cause conjunctivitis are pure parasites and do not long survive outside the body. The Morax-Axenfeld bacillus will, however, withstand drying for several days, and hence may be conveyed to the eye by the air.

The organisms which give rise to conjunctivitis are often present in the nose, and occasionally in the throat and mouth, during the attack where they may or may not set up inflammation. Many of the organisms, such as the pneumococcus and staphylococcus, are constant inhabitants of these cavities, while others, such as the Klebs-Loeffler bacillus, Morax-Axenfeld bacillus, may be present when epidemics of the disease are prevalent without producing any symptoms but at the same time may be responsible for the spread of infection.

There is no doubt that the discharge from the nose in cases of conjunctivitis must be looked upon as being infectious, and it is probable that the spraying from sneezing, coughing, etc., plays a part in the dissemination of the disease. Indeed, the use of nasal lotions or ointments is very

important from a prophylactic point of view; this is especially the case in infection by Morax-Axenfeld bacillus as, although the disease is comparatively easily eradicated from the eye for a time, the disease is very liable to recur due to reinfection from the nose where the organism may persist.

The method of the entrance of organisms into the body, causing endogenous infection, such as tubercle, syphilis, etc., is not within the scope of this volume.

An infective process may be divided into :

An incubation period which is the time the organism takes to form sufficient toxin in the tissue to produce a clinical effect. The duration depends on the amount of infected material introduced, its nature, its virulence, and its power of reproducing itself, together with the initial resistance of the tissue inoculated. In the conjunctiva, during the incubation period, the organisms cannot be found by bacteriological methods. Probably this is because they are present in such small numbers.

The period of greatest activity during which the organisms are most numerous in the tissues and give rise to an inflammation which may be either serous, *e.g.*, serous iritis; fibrinous, *e.g.*, plastic iritis; purulent, *e.g.*, gonorrheal conjunctivitis; croupous, *e.g.*, diphtheritic conjunctivitis; hemorrhagic, *e.g.*, Kock-Weeks conjunctivitis; necrotic, *e.g.*, kerato-malacia.

A period of Subsidence.—This may be gradual (lysis) as is usually the case, *e.g.*, in gonorrheal conjunctivitis, where the discharge and the organism gradually disappear from the conjunctival sac, or comparatively rapid (crisis), *e.g.*, in pneumococcal conjunctivitis, where the disease and organisms sometimes disappear in twenty-four to forty-eight hours.

Infection of the eye and its adnexa may take place from without by direct infection (ectogenous infection), by the spread of inflammation from the surrounding nasal cavities, or be implanted in the eye by the blood stream

from another focus of the disease elsewhere in the body (endogenous infection).

Ectogenous infection is the commonest form of infection for the outer coverings of the eye, namely, the lids, conjunctiva and cornea, while endogenous infection is more usual in the case of the uveal tract, retina and optic nerve.

Ectogenous Infection.—The infection may be pyogenic (pus-producing) or non-pyogenic. Ectogenous infection with pyogenic organisms is the most frequent, but as has already been pointed out they sometimes fail to produce any reaction that can be clinically regarded as suppuration. Besides the nature of the organism much depends on its point of entry into the eye; thus the staphylococcus epidermidis albus, when introduced into the conjunctival sac or even the anterior chamber, produces no symptoms, but when introduced into the vitreous may produce suppuration.

Endogenous or Metastatic Infection.—In this form of infection the organisms are brought by the blood stream from some focus of disease elsewhere in the body and deposited in the eye. There is yet no evidence that inflammation which is primary and local in any part of the eye can be produced by toxins alone circulating in the blood. When the organisms are of a pyogenic nature the disease is known as pyemia. Pyemic infection may be acute or chronic.

Acute Pyemia.—In acute pyemia suppuration always follows embolic infection. The veins in the neighbourhood of the original lesions become thrombosed; a piece of the clot, softened by the growth of organisms in it, becomes detached, is carried by the circulation until it becomes lodged in one of the capillaries in the eye where it sets up suppuration, *e.g.*, middle-ear disease with thrombosis of the jugular vein sometimes becomes associated with metastatic panophthalmitis.

Chronic pyemia more frequently gives rise to ophthalmic complications. It is probable that the organisms alone, free from any clot circulate in the blood and may lodge in the eye causing inflammation, but do not necessarily give rise to suppuration. For example, chronic iridocyclitis associated

with boils, pyorrhea alveolaris, etc., is in reality a chronic pyemia without suppuration, the organisms circulating in the blood without producing general symptoms. The probable reason why the primary lesion is of a suppurative nature and the other non-suppurative is partly due to the organisms becoming considerably decreased in virulence from their contact with the serum, and partly to the number which lodge in the eye being insufficient to produce suppurative inflammation in such a vascular tissue as the uveal tract.

The fact that bacteria cultivated in a certain soil always grow best on the same soil explains why tubercle may affect all the joints of the body and not affect any other tissue, and also the frequency with which tubercle affects both eyes. Going further, if we regard sympathetic ophthalmitis to be due to septic infection of the exciting eye, it may be inferred that a chronic pyemia is set up which causes an infection of the other eye by the blood stream without producing other infective lesions because the organism has no suitable similar soil elsewhere on which to grow. The reason that sympathetic ophthalmitis does not follow suppurative inflammation of an eye is probably due to the acuteness of the inflammation producing sufficient antibodies in the serum to destroy any organism which may gain entrance to the blood stream.

Wound Infection.—After operations on the eye, although organisms probably gain entrance to the wound in most cases, since the conjunctiva cannot be sterilised, suppuration is rare. In the preantiseptic days post-operative suppuration in the eye was less common than elsewhere. Non-suppurative iridocyclitis following operation must, however, be regarded as septic in nature.

The normal conjunctiva,¹ as has already been stated, is practically never aseptic; although cultivations taken from it with a loop may show no growth at one time it may do so at another, or a growth on media may be obtained by using different methods of obtaining the cultivation. The ordinary

¹ M. S. Mayou. *Ophthalmoscope*, VIII, 1910, 554.

test applied to the conjunctiva, of taking a cultivation from it with a platinum loop, is not a true test of sterility, but useful in that if many organisms be present a growth will be obtained. The number of organisms found in the normal conjunctiva vary with the surroundings in which the patient lives, his personal habits, and with the methods of obtaining the cultivation. Although the tears are not bactericidal in their action they play an important part in the mechanical cleansing of the conjunctival sac. The upper part of the conjunctival sac contains fewer organisms than the lower, whilst at the inner canthus, in the neighbourhood of the caruncle, they are usually most numerous.

The organisms most frequently found in the normal conjunctiva are the bacillus xerosis 94 per cent., staphylococcus albus 79 per cent., pneumococcus 9 per cent., streptococcus 5 per cent., diplobacillus 6 per cent., staphylococcus aureus 6 per cent. The xerosis bacillus and staphylococcus albus are almost constant inhabitants of the conjunctiva; although these organisms are non-virulent and rarely give rise to inflammation in the conjunctiva they may, when introduced into the interior of the eye, cause inflammation; indeed, the staphylococcus is by far the commonest cause both of suppurative and non-suppurative iridocyclitis following operations.

Sections into the anterior part of the globe seem highly resistant to infection. This is partly due to the mechanical action of the newly formed aqueous washing away any organisms that may have obtained entrance into the wound and partly to the newly formed aqueous containing protective bodies from the blood serum. The closure of a wound in the eye from the conjunctival sac is also accelerated by making a conjunctival flap in an operation wherever possible.

The vitreous humour has less power of resisting infection than the anterior part of the eye; indeed, the introduction of saprophites into it, such as the bacillus subtilis and even the bacillus xerosis, seem capable of causing suppuration.

It has been pointed out that the organisms found in the normal conjunctiva, although producing no inflammation in it, being largely saprophytic in nature, when introduced into the globe produce inflammation. It is therefore of the utmost importance to reduce their number as far as possible before operating upon the eye. Theoretically the conjunctiva should be tested for organisms in all cases. At any rate this should be carried out whenever there is a suspicion of discharge from the conjunctiva.

The number of organisms can be considerably reduced by mechanically washing out the conjunctival sac either with saline solution or a mild antiseptic.

Bandaging the eye considerably increases the number of organisms in the conjunctival sac. Wounds in the globe which have a conjunctival flap are usually shut off from it in forty-eight hours unless there be a prolapse of the iris or other complications. The closure of wounds in the globe is facilitated by restraining its movements and it is more important to effect a rapid shutting off of the interior of the globe from the conjunctival sac than to decrease the number of organisms. Thus, although postoperative conjunctivitis is not uncommon, wound infection is rare.

The lacrimal sac, if there be obstruction in the duct, is a frequent source of sepsis after operations; in such cases the pneumococcus is usually found; the organism developing in the stagnant fluid in the lacrimal sac regurgitates into the conjunctival sac with the result that infection of the wound takes place. In these cases the lacrimal sac should first be removed and the operation on the eye performed at a later date.

The eyelashes when free from blepharitis are not a common source of infection since they are comparatively sterile and lie entirely outside the conjunctival sac. It is, however, possible that instruments coming in contact with them might become contaminated and cause septic infection.

The glands of the lid margin may be infected, with

staphylococci, in which case it is probable that the conjunctival sac will contain organisms of the same nature.

The frequency of the staphylococcus, and according to some authorities of the pneumococcus, as a cause of sepsis has led to the use of vaccines and serums for the production of an artificial immunity as a protective agency against septic infection before performing major intraocular operations, such as cataract extraction. It has been suggested that this method of producing artificial immunity should always be carried out where these organisms are found in any number in the conjunctival sac. The use of staphylococcal vaccine after acute infection has taken place has been attended with good results. Serums containing protective bodies have not as yet yielded successful results in producing the subsidence of inflammation in these cases.

In rare cases after major intraocular operations, such as cataract-extraction, the eye will progress favourably, the wound healing with only slight infection, and then some weeks after the operation a hypopyon forms or even panophthalmitis sets in. In these cases it is probable that an organism of low virulence has gained entrance into the eye and has not caused immediate suppuration, but later, when, for some reason, the resistance of the patient's tissues is lowered it has been able to do so. A pure culture from one such case of the bacillus xerosis was obtained and in another of the staphylococcus albus. The wound in each instance was firmly healed. This prolonged incubation period might be termed **latent sepsis**.

Endogenous Infection of Wounds.—There is no doubt that injury plays a part in determining the settling of organisms from the blood stream. As general examples we may take the onset of tubercle in a joint which has been the subject of an injury. In the eye the onset of interstitial keratitis of syphilitic origin is not infrequent in an eye which has received an injury. This affection has arisen after needling the lens for high myopia. There is little doubt in rare instances that endogenous infection of an operation wound

can occur if there be some septic focus such as pyorrhea alveolaris in the body; indeed, panophthalmitis has been known to occur in an eye three months after a cataract extraction which had no sign of inflammation after the operation, obtained good vision, and where the wound was found firmly healed on microscopical examination.

CHAPTER VI.

PARASITIC DISEASES AFFECTING THE EYE.

The parasites causing diseases of the eye are divided into I. Bacteria. II. Fungi. III. Animalculæ.

I. Bacteria (Schizomycetes).

The following are **the ways in which all bacteria should be investigated** to determine their characteristics:

1. By examination of a smear preparation of the organism and as to how it stains with various dyes. Its motility by making a hanging-drop preparation.
2. Cultivation on fluid and solid media either in a tube, plate, or hanging-drop form—whether it is aerobic or anaerobic and, if the latter, in what form; thus by the exclusion of air, exhaustion of air, the absorption of oxygen, or the displacement of air by another gas.
3. Isolation by using different media also, by
Differential incubation, *e.g.*, at different temperatures;
Differential sterilisation, *e.g.*, at different temperatures;
Differential atmosphere cultivation;
Animal inoculation.
4. Morphology.
5. Biology.
6. Chemical products of growth.
7. Pathogenicity.

To differentiate between microorganisms all available means must be employed as bacteria which strongly resemble each other are frequently found on the same tissue, probably

because they require the same conditions for their growth; some of these may be pathogenic, while others are non-pathogenic. In some cases a group may give rise to two different forms of infection; thus, in the "influenza group," the bacillus of Koch-Weeks and the bacillus of influenza both give rise to conjunctivitis exhibiting different characters. Further, pathogenic microöganisms lose their pathogenicity after cultivation and at the same time may slightly alter their characteristics. Organisms may be exalted and made virulent by inoculation, but it is doubtful whether a non-pathogenic organism may be converted into a pathogenic one of the same group. As their pathogenicity is the most important point we have to consider they can hardly be regarded as indetical, and therefore every means must be employed to differentiate them.

The bacteria are divided into (i) Cocci, (ii) Bacilli:

(i) The Cocci.

The cocci are (a) Staphylococci, (b) Streptococci, (c) Diplococci.

(a) **Staphylococcus Pyogenes**.—The group of organisms known as the staphylococcus pyogenes is divided into the **albus**, **aureus**, and **citreus**, depending on the colour which they produce when they are cultivated outside the body. They are round in form and vary considerably in size. The staphylococcus albus is usually the largest, especially the form which is known as the epidermidis albus which is so frequently found in the skin, margins of the eyelid, and conjunctival sac. They **stain** readily with aniline dyes, have no capsule, are non-motile, and do not form spores. They retain the stain in Gram's method. On **cultivation** they grow readily on nearly all media in round colonies which increase in size and run together, especially in sub-cultivations. When grown on gelatine they all produce liquefaction of that media, with the exception of the epidermidis albus which occasionally does not do so. It is on this media

when grown in the cool incubator that the characteristic colour is best developed.

Microscopical examination of a cultivation shows the colonies to consist of masses of organisms arranged in the form of bunches of grapes.

Their **virulence** varies considerably, being greatest in the staphylococcus aureus and least in the epidermidis albus; in fact the latter organism may almost be regarded as saprophytic in nature and can only produce inflammation when the resistance of the tissues is lowered, or when it effects an entrance into a tissue which has naturally a low resistance, *e. g.*, the vitreous humour.

An **extraocular lesion** due to infection by staphylococci tends to become multiple owing to the discharge from it infecting the glands, hair follicles, conjunctiva, etc., in the neighbourhood. These organisms can grow in the secretion of the glandular structure of the skin and of the eyelids. **Acne vulgaris** is frequently due to the infection of the sweat glands of the skin with this organism. It is often associated with styes, chalazion, phlyctenulæ of the conjunctiva, and marginal corneal ulcers.¹ The staphylococcus albus and occasionally the staphylococcus aureus is found in the discharge.

In **pustular blepharitis** the staphylococcus albus is generally found. It is sometimes associated with the bacillus of Morax-Axenfeld, suppuration taking place in the hair follicle. If infection of Zeiss glands takes place and suppuration follows a **hordeolum externum** or styne is produced. If an eyelash is affected the hair usually falls out and the follicle may be entirely destroyed or a finer hair grow again; which is often maldirected owing to the distortion of the follicle from the formation of cicatricial tissue. The disease being liable to spread from one follicle to another, it may cause considerable loss of the lashes.

The infection of the Meibomian glands causes them to be inflamed with the result that the secretion from them is

¹ M. S. Mayou. *Ophthalmoscope*, 1908, 566.

semi-purulent in character.¹ When the epithelial cells lining them proliferate and do not break down into secretion the lumen of the gland may become blocked. A periadenitis occurs around the gland in the tarsal cartilage in which they are embedded and this becomes softened. The lumen above the obstruction becoming filled with inflammatory infiltration and epithelial debris, the softened tarsal cartilage allows it to expand into a swelling known as a **chalazion**. When the inflammation is not very acute the exudation consists principally of lymphocytes with giant cells. This granulomata may remain chronically inflamed and after a time become organised from the periphery so that the wall becomes thickened and converted into fibrous tissue. In more acute inflammation suppuration takes place and the exudation consists of polymorphonuclear leukocytes. The abscess formed may point toward the skin or conjunctiva, more frequently the latter, it being usually the line of least resistance, since in front of the tarsus there is the skin and orbicularis muscle while behind it there is only the conjunctiva. When it points through the conjunctiva it is known as **hordeolum internum**. The disease is liable to spread from one gland to another, so that many chalazion may be present at the same time or the disease may recur. The bacillus xerosis is found in all Meibomian secretion and it is therefore usually present in the contents of a chalazion but probably takes no part in its formation, being merely saprophytic in nature. Other organisms, such as diplobacillus of Morax-Axenfeld, pneumobacillus and the streptococcus have been found in the pus, but are rare.

The importance of the staphylococcus being a normal inhabitant of the conjunctival sac has already been pointed out under the infection of wounds.

Lesions produced by the **staphylococcus in the conjunctiva** occur in people of all ages. They differ, clinically, very considerably, depending on the virulence of the strain which has caused the infection. An abrasion of the epithelium

¹ R. W. Doyne. Trans. Ophth. Soc. of the U. K., XXX, 1910, 85.

seems necessary for the organism to grow in the tissue. Usually a muco-purulent conjunctivitis of moderate severity is set up, which is frequently accompanied by phlyctenulæ, and the appearance of follicles in the fornices toward the end of the attack.

Staphylococci¹ are often found in **Parinaud's disease** which is characterised by the formation of large follicles all over the palpebral conjunctiva and in the fornices. Some purulent discharge is usually present and there is enlargement of the preauricular gland which in rare cases may suppurate. Enlargement of the submaxillary glands is also of common occurrence.

Histologically, the epithelium shows the usual changes found in subacute inflammation; the subepithelial tissue is densely infiltrated with lymphocytic exudation which in the early stages contains comparatively few plasma cells; as these cells undergo necrotic changes fragments of them are found free in the tissue and within the phagocytic endothelial cells.

Streptococci and a special bacillus have also been described as having been found in this disease.

Staphylococcal infection of the cornea is usually the result of an injury. It gives rise to a purulent ulcer of moderate severity which may be situated in any position and be associated with hypopyon. As a rule the organisms do not penetrate very deeply into the tissue and hence the disease usually yields readily to treatment with the cautery. The staphylococcus aureus may give rise to a more severe form of ulceration which ends in sloughing of the entire cornea.

A phlyctenular form of ulceration associated with acne vulgaris due to the staphylococcus sometimes occurs.

Staphylococcal infection of the uveal tract may occur as the result of ectogenous or endogenous infection. In ectogenous infection it follows penetrating wounds inflicted accidentally or in the performance of operations. The

¹ Sinclair and Shennan. Trans. Ophth. Soc. of the U. K., XXVIII, 1908, 13.

infection may result in panophthalmitis as has already been described (see page 334) or possibly in chronic iridocyclitis which gives rise to sympathetic ophthalmitis (see page 437). It is probable, though by no means established, that this organism is a frequent cause of this latter disease since it seems sometimes to have the power of circulating in the blood of patients without producing much general disturbance. In endogenous infection the common primary lesions to which the ocular complications are secondary are pyorrhea alveolaris, boils, otitis media.¹ The favourite sites for the lodgment of organisms in the eye are the ciliary body and the choroid in the neighbourhood of the optic disc.² When the infection is virulent panophthalmitis occurs.

In less virulent cases there is a chronic cyclitis with keratitis punctata, or a local patch of choroiditis is produced which may also be associated with cellular deposit on the back of the cornea.

Staphylococcal infection of the retina may also take place by ectogenous or endogenous infection giving rise to suppuration ending in panophthalmitis. If suppuration does not take place it may produce local patches of inflammation such as are seen in retinitis septica (see page 339).

Staphylococcal infection of Tenon's capsule, both by ectogenous and endogenous infection has been described. Suppurative or non-suppurative inflammation may follow.

The staphylococcus is occasionally the cause of **orbital cellulitis**.

It is one of the common organisms found in the pus of a **lacrimal abscess**.

(b) **Streptococci**.—The **streptococcus pyogenes** is round in form and varies much in size, the smaller forms being usually most virulent. They are arranged in chains some of which are of considerable length (**streptococcus longus**) while others are comparatively short (**streptococcus brevis**). They

¹ M. S. Mayou. *Brit. M. J.*, 1910, Oct. 28.

² W. T. H. Spicer. *Trans. Ophth. Soc. of the U. K.*, XXVII, 1907, 235.

stain well with aniline dyes and retain the stain by Gram's method. They have no capsule and do not form spores. On **cultivation** it is a facultative anaerobe and grows on broth, ascitic fluid and milk, the latter of which it coagulates. On agar it forms very small colonies which do not show any tendency to run together. The organism is non-motile. In cultivation difficulty may arise in differentiating it from the pneumococcus which loses its capsule on cultivation. The elongated form of the latter, the fact that it again develops a capsule on inoculation into mice, and the fact that the streptococcus will sometimes grow on gelatine is generally sufficient to distinguish it. The presence of a small amount of taurochlorate of soda in the media prevents the growth of the pneumococcus but does not inhibit that of the streptococcus.

The **virulence** of the streptococcus varies considerably. It may produce the most acute infections which end in the death of the patient, or only comparatively innocuous lesions. The variations in the different strains of streptococci make the use of antisera of little value, unless by accident a similar strain be used in its preparation.

In the skin of the eyelids the organism is found in impetigo.

Affections of the conjunctiva due to streptococcus vary according to the virulence of the organisms. In mild cases, such as are associated with impetigo, a muco-purulent conjunctivitis of moderate severity is produced, phlyctenulæ often being present. In severe cases a membranous conjunctivitis is set up. This may be even more severe than that due to the Klebs-Loeffler bacillus. In the early stages there is intense chemosis and the eyelids are much swollen; there is often comparatively little discharge; the cornea frequently becomes ulcerated and destroyed and panophthalmitis may ensue. In the most acute cases there is a rise of temperature with the general symptoms of fever. Orbital cellulitis, thrombosis of the cavernous sinus and death from pyemia are possible sequelæ.

In mild cases of streptococcal infection of the **cornea**, such as are associated with impetigo, small grey ulcers are present, while in the severe cases sloughing of the whole cornea may result in twenty-four hours. This is especially liable to occur in badly nourished children, the condition being known as **keratomalacia**.

Infection of the uveal tract always ends in panophthalmitis.

The streptococcus is the commonest organism found in a lacrimal **abscess**.

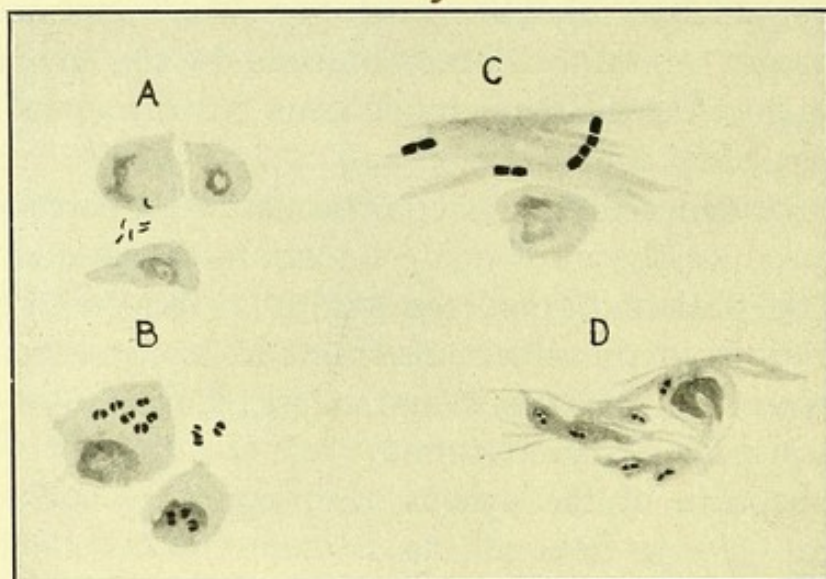


FIG. 180.—Shows the microorganisms found in smear preparations of the conjunctival secretion in different forms of ophthalmia. A, Koch-Weeks bacilli; B, gonococci; C, Morax-Axenfeld diplobacilli; D, pneumococci.

Infection of the orbit by streptococci, either from facial erysipelas, the conjunctiva, or by direct injury, may lead to a most acute form of orbital cellulitis, of which disease it is one of the common causes.

(c) **Diplococci** are divided into those which retain the stain in Gram's method (Gram-positive) and those which do not (Gram-negative).

Gram-positive Diplococci.—**Pneumococcus** (Fraenkel).—This organism is a small oval coccus about 1μ long occurring in pairs or arranged in chains of four to ten. It is lan-

ceolate in shape, and in the body is surrounded by a capsule (Fig. 180, D). It stains with all the aniline dyes and retains the stain in Gram's method—a most important point in differentiating this organism from the gonococcus. The capsules usually appear as clear areas around the organism, but they can be stained by a special capsule stain, such as MacConkey's.

Cultivation.—It is a facultative anaerobe, non-motile, and grows best on slightly alkaline media at a temperature of 37° C.; it will not grow below 23° C., and is destroyed by a temperature of 42° C. On blood-serum and blood-agar it appears in twenty-four hours in fine colonies scattered along the streak. The colonies are round and resemble those of the streptococcus pyogenes, from which organism in culture it is sometimes difficult to distinguish it.

It will also grow on agar and in broth, but not so readily on gelatine, and then only grow after sub-cultivation, as a rule, there is no growth on potato. Milk is coagulated by its growth.

Except in a few organisms found in the water of condensation after the primary culture on blood-serum, on whatever media it is grown its capsule disappears but reappears on inoculation.

Inoculation.—Like staphylococcus and streptococcus, the virulence of the pneumococcus varies enormously, some specimens killing mice with septicemia in twenty-four hours and others producing no reaction at all. A non-pathogenic form has been isolated from the mouth and conjunctiva which is characterised by slowly liquefying gelatine and growing on potato. Rabbits are less susceptible than mice, these latter animals being immune to the Friedlander bacillus, which is a point of distinction between the two organisms. The most virulent forms are rarely present in the eye, those of moderate severity being found in such lesions as corneal ulceration.

Inoculation into the human conjunctiva has produced results which vary considerably. In many cases a mucopurulent conjunctivitis has been set up forty-eight hours

after inoculation the organisms being principally found outside the leukocytes. Inoculation of a conjunctiva with the pus from an empyema did not produce any reaction for seven days. In eight cases inoculated no conjunctival reaction was produced.

The variability of these results, both as regards the human conjunctiva and that of animals, is no doubt due to the variability in virulence of the organism. It has also been suggested that it may be due to the varying power of resistance of the tissues inoculated, but before any conclusion can be arrived at as regards the latter point standardised cultures must be used and more than one person inoculated. On cultivation the virulence of the organism is not maintained. Mice are peculiarly susceptible and the virulence of the strain is raised by inoculation into them, but the organism becomes non-pathogenic to man—a point of importance in the preparation of antisera. There is practically no phagocytosis on the part of the leukocytes toward the pneumococcus in the early stages of infection. It has been shown that agglutination of the cocci in the presence of the antitoxin takes place, and it has been found that normal leukocytes become phagocytic toward the organism in the presence of the antitoxin (opsonin?)—all points in favour of the use of vaccines and antisera in the early stages of ocular infection.¹

Differential diagnosis of the pneumococcus from the streptococcus has already been pointed out (see page 361).

The pneumococcus is a constant inhabitant of the mouth and is found in the nose and, according to some authorities, is a common inhabitant of the conjunctiva.

Infection of the conjunctiva gives rise to a conjunctivitis the clinical signs of which are frequently sufficiently characteristic to render the diagnosis possible. The incubation period is forty-eight hours. There is a muco-purulent discharge from the conjunctiva and much lacrimation. There

¹ P. Römer. *Archiv. für. Ophth.*, LIV, 1902, 1, 99.

² Axenfeld. "Serum Therapie in Infection," 1905.

is little or no chemosis but a bright red injection of the vessels of the ocular conjunctiva, both superficial and deep. Frequently the ciliary vessels are also engorged which sometimes makes the diagnosis from iritis somewhat difficult. Indeed this organism is the cause of the only form of conjunctivitis which can give rise to iritis by the absorption of toxins into the anterior chamber without involving the cornea; the iritis produced is rarely severe unless the cornea is involved. Hemorrhages and phlyctenulæ are rare, frequently the affection is confined to one eye, these characteristics help to distinguish it from that conjunctivitis due to Koch-Weeks bacilli, which in other respects it resembles.

The disease terminates by crisis, the organism and frequently the discharge disappearing in forty-eight hours. This rapid termination accounts for the fact that follicles are rarely formed. In exceptional cases, especially in young and badly nourished children, the pneumococcus produces so severe an inflammation in the conjunctiva that a membrane is formed.

Although pneumococcal infection of the cornea is common in connection with lacrimal obstruction, the cornea is rarely affected in pneumococcal conjunctivitis. This is due to the fact that the toxins seem to have little effect on the corneal epithelium, the organism being unable to gain an entrance unless it is abraded.

Although the discharge is undoubtedly contagious, the susceptibility of men and animals for the same strain of pneumococcus varies very considerably which probably accounts for the frequency of sporadic cases in this country, in rare instances, however, epidemics have occurred. As a rule it is neither associated with nor the cause of pneumococcal lesion in other parts. A local immunity of short duration seems to be conferred on the patient as the result of an attack.

Infection of the Cornea.—The pneumococcus is the common cause of the typical *serpens ulcer*. This form of

ulcer is not seen in children. When pneumococcal infection of the cornea occurs in them it produces a deep and more rapid necrosis, probably owing to the substantia propria not being so dense. In adults the disease is very frequently associated with lacrimal obstruction. This is due to the fact that the organisms can be found growing in large numbers in the sac. For the pneumococcus to gain entrance to the corneal tissue an abrasion of the epithelium is necessary, which probably accounts for the fact that lacrimal obstruction may be present for years without infection taking place. The incubation period is twenty-four hours. In the very earliest stage the ulcer has the appearance of a colony of organisms on the cornea surrounded by slight infiltration. The cornea being infected the organisms spread laterally beneath the lamellæ of the substantia propria beyond the margin of the ulcer. They are found in groups surrounded by a dense infiltration of polymorphonuclear leukocytes. After a time as the deeper layers become involved a perforation may take place. Before this happens a severe iritis is usually set up due to the absorption of the toxins. For the same reason the ocular conjunctiva becomes swollen and edematous. For further complications of corneal ulceration (see page 313).

Pneumococcal infections within the globe may also give rise to ring abscess or ulcer of the cornea (see page 321).

Panophthalmitis due to the pneumococcus may follow penetrating wounds and ulcers. Endogenous infection of the globe is usually associated with pneumococcal meningitis. A condition is then produced which ultimately ends in what is known as "**pseudoglioma**."

Streptococci and staphylococci are the common causes of peridacryocystitis, rarely the pneumococcus; the latter, however, is the organism which is usually found in the discharge from a **mucocoele**, both purulent and non-purulent. The organism is probably not derived from the nose but makes its way into the lacrimal sac from the conjunctiva, growing readily in the fluid there.

The pneumococcus is the organism most frequently found in **orbital cellulitis**. This is probably accounted for by the fact that suppuration in the nasal sinuses is usually caused by it and that that disease is the commonest cause of orbital cellulitis.

The Gram-negative Diplococci.—These are the gonococcus, diplococcus, intracellularis meningitidis, and micrococcus catarrhalis.

The gonococcus is a kidney-shaped diplococcus. It varies in size from $.8\mu$ to 1.6μ long and $.6\mu$ to $.8\mu$ broad. The flattened sides of each coccus are opposed to each other; they often appear in tetrads and are frequently found within the cells of the discharge (Fig. 180, B). It **stains** strongly with aniline dyes. A good method of staining both the gonococcus and other non-Gram staining organisms is by means of Pappenheim's stain which consists of pyronine and methyl-green, the organisms being picked out in the red colour of the pyronine while the polymorphonuclear leukocytes are stained green. It is rapidly decolourised in Gram's method. It has no capsule and does not **form spores**. On **cultivation** it is a facultative anaerobe and grows best at the body temperature, it cannot be cultivated below 20° C. A medium containing human blood-serum should be used; the organism will, however, grow readily on agar if some of the pus is smeared over the surface, but sub-cultivations from such a specimen as a rule do not grow. It appears in small round colonies in about twenty-four to forty-eight hours. These have a peculiarly transparent slimy appearance. They reach their maximum size in four to six days after which they die out. They rapidly lose their pathogenicity on cultivation.

Inoculation on to the mucous membranes of animals produces no effect although if a quantity be applied to the conjunctiva of a young rabbit a slight discharge may be set up. Injection into the peritoneal cavity of animals of large numbers of the organism produces death from septicemia. The toxin is best obtained by cultivation in ascitic fluid. When dropped into the human eye it produces acute in-

flammation in the conjunctiva. The onset of this is about twenty-four hours after it has been instilled.

The **differential diagnosis** of the gonococcus from other Gram-negative diplococci may be difficult, but as a rule it is not of much importance in ocular diseases since the other organisms do not produce severe lesions. The organisms which resemble the gonococcus and are found in the eye are the micrococcus catarrhalis and the diplococcus intracellularis meningitidis. The micrococcus catarrhalis, which is commonly found in the nose and bronchial secretion, may cause a mild conjunctivitis. It is larger and rounder than the gonococcus, both points being specially marked on cultivation where the colonies are also larger and non-translucent; it will grow on milk and gelatine.

The diplobacillus intracellularis meningitidis is more a long oval in form and is not so readily decolourised by Gram's method. Agglutination yields a satisfactory means of distinguishing the three organisms. They can also be distinguished by the fermentation test. By using different varieties of sugar in a fluid media to which litmus has been added it is found that in the case of the gonococcus an acid reaction is only produced when dextrose is present; in the case of the meningococcus when dextrose or maltose are present; in the case of the micrococcus catarrhalis no acidity is produced with any of them.

The conjunctiva and cornea are the parts of the eye most frequently affected by the organism.

The conjunctiva may be affected at any age (gonorrheal conjunctivitis).

In ophthalmia neonatorum the gonococcus is the cause of 66.6 per cent. of all cases.¹ The source of infection is the vaginal discharge of the mother.

Infection of the child's eyes may take place before, during, and immediately after birth of the child or at an interval of some days.

Infection before Birth.—Children have been born with

¹ S. Stephenson. "Middlemore Prize Essay," 1908. M. S. Mayou, *Practitioner*, 1910.

fully developed ophthalmia neonatorum in which the membranes have only been ruptured three-quarters of an hour before birth. A child has been removed by Cesarean section with fully developed ophthalmia neonatorum. It therefore seems probable that infection of the child's eyes can take place either through the membranes or through an opening in them insufficient to produce the onset of labour. This infection must take place after the end of the fifth month as the lids are united up to that time.

Infection at Birth.—As a rule at birth the lids are tightly closed, the junction having been made water-tight by the fatty Meibomian secretion at the margins but it has been proved that they may be open. During the act of birth the discharge from the cervix and vagina may enter the eyes of the child; this is especially likely to occur in the cases where from pressure the upper lid overlaps the lower. The vaginal discharge may be carried into the eyes by forceps or, in the case of face presentation, by the finger of the accoucheur. The tightly stretched perineum may also carry the infected material into the eye.

Infection immediately after birth when the child first opens its eyes is probably the most frequent occurrence. It may also take place during the washing of the infant, some of the secretion being carried into the eyes.

Infection some time after birth is usually known as "secondary infection" and may take place from want of cleanliness on the part of the midwife, from the diapers, etc.

New-born children are especially prone to infection of the conjunctival sac with microorganisms for the following reasons: *a.* The absence of lacrimal secretion. *b.* The epithelium is not so thick and there is no flattened layer as in the conjunctiva of the adult. Numbers of the cells, especially in the fornix, are lost owing to mucoid change, which in places leaves the basement membrane almost bare. *c.* There is an absence of leukocytes from the lymphoid tissue.

In gonorrheal ophthalmia neonatorum the length of the incubation period has a definite relation to the severity

of the attack; the more acute the symptoms the shorter it is. The incubation period of the disease is from one to three days.

In the adult form infection usually takes place from the urethral discharge being conveyed to the eye by the fingers, towels, handkerchiefs, etc. In the case of nurses and doctors it may be conveyed from the eye of an infant afflicted with ophthalmia neonatorum by the squirting of the discharge on separation of the lids.

Endogenous infection of the conjunctiva with the gonococcus has been reported, but more evidence is required before this can be accepted.

The organism is found free in the discharge, within the leukocytes and epithelial cells, and occasionally in the sub-epithelial tissue.

In the early stage of the disease (infiltration stage) the discharge contains gonococci in great quantities and is generally free from other organisms. In the later stage (pyorrhea stage) the discharge often becomes contaminated with other organisms. As the attack subsides the organisms decrease in number, but virulent organisms can be found in the conjunctival sac for at least a month after the disease has subsided (chronic stage).

The microscopical examination of the tissues shows much papillary formation. There is desquamation and lateral separation of the epithelial cells in which organisms can be found. There is a large amount of exudation into the sub-epithelial tissue of polymorphonuclear leukocytes; toward the end of the attack leukocytes and plasma cells make their appearance, the latter breaking up as they approach the epithelium in which the organisms are growing.

Undoubtedly an immunity to the gonococcus seems to be produced in the conjunctiva, although it may not last very long. The evidence that the gonococcus does produce such immunity is that cases do eventually get well and the discharge ceases if left to themselves, although the sight may have been destroyed.

A chronic gleet of the conjunctiva has never been recorded.

If one eye be attacked sometime before the other, the second eye is not so severely affected as the first. Occasionally one eye only is infected, although no precautions are taken to prevent the other from becoming involved.

Gonorrheal urethral discharge has been inoculated into an eye without producing ophthalmia (natural immunity).

When the discharge has ceased the gonococcus can still be found in the conjunctiva as long as twenty-five days after.

Corneal infection with the gonococcus is always secondary to infection of the conjunctiva. The cornea is affected in 27 per cent. of all cases of ophthalmia neonatorum. These cases are nearly always of gonorrheal origin.

The cornea in the infant can be saved from infection if the disease be treated properly, and in this respect it differs from gonorrhea in the adult where, in spite of every care, the cornea may become involved. The reason of this is that in the latter there is much more chemosis of the ocular conjunctiva so that a sulcus forms around the cornea in which the discharge collects, lying in contact with it and giving rise to marginal ulceration. In the cornea of a new-born infant the epithelium has no flattened layer on the surface as in the adult; this renders it more prone to attack. The substantia propria is, however, thicker in the newly born than the adult. The lymph spaces are also more readily opened up allowing a freer circulation of lymph through its substance containing protective bodies and better paths for the migration of leukocytes, hence better protection against infection. The subsequent clearing up of opacities in the cornea is no doubt due to the free supply of lymph and the subsequent flattening of the scar by the growth of the cornea.

Corneal haze is the clinical condition which often precedes corneal ulceration. It is the early stage of infiltration of the cornea by polymorphonuclear leukocytes as the result of infection; if this infection be arrested, resolution takes place; if not, necrosis follows.

Corneal ulceration seems to be of two types—either a small localised ulcer or a large one, practically involving the whole cornea. Both these forms may lead to perforation, the first frequently, the second always; the first resulting in a leukoma with a portion of clear cornea left and possibly an anterior polar cataract, while the second leads to total anterior staphyloma. Granulomata at the site of perforation more frequently form in infants than in adults.

Hypopyon seems to be comparatively rare but, owing probably to the rapidity with which perforation takes place, it is not always noted.

Infection of the iris may follow a perforating ulcer but the toxins alone do not seem capable of producing iritis; hence no posterior synechiæ form unless the ulcer perforates.

Gonorrheal iritis is the result of an endogenous infection. It is usually preceded or accompanied by gonorrheal arthritis; indeed, if metastases in the joints do not occur it is probable that gonorrheal iritis cannot take place. Whether this is merely coincident with the blood infection or whether the organism gains a special proclivity to affect the iris after affecting the joints is not known. Whichever it may be the organism has the power of remaining latent a considerable time; the iris may be affected years after the urethral discharge has disappeared and has a tendency to relapse. The inflammation is of the serous type and does not as a rule give rise to many adhesions. It is always accompanied by intense injection of the ocular conjunctiva which possibly may be due to the toxins.

The gonococcus is occasionally found in the distended lacrimal sac in cases of congenital **lacrimal obstruction** but does not give rise to peridacryocystitis.

Diplococcus intracellularis meningitidis is a round or somewhat lanceolate shaped coccus found in pairs arranged end-to-end but rarely in tetrads. It **stains** well with thionine blue and is decolourised in Gram's method but not so readily as the gonococcus. It has no capsule, is non-motile, and does not form spores. On **cultivation** it grows best on blood-serum

at the body temperature in small round colonies which are about the same size as colonies of the gonococcus but are whiter in colour. It will grow on serum and glycerine agar. The differential **diagnosis** between this organism and the gonococcus has already been discussed.

In the conjunctiva a purulent conjunctivitis of moderate severity is set up. It is rare and has no distinguishing clinical characteristics as far as has at present been observed. It may or may not be associated with meningitis. Ophthalmia neonatorum has been found to be due to this organism.

Infection of the cornea has been recorded in a child. The ulcer produced was of a purulent variety and went on to perforation; it was not associated with meningitis.

Infection of the uveal tract and retina ectogenously has never been recorded. Endogenous infection is always associated with meningitis.¹ The organism is conveyed to the eye by the blood stream and not by a direct spread from the meninges. This has been shown by the examination of a case in a very early stage in which an embolus had lodged in the ciliary body setting up a purulent iridocyclitis with hypopyon. After about the end of the first week the hypopyon usually disappears but the exudate into the vitreous persists, subsequently organising into a fibrous cyclitic membrane producing the appearance termed "pseudoglioma." An embolus containing the organism may probably also lodge in the choroid and retina producing the same condition.

(ii) Bacilli.

(a) **The Influenza Group.**—The bacilli belonging to this group of organisms are found on mucous membranes. The following occur in the eye: The Koch-Weeks bacillus, the bacillus of Müller, and the influenza bacillus.

The Koch-Weeks bacillus is a narrow, straight or slightly curved bacillus (Fig. 180, A) and measures from 1μ to 2μ in

¹ M. S. Mayou. R. Lond. Ophth. Hosp. Reps, XVI, 1906, 565.

length; it occurs singly or in groups; it is non-motile, non-flagellated. Occasionally thickenings of one end of the bacillus occur. It **stains** badly with all aniline dyes, prolonged staining with thionine blue and subsequent decolourisation with alcohol being the best method of demonstrating the organism; it is decolourised rapidly in Gram's method—an important point in distinguishing this bacillus from the xerosis and diphtheritic bacilli, with the former of which it is frequently associated.

On **cultivation** it grows best at a temperature of 35° C., but, like the gonococcus and other parasitic bacteria, it is extremely difficult to cultivate; it is essential for its growth that the medium should be slightly alkaline.

On human blood-serum the organism will grow well.

On animals' inspissated blood-serum the organism does not grow or will only do so occasionally.

Human blood agar is the best of all media for its growth; over 100 generations of the organism have been obtained on it. On other media, *e.g.*, .5 per cent. agar, only three generations can be obtained, except from the most virulent cases. Pig's serum may be substituted for human serum, but it is not so satisfactory.

On glycerine pepto-agar with pig's serum the growth is also satisfactory; five generations have been obtained on this medium.

On broth, to which hydrocele fluid has been added, the organism will grow well, causing a slight cloud in the medium.

The organism was first cultivated on agar 0.5 per cent. At 35° C., which is the best temperature for growth, this medium is nearly fluid; therefore inoculations are best made into flat bottles or petri dishes.

The organism will not grow on potato or gelatine.

At the end of from twenty-four to forty-eight hours colonies appear on serum agar as semi-transparent dew-like drops; they are fixed very lightly to the surface and are easily removed with the platinum loop. Examined with a lens, the colonies are seen to be round in outline and have,

when magnified eighty times, slightly crenated edges. As growth takes place they are not actually limited to the streak of blood on the surface agar but spread out into the media beyond and run together to a slight extent. Growth continues for about 5 days, after which the culture still remains active for another sixty hours, and then usually dies.

In culture the organism varies somewhat in length, and long thread-like involution forms appear; conical forms, can also be seen which have been ascribed to spore formation, but this is very doubtful; these involution forms retain their virulence for some considerable time.

The organism is killed in three minutes at a temperature of 60° C., but will live for more than ten minutes at a temperature of 50° C. It is not killed by a temperature of 7° C. for one and one-half hours.

Drying of the discharge seems to kill the organism, so that infection is probably not carried in the air or dust. The bacillus will live in distilled water for seven hours, and it may therefore be conveyed from one person to another by washing in the same water.

All animals are immune, both to local inoculation into the eye or to subcutaneous inoculation. The bacillus is pathogenic to man only.

In human inoculation into the conjunctiva an increasing number of organisms are generally found up to the third day, when the symptoms appear. These continue up to the ninth day, the case being untreated. On the tenth day the symptoms begin to disappear, as well as the organisms from the conjunctival sac.

Primary cultures of 120 hours produce positive effects.

The toxins alone will produce inflammation. Dead cultures, dropped into the human conjunctival sac, produce reaction, but this is greatly lessened if the culture is previously filtered, from which it may be concluded that the toxin is contained principally within the organism.

A person may be inoculated several times with positive results, the shortest interval at which a positive reaction can

be obtained being four weeks; therefore it may be concluded that there is only a short period of local immunity after the attack. By experiments it has been also proved that inoculation from the same culture produced conjunctivitis of different intensity in different persons. Previous scarring of the conjunctiva either prevents or mitigates the attack.

In the conjunctiva the organism produces an inflammation which is usually so typical, except in the case of infants, that the disease can be in most cases recognised clinically.

The bacillus of this disease is one of the most common causes of purulent conjunctivitis and has been found in connection with that disease in all parts of the world. The disease, though of common occurrence both in adults and in children, is more frequent in the latter, but is rarely met with in the new-born. It occurs in sporadic and epidemic forms, often running through a whole school, as it is extremely infectious.

It almost invariably affects both eyes and is characterised clinically by intense injection of both the palpebral and ocular conjunctiva. The injection in the ocular conjunctiva is very marked and there are numerous hemorrhages scattered over its surface, but very little chemosis. Toward the end of the attack follicles form in the fornix which persist for some time after the disease has subsided. Phlyctenulæ are often associated with this disease.

In young badly nourished children a membrane may be formed on the conjunctiva.

Histologically the changes in the epithelium are those common to all acute inflammatory affections. Although the organisms have only been found in the epithelial cells deep localised changes also occur in the sub-epithelial tissue. These account for the phlyctenulæ and hemorrhages that occur in the ocular conjunctiva, and for the follicular formations in the retrotarsal folds after the acute attack has subsided.

In the early stages the exudation consists largely of polymorphonuclear leukocytes; later of lymphocytes and plasma cells of which the follicles are formed.

In the cornea a break in the epithelium is necessary for infection to take place. A marginal phlyctenular corneal ulcer may be associated with conjunctivitis due to this organism. A superficial purulent ulcer due to it also arises apart from conjunctivitis. Care must be taken to distinguish it from the ulcer produced by the bacillus of Zur Nedden. Although the ulcer may be extensive it rarely penetrates deeply into the substantia propria and usually heals readily under treatment. Hypopyon is usually present.

Intraocular infection has never been recorded.

The bacillus of Müller was discovered in the discharge from trachomatous conjunctivæ, but was not found constantly in all cases. It is of interest, since it fills the small gap in the morphological chain between the influenza bacillus on the one hand and Koch-Weeks bacillus on the other. It exhibits all the characteristics of the influenza bacillus with which organism it is supposed by most observers to be identical, but differs from Koch-Weeks bacillus in being able to grow on inspissated pigeon's blood.

Influenza Bacillus (Pfeiffer).—Mild conjunctivitis occurs in influenza, the discharge containing the influenza bacillus which exhibits very close if not identical characteristics with the Koch-Weeks bacillus; indeed, it is possible that these organisms are identical. That is to say that Koch-Weeks conjunctivitis is a local inoculation of a general disease, standing in the same relation to influenza as pneumococcus conjunctivitis does to pneumonia; but as yet proof is wanting that the discharge from the bronchial tubes in influenza will produce a typical Koch-Weeks conjunctivitis.

The differences between the two organisms are slight:

B. Koch-Weeks.

Length 1μ to 2μ (not constant).
Occurs singly or in pairs.
Does not grow on gelatine.

B. Influenza (Pfeiffer).

Length 5μ .
Generally in chains or networks.
Grows on liquid gelatine at 37° C.

B. Koch-Weeks.

Colonies. Small slightly crenated edge when magnified eighty times.

Short virulence (five days).

Blood streak on agar not limited to the blood area but spreads on to the agar.

Non-pathogenic to animals. No toxic symptoms when injected.

B. Influenza (Pfeiffer).

Colonies larger than Koch-Weeks. Homogeneous smooth edge.

Longer virulence (ten days or more).

Limited to the blood streak on agar.

Pathogenic to monkeys, hares, guinea-pigs, with toxic symptoms.

Epidemics of these two diseases do not noticeably occur together.

(b) **Diphtheroid Group.**—Belonging to this group occurring in the eye are the bacillus Klebs-Loeffler and the bacillus xerosis.

Bacillus Klebs-Loeffler is a straight or slightly curved organism, measuring about 3μ in length and is about the same thickness as the tubercle bacillus (Fig. 181). It is non-motile and non-spore bearing.

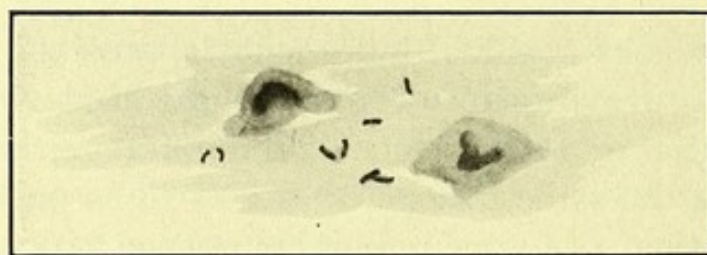


FIG. 181.—Shows a smear preparation from discharge from the conjunctiva containing Klebs-Loeffler bacilli.

It **stains** with thionine blue and other aniline dyes. Occasionally dots can be seen in the body and the ends are somewhat enlarged. It retains the stain in Gram's method. Twenty-four hours culture on Loeffler's blood-serum shows polar staining by Neisser's method.

On **cultivation** the Klebs-Loeffler bacillus grows best at 37° C. and ceases to grow entirely at 20° C. The media

most suitable for its growth are Loeffler's inspissated blood-serum, blood agar, or even ordinary agar.

On blood-serum it appears in twenty-four hours as small circular opaque discs of whitish colour, which reach their largest size, of about 3 mm., on the third day. On agar the growth is somewhat slower. It will grow on gelatine, but does not liquefy this medium. Broth containing glucose is rendered acid in from two to three days. It grows well on milk which becomes coagulated by the formation of acid.

Involution forms, with curious club-like ends, appear in from three to four days.

On **inoculation**, guinea-pigs are the most susceptible to this organism, being killed within forty-eight hours after inoculation, the exact time depending on the virulence of the organism. There is always local necrosis at the site of inoculation. As a rule after death the organisms are found at the site of inoculation in large quantities, but they are not present in the blood, showing that the disease is essentially a local infection, with general symptoms due to the absorption of toxins from the site of inoculation. In the exceptional more severe hemorrhagic forms of the disease the organism has been demonstrated in the other tissues of the body.

In the guinea-pig, the suprarenal capsules are found in a state of acute inflammation, no doubt due to the toxins. Rats and mice are immune to the organism. If animals inoculated with the organisms or toxins are kept alive, they develop the paralysis seen in the human subject.

To develop the toxins of the Klebs-Loeffler bacillus, it is best to use a medium which contains a large percentage of peptones and at the same time to have a free supply of oxygen. The medium should be free from glucose, as the formation of toxins is inhibited by the production of acid. A toxin of which .01 c.c. would kill a guinea-pig in twenty-four hours has been obtained. The toxin is an unstable compound and can only be kept for any length of

time by the total exculsion of light and air. It is destroyed by a temperature of 58° C. and can be precipitated by alcohol. Instillation of the toxin into the conjunctival sac produces reaction in about twelve hours; this is more intense, with the formation of a pseudo-membrane, if injected subconjunctivally.

The whole theme of antitoxin production cannot be dealt with here. Briefly, **antitoxin** is produced by the administration to an animal, generally a horse, of gradually increasing doses of toxin, until a stage is reached when the animal can stand enormous doses of a virulent toxin without reaction. It is then found that in the serum of the horse there is a substance which, if injected into animals, will prevent or modify an attack of diphtheria, that is, if it be administered at the time of inoculation, or shortly after. The strength of this antitoxin is standardised by finding the amount of toxin it will neutralise when injected together into a guinea-pig.

The differential diagnosis of the Klebs-Loeffler bacillus from the bacillus xerosis is often extremely difficult (see page 382), if in a membranous conjunctivitis, many organisms exhibiting the characteristics of this group are found in the discharge from the eye the case will almost certainly prove to be one of true diphtheritic infection.

In the conjunctiva infection with the Klebs-Loeffler bacillus is characterised by the formation of a membrane on its surface. This is generally most marked on the palpebral conjunctiva, to which it is firmly adherent and which when it is peeled off, bleeds readily. It consists of coagulated fibrin situated, not only on the surface of the epithelium, but also between the epithelial cells themselves. Throughout this membrane the Klebs-Loeffler bacilli are found scattered irregularly. Beneath the membrane the tissues are in a state of acute inflammation, the reticulum of the conjunctiva being greatly distended with lymph, also containing fibrinous exudation and leukocytes.

Diphtheritic conjunctivitis may or may not be asso-

ciated with a membrane in the throat or nose (fibrinous rhinitis). When found it is a point of considerable assistance in diagnosis. It is well to emphasize here that all membranous conjunctivitis is not due to the Klebs-Loeffler bacillus; streptococcus, staphylococcus, and even gonococcus may give rise to a membrane indistinguishable from that produced by the Klebs-Loeffler bacillus. Further, toxic bodies, such as jequirity, nitrate of silver, and snake poisons may give rise to a membranous conjunctivitis.

The effects on the conjunctiva vary considerably according to the severity of the attack, which may end either in complete resolution, with perhaps some slight scarring, or in gangrenous sloughing of the conjunctiva, with the formation of adhesions (complete or partial symblepharon), and destruction of the cornea by ulceration.

It occurs most frequently in children from two to eight years and in the severe type is associated with general symptoms. The temperature varies considerably; in mild cases and in the early stages it is not raised at all or only to about 100° , but in the more severe cases the temperature is often 101° to 103° C.; while again in the most severe cases of all the temperature is often subnormal at the commencement of the attack. Albumin is usually present in the urine in severe cases.

Infection of the cornea apart from the conjunctiva does not occur. Ulceration occurs in about 10 per cent. of all the cases. It may lead to complete destruction of the cornea or small sloughing ulcers.

Xerosis Bacillus.—This organism has been the cause of many fallacies; it is purely a saprophyte growing in the Meibomian secretion and bears no relation to xerosis or to diphtheria.¹

It is a straight or slightly curved bacillus 1.75μ long and 0.5μ broad. It is a non-motile, facultative anaerobe, and does not form spores.

It **stains** well with all aniline dyes and exhibits thicken-

¹ M. S. Mayou, Trans. Ophth. Soc. of the U. K., XXIV 1904, 9.

ings similar to those of the Klebs-Loeffler bacillus and, like this latter organism, shows Neisser's polar staining in twenty-four-hour blood-serum cultures. It retains the stain in Gram's method.

Cultivated on blood-serum it does not make its appearance till from thirty-six to forty-eight hours. It appears in round whitish colonies. As a rule it will only grow as a primary culture on a medium containing blood. After the primary culture it will grow on agar and gelatine, it will not liquefy the latter.

The differential **diagnosis** between this organism and that of diphtheria is only made by carefully following out its general characteristics, no single one except inoculation being sufficient to make a correct diagnosis.

The chief points in the differential diagnosis are:

Klebs-Loeffler-Bacillus.	Pseudo-Diphtheritic Xerosis Bacillus.
The bacillus is more or less uniform in size throughout its length.	Slightly more thickened toward the ends, seen best in Gram staining.
On blood-serum it appears in twelve to twenty-four hours.	Does not appear at all till from thirty-six to forty-eight hours.
Primary culture on agar will grow.	Does not grow or only very badly in primary culture.
In glucose, broth, and milk it produces acid.	No acid is produced.
Sub-cultures grow well on potato.	Does not grow on potato.
On gelatine (10 per cent.) it appears in twelve to twenty-four hours.	On gelatine forty-eight hours.
Inoculation (perhaps most important) kills a guinea-pig in forty-eight hours with local necrosis.	No effect on guinea-pig.

The agglutination test is not always reliable.

(c) **Diplobacilli.**—Belonging to this group are the Morax-Axenfeld bacillus and the bacillus of Petit.

The Morax-Axenfeld Bacillus.—The bacillus is a large one. Its average measurement is 2μ long and 1μ broad. It varies somewhat in size and shape and the ends are usually thickened; they are arranged end-to-end in pairs (Fig. 180, C). Sometimes long chains are formed. Although, strictly speaking, they are non-capsulated an area is occasionally seen around the bacillus which does not stain. They are non-motile, non-flagellated, non-sporing, obligate aerobes.

They **stain** strongly with all aniline dyes, but are decolourised in Gram's method. They take pyronine well in Pappenheim's method.

On **cultivation** they grow best at 30° to 40° C., but are killed in fifteen minutes by exposure to 56° C. They require a medium containing blood for their growth which should be slightly alkaline.

On Loeffler's blood-serum they begin to show growth in twenty-four hours and are well developed in forty-eight hours. The surface of the medium becomes pitted, the pits having a shiny appearance. This is due to liquefaction of the media which is a very characteristic feature of this group of organisms. On serum agar they form small colonies resembling pneumococci. On serum bouillon they form a cloud in twenty-four hours and fall to the bottom as a deposit. In this medium involution forms are not common during the first few days. On agar they do not grow, thus differing from the bacillus of Petit.

Involution forms appear on cultivation. On blood-serum in forty-eight hours long chains of organisms together with some distorted bacilli appear. They rapidly undergo degeneration.

The organisms usually die out on cultivation in about ten days. Dried organisms are still active after four days—an important point in the spread of the disease by dust, etc.

The action of sulphate of zinc is of interest, seeing the efficacy of this drug in the disease. Although the solution as used for the eye does not kill the organisms, traces of zinc sulphate in the media prevents their growth.

The organism is non-pathogenic to animals. **Inoculation** into the healthy human conjunctiva with a twenty-four-hour bouillon culture produces a typical diplobacillary conjunctivitis. A cultivation of four days old failed to do so; hence it may be supposed that the pathogenicity dies out on cultivation.

In the conjunctiva the inflammation produced occurs at all ages but is rather more common in adults than children. The palpebral conjunctiva is intensely red, the caruncle and plica semilunaris participating in the inflammation. The secretion accumulating at the outer and inner canthi causes excoriation and redness of the skin of the lids in those regions—a characteristic feature of the disease, hence the name **angular conjunctivitis**. Occasionally this redness may spread along the whole margin of the lid. The disease, unless treated, becomes chronic and in such cases is often associated with staphylococcus albus, especially when marginal blepharitis is produced.

The Morax-Axenfeld bacillus is a non-pyogenic organism, the discharge being merely a sticky secretion consisting of mucous, epithelial debris, organisms, and an occasional leukocyte.

Histologically the greatest change takes place in the epithelium which undergoes increased desquamation and mucoid degeneration. In the later stages of the disease it dips down into the subepithelial tissue and new glands are formed; the orifices of these new glands are very liable to become occluded, with the result that retention cysts are produced.

There is no increase in the polynuclear or mononuclear leukocytes in the subepithelial tissue, except in the regions where the epithelium dips down into it, or where there are cystic formations. Elsewhere the change consists in a large increase in the number of plasma cells; directly beneath the epithelium the cells are somewhat broken up, no doubt due to the presence of the toxin. Owing possibly to the low vitality of these cells the disease is not eradicated

spontaneously. There is also a considerable increase in the mast cells of the underlying tissue. In long standing cases hyaline degeneration of plasma cells takes place.

Corneal ulceration due to the Morax-Axenfeld bacillus is always associated with angular conjunctivitis. The ulcers are usually situated near the corneal margin and have a somewhat serpiginous outline with sharply cut edges and a grey infiltrated base. There is no purulent discharge.

Purulent ulceration with hypopyon has been ascribed to this organism, but in these cases it is probable that the organism is associated with others having a pyogenic character.

The diplobacillus of Petit presents the same characteristics as the bacillus of Morax-Axenfeld. The only difference between the two organisms is that the diplobacillus of Petit will grow on agar and media not containing blood. The diplobacillus of Petit has only been found in purulent ulcers with hypopyon and does not produce conjunctivitis. Whether it be a non-virulent form of the bacillus Morax-Axenfeld and not the actual cause of the hypopyon ulcer in which it has been found has not yet been fully demonstrated.

No case of intraocular infection has been recorded from this group of organisms.

(d) **Capsulated Bacilli.**—Belonging to this group of organisms are Friedlander's pneumobacillus, the bacillus mucosus capsulatus, and the ozena bacillus.

Friedlander's pneumobacillus is a large organism surrounded by a thick capsule which stains readily. It **stains** well with thionine blue, but is decolourised in Gram's method. It is a non-motile facultative anaerobe.

On **cultivation** it grows well on all media. It does not liquefy gelatine.

On **inoculation** into animals it produces corneal ulceration. When inoculated into the peritoneum the animal dies.

In the human **conjunctiva** the organism produces conjunctivitis of varying severity. Some of the recorded cases have been of the pseudomembranous type, while others

have not been so severe. The organism has been found in ophthalmia neonatorum.

Corneal ulceration with hypopyon has been ascribed to it. It has been found in one case of metastatic **panophthalmitis** following pneumonia and in one case of **orbital cellulitis**. It has also been found in **chalazion** and in the secretion of the lacrimal sac in the case of **dacryocystitis**.

The **bacillus mucosus capsulatus** and the **ozena bacillus** have never been recorded as giving rise to ophthalmic lesions although they have been found in the conjunctiva and in the contents of the lacrimal sac in **dacryocystitis**.

(e) **The coli group** of bacilli which affect the eye are the **bacillus coli communis** and the **bacillus typhosus**.

The bacillus coli communis is a short flagellated rod about 1μ to 3μ long and $.7\mu$ broad. It has rounded ends, **stains** well with thionine blue, but is decolourised in Gram's method. It is non-capsulated, motile, and does not form spores. On **cultivation** it is a facultative aerobe, growth taking place on media in the cool incubator. It appears in dirty white, circular patches with crenated edges. In fluid media acidity is developed and milk is rapidly coagulated. If grape sugar be present in the media gas is evolved. If potassium nitrate and sulphuric acid be added to a twenty-four-hour culture a red colour is produced—notroso-indol reaction.

The differential **diagnosis** from the **bacillus typhosus** is as a rule unimportant in the eye as the organisms practically do not occur in the same lesions.

In the **conjunctiva** the organism has been described in rare instances as the cause of purulent ophthalmia in the newborn or in young children. One case has been described in an adult. It has also been found in **corneal ulceration** with hypopyon and in the pus of **dacryocystitis**.

The bacillus typhosus exhibits the same appearance as the **bacillus coli communis** but has the following distinguishing characteristics: It is more motile, having eight to ten flagellae, whereas the *Bacillus coli* has only three to four; it does not coagulate milk; no gas or indol is formed on culti-

vation. The fermentation, agglutination, and Bordet-Grengou tests are reliable in distinguishing between the two organisms.

The **lesions of the eye associated with typhoid fever** are:

1. The local conditions associated with the typhoid state which are not directly due to the typhoid bacillus; namely, xerosis, conjunctivitis, and corneal ulceration.

2. The general conditions associated with the typhoid state which are due to changes in the condition of the blood leading to thrombosis of the cavernous sinus and retinal vein, embolism of the central artery, hemorrhage, **LOCAL** intra-ocular or into the optic nerve sheath, **GENERAL** into the intestine causing optic neuritis from anemia.

Cases of paresis of accommodation and punctate cataract have also been attributed to typhoid fever.

3. The only ocular lesion caused by the bacillus typhosus is panophthalmitis due to embolic infection.¹

(f) **The Acid-fast Bacilli.**—The organisms belonging to this group affecting the eye are the bacilli of tuberculosis and leprosy. Saprophytic organisms resembling these, such as the butter bacillus, do occur but are not of importance in ophthalmic bacteriology.

Tubercle Bacillus.—The bacillus is a straight or slightly curved rod measuring from 2.5 to 3.5 μ long and .3 μ thick. It is non-motile and non-flagellated. It is extremely doubtful if it forms spores, but the older members of a group show irregularities in staining which the younger do not; this is probably due to the degenerative changes taking place in the bacillus. Old cultures also show large clubbed and braided forms, which are supposed to be due to involution changes.

The tubercle bacillus is stained after long exposure to aniline dyes. It **stains** best with strong acid dyes, such as carbo-fuchsin, and it has the property of retaining that stain after the tissue has been decolourised in weak acid. This property is known as acid-fast and is limited to a small group of organisms of which the tubercle bacillus is one.

¹ M. S. Mayou. R. Lond. Ophth. Hosp. Reports, XVI, 1906, 565.

For **cultivation** the best temperature is 37° C. The growth appears on blood-serum in ten to fourteen days as a whitish raised "scab-like" growth of rounded irregular outline. On glycerine agar it grows best of all, but it will only do so as a sub-cultivation. On glycerine broth it forms a cloud which falls to the bottom of the tube. No growth takes place on ordinary agar or broth. The presence of glycerine strongly facilitates its growth. On potato and other vegetables, especially when glycerine is present, growth takes place. Primary cultivation of the organism is often very difficult owing to the presence of other more rapidly growing organisms. By the addition of erycholine, 2 per cent., to an egg-albumen media the other organisms are destroyed, but growth of the tubercle bacillus is not hindered.

The resistance of the tubercle bacillus is great; it is still active in dried sputum at the end of two months. It is killed by 1 in 20 carbolic in five minutes. It is also killed by direct sunlight.

The effect of **inoculation** on the tissues varies considerably according to the method employed. Guinea-pigs are peculiarly susceptible to the organism. If it be inoculated subcutaneously a mononuclear leukocytosis is first produced around the site of inoculation. About the fifth day epithelioid cells appear which are developed in all probability from the existing leukocytes. Later, giant cells are formed, probably from the endothelial cells, by division of the nuclei without division of the cytoplasm. The nuclei are arranged either to one side or at the periphery of these cells. Hyaline degeneration takes place in the epithelioid cells and caseous masses may be formed. The newly formed capillaries as the result of inflammation, around the nodule do not invade the mass, probably owing to the presence of the toxins.

These changes are very characteristic of tubercle, so much so that it is possible to make the diagnosis from the histological appearance of the tissue. At the same time

the presence of a giant cell alone or epithelioid cells alone is insufficient; the general characteristics of the lesion must be taken into account.

When inoculated into the cornea the tubercle bacillus occasionally produces ulceration which in some cases is followed by a general infection.

When introduced into the anterior chamber typical nodules are formed on the surface of the iris. These appear in from two to four weeks and are followed by general tuberculosis. A rabbit is the animal generally used for such an experiment. The tissue suspected of containing the tubercle bacillus is taken from a part which is likely to be free from other septic organisms, and is either introduced through an incision made with a keratome, or is first formed into an emulsion and injected into the anterior chamber. A negative result from such an inoculation does not exclude the possibility of the tissue being of a tuberculous nature.

Intraperitoneal inoculation produces a form of tabes mesenterica, while intravenous inoculation may be followed by general tuberculosis.

Dead tubercle bacilli, when injected, may produce a nodule in the conjunctiva which simulates a phlyctenule. The dead bacillus retains its staining reaction for sometime after injection.

Diagnosis.—The bacilli of tubercle and leprosy, unlike other pathogenic organisms, are "acid-fast." The clinical characteristics of the latter disease are usually sufficient to distinguish it from the former. (In the tissues the tubercle bacillus is found between the cells or within the giant cells. It occurs either singly or in groups of two or three.)

Inoculation or cultivation from the tissues may be successful.

The Bordet-Grengou reaction may be obtained either by using the blood-serum or the fluid from the anterior chamber.

In cases where it is not possible to obtain a piece of tissue for microscopical examination or fluid from the anterior chamber, reliance must be placed on subjective tests due to

the alteration of the tissues from the growth of the tubercle bacillus in the body. The chief of these is the reaction produced in a patient who is suffering from tuberculosis by the introduction of small doses of the tuberculous toxin into the tissue. This reaction, which follows the introduction of tuberculin (toxin), may manifest itself either as a general disturbance or by a local reaction (anaphorexis).

The forms of **tuberculin** in general use are old tuberculin (Koch), which consists of the filtrate of the fluid media in which the organisms have been grown, and which is standardised by estimating the lethal dose for a guinea-pig; the human dose is $1/2000$ to $1/250$ of a milligram; tuberculin T. R., which is the aqueous extract of the ground up tubercle bacillus, the dose of which is $1/2000$ to $1/200$ milligram; or bacillary emulsion, which is the ground up organism in suspension.

A **general reaction**, for which the old tuberculin is generally used, is manifested by a rise of temperature which is at its greatest height about twenty hours after the injection. Great care must be exercised before its use to exclude extensive lesions, such as phthisis, otherwise the activity produced in the lesion may cause dissemination of the organisms and general tuberculosis.

A **local reaction**, for which tuberculin T. R. is usually used, manifests itself in 48 hours by increased injection and in cases of cyclitis by increase of the keratitis punctata, ciliary flush, and increased haze in the cornea if the latter be affected.

The local application of tuberculin will also produce reaction. The **ophthalmo-tuberculin reaction** (Calmette) is applied by dropping into the conjunctival sac of an eye (not affected with tuberculosis) a glycerine-free extract of the tubercle bacillus (1 in 100). The reaction produced varies so much in severity as to make its result somewhat unreliable and occasionally it is so severe as to be a danger to the eye. Von Pirquet's reaction consists in scarifying the skin and rubbing in tuberculin (1 in 100). A local redness is produced in

some tuberculous patients. Control scarification should be made; the method is not always reliable.

Of all these tests the local reaction in the lesion is by far the most satisfactory as by its means the amount to be given for treatment can be regulated.

¹**Ocular lesions due to tubercle bacillus** occur either as a part of a general tuberculous infection (general tuberculosis), tuberculous meningitis, or as a local lesion. This may either be due to ectogenous or endogenous infection, the latter being by far the most common.

The predisposing causes of ocular tuberculosis are divided into three sets of influences.

1. Those which predispose the individual to tuberculosis. Thus there is frequently a history of tuberculosis in the family. This may imply a want of resisting power to the specific organism or to the increased risk of exposure to infection.

2. The predisposing cause to the location of the disease in the eye. Of all periods of life childhood is by far the most liable. Side and sex have no influence on its etiology. Injury, although occasionally causing direct infection, comparatively rarely acts as a predisposing factor. If one eye is affected with tuberculosis the other eye is liable to be involved probably because the organism growing in a certain tissue, when gaining access to the blood stream, is more likely to set up a fresh focus of inflammation in a similar tissue (see Infection, page 350).

3. Those which predispose certain parts of the eye to be starting-points of the affection. The tubercle bacillus, carried by the blood, is most likely to be arrested where the anastomosis of the vessels occurs, and where the capillary plexuses are finest. Hence it is not surprising to find that in tubercle of the iris the nodules characteristic of the disease generally appear first near its pupillary or ciliary margins, *i.e.*, in the regions of the anastomosis of its blood-vessels known as the larger and lesser circle of the iris.

¹Treacher Collins. *Ophthalmoscope*, V, 1907, 2, 63, 116.

In the ciliary body the copious vascular plexus of the ciliary processes situated between their epithelial covering and the ciliary muscle is the site at which the affection most frequently starts. In the choroid the close capillary plexus forming its inner layer is the seat of primary election. Not infrequently this is near the disc in the anastomosis between the vessels of the papilla and the choroid. Tubercle commencing in the retina is rare. It usually starts near the disc or in the nerve head just inside the lamina cribrosa, these being the portions of the retina most freely supplied with blood-vessels.

In the conjunctiva it has been shown that for ectogenous infection to take place there must be damage to the epithelium. A frequent site is the sulcus subtarsalis, which is also the most common situation for the lodgment of foreign bodies. In this case a nodule forms beneath the epithelium, which subsequently ulcerates, the base of the ulcer being covered with large granulations. A septic condition of the ulcer may follow leading to infection of the cornea.

Another form of ectogenous infection is the follicular, in which multiple follicles form over the fornix and tarsus some of which break down and form minute ulcers. These cases usually occur in quite young children.

The commonest way, however, in which tubercle of the conjunctiva manifests itself is by the formation of a coxcomb excrescence in the fornix. Such cases are frequently associated with tuberculosis of the lacrimal sac. Histologically they exhibit very characteristic giant cell systems but caseation in all conjunctival tubercle is very rare. The tubercle bacillus can frequently be found in and around the giant cells.

Lupus may spread directly to the conjunctival sac from the face, or it may be secondary, due to a local inoculation. In the case of infection directly from the face, lupus invades first the outer surface of the lids, causing ectropion, finally spreading to the conjunctiva. The conjunctiva becomes injected; lupus nodules forming in the subepithelial tissue

run together and ulcerate; cicatrisation subsequently bringing about obliteration of the fornices, with the formation of bands and pouches. As a result partly of the cicatrisation and partly of the drying caused by the exposure, a condition similar to that described under secondary xerosis is produced in the epithelium, while in the subconjunctival tissue typical lupus nodules with giant cells and epithelioid cells are found in great quantities, but as a rule the tubercle bacillus cannot be found in them. A condition strongly resembling the pannus of trachoma is found in the cornea with infiltration of the limbus. Sooner or later the cornea becomes infected with pyogenic organisms resulting in perforating ulceration and destruction of the globe.

Direct infection of the cornea is usually the result of injury. This is followed by ulceration with a large amount of infiltration of the substantia propria. If the disease progresses the anterior chamber becomes infected and multiple nodules form on the iris; indeed, the disease is not often diagnosed until this takes place.

The cornea may become **secondarily** infected from a tubercular ulcer of the conjunctiva, or from the spread of infection from the ciliary body along the fibres of the ligamentum pectinatum (see page 324, sclerosing keratitis) and from nodules in tuberculous iritis. These latter have a marked destructive effect on elastic tissue and coming in contact with the posterior surface of the cornea cause a softening and disintegration of Descemet's membrane; the disease then spreads into the layers of the substantia propria. If resolution takes place an anterior synechia is left. An interstitial opacity of the cornea may occur in tuberculous iritis without the formation of anterior synechiæ; this is probably the result of the toxin in the aqueous diffusing into it (See page 394).

Tuberculous scleritis has already been described (see page 324).

The infection of the uveal tract with tubercle sets up an inflammation which frequently spreads from one por-

tion of the tract to that lying next to it. At the same time the presence of the toxin in the eye may set up inflammation in other parts of the eye without it becoming infected; thus tubercle of the nerve head and choroid have set up iritis which on microscopical examination did not present any of the typical appearances of a tubercular lesion; it has also been pointed out that deep infiltration of the cornea may take place without bacillary invasion. The tubercle bacillus is not the only organism which generates a toxin which will produce such changes. Intraocular lesions, suppurative and non-suppurative, due to pyogenic and non-pyogenic organisms (*e.g.*, staphylococcus, *S. pallida*), will also cause changes in other parts of the globe away from the site of the lesion, from a diffusion of their toxins.

Tubercular iritis is clinically divided into three classes:

1. Cases in which miliary disseminated nodules are present.
2. Cases in which there is a circumscribed mass made up of conglomerate or confluent nodules.
3. Cases secondary to tubercle occurring in some other parts of the eye.

It may be pointed out that these different classes often merge into one another. Thus, in cases beginning with disseminated nodules, a conglomerate mass sometimes results as the affection progresses. A case which, when first seen, has one large mass springing from the iris, often subsequently develops several small satellites around it. An iritis of variable amount is frequently met with in association with miliary disseminated nodules, or a conglomerate mass.

The miliary disseminated nodules appear first, usually, as previously stated, at the ciliary margin of the iris and extreme periphery of the anterior chamber (Fig. 182), or at its pupillary border (Fig. 183); the lower part of the iris is more often involved than the upper.

The nodules measure usually from 2 to 3 mm. in diameter. They are of a greyish colour and semi-transparent,

or of a yellowish hue and more opaque. The yellowness and opacity is probably accounted for by necrotic change commencing in the nodule. Some difference in the appearance of the nodules may also be due to difference of depth in the iris at which they are situated. In microscopical sections of an affected iris nodules are sometimes seen situated right at its anterior surface, projecting some considerable dis-

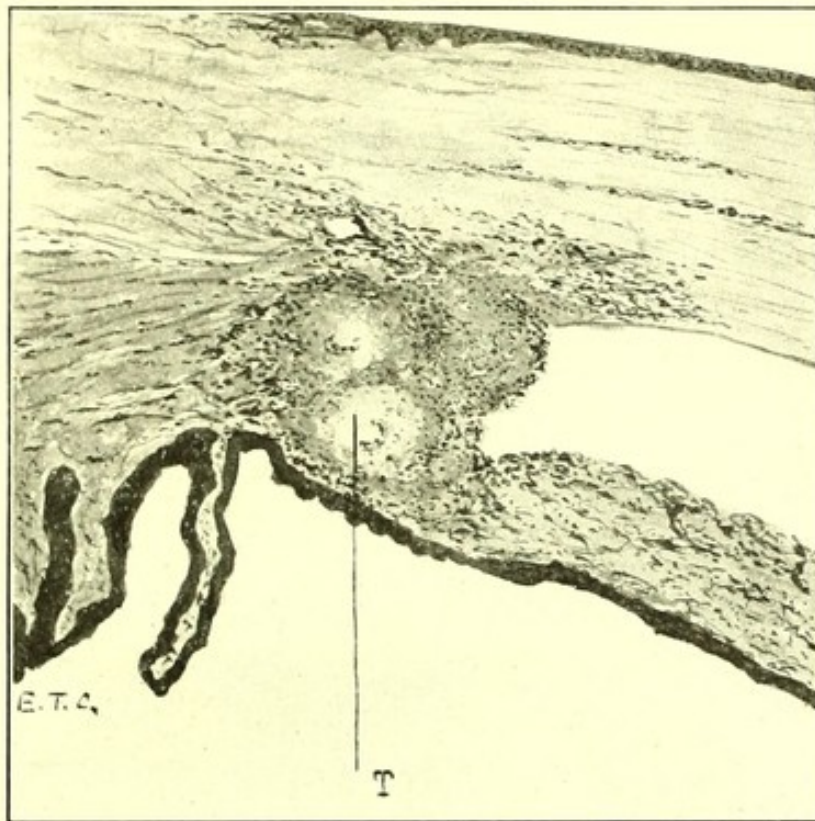


FIG. 182.—Tubercular nodules *T* involving the periphery of the anterior chamber and root of the iris. Eye removed from a patient aged eighteen years, in whom the first symptom noted was episcleritis, the nodules appearing in the iris later. Four and one-half years after removal of the eye she was in good health and showed no other signs of tubercle.

tance forward into the anterior chamber, the deep layers of the iris including the pigment epithelium passing beneath them and showing scarcely any sign of disturbance. In other cases the nodules are met with deep in the stroma of the iris, often breaking up and destroying the pigment epithelium on its posterior surface, so that no continuous line of pigment can any longer be traced and only scattered particles

of pigment are seen. Evidence of the depth of a nodule in the iris tissue is sometimes afforded clinically, apart from its colour, by the presence of blood-vessels on its anterior surface.

In association with the nodules in the iris there is

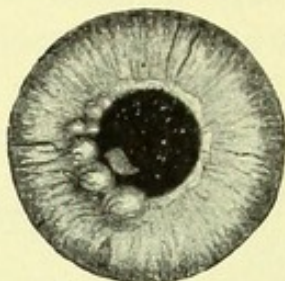


FIG. 183.—Shows the iris with tubercular nodules at its pupillary margin. The dots seen in the pupillary area are spots of keratitis punctata.

usually some ciliary injection, but very little photophobia or pain. Frequently deposits of a grey colour are seen on the back of the cornea; these may be of various sizes, some of them large and constituting what has been termed the

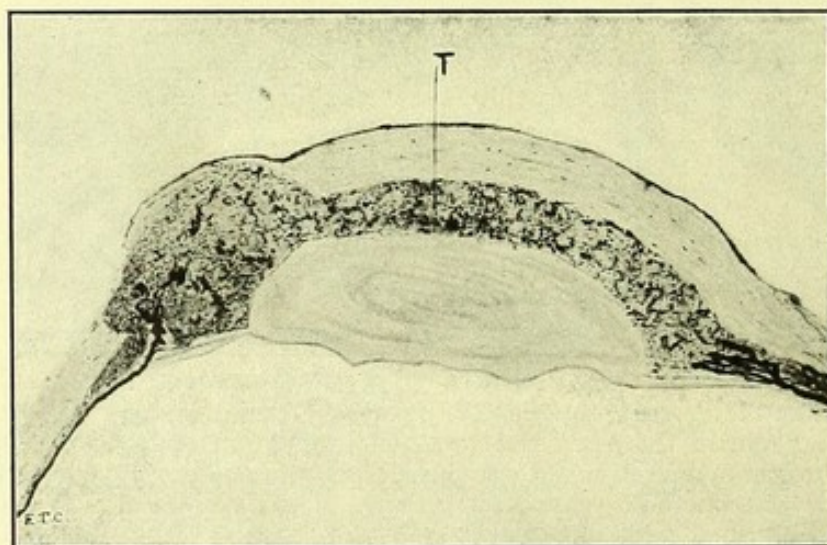


FIG. 184.—Tubercle of the iris. The whole of the iris has become involved in a conglomerate mass of tubercular nodules *T*, which fill the anterior chamber. Typical giant cell systems are shown. The cornea at its periphery has become invaded on the left side of the section.

“mutton” fat variety of “keratitis punctata” (Fig. 185). Microscopical examination of these deposits show them to consist of collections of mononuclear leukocytes on the inner surface of the endothelium of Descemet’s membrane.

Disseminated miliary tuberculous nodules may be met with in the iris without marked signs of iritis and with the formation of few, if any, posterior synechiæ. Microscopically, the lines of demarcation of the nodules may be seen to be very sharply defined with but little cell infiltration of the surrounding tissue.

The mode of termination of a case of disseminated miliary tuberculosis of the iris varies. The nodules may disappear and leave but little permanent damage behind them,

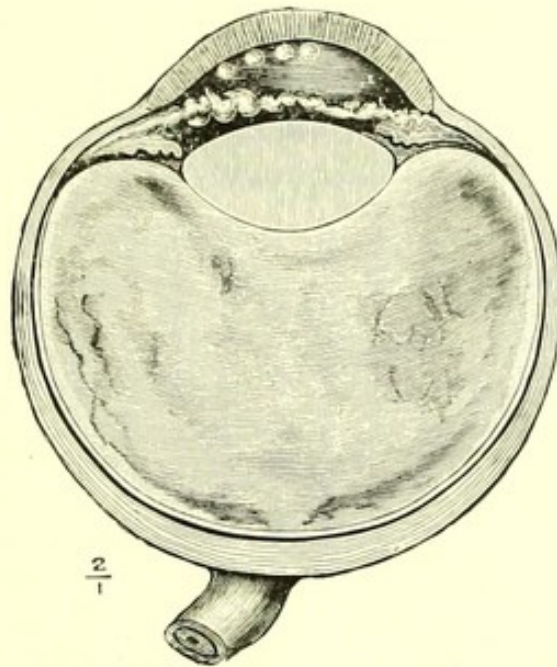


FIG. 185.—The lateral half of an eye of a child aged two years, showing the iris thickened with tubercular nodules. There are deposits on the back of the lower part of the cornea, the so-called "mutton-fat" variety of *keratitis punctata*. Specimen in the R. Lond. Ophth. Hosp. Museum.

constituting what has been termed attenuated tubercle. The disease may spread backward, involving the ciliary body, and by destroying the source of supply of the intra-ocular fluid bring about an atrophic or shrunken condition of the globe. The miliary nodules may run into one another, form a conglomerate mass which invades the cornea, and terminate in the way to be described later under the heading of conglomerate tubercle of the iris.

In some cases the affection remains localised in one eye, in others both become affected. A general diffusion of

tubercle throughout the body may precede or succeed a miliary tuberculosis of the iris.

These different modes of termination may be accounted for by the varying powers of attack on the part of the invading organisms or by the varying powers of resistance of the host. On the one hand, the attacking organisms may vary in number or in the virulence of their type; on the other, invaded individuals may vary in their phagocytic power or in their capability of generating antitoxins.

A circumscribed conglomerate mass of tubercle in the iris presents the appearance of a yellowish neoplasm of that membrane, often commencing without any sign of iritis. The mass continues to enlarge, secondary nodules sometimes forming around it until the anterior chamber becomes partly or completely filled by the growth (Fig. 184).

The cornea usually becomes first invaded in the region of the ligamentum pectinatum, for it is there that the protuberant mass most frequently first comes into contact with it. As destruction of the fibrous tissue of the cornea takes place, the tuberculous mass with the iris from which it springs protrudes forward into the gap left, and a staphylomatous condition is seen clinically in that situation. Perforation then follows and a fungating, ulcerated vascular mass forms which, ultimately undergoing caseation, disappears, leaving a shrunken globe.

Tubercular Cyclitis.—Tubercle may attack the ciliary body either on the outer or inner side of the ciliary muscle. When affecting its outer surface it usually invades the cornea and sclerotic (see page 393). When affecting the inner surface of the ciliary muscle it may be in the form of small scattered miliary nodules or of a large conglomerate mass. The latter rapidly spreads inward destroying the pigment epithelium and filling up completely the circumlental space in its vicinity. There seems a much greater tendency for tuberculous growth starting in this position to extend forward and inward than backward. It is remarkable how completely the space bounded by the back of the iris, side of the lens, and

anterior hyaloid of the vitreous may be found filled with tuberculous tissue, without the vitreous being involved, the fibres of the suspensory ligament being entirely destroyed, but the anterior limiting membrane of the vitreous remaining quite intact.

Where the ciliary body is affected with tubercle, the vitreous generally contains fibrinous exudate and excess of cells, but is not invaded by the tuberculous nodules. If, however, in association with tubercle of the ciliary body there is much cyclitis, as is sometimes the case, there will be a more plastic exudate into the vitreous humour which goes on to the formation of fibrous tissue.

In conglomerate tubercle of the choroid, the ciliary body, like the iris, may be effected by plastic inflammation without being the seat of tuberculous nodules, in which case the vitreous generally becomes shrunken and fibrous, a condition of "pseudo-glioma" being produced.

Tubercular Choroiditis.—There are two forms which tubercle of the choroid is definitely known to assume, either scattered miliary nodules which are seen ophthalmoscopically as grey patches or a conglomerate mass which gives rise to the symptoms of an intraocular tumour.

The scattered miliary nodules are met with in cases of acute miliary tuberculosis, and as they generally develop shortly before death, frequent opportunities are afforded of comparing the ophthalmoscopic appearances with the histological alterations in the acute stage of the affection.

The patches are mostly met with in the posterior part of the globe in the vicinity of the optic disc and yellow spot (Fig. 186). They are circular and vary in size, seldom exceeding that of one-third of the optic disc. Their actual measurement has been estimated at .5 to 2.5 mm. They have a grayish or grayish-yellow colour with a soft ill-defined edge which shades off gradually into the surrounding fundus. There is no pigmentation about them; a slight arching forward of the overlying retinal vessels shows the larger ones to be raised a little above the level of the surrounding choroid.

Histologically the patches are seen to be composed of one or more typical giant-cell systems situated in the vascular layers, in an early stage, or when small, not extending into the lamia suprachoroidea or up to the sclerotic (Fig. 187). The effusion, however, nearly always reaches up to the lamina

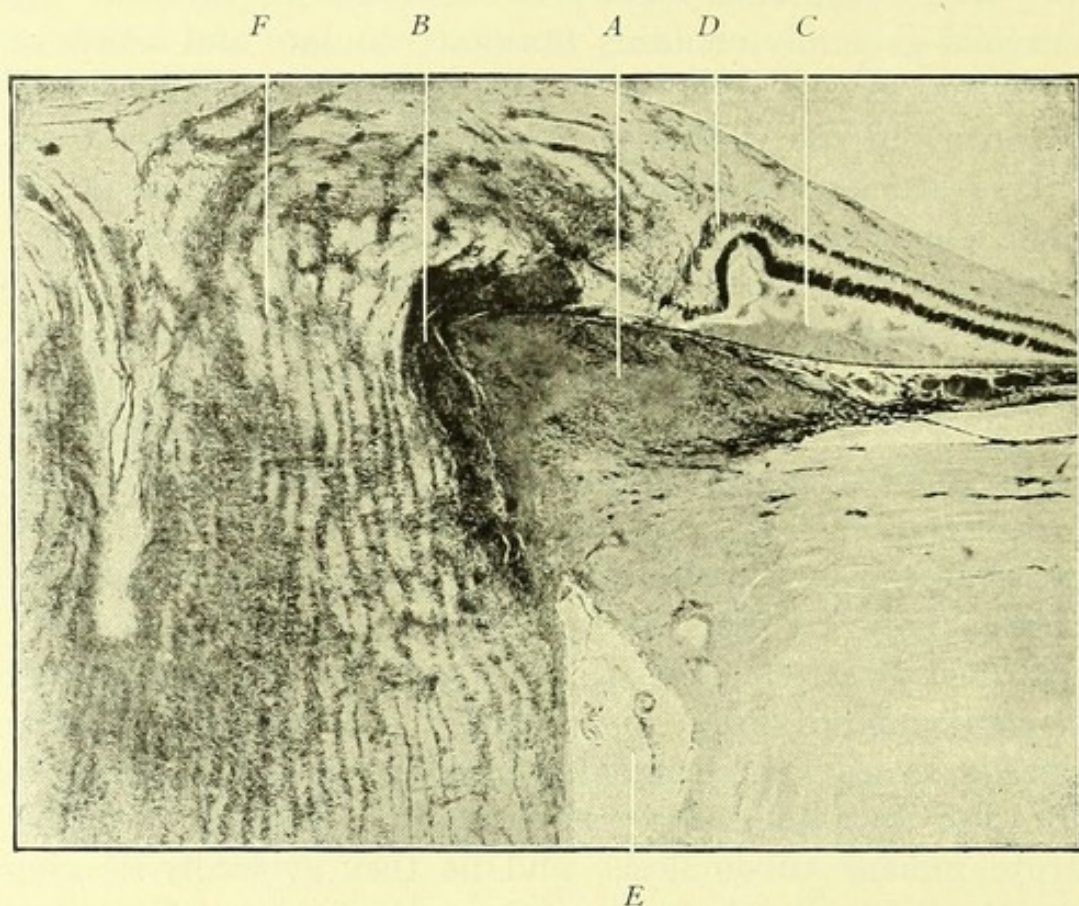


FIG. 186.—Section showing tuberculous mass in the choroid pressing on and invading the optic nerve and causing an intense neuritis. *A*, Caseating tubercle; *B*, round-cell exudation in the nerve; *C*, sub-retinal exudation; *D*, retinal edema; *E*, part of the distended nerve-sheath; *F*, edema of the optic nerve within the lamina cribrosa. Case recorded in Trans. Ophth. Soc. of the U. K., XXVI, 1906, 100.

vitrea which is usually arched slightly inward together with the pigment epithelium lining it.

In the largest patches, in which necrotic changes are seen, the lamina vitrea will sometimes be found to have disappeared, the pigment epithelium cells to have been destroyed, and the granules of pigment widely scattered.

In conglomerate tubercle of the choroid a large area, if not the whole of it, is involved in the affection. The

confluence of the nodules causes the choroid to become considerably thickened, large caseating patches forming in the centre of it (Fig. 188). The membrane of Bruch with the pigment epithelium lining it soon becomes destroyed. The retina becomes detached. Sometimes, owing to invasion of the retina in the neighbourhood of the disc, it undergoes extensive necrosis so that hardly any of its elements can be recognised microscopically. Where the retina is detached the sub-retinal fluid is of an opaque grumous consistency and is

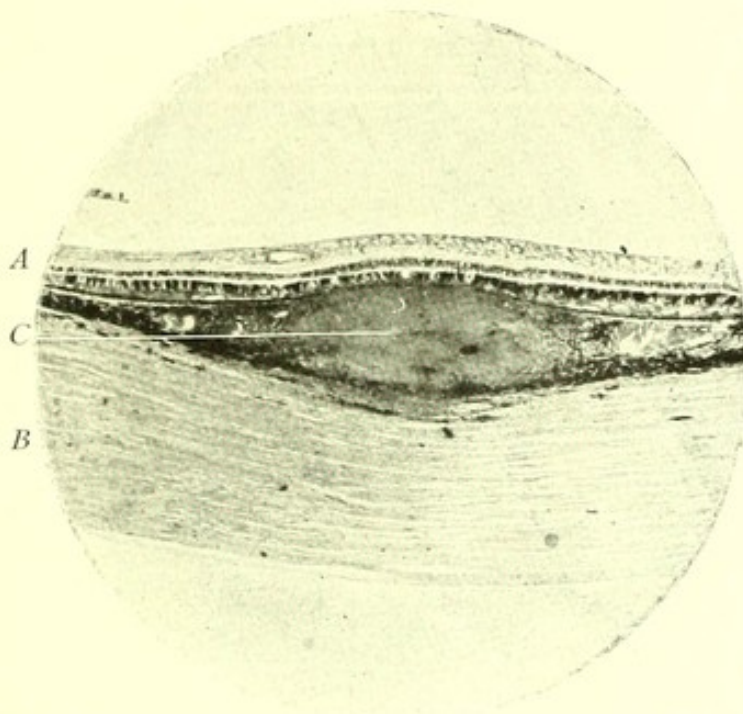


FIG. 187.—Section through the coats of the eye showing a tuberculous mass *C* in the choroid. *A*, Retina; *B*, sclerotic.

seen microscopically to contain a quantity of fatty globules in suspension.

Secondary foci of the disease may appear in the anterior portion of the uveal tract, and the whole tract be converted into a tuberculous mass. More frequently a plastic iridocyclitis is excited by the toxins liberated from the disease in the choroid. The root of the iris may be found in contact with the periphery of the cornea, and glaucoma may be set up. As the choroid becomes thickened the sclerotic is invaded, and later may be perforated.

Tubercle of the choroid when not involving the ciliary body does not give rise to exudation into the vitreous as long as the membrane of Bruch is intact, even when this latter structure is destroyed and the retina involved, the vitreous opacity is not marked.

Proliferation of the pigment cells of the retina occurs in the late stages. In miliary tuberculosis the patients as a

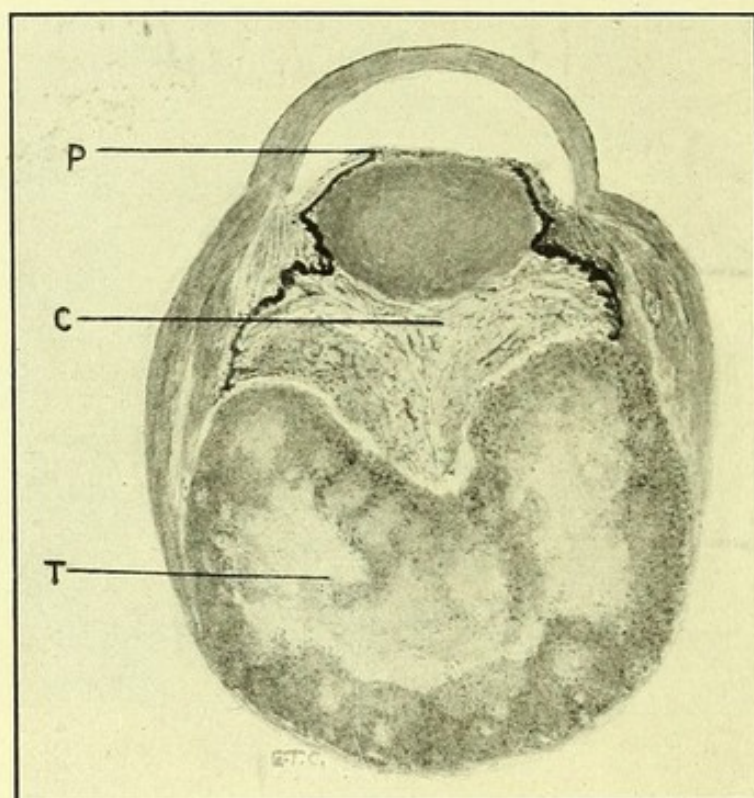


FIG. 188.—Section of the eye of a child aged two years, containing a conglomerate mass of tubercle *T*, starting in the choroid and undergoing caseation. The retina is detached in front of it and the vitreous converted into a fibrous membrane *C*, stretching across the ciliary region. An inflammatory membrane also fills the pupil *P*.

rule do not live long enough for it to become manifest, but in cases where patients survive a certain amount of pigmentation is usually seen.

Tuberculosis of the lens cannot occur primarily but opacity may be caused in it due to nutritional changes. The contact of a tuberculous focus softens the elastic tissue of the capsule to such an extent as to lead to perforation. Occa-

sionally, owing to the destruction of the suspensory ligament, dislocation of the lens occurs in tubercular iridocyclitis.

Tubercular Retinitis.¹—Primary tubercle of the retina is very rare, but secondary involvement of the retina following tubercle of the choroid is more frequent. In primary tubercular retinitis the clinical appearance is that of a white or yellowish-white swelling usually in the neighbourhood of the optic disc, or the swelling may be situated in the papilla, in which case the swelling is so marked that it may be mistaken for an intraocular tumour. It is sometimes accompanied by an iritis due to the toxins. Cases which have been examined pathologically exhibited round-cell infiltration with giant cells and epithelioid cells, but the tubercle bacillus has not usually been demonstrated.

Tubercle of the Optic Nerve.²—Miliary deposits in the pial sheath, chiasma and optic tract may occur associated with meningitis and general tuberculosis. Optic neuritis may also occur in meningitis owing to the increased intracranial pressure (see page 340). Localised tubercular masses may affect the nerve and its sheath anywhere along its whole course. When large masses are present in it, especially when situated near the globe, they may give rise to symptoms similar to optic nerve tumours. In these cases caseation is frequently very marked. The optic nerve may also be secondarily invaded by tubercle starting in the retina and choroid. In these cases the swelling of the nerve head is a prominent feature, partly due to the inflammation, and partly due to the edema caused by pressure on the central vein as it leaves the eye, which may be so great as to cause thrombosis.

The lacrimal sac may be the seat of tuberculosis from ectogenous infection and also probably from endogenous infection, but infection secondary to lupus of the nose or disease of the conjunctiva is by far the most frequent cause. At the same time it must be remembered that lupus of the

¹ W. I. Hancock. R. Lond. Ophth. Hosp. Reps., XVI, 1905, 150.

² G. Coats. R. Lond. Ophth. Hosp. Reps., XVI, 1905, 381.

nose may cause lacrimal obstruction and dacryocystitis without tubercle being present in the sac wall. Histologically tubercle of the lacrimal sac exhibits typical giant-cell systems with epithelioid and round-celled infiltration of its wall. Considerable fibrosis may take place leading to great thickening of the sac wall—a condition which is characteristic of the disease. The epithelial lining of the sac is often deficient and as other microorganisms are generally present an abscess may form which ruptures externally; the sinus becoming infected with tubercle will not heal and a fistula follows.

The lower orbital margin is the most frequent seat for tuberculous infection of the **orbit**. Occasionally in children the anterior surface of the frontal bone is sometimes the seat of the disease. In both instances the periosteum is the first portion of the bone to be affected and an abscess forms which ruptures externally with the formation of a sinus; the cicatricial contraction around which may lead to a depressed scar and varying degrees of ectropion.

Bacillus leprosa¹ is a small bacillus slightly shorter and rather thinner than the tubercle bacillus. It may be curved, straight, or somewhat thickened at the ends. It stains more readily than the tubercle bacillus and is acid-fast. Like the tubercle bacillus it shows inequalities in its staining which have been attributed to spore formation but which are probably due to commencing disintegration. It has never been cultivated or inoculated even in man and it is only from its constant presence in the disease that it is considered to be the cause. It is easily found in the expressed secretion from the nodules, but it is important to obtain the smear preparation free from blood.

Leprosy in the eye usually manifests itself in the tubercular form, although the anesthetic variety does occur.

When the disease attacks the **eyelids or eyebrows**, in

¹ Borthen and Lie. Die Lepra des Auges, Leipzig, 1899.
Treacher Collins. Trans. Ophth. Soc. of the U. K., XXIX, 1909,

which situation it commonly begins, it commences in the middle layer of the corium, most frequently in the wall of a blood or lymphatic vessel. The bacilli multiply and in the early stages are found in enormous quantities. Around the clumps are found round-celled infiltration and epithelioid cells. There are also enormous cells distended with bacilli which are known as "globi" or lepra cells, the whole constituting the nodule which is so characteristic of the disease. The disease may invade the hair follicles and sweat glands so that the eyelashes and eyebrows become destroyed. It attacks the nerves and, spreading along their sheaths, destroys them, so causing anesthesia and paralysis. The organism does not seem to readily invade the muscular or elastic tissue.

In the conjunctiva nodules form which frequently ulcerate. They may also spread deeply and affect the tarsus causing ectropion and trichiasis.

The globe may be affected either by a direct spread of the disease from the conjunctiva, or possibly by metastatic infection. The neighbourhood of the limbus is a common situation for the disease to commence. Nodules are formed in the episcleral tissue and the disease then may spread backward through the sclerotic involving the ciliary body or iris, in either of which nodules may arise. In the cornea it causes a vascular interstitial opacity, resembling in its appearance tubercular sclerosing keratitis and like it fails to resolve. Occasionally, when the bacillus lies directly beneath Bowman's membrane, a condition resembling superficial punctate keratitis may be produced.

The uveal tract may also be involved from metastatic infection. The disease almost invariably begins at the angle of the chamber spreading forward to the iris and backward to the ciliary body and choroid. Nodules are formed in the iris and ciliary body which may lead to shrinking and atrophy of the globe. Choroiditis occurs in the anterior part of the globe in direct continuity with the disease in the ciliary body, but in the posterior part of the globe it is

extremely rare. The retina is usually only affected secondary to the choroid and then only in the anterior part of the globe near the ora serrata.

g. **Unclassified Bacilli.**—The *bacillus mallei* glanders (**farcy**) is a slender rod and measures about 2 to 3 μ long. It is stained irregularly and feebly by aniline dyes and is not stained by Gram's method. It is non-flagellated, non-motile, and does not form spores. On cultivation it grows well on all media; on potato it forms a brown honey-like mass on the surface, which is very characteristic. Inoculation on the conjunctiva of animals has proved fatal. When introduced into the anterior chamber nodules are formed on the iris and general infection frequently follows. Guinea-pigs are peculiarly susceptible to the disease. The usual source of infection is from the horse, the organism being frequently carried in the discharge from the nose and mouth.

The disease is an infective granulomata, somewhat allied to tuberculosis only more rapid in its course.

When it affects the eyelids or conjunctiva nodules are formed which break down and ulcerate; there is usually early enlargement of the preauricular gland and those of the neck.

From the conjunctiva the disease may spread to the lacrimal sac and nose.

The globe is only invaded secondary to corneal ulceration. Metastatic deposits have never been recorded.

The **strepto-bacillus of Ducrey** is found in **soft sores** which occasionally affect the lids and conjunctiva. The organism can be found in the secretion scraped from the surface of the ulcers. The bacillus is about 1.5 μ long and .5 μ broad, slightly curved and tending to lie side by side in pairs or chains. It stains irregularly and badly with aniline dyes and does not stain by Gram's method. On cultivation it grows on agar forming whitish colonies which, when inoculated into apes, produce a typical soft chancre. It can be easily distinguished from the diplo-bacillus of Morax-Axenfeld by the faint irregular staining with aniline dyes and by it

growing on agar; from the *Bacillus Mallei* by not producing a brown growth on potato which is a typical characteristic of the latter organism.

Bacillus of zur Nedden is a straight rod $.7\mu$ long and $.6\mu$ broad, with rounded ends. It is about the same size and shape as the xerosis bacillus. It **stains** well with thionine blue and is decolourised by Gram's method. These bacilli have a superficial resemblance to the *Coli* group but are non-flagellated, non-motile obligate aerobes.

On **cultivation** they grow on all media and thus differ from the Koch-Weeks bacillus. Milk is coagulated. No gas is formed. On agar they form colonies 2 to 7 mm. in diameter in about 24 hours which have a bluish transparent appearance.

Inoculated into the cornea of rabbits they produce a severe corneal ulceration with hypopyon, but if inoculated into the vitreous merely produce a transient reaction which is probably due to the want of a free supply of oxygen.

Up to the present time the organism has only been found in corneal ulceration. The ulcer produced is a severe grey infiltration usually situated near the corneal margin. Hypopyon is rarely present.

Bacillus subtilis is a large rod of about 2.5μ long and $.5\mu$ thick. It varies considerably in length. It **stains** well with thionine blue and retains the stain in Gram's method. It is a flagellated motile aerobe. It forms spores situated about the centre of the organism.

On **cultivation** it grows best at body temperature and forms on solid media a yellowish-brown skin raised above the medium which has a very characteristic appearance.

Neither the organism nor the toxin produce any change when instilled into the conjunctival sac, but when rubbed in after scarification it produces reaction. Inoculation of the organism into the anterior chamber produces a severe iritis and when inoculated into the vitreous panophthalmitis ensues.

In the **conjunctiva** no case has been recorded in which the

organism could be said to have caused inflammation. It is of importance, however, as occasionally it occurs as a saprophyte in the conjunctival sac, wound-infection and panophthalmitis having been attributed to it, but more evidence is yet required before this can be regarded as proved.

Bacillus aerogenes (perfringens) (emphysematous gangrene).—This bacillus somewhat resembles the bacillus subtilis in its appearance. It stains irregularly with aniline dyes, but is well stained in Gram's method. It appears to have a capsule, but this is not a true one, being merely a retraction of the media around owing to a gaseous envelope formed by the bacillus. It is non-motile. On cultivation it will only grow anaerobically free gas being formed in a media which contains sugar. It does not grow on gelatine. Inoculated into the interior of the eye of an animal it causes panophthalmitis. It has only been found in cases of panophthalmitis following wounds of the globe and it is usually associated with other organisms, more especially the streptococcus. One of the chief characteristics of the panophthalmitis caused by this organism is that bubbles of gas appear beneath the conjunctiva, the inflammation being of a very violent character.¹

Bacillus pyocyaneus (bacillus of blue pus) is one of the chromogenic bacteria. It is a slender rod of about 1μ long armed with a terminal cilium. It stains moderately well with aniline dyes, but not by Gram's method. It is a motile facultative aerobe, growing readily in the cool incubator in all media. On gelatine, which it rapidly liquefies, it causes a greenish-blue fluorescence by its growth. It gives rise to free toxin in the media in which it is grown. Its virulence varies considerably, but all forms are pyogenic. In the conjunctiva one case of muco-purulent conjunctivitis attributed to it has been recorded.

In the cornea it causes severe serpiginous corneal ulceration. Intraocular infection generally follows wounds in the globe. It gives rise to a panophthalmitis which is fre-

¹ R. R. James. Trans. Ophth. Soc. of the U. K., XXX, 1910, 179.

quently associated with ring abscess of the cornea, probably owing to the presence of the free toxin diffusing into it.

II. Fungi.

Fungi which affect the eye are rare and as yet there is a want of accurate classification owing to the fact that in most of the recorded cases their peculiarities on culture have not been carefully investigated.

Streptothriceæ.—*Streptothrix fosterii*, *leptothrix* and *actinomyces* belong to this group.

Concretions which occur in the lower canaliculus are due to the ***streptothrix fosterii***. Much discussion has arisen as to

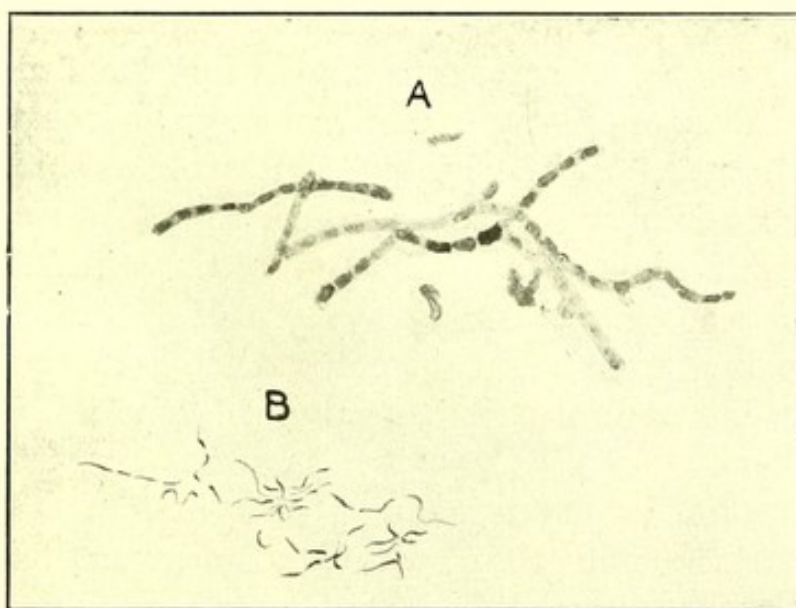


FIG. 189.—Two different specimens of the *streptothrix fosterii* removed from the canaliculus. A, Thick filaments; B, much narrower filaments.

whether the organisms found in these concretions are *leptothrix* or the *streptothrix fosterii*, but the balance of evidence in those cases in which cultivations have been obtained is entirely in favour of the *streptothrix*; indeed, it is extremely doubtful if the *leptothrix* ever occurs. *Leptothrix* can be distinguished from *streptothrix fosterii* by not usually exhibiting club-shaped bodies on cultivation and not yielding

the iodine reaction (turning blue on the addition of Gram's iodine solution owing to the presence of starch-like material).

ACTINOMYCES probably also does not occur in the canaliculus since in no case has the organism in these concretions been found to invade the tissues. *Actinomyces* occur as a rare affection of the eyelids.

The streptothrix *fosterii* is a branching mold with club-like ends. It is found in concretions in the canaliculi together with calcareous particles and other organisms. It stains badly with all aniline dyes but well with Gram's method, and is also turned blue by Gram's iodine. Irregularities in the filaments and variations in thickness are frequently seen (Fig. 189). On cultivation it can only be grown anaerobically and is difficult to obtain in pure culture owing to the presence of other microorganisms. These will sometimes die out at the end of two to three weeks, allowing the streptothrix to be obtained pure on recultivation. Peptone-glycerine agar (acid) is the best media for its growth. A stab culture should be made. It appears in from 4 to 6 days as greyish-white smooth granules at the bottom of the stab. In broth it forms a woolly mass at the bottom of the tube. Polymorphism is very marked on cultivation. On inoculation large doses injected intra-peritoneally will sometimes produce suppuration.

Aspergillus or mold fungus occurs in many varieties. The chief of these are the *aspergillus fumigatus*, *flavescens*, *niger*, *ficum*, *wenti*, *candidus*, all of which are pathogenic to animals; and the *aspergillus glaucus*, *ostranus*, *minimus*, *clavus*, *varians*, and *novus* which are non-pathogenic. The one which has been most frequently described as causing ocular lesions is the *aspergillus fumigatus*.

It consists of filaments (mycelium) attached to which are the reproductive organs consisting of radial arranged sterigmata and conidia (spores). These molds are best examined without staining in a hanging-drop glycerine preparation. They stain badly with aniline dyes, but are well stained with Gram's method. On cultivation they grow

well on all media, especially when acid. They give rise to a white, soft, furry mass which after a time becomes greenish toward the centre (*A. fumigatus*).

IN THE CORNEA it will only grow if a foreign body is implanted with the aspergillum. It gives rise to either small vascular ulcers or larger lesions causing destruction of the entire cornea. The appearance is very characteristic. The ulcer is a dry slightly raised area surrounded by a ring of demarcation and infiltration. Occasionally there is a leash of vessels running to it. The central area may sometimes be thrown off as a slough.

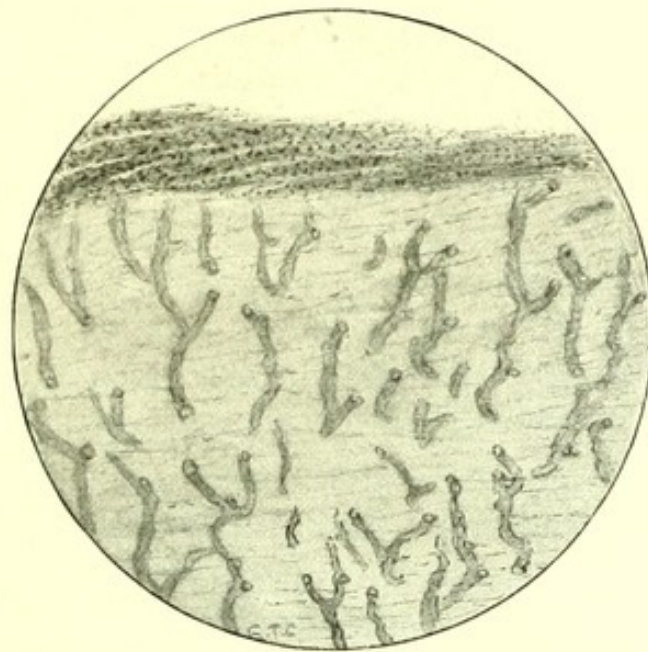


FIG. 190.—Aspergillus or mold fungus growing in the cornea.

Microscopical examination of the scraping from the ulcer is usually sufficient to make a diagnosis; the mycelium, being easily recognised though the reproductive organs, are rarely present (Fig. 190). If the ulcer perforates the fungus may in rare cases spread to the interior of the globe.

Infection of the vitreous and sclerotic accompanied by suppuration due to the aspergillus has been recorded.

Penicillium glaucum (Fig. 191) has been described as the cause of keratitis with hypopyon in one case. Though it is

pathogenic to animals it is somewhat doubtful if it occurs in the human cornea.

Botryomycosis and Hefæ have also been described in corneal ulceration with hypopyon. Botryomycosis has also been met with in a lesion of the lid resembling a styne.

Favus is due to the *Achorion schönleinii*. The organism is sometimes found affecting the eyelashes and eyelids.¹ It is recognised, by examining the unstained preparation

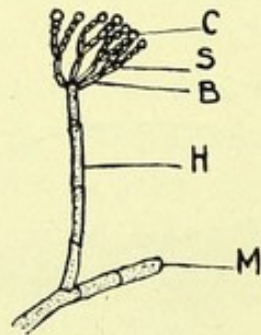


FIG. 191.—*Penicillium glaucum*. $\times 400$. C, Conidia; S, sterigmata; B, basidia; H, hyphæ; M, mycelium.

after the addition of acetic acid, by the ovoid spores, and by its trichotomus branching mycelium; for method of staining see page 532. The organism grows best in a culture on maltose agar.

Ringworm may be due to:

The **microsporon audouini** (90 per cent. of cases), a small spore fungus with mycelium principally in the hair and spores arranged in mosaic pattern outside; this destroys the outer sheath of the hair, a fact which serves to distinguish it from the other forms of ringworm and from favus.

The **trichophyton endothrix** distinguished from the above by the chain-like arrangement of the spores.

The **trichophyton ectothrix** attacks the hair only on the outside.

¹Treacher Collins. Trans. Ophth. Soc. of the U. K., XXIII, 1903, 1.

III. Animal Parasites.

Animal parasites are divided into (i) unicellular and (ii) multicellular organisms.

(i) **Unicellular organisms** (protozoa).

The diseases affecting the human eye and its appendages caused by this group are syphilis (*spirochæta pallida*), malaria (malarial parasite).

Trypanosomæ have been demonstrated in the eyes of animals but not in man's.

Syphilis.—That the *spirochæta pallida* is the cause of syphilis there is now little doubt, but as yet insufficient time has elapsed since its discovery for a demonstration of the organism, in the various intraocular lesions due to this disease, to have been made. Up to the present time it has been found in primary chancre of the eyelids and conjunctiva, in the aqueous in acute iritis, and in the cornea of syphilitic infants. It is extremely difficult to find in gummatous lesions.

The *spirochæta pallida* is a protozoa from 10 to 15 μ long and about 1/4 μ thick. It appears in spirals of about eight to ten sharp, regular and short turns, which serve to distinguish it from the *spirochæta refringens* in which the turns are less numerous and longer. Each end of the organism is pointed and provided with a cilium which by means of it moves freely. To demonstrate the organism, the dark ground illumination method, the indian-ink method, or prolonged staining by Giemsa's method, of smear preparations of scrapings from the tissue is the most reliable. By the latter method the organism is of a pink colour while other *spirochætæ* have a bluish tinge. The silver impregnation method can be used for staining them in the tissues, but fibres of the tissues, especially nerve fibrillæ, may be mistaken for the *spirochæta* (see page 534).

In infected persons the presence of mercury in the system causes the disappearance of the *spirochæta pallida* from the lesions.

Inoculation of the spirochæta into apes produces the most reliable results. Occasionally inoculation has proved successful in rabbits though the lesion produced is not typical. In making an inoculation the surface of the tissues should be scarified and the infected material rubbed in. Successful inoculation into the skin of the eyelid and eyebrow in apes has been made. Injection into the anterior chamber of an emulsion from a primary chancre has produced an interstitial keratitis of the cornea in rabbits. There is little doubt that the presence of the spirochæta pallida in the body gives rise to immune bodies which help to eradicate the disease since patients with syphilis cannot be reinfected. That this immunity does not last is shown by the fact that if the disease be completely eradicated from the system the person can again become infected with syphilis. But as long as the organism is still present the patient cannot be infected with syphilis, even if it gives rise to no symptoms as, for instance, in the mother of a syphilitic child. This is evident from the fact that as long as the spirochæta pallida is present in the body the blood of the patient will give the Wassermann reaction (see page 295). The administration of mercury does not interfere with this reaction.

The spirochæta pallida and its toxins during the secondary stages have the power of exciting a chronic inflammation, which especially affects the vessel walls since the organism is circulating in the blood. This endarteritis is also very marked in the local manifestations of the disease. It is followed by organisation and sclerosis of the vessel walls, a condition which is frequently seen clinically in the choroid and retina.

The infection is usually divided into three stages which are purely arbitrary, one stage merging into the other. The infection is limited for a short time to the primary sore; this is rapidly followed by the infection of the nearest lymphatic gland. The organisms then gain entrance to the blood stream, general dissemination of them taking place. This is the secondary stage and is manifested by general symptoms

of slight fever followed by local eruptions due to aggregations of the organisms in the skin, mucous membrane, and uveal tract. The reaction of the tissues to the organism may produce an immunity so that no further symptoms arise. If, however, they be not completely eradicated, they lie latent in the tissue and again become active as the general immunity subsides. The inflammation which is then excited is of a more localised character producing masses of an exudate known as gummata in which necrosis frequently takes place. In this, the tertiary stage, the disease is supposed to be non-contagious probably partly because the organisms, which are very scanty, are entirely limited to the local lesion.

A primary sore (Hunterian chancre) may affect the eyelids or conjunctiva. The infection is sometimes caused by the removal of foreign bodies from the surface of the eye by the tongue, a practice not uncommon among workmen. The incubation period is from two to four weeks; an ulcer with sharp-cut edges and an indurated sloughing base is formed; when near the limbus the cornea may be involved. Toward the end of the first week the preauricular and sub-maxillary glands begin to enlarge and may reach a considerable size. There is usually a large amount of conjunctival discharge as the ulcer becomes infected with pyogenic organisms. The spirochæta pallida has been found in scrapings from such ulcers. Microscopical examination of the ulcer shows a new formation of round cells and epithelioid cells, some of which are undergoing necrosis. In the later stages there is much formation of fibrous tissue. The vessels in the neighbourhood show intense sclerosis and are often thrombosed. A primary lesion of the eye is frequently followed later by interstitial keratitis in the same eye.¹

Secondary syphilis rarely affects the conjunctiva and eyelids. Mucous patches may occur at the angles of the eyelids in infants and ulceration of the palpebral conjunctiva may take place.

¹ Treacher Collins. R. Lond. Ophth. Hosp. Reps., XVI, 1904, 16.

The uveal tract is peculiarly liable to be affected in this stage of the disease, usually about the time the rash begins to disappear from the skin. The lesions in the iris and choroid are no doubt of a similar nature to those of the skin but more diffuse. The inflammation is of a plastic type and usually affects both eyes (see page 325.)

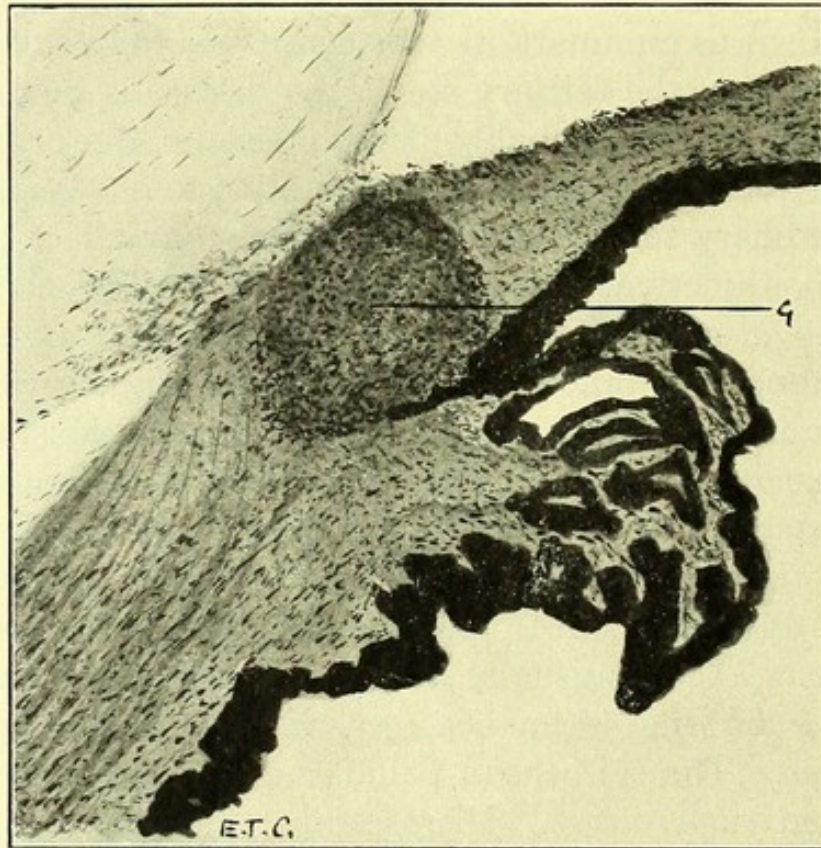


FIG. 192.—G, Gumma in the root of the iris in a child aged fourteen years, the subject of inherited syphilis.

In the iris vascular nodules may be formed which are most frequently observed in blue irides as rust coloured elevations near the pupillary margin where the capillary anastomosis is finest (Fig. 192). Extensive posterior synechiæ are common and may be followed by complications (see page 332). The *spirochæta pallida* has been found in the aqueous humour, but not as yet in these nodules. The ciliary body may be slightly involved, but this structure is more frequently affected in tertiary syphilis.

The choroid is affected by multiple localised patches or more or less diffused round-celled infiltration situated especially in its capillary layer. The overlying retina frequently becomes involved (chorioretinitis). This inflammation is subsequently followed by organisation and vascular sclerosis. If the outer layers of the retina are destroyed by the inflammation a loss of function corresponding to the area involved is the result, but if the nerve-fibre layer is also affected the retina to which these fibres are distributed will likewise be rendered functionless. Marked secondary pigmentation of the retina and choroid follows from the proliferation and migration of the pigment cells, the new fibrous tissue appearing ophthalmoscopically as white patches in the fundus. Some of the white patches are also due to atrophy of the choriocapillaris, allowing the sclerotic to be seen more plainly.

The retina may be affected secondarily to the choroid as has already been described, or the deposit of *spirochæta pallida* may be primarily situated in it. This, like all metastatic lesions of the retina, is more likely to take place in the neighbourhood of the disc where it is most vascular. The papilla also is usually involved, producing a condition of neuroretinitis. The swelling and pressure of the exudation in the papilla, accompanied by inflammation in the vessel wall, will sometimes cause secondary thrombosis of a retinal vein.

Lacrimal obstruction is a frequent sequela of the snuffles of congenital syphilis which causes periostitis and thickening of the bony wall of the lacrimal canal.

Tertiary syphilis rarely affects the lids and conjunctiva. Occasionally gummatous ulcers may form on the eyelid.

The cornea is affected by a gummatous infiltration of the deep layers of the substantia propria (interstitial keratitis). The disease usually occurs in children, the subjects of congenital syphilis, between the ages of ten and twenty, but it may occur as early as two and a half, or as late as forty years. It affects both eyes, though one is frequently

involved before the other. Probably most cases are accompanied by a gummatous infiltration of the ciliary body and iris. In adults in the acquired form it is often unilateral.

Since the disease in the cornea is due to endogenous infection or to extension from the ciliary body it begins usually at the corneal margin. There are, however, rare cases with but little opacity and no vascularity, apparently commencing near the centre, of the cornea which are always

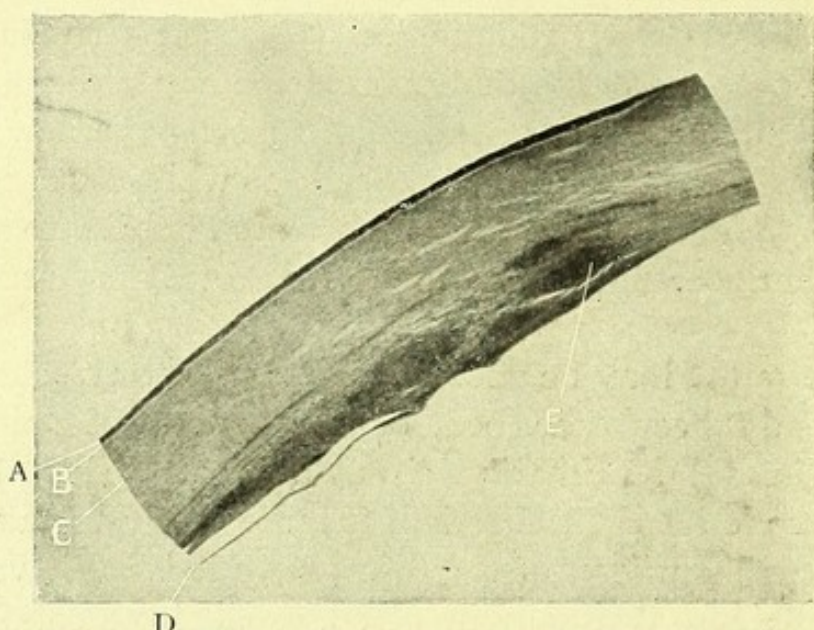


FIG. 193.—Shows a section through a cornea affected with interstitial keratitis. *A*, Corneal epithelium; *B*, Bowman's membrane; *C*, substantia propria; *D*, Descemet's membrane; *E*, round-cell infiltration in the deeper layers of the cornea.

accompanied by cyclitis; it is probable that they are due to diffusion of toxin from the aqueous through Descemet's membrane.

The *spirochæta pallida* has not been demonstrated in interstitial keratitis, partly because so far very few cases have been examined, and partly because the organism is very scanty in gummatous lesions. Histologically the cornea presents a round-celled infiltration in the deeper layers (Fig. 193) of its lamellæ of which are sometimes separated from each other by quite large masses of cells. Epithelioid and giant cells may also be present. The cells, especially toward the centre of the gummatous masses, undergo necrosis and

after a time the vessels from the sclerotic bud out and vascularise the cornea. These are fine straight vessels and may be so numerous as to give the area a uniform red appearance, a condition which is known as "salmon patch." The superficial layers of the cornea may also occasionally be affected and then vessels from the conjunctiva extend into it (Fig. 194). The epithelium on the surface is always edematous. In rare cases where the whole circumference of the cornea is affected and becomes vascular the central portion of it may break down and ulcerate.¹ The disease usually in-

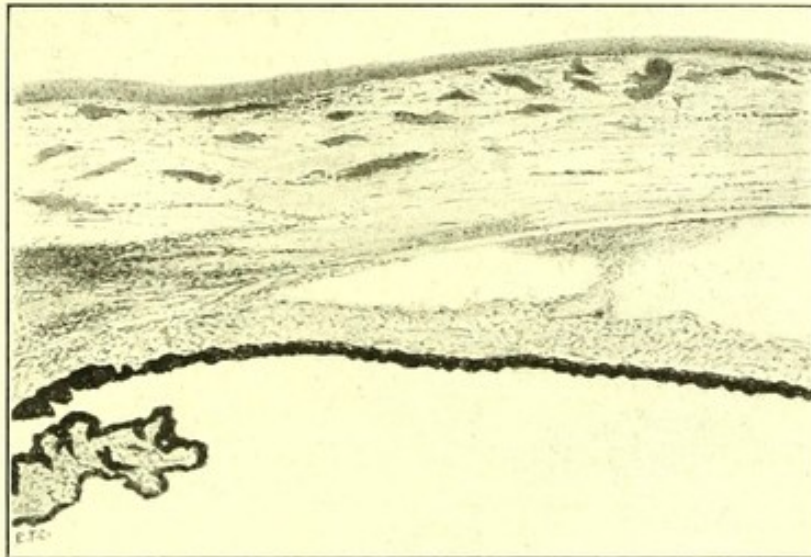


FIG. 194.—Shows a section through a cornea which had become vascularised as the result of interstitial keratitis of hereditary syphilitic origin.

volves the whole cornea spreading from the margin toward the centre, the lower and central portion of the cornea being the last to clear. The infiltration of the cornea leads to softening and the normal intraocular tension may give rise to a local ectasia, or general yielding, and deepening of the anterior chamber. Clinically the former condition must be distinguished from the swelling due to infiltration which is most marked when the anterior layers are involved. Yielding of the cornea may be so great as to produce a staphyloma. Occasionally in very rare cases the condition of

¹ Treacher Collins. R. Lond. Ophth. Hosp. Reps., XI, 1887, 338.

conical cornea is produced; such cases usually have an opacity at the apex of the cone.

The amount of permanent opacity which follows the disease varies very considerably according to the amount of the necrosis which has taken place. In extreme cases the cicatricial contraction may give rise to flattening of the cornea; the opacity may be so dense as to leave the patient with nothing more than a bare perception of light. In the mild cases the opacity left may be little more than a slight

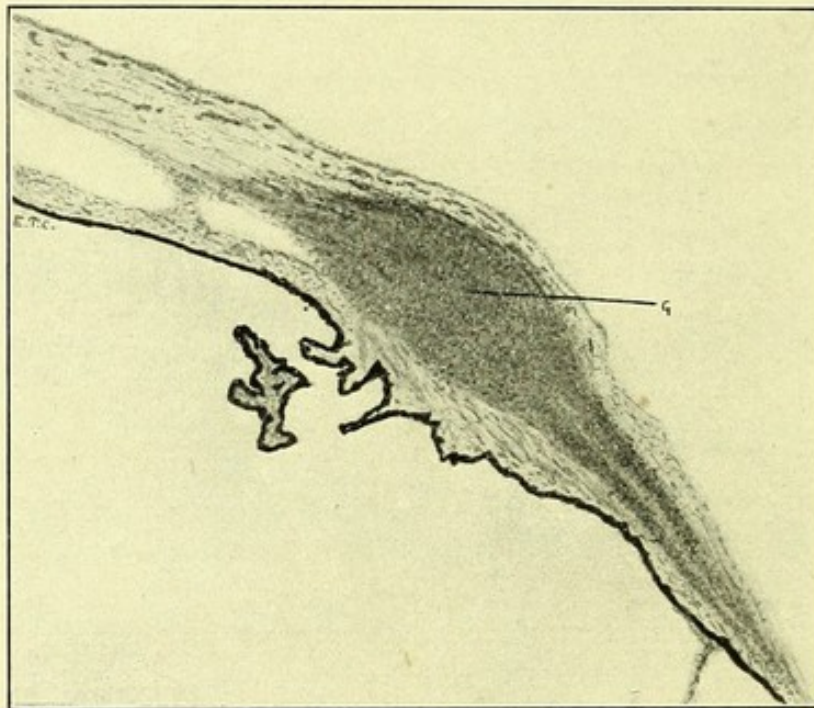


FIG. 195.—Shows a section through a gumma starting on the outer surface of the ciliary body and invading the sclerotic.

haze in the cornea the origin of which can usually be told by the straight hair-like remains of the vessels in the cornea which, after the disease has subsided, become so sclerosed as to contain no blood.

Another cause of opacity of the cornea is punctate keratitis which may be very extensive and undergo organisation into a membrane on its posterior surface, having usually a triangular shape. Other complications, such as are associated with iridocyclitis may also arise (see page 332).

Localised gummata of the ciliary body may occasionally occur apart from interstitial keratitis. The inflammation starts either on the inner or outer surface of the ciliary muscle. A gumma on the inner side of the ciliary muscle, which usually is unaccompanied by much iritis, may be seen by focal illumination protruding inwards behind the lens as a yellowish-red mass. One starting on the outer side of the ciliary muscle invades the sclerotic (Fig. 195) and may cause perforation. In both instances the ciliary muscle becomes involved, but it is rare for its attachment to the sclerotic to be destroyed. If the disease spreads forward it involves the cornea; if backward, the anterior part of the choroid.

Localised gummata of the choroid are rare except as a result of direct spread of infection from the ciliary body or optic nerve. A diffuse gummatous infiltration is more common. The disease usually starts in the capillary layer in the choroid, the retina often being secondarily involved. Histologically fatty degeneration of the inflammatory exudate is often a marked feature.

Gummata of the optic nerve occur most commonly in connection with a meningitis in the neighbourhood of the chiasma, in which case they may give rise to symptoms resembling an intracranial tumour with a defect in the field corresponding to the portion of the nerve involved.

In rare cases the disease may attack the neighbourhood of the optic papilla, giving rise to a swelling of the nerve head and symptoms which resemble an intraocular tumour.

Gummata of the orbit affect the periosteum, especially of the upper and outer, and lower and inner orbital margins. The disease starts in the deeper layers of the periosteum, causing a thickening of that structure. As the mass increases in size it undergoes necrosis, a glairy yellow fluid being formed in it. The mass softening may extend forward so that the skin becomes involved, and destroyed, a sinus being formed. From the supervention of sepsis an extensive necrosis of the bone may result. Gummata in the neighbourhood of the optic foramen give rise to symptoms of pressure on the optic

nerve (central scotoma) and later signs of an intraorbital tumour.

Malaria.—Cases of choroiditis, retinitis, and iridocyclitis associated with this disease have been recorded, but up to the present time the parasite has not been demonstrated in the lesions probably owing to the difficulty of obtaining material for examination. The changes are probably produced either by local deposits of the parasite, or by the vascular sclerosis caused by their presence in the blood stream. Carbo-thionin (see page 530) is the best stain for demonstrating the parasite; its ameboid movements can be examined in wet smear preparations on a warm stage.

Trypanosomiasis.—The diseases of the eye known to be due to animal parasites which have not already been described are nagana, surra mobori, souma, mal de caderas, dourine and sleeping sickness.

The ocular lesions in man which have been observed in **sleeping sickness** are iridocyclitis, choroiditis, and edema of the eyelids; as yet the organism has not been demonstrated in the lesions. In animals experimental inoculations have been found to give rise to similar lesions and the organisms have been found in the tissues. It is also of interest in view of the fact that syphilis is due to an organism belonging to the same group, that animals affected by these diseases develop an interstitial keratitis in which the organism has been demonstrated.

(ii) **Multicellular organisms** affecting the eye are divided into entozoa (worms) and insectivora.

Entozoa—Tapeworms.—The eye can be the seat of development of the intermediary stage of a tapeworm. The common forms which occur in the eye are the cysticercus (*tænia solium*) and hydatid (*tænia echinococcus*). The adult worm, living in the intestine of its host, from time to time throws off the last segments (proglottis) containing ova; these being swallowed by the intermediary host the envelope is dissolved and the embryo (proscolex) which they contain set free. They make their way through the wall of the in-

testine and getting access to the blood stream are carried to the eye.

Cysticercus¹ (*T. solium*) consists of a head with suckers, proboscis, and six hooklets. Attached to it by means of a segmented neck is a small bladder or cyst about the size of a pea; the head and neck are usually found inverted into the centre of the cyst.

The head of the **T. mediocanellata** is provided with four suckers but has no proboscis or hooklets. The duration of life of the embryo in the tissues may be as long as three years.

Nearly all parts of the eye may be the site of their development.

In the conjunctiva the fornices are the most frequent site for the cyst which appears translucent and in one situation may show an opaque area corresponding to the scolex.

The sclerotic has been affected in one recorded case.

The iris, or rather the anterior chamber into which it makes its way, may be the site of a cyst, in which case it is usually attached to the iris by a pedicle; if the organism is alive it may be seen to alter its shape from time to time and also protrude its head. It gives rise to a severe plastic iritis and occasionally hypopyon may be present.

In the posterior part of the globe the cyst may begin in the retina or choroid, subsequently making its way into the vitreous. The retina usually becomes detached. It sets up severe inflammation and even suppuration may result.

Hydatid (*T. echinococcus*).²—The embryo of this worm when it escapes from the ova into the intestine is provided with hooks. On gaining access to the eye it is converted into a cyst containing clear fluid in which hooklets may be found. The cyst consists of an outer laminated elastic layer and an inner parenchymatous layer containing granular matter, cells, etc.

In this sterile state it may remain or it may be repro-

¹ Hill Griffith. Trans. Ophth. Soc. of the U. K., XVII, 1897, 220.

² L. Werner. Trans. Ophth. Soc. of the U. K., XXIII, 1903, 193.

duced by the development of small cysts with scolices, suckers and hooklets (brood capsules), this is the only way by which reproduction has been recorded in the eye, but ectogenous or endogenous cyst-formation (daughter and grand daughter cysts) is met with elsewhere.

Cases of hydatids have been recorded affecting the vitreous and also situated between the retina and choroid. The eyes involved were removed for absolute glaucoma.

Filaria (thread worm).

FILARIA LOA is found almost exclusively on the west coast of Africa and affects both the native and white people. The worm has been compared in appearance to a piece of fishing gut, being round, firm, transparent and colourless, but it has minute bosses on its surface. The male measures from 25 to 30 mm. long and .3 mm. broad, the female being somewhat larger.¹ The head end is furnished with a mouth without armature. There is no neck, though there is a sort of shoulder .15 mm. behind the mouth. The tail end is sharply incurved and provided with five lateral alæ, the three in front of the anus being very large. How it gains access to the body is not known. There is no evidence that the worm can penetrate the skin or mucous membrane. It has been suggested that the female worm may give rise to ova which enter the blood of the host and from the host the ova are transferred by blood-sucking insects. These die in water which is used for drinking purposes and the embryo are taken into the human host in this medium. The worm is found in the skin of the eyelid and beneath the conjunctiva. There is no definite case on record in which it has been found within the eye. The reason that the region around the eye is so frequently affected is probably on account of the laxity of the tissue. When near the surface it causes irritation and lachrymation, with some edema. When it disappears into the deeper tissues it may not give rise to any symptoms. It has been observed to travel from one eyelid to the other. It has been said that warmth will bring the worm to the surface.

¹ Argyll Robertson. Trans. Ophth. Soc. of the U. K., XV, 1895, 137.

Cases of other filaria in the anterior chamber and vitreous have been reported, but their species have not been made out. They may give rise to inflammation, especially after the death of the parasite. The instillation of atropine into the eye seems to be fatal to them in the anterior chamber. A case of subretinal worm has been reported causing detachment of the retina. The worm was seen with the ophthalmoscope. In India filaria in the anterior chamber of horses are common, they also occur occasionally in Europe.

Insectivora may affect the eye in various ways: by

1. Stinging; a mosquito bite of the skin of the eyelids sometimes gives rise to extensive swelling.

2. Their irritating secretion; thus the great ant of Senegal has an acid secretion which when deposited in the conjunctiva excites an acute conjunctivitis.

3. Lying on the surface. Pediculosis of the eyelashes is due to the pediculus pubis or crab louse. It is 1 mm. long and 1 mm. broad, having an almost square body and six long legs and claws. The eggs or nits are firmly attached to the bases of the hairs. It differs from the head louse in being smaller and square in shape. The latter does not infest the eyelashes.

4. Burrowing beneath the epithelium. In San Domingo there is a variety of scabies which affects the lids.

5. Deposition of larvæ. DIPTEROUS LARVA, the maggot stage of the fly, probably gains entrance to the eye from ova deposited either in the conjunctival sac or nose and invades the eye directly. They are more common in horses than in men.

Larvæ of the various forms of the flies are difficult to recognise. *Calliphora erythrocephala* (blow fly), *hypoderma bovis*, Wolfhart's fly (*muscæ vomitoria*) have been recorded. It is probable also that the *sarcophaga* can occur.

In the conjunctiva they have been found beneath the epithelium associated with an acute muco-purulent conjunctivitis. They have also been found in the lacrimal sac. In the anterior chamber the larva and its movements have

been observed both by the patient (in the early stage) and the surgeon. After a time the larva dies and inflammatory changes are set up in the eye. Iridocyclitis and retinal detachment are frequent sequelæ.

6. Irritating hairs. Ophthalmia nodosa (see page 275).

7. Some flies in South America deposit an anterior horn in the cornea when they strike the eye.

8. Transference of discharge by flies. This is apparently a common method by which the infection of purulent ophthalmia and trachoma is carried in such countries as Egypt.

9. Transference of irritating pollen. In Cuba a fly lives on the *enforbia ferox*, the pollen of which, when transferred to the human conjunctival sac, causes an acute conjunctivitis with a vesicular eruption.

IV. The Diseases which are Probably Due to Microorganisms.

Trachoma.—Trachoma is a specific infective disease of the subepithelial tissue of the conjunctiva, characterised by infiltration and the formation of lymphoid follicles, which necrose. In the later stages of the disease there is a formation of fibrous tissue of variable amount; it may be so extensive as to cause obliteration of the conjunctival sac.

The term trachoma has been in use since the time of Hippocrates and was formerly applied to any condition in which there was an undue roughness of the inner surface of the eyelids. The specific disease to which it is now applied has only been differentiated from other inflammatory affections of the conjunctiva in comparatively recent times.

It has been proved by inoculating one patient with the discharge from another that the disease is directly contagious, and also that the different clinical forms which it presents are but different stages of the same disease.

So far no organism has yet been proved to be the cause of the disease. It has been attributed by different observers

to a coccus, a bacillus, and to ultra microscopic organisms. Bodies which it was thought might be the specific organisms were found in the endothelial cells, but subsequently they proved to be fragments of cells formed by necrotic changes in the tissue.

More recently minute ovoid bodies, considerably smaller than any known cocci, have been found, by the use of

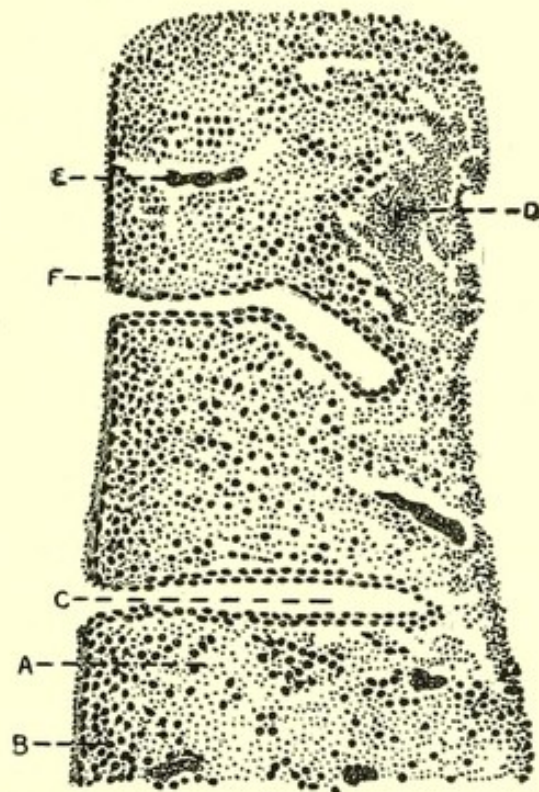


FIG. 196.—Section showing papillary formation in early trachoma. *A*, Papilla; *B*, plasma cells; *C*, crypt; *D*, portion of a trachomatous lymph follicle; *E*, blood-vessel; *F*, epithelium.

Giemsa's stain, in the epithelial cells. They occur massed together near the nucleus in the form of a cap but separated from it by a clear space. The area containing the granules and the whole cell enlarges rapidly, ultimately bursting, so that the granules are discharged.¹ So far these granules have not been cultivated or made to reproduce the disease. It may be that they are merely thickenings of the chromatin filaments in the cytoplasm produced from degeneration of the

¹ Halberstädter and Prowazek. *Deutsch. med. Wochenschrift*, 1907, No. 32. Greeff. *Lancet*, April 17, 1907.

cell either by pyknosis or hyperchromatosis. This is further supported by the fact that they have been found in the epithelial cells of the normal urinary tract and conjunctiva.

The disease beginning in either the upper or lower fornix appears first in the form of gelatinous-looking round swellings or follicles which become confluent and then resemble grains of boiled sago or frog spawn. When large these follicles easily rupture and their gelatinous contents is extruded.

The first sign of the disease in the tarsal conjunctiva is in the form of small, circular, pale, grey areas due to follicles embedded in the fibrous tissue; later these enlarge and form elevations on the surface which, like the follicles in the fornices may rupture.

In association with the follicular developments there is always hyperemia of the blood-vessels and papillary formation, the amount of which varies considerably in different cases. Where it is excessive the affection is spoken of as **the papillary form** of trachoma (Fig. 196). Where, on the other hand, the follicular formation is a more striking feature clinically than the papillary enlargement, the case is classed as **the follicular variety**.

In the later stages of the disease the subepithelial lymphoid tissue becomes replaced by newly formed fibrous tissue, which is seen as irregular white streaks on the inner surface of the lids; this is spoken of as the **cicatricial stage**. A band of fibrous tissue frequently forms along the line of the sulcus subtarsalis; it is termed **Arlt's streak** and the contraction caused by it is the commonest cause of entropion.

In some cases the infiltrate around the follicles undergoes hyaline degeneration and a peculiar waxy-like appearance is then seen in the conjunctiva, termed **Stelwag's brawny edema**.

In severe cases of trachoma the cornea is affected. It becomes opaque and vascular, **pannus**. The upper half is most frequently involved, a sharp line of demarcation separating the affected from the unaffected parts. In some cases the whole cornea is implicated.

The new blood-vessels in the cornea are derived from those of the conjunctiva and are located in its superficial layers. In the early cases where there is not much thickening and only slight vascularity it is spoken of as **pannus tenuis**; where the vascularity is very marked, as **pannus vascularous**. When the trachoma becomes cured the pannus as a rule disappears; in some cases, however, a permanent opacity and a few vessels are left; this is termed **pannus siccus**.

The amount of discharge in cases of trachoma varies considerably. In the disease which spread widely in Europe on the return of the troops from Egypt after the Napoleonic wars there was much purulent discharge; it was doubtless due to mixed infection of trachoma and purulent ophthalmia. The two diseases are still prevalent in association with one another in Egypt and other Eastern countries.

Muco-purulent discharge may be present in trachoma but is not an essential feature, in some cases a mucoid secretion being only met with. Acute exacerbations may occur when the discharge is muco-purulent, it being at other times mucoid.

It would seem that trachoma is essentially a chronic disease and that when these exacerbations occur there is a mixed infection, as pyogenic organisms are at these times always found in the discharge. The trachoma no doubt lowers the vitality of the tissue and provides a means of entrance to the organisms by the rupture of the follicles.

Histology.¹—In the earliest stage of trachoma the epithelium shows little change, but directly any discharge appears it becomes infiltrated with leukocytes. These leukocytes, unlike those in the deeper tissue, are largely of the polynuclear variety; and no doubt their presence is due to pyogenic organisms growing in the epithelium, since without infection they do not usually appear in any number. As the disease advances the epithelial cells undergo increased mucoid change. Over the tops of the follicles they at times

¹ M. S. Mayou. Hunterian Lectures, 1905.

become almost entirely destroyed. In the crypts between the follicles and in the folds produced by the swelling of the subepithelial tissue they give rise to new pseudo-glands (see page 305). In long standing cases of trachoma, if there is any deficiency in lacrimal secretion, keratinisation of the epithelium may take place (see page 443, secondary xerosis). This is specially liable to occur on the prominences produced by the newly formed fibrous tissue.

In the subepithelial tissue the changes are of two main types: 1. The formation of follicles; 2. infiltration. They always occur together, but one may be in excess of the other, producing the different clinical conditions previously described.

The follicles in trachoma differ considerably in structure from healthy follicles in lymphatic glands, and those met with in follicular formation due to other forms of conjunctivitis (Plate 2). They are usually found in the lymphoid layer, but may be more deeply situated. Their structure varies with their age.

In a newly infected trachoma follicle there is externally a single layer of somewhat elongated flattened cells, which appear to be of endothelial origin; their continuity is often much broken up, more so than in the follicles due to other forms of conjunctivitis. Within this external covering are other cells supported by an ill-defined reticulum. The outermost cells in the follicles are chiefly darkly staining lymphocytes. Toward the centre are a number of slightly larger cells epithelioid in character probably derived from the outer ones. They stain slightly, suggesting that degenerative changes have taken place in them due to the action of the toxin. Scattered in this central area there are also a few large endothelial cells, chiefly of the phagocytic variety.

Well-formed plasma cells are rarely found within a trachomatous follicle, probably because they tend to rapidly disintegrate in the presence of the toxin.

An older follicle (Plate 3, Fig. 1) consists of a capsule of connective tissue considerably infiltrated with lymphocytes,

Fig. 1.

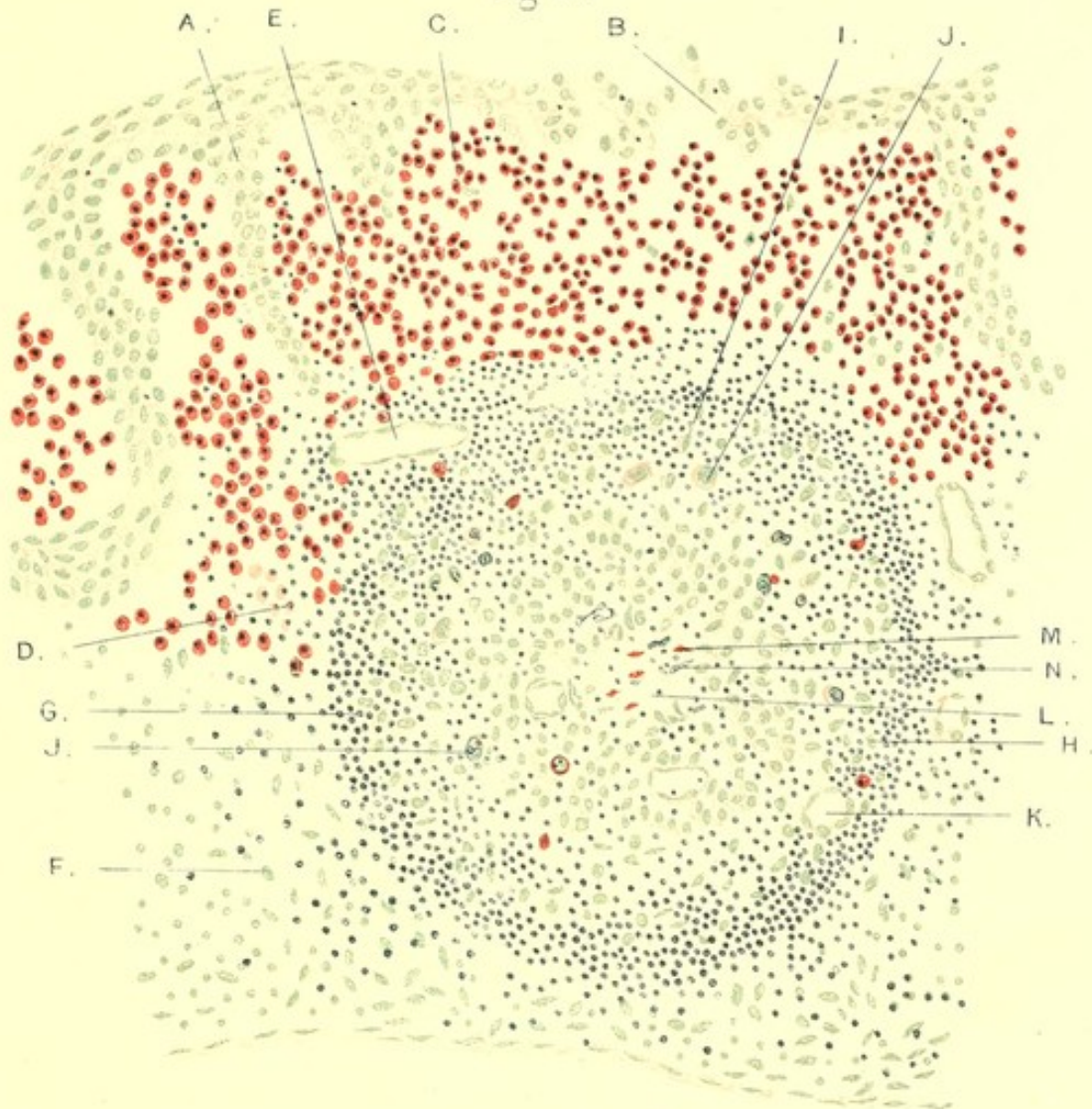


Fig 2

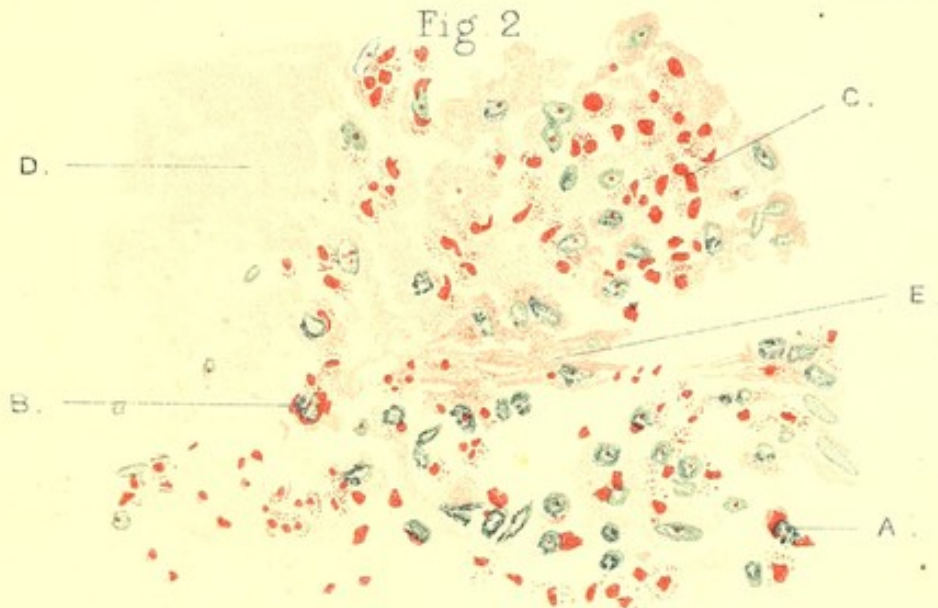

FIG. 1.—A fully-formed follicle infected with trachoma. A, Epithelium with papilla-like processes; B, epithelium becoming thinned over the surface of the follicle; C, papilla packed with plasma cells; D, degenerating plasma cells; E, blood-vessel; F, infiltration of sub-epithelial tissue; G, outer "radzone" of mononuclear leucocytes (mainly lymphocytes); H, epithelioid-like cells (degenerating leucocytes); I, large mononuclear leucocytes; J, endothelial cell containing the coccoid bodies of Leber (clasmatoctes); K, vessel with proliferating endothelium, with a plasma cell in its neighbourhood; L, central area of broken-down leucocytes; M, hyaline material; N, connective tissue cell.

FIG. 2.—Trachoma (Stelwag's brawny oedema) showing the necrosis of the plasma cells in the infiltration. A, Plasma cell; B, plasma cell breaking up; C, hyaline material due to the breaking up of the cells; D, fibrous tissue, staining slightly on account of the presence of hyaline; E, young connective tissue fibre. (Pappenheim staining.) $\frac{1}{2}$ obj. No. 4 eyepiece.

especially if the disease be spreading. As a rule no regular endothelial lining to the capsule can be made out. The connective-tissue cells are mostly well formed, many of them showing signs of proliferation. Numerous mast cells are present. The amount of stroma in the follicle varies considerably with its age, but it is only in the old degenerated ones that it is at all a conspicuous feature, and consists of delicate fibres which proceed from the true connective-tissue cells.

Numerous blood-vessels are found in the periphery of the stroma of the older follicles they spread inward toward the centre as the follicle becomes organised.

The cells found in the older follicles, like those in the more recent ones, consist externally of darkly staining lymphocytes, within which again are larger more faintly staining cells of an epithelioid type. The central endothelial cells, however, have large oval nuclei and a quantity of cytoplasm which often contains fragments of necrotic cells.

Plasma cells are absent from the follicle, although they are occasionally found in the outer zones and in the neighbourhood of the vessels. They seem to disintegrate very quickly and near the centre of the follicle rounded masses of hyaline material are sometimes found, which appear to be principally derived from the broken up cytoplasm of the plasma cells.

A trachoma follicle may finally become extruded, or undergo organisation and absorption.

Extrusion of the follicle may occur: a. As the result of operation. b. From contraction of surrounding fibrous tissue.

a. The results of extrusion of the follicle are seen in sections made from the conjunctiva after expression has been performed.

In sections through follicles shortly after expression the thick fibrous wall of the follicle encloses a space which communicates with the surface of the conjunctiva. The wall of the follicle and the epithelium in the neighbourhood of the rupture are infiltrated with polynuclear leukocytes

(spider cells), no doubt owing to the presence of septic organisms. Within the follicle are a number of blood-corpuscles, mononuclear leukocytes, plasma cells, etc.

Later fine bands of connective tissue stretch from one wall to the other, evidently derived from the proliferation of the connective-tissue cells of which they are composed. None of the original contents of the follicle remains, it having either been thrown off or destroyed by the polynuclear leukocytes.

b. As the result of contraction of the newly formed fibrous tissue around a follicle the contents is compressed and made to protrude. Between the follicle and the epithelium is a thin layer of plasma cells which do not develop into fibrous tissue; the epithelium overlying the follicle from the friction of the lids and the pressure produced by its protrusion becomes gradually thinned and ultimately the follicle ruptures, its contents being partly extruded. What remains becomes septic and is removed by the invading polynuclear leukocytes.

ABSORPTION AND ORGANISATION.—There is no doubt that large numbers of the lymphocytes in the follicles find their way into the blood stream and lymphatics, since small venous radicles in the neighbourhood of the follicles are often found packed with these cells. When pyogenic infection of the whole conjunctiva takes place the polymorphonuclear leukocytes at first are found chiefly in the walls of the follicles and do not readily invade it. Later, when its cells degenerate, the polynuclear cells enter the follicle and either remove its contents by phagocytosis, or filling the cavity rupture through the surface and discharge its contents. No doubt the beneficial effect of copper sulphate, jequirity, and an attack of gonorrheal ophthalmia on trachoma is due to the polymorphonuclear leukocytosis attacking the disease not only in the follicle but also in the infiltration.

The formation of fibrous tissue around and within the follicle has already been described.

The infiltration, like the follicles, is due to the disease setting up a chronic inflammation in the tissue. Unlike other forms of chronic conjunctivitis it is by no means limited to the layer lying directly beneath the epithelium, but spreads to the deeper layers of the tissue of the conjunctiva and varies in character according to its depth.

Situated directly beneath the epithelium and in the newly formed papillæ are masses of plasma cells. Comparatively few are seen between the epithelial cells notwithstanding which numbers are found in the discharge. Doubtless many make their way through breaks in the epithelium, indeed, the best way to obtain these cells in the discharge is by rubbing a cover-glass over the surface of the palpebral conjunctiva. In this superficial layer of plasma cells a number of new blood-vessels form, the endothelial cells of which are undergoing active proliferation. Somewhat deeper the infiltration consists chiefly of lymphocytes, a few large proliferating endothelial cells, and a few scattered plasma cells which become increased in cases of long standing and undergo disintegration. Deepest of all in long standing cases is a quantity of dense fibrous tissue which tends to grow up into the more superficial parts around the follicles. It is extremely rich in mast cells.

In long standing trachoma the upper palpebral conjunctiva is sometimes converted into a pale gelatinous-looking tissue—**braun edema** (Stelwag). It is usually associated with much scarring and represents one of the final changes in the infiltration.

The epithelium overlying it is thickened and often keratinised. The surface of the conjunctiva in the affected region is quite smooth.

The subepithelial layer consists entirely of infiltration much separated by bands of fibrous tissue; practically no follicular formation is left. The infiltration consists of a few mononuclear cells and a large number of plasma cells in all stages of degeneration, their cytoplasm being much broken up, and converted into a hyaline material (Plate III,

Fig. 2). Sometimes this hyaline material may go on to secondary amyloid and calcareous changes.

There is no doubt that the changes at the limbus and the subsequent pannus are due to a true infection of that region with trachoma since follicles are found in them which show typical necrosis. As the disease spreads to the cornea the cellular infiltration is at first superficial to Bowman's

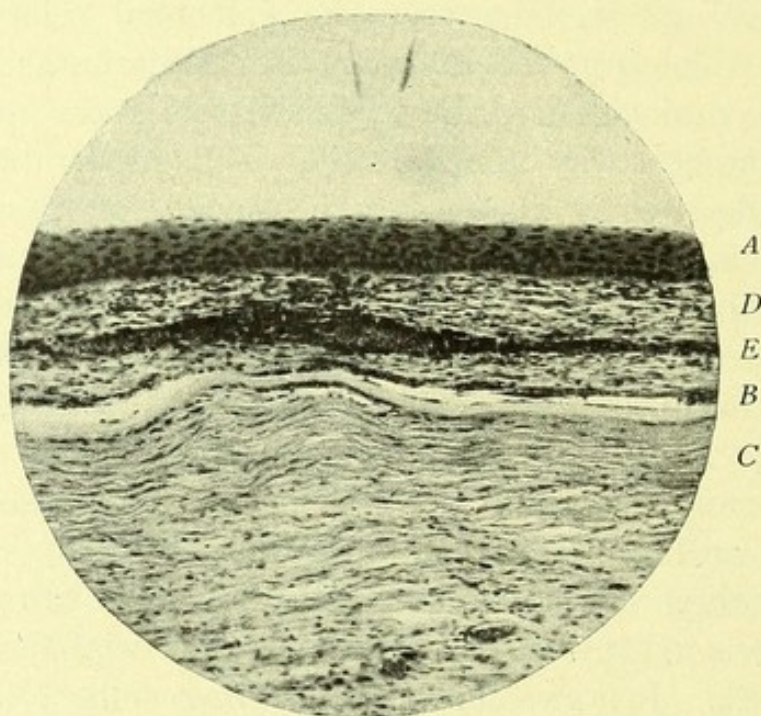


FIG. 197.—Shows a section through the front part of a cornea affected with trachomatous pannus. *A*, Epithelium; *B*, Bowman's membrane as yet undestroyed; *C*, substantia propria; *D*, cellular infiltration and fibrous tissue forming the pannus; *E*, blood-vessel.

membrane (Fig. 197), but this structure after a time becomes destroyed and the substantia propria invaded. In the thick fleshy pannus follicles are formed. Small ulcers are not infrequent in connection with the pannus, and polymorphonuclear leukocytes are then present.

Vernal catarrh is a disease which has been so named because its symptoms make their appearance or become accentuated during warm weather, while they subside or disappear altogether during the cold seasons.

The patient complains of irritation, photophobia, and

lacrimation. Broad flat papillæ, which have been compared to cobblestones, form on the tarsal conjunctiva, and the surface of the membrane presents a characteristic milky appearance. In cases of long standing the limbus is also involved, becoming thickened and nodular. It encroaches on the periphery of the cornea and may cause that structure to appear considerably reduced in size.

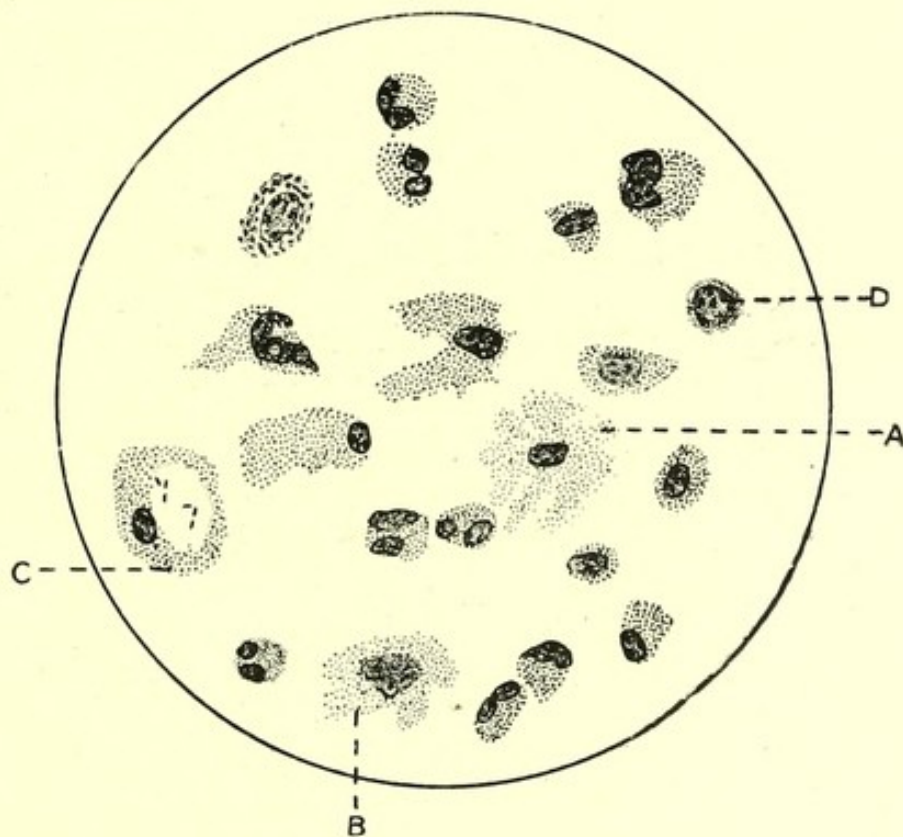


FIG. 198.—Discharge from a case of vernal catarrh showing eosinophiles.
A, B, C, Eosinophiles; D, lymphocyte.

There is but little conjunctival discharge. A thin layer of mucoid secretion usually covers the surface of the palpebral conjunctiva and becomes increased if it is subjected to the least irritation. In this discharge there are immense numbers of eosinophile cells—a point of considerable importance in the diagnosis of the affection. They are best demonstrated by staining with Leishmann's eosin-methylene-blue compound. The whole microscopic field under a $1/12$ objective may be found to consist exclusively

of these cells which are both polymorphonuclear and mononuclear (Fig. 198). They sometimes rupture, the granules in them becoming scattered.

There is no evidence that this disease is infective, and so far no microorganisms to which it may be due have been discovered.

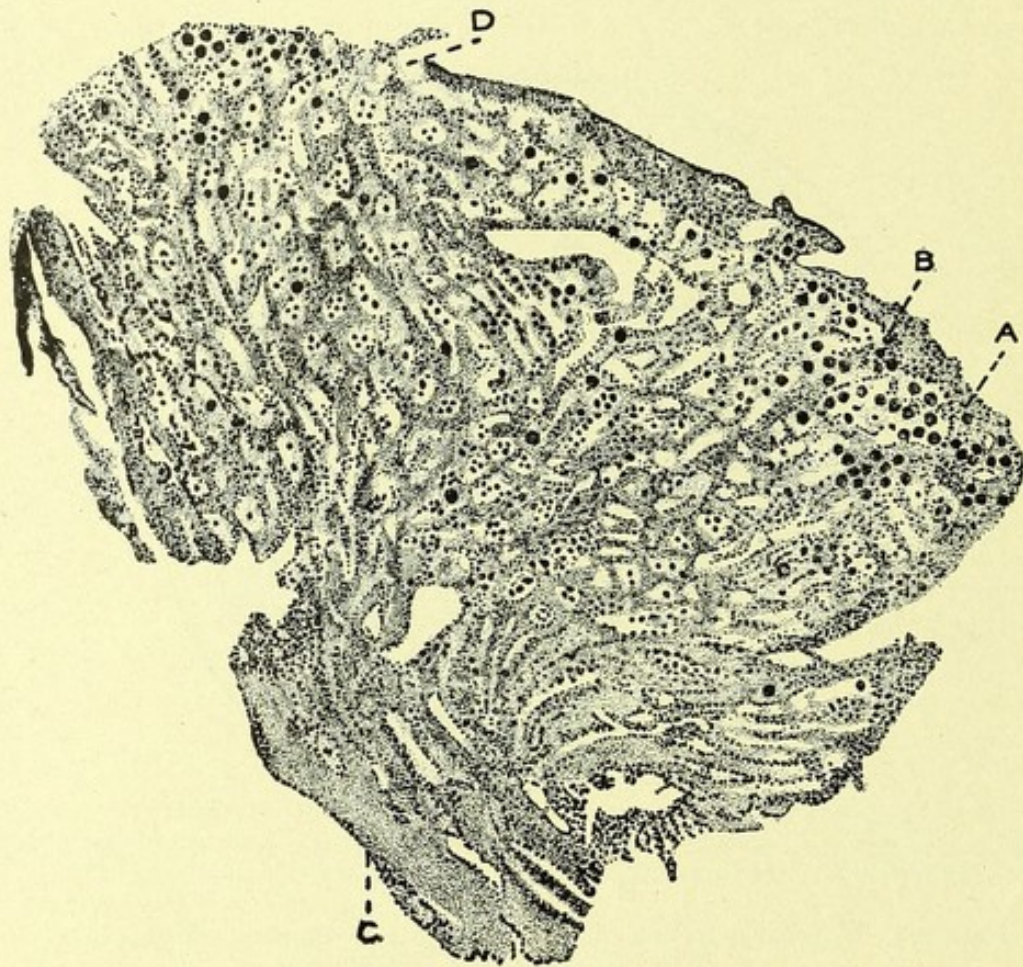


FIG. 199.—Shows a section of one of the papillæ from a case of vernal catarrh. A, Epithelium; B, eosinophiles; D, erosions of the epithelium; C, fibrous tissue.

Microscopical examination of the affected tissue shows the condition to be one of enormous papillary overgrowth of the conjunctiva.

The epithelium covering the tops of the papillæ is much thickened and appears to send finger-like processes down in the depressions between them. Comparatively little mucoid change takes place in the cells composing these processes.

The papillæ, which are very hard, consist of a quantity

of newly formed dense connective tissue. The cells found in it are the ordinary connective-tissue cells, leukocytes, and plasma cells.

Some of the leukocytes are eosinophiles, but they are proportionately less numerous in the tissue than in the discharge. They are derived from the blood and are seen principally in the small vessels lying beneath the epithelium, often making their way through the walls and through breaks in the surface epithelium or between the cells (Fig. 199). The appearance of such large quantities in the discharge is due to their great power of ameboid movement.

Plasma cells are present in considerable numbers in the tissue, most of them showing signs of necrosis due probably to the presence of some toxin. Necrosis of the plasma cells results in the formation of a hyaline material which is the cause of the milky appearance of the conjunctiva.¹

Sympathetic Ophthalmitis.—Sympathetic ophthalmitis is an inflammatory granulomatous infiltration of the uveal tract started by a lesion of one eye, and after a variable interval affecting the second eye. The first eye affected is termed the exciting or primary eye, and the other, which is subsequently involved, the sympathising or secondary eye.

The lesion which starts the affection in the exciting eye is almost always a perforating wound in which the uveal tract is involved. Wounds of the ciliary region are more frequently followed by the disease than those situated in other parts of the globe. It occasionally follows an operation such as extraction of cataract, or iridectomy for glaucoma. It has also been known to follow sub-conjunctival ruptures of the sclerotic and perforating ulcers of the cornea.

The length of time which usually elapses between the receipt of injury in the exciting and the appearance of the disease in the sympathising eye is from four to eight weeks. It has, however, been met with as early as two weeks, and in some cases has not made its appearance until after an interval of twenty years. When there has been a very long

¹ Mayou, M. S. Hunterian Lectures, 1905.

interval, inquiry will frequently elicit a history of some fresh attack of inflammation, or irritability, in the exciting eye shortly before the onset of the sympathetic disease. The inflammation in the sympathising eye may commence after the exciting eye has been removed, but not later than five weeks after its removal.

The character of the inflammation in both the exciting and sympathising eye is the same, and involves all three

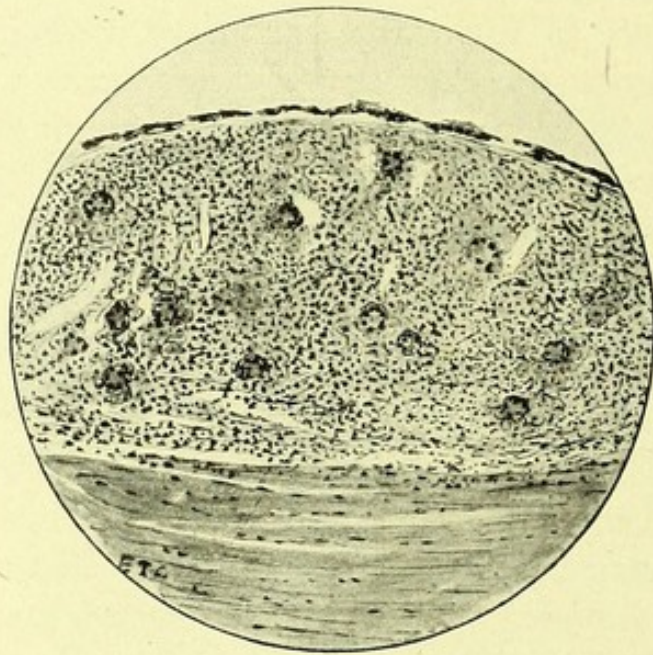


FIG. 200.—Section through the choroid in a case of sympathetic ophthalmitis showing conglomerate nodules of mononuclear lymphocytes, epithelioid cells, and giant cells.

divisions of the uveal tract—iris, ciliary body, and choroid. Scattered throughout it are numerous nodules composed of mononuclear lymphocytes, plasma cells, epithelioid cells and giant cells.¹ In some cases these nodules are discrete and separated from one another by healthy tracts of tissue. In others the nodules are in continuity with one another giving rise to a nearly uniform thickening of the uveal tract (Fig. 200). The nodules are histologically very similar in appearance to those of commencing tubercle, but they do not, as in that affection, tend to necrose or caseate; nor do they,

¹ E. Fuchs. *Archiv. für Ophth.*, LXI, 1905, 2, 365.

like tuberculous nodules, invade structures outside the uveal tract. Together with these nodules there is in sympathetic ophthalmitis much exudate of a serous or plastic character. The clinical manifestations of the affection are similar to those of other forms of serous or plastic inflammation of the uveal tract, which have already been described (see page 329).

The fact that the disease seems always to result from a perforating lesion of the exciting eye suggests that the cause of the inflammation is ectogenous. Microorganisms have been found in eyes which have excited sympathetic ophthalmitis, but so far no specific microorganism has been discovered. In some exciting eyes, which after excision have been most carefully examined, no microorganism could be detected.

The mode of transference of the cause of the inflammation from one eye to the other is probably by the blood stream. Profound hæmatogenous changes are produced, there being an increased mononuclear leukocytosis, but as yet sufficient investigation of the blood in these cases has not been carried out.

The staphylococcus (see page 359) is the common cause of ocular infection after penetrating wounds, and it has been found in cultivations taken from the exciting eye in some cases of sympathetic disease. This organism seems to have the power of circulating in the blood without producing much general change; it may possibly, therefore, be the cause of sympathetic ophthalmitis. The reason that the second eye is affected rather than the other tissues of the body is because the organism has a preference for a similar soil as that on which it originally grew.

Suppurating eyes do not give rise to sympathetic ophthalmitis probably because sufficient antibodies are produced in the serum, due to the severity of the inflammation, to protect the blood stream from infection by an organism of a comparatively low virulence.

CHAPTER VII.

DEGENERATIONS.

The degenerations which take place in the tissues are the result of defective nutrition. The nutrition is dependent on the tissue fluids which are derived from the blood; it necessarily follows that anything which interferes with the circulation of the tissue fluids in a part, such as vascular sclerosis, will cause a defect in the tissue metabolism which will be followed by degeneration in the cells.

If the cutting off of the nutrition is sudden and complete necrotic changes result in all the cells of the part (gangrene). When the degenerative process takes place slowly the cells gradually disintegrate and become absorbed (atrophy). The cells first affected are those which are most highly specialised and which require most tissue fluid for their nutrition, such as the retinal ganglion cells. The parts last affected are the supporting structures, such as the sclerotic, which require but a small amount of nutriment and therefore rarely degenerate.

The way in which degeneration manifests itself in the cells depends on the osmotic properties of their walls. There is either a loss of fluid from the cell with a considerable condensation of the cytoplasm, the granules and nucleus staining more distinctly, or an imbibition of water by the cell causing it to swell up, lose its granules, and finally burst. After disintegration of the cell the débris may be absorbed or remain in the tissues; if the latter takes place, the colloid material may subsequently undergo hyaline or amyloid change, or have calcium salts deposited in it.

The degenerations which take place in the tissues of the eyeball and its appendages may be divided into those occur-

ring in parts derived from epiblast and those derived from mesoblast.

The degenerations in structures derived from epiblast may be further divided into those of 1. cuticular epiblast; 2. lenticular epiblast; 3. neural epiblast.

I. Cuticular Epiblastic Degenerations.

It is characteristic of cuticular epithelium that its cells continue to proliferate throughout life. Mitosis occurs chiefly in the basal layers and the new cells as they form gradually get pressed forward toward the surface, where they undergo degenerative changes and are ultimately cast off. In some situations they undergo keratinisation and in others break down and form a secretion.

In the process of **keratinisation** the surface is dry, the cells as they are pressed forward toward it gradually lose their watery consistency, becoming first denticulated (prickle cells) and afterward flattened. The granules in the cytoplasm become more marked and composed of keratohyalin. As the loss of water progresses the condensation of the cytoplasm leads to its transformation into keratin, by that time the nucleus of the cell has undergone such changes that it is no longer recognisable. If these dried cells as they reach the surface instead of being cast off remain adherent, a condition of **hyperkeratosis** is produced.

When an epithelial surface is kept continually moist keratinisation does not occur, the cells are either thrown off from the surface or elaborated into a secretion. If the latter takes place granules form in the cytoplasm of the cells which are the precursors of the secretion. As they accumulate the cell enlarges and its nucleus becomes pushed more and more to one side. The cell may then either break down and form the secretion or discharge its contents without being destroyed.

The nutrition of cuticular epithelium is maintained by lymph which passes into it by a process of osmosis from the

underlying tissue. In laminated epithelium there are delicate intercellular channels passing outward from the basal to the central and superficial layers.

Pathological degenerations of the cuticular epiblast may be grouped under the following headings: a. Atrophy; b. edema and vesiculation; c. keratinisation and hyperkeratosis; d. mucoid, fatty, hyaline and calcareous changes.

a. **Atrophy of Epithelium.**—The **skin** of eyelids in elderly people becomes atrophied, assuming a thin, shiny, silky appearance due to a decrease in number of the prickly cells, and flattening out of papillæ. It is also often darkened in colour from an accumulation of pigment in the basal cells.

Atrophy of the epithelium of the **cornea** occurs over cicatrices in it especially when they are the seat of calcareous deposits.¹ There is a diminution in the number and the size of the cells. The superficial flat cells lose their nuclei and become thin scales, the middle polygonal cells are changed into flat ones, which lie directly on the cylindrical basal cells. Later on these also decrease in size, become flat, and in extreme atrophy entirely disappear. Atrophy of the epithelium exposes the underlying fibrous tissue to the risk of invasion by bacteria. It is in this way that destructive ulceration occurs in old leukomata which is termed **atheromatous ulceration** or **sequestrating cicatricial keratitis**.

b. **Edema, Vesiculation and Desquamation.**—Edema of the corneal epithelium is met with in glaucoma, iridocyclitis, and keratitis. It gives rise to a superficial haze which presents a stippled appearance on magnification. It is often associated with small vesicles forming little rounded elevations on the surface which after rupturing leave behind shallow depressions. Sometimes when a vesicle bursts a small clear dark spot is left in the surrounding haze, clearly showing that the opacity is limited to the epithelium. Small drops of fluid collect first between the basement cells and later also in the more anterior layers. The accumulation of fluid

¹ E. Fuchs. Trans. Ophth. Soc. of the U. K., XXII, 1902, 25.

in the interspaces between the cells in the central layers causes the intercellular bridges, which stretch from one cell to another, to become more pronounced, so that they resemble the prickle cells of the skin. If the edema extends the intercellular bridges give way and the spaces open into one another, small vesicles being formed; these are common in advanced cases of glaucoma. The cells themselves may become swollen by imbibition and have vacuoles form in them. Sometimes they burst on the surface and cause slight irregularities in it. In the deeper layers the swollen cells may be changed in places into a nearly homogeneous mass. The fluid effused between the cells loosens their coherence and favours the occurrence of desquamation. Single cells alone may become separated or whole layers of cells.

For further description of vesicle-formation and so-called **filamentary keratitis**, see page 321.

c. **Keratinisation and Hyperkeratosis.**—The epithelium of the cornea and conjunctiva under normal conditions does not become keratinised. This is due to its being kept constantly moist by secretions and to the protecting influence afforded by the eyelids.

The surface cells of the cornea though flattened do not lose their nuclei or have keratohyaline form in them; they become rubbed off by the friction of the margins of the eyelids before any such changes occur.

In late life the superficial epithelial cells of the ocular conjunctiva opposite the palpebral aperture may show a few granules of keratohyaline, especially when it becomes raised up by the formation of a pinguecula.

When from some arrest of secretion, or displacement of the eyeball or eyelids, the surface of the conjunctiva or cornea ceases to be kept moist keratinisation occurs, which clinically is termed **xerosis**. It is met with under the following conditions (Fig. 201):

1. When there has been extensive fibrous-tissue formation in the conjunctiva cutting off the secretion of the glands

opening into it, as in connection with trachoma and pemphigus.

2. In ectropion of the eyelid the exposed portion of the conjunctiva or cornea under the desiccating influence of the atmosphere tends to assume epidermoid characters. Not only does keratinisation take place but the epithelium extends down in processes into the subjacent tissue giving the appearance of papillary formation (Fig. 202).

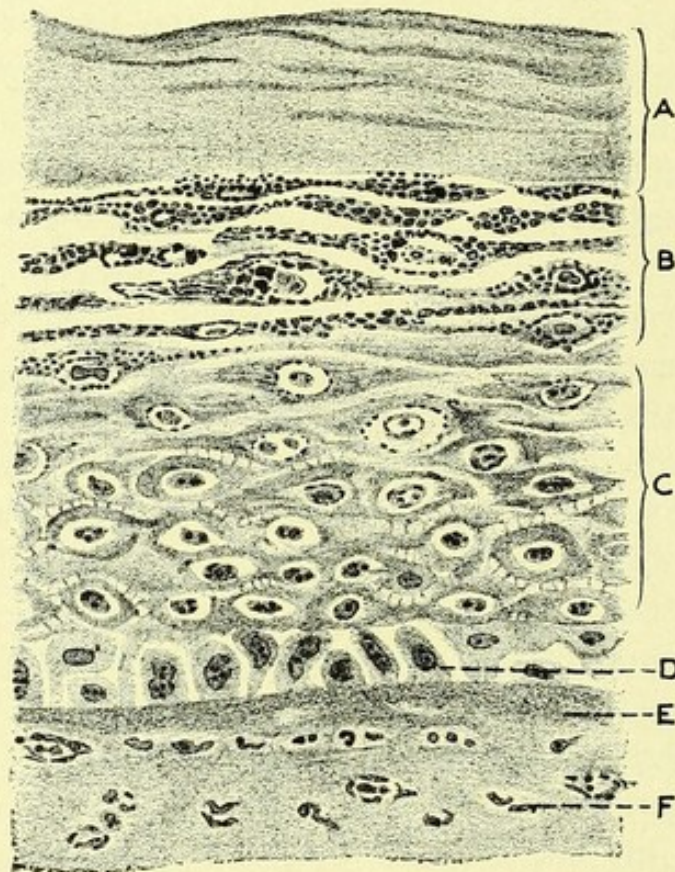


FIG. 201.—Section through the conjunctiva in a case of xerosis. *A*, Keratinised layer; *B*, layer of cells with keratohyaline granules. *C*, Prickle cells; *D*, basement cell layer; *E*, basement membrane; *F*, sub-epithelial tissue.

3. In cases of anterior staphyloma, where the bulging cornea protrudes through the palpebral fissure and the eyelids fail to close over it, so that it is not lubricated with moisture, keratinisation and often hyperkeratosis takes place, a dry crust or horn-like structure being formed on its surface.

4. In epithelial new growths on the surface of the globe keratinisation is always present.

5. In the asthenic stage of some general diseases, the conjunctival secretions are diminished and winking is abolished. The patient lies in an apathetic condition with the eyes rolled up and the eyelids only partially closed. The lower part of the cornea is left exposed in the palpebral fissure and the epithelium overlying it becomes dry and keratinised. Ulceration of the cornea in such a condition is not an uncommon sequela.

6. In marasmic children, and in adults who have become emaciated from exhausting diseases, such as dysentery

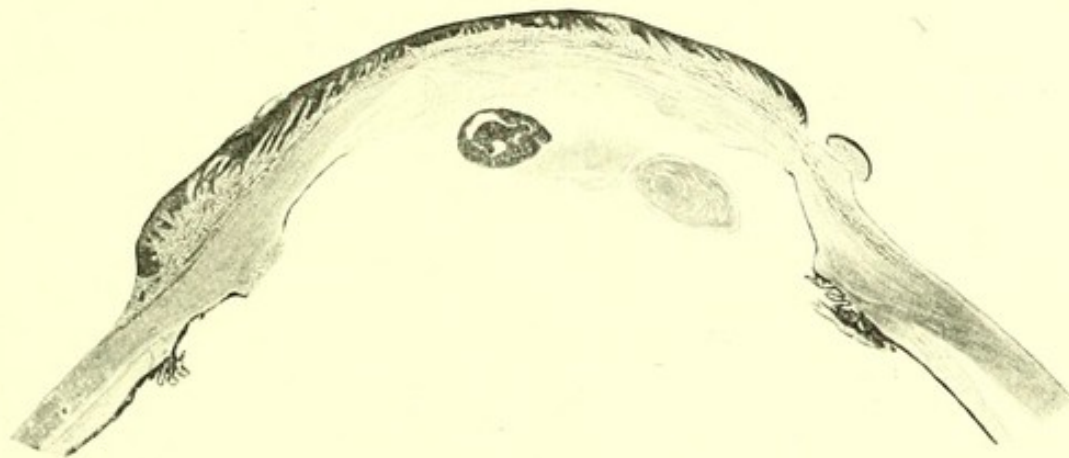


FIG. 202.—Section through the front part of the eye of a patient aged nineteen, who for many years had had a shrunken dry conjunctiva. The cornea was staphylomatous and he was unable to close the lids over the front of the eye. The epithelium which is keratinised at the surface is shown dipping down in the form of numerous finger-like processes into the deeper tissue. Case recorded by Treacher Collins, *Trans. Ophth. Soc. of the U. K.*, X, 1890, 62.

or from want of food in times of famine, a xerotic condition of the cornea and conjunctiva is met with. This is frequently a precursor of a rapidly destructive form of ulceration known as keratomalacia.

7. A milder form of xerosis of the conjunctiva occurs in association with night blindness and is known as **hemeralopic xerosis**. It occurs mostly in children in this country, but is met with also in adults in the tropics. Two factors seem necessary for its production; some defect in general nutrition and exposure to bright reflected light.

It is the ocular conjunctiva opposite the palpebral aperture on each side of the cornea which becomes affected.

Triangular dry patches are formed where the mucoid secretion ceases and the cells become keratinised. The surface tension of such patches is raised and the oily secretion of the Meibomian glands collects on them in the form of a white foam in which the so-called xerosis bacilli (see page 381), are always to be found.

As it is the most exposed part of the ocular conjunctiva which becomes affected it seems probable that the xerotic changes in it are the effect of drying on the epithelial cells, favoured by some debilitated condition of the individual affected. The bacilli do not appear to play any part in the causation of the disease.

No very satisfactory explanation has so far been given as to why these xerotic patches of the conjunctiva should be so frequently associated with night blindness. The latter symptom is probably due to a failure in the reformation of the visual purple which has been bleached by exposure to bright light, and which presumably is essential for clear vision in dim lights. It is a prolongation of the temporary condition which is experienced normally on passing from a bright light into a dark place.

d. **Mucoid, Fatty, and Hyaline Changes.**—Fatty changes in the epithelium of the cornea and conjunctiva are but seldom met with. In xerosis a few granules are found present on staining with osmic acid or with Sudan III.

The mucoid degeneration of the epithelial cells of the conjunctiva, which to a limited extent is a normal condition, becomes enormously increased in the various hyperemic and inflammatory conditions of that membrane. It is especially marked in diplobacillary conjunctivitis, the discharge in which affection is mainly composed of mucus so formed.

In the tubular epithelial recesses, or false glands, which become formed in the palpebral conjunctiva where papillary formation has taken place, mucoid and hyaline degenerative products frequently accumulate. They form concretions which are seen clinically as little yellow spots on the inner surface of the lids.

Microscopically these concretions are composed of a homogeneous or slightly granular laminated material. They do not contain lithia nor do they give any amyloid staining reactions. They are apparently composed of a hyaline material, the product partly of the degenerated epithelial cells and partly of degenerate leukocytes which have made their way in through the epithelium. After they have existed for some time calcareous salts may become deposited in them.

II. Lenticular Epiblastic Degenerations.

Opacity of the lens or cataract is due to degenerative changes. A primary inflammation of the lens or phakitis cannot occur, though secondary invasion by inflammatory cells from surrounding parts when the capsule has been perforated may take place.

Cataracts may be classified according to the region in which the changes are first chiefly located as follows: (a) capsular; (b) sub-capsular; (c) equatorial, and (d) nuclear or perinuclear. Such a classification serves to bring out the different ways in which degenerative changes in the lens may arise. In the capsular cataract the opacity is mainly due to a thickening of the epithelial cells lining the capsule; in the sub-capsular cataracts, to degeneration of the capsule cells, allowing diffusion of unaltered aqueous humour into the most cortical lens fibres, which then break up and become opaque. In equatorial cataract the lens fibres formed laterally, from deficient nutrient supply, undergo premature sclerosis and spaces containing albuminous globules collect between them. Nuclear and perinuclear cataracts originate generally in early life while the nuclear fibres are still soft; at the time the degenerative changes occur which cause the opacity the whole lens is involved, later new lens fibres are laid on and a clear cortical substance formed.

A cataract commencing in one region frequently spreads to others, so that in the examination of an advanced cataract, either clinically or pathologically, it may be impossible to

say in which of the above divisions it should be included. In some forms of cataract it is still uncertain which is the exact starting-point of the affection and an inclusion of them specifically under one or other of the above headings can only be provisional.

a. **Capsular Cataract.**—The hyaline capsule of the lens itself does not become opaque; so-called capsular cataracts are due to thickenings of the cells which line it. Normally these cells form a single layer extending round the anterior capsule to a little behind the equator. Their proliferative activity is to some extent controlled by the intracapsular tension, when it becomes lowered through a wound or from breaking down of some of the lens fibres, an increased mitosis of the capsule cells at once take place and in this way several layers instead of a single row are produced. In the later stages of many cataracts the intracapsular tension becomes lowered, capsular cataract is, therefore, frequently found associated with other forms, and is usually present in hyper-mature senile cataract where the cortex has become liquefied.

It is possible that proliferation of the capsule cells may also be excited as the effect of some toxic agent. ➤

Most capsular cataracts are secondary cataracts, *i.e.*, they follow on some disease of the surrounding parts. The commonest form of capsular cataract is an anterior polar cataract which is usually secondary to ulceration of the cornea.

A more widely spread capsular cataract occurs in connection with iritis where, as the result of the inflammation, the iris becomes adherent to the lens capsule.

The changes that take place in the proliferated cells of the capsule which constitute a capsular cataract are the same whether it is located at the anterior pole or elsewhere; a description of them, therefore, in connection with anterior polar cataract will suffice.

Anterior polar cataract most frequently occurs as a sequela of ulceration of the cornea in infancy, not necessarily a perforating ulcer. It may also be found as a congenital defect (see page 38).

The clinical and histological appearances of these cataracts are the same in the antenatal as in the postnatal cases.

Anterior polar cataracts vary in size and shape, they do not extend over the whole of the pupillary area, and may be less than 1 mm. in diameter. Sometimes they form a flat white patch which is not raised above the level of the sur-

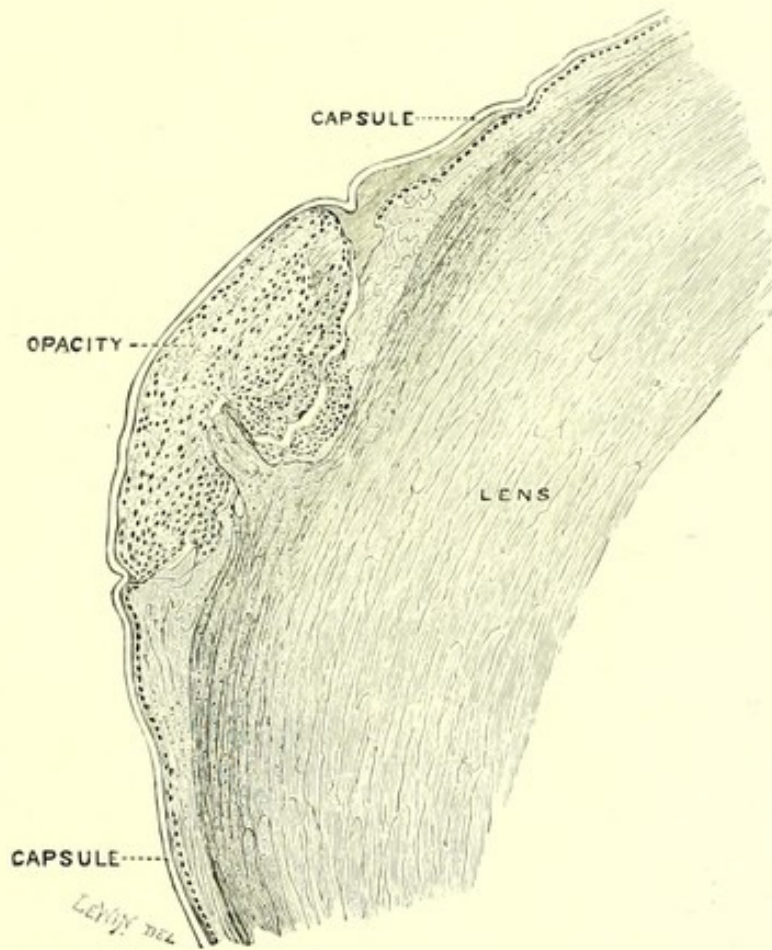


FIG. 203.—Section through an anterior polar cataract of less than six weeks' formation. The changes shown, which are entirely beneath the capsule, consist of proliferation of the capsule cells and degeneration of the cortical lens fibres.

rounding capsule, and at others a pyramidal-shaped mass which protrudes forward from the surface of the lens; hence the term "**pyramidal cataracts.**"

In cases where an anterior polar cataract has existed for several years, a second opacity at some little depth in the lens substance is sometimes seen lying under the one at the anterior pole, and separated from it by clear lens substance.

Occasionally the separation is incomplete, the two opacities being united by a narrow central opaque band simulating the appearance of a collar stud.

The changes which produce anterior polar opacities are situated within the capsule and are of two descriptions: degenerative changes in the subcapsular cortical lens fibres

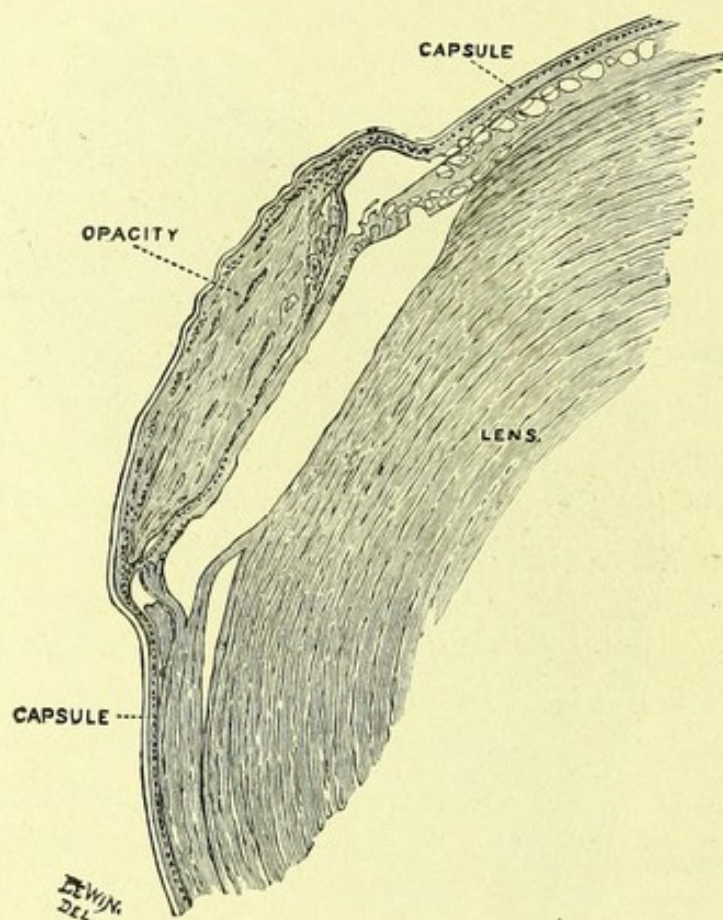


FIG. 204.—Section through an anterior polar cataract of seven months' formation. The mass of capsule cells has become converted into condensed laminated tissue. A layer of cells is shown beneath this new-formed tissue continuous with those lining the capsule elsewhere.

at the anterior pole and proliferation of the cells lining the capsule. The degenerate cortical fibres become broken up into irregularly shaped hyaline masses and a depression is formed (Fig. 203). The mass of proliferating cells may simply fill up this depression, but more frequently it raises up the lens capsule into a conical projection above the level of the surrounding part.

In course of time the newly formed capsular cells which are at first polygonal become flattened out, many of them losing their nuclei, so that a condensed laminated mass of tissue is developed studded here and there with elongated cells which have retained their nuclei. In long standing cases calcareous salts become deposited in the laminated mass.→

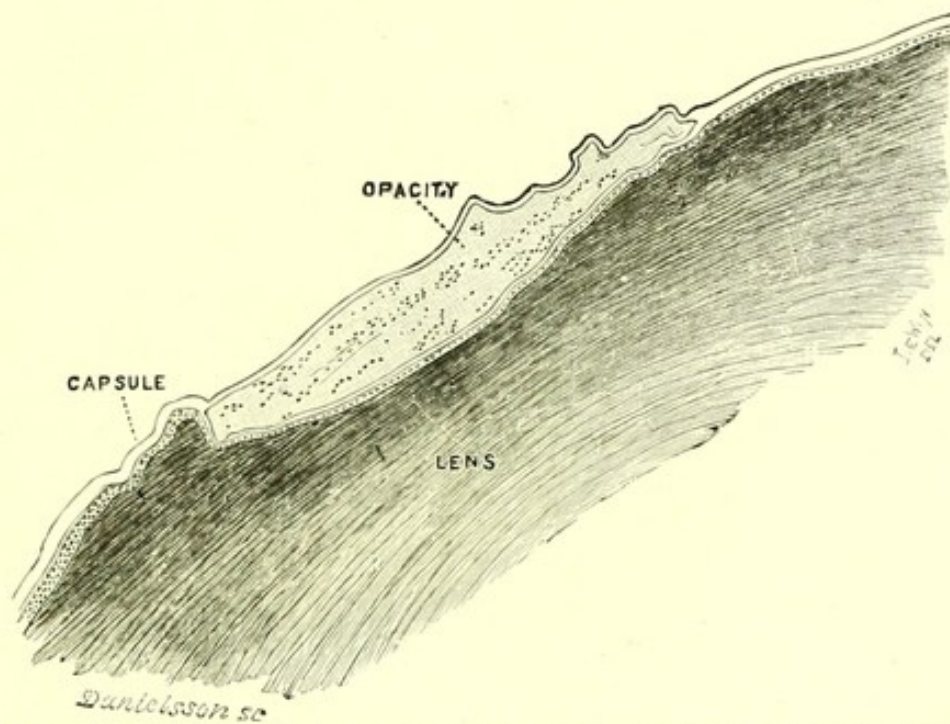


FIG. 205.—Section through an anterior polar cataract of eleven years' formation. A complete layer of hyaline capsule, lined by cells continuous with those lining the capsule elsewhere, is shown behind the opacity, and a hyaline layer in front of it.

At first the capsule cells which have proliferated and the degenerated cortical substance are in contact. In course of time they gradually become separated in the following manner:¹ When the mass of cells has become converted into laminated tissue, the cells lining the capsule at its margins gradually multiply and insinuate themselves between it and the cortex of the lens, ultimately forming a continuous single row of cells between the two (Fig. 204). In course of years, in front of this newly formed row of cells, as the result of their secretion, a layer of hyaline tissue like that compos-

¹ Treacher Collins. Trans. Ophth. Soc. of the U. K., XII, 1892, 89.

ing the capsule makes its appearance. The laminated mass is then enclosed entirely by hyaline capsule, the normal capsule at its margin appearing to divide into two parts, one going in front of it and the other behind (Figs. 205, 206). The shutting off of an anterior polar opacity by a layer of capsule from the rest of the lens accounts for the easy way in which it can sometimes be detached in the course of an operation.

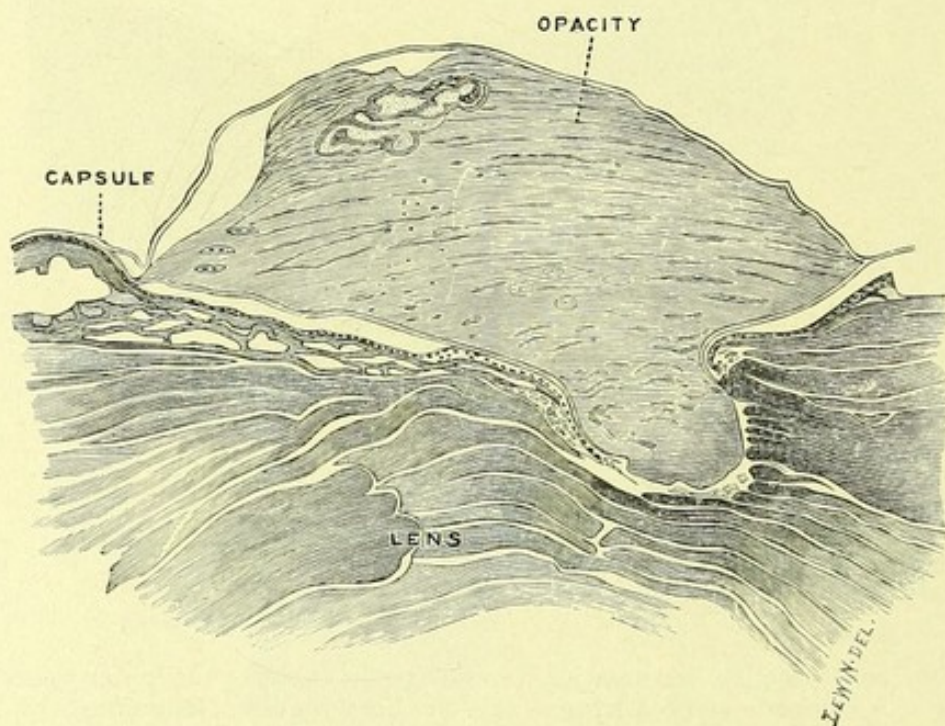


FIG. 206.—Section through an anterior polar cataract of twenty-one years' formation. A hyaline layer of capsule lined by cells is shown behind the opacity and a hyaline layer of equal thickness in front of it.

Anterior polar cataract usually forms early in life while the lens is comparatively small. The enlargement of the latter takes place by the laying on of fresh cortical fibres which grow between the laminated mass formed from the capsule cells and the degenerated fibres beneath it. In this way two opacities entirely or partially separated are produced (Fig. 207).

Two theories have been put forward to account for the origin of anterior polar cataract. One attributes the proliferation of the capsule cells to some toxic substance which

diffuses through the capsule in the affected area. As these cataracts usually occur in connection with ulceration of the cornea, it is suggested that the toxin is microbial in origin, generated at the seat of inflammation.

The other theory attributes the changes to contact of the lens at its anterior pole with the back of cornea. In an infant's eye the anterior chamber is exceedingly shallow, so

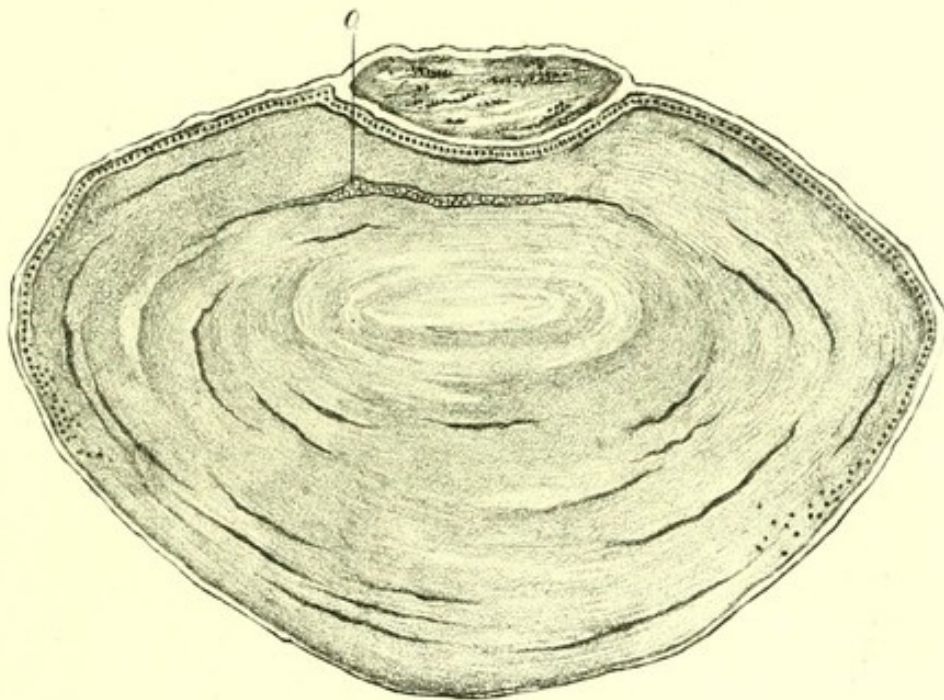


FIG. 207.—Section through a lens with an anterior polar opacity of eleven years' formation, in which there was a second opacity a little deeper in the lens. The opacity formed from proliferation of the capsule cells is shown enclosed between two layers of hyaline capsule. The second opacity due to degeneration of the cortical lens fibres is shown at *O*. New cortical lens fibres have grown in and separated the two opacities.

that very little swelling of the cornea suffices to bring it and the lens in contact in the pupillary area. Where the two come in contact there is obstruction to the passage of nutrient fluid through the capsule, and the lens fibres in that locality degenerate and break down. This breaking down of the lens fibres decreases the intracapsular tension in their vicinity, and so allows of a more rapid proliferation of the capsular cells which form the main mass of the opacity as above described.

The fact that anterior polar cataract is sometimes met with as a congenital defect, apart from all signs of ulceration of the cornea or any ocular inflammation, is against the first view.

The ¹ occurrence of changes similar to those met with in anterior polar cataract more peripherally in the lens where a sarcoma of the ciliary body has been in apposition with the capsule, is in favour of the latter (Fig. 208).

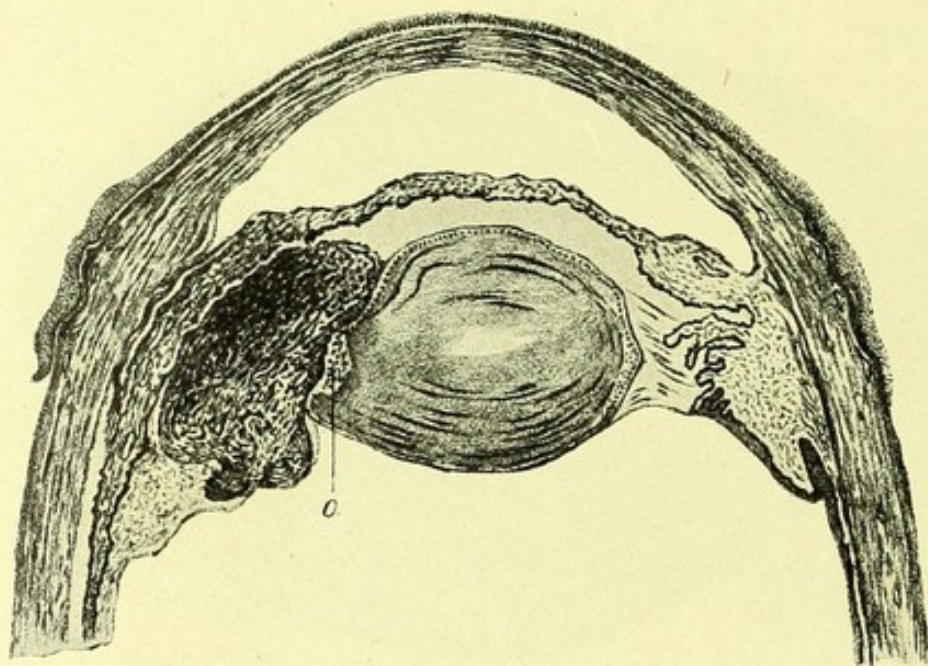


FIG. 208.—Section through the front half of an eye with a melanotic sarcoma of the ciliary body. It has pressed on the side of the lens and caused there a capsular cataract, *O*, similar in appearance to an anterior polar cataract.

b. Subcapsular Cataract.—The nutrition of the lens after the disappearance of its vascular sheath in fetal life is maintained by endosmosis of the fluid surrounding it through its capsule. Experiments seem to show that fluid never passes directly from the vitreous humour into the lens. It is from the aqueous that it obtains its nutrient material.

The composition of the lens and the surrounding fluid differ considerably during life so that the osmosis does not take place according to the ordinary law of diffusion. The

¹ Treacher Collins. Trans. Ophth. Soc. of the U. K., XVIII, 1898, 124.

cells lining the capsule must evidently have some selective power. After their death the ordinary law of diffusion does assert itself and the composition of the lens and aqueous tend to approximate.

In describing traumatic cataract (see page 270) it has been pointed out that globulin, the albuminous substance of which the lens is mainly composed, is soluble in a weak solution of chloride of sodium such as the aqueous humour. When the lens capsule is perforated and the aqueous gains entrance to the lens fibres they swell, break up, and become dissolved. The opacity in traumatic cataracts has frequently been observed to commence at the posterior pole in the form of feathered striæ or vacuoles, afterward extending to other subcapsular parts of the cortex.

The capsular cells must check the passage of the sodium chloride into the lens, and so protect it from the disintegrating action of the unaltered aqueous.

When degenerative changes take place in the capsule cells their selective power is destroyed, the unaltered aqueous humour with its chloride of sodium can then diffuse through the capsule and cause destruction of the lens fibres. These destructive changes commence immediately beneath the capsule, and very frequently, as in traumatic cataracts, the opacity is first noticed at the posterior pole.

The imbibition of fluid causes a condition which may be well described as edema of the lens. The cortical fibres become separated from one another and from the capsule, the spaces between them being filled with coagula so that the lens is enlarged (Fig. 209). Subsequently the fibres become broken up and dissolved, and the whole lens becomes opaque. In course of time these lenses tend to shrink, and in rare instances the whole of lens substance may enter into solution and become absorbed from the intact capsule. In specimens which have been examined where such spontaneous absorption of cataract in the closed capsule has taken place the capsular epithelium was found to be absent.

Degenerative changes in the capsular epithelium may

be brought about in a variety of ways, subcapsular opacities ensuing.

Friction of the outer surface of the lens capsule as in the operation for maturation of immature cataract has been found to produce changes in the capsule cells resulting in the formation of vacuoles in them. Subsequently the cortical subcapsular fibres become acted upon by the aqueous humour, which can then gain access to them, and the cataract becomes complete.

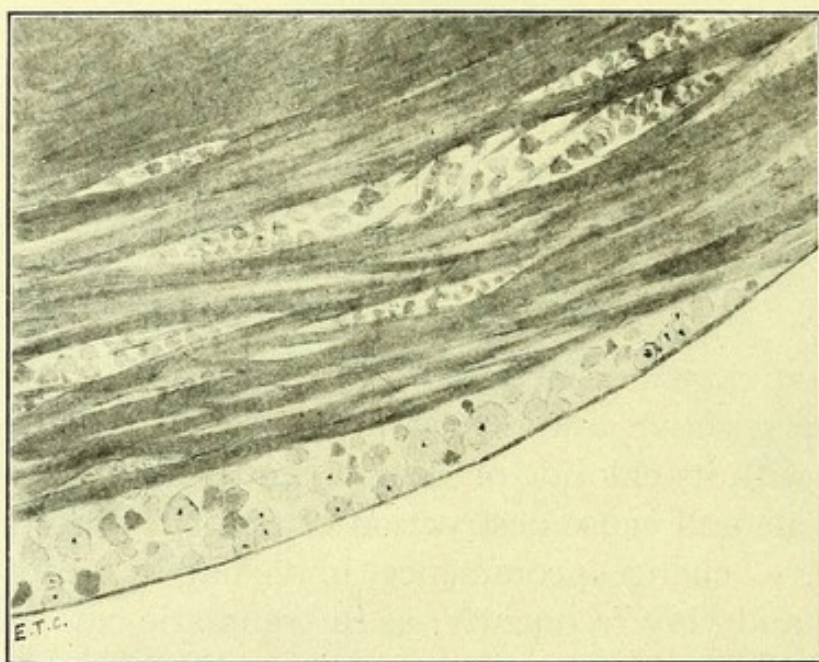


FIG. 209.—Section through the posterior part of a sub-capsular cataract, showing separation of the cortical from the capsule and one another, the spaces being filled with albuminous coagula, "Morganian globules." Between the capsule and the lens fibres there are some vesicular or bladder cells.

Death of the capsular epithelium and cataract together with hyperemia of the ciliary body and iris have been found in rabbits who have had the sparks of six combined Leyden jars directed against their heads in the supraorbital region.¹

In the cataracts which have been observed to follow lightning injuries or the accidental exposure to the effects of powerful electric discharges, destruction of the capsular cells from electrolytic action probably occurs.

Diabetic Cataract.—Cortical subcapsular cataract may

¹ K. Kiribuchi. *Arch. f. Ophth.*, B. L., 1900, 1, 1.

arise at any age in patients suffering from diabetes. It usually occurs in both eyes either simultaneously or with an interval of short duration. As a rule the amount of sugar in the urine in those affected with cataract is large, but the patients are not necessarily much debilitated or emaciated.

Some cataracts which are met with in elderly patients with glycosuria do not begin as subcapsular opacities and are indistinguishable from the ordinary senile form. The cataracts occurring in association with diabetes in early life are always subcapsular. The lens at first swells, the opacity progresses rapidly, and the whole of the cortex becomes converted into a milky white material. The nuclei of the cells of the capsule are found microscopically to stain unequally or to become replaced by vacuoles.

In a few cases where the opacity in the lens has been of only short duration it has been observed to decrease in amount, or even disappear altogether, as the result of improvement taking place in the patient's general condition.

Experiments have shown that the immersion of the human lens in 5 per cent. solution of sugar will, as the result of dehydration, cause it to become opaque. Diabetic cataract cannot, however, be attributed to such a change because the aqueous and vitreous humours never contain as much as 5 per cent. of sugar. In a patient¹ who had 8 per cent. sugar in the urine the aqueous was found to contain only .5 per cent. Five per cent. of sugar in the aqueous would, moreover, produce opacity of the cornea as well as of the lens.

Small traces of sugar have been discovered in clear lenses in diabetic patients, and diabetic cataracts have been found not to contain any sugar, so the opacity does not seem to be due to any direct action of sugar on the lens fibres.

In patients with diabetes changes have frequently been observed in the pigment epithelial cells on the back of the iris, they become swollen, vacuolated and depigmented. It has been suggested that some of the nutrient fluid of

¹ Deutschmann. *Archiv. f. Ophth.*, XXIII, 1877, 3, 143.

the lens may be derived from the iris, and that degenerative changes in the pigment epithelium interferes with its formation, so that cataractous changes in the lens ensue.

A more probable explanation of the degenerative changes in the pigment epithelium of the iris and the cells of the lens capsule is, that they are both due to some toxin circulating in the blood and generated by the defective metabolism of the tissues of those affected with diabetes, the cataract being produced by the removal of the protective influence which the capsular epithelium affords.

Naphthalin Cataract.—Cataract has been produced in rabbits by the introduction into their circulation of naphthalin.¹ Fine streaks appear first near the equator of the lens; these coalesce and in the course of ten days the entire subcapsular cortex becomes opaque. The lens swells quickly, fluid collects between the capsule and lens fibres and the capsular epithelium shows signs of degeneration. The cortical fibres first disintegrate and later those of the nucleus; finally crystals of phosphate of lime become deposited.

The changes in the eye produced by the ingestion of naphthalin are not limited to the lens, they occur also in the ciliary body, choroid, vitreous, and retina. There is congestion of the uveal tract accompanied by hemorrhages, edema of the retina, and later detachment. A high degree of edema of the ciliary body always precedes the formation of cataract. The aqueous humour contains an abnormal amount of albumin from the first appearance of the cataract, the amount increasing in quantity with the increase of opacity in the lens.

That the opacity in the lens is not due to the direct action of the naphthalin on the lens fibres, or on the capsular epithelium, is shown by the fact that large quantities of it have been introduced into the anterior chamber without causing any alteration in them, and that lenses immersed in naphthalin and olive oil do not become opaque. The primary change is probably in the ciliary body which secretes

¹ H. Magnus. *Arch. f. Ophth.*, XXXVI, 1890, 4, 150.

the aqueous humour from which the lens gains its nutrient material.

A defect in the nutrition of capsule cells allows of the permeation of aqueous humour into the subcapsular fibres and the formation of the subcapsular cataract.

Secondary Cataract.—Cataracts secondary to diseases in other parts of the eye are of different types. The capsular cataracts secondary to ulceration of the cornea and to iritis have already been described (page 449). Cataracts secondary to detachment of the retina and intraocular new growths are probably the result of contact of a vascular structure with the lens capsule causing a disturbance of osmosis and subsequent degeneration. Others which are the outcome of diseases of the uveal tract may, like the naphthalin cataracts, result from interference with the secretion of the nutrient fluid of the lens by the ciliary body.

The chronic cyclitis which manifests itself by bleaching of the stroma of the iris and keratitis punctata, often without any undue redness of the eye, is frequently accompanied by opacity in the lens. The changes commence at the posterior part of the lens and extend forward to the anterior subcapsular fibres. These cataracts, like others which commence subcapsularly, when extracted, come away very completely.

Cataracts secondary to retinitis pigmentosa and high myopia commence in the same way in the posterior subcapsular cortex.

In absolute glaucoma the ciliary processes are usually atrophied as the result of prolonged intraocular tension; and it is probable that the cataracts which occur in connection with that disease are due to the altered character of the aqueous humours.

Senile Degeneration of Capsular Epithelium.—The cells lining the lens capsule in early life are cubical in shape; as the pressure within it increases with age they become gradually flattened out. In old age they may shrink so much that in sections little more than their nuclei can be seen on the

inner surface of the hyaline membrane. It is possible that this physiological shrinking of the capsule cells may pass on into senile degeneration and that some cases of senile cataract are in this way brought about. The large majority of senile cataracts, however, commence not as subcapsular but as equatorial opacities.

c. Equatorial Cataract.—Experiments on animals, in which the effect on the lens has been observed of the introduction of various chemical and staining substances into their circulation, seem to show that fluid enters it chiefly at the equator in the region of the suspensory ligament, *i.e.*, in the position in which the most active changes take place. It is at the equator of the lens that new fibres are constantly being formed.

The cells lining the capsule, like epithelial cells generally, have the power of proliferating throughout life. As they divide they extend round the capsule until they reach the equatorial zone, there the large supply of nutrient fluid which they receive enables them to grow. Their expansion laterally is prevented by the pressure of surrounding parts, and they lengthen out anteriorly and posteriorly into long flat prismatic bands which are at first nucleated. Gradually the nuclei in them break down and disappear. The rapidity with which these new lens fibres are produced becomes lessened as age advances from the increasing intracapsular tension tending to check the proliferative activity of the capsule cells.

The continual laying on of fresh lens fibres causes gradual expansion of the capsule and condensation of its contents. Careful measurements of a large number of lenses at different ages has demonstrated that it continues to grow throughout life. Of a jelly-like consistency in early life it gradually becomes harder and heavier. As the new fibres are laid on laterally the centre of the lens is the part which becomes most compressed and hardest, forming what is termed its nucleus. The hard nucleus increases in size at the expense of the soft cortex with the advance of years.

The microscopical changes which take place in the lens where it is undergoing sclerosis are:—A closer approximation of the lens fibres (the interfibrillar cementing substance, which stains slightly deeper than the fibres themselves, becoming decreased); a diminution in the width of the fibres; and a crenation of their margins, sometimes amounting to dentation, the teeth on one fibre fitting into corresponding depressions in its neighbour. This dentation is exceedingly well marked in the hard round lens in a fish's eye.

Senile Cataract.—It has been estimated¹ that 93 per cent. of senile cataracts originate at the equator. In the large majority of these the changes are first seen in the lower and inner quadrant; they consist of streaks, cones or dots of opacity which stand out black against the red reflex of the fundus when viewed by reflected light and appear grey by focal illumination. The nucleus of the lens though not opaque is of yellowish colour and gives a grey reflex to the pupil. Peripheral opaque striæ frequently remain a long time without undergoing any alteration. When the cataract commences to extend the peripheral striæ and dots run into one another and the opacity spreads into the layers around the nucleus. The subcapsular fibres for a time remain clear so that the pupillary margin of the iris throws a shadow on the surface of the opacity. When in course of time the subcapsular cortex also becomes involved, the opacity extends right up to the posterior surface of the iris and a shadow from the pupillary margin is no longer formed, the cataract is then said to be "ripe." The fibres of the lens may be seen as striations on the surface of the opacity, and sometimes a star-shaped figure is formed where the ends of the fibres come into apposition. Even when a senile cataract has reached this stage of maturity the nucleus on extraction though amber coloured is frequently found transparent.

Following on the stage of ripeness comes one of hypermaturity in which the cortex liquefies, being transformed

¹ H. Magnus. *Arch. f. Ophth.*, XXXVI, 1890, 4, 150.

into an opaque milky fluid in which the nucleus sinks (Fig. 210). The surface of the opacity in the pupillary area then loses its radial markings and presents a homogeneous appearance, on the surface of which little bright white specks may sometimes be seen. These are due to calcareous deposits in secondary capsular cataracts, which form as the result of the diminished intracapsular tension.

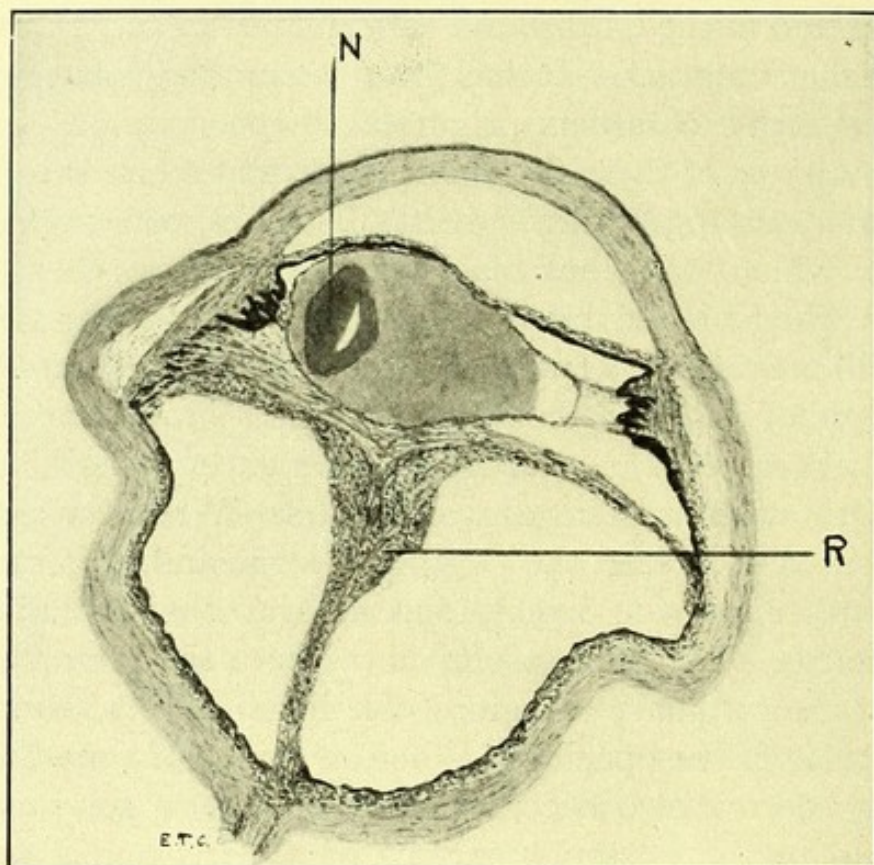


FIG. 210.—Section through a shrunken eyeball showing puckering of the sclerotic posterior to the insertion of the recti muscles and complete detachment of the retina *R* from the position of the ora serrata up to the optic disc. The cortex of the lens has become liquefied; *N* points to the nucleus lying in it, so-called Morgagnian cataract.

Sclerosis and shrinking which normally occurs in the nuclear lens fibres from compression, will also take place in some of the cortical fibres if insufficiently supplied with nutrient material. As the result of their shrinkage cleft-like spaces form between them, in which the interfibrillar fluid collects and coagulates into drops or spheroidal bodies,

the "**Morgagnian globules.**" They have a different refractive index to that of the lens fibres and, therefore, give rise to streaks or patches of opacity situated at the equator. The lens fibres at the margins of these fissures may later undergo a fatty degeneration, minute droplets form in them giving rise to a granular appearance; these run together and the fibre breaks down. In this way spaces become formed in the cortex of the lens containing a mixture of albuminous Morgagnian globules and drops of fat. As the cataract progresses these spaces open up into one another and more and more fibres undergo degeneration. Ultimately in the hyper-mature cataract the whole cortex becomes liquefied and sometimes contains cholesterolin crystals.

When cataractous changes affect the equatorial region, the capsule cells, probably from some defect in supply of nutrient material, frequently fail to grow into lens fibres and spread instead round the posterior capsule, in some cases lining it in its entire extent.

When the intracapsular tension has become decreased, capsule cells may become enlarged as they would if they were going to develop into lens fibres, but there being no pressure causing them to become flattened out into fibres, they swell up into large spherical cells, termed **vesicular or bladder, cells** which have a homogeneous contents and a faintly staining nucleus, this latter in time may disappear (Fig. 209).

d. Nuclear or Perinuclear Cataract.—The growth of the nucleus of the lens is the chief cause of the loss of its accommodative power with the advance of years, **presbyopia**. As the lens becomes harder it is less capable of altering its shape and adapting its focus for objects from different distances.

The harder the nucleus the more light there is reflected from its surface and the duller the pupillary reflex. The clear black pupil of youth is due to the soft nucleus reflecting little light; the dull eye of old age, to the hard nucleus causing much reflection. In association with this scleros-

ing process some pigmentation frequently takes place, the nucleus becoming an amber colour.

The degree of sclerosis of the nucleus and the rapidity of its growth varies in different individuals. Occasionally in elderly people the sclerosis of the nucleus is excessive and a great increase in its refracting power is produced contrasting markedly with that of the unsclerosed cortex. Such an eye may be found to be myopic in the centre of the lens and less myopic, emmetropic, or even hypermetropic at the periphery. Looked at by focal illumination it seems to have a greyish yellow nuclear opacity, when examined by reflected light the nucleus is found to be clear and to present the appearance of an oil drop in the centre of the lens. The retinal vessels seen ophthalmoscopically through the different refracting parts of the lens appear bent and distorted. The condition has sometimes incorrectly been mistaken for lenticonus posterior; it is best termed **sclerosis of the nucleus of the lens** or **lenticular myopic degeneration**.

Sometimes the sclerosing process becomes so extensive that it involves the whole lens, there being then no differentiation of it into a hard nucleus and softer cortex. In such cases the pigmentation is also excessive, the lens becoming dark brown in colour, so dark in some cases that on reflecting light into the eye no red reflex can be obtained from the fundus and the patient's sight is greatly impaired. This condition is somewhat inaccurately spoken of as **black cataract**. It is not strictly speaking a cataract at all, only an advanced stage of senile sclerosis, the whole lens having undergone a change which is usually restricted to the nucleus.

The pigment in such lenses does not give the spectroscopic characteristics of blood pigment. It is of the nature of melanin and comparable to that met with in the basal cells of cuticular epithelium in senile atrophy. Apparently epithelial cells are capable of elaborating pigment when they have lost much of their vitality.

The hard sclerosed nucleus of the lens has little tendency to undergo degenerative changes which result in the forma-

tion of opacity; it frequently remains clear and unaltered when the whole cortex has become opaque.

In a few cases of secondary cataract a band of irregularly shaped globules has been found extending transversely from side to side across the centre of a sclerosed nucleus (Fig. 211).

As a rule it is only in early life, while the nuclear fibres are still soft, that changes which give rise to opacity occur in them. Even then the perinuclear layers are generally affected to a greater extent than the more central ones.

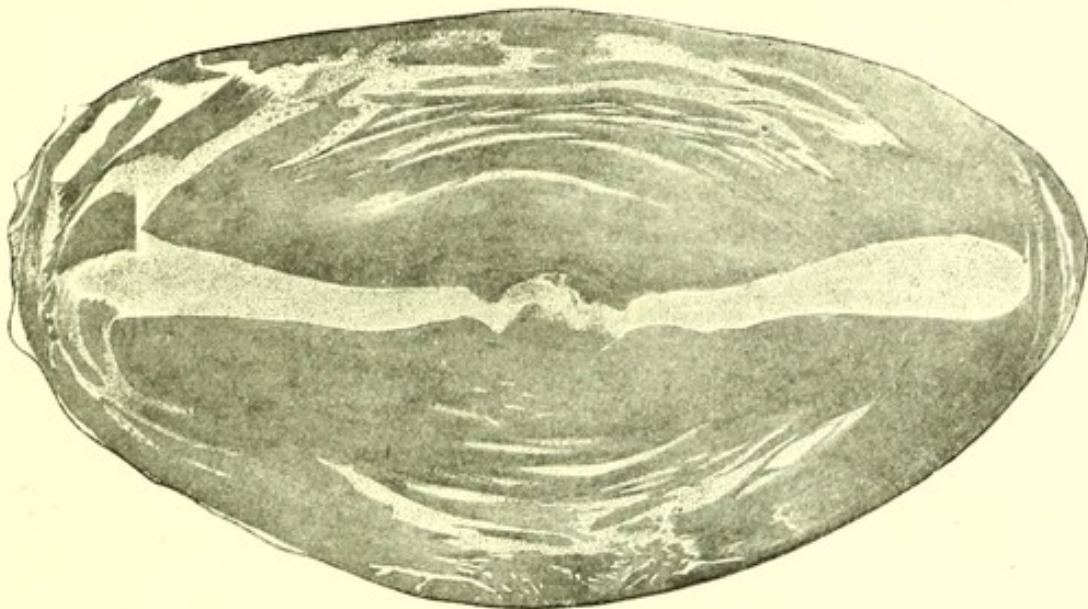


FIG. 211.—Section through a cataractous lens from an eye with a melanotic sarcoma of the choroid. Note the band of degeneration passing across the nucleus, composed of numerous small globules of coagula. There are spaces between the cortical fibres and some degeneration of the lens fibres bounding them filled with a similar material. Case recorded by Treacher Collins, *Trans. Ophth. Soc. of the U. K.*, X, 1890, 145.

Zonular or Perinuclear Cataract.—In both perinuclear and nuclear cataracts, when the pupil is dilated a grey circular opacity is seen with an area of transparent cortex around it. On examination by reflected light the affected area is found to present a duller reflex than the marginal unaffected zone. In a perinuclear cataract the margin of the opaque area is much darker than the centre, whereas in a nuclear cataract the centre is as dark or darker than the edge.

Pathologically no very sharp line can be drawn between perinuclear and nuclear cataracts; the same changes are met with in both, differing only in their locality and degree.

On the surface of the disc-shaped area of opacity in these cases, dots and streaks of denser opacity are often seen; the latter may project beyond the disc into the clear cortex, the so-called "riders." At times these riders are forked in shape the limbs of the fork embracing the two surfaces of the affected area.

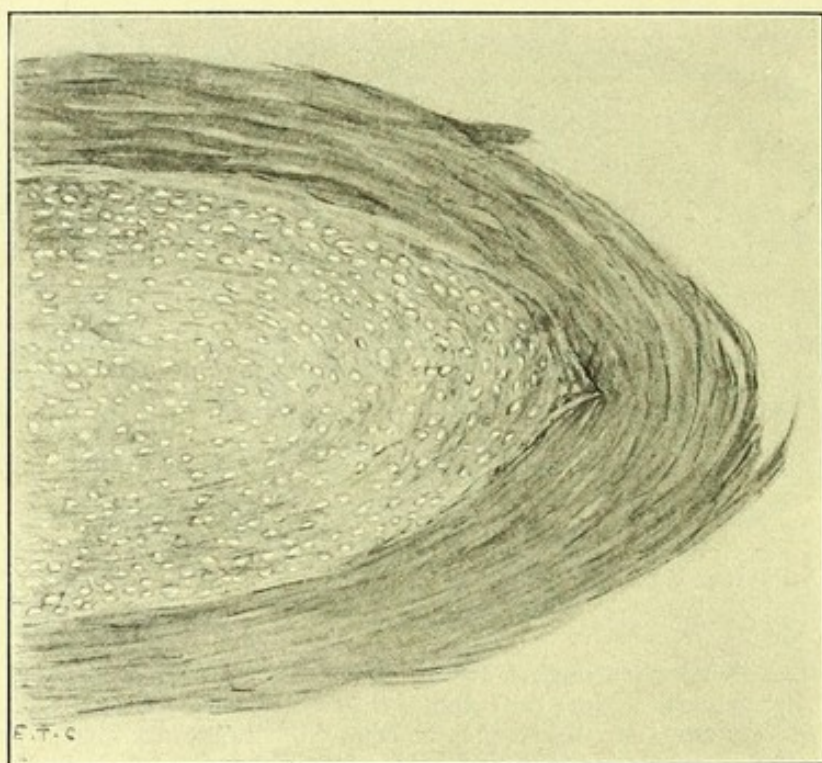


FIG. 212.—Section of a lens which had a zonular cataract, showing a number of small vacuoles scattered throughout the nucleus.

Microscopically the opacity in these cataracts is found to be due to a number of small vacuoles¹ (Fig. 212), the average diameter of which measures .005 mm. They are mostly round or oval, but in places seem to have run into one another, and present an elongated or beaded appearance. Some of them contain a hyaline substance which after prolonged immersion in hemotoxylin solution stains deeper than the surrounding lens fibres.

¹ O. Schirmer. *Arch. f. Ophth.*, XXXV, 1889, 2, 147.

In perinuclear cataract these vacuoles are most numerous in the region of the densest opacity, *i.e.*, around the nucleus, though they may be found distributed throughout the entire nucleus. In nuclear cataracts their distribution in the opaque discoid area is more uniform.

2 Besides the vacuoles, fissures are met with between the lens fibres which may or may not contain a granular substance, and which run concentric with the nucleus separating it from the cortex. They are produced probably by contraction of the nucleus and cause the "riders" above referred to.

3 A third change sometimes met with are spaces larger than the vacuoles, measuring on an average .02 mm. across, mostly circular with very irregular margins and containing a granular substance which stains deeply with hematoxylin. These correspond to the denser dots seen on the surface of the opaque zone. Some degeneration of the lens fibres apparently occurs in their formation.

The size of the opaque area, and consequently the size of the clear zone external to it, vary considerably in different cases. Direct measurement of the opaque area in ten cases¹ by different observers gave an average transverse diameter of 4.5 mm.; the largest being 6 mm. and the smallest 3.25 mm. Cases have been seen in which, external to the central complete disc of opacity, there was a second or third incomplete opaque zone.

There has been considerable discussion as to whether the perinuclear cataracts are formed before birth or after, *i.e.*, whether they are congenital or infantile. There can be little doubt that they are due to some general disturbance of nutrition, as they are bilateral and frequently associated with fits in infancy, rickets, and a defective condition of the enamel of the permanent teeth.

Of twenty-six cases of perinuclear cataract only four showed no abnormality of the teeth. Those most frequently

¹ Treacher Collins. "Researches into Anatomy and Pathology of the Eye," 1896, 33.

affected are the ones in which the enamel organ undergoes calcification during the first two years of life, viz., the permanent first molars, incisors, and cuspids.

The enamel of the teeth and the lens of the eye are both derived from downgrowths of surface epiblast, so it would seem probable that both might be affected by a similar nutritional disturbance.

The condition of the teeth has been attributed¹ to general disturbance of health caused either by errors in feeding in infancy or exanthematous fevers. It is only met with in association with perinuclear or nuclear cataracts not with other forms of congenital cataract.

The malnutrition to which perinuclear cataract is usually attributable occurs in early infancy. It is probable, however, that it may also arise from causes of similar character before birth.

The cases which occur without any dental defect may be accounted for by the disturbance having occurred before the date at which the enamel organs become calcified.

The transverse diameter of the lens at the ninth month of fetal life has been found to be 5.75 mm. and that of the lens under a year old 7.46 mm. When these measurements are compared with the transverse diameters of the opaque zone in perinuclear cataracts above mentioned, it will be seen that opaque area is always smaller than the lens at birth, sometimes very much smaller.

By the continual laying on of lens fibres at the sides the nuclear fibres gradually become more and more tightly compressed, so that under normal conditions the lens substance present at birth occupies a larger area than it does later in life when fresh cortex has developed.

The rate at which the capsular epithelial cells proliferate and develop into lens fibres is regulated by the intracapsular tension. As life advances and the intracapsular tension increases the rate at which new lens fibres are formed decreases.

If during the first year of life some disturbance of nutri-

¹ Norman Bennett. Trans. Ophth. Soc. of the U. K., 1910, XXI, 43.

tion causes the lens fibres to shrink, the intracapsular tension is lowered and an increased number of cortical fibres are formed. These being healthy fibres clear cortex would be formed surrounding the shrunken opaque area, the diameter of which, from shrinking and compression, would be less than that of the normal lens at birth.

The size of the opaque area gives some indication as to the date of its formation, small ones probably being formed before birth. It is in keeping with this view that small opaque zones are usually unaccompanied by defective enamel of the teeth.

Perinuclear cataract may be regarded as due to some general dystrophic influence acting on the lens, but not sufficient to cause complete disintegration of its fibres, only a shrinking and vacuolation of them. The whole lens is involved by the dystrophic influence, but the fibres which have been most recently formed, or those which are laid down while it lasts, are chiefly affected, the most central fibres being only slightly implicated and those laid on after the dystrophic influence has subsided escaping altogether.

Tetany Cataract.—As already mentioned in case of zonular cataracts a history of fits in infancy can frequently be elicited. The changes in the lenses have by some observers been attributed to cramp of the ciliary muscle occurring during the fits, which they consider interferes with the secretion of the nutrient fluid of the lens. Support for this view has been sought in the fact that cataract sometimes arises in later life, *i.e.*, between the ages of twenty and fifty, in individuals who suffer from repeated attacks of tetanic spasms, affecting besides other parts of the body the face and eyes.

In some of these cases the chief opacity is in the nucleus of the lens, but not in all. The cortex has been found completely opaque, and the nucleus, when extracted, clear. The microscopical changes in these tetany cataracts consist of clefts between and holes in the lens fibres, very similar to those met with in perinuclear cataracts. The changes do

not, however, as in perinuclear cataract, remain stationary. If they begin in the nucleus or perinuclear layers they tend to extend to the cortex.

The attacks of convulsions usually last for several years before the onset of the lens changes. A history of temporary obscurations of sight during the spasms is first noticed and later a permanent obscuration due to the formation of the cataract.

That spasm of the ciliary muscle would alone suffice to cause the lens-changes seems improbable, because they are not met with after even very prolonged use of eserine in cases of glaucoma. After each instillation of that drug a contraction of the muscle lasting some hours is induced.

Loss of hair, necrosis of the nails, and an eruption of the skin like pemphigus has been observed in association with tetany cataract. It seems likely that some toxin is generated which affects all the epithelial structures in the body including lenticular epithelium.

III. NEURAL EPIBLASTIC DEGENERATIONS.

The degenerations which take place in the tissues of the eye derived from neural epiblast will be described under the following headings: (a) Degenerations of the ganglion cells of the retina; (b) degenerations of the nerve-fibre layer of the retina and of the optic nerve; (c) degenerations of the outer layers of the retina and its neuroglia; (d) degenerations of the retinal pigment epithelium; (e) degenerations of the pars ciliaris retinæ and pars iridis retinæ.

a. Degenerations of the Ganglion Cells of the Retina.—

The earliest degenerative changes in the ganglion cells of the retina are best demonstrated by Nissl's method of staining (see page 538). This method picks out small granules called Nissl granules, which in the normal condition are scattered throughout the cytoplasm of the cell, their number and concentration being influenced by exposure to light,

which makes them become diffuse and disappear; absence of light favouring their reformation.¹

In degenerative conditions, whether the result of post-mortem changes; anemia, as in experimental ligature of the carotid artery; toxic conditions, such as quinine and alcoholic amblyopia; or detachment of the retina, these Nissl granules become smaller and grouped in the peripheral parts of the cell, finally disappearing altogether.

After the disappearance of the Nissl bodies in a degenerating ganglion cell, vacuoles form in its cytoplasm, most of them containing fat; these tend to run together. The nucleus also shows changes, ceasing to stain with the usual nuclear stains and then likewise becoming vacuolated. Finally the cell shrinks, and when completely destroyed leaves an empty space in the neuroglia where it was situated.

It has been suggested² that coagulative necrosis occurring in the ganglion cells and their axons may be the cause of the opacity of the retina which is seen in embolism of the central retinal artery, quinine amblyopia, and amaurotic family idiocy. The distribution of the opacity is in favour of such a view. It does not extend over the whole retina, as might be expected if it were due to edema, but is limited in cases of embolism and quinine poisoning to parts around the macula and optic disc, *i.e.*, to the parts in which the ganglion cells are chiefly located. It is absent at the macula where there are no ganglion cells and in the peripheral parts where they are very few in number.

Amaurotic Family Idiocy.—This is a disease of the brain and retina, the primary change being apparently in the nerve cells.³ It is only met with in Jewish children and frequently affects several members of the same childship. It manifests itself when the child is from three to six months old by a weakness in the muscles of the back and neck. The child is unable to sit up or hold its head erect. In associa-

¹ Birch-Hirschfeld. *Arch. f. Ophth.*, L., 1900, 166.

² W. I. Hancock. *R. Lond. Ophth. Hosp. Reps.*, XVII, 1908, 437.

³ Kingdon and Russell. *Med.-Chir. Trans.*, LXXX, 1897.

tion with this weakness a defect of vision is soon noticed. Ophthalmoscopic examination reveals in each eye a circular white opaque area in the retina around the macula, while the macula itself appears of an unusually dark red colour, much darker than the cherry-red macula seen in embolism of the central artery. The optic disc though not at first affected, later on becomes pale or even quite white, and the retinal arteries are markedly constricted. The muscular weakness increases and all the cases end fatally from marasmus.

Pathological examination of the brain has demonstrated changes in its cells and an increase of glial tissue. The former consists in the disappearance of the Nissl bodies from the cytoplasm, which chemical examination has shown is accompanied by a decrease of nuclear proteids.¹ Later swelling of the cells, vacuolation and disintegration takes place.

It has been difficult to differentiate the histological changes in the retina due to this affection from the post-mortem changes which set in rapidly in that structure after death. A slight rucking of the retina at the fovea and a subretinal albuminous exudate, together with some edema which has been found present in several cases may possibly be postmortem artefacts. Changes in the ganglion cells around the fovea quite comparable to those found in the cells of the nervous system elsewhere are doubtless the most important condition in the affection. The ganglion cells become swollen, lose their angular outline, vacuoles form in them, and the Nissl bodies disappear. The more degenerated ones shrink and become separated from the surrounding supporting tissue. The atrophy of the nerve is secondary to the changes in the ganglion cells.

b. Degeneration of the Nerve-fibre Layer of the Retina and of the Optic Nerve.—As most of the nerve fibres of the retina are the axons of its ganglion cells, degenerative changes in the latter necessarily entail degeneration of the former,

¹ F. Mott. *Archives of Neurology*, III, 1907.

and also of some of the fibres of the optic nerve (ascending atrophy).

It has been shown experimentally in animals¹ that a wound of the retina results in the degeneration of a corresponding tract of fibres in the optic nerve.

As the nerve fibres of the retina degenerate their outlines become obscured; sometimes hyaline material collects around them in irregular clumps; finally they break up and disappear altogether.

Should atrophy occur in a retina where there is an abnormal development of medullary sheaths around the nerve fibres (*i.e.*, opaque nerve fibres) the medullary substance breaks up and is removed. What was ophthalmoscopically an opaque white area in the retina then becomes transparent and allows the red reflex of the choroid to be seen through it.

Atrophy of the Optic Nerve.—Atrophy of the optic nerve may be due to changes starting in the retina, **ascending atrophy**; changes starting in the nerve itself, **trunk atrophy**; changes starting in the brain, **descending atrophy**.

Atrophy of the optic nerve may also be divided into that which is secondary to inflammation, **postneuritic**, and that which arises apart from any inflammation, **simple atrophy**.

Postneuritic atrophy, following papillitis, can be distinguished clinically from simple atrophy by the presence of newly formed tissue on the disc, which gives it a white or bluish-white appearance, obscures the markings of the lamina cribrosa, and fills in any depression on its surface. The swelling of the disc, moreover, on its subsidence leaves behind some irregularities in its margin and thickenings of the walls of the retinal blood-vessels which are seen as white lines along their course. In simple atrophy the optic disc has sharply defined margins, is pale, showing grey markings over a large part of its surface due to the exposed lamina cribrosa, and is slightly excavated.

¹ Usher and Dean. Trans. Ophth. Soc. of the U. K., XVI, 1896, 248.

The retinal blood-vessels are not thickened and so show no marginal white lines. Appearances similar to simple atrophy may follow retrobulbar neuritis which does not result in papillitis.

The early changes which take place in atrophy of the optic nerve are well demonstrated by Marchi's method of staining (see page 538). As the atrophic process proceeds the medullary sheaths break up into rows of globules along the whole course of the affected fibres. They are then slowly carried away either in the lymph stream or absorbed by the leukocytes. The axis-cylinders become beaded, then broken up, and finally disappear. As the nerve fibres be-

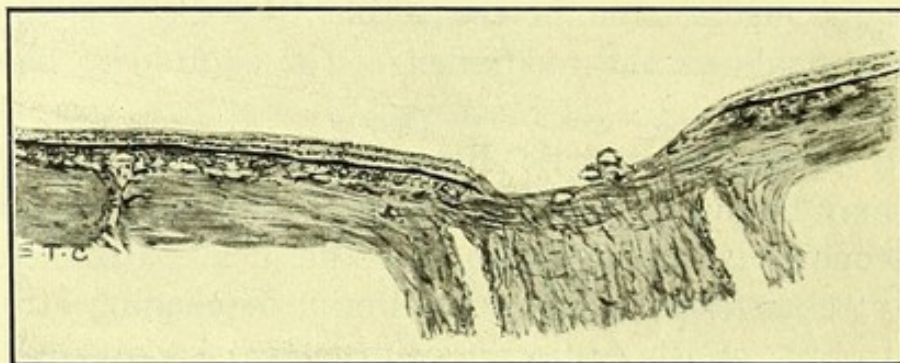


FIG. 213.—Section through the head of the optic nerve in a case of simple optic atrophy. Note the reduction in the size of the nerve, and that a depression has formed on the inner surface of the lamina cribrosa in the position normally occupied by the optic papilla.

come destroyed vacant spaces are left in the supporting connective tissue framework. The sides of which fall in so that the size of the nerve becomes considerably reduced (Fig. 213).

In simple atrophy there is no abnormal leukocytic invasion and no new formation of fibrous tissue, only a condensation of that which pre-existed, due to the disappearance of the nerve fibres.

Ascending Atrophy.—Atrophy of the optic nerve secondary to changes in the eye is the result of degeneration of the ganglion cells of the retina. A degeneration of these cells may arise in a variety of ways. It occurs in inflammation of the retina (page 336); in the disease called retinitis

pigmentosa (page 181); in detachment of the retina; in ischemic conditions such as follow obstruction in the central artery, quinine poisoning and profuse hemorrhages (page 201); secondary to intraocular pressure in glaucoma; and in toxic condition in which the poison acts directly on the ganglion cells (page 199). *10. General etc*

The atrophy of the optic nerve which occurs in connection with tabes dorsalis and general paralysis is a simple atrophy, the changes beginning in the periphery, *i.e.*, close to the eye. It would seem probable that the primary condition is an affection of the ganglion cells of the retina, which are always found degenerate. It usually occurs early in the course of the disease and is always bilateral though one eye is often involved before the other. The impairment of sight caused by it commences with irregular concentric contraction of the field of vision and defective colour perception, which is followed by impairment of the acuity of central vision. The frequency with which optic atrophy occurs in connection with tabes has been variously estimated by different observers, some putting it as high as 50 per cent., others as low as 10 per cent.

Trunk Atrophy.—Atrophy may start in the trunk of the optic nerve as the result of inflammation, injury, compression or sclerosis.

For trunk atrophy secondary to inflammation see ret-robular neuritis (page 339).

Injury to the optic nerve may be due to a direct wound or be caused indirectly by a fracture of the base of the skull extending into the optic foramen (page 273).

It might have been supposed, in accordance with the Wallerian law, that the optic nerve largely made up of the axons of the retinal ganglion cells, would not degenerate when divided. This, however, is not the case, after division all the fibres in the ocular portion slowly atrophy and the optic disc becomes quite white. The ganglion cells in the retina, moreover, when stained by Nissl's method show chromatolysis. The explanation of this is that the optic

nerve is an intercentral and not a peripheral nerve, to which latter the Wallerian law alone applies.

Pressure on the optic nerve or the chiasma causing atrophy may occur in a variety of ways. It may be due to new growths, orbital, nasal, or intercranial; to organised inflammatory exudates in connection with orbital cellulitis; to deformity in the skull; to hemorrhage into the sheath of the nerve; or the formation of callus after a fracture of the base of the skull.

Tumours of the orbit which produce optic atrophy from compression of the nerve may arise in structures around it or in the nerve itself; the latter may be extradural or intradural (see page 147). Tumours may sometimes start in the intercranial portion of the nerve.

Tumours which press on the chiasma start in the pituitary body or infundibulum and may be solid or cystic. They frequently produce a characteristic defect of vision, viz., **bitemporal hemianopsia**. At the chiasma the nerve fibres coming from the nasal half of each retina decussate, those coming from the temporal halves being continued on to the optic tract of the corresponding side without decussation. It is only from pressure on the chiasma at the point of decussation that atrophy of the fibres going to the nasal halves of the two retinae takes place and loss of the temporal halves of the two fields occurs.

A tumour at the chiasma which at first causes bitemporal hemianopsia may extend so as to involve the whole of the nerve or tract on one side and so produce complete blindness of one eye. On still further development both optic nerves may be involved and complete blindness result.

Though bitemporal hemianopsia is a typical symptom of tumour of the pituitary body other forms of defect of sight may occur from such growths. In twenty-two cases¹ in which the diagnosis was confirmed postmortem in 23 per cent. the loss of sight was bitemporal, in 23 per cent.

¹ Quoted by Macnab. Trans. Ophth. Soc. of the U. K., XXIX, 1909, 141.

unilateral temporal, in 22 per cent. concentric, in 13 per cent. central scotoma, in 9 per cent. homonymous, in 9 per cent. only sector remaining, and in 4 per cent. irregular.

Tumours in this region besides the loss of sight are frequently accompanied by acromegaly, abnormal adiposity, loss of sexual desire, or arrested growth.

In connection with the deformity of the skull known as "tower skull" or "oxycephaly" atrophy of the optic nerve simple and postneuritic has several times been observed. In some of these skulls the narrowing of the optic foramina has been discovered to which the atrophy may be attributed. In others the alteration in the position of the great wing of the sphenoid had pushed forward the dorsum sellæ turcicæ so that it caused pressure on the optic nerves or chiasma. Other deformities of the skull besides oxycephaly are sometimes accompanied by optic atrophy.

Hereditary Optic Atrophy or Neuritis.—As the sphenoid bone in which the optic foramen is situated does not complete its development until somewhat late in life it has been suggested that what is termed "hereditary optic atrophy" or "optic neuritis," which usually occurs at or soon after puberty, may be due to some irregularity in its growth.

It is difficult, however, to accept this explanation for all such cases, though at present little is known as to their pathology.

The disease commences usually at the age of twenty and occurs more frequently in men than women. It is transmitted usually through the mother who is unaffected. Direct is less common than collateral inheritance.¹

The affection comes on in both eyes either rapidly or gradually with failure of sight, due to the formation of a central scotoma which generally becomes absolute for white and colours. Peripheral vision as a rule is unaffected. After the central scotoma has become absolute the condition usually remains stationary, rarely some sight is regained,

¹ S. H. Habershon. Trans. Ophth. Soc. of the U. K., VIII, 1888, 190.

still more rarely the case goes on to complete blindness. Ophthalmoscopically no changes are at first seen; in some cases a slight papillitis occurs, the margin of the disc becoming blurred; and later atrophy sets in. In others pallor of the temporal half or of the whole disc slowly develops without any preceding symptoms of papillitis.

In the trunk atrophy which occurs in connection with **disseminated sclerosis**, isolated areas are found in the nerve in which there has been an active proliferation of the connective tissue and glia cells. As these newly formed cells organise and contract they compress the nerve fibres so that their medullary sheaths become broken up and absorbed. The axis-cylinders for a long time remain unchanged in the affected area in which particular there is a marked difference to that which occurs in tabetic atrophy; where the primary change being in the ganglion cells, the axis-cylinders soon become destroyed. The prolonged resistance of the axis-cylinders in sclerosis of the nerve allows of the transmission of visual impulses through the affected part until the late stages of the affection.

Descending Atrophy.—Lesions in the brain or optic tracts which lead to atrophy of the optic nerves, owing to the decussation of fibres which occur at the chiasma, affects the vision of both eyes. As such lesions are usually unilateral the symptom to which they give rise is **homonymous hemianopsia**, *i.e.*, the loss of the whole or part of the temporal field of vision in one eye and the whole or part of the nasal field of vision in the other.

In complete homonymous hemianopsia the dividing line between the blind and seeing halves of the fields of vision, when mapped out by the perimeter, is found to run in a vertical direction except in the vicinity of the fixation area. It there curves in such a way as to include that region in each of the seeing halves. Presumably fibres from each fovea extend to both sides of the brain.

The **hemiopic pupil reaction** or **Wernicke's light test** helps to differentiate lesions which give rise to homony-

mous hemianopsia that are situated above the basal or primary optic ganglia from those below. In the latter, light thrown on the blind half of the retina does not produce such a brisk reaction of the pupil as when thrown upon the seeing half, while in the former the amount of reaction is equal upon whichever half it is thrown.

The optic tracts themselves may be the seat of growths or become pressed upon by tumours in the brain. They also become affected by pressure in cases of hydrocephalus.

Optic atrophy secondary to lesions of the basal ganglia, optic radiations, or cortex are usually the result of new growths; the pathology of such condition belongs to that of the central nervous system and will not be dealt with here.

c. Degeneration of the Outer Layers of the Retina and its Neuroglia.—Degeneration of the bipolar cells in the inner nuclear layer soon follows on that of the ganglion cells; this is shown histologically by diminished staining and later by shrinking. Finally they disappear altogether.

The internuclear layer in degenerative conditions will sometimes become obliterated and the two nuclear layers appear to run together.

The cells of the outer nuclear layer and the rods and cones are more resistant to pathological degeneration than any of the other nervous constituents of the retina; they will remain for some time intact when the latter have disappeared, although ultimately they also break up and become destroyed. In advanced cases of retinal degeneration the neuroglia alone remains, the nervous elements having completely disappeared leaving the spaces formerly occupied by them filled with fluid. Such a condition is a common precursor of cystic formations in the retina. If the fluid in the spaces increases in amount due to exudate from the sclerosed vessels, the partitions between them become broken through, so that they open into one another and larger cavities are formed (see page 169).

In some degenerate retinae there is a hyperplasia of the neuroglia together with a new formation of fibrous tissue

from the cells composing the vessel walls. This may result in a localised thickening of the retina of a considerable size. The neuroglia in it undergoes fatty degeneration and hyaline masses are also formed. In connection with the former cholesterine crystals develop and in the latter lime salts may become deposited. Such a thickened degenerate area in the retina presents ophthalmoscopically a striking and beautiful appearance, the presence of the crystals causing it to sparkle and glitter with every movement of the mirror.

d. Degenerations of the Retinal Pigment Epithelium.—

In degenerations of the pigment epithelium the cells may either atrophy and disintegrate or reassume some of their embryonic characteristics, *i.e.*, they may proliferate at an increased rate and form hyaline material. This layer of cells is nourished by the capillaries of the choroid and it degenerates when the capillary layer is from any reason destroyed.

When the retina is detached and the choroidal circulation unchanged the pigment epithelial cells, though no longer required to fulfil their normal function, receive their usual nutrient supply. Under such circumstance they proliferate and become several layers thick. The cells in the innermost layers swell up and become vacuolated, globules of fat form in them, and finally they break down liberating fatty material and granules of pigment into the subretinal fluid. As the outcome of the fatty changes cholesterine crystals may be formed, either in the subretinal fluid or in the masses of cells on the inner surface of the elastic lamina. When the pigment epithelial cells rapidly proliferate they are often less deeply pigmented than usual and sometimes have only a few scattered granules in them.

In atrophic conditions of the retina and choroid when the two membranes become united, as after division of the posterior ciliary arteries, rupture of the elastic lamina, sclerosis of the choroidal vessels, and in the affection termed "retinitis pigmentosa," pigmentation of the retina takes place. This pigment is derived from degeneration of the pigment epithelial cells; they proliferate, acquire ameboid

movements and wander into the retina, its external limiting membrane in its atrophic condition affording no impediment to their passage through it. Some of them break down and discharge their pigment granules which may then be carried away by the lymph stream or be taken up by leukocytes. The pigment in the retina collects chiefly around the blood-vessels in the perivascular lymph spaces and gives rise to branching, irregularly shaped figures, when seen ophthalmoscopically.

The **membrane of Bruch** or elastic lamina of the choroid when stained with eosine appears a perfectly homogeneous structure. When, however, it is stained with Weigert's elastic tissue stain it is seen to be composed of two layers, an inner which is homogeneous and which becomes diffusely blue and an outer which is finely reticular and takes on the deep blue colour characteristic of elastic tissue.¹

The difference between the two layers shows best where the membrane is thickest, that is, in the vicinity of the optic disc. At the margin of the papilla they end at different levels, the inner one ceasing with the pigment epithelium and the outer continuing on for some little distance into the substance of the papilla.

These two layers of the membrane of Bruch have a different origin, the inner homogeneous layer, like the capsule of the lens and Descemet's membrane, which it closely resembles, being formed as a kind of secretion from the cells lining it,² namely, the pigment epithelium, and the outer reticular elastic fibre layer being continuous with the elastic fibre network of the choroid.

The inner homogeneous part of the membrane of Bruch, though it becomes slightly thickened with the advance of years, is mainly a product of the pigment epithelial cells during embryonic life. Under normal conditions the capacity which the cells have of producing hyaline tissue ceases

¹ G. Coats. R. Lond. Ophth. Hosp. Reps., XVI, 1905, 164.

² Treacher Collins. *Researches into the Anatomy and Pathology of the Eye*, 1896, p. 87.

in the fully developed eye. Under pathological conditions the pigment epithelium reacquires this hyaline-producing capacity and nodules of it may be formed on the inner surface of Bruch's membrane (Fig. 214). They occur in connection with various atrophic conditions of the choroid, but are sometimes met with as a senile affection when the other parts of the eye are apparently healthy, though possibly even in such cases some sclerosis of the choroid vessels is present. These senile hyaline or colloid formations are most frequently

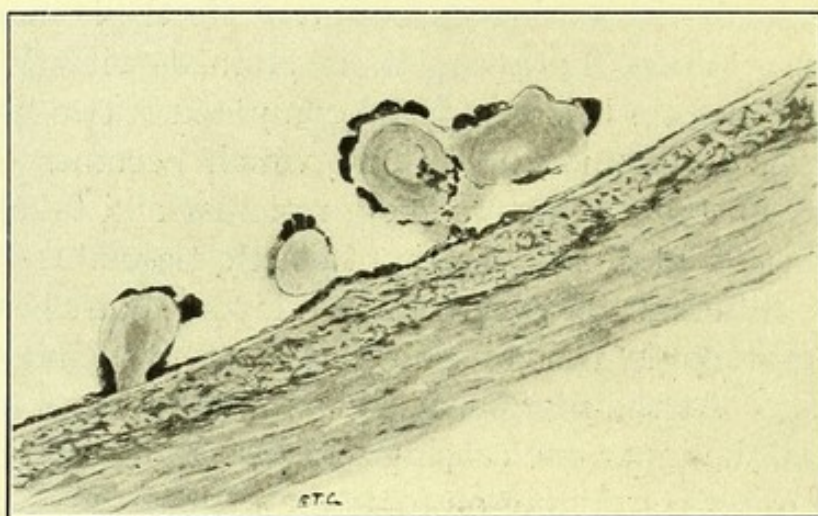


FIG. 214.—Hyaline formations on the inner surface of the elastic lamina of the choroid.

met with around the macula and give rise ophthalmoscopically to small oval or circular pale yellowish-white dots. The condition has been termed **central guttate choroiditis**, **Tay's choroiditis**, and also more accurately **hyaline infiltration of the retina**.

In rare cases similar hyaline nodules form in connection with the termination of the elastic lamina at the margin of the optic disc, giving rise to elevations in it (Fig. 215). These have to be differentiated from another form of hyaline degeneration met with in connection with the head of the nerve to be referred to later (see page 491). Their situation always at the margin of the disc and continuity with the elastic lamina are their chief distinguishing characteristics.

e. **Degeneration of the Pars Ciliaris Retinæ and Pars Iridis Retinæ.**—In the ciliary body the hyaline membrane external to its pigment epithelium may like the elastic lamina of the choroid show some increase of thickness with the advance of years. A senile hyperplasia also occurs in both the pigmented and unpigmented retinal layers of the ciliary body, the latter may become protruded inward in the form

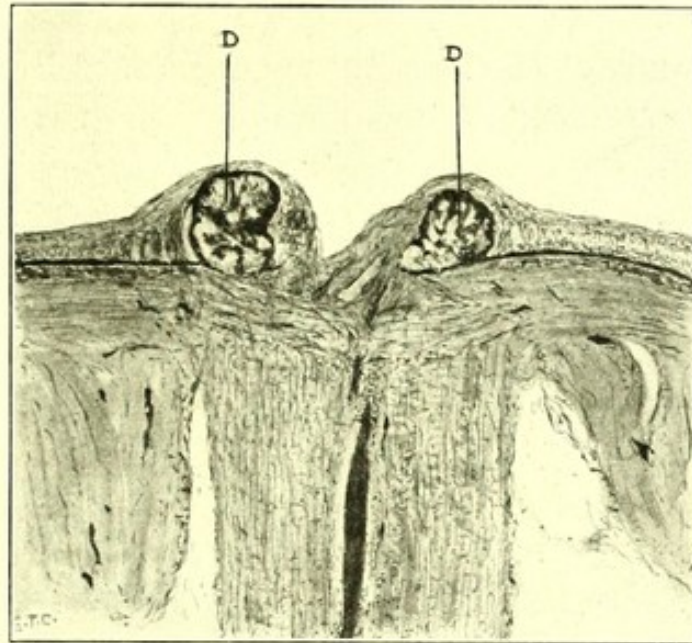


FIG. 215.—Hyaline formations in the head of the optic nerve at the termination of the elastic lamina of the choroid and pigment epithelium.

of folds and, as already described, give rise to cysts (see pages 121 and 167).

A peculiar form of degeneration is met with in the pigment epithelium on the back of the iris in cases of diabetes (see page 457).

IV. DEGENERATIONS IN TISSUES DERIVED FROM MESOBLAST.

The degenerations which take place in the tissues of the eye derived from mesoblast will be described under the following headings: a. hyaline; b. amyloid; c. fatty; b. calcareous and bone formation; e. staphylomata.

a. Hyaline Degeneration.—The histological characteristics of the material called hyaline are:

- ①. Its homogeneous structure and highly refractive power.
- ②. Its insolubility in strong acids and alkalies.
- ③. Its capacity of staining; deeply with eosine, acid fuchsin, carmine and picrocarmine; lightly with hematoxylin; and of not being turned brown by iodine.

The structures composed of hyaline in the normal eye are the capsule of the lens, the inner part of Bruch's membrane, and Descemet's membrane. The two former, as already pointed out, are produced by the epithelial cells lining them. Descemet's membrane is developed in the same way from its lining endothelial cells. Just as the epithelial cells lining the two first-named membranes under pathological conditions produce abnormal formations of hyaline, so may the endothelial cells lining Descemet's membrane and the endothelial cells which are of a similar character on the anterior surface of the iris.

After wounds of Descemet's membrane the endothelial cells which extend across the gap left by its retracted ends will, in course of time, secrete a new layer of hyaline tissue¹ (see page 258). As a senile change small hemispherical projections of hyaline material sometimes form on the inner surface of Descemet's membrane, usually toward its periphery (Fig. 216). They are comparable to the hyaline nodules which occur on Bruch's membrane.

In cases of glaucoma, especially glaucoma in early life (buphthalmos) where there is a peripheral adhesion of the iris to the cornea, a new formation of a hyaline membrane on the anterior surface of the iris may be produced beneath its layer of endothelial cells. This new membrane generally appears to be continuous with Descemet's membrane round the angle of the anterior chamber. A similar formation on the anterior surface of the iris is also sometimes found in connection with anterior synechiæ. Excrescences may form

¹ Treacher Collins. R. Lond. Ophth. Hosp. Reps., XIV, 1896, 305.

in these iritic hyaline membranes like those described in connection with Descemet's membrane.

Besides these hyaline formations, which are the products of endothelial cells, there are others which are the result of degeneration of plasma cells in inflammatory exudates or which are produced by deposition from the blood or lymph streams.

Coagulated fibrinous exudates are found in the cavities of the eye under a variety of conditions. A membrane composed of it may form in the anterior chamber from the

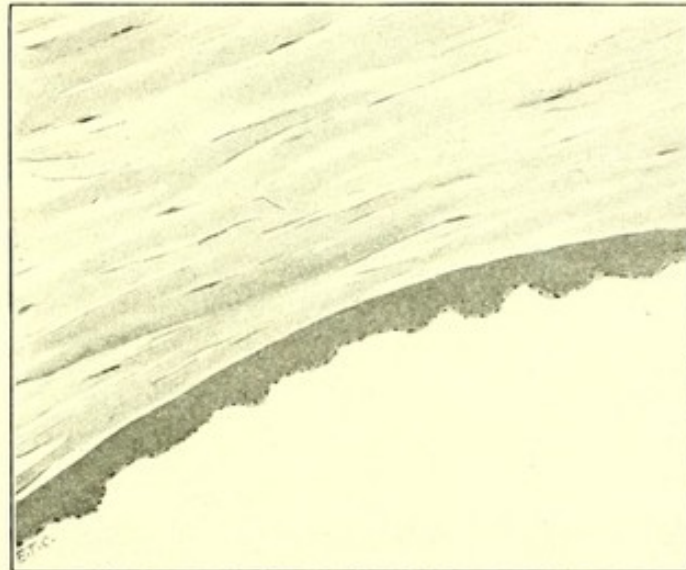


FIG. 216.—Hyaline excrescences on the inner surface of Descemet's membrane.

newly secreted aqueous humour produced after a paracentesis. The epithelium lining the ciliary body under similar circumstances sometimes becomes raised up by a fibrinous exudate beneath it. In inflammatory conditions of the uveal tract fibrinous reticula often form in the vitreous, posterior or anterior chambers. In the subretinal space formed from detachment of the retina fibrinous coagula are of frequent occurrence, and are also met with in the lymph spaces of the lamina suprachoroidea. Such exudates may form a matrix in which new connective tissue is developed or become redissolved and carried off in the lymph stream.

Fibrinous coagula when they form in the tissues may if retained become condensed and transformed into a substance giving rise to the characteristics of hyaline above described.

Hyaline material formed in one or other of the above ways is found in several different affections of the cornea, usually in the superficial layers of its substantia propria.

In old corneal leukomata hyaline may occur in the form of small granules, globules or large irregular shaped masses, the larger formations being produced by a coalescence of the

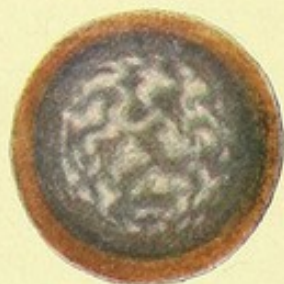

FIG. 217.—Nodular opacity of the cornea in a man aged twenty-six. Case recorded by Treacher Collins, *Trans. Ophth. Soc. of the U. K.*, XXII, 1902, 148.

smaller ones. Clinically they give rise to the appearance of yellow spots in the opaque area and sometimes calcareous granules become deposited in them.

The rare conditions termed "nodular opacity" and "reticular opacity" of the cornea have both been attributed to deposition of hyaline in its superficial layers.

Nodular opacity of the cornea is a condition which affects both eyes and often occurs in several members of the same family. Opaque grey patches, which vary in size and may be compared in shape to an ameba, form in the superficial layers of the centre of the cornea, the periphery as a rule being uninvolved (Fig. 217). Sometimes they contain a few dense white granules and the surface of the cornea overlying them is slightly raised. Hyaline material has been found in the patches. In one case¹ a small piece of the affected area was removed by a trephine; it showed microscopically an amorphous substance between the fibrous lamellæ.

¹ E. Fuchs. *Arch. für Ophth.*, LIII, 3, 1902.

Reticular opacity of the cornea (lattice-work keratitis)¹ is, like nodular opacity of the cornea, an affection of the centre of the superficial layers, affecting both eyes, and often occurring in several members of the same family. The opacity is composed of a network of fine grey lines having much the appearance of a cobweb (Fig. 218). Small grey dots of opacity may also be present. Ridge-like elevations of the surface of the cornea occur at the site of the opacities; as the affection progresses they slowly become denser and more numerous. Hyaline material has been found in the cornea

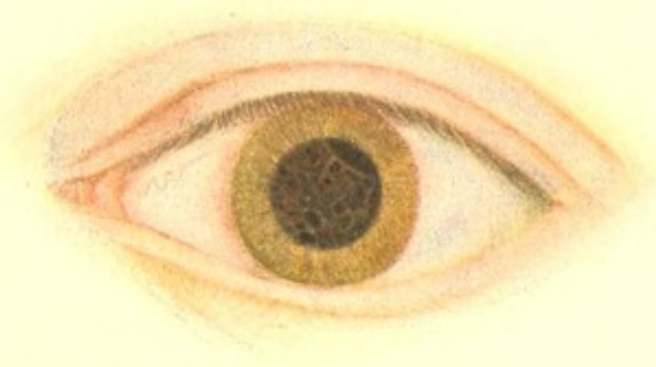


FIG. 218.—Reticular opacity of the cornea in a man aged twenty-four. Case recorded by Treacher Collins, Trans. Ophth. Soc. of the U. K., XIX, 1899, 30.

in this affection, and it is suggested that probably Bowman's membrane is raised in folds at the seat of the elevations.

In transverse films of the cornea hyaline deposits may occur but are not a constant feature (see page 495).

Hyaline degeneration in the conjunctiva occurs as a sequela of trachoma. It has been mentioned in describing that affection how the thickened, smooth, waxy condition of the palpebral conjunctiva termed "Stellwag's brawny edema" is due to hyaline degeneration of the plasma cells which are often present in large numbers. The hyaline degeneration following trachoma is not always limited to the palpebral conjunctiva, in rare instances thickened patches

¹ O. Haab. *Zeitsch. f. Augenheilk.*, II, 1899, 3.

due to it occur in the ocular conjunctiva, and in the cornea when it has been affected by severe pannus (see amyloid degeneration, page 491).

Hyaline degeneration of the ocular conjunctiva occurs also in pinguicula, giving to that affection one of its most characteristic features.

A **pinguecula** is a raised yellow patch in the ocular conjunctiva, of a triangular shape with the base toward the corneal margin. It most frequently occurs opposite the palpebral aperture, on the inner side of the globe, but is also often present on the outer. It is met with in people who have been exposed to much wind and dust, and is very common in those who have resided in the tropics.

Before its histological characters had been accurately investigated it was supposed, from its yellow colour, to be composed of fat hence the name applied to it. Really it does not contain fat, the yellow colour being due to collections of finely granular hyaline material fused together.¹ These on high magnification of the nodule can be seen as a number of small yellow spots. They are situated at varying depths in the tissue, some being immediately beneath the epithelium and others in the superficial layers of the sclerotic. In addition to the hyaline nodules there is a new formation of yellow elastic tissue, the fibres composing which are thick and show signs of degeneration. The blood-vessels in the affected area have thickened walls due to hyaline degeneration. The epithelium overlying the patch is thicker than normal, its superficial cells are flattened and sometimes contain granules of keratohyaline.

A **pterygium** is a triangular fold of the conjunctiva which extends on to the cornea. For descriptive purposes it is said to have a head or apex where it is attached to the cornea, a body or base where it springs from the conjunctiva covering the sclerotic, and a neck situated at the limbus where a pleat is formed at its upper and lower borders beneath which a probe can be inserted for a short distance. The arrangement of

¹ E. Fuchs. *Arch. f. Ophth.*, XXXVII, 1891, 111, 143.

the blood-vessels in the fold simulates somewhat that seen in the wings of some insects, hence the name by which the affection is known.

A true pterygium arises apart from any corneal ulceration or inflammation, and is always situated opposite the palpebral aperture on either the inner or outer side of the cornea, both eyes being usually affected. A false pterygium is the term applied to a fold of conjunctiva drawn over on to the cornea by the cicatrisation of a marginal ulcer, or a large abrasion, such as that following a lime burn. It may be present at any part of the corneal circumference.

A true pterygium arises under similar conditions and is situated in the same locality as a pinguecula, by which affection it is frequently preceded.¹ It, therefore, seems well to describe it here though it cannot be regarded as a hyaline degeneration.

It is an affection of later life, occurring in those whose occupations expose them to much wind and weather, hence it is more commonly met with in men than in women. It is especially common in dry and dusty districts.

A zone of cornea immediately in front of the head of the pterygium is opaque and grey; into this it tends to spread, advancing slowly further and further inward, ultimately reaching the pupillary area and affecting vision. In rare cases where there are two present in the same eye, on opposite sides of the cornea, they may extend inward until they meet in the centre. If a patient affected with a pterygium be removed from exposure to climatic conditions its progress is sometimes arrested. The apex then flattens down, the opaque zone in front of it disappears, the body becomes less vascular, and it ceases to spread.

A pinguecula frequently precedes the formation of a pterygium, but as the latter develops the pinguecula becomes flattened out and disappears. Where there is a large pterygium the semilunar fold also becomes decreased in size or even entirely obliterated. This shows that the condition is

¹ E. Fuchs. Arch. f. Ophth., XXXVIII, 1892, 2, 1.

more an extension of the conjunctiva on to the cornea rather than a new formation of tissue. The head of a pterygium unlike the conjunctiva covering the sclerotic is firmly adherent to the underlying fibrous tissue. On its surface there are several small horizontal folds or puckers. Microscopically these folds are found to be lined by laminated epithelium or goblet cells, and sometimes the appearance of tubular gland-like formations is produced. Occasionally the orifice of a surface depression, or tube-like formation, becomes occluded and a small cyst lined by epithelium is developed.

The subepithelial tissue in the head of a pterygium resembles the subepithelial tissue of the ocular conjunctiva at the limbus; it is composed of blood-vessels, white fibrous tissue, and yellow elastic fibres. The strands of the fibres appear tightly stretched and not waved. Collections of hyaline substance like that met with in pingueculæ may sometimes be found.

Underlying the head of the pterygium, Bowman's membrane becomes broken up by extensions into it of the overlying vascularised subepithelial tissue which may also penetrate into the anterior layers of the substantia propria. It is this involvement of the substantia propria which causes some opacity to be left after the head of the pterygium has been dissected up.

Prolonged congestion of the ocular conjunctiva is certainly one factor in the causation of a pterygium, but it is not the sole cause. In chronic inflammatory conditions of the conjunctiva there is prolonged congestion, and sometimes a slight extension of the terminal loops of vessels inward, but no development of such a condition as a pterygium. There is probably in addition to congestion some softening or necrosis of Bowman's membrane and anterior layers of the substantia propria, this giving rise to the grey zone around the advancing margin of the pterygium. The necrosis may be a senile change or the result of irritation caused by the exposure to climatic conditions.

Hyaline Nodules in the Optic Disc.—Hyaline bodies in the form of a mass of small rounded, translucent nodules sometimes protrude forward from the centre of the disc, but may proceed from its margins. Both eyes are usually affected; the vision is unimpaired. It is probably a condition which commences in early life and progresses with extreme slowness. It has several times been found associated with retinitis pigmentosa.

The nodules of hyaline material are found microscopically to be grouped around the central retinal vessels in front of the lamina cribrosa and show a faint lamination. Sometimes they contain calcareous granules.

It is clear from their position that they are not the product of the pigment epithelium or in any way connected with the membrane of Bruch (see page 482). They are probably formed as a deposition from the retinal blood-vessels.

b. **Amyloid Degeneration.**—Amyloid material like hyaline presents microscopically a homogeneous appearance; it is, however, distinguished from it by turning a brownish-red colour when stained with iodine and a purple-red colour with methyl violet. It is often found in association with hyaline material and also with an homogeneous substance which gives staining reactions that are not quite typical of one or the other. It seems probable that amyloid substance is derived from hyaline, and that the atypically staining material represents an intermediate stage in the transformation.

Amyloid degeneration of the conjunctiva is a rare condition; it usually occurs as a sequela of trachoma, but may arise independently. It has been met with mostly in Eastern Europe. It affects both the palpebral and ocular divisions of the membrane and also the semilunar folds and caruncle. The whole eyelid becomes much thickened, resulting in ptosis. The conjunctiva presents a yellowish translucent wax-like appearance. It is very friable and non-vascular. Clinically, in the early stages the affection cannot be distinguished from hyaline degeneration; it is of long dura-

tion and in the later stages calcification and ossification of the affected parts may occur.

Corpora Amylacea in the Optic Nerve.—Corpora amylacea, in every way similar to those found in the central nervous system, are met with in the optic nerve when it is atrophied and also, in elderly people, when it is otherwise normal. They consist of varying sized, round, or oval bodies of a homogenous laminated structure encircled by a capsule. They lie between the nerve fibres and are most frequently found in the intercranial portion of the nerve or the chiasma. It has been suggested from the appearance of the capsule around them that they may be depositions of amyloid substance in the cells of the neuroglia.

c. **Fatty Degeneration.**—Fatty degeneration is not simply a deposition of fat in the tissues, but actual change of the albumin into fat. Fat in the tissues is seen microscopically as highly refractive circular globules which are dissolved by ether and chloroform. When large they stain orange with Sudan III and when small, red. Some forms of fat, but not all, stain black with osmic acid.

Fatty degeneration in the tissues of the eye derived from mesoblast is met with in various atrophic conditions. It is a noticeable feature in connection with old inflammatory exudates and also in some forms of new growth. In the ossification which takes place in exudates in the uveal tract, a medullary substance containing large globules of fat becomes formed between the trabeculae of bone.

Arcus Senilis.—The opacity which forms in the periphery of the cornea in elderly people, termed "arcus senilis," is probably due to a fatty degeneration of the substantia propria of the cornea. It commences in the form of two narrow grey arcs, one at the upper and the other at the lower border of the cornea, which tend to lengthen at their extremities until they become united and a complete ring of opacity is produced. The outer margin of the opacity is sharply defined and is separated from the limbus by a semi-diaphanous zone. The inner margin, on the other

hand, shades off gradually into the clear central area of the cornea.

Microscopically the opacity is found to be due to a number of highly refracting globules of various sizes which are situated in Bowman's membrane, in the fibrous lamellæ, and in the corneal corpuscles. The sharp outer margin of the opacity corresponds in position to the termination of Bowman's membrane, which does not extend quite to the extreme periphery of the clear cornea. As a large number of the globules in the affected area are situated in Bowman's membrane, the extreme periphery where it is absent appears comparatively clear.

In the substantia propria the degeneration is most marked in the anterior layers fading off in the deeper ones, though the tissue immediately adjoining Descemet's membrane is often markedly affected. In an antero-posterior section through the cornea the opaque zone is seen to extend deeper toward the periphery than toward the centre. Some globules are occasionally found in the deep layers of the sclerotic.

There has been much difference of opinion as to the nature of the globules to which the opacity is due, mainly because they are not stained black by osmic acid. With that stain their outlines become sharply defined and they refract light more highly, but they do not turn black. With Sudan III,¹ however, they stain in every way like fat and their distribution and arrangement can then be clearly seen. They are dissolved by both ether and chloroform. It seems, therefore, that they must be regarded as a form of fat which does not turn black with osmic acid.

Cholesteroline crystals which are formed in connection with fatty degeneration are frequently met with in old hemorrhages and in degenerating inflammatory exudates. Large numbers of them may be found in the subretinal fluid or in the vitreous and aqueous humours where such conditions are present. They are soluble in alcohol and sections

¹ J. H. Parsons. R. Lond. Ophth. Hosp. Reps., XIII, 1893, p. 508.

of tissue containing them which have been treated with that reagent show characteristic sharply defined slit-like spaces where they were situated. **Synchisis Scintillans** is the name given to fluid vitreous containing cholesterine crystals which float up and down on movements of the eye. When viewed with the ophthalmoscope they reflect light from their flat surfaces giving rise to the appearance of a shower of gold and silver spangles. They occur sometimes in the eyes of elderly people without any other apparent disease. Fatty degeneration may take place in the fibrils forming the framework of the vitreous which, becoming destroyed, causes its liquefaction. It is also met with in the degenerative changes which take place in intraocular hemorrhage. From the breaking up of the fat cholesterine becomes deposited, tyrosin, margarin, and phosphates being also sometimes formed.

d. **Calcareous Degeneration and Bone Formation.**—In calcareous degeneration the salts deposited in the tissue are usually the carbonates and phosphates of lime. It generally represents the final stage in a series of degenerative changes, the tissue in which the deposition occurs having very low vitality or being absolutely necrotic.

The pathological hyaline formations already described in connection with the cornea, conjunctiva, choroid and optic disc frequently become calcareous. So also do necrosing inflammatory exudates; breaking down cells of rapidly growing neoplasms; and the laminated tissue formed on the inner surface of the lens capsule in capsular cataracts. If the affected part is non-vascular the deposition takes the form of granular incrustation; where blood-vessels are present osteoblasts form and bone is developed.

The hyaline nodules on the inner surface of the membrane of Bruch are shut off from the blood-vessels of the choroid by that membrane and usually only become petrified with lime salts. In rare cases where the membrane of Bruch has been ruptured they become vascularised and bone is formed in them. When the lens capsule is intact the calcareous changes which are met with in the lens are only of

the nature of granular deposition. In rare cases where the capsule has ruptured, and blood-vessels with fibrous tissue has extended into it, a formation of true bone within the capsule has been found.

Transverse Calcareous Film of the Cornea.—A transverse calcareous film of the cornea consists of a superficial band of opacity which extends across it in the line of the palpebral fissure, a little below the centre. Its upper border is usually concave and the lower nearly straight, hence its extremities are broader than the centre. It never quite reaches to the corneal margin on either side, a clear area always intervening. The two extremities of the film are usually denser than the centre and on magnification small grey and white dots are seen in it. In commencing it consists of two separate opacities, one on each side of the cornea, which gradually extend inward until they unite. Its formation is exceedingly slow and a complete band may take several years to develop. It is met with mostly in shrunken eyes which have had cyclitis, or blind glaucomatous eyes, but may form in the eyes of elderly people which in all other respects appear healthy.

On pathological examination,¹ the cornea, in the situation of the film, is found to be thicker antero-posteriorly than elsewhere. This thickening is due to the new formation of laminated non-vascular fibrous tissue anterior to Bowman's membrane. Bowman's membrane itself in the situation of the film is divided up into short pieces the gaps between which are filled with fibrous tissue (Fig. 219). Lying on the anterior surface of the membrane and encrusting it are calcareous granules which stain deeply with hematoxylin, and evolve bubbles of gas on the application of acids. The epithelium covering the film is either thickened or degenerate.

A new formation of fibrous tissue anterior to Bowman's membrane is also met with in eyes which have had glaucoma or inflammation of the uveal tract, when there has been a formation of vesicles on the cornea. These are due to

¹ C. H. Usher. R. Lond. Ophth. Hosp. Reps., XIII, 1893, p. 508.

edema of its anterior layers. The similarity of the condition pathologically to transverse film of the cornea suggests that it also may commence as a localised edema.

The lymph spaces which pass antero-posteriorly through Bowman's membrane become distended, and the surface epithelium raised in places, by the accumulation of albumin-

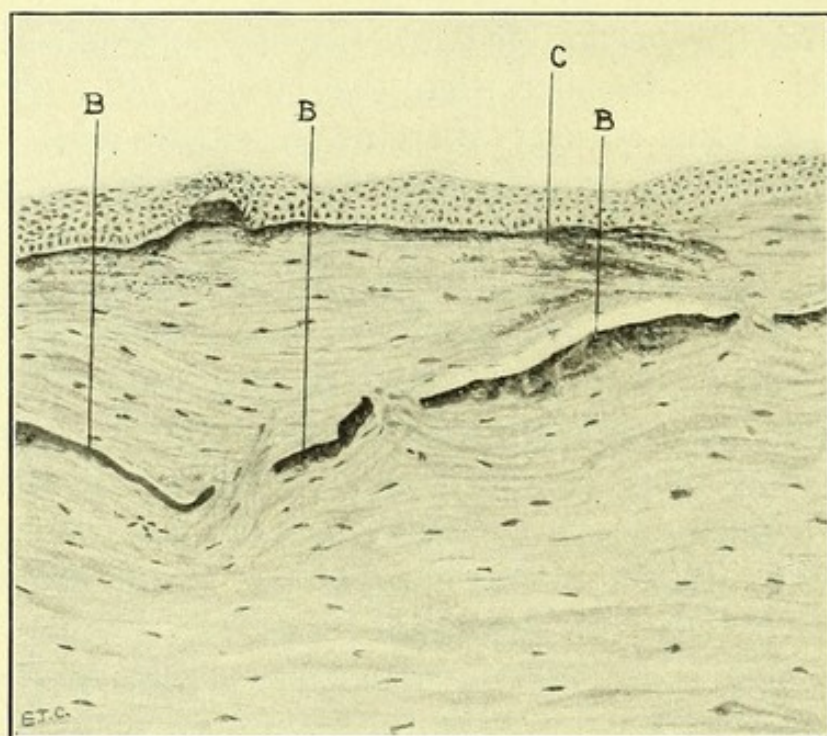


FIG. 219.—Section through a transverse calcaeous film of the cornea. *B*, points to pieces of Bowman's membrane encrusted with calcaeous granules. Anterior to Bowman's membrane and in the enlarged nerve channels in it is newly formed laminated fibrous tissue. *C*, points to calcaeous material in this fibrous tissue immediately beneath the surface epithelium.

ous coagulable fluid beneath it. Cells, formed by proliferation of those lining the lymph spaces of the substantia propria, then extend into the fibrinous matrix formed from the fluid in the dilated channels and beneath and the epithelium. From these cells fibrous tissue develops, which lying in the channels in Bowman's membrane split it up into separate pieces. The nutrition of these pieces of Bowman's membrane becoming impaired calcaeous salts are deposited about them.

A transverse calcareous film forms, as already stated, opposite the palpebral fissure, *i.e.*, on the part of the cornea most exposed to atmospheric influences and the part least pressed upon by the lid margins in winking. Though exposure may play some part in its production, it is not the sole cause. The affections of the conjunctiva opposite the palpebral aperture, which are due to exposure, *viz.*, pterygium and pinguecula, are not found associated with transverse calcareous film of the cornea.

It seems highly probable that a want of the normal amount of pressure of the lid margin over the front of the cornea is an important factor in its formation. The curved upper margin of the film corresponds to the curved margin of the upper lid. Normally in winking the edges of the lids have a sort of squeezing action on the surface of the cornea, being kept closely in contact with it by the muscle fibres of Riolani. They considerably depress the surface epithelium and flatten out any inequalities, thus tending to prevent any accumulation of fluid between it and Bowman's membrane. The conditions in which this action of the lids is interfered with are those which favour the formation of a transverse film. When the eyeball is shrunken it is recessed away from the lids. When the cornea is anesthetic, as in glaucoma, the normal afferent stimulus for winking is abolished.

Ossification of the Choroid.—In the inflammatory exudate which is thrown out in plastic choroiditis, degenerative changes sometimes take place resulting in the formation of bone. The commonest position in which this ossification occurs is immediately around the optic disc; it is also frequently met with in the neighbourhood of the ora serrata. The plate of bone which forms around the optic disc may extend forward, and the ring which forms around the ora serrata backward, until the two become united and a complete cup of bone is produced. At the posterior part of such a cup there is always a central hole through which the fibres of the optic nerve pass. The ring of bone at the ora serrata may, besides growing backward, extend inward into an inflam-

matory cyclitic membrane; the cup of bone will then have a lipped margin.

The development of bone in the choroid is usually a very slow process and occurs mostly in blind and shrunken eyes. When formed it presents all the characteristics of normal compact bone. It is transversed by blood-vessels lying in Haversian canals, and surrounded by Haversian systems with osteoblasts; sometimes also between its trabeculæ there is medullary fat (Fig. 220).

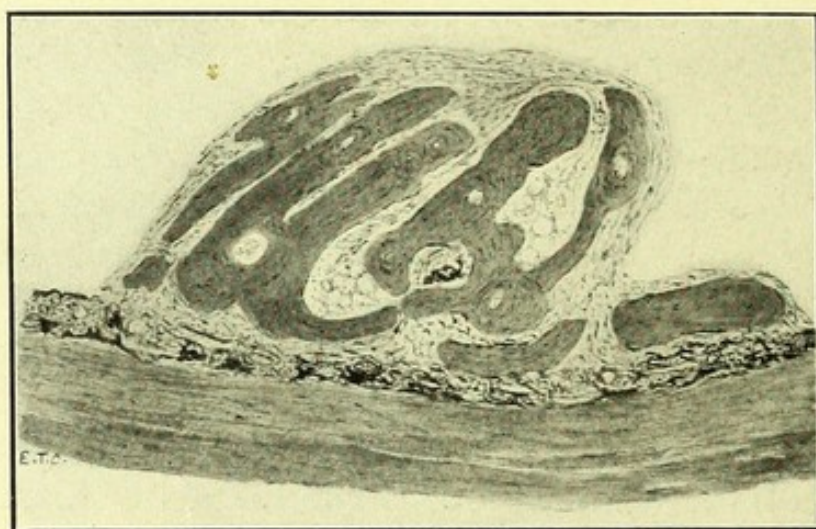


FIG. 220.—Section through a band of bone formed in a mass of organised inflammatory exudate from the choroid. The bone is shown consisting of numerous trabeculæ with medullary fat between them. The eye had been injured by a piece of steel fourteen years previous to removal. Case recorded by Treacher Collins, *Ophth. Review*, XI, 1892, 139.

As the result of plastic inflammation the choroid in which ossification takes place is much changed. Large areas of the capillary layer and elastic lamina become destroyed. The outer layers become atrophied and the walls of their blood-vessels sclerosed. The inflammatory exudate is transformed into fibrous tissue. The retina, if not detached, is intimately incorporated with the choroid. It is in the fibrous tissue formed from the exudate that the bone develops. Where the elastic lamina is still present this fibrous tissue may be found on either its outer or inner surface. The exudate from which it forms accumulating either in the

region of the capillary layer or extending through a gap in the elastic lamina to the inner surface. Hence bone formation in connection with the choroid is found situated sometimes on the outer and sometimes on the inner surface of Bruch's membrane.

The fibrous tissue previous to the deposition of the calcium salts in it assumes a homogeneous appearance resembling hyaline substance. When the salts are deposited it becomes granular and stains deeply with hematoxylin. The cells in the vicinity of the ossifying area which are about to become osteoblast are seen to assume an angular outline. The process begins on the outer surface of the exudate, concentric layers are gradually formed, and the Haversian systems built up.

e. Staphylomata.—The eyeball is a hollow chamber distended with fluid; in a state of health the toughness of its coats is such that they are able to withstand the normal intraocular pressure without stretching or bulging. If the intraocular pressure becomes increased, or the walls of the globe become softened, then some bulging may take place. Often both factors are present. Where the sclerotic bulges it is thinned and acquires a grey colour from the pigment in the uveal tract showing through. From irregular degrees of bulging the prominence often has a nodular outline, and a fancied resemblance which it may thus possess to a bunch of grapes has led to the condition being termed a staphyloma.

The factors favouring the formation of an ectasia of the walls of the eyeball may be considered under the following headings: 1. age; 2. inflammation; 3. anatomical peculiarities; 4, congenital abnormalities.

1. **Age.**—The cornea and sclerotic in early life are very expansile structures and gradually toughen as age advances. In glaucoma due to congenital malformation (buphthalmia, see page 70) the walls of the eye, though expansile, are nearly equally resistant in all parts so that the whole globe becomes enlarged and both cornea and sclerotic are thinned. In late life high intraocular pressure may exist for a consider-

able time without any appreciable alteration in the shape of the eyeball.

2. **Inflammation.**—As the result of inflammation a localised softening or thinning of the coats of the eye may take place so that their resistance becomes lowered and they stretch and bulge before the normal intraocular tension. Or, they may be sufficiently resistant to withstand normal tension and only stretch and become thinned when it is increased.

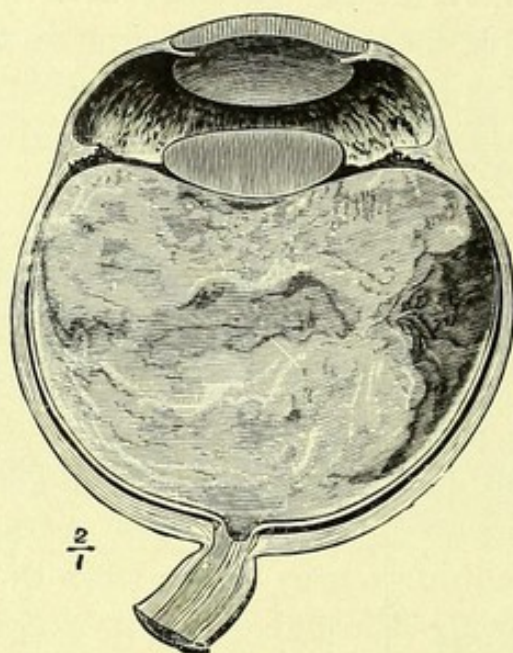


FIG. 221.—Shows an antero-posterior section of an eye lost from primary glaucoma. There is a staphyloma in front of the ciliary body in the region of the canal of Schlemm (intercalary). The optic disc is deeply cupped. Specimen in the R. Lond. Ophth. Hosp. Museum.

A staphyloma of the cornea is the outcome of an inflammation of that structure; frequently a perforating ulcer, which besides softening the cornea, causes increase of tension from anterior adhesion of the iris (see page 316).

3. **Anatomical Peculiarities.**—The strength of the fibrous tissue covering of the globe is not equal in all parts. It is weakened at certain positions by the passage through it of blood-vessels and nerves. Ectasias may occur in these positions as the result of increased tension apart from any inflammation.

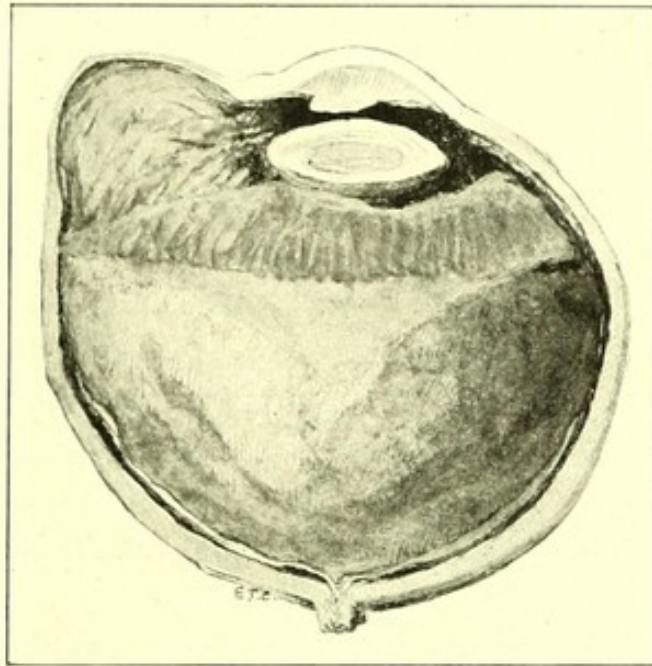


FIG. 222.—Shows an antero-posterior section $\times 2$ of an eye lost from primary glaucoma. On the left side there is a large ciliary staphyloma and considerable atrophy of the ciliary body lining it. Specimen in the R. Lond. Ophth. Hosp. Museum.

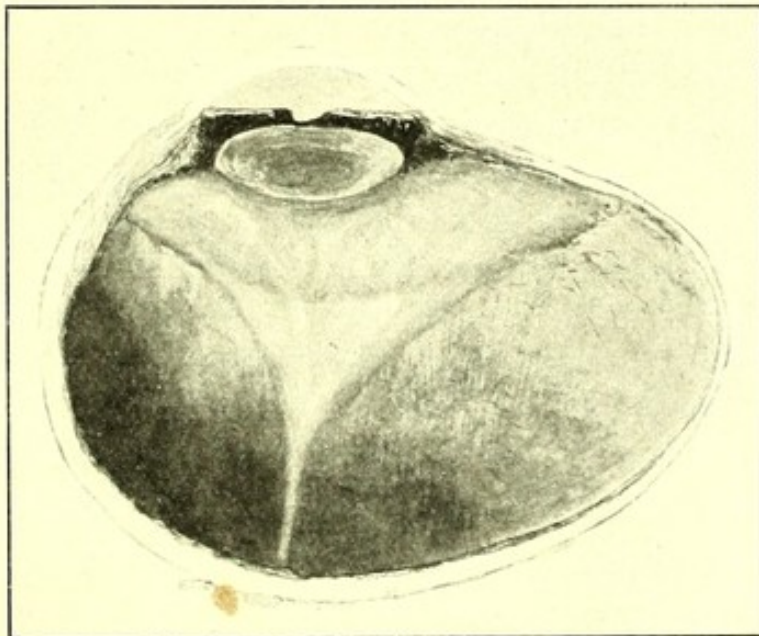


FIG. 223.—Shows an antero-posterior section $\times 2$ of an eye which went blind from primary glaucoma. On the right-hand side there is a large equatorial staphyloma with considerable thinning of all the coats of the eye. The vitreous humour is shrunk and detached except at the ora serrata and optic disc. Specimen in the R. London Ophth. Hosp. Museum.

An **intercalary staphyloma** is one which occurs in the region of the canal of Schlemm and the anterior ciliary veins, in front of the ciliary body (Fig. 221).

A **ciliary staphyloma** occurs in the region of the ciliary body where the anterior ciliary arteries perforate (Fig. 222).

An **equatorial staphyloma** is situated about midway between the corneal margin and the optic disc where the vortex veins pass out from the eye (Fig. 223).

A **posterior staphyloma** is situated at the posterior pole where the long and short ciliary arteries and the ciliary nerves enter the eye. It is the common cause of axial myopia (see page 503).

Cupping of the optic disc takes place where the optic nerve enters the eye and where the fibrous tissue coat is considerably reduced in thickness, being only represented by the lamina cribrosa. This is the weakest part of the walls of the globe and the first to become ectatic as the result of increased tension.

4. **Congenital Abnormalities.**—In the region of the fetal ocular cleft, as already pointed out (see page 14), some weakness in the walls of the globe may exist; frequently in association with a coloboma of the choroid. Ectasia may then occur as the outcome of normal intraocular tension, even sufficient in some cases to produce a cyst-like protrusion. A bulging in the region of the ocular cleft is frequently associated with a crescent at the lower margin of the optic disc, resembling in every way a myopic crescent. That there is some congenital weakness at the posterior pole of the eye, the nature of which is as yet undetermined, which predisposes to the production of axial myopia seems highly probable.

The view has been advanced that the bulging of the cornea which results in the **production of keratoconus** is occasioned by some congenital weakness near its centre. In support of this it has been pointed out that the mesoblastic elements, from which the substantia propria is developed, grow in from the sides between the surface epithelium and the

lens vesical, and that the point to which they converge may possibly be abnormally weak.¹

Posterior Staphyloma and Axial Myopia.—Myopia is the term applied to the refractive condition of the eye in which parallel rays falling on the cornea are brought to a focus in front of the retina. It may be due to an abnormal condition of the refractive media or a lengthening of the antero-posterior axis of the globe. The refractive media may have an increased refractive index or an abnormally strong curvature. The lens may be displaced forward or

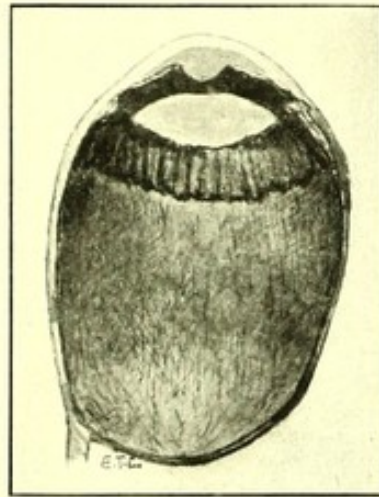


FIG. 224.—Shows an antero-posterior section through a highly myopic eye, actual size. There is considerable stretching and thinning of the whole posterior half of the globe. The specimen is preserved in the R. Lond. Ophth. Hosp. Museum.

the ciliary muscle act spasmodically. By far the commonest cause of myopia, however, is an increase in the length of the eyeball due to a bulging at the posterior pole (**axial myopia**). This bulging is entirely limited to the posterior half of the globe, the parts in front of the equator maintaining their normal dimensions. The characters of the ectasia vary; sometimes it is strictly localised to the region of the macula and optic disc and has a sharply defined margin; at others it is a general stretching of the whole of the hindmost half of the globe and there is a gradual slope into the unaffected

¹ J. Tweedy. Trans. Ophth. Soc. of the U. K., XII, 1892, p. 67.

area (Fig. 224). The former variety of ectasia, which has been described as "**staphyloma verum**," can be recognised ophthalmoscopically by the presence of a characteristic crescentic dark line most marked usually on the nasal side of the disc, and about one and a half discs' breadth from it. Around this dark line, which corresponds to the edge of the ectasia the retinal vessels curl in the same way as they do round the edge of a glaucomatous cup. The floor of the ectasia, which is inside the crescentic edge, is always at a deeper level than the surrounding parts; which can be recognised by the parallax displacement which occurs on movement of the ophthalmoscope lens and by its higher refraction. The choroid lining the ectasia being much stretched shows more signs of atrophy than elsewhere.

The diminution in the thickness of the sclerotic which occurs at the site of a posterior staphyloma varies with its extent. Sometimes it is so thin that after removal of the eye it fails to maintain its proper curvature and becomes dimpled inward.

The changes in the choroid in axial myopia can be seen ophthalmoscopically; they occur at the margin of the optic disc and in the macular region. As a general rule they are more extensive the higher the degree of the myopia, but some striking exceptions are met with.

The changes at the margin of the optic disc consists of the so-called "**Myopic crescent or conus**." It is chiefly situated on the temporal side of the disc, the small ones being restricted to that position, the larger ones extending to the upper and lower borders, or even entirely encircling it.

A conus appears as a white area with a pigment outer margin, varying in breadth from a narrow crescent to a patch the width of two or three optic discs in its largest diameter. The larger ones are frequently not of a uniform whiteness throughout, the external part being often pinkish in colour or showing a network of choroidal vessels on its surface. The floor of a conus can be recognised as situated at a deeper level than the surrounding part, the depth of the

ectasia being greater there than elsewhere. Microscopically, the choroid, elastic lamina, and pigment epithelium are found to be absent over these crescents, terminating some little distance away from the position where they usually end at the border of the disc (Fig. 225). The sclerotic which is thereby exposed to view gives rise to the white reflex when seen ophthalmoscopically. The changes at and around the macula in axial myopia, seen ophthalmoscopically, consist of

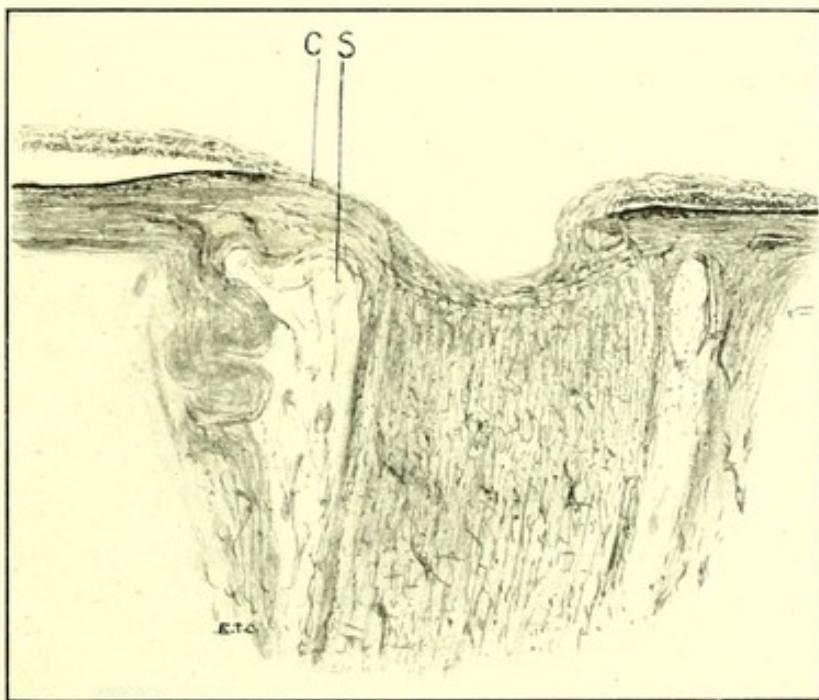


FIG. 225.—Section through the head of the optic nerve in an eye in which there was a myopic crescent. *C* points to the position of the "distraction crescent," the choroid and pigment epithelial layer being there absent. Note the tendency to the formation of a "supertraction crescent" on the opposite side. Also note the outward extension of the intervaginal space *S* on the side where the choroid is absent.

light coloured patches where the choroid is completely atrophied and the sclerotic exposed, and of areas where its capillary layer has disappeared and a network of the outer larger vessels is rendered visible. Sometimes there are also white irregular lines, and red patches which look like hemorrhages, but which do not alter in shape or size when kept under observation; they are probably dilated veins. Choroidal hemorrhage may occur at the macula in high degrees of

myopia and cause sudden loss of central vision; these hemorrhages gradually become converted into densely black patches.

All the above changes are directly attributable to the stretching and are not due to inflammation. Microscopically splits are sometimes found in the elastic lamina. As a case of myopia progresses these atrophic changes are seen to increase in size and extent, the white patches running into one another and forming larger ones. Patches of thinned choroid become converted into areas of complete atrophy. Patches of atrophy arising in the vicinity of the macula become joined to those extending from the temporal margin of the optic disc, and in the most extreme cases the whole posterior pole of the eye becomes converted into one large white area.

The changes in the retina in axial myopia are chiefly secondary to the choroidal atrophy. As the result of the stretching, in which the retina participates with the other two coats, the fovea tends to become flattened out and the retinal vessels assume a markedly straight course. From the traction backward the choroid, as already stated, becomes drawn away from the margin of the optic disc on the nasal side, a **distraction crescent** being formed. Traction acting in a similar way on the nasal side of the disc tends to draw the retina, and to a less extent the choroid, over its inner margin, which gives rise ophthalmoscopically to a hazy yellowish crescentic area at this side of the papilla, a **super-traction crescent**.

Where the choroidal blood-vessels have atrophied the outer layers of the retina cease to receive their nutrient supply and, together with the pigment epithelium, undergo degeneration. When the elastic lamina becomes ruptured, or destroyed, adhesions form between the remains of the two inner coats. If detachment of the retina occurs in myopia, and a fused area of retina and choroid exists, the retina either tears away around it, leaving an isolated piece of the retina adherent to the choroid; or the adhesion per-

sists and a tubular prolongation from the external surface of detached retina extends outward to the choroid.

In axial myopia the position of the optic disc is altered, the temporal border becoming displaced backward. Ophthalmoscopically this gives rise to an apparent change in its shape; it appears to be oval with the long axis vertical. Partly due to this tilting and partly to the dragging of the retina over from the nasal side as already mentioned, the physiological cup has a markedly overhanging inner margin from beneath which the retinal vessels are seen to emerge.

In sections through the head of the optic nerve where it enters the eye in axial myopia the intervaginal space is found to extend outward laterally at its termination to a greater extent on the temporal than on the nasal side.

With the enlargement of the vitreous cavity which takes place on the formation of a posterior staphyloma there is no compensating new formation of vitreous humour. Either the vitreous becomes rarefied and of more fluid consistency, or the hyaloid membrane becomes detached from the retina and a fluid of the consistency of the aqueous humour fills the intervening space. In high degrees of axial myopia both these conditions are frequently met with.

A detachment of the vitreous can sometimes be recognised ophthalmoscopically by its giving rise to a bright reflex which is evidently situated nearer the centre of the eye than the retina. When the vitreous humour becomes liquefied the delicate fibres which form its matrix become broken up and move freely in the thin fluid media in which they are situated. Hence most patients with axial myopia become conscious of floating opacities in front of their eyes. In time the strands of the matrix moving about in the fluid become entangled and collect into web-like masses which are not only seen by the patients but are visible ophthalmoscopically.

The ciliary muscle in eyes with axial myopia is flatter than normal and has scarcely any circular fibres (or muscle of Müller). In hypermetropia, on the other hand, there is

usually a marked development of these circular fibres. The inference is that as myopic patients read at their far point and do not use their accommodation those parts of the ciliary muscle most required for that purpose fail to develop. In hypermetropia, on the other hand, an excessive amount of accommodation is required and the parts of the ciliary muscle which are deficient in myopia become hypertrophied.

In myopia the anterior chamber is usually deep and in hypermetropia shallow, the difference in the two conditions in this respect may also be in part attributable to the condition of the ciliary muscle. An excess of circular fibres displaces the ciliary processes inward and these hold the base of the iris forward which in their absence tends to recede. Another factor, which probably influences the depth of the anterior chamber is the consistency of vitreous; a fluid vitreous does not form such a substantial support to the posterior surface of the lens as one of the normal jelly-like character. In keeping with this view is the fact that a slight tremulousness of the iris and lens is often found in association with a fluid vitreous.

Axial myopia is rarely a congenital defect; it usually commences at the school age and tends to increase with lessening rapidity up to the end of the second decade of life; after that it remains stationary. Very high degrees may go on increasing to later in life such cases have been termed **malignant myopia**.

The chief factor in the **causation of axial myopia** is prolonged application to near work, it being rarely met with in savage races. That the rate of progress should decrease with the advance of age can be attributed to the increasing toughness of the sclerotic. In the malignant cases the sclerotic has probably become so thinned that the natural toughening process does not suffice to arrest its further expansion.

There has been much speculation as to the reason why close application to near work should result in posterior staphyloma. Several theories have been put forward, some

have been definitely disproved, of the others, no one can be said to be entirely satisfactory.

Of the disproved theories, that which attributed the condition to a sclero-choroiditis posterior or to a rise of tension in association with the act of accommodation, nothing further need be said. Though not in itself congenital, there is probably in axial myopia often some developmental defect, such as a congenital weakness in the sclerotic, predisposing to its formation and accounting for the undoubted hereditary tendency which exists in some instances.

The theories which associate the bulging with the act of convergence would appear to have a more substantial basis. During convergence the posterior pole of the eyeball is displaced outward and therefore becomes pulled upon by the optic nerve which is attached a little to the inner side; the amount of traction would be increased where the nerve was comparatively short. Such traction it is suggested would account for the backward prolongation. It is difficult, however, to see why under such circumstances the greatest prominence should be to the outer side of the nerve and not at the nerve itself.

During convergence several of the extraocular muscles are brought into use, not only the internal recti. During the act of reading the eyes have to make excursions from one side of a line of print to the other and be kept steady all the time; this necessitates both the recti and oblique muscles being called into action. The two oblique muscles encircle the equator of the globe and the recti muscle, in spite of the check ligaments, may tend to compress its sides; the posterior part of the eyeball, the bulging of which produces axial myopia, is not touched by the muscles. It seems likely, therefore, that compression by the extraocular muscles may be the exciting cause.

A modification of the compression theory is that which accounts for the condition by congestion of the choroidal vessels from obstruction to the vortex veins which emerge beneath the tendons of the oblique muscles. It is, however,

doubtful if congestion of the choroid would result in softening of the sclerotic so as to cause an ectasia.

Keratoconus.—The condition termed keratoconus is a bulging of the central part of the cornea, occurring apart from any inflammation, and causing it to assume the shape of a cone. It is a rare disease which affects both eyes, commences usually about adolescence, and progresses with varying degrees of rapidity for some years, ultimately becoming stationary.

The ectasia is due to thinning of the substantia propria in the centre of the cornea and not to any increase in intra-ocular tension. The thinnest part forms the apex of the cone which in advanced cases involves the whole cornea. The apex is not quite in the centre, usually a little below; when touched with a probe it is easily dimpled. The thinning of the tissue is very apparent during operations, and has also been demonstrated in sections of pieces which have been removed by a trephine. The thickness of the cornea may be reduced to one-third its normal dimensions. At first it is perfectly transparent and the defect of vision to which the condition gives rise is entirely attributable to refractive error. Later an opacity forms at the apex of the cone, which sometimes appears rapidly and in many cases is due to a rupture in Descemet's membrane and its endothelium through which the aqueous humour filters into the cornea, causing it to become edematous and swollen.

These opacities remain permanent and there is never any tendency for the conicity to decrease; on the other hand, no complete rupture or ulceration of the apex of the cone is met with.

The **cause** of the thinning has not yet been definitely determined; as already stated, some observers think there is a congenital weakness which predisposes to its development. It is also noteworthy that the part which becomes thinned is the furthest removed from any vascular supply. If the disease is due to malnutrition it is probably of a general and not a local character, as both eyes are nearly always involved.

APPENDIX.

PRACTICAL METHODS.

In this chapter dealing with laboratory methods it is assumed that the reader has a practical knowledge of the elements of bacteriology and of the various ways of examining the blood such as are taught in the course of an ordinary medical curriculum. The only methods described are those likely to be required in connection with the work of an ophthalmic hospital or department.

Methods of Obtaining Material for Examination.

When a bacteriological examination is to be made the material to be examined should be obtained in an early and progressive stage of the disease, and every care taken to avoid contamination.

In taking material from styes, chalazion, or phlyctenulæ only unopened ones should be selected. The surface of the affected area should be thoroughly cleansed with antiseptic lotion and then washed with a sterile salt solution. The puncture into the affected tissue should be made with a sterilised knife and a platinum loop, which has been sterilised by holding it in the flame of a spirit lamp, passed through the opening. The material adhering to it is then inoculated in two tubes of culture media, one of which should consist of blood-serum.

In making the inoculation the tube should be held sideways between the base of the thumb and forefinger of the left hand with the mouth inward toward the palm. The plug of wool, after being passed through the flame of a spirit lamp, is removed with the right hand and held between the bases of the first and second finger of the left hand. The inoculation is made by passing the loop over the surface of the media from below upward. The plug of wool is then passed through the flame and replaced; the tube may be marked with a glass pencil with the name of the patient and the date, and then placed in the incubator in an upright posi-

tion. If blood-serum cannot be obtained blood agar should be used for taking the primary culture. In the case of the conjunctiva this is readily prepared by pricking a small conjunctival vessel and taking blood and pus together in the loop and smearing it over the agar media.

Two smear preparations on microscopic slides should also be made. With the platinum loop the material is smeared as thinly and evenly as possible over the slides and allowed to dry in the air, no heat being applied. These are subsequently fixed (see page 226), one stained by carbol

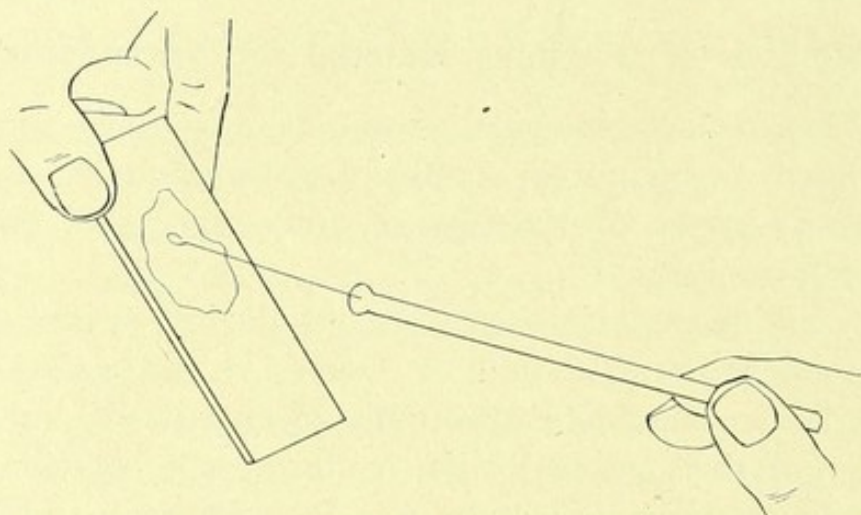


FIG. 226.—Showing the method of making a smear preparation with a platinum loop.

thionin and the other by Gram's method, and examined with $1/12$ oil emersion objective; no cover-glass need be applied if the preparation is not to be kept.

To examine the cytology of the cells of the conjunctiva in cases where there is little or no conjunctival discharge, the conjunctiva is exposed and the platinum loop drawn along the conjunctiva several times. Soon the irritation produced will give rise to mucus which can be taken up on the loop and a smear preparation made. This method is principally of use where it is desired to examine the character of the polymorphonuclear leukocytes as in cases of suspected spring catarrh. When it is desired to examine the lymphocytes the best method is to rub a cover-glass over the surface of

the conjunctiva or express a follicle, squeezing out the material obtained between two cover-glasses. To obtain smear preparations from a corneal ulcer take a sterile discission needle and with the blade lightly scrape the surface of the ulcer, then make smear preparations from the material so obtained.

The examination of the aqueous for organisms is surrounded by many difficulties unless the organism is present in considerable numbers, which is very rarely the case; they cannot be found by an ordinary microscopical examination of smear preparations but may sometimes be obtained after centrifugalisation of the fluid. For this purpose the fluid

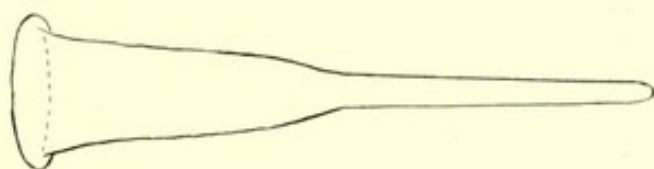

FIG. 227.—Glass tube for centrifugalisation of blood.

is collected in a capillary pipette (see page 227). The capillary end is sealed and it is placed in a centrifugaliser. After centrifugalisation a rubber teat is put on the open end of the tube and by its means the first drop squeezed out on to a slide, which is allowed to dry, then fixed, stained and examined microscopically.

Cultivations made from the aqueous give more satisfactory results, but the great difficulty is in obtaining the fluid uncontaminated. For this purpose a hollow needle having a spear point should be thrust into the anterior chamber at the limbus, the point of entrance being first touched with the cautery so as to ensure sterilisation of the wound of entrance. When this latter precaution is neglected the bacillus xerosis is not infrequently found in the cultivation, showing that contamination has taken place from the conjunctiva. Aqueous may be obtained for the application of the agglutination test by a simple paracentesis, the fluid being collected as it escapes from the anterior chamber over the surface of the keratome by a pipette.

In removing a piece of conjunctiva for microscopical examination care must be taken not to damage the tissue with forceps. A fine pair of straight iris forceps and sharp-pointed scissors are the best instruments to use for the purpose. After removal the piece should be washed in normal saline solution and pinned out on a piece of cork by means of glass pins which are made by drawing out a piece of capillary glass tubing in the flame of a spirit lamp. The specimen is then placed face downward in the fixing fluid.

In the examination of excised eyes the first thing to decide is what is the particular point of interest about the case that is to be investigated; *i.e.*, whether it be bacteriological or histological. If it be bacteriological the eye should be kept as aseptic as possible and examined immediately after excision. After its removal the globe should be cleansed with sterile salt solution and an external examination made; it is then dipped for fifteen seconds in boiling saline solution. This treatment destroys the organisms on the outer surface of the globe.

If the aqueous is to be examined the fluid should be withdrawn from the anterior chamber with a sterile hollow needle.

If the vitreous, the eye should be divided with a sterile knife, smear preparations and cultivations being taken from it. In cases where the organisms are likely to be very scanty the globe may, after treatment with boiling saline, be placed in a sterile bottle in the incubator for twenty-four or forty-eight hours and then examined; the fluids in the eye acting as a culture media, the organism will be found to have increased.

If a histological examination is to be made, and it is desired to examine the condition of the retinal blood-vessels, as much as possible of the optic nerve should be obtained when the excision is performed.

Postmortem Methods—Injection of the Eye.

Material should be obtained as soon after the death of the patient as possible before postmortem changes have had

time to take place. Such changes in the retina begin to show themselves six hours after death, but they may be inhibited by placing the body in an ice chamber or injecting undiluted formalin into the orbit immediately on the death of the patient.

After the brain has been taken out the bony roof of the orbit is chiselled through and removed, the ring of bone around the optic foramen being left intact. The periosteum of the orbit is then divided antero-posteriorly, and if the condition of the nerve sheath is to be examined the optic nerve should be ligatured close to the foramen to prevent the loss of fluid therefrom. Having exposed the globe it should be removed by dividing the conjunctiva from the front and the muscles from behind. To prevent the deformity being noticed the orbit may be filled with a piece of liver or an eye from an animal and the lids stitched together on their posterior surface. In cases in which permission cannot be obtained to remove the whole eye, the posterior half may be taken by isolating the globe posteriorly right up to the limbus and dividing the ora serrata with a sharp knife. Previous injection of the orbit with undiluted formalin renders this easier to perform.

Injection of the blood-vessels of the eye *in situ* is difficult. It should be carried out as soon as possible after death. Hot carmine-gelatine mass is the best substance to use. It is made as follows:

Pure carmine	4 gm.
Solution of ammonia	8 c. c.
Distilled water	50 c. c.

The ammonia is added to the carmine, the water poured on, and the solution filtered.

To this is added, after warming, 10 gm. of pure gelatine, which has been allowed to take up as much distilled water as it will. This having completely dissolved, a 10 per cent. solution of acetic acid is added drop by drop until the ammonia is quite neutralised; the carmine being precipitated,

produces a dull brownish-red colour. The addition of a little salicylic acid prevents decomposition.

The injection should be made through the internal carotid artery after removal of the brain. The artery is ligatured at the base of the skull on the proximal side of the ophthalmic artery.

A hot injection is made by means of a syringe the cannula of which is tied into the distal end of the vessel. It is well to have previously separated the skin of the forehead and eyelids so as to prevent the injection passing into the skin of the face. Before injection is made the tissues should be thoroughly heated by immersion of the head in hot water. The specimen is subsequently hardened in formalin which sets the carmine mass in the tissues.

Methods of Fixation and Hardening.

Smear preparations of cells can be examined in a fresh condition, but not much information can be obtained without first staining them. Wet preparations can be stained with acid methylene blue (see page 533) but fixation before staining is preferable. The ideal method of fixation is one which will rapidly coagulate the albuminous material of which the cells are composed without altering their form or their reaction to dyes. There are many fixing agents and the selection must be made according to the points which are to be investigated.

Heat is especially useful for smear preparations when examining for microorganisms. The slide on which the smear preparation has been made is passed rapidly through the flame of a spirit lamp or Bunsen burner three times. Blood films or smear preparations of cells may be fixed by holding the film some distance above the flame, thus applying a gentle continuous heat for about thirty seconds. Whole eyes are rapidly fixed by plunging them into hot water and raising it to boiling-point for three minutes. The method is especially useful in the examination of the vitreous, as

by its means, the consistency, and the various lymph paths in it, can be investigated. Small pieces of growth can rapidly be fixed by this method and sections be cut by freezing with ethyl chloride during an operation. The diagnosis of the nature of a tumour can then be made while the patient is still on the operating-table.

Ethyl alcohol is especially useful for small pieces of tissue, such as the conjunctiva, but is of little use for the whole globe as it will not penetrate the sclerotic readily. Further, it is impossible subsequently to freeze the globe without first removing the alcohol.

Methyl alcohol is one of the constituents of Leishmann's stain and so no fixative is required for smear preparations stained by his method.

Formalin, of which a 4 per cent. solution in normal saline is the best strength, is extremely useful where the preparation of a macroscopic specimen is desired, since the vitreous is not coagulated by its use and the tissues retain a considerable amount of their normal colour. It is also useful for hardening nerve tissue before transferring it to Müller's fluid. The disadvantages of this method are that it is rather slow in its action and therefore does not give good results with regard to the cytology of the cells, and being an acid it interferes with the staining reaction of the cell when aniline dyes are used.

Müller's fluid consists of

Bichromate of potash	2 parts
Sodium sulphate	1 part
Water	100 parts

It is especially used for hardening nerve tissue where it is desired to trace or examine the condition of the medullary sheaths. The specimen may or may not have been previously placed in formalin. It should be kept in the Müller's fluid for at least three weeks during which time the solution is changed every three or four days. The method is also useful in preparing lenses for microscopical examination.

The fixation is slow and therefore the condition of the cells from a cytological point of view is not good.

Saturated solution of perchloride of mercury or some mixture containing it, such as Zenker's fluid, which consists of

Glacial acetic acid	5 c.c.
Perchloride of mercury	5 grm.
Potass. bicarbonate	2.5 grm.
Sodium sulphate	1 grm.
Water to	100 c.c.

These preparations are extremely valuable for fixing smear preparations which need only be covered with the solution for half a minute, or for the rapid fixation of tissues where it is desired to examine the specimen for micro-organisms, or where the cytology of the cells is important. Whole eyes should be placed in the solution for twenty-four hours. It has the disadvantage that the vitreous is coagulated by its use and the tissues are rendered white and opaque. After its use the tissues should be thoroughly washed for twelve hours in water. This is best carried out by placing the tissues in a glass jar, inserting a glass funnel and allowing the tap to run into the funnel; this fills the jar and keeps the water circulating without damage to the tissue. A fragment of iodine should be added to the spirit in which the specimen is next immersed to remove all traces of the mercury from it, otherwise a black precipitate will appear throughout the sections.

Decalcifying Fluid.—After fixation in formalin the specimen is placed for twenty-four to forty-eight hours in sulphurous acid B. P. This is a very valuable method when the bone in the specimen is not very thick. An alternative solution is Ebner's which consists of

Sodium chloride	10 parts
Hydrochloric acid	1 part
Water	100 parts

A drop of fresh hydrochloric acid is added daily for two to three weeks until the specimen is soft.

Methodical Examination of an Eyeball After Removal.

Apart from the bacteriological examination already mentioned the eye should be treated as follows:

1. External examination.
2. Hardening in formalin or Zenker's fluid.
3. Freezing and division.
4. Macroscopic examination.
5. Embedded in celloidin or paraffin.
6. Cut, stained and mounted.
7. Microscopical examination.

1. **External Examination: Side to Which the Eye Belongs.**—This may be determined by the position of the insertion of the oblique muscles which are on the outer side of the globe, that of the superior differing from that of the inferior in being narrower, in the tendinous portion being longer, and in not running so close up to the optic nerve. If, therefore, the eyeball be held with the cornea forward and the surface over which the superior oblique passes upward, the insertion of the oblique muscles will be on the side to which the globe belongs. Assistance may also be gained in many cases in distinguishing the outer from the inner side, by observing the position of the optic nerve, it joining the eyeball to the inner side of the middle line.

Diameters of the Eyeball.—These can be most easily taken with a measure, in which two T-shaped pieces slide on one another. The eyeball is placed between the two cross-pieces of the T's, and the diameter read off on the scale. It is usual to measure an eye in three directions, viz., antero-posteriorly, laterally, and vertically. The averages for the normal adult eye in these three directions are antero-posterior 24.3 mm., lateral 23.6 mm., vertical 23.4 mm.

Palpation of the Eyeball.—The tension of the eyeball can be estimated in a similar way to that which is employed during life, by alternating the amount of pressure made by the two index-fingers placed on the globe. It should be taken as soon after removal as possible, to be of any value. In

cases of intraocular growth an abnormal amount of resistance is sometimes felt, which gives the impression of the presence of some solid substance. Where only a small tumour is present, its position can occasionally be distinguished by this sense of resistance being felt only in one part of the globe, viz., the seat of its attachment. A sensation of a hard substance felt through superficial soft structures is that which is experienced on palpation of an eye in which there has been a deposit of calcareous matter in the choroid. It is found in shrunken or degenerate eyes, and may be either a small nodule or a large shell of bone.

Reflex from the Fundus.—On holding a healthy eyeball up, with its posterior surface toward the light, a red reflex can be seen through the pupil. This is of course obscured when there are any opacities in the media. It may also be entirely or partly absent, or dimmer than usual, in cases of intraocular growth, intraocular hemorrhage, or detachment of the retina. The position of an intraocular growth may occasionally be localised by this red reflex, disappearing from view in certain positions of the eyeball and reappearing in others.

Condition of the Cornea.—The normal diameter of the adult cornea is 12 mm. It may in certain pathological states be increased or diminished in size, unduly prominent or flattened out. For purposes of describing the position of any wound, ulcer, or opacity it is convenient to consider the cornea as composed of four quadrants: the upper, outer and inner, and the lower, outer and inner. In a case of a wound it is always important to observe if it passes beyond the sclero-corneal margin into the so-called ciliary region, which extends backward nearly as far as the insertion of the recti muscles. A pin passed through the tunic of the eye at the insertion of the recti muscles would be found to emerge internally at the ora serrata; the most posterior part of the ciliary muscle ends a little in front of this.

Condition of the Sclerotic.—It may be altered in shape, being bulged or puckered in one or more directions. So-

called squaring of the globe occurs in two opposite conditions; when there is increased tension, from the coats of the eye yielding more in the intervals between the insertions of the recti muscles; and in the diminished tension of a shrinking eyeball, from the pressure caused by the drag of the recti muscles. The sclerotic may be thinned, which is rendered evident by the dark colour of the choroidal pigment showing through. It may be altered in colour, assuming a yellowness where there has been extensive intraocular hemorrhage or becoming pigmented from the invasion of a melanotic growth. It may be wounded or ruptured.

Condition of the Anterior Chamber and its Contents.—

The anterior chamber may be entirely obliterated, or its depth may be altered, either uniformly increased or diminished, or of different depths in different parts; as, for example, in the condition known as "iris bombé."

The character of the aqueous may be altered, being simply turbid or containing pus (hypopyon), or blood (hyphema).

Condition of the Iris.—Parts of the iris may have been removed, or it may have acquired altered relations to its surrounding structures. It may be altered in colour, which change is sometimes due to the condition of the aqueous; whether this is so or not can, if thought necessary, be readily determined by tapping the anterior chamber and allowing the aqueous to escape. An oscillating iris is nearly always indicative of an absent or displaced lens.

Condition of the Lens.—The lens may be absent or displaced, sometimes being completely loose and floating about in the vitreous on altering the position of the globe, at other times attached at one part and then only swaying backward and forward. It may have come forward entirely into the anterior chamber, or have been wounded, and some of the soft matter, semi-dissolved, rest in front of the iris. It may present various and different amounts of opacities.

2. The method of **fixing and hardening** has already been described.

3. **Freezing.**—The unopened eye should be wrapt in a piece of protective tissue and placed in a mixture consisting of one-third salt and two-thirds ice. A coffee tin with holes punched in the bottom is useful for the purpose of holding the mixture. After half an hour the eye may be taken out. It should be divided with a sharp table knife in such a direction as will be most likely to show the peculiar characteristics. A razor thickens too abruptly to make a clean section. After being opened, the eye should be placed in a basin of water and allowed to thaw. Before freezing the eye, it is as well to determine the direction the section is to take and to make an ink-mark on the sclerotic where the knife is first to enter, as after it is frozen there is more difficulty in distinguishing its surfaces from one another. Usually the best section to make is a vertical antero-posterior one, which divides the globe into two lateral halves. A horizontal, or oblique antero-posterior section can also be made, or an equatorial one dividing the globe into anterior and posterior halves. When an antero-posterior section is made, it should pass a little to the outer side of the optic nerve, the whole of which is then left for microscopical examination.

4. **Macroscopic Examination.**—At this stage of the examination, presuming an antero-posterior section has been made, attention may be directed to the following particulars:

Cornea, as to its thickness and the depth of any ulceration or infiltration there may be in it. Its normal thickness in the centre is 9 mm. and at the margins 1.2 mm.

Anterior Chamber.—The depth and contents of this can now be more readily appreciated, and also the condition of its angle, which may be narrowed by the approximation or adhesion of the root of the iris to the posterior surface of the cornea.

Iris, as to its thickness and its relation to surrounding structures, or any new growth starting from it. In the healthy state the posterior surface of the iris is in contact with the anterior capsule of the lens; in pathological condi-

tions these two structures often become separated and what is called the "posterior chamber" formed.

Lens and its Capsule.—The measurements of the lens may be taken; the normal diameters at the age of 20 are 3.7 mm. antero-posteriorly, and 8.67 mm. laterally; there is a gradual increase in the size of the lens throughout life, the lateral diameter between 80 and 89 is 9.62 mm.

Vitreous, as to its consistency and the presence of any infiltration or hemorrhages into it. It may have become shrunken and its hyaloid detached from the retina, in which case the fluid between the detached vitreous and retina should be examined.

Retina, as to any hemorrhages, pigmentation, or infiltration within it, or any growth springing from it. In pathological conditions it is often found detached from the choroid; a commencing detachment presents the form of a ruck; an umbrella-detachment is when the retina remains adherent only at the optic disc and at the ora serrata, it being collected in the form of a stalk passing through the centre of the globe and expanding anteriorly. In these cases the fluid between the detached retina and choroid requires examination.

Optic disc, which may be either cupped or swollen. If cupped, attention should be directed to the margin of the cup to see if it shelves gradually or abruptly.

Choroid, as to any patches of atrophy, pigmentation, or infiltration within it, or any rupture of it, or any new growth starting from it. It may become detached from the sclerotic or have calcareous matter deposited in it.

Method of Mounting Macroscopic Specimens.—All tags of tissue are removed from the sclerotic and the divided eye placed in a solution of 4 per cent. formalin and .6 per cent. chloride of sodium for twenty-four hours. The specimen is then mounted in the same solution in jars¹ specially

¹ The jars and plates can be obtained from Messrs Turner & Co., 11 Foster Lane, London E. C. or Messrs, Angus & Co., 83 Wigmore St., London W.

devised for the purpose (Fig. 228). These are narrow antero-posteriorly and polished on one surface. An opal glass plate which fits the jar laterally has a round hole about $3/4$ inch in diameter cut in it about one-third of the way up from the bottom (Fig. 229). The jar being two-thirds filled with the solution, the opal glass plate is inserted, and then the divided eyeball is dropped down in front of the plate so that the cut surface comes against the polished glass side of the jar. The eye is lowered until its convexity rests in the hole of the plate which keeps it in position. The space behind the plate

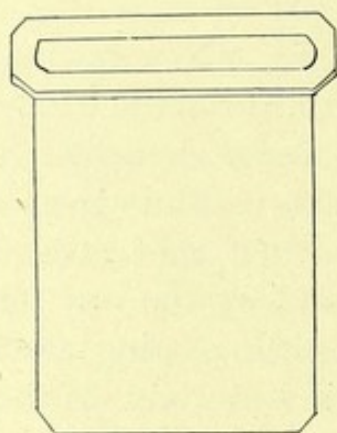


FIG. 228.



FIG. 229.

FIG. 228.—Museum jar with a polished glass side for mounting macroscopic eye specimens; it is high, broad and deep.

FIG. 229.—Opal glass plate to fit in the above jar to hold the eye in position; it is packed behind with wool. The hole in the plate into which the back of the eye fits measures $3/4$ inch in diameter.

is then packed loosely with wool to keep it in position. Melted paraffin is poured over one surface of the cover and while the paraffin is setting it is inverted and placed over the top of the jar. The jars are then labelled with the reference number of the specimens and put in the museum cupboard. For this purpose a modification of the Globe-Wernicke bookcases is very useful (Fig. 230). Special shelves are devised so that the shelf above has a piece that comes down and hides the tops of the jars and on which a label describing the specimen can be placed. The chief advantage of this method is that the specimen is mounted in a few min-

utes and it can be taken out at any time and microscopically examined.

If it be desired to mount the specimen in glycerine it should be treated as follows:

1. Place the specimen for three days in the following solution:

Sodæ sulph. 40 grm.

Mag. sulph. 40 grm.

Sod. chlor. 20 grm.

Dissolve in 2000 c.c. of hot water and add 160 c.c. of formalin.




FIG. 230—Globe Wernicke book case showing the method of arranging macroscopic specimens.

2. Transfer the specimen to 60 per cent. methylated spirit for three minutes; this will bring back its natural colour.

3. Mount in a jar in the following solution:

Glycerine (pure) 60 parts

Distilled water 40 parts

Sat. sol. of pot. acetate 2 parts

Formalin 2 parts

Filter before use.

5. **Embedding.**—The three chief materials used for embedding are celloidin, paraffin and frozen gum. Before embedding a portion of an eyeball for cutting microscopic sections it must first be decided what it is most desirable to show in the specimen. Thus if anatomical conditions are to be investigated celloidin is by far the preferable method to employ, while if microörganisms

are to be sought for in the tissues, or fine cytological changes for which aniline dyes have to be used, paraffin should be the method employed. Sometimes it is desirable to strip off the choroid and retina from the sclerotic and embed them separately, as the latter gets so hard in the process that it becomes difficult to cut it in paraffin. Some reagents, such as Sudan III for staining fat, and methyl-violet when used for amyloid changes, will not act if the specimen is brought in contact with spirit, and in this case the section must be cut with a freezing microtome.

Celloidin (Schering) is sold in chips kept in water. The water should be poured off, the chips dried and dissolved in equal parts of ether and alcohol. Two solutions should be kept; (*a*) thin celloidin, which is about the consistency of a liqueur and (*b*) thick celloidin, which is about the consistency of treacle. The specimen should be treated as follows:

1. Sixty per cent. of methylated spirit, twenty-four hours.
2. Ninety per cent. alcohol (pure methylated spirit) twenty-four hours.
3. Absolute alcohol twenty four hours. Instead of using alcohol methylated spirit dehydrated with anhydrous copper sulphate may be employed.
4. Equal parts of ether and alcohol twelve hours. Before placing in the celloidin, if half an eye is being embedded, it is advisable to remove a portion of the sclerotic from the convexity of the specimen with a sharp razor, as by this means not so much celloidin is required and the eye is less liable to tilt during the hardening of the celloidin.
5. Thin celloidin twenty-four hours.
6. Thick celloidin twenty-four hours.
7. Place the specimen in a paper box and fill it quite full with thick celloidin. Arrange the box so as to allow of slow evaporation under a bell jar for twenty-four to forty-eight hours when it will be found to have set. Strip off the paper box and place the specimen again beneath the bell jar over a vessel containing chloroform for another twenty-four hours. When hard remove all excess of celloidin which may be dried and used again.
8. When sufficiently hard place in 60 per cent. alcohol for three or four days.
9. Stick the embedded specimen firmly on a microtome block by means of photoxylin dissolved in equal parts of ether and alcohol.

Paraffin.—Only very thin pieces of tissue should be employed. The specimen should be treated as follows:

1. Methylated spirit six hours.
2. Absolute alcohol six hours.
3. Chloroform six hours.
4. Paraffin and chloroform six hours.
5. Melted paraffin in a hot bath one-half to one hour depending on the thickness of the specimen. The exhaustion of the chloroform with the air pump will accelerate embedding of the specimen.
6. Set in L-shaped brass molds.

Freezing.—The specimen is placed in gum and frozen on a special microtome either by ethyl chloride or CO_2 .

Cutting.—Apart from good embedding success in getting good sections depends on having a sharp knife. For this reason it is

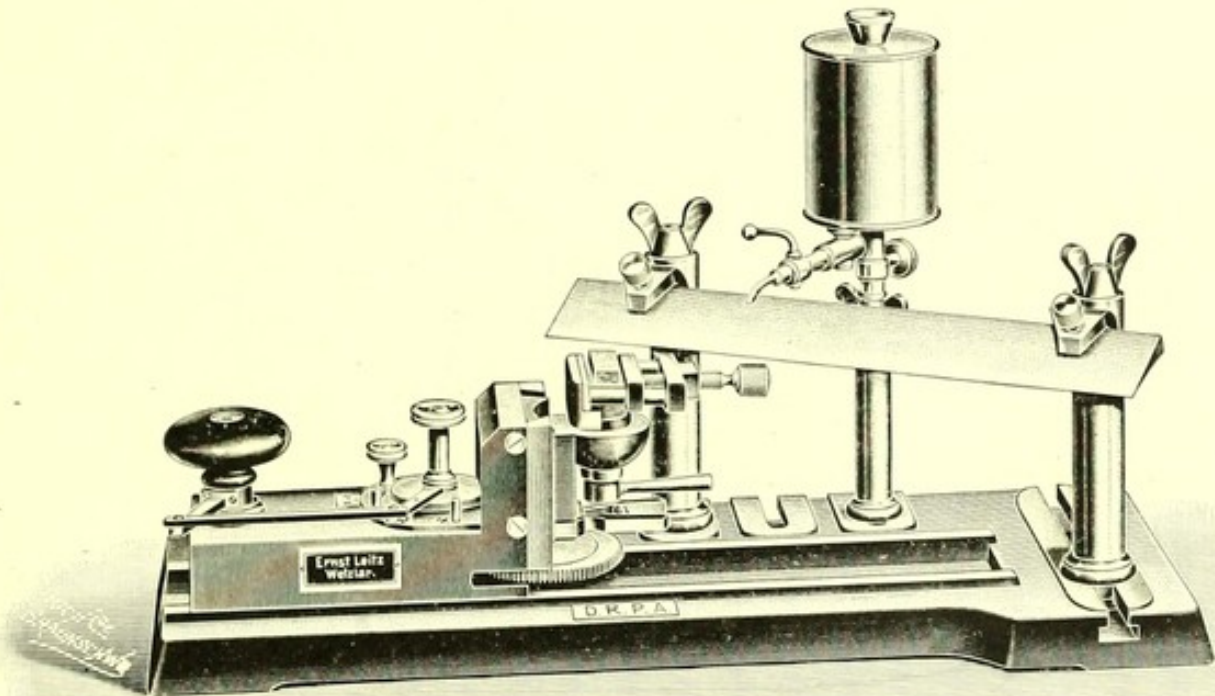


FIG. 231.—Leitz "base sledge" microtome in use for cutting celloidin section.

always desirable to cut off the part which is not required with an old blade using the sharp blade for the part from which it is desired to obtain good sections. The best form of microtome for paraffin and celloidin is the base sledge (Leitz.) (Figs. 231, 232). For paraffin alone Minot's or the Cambridge rocker are excellent, whilst for celloidin the Jung microtome is good.

In cutting celloidin the knife should be set at an oblique angle to the specimen and should be kept continuously wet with methylated spirit. In the base sledge model this is performed by means of a dripper. As the sections are cut they should be placed in 60

per cent. alcohol by means of a camel-hair brush and if it is desired to mount them **in series** a long dish or glass pen tray should be used to place them in order. In making serial sections by this method it is desirable to mount each one separately, but if it is not required to examine them under the high powers of the microscope, as in tracing the degeneration of nerve fibers, they may be mounted in the following manner:

A large glass plate is smeared with a solution of dextrin; over this is poured a solution of photoxylin in equal parts of ether and alcohol of about the consistency of treacle. When setting the celloidin sections should be arranged in order on the plate. After

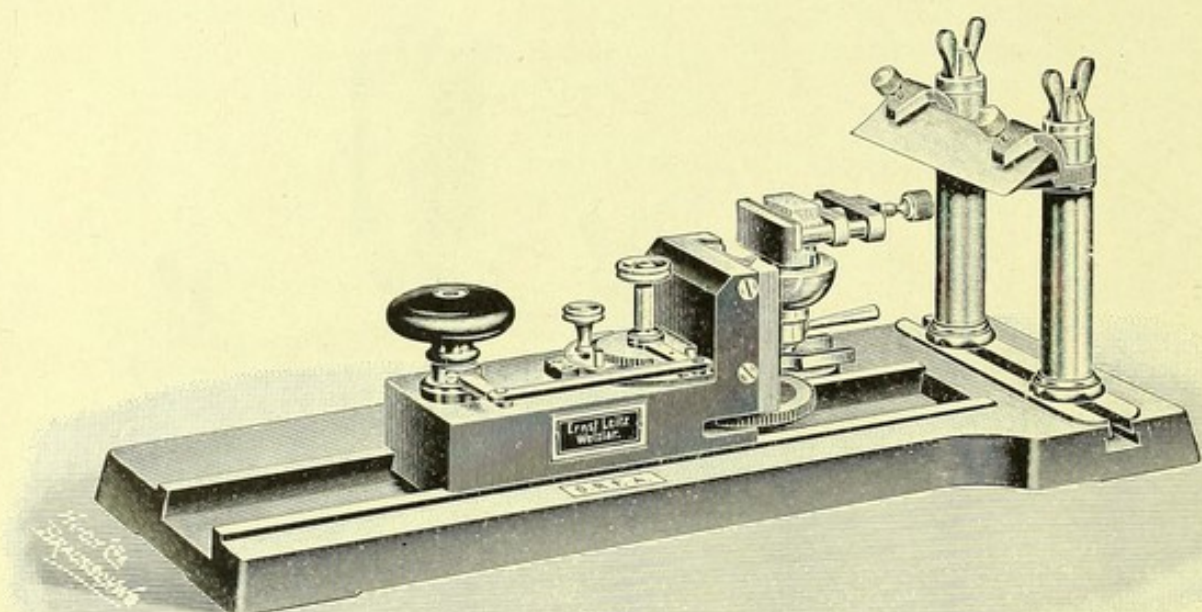


FIG. 232.—Leitz "base sledge" microtome in use for cutting paraffin sections.

it is set the whole is plunged into methylated spirit; the film containing the sections can then be readily stripped from the glass and the sections treated in the ordinary way.

In cutting paraffin the knife should be set at right angles to the specimen. The sections are removed with a dry camel-hair brush, and floated out on the surface of warm water which flattens out any folds there may be in them. They are then floated on to microscope slides and blotted on to the surface of the glass with cigarette paper. The slide is next placed to dry in the incubator for twenty-four hours when it will be found that the sections are firmly adherent to it. If the block is carefully squared ribbons of serial sections may be obtained.

The following is the method of preparing and **staining celloidin sections with logwood and eosin**. The section should be transferred from one fluid to another on a large section lifter. All excess of fluid should be drained away on to blotting paper. The celloidin remains permanently in the section; therefore the section should not be put into absolute alcohol or the celloidin will be so softened as to destroy the specimen.

1. From the spirit it is transferred into hematoxylin for five minutes.
2. Acid distilled water 1 per cent. for one-half hour to take out the excess of stain. No stain should show in the celloidin.
3. Tap water to which a trace of ammonia may be added. The section should remain in this until blue which usually takes from three to five minutes.
4. Transfer to 1 per cent. aqueous solution of eosin for about one minute.
5. Methylated spirit 70 per cent, five minutes, to take out the excess of eosin.
6. Methylated spirit, pure, for ten minutes to dehydrate.
7. Carbol-xylol for ten minutes to clear. (Ac. carbolic crystals iii, xylol i.)
8. Place flat on a slide and add at once a sufficiency of Canada balsam and a cover-glass. Sections clear gradually during the first twenty-four hours after mounting, or more rapidly if warmed over a spirit lamp.

Care must be taken to keep the hematoxylin, spirit and carbol-xylol covered during the preparation of the sections.

Paraffin sections stuck to the slide are best prepared and stained by passing them through fluids in stoppered glass bottles with necks sufficiently wide to take the slides.

1. Xylol five minutes to remove the paraffin.
2. Absolute alcohol 1 minute to remove the xylol.
3. Stain.
4. Absolute alcohol—two different bottles for two minutes each to dehydrate.
5. Xylol three minutes to clear.
6. Mount in Canada balsam.

As the slide is transferred from one bottle to another it should be wiped free from all excess of fluid.

Specimens which are cut by the freezing method may be treated in the same way as celloidin sections but where stains are used, such as Sudan III, which will not stand the alcohol, they are best mounted in glycerine jelly. A fragment of glycerine jelly is

placed upon the slide and gently warmed over the Bunsen burner until melted. The section is then placed upon the slide and covered with a cover-glass.

Stains.—The principle on which stains act is either: 1. the dye stains all the tissues equally and the excess is then washed out from the section leaving the parts, such as the nuclei, which retain the stain more tenaciously, coloured. Sometimes, as is the case with hematoxylin, this can be mordanted in the tissue and the rest of the tissue counter-stained with another dye. 2. A chemical is applied to the specimen which will enter into a chemical combination with another substance in the tissue giving rise to a colouration of the tissue in which it is contained. As, for example, the ferrocyanide reaction with iron; osmic acid and Sudan III for fat; Gram's method; Weigert's method for staining the medullary sheaths of the nerve after the latter has been treated with the salts of chromic acid.

In some instances, such as after using the eosin methylene blue compounds, both factors come into play; *e.g.*, one set of granules in the cytoplasm takes up the eosin (oxyphile or acid granules) whilst other granules take up the methylene blue (basophile). It is obvious that specimens which are to be stained in such a manner should not come in contact with anything but neutral fluids.

The following are some of the stains in general use:¹

Carbo-thionin.

Thionin 1 grm.

Solution (1-40) carbolic acid to 100 c.c.

Filter immediately before use.

Fixation.—Heat, alcohol, or perchloride.

Use.—For staining organisms in smear preparations, blood films and nerve cells.

Allow the stain to remain on the specimen for five minutes, wash in water, dry and mount.

The following modification is useful for blood films:

Thionin 1.5 grm.

Absolute alcohol 10. c.c.

Solution of 5 per cent. carbolic acid to 100 c. c.

Keep for two weeks, then dilute four times with water before use. Stain for ten minutes.

¹ Grüber's make is the best and may be obtained from Messrs. Baird and Tatlock, Hatton Garden, London, W. C.

Borax Methylene Blue.

Methylene blue	2 gm.
Borax	5 gm.
Water	100 c.c.
Dilute with water five times before use.	

Fixation.—Heat, alcohol, or perchloride.

Use.—It can be employed in place of Loeffler's methylene blue. It is used for the same purposes as the thionin already described.

Carbol-fuchsin.

Fuchsin	1 gm.
Solution (1-20) carbolic acid	100 c.c.
Glycerine	50 c.c.

The stain may be diluted with four times its amount of water before use.

Fixation.—Heat, alcohol or perchloride.

Use.—For staining acid-fast bacilli and other organisms; it is especially useful when photographs of organisms are required.

For Staining for Tubercle Bacilli.—Heat the stain in the test-tube till it steams. Flood the slide with the stain and allow it to remain on for five minutes. Place the slide in acid sulph. dil. B.P. till the colour is discharged. Wash in tap water and counter-stain with borax methylene blue. Dehydrate and mount.

Carbol-gentian Violet (Gram's stain).

Saturated alcoholic solution of gentian violet	1 part.
Solution of carbolic acid (1-20)	9 parts.
Filter before use.	

The stain should be made immediately before use; when mixed the solution will not keep more than one week.

Fixation.—Heat, alcohol or perchloride.

Gram's Iodine Solution.

Iodine	1 part.
Potassium iodide	2 parts.
Water	300 parts.

Flood the stain with carbol-gentian violet and allow it to remain on for three minutes. Rinse in water, pour on Gram's iodine solution and allow it to remain on for one-half minute. Decolourise

in absolute alcohol or aniline oil and xylol (aniline oil, 2 parts; xylol, 1 part). Counter-stain with safranine one-half minute, wash, dry and mount.

Safranine.

Saturated aqueous solution of safranine, 1 part.

Water 10 parts.

Use.—To demonstrate microorganisms staining by Gram's method either in the tissues or in smear preparations. It can also be used for staining the keratohyaline granules in the epithelium. In the latter case the decolourisation should not be so thorough as in the former.

Gram's Method of Staining Hair, Scales, etc.—Take a suspected hair or hairs and cut off all but $\frac{1}{4}$ inch from its root. Wash in ether. Stain with carbol-gentian violet fifteen minutes. Place the hairs on a microscopic slide and blot with cigarette paper. Cover with Gram's iodine for ten minutes. Decolourise with hydrochlorate of aniline (aniline oil 1 dram, strong hydrochloric acid 3 minims) frequently changing the solution. Cover with aniline oil one hour. Xylol, balsam.

Weigert's Fibrin Stain.

Fixation.—Formalin, perchloride, or alcohol.

Embedding.—Paraffine or freezing.

Pass the section into water. Stain with carbol-gentian violet five minutes. Drain off the stain, pour on Weigert's iodine and let it remain for one-half minute.

Weigert's Iodine.

Iodine 1 gm.

Potassium iodide 2 gm.

Water 100 c.c.

Drain quite dry and differentiate with aniline oil and xylol until no more blue colour comes away. Xylol, balsam.

Weigert's Elastic Tissue Stain.—This stain is best bought ready prepared for use, but it can be prepared as follows: Place in a porcelain dish and warm 200 c.c. of water containing resorcin 2 per cent. and fuchsin 1 per cent. After the mixture has been heated add 25 c.c. of Ferric-Chloride solution (German pharmacopeia). Heat and stir for five minutes. Cool and filter, keeping the residue dry. Put filtrate and residue in a dish with 200 c.c. of 94 per cent.

alcohol and boil, stir and lift out the filter-paper. Cool, filter and make up to 200 c.c. with alcohol 94 per cent. then add 4 c.c. of hydrochloric acid pure.

The sections are best cut in paraffine. The section is placed in the stain which should be kept covered. The stain is allowed to act for five minutes. Decolourise with 1 per cent. acid alcohol. The sections can subsequently be counter-stained with safranine.

Sudan III.

Fixation.—Formalin or Müller.

Embedding.—Freezing.

Stain.—Sudan III, saturated solution in 96 per cent. alcohol. Filter and add two-thirds of its bulk of 50 per cent. spirit. Filter again before use.

Stain frozen sections with Sudan III, for three minutes. Wash in 30 per cent. methylated spirit. Counter-stain with borax methylene blue. Mount in glycerine jelly.

Acid Methylene Blue.

Borax methylene blue 2 parts (see above).

Glacial acetic acid 1 part.

Water 7 parts.

Filter before use.

Use.—For examining wet cytological preparations. It has the advantage of dissolving any red blood corpuscles that may be present and so allows a better examination of the other cells.

Methylene Blue (Neissler).

Methylene blue 1 gm.

Alcohol 96 per cent. 20 c.c.

Glacial acetic acid 50 c.c.

Water 950 c.c.

Bismark Brown.

Bismarck brown 5 gm.

Water 1000 c.c.

Use.—To stain Klebs-Loeffler and xerosis bacilli to show polar granules. A twenty-four hour culture of the organism on blood serum is made. Films are made and stained with methylene blue for one-half minute. Wash in tap water and treat with bismarck

brown for one-half minute. Wash, dry and mount. The polar bodies appear at each end of the bacillus as dark brown dots, the body of the bacillus being stained blue.

Leishmann's Stain (eosin methylene blue compound).

The stain should be freshly made and can be bought in tabloids from Burroughs, Wellcome & Co. These are dissolved in pure methyl alcohol. No fixation is required as the stain is made up with alcohol. Flood the film with the stain and allow it to remain on for two minutes. Then add a few drops of distilled water and allow it to act for another two minutes. Wash in distilled water and dry in the air.

Use.—Can only be used satisfactorily for smear preparations. The basic radicle (methylene blue) picks out the nuclei, the organisms, and the basophile granules, whilst the acid radicle (eosin) picks out the acid oxyphile or eosinophile granules. It is especially useful for blood films.

Leishmann's Method of Staining the Spirocheta Pallida.—Smear preparations are made from the lesions by scraping its surface. Dry in air and fix for five minutes in methyl alcohol. Dry. Smear over the surface of the film a little fresh blood serum and allow it to dry. Flood the slide with Leishmann's stain diluted with an equal part of distilled water and allow it to act for one hour; then dry and mount.

Giemsa's Method of Staining the Spirocheta Pallida and so-called Trachoma Bodies.—The stain is prepared by taking 10 c.c. of tap water and adding to it 1 drop of a solution of 1 to 1000 solution of potassium carbonate and 10 minims of Giemsa's stain (eosin azur). Place in a test-tube and mix by gently inverting the tube once or twice. Do not shake it violently. Very thin smear preparations should be made on clean slides and fixed by a gentle heat. Pour on the stain and heat the slide over a flame until it steams. Allow the stain to remain on for fifteen seconds and then pour it off repeating the same process four times. At the last application it should be allowed to act for one minute. Wash in tap water, dry and mount.

Method of Demonstrating the Spirocheta Pallida on a Dark Background.—This is the easiest way of demonstrating the protozoon in smear preparations.

Take a drop of a solution of ordinary Indian ink and place on a slide. Add to this the scraping from the suspected lesion. Mix thoroughly and make a smear by drawing another slide along the surface. Allow to dry and examine under oil immersion one-twelfth objective. The cells and spirocheta appear white on a dark background.

Silver Method of Staining the Spirochaeta Pallida in the Tissues.
Fixation.—Formalin, alcohol.

Place in an amber bottle suspended by a thread the pieces of the tissues and cover with the following solution:

1.5 per cent. nitrate of silver	90 c.c.
Pyridin	10 c.c.

for three hours in the cold and three hours in the incubator at 45° C.

Remove the tissue and place for twelve hours in the following developing solution:

4 per cent. pyrogallol	90 c.c.
Acetone	10 c.c.

Add 15 c.c. of pyridin to every 85 c.c. of the mixture.

Embed in paraffin and counter-stain.

The solution should be freshly prepared.

Care must be taken to distinguish connective-tissue fibrillæ from the spirocheta pallida.

The method is not so satisfactory as the previous methods which should be applied wherever possible.

To demonstrate capsules of bacteria (McConkey's method).

Dahlia	5 grm.
Methyl green (100 crystals)	1.5 grm.
Distilled water	100 c.c.

Rub these together in a mortar and add saturated alcoholic solution of carbol-fuchsin, 10 c.c., followed by 90 c.c. of distilled water.

Filter and allow to stand two weeks before use. It should be kept in an amber glass bottle.

Method.—Fix the film by heat. Flood the slide with the stain and allow it to remain on for seven minutes. Wash with distilled water, dry and mount.

To Demonstrate Flagella of Bacteria.—Examine a wet preparation for motility by making a hanging drop preparation.

To Make a Hanging Drop Preparation.—Take a slide and with a wooden match make a ring of vaseline on the slide. Take a perfectly clean cover-glass and with the platinum loop place a single drop of water on the surface. A loopful of a twenty-four hour cultivation of the organism is then mixed with the water on the cover-glass. With forceps the cover-glass is inverted on to the ring of vaseline so that the drop hangs downward in the cell so formed. Examine under one-twelfth objective. When finished

with the preparation should be thrown into a bowl of lysol which should be always kept on the bench for used slides and cover-glasses.

Bacteria exhibit three kinds of movement: (a) molecular or Brownian movement, (b) streaming, due to currents in the fluids, and (c) true motility, due to flagella. This is best identified by watching a single organism and comparing its movements with others.

Staining Flagellæ. (Pitfield Method Modified).

Make a smear preparation of a twelve hour culture after emulsifying it with water in a watch glass. Care should be taken not to damage the organisms in making the smear. When dry it should be fixed by gentle heat.

Mordant.

Tannic acid 10 per cent. aqueous solution,	10 c.c.
Perchloride of mercury saturated aqueous solution	5 c.c.
Alum saturated aqueous solution	5 c.c.
Carbol-fuchsin	5 c.c.

Mix well and a precipitate forms. This should always be removed by centrifugalisation immediately before use. The mordant is poured over the film and held high up over a Bunsen burner till it steams. Allow it to remain in contact with the films for two minutes, wash and dry. Pour on the following stain freshly prepared for each occasion:

Saturated aqueous solution of alum	25 c.c.
Saturated alcoholic solution of gentian violet	5 c.c.

Gently heat the slide above a Bunsen burner till steaming and allow the stain to remain in contact for three minutes. Wash in water, dry and mount.

Flagellæ may be polar or diffuse.

A single one at one pole is termed monotrichous (*B. pyocyaneus*).

A single one at each pole is termed amphitrichous.

A bunch at one pole is termed lophotrichous.

Diffuse is peritrichous (*B. typhosus*; *B. coli*).

Pappenheim's Stain.

Methyl green	2 knife points.
Pyronine	4 knife points.
Distilled water	$\frac{1}{2}$ large test-tube.

Plasma cells.

Test the stain by dropping on to filter paper. Good rings of individual colour should be produced. The stain does not keep good for more than about two weeks.

Fixation.—Alcohol or perchloride.

Embedding.—Paraffine.

Stain the sections for five minutes and differentiate with resorcin (two knife points) in absolute alcohol (one-half test-tube). This usually takes about five seconds. Dehydrate rapidly and clear in xylol.

Use.—The stain is useful to demonstrate the gonococcus and bacillus of Morax-Axenfeld. It is also the best stain for examining the cytology of the cells, more especially the lymphocytes and plasma cells and cells of the central nervous system.

Eosin Aqueous.

Eosin	1 part.
Water	100 parts.

The stain is useful for staining the cytoplasm and acid granules (eosinophiles) in the cells. When used for the later purpose a very diluted solution (1-1000) should be employed, the specimen being allowed to remain in it one hour or more and the excess of stain being removed by 50 per cent. methylated spirit.

Ehrlich's Hematoxylin.

1. Hematoxylin 2 gm.
- Absolute alcohol 60 c.c.
2. Equal parts of glycerine and distilled
- water 60 c.c.
- Glacial acetic acid 3 c.c.
- Add alum to saturation.

Mix 1 and 2 together and ripen for at least three weeks in the dark. The stain should be filtered before use.

Method of Staining the Medullary Nerve Sheaths.

Kultschutzky's Hematoxylin (acid).

Hematoxylin	1 gm.
Glacial acetic acid	2 c.c.
Water	100 c.c.

This stain is preferable to Weigert's as it keeps well.

Decolouriser (Weigert's Method).

Sodium baborate	4 gm.
Potassium ferrocyanide	5 gm.
Water	200 c.c.

The tissue which has been hardened in Müller's fluid is cut in celloidin and then treated as follows:

1. Copper acetate one-half saturated solution one-half hour.
2. Rinse in spirit and water.
3. Place in Kultschutzky's hematoxylin for twelve to twenty-four hours in the incubator taking care to cover the vessel in which it is contained.
4. Wash in spirit and water.
5. Place in the decolouriser and allow it to remain until the colour is removed from everything but the nerve fibers. Wash in distilled water for five minutes and then place in tap water for several hours. Counter-stain, dehydrate and mount.

Method of Staining Early Fatty Degenerations in the Medullary Sheaths of Nerve Tissue.

The tissue should not be more than 1 cm. in thickness. It should be hardened in Müller's fluid from two to three weeks. It is then placed in Busch's fluid.

Osmium tetroxide	1 gm.
Sodium iodate	3 gm.
Water	300 c.c.

The specimen should be placed in a vessel on glass wool and covered with a solution for 6 to 7 days, a drop or two of fresh osmic acid being added daily. It is then washed for twenty-four hours in water. Dehydrate in alcohol and embed.

Nissl's Method of Staining Nerve Cells.

Nissl's blue (patent B)	3.75 gm.
Venetian soap	1.75 gm.
Water	1000 c.c.

Stain the section for five minutes in the cold. Then warm till the steam rises. Decolourise in aniline alcohol (aniline 1 part, absolute alcohol 9 parts); xylol, balsam.

Mallory's Axis-cylinder Stain.

Stain the sections for twenty minutes to one hour in sunlight in the following mixture:

Phosphomolybdate, 10 per cent. 10 c.c.
 Hematoxylin 1.75 gm.

Wash in 50 per cent. alcohol five to twenty minutes. Counter-stain. Axis-cylinders and glia stained dark blue.

Ehrlich's "intravital" Methylene Blue Method of Staining Axis-cylinders of Nerves.

Ehrlich intravital methylene blue 4 gm.
 Saline solution 0.6 per cent. 100 c.c.

Inject one-half hour before death. For fresh tissue immerse for one hour in 0.2 per cent. solution in the incubator. Then place in solution of bipicrate of ammonia, 10 per cent., for two hours and transfer to equal parts of the same solution and glycerine for six to twelve hours. Tease out tissue and mount in glycerine jelly.

Methyl Violet for Demonstrating Amyloid Changes.

The section should be made by freezing and no alcohol must be applied to the specimen. The section is then placed in 1 per cent. solution of iodine. Wash in dilute sulphuric acid till blue. Then place in methyl violet for five minutes; wash in dilute potassium acetate until a pink colour is obtained.

Mount direct in glycerine jelly.

Bleaching Fluid (Permanganate and Oxalic Acid Method).—Immerse the section in one-half saturate solution of potassium permanganate for fifteen minutes; rinse and transfer to 10 per cent. solution of oxalic acid until decolourised; wash for one hour and then stain with logwood and eosin.

Table Showing the Decimal System Equivalent in English Measure.

100 c.c.	=	35.25 fluid oz.
1 litre	=	35 fluid oz.
1 gram	=	15.43 grains
28.4 c.c.	=	1 fluid oz.
3.5 c.c.	=	1 fluid dram
.064 gram	=	1 grain.

To convert c.c. per litre into minims per oz. (approximately) divide by 2; e.g., 12 c.c. per litre $12 \div 2 = 6$ mm. per oz.

To convert gram per litre into grains per oz. multiply by $7/16$ which gives grains per oz.

To convert degrees centigrade to fahrenheit multiply by $9/5$ and add 32.

The following methods applicable to the examination of blood and various fluids of the eye are given, but for the details of the clinical examination of the blood a larger work on clinical pathology should be consulted.

Cleaning Slides and Cover-glasses for Making smear preparations.—The slides should be cleansed by boiling in 5 per cent. lysol and kept subsequently in the same solution.

Cover-glasses are cleaned by immersing in nitric acid for an hour, washing them and placing for three hours in 5 per cent. ammonia. Subsequently they should be kept in absolute alcohol.

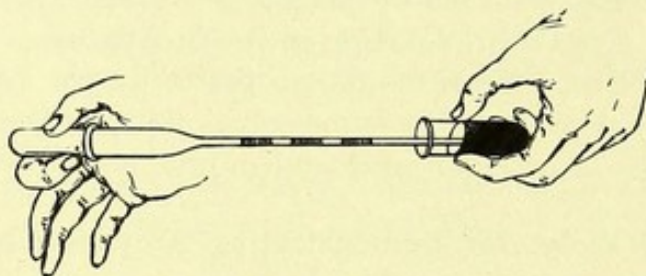


FIG. 233.—Showing the method of drawing up equal volumes of fluid into a capillary pipette. The clear spaces in the tube represent air bubbles.

The best method of wiping slides and cover-glasses is to use an old piece of linen. It is most important in preparing cover-glasses for blood films that no trace of grease from the fingers should be present.

Pipettes (Fig. 233) are useful for the collection of aqueous from the anterior chamber and also for mixing minute quantities of fluid in equal proportions. They are made in the following way:

A piece of glass tubing 6 inches long about the thickness of a lead pencil is heated in the flame of a blowpipe till thoroughly soft. It is then removed from the flame and drawn out until of sufficient length. The capillary tube thus formed should be about the thickness of a knitting needle. It is then allowed to cool and broken in two. The capillary tube so formed is heated near its end in a small flame and again drawn out so that the capillary tube has a pointed end. When the pipette is required for use a rubber teat is placed on the large end and the fine tip of the capillary end is broken off. The fluid is sucked up into the tube by means of the teat. The end may be again sealed leaving the fluid in the capillary part of the tube. When it is required to mix

equal parts of a fluid the capillary tube is marked and the fluid drawn up into the tube to the mark. An air bubble is then allowed to enter and the other fluid, with which it is required to mix the first, is drawn up into the tube up to the same mark. They are then blown out on to a slide and mixed.

To Make a Sterile Glass Needle.—Take a piece of capillary glass tubing, such as the thin end of a pipette, and draw it out in the flame of a spirit lamp or wax match; two sterile needles are thus obtained.

Wright's blood Capsules (Fig. 234) are the best for taking specimens of blood. They can be bought of R. B. Turner, 11 Foster Lane E. C. or made in the laboratory. They are used as follows:

Method of collecting blood for Wassermann reaction, opsonic index, etc.—Let the patient hang his arm downward or swing it

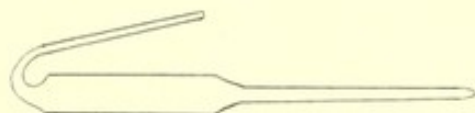

FIG. 234.—Wright's blood capsule.

for a time. Place a piece of rubber baby's bottle tubing round the finger so as to stop the venous return. After cleansing the skin with alcohol prick the finger on the back above the nail. Hold the blood tube with the curve downward and apply the open curved end to the drop of blood when it will be found that the blood will run into the tube. When the tube is about half full, still holding the loop downward, the other end is heated in the spirit lamp and the capillary end finally sealed. As the air contracts in the lower end of the tube the blood will be sucked up into the body of the tube. The curved end of the tube can then be hooked over the side of a vessel. The capsules should be carefully marked so as to recognise the case from which the blood is taken. In children or where a larger amount of blood is required the ear is preferable to the finger. It should be rubbed well before making the puncture which should be performed with a glass needle and the blood subsequently squeezed out.

As the blood clots in the tube the serum separates. This can be removed by notching the upper part of the body of the tube with a glass knife or file and breaking off the curved end in a cloth. The serum is removed with a pipette as already described.

When large quantities of blood are desired, as for the examination of it for microorganisms in sympathetic ophthalmia and other metastatic infections of the eye, the following method

should be employed: the skin of the arm in the anticubical fossa is thoroughly cleansed with antiseptics. A firm bandage is then placed around the arm sufficiently tight to obstruct the venous return. With a sharp sterile hypodermic needle having an all glass syringe attached, which should contain at least 20 c.c., a puncture of one of the largest superficial veins is made, the point of the needle being directed away from the patient's body so that it faces the blood flow. The piston of the syringe is then gently withdrawn till sufficient blood is obtained. The contents of the syringe should be expelled into at least two culture tubes, broth and agar being best for the purpose. If the former is used the blood clot retains the organisms but they will eventually spread out into the media in the course of a few days in the incubator. The bandage should be removed from the arm immediately the syringe is withdrawn, otherwise the blood will be extravasated into the tissue.




FIG. 235.—Ehrlich eye-piece which divides the field into squares.

To Make Blood Films.—Prick the finger and wipe away the first drop of blood. When enough has again accumulated take two cover-glasses, one in each hand, and hold them by their opposite corners with the finger and thumb; touch the drop of blood with the surface of one of them; now place the other on it and a thin film will be found between them. Do not squeeze the cover-glasses together. Slide one gently and evenly off the other and allow them to dry in the air. They may subsequently be fixed by heat, alcohol, or perchloride of mercury.

Method of preparation of vaccines (see page 297).—The following are the steps:

1. Determine the organism causing the disease.

2. Make a forty-eight hour culture on solid media from the patient suffering from the disease taking care to select a lesion that is likely to be free from contamination with other organisms.

3. Add to the tube a small quantity of sterile normal saline solution and shake gently so that the colonies are washed off from the media.

4. Pour off the fluid and dilute with sterile normal saline solution until the fluid is slightly opalescent.

5. Standardise the solution by estimation of the number of organisms. This is best performed by mixing equal parts of the emulsion and diluted blood and counting the number of corpuscles and organisms in several fields of the microscope. This is performed as follows:

a. Prick the finger and wipe away the first drop of blood. When the second drop forms draw it up to a mark on the capillary tube.

b. Allow a small air bubble to enter and then draw up four times the quantity of 1/2 per cent. sodium citrate in normal saline. (Tabloids are prepared of this mixture by Burroughs, Wellcome & Co., as the solution does not keep.)

c. Blow the whole out on to a slide and mix thoroughly. There is then a mixture which contains a million red corpuscles to the cubic millimetre of fluid.

d. Draw up into another tube equal parts of this mixture and of the fluid containing the organism. Mix thoroughly on a slide.

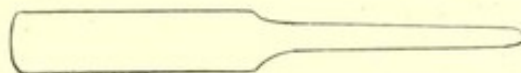


FIG. 236.—Sealed glass capsules for vaccines, serum, etc.

e. Make a smear preparation of the mixture and stain with carbo-thionin and count the organisms and corpuscles in ten fields of the microscope. This is much facilitated by the use of Ehrlich's eye piece which divides the field into squares (Fig. 235).

f. Having estimated the proportion between the red blood corpuscles and the organisms it is easy to calculate the number of organisms to the cubic millimetre; thus if there are 500 red blood corpuscles and 10 organisms the proportion will be as 1 to 5. In a cubic millimetre of diluted blood there are 1000 red blood corpuscles, therefore in a cubic millimetre of the fluid there is one-fifth of that amount, namely 200 organisms.

6. Bottle off the fluid containing the organisms into sterile capsules (Fig. 236) and heat them in hot water at 60° C. for an hour, taking care that the water covers the capsules.

7. Test for sterility. Open a capsule, make a cultivation from the contents and place in the incubator. If sterile it is ready for use.

For the practical estimation of the opsonic index practical pathological text-books must be consulted. It is rarely required in ophthalmology.

Wassermann serum reaction (Emery's method).

Materials required.

a. Immunised Rabbit's Blood serum.—A rabbit is immunised by injecting intraperitoneally once a week with 10 c.c. of human red blood corpuscles which have been previously thoroughly washed three times. Three injections are usually sufficient, given at intervals not greater than one week. The rabbit is then killed and bled. The blood is allowed to clot in an aseptic vessel, the




FIG. 237.—Small glass capsules for holding blood organism, etc.

serum collected, standardised and diluted with saline solution until the minimal hemolytic dose is obtained. It is then put into sterile capsules (and heated to 60° C for one-half hour). In this manner the immunised serum may be kept for a considerable time.

b. Human red blood corpuscles obtained by drawing off 1 c.c. of blood from the finger or ear. The corpuscles are washed in normal saline solution and centrifuged three times (Fig. 237). They are then diluted with 1 and 5 normal saline.

c. Patient's serum obtained by bleeding the patient after pricking the finger or ear and collecting the blood in a Wright's blood capsule. At least half the tube should be filled with blood. It is allowed to clot and the serum withdrawn with a pipette when required.

d. Control serum from a normal person treated in the same way as the serum from the patient.

e. Extract of human heart muscle (antigen) obtained by grinding up one part of fresh heart with 4 parts of absolute alcohol. This mixture is diluted to 1 in 5 with normal saline solution.

To Make the Test.—The following is the method of carrying out the test in the words of its originator:¹ "Take two glass tubes A and B made by sealing one end of a piece of glass tubing about the thickness of a lead pencil and a marked pipette.

"Into A put 4 parts of normal saline solution.

"Into B put 4 parts of extract of heart muscle.

¹ *Lancet*, September 3, 1910.

"To each tube add 1 part of the patient's serum and place in incubator at 37° C. for half an hour.

"Remove from the incubator and add to each tube 1 part of human blood corpuscles and 1 part of immunised rabbit's blood serum. Incubate for half an hour. Hemolysis will be found to have taken place in A, but no hemolysis will have taken place in B if the reaction is positive. A similar experiment should always be performed with a normal control serum.

"The details of the test are as follows:

"No complement is added, that which is present in the serum being sufficient. The corpuscles used are human, a point of great advantage to workers who have not access to living animals or to the slaughter-house. The only substance used which necessitates the use of animals is the immune body which joins up human complement and human red corpuscles. This is prepared by injecting thoroughly washed human corpuscles into a rabbit. It is not necessary to give more than two or three injections, which should not be at a greater interval than a week, each dose consisting of about 10 cubic centimetres of 50 per cent. emulsion, given intraperitoneally. The serum will probably not be very powerful, but this is not of much importance, since a very small amount is used in the reaction, and the serum from one rabbit will serve for many hundreds of tests. It is prepared for use as follows: The animal is bled to death and the blood collected under aseptic conditions. The serum is then standardised with human corpuscles and fresh human serum so as to determine the minimal hemolytic dose under the conditions of the experiment. It is then diluted with sterile normal saline solution in the proportion indicated in the standardisation experiments, pipetted off into sterile vaccine bulbs ($1/2$ - 1 cubic centimetres in each), sealed, and heated to 60° C. for half an hour. If there is any doubt as to its sterility the heating should be repeated on two other successive days.

"The method of standardisation will be seen from an example. The requisites are: 1. A 20 per cent. emulsion of human red corpuscles in normal saline; it should have been rewashed at least three times. 2. Fresh normal human serum. 3. Normal saline. 4. The serum to be tested, which must have been previously heated to 60° C. for half an hour. The following tubes were prepared:—

- a. Emulsion 1 vol. + serum 5 vols. + immune serum 1:0 1 vol.
- b. Emulsion 1 vol. + serum 5 vols. + immune serum 1:3 1 vol.
- c. Emulsion 1 vol. + serum 5 vols. + immune serum 1:5 1 vol.

- d. Emulsion 1 vol. + serum 5 vols. + immune serum 1:10 1 vol.
- e. Emulsion 1 vol. + serum 5 vols. + immune serum 1:20 1 vol.
- f. Emulsion 1 vol. + serum 5 vols. + immune serum 1:50 1 vol.
- g. Emulsion 1 vol. + serum 5 vols. + immune serum 1:100 1 vol.

The mixtures of the ingredients were made by means of an ordinary Wright's opsonic pipette with a unit mark about 1 inch from the end and the serum dilutions prepared in a similar way. The mixtures were placed in a small test-tube about 1/8 inch internal diameter, well stirred with the pipette, and incubated at 37° C. for one hour. (They were thoroughly stirred after half an hour.) The following was the result: with *a*, *b*, *c*, and *d* there was complete hemolysis; with *e* there was a trace of hemolysis and much agglutination; with *f* there was agglutination, but no hemolysis; and with *g* there was partial agglutination. This serum was only diluted 1 in 4 for use, so as to make sure of there being an excess of immune body in the conditions of the experiments. I may say that the 5 volumes of serum contain a large excess of complement.

"The blood for the test is collected in the ordinary way from a skin puncture, and about 1/4 cubic centimetre of blood is ample, even if the test has to be repeated. I may point out, what I find is not known as generally as it should be, that if a large crop of serum is desired it is advantageous (*a*) that the blood shall not be allowed to cool after it is collected, and (*b*) that the clot shall be separated from the sides of the vessel in which it is contained, so as to allow of free retraction. To meet the former indication it is a good plan to put the pipette in the incubator as soon as possible after it has been filled; to meet the latter shake the clot as soon as it has formed toward the curved end of the pipette and back again.

"The 'antigen' used has been the ordinary alcoholic extract of normal heart, prepared by grinding up a weighed amount of heart muscle with four times the number of cubic centimetres of absolute alcohol that there are grams of muscle, allowing it to stand twenty-four hours and repeating the grinding, repeating the maceration for another twenty-four hours, after which it is heated to 60° C. for one hour. It must be quite clear when used, a little being withdrawn from the top layer by means of a pipette. It is diluted with nine times its volume or more, as determined by experiments, of normal saline for use. Before use and afterward occasionally it is in the highest degree necessary to test this extract. To be of use it should (*a*) give complete deviation of the complement in a known case of late secondary or early tertiary syphilis, even when 1 volume of fresh normal serum from a healthy person

is added; and (b) used in the conditions of the test about to be described should cause very little absorption (or destruction?) of complement in a normal blood. This is tested simply as follows: Two tubes are prepared, of which the first contains 1 volume of normal serum, 4 volumes of normal saline, and the second 1 volume of the same serum, and 4 volumes of the diluted extract. These are incubated together for half an hour, and to each is added 1 volume of the immune serum prepared as above, and an excess (5 volumes is usually enough) of 20 per cent. emulsion of washed human corpuscles. The incubation is repeated for one hour, the tubes being stirred once or twice. At the end of that time they are centrifugalised, and a definite quantity of the clear blood-stained fluid pipetted off and examined in a hemoglobinometer. In a good extract there should be *no* difference between the two and this is sometimes the case. Usually there is a slight difference which naturally tends to interfere with the accuracy of the reaction. This of course, is common to all methods. I am not prepared to give exact figures, but if there were a marked difference between the amount of hemoglobin dissolved in the two tubes the extract should be discarded or tested again at a higher dilution.

"The only other ingredients—normal saline and a 20 per cent. emulsion of human corpuscles, well rewashed—do not call for mention.

"The only apparatus required consists of (1) a Wright's pipette, rather wide—*i.e.*, about 1 mm. in internal diameter, with a 1 unit mark about 1 inch from the end and a 4 unit mark; (2) a series of small test-tubes about 1/8 inch internal diameter and 2 inches long; and (3) an incubator. Good results can be obtained with an ordinary biological incubator at 37° C., and, indeed, most of my results have been obtained in this way. It is, however, a very great advantage, as will appear subsequently, that the mixtures shall not be cold at the final stage. To avoid this the stand in which the tubes are held may be placed in a water bath at 37° C., and the last addition made whilst they remain *in situ*. I have recently devised a form of incubator specially for the purpose. It is a modification of Hearson's opsonic incubator, part of the top of which is removable and forms a stand adapted to twenty-four tubes such as I have described. This can be removed and placed on a table and the tubes filled in the ordinary way. It can then be returned to the incubator for the rest of the process. The final additions—of immune serum and emulsion—can be made with the tubes *in situ* and surrounded by warm water. The emulsion and serum may be warmed in the incubator, so that

the test mixture need never be cooled at all. I think bacteriologists will find this incubator useful for many purposes.

"The process is as follows: Prepare a Wright's pipette with a 1 and 4 unit mark. Place in each of the tubes of the front row of the incubator 4 units of normal saline solution; these are to serve as controls in order to make sure that the serum to be tested contains sufficient free complement and that the hemolytic system is in working order. In each of the tubes of the back row 4 units of the diluted extract are placed and the pipette carefully washed out.

"One unit of the first specimen of serum is now added to each of the first two pairs of tubes, that containing the normal saline solution receiving its addition first, then that containing the extract; this is to avoid carrying over a little extract into the control. In each case the fluids are thoroughly mixed by repeatedly sucking them into the pipette and expelling them, and in each case it is advisable to see that the mixture forms a continuous column. The pipette is then rinsed out with normal saline solution, and the process repeated with as many sera as are to be tested.

"Then the hemolytic system is prepared thus: Take 1 unit of red corpuscles which have been centrifugalised three or four times, and mix them with four times their volume of the prepared rabbits' serum. This will be more than enough to saturate them with amboceptor and also with agglutinin. Put them in the incubator so as to hasten the combination of the corpuscles and the antibodies.

"The final stage of the test consists in the addition of these sensitised and agglutinated corpuscles to the tubes containing the diluted serum. A point which I particularly wish to emphasise is that it is not necessary to wait for an hour before this addition is made. Numerous tests have shown me that the combination in the extract tube is complete in five minutes after it has reached 38° C., and almost complete in two and a half minutes. Of course, if the tubes are incubated in air these times are greater, since the tubes and their contents take an appreciable length of time to get heated up to this temperature; but when the two substances are placed in a narrow tube surrounded with warm water the combination takes place, as I have stated, in five minutes. This is one of the advantages of the incubator made by Messrs. Hearson for me. When a series of half a dozen sera have to be tested the first is ready for the sensitised corpuscles as soon as the last mixture has been prepared.

"The sensitised corpuscles are strongly agglutinated and form a mass at the bottom of the tube. They are thoroughly stirred up

by alternately sucking them into the pipette and expelling them into the tube (still surrounded by warm water in the incubator), and then 1 unit of the mixture is added rapidly (so that agglutination does not have time to take place again) to each tube of diluted serum. In making these additions, I am in the habit of making the first of each pair to the tube containing serum and extract, then to that containing serum and saline; by so doing I avoid carrying over a trace of complement to the second tube. In each case the corpuscles are very thoroughly mixed in."

Agglutination Test. (Emery).—Macroscopic method. For aqueous or blood serum.

Materials Required.—1. Sedimentation tubes containing a known strength of an emulsion of the organism at the bottom of which is a bead of mercury.¹

2. Aqueous or clear blood serum which has been collected in a pipette or blood capsule.

3. A fine piece of capillary tubing having a known capacity in relation to the amount of emulsion in the sedimentation tubes.

To Apply the Test.—Break off the top of the sedimentation tube containing the emulsion. Take the fine piece of capillary tubing with the known capacity and touch the surface of the blood serum or aqueous, which may have been blown out on to a clean slide so that the capillary tube becomes filled with the fluid. Drop the capillary tube containing the aqueous into the emulsion of the organisms and seal up the broken end of the sedimentation tube in the flame. When cool shake so as to make the bead of mercury mix the aqueous and emulsion of organisms together. Stand in a rack and beside it place a sedimentation tube containing an emulsion of the same organisms. If the reaction be positive in the course of two to eight hours a more or less flocculent precipitate will form in the tube containing the aqueous, while in the other tube the organisms will settle down evenly to the bottom of the tube.

¹For details, see Emery, "Clinical Bacteriology and Hematology."

INDEX.

- Acne vulgaris, affections connect-
 ed with, 357
 Actinomyces, 410
 Adenoma, 106
 of glands in eyelid, 113
 of lacrimal gland, 113
 of pars ciliaris retinae, 121
 Agglutinogens, 290
 Agglutins, 292
 Agglutination test, 549
 Aggressinogens, 290
 Aggressins, 299
 Albinism, 2, 5, 65, 88
 Albuminuric retinitis, 182
 Alcohol amblyopia, 200
 Amaurotic family idiocy, 471
 Amblyopia, 197
 alcoholic 200
 aniline, 202
 aryolarsenates, 202
 carbo-disulphide, 200
 congenital, 30
 diabetic, 198
 ergot, 202
 filix mas, 203
 in puerperal state, 108
 in uræmia, 198
 iodoform, 200
 lead, 203
 nitrobenzol, 202
 quinine, 201
 salicylic acid, 204
 tobacco, 199
 toxic, 197
 Amyloid degeneration, 491
 Anæmia, pernicious, 194
 Anaphorexis, 288, 390
 Aneurism, miliary, 176
 varicose, 193
 varix, 192
 Angioma, 127, 150
 Angio-sarcomata, 133, 141, 150
 Anilin amblyopia, 202
 Animal parasites, 413
 Aniridia, 64, 75
 Ankyloblepharon, 93, 103
 Anophthalmia, 4, 5
 Anterior polar cataract, 315
 Anterior staphyloma, 68, 316
 Antigens, 290
 Antitoxin, 291
 Aphakia, congenital, 32
 Arcus senilis, 492
 Argyrosis, 281
 Arteria centralis retinae, abnor-
 malities of, 49
 Aryolarsenates, 202
 Ascending atrophy of the optic
 nerve, 474
 Aspergillus, 410
 Atavism, 2
 Atheromatous ulcer of cornea, 442
 Atypical development of vitreous
 humour, 50
 Axial fusiform cataract, 31, 40
 Axis cylinders, development of, 3
 Bacillus aerogenes, 408
 coli communis, 386
 mallei, 406
 of Ducrey, 406
 of Friedlander, 385
 of influenza, 377
 of Klebs-Loeffler, 378
 of Koch-Weeks, 373
 of leprosy, 404
 of Morax-Axenfeld, 383
 of Müller, 377
 of ozena, 386
 of Petit, 385
 of tubercle, 387
 of typhoid, 386
 of xerosis, 381
 of zur Nedden, 407
 pyocyaneus, 408
 subtilis, 407
 Bacteria, 355
 Birth injuries, 254
 Blepharitis, 344
 Blood-coagulability, 194
 Blood-serum in inflammation, 289
 Blood-staining of cornea, 187, 251
 Blood-supply to the interior of the
 eye, 172
 Botryomycosis, 412
 Buphthalmia, 70
 Burns, 280
 Calcareous degeneration, 494
 Calcareous film of cornea, 495
 film of cornea, 495
 incrustation, 281

- Canal of Cloquet, 44
 Canaliculus, abnormalities of, 93, 98
 development of, 90
 streptothrix in, 409
 Capsule of Tenon, distention of, 171
 inflammation of, 345
 Carcinoma, metastatic intraocular
 155
 of lacrimal gland, 113
 of Meibomian glands, 112.
 Carotid artery, embolism of, 196
 Cataract, anterior polar, 448
 axial fusiform, 40
 axial coralliform, 41
 black, 464
 capsular, 448
 concussion, 246
 diabetic, 456
 disc-shaped congenital, 37
 equatorial, 460
 glassworkers', 283
 Morgagnian, 39, 463
 naphthalin, 458
 nuclear, 32, 463
 perinuclear, 465
 posterior polar, 455
 punctate congenital, 43
 secondary, 459
 senile, 461
 shrunk fibrous tissue, 35
 subcapsular, 454
 tetany, 469
 traumatic, 209
 zonular, 465
 Cavernous sinus, thrombosis of, 196
 Cellulitis, 345
 Chalazion, 358
 Chancre Hunterian, 415
 soft, 406
 Chemiotaxis, 300
 Chemosis, 307
 Chiasma, tumours pressing on, 476
 Chlorosis, 194
 Cholesterine crystals, 493
 Chorioplaques, 302
 Choroid, coloboma of, 65, 83
 carcinoma in, 155
 cysts of, 171
 in glaucoma, 224
 in hemorrhage form, 188, 253
 inflammation of, 325
 neuro-fibromatosis of, 147
 rupture of, 248
 sarcoma of, 127
 vascular sclerosis, 180
 wounds of, 268
 Cilia, inflammation of follicles of, 344
 Cilia, in wounds of eyeball, 279
 pearl tumours from root-sheath of, 158
 Ciliary body, cysts of, 164
 glands of, 206
 in glaucoma, 223
 inflammation of, plastic, 330
 serous, 329
 suppuration, 333
 melanotic carcinoma of, 124
 myoma of, 154
 rupture of, 241
 sarcoma of, 127
 staphyloma of, 502
 wounds of, 268
 Cilio-retinal arteries, 46, 49, 173
 Circle of Zinn, 173
 Circulus arteriosus iridis, major and minor, 174
 Cleft, fetal ocular, 3, 13
 Cloquet, canal of, 44
 Cocci, 356
 Coloboma of choroid, 65, 83
 of eyelid, 93, 94
 of iris, 64, 79
 of lens, 58
 of retina and optic nerve, 4, 13
 Colour blindness, congenital, 4, 28
 Commotio retinae, 249
 Concussion injuries, 239
 Conjunctiva, argyrosis of, 281
 cysts of, 306
 dermoid growths of, 99
 epithelial plaques of, 111
 follicular formation in, 310
 fibro fatty growths of, 101
 in glaucoma, 217
 inflammation of, 304
 hemorrhage beneath, 266
 lymphangiectasis of, 153
 malignant growths of, 113, 137
 moles or nevi of, 113
 new gland formation in, 305
 papilloma of, 109
 phlyctenulae, 308
 wounds of, 266
 xerosis of, 307
 Copper sulphate staining of cornea, 281
 Conus myopic, 504
 Corectopia, 64, 82
 Cornea, abrasion of, 255
 annular peripheral infiltration, 313
 blood staining of, 187, 251
 congenital opacities of, 64, 65
 conicity of, 510
 cysts of, 158

- Cornea, in glaucoma, 219
inflammation of, 312
internal ulcer of, 313
leukoma of, 313
Mooren's ulcer of, 322
nebula of, 313
serpiginous ulcer of, 313
wounds of, 255
 complicated, 259
 simple perforating, 257
- Corpora amylacea in optic nerve, 492
- Couching, 246
- Crater-like hole in the optic disc, 4, 26
- Crescent, congenital, 86
 myopic, 504
- Cryptophthalmia, 93, 99
- Cyclodialysis, 233
- Cyclopia, 4, 6
- Cylindroma, 141
- Cysticercus, 423
- Cystic eyeball, congenital, 4, 11
- Cystoid cicatrix, 261
- Cysts, 156
 cuticular epiblastic, 157
 dermoid, 157
 implantation, 159
 intraocular, 171
 mesoblastic, 170
 of ciliary body, 166
 of Henlé's glands, 163
 of iris, 164
 of Krause's glands, 163
 of lacrimal gland, 161
 of lymphatic glands, 170
 of Meibomian glands, 162
 of Moll's glands, 162
 of Zeiss's glands, 162
 parasitic, 423
 with microphthalmia, 4, 13
- Cytolysin, 293
- Dacryoadenitis, 341
- Dacryocystitis, 343
- Degenerations, 440
 calcereous, 494
 choroid, 482
 cuticular epiblast, 441
 fatty, 492
 hyaline, 484
 lenticular epiblast, 447
 mesoblast, 483
 neural epiblast, 470
 of the ganglion cells of the retina, 470
 of the retinal pigment epithelium, 480
 of the optic nerve, 472, 473
 vascular, 174
- Derangements in the circulating fluids of the eye and of the vessels in which they are contained, 172
- Dermoid cysts, 93, 96
 growths, 99
- Detachment of the retina, 167, 168
 of the vitreous, 311, 507
- Development of the eye, 2
 cornea, 65
 lens, 30
 optic nerve, 24
 retina, 13
 uveal tract, 90
- Diabetic amblyopia, 198
 cataract, 456
 retinitis, 184
- Dilatation of the orbital vessels, 192
- Diplococci, 362, 367
- Discoria, 64, 82
- Disc-shaped cataract, 31, 37
- Dislocation of the lens, 343
- "Drusen," 482, 483
- Duct, lacrimal development, 90
 obstruction of, 343
- Echinococcus, 423
- Eclipse blindness, 281
- Ectogenous infection, 349
- Ectopica lentis, 56
- Ectropion of the uveal pigment, 4, 20
- Edema of the corneal epithelium, 219
 conjunctiva, 307
 iris, 331
 iris (diabetes), 457
 retina, 336, 183
- Effects of increased tension on the various structures of the eye, 217
- Elastic tissue choroid, 482
 conjunctiva, 488
 vessel walls, 174
- Electric injuries to the eye, 281
- Embolism, 195
- Emphysematous gangrene, 408
- Encephalocele, 314
- Endothelioma, 133, 135, 139, 141
- Endogenous infection, 349
- Entozoa, 422
- Entropion (congenital), 104
- Epibulbar sarcoma, 137
- Episcleritis, 323
- Epithelioma, 107
- Epithelioid cells, 302
- Erysipelas, 362
- Erythroptosis, 282
- Exophthalmic goitre, 193

- Extradural tumours of the optic nerve, 147
- False membrane on the conjunctiva, 381
- Fatty degeneration, 492
- Favus, 412
- Fibromata, choroid, 147
eyelids, 150
optic nerve, 147
orbit, 143
- Fibro-fatty growths of the conjunctiva, 101
- Filaria, 422
- Fistula of the lacrimal sac, 344
- Flat sarcoma, 136
- Fluid, vitreous, 507, 168
- Folding of the retina, 337
- Foreign bodies in the eye, 274
- Formation of bone in the choroid, 497
- Fungi, 409
- Fungus hæmatodes, 117
- Ganglion cells in glioma, 119
method of staining, 538
- Giant cells, 302
- Glandular cancer choroid, 113
ciliary body, 124
lacrimal glands, 112
Meibomian glands, 113
skin, 111
- Glassworkers' cataract, 283
- Glaucoma, alteration of the aqueous, 215
blocking of the angle of the anterior chamber, 209
cause, 217
effect on the various structures, 217
anterior chamber, 221
choroid, 224
ciliary body, 223
cornea, 219
iris, 221
lens, 224
optic disc, 227
retina, 225
treatment of, 228
- Glaucoma in glioma of retina, 117
- Glaucoma in sarcoma of the choroid, 131
- Glioma, 115
degeneration of, 118
endophytum, 116
exophytum, 116
histology, 116
in shrunken eyes, 121
metastatic deposits, 117
- Gunshot injuries, 253
- Heat injuries, 280
- Hefæ, 412
- Hemangioma, 150
- Hemolysin, 294
- Hemorrhage, choroid, 188
iris, 186
optic nerve, 182
retina, 189
vitreous, 187
- Hemosiderin, 251
- Heredity in the causation of some conditions, 2
- Hereditary optic neuritis and atrophy, 477
- Hetrachromia iridis, 89
- Holes in the retina, macula 250
with detachment, 168
- Hole at the optic disc, 26
- Hyaline degeneration, 484
nodules at the disc, 491
at the choroid, 482
- Hyaloid artery, 45
- Hydatid cysts, 423
- Hyphemia, 186
- Hypopyon, 311
- Implantation cysts, 157
- Infection, definition, 346
endogenous, 349
exogenous, 349
- Inflammation, 286
cause, 288
definition, 287
intrauterine, 203
varieties, 303
- Injuries of the eye, 235
from chemicals, 280
from light, electricity and rays, 281-285
of the ciliary body, 246
conjunctiva, 266
cornea, 255
iris, 269
lens, 269
optic nerve, 273
sclerotic, 236
- Innocent growths of the uveal tract, 121
- Inoculation for staphylococcal lesions, 357
tubercular lesions, 390
- Insectivora, 425
- Interstitial keratitis, 417
- Intradural tumours of the optic nerve, 147
- Intraocular hemorrhage, 185, 251
- Intrauterine inflammation, 303
- Iodoform amblyopia, 200
- Iridectomy, 229

- Iridocyclitis, 327
 in glioma retinae, 121
 in new growths of the choroid,
 135
 plastic, 330
 serous, 329
 suppurative, 333
 Iridodialysis, 240
 Iridodonesis, 244
 Iris, congenital absence, 75
 coloboma of, 79
 cysts of, 158, 164, 166
 inflammation of, 324
 injuries of, 259
 sarcoma of, 127
 tremulous, 244
 Iritis, 324
 gonorrheal, 372
 malaria, 422
 staphylococcal, 359
 sympathetic, 437
 syphilitic, 416
 Iron, test for, 278
 in pigment, 279
 Ischemia of the retina, 201, 194

 Keratitis in gonorrheal infection,
 371
 Keratinisation, 443
 Keratocele, 341
 Keratoconus, 510
 Keractesia, 322
 Keratomalacia, 362

 Lacrimal canals, 343
 calculi, 409
 Lacrimal gland, 342
 cysts of, 161
 inflammation of, 342
 tumours of, 141
 Lacrimal sac, abscess of, 344
 fistula of, 344
 inflammation of, 343
 Lagophthalmos, 101
 Lamellar cataract, 465
 Lead poisoning, 203
 Lenticonus anterior, 60
 posterior, 35
 Lens, development, 30
 foreign bodies in, 277
 size of, 468
 see also cataract
 Leprosy, 404
 Leptothrix, 409
 Leucoma, 313
 Leucosarcoma, 132
 Leukemia, 194
 Lice of the lashes, 425
 Lupus, 392
 Lymphangioma, 153

 Lymphoma, 154
 Lymphosarcoma, 141
 Lysinogens, 290
 Lysins, 293

 Macula lutea, nutrition of, in toxic
 amblyopia, 199
 Medullated nerve fibres, 14, 25
 Melanoma, 122
 Melanosis, 65, 89
 Melanotic carcinoma, 124
 sarcoma, 124
 Metastatic growths, 155
 intraocular, 155
 orbital, 156
 Metastatic uveitis, 372, 394, 417,
 439
 retinitis, 360, 403, 417
 Methods of examination of the eye
 after removal, 519
 collecting blood, 541
 decalcification, 518
 embedding, 525
 fixing, 576
 fluids, 513
 injection of the eye, 515
 making blood films, 542
 making glass instruments, 541
 mounting macroscopic speci-
 mens, 523
 microscopic specimens, 529
 post-mortem examination,
 514
 Microcoria, 64, 82
 Microblepharon, 101
 Moles or nevi, 113
 Mooren's corneal ulcer, 322
 Morgagnian cataract, 462
 Muscæ volitantes, 46, 54
 Myoma, 154

 Nevi, 105
 Necrosis in the cornea, 313, 362
 in glioma retinitis, 118
 in sarcoma of the choroid, 134
 Neoplasms, 105
 Neuritis optic, 477
 Neuro-epithelioma of the retina,
 115
 Neurofibroma, 143
 Neurofibromatosis, 143
 Night blindness, 282
 Nitrobenzol amblyopia, 202
 Nodular opacity of the cornea, 486

 Obstruction to the central retinal
 artery, 176
 Opaque membrane behind the
 lens, 31-33
 Opaque nerve fibres, 4, 24

- Ophthalmia, diphtheritic, 378
 electrica, 283
 gonorrheal, 367
 membranous, 379
 neonatorum, 368
 nodosa, 375
 phlyctenular, 308
 sympathetic, 437
 Opsonic index, 298
 Opsonins, 296
 Opsoninogens, 290
 Optic nerve, atrophy, 290
 colobomata, 473
 corpora amylacea, 492
 cupping, 473
 degeneration, 473
 Drusen, 482
 inflammation, 339
 tumours of, 147
 Orbit, abscess of, 45
 cysts, 171
 inflammation of, 545
 toxic amblyopia, 197
 tumours of, 150
 Orbito-meningo-encephalocele, 93-96
 Ossification choroid, 497
 Osteosarcomata, 41
 Oxycephaly, 95

 Pannus, 434
 Panophthalmitis, 315, 366
 Papillitis, 340
 Papillomatous horns and epithelial plaques, 106, 109, 110, 111
 Parasitic diseases, 355
 Pars ciliaris retinae, growth of, 121
 cysts of, 165
 Perineuritis, 340
 Pernicious anæmia, 194
 Persistence of the hyaloid artery, 45, 46
 Persistent pupillary membranes, 64-73
 Peritheliomata, 133
 Phthisis bulbi, 335
 in glioma, 121
 in sarcoma of the choroid, 135
 Physiological cupping of the disc, 4-27
 Pigmentation hematogenous, 132
 of tumours, 132
 Pinguecula, 488
 Plexiform neuroma, 143
 Plica semilunaris, developmental abnormalities, 103
 papilloma, 109
 Pneumococcus, 362
 Pneumobacillus, 385

 Poisons acting on the nerve elements of the retina, 199
 affecting the cerebral centres for vision, 204
 affecting the kidneys and producing secondary retinal changes, 203
 causing retinal ischemia, 201
 Polycoria, 64, 81
 Polymorphonuclear leucocytes, 299
 Positive chemiotaxis, 300
 Posterior lenticonus, 31, 35
 Posterior polar cataract congenital, 455
 acquired, 455
 Precipitinogens, 290
 Precipitins, 292
 Presbyopia, 462
 Primary optic vesicle, 3
 Pseudo-coloboma of the iris, 64
 Pseudo-glioma, 334
 Pseudo-neuritis, 4, 27
 Pterygium, 488
 Puncta lacrimal, development and malformations of, 93
 concretions in, 409
 Punctate cataract, 42
 Pupillary membrane, 64, 66
 Pupil, congenital deformities of, 75
 occlusion of, 332
 pulsation of retinal vessels, 225
 seclusion, 332
 Pyemia, 349
 Pyramidal cataract, 449

 Quinine amblyopia, 201

 Retention cysts, 161
 Reticular opacity of the cornea, 487
 Retina, cysts of, 169
 degeneration, 470
 detachment of, 168
 edema of, 336
 inflammation of, 336
 tumours of, 115
 Retinitis circinata, 191
 pigmentosa and sine pigment, 181
 proliferans, 338
 Retrobulbar neuritis, 339
 Ring sarcoma, 129
 Rosettes, 119
 Rupture of the choroid, 248
 eyeball, 236
 ligamentum pectinatum, 241
 retina, 249
 sphincter pupillæ, 248

- Sarcoma, 126
 choroid, 129
 ciliary body, 128
 epibulbar, 137
 intraocular, 127
 iris, 127
 lacrimal gland, 141
 metastatic, 140
 optic nerve, 143
 orbit, 139
 uveal tract, 127
 Schirrus of the choroid, 155
 Scleritis, 464
 Sclerosis of the nucleus of the lens, 464
 Sclerosis of the blood-vessels, choroid, 180
 ligamentum pectinatum, 216
 retina, 174
 Secondary optic vesicle, 3
 Senile cataract, 461
 changes in the retina, 169
 degeneration in the capsular epithelium, 459
 of the lens, 464
 Shot silk retina, 4, 12
 Shrunk fibrous tissue cataract, 31, 35
 Siderosis bulbi, 278
 Snow blindness, 283
 Squamous epithelioma, 106
 Staphylococci, 356
 Staphyloma, 499
 Stelwag's brawny edema, 433
 Streptobacillus of Ducrey, 406
 Streptococci, 360
 Streptothrix, 409
 Styes, 357
 Supernumerary lacrimal puncta, 93
 Suspensory ligament of the lens, 54
 Suppurative uveitis, 324
 Suprachoroiditis, 327
 Symblepharon, 280
 Sympathetic ophthalmitis, 437
 Synchronic scintillans, 494
 Syphilis, 413
 choroid, 417
 cornea, 417
 lacrimal sac, 417
 organisms in, 413
 optic nerve, 421
 retinitis, 417
 uveal tract, 415
 Tape worms, 422
 Tarsal cysts (chalazion), 357, 162
 Teleplasms, 105
 Tenon's capsule, 345
 Thrombosis of central vein, 178
 cavernous sinus, 196
 of vessels in choroid, 180
 Toxic amblyopia, 197
 Toxins, 290
 Trachoma, 426
 Transverse calcareous film, 495
 Triradiate opacities, 31, 41
 Trunk atrophy of the optic nerve, 475
 Trichiasis, congenital 104
 Trypanosomiasis, 422
 Tobacco amblyopia, 197
 Toxic amblyopic, 197
 Tubercle, organisms of, 387
 choroid, 399
 ciliary body, 398
 conglomerate, 394
 conjunctiva, 392
 cornea, 393
 diagnosis of, 389
 iris, 394
 lens, 402
 miliary, 394
 optic nerve, 403
 predisposing causes, 391
 retina, 403
 Tuberculin, reaction to, 390
 administration, 390
 Tumours, 105
 Tylosis, 345
 Ulcer of the cornea, 310
 rodent, 111
 Uræmia, 198
 Uveal tract, adenomata, 121
 carcinoma, 125
 inflammation of, 324
 melanoma, 122
 sarcoma, 128
 Vaccines, 297
 preparation of, 542
 Vascular sclerosis, 174
 Vascular degeneration in choroid, 180
 vessels of the eye, 172
 Vesicular keratitis, 318
 Vernal catarrh, 434
 Vitreous, atypical development of, 50
 cholesterine in, 494
 detachment, 311, 507
 fluid, 169
 foreign bodies in, 277
 in glaucoma, 213
 organisation in, 188
 shrunk, 311, 507
 Warts of the eyelid, 110

Wassermann reaction, 294, 544
Wound infection, 350
Wounds, conjunctiva, 266
 cornea, 255
 complicated, 259
 operation, 265
 simple, 257
iris, 269
lens, 269
of the globe, 268

Wounds, optic nerve, 273

Xerosis bacillus, 381
Xerosis bacillus, 381
Xerosis of the conjunctiva, pri-
 mary, 445
 secondary, 306

Zinn, zonule of, defects of, 54
Zonular cataract, 466

