

## **A manual and atlas of medical ophthalmoscopy / by W. R. Gowers.**

### **Contributors**

Gowers, W. R. 1845-1915.  
University College, London. Library Services

### **Publication/Creation**

London : J. & A. Churchill, 1879.

### **Persistent URL**

<https://wellcomecollection.org/works/ceyhrvvj>

### **Provider**

University College London

### **License and attribution**

This material has been provided by This material has been provided by UCL Library Services. The original may be consulted at UCL (University College London) where the originals may be consulted.


This work has been identified as being free of known restrictions under copyright law, including all related and neighbouring rights and is being made available under the Creative Commons, Public Domain Mark.

You can copy, modify, distribute and perform the work, even for commercial purposes, without asking permission.



Wellcome Collection  
183 Euston Road  
London NW1 2BE UK  
T +44 (0)20 7611 8722  
E [library@wellcomecollection.org](mailto:library@wellcomecollection.org)  
<https://wellcomecollection.org>







No. 5090/H

150



THE INSTITUTE  
OF  
OPHTHALMOLOGY  
LONDON

EX LIBRIS







IX 2809392230 ✓


A 7

3<sup>rd</sup> & 4<sup>th</sup> Editions B3  $\frac{1}{23-24}$

OPHTHALMOLOGY HC256 LOWERS [17]



B31  
22



A

MANUAL AND ATLAS  
OF  
MEDICAL OPHTHALMOSCOPY

BY

W. R. GOWERS, M.D., F.R.C.P.

ASSISTANT-PROFESSOR OF CLINICAL MEDICINE IN UNIVERSITY COLLEGE,  
ASSISTANT-PHYSICIAN TO UNIVERSITY COLLEGE HOSPITAL, AND TO THE NATIONAL HOSPITAL FOR THE  
PARALYSED AND EPILEPTIC



LONDON

J. & A. CHURCHILL, NEW BURLINGTON STREET

—  
1879





Digitized by the Internet Archive  
in 2014

<https://archive.org/details/b21285688>



## P R E F A C E.

---

THE first intention in the preparation of the following work was the publication of the series of illustrations of medical ophthalmoscopy contained in the appended plates, and of the cases from which they were made. I have thought, however, that the utility of these would be increased by the addition of a systematic account of the subject which they illustrate.

With one or two exceptions all the cases described and figured were met with in the course of purely medical work, chiefly at University College Hospital, and at the National Hospital for the Paralysed and Epileptic. In the preparation of the illustrations, great care has been taken to secure the utmost possible exactness. The autotype plates are reproductions of sepia drawings; and this method has been chiefly employed because by it a more exact representation of delicate pathological appearances can be obtained than by chromo-lithography. This method has also the advantage of fixing the attention on the changes of form, rather than upon the alterations in colour, which, important as they are, very often mislead the inexperienced. Chromo-lithography has been employed for some subjects in which the changes of tint are of predominant importance. It is intended that the autotype plates should be studied by the aid of the descriptions prefixed to them, and it is believed that, thus examined, those who are accustomed to the use of the ophthalmoscope will not miss the absent colours. With



one or two exceptions, specified on p. 321, the drawings were all made by the direct method of examination.

The cases appended are for the most part those of which the ophthalmoscopic appearances are figured in the plates. A few others, which furnish examples of important facts, have been added. The majority are published now for the first time. Many are suggestive in their medical as well as in their ophthalmoscopic aspects, and, since the work is designed especially for medical workers, the general symptoms are narrated, and in some cases, their significance is briefly pointed out. The descriptions of the cases have been abbreviated, as much as was practicable, from more lengthy reports. The ophthalmic surgeon may miss some details in the notes of the ocular condition, but those which are absent are, I trust, for the most part unimportant.

I have included in the appendix three pages of test-types, partly for the convenience of medical workers who may not possess other test-types. The  $1\frac{1}{2}$  in these types corresponds exactly to the .5 (metre—the old  $1\frac{1}{2}$  feet) of Snellen.

In the preparation of the systematic part of the work I have been much indebted to the writings of Dr. Hughlings Jackson, the value and suggestiveness of which it is difficult to exaggerate; to Dr. Clifford Allbutt's important work on "The Ophthalmoscope in Diseases of the Nervous System and of the Kidneys;" to the writings of Leber, for the most part summarized in his excellent treatise on Diseases of the Optic Nerve and Retina, in the "Handbuch" of Graefe and Saemisch; and to the account by Förster, in the same work, of the connection between morbid states of the eye and of the general system.

I have to express my thanks to several colleagues and friends who have kindly allowed me to make and publish drawings of cases under their care, and have referred, in the several places, to the help thus afforded. To two of my colleagues, Dr. Radcliffe and Dr. Hughlings Jackson, I am particularly indebted for the readiness with which they have permitted me to use my notes and drawings of cases under their care, in the charge or observation of which I have



had the advantage of sharing. To Dr. Wilson Fox and Dr. Stephen Mackenzie, I also owe special thanks.

The reader may perhaps look for information upon one topic not alluded to in the following pages, viz., the use of the ophthalmoscope in the study of the action of drugs. It was my intention to include a section on this subject, but I soon found that such a chapter would be merely a collection of contradictory assertions. There is hardly a statement on this subject, made by one observer, which has not been contradicted by some other observer, apparently of equal competence. Unfortunately, such diversity of statement is not confined to this point. A similar discrepancy is observable in the statements which have been made regarding the changes in functional diseases of the nervous system, and the conclusion is unavoidable that many observations on this subject possess a value very disproportionate to the general authority of the observers. Possibly, by some, slight morbid changes have been overlooked; certainly, by others, appearances have been regarded as pathological, which are to be found with equal frequency in normal individuals.

I venture to direct the attention of those occupied in teaching to a point referred to in the appendix—the advantage which it is to students to acquire a knowledge of the use of the ophthalmoscope early in their practical work, instead of, as at present, leaving its acquisition to the last. Strictly, indeed, the use of the instrument, and the examination of the normal fundus, are parts of practical physiology, and might with great advantage be taught in that course in conjunction with the study of the anatomy and histology of the eye. But whether this is done or not, the advantage to the student of a knowledge of the use of the instrument early in his hospital work is very great. Its efficient employment, and still more, a correct knowledge of the nature of the various appearances, are only to be acquired by a considerable amount of practice. When the student, as is now too often the case, only succeeds in seeing the optic disc just before he leaves the hospital, his knowledge of the use of the ophthalmoscope, in most cases, ends with this. Whereas the whole of




his practical work, in the medical and surgical wards, and in the medical out-patient room, supplies him with opportunities for practice and education in the use of the instrument, and the study of the various aspects of the normal fundus, without any interference with other work—opportunities, which, if lost, rarely return, and are not to be found in the practice of the ophthalmic surgeon. I think, indeed, that a perusal of the account contained in the following pages of the large number of diseases in which significant changes in the eye are common, will support the opinion that the condition of the fundus should be systematically described in medical case-taking, and it is only by early education in the use of the ophthalmoscope that such a result can be obtained.

QUEEN ANNE STREET, *May*, 1879.



# CONTENTS.



INTRODUCTION .. .. .	PAGE 1
----------------------	-----------

## PART I.

### CHANGES IN THE RETINAL VESSELS, OPTIC NERVE, ETC., OF GENERAL MEDICAL SIGNIFICANCE.

The Retinal Vessels .. .. .	7
Size .. .. .	8
Arrangement .. .. .	13
Structure .. .. .	14
Aneurism .. .. .	16
Circulation .. .. .	18
Pulsation .. .. .	18
Anæmia .. .. .	20
Hyperæmia .. .. .	22
Hæmorrhage .. .. .	24
Thrombosis .. .. .	27
Embolism .. .. .	28
The Optic Nerve .. .. .	34
Congestion .. .. .	37
Neuritis .. .. .	40
Pathological Anatomy .. .. .	50
Symptoms .. .. .	54
Causes .. .. .	61
Relation to Encephalic Disease .. .. .	63
Varieties .. .. .	74
Diagnosis .. .. .	76
Prognosis .. .. .	81
Treatment .. .. .	82
Atrophy .. .. .	84
Simple .. .. .	84
Causes .. .. .	89
Anatomy .. .. .	94
Symptoms .. .. .	96
Consecutive .. .. .	101

	PAGE
Atrophy of Optic Nerve ( <i>continued</i> ):—	
Choroiditic .. .. .	104
Diagnosis .. .. .	104
Prognosis .. .. .	105
Treatment .. .. .	107
The Retina .. .. .	107
The Choroid .. .. .	111

## PART II.

## OPHTHALMOSCOPIC CHANGES IN SPECIAL DISEASES.

## Diseases and Injuries of the Nervous System:—

Diseases of the Brain .. .. .	113
Anæmia and Hyperæmia .. .. .	113
Inflammation .. .. .	115
Hæmorrhage .. .. .	117
Softening .. .. .	119
Embolism .. .. .	120
Thrombosis .. .. .	122
Abscess .. .. .	125
Tumours .. .. .	126
Intra-cranial Aneurism .. .. .	135
Internal Hydrocephalus .. .. .	136
Diseases of the Meninges of the Brain:—	
Meningeal Growths .. .. .	137
Meningitis .. .. .	138
Simple .. .. .	138
Tubercular .. .. .	139
Syphilitic .. .. .	143
Epidemic .. .. .	143
Traumatic .. .. .	143
Diseases of the Cranial Bones .. .. .	143
Diseases of the Orbit .. .. .	145
Injuries to the Head .. .. .	146
Diseases of the Spinal Cord:—	
Inflammation .. .. .	149
Sclerosis .. .. .	149
Posterior: Locomotor Ataxy .. .. .	149
Lateral .. .. .	153
Insular .. .. .	153
Caries of the Spine .. .. .	154
Injuries to the Spine .. .. .	155
Functional Diseases of the Nervous System:—	
Exophthalmic Goitre .. .. .	156
Chorea .. .. .	156
Neuralgia and Migraine .. .. .	157
Epilepsy .. .. .	157
Hysteria .. .. .	160



Functional Diseases of the Nervous System ( <i>continued</i> ):—	PAGE
Insanity .. .. .	161
General Paralysis .. .. .	161
Mania .. .. .	163
Melancholia .. .. .	163
Dementia .. .. .	163
Diseases of the Urinary System:—	
Bright's Disease .. .. .	164
Diabetes .. .. .	178
Diseases of the Circulatory System:—	
Diseases of the Heart .. .. .	180
Diseases of the Vessels .. .. .	183
Diseases of the Blood:—	
Plethora .. .. .	183
Anæmia .. .. .	184
Acute .. .. .	184
Chronic .. .. .	188
Pernicious .. .. .	189
Leucocythæmia .. .. .	190
Purpura .. .. .	195
Scurvy .. .. .	196
Diseases of the Lungs .. .. .	196
Diseases of the Digestive System .. .. .	196
Diseases of the Sexual Organs .. .. .	197
Diseases of the Skin .. .. .	198
Chronic General Diseases:—	
Tuberculosis .. .. .	198
Syphilis .. .. .	202
Rheumatism .. .. .	205
Gout .. .. .	205
Lead Poisoning .. .. .	206
Alcoholism .. .. .	209
Tobacco Poisoning .. .. .	210
Other Poisons .. .. .	212
Acute General Diseases:—	
Typhus Fever .. .. .	212
Typhoid Fever .. .. .	213
Relapsing Fever .. .. .	214
Measles .. .. .	214
Scarlet Fever .. .. .	215
Variola .. .. .	216
Acute Rheumatism .. .. .	216
Malarial Fevers .. .. .	216
Erysipelas .. .. .	219
Diphtheria .. .. .	220
Parotitis .. .. .	220
Tonsillitis .. .. .	220
Whooping Cough .. .. .	220
Cholera .. .. .	221
Pyæmia and Septicæmia .. .. .	221
Ophthalmoscopic Signs of Death .. .. .	226

## APPENDIX I.—NOTES.

NOTE	PAGE
I. On Ophthalmoscopes. . . . .	228
II. On Learning the Use of the Ophthalmoscope . . . . .	229
III. Ophthalmoscopic Micrometry . . . . .	231
IV. On the Examination of Colour-vision . . . . .	233

## APPENDIX II.

Test-Types . . . . .	237
----------------------	-----

## APPENDIX III.—CASES.

CASE	
1. Unilateral neuritis, in caries of sphenoid bone . . . . .	240
2. Neuritis in chronic meningitis . . . . .	242
3. Neuritis; tumour of corpora quadrigemina . . . . .	245
4. Neuritis; chronic meningitis; inflammatory growths . . . . .	248
5. Neuritis; tubercles of brain . . . . .	250
6. Neuritis; syphilitic cerebral disease . . . . .	251
7. Neuritis; syphilitic cerebral disease . . . . .	254
8. Neuritis; tumor cerebri . . . . .	255
9. Neuritis; syphilitic cerebral disease . . . . .	256
10. Neuritis; syphilitic cerebral disease . . . . .	259
11. Neuritis; symptoms of cerebral tumour; partial recovery . . . . .	261
12. Neuritis; symptoms of cerebral tumour . . . . .	264
13. Intense neuritis with retinal hæmorrhages; tumor cerebri (?) . . . . .	264
14. Neuritis; tumour of lenticular nucleus . . . . .	266
15. Neuritis (late) in cerebral tumour . . . . .	267
16. Neuritis; hæmorrhagic glioma of brain . . . . .	269
17. Unilateral neuritis: syphilitic cerebral disease . . . . .	272
18. Neuritis and hemiopia in syphilitic disease . . . . .	273
19. Neuritis; cerebellar tubercle . . . . .	274
20. Neuritis; cerebral tumour . . . . .	276
21. Neuritis; tumour of third ventricle . . . . .	277
22. Neuritis; tumour of hemisphere . . . . .	279
23. Chronic neuritis; epilepsy (?) . . . . .	280
24. Chronic neuritis; epilepsy; hypermetropia . . . . .	282
25. Congestion of discs; cerebral embolism . . . . .	283
26. Chronic neuritis; obscure cerebral symptom; hypermetropia . . . . .	285
27. Neuritis; chronic cerebritis . . . . .	286
28. Neuritis; lead poisoning . . . . .	288
29. Intense neuro-retinitis: chlorosis . . . . .	289
30. Atrophy from cerebral disease . . . . .	293
31. Atrophy from post-orbital disease . . . . .	294
32. Atrophy after fall on the head . . . . .	296
33. Atrophy, early, in locomotor ataxy . . . . .	296
34. Atrophy in lateral sclerosis . . . . .	297



CASE	PAGE
34A. Atrophy in insular sclerosis .. .. .	298
35. Acute tuberculosis; tubercles of choroid .. .. .	299
36. Renal disease; optic neuritis .. .. .	299
37. Renal disease; optic neuritis .. .. .	301
38. Renal disease; neuritis; recovery .. .. .	302
39. Renal disease; acute retinal changes .. .. .	302
40. Renal disease; chronic retinal changes .. .. .	305
41. Renal disease; development of retinal changes .. .. .	307
42. Renal disease; perivascular changes and aneurisms .. .. .	308
43. Renal disease; hæmorrhage into vitreous .. .. .	310
44. Anæmia; optic neuritis .. .. .	310
45. Pernicious anæmia; retinal hæmorrhages .. .. .	311
46. Leucocythæmia; retinal hæmorrhages .. .. .	312
47. Mitral disease; embolism of retinal and cerebral arteries .. .. .	313
48. Mitral disease; partial embolism of retinal artery .. .. .	318
49. Fracture of the skull; retinal hæmorrhages .. .. .	318
50. Fracture of the skull; hernia cerebri; optic neuritis .. .. .	319

## DESCRIPTION OF THE PLATES.

PLATE	
I.—Congestion and inflammation of optic disc in cerebral embolism and tumour .. .. .	321
II.—Atrophy of disc, consecutive and simple, in cerebral, orbital, and spinal disease .. .. .	323
III.—Optic neuritis in caries of bone, chronic meningitis, and cerebral tumour .. .. .	325
IV.—Optic neuritis in syphilitic disease of brain .. .. .	326
V.—Optic neuritis in cerebral tumour.. .. .	328
VI.—Optic neuritis in cerebral tumour.. .. .	329
VII.—Optic neuritis in syphilitic disease (unilateral); epilepsy, anæmia, and lead poisoning .. .. .	331
VIII.—Neuro-retinitis in chlorosis.. .. .	332
IX.—Retinal hæmorrhage, optic neuritis, &c., in kidney disease .. .. .	333
X.—Acute and chronic retinal changes in kidney disease .. .. .	334
XI.—Retinal changes in pernicious anæmia and leucocythæmia .. .. .	334
XII.—Retinal changes, aneurisms, &c., in kidney disease; embolism of retinal artery in cardiac disease .. .. .	335
XIII.—Tubercles of choroid; microscopical appearances in optic neuritis .. .. .	337
XIV.—Microscopical appearances in optic neuritis .. .. .	338
XV.—Microscopical appearances in optic neuritis .. .. .	340
XVI.—Microscopical appearances in optic neuritis, optic nerve atrophy, and albuminuric retinitis .. .. .	341

#### ERRATA.

Page 33, line 8.—For “inwards” read “outwards.”


„ 33, „ 9.—For “outwards” read “inwards.”

„ 33, „ 12 (description of figure).—For “Left” read “Right.”

The note on page 122 should have been placed on page 124 and appended to the sentence ending on line 7 with the word “mind.”



# MEDICAL OPHTHALMOSCOPY.



## INTRODUCTION.

THE ophthalmoscope is of use to the physician because it gives information, often not otherwise obtainable, regarding the existence or nature of disease elsewhere than in the eye. The characters of the changes which possess this general significance, and of the special alterations in the fundus oculi in individual diseases which come under the physician's care, constitute the subject of the following pages.

The information furnished by the ophthalmoscope depends upon the circumstance that we have under observation—  
1. The termination of an artery and the commencement of a vein, and the blood circulating within them. 2. The termination of a nerve, which, from its close proximity to the brain, and from other circumstances, possesses significant relations to the rest of the nervous system. 3. A nervous structure—the retina, which suffers in a peculiar way in many general diseases. 4. A vascular structure—the choroid, which also presents changes in certain constitutional affections.

For the efficient use of the ophthalmoscope in medical practice, the student must be familiar, first, with the use of the instrument; and, secondly, with the normal fundus oculi, with the changes in its appearance (congenital, &c.) which are of no significance, and also with those which are of purely ocular significance, such as posterior staphyloma, glaucomatous



excavation, and the like. An acquaintance with these should be gained from the ophthalmic surgeon before inferences can safely be drawn regarding the general significance of alterations met with in extra-ocular disease. The following pages suppose the possession of a general knowledge of the use of the instrument, but a few words regarding some points which are of special importance may be of service. A note on the most convenient form of ophthalmoscope is given in the appendix.

A first requisite in medical ophthalmoscopy is familiarity with the direct method of examination. The degree of magnification, three or four times that obtained by the indirect method, often reveals changes of the highest significance, which cannot otherwise be seen, or shows the true nature of appearances which, seen by the indirect method, are obscure. At the same time, both methods should be employed. Not only has each its special advantages, but the two together often give information which neither alone affords.

Another requisite is skill in the examination of eyes without the use of atropine to dilate the pupil. In most eyes much can be seen with the pupil undilated, often all that is necessary, and almost always enough to determine whether or not there is more to be learned by examination under atropine. The paralysis of accommodation from atropine is a source of annoyance, and is especially resented by patients whose eyes are examined on account of general, not ocular, disease, in whom the sight may have been previously unaffected. It very commonly happens that in these cases there is a subsequent failure of sight, the examination having been made on account of slight changes, neuritis, atrophy, &c., which afterwards progressed. The failure of sight in such cases will almost certainly, and not unnaturally, be ascribed by the patient to the effect of the atropine.\* For the same reasons atropine, when

\* "If we use the ophthalmoscope, or if we use atropine, or if we apply a blister to the head, or adopt any new kind of treatment, the patient may blame us for his blindness, if he saw well before such procedures. A patient who reads the smallest print and supposes his sight to be good, may have double optic neuritis. The use of atropine affects his sight for near objects gravely, and if, from the advance of the neuritic process, what I may call



necessary, should be applied to one eye at a time, unless the sight of both is already impaired. If one pupil only is to be dilated, and it is a matter of indifference which, an eye, the sight of which is impaired, should be chosen in preference to the other.

In making an examination with the ophthalmoscope, it is best first to look at the eye from a distance, in order to ascertain whether the red reflection from the fundus is clear. This at once gives information regarding the presence or absence of opacity of the lens or vitreous, or may reveal iritic adhesions—conditions which convey important information, and explain what would otherwise be a puzzling obscurity of detail. Next, the refraction of the eye should be roughly estimated by observing if the vessels of the retina can be distinctly seen from a distance, and, if so, whether they move in the same direction as the observer's head (hypermetropia), or in the opposite direction (myopia). The knowledge of the condition of the eye thus gained is of much importance, since in myopia the details of the fundus appear, by the indirect method, small, and in hypermetropia they appear large. If necessary, the degree of refraction may be more accurately ascertained by the use of test-types and lenses.

It is frequently necessary to examine patients in bed. The indirect method of examination can be applied as readily to a patient in bed as to one sitting on a chair, the most convenient place for the light being on the pillow above the patient's head. Even in daylight little difficulty is experienced unless the pupil is small, but the examination is facilitated by employing a lens in a short tube

retinal sight fails before the effect of the atropine has passed off, he very naturally blames us for the subsequent permanent affection of his sight. A patient, when asked how long his sight had been bad, replied, 'Only since the drops had been put in.' We must, then, when we discover neuritis, sight being good, tell the patient that his eyes are not really good, and that we are anxious about his sight. Whether we give this warning or not, we shall be blamed by an unintelligent patient for 'tampering with his eyes.' We must, however, act for our patient's good, regardless of selfish considerations. In very many cases we can see enough for diagnostic purposes without using atropine."—Hughlings-Jackson, *Lectures on Optic Neuritis*, "Med. Times and Gaz.," September 16, 1871.



from which a curtain falls on to the patient's face, as recommended by Clifford Allbutt and by Galezowski. The examination of a patient in bed by the direct method presents some difficulty to a beginner; the most convenient way is to stand at right angles to the patient, and place the lamp on the opposite side of the patient's head.

All who have employed the ophthalmoscope in medical practice will agree with Dr. Hughlings Jackson in urging the routine use of the instrument in all diseases in which ophthalmoscopic changes are, even occasionally, met with. It often happens that unexpected information is gained regarding the nature of the disease, or its probable consequences.

It has been remarked that the medical ophthalmoscopist should possess familiarity with those changes in the eye which are of purely ocular significance. It is equally important that he should be familiar with those congenital changes in the eye which are of no significance. Many of these will be alluded to in describing the morbid appearances with which they are most liable to be confounded. One or two, which give rise to special trouble to the beginners, may be here briefly mentioned. One of these is the remarkable variation which is met with in the colour of the optic disc. It has been well remarked that the tint of the optic disc may vary as much as the tint of the cheek. It is always redder in the young than in the old. In the latter the redness has often a grey tint mingled with it. In rare cases, in young persons, the tint may be scarcely lighter than that of the adjacent choroid.\* In cases in which the choroid is bright in tint, the apparent redness of the disc is increased by indirect examination with a wide pupil and a bright light. It is the sharpness of the edge of the disc to which attention should be especially directed.

When the physiological cup is very large, the vascular

\* As in a case attending some years ago at the Queen Square Hospital, in which, to indirect examination, although the edge of the disc was clear, there was no recognizable difference in tint between it and a bright choroid. On direct examination, and with feeble illumination, a difference could be seen. The view that the disc was normal was supported by the authoritative opinion of Liebreich, and the subsequent history of the case.



portion of the disc is confined to a narrow rim at the side, often much narrower than that shown in Pl. III. 1, which represents a large but not very large cup. When the part of the disc occupied by the nerve fibres is reduced to, say, one-half of that shown in the figure, the fibres are so crowded together that the choroidal limit is often less distinct than normal, and the central white cup may be mistaken for the disc, the edge being regarded as part of the fundus. The mistake will not occur, however, if its danger is known, and attention be paid; there is no confusion with the direct examination.

The white patches near the disc, which are due to choroidal atrophy and to opaque nerve fibres, sometimes present puzzling appearances. The recognition of choroidal atrophy by the bluish white tint of the sclerotic and the pigment disturbance, and the unchanged retinal vessels, is usually one of the first points learned. Now and then a narrow posterior staphyloma may surround, or almost surround the disc, and its edge may be mistaken for the edge of the disc, which then appears white with a red centre, an appearance with which I have known beginners to be much puzzled. (It is well to remember that posterior staphyloma may be seen occasionally in hypermetropic eyes, as well as in the myopic eyes, in which it is so common.)

The white patches of opaque nerve fibres are characterized by the partial concealment of the vessels, the feathery edge, and by the centre of the disc being commonly unconcealed. When a small patch lies near, but separated from the disc, the resemblance to an inflammatory exudation may be puzzling; the characters of its edge will usually enable its nature to be recognized.

Peculiar white films sometimes lie in front of the vessels on the disc, looking like fragments of tissue paper or white gauze, and allowing the vessels behind to be dimly seen. These may be left by a pathological process, but they are also frequent as a congenital condition, owing to an undue development of tissue at the back of the vitreous. When congenital, the vessels are merely concealed; when pathological, they are constricted. In one case which came under my observation, a

congenital film extended over the upper half of the disc, and ended on one side in a reflected edge.

To acquire a knowledge of the exact appearance of these ocular changes, the reader is advised to study carefully the plates in the admirable atlas of Liebreich.

In considering what may be learned regarding the conditions of the general system by observation of the fundus oculi, it will be convenient first to consider specially those intra-ocular changes which are of general medical significance, viz., the changes in the vessels and the circulation; the changes, inflammatory and atrophic, in the optic nerve; and, more briefly, the alterations in the retina and choroid; and in the second place, the changes which are met with in special diseases of the nervous and general systems.



## PART I.

### *CHANGES IN THE RETINAL VESSELS AND OPTIC NERVE OF GENERAL MEDICAL SIGNIFICANCE.*

#### THE RETINAL VESSELS.

IN no other structure of the body are the termination of an artery and the commencement of a vein presented to view, and information regarding the general state of the vascular system is often to be gained from an inspection of their size, texture, and the conditions of the circulation within them. It must be remembered, however, that the vessels there seen are of very small size. One of the primary divisions of the retinal artery, large as it appears to direct ophthalmoscopic examination, is actually so small as to be scarcely visible to the unassisted eye, being less than the  $\frac{1}{100}$ th of an inch in diameter, and the smallest vessels visible with the ophthalmoscope are not more than the  $\frac{1}{700}$ th of an inch in diameter. But these, it must also be remembered, are considerably larger than capillaries. The retinal capillaries are always invisible, and, away from the optic disc, they are never so numerous as to occasion any recognizable reddish tint.

A second point to be remembered is that the red lines spoken of as the retinal arteries or veins are not the vessels themselves, but the columns of blood within them. The walls of the vessels are, as a rule, invisible; they are always invisible to the indirect method of examination, but by the direct method the walls of the larger branches may be sometimes seen, as fine white translucent lines along the sides of the red column of blood, most distinct where one vessel passes over another. They are best seen by feeble illumina-



tion, and especially by so moving the mirror as to render the illumination slight and oblique. Sometimes, as will be described immediately, the outer coat of the vessel is so thick as to be very conspicuous.

The paler line which runs down the centre of each vessel is generally regarded as a reflection from the middle of the anterior surface of the column of blood. It is certainly due to a reflection from the convexity of either the contained blood or the containing wall.\* It is distinct only when the vessel lies in a plane at right angles to the line of observation. If the vessel, in consequence of an antero-posterior curve, ceases to be a plane at right angles to the line of observation, this central reflection is no longer visible, and the whole width of the vessel is the same dark colour as the edge. In the case of veins this change is very striking, and the greater amount of colour makes these portions appear even darker than the rest. Many examples of this will be found in the appended plates, as in I. 4, II. 1, III. 2, 4, V. 5, 6, &c.

SIZE.—In estimating variations in size of the retinal vessels allowance must be made for the refraction, *i.e.*, magnifying power of the eyeball, remembering that by the indirect method of examination, in myopic eyes the details appear small, while in hypermetropic eyes the objects appear large. In the direct method there is less variation, because, for distinct vision, the abnormal refraction requires correction by a lens. The apparent size of the disc may be taken as the guide to the amount of magnification. There is no very exact method of estimating the absolute size of the vessels.† Sometimes, however, the alteration is such as to be at once

\* A case lately under my observation, in which the ordinary central reflection from the veins is, in many vessels, *replaced* by an irregular, patchy and granular reflection, which changes as the vein pulsates, and can be removed by pressure, seems to reopen the question of the nature of the normal reflection. In another case lately seen, in which there was much tissue about the vessels at their emergence (probably congenital), portions of veins near presented a central reflection of the exact tint of that of the adjacent arteries, the reflection elsewhere being normal. These cases suggest that the wall of the vessel has an important influence on the character of the reflection.

† See appendix—Ophthalmoscopic Measurement.



evident and unquestionable. A little custom will enable a distinct deviation from the normal to be readily recognized. Special attention must be given to the number of primary branches of the vessel. It often happens that veins are thought to be pathologically large, merely because they are few.

The relative size of the arteries and veins can be observed with more exactness than their absolute size. In comparing the two it is usually desirable to have the pupil dilated with atropine, since the vessels have often to be traced for a considerable distance from the disc. A difficulty arises from the fact that the distribution of the arteries and veins corresponds approximately, but not exactly. Sometimes two arterial branches accompany one venous trunk: sometimes two veins accompany one artery. But in each eye there is usually at least one set of vessels which have a nearly identical course and distribution, run side by side, and are available for comparison. When this is the case it will be found that, as a rule, the width of the artery is about two-thirds or three-quarters that of the vein. An alteration in this relation may arise from a change in the size of the artery or of the vein. The change may be so considerable that its nature is at once evident: *e.g.*, the veins may be obviously wider than normal, or the artery unquestionably narrow, perhaps visible as a mere line, even by the direct method of examination (Pl. IX. 4, XII. 2, 3). When the difference is slighter, we have to form an opinion as to the change on which it depends (whether enlargement of vein or diminution of artery) by our knowledge of the normal size of the vessels—an approximate absolute estimation. A little familiarity with the appearance of the vessels under normal conditions will commonly enable an opinion to be formed as to the direction in which the change exists.

Equality in size of the artery and vein is usually due to dilatation of the artery. When the relative size of the artery is smaller than that given ( $\frac{3}{4}$  or  $\frac{2}{3}$ ) it is generally due to one of three causes: (1) Venous distension, general or local; (2) Imperfect filling of atonic veins, in consequence of



which they are flattened at right angles to the plane of observation; (3) Contraction of the arteries, which may occur from general anæmia, in which case the veins are large and atonic, or from primary arterial contraction, as sometimes in Bright's disease (in which the veins also are commonly small), or from local obstruction to the entrance of blood.

*Veins.*—Increased width of the veins, therefore, usually means their dilatation, either from distension or from atony, and this is commonly uniform. The central reflection is preserved in normal characters. Irregular dilatation, varicosity, has been observed in a few cases, but is of little medical significance. A remarkable example of moniliform dilatation has been figured by Liebreich. The distension may be part of general venous fulness, as in cases of cardiac or pulmonary obstruction; or it may be of local origin. Increased intra-cranial pressure of rapid development will probably cause at least a transient increased fulness of the retinal veins. When of slow development, this effect is rare, in consequence of the anastomoses of the orbital and facial veins. Thus the veins may become large in acute, and not in chronic hydrocephalus. The same effect may be, it is commonly believed, the consequence of distension of the sheath of the nerve, and of pressure within the sclerotic ring. It will be shown subsequently that distension of the nerve-sheath is always related to a condition, increase of the sub-arachnoid fluid, which involves increased intra-cranial pressure, and the precise influence of the vaginal dropsy is difficult to estimate. The occurrence of compression at the sclerotic ring cannot be regarded as demonstrated beyond question. Probable as such a mechanism seems on *a priori* grounds, I have never been able to detect any evidence of it on microscopical examination. A very efficient cause of distension is the compression of the veins by inflammatory products within the optic papilla.

Increased width of vein, however, does not always mean over-distension. A vein which is underfilled may present an increased width. Usually, if the quantity of blood within a vein is less than normal, its contractile power enables it to



adapt itself to the diminished bulk of the contents ; it retains its cylindrical form, and both appears and is narrower. But in states of anaemia, the atony of the vein may prevent it from following the contents in calibre, and retaining the cylindrical form. It may then have a more or less elliptical outline (the same circumference enclosing a smaller area as an ellipse than as a circle), and in the retina the flattening always, in consequence of the intra-ocular pressure, takes place in the plane of the retina, at right angles to the line of vision,

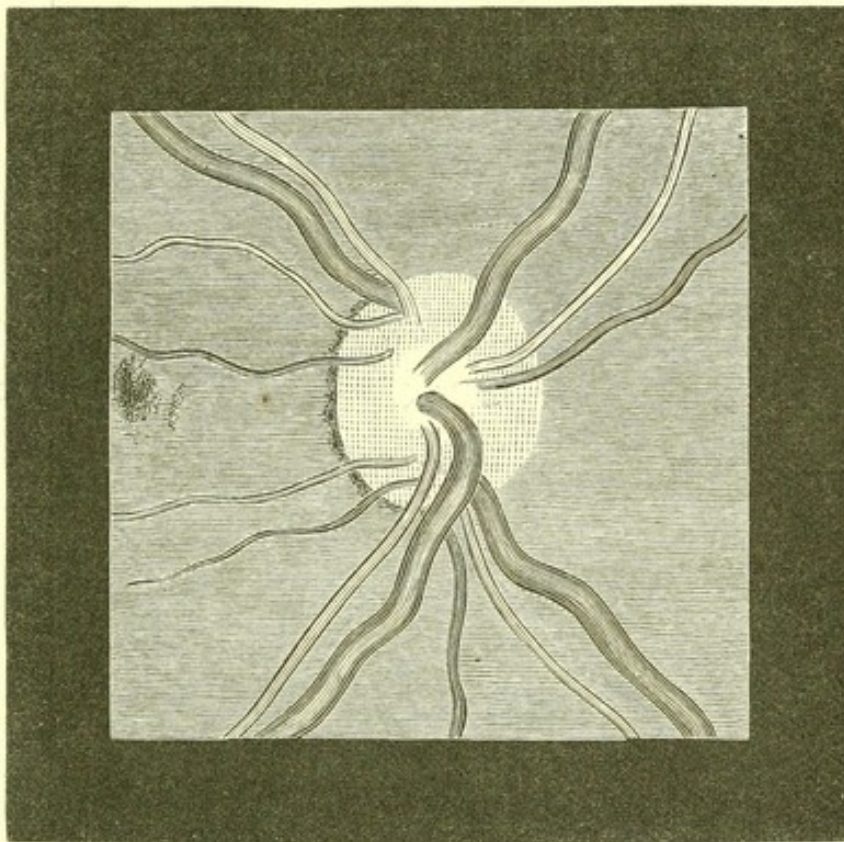


Fig. 1.—Broad Retinal Veins and Narrow Arteries—from a case of leucocythæmia.

and the vein appears of undue width. At the same time the central reflection is altered, becoming commonly indistinct, but sometimes unduly broad.

This condition of the veins is seen especially in great anaemia, and in leucocythæmia, as in the accompanying figure (see also Pl. XI. 1 and 2.) In these cases the arteries are usually smaller than normal, and so the contrast between the veins and arteries is enhanced.



Diminution in the size of the veins is probably always the result of diminished supply of blood.

*The arteries* may be diminished in size by similar causes to those which lead to increased width of the veins, such as local obstruction to the entrance of blood. The latter does not appear to result from general intra-cranial pressure, probably because of the resistance afforded by the strong walls of the arteries. It is doubtful whether effusion into the sheath of

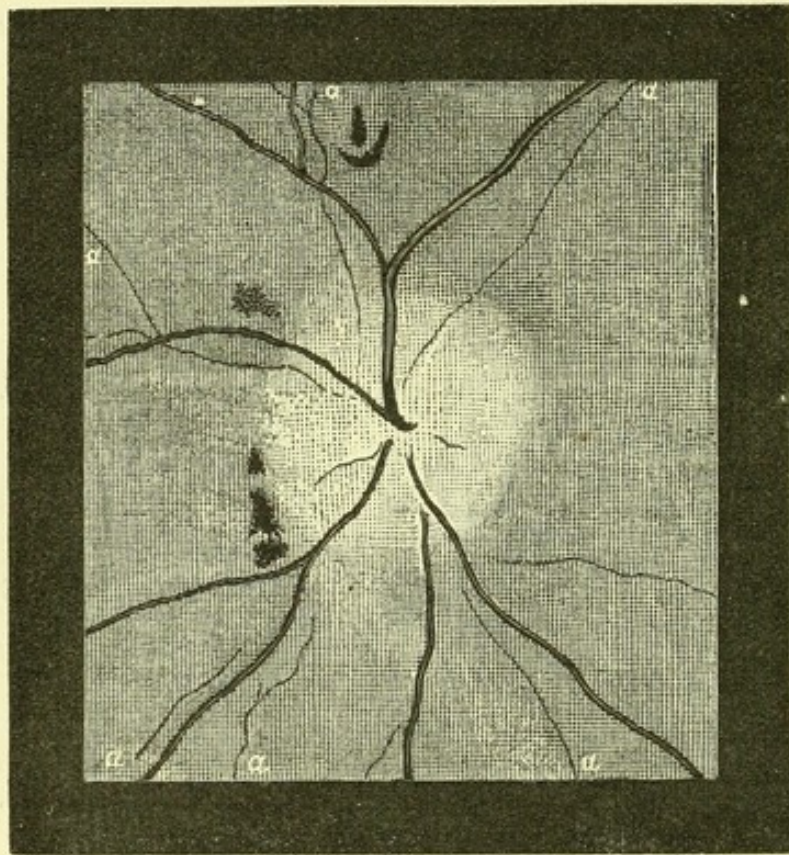


Fig. 2.—Extreme Contraction of Retinal Arteries (*a, a, a*), most of which are visible as lines only, even to the direct examination.—Subsiding papillitis, Bright's disease.

the nerve is capable of diminishing the blood supply. It is certain, however, that the pressure of inflammatory products within the papilla, and especially their cicatricial contraction, may cause sufficient constriction of the artery to lead to a great diminution in the size of its branches. Hæmorrhage around the vessel or the pressure of growths may have the same effect. In no condition, however, does the diminution in the size of the vessel reach such a degree as in obstruction



by embolism (Pl. XII. 2 and 3.) General underfilling of the arterial system, as in cholera, may lead to a great diminution. The strong muscular coat of the arteries maintains their adaptation to the blood within them, so that we never see the increase in width from atony which is observed in the veins.

Persistent spasm of the arteries is probably capable of causing a permanent diminution in their size. I believe that this condition is common in cases of Bright's disease, in which, however, it is more conspicuous in the branches beyond, than in those upon, the disc. It reaches its height when papillary obstruction is superadded, as in the accompanying figure (Fig. 2), when a degree of diminution in the size of the arteries may be seen, rarely if ever observed in simple neuritic obstruction (see Pl. IX. 3 and 4.)

Dilatation of the arteries is due to a vasomotor influence, and is conspicuous in some cases of exophthalmic goitre, in which over-action of the heart is superadded. It is doubtful whether the latter cause alone ever produces dilatation of the retinal vessels.

ARRANGEMENT.—The anatomical arrangement of the vessels varies considerably in different individuals, and is, in itself, of little medical significance. The number of branches into which the primary trunk divides and the number of tributary veins should be noted in connection with the apparent size of the vessels. There is one point, however, which does possess considerable medical significance. The general arrangement of the vessels in the two eyes is usually similar. Moreover, similarity in vascular arrangement may be inherited. I have seen, for instance, a peculiarity in the course of the retinal vessels in a mother exactly reproduced on the eye of her daughter. This is a striking proof of the transmission of vascular arrangement. But upon the vascular arrangement depends the vascular strain, and, in part at least, the occurrence and locality of vascular degeneration, and often of vascular rupture. Thus, inspection of the retinal vessels suggests to us one way in which a tendency to cerebral hæmorrhage may be inherited.



COURSE.—The course of the retinal vessels usually presents few tortuosities, and those which exist are lateral, in the plane of the retina. When the vessels are elongated by their distension or atony, these lateral curves are exaggerated. Antero-posterior curves, at right angles to the plane of the retina, are indicated by the change in the central reflection already mentioned, and sometimes by slight obscuration of the vessel at the lowest point of the curve. They always indicate irregularities in the retina in which the vessels lie, commonly parenchymatous swelling, as in retinitis.

STRUCTURAL CHANGES.—Most changes in the tissue of the retinal vessels are visible only to the direct method of examination. The commonest change is an increase in the amount of tissue of the wall, especially of the outer coat, so that the red column of blood is bounded by distinct white lines. Such an appearance may be seen in most cases near the centre of the disc. At the point at which the vessels emerge from the disc they are, the arteries especially, often surrounded by this white tissue, sometimes like a little cloud upon them, and from it prolongations may be traced along the chief vessels. When a vessel curves over the edge of a hollow central cup, and is seen foreshortened, the white tissue of the wall often appears as a ring around the blood column. When a disc is very full coloured, whether normally or from pathological causes, this white tissue is rendered by contrast very conspicuous, and may easily be mistaken for a pathological condition (Pl. I. 2). The difficulty is increased by the circumstance that it is sometimes a morbid appearance, left by preceding inflammation. In this case, however, it is usually accompanied by distinct constriction of the vessels, and often extends along the vessels beyond the limits of the disc. It has seemed to some observers probable that it is sometimes left by a state of chronic congestion of the disc, insufficient to cause such an "exudation" as shall constrict the vessels. The conclusion formed after a careful attention to the point for many years is that it does result from congestion, but that it is so common without either congestion or inflamma-



tion that the presence of this appearance alone deserves little weight.

An undue visibility of the wall of the vessel is said to be sometimes due to a "sclerosis" of the middle coat, a condition of thickening of the coat which, under the microscope, bears considerable resemblance to the appearance presented by lardaceous degeneration.

In rare cases, there is such a thickening of the outer coat of the vessel, or an increase in its perivascular sheath, that the tissue is visible, not merely at the sides of the vessel but in front of it, concealing the red reflection from the column of blood within it, and broad white bands then indicate the position and course of the vessel. These may cease suddenly and lengths of red blood may alternate with the white bands. This condition is occasionally, though rarely, seen in Bright's disease, and is then perhaps similar to the fibroid thickening around the vessels found in other organs. A striking example is seen in Pl. XII. Fig. 1. Sometimes a vessel may be narrowed at the affected area; more commonly its calibre is unaffected. It is seen to affect the arteries only.

In all inflammatory conditions leucocytes may accumulate in the perivascular sheaths of vessels, and in the retina they may give rise to an appearance similar to that just described, and which has been termed "perivasculitis." It has been said by Liebreich that by a careful comparison of the relative width of the column of blood and of the white band, an opinion may be formed of the position of the new tissue, whether in or outside the wall of the vessel.

Fatty degeneration of the vessels is sometimes met with as a senile change, or after inflammation. It affects chiefly the outer coat. It has only been recognized by microscopical examination, and it is doubtful whether it can be detected during life.

In senile fatty degeneration of the outer coat of the retinal vessels, calcification of the degenerated portion has been found after death. Actual atheroma, *i.e.*, endarteritis deformans, has not, as far as I am aware, been found in the retinal



vessels after death ; and in cases in which it is well marked elsewhere I have often looked for appearances in the retina suggesting its existence, but without success. The retinal arteries are far below the size in which atheromatous changes are common. They have been said to present undue tortuosity in this condition.

ANEURISM.—The retinal artery is occasionally the seat of aneurismal dilatation. Instances of it are, however, rare, probably on account of the support which is afforded to the vessels by the intra-ocular tension. When aneurism does occur, its significance is important, because in no other way can the existence of aneurisms on vessels so small as those of the retina be ascertained. Aneurisms of such small arteries are commonly not associated with aneurisms on larger trunks, but when aneurisms exist in the retina they almost always exist also in other organs.

Two forms of aneurisms have been observed : (1) aneurisms of some size on the primary branches of the central artery on the disc ; (2) miliary aneurisms of the arterial twigs upon the retina, and of the small capillary vessels.

1. Very few instances of the larger aneurismal dilatations are on record. One, which was described by Sous,\* occupied the upper two-thirds of the disc, was oval in form, and presented distinct pulsation, synchronous with the radial pulse. The arterial branches in the retina were very narrow. The patient was a woman, aged sixty-four.

2. Miliary aneurisms were found post-mortem by Liouville,† in cases in which cerebral hæmorrhage resulted from the rupture of similar aneurisms in the brain. The largest was about the size of a pin's head ; they were chiefly situated at the branchings of the vessels. In one case they were widely distributed through the body, being found on the minute arteries of the pericardium, mesentery, &c. I have seen them during life on small arteries in a case of Bright's disease, in which there was extensive cardiac and vascular disease (Pl. XII. 1). The lower branch of the artery is seen to present

\* "Ann. d'Ocul." 1865, liii. p. 241.    † "Comptes rend." 1870, lxx. p. 498.



three globular dilatations in its course, the third being just in front of a narrowed segment. The general characters of these aneurisms are there seen. The central reflection of the artery is widened at the dilatation in accordance with the altered surface of the blood within the vessel. The wall of the aneurism is, of course, invisible, just as is the wall of the vessel elsewhere; its existence is declared by the change in the form of the column of blood. Bouchut\* has figured two examples of a series of fusiform dilatations of the retinal arteries in general paralysis of the insane. His figures, however, suggest considerable exaggeration.

The recognition of these minute arterial aneurisms presents little difficulty. The contours of the arteries must be followed from the disc to the ora serrata by the direct method of examination. A twist in a vessel may cause the appearance of a local bulging which may look like an aneurism, but a careful examination will prevent error. Minute hæmorrhages in the course of the vessels can be readily distinguished from aneurisms by the irregularity of the outline of the clot. Aneurisms, as a rule, contain fluid blood, and present a bright central reflection, which is absent in the extravasation. It must be remembered, however, that a miliary aneurism has been found surrounded by a halo of extravasation. The centre of any hæmorrhage situated at the bifurcation of a vessel should therefore be carefully scrutinized. A very rare condition has been figured by Galezowski, which might easily be mistaken for multiple sacculated aneurisms. It consists of numerous minute secondary gliomatous growths, connected with the retinal arteries. Some, however, were of large size, and unconnected with the vessels, and none presented any visible reflection.

The retinal capillaries may present aneurismal dilatations sacculated in form, and also varicose dilatation. Examples of these are figured in Pl. XVI. Fig. 11, from a case of glycosuria described by Dr. Stephen Mackenzie.† Hæmorrhages into the retina and vitreous were observed during life.

\* "Atlas d'Ophthalmoscopie Médicale et Cerebroscopie."

† "Oph. Hosp. Rep.," December, 1877.



## CHANGES IN THE CIRCULATION.

The central artery of the retina brings blood to the eye from within the cranial cavity, from an artery which also supplies part of the cerebrum and meninges, and the retinal vein returns blood chiefly to a cranial sinus. Hence the intra-ocular circulation has been regarded as a portion of the cerebral circulation, as participating in the same influences, and presenting the same modifications. This is, no doubt, true to some extent. At the same time it is probable that the consequences of the common origin of the cerebral and ocular blood supply have been exaggerated. It is important to bear in mind that the intra-ocular circulation is peculiar in its rigid enclosure in a small chamber, in which it is always exposed to a certain amount of elastic pressure. The relation between the cerebral and ocular circulation is unquestionably modified by this and other causes.

PULSATION.—*Arterial*.—As a rule, before reaching arteries as small as those of the retina, the pulse-wave has become so feeble, the current so equable, that visible pulsation can no longer be perceived. If, however, the pulsation be rendered less equable by increasing the disproportion between the continuous flow and the intermitting wave, arterial pulsation may be sometimes perceived. In conditions of acute anæmia, from hæmorrhage, the continuous flow of blood into the small vessels may be very feeble or even absent, and the pulse-wave becomes distinctly visible. The constant flow may also be lessened by increasing intra-ocular tension, as by pressure on the globe by the finger, but it is rarely that distinct arterial pulsation can be thus produced. Occasionally, however, it may be noted in an artery which, by a foreshortening curve down the sides of the central cup, is in a favourable position for observing a change of shape.

It is especially when the pulse-wave is increased in strength and suddenness that it becomes visible in the retinal arteries. This increase is developed in aortic regurgitation,



and in that condition spontaneous pulsation of the retinal arteries is especially frequent, as Quincke\* and Becker† first pointed out. It is more distinct, the stronger is the hypertrophy of the left ventricle, and is absent only when the heart is greatly weakened, or much aortic constriction coexists, or the amount of regurgitation is small. It may be seen best in the vessels in the disc, but in rare cases, far towards the periphery of the retina. It consists, like the pulsation of other vessels, in a widening and an elongation. The widening is best seen behind a division, at a considerable angle, and is best recognized by attending to the central reflection. The elongation of the vessel is best seen where an artery lies in an **S** curve, especially towards the periphery, or when it forms a curve along the edge of the disc (Becker.) In a case of supposed aneurism of the arch of the aorta, Becker found marked pulsation in the left eye, while in the right only a trace of pulsation could with difficulty be detected.

Capillary pulsation has been described in aortic regurgitation—a pulsatile redness of the disc—due to the intermitting distension of the capillaries in consequence of the great fall of pressure between the successive pulses. Such an appearance is, however, very rare.

*Venous.*—Pulsation in the retinal veins may also sometimes be observed as a normal condition, commonly only in the large branches upon the optic disc. Several explanations of this have been given. Coccia suggested that it depends directly on the intra-ocular tension, and is analogous to that which occurs in glaucoma and may be produced artificially by pressure on the eyeball. Every time the pulse-wave reaches the intra-ocular arteries their distension causes a sudden increase in the intra-ocular tension, which effects a compression and transient emptying of the thinner walled veins. Hence the contraction of the veins should correspond to the arterial diastole, to the pulse-wave, and the dilatation of the veins to the arterial systole, to the interval between the

\* "Berlin Klin. Wochenschr.," 1868, No. 34, and 1870, No. 21.

† "Arch. f. Ophth.," xviii. 206—296. Dr. Stephen Mackenzie has also recorded several cases ("Med. Times and Gaz.," 1875, vol. i).



pulse-waves. Stellwag von Carion imagined that the extension of the sclerotic by the increased intra-ocular pressure at each pulse, stretched the lamina cribrosa, and narrowed its meshes so as to compress the vein. According to Donders the increased intra-ocular pressure acts directly on the venous trunks in the optic disc, hindering the return of blood. On this view the venous diastole should accompany or immediately succeed the arterial diastole.

Jacobi, on the other hand, suggests that the common limitation of the pulsation to the papilla, indicates that the increased intra-ocular pressure bulges the papilla, and the augmentation in the curve of the veins causes a sudden obstruction to the circulation through them.

Another theory explains the pulsation by supposing that where the artery and vein are in contact, in the optic nerve, the wave of arterial distension compresses the vein and causes a temporary obstruction to the return of the blood.

Drs. Putnam and Wadsworth (of Boston, U.S.A.) have recently described\* an intermitting variation in size of the retinal veins, occurring independently of the pulsation synchronous with the heart's action, and having a period of about five respirations, *i.e.*, about that of the variations in arterial tension found to occur in animals. I have looked for this rhythmical variation, but have not hitherto been able to detect it.

ANÆMIA OF THE RETINAL VESSELS may be part of general anæmia, or may be due to local pressure upon the artery.

When due to local causes ("retinal ischæmia" of the Germans) there is usually simultaneous pressure on the retinal vein, which runs side by side with the artery. The arteries are then unduly narrowed, and the veins dilated. This condition is constantly seen during the contraction of inflammatory tissue in the papilla. In rare cases, in which the pressure is on the artery immediately after its entrance into the optic nerve, and behind the vein, which enters a little in front of

\* "Journal of Nervous and Mental Disease," October, 1878.



the artery, the arteries may be narrowed without any distension of the veins.

Spasm of the retinal vessels has been supposed to occur sometimes in epilepsy, and also to be the cause of "retinal epilepsy," *i.e.*, epileptiform amaurosis. In such a condition Dr. Hughlings Jackson once saw a vessel disappear. I have examined the retina in many cases of epilepsy immediately after fits without observing any marked change in the arteries. During an epileptiform convulsion from meningeal hæmorrhage, I once kept an artery and vein in view throughout, by the direct method of examination, but saw no change in the artery. The vein was distended during the cyanotic stage.

General defective blood supply is much less evident in the vessels of the eye than elsewhere: probably because the intra-ocular tension effects a regulation of the size of the retinal vessels (Donders). Loss of blood, for instance, causes but a slight change in the retinal vessels, except an increased disproportion between the arteries and the veins, due in part to contraction of the arteries, and in part to atony and flattening of the underfilled veins. The effect of hæmorrhage on the size of the vessels soon passes off, because the volume of the blood is quickly reproduced by the passage into, and retention in it, of liquid from the tissues and alimentary canal.\* A similar condition of the retinal vessels to that seen in acute anæmia was observed by v. Graefe in cholera. During the stage of collapse the arteries became narrow, the veins dark, but of normal width. Spontaneous pulsation appeared in the arteries, and was attributed to cardiac weakness, but may, perhaps, have been due to the diminution of the volume of the blood, rendering the amount ejected from the left

\* In some observations on the effect of venesection in the corpuscular richness of the blood, kindly made for me by Mr. W. S. Tuke, on some patients of Mr. Wharton Jones, it was found that the fall in the number of blood corpuscles indicating the dilution of the circulating blood to reproduce its volume, took place in the course of an hour. It was found also that the fall was greater than the amount of blood lost could account for, *i.e.*, that the hydræmia became for a time excessive, a fact which may account for the reputed influence of slight, quick loss of blood.



ventricle at each systole so small that the shock (pulse-wave) predominated over the movement of the blood.

The acute cerebral anæmia of syncope is probably attended by a similar condition of the retina, and to it the transient blindness which sometimes succeeds syncope may be due.

Conditions of general defective blood supply render the disc paler, but the variations in the tint of the disc, under physiological conditions, are so great that it is only by comparison of the state of the disc with its appearance in the same patient at another time, that any information can be gained from it. The other eye is usually affected in the same degree, and not, therefore, available for comparison.

**HYPERÆMIA OF THE RETINAL VESSELS.**—(A.) *Active Congestion.*—Apart from the active congestion of commencing inflammation (which is not considered here), an increased supply of blood to the retina may be due to whatever causes an overfilling of the whole or part of the arterial system of which the retinal artery forms part. Of these, excited action of the heart is the most potent. The retinal arteries may be seen to be large, and sometimes, though rarely, to pulsate, and the communicated pulsation in the retinal veins may also, commonly, be observed. When the overaction is long continued, hæmorrhages may occur. A similar overfilling may occur from obstruction in another region of the internal carotid. Dilatation of the arteries, as in exophthalmic goitre, may also cause active hyperæmia.

(B.) *Passive Congestion.*—Passive congestion of the retinal vessels may occur from local or general causes. The causes of local obstruction to the return of blood from the eye are the same as those of local arterial anæmia. Pressure farther back, on the cavernous sinus, only causes transient passive congestion of the retinal veins, on account of the free connection of the orbital and facial twigs. Passive congestion from general causes is very common, and results from whatever hinders the return of the blood from the head, or obstructs the circulation through the chest. The congestion of the eye is thus part of a cephalic congestion, or of a general venous



stasis. The former commonly results from pressure in the jugular or innominate veins. The general congestion is the result of some pulmonary or cardiac obstruction, acute or chronic. The common acute causes are—cough, effort, and an epileptic fit. The ophthalmoscope shows the retinal veins in these conditions to be greatly distended. Unless, however, there is also disease of vessels, hæmorrhages rarely occur, no doubt in consequence of the support afforded to the vessels by the vitreous humour. The intra-ocular tension, and therefore the external support, is probably augmented during these conditions of increased strain, in consequence of the fulness of the capillary vessels. It is true that the most intense congestion, such as that of suffocation, sufficient to cause death, does usually lead to retinal hæmorrhages, but minor degrees of congestion rarely do so. It is very common, for instance, for a violent cough, or an intense asphyxial stage of an epileptic fit, to cause rupture of a subconjunctival vessel, and a consequent extravasation, but it is extremely rare for any retinal vessel to give way. I have often, in such cases, searched the retina for extravasation, but the search has always been unsuccessful.

Chronic general causes of passive congestion are chiefly heart disease (especially mitral) and emphysema of the lungs. In the general venous distension of congenital heart disease—cyanosis—the retinal vessels participate, often conspicuously. The venous distension may be extreme, and may be accompanied by normal arteries, or the arteries may be also large. The blood in the arteries and veins may be abnormally dark. Sometimes the retinal tissues are thickened. The congestion from emphysema of the lungs, and from dilatation of the right heart, is also often very marked. The retinal veins become much distended and tortuous, and the smaller branches, ordinarily invisible, may become very conspicuous.

With degenerated vessels, *e.g.*, in the old, cough may produce small extravasations in the retina, which, in most cases, quickly disappear. They are also seen when passive congestion is associated with hypertrophy of the left ventricle. (See next section.)



**HÆMORRHAGE.**—Rupture of retinal vessels and consequent extravasations of blood are very common in many morbid states, and are frequently of important general significance. They may occur as part of inflammation of the retina, and such cases will be considered subsequently. More frequently they are dependent directly on general conditions, or on retinal degeneration consequent on general conditions.

They vary much in size, number, position, and aspect. They may be so small as to be visible only as a spot or line on direct examination, or they may be three or four times the diameter of the optic disc. There may be only one or two, or innumerable extravasations may exist over the whole fundus. When few they are commonly seated near the disc or in the neighbourhood of the macula lutea, and often follow the course of vessels, especially the veins, but not unfrequently the arteries. Their shape and aspect depend very much on their position in the substance of the retina. The commonest seat is in the layer of nerve fibres. The fibres are separated, not torn, by the extravasation, and the blood lies between the fibres, and extends along their course in the direction of least resistance. Hence the smaller hæmorrhages are linear, and the larger striated in part or altogether, and they often radiate from the disc. Such hæmorrhages are shown in Pl. V. 4, VI. 1, X. 1, 2, X. 1, XI. 1. The next most frequent seat is in the inner nuclear layer. Here there is no tendency to striation; the extravasations are round or irregular (as in Pl. VI. 4, XII. 1). If the extravasation in this position is large it may separate the retina from the choroid, while a hæmorrhage in the nerve-fibre layer may break through into the vitreous. This sometimes happens in Bright's disease, as in one case which came under my observation (Case 43).

Now and then, especially in the neighbourhood of the macula lutea, the blood may be extravasated in a thin film between the retina and the vitreous. Such an extravasation is commonly very irregular in shape, the irregularity being sometimes increased by the extension of processes of blood into the vitreous. The more recent the hæmorrhage the brighter is its colour. Old hæmorrhages may be almost black, and the



blood effused into the vitreous very quickly assumes a black colour.

It is doubtful whether extravasations into the retina occur, however small, except from actual rupture of vessels; probably the extravasations are conditioned by degeneration of minute vessels, sometimes by such capillary aneurisms as are shown in Pl. XVI. 11. White spots are often seen in the retina adjacent to, or left by, extravasations (Pl. XI. 1). They may be, when small, granular; when large, they may be filmy. They are probably due to fatty degeneration of the disturbed retinal elements, or of the effused blood.

Small extravasations are readily absorbed; larger ones more slowly. Sometimes pigmentary degeneration results, and an irregular black spot is left. The white spots disappear very slowly, and white granules may remain for a long time.

*Symptoms.*—Small hæmorrhages, away from the centre of the retina, may give rise to no symptoms. Larger ones cause loss of vision at the spot from the local damage to the retina, the loss being serious in proportion to the proximity to the macula lutea, in which a small extravasation may cause permanent loss of central vision. A ring of hæmorrhage around the macula may cause considerable central amblyopia (Pl. XI. 2). Occasionally the patient is conscious of the red colour of the extravasated blood. At the moment of extravasation there may be no symptoms, or there may be sudden dimness of sight, or there may be ocular spectra.

*Causes.*—Hæmorrhage into the retina, as elsewhere, depends on one or both of two causes—increased intra-vascular pressure, decreased strength of vascular wall. Local increased blood pressure is a common cause. In optic neuritis with much constriction of the veins, the whole fundus may be covered with extravasations (Pl. VI. 1). Similar extravasations may attend all forms of retinitis. General increased blood pressure is a rare cause, no doubt from the efficient support of the retinal vessels, as just explained. Now and then it is seen when hypertrophy of the left ventricle can tell unduly on the vascular system. It sometimes occurs in the peculiar vascular



condition which attends arrested menstruation; more rarely still in suppression of some other habitual discharge.

In some cases of heart disease, especially when conjoined with degenerated vessels, and occasionally in cases of arrested menstruation, numerous extravasations occur into the retina, with signs of parenchymatous retinitis, vascular distension, and diffuse cloudiness. This condition has been called "hæmorrhagic retinitis." It may occur without any recognizable cardiac disease, and is often unilateral, in apparently healthy persons after middle life. Mr. Hutchinson believes that it is often associated with gout (q. v.).

Degeneration of the retinal vessels is a frequent cause of hæmorrhage, although it is not often that it can be demonstrated post-mortem. It is probably owing to this degeneration that retinal extravasations are so common in certain general blood diseases, especially in kidney diseases and diabetes, pernicious anæmia, leucocythæmia, ague, purpura, scurvy, and pyæmia, and many exhausting conditions, such as over-lactation. In some of these cases, as pyæmia and leucocythæmia, the blockade of vessels may assist. Capillary aneurisms from a case of retinal hæmorrhage in diabetes are shown in Pl. XVI. 11, and diseased capillaries in renal retinitis in Fig. 10 of the same plate. Jaundice is commonly given as a cause of retinal hæmorrhage, but only one or two instances are on record.

Apart from these blood diseases, retinal hæmorrhage is common in simple senile vascular degeneration. In all conditions its occurrence is of importance, on account of its occasional association with cerebral hæmorrhage.

Sometimes retinal hæmorrhage results from blows upon the eye or skull. Rarely hæmorrhages are observed in young persons without discoverable cause.

The prognosis depends on the position of the hæmorrhage, and on the extent to which its causes are under control. It is worse when there are signs of general retinitis.

The chief local treatment is the application of cold and gentle pressure on the eyeball, to give temporary support to the vessels, and obtain contraction. Other measures are



those suited for the general state, and for hæmorrhage elsewhere.

Hæmorrhages from the choroidal vessels are extremely rare, and possess little medical significance.

**THROMBOSIS.**—Thrombosis in retinal vessels is not common, but is occasionally observed in smaller branches of the veins. The vessels lose their double contour—*i.e.*, their central reflection disappears, and they appear dark and large, their branches being unduly conspicuous. The condition usually depends on local causes, and has little general significance.

Thrombosis has been observed in the retinal artery with ocular signs identical with those of embolism, to be described immediately. In a case recorded by Sichel it was conjoined with foci of softening and small hæmorrhages in the brain. Thrombosis in the ophthalmic artery occurs as a very rare event, and probably always as the result of thrombosis in the internal carotid. I am not aware that any case has been observed during life, but the signs of its occurrence would probably be those of incomplete obstruction of the retinal and choroidal vessels, a partial circulation being maintained by the communication between the orbital and facial arteries.\*

\* Some years ago I made a necropsy on a case in which this accident had occurred. The patient, an aged man, had suffered from cerebral softening in the region supplied by the left middle cerebral artery, which was much diseased. A fortnight or three weeks before his death, there was no ocular or ophthalmoscopic change. He lay in a comatose condition, and his eyes were not again examined. Post-mortem a recent clot was found extending down into the intra-cranial portion of the left internal carotid, fully distending it, and passing also into the commencement of the ophthalmic artery, which was, however, near the eyeball, pervious, being only narrowed by clot. The eyeball was quite rotten, the sclerotic of a brownish colour, and giving way before the scissors like brown paper. The retina was greatly atrophied, reduced to two-thirds of its normal thickness. Its several layers were no longer recognizable. The outer half was occupied by a thick layer of nuclei, apparently representing the two nuclear layers. Its inner half consisted of a series of lacunæ, limited by the remains of the thickened vertical fibres. No nerve-fibre layer, ganglion cells, or molecular layers could be discovered. A case of the same character, but in which a freer collateral circulation was established and the retinal changes were slighter, has been recorded by Virchow, and is described further on in the section on Softening of the Brain.



**EMBOLISM.**—The central artery of the retina is not unfrequently occluded by an embolus, and the occurrence is of much medical interest. Nowhere else can the phenomena of vascular occlusion be observed during life. The accident is commonly the consequence of heart disease, and sometimes is the first thing which draws attention to the existence of the cardiac affection. It was so in Case 48 appended. Embolic infarction in other organs always coexists, and the ocular accident may indicate the nature and disturbance elsewhere. It occasionally coexists with cerebral embolism, and may furnish a warning of the probability of the latter, as in one case recorded by Landesberg, in which the ocular embolism was followed, a week later, by loss of consciousness and hemiplegia. The patient suffered at different periods from embolism of each retinal and one cerebral artery. The cerebral and ocular accidents may occur simultaneously, as in Case 47. The diagnosis of cerebral embolism is usually sufficiently clear without it, but its occurrence is an important corroborative, and almost demonstrative, proof of the nature of the cerebral lesion. Retinal, as cerebral, embolism is rather more frequent on the left than on the right side. Its common origin is, as already stated, cardiac disease, especially mitral. It has also been observed in atheroma of the aorta and in febrile diseases, pregnancy, and Bright's disease, probably from the formation of a clot and its detachment.

The position of the obstruction may be in the trunk, or in one of the branches. In each case there is sudden and complete loss of sight, persistent when the obstruction is in the trunk and is permanent. In rare cases the loss of sight is not instantaneous, but comes on in the course of a few minutes, commencing at the periphery. When the obstruction is in a branch, the loss of sight usually rapidly clears, except from that portion of the retina which is supplied by the occluded vessel.

The arteries beyond the obstruction are deprived of their supply of blood and contract, so that to the ophthalmoscope they appear as fine lines only (Pl. XII. 2). They commonly, however, retain their red colour, because the contraction does not obliterate their cavity, although reducing it almost to



capillary dimensions, and there is still a narrow column of blood within them. Towards the periphery, however, they are so small as to be invisible. The delicate wall of the vessel is unrecognizable, except in the larger vessels, where, on account of its contracted state, it is more distinct than normal, and appears as a white line on each side, bounding the narrow, red column. When the obstruction is complete and a collateral circulation is established, the red column may disappear, and only a white line indicate the position of the empty vessel, which gradually becomes transformed into fibrous tissue (Pl. XII. 3). The arterial branch which passes upwards and to the left is represented only by a branching white line, while one which passes vertically upwards, and is not quite empty, is bounded on each side by a white line.

The veins are narrowed, but less than the arteries. They are sometimes, but not always, broader towards the periphery than near the disc.

The optic disc is, at first, and usually always, much paler than normal. The retina undergoes very marked changes, consequent on the disturbance of its nutrition. It presents a greyish or white opacity, always most marked around the macula lutea (Pl. XII. 2.) and commonly also conspicuous around the disc. This opacity may come on in a few hours, but sometimes not for some days. The opacity usually stops short of the fovea centralis, leaving it of a bright red colour, so red that it was thought to be extravasation, but it is now generally believed that the tint is merely the effect of contrast with the adjacent pale opacity. The latter is believed to depend on œdema of the nerve-fibre layer, and the thinness of that layer at the fovea centralis to be the cause of the usual freedom of that part from opacity (Liebreich). But occasionally the fovea may be as opaque as its vicinity, as in Case 47 (Pl. XII. 2). Here I found the opacity to depend on much graver structural alterations than are usually supposed to exist. Besides evidences of œdema, there was an infiltration of all the retinal layers with lymphoid cells, similar to those of the nuclear layers, so that the thickened vertical fibres were the only structural elements which could be



distinguished. The layer of rods and cones was destroyed, probably during life, in the region of the macula, because the pigment-epithelium was in contact with, and adherent to, the outer nuclear layer. In other places, the thickened vertical fibres were widely separated.

Hæmorrhages are rare in embolism of the trunk of the retinal artery. The opacity commonly disappears in the course of a few weeks, but may leave white spots, due to foci of degeneration. The optic disc, white from the first, may have

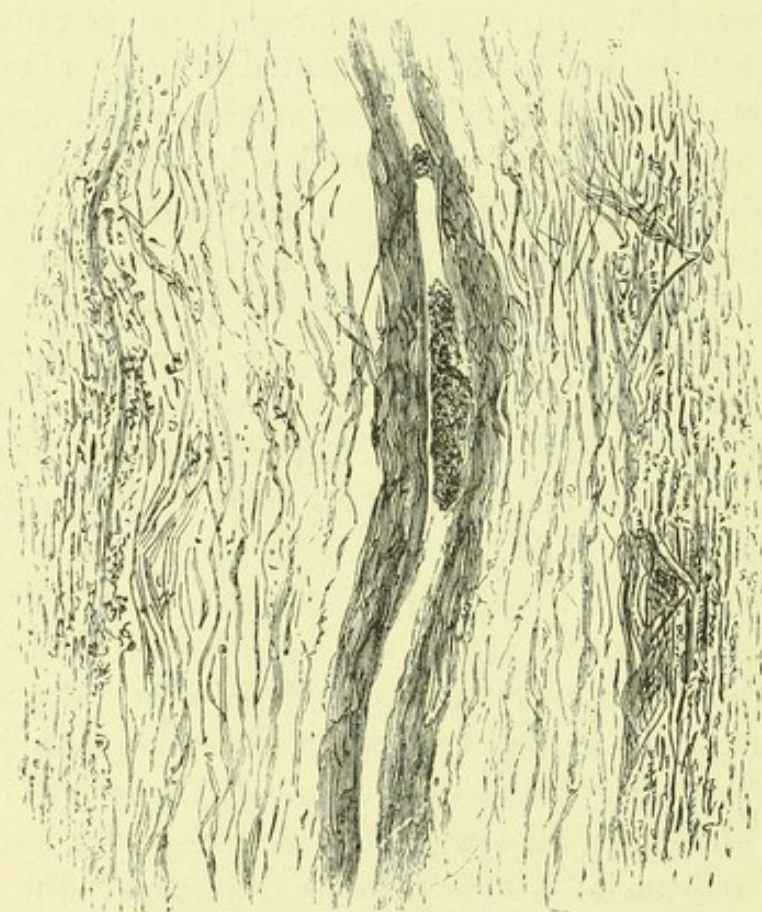


Fig. 3.—Embolism of the Central Artery of the Retina (Case 47; Pl. XII. 2)  
—Longitudinal section through the artery, one-eighth of an inch (3 mm.) behind the eyeball. On each side the nerve fibres are indicated, and between these and the vessel is much loose connective tissue. Within the contracted vessel is an oval granular mass, and in front of this is a small round body ( $\times 300$ ).

its edges a little clouded, when the opacity in its neighbourhood is considerable, or it may remain clear. In most cases the pallor persists and increases, and passes into the whiteness



of atrophy, which resembles closely simple atrophy, except in the extremely small size of the vessels.

The plug has in several cases been found after death, commonly just behind the bifurcation of the artery, in other cases in its course. In Case 46 (Pl. XII. 2), the artery in the nerve contained an oval granular embolus (Fig. 3). Other smaller fragments were seen in the narrowed arteries, upon the disc.

Very rarely the circulation gets re-established by the normal course. Columns of blood appear in the arteries, in part broken, and for a long time easily broken by pressure. The arteries continue below normal size. Vision may be recovered, especially at the periphery, rarely at the centre. Commonly, however, obstruction remains complete.

The retinal artery is regarded as a "terminal" artery, *i.e.*, one that has no anastomoses. In most cases very little collateral circulation is set up: the arteries remained narrowed to lines as far as they can be traced. But they are visible in almost all cases as red, not as white, lines. Hence they must contain blood, persistent and therefore circulating, which has come from some slight collateral anastomoses, or from the obstruction being incomplete.

Sometimes a much more considerable circulation is established. In Pl. XII. 2, for instance, the arteries are filiform only upon the disc, and as far as they remain unbranched; beyond this, they have nearly their normal size. A similar case has been recorded by Knapp. This points strongly to the establishment of a collateral circulation, probably by connection with the long ciliary arteries, although, in the researches of Leber, such connections could not, in the normal condition, be demonstrated. It is commonly supposed that the chief connection between the retinal and ciliary vessels is by means of the vessels of the optic disc, but it is certainly not by such means that a collateral circulation takes place, for the pallor of the disc is due to anæmia, and is almost universal in cases of embolism. Moreover, the arteries are never filled in the neighbourhood of the disc, but at a distance from it. A collateral circulation in the disc



may maintain the blood supply needful to preserve the red colour of the filiform arteries, but certainly does not maintain the peripheral circulation in most of the cases. Probably, as Mauthner has suggested, there are, in different cases, very variable anastomoses.

In Pl. XII. 3, the vessel, which is still pervious, though narrowed, is bordered for a distance by the fine white line indicating the wall thickened by contraction. The blood column within it, narrow as it is, still presents a central reflection, and towards the periphery the vessel again widens out exactly as in the other case, shown in Fig. 2 of the same plate. This broadening of the peripheral portion of the vessel nearly to its normal calibre indicates that blood enters it beyond the narrowed portion by some junction with other arteries.\*

In partial embolism the segment of the retina, to which the occluded branch goes, becomes opaque, and is sometimes the seat of numerous hæmorrhages. Both opacity and extravasations ultimately disappear. The corresponding portion of the optic disc may be normal, as in the case shown in the figure, or it may be atrophied. In one case on record it was hyperæmic (De Wecker). The corresponding vein is at first distended, afterwards smaller than normal.

Embolism of the trunk of the central artery commonly causes complete and persistent loss of sight. When the occlusion is of a single branch, there may be a complete initial loss of sight, due probably to the plug causing a temporary obstruction in the trunk of the artery before it passed on to the branch in which it was arrested. Occasionally in such cases, the blindness has remained complete, although the ophthalmoscope afterwards demonstrated that only one branch of the artery was occluded. The general retinal anæmia may, in such cases, have been so prolonged that the nerve elements suffered a shock, damaging their nutrition

\* It is greatly to be desired that, in any post-mortem examination of a case, in which there has been embolism of the retinal artery, and in which such collateral circulation is established, a ligature should be placed around the artery, or around the optic nerve, in front of the entrance of the artery, and the ophthalmic artery then injected, so as to discover the channels by which the circulation is established, and which elude observation under normal conditions.



beyond the power of recovery on the succeeding restoration of the circulation. Commonly, in such cases, the permanent loss is of a portion of the field corresponding to the distribution of the branch plugged. When this is one of two primary divisions of the artery, the loss may amount to one half of the field; when of a smaller branch, to a quadrant, or the like. There was a loss of nearly one-half in Case 48 (Pl. XII. Fig. 2), in which one branch running upwards and inwards is completely obliterated, and others running upwards and outwards are partially obliterated. The loss was that shown in the adjacent diagram of the field of vision (Fig. 4).

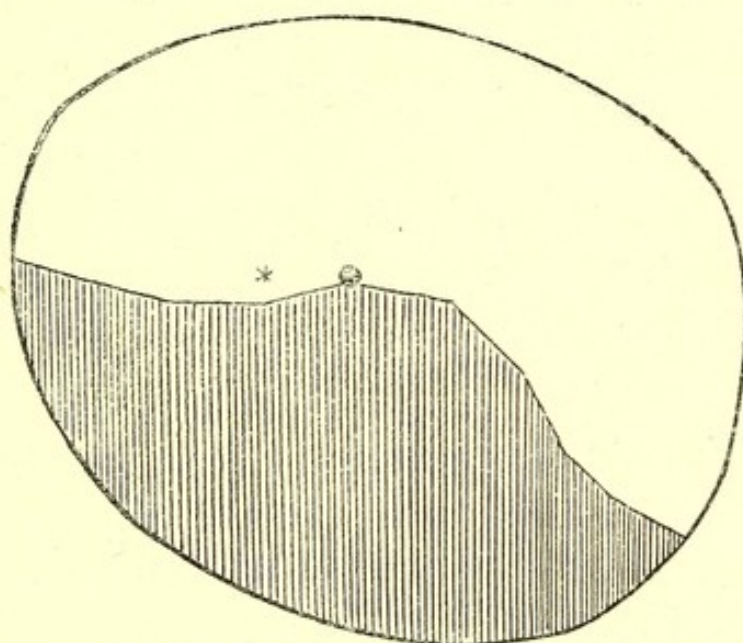


Fig. 4.—Diagram of Left Field of Vision in partial embolism of the central artery of the retina (Case 48).—The shaded area indicates the portion of the field in which sight was lost. The asterisk indicates the position of the fixing point, the dot that of the blind spot.

Occasionally, sudden blindness has occurred, and the retinal arteries have appeared narrow, recovering their normal size after a short time, with restoration of vision. This has been attributed to a plug in the ophthalmic artery behind the origin of the retinal artery, but moved on into an orbital branch of the artery which possesses anastomoses.

Arterial ischæmia, similar to that which results from embolism, may occur in consequence of a retro-ocular hæmorrhage around the artery compressing it. The ophthalmoscopic distinction of this from embolism is uncertain, and



probably depends rather on the incompleteness of the ultimate obstruction, than on any differences in the early retinal appearances. It may occur in cases in which there is a general tendency to hæmorrhage, and may be the precursor of cerebral extravasation. An interesting case, probably of this character, is related by Mr. Hutchinson.\*

## THE OPTIC NERVE.

The alterations in the optic nerve, as seen at its entrance into the eye, are among the changes in the fundus oculi of greatest importance to the physician. It may be well, before describing those changes, to consider some points, regarding its structure and appearance, a knowledge of which is essential for a correct understanding of the pathological changes.

In the optic disc we have presented to view the termination of a nerve—a structure consisting of nerve fibres, a little supporting connective tissue (especially abundant around the central vessels), and a number of blood vessels, for the most part capillaries, which confer on the disc its tint. The nerve fibres radiate and spread out in the retina, but not equally on all sides, being few on the temporal side, towards the macula lutea, and numerous on the nasal side and especially above and below. The minute vessels of the disc are derived partly from the posterior ciliary (choroidal) arteries, and partly from the central retinal artery, twigs from both of which commonly unite in forming the “circle of Haller,” a series of vessels which surround the optic nerve behind the disc. The connective tissue between the bundles of nerve fibres is small in quantity, but contains a few nuclei. The opening in the sclerotic is funnel-shaped, the wider part being posterior. The termination of the nerve fits pretty closely into the inner, smaller part of the opening, while the space between the nerve and its outer sheath, “vaginal space,” passes up into the posterior part of the opening (Pl. XIII. Fig. 4).

\* “Oph. Hosp. Rep.,” October, 1874, p. 51.



The separation of the optic nerve fibres to radiate into the retina leaves the central hollow known as the physiological cup, the size and depth of which are determined by the arrangement of the nerve fibres. The vessels are chiefly developed among the nerve fibres and towards the surface of the disc, and hence the central cup is always much paler than the periphery. It is commonly white, but sometimes mottled grey from the reflection of the white trabeculae of the "lamina cribrosa," which closes in the sclerotic foramen, and through the meshes of which the greyer nerve fibres pass. The tint of the circumferential portion of the disc is, as already explained, deepest where the nerve fibres are most numerous, and hence the nasal half of the disc is naturally much redder than the temporal half. The arrangement of the nerve fibres also causes the side of the central cup to be steep on the nasal and shallow on the temporal side, the difference being proportioned to the inequality with which the nerve fibres are distributed. When the fibres are almost all packed on the nasal side, the cup may be very large, and extend on the temporal side to the margin of the disc. Often, however, there is no paler central cup.

The boundary of the "disc," as commonly recognized, is the choroidal ring, *i.e.*, the edge of the opening in the choroid corresponding to that in the sclerotic. The latter is usually the smaller of the two, and hence a narrow rim of sclerotic commonly appears within the choroidal edge, and is known as the "sclerotic ring." It is often visible only on one side. At the passage of the nerve fibres over the edge of the sclerotic, they curve a little above the level of the retina, and this slight prominence has suggested the name of "optic papilla," as a designation for the termination of the optic nerve.

The trunk of the optic nerve possesses a double sheath: the inner is delicate, closely invests the nerve, and is continuous with the pia mater of the brain. The outer sheath is thicker and fibrous, blends in front with the sclerotic, and is continuous at the optic foramen with the dura mater. There is not, as was once thought, a reflection of the arachnoid at



the optic foramen, and thus the vaginal space of the optic nerve, *i.e.*, that within the outer sheath, is continuous with the subarachnoid space around the brain. This vaginal space is traversed by tracts of tissue connecting the two sheaths. At the anterior extremity of the nerve, it passes within the posterior part of the sclerotic opening, and is, according to some authorities, closed; but, according to others, it is continuous with lymphatic spaces in the substance of the optic nerve, and probably also in the retina.

The optic nerve, at its entrance into the eye, undergoes certain pathological changes in common with the retina. When the retina is generally inflamed, and when it is atrophied the optic "papilla" participates in the change. But it also undergoes inflammatory changes independently of the retina.

The pathological conditions of the disc resolve themselves, from their clinical features, into two groups,—increased vascularity, commonly with increased prominence; diminished vascularity, commonly with shrinking. The states characterized by the former are more or less inflammatory, and are often included under the generic term "optic neuritis." Those characterized by the latter signs are accompanied by wasting of the nerve tissues, and are included under the generic term "optic nerve atrophy."

It must be remembered that the term "optic nerve" is employed in two senses—to designate the whole nerve and also its intra-ocular termination as seen with the ophthalmoscope. To prevent the confusion arising from this double use of the words, it has been proposed by Leber to restrict the terms "optic nerve" and "optic neuritis" to the whole nerve, employing only the words papilla and papillitis, to designate the intra-ocular termination of the nerve and its inflammation. This distinction has not, however, come into general use in this country. The custom of employing the term "optic neuritis" as a designation for the intra-ocular inflammation, makes it inconvenient to restrict it to inflammation of the nerve trunk, but for the former condition the name "papillitis" is very useful.



The characters of these morbid states may be thus tabulated:—

A.—Morbid states of the optic nerve, characterized by increased vascularity or signs of inflammation.

1. Simple congestion of the disc; undue vascularity, redness, the edge softened, but not obscured, and no swelling.
2. Congestion with œdema of the disc (slight neuritis or papillitis); increased redness, with slight swelling; obscuration of the edge of the disc, complete to the direct examination, incomplete to indirect examination.
3. Neuritis, or papillitis; increased redness and swelling, with obscuration of the edge of the disc, complete in degree, partial or total in extent.

B.—Diminished vascularity and signs of wasting.

1. Simple atrophy; increased pallor from the first; "primary atrophy."
2. Congestive atrophy; secondary to congestion; pallor slowly succeeding simple congestion.
3. Neuritic atrophy, succeeding pronounced neuritis; "consecutive atrophy," "papillitic atrophy."

A. — MORBID STATES CHARACTERIZED BY INCREASED VASCULARITY OF THE DISC, OFTEN WITH SIGNS OF INFLAMMATION.

### 1. SIMPLE CONGESTION.

Increased redness is the universal expression of tissue hyperæmia. But it is of less value as a sign of hyperæmia of the optic disc than in the case of most tissues, on account of the great variation in the amount of natural redness (p. 4). Attention to tint of disc alone is a prolific source of error in ophthalmoscopy. It is as if a small portion in the centre of the cheek were examined to determine whether or not there



was pathological hyperæmia. Nevertheless, abnormal redness of the disc does occur as a morbid state, and, although in itself a sign of little value, it derives importance from certain concomitant conditions. It is significant (*a*) when it possesses special characters to be immediately described; (*b*) when developed under observation; and (*c*) when it is notably greater in one eye than in the other: and even in the latter case there is room for error in the possibility of a natural difference, or that the paler eye may present an abnormal decrease in redness.

There are certain characters which aid very much in the recognition of the pathological increased vascularity. First, morbid redness always has a tendency to invade the physiological cup, and often, especially when the cup is small and shallow, to obscure it altogether. Secondly, pathological redness has a tendency to render the sclerotic ring or the edge of the choroid indistinct; to blur the sharpness of the outline of the disc. The change, when *very slight*, may be best appreciated by examination with the indirect image (Pl. I. 1). It is due to the circumstance that the seat of the vascularity is the layer of nerve fibres, and it may extend in front of the edge of the disc; and it is often attended with a little swelling of the nerve fibres or effusion of fluid, which conceal the structures beyond. The term "congestion" is, I think, best restricted to those cases in which the increased vascularity exists alone, with so little structural change, that the edge of the disc can still be perceived, by both methods of examination, although not so sharp as natural.

The redness is different from the ordinary tint of the discs. It is brighter, softer, somewhat velvety in aspect, sometimes finely stippled. Occasionally, however, the tint of a disc thus changed may be positively paler than normal, although the uniformity of the colour, and the softened edge, afford evidence of the pathological character of the change on which it depends. This paler tint is often seen when the condition is passing into atrophy. The retinal vessels are usually unchanged; their walls are often conspicuous, by contrast with the redness of the disc, as white lines



bounding the blood column, and any white connective tissue which surrounds them at the point of emergence is also unduly conspicuous (Pl. I. 2). The appearance is suggestive of the white tissue being a pathological result of the hyperæmia. It is probable that it is so, but it is too common as a physiological condition for its presence to have much value. Its distinctness possesses a little significance, as due to the invasion of the middle of the disc by the hyperæmia. Occasionally, when the hyperæmia of the disc is the expression of graver changes behind the eye, the vessels may be narrowed in consequence of retro-ocular pressure.

The condition thus described as "simple congestion" of the disc is usually a chronic state, and corresponds, probably, to the condition which has been described by Dr. Clifford Allbutt as "chronic neuritis." The evidence that there is actual inflammation does not seem sufficient to warrant the application to this state of the term "neuritis," especially as there are forms of true neuritis characterized by extreme chronicity. It is rare, I think, that such simple hyperæmia is the first stage of an actual neuritis. In the latter, swelling comes on *pari passu* with the hyperæmia—*i.e.*, congestion with oedema, rather than simple congestion, is the first stage of neuritis. The simple congestion is seen as a substantive condition in many cases, commonly preceding atrophy. It is sometimes the expression of a state of congestion and degeneration in the whole optic nerve, but is sometimes apparently limited to the optic disc. It may occur as a consequence of injuries, blows, &c., in the neighbourhood of the eye, and may constitute the first stage of the condition described by Mr. Hutchinson as tobacco amaurosis. It occurs also, probably, from other toxic agents, as lead. It has been observed by Dr. Allbutt in general paralysis of the insane; and, although some other observers have failed to find it, one case under my observation presented it very distinctly. It has also been described by Dr. Allbutt as accompanying atrophy in locomotor ataxy; but in that disease, although often looked for, it has not been found by others or by myself. It is sometimes present in cases in which there is



reason to believe a similar condition exists in the brain. The figures Pl. I. 1 and 2 are from a patient with cerebral embolism in whom the condition came on in association with secondary brain irritation—mental failure and rapid wasting in the paralyzed limbs (Case 25). I have seen a similar appearance in acute mania. Microscopical examinations of the disc in this state are rare. Dr. Clifford Allbutt examined one case and found only distension of the minute vessels with that granular degeneration of the nerve fibres found in all forms of atrophy.

#### OPTIC NEURITIS OR PAPILLITIS.

CONGESTION WITH ŒDEMA (Pl. I. 3 and 4) is really the first stage of papillitis. The normal rosy tint of the disc becomes increased; its edge is blurred, but is recognizable on indirect examination. There is a pale reflection from the adjacent retina, surrounding the disc with an indistinct halo. On examining the disc by the direct method, the morbid appearance is much more marked. The edge of the disc is lost, especially on the nasal side, and the opacity is seen to be in part the result of an undue distinctness of the radiating striation of the nerve fibres as they course on to the retina. It must be remembered that this striation is often visible as a normal condition, especially above and below. Where the aggregation of the fibres is very close, the central cup being of large size, the appearance of commencing œdema may be closely simulated. In the latter condition, however, there is from the first more or less invasion of the central cup, which soon becomes obscured. The increased vascularity of the disc may be striated at the periphery. There is often distinct swelling. The centre of the papilla may be, as in the figures referred to, much redder than the periphery, on account of the slighter central swelling allowing the vascularity of the disc to be perceived. In the periphery the tint of the choroid is concealed. The retinal vessels may be normal, or the vein may be enlarged.

It is important to note that the direct examination renders



these changes more distinct. If the obscuration of the edge of the disc is apparent only, in consequence of the similarity in tint of the disc and the adjacent choroid, the edge of the disc is more distinct on direct than on indirect examination. When the indistinctness of the edge is due to the opacity of the structures in front of it (except in the very slightest form), the edge is less distinct on direct than on indirect examination. This is no doubt due mainly to the fact that the plane of focus is less exact in the indirect method, so that the choroidal edge and the tissue in front of it are in view at the same time; whereas the higher magnification and more exact focus of the direct method of examination illuminates the tissues in front of the edge so as to increase the concealment of the latter. This fact will often be found of service in distinguishing between a normal redness and an abnormal obscuration of the disc. Of course, it will not distinguish the latter from the cases just mentioned, in which there is a slight physiological obscuration of the edge by nerve fibres.

This condition of oedema is usually an acute affection, and is commonly the first stage of neuritis. It is said to be an effect of pressure on the retinal vein, causing passive congestion of the retinal vessels, and it has been described as the result of the general passive congestion of heart disease. In these cases it may be associated with retinal hæmorrhages. It may, however, occur as the first stage of neuritis without the least sign of mechanical congestion. In the case figured, there was probably a syphilitic intra-cranial node or growth.

NEURITIS (PAPILLITIS).\*—From congestion with oedema to actual inflammation the transition is one of degree. It seems better to restrict the term neuritis, or papillitis, to those cases in which the swelling and opacity are sufficient to conceal the edge of the disc to both direct and indirect examination. This condition is found in most cases to result, not merely from vascular congestion and oedema, but from changes in the nerve fibres and connective tissue, such as we regard as evidences of inflammation. The change may completely veil

\* Pl. I. 5, 6, II. 1, III., IV., VI., VII.



the whole or only half the disc, and from such a slight degree of neuritis to the most intense form, we may have every gradation, characterized by very considerable differences in appearance.

These differences in the appearance of the discs in different cases, and supposed differences in their origin, have led to the establishment of certain varieties of the affection, "descending neuritis" and the "choked disc," "stauungs-papilla." The grounds on which these divisions have been made are, as will be shown, so uncertain, that it is better in the first place to consider the common features which all forms of papillitis possess. The supposed varieties and theories of this origin will be then better understood.

A case of optic papillitis of considerable intensity presents, in the course of its development, certain stages, the general features of which are usually recognizable. The transition from one to the other is, of course, a gradual one, and discs are seen which present appearances intermediate between the several stages. Moreover, at any stage, the morbid process may stop and remain stationary for a time and then recede. This may occur spontaneously or as the result of treatment. Thus certain *forms* of neuritis may be distinguished according to the intensity of the changes, but our knowledge of the conditions on which they depend seems insufficient at present to distinguish them as varieties otherwise than as varieties of intensity, on whatever differences of mechanism they may ultimately be proved to depend.

The first stage of optic neuritis is that which has been already described as "congestion with œdema;" a condition of increased redness, swelling, and cloudiness, masking the edge of the disc to direct, but leaving it perceptible to indirect examination. In this condition the microscope reveals no sign of tissue inflammation. The second stage, that of actual, but slight, neuritis, is characterized by the disappearance of the edge of the disc even to indirect examination. (Pl. I. 5). The transition from the disc to the retina is gradual, the edge is "blurred," and its position has to be guessed at. When this is the case the disc always, I believe, presents changes in its tissue elements which indicate a process of inflammation—



proliferation of nuclei, escape of leucocytes, and degeneration of nerve structures—changes similar to those which are regarded in all organs as indicative of inflammation.

The red tint of the disc becomes more marked, so that it may be almost the same as that of the adjacent choroid, or it assumes a reddish grey tint, which is very characteristic. The swelling increases, and is easily recognized, even on indirect examination, by the relative displacement of different parts on lateral movements of the lens. The striation of the periphery, perceptible in the first stage, increases, but becomes redder. It is due not only to the swelling and opacity of the nerve fibres, but also to the minute vessels which course between them. In the centre of the disc the redness is stippled or uniform, not striated, and the centre is commonly distinctly darker red than the peripheral portion (Pl. I. 6). The centre may be red, and the periphery grey red. The striated edge passes, by gradation, into the tint of the adjacent fundus. The physiological cup often disappears during the stage of oedema; if large, a trace of it may remain to the stage of commencing neuritis, but is rapidly encroached upon and covered in by the swelling of the papilla (see Pl. III. 2, in which it has almost disappeared).

White lines and spots are not uncommon, especially in the cases in which the changes remain of slight degree. They often correspond to the position of arteries (Pl. III. 3). The swelling and obscuration may involve all parts of the disc equally, especially in the more acute forms of neuritis, or it may be much more marked on the nasal than on the temporal side of the disc. The difference may be so great that the position of the edge of the disc may be distinct on the temporal side, while the nasal edge is completely obscured by opaque tissue—a condition which may for brevity be termed “hemi-neuritis.” (Pl. V. 1, 2, 4). Hæmorrhages are not uncommon in this stage, sometimes on the surface of the swelling, or even on the least changed part of the disc (Pl. V. 1) or just beyond its edge (Pl. V. 4). They are always small. The arteries usually present little change in the slighter stage of neuritis,



although often recognized with difficulty on account of the colour of their blood corresponding to the tint of the disc. They are a little concealed at their emergence, but have a nearly straight course. The veins lose their central reflection as they pass down the sides of the swelling, and appear dark. They may or may not present dilatation, indicative of mechanical congestion. In the early stage of papillitis from tumour, as a rule, they less frequently present dilatation than in that from meningitis.

As the papillitis goes on, the swelling increases, and becomes often so great, that there may be a difficulty in seeing the surface of the swelling by the direct method without the use of a convex lens. The veins, as they curve down the sides of the swelling, appear still darker and foreshortened, and are concealed just beyond its edge in the adjacent retina (Pl. III. 4, IV. 1, V. 6). The veins commonly now present some enlargement, often considerable, and the arteries are narrowed. They may be indistinct upon the disc, being concealed by the tissue. The arteries are always more concealed than the veins. The vessels are often lost to view at the centre of the swelling (Pl. I. 6, IV. 3, V. 5), although there may be a depression where they emerge. This central depression is sometimes large, in consequence of the neuritic swelling being chiefly located on the edge of the disc (Pl. VII. 1) a condition which has been distinguished as "perineuritis." The swelling increases, not only in height but in lateral extent, and partly displaces, partly invades, the adjacent part of the retina, often having a diameter two or three times that of the optic disc. There are, however, rarely signs of any general disturbance of the retina. Extravasations of blood may occur on the surface of the swelling, and not uncommonly white, flake-like spots may appear upon it, often concealing the vessels (Pl. III. 3, V. 1, VI. 2). Occasionally a white spot is surrounded by a halo of hæmorrhage (Pl. VI. 2). Sometimes similar spots exist in the retina close to the edge of the disc.

A large number of cases proceed no farther than this stage. Signs of passive congestion of the veins may or may not be



present. If not present before, they may be developed during the subsidence of the neuritis, especially if absorption of the inflammatory products cannot be obtained. Neuritis of this stage may clear completely (Pl. IV.), the inflammatory products being for the most part removed, and those which remain merely causing a little increase of tissue in the middle of the disc. The subsidence is marked by a diminution in the height and extent of swelling, and in its redness. At first it may appear somewhat more opaque (Pl. VI. 4), but this becomes less as the swelling subsides. The position of the edge of the choroid becomes appreciable, and gradually clearer, first on the temporal, and then on the nasal side. The disc has at first a "filled in" aspect (Pl. VI. 5), and both arteries and veins may be narrowed and partly concealed on its surface. This is especially the case when the new tissue-elements in the disc have been sufficiently abundant to develop signs of strangulation during the inflammatory stage (Pl. VI. 1 and VIII. 1). When this is not the case as in Pl. III. 5 and 6, IV. 1 and 2, the disc may rapidly clear in the centre, as well as in the periphery, and the physiological cup be quickly reproduced. Often, however, white lines along the vessels indicate the remnants of preceding inflammation (Pl. IV. 2, II. 4), and the vessels may be a little narrowed. Commonly, when the inflammatory swelling has been marked, a disturbance of the choroid, near its edge, leads to a narrow zone of atrophy adjacent to the disc (Pl. IV. 4).

Whether or not there are signs of mechanical congestion in the stage of neuritis just described, a further increase in the inflammation is accompanied invariably with signs of compression of the vessels, and strangulation of the inflamed papilla, with a rapid and intense increase in the mischief. The tumour formed by the swollen papilla becomes much more prominent, and extends laterally in all directions, even as far on the temporal side as the macula lutea. The form of the swelling varies; sometimes it remains conical, but usually the sides become steeper, and the top more or less flattened. The sides may even overhang, so that the tumour has a fungi-



form shape, and the vessels, as they pass over the side, may be concealed by the edge of the swelling, and reappear in the fundus in a different position. A good example of this intense strangulated neuritis is figured at Pl. VI. 1.

The arteries are much narrowed and often altogether invisible on the swelling, being buried in its substance, and appearing first in the retina, a little distance from its edge. The veins, also, are often concealed on the disc, at least in part, but some of them are usually visible towards the edge of the swelling, and are at first greatly distended. When the amount of swelling is extreme, all the vessels may be concealed, as in Pl. VI. 1. Hæmorrhages are frequent and extensive, and are commonly situated on the edge rather than on the surface of the swelling (Pl. VI. 1 and VIII. 1). The overhanging edge may be infiltrated with blood. The veins may be concealed beyond the edge of the swelling, and often present many curves and twists, sometimes corkscrew-like from their elongation. The tint of the strangled swelling is usually a full red, mottled and streaked from enlarged vessels and small extravasation. The striation due to the nerve fibres is commonly lost. The retina adjacent is often the seat of hæmorrhages which may extend along the vessels from the disc. Not unfrequently secondary changes occur in the retina over a wide extent. Hæmorrhages usually striated and situated in the nerve-fibre layer, may be scattered over the whole fundus (Pl. VI. 1). The veins are often distended, and may be tortuous for a long distance from the disc. The ultimate distension of the veins may be as great in the papillitis which succeeds a descending neuritis (see Pl. XVI. 3), as in that which is supposed to be limited to the eye. The retina may, in rare cases, present areas of opacity, diffuse and cloudy, or localized and white, and often occurring along the course of the vessels (Pl. VIII. 1).

Sight, if not previously lost, fails entirely, and often very rapidly, during the stage of strangulation. The time taken for the development of these changes varies within wide limits. A neuritis may remain for months and even years in



the slighter stage, or most intense strangulation may be developed in a few weeks.

*Subsidence of Neuritis.*—The gradual subsidence of the slighter degrees of neuritis has been already traced. In the more intense forms, in which strangulation has occurred, the stage of subsidence presents certain peculiar features. The venous distension gradually lessens after the strangulation has existed for a time, and the veins may become narrow before other signs of strangulation subside. In Pl. VI. 1, they are much smaller than in the earlier stage of strangulation shown in Pl. VIII. 1. This is probably because the compression of the arteries becomes sufficient to lessen the blood-supply to such an extent as to permit the veins to recover nearly their normal calibre. When the strangulation is less intense, the commencement of subsidence may be attended with an increase in the mechanical distension of the veins, and in increased narrowing of the arteries. The redness of the swelling lessens, hæmorrhages, as a rule, cease to occur,\* and some of the blood, already extravasated, disappears. The tumour lessens in height and in extent, and, if fungiform, again becomes conical (Pl. VI. 3.) The highest portions of the swelling gradually become pale, the sloping sides and adjacent part of the retina presenting a darkish discoloration, and the central pallor passing very gradually into the lateral redness (Pl. II. 1, IV. 5, V. 6, VI. 3.) The centre of the swelling soon presents a distinct depression from which the vessels emerge, often concealed by whitish tissue. Over the swelling the course of the veins is more distinct. The arteries are still often concealed, their more rigid, straight course having caused them to be buried in the new tissue more deeply than the veins, which were pushed up before it, and the paler tint of the arteries also renders them less conspicuous. The concealment of the veins beyond the edge of the disc is even greater than it was before, in consequence of the curve of the inelastic vessels into the retina being increased as the swelling subsides (Pl. VI. 4 and 5.) Slowly the

\* Very rarely fresh hæmorrhages form adjacent to the papilla during the stage of subsidence, as in Pl. VI. 4



pallor increases and the swelling lessens, the constriction of the vessels even increasing, the changes being due to the cicatricial contraction of the newly-formed tissue. Occasionally, when large vessels appear on the papilla during the neuritis, these become tortuous, and gradually disappear during subsidence (Pl. IV. 5). As the white area narrows to near the limits of the disc, the edge of the choroid and sclerotic appear, dimly at first (Pl. VI. 4, left edge), then more distinctly. The disc has a white "filled-in" look (Pl. VI. 5, VIII. 2), the vessels are constricted, and it is very long before any central depression is developed on the disc, although ultimately the contraction of the fibrous tissue, as in other cicatrices, proceeds to an extreme degree, and the disc may again become hollow (Pl. IV. 6). The lamina cribrosa is, however, usually permanently veiled, an important differential character of this form of atrophy. The choroid is usually disturbed near the disc, and a zone of irregular choroidal atrophy is left, causing the disc to have irregular edges, but this zone is not always proportioned to the amount of inflammatory disturbance, and if slight the disc may ultimately come to have a clean cut edge. At first the disc is usually very white, rarely grey with white lines along the vessels (Pl. II. 2, upper half). When it has reached the retinal level, however, although it may appear white to the indirect image, a faint grey tint is usually perceptible on direct examination, and as the contraction increases this grey tint becomes more marked, and the ultimate appearance of the disc is usually distinctly grey to direct examination, although often white to indirect examination. Very rarely inflammation may subside irregularly, clearing from one part of the disc, while the other still presents the characters of neuritis (Pl. II. 2).

The retina undergoes certain changes during this period of subsidence. Hæmorrhages upon it usually are soon absorbed, but sometimes undergo transformation into spots of pigment. Some extravasations lead to the formation of white spots in the retina. This is especially the case near the disc, where the nutrition of the retina is always a good deal disturbed by the adjacent inflammation. These white spots, which depend



on fatty degeneration, either of fibrin or of the retinal elements, and persist after the blood has been removed, commonly originate close to the borders of the neuritic swelling; but as the latter subsides and contracts, they are left behind, and are often one or two discs breadth from the edge of the sclerotic ring, and they may then puzzle the observer from their resemblance in character and position to the spots of albuminuric retinitis. A group of such spots, midway between the disc and macula lutea, is seen in Pl. VI. 3. The degenerative changes which occur when the neuritis is very intense, and the swelling wide, may leave an appearance strikingly similar to that of the albuminuric affection. If the swelling approaches the macula, degeneration occurs among the radiating fibres of the fovea centralis, identical in appearance, and probably in nature, with those which in renal disease form the familiar stellate figure around the macula. A striking instance of this is shown in Pl. VIII. 2. The distinction, as will be subsequently explained, consists mainly in the evidence the disc affords of a considerable antecedent neuritis. Frequently, as the retina becomes atrophied, slight pigmentary deposit takes place in it, especially around the macula lutea, and sometimes the atrophy is accompanied by wide-spread slight disturbance of the choroidal pigment, probably only that of the epithelium.

When a neuritis has lasted a long time, and the veins have been for long stretched over the swelling, they may be so permanently elongated that the subsidence of the neuritis, instead of being attended with a diminution in their tortuosity, is accompanied by an increase in their curves. This is shown in Pl. VI. 4 and 5, in which also a very rare circumstance is presented—the occurrence of recent extensive hæmorrhages during the stage of subsidence.

*Second Attacks of Neuritis.*—If a disc has become completely atrophied it is never again the seat of inflammation. When, however, atrophy is partial or absent, in rare cases two attacks of neuritis may occur. In one case, for instance, a patient suffered without doubt from a cerebral tubercle, and died from an attack of tubercular meningitis. The former



had probably become quiescent, and the neuritis which it caused subsided, leaving partial atrophy. The discs again became swollen and obscured with the symptoms of meningitis. A second slight attack of neuritis occurred also in Case 15.

**PATHOLOGICAL ANATOMY.**—In the condition described as congestion with œdema, the microscope reveals less prominence than was observed during life, because the swelling depended on distended vessels and effused serum. The nerve fibres are separable with abnormal readiness, and are divided by spaces which during life were occupied by serum (Pl. XV. 8). The fibres themselves may present slight varicosity. There is no increase in the connective tissue elements, and there are no products of degeneration of the nerve fibres. The retina is normal to the edge of the choroid, its nerve-fibre layer being alone increased in thickness by the conditions mentioned as causing the swelling of the papilla. Sometimes the retinal layers may be displaced outwards a short distance.

In the stage of developed neuritis (Pl. XIII.—XVI.) the microscope usually reveals a considerable swelling, often two or three millimetres above the level of the choroid. There is usually a central depression, often larger and deeper than the ophthalmoscopic examination suggested. The swelling may be very distinct to naked eye examination (Fig. 6, p. 53), and hæmorrhages may be seen upon it. Thus, mere inspection of the fundus after removal may show the previous existence of papillitis. The swelling is due to several conditions, the relative degree of which varies much in different cases:—(1) The vessels, large and small, are distended with blood (Pl. XIII. 6). (2) Spaces between the nerve fibres sometimes indicate the persistence of œdema. (3) Many nuclei are seen, some of which are leucocyte-like corpuscles, most abundant around the vessels, which may be encrusted by a thick layer (Pl. XIII. 6, XV. 1), and sometimes grouped into dense masses (Pl. XIII. 5). Similar corpuscles lie in greatly increased numbers between the bundles of nerve fibres.



Some of these are nuclei belonging to a system of connective tissue fibres which run at right angles to the nerve fibres (indicated in Pl. XIII. 6 and XIV. 6). These fibres may be themselves swollen (Pl. XV. 9). (4) The nerve fibres present changes, which contribute, in varying degree, to the production of the swelling. They are irregularly thickened, and the enlargements may be varicose, moniliform, or knob-like (Pl. XV. 11), often containing granules or fatty globules from degeneration of the myelin. The swellings may attain a large size, as in the accompanying figure (Fig. 5). Free aggregations

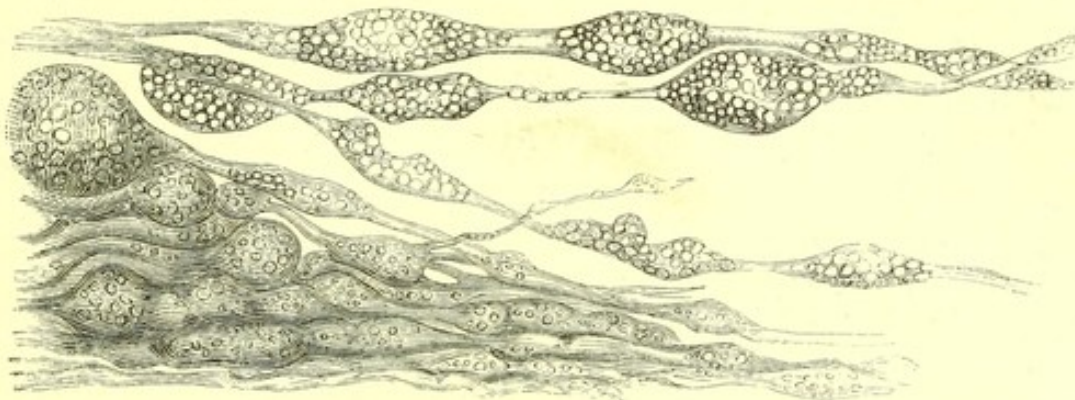


Fig. 5.—Degeneration of Nerve Fibres, from the substance of an inflamed papilla in a case of tumour of the lower part of right middle cerebral lobe. Highly magnified. (After Pagenstecher and Genth.)

of fatty globules and granules may also be found, commonly enclosed in a cell wall (Pl. XVI. 2). They may assume a colloidal appearance ("corpora amylacea.") Many of these are simply the detached degeneration-swellings of the nerve fibres. They are best seen in glycerine preparations. These products of degeneration give rise, by their aggregation, to the larger white spots seen with the ophthalmoscope. Other spots are due to aggregations of leucocytes. *like cells.*

The vessels may have their walls thickened by nucleated tissue, and sometimes by a clear, finely fibrillated substance (Pl. XIV. 7). The vessels do not usually present any evidence of compression in the sclerotic ring, but commonly appear to be narrowed, often considerably, in the thickest part of the swelling, and the veins are again enlarged as they pass down the outer sides (Pl. XIII., XIV.). The veins are usually very large, the arteries narrow. The former, after



curving down the sides of the swelling, descend into the substance of the swollen retina, even into the nuclear layers, and rise again into the layer of nerve fibres. Sometimes two such curves may exist (Pl. XVI. 1). The retina is displaced from the edge of the choroid often as far as a millimetre from the sclerotic ring. Its layers at the commencement usually present considerable change. The nerve-fibre layer is thickened by a slighter degree of the changes which cause the swelling of the disc. The nuclear layers are increased in thickness and often blended together, and the nuclei more or less separated and grouped into vertical columns by the displaced fibres of Muller (Pl. XV. 1). The retina may present (as here) slight curves due to its displacement, most marked in its outer (deepest) layers, and effecting detachment of the retina, the space between the bacillary layer and choroid being occupied by serum. These curves may be visible with the ophthalmoscope as narrow, pale lines, parallel to the edge of the papilla (Pl. I. 6, VII. 1).

The pigment-epithelium may persist up to the edge of the sclerotic, or it may disappear from the area from which the retina has been displaced (Pl. XVI. 1). Often the choroid undergoes atrophy close to the edge of the sclerotic.

The changes in the papilla always become much slighter at the sclerotic ring, and often appear to cease there. Commonly, however, large numbers of nuclei lie among the nerve bundles in and just behind the lamina cribrosa. The sclerotic ring may appear distended, the nerve tissue occupying closely its funnel-shaped area. The appearance of distension is partly, if not entirely, due to the shape of the ring, as may be seen by comparing Pl. XIII. 5 with Pl. XVI. 1. In the latter the appearance of excavation of the edge of the sclerotic is present on the right side only, and an interval exists between it and the nerve fibres, occupied only by the fibres of the lamina cribrosa.

The sheath of the optic nerve is often distended with fluid, sometimes slightly, sometimes considerably. The distension is greatest a short distance behind the eye, and narrows close to the sclerotic, having thus a pyriform shape



(Fig. 6). In cases of old neuritis the sheath may be found flaccid, having evidently been distended at a previous time. Microscopically the nerve may appear normal, the nuclear increase near the lamina cribrosa gradually ceasing. More commonly the nuclei are increased in quantity throughout the nerve, and the trabeculae may be thickened and the vessels distended (Pl. XIII. 8 and 9). The inner sheath also

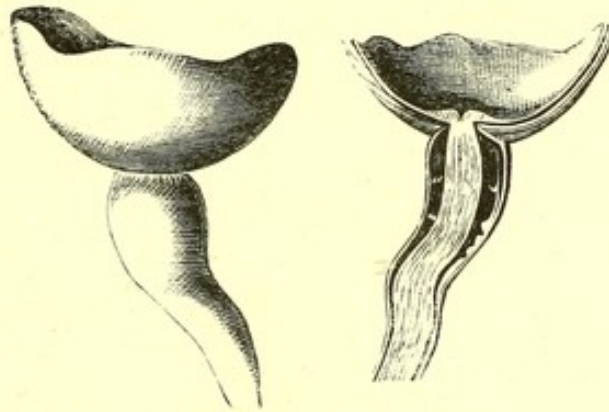


Fig. 6.—Posterior Segment of Eyeball and Optic Nerve (from a case of chronic traumatic meningitis), showing the distension of the sheath of the nerve and the swelling of the papilla. (Natural size, after Pagenstecher and Genth.)

may be crammed with nuclei, and the connective tissue between the inner and outer sheath increased. The nerve fibres may present evidence of degeneration. These changes, slight or considerable, may often be traced back as far as the chiasma, in front of which they are sometimes much more intense than anteriorly, and most intense near the surface of the nerve, especially in cases of meningitis,—evidence of extension of inflammation from the meninges. An increase of nuclei may sometimes be traced into the chiasma, and even into the optic tract (Pl. XIV. 5), where they may even be aggregated into “miliary abscesses” (Pl. XVI. 4).

The anatomical changes which correspond to the progressive subsidence to atrophy are—the diminution of the cellular elements in the papilla, probably, in part, in consequence of their transformation into fibres. The products of the degeneration of the nerve fibres are slowly removed. Ultimately the substance of the papilla appears to consist of a felty mass of interlacing fibres sprinkled with nuclei, in which at last scarcely any indication of nerve fibres is to be traced.

Posterior  
retina



**SYMPTOMS.**—These may be, when the inflammation is of moderate intensity, entirely absent. Vision may be unimpaired—acuity and colour-vision perfect, and the field unrestricted. An increase in the size of the blind spot may usually be ascertained by mapping it out with the perimeter, but of this the patient is unconscious. The degree of neuritis which may exist with no impairment of acuity of vision, is remarkable. In the cases shown in Pl. I. 4, 6, III. 5, IV. 1, 3, V. 1, 2, VI. 4 and 5, when the drawing was made, the acuity of vision was scarcely or not at all impaired. It is often said that

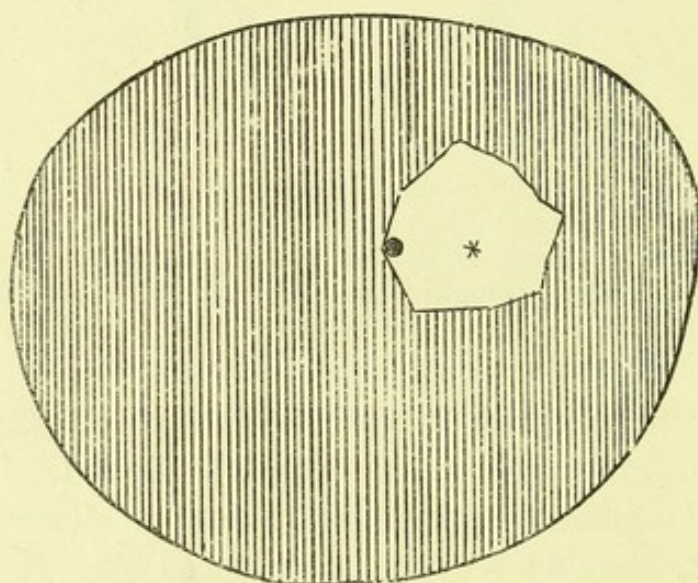


Fig. 7.—Diagram of the Field of Vision in a case of subsiding optic neuritis in cerebellar tumour, left eye.—The outer boundary of the figure is the limit of the average normal field. Vision was lost in the shaded area, preserved only within the inner line around the fixing point, the position of which is indicated by the asterisk.

“descending neuritis” causes much earlier affection of sight than limited intra-ocular papillitis. But acuity of vision may be unimpaired even with a considerable degree of descending neuritis. In more intense cases, however, sight is impaired or lost, and this constitutes the chief symptom of optic neuritis. Photophobia may occur in simple congestion, but is practically unknown in neuritis. Pain in the eye is very rare. Pain in the head may occur in cases of apparently idiopathic papillitis. It is, of course, a very common accompaniment of symptomatic



inflammation, but is then generally to be accounted for by the intra-cranial disease.

The affection of vision usually occurs in one eye before it

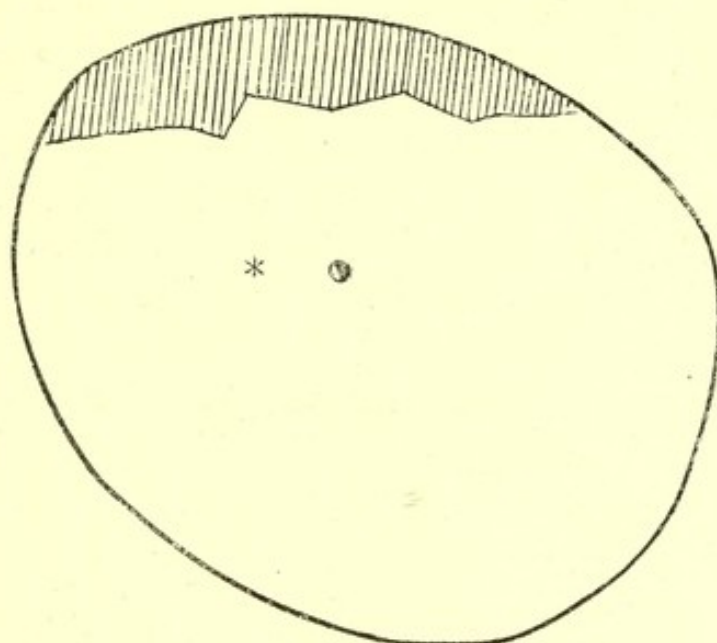


Fig. 8.—Diagram of Field of Vision in a case of unilateral optic neuritis: limitation above only (Case 17).

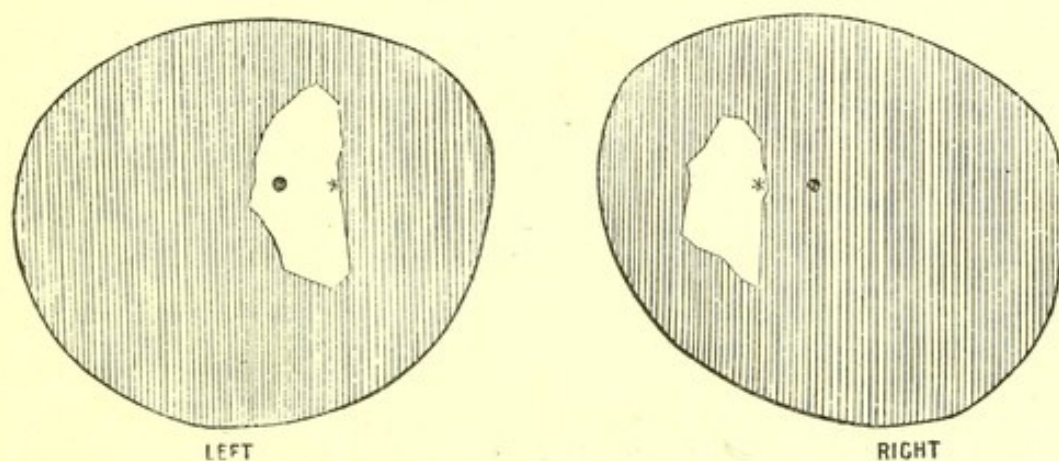


Fig. 9.—Diagram of the Fields of Vision in a case of hemiopia and double optic neuritis (Case 18). — The star represents the fixing point, the dot the position of the blind spot. The outer boundary of the shading is the normal limit of the field, the shading the area in which sight was lost. There is seen to be loss of the whole right half of each field, with concentric limitation of the left halves.

occurs in the other. It may come on rapidly or slowly; never instantly. Sometimes the rapidity of its progress may be great; sight may fail completely in the course of a few days.



Restriction of the visual field usually accompanies considerable change in the acuity of vision. It may be extensive, and often reaches its height during the stage of subsidence. Only a small area around the fixing point may remain, as in the diagram (Fig. 7), from a case of subsiding neuritis in cerebellar tumour. Occasionally the limitation of the field of vision may be irregular, one part being more or less affected than the rest, as in Fig. 8, in which the upper part only is restricted (Case 17). In some cases a change in the field of vision, due to the intra-cranial disease, may accompany the peripheral limitation due to the optic neuritis, as in the diagram (Fig. 9) of the

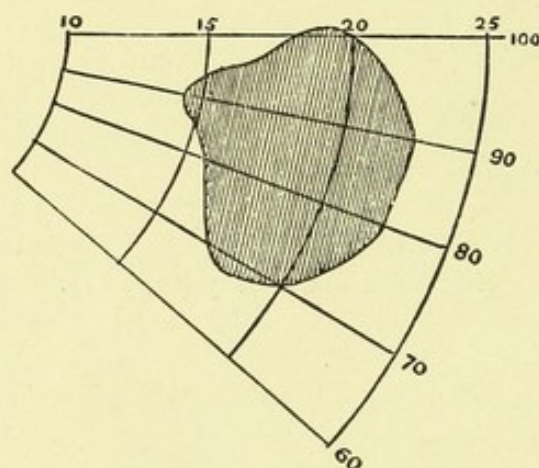


Fig. 10.—Diagram of the Blind Spot (shaded area) in a case of optic neuritis from intra-cranial disease (Case 9; Pl. IV. 3).

fields of vision in Case 18, in which hemiopia, owing to the intra-cranial disease, accompanied the peripheral limitation. Not unfrequently there is marked peripheral amblyopia, and a small object cannot be recognized in the periphery although a large object, as the hand, is well seen. The increase in size of the blind spot is proportioned to the size of the papillary swelling. The accompanying diagram (Fig. 10) shows its area in a case of optic neuritis figured in Pl. IV. 3 (Case 9). It is a little, but not much larger than normal.

When there is distinct amblyopia there may be a defect in colour-vision, and the latter may exist even when acuity of vision is very little impaired. To this point Galezowski has called special attention. The order of loss is sometimes (as in atrophy, *q.v.*) that of the normal peripheral arrangement



of the colour fields in the accompanying figure (Fig. 11), red and green being lost before yellow and blue. In Case 20, for instance, yellow was the only colour which could be recognized. More frequently, however, the loss is irregular. In three cases I have seen yellow alone lost. In Case 29 at one time, in one eye, yellow was alone lost, and in the other eye yellow, blue, and green were lost, red being seen, and recovery was in the order of the fields, the yellow last. Now and then (as in

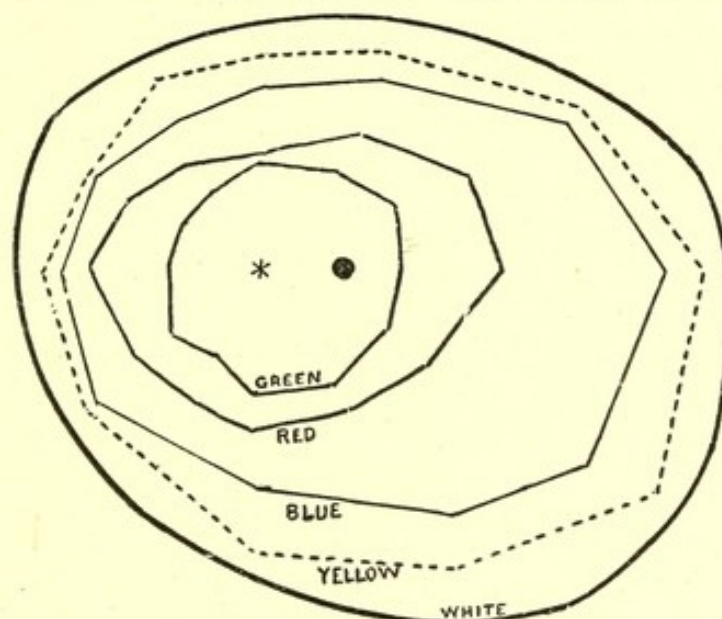


Fig. 11.—Diagram showing the Fields of Colour Vision in a normal emmetropic eye on a dull day.\* The fields are each rather smaller than on a bright day. The asterisk indicates the fixing point, the black dot the position of the blind spot. (Usually the blue field is larger than the yellow.) See the section on Atrophy of the Optic Nerve.

Case 8) colour-vision may be little affected, even when there is considerable peripheral limitation of the field of vision.

When sight is completely lost, the sensibility of the retina to electrical stimulation may or may not be impaired. It may be lost during blindness, and return with some recovery of sight, as in Case 10.

It is very important to be aware, as far as possible, of the mechanism by which sight is impaired, since the prognosis must, in the main, depend thereon. The loss of sight which occurs in cases of idiopathic isolated papillitis is, of course, due to the process which can be seen with the ophthalmoscope.

\* I am indebted to Mr. Nettleship for the charts from which this diagram was made.



But the papillitis which occurs in intra-cranial diseases may be accompanied with loss of sight due, not to the intra-ocular changes, but to mischief in the course of the optic fibres or in the centres in which they are connected. The first point to ascertain, therefore, is whether the amblyopia is due to the intra-ocular changes or to mischief farther back. It is not always possible to determine this point, but very often an accurate opinion may be formed.

Concomitant affection of sight from intra-cranial processes, it may be thought, should be more frequent in cases of descending neuritis, than in cases of supposed isolated papillitis; because descending neuritis is due to, and involves, organic changes in the optic path. This is true, but this distinction does not afford much assistance, because it is not often

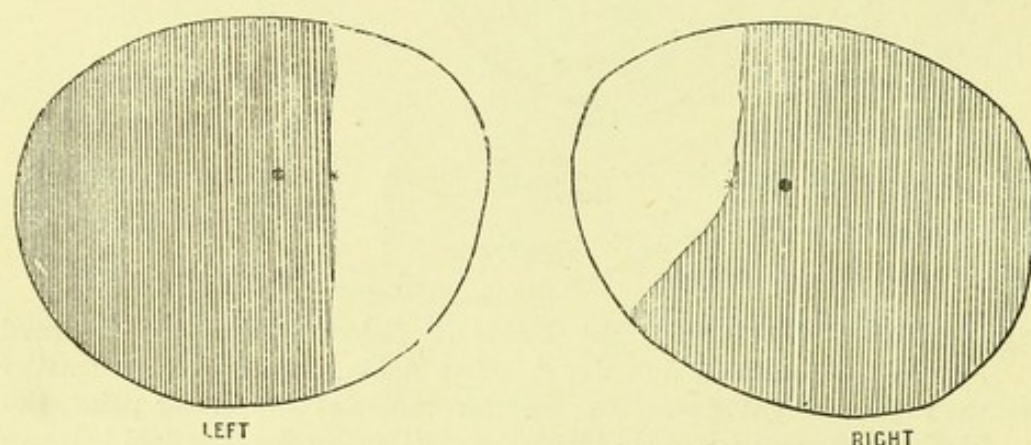


Fig. 12.—Diagram of the Fields of Vision in a case in which sight was probably lost from pressure on the chiasma.—The shaded area indicates the part in which vision was lost—viz., the temporal portions of both fields, the nasal portions alone persisting.

that we can rely upon the ophthalmoscopic distinction of descending and isolated neuritis.

Another distinction is derived from the manner in which the loss of sight comes on. Blindness from optic neuritis never comes on instantly; it occasionally, though rarely, comes on instantly in concomitant brain disease. From optic neuritis, however, as just stated, it may come on in the course of two or three days. More important indications are derived from the form in which sight is lost. A symmetrical hemiopic defect in the field (such as Fig. 9) means an



intra-cranial cause ; an unsymmetrical lateral defect, especially a loss of the temporal halves (as Fig. 12), commonly means pressure on the chiasma, a very common cause of blindness in these cases, the pressure being exerted by a distended third ventricle. Complete loss of sight of one eye, and loss of the adjacent half of the other field (as in Fig. 13) is probably of cerebral origin (Case 30). A peripheral restriction of the fields usually means damage in front of the optic commissure, and, in most cases of intra-ocular neuritis, damage from the visible changes. A central scotoma is observed only when there is a conspicuous lesion at the macula lutea.

Lastly, important assistance is derived from the degree of intra-ocular damage—is it sufficient to account for the loss of sight? The question is one difficult in many cases to

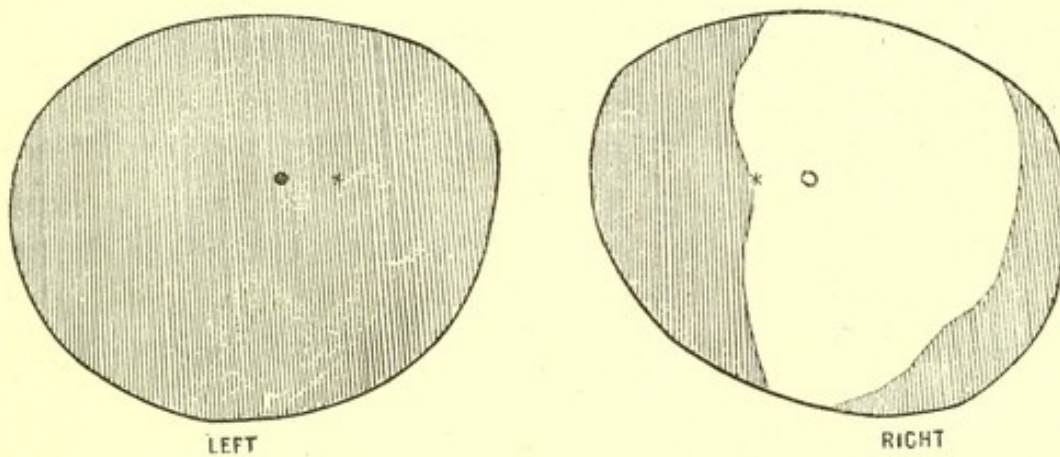


Fig. 13.—Diagram of the Fields of Vision in a case of loss of sight from disease of the right cerebral hemisphere.—Loss of the whole of the left field and of the left half of the right, with a little peripheral defect on the temporal (right) side.

answer, and an approximate answer can only be given, afforded by a knowledge of the conditions on which the loss of sight, in these cases, depends. The study of intra-ocular neuritis in relation to affection of sight makes it probable that vision may suffer in two ways, apart from the involvement of the retina. The first is damage to the nerve fibres by the process of inflammation around them. We know that acute inflammation has a tendency to stop the conducting power of nerve fibres, apparently by some direct damage to their finer structure, and that the subsidence of



the inflammation may be followed by a recovery of function. The second is by pressure on the fibres, by the products of inflammation. This occurs both during the inflammation and while it is subsiding. During subsidence, the newly-formed elements are undergoing a transformation into contracting fibrous tissue. A similar compression probably also occurs during the height of the inflammation, from the excessive amount of tissue produced, because at that period loss of sight may often be observed to coincide with a marked increase in the "strangulation" of the swollen disc. Damage to vision from compression of the fibres during subsidence of the neuritis is very common and very serious. It may cause considerable damage to sight, which has been unimpaired by the active neuritis, and it constantly succeeds and intensifies impairment by inflammatory compression during the active stage. The amblyopia, which occurs during the height of the inflammation, may lessen as the inflammation subsides, and be again renewed by the contraction of the new tissue as the subsidence of the swelling advances. The latter constitutes by far the greatest danger, because the contraction which causes it continues, and increases for a long time, and the amblyopia due to it usually continues and increases until, and even after, the disc has reached its normal level. The progress of the amblyopia from this cause may, however, be interrupted by the recovery of fibres damaged during the active inflammatory stage, and when the amount of permanent tissue element formed is small in proportion to the irritative changes in the disc (as in many cases of syphilitic disease duly treated), a considerable inflammatory amblyopia may clear away and be followed by very slight consecutive defect. The latter is usually more or less permanent, but, after it has reached its height, considerable subsequent improvement does, in some cases, slowly occur.

Not unfrequently after a neuritis has subsided, with or without impairment of vision, a further loss of sight, complete or incomplete, may occur from intra-cranial causes without any fresh ophthalmoscopic appearances, as in Case 6. It will thus be seen that a considerable disparity between the degree



and course of the papillitis indicates the influence of retro-ocular, probably intra-cranial, mischief. A good illustration of this is afforded by Case 17 (Pl. VII. 1 and 2) in which the papillitis was unilateral, the other eye presenting normal characters throughout; but the sight of both eyes failed after the subsidence of the papillitis.

CAUSES.—The most common causes of optic neuritis are encephalic diseases, and of these tumour is incomparably the most frequent. Neither the nature, size, nor the seat of the tumour appears to exercise much influence on the occurrence of neuritis. The next most frequent cause is certainly meningitis, and then come abscess of the brain, hydatid disease of the brain, and softening of the brain from vascular obstruction. In some cases, as in Case 27, it appears to result from an irritative process in the brain, revealed only by the microscope. It also results, in rare cases, from diseases of the upper part of the spinal cord. Other causes, outside the nervous system, are — albuminuria, lead poisoning, certain febrile diseases, and blood states. It may occur as an idiopathic affection, without obvious exciting cause, or from disturbances of menstruation, anæmia (especially from loss of blood) or exposure to cold. In all these cases it is, as a rule, double; now and then, in cerebral disease, and after acute febrile diseases and loss of blood, it may be single. Unilateral optic neuritis may result from mischief in the posterior portion of the orbit—inflammation or growth invading the optic nerve.

In the general diseases, such as albuminuria, lead poisoning, anæmia, &c., optic neuritis is often associated with encephalic symptoms. In Case 28 of lead poisoning (Pl. VII. 6), the neuritis was associated with great mental excitement, and so also in Case 36 of albuminuria (Pl. IX. 2), while in the similar case figured in Pl. IX. 3 (Case 37), intense headache was present. It seems probable that, in these cases, either the cerebral disturbance is concerned in the production of neuritis, or the neuritis and cerebral disturbance may be the indication of a general effect of the toxæmia on the nerve tissues.



**DURATION.**—The duration of optic neuritis varies very much in different cases. The cases of most rapid course may reach their height in two or three weeks, maintain it for about the same time, and then subside. These are of two classes—the most trifling and the most severe. The former are, for the most part, those which depend on an ocular condition, such as hypermetropia, or upon a cerebral condition which soon subsides, such as a transient attack of meningitis, syphilitic or scrofulous disease, which is influenced by treatment before the neuritis reaches its height. Now and then, however (as in Case 15), a neuritis rapidly subsides, although the cerebral disease progresses. But this is the rare exception. In these transient cases the subsidence may occupy the same time as the development—two or three weeks—and be complete; so that at the end of six or eight weeks the discs are again normal. In some very intense cases, such as the case of apparently idiopathic neuritis, figured in Pl. VIII., the development of the affection may be equally rapid, an intense degree of swelling being soon attained, and subsidence commencing in a few weeks. In these cases, however, the retrocession of the neuritis is always slow, and commonly occupies many weeks; often months pass before the edges of the disc are again perceptible.

On the other hand, the course of neuritis may be so chronic that months, even a year, may pass without the least change in the condition of the discs being perceptible. Cases 23, 24, and 26 are instances of this. Most cases of this extreme chronicity that have come under my observation, have accompanied symptoms of brain disease, which were not, in themselves, suggestive of “coarse” brain disease, tumour, &c. In other cases an equally chronic neuritis may accompany tumour. That shown, for instance, in Pl. V. 1 and 2, presented no alteration, tested by comparison with the drawing, for eighteen months, and two years later was still marked, the red, congested half being similar in area, although on the clearer half the disc was seen to be grey, and sight was lost. It is to be noted that in this case the symptoms of tumour, although intense, also progressed very slowly, and the chronicity



of the neuritis probably may be taken as an indication of chronicity of the cerebral disease. The converse proposition, however, that all forms of very chronic brain disease entail a chronic form of neuritis, does not, by any means, hold good.

In most cases the duration of neuritis is intermediate between the extremes mentioned, reaching its height in a month or two, and often remaining for some weeks or months with little change, and then subsiding. A rapid strangulation usually precedes subsidence at no long period, the products of inflammation perhaps checking the inflammatory process.

THE RELATION OF OPTIC NEURITIS TO ENCEPHALIC DISEASE.—The first definite theory of the mechanism by which intra-cranial disease acts was put forward by Von Graefe in 1859,\* and further developed by him in 1866.† It was founded on the observation that in some cases of intra-ocular neuritis, with hæmorrhages, in cerebral tumour, no signs of inflammation were perceptible on naked eye examination in the trunk of the optic nerve; whereas in a case of meningitis in which the ophthalmoscopic changes had been less intense, inflammation of the nerve trunk was found by Virchow—inflammation which was naturally assumed to have been communicated to the optic nerve from the inflamed meninges, and to have descended the nerve to the eye. This condition Von Graefe designated “descending neuritis,” and gave as its characteristics a slight degree of change in the discs and a tendency to invade the adjacent retina. On the other hand, the cases of tumour, with great intra-ocular change, hæmorrhages, &c., and no evidence of inflammation in the optic nerve trunks, he explained by the theory that they were due to the effects, in the circulation of the eye, of the increased intra-cranial pressure, which he assumed to be invariable in these cases, and to obstruct the return of blood from the eye by com-

\* In a communication to the Société de Biologie of Paris in November, 1859 (“Gazette Hebdom.,” 1859), and more fully described in the “Arch. f. Ophth.” vii. 1860, pt. 2, p. 58.

† “Arch. f. Ophth.,” xii. p. 100.



pressing the cavernous sinus. He suggested further that this mechanical effect was greatly intensified by the unyielding character of the sclerotic ring, which would act, he assumed, as a multiplier of the mechanical obstruction. In accordance with this view he applied to the condition of disc met with in these cases—considerable swelling and hæmorrhage and vascular distension—the term “*stauungs-papilla*” (*stauung*, a damming back) in distinction from the “descending neuritis.” In this country, by the suggestion of Dr. Clifford Allbutt, the term “choked disc” has come into use as a synonym for “*stauungs-papilla*.”

It was soon pointed out as strange that an actual inflammation should result from a mechanical congestion, and as still more strange that the inflammation thus excited should remain limited so nearly to the papilla. But graver difficulties awaited this theory of the “*stauungs-papilla*.” It was soon found that the ophthalmoscopic signs of the two forms of neuritis could not always be relied upon. The condition supposed to be characteristic of descending neuritis was discovered, in some cases, to be but the first stage of that supposed to indicate mechanical obstruction. It was found, also, that in cases in which the character of one of the two forms was clear, the necropsy showed the case to be really one of the other variety. Cases of this character were frankly published by Von Graefe, although he still held that the distinctions were, in the majority of cases, accurate, and the supposed mechanism of the *stauungs-papilla* effective. This theory, however, was destroyed in its substantive form in 1869 by the demonstration by Sesemann\* that the communication between the superior orbital and the facial vein was so free that the effect of pressure on the cavernous sinus was at once relieved, and did not cause more than a very transient fulness of the retinal veins, and that even obliteration of the cavernous sinus caused no intra-ocular changes. This has since been well corroborated, as an observation of Mr. Hutchinson’s in which no distension of the retinal veins was produced, although the cavernous sinus was completely obliterated by the pressure of

\* “Reichert u. Du Bois Reymond’s Archiv.,” 1869, p. 154.



an aneurism. It has, indeed, been said that the openings from the orbital into the facial vein are often larger than the communication with the cavernous sinus.

It was discovered by Schwalbe\* that the subvaginal space around the optic nerve is, at the optic foramen, continuous with, and can be injected from, the subdural space around the brain. This gave significance to some earlier observations of Stellwag von Carion† and Manz‡ that the sheath of the nerve may be distended in optic neuritis from tumour and meningitis. The two facts suggested to Schmidt§ that intra-cranial pressure may influence the intra-ocular termination of the optic nerve by this mechanism, since, as already described, the distension of the sheath is greatest just behind the globe. The theory received support from Manz,|| who showed how frequent distension of the sheath is in optic neuritis, and believed it to be invariable in cases of increase of intra-cranial pressure or increase of subarachnoid fluid. He urged that the simple pressure on the nerve and vessels might cause the intra-ocular changes, and endeavoured, by experiment on animals, to demonstrate the effect of the vaginal distension. Injections into the subdural space passed into, and distended, the sheath, and caused fulness of the retinal veins, and in some cases transient redness and swelling of the papilla.

Schmidt, however, found that a coloured liquid injected into the sheath passed into lymph spaces in the nerve at the lamina cribrosa, and he suggested that neuritis is produced, not by the simple pressure outside the nerve, but by the influence, perhaps irritation, of the liquid passing into these lymph spaces. The theories of Schmidt and Manz have been largely accepted in Germany as affording the most satisfactory explanation of the origin of optic neuritis.

It was suggested in 1863 by Dr. Hughlings Jackson, that intra-cranial tumour causes optic neuritis by its irritating effect,

\* "Centralblatt f. Med. Wiss.," 1869, p. 465. "Arch. f. Mikroskop. Anat.," Bd. vi. 1870, p. 1.

† "Ophthalmologie," vol. ii. 1856, p. 617.

‡ "Zehender's Monatsbl.," vol. iii. 1865, p. 281.

§ Of Marburg, now Schmidt-Rimpler. "Arch. f. Ophth.," vol. xv. 1869, p. 193.

|| "Deutsch. Arch. f. Klin. Med.," vol. ix. 1871, 339.



acting as a "foreign body,"\* and this view was supported a little later by Brown-Sequard, who compared the origin of neuritis in intra-cranial tumour to the production of atrophy of the optic nerve from a distant source of irritation. It was formulated by Benedikt† in 1868, by ascribing the mechanism to the vaso-motor nerves, and it is generally known, somewhat inaccurately, as his theory.‡ This view assumes that the tumour acts as a source of irritation which has a reflex influence through the vaso-motor nerves upon the optic disc, leading to its inflammation. It has been accepted by some authorities as satisfactory, but rejected by most writers on the grounds stated by Leber,§ as involving a mechanism not known to exist, and a complex relation of the optic nerve to all parts of the brain difficult to conceive; and by Clifford Allbutt, on the ground that he has failed to find around tumours the signs of irritation. The theory is, however, still held by Dr. Hughlings Jackson as that which best explains the phenomena of neuritis. Dr. Jackson has always urged that the occurrence of optic neuritis is not related to increased intra-cranial pressure. Lastly, Galezowski believes that neuritis is always descending, maintaining, contrary to most observers, that the intra-ocular change is in all cases the visible manifestation of an inflammation propagated by continuity from the brain.

This remarkable difference of opinion regarding a fact so fundamental, is a striking proof that much more careful observation is needed of the conditions of origin of optic neuritis, the pathological changes which can be traced in it, and the allied conditions in which it does not arise, before an adequate theory of its causation can be framed, or any effective distinction into varieties can be made. The following considerations are intended rather to further this end than to establish any definite theory of its causation.

\* "Oph. Hosp. Rep.," vol iv. † "Allg. Wien. Med. Zeit." 1868, No. 3.

‡ Schneller, in 1860, put forward a similar theory when he suggested that some retinal changes in intra-cranial disease might be due to a "primary affection of the centres of those nerves which regulate the course of the blood in the ocular vessels."—"Arch. f. Ophth.," Bd. vii. 1860, I. p. 71.

§ In "Graefe u. Saemisch's Manual," Bd. v.



The first point to be borne in mind is that optic neuritis limited to, or at least most intense, in the optic papilla, may occur without any obvious cranial or cerebral disease. The intense neuritis shown in Pl. VIII. 1, was apparently a primary papillitis involving the retina only secondarily, and occurred in a patient in whom no symptom of cerebral disease, save some headache, could be detected during two years she remained under observation. The neuritis reached its height in about a fortnight from its commencement, a rapidity which is seen in neuritis from intra-cranial disease only in the most acute cerebral affection; a circumstance which, with the absence of cerebral symptoms, quite excludes, I think, the supposition that there existed intra-cranial disease. From these considerations it seems to follow that the intra-ocular termination of the optic nerve is a structure, for some reason which we do not know, peculiarly prone to suffer inflammation. The common localization of the inflammation to the papilla points also to the same fact.

The facts of medical ophthalmoscopy certainly make it difficult to connect papillitis with increase of intra-cranial pressure. If we consider the cases in which intra-cranial pressure is raised to the highest point it ever reaches—chronic hydrocephalus—we find optic neuritis the rare exception, and, when it occurs, never intense. The difficulty cannot be met by attributing it to the slowness with which the pressure is raised, because the growth of many tumours which by themselves cause intense optic neuritis is equally slow.

On the other hand, as I have many times seen, in cases of tumour with neuritis there may be no sign of increased intra-cranial pressure during life or after death. "In the cases of vast tumours the optic neuritis does not differ from that caused by small tumours at the vertex of the brain, which cannot exercise any pressure of consequence on the base. The neuritis runs through its stages, and the swelling of the discs subsides, although the intra-cranial pressure goes on increasing."\* There may also be signs of increased pressure

\* Hughlings Jackson: Lecture on Optic Neuritis, "Med. Times and Gaz.," 1871.



in tumour without optic neuritis. But while pressure upon the cavernous sinus cannot be regarded as the cause of neuritis, its effect on the retinal vessels cannot be altogether excluded. Experiments show that a quickly induced increase of pressure within the skull causes a transient distension of the retinal and papillary vessels. In tubercular meningitis (*q.v.*) Dr. Garlick's careful observations\* have shown that, while papillitis is not—fulness of veins is related to an increased intra-cranial pressure.

To what is the distension of the optic sheath related? It is certainly very frequent in cases of optic neuritis. It is not, however, as has been alleged, invariable, either in cases of cerebral tumour with optic neuritis, or in conditions of increased intra-cranial pressure. It may be absent in tumor cerebri with characteristic neuritis—for instance, in Case 16 a large glioma of the right frontal lobe, with hæmorrhage into it, was attended by optic neuritis, but with no distension of the sheath. It may be absent in tumour with internal effusion. Great distension of the lateral and third ventricles was caused in Case 3 by a tumour near the corpora quadrigemina; there was optic neuritis but no distension of the sheaths. (In both these cases, however, the neuritis was found to have been “descending.”) In Case 21 of old neuritis, due to a tumour occupying the whole of the third ventricle and interpeduncular space, and extending in front of the optic commissure and causing enormous distension of the lateral ventricles, the optic sheaths carefully examined in situ were quite empty. They were loose and had evidently been much distended. This case suggests that pressure at the base of the brain may even be incompatible with continued distension of the sheath. In tubercular meningitis, again, the condition to which the distension of the sheath appears to be related is not distension of the ventricles, or increased intra-cranial pressure, but increase of the subarachnoid fluid, and it bears in this disease certainly no relation to the occurrence of neuritis. Of six cases with changes in the papilla, in which the state of the

\* Recorded in a paper lately communicated to the Medical and Chirurgical Society.



optic sheaths was carefully noted by Dr. Garlick, in four, in which excess of subarachnoid fluid was absent, the sheath was normal, although in several there was great distension of the ventricles, while in the remaining two cases, in which there was an excess of subarachnoid fluid, there was also dropsy of the optic sheath. Moreover, the sheath is often distended in the cases of senile wasting of the brain, with a compensatory excess of subarachnoid fluid.

Of the frequent association of dropsy of the sheath and optic neuritis there can be no doubt, but of the relation of one to the other, little evidence has yet been adduced. Manz admits that there are probably various kinds of effusion into the sheath, and that all may not lead to neuritis. It is certain, too, that distension of the optic nerve may occur even in meningitis without causing neuritis, as in a case recorded by Dr. Broadbent. But such cases prove little, because the duration of the dropsy may not have been sufficient for the inflammatory changes to arise. It has been suggested that the fluid may be formed in the sheath where it is found, being prevented from passing to the cranium by the intracranial pressure. If the sheath of the optic nerve is the chief lymph channel by which fluid is conveyed away from the eye—and the observations of Schmidt on its communication with lymph spaces at the lamina cribrosa render this probable—its distension in optic neuritis, by fluid escaping from the papilla, is intelligible. We want, therefore, to know whether the sheath is distended in cases in which the nerve is constricted at the optic foramen and the sheath is closed. Unfortunately the point has not been noted in the few cases hitherto reported. Until these points are ascertained the influence of dropsy of the sheath in causing neuritis must remain doubtful. The occurrence of papillitis without it, is of little significance, since in those cases there may have been a descending neuritis. The facts above mentioned suggest, however, that it is not the chief mechanism by which papillitis is produced. But, it is probable that, although not the chief cause, it may still exercise an important influence in leading to œdema in the



spaces of the papilla which probably communicate with the sheath.

The study of cases of papillitis from tumour, early in their history, lends, as far I have seen, little support to the theory that their cause is any form of mechanical congestion. Distension of veins and narrowness of arteries are not characters of the commencing papillitis of tumour, and do not commonly appear until the neuritic process, swelling, &c., is considerably developed.

In examining the trunk of the optic nerve behind the eye, in cases of papillitis from cerebral tumour, I have found the optic nerve to present traces of inflammatory change, increase of nuclei and trabecular connective tissue, much more frequently than has been stated by other observers. In not one case examined could the nerves be said to be in a perfectly normal state. The significance of the changes is open to question. They may possibly be regarded, in some cases, as indications of an ascending neuritis. But in some they were the most intense in the neighbourhood of the optic commissure, and there was evidence that a neuritis had taken place there by extension from the meninges. In several cases in which this was most distinct, the change in the optic nerve, mid-way between the commissure and the eye, was so slight that it might almost have been passed as normal. The extension to the nerve was very distinct in two cases of intra-cranial tumour appended. In one (Case 3) there was distinct, although very slight, evidence of meningitis beneath the orbital lobules, which had evidently, by the naked eye and microscopic appearances, extended to the nerves. In the other case the papillitis was considerable, and such as is most common in cerebral tumour (Pl. XIV. 8). The changes in the middle of the optic nerves were slight but distinct (Fig. 9). In front of the optic commissure (Fig. 10) the changes from old inflammation were intense. No sign of meningitis was noted at the post-mortem examination. There were, however, signs of old meningitis over the tumour on the upper part of the frontal lobe. In this case it seems probable that descending neuritis had taken place, and that



the link between the intense neuritis behind, and the intense papillitis in front, was the slight change in the trunk of the nerve. Hence it seems that a very slight amount of descending change may lead, in cerebral tumour, to an intense papillitis. With this case may be compared the facts of Case 27. Here the appearance of the papilla was declared by an authority so decisive as that of Mr. Couper to be that of a "choked disc." No tumour, meningitis, or mechanism for "choking" was, however, discovered within the cranium. But the trunk of the nerve presented changes very similar to those in the case just mentioned, not, however, more intense at its posterior portion. Similar changes were found throughout the brain by Dr. Sutton, and it can hardly be doubted, taking the symptoms and anatomical changes together, that a condition, which must be regarded as "chronic irritation or inflammation" affecting the brain, had passed down the optic nerves and appeared as an intense papillitis, with signs of strangulation, due to the compression of the vessels within the papilla.

With these may also be compared the facts of Case 22 (Pl. XIV. Figs. 1—5). Here a similar condition of disc to that in Case 3, but of greater intensity, was associated with a similar condition of nerve, and the morbid state could be traced into the optic tracts.

It seems from these facts that (1) a descending neuritis cannot be excluded from an examination of a small portion of the trunk of the nerve, and (2) that a change in the nerve revealing itself as a very slight deviation from the normal, may serve to convey a condition of irritation to the eye sufficient to light up considerable papillitis.

These facts, and those above adverted to, suggest the following conclusions regarding the production of papillitis in intra-cranial disease:—

That in cases of cerebral tumour evidence of descending neuritis may be traced, much more commonly than current statements suggest, while in cases of meningitis the evidence of descending neuritis is almost invariable.

That the resulting papillitis may be, and remain, slight, or



may become intense and present the appearances of mechanical congestion. The causes of this difference we do not yet know.

That such mechanical congestion does not, as a rule, result from compression of the vessels in or just behind the sclerotic ring, but always, when intense, from compression by inflammatory products in the substance of the papilla. It must not be forgotten that an increase in the size of vessels may be of reflex vaso-motor origin as in all inflamed parts.

That while slow increase of intra-cranial pressure has no effect on the retinal vessels, a sudden increase hinders the escape of blood from the eye for a time, and may intensify a papillitis originating in another way.

That distension of the sheath of the nerve alone is probably insufficient to cause papillitis, but may perhaps intensify the process otherwise set up, leading to retention or augmentation of fluid in the lymphatic spaces in the eye, fluid which may in some cases possess an irritative quality.

In the cases, certainly rarer than is commonly supposed, in which no trace of descending neuritis can be detected, two possibilities may be borne in mind—(1) that the effect of a sudden increased intra-cranial pressure and of distension of the sheath together may possibly be sufficient to set up papillitis, and (2) that a condition of irritation may be propagated down the nerve which cannot be recognized by the microscope, but which, reaching the papilla, may excite a papillitis.

The theory that the inflammation is the result of a reflex vaso-motor influence depends for its support chiefly on the absence of any other explanation. The only positive fact adduced in its favour is that in which Dr. Hughlings Jackson has often insisted, that neuritis occurs especially in conditions in which there is such cerebral disease as may act as a "foreign body." If, however, papillitis is in many cases unquestionably the result of a local mechanism (extension of inflammation for instance), it is probable that it is the result of some local mechanism in all cases, and a rigorous proof that it is not so must be furnished before a vaso-motor theory can be accepted.

The only cases in which I have observed distension of veins



to coincide with the early period of neuritis have been some, not all, cases of tubercular meningitis, the condition in which, as v. Graefe believed, descending neuritis, and not mechanical congestion, occurs; and in it the distension is, as has been said, related to intra-cranial pressure. In the course of a descending neuritis the distension of veins may be very great, as I have several times observed both during life and after death (Compare Pl. XVI. 3). In tumour the veins at first and often throughout (when the neuritis does not reach a considerable degree of intensity), are little above the normal size, and present no tortuosities except those which are given them by the prominence of the papilla. The great distension of veins and narrowing of arteries occurs when the inflammation has reached a certain degree of intensity. This points to the neuritic process in the papilla as causing the strangulation by pressure in, and constriction of, the vessels. This view is entirely borne out by pathological investigation. I have never been able to discover any evidence of constriction of the vessels in the sclerotic ring or behind it. Their calibre here is always uniform (see XIII., XIV., XV). This statement is based on the most careful search for any evidence of such compression in a number of cases of papillitis from various intra-cranial diseases. In one case only was there an appearance, of narrowing, and in this, from the unaltered course of an adjacent vessel, it was evidently due to a slight alteration in the position of the vessel at the spot, in consequence of which the sections ceased to pass through its widest part. It is always in front of the sclerotic, in the substance of the swollen papilla, that the vessels present conspicuous constriction, and are pressed upon and have their walls thickened by new tissue (Pl. XIII., XIV., XV.). Further, the most intense strangulation may occur in cases in which, as in Case 29 (Plate VIII. Fig. 1), there is reason to believe that there is no intra-cranial disease; and in Case 27, in which there was no intra-cranial condition which could cause any mechanical effect, the intra-ocular signs of constriction and mechanical congestion were very marked.

Thus I think that the use of the term "choked disc" as



significant of a supposed mechanism is to be deprecated in the present state of our knowledge. The terms intra-ocular neuritis, or papillitis, are pathologically accurate, and are preferable until our knowledge of the origin of the changes is more definite.

VARIETIES.—The distinction drawn by v. Graefe between “descending neuritis” and the “choked disc” has obtained wide currency, and is commonly accepted by English ophthalmoscopists, although for the most part discarded in Germany. It is, however, generally admitted that the supposed distinctions cannot be universally relied upon, and the facts already mentioned make it doubtful whether the pathological basis of the distinction is correct. A long list of supposed distinctive characters between the two varieties is often given, many of which are certainly inaccurate. The aspect of the disc varies very much in the same case at different times; at one time the characters may be those supposed to be indicative of a descending neuritis, and at another time those ascribed to the “choked disc.” But the appearance in different cases is also frequently different throughout their whole course. These various characters are such, and the intermediate forms are so numerous, that it is exceedingly difficult to separate any varieties as special “forms.” Some cases certainly present throughout characters which are regarded as those of descending neuritis—especially slightness of swelling, a tendency for the changes to be most intense in the peripheral part of the papilla, leaving the centre little affected; absence of hæmorrhages, and the presence of white spots, isolated or about the vessels, and a striation depending rather on conspicuousness of nerve fibres than on vascularity. These changes are seen, for instance, in Pl. III. 3 and 5, and also of wider extent and greater intensity in Pl. VI. 2. On the other hand, great swelling, with vascularity and distended veins, such as is seen in Pl. I. 6, III. 4, I. 6, and still more in Pl. VI. 1, characterize other forms. But Pl. III. 2 (descending neuritis) presents many of the characters of the choked disc,



while the changes in Pl. V. 1 and 2, 3 and 4, slight as they are, are in every case associated with the symptoms of intra-cranial tumour.

Until we know more of the relation between pathological process and ophthalmoscopic appearances, it seems far better to found any varieties purely on clinical characters. Of such the following varieties have seemed to me the most marked.

1. *Slight Papillitis*, including the condition described above as congestion with œdema, in which the changes are so slight as to dim, but not obscure, the edge of the disc on indirect examination, although it may be invisible, wholly or in part, to direct examination (Pl. I. 3, 4, III. 3, 5, V. 1, 2, 3, 4).

2. *Moderate Papillitis*.—Obscuration of the edge of the disc, or of the affected portion, complete, even to indirect examination; swelling moderate, commonly reddish; veins natural or large; sometimes white tissue about the vessels, close to them or extending for some distance in the disc (Pl. I. 5, 6, III. 3, IV. 1, 3, V. 5, 6, VI. 2).

3. *Intense Papillitis*.—Great swelling; veins at first large and arteries small; many hæmorrhages; retina often involved by direct damage or by hæmorrhages. Always succeeds a slighter stage in which the evidence of strangulation may be at first little marked (Pl. VI. 1, VIII. 1).

The forms in which the changes involve the adjacent retina are often termed “neuro-retinitis circumscripta;” and such wide-spread change as is presented in Pl. VIII. 1, although originating in the papilla, merits such a designation. But in most cases, even in such as Pl. VI. 1, the retina only is affected which is adjacent to the papilla, or elsewhere is the seat of extravasations only; and since there is no general inflammation of the retina, the term “retinitis” seems unnecessary.

*Retro-ocular Neuritis*.—The change known as such—an interstitial inflammation of the nerve—is a mixed condition of congestion and atrophy, revealed in the disc, if revealed at all, by the signs of simple congestion, soon passing on to atrophy with narrowed vessels. Little is known of the exact anatomical changes in this form.



*Retro-ocular Perineuritis* is a condition of chronic inflammation of the sheath of the nerve leading to thickening of its tissues, and purulent infiltration among the trabeculæ. The nerve may suffer from compression, or from a state of interstitial neuritis which may spread to it from the sheath. It has been found in periostitis of the orbit (Horner), and in thickening of the cranial bones constricting the optic nerve (Michel). It causes papillitis in some, perhaps in all cases, which does not necessarily assume the appearance described as "perineuritis."

DIAGNOSIS.—The diagnosis of optic neuritis is often easy, but sometimes presents great difficulty. Of all its signs that which first attracts attention as the most conspicuous feature—the increased redness—is of least value, except in conjunction with other characters. As already more than once stated, the redness of a disc free from neuritis may nearly equal that of the adjacent choroid. The signs which are of greatest diagnostic value are (1) obscuration of the edge of the disc and (2) swelling. These, in conjunction with increased redness, or change of colour to a tint not normally seen (such as the peculiar lilac-grey so often presented), constitute the characteristic symptoms. The obscuration of the edge is especially significant. It indicates undue opacity of the tissue (layer of optic nerve fibres) in front of the edge. Most of the nerve fibres pass along the course of the great vessels, above and below the disc, and they often obscure the edge of the disc slightly in these situations. Sometimes they are densely packed, also, on the nasal side, especially when the central cup is very large, and a slight obscuration is produced there also; but in these cases, as a rule, the large size of the physiological cup indicates the close arrangement of the fibres, the obscuration is slight and occurs in the normal situations, and the edge of the disc is elsewhere quite sharp. In these cases another character may be observed in a slight degree, which, in more intense form is conspicuous in neuritis—the radiating striation at the edges of the disc. Physiologically this is seen where the nerve fibres are



most closely aggregated, especially above and below; pathologically it is to be observed all round the disc, although most intense where the nerve fibres are grouped, and it is due not merely to pale lines (from swollen fibres with increased opacity), but in part, also, to red lines, fine vessels lying between the fibres.

The second indication of neuritis is the existence of distinct swelling. The prominence of one object in the fundus above the level of an adjacent object, *e.g.*, of a vessel on the edge of the physiological cup above a vessel at its bottom, is appreciated in the direct method of examination by moving the head of the observer from one side to the other as far as possible without losing sight of the objects. Their relative position undergoes an appreciable alteration proportioned to the difference in level, and is easily recognized. By the indirect method of examination the same result may be obtained by a lateral or vertical movement of the lens, which produces the same effect as a corresponding movement of the observer's head (the "parallactic test" of Liebreich). With the binocular ophthalmoscope these measures are unnecessary, the difference of level being apparent just as with the stereoscope. When the difference of the level of two objects is very great, as, for instance, in great swelling of the disc, a convex lens behind the mirror may be necessary before a clear view of the top of the swelling is obtained, the eye being normal and the fundus visible without a lens. The strength of the convex lens required to bring the apex of the swelling into view, furnishes an indication of the height of the swelling. In the same manner the depth of the physiological cup may be approximately estimated.

Normally the surface of the papilla is a little anterior to the plane of the retina, hence the term "papilla." The amount of this prominence varies in different cases. It is always greater where the nerve fibres are chiefly aggregated along the course of the retinal vessels, so that a transverse section through the disc may show scarcely any appreciable prominence, while a vertical section may present distinct prominence. The more closely the nerve fibres are aggregated



in one part of the circumference of the nerve, the greater is the prominence. Occasionally, but not often, it is sufficient in a normal eye to be readily appreciable by the movement of the head in the direct examination. As a rule, a prominence which is readily recognized is pathological. In morbid states, every degree of elevation may be met with.

*The Diagnosis of the Cause of Papillitis.*—The first question which presents itself in a given case is—Is the neuritis due to intra-cranial disease or to some other cause? The answer to this must, of course, depend on the presence or absence of indications of disease of the brain, or of such disease of the general system as is known to be accompanied by optic neuritis. The ophthalmoscopic characters of the neuritis will lead us a little way, but not far. A high degree of neuritis, with intense strangulation (such as the discs shown in Pl. VI. 1 and VIII. 1), are confined to cerebral tumour and idiopathic primary neuritis. The slighter degree of neuritis not uncommon in cerebral tumour, chronic meningitis, and other intra-cranial diseases, and the neuritis which occurs in Bright's disease, lead poisoning, &c., may resemble one another very closely. The neuritis of Bright's disease sometimes presents white spots in and close to the disc, but the same appearance may be, and often is, seen in the neuritis of intra-cranial disease. White spots in the retina away from the disc, with papillitis of a slight degree, and presenting no evidence of a preceding more intense affection, is very suggestive of renal neuritis. The small cloudy spots seen, for instance, in Pl. IX. 2 (near the left edge of the figure), are of more significance than the minute white spots near the macula, such as are shown in Pl. IX. 3, although the latter are suggestive of renal disease when they occur with a papillitis of slight degree and recent origin. Succeeding neuritis, or accompanying a neuritis which is subsiding, they are of much less significance, being often less by the mischief caused by simple inflammation, and how closely these may simulate the appearance of a renal retinitis Pl. VIII. 2 shows. Although an appearance of so striking an aspect is very rare, a few white spots near the macula lutea

left



are very commonly left by neuritis—such as are seen in Pl. VI. 1 and 3. The signs of a previous neuritis of considerable intensity—a prominent mass of tissue in front of the disc, such as is seen there in Fig. 3, or a “filled-in” disc with evident compression of vessels, as in Pl. VIII. 2—rarely coincide with a similar appearance in renal retinitis, although such a coincidence is seen in Pl. IX. 4. In such cases I believe that some diagnostic help may be afforded by the fact that in the renal form the retinal arteries undergo a degree of contraction never seen after ordinary papillitis.

It is, however, upon the independent signs of one or the other causal condition that the diagnosis must chiefly turn. In referring neuritis to cerebral mischief, it must not be forgotten that, on the one hand, optic neuritis due to a cerebral tumour may be accompanied for a time by no signs of intra-cranial disease, and, on the other hand, that an optic neuritis due to a general disease may be accompanied by symptoms suggestive of cerebral disturbance, especially headache, vomiting, and even, in some cases, convulsions. Striking instances of the former were afforded by two children who not long ago were in the Great Ormond Street Hospital at the same time. One was the boy, under the care of Dr. Barlow (Case 5), with a tubercular growth within the right eyeball, and well marked neuritis to be seen in the left eye (Pl. III. 4). The only other symptom suggestive of intra-cranial mischief was an occasional attack of vomiting during many months that he remained under observation. The neuritis was of the character highly suggestive of intra-cranial tumour, but the possibility that the mischief in one eye might have caused the neuritis in the other, suggested extirpation of the eye which was the seat of the tumour. It had, however, no influence; and when the boy died, about a year after, scrofulous cerebral tumours were found. The other case (under the care of Dr. Gee) was a child aged nine years, who was admitted having had occasional attacks of headache and vomiting. During the intervals she seemed perfectly well. No symptoms referable to the nervous system could be detected. She had, however, double optic neuritis of the



lilac-grey variety so suggestive of intra-cranial tumour. Gradually unsteadiness of gait showed itself and increased until she was unable to stand, and she ultimately presented all the symptoms of cerebellar tumour.

These cases show that suspicion of intra-cranial disease in optic neuritis can only be discarded after long observation of a case. This is especially the case when the neuritis is chronic. It is rare that very acute neuritis is unaccompanied by symptoms of its originating disease.

On the other hand, neuritis due to general disease may be accompanied by symptoms suggestive of cerebral mischief. The disc shown in Pl. IX. 3 is that of a man (Case 37) who complained of almost constant severe headache and occasional attacks of sickness. The ophthalmoscope showed well marked neuritis, moderate in degree, and on first inspection no retinal disturbance was detected. It was thought, for the moment, to be a case of cerebral tumour. On looking more carefully by the direct method, however, near the macula lutea there were a number of minute white spots inconsistent with the slight degree of neuritis. The urine was at once examined, and found to be loaded with albumen, and on further examination hypertrophy of the heart and a hard pulse were found, with some signs of uræmic mischief. He died of uræmia not long after. The history of the case shown at Pl. IX. 2 is similar, except that the evidence of cerebral disturbance here was mental change, not headache. A case of this kind impressed itself very strongly upon me many years ago, when, as a resident in University College Hospital, I was first working with the ophthalmoscope. A man was admitted with convulsions, and comatose. An examination of the eyes in the intervals of the convulsions showed double optic neuritis, and a diagnosis of cerebral tumour was at once ventured on. The patient died in a few hours, and the necropsy revealed contracted kidneys and a normal brain. A mistake of this kind is easily made, especially if the examination is confined to the indirect method; but I think that the mistake may generally be avoided by the direct method of examination, which has, in all cases I have



since seen, disclosed slight retinal alteration inconsistent with the form of the neuritis. Examination of the urine should, of course, never be neglected.

Headache and vomiting are, then, the signs of least value as indications of an intra-cranial cause of neuritis. Convulsion is also of little value unless it is of a form which indicates local brain disease, *i.e.*, local in distribution or in commencement.

In all obscure cases, search must be made for any other cause of optic neuritis, especially lead poisoning. In cases of lead poisoning, renal disease is very frequent, and that cause for neuritis must be excluded before the affection can be referred to plumbism. In these cases also doubt may be felt as to whether the mischief is not due to cerebral disease, because lead poisoning is sometimes accompanied with two forms of cerebral disturbance—delirium and convulsion. In the case presenting the neuritis shown in Pl. VII. 6 (Case 28) there was extreme cerebral disturbance, apparently the consequence of the lead poisoning; and, on the other hand, I have lately had under my care several cases in which recurring convulsions, precisely like those of idiopathic epilepsy, were due to the same cause.

One other fact must be mentioned in connection with the diagnosis of the cause of optic neuritis. In many cases in which slight neuritis of chronic course is associated with symptoms which would scarcely suggest the existence of disease such as would cause neuritis, hypermetropia exists. This combination may be noted, for instance, in chlorosis (as in Case 44, Pl. VII. 5) in epilepsy, apparently idiopathic, (Case 24), and other slight symptoms of cerebral disturbance (Case 26). It is doubtful, in the present state of our knowledge, what share is to be attributed to the hypermetropia in the production of the neuritis, but the fact may be borne in mind.

PROGNOSIS.—The prognosis in optic neuritis is necessarily a source of considerable anxiety. In few cases can it be said that vision is not in danger of impairment and even of loss. An exception, perhaps, is presented by the slight neuritis



associated with hypermetropia, and no evidence of grave disease elsewhere. The prognosis must be formed in other cases by a careful study of the condition on which impairment of sight depends in these cases, as stated on p. 57. It is better in the slighter degrees of papillitis, and better in proportion to chronicity of course, and dependence on causes which can be treated. It is worse when there is reason to believe that there is much retro-ocular mischief; worse in proportion to the evidence the ophthalmoscope affords of a process of compression going on in the disc; worse in proportion to the intensity of the changes; and worse in the loss of sight which comes on during the recession of the inflammation than in that which comes on during its height.

The cause of the optic neuritis must influence our prognosis more than any other condition. It is better in syphilitic than in scrofulous causes, and better in these than in cases of disease of other forms. Even in syphilitic mischief, however, the prognosis must be guarded if the intra-ocular changes are considerable. It is not probable that the optic neuritis is, itself, syphilitic in nature. Its subsidence depends rather on the subsidence of the syphilitic intra-cranial disease, than on the influence of the remedy on the intra-ocular process, and it is not uncommon to have considerable failure of sight during the subsidence of the neuritis in such cases.

**TREATMENT.**—Very little can be done for the direct treatment of optic neuritis. The treatment is that of the intra-cranial mischief, or general disease, which is its cause. Beyond this, local measures, leeches and the like, are little likely to influence the progress of the disease. The puncture of the distended nerve-sheath has been advocated by De Wecker, and performed by him and by Mr. Power. It is based on the theory that the distension of the sheath is the cause of the intra-ocular neuritis, a theory which, it has been seen, cannot yet be considered as proved. Improvement has been said to follow the operation, but the benefit was not very clear, and it must be tried in a larger number of cases before an opinion can be formed.



During neuritis the eyes should be used as little as may be, and such conditions as intensify intra-ocular congestion should be avoided, *e.g.*, exposure to cold, and all causes of mechanical congestion, straining, cough, &c.

Optic neuritis is so frequently associated with syphilitic disease of the brain and its membranes, and the evidence which may seem to exclude the suspicion of syphilis is so often misleading, that the administration of iodide of potassium should be a rule in almost all cases in which the age of the patient is such that acquired syphilis is possible. Iodide, in large doses, secures a more prompt improvement than mercury, and does no harm if the disease is not syphilitic in nature. Additional benefit may, however, result from the subsequent use of mercury. The completeness of recovery depends on the promptness with which the progress of the disease can be checked. Even in syphilitic cases it must be remembered that, the intra-ocular neuritis being probably not syphilitic in nature, although the consequence of syphilitic brain disease, the remedy employed does not influence the inflammatory products in the papilla, as it does the disease in the brain. As it has just been stated, in many cases of syphilitic disease of the brain with optic neuritis, in which the cerebral symptoms have cleared, and the neuritis has subsided under appropriate treatment, sight has become damaged during the subsidence of the neuritis, apparently very much as it would have been, had the cerebral disease not been syphilitic in nature. It is the recession of the cerebral trouble which permits the recession of the neuritis, and the ocular damage bears, in most cases, a direct proportion to its duration.

Where the disease is not syphilitic it is often scrofulous, and here also great good can be done by appropriate—especially tonic—treatment. Commencing neuritis may subside entirely and leave no trace upon such treatment (as in Case 11). But unfortunately we are able to influence such disease much more slowly than we can influence syphilitic disease, and if neuritis be already well developed, it is rarely that loss of sight can be prevented.



B.—*MORBID STATES OF THE OPTIC DISC CHARACTERIZED  
USUALLY BY LESSENED VASCULARITY AND SIGNS OF  
WASTING. ATROPHY OF THE OPTIC NERVE.*

Under many circumstances the fibres of the optic nerves undergo wasting or degeneration. This occurs when the eye has been greatly damaged by any cause, and when complete opacity has rendered the cornea or lens, for a long time, impermeable to rays of light. It has been seen to occur as a consequence of the inflammation of the intra-ocular end of the nerve, or of its whole trunk; the wasting thus produced is termed "consecutive atrophy." In many cases the wasting is preceded by no visible inflammatory disturbance, and such cases are termed "simple atrophy." Nevertheless, in rare cases, an atrophy is preceded by the signs of simple congestion of the disc, and such cases may be termed "congestive atrophy." It is convenient to commence a description of these forms with that of simple atrophy of the nerve, including the "congestive" variety, which does not differ from simple atrophy by such sharp lines as to necessitate its separate description.

Atrophy, not consequent on any obvious ocular change, was found by Vulpian in about four per cent. (19 out of 500) autopsies on old persons at the Salpêtrière. In an equal number (21) there was atrophy consequent on an ocular disease.\*

SIMPLE ATROPHY.

The nutrition of the nerve fibres, and that of the capillary vessels which confer on the disc its normal rosy tint, are so associated that atrophy of the fibres is accompanied in nearly all cases by an atrophy of the capillaries, and the pallor thus produced constitutes the most salient sign of the atrophy of the nerve. The atrophied nerve commonly shrinks, and occupies less bulk than the normal nerve. This is not attended

\* Table given by Galezowski, "Sur les Atrophies de la Papille du Nerf Optique." "Journal d'Ophthalmologie," Jan., Feb., and March, 1872.



by any diminution in the size of the optic disc, since the latter is determined by the size of the sclerotic opening. The shrinking is indicated by a slight recession or "excavation" of the disc. In some cases there is a diminution in size of the retinal vessels, but this is an inconstant character. These signs will be considered in detail.

*Pallor.*—The vascularity of the optic nerve, as has been before pointed out, is estimated by the tint of its intra-ocular termination, the "optic disc." In judging of the colour of the disc it is important to examine it with a weak illumination, and with the direct method, in order to let as little light as possible be reflected. In a strong light a faintly-tinted object will appear white.\* Hence the importance, to recognize a slight coloration, of employing a weak illumination. The ophthalmoscope of Helmholtz, consisting of thin plates of tinted glass, is especially useful for this purpose. A plane mirror may be employed instead. If this is not available, the light of the illuminating lamp should be turned low, so as to have a feeble illumination of a small area of the fundus.

For the estimation of a pathological pallor of the optic disc, it is as essential to be aware of the normal variations in colour which it presents, as for the recognition of congestion. The variations on the negative side are not, perhaps, so considerable as are those on the positive side, but they are sufficient to render familiarity with the appearance of the normal disc essential to prevent mistakes in estimating the slighter degrees of atrophy. As a rule, the disc becomes paler as life advances, and a slight grey tint becomes mingled with the red, but the latter is still perceptible. The physiological cup, if slight, is often indistinct late in life. Thus, a tint which is normal in the old, would be suggestive of atrophy in the young. In anæmia, also, the disc may become paler, but the change of

\* With very intense illumination, even a strongly-tinted object will appear white. This is because all objects reflect some of all rays, and absorb none entirely. If the waves impinging be sufficiently numerous, *i.e.*, the light very intense, so many waves of all lengths are reflected that the object appears white, the waves of the length not absorbed being no longer preponderant, although they become preponderant on weakening the light.



tint from this cause is not considerable, and is insignificant in comparison with the normal variations in colour of the disc. It never constitutes an element of difficulty in the recognition of atrophy.

When a pathological pallor of the disc is pronounced it extends over the whole area of the disc, but commencing pallor may be most marked in that part of the disc which is normally palest, *i.e.*, the temporal side, where the nerve fibres are least numerous. The change in this part, however, is only of significance in individuals in whom the "physiological cup" is small, and the temporal half of the disc normally possesses a distinctly vascular tint. In a large number of cases, in which the physiological excavation is large, and slopes gradually to the sclerotic ring on the temporal side, this portion of the disc may be normally as pale as in advanced atrophy. The part on which attention should be chiefly fixed is, therefore, that which normally possesses considerable vascularity, the nasal portion. The tint may be observed to become gradually paler, the red sometimes simply fading, and leaving a white colour in its place; in other cases a grey becomes mingled with the red, and gradually preponderates as the red tint fades, and ultimately a pure bluish or greenish-grey is left. These two varieties constitute in their extreme forms the white and grey forms of atrophy respectively. Intermediate forms are often seen, and to the direct method of examination some grey tint may always be distinguished, even in the discs which appear of tendinous and even chalky whiteness to the indirect method of examination. This grey mottling tends to increase as time goes on. The slight grey tint in "white atrophy," is similar to that normally seen at the bottom of the physiological cup. This tint is, however, scattered over the disc, and the central cup is often distinguishably whiter or greyer than the rest.

The atrophy leaves the edge of the disc very distinct and sharp. The sclerotic ring is much more clear than it is normally, but it may not at first be recognized by the indirect method as it is not differentiated from the white surface of the disc, as it is from the rosy tint of the normal disc. The



sharpness of the edge is due, not only to its clearness, but also to the fact that the choroid presents its normal characters to the margin, and gives to the clear outline a peculiar sharp-cut aspect, which is the characteristic of "simple atrophy." Pigmentary deposits on the edge of the disc are, like the edge itself, abnormally distinct.

*Excavation.*—In simple atrophy of the nerve, the surface of the disc is depressed in proportion to the wasting of the nerve trunk. This varies, however, in the different forms of atrophy, because the wasting of the nerve fibres is, in some forms, combined with wasting of the connective elements, and a great shrinking of the nerve in size, while in other cases the wasting of the nerve is accompanied with an overgrowth of connective tissue, which may to some extent compensate for the shrinking due to the atrophy of the nerve fibres, and even prevent any diminution in bulk of the nerve. Thus, in some cases, the depression of the disc is considerable, and in others it is slight or absent. Its special character is that it affects the whole disc, and commences at the sclerotic ring, and may often be recognized by the change of level of the retinal vessels at the spot, most distinct on lateral movement of the observer's head. Normally, it will be remembered, the depression of the centre of the disc never begins at the sclerotic ring, except that in some cases of large normal cups it may commence at the ring on the temporal side. Above, below, and at the nasal side, *i.e.*, in the position of the large vessels, the normal excavation never commences at the ring, within which there is always a zone of nerve tissue, commonly the most prominent portion of the disc. Hence the change of level of the large vessels at the ring becomes an important sign of the atrophic excavation. The size and form of the resulting excavation depend on two things, the amount of shrinking of the nerve, and the size and form of the normal cup. The wasting of the edge of the cup tends to render the steep side or sides, sloping, and to render its form a funnel-shape.

The mottling of the lamina cribrosa may become very distinct at the bottom of the excavation, and this in some



cases, it is said, in which before the atrophy no physiological depression existed. Where the normal cup was large, the excavation may reveal the lamina cribrosa in almost the whole extent of the disc, the grey mottling corresponding to the bundles of degenerated nerve fibres, the white intervals to the meshes of the lamina.

It is believed that some share in the excavation is due to the atrophy of the small vessels, which conferred on the normal disc a certain amount of turgescence. De Wecker suggests that as the nerve has its consistence lessened, the normal intra-ocular pressure may assist in producing the excavation.

It has been said that the more connective tissue there is developed in the atrophied nerve, the slighter is the shrinking of the trunk. This is especially the case in the grey atrophy, in which the nerve may retain its normal size. The depression in the disc may be less in these cases than in the whiter form of simple atrophy, but it is not, as has been said, absent, and it is often considerable. Among the remains of the diverging nerve fibres, there is little connective tissue developed, and the wasting of the fibres here is compensated for to a much less extent than in the trunk of the nerve.

*The Retinal Vessels.*—In some cases of simple atrophy of the optic nerve the retinal vessels become reduced in size, in others they do not. In the grey atrophy, as a rule, these vessels undergo little or no change. In simple white atrophy they may present in some cases no alteration; in others, the arteries gradually become smaller, the veins undergoing little diminution. After a time the veins also may shrink. They are reduced in size in cases in which there is a retro-ocular neuritic process, but this, without evidence of neuritis in the disc, cannot be regarded as the cause of their shrinking in all cases. Their atrophy seems sometimes to be part of the atrophy of the nerve-fibre and ganglion-cell layers of the retina, which is usually associated with atrophy of the nerve. Why they should shrink in some cases and not in others is at present unexplained.

*Initial Signs of Congestion.*—In describing simple conges-



tion of the disc, it was pointed out that it may terminate in atrophy. The disc has, at first, a dull-red tint, with a soft-looking surface, the redness being uniformly distributed over the disc. The edges of the disc are less sharply defined than in health; they are visible, but are softened. It is this uniform distribution of the tint, and softness of the edge, which give to the disc its special character. The congestion may persist for a long time, but, commonly, as time goes on, the disc slowly becomes paler, and ultimately a condition of greyish-white atrophy is reached.

Occasionally the disc presents at first, for a short time, a slight degree of œdema as well as congestion, shown by slight swelling. This is especially the case when there is reason to believe that behind the eye there is a more intense degree of inflammation—retro-ocular neuritis. The vessels then present much earlier and more considerable narrowing than in simple atrophy, and in the disc around them much white tissue becomes developed. It is to be noted, however, that in some conditions of undoubted retro-ocular neuritis, there may be no signs of inflammation or congestion of the disc, but only that of simple atrophy. In these cases the mischief is commonly at some distance behind the eye.

CAUSES.—Simple atrophy of the optic nerve may be a primary change, or may be secondary to some lesion, traumatic or other, which interferes with the structural integrity of the nerve. These two varieties may be distinguished as “primary” and “secondary” atrophy, and are especially characterized by the circumstance that in primary atrophy the loss of sight coincides in origin and progress with the visible atrophy, but in secondary atrophy the loss of sight occurs first, and the signs of nerve degeneration are not observed until a subsequent period. It is doubtful whether the two forms can be distinguished by the ultimate aspect of the disc.

It has been proposed to divide the primary atrophies into two classes, according as the process commences by degeneration of the nerve elements, or by growth of the interstitial tissue, with secondary damage to the nerve fibres. The distinction



has been especially insisted on by Charcot, and by Abadie, on grounds of etiology, pathology, and symptoms. These distinctions will be more fully considered further on, but our knowledge of them is scarcely at present sufficiently definite to make a sharp distinction generally useful.

*Primary Atrophy* often comes on without known causes. It is sometimes, however, distinctly hereditary, and one very remarkable form (carefully studied by Leber) affects all the males of a family soon after puberty. The male sex is, apart from this variety, more prone to optic nerve atrophy than the female. Seventy-five per cent. of all cases occur in men, and of primary atrophies the proportion is probably still greater. The neuropathic dyscrasia is often well marked, and this is sometimes the form in which heredity acts. Most cases occur in adults. Cold is apparently an occasional cause, and so is sexual excess. Toxaemia sometimes produces it, especially from alcohol, tobacco, and lead. Tobacco may also cause the congestive variety of atrophy; lead that which is consecutive to neuritis. Blows in the neighbourhood of the orbit, or on the eye, frequently cause atrophy of the optic nerve, which is not unfrequently preceded by signs of congestion. The ultimate state of the disc may be one of white or of grey atrophy. Over use of the eyes is an occasional cause. Atrophies from these causes are rather of ophthalmic than of medical importance.

Another group of primary atrophies of the optic nerve, and one of great medical interest and practical importance, is constituted by those which are due to an isolated degeneration, associated with a similar degeneration somewhere else in the nervous system. The most important of these is that which so often accompanies locomotor ataxy. It is usually a grey atrophy in ophthalmoscopic aspect, without diminution in the size of the vessels. This form is regarded as the most typical example of the "parenchymatous," *i.e.*, primarily neural form. A large number of primary atrophies are of this variety. The tabetic symptoms may be long delayed, and many such cases have been regarded as independent atrophy (see Part II., Diseases of the Spinal Cord.)



A similar atrophy may be observed occasionally in general paralysis of the insane, and also, although rarely, in disseminated (insular) sclerosis, and in lateral sclerosis of the cord. The form which occurs in general paralysis is described by Dr. Clifford Allbutt as often preceded by distinct signs of congestion of the disc. This is doubted by many, and is certainly very often not to be observed, but in one or two cases I have seen marked congestion of the discs in general paralysis, although unable to follow them to the atrophic stage. Other causes to which atrophy has been attributed are gastro-intestinal affections, syphilis, diabetes, menstrual disturbances, sexual excess, migraine, intermittent, typhoid, and other fevers. The special characters of the atrophy in these various states will be described in Part II. under the special diseases.

Primary atrophy usually affects both eyes, commonly one much more, and earlier than, the other, and in rare cases one only.

*Secondary Atrophy* results from lesion of the optic centres or fibres. A cortical lesion in the brain about the supra-marginal gyrus (Ferrier) may, there is reason to believe, entail loss of sight of the opposite eye. This, although the decussation at the chiasma is certainly in man incomplete, is explicable by Charcot's at present unproved theory of a complementary decussation at the corpora quadrigemina. A lesion outside the hinder part of the optic thalamus causes, according to the theory, loss of sight of the opposite eye and of the opposite half of the field of vision of the same side. It is probable that such damage does not for a long time cause atrophy of the disc, but Case 30 (Pl. II. 5) makes it probable that such atrophy after a time does ensue; and the same conclusion is suggested by a case recorded by Bernhardt.\* Lesions of one optic tract cause bi-lateral symmetrical hemiopia, unaccompanied by ophthalmoscopic changes until after some years. Some observers have described an ultimate slight pallor of the corresponding halves of the discs, but I have never been able to detect this in any of the cases of hemiopia (about thirty) in which I have carefully looked for

\* "Berl. Kl. Wochenschrift," 1872, No. 30.



it. In the case of longest duration, in which the hemiopia was persistently complete, in the course of years the whole of the disc of the eye in which the area lost was on the temporal side (and therefore greatest), became perceptibly paler than the other, the tint of the two being at first equal. A similar slight pallor of the disc opposite to the cerebral lesion has been noted by others in cases of hemiopia of long duration.

Pressure on the chiasma or nerves at the base of the brain is a common cause of optic nerve atrophy without neuritis. In Case 6 (Pl. II. 4), although there had been slight neuritis, the atrophy was probably due to this cause. The pressure may be that of tumours growing from any of the adjacent structures, exostoses from the bone, or aneurisms from the adjacent arteries. It not uncommonly results from internal hydrocephalus—the distended third ventricle compresses the chiasma directly, pressing first on the upper and posterior aspect, as Türck showed. Meningitis is another cause which, while commonly producing (if extending to the nerve) optic papillitis, may, in rare cases, cause blindness and atrophy without intra-ocular inflammation, by external pressure without inflammatory invasion, or it may cause blindness and atrophy out of proportion to neuritic mischief, and often after the inflammation of the papilla has subsided. It is probable that the local neuritis in these cases is often much more intense than is suggested by the degree of intra-ocular inflammation. It is said that obstruction, by embolism or thrombosis, of one middle meningeal artery, which supplies the dura mater around the optic foramen, may be followed by atrophy of that optic nerve. Tumours, exostoses, and meningitis may damage the nerves in front of the chiasma, and so affect the two eyes equally, or one to a much greater extent than the other, or one exclusively. The atrophy from these causes is white or grey.

Damage to the optic nerves causing atrophy may also occur in the optic foramen or in the course of the nerve through the orbit. Narrowing of the foramen by bony thickening, and rheumatic or syphilitic or traumatic mischief, causing pressure at the back of the orbit, close to the foramen, are not rare



causes of atrophy. Blows on the head, apparently, sometimes produce atrophy by direct injury to the nerve, sometimes by causing secondary compression, and sometimes by setting up (in consequence of the concussion, and especially in neuro-pathic individuals) a slow wasting, simple, or accompanied with congestion. The ultimate atrophy which results from these causes is usually more or less distinctly grey in aspect, and the grey tint may be as marked as in the form supposed to be characteristic of spinal disease (see Pl. II. Fig. 3 and Cases 31 and 32).

Mischief in the orbit may cause a process of "retro-ocular neuritis." This is assumed when transient signs of congestion are present in the disc, accompanied by constriction of vessels and the development of tissue adjacent to them; so that ultimately there is considerable narrowing of the retinal vessels, as in the atrophy which is consecutive to intra-ocular neuritis.

Lastly, damage to the retina entails an atrophy of the optic nerve, which progresses, sometimes slowly, sometimes quickly, and is usually white. Now and then atrophy of the optic nerve follows a cause which seems to act by giving a shock to the retina, that leaves no trace behind—*e.g.*, the complete amaurosis, which may accompany the onset of embolism of one branch of the retinal artery, and is usually temporary, may sometimes be permanent, even though all the other branches of the retinal artery are pervious. Atrophy sometimes follows a blow on the eye, as in a case related by Laqueur, in which a blow caused complete amaurosis without visible changes in the fundus, and simple atrophy followed. Such cases are of medical interest on account of the light they throw on the action of some general causes. Commonly, the cause of retinal atrophy is obvious on ophthalmoscopic examination, and the medical interest of this form is subordinate to that of the retinal change. When there is simultaneous choroiditis the disc has often a yellowish-red tint, which will be described farther on. Secondary atrophy affects one eye alone when the mischief is far in front of the commissure.

The relative frequency of the several causes of atrophy may be estimated from the accompanying table given by



Galezowski\* of the traceable causes in 166 cases. Instances of atrophy consecutive to neuritis are, however, included. The causes are arranged in the order of frequency:—

Cerebral .. .. .	40
Locomotor Ataxy.. .. .	33
Traumatic .. .. .	22
Alcoholism .. .. .	13
Syphilis .. .. .	12
Gastro-intestinal Affections .. .. .	7
Erysipelas .. .. .	6
Congenital and Dentition Troubles .. .. .	6
Hereditary .. .. .	4
Diabetes .. .. .	4
Menstrual Disturbance .. .. .	4
Sexual Excesses .. .. .	4
Exposure to Sun or Bright Lights .. .. .	3
Cessation of Migraine .. .. .	2
Intermittent Fever .. .. .	2
Typhoid Fever .. .. .	2
Albuminuria .. .. .	1
Lead Poisoning .. .. .	1

---

166

Thus very nearly 50 per cent. of the cases of atrophy are associated with disease of the brain and spinal cord.

ANATOMICAL CHANGES.—Atrophy of the optic nerve is never confined to the papilla: the changes are marked throughout the whole length of the nerve, and in primary atrophy are usually equally distributed. The size of the nerve varies very much; in some forms of primary atrophy it is markedly smaller than normal, somewhat translucent but scarcely grey, and under the microscope may present merely a wasting of all the structures of the nerve, fibres and connective elements, with, especially in recent cases, products of the degeneration of the nerve-fibres, granules and globules of fat, compound granule cells, "corpora amylacea," and other products of degeneration of the nerve-fibres. The position of the latter may at first be marked by rows of fatty particles. In other cases the nerve may be little diminished in size, but may present under the microscope a great

\* "Journ. d'Ophth." No. 2, 1872.



increase in the interstitial connective tissue, fibres, and cells, with disappearance of the nerve tubules. Commonly the change is greater in the circumferential portions of the nerve than in the central.\* Occasionally the reverse is the case. In atrophy from pressure on the nerve, its size is usually greatly reduced, and the increase of connective tissue is very considerable.

In primary grey atrophy the nerve trunk is usually little reduced in size, and is grey and gelatinous in appearance. Microscopically, it presents an increase in the connective tissue trabeculæ, and an atrophy of the nerve fibres. Their medullary sheath first disappears, and afterwards the axis cylinder. It is said that the nerve fibres may be reduced to fine fibrous threads. Products of myelin degeneration may be found in the earlier stages. Sometimes the change is peculiar; there develops round the vessels a peculiar gelatinous-looking tissue containing a few nuclei and indistinct concentric fibrillation. The normal arrangement of the trabeculæ disappears, and a section of the nerve (Pl. XVI. 5) shows islets and tracts of this tissue, in the centre of each of which a vessel can be traced. They may occupy at least half the area of the section. Between them lie the fasciculi of degenerated nerve fibres with little increase in their interstitial tissue. In the case figured, the atrophy was confined to one optic nerve, and its cause was obscure. The same histological condition may be present in the grey atrophy of locomotor ataxy.† In other cases of grey degeneration (according to Leber's observations) the change may be more uniformly distributed through the fasciculi. The degeneration is sometimes found in certain areas much more intensely than elsewhere. In a case of locomotor ataxy in which sight was not known to be impaired, I found only a great increase of tissue, consisting of nuclei and fibres, at the nodal points of the trabeculæ, and a little gelatinous-looking tissue immediately adjacent to the wall of the vessel. It would probably be unjustifiable to

\* Leber, "Arch. f. Ophth." xiv. p. 182.

† Cf. Perrin and Poncet's "Atlas"—Atrophy of the Optic Nerve.



assume that this represents the commencement of the process of change. Histology has not hitherto afforded much information as to the initial lesion in these cases. It is on the symptoms that the theory of a primary nerve degeneration is based.

In cases of primary degeneration of the nerve the retina is degenerated only in its inner layers—nerve-fibre and ganglion-cell layer, as Virchow first showed.\* The other retinal elements may persist in a perfectly normal condition even for many years. Perrin and Poncet could find no change, except in the two inner layers, in a case of ataxy in which sight had been lost for thirty years.

The degeneration from damage to the trunk of the nerve ascends to the chiasma, and descends to the eye. It is long in passing the chiasma, and, even with complete atrophy of one optic nerve, the optic tracts are only slightly reduced in size, that on the side opposite the affected nerve being rather smaller than the other, without naked eye evidence of degeneration; and I have found that the microscopic changes are nearly equally distributed through the two.† When both optic nerves are degenerated the optic tracts may present the same condition, traceable (as Türcck pointed out) as far as, and involving, the external corpora geniculata.

**SYMPTOMS.**—The symptom of atrophy is affection of sight proportioned to the damage to the nerve fibres. The patient becomes conscious of a cloud over objects, which increases; of difficulty in seeing certain minute objects, such as small print; and sometimes of a dark spot in the centre of the field of vision. Examination shows a change in sight in three directions—(1) diminished acuity of vision; (2) alterations in the field of vision; (3) altered perception of colours.

1. Diminution in the acuity of vision is invariable when the atrophy is pronounced; it is almost always more considerable in one eye than in the other. In estimating it care must be taken to ascertain and correct any errors of refraction and defects of accommodation. It may vary from

\* Virchow's "Archiv." vol. x. 1856.

† "Centralblatt f. die Med. Wiss." 1878, No. 31.



a slight degree to complete loss. It is commonly, but not always, proportioned to the degree of change in the optic nerve visible with the ophthalmoscope.

2. Alteration of the field of vision may be of several kinds. It is almost as constant as the diminution in the acuity of vision. The form is commonly a limitation at the margin of the field, progressing concentrically until only a small central area is left, such as is shown in Fig. 14. Such a concentric limitation may progress much more on one side of the field than on the other, or it may progress much more in one part of the field than in another, so as to cause a sector-like defect.

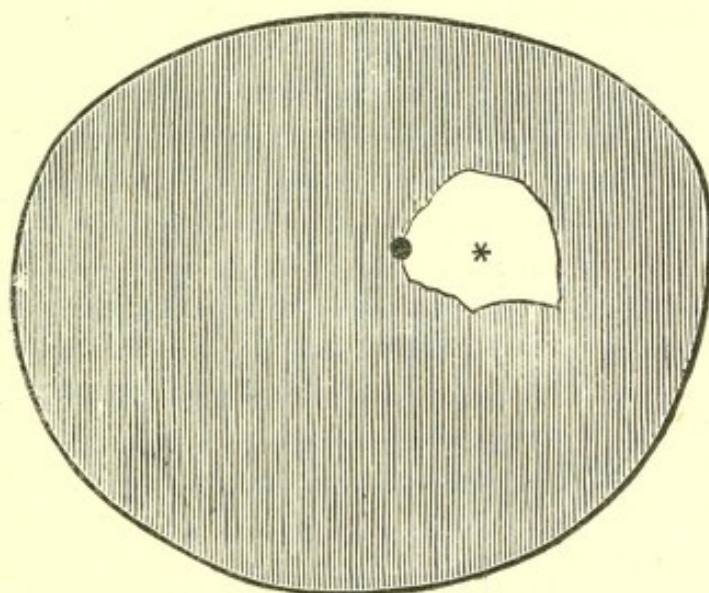


Fig. 14.—Concentric Limitation of Left Field of Vision in a case of atrophy of the optic nerve.—The outer boundary of the figure is the limit of the normal field. The inner white area is the area of the restricted field.

This is probably occasioned by a segmental degeneration of the nerve trunk. Occasionally the diminution is limited to one half of the field, vertical or lateral. This is especially the case in secondary atrophies. In pressure on the chiasma, for instance, if the pressure be on the posterior part of the chiasma, the inner halves of the fields are lost, and if upon the anterior portion of the chiasma the two outer halves of the fields (see *antea*, p. 58). A lateral loss may, however, result from a change in the nerve trunk, but probably never without considerable concentric limitation of the rest of the



field. Lastly, in some cases, the first loss is a central one, in the middle of the field, a "central scotoma," as it has been termed. There is often in these cases dimness of the peripheral vision, and often also concentric narrowing of the field. This form is seen in the atrophy from toxic causes—tobacco, alcohol—and is especially marked for colour vision.\*

*Colour Blindness.*—In many cases the perception of colours is perverted, as Galezowski and others have shown. The methods of testing colour vision are described in the appendix. If the patient possesses sufficient intelligence, he may be asked to identify certain colours. If the patient is unintelligent, the "confusion method" must be adopted, by which the colours which are seen alike are ascertained. The former method, however, sometimes gives the more valuable information.

Modern physiological speculation suggests that there are four fundamental colours, related in complementary pairs, red and green, yellow and blue. The area of the field of vision in which these colours are seen varies for each. If coloured objects are moved from the centre of the field to the periphery, the first simple colour to be unperceived is green, the next red, and yellow and blue are lost near the edge of the field for white. Commonly yellow is lost before blue, but sometimes the latter is lost first. If the distance at which each colour ceases to be distinguished in various parts of the field is marked upon a chart, we have a series of concentric lines such as shown in Fig. 15, in which the most internal is the field for green, and the most external the field for yellow,

\* Leber has suggested that the affection of the periphery or centre of the field is due to the position of the lesion in the optic nerve, on the theory that peripheral fibres of the nerve end soonest on the retina, and the central fibres of the nerve, which are most superficial in the papilla, go to the peripheral parts of the retina. Hence he assumes that an affection of the circumference of the nerve causes a central loss in the field of vision and an affection of the centre of the nerve a peripheral affection of the field. At present this is little more than a theory. We cannot rely on the regularity of the arrangement of the fibres in the papilla; and although Leber has adduced some pathological facts in support of the theory, they are too imperfect to be conclusive. Förster ("Handbuch of Graefe and Saemisch," Bd. vii. p. 132) has, apparently by a misconception, reversed Leber's theory, and finds it thus equally satisfactory.



the outer circle being that for white. The amount of light influences very much the area of the fields, and those shown in Fig. 15 were taken upon a dull day, and present the minimum normal fields. Fig. 16 shows the respective fields of larger size, and the blue field the most extensive. Compound colours are lost sooner than their constituents, and the inner circle in Fig. 16 represents the field for violet, which is even smaller than that for green.

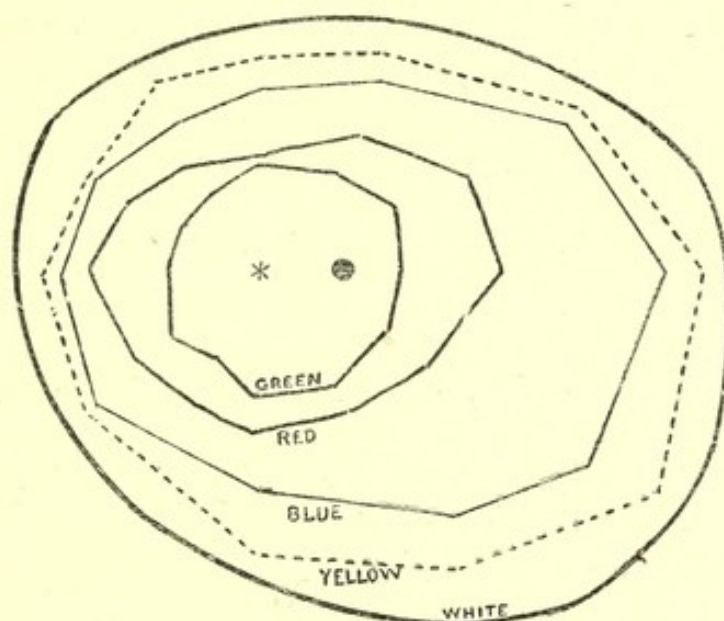


Fig. 15.—A repetition of Fig. 11. Diagram showing the Fields of Colour Vision in a normal emmetropic eye on a dull day.\* The fields are each rather smaller than on a bright day. The asterisk indicates the fixing point, the black dot the position of the blind spot. (Usually the blue field is larger than the yellow.)

Commonly, in atrophy of the nerve, the first defect is for green and red, and blue and yellow are lost subsequently. The order of affection is commonly that in which the fields are arranged on the retina. The simple colour first lost in passing from the centre to the periphery of the retina is that first lost in atrophy, green; and the last to be lost is blue or yellow.† Thus a girl, lately under observation (Case 34*a*), suffering from disseminated sclerosis and commencing grey atrophy, recognized, with the affected eye, every colour

\* I am indebted to Mr. Nettleship for the charts from which this diagram was made.

† It is doubtful whether this is true of violet, which is a compound colour. In some cases (it is said in hysterical amblyopia—Charcot) violet is first lost. Sometimes, however, it persists to the last.



except green, which she called red or brown. Occasionally red appears to be lost first. A patient with ataxy and advanced atrophy (under the care of Dr. Buzzard) stated that the first loss of the sense of colour of which he was conscious, was that he could see no colour in a scarlet geranium. Red gravel looked grey to him. Soon afterwards the grass also looked grey, and he could not, at a little distance, distinguish it from the gravel. When examined the only colour to be recognized was violet, which he said looked blue. A medium blue was seen as white.

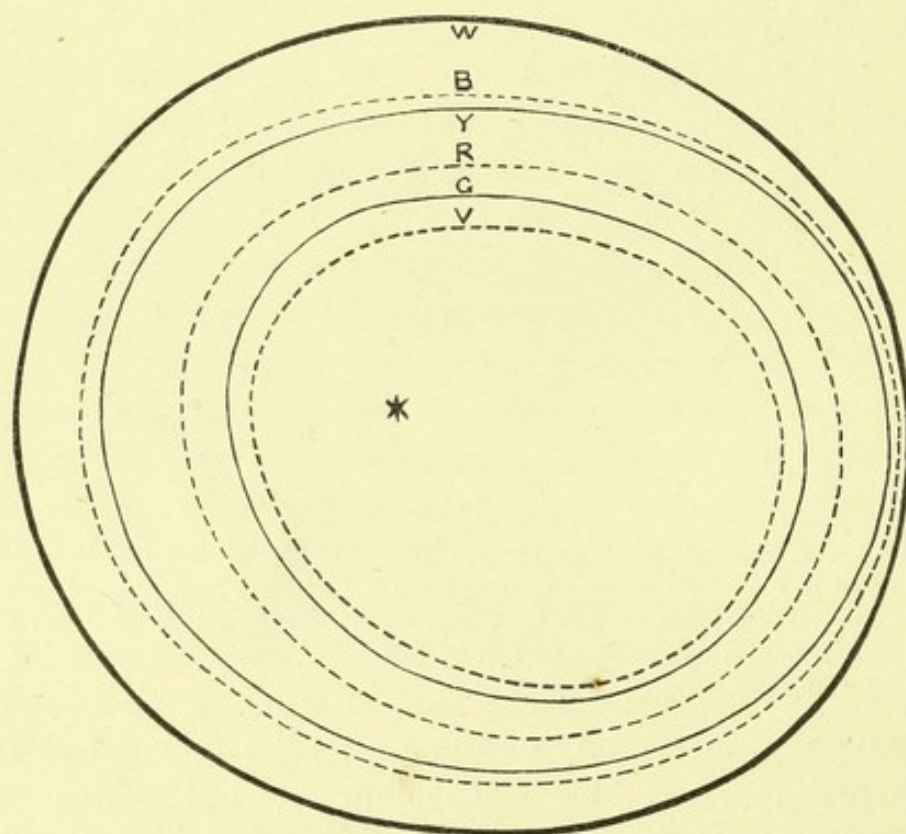


Fig. 16. — Fields of Vision for Different Colours (after Snellen and Landolt).  
w, white; B, blue; Y, yellow; R, red; G, green; V, violet. These are probably the maximum normal fields for each colour.

The loss of colour vision is especially marked in the atrophy which occurs in spinal diseases (the "parenchymatous" atrophy of Charcot), as Galezowski, Benedikt, and others have pointed out. Abadie\* has lately attributed especial importance to this sign as distinguishing the parenchymatous from the interstitial forms. He has even formulated the rule that

\* "Ann. d'Oculistique," 1878, and Lebris, "Thèse sur les Différentes Formes de l'Atrophie de la Nerf Optique." Paris, 1878.



if colour vision is affected when the acuity of vision is more than one-fifth, the atrophy is "parenchymatous," *i.e.*, primarily neural, whereas if, with a vision of one-tenth, colour vision is unaffected, the atrophy is "interstitial."\*

*Congestive Form.*—In the congestive form of atrophy, considerable amblyopia may be present during the hyperæmic stage, often with great restriction of the field of vision, and the anomaly of a fairly well coloured disc, with an affection of sight such as is met with in advanced atrophy, may be puzzling. I have seen, for instance, with congestion of the discs, not to be called neuritis, the fields gradually lessen until only a small area around the fixing point remained, even smaller than that shown in Fig. 14.

In atrophy from toxic causes, as tobacco, alcohol, there is usually a central defect, sometimes recognizable by the patient as a central cloud, or even a dark spot. In such cases there is generally a still greater central loss for colour vision, especially green or red, and this may exist before there is any central loss for white. There may be a peripheral limitation of the colour-field as well as a central loss. In the accompanying figure, for instance (Fig. 17), which represents the field for red in a case of tobacco amblyopia, there is a central defect and a peripheral limitation of the red field.

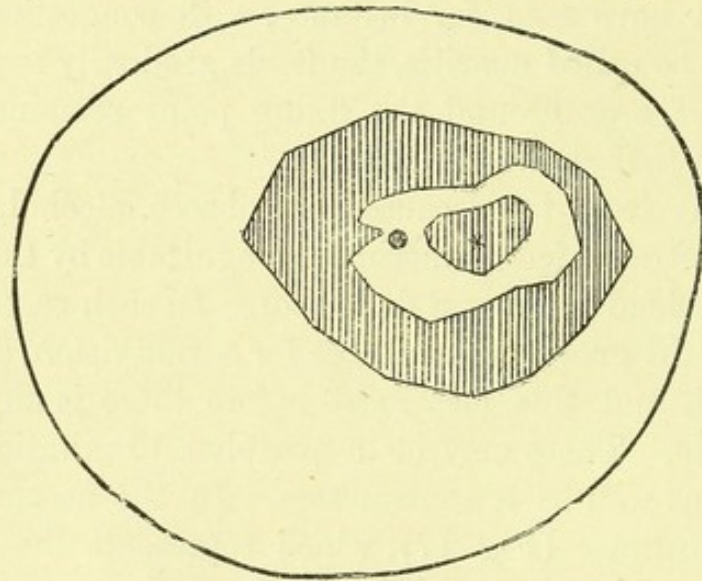
#### ATROPHY AFTER INTRA-OCULAR NEURITIS; "CONSECUTIVE ATROPHY," OR "PAPILLITIC ATROPHY."

The newly-formed inflammatory tissue-elements of papillitis are in part removed, and in part transformed into connective tissue, which gradually shrinks. The pale swelling left by the inflammation (Pl. II. 1, IV. 5, VI. 3), large in proportion to the intensity of the process, slowly subsides, until it is confined within the limits of the disc, and slowly reaches the level of the retina (Pl. XV. 2). The soft edges which at

\* Abadie suggests, on the theory that the same fibres conduct all colour impressions, that the first degenerative change in the fibre interferes with its power of conducting the special impression excited by green rays, and the further changes abolish its power of conducting the impressions excited by other rays, in the order above given.



first limit the pale swelling, gradually become more sharply outlined, but the recession of the swelling from the edge of the choroid often shows that the latter has been damaged, and has undergone irregular atrophy adjacent to the edge of the disc (Pl. II. 3, IV. 4), which thus has a more or less irregular outline. The substance of the disc has a "filled-in" look, from the new tissue within it (Pl. VI. 10, VIII. 2), and is commonly white, or rarely greyish in tint (Pl. II. 2, upper half). The vessels, whether previously narrowed or



LEFT

Fig. 17.—Diagram of the Left Field of Vision for Red in a case of tobacco amblyopia.—The outer line is the boundary of the normal field for white. The boundary of the outer shaded area is the minimum normal field for red. Red could, however, be seen only in the inner white area, and it could not be seen in the central shaded area around the fixing point (\*). The black dot indicates the position of the blind spot. (For the chart from which this diagram was prepared I am indebted to Mr. Nettleship.)

not, usually become narrowed by the contraction of this new tissue, and may be partly concealed by it at their origin, or in their course over the disc. The tissue along their walls is often distinctly whiter than the rest of the disc, and when the latter is grey the contrast between it and the perivascular tissue may be very marked (Pl. II. 2). Often white lines are to be traced along the narrowed vessels for some distance from the disc (Pl. II. 4). They are probably due to thickening of the outer coat, perhaps originating in the migration of white corpuscles along the perivascular sheaths (Pl. XIV. 6), and



the transformation of these into connective tissue elements. Ultimately, the contraction of the tissue may cause an excavation of the disc, even in the centre (Pl. II. 4, IV. 6), and there is only the adjacent choroidal disturbance and the narrowing of the vessels, to indicate the origin of the atrophy. The excavation rarely, however, becomes sufficient to reveal the lamina cribrosa. (Cf. Figs. 3 and 4, Pl. II.) The disc usually remains for a long time white to the indirect examination; sometimes its tint is slightly rosy. Ultimately, however, it becomes distinctly greyish, especially on direct examination, and with feeble illumination. In some cases the inflammation may not have damaged the choroid, although causing destruction of the nerve fibres, and in such a case the edge of the disc may be sharply defined, and if, as is the case sometimes when the inflammation is moderate, the narrowing of the vessels is slight in degree, the appearance of the disc may resemble very closely the disc in simple atrophy, and be quite indistinguishable from that left by retro-ocular neuritis.

The microscope shows the substance of the disc to be occupied by nucleated connective tissue fibres, among which, commonly, few or no traces of nerve fibres are to be discerned. Often, however, the nuclei, by their grouping, indicate the position of the intervals between the fasciculi of former nerve fibres. The retinal layers are displaced outwards (Pl. XV. 5), an important sign of the preceding swelling, and both they and the commencement of the choroid may present some disturbance. The atrophy of the rest of the retina is confined to the inner layer, especially affecting the layer of nerve fibres.

The progressive damage to vision which results from the continued contraction of the new tissue in the disc has been described under "Neuritis." It usually goes on until, and even after, the normal level is reached, although there may be intermissions in the progress consequent on the recovery of nerve fibres damaged by inflammation. After the contraction has ceased, a slow improvement of sight often occurs, rarely, however, considerable, but which may continue slowly for several years, and apparently be furthered by treatment.

The atrophy which succeeds embolism (Pl. XII. 2) is



distinguished only by the extreme narrowing of the arteries, which reaches a degree never seen in any other form of atrophy, even in extreme neuritis.

**CHOROIDITIC ATROPHY.**—The atrophy of the disc, which is often seen after choroido-retinitis, is sometimes white or grey and resembles primary atrophy, but often presents special characters, being characterized by a peculiar reddish, or yellowish-red tint of disc, uniform in distribution, the edges slightly blurred (or appearing so, from the tint of the disc), and a marked wasting of the retinal vessels, which may be diminished in number as well as in size.

The recognition of this variety of choroiditic atrophy is of considerable importance, because, unless the result of retinitis pigmentosa, it is almost always the consequence of syphilitic disease, acquired, or more frequently, inherited. It constitutes a sign of inherited syphilis of great importance. In inherited cases the disturbance of the choroidal pigment is not always considerable, but in acquired syphilis it may be very marked.

In the grey atrophy resulting from choroiditis, the vessels are, as in the redder variety, usually small and may be few.

**DIAGNOSIS.**—The diagnosis of simple atrophy of the optic nerve rests especially on the change of colour, and the chief difficulty in the diagnosis is due to the degree of pallor sometimes seen as a physiological condition. The existence of amblyopia, otherwise unexplained, is strong evidence that the pallor is pathological. The pallor of the temporal half of the normal disc may be great when the physiological cup is large, and, as already stated, may easily be mistaken for atrophy. It is certain that many normal cases have been described as "atrophy of the temporal half of the disc." It is doubtful whether an atrophy is ever confined to the temporal half of the disc, in which, ordinarily, the nerve fibres are very few. Although it is true that a slight degree of atrophy may produce the most distinct changes in this half of the disc, yet some pallor is always to be recognized, in such cases, in the



nasal as well as in the temporal half. The diagnosis of the congestive variety of atrophy presents greater difficulties, but rests on the uniform distribution of the redness, its soft, velvety surface, the slight blurring of the edge of the disc, in combination with defective vision.

Beginners sometimes mistake the white crescent of "posterior staphyloma" for part of the disc, and thus think the outer part of the disc, the colour of which is of such special significance, is white. Occasionally, in myopic eyes, the choroid presents a zone of atrophy, soft edged, around the entire circumference of the disc, which then has an unusual and puzzling appearance. In both these cases, however, attention to the fact that the pale zone encloses a well-coloured disc will prevent mistake as to its real nature.

The excavation which accompanies the pallor is of secondary diagnostic importance, and it is not often that a difficulty in distinguishing atrophy from other forms of excavation arises. It may, however, occur. A large physiological cup may be bounded by a narrow rim of deeply-coloured disc, the boundary of which from the choroid may not be apparent on a cursory inspection by the indirect method of examination, and the large, deep, sometimes grey, cup may be mistaken for the disc. A careful inspection of the edge will prevent doubt, and the examination by the direct method at once shows the source of the error.

The excavation of atrophy commences at the sclerotic ring, and this is a character also of another form of excavation, namely, that of glaucoma. But the depth of the glaucomatous cup, its vertical sides, and the course of the vessels over the edge, and their subsequent disappearance, are diagnostic, especially since the pain which is so common in glaucoma is never present in simple atrophy.

PROGNOSIS.—The prognosis of atrophy of the optic nerve, on whatever cause it depends, is always unfavourable in proportion to the actual destruction of fibres which has taken place, and to the extent to which the causes influencing the disease are beyond control. Simple primary atrophy is



usually due to a tendency to degeneration beyond all influence, and the prognosis is, in this form, the least favourable. This is especially the case when the atrophy is associated with symptoms of degeneration elsewhere in the nervous system. Secondary degeneration is often the consequence of the operation of causes which may pass away, and the prognosis is less uniformly grave than in primary degeneration. It must, however, always be somewhat uncertain, since it is often very difficult to form an accurate opinion of the nature of the process causing the damage to the nerve, on which the secondary degeneration depends. In the congestive form the prognosis is perhaps rather better than in the other forms. In the atrophy which is consecutive to intra-ocular neuritis, we are able to form a more accurate estimate of the course of the affection by the fact that, as long as the new tissue of the disc goes on contracting, the damage to the nerve fibres increases, and the sight will go on failing. If sight is lost from such contraction some time before it reaches its maximum, the prognosis is very grave. If, however, the loss of sight is incomplete, or only becomes complete when the subsidence is nearly over, some subsequent slow improvement may be hoped for. Under all circumstances, it is unhappily true that a disc which has lost all its normal tint never regains its vascularity, and useful vision is scarcely ever recovered.

Some prognostic indications may also be drawn from the form of the affection of sight. The gravest, that which indicates not merely damage, but destruction of nerve fibres, is the alteration in the field of vision. In proportion as this is extensive the prognosis is grave. Lessened acuity of vision is of less serious prognostic significance, and the change in colour vision is least grave when this depends on a toxic cause, or on neuritis; but is most grave when it is due to a primary degeneration, and occurs early.

Although the chance of restoration of useful vision in pronounced atrophy is small, in some cases the progress of the disease may be arrested for a time or permanently, and even improvement obtained, occasionally considerable in degree.



**TREATMENT.**—The treatment of optic atrophy is essentially that of the general condition on which it depends—toxic influences; excesses, sexual, physical, mental; cerebral and spinal disease, the “neuropathic constitution,” &c. The treatment of many forms of atrophy which are due to an isolated ocular condition is beyond the scope of the present work. Cerebral processes may be to some extent influenced by treatment. Although it is not certain that there is such a thing as an actual syphilitic atrophy, yet atrophy does often result from syphilitic intra-cranial disease, and may greatly improve with the removal, by appropriate treatment, of its cause. Scrofulous brain disease, again, may often be beneficially influenced, and its effects greatly lessened. In other cases counter-irritation, local depletion, purgation, and the like, effect good.

In cases of primary atrophy, which are the result of a neuropathic tendency, the treatment has to be directed to the general health, and nervine tonics are the chief agents to be employed. Nitrate of silver has been found useful in some cases; in others phosphorus, in others strychnia. The hypodermic injection of strychnia, so useful in amblyopia without ophthalmoscopic signs of atrophy, is of little use where these are present. Quinine and iron are in some cases very useful.

When perception of light is not entirely lost, the retina may be readily stimulated by an interrupted voltaic current, so as to give rise to a sensation of light, and this has suggested repeated stimulation of this character as a means of treating optic nerve atrophy. Some observers have obtained good results; the experience of others has been unfavourable. I have tried it in many cases, but without results which could reasonably be ascribed to the treatment.

## THE RETINA.

Apart from the vessels and the optic disc, the changes in the retina which are of medical importance, are those which are special to certain general diseases, such as syphilis, albuminuria, leucocythæmia, pernicious anæmia,



and the like. They will be described in detail in Part II., in the sections on the ophthalmoscopic changes in the several diseases. The only common feature which these morbid states possess, is the development in the retina of hæmorrhages and white spots and patches. The hæmorrhages, their characters and significance, have been already described. It may be convenient briefly to describe the forms of white patches which the retina may present under pathological conditions.

A diffuse, slight opacity of the retina may be due to the derangement of its normal structure, resulting from the effusion of serum among the structures which compose it (Pl. XVI. 9). Such diffuse opacity occurs in embolism, neuritis, and albuminuric retinitis, but in all, and especially in the latter, it is apt to be associated with structural changes. Circumscribed opaque white spots are due to change other than that of simple cedema, and commonly of four varieties: (1) Fibrinous exudations which undergo coagulation; (2) the accumulation of corpuscles, similar in appearance to those of the nuclear layer, and also to the white corpuscles of the blood, so that it is doubtful from which source they are derived; (3) fatty degeneration of the retinal elements, perhaps also in part of fibrine from the serum effused in simple cedema, and of the remains of blood clot; (4) a fibroid change, a process of "sclerosis" of the retinal elements is described as an occasional cause of a white spot, but is more frequently confined to the perivascular tissues and vessel wall.

These conditions are frequently combined. The fatty degeneration may exist alone, as the sole cause of a white spot. Corpuscular accumulation usually involves a good deal of fatty degeneration in the cells and in the disturbed retinal elements. Sclerosis of the retinal structures is also in most cases associated with fatty degeneration.

It is often impossible to say, from the ophthalmoscopic appearance, on what change the white spot depends. Minute granular-looking spots, brilliantly white, are commonly due to fatty degeneration of retinal structures or of leucocytes, &c. Larger white spots, especially if soft edged, are commonly



effused fibrine or accumulations of leucocytes, especially if situated beneath the nerve-fibre layer. Fatty degeneration of the retinal structures is, however, commonly associated. White spots in the superficial layer of the retina, most common in Bright's disease, are due usually to degeneration of the nerve fibres.

Growths in the retina sometimes occur in cases in which there are other growths elsewhere. The disc shown in Pl. III. 4 was from a boy who had cerebral tubercles and whose other eye was the seat of a tubercular growth behind the retina.

The occurrence of miliary tubercles of the retina has been suspected by many observers. White spots are sometimes seen adjacent to the disc in cases of tubercular meningitis, and such a spot in one case I found to be made up of lymphoid cells like those of the nuclear layers in which it was situated. Bouchut has seen white spots at a distance from the disc, near the vessels. Microscopically, he always found them to contain only products of fatty degeneration. He suspected them to be caseous tubercles, but there was no direct evidence that this was their nature (see Part II., Tuberculosis).

Since the white spots in the retina, which have been described, are present in many forms of retinal disease which occur secondarily to, and are significant of, general diseases, it is of great importance to distinguish them from other appearances which have a different significance.

First it is necessary to distinguish whether the white spot is in the retina or in the choroid. Most choroidal white spots are due to atrophy of the choroid, and their distinction is easy. The atrophy of the choroidal pigment permits the white or bluish-white sclerotic to shine through; some choroidal vessels may have escaped destruction and course across the white patch; its edge is always more or less irregular, and usually much pigmented, or the choroid may exhibit adjacent slighter disturbance. It is easy to recognize by the "parallactic test" (also in the direct method by attention to the required effort of accommodation), that the exposed sclerotic is some distance



behind any retinal vessels which pass in front of it. Occasionally, however, a white spot in the choroid is due to a recent formation, an inflammatory "exudation," or a growth such as tubercle. This is prominent, and may be difficult to distinguish from a white spot due to change in the nuclear layers of the retina. In some cases a little pigmentary disturbance in the neighbourhood may be seen; in others it is distinctly so far behind the retinal vessels as to be obviously in the choroidal level. If sufficiently prominent to disturb the course of the retinal vessels, the prominence may be recognized and seen to be considerable in degree. In other cases, the conditions of origin of the spot may assist the diagnosis.

White spots due to the persistence of the white substance of the retinal nerve fibres, or to connective tissue at the back of the vitreous, may be mistaken for new formations in the retina. The former are recognized by their position, adjacent to the disc, and by the peculiar shape and course of the patch, corresponding to that of the nerve fibres, and by the "feathery" striated edge with which they terminate, and by the partial or complete obscuration of the retinal vessels, which indicates the position of the opacity in the layer of nerve fibres. The most puzzling cases are those in which such a patch is a little distance from the disc, and is isolated and small in size. Attention to the characters above indicated will, however, usually enable the real nature of the spot to be recognized.

The connective tissue which in some rare cases persists behind the vitreous is usually seen only over the disc. Its nature may be recognized by its transparency, which enables the vessels to be seen through it, and their unaltered course to be recognized. The edge of the film may often be seen as a sharp, well-defined line. The similar spots which are sometimes left after neuritis are always accompanied by the signs of previous inflammation, and evidence of constriction of the vessels, the tissue being around as well as in front of them.

Pigmentary deposits in the retina may be left after extra-



vasation of blood, but such are always small. More extensive pigmentation is commonly the result of the accumulation in the retina of disturbed choroidal pigment, and is a consequence of choroido-retinitis, or it is a result of the so-called retinitis pigmentosa.

Retinitis pigmentosa appears to have some obscure connection with morbid states of the nervous system. It occurs, as Liebreich first pointed out, very frequently in the offspring of marriages of consanguinity. It has been thought to be connected with inherited syphilis, but the evidence on the subject scarcely supports the theory. It often occurs, however, in families in which there is a history of nervous disease. This is well illustrated by three out of four cases of the disease narrated by Mr. Nettleship ("Oph. Hosp. Rep." ix. 170). Of the first patient, two cousins were epileptic and two insane. Of the second, the grandfather and great aunt were insane, and an aunt half imbecile, and a brother paraplegic. Of the third patient, the mother was epileptic and probably also suffered from retinitis pigmentosa.

## THE CHOROID.

Choroidal changes, like those of the retina, are for the most part the result of special diseases, and their characters will be described in greater detail in Part II. Hæmorrhages are rarely seen, although their consequences are sometimes met with. The common changes consist in white spots and the disturbance of the choroidal pigment, which so constantly results from any changes in its structure. The white spots are either new formations or patches of atrophy. The distinctions between them have just been alluded to in describing the diagnosis from retinal changes. White spots, not atrophic, are the result of inflammation, or growths—tubercle or lymphadenoma. The latter are extremely rare, and only occur when the general lymphatic disease is well marked. Tubercles are isolated and small—rarely large. Pigment may be seen adjacent to the older formations. The evidence of the general disease is almost always so prominent as to



prevent the possibility of error. In acute choroiditis the white patches are large and numerous: the signs of the dyscrasiæ associated with growths are absent, and there is often a well-marked history of syphilis. The results of previous choroiditis are very conspicuous atrophic and pigmentary changes, often associated with pigmentary deposits in the retina. It must be remembered that this pigment frequently occupies only or chiefly the peripheral portions of the choroid, and an examination confined to the neighbourhood of the optic disc may be insufficient to discover it. The changes are very important on account of the frequency with which the inflammation causing them is the result of syphilis. They are also interesting to the physician as associated, in some other cases, with evidence of a family tendency to nervous disease.\* It is possible that inherited syphilis may be the link between these morbid states.

Choroidal exudations (local) occurring near the age of puberty, resembling in general aspect choroidal tubercles, sometimes occur, and it has been suggested by Mr. Nettleship that these are really foci of serofulous or tuberculous inflammation.

Chronic choroidal degenerations sometimes occur in the old as a senile change, possibly in consequence of general arterial degeneration.† Circumscribed changes may result from hæmorrhage. Amyloid degeneration of the choroidal arteries was found by Knapp in a case in which hæmorrhage occurred.

Embolism of choroidal vessels was believed by Knapp to be the cause of morbid appearances in two cases of heart disease observed by him.‡ In each there was sudden affection of sight, at first general and then central, accompanied by chromatopsy. Corresponding to the scotoma, there was a localized retinal opacity with hyperæmia. The opacity, ascribed to effusion, extended to the optic disc. Sight, and the appearance of the fundus, ultimately became normal.

\* Instances of this have been related by Mr. Nettleship. ("Oph. Hosp. Rep." ix. 178.)

† Poncet, "Ann. d'Oculist." 1875.

‡ "Arch. für Ophth." Bd. xiv.



## PART II.

### *OPHTHALMOSCOPIC CHANGES IN SPECIAL DISEASES.*

#### DISEASES AND INJURIES OF THE NERVOUS SYSTEM.

##### *DISEASES OF THE BRAIN.*

IN diseases of the brain, two forms of ophthalmoscopic change may be met with:—First, those which are a consequence of the general condition on which the cerebral disease remotely depends — associated changes ; and, secondly, those which are the consequence of the cerebral disease—consecutive changes.

##### ANÆMIA AND HYPERÆMIA OF THE BRAIN.

It has been supposed that the state of the circulation in the eye and brain correspond, and that the anæmia and hyperæmia of the brain are revealed by similar conditions in the fundus oculi. But, as has been already said, such a statement, if true at all, is true only within certain narrow limits. The intra-ocular tension so regulates the state of the vessels of the eye, that very little alteration occurs in them, when changes occur in the condition of the vessels of the brain. The eyeball participates in variations in the blood-supply to the whole head, but it does not share simple vascular states of the brain (in which the rest of the head does not participate) to a degree which can render it a sensitive index of the existence of those states. This statement applies especially to the retinal vessels. The optic



nerve exhibits encephalic changes more readily, but still not to the extent which is implied in many statements which have been made.

*Cerebral Hyperæmia.*—There is no sufficient evidence to show that the vascularity of the disc or retina participates in any transient cause of cerebral congestion, in which the rest of the head does not share. But in some cases of long-continued vascular disturbance, and in morbid states which are ascribed to cerebral congestion, there may be ophthalmoscopic changes, but they are cases attended with grave functional disturbance of the brain and prolonged vascular disturbance; in such cases the optic disc does, not unfrequently, present slight changes. Instances are such congestion as are shown in Pl. I. 1 and 2 (Case 25), and the bright injection of the discs described by Macnamara as occurring during the headache produced by exposure to the sun, a condition which may apparently increase to papillitis when actual meningitis is developed.

This conclusion—the absence of any marked vascular alteration in the eye in changes in the cerebral circulation—is at variance with early statements and *a priori* theories; but it is abundantly supported by the conclusions of many skilled observers.\*

*Anæmia of the Brain* is rare as a primary vascular condition, except as the result of vascular spasm, or as part of a cephalic anæmia. It is possible that the initial stage of an epileptic fit, which is attended by pallor of the face, may be accompanied by pallor of the disc, and perhaps spasm of the retinal arteries; but very little evidence of this fact has at present been obtained.

When the cerebral anæmia is part of a similar state affecting the whole head, the retina certainly participates, although it is not often that an opportunity is obtained of observing this with the ophthalmoscope. But the loss of function of the retina affords evidence of its participation,

\* See, for instance, the statements of Manz, Schmidt-Rimpler, and others, at the discussion at Heidelberg, reported in the "*Ann. d'Oculistique*," vol. lxxiv. 1875, p. 262, *et seq.*



as is shown by the occasional occurrence of transient loss of sight, probably from this cause, in syncopal seizures. In an instance which came under my observation, a lad engaged in a stooping occupation in a hot crowded room, felt faint, and went out into the cool night-air. On re-entering the room, he exclaimed that he could not see: the room was absolutely dark to him. After sitting still for a few minutes sight slowly returned. It is hardly conceivable that the loss of sight was the result of anæmia of the perceptive centres, because the other functions of the brain were scarcely affected, and the loss of sight persisted after he otherwise felt quite well. It was probably due to the retina sharing in the cephalic anæmia, and suffering in function more and longer than the nervous centre.

#### INFLAMMATION OF THE BRAIN.

Acute inflammation of the brain is very rare, except in association with meningitis. The latter is the predominant lesion, and to it the symptoms are customarily ascribed. Certainly, of ophthalmoscopic changes in acute inflammation of brain without meningitis, we know nothing. Of course such cases of "active hyperæmia" as those described in the last section, as occurring from the effects of insolation, may be regarded as cases of encephalitis. The boundary between "active congestion" and "inflammation" is one of gradation, but there appear to be no pathological facts to warrant us in regarding the morbid process in these cases as actual inflammation.

There is, however, a class of cases to which the term "chronic encephalitis," or, perhaps, more accurately, "chronic cerebritis," appears fairly applicable, and in which there may be very marked ophthalmoscopic changes. These cases present evidence of mental and motor failure, the latter may be local and attended by convulsion. Death may be preceded by coma. Headache is often severe. There are not the tremors or mental peculiarities of general paralysis, the symptoms



resembling much more closely those of cerebral tumour. Post-mortem there is no sign of meningitis; the brain may present evidence of degeneration, sometimes of wasting, but no "focal" disease. Such cases may be attended by optic papillitis very similar to that found in cerebral tumour, due most probably to the propagation of an irritative process from the cerebrum along the nerves. A well-marked case of this kind has been described by Dr. Hughlings Jackson, and is given in the Appendix (Case 27.) Dr. Sutton's microscopical examination of the convolutions showed only an undue number of the "spherical nuclear bodies," and in places, instead of the normal pyramidal nerve cells, were large numbers of staining nuclei, with unstaining cell-bodies around them. In places these nuclei were aggregated into groups of ten or twenty. The neuroglia was more granular than that of a healthy brain. The optic nerves, examined by myself, presented the characteristics of moderate papillitis, the swollen papillæ being infiltrated with nuclear bodies similar to those seen by Dr. Sutton in the brain. Similar corpuscles were so abundant throughout the optic nerves as to justify the assumption that the neuritis had been "descending" (Pl. XV. 4—7).

It is probable that the congestion or inflammation of the papilla, sometimes seen to supervene slowly in obstruction by embolism of a cerebral artery, and which may coincide with signs of extending mischief (Case 25), is to be ascribed to secondary inflammatory changes around the softened area.

Cases are sometimes met with in which we have a difficulty in assigning to inflammation or growth the chief share in the morbid process. Such cases may be accompanied by descending neuritis, and simulate closely the symptoms of cerebral tumour. Pl. VI. Fig. 2 shows the optic disc in such a case (Case 4 appended). In this, local injury, years before, had caused the production of cheesy degenerating tissue beneath the membranes over certain convolutions, and a more widely-spread but irregularly distributed meningitis had led to vascular disease, from the effects of which the patient died.



The optic nerves were infiltrated with leucocytes, and "miliary abscesses" were found in the optic tracts (Pl. XVI. 1 and 4).

#### CEREBRAL HÆMORRHAGE.

*Associated Changes.*—The conditions which give rise to cerebral hæmorrhage frequently affect the retina as well as brain, and may produce the same effect in it as in the cerebral tissue. *Miliary aneurisms* have been found post-mortem in the retinal vessels by Liouville, in cases in which a similar change existed in the arteries of the brain, and caused extravasations. In Pl. XVI. 11 are shown minute capillary aneurisms from a case in which cerebral and retinal hæmorrhages co-existed. They have not, however, been observed during life in cases of cerebral hæmorrhage, although those which are depicted on the lower artery in Pl. XII. 1, are from a case (42) in which all the conditions for the production of cerebral hæmorrhage were present in extreme degree.

*Retinal Hæmorrhages*, however, are present in a considerable number of cases of cerebral hæmorrhage, and furnish an indication of considerable value. Their most frequent cause is that which is the most frequent cause of cerebral hæmorrhage, Bright's disease, especially the granular kidney. They may exist, as in Pl. IX. 1, without any other retinal change, or may form part of the special retinitis (Pl. X. 1 and XII. 1). In either case they indicate the existence of the conditions which favour vascular degeneration and rupture. In the retina shown in Pl. X. 1, for instance, capillary dilatations and other changes were found (Pl. XVI. 7). The retinal hæmorrhages are often associated with cardiac hypertrophy. They thus may accompany all the most potent causes of cerebral hæmorrhage. It must not be concluded, however, that the presence of albuminuric retinitis proves a cerebral lesion to be hæmorrhagic. The disease of the kidneys is a cause of such vascular degeneration as leads also to thrombosis and softening, and this is often associated with retinal changes due to the kidney disease.

In other conditions retinal hæmorrhages have a similar and less equivocal significance. They occur, for example, in



pernicious anæmia (Pl. XI. 1) and in leucoeythæmia (Pl. XI. 2), and in the latter disease the brain stands second in frequency as the seat of internal hæmorrhage.\*

But although retinal hæmorrhages point to the existence of conditions such as may lead to cerebral hæmorrhage, and are thus of great importance as indications of the need for care in avoiding the exciting causes of hæmorrhage, their significance as indications of the probability of the occurrence of apoplexy may be overrated. They are not uncommon, as Dr. Clifford Allbutt and Mr. Hutchinson have insisted, in the old and gouty, who do not suffer subsequently from cerebral hæmorrhage. Perhaps this is, in part, due to the fact that the conditions in which they arise are such that many other causes of death co-exist.

*Consecutive Changes.*—Hæmorrhage into the substance of the brain is not usually attended with any ophthalmoscopic changes. So rarely have any alterations in the fundus been seen, that they may be said almost never to occur during the early period. Even at a later period ophthalmoscopic changes are extremely rare. The only well authenticated early case is one recorded by Dr. Hughlings Jackson. Ten weeks after an attack of cerebral hæmorrhage, the discs presented the appearances of the later stage of neuritis. The patient died a week subsequently, and the necropsy revealed a large extravasation into the middle cerebral lobe, and a few specks of hæmorrhage into the corpora quadrigemina. Dr. Allbutt has suggested that the meningitis sometimes set up by clot may in rare cases lead to changes in the papilla.

There are several possible sources of error in ascribing optic neuritis to cerebral hæmorrhage, which must be excluded before the connection between the two can be assumed in a given case. One of these is that the neuritis may be due to albuminuria, being such as those shown in Pl. IX. Another possible source of error is indicated by Case 16 appended, viz., an overlooked hæmorrhagic glioma. In this case, in which the neuritis had been watched during life, a careful observer

\* Retinal hæmorrhages not included. See the writer's article on "Leucoeythæmia," "Reynolds' System of Medicine," vol. v.



who made the post-mortem reported it to be a large extravasation and adjacent softening—the latter being really a very soft grey tumour into which the hæmorrhage had occurred.

When, however, the hæmorrhage is into the meninges, ocular changes may exist—slight optic neuritis. The hæmorrhage may pass into, and distend, the sheath of the optic nerve, as has been found in meningeal hæmorrhage from fracture of the skull (Case 49), rupture of an aneurism of the middle cerebral (Mackenzie), rupture of an intra-cerebral extravasation into the meninges (Michel), and hæmorrhagic pachymeningitis (Manz). Opacity and blurring of the outline of the disc with slight swelling may be thus produced. Retinal extravasations may co-exist, as in a case figured by Poncet.\* Early changes in the papilla, in a case of undoubted cerebral hæmorrhage, would thus be evidence that the blood was effused into the meninges. It is said (by Knapp and Liebreich) that a peculiar pigmentation of the outer part of the peripheral disc, within the sclerotic ring, may be an ultimate consequence of such hæmorrhage.

In rare cases optic nerve atrophy has been seen in association with cerebral hæmorrhage. Thus a case is recorded by Vulpian† in which blindness supervened on an attack of apoplexy. Death occurred fifteen years later, and the remains of an old hæmorrhage were found in the left corpus striatum. Both optic nerves and optic tracts presented grey atrophy.

#### CEREBRAL SOFTENING.

In softening of the brain, marked ophthalmoscopic changes are rare as the result of the cerebral mischief, although occasionally present, as several reliable cases testify; and I believe that slight changes are more common than in cerebral hæmorrhage. Most of the cases in which alterations have been found have been cases of softening from embolism, not from thrombosis secondary to vascular disease. Changes in

\* "Atlas" of Perrin and Poncet.

† Galezowski: "Journal d'Ophthalmologie," Jan. 1872.



the fundus oculi, moreover, sometimes result from the same causes as those which lead to the cerebral mischief.

1. EMBOLIC SOFTENING : (a) *Associated Ocular Changes*.—Embolism of the trunk or a branch of the central artery of the retina may occur before or after embolism of a cerebral artery ; very rarely, as in Case 47 (Pl. XII. 2), at the same time (see *antea*, p. 28).

(b) *Consecutive*.—When the artery plugged is the middle cerebral, marked disturbance of the circulation might be expected in the eye which derives its blood supply from the same trunk. Any signs of such disturbance have, however, hitherto escaped attention, and probably the free anastomoses of the circle of Willis carry off any excess of pressure.

If the condition of the discs is carefully observed from time to time, I believe that a state of congestion may often be observed a few weeks after the onset of embolic softening, especially in those cases in which the cerebral damage is extensive and leads to mental change. Pl. I. Figs. 1 and 2 show the appearance of the right disc of a young man with mitral disease and left hemiplegia. The increased redness of the disc, with slightly softened outline to indirect image, developed in both eyes under observation, and was so marked that I thought neuritis was coming on. It became stationary, however ; soon lessened in the left eye, and much more slowly in the right. Coincidentally with it there was marked and increasing mental failure, persistence of the complete hemiplegia, and rapid development of the ankle-clonus which was marked three weeks after the onset of the hemiplegia. Actual neuritis has been observed in a few cases, distinct, moderate in intensity, coming on a few days or weeks after the cerebral lesion, and running a subacute course, and slowly subsiding. One of the best marked cases of the kind has been recorded by Dr. Broadbent.\* A man, aged nineteen, with mitral disease, was seized with left hemiplegia and impairment of sensation, having had, five days previously, a transient attack of loss of sight. The right limbs were in constant motion, and there was a tendency to roll over to the

\* "Clin. Trans." vol. ix. 1876, p. 62.



left. Nine days after the onset the margins of the optic discs were ill-defined; they were swollen with an unduly vascular "woolly" appearance, the retinal veins large, dark, and tortuous, the arteries visible, but small. By the eighteenth day the paralysis had improved considerably, but the optic papillitis persisted, sight being normal. Six weeks after the onset, he was walking about the ward, and the papillitis was subsiding. A fortnight later the outlines of the discs were becoming perceptible, still red, and rather prominent. He subsequently had some convulsive attacks and symptoms of ulcerative endocarditis, and died four months after the onset of the hemiplegia. There was softening below the posterior corner of the right lateral ventricle, extending to the tip of the occipital lobe, and involving the tail of the corpus striatum and the fibres of the thalamus, passing to the occipital lobe. The part softened was in the region of the posterior cerebral, but no obstruction of this vessel was found; the calcarine artery could not be traced.

Double neuritis, with slight changes in the contiguous retina, was seen by Dr. Stephen Mackenzie\* in a case of left hemiplegia, no doubt the result of embolism of the right middle cerebral artery. The softening found five weeks after the onset was slight, and the middle cerebral was pervious, although thickened, the probability being that the plug had broken up and had been carried on into some of the terminal branches of the artery. Splenic infarctions were also found. Three days after the onset the discs (previously normal) were swollen, and three weeks later the swelling persisted, without hæmorrhages, but with a good deal of opacity, the vessels being "buried in exudation." One or two hæmorrhages existed close to the discs. The appearance of the discs, Dr. Mackenzie has informed me, was precisely that often seen in cerebral tumour.†

\* "Brain," Jan. 1879.

† The following case has been recorded by Drs. Darby and Upham ("Boston Med. and Surg. Journal," vol. 72) as one of softening, in which, however, there was no evidence of embolism. A man aged twenty-six had a hemiplegic attack, followed by fits and double "neuro-retinitis" with hæmorrhages. A necropsy some months later revealed a peculiar softening of the corpus



A grey infiltration, incompletely veiling the disc, and extending into the adjacent retina, is figured by Bouchut from a case of hemiplegia in a child of seven years with mitral regurgitation.

Most of the above cases seem to be distinct instances of the association of neuritis and softening. It may be well, however, again to remark how easily the error may be made of mistaking a soft glioma for a patch of softening, as in Case 16.\*

In another similar case (recorded by Leber) of supposed neuritis from softening, the nature of the cerebral lesion (a glioma) was only discovered on microscopic examination.

Atrophy of one optic nerve may succeed softening, embolic or other, just as it succeeds hæmorrhage when the lesion has a certain seat, as to damage the nutrition of some part of the brain to which the optic fibres are related. Embolism of the middle meningeal artery, which supplies the dura mater near the optic nerve, is said to cause atrophy of the latter (see p. 92).

**SOFTENING FROM THROMBOSIS.**—(1) *Arterial*.—This may be due to syphilitic or degenerative disease of the vessels or to blood changes.

*Syphilitic Disease*.—In softening from syphilitic disease of vessels, associated ophthalmoscopic changes are common,

striatum and optic thalamus, grey and white gelatinous soft tissue, to the naked eye very like a glioma, but, on microscopic examination, only the signs of degeneration were visible. It is to be remarked, however, that the peripheral parts of these tumours may contain, and even appear to consist only of, products of degeneration. A careful search may be necessary for the very delicate cells of which they consist.

\* A case is recorded by Wurst, for instance (Virchow's "Jahresbericht," 1877, ii. 463, from the "Przegląd lekarski"), in which optic neuritis, "stauungs papilla," was associated with cerebral softening—a spot the size of a walnut in the posterior portion of the left hemisphere, and a second, the size of a bean, in the pons Varolii. Sudden complete amaurosis had come on a few days before. There was, however, interstitial nephritis and hypertrophy of the heart, and it is most probable that the optic neuritis was due to the renal disease. In the remarkable case figured in Pl. VI. 2 (Case 4), optic neuritis co-existed with softening from extensive arterial disease, the results of old traumatic meningitis, but inflammatory (?) growths existed beneath two old fractures of the skull. The man had had syphilis, but the lesions presented no syphilitic character.



consecutive changes are very rare. The associated conditions are the various changes which are due to syphilis, and which are fully described farther on. Their recognition is often of the highest importance in diagnosis. They are, of course, of the greatest significance in cases of softening in persons who have not reached the period of life at which vascular degeneration is common. In the latter condition, the recognition of constitutional syphilis leaves us still in some doubt, and care must be taken to avoid attaching undue weight to its signs. But, on the other hand, it must not be forgotten that syphilitic vascular disease does occur, and not rarely, in the degenerative period. I lately examined the body of a woman, aged fifty-six, who died from the effects of unmistakable syphilitic disease of the basilar artery. In doubtful cases, the recognition of the ocular signs of syphilis should always lead to a trial of the special remedies.

Although associated changes are common, consecutive alterations in the eye are very rare in softening from syphilitic disease of vessels. I am not aware that any instance has yet been recorded in which congestion or inflammation of the optic papilla was due to this cause. In the few recorded cases in which it was observed, syphilitic growths in the brain were associated with the vascular disease, and the ocular change was due to the former, not to the latter.

*Degenerative Disease: "Atheroma."*—Cerebral softening from this cause is rarely associated with any similar morbid states of the retinal arteries, which are below the size in which "endarteritis deformans" is common. Occasionally, thickening of the wall or undue tortuosity of the retinal arteries has been observed. Atheroma of cerebral vessels is, however, very common in cases of chronic kidney disease, and albuminuric retinitis is often found in such cases associated with cerebral softening. Hæmorrhages from this cause are evidence, therefore, of probable vascular disease of the brain rather than of cerebral hæmorrhage. In the case figured in Pl. IX. 1, for instance, although there was a retinal hæmorrhage due to the effect of chronic renal disease, the cerebral



symptoms pointed unmistakably to softening rather than to hæmorrhage.

Consecutive changes are very rare in senile arterial thrombosis. Optic neuritis has not yet been observed unequivocally due to this cause. In one case on record it is most probable that the papillitis was nephritic—a source of fallacy to be carefully borne in mind. Atrophy of the discs has, in rare cases, been observed to supervene.

In some cases, however, the obstruction by thrombosis of the internal carotid may give rise to alterations in the eye, which have been hitherto observed only after death, but which must be attended by marked ophthalmoscopic changes. Such a case was described long ago by Virchow.\* A man aged forty-six who had an attack of apoplexy, leaving right hemiplegia, died from a melanotic cancer of the liver. The internal carotid was obstructed by a thrombus, probably spontaneous, since no embolon was found, and there was fatty and calcareous degeneration of the wall of the vessel. There was a large area of softening in the left hemisphere. The ophthalmic artery was patent, evidently by a collateral circulation having been set up. The vitreous was transparent, the retina thickened, and around the papilla four opaque white spots, which were, however, found to be due to the persistence of the medullary sheath of the nerve fibres. The ganglion cells were granular. The elements of the nuclear layers showed a tendency to arrange themselves in lobular cylinders. Another case of the same character which came under my observation has been before alluded to (p. 27 *note*), and in it the ophthalmoscopic changes would probably have been much more striking. Although the origin of the ophthalmic artery was closed by clot, the central artery of the retina retained a channel, narrowed by clot formed upon its walls. Some retinal branches were pervious, others closed. The retina presented atrophy of all its structures, and was reduced to about two-thirds of its normal thickness.

It is important then to watch the fundus continuously in cases of thrombosis in the region of the internal carotid. It

\* "Arch. für Path. Anat." Bd. x. 1856, p. 189.



is probable that the obstruction of the carotid would always be accompanied by a sudden diminution in the size of the retinal artery, the degree of which, and the occurrence of parenchymatous changes in the retina, depending on the character of the anastomoses of the orbital artery. These are usually abundant, chiefly with the facial, but also to a less extent with the middle meningeal.

*Softening from Arterial Thrombosis due to Blood State.*—In this condition, which is rare, except in the puerperal state, ophthalmoscopic signs have been found only in cases of septicæmia (*q.v.*)

(2.) *Softening from Venous Thrombosis.*—Ophthalmoscopic changes are unknown. In thrombosis of the cavernous sinus, it is said that there may be double optic neuritis and exophthalmus. Slow obliteration of this sinus, however, may cause no ophthalmoscopic changes.

(3.) *Inflammatory Softening.*—Apart from abscess, ophthalmoscopic changes have been found only in traumatic cases, in which slight neuritis has been observed (see “Injuries to Brain”).

## ABSCESS OF BRAIN.

The only changes known are consecutive. Frequently there are none. In a minority of cases, optic neuritis is found, differing in no respect from that which is due to cerebral tumour. The papillæ are swollen, red, and opaque, the vessels concealed, and hæmorrhages may be present. Dropsy of the sheath has not often been looked for, but was found in one case (Peipers), the abscess being in the right temporal lobe.

There is no conspicuous difference between the cases of abscess with, and those without, optic neuritis. In perhaps a larger proportion of the cases with neuritis the bone disease causing the abscess was the result of injury. In two cases recorded by Dr. Hughlings Jackson this was the case. The position of the abscess has been in the temporal and posterior parts of the parietal lobes, beneath the surface. In a case recorded by Benedikt it was outside the optic thalamus.



## TUMOURS OF THE BRAIN.

## A. GROWTHS.

*Associated Conditions.*—Growths may occur in the eye, of the same nature as the growth in the brain. Such cases are not common, but are occasionally met with. The disc shown in Pl. III. 4, is the left disc of a boy, whose right eye was the seat of a tubercular growth, in whose brain there was another similar growth, of which vomiting and optic neuritis were the only signs. In such a case the ocular growth becomes an important symptom. Choroidal miliary tubercles may be expected to be found occasionally in cases in which a tubercular mass exists in the brain, but they occur rather in acute general tuberculosis, in which meningitis is more frequent.

*Consecutive Changes.*—Optic neuritis is the ocular lesion in intra-cranial growths, which are, on the other hand, its most frequent causes. It is present, in various degrees, in a large proportion of the cases of intra-cranial tumour. In what proportion cannot be determined by statistics from published cases, on account of the selection for publication on special grounds. From my own experience I should say that neuritis occurs in about four-fifths of the cases. This is a much smaller proportion than has been deduced from published cases. Annuske and Reich, for instance, collected eighty-eight cases with ophthalmoscopic examination and autopsy, and found that there was no ophthalmoscopic change in only five per cent. But these cases have all been recorded during the period when ophthalmoscopic observation possessed the interest of novelty, and a far larger proportion of cases with neuritis have probably been published than of cases without neuritis.

It does not seem possible at present to say on what the occurrence of optic neuritis depends; why it is present in the majority, absent in the minority. Position of growth has apparently no influence on its occurrence. It has been met



with in tumours of every part of the cerebral hemispheres, of the pons Varolii, the crura cerebri, the cerebellum. I am not aware that neuritis has been found in tumours limited to the medulla below the pons. It is common in tumours of all parts of the hemispheres. Dr. Clifford Allbutt thinks that tumours of the anterior lobes are more uniformly attended with neuritis than those of other parts, but I have seen a large growth in the anterior hemisphere with normal discs throughout.

Nor does the nature of the tumour apparently influence the development of neuritis. It occurs with every variety—glioma, sarcoma, tubercle, syphiloma. The most frequent forms of tumour are those which are met with most frequently in association with optic neuritis; and they are also those in which neuritis is most frequently absent—syphilomata, tubercles, and gliomata.

The size of the tumour also seems to have little influence in producing neuritis. I have twice seen syphilomata the size of half an egg without optic neuritis. One of the largest intra-cranial tumours I have met with was a sarcomatous growth, the size of the closed fist, growing from the dura mater, and compressing, not invading, the brain over the posterior portion of the parietal lobe, a tumour which must have increased the intra-cranial pressure as much as it is ever increased directly by a growth, and in this case the discs, repeatedly examined from soon after the onset of the symptoms until death, about six months later, were perfectly normal. On the other hand, Benedikt has recorded a case of well-marked neuritis with much swelling and hæmorrhages, due to a tubercle of the pons Varolii no larger than a cherry. There were no signs of meningitis.

The chief facts at present known regarding the mechanism by which optic neuritis is produced have been already discussed (p. 63). Some points having special reference to tumour may be again adverted to. It is clear from the facts stated above, and a long list of similar cases might be given, that encephalic tumours do not cause neuritis by the direct effect of their mass on the intra-cranial pressure. Perhaps no form of cerebral tumour is attended with optic neuritis in a



larger proportion of cases than glioma, which commonly does not press upon, but invades, the brain substance, and often occupies the invaded tissue almost bulk for bulk.

It has been thought that the rapidity of growth of a tumour influences the occurrence of optic neuritis, but a limited experience of these cases, or a very short search among recorded cases, disposes of the hypothesis, at any rate in an absolute form. Rapidity of growth may be one factor in the production of neuritis, and an important factor in determining the rapidity or slowness of the course of the neuritis, but it certainly does not alone determine its occurrence.

There is, however, one mode in which neuritis is produced which may sometimes be distinctly traced, post-mortem—by the mechanism of meningitis. The disc shown in Pl. III. 3, for instance, was in a case (3) of tumour originating in the pineal body and invading the anterior corpora quadrigemina. The changes in the disc were very gradual in development, and moderate in degree. There was no general meningitis, but the orbital lobules were gently adherent, and fine shreds of lymph were visible on the dura mater after their separation. The optic nerves in front of the commissure were swollen and reddened. Microscopical evidence of neuritis of the nerve trunk was very distinct. In another case (16) of tumour (glioma) of the anterior lobe, in which the neuritis was of the form most characteristic of tumour, greyish-red, with much swelling, the microscopic changes in the nerve trunk, most intense behind the foramen, indicated a communicated descending neuritis, and old adhesions over the tumour showed that there had been local meningitis. It must be remembered that in such cases, whatever mechanism leads to the occurrence of neuritis without meningitis, may influence the degree and course of that which is set up by meningitis.

In most cases optic neuritis is a transient event in the history of a cerebral tumour, not a constantly-associated condition. A tumour may exist and cause symptoms for a considerable time without leading to any change in the eyes, and then optic neuritis may be rapidly developed, run its course, and



pass away, in many cases leaving atrophy of the discs, while the symptoms of the tumour continue or increase for months or years. It is not only that a tumour takes a certain time to cause optic neuritis, but it often exists for a considerable time before the mechanism for the production of neuritis, whatever that may be, is set in operation. A tumour may exist and cause symptoms for years before optic neuritis is produced. A striking instance of this is afforded by Case 15; the microscopical appearance of part of the papilla is shown in Pl. XIV. 7. The case was under the care of Dr. Hughlings Jackson, who had examined the eyes repeatedly during nine months and always found them normal. Then neuritis came on, but subsided, and in six weeks the discs were again normal, and continued so till death. Dr. Jackson has recorded\* a still more significant case in which a man had had symptoms of cerebral tumour for nine years: during the last three years his discs had been repeatedly examined and found normal. Six weeks before death neuritis was discovered.

In many cases in which neuritis occurs long after the symptoms of tumour have existed, its occurrence precedes death by no long interval.

The appearance of the discs in intra-cranial tumour is that of neuritis in its most typical forms, as described in a preceding page (p. 42). The stages indicated may be seen, and the neuritis may stop at one or another of those stages, constituting what may be termed varieties of neuritis. As already stated, until our knowledge of the relation of the appearances to their causes is much more extensive, and founded on more minute and full observation of the conditions of origin, macroscopic and microscopic, a division of neuritis into varieties according to its degree is much more useful than a separation of forms according to hypothetical modes of origin. Those varieties or stages have been already enumerated (p. 75). Each of the earlier stages may or may not be accompanied by obvious over-distension of veins, and each may be accompanied by extravasations.

\* "Med. Times and Gazette," Sept. 4, 1875.



The neuritis of tumour is in most cases double, sometimes equally advanced in the two eyes, often more intense and subsiding earlier in one than in the other. Rarely the affection of the disc is unilateral (as in Case 17), and this, although the tumour may be in the brain, where growths commonly cause double neuritis. In two cases of this character recorded by Dr. Hughlings Jackson, the neuritis was on the opposite side to the tumour.\*

*Symptoms.*—The symptoms of the neuritis which accompanies cerebral tumour have been already fully described (p. 54). It must be remembered that all symptoms may be absent, the acuity of vision, the fields of vision, and colour vision may all be unaffected, as in many of the cases figured in the plates and referred to in the description of the symptoms of neuritis. It must also be remembered that affections of sight of various kinds may co-exist with neuritis, and be due, not to the intra-ocular, but to the intra-cranial disease.

*Course and Duration* of the neuritis in cerebral tumour.—It is important to note that the neuritis often coincides at its onset with an obvious increase in the other symptoms of the cerebral tumour. This has been pointed out, long ago, by Dr. Hughlings Jackson. Instances of it are frequent, but at the same time exceptions are not rare. It is probably true, however, that *the occurrence of optic neuritis indicates progress in the morbid growth and its consequences.*

With regard to the course of the neuritis, it is necessary to distinguish two classes of cases. One of these is where the progress of the tumour, either spontaneously, or under the influence of treatment, becomes lessened or arrested after the onset of the neuritis; the other, where the progress of the tumour to which the neuritis is due is uninterrupted.

In the first event, the neuritis commonly subsides. It may pass away completely, even although it has reached the stage of considerable swelling and obscuration of disc and vessels, with distended veins and narrowed arteries, and sight may throughout be unimpaired. This occurred, for instance, in the cases shown in Pl. IV. 1, 2, 3, 4, V. 3, 4. Or, less

\* "Oph. Hosp. Rep." 1871, and "Brit. Med. Journal," July 20th, 1872.



commonly, a slight or moderate damage to sight, from the inflammatory swelling and damage to nerve fibres, may pass away. Very frequently, however, although the neuritis subsides, amblyopia occurs or increases as the nerve fibres suffer from compression from the contracting tissue. The last is the more likely to occur the longer the neuritis has lasted, because there is then more tissue formed, incapable of removal.

Instances of each course are seen often enough in syphilitic tumours, and not rarely where there is strong reason to believe that a scrofulous tumour exists — a cerebral or cerebellar tubercle. In cases in which the neuritis is slight and commencing, a subsidence of the neuritis may be the first sign of the improvement. It was so in Case 11 (Pl. V. 4), in which the neuritis passed away before there was any improvement in the symptoms, and then slowly the paralysis lessened, and improved up to a certain point, at which it became stationary, no doubt from the tubercular mass ceasing to grow, and becoming, from partial degeneration, smaller, and thus permitting damaged tissue near it to recover, while the destruction, which had before taken place, persisted. In syphilitic tumours, arrest can be obtained much more rapidly than in tubercular growths, and a considerable neuritis may pass away without damage to vision (Pl. IV. 1 & 2, 3 & 4, VI. 4 & 5.) In these cases, however, if a considerable neuritis exists before the treatment affects the tumour, tissue-changes too often progress in the disc to an extent which leads to loss of sight, even though ultimately the cerebral lesion ceases to increase and becomes quiescent (Pl. IV. 5, 6). Occasionally, although rarely, an analogous arrest of growth occurs in other tumours, often attended with degeneration and calcification. The neuritis may, in these cases, subside with the change in the growth.

In the cases in which the tumour causing the optic change continues its growth, as most tumours of other descriptions than the tubercular and syphilitic growths, the course of the neuritis differs according to the intensity of the inflammation. When this is considerable, the neuritis remains for a time at its height; commonly the signs of strangulation are developed,



and then the neuritis subsides slowly into atrophy. The inflammation, as it were, terminates itself, and its consequences remain. When the neuritis does not reach so intense a grade it has a much longer duration. The lilac-grey neuritis, with little sign of strangulation, may persist for months without much change, and then slowly subside to atrophy; sight perhaps being little damaged until the subsidence, when the tissue formed during the long duration of the inflammation compresses the nerve fibres. In a still slighter degree, that of slight neuritis, for instance (p. 75), the change may persist without alteration for a very long time. In the case represented in Pl. V. Figs. 1 and 2, the appearance of the discs was unchanged for a year and a half, and when the patient was again seen a year later, the neuritis was nearly in the same degree, although the least inflamed portion of the disc had become grey and sight was gone.

There is at present little direct information regarding the conditions which determine the course and duration of neuritis in the cases in which the cerebral tumour continues its progress. But it has been seen that the onset of neuritis may accompany, or succeed, an increase in the symptoms due to the tumour, such as indicates an increase in the size or irritative action of the growth itself. And we have seen also that the early subsidence of neuritis may attend a diminution in the other effects of the tumour such as may be taken as indicative of an arrest of growth, or even a diminution in size. These facts taken together indicate that the course of the neuritis is, to some extent at least, dependent on, and influenced by, the course of the tumour. This conclusion is corroborated by the fact that in some cases of tumour of very chronic course, the course of the neuritis is equally chronic. The case mentioned above (Pl. V. 1 & 2) is a striking illustration of this, since the progress of the very marked symptoms was but slight during the year and a half, in which the neuritis was absolutely stationary.

*Significance.*—The value of optic neuritis as an indication of the existence of an intra-cranial tumour is very great. Tumour is the cause of the great majority of cases of neuritis



due to organic disease, and not the result of toxæmia. On the other hand, neuritis is present, at some period, in at least four-fifths of the cases of tumour, and it may be the only unequivocal sign of organic intra-cranial disease.

It is important to remember that neuritis is a transient condition, however long its duration, and that its effects continue a much longer time than the inflammation. The atrophy left by neuritis may constitute unequivocal evidence of the antecedent inflammation, and where actual atrophy is not left, the state of the disc and the narrowing of the vessels may show clearly that there has been previous neuritis. Unfortunately it is not always possible, in old-standing cases, to say from the aspect of the discs how the atrophy originated. If the neuritis was moderate, the choroid adjacent undisturbed, a clean cut disc may be left, and the narrowing of the vessels may not be greater than is sometimes seen in cases of atrophy of the disc of other forms. The concealment of the lamina cribrosa is, however, usually complete. Valuable information may also be gained by the circumstances under which the loss of sight came on; the existence at the time of cerebral symptoms points strongly to the origin of the atrophy in neuritis.

It is not only during life that neuritis may assist the diagnosis of tumour. As an instance, I may mention the case of a man who died soon after his admission, with hemiplegia, into University College Hospital. The autopsy revealed a soft area, bounded and crossed by trabeculæ of firmer tissue, which was at first thought to be an area of old softening with some connective tissue formation in and about it. It was suggested, however, that it might be a tumour. Before it was examined with the microscope, the backs of the eyes were removed, and found to present distinct evidence of neuritis—swollen papillæ with hæmorrhages. A diagnosis of probable tumour was therefore made, and was fully confirmed by the microscope.

From the facts given above it is evident that optic neuritis may, in some cases, afford not only diagnostic, but prognostic indications. A subsidence of neuritis which has not reached



any considerable degree of intensity, may be taken as indicating, in most cases, a retrocession of the growth, and a neuritis of very chronic course affords evidence that the progress of the tumour is equally chronic. It might be supposed, therefore, that the absence of neuritis would indicate still greater chronicity. This, however, cannot be inferred, since tumours of very rapid course may be unattended with neuritis, and it is only when neuritis is actually present that a prognostic inference can be drawn.

It has been remarked that optic neuritis in tumour of slow growth often occurs not long before death. In such cases, also, it affords some prognostic indication. In more acute cases, or in those in which it develops early, it has not the same significance. It would appear as if the mechanism for the production of neuritis were, in the latter cases, readily excited, while in the former it is the result of changes of such a degree as to be incompatible with the long continuance of life.

*Simple atrophy* of the optic nerves occurs in cerebral tumour more frequently than in any other form of cerebral disease, since it is due not only to the effect of the growth in destroying by invasion the fibres or centres of the optic nerves, but also to the secondary consequences of the tumour—its indirect pressure, the pressure of ventricular effusion on the chiasma, and the effects of the meningitis which occasionally accompanies growths. Such atrophy has the characters of secondary atrophy of the optic nerves, the features and origin of which have been already described. But simple atrophy is far less common in cerebral growths than the atrophy which is consecutive to neuritis. Great caution is also necessary in inferring, from the appearance of discs long after the onset of the atrophy, that was simple and not consecutive, since, as already many times stated, the characters of the latter may ultimately resemble very closely those of the former. It is to be noted that in many cases, as in Case 6 (Pl. II. 4) the mischief which results in indirect pressure on the optic nerves or commissure, or tracts, occurs later in the history of



the tumour than optic neuritis, and it is not uncommon for sight, damaged much or little by the neuritic process, to fail rapidly at a subsequent period from secondary pressure effects.

### B HYDATID CYSTS

*Associated Changes.*—A cysticercus has been occasionally observed in the vitreous humour, but the coincidence of one there with the symptoms of cerebral tumour due to another in the brain, has not, I believe, hitherto been recorded.

*Consecutive Changes.*—Optic neuritis is frequent in hydatid cysts, having all the characters of the neuritis which occurs in growths—swollen papilla, obscured and tortuous vessels, hæmorrhages. It has been observed with hydatid cyst of both cerebrum and cerebellum. It may go on to consecutive atrophy, life being prolonged for years. The few cases on record of neuritis associated with cysts in the brain, the nature of which was not ascertained, were probably examples of hydatid disease.

### INTRA-CRANIAL ANEURISM.

Miliary aneurisms have been spoken of in connection with cerebral hæmorrhage. Intra-cranial aneurisms of larger size are not, as a rule, accompanied by any *associated* ocular changes: those of the central artery of the retina being too rare to be of significance. Nor do they often cause *consecutive* changes, except their position is such as to press upon the optic nerve (causing unilateral amaurosis and secondary atrophy), on the chiasma (bilateral atrophy), or, very rarely, on the optic tract (causing hemiopia). An aneurism of the internal carotid may obstruct the cavernous sinus, and cause transient fulness of the retinal veins without papillary changes. Commonly the pressure is relieved by the free communication of the ophthalmic and facial veins, and the enlarged angular vein may be conspicuous beneath the skin. In rare cases, however, an aneurism in this situation has led to optic neuritis, as in a case recorded by Michel,\* in which double neuritis, with evidence

\* "Arch. f. Oph." xxxiii. 2, p. 225.



of obstruction, was the first sign of a cirroid aneurism of the two internal carotids which had pressed on the optic nerves. The optic nerves at the spot showed evidence of interstitial inflammation. Dr. Holmes, of Chicago, has recorded several cases in which optic neuritis co-existed with intra-cranial bruits, and in the only one on which a post-mortem was obtained an aneurism of the internal carotid was found; but there was also an adjacent growth in the pituitary body.

In an interesting case, lately published\* by Mr. Jeaffreson, of Newcastle-on-Tyne, although there was no post-mortem, an aneurism of the internal carotid probably existed, and caused unilateral papillitis ("stauungs-papilla": congestion with oedema"). The other symptoms were, a loud murmur arrested by compression of the carotid, paralysis of the third nerve, and subsequently aphasia.

It is probable that in these cases the neuritis is descending, the result of the involvement of the nerve in inflammatory changes around the aneurism, and not due to pressure on the cavernous sinus. The evidence of this is that, apparently, aneurisms which produce the same effect on the sinus may or may not be accompanied by papillitis, and that when the latter is present the enlarged communications with the facial vein may (as in Mr. Jeaffreson's case) afford the same evidence of relief to mechanical obstruction.

#### INTERNAL HYDROCEPHALUS.

In simple internal hydrocephalus without growth there is commonly at first no ophthalmoscopic changes, and there may be none, even though the distension of the ventricles is such as to cause a marked increase in the size of the head. Sometimes there may be slight fulness of the retinal veins. At a later period, and sometimes early, sight commonly fails, and the signs of simple white atrophy of the optic nerve are then present. In several cases the onset of the atrophy has been watched, and the occurrence of any neuritic process excluded. In a few cases signs of neuritis have been observed to precede

\* "The Lancet," March 8, 1879.



the atrophy (Allbutt), the neuritis being similar to that seen in tumour, but slight in degree.

The simple atrophy of the nerves is usually due, as Türk pointed out, to the pressure of the distended third ventricle on the optic chiasma, and even on the tracts. In one case in an adult the distended ventricle appeared at the base as a bladder measuring ten lines by eight (Förster).

It has been remarked by Bouchut that the ophthalmoscopic changes may serve to distinguish chronic hydrocephalus from the large head of rickets; but from the lateness of the optic changes the cases must be very rare in which the nature of the disease is not clear long before ophthalmoscopic signs are present.

### *DISEASES OF THE MENINGES OF THE BRAIN.*

#### MENINGEAL GROWTHS.

Tumours springing from the pia mater always involve the cerebral substance to a greater or less extent, and their effects have been included in the account of cerebral tumours.

Tumours springing from the dura mater over the convexity also commonly cause the same effects, in the brain and on the eye, as growths in the brain itself.

Growths springing from the dura mater of the base of the brain also frequently cause optic neuritis. They do this sometimes by the direct influence on the optic fibres. Sometimes, when remote from these, growths which merely damage the nerve centres by pressure cause optic neuritis in its most intense form. Cases are on record, moreover, in which the optic neuritis was for a long time the only symptom of such a growth; as in one case in which, after months, hemiplegia came on, and was found to be due to a sarcoma springing from the periosteal dura mater, and which had compressed the left hemisphere of the cerebellum and the left side of the pons Varolii.\* In the case figured in Pl. V. 5, optic neuritis, although not the earliest symptom, reached its height before

\* Pagenstecher and Genth's "Atlas of the Path. Anat. of the Eyeball." Pl. xxxiv. Fig. 3.



any motor paralysis occurred. The tumour sprang from the dura mater, and had compressed the right side of the pons and right hemisphere of the cerebellum.

Meningitis accompanies meningeal growths even more frequently than tumours in the substance of the brain, and may give rise to the changes in the eye described in the next section.

### MENINGITIS.

The effects of meningitis on the eye vary much according to its seat, being slight when the inflammation is on the convex surface of the hemisphere, and often marked when the meningitis is at the base. In many cases, ophthalmoscopic changes are entirely absent, and when present they are apparently rather consecutive to, than concomitant with, the encephalic vascular disturbance. They afford, as Manz and others have pointed out, little support to the doctrine that the intra-ocular circulation shares and reveals disturbances of the encephalic vessels. It will be convenient to consider separately the changes in the several forms of meningitis.

**SIMPLE MENINGITIS.**—Acute simple meningitis of the convexity is usually unaccompanied by ophthalmoscopic changes; if it lasts for a considerable time some hyperæmia of the disc may be present. In a case of purulent meningitis, suppurative inflammation of the eye (chemosis and post-mortem infiltration of the retina with pus) was observed by Berthold.\* Leube† has recorded a case of purulent meningitis of the convexity secondary to septicæmia in which there was intense inflammation of the optic nerve in front of the commissure. The only changes in the eye were distension of the retinal veins and hæmorrhages.

Chronic simple meningitis of the convexity, slight in degree (such as that of which traces are often found in the brains of drunkards), is also commonly unattended by any optic change. The slight oedema and congestion of the disc,

\* "Arch. f. Ophth." Bd. xvii. 1874.

† "Deut. Arch. f. Kl. Med." 1878, xxii. 263.



sometimes seen in chronic alcoholism, is probably the result of the toxæmic condition as well as of the encephalic change.

Simple meningitis of the base is very rare, except in association with tumour or some bone disease. Optic neuritis may occur by direct propagation, and in those cases, in which the disease is chronic (as in Cases 1 and 4), the visible changes in the disc may be considerable in degree and duration. Basilar meningitis is, however, in most cases tubercular or syphilitic.

**TUBERCULAR MENINGITIS: *Associated Condition.***—Tubercles of the choroid may now and then be found in tubercular meningitis, and furnish valuable diagnostic information, as in Case 35. But their occurrence is rare, and they are much rarer, as Cohnheim pointed out, in tubercular meningitis than in general tuberculosis without meningitis. Dr. Heinzel\* never saw them in forty-one cases of tubercular meningitis which he examined with the ophthalmoscope, and the case figured (Pl. XV. 1) was the sole instance in which they were found in twenty-six cases examined by Dr. Garlick at the Hospital for Sick Children.

***Consecutive Changes.***—A peculiar marbled reflection from the retina has been described by Leber and Hock, occurring especially along the neighbourhood of the veins. They have seen it in conjunction with tubercles of the choroid. It is not due to neuritis, but may precede the latter. Nevertheless, redness of the disc is sometimes observed in association with this reflection. A somewhat similar reflection, chiefly around the disc, has been described by Manz as the most frequent change. He associates it with cedema of the sheath of the optic nerve. It is no doubt due to a slight cedema of the retina (compare Pl. I. 3).

Changes in the optic discs of more considerable degree are, however, present in tubercular meningitis in such a proportion of the cases as to constitute a very important symptom of the disease. The frequency of the occurrence has been variously

\* 'Jahrbuch für Kinderheilkunde,' 1875, p. 334.



stated. They do not occur in the rare cases in which the tubercular inflammation is confined to the convexity of the brain. In the cases of basal meningitis changes are, in some, entirely absent. Dr. Garlick,\* of twenty-six cases carefully watched at the Children's Hospital, found the discs normal throughout in five; distinct swelling was developed in about half the whole number, increased redness only in one quarter, and in a few others only distension of veins. In many of these cases, however, the changes were slight, and their pathological character was recognizable only by their development under observation. It is probable, then, that considerable changes are present in one half the cases, and that in two-thirds of the remainder, slight alterations will be found if the discs are watched with care from day to day. The occurrence of congestion and oedema of the disc seems to be especially related to the occurrence of inflammation, and the formation of lymph, in the anterior part of the base about the chiasma and the optic nerves.

The degree of change is rarely great. The disc becomes full-coloured and its outlines hazy. Sometimes this and distended veins constitute the only morbid appearance. More often swelling, with undue striation, becomes visible to direct examination, and the edges of the disc gradually cease to be recognizable. The disc has sometimes a reddish-grey look. In several recent cases I have noted that the colour of the swollen papillæ was much paler, especially on examination by the indirect method, than the neuritis of cerebral tumour, the aspect suggesting the idea of a subsiding neuritis rather than one that is commencing, and this in cases in which the neuritis was quite recent. The neuritis rarely passes into a more intense degree. The veins are often, though not always, over-distended from the first. In Dr. Garlick's observations their distension was especially related to excess of subarachnoid or ventricular fluid. Occasionally white lines along the sides of the vessels are unduly conspicuous. Hæmorrhages are rare. Sometimes white spots are seen in the neighbourhood of the

\* Paper communicated to the Royal Medical and Chirurgical Society in the present session (1878-9).



swollen disc. They are in the substance of the retina, and consist of an accumulation of lymphoid corpuscles in the nuclear and molecular layers, or on degeneration of nerve fibres. They may readily be mistaken for tubercles of the choroid. It has been thought that they are of the nature of tubercles, and they have accordingly been described as retinal tubercles, but very similar spots are seen in neuro-retinitis from other causes. Occasionally a gauze-like opacity is seen over a wide area of the retina, with scattered white points and flakes (Heinzel). Very rarely retinal hæmorrhages are associated with the papillitis.\*

The changes which occur in tubercular meningitis are always double, though often more advanced on one side than on the other. In some cases the excess was found by Dr. Garlick to be on the side of the chief cerebral change, but in a few it was on the other side. In most cases the patients die not long after its development. It is doubtful how far it affects vision. Dr. Clifford Allbutt believes that cases of meningitis often recover, the neuritis passing away, and sight being preserved or restored. This observation is supported by two cases described by Dr. Garlick. The symptoms were headache, vomiting, constipation, irregular pulse, normal temperature, and the development of ophthalmoscopic changes under observation. In both cases recovery was complete. In another case observed by him an increase in pulmonary symptoms was attended by a marked decrease in the cerebral symptoms, and in the optic changes, for five days before death.

Cases of optic nerve atrophy of old-standing are occasionally seen in which sight was lost in early life with acute cerebral symptoms very like that of an attack of meningitis. Several such cases have been related by Mr. Hutchinson.† Incipient atrophy was noted by Heinzel in one case of long duration, and in two others he observed the initial stage of consecutive atrophy.

The neuritis which accompanies tubercular meningitis was

\* Heinzel, loc. cit. p. 341, Cases 6, 16, 19, 26.

† "Oph. Hosp. Rep." v. 310 and ix. 124.



regarded by v. Graefe as affording the typical example of descending neuritis, the inflammation passing directly from the membranes to the optic nerves. With this my own experience accords. In some cases the existence of inflammation in the trunk of the nerve is obvious on naked eye examination. The nerve is swollen, softened, and reddened. In most cases it may be demonstrated by microscopical examination.

But the discovery that the optic sheath is often distended with fluid, just as in the neuritis of tumour, has led Manz and Leber to the conclusion that the neuritis of meningitis is probably produced in the same manner as that which they assume to occur in cerebral tumour, viz.: the increase of intra-cranial pressure forcing the subarachnoid fluid into the sheath, and so constricting the end of the nerve. There is, however, no correspondence in these cases between the occurrence of neuritis, the existence of increased intra-cranial pressure, and the distension of the sheath. The latter is probably related solely to an increase of the subarachnoid fluid, without which even great distension of the ventricles not only does not cause dropsy of the sheath, but may even remove it.\* For the settlement of the question more facts are needed regarding the relation of the supposed factors, and especially regarding the microscopical evidence of a descending neuritis.

In a considerable number of cases the symptoms of meningitis are distinct before the ocular changes are developed. In such cases the ophthalmoscope corroborates rather than assists the diagnosis. But in some cases the cerebral symptoms are latent or dubious, and in these the examination of the eyes may afford very valuable help, and it is probable that it would do so in at least one-third of the cases. Of the twenty-six cases watched by Dr. Garlick, the ophthalmoscope was of real diagnostic assistance in six, and probably would have been so in a larger number had earlier examination been practicable. In one case, which lasted twenty-six days, the symptoms were indefinite until the nineteenth day, whereas on the fourteenth day the ophthalmo-

\* For an instance of this effect in cerebral tumour see Case 21.



scopic changes were so unmistakable that the diagnosis of meningitis was confidently made. In another case, ophthalmoscopic changes were distinct on the ninth day, the symptoms were diagnostic only on the fifteenth day, the patient dying on the twentieth day. In both these cases, the changes about the optic commissure were much more marked than those elsewhere.

During the course of meningitis a diminution of the cerebral symptoms may be accompanied by a diminution in the ocular changes.

**SYPHILITIC MENINGITIS.**—Syphilitic meningitis may be associated with the ocular signs of syphilis, and may cause optic neuritis. When localized at the base the signs are similar to those of tubercular meningitis, but more chronic in course and more considerable in degree. When localized in the convexity, ocular symptoms may be entirely absent. If the case is not subjected to proper treatment, and local chronic meningitis persists, the disc may pass into a condition of intense neuritis, similar to that which is seen in cerebral tumour, as in the disc shown in its later stage as Pl. II. 1 (Case 2).

**EPIDEMIC CEREBRO-SPINAL MENINGITIS.**—Optic neuritis may occur, although it is rare. Schirmer found it in only one of twenty-seven cases examined. A purulent irido-choroiditis is much more frequent.

**TRAUMATIC MENINGITIS** often causes ophthalmoscopic changes, of which an instance is shown in Pl. III. 5, a case in which fever, delirium, and convulsions succeeded a fall on the head. The neuritis subsided with the symptoms. (These cases are considered farther on—"Injuries to the Nervous System.")

#### DISEASES OF THE CRANIAL BONES.

**CARIES.**—In caries of the sphenoid bone, or suppuration beneath the periosteum, the inflammation may extend to the optic




nerve, damaging it, and causing simple atrophy, or, descending the nerve, may produce intra-ocular neuritis. The disc shown in Pl. III. 2 (Case 1, appended), is an illustration of this effect. The damage to the nerve was just in front of the chiasma; the neuritis coincided in onset with an increase in local symptoms, which ended in an attack of meningitis, from which the patient died. When the drawing was made, the neuritis was confined to the eye corresponding to the damaged nerve; soon after the onset of the meningitis, a day or two later, similar neuritis made its appearance in the other eye. In this case there was no change in the sheath of the nerve. In a case recorded by Horner, of caries of the sphenoid, the sheath of the optic nerve was distended by purulent material as far as the eyeball.

Caries of the bone, at a distance from the optic nerves, does not cause ophthalmoscopic changes unless it excites meningitis or cerebral abscess.

**THICKENING OF THE CRANIAL BONES.**—General thickening of the cranial bones may cause optic neuritis and consecutive atrophy. Neuritis, with great swelling of the papilla, was present in a case of this description in the Queen Square Hospital under the care of Dr. Buzzard. The general thickening of the bones of the skull appeared to be of a sub-inflammatory character. There was no post-mortem examination, as the patient recovered, but Michel has recorded the case of a boy who was blinded by neuritis and consecutive atrophy early in life, and who died *æt.* fifteen. The necropsy revealed great hyperostosis of the bones of the skull, by which both optic foramina were considerably narrowed. The optic nerves were atrophied from the chiasma to the eye, but the orbital portion was greatly thickened by hyperplasia of the cellular tissue in the subvaginal space. A similar case has been described by Manz, in which the tissue between the sheath and the nerve had a semi-gelatinous aspect. Michel explains this change, by assuming that the narrowing of the foramen leads to retention within the sheath of lymphatic fluids, which cause irritation.





In other cases, similar condition of bone, exostoses, &c., narrowing the optic foramen, have caused only simple atrophy of the optic nerve.

### DISEASES OF THE ORBIT.

*Inflammatory processes in the orbit*, cellulitis, as in facial erysipelas, inflammation at the back of the orbit, or periosteal affections, may cause either simple atrophy or neuritis and consecutive atrophy. In the one case, the nerve is simply compressed by the inflammatory products, or, if inflamed, the inflammation is localized. Sight is lost sometimes very rapidly, and simple secondary atrophy of the lower portion of the nerve results, with occasionally ultimate narrowing of the vessels (Allbutt and Teale). In the other case, the inflammation is communicated to the nerve, and descends along it to the eye, or inflammatory processes in the sheath lead to a secondary papillitis.

Case 31 appended (Pl. II. 3) affords an example of the occurrence of simple atrophy of the nerve due to this cause. It is a type of which a good many cases are recorded in medical literature,\* in which loss of sight of one eye comes on simultaneously with paralysis of all the ocular muscles, sometimes with tenderness on pressing the eyeball back into the orbit. The symptoms have been ascribed to hæmorrhage (v. Graefe) or inflammatory mischief (Baumeister) at the back of the orbit. In the case illustrated, the cause was almost certainly "rheumatic" inflammatory mischief, for the symptoms came on suddenly, with much pain, after exposure to cold, in an intensely rheumatic woman, who had previously had an attack of "rheumatic" paralysis of the facial nerve. The paralysis of the ocular muscles slowly passed away, that of the optic nerve persisted, and the disc slowly passed into atrophy without the least sign of neuritis.

A very similar state of the nerve may result from a blow

\* *E.g.*, those recorded by v. Graefe, "Arch. f. Ophth." Bd. i. Heft. 1, p. 424, and Baumeister, *ibid.* Bd. xix. Heft. 2, p. 264.



on the head (Case 32). These conditions are considered farther on in the section on "Injuries to the Head."

*Tumours in the Orbit.*—A tumour at the back of the orbit or of the optic nerve, may cause neuritis such as results from intra-cranial tumour, but it is always unilateral and commonly associated with exophthalmos, which constitutes the distinctive sign of the affection.

### INJURIES TO THE HEAD.

Injuries to the head, blows, falls, &c., frequently cause ocular symptoms and often very marked ophthalmoscopic signs. The forms of ocular affection are of several varieties.

1. Damage to, or loss of sight, without ophthalmoscopic changes, or with very slight alterations—simple congestion of the disc, easily overlooked. This may result from blows on the anterior portion of the head. In many cases the mischief is probably direct damage to the retina, for in slight cases an alteration of vision has been noted such as must be ascribed to disturbance of the retinal elements. For instance, in a case recorded by Gosetti, after a blow on one angle of the orbit, near objects appeared unduly large, and there was some colour-blindness, but no ophthalmoscopic change.

2. Optic neuritis has followed injuries to the head in many cases, at an interval of a few days or weeks. It is apparently due to secondary results of injury, especially to meningitis (Pl. III. 5), less commonly to traumatic inflammatory softening of the brain or hernia cerebri (Case 50). The neuritis may be slight or considerable, and may entail loss of sight and consecutive atrophy. When occurring long after an injury it may be due to abscess of the brain, as was possibly the case in a patient who presented double papillitis a year after a violent blow from an exploded shell, over one eyebrow, causing ultimately necrosis of bone.\*

3. Simple atrophy of the optic nerves, unilateral or bilateral, may result from injuries which damage the optic nerves, directly or by pressure from secondary inflammation; in

\* Recorded by Boncour, "Journ. d'Ophth." July, 1872.



some cases it apparently results from simple concussion of the nerves and retina. An example of this condition was presented by Case 32 appended. A fall on the right side of the head and shoulder, injuring the circumflex nerve, was followed by slow grey atrophy of the right optic nerve. In such cases sight often fails some time before the ophthalmoscopic signs of atrophy are apparent.

*Concussion of the Brain* is attended by no ophthalmoscopic change. Simple concussion of the nerve and retina may, however, as just stated, cause loss of sight and slow atrophy.

*Contusion and Laceration of the Brain* may entail optic neuritis, commonly slight in degree, although sometimes marked, with increased vascularity, and redness and opacity of the adjacent retina. It is apparently due, in some cases, to a secondary meningitis, but may occur from the direct effect of the blow. It may constitute a valuable indication of the occurrence of greater mischief than a mere concussion. For instance, in a case recorded by Gazet,\* the symptoms of concussion were followed by neuritis and consecutive atrophy, and ten weeks after the injury a necropsy showed two foci of red softening in the right anterior lobe and one in the corpus callosum. Panas has found in such cases distension of the sheath of the nerve, and it is assumed, on the Schmidt-Manz theory, that thus the neuritis is produced, but this is at present unproved.

*Fracture of the Skull.*—Fracture of the base passing through the sphenoid bone may cause direct damage to one optic nerve with loss of sight and subsequent neuritis and atrophy. When neuritis occurs early, direct damage to the nerve should be suspected. In such cases blood is sometimes found extravasated into the sheath of the optic nerve, and cedema of the disc with retinal extravasations may accompany the condition (Case 49).

*Compression of the Brain* may, it is said, be attended by changes in the fundus oculi—distension of the retinal veins, congestion and cedema of the papilla. Such appearances are, however, certainly rare.

\* "L'Un. Méd." 1865, ii. 3, No. 63.



*Traumatic Meningitis* entails, very commonly, ophthalmoscopic changes similar, for the most part, to those which are found in tubercular meningitis. Meningitis often results from fracture of the base of the skull, and is as often attended with neuritis as is tubercular meningitis. An instance of traumatic mischief with neuritis is afforded by the case figured in Pl. III. 5. The neuritis came on with mental disturbance and convulsions, following, at an interval of a week, a fall on the head. The change was slight in degree, although very distinct, and passed away soon after the cerebral symptoms subsided, leaving no trace. When the neuritis is more intense, blindness may result. Hock\* has described the case of a child who had symptoms of meningitis five months after a fall on the head. Optic neuritis ("descending") was found with the ophthalmoscope, sight being little impaired. Four years later, however, the child was healthy but blind, with atrophy of both optic nerves. In other cases of the kind actual meningitis has been found. The neuritis may be associated with the signs of mischief at the base of the brain, paralysis of ocular muscles, &c. The chronic inflammatory consequences of an injury (chronic meningitis, inflammatory "growths," &c.) may persist and progress for a long time, even for years, as in Case 4 (Pl. VI. 2), in which meningeal growths, apparently the result of chronic inflammation, were found beneath two old fractures of the skull, the result of injuries received several years previously, and at the base the results of chronic meningitis damaging the arteries (and causing fatal softening), but no recent change.

*Hernia Cerebri*, resulting from fracture of the skull, with loss of bone, may be accompanied with neuritis, as in Case 50.

*Necrosis of the Cranial Bones*.—The damage to bone by injury may cause necrosis and meningitis or abscess of the brain, both of which may entail inflammation of the optic nerve. As Dr. Hughlings Jackson has pointed out, the relation of the symptoms to the injury may be obscure and unsuspected by the patient or friends, so that careful attention

\* "Oest. Jahrb. für Pädiatrik," vol. v. 1874, p. 1. "Nagel's Jahresb." vol. v. p. 427.



should be paid to any sign of injury, such as puffy swelling, &c., and the occurrence of a blow or fall should be carefully asked about in all cases of local brain disease.

### *DISEASES OF THE SPINAL CORD.*

#### ACUTE INFLAMMATION.

Primary myelitis and spinal meningitis are, as a rule, unattended by any changes in the fundus oculi. The only published exceptions to the rule have been recorded by Dr. Clifford Allbutt, who has described one case of partial atrophy of the discs after a myelitis of the dorsal cord, and a case of chronic myelitis in the upper dorsal region, with tenderness at the second dorsal vertebra, in which there was reddening of the discs, and so much effusion that the edges of the discs could not be seen. The tint afterwards slowly changed to grey, and a condition of partial atrophy persisted.

#### SCLEROSIS OF THE CORD.

##### POSTERIOR SCLEROSIS : LOCOMOTOR ATAXY.

Atrophy of the optic nerves is, as is well known, frequent in locomotor ataxy. In what proportion of the cases it occurs is difficult to say. Ophthalmic surgeons have been impressed with its frequency. It constitutes a large proportion of the cases of simple atrophy. Charcot believes that almost all cases of so-called simple atrophy ultimately present spinal symptoms. But we must not infer from this the converse proposition that most cases of ataxy present optic nerve atrophy. No statistics at present published afford any guide, because cases of ataxy are of too ordinary a character to obtain publication, and the opportunity for seeing cases of ataxy on a sufficiently large scale to afford any trustworthy basis for statistics is rare. Moreover, the whole history of a case is necessary, up to its close, before the occurrence of optic nerve atrophy can be excluded.



My own experience, mainly at the National Hospital for the Paralysed and Epileptic, suggests that atrophy of the disc is not nearly so common in ataxy as is often stated. Out of thirty consecutive cases, only three presented optic nerve atrophy. Caution is of course necessary in drawing an inference from this, because many of the cases were only under observation for a short period of their history, and it is possible that the occurrence of atrophy may take patients to other institutions. Still, from these cases in connection with others (not included in the above), and which I have been able to watch for a long period—some of them until death—I do not think that optic nerve atrophy occurs in more than fifteen per cent. of ataxies. When it does occur, it is more frequently an early than a late symptom, occurring before rather than after the difficulty in walking has become considerable. When sight is lost, the inco-ordination is greatly increased—the condition which the physician employs as a test to exaggerate the difficulty, the withdrawal of the guiding visual sensation, being permanent. But advanced atrophy is often seen in cases in which the ataxic symptoms are, even as increased by the blindness, so slight that a careful investigation is necessary to discover them. Blind people often walk in a more or less hesitating and uncertain manner, and the uncertainty of slight ataxy is easily attributed to the blindness. Inquiry, however, elicits other symptoms, as pains in the limbs, especially “lightning pains,” and loss of sexual power, and careful observation of the gait shows an unsteadiness in turning, and in standing with the feet, toes and heels, close together. It is, however, well known that the atrophy may occur before any obvious symptoms referable to the cord. One extreme instance of this early atrophy has come under my own observation, in which the atrophy of the discs<sup>]</sup> was complete, and vision lost for twenty years before the first symptoms of ataxy showed themselves. But in many such cases the loss of the “knee reflex,”\* an early symptom in ataxy to which Westphal abroad, and Grainger

\* *I.e.*, the normal jerk of the leg when the patella tendon is struck, the leg being in a position in which it is free to move. The most convenient posture is with one thigh placed across the other, or (especially in stout



Stewart and Buzzard in this country, have drawn special attention, precedes other symptoms, and if looked for will often be found to co-exist with optic nerve atrophy when other symptoms of ataxy are absent. A very marked example of the same relation, in which the atrophy existed for fifteen years, associated only with lightning pains and loss of the knee reflex, has been related by Dr. Buzzard.\* An instance of the occurrence of atrophy when the spinal symptoms are very slight is afforded by Case 33.

When the atrophy is advanced, the optic discs are usually grey, even to indirect examination, and to direct examination very grey and mottled, the meshes of the lamina cribrosa distinct, the excavation considerable, the edges sharp and clear, the sclerotic ring distinct. To ordinary daylight the tint is a greenish grey; to gaslight a bluish or iron grey. Its characters are shown in Pl. II. 6. Less commonly, the discs appear white to the indirect method of examination, but a grey mottling can always be seen with the direct method. The vessels usually are of the normal size. The grey disc and normal vessels have been supposed to be peculiar to this form of atrophy, but this is incorrect. The disc in atrophy from post-orbital pressure on the nerve, such as that shown in Pl. II. 3 (Case 31), may present exactly the characters of the atrophy of ataxy.

A stage of hyperæmia, "chronic optic neuritis," has been described by Dr. Clifford Allbutt as sometimes preceding the atrophy, but the occurrence of this condition has not been confirmed by other observers. I have frequently looked for it, but without success.

The anatomical characters of the atrophy have been already described (p. 95). The trunk of the optic nerve is commonly nearly normal in size, but is grey and semi-translucent. The grey degeneration may stop at the chiasma, but often, as

persons) with the thigh resting just above the knee on the observer's arm, his hand being placed on the other leg. The leg which is tested should depend not quite vertically. In commencing ataxy no jerk occurs. It must not be hastily inferred, however, from the occurrence of the jerk, that the atrophy is unconnected with disease of the cord, because lateral sclerosis, in which there is an excess of the knee reflex, may, in rare cases, be accompanied by optic nerve atrophy.

\* "Brain," No. II. 1878, p. 168.



Türk pointed out, involves also the optic tracts, and can be traced to the external corpora geniculata. The microscopical investigations (of Leber especially) have shown that the change in the nerve consists of an increase in the interstitial tissue, and sometimes the formation of translucent colloidal tissue around the vessels as in Pl. XVI. 5, together with a wasting of the nerve fibres. The histological resemblance to the change in the posterior columns is not so close as has been asserted. Charcot has suggested that the change commences in the nerve fibres, and is essentially parenchymatous, and the view has much probability, but it rests on the clinical rather than histological evidence.

The affection is usually bilateral, although often more advanced in one eye than in the other. In rare cases, one eye may be much affected, and the other very little.

*Symptoms.*—The affection of sight is characterized, very uniformly, by a progressive peripheral defect in the field of vision, especially extensive on the outer side (Förster). It progresses until only a small portion is left, situated to the inner side of the blind spot and enclosing the fixing point. Central vision may be little impaired even after the peripheral defect has become very great. When the acuity of vision is thus preserved, patients may, for a long time, be unaware of the affection of sight, until indeed the field is greatly reduced. Sometimes a sector-like defect occurs, which, according to Förster, always has its apex at the blind spot, never at the fixing point.

Colour blindness is frequent, and is almost always an early symptom, as Galezowski and Charcot have rightly insisted. The first change is commonly a loss of perception of green, then of red (see p. 98). It is this early affection of perception of colour vision which affords the strongest evidence of the commencement of the atrophic process in the nerve elements and not in the interstitial tissue.\* There is occasionally a peculiar sensitiveness to bright light, and the defect in the field may at first be more perceptible in a bright than in a dim light, and the latter is preferred by the patient.

\* Charcot, "Leçons sur les Maladies du Syst. Nerv." Abadie, "Ann. d'Oculistique," 1878. Lebris, "Thèse de Paris," 1878.



The manner in which the atrophy often precedes the symptoms of spinal mischief points to the mutual independence of the two affections, whatever may be their relation to a common cause. Anatomy corroborates this conclusion, for in cases in which both posterior columns and optic nerves are affected, no anatomical continuity of degeneration can be traced. At first the degeneration is confined to the optic nerve, in which it evidently begins. The two are thus not parts of a progressive degeneration, but are an example of the independent simultaneous affection of parts exposed to the action of a common cause, of the nature of which we are at present ignorant.

The course of the optic nerve atrophy is very like that of the cord degeneration. Recovery, if ever observed, is indeed a still rarer event than in the ataxy. The interference with the function of the posterior columns of the cord may, in a recent case, be out of proportion to structural change, but in the eye this is rare, and the structural change is that on which our prognosis is based. At the same time, an arrest of progress is sometimes obtained, as it is in the ataxy. Although ultimately almost all cases increase, yet the progress is often very slow, and many years may pass before even a small field is finally lost. The perimeter affords valuable aid in estimating changes, which patients are apt to regard too favourably.

#### LATERAL SCLEROSIS.

Ophthalmic changes are very rare in cases which present the symptoms of primary lateral sclerosis of the cord. In one or two cases, however, I have seen grey atrophy slowly supervene, similar in character to that met with in locomotor ataxy. One such case is appended (Case 34). In another case, a girl in which it was well marked, the symptoms were of combined lateral and insular sclerosis.

#### INSULAR (DISSEMINATED) SCLEROSIS.

Amblyopia occasionally occurs in insular sclerosis of



the brain or cord, but very rarely goes on to complete loss of sight. It is often unattended by the ophthalmoscopic signs of atrophy; the examination is frequently difficult on account of the associated nystagmus. In such cases the optic nerves may be found to be occupied by patches of sclerosis, similar to those which occur elsewhere.\* The nerve fibres passing through are not destroyed, their axis cylinders persist, and retain impaired functional power, although their medullary sheath may disappear.

Occasionally, however, atrophy of the optic nerves is observed in this affection quite similar in its character to that seen in ataxy, attended by a similar loss of vision, progressing to complete blindness.† An instance of this is afforded by Case 34*a*, appended.

#### CARIES OF THE SPINE.

Caries of the spine in the dorsal region is unattended by ocular changes. Bull‡ has recorded an examination of fifty cases, but the changes he met with, confessedly rare, are of doubtful pathological character, being confined to fulness of the retinal vessels, and sometimes dilatation of the capillaries of the disc. When the caries is in the cervical region, marked congestion of the disc has been described. In one case under my own observation the discs were red, and there was much white tissue about the vessels, very conspicuous against the red disc (as in Pl. I. 2), but the margins of the side were quite clear and the pathological nature of the appearance was somewhat doubtful. Abadie§ has recorded a case in which atrophy of the optic nerves supervened, and attributes it to meningitis ascending to the base of the brain, of which, however, there was no other evidence.

\* Charcot, "Leçons sur les Maladies du Système Nerveux," t. i. p. 206.

† Magnan, "Arch. de Physiologie," t. ii. p. 765. Liouville, "Mémoires de la Soc. de Biologie," 1868, p. 231.

‡ "Am. Journal of Med. Science," July, 1875.

§ "Bull. de la Soc. de Chir." Jan. 12, 1876.



## INJURIES TO THE SPINE.

The subject of the changes in the optic discs in spinal injuries has received a large amount of attention in consequence of the prominence which "railway cases" have given to this class of accident. In its scientific relations the subject has not escaped the sinister influence which litigation exercises on the investigation of facts, and there is no doubt that the pathological nature of many of the appearances described in these cases has been the result of an affection of the mind of the observer, rather than of the eye observed. Still, it seems well established that in some cases of spinal injury ocular changes supervene, and the observations of Clifford Allbutt especially show that they occur with greater frequency the higher up the injury is. The changes are those of simple congestion, congestion with œdema, and slight neuritis, uniform redness of the disc, and concealment of the outlines so that the position of the disc may ultimately be recognized only by the convergence of the vessels. In one case a "daffodil colour" was described. Sight is a little, but not much, affected, and the condition, which is of slow onset and course (coming on some weeks after the injury), usually passes away. A remarkable case of this kind has been described by Thorowgood.\* A girl, æt. twelve, after a blow on the lower part of the back, complained of pain and tenderness at the neck, with muscular stiffness. A week after this some dimness of sight came on and increased, until five weeks after the blow sight was lost, and well-marked optic neuritis was found. Leeches and mercury were employed, and the discs and sight recovered completely.

It has been supposed (especially by Mr. Wharton Jones) that a disturbance of the sympathetic is the cause of the ocular symptoms in spinal injury. In cases of actual disease of the sympathetic, however, no ophthalmoscopic change has been found (Hughlings Jackson, Riegel, and Jolly). Dr. Allbutt suggests that they may be the result of "meningeal irritation" passing up to the base of the brain, but other evidence of such irritation has not been recognized.

\* "Clin. Trans." viii. 1875, p. 80.



*FUNCTIONAL DISEASES OF THE NERVOUS SYSTEM.*

## EXOPHTHALMIC GOÎTRE.

The conspicuous ocular symptoms which form part of Graves' disease might lead to the expectation that changes in the fundus oculi would be found in that affection. As a rule, however, it is not so. The prominence of the eyeballs does not lead to any alteration in the optic nerve. The retinal arteries participate in the general arterial dilatation, which occurs so uniformly in the disease, and is ascribed to a paralysis of the sympathetic vaso-motor fibres. The arteries are larger than normal, and when their course is favourable for their comparison with the veins, the two may be observed to be nearly equal in size, clearly in consequence of arterial dilatation. The strong pulsation which occurs in the arteries of the head and neck, in consequence of their dilatation, and of the excited action of the heart, may be visible in the retina as a spontaneous arterial pulsation, as Becker first pointed out.

## CHOREA.

Embolism of the central artery of the retina is an extremely rare result of the endocarditis, which is generally found (post-mortem) to be associated with the disease in severe cases. Only two instances have been recorded; the best marked case is that of Swanzy, of Dublin.\* The embolism occurred at the time of the commencement of the chorea, and was in the left eye. The chorea was most severe on the left side. The state of the heart is not mentioned. The other case is recorded by Förster, but was not seen until some time after its occurrence. The patient, a child, had suffered from chorea for some years, and during the chorea had lost the sight of one eye. The disc was atrophied, and the arteries very small.

It is probable that double optic neuritis, slight in degree, may, in rare instances, occur during the height of the chorea,

\* "R. L. Ophth. Hosp. Rep." viii. 181.



just as it does in other diseases attended with intense functional disturbance of the brain. Such a condition was seen by Dr. Hughlings Jackson in a case of hemichorea, right-sided. When first observed the discs were hyperæmic, badly margined, the veins large and irregular. The change was most marked in the left eye. The appearance increased with the chorea, and disappeared with recovery. In the only case of chorea in which I found optic neuritis the change was distinctly due to albuminuria. Whether any influence can be ascribed to the cerebral disease is doubtful. Bouchut has figured white exudation on and about the disc in a case of severe chorea, third attack.

#### NEURALGIA AND MIGRAINE.

Occasionally atrophy of the optic nerve has been observed in cases of severe neuralgia. Its origin is obscure. Temporary amaurosis, supposed to be "reflex," is more common. The transient disturbances of sight, temporary amaurosis, hemiopia, &c., which accompany migraine are well known. Now and then atrophy of the optic nerve has been observed to follow repeated attacks, and Mr. Hutchinson has associated the three symptoms of migraine, amaurosis, and xanthelasma. It is probable that severe neuralgia of the fifth nerve may induce glaucoma. It has been proved that irritation of the fifth nerve may increase the intra-ocular tension,\* and Abadie has recorded a case in which the glaucoma appeared to be due to this cause.

#### IDIOPATHIC EPILEPSY.

*Inter-paroxysmal State.*—In idiopathic epilepsy the appearance of the fundus oculi between the paroxysms is, as a rule, normal. Some observers have described changes in the optic discs, and increased vascularity, distended retinal vessels, and the like. I have examined very carefully about a thousand epileptics, and have found that in most cases every character

\* Hippel and Grünhagen, "Arch. f. Ophth." vols. xiv. and xvi.



of the fundus was such as is presented by persons not epileptic. Now and then an unduly red disc is to be seen, but not more frequently than in persons not epileptic, and in most cases it is explicable by the ocular conditions—a point too little attended to in medical ophthalmoscopy. The only deviation from the normal state of the fundus which has seemed to me frequent, is an unusual equality in size of the retinal arteries and veins. The latter are not, as a rule, larger than normal, and the arteries appear as if large from a lax state of wall. Spontaneous pulsation in the veins has been described by Kostl and Niemetschek\* as especially frequent in epileptics: it is certainly not more frequent in them than in individuals who are not epileptic.

*During the paroxysm* the appearance of the fundus has been described variously by different observers. For obvious reasons, the difficulties in the examination are great, and opportunities are rare. The only change which seems well established, is that the retinal veins, during the stage of lividity, become much distended. Regarding the state of the arteries, there is considerable doubt. On theoretical grounds, because contraction of the cerebral arteries is supposed to be the immediate cause of a fit, it has been expected that contraction of the retinal arteries would also be seen, and De Wecker has described a sensible diminution in the size of the arteries during this pallor, but Kostl and Niemetschek thought that they recognized in one case dilatation of the arteries during an attack. Observation, however, of the size of the vessels by the indirect method, is of small value.

In a case of convulsions from meningeal hæmorrhage, in which there was, however, no initial pallor of face, I was once able to keep a retinal artery and vein under view through the whole of a severe fit, from before its commencement until after its close. The retinal artery throughout presented not the slightest change in size. During the stage of lividity, the vein became large and dark.† In a case of chronic local meningitis of the motor region of the left hemisphere (Case 2), by galvanizing the region of the cervical sympathetic, I was

\* "Prager Vierteljahreschr." vols. cvi. and cvii.    † "Lancet," 1875, ii. 655.



able to produce the aura with which the fits commenced, and once watched the retinal vessels by the direct method during the operation, but no change in their calibre was to be observed, although the aura was so intense as almost to pass into a fit. Dr. Allbutt, during a fit, has observed pallor of the discs, and a similar condition has been seen by Dr. Hughlings Jackson and Dr. Arlidge,\* immediately after a fit, in several cases. During an attack of epileptiform amaurosis, Dr. Jackson failed to see any change in the fundus which he was at the time comparing with a drawing of it. After a second attack the veins appeared a little paler than before.† I have repeatedly examined patients immediately after fits, but without being able to satisfy myself that there was any difference from the appearance of their discs and vessels at other times.

In cases of epilepsy in which the fits were frequent, Dr. Allbutt has seen hyperæmia of the discs, and even some exudation into them. As a rule, my own observations have given quite negative results. In one case, however, I met with marked changes in the discs, developed under observation during a series of exceedingly severe convulsive attacks, recurring at short intervals for several days. The patient was a young man, and the convulsions were of the kind best described by the term "co-ordinated," which some would term hystero-epileptic—paroxysms of struggling, arching of back, throwing about of head and limbs, so intense that the united strength of three or four persons was required to keep the man in bed. They were accompanied by loss of consciousness. Bromide and other remedies produced no effect, and the convulsions continuing unabated until ice was applied to the cervical spine, when the attacks at once ceased. The optic discs, after some days of convulsion, became reddened and veiled, so that their edges were quite invisible, and there was distinct swelling. After the cessation of the fits the discs gradually resumed their normal appearance. This patient, about three months later, died, after a series of true epilepti-

\* "West Riding Asylum Reports," vol. i.

† "Lancet," Feb. 17, 1874.



form convulsions beginning in the left hand. Post-mortem, no trace of disease was visible in the brain to naked eye examination.

It might be expected that the retinal vessels would often give way during the violent venous stasis of an epileptic fit, just as do those of the conjunctiva. As already stated, retinal hæmorrhage is rarely observed under the circumstances, no doubt on account of the support afforded to the walls of the vessels by the intra-ocular tension.

It must be remembered that many cases of apparently idiopathic epilepsy may present traces of old optic neuritis or choroiditis—indicative, the former certainly, the latter probably, that the convulsions originated in organic brain disease; the choroiditis indicating former syphilis. Traces of old optic neuritis are especially common in cases of epilepsy due to blows on the head. It must also be remembered that chronic convulsions resembling idiopathic epilepsy may occur in the subjects of lead-poisoning and chronic renal disease, in each of which simple optic papillitis may be present.

### HYSTERIA.

Although functional disturbances of sight (single or double amblyopia, hemiopia, colour-blindness, often with pain on use of the eyes) occur occasionally in the hysterical, ophthalmoscopic changes are very rare. Atrophy of the optic nerve has been met with in one or two cases. When there is extreme amblyopia, dilatation of vessels and serous transudation into the retina has been seen by Landolt. The chronic perineuritis described by Galezowski in one case must be regarded as altogether exceptional. In hystero-epilepsy also there are, as a rule, no ophthalmoscopic changes, but after extremely severe and repeated fits, slight alteration may be met with, as in the case described in the section on "Epilepsy."



## INSANITY.

The frequency with which pathological appearances are to be recognized with the ophthalmoscope in cases of insanity has been very variously stated. The discrepancy between observers is so great, that it seems certain undue weight has been given by some to appearances which are not uncommon in normal conditions. The observations in which changes were found in a large proportion of the cases examined must therefore be received with considerable reserve. As an instance of the different conclusions which have been reached may be cited the observations of Tebaldi,\* who found changes in three-quarters of the cases examined; and of Schmidt-Rimpler,† who found changes only in thirteen out of 128 cases, and some of the thirteen he considered as doubtful. An even more striking instance of this discrepancy is afforded by two observers of the appearances in general paralysis, one of whom described atrophy as existing in eight out of every nine cases examined, while the other found hyperæmia in about the same proportion.

It must be remembered, in estimating the significance of the considerable changes sometimes found, that cases of "organic" brain disease, tumour, softening, chronic meningitis, and the like, in which mental disturbance is prominent, often find their way into asylums.

GENERAL PARALYSIS OF THE INSANE.—This disease is more closely allied to some spinal degenerations than to other forms of mental derangement. Unequivocal changes in the eye have been found much more frequently than in any other form of insanity. Loss of sight has been known since the time of Calmeil as an occasional complication; but in a considerable degree it is rare. Billod noted complete blindness in only three out of 400 cases.‡ The loss of sight has been proved to depend on grey atrophy

\* Nagel's "Jahresbericht," 1870, p. 374, from the "Rivista Clinica," 1870.

† "Ann. d'Oculist." vol. lxxiv. 1875, p. 267.

‡ "Ann. Med.-Psychologiques," 1863.



of the optic nerves, similar to that which occurs in spinal disease, and commonly without diminution in the size of the retinal vessels. In its slighter degrees, it affects one eye more than the other, and its occurrence may easily be overlooked unless the ophthalmoscope is used. Even in slight degree it is not a very frequent symptom. Galezowski found it in one only of forty cases examined.\* Boy, of eighty cases very carefully examined, found commencing atrophy, with amblyopia, in four only.† Jehn found distinct atrophy in seven cases out of forty-seven: in four double, in three single.‡

As in locomotor ataxy, it is often an early event, and may even precede the other symptoms of the disease. Magnan has observed the affection of sight to commence two and four years before the other symptoms of general paralysis. In a case recorded by Nettleship, grey-white atrophy of the disc in a man aged thirty-five, with slight unsteadiness of gait, was followed, nine months after the onset of the amblyopia, by mental symptoms which developed into general paralysis.§

It is said by Jehn and Boy that the amblyopia commences with defective colour vision, just as it may do in locomotor ataxy. As another point of contact between the two diseases, it is of interest to note that Westphal has shown that sclerosis of the posterior or lateral columns of the cord is occasionally found in general paralysis. It has not yet been ascertained whether atrophy of the optic nerves is especially common in such cases.

The atrophy usually begins as such in the simple form, but Magnan and Clifford Allbutt have described an initial stage of hyperæmia—uniform redness of the optic discs, with softened edges. Leber and other observers have failed to find this. Well marked papillitis was found by Boy in one case, and in another he observed small hæmorrhages along a few of the veins. Neuritis was also seen in one case by Jehn. "Peripapillary œdema," a "brownish circle around the

\* "Union Médicale," 1866, vol. xxxi. p. 404.

† "Thèse de Paris," 1879.

‡ "Allg. Zeitsch. für Psychiatrie," xxx. 519.

§ "Oph. Hosp. Rep." vol. ix. p. 178.



papilla,"\* was observed in some cases by Magnan and Galezowski. Voisin described an undue tortuosity and dilatation of the retinal arteries, while by Magnan and others a grey or white line along the vessels was frequently observed. Jehn described the arteries as of very small size in some cases. Bouchut has figured aneurisms of the branches of the central artery from two general paralytics. Most of the cases I have examined in various stages of the disease presented perfectly normal conditions. In one case only was there the appearance of simple congestion of the disc.

MANIA.—During a paroxysm, Clifford Allbutt in one case found pale discs; in others the discs were hyperæmic. Noyes† described hyperæmia in fourteen and anæmia in six out of twenty-six cases. Dr. Savage, of Bethlem Hospital, has informed me that he has noted pallor of the discs in some cases, and in others undue fulness of retinal veins, but no other change. Of several cases I have examined, in one only was there a pathological appearance, undue and uniform redness of the discs, with distinctly softened edge.

MELANCHOLIA.—Most observers have reported the ophthalmoscopic appearances in melancholia to be normal, and with this my own observations entirely agree. Jehn, however, described hyperæmia in some of forty cases examined, and in two there was actual neuritis, which he supposes to be due to meningitis.

DEMENTIA.—In *chronic dementia*, Dr. Clifford Allbutt, classing "worn out lunatics of all sorts" in the category, found changes in twenty-three cases out of thirty-eight—in some atrophy, in others hyperæmia. Noyes found hyperæmia in two-thirds of the cases examined, atrophy in none. Jehn and Klein could find no change in the discs in any cases examined.

In *acute dementia* Clifford Allbutt found no change. "Anæmia of the fundus" with "œdema of the retina around the disc" have been described by Aldridge.‡

\* The nature of this appearance is questionable. Œdema usually causes a pale halo around the disc as in Pl. I. 3.

† "American Journal of Insanity," 1872.

‡ "West Riding Asylum Reports," vol. iii.



## DISEASES OF THE URINARY SYSTEM.

## BRIGHT'S DISEASE.

In all forms of renal disease loss of sight from uræmic poisoning may occur.\* Its characteristics are the sudden onset, completeness, the occasional absence of ophthalmoscopic changes (of course, changes due to the renal disease may co-exist), the preservation of the reaction of the pupil, and the quick disappearance of the symptom when the blood state is relieved by purgation or diaphoresis.

In diseases of the kidney of considerable duration, the vessels of the retina may present changes which they undergo in common with the vascular system of the body generally. The tendency to hæmorrhage which exists in so marked a degree in many cases of chronic Bright's disease may lead to simple retinal hæmorrhage. Lastly, considerable changes are often seen in the retina, which vary greatly in different cases, and are commonly described by the general, but not very accurate, term of "retinitis albuminurica."

*Vessels.*—According to my own observations,† in many cases of chronic renal disease, especially of the contracting form, there is to be seen a notable diminution in size of the retinal arteries, independently of the existence of any special retinal disease. The veins are in such cases not larger than the normal, but the arteries are not more than one-half or even one-third the diameter of the veins (Pl. IX. 2), instead of being two-thirds or three-quarters the diameter. The comparison can only be made, as already stated (p. 9), between arteries and veins which run side by side and correspond in distribution. Sometimes the arteries can be

\* The association of transient amaurosis with dropsy after scarlet fever was noted in 1812 by Wells ("Med.-Chir. Trans." vol. iii.). The first observation of actual changes in the retina was made (post mortem) by Türk in 1850 ("Zeitschrift der Wiener Aerzte," No. 4, 1850). The microscopical changes were carefully studied by Zencker ("Arch. für Ophth." ii. 142), and Virchow ("Arch. für. Path. Anat." x. 1856, p. 178).

† "British Medical Journal," December 9, 1876.



seen, even by the direct examination, as lines only (Pl. IX. 4). I have only observed this, however, when papillary obstruction co-existed. The size of the arteries may then be less than is ever seen in simple papillitic obstruction without Bright's disease. Very often, when slight swelling of the retina co-exists, the arteries are invisible beyond the papilla (Pl. IX. 3, X. 1), due in part, I believe, to their extremely small size. When this reduction in size exists the pulse usually presents marked incompressibility. A reduction in size, in one case of acute passing into chronic Bright's disease, was observed to coincide with a very marked increase in the tension of the pulse. The contraction is not visible, however, in all cases in which the arteries are tense. In the absence of any cause for the reduction, it must be ascribed to arteriole contraction, and constitutes evidence of some weight in support of the view of Dr. G. Johnson that such contraction exists, and causes the hypertrophy of the muscular coat of the artery. It is, as just stated, to be seen in some cases, independently of any retinal disease, but is not invariable even when the tension of the pulse is very high. This may in some cases be due to degenerative changes in the walls of the vessels, as in Pl. XII. 1, in which no contraction can be perceived.

When the retina is diseased, conspicuous white lines are sometimes seen along the vessels, apparently due to a sclerosis of the outer coat. I am not aware that this condition has been observed in any case in which the retina was otherwise normal. The remarkable appearance shown in Pl. XII. 1 presents, however, a still more extreme condition of perivascular change. The arteries are, in part, concealed by a white opaque sheath, ceasing in places suddenly, and presenting the normal vessel emerging from the sheath.

In the same fundus one artery presented two small aneurismal dilatations—an interesting evidence of the vascular degeneration which is a well-known consequence of chronic renal disease.

In the retinal capillaries irregular dilatations may be found, especially in cases of retinal degeneration, as in



Pl. XVI. 10. In this figure an increase of the nuclei of the capillary wall is seen in places, thickening it. It is probable that the degeneration of such nuclei, and the formation of such aneurismal dilatations, are the conditions which lead to hæmorrhages, which were numerous in this case (Pl. X. 1).

*Hæmorrhages* form, as will be immediately described, a conspicuous feature of most cases of retinal disease in albuminuria. Their common seat is the nerve-fibre layer, in which they are striated and flame-shaped, and often follow the course of the vessels. Less commonly they may occur in other layers, and are then rounded and irregular. They may detach the retina from the choroid or burst through into the vitreous. They sometimes occur, however, apart from other changes, as isolated evidence of the hæmorrhagic tendency. An instance of this is shown in Pl. IX. 1. The retina which presented this extravasation, even up to the time of the patient's death, several months later, showed no sign of other changes. They are probably due to the weakening of the wall of the minute vessels (by such changes as have been just described), and to the increased intra-vascular tension, causes which are the same as those which give rise to the extravasation into the brain, so common in the same cases.

“ALBUMINURIC RETINITIS.”—The special retinal alterations which occur in renal disease are perhaps the most frequent ocular changes to come under the notice of the physician. They are met with only in chronic forms of renal disease—those which are chronic from the beginning, or which are chronic as resulting from an acute attack. They have been met with in most chronic forms of kidney disease—granular kidneys, large white kidney, sequential to an acute attack, and lardaceous kidney. They are by far the most common in the granular form, and least common in the lardaceous kidney.\* Their frequency cannot at present be determined.

\* It has been said that retinal changes do not occur with lardaceous disease of the kidney. Cases have, however, been recorded by Beckmann, Traube, Alexander, and Argyll Robertson, and one case has come under my own observation.



Published statistics vary between 7 and 33 per cent. This is doubtless due mainly to their relation to the chronicity of the disease. Only after the kidney disease has been exerting its influence on the system for a considerable time, do the retinal changes occur. They commonly correspond in time with the development of cardiac hypertrophy. Not that there is any necessary connection between the retinal and the cardiac change, other than that both indicate a pronounced and prolonged effect of the renal disease upon the system. It is indeed well known that the renal disease is often first ascertained by the discovery of the existence of the ocular change, but this is not opposed to the fact just stated, since the retinal change is only the earliest discovered symptom in those cases in which the renal affection has been insidious in its onset, and has existed for a long time, and reached an advanced stage, before its symptoms obtrude themselves upon the patient's notice.

It has been suggested that the retinal changes may sometimes precede the onset of the renal affection, but all observed facts concur in showing that the relation above described is the invariable one, that renal disease, with more or less albuminuria, precedes the retinal affection.

The retinal disease presents certain elements which are variously combined in different cases. These are—(1) diffuse slight opacity and swelling of the retina, due to œdema of its substance; (2) white spots and patches of various size and distribution, due for the most part to degenerative processes; (3) hæmorrhages; (4) inflammation of the intra-ocular end of the optic nerve; (5) the subsidence of inflammatory changes may be attended with signs of atrophy of the retina and nerve.

In most cases one or other of these changes predominate, especially in the early stage of the affection, and, according to the element most conspicuous, four types of disease may be distinguished. These are, the degenerative, the hæmorrhagic, the inflammatory, and the neuritic, according as white spots of degeneration, extravasations of blood, parenchymatous retinal inflammation, or inflammation limited



to the optic nerve, predominate. It is, however, to be observed that degeneration and hæmorrhage commonly accompany or succeed the inflammatory changes, and that forms are often seen combining the characters of these varieties. In the typical degenerative and hæmorrhagic forms the signs of inflammation are inconspicuous or subordinate.

The *degenerative form* (Pl. IX. 2) is the most common. It commences usually without signs of inflammation, by the appearance of small whitish spots on the substance of the retina, sometimes near the optic nerve entrance, sometimes at a distance. They are commonly at first soft-edged and rounded, and as they get larger become irregular. Generally, small very white spots, often punctiform or elongated, make their appearance around the macula lutea, arranged in a radiating manner, although frequently not forming a complete circle. These are sometimes so minute as to be only visible on careful direct examination; sometimes they are large and very conspicuous, and are often arranged irregularly, end to end, so as to form radiating streaks, beyond which dots may be scattered (Fig. 18). Often a less intense and diffuse opacity is visible in tracts here and there. Sometimes the larger spots coalesce into white areas which may surround the disc.

Hæmorrhages, almost constant in all forms of renal retinal affection, are slightest in the most chronic degenerative forms. They often are adjacent to the white spots due to the changes in the nerve fibres, and, lying for the most part in the nerve-fibre layer, they have a more or less striated arrangement, determined by the nerve fibres, the direction of which the striæ follow. Sometimes linear hæmorrhages are seen. When larger, the extravasations are more or less flame-shaped. When small they often lie adjacent and parallel to vessels, but it is not often that the vessel from which they originate can be traced. When large they may be irregular in shape and occupy the deeper layers of the retina.

The diffuse opacity already described is sometimes con-



siderable and accompanied by a little swelling here and there. Such a change is, however, rarely considerable in the form which begins with simple degeneration.

The retinal changes in this form may be considerable without any change in the optic disc. Often, however, its edges become blurred, the physiological cup indistinct, and the tint abnormal, reddish-grey.

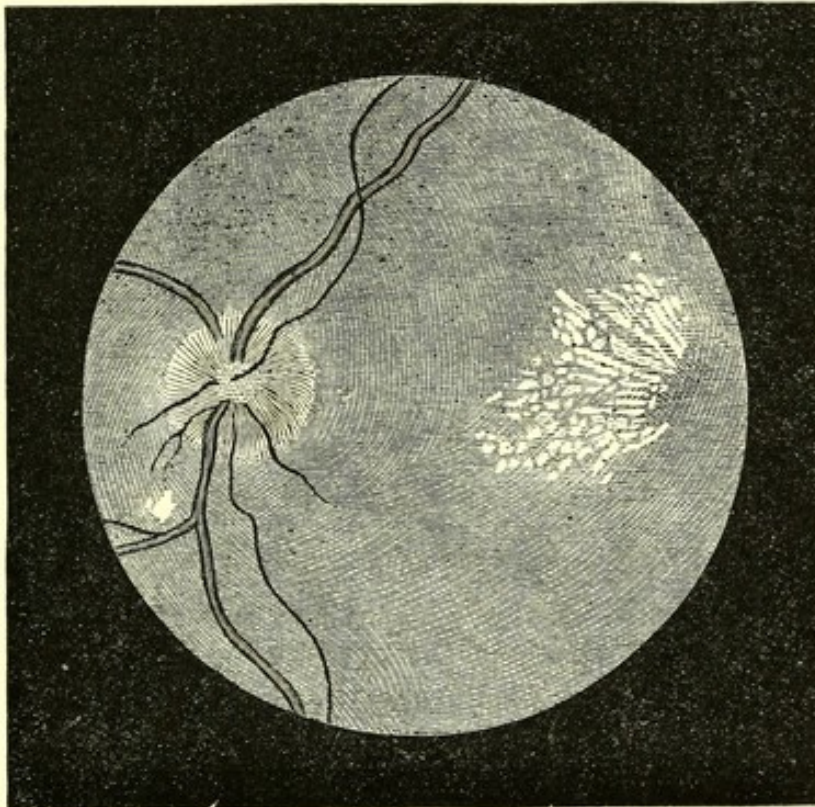


Fig. 18.—The Retinal Changes in Albuminuria. A fan-shaped group of white spots radiating from the macula lutea; small arteries; slight papillitis.

In the *hæmorrhagic* form, the conspicuous change is the occurrence of a large number of hæmorrhages, with but little degenerative change and but slight signs of inflammation of disc or retina. Commonly, especially after a time, there is more or less degeneration adjacent to the hæmorrhages, and traces of the halo of spots around the macula are rarely absent. The hæmorrhages, for the most part, resemble those just described, differing only in their number, size, and predominance.

In the *inflammatory* form (Pl. IX. 1) there is a general parenchymatous swelling of the retina with complete obscuration of the disc. The vessels are concealed, the arteries



especially. The veins are distended, and sometimes have an extremely irregular and tortuous course over the fundus; the arteries are narrow. Hæmorrhages invariably occur in considerable number, and are often large and striated. White spots are commonly numerous, and more or less uniform in character, especially in the acute cases, in which they are large, rounded (as in the figure), and soft edged. In these cases there is rapid degeneration of the tissue elements, and abundant infiltration with lymphoid cells. If the inflammation subsides, the signs of degeneration may become more predominant, and the optic nerve may present evidence of secondary atrophy. I believe, however, that it is rare for any subsidence of this form to occur, because it is confined to cases in which the effect of the renal disease on the system is intense, and usually soon leads to death.

*Neuritic Form* (Pl. IX. 2, 3, 4).—In some cases the inflammation of the optic nerve predominates over the other retinal changes to such an extent that it may appear to be the only alteration, and may present closely the aspect which is common in intra-cranial disease. The edges of the disc are veiled under a greyish-red swelling, of moderate prominence, which may extend a little distance beyond the normal edges of the disc. The prominence may be slight, or such that the veins form conspicuous curves over the sides. The arteries are usually narrow, and often concealed in the swelling; even the veins may be concealed. On direct examination it is generally conspicuously striated. Frequently, on the surface of the swelling, or rather apparently beneath its surface, there is a conspicuous white reflection in certain spots (Pl. IX. 2), often most visible on oblique illumination. Occasionally on the surface of the swollen papilla may be very minute white dots (just recognizable in Pl. IX. 3).

A careful examination will, in almost all cases, show signs of slight retinal degeneration, sometimes so slight as to require close attention and careful focussing by the direct method to detect them. Sometimes, as in Pl. IX. 2, there are one or two white spots in the retina, near the neuritic



swelling. At others, as in Pl. IX. 3, 4, minute white spots are to be detected near the macula lutea. Frequently, small hæmorrhages are to be seen somewhere about the fundus (Pl. IX. 4). It is remarkable that there is little tendency for hæmorrhages to occur in the swollen papilla in this form. If the neuritis subsides, a condition of consecutive atrophy may be left—a filled-in looking disc, greyish, with paler lines along the vessels, and often extremely small arteries. Such a condition is shown in Pl. IX. 4.

*Anatomical Changes.*—The scattered white spots depend commonly on degeneration of the layer of nerve fibres, which

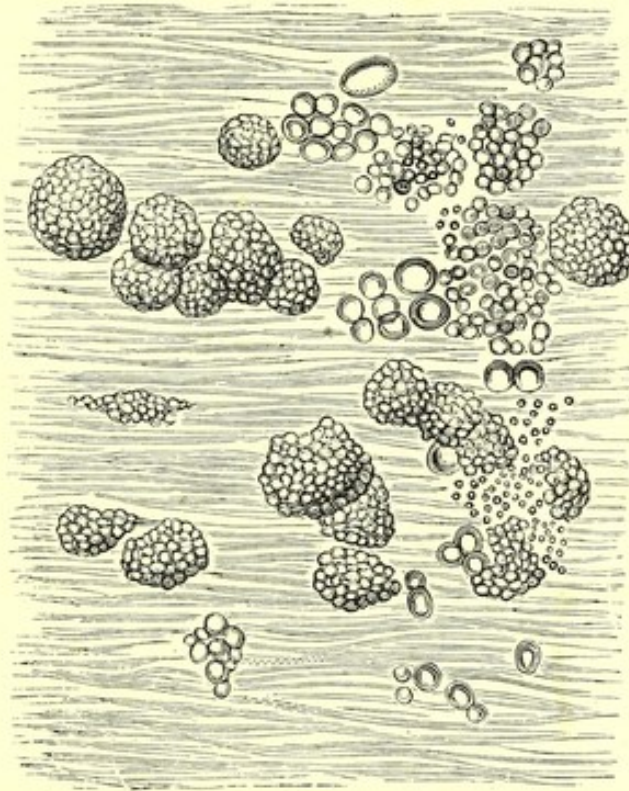


Fig. 19.—Surface View of a White Spot on the Retina in albuminuric retinitis. The transverse lines indicate the nerve fibres. Among these are large and small oil globules and spherules consisting of similar still smaller globules. (After Pagenstecher and Genth).

are found to be greatly thickened, sometimes both axis cylinder and medullary sheath. They often present varicosities, which may attain a large size and become crammed with fat-like globules. These ultimately become isolated as large fat-containing spheres, which, with free globules of fatty matter, are found abundantly on micro-



scopical examination of recent specimens (Pl. XVI. 8), and are very conspicuous in a surface view (Fig. 19). The degeneration occurs also, and sometimes chiefly, in the deeper layers, which may also be infiltrated with the "compound granule cells." Degeneration of other retinal elements, round corpuscles, and vertical fibres of Müller may sometimes be found. The latter are swollen and contain minute oil globules (Pl. XVI. 7). When swollen they have an undue refraction, and have been said, rather unnecessarily, to be "sclerosed." It is to the position of these that the stellate zone of spots around the macula is mainly due. The fibres here have a less vertical direction, radiating from the fovea centralis, and the degeneration of these fibres and the grouping by them of the degeneration of other retinal elements produces the radiating group of spots, most conspicuous near the margin of the fovea, where the fibres become placed more closely together. The diffuse opacity of the retina is in part due to oedema. The elements of the nerve-fibre layer may be separated by clear spaces, and similar spaces may form in the ganglion-cell layer, in the molecular, and even in the nuclear layers. In this condition the ganglion cells often fall out of the section (Pl. XVI. 9). The diffuse opacity is also partly due to an infiltration of the retinal interspaces with a coagulable fluid which, after hardening processes, presents an appearance of interlacing fibrillæ with granules at their points of intersection. This may occupy, as in Pl. XVI. 10, large areas, especially in the outer molecular layer, where cavities, containing this substance and separated by the remains of the vertical fibres, may alone be perceptible. A similar effusion may also separate the "membrana limitans interna" and bases of Müller's fibres from the rest of the nerve-fibre layer. Occasionally the layer of rods and cones presents remarkable thickening, such as is shown in Pl. XVI. 10, and is sometimes seen in other morbid states of the retina.

*Choroidal Changes.*—Occasionally, although rarely, choroidal hæmorrhage may occur in Bright's disease, and may lead to circumscribed atrophy of the choroid with adjacent pig-



mentary disturbance. A peculiar "colloid" degeneration of the vessels of the choroid in old cases of albuminuric retinitis has been figured by Poncet. It leads to a thickening of the tissue of the choroid. Liebreich has called attention to the occurrence of small angular grey spots of pigment, often arranged in groups, and appearing first in the periphery. They are due to changes in the epithelium of the choroid, and are seen especially in cases in which a parenchymatous inflammation has passed away.

*Symptoms.*—In the slighter forms of the degenerative, hæmorrhagic, and neuritic changes, vision may be unaffected. More considerable alteration, and even slight parenchymatous inflammation, commonly entails amblyopia, without limitation of the field or changes in colour vision. In rare cases colour vision may be affected. As the changes progress, the interference with vision increases. When the macula lutea is damaged, central vision is lost, but this is rare. Degenerative changes rarely reach the centre of the fovea centralis, no doubt because the structures in which the degeneration occurs do not extend to the macula itself. Hæmorrhages, from the paucity of vessels, are also rare in this situation. The hæmorrhage may, however, encircle the macula, and cause an annular defect in the field. With a central loss of sight, some adjacent colour blindness was found by Galezowski. It is rarely that sight is altogether lost. Attacks of uræmic amaurosis often accompany and complicate the amblyopia due to the retinal disease.

*Pathology.*—We know little of the relation between the renal and the retinal affection. The degenerative changes have been ascribed to the tendency to fatty degeneration which renal disease entails; but this scarcely explains their localization in the retina. Some facts, however, seem to show that a careful recent microscopic examination of the nervous tissues elsewhere may reveal the occurrence of similar changes in them. We know, especially through the researches of Sir William Gull and Dr. Sutton, that an extensive increase in the supporting tissue of the nerve centres may be found in chronic Bright's disease, and the thickening in



the supporting tissue of the retina may be part of this change. Knob-like degenerations of the nerve fibres have also been found elsewhere in the nervous centres.

The hæmorrhages have been ascribed, with reason, to the double effect of the degeneration in the minute vessels and the increased arterial pressure from the cardiac hypertrophy. It has been speculated that the neuritis may be due to the effusion of serum into the sheath of the optic nerve, but the view rests on no post-mortem evidence.

In several cases in which I have found neuritis predominating, symptoms of cerebral disturbance were conspicuous, intense headache, delirium, convulsions, due apparently to the effects of blood state. It seems probable that in these cases there is much cerebral disturbance, and that this may determine the occurrence of the excessive change in the optic nerve.

*Complications.*—*Detachment of the retina* is an occasional, although not frequent, accident. It may be double and extensive, as in one case under my own observation. It is apparently due to serous effusion between the retina and choroid. An example of it in slight degree is figured in PL XVI. 10, which shows that the pigment epithelium may be detached with the retina.

*Hæmorrhage into the vitreous* occasionally occurs from the rupture of an extensive extravasation in the superficial layers of the retina. It is always single and may occur, as in Case 43 under my observation, without the patient's knowledge. One day the fundus was distinct, and vision good; the next, nothing but a black reflection from the interior of the eyeball could be seen, and sight was lost. It is hardly necessary to say that the damage to vision is permanent. It may probably determine glaucoma (see Case 42).

*Embolism* is said to be an occasional complication of albuminuric retinitis (Voelcker). But this statement must be accepted with considerable reserve. Embolism elsewhere is extremely rare. Thrombosis sometimes occurs in the cerebral arteries, and the signs of embolism may have been due to that cause, and on the other hand the contraction of the retinal arteries may simulate that in embolism; but there is



no corresponding defect of the field of vision in these cases, such as would certainly have been present if embolism or thrombosis existed. As I have suggested, the explanation of these appearances which seems most probable, is that the tendency to arterial contraction, which is often traceable in normal arteries in this disease, leads to an extreme degree of narrowing, when the changes in the disc lessen the flow of blood into the arteries.

*Course.*—In most cases the retinal changes persist, some lessening, others increasing; until the patient's death. Not rarely, however, they diminish notably, and the retrogression may proceed until the changes almost or quite disappear. This is especially the case when the affection comes on in the course of the chronic renal disease which results from an acute attack, in which considerable improvement in the renal affection is often obtained, and in other chronic cases when prompt treatment soon after the onset of the retinal disease can improve the action of the kidneys. It is often noted in the albuminuria of pregnancy, a form which is very prone to lead to retinal changes, but which commonly improves or even disappears when the pregnancy is over. The greatest improvement is gained in the cases of slight papillitis. Hæmorrhages constantly disappear, and if the formation of fresh ones can be prevented considerable improvement in the retinal state may result. Even the degenerative changes may pass away, especially those which depend on the presence of the granular bodies in the layer of nerve fibres. Most of the white spots shown in Pl. X. 2 disappeared. The most persistent changes are those which result from the degeneration (or sclerosis?) of the fibres of Müller. The white specks around the macula lutea, which result from this cause, rarely disappear.

*Diagnosis.*—The recognition of the degenerative changes in the retina is only a matter of difficulty when the changes are slight and limited to the region of the macula. The strong contraction of the pupil, when this part is examined, very often renders the use of atropine indispensable for a thorough exploration.



The aspect of the degenerative form is most closely simulated by the retinal degeneration which results from a neuroretinitis of wide extent (Pl. VIII. 2). It is probable, indeed, that the changes are, to a considerable extent, identical. The damage to and between the radiating fibres around the macula lutea may leave a stellate group of shining spots quite indistinguishable from those which occur in renal disease, and the diffuse white areas nearer the disc may also resemble those seen in the latter form. If the patient have come under observation during the acute period of the inflammation, there will be no question as to the nature of the retinific change. It will be seen that, as in Pl. VIII. 1, the neuritic swelling reaches as far as the neighbourhood of the macula, and that the development of the white spots around the latter is part of the changes in the retina occurring near, and evidently excited by, the inflammation. If, however, the patient come under observation at a later stage, the distinction may be less easy. This is especially the case when a neuritis from a cerebral tumour has been unnoticed till the loss of sight which accompanies its subsidence.

The signs of one or the other classes of disease—encephalic affection or renal disease—are usually, however, sufficiently clear to leave little doubt after a general survey of the symptoms. But this does not always afford so clear a guide as might be expected. A cerebral tumour may be accompanied by a trace of albumen in the urine. This was the case in a child whom I saw some years ago with the late Dr. Anstie. The only symptoms were headache, the retinal changes, and the trace of albumen. On the other hand there may be no symptoms of intra-cranial disease, except headache, which can, alone, hardly be regarded as such, and may accompany the neuritis of albuminuria, as in the case of the patient whose eye is shown in Pl. IX. 3. Lastly, a neuritis, primary in the eye, may occur after diseases, as scarlet fever, which are liable to be attended with albuminuria.

But attention to the following points will, in most cases—I think in all cases—enable a correct diagnosis to be made by the ophthalmoscopic signs alone, or in conjunction with the



other symptoms. In the first place, there are always present the signs of a considerable preceding neuritis. Commonly, at the time the failure of sight calls attention to the eye, and the white spots are discovered, there is a prominent pale swelling over the disc, as in Pl. IX. 3. It is very rare for albuminuric neuritis to leave a swelling of this prominence, and pallor. If atrophy results from an albuminuric neuritis, the disc, by the time it becomes pale, is very little above the retinal level, as in Pl. IX. 4. Moreover, the neuritic form never occurs, at least as far as recorded facts and my own observation have gone, except in cases of advanced chronic renal disease, commonly of contracting kidney,\* in which the signs of Bright's disease are always obvious enough. (Regarding these distinctions, see also p. 80.)

In the degenerative changes of neuro-retinitis, of such an extent as to simulate closely the appearance of the albuminuric form, as in Pl. VIII. 2, all the features of the change are those of past, retrogressive mischief. The disc is atrophied, the arteries evidently compressed, and there are, as a rule, no hæmorrhages. In the renal form, of corresponding extent, there are always signs somewhere of active progress. The disc is commonly still inflamed, and there are usually hæmorrhages. Lastly, when the retinal degeneration is present as a consequence of neuritis, at the time any difficulty in diagnosis might arise, sight is almost always lost. Whereas complete loss of sight is an event of great rarity in the albuminuric form.

The form in which hæmorrhages and spots of degeneration are combined, may resemble closely the changes in the retina in pernicious anæmia. But in the latter the perimacular circle is commonly not recognizable, and the degeneration is for the most part connected with, and secondary to, the retinal hæmorrhages. The degeneration does not attain the same extent, and the disc is usually unaffected. The same remarks apply, in the main, also to leucocythæmic retinitis. In the latter, the white spots are much more common in the

\* In one case I have seen it in the late stage of the large pale kidney, in which induration was commencing.



peripheral portions of the retina than they are in the renal form, and in the latter it is very rare to see the circular spots, surrounded by a halo of hæmorrhage, which are so frequent in leucocythæmia. In the latter the tint of the fundus is commonly very different from that in albuminuria. In both pernicious anæmia and leucocythæmia the independent symptoms of the malady usually leave little room for doubt as to the nature of the retinal changes, but it must be remembered that, in the latter especially, renal degeneration is often present.

*Treatment.*—Local treatment is of doubtful value. Good can only be effected by improvement in the renal condition, and by this means considerable improvement may often be effected in the retinal state.

#### DIABETES.

DIABETES MELLITUS.—Defects of sight are common in diabetes (as Bouchardat pointed out many years ago), but changes in the fundus oculi are rare. The most frequent cause for the defect is cataract, which is apt to occur in these cases. Occasionally, considerable amblyopia occurs without ophthalmoscopic changes, probably due to the blood state and comparable to uræmic amaurosis, although probably the result of a different condition of blood.

Simple atrophy of the optic nerve has been observed in some cases.

Occasionally retinal changes are visible; first observed by Ed. Jäger\* and afterwards by Desmarres and Galezowski. A careful study of them has been made by Leber.† They are only seen when the disease is advanced. In advanced cases of diabetes, albumen is often present in the urine as well as sugar, but the occurrence of these retinal changes is not related to the albuminuria, since they have been observed in many cases in which not a trace of albumen was present.

The changes in the retina bear considerable resemblance to

\* "Beiträge zur Pathol. des Auges." Wien, 1855, taf. xii.

† "Arch. f. Ophth." xxi. 306.



those of albuminuria, and still greater resemblance to those seen in some cases of pernicious anæmia. Hæmorrhages are conspicuous in almost all cases, commonly situated in the nerve-fibre layer and often of considerable size. They may exist alone or may lead to a secondary parenchymatous retinitis. In one case, figured by Jäger, a condition of parenchymatous retinitis existed in the posterior segment of the eyeball, with obscuration of the disc, concealment of the veins in places, a few large whitish spots, and a few striated hæmorrhages, the arteries being unconcealed. White spots of degeneration are frequently present, commonly of moderate size, scattered over the fundus. Sometimes, although rarely, there may be a perimacular circle of spots, and this in cases, as those described by Noyes and Desmarres, in which there is no albumen in the urine. The simple atrophy of the optic nerve, which occasionally exists alone, may, in rare cases, accompany the retinal changes (Galezowski).

A marked difference from the forms of retinitis which it most resembles is afforded by the frequent association, in diabetes, of opacities in the vitreous. They appear to be produced by the escape of blood in small quantities from the retinal hæmorrhages. Leber has traced the development of a complete opacity of the vitreous by this mechanism of repeated hæmorrhagic infiltration. Occasionally, hæmorrhagic glaucoma is the result.

Few microscopical examinations have been made. One by Mr. Nettleship is recorded by Dr. S. Mackenzie.\* The chief change, beyond oedema, was a peculiar hyaloid degeneration of the interna of the arteries, and numerous capillary aneurisms, some of which are shown in Pl. XVI. 11. These vascular changes afford an explanation of the tendency to hæmorrhage. In this case the vessels of the brain (and of the kidneys and spleen) were similarly affected, and a small cerebral hæmorrhage had occurred.

Both eyes are commonly affected in diabetes. The disturbance of sight may be slight or considerable. Blindness is usually the result of the extravasations, or of secondary

\* "Oph. Hosp. Rep." ix. p. 150.



changes in the vitreous. In Dr. Mackenzie's case, just described, the disease was discovered by Mr. Waren Tay in consequence of the result of the ophthalmoscopic examination. There is nothing in the characters of the affection which are pathognomonic, since they closely resemble the albuminuric form. The most suggestive indications are, as Leber points out, the combination of the retinal change with opacity of the vitreous, and also with atrophy of the optic nerve having the characters of a simple atrophy. In albuminuria, atrophy is very rare, except as the result of neuritis.

The retinal affection is apt to relapse, even though temporary improvement be obtained under the influence of dietetic treatment. The advanced stage of the disease at which it occurs also renders the prognosis unfavourable. The treatment is in the main that for the general disease. Carbolic acid is suggested by Leber, but is more likely to be useful in the diabetic amblyopia, without retinal changes, than in the latter.

DIABETES INSIPIDUS.—In a very few cases of diabetes insipidus ophthalmoscopic changes have been observed, which have not, however, much analogy with those observed in diabetes mellitus. Atrophy of one optic nerve was observed by Laycock,\* and double optic neuritis was present in a case described by Van der Heyden.† The connection of these changes is probably with the cause, rather than with the condition, of polyuria.

## DISEASES OF THE CIRCULATORY SYSTEM.

### DISEASES OF THE HEART.

The veins and arteries of the retina participate in any general changes in the circulation which result from diseases of the valves and walls of the heart, although the changes in them are commonly less marked than those in other vessels. For this there are two reasons—(1) their size is far below that of the other vessels accessible to physical examination ;

\* "Lancet," 1875, ii, 242.

† "Leyden Thesis," 1875.



(2) the conditions of the intra-ocular tension keep the circulation more uniform in the eye than in other parts.

The over-filling of the venous system, from over-distension and dilatation of the right heart, consequent on congenital disease of the pulmonary orifice, on emphysema, and other causes of pulmonary obstruction, and on disease of the mitral orifice, may be revealed by an over-distension of the retinal veins, the chief trunks being large, and the smaller veins unduly visible, and therefore apparently more numerous. It is commonly unattended with visual disturbance, although a case in which it was accompanied with transient attacks of amblyopia has been described by Galezowski. This condition is most marked in congenital cyanosis. In that disease the retinal veins may be enormously dilated (as in a case figured in the first edition of Liebreich's Atlas), and they afford proof of the degree to which the distension of the venous radicles contributes to the cyanotic tint. In acute venous over-distension, such as occurs during effort, during severe cough, or during an epileptic fit, the venous congestion may also be very marked.

Under-filling of the arterial system, if chronic, such as occurs in aortic obstruction and in mitral disease, is rarely evidenced by a corresponding state of the retinal vessels, no doubt on account of the second local influence just mentioned.

Nor is chronic over-action of the left ventricle, if sustained, evidenced, as a rule, in the retinal arteries, probably because the cause of such over-action commonly lies between these minute vessels and the heart. Exceptions are, however, met with. In exophthalmic goître, in which the over-action of the heart depends on a primary nervous disturbance, and not on an obstruction to be overcome, distension (and even pulsation) of the arteries may be visible. The former is probably in part due to dilatation of the vessels from vaso-motor paralysis.

Sudden over-action of the heart, as from an emotional cause or violent exertion, may also show itself in visible pulsation of the retinal vessels; rarely in the arteries, more frequently in the veins, to which it is transmitted from the arteries.



In aortic regurgitation pulsation in the veins is common, and pulsation in the arteries is not rare, as Quinke and Becker have shown. This depends on the fact that the force of the pulse-wave becomes increased out of proportion to the actual movement of the blood, and the conditions which obtain in the larger arteries pass on, so to speak, into the smaller vessels, and even overcome the regulating influences of the eye (see p. 18). In one case described, the existence of the valvular lesion was first suspected from this pulsation.

For the above-mentioned reasons, neither simple dilatation nor simple hypertrophy of the left side of the heart usually affects the size of, or circulation within, the retinal vessels. Dilatation only acts when it involves the right side of the heart in an extreme degree, and then may cause some venous congestion. But hypertrophy, when its cause is such as permits it to act on the smaller vessels, may cause, although rarely, retinal hæmorrhages. It is doubtful whether it is capable of doing this unless rupture be permitted by vascular degeneration. The hæmorrhages which result may lead to degenerative white spots, which may persist after the disappearance of the effused blood.

Embolism of the central artery of the retina is an occasional consequence of valvular disease of the heart, and is probably the most common cause of amaurosis associated with cardiac disease—a coincidence which was first noted by Seidl and Kanka in 1846.\* Its occurrence is governed by the same conditions as those which determine it elsewhere. It is most common in mitral disease, especially, like cerebral embolism, in mitral constriction. Its signs have been already described (p. 28).

Transient failure of sight without ophthalmoscopic changes is common in heart disease, and may be unilateral and considerable. To the latter form attention has been lately called by Mr. Nettleship.

*Malignant Endocarditis.*—In the rare form of “ulcerative endocarditis” attended with fever and pyæmic symptoms

\* Canstatt's “Jahresb.” 1846, iii. 115.



(which Litten better designates "malignant endocarditis"),—the "diphtheritic endocarditis" of some German writers, due, probably, to the circulation in the blood of organized elements derived from some septic source—retinal hæmorrhages are almost invariable, and of considerable diagnostic importance. Most of the observed instances have occurred after childbirth,\* and they are described under the head of septicæmia (*q. v.*). Rosenbach,† in two cases in which ulcerative endocarditis resulted from experimental damage to the valves of the heart of dogs, found retinal hæmorrhages, minute, in streaks and dots. In these cases, hæmorrhagic infarcts, with abundant micrococci, were found in various organs. Virchow has described‡ an interesting case of panophthalmitis (exudation in the iris, vitreous, retina, and choroid) in a case of ulcerative endocarditis in a man, and he found minute bodies in the damaged spots, which would probably be now regarded as micrococci. He also proved by experiment that embolic obstruction of the minute vessels caused punctiform extravasations in the retina.

#### DISEASES OF THE VESSELS.

These rarely reveal themselves by retinal signs. Those which do occur, the rare coincidence of aneurisms or signs of degeneration of the retinal vessels, with a similar change elsewhere, have been already sufficiently considered in the general account of the changes in the retinal vessels.

#### DISEASES OF THE BLOOD.

##### PLETHORA.

In states of plethora it is said by Jäger that the vessels are large, and the blood column dark. The changes are not, however, sufficiently well marked to be of practical importance.

\* In a case of chronic mitral disease now under my care, with persistent pyrexia without obvious cause, hæmorrhages have suddenly appeared in both retinæ simultaneously with the signs of renal embolism.

† "Arch. für Exp. Path. u. Therapie," 1878.

‡ "Arch. für Path. Anat." Bd. x. 1856, p. 179.



## ANÆMIA.

ACUTE ANÆMIA FROM HÆMORRHAGE.—Loss of blood is occasionally followed by affection of vision, and the loss of sight may be slight or complete, transient or permanent, and may come on at the time of the hæmorrhage or not until after several days.

It is remarkable that sight is affected much more frequently after spontaneous than after traumatic hæmorrhage, and that of the latter form, venesection is the most frequent antecedent, accidental or surgical wounds being very rare causes. This may be related to the circumstance that in traumatic and surgical cases the health is less frequently impaired before the loss of blood than in the cases in which spontaneous hæmorrhage occurs, or in cases in which venesection is performed. I am not aware that it has ever been noted in cases of the hæmorrhagic diathesis.

For a valuable compilation of the statistics of these cases we are indebted to Fries.\* Of 96 cases in which the form of the hæmorrhage was noted, in 34 (35 per cent.) the hæmorrhage was from the gastro-intestinal tract; in 24 (25 per cent.) it was from the uterus, in most cases after childbirth, in a few from menorrhagia; 24 (25 per cent.) were due to the artificial abstraction of blood (21 by venesection, 2 by leeching, 1 by cupping); in 7 cases it was due to epistaxis; in 5 to wounds; in 1 case to hæmoptysis; and in 1 to urethral hæmorrhage.

The loss of sight commonly follows a large hæmorrhage, and especially repeated hæmorrhages, but sometimes occurs after a small one. Now and then it follows immediately on the loss of blood (in 26 per cent. of the cases): the patient wakes from the faint to find himself blind. In 19 per cent. it occurs during the first twelve hours after the hæmorrhage. More frequently an interval of two or three or four days occurs between the two events; 33 per cent. occur after the first twelve hours and before the eighteenth day. Fries

\* Inaug. Diss., Tübingen, "Beilageheft zu den Klin. Monatsbl. f. Augenheilk," 1876.



found that the prompt onset is most common in the cases which occur after venesection, the tardy onset after spontaneous hæmorrhage. Commonly, the loss of sight is sudden; rarely, it is preceded by photopsy and pain in the head and back. In one case under my observation neuralgic pain above the eyes occurred after the (post-partum) hæmorrhage, and lasted for several days after the onset of the blindness. In this case each previous confinement had been followed by a similar pain, without affection of sight. Occasionally the same individual has suffered from transient affection of sight after hæmorrhage on more than one occasion, as in a case recorded by Samuelsohn, in which temporary blindness occurred after each of several attacks of hæmatemesis.

The blindness is commonly double (in 90 per cent.—Fries), rarely one eye being much more affected than the other. In 10 per cent. of the cases one eye is affected exclusively; in 5 per cent. one eye becomes blind and the other is but slightly affected. The loss is often permanent and complete (in 65 per cent.), the pupils being dilated and not acting to light. Partial or complete recovery takes place in about half the cases (partial, 30 per cent.; complete, 20 per cent.). Leber\* thinks the loss is commonly more complete when the hæmorrhage is from the stomach, than when from the intestines or uterus, and this agrees with the conclusions of Fries, that improvement, in spontaneous hæmorrhage, is most common after hæmorrhage from the bowels. Complete restoration of sight has been observed after hæmorrhage from the uterus, venesection, from the intestines, traumatic hæmorrhage, and from the nose; never after hæmorrhage from the stomach. Recovery may be much greater in degree in one eye than in the other. It may be complete in both eyes. When the recovery is partial, the field may be limited, but the limitation varies much in different cases. In the case after childbirth, above mentioned, although the sight of both eyes was lost at first, the right recovered with a normal field, while in the left vision was only  $\frac{1}{8}$ , and the

\* In Græfe u. Saemisch's "Handbuch," vol. v.



right half of the field was lost. In one case on record, the permanent loss was in the lower half of each field, and was greater in the left than in the right. In a case of Samuelsohn's, in one eye central, in the other peripheral, vision was left. Recurrent transient amaurosis marked one case (Leber).

The ophthalmoscopic appearances some time after the onset have, in rare cases, been normal. In most cases the disc is atrophied, with small vessels, as in the case I have mentioned, in which the disc was greyish-white, the arteries much narrowed, the veins small also, and much new tissue about the vessels in the disc. The degree of narrowing of the vessels, and the time at which pallor appears, have varied in different cases.

In the few ophthalmoscopic examinations which have been made early in the history of the cases, there have commonly been signs of inflammation, usually slight, sometimes intense. The slight changes consist in diffuse opacity of the retina with some œdema of the disc,\* the more intense in a neuro-retinitis with hæmorrhages. The larger the number of early observations, the more does it appear that the permanent damage to sight is related in degree to the intensity of the inflammation.

In one case, recorded by Hirschberg, three days after the hæmorrhage there was slight opacity of the left papilla; distinct neuritis in the other eye without swelling; sight nearly normal. Five days later—R., intense neuro-retinitis, V.  $\frac{1}{30}$ ; L., commencing neuritis, V.  $\frac{1}{6}$ . The sight of the right eye was lost next day. Three weeks later—R. disc as in neuritic atrophy, V. 0; L. disc merely reddish and indistinct, V.  $\frac{1}{4}$ . A very similar case has been recorded by Landesberg. The day after a hæmorrhage from the nose, dimness of sight of one eye was complained of, and the ophthalmoscope showed in both eyes diffuse opacity of the retina with some swelling of the papilla. In one eye the appearances soon lessened and sight was normal; in the other a neuro-retinitis with hæmorrhages developed, with ultimate amaurosis. Retinal hæmor-

\* Hirschberg, "Kl. Monatsbl. f. Augenheilk," 1877. Supplement, 53-85.



rhages and neuro-retinitis were observed by Woinow after the application of four leeches to the uterus.

Förster has recorded a case, in which, twelve days after a hæmorrhage, there was a peculiar white opacity of the retina, with small hæmorrhages around the disc; vessels small, but not as in embolism. There was no affection of sight. The opacity slowly disappeared without neuritis. So in a case seen by Horstmann, three days after a hæmatemesis, disturbance of sight occurred ( $\frac{1}{2}$ ) with slight opacity of the optic nerves and adjacent retina. The changes gradually lessened and sight became normal. On the other hand, ten days after loss of sight, which occurred seven days after an abortion, Hester found neuro-retinitis with hæmorrhages, quickly subsiding to atrophy; loss of sight permanent in both eyes. Colsmann, however, four days after onset, found only pallor of disc, small arteries, large veins, and no neuritis.

Many theories have been framed to account for the phenomena, but the variety in the changes renders the appearances very difficult to explain. The theory which has obtained most acceptance is that of v. Graefe, that there is a retro-ocular hæmorrhage situated sometimes near, sometimes far from the eye. The evidence in favour of this theory is that small retinal hæmorrhages have been seen, that there are sometimes hæmorrhages into other organs in cases of loss of blood, and that in one case there were simultaneous symptoms of a cerebral lesion. But this affords a very inadequate explanation for the cases in which both eyes suffer. To assume, as has been done, that the mischief is at the chiasma, seems unjustifiable, in the entire absence, in all such cases, of other symptoms of mischief at the base of the brain. Förster attributed the slight changes in his case to serous effusion. Samuelsohn thinks that the nervous connection between the stomach and the corpora quadrigemina (lesions of which are said to cause gastric hæmorrhage) affords the best explanation.

It is evident, however, that in the majority of cases there is inflammation, and there is at present no evidence to show that this is not of intra-ocular origin. It seems probable



that the mechanism may vary in different cases, and one effect of loss of blood may be upon the retinal elements themselves. The shock to the nervous structures from the anæmia may, in some cases, cause transient loss of function, of sudden or slow onset, and recovery take place without ophthalmoscopic changes. In other cases no recovery may take place, and atrophy supervene. In some cases the damage to the nutrition of the retina may lead to a primary inflammation on the restoration of the blood supply, variable in degree, sometimes slight and general, sometimes most intense in the papilla, where inflammation occasionally occurs in chlorosis as in Cases 29 and 44.

It is probable that more light will be thrown on the pathology of this mysterious accident when physicians are more generally aware of the ocular symptoms which may accompany hæmorrhage, and use the ophthalmoscope in all cases in which the phenomena are likely to occur, since only too many of such cases afford opportunity for post-mortem investigation.

#### SIMPLE CHRONIC ANÆMIA.

The colour of the fundus is pale in proportion to the anæmia, but the physiological variations in the tint of the choroid and of the disc prevent the tint of the fundus from affording any absolute indication. In extreme cases the choroidal pallor may, however, be striking, as it was in a girl with chlorosis, lately under my care, in whom the red corpuscles were only 26 per cent. of the normal.

The retinal vessels often present distinct characters. The veins are especially pale, often only a little darker than the arteries. When the choroidal pigment is abundant, it may be noted that its influence on the apparent tint of the veins is greater than in health; they undergo a greater change of tint in passing from the dark choroid on to the pale disc. The veins are also often broad, in consequence of the defective distension and consequent flattening in their atonic state by the intra-ocular pressure (see p. 10). The reflection



from them varies, commonly being broad, no doubt in consequence of the diminished convexity. The arteries are usually narrower than normal, not merely in comparison with the veins, but absolutely; their pallor is much less noticeable than is that of the veins. The reflection from them may also be broad. Hæmorrhages are said to occur, but are certainly very rare in simple anæmia and probably only take place where there is a great absolute deficiency in the number of red corpuscles. I have found them absent in a case in which the corpuscles were as few as 26 per cent. of the normal. Neuritis occasionally occurs. This has been noted by Hirschberg, and an instance of it is figured in Pl. VII. 5 (Case 44). Intense neuro-retinitis may occasionally occur, as in Case 29 (Pl. VIII. 1 and 2).

#### PROGRESSIVE PERNICIOUS ANÆMIA.

In pernicious anæmia (Case 45) the tint of the fundus and the appearance of the arteries and veins are such as are seen in the most intense cases of simple anæmia. The rather narrow arteries and broad pale veins are seen in Pl. XI. 1. The figure shows also that which is a characteristic feature in pernicious anæmia, the tendency to hæmorrhage. Common in other situations, it is far more frequent in the retina than elsewhere. Of sixteen cases examined by Quinke, retinal hæmorrhages were absent in one only. In thirty cases examined by Horner, extravasations were present "almost without exception." The extravasations are often, as in the figure, numerous, and more or less striated or flame-shaped, from their situation in the layer of nerve fibres. They are usually most abundant around the optic nerve entrance. They are frequently associated with white spots and areas, due in part to leucocyte-like cells, in part to degeneration in the disturbed retinal tissues. Occasionally a pale spot may occupy the centre of a small hæmorrhage. In such cases Manz\* found the pale centre to consist of round colourless cells, sometimes enclosed in a capsule. He found also ampulli-

\* "Centralblatt f. d. Med. Wiss." 1875, p. 675.



form and sacculated dilatations of the capillaries (no doubt similar to those figured in Pl. XVI. 11, from a case of diabetes). Some of these were empty, others contained a granular material, others contained red blood corpuscles or colourless cells. He supposes that the capsule found to enclose the pale cells within the hæmorrhages was really the wall of such a capillary dilatation. A stellate arrangement of white specks around the macula lutea was seen by Quinke in one case, but is certainly rare in this disease. Œdema of the retina was also observed in one case by Quinke, the vessels being dimmed by a bluish-white cloud. The optic disc is usually normal, but its edges may be blurred, and optic neuritis may, in rare cases, be present in excess of the other retinal changes, as in the case of a boy described by Dr. Stephen Mackenzie ("Lancet," Dec. 7, 1878).

The hæmorrhages are, in many cases, quickly absorbed, lasting only a few weeks. They cause no disturbance of vision except when located in or near the macula lutea. It is probable that when the actual diminution of the blood corpuscles is ascertained in these cases, a relation may be traced between a certain degree of diminution and the occurrence of these hæmorrhages.

#### LEUCOCYTHÆMIA.

In all cases of leucocythæmia in which the change in the blood is considerable, the retinal and choroidal vessels are remarkably pale. The tint of the choroid is an orange-yellow. The retinal veins appear broad, and very pale. This apparent increase in width is sometimes very great (Fig. 20), and is probably due to atony and flattening rather than passive distension. They are often very tortuous. Their central reflection may at first be broad and indistinct; ultimately, in the large tortuous vessels, a very narrow, almost white, reflection appears. The retinal arteries are orange rather than red, and in extreme cases they are small.

Besides these appearances, there are, in a considerable number of cases, actual changes in the retina. These vary greatly in different cases, and rarely present the appear-



ance described by their discoverer, Liebreich, as "leukæmic retinitis." They are almost confined to the splenic variety, and are usually double, one eye being often more affected than the other.

The commonest change is the occurrence of retinal hæmorrhages. The tendency to hæmorrhage in this disease is extremely strong, and leads to extravasations into the retina in a large number of cases. Statistics which I have collected\* show that the most common recorded seat of extravasation into tissues is the subcutaneous cellular tissue. A more constant

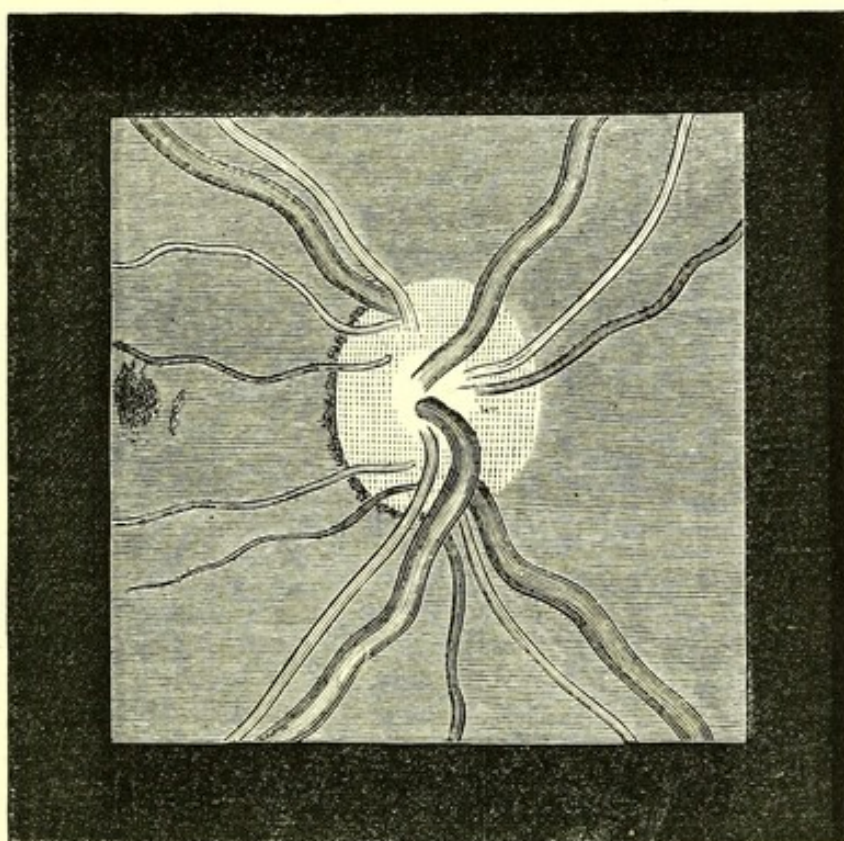


Fig. 20.—Broad Retinal Veins and Narrow Arteries—from a case of leucocythæmia (Case 46).

use of the ophthalmoscope will probably show that retinal hæmorrhage is as frequent, if not more so. Of five cases of leucocythæmia which I have examined with the ophthalmoscope, retinal extravasations were visible at some period in four. Of the tendency to hæmorrhage these extravasations constitute a striking indication. The tendency to retinal hæmorrhage is apparently far greater in leucocythæmia than

\* Art. Leucocythæmia, "Reynolds' System of Medicine," vol. v. p. 257.



in simple anæmia, for it occurs with a percentage of red corpuscles greater than is usual in cases of simple anæmia which present retinal hæmorrhages. I have twice met with them in leucocythæmia when the blood contained 50 per cent. of red corpuscles. One of these cases is figured in Pl. XI. Fig. 2 (Case 46). The hæmorrhage encircles the fovea centralis in a curious series of extravasations, and several smaller ones lie adjacent. Commonly the hæmorrhages are more widely scattered, and more or less striated. The hæmorrhages are in these cases usually in the nerve-fibre layer, but a large extravasation may infiltrate the whole thickness of the retina. When the excess of white corpuscles is considerable, the effused blood has a pale, chocolate, tint here as in other situations. Extravasation may take place into the substance of the papilla or hæmorrhage may occur into the vitreous.\*

Besides the hæmorrhages, white or yellowish spots are commonly present, often most abundant in the periphery, or near the macula lutea. These are sometimes irregular, but often rounded, and edged by a halo of extravasation. When large, they are sometimes distinctly prominent, and may be as much as 2 mm. in diameter (Reincke). They consist commonly of leucocytes, similar to the leucocytes of the blood, and they have been regarded as lymphoid growths such as occur in other organs. In rare cases actual growths of some size have been met with, but it is doubtful whether the smaller spots are of this nature. It is common for the pale corpuscles to be aggregated in the middle of an extravasation. In some cases the white spots are due to degeneration of the retinal elements. The capillaries are full of white corpuscles, and it seems more probable that these spots arise by the escape of the corpuscles by diapedesis or by rupture. In one case Saemisch found an irregular thickening of the inner granule layer, in some places extending into the ganglion-cell layer. He attributes the thickening to escaped leucocytes, which are indistinguishable from the corpuscles of the granule layer. Poncet has found a similar infiltration extending, not only into all the layers of the retina, but also

\* *Vide* Perrin and Poncet's "Atlas," pl. 65.



into the substance of the optic nerve. Swelling of the nerve fibres was the cause of small white spots in a case described by Deutschmann.\* The capillaries of the retina may be dilated and varicose, such as are shown (from a case of diabetes) in Pl. XVI. 11.† The lymphatic sheaths of the vessels may be filled with white blood corpuscles.

Occasionally a diffuse opacity of the retina is met with, said by Roth to be due to a thickening of the vertical fibres of the retina, but probably sometimes due to cedema—of the ganglion cell layer in a case described by Deutschmann.\* When more considerable it is in part due to a diffuse infiltration of leucocytes, as described by Poncet and Oeller. This opacity, with some swelling and great tortuosity of the veins, was the chief appearance in one case under my own observation. The patient was a woman, aged 36, in University College Hospital, under the care of Dr. Wilson Fox. Both eyes were affected in a similar manner. The discs were clear, the sclerotic ring distinct, and the physiological cup quite normal. The tint of the periphery of the disc was rather deep, but there was no punctiform redness. There was a diffuse, slight opacity of the retina, chiefly marked near the disc and somewhat striated on direct examination. Towards the periphery of the retina, a few small white spots were seen, and one small hæmorrhage. The arteries were nearly normal in size, but unduly tortuous. The veins were greatly increased in diameter, and much paler than natural. Their central reflection was everywhere distinct and broad. The smaller veins were conspicuous and could be followed for a longer distance than normal. The larger veins were very tortuous, the curves being chiefly in the plane of the retina, but some antero-posterior. One or two small veins on leaving the disc were lost in the opacity of the retina, but the larger veins were not concealed.

A remarkable change was observed by Heinzl,‡ in a case of lymphatico-splenic leucocythæmia in a child,  $4\frac{1}{2}$  years of age.

\* "Kl. Monatsbl. für Augenheilk." 1877, p. 231.

† Such capillaries are figured by Poncet, "Atlas," pl. 66.

‡ "Jahrbuch für Kinderheilk." 1875, p. 346.



There was at first an enormous swelling of both papillæ, which were occupied by a striated opacity, completely concealing the disc, without redness, ceasing two discs' breadth from the edge. The retina presented here and there a little opacity. There was moderate tortuosity of the veins, and the vessels were bordered by pale lines of variable width. Numerous hæmorrhages appeared and disappeared in each retina. All the pathological appearances passed away in four weeks, the fundus appearing normal but pale, and it was also found normal after death. Heinzel remarks that the appearance had not the aspect of an inflammatory process, but rather that of mechanical congestion with consequent œdema and ecchymoses. Such a condition was presented in the same case by the conjunctiva, and several times by the skin, and was ascribed to the constitutional state.\*

In cases of general thickening of the retina, the optic papilla has been found swollen (to .9 mm.—Oeller) in consequence of leucocytal infiltration and œdema. The disc is not usually changed, however, except when the parenchymatous retinal changes are considerable.

The hæmorrhages may be, in some cases of leucocythæmia, so numerous as to give to the changes the aspect of a hæmorrhagic retinitis, such as is met with occasionally in other conditions. A large extravasation may burst through into the vitreous, and cause secondary glaucoma. The vessels are sometimes accompanied with conspicuous white lines.

Besides the changes which appear related to the blood state, the complication of kidney disease may lead to retinal changes identical in appearance and structure with those met with in cases of primary renal disease, as in a case figured by Poncet.†

The degree to which the changes interfere with sight depends on their extent and position. If abundant they cause considerable amblyopia; if slight the vision may be unimpaired, and the retinal changes may easily be overlooked,

\* The ophthalmoscopic appearances may have been due to thrombosis in the orbital vein, the anastomoses with the facial ultimately sufficing to restore the normal circulation. Venous thrombosis is common in this disease.

† Perrin and Poncet: "Atlas," pl. 66.



unless systematic examination is made with the ophthalmoscope. When situated near the macula, central vision is much impaired. In the case figured, for instance (Pl. XII. 2), it was very dim, but not lost. Occasionally the disturbance of the retinal elements leads to a curious change in vision, as in one case in which parallel lines appeared to come near together, and again to diverge.

Sometimes the choroid is found infiltrated with leucocyte-like cells, and its vessels may be, at the same time, greatly dilated. Poncet has figured an infiltration of the iris with leucocytes, supposed to indicate a leucocythæmic iritis.

## PURPURA.

The tendency to rupture of vessels in purpura leads to retinal as well as to subcutaneous extravasation. How frequently retinal hæmorrhages occur cannot be ascertained until the ophthalmoscope is more generally used by physicians, but they are certainly very common, perhaps invariable in the severer forms of the affection. Cases have been recorded by Rue,\* Stephen Mackenzie,† and others. In each of two fatal cases recently under the care of Dr. Hunt, of Wolverhampton, retinal hæmorrhages were present, and numerous.‡ The extravasations are for the most part striated, and adjacent to vessels, and most abundant in the neighbourhood of the optic disc. In a case recorded by Dr. Goodhart,§ a large subretinal extravasation was present, and was thought to be in the choroid. It had a white edge, and white spots have been seen in connection with the retinal hæmorrhages in this as in other affections. Hæmorrhage into the choroid was also found post-mortem by Rue, in a case in which a large number of retinal extravasations were observed during life. The latter may cause considerable amblyopia if numerous, and, as in other cases, if near the macula lutea, may damage central vision.

\* "Union Méd." 1870

† Oral communication.

† "Med. Times and Gaz." 1877.

§ "Lancet," 1878, i. 123.



## SCURVY.

Retinal hæmorrhages have been found in scurvy, but less commonly than in purpura; perhaps because they have not been looked for. They are, as in purpura, commonly in the neighbourhood of the optic nerve. In one case recorded by Wegscheider,\* numerous small extravasations into the brain co-existed.

## DISEASES OF THE LUNGS.

Pulmonary affections rarely cause ocular troubles. Emphysema of the lungs may lead to mechanical congestion of the venous system generally, which may be conspicuous in the eye. The same influence has been ascribed, but on very doubtful grounds, to phthisis, in which amblyopia occasionally occurs. Tubercles in the choroid may be met with in cases of acute tuberculosis, but never when the tubercular affection is confined to the lungs. Acute pneumonia is said, in one case, to have been associated with neuro-retinitis. A febrile intense bronchial catarrh in a young woman, with much cyanosis, was observed by Litten† to be accompanied with neuro-retinitis, in and around the papilla, of gradual development, and with numerous extravasations, some with white centres, near the equator of the eye. Many of the extravasations were regularly arranged, and situated upon small veins; and he suggests that the changes were probably set up by the great distension of veins. The retinal affection subsided with the bronchitis.

## DISEASES OF THE DIGESTIVE ORGANS.

The occasional effect of hæmorrhage from the stomach and intestine has been already described. Galezowski ‡ associates atrophy of the optic nerve, in some cases, with chronic

\* "Deutsche Med. Wochenschr." Nos. 17 and 18, 1877.

† "Charité Annalen" for 1876. Berlin, 1878.

‡ "Journ. d'Ophthalmologie," March, 1872. "L'Un. Méd." 1876, i. 36°.



gastric troubles. He has described several remarkable cases in which great improvement occurred in amblyopia, previously obstinate, on correcting gastric or intestinal troubles. In some cases there was also tenderness of the lower cervical spine.

Chronic diarrhœa may also, in the opinion of the same author, lead to a "perivascular retinitis," in which an infiltration of the retina, causing opacity, may extend around the vessels.

The association of these conditions has not, however, been generally recognized.

*Jaundice.*—The changes in the blood from jaundice may, it is said, cause retinal hæmorrhage, but the statement is supported by one case only. Jäger says that the blood in the vessels may have a yellowish tint, but the appearance is probably due to a tint in the media, such as in rare cases causes yellow vision.

## DISEASES OF THE SEXUAL ORGANS.

Sexual excess in men has been said to cause atrophy of the optic nerve, but the evidence in support of the relation of the two is not strong.

Sudden suppression of the menses has been observed to be followed by acute optic neuritis, such as accompanies meningitis, and often attended with unpleasant sensations in the head. The occurrence of the neuritis is probably analogous to the occasional production of other acute changes in the nervous system, such as acute myelitis, from the same cause—a well-established fact.

In chronic menstrual irregularities, optic neuritis, of chronic course, has been found, and occasionally other disturbances, such as retinal hæmorrhages. It is probable that in most cases of this character the two conditions—the ocular and menstrual changes—are related to a common cause.

The occurrence of loss of sight, sometimes with neuritis, after uterine hæmorrhage has been already mentioned (p. 184).



## DISEASES OF THE SKIN.

It has been said by some, especially by Mooren, that general skin diseases may be accompanied by inflammation of the retina and papilla; that eczema of the head may be accompanied by optic neuritis, ending in atrophy. The statement has, however, received no confirmation, and the relation of the two conditions must be considered as exceedingly doubtful. If such a sequence occurs, it is possibly by the production of a local orbital cellulitis. The suppression of a customary cutaneous discharge, such as that of eczema, has also been said to cause neuritis, but the fact needs corroboration.

A case of slow atrophy of both optic nerves, associated with a general herpetic eruption on the skin, diagnosed by Hebra as "chronic herpes zoster," has been recorded by Hubsch.\* But the patient passed through a condition of delirium to one of imbecility, and the atrophy was probably part of a widely spread degeneration of the nervous system, of which the skin eruption may have been an effect.

## CHRONIC GENERAL DISEASES.

## TUBERCULOSIS.

The grey granulations which constitute the anatomical lesion in tuberculosis may form in the vascular structures of the eye, chiefly in the choroid, rarely in the iris and retina. When present in the fundus, they may readily be seen with the ophthalmoscope, and it is the only situation in which the isolated granulation can be seen during life.†

*Tubercles in the choroid* (Pl. XIII. 1) appear to the ophthalmoscope as white, yellowish-white, or reddish-yellow spots, usually isolated, and more or less rounded in form. They are palest in the centre, and commonly redder on their outer portions, and the peripheral redness passes

\* "Ann. d'Oculist." 1872, p. 239.

† That tubercles occurred in the choroid as a post-mortem observation has long been known. They were described by Autenrieth in 1808. They were first observed with the ophthalmoscope by Ed. Jäger in 1855.



gradually into that of the adjacent choroid. They commonly develop in the substance of the choroid, and the pigment and vessels atrophy before the growing nodule, first, and more completely, at the centre, so that the diameter of the tubercle on section may be found to be twice or three times as great as that of its exposed portion (Pl. XIII. 2). In size they vary from one-third of a millimetre, to two, or two and a half millimetres, *i.e.*, from about one-fourth to half or three-quarters the diameter of the optic disc. The larger sizes are rare. Occasionally several are aggregated together to form a mass which may be the size of the disc or even larger—seven or eight millimetres in diameter. These larger masses project considerably into the eye. Slight prominence may commonly be recognized in all the larger tubercles, and assists the diagnosis. The smaller ones may resemble spots of choroidal exudation or atrophy. From the former, their rounded shape and yellowish tint distinguish them. From atrophy, the tint, regular form, concealment of the choroidal vessels, and the (common) absence of any adjacent pigmentary disturbance are sufficient distinctions. They are distinctly behind the retinal vessels. In structure they consist of the same lymphoid cells as constitute the granulations elsewhere. The cells are distinct in the periphery, degenerated in the centre (Pl. XIII. 3). Extravasations of blood existed in the substance of a granulation in one case examined by myself. They are situated chiefly at the middle of the fundus, not far from the optic nerve entrance. Usually only three or four are present; sometimes, however, as many as twelve or twenty or even fifty (Cohnheim). They may form rapidly, and according to Stricker, may be recognizable in from twelve to twenty-four hours after no trace of them was previously visible. But it must be remembered that they attain a considerable size, without disturbance of the epithelium, and the partial removal of this may rapidly increase their distinctness.

Choroidal tubercles occur in both children and adults, and in the chronic as well as in the acute forms of tuberculosis, but are most frequent in the acute forms. They



are practically confined to the cases in which tubercle is widely distributed, being almost never found when the disease is confined to the lungs. Their actual frequency in these cases cannot yet be stated. It is evident, from the rapidity of their appearance, that repeated examination is necessary to exclude their occurrence. Cohnheim described them as very commonly to be found after death. This is, according to the experience of all subsequent observers, quite incorrect so far as concerns their recognition without the microscope.\* In this country, at any rate, they appear to be comparatively rare. Dr. Allbutt, at the time his work was written, had repeatedly searched for them during life and after death, and had not then met with a single case. Dr. Garlick, an excellent observer and a skilled ophthalmoscopist, during two years' experience as Registrar at the Children's Hospital, constantly searched for them and found them in one case only. Their rarity is such as to deprive them of much of the clinical importance they would otherwise possess. As a rule, when they do occur, it is not until the disease has become advanced. Exceptions to this have, however, been recorded, as in one case in which they were present before fever or other symptoms of the disease were developed.† Steffen,‡ again, found them in one case six weeks before the commencement of tubercular meningitis. In such a case they may afford great assistance to diagnosis. Their presence, then, is of value as evidence of general tuberculosis, especially in cases in which the diagnosis of acute tuberculosis from other acute febrile conditions is difficult; their absence is of no significance.

As a rule choroidal tubercles cause no symptoms. Transient disturbances in sight have, however, been described.

Occasionally, although rarely, a tubercular mass develops in the deeper structure of the eye, quite similar to the masses of the same nature which are found in the brain. A case, in

\* It must be remembered that they are much more distinct after the choroid has been preserved in spirit or Müller's fluid than in the recent state.

† Fraenkel: "Berl. Kl. Wochenschr." 1872. "Jahrbuch für Kinderheilk." Bd. ii.

‡ "Jahrbuch für Kinderheilk." 1870.



which such growths were associated in these two situations, is narrated in the Appendix (Case 5). A tubercular mass, with granulations in the neighbourhood, infiltrated the greater part of one optic nerve, and invaded the eye, in a case described by Chiari.\*

Choroidal tubercles were found by Cohnheim in a guinea-pig rendered tubercular by inoculation.

*Retina.*—The occurrence of tubercles of the retina, in very rare cases, has been recorded. The aggregation of lymphoid cells which may occur in the nuclear and molecular layers, adjacent to an inflamed disc in tubercular meningitis, have been regarded as such. The tubercular nature of such is uncertain. Unequivocal tubercles in the retina (often containing giant cells) have usually been associated with tubercular growths in almost all the structures of the eye (Perls, Manfredi), in rare cases with a tubercular papillitis only (Weiss, Sattler). In the case of tubercle of the optic nerve referred to above, the optic papilla was the seat of a large mass of caseating tubercle, and miliary tubercles were scattered through all the layers of the adjacent retina.†

Tubercles in the eye are, as already stated, almost invariably part of general tuberculosis. In one case, however, they were found in all parts of the eye, although absent elsewhere.‡

Local deposits of tubercle in the encephalon may, as already described, give rise to ophthalmoscopic changes, producing optic neuritis, as do other cerebral tumours. In rare instances tubercular masses are situated in the intra-cranial portion of the optic nerves§ or in the chiasma,¶ and may cause a corresponding affection of sight (probably with or without evidence of descending neuritis). The inflammation which accompanies the formation of tubercle in the meninges may also be accompanied by neuritic changes in the eye.

\* "Wien. Med. Jahrbuch." 1877, p. 559. Sattler, "Arch. f. Ophth." Bd. 24, Pl. iii. p. 127.

† "Arch. f. Ophth." xxiv. iii. 150.

‡ Weiss, "Arch. f. Ophth." xxiii. 4, p. 57.

§ Cruveilhier, "Anat. Path. Gén." 1862, Bd. iv.

¶ Hjort, "Kl. Monatsbl." 1867, p. 166.



Tubercular disease of the lungs has been described by some observers as accompanied by mechanical congestion of the retinal veins, and by disturbed vision, but it is very doubtful whether these are in any cases related to the pulmonary affection.

### SYPHILIS.

ACQUIRED SYPHILIS.—The syphilitic diseases of the eye, during their active stage, commonly come under the care of the ophthalmic surgeon. Their consequences in the fundus oculi are, however, among the appearances which the physician encounters most frequently in his own work, and which often furnish him with very useful information. A knowledge of these changes is, therefore, of great importance.

Although not strictly an ophthalmoscopic sign, the evidence of a past attack of iritis is often first discovered by the ophthalmoscope revealing the presence of uveal pigment on the anterior surface of the lens. In the immense majority of cases iritis is due to, and its traces are signs of, constitutional syphilis, and the importance of the evidence thus afforded, from its frequency and easy recognition, can hardly be overrated. Over and over again it must have occurred to all physicians who use the ophthalmoscope, when looking for changes in the fundus oculi, to encounter these signs of past iritis, in cases in which syphilis had not been suspected, and often in which no other indication of it, in history or symptoms, was to be obtained.

Next to the iris, the choroid is affected by syphilitic disease more frequently than any other part of the eye. In spite of the opinions which have been expressed by some authorities, there is strong reason to believe that disseminated choroiditis, is, in the great majority of cases, syphilitic. In its active stage, in which extensive areas of white exudation, comparable, in Mr. Hutchinson's opinion, to gummata, are the conspicuous features, it rarely comes under the notice of the physician. In its later stage, in which extensive regions of atrophy alternate with scattered stellate and crater-like



pigmentary deposits, and sometimes with hæmorrhages, it is often met with. It is to be remembered that the pigment is deposited in the retina as well, and care must be taken to avoid confounding the change with retinitis pigmentosa. The choroiditis of acquired syphilis is usually unilateral.

*Retina.*—Isolated syphilitic retinitis is far rarer than syphilitic choroiditis. It is characterized by areas of diffuse opacity, parenchymatous swelling, tortuous vessels, and a blurred disc. Sight is considerably impaired. This form also comes chiefly under the ophthalmic surgeon's notice.

*Optic Nerve.*—*Neuritis*, limited to the papilla, is common in syphilis, as secondary to brain disease, but is very rare as a primary syphilitic affection, if it ever occurs. Neuritis has, however, been met with secondary to a syphiloma of the trunk of the optic nerve.

*Simple Atrophy* of the nerve is said occasionally to occur, as the consequence of syphilis, double, unaccompanied by spinal symptoms (Galezowski).<sup>\*</sup> Locomotor ataxy, primary degeneration of the posterior columns, may also occur as the consequence of syphilis, I believe, very commonly,<sup>†</sup> and may be accompanied by optic nerve atrophy, although perhaps less commonly than the ordinary form. Galezowski has found the course of the atrophy to be commonly rapid and uninfluenced by anti-syphilitic treatment. The latter fact harmonizes with my own experience of ataxy and other late "neural" consequences of syphilis.

**INHERITED SYPHILIS.**—The characteristic indication of inherited syphilis, which is afforded by interstitial inflammation of the cornea, and a knowledge of which we owe to Mr. Hutchinson, is well known, and does not come within the scope of the present work.

The only deeper structure of the eye, which is liable to be affected with any frequency, is the choroid, which is often the seat of disseminated inflammation, in infancy or later. Scattered areas of atrophy may be left. The course of the

\* "Journ. d. Ophthalmologie," March, 1872, p. 139.

† Syphilitic Neuroses, "British Med. Journal," March 1, 1879.



affection is well illustrated by two cases described by Dr. T. Barlow.\* In one of these the autopsy showed chronic syphilitic disease of the cerebral membranes. The choroid presented, in each case, brownish flecks of exudation without disturbance of pigment or atrophy. The microscopical examination (by Mr. Nettleship) showed the chorio-capillaris beneath these flecks, to be infiltrated with pus-like cells, and in several instances there was a layer of flattened cells on the surface next to the retina. In the other case, Dr. Barlow traced the progress of similar flecks to a stage of atrophy, such as is seen in disseminated choroiditis—the condition occasionally met with later on in life. Sometimes it bears a superficial resemblance to retinitis pigmentosa. Several cases of this character have been recorded by Mr. Hutchinson,† and one is figured in the "Oph. Hosp. Rep." vii. Pl. 4, Fig. 3.

Simple choroiditic atrophy of the disc has several times come under my notice in children the subjects of this disease. The disc has a uniform reddish tint, the edges are not well defined, and the vessels are small. There has not commonly been any atrophy of the choroid or pigmentary accumulation. Several times, since first observing the connection between the two conditions, this choroiditic atrophy has drawn my attention to the existence of inherited syphilis, which had otherwise escaped notice. Sight is usually impaired, sometimes considerably.

A case of retinal changes in inherited syphilis is mentioned by Dr. Allbutt, as related to him by Mr. Oglesby. Above and below the disc was an irregular white patch without relation to the vessels, singularly like the patches of opaque nerve fibres. Under cod liver oil and tonics it gradually disappeared.

Retinitis pigmentosa is, by some, believed to be connected with inherited syphilis, and an instance of the association of the two diseases has been described by Mr. Swanzy. Probably

\* "Path. Trans." 1877, p. 287.

† Mr. Hutchinson has suggested that the condition of choroidal atrophy and choroidal and retinal pigmentation may occur without an exudative stage.



deposits of pigment in the retina may accompany the atrophic changes in disseminated choroiditis, but the connection of true retinitis pigmentosa with syphilis is generally considered to be very doubtful.

#### CHRONIC RHEUMATISM.

Chronic rheumatism has only accidental associations with changes in the fundus oculi. Neuro-retinitis is sometimes loosely ascribed to rheumatism, but only on the ground that it has sometimes appeared to be due to cold. It must be remembered that the optic nerve, like the other orbital nerves, may be damaged by rheumatic inflammation at the back of the orbit (see p. 145).

#### GOUT.

The direct relation of any changes in the fundus oculi to gout cannot be considered as established. Mr. Hutchinson has, it is true, described, as probably a consequence of gout, a form of hæmorrhagic retinitis in which the extravasations are small, flame-shaped, scattered over the whole fundus, and commonly present in one eye only. He suggests that they are due to thrombosis in the retinal vein behind the eye. The evidence of the direct relation to gout is not very clear. Only six (of fifteen) cases had suffered from distinct attacks of gout, and all were past middle life. But it is certain that the conditions favourable to the occurrence of gout, as well as those resulting from the developed diathesis—plethora, high living, granular degeneration of the kidneys, hypertrophy of the heart, and fatty degeneration of vessels—are conditions which may predispose to or excite the rupture of retinal vessels.

Galezowski has also described hæmorrhages leaving white patches of "sclerosis" as occurring in gouty persons. Some Continental writers are accustomed to refer to gout as a cause of optic neuritis, but I am not aware that the relation is established by any carefully observed cases, and it certainly has not been observed in this country.



## LEAD POISONING.

The eye is occasionally affected in lead poisoning, apart from the effects of induced kidney disease. The eye may be affected in three ways. There may be (1) amblyopia, usually transient, without ophthalmoscopic changes; (2) atrophy of the optic nerve; (3) optic neuritis.

The occurrence of blindness in lead poisoning has long been known. Some well-marked cases were published by Duplay in 1834.\* In what v. Graefe called "the pre-ophthalmoscopic period," the transient amblyopia attracted, however, more attention than the graver forms of affection, so that Tanquerel des Planches spoke of the amblyopia as almost invariably passing away. Optic nerve atrophy in lead poisoning was first described by Hirschler in 1866,† and optic neuritis by Meyer in 1868.‡ Attention was, however, especially called to the affection by the publication of an important series of cases by Mr. Hutchinson in 1871.§

(1.) The transient amblyopia, without ophthalmoscopic changes, is usually sudden in onset, and may be complete. It has been observed in some cases of acute saturnism after but short exposure to the exciting cause. It commonly soon passes away, and is probably due to a direct effect of the lead on the nerve centres, analogous to the temporary amaurosis of uræmia and diabetes. In one case recorded by Fano there was, for some months, a periodical transient failure of sight at the same hour each day.

(2.) In amblyopia of long duration it is common to find the signs of atrophy of the optic nerves. The discs are sharp-edged, pale, and often greyish, the arteries small. It is said that the atrophy may be from the first unattended by vascular changes (Horner). In a considerable number of cases, however, which have been seen in an early stage, a condition of simple congestion of the discs has been found. The tint is uniformly red, with softened

\* "Arch. Générale de Méd." 1834.

† "Wien. Med. Wochenschr." 1866, Nos. 6 and 7. It is not easy to say, from the account of the case, whether neuritis was present or not. The disc is spoken of as being grey, and having lost its transparency.

‡ "L'Union Méd." No. 78.

§ "Oph. Hosp. Rep." vol. vii. p. 6.



edges, with little or no swelling. Gradually the redness fades, and a reddish-grey atrophy results, often with distinct white lines along the narrowed vessels. Sight has been much affected in all the recorded cases, the acuity of vision impaired, and the field presenting a central or peripheral defect. The loss commonly progresses until even quantitative perception of light may be lost. This congestive atrophy is usually double, but, as a case recorded by Mr. Hutchinson shows, the affection of one eye may precede that of the other.

(3.) Occasionally cases of lead poisoning present much more pronounced inflammatory changes—considerable papillitis, with swelling, obscuration of the margins of the disc, concealment of vessels, and hæmorrhages, especially at the margin of the swelling. The arteries beyond the swelling are commonly narrow; the veins may be distended or of normal size. An instance of this form of neuritis is shown at Pl. VII. 6. The affection is almost always double, and usually entails considerable amblyopia. It is probable, however, that slight degrees of neuritis are not uncommon in lead poisoning without any affection of sight. I have seen one such case, and the general use of the ophthalmoscope in medical practice will probably show it to be not an infrequent occurrence. Pronounced neuritis may subside into atrophy having the characters of “consecutive atrophy,” leaving a dull-white, full-looking disc, with narrow arteries. Or the neuritis may clear and sight be recovered, as in the case figured (Case 28). It is important to remember that the affection of sight in these cases may be in part due to the direct effect of the lead on the nervous system, which has been already mentioned. This is the more likely when, as in many recorded cases, loss of sight comes on suddenly. The periodical amblyopia, mentioned above, has been noted in association with neuritis\* as well as with normal ophthalmoscopic appearances.

These ocular changes commonly occur in chronic cases of lead poisoning, which have presented toxic symptoms for

\* A case reported by Stricker from Traube's Clinique, and quoted by Abadie (Mal. des Yeux.).



some time, often for years, previously, and they may coincide with an increase of the other symptoms. It must be remembered, however, that the manifestations of lead are very irregular, and any one may be absent or may alone be present. In cases of very recent intense lead poisoning, toxic amblyopia and neuritis are apparently more common than atrophy.

In many cases the occurrence of neuritis coincides with symptoms of cerebral disturbance, headache, convulsions, delirium,\* &c. The neuritis figured in Pl. VII. 6 (Case 28) presented, at the same time, much mental disturbance, and both symptoms passed away together. In a fatal case of this description, recorded by Mr. R. Atkinson,† there were no naked-eye changes in the meninges or brain, but lead was found in it in quantity equivalent to five grains in the whole brain. This association of cerebral disturbance with optic neuritis in these cases is probably more than a coincidence, and the analogous fact as regards albuminuric neuritis (p. 174) may be borne in mind.

The diagnosis of saturnine atrophy and neuritis rests especially on the recognition of the signs of lead poisoning, especially the line on the gums, the occurrence of gout, of colic, of wrist-drop, and the presence of anæmia. It is only by these symptoms that the neuritis can be distinguished from that of primary encephalic affections. The possibility of a renal neuritis in cases of lead poisoning must be borne in mind. It is highly probable that in at least one published case the retinal change was due to the albuminuria rather than to the lead. Albuminuric retinitis is, it must also be remembered, extremely common in cases of chronic lead poisoning of long duration.

The prognosis in all forms of change in the optic disc must be cautious. It is least grave in the case of toxic amblyopia, next in cases of pronounced neuritis, especially of acute

\* This is an old observation. Tanquerel des Planches described saturnine amaurosis as the accompaniment of Encephalopathia and Colica Saturnina, and stated that in cases of this kind no material change is to be found in the brain. "Traité des Mal. de Plomb." 1839, Tom. II., pp. 211 and 235.

† "Lancet," 1878, i. 784.



course, less so in cases of chronic congestive change, and in pronounced atrophy it is very unfavourable. Of fourteen cases of various forms, collected by Lespille-Moutard,\* nine progressed to blindness.

The treatment is essentially that for the general state, but local applications, leeching and counter-irritation, have appeared useful in some cases.

### CHRONIC ALCOHOLISM.

Atrophy of the optic discs, sometimes of one only, sometimes of both, is occasionally met with in the subjects of chronic alcoholism, to which it is apparently due. It is said to occur especially in sedentary drinkers, and to be more common on the Continent than in this country. Amblyopia may precede any ophthalmoscopic change, and is characterized by a central dimness or defect. Förster states that before there is recognizable defect for white light, a defect for red may be discovered, extending from the fixing point to the blind spot and a little beyond each. To detect it the ordinary colour tests do not suffice in slight cases, since the coloured object should not be more than five millimetres in diameter. Extensive loss of vision for certain colours, as green and violet, has also been described by Galezowski as a symptom of retinal anæsthesia in some cases of chronic alcoholism. It is probable indeed that the perception of green is commonly lost as well as that of red, both colours appearing grey.†

A stage of congestion, before the onset of the atrophy, has been described by Allbutt and others. The appearances were generally those already described as "Simple Congestion" (p. 37), uniform redness of the disc, with softened edges. The disc gradually becomes paler, and ultimately passes into white or greyish atrophy, often with small vessels. When the condition of the nerve has been ascertained by microscopical examination only granular degeneration of the nerve fibres has been found. I believe that congestion, sometimes with

\* "Thèse de Paris," 1878.

† Nuel, *Ann. d'Oculistique*, Sept., 1878.



slight œdema, is often to be recognized in the cases of chronic alcoholism. It is no doubt an analogous condition to that change in the meninges which leaves the thickening and opacity often to be found after death.

The progress of the atrophy is slow, and the prognosis better than in many other forms: considerable good being effected, especially in the pre-atrophic stage of amblyopia, by strychnia and tonics.

In acute alcoholism ophthalmoscopic changes are not commonly present. In one case Jäger found a condition of diffuse retinitis, with numerous hæmorrhages in a patient suffering from delirium tremens.

#### TOBACCO POISONING.

The occurrence of defective sight from tobacco smoking was described in 1854 by Mackenzie, who was inclined to attribute most cases of amaurosis to this cause. Evidence of great weight has been brought forward by Mr. Hutchinson.\* The relation between the two conditions has been doubted by some writers, who have urged especially the commonness of the habit and the comparative rarity of the change, and the absence of evidence of its occurrence among nations who smoked much more than the English. But in other diseases, nervous as well as general, marked differences in susceptibility are noticeable in different nations, and the observation of a few cases of defective sight in smokers, improving when the only new element introduced into the conditions of their life is the cessation of smoking, must be regarded as of much greater weight than the facts of the absence of the disease among the Turks, or its rarity among the Germans.

Förster has remarked that the sight suffers from tobacco generally between thirty-five and sixty-five years of age, and remarks that tobacco is not so well borne during the second half of life as during the period of full vigour.

\* "Lond. Hosp. Reports," 1864; "Medico-Chir. Trans." 1867; "Oph. Hosp. Rep." 1871 and 1876. Cases, fully corroborating Mr. Hutchinson's assertions, have been published by Förster, Hirschberg, and others.



Several of Mr. Hutchinson's cases, however, were under thirty. He believes that the disease occurs more frequently among abstainers from alcohol than among those who take alcohol. The failure of sight is gradual and equal in both eyes, unaccompanied, as a rule, with headache or other cerebral symptoms. He has found the amblyopia to present the same characters as in chronic alcoholism—a primary central cloud in the field. The defect is commonly, as in alcoholism, first and most marked for colour-vision, especially for red and green. The accompanying diagram represents the field for red, in a case of this description. It presents both a central and a peripheral defect. The ophthalmoscopic changes

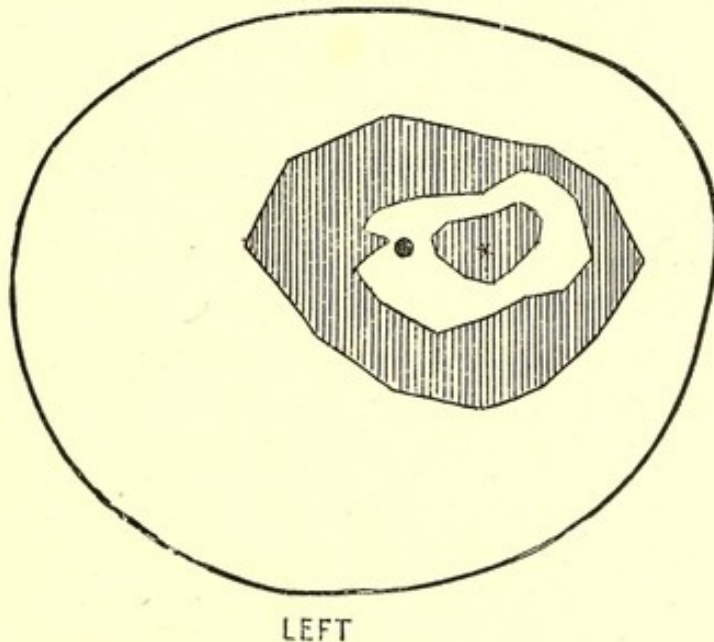


Fig. 21.—Diagram of the Left Field of Vision for Red in a case of tobacco amblyopia.—The outer line is the boundary of the normal field for white. The boundary of the outer shaded area is the minimum normal field for red. Red could, however, be seen only in the inner white area, and it could not be seen in the central shaded area around the fixing point (\*). The black dot indicates the position of the blind spot. (For the chart from which this diagram was prepared I am indebted to Mr. Nettleship.)

are also very similar to those of alcoholism. In many cases they are entirely absent. In some a stage of simple congestion, a "hazy disc," slight uniform redness, with soft edges, without noticeable swelling, may apparently be the first change. Later there is atrophy, white or greyish-white.

The treatment consists essentially in the removal of the



cause. Tonics and hypodermic injections of strychnine are also of use, especially in the pre-atrophic stage. Mr. Hutchinson believes the prognosis in most cases to be good, three-quarters of his cases having recovered, or presented great improvement in sight. Age does not render the prognosis worse.

### OTHER POISONS.

*Silver poisoning* is said to be accompanied by amblyopia, in addition to the other symptoms of argyria. No ophthalmoscopic changes have, however, been recorded, but silver has been found in the eyeball (sclerotic sheath of the optic nerve, &c.), by Reimer, deposited in small round granules. The effect of silver is closely analogous to that of lead. It may, as I have seen, lead to wrist-drop, gout, and albuminuria, and it is therefore highly probable that the same ocular changes may, in some cases, result.

In *mercurial poisoning* amblyopia has been observed; in one case optic neuritis existed,\* and in another optic nerve atrophy.† Of ocular changes in copper and phosphorus poisoning nothing is known.

*Quinine* and *salicylic acid* may cause amblyopia, but without changes in the fundus oculi.

*Sulphide of carbon* was the apparent cause of a "perineuritis," ending in partial atrophy, in a case recorded by Galezowski.† Atrophy of the optic nerves is also seen, not very rarely, among the workers in india-rubber works, in which sulphide of carbon is used.

## ACUTE GENERAL DISEASES.

### TYPHUS FEVER.

Loss of sight has been many times observed during convalescence from typhus fever,‡ and subsequently atrophy of

\* Square: "Oph. Hosp. Rep." vi. 54.

† Galezowski, "Des Amblyopies et Amauroses Toxiques," p. 141.

‡ In a considerable number of the cases recorded abroad it is doubtful whether the disease was typhus or typhoid fever.



one or both optic nerves has been found. In some of these cases there have also been cerebral symptoms, as in a case recorded by Benedikt, in which left hemiplegia was accompanied by atrophy of the right optic nerve. In such cases, probably, the atrophy was the result of a cerebral lesion. In other cases there were no symptoms except those in the eye, and a primary affection of the optic nerve appeared to have occurred. In some cases these ophthalmoscopic changes have been those of simple atrophy, but in others, where the affection of sight was first noticed during convalescence, optic neuritis has been found.\* Of the origin of the neuritis nothing is known.

### TYPHOID FEVER.

The occurrence of amblyopia and amaurosis during convalescence from typhoid is well established,† although rare. It may or may not be attended with ophthalmoscopic changes. In the latter case, the prognosis is favourable; it usually passes away in the course of two to eight weeks. The form of amblyopia varies; anæsthesia of the retina has been observed by Leber, and an annular defect in the field by Hersing.

When ophthalmoscopic changes are observed, there may be simple atrophy, single or double, without preceding inflammation; or double neuritis may be present, ending in atrophy, partial or complete, or less commonly, in recovery. Mr. Hutchinson, has, for instance, recorded‡ a case of a boy whose sight failed at  $3\frac{1}{2}$ , two to four weeks after a fever with diarrhoea and headache, a sister having suffered from similar symptoms at the same time. Symmetrical neuritis was found, and ten years later white atrophy with small vessels. The neuritis is so rare that Leber suggests, as Stellwag v. Carion had suggested long before,§ that the cases in which it is found may really have been cases of meningitis which have been mistaken for typhoid fever, an error not very

\* Teale, "Med. Times and Gazette," May 11, 1867. Chisholm, "Oph. Hosp. Rep." vol. vi. p. 214.

† Nothnagel, "Deut. Arch. für Kl. Med." 1872, ix. 480.

‡ "Oph. Hosp. Rep." ix. 125.

§ "Ophthalmologie," Bd. ii. Abt. I. 1855, p. 662.



rare. It must be remembered, however, that neuritis does occasionally follow other acute specific diseases. It has been suggested that the cases accompanied by hyperæmia of the discs are cases complicated by meningitis; but meningitis, except as secondary to suppuration in the ear, is exceedingly rare in typhoid fever. Sir William Jenner has informed me that he has never seen it. It does not appear from Dr. Murchison's work on Fevers that he had ever met with a case. To infer meningitis in consequence of extreme delirium or coma, is certainly not warranted by pathological facts.

Extreme narrowing of the retinal arteries, on both sides, with pallor of the disc and loss of sight, was found by Heddaens\* in a case of great emaciation after typhoid. On good food the arteries regained their normal size, but the disc remained pale and sight did not improve beyond  $\frac{1}{20}$ .

Galezowski† has observed embolism of the central artery of the retina during convalescence from typhoid.

#### RELAPSING FEVER.

It is well known that a peculiar form of general ophthalmia is apt to follow relapsing fever. Beyond this, which is announced by very obvious ocular symptoms, no special ophthalmoscopic changes have been observed.

#### MEASLES.

Amblyopia, without ophthalmoscopic changes and ultimately improving to the normal, has been seen, as a sequel to measles, by v. Graefe and Nagel; in some cases accompanied by cerebral symptoms, convulsions, and sopor. Nagel has also met with three cases of optic neuritis after measles, but in the epidemic in which they occurred there were many cases of meningitis. As Förster remarks, the commonness of the disease, and the rarity of affections of sight in it, shows that the connection between the two cannot be a very close one.

\* "Monatsbl. für Augenheilk." Aug. 1865.

† "Traité Iconographique," p. 188.



## SCARLET FEVER.

The frequency with which renal disease accompanies and succeeds scarlet fever renders affections of sight not very rare consequences of the disease. Occasionally, however, they arise independently of any renal disturbance.

Uræmic amaurosis is common in scarlatinal dropsy. It comes on suddenly, when the renal disease is at its height, is commonly complete, double, unattended by ophthalmoscopic changes, and passes away. Occasionally, cerebral symptoms accompany it—convulsions, and, in rare cases, hemiplegia, from a cerebral thrombosis or embolism, which persists after the cessation of the convulsions, and the return of sight.

Neuro-retinitis has, however, been observed to succeed scarlet fever when there has been no renal disease or albumen in the urine. Betke\* has recorded a case in which there was great dimness of sight seventeen days after desquamation. There was no albuminuria, but a marked neuro-retinitis was found on ophthalmoscopic examination, less developed in the right eye than in the left. There was no sign of meningitis, past or present. The neuritis entirely disappeared and sight was restored in eight weeks.

It is not uncommon to meet with atrophy of the optic nerve after scarlet fever, and the atrophy may have all the aspects of a consecutive atrophy. It has been observed in association with the symptoms of a local cerebral lesion, hemiplegia, &c. (Loet), but in some cases has occurred alone. Two remarkable cases have been recorded by Bayley,† in which, in two sisters, sight gradually failed some months after an attack of scarlet fever, without albuminuria or dropsy. One became blind and idiotic, and the other epileptic. The optic discs were "pale but not the bluish-white of atrophy," and the fundus in each case showed accumulation of pigment.

It must be remembered that an intense albuminuric inflammation may leave partial atrophy of the optic nerve.

\* "Monatsbl. für Augenheilkunde," Bd. viii. 1869, 201.

† "Lancet," Sept. 15, 1877.



## VARIOLA.

Leber has observed diffuse neuro-retinitis in variola during the stage of drying of the eruption.

## ACUTE RHEUMATISM.

Acute rheumatism is not usually associated with any changes in the fundus oculi. Embolism of the cerebral arteries sometimes, though rarely, occurs during the course of an attack, but embolism of the retinal arteries has not, I believe, been observed, except as a late sequel of the resulting endocarditis. Schmidt once observed irido-choroiditis (such as is common in relapsing fever) after an attack of acute articular rheumatism without endocardial complication.\*

## MALARIAL FEVERS.

Changes in the fundus oculi are present in some cases of malarial fever; rarely in the intermittent of this country, but not uncommonly in the severer forms of malarial fever, especially in tropical climates. Poncet,† for instance, found changes in ten per cent. of the cases of malarial cachexia in Algeria. The changes which have been observed consist of retinal hæmorrhages, neuro-retinitis, and atrophy of the optic nerve.

Hæmorrhages may occur without other change, sometimes in the posterior segment of the eyeball, sometimes chiefly in the ciliary region (Poncet). Three instances of retinal hæmorrhages in ague have been recorded by Dr. Stephen Mackenzie.‡ One was a young man, aged twenty, who had one attack of ague on his way home from India, and a severe paroxysm immediately after his arrival. The attacks recurred

\* "Arch. für Ophth." Bd. xviii.

† "Ann. d'Oculistique," May, 1878.

‡ In a paper on "Retinal Hæmorrhages and Melanæmia as Symptoms of Ague." "Med. Times and Gaz." 1877. I am much indebted to Dr. Mackenzie for the woodcuts from his paper.



daily for a fortnight, when he came under treatment and numerous retinal hæmorrhages were found, most numerous near the disc, chiefly along the course of the larger vessels, especially arteries, which they in places obscured (Fig. 22). Sprinkled about the fundus, and most numerous near the disc, were many small round bright spots, resembling pin-holes pricked in a piece of paper held up against the light. The retinal vessels were of normal size, and their sheaths did not appear thickened. These hæmorrhages were carefully observed day by day, and were seen to fade away gradually ;

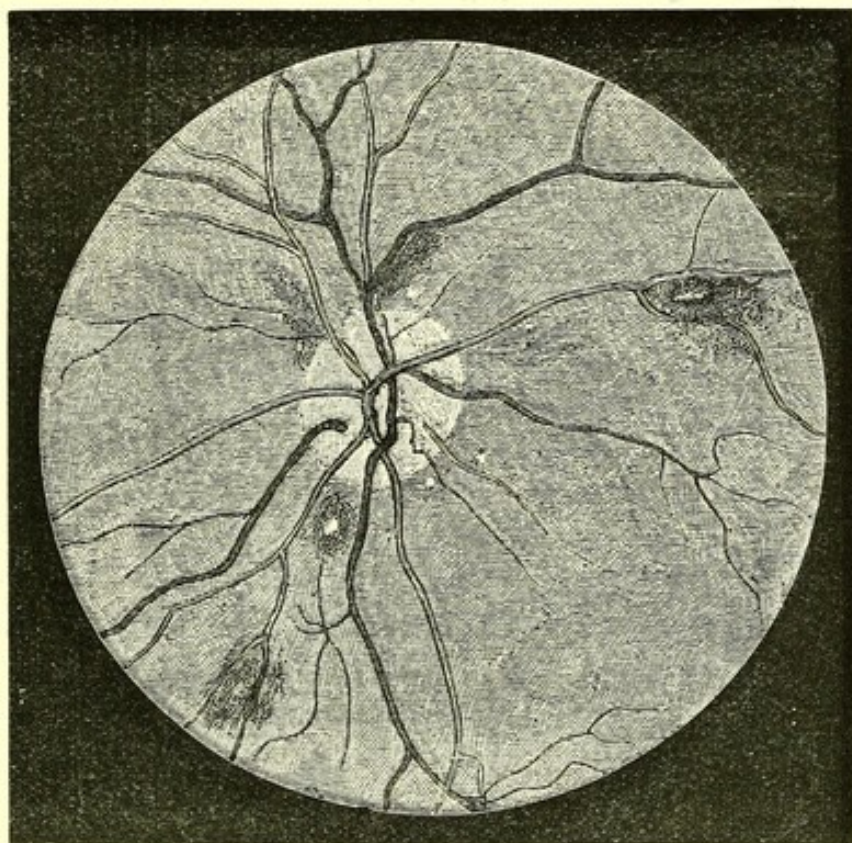


Fig. 22.—Retinal Hæmorrhages in Ague (Mackenzie).

and, as each died away, it left, to mark its former situation, one of the shiny white spots of which mention has been made above. There was no albuminuria or other symptom of Bright's disease. The spleen was large. The blood at first contained much pigment, but after the first few days no more could be found.

In two cases, at the Seamen's Hospital—a man, aged twenty-nine, with quotidian ague, and another, aged eighteen, with tertian ague—hæmorrhages were found, in the former



case, numerous, large, and superficial, leaving white patches. One was paler in the centre than in the periphery (Fig. 23). They quickly disappeared. Neither of these patients had melanæmia. In several cases subsequently examined, no hæmorrhages were found.

Poncet found, in Algeria, besides hæmorrhages, peripapillary œdema and even considerable neuro-retinitis, accompanied, in some cases, by hæmorrhages. Neuritis has also been seen in one case by Galezowski,\* and in two by Hammond,† in one eye, with stellate deposits of pigment in the retina following the course of the vessels.

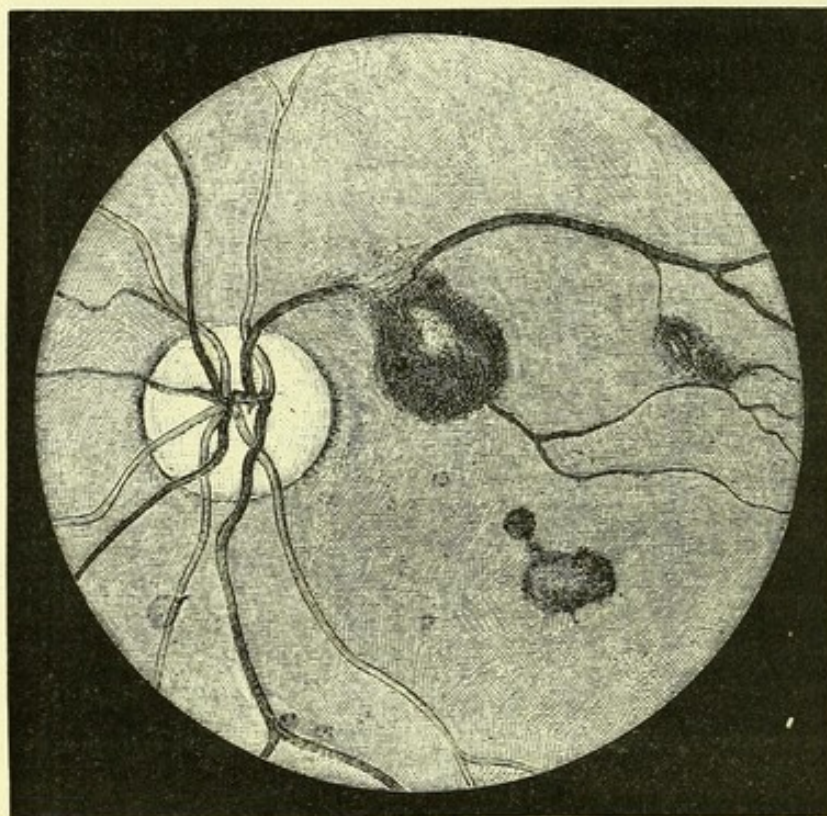


Fig. 23.—Retinal Hæmorrhages in Ague (Mackenzie).

Atrophy of the optic nerve has also been observed to succeed malarial fever. It is very rare, however, as a consequence of the intermittents of temperate climates, although a few cases are on record. After the severe malarial fever of hot climates it is not infrequent. Several cases are narrated

\* "Traité Iconographique," p. 190.

† "Trans. American Neurological Society," 1875.



by Galezowski.\* The disc is white, and the vessels small, and the field of vision greatly restricted. The pathology of these retinal changes is still obscure. The retinal hæmorrhages have been ascribed to pigmentary embolism, and they are, as Dr. Mackenzie has shown, to be found when there is no melanæmia. Poncet attributes them to the blockade of minute vessels by leucocytes. The atrophy was ascribed by Galezowski to pigmentary embolism. It seems possible that the atrophy may be the result of such neuro-retinitis as is described above, and which, damaging sight only during the stage of atrophy, attracted no attention during its acute stage.

### ERYSIPELAS.

Erysipelas of the face is sometimes followed by loss of sight and the signs of atrophy of the optic nerve (v. Graefe, H. Pagenstecher, Hutchinson, and others). It is probably produced by the extension of the cellulitis into the orbit, and the resulting damage to the trunk of the optic nerve by invasion or pressure. V. Graefe has pointed out that there is commonly some exophthalmos, but this may be very slight and may bear no proportion to the subsequent damage to sight. In most recorded cases any symptoms suggestive of orbital cellulitis have escaped notice. In one, however (that of Storey†), there was permanent limitation of the ocular movements. The loss of sight often comes on rapidly. In one of Pagenstecher's cases the loss of sight was complete at the end of fourteen days. There is always pallor of the disc and remarkable narrowing of the vessels, the arteries especially. Jäger has recorded, for instance, a case in which an adhesion of the eyelids required division with the knife five weeks after the erysipelas: the optic disc was grey and atrophied; one branch of the central artery and its corresponding vein were normal, the others reduced to lines with white borders. In Storey's case some arteries were bloodless, and occluded veins were represented by dark radiating lines. In one of Pagenstecher's cases there was a central scotoma and also peripheral

\* Loc. cit.

† "Brit. Med. Journal," March 16, 1878.



limitation of the field. Opacity of the vitreous and glaucoma have also been seen after erysipelas.

### DIPHTHERIA.

The defect of sight which so often follows diphtheria, and is due to a paralysis of accommodation, is not attended with any ophthalmoscopic change. In rare cases, however, vision is defective, apart from the paralysis of accommodation, and in such cases one or two observers (especially Bouchut) have found congestion of the disc, simple or with œdema sufficient to veil the edges and even, in part, the vessels, and in very rare cases an actual neuritis which may go on to atrophy. The atrophy may be unilateral, as in one case figured by Bouchut. This case, however, was accompanied with partial right hemiplegia and defect of speech. The congestion and œdema are usually bilateral, but may be more intense on one side than on the other.

### PAROTITIS.

Transient dimness of sight may succeed mumps, and a coincident congestion of the optic nerve has been described by Hating.

### TONSILLITIS.

In a case of tonsillitis v. Graefe once saw signs of diminished blood supply to the retina accompanying sudden loss of sight. The known relation of tonsillitis to rheumatism suggests the probability of embolism in this singular case.

### WHOOPING COUGH.

Blindness has been observed to come on during the progress of whooping cough, and in one case Knapp\* found the discs white, and the retinal arteries invisible in one eye

\* "Arch. of Ophthalm. and Otol." vol. iv. Nos. 3 and 4, p. 448.



and mere lines in the other. The patient was very weak, and Knapp suggests as explanations, anæmia from cardiac weakness, or hæmorrhage into the nerve sheaths. According to Loomis (quoted by Knapp), loss of sight generally occurs, in this disease, in children who are much prostrated, and who commonly die from lobular pneumonia.

### CHOLERA.

In cholera, v. Graefe found that, during the stage of collapse and cyanosis, the circulation in the smaller, and even in the middle-sized, arteries may apparently cease. When the weakness of the heart was moderate, the artery pulsed on slight pressure with the finger on the eyeball; but when the heart was strong this could not be well produced. If the heart was so weak that the radial pulse could not be felt, and the second sound of the heart was inaudible, slight pressure on the eye caused emptying of the arteries without pulsation. The veins were large and dark, visible in the finest divisions. The papilla was of a pale lilac tint.

### PYÆMIA AND SEPTICÆMIA.

The occurrence of a general inflammation of the eye in cases of septicæmia of various kinds, "metastatic panophthalmitis," has long been known, but it is only during the last few years that the use of the ophthalmoscope in medical and surgical practice has revealed the fact that slighter retinal changes are present in a large proportion of the severer forms of these affections, and constitute a symptom of considerable diagnostic and prognostic importance, as well as of great pathological interest. The knowledge of their character is largely due to the labours of Heiberg,\* Roth,† and especially of Litten.‡ All forms of affection are most common in the

\* "Med. Centralblatt," 1874, No. 36.

† "Deut. Zeitschrift für Chirurgie," 1872, p. 471; Nagel's "Jahresbericht," 1872, p. 349.

‡ "Charité Annalen" for 1876, p. 160.



intense septicæmia of puerperal women, but are also met with in other cases.

*Panophthalmitis*.—The general inflammation of the eye, "pyæmic or metastatic ophthalmia," is usually attended with suppuration in the various structures—iris, choroid, retina, vitreous—with rapid destruction of the eyeball. It was shown by Virchow\* to depend upon septic embolism, and later researches have fully confirmed the fact. Plugs in the vessels have been found by Virchow, Roth, and Heiberg. The latter found micrococci in the emboli. It is usually associated with the endocarditis which is so common in septicæmia. Virchow found yellowish granular masses in the capillaries of the retina, similar to those which were present in the cardiac valves, and he, with most subsequent observers, regarded the cardiac valves as the source of the emboli. The condition may, however, occur independently of any endocarditis.† Even in such cases, however, the presence of infarcts in other organs, and of suppurating thrombi in the source of the septicæmia, demonstrated the probability of embolism, although not directly from the heart. It is well known that pyæmic emboli may pass through the lungs and lodge in the general system. The septic inflammation excited in the eye may start from the choroid or the retina, as is demonstrated by two cases of Litten's, in which the process commenced a short time before death, and he found plugging in the one case of choroidal and in the other of retinal vessels. A case in which the mischief apparently commenced in the retina has also been described by Roth. When the retinal vessels are plugged, hæmorrhages in the retina are invariable, as Virchow demonstrated, and the commencement of the process in retinal hæmorrhages, with opacity of the retina and vitreous, may be watched with the ophthalmoscope.‡ The opacity of the retina depends apparently in most cases on acute degeneration. It was found by Roth to be merely softened, and

\* "Archiv. für Path. Anat." Bd. x. 1856.

† Litten, loc. cit. Case 8; Meckel, "Charité Annalen," Bd. v.; Virchow, "Ges. Abhand.," p. 539; Schmidt, "Arch. für Oph." xviii. p. 1.

‡ Litten: Case 8.



containing granule cells, although the other structures of the eye were infiltrated with pus. A layer of pus has, however, been seen on the surface of the retina, and pus is said to have been found in some cases in the nerve-fibre layer. Rarely, the changes have been found limited to a small area of the retina and the adjacent choroid.

The affection is usually single, but in many cases both eyes are affected, it may be unequally. It occurs only in intense forms of septicæmia, commonly not long before death. In rare cases it may occur when the general symptoms of the disease are not advanced, as in a case mentioned by Litten, in which a woman came to the hospital with one eye in a state of complete suppuration, but with so little subjective symptom of the considerable fever which was found to exist, that she was unwilling to remain. Death occurred some weeks after the eye was lost. Ophthalmoscopic examination of the sound eye revealed no change for some time after admission. One day choroiditis and infiltration of the vitreous was discovered: the same day rigors and joint inflammation occurred, and in three days later the patient was dead.

*Retinitis Septica.*—Roth has described a peculiar form of retinitis in cases of pyæmia, characterized by the appearance of small white flecks in the neighbourhood of the papilla and macula lutea, varying in number, and occurring in most cases in both eyes. Sometimes small hæmorrhages were present. The white spots were found to consist of groups of swollen nerve fibres, among which were granule cells, fattily-degenerated capillaries, and pigment granules. The affected spots were of small size, and showed little tendency to extension, or to the involvement of the vitreous or choroid. In no case was any plugging of vessels discovered, or any deposits on the cardiac valves. Roth, therefore, believes that the change is due to the chemical alteration of the blood. It was found especially in cases in which decomposition was occurring in inflamed parts, such as extensive sloughing with secondary suppuration, and especially in pronounced septicæmia. It was found also in one case of putrid bronchitis.



*Retinal hæmorrhages* constitute, however, by far the most common and most important change in the fundus in cases of septicæmia. They usually accompany the suppurative panophthalmitis, especially when the process commences in the retina. They may also occur in the form described by Roth. But they may exist alone, without any sign of retinal inflammation, and as such constitute the most common ophthalmoscopic change in these cases. They have been very carefully studied by Litten, in cases of puerperal septicæmia, in which they almost invariably occur during the last two or three days of life. They are always bilateral, round, or irregular in form, and of variable size, sometimes very large. They are commonly adjacent to vessels, especially veins, but occasionally are situated apart from visible vessels. Most of the round extravasations present pale or white centres, which are often distinct as soon as the hæmorrhage appears. They are recognized without difficulty, some being always in the posterior portion of the fundus.

In some of the cases in which these hæmorrhages were seen, there was endocarditis, but in several cases recorded by Roth and Litten the heart was healthy. There is thus no necessary connection between the cardiac and the ocular condition. Moreover, the retinal change appears comparatively innocent; no adjacent inflammation is excited. In no case could Litten find any plugging of the retinal vessels, and from these facts, he concludes with Roth, that embolism is not the cause of these extravasations, but that they are to be ascribed to the chemical change in the blood. This view is also supported by a case described by Leube,\* but the same observer has recorded another case of septic pyæmia, secondary to double caseating epididymitis, in which retinal hæmorrhages existed, and, post-mortem, bacterial plugs were found in many other organs. The retinæ apparently were not examined. Rosenbach,† however, found a similar condition of multiple hæmorrhages in the retinæ of dogs, in which a septic endocarditis had resulted from experimental lesions of the

\* "Deut. Arch. für Klin. Med." xxii. 1878, p. 235.

† "Arch. für Exp. Path. und Pharmak." 1878.



valves, and he found micrococcal plugs in the retinal vessels after death. From these facts we may conclude that, although simple hæmorrhages usually arise independently of embolism, they may sometimes be due to the plugging of vessels. In connection with the remark, that adjacent inflammation is often not excited, it may be noted that of six cases with endocarditis observed by Litten, in only three did the cardiac change present the aspect of malignant ulcerating endocarditis; in the other three the valves presented only innocent looking vegetations. It is probable that the endocarditis varies in its degree of septic character in different cases of blood poisoning. In several cases of pyæmia similar hæmorrhages have been noted on the mucous membrane of the conjunctiva or mouth (Litten, Leube).

From the fact that the retinal hæmorrhages usually precede death by a few days only, they afford important and very grave prognostic information. Now and then they are useful also in diagnosis, since they are apparently not found in acute specific diseases, even in those severe cases in which cutaneous hæmorrhages are present. Litten mentions two cases of women admitted with high fever, cutaneous extravasations, and cardiac murmurs. One had been recently confined. They had the aspect of cases of septicæmia rather than of typhoid, but the absence of retinal extravasations led to a diagnosis of typhoid fever, which, in each case, was confirmed by the post-mortem examination.

The effect of the retinal hæmorrhages on vision could not be ascertained with exactness, on account of the general state of the patients, but they appeared to cause little impairment.

Purulent meningitis sometimes occurs in cases of septicæmia. In one such case, recorded by Leube,\* there were retinal extravasations, but after death intense inflammation of the optic nerves adjacent to the inflamed membranes was found.

\* "Deut. Arch. für Kl. Med." Bd. xxii. 1878, p. 263.



## THE OPHTHALMOSCOPIC SIGNS OF DEATH.

The stoppage of the heart's action and the consequent arrest of the circulation of the blood, which constitute the chief events in the cessation of systemic life, lead to striking changes in the fundus oculi, changes which are among the most unequivocal signs of death. Attention was first called to them by Bouchut in 1863,\* and they have since been studied by many observers, especially by Poncet,† Arlidge,‡ and Gayet.§

As the heart's action is failing, the arteries may be observed to diminish in size (Arlidge). On the cessation of its contractions, the diminution in their size becomes more marked. A few minutes after death the capillary redness of the disc disappears, and its surface becomes of papery whiteness, in which, however, the central cup, if present, may appear of still more brilliant whiteness. The arteries quickly cease to be recognizable upon the disc, appearing to commence at its edge. On the fundus they are at first distinct, usually narrow, but otherwise of normal appearance. The veins may present normal characters or may, like the arteries, quickly become indistinct upon the disc, appearing to start from its edge. Commonly the columns of blood within them soon become interrupted, broken up into segments, which give the vessels a beaded appearance. The indistinctness of the arteries, which is due to their contraction emptying them of blood, quickly extends towards the periphery, and in the course of half an hour, sometimes in ten minutes, they are irrecoznizable. The veins remain distinct, but in most cases the beaded appearance increases. The choroid, during the first few minutes, presents nearly its normal tint, but this

\* "Traité des Signes de la Mort."

† "Arch. Gén. de Méd." 1870, p. 408.

‡ "West Riding Asylum Reports," i. 1871, p. 73.

§ "Ann. d'Oculistique," t. lxxiii. 1875, p. 5.



quickly lessens in intensity, and the colour which is presented depends on the amount of pigmentation. In dark eyes it acquires a yellow-brown colour, in lightly pigmented eyes it gradually assumes a pale, reddish-yellowish, sometimes a greyish, tint. Commencing opacity of the retina may sometimes be distinguished and may be accompanied by a red spot at the macula lutea (Gayet), due to its freedom from opacity, and similar to that seen in embolism of the central artery.

These appearances persist until, generally after five or six hours, the progressive opacity of the media prevents further observation.



## APPENDIX I.

### NOTES.

#### I.—ON OPHTHALMOSCOPES.

The question is often asked, which of the many forms of ophthalmoscope is to be recommended? The instruments with a revolving disc of lenses behind the mirror have practically superseded the older forms. Their great convenience more than compensates for slight drawbacks which

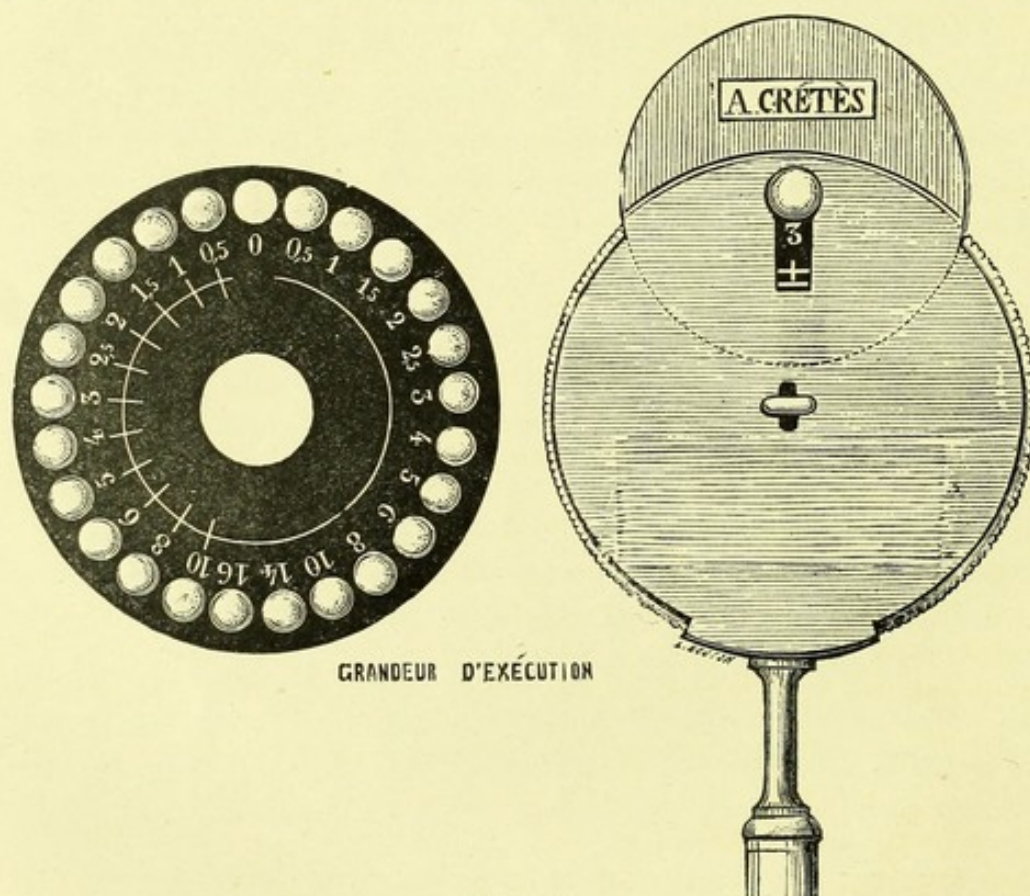


Fig. 24.

they possess. The ophthalmoscope of the kind which has come into most general use is that of De Wecker. There are, however, two instruments known by his name. The larger of these possesses a set of



twenty convex lenses, which are all rendered of minus power by the interposition of a single strong concave lens. Thus, a series of forty modifications is obtained. The instrument is, however, a little complex, heavy, and somewhat clumsy, and has the disadvantage that either two or three thicknesses of glass are always interposed, and the least dust on the glasses dims the image. Moreover, I have found that in use the instrument is apt to get unsteady.

The other form of De Wecker's ophthalmoscope (Fig. 24) is a smaller, lighter, and convenient instrument. It has a dial of twenty-four lenses, eleven convex and thirteen concave, which are sufficient for all ordinary purposes. The latest form of this instrument differs in some respects from that previously made, being neater and more compact. Both instruments are made by Crétès, 66, Rue de Rennes, Paris, and are kept by Krohne and Sesemann, 8, Duke Street, Manchester Square, London, and other instrument makers. An ophthalmoscope on the exact model of the smaller of these instruments is also made by Messrs. Pillischer and Son, of New Bond Street.

The large size of the disc of lenses in these instruments is somewhat inconvenient in their use, especially for the direct method of examination. Messrs. Pillischer have made, by my directions, an ophthalmoscope in twenty-six lenses, two more than in De Wecker's smaller instrument, are contained in a disc, which is scarcely wider than the mirror. The instrument is shown in Fig. 25.

The lenses are arranged in two series, the weaker, those most frequently needed, outside; the stronger, those least frequently needed, inside. The pivot on which the disc revolves, rotates securely on either of two points, one for each series of lenses, and can be moved from one to the other with facility, in any position. By this means the size of the instrument is reduced, and it is thus more convenient for examination by the direct method, and for the pocket \*

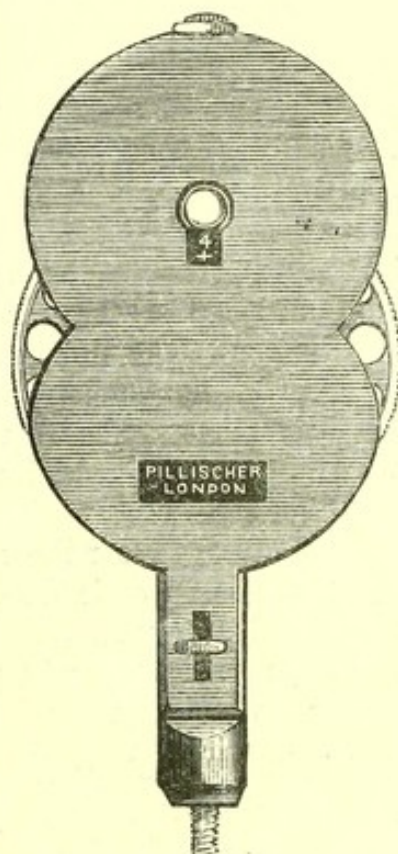


Fig. 25.

## II.—ON LEARNING THE USE OF THE OPHTHALMOSCOPE.

It is very desirable that students should learn the use of the ophthalmoscope early in their practical work. As a rule, it is one of the last things acquired, and too often it is postponed until the work for final

\* I have been informed that the same principle has been adopted by Loring, but have not been able to find an account or figure of his instrument. While this sheet is passing the press, a description has appeared of a new ophthalmoscope by De Wecker, with two revolving discs, giving fifty-two combinations ("Ann. d'Oculist," May, 1879).



examinations absorbs the student, to the exclusion of other things, and in consequence, it is often not learned at all. The ordinary ward work of the student supplies him with numberless convenient opportunities of acquiring a knowledge of the normal and abnormal appearances of the fundus, opportunities which are lost if he has not learned how to use the instrument.

To acquire the necessary skill, it is very desirable that the student should possess an instrument, as it is difficult for him otherwise to obtain sufficient practice in its manipulation. The cost of an instrument probably prevents many students from obtaining one at the beginning of their work. It may, therefore, be worth while to mention that the use of the ophthalmoscope may be learned, and dexterity with it acquired, with an instrument which every student can make for himself at the cost of a few pence. A piece of looking-glass, two inches long by one wide, with the corners rounded off, is all that is necessary. Paper should be pasted on to the back of it, and over one half of the front, and turned over the edge of the glass in the other half, so as to cover the sharp edge. A small hole should be made in the paper at the back opposite the middle of the uncovered part of the mirror, and the silvering scraped away at the spot. By the covered half of the glass the instrument may be held. With this simple ophthalmoscope, and a two-and-a-half or three-inch lens, the fundus, disc, and vessels can be clearly seen. The illumination is, of course, feebler than with a concave mirror, but sufficient for the purpose—that of enabling the use of the instrument to be acquired. Emmetropic and hypermetropic eyes may also be examined with it by the direct method.

By far the best method of acquiring dexterity in the use of the ophthalmoscope is for the student to attempt to make a sketch of some fellow-student's optic disc. The instrument has to be laid down, and readjusted at every stroke, and the repetition of the operation under the same conditions, will very quickly enable him to do it with an accuracy which he is much longer in acquiring in the examination of patients, when every occasion of use is under different conditions. In practising upon a fellow-student he has, it is to be presumed, an intelligent subject, a point of the greatest importance to the beginner. If he in his turn submits to a similar examination, he will be better able to exercise consideration for the patients whom he examines. Dilatation of the pupil is unnecessary, and indeed, undesirable for this "practice."

Artificial eyes are made for ophthalmoscopic practice, and are useful for the acquisition of familiarity in the adjustment of the instrument. A rough apparatus can, however, be made, which will answer for this purpose very well, with an ordinary botanical lens at half or two-thirds of an inch focus. Let a diagram of an optic disc and vessels be sketched upon a piece of cardboard, the disc being about one-tenth of an inch in diameter. Fix this on the focus of the lens. A botanical lens, the case of which is provided with a hole on each side, answers



very well, since a rod can be placed through the holes, and on the rod the cardboard fixed. Place in front of the lens another piece of cardboard with an aperture to represent the pupil. With this apparatus the indirect and direct methods of examination may be practised, and the use of convex lenses to magnify the inverted image. By moving the diagram forwards or backwards, the conditions of the hypermetropic or myopic eye may be obtained, and the different effect, on the image of the vessels, of movement of the head can be observed.

### III.—OPHTHALMOSCOPIC MICROMETRY.

The measurement of the size of the details in the fundus oculi presents many practical difficulties arising from the variations in the length of the eyeball, in the refraction, and in the accommodation. The employment of any method is especially difficult where it is most wanted, in the direct mode of examination, in which alone is the magnification sufficient to render the exact measurement of small objects possible.\*

Donders, in 1853, soon after the invention of the ophthalmoscope, devised an instrument for measuring the details by the direct method. It consists essentially in a tube conveying the light to the mirror, which is placed in a small square box, through which the examiner looks at the patient's eye. At the end of the tube next the light, two rods are placed, the points of which can be approximated or withdrawn from one another. The image of these is seen on the retina when the eye is accommodated to the distance of the points. They are moved until they correspond, in the image, to the diameter of the object to be measured, and a simple mathematical formula gives the relation which the actual distance between the points bears to the distance between them in the image upon the retina. To make the punctum remotum of an emmetropic eye correspond to the points, a convex glass before it may be necessary. The instrument has never come into general use.

For the same purpose it has been proposed during the ophthalmoscopic examination for the observer to look with his other eye at a divided surface, when the divisions will be seen as if upon the retinal image. But for this, as Giraud-Teulon has remarked, the two eyes of the observer must correspond in accommodation, a condition difficult to secure under the circumstances. Landolt† has suggested that the same effect may be obtained with one eye by employing an ophthalmoscope, the back of which reflects as well as the front. The divided surface, used as a gauge, must be placed at a certain distance from the mirror (28 cm. of the mirror is 2 cm. from the eye and the latter is emmetropic) or it may

\* A full account of the subject will be found in the article on "Ophthalmometrologie," by Snellen and Landolt, in the "Handbuch d. Gesamt. Augenheilkunde" of Graefe and Saemisch (vol. ii. pt. 1), and in a pamphlet on "Le Grossissement des Images Ophthalmoscopiques," by Landolt, Paris, 1874.

† Loc. cit. p. 76.



be fixed on to the ophthalmoscope, and the divergence of the rays corrected by a suitable convex lens.

The measurement of the details of the inverted image is much more simple. It is only necessary to place the measure in the position of the image, *i.e.*, a certain distance behind the lens. Schneller\* adapted Donders' method by placing the measuring rods, or a glass ruled with parallel lines, in the focus of the intermediate lens, which was fixed for the purpose on the end of a short glass tube. Liebreich† placed in the corresponding position in the tube of his demonstrating ophthalmoscope, a plate of glass bearing vertical and horizontal lines, and so arranged that it could be moved forwards or backwards, rotated or inclined, to get rid of the reflection.

Landolt suggests the use of a similar apparatus in which also the diaphragm is movable, so as to be placed in the exact position of the




Fig. 26.—Micrometer Screen for Ophthalmoscopic Measurements.

image, whatever be the refraction of the eye examined. The position of the diaphragm is indicated by a scale on the outside of the tube. This scale affords a guide to the degree of magnification and consequent value of the divisions of the diaphragm, according to certain formulæ which are given by Landolt. The instrument is, of course, available for relative measurements without this calculation.

It has been proposed by Mr. Renton, of Glasgow,‡ to carry the quadrilled diaphragm at the distance behind the lens at which the image is formed, by fixing the two upon a rod of wood. This rougher method is, of course, only available for relative measurements.

\* "Arch. f. Opth." Bd. iii. 1857, p. 51.

† "Arch. f. Opth." viii. 1860, ii. p. 134.

‡ "Journal of Physiology," January, 1879.



I have employed the instrument shown in Fig. 26 for purposes of ophthalmoscopic measurement and have found that it answers both for the direct and indirect method of examination. It consists of a metal screen, the central part of which can be rotated. In the middle is an opening, across which vertical and horizontal wires are stretched at such distances that of the spaces they enclose one horizontal corresponds to five vertical. At the back are two springs by which it is attached to the chimney of the ophthalmoscope lamp. This screen being placed before the flame, an image of the opening and bars is obtained on the fundus in either the erect or in the inverted image. In the direct method the distance from the mirror at which the screen must be placed depends on the focal distance of the mirror, and the condition of refraction and accommodation of the eye. It is usually about nine inches. The relation between the size of the divisions and their size in the retinal image, *i.e.*, the absolute value of the divisions as seen upon the retina, can be calculated by means of the formulæ to be found in works on physiological optics. In order to measure the size of the retinal vessels, &c., the inner part of the screen may be rotated so that the smaller divisions are in the required direction for exact measurement. The instrument is made by Hawksley, 300, Oxford Street.

#### IV.—ON THE EXAMINATION OF COLOUR-VISION.

The foregoing pages show how frequently the ocular changes which occur in cerebral and spinal diseases entail an affection of colour-vision, and that this may precede other damage to sight. It is important therefore for the physician to be cognizant of the methods of testing the perception of colours. The following brief note may therefore be useful, the more so as I am not aware that any account of the latest and most useful method has yet appeared in this country.

The methods which have been adopted for the detection of colour-blindness proceed upon three principles.

1. To ascertain whether the patient can or cannot identify and name certain colours. For this purpose colour scales have been employed, of which one of the best is that of Galezowski \* in which eleven colours, red, red-orange, orange, orange-yellow, yellow, yellow-green, green, green-blue, blue, blue-violet, and violet are arranged in the order in which they occur in the spectrum. Each of these is figured in four degrees of intensity, and, although many of them are not good, the series answers its purpose very well. The coloured wools, described below, can also be used for this purpose. The spectroscope can also be employed. By means of a diaphragm any colour of the spectrum may be isolated.† This method of asking the patient to name colours, has, however, as a method of ascertaining loss of colour-vision, considerable drawbacks

\* "Échelles Typographiques et Chromatiques," Paris, Ballière, 1874.

† Such an apparatus has been made, at my suggestion, by Mr. Browning, of 63, Strand.



arising from the ignorance of the names of colours which many patients present, and from the difficulty of ascertaining, especially in the case of the congenitally colour-blind, how far the terms they use correspond in meaning with the same terms as employed by those who possess normal colour-vision. In the case of acquired colour-blindness, however, especially when one eye only is affected, and in those who previously (as most women) possessed an accurate knowledge of the names of colours, this method possesses special advantages which have certainly been underrated by some recent writers, since it affords information, to be obtained in no other way, of the character of the perverted sensation of such patients.

2. The recognition of the presence of colours of weak intensity without attempt to identify them. This method has been advocated by Stilling, who employs for the purpose the tints which are seen in the shadow of an opaque object in coloured light. If, for instance, the light of a lamp or even of a candle is rendered red by a red glass being placed in front of it, and allowed to fall on a piece of white paper, the shadow of a pencil upon the paper appears green. Conversely on a green light the shadow appears red. This method, however, does not possess the advantages which have been claimed for it. The slighter tints of Galezowski's colour table, or the coloured wools, may be employed in the same way.

3. The method of examination which is of the greatest utility and which should alone be employed in the case of those who are congenitally colour-blind, is that of the comparison of colours by which those which appear alike to the colour-blind are ascertained and the nature of their defect is thus learned. The method was originated by Maxwell, and for it the ordinary colour charts, if sufficiently extensive, may be employed, although not very conveniently. In the hands of Holmgren, of Upsala, by the adoption of skeins of coloured wool as the objects to be compared, the method has assumed a very convenient and practical form. The following account of the method and its employment is condensed from Holmgren's latest work upon the subject.\*

The skeins of wool employed are of various colours red, orange, yellow, greenish-yellow, pure green, greenish-blue, blue, violet, purple, rose, brown, and grey, and several shades of each colour. These are laid in a heap upon the table. One of these, of a colour specially suited for the purpose, is picked out and laid on the table, and the individual examined is told to select all the other wools which appear to him to correspond in colour to the selected skein. The way in which the attempt is made, indicates the character of the colour-vision of the individual. In order to ascertain if there is any defect, a pale-green skein is the best to select in the first instance, because, according to the

---

\* "Die Farbenblindheit in ihren Beziehung zu den Eisenbahnen und der Marine" (German translation). Leipzig, 1878.



Young-Helmholtz theory of colours,\* green is the whitest of the colours of the spectrum, and is therefore most readily confounded with grey, if the individual is colour-blind. For the diagnosis of the special form of complete partial colour-blindness (*i.e.*, complete red, green, or blue blindness) rose-purple is selected—*i.e.*, the whole group of colours into which red and blue enter in so nearly equal parts, that to normal colour-vision the tint would not be called either red or blue. Hence the series of skeins may be divided into three classes: (1) The test colours; (2) Those which a colour-blind person regards as similar, but which are different to normal colour-vision—"confusion colours;" (3) The series of colours and shades to furnish a sufficient variety for choice. A plate of the tints of the test colours (I., IIa. and IIb.), and of the "confusion colours" (1—13) which indicate colour-blindness, is given by Holmgren, as follows (the test colours are printed in capitals, the confusion colours in small type):—

I. PALE GREEN.—1, grey; 2, brown; 3, yellow; 4, light-red; 5, brownish-red—all very pale tints.

IIa. ROSE-PURPLE.—6, deep-blue; 7, violet; 8, grey; 9, bright (spectrum) green—all strong tints.

IIb. BRIGHT-RED (Vermilion).—10, olive-green; 11, brown; 12, bright yellowish-green; 13, reddish-brown—all strong tints.

The method of proceeding is as follows: *Test 1.*—The pale-green skein is first laid down (it should be the palest tint which contains enough pure green to appear neither yellowish-green nor bluish-green), the individual must lay by its side all the skeins which appear to him of the same tint, or until he picks out one of the confusion colours, 1—5, which declares him to be colour-blind. This test does not give much information as to the nature of the colour-blindness, whether for red or green. If, however, blue is selected, the patient *may* be violet (= blue) blind.

*Test 2.*—The rose-purple skein is then placed before him (the tint should be midway between the darkest and lightest shades of the rose-purples). The individual must select the skeins which appear to him similar, proceeding until he has picked out all such or one or more of the confusion colours, 6—9. If he picks out 6 or 7 (dark blue or violet), either alone, or in addition to purples, he is completely red-blind. If he selects 8 or 9 (green and grey) alone, or in addition to purple, he is completely green-blind. (The red blind person never selects the same confusion colours as one who is green blind.) If he

---

\* Holmgren bases his method on this theory of colour-vision, but it appears to be founded rather on this theory of colours, as a concrete statement of the fact of the gradation of colours in the spectrum, than on the specific theory of the mode of (retinal) perception of colours with which Holmgren especially connects it.



selects red and orange he is violet (= blue) blind. If a person, found by the first test to be colour-blind, picks out in Test 2 only the rose-purples, his colour-blindness is incomplete. It is not always possible to determine the exact nature of a slight degree of colour-blindness.

*Test 3.* (Corroborative and not essential).—A bright red skein is selected as a test, and the individual should pick out the skeins of the same shade, proceeding until he has selected all or some of the confusion colours, 10—13. The red blind will choose, besides red, shades of green and brown (10 and 11), which appear, to normal vision, darker than red. The green blind person will select the opposite shades (12 and 13), which appear lighter than red.

In order to expedite the examination, in Test 1 all the greens may be left out of the wools, except the different shades of the test-green. Thus facilitated, Holmgren states that under favourable circumstances individuals can be examined at the rate of 100 per hour.

Probably, for practical purposes, a similar method might be adopted with the other sets of test colours. Each may consist only of the several shades of the test colour and the several confusion colours. The examination is facilitated by keeping the several sets separate, and for this purpose they may be fastened together at one end. In use they may be spread out, fan-like, upon the table, and the test colour laid next the patient, who can then lay by its side those colours which appear to correspond.

In a convenient set of pocket test-types arranged by Mr. Nettleship,\* coloured stuffs are provided for use in the same way as Holmgren's wools.

The disadvantage of the confusion method is, that it gives no information regarding the character of the disordered perception in pathological (acquired) colour-blindness, and that in such cases the past experience of the individual often enables him to choose with an accuracy which leads to an erroneous impression of the degree of the deranged sensation. For instance, the girl with unilateral atrophy and disseminated sclerosis (Case 34a), confused, in the first test, the pale green and grey, but matched the strongly-marked colours (including greens), with perfect exactness. Nevertheless, these strong greens appeared to her to be shades of brown or red. With the normal eye she recognized their true colour instantly.

---

\* Sold by Hawksley, 300, Oxford Street.



## APPENDIX II.

### TEST-TYPES.

*The following types are numbered according to the distance in feet at which they can be read by a normal eye. The acuity of vision is expressed by a fraction of which the denominator is the number of the test-type, the numerator the distance in feet at which it can be read.*

#### No. 1.

The mouth of this hollow was at the bottom of a great rock, where, by mere accident, I was cutting down some thick branches of trees to make charcoal, and perceived that, behind a very thick branch, there was a kind of hollow place: I was curious to look in it; and getting with difficulty into the mouth of it, I found it was pretty large, that is to say, sufficient for me to stand upright in it, and perhaps another with me: but I must confess to you that I made more haste out than I did in, when, looking farther into the place, and which was perfectly dark, I saw two broad shining eyes of some creature, which twinkled like two stars; the dim light

#### No. 1½.

from the cave's mouth shining directly in, and making the reflection. However, after some pause, I recovered myself, and began to look round me, when I found the cave was but very small,—that is to say, it might be about twelve feet over, but in no manner of shape, neither round nor square, no hands having ever been employed in making it. I observed also that there was a place at the farther side of it that went in further, but was so low

#### No. 2.

that it required me to creep upon my hands and knees to go into it, and whither it went I knew not; so, having no candle, I gave it over for that time, but resolved to come again. The next day I came provided with six large candles of my own making; and going into

#### No. 3.

this low place I was obliged to creep, as I have said, almost ten yards, which, by the way, I thought was a venture bold enough, considering that I knew not how far it might go, nor what was beyond it. When I had got

#### No. 3½.

through the strait, I found the roof rose higher up, I believe near twenty feet; but never was such a glorious sight seen in the island, I dare say, as it was to look round the sides and roof of this cave—the



*No. 4.*

wall reflected a hundred thousand lights to me from my two candles. What it was in the rock, whether diamonds or any other precious stones, or gold—which I rather supposed it to be—I knew not.

*No. 5.*

The place I was in was a most delightful cavity, or grotto, though perfectly dark; the floor was dry and level, and had a sort of a small loose gravel upon it, so that there was no

*No. 6.*

venomous creature to be seen, neither was there any damp or wet on the sides or roof; the only difficulty in it was the entrance,—which, however, as it was a

*No. 8.*

place of security and such a retreat as I wanted, I thought was a con-

*No. 10.*

venience,—so that I was really rejoiced at the discovery, and

*No. 12.*

resolved, without any delay, to bring some of



*No. 15.*

**those things which  
I was most anxious**

*No. 20.*

**about into  
this place of**

*No. 30.*

**safety**



## APPENDIX III.

---

### CASES.

CASE 1.—*Caries of the sphenoid bone; descending neuritis, at first unilateral; meningitis; death; necropsy.\** (Pl. III. Figs. 1 & 2.)


LYDIA H., aged sixteen, applied to Mr. McHardy, at the South London Ophthalmic Hospital, in July, 1875, on account of dimness of sight in the left eye, of a fortnight's duration. Signs of intra-cranial mischief being present, he kindly sent her on to me on July 13.

Family history irrelevant; previous health not good: a suspicion of lung mischief. A year and a half earlier a troublesome alveolar abscess in the upper jaw. Some months before she had a fall and struck her head, but no notice was taken of it. Much headache for the last two months; left frontal region constant with paroxysmal exacerbations and superficial tenderness of the head: the pain sometimes passed over the head to the back, and to the ears, and down the left cheek. When seen, no symptoms of paralysis could be detected. No affection of hearing. Pupils equal. Vision, right eye  $\frac{24}{11}$ . Left eye, quantitative perception of light only. The right optic disc and vessels were in every way normal; the physiological cup large (Pl. III. Fig. 1). The left eye presented well-marked neuritis (Fig. 2). The edges of the disc were veiled by a greyish-red striated swelling, over which the vessels curved; the veins were concealed beyond the edge, but neither arteries nor veins were concealed on the swelling itself. In the centre they passed into a depression, in which a narrow white area marked the position of the central cup, which was almost obliterated. Her chest presented signs of old pleurisy, but no evidence of phthisis. Next day the pains increased in severity, and were felt in the face, nose, ears, &c. Some vomiting occurred. Two days afterwards she was admitted, under my care, into the Queen Square Hospital, slight drooping of the left upper eyelid, and defective action of the left superior rectus, having come on. During the next day or two the pain continued, and she was restless and somewhat obtuse. Temp. 99°. On the 18th the right optic disc was still quite normal. On July 19 the somnolence increased, and on the 20th it was with difficulty that she could be roused. She fre-

---

\* Condensed from notes taken by Dr. Allen Sturge.





quently put her hand to her head and uttered expressions of pain. Her temperature had risen to  $101^{\circ}$ , the pulse varying between 96 and 98. There was retention of urine. Paralysis of left third nerve not greater, but left pupil widely dilated. The right optic disc was found to present distinct signs of neuritis; the peripheral part swollen, greyish-red, margin obscured, and the central cup encroached upon. In the evening the temperature rose to  $102^{\circ}$ ; next morning, the 21st, it was  $101^{\circ}$ . Apparently more conscious but not speaking. Almost complete paralysis of the right arm and leg, with slight rigidity (increased by passive movement), and diminished reflex action. Optic discs: little change; the central depression still not quite obliterated. The pupils nearly equal. On July 22 the right pupil was the larger; face alternately flushed and pale; no *tâche cérébrale*; unconscious. Left arm and leg moved less than formerly. Temp.  $103^{\circ}$ . During the day the patient's condition and temperature were nearly the same; but she gradually became weaker, and died early the next morning.

*Necropsy* (confined to head).—Dura mater injected; pia mater over convexity intensely hyperæmic, most so over left frontal lobe; tint, bright red; in places semi-opaque, but no lymph or trace of tubercle; an excess of subarachnoid fluid. Changes at base similar, but more intense. On left optic nerve, in front of chiasma, was a small lump, the size of a pea, soft, greyish-red, situated just behind optic foramen. It had to be cut through before the nerve could be removed. On microscopic examination it was found to be composed of lymphoid corpuscles. The nerve at the spot was surrounded by pus, which did not, however, extend through the optic foramen; nor was there any abnormality about the contents of the left orbit. The nerve and chiasma both appeared considerably swollen. On removing the dura mater, a small collection of pus was found beneath it, over a piece of rough, carious bone, about the size of sixpence, extending from one side of the body of the sphenoid bone to the other, in front of the sella turcica. It had no connection with the ethmoidal cells. No coagulation in the venous sinuses, including the cavernous. The vessels of both hemispheres were full of blood. There was slight distension of each optic sheath.

REMARKS.—By an accident the optic nerves were thrown away; but it is probable that the neuritis in the left eye was the result of the propagation downwards of the inflammation of the trunk. The affection of sight was out of proportion to the inflammation of the papilla. That of the right eye came on when the meningitis was developed, and may have been the result of this, or of the extension to the right nerve, of the local inflammation which lighted up the meningitis. The disease of the sphenoid bone was perhaps the result of the fall, which occurred some months before the symptoms came on.



CASE 2.—*Epileptiform attacks beginning in the right hand, leg, or the throat; double optic neuritis; partial right hemiplegia; unsteadiness of both arms, followed by paralysis of all four limbs; death; chronic meningitis of left hemisphere; tumour in spinal cord.* (Pl. II. Fig. 1.)

HARRIET P., aged twenty-five, single, schoolmistress, came under treatment at the National Hospital for the Paralysed and Epileptic, in August, 1870, suffering from epileptiform attacks. No family or personal history of neuroses, phthisis, or syphilis. The left leg was weak from infancy, and was generally smaller than the other.

First symptoms of illness occurred nine months before her admission—a sudden, strange sensation, something like “pins and needles,” in the right arm, commencing in the index and middle fingers, and spreading up the arm to the right side of the face (right side of lips and cheek). These attacks had recurred since about once a week; of late, however, they generally commenced with a cough, and a sensation in the throat, spreading over the rest of the mouth and that half of the face, then felt in the forefinger, and passing up the arm, and down that side of the body to the right thigh, sometimes going below the knee, but not often. She turned to the right until she fell, then the right arm jerked, and both legs, but the state of the left arm was doubtful. Consciousness was sometimes, but not always, lost. Of late, there had been some difficulty in speech. For some months she had several “sensations,” as above described, but no severe fit. Hesitation in speech was very marked, especially after an attack. Often she could not find the word she wanted. Her mind was unaffected.

In January, 1871, it was found that the right side of the face, and the right arm and leg, were becoming weak, and that there was distinct optic neuritis, each optic papilla having a soft outline, the swelling distinct, red in the centre, greyish in the periphery; the veins large and tortuous; arteries of normal size; the surface striated. Vision: right, No. 1 Jäger; left, No. 2. Fields: normal in right eye; left, a little limited on nasal side. The sensations continued, sometimes of similar character to the previous attacks, beginning in the lips and face, and passing down to the shoulder, to meet a similar sensation commencing in the hand; sometimes, however, beginning in the foot, and going up the leg, and occasionally felt in the right side of the trunk, and not in the limbs, sometimes in one part, sometimes in another. Frequently the sensation began with a sense of a ball rising in the throat, instead of the cough. During March she had much pain in the temporal regions, extending to the ears, and stooping caused transient dimness of sight. Right arm still weak and slightly less sensitive to all forms of stimulation. Frequent attacks of transient amaurosis. In the beginning of April, sight began to fail. Right, No. 4 Jäger, and left, No. 6, on April 5, and the limitation of left field involved nearly the whole right half. The swelling of the discs had increased considerably; the veins were large and tortuous, and both veins and arteries were concealed near the edge of the disc. On April 6: right, No. 8 Jäger; left, No. 12. The defect in the left field



had extended a little beyond the middle line in the upper half. On April 7 the pain was severe in the head (occiput) and backs of eyes. Several more "sensations." Vision: right, No. 6; left, No. 16 Jäger. Only one-third of the left field remained—a sector, the apex at the fixing point, and the left edge in the vertical meridian. In the right eye there was a loss of one (lower and left) half of the field, the limitation being an oblique line, and the loss above falling short of, and below extending beyond, the vertical meridian. Pulse infrequent (50—70), and sometimes irregular. The sight gradually failed, until, on April 1, she could only see a large object dimly in each lower and outer quarters of the fields. The discs were now becoming paler; the swelling still great, and veins full. Pupils varied in size under examination without obvious cause. On April 17 I had an opportunity of watching a fit. It commenced with twitching of the right side of the mouth; then the first and fourth fingers of the right hand became flexed and rigid, and almost simultaneously the whole of the right arm and leg became rigid, and then jerked in clonic spasm. Immediately afterwards the left side became rigid and jerked, although to a less extent than the right. The features became dusky, respirations infrequent and laboured. Consciousness was lost during the fit, and obscured for some time afterwards. Her pulse just before the fit was 80, just afterwards 60, and irregular in rhythm: an hour afterwards it was 80 and again regular. During the next few weeks the "sensations" continued, and several other convulsions occurred, similar to that described. The pain in the left side of the head, forehead, and temporal regions, became very acute; sight continued about the same; temperature was about 100°. In two fits, which began as usual in the right side of the face, and then in the right hand, before the sensation commenced in the hand, there was a similar feeling in the little finger of the left hand, which did not extend to the other fingers, but passed up the arm, and she then lost consciousness; but the convulsion commenced in the right side, and affected the left later than the right. She had after these many similar sensations in the left hand.

In the beginning of May she had many sensations which began in all the toes of the right foot, then passed up as far as the right hypochondriac region, staying there for a little time, with a considerable pain there; then felt in the right hand, and passing gradually up the arm, but not reaching the mouth or the face. The pain in the right hypochondriac region continued some time after the other sensations ceased. Her sight now improved considerably in the outer part of each field. Right eye could spell No. 16 and left No. 12 Jäger.

In the first week of June there was rapid loss of power in the right arm and leg. Any movement could be executed, but very feebly; sensation became duller; some difficulty in guiding the movements of the arm. The sight rapidly failed, and the right eye became quite blind, and vision in the left qualitative only. Occasional subjective flashes of light, especially before the left eye. The optic discs had become



much paler, and now presented reddish-white swellings, depressed in the centre; veins smaller; arteries partially concealed (Pl. II. 1). By the middle of June the arm could scarcely be moved. "Sensations" continued. In the beginning of July she complained of constant "numbness" in the second finger of the *left* hand; sensation not notably lessened upon it. Power in the right arm then improved a little, but its movements became still more unsteady, and some unsteadiness in the movements of the left arm was noted, so that she became unable to feed herself with either hand. On July 11 she was observed to be very dull and heavy, and was ordered to lie in bed. Towards evening she was found to have lost all power of moving her arms and legs. She was very lethargic but not comatose. Next day she was unconscious, and on the following day she died.

After death it was found that the pia mater was much thickened and adherent over the central portion of the left hemisphere, especially over the ascending frontal convolution, and to a less extent over the posterior portions of the transverse frontal convolution, and over the ascending parietal convolution—the maximum change being about the middle of the ascending frontal. Beneath the thickened pia mater, indurated tissue extended into the substance of the convolutions, but there was no distinct growth; under the microscope the large nerve cells of the convolutions were mingled with fibre cells, apparently from chronic inflammation.

Opposite the seventh and eighth pairs of cervical nerves was a tumour, situated in the middle line, apparently commencing behind the grey commissure, but having a transverse diameter about two-thirds the normal width of the cord. It had destroyed the anterior part of the posterior columns and adjacent grey matter. It had the aspect and structure of a syphilitic growth.

REMARKS.—It was thought during life, from the patient's circumstances, that syphilis could be with certainty excluded, and no anti-syphilitic remedies were given. From the post-mortem appearances, the lesions were almost certainly syphilitic. The spinal growth was identical in position, appearance, and structure, with one met with in a case of syphilitic disease of brain (chronic meningitis and growth) which I have published in the "Pathological Transactions," Vol. xxviii. p. 281. In each case the spinal growth occurred at the end of a life, and was evidenced only by weakness, before unilateral (from cerebral disease), becoming bilateral. In the above case the occasional "aura" in the left arm was probably reflected and of cerebral origin. The paralysis of the right arm was doubtless due to the cerebral disease. The unsteadiness in movement which occurred late, in both arms, was the first evidence of the disease of the posterior columns of the cord. The case is chiefly interesting, in its ophthalmoscopic aspect, as evidence that unrestrained local meningitis, of long duration, may lead to optic neuritis as intense as, and very similar to, that which accompanies tumour.



CASE 3.—*Subacute cerebral symptoms; paralysis of both auditory, right sixth, and partial of right facial nerves; general weakness of limbs; optic papillitis; hyperpyrexia; tumour in front of and involving corpora quadrigemina; descending neuritis.\** (Pl. III. Fig. 3, XIII. 4—9.)

ROBERT P., aged twenty-four, unmarried, a police-constable, admitted into University College Hospital on July 30, 1878, with subacute cerebral symptoms. No family history of nervous disease, of phthisis, or of tumour, and no personal history of syphilis. The head symptoms had come on after several days' exposure to hot sun, to which they were ascribed. It was, however, afterwards ascertained that he had complained of headache for a month previously. Severe headache, and mental dulness, with paralysis of one sixth nerve, were the symptoms on admission. There was no delirium, convulsion, or paralysis of limbs; no affection of special senses. The right external rectus was paralysed, but not completely. Other movements of the eyes were free, and the pupils equal. It was impossible to ascertain the degree of vision; he tried to read any type that was given to him, but closed one eye, as if there were diplopia. There was no fever; bowels constipated.

This state continued with little alteration. He was at first under the care of my colleague, Dr. Poore, and came under my care on August 12. It was then impossible to obtain any answers to questions from him, although he did what he was told. During the next three or four days, however, he gradually became deaf, first partially, but, in the course of a week, absolutely. An ophthalmoscopic examination showed the existence of optic neuritis, moderate in degree, equal in the two eyes (Pl. III. 3). The outline of the disc was obscured, except on the outer side, where it could be faintly traced; elsewhere it was lost under a swelling, of a reddish-grey colour, striated, and extending a little beyond the limits of the disc. The veins were moderately distended, curving down the sides of the swelling, and obscured for a short distance at its edge. The arteries were considerably narrower than normal, and could be traced on the surface of the disc with difficulty. There was a good deal of white tissue about the centre of the swelling at the point of emergence of the arteries and accompanying them; one artery, passing upwards and outwards, lay in the middle of a broad white tract, which extended nearly to the edge of the swelling. Below the centre of the disc a white area lay in front of, and partly concealed, a vein, while an artery, which passed in front of the vein, was not obscured; on the inner and lower edge of the disc was another small white spot. The other eye was similar.

These symptoms continued with very little change. About August 20, first retention, and then incontinence, of urine came on and continued. The pulse, previously 70—80, became infrequent (50—60). On August 24 his temperature, previously normal, rose to 100°, and continued to the end of the month varying from 99·5° to 101°. The swelling of the optic discs became more considerable, but there were no hæmorrhages. Two or three white spots, irregular in shape, were visible in the retina, just

\* "Lancet," March 15, 1879.



beyond the edge of the swelling, on the outer side, above and below. A trace of albumen appeared in the urine; no sugar. From this date the patient was in a state of almost constant semi-coma, and the elevation of temperature was greater, varying between  $102^{\circ}$  to  $104^{\circ}$ . He was observed also to move his limbs very little, but there was no loss of sensation to pain; when either arm was pinched it was moved, and the features expressed pain. The right side of the face was, however, moved much less than the left, and was evidently paralysed, chiefly in the lower parts, just as in the facial paralysis of hemiplegia. Observations on the pupils were unfortunately interfered with by the previous application of atropine. His pulse became frequent (90—100) and irregular. The paralysis of the sixth nerve was the same; no other oculo-motor paralysis could be discovered. On September 7 the temperature was  $104.6^{\circ}$ , but on the 8th it rose to  $106^{\circ}$ ; râles were heard throughout the chest; and he died, apparently from exhaustion.

*Necropsy.*—A sarcomatous tumour was found lying between the posterior portions of the optic thalami, above the crura cerebri, and in front of the corpora quadrigemina, which were invaded and otherwise damaged. The tumour was lobulated and irregular in shape, and measured an inch and a half transversely, and three-quarters of an inch from before backwards. From its middle a long pedunculated process of growth extended backwards above the tentorium. It measured an inch and a half in length, and about half an inch in its greatest width, the base being about a quarter of an inch wide. No trace of the pineal gland could be found, and this pedunculated growth appeared to have formed in it. The tumour had invaded the corpora quadrigemina, destroying the whole of the left anterior tubercle and the inner half of the right, extending a little below the level of the iter. Backwards from this point it extended a short distance only along the iter. The right posterior tubercle was normal; the left flattened by pressure. The growth had damaged the most superficial fibres of each crus cerebri, the left much more than the right. It had not damaged the optic thalami, although contiguous and adherent to their inner surfaces. Slight traces of meningitis were found beneath the orbital lobules, but not elsewhere. No damage to the nerves at the base could be discovered. The ventricles were distended.

*Microscopical Examination of Eyes.*—Each optic papilla presented considerable swelling, with a deep central depression, the diameter of the swelling being about double that of the optic disc. The greatest height was about  $\frac{1}{25}$ th of an inch above the level of the choroid. The width of the central depression, at its mouth, was about  $\frac{1}{20}$ th of an inch, and extended almost to the level of the choroid (Pl. XIII. 4 & 5). The sides of the swelling were steep, the nerve-fibre layer of the retina soon assuming its normal thickness. The retina was displaced to about  $\frac{1}{50}$ — $\frac{1}{20}$ th of an inch from the edge of the choroid, and at its commencement the granule layers were thickened and (the outer especially) thrown into folds. In the swelling the nerve fibres could still be seen



pursuing their normal direction, but they were separated by oval spaces (œdema) and were somewhat varicose. The vessels pursued a normal course through the sclerotic ring, but in the substance of the papilla, the small veins and capillaries were tortuous, dilated, and distended with blood-corpuscles. Throughout the papilla were large numbers of corpuscles staining deeply with logwood. Some of them were small and oval, and attached to delicate (supporting) fibres, running at right angles to the course of the nerve fibres. The majority were apparently leucocytes and were aggregated around the larger vessels, and in places accumulated into masses of considerable size, especially between the bundles of nerve fibres and near the surface. There were a few small hæmorrhages, chiefly into the molecular and nerve-fibre layers of the retina, immediately adjacent to the disc. The retina, a short distance from the disc, assumed and maintained normal characters.

Throughout the sclerotic ring, and up the trunk of the nerve, leucocytes thickly infiltrated the bundles of nerve fibres, and were accumulated in rows and groups between them. The accumulation between the fibres was more marked close to the eye than a centimetre farther back. The nerve fibres were of normal size and course, but had irregular outlines and were cloudy and granular—evidently degenerating. The vaginal sheath was not at all dilated, but its walls were infiltrated with corpuscles. Near the eye the superficial part of the nerve was not more infiltrated than the central portions. Behind the optic foramen the central portions of the nerve were affected in the same manner and degree as in the anterior part. The superficial bundles of fibres were, however, much more densely infiltrated, and the tissue between them was thickened slightly and contained many leucocytes. The sheath of the nerve was crammed with similar cells, among which distended vessels were seen. The optic tracts presented only a slight excess of scattered corpuscles.

REMARKS.—The onset of this patient's symptoms after exposure to a hot sun, and their subacute character, led to a frequent bedside discussion of the question whether they were due to chronic meningitis or to tumour. Always, against the theory of meningitis, were the facts that there was no history of acute onset, and that the symptoms pointed to the base of the brain as the seat of the disease rather than to the region—the convexity—in which the meningitis of insolation commonly occurs. The ophthalmoscope did not help us, because, although neuritis was present, it was moderate in degree, the swelling being slight. It was such neuritis as is met with in chronic meningitis. The necropsy showed that although there was a tumour, there was also slight—very slight—meningitis contiguous to the optic nerves, and the microscope proved that the neuritis was really "descending." The most noteworthy symptom in the case is the paralysis of the auditory nerves. The sixth nerve was probably damaged by pressure. Paralysis of the sixth is of less significance than that of any other cranial nerve, on account of its exposure to pressure by its course over the most prominent part of the



pons. As regards the auditory nerves, no lesion of the trunks could be found to explain it. They were perfectly normal, and there was no trace of lymph or of pressure. A possible explanation may be that the paralysis was due to the damage to the most superficial fibres of the tegmentum of the crus cerebri. If these contain the fibres from the auditory nerves, the symmetrical paralysis would be explained, since the most superficial fibres of each were damaged.

*CASE 4.—Paralysis of right arm, with double optic neuritis; convulsive attacks; defect of speech; mental derangement; double hemiplegia; death; results of old fractures of skull; inflammatory growths in right and left hemispheres; old chronic meningitis; vascular disease; softening of both crura cerebri.\** (Pl. VI. §, XVI. 1). 2

ROBERT P., aged forty-nine, cattle drover, admitted into the National Hospital for the Paralysed and Epileptic under my care, November 18, 1878, with weakness of the right arm of two weeks' duration, he having had a left-sided convulsion and some subsequent weakness of the left side four months previously, with much occipital headache since. There was a doubtful syphilitic history. It was subsequently ascertained that nine years previously he had received severe injuries to the head in a fight.

On admission he was intelligent; speech drawling, but otherwise unaffected; no paralysis of face; considerable weakness of right arm, slight of leg. There was well marked double optic neuritis. By the indirect examination the position of the edge of each disc could just be seen, but it was softened, and the area of the disc bright red, surrounded by a pale, semi-opaque, wide halo. On direct examination (Pl. VI. 3) the disc was concealed by a striated opacity, extending in each direction a disc's breadth from the edge, and of moderate prominence. On the outer part of the opacity were several small hæmorrhages and white spots. Veins large, arteries narrow, both visible to the centre of the disc. The changes were more marked in the left eye than in the right. V.,  $\frac{1}{12}$  each; no hemiopia; urine free from albumen. For a fortnight he improved. Then he manifested some mental weakness, and one day, after an hour's speechlessness, he had a convulsion, beginning in the right side of the face and right arm, extending to the right leg and then to the left limbs, and lasting twenty minutes, succeeded by increased weakness and much headache. For a fortnight afterwards he had much pain and discomfort in the arm, accompanied by delusions that he was being beaten or bitten. Some improvement occurred, but towards the end of December the mental disturbance increased. He had some defect in speech, often using wrong words, and being unable, except with difficulty, to find words with which he was familiar. The ophthalmoscopic appearances continued unchanged. The weakness in the arm increased, and extended to the face and tongue. On January 12

\* Abstracted from notes taken by Mr. A. E. Broster.



he became semi-comatose, with evidence of complete right hemiplegia, and in a few days of left hemiplegia also. He died on January 17 with signs of congestive pneumonia, the temperature rising on the last day to  $106.2^{\circ}$ .

At the post-mortem examination the scars of two fractures of the skull were found, one on the right side and one on the left, and beneath these the dura mater was adherent, and on the surface of the convolutions was a firm cheesy substance like caseous tubercle,  $\frac{1}{6}$  to  $\frac{1}{3}$  inch deep. The areas damaged were the posterior and upper corner of the right parietal lobe, and on the left side, the middle third of the ascending parietal convolution, and the ascending frontal in a smaller extent, the lower half and upper fourth being normal. Both posterior communicating arteries were much diseased, and indurated tissue surrounded the divisions of the internal carotid. Outside and above these, in the lowest part of each internal capsule, at its junction with the crus, was a focus of recent hæmorrhagic softening, the size of a small nut. The left Sylvian artery was also surrounded by indurated tissue, and adjacent to its posterior branch, was a small focus of softening beneath the inferior extremity of the ascending parietal convolution. In the upper part of the pons was another very minute focus of commencing softening.

Under the microscope the optic papillæ (Pl. XVI. 1) were found to present considerable swelling, with steep sides and a large central depression. In each eye the top of the swelling was 1 mm. above the surface of the choroid, and the prominence commenced on each side about 1.3 mm. from the edge of the choroid. The diameter of the swelling was in each eye nearly three times the diameter of the sclerotic ring. The retina was displaced on each side about 0.6 mm. from the edge of the choroid. The choroidal pigment-epithelium had disappeared on one side (the right in Pl. XVI. 1) in the area from which the retina was displaced. At its commencement the nuclear layers of the retina were thickened for a short distance. The central vessels showed no evidence of compression in the sclerotic ring or behind it. At the height of the papillary swelling the vessels were some distance from the surface, which they approached towards the outer side, and beyond its edge the veins formed one or two vertical curves in the substance of the thickened nerve-fibre layer, the lowest part of the curves entering and disturbing the nuclear layers (shown on the left hand side of the figure). In the substance of the swelling were many nuclei, grouped especially between the bundles of nerve fibres, and towards the surface—not specially accumulated about the vessels. The nerve fibres were irregularly swollen, and separated by spaces which were clear (even in glycerine preparations) and probably due to œdema. Scattered through the swelling were large numbers of irregular, more or less spherical and oval bodies (Pl. XVI. 2), containing granules and irregularly-shaped globules of highly-refracting substance, no doubt fatty and resulting from the degeneration of the myelin. Some of these were distinctly formed by the junction of drops of myelin. They were aggregated in groups, and were especially numerous,



adjacent to vessels, and in the portion of the swelling which had displaced the retina. They had evidently given rise to the white patches observed during life and shown in Pl. VI. 2. The retina was, for the most part, normal; but some of the veins were greatly distended and tortuous, their tortuosities disturbing the nuclear layers (Pl. XVI. 3). Behind the eye, the optic nerve presented, throughout its course, large numbers of nuclei, especially abundant towards the surface in front of the commissure. The sheaths of the nerves were slightly, but not much, distended. The optic tracts were found to contain a large excess of nuclei, and these were in places aggregated into dense masses, many of them larger than that shown in Pl. XVI. 4. Some of these were distinctly around vessels.

REMARKS.—The patient died from the effects of vascular disease—symmetrical softening at the expansion of the crura into the internal capsules. The vascular disease was distinctly the effect of previous adjacent inflammation, no doubt traumatic. The paralysis of the right arm was doubtless the result of the inflammatory growth over the ascending parietal and frontal convolutions. The growth had in its aspect nothing syphilitic, and symptoms were uninfluenced by iodide or mercury. The position of the growth and that of the similar mass on the other side, clearly indicated their origin in the damage produced by the blows which had fractured the skull. The optic neuritis was probably due to these growths, perhaps in part also to the old meningitis, although the interval since the active inflammation renders it difficult to ascribe the neuritis to the basal changes. The alterations in the optic nerves, commissure, and tracts were, however, very considerable.

CASE 5.—*Vague cerebral symptoms with optic neuritis (left), and evidence of an intra-ocular growth (right), found after excision to be tubercular; death a year later; tubercular growths in cerebrum and cerebellum.\**

ERNEST N., aged seven years and ten months, came under Dr. Barlow's care at the Hospital for Sick Children in January, 1877, on account of pain in the right leg, and occasional headaches (six months) and vomiting (one month). He improved under treatment, the symptoms continuing, although slighter. On March 5 a peculiar reflection from the right eye attracted notice, and it was found that an opaque greyish body occupied the lower half of the fundus, branching retinal vessels being visible in the upper half. Vision quantitative only. In the left eye there was distinct, though slight, optic neuritis. An occasional internal squint of the right eye was noted; some headache and vomiting continued, the left optic neuritis increased, and vision failed slightly. Temperature, usually at or below normal, rose

---

\* For an opportunity of seeing this case, and for the notes of it, I am indebted to Dr. Barlow.



once or twice to  $101^{\circ}$ . On April 4 the right eye presented, inwards, an extensive detachment of the retina, the vessels of which were visible on a grey ground. Tension normal or slightly increased. Neuritis in left eye more considerable (see Fig. 4, Pl. III., and description). There was slight prominence of both eyeballs, most of the right; but no interference with its mobility. Soon afterwards a slight protrusion of the lower part of the right eyeball was noticed, where previously some increased vascularity of the sclerotic had been remarked. The eyeball was excised by Mr. Marsh on June 2. Mr. Nettleship found a large growth between the choroid and sclerotic in the lower half of the eyeball, extending from the optic disc to the ora serrata, and it had at one point perforated the sclerotic. The greater part was softened and creamy. The microscopical characters were those of confluent tubercles. The wound healed well, but the sight of the left eye failed, until, on June 15, only shadows could be seen. The vomiting and headache recurred for a time and then lessened, and had stopped by the beginning of September, the left disc then presenting the appearance of consecutive atrophy. Six months later he began to suffer from pains in limbs and back, and his head was observed to be larger. He died in July, and after death considerable internal hydrocephalus was found, with a caseous (scrofulous) mass in one hemisphere, another in each temporo-sphenoidal lobe, and another, the size of a small orange, in the middle lobe of the cerebellum. There was no disease visible at the back of the right orbit, or connected with the left optic nerve. The other organs of the body were healthy, except some caseous bronchial glands.

CASE 6.—*Optic neuritis, with sub-acute cerebral symptoms, probably syphilitic; failure of sight, rapidly improving under treatment; subsequent loss of sight, with symptoms of pressure on chiasma; ultimate optic nerve atrophy.\** (Pl. II. Fig. 4.)

HENRY G., aged thirty-four, carpenter, presented himself at the National Hospital for the Paralysed and Epileptic, June 10, 1872. Primary venereal sores ten years previously. Sensations of left-sided numbness occurred for a time a year before; then ceased, to return nine months later, with transient double vision. During the last year he had three attacks of giddiness, with loss of consciousness. Double optic neuritis was found on examination in each eye, each disc presenting reddish swelling, with concealment of outline and numerous small vessels. He could read No. 1 Jäger with either. He was ordered pot. iod. gr. x. ter die. During the next week he had much pain in the right side of the head and vomiting, and several attacks of sudden dimness of sight, each lasting a few minutes, accompanied with headache. He had also one attack of loss of consciousness, probably with convulsions. The attacks of transient loss of sight afterwards became more frequent,

---

\* Under the care of Dr. Hughlings Jackson.



and were accompanied with trembling. His vision also failed in the latter end of June, so that on the 27th it was  $\frac{1}{11}$  each. In the hospital, it was noted that, at each attack of loss of sight, he complained of cold and rubbed his hands as if cold. In each the "darkness" came first, then pain in the head, and in some attacks a little general tremor came last of all. At first about twelve attacks occurred each day. Vision rapidly failed—by July 1 he could only count fingers with the left eye, scarcely with the right. Neuritis about the same. On July 4, during an attack of transient complete loss of sight, Dr. Hughlings Jackson examined the eyes, but found no change, except that the veins in the left eye appeared darker. As sight was returning, the same veins appeared smaller, as if collapsed, with slightly irregular outline. After July 5 (under iodide) the attacks of blindness ceased, and sight improved, so that on July 8 V. = R.  $\frac{1}{6}$ , L.  $\frac{1}{13}$ . The right disc had cleared considerably; the edges could be seen, but were soft, and not perfectly even; slight swelling. The left disc was less red than a few days before; the edges still blurred. By July 14 the right disc had become quite clear, but was more uniformly, and rather more deeply, coloured than normal, and its outline not quite sharp. Vision had improved to  $\frac{1}{15}$  each. On August 1 he left the hospital; on August 27 he was still well. Right optic disc natural, sharp edged, pale; vessels normal; left, edge not sharp, uniform soft pink tint. Vision same; fields of vision normal. October 10: Right disc almost too pale; left, tint normal, edges as at previous examination. About the middle of October the attacks of blindness returned, with chromatopsy during return of sight; severe pain in the head, over the eyes, and transient weakness of the legs. V. had deteriorated to  $\frac{1}{2}$  each. Discs: right, same; left, still not sharply defined, and slightly swollen. Some inability to distinguish slight differences of colour; strong colours distinguished well, except yellow, which was not recognized. October 31: V.  $\frac{1}{34}$  each. November 3: V., R.  $\frac{1}{20}$ , L.  $\frac{1}{30}$ ; left disc thought to be a little pinker; attacks of transient amaurosis continuing. November 11: Attacks less frequent; V., R.  $\frac{1}{6}$ , L.  $\frac{1}{7}$ . By December 5 sight had improved to  $\frac{1}{3}$ . December 23: Attacks of amaurosis ceased; sight not quite so good. L.  $\frac{1}{24}$ , R.  $\frac{1}{34}$ . No change occurred until the beginning of March, 1873, when sight again deteriorated, with some headache. On March 3 he could only read No. 14 Jäger. Next day the amaurotic attacks recommenced, also with transient weakness of the legs; V.  $\frac{1}{12}$  each. Fields normal, each eye; no ophthalmoscopic change. March 17: Slight improvement in vision, which increased to No.  $\frac{1}{4}$  each by March 24, at which it was maintained till June, when further improvement occurred. In August, vision  $\frac{1}{3}$  with each eye. In September and October the amaurotic attacks recurred; he had occasionally a foetid smell in the left nostril. On November 17 slight ptosis on left side was noted; vision had failed to R.  $\frac{1}{8}$ , L.  $\frac{1}{11}$ , and a defect was found in the right half of the right field of vision. During the winter he improved slightly in all respects, although occasional attacks occurred. Vision slowly improved to R.  $\frac{1}{2}$ ,



L.  $\frac{1}{3}$ . In the beginning of April, 1874, after a severe cold and cough, the pain in the head returned; vomiting and giddiness; he had an attack of loss of consciousness, with general rigidity. On April 29 he was re-admitted with general weakness; great failure of sight, being only able to count fingers with each eye. The left pupil was larger than the right. Next day he could just spell No. 30 Jäger with left eye. The left field of vision was very dim in the left half; the dimness extending below the middle a little to the right; the right presented absolute loss in the outer half. There was no perceptible change in the appearance of the optic discs. Hearing, left reduced to one-third of right; no weakness of limbs. On May 1 slight defective movements of the eyes inwards were noted. Sight and fields of vision about the same; but in the right the loss had extended a little beyond the middle line below, and in the left it was almost lost in the defective area. (Fig. 12, p. 58). On the morning of May 3 he found he had lost all appreciation of light with each eye. The drooping of the left lid was greater, and there was more defect in the upward and inward movements of the eye. This increased, in spite of treatment, and by May 7 the paralysis of the left third nerve was almost absolute. He complained also of "numbness" of the right cheek and right half of the tongue, and there was some hyperæsthesia of these parts, followed, on May 10, by diminished sensitiveness of the right fifth nerve, and some defect in swallowing. Discs unchanged; slight delirium. On May 31 the paralysis of the left third suddenly disappeared, it having been almost complete the day before. During the next fortnight he improved, but on the 14th it was found that the sense of smell was absolutely lost. By July 1 the affection of the right fifth nerve had passed away, and qualitative perception of light had returned; the optic discs had become greyish-white; the right more so than the left, which still retained a red tint. In each, one or two vessels were accompanied by a little white tissue.

From this time, July, 1873, to the present (February, 1879), his condition has been unchanged. Large objects can just be discerned, but the appearance of the discs is now precisely as then, and as shown in Fig. 4, Pl. II., and described in the account of the plate—being that of atrophy after neuritis. The sense of smell remains lost.

REMARKS.—The initial loss of sight was no doubt due to the direct effect of the neuritis, and its rapid improvement under treatment is worthy of note. The subsequent failure of sight, simultaneous with evidence of mischief at the base of the brain (paralysis of olfactory nerves, of left third and of right fifth), was accompanied by loss of the outer half of each field of vision, such as is known to result from damage to the anterior part of the chiasma, and it is probable that it was by this mechanism that the ultimate failure of sight resulted. The defect in the right field had, however, existed for some time previously, and so the chiasma had probably suffered slightly before the greater damage.



CASE 7.—*Right-sided convulsive attacks, beginning in hand and afterwards in face; double optic neuritis; recovery.\** (Pl. IV. 1 & 2.)

JOHN K., compositor, aged thirty-three, admitted as out-patient at the National Hospital for the Paralysed and Epileptic, on June 4, 1873, under the care of Dr. Buzzard. Primary syphilis at twenty, followed by sore tongue. First child born dead. Convulsive attacks during preceding two months, recurring at short intervals. They usually began with an odd feeling in the right hand, and then, first the thumb, and afterwards the fingers, "drew up," then the wrist was flexed on the forearm, then the elbow bent, and after that he usually had an odd feeling in his head and lost consciousness completely for a few minutes; and during the unconsciousness there was convulsion, confined to the right arm and leg. By the advice of a neighbour he had arrested many fits by plunging the hand into hot water as soon as he felt the sensation. Occasionally, a sudden pain across the forehead was the first symptom, and then the arm would begin to shake instead of "drawing up." After one attack he lost the use of his right side and his speech for a quarter of an hour. On iodide and bromide his fits ceased for a time. On November 26 he complained of weakness of his legs and pain across his eyes, and said that for six weeks his sight had been much weakened. Ophthalmoscopic examination showed double neuritis. Right: no outline to the disc, papilla pinkish grey, swollen, and prominent, and merging by imperceptible gradations of colour into the choroid; arteries small and lost at various points; veins large, dark, and sinuous. Left: similar appearances, but less pronounced. Vision: read No. 1 Jäger each.

On admission into the Hospital, on December 11, some mental obtuseness was noted. His pupils were large and equal; he could still read No. 1 Jäger at six inches, with either eye, but with some difficulty, especially with the right eye. The ophthalmoscopic appearances noted above continued; the redness was punctiform on direct examination. Grasp of the right hand was not quite so strong as that of the left. Iodide of potassium and mercury were ordered. On November 29 he had eleven fits, in only one of which, the first, did he lose consciousness. These fits began in his face; the mouth was twisted to one side, and the jaws fixed, then the hand became drawn up. If the hand was forcibly held down the attack was stopped. On December 22 the appearance of the discs was nearly the same, and the sketch of the right disc was made (Pl. IV. Fig. 1). The attacks continued, but were of slighter character. In the beginning of January he had several in which speech was lost first, then the jaw became fixed, and then the mouth was drawn to the right. Each lasted about two minutes, and then passed away by the jaw first becoming relaxed, then the mouth returning to its normal

---

\* Case published in Dr. Buzzard's "Clinical Aspects of Syphilitic Nervous Diseases," p. 97.



position, and then speech being recovered ; but for a day afterwards he spoke in a peculiar way, would say half a word, wait for a time, and then say the remainder. The arm was unaffected in these attacks, and was gaining strength. The swelling of the optic discs had greatly lessened ; the arteries could be traced clearly to the centre. The veins were less distended. In the left eye the outer edge of the disc was apparent, the inner being still concealed. Sight : still able to read No. 1 Jäger with ease.

On January 17 it was noted that the vision continued unimpaired, the field unlimited, and colours recognized accurately with either eye. He had another fit, beginning in the right hand, with flexing of the fingers, followed by shaking of the arm, without drawing up. The mouth was said by the attendant to be drawn first to the left and then to the right, and then convulsion was noticed in the leg. For a time afterwards he could not speak. Under larger doses of mercury the attacks became less frequent, and on February 16 the optic discs had recovered their normal appearance. On April 11 he had had no attack for two months, but he complained that at night time, when going to sleep, he had frequent "jumping" of the hands and twitching of the right eyebrow. He complained only of numbness in the tip of the right forefinger and thumb, and, on examination, it is found that these are distinctly less sensitive to both touch and pain than are the other fingers. If he put his hand in his pocket he could not detect a small coin there, and the numbness unfortunately made it impossible for him to follow his occupation as a compositor. The optic discs were quite normal, and the second drawing was made (Pl. IV. 2).

CASE 8.—*Right-sided fits, beginning in face ; weakness of right arm ; double optic neuritis ; concentric limitation of fields without change in acuity of vision or colour vision.\** (Pl. I. 5 and 6.)

JOHN L., aged thirty, admitted into the National Hospital for the Paralysed and Epileptic, under the care of Dr. Radcliffe, February 3, 1879. Occupation : pointsman on railway. Nothing significant in either family or past history, except that when aged twelve he had a fall, which rendered him unconscious for some time, and two years ago he had an attack of gonorrhœa ; no history of syphilis. For two years acute headache, paroxysmal, shooting from front to back. Occasionally, a throbbing pain in right posterior inferior parietal region. Occasional attacks of vomiting during last twelve months. For last six months occasional feelings of "cramp" in right side of face and neck, extending to right side of tongue, throat, and right arm. One of these attacks extended to the legs, which trembled. After it was over the right side was weak for a time, and for twenty minutes he could not speak. Other similar attacks have occurred since. Sometimes after them he feels a sense of numbness beginning in the right hand, extending gradually up

---

\* Notes taken in part by Mr. A. E. Broster.



to the right shoulder, and then down the right side of the trunk to the right leg; occasionally this is accompanied by considerable weakness of the limbs. After an hour it passes gradually and leaves him exhausted and emotional. Since the fits commenced he has had less headache and has not vomited. Eighteen months ago he had for a time some dimness of sight; six months ago transient diplopia, and, during the last six months, he has noticed that in looking in a glass he could only see one eye.

On admission intellect was clear; there was some weakness of the right external rectus; slight weakness of right side of face and right arm; no noticeable difficulty in speaking, but said he had some difficulty in finding unaccustomed words and in reading. "I recognize the letters and the word, but I cannot speak it out straight."

Several attacks were seen. They commenced with twitching of the right side of the face, followed by drawing of the head towards the right shoulder, and then the attack ceased.

Both optic discs presented well marked neuritis. In the left eye (Pl. I. Figs. 5 & 6) the disc was concealed by a reddish swelling, most deeply-coloured in the centre. Its prominence was considerable. Arteries and veins were both of nearly normal size. The latter were dark as they passed down the edge of the swelling, and then were partly concealed. In the right eye the swelling was similar, but much paler. The neuritis appeared in both eyes to have passed its most acute stage, and the subsidence to be further advanced in the right than in the left. Right V. =  $\frac{2}{2}$ ; field much limited, especially towards right and below. Left V. =  $\frac{2}{2}$ ; field limited peripherally, especially down and in, but in all directions much less than right. The correspondence in the limitation on the right side was not very close, and it was doubtful whether there was hemiopia. No affection of colour vision in either eye.

During February and March there was little change either in the patient's state or the ophthalmoscopic appearances. Similar attacks to those above described continued, but there was less headache and no increase in the paralysis. On April 7 the sight of the right eye was not quite so good. V. R.  $\frac{1\frac{1}{2}}{2}$ , L.  $\frac{1\frac{1}{2}}{1\frac{1}{2}}$ . Optic papillæ unchanged.

CASE 9.—*Unilateral fits beginning in hand; brachial monoplegia; double optic neuritis; probable syphilis; recovery from neuritis and paralysis; fits persisting.\** (Pl. IV. Figs. 3 & 4.)

SUSAN S., a married woman, aged thirty-seven, came under treatment at the National Hospital for the Paralysed and Epileptic in September, 1872. No family predisposition. History of nodes on forehead a year and a half before, and loss of hair. Much frontal headache for two or three years. After the nodes, neuralgia for some months on the left side of the face. During the fifteen months before admission, she had had twenty fits, all limited to the right side, and

\* Under the care of Dr. Bastian, to whom I am indebted for permission to publish the case.



preceded by a sensation in the right hand, not passing up the arm before loss of consciousness. Since the first fit the right arm had gradually become weak and painful. During the last three months she had occasional sensations in the right hand as if a fit were coming on, sometimes extending up to the shoulder, but passing away when the hand was bathed in vinegar and water. For about the same time, movement of the fingers, or allowing the arm to hang down, had brought on a fit, and she was consequently obliged to carry it in a sling. Two months before admission she occasionally, after sleeping in the day-time, and suddenly rising from the recumbent posture, lost her sight for a few seconds.

*State on admission.*—An intelligent woman, presenting no mental disturbance. Slight thickness of speech, and occasional mistakes in words—*e. g.*, when intending to say, "Shall I take off my bonnet?" she said, "Shall I take off my woke?" Paralysis of right arm almost complete; no power of moving fingers or wrist; very little of elbow and shoulder; the attempt occasions pain, and excites some irregular tremor in the limb, and such a sense of faintness that she almost fainted away. Passive movement at any joint also occasions pain, excites resisting spasm in the muscles, and, when the wrist is moved, a sensation is produced as if a fit were coming on. Sensation unaffected. Moderate general wasting of the limb. The right leg is not quite so strong as the left, when carefully tested, but she can walk without any consciousness of weakness. Slight difficulty in micturition. No obvious paralysis of face or tongue or other cranial nerve, but the movements of the tongue, and to a less degree of the face, are tremulous. Pupils equal.

*Ophthalmoscopic Examination* (Pl. IV. 3).—Both eyes present a moderate degree of neuritis; the discs are quite lost under a greyish-red, soft-looking swelling, of moderate prominence, and nearly twice the normal diameter of the disc. Centre redder than periphery and finely mottled. Surface finely striated; many new, fine, radiating vessels. One extravasation near the centre of left papilla. Veins a little larger than natural, especially in left eye; both arteries and veins concealed on the surface of the swelling, losing reflection on side of swelling, but not concealed beyond edge. Arteries slightly veiled on the papilla, normal on the retina. In the left eye the mottling is coarser, and the veins more distended.

*Sight.*—Right reads No. 1 Jäger; left No. 2 with ease, and No. 1 with a little difficulty. Fields of vision: no peripheral limitation; blind spot of about double the normal diameter, and rather the larger on the right side (see Fig. 10, p. 56).

September 13.—Considerable increase in swelling of discs and the redness in the centre is more blotchy. Vessels more tortuous; the veins scarcely larger than before. Since admission some pain in the *left* arm, especially in joints, constant, with paroxysmal increase; slight



tremor of arm on movement. Right arm, same. Cannot walk quite so well on account of some pain in the right thigh.

She was treated with iodide and mercury and galvanism, and gradually lost the pain in the arm and the fits ceased. Towards the end of November she complained of "numbness" of the left hand. The tremor in the right arm on slight movement became coarser. The optic discs had become much clearer, the swelling was almost gone, and the outline of the discs could be seen on the outer (temporal) halves, the nasal halves being still veiled. The course of the vessels had become almost normal. Sight, same.

By the beginning of January a little movement had returned in the fingers. The neuritis had cleared up almost completely. The outline of the right disc was distinct all round; still a little softened on the inner side. The veins and arteries were for the most part of normal size; the former a little narrowed on the disc near the centre. Surface greyish red, paler in the centre. Left disc still obscured on inner edge and surface much redder.

After her discharge from the hospital there was a steady improvement in the paralysed arm, normal power being regained. The fits, however, persisted, beginning in the hand, and confined to the right side. Two months after discharge the discs were clear, still showing traces of the past neuritis (see Pl. IV. 4, and description).

The patient was not seen by me again until March 2, 1874. The right arm was a little thinner than the left; power was still much less than in the left, and less in the hand than in the upper arm. No weakness of leg or paralysis of the face or tongue. Occasionally much pain in the right arm; none in the left. Movement of right arm no longer caused a fit. The attacks still occurred at intervals of one to three months, and commenced with a sensation in all the fingers of the right hand, which passed up the arm—"a nasty feeling, as if she were throwing the arm about"—not passing beyond the arm, but followed by loss of consciousness and jerking of the right arm, leg, and side of the face. *Ophthalmoscopic Examination.*—Left eye: vessels, normal size and appearance; disc rather full coloured, reddish-grey, slightly paler in the centre at the emergence of vessels; tint deeper on nasal than on temporal side. On the latter the sclerotic ring is distinct; beyond that there is a little heaping up of pigment and slight atrophy of the choroid. On the nasal side the edge of the vascularity of the disc is well-defined, but there was an adjacent zone of choroidal atrophy, beyond which the fundus had a quite normal appearance. The arteries in the disc were normal; the veins are still distinctly narrowed upon the disc near the centre, one vein appearing narrowed to one-third of its previous size; towards the middle all veins are partly concealed by tissue. Right eye: Surface of disc paler than left. A band of atrophied choroid on the inner side, about the width of the normal sclerotic ring. All round the edge of the choroid was soft, and in places irregular, and the veins reduced in size and partly con-



cealed. Vision : each eye, No. 1 Jäger at 14 inches ; perception of colour and fields of vision natural.

I have lately learned (March, 1879), that the convulsive attacks still continue.

REMARKS.—In this case the paralysis, practically confined to the arm, and the fits beginning in the hand, were, no doubt, the consequence of a syphilitic growth on the surface of the left hemisphere in the region which is related to the movement of the hand, probably the middle of the ascending parietal convolution. The effect of reflex irritation, proceeding from the arm, in exciting and arresting a fit, is of much interest. An attempt at voluntary movement of the hand would cause a fit, *i.e.*, the voluntary stimulation of the cells already irritated by the tumour, sufficed to lead to their explosive discharge. Passive movement of the arm had a similar effect, possibly by reflex excitation of the nerve cells of the hemisphere, or of lower centres which, by the cerebral disease, were rendered unduly irritable. The movement occasioned great pain and excited a reflex rigidity. This may be associated with the marked and rapid wasting, indicative of a morbid state of the nerve cells of the lower centres, induced by the cerebral lesion.

The ophthalmoscopic change was that of a moderate neuritis, without evidence of much mechanical congestion ; subsiding with the symptoms. Sight was almost unimpaired, even during the subsidence of the neuritis, the increase in the blind spot being related merely to the size of the swelling.

CASE 10.—*Convulsions ; probably cerebral syphiloma ; optic neuritis ending in consecutive atrophy ; transient loss of electric irritability during the neuritis.* (Pl. V. Figs. 5 & 6).

JAMES C., aged thirty-four, confectioner, admitted under the care of Dr. Radcliffe, June 1, 1872. Family and personal history negative. No evidence of syphilis, direct or indirect, could be elicited. Married nine years ; three healthy children ; wife no miscarriages. History of gonorrhœa fourteen years previously. (Indubitable symptoms of syphilis occurred four years after the cerebral attack.) Never lead poisoning or gout. Much frontal headache for a year. In February, 1872, four months before admission, three fits occurred, without warning, with loss of consciousness and much general convulsion. Frontal headache worse after the fits, sometimes on one side, sometimes on the other. In the beginning of April he lost for a month the sense of smell and all appreciation of flavours ; sour and sweet substances been still perceived as such ; return gradual. In May eyesight became dim.

*State on admission.*—A strongly-built man, presenting no evidence of disease of heart, lungs, or kidneys ; no motor or sensory paralysis ; special senses, except sight, normal.

*Ophthalmoscopic Examination.*—Right disc obscured by a reddish-grey prominent swelling ; veins full, curving over the swelling, and then lost to view for a short space beyond its edge. On the swelling were a few



small hæmorrhages, and in the retina, near, were several whitish spots. Left disc similar, but swelling less and hæmorrhages fewer. Vision: right, No. 18 Jäger; left, No. 19 Jäger. Considerable hypermetropia. Fields of vision much limited peripherally; sight only in a small area around central point; limitation in each eye greater on inner than on outer side of field.

At the end of a week (mercury being given) there was less headache, less swelling of disc; vision had improved to R. No. 10 and L. No. 12 Jäger, but the fields were still more contracted. A fortnight later (June 25) sight had improved to R. No. 8 and L. No. 6 Jäger; fields of vision the same. Both discs were much paler and less swollen; the hæmorrhages almost disappeared. July 7, sight rather less acute, each No. 12 Jäger. During the following week he had two fits, each with loss of consciousness and general convulsion. Acuity of vision lessened to R. No. 16, and L. No. 19 Jäger. Fields of vision difficult to ascertain, but seemed confined to a small area around centre, chiefly on outer side, the inner halves of the fields being almost gone. He had several transient attacks of extreme dimness of sight, in which he could scarcely discern objects in the room. Discs still paler and less prominent: each presenting a soft-edged swelling, nearly double the normal diameter of the disc and rather paler than the adjacent fundus. Veins still larger than natural; arteries perhaps a little smaller, but numerous, and tortuous on the disc. Minute extravasations and dotted streakings in each eye, but no large hæmorrhages. The sense of smell was again lost; camphor, nutmeg, or peppermint could not be recognized; sugar and quinine were at once distinguished as sweet and bitter.

In a few days more, about July 18, sight failed completely so that he ceased to be able to distinguish light from darkness. Headache, severe, chiefly on right side, and increased by lying on the back. Ophthalmoscopic appearances nearly the same. During the next month there was no improvement in the sight; the swelling of the discs slowly subsided. On August 29 the ophthalmoscopic appearances were:—Right disc, moderate swelling, having a diameter of about a disc and a half; pale in centre, red on peripheral portion; edge very soft; veins not much above normal size, curve down the side of the swelling; arteries concealed upon the swelling, normal beyond its edge. Left optic disc had a similar appearance but presented several vessels in process of obliteration (see Plate IV. 5, and its description). At this time no subjective flash could be obtained with constant current, even with as much as twenty cells; giddiness and pain were caused but no flash.

In the beginning of September there was transient perception of light, chiefly in the outer part of the right field. He had several subjective spontaneous flashes of light. The swelling of the discs was subsiding, and the new vessels on them were less numerous and smaller. The arteries on the disc became more distinct; several formerly lost at the edge could be traced up to their junction with the larger trunks. During the next few weeks he had much less headache; no return of



distinct vision, but in the daytime he had a sense of a red glare in the right eye, sometimes in the left, disappearing when he shut his eyes. By the end of September the discs had become very pale, all swelling had gone, but the discs had still a "filled-in" look; arteries narrowed and partly concealed on the disc (Pl. IV. 6; see description of which for further details of the remarkable changes in the vessels).

At the end of October the sight and the ophthalmoscopic appearances were nearly the same. The constant current now produced a flash of light when the circuit was made and broken. Subsequently the fits recurred from time to time, and he had attacks of headache, the symptoms disappearing on bromide and iodide. Subsequently he had a syphilitic subfascial swelling in the forearm, disappearing rapidly on iodide.

Two years later the sight was nearly the same. The discs had become sharp edged, with a little adjacent disturbance of choroidal pigment. They were hollow and grey, the grey being greenish-grey by daylight. Examined with the direct image it was mottled, and finely stippled over the white tissue of the excavation. A well-marked central cup, at the edge of which the vessels terminated as they passed apparently into the connective tissue. No lamina cribrosa visible. The arteries were smaller than normal, and smaller than in the drawing (Fig. 6) with which the disc was compared, but not very small. The veins of normal size, as in the figure. The sclerotic ring was distinct and very sharp all round.

Vision: Left, quantitative only in temporal half of field; none in medial half. Right, quantitative; can see hand move across, but cannot count fingers. The electrical reaction was tested and found to be—

L.,   Anodal closure    }  
       Kathodal closure } 4 cells.  
       Kathodal opening, 6 cells.  
       Anodal opening, 8 cells.

REMARKS.—The case affords an illustration, as do many others of those here related, of the well-known and important fact that the absence of history of primary or secondary syphilis does not in any appreciable degree lessen the probability that a disease is syphilitic. Here the diagnosis was subsequently confirmed in an unequivocal manner. The case affords an example (1) of the progress of the ocular damage in spite of the apparent removal of its cause; (2) of the disappearance of sensitiveness to electrical stimulation, most when the effect of the neuritis was greatest, and its subsequent return; (3) the ultimate reaction being abnormal in the early anodal closure and late anodal opening stimulation; (4) the interesting changes in the vessels of the disc during the subsidence of the neuritis.

CASE 11.—*Symptoms of cerebral tumour; hemiplegia and hemiopia, with commencing optic neuritis; partial loss of colour-vision, afterwards regained; recovery, with mobile spasm in the affected limbs.* (Pl. V. Fig. 4.)

HANNAH B., aged fifteen, admitted into the National Hospital for the



Paralysed and Epileptic, under my care, January 5, 1877. Neither family nor past personal history of significance, except that one sister was paraplegic. In the preceding November she was believed to be quite well. In December she fell down once or twice, and first the left leg and soon afterwards the left arm were found to be weak. About the middle of the month her sight failed gradually. About Christmas there was much pain in the head, relieved by warmth.

*State on Admission.*—Well nourished; intellect clear. Almost complete paralysis of the left arm, a little movement at the shoulder only remaining. The leg less paralysed, but so weak that she could not stand. There was slight paralysis of the left side of the face; none of the tongue. The outward movement of the left eye was a little limited. Sensation of touch in the left limbs seemed little impaired—of pain lost; a prick felt only as a touch, localized accurately. Loss slighter in leg than arm. Sight: right reads only No. 15 Jäger; the left No. 10 Jäger at one foot. Fields of vision: distinct hemiopia in each eye, left half of each field being lost, and the loss extending to the middle line above and below, but not in the equator. There was also a defect in each field in the upper and right portion. Colour-vision: right—red, blue, and yellow all recognized, but green was invariably called white; with the left she was unable to recognize any colour. *Ophthalmoscopic Examination:* Both discs unduly and too uniformly red. The outline was not lost in the indirect image, but on the direct examination it could be recognized only on the outer half of each disc, the inner margin of each being concealed by a reddish grey swelling of slight prominence, striated. In the left eye there was a small hæmorrhage not far from the disc.

During the first four weeks after admission, her symptoms increased a little, and in the beginning of February the sight had failed to No. 20 Jäger. The morbid appearances in the optic discs had not, however, increased, and during the following fortnight, they lessened, so that on February 13 it was noted that the swelling was so slight as easily to escape notice. The redness continued marked, and abnormally uniform. The outline, in the erect image, was still blurred by striation. The locality of the hæmorrhage was marked by a paler and more conspicuous striation than elsewhere. Sight was about the same.

In the beginning of March there was much less headache. The paralysis of the arm was about the same. Sight was unimproved. The optic discs now, however, presented little evidence of the neuritis. Their redness, though marked, was within the limits of health, but its uniform distribution continued. In the position of the old hæmorrhage in the left eye, a little blood was apparently left in the perivascular sheath of the vessel, thickening it at the spot. By the middle of March the leg had improved considerably, so that she was able to stand; and sight was a little better. In the latter part of March some power was also regained over the arm, so that by the beginning of April she could move it freely at the shoulder and elbow, although the movement was accompanied by some jerky tremor. The hand, however, was closed by spasm, and a



voluntary attempt to open it produced, at first, only increased flexion of the fingers; presently they could be straightened, but there remained some jerky, spasmodic movements in the interossei. Sensation on the arm the same; a touch was felt anywhere, but a prick, although felt as such in the fingers, was not felt on the forearm, and although felt in the upper arm was referred to the fingers. A prick over the deltoid, for instance, she felt as on the fingers. The hemiopia remained unchanged, but vision had improved so much that she could read No. 6 Jäger with either eye, and colour-vision was also normal in each eye. The optic discs remained the same, the only pathological appearance being the too uniform distribution of the redness. The edges were sharp, but the sclerotic rings indistinct. The vessels had a normal course; the veins were a trifle larger than normal, the arteries a trifle smaller.

During April the improvement in the power of the limbs continued, but the spasm in the arm increased, and it was almost always stiff and rigid, and extended out before her at an angle of 30 deg. with the trunk. The rigidity involved the deltoid and pectoral, and, it was thought, the trapezius also. The fingers could be extended, and kept straight for a few seconds, and then were slowly flexed by an involuntary contraction of the interossei. When asleep the arm was free from spasm. The leg was also stiff, but less so than the arm, and it was raised too high in walking. By the beginning of June she was able to walk fairly well, still with the peculiarity described. She could not raise the toes from the ground, but the elevation of the foot on walking was even greater than this would account for. The knee was rigid like the arm. The spasm in the arm prevented any voluntary extension of the fingers. The head was habitually turned to the left, apparently not on account of the hemiopia so much as from rigidity of the right sterno-mastoid. Considerable movements of the face were equal on the two sides, but a smile was greater on the left than on the right. In closing eyes, however, the right eye closed more forcibly, and sooner than the left. The hemiopia remained the same, but sight continued good, and small print could be read with either eye. The optic discs remained clear. Treatment: cod liver oil and tonics. She then left the hospital, and was seen again in August. State practically unchanged. Arm still rigid; could grasp with the hand, but not relax her grasp. The analgesia and hemiopia continued. During the next six months there was no change in her condition, but the spasm in the arm became somewhat tremulous and quivering. The optic discs were the same, but many white lines were now seen along the vessels on direct examination. In April, 1878, it was noted that the spasm in the arm affected the interossei more than it did, causing strong flexion of the metacarpo-phalangeal joints, and sometimes of the wrist also, and there was strong pronation of the hand, the thumb often going between the first and second fingers. Her state since has presented no alteration.

REMARKS.—The hemiopia and hemiplegia with spasm were probably due to a tubercular tumour of the right hemisphere—optic thalamus



region. The amblyopia was out of proportion to the neuritis, and evidently due to an intra-cranial change of which the visible neuritis was part. The diminution in the latter was the first evidence of improvement, and was succeeded by that of sight. The loss of colour-vision and its return when the amblyopia passed away are worthy of note.

CASE 12.—*Symptoms of cerebral tumours; double optic neuritis; loss of sight; chromatopsy.* (Pl. V. Fig 6.)

MARY D., aged thirty-three, admitted into the National Hospital for the Paralysed and Epileptic, under my care, February 4, 1876. Father, consumption; mother, cancer. No distinct history of syphilis—one child died five hours after birth two years ago, its death attributed to a fall two months previously. Headache commenced soon afterwards, occipital at first and severe, lessening after a time, but persisting in various degrees, and of late accompanied with sickness. Six months ago suffered from occasional transient failure of sight, with attacks in which she could not move for a quarter of an hour, followed by headache. Failure of sight for three months with flashes of light and colours, "red or brown." Noises in the head at times "like a railway bell." Some right-sided weakness during the last few months.

On admission she was suffering from slight weakness of right limbs. Cranial nerves unaffected, except the optic. No loss of sensation. Vision: L., qualitative; R., No. 12 Jäger; limitation of field of vision on left side. Ophth. exam.: Right disc concealed by a soft, woolly-looking swelling, reddish in tint, mottled; veins moderate size, arteries small (Pl. V. 6, and description). Left similar, much paler. In March she had a sudden attack of loss of power in both legs, passing away in a quarter of an hour. Discs similar. In May she had some tremor of both hands.

She was not seen for a year, and then presented much loss of mental power and general weakness. Vision had failed to mere perception of light. Habits dirty.

CASE 13.—*Symptoms of cerebral tumour; difficulty in speech; right-sided paralysis; left-sided convulsion; intense optic neuritis, with retinal hæmorrhages; death.* (Pl. VI. 1.)

FRANK C., single, aged thirty-six, admitted into National Hospital for the Paralysed and Epileptic, under my care, February 19, 1878, with difficulty in speech, headache, right-sided convulsions, and double optic neuritis. History imperfect, but none of syphilis; the duration of symptoms about three months. Mental state dull; responses slow and often not to the point; always with hesitation in using words. Much headache; vertical. Occasional vomiting. Marked weakness of the right hand; slight weakness of the right side of the face; none of the leg. Sensation distinctly defective in the right hand and arm, not elsewhere. Pupils equal; no defect in ocular movements. Optic discs: right, masked by a pale red, soft-looking swelling, over which the vessels curve; the veins large



and tortuous; one or two which pass upwards, very tortuous; the arteries concealed near the middle of the swelling; one or two small hæmorrhages; not much striation. Reads No. 8 Jäger. *Left*, similar in appearance. The prominence is so great, that although the eye is emmetropic, the vessels on the surface of the swelling are visible at a distance of twelve inches from the eye without a lens. No. 10 Jäger. No affection of other cranial nerves; no albumen in urine.

For a few weeks after admission, iodide of potassium being given in large doses, his mind and aspect became brighter; his general symptoms remained the same, but his optic neuritis steadily increased in intensity. On March 29, in the right eye, the portion of the disc and adjacent part of the retina was occupied by a very large swelling with many hæmorrhages, especially at the margin of the swelling close to its side, which appeared vertical or overhanging. Left eye similar; the swelling extending almost as far as the macula lutea, and around the latter were a number of white spots similar to the smaller spots seen in albuminuric retinitis. In each eye the veins were large and tortuous in the swelling, and in the adjacent fundus, but were lost to view as they pass down the steep side. The arteries were indistinct upon the swelling; distinct but very small upon the fundus. Vision: right eye  $\frac{1}{12}$ ; left, could not read even largest test-type.

After this date he had several attacks of loss of consciousness followed by vomiting. In the beginning of May the swelling of the optic discs became still greater (Pl. VI. 1); over the surface of the swelling the vessels were almost completely veiled by a reddish tissue. The veins became smaller. The hæmorrhages on the edge of the swelling were very large, and smaller hæmorrhages were scattered over the whole fundus. Vision in each eye became reduced to quantitative perception of light. He had several transient attacks of loss of consciousness, followed by great mental dulness and considerable increase in the weakness of the right arm. The right external rectus and right side of the face became weak, and there was also a marked indisposition to move the eyes to the right. He could do so, but apparently only with effort, and they were almost always directed a little to the left. The hesitation in speech became again very marked. On June 11 the optic discs were the same, and there were very few fresh hæmorrhages, but the white spots on the left eye, adjacent to the macula lutea, were more conspicuous than before. Soon after this he had another fit, in which the left arm was jerked and not the right. Afterwards he lay unconscious, but on cutaneous stimulation moved the left limbs and not the right. During the next week such attack recurred several times. After the end of June he had several fits daily. Each began with loss of consciousness and he would fall; then the left arm and both legs were jerked in clonic spasm, the right arm always remaining still. The paralysis of the right arm became absolute, but he retained considerable power over the leg, and he complained of pain in the left arm. The optic neuritis continued. The swelling remained as great, but its tint was



becoming greyer, the vessels getting smaller, and the hæmorrhages fewer. On July 13, after an hour's stupor, he rather suddenly died. His friends refused to permit a post-mortem examination.

REMARKS.—The main interest of this case is in the ophthalmoscopic changes. The symptoms left little doubt of the existence of a cerebral tumour, but the unfortunate absence of a post-mortem examination lessens their interest. Attention may be drawn, in passing, to the character of the convulsion—spasm of the unparalysed side, sometimes extending to the other leg; increased weakness without spasm in the paralysed arm. The neuritis was remarkable from its intensity, being such as is rarely seen in intra-cranial disease. So extensive extravasations into the retina are also rare in such cases. It is also worthy of note, as an instance of the prognostic information to be derived from neuritis, that it did not participate in the transient improvement which occurred after admission into the hospital, but steadily increased, and was soon followed by an increase in the symptoms.

CASE 14.—*Tumour of right lenticular nucleus; early failure of sight from optic neuritis.\**

MARIA P., aged forty-three, widow, applied at the National Hospital for the Paralysed and Epileptic, August 13, 1875. No history of syphilis. In January, 1875, began to suffer from pain in the head (occipital and vertical), sickness, and giddiness; would stagger and fall forwards three or four times a day. At Easter, sight began to fail, and in about a month only perception of light remained. Examination showed very slight weakness of the left side of the face. Both arms and legs were weak; dynamometer, right hand 12 kilogrammes, left 10 kilogrammes. The optic discs presented subsiding neuritis, pale striated swelling, obscuring the outline. Arteries and veins of normal size; no hæmorrhages. Vision: left, qualitative; right, large objects dimly seen in right half of field. A fortnight later, the left arm and leg gradually became distinctly weaker than the right. On September 10 she was admitted into the Hospital under my care. The left pupil was a little the larger. The eyes could be moved freely in all directions, but were commonly directed to the right. The weakness of the left side of the face had increased, and there was marked deviation of the tongue to the left. Arms: dynamometer, right 14 k., left 7 k. Legs: left a little the weaker; no loss of sensation. Towards the end of September she complained of great pain in the right side of the head, and there was an intensely tender spot on the middle of the parietal bone. She became rather weaker. In the beginning of October there was some delirium with pyrexia (temp. 100°—102°) and she became drowsy. Deviation of the head to the right was added to that of the eyes. The hemiplegia increased, the paralysis of the arm being absolute by the 12th. The optic discs remained the same, only becoming paler. The coma increased, and she died on October 14.

---

\* Condensed from notes by Dr. Allen Sturge.



The necropsy revealed a small tumour of the right hemisphere, situated in the lenticular nucleus of the corpus striatum. Size about one inch by half inch. The intra-ventricular nucleus and optic thalamus were normal. The growth was situated at the lower part of the lenticular nucleus, adjacent to the crus, which was infiltrated by it outside the optic tract, the latter being softened but not invaded. Anteriorly it extended as far as the anterior perforated spot, where a branch of the middle cerebral artery was invaded, and inseparable, although its lumen was not diminished. The tumour presented no capsule or sharp limitation. It was reddish-grey, and scattered through it were hard opaque nodules, about  $\frac{1}{16}$  inch in diameter, undergoing fatty degeneration. It was composed of delicate rounded cells with large nuclei.

REMARKS.—The chief point of ophthalmoscopic interest is the early period of the history at which sight failed. No doubt this failure was from the optic neuritis, which must have existed at or soon after the onset of the symptoms. As those symptoms were themselves somewhat vague, the recognition of optic neuritis would have afforded a diagnostic symptom of the highest importance.

CASE 15.—*Right-sided convulsive seizures, and right hemiplegia; optic neuritis late in the case, subsiding and reappearing before death; growths in left cerebral hemisphere (upper frontal and parietal lobes).*\*

THOMAS W., aged fifty-two. Occasional severe headache as long as he could remember, chiefly frontal, and failure of memory for some years. First seen December, 1873. He had had two severe convulsive seizures. The first, in November, 1872, was preceded, for three weeks, by attacks of severe pain in the right arm, and it consisted in right-sided convulsion, beginning with acute pain in the shoulder, passing down the side to the knee, and up to the face, but not down the arm, which was "as if dead," and was powerless for some time after the fit, and the seat of "racking pain." He had very frequent slight seizures, also beginning with pain in the upper arm, which went up to the shoulder, down the right side, up the side again, and worked off at the fingers, leaving the little finger last. When the pain reached the fingers the arm became rigid, the elbow bent at a right angle, the wrist extended, the first phalanges extended, the second and third bent, except the first, which was straight. The limb was rigid, in this position, for twenty or thirty seconds, and then the middle, ring, and little fingers, were gradually flexed into the palm, while the index was straightened and the thumb completely extended. Under treatment the fits ceased, but recurred a few months later, similar in character, except that they began with pain in the little finger. The arm was weakened in grasp of hand, but not to other movements. *There was no optic neuritis.* During the summer he continued to have

\* In the London Hospital, under the care of Dr. Hughlings Jackson, who has recorded it in the "Med. Times and Gazette," June 19, 1875. The account of the microscopical appearances in the optic nerves is published now for the first time.



fits with variable frequency, and at one time he was in a semi-conscious state, in which he could be made to speak with difficulty; but there was no aphasia. He was readmitted into the hospital in the beginning of September, with paralysis of the whole of the right side.

On September 19 his optic discs, which had been frequently examined, first showed signs of commencing neuritis. The neuritis gradually increased for a fortnight, to considerable swelling, obscuration of edge, engorgement of veins, &c., and then slowly subsided until, at the end of six weeks from the onset of the neuritis, the discs again appeared perfectly normal. There was always more change in the left than in the right disc. At the height of the neuritis his sight with each eye was  $\frac{20}{80}$ , and this was probably less than his usual vision; it was difficult to be sure that he read his best.

After being in the hospital a fortnight, he began to improve, and by October 5 he was in fair mental condition. Then his paralysis began to improve; the face first, the leg recovering before the arm, and the upper arm before the hand; but the recovery was imperfect, so that he could not walk, and could never use the right hand. On November 15 he had two fits, confined to the right hand, and on the 19th one, which lasted half an hour, confined to the right leg. He continued to gain power, but the attacks persisted, commonly right-sided; but in one the left side only was affected. On December 15 there was a reappearance of slight indistinctness and swelling of the left disc; next day he could not be roused so easily, and this deepened into coma, and he died on December 20.

“Examination of the brain by Dr. Gowers:—The left hemisphere contained several growths, the largest in the upper part of the left parietal lobe,  $2\frac{1}{2}$  inches by  $1\frac{1}{2}$  inches, the deepest part being on the level of the calloso-marginal fissure. The parietal convolutions were displaced rather than invaded by the growth, and softened in their interior so as to resemble mere bags of fluid. The tumour was not encapsuled; but adjacent to it was much softening of the cerebral substance. Within the growth was a recent extravasation. A small pedunculated growth was attached to the middle of the ascending parietal convolution. Another tumour,  $\frac{3}{4}$  inch in each diameter, existed in the substance of the hemisphere beneath the posterior extremity of the superior frontal convolution, close under the grey substance extending downward almost to the level of the fibres of the corpus callosum. The structure of the tumours resembled most nearly that of gliomata.”

*Microscopical Examination of Eyes*—The optic discs present a slight degree of swelling, the greatest height above the choroid being, in each eye, about  $\cdot 035$  inch, with a moderate central depression. In one eye, in which there is a hæmorrhage around the vessels at the bottom of the cup, the vessels are narrow in and behind the sclerotic ring. In the other eye they are very wide, both in the ring and behind it: the artery is especially dilated and is fully as large as the vein. There is much tissue around the vessels at the bottom of the central depression, and both



artery and vein have their walls greatly thickened by layers of connective tissue outside them (Pl. XIV. 7). There is no distension of the sheath of the nerve in either eye. The substance of the papilla presents the nerve fibres of normal course, slightly swollen and varicose, but without any knob-like enlargements. Throughout, the capillaries are distended, and the nucleus-like corpuscles are very abundant. The displacement of the retinal layers is slight, and the layers at the commencement are nearly normal, within the ring and behind it. The corpuscles between and within the bundles of nerve fibres are very abundant, and a few millimetres farther back, there is, in addition, a great increase in the connective tissue between the bundles. This extends back, although slighter in degree, as far as the commissure, in front of which, as well as within the commissure and the optic tracts, the small vessels are everywhere distended and the corpuscles of the tissue much more abundant than normal.

REMARKS.—The point of special ophthalmoscopic interest in the case is the late period at which the neuritis came on, and its transient character. Its changes appeared to correspond with the changes in the cerebral disease, but to succeed them, coming on after a marked increase in the cerebral symptoms, and passing away after these had undergone considerable improvement, to reappear just before death. The changes in the optic nerves point to a descending neuritis.

CASE 16.—*Epileptoid attacks, mental disturbance, and double optic neuritis; afterwards left hemiplegia; glioma of right frontal lobe; hæmorrhage into new growth.\** (Pl. XIV. Figs. 8-10.)

MARTHA B., married, aged thirty-two, was admitted into the National Hospital for the Paralysed and Epileptic, under my care, on August 26, 1878. A delicate-looking woman, with family history of phthisis (father and grandfather), none of nervous affection. Marital history suggestive of phthisis; two children born dead (one at the full time, one at seven months), and three died in infancy. Much knocked about by husband, even to unconsciousness; he had lately deserted her. For some three months she had had headache, with sickness and sudden fainting attacks; in one, a fortnight before, she had fallen, and the mouth was said to have been "drawn to the left." For about two months, increasing mental dulness, and restlessness, getting up in the night. After admission her mental state was very variable; her aspect was dull; she was as a rule restless; turning about in bed, picking imaginary black-beetles off the bedclothes, &c. In the evening she generally imagined she was doing some domestic work. Urine and fæces were passed beneath her, apparently from mental dulness. When spoken to, however, she would often answer quickly and correctly, although usually in few words. Liquids were swallowed readily, but solids were allowed to accumulate in the mouth before being swallowed

*Syphilis?*

\* From notes by Mr. A. E. Broster. Published, "Lancet," March 7, 1879



When placed on a chair she almost fell off; but she was able, nevertheless, to walk a few steps with an unsteady gait. Both legs seemed equally weak. The arms were weak, the left a little more so than the right. Her tongue deviated slightly to the left, and there was thought to be rather less movement on the left side of the face. No obvious affection of sensation. No affection of ocular muscles. Right pupil acted to light more than the left; in a dim light they were equal. Well-marked double optic neuritis; area of swelling large; prominence great; tint grey-red, to indirect image almost as red as the fundus; vessels concealed on the surface, the veins forming a large curve as they course down the sides; the arteries narrow; many hæmorrhages. The neuritis was more intense in the right than in the left eye. Vision: right eye,  $\frac{1}{6}$ ; left,  $\frac{1}{8}$ . No defect ascertainable in fields of vision. During the next fortnight her mental disturbance was very troublesome. At night she would get up and threaten the other patients or remove their bedclothes. She did not do this when observed. It was found also that she could walk much better when no one was looking at her, and one day she was found in the bath-room washing herself. Nevertheless, she could not feed herself, but upset the food about her bed. Stools and urine were still passed without her attention.

About the middle of September it was noticed that she would often pass suddenly into a state of coma, from which she could be roused completely, but with difficulty. When lying asleep the eyelids could be raised without waking her. The pupils were first large, and then, under the light, very slowly became smaller, until they were below medium size. When she was fully roused, however, they dilated again. She then complained of severe frontal headache, and became restless, picking the bedclothes. The arms were both moved freely, but the left was evidently weaker than the right, and much less sensitive. The optic neuritis continued without change. During the next few days, coma alternated with extreme restlessness and irritability. When excited she used violent language, and threatened the nurses. After September 19 the coma increased. On the 21st she could be made to open her eyes and stare about, but could not be roused further. The weakness of the left hand had increased to complete paralysis, and it was much colder than the right. She swallowed very little, allowing liquid to remain in her mouth and trickle out again or down the throat. On the 22nd her temperature rose to  $101^{\circ}$ , on the 23rd to  $102^{\circ}$ , and on the 24th to  $104^{\circ}$ , with signs of congestive pneumonia at the bases of the lungs; and from the resulting interference with respiration she died on the 25th. The treatment consisted in first iodide of potassium in full doses, and afterwards sedatives.

*Necropsy.*—Dura mater adherent to pia mater over anterior part of right superior frontal convolution, and beneath this was a recent extravasation, connected with a clot the size of a walnut, beneath the convolution. Around this was a quantity of grey soft tissue, which at first was thought to be softening, but was evidently, on closer examina-



tion, a large soft growth, not separated by any sharp demarcation from the adjacent white substance. The tumour occupied the inner two-thirds of the anterior half of the frontal lobe in the white substance, not involving the grey matter of the convolutions, extending outwards as far as the level of the fissure between the middle and inferior frontal convolution, backwards as far as the anterior extremity of the corpus striatum, but not involving it, and forwards to within an inch of the anterior extremity of the hemisphere. The ascending frontal convolution was altogether behind it. In its upper part the hæmorrhage had occurred; the anterior part was pink-grey in colour and consistence; the posterior part was softer, and somewhat spongy in aspect from paler trabeculæ. The aspect and structure of the tumour were those of a glioma. The right corpus striatum appeared a little larger than the left, but on section was quite healthy. Outside the left corpus striatum, and a little above its level, was another clot, the size of a mulberry. No adjacent growth could be distinguished here; if any existed, it was infiltrated with the clot. In the inner part of the left temporo-sphenoidal lobe, adjacent to, but not involving, the optic tract, was a small superficial area of softening the size of a threepenny-piece. Elsewhere the cerebrum, cerebellum, membranes, and arteries, were healthy. The microscopical examination of the optic nerves showed the usual changes in papillitis, and slight traces of inflammation through the nerve-trunks, becoming very intense in front of the commissure, where an invasion of the nerves from the meninges had apparently taken place. (The appearances are shown in Pl. XIV. Figs 8, 9, & 10; for fuller details see the description of the plate.)

REMARKS.—The symptoms of mental derangement in this case were so predominant and well-marked that the patient would probably have been sent away to an asylum, had it not been for the existence of well-marked optic neuritis of the considerable degree, and lilac-grey aspect, which are very rarely seen except in conjunction with cerebral tumour.

The history of the patient gave the strongest reason for suspecting constitutional syphilis. A dissolute husband, and two children born dead near the end of pregnancy, constitute together strong presumptive evidence of syphilis, and it is most likely that the woman had had constitutional syphilis. But anti-syphilitic remedies produced no effect, and the tumour was characteristically non-syphilitic in its structure. The case thus illustrates the fact, rare no doubt, but always to be remembered, that simple cerebral tumours are met with in the subjects of constitutional syphilis just as in other persons.

The neuritis, while in appearance such as is common in tumour, was apparently "descending," and the changes in the middle of the nerve-trunk were much slighter than at the commissure or in the eye.

The case also illustrates a possible source of fallacy in the association of optic neuritis with cerebral softening. The existence of a tumour had, during life, from the character of the neuritis, been confidently diagnosed. The post-mortem examination was made in my absence, and



I was told that there was no tumour, but a mixture of hæmorrhage and softening. The resemblance to softening was, in a bad light, extremely close; in a good light, however, the peculiar grey gelatinous look of a soft glioma was distinct, and was confirmed by microscopical examination.

CASE 17.—*Unilateral optic neuritis (right); attacks of petit mal with right-sided weakness (probably cerebral syphiloma); subsequent amblyopia of left eye without neuritis; ultimately appearance of simple atrophy in both eyes.* (Pl. VII. Figs. 1 & 2.)

JOHN W., a healthy-looking man, aged forty-four, married, came under my care in May, 1876. No history of neurotic disease. A venereal sore twenty-five years previously. Four years ago he had a fit; three years ago another, which "took away the use of his right arm for ten minutes and rendered him unable to speak, before he lost consciousness." After the fit the arm was strong again, but he had much headache and disturbed dreams at night. Since that time he had two other slight attacks. Of late much headache, referred to the right side, passing to the face, and then back again. When first seen, no affection of smell, of the fifth nerves, or of the tongue. Arms and legs strong; urine normal.

Eyes: Right pupil a shade larger than the left. Left eye, ocular movements normal. Left optic disc (Pl. VII. Fig. 2) normal, clear; physiological cup distinct; sclerotic ring clear on outer side. Vessels numerous, but normal in course. Vision unaffected; field normal.

Right optic disc (Fig. 1) the seat of a well-developed neuritis; the surface and outline of the disc quite lost, the swelling considerable and annular, the centre being depressed, and showing the entrance of the vessels into the physiological cup. Surface reddish in tint, and striated by many fine lines and visible vessels. The sides of the central depression have a much darker tint than the highest part of the swelling, and are stippled with red, the outer part being greyish. The veins are a little larger than normal, the arteries rather smaller. On the sides of the central depression the veins pass behind the arteries, and are unduly concealed by the swollen tissue. One artery (above) is also concealed. In the central cup the arteries and veins can be traced almost up to their junction. Just beyond the outer edge of the swelling is a series of pale lines, curved concentrically to the disc and apparently due to a detachment of the retina, limited, above and below, by a small vein. Vision: can count fingers only. Iodide of potassium in ten-grain doses was given. During the next few weeks the pain in the head lessened considerably. The left disc remained normal. The neuritis in the right lessened, and on June 26 the sclerotic ring on the outer side became visible, although the swelling on the inner side remained considerable. Sight had improved to  $\frac{1}{12}$ .

A fortnight later, July 12, the right disc was so clear that its outline was distinct all round, and it was difficult to say that there had been anything the matter with it. The arteries were still a trifle smaller



than in the other eye, and the veins also had become a little smaller. Sight had improved to  $\frac{1}{6}$ . No peripheral defect in the field could be found (roughly tested). By August 4 the physiological cup in the right eye had become so clear that the mottling of the lamina cribrosa could be seen at the bottom of it. The tint of the disc was the same as in the left eye. Sight, however, was less good =  $\frac{1}{15}$ ; field normal; left eye still normal. On August 18 there was no change in the discs, but the right was not quite so good, and the sight of the left eye had become defective. Right,  $\frac{1}{20}$ ; left,  $\frac{1}{45}$ . On October 26 it was noted that the right disc was becoming much paler, and a little more hollow than the left. The sight of the right eye after this date remained the same, but that of the left deteriorated. In December he could read, right, No. 19 Jäger, left No. 12. In February he had slight symptoms of a recurrence of the fits, ceasing when bromide was given. After this date his sight improved, and in May, when he ceased to attend, it was—right,  $\frac{5}{15}$ , left  $\frac{5}{6}$ . The right eye presented the same distinct atrophy, and the left eye was a little paler than before.

The patient was seen again two years later. He had continued free from cerebral symptoms, but his sight had failed further, and there was distinct atrophy of the discs. Left: tint of periphery of disc reddish grey; central cup large and deep; lamina cribrosa visible at the bottom (compare with the earlier condition, Pl. VII. 2); vessels of normal size; V.  $\frac{1}{8}$ ; colour-vision normal. Right: central cup as large as in the left eye; lamina cribrosa very conspicuous; outer parts of disc pale greyish-white; V.  $\frac{1}{18}$ . Confuses pale green with grey and orange. Other colours apparently recognized accurately.

REMARKS.—The unilateral neuritis was probably, as in most cases in which it is unilateral, on the side opposite to the cerebral lesion. The completeness with which it disappeared was remarkable. The exposure of the lamina cribrosa, so rare in such a case, may be due to the inflammatory changes having been greater in the periphery than in the centre of the disc. The subsequent failure of sight was clearly due to an intra-cranial cause. It is possible that both nerves were damaged in front of the commissure, as in the last case, and that in one only did the inflammation descend to the eye.

CASE 18.—*Optic neuritis and convulsive attacks; probably syphilitic disease of brain; recovery from neuritis with subsequent failure of sight; limitation of fields of vision and hemiopia.*

WILLIAM H. L., aged thirty-nine, came under my care at the National Hospital for the Paralysed and Epileptic on August 7, 1876, suffering from convulsive attacks and from well-marked optic neuritis. Syphilis at eighteen, communicated to his wife at twenty-seven. For three months before he came under treatment he suffered from sudden attacks of giddiness, sometimes accompanied with a sensation at the back of the head as if some one were inside it with a hammer. Two months before, for four hours he was unable to speak. Sometimes he



had attacks of tingling in the legs, and sometimes saw double, the two objects being side by side. No actual headache; no sign of motor paralysis; no vomiting.

Well-marked double optic neuritis; discs veiled under swelling, very red in the centre, grey red in the periphery, the prominence considerable, the veins large, the arteries of normal size. Vision: each eye  $\frac{1\frac{1}{2}}{14}$ , less readily with right than with left.

Bromide and iodide were given, and a week later he was a little better, although his sight was occasionally dim. The discs were the same, sight unchanged. August 25, no fresh attacks, sight rather worse, but  $1\frac{1}{2}$  Snellen still read with each eye with difficulty. During the next four weeks the neuritis subsided a little, and he continued free from other symptoms. His sight, however, became worse. In the beginning of November the neuritis was much less; a little redness of the outer parts of the discs alone remained with slight swelling.

He was not seen again for three months, having been in another hospital, and while there his fits recommenced, preceded by general tremors. The discs were now pale, slightly swollen, the vessels small. Around the disc was a good deal of irregular pigmentation of the choroid. In each eye the left half of the field of vision was gone, and there was extreme peripheral limitation of the field. (The fields are shown in Fig. 9, p. 55.) A month later his headache had increased, and his sight had deteriorated so that he could only count fingers. The discs were distinctly paler.

CASE 19.—*Tubercles in cerebellum and medulla oblongata; optic neuritis; consecutive atrophy; death from meningitis.\** (Pl. VI. Fig. 3.)

HENRY C., aged eleven (at death). Mother's three brothers died of phthisis. Patient's health failed, after scarlet fever, at eight. At nine and a half he began to suffer from attacks of pain in head (through the temples or from vertex to occiput), and from fits. Each fit began with "snorting and fretting," then the arms were stretched out rigidly; he was stiff for a few minutes, and on recovering consciousness vomited. After a fit there was much pain in head and eyes, and sometimes vomiting. At ten, when he came under treatment (December 17, 1873), there was general weakness of limbs (greatest on the left side) and tottering gait. The left eye was usually turned a little out, and there was some defective movement inwards and upwards. Both pupils were large; the right acting readily to light, the left not at all. Double optic neuritis was found. The following is my note of the ophthalmoscopic condition on January 13, 1874, a fortnight after admission:—Left optic disc (Pl. VI. 3) greatly swollen, pale, with reddish-grey, soft edges. The veins concealed by a whitish film at their convergence; their central reflection, distinct on surface, lost in their curve down the sides of the swelling; and at its edge the veins them-

\* Under the care of Dr. Buzzard, who has published the case, "Clin. Trans." vol. vii. 165.



selves are lost, or almost lost, to view, reappearing a short distance from the edge. One or two small twigs disappear abruptly at the side of the prominence, to reappear at some distance laterally. Of three large arteries only one can be seen on the disc; the rest appear on the fundus about the distance from the disc at which the veins reappear. There is much pigment about the macula lutea, and at its position there is a small area, nearly > shaped, which presents less pigment, and is somewhat paler than the rest of the fundus. Midway between this and the disc, is a group of minute, very white, granular spots, a little behind the level of an adjacent small retinal vessel. The right disc is similar, but the amount of swelling less. The large arteries are all visible on the surface of the swelling, and the obscuration of the veins, as they pass on to the retina, is slighter—no white spots. Vision: Left, 0; right, counts fingers only; no limitation of field. Yellow, blue, and green are named accurately; red is called brown. Twelve days before, with the left eye, he could count fingers in the left half only; but could not recognize colours. With the right eye he could read No. 1 Jäger and named all colours accurately. On January 17, however, sight of the right eye had failed to qualitative perception. The ophthalmoscopic appearances were similar, except that in the left eye the arteries could all be seen on the swelling, but there they had not more than one-third of their diameter upon the retina. On February 2 the swelling of the discs had lessened considerably, and the edge of the choroid could be distinguished at the outer side of the left. The white spots on the retina were still visible, but smaller than before. From this time the subsidence of the swelling progressed, until, by the middle of March, both discs were clear in outline; the surface grey, with whitish tissue about the vessels. There was a little atrophy of the adjacent choroid. Some minute white specks could just be distinguished in the retina. The veins were of normal size; the arteries much smaller than normal. By this time he had lost even qualitative perception of light in the right eye. Towards the end of March, it was noticed that his tongue was wasted in the right half. He became febrile, then delirious, and died on April 7. *Necropsy*.—A tubercular mass, the size of a Maltese orange, was found in the left hemisphere of the cerebellum. The right half of the medulla, as far as the decussation of the pyramids, was enlarged in consequence of the presence of a smaller mass, the size of a hazel nut. The prominence extended up to the pons, and was chiefly between the middle line and the origin of the eighth nerve, and in the centre of it the hypoglossal nerve was situated. A quantity of yellowish lymph was found at the base of the brain.

*Examination of eyes.* (Pl. XV. 2 & 3.)—Each optic papilla presented only a slight degree of swelling, its greatest height being .025 inch from the sclerotic. The surface was flattened, the central depression being slight. The substance of the papilla appeared composed of an irregular, felty mass of fibres and nuclei. The direction of the nerve fibres could no longer be perceived. The optic sheath was greatly distended, the two layers widely separated, and connected by irregular, nucleated bands



and films of tissue. The central vessels were large, and presented no evidence of compression within the nerve or sclerotic ring. The divisions of the vessels within the swollen papilla were narrow. The nerve fibres behind the eye presented advanced degeneration. The connective tissue between the bundles was much increased in quantity and many nuclei lay between and within them. This condition extended back through the whole length of the nerves.

REMARKS.—The apparent cause of death, in this case, was meningitis, probably tubercular. The discs having before been wasted by inflammation, no changes occurred during the meningitis. The minute white spots in the retina were no doubt the results of degeneration of the retinal elements, caused by damage during the acute, and probably more extensive, stage of the neuritis, which was over before the patient came under observation.

CASE 20.—*Convulsions, beginning in the orbicularis oris; optic neuritis; loss of colour-vision.*

RHODA H., aged fourteen, admitted into the National Hospital for the Paralysed and Epileptic, under the care of Dr. Radcliffe, June 30, 1873. She was well until ten years of age, when convulsive attacks commenced and continued. Six weeks before admission she had three fits more severe than usual, and since that time her sight had failed. The character of all the fits had been the same; they commenced with a peculiar "rising in the throat"—a choking sensation, followed by twitching about the mouth, described spontaneously as like "the cramp all round the month;" the sensation then passed down the left arm to the hand, when consciousness was lost.

Patient was an intelligent child, presenting no weakness of the limbs. Smell and taste unimpaired. Slight divergence of eyeballs, but ocular movements free in all directions. The right optic disc presented all the characters of subsiding neuritis, a swollen papilla becoming pale, the edges concealed, the vessels curving over it, veiled by filmy tissue near the centre, and lost to view for a short space just beyond the edge of the swelling. Vision, 0. The position of the left disc occupied by a pale prominence; swelling, less than in the right eye; the vessels sank, near the centre, into the tissue, but were not lost to view beyond the edge of the disc, as in the other eye. Vision: could just discern large objects, but not count fingers. The field seemed to be normal in extent. The only colour named accurately was yellow. Pink, green, and light blue, were called white; dark blue and violet, black. She had a blue ribbon on, and on being asked its colour said, "Blue; my mother gave it me;" but when asked what it looked like, she replied, "Black." Similarly, a pink apron she said looked white, although she knew it was pink. No change in the symptoms occurred during some weeks, in which the patient was under observation.



CASE 21.—*Double optic neuritis; headache and vomiting; loss of sight; transient cranial nerve paralysis; nystagmus; convulsive attacks with opisthotonos; tumour in third ventricle.\**

MARY L., aged thirteen, sent to me, at the Queen's Square Hospital in December, 1877, by Mr. Wordsworth, under whose care she had been at Moorfields. In June, 1877, she was taken ill with headache and vomiting; soon afterwards sight began to fail. When first seen she complained only of headache and loss of memory. She had a querulous, childish manner. Both optic discs presented subsiding neuritis; outlines blurred, vessels small, and partially concealed over the disc. Vision: R., counts fingers only; L.,  $\frac{2}{3}$ . No change occurred for some months. In February, 1878, the discs were similar. Vision: R. qualitative; L.  $\frac{1}{6}$ . In March the headache had ceased and her manner had much improved. Right optic disc clear on nasal side, still blurred elsewhere. Much new tissue in the disc concealing the vessels; arteries small; veins still rather large. Many new vessels on outer half. She was admitted into the Hospital under my care on April 13. There was then no affection of the cranial nerves or limbs, motor or sensory, except a doubtful diminution in power in the left side of the face and the left leg. Ophth. appearances unchanged. Vision: R., extreme concentric limitation; large objects at three feet recognized only in a central area six inches in diameter; L.,  $\frac{1}{5}$ ; defect in the field only at the lower temporal quadrant. Blue and yellow recognized at once; red thought to be drab, and green thought to be yellow. In June there was more headache—vertical. Slight weakness in the left side of the face was noted on June 15. Sight had failed to—R., 0; L., counts fingers. The margins of the optic discs had become clear, and the swelling was slight—"consecutive atrophy." By August 16 loss of sight was complete and the headache increasing. She then complained of slight weakness of the right leg, but there was no noticeable loss of power. In September the discs were becoming grey, and nystagmus came on, constant in both eyes—a short, sharp movement to the right and a slower movement to the left. No subjective sensation of light could be excited by the voltaic current. In the beginning of October the nystagmus had changed, the slow movement being to the right and the quick movement to the left. Intense headache came on, vertical, and in the right occipital region, attended with frequent vomiting. The weakness of the left side of the face more marked; her gait became staggering. In the course of ten days these symptoms increased. Her speech became muffled, and she choked in swallowing. She seemed unable to close her mouth. On October 28, after an intense paroxysm of pain at the back of her head, she had a convulsive attack; the head and eyes were turned to the right as far as possible, and the body twisted; the hand and forearms flexed and rigid. Consciousness was lost. On the 30th, after much pain in her legs, they became rigidly flexed, and she was found to be unable to swallow. Dr. Hughlings Jackson (who

---

\* Notes taken chiefly by Mr. A. E. Broster.



kindly saw her in my absence) found the right side of the palate paralysed, and the right vocal cord was found by Dr. Brandis to be motionless. Her speech was nasal, and liquids returned through the right nostril. She was unable to cough. Anæsthesia was found in the region supplied by the supra and infra-orbital branches of the right fifth nerve. The masseters were weak; after leeching and blistering the symptoms gradually subsided and the headache almost disappeared. On November 18 the facial paralysis on the left side was slight and confined to the lower part. The right masseter was much weaker than the left. The tongue on protrusion deviated a little to the right. The paralysis of the right side of the palate was barely recognizable, and the movements of the right vocal cord were perfect. Optic discs grey and "filled in;" vessels extremely small, both arteries and veins. Nystagmus less marked. In the beginning of December she had more headache and sickness; the pain was referred to the back of her eyeballs. The grasp of the left hand became distinctly weaker. These symptoms again improved. On January 10, 1879, she had another convulsive attack, general, but greater in right side; commencing with rotation towards the left. During the next few days she had several other attacks, in some of which the eyes were directed to the right, and there was opisthotonos. The nystagmus became much more considerable, and varied, usually lateral, sometimes vertical—thirty movements in fifteen seconds. She then left the hospital; but was again admitted, a month later (February 28), with frequent convulsive attacks in which general tonic spasm occurred, the head and eyes being turned to the right, and there was extreme opisthotonos which persisted for about half an hour after each attack. In each attack there was, at first, violent nystagmus, ending by the eyes being directed to the right so far that the pupils were invisible. Blistering arrested the attacks. In the beginning of March there was much drowsiness and mental dulness. The weakness of the right masseter persisted. Limbs weak, but equally so; just able to stand. The constant nystagmus was sometimes lateral, sometimes vertical. On March 22 she died rather suddenly after a fit. Her urine throughout was normal.

The necropsy revealed no excess of cerebro-spinal fluid, but extreme distension of the lateral ventricles, the convolutions being flattened. In the third ventricle was a grey, soft tumour, which occupied the whole space between the corpora striata and optic thalami, but had not invaded them. It pressed upon, and extended, the corpora quadrigemina, and had closed the iter, the fourth ventricle being normal. At the base, the tumour occupied the whole interpeduncular space, forming a prominence between the crura and appearing in front of the optic commissure, which was stretched over it and softened. No damage to the cranial nerves was found, and no evidence of meningitis. The sheaths of the optic nerves were very lax; they had evidently been greatly distended, but were flaccid and empty (carefully examined *in situ*). The base of the skull was perfectly normal. The tumour had the histological characters of a round-celled sarcoma.



REMARKS.—The case presents an illustration of the diagnostic importance of neuritis early in the history of cerebral tumour, since it probably preceded all other symptoms. The early and complete loss of sight was no doubt the result, in part, of the damage to the optic commissure by the tumour. The condition of the sheaths of the optic nerves is of much interest. They were found empty, although they were carefully examined before the optic foramen was cut away. They had evidently been distended, and the removal of the fluid had occurred in spite of, perhaps because of, the extreme distension of the lateral ventricles. This, together with the growth at the base, must have prevented any accumulation of cerebro-spinal fluid in the subdural spaces.

CASE 22.—*Tumour of right cerebral hemisphere; death; optic neuritis found post-mortem; microscopical examination of optic nerves.* (Pl. XIV. 1—5.)

HENRY F., aged fifty-one, admitted into University College Hospital, February 10, 1874, under the care of Dr. Wilson Fox. No syphilitic history. Illness commenced some months before, with pains in the right side of the head accompanied by sickness. Five weeks before admission he had a sensation of twitching at the back of his tongue, and afterwards a feeling as if his whole body were turning round. From that time his left arm gradually became powerless. Ten days before admission he had twitching of the muscles of the left side of the face and eye, without unconsciousness, and after a similar attack the next day he found that he could not move the left leg. After this he became more drowsy. On admission he was dull and sleepy, but could be roused, and then answered questions sensibly. There was complete motor paralysis of the left arm and leg, without loss of sensation, with rigidity of the arm, not of the leg. Slight paralysis of the left side of the face. No strabismus or difficulty in swallowing. He continued in the same state for a fortnight and then became unconscious, lost the power of swallowing, and died. No ophthalmoscopic examination was made during life. At the necropsy, a tumour was found in the outer part of the right hemisphere, to which the membranes were adherent. It occupied the lower portions of the ascending frontal, and of the ascending parietal convolutions, partly obliterating the fissure of Rolando, and extending into the lower part of the supra-marginal convolution. On section the mass appeared wedge-shaped, about the size of a Maltese orange, somewhat rounded externally, and extending inwards about two inches. Below, it reached, but did not perforate, the roof of the lateral ventricle; inwards, it reached to about half an inch from the posterior (caudate) portion of the corpus striatum. It was indistinctly lobulated, yellow at the centre, containing semi-transparent spots about the size of a hemp seed; scattered through it were lines of vascularity. The softer parts consisted entirely of spindle cells, lying among tracts of fibrous tissue.

The optic discs, examined after death, showed to the naked eye distinct swelling and several small hæmorrhages. Microscopical exami-



nation after hardening. (Pl. XIV. 1—5.)—Both papillæ were very prominent, the greatest height being  $\cdot 06$  inch above the level of the choroid. There was a deep but narrow central depression almost reaching the choroidal level. The retina was displaced  $\cdot 02$  to  $\cdot 04$  inch from the edge of the choroid. In the substance of the disc, the nerve fibres were still perceptible, although in places swollen and separated. Large numbers of nuclei and leucocyte-like cells were scattered through the swelling. The nuclear layers of the retina were considerably thickened. There was no distension of the sheath of the optic nerve. The nuclei of the nerves were much increased in number immediately behind the eye and to a less extent throughout the nerve. They were small, smaller than in ordinary descending neuritis, and angular. The nerve fibres presented a granular and irregular appearance, and were separated by many minute granules. About the same degree of change was found a quarter of an inch from the eye, midway between the eye and the chiasma, in front of and through the chiasma. In the optic tracts there was also a slight excess of nuclei, in places aggregated into linear groups.

CASE 23.—*Epileptoid convulsions; slight difficulty in speech with some transient right-sided weakness; very chronic optic neuritis.* (Pl. VII. Figs. 3 & 4.)

MARY ANN H., a domestic servant, single, aged fifteen, admitted into the National Hospital for the Paralysed and Epileptic, under the care of Dr. Buzzard, February 15, 1871. No family history of disease of the nervous system. Personal history good; no symptom suggestive of syphilis. Catamenia commenced four months ago.

The first fit occurred a week before the first menstruation; while dancing in a hot room fell unconscious, and for a time afterwards she could hear what was said, but could not speak or move. She did not bite her tongue, and it was doubtful whether there was any convulsion; much headache afterwards. Three days later another fit while dressing in the morning; of the same character. Her mother states that she foams at the mouth, kicks out, and strikes with both arms and legs, and she sleeps afterwards for some hours. Since then they have recurred at intervals of from one to seven days, and were preceded by giddiness; not worse at menstrual periods. Constant headache, frontal, not very severe; since the attacks became frequent. Some failure of memory, and a peculiar difficulty in speaking, always present in slight degree, and sometimes preventing her from speaking for half an hour.

On admission a fairly intelligent girl, with a rather large thyroid; no indication of cardiac or renal disease, or evidence of motor or sensory disturbance in limbs or cranial nerves. The hesitation in speech mentioned above, consists in a moment's pause before beginning to speak, and sometimes during a sentence. When the pause is long, she puts her hand on her chest, and being asked why she does so, says "there seems to be some difficulty there"—*e.g.*, asked if she caught a cold in coming to the hospital, she says: "(Pause) Yes, sir, I (pause) I



had not a cold before." No misuse of words. I gave her a book to read a sentence commencing with *If*. She tried but could make no audible attempt at uttering the word. She put her hand to the epigastrium and said that something there seemed to stop her. I then told her to say "if" after me. She could not; after waiting a moment, she said "I can't say '*if*,' sir," but even after having just uttered it she could not repeat it. Another passage, however, she read fairly well, making only the mistakes natural to an ill-educated person, but after each few words she paused, and seemed unable to go on except by repeating the last words which preceded. No misuse of words in writing impromptu, but some mistakes in spelling such as a slightly aphasic patient will make—*e.g.*, "I came by trane on Whensday morning, and took a cap at the tasion, and came to the hospitle."

Both optic discs presented slight but distinct neuritis. The left is shown in Pl. VII. 3. The outline was concealed under a red swelling, nearly the colour of the fundus and of moderate prominence; the centre redder than the periphery, the sides a little paler than the adjacent fundus, the redness punctiform in the centre, and striated on the outer part. Veins larger than normal, and some concealed near the centre of the disc, where was a little whitish tissue about them. On the sides of the swelling the double colour of all the vessels is lost. V., No. 2 Jäger, not No. 1. The right disc was similar to the left. V., No. 1 Jäger.

After admission she had occasional transient attacks of faintness with pallor, and several severe attacks. She tried to call for help, but could not, then became unconscious and made a gurgling noise which roused the nurse's attention, who found the face drawn to the right, and a little struggling in both arms and legs, most in the right. The limbs afterwards became stiff. It lasted about two minutes, and afterwards she seemed stupid and could not be roused. In another fit she was close to the nurse when it commenced. The nurse spoke to her, but she did not reply: she seemed to know what the nurse had said, but could not speak, putting her hand up to her mouth to indicate this. Immediately she went off into the fit, making a noise in her throat and losing consciousness. Other attacks, in the beginning of April, were preceded by some sensation in the hands, which shook for a minute before consciousness was lost. A little later she had an attack in which she states that consciousness was not lost; she could hear and see all that occurred but could not speak, and the power of articulation returned slowly; for a minute or two she could only "mumble." As she became able to speak her right arm appeared suddenly to become powerless and insensitive. This she described as beginning with a feeling of numbness in the second finger, passing next to the third, then to the fourth and first, and then to the thumb and back of the hand, and then up the arm. Wherever it passed she was quite unable to feel on the part or to move it. It was rubbed by the nurse, and the feeling and power returned in a few minutes, so that she was able to raise it to the head, but it continued weak. The hesitation in speech had nearly



disappeared, but after this attack became more marked. The next day the weakness of the arm was still considerable. Grasp: left, fifteen kilogrammes; right, two. Sensation normal; power of leg normal; much pain over eyes. Ophthalmoscopic appearances quite unchanged.

The weakness passed away in a day or two. At the end of June she had had no attack for six weeks; the arm had recovered power. Her speech had again become normal. The optic discs presented precisely the same appearance as on her admission four months previously, except that perhaps the swelling was a little greater, and there was in the right a small extravasation. She then went home into the country.

She was seen again two years later when, by Dr. Buzzard's courtesy, she was readmitted under my care. After returning home the attacks recurred and had continued of the same character. The optic neuritis had for the most part subsided, but the discs were still redder than normal but not swollen, but the vessels were even more concealed in the centre, although quite normal on the periphery of the disc. The edge of the ring was clear on the outer side (see Pl. VII. Fig. 4, and description). Vision the same as before. The fits again ceased under treatment.

REMARKS.—Apart from the optic neuritis the symptoms were suggestive of organic disease of the left cerebral hemisphere, although not decisive. The extreme chronicity of the neuritis was its most striking feature. Unfortunately I made no note of the condition of the presence or absence of hypermetropia, but the degree and character of neuritis, especially the occurrence of an extravasation, can scarcely have been accounted for by hypermetropia.

CASE 24.—*Epilepsy; vague cerebral symptoms; optic neuritis; hypermetropia.\**

WM. M., aged twenty-four. Father's two brothers epileptic. Patient's first fit at sixteen months old. The attacks continued for nine years, and ceased from ten to fourteen, and then recurred at intervals of three to twelve months. In 1873 he had an attack of neuralgia in the right side of the face, lasting for a month. After another month he began to suffer from severe pains in the head, upper frontal region, almost constant, but with exacerbations accompanied by giddiness. These continued for a year and a half, and then he had frequent sickness. When he came to the Queen Square Hospital, in November, 1874, well-marked double optic neuritis was found, the outlines of the discs being concealed; swelling moderate; veins not much larger than normal; centre of swelling more deeply tinted than periphery. Moderate hypermetropia and frequent attacks of spasm of the ciliary muscle. Vision: The smallest test-type read with either eye. No motor or sensory defect could be discovered. The attacks commonly occurred in the morning, before breakfast. Aura

---

\* Under the care of Dr. Bastian, to whom I am indebted for permission to publish the case.



visual, objects appeared floating before his eyes—sometimes sparks, sometimes such objects as are seen “after you look at the sun and cannot see clear afterwards;” sometimes such an appearance as is seen “when, on a very hot day you see heat rising from the fields, only stronger, and on the work.” It seems to get nearer and more intense, until he loses consciousness: sometimes, however, it suddenly ceases without any loss of consciousness. Occasionally he is conscious of a commencing painful cramp beginning in the right hip, and sometimes going down the leg and the leg is jerked outwards; the sensation goes up the right side of the trunk to the shoulder, and the arm feels dead and he cannot move it. Sometimes the cramp goes from the shoulder to the right side of the face. On stooping or blowing his nose, sparks readily appear before the eyes. At night, when in the dark, if he thinks of any object, he fancies he can see it quite distinctly. If, for instance, he were to think of green trees or a certain house, it would appear before him, and he would see it as plainly as possible.

During four months, in which he remained in the hospital, the attacks ceased; but the neuritis persisted, unchanged in any particular. After leaving the hospital in April the attacks returned. On June 25 the optic discs were clearer; in the left disc the sclerotic ring was distinct on the outer side; elsewhere the edge was obscure, and there was still some swelling. The right disc was similar. The vessels were accompanied by distinct white lines.

In November the discs were quite clear, and the outline regular. In the left there was a little disturbance of pigment near the edge. Vision: R.,  $\frac{1}{1}$ ; L.,  $\frac{1}{2}$ .

He was seen again in August, 1878. His discs were still clear and normal. The attacks persisted similar in character to those described above.

REMARKS.—The history of this case, especially the family history and the early commencement of the convulsions, suggested idiopathic epilepsy. The localized commencement of the convulsions and the definite visual aura, point to localized organic changes in the brain, although it afforded no evidence as to their nature, whether coarse adneurial, or finer neural changes. The optic neuritis, although its presence commonly affords strong reason for believing that there is coarse adneurial disease, in this case afforded less decisive evidence. Its moderate degree, slow course, and its association with hypermetropia are, however, noteworthy. In a neuropathic individual, with cerebral irritation going on and convulsive attacks frequent, it seems possible that hypermetropia assists in the production of neuritis. The case presents many interesting points of analogy with that last described.

CASE 25.—*Hemiplegia, probably from embolism: simple congestion of optic discs.* (Pl. I. 1 & 2.)

THOMAS D., aged thirty, admitted into the National Hospital for the Paralysed and Epileptic, under my care, December 6, 1878. When



thirteen years of age he had an attack of rheumatic fever. Five days before admission he fell unconscious: duration of unconsciousness uncertain. On recovery, left hemiplegia was found. On admission there was weakness of the left side of the face, deviation of the tongue, and complete loss of power in the left arm and leg. Sensation in the left limbs was diminished. The cardiac impulse was diffused, and at the apex there was a loud systolic murmur. Optic discs normal. After admission it was found that there was some mental change. He was generally asleep, and when awake often rambled in his talk, and his answers to questions were not to be relied upon. The hemiplegia continued, and rapid wasting of the limbs was observed. On December 10 the left thigh measured one and a half inches less than the right, and the left forearm one inch less than the right.

On December 19 there was still no improvement. Distinct ankle clonus could be obtained on dorsal flexion of the foot. Both optic discs now appeared red, the redness being uniform over the whole disc. The position of the edge could be seen by indirect examination, but it was not sharp (Pl. I. 1). In the upright image the edge could be seen only on the outer side, elsewhere it was indistinct (Pl. I. 2). The tint of the inner part of the disc was the same as that of the adjacent choroid. No striation or swelling could be perceived. The veins were large, the arteries normal or a little above the normal size. There was a good deal of conspicuous white tissue about the vessels in the middle of the disc. The changes were similar in the two eyes, but were most marked in the right. December 27: No improvement in paralysis, or mental state. Discs nearly the same. During the next month there was no change. On February 4 the right disc continued in nearly the same state, while the redness of the left disc was much less; its outline was distinct and its aspect nearly normal.

A few weeks later the congestion of the right disc lessened notably. Subsequently, however, irregular pyrexia came on, the paralysis remained absolute, and the wasting very great. In the beginning of April hæmorrhages, rounded with white centres, were found over both retinæ. The urine, previously normal, contained much blood and albumen. A week later fresh hæmorrhages had occurred, and distinct neuritis had developed in the right eye, the left disc being normal. The patient died on May 4. The right middle cerebral artery was obstructed by a plug at its commencement. The corpus striatum (both parts) was destroyed by softening. Traces of slight old meningitis were apparent over both hemispheres. The spleen was full of infarcts. The kidneys were "large white," also with several small infarcts. There was extensive disease of the aortic orifice, with ulceration, and vegetations on the mitral valve.

REMARKS.—The condition of the discs greatest on the side of the cerebral lesion was an example of the rare condition of simple congestion, probably the result of the irritative changes in the right hemisphere of which the rapid wasting of the paralysed limbs was also evidence,



or of irritation communicated from the contiguous embolism. The subsequent retinal hæmorrhages were apparently unconnected with the cerebral lesion, and due to the blood state. They resembled those which have been found in malignant endocarditis much more than the hæmorrhages of renal disease. The occurrence, with them, of distinct neuritis on the side of the cerebral lesion is of great interest.

*CASE 26.—Very chronic optic neuritis; obscure cerebral symptoms; hypermetropia.*

Mrs. T., aged thirty-five, married, came under my care in 1875, at the National Hospital for the Paralysed and Epileptic, on account of attacks of headache, frontal and vertical, and vomiting, from which she had suffered for four years, having commenced three days after a confinement. The headache was often accompanied by violent sickness, which rather aggravated than relieved the pain. When first seen there were no symptoms indicative of local brain disease, but an ophthalmoscopic examination showed marked optic neuritis, equal in the two eyes. A careful drawing was made soon after she first came under treatment. The outline of the right disc was entirely concealed by a greyish swelling, of slight prominence, the peripheral part grey and striated, the central part redder and stippled. On the right side was an area much paler than the rest. The distension of the veins was slight, but most of them lost their central reflection as they curved down the sides of the swelling. The arteries were of nearly normal size. At the point of their emergence in the centre of the papillæ both veins and arteries were concealed, and one artery was surrounded by white tissue. One vein presented conspicuous antero-posterior curves beyond the edge of the swelling. Refraction; considerable hypermetropia; vision, each  $\frac{1}{12}$ . The pain was never excited by use of the eyes. The appearance of each disc was similar.

A year later (July, 1876) there was scarcely any change in the appearance of the discs. The swelling was, however, slighter, and the outline could be just perceived. The catamenia had become regular and the headache less, but attacks of "giddiness" occurred, two or three weekly; she would tremble and then see objects double, one image being above the other. On several occasions she felt weakness in the right arm, lasting only a few minutes; once accompanied by weakness in the right leg. At this time she was three months advanced in pregnancy, and she was not seen again until some time after her confinement. A week before confinement she had an attack of sickness and severe pain in the head, with weakness in both legs, so that she had to be lifted in and out of bed. This gradually lessened after her confinement so that in six weeks she could walk alone. She also gave an account of loss of sensation in the left arm and leg. When seen, however, in May, 1877, all these symptoms had passed away. In the right eye the disc had cleared but was still too red; there was no swelling and no striation; the outline could be seen all round but was not sharp on the inner side. The veins were still



a little tortuous. The left eye presented nearly the same appearances, and the tortuosity of the veins was still marked; the one especially forming a distinct corkscrew curve just beyond the edge of the disc. In November, 1877, the appearances were nearly the same: headache was rather more troublesome, but there were no fresh symptoms of intracranial disease. Since then the discs and symptoms are unchanged.

REMARKS.—The case may be grouped with Cases 24 and 25, as presenting very chronic optic neuritis, associated with vague cerebral symptoms, in themselves suggestive rather of "functional" than of "organic" disease. Here, as in Case 25, the existence of considerable hypermetropia raises the question of its possible joint dependence on the ocular and cerebral conditions.

CASE 27.—*Vague cerebral symptoms; headache and vomiting; photopsy; sudden amaurosis; double optic neuritis; death; no tumour but minute changes in brain.\** (Plate XV. Figs. 4, 5, 6, & 7.)

HENRIETTA S., aged thirty-four, gave a history of pain in the head for many years; no evidence of syphilis. After two miscarriages early in pregnancy, she had (aged thirty-three) an attack of severe vertigo, with momentary unconsciousness, followed by other similar attacks, and occasional vomiting. She also complained of "dark shadows coming over her eyes," and noises in her ears. At times she could scarcely see, and occasionally, while thus sightless, she had subjective impressions of light. Three months before admission, after an impression of brilliant light, her sight suddenly failed, and she became permanently blind. On admission there was no evidence of local brain disease, but marked double optic neuritis with great swelling, and extreme tortuosity of the veins. A few days later, an attack of very intense pain in the head came on, increasing, with frequent vomiting; her temperature was  $98.4^{\circ}$  to  $99.4^{\circ}$ . On January 10 her head was actually steaming, and from this time she gradually sank, becoming comatose, and dying on January 12, the general venous congestion before death being extreme. Dr. Sutton found at the autopsy no change in brain or membranes, except intense venous congestion, the condition of all the organs of the body. Microscopical examination showed distinct morbid changes. In the convolutions the spherical nuclear bodies were much more numerous than normal, and the pyramidal ganglion cells less so. In places nuclear bodies were surrounded by pale protoplasm, and in some spots were aggregated in groups, ten or twenty together, and then very little protoplasm could be seen around them. They were most abundant in the second and third layers of the convolution. The neuroglia was unduly granular, and in places apparently broken down.

The backs of the eyes were sent to me for examination, and their condition, after preservation in Müller's fluid, was as follows:—

*Eye 1.*—The optic nerve entrance is the seat of a swelling of moderate

---

\* In the London Hospital under the care of Dr. Hughlings Jackson; case published, "Oph. Hosp. Rep." viii. p. 445.



prominence, which extends on each side beyond the edge of the disc, and then gradually subsides to the retinal level. The subsidence is so gradual that it is difficult to measure its diameter; it probably is about the  $\frac{1}{10}$ th of an inch. There is a central depression with rather steep sides, the bottom of the depression being  $\frac{1}{50}$ th of an inch below the highest portion of the swelling. The greatest thickness of the latter is opposite the edge of the choroid, and there amounts to  $\frac{1}{25}$ th of an inch. The central vein and artery are both large, the vein especially; they show no trace of constriction in passing through the sclerotic ring (Fig. 5). They divide close to the bottom of the central pit. Soon after its division the branches of the vein show distinct narrowing within the substance of the swelling (Fig. 4). Section of the swelling shows that it is infiltrated with small round nucleus-like bodies,  $\frac{1}{6000}$  to  $\frac{1}{3000}$  inch in diameter, which are aggregated densely in the neighbourhood of the vessels. They are scattered among abundant delicate fibres of connective tissue, which compose the chief bulk of the swelling, and course in various directions. Numerous small vessels exist throughout its substance, and many of the connective-tissue fibres are arranged concentrically around these. Others are distinguishable only by their direction and wavy character from the nerve fibres, which may be traced uninterruptedly through the swelling.

The retina on each side is pushed away from its normal place of commencement, being  $\frac{1}{50}$ th of an inch on each side from the edge of the choroidal ring. For a little distance it is greatly thickened, measuring  $\frac{1}{40}$ th of an inch in thickness at its commencement. The increased thickness depends chiefly on thickening of the inner and outer nuclear layers, the molecular layers being much narrowed. The nuclear layers present only a dense aggregation of such round corpuscles as those already described, and which resemble those normally constituting these layers. The layer of nerve fibres is also thickened, and contains similar nuclei. The retina farther outwards gradually assumes perfectly normal characters.

The optic nerve contains many similar corpuscles, some aggregated along the vessels, others lying between the bundles of nerve fibres, others scattered through these bundles. They are more abundant just behind the sclerotic than farther back, but are at present in about equal numbers throughout the whole length of optic nerve received (Figs. 6 and 7). The section of the bundles shows a granular appearance, the nerve fibres being less distinct than usual, but there are no other evidences of degeneration. The amount of connective tissue between the bundles is not noticeably increased. That in the inter-vaginal space is, however, very abundant, the trabeculae being numerous and thick. There was no distension of the sheath.

*Eye No. 2.*—The appearances of this disc, retina, and optic nerve are essentially similar, except that the amount of swelling is rather less. The height of swelling above the level of the choroidal ring is  $\frac{1}{30}$ th of an inch on the side on which the swelling is greatest, and rather less on the opposite side. The commencement of the



retina is not displaced outwards so far as in the other eye. There is the same infiltration of the new connective-tissue and of the nerve-fibre layer with minute nuclei.

REMARKS.—The case is of great interest as a demonstration of the occurrence of optic neuritis in association with histological changes in the brain (chronic cerebritis?) very similar to those found in the trunks of the optic nerve, and which, in the latter, must be regarded as evidence of a "descending neuritis." The appearances during life were pronounced by a skilled ophthalmic surgeon (Mr. Couper), to be those of the "choked disc." The anatomical condition shows that the "choking" occurred in the substance of the inflamed papilla.

CASE 28.—*Lead poisoning; mental disturbance; double optic neuritis; recovery.\** (Pl. VII. Fig. 6.)

J. S., male, aged forty-five, employed occasionally in lead works for four years, but often not more than three days in a month. Three weeks before admission got regular daily employment at the works. Three months before admission had an attack of lead colic, during which he became "light-headed." He was ill seven weeks with the attack, and it left him very drowsy, so that he would fall asleep at his meals, when he came home at night, and sleep the whole evening and night. He went through his work mechanically; seemed quite an altered man after the attack. "Had not drunk a drop" for months, owing to his having a stricture. Three weeks before admission he commenced regular work, and continued at it until February 14, when he stayed at home on account of pain in the back; he had no vomiting or constipation. He went to work next day, but came home in the evening very ill. He had been vomiting all day, and the pain was so bad that he could not keep in any one position for more than a few minutes. On the following day, February 16, 1878, whilst at a chemist's, he was seized with a fit, and was brought home in a cab, quite unconscious of his surroundings, and talking incoherently. He was brought to the London Hospital the same day, and had a fit (according to account furnished, chiefly right-sided) on his way to the hospital.

On admission, he was semi-collapsed, and quite unconscious; he vomited frequently. He rallied after some hours and then talked incoherently. He was an anæmic, slightly wasted, but well-built man. His gums were very anæmic, and there was a well-marked blue line at their junction with the teeth. No disease in thorax or abdomen. Urine contained no albumen.

He had another fit the day following his admission, and again on the 25th and 28th. That of the 25th, watched by Dr. Newton, the assistant, was bilateral. His mental state was most peculiar. He was drowsy and indifferent usually, but when roused up would reply to

---

\* In the London Hospital under the care of Dr. Stephen Mackenzie, whom I have to thank for permission to see the case, and for the notes.



questions. He did not in the least know where he was. As I noted at the time, "his mental condition is like that of the jolly kind produced by alcohol. He is quite good tempered, and whilst he has most indistinct ideas as to where he is and about things in general, some of his replies have a repartee-like smartness."

Six days after admission an ophthalmoscopic examination was for the first time obtained, and then with difficulty. The discs were swollen, and had a translucent appearance as though oedematous; the margins were lost, and the surrounding retina infiltrated. No hæmorrhages were then seen. On the 25th the exudation into, and swelling of, the discs were greater, and a few hæmorrhages were seen at the margin of the discs. The arteries were now noted to be rather small, and the veins enlarged and tortuous. From this time till about the middle of April the discs remained much swollen and had a halo of flame-shaped hæmorrhages around the margins (Pl. VII. Fig. 6). The hæmorrhages in many cases were immediately upon or surrounding small vessels.

His vision, owing to his mental state, could not be accurately tested, but it was considerably impaired, and he seemed to have visual illusions.

Under the influence of iodide of potassium all his symptoms gradually passed off. He eventually completely regained his mental faculties, his sight improved, the hæmorrhages disappeared from his fundi oculorum, and the swelling of discs and retinæ greatly subsided, so that the margins of the discs could be seen, and the course of the vessels could be much more clearly traced.

I sent him to a convalescent institution for a month, and at the end of that time (May 31) he returned to show himself. I then noted—"No hæmorrhages visible in retinæ: swelling of discs quite subsided."

His urine was examined many times. The specific gravity varied from 1020 to 1025: the daily excretion of urea was natural. Albumen was never present.

*CASE 29.--Intense neuro-retinitis (idiopathic?) in chlorosis; recovery with damage to retina simulating albuminuric retinitis. (Pl. VIII. Figs. 1 & 2.)*

ELIZABETH B., aged eighteen, a pale, chlorotic looking girl. Family history irrelevant. No evidence of syphilis. For many years subject to headaches; health otherwise good. For three months (since a mental shock) occasional giddiness and morning sickness. On June 30, 1876, and for the next three days had constant nausea and frequent vomiting. Admitted into University College Hospital July 3. Before admission fundus oculi had been examined by Mr. Tweedy (who had been treating her for some defective accommodation) and found normal. Urine free from albumen. The sickness ceased in a day or two, but there was some faintness and giddiness. These lessened on rest, and the gastric symptoms disappeared. On July 14 she was discharged apparently well. On July 18 she applied again to Mr. Tweedy on account of considerable failure of sight, and he found intense optic neuritis. She was readmitted on July 21 under



my care. Each disc was concealed (as in Pl. VIII. 1) by a large pale swelling extending more than half way to the macula lutea, mottled with white and pink areas; a little redder where the vessels converged than elsewhere. The edge of the swelling steep. The veins were partly concealed in the surface of the swelling, but enormously distended. Several hæmorrhages in its margins. The right disc was concealed by a swelling of similar characters but of still larger dimensions, especially on the outer side, where it ended suddenly and steeply. Surface pinkish grey, mottled with whitish areas and small extravasations. Near its temporal margin, adjacent to the yellow spot, were many white flecks, resembling closely those found in albuminuric retinitis. V., R. No. 19 Jäger; field limited peripherally, especially upwards and inwards; loss of all colour vision except for red. L. No. 15 Jäger; loss of colour vision for yellow only—the others recognized at once. The headache was severe; referred to the vertex and back of the head. No vomiting. No motor or other nervous symptoms. Blood: no increase of pale corpuscles. Urine: still no albumen. Iodide of potassium was given. For a day or two there was a slight improvement in sight; ophthalmoscopic signs unchanged. July 26.—Vision, R.  $\frac{1}{8\frac{1}{2}}$ ; L.  $\frac{1}{6\frac{1}{2}}$  (Snellen). She recovered vision for blue and green with the right eye, that for yellow remaining lost.

On July 28 sight became much worse. R.  $\frac{1}{30}$ ; all perception of colour lost. Left  $\frac{1}{8\frac{1}{2}}$ , perception of green lost as well as yellow. Mercury was added to the iodide. July 29.—V., R.  $\frac{1}{30}$ ; L.  $\frac{1}{12}$ . July 30.—R.  $\frac{1}{60}$ ; L.  $\frac{1}{xx}$  (Snellen); condition of discs unchanged, but there were more hæmorrhages. August 4.—Right eye; inflamed area and distension of veins nearly the same. Arteries smaller; most were mere threads. Here and there the retina beyond presented a whitish reflection behind the vessels. Towards the edge of the swelling the opacity of the retina looked like a granular cloud, in some places striated. The sudden ending of the swelling towards the macula continued, and beyond it the white flecks were larger and stellate in arrangement. Vision qualitative only, R.  $\frac{1}{40}$ . On August 7 more extravasations were noted and greater concealment of veins. No improvement having taken place on iodide and mercury,  $\text{mxx}$ . doses of tincture of perchloride of iron were substituted. On August 9 vision had improved; L. V. =  $\frac{1}{20}$  (Snellen), and yellow, red, and green distinguished, but not blue. On August 11, L. V. =  $\frac{1}{15}$  (Snellen), and blue perceived in addition to the other colours. R. still qualitative vision only. No fresh hæmorrhages, and vessels rather more distinct.

From this date there was little change till August 21, when she complained of a constant light before her eyes and momentary attacks of darkness, and as these passed off she saw colours—blue, red, green, &c. Swelling of discs rather less, and in the right eye at the macula lutea the converging lines and spots more distinct, the edge of the swelling having receded to a group of hæmorrhages midway between the centre of the swelling and the macula, the intervening space having a dark granular look. To the nasal side greyish white lines and areas appeared,



considerably beyond the original limit of the swelling, and especially along the vessels and sometimes concealing them; soft-edged, some flocculent. Similar spots and areas in each eye. The large veins on the disc daily becoming more distinct.

On August 29 still further subsidence was noted. In the right eye the outline of the disc could be dimly seen, surrounded by a greyish-white area, ending, in some places, suddenly, in others, gradually, and from its margin whitish areas extended along the retina, especially upwards and inwards. The perimacular spots persisted; veins not more than half former size; arteries still small, but larger than before. Vision qualitative. Rather more swelling in left eye than in right, but disc visible. Beyond the steep outer edge was a little choroidal atrophy. Attacks of darkness less frequent, and no chromatopsy. The headache continued, and there was some deafness in the right side. Urine and temperature always normal. The iron was continued until she left the hospital, in the beginning of September; V.  $\frac{1}{64}$  L.

September 15.—Much frontal headache continues, more on the right side than on the left. Hearing: R.  $\frac{1}{2}$ , L. normal. Right eye (Pl. VIII. 2): outline of disc soft; nowhere any indication of sclerotic ring; still slight prominence; arteries and veins both small; an artery passing upwards, still a mere thread; around the disc the retina has a grey tint, and several veins are lost to view for a short distance; the scattered pale areas and perimacular flecks continue, and above this group are many other spots, somewhat soft and apparently behind the vessels; vision 0. Left fundus similar in chief features; V.  $\frac{1}{19}$  Jäger, considerable concentric limitation of field.

October 10.—Headache continues; some superficial tenderness at the back of the head; no sickness. Vision: Left, same; all colours recognized except green. Retinal changes less. Right optic disc clear, but edges still not sharp; disc dull-white, with "filled-in" look and distinctly prominent. Vessels same as in last note; greyish granular look around the disc, most marked on outer side, where the appearance is of a stippling of white and red. Vessels in this part all accompanied by whitish lines. Further out the white spots are less numerous, but still very distinct in all directions. Some pale lines ramify, as if marking the position of large choroidal vessels. The group of rods and spots radiating from the macula lutea is still very conspicuous. Qualitative perception of light in a small part of outer half of field. Left eye: appearance similar; the ramifying pale lines even more distinct than in the other eye. V. same; all colours recognized except green. October 25.—More pain in head (severe catarrh). Discs clear, even sharper. The irregular white patches are resolving themselves into white dots and granules. Sight same. November 14.—Less headache of late. Outlines of discs sharp, but "filled-in" look persists; appearances otherwise the same.

During the next two months the headache continued, and there was little change in vision. On January 8, 1876, many of the white spots had disappeared, but the larger remained, and those around the macula



had undergone little change; the vessels still very small, and distinctly smaller in the right eye than in the left. On February 20 the discs were noted to be becoming grey—the sclerotic ring could just be seen; the white spots still visible, and the vessels near the disc were still accompanied by white lines. April 10.—Less pain in head. Right eye, no improvement in sight; left, No. 18 Jäger. Right disc greyer than left; white spots much less numerous, chiefly about the macula.

Throughout the summer the pain in the head continued. No objective nervous symptom presented itself; vision remained just the same. Slight divergent strabismus came on, apparently due to the blindness of the right eye; no paralysis of movement. On December 21 the edges of the right disc were a little uneven, with some irregular pigmentation. The white spots around the macula had disappeared, but there were two white lines between it and the disc, parallel to the edge of the disc. The left disc was less white and presented no pigment. Vision, R. 0.; left, No. 19 Jäger. The patient was seen again at intervals during the next six months, but presented no change. At no time was there any definite symptom of central nervous disease, and at no time the faintest trace of albumen in the urine.

REMARKS.—This case must be called neuro-retinitis, but the retinal affection was secondary to that of the papilla. There was no general retinitis. The entire absence of any symptoms of brain disease seems in such a case, observed during so long a time, to afford grounds for excluding its existence, especially when the degree and rapidity of the intra-ocular changes are taken into consideration. The latter differed from the neuritis of intra-cranial disease in its degree, in the wide extent of parenchymatous retinal changes, and also in its extremely rapid, almost *foudroyant*, course.

No evidence to justify an association with syphilis could be obtained, and the failure of anti-syphilitic treatment was conspicuous. The case must apparently be regarded as one of idiopathic neuro-retinitis occurring in a chlorotic girl. It is interesting in a medical aspect chiefly in the contrast which it presents to the characters of neuritis from intra-cranial disease. The nearest approach to it which I have seen from cerebral affection is the condition shown in Pl. VI. Fig. 1, but the lateral extent of the neuritis, and the amount of parenchymatous retinal change, are far less. The case is also of great interest on account of the resemblance of the results of the retinal change to the aspect of the fundus in albuminuric retinitis. The white spots often seen in the adjacent retina in subsiding neuritis, such as are shown in Pl. VI. Fig. 3, and which sometimes puzzle the observer, are here grouped just as in the nephritic form, while the diffuse change increased the resemblance. The distinctions depend on the granular aspect of the diffuse pallor, on the absence of hæmorrhages such as are so common in the renal change, and especially on the distinct evidence the disc presents of a recent intense inflammation.



CASE 30.—*Sudden cerebral lesion causing left hemiplegia, and persistent loss of sight of the left eye, and of the left half of the right field.\** (Pl. II. Fig. 5.)

HENRY C. B., aged fourteen, at eight years old fell off a wall and fractured his skull. The accident was followed by delirium, but no convulsions. Three months afterwards, at St. Bartholomew's Hospital, a piece of depressed bone was raised by Sir James Paget. (There is now a soft depression in the upper part of the right side of the frontal bone, close to the coronal suture, an inch in diameter.) He returned home apparently well, but suddenly, a year after the accident, he had a fit after which the left side became paralysed and the left eye blind. The fits recurred frequently, and have continued ever since.

*State on admission.*—An intelligent but mischievous boy. The left leg is not strong, but he can walk well. The left arm is much weaker than the leg. It can be moved freely but with little power. The limb is much thinner than the other. When his attention is not directed to it, the hand is still; hanging by his side. When any attempt is made to move it, or even his attention directed to it, involuntary spasm comes on in it, the wrist being over-extended, the fingers flexed at the metacarpo-phalangeal, extended at the other joints (interosseal position), and the thumb being pressed against the first finger. Occasionally, even when in spasm, the distal joints of the fingers are flexed. There is no rigidity of the arm, and no weakness of the face or tongue.

*Eyes.*—Left pupil dilated; reacting very slightly to light. Very slight perception of light. Optic disc, greyish atrophy with normal vessels, having the appearance of simple atrophy (see Pl. II. Fig. 5, and description). Right eye: loss of left half of field of vision, as in the diagram (Fig. 13, p. 59); disc pale; only the inner segment reddish, the outer being pale, but not nearly so grey as the other eye. No apparent "filling up" of the disc. Choroid a little disturbed near the edge.

REMARKS.—The interest in this case arises from the circumstance that a sudden cerebral lesion caused the left hemiplegia and the peculiar affection of vision. There was no appearance of previous neuritis, and the suddenness of the loss of sight (synchronous with the paralysis) and the hemiopic defect in the right eye, both point to the probable cause being cerebral lesion. The only theory on which the affection of sight can be explained is that of Charcot, which supposes the hemi-decussation in the chiasma to be supplemented by another farther back, so that each eye becomes represented in the opposite hemisphere, although only half of each eye is represented in each optic tract. Charcot's theory is still a hypothesis only, but it is noteworthy that on this theory a lesion about the right corpora geniculata, so extensive as to destroy the fibres which come from the right optic tract (and the right halves of each retina=left halves of the fields) and also to

\* Published in a paper on "Athetosis," "Med.-Chir. Trans." vol. lix.



destroy the decussating fibres supposed to come by the corpora quadrigemina from the left optic tract, would give precisely the condition present in this case, the only optic fibres undestroyed being those from the inner half of the right retina (outer half of field) which pass by the left optic tract to the left hemisphere. It is almost impossible to conceive that the affection of sight could have resulted from damage to the chiasma, since a lesion there, which destroyed all the fibres of the left optic nerve and damaged one half of the right, would affect the inner half of the nerve and therefore the nasal half of the retina and the temporal half of the field, *i.e.*, that half which in the patient was unaffected. Moreover, damage in such a situation would not explain the cerebral symptom. A lesion so placed as to explain these (probably involving, or beneath, the lower part of the parietal lobe and angular gyrus) could hardly be the direct effect of the injury which occurred some time previously, but must have resulted from some secondary changes set up by the accident. (Compare Case 4.)

CASE 31.—*Right facial paralysis; afterwards paralysis of the left optic and motor nerves of orbit; slow grey atrophy of left optic disc.* (Pl. II. Fig. 3.)

HARRIET S., married, aged fifty-nine, came under my care at the National Hospital for Paralysis and Epilepsy, in March, 1874, for facial palsy. There was no family history of neuroses or personal history of syphilis, except that one child had been born dead at the full time without any known cause for its death. She suffered much from rheumatism, apparently due to living in a damp locality—not, as afterwards appeared, capable of being improved by anti-syphilitic remedies. Much neuralgia in right side of face for three winters. The facial paralysis came on after exposure to a draught. It had the ordinary characters of rheumatic facial paralysis from pressure on the nerve, severe in degree, with degenerative reaction in nerve and muscle.

A year and a half later, after exposure to cold, she suddenly had severe pain about the left frontal and temporal region, followed, in a few days, by loss of sight of the left eye, and complete paralysis of all the muscles of the left orbit; ptosis, immovable eye, and moderately dilated pupil. She was admitted into the hospital and treated by blistering, iodide of potassium, and sulphide of potassium. The power over the orbital muscles gradually returned, but in spite of all treatment, not even perception of light was regained in the eye. The optic disc was at first well coloured and similar to the other, both being much more deeply tinted than the average. The disc was frequently examined but never presented any trace of inflammation. Three months later, July, 1875, the right disc had a deep central cup in which, however, the lamina cribrosa could not be seen. The outline was normal, sharp, with a very distinct sclerotic ring, the surface fully tinted, the veins rather large, but the arteries of moderate size. Vision: presbyopia; reads  $5\frac{1}{2}$  Snellen with convex glasses (+ 12). The left disc was still red, but a little greyer



than the right, with a large central cup, at the bottom of which the lamina cribrosa was distinct. The veins and arteries were the same size as the other eye. In August this disc had become considerably greyer than the other, the cup deep, but the vessels presented little change. In the following October she was much troubled with neuralgia in the left temple. The ocular movements remained uniform. The sight and appearance of the right eye were the same. In the left eye the reddish-grey of the disc was replaced by a bluish-grey tint. The sclerotic ring was rather more distinct than in the other eye, the arteries very slightly smaller; the veins of normal size.

In 1876 she had much general rheumatic pain and also swelling of some of the joints. In August both optic discs had the same appearance as above described; in the left the grey tint of the outer portion of the disc had a granular look and passed gradually at the slope of the cup, into the grey mottling of the lamina cribrosa (Pl. II. Fig. 3). Throughout the following winter there was still much neuralgia. In May, 1876, the left eye commonly diverged a little from the other, although its movements were normal. The optic disc was in precisely the same condition. The slightest possible quantitative perception of light had been regained. The only fresh symptom was an occasional attack of cramp in the right side of the neck and right side of the tongue. She was again seen in February, 1877, but her state was unchanged except for some rheumatic thickening in the metacarpal joints of the left hand.

REMARKS.—The paralysis of several cranial nerves is rare, except as the result of syphilis, but is sometimes due to "rheumatic" inflammation. Here the evidence of syphilis was not strong and specific treatment had no effect on the paralysis of the optic nerve. On the other hand, the evidences of rheumatism were very marked and persistent, and suggested simple and not syphilitic rheumatism. But whatever may have been the pathological nature of its cause, the loss of sight of the left eye was almost certainly due to a lesion at the back of the orbit, involving all the motor nerves of the orbit and the optic nerve, diminishing, and allowing the motor nerves to recover, while the optic nerve remained permanently damaged, either because its fibres were less capable of recovering from a given damage, or because the constriction of the nerve at the optic foramen by the bony ring, rendered the damage to it from a rheumatic swelling around it more considerable, just as the facial nerve so often suffers gravely because its narrow canal exposes it to dangerous pressure from slight perineural effusion.

The course of the affection shows that the nerve may undergo atrophy, from a post-ocular pressure, slowly, without any trace of neuritis, and that the aspect of such atrophy may be indistinguishable from that of spinal disease. The extremely grey tint is perhaps to be associated with the considerable vascularity of the disc which was the normal condition in this patient.



CASE 32.—*Grey atrophy of right optic nerve after a fall on right side of head; unusual affection of colour vision.*

Mr. C., a farmer, aged forty-six, eight months before being seen, had a heavy fall when riding at a gate, was stunned for some hours, and then had great pain in the head. His face became swollen, and when the swelling subsided he found that he could not see with the right eye. He had great pain in the right shoulder, and when this subsided he found that he could not move the right arm. When seen he had evidently injured the circumflex nerves; the deltoid, supra-spinatus, and infra-spinatus, being powerless and wasted, without a trace of faradaic or voltaic irritability. The left optic disc was normal, but full-coloured. Vision normal. Right optic disc grey, with a faint red tint; excavation deep; lamina cribrosa conspicuous; edge not quite regular, with a little pigmentation; outer half of disc much paler than inner half. Vessels small; veins not more than two-thirds the size of those of the other eye, but arteries still smaller, only half the size of the narrowed veins. V.  $\frac{1}{18}$ ; no colours recognized, except green indistinctly. Field, defect below, but not much limitation in other directions. During the summer, vision improved to  $\frac{1}{12}$ . Six months later there was a slight trace of reaction to be obtained in the paralysed muscles (voltaism having been regularly applied). A year and a half after the accident, vision of left eye had improved to  $\frac{1}{6}$ ; green and brown instantly recognized; blue (every shade) always called green (though recognized instantly with left eye); red recognized in large objects, not in small. Ophthalmoscopic appearances unchanged, except that the red tint is scarcely visible, only the grey being present. Six months later, optic disc same, but vision =  $\frac{2}{9}$  occasionally—"in flashes and gone again."

REMARKS.—The loss of sight was clearly the result of injury to the optic nerve, whether direct or by orbital inflammation there was no evidence to show. The narrowing of vessels without signs of inflammation in the disc suggests retro-ocular neuritis. The form of affection of colour-vision is another instance of the irregularity of the loss which occurs in inflammatory affections in comparison with that which accompanies primary atrophy.

CASE 33.—*Atrophy of optic nerves in early stage of locomotor ataxy.*

JAMES C., aged forty-three, a gasfitter, admitted into the ophthalmic ward in University College Hospital, by Mr. Wharton Jones, who afterwards kindly transferred him to my care. Family history of epilepsy. At seventeen years of age a slight venereal sore, not followed by constitutional symptoms. A year before admission, patient's sight began to fail rapidly. In about six months he had become quite blind, and on admission he could not perceive light in either eye. On examination grey atrophy of both optic discs was found, the vessels being of good size, the disc hollow, its surface mottled with grey. No nervous symptoms were obtrusive; the patient walked about the wards without



more difficulty than a blind person usually manifests. But closer questioning and examination revealed very distinct ataxic symptoms. He had slight paralysis of the left third nerve; the eyelid was lower than the right, and the internal rectus was weak. There was also slight weakness of the right superior rectus. In walking, he raised the feet a little higher, and brought them down a little more suddenly than natural. Sensation to touch and pain were normal in degree, but sensation of heat was distinctly interfered with; he thought that hot bottles were cold and cold bottles applied to the feet were hot. He had occasional "tearing" pain in his legs, coming on suddenly, lasting a minute or two, and making him feel as though he could not stand, and these pains had been felt occasionally for five years. He also had occasional sudden, brief, sensations of coldness and weight on the legs. Sexual power and desire lessened and disappeared a little before the commencement of the ocular trouble. (The state of his patellar tendon reflex was not noted.)

REMARKS.—His condition was clearly that of the early stage of locomotor ataxy with early and disproportionate affection of the optic nerves.

CASE 34.—*Repeated transient attacks of amblyopia, followed by optic nerve atrophy; weakness in legs of similar mode of onset (lateral sclerosis?)*

THOMAS A., aged forty-five, married. No distinct history of syphilis, but at 31 he had a sore on the penis, followed by a suppurating bubo. At 36 the sight of the right eye failed, but recovered under treatment, at Moorfields. Two years later it failed again and recovered a second time, so that he could read the smallest print with it. A year and a half ago (aged 43), it again failed, and did not subsequently improve: soon afterwards the sight of the left eye became impaired, in consequence, he maintained, of the instillation of atropine. At 41 the left leg gradually became weak, and recovered after a few months. At 42 the right leg became "shaky" and then improved. The weakness returned, a year later, at 43, and again, a year ago, at 44. During the last nine months both legs had been getting weak.

When seen, in November, 1876 (having been formerly under my care and sent back to me by Mr. Nettleship), the arms were strong, but the grasp a little shaky. He could walk, but not far. Resistance to passive movements of the legs fairly strong. Some difficulty in co-ordinating movements—unable to stand with feet close together. Closure of eyes made a little, but not much, difference. No defective sensation to touch, but slight defect in each leg to pain. Marked excess of reflex action; tickling or pricking either sole causes an attack of clonic spasm in the leg—about half a dozen jerks. Knee-reflex excessive in each leg; ankle-clonus can be obtained, but is brief, soon ceasing. No defective power over sphincters. Iodide of potassium and calabar bean were given, and two months later he could stand with the feet close together, and eyes shut. Sight and optic discs about the same.

REMARKS.—The symptoms were those of "lateral sclerosis" of the



cord, with a slight degree of posterior sclerosis. The occurrence of atrophy of the optic nerves in association with lateral sclerosis, is rare. In this case the failure of sight and the leg weakness corresponded, in a remarkable manner, in their mode of onset; several attacks, with recovery, preceding the permanent condition.

CASE 34a.—*Disseminated sclerosis; atrophy of optic nerves.\**

MARIA R., aged twenty, general servant. Mother, and mother's father and sister all suffered from epilepsy. The patient was never very bright or strong. In March, 1876, catamenia ceased, and it was noticed that she often dropped objects, and staggered occasionally, and that her speech was thick. She complained of giddiness; these symptoms were slight at first, and gradually increased. In January, 1878, she was an in-patient at the National Hospital for the Paralysed and Epileptic, with weakness in the legs, unsteadiness of gait, some coarse tremor of limbs on movement, and some mental weakness. These rapidly increased for some weeks, and then lessened. She improved very much in May, at the country branch of the hospital, at Finchley. From June to December, 1878, she steadily got worse.

Readmitted, April 1, 1879 (under the care of Dr. Radcliffe). A dull, apathetic girl, taking little interest in things, but often answering sharply. Memory and intellect generally very deficient; will sit over a book all day long without turning a page. Nevertheless, answers questions accurately and with fair readiness. No delusions. She generally sits with head bent forward, and when it is at rest it is perfectly still. If she moves her head in any way, as long as the muscular action continues, there is slight irregular shaking of the head. When she opens her mouth, there is tremor of the lower jaw, and the masseters can be felt vibrating. The tongue is protruded with a slight jerk, and is tremulous, the tremor being due to the genio-glossus and to the intrinsic muscles. When looking straight before her, the eyeballs are still; if she looks up or down there is slight nystagmus, and if she looks to right or left, this becomes considerable. Articulation is distinct, but syllabic and jerking. Her arms are perfectly still when at rest, but every movement is accompanied by coarse tremor, not, however, sufficient to prevent her from slowly feeding herself. Power deficient; grasp, R. 22 kilogrammes; L. 24 kilogrammes. Legs, moderate power—can just stand alone; when at rest, they are still; when moved they are the seat of jerking tremor, and the movements are irregular when she stands; the jerking tremor involves all the muscles of the legs and the whole body jerks. Knee reflex excessive; no ankle-clonus.

Sensation in limbs normal. Special senses intact, except sight. Pupils equal; medium size. Both eyes slightly myopic (2.5 dioptries). Left optic disc, outline clear; temporal half, fairly rosy tint—perhaps

---

\* Reported by Mr. A. E. Broster.



a little paler than normal, nasal half uniformly grey. Vision,  $\frac{1}{3}$ ; colour vision, normal. Right eye: disc clear, outline a little irregular; whole disc grey, no rosy tint in any part; central cup large and deep; vessels normal. Vision,  $\frac{1}{10}$ . Colours recognized accurately, except green, which is called red or brown. She confuses grey with green in Holmgren Test I., but matches the strongly marked greens very well. But when asked what colour it is, she calls the light green yellow, and the dark green brown or red. But with the left eye she at once names the greens quite accurately.

CASE 35. — *Acute tuberculosis; tubercles of choroid.\** (Pl. XIII. Figs. 1, 2, & 3).

The patient was a girl, aged seven years, who died a few hours after admission into the Children's Hospital. The child's mother and mother's father had died of phthisis. There was a history of cough for some years, and of fever, delirium, and headache for a fortnight, without diarrhœa. When admitted the child was prostrate, with a temperature of  $101^{\circ}$ , furred tongue, offensive breath; no abdominal symptoms, or eruption; mucous and sonorous râles throughout the lungs, but not enough to account for the considerable dyspnœa which was present. No strabismus; very active delirium, getting up and tearing screen with mouth, saying she saw cats. Subsequently, left-sided convulsions came on and continued until death. The urine contained a trace of albumen, and gave a marked indican reaction. Ophthalmoscopic examination difficult: discs quite normal, but in right fundus, internal to the optic nerve, a shining white defined patch was noted, with some pigment in the margin.

At the autopsy the lungs were crammed with small grey tubercles, and tubercles were abundant in liver, spleen, and kidneys, and there was one tubercular ulcer in the intestine. In the brain, in the convexity, were three caseous tubercles. The convolutions were not flattened; the veins of pia mater contained a medium amount of blood; the longitudinal sinus contained no blood, and was not compressed. At the base there were tubercles and lymph in the right Sylvian fissure; slight excess of subarachnoid fluid, but no excess in the ventricles. No lymph or evidence of inflammation about the optic nerves or commissure. The choroid of each eye contained near the centre of the globe several round white prominent bodies; some just visible, one or two the size of a pin-head. (See Pl. XIII. and description).

CASE 36. — *Bright's disease; epilepsy; mental derangement; optic neuritis, with commencing retinal changes.†* (Pl. IX. Fig. 2.)

WILLIAM H., aged fifty-one, a plumber, admitted into the National Hospital for the Paralysed and Epileptic, under my care, May 17, 1878,

\* For the specimens and history of this case I am indebted to my friend Dr. Garlick.

† Reported by Mr. A. E. Broster.



suffering from convulsive attacks of six months duration. His father had suffered from chorea and fits. He had never had lead colic or wrist-drop, and his gums presented no lead line, but he had had several attacks of gout during the preceding four years. Fourteen years before he had had dropsy for six months, coming on without apparent cause, and not recurring. His urine on admission had a specific gravity of 1012, contained one-half albumen and very granular casts, medium and large. There was no cardiac murmur, but evidence of considerable hypertrophy and dilatation of the left ventricle. Pulse full and strong and incompressible; no sign of uræmia.

The convulsive attacks had occurred at intervals of a week. After admission they commenced by the head turning to the left, the movement being slow and not uncontrollable. Then he went on his knees and exclaimed, "Oh dear, I am falling," although he was being held up at the time. He looked frightened, and then lost consciousness. There was jerking of the left arm (beginning, the attendant thought, in the shoulder), and of both legs; the pupils were dilated, the lips livid, and his tongue was bitten. The jerking lasted  $3\frac{1}{2}$  minutes and then he began to breathe heavily, his pulse became quickened, and he went to sleep. On waking he seemed to have forgotten everything. His bowels acted after each fit. Urine passed immediately after the fit had a specific gravity of 1005 and contained the same amount of albumen ( $\frac{1}{2}$ ). All the attacks were similar, but in some there was distinct jerking in the left side of the face, and in some, at the commencement of the jerking in the left side, he gave a sudden start to the left so strong as to throw himself out of bed on to the floor.

Ophthalmoscopic examination (Plate IX. Fig. 2).—Optic neuritis present in each eye. The arteries of the retina small; not more than one-third the size of the corresponding veins. In the right eye the swelling of the papilla was considerable, edges of the disc quite concealed, the surface of the swelling mottled with numerous dark vessels, more being conspicuous than is common in optic neuritis. All the central vessels were visible on the swelling. Small irregular white areas could be seen on the surface of the swelling, ill-defined. Another, below, extended on to the retina, and two others were situated in the retina above and to the inner side of the disc. There was not a trace of any perimacular circle. The other disc presented similar appearances. Vision: each eye could read only No. 12 Jäger.

About a week after admission he began to manifest evidence of mental derangement, often sitting in a reverie for a long time, and micturating into whatever vessel was near at hand, and on to the floor if none was accessible. He often sat doing imaginary work with his hands. On June 21 the white spots were increasing in size, so that in the right eye one which occupied the middle of the papilla had extended over the whole lower and inner quadrant. At a little distance from the disc was a small hæmorrhage.

After this date his habits became so filthy and demoralized that he had



to be discharged. He died three days after his discharge, but no post-mortem was obtained.

REMARKS.—The case presents a good example of the cerebral disturbance which may result from renal disease. The convulsions may be thought to have been due to a local cerebral lesion, but I have met with many instances in which epilepsy, apparently due neither to local brain disease, nor to ordinary uræmia, occurred in cases of chronic Bright's disease. In several other cases also a similar cerebral disturbance has come on. Both fits and mental derangement were probably due to the influence of the changed blood on the brain, and the association of neuritis albuminurica with these symptoms is of great interest. The retinal affection was apparently in its earliest stage, and the neuritis was probably the result of a double cause—the effect of the blood state, and of the cerebral irritation, of which it was in part the consequence and the sign.

CASE 37.—*Albuminuric neuritis; small arteries; cerebral symptoms; death from uræmia.* (Pl. IX. 3.)

EDWARD K., a plumber, aged thirty-four. Father also a plumber and gouty. Patient had had symptoms of lead poisoning some years before. When seen (February, 1878) there was no line on his gums. During the last four or five years he had had several attacks of gout. For four years much occipital headache, increased by stimulants. Urine pale; low specific gravity; moderate quantity of albumen. Pulse small, very incompressible. Distinct hypertrophy of heart. Ophthalmoscopic examination.—Right eye: disc concealed by a swelling of moderate prominence, striated and red, the tint being almost that of the choroid; edge very soft; no white spots on surface. Between the papilla and the macula lutea is a pale area like a film in the retina, and below this a few minute white spots. The veins are scarcely larger than natural, curve over the swelling, and are for the most part obscured or lost beyond its edge, and one or two present a second curve a little distance from the edge. The arteries on the disc can be seen, and are small, but not out of proportion to the veins. At the edge of the swelling they are lost, and no trace of them can be seen beyond on the fundus on the most careful search in the upright image. One hæmorrhage exists below the disc. The right disc (Pl. IX. 3) presents a similar condition, the swelling being a little paler, and above the swelling is a diffuse pallor ending suddenly a short distance beyond the edge. The veins are of the same size as in the other eye, concealed, in places, on the disc and beyond its edge. Two arteries can be followed beyond the edge of the papilla, and are seen to become greatly contracted immediately after leaving the disc (although of nearly normal size upon it), that they are seen only as fine lines upon the retina. Two other arteries, distinct on the papilla, cannot be seen on the fundus. There are no hæmorrhages, but similar white spots exist between the disc and the macula. Vision, right eye, No. 6; left, No. 5, Jäger. The patient returned to Rugby, and was under the care of Dr. Clement Dukes, who



has kindly informed me, that immediately after his return, he became ill, with uræmic twitching, both during sleeping and waking. He then suffered from temporary paralysis; one arm, or one arm and leg, would become "numb" and almost powerless for hours, and then suddenly become right again. He died a few weeks later, with many uræmic convulsions during the last week of life. His urine was always pale; the quantity averaged five pints, sometimes it contained only a trace of albumen, at other times it was loaded. It contained large and small granular casts in great numbers and some hyaline casts.

REMARKS.—The case illustrates the coincidence of optic neuritis and cerebral symptoms, both due to renal disease; a combination which may prove a ready source of error in diagnosis (see p. 80). The patient was sent to me, because his intense headache suggested intra-cranial disease, a suspicion which the neuritis at first sight seemed to confirm. The case is an illustration of a combination of hereditary influences, not very rarely met with, in which a father suffers from lead poisoning and gout, and probably transmits to his son a tendency to the latter and the conditions for the origin of the former. In such cases the constitutional results of the saturnine gout are very early developed.

CASE 38.—*Renal epilepsy; headache; albuminuric neuritis, disappearing under treatment.*

M. P., a man, aged forty-five. Syphilis at twenty-five. At forty-one, popliteal aneurism, for which leg was amputated. Severe frontal headache, five months before he was first seen. First fit two months after the headache commenced; eight fits occurred during the next two months without warning, with loss of consciousness. Albuminuria and signs of chronic Bright's disease.

Optic discs: outlines indistinct; striated; arteries extremely small. Right, considerable swelling; outline of disc concealed; veins full, curving over the prominence. No extravasation or white spots in either eye. Sight, R.  $\frac{1}{8}$ , L.  $\frac{1}{4}$ ; fields normal. Treatment: purgatives and Turkish baths. After four months he left the hospital free from fits and discs normal.

CASE 39.—*Acute renal retinitis, fourteen years after acute Bright's disease; death; necropsy; microscopical examination of the retina.* (Pl. X. Fig. 1, XVI. 7—10.)

JOHN V., a carman, aged twenty-one, came under my care at University College Hospital, February 28, 1876. At seven years of age he had an attack of some fever, followed by dropsy. Since then his health had been pretty good. He had a venereal sore at nineteen, probably a soft chancre.

At fifteen, severe pain in the front of the head and in the back, and noticed that his urine at the time was very dark in colour. No œdema. This headache recurred from time to time. For a fortnight before admission, his sight had been failing.



There was slight general œdema. Headache, from forehead to occiput, constant. Urine: specific gravity 1012;  $\frac{1}{4}$  to  $\frac{1}{3}$  albumen; a little blood; many casts, straight and convoluted. *Ophthalmoscopic Examination* (Pl. X. 1).—Both optic discs concealed under a whitish opaque area, this position being just perceptible. Swelling moderate, and the opacity slighter over the disc than just outside it. The white patches, in average size about half a disc's area, greyish-white in tint, were scattered pretty equally around the disc, through the posterior segment of the retina. Numerous hæmorrhages existed outside the limits of the papillary area, for the most part linear, or the lines group into oblong or triangular masses—the direction of the lines of hæmorrhage being that of the nerve fibres. Over the discs the arteries and veins were quite distinct and of normal size. Most of the veins, a short distance from the disc, were concealed either by opacity or hæmorrhages; farther on they were as distinct as before, with slightly diminished calibre; they could be traced to the farthest part of the retina. Every artery was lost to sight about the normal edge of the disc or beyond it—near the outer part of the pale papillary area. A careful examination showed one or two of the arteries as single lines extending along the retina, but others could not be seen at all beyond the papilla. Field of vision, normal. Vision: R.  $\frac{1}{18}$ ; L.  $\frac{1}{12}$ . Colour-vision normal, except that with the right eye yellow was not recognized as such.

On April 29 the patient was admitted under the care of Dr. Wilson Fox. On March 2 the œdema had much increased, and he had vomited twice. *Ophthalmoscopic Examination*.—Left eye nearly the same. Right eye a marked change. The white opacity noted around the disc had extended over a much larger area, veiling the choroidal tint in the posterior portion of the eyeball, and on the diffuse white opacity the smaller patches stood out with shining whiteness. The hæmorrhages were much larger and more numerous. There was more papillary swelling, the veins presenting tortuosities, curving and disappearing more than before. In the centre, over the disc, the vessels were all clear, but decidedly smaller; arteries and veins being narrower than when the sketch was made. Both arteries and veins had a very white central reflection. The veins were a little larger beyond the disc than over it. The arteries, as before, were lost to view beyond the swelling; in the centre of the disc they were distinct, and only a little smaller than normal, but beyond the disc only one or two could be seen as single lines.

Little change occurred in the patient's state during the next few days. The vomiting continued in spite of treatment. On March 10 he insisted on leaving the hospital. Soon after reaching home he became comatose, ceased to pass urine, and died in two days.

A post-mortem was kindly made for me by Dr. S. H. Burton. The kidneys were small and granular; the capsule thickened; weight, right  $4\frac{1}{2}$ -oz., left  $3\frac{1}{2}$ -oz. The granulations were opaque and yellowish, separated by red depressions, and a similar mottling of yellow opaque



areas and red interstices was seen on section. The cortex was much narrowed, varying from  $\frac{1}{4}$  to  $\frac{1}{8}$  inch in thickness. The heart was considerably hypertrophied, the left ventricle firmly contracted; the thickness of its wall being, after relaxation,  $\frac{5}{8}$  inch, and the septum  $\frac{3}{4}$  inch in thickness. The valves were healthy.

An examination of the eyes was made in the recent state. Left retina, viewed with the naked eye, presented many white spots and diffuse opacity in an area, about half an inch in diameter, around the optic disc. Elsewhere, in the peripheral parts, no abnormality could be seen. A diffused reddish tint in places indicated the position of the hæmorrhages. Under the microscope the structure of the peripheral part of the retina appeared normal. The white spots appeared to be made up of large spherules with a distinct wall, distended with fat globules (Pl. XVI. Fig. 8), and similar minute globules, and highly refracting granules lay amongst the retinal elements. Many fine fibres were seen (probably fibres of Müller) containing rows of fat globules similar to those which were free (Fig. 7), and in places the fibres were swollen, and at the swellings were groups of four or five globules. The vessels presented little degeneration of their walls. One or two presented slight granular degeneration; most were healthy. Here and there were aggregations of brownish pigment granules massed irregularly and apparently the result of degeneration of extravasated blood. They were chiefly in the nerve-fibre layer. This layer was slightly thickened, and the fibres were granular. The thickening depended upon irregular swellings of the nerve fibres, in places reaching  $\frac{1}{200}$  inch in diameter. The fibres in places were matted together into dense, faggot-like masses. The nuclear layers were greatly thickened. In some places spherical aggregations of fat globules lay beneath the inner nuclear layer. The appearances in the right eye were similar.

After hardening in Müller's fluid, and staining with logwood, sections (kindly prepared by Mr. V. A. Horsley) showed in the peripheral parts little change, the only alteration (Pl. XVI. 9) being one which seemed to show slight general retinal œdema. In places the nerve-fibre layer presented small spaces among the fibres (see description of Pl. XVI.). The perivascular sheaths of the vessels were large, and had the appearance of having been distended.

In the neighbourhood of the disc (in the part of the retina shown in Pl. X. Fig. 1) the changes were much greater (Pl. XVI. 10). The fibres of the nerve-fibre layer were separated by clear spaces, and among them were many large nuclear bodies, and large spherical and oval bodies, some granular, others apparently homogeneous, but no doubt "compound granule corpuscles" rendered homogeneous by the clearing agents. These were, in some places (probably at the white spots shown in Pl. X.), aggregated so densely on the superficial part of the nerve-fibre layer as to render it almost equal to the normal thickness of the retina. In other parts the "membrana limitans interna" was separated from the rest of the layer by a thick "effusion" in which no cells were



visible, but the hardening agents had produced an appearance of a network of fine interlacing fibrils with granules at their points of intersection. Through this effusion the fibres of Müller passed, widening out at their inner ends. The capillaries of the nerve-fibre layer were everywhere conspicuous, and in places bulged out into minute aneurismal dilatations, with increase of the nuclei upon them. The ganglion-cell layer presented wide spaces, and many nuclear bodies; few ganglion cells could be recognized. Between this and the next layer was in many places a thin reddish-brown irregular lamina, probably the result of hæmorrhage, although no remains of blood corpuscles could be perceived in it. The inner molecular layer was nearly normal but irregular. The inner nuclear layer was very irregular. The outer molecular layer was greatly widened, and irregular bands of vertical fibres were conspicuous, and the intervals between them were occupied by a fibrillated and granular effusion similar to that just described within the nerve-fibre layer. The outer nuclear layer was nearly normal but somewhat irregular. The layer of rods and cones was in this region greatly thickened and altered, presenting a fine vertical fibrillation. In many places the retina was detached from the choroid by a layer of effused material presenting a somewhat laminated appearance, and a structure similar to that in the retinal layers already described. In the part figured the pigment-epithelium remains adherent to the changed layer of rods and cones. (See for other details the description of the Plate.)

REMARKS.—The case presents a good example of the diffuse retinitis of Bright's disease occurring in the last period of chronic, supervening on acute, nephritis. The histological changes illustrate very well the origin of the diffuse opacity, white spots, and the hæmorrhages. The latter were no doubt permitted by such vascular disease as that depicted in the capillary vessels.

CASE 40.—*Retinal changes in acute Bright's disease, improving before the general state.* (Pl. X. Fig. 2.)

ELLEN McL., aged twenty-four, admitted into University College Hospital, under the care of Dr. Ringer, March 3, 1876. On February 17 her legs began to swell. Previously she had been, as far as she could tell, in good health, and no cause for the attack could be ascertained. On admission the œdema was general, the urine was scanty (one pint), loaded with albumen, and containing hyaline and granular casts. Soon after admission she had some uræmic vomiting, which passed off under treatment. In the beginning of April, mitral regurgitant murmur developed. Soon after admission, an examination of the eyes had been made by a practised ophthalmoscopist, who found no change. On April 20, two months after the onset of the symptoms, I found the following condition:—Right eye (see Fig.): Disc clear. Several white soft edged spots near the disc, most numerous on the side next the macula lutea, where one of considerable size was irregular in shape, very white in one part, less so at the margins, soft-edged. One of the smaller spots



lay in front of a vein. Around the macula was a halo of white dots, large and small. Two or three small hæmorrhages were near the white spots. Above the upper edge of the disc there was an extravasation along the course of a small vessel, bulging out at intervals, as if the perivascular sheath were distended with blood. Could read (after atropine) No. 12 Jäger. Left eye: appearances similar; the same white spots around the macula; one large hæmorrhage between the macula and the disc; could read No. 14 Jäger. On April 24 one extravasation had entirely disappeared. In the right eye were one or two fresh white spots and fresh hæmorrhages. On April 28 there were no fresh spots, but in the right eye a fresh hæmorrhage extended from the large spot to the disc. Vision (no atropine), R. No. 8, L. No. 12 Jäger, at twelve inches. Pulse moderately compressible; small, regular. No evidence of hypertrophy of the heart. On May 18 the discs remained clear. In the right eye, several of the soft white areas shown in the drawing had disappeared. There was one large fresh hæmorrhage; all the smaller extravasations had gone. A few days afterwards an attack of delirium, with fever, occurred. On May 26 the discs were a little obscured, soft-edged, and reddish. The arteries were a little smaller than before; not more than one-half the size of the veins. On May 29 the cloudiness of the discs had increased, and the white patches towards the macula lutea were more numerous, many of them being granular-looking. The arteries were small; after one or two divisions, the double contour could scarcely be seen. During June the patient's general state and urine remained the same; but a distinct improvement was observable in the eyes. June 26.—Right eye: edges of disc still dimmed, and tint of disc reddish; all the extravasations of blood had disappeared. No large white patches could be seen; but around the macula lutea were many small white flake-like spots, extending almost to the disc, arranged in a zone around the macula; but less regularly a little distance from it. A few similar spots were seen on the inner side of the disc. These appeared to be behind the level of a few small vessels which were near them. In the left eye there was some diffuse opacity of the retina, here and there, near the disc, veiling the vessels, away from the disc becoming less uniform and somewhat radiate. The disc was still red, but clearer, and the central cup more distinct. The spots near the macula lutea were of a more brilliant white than before, and there were few spots, except in this situation. Sight had improved so that she could read—Right, No. 1 Jäger, Left, No. 3. Subsequently to this, the patient had an attack of hydrothorax, needing paracentesis, and followed by uræmic convulsions. She then rapidly improved, the urine increased in quantity, the albumen diminished to a twelfth, and she left the hospital in August. The retinal condition continued nearly the same.

REMARKS.—The chief points of interest in this case are—(1) the rapid development of retinal changes, probably between the fifth and the eighth week after the onset of the œdema, the attack being apparently one of acute Bright's disease.



2. The occurrence, first of acute degenerative, or subinflammatory, changes, characterized by the large white areas, situated chiefly in the nerve-fibre layer, with extravasations, without participation of the disc until an attack of delirium with fever, after which the disc was hyperæmic and its edges obscure.

3. The disappearance of the acute superficial changes, large white areas and hæmorrhages, with corresponding improvement in sight, before the renal symptoms improved, the more deeply-seated and more chronic degenerative changes persisting, and even increasing.

4. The diminution in the calibre of the arteries, which coincided with an increase in the tension of the pulse.

CASE 41.—*Uræmic amaurosis ; subsequently albuminuric retinitis developed under observation.*

HENRY B., aged thirty, bricklayer, admitted into University College Hospital under the care of Dr. Wilson Fox, January 30, 1874. Well till January 11, when he had been exposed to cold. The same evening complained of headache and swelling of the legs, and scantiness of the urine was noticed next morning. These symptoms increased till admission, when general œdema was present, with severe headache; no delirium. The first sound of the heart was reduplicated. Urine, 30 to 40 fl. oz., dark from blood, albumen  $\frac{1}{3}$  to  $\frac{1}{2}$ , casts epitheliated, granular, and hyaline. Slight defect of sight was complained of on admission. On February 1, after more pain in the head and drowsiness, he suddenly became quite blind, and a few minutes afterwards he lost consciousness and had a convulsive attack, followed by coma, with very hard pulse. Dry cupping and a vapour bath having no effect, venesection was performed (10 fl. oz.), with partial restoration of consciousness. Next morning he was much better; could count fingers only, but in the course of the day normal vision returned. Mr. Streatfeild examined his eyes and found nothing abnormal in the fundus. In a few days he had lost all uræmic symptoms, but the albumen persisted, the quantity of urine increasing, however, to 50—70 fl. oz. (sp. gr. 1013 to 1023). On February 16 he again complained of dimness of sight, and of seeing a circle of light before each eye, especially the right. On ophthalmoscopic examination I could find nothing abnormal in the left fundus, but the right disc appeared a trifle redder than the left, and its outline less sharp, though still quite evident (simple congestion). No hæmorrhages or white spots could be seen. On February 27, his renal symptoms remaining the same, the congestion of the right disc was still more marked, and beside a vein running downwards and outwards was a linear hæmorrhage, extending for about a disc's breadth, and beside a vein running in the opposite direction were two soft-edged white spots. In the left eye several smaller white spots were seen around the disc. On March 4 the linear hæmorrhage in the right eye had disappeared, but two small fresh extravasations were observed close to the disc. On March 9 the right disc was noted to be bright red, but without swelling,



and with very little obscuration of outline. In the position of the lower of the two small hæmorrhages just described, was a linear extravasation, extending towards the yellow spot, and partly divided into two, and a white spot which a week before had been quite clear, was now the seat of an extravasation over two-thirds of its area. Here and there in the fundus were a few minute white spots and hæmorrhages. The left fundus presented also a few similar white spots and hæmorrhages. Sight had failed so that he could no longer see to read.

On March 30, the patient's general condition having continued the same, the outline of the right disc was a little less distinct, without apparent swelling. A few fresh small extravasations were visible, and close to the macula lutea was a small, very white spot, and below it several small scattered dots. Above the disc the white patches had increased considerably in size, the appearance of the fundus being now that of a typical albuminuric retinitis. The outline of the left optic disc was fairly clear, but not sharp, and between it and the macula lutea were many white spots, but no grouping of spots around the macula. Small extravasations were dotted here and there over the fundus. The arteries were very small, and the veins large.

The patient lingered on, having frequent attacks of uræmic convulsions, until June 18. Post-mortem, the kidneys were large, indurated (extremely hard), but not granular; the heart was hypertrophied; the other organs healthy.

REMARKS.—This case presents a typical example of the two forms of amblyopia of Bright's disease. (1) Uræmic amaurosis, sudden in onset, accompanied by other evidence of uræmia, soon passing, and unattended by visible changes in the fundus oculi. (2) Amblyopia due to the special changes in the retina, gradual in onset, persistent, increasing. The retinal changes could be followed from their commencement, and ran a subacute course. It is noteworthy that congestion of the disc, hæmorrhages, and small soft-edged patches were the earliest appearances, and preceded the zone of dots around the macula.

CASE 42.—*Retinal changes in chronic renal disease; concealment of arteries by perivascular changes; aneurisms.* (Pl. XII. Fig. 1.)

JANE H., aged thirty-six, married, was first seen (through the kindness of Mr. McHardy) January 2, 1879. She presented no history of syphilis, and was said to have been well until the preceding October, when, being six months advanced in pregnancy, she had a severe fright. Six weeks later she was delivered of a child, which had evidently been dead for some weeks. She had had eight children previously, but never dropsy or any symptom indicative of renal disease. In November her sight began to fail, both eyes simultaneously, the present loss of sight having been reached in two days. She was a pale woman with great hypertrophy of the heart, without murmur, very hard pulse, and much albumen in the urine, which was of low specific gravity, and contained granular casts. Vision: Right eye counted fingers only in the left half



of the field; absolute loss in the right half, but not quite up to the middle line. Left eye, slight perception of large objects in the left half of the field and below. The appearance of the left fundus is shown in Pl. XII. 1. Disc partially obscured by a whitish soft opacity, and near it two other white areas of similar aspect, one extending almost to the macula lutea. Close to the latter are a few minute very white dots and a large hæmorrhage, rounded above, and ending below in a horizontal line, darker in the centre than in the periphery. In three arteries which course upwards, the column of blood is concealed by white tissue, apparently situated in the outer coat, and appearing as a white band corresponding in position to the vessel, and ceasing abruptly. On one branch, the white sheath presents, before it ceases abruptly, two interruptions in which the artery is seen to present a normal appearance and course. Another vessel, which passes upwards and inwards, presents a more irregular appearance, apparently due to the course of the vessel, for in places where the white band appears to be interrupted, it is apparently indistinct from tortuosity, for the artery cannot be seen in the intervals, although where the white band ends the vessel courses along with normal aspect. Only one artery passes downwards, and this has a normal course on, and for a little distance beyond, the edge of the disc, and then, where it crosses a vein, is concealed by opaque retina. Further on it is enveloped in an extravasation which passes from it, narrowing and then widening, along the course of a small vessel, probably in its perivascular sheath. The artery where it emerges from the extravasation has a normal appearance, but some distance farther on it presents four small aneurismal dilatations. The veins on the white opaque areas near the disc are partially concealed. They have for the most part a normal course. One which runs upwards and inwards passes through a striated hæmorrhage, a little distance from the edge of the disc, and for a short distance further the vein is not quite distinct, so that its central reflection is invisible. The vein which passes directly downwards is, on and just beyond the disc, concealed by an extravasation, corresponding to the vessel in form (and possibly within the perivascular sheath); this ceases as the vein becomes concealed with the artery by the opaque retina. Farther on the vein assumes and maintains a normal appearance. A minute branch passes from this vein to the large extravasation near the macula lutea. On the fundus are several other small hæmorrhages, and several accumulations of pigment, probably the remains of previous extravasations. (See also description of the Plate.) The left eye presented a similar appearance; there were several white areas, and the vessels were obscured, with several hæmorrhages. A day or two after she was first seen this eye became glaucomatous, no doubt from a further intra-ocular hæmorrhage, and the fundus was completely obscured. The patient was admitted into St. George's Hospital under the care of Mr. Brudenell Carter, and was afterwards transferred to that of Dr. Dickinson, but after a short time she left to return home, where she died about a month later.



CASE 43.—*Bright's disease; hæmorrhage into the vitreous; probable cerebral hæmorrhage.*

ELLEN D., aged seventeen, admitted into University College Hospital, under the care of Sir William Jenner, October 7, 1873, suffering from chronic Bright's disease and a recent attack of hemiplegia. Of the origin of the renal affection no history could be obtained, but her urine constantly contained a quarter albumen, had a low specific gravity (1010—14), and presented granular casts. There was no evidence of valvular disease of the heart. Ten days before admission she woke up at 3 a.m. with pain in the head and vomiting, and at 6 a.m. was found conscious, but with complete right hemiplegia and loss of power over the sphincters. After three days the paralysis lessened, but there was still considerable hemiplegia when she was admitted, face, arm, and leg being affected. In a few days this lessened so that she was able to walk, and in about a fortnight the weakness was almost gone. On admission the fundus of each eye was distinct and clear throughout, but the optic discs were concealed by opaque swelling (albuminuric neuritis).

A fortnight later a second examination showed no change in the right eye, but in the left no fundus could be at first seen, a purplish-black reflection alone being perceptible. Further examination showed that the vitreous had been displaced by a hæmorrhage which was connected with the retina by a pedicle on which was a white spot. Beneath the lower border of the hæmorrhage it was possible to partially illuminate the fundus. She left the hospital a few days later, and going into the country, was lost sight of.

CASE 44.—*Anæmia; hypermetropia; optic neuritis.* (Pl. VII. Fig. 5.)

MATILDA M., aged seventeen, housemaid, presented herself among my out-patients, November 27, 1878, with great pallor of three months' duration, during which time she had also suffered from amenorrhœa, tinnitus, dyspnœa on exertion, infra-mammary pain, and palpitation. There was distinct cardiac dilatation. Red corpuscles 60 per cent. of normal; hæmoglobin 30 per cent. Refraction of eyes hypermetropic,  $\frac{1}{20}$ . Vision, uncorrected, R.  $\frac{1}{5}$ , L.  $\frac{1}{8}$ . Colour-vision normal. "The optic discs are partly concealed by a striated redness, with moderate prominence, sufficient to alter distinctly the curve and reflection of the veins. In the outer side of the discs the edge can still be seen with the direct, not with the indirect, method. Veins and arteries of normal size, but central reflection of both indistinct, with much white tissue outside them in the centre of the disc."

The patient was admitted into the hospital and very slowly improved upon iron. On January 8 the discs were a little clearer. "The outline of the left optic disc can be dimly seen all round, even on direct examination; an opaque striation extends from the disc on to the retina. The swelling is still distinct, although slight, and has a soft gelatinous look. Right disc: concealment of disc greater than on left; the veins narrower at the disc than away from it. The sclerotic ring is invisible except for



a short space on the outer (temporal side). Very little pressure developes the venous pulse."

February 5.—Great improvement in patient's appearance. Left disc still clearer, but scarcely yet normal. Right also clearer but less than left. The edge can just be seen below and on the inner side. Vision (uncorrected), each eye, about  $\frac{1}{2}$ . Blood corpuscles 78 per cent. of the normal.

REMARKS.—In this patient the use of the eyes brought on discomfort, and it seems reasonable to associate the slight but distinct neuritis with the hypermetropic strain. But the hypermetropia (kindly estimated by Mr. Streatfeild) was moderate in degree, and it seems reasonable also to ascribe some influence in the causation of the neuritis to the anæmia. The neuritis had similar characters to that which I have described as extremely chronic, lasting for years, and which, in most of the cases I have seen, was associated with hypermetropia. The latter condition may aid in the production of neuritis in conjunction with general or cerebral causes. It is of interest that the patient's uncorrected sight improved from  $\frac{1}{8}$  to  $\frac{1}{2}$  under the influence of hæmatinics only.

CASE 45.—*Pernicious anæmia; retinal hæmorrhages; death.\** (Pl. XI. 1.)

JOSEPH C., aged forty-seven, bricklayer. Never ague or syphilis. In October, 1877, unusual fatigue after work, and morning vomiting two or three times a week ("a free beer drinker but not intemperate"). In December, 1877, his friends noticed his pallor, which on February 16, 1878, was very striking. The urine and eyes were normal. Admitted March 2, and then retinal hæmorrhages were found. The absence of colour was conspicuous over the whole skin, the aspect being wax-like. There was a harsh systolic murmur at the apex, heard also over the aorta and middle of the sternum. The corpuscles formed rouleaux, but not long ones. A few were of smaller size than the majority, of deeper colour, with a distinct nucleus. Pale corpuscles not increased. Much refractive granular matter was present. Red corpuscles, 18·6 per cent. of the normal, or 930,000 per cubic millimetre. *Ophthalmoscopic Appearances.*—In the right eye many hæmorrhages are scattered over the fundus, most abundant towards the disc. Some are apart from visible vessels; others are along the course of veins. Almost all of them are striated, and many of them are mere groups of fine striæ following the course of the nerve fibres. A few, above the disc, are punctiform. The extravasations for the most part conceal the branches of the retinal vessels to which they are contiguous, but there is one exception to this; an artery running inwards passes superficially to a small hæmorrhage. In the neighbourhood of two hæmorrhages are white spots: one of these is situated above, and to the outer side of the disc; another is

---

\* In the London Hospital under the care of Dr. Stephen Mackenzie, whom I have to thank for the opportunity of making the drawing. The case is narrated in Dr. Mackenzie's "Lecture on Pernicious Anæmia," "Lancet," December 7, 1878.



below and to the inner side. The upper one is irregular in shape with a large hæmorrhage on its margin, and between it and the disc. An artery which passes near the white spot is concealed for a short distance. There are no changes near the macula lutea. The arteries are all very small, much smaller than normal. The veins, on the contrary, are broader than normal, especially near the disc, where they appear as if flattened out. Colour of veins very pale. The left fundus is similar.

The patient continued for several weeks in the same state. The corpuscles, for some time nearly the same, sank by June 3 to 13 per cent. The temperature, at first normal, afterwards rose to 100°—102°. His hearing got so dull that he could scarcely hear a watch; his sight also became very dull, and his memory failed so that he often forgot what he was in the act of saying. He died on June 18. No post-mortem examination could be obtained.

CASE 46.—*Leucocythæmia ; retinal hæmorrhages.* (Pl. XI. 2.)

FREDERICK H., aged twenty-seven, admitted into University College Hospital in August, 1878. Family history, nothing relevant. Patient lived in Ireland, and there, nine years ago had a febrile attack, supposed to be intermittent, which lasted for six weeks. Four years ago he had an attack of rheumatic fever, and in the spring of 1878 an attack of scarlet fever, followed by dropsy, soon after which enlargement of the abdomen was noted, and on August 3 he was admitted with a large spleen and well-marked leucocythæmia.

In the beginning of September he complained of dimness of sight of the right eye. Ophthalmoscopic examination on September 7 (Pl. XI. 2): the disc clear; physiological cup distinct and rather large; veins very large, tint pale, reflection broad, but very irregular; arteries small, not half the diameter of the veins, orange tint, reflection bright. The tint of the smaller veins being much lighter than that of the larger trunks, the small veins and arteries are not easily distinguished. Around the macula lutea is an irregular circle of extravasation, narrow, enclosing a space of quite normal appearance. Above and below, on the inner side, the retina beyond the extravasation has a grey tint, which, close to the hæmorrhage, became white. Midway between this and the disc is another small irregular hæmorrhage, and between this and the larger extravasation are one or two white spots. To the outer side of the annular hæmorrhage is a small spherical zone of extravasation, which surrounds a pale centre.

October 3.—General state nearly the same; white corpuscles the same number; red slightly increased. The general ophthalmoscopic appearances are nearly the same. There are no fresh hæmorrhages. The annular zone of extravasation is much narrower and darker, especially below, where it appears black, as if in the process of transformation into pigment. The area enclosed by the extravasation has become much paler, and more granular, as if atrophy of the choroid were taking place within it. The smaller hæmorrhages on the temporal and nasal sides of



the larger one are no longer recognizable, nor is the pale spot enclosed by the small hæmorrhage still visible.

He left the hospital in September, *in statu quo*, soon to return, on December 18, much worse, the spleen occupying the greater part of the abdomen. An increase in the blood state; red corpuscles 59, and white 13 per hæmic unit (about 1 in 4). The optic discs were still normal, the veins even broader than before. One or two small recent extravasations, one with a white centre. Most of the annular extravasation had disappeared, being replaced by white spots and lines.

At the present time (April, 1879) there are about one white to two red (16 and 32 per cent.). Attacks of epistaxis are frequent, but there are no fresh hæmorrhages into the retina. The veins have, however, progressively increased in apparent width. They are now about three times the diameter of the arteries, are pale in tint, almost the same colour as the arteries, and tortuous, even more so than in Fig. 1 (p. 11), which represents the condition in the beginning of March. The curves now are antero-posterior as well as lateral. In the prominent parts of the curves there is a very narrow, almost white reflection. There are no hæmorrhages or white spots.

CASE 47.—*Simultaneous embolism of central retinal and middle cerebral arteries; death; necropsy; microscopical examination.\** (Pl. XII. Fig. 2.)

C. H. H., aged thirty, carpenter, admitted into University College Hospital, under the care of Sir William Jenner, January 29, 1870. In early life he had an attack of "low fever," attended by pains in the joints, followed by chorea and by weakness in his right arm. A year later he had a similar, less severe, febrile attack. During the six months before his present illness he suffered from cough, shortness of breath, and occasional slight hæmoptysis.

Without premonitory symptoms, he suddenly, when out walking, lost consciousness, was picked up insensible, and brought to the hospital. Soon after his admission he had partly recovered consciousness. There was then complete paralysis of the right arm and leg, and slight paralysis of the face. At the heart there was a loud systolic apex-murmur, and evidence of dilatation of the left ventricle. The urine contained no albumen. On the following day he had so far recovered consciousness as to be able to speak, but answered "Yes" to all questions, uttering no other word. In this state he continued for some weeks. On February 21 it was noted that there was slight improvement both in limbs and speech.

In the beginning of March he became worse, began to vomit food and cough up blood. The heart's action became more feeble and irregular, so that the murmur could be heard only with a few beats of the heart. The legs became œdematous. The urine contained blood. By the middle of March all the evidences of cardiac failure were more intense, and on the 20th there was œdema of the left arm, with hæmorrhagic spots up to the bend of the elbow. Signs of effusion into the right pleura showed

\* The case is published in full in the "Lancet," 1875, ii. 794.



themselves. On the 25th the distension of the left arm became extreme, bullæ formed on the right foot, and hæmorrhage occurred from the nostril. He lingered until the 29th, when he died.

*Condition of Eye.*—Four days after his admission into the hospital, and five days after the onset of the paralysis, an ophthalmoscopic examination was made for the first time. The fundus of the right eye was normal. In the left eye the optic disc could not be distinguished, being veiled by a greyish-white cloud; its position was indicated by the convergence of the vessels. Another white cloudy opacity of considerable size existed in the retina near the yellow spot, without any central red area. Both these had soft edges, were moderately white, and the retinal vessels appeared partly concealed by them. The arteries were small, the veins large and distinct. On the following day the appearances in the eye were nearly the same, the white opacity in the centre of the fundus being continuous with that near the optic disc. In front of the former a distended vessel crossed transversely just above the position of the yellow spot, and small twigs passing from this vessel at right angles on each side were abnormally conspicuous against the white background. On examination it was evident that he could not see with this eye.

During the next week these white patches gradually lessened, and the outline and surface of the disc became clear. As the vessels became more visible the diminished size of the arteries was distinct. By February 18 the large white patch near the yellow spot had gone, leaving only a little irregular cloudy and granular whiteness. The optic disc was quite distinct in its inner portion, while the outer half was still somewhat hazy. A line of whitish opacity extended upwards and outwards towards the yellow spot, and, curving round and becoming fainter, blended with the traces of the mischief near the yellow spot. In the first part of its course it accompanied a vessel. Below the disc was another limited opacity bounded on each side by a vessel. The veins were all perceptible and tolerably uniform. The arteries were much narrowed on the optic disc and for some distance around; they appeared mere threads. Not very far from the disc, at a distance variable in different vessels, but usually about twice the diameter of the disc, they again became conspicuous. There was a distinct darkish opacity of the retina all round the optic disc.

On March 1 the optic disc remained clear; the vessels, both arteries and veins, had diminished in size, the former, on the disc, being reduced to the merest threads. They were narrower at a distance from the disc than formerly. In one vein the column of blood was interrupted, for the vessel appeared as if empty for a little space. On March 13 the disc had become whiter, and its edges well-defined and clear, but a little uneven (Pl. XII. 2—the disc appears too deeply tinted). The remains of opacity below and above the disc were still there, but less conspicuous. The veins were rather smaller than when last examined, and the diminution in size was chiefly noticeable near the disc, where they appeared considerably narrower than in the equatorial region. One or two veins



could not, with the indirect image, be seen upon the disc, but appeared near its edge. The arteries on the disc itself were just visible as lines, and some of them could not be distinguished against the choroid near the disc. All, however, became more perceptible at about two disc-breadths from its edge, and towards the equatorial region became much larger than near the disc, though smaller than when first observed. This condition continued until he died.

*Post-mortem Examination.*—Brain: The right hemisphere was healthy throughout. In the left hemisphere were two lesions. (1) The smaller was an area of softening on the outer surface, at the posterior part of the parietal lobe; it measured one inch by three-quarters. (2) The left corpus striatum at its junction with the optic thalamus was softened over an area three-quarters of an inch in diameter, and of a yellowish colour. On section the disease did not extend into the optic thalamus, but passed outwards to the fissure of Sylvius, the tint of the softened portion varying from creamy white to pale orange. Convolutions of the island of Reil destroyed; lowest frontal convolution a little damaged. The arteries at the base appeared healthy. The right middle cerebral contained fluid blood. In the left middle cerebral, within the Sylvian fissure, was a clot half an inch long, colourless, firm, easily detached near the orifice of the artery, but above adherent to the inner coats. On each side of the clot was a little fluid blood. Branches from this occluded artery passed directly into the diseased portion of the corpus striatum. The anterior cerebrals and anterior communicating arteries were empty. The heart was much diseased. The mitral orifice was thickened and roughened, and calcareous on its auricular surface. Old clots were contained in the auricular appendices and in the apex of the right ventricle. In the lungs were numerous angular patches of pulmonary apoplexy. Each kidney contained an infarct, and a similar infarct was contained in the spleen.

*Eye.—Microscopical Examination.*—The central artery in the optic nerve was dilated here and there, but for the most part so contracted that its calibre was reduced in places to a mere line. The walls were thick, but only in proportion to the contraction of the artery. There was no plication of the inner layer. The dilated portions corresponded in some instances to the passage of a branch from the artery into the substance of the optic nerve. Just behind the division of the artery in the disc was a dilatation of some size. But in the disc itself, the main branches of the artery were reduced to very narrow dimensions, the cavity of one being only  $\frac{1}{2000}$  in. in diameter.

Here and there, chiefly in the substance of the nerve, but to a less extent also in the disc, minute granular masses could be seen in the artery. The largest of these (represented in Fig. 3, p. 30) was situated in the main trunk in the substance of the optic nerve, about one-eighth of an inch behind the lamina cribrosa. It is an elongated plug,  $\frac{1}{300}$  of an inch in length, and about  $\frac{1}{800}$  of an inch in width, coarsely granular in appearance, containing many dark points. It apparently did not



quite fill the vessel, having, doubtless, shrunk from the sides while the specimen was being hardened. A little distance in front of this was a small spherical mass. Farther back the vessel was for some distance reduced to a very narrow size, hardly any cavity being visible; but here and there a little granular mass could be noticed within it. Farther back it again widened out, and then narrowed. In one of the narrowed arteries on the disc a quantity of granular material could be perceived. The veins on the disc were reduced in bulk, but were much larger than the arteries. No capillaries in the disc or about the lamina cribrosa could be perceived. In the retina beyond the limits of the disc, however, about a disc's breadth from its edge, numerous dilated capillaries could be seen, running inwards through the nerve-fibre layer, some vertically, others at an inclination. They appeared as if passing from the choroid to the surface of the retina; but they could not be traced towards the choroid beyond the inner layer of the retina.

The nuclei in the optic nerve were not more abundant than normal, but the nerve fibres showed some commencing degeneration, a few globules of myelin being scattered among them. The papilla was not swollen. The minute round nuclei which commonly lie among the nerve fibres in the disc were increased in number, and in places were accumulated in oval heaps between the bundles of nerve fibres. The layer of nerve fibres passing on to the retina appeared a little swollen; but its thickness, a disc's breadth from the edge of the disc, was only  $\frac{1}{300}$  of an inch, the fibres being here and there very slightly varicose, and lying less closely together than is usual. The cellular layers of the retina near the disc were in some parts normal, or nearly so, the ganglion-cell layer, the two nuclear and the molecular layers being distinct, the former only in places a little thickened by the increase in the number of corpuscles composing them. (The layer of rods and cones was not distinguishable as such, doubtless from the time which elapsed after death before the post-mortem examination was made.) On another side of the disc, however, probably where the opacity was noticed during life, the whole thickness of the retina was infiltrated with minute corpuscles resembling those of the nuclear layers. In these layers they were more closely aggregated, but they filled also the outer molecular layer, and were scattered less closely through the inner molecular layer. The retinal layers were also a little sinuous. These changes were noted especially in the portion of the retina beneath the thickened nerve-fibre layer.

Near the macula lutea some irregularities in the surface of the retina could be noticed on looking at it with a simple lens. These depended partly on ramifying vessels and partly on the retina being raised in minute folds. The microscopical examination showed considerable though variable change. In some places all distinction of layers was lost; small round corpuscles resembling those of the nuclear layers, but staining less readily with logwood, infiltrated the whole thickness of the retina, the only other structure perceptible being the remains of the vertical fibres of the retina, themselves thickened, among which the



nuclei lay. In other places the vertical fibres in the outer molecular layer were widely separated, spaces between them being left, and the nuclear layers being normal, as if from œdema. In some places round corpuscles were scattered through this (outer molecular) layer; in other parts the layer was infiltrated with small round corpuscles lying amid a granular matrix. The external nuclear layer was also in places considerably thickened. Where the retina was raised in a fold, this layer on the concave side was sinuous, and between the contiguous folds the layer of rods and cones had disappeared, and the space was filled up by a considerable quantity of granular material, in which a few round corpuscles could be distinguished. The pigment-epithelium was in this part in close contact with, and adherent to, the external nuclear layer.

REMARKS.—It is in the highest degree probable that the embolism of the retinal and cerebral arteries were simultaneous, and it is, I believe, the only recorded case in which the two accidents occurred at the same time. The ocular condition presented many instructive points. A ready collateral circulation in the retina must have been established in this case, for the arteries, as seen with the ophthalmoscope, maintained their thread-like dimensions only for a very short distance after leaving the disc, and then resumed a distinct though narrowed double contour. The blood reached them probably from the posterior ciliary arteries. It is often assumed that the vessels of the disc form an important part of the means of communication. But the marked and increasing pallor of the disc in this and in almost all cases of embolism is in contradiction to the assumption. The pallor depends, as Gradenigo\* has pointed out, on anæmia, rather than on tissue proliferation. No capillaries were visible, although carefully looked for, in the case I have just described; and neither the tissue-formation nor the degeneration of the nerve fibres was sufficient to account for the pallor. But there was distinct distension of small vessels in the retina outside the limits of the disc, and it is, I think, clear that it was by the vessels near the papilla, and not by those in the disc, that the collateral circulation had been set up.

The retinal appearances, as seen with the ophthalmoscope, do not differ in any material point from those of most other cases recorded. It is, however, to be noted that when first examined, five days after the presumed onset, the opacity of the retina was as marked around the disc as around the macula lutea. Moreover, the red spot at the macula lutea, so often described, was absent. This fact is of interest in connection with the diagnosis of embolism within the artery from hæmorrhage around it. The absence of a red spot at the macula and the presence of early infiltration around the disc are given by Magnus as diagnostic indications of hæmorrhage around the nerve. In the case now described, unquestionably embolic, the spot at the macula was absent, and by the fifth day the infiltration around the papilla was very marked.

---

\* Gottardi: "Giornale de Med. Mil." July, 1875, p. 22.



The anatomical changes in the retina corresponded to the opacity observed during life, and still present, although in less degree, at the time of death. They indicate more structural change than is, I think, commonly supposed to occur in these cases. The adhesion of the pigmentary epithelium to the outer nuclear layer may perhaps be taken as evidence that the destruction of the layer of rods and cones at this part was not a mere post-mortem change, but occurred during the active processes consequent on the arterial obstruction.

CASE 48.—*Mitral constriction; embolism of one branch of the retinal artery.\**

LOUISA P., single, aged twenty, came under observation in April, 1874. In the preceding February she was quietly sitting at work when a dark shade seemed to come over the right eye. She closed her left eye, and found that she could not see with the right. She had no pain in the eye or head. After a few days some return of sight followed, which gradually improved up to a certain point. When seen, with the left eye she could read No. 1 Jäger at six inches; with the right only No. 5 Jäger at six inches. Left field of vision normal; right presents a large defect below, involving about nearly half the field, extending higher on the nasal than on the temporal side, the base below the apex at the blind spot (Fig. 4, p. 33).† Ophthalmoscopic examination showed the appearances depicted in Pl. XII. Fig. 3. The lower branch of the central artery is normal. Of three upper branches, that on the nasal side is completely obliterated, its commencement being visible only as a fine, white, branchy thread. Two other branches are much narrowed for a long distance from the disc, but about half way to the equator of the globe they widen out. Where narrowed, a fine white line can be seen on each side of the upper branch.

At the heart there was a well-marked, loud, presystolic, mitral murmur. No history could be obtained of rheumatic fever, scarlet fever, or chorea. She had never suffered from palpitation of the heart. As long as she could remember she suffered from attacks of momentary dimness of sight.

CASE 49.—*Fracture of the skull passing through the left orbit; hæmorrhage into the optic nerve sheaths; extravasations in the left retina.*

A CHILD, aged twenty months, admitted into University College Hospital, March 31, 1876, with a history of having fallen out of a first-floor window on to its head, about ten minutes previously. When seen by Dr. S. H. Burton, the house surgeon (to whom I am indebted for the notes of the case), it was insensible, with stertorous breathing, the whole muscular system being in a state of tonic spasm with exacerbations, pedo-

\* For an opportunity of seeing this case I am indebted to my colleague, Mr. Streatfeild, to whom she applied at the Moorfields Hospital.

† By an error on p. 33 the field is said to be that of the left eye.



carpal inversion well marked, distinct opisthotonos. Pupils slightly dilated, but equal and insensitive to light. A depressed fracture of the skull was found extending vertically across the left side of the skull, an inch and a half behind the position of the ear, being about three inches in length. The left eyelid was discoloured, and the left eyeball a little more prominent than the right. A few hours later the left optic disc was found to be hyperæmic, but its outline was distinct. The veins were full and distended, the arteries normal. Three extravasations of blood were seen at the apparent lower margin of the disc, and four other smaller hæmorrhages were seen at a distance from the disc. The fundus of the right eye was normal, the disc clear, but the veins appeared somewhat distended. No extravasations could be seen. The muscular spasms ceased after the child was put to bed; but, in a few hours, convulsions came on, and recurred with increasing frequency until death, five and a half hours after admission. *Post-mortem*, over the fracture there was a considerable quantity of brain matter mixed with blood, outside the skull. Two fractures of the skull were found, one in the position mentioned, and another on the right side, extending from the sagittal suture to the base. Each fracture extended to the petrous bone. From the anterior end of the sagittal suture the left fracture passed obliquely forwards to the margin of the left orbit, close to the supra-orbital notch, and back through the roof of the orbit to the posterior end of the ethmoid bone. The dura mater was torn on each side beneath the lateral fractures. Blood covered the convex surface and base of the brain, and filled the ventricles. In the left orbit there was a clot above the superior rectus, none in the right orbit. The sheath of each optic nerve was distended with black fluid blood, the distension being greatest near the eye. The small hæmorrhages seen with the ophthalmoscope in the left retina, were just visible. None were seen in the right eye.

*CASE 50.—Compound depressed fracture of the left parietal bone; elevation; hernia cerebri; optic neuritis; left hemiplegia; erysipelas; death; extensive disorganization of the brain.*

EDWARD M., aged twenty-three, admitted into University College Hospital, May 11, 1876, under the care of Mr. Heath, having been kicked on the head by a horse. The kick occasioned no loss of consciousness. A slightly depressed compound fracture of the left parietal bone was found. On June 15 there was constant vomiting and pain in the head, and infrequent pulse. The depressed fragments were removed. There was no clot under the bone, or wound of the dura mater. Some pain in the head continued, and on the 23rd two other pieces of the parietal bone were removed. The dura mater thus exposed presented inflammatory matter and granulations. On the 24th a yellowish-brown projection was noticed from the anterior part of the exposed dura mater, about the size of an acorn, not pulsating, but showing pulsation beneath it. On this day I examined the eyes for the first time, and found the left optic disc normal. Around the right there was some opacity,



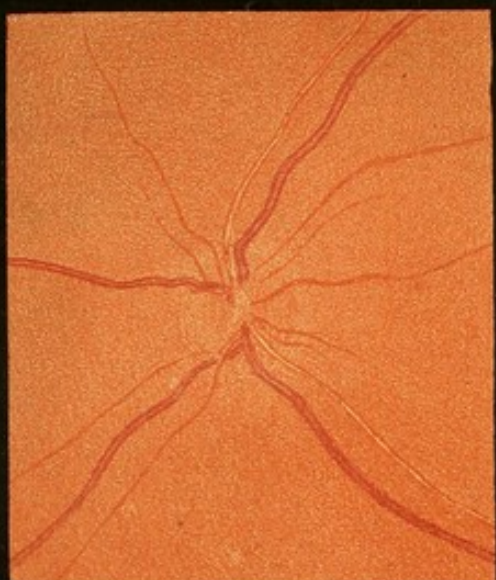
masking the outer edge of the disc, and slightly prominent. The tint of this disc was a little redder than the other. Vessels normal. On the 25th the swelling had increased in size, and pulsated distinctly. There was some pain in head and sleeplessness. *Ophthalmoscopic examination.*—Right eye: veins large and dark; arteries rather below normal size. Outline of disc veiled on all sides, but not quite concealed; slight swelling of opaque retina in front of it, with a darker tint on the sides of the swelling. Left eye: appearance similar to the right, but on the nasal side only, where the obscuration of the edge was greater than on the right eye. Temporal edge of disc clear. No hæmorrhages. May 27.—The hernia cerebri continued to increase in size. The left optic disc remained almost as on the 25th, the right was certainly more swollen, so that the veins lost their central reflection as they coursed down its slope. On the 29th, the hernia having attained the size of a pigeon's egg, it was shaved off to the level of the adjacent granulations, and compression applied. On the 31st the hernia returned, the temperature rose to 103°, and symptoms of erysipelas appeared. On June 1 the ophthalmoscopic appearances presented no change. The erysipelas in a day or two extended over the whole scalp, and a fungus cerebri rapidly formed at the wound, quickly attaining the size of an apple. On the 7th its summit was sloughing, and the first paralytic symptom was noted, slight paralysis of the lower part of the face on the right side. The pupils were equal, and the limbs presented no paralysis. On the 8th the patient pulled off half the fungus, and it was noted that the left arm and leg were moved less than the right. Sensation unimpaired. During the next day or two sloughs came away from the hernia at each dressing. Left hemiplegia became complete, and was accompanied by some rigidity. On the 11th the patient died.

At the post-mortem examination it was found that, beneath the dura mater, the surface of brain immediately around the hernia, and also along the right side of the superior longitudinal fissure, was covered with a thick layer of pyo-lymph; vessels over the rest of the surface full and prominent, more so on right side than on left. Base of brain thickly covered with pyo-lymph. On right side, the brain substance had degenerated into a greenish pulpy mass, as far down as the lateral ventricle. Fornix softened. Right corpus striatum softened, with small extravasations of blood around, evidently due to the softening and secondary rupture of the vessels; optic thalamus comparatively healthy. The fractures extended into roof of sphenoidal sinuses, and there was also a fracture on outer side of orbit, which extended into spheno-maxillary fissure. No note was made of the condition of the optic nerves.

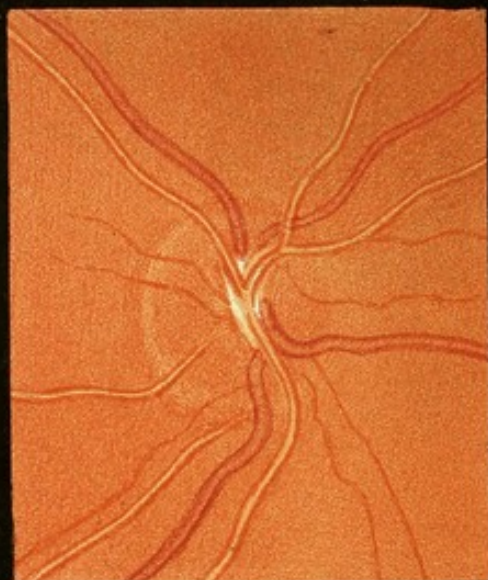



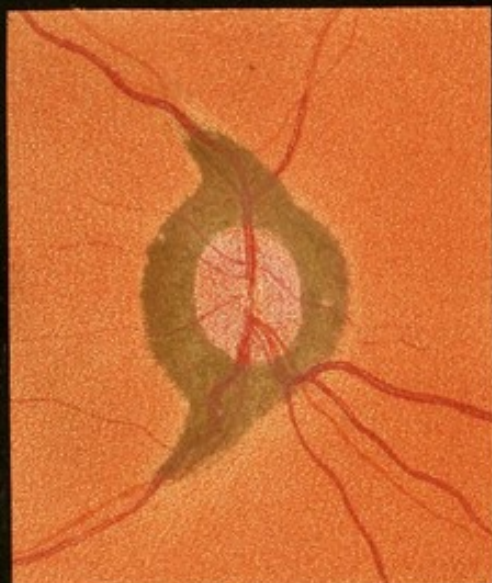




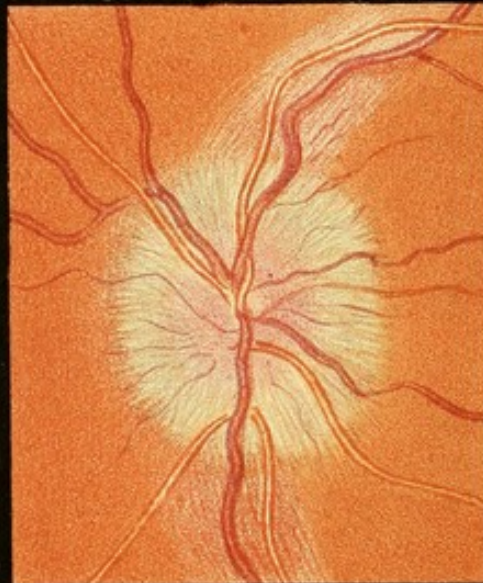1



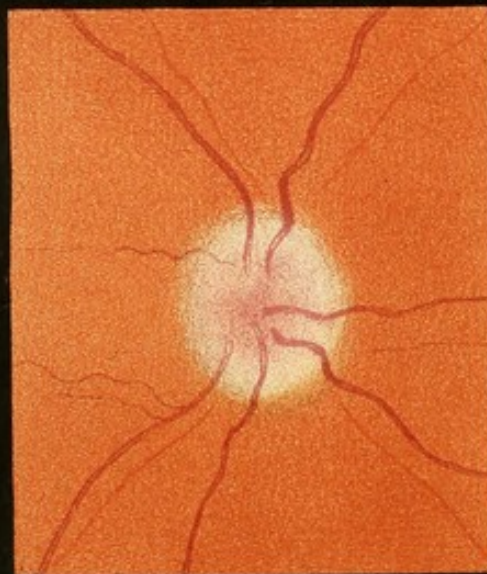2



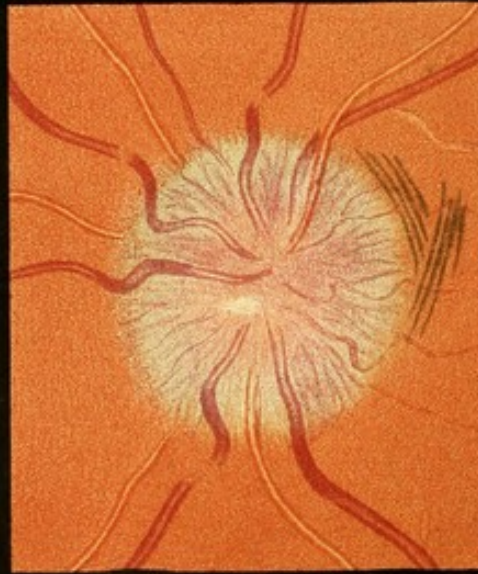
3



4



5



6



## DESCRIPTION OF PLATES.

---

THE ophthalmoscopic illustrations contained in the following plates are from drawings of the erect image, with the exception of Pl. I. Figs. 1, 3, & 5; Pl. VI. Fig. 1, and Pl. XII. Fig. 2, which are of the inverted image. In some of the other figures, however, the drawings, although of the erect image and made on a large scale, have been reduced in the photographic reproduction nearly to the dimensions of the inverted image.

### PLATE I.

FIGS. 1 & 2.—*Simple congestion of the optic disc in a case of embolic softening in right cerebral hemisphere, causing left hemiplegia. Right optic disc five weeks after onset. (Case 25, p. 284.)*

FIG. 1 represents the disc as seen by the indirect method of examination. The tint is nearly that of the adjacent fundus, and is uniformly distributed over the disc. The edge is dimly seen as a pale zone, most distinct on the right (temporal, apparent inner) side. The veins are large, especially one which passes apparently upwards (really downwards). The arteries are about normal size. Several small vessels passing from the disc are unduly visible. ( $\times 8$ .)

FIG. 2.—*The same disc as seen by the direct method (upright image)—reduced.* The uniform red tint is as conspicuous as by the indirect method. The sclerotic ring is visible on the left (temporal) side, but nowhere else is the boundary of the disc recognizable. The large size of the veins is very conspicuous, and there is white tissue about the vessels, arteries especially, in the centre of the disc, very conspicuous against the red surface.

The left disc presented nearly, but not quite, the same appearance, and after a few weeks its congestion lessened much more than that of the right.

FIGS. 3 & 4.—*Commencing optic neuritis; "congestion with edema;" probable cerebral syphiloma. Left eye.*

The patient, aged twenty-five, had had a hard chancre at twenty; subsequently cranial nodes; an attack of right hemiplegia at twenty-three, and headache and convulsions for six months. Right optic disc full



coloured, but otherwise normal. The appearance of the left is shown in the figures.

FIG. 3.—*Appearance on indirect examination.* The edge of the disc is fairly distinct, but its surface is uniformly red—a deeper and more carmine red than the adjacent choroid. Around it is a halo of paler reflection from the adjacent retina, and this can be traced upwards and downwards along the course of the larger vessels, in the situation in which the nerve fibres are most numerous. The retinal vessels are of nearly normal size, clear to their emergence in the middle of the disc. (The arteries in the figure are rather too small.)

FIG. 4.—*Appearance of the same disc on examination by the direct method (reduced).* The aspect is very different from that presented on examination by the indirect method. The edge of the disc can nowhere be seen; the halo of paler reflection is seen as a striated, reddish-grey, slightly prominent opacity, completely veiling all behind it. The increased redness in the centre is the only indication of the position of the optic disc. The striation is radiating from the centre of the disc, and evidently depends on the nerve fibres. The opacity ceases abruptly about a disc's breadth from the probable position of the edge of the disc, except above and below, where a fine pale striation accompanies the vessels—the pale reflection recognized in the inverted image. The veins are a little larger than normal; they curve down the sides of the swelling, but the prominence being slight, the change of plane causes only a slight diminution of the central reflection. The edge of the swelling is steepest on the temporal side (to the right), and there a small vein forms a conspicuous curve down the side.

Vision  $\frac{1\frac{1}{2}}{13}$ . Field unrestricted. Colour-vision (with Holmgren's wools) normal.

FIGS. 5 & 6.—*Optic neuritis. Right optic disc of a patient suffering probably from a cerebral tumour, causing fits beginning in the right side of the face.* (Case 8, p. 255.)

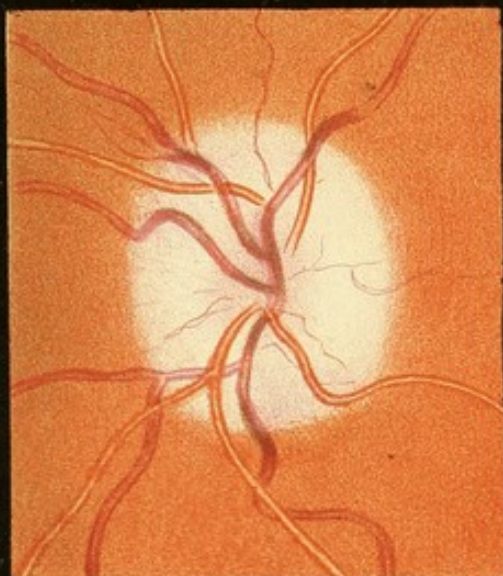
FIG. 5 represents the papilla as seen by the indirect method. The outlines of the disc cannot be seen; its position is occupied by a roundish prominent swelling, the centre of which is red, the outer part pale, and the sloping side greyish-red. The veins appear of nearly normal size, but present conspicuous curves as they slope down the sides of the swelling. They cannot be traced to the middle of the swelling, their terminations being concealed in the red centre. The arteries cannot be recognized on the swelling, being visible only beyond its edge, where they have a normal course. (In the figure they are rather too narrow.)

FIG. 6.—*The same disc as seen by the direct method of examination (reduced).* Its prominence is less conspicuous, as the shading of the edge cannot be so well seen. It is indicated by the curves of the veins. The swelling was, however, such that, although the fundus was distinct without a correcting lens, the top of the swelling could only be seen with + 2 diop. The centre is red, and presents a fine stippling; the

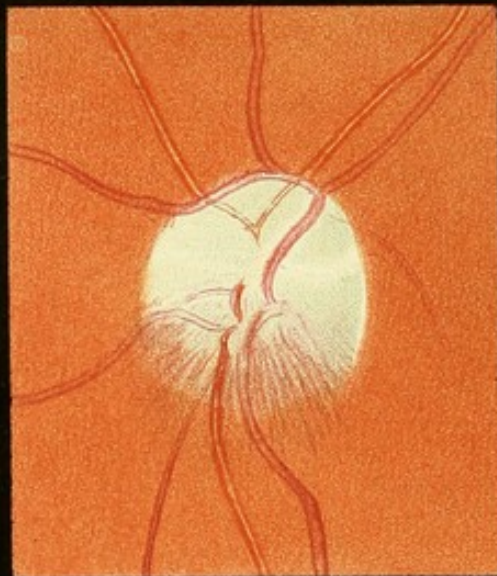




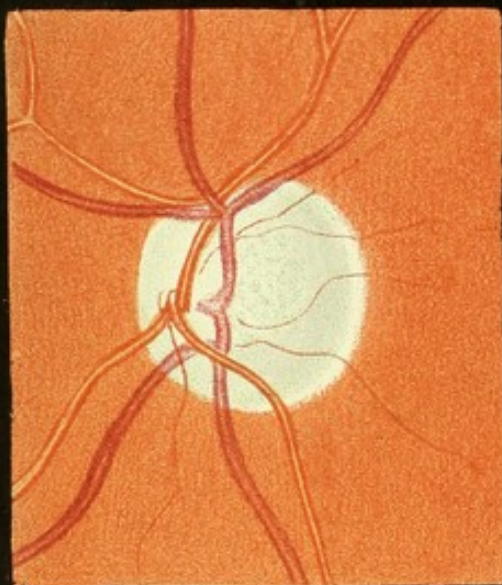




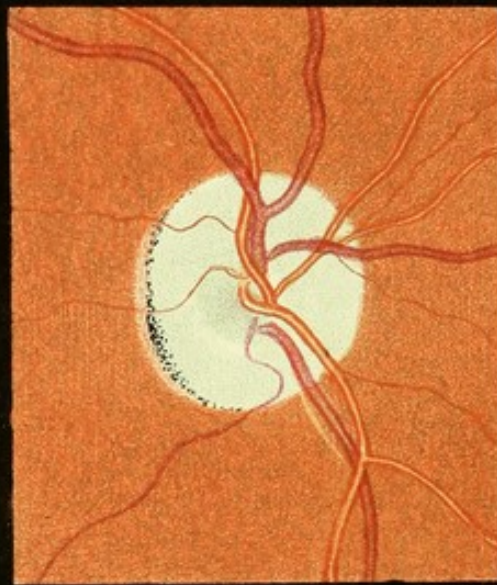1



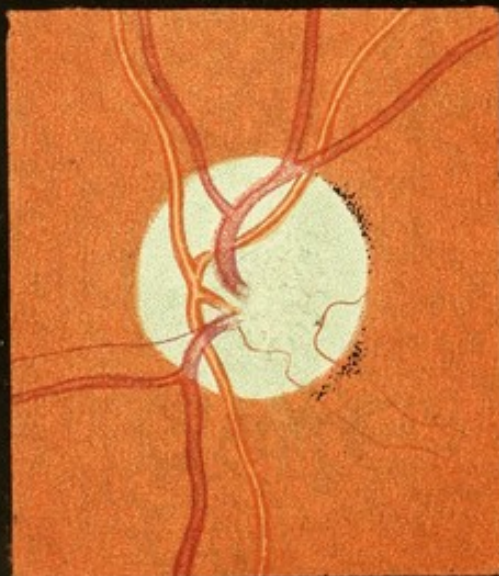2



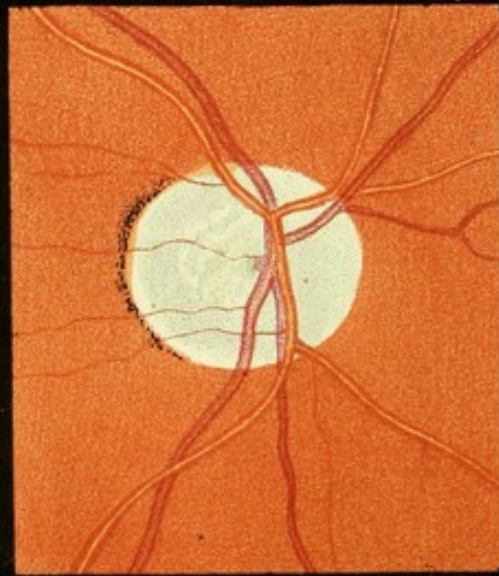
3



4



5



6



outer part reddish-grey, striated. The large veins are larger than normal, and are numerous, and so considerably enlarged. Over the prominence of the swelling their reflection is bright, but it is lost, and the vessels appear dark, as they slope down the sides of the swelling. Beyond its edge several of them are partially concealed as they dip into the substance of the retina before assuming a normal course upon the fundus. Towards the slightly-depressed centre they are lost in the tissue, some, as the lower veins, gradually, others suddenly after a slight curve, in which their central reflection is again lost. One or two arteries can be traced over the outer part of the swelling, and present there a bright reflection. Others are concealed completely by the tissue, and only appear beyond its edge. Near the centre of the disc is a small oval white spot. On the right (temporal or macular) side of the disc the red of the choroid is varied by a series of paler lines, most being concentric to and adjacent to the edge of the swelling. They depend on the folds into which the retina (perhaps only its nuclear layers) is thrown, in consequence of its displacement from the edge of the choroid—partial detachment. (Compare Pl. VII. 1 and Pl. XV. 1.) Vision  $\frac{2}{2}$ , but considerable concentric limitation of the field.

## PLATE II.

FIG. 1.—*Subsiding neuritis; commencing consecutive atrophy. From a case of local chronic meningitis, with changes (induration, &c.) in the subjacent convolution, probably syphilitic. Left eye. (Case 2, p. 242.)*

The position of the disc is occupied by a pale swelling with very soft edges and depressed centre, in which a little of the redness still remains. The area of the swelling is considerably larger than the disc, and its prominence is considerable, as is shown by the curves formed by the veins as they course down its sides. Several are slightly concealed beyond the edge of the swelling. The arteries have an almost straight course. Both veins and arteries are a little more concealed at the centre. The veins, on the fundus especially, are distinctly smaller than they were in an earlier stage. The small vessels are also much smaller, many having disappeared, and others can only be traced as fine lines. Vision 0.

FIG. 2.—*Neuritis subsiding irregularly, clearing from the upper half of the disc before the lower, in a case of syphilitic disease of the brain. Left eye.*

The lower half of the disc is concealed by a greyish-red, striated swelling, of moderate prominence. The veins curve over it. An artery is partially concealed by it. The upper portion of the disc—rather more than half—is clear, but has a “filled-in” look, being occupied by new tissue of a pale grey tint. A large vein has a peculiar course, curving round the upper edge of the disc. The arteries are partially concealed by the new tissue; they appear narrow and indistinct, and both these and



the vein are bordered by whiter tissue. Similar white tissue marks the position of several small vessels, which can scarcely be distinguished.

FIG. 3.—*Grey atrophy of optic nerve, probably from post-orbital pressure on the nerve trunk. Left eye. (Case 31, p. 295.)*

The disc presents an iron grey tint, greenish in certain lights, uniform in the outer part, but mottled at the bottom of the central cup, grey flake-like spots being separated by the white trabeculae of the lamina cribrosa. The central cup is deep and wide. The sclerotic ring is visible in almost the whole circumference of the disc. The vessels present no reduction in size. They are distinct to their emergence. The veins joining to form a trunk, which can be seen dimly as it passes down into the substance of the nerve in the central cup. Along one artery, which passes downwards and crosses two veins, white lines, indicating the position of the wall of the vessel, are distinct against the darker veins. Vision 0.

FIG. 4.—*Atrophy of optic disc of six years' duration secondary to pressure on optic commissure after previous slight damage by neuritis. Right eye. (Case 6, p. 251.)*

To indirect examination the disc appeared white, but on direct examination it is everywhere of a faint greenish-grey tint, strongly marked at the bottom of the central depression (rather too strong in the figure). The veins and arteries are of nearly normal size. The edge of the disc is a little irregular in shape, and the appearance of irregularity is increased by a narrow zone of atrophy of the choroid on the temporal (left) side, within which pigment is accumulated in a narrow line at the edge of the disc. This is probably a trace of the attack of neuritis, and so also is the appearance of white lines along the lower vein; the latter was much more conspicuous soon after the neuritis subsided. The disc has a "filled-in" look, the excavation being slighter than in the case of simple atrophy shown in Figs. 3 & 6, the lamina cribrosa being visible. Vision 0.

FIG. 5.—*Atrophy of the left optic nerve in a case of cerebral disease, causing left hemiplegia, amaurosis of left eye, and loss of the left half of the field of vision in the right eye. (Case 30, p. 293.)*

The disc appeared white and sharp-edged to the indirect method, but by the direct method is pale grey (too grey in the figure), pale and uniform in the outer part, and in the centre a deeper grey mottling within the lamina cribrosa. The edge is clear and sharp all round. On the temporal side (to the right) is a little accumulation of pigment. The veins and arteries are of normal size, and can be traced to the bottom of the large central cup. A small vessel passes on to the disc from the choroid, and thence on to the retina. Vision 0.

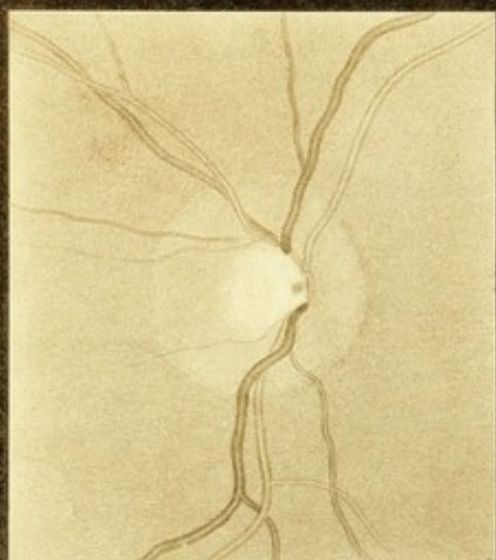
FIG. 6.—*Atrophy of the optic nerves of three years' duration in a patient presenting slight spinal symptoms (rheumatic pains in legs, darting pains in back, satyriasis, and excessive knee-reflex). Right eye.*

The optic disc is sharp-edged, the sclerotic ring conspicuous on the temporal side, and beyond it a little pigment accumulation. The nasal

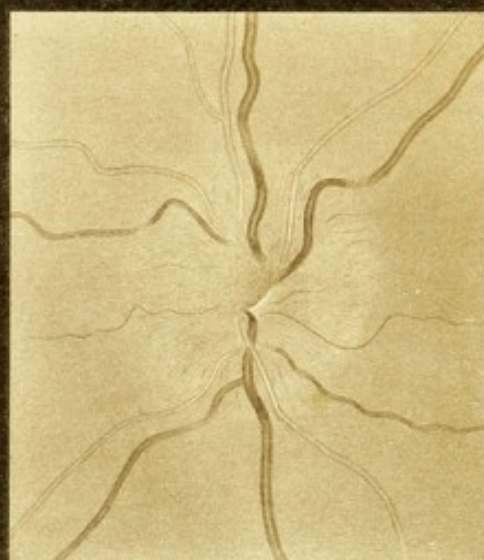




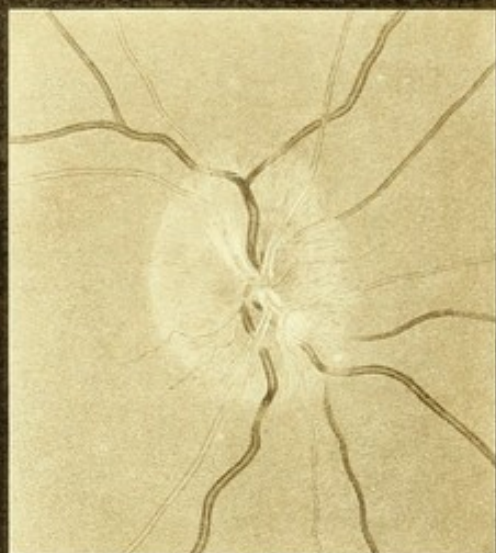



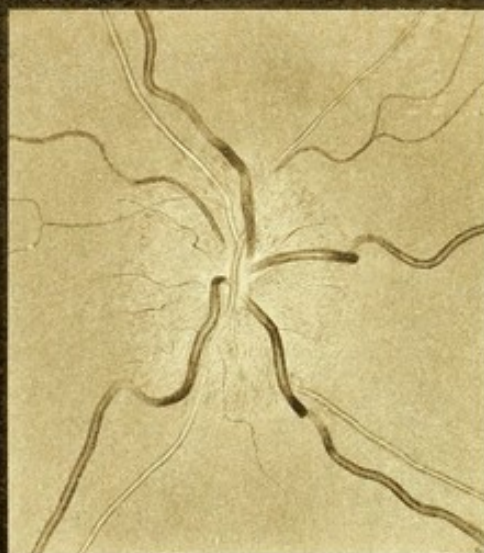1



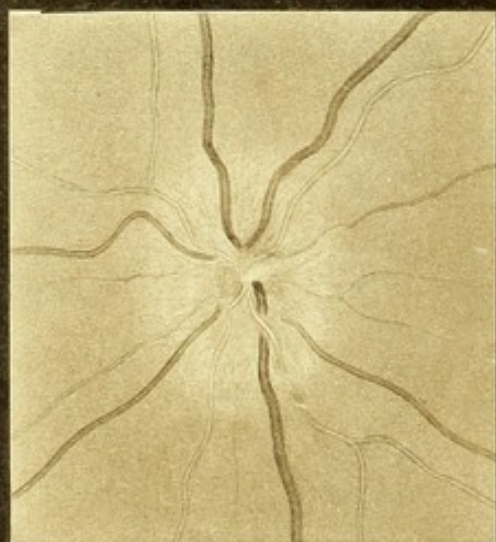
2



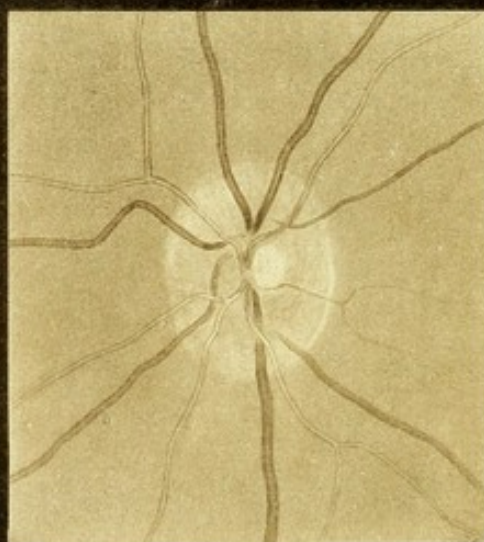
3



4



5



6



half of the disc (to the right) is a soft uniform grey; the temporal half to the left is darker grey mottled. The excavation is large, and at the bottom the lamina cribrosa is visible. Vision—quantitative perception of light only. Both discs similar.

### PLATE III.

FIGS. 1 & 2.—*Right and left optic discs; caries of sphenoid bone, with secondary meningitis.* (Case 1, p. 240.)

FIG. 1.—*Right optic disc.* Characters normal. Outline clear; central cup deep; vessels lost to view as they pass down its sides. The termination of the vein can be dimly seen in the middle beneath the nasal edge of the hollow. (Vision normal.)

FIG. 2.—*Left optic disc.* Well marked neuritis. Edge of disc invisible; concealed by a reddish-grey swelling, which extends beyond the normal limits of the disc. The central cup is encroached upon but not quite obliterated, a small area of white reflection from it being still visible. Vessels of normal size. The veins emerge from the central depression; one, which passes directly upwards, being partly concealed at its emergence; they present conspicuous curves and lose their central reflection as they course down the sides of the swelling. The arteries present a straighter course, but cannot be easily distinguished upon the papilla. The degree of swelling is moderate; it presents fine striation, partly due to minute radiating vessels and partly to the nerve fibres. (Vision quantitative only.)

FIG. 3.—*Descending neuritis in cerebral tumour.* (Case 3, p. 245.)

Right optic disc. Outline recognizable on the temporal side, although not sharp; concealed on the nasal side. Tint, greyish-red, finely striated. Swelling distinct but slight. Veins, of normal size, lose their bright reflection on the sides of the swelling and are concealed just beyond its edge; one, which passes downwards and to the right, is concealed near the middle of the papilla by a white opaque spot. The arteries are narrow and near the middle of the papilla are bordered by white lines. (Vision could not be ascertained.) For the microscopical appearances at a later stage, when the inflammation was greater, see Plate XII. 4—9, and XIV. 1.

FIG. 4.—*Optic neuritis in cerebral tumour; tubercular masses in cerebral hemispheres, cerebellum, and the other eye.* (Case 5, p. 250.)

Left optic papilla. Disc concealed by very prominent swelling with a marked central depression. Veins large, and form conspicuous curves as they course down the steep sides of the swelling, some being even lost to view in their course on account of the steepness. Beyond the edge they are obscured for a short distance. Arteries partly concealed. Minute red stippling of swelling but no hæmorrhages. Much white tissue about the vessels in the central depression. Vision, slight failure only.



FIGS. 5 & 6.—*Optic neuritis in traumatic meningitis, and after recovery. Right eye.* (Case mentioned on p. 148.)

FIG. 5.—*Appearance ten days after the injury.* A pale red, striated opacity conceals the whole disc, the edge being nowhere visible; prominence slight but distinct. The central cup is not quite obliterated; its white reflection is visible at the bottom of the central depression. Veins of normal size; the upper branches, where the swelling is greatest, lose their reflection at the edge. Arteries of normal course. Vision: no evidence of impairment.

FIG. 6.—*The same disc a month later, presenting normal characters.* Edge clear and fairly sharp; sclerotic ring visible on nasal side (to the right). Central pit clear and apparently normal; steep on the temporal (left), sloping on the temporal side. The edge of the disc is seen by its relation to the vessels to be considerably within the limits of the swelling shown in the preceding figure. The vessels have a normal course. Vision normal.

#### PLATE IV.

FIGS. 1 & 2.—*Optic neuritis in a case of probable syphiloma of brain, and disc after recovery. Right eye.* (Case 7, p. 254.)

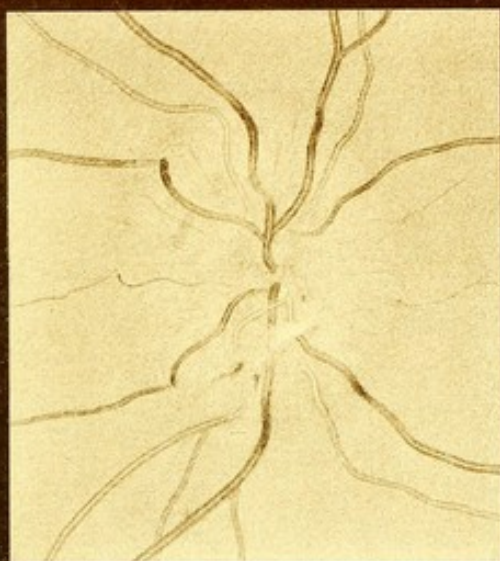
FIG. 1.—*Inflamed papilla.* Disc concealed by a prominent, red, striated swelling about twice the normal diameter of the disc. A slight central depression can be seen. The veins, not larger than normal, appear dark as they pass down the sides of the swelling. A white patch lies across and conceals one which passes downwards. On the lower part of the swelling is a small hæmorrhage. Vision: No. 1 Jäger at six inches with a little difficulty.

FIG. 2.—*The same disc three months later, presenting very little trace of the preceding inflammation.* Outline quite clear and sharp; sclerotic ring distinct; no disturbance of adjacent choroid. Central cup small but not apparently "filled-in," as the veins can be traced down its sides to their junction at the bottom. Some of the arteries on the disc are accompanied by white lines, especially one which curves downwards. A comparison of the vessels with that in the last figure will show how much they were altered in their course by the swelling. (A vein which passes upwards and to the left has by an error been figured as an artery.)

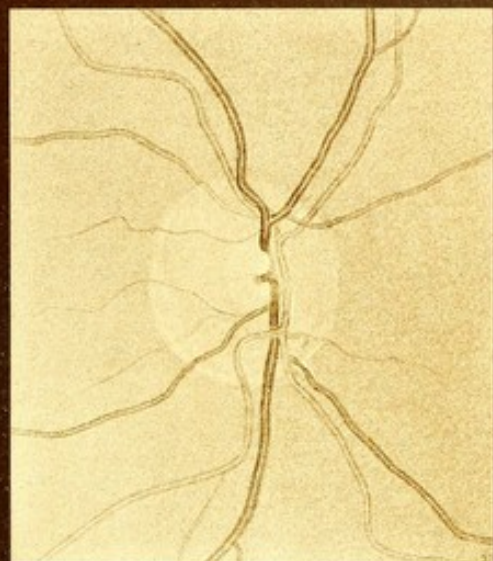
FIGS. 3 & 4.—*Optic neuritis from cerebral syphiloma, and same disc after the subsidence of the neuritis.* (Case 9, p. 256.)

FIG. 3.—*Inflamed papilla.* Disc concealed under a swelling of moderate prominence, and about twice the diameter of the normal disc, concealing the veins and arteries. Colour red, and finely punctate in the centre; greyish-red and striated on the peripheral portions of the swelling. The central reflection of the veins is lost as they slope down the sides of the swelling. Veins a little larger than normal; arteries nearly of normal size. One vein which courses from below passes over

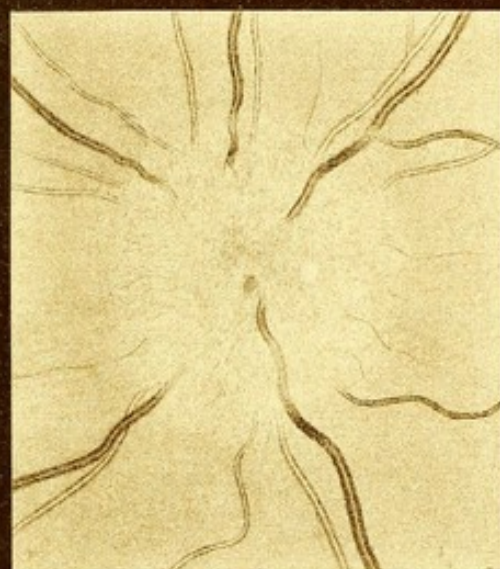




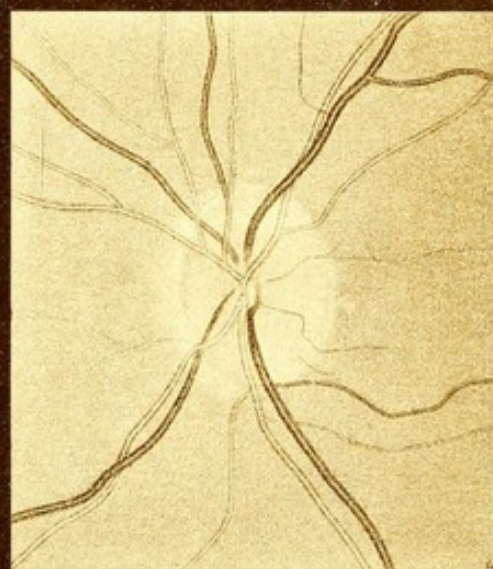
1



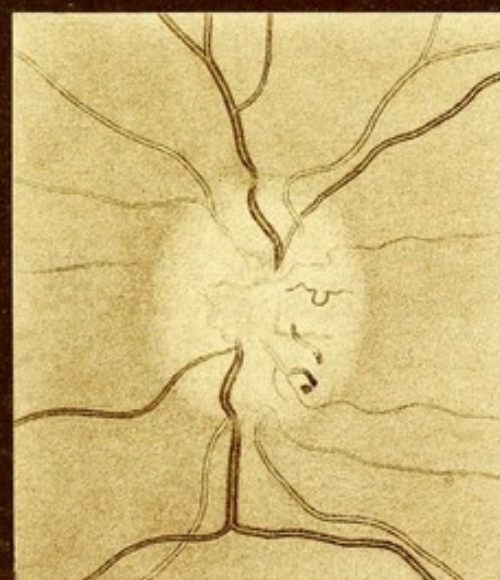2



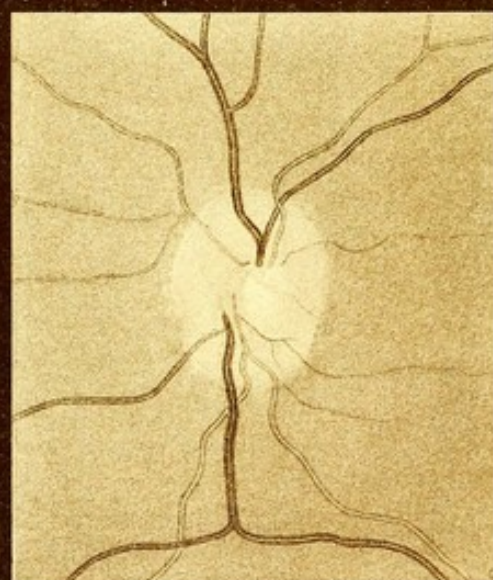3



4



5



6







the disc more superficially than the others and presents a double curve. There is a small hæmorrhage in the centre of the disc, and a faint white spot to the right of the centre.

Vision =  $\frac{1}{15}$  and  $\frac{8}{10}$ . Field normal. Blind spot double normal size (Fig. 10, p. 56).

FIG. 4.—*The same disc two months later.* Neuritis gone; outline of disc clear in whole circumference. There is a fringe of pallor beyond the nasal edge, to the left (atrophy of choroidal pigment). Tint of disc normal, but too uniform, and the disc has a "filled-in" aspect, the two lower veins being narrowed and partly concealed by new tissue at the centre left by the inflammation. The normal central "cup" is being re-established, as shown by the curve at the central end of the lower vein; its bright reflection is lost as it curves down the edge of the cup; at the centre it is still almost concealed. Arteries normal.

Vision the same.

FIGS. 5 & 6.—*Subsiding neuritis and subsequent atrophy (cerebral syphiloma); process of obliteration of vessels. Left eye.* (Case 10, p. 259.)

FIG. 5.—*Neuritis subsiding.* A month previously intense inflammation with hæmorrhages. Now a pale reddish-white prominence remains, with soft edges, paler in the centre than at the margin. The veins, large and dark, curve over the side of the swelling, and are obscured just beyond the edge. The arteries are small and partially concealed by the new tissue. On the surface several vessels are seen in process of obliteration. One, apparently an artery, ends suddenly at a small extravasation, and the terminal portion of the vessel is very dark, as if plugged. From the central portion of the vessel two small branches proceed.

Vision 0; galvanic stimulation, no effect.

FIG. 6.—*The same disc six weeks later.* The swelling has subsided almost to the level of the retina; the surface of the disc is white, the centre (in the position of the physiological cup) being a little whiter than the rest. Veins and arteries are somewhat smaller than normal, the latter especially. The former have now a straight course, and the latter can be traced, although narrowed and obscured, to their emergence near the centre of the disc. The small vein in the other figure which had a peculiar serpentine course has disappeared. The artery which appeared to be in part plugged presents a very different appearance. The distal part has disappeared, and the proximal portion has dwindled in size to that of the branch, which appears to be carrying on the blood from it. Its origin from a larger trunk is now clear.

Vision—very slight perception of light; retina again sensitive to electrical stimulation.



## PLATE V.

FIGS. 1 & 2.—*Optic neuritis (right and left eyes) in cerebral tumour.*

The patient (in the National Hospital for Paralysis and Epilepsy, under the care of Dr. Hughlings Jackson), was a man aged thirty-five, suffering from left-sided convulsions, beginning with a visual and auditory aura (referred to the left ear), and from left hemiopia of both eyes. Subsequently, coarse tremor came on in the left arm, with weakness, which gradually increased to complete left hemiplegia. The symptoms were thought to be due to a tumour of the right hemisphere, in the parietal and temporo-sphenoidal lobes, extending inwards.

FIG. 1.—*Left disc.* Inner half veiled beneath a reddish striated swelling of slight prominence, sufficient to alter a little the course of the veins, and partially conceal the arteries. The outer half is much less red, and its outline can be seen but is soft. A flame-shaped hæmorrhage lies across the edge, having one extremity adjacent to a small vein. There is another small extravasation near an artery on the lower margin. Vision normal except for the hemiopia.

FIG. 2.—*Right disc* presenting a similar appearance; the inner half concealed, the outer visible, but not clear. No extravasation.

During about six months that the patient remained under observation not the slightest change could be seen in the discs except the disappearance of the hæmorrhages. A year and a half later, two years after the drawings were made, vision had entirely failed. The inner halves of the discs were still concealed under a reddish striation, but the outer halves had become grey without any redness.

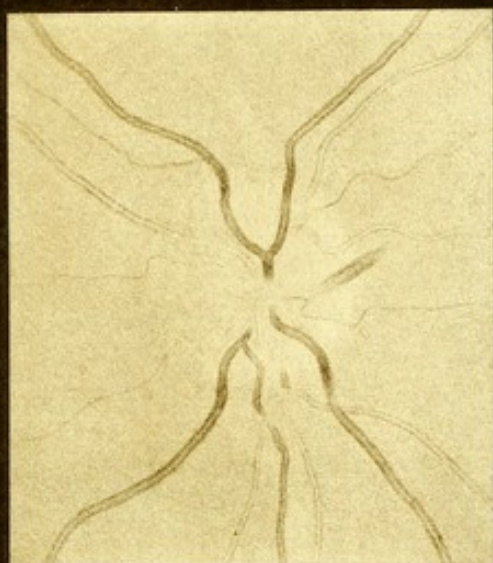
FIG. 3.—*Optic neuritis in a case of cerebral syphilitic disease, causing left-sided weakness and convulsions beginning in the hand. Left eye.*

Disc completely concealed on nasal side (to the left) while on temporal side (to the right) the position of the edge can just be detected. Swelling moderate, altering the course of the veins, which can, however, be traced up to their emergence in the centre. The curve they present at the edge of the swelling is gentle, but their central reflection is lost there. The more abrupt backward curve presented just beyond the edge of the disc, by a vein which passes directly downwards, is apparently determined by the position of an artery which crosses it, and which a little above this point, in crossing it again, has again depressed it. A small vein which passes upwards and to the left (in the figure) is concealed for some distance by the striated opacity. On the upper edge of the swelling is a small hæmorrhage. Neuritis bilateral. Vision  $\frac{1}{5}$ . Colour vision normal.

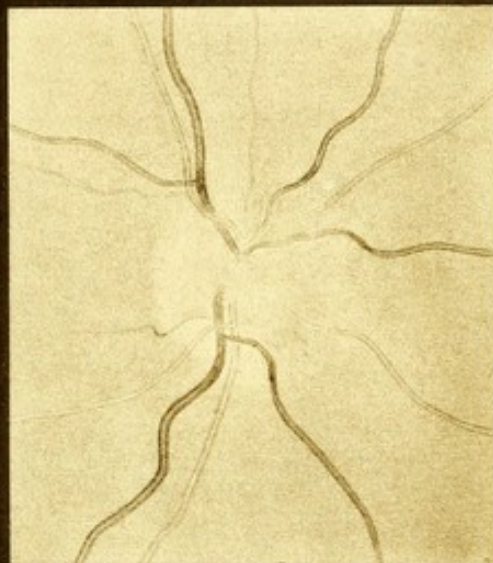
FIG. 4.—*Optic neuritis in cerebral tumour, probably tubercular, causing left hemiplegia and hemiopia. Left eye. (Case 11, p. 261.)*

The temporal part of the disc (to the right in the figure) is clear, its outline being quite distinct. Elsewhere the margin of the disc is concealed by a (reddish) striated opacity, of slight prominence. The veins are large,

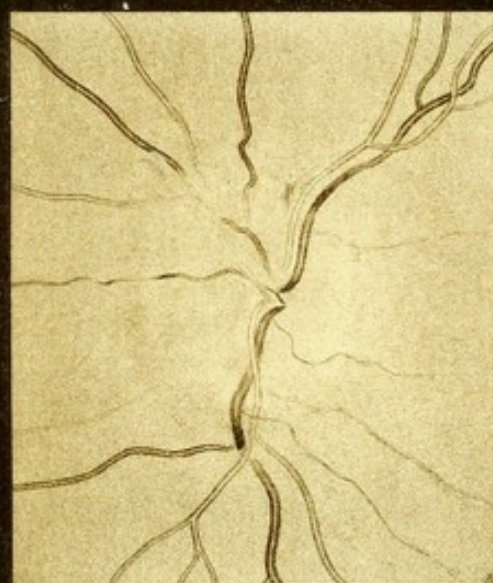



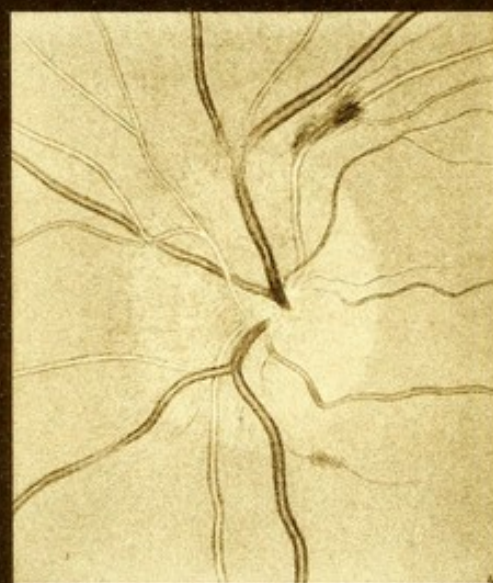
1



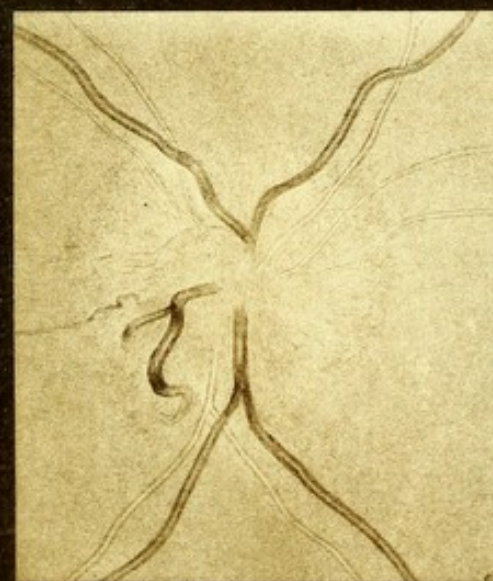2



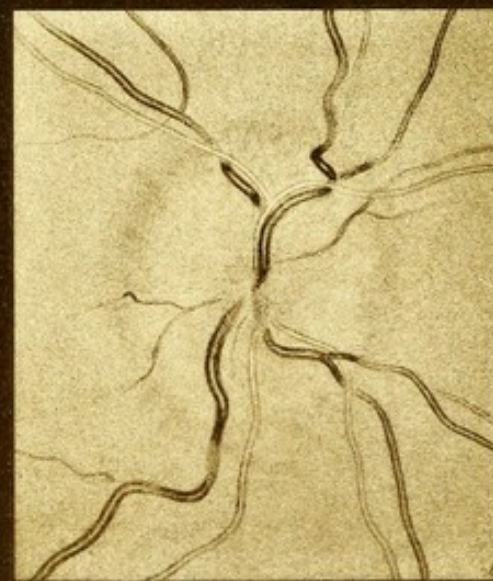3



4




5



6

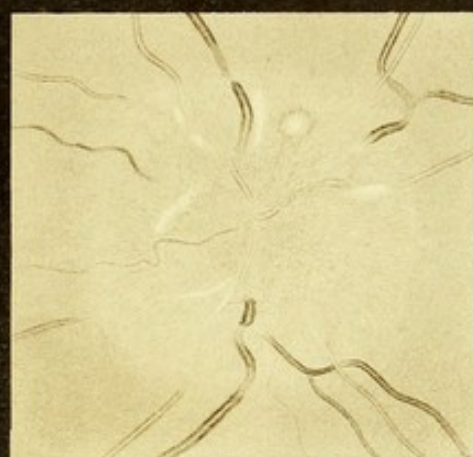
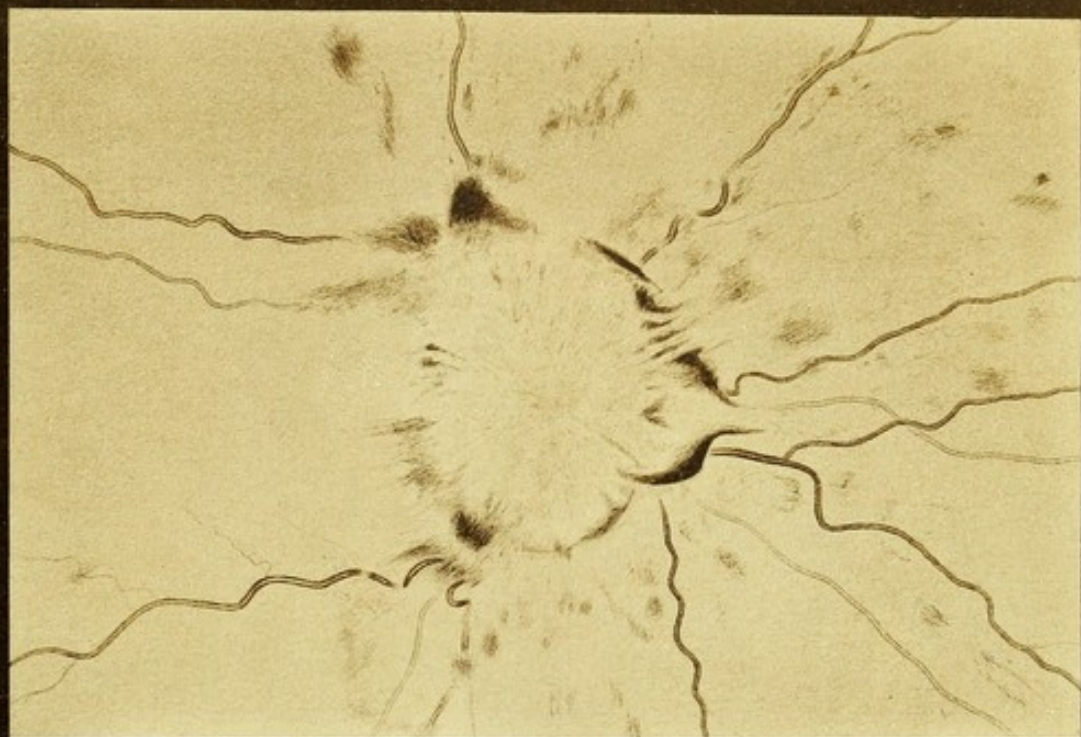


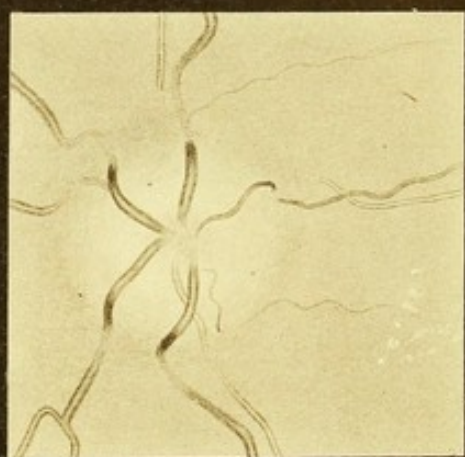




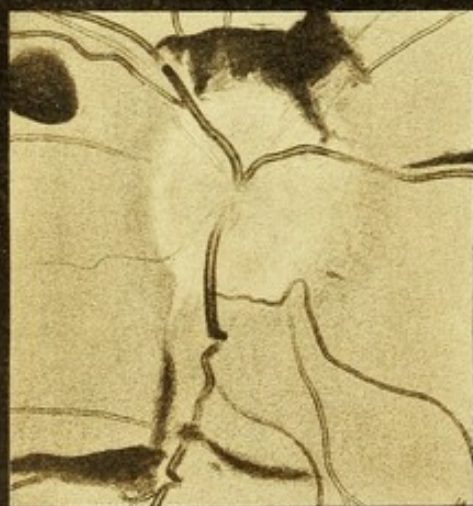




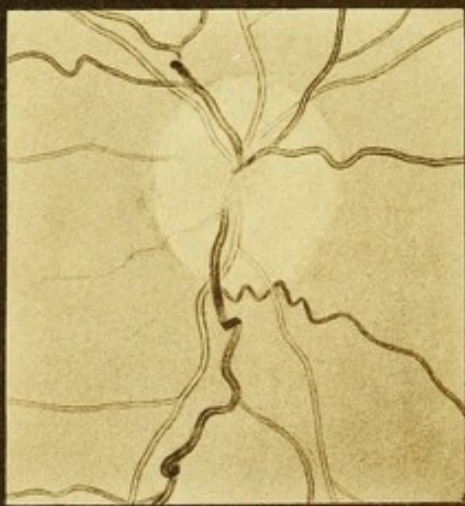2



3



4



5



and those which pass downwards curve a little over the edge of the swelling, while one, which passes upwards and does not curve, is concealed at the edge. A small striated hæmorrhage lies over an artery above, the striation being in the direction of the nerve fibres. The course of the artery is not changed. Below is a still smaller extravasation upon a minute branch of a vein. Vision: No. 10 Jäger at one foot; hemiopia; all colour-vision lost. Both eyes similar. The patient improved under treatment, the disappearance of the neuritis being the first sign of the improvement. In a few weeks the aspect of the discs became perfectly normal and has continued so now for two years.

FIG. 5.—*Optic neuritis in cerebral tumour.* Glio-sarcoma, springing from the membranes, and compressing, without invading, the right side of the pons and right hemisphere of the cerebellum, causing right-sided convulsions beginning in the hand, and afterwards left-sided attacks beginning in the face: weakness and coarse tremor in the right limbs, deafness in the right ear, and trophic changes in the right eye.

The drawing was made as the neuritis was beginning to subside. Disc concealed beneath a considerable swelling, red and striated. Veins large (beginning to lessen in size), curve over the edge of the swelling. One which passes down cannot be traced beyond the edge, where it apparently disappears. (Even when the neuritis had subsided still more, its further course could not be detected.) Arteries small, not more than one half the size of the veins. Vision 0.

FIG. 6.—*Neuritis in cerebral tumour. Right eye.* (Case 12, p. 264.)

The neuritis was in course of subsidence. Swelling considerable, completely concealing the disc, pale but still reddish, darker around the margin. The veins form conspicuous curves at the edge of the swelling, one above forming a double curve in consequence of passing beneath an artery just within the edge of the swelling. All the veins are concealed for a short distance beyond the edge, and then resume a normal course upon the retina. Vision: reads No. 12 Jäger at a foot. The neuritis subsided into consecutive atrophy, sight gradually failing until vision was completely and permanently lost.

## PLATE VI.

FIG. 1.—*Intense optic neuritis, with retinal hæmorrhages, in a case of cerebral tumour. Right eye.* (Case 13, p. 264.)

The region of the optic disc is occupied by a large swelling, in width about four times the diameter of the disc. It is irregular in outline, with very steep sides, and is bounded in every direction by extravasations. Some of these are more or less striated, others have a sharp convex edge, due to their position in the over-hanging edge of the swelling. The surface of the prominence is about the same tint as the fundus. The vessels are concealed in the substance of the swelling, except one or two, the position of which is dimly seen. Most of them



appear first beyond its edge, and are then of about normal size, but at first they form conspicuous curves, the deeper portions of which are concealed. They then assume a nearly normal course. The arteries are narrow, some being scarcely visible. Numerous hæmorrhages, small and striated, are scattered over the retina in the posterior half of the eyeball, except on the temporal side (to the left). In this direction the swelling reaches almost to the position of the macula lutea, in the neighbourhood of which are many minute white dots adjacent to the edge of the swelling. Vision 0.

FIG. 2.—*Optic neuritis in a case of old fractures of the skull; inflammatory growths beneath them; at the base the results of previous meningitis.* (Case 4, p. 248.)

The position of the disc could be recognized by the indirect method of examination, but by the direct method it is completely concealed by a greyish-red swelling, of nearly three times the diameter of the disc, striated. Upon it are many white spots and lines (due to granule corpuscles, &c.), some of which correspond to the course of the arteries. One, above, is surrounded by a narrow zone of hæmorrhage. The vessels are concealed in the middle of the swelling; the veins more completely than some of the arteries. The course of the veins is very tortuous. Vision  $\frac{1}{12}$ . (The microscopical appearances are shown in Pl. XVI. Figs. 1—4.)

FIG. 3.—*Neuritis subsiding into atrophy; slight retinal changes; tubercle of cerebellum. Left eye.* (Case 19, p. 274.)

The disc is invisible beneath a pale, almost white swelling, depressed in the centre. Over this the veins curve. After sloping down its sides, they are concealed by the adjacent opacity of the retina for a short distance. One artery, which passes downwards, is visible on the surface of the swelling, but is also concealed beyond its edge. The other arteries appear only some distance from the edge. Midway between the retina and the macula lutea is a group of small white granular-looking spots, apparently just behind the level of a retinal vessel which passes among them.) They slowly lessened under observation. The swelling gradually subsided, the edges of the disc reappearing and its aspect becoming that of "consecutive atrophy." Its appearance is shown in section in Pl. XIV. Fig. 2.) Vision 0.

FIGS. 4 & 5.—*Subsiding neuritis, recent hæmorrhages, and same disc after recovery.*

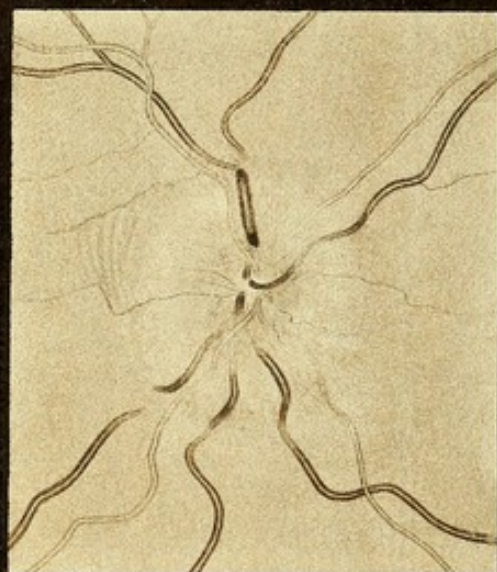
The patient had been in the London Hospital, under the care of Dr. Hughlings Jackson, suffering from the symptoms of cerebral tumour, and presenting intense optic neuritis. Under treatment the symptoms subsided, and the neuritis gradually lessened, but during subsidence several fresh hæmorrhages appeared. He died some years later, and the cicatrix of a syphilitic growth was found on the surface of the brain.

FIG. 4.—*Subsiding neuritis.* The outline of the disc can be seen, but is not clear; its surface is reddish in tint, and the swelling of the papilla is still considerable, as evidenced by the curves formed by the veins in passing over its edge. Several large extravasations are seen.

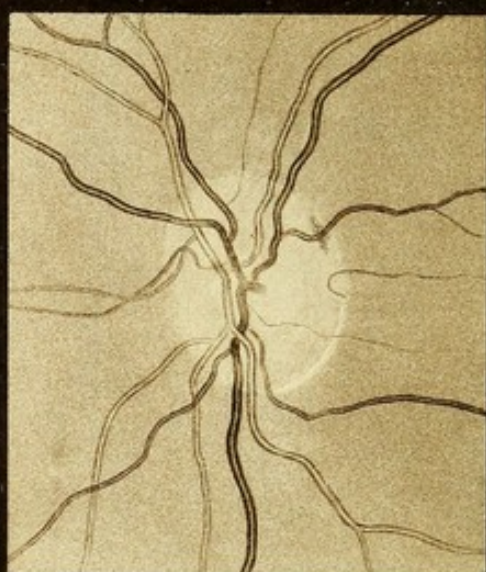



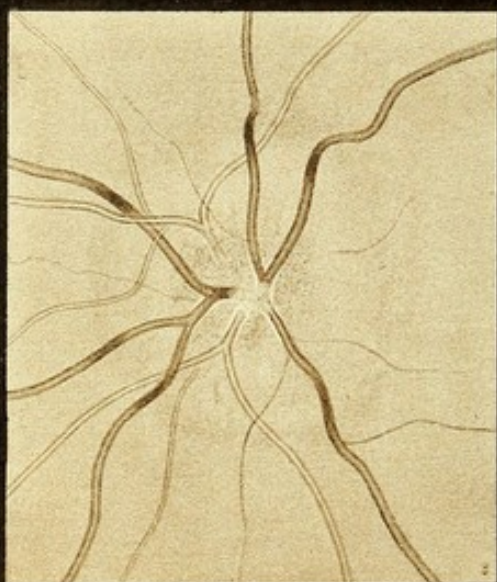




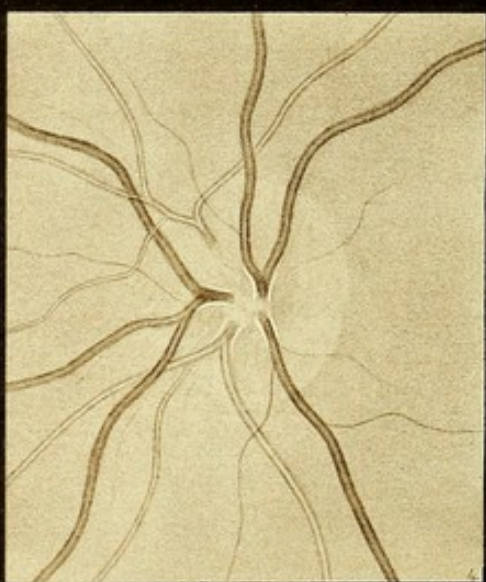
1



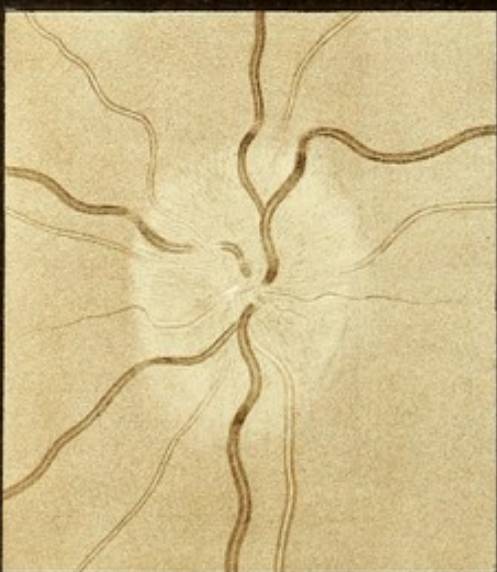2



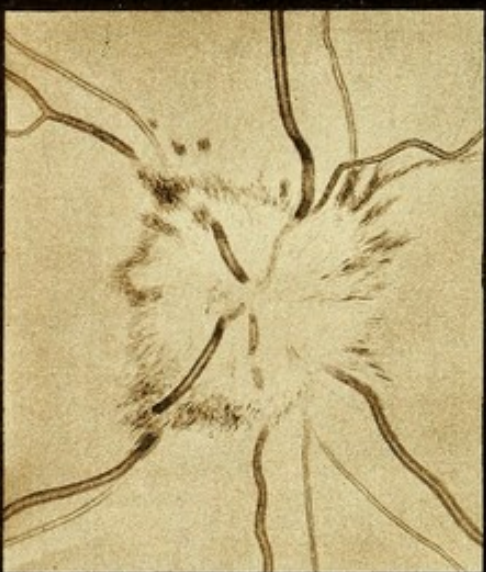3



4



5



6



One of these, below, follows the course of an artery. Another above and to the left is round, not striated, and therefore probably situated in the deeper layers and not in the nerve-fibre layer. Vision normal. Can read the smallest test type.

FIG. 5.—*The same two months later.* The hæmorrhages have entirely disappeared. The disc is clear, and its swelling has almost subsided. But the tortuosity of the vessels has increased, probably on account of their permanent extension by the long swelling.

## PLATE VII.

FIGS. 1 & 2.—*Unilateral optic neuritis; probably cerebral syphiloma.* (Case 17, p. 272.)

FIG. 1.—*Left eye* presenting considerable optic neuritis. The disc is concealed in its whole extent by a swelling—reddish, striated, extending a little beyond the normal limits of the disc. It presents a considerable depression in the centre, so as to cause the prominence of the outer part to be annular in form. The veins, a little larger than normal, form conspicuous curves over it, lose their reflection as they slope down the rather steep sides, and some are concealed beyond the edge for a short distance. In the central depression the veins pass behind the arteries and are unduly concealed by the swollen tissue. The artery which passes upwards is visible throughout; those which pass downwards are distinct at their emergence in the depressed centre, but are concealed by the swelling, to reappear at its edge. No hæmorrhages. Just beyond the edge of the papilla is a series of pale concentric lines parallel to the edge, due to the folds in the displaced retina; they are limited above and below by a small vein. Vision, counts fingers only.

FIG. 2.—*Right optic disc* presenting normal characters. Outline clear; central cup distinct; vessels of normal course; the veins can be traced to their origin at the bottom of the cup. A small deposit of pigment lies within the edge of the disc, across a vein.

FIGS. 3 & 4.—*Very chronic optic neuritis, in a case of epileptoid convulsions.* (Case 23, p. 280.)

FIG. 3.—*Left disc.* Outline obscured by neuritic swelling of slight prominence; the centre stippled red, the periphery only slightly lighter in tint than the fundus. Veins, of nearly normal size, concealed in centre by whitish tissue, which accompanies the larger trunks of both arteries and veins for a short distance. The double contour of the veins lost as they slope down the sides of the swelling; arteries nearly normal. Vision: No. 2 Jäger, spells No. 1. Appearances unchanged during four months' observation.

FIG. 4.—*The same disc two years later.* All swelling is now gone. The outline of the disc is clear in the greater part of its circumference, especially so in the outer (temporal) side; indistinct on the inner (nasal) side. Surface rather deeply tinted. Veins large; at their junction in



the disc they are even more concealed than before, and the white tissue about them is still very conspicuous. Vision, same.

FIG. 5.—*Slight optic neuritis in a girl, with great anæmia and moderate hypermetropia ( $\frac{1}{20}$ ).* (Case 44, p. 310.)

The outline of the disc is lost under a pale, reddish-grey swelling, of slight prominence, a little larger than the disc. The veins, of normal size, lose their reflection as they curve down the sides of the swelling, and some are obscured beyond its edge as they dip into the substance of the retina. Some of the arteries are concealed; others distinguishable with difficulty. The veins are unconcealed, except one where it passes beneath an artery. There is a small white spot near the centre of the swelling. Vision (uncorrected)  $\frac{1}{8}$ .

FIG. 6.—*Optic neuritis in a case of lead poisoning, with cerebral symptoms.* (Case 28, p. 288.)

The disc is concealed by a swelling of moderate prominence, bordered by a fringe of striated hæmorrhage, and of a colour nearly that of the fundus. Veins a little larger than normal. Arteries concealed by the swelling, and most of them very narrow on the retina.

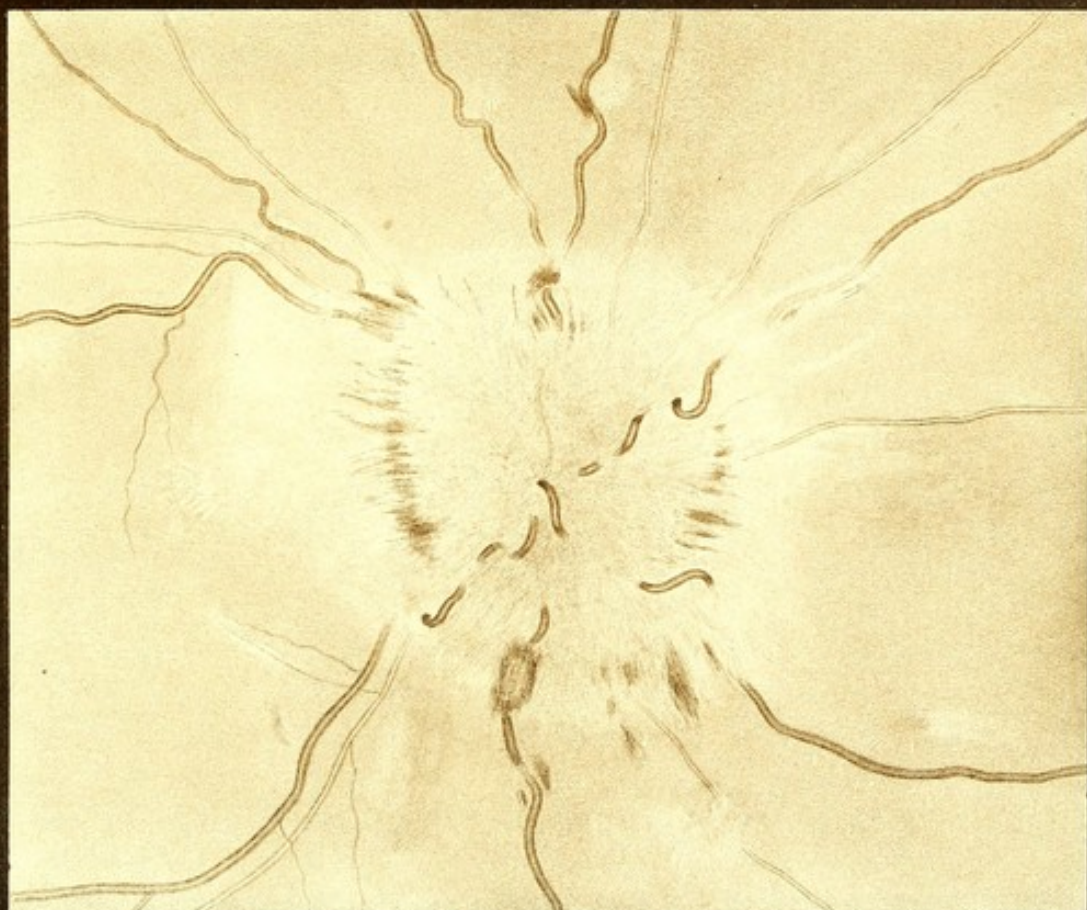#### PLATE VIII.

FIGS. 1 & 2.—*Intense neuro-retinitis, probably idiopathic, in a chlorotic girl, leaving changes simulating albuminuric retinitis.* (Case 29, p. 289.)

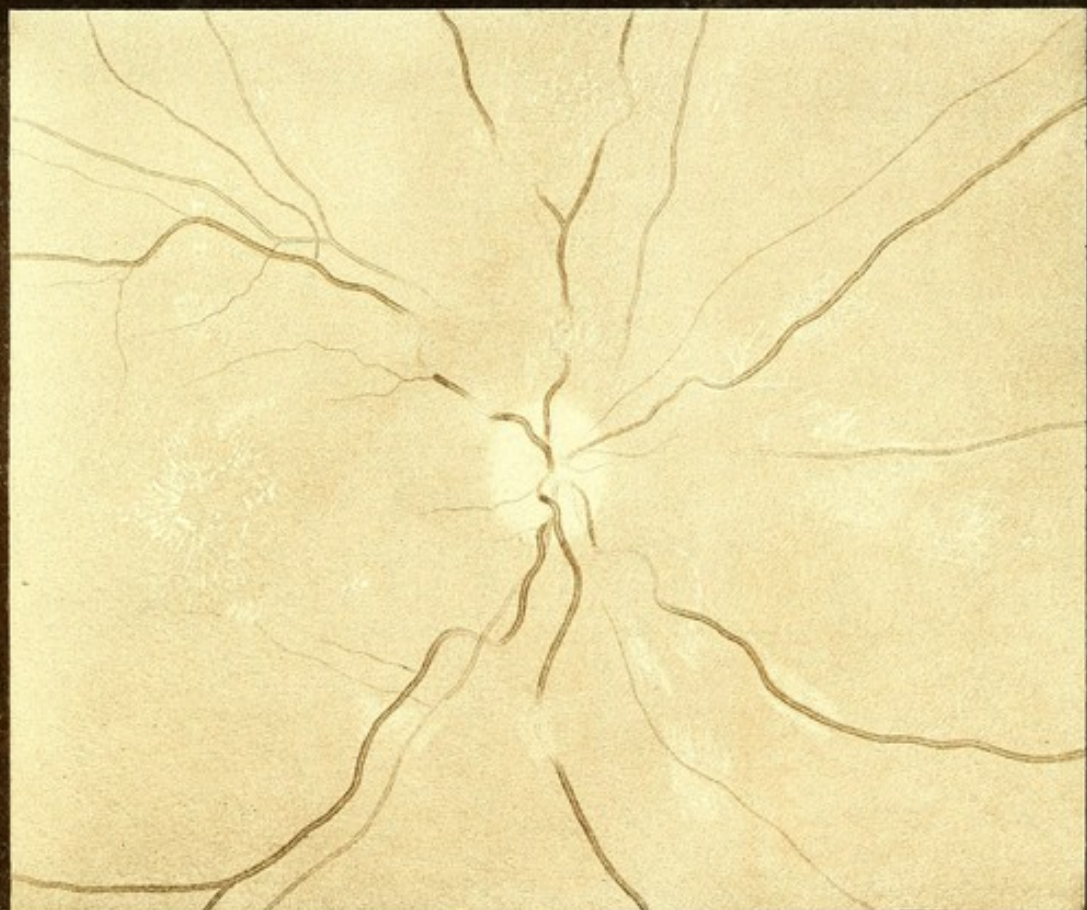FIG. 1.—*Right fundus oculi during the height of the neuritis.* The papilla presents a very large pale red swelling, five times the transverse and six times the vertical diameter of the disc. The peripheral portions are paler than the central. Its sides are steep, and marked by scattered striated hæmorrhages. Even the tortuous veins are almost completely concealed by the swelling, the highest parts of their curves alone being seen. At the edge all reappear, are greatly distended, and form conspicuous curves, most of them being again lost for a short space in the retina. The arteries are all concealed. Many extravasations fringe the swelling. The largest lies over a vein which passes downwards: it is striated, and has a paler centre. The pale edge of the swelling is irregular, presenting several projections, and beyond it are many pale spots in the retina. The swelling on the temporal (left) side reaches as far as the macula, and just beyond it is a group of white, rod-shaped spots, arranged in a fan-like manner, and evidently situated on the temporal side of the macula. There are a few small hæmorrhages here and there in the fundus beyond the limits of the swelling. Vision: No. 19 Jäger; considerable limitation of field, especially upwards and inwards. Loss of colour-vision except for red.

FIG. 2.—*The same fundus three months afterwards.* All the swelling has disappeared. The disc is clear, but has a "filled-in" look, the vessels being partly concealed at their emergence. Both arteries and veins are very narrow. The extravasations have disappeared: the white spots in the retina persist, but have a more granular aspect. Some extend along the vessels, and one or two have an irregular linear course





1



2

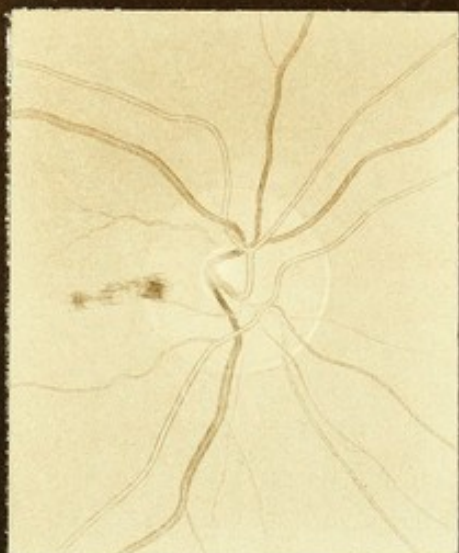




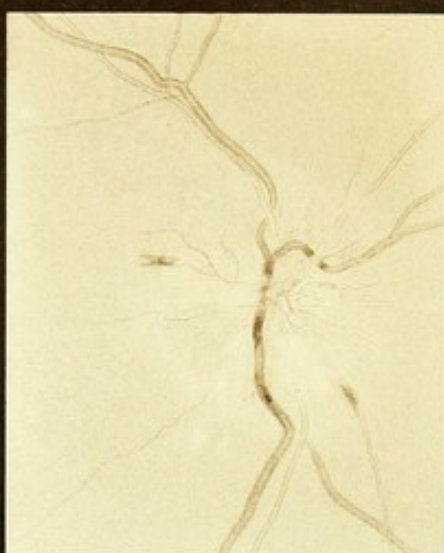




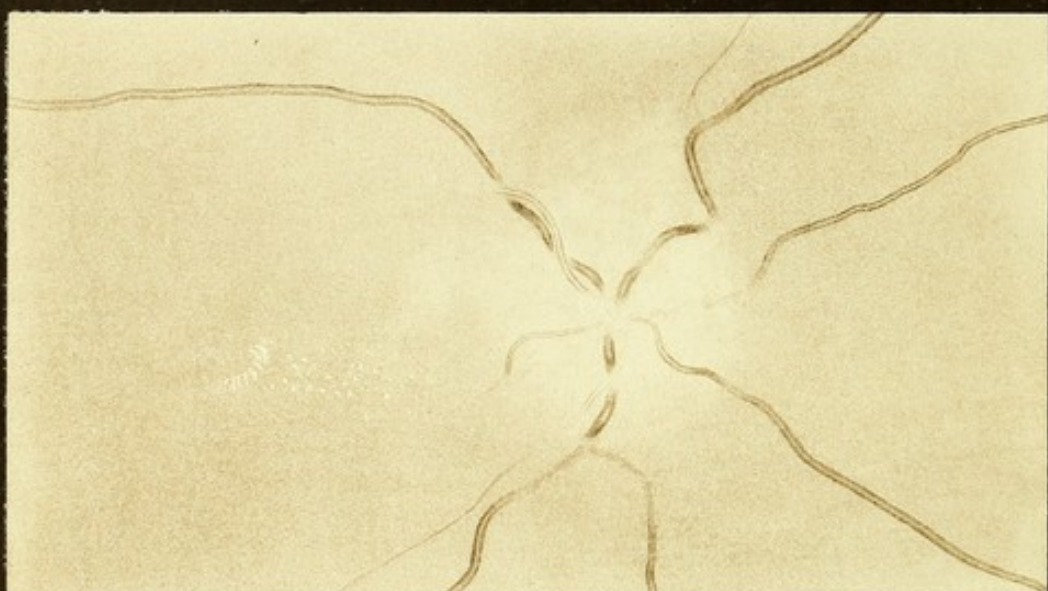



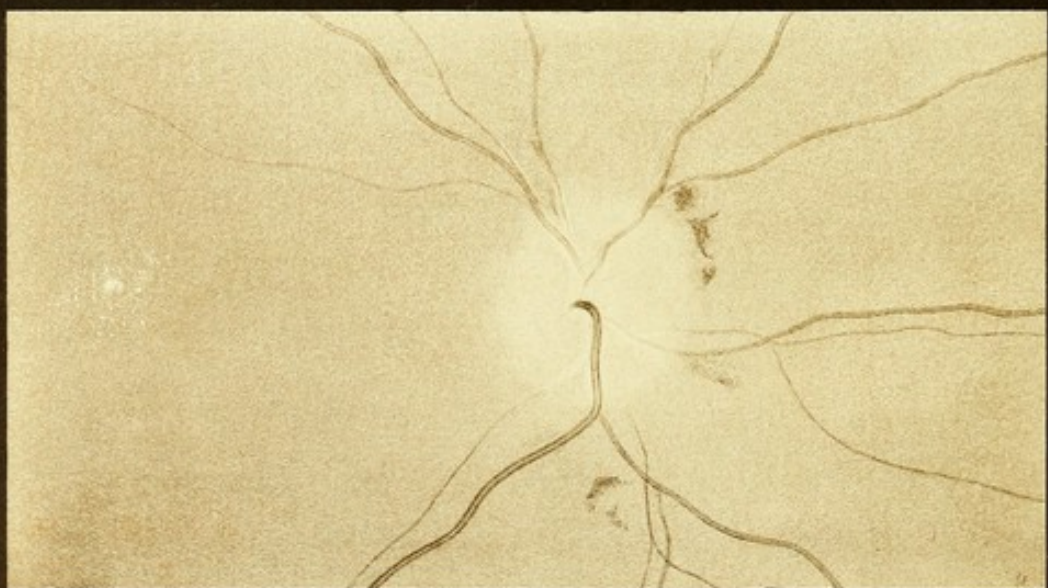1



2



3



4



as if corresponding to the position of choroidal vessels. Many white areas lie in the part of the retina around the disc which was formerly occupied by the swelling. The fan-like group of spots, adjacent to the macula, has become still more conspicuous, and others appear adjacent to them, and of similar arrangement; so that the aspect of albuminuric change is very closely simulated. Vision: quantitative perception of light only.

## PLATE IX.

FIG. 1.—*Hæmorrhage on optic disc in a case of renal disease, arterial disease, and acute cerebral lesion. Right eye.*

The optic disc is otherwise normal; the central cup distinct, narrow but deep; the arteries and veins of normal size. On the temporal side of the disc is a small extravasation, striated, extending on the retina about a disc's breadth. It has apparently arisen from the rupture of a small vessel, which can be traced to, but not beyond, the hæmorrhage. It had given rise to no symptoms.

FIG. 2.—*Neuritis albuminurica. Right optic disc of a man suffering from chronic renal disease, convulsions, and mental derangement. (Case 36, p. 299.)*

The disc presents the signs of slight but distinct neuritis. Its outline can be nowhere seen; there is slight swelling; the tint of the papilla is red, and the redness is striated. Many small vessels radiate from it on to the retina—more than is common in neuritis. The veins are rather large. The arteries are very narrow—not more than one half the diameter of the veins. One small hæmorrhage exists on the temporal (left) edge of the disc. On the surface of the papilla are several white spots, irregular in shape. One is situated over an artery, another near the middle of the disc, and one near the lower edge. One small soft whitish spot can be seen on the retina near a vessel above the disc, but this is the only trace of retinal affection. (There were no spots near the macula lutea.) Vision: No. 12 Jäger.

FIG. 3.—*Albuminuric neuritis in a man suffering from chronic renal disease (granular kidney), intense headache, and who died shortly afterwards of uræmia. Right eye. (Case 37, p. 301.)*

The disc is concealed by a considerable greyish-red swelling, stippled and striated. The veins are concealed at their point of emergence, curve over the prominence, and are again concealed at its edge. Beyond, they have a normal course and size upon the retina. The arteries, where visible upon the papilla, are a little below the normal size; but beyond, upon the retina, they are much smaller than normal, some being scarcely visible as mere lines, and two cannot be detected beyond the edge of the papilla. There are a few very minute shining white spots upon the centre of the swelling; between it and the macula are several white flecks, and close to the macula a few radiating dots and lines are arranged in a fan-like form. Vision: reads No. 6 Jäger.



FIG. 4.—*Subsiding albuminuric neuritis. The fundus of a patient suffering from chronic Bright's disease (probably granular kidney), with a pulse of very high tension.*

The papilla is slightly prominent, greyish-white, the edges of the disc being concealed by it. The veins are narrow, and the arteries extremely small, recognizable only in narrow lines. One or two small extravasations are seen near the disc, and farther off are several small collections of pigment, probably the remains of former extravasations.

## PLATE X.

FIG. 1.—*Acute nephritic retinitis, in a patient suffering from chronic renal disease, consecutive to an acute attack twelve years previously. (Case 39, p. 302.)*

The disc is veiled by a pale opacity, not prominent, which extends on to the adjacent retina. Many soft white areas and striated hæmorrhages are scattered over the posterior segment of the retina. The veins are a little larger than normal. Many of them are much concealed at the edge of the papilla. The arteries are large and conspicuous over the disc, but cannot be traced beyond (probably because they become contracted in size, and are concealed by the retinal opacity). For the microscopical appearances, see Pl. XVI., Figs. 7, 8, 9, & 10.

FIG. 2.—*Chronic retinal changes in albuminuria; from a case of acute renal disease passing into the chronic form. Right eye. (Case 40, p. 305.)*

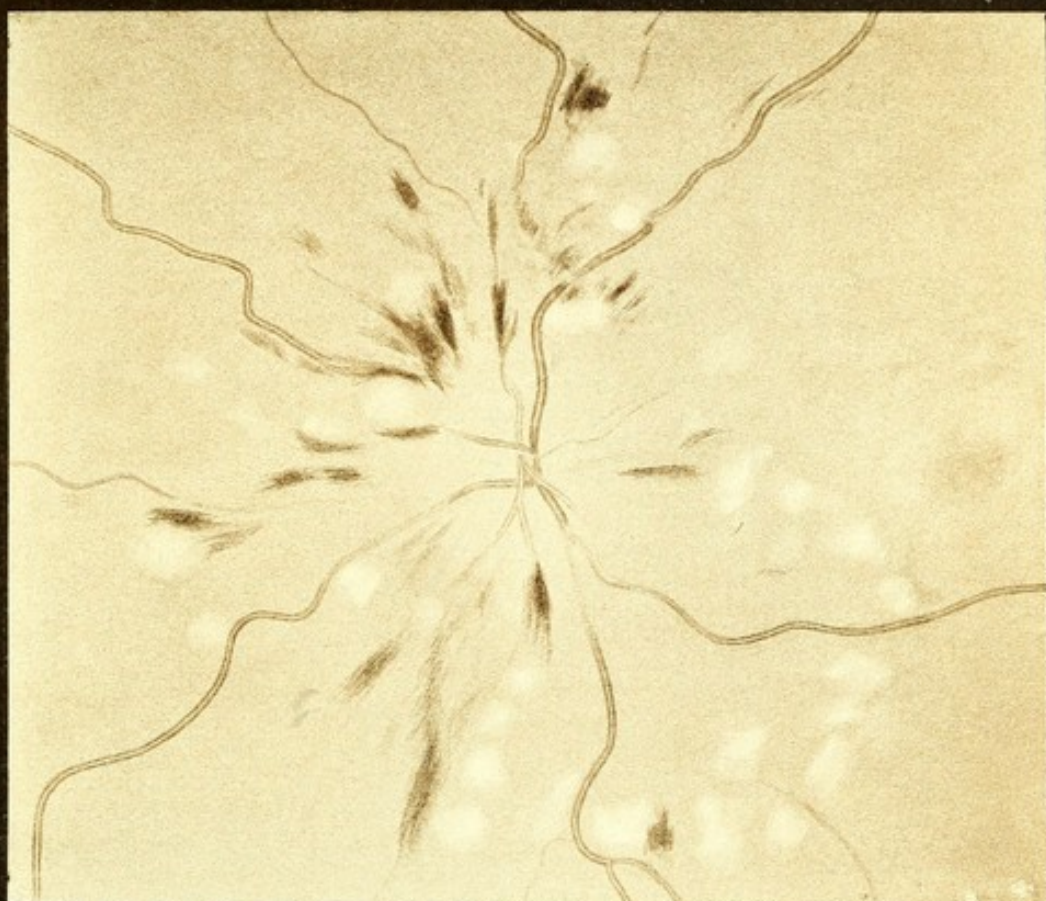The disc and its central cup are normal. The vessels have a normal course. Many irregular white spots lie around the disc, especially between it and the macula, around which is a halo of small spots, for the most part very minute; one or two larger and very white. The other spots are soft-edged; some of them are superficial to the veins. There are a few small hæmorrhages, most of them adjacent to white spots. A small vessel which passes upwards is accompanied by extravasation, as if into its perivascular sheath. Vision: reads No. 12 Jäger.

## PLATE XI.

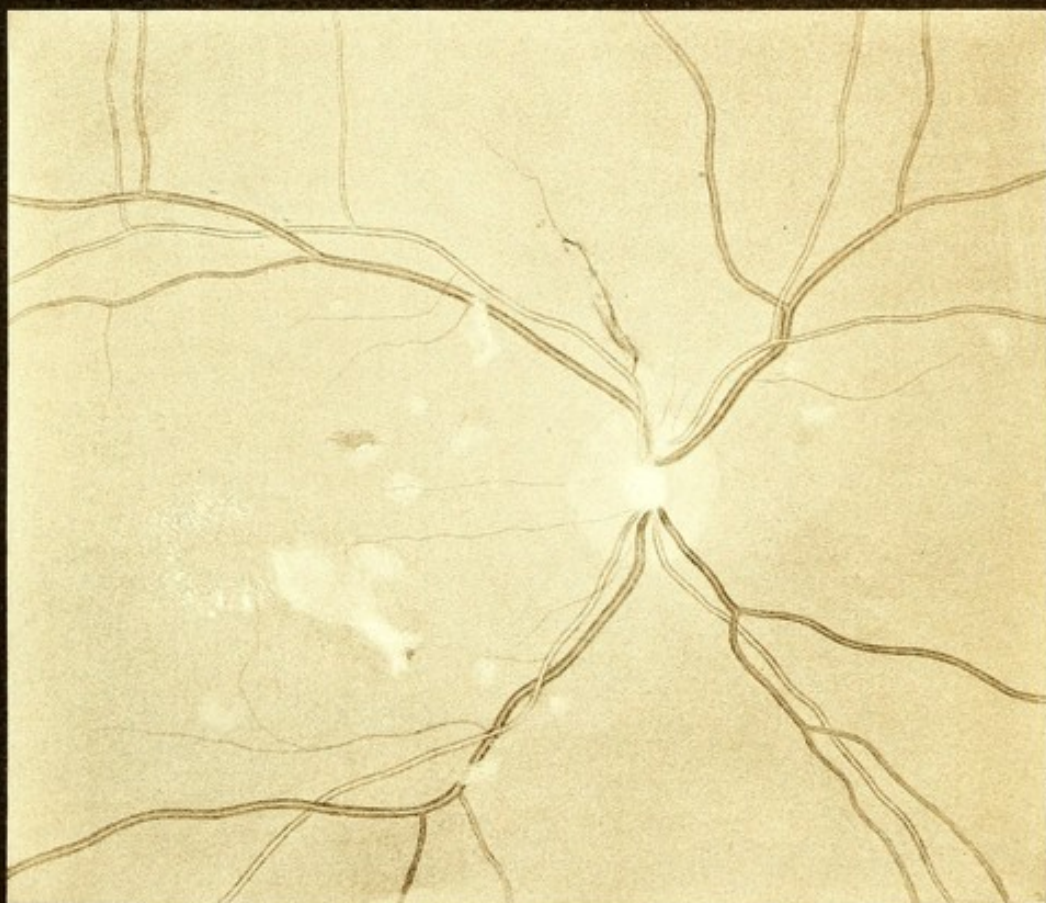FIG. 1.—*Retinal changes in a case of progressive pernicious anæmia. Right eye. (Case 45, p. 311.)*

The general tint of the fundus is paler than normal. The disc is clear and the vessels distinct almost to their origin in the centre. The veins are very broad and pale, scarcely darker than the arteries. Their central reflection is broad and indistinct. The arteries are rather narrower than normal, and very narrow in proportion to the veins. A large number of striated hæmorrhages lie around the papilla. Many of these are adjacent to vessels, in front of or beside them, but the course of the vessels is not disturbed. Some white spots are seen, most of which are adjacent to





1

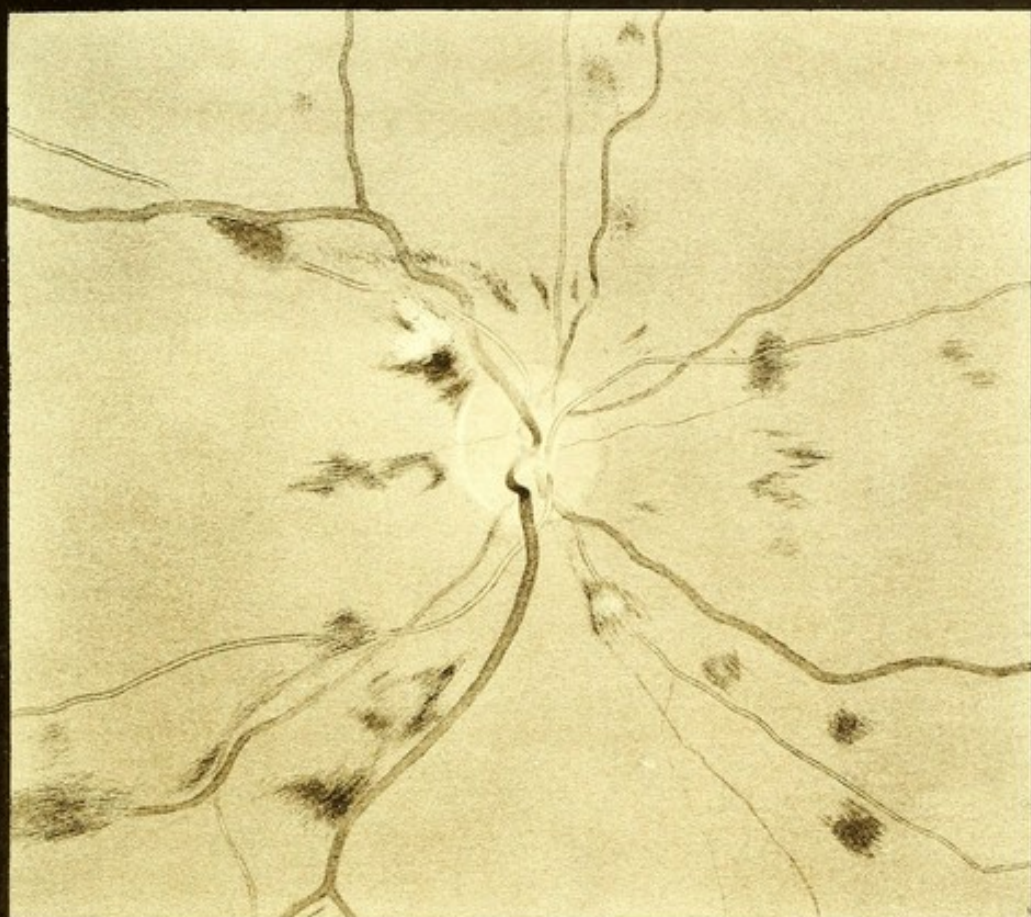


2

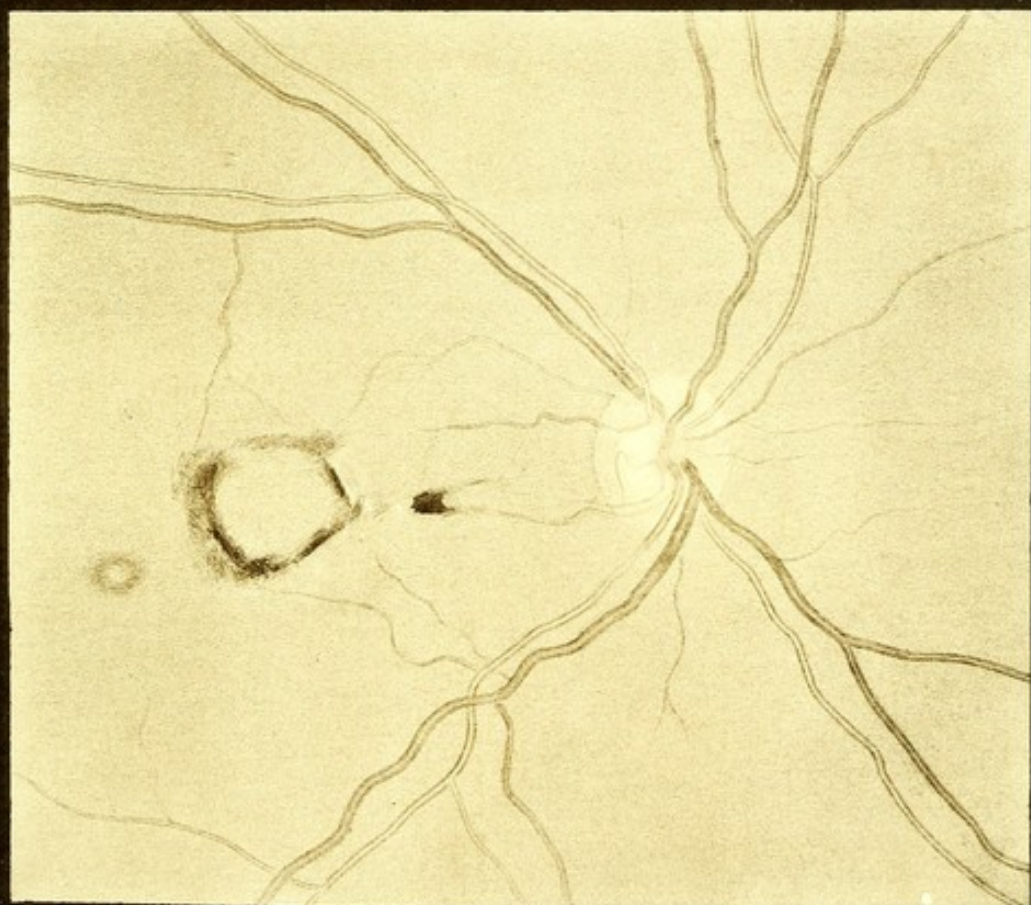








1



2

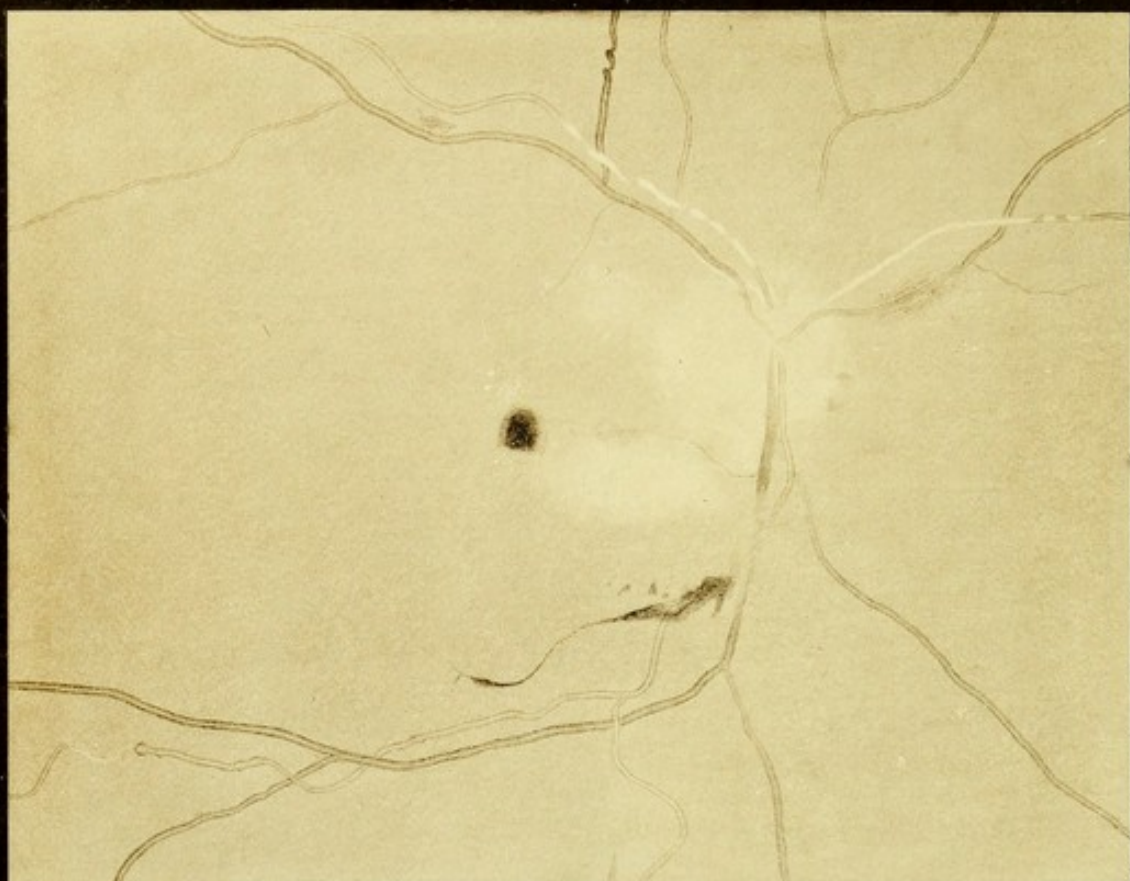




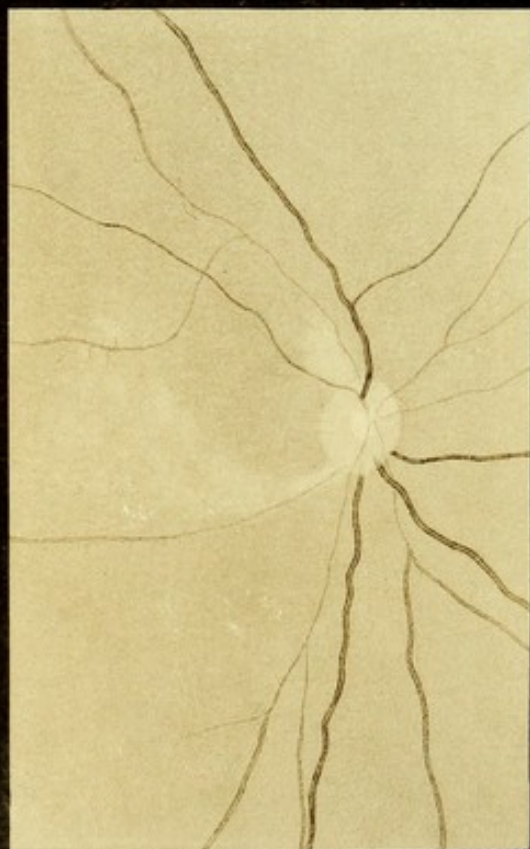


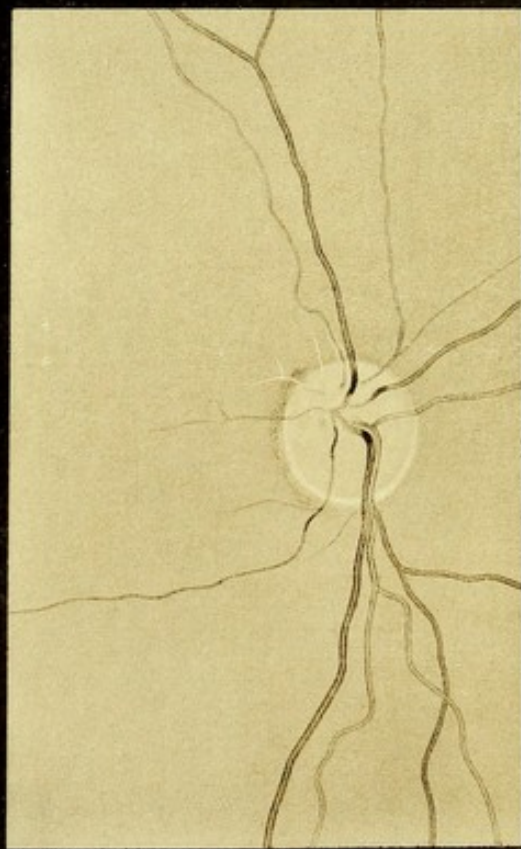




1



2



3



extravasations, one or two being surrounded by a halo of hæmorrhage. One large white spot above the disc has an irregular extravasation below it, but only a few small spots of blood above it.

FIG. 2.—*Retinal changes in leucocythæmia. Right eye.* (Case 46, p. 312.)

The optic disc is clear and normal. The course of the vessels is normal. The retinal veins are very broad—at least twice their normal width. Their central reflection is in some veins narrow and indistinct, in others it is broad. The disproportion in size between the arteries and veins is thus very great. They are exceedingly pale, scarcely darker than the arteries. An annular zone of hæmorrhage surrounds the macula lutea, broader on the temporal than on the nasal side. On the latter, adjacent to it, the retina presents a grey reflection. Between this and the disc is a striated hæmorrhage, in which are one or two white spots. On the outer side of the annular extravasation is a small, soft, white spot surrounded by a halo of hæmorrhage. The extravasation had caused a corresponding central defect in the field of vision. (Subsequently the veins became still larger and more tortuous as in Fig. 1, p. 11.)

## PLATE XII.

FIG. 1.—*Retinal changes (perivascular disease, aneurisms, &c.) in a case of chronic renal disease. Right eye.* (Case 42, p. 308.)

The outline of the optic disc can be seen on the nasal (right) side, but is not very distinct. Its temporal portion is concealed by a white opacity, which extends on the adjacent retina towards the macula lutea. Near the latter are a few minute white spots. Several small extravasations are seen: one, rounded in form, near the macula, and another below, which extends for a long distance along the course of a small vessel, wider at parts than at others, and in one place interrupted. Another extends, as a linear extravasation, along the course of a vein which passes directly downwards. Three arteries which pass upwards present a peculiar appearance, being concealed more or less completely by white bands, corresponding in width to the vessels. One, which passes upwards and to the right (in the drawing) is masked for a considerable distance by such a band, which ceases suddenly, and, before its termination, presents two interruptions. The vessel beyond the sheath, and in the interruptions, is seen to present perfectly normal characters. Another artery, which passes upwards and to the left, is free at its origin, but just beyond the edge of the disc is concealed by a similar band. It pursues a somewhat wavy course, the lower parts of the curves being indistinct. Like the other, the band ends abruptly, and the vein beyond presents a normal appearance. Another artery, which arises in the disc from that last described, presents a similar white sheath from its commencement to its disappearance behind an artery. It emerges some distance beyond, free. A vein passing upwards presents



peculiar corkscrew-like curves. The vein which passes downwards is invisible for a short distance, beyond the extravasation just described, together with its accompanying artery. The arteries are, for the most part, otherwise normal, but one, which passes directly downwards, presents, some distance from the disc, several—at least four—distinct dilatations, evidently minute aneurisms. The central reflection from the vessel broadens out in these dilatations. The last one is globular, and appears at first sight to terminate the vessel, but closer inspection reveals a narrow white band passing from it, which farther on broadens, and gives origin to a branch of an artery of normal appearance. Here and there in the retina are small collections of pigment. Vision—counts fingers only.

FIG. 2.—*Embolism of the central artery of the retina, occurring simultaneously with an embolism of the middle cerebral artery. Left eye, indirect image. (Case 47, p. 313.)*

The drawing was made about a fortnight after the occurrence of the embolism. The disc (previously veiled by opacity) is clear and pale (not quite pale enough in the figure), the peripheral part almost, but not quite so clear as the central cup. Its edges are sharp. The veins have a normal size and course. Several of them, however, disappear at the edge of the disc. The arteries are filiform on the disc and for some distance beyond. Some remain, as far as they can be seen, narrow (even to the periphery of the retina); others become wider at a distance from the disc, which varies in the case of different branches. From the upper part of the disc a white opacity extends a short distance on to the retina. A similar but narrower white area extends from the lower part of the disc, being evidently situated behind the level of an artery, and it gradually widens and becomes less intense, and is continuous with a mottled opacity which occupies the region of the macula, and is the remains of a large white area which at first occupied this region. A branch of an artery which courses across the upper part of this area is evidently dilated, and the minute branches which come from it are abnormally distinct. Vision 0.

FIG. 3.—*Partial embolism of the central artery of the retina. Right eye, direct image. (Case 48, p. 318.)*

The disc is clear; the central cup and sclerotic ring distinct. The veins are of normal course and character. One division of the central artery, comprising the branches which course downwards and to the right (in the figure), is perfectly normal. The branches of the other division emerge from the upper part of the disc. Of these, two which pass upwards and outwards (to the left) are completely obliterated, visible only for a short distance as white threads. Two others which pass upwards are very narrow, but their central reflection can just be distinguished. One of them is accompanied for a short distance by fine white lines along its sides. Both vessels, some distance from the disc, become wider and resume their normal appearance; a branch of one, which passes to the right, remains filiform throughout. No changes







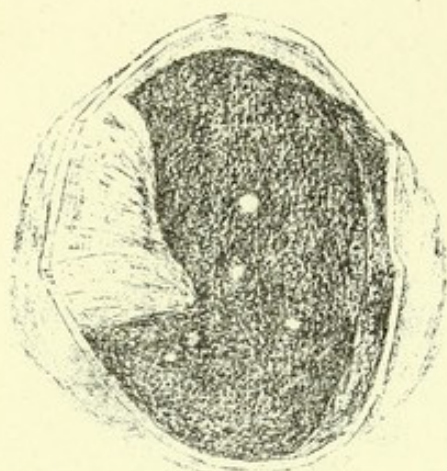


Fig. 1

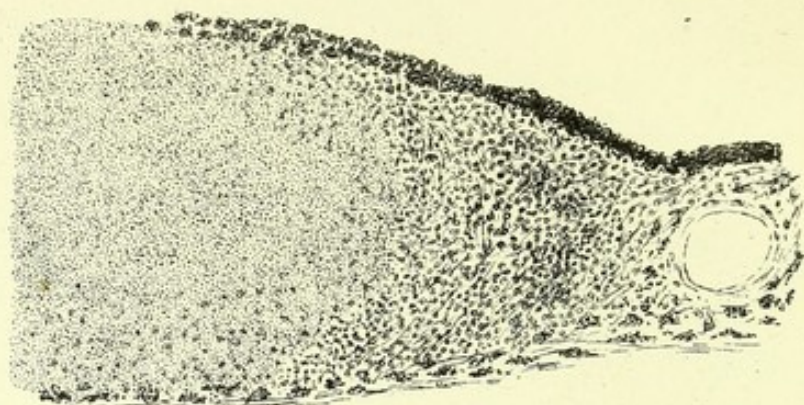


Fig. 3

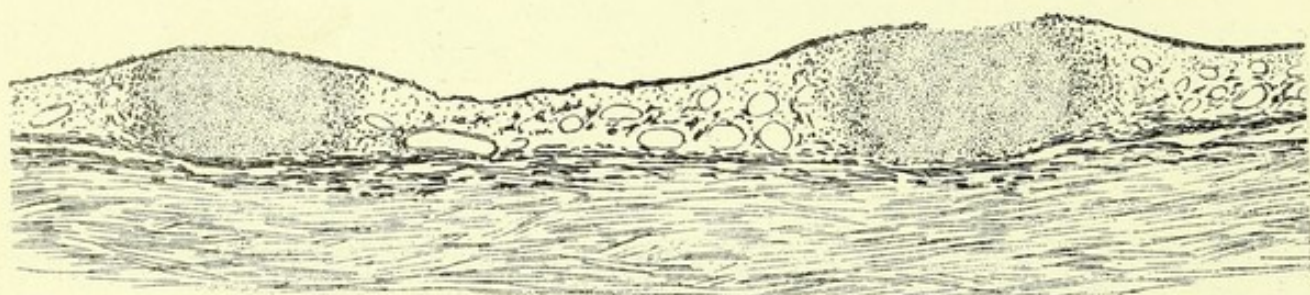


Fig. 2

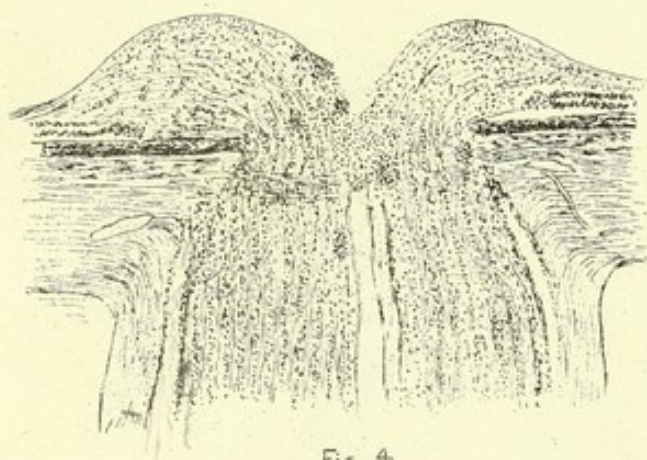


Fig. 4

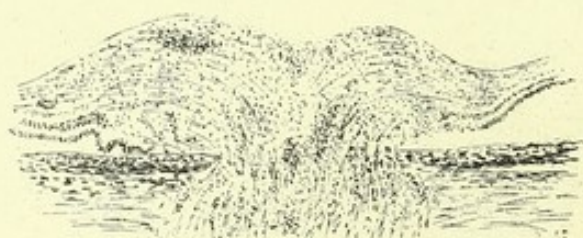

Fig. 5



Fig. 7

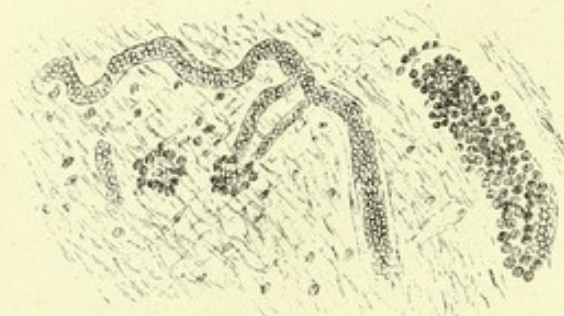


Fig. 6

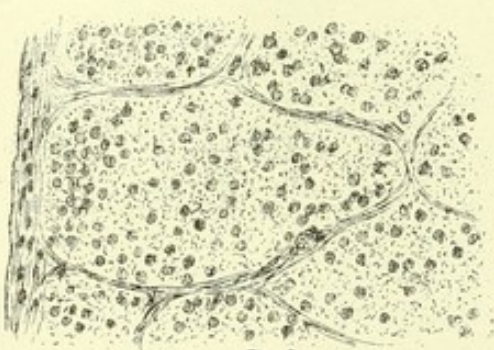


Fig. 8

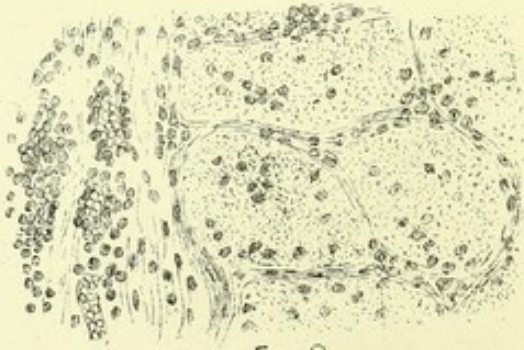


Fig. 9



visible in the neighbourhood of the macula. Vision: the field presented a defect corresponding to the area supplied by the obstructed vessels (see case, p. 318, and Fig. 4, p. 33, where by an error the field is said to be of the left eye).

### PLATE XIII.

FIGS. 1, 2, & 3.—*Tubercle of the choroid.* (Case 35, p. 299.)

FIG. 1.—*Posterior segment of eyeball* from a case of acute tuberculosis in a child. Choroidal tubercles were seen with the ophthalmoscope the day before death as whitish spots, one, nearly as large as the disc, with a little accumulation of pigment near it. After death the anterior segment of the eyeball was removed, and the retina drawn to one side (the left in the figure); six round white prominent tubercles are seen in the choroid, the largest nearly a millimetre in diameter, the others about half that size. The prominence of each extends beyond the limits of the white area, and was much more conspicuous after the eye had been placed in spirit than when the drawing was made. ( $\times 2$ .)

FIG. 2.—*Section of two of the smaller of these tubercles.* They are seen to occupy the whole thickness of the vascular layer of the choroid, and to be nearly double its depth, pushing forwards the layer of pigment-epithelium. Over one, the epithelium, at the place where the section passes through it, is unbroken, in the other the tubercle is exposed in a space equal to about one-half its diameter. The prominence due to the tubercle is seen to be double the width of its exposed area. Below the choroid the deeper layers of the sclerotic are shown, with flattened pigment cells in the portion next to the choroid. ( $\times 30$ .)

FIG. 3.—*One half of a tubercle.* The outer part consists of cells and fibres, which pass gradually into the choroidal stroma. A large choroidal vessel is seen, in section, in the right side of the figure, and around it are some of the pigment cells of the choroid. The central part of the tubercle (to the left) is in a state of granular degeneration, the constituent tissue-elements being no longer recognizable. Above it is the pigment-epithelium, and below are the pigment cells of the deepest layer of the choroid adjacent to the sclerotic. ( $\times 100$ .)

FIGS. 4—9.—*Descending neuritis in a case of cerebral tumour.* (Case 3, p. 245.) The disc is shown, in an earlier stage of neuritis, Pl. III. 3.

FIG. 4.—*Section through the middle of the optic nerve entrance,* showing considerable and rather steep swelling of the papilla, with a deep central depression. The highest part of the swelling is, on the temporal side (to the right), opposite the edge of the sclerotic, while on the nasal side (to the left) the highest part is a little beyond this point. The central depression is seen to extend almost to the choroidal level. The retinal layers are displaced outwards on each side. The course of the nerve fibres can still be seen in the swollen papilla, but among them are scattered large numbers of leucocytes and nuclei (shown as black dots). They are especially abundant at the bottom of the central depression, and are in places aggregated into dense groups, which, near



the surface, appeared during life as white spots. The same infiltration of leucocytes can be traced through the sclerotic ring, and down the optic nerve, where they are especially abundant between, and separating, the fasciculi of the nerve. The retinal vessels are seen dilated within the nerve, but in the sclerotic ring they have passed out of the plane of the section. The sheath of the optic nerve is not distended, but its walls are infiltrated with leucocytes. ( $\times 20$ .)

FIG. 5.—*A section through the same papilla, near the edge.* The central depression is not divided. Groups of leucocytes are seen to lie in the substance and near the surface of the papilla. To the left the deeper layers of the displaced retina are thrown into folds. ( $\times 20$ .)

FIG. 6.—*A portion of a section through the substance of the same papilla.* Small vessels are seen distended with blood corpuscles. Two small vessels divided transversely in the middle, and a larger vessel divided longitudinally on the right, are surrounded by leucocytes. The nerve fibres course upwards and to the left; they present in places slight varicose swellings, and are everywhere separated by spaces (œdema). Coursing at right angles to these fibres are delicate connective tissue (supporting) fibres, with oval nuclei corresponding in direction to that of the latter. ( $\times 150$ .)

FIG. 7.—*A portion of a longitudinal section of the optic nerve just behind the sclerotic,* showing the irregular outlines of the degenerating nerve fibres, and the infiltration of leucocytes into, and especially between, the fasciculi. ( $\times 150$ .)

FIG. 8.—*A transverse section of the nerve about a centimetre behind the sclerotic.* The surface of the nerve is divided on the left side of the section. The divided nerve fibres present only an irregular granular appearance, the axis-cylinders being no longer demonstrable by any mode of staining. Leucocytes thickly infiltrate the bundles, but are less abundant in the interspaces. The sheath presents many compressed nuclei. ( $\times 150$ .)

FIG. 9.—*A transverse section through the same optic nerve, just in front of the optic commissure.* The tissue on the surface of the nerve (to the left of the figure) contains dilated vessels and large numbers of leucocytes, which are also very abundant in the inter-fascicular septa, and are also infiltrated into the substance of the bundles of fibres. ( $\times 150$ .)

#### PLATE XIV.

FIGS. 1—5. *Sections of optic disc, nerve, and tract, from a case of optic neuritis in tumour of the outer surface of the right cerebral hemisphere.* (Case 22, p. 279.)

FIG. 1.—*A section through nearly the middle of the papilla.* The swelling is considerable, greater on one side than on the other. The commencement of the retina is displaced some distance from the edge of the choroid. The course of the nerve fibres can be well seen, but among



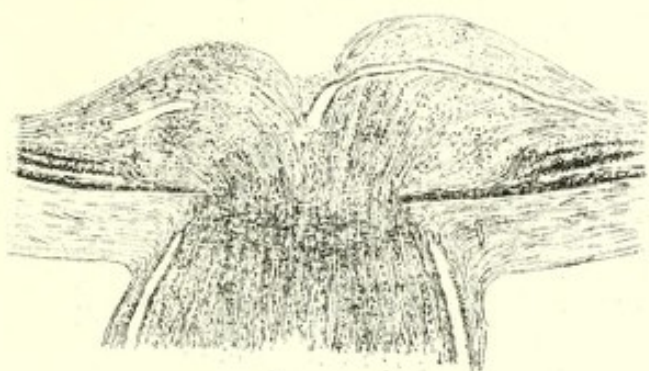

Fig. 1

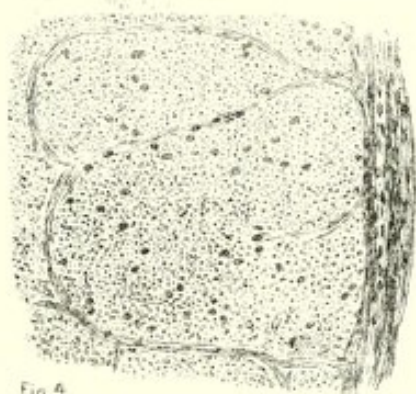


Fig. 4



Fig. 2



Fig. 3



Fig. 5

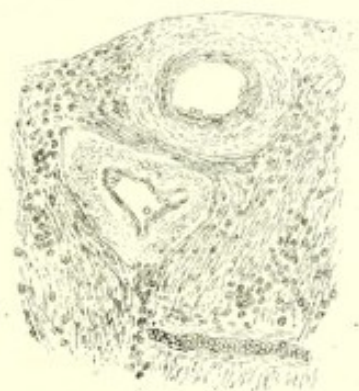

Fig. 7

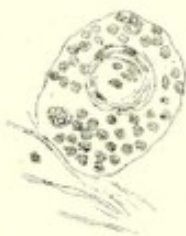

Fig. 6

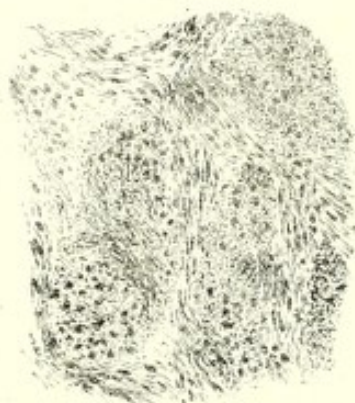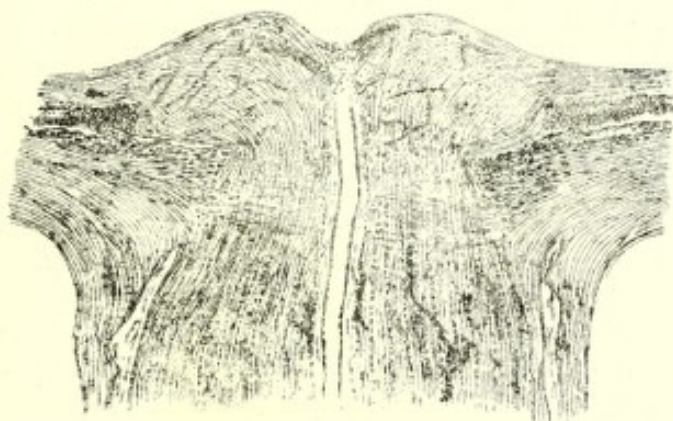 $f: g \rightarrow \mathbb{C}$ 

Fig. 8

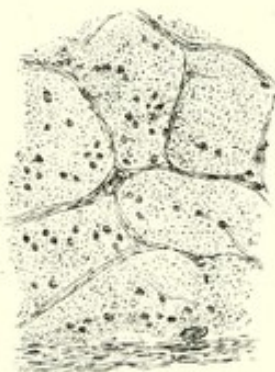

Fig. 9.

V.R.G. dell'







and between the bundles lie large numbers of nuclei, shown as dots. At the bottom of the central depression a large vessel is seen emerging; and, as it passes into the tissue, it becomes much narrowed, as if from compression in the substance of the papilla (cf. next figure). The nerve behind the lamina cribrosa presents many nuclei, but its sheath is scarcely distended. ( $\times 15$ .)

FIG. 2.—*Another section of the same disc, through the deepest part of the persistent narrow central depression.* A vessel is divided longitudinally, and it is seen that neither in the sclerotic ring, nor behind it, does it present any trace of compression. On the right side, at the highest part of the swelling, the section has divided a small portion of a vein and artery, which are shown more highly magnified in the next figure. ( $\times 8$ .)

FIG. 3.—*A portion of the section shown in Fig. 2.* Above (at *a*) is seen the section of a distended vein, close to the surface. Below (at *b*) is an oblique section through a contracted artery with thick walls. In the intervening space, leucocyte-like corpuscles are densely infiltrated among the nerve fibres, the course of which can be distinguished. ( $\times 150$ .)

FIG. 4.—*Part of a transverse section through the optic nerve, half an inch behind the globe.* The connective tissue trabeculae are not thickened, but the inner sheath of the nerve (seen on the right) contains a large number of corpuscles, and similar corpuscles are scattered among the nerve fibres, a little more abundantly than normal. The nerve presented similar appearances as far back as the commissure. ( $\times 150$ .)

FIG. 5.—*A portion of a longitudinal section through one optic tract in the same case.* The corpuscles lying among the nerve fibres are distinctly, though moderately, increased in number. ( $\times 150$ .)

FIG. 6.—*From the substance of a swollen disc in tubercular meningitis.* Collections of leucocyte-like corpuscles lie within a sheath which surrounds two vessels, one small, containing a few red blood-corpuscles, the other larger, presenting conspicuous fibre cells in its wall and a few leucocyte-like cells in its interior. ( $\times 150$ .)

FIG. 7.—*Part of a section of an inflamed papilla in cerebral tumour.* (Case 15, p. 267.)

Transient optic neuritis had existed three months previously, and had returned shortly before death. The section is just below the surface of the central depression. Two vessels are seen in transverse section, an artery (below) and a vein (above), with their outer coats greatly thickened by substance, presenting slight fibrillation. Below, a small vessel is seen distended with blood, and with walls similarly changed. The tissue around is infiltrated with corpuscles. ( $\times 100$ .)

FIGS. 8, 9, & 10.—*From a case of optic neuritis in tumour of the right frontal lobe.* (Case 16, p. 269.)

FIG. 8.—*A section of the termination of the optic nerve.* The papilla presents considerable swelling. The retina is displaced outwards a



considerable distance, and the nuclear layers are at first much thickened. Corpuscles are scattered through the substance of the swelling, and are aggregated into masses and along the vessels, the course of which is thus indicated. Through the optic nerve, behind the lamina, there are also numerous corpuscles, some of which are similarly collected along the vessels. The central vein passes through the sclerotic ring without exhibiting any trace of compression. The sheath of the optic nerve is not distended. ( $\times 15$ .)

FIG. 9.—*A portion of a transverse section through the optic nerve of the same eye, midway between the globe and the optic foramen.* The corpuscles scattered through the nerve fibres are rather more abundant than normal, and there is some degeneration in the nerve fibres. ( $\times 100$ .)

FIG. 10.—*A transverse section of the same nerve just in front of the commissure.* The bundles of nerve fibres are separated by much fibrous tissue, containing many nuclei, oval and fusiform. The fasciculi of the nerve are apparently being encroached on by the fibrous tissue, and in some an indistinct fibrillation can be seen passing through them. The nerve fibres are much degenerated, and corpuscles are scattered among them. ( $\times 100$ .)

#### PLATE XV.

FIG. 1.—*Section through the outer part of an inflamed papilla, in a case of descending neuritis* (Pl. XIII. 4—9, Case 3, p. 245, Pl. III. 3), showing the changes in the commencement of the displaced retina. Above, to the right, the section is bounded for a short distance by the hyaloid membrane, the margin being oblique from the shape of the papillary swelling. (a) The choroidal epithelium. (b) The layer of rods and cones with the elastic lamina below it. It is thrown into folds by the displacement. (c) The outer nuclear layer; and (d) the inner nuclear layer. On the right these are fused together, apparently by an increase of their nuclei, but in the middle of the figure they are still separated by the outer molecular layer. (e) The inner molecular layer, and (f) the ganglion-cell layer, little changed. Towards the left these layers become irregular, the nuclei of the inner nuclear layer becoming separated, and between these groups of nuclei the remains of the vertical fibres of Müller can be seen. (g) The layer of nerve fibres, thickened, and containing many lymphoid corpuscles, and several vessels distended with blood; the walls of one being encrusted with leucocytes. To the left the lowest layer of nerve fibres curve down and come in contact with the choroid, in consequence of the swelling of the papilla, determining thus the displacement of the retina. ( $\times 150$ .)

FIGS. 2 & 3.—*Sections of an optic nerve in a case of tubercle of the cerebellum and tubercular meningitis; consecutive atrophy.* (Case 19, p. 274, Pl. VI. Fig. 3.)

FIG. 2.—*A section through the end of the nerve.* The papilla presents no prominence, but shows evidence of old neuritis in the displacement of



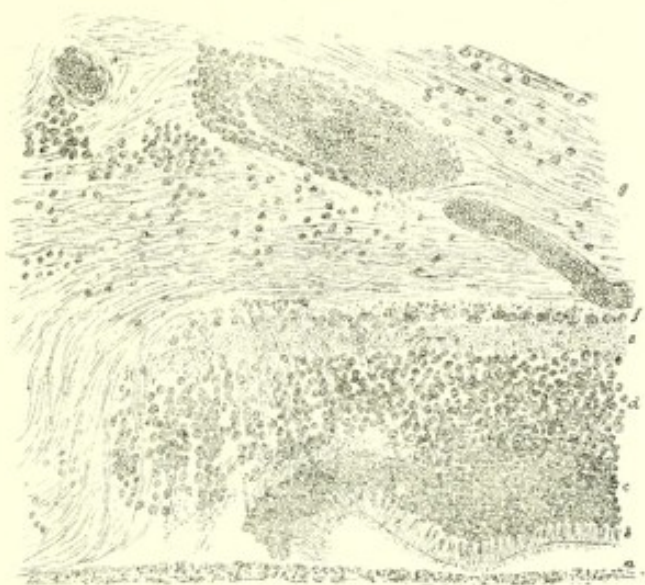


Fig 1

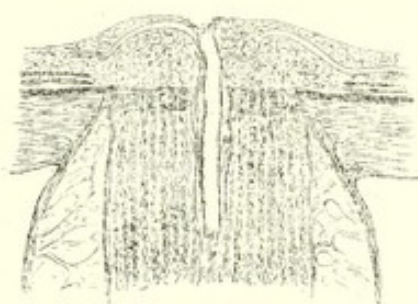

Fig 2

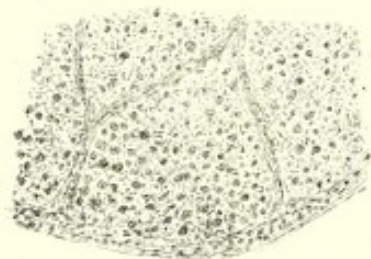


Fig 3

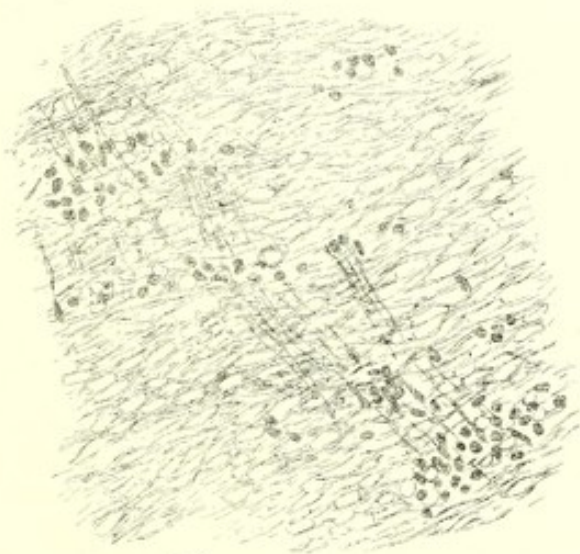

Fig 4

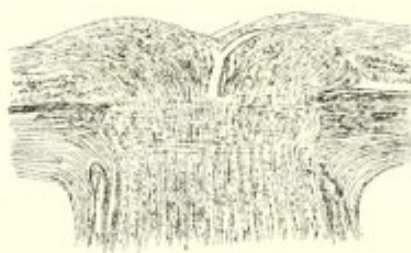

Fig 5

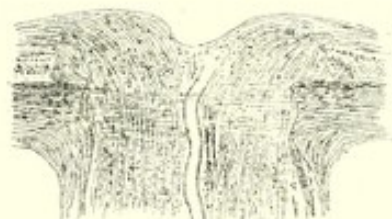

Fig 6

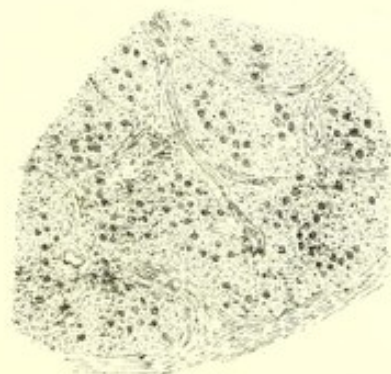


Fig 7



Fig 8

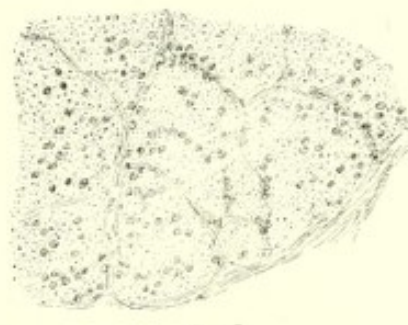


Fig 9

W.R.G. 1897











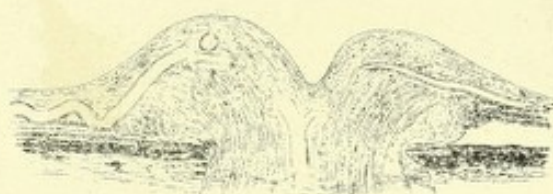

Fig. 1

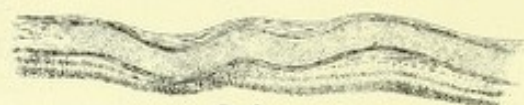

Fig. 3



Fig. 2

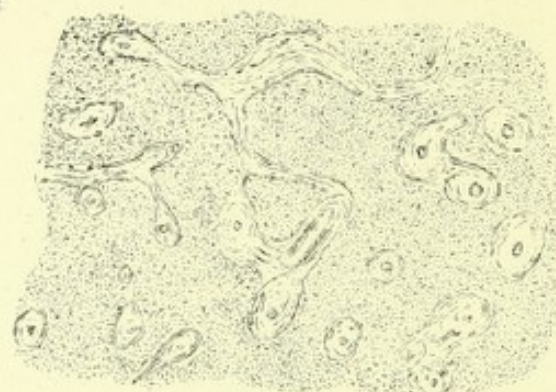


Fig. 5



Fig. 4

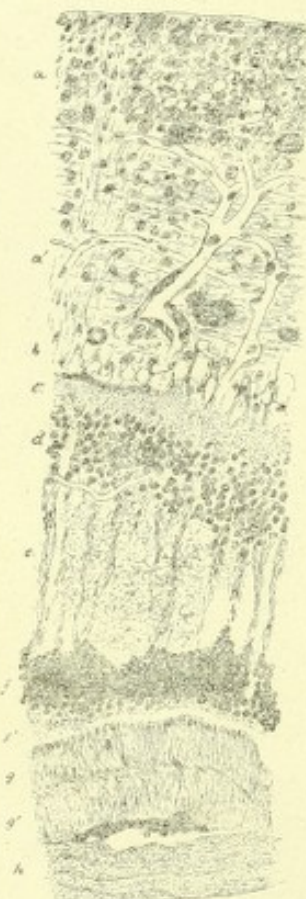

Fig. 10

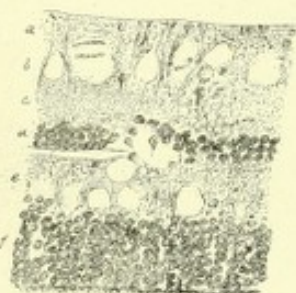


Fig. 9

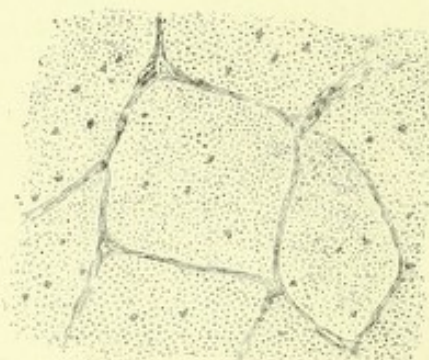


Fig. 6

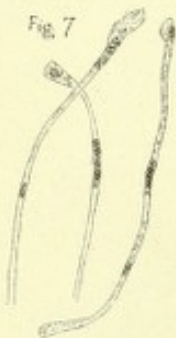

Fig. 7

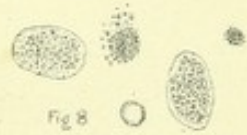

Fig. 8

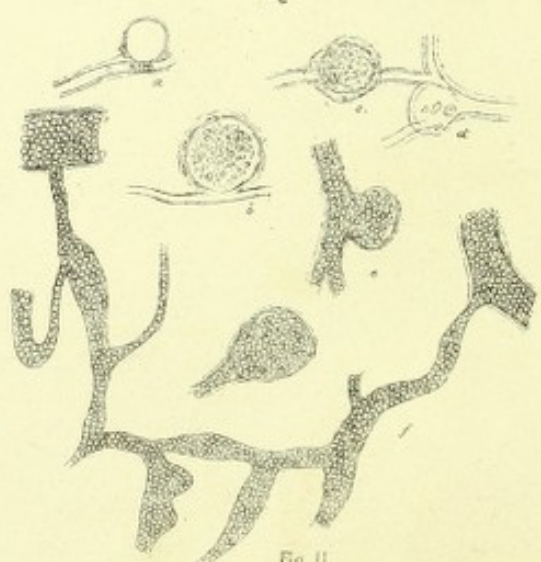


Fig. 11

W.R.O. delt



the retinal layers, and in the structure of the papilla, all the nerve fibres having been destroyed. Behind, in the nerve, the separation between the bundles of nerve fibres can be distinguished, but the fibres are degenerated. The sheath of the optic nerve is greatly distended, and delicate trabeculae connect the two layers. A vessel is divided longitudinally, but neither within the sclerotic ring nor behind it, is it compressed. Within the papilla, however, its branches are very narrow. ( $\times 15$ .)

FIG. 3.—*A transverse section through the same optic nerve near the back of the orbit.* The fasciculi of degenerated nerve fibres are infiltrated with nuclei and cells of irregular size and shape. The septa between the bundles are a little thickened. ( $\times 100$ .)

FIGS. 4—7.—*Section through the optic disc and nerve in a case of optic neuritis due to chronic cerebritis* (Case 27, p. 286.)

FIGS. 4 & 5 are sections through the termination of the optic nerve. The papilla is but slightly swollen, contains, however, many nuclei, and has displaced the retinal layers. In Fig. 5 a vein is divided longitudinally, and presents no constriction in or behind the sclerotic ring. A small portion of an artery lying beside it has been included in the section. In Fig. 4, one of the primary branches of the vein is seen to be much narrowed in the substance of the papilla (compare Pl. XIV. 1). There is little distension of the optic sheath. ( $\times 15$ .)

FIG. 6.—*A portion of a section of the optic nerve a short distance behind the globe.* It contains a large number of corpuscles within its fasciculi. ( $\times 100$ .)

FIG. 7.—*The same optic nerve in front of the commissure.* The infiltration with corpuscles is greater than further forwards, and the connective tissue septa are thickened and irregular. ( $\times 100$ .)

FIG. 8.—*A portion of a section through an inflamed papilla in a case of tubercular meningitis.* The chief change is the separation of the nerve fibres by round and oval spaces (œdema). The corpuscles of the nerve are unduly numerous and lie in groups, indicating the division into fasciculi. The position of the nuclei is apparently determined by the existence of a series of sustentacular fibres which have a direction at right angles to the nerve fibres. ( $\times 150$ .)

FIG. 9.—*Some of these fibres and their nuclei more highly magnified.* The fibres are swollen and some of them present knob-like projections in the position of the nuclei. ( $\times 20$ .)

FIG. 10.—*Varicose nerve fibres from the same case.* ( $\times 20$ .)

## PLATE XVI.

FIG. 1.—*Section through the swollen papilla in a case of old chronic meningitis, with inflammatory growths in the convexity of the brain.* (Case 4, p. 248, Pl. VI. 2.)

The prominence of the papilla is considerable, its sides steep, and the



central depression large, but not extending more than half way to the level of the choroid. The vessels within the sclerotic ring show no sign of compression. At the edge of the swelling a large vein forms two vertical curves in the substance of the thickened retina, the lower curve reaching the inner nuclear layer. The retinal layers are displaced. On the right side the choroidal epithelium has disappeared from the portion from which the retina has been pushed away. On the left side the epithelium persists in this situation. The edge of the sclerotic opening is seen to be straight on the left side, and oblique on the right; the latter, however, is evidently due to the shape of the opening, and not to any stretching by swelling of the nerve, for the nerve fibres have a straight course, and do not correspond to the edge of the ring, the space between the two being occupied only by the transverse fibres of the lamina cribrosa. ( $\times 15$ .)

FIG. 2.—*Corpuscles containing fatty globules and granules from the substance of the papilla shown in Fig. 1, and to aggregations of which the white spots shown in Pl. VI. 2 were due.* (Glycerine preparation.)

The corpuscles are of large size; some evidently crammed with masses of fatty matter; in many, however, the globules and granules are aggregated in the centre, and the outer part is clearer, although highly refracting: *a*, *b*, and *c* perhaps indicate stages in the formation of these bodies. In *a* a number of globules are simply aggregated together; in *b* a similar aggregation appears in part fused together and bounded by a membrane; in *c* the process of union has gone still further. ( $\times 100$ .)

FIG. 3.—*Section of the retina from the same case, some distance from the disc, showing an enormously distended vein, occupying in places about two-thirds of the thickness of the retina. It presents vertical curves, and at the lowest part has disturbed the nuclear layers of the retina.* ( $\times 50$ .)

FIG. 4.—*From a section of the optic tract, same case.* The nucleus-like bodies are very numerous, and are aggregated into a dense group resembling a "miliary" abscess, such as is seen in the medulla in hydrophobia. ( $\times 100$ .)

FIG. 5.—*Grey atrophy of optic nerve: transverse section, midway between the eyeball and the optic foramen.* The trunk of the nerve was grey, and gelatinous in aspect, and was not diminished in size. The other optic nerve was healthy.

The appearances are precisely those seen in cases of grey atrophy of both optic nerves, such as is met with in locomotor ataxy. The nerve fibres are completely degenerated, a granular tissue representing them. The normal trabeculae have disappeared, and through the section of the nerve are scattered tracts and islets of a slightly fibrillated, in places almost homogeneous, colloid-looking tissue. These tracts enclose vessels which can be distinguished, small in size, and with thickened walls, in the centre of each. The fibrillation is concentric to the vessel, and is most marked in the periphery of the tissue. In many parts these tracts



of tissue occupied a larger area than the degenerated nerve fibres. ( $\times 150$ .)

FIG. 6.—*Section of a normal optic nerve, for comparison.*

The trabeculae are regular and contain only a few nuclei. Other nuclei are sparsely scattered through the section of the bundles of nerve fibres; the divided ends of the fibres are represented by dots. In many sections of the same nerve no nuclei could be seen among the fibres. ( $\times 150$ .)

FIG. 7.—*Degenerated fibres of Müller from the retina in a case of acute albuminuric retinitis.* (Case 39, p. 302, Pl. X, Fig. 1). Recent preparation.

The fibres are swollen and cloudy, especially in the enlarged extremities. Here and there are minute refracting globules, no doubt fatty, and arranged in the fibre in a moniliform row. ( $\times 250$ .)

FIG. 8.—*Products of retinal degeneration—same case.* (Recent specimen.)

Two "compound granule corpuscles" are seen filled with globules and granules of fat. Two other aggregations of similar character, but without an enclosing cell wall. A free fat globule is also seen. Similar bodies were very abundant in the opaque parts of the retina, and, by their aggregation, had caused the white spots seen in Pl. X.

FIG. 9.—*Section of the same retina after hardening in Muller's fluid, showing the condition of œdema of the retina.*

The section is taken some distance from the optic disc. The nerve-fibre layer (*a*) is normal. In the ganglion-cell layer, no nerve corpuscles are to be seen; it is occupied by large spaces apparently due to œdema around the nerve cells, and from which the nerve cells have fallen out, probably in the preparation of the section. The inner molecular layer (*c*) is normal. The inner nuclear layer (*d*) is in some parts normal, but is interrupted by a large empty cavity. Other similar cavities lie in the outer nuclear layer (*e*), and cause it to be much wider than normal. The outer nuclear layer (*f*) presents only indications of a tendency to dissociation of its elements. The layer of rods and cones has disappeared (post-mortem change). ( $\times 150$ .)

FIG. 10.—*Section through the same retina near the disc (in the position of one of the white spots shown in Pl. X. 1.)*

The retina is greatly thickened, as may be observed by comparison with Fig. 9, which is drawn upon the same scale. It also presents evidence of detachment from the choroid. All the layers, except the outer nuclear layer, participate in the thickening, but it is chiefly due to the changes in the nerve-fibre layer (*a a'*), which occupies about one half of the thickness of the retina. The inner portion of this is occupied by large, round, or oval bodies, some granular, others homogeneous, but all certainly the granular and fatty bodies shown in Fig. 8, and altered in appearance by the mode of preparing the specimen. Among them are clear empty cavities, and many nuclei. Similar bodies are scattered, although more sparingly, through the outer (lower) half of this layer



which contains also many nuclei. The nerve fibres have a somewhat irregular course, and are separated by clear spaces. Several capillaries shown in the section are conspicuously altered. They are dilated; the nuclei upon them are more numerous than normal. On the larger vessel the wall is distinctly thickened at places by a group of such nuclei. Another capillary (near the right edge of the figure) presents a series of aneurismal dilatations, on each of which are one or more nuclei. A small artery with thickened wall is divided transversely near the lower part of the layer. The ganglion-cell layer (*b*) contains no nerve cells, but merely a series of empty cavities with nuclei between them. The inner molecular layer (*c*) presents nearly normal characters, but is rendered irregular by the changes in the adjacent layer. The inner nuclear layer (*d*) is changed chiefly by the separation of its constituent corpuscles. In places, as on the left, a vertical cleft extends through it, corresponding to the position of some of the vertical fibres. Its outer (lower) boundary is very irregular in consequence of the extension of the nuclei in places into the next layer, especially along some of the fibres of Müller. The outer molecular layer (*e*) is much increased in depth, and presents none of its normal appearance. Irregular fibrous tracts extend vertically through it (altered fibres of Müller); the spaces between them are in part occupied by a material which presents delicate interlacing fibrillæ and granules; in part they are empty. The outer nuclear layer (*f*) is irregular, especially in its inner (upper) surface, the nuclei extending in places into the last layer along the vertical fibres. Outside it is a layer of granular material (*f'*), which separates it from the layer of rods and cones (*g*). The latter is much thickened; its normal structure is replaced by a very delicate vertical fibrillation, but on its inner surface indications of the position of the cones can be distinguished. The striation of the layer presents a slight curvature, which differs in direction in the outer and inner parts (*g* and *g'*), and the transition between the curves together with a few molecules indicates the boundary between the inner and outer portions of this layer. A few nucleus-like bodies are seen within it. In the outer surface a little pigment-epithelium adheres. Below this is an indistinct laminated layer (*h*), the effused material by which the retina is detached from the choroid. It presents the same appearance of reticulated fibrillation as the substance which occupies the outer molecular layer (*e*), but presents also an indistinct horizontal fibrillation, which gives an appearance of separate layers. ( $\times 150$ .)

FIG. 11.—*Capillary aneurisms and varicose capillaries from the retina in a case of diabetes with retinal hæmorrhages.\** (The vessels are shown as seen in a surface view of the retina.)

In the upper part of the figure are a series of capillary aneurisms.

\* The case is detailed by Dr. Stephen Mackenzie in the "Ophth. Hosp. Rep." vol. ix. p. 150. For the opportunity of examining preparations of the retina I am indebted to Mr. Nettleship.



Most of these are evidently in the side of the vessel three ; (*a*, *b*, *e*) are situated laterally, and one (*c*) in front. At *d* an aneurismal dilatation is seen to occupy the bifurcation of a vessel. In *a* and *d* the cavity of the aneurism is empty ; in *e* both the vessel and the aneurism are distended with blood, and the communication between them can be distinctly seen. In *b* and *c* the aneurisms contain granular material the results of degeneration of blood, which had probably coagulated in them during life.

The lower figure (*f*) represents irregular varicose dilatation of a small vessel, which is distended with blood. It is probably a capillary, but the trunks into which it opens were parts of the same vessel. ( $\times 150$ .)







# INDEX.

*The Index does not contain references to the Cases or to the Description of the Plates. The subjects of these are enumerated in the Table of Contents.*

- Abscess of brain, 125
- Ague, 216
- Albuminuria, 164
- Albuminuric retinitis, 166  
(See "Retinitis.")
- Alcoholism, chronic, 209  
acute, 210
- Amaurosis, epileptiform, 21  
saturnine, 206  
uræmic, 164
- Amblyopia in alcoholism, 209  
diabetes, 178  
mercury poisoning, 212  
silver poisoning, *ib.*  
tobacco poisoning, 210
- Anastomoses of retinal artery, 31
- Anæmia, acute, 184  
chronic, 11, 188  
pernicious, 189  
of retinal vessels, 20
- Aneurism, intra-cranial, 135  
of internal carotid, *ib.*  
of retinal arteries, 16  
capillary, 17  
miliary, *ib.*  
in Bright's disease, 165  
cerebral hæmorrhage, 117  
diabetes, 179
- Aortic regurgitation, 18, 182
- Artery, internal carotid, aneurism, 135  
thrombosis, 124  
ophthalmic, 27, 124
- Arteries, retinal, 7  
aneurism, 16  
embolism, 28  
variations in size, 16  
(See also "Vessels, retinal.")
- Argyria, 212
- Ataxy, locomotor, 149
- Atrophy of optic nerve, 84  
causes, 89  
table of, 94  
congestion preceding, 88  
congestive form, 101  
consecutive, 101  
diagnosis, 104  
from damage to retina, 93  
pathological anatomy, 94  
primary, 90  
secondary, 91  
simple, 84  
symptoms, 96  
treatment, 107  
in cerebral hæmorrhage, 119  
softening, 120, 122  
tumours, 134  
chronic alcoholism, 209  
hydrocephalus, 136  
diabetes mellitus, 178  
insipidus, 180  
diphtheria, 220  
erysipelas, 219  
gastro-intestinal disorders, 196  
general paralysis, 161  
hysteria, 160  
injuries to the head, 146  
insular sclerosis, 153  
lateral sclerosis, 153  
lead poisoning, 206  
locomotor ataxy, 149  
loss of blood, 184  
malarial fevers, 219  
neuralgia, 157  
scarlet fever, 215  
syphilis, 203  
tubercular meningitis, 141



- Atrophy, in typhoid fever, 213  
 typhus fever, 212  
 Atropine, use of, 2
- Bed, examination of patients in, 3  
 Blind spot, in neuritis, 56  
 Blood, diseases of the, 183  
   loss of, effect on retinal vessels, 21  
   amaurosis from, 184  
 Blows on eye, a cause of atrophy, 93  
 Bones, cranial, diseases of, 143  
   caries, *ib.*  
   necrosis, 148  
   thickening, 144  
 Brain, abscess of, 125  
   anæmia of, 114  
   diseases of, 113  
   hyperæmia of, 114  
   inflammation of, 115  
   injuries to, 147  
 Bright's disease, 164  
   arteries in, 13, 164  
   optic neuritis in, 78  
   retinal changes in, 166  
   (See "Retinitis.")  
 Bronchitis, 196
- Capillaries, retinal, aneurisms of, 17  
   in Bright's disease, 165  
   in diabetes, 179  
   varicose, 17
- Carbon, sulphide of, poisoning by, 212  
 Cavernous sinus, thrombosis in, 125  
   pressure on, 64  
 Cerebral anæmia, 114  
   circulation, relation of retinal to, 18  
   congestion, 114  
   diseases, atrophy in, 91  
   hæmorrhage, 117  
   softening, 119  
   from atheroma, 122  
   embolism, 120  
   syphilitic disease, 122  
   (See also "Brain.")  
 Cerebritis, chronic, 115  
 Chiasma, optic, effects of pressure on, 58  
   a cause of atrophy, 92  
 Choked disc, 42, 64, 71  
 Cholera, 21, 221  
 Chorea, 156
- Choroid, morbid states of, 111  
   in leucocythæmia, 195  
   tubercles of, 198  
 Choroidal arteries, degeneration, 112  
   embolism, *ib.*  
   hæmorrhage in purpura, 195  
 Choroiditic atrophy, 104, 204  
 Choroiditis, syphilitic, 203, 204  
 Circulation, retinal, 18  
   obstruction to, 22  
 Colour-vision, examination of, 233  
   affection of, in atrophy, 98  
   chronic alcoholism, 209  
   neuritis, 57  
   tobacco poisoning, 211  
 Congestion of brain, 114  
   of optic disc, 37  
   in caries of spine, 154  
   cerebral softening, 120  
   chronic alcoholism, 209  
   diphtheria, 220  
   general paralysis, 162  
   lead poisoning, 207  
   mania, 163  
   parotitis, 220  
   tobacco poisoning, 210  
   with œdema, 40  
 Cough, effect on retinal circulation, 23  
 Cyanosis, 181  
 Cysts in brain, 135
- Daylight, examination in, 3  
 Death, ophthalmoscopic signs of, 226  
 Dementia, 163  
 Diabetes mellitus, 178  
   insipidus, 180  
 Diarrhœa, 197  
 Digestive organs, diseases of, 196  
 Diphtheria, 220  
 Disc, optic, appearance of, 35  
   congestion, 37  
   with œdema, 40  
   in anæmia, 22  
   structure, 35  
   variations, 4, 37  
   vessels of, 34  
   (See also "Nerve, optic.")
- Electricity, sensitiveness of retina to,  
   in neuritis, 57



- Electricity in treatment of atrophy, 107
- Embolism of cerebral arteries, 28, 120  
 of middle meningeal, a cause of atrophy, 92, 122  
 of retinal artery, 28  
   in Bright's disease, 174  
     cerebral embolism, 120  
     chorea, 156  
     heart disease, 182  
     typhoid fever, 214  
 capillary, of retina, in pyæmia, 222
- Emphysema of lungs, 196
- Encephalitis, acute, 115  
 chronic, *ib.*
- Endocarditis, malignant, 183, 224  
 septic, 224
- Epilepsy, 157
- Erysipelas, 219
- Examination, methods of, 2
- Excavation of optic disc, 87
- Fever (*see* "Relapsing," "Typhoid," "Typhus," "Scarlet").
- Field of vision—  
   in alcoholism, 209  
   atrophy, 97  
   neuritis, 56  
   tobacco-poisoning, 211  
   for colours, 99
- Foramen, optic, narrowing of, 145
- General paralysis of the insane, 161
- Glaucoma, hæmorrhagic, in albuminuria, 174  
   in diabetes, 179  
   leucocythæmia, 194  
   neuralgia, 157
- Glioma, mistaken for cerebral hæmorrhage, 118  
   softening, 122
- Goître, exophthalmic, 156
- Gout, 205
- Growths in the brain, 126  
   in the retina, 126  
   (*See also* "Tumours.")
- Hæmorrhage, general, 184  
   cerebral, 117
- Hæmorrhage, cerebral, indication of  
   how transmitted, 13  
   in optic nerve, 43  
   retinal, 24  
   symptoms, 25  
   in ague, 216  
     anæmia, 189  
     Bright's disease, 166  
     bronchitis, 196  
     cerebral hæmorrhage, 117  
       softening, 123  
     leucocythæmia, 191  
     malarial fevers, 216  
     meningeal hæmorrhage, 119  
     meningitis, purulent, 138  
     tubercular, 141  
     pernicious anæmia, 189  
     purpura, 195  
     optic neuritis, 46  
     septicæmia, 224  
     scurvy, 196
- Haller, circle of, 34
- Head, injuries to, 146
- Heart, diseases of, 180
- Hemi-neuritis, 43
- Hemiopia from cerebral disease, 59  
   pressure on chiasma, *ib.*  
   state of optic nerves in, 91
- Hernia cerebri, 148
- Hydatid cysts in brain, 135
- Hydrocephalus, chronic, 136  
   atrophy in, 92
- Hypermetropia, neuritis in, 81  
   recognition of, 3
- Hysteria, 160
- Insanity, 161
- Ischæmia, retinal, 20
- Jaundice, 197
- Kidneys, diseases of, 166
- Knee-reflex, absence with optic nerve atrophy, 151
- Lardaceous kidney, retinitis with, 166
- Lead-poisoning, 206
- Leucocythæmia, 190  
   retinal veins in, 11, 190
- Malarial fevers, 216



- Mania, 163  
 Measles, 214  
 Measurements, ophthalmoscopic, 231  
 Melancholia, 163  
 Meninges, hæmorrhage into, 119  
     growths in, 137  
 Meningitis, 138  
     cerebro-spinal, epidemic, 143  
     chronic, 138  
     in cerebral hæmorrhage, 118  
         cerebral tumour, 128  
         meningeal growths, 138  
         septicæmia, 225  
     purulent, 138  
     simple, *ib.*  
     syphilitic, 143  
     traumatic, 143, 148  
     tubercular, 139  
 Menstrual disorders, 197  
 Mercurial poisoning, 212  
 Micrometry, ophthalmoscopic, 231  
 Migraine, 157  
 Miliary abscesses in optic tracts, 117  
     aneurisms in retina, 17  
 Mumps, 220  
 Myelitis, 149  
  
 Nerve fibres, opaque, 5, 110  
 Nerve, optic, atrophy of, 84  
     (See "Atrophy.")  
     changes in, 34  
     congestion, 37  
     inflammation, 40  
     (See "Neuritis.")  
     morbid states of, 37  
     trunk of, changes in, 53  
     sheath of, 35  
     (See "Sheath.")  
 Nervous system, diseases of, 113  
     functional, 156  
 Neuralgia, 157  
 Neuritis, optic, 40  
     descending, 42, 54  
     frequency, 70  
     in cerebral tumour, 126  
         tubercular meningitis, 142  
     intra-ocular (papillitis), 40  
         causes, 61  
         diagnosis, 76  
         pathological anatomy, 50  
     Neuritis, intra-ocular, prognosis, 81  
         relation to encephalic disease, 63  
         second attacks, 49  
         stages, 44  
         subsidence, 47  
         symptoms, 54  
         treatment, 82  
         unilateral, 130  
         varieties, 74  
     in alcoholism, 209  
         anæmia, acute, 186  
         chronic, 189  
         pernicious, 190  
         aneurism of internal carotid, 136  
     Bright's disease, 78, 170  
     bronchitis, 196  
     caries of sphenoid bone, 144  
     cerebral abscess, 125  
         softening, 120  
         tumour, 78, 126  
     chorea, 156  
     diabetes, 180  
     epilepsy, 159  
     general paralysis, 162  
     hydrocephalus, 136  
     hypermetropia, 81  
     injuries to the head, 146  
         spine, 155  
     laceration of the brain, 147  
     lead poisoning, 81, 207  
     leucocythæmia, 194  
     loss of blood, 186  
     malarial fever, 218  
     measles, 214  
     meningeal tumours, 137  
     meningitis, 139  
         tubercular, 140  
     menstrual disorders, 197  
     myelitis, 149  
     scarlet fever, 215  
     syphilis, 203  
     typhoid fever, 213  
     typhus fever, *ib.*  
 Neuritis, retro-ocular, 75  
     from orbital disease, 93  
 Neuro-retinitis, 46  
     in malarial fevers, 218  
  
 Œdema of optic papilla, 40



- Œdema of optic papilla in tubercular meningitis, 140  
     of retina in Bright's disease, 172  
 Ophthalmia, pyæmic, 222  
 Ophthalmic artery, thrombosis in, 27, 124  
 Ophthalmoscope, on learning the, 229  
     forms of, 228  
     use of, in medicine, 1  
 Ophthalmoscopy, medical, objects, 1  
 Orbit, diseases of, 145  
     inflammation, *ib.*  
     injuries, *ib.*  
     tumours, 146  
  
 Pallor of optic disc in anæmia, 188  
     in atrophy, 84  
 Papilla, optic, 35  
 Papillitis, 36, 41  
     (*See also "Neuritis."*)  
 Papillitic atrophy, 101  
 Parotitis, 220  
 Perineuritis, 44  
     retro-ocular, 76  
 Perivascular changes in retina, 15  
     in Bright's disease, 165  
 Pernicious anæmia, 189  
 Phthisis, 196  
 Plethora, 183  
 Pressure, intra-cranial, relation to optic neuritis, 63, 67  
     intra-ocular, influence on circulation, 18  
     on apparent size of vessels, 11  
 Pulsation of retinal vessels —  
     arterial, 18  
     capillary, 19  
     veins, *ib.*  
     rhythmical, 20  
 Purpura, 195  
 Pyæmia, 221  
  
 Reflex theory of optic neuritis, 66, 72  
 Refraction, estimation of, 3  
 Relapsing fever, 214  
 Retina, affection in neuritis, 48  
     tubercular meningitis, 139  
     aneurisms in, 16  
     detachment of, in Bright's disease, 174  
  
 Retina, growths in, 109  
     hæmorrhage in, 24  
     morbid states of, 107  
     vessels of, 20  
         (*See "Vessels."*)  
     white spots in, 108  
 Retinitis, albuminuric, 166  
     anatomical changes, 171  
     complications, 174  
     course, 175  
     degenerative form, 168  
     diagnosis, 175  
     forms, 168  
     hæmorrhagic form, 169  
     inflammatory form, *ib.*  
     in leucocythæmia, 194  
     neuritic form, 170  
     degenerative changes from, 176  
     diabetic, 178  
     from loss of blood, 188  
     leucocythæmic, 191  
     pigmentosa, 204  
     rheumatic, 205  
     septic, 223  
     syphilitic, 203  
 Rheumatism, acute, 216  
     chronic, 205  
  
 Scarlet fever, 215  
 Sclerosis of cord, insular, 153  
     lateral, *ib.*  
     posterior, 149  
     of optic nerve, 154  
 Scurvy, 196  
 Septicæmia, 221  
 Sexual organs, diseases of, 197  
 Sheath of optic nerve, 35  
     distension of, 53  
     effect on veins, 10  
     in laceration of brain, 147  
     relation to neuritis, 65, 69  
     to excess of sub-arachnoid fluid, 68  
     hæmorrhage into, in meningeal hæmorrhage, 119  
 Sight, how affected in neuritis, 57  
     in intra-cranial disease, 58  
 Silver poisoning, 212  
 Sinus, cavernous, effects of pressure on, 64



- Sinus, thrombosis in, 125  
 Skin, diseases of the, 198  
 Skull, fracture of the, 147  
 Small-pox, 216  
 Spinal cord, diseases, 149  
     (See also "Sclerosis" and  
     "Myelitis.")  
 Spine, caries of, 154  
     injuries to, 155  
 Staphyloma, posterior, 5, 105  
 Stauungs papilla, 42, 64  
 Strangulation in optic neuritis, 45  
     mechanism, 72  
 Sulphide of carbon, poisoning by, 212  
 Sunstroke, 114  
 Syncope, retinal vessels in, 23, 115  
 Syphilis, 202  
     inherited, 203  
 Syphilitic disease of vessels, 122  
  
 Tension, intra-ocular, influence on  
     circulation, 18  
 Test-types, 237  
 Thrombosis in cerebral vessels, 125  
     internal carotid, 124  
     ophthalmic artery, 27  
     retinal vessels, *ib.*  
 Tissue, white, in front of disc, 5  
 Tobacco poisoning, 210  
 Tonsillitis, 220  
 Tracts, optic, changes in atrophy,  
     96  
     neuritis, 53  
 Tubercles of choroid, 198  
     in tubercular meningitis, 139  
     of optic nerve, 201  
     of retina, *ib.*  
 Tubercular meningitis, 139  
 Tuberculosis, 198  
 Tumour of brain, 126  
     atrophy in, 134  
     neuritis in, 78, 126  
 Typhoid fever, 213  
     diagnosis of from septicæmia, 225  
 Typhus fever, 212  
  
 Urinary system, diseases of, 164  
  
 Variola, 216  
 Vaso-motor theory of neuritis, 66  
 Vein, orbital, communication with  
     facial, 64  
 Veins, retinal, atony of, 10  
     dilatation of, *ib.*  
     diminution in size of, 12  
     increased width of, 10  
     in anæmia, 188  
     cyanosis, 181  
     death, 226  
     leucocythæmia, 190  
     neuritis, 46  
     varicose, 10  
 Venesection, effect on blood, 21  
 Vessels, retinal, anæmia of, 20  
     arrangement, 13  
     atheroma, 15  
     calcification, 15  
     congestion, 22  
     course, 14  
     degeneration, 15  
     in atrophy, 88  
     Bright's disease, 164  
     convulsions, 21  
     general paralysis, 162  
     neuritis, 46  
     reflection from, 8  
     sclerosis of, 15  
     size, 7  
     variations in, 8  
     structural changes, 14  
     tissue around, 14  
     wall of, thickened, 15  
     visibility, 7  
     (See also "Arteries.")  
 Vision (see "Sight").  
     colour (see "Colour-vision").  
 Vitreous, hæmorrhage into, 24  
     in Bright's disease, 174  
     diabetes, 179  
     opacity of, in diabetes, *ib.*  
     in pyæmia, 222  
  
 Whooping cough, 220  
  
 Xanthelasma, 157





*London, New Burlington Street.  
May, 1879.*

SELECTION

FROM

MESSRS J. & A. CHURCHILL'S

General Catalogue

COMPRISING

ALL RECENT WORKS PUBLISHED BY THEM

ON THE

ART AND SCIENCE

OF

M E D I C I N E



# INDEX

	PAGE		PAGE
Acton on the Reproductive Organs . . .	8	Domville's Manual for Hospital Nurses .	15
Adams (W.) on Clubfoot . . .	6	Druitt's Surgeon's Vade-Mecum . . .	4
— (R.) on Rheumatic Gout . . .	19	Duncan on the Female Perineum . . .	14
Allingham's Diseases of the Rectum .	7	Dunglison's Medical Dictionary . . .	22
Anatomical Remembrancer . . .	11	Ellis's Manual of Diseases of Children .	12
Anderson (McC.) on Eczema . . .	19	Emmet's Gynæcology . . .	14
— (McC.) on Parasitic Affec- tions . . .	19	Eulenburg and Guttmann's Sympa- thetic System of Nerves . . .	19
Aveling's Influence of Posture . . .	14	Fayrer's Observations in India . . .	4
Balfour's Diseases of the Heart . . .	16	Fergusson's Practical Surgery . . .	4
Bantock's Rupture of Perineum . . .	14	Fenwick's Guide to Medical Diagnosis .	12
Barclay's Medical Diagnosis . . .	12	Flint on Phthisis . . .	16
Barker's Puerperal Diseases . . .	13	— on Percussion and Auscultation .	16
Barnes' Obstetric Operations . . .	14	Foster's Clinical Medicine . . .	11
— Diseases of Women . . .	14	Fox (C. B.) Sanitary Examinations .	21
Basham on Diseases of the Kidneys .	8	Fox (T.) Atlas of Skin Diseases . . .	20
Beale on Kidney Diseases . . .	8	Frey's Histology . . .	9
— on Microscope in Medicine . . .	11	Gamgee on Fractures of the Limbs . .	4
Bellamy's Guide to Surgical Anatomy .	10	— on Treatment of Wounds . . .	4
Bennet's Winter and Spring on the Mediterranean . . .	17	Gant's Science and Practice of Sur- gery . . .	4
— Pulmonary Consumption . . .	17	— Diseases of the Bladder . . .	8
— Nutrition . . .	18	Gaskoin on Psoriasis or Lepa . . .	20
Bennett (J. R.) on Cancerous Growths .	19	Glenn's Laws affecting Medical Men .	20
Berkart's Asthma . . .	15	Godlee's Atlas of Human Anatomy . .	11
Bigg's Orthopraxy . . .	6	Gowan on Consumption . . .	15
Binz's Elements of Therapeutics . . .	12	Habershon on Diseases of the Liver .	18
Black on the Urinary Organs . . .	8	— on Diseases of the Abdo- men . . .	18
Blakiston's Clinical Reminiscences .	11	— on Diseases of the Stomach . . .	18
Bose's Rational Therapeutics . . .	11	— on the Pneumogastric Nerve . . .	18
— Recognisant Medicine . . .	11	Hamilton's Nervous Diseases . . .	18
Braune's Topographical Anatomy . . .	11	Hancock's Surgery of Foot and Ankle .	6
Brodhurst's Orthopædic Surgery . . .	6	Harris on Lithotomy . . .	7
Bryant's Practice of Surgery . . .	4	Harrison's Stricture of Urethra . . .	7
Burdett's Cottage Hospital . . .	15	Hayden on the Heart . . .	16
Burnett on the Ear . . .	6	Heath's Minor Surgery and Bandaging .	5
Buzzard on Syphilitic Nervous Affec- tions . . .	8	— Diseases and Injuries of Jaws . .	5
Carpenter's Human Physiology . . .	10	— Operative Surgery . . .	5
Carter (H. V.) on Mycetoma . . .	20	— Practical Anatomy . . .	10
Carter (W.) on Renal and Urinary Diseases . . .	8	Higgins' Ophthalmic Practice . . .	22
Cauty on Diseases of the Skin . . .	20	Holden's Landmarks . . .	10
Chapman on Neuralgia . . .	19	— Human Osteology . . .	10
Charteris' Practice of Medicine . . .	11	Hood on Gout, Rheumatism, &c. . .	19
Clark's Outlines of Surgery . . .	4	Hooper's Physician's Vade-Mecum . .	11
— Surgical Diagnosis . . .	5	Horton's Tropical Diseases . . .	17
Clay's Obstetric Surgery . . .	13	Hutchinson's Clinical Surgery . . .	5
Coles' Dental Mechanics . . .	23	Huth's Marriage of Near Kin . . .	9
Cormack's Clinical Studies . . .	12	Ireland's Idiocy and Imbecility . . .	21
Cottle's Hair in Health and Disease .	20	James' Sore Throat . . .	16
Cullingworth's Nurse's Companion . .	14	Jones (C. H.) and Sieveking's Patho- logical Anatomy . . .	10
Curling's Diseases of the Rectum . . .	7	— (C. H.) on Functional Nervous Disorders . . .	18
— Diseases of the Testis . . .	7	Jones (H. McN.) Aural Surgery . . .	6
Dalby on the Ear . . .	6	— Atlas of Diseases of Membrana Tympani . . .	6
Dalton's Human Physiology . . .	9	Jones (Wharton) Ophthalmic Medi- cine and Surgery . . .	23
Day on Children's Diseases . . .	13	Jordan's Surgical Inflammations . .	6
— on Headaches . . .	18		
Dobell's Lectures on Winter Cough . .	15		
— Loss of Weight, &c. . .	15		



	PAGE		PAGE
Jordan's Surgical Inquiries . . .	6	Steiner's Diseases of Children . .	13
Leber and Rottenstein's Dental Caries	23	Stillé and Maisch's Dispensatory .	12
Lee (H.) on Syphilis . . . . .	8	Stocken's Dental Materia Medica .	12
Leared on Imperfect Digestion . .	18	Stowe's Toxicological Chart . . .	20
Liebreich's Atlas of Ophthalmoscopy	22	Sullivan's Tropical Diseases . . .	17
Living on Megrim, &c. . . . .	18	Swain's Surgical Emergencies . . .	5
Macdonald's (A.) Disease of the heart	16	Swayne's Obstetric Aphorisms . .	14
Macdonald's (J. D.) Examination of		Taft's Operative Dentistry . . . .	23
Water . . . . .	21	Tait's Hospital Mortality . . . .	15
Mackenzie on Diphtheria . . . .	16	Taylor's Principles of Medical Juris-	
Macnamara on Diseases of the Eye .	22	prudence . . . . .	20
Madden's Health Resorts . . . .	17	— Manual of Medical Juris-	
Marsden on certain Forms of Cancer	19	prudence . . . . .	20
Mason on Harelip and Cleft Palate .	5	— Poisons in relation to Medical	
— Surgery of the Face . . . . .	5	Jurisprudence . . . . .	20
Maunder's Operative Surgery . . .	4	Teale's Dangers to Health . . . .	21
— Surgery of Arteries . . . . .	4	Thomas on Ear and Throat Diseases	6
Mayne's Medical Vocabulary . . . .	22	Thompson's Stricture of Urethra .	7
Morris (H.) Anatomy of the Joints .	10	— Practical Lithotomy and	
Ogston's Medical Jurisprudence . .	20	Lithotripsy . . . . .	7
Osborn on Hydrocele . . . . .	7	— Diseases of Urinary Organs	7
Parkes' Manual of Practical Hygiene	21	— Diseases of the Prostate . . .	7
Parkin's Epidemiology . . . . .	23	— Calculous Disease . . . . .	7
Pavy on Food and Dietetics . . . .	18	Thornton on Tracheotomy . . . .	16
— on Diabetes . . . . .	18	Thorowgood on Asthma . . . . .	15
Peacock's Valvular Disease . . . .	16	— on Materia Medica . . . . .	12
Phillips' Materia Medica . . . . .	12	Thudichum's Pathology of Urine .	8
Pirrie's Surgery . . . . .	4	Tibbits' Medical Electricity . . .	22
Pollock's Rheumatism . . . . .	19	— Map of Motor Points . . . . .	22
Ramsbotham's Obstetrics . . . . .	13	Tilt's Uterine Therapeutics . . . .	13
Reynolds' Uses of Electricity . . . .	22	— Change of Life . . . . .	13
Roberts' (C.) Manual of Anthro-		— Health in India . . . . .	17
pometry . . . . .	9	Tomes' (C. S.) Dental Anatomy . .	23
Roberts' (D. Lloyd) Practice of Mid-		— (J. and C. S.) Dental Surgery	23
wifery . . . . .	13	Take on the Influence of the Mind	
Roussel's Transfusion of Blood . .	5	upon the Body . . . . .	21
Routh's Infant Feeding . . . . .	13	Van Buren on Diseases of the Genito-	
Roy's Burdwan Fever . . . . .	17	Urinary Organs . . . . .	8
Royle and Harley's Materia Medica .	12	Veitch's Handbook for Nurses . . .	15
Rutherford's Practical Histology . .	9	Virchow's Post-mortem Examinations	10
Salt's Medico-Electric Apparatus . .	22	Wagstaffe's Human Osteology . . .	9
Sanderson's Physiological Handbook .	9	Walton's Diseases of the Eye . . .	22
Sansom's Diseases of the Heart . . .	16	Ward on Affections of the Liver .	17
Savage on the Female Pelvic Organs	4	Waring's Practical Therapeutics . .	12
Savory's Domestic Medicine . . . .	15	— Bazaar Medicines of India . .	17
Sayre's Orthopædic Surgery . . . .	6	Wells (Soelberg) on Diseases of the Eye	23
Schroeder's Manual of Midwifery . .	13	— Long, Short, and Weak Sight .	23
Semple on the Heart . . . . .	15	Wells (Spencer) on Diseases of the	
Sewill's Dental Anatomy . . . . .	23	Ovaries . . . . .	14
Shapter's Diseases of the Heart . .	16	West's Diseases of Women . . . .	14
Sheppard on Madness . . . . .	21	Whistler's Syphilis of Larynx . .	17
Sibson's Medical Anatomy . . . . .	10	Wilks' Diseases of Nervous System .	18
Sieveking's Life Assurance . . . .	21	— Pathological Anatomy . . . . .	10
Smith (E.) Wasting Diseases of Children	13	Wilson's (E.) Anatomist's Vade-Mecum	11
— Clinical Studies . . . . .	13	— Diseases of the Skin . . . . .	19
Smith (Henry) Surgery of the Rectum	8	— Lectures on Ekzema . . . . .	19
Smith (Heywood) Gynæcology . . . .	14	— Lectures on Dermatology . . .	19
Smith (J.) Dental Anatomy . . . . .	23	Wilson's (G.) Handbook of Hygiene .	21
Smith (W. R.) Nursing . . . . .	15	Woodman & Tidy's Forensic Medicine	21
Spender's Bath Waters . . . . .	17		



**THE PRACTICE OF SURGERY :**

a Manual by THOMAS BRYANT, F.R.C.S., Surgeon to Guy's Hospital.  
Third Edition, 2 vols., crown 8vo, with 672 Engravings, 28s. [1878]

**THE PRINCIPLES AND PRACTICE OF SURGERY,**

by WILLIAM PIRRIE, F.R.S.E., Professor of Surgery in the University  
of Aberdeen. Third Edition, 8vo, with 490 Engravings, 28s. [1873]

**A SYSTEM OF PRACTICAL SURGERY,**

by Sir WILLIAM FERGUSSON, Bart., F.R.C.S., F.R.S. Fifth Edition,  
8vo, with 463 Engravings, 21s. [1870]

**OPERATIVE SURGERY,**

by C. F. MAUNDER, F.R.C.S., Surgeon to the London Hospital.  
Second Edition, post 8vo, with 164 Engravings, 6s. [1872]

BY THE SAME AUTHOR.

**SURGERY OF THE ARTERIES :**

Lettsomian Lectures for 1875, on Aneurisms, Wounds, Hæmorrhages,  
&c. Post 8vo, with 18 Engravings, 5s. [1875]

**THE SURGEON'S VADE-MECUM,**

a Manual of Modern Surgery, by ROBERT DRUITT. Eleventh Edition,  
fcap. 8vo, with 369 Engravings, 14s. [1878]

**THE SCIENCE AND PRACTICE OF SURGERY :**

a complete System and Textbook by F. J. GANT, F.R.C.S., Senior Sur-  
geon to the Royal Free Hospital. 8vo, with 470 Engravings, 24s. [1871]

**OUTLINES OF SURGERY AND SURGICAL PATHOLOGY,**

including the Diagnosis and Treatment of Obscure and Urgent  
Cases, and the Surgical Anatomy of some Important Structures and  
Regions, by F. LE GROS CLARK, F.R.S., Consulting Surgeon to St.  
Thomas's Hospital. Second Edition, Revised and Expanded by the  
Author, assisted by W. W. WAGSTAFFE, F.R.C.S., Assistant-Surgeon  
to St. Thomas's Hospital. 8vo, 10s. 6d. [1872]

**CLINICAL AND PATHOLOGICAL OBSERVATIONS IN INDIA,**

by Sir J. FAYRER, K.C.S.I., M.D., F.R.C.P. Lond., F.R.S.E., Honorary  
Physician to the Queen. 8vo, with Engravings, 20s. [1873]

**TREATMENT OF WOUNDS :**

Clinical Lectures, by SAMPSON GAMGEE, F.R.S.E., Surgeon to the  
Queen's Hospital, Birmingham. Crown 8vo, with Engravings, 5s. [1878]

BY THE SAME AUTHOR,

**FRACTURES OF THE LIMBS**

and their Treatment. 8vo, with Plates, 10s. 6d. [1871]

**THE FEMALE PELVIC ORGANS,**

their Surgery, Surgical Pathology, and Surgical Anatomy, in a  
Series of Coloured Plates taken from Nature: with Commentaries,  
Notes, and Cases, by HENRY SAVAGE, M.D. Lond., F.R.C.S., Consulting  
Officer of the Samaritan Free Hospital. Third Edition, 4to, £1 15s.

[1875]



**SURGICAL EMERGENCIES**

together with the Emergencies attendant on Parturition and the Treatment of Poisoning: a Manual for the use of General Practitioners, by WILLIAM P. SWAIN, F.R.C.S., Surgeon to the Royal Albert Hospital, Devonport. Second Edition, post 8vo, with 104 Engravings, 6s. 6d. [1876]

**TRANSFUSION OF HUMAN BLOOD:**

with Table of 50 cases, by Dr. ROUSSEL, of Geneva. Translated by CLAUDE GUINNESS, B.A. With a Preface by SIR JAMES PAGET, Bart. Crown 8vo, 2s. 6d. [1877]

**ILLUSTRATIONS OF CLINICAL SURGERY,**

consisting of Coloured Plates, Photographs, Woodcuts, Diagrams, &c., illustrating Surgical Diseases, Symptoms and Accidents; also Operations and other methods of Treatment. By JONATHAN HUTCHINSON, F.R.C.S., Senior Surgeon to the London Hospital. In Quarterly Fasciculi, 6s. 6d. each. Fasciculi I to X bound, with Appendix and Index, £3 10s. [1876-9]

**PRINCIPLES OF SURGICAL DIAGNOSIS**

especially in Relation to Shock and Visceral Lesions, by F. LE GROS CLARK, F.R.C.S., Consulting Surgeon to St. Thomas's Hospital. 8vo, 10s. 6d. [1870]

**MINOR SURGERY AND BANDAGING:**

a Manual for the Use of House-Surgeons, Dressers, and Junior Practitioners, by CHRISTOPHER HEATH, F.R.C.S., Surgeon to University College Hospital, and Holme Professor of Surgery in University College. Fifth Edition, fcap 8vo, with 86 Engravings, 5s. 6d. [1875]

BY THE SAME AUTHOR,

**INJURIES AND DISEASES OF THE JAWS:**

JACKSONIAN PRIZE ESSAY. Second Edition, 8vo, with 164 Engravings, 12s. [1872]

BY THE SAME AUTHOR.

**A COURSE OF OPERATIVE SURGERY:**

with 20 Plates drawn from Nature by M. LÉVEILLÉ, and coloured by hand under his direction. Large 8vo. 40s. [1877]

**HARE-LIP AND CLEFT PALATE,**

by FRANCIS MASON, F.R.C.S., Surgeon and Lecturer on Anatomy at St. Thomas's Hospital. With 66 Engravings, 8vo, 6s. [1877]

BY THE SAME AUTHOR,

**THE SURGERY OF THE FACE:**

with 100 Engravings. 8vo, 7s. 6d. [1878]



**DISEASES AND INJURIES OF THE EAR,**

by W. B. DALBY, F.R.C.S., M.B., Aural Surgeon and Lecturer on Aural Surgery at St. George's Hospital. Crown 8vo, with 21 Engravings, 6s. 6d. [1873]

**AURAL SURGERY ;**

A Practical Treatise, by H. MACNAUGHTON JONES, M.D., Professor of the Queen's University in Ireland, Surgeon to the Cork Ophthalmic and Aural Hospital. With 46 Engravings, crown 8vo, 5s. [1878]

BY THE SAME AUTHOR,

**ATLAS OF DISEASES OF THE MEMBRANA TYMPANI.**

In Coloured Plates, containing 62 Figures, with Text, crown 4to, 21s. [1878]

**THE EAR :**

its Anatomy, Physiology, and Diseases. A Practical Treatise, by CHARLES H. BURNETT, A.M., M.D., Aural Surgeon to the Presbyterian Hospital, and Surgeon in Charge of the Infirmary for Diseases of the Ear, Philadelphia. With 87 Engravings, 8vo, 18s. [1877]

**EAR AND THROAT DISEASES.**

Essays by LLEWELLYN THOMAS, M.D., Surgeon to the Central London Throat and Ear Hospital. Post 8vo, 2s. 6d. [1878]

**CLUBFOOT :**

its Causes, Pathology, and Treatment: Jacksonian Prize Essay by WM. ADAMS, F.R.C.S., Surgeon to the Great Northern Hospital. Second Edition, 8vo, with 106 Engravings and 6 Lithographic Plates, 15s. [1873]

**ORTHOPÆDIC SURGERY :**

Lectures delivered at St. George's Hospital, by BERNARD E. BRODHURST, F.R.C.S., Surgeon to the Royal Orthopædic Hospital. Second Edition, 8vo, with Engravings, 12s. 6d. [1876]

**OPERATIVE SURGERY OF THE FOOT AND ANKLE,**

by HENRY HANCOCK, F.R.C.S., Consulting Surgeon to Charing Cross Hospital. 8vo, with Engravings, 15s. [1873]

**THE TREATMENT OF SURGICAL INFLAMMATIONS**

by a New Method, which greatly shortens their Duration, by FURNEAUX JORDAN, F.R.C.S., Professor of Surgery in Queen's College, Birmingham. 8vo, with Plates, 7s. 6d. [1870]

BY THE SAME AUTHOR,

**SURGICAL INQUIRIES.**

With numerous Lithographic Plates. 8vo, 5s. [1873]

**ORTHOPRAXY :**

the Mechanical Treatment of Deformities, Debilities, and Deficiencies of the Human Frame, by H. HEATHER BIGG, Associate of the Institute of Civil Engineers. Third Edition, with 319 Engravings, 8vo, 15s. [1877]

**ORTHOPÆDIC SURGERY :**

and Diseases of the Joints. Lectures by LEWIS A. SAYRE, M.D., Professor of Orthopædic Surgery, Fractures and Dislocations, and Clinical Surgery, in Bellevue Hospital Medical College, New York. With 274 Wood Engravings, 8vo, 20s. [1876]



**DISEASES OF THE RECTUM,**

by THOMAS B. CURLING, F.R.S., Consulting Surgeon to the London Hospital. Fourth Edition, Revised, 8vo, 7s. 6d. [1876]

BY THE SAME AUTHOR,

**DISEASES OF THE TESTIS, SPERMATIC CORD, AND SCROTUM.**

Third Edition, with Engravings, 8vo, 16s. [1878]

**FISTULA, HÆMORRHOIDS, PAINFUL ULCER, STRICTURE,**

Prolapsus, and other Diseases of the Rectum: their Diagnosis and Treatment. By WILLIAM ALLINGHAM, F.R.C.S., Surgeon to St. Mark's Hospital for Fistula. Third Edition, 8vo, 10s. [1879]

**HYDROCELE:**

its several Varieties and their Treatment, by SAMUEL OSBORN, F.R.C.S., late Surgical Registrar to St. Thomas's Hospital. With Engravings, fcap. 8vo, 3s. [1878]

**STRICTURE OF THE URETHRA**

and Urinary Fistulæ; their Pathology and Treatment: Jacksonian Prize Essay by Sir HENRY THOMPSON, F.R.C.S., Emeritus Professor of Surgery to University College. Third Edition, 8vo, with Plates, 10s. [1869]

BY THE SAME AUTHOR,

**PRACTICAL LITHOTOMY AND LITHOTRITY;**

or, An Inquiry into the best Modes of removing Stone from the Bladder. Second Edition, 8vo, with numerous Engravings. 10s. [1871]

ALSO,

**DISEASES OF THE URINARY ORGANS:**

(Clinical Lectures). Fifth Edition, 8vo, with 2 Plates and 71 Engravings, 10s. 6d. [1879]

ALSO,

**DISEASES OF THE PROSTATE:**

their Pathology and Treatment. Fourth Edition, 8vo, with numerous Plates, 10s. [1873]

ALSO,

**THE PREVENTIVE TREATMENT OF CALCULOUS DISEASE**

and the Use of Solvent Remedies. Second Edition, fcap. 8vo, 2s. 6d. [1876]

**STRICTURE OF THE URETHRA,**

and other Diseases of the Urinary Organs, by REGINALD HARRISON, F.R.C.S., Surgeon to the Liverpool Royal Infirmary. With 10 plates, 8vo, 7s. 6d. [1878]

**LITHOTOMY AND EXTRACTION OF STONE**

from the Bladder, Urethra, and Prostate of the Male, and from the Bladder of the Female, by W. POULETT HARRIS, M.D., Surgeon-Major H.M. Bengal Medical Service. With Engravings, 8vo, 10s. 6d. [1876]



**THE SURGERY OF THE RECTUM:**

Lettsomian Lectures by HENRY SMITH, F.R.C.S., Professor of Surgery in King's College, Surgeon to King's College Hospital. Fourth Edition, fcap. 8vo, 5s. [1876]

**KIDNEY DISEASES, URINARY DEPOSITS,**

and Calculous Disorders by LIONEL S. BEALE, M.B., F.R.S., F.R.C.P., Physician to King's College Hospital. Third Edition, 8vo, with 70 Plates, 25s. [1868]

**DISEASES OF THE BLADDER,**

Prostate Gland and Urethra, including a practical view of Urinary Diseases, Deposits and Calculi, by F. J. GANT, F.R.C.S., Senior Surgeon to the Royal Free Hospital. Fourth Edition, crown 8vo, with Engravings, 10s. 6d. [1876]

**THE DIAGNOSIS OF DISEASES OF THE KIDNEYS,**

with Aids thereto, by W. R. BASHAM, M.D., F.R.C.P., late Senior Physician to the Westminster Hospital. 8vo, with 10 Plates, 5s. [1872]

**RENAL AND URINARY DISEASES:**

Clinical Reports, by WILLIAM CARTER, M.B., M.R.C.P., Physician to the Liverpool Southern Hospital. Crown 8vo, 7s. 6d. [1878]

**THE REPRODUCTIVE ORGANS**

in Childhood, Youth, Adult Age, and Advanced Life (Functions and Disorders of), considered in their Physiological, Social, and Moral Relations, by WILLIAM ACTON, M.R.C.S. Sixth Edition, 8vo, 12s. [1875]

**URINARY AND REPRODUCTIVE ORGANS:**

their Functional Diseases, by D. CAMPBELL BLACK, M.D., L.R.C.S. Edin. Second Edition. 8vo, 10s. 6d. [1875]

**LECTURES ON SYPHILIS,**

and on some forms of Local Disease, affecting principally the Organs of Generation, by HENRY LEE, F.R.C.S., Surgeon to St. George's Hospital. With Engravings, 8vo, 10s. [1875]

**SYPHILITIC NERVOUS AFFECTIONS:**

Their Clinical Aspects, by THOMAS BUZZARD, M.D., F.R.C.P. Lond., Physician to the National Hospital for Paralysis and Epilepsy. Post 8vo, 5s. [1874]

**PATHOLOGY OF THE URINE,**

including a Complete Guide to its Analysis, by J. L. W. THUDICHUM, M.D., F.R.C.P. Second Edition, rewritten and enlarged, with Engravings, 8vo, 15s. [1877]



**GENITO-URINARY ORGANS, INCLUDING SYPHILIS:**

A Practical Treatise on their Surgical Diseases, designed as a Manual for Students and Practitioners, by W. H. VAN BUREN, M.D., Professor of the Principles of Surgery in Bellevue Hospital Medical College, New York, and E. L. KEYES, M.D., Professor of Dermatology in Bellevue Hospital Medical College, New York. Royal 8vo, with 140 Engravings, 21s. [1874]

**HISTOLOGY AND HISTO-CHEMISTRY OF MAN:**

A Treatise on the Elements of Composition and Structure of the Human Body, by HEINRICH FREY, Professor of Medicine in Zurich. Translated from the Fourth German Edition by ARTHUR E. J. BARKER, Assistant-Surgeon to University College Hospital. And Revised by the Author. 8vo, with 608 Engravings, 21s. [1874]

**HUMAN PHYSIOLOGY:**

A Treatise designed for the Use of Students and Practitioners of Medicine, by JOHN C. DALTON, M.D., Professor of Physiology and Hygiene in the College of Physicians and Surgeons, New York. Sixth Edition, royal 8vo, with 316 Engravings, 20s. [1875]

**HANDBOOK FOR THE PHYSIOLOGICAL LABORATORY,**

by E. KLEIN, M.D., F.R.S., Assistant Professor in the Pathological Laboratory of the Brown Institution, London; J. BURDON-SANDERSON, M.D., F.R.S., Professor of Practical Physiology in University College, London; MICHAEL FOSTER, M.D., F.R.S., Prælector of Physiology in Trinity College, Cambridge; and T. LAUDER BRUNTON, M.D., F.R.S., Lecturer on Materia Medica at St. Bartholomew's Hospital; edited by J. BURDON-SANDERSON. 8vo, with 123 Plates, 24s. [1873]

**PRACTICAL HISTOLOGY:**

By WILLIAM RUTHERFORD, M.D., Professor of the Institutes of Medicine in the University of Edinburgh. Second Edition, with 63 Engravings. Crown 8vo (with additional leaves for notes), 6s. [1876]

**THE MARRIAGE OF NEAR KIN,**

Considered with respect to the Laws of Nations, Results of Experience, and the Teachings of Biology, by ALFRED H. HUTH. 8vo, 14s. [1875]

**MANUAL OF ANTHROPOMETRY:**

A Guide to the Measurement of the Human Body, containing an Anthropometrical Chart and Register, a Systematic Table of Measurements, &c. By CHARLES ROBERTS, F.R.C.S., late Assistant Surgeon to the Victoria Hospital for Children. With numerous Illustrations and Tables. 8vo, 6s. 6d. [1878]

**STUDENTS' GUIDE TO HUMAN OSTEOLOGY,**

By WILLIAM WARWICK WAGSTAFFE, F.R.C.S., Assistant-Surgeon and Lecturer on Anatomy, St. Thomas's Hospital. With 23 Plates and 66 Engravings. Fcap. 8vo, 10s. 6d. [1875]



**PRINCIPLES OF HUMAN PHYSIOLOGY,**

by W. B. CARPENTER, C.B., M.D., F.R.S. Eighth Edition by HENRY POWER, M.B., F.R.C.S., Examiner in Natural Science, University of Oxford, and in Natural Science and Medicine, University of Cambridge. 8vo, with 3 Steel Plates and 371 Engravings, 31s. 6d. [1876]

**LANDMARKS, MEDICAL AND SURGICAL,**

By LUTHER HOLDEN, F.R.C.S., Member of the Court of Examiners of the Royal College of Surgeons. Second Edition, 8vo, 3s. 6d. [1877]

BY THE SAME AUTHOR.

**HUMAN OSTEOLOGY:**

Comprising a Description of the Bones, with Delineations of the Attachments of the Muscles, the General and Microscopical Structure of Bone, and its Development. Fifth Edition, with 61 Lithographic Plates and 89 Engravings. 8vo, 16s. [1878]

**PATHOLOGICAL ANATOMY:**

Lectures by SAMUEL WILKS, M.D., F.R.S., Physician to, and Lecturer on Medicine at, Guy's Hospital; and WALTER MOXON, M.D., F.R.C.P., Physician to, and Lecturer on Materia Medica at, Guy's Hospital. Second Edition, 8vo, with Plates, 18s. [1875]

**PATHOLOGICAL ANATOMY:**

A Manual by C. HANDFIELD JONES, M.B., F.R.S., Physician to St. Mary's Hospital, and EDWARD H. SIEVEKING, M.D., F.R.C.P., Physician to St. Mary's Hospital. Edited by J. F. PAYNE, M.D., F.R.C.P., Assistant Physician and Lecturer on General Pathology at St. Thomas's Hospital. Second Edition, crown 8vo, with 195 Engravings, 16s. [1875]

**POST-MORTEM EXAMINATIONS:**

a Description and Explanation of the Method of Performing them, with especial Reference to Medico-Legal Practice. By Professor RUDOLPH VIRCHOW, of Berlin. Fcap 8vo, 2s. 6d. [1876]

**STUDENT'S GUIDE TO SURGICAL ANATOMY:**

a Text-book for the Pass Examination, by E. BELLAMY, F.R.C.S., Surgeon and Lecturer on Anatomy at Charing Cross Hospital. Fcap 8vo, with 50 Engravings, 6s. 6d. [1873]

**ANATOMY OF THE JOINTS OF MAN,**

by HENRY MORRIS, F.R.C.S., Senior Assistant-Surgeon to, and Lecturer on Anatomy and Demonstrator of Operative Surgery at, the Middlesex Hospital. With 44 Lithographic Plates (several being coloured) and 13 Wood Engravings. 8vo, 16s. [1879]

**MEDICAL ANATOMY,**

by FRANCIS SIBSON, M.D., F.R.C.P., F.R.S. Imp. folio, with 21 coloured Plates, cloth, 42s., half-morocco, 50s. [1869]

**PRACTICAL ANATOMY:**

a Manual of Dissections by CHRISTOPHER HEATH, F.R.C.S., Surgeon to University College Hospital, and Holme Professor of Surgery in University College. Fourth Edition, crown 8vo, with 16 Coloured Plates and 264 Engravings, 14s. [1877]



**AN ATLAS OF HUMAN ANATOMY :**

illustrating most of the ordinary Dissections, and many not usually practised by the Student. To be completed in 12 or 13 Bi-monthly Parts, each containing 4 Coloured Plates, with Explanatory Text. By RICKMAN J. GODLEE, M.S., F.R.C.S., Assistant Surgeon to University College Hospital, and Senior Demonstrator of Anatomy in University College. Parts I to VII. Imp. 4to, 7s. 6d. each Part. [1877-9]

**THE ANATOMIST'S VADE-MECUM :**

a System of Human Anatomy by ERASMUS WILSON, F.R.C.S., F.R.S. Ninth Edition, by G. BUCHANAN, M.A., M.D., Professor of Clinical Surgery in the University of Glasgow, and HENRY E. CLARK, F.F.P.S., Lecturer on Anatomy at the Glasgow Royal Infirmary School of Medicine. Crown 8vo, with 371 Engravings, 14s. [1873]

**ATLAS OF TOPOGRAPHICAL ANATOMY,**

after Plane Sections of Frozen Bodies. By WILHELM BRAUNE, Professor of Anatomy in the University of Leipzig. Translated by EDWARD BELLAMY, F.R.C.S., Surgeon to, and Lecturer on Anatomy, &c., at, Charing Cross Hospital. With 34 Photo-lithographic Plates and 46 Woodcuts. Large Imp. 8vo, 40s. [1877]

**THE ANATOMICAL REMEMBRANCER ;**

or, Complete Pocket Anatomist. Eighth Edition, 32mo, 3s. 6d. [1876]

**THE STUDENT'S GUIDE TO THE PRACTICE OF MEDICINE,**

by MATTHEW CHARTERIS, M.D., Professor of Medicine in Anderson's College, and Lecturer on Clinical Medicine in the Royal Infirmary, Glasgow. Second Edition, with Engravings on Copper and Wood, fcap. 8vo, 6s. 6d. [1878]

**THE MICROSCOPE IN MEDICINE,**

by LIONEL S. BEALE, M.B., F.R.S., Physician to King's College Hospital. Fourth Edition, with 86 Plates, 8vo, 21s. [1877]

**HOOVER'S PHYSICIAN'S VADE-MECUM ;**

or, Manual of the Principles and Practice of Physic, Ninth Edition by W. A. GUY, M.B., F.R.S., and JOHN HARLEY, M.D., F.R.C.P. Fcap 8vo, with Engravings, 12s. 6d. [1874]

**A NEW SYSTEM OF MEDICINE ;**

entitled Recognisant Medicine, or the State of the Sick, by BHOLANOTH BOSE, M.D., Indian Medical Service. 8vo, 10s. 6d. [1877]

BY THE SAME AUTHOR.

**PRINCIPLES OF RATIONAL THERAPEUTICS.**

Commenced as an Inquiry into the Relative Value of Quinine and Arsenic in Ague. 8vo, 4s. [1877]

**CLINICAL MEDICINE :**

Lectures and Essays by BALTHAZAR FOSTER, M.D., F.R.C.P. Lond., Professor of Medicine in Queen's College, Birmingham. 8vo, 10s. 6d. [1874]

**CLINICAL REMINISCENCES :**

By PEYTON BLAKISTON, M.D., F.R.S. Post 8vo, 3s. 6d. [1878]



**THE STUDENT'S GUIDE TO MEDICAL DIAGNOSIS,**

by SAMUEL FENWICK, M.D., F.R.C.P., Physician to the London Hospital. Fourth Edition, fcap. 8vo, with 106 Engravings, 6s. 6d. [1876]

**A MANUAL OF MEDICAL DIAGNOSIS,**

by A. W. BARCLAY, M.D., F.R.C.P., Physician to, and Lecturer on Medicine at, St. George's Hospital. Third Edition, fcap 8vo, 10s. 6d. [1876]

**CLINICAL STUDIES:**

Illustrated by Cases observed in Hospital and Private Practice, by Sir J. ROSE CORMACK, M.D., F.R.S.E., Physician to the Hertford British Hospital of Paris. 2 vols., post 8vo, 20s. [1876]

**ROYLE'S MANUAL OF MATERIA MEDICA AND THERAPEUTICS.**

Sixth Edition by JOHN HARLEY, M.D., F.R.C.P., Assistant Physician to, and Joint Lecturer on Physiology at, St. Thomas's Hospital. Crown 8vo, with 139 Engravings, 15s. [1876]

**PRACTICAL THERAPEUTICS:**

A Manual by E. J. WARING, M.D., F.R.C.P. Lond. Third Edition, fcap 8vo, 12s. 6d. [1871]

**THE ELEMENTS OF THERAPEUTICS.**

A Clinical Guide to the Action of Drugs, by C. BINZ, M.D., Professor of Pharmacology in the University of Bonn. Translated and Edited with Additions, in Conformity with the British and American Pharmacopœias, by EDWARD I. SPARKS, M.A., M.B. Oxon., formerly Radcliffe Travelling Fellow. Crown 8vo, 8s. 6d. [1877]

**THE NATIONAL DISPENSATORY;**

containing the Natural History, Chemistry, Pharmacy, Actions and Uses of Medicines, including those recognised in the Pharmacopœias of the United States and Great Britain. By ALFRED STILLÉ, M.D., and JOHN M. MAISCH, Ph. D. 1628 pp., with 201 Engravings, royal 8vo, 34s. [1879]

**THE STUDENT'S GUIDE TO MATERIA MEDICA,**

by JOHN C. THOROWGOOD, M.D., F.R.C.P. Lond., Physician to the City of London Hospital for Diseases of the Chest. Fcap 8vo, with Engravings, 6s. 6d. [1874]

**MATERIA MEDICA AND THERAPEUTICS:**

(Vegetable Kingdom), by CHARLES D. F. PHILLIPS, M.D., F.R.C.S.E. 8vo, 15s. [1874]

**DENTAL MATERIA MEDICA AND THERAPEUTICS,**

Elements of, by JAMES STOCKEN, L.D.S.R.C.S., Lecturer on Dental Materia Medica and Therapeutics to the National Dental Hospital. Second Edition, Fcap 8vo, 6s. 6d. [1878]

**THE DISEASES OF CHILDREN:**

A Practical Manual, with a Formulary, by EDWARD ELLIS, M.D., late Senior Physician to the Victoria Hospital for Children. Third Edition, crown 8vo, 7s. 6d. [1878]



**THE WASTING DISEASES OF CHILDREN,**

by EUSTACE SMITH, M.D., F.R.C.P. Lond., Physician to the King of the Belgians, Physician to the East London Hospital for Children. Third Edition, post 8vo, 8s. 6d. [1878]

BY THE SAME AUTHOR,

**CLINICAL STUDIES OF DISEASE IN CHILDREN.**

Post 8vo, 7s. 6d. [1876]

**INFANT FEEDING AND ITS INFLUENCE ON LIFE;**

or, the Causes and Prevention of Infant Mortality, by CHARLES H. F. ROUTH, M.D., Senior Physician to the Samaritan Hospital for Women and Children. Third Edition, fcap 8vo, 7s. 6d. [1876]

**COMPENDIUM OF CHILDREN'S DISEASES:**

A Handbook for Practitioners and Students, by JOHANN STEINER, M.D., Professor in the University of Prague. Translated from the Second German Edition by LAWSON TAIT, F.R.C.S., Surgeon to the Birmingham Hospital for Women. 8vo, 12s. 6d. [1874]

**THE DISEASES OF CHILDREN:**

Essays by WILLIAM HENRY DAY, M.D., Physician to the Samaritan Hospital for Diseases of Women and Children. Second Edition, fcap 8vo. [In the Press.]

**PUERPERAL DISEASES:**

Clinical Lectures by FORDYCE BARKER, M.D., Obstetric Physician to Bellevue Hospital, New York. 8vo, 15s. [1874]

**THE STUDENT'S GUIDE TO THE PRACTICE OF MIDWIFERY,**

by D. LLOYD ROBERTS, M.D., F.R.C.P., Physician to St. Mary's Hospital, Manchester. Second Edition, fcap 8vo, with 111 Engravings, 7s. [1879]

**OBSTETRIC MEDICINE AND SURGERY,**

Their Principles and Practice, by F. H. RAMSBOTHAM, M.D., F.R.C.P. Fifth Edition, 8vo, with 120 Plates, 22s. [1867]

**OBSTETRIC SURGERY:**

A Complete Handbook, giving Short Rules of Practice in every Emergency, from the Simplest to the most Formidable Operations connected with the Science of Obstetrics, by CHARLES CLAY, Ext.L.R.C.P. Lond., L.R.C.S.E., late Senior Surgeon and Lecturer on Midwifery, St. Mary's Hospital, Manchester. Fcap 8vo, with 91 Engravings, 6s. 6d. [1874]

**SCHROEDER'S MANUAL OF MIDWIFERY,**

including the Pathology of Pregnancy and the Puerperal State. Translated by CHARLES H. CARTER, B.A., M.D. 8vo, with Engravings, 12s. 6d. [1873]

**A HANDBOOK OF UTERINE THERAPEUTICS,**

and of Diseases of Women, by E. J. TILT, M.D., M.R.C.P. Fourth Edition, post 8vo, 10s. [1878]

BY THE SAME AUTHOR,

**THE CHANGE OF LIFE**

in Health and Disease: a Practical Treatise on the Nervous and other Affections incidental to Women at the Decline of Life. Third Edition, 8vo, 10s. 6d. [1870]



**OBSTETRIC OPERATIONS,**

including the Treatment of Hæmorrhage, and forming a Guide to the Management of Difficult Labour; Lectures by ROBERT BARNES, M.D., F.R.C.P., Obstetric Physician and Lecturer on Obstetrics and the Diseases of Women and Children at St. George's Hospital. Third Edition, 8vo, with 124 Engravings, 18s. [1875]

BY THE SAME AUTHOR,

**MEDICAL AND SURGICAL DISEASES OF WOMEN:**

a Clinical History. Second Edition, 8vo, with 181 Engravings, 28s. [1878]

**THE DISEASES OF WOMEN.**

By CHARLES WEST, M.D., F.R.C.P. Revised and in part Re-written by the Author, with numerous Additions by J. MATTHEWS DUNCAN, M.D., Obstetric Physician to St. Bartholomew's Hospital. Fourth Edition, 8vo, 16s. [1879]

**OBSTETRIC APHORISMS:**

for the Use of Students commencing Midwifery Practice by J. G. SWAYNE, M.D., Consulting Physician-Accoucheur to the Bristol General Hospital, and Lecturer on Obstetric Medicine at the Bristol Medical School. Sixth Edition, fcap 8vo, with Engravings, 3s. 6d. [1876]

**DISEASES OF THE OVARIES:**

their Diagnosis and Treatment, by T. SPENCER WELLS, F.R.C.S., Surgeon to the Queen's Household and to the Samaritan Hospital. 8vo, with about 150 Engravings, 21s. [1872]

**PRACTICAL GYNÆCOLOGY:**

A Handbook of the Diseases of Women, by HEYWOOD SMITH, M.D. Oxon., Physician to the Hospital for Women and to the British Lying-in Hospital. With Engravings, crown 8vo, 5s. 6d. [1877]

**THE PRINCIPLES AND PRACTICE OF GYNÆCOLOGY.**

By THOMAS ADDIS EMMET, M.D., Surgeon to the Woman's Hospital of the State of New York. With 130 Engravings, 8vo, 24s. [1879]

**RUPTURE OF THE FEMALE PERINEUM,**

Its treatment, immediate and remote, by GEORGE G. BANTOCK, M.D., Surgeon (for In-patients) to the Samaritan Free Hospital for Women and Children. With 2 plates, 8vo, 3s. 6d. [1878]

**PAPERS ON THE FEMALE PERINEUM, &c.,**

by JAMES MATTHEWS DUNCAN, M.D., Obstetric Physician to St. Bartholomew's Hospital. 8vo, 6s. [1878]

**INFLUENCE OF POSTURE ON WOMEN**

In Gynecic and Obstetric Practice, by J. H. AVELING, M.D., Physician to the Chelsea Hospital for Women, Vice-President of the Obstetrical Society of London. 8vo, 6s. [1878]

**THE NURSE'S COMPANION:**

A Manual of General and Monthly Nursing, by CHARLES J. CULLINGWORTH, Surgeon to St. Mary's Hospital, Manchester. Fcap. 8vo, 2s. 6d. [1876]



**A MANUAL FOR HOSPITAL NURSES**

and others engaged in Attending on the Sick by EDWARD J. DOMVILLE, L.R.C.P., M.R.C.S., Surgeon to the Exeter Lying-in Charity. Third Edition, crown 8vo, 2s. 6d. [1878]

**LECTURES ON NURSING,**

by WILLIAM ROBERT SMITH, M.B., Honorary Medical Officer, Hospital for Sick Children, Sheffield. Second Edition, with 26 Engravings. Post 8vo, 6s. [1878]

**HANDBOOK FOR NURSES FOR THE SICK,**

by ZEPHERINA P. VEITCH. Second Edition, crown 8vo, 3s. 6d. [1876]

**A COMPENDIUM OF DOMESTIC MEDICINE**

and Companion to the Medicine Chest; intended as a Source of Easy Reference for Clergymen, and for Families residing at a Distance from Professional Assistance, by JOHN SAVORY, M.S.A. Ninth Edition, 12mo, 5s. [1878]

**HOSPITAL MORTALITY**

being a Statistical Investigation of the Returns of the Hospitals of Great Britain and Ireland for fifteen years, by LAWSON TAIT, F.R.C.S., F.S.S. 8vo, 8s. 6d. [1877]

**THE COTTAGE HOSPITAL:**

Its Origin, Progress, Management, and Work, by HENRY C. BURDETT, the Seaman's Hospital, Greenwich. With Engravings, crown 8vo, 7s. 6d. [1877]

**WINTER COUGH:**

(Catarrh, Bronchitis, Emphysema, Asthma), Lectures by HORACE DOBELL, M.D., Consulting Physician to the Royal Hospital for Diseases of the Chest. Third Edition, with Coloured Plates, 8vo, 10s. 6d. [1875]

BY THE SAME AUTHOR,

**LOSS OF WEIGHT, BLOOD-SPITTING, AND LUNG DISEASE.**

With Chromo-lithograph, 8vo, 10s. 6d. [1878]

**CONSUMPTION:**

Its Nature, Symptoms, Causes, Prevention, Curability, and Treatment. By PETER GOWAN, M.D., B. Sc., late Physician and Surgeon in Ordinary to the King of Siam. Crown 8vo. 5s. [1878]

**NOTES ON ASTHMA;**

its Forms and Treatment, by JOHN C. THOROWGOOD, M.D. Lond., F.R.C.P., Physician to the Hospital for Diseases of the Chest, Victoria Park. Third Edition, crown 8vo, 4s. 6d. [1878]

**ASTHMA**

Its Pathology and Treatment, by J. B. BERKART, M.D., Assistant Physician to the City of London Hospital for Diseases of the Chest. 8vo, 7s. 6d. [1878]

**DISEASES OF THE HEART:**

Their Pathology, Diagnosis, Prognosis, and Treatment (a Manual), by ROBERT H. SEMPLE, M.D., F.R.C.P., Physician to the Hospital for Diseases of the Throat. 8vo, 8s. 6d. [1875]



**PROGNOSIS IN CASES OF VALVULAR DISEASE OF THE**  
Heart, by THOMAS B. PEACOCK, M.D., F.R.C.P., Honorary Consulting Physician to St. Thomas's Hospital. 8vo, 3s. 6d. [1877]

**CHRONIC DISEASE OF THE HEART:**

Its Bearings upon Pregnancy, Parturition and Childbed. By ANGUS MACDONALD, M.D., F.R.S.E., Physician to, and Clinical Lecturer on the Diseases of Women at, the Edinburgh Royal Infirmary. With Engravings, 8vo, 8s. 6d. [1878]

**PHTHISIS:**

In a series of Clinical Studies, by AUSTIN FLINT, M.D., Professor of the Principles and Practice of Medicine and of Clinical Medicine in the Bellevue Hospital Medical College. 8vo, 16s. [1875]

BY THE SAME AUTHOR,

**A MANUAL OF PERCUSSION AND AUSCULTATION,**  
of the Physical Diagnosis of Diseases of the Lungs and Heart, and of Thoracic Aneurism. Post 8vo, 6s. 6d. [1876]

**DIPHThERIA:**

its Nature and Treatment, Varieties, and Local Expressions, by MORELL MACKENZIE, M.D., Physician to the Hospital for Diseases of the Throat. Crown 8vo, 5s. [1878]

**DISEASES OF THE HEART AND AORTA,**

By THOMAS HAYDEN, F.R.C.P. Irel., Physician to the Mater Misericordiae Hospital, Dublin. With 80 Engravings. 8vo, 25s. [1875]

**DISEASES OF THE HEART**

and of the Lungs in Connexion therewith—Notes and Observations by THOMAS SHAPTER, M.D., F.R.C.P. Lond., Senior Physician to the Devon and Exeter Hospital. 8vo, 7s. 6d. [1874]

**DISEASES OF THE HEART AND AORTA:**

Clinical Lectures by GEORGE W. BALFOUR, M.D., F.R.C.P., Physician to, and Lecturer on Clinical Medicine in, the Royal Infirmary, Edinburgh. 8vo, with Engravings, 12s. 6d. [1876]

**PHYSICAL DIAGNOSIS OF DISEASES OF THE HEART.**

Lectures by ARTHUR E. SANSOM, M.D., F.R.C.P., Assistant Physician to the London Hospital. Second Edition, with Engravings, fcap. 8vo, 4s. 6d. [1876]

**TRACHEOTOMY,**

especially in Relation to Diseases of the Larynx and Trachea, by PUGIN THORNTON, M.R.C.S., late Surgeon to the Hospital for Diseases of the Throat. With Photographic Plates and Woodcuts, 8vo, 5s. 6d. [1876]

**SORE THROAT:**

Its Nature, Varieties, and Treatment, including the Connexion between Affections of the Throat and other Diseases. By PROSSER JAMES, M.D., Lecturer on Materia Medica and Therapeutics at the London Hospital, Physician to the Hospital for Diseases of the Throat. Third Edition, with Coloured Plates, 5s. 6d. [1878]



**SYPHILIS OF THE LARYNX**

(Lesions of the Secondary and Intermediate Stages). Lectures delivered at the Hospital for Diseases of the Throat and Chest, London, by W. MACNEILL WHISTLER, M.D., M.R.C.P., Physician to the Hospital; Honorary Physician to the National Training School for Music. With Engravings, crown 8vo, 4s. [1879]

**WINTER AND SPRING**

on the Shores of the Mediterranean. By HENRY BENNET, M.D. Fifth Edition, post 8vo, with numerous Plates, Maps, and Engravings, 12s. 6d. [1874]

BY THE SAME AUTHOR,

**TREATMENT OF PULMONARY CONSUMPTION**

by Hygiene, Climate, and Medicine. Third Edition, 8vo, 7s. 6d. [1878]

**PRINCIPAL HEALTH RESORTS**

of Europe and Africa, and their Use in the Treatment of Chronic Diseases. A Handbook by THOMAS MORE MADDEN, M.D., M.R.I.A., Vice-President of the Dublin Obstetrical Society. 8vo, 10s. [1876]

**THE BATH THERMAL WATERS:**

Historical, Social, and Medical, by JOHN KENT SPENDER, M.D., Surgeon to the Mineral Water Hospital, Bath. With an Appendix on the Climate of Bath by the Rev. L. BLOMEFIELD, M.A., F.L.S., F.G.S. 8vo, 7s. 6d. [1877]

**ENDEMIC DISEASES OF TROPICAL CLIMATES,**

with their Treatment, by JOHN SULLIVAN, M.D., M.R.C.P. Post 8vo, 6s. [1877]

**DISEASES OF TROPICAL CLIMATES**

and their Treatment: with Hints for the Preservation of Health in the Tropics, by JAMES A. HORTON, M.D., Surgeon-Major, Army Medical Department. Second Edition, post 8vo, 12s. 6d. [1879]

**HEALTH IN INDIA FOR BRITISH WOMEN**

and on the Prevention of Disease in Tropical Climates by EDWARD J. TILT, M.D., Consulting Physician-Accoucheur to the Farringdon General Dispensary. Fourth Edition, crown 8vo, 5s. [1875]

**BURDWAN FEVER,**

or the Epidemic Fever of Lower Bengal (Causes, Symptoms, and Treatment), by GOPAUL CHUNDER ROY, M.D., Surgeon Bengal Establishment. New Edition, 8vo, 5s. [1876]

**BAZAAR MEDICINES OF INDIA**

and Common Medical Plants: Remarks on their Uses, with Full Index of Diseases, indicating their Treatment by these and other Agents procurable throughout India, &c., by EDWARD J. WARING, M.D., F.R.C.P. Lond., Retired Surgeon H.M. Indian Army. Third Edition. Fcap 8vo, 5s. [1875]

**SOME AFFECTIONS OF THE LIVER**

and Intestinal Canal; with Remarks on Ague and its Sequelæ, Scurvy, Purpura, &c., by STEPHEN H. WARD, M.D. Lond., F.R.C.P., Physician to the Seamen's Hospital, Greenwich. 8vo, 7s. [1872]



**DISEASES OF THE LIVER:**

Lettsomian Lectures for 1872 by S. O. HABERSHON, M.D., F.R.C.P.,  
Senior Physician to Guy's Hospital. Post 8vo, 3s. 6d. [1872]

BY THE SAME AUTHOR,

**DISEASES OF THE STOMACH: DYSPEPSIA.**

Third Edition, crown 8vo, 5s. [1879]

BY THE SAME AUTHOR,

**PATHOLOGY OF THE PNEUMOGASTRIC NERVE,**

being the Lumleian Lectures for 1876. Post 8vo, 3s. 6d. [1877]

BY THE SAME AUTHOR,

**DISEASES OF THE ABDOMEN,**

comprising those of the Stomach and other parts of the Alimentary  
Canal, Œsophagus, Cæcum, Intestines, and Peritoneum. Third  
Edition, with 5 Plates, 8vo, 21s. [1878]

**FUNCTIONAL NERVOUS DISORDERS:**

Studies by C. HANDFIELD JONES, M.B., F.R.C.P., F.R.S., Physician  
to St. Mary's Hospital. Second Edition, 8vo, 18s. [1870]

**LECTURES ON DISEASES OF THE NERVOUS SYSTEM,**

by SAMUEL WILKS, M.D., F.R.S., Physician to, and Lecturer on  
Medicine at, Guy's Hospital. 8vo, 15s. [1878]

**NERVOUS DISEASES:**

their Description and Treatment, by ALLEN McLANE HAMILTON, M.D.,  
Physician at the Epileptic and Paralytic Hospital, Blackwell's Island,  
New York City. Roy. 8vo, with 53 Illustrations, 14s. [1878]

**NUTRITION IN HEALTH AND DISEASE:**

A Contribution to Hygiene and to Clinical Medicine. By HENRY  
BENNET, M.D. Third (Library) Edition. 8vo, 7s. Cheap Edition,  
Fcap. 8vo, 2s. 6d. [1877]

**FOOD AND DIETETICS,**

Physiologically and Therapeutically Considered. By FREDERICK W.  
PAVY, M.D., F.R.S., Physician to Guy's Hospital. Second Edition,  
8vo, 15s. [1875]

BY THE SAME AUTHOR.

**CERTAIN POINTS CONNECTED WITH DIABETES**

(Croonian Lectures). 8vo, 4s. 6d. [1878]

**HEADACHES:**

their Causes, Nature, and Treatment. By WILLIAM H. DAY, M.D.,  
Physician to the Samaritan Free Hospital for Women and Children.  
Second Edition, crown 8vo, with Engravings. 6s. 6d. [1878]

**IMPERFECT DIGESTION:**

its Causes and Treatment by ARTHUR LEARED, M.D., F.R.C.P.,  
Senior Physician to the Great Northern Hospital. Sixth Edition,  
fcap 8vo, 4s. 6d. [1875]

**MEGRIM, SICK-HEADACHE,**

and some Allied Disorders: a Contribution to the Pathology of Nerve-  
Storms, by EDWARD LIVEING, M.D. Cantab., F.R.C.P., Hon. Fellow  
of King's College, London. 8vo, with Coloured Plate, 15s. [1873]



**NEURALGIA AND KINDRED DISEASES**

of the Nervous System : their Nature, Causes, and Treatment, with a series of Cases, by JOHN CHAPMAN, M.D., M.R.C.P. 8vo, 14s. [1873]

**THE SYMPATHETIC SYSTEM OF NERVES:**

their Physiology and Pathology, by A. EULENBURG, Professor of Medicine, University of Greifswald, and Dr. P. GUTTMANN, Priva Docen in Medicine, University of Berlin. Translated by A. NAPIER, M.D., F.F.P.S. 8vo, 5s. [1879]

**RHEUMATIC GOUT,**

or Chronic Rheumatic Arthritis of all the Joints; a Treatise by ROBERT ADAMS, M.D., M.R.I.A., late Surgeon to H.M. the Queen in Ireland, and Regius Professor of Surgery in the University of Dublin. Second Edition, 8vo, with Atlas of Plates, 21s. [1872]

**GOUT, RHEUMATISM,**

and the Allied Affections; with a chapter on Longevity and the Causes Antagonistic to it, by PETER HOOD, M.D. Second Edition, crown 8vo, 10s. 6d. [1879]

**RHEUMATISM:**

Notes by JULIUS POLLOCK, M.D., F.R.C.P., Senior Physician to, and Lecturer on Medicine at, Charing Cross Hospital. Second Edition, with Engravings, fcap. 8vo, 3s. 6d. [1879]

**CERTAIN FORMS OF CANCER,**

with a New and successful Mode of Treating it, to which is prefixed a Practical and Systematic Description of all the varieties of this Disease, by ALEX. MARSDEN, M.D., F.R.C.S.E., Consulting Surgeon to the Royal Free Hospital, and Senior Surgeon to the Cancer Hospital. Second Edition, with Coloured Plates, 8vo, 8s. 6d. [1873]

**DISEASES OF THE SKIN:**

a System of Cutaneous Medicine by ERASMUS WILSON, F.R.C.S., F.R.S. Sixth Edition, 8vo, 18s., with Coloured Plates, 36s. [1867]

BY THE SAME AUTHOR,

**LECTURES ON EKZEMA**

and Ekzematous Affections: with an Introduction on the General Pathology of the Skin, and an Appendix of Essays and Cases. 8vo, 10s. 6d. [1870]

ALSO,

**LECTURES ON DERMATOLOGY:**

delivered at the Royal College of Surgeons, 1870, 6s.; 1871-3, 10s. 6d., 1874-5, 10s. 6d.; 1876-8, 10s. 6d.

**ECZEMA:**

by MCCALL ANDERSON, M.D., Professor of Clinical Medicine in the University of Glasgow. Third Edition, 8vo, with Engravings, 7s. 6d. [1874]

BY THE SAME AUTHOR,

**PARASITIC AFFECTIONS OF THE SKIN**

Second Edition, 8vo, with Engravings, 7s. 6d. [1868]



**ATLAS OF SKIN DISEASES :**

a series of Illustrations, with Descriptive Text and Notes upon Treatment. By **TILBURY FOX, M.D., F.R.C.P.**, Physician to the Department for Skin Diseases in University College Hospital. With 72 Coloured Plates, royal 4to, half morocco, £6 6s. [1877]

**PSORIASIS OR LEPROA,**

by **GEORGE GASKOIN, M.R.C.S.**, Surgeon to the British Hospital for Diseases of the Skin. 8vo, 5s. [1875]

**MYCETOMA ;**

or, the Fungus Disease of India, by **H. VANDYKE CARTER, M.D.**, Surgeon-Major H.M. Indian Army. 4to, with 11 Coloured Plates, 42s. [1874]

**DISEASES OF THE SKIN,**

in Twenty-four Letters on the Principles and Practice of Cutaneous Medicine, by **HENRY EVANS CAUTY, M.R.C.S.**, Surgeon to the Liverpool Dispensary for Diseases of the Skin, 8vo, 12s. 6d. [1874]

**THE HAIR IN HEALTH AND DISEASE,**

by **E. WYNDHAM COTTLE, F.R.C.S.**, Senior Assistant Surgeon to the Hospital for Diseases of the Skin, Blackfriars. Fcap. 8vo, 2s. 6d. [1877]

**THE LAWS AFFECTING MEDICAL MEN :**

a Manual by **ROBERT G. GLENN, LL.B.**, Barrister-at-Law ; with a Chapter on Medical Etiquette by **Dr. A. CARPENTER.** 8vo, 14s. [1871]

**MEDICAL JURISPRUDENCE,**

Its Principles and Practice, by **ALFRED S. TAYLOR, M.D., F.R.C.P., F.R.S.** Second Edition, 2 vols., 8vo, with 189 Engravings, £1 11s. 6d. [1873]

BY THE SAME AUTHOR,

**A MANUAL OF MEDICAL JURISPRUDENCE.**

Tenth Edition. Crown 8vo, with Engravings, 14s. [1879]

ALSO,

**POISONS,**

in Relation to Medical Jurisprudence and Medicine. Third Edition, crown 8vo, with 104 Engravings, 16s. [1875]

**MEDICAL JURISPRUDENCE :**

Lectures by **FRANCIS OGSTON, M.D.**, Professor of Medical Jurisprudence and Medical Logic in the University of Aberdeen. Edited by **FRANCIS OGSTON, Jun., M.D.**, Assistant to the Professor of Medical Jurisprudence and Lecturer on Practical Toxicology in the University of Aberdeen. 8vo, with 12 Copper Plates, 18s. [1878]

**A TOXICOLOGICAL CHART,**

exhibiting at one View the Symptoms, Treatment, and mode of Detecting the various Poisons—Mineral, Vegetable, and Animal : with Concise Directions for the Treatment of Suspended Animation, by **WILLIAM STOWE, M.R.C.S.E.** Thirteenth Edition, 2s. ; on roller, 5s. [1872]



**A HANDY-BOOK OF FORENSIC MEDICINE AND TOXICOLOGY,**  
by W. BATHURST WOODMAN, M.D., F.R.C.P., Assistant Physician  
and Co-Lecturer on Physiology and Histology at the London Hospital;  
and C. MEYMOTT TIDY, M.D., F.C.S., Professor of Chemistry and of  
Medical Jurisprudence and Public Health at the London Hospital.  
With 8 Lithographic Plates and 116 Engravings, 8vo, 31s. 6d. [1877]

**THE MEDICAL ADVISER IN LIFE ASSURANCE,**  
by EDWARD HENRY SIEVEKING, M.D., F.R.C.P., Physician to St.  
Mary's and the Lock Hospitals; Physician-Extraordinary to the  
Queen; Physician-in-Ordinary to the Prince of Wales, &c. Crown  
8vo, 6s. [1874]

**IDIOCY AND IMBECILITY,**  
by WILLIAM W. IRELAND, M.D., Medical Superintendent of the  
Scottish National Institution for the Education of Imbecile Children  
at Larbert, Stirlingshire. With Engravings, 8vo, 14s. [1877]

**MADNESS :**  
in its Medical, Legal, and Social Aspects, Lectures by EDGAR  
SHEPPARD, M.D., M.R.C.P., Professor of Psychological Medicine in  
King's College; one of the Medical Superintendents of the Colney  
Hatch Lunatic Asylum. 8vo, 6s. 6d. [1873]

**INFLUENCE OF THE MIND UPON THE BODY**  
in Health and Disease, Illustrations designed to elucidate the Action  
of the Imagination, by DANIEL HACK TUKE, M.D., F.R.C.P.  
8vo, 14s. [1872]

**A MANUAL OF PRACTICAL HYGIENE,**  
by E. A. PARKES, M.D., F.R.S. Fifth Edition, by F. DE CHAUMONT,  
M.D., Professor of Military Hygiene in the Army Medical School.  
8vo, with 9 Plates and 112 Engravings, 18s. [1878]

**A HANDBOOK OF HYGIENE AND SANITARY SCIENCE,**  
by GEORGE WILSON, M.A., M.D., Medical Officer of Health for Mid-  
Warwickshire. Third Edition, post 8vo, with Engravings, 10s. 6d.  
[1877]

**SANITARY EXAMINATIONS**  
of Water, Air, and Food. A Vade Mecum for the Medical Officer of  
Health, by CORNELIUS B. FOX, M.D., Medical Officer of Health of  
East, Central, and South Essex. With 94 Engravings, crown 8vo,  
12s. 6d. [1878]

**DANGERS TO HEALTH :**  
A Pictorial Guide to Domestic Sanitary Defects, by T. PRIDGIN  
TEALE, M.A., Surgeon to the Leeds General Infirmary. With 55  
Lithographs, 8vo, 10s. [1878]

**MICROSCOPICAL EXAMINATION OF DRINKING WATER :**  
A Guide, by JOHN D. MACDONALD, M.D., F.R.S., Assistant Pro-  
fessor of Naval Hygiene, Army Medical School. 8vo, with 24 Plates,  
7s. 6d. [1875]



**HANDBOOK OF MEDICAL AND SURGICAL ELECTRICITY,**

by HERBERT TIBBITS, M.D., F.R.C.P.E., Senior Physician to the West London Hospital for Paralysis and Epilepsy. Second Edition, 8vo, with 95 Engravings, 9s. [1877]

BY THE SAME AUTHOR.

**A MAP OF ZIEMSEN'S MOTOR POINTS OF THE HUMAN BODY :**

a Guide to Localised Electrification. Mounted on Rollers, 35 × 21. With 20 Illustrations, 5s. [1877]

**CLINICAL USES OF ELECTRICITY ;**

Lectures delivered at University College Hospital by J. RUSSELL REYNOLDS, M.D. Lond., F.R.C.P., F.R.S., Professor of Medicine in University College. Second Edition, post 8vo, 3s. 6d. [1873]

**MEDICO-ELECTRIC APPARATUS :**

A Practical Description of every Form in Modern Use, with Plain Directions for Mounting, Charging, and Working, by SALT & SON, Birmingham. Second Edition, revised and enlarged, with 33 Engravings, 8vo, 2s. 6d. [1877]

**A DICTIONARY OF MEDICAL SCIENCE ;**

containing a concise explanation of the various subjects and terms of Medicine, &c. ; Notices of Climate and Mineral Waters ; Formulæ for Official, Empirical, and Dietetic Preparations ; with the Accentuation and Etymology of the terms and the French and other Synonyms, by ROBLEY DUNGLISON, M.D., LL.D. New Edition, royal 8vo, 28s. [1874]

**A MEDICAL VOCABULARY ;**

being an Explanation of all Terms and Phrases used in the various Departments of Medical Science and Practice, giving their derivation, meaning, application, and pronunciation, by ROBERT G. MAYNE, M.D., LL.D. Fourth Edition, fcap 8vo, 10s. [1875]

**ATLAS OF OPHTHALMOSCOPY,**

by R. LIEBREICH, Ophthalmic Surgeon to St. Thomas's Hospital. Translated into English by H. ROSBOROUGH SWANZY, M.B. Dub. Second Edition, containing 59 Figures, 4to, £1 10s. [1870]

**DISEASES OF THE EYE :**

a Manual by C. MACNAMARA, F.R.C.S., Surgeon to Westminster Hospital. Third Edition, fcap. 8vo, with Coloured Plates and Engravings, 12s. 6d. [1876]

**DISEASES OF THE EYE :**

A Practical Treatise by HAYNES WALTON, F.R.C.S., Surgeon to St. Mary's Hospital and in charge of its Ophthalmological Department. Third Edition, 8vo, with 3 Plates and nearly 300 Engravings, 25s. [1875]

**HINTS ON OPHTHALMIC OUT-PATIENT PRACTICE,**

by CHARLES HIGGENS, F.R.C.S., Ophthalmic Assistant Surgeon to, and Lecturer on Ophthalmology at, Guy's Hospital. Second Edition, fcap. 8vo, 3s. [1879]



**OPHTHALMIC MEDICINE AND SURGERY :**

a Manual by T. WHARTON JONES, F.R.C.S., F.R.S., Professor of Ophthalmic Medicine and Surgery in University College. Third Edition, fcap. 8vo, with 9 Coloured Plates and 173 Engravings, 12s. 6d. [1865]

**DISEASES OF THE EYE:**

A Treatise by J. SOELBERG WELLS, F.R.C.S., Ophthalmic Surgeon to King's College Hospital and Surgeon to the Royal London Ophthalmic Hospital. Third Edition, 8vo, with Coloured Plates and Engravings, 25s. [1873]

BY THE SAME AUTHOR,

**LONG, SHORT, AND WEAK SIGHT,**

and their Treatment by the Scientific use of Spectacles. Fourth Edition, 8vo, 6s. [1873]

**A SYSTEM OF DENTAL SURGERY,**

by JOHN TOMES, F.R.S., and CHARLES S. TOMES, M.A., F.R.S., Lecturer on Dental Anatomy and Physiology at the Dental Hospital of London. Second Edition, fcap 8vo, with 268 Engravings, 14s. [1873]

**DENTAL ANATOMY, HUMAN AND COMPARATIVE :**

A Manual, by CHARLES S. TOMES, M.A., F.R.S., Lecturer on Dental Anatomy and Physiology at the Dental Hospital of London. With 179 Engravings, crown 8vo, 10s. 6d. [1876]

**A MANUAL OF DENTAL MECHANICS,**

with an Account of the Materials and Appliances used in Mechanical Dentistry, by OAKLEY COLES, L.D.S., R.C.S., Surgeon-Dentist to the Hospital for Diseases of the Throat. Second Edition, crown 8vo, with 140 Engravings, 7s. 6d. [1876]

**HANDBOOK OF DENTAL ANATOMY**

and Surgery for the use of Students and Practitioners by JOHN SMITH, M.D., F.R.S. Edin., Surgeon-Dentist to the Queen in Scotland. Second Edition, fcap 8vo, 4s. 6d. [1871]

**STUDENT'S GUIDE TO DENTAL ANATOMY AND SURGERY,**

by HENRY SEWILL, M.R.C.S., L.D.S., late Dentist to the West London Hospital. With 77 Engravings, fcap. 8vo, 5s. 6d. [1876]

**OPERATIVE DENTISTRY :**

A Practical Treatise, by JONATHAN TAFT, D.D.S., Professor of Operative Dentistry in the Ohio College of Dental Surgery. Third Edition, thoroughly revised, with many additions, and 134 Engravings, 8vo, 18s. [1877]

**DENTAL CARIES**

and its Causes: an Investigation into the influence of Fungi in the Destruction of the Teeth, by Drs. LEBER and ROTTENSTEIN. Translated by H. CHANDLER, D.M.D., Professor in the Dental School of Harvard University. With Illustrations, royal 8vo, 5s. [1878]

**EPIDEMIOLOGY ;**

or, the Remote Cause of Epidemic Diseases in the Animal and in the Vegetable Creation, by JOHN PARKIN, M.D., F.R.C.P.E. Part I, Contagion—Modern Theories—Cholera—Epizootics. 8vo, 5s. [1873]



The following CATALOGUES issued by MESSRS CHURCHILL  
will be forwarded post free on application :

1. *Messrs Churchill's General List of nearly 600 works on Medicine, Surgery, Midwifery, Materia Medica, Hygiene, Anatomy, Physiology, Chemistry, &c., &c., with a complete Index to their Titles, for easy reference.* N.B.—*This List includes Nos. 2 and 3.*

2. *Selection from Messrs Churchill's General List, comprising all recent Works published by them on the Art and Science of Medicine.*

3. *A selected and descriptive List of Messrs Churchill's Works on Chemistry, Materia Medica, Pharmacy, Botany, Photography, Zoology, the Microscope, and other branches of Science.*

4. *The Medical Intelligencer, an Annual List of New Works and New Editions published by Messrs J. & A. Churchill, together with Particulars of the Periodicals issued from their House.*

[Sent in January of each year to every Medical Practitioner in the United Kingdom whose name and address can be ascertained. A large number are also sent to the United States of America, Continental Europe, India, and the Colonies.]

---

MESSRS CHURCHILL have a special arrangement with MESSRS LINDSAY & BLAKISTON, OF PHILADELPHIA, in accordance with which that Firm act as their Agents for the United States of America, either keeping in Stock most of Messrs CHURCHILL's Books, or reprinting them on Terms advantageous to Authors. Many of the Works in this Catalogue may therefore be easily obtained in America.







