

Textbook of ophthalmoscopy / by Edward G. Loring.

Contributors

Loring, Edward G. 1837-1888.
University College, London. Library Services

Publication/Creation

New York : D. Appleton and Company, 1886.

Persistent URL

<https://wellcomecollection.org/works/gkrwnj3m>

Provider

University College London

License and attribution

This material has been provided by This material has been provided by UCL Library Services. The original may be consulted at UCL (University College London) where the originals may be consulted.

This work has been identified as being free of known restrictions under copyright law, including all related and neighbouring rights and is being made available under the Creative Commons, Public Domain Mark.

You can copy, modify, distribute and perform the work, even for commercial purposes, without asking permission.



Wellcome Collection
183 Euston Road
London NW1 2BE UK
T +44 (0)20 7611 8722
E library@wellcomecollection.org
<https://wellcomecollection.org>



2809394705

No. 805 | 14

II
Q. 3.

JF 13

34

100





THE INSTITUTE
OF
OPHTHALMOLOGY
LONDON

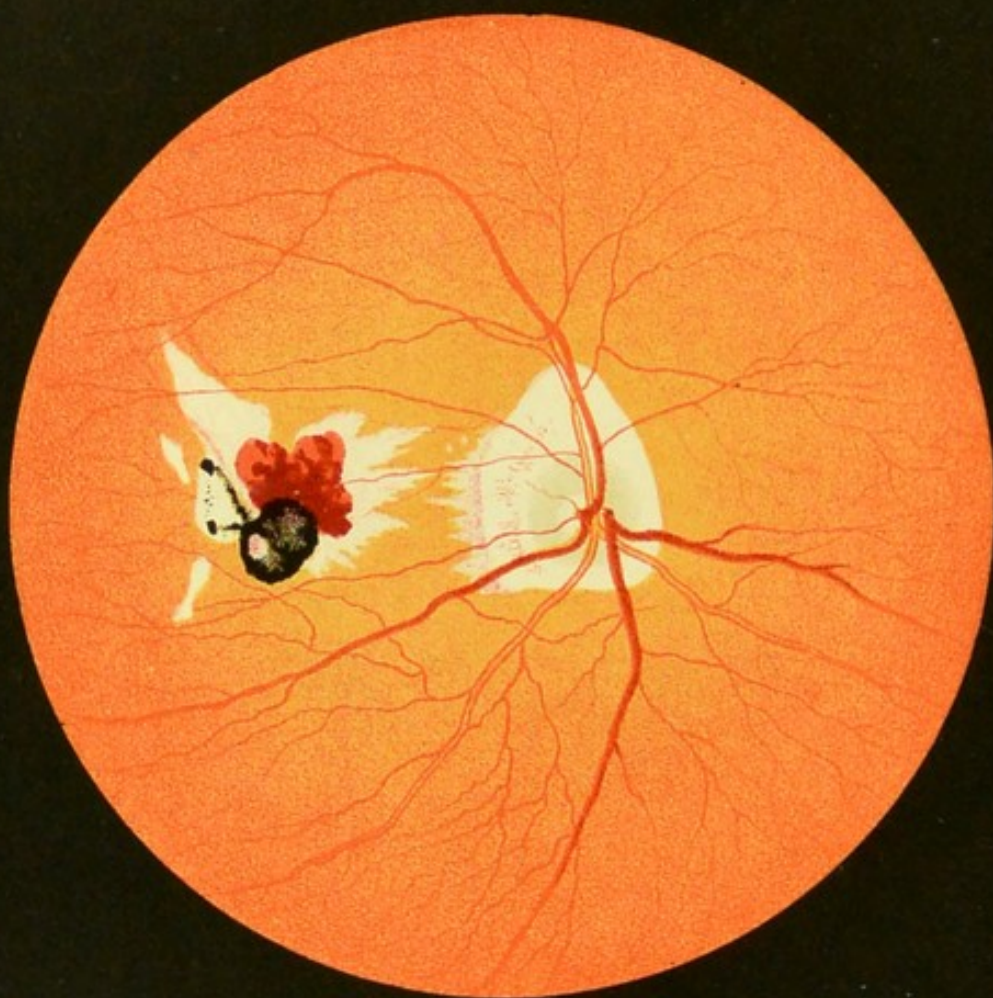
EX LIBRIS

OPHTHALMOLOGY HC453 LORING

~~42 SEP 1975~~







TEXT-BOOK
OF
OPHTHALMOSCOPY.

BY
EDWARD G. LORING, M. D.



PART I.

THE NORMAL EYE, DETERMINATION OF REFRACTION,
DISEASES OF THE MEDIA, PHYSIOLOGICAL OPTICS,
AND THEORY OF THE OPHTHALMOSCOPE.

NEW YORK:
D. APPLETON AND COMPANY,
1, 3, AND 5 BOND STREET.
1886.

OPPOSITE ALMODOVAR

COPYRIGHT, 1885,
By D. APPLETON AND COMPANY.

1885

REPRODUCED BY THE UNIVERSITY OF CHICAGO
LIBRARY OF THE UNIVERSITY OF CHICAGO
FROM THE ORIGINAL IN THE POSSESSION OF THE
LIBRARY OF THE UNIVERSITY OF CHICAGO

LIBRARY OF THE UNIVERSITY OF CHICAGO
1885

1801871

C O N T E N T S .

CHAPTER I.

	PAGE
Remarks on the ophthalmoscope.—Examination by daylight.—	
Examination of the eye by artificial light	1-7

CHAPTER II.

Examination with the ophthalmoscope.—Method of examination.	
—Examination by the inverted image.—Examination by the	
upright image	8-20

CHAPTER III.

The anatomy of the fundus of the normal eye	21-42
---	-------

CHAPTER IV.

The fundus of the normal eye as seen with the ophthalmoscope.—	
Anomalies	43-105

CHAPTER V.

Determination of the optical condition of the eye with the oph-	
thalmoscope.—Refraction.—Astigmatism.—Refraction accord-	
ing to the standard of the inch.—Directions in case the observ-	
er is ametropic.—Determination of the refraction of an eye	
by the mirror alone, and by means of the inverted image.—	
Astigmatism with the mirror alone.—Astigmatism with the	
inverted image.—Amount of enlargement produced by up-	
right image	106-145

CHAPTER VI.

PAGE

Examination of the media of the eye.—Oblique illumination.—The aqueous humor.—The iris.—The lens.—Opacities of the lens.—Examination of the media by the ophthalmoscope.—The iris.—The lens.—Vitreous humor, and fundus of the eye.—Differential diagnosis of troubles in the media.—Entozoa . . .	146-194
--	---------

APPENDIX.

General principles of the ophthalmoscope.—Physiological optics.—Theory of the ophthalmoscope.—The metric system.—Ophthalmoscopes.—Adjuncts to the ophthalmoscope . . .	195-259
--	---------

TEXT-BOOK OF OPHTHALMOSCOPY.

CHAPTER I.

REMARKS ON THE OPHTHALMOSCOPE.

IN the whole history of medicine there is no more beautiful episode than the invention of the ophthalmoscope, and physiology has few greater triumphs. With it it is like walking into Nature's laboratory and "seeing the Infinite in action," since by its means we are enabled to look upon the only nerve in the whole body which can ever lie open to our inspection under physiological conditions, and to follow in a transparent membrane an isolated circulation from its entrance into the eye through the arteries to its exit in the veins. We are further enabled to watch and study daily, or even hourly, morbid processes in each and every phase, from simple hyperæmia to absolute stasis, and from passive œdema to the most violent inflammation; while oftentimes through its agency also we get the first intimation of disease in remote and seemingly unconnected organs, so as to read, as if in a book, "the written troubles of the brain," the heart, the spleen, the kidneys, and the spine.

It is little wonder, then, that the adept learns to look upon the ophthalmoscope as one of the most beautiful in theory, the most perfect in practice, and the most far-reaching in results, of any of the instruments known to medical science, or that he should be brought to consider the invention of Helmholtz as the most potent factor in bringing the art of ophthalmology to the highest plane of medical diagnosis and treatment.* Nor is it surprising that even the student, once entered upon its investigation, finds the study of the instrument as fascinating as it can be made profound. It is to enable him to prosecute such studies with greater ease and with more expedition than if left to himself, that the following pages are written.

* Virchow, "Trans. Internat. Congress," London, 1881.

That the ophthalmoscope has become a necessity in the detection of disease is now universally admitted. Physicians, therefore, at the present time are much more interested in the facts which the mirror reveals than in the principles upon which it depends. To understand, however, the practical working of the instrument and the full extent of its application, the few fundamental laws upon which it depends must be thoroughly understood. For such as are not already acquainted with them, these laws, briefly and simply stated, will be found in the Appendix at the end of the volume.

In making an ophthalmoscopic examination three principal things are to be considered :

1. The instrument and the illumination used.
2. The optical condition of the observer's eye.
3. The optical and physical condition of the eye to be observed.

The great aim in an ophthalmoscope should be largeness of field of view, with suitable and sufficient illumination. These requirements seem to be fulfilled best in the general shape and construction of what is known as Liebreich's small ophthalmoscope, which consists of the concave mirror with a central aperture attached to a short, straight handle. The mirror is usually about seven inches focal length, with a clip at the back for the necessary correcting-glasses. Unfortunately, these instruments as made abroad, though cheap, are comparatively worthless, from the mirrors not being true, and from the annoying reflections arising from the edges of the perforation and back-plate of the mirror. For lightness, freedom from reflections, and durability, there are no superior instruments to those now made in New York, notably by Messrs. Hunter and Meyrowitz, whose instruments in the way of workmanship and optical accuracy are unsurpassed. Almost every ophthalmologist has taken a hand in perfecting or at least altering the instrument, and from the first I have, perhaps, done more than my share. To mention all the modifications now known and in use would make a book of itself, and I must refer those who are curious as to the evolution of this beautiful instrument to the current literature of the day. My advice to the student is in the beginning to get the best instrument of its kind, not necessarily the most complex and the highest priced, assuring him that it makes no difference whatever whose instrument he uses, provided it is comprehensive enough to suit his wants, and that he learns how to use it with judgment and skill. Beginning with the simpler ones, he can pass to those which are more complex, should occasion require. In the Appendix will be found a description of some of the forms sug-

gested by the writer, not because they are in any way better than others, but simply because he is better acquainted with their qualities, good and bad. Of his rather voluminous contributions in this line, only those are mentioned which have stood the test of time and proved their usefulness.

The Illumination.—The great convenience attending the use of gas, and its universal adoption as a source of light in this country, would give to its use for the purposes of ophthalmoscopy a decided preference, even if it did not possess the most suitable quality of light. As, however, there can be but little objection to it even on this score, all that need be considered is the shape in which it shall be employed.

The best form for an ophthalmoscopic lamp is that made after the English pattern, consisting of two parallel tubes with such an arrangement of joints as to give a wide extent of vertical and lateral movements.* From their somewhat elaborate construction they are perhaps better fitted for institutions and the offices of specialists than for those of the general practitioner. A form of lamp which answers every purpose in an admirable way is the common drop-light, with a flexible tube and Argand burner fitted to a stand with a sliding-bracket, by which the height of the light can be regulated at will.

Kerosene gives an admirable light, especially some of the purer qualities; but, if used, the old-fashioned lamp, where the flame is a broad one, is better than the German student-lamp, where the flame, though very brilliant and white, is so narrow that the circle of dispersion on the retina is very much drawn out in a vertical and reduced in a lateral direction. To the fastidious, some improvement in all these sources of illumination can be obtained by the use of a light-blue chimney or a screen of blue glass placed before the lamp.

Any lamp, however, which gives a good light may be used, and its position, if the flame be of the larger kind, should be a little behind and a little to one side of the patient's head, and about on a line with the eye to be observed. It should, however, be as close to the head as is comfortable, so that the angle of the incident and reflected light should be as small as possible, so as to prevent a too great rotation of the ophthalmoscope on its vertical axis.

When, however, the flame of the lamp is small and the inverted image is used, as, for example, a candle-flame at the bedside, this should then be placed between the patient and the observer, and nearer to the latter than the former. The lateral distance should be about the same as in an ordinary examination. In this way we get a

* These lamps, which carry an Argand burner, can be had from the firm of Mitchell & Vance, New York.

larger and brighter circle of dispersion, and use to the best advantage the little light at our disposal.

In regard to the quantity of light given by different mirrors, of course those which are silvered produce a greater illumination than those which are not; and those which are concave, greater than those which are plane. Each kind of mirror has its advantages, and it would be better theoretically to use different mirrors, embracing also different degrees of curvature for different kinds of work. This is, however, so inconvenient as to render it practically impossible; still, a word must be said as to the great and positive advantage in some cases of what is known as Helmholtz's or the weak-light mirror, which consists of three parallel plates of thin plane glass.* No mirror gives a more beautiful illumination than this when all the conditions for its use are favorable, such as a sufficiently dilated pupil and clearness of the media; for by its subdued light slight changes in the fundus of the eye, and even slight variation in shade of color—especially, as will be seen later, in the optic nerve—are made manifest; changes which under a brighter illumination are lost in an excess of light.

As would naturally be inferred, this mirror is of great advantage where there is a marked dread of light on the part of the patient. It is not, however, serviceable for general work, as it can not be used for the inverted image, while some of its virtue can be obtained, in great part at least, with the "strong-light" mirrors by reducing the quantity of light coming from the source of illumination.

Simple concave mirrors of such a strength as are ordinarily used in ophthalmoscopy throw upon the eye a converging cone of light, the base of which is equal to the surface of the mirror, though, of course, as we bring the mirror more closely to the eye only those rays which are reflected from its central portions will enter the pupil. The shorter the focus the greater is the condensation of the light; but experience as well as theory shows that only mirrors of moderately short focal lengths are suitable for ophthalmoscopy. As a rule, the mirror should not have a focus shorter than seven nor longer than ten inches.

EXAMINATION BY DAYLIGHT.

This consists simply in substituting natural for artificial illumination, and can be accomplished by having a small slit cut in the shutter.

Its only advantage is that we see the fundus more nearly under its natural color, as the reflection from the bottom of the eye is free from

* See description in Appendix, p. 230.

the yellow it receives from either oil or gas. When thus seen, its color varies from a pure red to a delicate reddish-pink. The method is, however, inconvenient in its application, and, as artificial light becomes from force of habit our natural criterion, the method is really of little practical use. It is, however, in those very rare cases of retinitis from leucæmia, of decided advantage, as under dispersed daylight the fundus maintains the characteristic orange-color, while the normal eye loses all trace of it. To obtain the best results, the pupil of the eye should be dilated, and the only light admitted to the room should be through the narrow aperture which serves as the source of illumination. I have, however, often obtained a perfectly clear view of the fundus when the pupil was dilated, by placing the patient with his back to the window.

EXAMINATION OF THE EYE BY ARTIFICIAL LIGHT.

Oblique Illumination.—The first step toward an ophthalmoscopic examination of the fundus of the eye should be the consideration of the condition of the interposing media—the cornea, aqueous humor, lens, and vitreous body.

This is a most important step, and as a precautionary measure should never be omitted, for disturbances in any of these bodies, although so slight as to readily escape observation, may nevertheless have a considerable effect on the character and clearness of the image, and any want of attention to this particular may lead the practitioner not only into error but even into disgrace. The habit of picking up an ophthalmoscope and making straight for the optic disk is fatal to exact ophthalmoscopy, and many a “slight effusion or œdema into the retina” has in other and more careful hands resolved itself into a diffuse opacity of the vitreous, the lens, or even the cornea—and that too, not only in the hands of a beginner, but also in those of an adept.

One of the principal ways of ascertaining the condition of the media is by means of a condensing lens. This method of examination is called that by oblique illumination, because a cone of light is thrown by the lens upon and obliquely through the anterior parts of the eye.

The manner in which the lenses are used will be understood readily from the drawing, Fig. 1.

The light should be placed at a little distance from the head of the patient—a foot, more or less—and on the same side as the eye to be examined, and at about the same height, but in a somewhat more advanced plane.

Any convex lens of a moderately short focal length may be used, the ordinary two-and-a-half-inch glass of the ophthalmoscope answer-

ing every purpose. The lens should be held between the light and the eye, at a little less than its focal length. A converging cone of light is thus thrown upon and into the eye, and this should be made to play about by slight lateral displacements of the glass, so that the

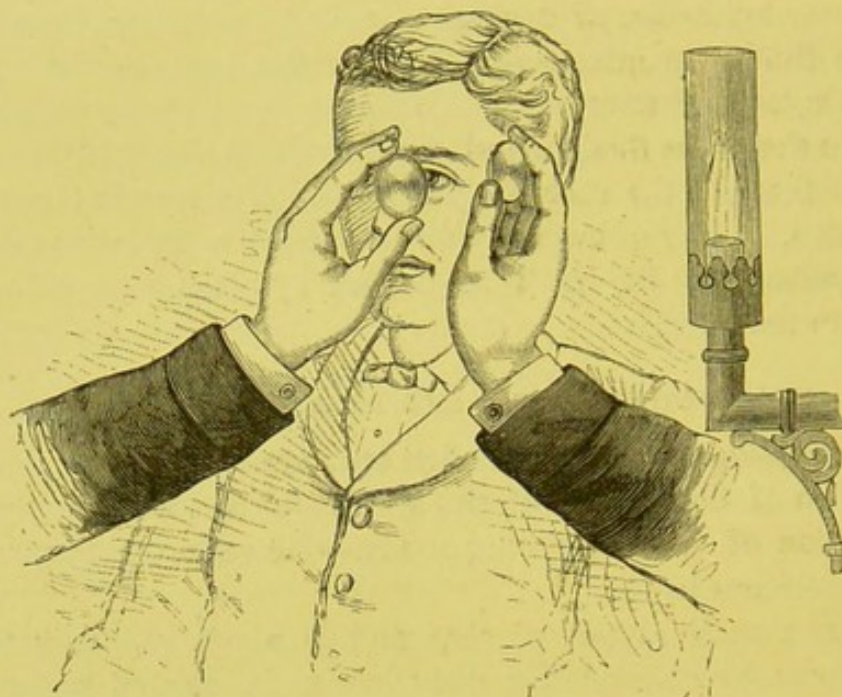


FIG. 1.

illumination may reach successively different parts of the surface of the cornea. When a general survey of this is to be made for the purpose of detecting any change, and of contrasting such a change with the surrounding tissue in a general way, the lens should be held nearer to the eye, so that the surface of the cornea may cut the cone of light thrown upon it some way from its apex. The circle of illumination is in this way increased, though the light is at the same time less condensed. If a small and isolated portion of the surface is to be carefully examined, as, for example, the seat of a minute foreign body, then the lens should be gradually withdrawn till this comes just within its focus, so as to obtain the greatest amount of illumination.

The cornea, aqueous humor, iris, and lens should in turn be carefully observed, and the examination should be further helped by causing the patient to move his eyes in various directions; for oftentimes a sudden turn of the eye will bring to view a delicate and comet-like opacity which would otherwise have escaped detection.

The first lens can be supplemented by a second, as seen in the drawing. This is placed immediately in front of the observed eye, and in the path of the rays coming to the observer. This second

glass acts simply as a magnifier, and as such should be held at about the focal distance of the glass from the cornea.

Simple as all this appears, it nevertheless requires a good deal of skill and experience to reap the full benefits of the method of examination by oblique illumination, and especially in regard to the troubles of the lens and deeper structures. To do this thoroughly, the pupil should be dilated by atropine. In such cases it is often advantageous to have the lamp placed directly above and a little in front of the patient's head, which should then be thrown slightly back. The observer should then stand a little to one side, so as not to interfere with the light entering the eye, but still be in the track of the returning rays. By this means the angles of incidence and reflection are made a little larger, and a better view is obtained.

The conditions of the posterior capsule and anterior portions of the vitreous can be, and often are, advantageously examined by this method; but, from the difficulty of the illumination, most observers prefer, rather than to waste time and run the risk of overlooking minute disturbances in these deeper parts, to use the direct light from the ophthalmoscope. Still, lateral illumination has advantages of its own, even for these parts, especially when the disturbances are of a diffused nature, and it should never be neglected.

CHAPTER II.

EXAMINATION WITH THE OPHTHALMOSCOPE.

VERY little, I had almost said nothing, can be learned of the technical working of the ophthalmoscope from a book. The necessary skill must be acquired in the presence of the subject, and with the instrument in the hand.

That ophthalmoscopy in its widest sense is a very difficult art must certainly be admitted. But it has always struck me that its difficulties have been exaggerated, so far as its practical working is concerned, by the abstruse manner in which its principles have been inculcated. In this way a sort of dread of the instrument has been created in the minds of many practitioners in whose hands, with a trifling effort in overcoming a few technicalities, it might have been a source of increased knowledge to themselves and of absolute advantage to their patients.

The greatest good to the greatest number is, or ought to be, as much the watchword of medicine as it is of politics; and I sincerely hope that the time is not distant when the ophthalmoscope will be in the hands of every thoughtful and observant physician, to be used by him just as the microscope now is, without affectation, as a means for the detection of disease.

It would be a sorry day for the sick and suffering if every physician who used the microscope had to be a Virchow, or who used the ophthalmoscope a Helmholtz. The ability to add and subtract vulgar fractions is all the mathematical knowledge which is required to put the ordinary physician, clinically speaking, on a par with the profoundest mathematician, and, now that the metric system has been adopted, one can dispense with even this small amount of knowledge.

Strictly speaking, before looking into the condition of another's eye, the observer should have a knowledge of the visual power and refraction of his own eye, and should possess the ability of correcting any defects should they exist. Some methods of examination require this, others do not; at least where the error of refraction is still within moderate limits, as, for example, in the examination by the "inverted

method." It is, however, absolutely necessary when the "upright method" is employed, and more will be said on the matter under that heading.

The first step in the examination of an eye with the ophthalmoscope is to illuminate the eye in a suitable manner.

One of the greatest obstacles to this with inexperienced observers, and one which, more than any other, has discouraged the general practitioner at the very outset from pursuing his studies, has arisen from the fact that his first essays have been made with subjects where the pupil has been undilated.

A good deal of prejudice exists in the minds of many writers against the use of atropine, especially when, after many years of experience, they themselves have become emancipated from its use. It certainly must be admitted that it is an inconvenience to the patient for the time being, but the duration of this inconvenience can be so shortened that it is not to be weighed against the positive advantage gained by a thorough and minute examination. Delicate changes often escape detection, even in the hands of skilful observers; and, when this is the case, it is usually from two causes: either the inverted image alone is used, and thus a sufficient enlargement is not obtained, or the examination is made through an undilated pupil. Thus, even if the upright image has been used, the examination often proves fruitless from the fact that the observer, from a natural dread of subjecting his patient to the annoying effect of atropine, has failed to get anything like an adequate view of those parts of the eye in which these changes are apt to occur; that is to say, of the peripheral parts of the lens, and of the region of the macula lutea.

For the purposes of an ophthalmoscopic investigation it is only necessary to employ the drug in the mildest possible form, so as to limit its action to a single day. By far the best way of using it seems to me to be by the gelatine wafers* or disks prepared by Savory & Moore, of London. These disks come of three degrees of strength, each disk containing $\frac{1}{20000}$, $\frac{1}{50000}$, and $\frac{1}{100000}$ of a grain of atropia. One of the first, or even one of the second strength, placed in the *cul-de-sac* of the conjunctiva, is sufficient to dilate the pupil fully, unless unnatural irritation is present, in the course of an hour or two. Even if it fails to do this completely, it produces a partial dilatation, and with it a rigidity of the iris, which is usually all that is needed. If these wafers can not be procured, then a very weak solu-

* The officinal name of these wafers is "Ophthalmic Gelatine Disks—atropized. Savory & Moore, 143 Bond Street, London." They can also be had of Caswell, Hazard & Co., New York City.

tion, gr. j of the neutral sulphate of atropia to aqua des. \mathfrak{z} iij, may be employed, or a drop of a two-per-cent solution of the hydrochlorate of cocaine, which produces usually a sufficient but temporary dilation of the pupil.

As skill in the use of the instrument increases, the necessity for the use of atropine will become less and less, until it is finally reserved for rare occasions. I never hesitate, however, to use a wafer when trouble either in the periphery of the lens or at the macula lutea is suspected.

It should, however, be stated that in the minds of some of the profession a belief exists that the use of atropine has a tendency to bring on an acute attack of glaucoma in eyes which are predisposed that way. Luckily the part affected, limited as it chiefly is ophthalmoscopically to the optic nerve, is the part of the eye most readily seen and studied with an undilated pupil.

METHOD OF EXAMINATION WITH THE OPHTHALMOSCOPE.

Simple Illumination of the Fundus.—The patient should be placed in a darkened room, with his back to a well-burning lamp without any shade or globe. This should be on the same side and on about the same level as the eye to be observed. It should, however, be placed a little behind the head, say five or six inches, and somewhat removed from it laterally. The observer's seat should be a little higher than the patient's, and he should sit not directly in front of the latter, but to one side, so that his chair should come, not in front of the patient's chair, but by the side of it. This gives plenty of room for movements, both on the part of the observed and the observer, and avoids the necessity of the latter being compelled, when he wishes to approach closely to the eye examined, to be directly in the face of the patient. The observer's eye should be about eighteen or twenty inches from that of the patient, who should be made to direct his gaze in front of him, and, if the right eye is to be examined, a little to the left, and if the left, a little toward the right.

Light is now thrown from the ophthalmoscope directly upon the observed eye, and the observer, looking through the hole of the mirror and in the direction of the reflected rays, sees the pupil glow. This glow is nothing but the reflection of light from some portion of the fundus which has become illuminated through the pupillary space. We, therefore, speak of the presence or absence of the "reflex" of the fundus, according as the pupil shines or does not shine.

The illumination of the pupil, or, more properly speaking, of the fundus, having been obtained, when the patient is looking straight

ahead he should be made to change the direction of his gaze by looking up and down and to the right and left, first slowly and then quickly, the observer all the time covering the eye with the light cast from the mirror, thus keeping the pupillary space constantly brilliant. In this way different portions of the eye are successively illuminated.

The mirror should also be gently rotated from side to side on its vertical axis by a slight movement of the wrist, so as to get the advantage of the alternate play of light and shade, oftentimes in itself an all-important factor in the detection of disease.

This done, the observer should learn to move his own head back and forth, directly toward and then away from the patient. By this means he is often able to detect the presence of membranes, growths, and separations of the retina, and their probable antero-posterior position. He should also move his head from right to left, and *vice versa*, keeping the pupil of the observed eye always brilliant. All these various movements should be practiced over and over again, first with an enlarged and then with an undilated pupil, till the ability to "get the reflex" in all possible positions and movements of the eye is acquired with ease and precision.

Having illuminated the back of the eye, the next step is to resolve this indefinite glow into a definite picture or image. It will have already been noticed by the attentive observer, however inexperienced, that whereas we usually get with the illumination from the mirror alone merely a diffuse brilliancy in the pupillary space, we do, nevertheless, with some eyes obtain a distinct image of a small portion of the fundus, as, for example, a limited section of a retinal vessel or a small segment of the optic nerve. This is due to some error in the refraction of the eye observed, and is present notably in myopic eyes, and the more so the greater the degree of myopia.

If the eye be myopic, an inverted and aërial image will be formed in front of the observed eye, and at a distance equal to the degree of the myopia present. It is this aërial image which the observer sees, and not a part of the fundus itself. On the other hand, if the eye observed is hypermetropic, the observer gets a direct view of a small part of the fundus itself seen through the patient's pupil. To tell whether the image in any case is inverted or erect, the observer has simply to move his head. If the image is inverted, and the eye observed consequently myopic, the image will appear to move in a contrary direction to the movement of either the observer's or patient's head. If the image is upright, and the eye consequently is hypermetropic, then it will seem to move in the same direction. The optical reasons for the formation of these images with myopic and hyperme-

tropic, as well as occasionally with emmetropic eyes, their comparative enlargement and extent of the fundus seen, are discussed in the chapter on the theory of the ophthalmoscope.

EXAMINATION BY THE INVERTED IMAGE.

The view of the fundus seen as just described with the mirror alone, even if it could be always obtained, would be entirely too restricted to be of any clinical value; and another means of producing an image, and at the same time of enlarging the field of view, would be an absolute necessity. One way of obtaining this object is by supplementing the use of the mirror with that of a convex lens. This is held by the observer before the eye of the patient, and directly in the path of the returning rays, as shown in the drawing (Fig. 2).

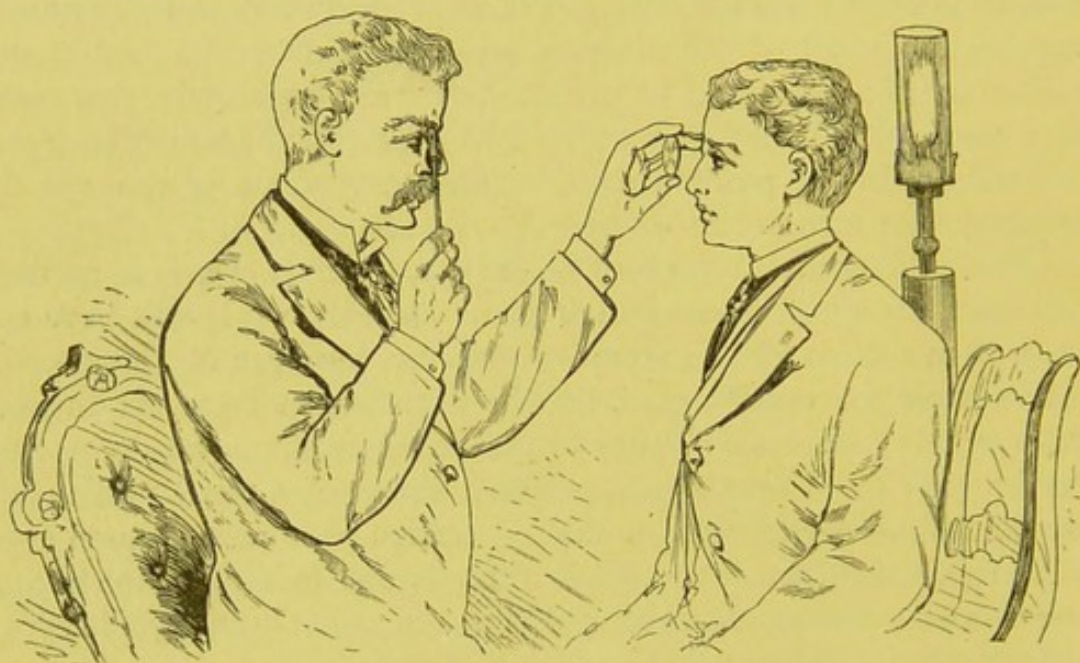


FIG. 2.

A lens so held not only increases the circle of illumination on the retina, but intercepts the rays leaving the fundus, which are by its means brought to a focus, and thus an aerial image is formed between the glass and the observer's eye, as is fully explained in another place; moreover, a great number of peripheric rays which would have passed outside of the observer's line of vision are brought directly into it by having their direction changed by the lens, and thus the field of view is enlarged, this enlargement depending, as we shall see later, on the strength of the glass used.

The most conspicuous portion of the fundus, and one which serves as an objective point for the examination, is the optic disk. To bring this opposite the pupil of the eye to be observed, and in the observ-

er's line of vision, the patient must be directed to look a little inward, that is, toward the nasal side of his field of view. When the nerve is opposite the pupil, the observer will at once become aware of the fact by the peculiarly white reflex filling the pupillary space.

For the purpose of bringing the nerve-entrance easily into view, and at the same time of furnishing to the patient a definite object to look at, it is a common expedient with many observers to hold the instrument not in a vertical direction, with the handle downward, as shown in the drawing, but to place this horizontally outward, across the patient's field of view, and then to elevate the little finger, at which he is told to direct his view; or the patient may be told to look at the right ear of the surgeon if it be the right eye, or the left ear if it be the left eye, which is under examination.

The white reflex from the disk having been obtained, the object-glass should be brought into position, as shown in the drawing (Fig. 2), directly in front of the pupil, and in the path of the returning rays. The glass should be held between the thumb and forefinger, and the observer should place his little finger of the same hand on the patient's forehead, for the purposes of a rest.

The observer should then practice until he acquires a perfect facility in moving the glass backward and forward in the line of vision for the purpose of focusing. The glass should not be held in a plane exactly at right angles to the visual axis, but should be turned a little on its vertical axis, so as to lie obliquely across this line. By this manœuvre the images of the lamp formed by the anterior and posterior surfaces of the glass are separated from each other, and a space in the centre of the field is obtained free from these annoying reflexions. This to-and-fro movement of the glass having been acquired, the observer should then learn to move the glass back and forth directly across the visual line, and upward and downward. The image is in this way displaced from side to side, and a parallax is obtained between objects occupying different planes in the eye. One can thus form an estimate of differences in level formed by projections and excavations, as, for example, that of the nerve in glaucoma. The explanation of this effect may be illustrated as follows (Fig. 3):

Let L be a convex lens, o its optical centre, and the line $a o a'$ its principal axis. Let a and b be two points on this line behind the lens, and at a distance greater than its focal length. The images of a and b will be formed at a given distance in front of the lens and on its principal axis, say at a' and b' . If, now, the lens be moved into the position shown by the dotted line, then o , the optic centre, passes to o' . The image of a will then be formed at a'' , and that of b at b'' . By

the displacement of the lens the image of b makes a greater excursion than that of a , and will lie farther from the line $a o a'$. The nearer one of the objects is to the lens, the greater the displacement it undergoes. We can thus make some anterior point either move disproportionately to, or even pass over, a posterior one, and thus learn that

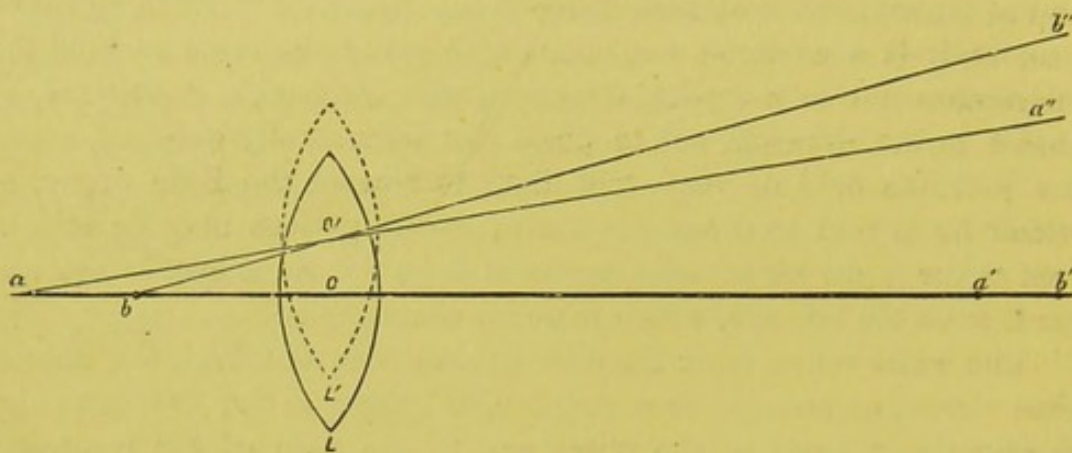


FIG. 3.

the former must lie in front of the latter. In this way the edge of an excavated optic nerve can be made to pass over the lamina cribrosa and shut out portions of the vessels lying in its plane, and from the degree in which this takes place we can form an estimate of the depth of the cavity.

Though this method is of considerable use in detecting the existence of inequalities in the bottom of the eye while taking a general and rapid survey of the fundus, it is, however, vastly inferior to the upright image for the purposes of ascertaining their exact amount, as is explained in the chapter of "Determination of the Errors of Refraction."

The rule laid down in the books, in making an examination by this method, is to hold the object-glass at a distance in front of the eye equal to its focal length. Practically it is better to make this distance a little greater. This is done to sink the image of the iris, for by gradually withdrawing the glass from a close proximity to the eye outward the pupillary space becomes larger and larger, till the rim of the iris passes out of the observer's field of view, and the only rays which can then enter the observer's eye are those coming through the pupil from the fundus itself.

The stronger the object-glass the larger will be the extent of the fundus seen at one time, but the smaller will its individual details appear, and *vice versa*; the weaker the glass the smaller the field, but the greater the enlargement of its component parts. It is, therefore, always an advantage, sometimes a necessity, to make use of glasses of

different strengths. Thus we often find it serviceable when we wish to make a general inspection of the fundus, and thus learn the relations of morbid changes to definite and recognized landmarks, to use a comparatively strong glass, such as a two or, less advantageously, a two-and-a-half-inch lens; but, when we wish to examine a certain spot under an increased enlargement and more in detail, we employ a weaker number, say a three, four, or even a five-inch lens. Some observers strike a mean, and use a two-and-a-half or even a three-inch lens for all work.

The writer feels sure that he has been able to observe changes in a comparatively satisfactory manner, which would otherwise have remained undetected, by sometimes using a one-and-a-half-inch lens. The advantages of so strong a glass are particularly well shown in cases where the pupil is abnormally small, reduced as it sometimes is to a pin-point, or where this is bound down by adhesions, and the pupillary space is the seat of minute deposits or thin membranes, which are, however, still permeable to strongly condensed light. So, too, with troubles in the lens which partly occlude the pupil, or those in the vitreous, or in fact in any case where we wish to see through a narrow opening where a large field is desired and a suitable illumination is difficult to obtain.

As the observer gains skill in the use of the instrument, the aerial image formed by the first glass, which we have spoken of as the object-glass, may be magnified by placing a convex lens behind the ophthalmoscope, which then acts the part of an eye-piece. In making use of this glass the observer should endeavor to relax his accommodation as fully as he can, so as to use the strongest glass practicable, and thus get as great a magnifying power as possible. To facilitate this, the observer may resort to the same expedient as is used with the microscope, namely, to keep both eyes open and to exclude one from the visual act by keeping the visual axes parallel as when looking at a distance; moreover, this glass, besides its magnifying power, is often a relief to the eye by removing the strain from the accommodation. This applies particularly when the observer is hypermetropic, in which case the glass may be an absolute necessity, especially when the error of refraction is of a high degree. It must be used, of course, where the observer is presbyopic in any but the most moderate degree, or where from any cause there is a limited range of accommodation. When either of the above conditions is present, even a myope of a low degree may require a weak eye-piece. An observer who is myopic to a moderate degree, say from $\frac{1}{18}$ to $\frac{1}{3}$ (2 to 4 D.), sees the inverted image under peculiar advantages, as his eye is

adapted to receive the rays coming from the aerial image without any eye-piece behind the mirror, and with little or no effort at accommodation. The myopia may, however, be so great as to necessitate the use of a concave glass, so as to make vision distinct for the distance at which the image lies. Suppose the observer is myopic $\frac{1}{3}$, then his farthest point of distinct vision lies at five inches before his eye, and, provided he occupies the usual position, the image is at ten to twelve inches from his eye, and his far point must be carried out to this distance, $\frac{1}{3} - \frac{1}{10} = \frac{1}{10}$ (7 D. - 3.5 = 3.5 D.), which will be the glass that such an observer requires. He could, however, by moving his head forward, lessen the distance between his eye and the image till he saw this clearly.

It is sometimes extremely difficult, if not impossible, when the eye under observation is very myopic, say above $\frac{1}{3}$ (12 D.), to get a satisfactory view of the fundus with the upright image, because the correcting-glass must be so strong that it necessarily consumes a great deal of light.

Liebreich's * method of obtaining the same degree of enlargement as that of the upright image by means of the inverted, while preserving the clearness and brilliancy of the latter, is as useful as it is ingenious. Suppose the eye is myopic $\frac{1}{3}$ (12 D.), then the aerial image formed by the lenticular system of the eye itself will be three inches in front of the eye. This image will, of course, be inverted and considerably enlarged. A lens of a low power, $\frac{1}{4}$ (9 D.) or even $\frac{1}{5}$ (7 D.), is now held in front of this image, and at about four or five inches in front of the eye. So used, it acts like any magnifier; but, as the image is considerably within the focal length of the glass, its magnifying power is much limited. Still, this is sufficient to so enlarge the area of the pupil that the image of the iris passes out of sight and the field of view is enlarged. The writer has found it advantageous to use a second weak convex glass behind the mirror, say $+\frac{1}{18}$ or $+\frac{1}{14}$ ($2\frac{1}{2}$ to 3 D.). As the object-glass—one of the common magnifiers sold in the shops—has a diameter of two and a half inches, it is broad enough to throw into the eye a large quantity of light, and the resulting picture is therefore not only very large but very brilliant, and perfectly well defined. Each observer can readily find for himself, by a few trials, what combination is best adapted for his own eye; those unable to relax their accommodation find it easier to use a weaker glass, say $+\frac{1}{24}$ (1.5 D.) behind the mirror.

The optic disk and its immediate neighborhood having been sufficiently examined, the other parts of the fundus should be brought

* Graefe's "Archiv," 7. Ab., 11, p. 130.

successively into view by making the patient look up and down and to the right and left, first to a moderate degree and then to his utmost capacity, according as the equator, or the parts toward the ora serrata, are to be inspected. The region of the yellow spot is brought into view by the patient looking directly at the hole in the mirror. When he does this, however, the corneal reflex comes exactly over his pupil, and thus obscures or obliterates the image of the fundus. The pupil must be dilated to get a satisfactory view of this part of the fundus, except in case of the young. The difficulty is further increased by the light falling directly on the most sensitive part of the retina, and to the stimulation of which the iris most readily responds. Something can be done toward avoiding these difficulties by making the patient look, not at the centre of the mirror, but at its edge, or even a little more to his temporal side. In this way, by a little patience and skilful manipulation, one can see round the corneal reflex, and thus bring the part into a comparatively fair view.

The examination of the region of the macula lutea by the inverted image, even at the best and with a dilated pupil, is very inferior, as a rule, to that with the upright image. It is, however, sometimes indispensable, as, for example, when there are changes and opacities in the different media which it requires a very strong light to overcome. This is especially the case in commencing cataract where the nucleus of the lens has become opaque, with more or less diffuse opacity in the cortical substance. Changes at the yellow spot can often be detected in this manner, when by the upright image nothing can be seen.

It is usually assumed that the examination by the inverted is easier and more convenient than that by the upright image. It has been certainly, until lately at least, much more frequently used than the latter, and by some, as it never should be, exclusively. The one is, or should be, the necessary supplement of the other, and both should be employed in every case, and the final preference of the one over the other should depend on the nature of the trouble then under investigation. In regard to the comparative difficulties of the two methods, it has always appeared to me that there was but little choice between them. It may often be easier—and it certainly is when the pupil is small or bound down—to get a picture of the fundus by the indirect than by the direct method. But to use either so as to bring out its full capabilities requires a certain though very limited amount of optical knowledge. This once acquired, the upright is, to my mind, the easier of the two, as the manipulation of the instrument is simpler. No one, however, can be a good or even passable ophthalmoscopist who can not make use of both.

If the illumination of the eye by oblique light is the first step in an ophthalmoscopic examination, the second should be that by the inverted image. With it a general survey of the fundus is obtained, and, from the extent of the field seen, the entire seat of the disease may be taken in at once and contrasted with the surrounding and healthy tissue. So, too, from the comprehensiveness of the view, the relations of changes to certain fixed objective points, such as the optic disk, the macula lutea, the equator of the eye, and the neighborhood of the ora serrata, are readily determined. Peculiarities of shade and color are sometimes for the same reason made more manifest than with the upright image. That the inverted image is often indispensable where, from any cause, an increased illumination is desired, has already been pointed out.

EXAMINATION BY THE UPRIGHT IMAGE.

If the ophthalmoscope was one of the most brilliant inventions ever known to medical science, it was certainly, also, one of the most complete, for the very method first proposed by Helmholtz still remains by far the most beautiful, comprehensive, and truthful of all the means yet in our possession for the exploration of the bottom of the eye.

As a knowledge of this method is absolutely necessary for the determination of the optical condition of the eye, a few words as to the manner in which it should be performed in general may be of service to the reader before proceeding to the more difficult task of determining in a given case the nature and exact degree of refraction.

The position of the patient and examiner is not without importance. The observer should sit well to the side of the patient, and on the side, of course, of the eye to be examined. If the right eye is to be examined, the patient should be directed to look slightly toward the right; if the left eye, then toward the left.

In fact, the directions are exactly opposite to those given for the inverted image, and just the contrary to what are usually laid down in the books. This position in the examination throws the optic axis away from the median line, places the optic nerve just opposite the pupil, and allows the observer to approach very near the observed eye without bending too much over the person examined.

The observer must learn to use either eye and either hand as occasion may require, so as to be able to examine the patient's right eye with his right, and the left with his left, holding the ophthalmoscope in the right or left hand, as the case may be.

As the examination by the upright image consists, as shown in the drawing (Fig. 4), of looking directly through the pupil to the fundus beyond, the observer should bring his own eye as closely to the observed eye as is possible; for, when obliged to look through a nar-

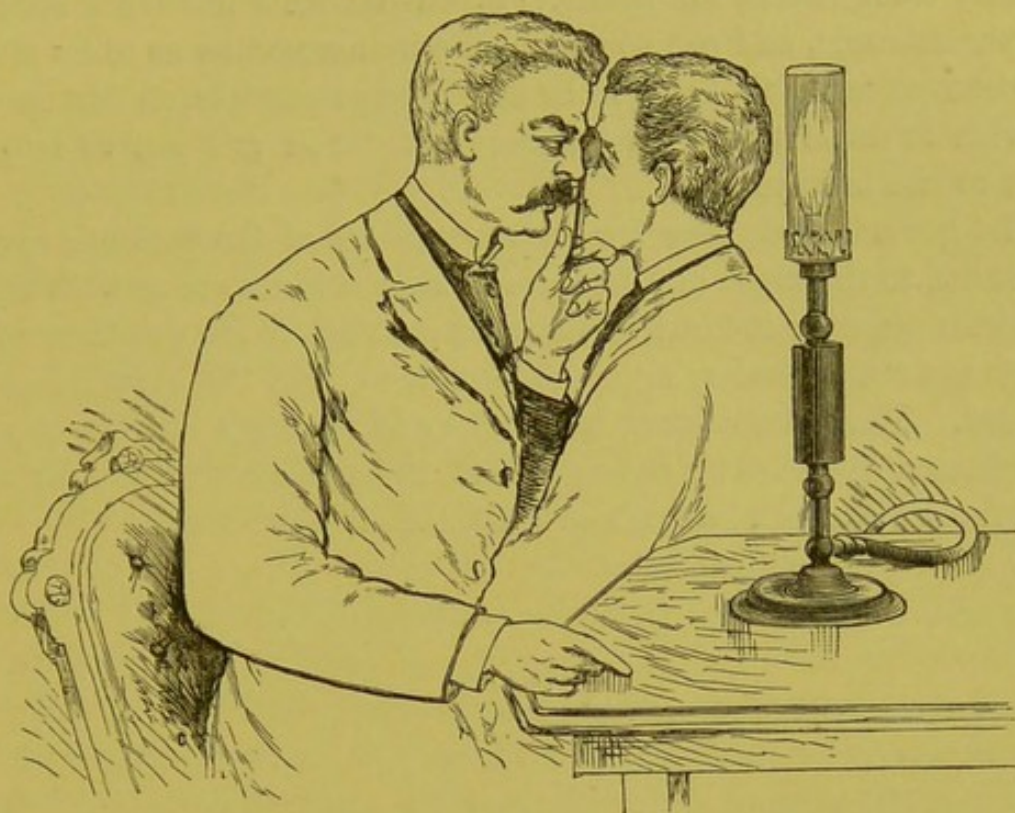


FIG. 4.

row opening, the nearer we bring our eye to the edges of the aperture, the wider will be the field of view of what lies beyond. Also, as a matter of course, the larger the pupil, the easier the inspection and the greater the extent of fundus seen. For this reason the first attempt of the observer should be with a dilated pupil.

For an observer to see the details of the fundus clearly with the upright image, some knowledge of the optical condition of his own eye is necessary, as well as that of the eye to be observed, and any existing fault should be corrected by the proper neutralizing glass.

The inexperienced observer, even if emmetropic and able to relax his accommodation perfectly for distant objects, is usually a little, sometimes a good deal, myopic for the ophthalmoscope. This comes from the fact that he is unable to adjust his eye for parallel rays when looking into an eye which he knows to be only a short distance from him. He instinctively accommodates and transforms his eye for the time being from an emmetropic to a myopic eye. This must be corrected by a suitable concave glass behind the mirror.

It is better for the beginner not to waste too much time in trying to correct his myopia, either natural or acquired, too exactly; but to

take such a glass as will enable him to see the fundus with ease and distinctness, and, this having been attained, the observer will gradually learn to discard the use of too strong a glass by gradually substituting for it a weaker one. The weaker the concave glass, consistent with perfectly clear vision, the better. If, on the other hand, the observer is hypermetropic, and can so relax his accommodation as to be able to use a convex glass, this should be as strong as possible, so that he may see with as little strain on his accommodation and get as large an image as can be secured.

The general directions for the movements of the patient's eye, up and down, to the right and left, are of course the same as with the inverted image, only it must be borne in mind that the positions of the objects are really as they appear, and not, as with the inverted image, reversed. The macula lutea is found by following a line directly outward from a little below the centre of the optic nerve, and for a distance from its edge of a little over two of its diameters.

CHAPTER III.

THE ANATOMY OF THE FUNDUS OF THE NORMAL EYE.

NOWHERE, except perhaps with the microscope, is the difference between mere sight on the one hand and observation on the other so clearly exemplified as in the use of the ophthalmoscope. It is easy enough after the requisite practice to see with the instrument; but to appreciate properly what is seen, and especially to differentiate between slight variations, whether of health or disease, requires not only a perfect perception of the picture as a whole, but an intimate and exact observation and analysis of each and every constituent of the part under consideration.

To appreciate every detail of the picture, and to give to each its due significance, necessitates therefore an intimate acquaintance with the anatomical elements of the part and their relationship with and dependence upon each other; and I earnestly recommend to those who wish to acquire the art of ophthalmoscopy, so as to use it with ease and surety, to become as conversant as their opportunities will permit, not only with the grosser anatomical construction, but also with the essential details of the minute anatomy of the parts which contribute either directly or indirectly to what is seen with the mirror. As the works by which this would be accomplished are often inaccessible to the student and practitioner, I have thought it advisable to preface what I shall have to say in regard to the ophthalmoscopic picture of the normal eye by a short account of the principal anatomical factors out of which the picture is developed.

The optic nerve, in its passage through the orbit, is invested by two sheaths, an "inner" and "outer sheath." The outer sheath, since it is continuous with the dura mater, if not a part of it, is called the dural sheath, while the inner, being derived from the pia mater, is called the pial sheath. The entire space between these two sheaths—that is to say, between the dural and pial sheath—is called the inter-vaginal or subvaginal space, but it is important to notice here that this space taken as a whole is divided longitudinally by another sheath, the arachnoidal sheath, which is shown in the drawing by the letter (*a*).

This subdivides the intervaginal space into two spaces. The space lying between the outer, or dural sheath, and the arachnoidal sheath (*a*) is called the subdural space, and is continuous with the subdural or arachnoidal space of the cranium. This space, as will be seen from

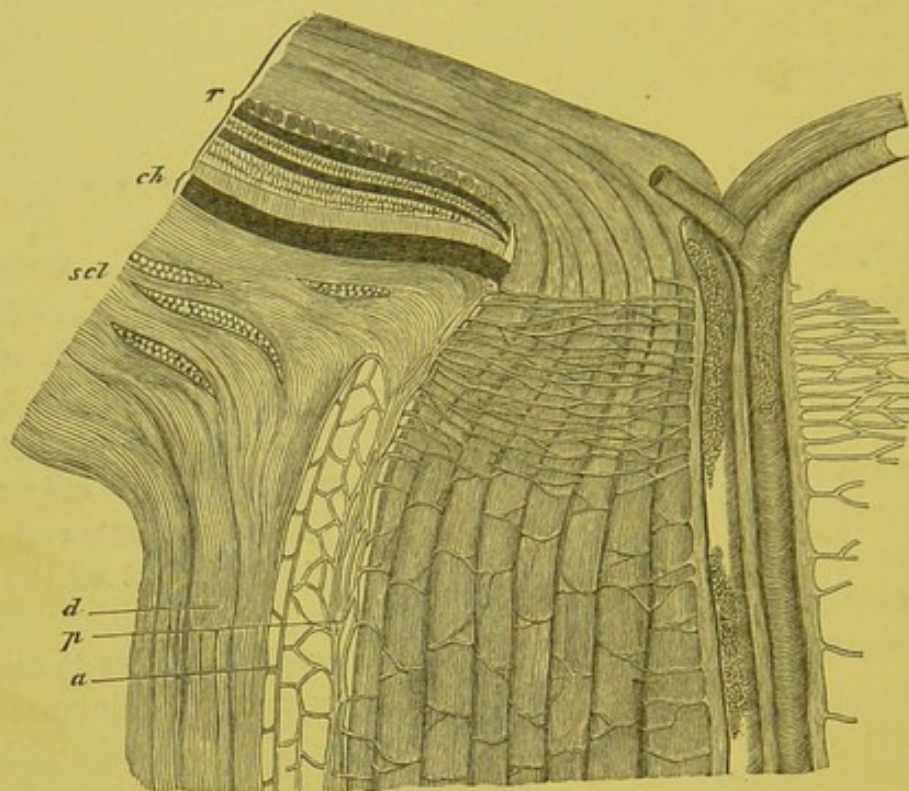


FIG. 5.—Section through the optic-nerve entrance. (From Henle, modified by Schwalbe.) *r*, retina; *ch*, choroid; *scl*, sclera; *d*, dural sheath; *a*, arachnoidal sheath; *p*, pial sheath of the nerve-stem; space between *d* and *a*, subdural space; between *a* and *p*, subarachnoidal space of the optic nerve. The central vessels and connective-tissue string appear at the right. (G. and S., vol. i., p. 328.*)

the drawing, is very narrow; indeed, in the normal eye it is separated from the dural by only a split-like interval. The second space, or that which lies between the arachnoidal sheath (*a*) and the pial sheath (*p*), is called the subarachnoidal space, and is continuous with the subarachnoidal space of the brain. This is much larger than the preceding space. These are the spaces which become distended in disease of the brain or its membranes, and which have played so conspicuous a part of late years in the discussions as to the cause of that form of optic neuritis known as choked disk.

As they reach the bulb, both spaces terminate with a more or less

* The German publication entitled "Handbuch der Gesamten Augenheilkunde," edited by Graefe and Saemisch, will in the following pages be denoted by the letters G. and S.

pointed end. The outer, or subdural, ends sooner than the inner, or subarachnoidal space, which passes close up to the choroid, and is only separated from it by the thin lamella of sclera which is continuous with the pial sheath. As will be seen from the drawing, the sheaths mentioned above are connected together, that is to say, the dural with the arachnoidal, and this latter with the pial, by fine, loose bands of connective tissue which run transversely between them. There is a free communication for fluid between the two spaces by means of minute perforations in the arachnoidal sheath. The entire subvaginal space and its two compartments have an endothelial lining, and are lymph-spaces.

Although the termination of the intervaginal space, taken as a whole, is more or less pointed, it differs very much in all eyes, even those which are normal, in extent and configuration, as will be seen in comparing the two sides of the drawing, which is diagrammatic.

In all myopic eyes, as pointed out by Jaeger, and even in some normal eyes, the end of this space becomes exceedingly pointed and extends farther into the sclera, and in doing this is compelled to form, in well-marked cases

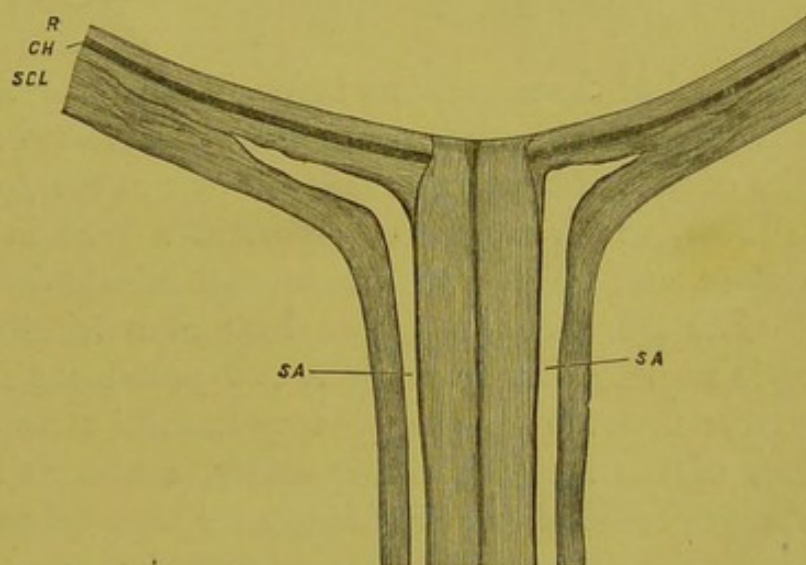


FIG. 6.—Longitudinal section through optic-nerve entrance, showing the different forms of the end of the subarachnoidal space in the sclera: *sa*, subarachnoidal space; *scl*, sclera; *ch*, choroid; *r*, retina. (G. and S., vol. i., p. 331.)

at least, almost a right angle with its earlier course. These conditions can be seen from the following figure from Jaeger,* which is a section of a myopic eye at the nerve-entrance (Fig. 7).

That this anatomical peculiarity is connected in some way with the origin and development of myopia, and therefore with the ophthalmoscopic appearances peculiar to it, there can hardly be a question; all the more as it is at the outer side of the eye, where the space is found more pointed and more extended into the sclera.

When the two sheaths have arrived at the bulb, the outer or dural sheath passes directly into the outer two thirds of the sclera, with the fibres of which it is inseparably fused.

* "Über die Einstellungen," etc., Pl. II., Fig. 27.

The inner or pial sheath is intimately connected with the trunk of the nerve, and invests it closely as far up as the choroid. At this place the greater part of its fibres makes an acute bend and passes into

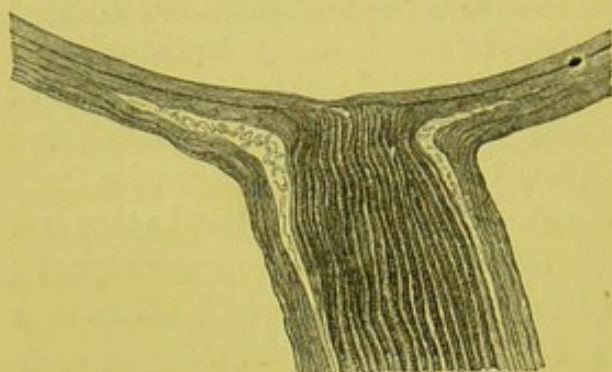


FIG. 7.

the inner third of the sclera, while a smaller portion can be traced into the choroid, which at this place is firmly attached to the sclera. Besides these fibres just mentioned—those which pass into the inner portion of the sclera and those which extend into the choroid—there are still others which branch off at right angles near

the head of the nerve, just before the level of the choroid is reached, and then pass in a transverse direction through and between the bundles of nerve-fibres, and thus take part in the formation of the lamina cribrosa, which forms so important a part in the ophthalmoscopic picture, and which will be more particularly described a little later.

The Nerve-Stem.—If we look at a longitudinal section of the optic nerve in its fresh state, two prominent features present themselves: first, a remarkable change in color at a certain point in the surface of the section; and, secondly, a change in form. Both these changes occur at the place where the stem meets the bulb. The color of the section, which up to this point has been of a glittering white, changes suddenly to a transparent, grayish tinge. The line of demarkation is sharply defined just as the nerve reaches the level of the sclera, and is slightly concave toward the interior of the eye. This sudden change in color is due to the fact that at this place the nerve-fibres lose their medullary sheath, which has the quality of reflecting a large amount of white light, while the non-medullated portion of the fibre becomes transparent and passes on to be distributed over the surface of the retina, of which it forms the inner layer. The transition from the non-transparent to the transparent portion is not always so sudden as here described, and the medullary sheath is often here and there carried along the fibre for a greater or less extent, sometimes even beyond the papilla and into the retina itself, where it produces a very singular appearance with the mirror, which will be described later.

This transparent portion of the nerve is the part which interests us most, so far as the ophthalmoscope is concerned, and may be divided into two parts: 1. That occupied by the lamina cribrosa, which

is a fine network of transverse fibres which surround the nerve-bundles from their entrance into the sclera up to the level of the choroid. 2. The papilla optici, which lies entirely within the level of the choroid and extends to where the nerve-fibres make a sudden bend, to be distributed over the inner surface of the retina (see Fig. 5).

The effect of this anatomical arrangement is that, although the nerve-fibres, as a rule, lose their medullary sheath and thus become transparent, either before or as they pass through the sieve-like partition of the lamina cribrosa, they are, nevertheless, surrounded by the opaque transverse fibres which go to form the lamina cribrosa, and which still reflect large quantities of white light, so that with the ophthalmoscope we get the representation of a flat, white surface extending across the choroidal opening, and on the same plane with the membrane, instead of the head of the nerve appearing, as it often is, an actual protuberance.

The Form of the Stem of the Nerve.—This undergoes a sudden change in the same region as that in which the change in color took place, and principally for the same reason. The nerve-fibres here suddenly become reduced in size from losing their medullary sheath, and from the fact that the fibre itself becomes finer. The result is that at the lamina cribrosa (Fig. 5) the nerve appears to be tightly constricted, as if by a string. The diameter of this part of the nerve is consequently much reduced, and the narrowest portion will be seen to be precisely that which corresponds with the level of the choroidal opening which determines the extent of the disk seen with the ophthalmoscope.

Cross - Section of the Nerve - Stem.—The optic nerve differs from other nerves on cross-section (Fig. 8) from the fact of the very much greater number of nerve-bundles, and also from the fact that each bundle is

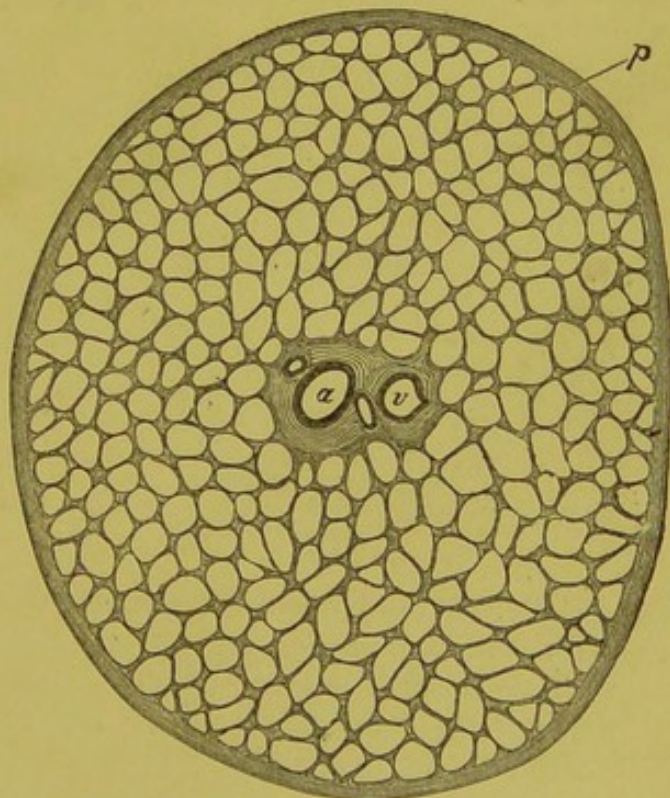


FIG. 8.—Section through optic-nerve stem, showing connective-tissue partitions, connective-tissue string and vessels: *a*, central artery; *v*, vein; *p*, pial sheath. (Schwalbe.) (G. and S., vol. i., p. 345.)

not surrounded by a lamellated sheath, but, on the contrary, many bundles are grouped together and are parceled off in a loose way by a peculiar staging of connective tissue. This staging is derived from the pial sheath, and is a thick, tough, fibrillar tissue, the fibres of which are bound together by a very resisting and cement-like substance much more strongly than ordinary connective tissue. This substance resembles in its chemical and physical properties the tissue of the bands of the ligamentum pectinatum. The staging also carries the blood-vessels which run among the nerve-bundles, but which never penetrate into them. There is a capillary space between the connective-tissue partitions and the nerve-bundles which is probably a lymph-space. The nerve-bundles generally run in a longitudinal course, but they interlace with each other, so that the optic nerve may be looked upon as a nervous plexus with an extraordinarily small and long-drawn-out meshwork, which is consequently split-like in character.

Lamina Cribrosa.—The lamina is, as its name implies, a sieve-like layer of fibres which pass transversely across the head of the nerve (Fig. 5), and which arise from various sources: 1. Those fibres derived from the inner and pial sheaths, and which have already been alluded to. 2. Those which come from the sclera. These latter fibres are coarser and more compactly arranged than those from

the inner sheath. There are also, according to some authors, still other fibres, which come from the choroid and take part in the formation of the lamina. All the fibres taken together form a much closer and firmer network than is present in other parts of the nerve-stem, the character of which and the condensation which the tissue undergoes will be understood by comparing Fig. 8, which

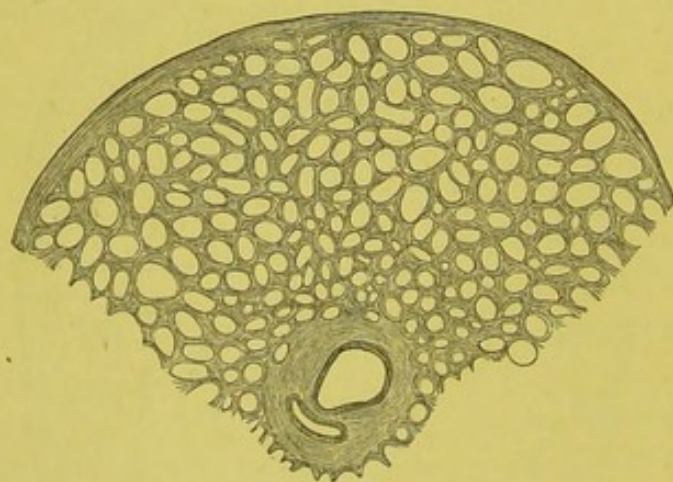


FIG. 9.—Portion of transverse section of the optic nerve, within the region of the lamina cribrosa, with the central vessels and the connective-tissue string surrounding them. (Schwalbe.) (G. and S., vol. i., p. 348.)

represents a cross-section posterior to the lamina, and Fig. 9, one which is within it.

The Nerve-Fibres.—The fibres of the optic nerve, considered as a whole, are medullated fibres, and the greater part of them are the

finest known. They have no sheath of Schwann, and so the medullary substance breaks up easily when the fibres are manipulated. The dividing membranes, composed of the connective-tissue elements already mentioned, do not penetrate into the nerve-bundles, but the fibres are cemented together by a peculiar substance which surrounds each nerve-fibre, and which is identical with the so-called neuroglia of the central organ. The fibres, after passing through the lamina cribrosa, and after forming the papilla, bend at an acute angle to be distributed in a radiating manner to the retina. In doing this the fibres are not evenly distributed, more passing upward and downward than to the sides, and more to the inner than to the outer side.

Lymphatic Spaces.—Besides the lymph-spaces already mentioned—that is, the subvaginal space, which is subdivided into the subdural and subarachnoidal space—there is, communicating with these, a fine network of split-like spaces which traverses the entire stem of the intra-orbital portion of the nerve. At the lamina cribrosa these split-like spaces are more abundant and of wider calibre than in other portions of the nerve. All these spaces communicate with each other, and also with those other spaces which serve to drain the posterior part of the sclera, retina, and vitreous humor. The normal direction of the current of lymph is from the bulb toward the brain; and, although the subdural and subarachnoidal spaces can be filled by injecting in an opposite direction—that is, from the brain toward the eye—such injections will not pass into the lamina cribrosa. If, then, these spaces and their contents have any influence upon the ophthalmoscopic picture, it is not by fluid migrating from the brain, but by the natural current being stopped, by which a stasis of lymph occurs in the head of the nerve and its surrounding parts.

We come now to a consideration of perhaps the most important element in the formation of the picture of the optic nerve-disk and retina, and one which, perhaps, more than any other, contributes to the individuality of its features, and which, as a rule, marks the first indications between health and disease.

The Circulation of the Optic Nerve.—The intra-cranial portion of the optic nerve is supplied by the vessels which are distributed to the adjacent membranes and substance of the brain, and also from the pia mater, which only loosely surrounds the nerve until it reaches the chiasma. After leaving the chiasma, however, the stem of the nerve is closely invested by the pia mater, the vessels of which then form a fine network which surrounds the nerve, and from which fine vessels penetrate into the substance of the nerve. These fine vessels ramify along the partitions of connective tissue by which the nerve-bundles

are divided. While passing through the bony canal the nerve receives some fine twigs from the ophthalmic artery which passes through the canal in company with it. After the nerve has passed through the optic foramen and entered the orbit, it is now invested, as has been mentioned, with an external sheath. This external sheath is first supplied by means of the ciliary vessels. These then pierce the outer sheath, and, passing through the arachnoidal sheath, which is destitute of vessels, form a network in the pial or inner sheath which closely surrounds the nerve, and from which fine branches penetrate into the substance of the nerve in precisely the same manner that has been just described as taking place in the intra-cranial portion of the nerve-stem. At the foramen opticum there is a direct connection between the vessels of the intra-cranial and intra-orbital portions of the inner sheath, and in the orbit again between the vessels of both the outer and inner sheaths.

This system of circulation is continued forward along the sheaths to the bulb and lamina cribrosa, where the network of vessels becomes closer and finer and the meshes narrower, corresponding in this respect with the network of connective tissue, as has already been pointed out. The anatomical distribution of the vascular supply of this part of the nerve will be seen from the following drawing.

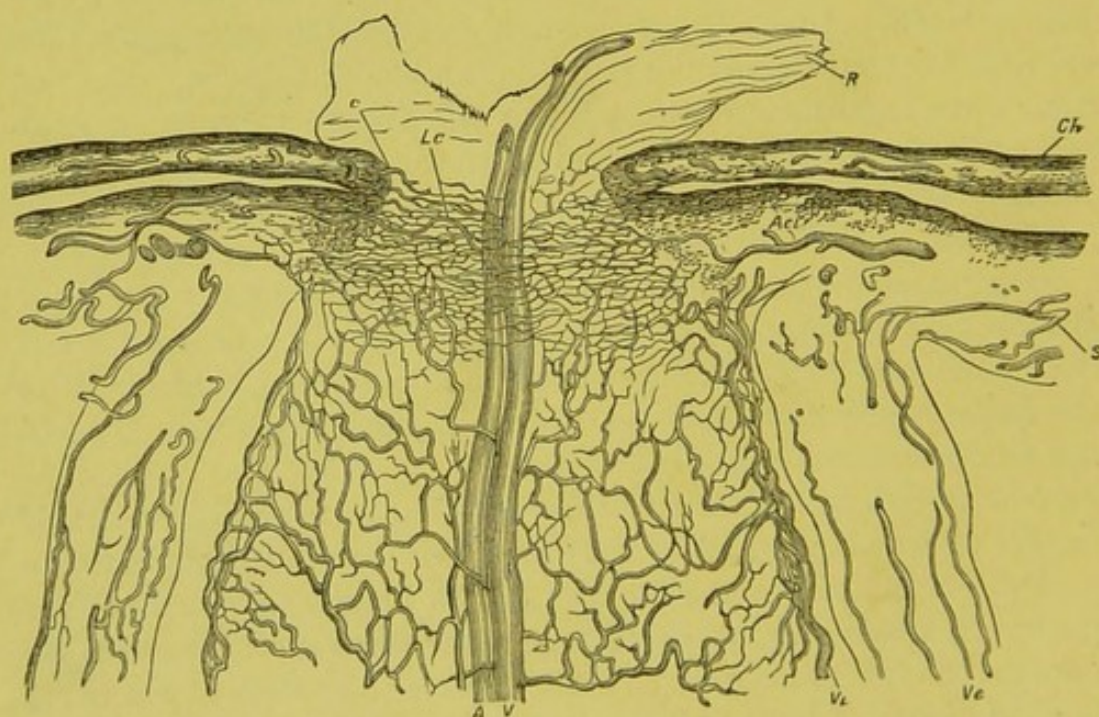


FIG. 10.—Longitudinal section through the entrance of optic nerve: *s*, sclera; *ch*, choroidea; *R*, retina; *vi*, inner optic sheath; *ve*, outer; *A*, arteria centralis retinae; *Lc*, lamina cribrosa; *Aci*, short posterior ciliary artery, which gives off a twig to the nerve. (G. and S., vol. ii., p. 305.)

But, besides the vessels which naturally belong to the posterior parts of the optic nerve, and run forward along its sheaths, and spring *pari passu* from the ciliary arteries as they proceed through the orbit, there are other branches of the same vessels, the short ciliaries, which just before they enter the sclera send off branches, which, running backward along the sheaths, form a network upon them, from which minute vessels penetrate into the substance of the nerve (Fig. 10).

The Central Vessels.—This system of circulation just described is re-enforced by the addition of the central vessels—vena centralis and arteria centralis retinae. These enter the stem of the optic nerve at a short distance, some ten or fifteen millimetres, from the bulb. The arteria centralis is usually a branch of one of the ciliary arteries. Both artery and vein lie close together in the central canal (Fig. 10, *A* and *V*), and contribute to the vascular supply of the anterior parts of the nerves by forming a network of vessels, which, branching from the main trunk, ramify between the nerve-bundles. These vessels form a connection with those coming from the sheaths, and also with those from the sclera and choroid.

Connective-Tissue String.—In their passage through the central canal the vessels are surrounded by a mass of connective tissue, which, it is important to notice, is considerably larger in diameter than the circumference of the two vessels. This is called the connective-tissue envelope or string (Fig. 8). It varies somewhat in amount and density, and is loose and feathery in some instances, and more compact and firm in others where it fills up the entire canal. Schwalbe states that, inside the sclera, and consequently in the district of the lamina cribrosa, he could not discover in this connective-tissue string any vessels except the central artery and vein. Fig. 8 shows the connective-tissue cord surrounding the central vessels, and Fig. 9 gives the same at the lamina cribrosa.

This lack of vessels in the connective-tissue string corresponds with what we see commonly with the ophthalmoscope, for there is a central portion of the nerve—that is to say, a circuit immediately around the vessels—which shows either an entire want of vascularity, or one which is much less marked than in that zone of the nerve which lies between the connective-tissue string and the circumference of the nerve.

The intra-scleral portion of the nerve—that is to say, the lamina cribrosa and the papilla—receives, besides the vessels coming from the sheaths and from the central vessels, also branches from the ciliary vessels and from the choroid. In this way a connection is established between the retinal and ciliary system, which is effected in a great

measure by a peculiar arrangement of vessels which is known as the arterial circle of the optic nerve, or more commonly the scleral circle. This circle is formed within the sclera by two or three small branches from the short ciliary arteries. These pierce the sclera at the posterior pole of the eye at a short distance from the nerve, and then form within the substance of the sclera a vascular circle, which surrounds the head of the nerve at about the level of the lamina cribrosa. From this circle branches pass in a transverse direction directly into the substance of the nerve (*Ac*i, Fig. 10, and *a a*, Fig. 21). Here they form an anastomosis with the vessels coming from the central artery, and with other vessels distributed to the head of the nerve.

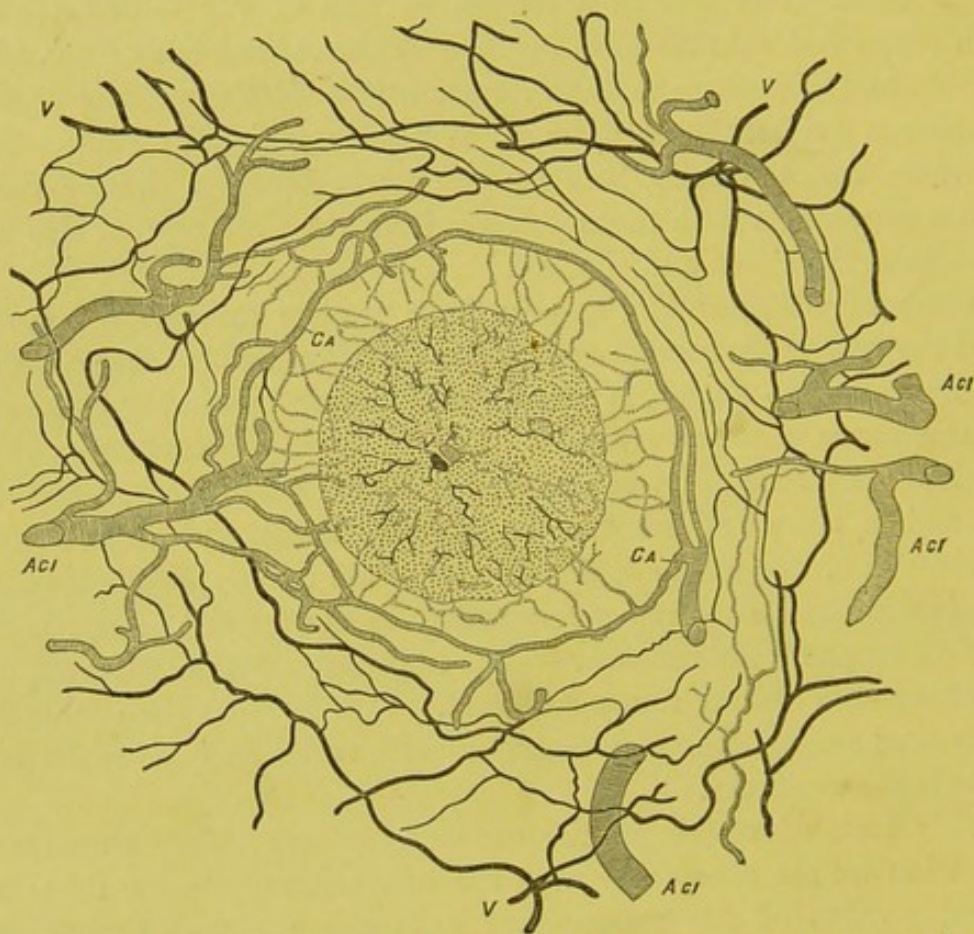


FIG. 11.—Surface preparation. The choroid and retina have been removed. The striped vessels are the arteries; the dark vessels the veins: *Ac*i, short ciliary arteries; *v*, ciliary veins; *ca*, scleral circle; *a*, central artery; *v*, central vein. (Leber.) (G. and S., vol. ii., p. 306.)

Fig. 11 represents a surface view of the scleral circle. The section shows the nerve and surrounding sclerotic at the level of the circle.

Besides these vessels which come from the scleral circle, there are other very fine ones—both arteries and veins—which pass directly from the border of the choroid into the head of the nerve, and the

fine capillary network of the choroid merges itself directly into the coarser network of vessels which surround the nerve-bundles. Thus an anastomosis takes place in this region between what is known as the ciliary and retinal system. This in the normal eye is carried on by very fine vessels, which are hardly more than capillaries, and which do not extend, except in very rare cases, to any appreciable distance into the retina. The head of the nerve is the only place where there is an anastomosis between retinal and choroidal vessels.

ANATOMY OF THE RETINA.

The retina for the use of the ophthalmoscope may be looked upon as the expansion of the optic nerve into a membrane which lines the inner surface of the choroid. However complicated and intricate the structure of this may be as revealed by the microscope, so far as the mirror is concerned, it may be considered, excluding the epithelial layer separating it from the choroid, as a perfectly transparent membrane which reveals nothing of its structure and but very little, and that only in certain places, of its presence. Moreover, as it lies within a cavity which is open to inspection, its grosser anatomical details are better studied with the mirror than in any other way. A consideration of these will, therefore, be postponed until the ophthalmoscopic appearances are described.

There are, however, a few details in the minute anatomy which are not visible with the instrument, but which have an effect upon the ophthalmoscopic picture which it is useful to know and bear in mind, as it is indeed of certain measurements, and the relative bearing of certain localities to each other.

Taken as a whole, the thickest part of the retina is near the entrance of the optic nerve, where, according to Müller, it measures 0.428 mm. From this place forward it gradually decreases to 0.140. Its anterior border, from the fact that it presents a serrated edge when torn from its attachments at the zonula Zinnii, is called the ora serrata. There is one exception to the general decrease in the thickness of the retina, and this is at the macula lutea. The retina, at a short distance from the outer side of the nerve, rises in a knoll-like fashion until it reaches at the yellow spot a height of 0.49 mm., when it again decreases to the bottom of the fovea, which is the thinnest part of the retina, and amounts to only 0.1 mm. Fig. 12 shows, in a diagrammatic way, these differences in level with the gradually decreasing thickness of the retina as it proceeds to the anterior portions of the eye.

The region of the macula lutea extends in an elliptical shape

around the fovea as a centre. It gets its name from the fact that this portion of the retina assumes a yellow shade after death. It is situated to the outer side of the optic nerve, and its centre is a little below the meridian which passes through the centre of the nerve. The distance from the centre of the disk to the centre of the yellow spot—that is, the fovea—is, on the average, 4 mm., although some variations occur in this even in the normal eye. It varies also in

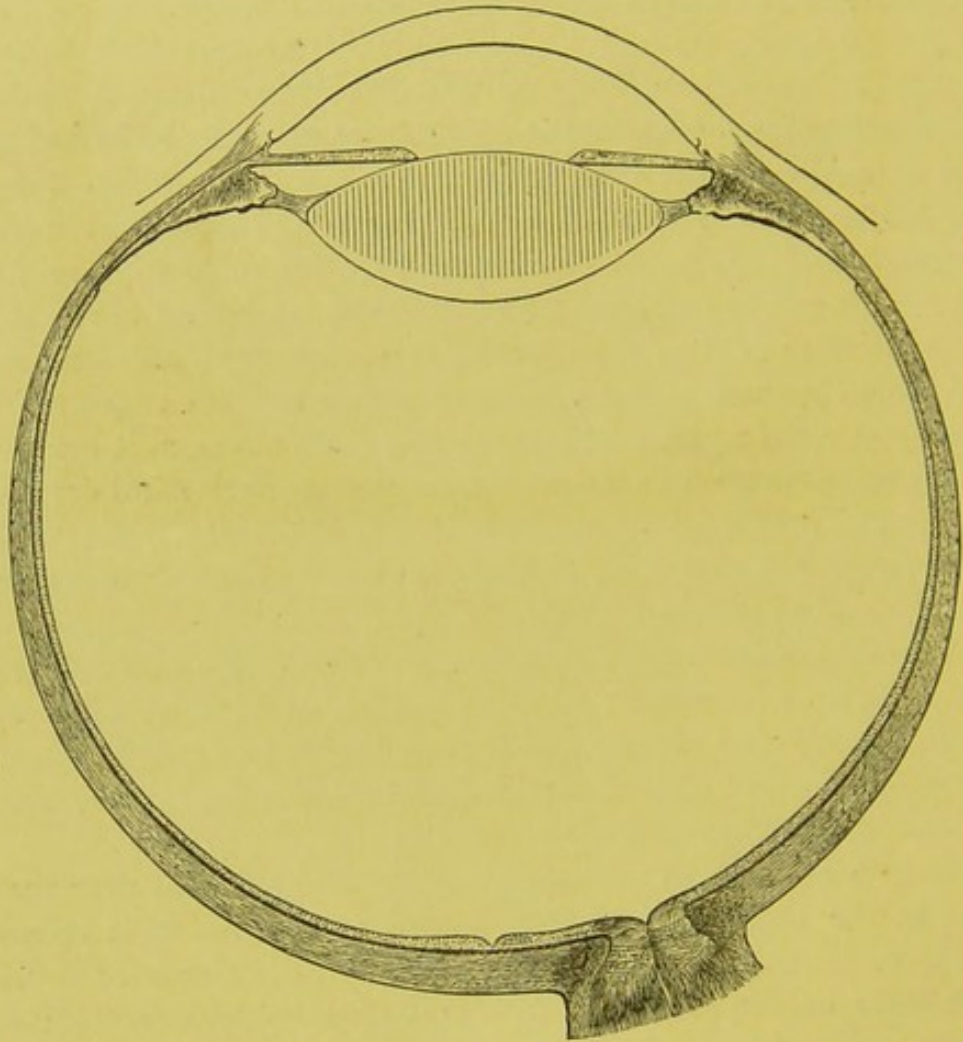


FIG. 12.—Diagrammatic horizontal section from Merkel, showing gradual decrease of thickness of retina and depression at the macula lutea. (G. and S., vol. i., p 43.)

shape from a circle to an ellipse. This latter is by far the commonest form, and the proportion of the horizontal to the vertical diameter is as 4 to 3. It is not exactly in a horizontal line with the disk, as will be seen from Fig. 13, in which the dotted line, which is diagrammatic, marks the position and extent of the macula lutea.

The distance from the centre of the optic nerve to the inner border of the yellow spot varies from 2.2 to 2.45 mm. The horizontal

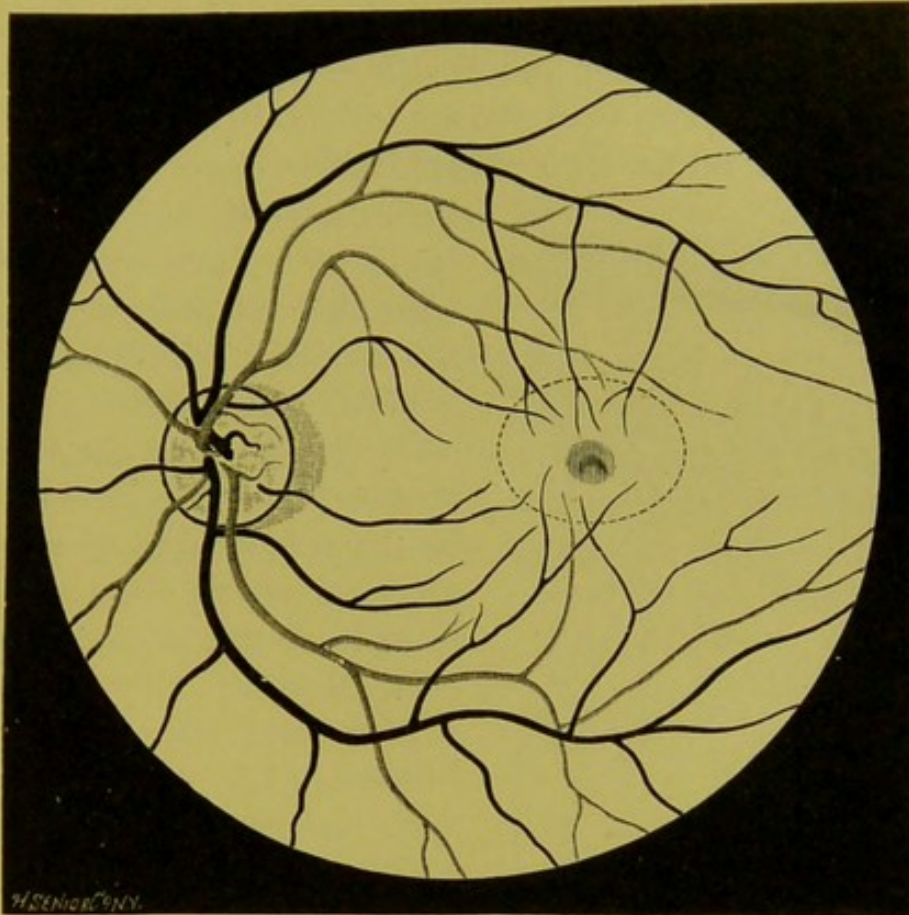


FIG. 13.—Ophthalmoscopic appearances of blood-vessels of retina, from life. (Magnified $7\frac{1}{2}$ times.) The light vessels are the arteries; the black, veins.

diameter of the spot itself varies in different eyes very much, as can be seen with the ophthalmoscope. Sometimes it reaches as high as three millimetres—nearly twice that of the nerve. On the average it is about two millimetres. The “maculea lutea,” or region of the

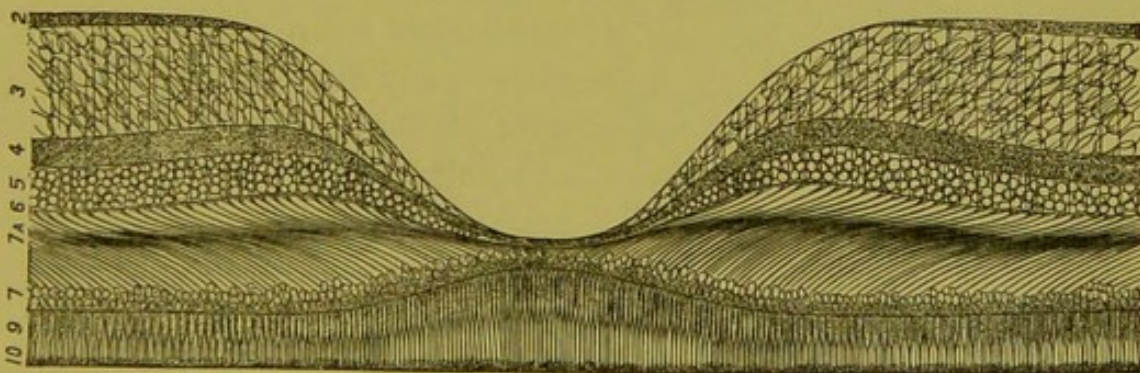


FIG. 14 gives a diagrammatic section of the retina through the region of the macula lutea and fovea, and shows the depression formed in this portion of the retina by thinning of the layers. (“Handbuch der Lehre von den Geweben.” S. Stricker, part v., p. 1024.) (Half size.)

yellow spot, must not be confounded, as it often is in ophthalmoscopic parlance and literature, with the fovea centralis, which is the central spot of the ellipsoidal region, as will be seen from the diagram. The

fovea does not, however, lie directly in the centre of the ellipse which marks the boundary of the yellow spot, but a little below it, and a little nearer to the inner than the outer side. The fovea is a minute depression in the retina, with usually rather steep sides. In life it

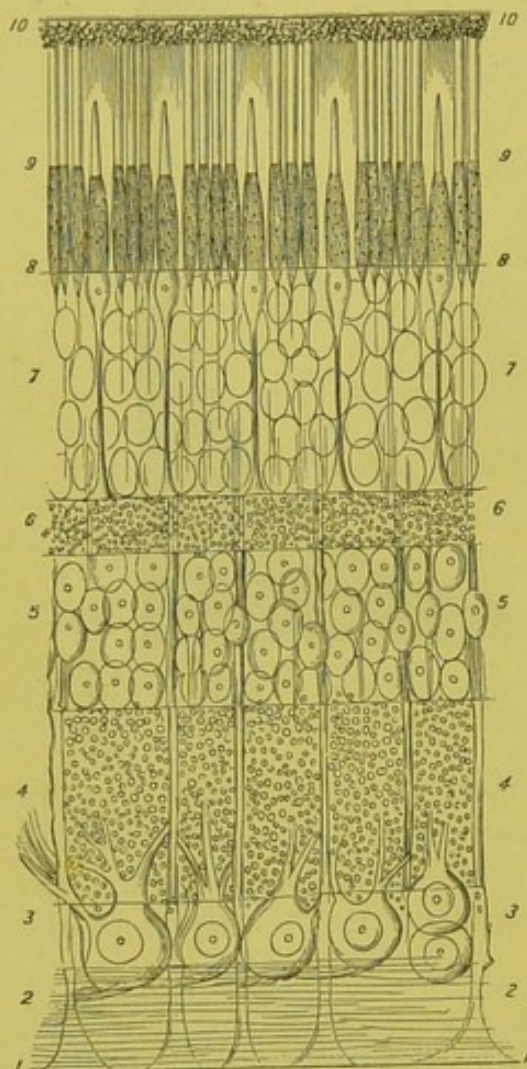


FIG. 15.—Diagrammatic section of retina, showing the different layers. (Schultze, altered by Schwalbe.) 1, membrana limitans interna; 2, layer of optic-nerve fibres; 3, layer of ganglion-cells; 4, internal molecular layer; 5, layer of internal granules; 6, external molecular layer; 7, layer of external granules; 8, membrana limitans externa; 9, layer of rods and cones; 10, pigment layer; *a*, position of first network of capillaries; *b*, second network of capillaries. (G. and S., vol. i., p. 358.)

varies a good deal, both in shape and size, as can readily be seen with the ophthalmoscope by the reflexes that take place from its borders. Just behind the fovea centralis, and for a little space immediately around it, the pigment in the epithelial layer which separates the retina from the choroid is more abundant and of a deeper color than in other parts of the fundus, and the pigment membrane itself is more closely united with the retina than in any other place; so much so that in tearing them apart this portion of the epithelial membrane often remains attached to the retina.

The Vessels of the Retina.—

The arteries and veins are subdivisions of the arteria and vena centralis, and the manner in which they are distributed will be better understood by a study of Fig. 13 than by any detailed verbal description. Their appearance with the ophthalmoscope will be given later under its appropriate heading. The larger branches of the vessels run in the nerve-fibre layer, and are immediately beneath the internal limiting membrane. They lie so superficially that in a cross-section they are seen with the microscope to project above the general level of the retina toward the vitreous humor. While the large vessels run in the plane of the inner sur-

face of the retina, smaller vessels penetrate the substance perpendicular to its surface as far as the internal granular layer (Fig. 15, 5). These vessels resolve themselves in penetrating into the retina into two layers of capillaries—one in the outer part of the internal molecular layer (4), and one in the outer part of the layer of internal granules (5). The layers external to this layer are, consequently, without vessels, and a glance at the diagram will show that this portion embraces the larger half of the entire retina.

It will be seen from Fig. 13 that the macula lutea, or the ellipsoidal space inclosed by the dotted line, contains a number of fine vascular twigs which, coming from above and below, radiate toward the spot in the centre which marks the position of the fovea centralis. It is well to remember that the macula lutea is the place of the entire retina which is the richest in blood-vessels, many of which can be

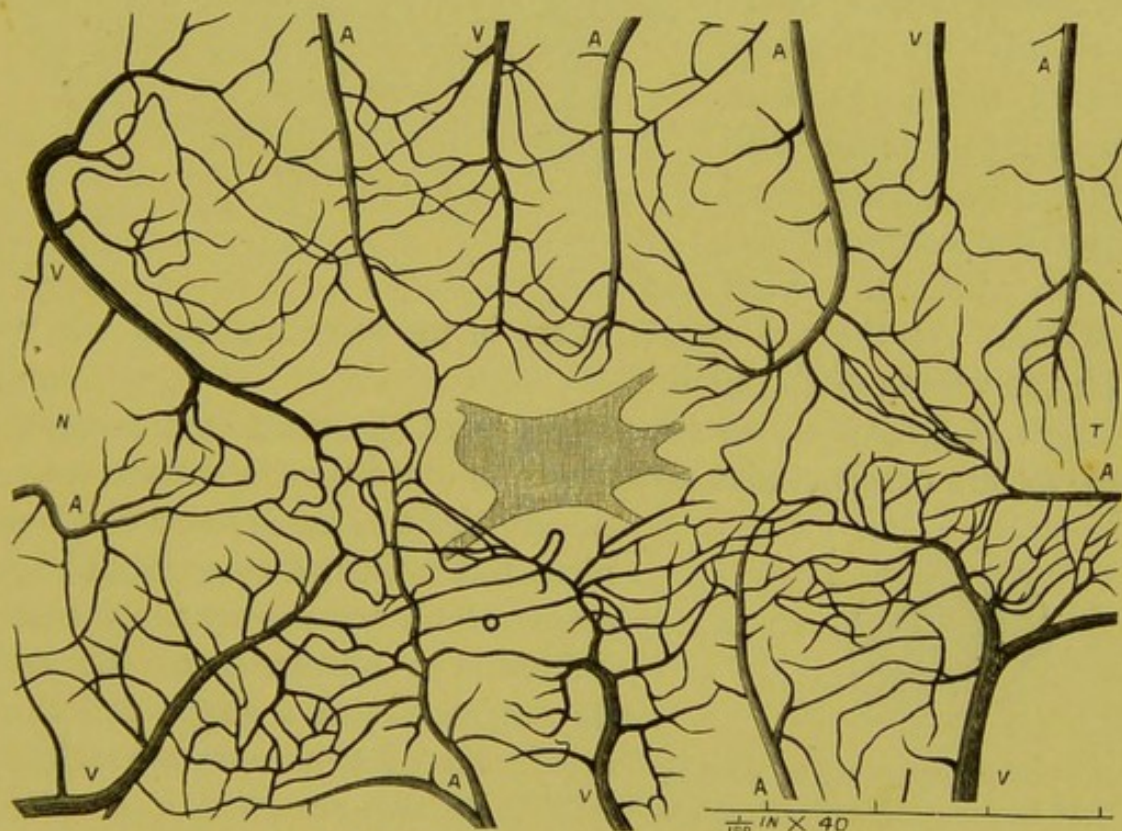


FIG. 16.—Blood-vessels of the yellow spot of the human retina injected: *A*, arteries; *V*, veins; *N*, nasal side of yellow spot (toward optic disk); *T*, temporal side. The shaded area in the middle is the *fovea centralis*. (Nettleship, "Ophth. Hosp. Rep.," vol. iii., part ii., p. 40.)

plainly seen with the ophthalmoscope, while the microscope shows that the capillary plexus is richer and finer here than in any other part of the retina. As will be seen from the drawing above, Fig. 16, it is only the fovea itself that is devoid of vessels.

A more instructive figure still of the finer vessels of this region is that furnished by the entoptic appearances, as will be seen from the

drawing (Fig. 17) given by Dr. Ayres. It must be borne in mind, however, that the enlargement by this method is not nearly so great as with the microscope, and that the space here free from vessels is not, as in the drawing above, the fovea itself, but the region of the yellow spot. The fovea is seen as a small spot in the centre.

The retinal arteries do not anastomose with each other. They simply continue on to the periphery of the retina, bifurcating as they go, until they pass at the ora serrata into a mesh-work of very fine capillaries, which in turn empty into minute veins which pass backward along the course of the arteries into the vena centralis. At the ora serrata there is no communication whatever with the vessels of the choroid.

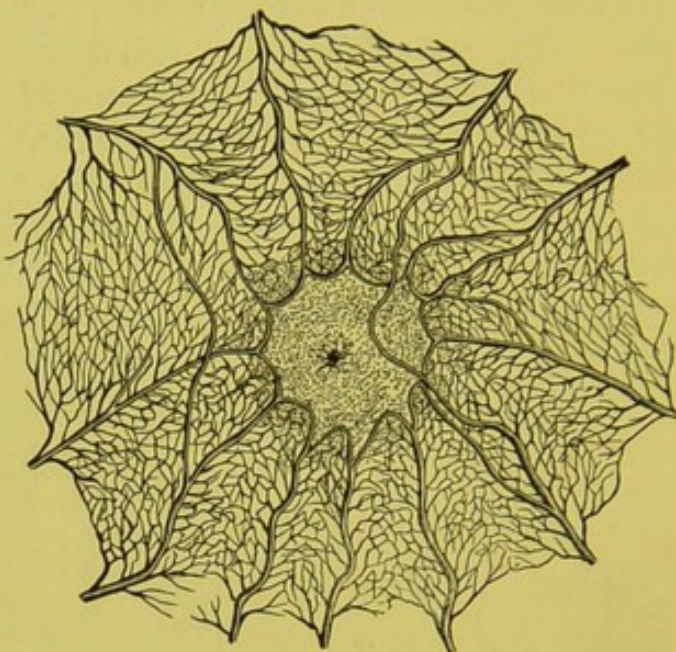


FIG. 17.

Lymph-Spaces.—The lymph-spaces of the retina are formed by perivascular canals, which surround the blood-vessels themselves. In

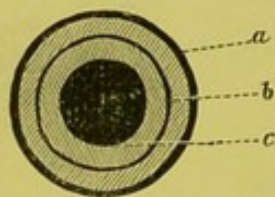


FIG. 18.—Diagrammatic section of vein: *a*, outer wall; space between *a* and *b*, lymph-space; *b*, inner endothelial cylinder; between *b* and *c*, plasmic current of blood-column; *c*, red-blood column.

the arteries this investment is not complete, but is formed by sheath-like processes which accompany the vessels in striæ. The capillaries of the retina do not consist of a single endothelial canal, but of two separable cylinders which lie the one within the other. It is precisely the same with the veins, except that the outer endothelial layer is re-enforced by a tissue which is not unsimilar to reticulated connective tissue. The column of blood, then, is

only separated from that of the lymph by means of a single thin endothelial membrane, as is shown diagrammatically in Fig. 18.

Pigment-Layer of the Retina.—Between the choroid and the retina lies a delicate membrane, which, from the very important effect that it has, according to some observers, upon the ophthalmoscopic

picture of the normal eye, as well as that of morbid conditions, deserves attention. The pigment-membrane consists of a single layer of hexagonal cells which rest upon the thin transparent membrane—the lamina vitrea—and which are joined with each other by a thin and transparent cement-like substance in such a manner as to leave a transparent space between the borders of the cells, as will be seen from Fig. 19.

The pigment-granules within the cell are very fine, and may be looked upon as held in solution in a colorless vitreous substance,

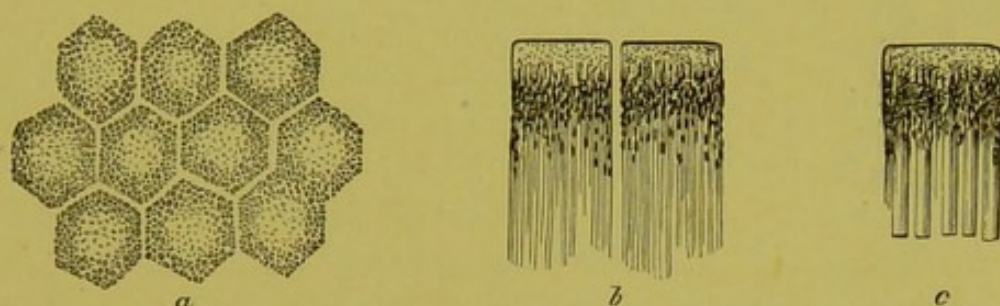


FIG. 19.—Cells from the pigment-layer of the human retina: *a*, surface view, showing the cells connected together; *b*, side-view, showing the long, hair-like processes, some of which are pigmented and some free from pigment; *c*, side-view of a single cell, showing its connection with the outer member of the rods of the retina. (Stricker, "Handbuch," part v., p. 1013.)

which during life is exceedingly soft. The pigment is so arranged that it occupies the peripheral portion of the cell, leaving the centre comparatively free, as shown in the drawing; moreover, it is only the inner portion of the cell, or that nearest the retina, which is pigmented. The thickness of the cell amounts to about $\frac{1}{250}$ of a line. The pigmented portion, therefore, would be only $\frac{1}{500}$ of a line. Here, as in the stroma, the quantity of pigment in the cell may vary in different eyes or in different cells of the same eye; it is also of lighter color in pronounced blondes and darker in the negro. Still, in the ordinary individual, whether of medium pigmentation or inclined to the blonde or dark, not only are the anatomical elements very uniform in character and appearance, but, as a rule, so also is the pigmentation.

Lymph-Spaces.—The external surface of the choroid is provided with an endothelium, and the space between it and the sclera is called the perichoroidal space. The arteries, capillaries, and veins are provided with perivascular sheaths, by which the lymph is carried into the perichoroidal space, from which it finds an exit into the orbital spaces by a fissure-like space at each side of the vena vorticiosa as it passes through the sclera, as shown in the drawing (Fig. 20):

The lymph from the retina finds an exit at the lamina cribrosa

into the opticus, the lymph-spaces of which, as already shown, communicate with those of the brain.

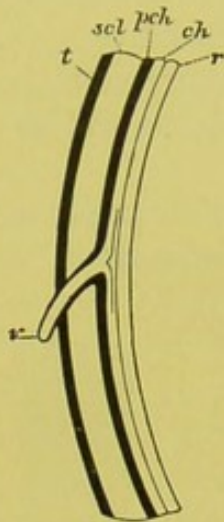


FIG. 20.—Diagrammatic representation of a section of a vena vorticiosa and its perivascular spaces in the pig's eye: *r*, retina; *ch*, choroid; *Pch*, perichoroidal space, injected; *Scl*, sclera; *t*, space of tenon; *v*, vena vorticiosa. ("Handbuch der Lehre von den Geweben des Menschen und der Thiere." S. Stricker, part v., p. 106.)

The Choroid.—So far as the grosser construction is concerned, the choroid is better studied with the mirror than in any other way. Still, it is interesting as well as instructive to know, at least in a cursory manner, the anatomical elements of which it is composed, and, as it is the great purveyor of the eye, the sources from which it draws its vascular supply. The choroid may be looked upon as a vascular web or membrane in which the vessels are loosely woven together by a sort of connective tissue, which, taken with the vessels, forms a vascular parenchyma or stroma. The non-vascular part of this consists of a small quantity of connective tissue, some elastic fibres, pigmented and non-pigmented cells, which vary both in quantity and amount of pigmentation in different layers. The inner layer, or that of the finer vessels, contains but very little, and, according to some authorities, no pigment at all. In the outer layers, though always present to a greater or less degree, it may vary greatly in different individuals not only in quantity but also

in intensity. The choroid varies in thickness from .08 to .16 mm., or only about one fourth or fifth as thick as the retina, a fact seldom held in mind by the ophthalmological student. The choroid lines the inner surface of the sclera from the optic-nerve entrance to the ciliary processes. It is loosely connected by its outer surface by fine shreds, which taken together form a membrane which has received the name of the *membrana supra-choroidea*.

The external surface of the choroid is provided with an endothelial membrane, while its inner surface is covered by a smooth and perfectly transparent membrane, the *lamina vitrea*. The choroid is attached in a firm manner to the sclera in only two places—first, anteriorly, near the junction of the sclera and cornea; and, secondly, which it is important to remember, at the optic-nerve entrance, which it closely surrounds. Here the layers of the choroid pass into a thin

ring, which consists of concentric fibres which form the opening known as the choroidal foramen, which is 1.4 mm. in diameter. Besides this direct attachment, there is an indirect one by means of numerous nerves and vessels which pass between the choroid and sclera. At the macula lutea the number of these small vessels is so great that a rather close adhesion is formed between the two membranes. The inner surface of the choroid formed by the lamina vitrea is not directly attached to the retina, although the close adaptation of the pigment-layer and the hair-like processes which pass from it for a slight distance, at least, between the rods and cones, occasion a certain amount of adhesion, which is sometimes so great that the pigment-layer remains attached to the retina at the macula lutea when the two membranes are torn apart. As a rule, however, and in all other portions except the macula lutea, the pigment-layer, at any attempt at separation, goes with the choroid.

The Vessels of the Choroid.—Although the vessels form a more or less interwoven mass, they may, for convenience' sake, be considered as arranged in three layers: 1. The inner layer, or capillaries. 2. The middle layer, or fine vessels, mostly arteries. 3. The outer layer, or large vessels. The origin of the vessels and the manner in which they are distributed will be seen from the diagram (Fig. 21).

The short ciliary arteries which chiefly supply the blood for the choroid arise, by means of from four to six small stems, from the ophthalmic artery. While following the trunk of the nerve in the orbit they divide themselves into numerous branches, some twenty in number, which surround the nerve and pierce the sclera at a short distance from the entrance of the nerve-stem, in a perpendicular direction, as shown in the diagram by the vessels marked *a*. The greater part of these vessels proceed forward, branching as they go, and extending themselves over the inner surface of the sclera to form the principal arterial supply of the choroid. Other branches pass backward toward the head of the nerve, where they anastomose with the vessels which belong to the sheaths, and also with the branches coming from the central artery. Still other smaller branches, while yet in the sclera, form the scleral ring. From these, branches are sent out into the substance of the opticus, as has already been described. It is well to repeat here, that all these vessels form an anastomosis with each other at the head of the nerve, and this is the only place where there is any connection whatever between the retinal and choroidal circulation.

The long ciliary arteries, *b*, two in number, lie on each side of the eye. They pierce the sclera very obliquely, and then run forward in

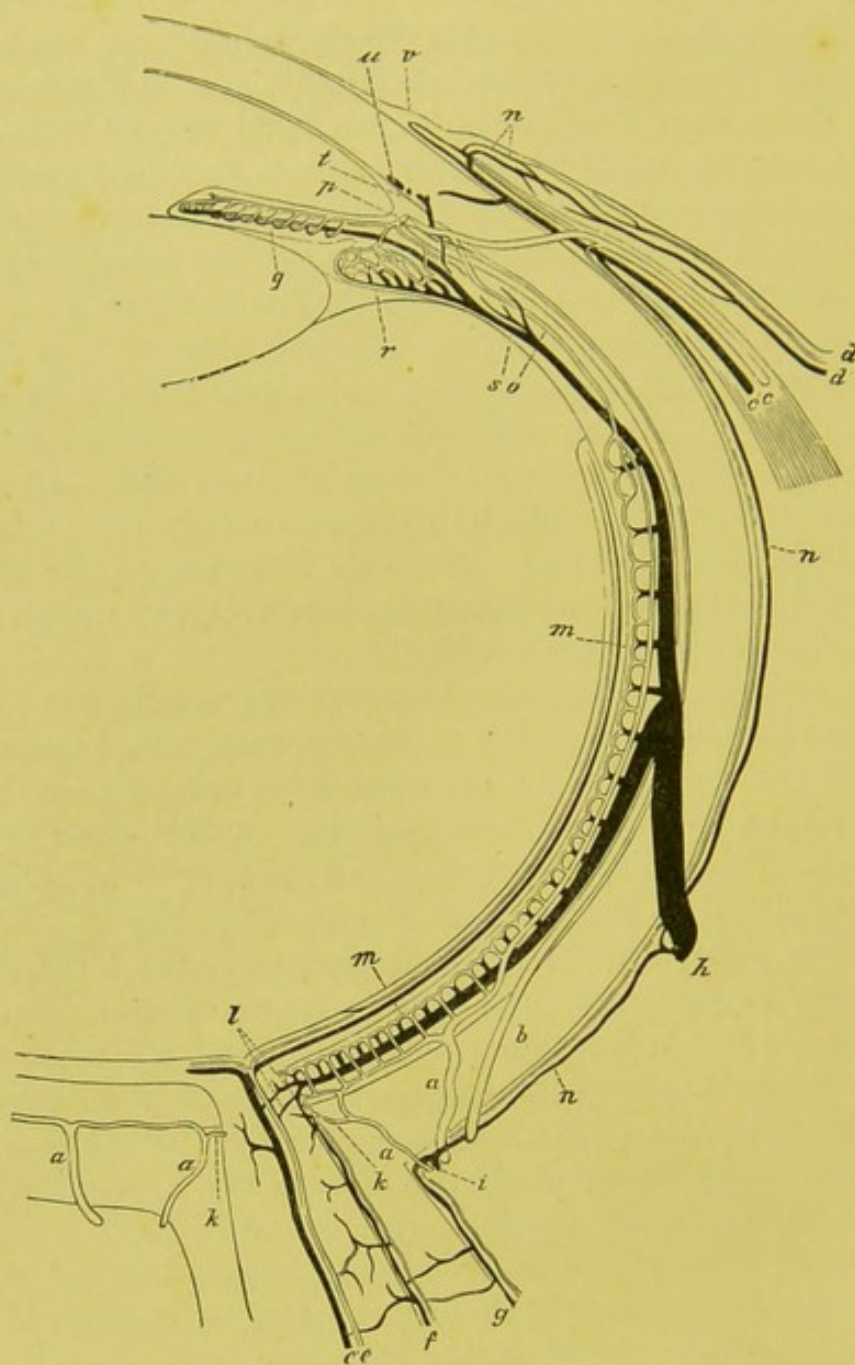


FIG. 21.—Diagrammatic representation of the circulation of the eye, horizontal section. Veins, black; arteries, clear: *a*, short posterior ciliary arteries; *b*, long posterior ciliary arteries; *cc'*, anterior ciliary artery and vein; *dd'*, posterior conjunctival artery and vein; *ee'*, central artery and vein; *f*, vessels of the inner; *g*, those of the outer optic sheath; *h*, one of the venae vorticosae; *i*, short posterior ciliary vein; *k*, branch of a short posterior ciliary artery which passes into the opticus; *l*, anastomosis of the choroidal vessels with those of the nerve; *m*, chorio capillaris; *n*, episcleral branches; *o*, recurrent choroidal artery; *p*, major arterial circle of the iris; *q*, vessels of the iris; *r*, ciliary processes; *s*, branch of a vena vorticosa coming from the ciliary muscle; *t*, branch of the anterior ciliary veins coming from the ciliary muscle; *u*, venous circle; *v*, network of vessels at the border of the cornea; *w*, anterior conjunctival artery and vein. (G. and S., vol. ii., p. 303.)

the horizontal meridian of the eye, on the outside of the choroid and between it and the sclera, to be distributed to the anterior parts of the choroid, iris, and ciliary body. These latter, however, contribute but little or nothing to the ophthalmoscopic picture, and the same may be said of the anterior ciliary arteries, *cc*, and the recurrent arteries, *rr*, of the choroid, which are branches of the long ciliary and anterior ciliary arteries which run in a posterior direction from the most anterior parts of the choroid.

The short ciliary arteries lie, when they first pierce the sclera, in the outermost portion of the choroid, surrounded by the loose and

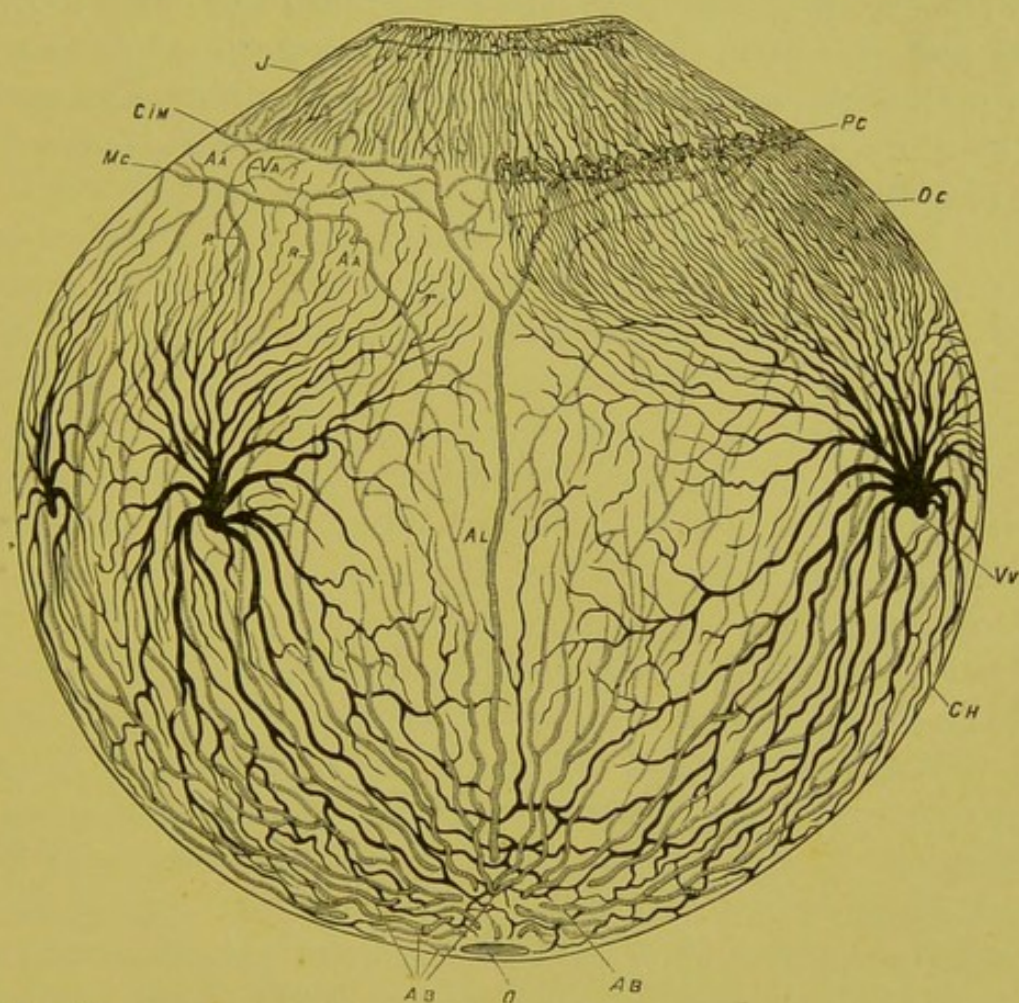


FIG. 22.—Diagrammatic representation of the circulation in the choroidal tract. On the left side the ciliary processes are covered by the ciliary muscle; on the right the ciliary muscle is removed so as to show the processes: *I*, iris; *Mc*, ciliary muscle; *Pc*, ciliary processes; *oc*, orbiculus ciliaris; *ch*, choroidea; *o*, optic-nerve entrance; *Ab*, short ciliary arteries; *Al*, long ciliary arteries; *A'a*, anterior ciliary arteries; *Cim*, circ. art. irid. major; *Vv*, venæ vorticosæ; *Va*, ven. cil. ant.; *rr*, recurrent arteries of the choroid. (Leber, G. and S., vol. ii., p. 315.)

highly pigmented tissue of the supra-choroidea. They then pass, dividing and becoming smaller as they go into the inner layers of the choroid, until by subdivision the finer branches resolve themselves

into a uniform layer of minute capillaries which cover the entire surface of the choroid from the nerve-entrance to the ora serrata. The network of capillaries in the region surrounding the nerve, and especially in that of the macula lutea, is the finest anywhere in the body. At the entrance of the nerve the capillaries of the choroid are in communication with those of the papilla, even if this layer does not, as some say, pass directly over into the head of the nerve.

The Veins of the Choroid.—These vessels are, from their peculiar conformation, usually called the venæ vorticosæ. These vortices are usually four, though they occasionally amount to six in number. The various branches of these veins collect the blood from both the anterior and posterior parts of the eye, and, piercing the sclera near the equator of the eye, empty into the veins of the orbit. The surface distribution of these veins and that of the arteries will be seen from the drawing (Fig. 22).

CHAPTER IV.

THE FUNDUS OF THE NORMAL EYE.

THE two most prominent features of the back, or, as it is commonly called, the fundus of the eye, may be considered, first, a red background ; secondly, a whitish, disk-like circle, from the centre of which radiates a delicate tracery of vessels.

It is certainly one of the most curious facts in the entire art of ophthalmoscopy that there should be any difference of opinion as to the cause and origin of the color of the fundus. Such, however, is the fact, for, while some observers attribute the general red hue to the light reflected by the expansion of the network of the choroidal vessels and capillaries, others maintain, such as Jaeger and Mauthner, that the color is due solely to the light reflected from the pigment-epithelium layer, and that no light passes beyond this, when in its normal condition, to the vessels below, and consequently that none is reflected back to the observer. This is a fact of great importance, for, if it were true, then physiological as well as pathological details and processes in the choroid would be concealed from the observer. It is maintained by those who hold this view that this is precisely what takes place, and that the general uniformity in color and want of detail in the back of the eye are due to the fact that the light strikes the pigment-layer and is reflected from it just as it would be from a thin but untransparent fabric which, while it gave evidence of its own material and color, would conceal everything below it. It is well known, however, that there are many cases in the normal eye in which the details of the choroid, such as the larger vessels and their interstices, are exposed to view, and this objection, which would be fatal to the theory that light did not penetrate the pigment-layers, is met by the statement that where such details are evident there the pigment-epithelium is wanting in pigment, and that the degree of pigmentation of this layer may and does vary in such eyes.

The objections to the theory that the color of the fundus is due solely to the pigment-layer, and that light does not pass through it, are so strong and so numerous as to need some little comment.

In the first place, if it were true that light did not pass through the membrane, then the general coloration of the fundus would not be, as it almost invariably is, either red or of a reddish hue, but of the color of the pigment, which, when seen even by strong daylight, is either of a pure black, or, at the most, of the darkest possible shade of brown, and under the comparatively feeble light of the ophthalmoscope would be even of a darker shade than by daylight. Moreover, anatomy teaches that the pigment-layer is an exceedingly thin and delicate membrane, consisting of a single layer of hexagonal cells, which are pigmented for only half their thickness, with interspaces of clear, transparent tissue between the individual cells, as will be seen from the accompanying cut (Fig. 23).

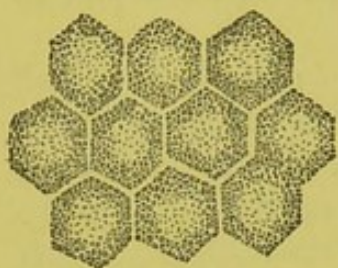


FIG. 23.

That large quantities of light must pass through such a membrane is self-evident, and the pigment-layer may be looked upon, so far as its effect upon the color of the fundus is concerned, as a very delicate and transparent membrane holding in suspension a certain quantity of pigment-granules, so fine as to be almost vitreous in nature; and which covers the choroid, but which, while it may alter, according to its richness in pigment, the shade of color belonging to the choroidal vessels, can not in itself alone conceal them from view.

The fact that we do not always see the larger vessels depends, I believe, not on the pigment-layer alone, but upon the nature and anatomical construction of the choroid itself; and that the general uniformity of surface which we notice, as a rule, is due principally to the great number and closeness of the small vessels and capillaries, which, knit and woven together like a fabric, lie over the larger vessels, and which, too small to be seen individually with the low magnifying power of the ophthalmoscope, yet give the appearance, as a whole, of a more or less uniform and homogeneous texture. It will be well to remember, in this connection, that the vessels of the choroid are arranged in such a manner that the capillary layer is the most internal, that is, nearest to the observer, while the smaller vessels, mostly arteries, come next, and the larger vessels, mostly veins, form the most external layer—moreover, that the network of capillaries and small veins and arteries is the finest and closest near the posterior pole of the eye, where, according to Leber, there is “an almost inseparable entanglement of vessels”; and this is especially true of the region opposite to the macula lutea, where the network of capillaries is the finest in the body.

The anatomical distribution of the vessels and the different degrees of the fineness and density of the network in the different regions of the fundus are shown in the drawing below from Leber.

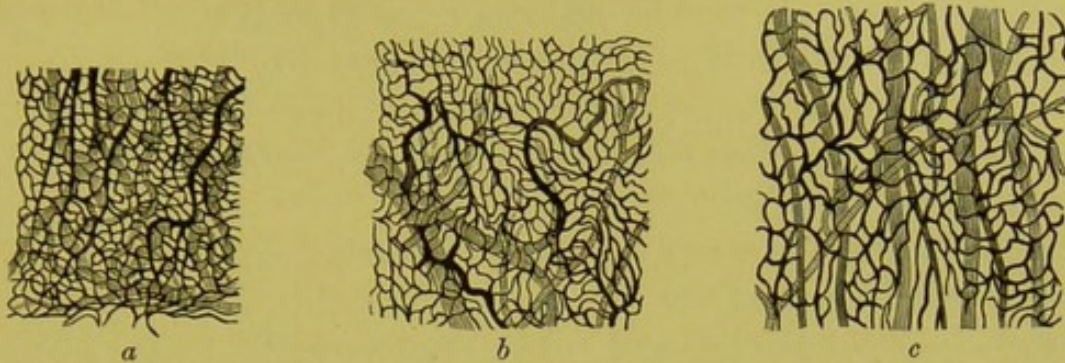


FIG. 24.—Capillary network of the choroid: *a*, in the neighborhood of the nerve-entrance; *b*, in the region of the equator; *c*, in the neighborhood of the anterior end of the choroid—veins striped longitudinally; arteries striped cross-wise; capillaries solid. These latter, as represented in the woodcut, are too fine by about one half. (G. and S., vol. ii., p. 318.)

It will be seen that even under the microscope the network of vessels is exceedingly fine and close. To get some idea of how impossible it would be to distinguish any of the details of such a complication of small vessels—arteries, veins, and capillaries—with the low magnifying power of the ophthalmoscope, the student has only to make a strong concave glass from the test case, and to hold this at such a distance from the drawing that the reduction in the image shall be about one fifth of the actual size of the woodcut. Under even this very trifling reduction it will be observed that every detail of the drawing is lost, and an idea can be formed of what it would be in nature if the enlargement produced by the microscope was removed. This part of the choroid would then in the ordinary eye appear as one uniform layer of a red texture.

It should also be remembered that the innermost vascular layer of the choroid—the capillaries and small vessels—ramify in a sort of structureless membrane, which in the normal eye contains but little or no pigment, so that, in point of fact, the only thing which lies between the observer's eye and what may be looked upon as a thin column or layer of blood is a delicate single layer of hexagonal cells, the pigmented part of which is less than $\frac{1}{500}$ of a line thick, and in which and between which there are numerous interstices of clear tissue.

The smaller vessels become less numerous as the ora serrata is approached, and the meshes between them larger and more elongated; and the ophthalmoscopic picture agrees with this anatomical distribution of the vessels.

The color of the fundus, then, according to this view, would be

due to reflection from the blood contained in all the choroidal vessels combined, tempered by the pigment contained in the epithelial layer, and influenced to a far greater degree by that of the general stroma of the choroid. To this may be added a certain portion of white light reflected from the sclera, for that a certain quantity of light from the mirror does filter through to the external membrane of the eye, and in some cases to a considerable degree, and is then reflected back, I think can not be doubted.

Such being the cause of the color, it remains only to say, what the observer will soon find out for himself, that this may vary in shade and tone from the lightest and most delicate pink, as I have seen it in some pronounced blondes, to a shade which, passing through a yellowish orange-red, comes to a pure and vivid red, and even to a maroon. If, however, there is one shade which the normal eye never assumes it is that of the blood itself, for there is never a time when the contrast between the color of the blood in the retinal vessels and that of the general fundus is not clearly defined.

This variation in shade and tone, as well as that in detail and design, depends in a great measure on the general coloring or complexion of the individual examined. Thus, when the complexion is dark, and the pigmentation of the hair and iris is marked, the fundus of the eye will as a usual thing present a deeper shade of red, and the general details of the fundus will be more obscured than where the hair and iris are of a light color. Indeed, when the fundus is exceedingly rich in pigment the ordinary yellowish or ochre-red reflex is not present, and the tint approaches a grayish-red, in which at times the gray predominates. In those cases, moreover, in which the pigment is really what may be called excessive in quantity, as in some pronounced negroes, the whole fundus seems to have a slaty, grayish hue, or even a silvery, sheen-like appearance, with but little or no red tinge in it. Here, if ever, we get the effect from the pigment-layer alone in great part, and the ophthalmoscopic picture then corresponds in its lack of color with what would be expected when most if not all of the light was reflected from the pigment-membrane without penetrating to the vessels below. Still, that the appearance of the fundus corresponds with the degree of pigmentation of the hair and iris, is not as common a rule as is usually supposed, for I have seen many blondes, even those approaching an albinotic type, in whom the same uniformity in coloration, the same stippled appearance, and the same want of detail as to the visibility of the larger vessels existed, as in persons with the average amount of coloring material, or even in those who were deeply pigmented.

Here, too, besides the amount of pigment in the pigment-layer and in the stroma of the choroid, the comparative number of small vessels and capillaries take their share in producing the difference in shade, since the vascularity, that is to say, the number of smaller vessels and capillaries, varies in different individuals, even in persons of the same coloration and general complexion. Where, therefore, the vessels—large and fine—are numerous, and the pigment also rich in quantity, there will be, no matter what the complexion may be, a more general uniformity in texture and a deeper and more pronounced color to the fundus. Where the smaller vessels and capillaries are poorly developed, and at the same time the pigment is also deficient in quantity, there the fundus will be less uniform in character, less compact in substance, and the larger vessels, especially toward the equator of the eye, will be seen in greater detail.

The picture produced under these conditions is exceedingly variegated and beautiful. In the posterior pole of the eye, in the neighborhood of the nerve, and especially at the region of the macula lutea, where the finer vessels are the thickest and the most intricate, and the pigment in the epithelial layer the most abundant, there will be as a rule a uniform surface with no definite details apparent, except here and there one or two of the larger and deeper-lying vessels of the stroma may struggle into view in subdued contrast with the general uniformity of the rest of this portion of the fundus. As we proceed toward the equator of the eye, this uniformity in color and texture gives place to a more detailed pattern formed by the interlacing and anastomosing of the vessels which form a network, the meshes of which are more or less circular, ovoid, or rhomboidal in shape. Near the equator these meshes become more open in shape and more elongated in form. The branches of the vessels anastomose and interlace less frequently, and run more parallel to each other and assume a meridional course. Here the tapering commencements of the *venæ vorticosæ* can be seen, gradually increasing in size and radiating toward a common centre, while at the extreme limit of the ophthalmoscopic field the branches of the outgoing veins come into view. These *venæ vorticosæ* vary in number from four to six, or even more.

Under such circumstances the intervacular spaces are clearly defined, and appear in the more posterior parts of the fundus of a delicate pinkish-white, or even, especially toward the periphery, of a pure white, from reflexion from the surface of the sclera, or, to put it in other words, the vessels appear sharply defined against a whitish background.

On the other hand, where the pigment is richly or excessively developed in the stroma of the choroid, while there is a deficiency of smaller vessels and capillaries, we may have precisely the same configuration as to the convolutions of the vessels, the only difference being as to the color of the intervascular spaces, which are then, instead of being of a whitish hue, either of a dark gray or even black. When this pigment of the stroma is very abundant, and is collected into masses between the interstices of the vessels, it then follows their radiations, and gives a peculiar striped appearance which resembles the markings of a tiger's skin, for which reason it is often spoken of in the books as the *choroid tigré*. It occurs in various degrees, and is, as a rule, from the anatomical reasons already pointed out, most marked in the periphery of the fundus. This should not be confounded with displacements and accretions of pigment through morbid processes, from which it is usually easily distinguished by its regularity in design, its uniformity of surface and color, and its sharpness of outline.

This difference of effect, due to the greater or less quantity of the smaller vessels, may be observed not only in different individuals, but also in different parts of the same eye. Thus there may be one district of the fundus which will present a uniform coloring, while another portion lying adjacent to it will reveal all the details of the stroma and its larger vessels (see Plate II., Fig. 1). Or we sometimes find one portion of one of the larger vessels covered over and obscured for a considerable distance by what appears to be a homogeneous and continuous surface, while another part of the same vessel or one lying close to it will be seen with perfect distinctness. It would certainly appear to be more natural to attribute such diversity of appearance in the background of the same eye to different degrees of vascularity than to different degrees of pigmentation in the pigment epithelial layer, which anatomy teaches us is remarkable for containing, as a rule, a uniform amount of coloring-matter in its cells over the entire surface of the membrane as far as the ciliary processes.

Schweigger, however, takes a somewhat different view ; for, while he believes that the vessels of the choroid, and even the white light reflected from the surface of the sclera, have a share in the production of the color and detail of the fundus, he nevertheless attributes the predominating influence to the pigment-layer, and even goes so far as to say that in those cases in which in certain places there is a uniform hue, while in others the details of the fundus are clearly seen, there is in these latter portions a local lack of pigment in the epithelial layer.

Besides there being a finer and closer network of vessels at that part of the choroid which corresponds to the macula lutea, there is

also an increased amount of pigment both in the epithelial layer and in the stroma of the choroid, which, as a rule, gives a deeper and richer tone to this region than to the rest of the fundus; and I have also, on one or two occasions, with the inverted image, seen the fovea appear as a minute dot in the very centre of this region, much as the bull's-eye does on a target. This region is also the seat of various reflexes, which will be dwelt upon later.

As seen with the ophthalmoscope, the red background of the eye closely encircles the stem of the optic nerve. This is due to the fact that the choroid passes beyond what is usually called the scleral opening, as will be seen in the drawing, into the constriction, which takes place in the optic nerve, in the neighborhood of the lamina cribrosa, *ch* (see Fig. 25, also Fig. 5). The scleral opening, therefore, even if it existed, could not be seen with the mirror, though the name still holds its place in the litera-

ture. Strictly speaking, also, the choroidal foramen is not a foramen, as fibres are sent out from the choroid into the optic nerve and the lamina cribrosa. So far as the ophthalmoscope is concerned, it may be looked upon, however, as an opening, through

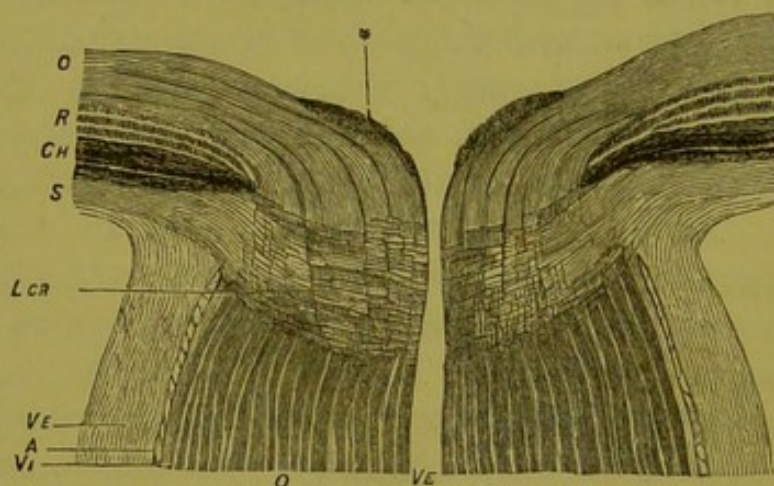


FIG. 25.—G. and S., vol. i., p. 18.

which the optic nerve protrudes, or, better still, as an opening in a membrane by which the head of the nerve is encircled, the margin of which is formed from concentric fibres from the choroid. This opening determines the area of the optic nerve seen with the instrument, and its transverse diameter is on the average 1.4 mm.

The margin of the opening from the concentric way in which the fibres forming it run, and from the fact that the vascular layer of the choroid is carried up to its edge, is usually clear and well defined, sometimes so sharply cut as to really resemble the drawings made from it, so that in some cases the head of the nerve appears to be surrounded by a very fine dark line. The border may, however, be more or less irregular, and may at times show a variation in color from the rest of the fundus, especially at the outer side, where not infrequently there is a crescentic figure of a deeper shade than the surrounding tissue. This is due to an increased amount of pigment

mixed with the general red of the part, and this pigment may be so increased in quantity as to form small fragmentary patches here and there around the edges of the disk, which gives to the bordering tissue a more or less frayed appearance; or the pigment may be gathered together into a crescentic figure like the young moon. This usually surrounds the outer edge of the nerve, or may be separated from it by a narrow strip of the ordinary red color of the fundus. It may, however, lie at the inner side of the nerve, or, in very rare cases, above or below it; or, in rarer cases still, there may be two crescentic figures, one at the outer and the other at the inner side of the nerve, or, indeed, a narrow circle of pigment may extend round the entire circumference of the disk. On the other hand, instead of a deeper coloring at the outer side of the nerve with an increased pigmentation, the fundus at this place may show a paler hue and a lesser pigmentation than the surrounding parts. Aggregations of pigment sometimes occur in other parts of the fundus in normal eyes and are usually congenital defects, and are sometimes of a bizarre appearance, and then deserve, from their rarity, the name of anomalies of pigmentation, and as such will be alluded to later.

As the background varies in color and tone, so too it may vary to a considerable degree in what may be called its texture. Thus it has usually a more or less stippled appearance, no matter how uniform its coloring may be. This granular or shagreen effect is thought by most authors to be produced entirely by an increased amount in quantity and intensity of the pigment in the epithelial *layer*, and Liebreich goes so far as to say that in certain conditions the individual cells of the layer can be detected with the ophthalmoscope. This is probably, however, not the case, as the enlargement with the ophthalmoscope is too small to permit of seeing so minute an object upon such a confusing background and surroundings. But the appearance claimed for a single cell may be, and probably is, sometimes due to an aggregation of cells. My own opinion is, that it is also due in part to the varying degrees of pigment in the stroma of the choroid, and to the fact that light is alternately reflected and interrupted from surfaces which lie in different planes. Sometimes the surface appears smooth and hard like a cloth with no nap to it, and then again like one that has a plush or "velvety feel." This latter condition when well marked is, I believe, more often pathological than physiological, and a sign of congestion and slight oedema in the choroid.

It should not be forgotten that the general color and tone of the fundus change somewhat with the quality of the light employed in the illumination. The whiter the light the less vivid the red, until

with ordinary daylight it becomes a delicate rose-pink. Moreover, the stronger the illumination the more pronounced is the red hue, and the inexperienced observer will often be surprised to find that a fundus which, seen under the strong illumination and small enlargement of the inverted image, appears to be of a vivid red, is, under the reduced illumination and increased enlargement of the upright, a pale, yellowish ochre.

The variations in appearance of the background of the eye are as unlimited as the number of persons examined, for no two are alike; still, with all this infinite variety of shade of color and of detail, there is nevertheless a certain appearance and tone to a normal fundus which enable the observer after the requisite practice to distinguish at once a healthy fundus from one that is either congenitally or pathologically abnormal.

To give an adequate description of all the diversities of shade or design would be almost as useless as it would be impossible. The student may, however, profit by taking a glance at the chromo-lithographic plates at the end of the volume, representing the background of various normal eyes, and showing different degrees of pigmentation and vascularity (Plates I and II).

The second, and without doubt the most prominent, feature in the fundus, and one toward which the experienced as well as the inexperienced observer turns as a basis for further observations, is the white circle or disk which may be said to mark the centre of the ophthalmoscopic field. This is known in the books under different names, from the various characteristics which it possesses. Thus, from its shape it is most frequently spoken of as the "disk"; while, from the fact that, anatomically speaking, it sometimes rises above the level of the retina, it is called the "papilla"; or, again, as it marks the place where the optic nerve passes through the sclera, it is often designated as the "optic-nerve entrance."

The disk, though always circular in form, is seldom a perfect circle, though this, so far as the eye can detect, is sometimes the case. It is usually, however, more or less oval in shape, and, when such is the case, the long diameter is usually vertical. The reverse, however, may occur, and the largest diameter run in an oblique direction. Here, as elsewhere in the body, variations may occur which are very marked, and the preponderance of one diameter over the other in the proportion of nine to seven and a half, or even seven, can be considered of common occurrence and strictly within physiological limits. A greater discrepancy than this must, however, be considered as excessive, and in this sense abnormal. I have, occasionally, seen

the oval carried so far as to be fairly considered a distortion, in eyes, too, which certainly had no appearance of disease, and in which there was no optical error. Fig. 26 represents such an eye, the diameters

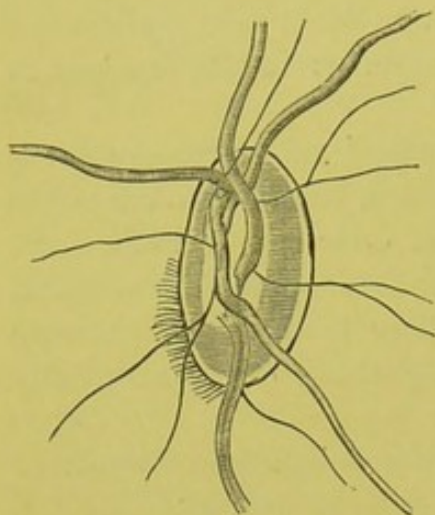


FIG. 26.

being as 25 is to 13, or nearly two to one. These exaggerations in shape, as well as the marked obliquity of the long diameter, are often accompanied with a reduction of vision, which would lead to the belief that they were really the expression of congenital malformations or arrests of development.

This diversity in shape of the optic nerve, and the various inclinations of its long diameter which are due to anatomical construction, must not be confounded with the same appearances sometimes produced by astigmatism, and which disappear as soon as the optical error

is corrected by the methods to be pointed out in the chapter on refraction.

The diameter of the optic nerve itself at the level of the choroidal foramen varies considerably, ranging in the normal eye from 1.2 to 1.6 mm. If we now take the enlargement under which the fundus of an emmetropic eye is seen with the ophthalmoscope as $14\frac{1}{3}$ times, and take also the smallest measurement given above as the diameter of the disk, this latter is seen as if equal in round numbers to 17 mm.; while, if the largest measurement is taken, the diameter of the disk would reach nearly 23 mm., or one third larger. If, now, instead of taking the extremes, we take the general average of the diameter of the nerve as 1.4 mm., which agrees with the average dimensions of the choroidal foramen, the diameter of the disk would be, under the same enlargement, 20 mm., and Liebreich has drawn in his Atlas (Tab. II, Fig. 1) the disk of a normal eye with such dimensions. There can be but little question that to the ordinary observer the diameter of this disk appears altogether too large. But it must be borne in mind that the apparent size of an object and its actual size are very different things. In looking at the fundus of a normal eye there is no object to compare it with; and as the observer, though his own eye is accommodated for an infinite distance, knows that the object viewed is not only not at an infinite distance, but is actually at a few inches from his own eye, objects of the fundus appear smaller than they really are. To imitate on paper, therefore, the size of the disk as it

really appears to the ordinary observer, the diameter of the disk would have to be reduced to 16 or even 15 mm. It is for this reason that the beautiful and thoroughly artistic drawings of Liebreich, representing the fundus of various normal eyes,* appear to be so untrue to nature in respect to size.

The five drawings given by Liebreich and taken collectively as they stand, and independent of the scales upon which they are drawn, represent very well the great discrepancy which may exist in the size of the disk in the normal eye. As has already been stated, the size of the choroidal foramen would also affect the size of the disk in different cases even where the diameter of the nerve itself is the same, since the larger the foramen and the less closely it invests the head of the nerve, the greater the extent of surface of the nerve or its sheath exposed to view (Plate II., Fig. 3). This is often made manifest by the ophthalmoscope when the edge of the choroidal opening seems to be drawn to one side. When this apparent traction is present, it is usually at the outer side of the nerve, though other portions of the circumference may at times appear to have suffered from the same want of close adjustment of the choroidal opening or foramen to the constricted portion of the head of the nerve.

Thus we see from anatomical reasons alone, and quite independent of those of an optical nature, that the size of the normal disk may pass through wide fluctuations; and, what is true of the disk is true also of its component parts—as, for example, the vessels—so that it may happen that the disk shall be so much larger than common that the vessels, although of normal size, shall, in comparison, seem abnormally small; and, *vice versa*, the disk may, from anatomical construction, be so small that the vessels may seem abnormally large. Experience and practice, however, soon enable the observer to make allowances for even the larger deviations from the standard, and to tell at a glance what is normal, though peculiar, from what is either congenitally or pathologically abnormal.

The surface of the disk appears to lie in the same plane with the background formed by the choroid. This is due to the fact that all that part of the head of the nerve which lies anteriorly to the plane of the choroid is so transparent as not to be visible in its normal condition except under the closest inspection. This transparent condition of the head of the nerve is due principally to the fact that the optic nerve-fibres, after entering the lamina cribrosa, lose their medullary sheath (page 24). What really produces the white surface of the disk is the combined mass of nerve-fibres, with their sheaths, the transverse

* "Atlas d'Ophthalmoscopie," Tab. II.

interlacing fibres of the lamina cribrosa, and those from the choroid, which, taken together, reflect a large quantity of white light. Practically, we look through a thin portion of the head of the nerve, which is transparent, down upon a slightly more posterior portion which is opaque, and which reflects a large amount of white light. What we see is really the anterior surface of the lamina cribrosa, together with the abrupt endings of the medullary sheaths of the nerve-fibres (Fig. 25, *ler*).

It follows from this that even if the head of the nerve were a real papilla, and did project above the surface of the retina, this projection would, in the great majority of cases, be overlooked, as the attention of the observer is directed to a plane slightly posterior to the internal surface of the nerve, just as we sink the consciousness of the glass in looking at the picture behind it. That the papilla should reveal itself in the normal eye in microscopic sections so much more frequently than with the mirror is, therefore, natural. Still, by very accurately focusing the vessels, one can often convince one's self, even where it is not at first apparent, that the head of the nerve does rise above the level of the retina, and thus become a true papilla, especially toward the nasal side.

To the inattentive observer the disk presents merely a circular surface of a white or pinkish color, from the centre of which a system of vessels emerge to ramify over the surface of the retina. Closer inspection, however, shows that even the surface of the disk is by no means so uniform in structure or appearance as it seems at the first glance, but that its surface is variegated by certain dispositions of light and shade, and by certain accentuations of color which arrange themselves in more or less pronounced and constantly occurring features. A true appreciation of these is absolutely indispensable to a proper knowledge of physiological as well as pathological conditions.

Discarding, for the moment, the effect of the vessels, and admitting that the fundamental color is of a creamy white, even then we very rarely, if ever, have a uniform appearance of the disk, either in color or texture. On the contrary, the surface is usually more or less variegated; sometimes markedly so, according to the different proportions and arrangements of this part of the nerve. If the medullary sheath is discontinued upon all the nerve-fibres in a uniform manner just at the lamina cribrosa, then the surface of the disk will appear to be flat, and lie in one and the same plane, and be more uniform in character. When, however, the sheaths are discontinued in an irregular manner—some before they reach the lamina, and others after they have passed it—then the surface has a more or less mottled

appearance, which is expressed by alternate patches or spots of gray on a white ground. Contrary to what would be supposed, these grayish flecks or spots, according to some authorities, are not due to a more opaque tissue, which reflects a grayish color, but to the fact that the sheath is discontinued earlier upon the fibres which correspond to these spots, and that, as a consequence, the transparent fibres allow the light to penetrate their substance without being reflected back to the observer in an equal degree. These places, therefore, appear of a darker shade than the surrounding nerve-substance, the fibres of which, as they still possess their sheaths, strongly reflect the light. This effect can be carried so far as to give a reticulated or honeycombed appearance, especially where there is an excavation of any kind, physiological or pathological, in the head of the nerve. This appearance is very well shown in Fig. 27, which is a normal eye, from Liebreich (Atlas, Tab. I, Fig. 5). That the above explanation is true in some cases is probably correct; still, there is a very similar condition which is really due to some peculiarity in the nerve-fibre itself, or to some slight pigmentary deposit, which reflects a grayish kind of light, that is, at times, exceedingly difficult if not impossible to tell with the instrument alone from that which comes from gray atrophy of the tissue.

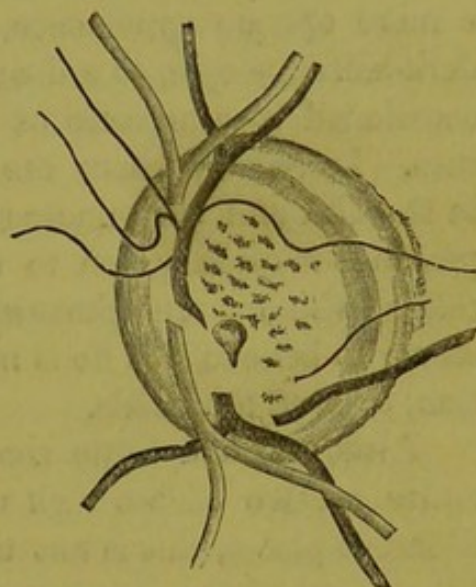


FIG. 27.

Admitting that the fundamental color of the disk is white, it remains to be considered how this is affected by the vascularity of this portion of the nerve which, as has already been shown in the chapter on anatomy, page 27 *et al.*, draws its blood-supply from so many and such different sources. It is this vascularity of course which imparts to the nerve the reddish tinge which it always possesses to a greater or less degree in a state of health. First, as to the shade of color. This may differ from a delicate pink to a pure reddish hue, which depends a great deal, not only on the richness of the smaller vessels and capillaries, but also on the comparative amounts of connective-tissue elements and opaque fibres which form the background of the disk. Where there is little of this kind of tissue the disk has a more translucent appearance, and we get the consciousness, at least a careful observer does, besides the effect of the small, isolated vessels that lie superficially, also that of a deeper-lying set of vessels which, though too small and

too close together to be seen as individual vessels, yet which nevertheless give a perceptible indication of their presence by a more or less general pink or reddish hue.

This appearance is sometimes increased in inflammations of the choroid, so that we become convinced of a deeper-lying congestion than what comes from the anterior surface of the disk, just as we become conscious in some forms of episcleritis of an injection of the underlying sub-conjunctival and scleral tissues. Where, on the other hand, the connective-tissue elements are more abundant, the disk has a more opaque appearance, and the color approaches, especially in dark-haired people, to a deep red with even a maroon tinge, probably occasioned by a mixture of very minute pigment-cells among the tissues. Moreover, where the connective-tissue elements are abundant in the disk and surrounding parts of the retina, a certain striated appearance is often given to the nerve and the adjacent parts of the retina, which is sometimes so marked as to lead the inexperienced observer to believe that he is in the presence of a high degree of congestion, or even a neuritis.

Although a delicate shade of pink or red may extend over the entire surface of the disk with but slight variations in intensity in different places, this is not the usual presentation. On the contrary, the surface of the disk is, as a rule, variegated by different degrees of color depending upon the different degrees of vascularity of the various parts. Thus the reddish tinge is more marked and more homogeneous toward the nasal side of the disk than the temporal because the vessels and capillaries are thicker in this region. Nor does the color as a rule extend to the centre of the disk on the one hand, nor to the extreme circumference on the other. From this disposition of color it generally results that the centre of the optic nerve, or that part which corresponds to the connective-tissue string, Figs. 5, 8, and 9, is to a large degree free from color, and is sometimes spoken of as the clear spot. (See also chromo-lithographic Plate II, Fig. 2.) Just outside of this clear spot comes a band or zone of vascularity of greater or less breadth which encircles the connective-tissue string and *porus opticus*. This may be looked upon as the vascular portion of the disk. Sometimes, instead of being a complete zone or circle of injection, it is narrower at the top and bottom of the disk so as to form two crescents, one on the nasal and one on the temporal side of the nerve, of which the inner one, as before mentioned, is usually the most prominent, both as to extent and shade of color. Outside of this injected portion of the nerve comes a white narrow circle, which is sometimes so free from vascularity and of so white a color that it

seems to bind the circumference of the disk as a tire binds the wheel. Usually, however, this ring is not of a uniform diameter in all its extent, but narrows itself at the upper and lower portions of the disk so as to form an inner and outer crescent, which then appear to embrace the head of the nerve. Sometimes only one crescent is present, and then it is usually the outer one.

This narrow white circle has received the name of the scleral ring, from the belief that it marked the edge of the "scleral opening." This would appear to be erroneous, as there is no such thing as the scleral opening, the outer sheath of the nerve being so merged with the sclera as to form a continuous membrane. A better name for it is that given to it by Jaeger, of the "connective-tissue ring," since it is formed from the connective-tissue elements of the inner sheath of the nerve as it is continued upward into the innermost layers of the sclera and into the choroid itself (Fig. 5). The scleral ring, properly speaking, is indeed another and entirely different ring, and is only seen in abnormal and pathological conditions. This is a broader white ring which encircles the optic nerve and owes its existence to the fact that the portions of choroidal tissue which surrounds the head of the optic nerve have become atrophic and been absorbed. This effect is seen at its height in certain cases of glaucoma. It is then seen that it is entirely outside of the circumference of the nerve, while the connective-tissue ring appears to form the outer boundary of the nerve itself. The appearance of the connective-tissue ring is due to the fact that we look through the transparent fibres of the head of the nerve, which is spread out more or less like a mushroom, to the connective-tissue elements of the inner sheath and those of the lamina cribrosa which lie below (see "Anatomy," page 24).

The connective-tissue ring varies, therefore, not only in size but also in shape and color, according to the predominance of the connective-tissue elements in the sheath and in those portions of the head of the nerve bordering upon it. Sometimes in elderly people this tissue is so abundant in this part of the nerve, and reflects so much white or grayish-white light as to lead to the supposition that there is a local atrophy of the nerve. I have, moreover, occasionally seen the same appearance in youthful eyes which were otherwise normal, both as to the ophthalmoscope and amount of vision. When the ring is thus prominent in appearance, it is also probable that the medullary sheath has been continued along the fibres of the nerve-bundles which lie near the periphery of the disk, a little beyond the lamina cribrosa. This would also account for the optical effect of a cup-like excavation of the head of the nerve where there was no bending of the vessels.

We have then four concentric markings in and around the disk:

1. The innermost or non-vascular portion or "clear spot," Fig. 28, *a*.
2. The vascular portion, *vp*.
3. The connective-tissue ring, *ctr*.
4. The choroidal or pigment ring, *chr*. (See also chromo-lithographic Plate II, Fig. 2.)

It is essential to the student to note carefully these concentric markings, as they are important, as will be seen later, in making a differential diagnosis.

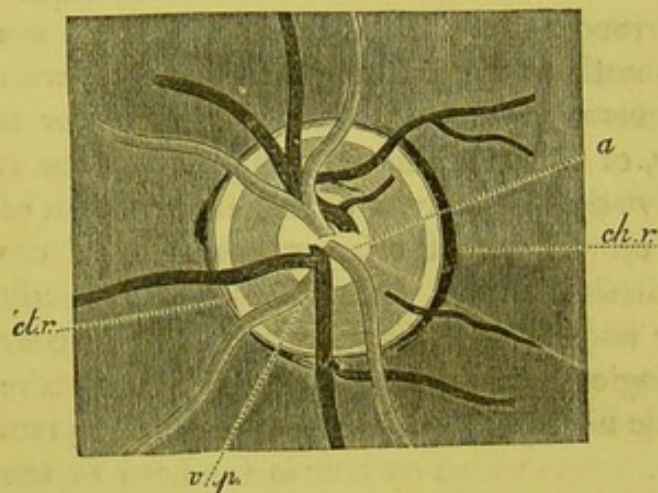


FIG. 28.—Diagrammatic representation of the surface of the disk, showing its concentric markings: *a*, non-vascular portion, or "clear-spot," formed by connective-tissue string; *vp*, vascular portion; *ctr*, connective-tissue ring; *chr*, choroidal ring.

In diseased conditions we have, as already observed, still another concentric marking known as the scleral ring. In some rare cases even in normal eyes, where the choroid seems to be drawn aside, portions of the sclera may be seen, which then, instead of forming a complete ring, give rise to a small white crescentic or semilunar figure. When this occurs only at the outer side of the nerve, it produces the ap-

pearance of a small conus. This appearance is due, at least most frequently, to a congenital defect, and not as in the ordinary cone to a distention of the coats of the eyeball and traction upon the choroid.

If there is this diversity in the general surface aspect of the disk, there is a like diversity in what may be looked upon as its elevation. If we look at a perpendicular section of the optic nerve, we see that the vessels which supply the retina run through a canal which pierces the centre of the anterior portion of the nerve (Fig. 5, p. 22). The expanded part of this canal at the head of the nerve is called the porus opticus, and varies to a great degree in different eyes, both as to width and depth. Sometimes the tissue of the head of the nerve embraces the retinal vessels so closely, up to the very angle which they make as they pass into the retina, that, so far as the ophthalmoscope is concerned, there does not appear to be any porus opticus. In this case the vessels seem to emerge from a close-fitting tissue. At other times there is a gentle separation of the mouth of the canal, which may be so increased as to offer a wide, funnel-shaped excavation like

that of a calla lily or convolvulus. Again, the excavation may be very shallow and extend itself with a gentle curve outward like an exceedingly shallow Grecian or Etruscan cup, so shallow indeed as to be barely recognizable, and it is this form which predominates and which is considered the typical physiological excavation of the optic nerve, in contradistinction to the abnormal excavations which are the results of disease.

The most prominent feature of a physiological excavation and the one that is looked upon by some authors as pathognomonic is, that it does not extend to the edges of the nerve, and that the vessels are not pressed backward so as to rest upon the floor of the depression. This rule, however true it may be in the majority of cases, especially where it includes the entire circuit of the nerve, has not a few exceptions, at least where the excavation is limited to certain portions of the circumference; for I have seen many cases, even in young children, where there was no sign or symptom of disease, in which the excavation, especially at the temporal side, passed clear up to the edge of the nerve, and in which at times the vessels followed pretty nearly the plane of the floor of the excavation. Sometimes the excavation, instead of spreading out from the axis of the nerve with sloping sides, has from the beginning a wide floor, forming almost a tubular or cylindric opening, the sides of which are so steep as to be almost at right angles with the surface of the disk, and giving much the appearance as if drilled out with a punch. Such an opening may occupy a considerable portion of the centre of the nerve, the abrupt rim of which is then usually pierced by the vessels, as is shown in the drawing (Fig. 29), which is a sketch from the normal eye of a child of ten years, with a vision in this eye of over $\frac{20}{20}$.

This sharp rim may extend round the entire excavation, but most frequently at some portion of its circumference, and then usually at the temporal side, it loses its abrupt brim and slopes gradually to the edge of the nerve as if it had been drawn away from its former position, and, when this is so, some parts of the lamina cribrosa come into view and reveal themselves by the darkish spots on a white ground which have already been alluded to, and which are shown in Fig. 27, p. 55.

Sometimes these excavations do not preserve a continuous plane or floor, but the ascent from the centre of the nerve toward its edge is

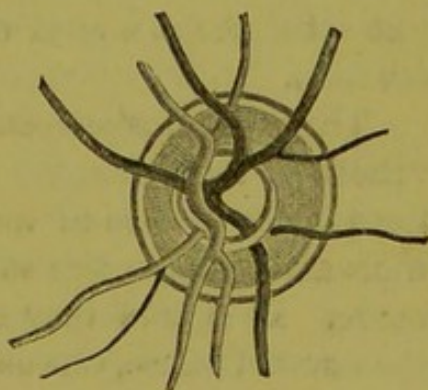


FIG. 29.

broken by a slight rise or step to a higher level, which may be either abrupt and steep or very sloping, as seen in the two sides of Fig. 30. It is this kind of an excavation which requires particular attention on the part of the observer in determining whether the floor of the excavation, which is on two different planes, is entirely congenital, or

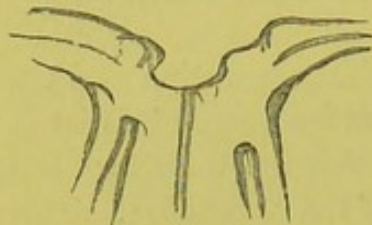

FIG. 30.

whether a pre-existing physiological excavation is not having a second and abnormal one of a lesser circumference grafted upon it.

It is claimed by some writers that some of these excavations, especially those in which the floor is broad and flat and the sides steep, are not real but only "apparent excavations," due to the fact that where

there appears to be an actual want of tissue there is none in reality; but that the tissue, though present, is so transparent as not to reveal itself under the illumination of the ophthalmoscope. If this is true, of course there is no means of determining with the instrument with positive certainty whether an absolute want of tissue exists or not, or whether in a given case an excavation is real or only apparent, due to the early discontinuance of the medullary sheaths of the nerve-fibres and absence of connective-tissue elements. Still the writer on rare occasions has been led to believe that he was dealing with one of these apparent excavations from the detection of a small bit of feathery tissue, which appeared to lie in a perfectly transparent medium and which was destitute of all motion; or, again, from the fact that here and there minute vessels could be detected as if suspended in a jelly-like substance at a level which was in advance of the floor of the excavation.

The great characteristic of these physiological and congenital excavations is that, although they may occupy different and various positions in the surface of the nerve, and although they may have steep walls and overhanging sides, they do not extend up to the edge of the nerve. It is true they may occasionally touch this at some part of the circumference, especially at the outer side toward the macula. But this is very different from the excavation made by the pressure of the contents of the globe, which, as a rule, depresses the entire surface of the disk below the original level, and produces a crater-like opening with shelving edges, that undermine the entire extent of the disk up to and even beyond the choroidal foramen.

There are some congenital excavations so great that they must certainly be looked upon as abnormal, and either the result of malformation or intra-uterine disease, and in this sense the word congeni-

tal must not be confounded, as it often is, with the term physiological. Such an excavation is shown in Fig. 31. It was taken from the eye of a lady in the prime of life, who came to me with the complaint that she was unable to use her eyes for any length of time without discomfort and pain. I am inclined to think that most observers would, at the first glance, think as I did, that this enormous excavation was of a glaucomatous character. A moment's inspection, however, led me to change my mind. In the first place the excavation, though occupying nearly the entire surface of the nerve, did not extend at any part of its circumference to the edge of the disk.

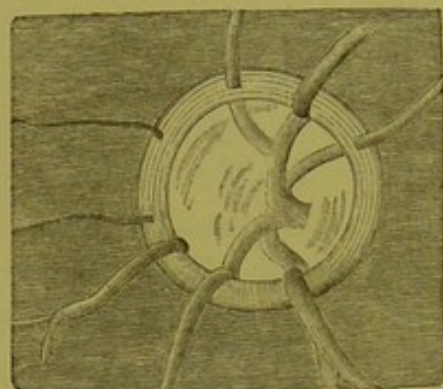


FIG. 31.

The sides of the excavation, though very steep, and all along the upper border beveled backward, nevertheless had a sharp edge—so sharp, indeed, and so transparent, that in certain positions a very fine but perfectly marked dark line came into view along the border, caused, I thought at the time, by total reflection as we sometimes see it in a dislocated lens. Had the excavation been due to pressure, the edges would have been rounded off, since the excavation does not reach the rim of the nerve, and the vessels, instead of piercing the border, as they did in various places, would have curled over the rounded brim, as they do in the lower portion of the disk. These facts were, in my mind, highly corroborative of the excavation, extensive as it was, being physiological and not pathological, or at least glaucomatous. Again, there was no pulsation in either veins or arteries. The opinion that the excavation was congenital was strongly corroborated by the fact that a similar one existed in the lady's other eye, and also by the fact that her little daughter, some six years old, had nearly the identical appearances in both eyes. Moreover, vision was more than $\frac{20}{20}$ in both mother and daughter, and the field normal. I have had this patient under observation now for over three years, and no change has taken place in the ophthalmoscopic picture nor in the vision. I have been particular to emphasize this case, as I have known more than once eyes to have an iridectomy performed upon them in which such excavations existed under the belief that the surgeon was dealing with a glaucomatous affection instead of a congenital anomaly. When such excavations occur in young persons, they are apt in later life to become really glaucomatous.

As it is with the excavations of the head of the nerve, so it is also with the elevations of its surface above the level of the retina.

These may vary from a slight local elevation, especially toward the nasal side, since the nerve-fibres are much more abundant here than at the temporal side, to a general mound-like swelling of the entire surface of the nerve. This, though usually of a very slight degree, and not to be detected with the mirror, may in rare cases be carried at the nasal side, or, indeed, at any part of the circumference, to a considerable if not an enormous extent, so as to resemble a precipitous rising when contrasted with the outer parts of the disk, which then have the appearance of having fallen away from their original position or sunk to a lower level. These variations in elevation, so far as relates to the ophthalmoscope, depend principally on whether the mass of nerve-fibres, as they pass into the retina, are distributed evenly, or whether they are congregated together in one place to a greater degree than in another; and again, also, whether the outer layers of the retina are carried in their ordinary thickness close up to the edge of the choroidal foramen, which makes a steep ascent for the fibres, or whether these outer layers of the retina begin to decline in thickness as is usually the case at a little distance from the head of the nerve; and, finally, upon the fact whether the tissue of the head of the nerve is to a greater or less degree transparent. All these variations produce countless differences in effect, which it would be futile to try to

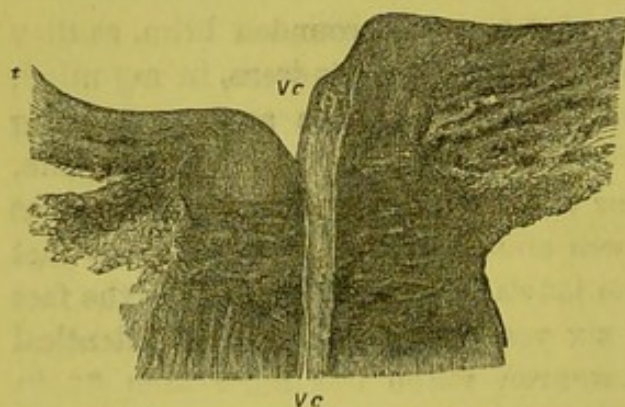


FIG. 32.—*t*, temporal side; *m*, nasal side; *vc*, vena centralis. (Schweigger, "Handbuch," p. 389.)

describe, but which the learner must endeavor to recognize and appreciate by practice and experience in order to discriminate correctly between what is normal and what is pathological. This is not so difficult as it seems, for, if the observer has once seen any such pronounced difference in the two sides of the nerve as that rep-

resented in Fig. 32, from Schweigger, he is at once prepared to recognize and accept the lesser variations as a matter of course, especially if they are accompanied by the normal amount of vision, or even if this should be slightly decreased.

THE RETINA.

So far as the ophthalmoscope is concerned, and speaking in general terms, the retina may be looked upon as a transparent membrane, in

the inner layers of which the vessels are seen to ramify—a membrane which reveals nothing of its intricate structure, and only a trace of its existence, and this, too, only in certain portions. In the immediate neighborhood of the disk some observers claim that by using the weak-light mirror the retina gives indications of its presence by a very faint grayish tinge, which appears to lie above the choroid. This appearance is the more marked the deeper the pigmentation of the eye, until, in the negro, the retina betrays its existence by a light, opalescent sheen.

From the translucent nature of the retina we are unable to form directly an estimation of its thickness. Anatomy teaches us, as we have seen (page 31), that the retina is a membrane of considerable thickness at the nerve, and which gradually becomes thinner toward the anterior part of the eye. To the observer with the ophthalmoscope, especially if he be inexperienced, the retinal vessels appear to ramify over the surface of the background, of which they seem to form a part. It is only by a mental effort that the observer can picture to himself that there is an appreciable if not a considerable distance, at least in the posterior parts of the eye and near the nerve, between the larger vessels and the underlying choroid. The effort to realize this fact and to appreciate the amount of the antero-posterior thickness of the retina is helped, besides the anatomical knowledge, by the observation of the vessels under certain morbid conditions—as when, for example, an exudation lies immediately behind the vessel in the most external layers of the retina, or in the choroid, or, more conspicuously still, when the vessel passes over a spot of atrophy of the choroid. Under such conditions the observer, mindful of the anatomical relations, and looking attentively at the vessel, is made aware, especially if he moves his head slightly from side to side, that the retinal vessel lies in a plane considerably anterior to that of the exudation or atrophic spot. The effect, when one's attention is called to it, is quite startling at times. Should the observer, however, not succeed in his attempt to get this appearance with the upright image, he may be helped in his efforts by the use of the inverted, by getting in the manner already pointed out the parallax displacement of the vessel over the surface of the plaque (page 13). If he employs this, he will see that the vessel lying over the plaque appears to move a little over the surface as he moves his lens from side to side, so that more of the surface of the spot is seen to lie on one side of the vessel and less on the other than before the movement of the lens took place.

When this effect has been once fixed upon the mind by the aid of

a different and well-defined background which reflects a large quantity of light, the student soon gets to carry the impression in his mind even in the normal eye where no such background exists, and it is often of the greatest service to him in making a differential diagnosis as to the exact seat of a morbid process, as, for example, a hæmorrhage or exudation.

Although this perfect or nearly perfect transparency may be looked upon as the normal or typical condition of the retina, yet there are cases, especially in young and growing children, where the connective-tissue elements are so abundant that they produce in the neighborhood of the disk a lack of perfect transparency in the retina, which then shows itself when taken as a whole in the form of minute striæ, that radiate as a usual thing from some part or the whole of the disk as a centre.

In rare cases, and especially where there is reason to believe that the highest and most perfect development of the eye has not taken place, as, for example, in some hypermetropic eyes, this appearance is so marked, and the reflection from the connective-tissue elements so brilliant, as to show a silvery or metallic lustre which then seems to stream out from the papilla in fine radiating lines. Sometimes when these connective-tissue elements are very abundant and fine feathery striæ accompany the minuter vessels, which also happen to be more abundant than usual in the neighborhood of the disk, this striated appearance may be carried so far as to obscure the outlines of the disk, and thus lead an inexperienced observer to believe that instead of a normal condition there is an abnormal congestion of the part, if not an actual inflammatory process present, in the shape of a mild and commencing neuro-retinitis. This appearance, from the anatomical nature of the part, is most marked toward the nasal side of the disk, where the nerve-fibres are more abundant and the blood-supply more copious, and least of all directly at the temporal side toward the macula, where the nerve-layer is thinner and the vessels less numerous.

These are the only circumstances under which the tissue of the retina itself is visible as a membrane with the ophthalmoscope in a normal eye. It must be remembered that the details of certain portions of the fundus are seen with more distinctness than others, as, for example, the periphery of the field, while others appear with a greater accentuation of color, as, for example, the region of the macula lutea. But, as has already been explained, these differences and contrasts are due to the composition of the pigment-layer and choroid, not at all to the retina. The yellow color of the region of the yellow spot seen on the cadaver is not visible in life with the

ophthalmoscope, and is probably a post-mortem change. Neither is the visual purple of the retina to be detected with the instrument in the ordinary methods of examination, though some claim to have seen it when certain special conditions and methods are observed. The only portion of the tissue of the retina which seems to have a distinct and visible appearance is the minute spot which in some cases marks the seat of the fovea itself, and which is situated in the centre of the region of the yellow spot. This will be described more in detail a little later when the various reflexes which are found at this region are considered.

The great transparency of the retina and the inability to see the membrane while in a normal state are more than compensated for by the fact that from its very translucent nature we are enabled to trace an independent circulation for almost its entire extent from the time it enters to the time it leaves the eye, and we are thus permitted to detect and watch minute processes, both physiological and pathological, which would certainly escape observation were the membrane non-transparent.

From this fact alone the vessels of the retina are as clearly seen and as readily followed as if pictured in a drawing, while they possess a beauty of design and form and a brilliancy of color which no artistic imitation, however well executed, can ever approach.

The vessels of the retina are subdivisions of the arteria and vena centralis. The first division of both the artery and vein takes place as a rule in the stem of the nerve before the vessels have reached the papilla or transparent portion of the nerve. The effect of this is to give the appearance, as the vessels issue into the retina, of a superior and inferior artery and a superior and inferior vein (Fig. 33, s. v., s. A., IN. V., IN. A.). Sometimes, however, the first division takes place upon the surface of the papilla, and then the two branches, upper and lower, make a very sudden right angle with the parent stem, which in such a case is very seldom seen, as it is covered by the branches in question. The four principal branches—that is, the upper and lower artery and vein—issue and find their exit through the porus opticus and in the centre of the nerve. The central canal is sometimes, however, displaced from some faulty development, so that the vessels, instead of occupying the centre of the disk, have an excentric position usually toward the temporal side, more rarely toward the nasal side, and more rarely still above or below the centre of the disk. I have as a rarity seen the principal vein, or more frequently one of its branches, find its exit at the very margin of the disk at or very near the sheath of the nerve. When these physiologi-

cal variations become exaggerated, they are usually congenital anomalies, and will be further described a little later under that heading.

As has already been mentioned, the "connective-tissue string" which accompanies and surrounds the vessels in the central canal has

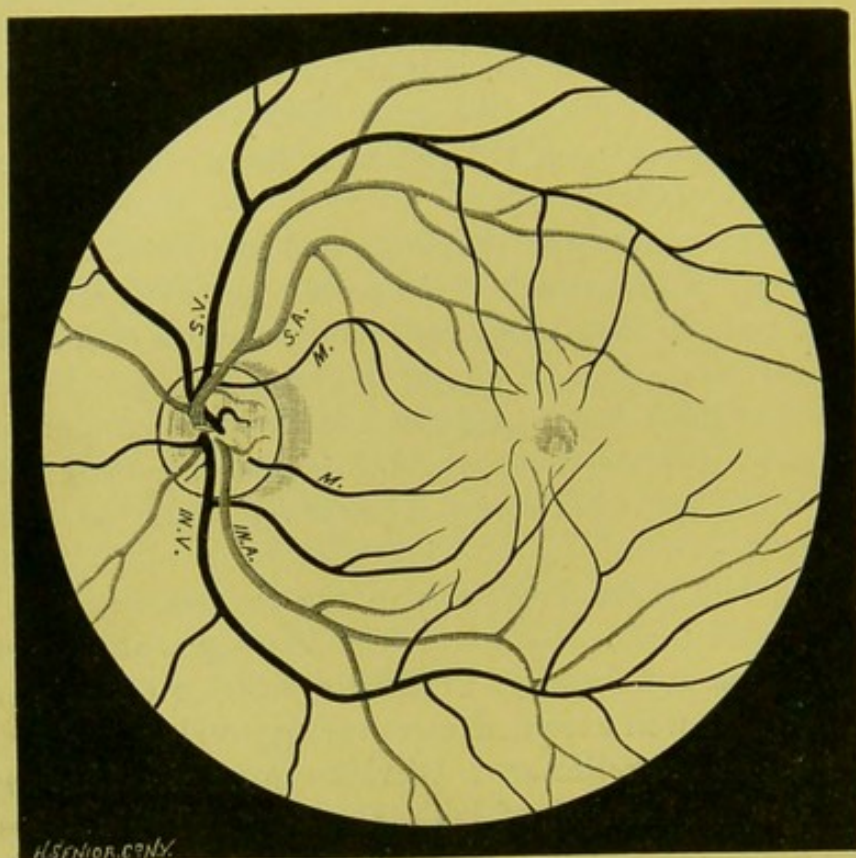


FIG. 33.—s. v., superior vein ; s. a., superior artery ; in. v., inferior vein ; in. a., inferior artery ; mm, macula branches.

an influence upon the appearance of the vessels as they issue into sight from the head of the nerve. If this string or fascia is well developed and carried well forward along the vessels up to the head of the disk, then the porus opticus is either in part or entirely obliterated, and the vessels appear to issue from a solid substance, and not from any excavation or canal.

The superior and inferior artery and vein divide again, as a rule, upon the surface of the disk, though the second branch of each may not be given off until the vessels have passed into the substance of the retina. Here the vessels undergo a further subdivision and send out branches in an arborescent manner in different directions, as will be seen from the drawing (Fig. 33). These branches are designated, according to the region which they supply, as the superior and inferior nasal and temporal branches. The fine vessels which leave the temporal side of the disk, *m m*, are sometimes called the macula branches.

The temporal branches, or those which pass toward the right in the drawing, will be seen to be larger than the nasal. When the field of view is extensive, and yet the enlargement is small, as happens with the inverted image, these temporal vessels, the inferior as well as superior, appear to arch round the region of the macula, leaving, however, its immediate neighborhood free from vessels. It is from this fact that it has been so often asserted that the yellow spot is devoid of vessels, and in accordance with which this region has been represented as free from vessels in almost all even of the best drawings of the fundus. When viewed with the upright image, however, where the enlargement is greater, the appearances are entirely different, and, as is shown in Fig. 13, p. 33, which is by the upright image, the region of the macula lutea, or the space inclosed by the dotted line, contains a number of fine vascular twigs, which, coming from above and below, extend toward the spot in the centre of the oval which marks the position of the fovea. So far, then, from its being true that the region of the yellow spot is devoid of vessels, it is the one portion of the retina which contains, as seen by the ophthalmoscope and demonstrated by the microscope, the greatest number of minute vessels and capillaries (p. 35).

The larger vessels occasionally cross each other and the smaller ones do very frequently—that is to say, the arteries cross the veins and the veins the arteries; but it must be very rare if it ever occurs that the veins cross other veins and the arteries other arteries, though it has been alleged that this sometimes happens with the veins. Neither do the vessels anastomose with each other, or at least those do not which can be seen under the enlargement of the ophthalmoscope in the normal condition. In abnormal conditions they can occasionally be seen to do this.

This is, then, in brief, the general plan or arrangement of the vessels; but the variations which take place inside the limits of such a general plan are almost infinite in number, and it would be as impossible to give a detailed description of the variations in arrangement which might take place in two different normal eyes as it would be to describe the variations in two different vines which have the same general characteristics and the same general directions, but which possess an infinite number of individual differences, and this, too, when at the first glance they appeared to be almost identical.

Among these variations there is, however, one which deserves particular attention, and one which the student should be early acquainted with. This is the degree of tortuosity that the vessels in a normal eye often possess, and which may be so great as to lead an inexperienced

observer into error, and cause him to attribute to disease what is strictly within physiological limits. A glance at the drawing (Fig. 34), and a comparison of the appearance of the vessels figured there with those

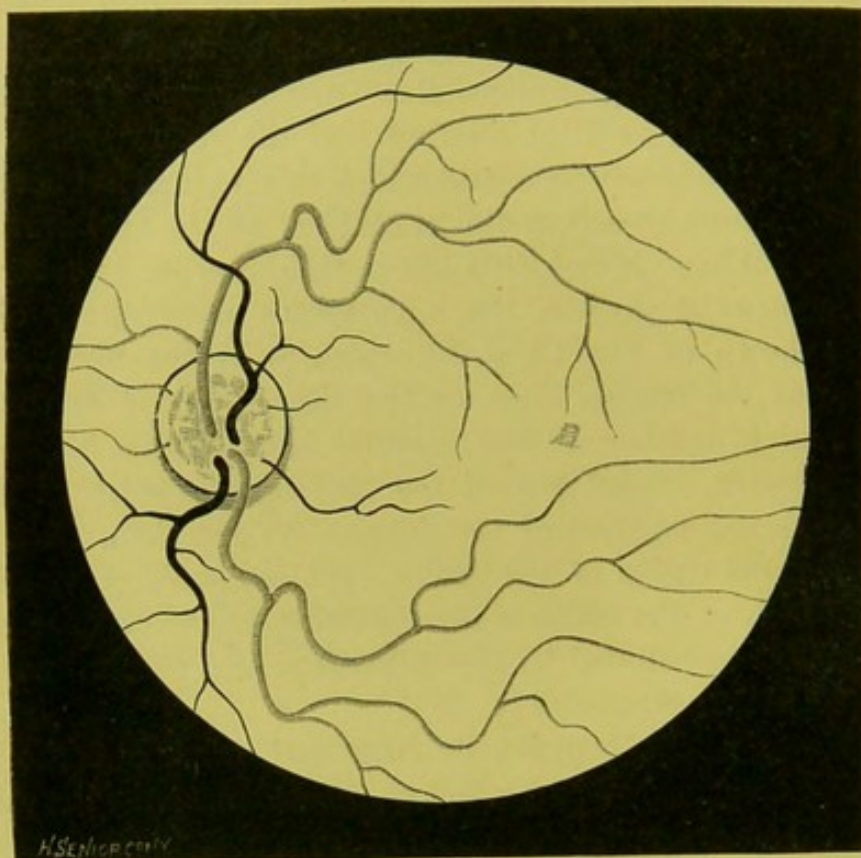


FIG. 34.

in Fig. 33, will show how great a difference may exist compatible in each case with a perfect state of health and full amount of vision. Sometimes the vessels are entwined about each other like the twist-

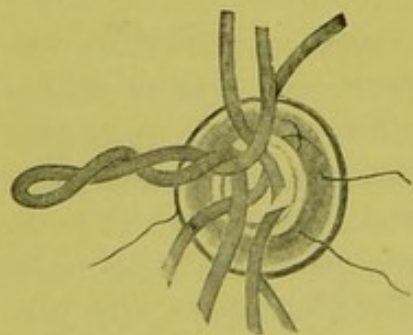


FIG. 35.

ing of two vines, especially in the neighborhood of the disk, and when this takes place it is usually, but not always, the artery which maintains its natural course and the vein which encircles it, or one vessel may double upon itself like the twist in a rope. This, too, happens near the disk, the vessel returning upon itself and then continuing on its course (Fig. 35).

IN determining whether the tortuosity is a physiological or pathological condition, it is important to note the following facts: In the normal eye the tortuosity almost invariably occurs in both eyes, and is of a similar character in each organ, and the vessels, both veins and

arteries, assume more or less the same kind of deflection. The tortuosity, moreover, when physiological, is always a lateral one—that is to say, in the same plane as the inner layers of the retina, and does not take on, as it does in inflammatory conditions, an antero-posterior bend in any portion of the field.

The largest diameter of the vessel is usually at the porus opticus. This, however, is not always the case, even in the normal eye. Not infrequently one or both of the principal branches of the vein taper toward the central canal, and are thus smaller at their point of exit than at the circumference of the disk, or even in the neighboring portion of the retina. Where this is carried to excess it gives a leech-like appearance to the vessels, which is a common symptom in some diseases, especially those which indicate a lack of blood-pressure from behind or an increased intra-ocular pressure, which is greater than the lateral pressure in the veins. This appearance, which may also occasionally occur in the arteries, is often more apparent than real, and is then produced by the manner in which the connective tissue is wrapped around the vessels in the porus opticus, or the foreshortening which may take place from the oblique direction in which the vessel enters or leaves the central canal.

A remarkable characteristic in the retinal vessels, and one which it is important to notice and to fully appreciate, is the great variation which may take place in different individuals in the diameter of the vessel. This may vary a quarter, a third, or even one half, so that on this account it may be very difficult to determine in a given case whether the increase or decrease in size is physiological or pathological.

Though there is this difference in the size of the vessels in different cases, the veins are usually larger than the arteries in the proportion as four is to three, and continue so in their successive divisions, so that the venous system, as a whole, predominates over the arterial, which is lighter, as a rule, and more superficial, and at the same time less tortuous. Still, there are many exceptions to this rule, and the arteries often approach and sometimes equal the veins in size, and indeed they may be more tortuous than the veins.

The circulation of the retina does not seem to bear any fixed proportion or relationship to that of the body in general, and a finely developed physique is often seen with a small or even insignificant retinal system, and the reverse, a poorly developed general system and a well-developed and copious retinal circulation.

But, what is more important, Jaeger declares that the circulation of the eye bears a direct relationship to that of the brain.

The walls of the retinal vessels, in what may be considered the most perfect state of development, are so transparent and possess an index of refraction so nearly that of the surrounding media as not to be visible with the ophthalmoscope, as can readily be proved by pressing upon the globe with the finger to such a degree that the arterial blood is prevented from entering the eye. The arteries, even those of a considerable size, are then seen to be obliterated under the pressure, and show no trace of their existence. Still, that the index of refraction of the wall, though nearly the same, is not identical with that of the surrounding retinal tissue, but is to a slight degree higher, is shown by the fact that by careful observation, even in the most perfectly developed eyes, a very narrow streak of increased illumination is seen along and close to the side of the vessel, as if a very narrow portion of the fundus lying in immediate contact with the vessel, or rather just to one side of it, was subject to a more condensed light than what falls upon the parts just outside of it. The walls, then, must reflect some light, but too little to make themselves visible. This being the rule, there are exceptional cases where the wall, or at least the adventitia surrounding it, is opaque enough to be visible, which then gives evidence of its presence by very narrow streaks of a very pale yellow or whitish color running along the sides of the red-blood column. This commonly happens only upon the surface of the disk itself, and very rarely extends, except in those anomalous cases to be mentioned later, to any length into the retina, though I have occasionally become conscious of the wall of the vessel, even at some distance from the margin of the disk, and oftentimes when I least expected it, by a fortunate turn of the mirror and a favorable play of light.

These narrow, band-like striæ must not be confounded with similar striæ of a fine feathery character which often run along the sides or over the surface of the vessels, or cross from one vessel to the other in long and sweeping arches, which under the play of light give a beautiful silvery or frosted appearance to the vessel itself, or even to large tracts of the neighboring tissue.

It will be remembered, from the anatomical description given elsewhere (p. 36, Fig. 18), that there are two parts to the current of blood—a central or red column, and an external or colorless portion known as the plasmic current, which surrounds it and lies between the red-blood column and the wall itself. According to Jaeger, this colorless portion, including the wall, amounts to one half of the diameter of the entire vessel—that is to say, there is one fourth of the diameter of

the vessel on each side of the red-blood column. Strictly speaking, then, what one sees with the mirror is not the entire diameter of the vessel, but only that portion of it which is represented by the red-blood column.

By means of the ophthalmoscope we are enabled to distinguish, while the current is still going on in the vessel, the difference in color between arterial and venous blood. In the normal eye this discrepancy always exists, though it may vary to a certain degree, the venous blood being darker or the arterial lighter than common, or *vice versa*. Thus the color in the arteries may vary from a deep scarlet to a yellowish red, or even to a reddish yellow, and that in the veins from a dull light red to a dark-bluish or purplish red.

The quicker the current the brighter is the color, while the slower it is the darker is the blood, especially in the veins. This difference in color between arterial and venous blood is, of course, due to the same physiological and chemical variations which affect it elsewhere, and is dependent mostly on the rapidity of the circulation, the degree of oxidization, and the proportion of red and white corpuscles, of hæmoglobin, and the amount of albuminous compounds. As a rule, the lighter the general background the darker do the retinal vessels appear, and the darker the fundus the lighter the vessels. But there are exceptions to this rule.

As the retinal circulation is derived directly from the general, it would be supposed that the former would be stamped at least with the most marked features of the latter, but a glance with the mirror shows that the retinal differs from the general in one of its most prominent characteristics; that is to say, there is no visible pulsation in the retinal vessels in what must be considered as the examples of the highest development in the normal eye. The stream passes steadily along without any apparent movement of the vessels themselves or any visible change in their calibre, and nobody in looking into the typical eye would ever imagine that the retinal circulation was subject to the interrupted and rhythmical action of the heart. But although such typical eyes are by no means rare, where the lateral pressure in the blood-vessels is exactly counterbalanced by the pressure of the surrounding media, and where consequently there is no pulsation, nevertheless there are very many other cases—perhaps the majority—where we do see plainly enough that the retinal circulation is subject to the action of the heart, the rhythmical beat of which is expressed not as elsewhere by a movement in the arteries, but by a pulsation in the veins.

The Venous Pulse.—This consists of an alternate contraction and

dilatation of a portion of the vein, unaccompanied, in the normal eye at least, with any movement of the vessel. These variations of calibre are usually only observed at the central portion of the disk, just where the vein makes a turn to pass into the central canal. They very rarely extend as far as the circumference of the nerve, and more rarely still beyond this. I have, however, occasionally seen the pulsation on the peripheral portions of the disk, and as a great rarity even beyond it in the retina itself. It is a question, however, whether in these rare cases the eye can be looked upon as a normal one, although no other evidences of disease may be detected. The point of pulsation where the dilatation of the vein takes place is usually of a darker color than the rest of the vessel: first, because of a slight temporary impediment to the circulation; and, secondly, from the turn of the vessel as it enters the canal, less light is reflected from it to the observer.

The flatter the vessel the more tapering it is, and the quicker its turn into the *porus opticus*, and, the greater the physiological excavation, the more readily does the pulsation occur. Usually only one branch of the vein pulsates, and then it is most commonly the lower principal vein. Sometimes, however, two or even more branches are seen to pulsate; moreover, a pulse may exist at one time and not at another.

The emptying of the small portion of the vein takes place from the centre toward the periphery, and the refilling in the opposite direction from the periphery toward the centre. The contraction, or emptying of the vessel, occurs with the contraction of the heart, and therefore with the diastole of the arteries, and synchronous, or nearly so, with the radial pulse. The refilling is synchronous or nearly so with the diastole of the heart, and therefore with the systole of the arteries. The refilling occupies a shorter period of time than the emptying, and there is a slight pause at the maximum of distention.

The prevailing theory as to the cause of the venous pulse is that advanced by Donders, although others had previously described its essential principles. Briefly stated, it is as follows:

At each contraction of the heart, blood is forced into all the arteries of the eye, those distributed to the choroid, ciliary body and iris, as well as to the retina. The lateral pressure thus produced in the arteries during their diastole is propagated to the fluid contents of the globe. Thus the intraocular tension for the time being is increased, and the effect of such increased tension is naturally felt at the place of least resistance—that is to say, upon the venous system where the blood-column possesses the least lateral pressure. Moreover, the precise

place where the force will be the most exercised will be the spot most distant in the circle from the entrance of the blood, and nearest, in its return, to the heart, or, in other words, at its exit from the globe at the porus opticus. The vein yields here to the pressure and becomes reduced in size; but this reduction in calibre will be limited to a small portion of the vessel, because when the compression takes place part of the blood is forced out of the eye, while another portion is forced backward, which keeps the vessel from collapsing, so that the compression is in the nature of a constriction, which is limited to a small part of the vein, just at its turning-point in the centre of the disk. When the diastole of the arteries begins to decline, the pressure on the vein is removed, and the blood rushes forward from the periphery toward the centre to refill the space; and it is this alternate contraction and refilling of the vessel which constitute the venous pulse. The pulse is, therefore, synchronous or nearly so with the systole of the heart and the diastole of the arteries. In point of fact it begins a little before the diastole, and is, therefore, a little in advance of the pulse at the wrist.

Since the discovery of the venous pulse by Van Trigt in 1852, and independently by Coccius in 1853, the cause of its occurrence has been widely discussed and speculated upon, even up to the present date, by all the great writers of ophthalmoscopic literature, and, it must be confessed, with no very satisfactory or decisive result, as no explanation has ever been given which completely fulfils all the conditions of the problem. For a more extended discussion as to the nature of the venous pulse, and speculations as to its cause, the reader is referred to the following articles: "Studien über die Circulation im Auge," von Dr. Jos. Jacobi, "Archiv für Ophth.," Bd. xxii, Ab. i, S. 111, 1876; "Zur Lehre vom Venenpuls der Retina, etc.," von Dr. F. Helfreich, "Archiv für Ophth.," Bd. xxviii, Ab. iii, S. i, 1882.

It would appear, however, to be safe to assume, as the result of these investigations and deductions, that the venous pulse is the expression of a want of equilibrium, dependent upon the action of the heart, between the amount of lateral pressure exercised by the blood-column within the vein and that exercised from without by the surrounding media. Furthermore, that the effect of this rhythmical variation incident to the action of the heart may be increased or lessened by the anatomical peculiarity of the part, such as the arrangement of the vessels at the centre of the disk and their relations to each other in the porus opticus or in the nerve-stem itself, as well as by the nature and shape of the physiological excavation. Thus an impedi-

ment might occur from some anatomical variation in the vein or in its relation to the artery, by which the flow of blood would be impeded in its exit from the eye; while, on the other hand, the vein might from some other variation empty itself faster than it could be supplied from behind.

Now, whether from the action of the heart the intraocular tension is increased temporarily, or whether, as some think, this always remains the same, and the lateral pressure in the veins is reduced during the contraction of the arteries, or whether both occur, are matters for further physiological investigation. The salient point remains, that it is the discrepancy between the two forces which produces the pulse.

That the venous pulse is simply the expression of a want of equilibrium between the pressure outside and inside of the vein, is shown by the fact that, in those eyes in which under ordinary conditions there is no pulse, this can be produced at will by increasing the intraocular tension by exerting pressure with the finger upon the globe. This is a valuable fact to know, in a diagnostic point of view, as it shows in certain morbid conditions the degree of existing tension, and whether the circulation is still going on. It is, therefore, well for the beginner to practice its production and to watch its effect.

In a paper published in the "Transactions of the American Ophthalmological Society for 1878," Drs. Wadsworth and Putnam call attention for the first time to rhythmical changes which may take place in the venous pulse, which recall the rhythmical changes in arterial tension described by Traube, Hering, and others, and which may be the cause of the long waves of movement of the brain noticed by Mosso and others, besides one of themselves. In three cases the vein, besides pulsating in the usual manner, was seen to dilate and contract gradually in periods corresponding to about five respirations.

The Arterial Pulse.—Although Donders had in the earliest days of the ophthalmoscope pointed out that he had in some cases seen the arteries undoubtedly increase somewhat in size during the systole of the heart, nevertheless it was commonly held, by the great majority of observers, that there was no visible pulsation in the arteries of a normal eye, and it is so stated by Mauthner in his admirable work on the ophthalmoscope.

Later investigation and more accurate observation have shown that occasionally a variation in calibre or movement of the artery may be observed, and Becker* says that he has seen in some eyes which were perfectly sound, and where there was no heart-disease, undoubted

* "Archiv für Ophth.," Bd. xviii. Ab. i, S. 271.

rhythmical dilatations and displacement of the vessel in the arteries of the disk and the retina, and this has been corroborated by other observers. This pulsation is systolic, and due to the fact that the lateral pressure in the arteries is less than the intraocular pressure, which may happen from some reduction in the heart's impulse or by some obstruction to the current, by which the influx of blood into the eye is either reduced in quantity or in force. Under these conditions the artery is seen to empty and refill alternately, and the pulsations, though by no means so common or so marked as those in the veins, have the peculiarity, when once they do occur, of extending over a large portion of the vessel in the disk and into the substance of the retina.

An arterial pulse can be produced artificially in almost all eyes by pressure of the finger upon the globe, just as in the case of the veins, though more force is required to produce it. The presence of the pulse and the facility with which it is produced under pressure give some indication of the force and rapidity of the circulation, and the amount of intraocular tension, while its absence proclaims the fact that the circulation has ceased, or very nearly so, as in some cases of embolism and thrombosis.

But besides this actual pulsation in the arteries, there is what is known as an apparent pulsation, which was pointed out by Becker. This consists not in a real variation in the calibre of the artery, but in its displacement by the vein which lies in contact with it. That is to say, when the artery lies in contact with the vein, or crosses either directly or obliquely over the portion which pulsates, this pulsation is imparted to the artery, which then undergoes a displacement, and rises and falls in unison with the vein, and thus appears to dilate and contract. That this apparent pulsation is imparted to the artery is shown by its being synchronous with that of the vein. If it was an independent pulsation in the artery itself, it would alternate with that of the vein.

The Light-Streak.—The summit of the cylindrical surface of the vessels is marked by a luminous band which is usually known as the light-streak. This runs longitudinally along the crest of both the arteries and veins. It is of a pale straw color, and occupies, as a rule, about one third of the diameter of the vessel. Its breadth, however, often varies even in normal eyes, being sometimes greater and sometimes less than the above dimensions. It is usually more brilliant, broader, more sharply defined, and of a lighter color upon the arteries than upon the veins, and it is the more uniform and more clearly defined the more transparent are the walls of the vessel, the superim-

posed retinal layers, and the media of the eye. The quicker the current the brighter is the light-streak, especially upon the veins. Retardation of the current dulls its brilliancy and reduces its diameter, on the veins at least. It is a very valuable factor in diagnosis, and its various phases and characteristics in different eyes should be carefully noted.

Various theories have been advanced in explanation of the presence and peculiarities of the light-streak. Van Trigt was the first to ascribe this light-streak to the reflection toward the observer of those rays of light which under the ophthalmoscope strike upon the anterior surface of the arteries. Jaeger in 1854 accepts this explanation, and gives the following account of it: The lighter and clearer centre of the arterial as well as venous vessels is in fact only produced by increased reflection of the rays from the surface of the vessels. Those rays which fall on the summit of the curvature of the vessel are mostly reflected back in the direction of the rays entering the eye, while, on the contrary, the rays which fall upon the descending portions of the curved surface of the vessel are for the most part reflected in a side-wise direction.

Mauthner, also, in his work on the ophthalmoscope, accepts Van Trigt's and Jaeger's explanation of the phenomena, and remarks that, "Since the wall of the vessels reflects sufficient light to make itself independently visible, so must the light-streak be the expression of this light-reflection." In a later work, however, Jaeger gives up the idea that the light is reflected back from the walls themselves, as they are too transparent to produce sufficient reflection, and says the walls of the vessels and the retina are very nearly of the same refraction, so that with the ophthalmoscope under physiological conditions it is only the red-blood columns and not the walls of the vessels that are seen. The red-blood column reflects back toward the mirror the greater part of those rays of light which are thrown by the ophthalmoscope on its central portion, which therefore appears illuminated and brilliant, while on the other hand the lateral portions reflect the light falling upon them in a sidewise direction, and consequently appear dark.

In 1870 the writer advanced the theory that the light striking the wall nearest the observer passes through this without being reflected to any considerable degree, traverses the contents of the vessel, and is then reflected back slightly from the opposite wall, but principally from the subjacent tissues, and consequently that the light-streak was the product of reflection and refraction. This explanation was accepted by Giraud Teulon, who supported the theory not only by a repetition of the experiments which had been made, but by some addi-

tional ones of his own. It was also corroborated, to a degree at least, by some experiments with the microscope by Becker on the circulation in the frog's foot. It was, however, opposed by Donders and Nagel, who adhered to the old explanation of the theory of reflection from the anterior wall. Schneller, in 1872, expressed the opinion that the light-streak was the image of the source of light formed by regular reflection.

Objections to this view and the arguments upon which it was founded were raised by the writer, based upon the indices of refraction of the blood-column and surrounding media, and it was shown, not only mathematically but experimentally, that even if the view of Schneller was correct his explanation of it was untenable. In 1876, Jaeger again returned to the subject, and reiterated his former opinion that the light-streak was the product of regular reflection, not from the wall of the vessel, but from the blood-column, and to maintain his position was obliged to assume that the index of refraction of the blood-column is *less* than that of the surrounding media.

It will be seen, then, from these various opinions, that no thoroughly satisfactory and acceptable explanation of the presence of the light-streak on the centre of the retinal vessels has as yet been given.

The Region of the Macula Lutea.—To the careful observer, the region of the yellow spot presents some very interesting phenomena, and care must be taken at the outset to draw a sharp distinction between the region of the macula as a whole and its central point—the fovea centralis—which, unfortunately, has not always been the case even in formal discussions and writings, the term yellow spot, or macula, being used as synonymous with fovea. They are, however, widely different, the fovea occupying but a small portion of the yellow spot and marking its centre (Fig. 13, p. 33). Fortunately, with a little attention and skill, the boundary lines of both the yellow spot and the position of the fovea can be easily distinguished from each other with the mirror by the glittering reflections which arise here from the light thrown upon them with the ophthalmoscope. These reflections are of two kinds: one that marks the outer border of the entire region, and to be seen with the inverted image; and the other that which marks the fovea, to be seen, as a rule, only with the direct or upright method.

The Reflex seen round the Macula Lutea with the Indirect Image.—In order to obtain this in the best and easiest manner, the patient should be directed to look, not as usually recommended, at the hole of the mirror, but a little to the side of this—that is to say, the patient should turn his eye a little toward the temporal side; or, in

other words, a little to the right if it is his right eye, and a little to the left if it his left eye which is to be examined. The observer, then, with a little care and patience, especially if he makes a slight lateral displacement of the lens, will become conscious of a luminous or silvery ring which appears, as the inverted image is used and the details of the fundus are reversed, to lie, not to the outside, but to the inside, of the nerve, and to inclose an oval-shaped portion of the fundus, the centre of which is marked by a minute spot of a darker color. The inner edge of this ring is about $1\frac{1}{2}$ diameters of the disk from the outer edge of the nerve, and small portions of both the nerve and ring can sometimes be seen at the same time (Fig. 13). It is impossible to give even an approximate idea of this phantom-like reflex, and I have never seen any adequate representation of it, but the accompanying diagram (Fig. 36) may




FIG. 36.

serve to give an idea of the general shape and outline. This is almost invariably an oval, in which the horizontal diameter is the larger in the proportion of about four to three. The internal border, or that turned toward the fovea, is sharply defined and clearly cut, while the external varies under the play of light, now broader and then narrower, extending at times with tongue-like projections out over the surface of the retina, and giving a frosted appearance to the neighboring tissue. That there is, in fact, a considerable amount of general irregularity of the surface of this region, especially in young children, follows, I think, from the irregularity of these reflections, due, probably, to the projection of small vessels which occupy so thickly this region.

This reflex, or, as it is sometimes called, halo, varies a good deal in size, being at times much smaller than at others. It differs in shape, too, which sometimes approaches a circular form instead of being, as is commonly the case, a pronounced oval.

The color of the inclosed space is not, as would seem natural from its name, yellow, or even of a yellowish tinge. Still we are hardly justified in saying that the region of the macula lutea is not actually of a faint yellowish color during life, from the fact that it does not appear so with the ophthalmoscope, as the retina is so transparent that any light shade of yellow would be dominated and quenched by the greater amount of transmitted red light from the choroid. Though not yellow, the color of the inclosed space differs from the rest of the fundus, and certainly, when the ring is clearly perceived, seems to

lack definition and to be of a somewhat grayish or brown color, rather than of a pure red. The shade is brighter near the periphery of the oval, and grows darker toward the centre, which, as a rule, as before mentioned, is marked by a small spot or dot, which is usually circular in shape, and which is called the fovea. Occasionally these markings are so clearly defined as to make, with the halo, three concentric rings or zones with the minute dot in the centre, not unlike the bull's-eye on a target, which may then, as a great rarity, appear, not as it usually does, the darkest point in the region, but as a minute, pale, straw-colored dot, so light, indeed, that I have on one or two occasions imagined, at least, that it was actually a minute point of reflection. This minute point, which marks the fovea, though always in a central position, is not usually in the exact centre of the ellipse, being a little nearer the upper than the under border. As a rule no vessels are to be seen within the circuit of the halo, simply because the enlargement of the inverted image is not sufficient to render them visible.

It must be remembered that the halo round the macula is not seen in all eyes, and, even in some of those where it is present, it is difficult, if not impossible, to produce it in its entire circuit. The younger the individual, the easier it is to see and the brighter it appears, while in the adult it is often but slightly marked or not to be detected at all. In the senile eye I do not remember to have seen it.

The Region of the Macula Lutea with the Upright Image.—The proper examination of this portion of the fundus with the direct method, though not so difficult as that with the indirect, nevertheless offers a good many embarrassments to the student, both from the optical condition of the eye and from the fact that the appearances are so different from those which are shown by the indirect method. The best way to pursue is first to obtain a view of the lower border of the nerve, and then to travel outward toward the temporal region until the spot at the fovea is reached. This is usually at about two diameters of the disk from the edge of the nerve, but often, from the increased enlargement, seems to the inexperienced eye to be much farther, and the observer is thus apt at first to fall short of the spot in his estimate. This distance, however, between the nerve and the fovea differs somewhat even in emmetropic eyes, and the apparent variation with the ophthalmoscope is sometimes very marked. Even if the observer takes all these and other precautions, he is apt at first to be disappointed by finding that he sees nothing distinctly, although he is conscious that he is directly over the yellow spot, the reason being that he is probably endeavoring to see through the corneal reflex, which throws a disturbing influence over the whole picture. He

must, therefore, be careful to avoid this reflex by looking just over, under, or to the side of it—or, in other words, by dodging it from side to side as occasion requires—and he will often be rewarded by finding that what was at first obscured by an indistinct haze, and occasionally also by an undefined reflex, comes out fair and bright, with all the details clearly and sharply defined.

The vessels no longer appear to arch over and around the macula, as with the inverted image, but to pursue at the upper and lower edges of the field a more rectangular and almost horizontal course, as shown in the diagram (Fig. 37). From these vessels finer branches are seen to descend and ascend in a slightly radiating course in the direction toward the fovea, which they sometimes very nearly reach.

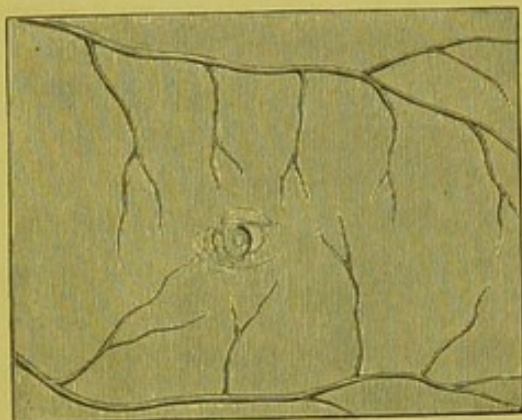


FIG. 37.

In examining this region the student is very apt to forget the change in conditions, and to be unmindful of the fact that, with an enlargement of fourteen times, his gaze can not take in at once more than the region of the yellow spot, even if it does that, and he is thus led to believe, from the fact that the vessels stop short of the fovea, that the macula is, even with the upright image, devoid of

vessels, when in truth it contains a greater number, visible even to the ophthalmoscope, than any other portion of the retina. In fact, all the vessels, for same distance round the fovea, are within the region of the macula.

But the most striking fact in reference to the differences between the two methods of examination is that, as a rule, there is not a trace of the brilliant circle which surrounds the yellow spot when the inverted image is used. That is to say, the periphery of the region does not show any demarcation from the rest of the fundus by any reflex, or even by any change in color. It is only in the immediate neighborhood of the fovea centralis that anything peculiar is noticeable. Toward the centre of the region, however, and for a small circuit round about the fovea, there is generally a concentration of color, and even when this is not marked there is a consciousness on the part of the observer of an increased amount of pigment in the choroidal epithelium and stroma, as well as a deeper red color, which arises from the increased amount of vessels and capillaries in the choroid immediately behind the fovea. Sometimes, however, this gradual accentua-

tion in shade toward the centre is wanting, and the fovea alone is marked by a small spot which is darker and more granular in appearance than the surrounding tissue. Sometimes again, though rarely, this central spot, instead of being darker, is lighter than the rest of the fundus, and then usually has the appearance of a pale straw-colored spot which has been delicately applied with a brush, and sometimes, as a greater rarity, the immediate neighborhood of the fovea, or even the more peripheric portion of the yellow spot, is the seat of one or more very minute dots of a bright but light-yellow color, which are not cholesterine, though they occasionally have a slightly glittering aspect. The true character of these dots and their significance have not yet been determined.

Now, while there is almost invariably a total absence of the reflex which marks the boundary-line of the yellow spot with the inverted image, the fovea is itself under the upright image the seat of a reflex which is quite as remarkable in its way as that seen by the indirect method.

The usual shape of this reflex is that of a horse-shoe or minute crescent, which changes from side to side according to the movements of the observed eye and displacements of the mirror. It is not, however, always of a crescentic or half-moon shape, with attenuated horns, but sometimes has the appearance as if it were only the segment of a small circle, or as if the depression at the fovea was triangular in shape, and light was reflected from only one side of it at a time, in which case the reflection streams out into the surrounding tissue like the tail of a very minute comet; or again, it has the appearance of a very delicate and phantom-like veil stretched across the fovea. These are some of the common appearances. As a rarity, I have occasionally seen a completely-illuminated circle of very minute dimensions, and, as a greater rarity still, the centre of the circle is in addition marked by a very small but perfectly-shaped dark spot—the fovea centralis itself.

In regard to the fact which Mauthner and others emphasize as so curious and unaccountable, that we do not see with the upright image any indication of the halo which surrounds the region of the yellow spot, it would appear to me to be sufficiently explained by the fact that the diameter of the surface of the macula lutea as a whole, under the enlargement of the upright image, is much too great for the rays reflected from the border of the ellipse to return to the observer, and thus allow the entire circuit to be in view at once; and furthermore, that the illumination with the upright image is never so strong or so concentrated upon a small surface as it is with the inverted method.

But, while admitting Mauthner's statement that in the vast majority of cases we do not get the entire ring, or, indeed, any trace of it, nevertheless I would add that I have occasionally obtained a very faint but distinct segment of reflection, which I could make play about in that portion of the retina where the boundary-circle of the yellow spot should be. In speaking about this to Dr. Wadsworth, he informed me that he had several times seen the entire ellipse with the upright image in emmetropic and myopic eyes, and shortly after this I myself observed the same thing in a young child with a myopia $\frac{1}{2}$ (7 D.).

The explanations of the cause of the glittering ring, which has been described as marking the circumference of the region of the yellow spot, and as given by Liebreich, Schweigger, Schirmer, and others, have never been accepted by physiologists as conclusive, and Mauthner, in his work on the ophthalmoscope, brings a comprehensive review of the many attempts to solve the problem to a close with the assertion that the phenomenon can not be accounted for on anatomical grounds with the knowledge of the part now in our possession. Shortly after this the writer published an explanation of these reflections, which was founded upon the anatomical construction of the part as described and figured by Max Schultze. The outlines and

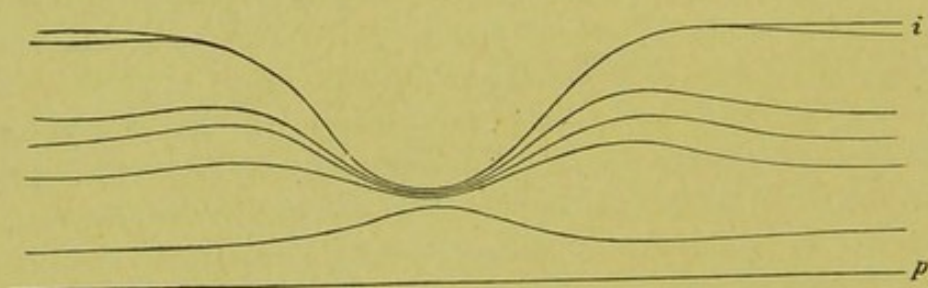


FIG. 38.

curvatures shown in Fig. 38 are *fac similes* of Schultze's original drawing (Taf. vi, Fig. 1). The scale is, however, reduced one half, and the details of the tissues are omitted.

As will be seen, this region, as figured in the diagram and also in the more comprehensive drawing on p. 33, bears in its formation a strong resemblance to a shallow cup, the rim of which is represented by a convex and the bowl by a concave surface. If we look upon these curved surfaces as mirrors, they would each have their foci, one lying behind, the other in front, according to their respective degrees of curvature. If light should be now thrown perpendicularly against such a combination of curves, the apex of the outside rim, or convex surface, would, from well-known optical laws, appear illuminated,

while the inside, or concave surface, would appear more or less in shadow.

To illustrate this view several experiments were instituted and described. These were subsequently so much misunderstood, and consequently misrepresented, in the foreign journals, that I should advise the reader who happens to be interested in the matter to consult the original articles, and not the abstracts made from them.

This cup-like excavation might, then, vary in different eyes, both as to extent and depth, so that in some it might be limited to the fovea alone, and in others extend, getting shallower as it goes, even up to or near the boundary line of the entire macula; or there might be two depressions, one shallow at the circumference of the yellow spot, extending over the surface of the whole region, and a deeper and narrower one at the fovea. These variations would account for the presence of the ring in some eyes and its absence in others, and its frequent and not inconsiderable deviations, when present, in size and shape. Moreover, inasmuch as the nerve-fibre layer ceases to exist as such at the macula lutea (and the nerve fibres make a peculiar bend here), a difference in level might be occasioned which would be sufficiently marked in many eyes to give the effect in question. It was furthermore shown by experiments that the effect might be produced by a difference in level in the nerve-fibre layer alone, without taking into consideration the thinning of the other layers of the retina at this place. It is, therefore, this difference of level which would appear to be the essential factor in the production of the phenomenon, assisted, no doubt, by the peculiar arrangement of the anatomical elements which enter into the construction of this part, and which go to make this inequality of level, aided also by the different indices of refraction of the retinal elements and the amount of connective tissue. Another argument in favor of this difference of level being the cause of the halo is the fact that there is another reflex, first pointed out by Coccinus, with the upright image at the fovea; and we know for a certainty that the fovea is a more or less narrow fossa with pretty sharply descending walls, and the shape of the reflex is just such as would come from a narrow-mouthed pit; for, while one side was turned so as to catch the light and reflect it, the other edge would be turned so that no reflex would come back from it, consequently we should have a crescentic-shaped reflex. Moreover, the reflex is occasionally a perfect circle, very small, it is true, but perfect in detail. Now, if a small circular reflex can come from the edges of a minute depression, why may not a larger though shallower depression be the cause of a larger reflex which really varies from it only in size and not in character?

Such being the general outline of the principal features and characteristics of the fundus of the eye as seen with the ophthalmoscope, it is necessary, before passing to a consideration of the actual anomalies of construction, to say a word in regard to the manner in which the fundus, although perfectly normal in itself, may be affected at different epochs of life, and by certain optical conditions which may and often do materially alter its appearance.

The aspect of the fundus of the young eye differs as much from that of the adult as the countenance, and bears all the peculiar look of freshness which youth always possesses. The fundus is more brilliant in hue and the various tissues have a greater transparency, the outlines of the nerve and vessels are sharper cut, while at the same time there is usually a greater development of connective-tissue elements, which are shown often by feathery if not glittering reflections from various parts of the fundus, notably along and over the course of the vessels and around the region of the yellow spot. In the infantile eye anatomy teaches us that the pigment is less abundant within the hexagonal cells and increased in the stroma proper, and the ophthalmoscope shows this increase in the neighborhood of the nerve by a more frequent appearance and a greater development of the pigment-ring than in later life.

The adult eye, on the other hand, while freer from connective-tissue elements, is less transparent and less fresh in its appearance, and often shows as plainly as the face the effects of over-use and constitutional disease; while the fundus of the senile eye is lacking in color and vivacity of expression, if the term may be used, and shows all the wear and tear that characterizes the other organs. The fundus, as a rule, is of a paler and less vivid red, with a washed-out appearance; the nerve is pale and anæmic, with ill-defined and ragged edges, and marked by disturbances of an atrophic nature in the choroid which surrounds it, combined oftentimes with a mild degree of maceration of the entire membrane. The vessels, too, appear smaller, and the difference in color between the arteries and veins is but slightly marked, and there is a reduction in the breadth and brilliancy of the light-streak, and altogether to an attentive observer there is often a general appearance of decrepitude and decay. From a deposition of peculiar minute hyaline bodies immediately under the *membrana limitans*, the retina of aged people has sometimes a stippled or granular appearance; moreover, prematurely old people have prematurely old eyes, and I have often seen emaciated and wizened-up children, bearing the marks of rickets and scrofula, and not yet in their teens, with the eyes of elderly and ill-nourished old people. It is

often important to bear in mind the discrepancy in young people between the amount of labor imposed upon the eye and the capacity, from imperfect nourishment or want of development, to fulfil it. If this was done there would be fewer glasses ordered of an almost imperceptible strength, and more tonics and a better regimen prescribed.

Variations in the optical condition of the eye lead also to variations in appearance of the fundus. Thus, a myopic eye in which there is no conus, or indeed any other variation from the normal, has a different appearance in certain respects from an emmetropic eye, due in part, no doubt, to a difference in anatomical construction, especially in regard to the inner sheath of the nerve, but also due in part to its optical condition and the method by which the examination is made. With the inverted method, since the aerial image is smaller than that of the emmetropic eye, the vessels seem to be abnormally small, and from distention of the membranes are straighter in their course and show, since they appear smaller, a less discrepancy in color between the arterial and venous system, while the nerve looks smaller, whiter, and less distinct in outline. With the upright image, on the contrary, as the image is larger than that of an emmetropic eye, the vessels and the nerve seem disproportionately large, and especially is this the case with the nerve, as the effect is increased by the behavior of the inner sheath seen through the choroidal opening, which in myopic eyes, even where there is no posterior staphyloma, does not fit up as closely to the stem of the nerve as in the normal eye.

It is the reverse with the hypermetropic eye, since the reduction of the image is less with the object-glass than in the emmetropic eye, the vessels and nerve seem to be enlarged, the former then often appearing disproportionately large in respect to the nerve.

With the upright image, as the enlargement is less than with the normal eye, the nerve often appears too small, sometimes markedly so, while the vessels, although not as much magnified in reality as in a normal eye, appear to be larger, and oftentimes here, as with the inverted image, disproportionately large in respect to the size of the nerve; probably, indeed, because they are so, in fact. That is to say, as the hypermetropic eye is usually an undeveloped eye, the nerve may be in reality too small and yet the vessels be of normal calibre. From the same want of perfection in development there is usually a greater amount of connective tissue to be seen in the retina of the hypermetropic eye, and this, as has already been mentioned, oftentimes gives a striated appearance to that part of the fundus which immediately surrounds the nerve. Sometimes the striæ seem to radiate

from the porus opticus as a centre beyond the borders of the nerve, the boundary-line of which they obscure, and thus lead an inexperienced observer, especially when, as is often the case, there is increased vascularity of the part, to believe that he is dealing with a morbid process of an inflammatory character.

Astigmatism also, especially when of a high degree, produces a curious and noteworthy effect on the fundus, which is particularly shown in the contrast between the appearances with the inverted and those with the upright image. With the inverted image little or nothing is observed in regard to any lack of clearness and definition. Although the nerve may appear to be elongated more in one meridian than in another, and alter its length in the two principal meridians under the to-and-fro movements of the lens (see p. 140), yet all the details of the disk and that of the general fundus appear sharply defined. But the minute the upright image is used the observer is often astonished to find that what was clearly and sharply defined before now seems indistinct and indefinite, with a general out-of-focus look. The whole nerve seems to be out of shape, and to be drawn out in one particular direction; sometimes only the larger vessels are to be seen, and these seem to be distorted—here and there clearly defined with a well-marked light-streak, and then again, as they change their course, they appear to be hazy and indistinct, with no light-streak, and as if they were running through tissue which was slightly œdematous (Plate III, Fig. 5).

I have known such cases to be pronounced by some observers—and those, too, not the inexperienced ones so often alluded to in these pages—as cases of neuritis, especially where a considerable degree of amblyopia existed, and no careful correction of the optical condition had been previously made.

ANOMALIES.

Variations from the normal standard, when sufficient to warrant the name, are classed under the head of anomalies, and it is essential for the student to be acquainted with the most important of these in order to avoid errors in diagnosis.

Anomalies of the Media.—The media of the normal eye, so far as the ophthalmoscope is concerned, may be looked upon as perfectly transparent, since the slight cloud-like opacity which is present under oblique illumination is absent as the rays of light enter the eye to a large degree parallel to the axis of vision.

When, however, the curvature of the cornea is congenitally irregular—as, for example, in high degrees of irregular astigmatism—we

obtain a series of shadows which play around the periphery and over the surface of the cornea, especially when the mirror is made to rotate in the hand. These shadows, as has been explained more fully elsewhere in the determination of refraction, are due to the fact that the return rays from the fundus are unequally refracted by the distorted cornea, so that fewer rays enter the observer's eye from one part of the membrane than from another.

Anomalies of the Lens.—As it is with the cornea, inequalities in the curvature of the lens may cause a different refractive power, and so give rise to a series of shadows which play over the surface of the lens under movements of the mirror. Though much more rare and difficult to determine than in case of the cornea, I have occasionally convinced myself of the presence of such shadows, which then occupy the central portions of the pupillary space, and do not pass to the periphery of the cornea, as is the case when this membrane is at fault. A unique case of marked alteration in the curvature of the lens has been published by Dr. Agnew in Knapp's "Archives of Ophthalmology," vol. iv, p. 382. Here the protrusion of the central part of the lens was so great as to justify the title bestowed upon it of "lenticonus."

Opacities in the substance of the lens, whether congenital or acquired later in life, are classed under the general name of cataract, and will be described under their proper heading. It will simply be necessary here to remind the student that care must be taken not to confound these formed opacities with dust-like aggregations and minute dark spots. The former usually occupy the peripheral portions of the lens, while the latter are usually situated at the posterior pole. These formations are congenital, and apt to lead a beginner to form a diagnosis of commencing cataract.

As a great rarity, the three radii which form the suture of the fibres of the lens in the embryo persist in later life, and a casual observer might mistake these for the dark striæ so characteristic of commencing cataract. The examples which I have seen have usually been in young children. These radii and striæ are not to be confounded with the natural stellation of the lens, which can be seen in every normal eye by means of oblique light.

Coloboma of the Lens.—This will be described a little later on under coloboma of the choroid and uveal tract, of which it is usually, though not always, the accompaniment.

Ectopia Lentis, or Dislocation of the Lens.—Besides being the result of violence or ordinary concurrent disease, ectopia lentis may occur in very rare cases as a congenital malformation. Sometimes this mal-

position does not show itself in the early years of childhood, but only later, and then assumes a progressive character. It is apt to be hereditary and to exist in the several members of the same family. So far as the ophthalmoscope is concerned, it presents very nearly the same appearances as the ordinary dislocation of the lens.

The drawing below (Fig. 39) represents a case of double congenital displacement of the lens which is symmetrical in character, and which

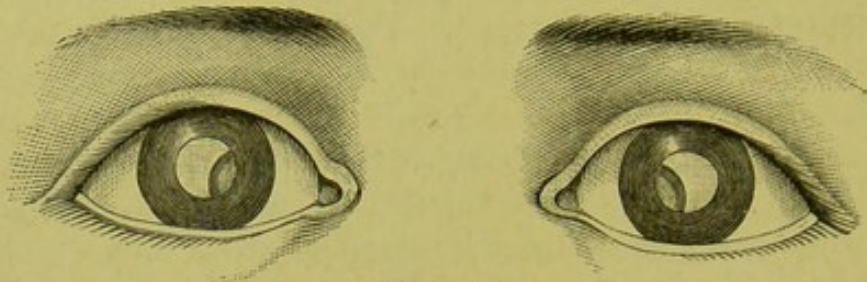


FIG. 39.

was reported by Dr. Little, of Philadelphia ("Transactions American Ophth. Soc., 1883," p. 523).

Coloboma of the Vitreous.—I am not aware that this has ever been detected by the ophthalmoscope, though it has been found on section.

Anomalies of Pigmentation—the Choroid.—The pigment of the choroid, instead of being distributed in a uniform manner over the surface of the membrane, or collected between the meshes of the stroma and vessels, so as to form a more or less regular design, as in the *choroid tigré*, is sometimes distributed in an irregular manner and without any particular design. A favorite place for the aggregation of pigment is the neighborhood of the optic-nerve disk, and here, instead of forming the sickle-shaped and crescentic form at the outside of the disk known as the choroidal ring, the pigment may be gathered together irregularly in small aggregations, or be combined into one or two larger or more pronounced patches, such as we see sometimes as the remains of a hæmorrhage. So, too, the region of the macula may be the seat of an anomalous distribution of pigment which then sometimes simulates the appearance of the remains of some morbid process, but which to a careful observer gives evidence of being some congenital defect, or the result of some intra-uterine process, since the tissue does not show any of those atrophic spots, the remains of a previous choroidal inflammation, and which allow the sclera to show through; and especially, too, since the patient himself asserts that his vision has always been defective, and he is not aware of any deterioration. These aggregations of pigment about the yellow spot are not always, however, incompatible with a fair amount of vision; and I

have even seen a case myself, and others have been reported, where there seemed to be the atrophic remains of an intra-uterine choroiditis with a white spot of considerable dimensions and much irregular distribution of pigment, and yet where a considerable amount of vision was present. The chromo-lithograph (Plate II, Fig. 5) gives a remarkable example of this irregular conglomeration of pigment in the eyes of a young lady of twenty. As will be seen, there are no signs of present or past inflammation, and the eye proved to be normal in every respect, with no scotoma and vision equal 1. Jaeger, also, gives a picture in his "Hand Atlas" (Taf. xix., Fig. 85), where the pigment situated at the upper and outer portion of the fundus has the appearance of a black smutch laid on with a brush. It is, however, in the choroid, and close examination shows it to be made up of collections of minute particles of pigment.

Pigmentation of the Nerve.—Small patches of pigment often appear either just around or within the circumference of the nerve-disk. These are of choroidal origin, as the pigment-cells of this membrane are continued over into the lamina cribrosa, and have been frequently found there on section. They must not be confounded with the deposits of pigment which sometimes occur within the circumference of the disk after hæmorrhage or other morbid processes. The drawings, somewhat enlarged (Figs. 40 and 41), are taken from the chromo-lithographs by Jaeger ("Hand Atlas," Figs. 38 and 39).

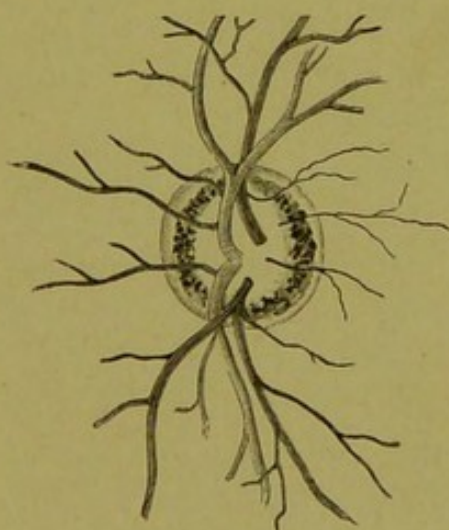


FIG. 40.

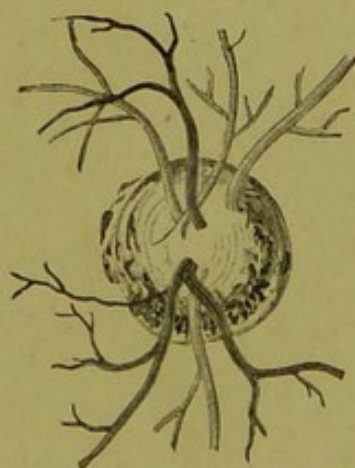


FIG. 41.

Liebreich, also, gives a remarkable drawing of a congenital variation in the distribution of pigment in the condition known as cyanosis of the bulb ("Atlas de Ophthalmoscopie," Tab. xii., Fig. 3).

This consists of a marked and general increase of pigmentation over the entire surface of the fundus, which there has a deep maroon aspect. The region of the macula appears almost black, the fovea

being surrounded by a red ring of a brownish hue. The vessels at their point of emergence at the porus opticus are enveloped in a mass of pigment which covers about one third of the centre of the papilla. (See chromo-lithograph Plate III, Fig. 2.)

Instead of an abnormal increase of pigment, there may be a diminution varying in different degrees from a hardly perceptible want of color to a total lack of it, as in some albinotic eyes, in which the larger choroidal vessels are sharply defined upon a white background (Plate III, Fig. 1).

Coloboma of the uveal tract occurs from arrest of development in the embryonic eye, in the iris, ciliary body and choroid, to which may be added also a coloboma of the lens.

Coloboma of the Iris.—This usually occurs, in the great majority of cases, directly downward, more rarely downward and either a little inward or outward. It manifests itself under the ophthalmoscope as an illuminated and split-like hiatus in the iris, through which the glittering white aspect of the coloboma, which usually accompanies it, is observed. The coloboma of the iris usually extends as far as the ciliary body. The space included in the deficiency appears ordinarily at first sight as perfectly transparent and free from interruptions. Closer inspection, however, shows that although the pigment-layer of the iris is completely wanting, there are usually the remains of the tissue itself in the form of a very delicate and transparent membrane to be detected, which sometimes extends directly across the coloboma, either above or below, or in the shape of a bridge thrown across from the edges of the iris bordering upon the defect.

Congenital Absence of the Iris (Iredemia).—This anomaly gives, on a cursory examination, the same appearance as if the pupil was dilated to its utmost under atropine. So great is this defect at times, that it can not be determined with the ophthalmoscope whether there is any rim at all of iris-tissue or not. Iredemia is of two kinds: either "total," as that described above, or partial; and the word is used not to describe a lack of development of the entire membrane, but a hiatus in the circumference of the iris of a greater or less extent, which then closely resembles the true coloboma of the iris. It differs, however, from that in this respect, that there is no accompanying coloboma of the choroid; and whereas a "partial" and "total" iredemia may exist in the same individual, a contemporaneous existence of both iredemia and coloboma has not yet been observed. With this condition of iredemia there is usually some derangement of the cornea and its curvature, which may be carried so far as to amount to conical cornea.

Eccentric Position of the Pupil (Corectopia).—This shows itself

with the ophthalmoscope simply as a displaced pupil, and offers but little difficulty in its diagnosis. It varies in degree from the slightest displacement to one that approaches the limits of the cornea. It is usually not round, but of an oval shape. Its position is mostly downward, or downward and inward; but it may lie in other directions. It is often found combined with coloboma of the choroid, and then its origin is apparent. It is, however, difficult to assign this as a cause when the displacement of the pupil is upward or outward unless we assume that there is an abnormal position of the foetal split. Eccentric pupil may exist in both eyes.

Persistent Pupillary Membrane.—This anomaly gives a striking ophthalmoscopic picture. It appears to occur more frequently than it really does, from the fact that it has often been confounded with the remains of adhesions formed by some intra-uterine inflammation of the iris. This confusion need never occur, since the true nature of the origin of the membrane has been determined. The differential characteristic of a real pupillary membrane, as will be seen from the drawing, is that the fibres of which it is composed take their origin from the anterior surface of the iris, leaving the pupillary border free and movable. The fibres usually stretch across from the anterior surface of the iris to the centre of the lens, where they may form a plaque of considerable size, as shown in the drawing (Fig. 42), taken from a case reported by Dr. Agnew ("Trans. American Ophth. Soc., 1880," p. 110).




FIG. 42.

Although not actually determined, it is fair to assume, especially since they have been found together, that this membrane has oftentimes something to do with the existence, if not with the formation of pyramidal cataract. In other cases single fibres are continued as such directly across the entire pupil, where they anastomose with each other ("Manz., G. and S.," vol. ii., p. 94).

The pupil in these cases of persistent membrane usually expands and contracts to the fullest extent under atropine and eserine respectively, which is not the case when the adhesions and bands are due to intra-uterine inflammation.

Coloboma of the Lens.—This consists of a deficiency at the periphery of the lens, and may vary in size from the slightest indentation to about one fourth of the substance of the lens. It is always at the borders of the lens, and never invades the centre. It is, according to some authorities, invariably in the lower margin, but Dr. Knapp reports a case where the defect was at the upper border. The refraction of the eye in which it is found is usually myopic, sometimes to a great degree. Hypermetropia may, however, be present. With the ophthalmoscope the deficiency sometimes shows itself with a straight edge, as if a small slice of the lower periphery had been cut off in a more or less horizontal direction. As a rule, however, the edge is curved, the convexity looking upward, or the defect may manifest itself as a small, dark stripe running in a vertical direction. It is apt to be mistaken for simple dislocation of the lens.

Coloboma of the Choroid.—Beginning at the posterior part of the eye, the coloboma in the choroid usually extends directly downward, sometimes, however, deviating slightly either inward or outward. It may extend as far as the eye can reach with a fully dilated pupil. It is usually connected with that of the iris by a broad deficiency in the ciliary body, or by means of a raphé, which extends through it, and along the sides of which the ciliary processes, shortened in size and somewhat flattened from before backward, are arranged.

The coloboma may include the optic nerve and its sheath, or there may be a portion more or less broad of healthy choroidal tissue before the coloboma begins, as is shown in the chromo-lithograph (Plate III, Fig. 3). That portion of the sclera which corresponds to the defect in the choroid usually protrudes backward in varying degrees, though there are cases where it has a uniform surface with the neighboring parts. As a rule, the surface is divided into several shallow compartments, or protrusions of different levels, and the deepest of these is usually that which is nearest the nerve. The general surface of these compartments, or ectatic portions, may be further broken by small ridges or furrows which run in a transverse direction, and which are not unlike in appearance those minute furrows formed on a sandy beach by the action of the sea; or a raphé may extend vertically for a greater or less distance, which then divides the coloboma longitudinally into two compartments.

Although the general effect of the color of the region of the coloboma is a bright, oftentimes a glittering white, with a mother-of-pearl sheen to it, yet these compartments often vary among themselves in color from a delicate pinkish-white to a peculiar bluish-green. The existence of the protruding, or staphylomatous parts, is shown by the

play of light which passes over them on the rotatory movements of the mirror, and by the varying strength of the glass which is required to bring the different portions into view by the upright image.

The distribution of the vessels over the surface of the coloboma is peculiar, and depends somewhat upon the size and extent of the defect. If the optic nerve has arrived at a full or fair state of development, and is not included within the coloboma, the retinal vessels pursue their usual course downward up to the borders of the defect, along which they run, but over which, as a rule, the main trunks do not pass. Smaller branches, however, which arise from them, do cross the edge, and then ramify over the surface of the coloboma. Occasionally, however, the larger vessels do this also, and then usually give evidence of a change in the level of the sclera by a sudden bending in their walls. Usually these vessels have a very abnormal appearance, and pursue a very irregular and tortuous course, following the irregularities of the surface.

Sometimes, however, instead of following the surface of the excavations, the retina may stretch directly across these, and in this case the retinal vessels can be readily distinguished from those lying below them by the parallax movements which they undergo, and the different adjustment of glasses which it is necessary to employ to bring the more distant vessels into focus, and, according to Jaeger, the shadows which they cast upon the whiter surface below by displacements of the mirror. Besides the retinal vessels and the scantily developed vessels of the choroid proper, there are other vessels which come from the sclera and are, in fact, offshoots of the short posterior ciliary vessels, which show themselves as a fine and delicate network, of which isolated branches, here and there, can be traced directly into the sclera or followed across the white surface of the coloboma into the normal district of the choroid. It is sometimes extremely difficult to tell the retinal from some of the finer choroidal vessels, especially as it can occasionally be determined, by a careful inspection, that the two anastomose with each other.

The entrance of the optic nerve may be either partially or entirely included within the coloboma, as is shown in the woodcut taken from the chromo-lithograph by Jaeger ("Hand Atlas," Fig. 88). The nerve, as is the case in the drawing (Fig. 43), is usually of the oval form, and can, as a rule, be easily distinguished from the surrounding tissue; but there are cases where this is very difficult, if not impossible. Although the nerve does usually preserve its oval form, the largest diameter is not usually in a vertical direction; on the contrary, the nerve seems frequently to have been turned on its axis until it as-

sumes an oblique direction, or it may be turned completely round, to an angle of 90° , so that the principal vessels, instead of running vertically, run horizontally across the field. Even when this is not the

case, the vessels are usually arranged in a bizarre and abnormal manner.

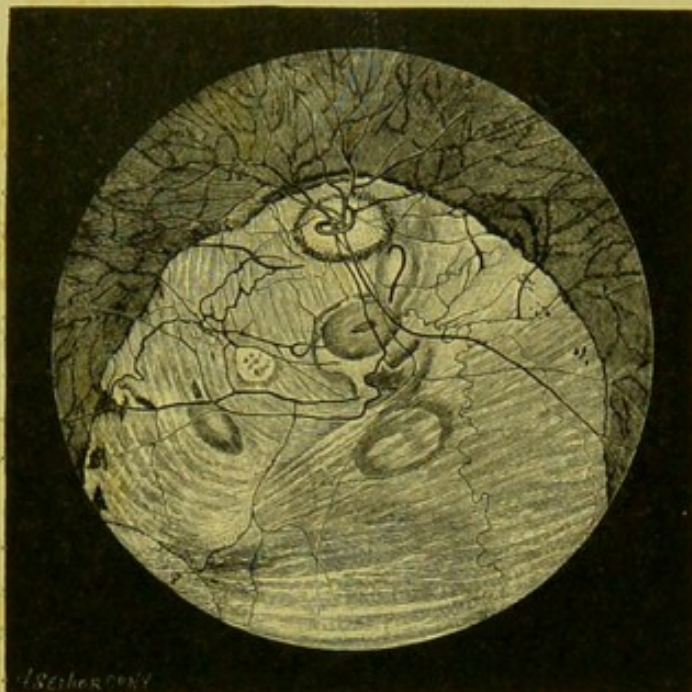

FIG. 43.

Anatomical examination shows the protuberance of the sclera, as well as a want of the choroid within the district of the coloboma. Still, traces of the choroid betray themselves as a delicate membrane which lines the staphylomatous parts, while the retina, as a rule, is completely wanting within the region of the colobo-

ma, though there are some cases in which it would appear still to be present and to extend across the coloboma. The defect may exist either in both eyes or in one eye, and then, in the great majority of cases, in the left. The eye affected with coloboma is generally smaller than normal, or shows a varying degree of microphthalmus, and there is usually corresponding to the defect a complete loss of the field of vision upward, which shows that there is a very low state of development of the retina.

Coloboma of the Macula.—This occurs as a rare anomaly, and consists usually in an isolated defect of the choroid at the region of the yellow spot, which varies considerably in size and shape, but which is usually circular and somewhat larger than the disk. It presents itself with the mirror as a pigmentless spot, showing the peculiar reflex of the sclera and other appearances due to an ordinary coloboma of the choroid, upon which may be seen traces of the choroidal vessels or those coming from branches of the ciliary arteries. In some cases an inequality in the surface of the region can be detected, with a slight protrusion backward of the sclera. Instead of a single spot there may be two, as seen by me and shown in the drawing (Fig. 44, also Plate III, Fig. 4). In this case the second spot lay in the horizontal me-

ridian, between the macula and the nerve. Care must be taken not to confound this congenital defect, which is a want of closure of the choroidal split, with those spots of atrophy which may occur as the remains of hæmorrhage just at this region, or, more frequently still, from choroiditis, which may also be congenital, inasmuch as the inflammatory process may have been intra-uterine.

In one case seen by me, in addition to the coloboma at the region of the macula, there was starting from the temporal side of the defect what appeared to be a fold of the retina protruding into the vitreous, as the retinal vessels could be traced from the normal retina directly over on to the fold.

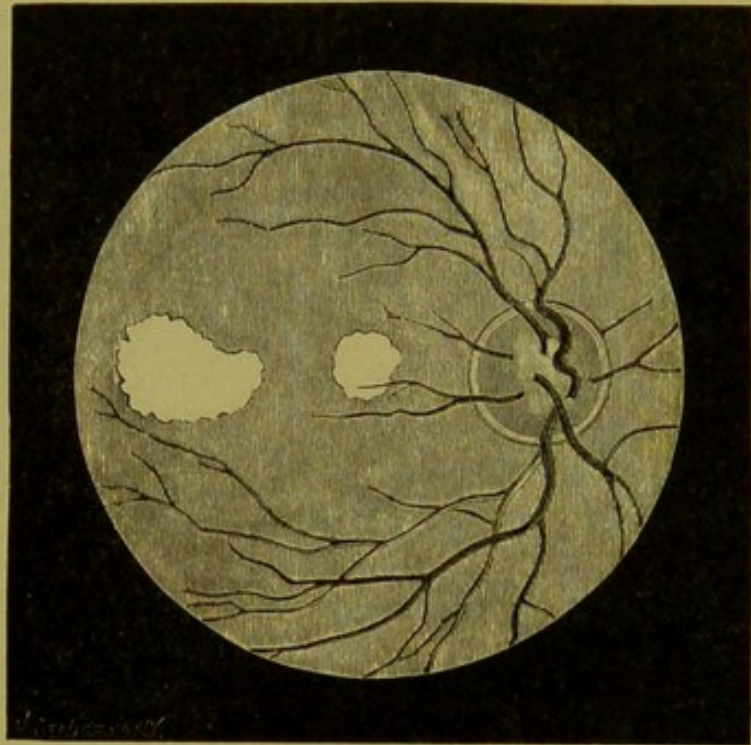


FIG. 44.

Vision is, as a rule, very much reduced, although there is a case reported by Reich, in which it was almost normal. Burnett (*"Knapp's Archives of Ophthalmology,"* vol. xi, p. 461) also reports an interesting case of this defect in which the vision, though comparatively good for the moment, faded away when the eye, which was affected with strabismus, was fixed directly upon any object, which may indeed be the case with simple cross-eye.

I have also seen one or two cases where there was a distinct circular spot, the size of the optic disk and not unlike it in appearance—minus, however, the vessels—and which was unmarked by any deposit of pigment. These whitish-pink spots occupied the region of the macula lutea, and the fovea formed the centre. The vision in these cases was somewhat defective. In one case, which I saw with Dr. Rushmore, of Brooklyn, the patient was suffering from an attack of retino-choroiditis, of a low type, in the left eye, and in this eye vision was, for the time being, very much reduced. But the vision of the right eye was, the patient said, as good as it ever was ($\frac{2}{8}$), and declared that there was nothing the matter with it. I looked upon these peculiar spots occurring in both eyes as of congenital origin, with a super-added retino-choroiditis in the left eye, due perhaps to a reduced state

of vitality of the part from some intra-uterine inflammation or faulty development. Mr. J. E. Adams reports a similar case, and gives a chromo-lithographic picture of the appearance at the macula: "On examination, it was found that the change shown in the plate occupied the region of the macula lutea, and it was assumed that it was the cause of the diminished visual acuteness ($V = \frac{2}{3}$), but an almost precisely similar condition was discovered in the right eye, in which the vision was absolutely normal. The patches are not raised, but appear simply as alterations in texture and color, and concerning the exact nature of them one can do little more than guess" ("Trans. Ophth. Soc. of the United Kingdom," vol. iii., p. 113). It would appear to me that both Mr. Adams's case and my own are the expressions of a faulty development at the macula lutea of a congenital origin, suggestive of a modified coloboma at this place, in which, although the closure had taken place in all the membranes, there was an insufficient development of tissue, which showed itself particularly in a reduced number of the minuter vessels of the part, and in their arrangement and distribution.

Coloboma of the Sheath of the Optic Nerve.—The want of closure in the foetal split may affect the sheath of the nerve, and probably also the substance of the nerve itself. Liebreich ("Atlas D'Ophthalmoscopie," Taf. vii., Fig. 4) first gave a drawing of this defect, under the title of "Coloboma of the Sheath." The nerve-entrance seemed to be some three or four times as large as the normal disk, and was sharply defined by the surrounding choroid, which was normal, and in which there was no coloboma. A thin diaphanous membrane was thrown across the lower two thirds of the disk, which concealed beneath its folds two deep oblong excavations, which were separated from each other by a small raphe. The principal vessels arose in the upper third of the disk, the larger branches proceeding upward, while only a few delicate vessels ran downward, which were more or less covered in by the folded membrane, and which showed at the border of the disk a sharp bend.

Nieden publishes a long and interesting account of four cases of this very rare anomaly ("Knapp's Archives of Ophthalmology," vol. viii., p. 501), of which the general characteristic was an optic disk about twice as large as the normal optic papilla, surrounded by a normal appearing choroid in which there was no coloboma. The surface of the disk had the appearance of having yielded backward and downward, as can be recognized from the color and course of the vessels, and exhibits the picture of a deep and even excavation, from the bottom of which the lower retinal vessels start forward, and become first visi-

ble as they mount into view over the lower edge of the disk, as seen in the drawing (Fig. 45). The scleral and choroidal rings are united into a single line. This excavation of the substance of the disk is formed by the non-closure of the embryological furrow in the optic nerve which should naturally unite, and through which the vessels are to be led to the retina.

An excavation of the same nature, although of a less degree, is to be seen in the chromo-lithograph (Plate III, Fig. 3, reproduced from "Jaeger's Atlas," Taf. xix., Fig. 87). Dr. Pooley also reports a case of this anomaly in the "Transactions of the Sixth International Congress at Milan."

I once observed a case in which there seemed to be no coloboma of the sheath of the nerve, but simply one of the embryonic furrow alone, as the disk was no larger than it usually is, and the choroidal and scleral rings were perfectly formed. There was, however, a pronounced and split-like excavation at the lower portion of the nerve, with steep and crater-like sides over which the lower vessels curved forward into the retina.

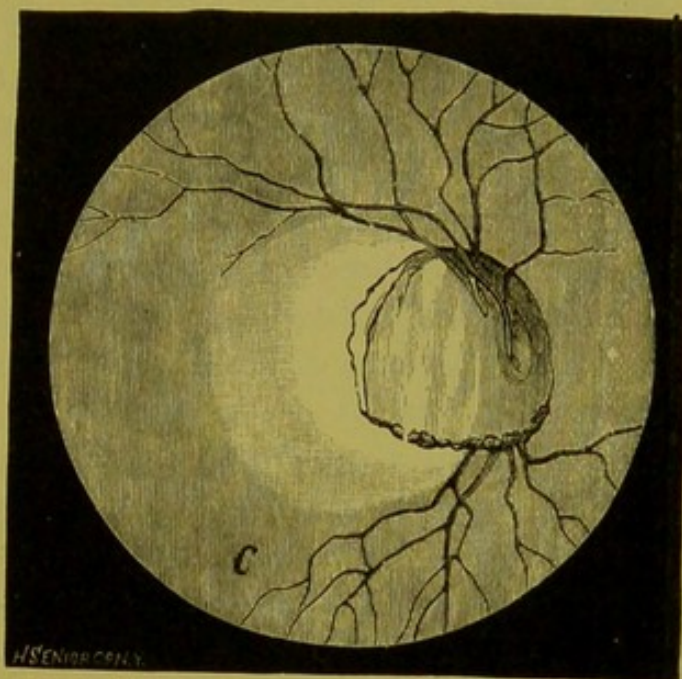


FIG. 45.

Anomalies of the Disk.—The shape and size of the optic disk and the inequalities in its surface vary so much in the normal eye, that it is difficult oftentimes to say where physiological variations leave off and anomalies begin. Irregularities in the close adjustment of the choroidal opening occur to a greater or less extent in many eyes, and sometimes produce the effect of the crescentic figure known as a "conus." This occurs usually at the outer edge of the disk, or directly downward, less frequently inward, sometimes, but very rarely, upward. It is not to be confounded with the "cone," the result of progressive myopia. Fuchs, in his paper on congenital anomalies of the optic nerve,* gives some marked cases of malformation of the nerve-entrance and its immediate neighborhood, due to the presence of a cone directly below the disk, of which Fig. 46 is an example. With this defect there is usually also a distorted condition of the vessels. The

* "Archiv für Ophthalmologie," B. xxviii., Ab. 1, p. 139, 1882.

defect commonly occurs in both eyes to a greater or less degree, but sometimes only in one. This cone is always congenital, and may be looked upon as the analogue of the ordinary coloboma, only of a less degree.

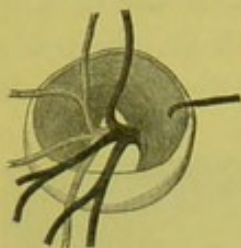


FIG. 46.

Fuchs also gives a drawing of a congenital anomaly in which the papilla is covered by a membrane, which crosses the entire nerve and completely conceals the entrance of the vessels. Of such membranes, Fuchs has seen three. I have myself observed one which was evidently a congenital formation, consisting of a delicate but at the same time untransparent membrane, which covered the entire nerve-entrance, and which extended out over the retinal vessels for some distance beyond the borders of the disk. The vision of the eye was but slightly below the normal.

It has been already mentioned that sometimes the borders of the choroidal opening do not fit as closely as usual to the head of the nerve, so that, instead of a crescentic figure being formed which resembles a cone, the entire circuit is increased, and the disk, therefore, appears to be abnormally large. (See chromolithograph, Plate II., Fig. 3.)

Sometimes, though very rarely, the choroidal opening instead of being larger than normal is smaller; that is to say, the choroidal tissue seems to extend over the limits of the disk. I have seen several such cases, and of these Fig. 47 is the most marked example. This was sketched from the eyes of a patient in middle life, with a high degree of compound myopic astigmatism, and two other members of the family had the same anomaly, only to a less degree. (See also chromolithograph, Plate II., Fig. 4.)

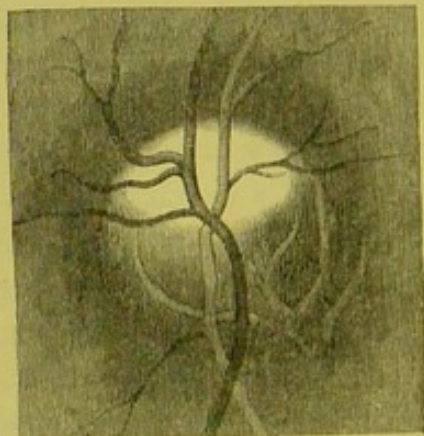


FIG. 47.

Opaque Nerve-Fibres.—One of the most striking and in some cases one of the most confusing, to the beginner, of all ophthalmoscopic pictures is that presented by the peculiar condition known as “opaque nerve-fibres.” As was shown in the anatomical description, p. 24, the fibres of the stem of the optic nerve discard their outer or medullary sheath, which is opaque, as soon as they have arrived at the lamina cribrosa, and continue on in their course to the retina as simple axis cylinders, which are perfectly transparent. The same thing takes

place in the condition now under consideration. The fibres lose their medullary sheath at the lamina cribrosa so that the head of the optic nerve or disk has its usual degree of transparency, but the medullary sheath is reinstated again just as the fibres leave the edge of the papilla to be distributed to the retina and become again opaque. The combined effect of these opaque fibres is to produce at the border of the disk a very conspicuous figure of greater or less extent, which is either of a dull opaque white, or, on the other hand, of considerable brilliancy, with a mother-of-pearl or watered-silk sheen to it, and with occasionally a bluish or even a greenish tinge. The usual place for the appearance of this figure is either at the upper or lower margin, singly or at both places at once. It is very rarely situated at the inner side of the disk, and according to some authorities never on the outer side, or that toward the macula lutea. I certainly have never seen it there. This white figure or plaque is ordinarily of about the diameter of the disk in extent, and with the disk as a base extends out over the surface of the retina, the outer border being more or less convex. It is when it is of these dimensions and shape that it is most likely to be taken for an exudation due to some form of retinitis or neuro-retinitis, especially in those cases where the fibres are very abundant and dense, and the outer sheath well developed, as then the level of the opaque fibres is somewhat more advanced than the general surface of the retina. The chromo-lithograph (Plate II., Fig. 6) is taken from Liebreich, and gives an admirable representation of the anomaly as it commonly appears, though necessarily lacking in brilliancy and contrast ("Atlas," Taf. xii., Fig. 2).

As a rule, the opaqueness of the fibre does not leave off abruptly, but gradually becomes thinner and thinner toward the edge of the plaque, which then ends in tongue-like extensions or flame-like processes. The larger vessels in the immediate neighborhood of the papilla are usually more or less covered in by the opaque mass, and the smaller ones completely concealed by it. The vessels, however, reappear again, and, meandering in and out of the opaque plaque, offer a very striking and beautiful appearance.

The disk itself sometimes, though comparatively rarely, participates in this want of transparency of the fibres; that is to say, the medullary sheath is re-established before the fibres reach the border of the papilla, as shown by one of the drawings by Liebreich (Taf. xii., Fig. 1). Sometimes in conjunction with the trouble bordering upon the disk there may be a second isolated spot separated from that at the papilla by a portion of the fundus which has a perfectly normal appearance, and which may in some cases be of considerable extent, as

shown in the picture by Liebreich, Taf. xii., Fig. 1; also Jaeger ("Hand Atlas," Taf. vi., Fig. 36).

The drawing (Fig. 48) is taken from Jaeger ("Hand Atlas," Taf. vi., Fig. 36), and is reproduced here, not because this is the common

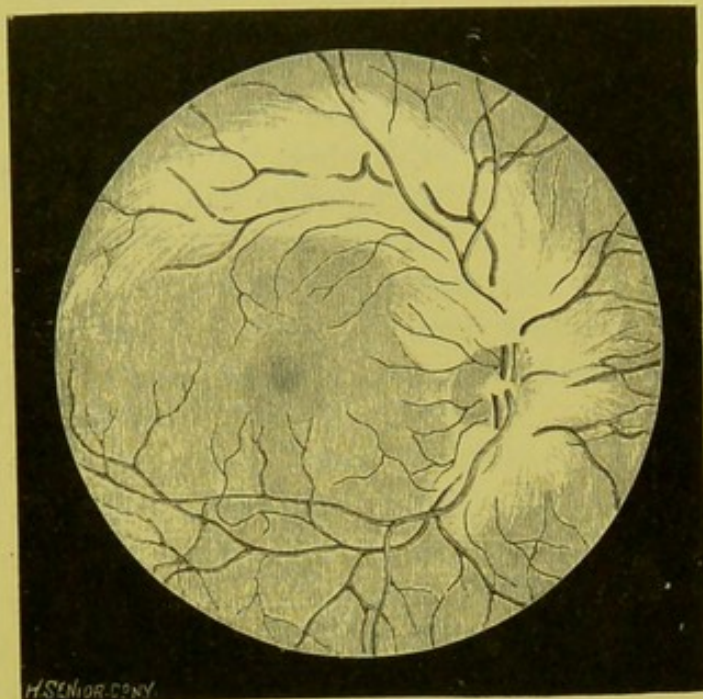


FIG. 48.

form under which the anomaly presents itself, as this is better shown in the chromo-lithograph (Plate II., Fig. 6), but as an exaggerated example of what may occur, and which when once seen places the learner on his guard as to what may take place in this direction. I have seen the exact counterpart of this picture, but I must say that, from the light and feathery appearance which the plaque presented, I was led to

believe that the effect was largely due besides the opaque fibres to a redundancy of connective tissue. There is usually no disturbance of the amount of vision in these cases, although careful examination will often show that Mariotte's blind spot is increased in size.

Abnormal Transparency of the Nerve-Fibres.—Instead of the above condition, or want of transparency of the nerve-fibre, the opposite may occur, and the fibres of the head of the nerve show too great a transparency. According to Jaeger, who described it anatomically, such a condition is due to the fact that the nerve-fibre loses its outer sheath some distance before it reaches the lamina cribrosa, and, for this reason, our view can penetrate to a deeper extent into the stem of the nerve, which gives the effect of what Jaeger has called an apparent excavation of the optic nerve. This would presuppose that the transverse fibres and vessels of the lamina were also transparent. A better explanation would perhaps be, that the lamina was situated more posteriorly than normal. I have never seen myself exactly the condition described by Jaeger, and after him by Mauthner ("Lehrbuch der Ophth.," p. 258), but I have seen what seemed to me to be an abnormally transparent head of the nerve, in which minute

vessels appeared to be imbedded, as if in some gelatinous substance. This I attributed to a lack, or almost entire want, of connective-tissue elements, and to a paucity of the smaller vessels.

Bifurcation of the Optic Fibres.—Under this title Mauthner ("Lehrbuch der Ophthalmoscopie," p. 267) gives a description of an anomaly which he had seen but once in his experience, and of which Jaeger furnishes the drawing ("Hand Atlas," Taf. vi., Fig. 31). In this case, that of a boy, the optic nerve-fibres seemed to be collected to a great degree into bundles, which ran upward and downward. The vessels also ran upward and downward within the region of these bundles, while the outer and inner portion of the retina appeared to be free from vessels. The fibres were not opaque fibres, nor did they have a white color, but still they were clearly defined as fibres, as by their superimposed condition the upper and lower borders of the disk were obliterated, and the fibrous structure of the retina at this part clearly denoted. The picture given by Jaeger certainly has the appearance which a highly astigmatic eye would produce, but it was shown by careful examination that the appearance was not due to this or any other optical error. I have myself seen not infrequently in highly myopic eyes appearances something similar, though in a less degree, to those described by Mauthner, and have attributed them to some faulty development of the optic nerve as well as that of the entire fundus, and especially of the vascular supply of the retina.

Discoloration of the Optic Nerve.—Mauthner also mentions (p. 267) some remarkable cases of discoloration of the optic nerve independent of the infinite variety in shade, if not in color, which is common to the disk in physiological conditions. Chief among these is an optic nerve of a sky-blue or dark-brown color, and he refers to an example figured by Jaeger (Taf. vii., Fig. 40) in which the color is very pronounced and clearly defined by the use of the upright image and weak illumination. The color in the picture referred to seems, to my eye, much more of a green than a blue, though it is described as the latter by Jaeger. I have myself never seen any such marked cases, or, indeed, any which approached them except in morbid conditions.

Anomalies of the Vascular System.—In regard to the variations in the vessels of the retina, attention has been called already to the great differences which may exist in the perfectly normal eye, as to the earlier or later divisions of the principal branches and their wide fluctuations in color, diameter, and tortuosity. So great, indeed, are these variations that it is difficult to say where a physiological peculiarity leaves off and a congenital abnormality begins. Under this

latter head may, I think, be classed the examples of great tortuosity of the vessels, reported by Mr. Benson and Mr. Nettleship ("Trans. Ophth. Soc. United Kingdom," vol. ii., pp. 56, 57, Plate III, 1882). In Mr. Benson's case, as shown by an excellent drawing, the veins and arteries were very large, very numerous, and excessively tortuous, and exhibited these peculiarities in each eye. There was no appearance of past neuritis; no exudation into the retina or thickening of the adventitia of the vessels; and yet, so great was the tortuosity and snake-like character of the vessels, that all but a very experienced observer would be led to believe that he was in the presence of a commencing neuro-retinitis or choked disk, especially of that form known as the "Medusa" nerve. (See, also, drawings published by Dr. S. Mackenzie, *ibid.*, vol. iv., p. 152, Plate V.)

It is only very seldom that an increase in the actual number of the retinal vessels is to be determined, either in the veins or arteries, and, when it does occur, it does so more frequently with the former than with the latter. Occasionally we see, on the other hand, an abnormal decrease in the number of vessels, as a whole, or an arrest of development in a particular branch.

According to Jaeger,* a decrease in the transparency of the walls of the vessel may take place. This may vary from a slight want of clearness, which is hardly perceptible, to a complete want of transparency. This may show itself either as a cloud-like disturbance in the wall of the vessel, or as a granular or punctiform striation, which may run either crosswise or lengthwise of the vessel. It has no regular formation, and may be limited sharply to one spot, or extend itself gradually into the transparent portion. These disturbances have usually a grayish-white or yellowish-brown color, or they show themselves as completely untransparent patches, which strongly reflect the light, and which have at times a silky lustre. These longitudinal discolorations or patches may occur here and there on different vessels, or in different parts of the same vessel. They are most frequently met with, and are larger and more pronounced in character, within the region of the head of the nerve and its immediate neighborhood, and less frequently found at the periphery of the fundus. On account of these disturbances, the actual walls of the vessels are delicately defined or even strikingly manifest. The light-streak may be either increased or diminished in size or brilliancy, and take on a granular or striped appearance. The color of the blood-column becomes of a lighter aspect and has a greenish-brown or a grayish-red tinge.

The index of refraction of the wall of the vessel also affects the

* "Ergebnisse der Untersuchung mit dem Augenspiegel," 1876, p. 61.

appearance of the blood-column. Under its influence the column of blood appears to be bounded on each side, to a greater or less extent, by narrow translucent bands, which correspond to the thickness of the walls. These longitudinal bands, although transparent, possess, from a difference in refraction from the surrounding tissue, a peculiar smoke-like and hazy appearance, which distinguishes them by contrast from the surrounding tissue, and which gives them the appearance of being slightly in shadow.

These disturbances of the vascular system which have been described, do not usually, unless of a very high degree, produce any functional disturbance.

Persistent Hyaloid Artery.—As is known, the hyaloid artery in embryonic life passes through the central canal of the vitreous body on its way to the posterior surface of the lens. This vessel usually disappears before birth, but sometimes persists as a great rarity in after-life, and then reveals itself to the ophthalmoscope, usually as a minute thread-like band which, leaving the central portion of the disk, stretches out into the vitreous for a greater or less extent. It may, indeed, traverse the entire vitreous body and be attached to the posterior surface of the lens. Usually, however, the anterior end is unattached, and the body then commonly undergoes a serpentine movement with the varying motions of the eyeball, though it may sometimes remain motionless even under these conditions. With the mirror the artery or its remains usually appear black, or at least of a deep gray color, either in part or in whole, but it must not be inferred from this that the vessel does not contain blood, for as with other bodies in the vitreous we, under ordinary circumstances, see the vessel not by the light which is reflected from its own surface, but by contrast with the light which is reflected from the fundus beyond it. Zehender reports a case in which the red color of the ordinary vessels was present at the point of origin of the artery at the disk, was wanting in the central portions, and again present in the very anterior portions when oblique light was used, thus showing that the vessel was patulous for its entire extent. Cases of this anomaly of late years have been reported by most of the well-known observers, and it is no longer the rarity it once was. The only case which I have seen myself was in the eye of a young adult. Here the vessel or its remains had the appearance of a fine, dark-colored string, which was attached to the central portion of the disk. It tapered gradually toward its anterior end, which was surmounted by a small, flattened projection, which was not unlike the head of a serpent, and by which it had been evidently attached to the posterior surface of the lens in the embryonic

state (Fig. 49). On the posterior surface of the lens there was also a small, dark opacity, which was the point of its original attachment. Whether the vessel contained blood or not could not be determined,

but it had rather the appearance of a vessel which had been obliterated than one which still carried blood.

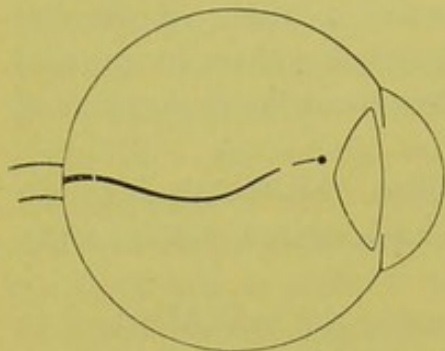


FIG. 49.

This artery usually arises from the central artery, but it may occasionally arise from one of the smaller branches. Dr. Kipp reports a case where the anomaly was present in both eyes ("Knapp's Archives of Ophthalmology and Otology," vol. iii., p. 70).

Dr. W. Seely reports a case of the remains of the hyaloid system, where the attachment instead of being at the disk was at the posterior pole of the lens. The posterior portion of the string was freely movable in the vitreous ("Trans. American Ophth. Soc., 1882," p. 345).

Anastomosis of the Retino-choroidal Vessels.—It is certainly a little curious, since a connection has been shown to exist between the central and ciliary system in the immediate neighborhood of the disk, that no such anastomosis has ever been actually seen in normal eyes with the mirror. Anomalies in distribution and course of both retinal and choroidal vessels are common enough, but a true case of a direct communication visible with the ophthalmoscope in a normal eye has, I believe, never been reported. The nearest approach to such a condition, so far as I know, is the case reported by me in a myopic eye, in which a retinal vessel appeared to lead directly into a choroidal vessel ("Knapp's Archives," vol. ii., part ii., 1872).

Leber mentions the fact that in the immediate neighborhood of the nerve a choroidal vessel may penetrate as far as the retina, and can be seen to do so with the mirror, but he does not say that any communication between such vessel and a retinal vessel takes place, much less that such a connection is visible with the instrument (G. and S., vol. ii., p. 307, 1876).

Nettleship, under the title of cilio-retinal blood-vessels, gives a series of cases in which, although no communication was seen to take place, yet in which it was inferred that it must do so from the fact that a retinal vessel was observed to approach as far as the edge of the disk, and then instead of entering or emerging from the porus opticus, to bend round and pass behind the choroid ("Ophth. Hospital Reports," vol. ix., Pt. ii., p. 161, 1877). In these cases, as in those earlier reported

by me, either the vessel penetrates the sclera and makes an outlet for itself, or passes down along the sheath of the nerve to the central system beyond the point of view, or again joins some choroidal vessel, as really seemed to be the fact in the cases which were reported by the writer.

Arterio-venous Anastomosis.—In the “Transactions of the Ophthalmological Society of the United Kingdom,” vol. iv., p. 156, 1884, Mr. Gunn publishes a case of “direct arterio-venous communication on the retina.” The drawing shows in the left eye the presence of a large vessel, running vertically, immediately to the inner side of the yellow spot. This was found to be a branch of the inferior temporal vein, running directly upward; the vessel bifurcated soon after passing the level of the yellow spot. One of the terminal branches continues upward in the line of the vessel, while the other passes upward and inward for a short distance and then opens directly into an artery. There was a cilio-retinal anastomosis in the other eye, so that the condition is probably congenital.

I can not conclude this chapter without again urging the student to perfect himself in the anatomy of the part, and then to make himself thoroughly acquainted with the appearances of the normal eye in all its phases, and never to assume that appearances are abnormal, no matter how peculiar they may be, until he has convinced himself that they are not within physiological limits or the result of some anomalous development. It is only in this way that he can avoid falling frequently into error, which may subject his patient to a long and useless medication, or even to all the annoyances and dangers of an uncalled-for and oftentimes dangerous operation. It is the same old story of the musician and his scales. Five sixths of the art of ophthalmoscopy are contained in a knowledge of the normal eye, the rest is a series of representations which can be read almost at sight.

CHAPTER V.

DETERMINATION OF THE OPTICAL CONDITION OF THE EYE WITH THE OPHTHALMOSCOPE.

THE observer having become so at home with the upright image that he can readily obtain a perfectly distinct view of the fundus through an undilated as well as a dilated pupil, should then, but not before, turn his attention toward what may be called some of the niceties, if not the beauties, of the art, chief among which is the ability to determine the optical condition of the eye.

Beautiful and comprehensive as the upright image is, as a whole, it has one particular advantage above all others, which, as Helmholtz himself mentioned, is "the ability to determine the optical condition of the eye, independent of its visual power, or the statements of the person examined."

Since Helmholtz first pointed out this fact in 1851, Ed. Jaeger, Donders, and others have written upon the subject, but it is to Mauthner, in his admirable work on the ophthalmoscope, that we are indebted for the most exhaustive treatise which exists on this important branch of ophthalmoscopy.

Any ophthalmoscope which is provided with an apparatus at the back for holding the necessary glasses may be used. Here it is that the modern instruments have such an advantage over the older—so much so, indeed, that little can be done in this respect without one.

The kind of mirror, too, is rather a matter of preference than necessity, some examiners preferring a plane, others a concave silvered one. For the simple determination of errors of refraction, I must say that I have a decided preference for the latter wherever it is not directly contraindicated by a dread of light on the part of the patient. There are, it is true, cases where the iris is unusually responsive to light, where it is necessary to use the weak illumination, and even here the difficulty can be usually met by reducing the volume of light employed.

As the very word refraction implies the true optical value of an eye independent of its accommodation, it follows that this condition can only be ascertained when the eye examined is in a state of rest. Further, that it is indispensable that the observer should be aware of

the exact state of refraction and accommodation of his own eye, before he can estimate that of another.

Perfect relaxation of the accommodation in the observed eye can of course be obtained by atropia, no matter what the nature of the refraction is. But, usually, sufficient relaxation can be secured in emmetropia by causing the patient to look into the distance, and, as much as possible, into vacancy, which is induced somewhat by having the walls of the ophthalmoscopic room painted black. For a myope it will only be necessary that he should look at some object which is at a greater distance than his far point. The ability and disability which hypermetropes have in relaxing their accommodation will better be considered a little later under its special heading.

As far as the observer is concerned, it can be laid down as a rule, at least for beginners, that the nearer the refraction of his eye approaches emmetropia, and the more completely he can relax his accommodation, the better. This ability to relax the accommodation varies with different people, some acquiring the power completely, others only partially. Practice here, as elsewhere, increases the ability. If the observer is emmetropic, one of the best methods of acquiring this control over the accommodation is to take a convex glass of a moderate power, say 3 D, and ascertain the farthest point at which fine type can be read with perfect distinctness through the glass, the other eye being closed, or better still, opened but excluded from the visual act by a screen. Under this condition there is a tendency for the visual axes to assume a parallel position, and with it that perfect state of rest usual to the eye when looking at the most distant objects. If the object can be moved in this case to a distance of twelve inches, it is proof positive that the accommodation is entirely relaxed, since, as the object viewed is situated at the principal focus of the glass, only parallel rays can enter the eye, and such rays can only be brought to a focus on the retina of an emmetropic eye when it is in a state of perfect rest. This experiment should be repeated with glasses of various strengths till the ability is acquired of always seeing the test-object at the focal distance of the glass used. This once acquired, a little further practice with the ophthalmoscope will also enable the observer to relax his accommodation during the examination.

If, however, the object viewed can not be removed from the eye to a distance equal to the focal length of the glass, then it is evident that the accommodation is not entirely relaxed. If, for example, convex 3 D be used, and the object, instead of being seen distinctly at twelve inches, the focal length of 3 D expressed in inches, can only be so seen at nine, then it is evident that some accommodation is still

going on, and the exact amount of this will be equal to the difference between 4 D and 3 D = 1 D. Continued practice may soon enable the observer to overcome this involuntary contraction of the accommodation. Sometimes, however, in spite of all his efforts, it still remains, but he soon finds that the amount used is always the same. This, then, represents the optical condition of his eye. If, for example, he finds that the amount of accommodation which he still uses is 2 D or 3 D, his eye is then, practically speaking, no longer emmetropic, but myopic, equal in fact to 2 D or 3 D, as the case may be. Consequently he must use a concave 2 D or 3 D, in order to see clearly a near object, the rays from which, however, enter his eyes as parallel. Having thus ascertained the optical condition of his eye in its greatest state of rest, he should, having selected some one whose eye has been proved to be emmetropic, practice with the ophthalmoscope through the glass which he has previously found neutralizes the amount of accommodation which he involuntarily employs.

As a rule, then, the weakest concave glass through which the fundus of an emmetropic eye can be distinctly seen should be taken as the criterion on which the emmetropic observer, who can not entirely relax his accommodation, should base his estimate of refraction.

If the observer is ametropic, the simplest way for him is to reduce his ametropia by the suitable glass. When the observer is astigmatic, he must either wear the proper correcting glass or, better still, have one of small diameter attached by means of a clip or slide to the back of his instrument. More, however, in regard to this matter will be found later under its appropriate heading.

It is, of course, very essential, for an accurate determination of the refraction, to have some object-point in the eye examined, which shall be fine enough not only to let us judge when we see, but when we are seeing with the most perfect sharpness.

The most conspicuous object, and one for which we at first instinctively look, is the papilla, but this should never be chosen, as it very frequently is, however, as an object on which to found our observations, for the disk often protrudes, sometimes to a considerable degree, above the general plane of the rest of the retina,* and would thus frequently lead to the supposition that an eye was hypermetropic, sometimes markedly so, which was in reality emmetropic or even myopic. An eye lately examined by the writer was, for example, hypermetropic 1 D at the disk, but myopic 2 D in the region of the macula, and Dr. Mathewson showed a case at the New York Ophthalmological Society which was emmetropic at the disk and myopic 6 D at the macula.

* See Chapter IV., Fig. 32.

The main trunks of the central artery, besides being often on an advanced plane at the nerve-entrance, are in themselves seen under too great an enlargement to admit of nice discrimination in focal adjustment. There are, however, some very fine vessels which always leave the edge of the nerve, running out horizontally on both sides. These are admirably adapted for the purpose when viewed at a little distance from the disk, especially toward the inner side. The best of all objects, however, at least for those who are skilful in this kind of examination, is the choroidal epithelium in the neighborhood of the macula, though the advantages which this region offers are often more than counterbalanced by the difficulties which attend its examination.

The observer having found out the exact optical condition of his own eye, it remains for him, first, to ascertain the nature of the refraction of the eye under examination, and then, if ametropic, to determine the exact degree of the anomaly.

If the observer is emmetropic, and relaxes his accommodation entirely, he knows that his eye is adjusted for parallel rays only. Now, the only kind of eye from which rays emerge parallel is an emmetropic eye; consequently, if the fundus of the eye examined is focused sharply on the observer's retina, the rays which enter his eye must be parallel, and the eye observed must be emmetropic.

If, in a given case, the observer finds that he does not gain a clear view of the eye examined when his own eye is in a state of rest, but that it becomes clear by using his accommodation, he then knows that the observed eye must be hypermetropic, since his own eye under tension of the accommodation is no longer adjusted for parallel but for divergent rays, and there is no eye but a hypermetropic eye from which divergent rays can possibly come.

If the observer finds, however, that he can get no clear view of the fundus, either by relaxing or calling forth his accommodation, he knows that the rays coming from the observed eye can not be either parallel or divergent, consequently they must be convergent, and the eye examined myopic.

Having thus ascertained in a general way the *nature* of the optical condition present, the next step is to determine the exact degree of the refraction, it being presupposed in all cases that the examined eye is in a state of rest, as it usually is under the ophthalmoscope.

If the observer has already perfected himself in the use of the ophthalmoscope, and can readily catch the fundus and so approach his own eye to the observed eye as to place his instrument at the distance from the cornea in which trial-glasses and spectacles are usually placed, then the determination of the errors of a fraction, thanks to

the system of dioptries, is exceedingly simple, and but few calculations are necessary. The observer has only to ascertain by successive trials the glass through which he sees the fundus with perfect distinctness; and as the distance between the two eyes is so small that it may be neglected, the observer has only to remember that in hypermetropia it is the *strongest* and in myopia the *weakest* glass through which the details of the fundus remain sharply defined, which is the correct representation of the existing degree of H or M .

If, for example, the eye being hypermetropic, the strongest glass through which the fundus remains clear is $+4$ D, then $H = 4$ D.

If, on the other hand, the weakest glass through which the fundus becomes perfectly distinct is -4 D, then $M = 4$ D.

Such being the theoretical rules, it remains to be seen how far they are applicable to the wants of the practitioner. The advantages offered by this method may be summed up as follows:

(1.) In the ability to tell the optical condition of the eye examined independent of the statements of the patient, or amount of vision of the eye.

(2.) In measuring the amount of elevation or depression of given parts of the fundus.

Under the first heading, the point which, without doubt, is the most important in a practical point of view is the determination of the degree of latent hypermetropia.

The use of atropia, combined with the trial by glasses is, and must remain in the vast majority of cases, the most certain test possible; still, its employment is attended with more or less inconvenience to all, and to some with so much that its use is often impossible. Consequently, any means of diagnosing the amount of total hypermetropia, which is on the one hand accurate, and on the other free from inconvenience to the patient, can not fail of being of the greatest value to the practitioner. The only question is, Can the ophthalmoscope do this?

From the result of a series of trials with the ophthalmoscope, both before and after the use of atropia, Mauthner does not hesitate to answer this question in the affirmative, laying it down as a law that "*in examinations with the ophthalmoscope (by the upright image) the total hypermetropia is revealed.*"* This opinion is supported by the citation of the following remarkable case:

A boy of twelve years presented the usual symptoms of asthenopia. Both concave and convex glasses were declined for distant vision. Even convex .5 D was obstinately rejected. The ophthalmoscopic

* Mauthner, "Lehrbuch der Ophthalmoscopie," Ab. 1, S. 174.

examination brought to light a hypermetropia of 7 D. The eye was then paralyzed with atropia, and the total H was found to be by glasses 7 D.

Inasmuch as I have never seen a case of total H of so high a grade as 7 D where there was no manifest at all, I am unable to corroborate the above case with a precisely similar one from my own practice. I could, however, cite many where the degree of the manifest was very trifling in proportion to the total revealed by the ophthalmoscope, and where the latter obtained by this means differed but slightly from what was subsequently obtained by the use of atropia and glasses. For example, 1 D with glasses, 3 D with the ophthalmoscope; 1.5 D with glasses, 6 D with the ophthalmoscope, 6 D with atropia; 2 D with glasses, 6 D with the ophthalmoscope, 7 D with atropia; 3 D with glasses, 8 D with the ophthalmoscope; 4 D with glasses, 7 D with the ophthalmoscope, 7 D with atropia, etc., etc. Such glittering results as these certainly need but little comment, and their practical application but little explanation, the only wonder being that examinations of this kind are not as universal as the use of the ophthalmoscope itself.

There is one point which at first appears curious, and that is, that we get the most exact, and certainly by far the most brilliant results, just where we should expect them least; that is, with the highest grades of hypermetropia, at least such has been my experience, so much so that I feel convinced that it is very difficult, sometimes impossible, with young people to tell the lighter degrees of H (less than .75 D) with the ophthalmoscope, unless indeed atropia has been used. This I believe to be owing to the fact that hypermetropes of a high degree often relax their accommodation entirely while looking inattentively into the distance, and make no effort to call forth their accommodation till their attention is aroused. When, however, their attention is called to some particular object, they instinctively call forth that amount, or very near it, which is demanded for parallel rays. Consequently, under glasses where particular attention is required of them in deciphering the smaller letters of the test-card, they refuse to relax their accommodation except to a trifling degree; but when placed in a dimly-lighted room and told to look at a wall which offers a black and diffused surface, and which will appear to them but a little less distinct even when seen in circles of dispersion, they have no difficulty in relaxing their accommodation. But young persons, who have, say, H .75 D or less, see clearly in the distance with so little effort that they probably never relax their accommodation, preferring to make slight demands on their ciliary muscle rather than to see in

circles of dispersion. Their condition is practically emmetropic, and in the ophthalmoscopic room they relax their A no more than they are accustomed to, accommodating for the plane of the wall which they see distinctly, or at most for parallel rays. We may, however, lay it down as a rule, even in these cases, that where little or no H can be detected, either by glasses or the ophthalmoscope, little or none exists.

Without being able to accept, then, unreservedly Mauthner's general statement, that the total H can be invariably determined with the ophthalmoscope, we nevertheless believe that a very close approximation to it can almost invariably be obtained, even where a spasm of the ciliary muscle exists. The following pronounced case is an example in point: A lad of twelve years was brought to me by his father with the statement that his son was near-sighted; that he had become so rather suddenly, and he wished to see if he were wearing the proper glasses. The glass the boy had on at the time was -1 D. With this glass $V=1$. On looking into the eye with the mirror, it was seen at once that the boy was not myopic, although he had rejected all other glasses, but was in fact hypermetropic to a considerable degree. The fundus could be distinctly seen with $+3.5$ D, and atropia afterward showed the total H to be 4 D.

So much for the ophthalmoscope where atropia has not been used; but there are cases in which it is even superior to the test by atropia and glasses, where the latter indeed utterly fail in giving an idea of the amount of hypermetropia, as the following case will show:

A bright little girl was brought to me for the purpose of having the exact optical condition of the eyes determined. With a convex 1.5 D vision was decidedly improved, amounting, however, even with the glass, only to $\frac{1}{2}$ in the right eye, $\frac{1}{10}$ in the left. The same result was obtained under atropia. Glasses of various strengths from 1.5 D to 3 D were tried, and still the vision remained about the same. Recourse was now had to the ophthalmoscope, when a total H of 5 D was found in the right, 6 D in the left eye. The discrepancy between the glass selected by the child and the amount of H as given by the ophthalmoscope was so great that an independent examination was made by another oculist, with precisely the same result in each eye. There was evidently a large amount of congenital amblyopia, the only hope of relieving which certainly lay in careful and systematic exercise through that glass which would produce sharply defined images upon the retina, and this glass could only be ascertained through the ophthalmoscope.

So, too, in strabismus in children it is often impossible, from their inability to read, or the irrelevancy of their answers, to get an ade-

quate idea as to the condition of the refraction, even where atropia has been used. And yet the whole question in regard to operative interference may turn on the presence or non-presence of H and its degree. With the ophthalmoscope, however, with a little care and with a dilated pupil, the exact amount, or what approximates to it very closely, can, as a rule, be ascertained, even with children in arms.

So, too, in any disease in which amblyopia is an element.

One of the most interesting attributes of the upright image is the means which it affords us for determining the various planes which different parts of the fundus often occupy; for, inasmuch as a certain amount of refraction corresponds to a given length of the axis of the eye, we have only to know the refraction of a certain point to know its exact antero-posterior position, and the difference of refraction between two given points must represent their differences of level. We are thus enabled to measure numerically, for example, the amount of excavation of the optic nerve or its projection above the level of the retina, the projection of the choroid or retina from underlying effusion, the height of tumors and their rate of increase, the amount of swelling in the retina, the situations of membranes in the vitreous, etc.

Taking the emmetropic eye as a standard, calculations have been made to determine what amount of increase or decrease in the length of the optic axis corresponds to a given degree of hypermetropia or myopia. I have calculated, for the easy reference of the reader, from the formulas given by Helmholtz,* the two following tables, the first representing the amount of decrease in length of the axis due to H , and the second the increase due to M .

TABLE I.

+	0.25 D	equals a shortening of 0.70 mm.	
+	0.5 D	"	.14 "
+	1 D	"	.29 "
+	2 D	"	.56 "
+	3 D	"	.83 "
+	4 D	"	1.09 "
+	5 D	"	1.33 "
+	6 D	"	1.57 "
+	7 D	"	1.80 "
+	8 D	"	2.03 "
+	9 D	"	2.24 "
+	10 D	"	2.45 "

* "Handbuch der physiologischen Optik," S. 54; Mauthner, "Lehrbuch der Ophth.," S. 67-226, Ab. 1.

+ 11 D	equals a shortening of 2.65 mm.		
+ 12 D	"	"	2.84 "
+ 13 D	"	"	3.04 "
+ 14 D	"	"	3.21 "
+ 15 D	"	"	3.38 "
+ 16 D	"	"	3.56 "
+ 17 D	"	"	3.73 "
+ 18 D	"	"	3.89 "
+ 19 D	"	"	4.03 "
+ 20 D	"	"	4.19 "
+ 21 D	"	"	4.34 "
+ 22 D	"	"	4.48 "
+ 23 D	"	"	4.63 "
+ 24 D	"	"	4.78 "

TABLE II.

- 0.25 D	equals an increase of 0.07 mm.		
- 0.5 D	"	"	0.15 "
- 1 D	"	"	0.30 "
- 2 D	"	"	0.61 "
- 3 D	"	"	0.94 "
- 4 D	"	"	1.28 "
- 5 D	"	"	1.63 "
- 6 D	"	"	2.00 "
- 7 D	"	"	2.38 "
- 8 D	"	"	2.80 "
- 9 D	"	"	3.22 "
- 10 D	"	"	3.67 "
- 11 D	"	"	4.14 "
- 12 D	"	"	4.64 "
- 13 D	"	"	5.17 "
- 14 D	"	"	5.70 "
- 15 D	"	"	6.27 "
- 16 D	"	"	6.90 "
- 17 D	"	"	7.58 "
- 18 D	"	"	8.25 "
- 19 D	"	"	8.95 "
- 20 D	"	"	9.76 "
- 21 D	"	"	10.61 "
- 22 D	"	"	11.51 "
- 23 D	"	"	12.57 "
- 24 D	"	"	13.51 "

The application of the above tables will perhaps be made clearer by some examples, thus:

In a case of glaucoma the edge of the nerve is emmetropic, while the bottom of the excavation is myopic 4 D. As myopia 4 D signifies a lengthening of the axis equal to 1.28 mm. (see Table II.), the depth of the excavations must be, since the edge of the nerve is emmetropic, equal to 1.28 mm. In a second case the border of the nerve and general fundus is myopic 1.5 D, the bottom of the excavation is myopic 4 D; the true extent of the excavation will then be equal to 4 D — 1.5 D = 2.5 D, $M\ 2.5\ D = 0.76\ \text{mm.}$ In a third case the edge of the nerve is $H\ 1\ D$; the bottom of the excavation is myopic 4 D. As $H\ 1\ D$ represents a shortening of the axis 0.29 mm., and $M\ 4\ D$ an increase of 1.28, the true extent of the excavation will be $1.28 + 0.29 = 1.57\ \text{mm.}$

In a case of neuritis, following sunstroke, the centre of the nerve to which the disease was almost entirely confined was hypermetropic 3 D; the neighboring region was emmetropic. As $H\ 3\ D$ represents a shortening of the axis = 0.83 mm., the protrusion of the nerve was 0.83 mm.

In another case of violent neuro-retinitis in the left eye the centre of the nerve was $H\ 6\ D$; a little farther onward, $H\ 3\ D$; a little farther still, $H\ 1.5\ D$; and, at the farthest extremity of the field, toward the ora serrata, $H\ 1\ D$. In the other eye, in which the process had just commenced, the general refraction was $H = 1\ D$. Assuming, then, that the refraction of the eyes when in a state of health was emmetropic—and it could not have been far from this—a plan might easily be drawn (as, indeed, was done) representing the amount of swelling due to the morbid process. This might be subsequently compared with the future progress and recession of the disease, under atrophy, etc., and some interesting results obtained. It is, of course, very difficult to follow these cases of retinal swelling, such as are common to Bright's disease, from their beginning to their end; still, such opportunities do occur, even where the cause is renal, and it appears to me many interesting facts might be obtained from such investigations.

In a certain case a well-marked tumor was observed, situated exactly above the optic nerve, the upper edge of which it overhung. As the media were perfectly clear, a distinct view of the growth in all its detail was obtained. The crest of the tumor was, at the first examination, hypermetropic 6 D. The lower half of the nerve and all the surrounding fundus was emmetropic; the protrusion of the growth was then 1.57 mm. A subsequent examination was made and the crest of the tumor was found to be $H\ 9\ D$, the protrusion was then 2.24

mm., and the increase between the two examinations was $2.24 - 1.57$ mm. = 0.67 mm.

In another case a membrane in the vitreous appeared clearly defined when $+18$ D was used; consequently there would have been, if the retina had occupied the plane of the membrane, $H = 18$ D. The fundus was, in fact, emmetropic; the membrane was, therefore, in front of the retina to a degree equal to $H \ 18 \text{ D} = 3.89$ mm.

THE DETERMINATION OF ASTIGMATISM.

The determination of astigmatism by means of the ophthalmoscope has always been considered one of the most difficult, and, from its want of accuracy, one of the least satisfactory applications of the instrument, and there is no doubt that this is, to a great extent, true. Still, the difficulty in ascertaining the existence of astigmatism and the uncertainty in establishing its degree are, I think, due in a great measure to the method adopted, which has usually depended on the fact, first pointed out by Knapp* and Schweigger,† that in astigmatism the disk was seen elongated in one direction with the upright image, and in the opposite by the inverted.‡ The effect involved in this fact is due to the following causes:

If we look through a convex lens at an object which is placed within its principal focus, we see it magnified to a certain degree, according to the power of the lens.

If we make, for example, a small cross, the arms of which are of equal length, and view it through a common convex glass, say of three inches focal distance (12 D), it appears enlarged, but equally in both directions, as the magnifying power is the same for each arm. If we now add, however, a convex cylindric glass 6 D to the spherical, we increase the magnifying power in one principal direction without altering it in the other. The lens is, therefore, equal in one direction to 12 D, but in the other to $12 \text{ D} + 6 \text{ D} = 18 \text{ D}$. If we now turn the glass in such a way that the strongest magnifying power shall correspond with the vertical arm of the cross, this will be more enlarged than the horizontal, which is seen through a weaker power, and will consequently appear longer. If we now draw a circle round the arms of the cross in such a way that these shall be the radii, the effect will still be the same, and the circle will appear elongated in the vertical

* Congress at Heidelberg, 1861.

† "Arch. f. Ophth.," IX., Ab. 1, p. 178.

‡ This is, however, only true when in the inverted image the glass is held within the focal length of the lens from the eye, a fact which the observer being aware of he can always readily provide for.

direction because it is more magnified in that direction, consequently it will appear no longer a circle, but an oval.

If, however, we now take a second lens and hold it in the other hand at a certain distance in front of the first lens, just as we do in the indirect method with the ophthalmoscope, then we get an inverted image of the cross and circle round it, elongated no longer in the vertical but in the horizontal position. The reason of this is that the rays passing through the first lens, whose principal meridians are of different focal power, are refracted unequally, those passing through the vertical meridian where the lens is of two inches focal power more than those passing through the horizontal where it is only three inches. As the rays passing through the vertical meridian are more refracted by the first lens, they will, after passing through the second, come to a focus sooner behind it; and the nearer the rays meet behind a lens the smaller is the image, consequently the vertical line of the cross will now appear smaller than the horizontal, and the circle will now be elongated horizontally.

Applying this principle to the eye, Schweigger deduced the fact that with the upright image the disk in astigmatism is seen elongated in the direction of the meridian of greatest refraction; with the inverted image in the meridian of the least refraction. This gives us at once the directions of the principal meridians, and we have only to find the glass which reduces the distortion to know the kind and amount of astigmatism.

It will be seen at once that an examination must be made by *both* methods, for it may happen that the disk may be elongated anatomically in a vertical, horizontal, or oblique direction, the effect of which might be so counteracted by astigmatism as to make the disk appear round when the ophthalmoscopic examination was made by only one method, but never when both are employed.

Simple and true as all this is on paper, its application to practical wants is limited from the fact that the distortion under the degrees of astigmatism which usually occur in the human eye is not sufficient to form a basis for accurate calculation. It may be well to state, however, that the effect is always increased by the observer's alternately withdrawing from and approaching the eye examined, watching as he does so the change in the contour of the nerve.

From the uncertainty and want of delicacy attending this method of examination, it is evident that, in order to make the ophthalmoscope of practical use in astigmatism, we must look for some more sensitive test to act either as a supplement to or a substitute for the one mentioned above.

This we have in the vessels, and especially in the light-streak on their centre of curvature. The streak begins to lose its brilliancy and its lateral borders their sharpness of definition the moment the vessel, particularly if of the smaller kind, becomes out of focus even to a very trifling degree. Low degrees of astigmatism, certainly as low as .75 D, can be detected by this test, provided the accommodation in both the observed and observing eye is perfectly relaxed. On this account, it is much easier to determine the effect, if slight, when due to *M* than to *H*, and I do not think it is too much to say that in the former condition even .5 D can then under favorable conditions be pronounced upon.

If we consider the optic disk as the centre of a circle, and all the vessels large and small radiating from it as so many straight lines, we have in the fundus of the eye itself a representation of Dr. Green's test for astigmatism, in which the principal branches of the central artery and veins represent the vertical lines, and the small vessels leaving the edge of the disk the horizontal and oblique. It may be said that the principal trunks of the central artery and vein do not always run exactly vertical. This is true; but such is their general tendency, and the fact that the vessels do not continue in their original vertical course is of itself an assistance to the diagnosis.

The practical application of this is as follows: If we look with the ophthalmoscope through the cornea of an astigmatic eye to the retina beyond, the effect is precisely the same as if we were looking through an astigmatic glass, and the vessels radiating from the optic nerve will then appear just as the radiating lines do in the common test when seen through a cylindric glass, *most distinct in the meridian of greatest ametropia*. This gives us at once the direction of one of the principal meridians, and we know that the direction of the other must be at right angles to it. Having thus found out the direction of the principal meridians, we have then only to determine the refraction of each meridian separately, and the difference between the two will be the amount of astigmatism.

If, for example, in a certain case the vertical vessels appear perfectly distinct, and are only rendered less so by glasses, one of the principal meridians of the eye must be emmetropic. If, however, the fine horizontal vessels are only made distinct by a concave 1.5 D, then the second principal meridian must be myopic 1.5 D, and, inasmuch as the first was emmetropic, the amount of simple astigmatism present must be 1.5 D. So also if it had been *H* instead of *M*, and convex instead of concave glasses used. (See chromo-lithograph, Plate III, Fig. 5.)

If both meridians are myopic, but one more so than the other, then compound astigmatism is present with M in all meridians, but more pronounced in one. If, for example, the horizontal vessels are seen distinctly only with -3 D, while the vertical ones can be seen with -1.5 D, the general myopia then equals 1.5 D, and the astigmatism, that is, the discrepancy between the two principal meridians, is 3 D $- 1.5$ D $= 1.5$ D. The neutralizing glass would then be -1.5 Ds $\bigcirc -1.5$ Dc. Axis horizontal.

So too if it had been H instead of M , and plus instead of minus glasses had been employed.

It is a little puzzling, for those who are not much accustomed to the determination of astigmatism, to understand how it is that the vessels, as do radiating lines, always appear most distinct to an emmetropic eye, in the meridian of the greatest ametropia, instead of, as would appear more rational, in that of the least. It would, for example, seem more natural that, inasmuch as the vertical vessels were seen in the above case most distinctly, the vertical meridian should be the one which deviated least from the normal. But it must be borne in mind that the rays which form the vertical boundary of these vessels are, in fact, horizontal rays, and as such pass through, not the vertical, but the horizontal meridian, and, as this is emmetropic, they are readily focused on the observer's retina. On the other hand, the rays which form the boundary of the horizontal vessels are vertical rays, and pass through the vertical meridian, which is myopic, and consequently the horizontal vessels are indistinct, although this meridian is, in fact, emmetropic. This of course holds good for all kinds and degrees of astigmatism.

The writer readily admits that this method is also, though by no means in the same degree, wanting in accuracy, and is not to be looked upon at all as a substitute for the trial by glasses, but is to be used in co-operation with it. When so employed, the ophthalmoscope often renders important service in revealing to us at a single glance, the nature of the anomaly and the general direction of the principal meridians, when to have obtained them by glasses would have been an affair of hours. In cases of mixed astigmatism this holds true in a marked degree, and I can not forbear, for the sake of their practical bearing, from citing the two following cases:

A young lad was examined by me, who, it was alleged by his parents, was nearly "blind" in one eye. On testing the eyes, the left was found to have a trifling degree of hypermetropia ($.75$ D) with vision one. In the right eye, however, vision was reduced to $\frac{1}{20}$, that is, Snellen C. could only be read at five feet. A few trials were made

with glasses with no material improvement in vision. In looking into the eye with the ophthalmoscope the nerve appeared distorted and drawn out vertically, while at the same time its outline was indistinct in all directions, as were also all the vessels. On using the accommodation, however, the vertical edge of the nerve became well defined, as did all the vessels, so long as they ran in a vertical direction, but as soon as they deviated from this they at once became indistinct, and in proportion to the amount of the deviation. This was very apparent at a certain place where one of the larger vessels divided, sending off a branch almost at right angles to the original direction of the vessel. The branch which continued in the vertical direction remained perfectly distinct, and the light-streak in the centre of its walls clearly defined, while that running at right angles to it, that is, horizontally, was indistinct and evidently much out of focus, as were, in fact, all the vessels, large and small, running in this direction, and no amount of tension or relaxation of the accommodation made them clearly defined.

It was manifest that astigmatism was present, and that the directions of the principal meridians were vertical and horizontal. It was evident, too, that, as it required the action of the accommodation to make the vertical vessels distinct, there must be hypermetropia in the horizontal meridian. In determining the degree, it was found that the strongest glass through which a certain fine vertical vessel remained distinct at two inches distance was a convex 2 D, the hypermetropia in the horizontal meridian was therefore equal to 2 D.

As the horizontal edge of the nerve and all the vessels running horizontally remained indistinct, even when the observer's accommodation was perfectly relaxed, it was evident that the rays which formed the horizontal boundary of the nerve and vessels must leave the eye as convergent, and, as these rays are vertical rays, the eye must be myopic in the vertical meridian. It was found that the weakest glass under which the horizontal boundary of the nerve and vessels became sharply defined was 3 D, the vertical meridian was therefore myopic equal to -3 D. The case was therefore one of mixed astigmatism, in which the vertical meridian was myopic 3 D, and the horizontal hypermetropic 3 D, and the discrepancy between the two meridians was 6 D. With a bicylindric glass -3 D and $+3$ D, vision at once rose from $\frac{1}{20}$ to $\frac{8}{20}$. It was in fact increased eightfold. It was subsequently found from a careful examination that -2.75 Dc. and $+3$ Dc. was preferred. With this glass, vision became one half.

In another case, where the patient suffered a great deal from asthenopic symptoms, vision was found to be only one fifth in either eye.

Reading was performed at six inches, while in sewing the patient declared that she had to exercise great care to keep from wounding her nose with the needle. As in the former case, spherical glasses were tried with but little improvement of vision. On looking into the eye, here too neither the nerve nor any of the vessels appeared distinctly defined. On accommodating, however, it was seen that, although the vertical and horizontal vessels still remained comparatively indistinct, those that originally ran, and those which later in their course assumed an oblique direction upward and inward and downward and outward, suddenly came sharply into view, while those which ran at right angles became the most indistinct of all. The same effect was noticed all over the fundus, especially in following along the course of a vessel, some of the branches of which appeared perfectly distinct, while those running at right angles were much out of focus. This meridian was found to be myopic 1.5 D, the opposite hypermetropic 3 D. With these glasses properly arranged, vision rose from one fifth to two thirds, and the patient could read Jaeger No. 4 at ten inches, and sew with ease at twelve. The left eye was $+2$ Dc. $\cap -1.5$ Dc. $V = \frac{1}{2} +$.

Irregular Astigmatism.—This can, as a rule, be readily detected by the fact that a given vessel, while maintaining an undeviating course, can only be clearly defined for a comparatively short distance at a time, no matter what glass is used.

The vessel, while continuing in precisely the same direction, will for a short distance appear in focus with the light-streak perfectly defined, and then be suddenly interrupted by a portion which is out of focus, and perhaps a little displaced laterally; and, of two neighboring vessels, one will be sharply defined and the other not. A change of glass, or sometimes a change in the observer's accommodation, will reverse the original order of things, making the part which was indistinct clear and the other blurred. This very often happens when such cases are examined with a dilated pupil through portions of the cornea which are widely separated from each other, as, for example, through the upper and lower borders. The ability to diagnosticate irregular astigmatism with the ophthalmoscope is not a difficult matter, as a rule, and it will often save the surgeon a world of trouble in uselessly trying to make an accurate adaptation of glasses, an approximate one being all the circumstances will allow.

It may be well to mention here that irregular astigmatism, at least of large degrees, can be detected, by the use of the mirror alone at a distance, by the play of light and shadow which takes place on rotary movements of the mirror, and oftentimes by the distorted image of a

portion of the fundus with its sudden appearance and disappearance. This method of examination, and the appearances which follow, are similar to those obtained in examination for conical cornea.

DETERMINATION OF REFRACTION ACCORDING TO THE STANDARD OF THE INCH.

In what has preceded, it has been assumed that from practice on the normal eye the observer had become more or less an adept in the use of the instrument, so that he is enabled to approach very close to the eye examined; also that he had a sufficient knowledge of optics not only to understand the principles of lenses upon which the determination of refraction is based, but also the expression of their refractive power by the modern system of dioptries. Should this not be the case, however, and should the learner be unacquainted with the fundamental principles upon which refraction depends, then it would appear to the writer much simpler for him to first master the subject by means of the old system of notation, in which the focal length of a biconcave or biconvex glass is equal to the radius upon which each surface is ground expressed in inches.

This method, besides being easier of comprehension to the English-speaking student than the metre or dioptric, is, in fact, the more exact of the two, inasmuch as the distance between the two eyes can be readily and easily taken into consideration. The great discrepancies which often occur with the dioptric system when these conditions are neglected may be forcibly illustrated by an example which very frequently takes place when the error is of high degree: Two competent observers or students examine the same case. The first who approaches the eye so closely that the mirror nearly touches the cornea, sees the fundus sharply defined with -9 D. The second, only a single inch more remote than the first, requires 12 D—a difference of *three dioptries*. Such a discrepancy as this could not have occurred between two observers with the old method, which permits a ready and exact compensation for the different distances at which the examination is made. When the principle upon which the determination of the various errors of refraction depends is once understood, the result in inches can be readily reduced to dioptries. The French inch has been adopted as the standard, as it is used in general ophthalmology when the old system is employed. The reader must bear in mind, however, that the metric system has supplanted the old system of focal lengths in ophthalmoscopy, and that it is adopted here merely for the purposes of illustration. Methods for the transposition of the two systems will be found in the Appendix, p. 241. For the

sake of simplicity and clearness, the principles involved will be illustrated by a series of propositions.

PROPOSITION I. *For an emmetropic eye to determine that the observed eye is emmetropic.*—Let *A* (Fig. 50) be the observed eye illumi-

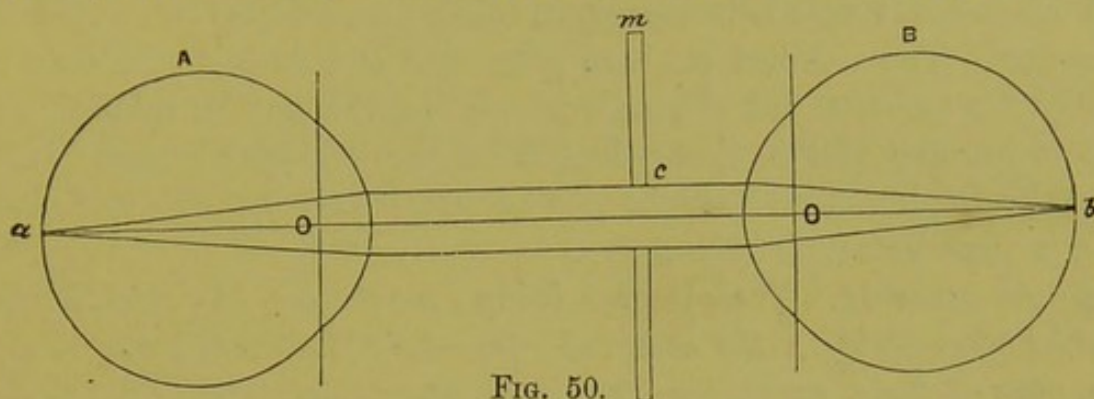


FIG. 50.

nated by the ophthalmoscopic mirror *m*. Since the eye is emmetropic and in a state of rest, rays radiating from an illuminated point *a* on the retina must leave the eye as parallel, and as such pass through the hole of the mirror *c*. If, now, the observer's eye is placed behind the mirror, the rays which strike his cornea being parallel, will, since his own eye is emmetropic and in a state of rest, just come to a focus on his retina at the point *b*. A distinct image of the fundus will therefore be obtained, as what is true of one point is of all. As his eye is adjusted for parallel rays and for no others, he knows the eye examined must be emmetropic; consequently the fundus of an emmetropic eye can be distinctly seen by another emmetropic eye without the aid of any correcting-glass, provided, however, that the observer's eye is also in a state of rest.

If, however, the observer is unable to relax his accommodation entirely, it is evident that the parallel rays entering his eye must come to a focus in front of the retina; that is to say, rays coming from the point *a* (Fig. 50) will no longer come to a focus at *b*, but will unite in front of it at *e* (Fig. 51). Circles of dispersion will consequently be formed on *B*'s retina, and an indistinct image of *A*'s fundus will be the result.

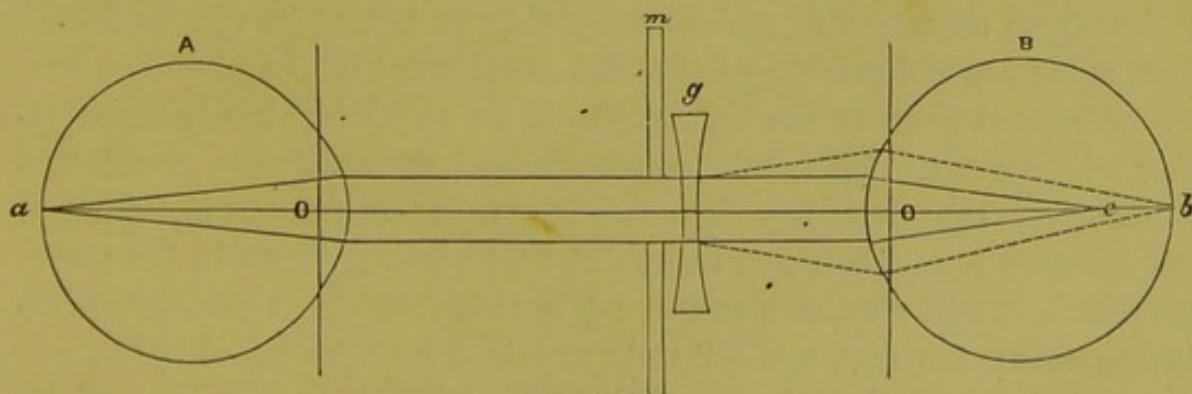


FIG. 51.

The reason of this is that *B's* eye—as has been formerly explained—though emmetropic while looking at distant objects, is, as far as ophthalmoscopic examinations are concerned—since he can not relax his accommodation—virtually myopic, and a concave glass (*g*) must be used behind the ophthalmoscope, to bring parallel rays to a focus on his retina. The weakest concave glass that will do this will then be exactly the amount that *B's* accommodation can not be relaxed, and with it his eye will be just adapted for parallel rays; consequently, when the fundus of an eye can only be seen clearly through this glass, the eye must be emmetropic.

PROPOSITION II. *The observer being emmetropic, to determine the amount of myopia in the observed eye.*—As the observed eye is myopic, rays of light emerging from it are convergent, and will meet at a point in front of the eye, at a distance just equal to the amount of the myopia. If, for example, the myopia equals $\frac{1}{6}$, then the rays will meet at six inches in front of the nodal point. As the observer's eye, however, is emmetropic, and in a state of rest, it is accommodated, not for convergent but parallel rays, so that, before the convergent rays coming from a myopic eye can be focused on the observer's retina, they must be made parallel. This will be made clear by the following diagram (Fig. 52).

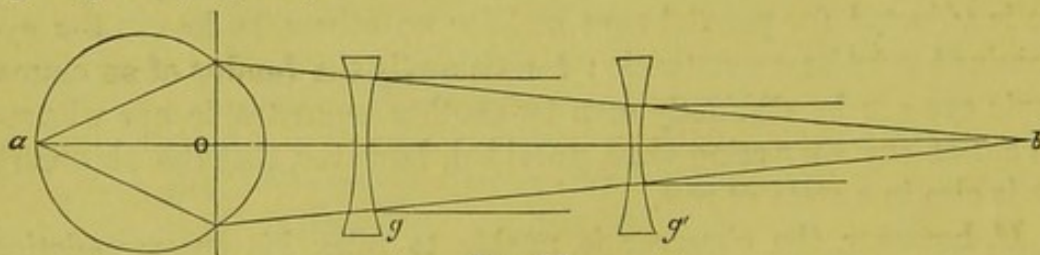


FIG. 52.

Let *A* be an eye myopic $\frac{1}{6}$; rays of light leaving its retina will emerge convergent, and come to a focus six inches in front of the nodal point *o*, at the point *b*. If we could place a concave lens $\frac{1}{6}$ at the nodal point *o*, we should neutralize the myopia, and the rays would then leave the eye as parallel, since the glass would then be just six inches from the point *b*, which would then represent its virtual focus. But, as we can not put the glass at the nodal point of the observed eye, we place it as near as the conditions of an ophthalmoscopic examination will permit. This distance is generally assumed to be about two inches. As the glass (*g*) is then two inches in front of the nodal point, the distance between it and the point *b* will be only four inches; consequently, it will require a concave $\frac{1}{4}$ to render the rays parallel at two inches from the eye, while it only required $\frac{1}{6}$ at the nodal point. If the glass (*g'*) is at three inches from the nodal point, then it will be

only three inches from the point *b*, and it will require a glass of $\frac{1}{3}$ to reduce the rays to parallel; consequently, $\frac{1}{3}$ three inches from the nodal point is equal to $\frac{1}{6}$ at it. That is to say, the glass required is just as much too strong as it is distant from the nodal point. We must, therefore, reduce it by this quantity. In the above cases it will be $\frac{1}{4} + \frac{1}{2} = \frac{3}{4}$. $\frac{1}{3} + \frac{1}{3} = \frac{2}{3}$. From which we deduce—

For an emmetropic observer whose eye is at rest, the myopia in a given case will equal the weakest concave glass through which the fundus is seen distinctly, plus the distance of the glass from the nodal point of the observed eye.

This will give the exact amount of the myopia present, but inasmuch as we usually measure degrees of ametropia by that glass which brings parallel rays to a focus on the retina, placed not at the nodal point, but half an inch in front of it, we may for ordinary calculations omit this half inch. For example, we say a man is myopic $\frac{1}{6}$ when a concave $\frac{1}{6}$ placed one half inch in front of his nodal point brings parallel rays to a focus on the retina; he is really, however, myopic only $\frac{1}{12}$. So, too, with the ophthalmoscope we may neglect this half inch, and then the result will give the amount of ametropia, as it is usually expressed in glasses.

We have taken the distance between the glass and nodal point as two inches simply as a matter of convenience, and because it represents about the distance common to those who are not adepts in this kind of examinations. With a little practice the observer can reduce this distance to one inch instead of two, and if he uses an ophthalmoscope, the mirror of which lies in the same plane with the handle, or, better still, one with the tilting mirror, he can, with a little skill, approach so near the eye as to place the glass he looks through nearly in the position which the patient would in wearing his glasses. In this case the glass used would represent the amount of ametropia without further addition of the distance.

If the observer is unable to relax his accommodation when using the ophthalmoscope, he is, as has already been explained, no longer emmetropic but virtually myopic to the amount of accommodation that he involuntarily calls forth. He has then to simply reduce his own eye to the condition of an emmetropic one by adding the suitable glass and then proceed as above.

PROPOSITION III. *The observer being emmetropic, to estimate the degree of hypermetropia in a given case.*—As the observed eye is hypermetropic, rays emerging from it will have a direction as if they came from a point situated behind the eye observed, equal to the degree of the hypermetropia. Thus the rays coming from an eye hy-

permetropic $\frac{1}{8}$ will emerge from it as if they came from a point eight inches behind the nodal point. For example, let A (Fig. 53) be hypermetropic $\frac{1}{8}$, then the rays, coming from the point a on the retina, will, after they leave the eye, diverge as if they came from a' eight inches behind the eye. As the observer's eye is emmetropic and at

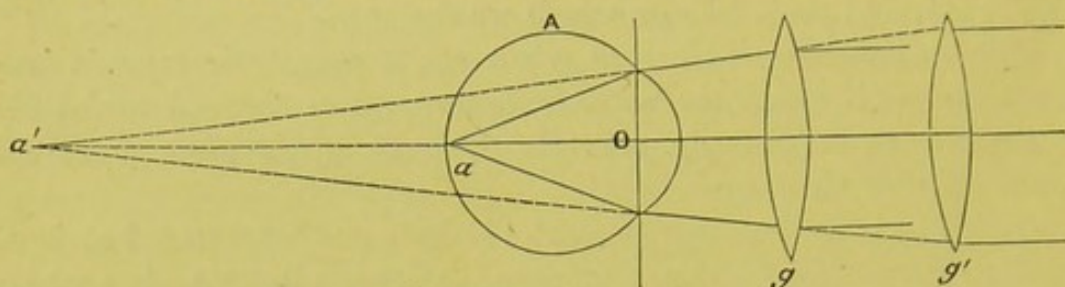


FIG. 53.

rest, we must render these rays parallel before they can come to a focus on his retina. If we could place a convex glass at the nodal point of A , it would require just $\frac{1}{8}$ to make the rays parallel, inasmuch as a' , which may be considered as the principal focus, is just eight inches distant, and this glass then would just equal the amount of H . If, however, we place the glass (g) behind the ophthalmoscope two inches in front of the observed eye A , then, as a' is ten inches from the glass, it will only require $\frac{1}{10}$ to render the rays parallel. If the glass (g') is at four inches from the eye, then a' will be twelve inches from the glass, and it will only require $\frac{1}{12}$. Consequently, the glass used is as much weaker than the hypermetropia is as it is distant from the nodal point; we must therefore make it so much stronger before it can represent the true degree of H in the observed eye. In the above case, $H = \frac{1}{10} - 2 = \frac{1}{8}$, $H = \frac{1}{12} - 4 = \frac{1}{8}$.

The hypermetropia in the observed eye is, therefore, for an emmetropic observer always equal to the glass used, minus the distance of the glass from the nodal point of the examined eye.

As the accommodation is equivalent to a convex glass of different focal lengths, it is evident that the observer may substitute his own accommodation for the glass, provided he knows just how much he is using, and how far his nodal point is from that of the examined eye. For example, if the observer sees an eye distinctly, while he is conscious that he is accommodating for ten inches, he knows that the H in the observed eye must be equal to $\frac{1}{10}$ minus the distance between the nodal points of his own and the observed eye. If this is two inches, then $H = \frac{1}{10} - 2 = \frac{1}{8}$.

The ability to judge of refraction by the degree of tension required of the accommodation can only, of course, be brought into play in one condition—that is, where the observed eye is hypermetropic, and

even here it is rather a *tour de force* than an essential advantage. We can all of us, by a little practice, get an approximate idea as to the amount of hypermetropia in a given case by the amount of tension required of our accommodation in getting a clear view of the fundus, but very few, even with any amount of practice, ever approximate that precision which can be obtained with infinitely less trouble by means of glasses.

As in the above cases the rays of light passing through the hole of the mirror are parallel, and will continue so if uninterrupted to infinity, it makes no difference in the result whether the observer's eye is close against the instrument or a little removed from it. The only calculation necessary is the distance between the glass and nodal point of the examined eye.

The above directions, which are sufficient for an emmetropic observer whose eye is in a state of rest to determine any condition of refraction, may be summed up in this general rule:

The ametropia in a given case is equal to the glass used plus the distance between it and the nodal point if the eye examined be myopic, minus the distance if it be hypermetropic.

If, however, the observer is so unfortunate as to be ametropic, then the simplest way for him is to reduce his eye to a condition of emmetropia—that is to say, to that condition of refraction that parallel rays unite on his retina, considering that portion of the accommodation which can not be relaxed as part and parcel of the refraction.

If the ametropic observer does this, then of course the preceding directions will be all that he will have to bear in mind. Should he not wish, however, to pursue this course, he will find a little later the methods which he must follow.

The following tables show the amount of decrease and increase in the length of the optical axis in various degrees of hypermetropia and myopia, according to the old system:

TABLE III.

$H \frac{1}{2}$ equals a shortening of 3.97 mm.				$H \frac{1}{12}$ equals a shortening of 0.85 mm.			
" $\frac{1}{8}$	"	"	2.9	" $\frac{1}{4}$	"	"	0.74
" $\frac{1}{4}$	"	"	2.3	" $\frac{1}{8}$	"	"	0.65
" $\frac{1}{5}$	"	"	1.89	" $\frac{1}{16}$	"	"	0.58
" $\frac{1}{6}$	"	"	1.6	" $\frac{1}{20}$	"	"	0.52
" $\frac{1}{7}$	"	"	1.4	" $\frac{1}{24}$	"	"	0.45
" $\frac{1}{8}$	"	"	1.25	" $\frac{1}{30}$	"	"	0.35
" $\frac{1}{9}$	"	"	1.12	" $\frac{1}{40}$	"	"	0.26
" $\frac{1}{10}$	"	"	1.	" $\frac{1}{50}$	"	"	0.21
" $\frac{1}{11}$	"	"	0.92	" $\frac{1}{60}$	"	"	0.18

TABLE IV.

$M \frac{1}{2}$ equals an increase of 8.6 mm.				$M \frac{1}{12}$ equals an increase of 0.97 mm.			
" $\frac{1}{8}$	"	"	4.81	"	" $\frac{1}{14}$	"	0.82
" $\frac{1}{4}$	"	"	3.34	"	" $\frac{1}{16}$	"	0.71
" $\frac{1}{5}$	"	"	2.56	"	" $\frac{1}{18}$	"	0.63
" $\frac{1}{6}$	"	"	2.07	"	" $\frac{1}{20}$	"	0.56
" $\frac{1}{7}$	"	"	1.97	"	" $\frac{1}{24}$	"	0.46
" $\frac{1}{8}$	"	"	1.5	"	" $\frac{1}{30}$	"	0.37
" $\frac{1}{9}$	"	"	1.31	"	" $\frac{1}{40}$	"	0.27
" $\frac{1}{10}$	"	"	1.17	"	" $\frac{1}{50}$	"	0.22
" $\frac{1}{11}$	"	"	1.06	"	" $\frac{1}{60}$	"	0.20

It should be remembered that these tables are calculated for the actual degree of ametropia present, and not for the glass used in correcting it. The observer must consequently make the proper addition or subtraction according as the glass is positive or negative, and according to the distance at which it is placed from the nodal point. This varies with different observers from about an inch to two or even three inches from the nodal point. If, for example, the observer sees the bottom of a hypermetropic eye with $+\frac{1}{8}$, and the distance of his eye from the nodal point is two inches, then the real hypermetropia is not $\frac{1}{8}$, but $\frac{1}{8} - 2 = \frac{1}{8}$, and it is for the latter degree that the observer must consult the table for the true amount of shortening of the axis.

So, too, with the negative glass, except that the distance between the glass and the nodal point must be added. If the observer uses $-\frac{1}{8}$ two inches distant, then the real M is $-\frac{1}{8} + 2 = \frac{1}{16}$. As the distance from the anterior surface of the cornea to the nodal point is only a little over a quarter of an inch, the observer may, for all practical purposes, make his calculations as between his own and the observed eye.

The formula used in the construction of the table given in the text is that used by Helmholtz.*

This is $l_1 l_2 = F_1 F_2$. In this equation l_1 signifies the distance of the object from the first focal point when the object lies in front of it; l_2 is the distance of the image of the object behind the second focal point. F_1, F_2 are the two principal focal lengths.

From $l_1 l_2 = F_1 F_2$ we get directly $l_2 = \frac{F_1 F_2}{l_1}$. As the value of l_1 , the distance of the object, is given, and F_1 and F_2 are already established values, we can at once calculate that of l_2 .

In case, however, the object lies behind the first focal point, l_1 will

* "Handbuch der physiolog. Optik," p. 64.

lie in front of the second point, and then both l_1 and l_2 have a negative significance.

The practical application of the formula is as follows: Suppose $M\frac{1}{2}$ exists, what is the increased length of the antero-posterior axis?

The far point of such an eye, calculated from the first nodal point, is two inches or 54.2 mm. But as l_1 , the distance of the object, is not calculated from the first nodal point but from the anterior focal point, which is 19.875 mm. in front of it, l_1 therefore equals $54.2 - 19.875 = 34.3$ mm. We have then the following values: $l_1 = 34.3$ mm.; $F_1 = 14.858$; $F_2 = 19.875$. Substituting these values in the equation

$$l_2 = \frac{F_1 F_2}{l_1} \text{ we get}$$

$$l_2 = \frac{14.858 \times 19.875}{34.3} = \frac{295.3}{34.3} = 8.6 \text{ mm.}$$

The increase of the antero-posterior axis in $M\frac{1}{2}$ equals 8.6 mm., as seen by the table.

Supposing on the other hand $H = \frac{1}{2}$ is present. l_1 is negative and lies two inches behind the second nodal point, which, in its turn, is 20.3 mm. behind the first focal point; $-l_1$ therefore equals $54.2 + 20.3 = 74.5$ mm. $F_1 F_2$ as before equals 295.3 mm. Therefore $l_2 = \frac{295.3}{74.5} = -3.97$ mm. Thus a hypermetropia of $\frac{1}{2}$ corresponds to a decrease of the antero-posterior axis of 3.97 mm.

DIRECTIONS TO BE OBSERVED IN CASE THE OBSERVER IS AMETROPIC.

The observer being myopic.

PROPOSITION I. *For a myope to examine an emmetropic eye.*—It is very evident that, as the rays which leave an emmetropic eye are parallel, the myopic observer, provided he can relax his accommodation, will simply have to use the glass behind the mirror which neutralizes his myopia—that is to say, which brings parallel rays to a focus on his retina. If a concave $\frac{1}{8}$ does this, then $\frac{1}{8}$ will be the glass employed, and whenever he sees an eye distinctly with this glass, he knows that the rays which leave it must be parallel, and consequently it must be emmetropic.

But it may happen that the myopic observer, like the emmetropic, can not relax his accommodation while using the ophthalmoscope. This will make him just so much more myopic, and instead of using, say, $\frac{1}{8}$, which fully neutralizes his myopia, he will with the ophthalmoscope have to use, in order to bring parallel rays to a focus on his retina, $\frac{1}{6}$ or $\frac{1}{5}$. Under these conditions his eye is equivalent to a

myope's of $\frac{1}{6}$ or $\frac{1}{3}$, whose accommodation is entirely relaxed. The observer will then know that when the eye under examination is seen clearly with this glass it must be emmetropic.

As the rays leaving the emmetropic eye will always strike upon the glass used as parallel, it is evident that the distance between the two eyes need not be here taken into account, and that, consequently, the observer may be one or more inches from the observed eye, as he pleases.

PROPOSITION II. *For a myope to determine the degree of myopia in the observed eye.*—If the observer does not wish to wear a correcting-glass, which is often inconvenient and clumsy, the simplest way for him is to proceed with the examination just as an emmetrope would, and find by trial with what glass he sees the fundus most distinctly, his accommodation being, of course, relaxed, and then to take into account the amount of his error in refraction; saying, for example, a myope of $\frac{1}{6}$ finds that he sees the fundus of the examined eye with concave $\frac{1}{3}$, what is the amount of M present?

The observer knows that a part of this glass = $\frac{1}{6}$ is employed in neutralizing his own myopia, consequently, to get the true glass through which the fundus would be seen independent of his error of refraction, he must subtract this $\frac{1}{6}$ from $\frac{1}{3}$ used, $\frac{1}{3} - \frac{1}{6} = \frac{1}{6}$. Now, assuming the distance to be two inches, we have $\frac{1}{6} + 2 = \frac{1}{8}$. The amount of myopia in the examined eye is, therefore, equal to $\frac{1}{8}$, and a myope of $\frac{1}{6}$ will have to use $-\frac{1}{3}$ at two inches in order to see the fundus clearly.

From this it will be seen that the myope of even a medium degree will have to use very strong glasses to see the fundus of an eye which is only moderately myopic.

PROPOSITION III. *For a myopic eye to determine the degree of hypermetropia in a given case.*—Let A represent a hypermetropic eye

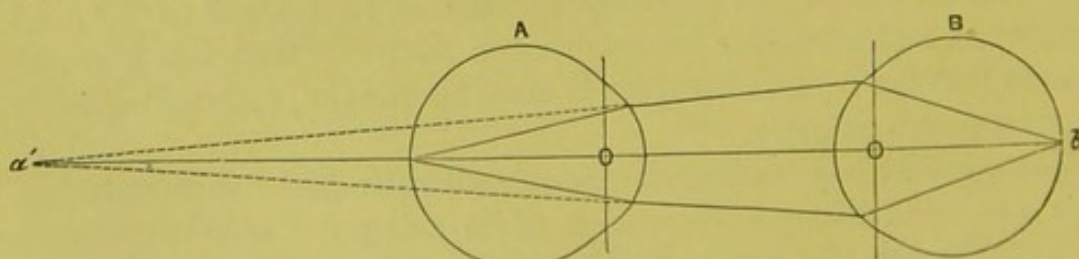


FIG. 54.

of $\frac{1}{8}$; rays coming from the fundus of such an eye will diverge as if they came from a point eight inches behind the nodal point at a' . If

now a myope of $\frac{1}{10}$ (B) place his eye two inches in front of the observed eye, then the rays which enter his eye will diverge as if they came from a point ten inches in front of his nodal point, that is to say, his far point, and, as his eye is just adapted for such rays, they will come to a focus on his retina, and he will get a clear view of the fundus without the use of any glass (Fig. 54).

If the observer's eye is at four inches from the observed eye, then the rays which enter his eye will diverge as if they came from a point twelve inches in front of his nodal point, and the observer will only have to be myopic $\frac{1}{12}$ to bring such rays to a focus. The hypermetropia in the observed eye is then always greater than the observer's myopia by as much as the observer's eye is distant from the observed. In the above case $H = \frac{1}{10} - 2 = \frac{1}{8}$. $H = \frac{1}{12} - 4 = \frac{1}{8}$.

If the hypermetropia in the observed eye is greater than the observer's myopia (the distance between the two eyes being taken into consideration), it is evident that the rays will emerge so divergent that they will no longer meet upon the observer's retina, but behind it. In order to bring such rays to a focus, he must make himself so much more myopic. This he does by a convex glass which he finds by trial just as an emmetrope would. For example, a myope of $\frac{1}{18}$ finds that he needs a *convex* $\frac{1}{18}$ to see the fundus distinctly. If he adds this glass he is no longer myopic $\frac{1}{18}$, but $\frac{1}{18} + \frac{1}{18} = \frac{1}{9}$. Now we have just found that the H equaled the M minus the distance, and as the $M = \frac{1}{9}$ we get $H = \frac{1}{9} - 2 = \frac{1}{7}$.

The observer in this case may use his A instead of a lens, providing he can estimate the amount.

If, however, the hypermetropia in the observed eye is less than the myopia of the observer (the distance between the eyes being taken into account), it is evident that the rays emerging from the eye will be so little divergent that the stronger myopia of the observer will cause them to meet in front of his retina. The observer must make himself less myopic in order to bring such rays to a focus on his retina; this he does by means of a *concave* glass. For example, a myope of $\frac{1}{6}$ can only see the fundus in a given case with $-\frac{1}{18}$, what is the H of the observed eye? By placing the concave glass before his eye, he has reduced his myopia so that he has no longer $M = \frac{1}{6}$, but $\frac{1}{6} - \frac{1}{18} = \frac{1}{9}$. As we have previously found that $H = M$ minus the distance, we have $H = \frac{1}{9} - 2 = \frac{1}{7}$.

The observer being hypermetropic.

PROPOSITION IV. *For a hypermetropic observer to see an emmetropic eye.*—Inasmuch as the rays leaving an emmetropic eye are

parallel, the observer, in order to bring such rays to a focus on his retina, will simply have to neutralize his manifest hypermetropia. If he is $H \frac{1}{2}$, then he will simply have to place a convex $\frac{1}{2}$ behind the mirror.

He may find, however, that with the ophthalmoscope he does not relax his accommodation. His hypermetropia, consequently, will be reduced by just the amount of accommodation which he is using. And he may find that instead of using say a convex of $\frac{1}{2}$, which fully neutralizes his manifest H , he will, with the ophthalmoscope, require only $\frac{1}{4}$ to bring parallel rays to a focus. Under these conditions his eye is in fact equal to a hypermetrope's of $\frac{1}{4}$, who can entirely relax his accommodation, and the observer will then know that an eye seen distinctly through this glass must be emmetropic. It may happen in this way that a person, who is slightly hypermetropic for the distance, becomes for the ophthalmoscope emmetropic, and so has to use no glass. For example, a hypermetrope of $\frac{1}{6}$ may find, on account of his inability to relax his accommodation, that in order to see an emmetropic eye he needs a concave $\frac{1}{6}$. The amount of accommodation which he uses would then only be $\frac{1}{6}$, and many inexperienced observers use $\frac{1}{2}$. In this case the observer is virtually myopic, and must proceed as such.

The observer may of course use his accommodation in all cases instead of a convex glass, that is to say, the lens in his own eye instead of one behind the mirror. He would, however, in this case have to know just what amount of tension of his ciliary muscle corresponds to a given glass.

PROPOSITION V. *For a hypermetropic observer to determine the amount of myopia in the observed eye.*—Let A be myopic $\frac{1}{8}$ (Fig. 55);

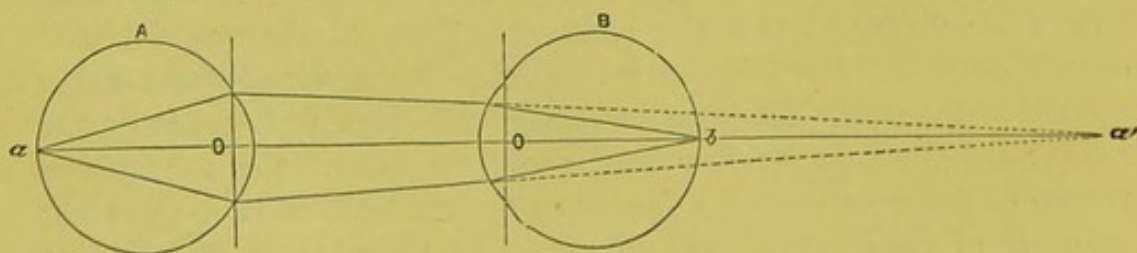


FIG. 55.

rays of light coming from a will meet eight inches in front of A 's nodal point at a' . If B , who is hypermetropic $\frac{1}{6}$, places his eye two inches from A , then rays from A would meet, if uninterrupted, at a point just six inches behind B 's nodal point. Now, as B 's eye being hypermetropic $\frac{1}{6}$ is adapted for such rays, they will be brought to a focus on the retina. Consequently A 's myopia must be equal to B 's

hypermetropia plus the distance, $M = \frac{1}{6} + 2 = \frac{1}{3}$. From this it follows that a hypermetrope of a certain degree can see the fundus of a myope of a certain degree without any glass.

If, however, the myopia of the observed eye is greater than the observer's hypermetropia, it is evident that the rays emerging from the eye examined will be so convergent that they will meet in front of the observer's retina; to bring them to a focus he must make himself more hypermetropic. This he does by means of a concave glass, which he finds just as an emmetrope does by trial. For example, a hypermetrope of $\frac{1}{18}$ finds that he, with his accommodation relaxed, sees the fundus distinctly in a given case with concave $\frac{1}{9}$, what is the myopia in the observed eye?

By putting the concave $\frac{1}{9}$ before his eye, the observer has made himself just so much more hypermetropic. He is consequently no longer hypermetropic one eighteenth, but $\frac{1}{18} + \frac{1}{9} = \frac{1}{6}$. Now, as the myopia in the observed eye is equal to the observer's hypermetropia, plus the distance, we get $M = \frac{1}{6} + 2 = \frac{1}{3}$.

If, however, the myopia in the observed eye is less than the observer's hypermetropia (the distance between the two eyes also taken into consideration), rays emerging from the observed eye will not be convergent enough to meet on the retina, but behind it. To make such rays meet on his retina he must make himself less hypermetropic. This he does by a convex glass which he finds by trial. For example, a hypermetrope of $\frac{1}{9}$ sees in a given case with a convex $\frac{1}{18}$, what is the degree of myopia present in the examined eye? By adding the convex $\frac{1}{18}$ to his eye, the observer has reduced his hypermetropia, making himself no longer hypermetropic $\frac{1}{9}$, but $\frac{1}{9} - \frac{1}{18} = \frac{1}{18}$. Now, as the myopia equals the hypermetropia plus the distance, we get $M = \frac{1}{18} + 2 = \frac{1}{20}$. Thus we see that a hypermetrope may, according to circumstances, in estimating myopia, use no glass at all, or a convex, or a concave one.

PROPOSITION VI. *For a hypermetropic observer to estimate the amount of hypermetropia in the examined eye.*—The best way in this case is for the observer to find by trial with what glass he sees the fundus most distinctly, and then to take his own error of refraction into consideration. For example, a hypermetrope of $\frac{1}{18}$ sees the examined eye with convex $\frac{1}{9}$, what is the hypermetropia present? The observer knows that a part of this, equal to one eighteenth, is employed in neutralizing his hypermetropia; consequently, to get at the true glass which would be used independently of his error in refraction, he must subtract this $\frac{1}{18}$. $\frac{1}{9} - \frac{1}{18} = \frac{1}{18}$. As the observer has thus

neutralized his hypermetropia, he is virtually emmetropic, and knows that the H present must be equal to the glass used minus the distance.

$$H = \frac{1}{18} - 2 = \frac{1}{16}.$$

THE DETERMINATION OF THE REFRACTION OF AN EYE BY THE MIRROR ALONE, AND BY MEANS OF THE INVERTED IMAGE.

It has been already shown how, with a myopic eye, we get with the mirror alone an inverted aerial image of a small portion of the fundus, an image which is situated in front of the eye, and at the distance of its far point.

With a hypermetropic eye, on the contrary, we get a virtual and erect image behind the eye, and at a distance equal to the degree of the hypermetropia.

If, then, we could only tell in a given case whether the image which we see is inverted or upright, then we should know at once whether the eye examined was myopic or hypermetropic. There are various ways of ascertaining this:

(1.) Both the image and the field of view are larger (except in very extreme degrees) in myopia than in hypermetropia.

(2.) In myopia the image moves in a sense contrary to that of the observer's head, and the more so the farther it is in front of the observed eye. In hypermetropia it moves with the head of the observer, and the excursion is less.

(3.) The observer, as a rule, can tell whether he is accommodating for an image which lies in front of the eye examined, or behind it, the difference in the position of the images even in high degrees of the two kinds of ametropia being considerable.

Suppose, in this connection, the observer is emmetropic, and that his near point lies in six inches. He can then accommodate for an object at that distance, but no nearer. In a given case in putting up the mirror he gets an image which, on his gradually approaching his head and exerting in a corresponding degree an increased tension on his accommodation, remains distinct up to a certain point, when suddenly it begins to grow a little indistinct. Withdrawing his head a trifle till the image is clearly defined again, the observer knows that the image must lie six inches in front of his own eye. And, if the distance between this and the observed eye is greater than six inches, the image must then lie in front of the eye examined, which is consequently myopic.

But, on the other hand, supposing the image does not grow indistinct at all till the observer gets close up to the observed eye—say two inches from it—he then knows that the image can not lie in front of

the observed eye, which is only two inches distant, for if it did it would be so blurred as not to be recognizable, being so far within the limits of his accommodation. The image must lie behind the eye, which must be consequently hypermetropic.

The nature of the refraction having been ascertained in this way, it remains to determine its degree. The application of the mirror in this manner and for this purpose is at the best but limited, as it is only in cases of high degrees of ametropia that it is of any service at all, and only in cases of great myopia where its advantages outweigh its difficulties and give it a practical importance. Theoretically it would, of course, be just as applicable to H as M , the only difficulty being the telling just how far behind the observed eye the virtual image of a small segment of the fundus really is. The difficulty is, however, so great, either by means of the accommodation or with glasses, that it is hardly worth while attempting it, especially when with the upright image the fundus of a hypermetropic eye is so readily and distinctly seen—an advantage which does not obtain from the very construction of the eye in myopia of high degrees, the illumination of which, for many reasons, is difficult and insufficient. It is therefore to the illustration of this latter condition alone that our examples will be applied.

We will begin, for the sake of simplicity, by supposing that the observer is himself myopic, for example, $\frac{1}{8}$. His far point would then lie at eight inches, and any object at a greater distance than this would appear indistinct. Such an observer in a given case gets an image with the mirror alone, and at the ordinary distance—say sixteen inches—an image which, though recognizable as to its general outlines, is not sharply defined. Approaching the eye till the definition becomes perfect, and stopping the moment it does so, the observer knows that the image must lie at his far point, or eight inches in front of him. The observed eye is still, however, twelve inches from him; consequently the image must lie four inches in front of it, and the myopia be equal to $\frac{1}{4}$. Suppose, however, the distance between the two eyes had been ten instead of twelve inches, then the distance of the image in front of the observed eye would have been $10 - 8 = 2$ inches, and the myopia would have been equal to $\frac{1}{2}$. Again, suppose the observer had been myopic $\frac{1}{6}$, and the distance between the eyes was ten inches, then the place of image would have been $10 - 6 = 4$, and $M = \frac{1}{4}$. The observer has then only to know his own myopia and the distance between the two eyes, and to subtract the former from the latter, to know the amount of M in the observed eye.

If, however, the observer is not myopic naturally, he can make

himself so very readily by putting a convex glass behind the mirror. If he be emmetropic and can fully relax his accommodation, and uses $+\frac{1}{8}$, his far-point will then lie at eight inches, as in the former case, and he now proceeds in precisely the same way as if he were naturally myopic, and in the manner just related. If he can not fully relax his accommodation, then allowance must be made for this. If, for example, he involuntarily uses what is equal to $+\frac{1}{24}$, then he is already myopic $\frac{1}{24}$, and will have to add the difference between that and $\frac{1}{8}$. $\frac{1}{8} - \frac{1}{24} = \frac{1}{12}$, and with this glass he will be in precisely the same condition as a myope of $\frac{1}{8}$ or an emmetrope with $+\frac{1}{8}$, who can relax his accommodation entirely. If, on the other hand, the observer is hypermetropic, he must first neutralize this. If, for example, he has $H = \frac{1}{24}$, he will, in order to make himself equal to a myope of $\frac{1}{8}$, have to use $\frac{1}{8} + \frac{1}{24} = \frac{1}{6}$, and so on.

In all these cases requiring the addition of a convex lens the observer might have used his accommodation instead of the glass, provided he had such a control over it as to be able to estimate precisely what amount he was using.

It may even happen that the observer's myopia is so great that he will be forced to use a concave glass in order to bring his far-point to six or eight inches. It is better to do this when the M is greater than $\frac{1}{6}$, as the difficulty increases when the observer has to approach closer than this to the image. If he has $M = \frac{1}{4}$, then he will need to carry his far-point out to eight inches, $\frac{1}{4} - \frac{1}{8} = \frac{1}{8}$.

DETERMINATION OF ASTIGMATISM WITH THE MIRROR ALONE.

Many years ago, Mr. Bowman* pointed out the fact that he had been led to the detection of regular astigmatism and the directions of the chief meridians by the use of the mirror of the ophthalmoscope in the way which he had previously suggested for conical cornea. The mirror is to be held at about two feet from the eye, and its inclination rapidly varied so as to throw the light on the eye at small angles to the perpendicular, and from opposite sides, in successive meridians. The area of the pupil then exhibits a somewhat linear shadow in some meridians rather than in others. Little or no effect occurs, however, from moderate or even from comparatively well-marked deviations from the normal curvature.

Mr. Couper, in 1872,† dilated somewhat upon this method, and proposed the use of a special mirror of thirty inches focal length, with which the eye is illuminated from a distance of some three or four

* See "Refraction and Accommodation," Donders, p. 490, 1864.

† "Fourth International Congress Report," London, 1872, p. 109.

feet. In this way Mr. Couper asserts that very low degrees of astigmatism can be detected, and the directions of the principal meridians ascertained. There are many objections, theoretical as well as practical, to this method in the author's mind, and in his hands it has not proved either "easy or expeditious." Mr. Couper himself admits that it is not very well adapted to several of the commonly occurring forms of astigmatism, and it would hardly seem advisable to take the trouble of procuring a special and uncommon form of mirror for so limited a sphere of action, especially when not only the presence and kind, but even the degree of every form of astigmatism can be accurately and easily measured with the ordinary mirror by the use of the upright image in the manner already explained in the foregoing pages.

Since Mr. Bowman's article, others have taken the matter up and produced many and voluminous essays upon the subject of determination of refraction with the mirror alone under the titles of "Keratotomy," "Pupiltomy," and "Retinotomy." It still remains, however, in my opinion, the most difficult and least satisfactory of any of the methods of determining the refraction of an eye, and contributes nothing which can not be more easily and more expeditiously performed by the upright image.

I would refer the curious, however, and those fond of optical problems for their own sake, to papers on the subject by Cuignet, "Keratotomy," "Recueil d'Ophth.," 1873, p. 14; *ibid.*, 1874, p. 316; *ibid.*, 1877, p. 59; *ibid.*, June, 1880. Mengin, "Recueil d'Ophth.," April, 1878. Litton Forbes, "On Keratotomy," "Royal Ophth. Hosp. Reports," vol. x., part i., p. 62, 1880. Morton, "Refraction of the Eye," London, 1881. Charnley, "Royal London Ophth. Hosp. Reports," vol. x., part iii., p. 344, 1882. Landolt, "Traité Complet d'Ophthalmologie," vol. iii., part i., p. 265, 1883; and others.

DETERMINATION OF THE REFRACTION BY MEANS OF THE INVERTED IMAGE.

Since the nearer an image is formed behind a lens the smaller it will be, it follows that the inverted image with a myopic eye, from which the rays already emerge as convergent, must be smaller than with an emmetropic eye when the same lens is used with each, and is held at or within its focal length from the eye. On the other hand, the image will be larger with a hypermetropic than with a normal eye under the same conditions.

In this way we can often tell by the size of the image alone whether an error in refraction is present, and what its character is;

but only in a general way, and only when the defect is of a marked degree.

We are able, moreover, to supplement the evidence gained in this manner by slight to-and-fro movements of the lens.

With a myopic eye, the size of the image, for example, of the disk, increases as we draw the lens away from the observed eye. With hypermetropia, on the contrary, it decreases as the lens recedes. In emmetropia the image remains the same for all distances of the lens.*

Various appliances have from time to time been brought out for the purpose of ascertaining the exact position and size of the inverted image formed through the objective glass in different degrees of ametropia, with the aim of determining thereby its exact degree. Thus, Hasner produced an ophthalmoscope with sliding tubes and a graduated scale on the principle of some of the optometers; Coccius, an ocular composed of two lenses, also in a sliding tube; Colsmann, a plano-convex lens, with a scale engraved transversely on the plane surface, by which the size of the image could be numerically measured and some idea of the degree of refraction estimated. But all these, together with other devices, even the most recent, would seem to be either useless or inexpedient.

The observer can, however, if he thinks it of sufficient importance, gain some insight not only into the kind of ametropia present, but also, approximately at least, as to its degree.

To do this he has only to reduce all eyes to a greater or less degree of myopia by putting before them a convex lens of a constant strength, and then proceed to estimate the place of the image precisely as if the observed eye were really myopic. Let $+\frac{1}{6}$ be either held close before the eye, or, better still, placed in the spectacle-frame of the test-case. Rays leaving an emmetropic eye are parallel, and consequently such rays, after passing through the lens, will come to a focus at six inches in front of the glass where the image would lie.

Rays from a myopic eye would strike the glass as already convergent, and the image would then be inside of the focal distance, and to a degree corresponding to the amount of the *M*. On the other hand, the image would lie with the hypermetropic eye farther from the glass than its principal focus, and the farther the greater the degree of *H*.

In a given case the observer sees the image distinctly, while his *A* is perfectly relaxed through $+\frac{1}{6}$. The image must then be six inches in front of him. The distance between his and the observed eye—or rather between his eye and the glass—is twelve inches; the image of the observed eye must be then six inches in front of the glass, or at its

* Giraud Teulon, "Annales d'Oculistique," September, 1869, p. 95.

principal focus. To produce an image at this place the rays must leave the observed eye as parallel; consequently, the observed eye must be emmetropic. In a second case the observer, through $+\frac{1}{6}$, sees the image while he is only nine inches from the glass; consequently, the image must be only three inches in front of the observed eye, considerably within its principal focus. To produce an image in this place, the rays leaving the eye must have been convergent; consequently, the observed eye is myopic, and the $M = \frac{1}{3} - \frac{1}{6} = \frac{1}{6}$.

Again, the observer sees the image clearly when the distance between his eye and the glass is sixteen inches. The image must be therefore ten inches in front of the observed eye, and beyond the principal focus. The rays coming from the observed eye must have been divergent, and the eye hypermetropic. $H = \frac{1}{6} - \frac{1}{16} = \frac{1}{16}$.

The distance between the glass and the nodal point has been neglected, as the method, at the best, has no sufficient claim to exactness. Its range of usefulness is indeed very limited; still, it may often be of advantage to those who use the inverted image, and that only.

THE DETERMINATION OF ASTIGMATISM BY MEANS OF THE INVERTED IMAGE.

From what has already been said in connection with astigmatism, as observed by the upright image, it will be remembered that, when this irregularity of refraction is present, we see in the direct method the disk elongated in the meridian of greatest curvature, because, the lenticular system being stronger in that direction, the magnifying power is greater. With the inverted image we see the disk elongated in the opposite direction, that is, in the direction of the weakest meridian, because, the image being formed behind the lens, it is less reduced in that meridian than the others.

Thus, as Knapp and Schweigger showed by the alternate use of the upright and inverted image, we can not only detect the presence of astigmatism, but also the direction of its principal meridians. This, however, only holds good, as will be explained a little later, when the glass is held at a distance less than its focal length from the eye observed.

It was in accordance with this restriction that Javal* pointed out the fact that it was not necessary to have recourse to the alternate use of both methods, but that the same interchange in the form of the disk could be effected with the inverted image alone, with the great advantage of keeping a continuous picture of the disk before the eye of the

* "Études Ophth.," Wecker; tome ii., fasc. 2, p. 836, 1867.

observer—a picture which gradually changed its form, through all the phases of an oval with its longest diameter in one direction, to a circle, and then to an oval again, with its longest diameter in the opposite direction. The change is brought about by simply varying the distance of the object-glass from the observed eye within the limits set by the image of the disk becoming smaller than the pupillary space, either from too close an advancement toward or too great a separation of the lens from the eye.

Giraud Teulon * has amplified this idea of Javal's in a most extended and elaborate mathematical discussion, with a clearness of style and a wealth of formula as varied as it is vast. To this essay, which is beyond the scope and character of the present work, the mathematical reader is referred for particulars. To such as are not, the following *résumé*, condensed from the original so far as its ophthalmoscopic bearing is concerned, will be of service as well as interest :

(1.) In the emmetropic eye, when the accommodation is relaxed, the image of the optic disk remains identically the same in character, and of the same size for every distance of the lens.

(2.) In an eye which is regularly ametropic the image decreases (*H*) or increases (*M*) with the distance of the lens. It always preserves, however, its original form, remaining circular if the disk is circular, and oval if it is oval.

(3.) In an astigmatic eye the recession of the lens causes a variation not only in the dimensions but also in the form of the image itself, i. e., of the disk. If the image be oval, with its long axis in a certain direction, when the lens is a short distance from the eye, it becomes exactly circular when this distance equals the focal length of the lens. At a greater distance, however, the direction of the long axis of the oval changes, becoming perpendicular to its former direction.

Thus nothing is easier than to determine whether an eye is or is not astigmatic. Any positive lens which is suitable to produce an inverted image of all the diameters of the optic disk will solve the problem and indicate at the same time the direction of the principal meridians, and will, moreover, with a little care on the part of the observer, point out the nature of the defect; thus :

When the lens is close to the eye, the long diameter of the oval belongs to the meridian of the least refraction. From this position of the lens to one which is equal to its focal length from the eye,† when the image is exactly circular, the different diameters of the image have

* "Ann. d'Oculistiques," Sept. et Oct., p. 95, 1869.

† Plus the distance of the anterior focus, about one half inch.

either increased or decreased. Those which have increased indicate myopic, those which have decreased hypermetropic meridians.

If the two principal meridians have decreased or increased at once, that which has done so most rapidly belongs to the most ametropic meridian. This shows compound astigmatism—general M or H , with increased M or H in one meridian.

Beyond the distance at which the image is exactly circular the conditions are reversed and become the same as in the upright image—that is, the long diameter of the oval is in the meridian of the greatest curvature.

The principle contained in the above may perhaps be more tersely expressed as follows:

If the long diameter of the oval contracts when the lens is moved from the eye so as to become equal to the short, and thus make a circle, then the astigmatism is due to H . If, on the contrary, the short diameter expands so as to become equal, at the focal distance of the lens, to the long, and thus make a circle, then it is due to myopia.

If all the diameters contract—but one contracts more than the rest—then general H is present with H increased in one meridian. If all increase—but one more than the rest—then M is present with M increased in one principal meridian. The astigmatism is compound.

If one diameter expands and one contracts, then both M and H are present, and the astigmatism is mixed.

We see from this that astigmatism may be detected in two stages in the passage of the lens: first, when it is moved from a point close to the eye to a distance equal to its focal length; secondly, from this point outward to a distance limited to the contracting field of view by which the image of the disk is rapidly shut out by that of the iris.

It is in this last stage from the focal distance outward that the effect is most pronounced, as a rule. It is, however, better to make the lens move through the entire course. Great care must be taken not to rotate the lens at all, but to maintain it as exactly as possible in a plane perpendicular to its line of motion.

So sensitive is this test that Javal declares that 1 D or less can be detected by it. Thus this method should never be omitted in making the preliminary examination with the inverted image, for, by a few passes back and forth with the lens, we can determine not only the existence of ametropia, but also its nature, and moreover gain an approximate idea as to its degree.

To determine this latter, however, with any exactness, it is far better as well as simpler to go at once to the upright image, which, in the comprehensiveness and delicacy of the test mentioned in the

light-streak of the vessels, amply fulfils all requirements either theoretical or practical. By this means the determination of astigmatism of any form or degree becomes almost as simple as that of regular refraction.

THE AMOUNT OF ENLARGEMENT PRODUCED BY THE UPRIGHT IMAGE.

Looking through the lenticular system of the eye at an object beyond—say the optic nerve—is precisely like looking through any lens of an equivalent power. The object thus seen appears enlarged, and the question is to determine, in case of the eye, how great this enlargement is.

Since the relative dimensions of the images of the same object on the retina are to each other as the respective distances of the object in front of the eye, that is in front of the nodal point, all that is needed to determine the comparative size of the image on the retina is to know the distances at which the object is seen. If, for example, a given object is at eight inches from our nodal point it will produce an image on our retina of a certain size. If moved to two inches—and it is assumed that through the accommodation the object remains clear—then the size of the image of the object at two inches will be, to that when it is at eight, as $8 : 2 = 4$. The image in the last case will be four times as large.

The result would have been precisely the same if, instead of our accommodation, we had used $+\frac{1}{2}$ placed close against the eye, and we had neglected the distance between the glass and our nodal point.

To get, therefore, the magnifying power of any glass when the object viewed is at its focal length, we have simply to divide some distance taken as a standard by the focal length of the lens used. A distance of eight inches has been agreed upon. The magnifying power, therefore, of a two-inch lens $= \frac{8}{2} = 4$; of a one-inch lens $\frac{8}{1} = 8$; of one-half-inch lens $\frac{8}{\frac{1}{2}} = 16$, and so on.

Now, the focal length of the lenticular system of the eye has been calculated to be equal to 6.7 Paris lines—that is to say, the distance from the nodal point of the eye to the retina is 6.7 lines. The mag-

nifying power of such a lens is consequently $\frac{8''}{6.7''}$ or $\frac{96''}{6.7''} = 14\frac{1}{8}$.

The fundus of an emmetropic eye is therefore seen under an enlargement of $14\frac{1}{8}$ diameters.

Moreover, when we look through a magnifying-glass placed close to our eye at an object, say, at its focal length, we do not see the object itself but its virtual image, and this image becomes, for the time being, a defined picture, which the observer can project to

any distance, finite or infinite, that he pleases. The greater the distance to which the image is projected, the greater the space which it appears to cover—just as a small scotoma in one's eye may appear, when projected upon a piece of white paper held near the eye, to cover only a small circumference, but yet seem, when projected against the neighboring wall, to occupy a large extent of surface. This is due, of course, merely to the increased opening of the visual angle.

This may be illustrated in a very simple way by imitating the condition of a normal eye. Set, for example, a one-inch lens so that it shall be just one inch from a piece of card on which some object—as a picture of the fundus, for instance—has been drawn. This is a rough but sufficiently exact imitation of the eye.* If we now place the model of the eye close to our own eye, we see an enlarged image of the picture beyond, which, by keeping the other eye open, can be projected to any distance we see fit. So, too, with the real eye as well as with the model, the optic nerve being thrown up against the opposite wall, and to all appearances covering a wide extent of surface.

If we vary the experiment a little and draw, instead of the fundus, a square, each side of which is a determined length, say one line, and then rule a sheet of paper with squares of the same dimensions, we can then have ocular proof of the amount of enlargement. To do this we have simply to hold the model as close to our eye as possible, and then to hold the sheet of paper previously ruled into squares at exactly eight inches, since this distance is taken for the standard. If, now, the experiment is correctly performed, and the different measurements are likewise correct, we shall see, by keeping both eyes open, that the single square seen by one eye, and projected against the paper seen by the other, covers eight squares in each direction. Thus, the square seen with the glass forms on the retina the same size image as eight squares do without the glass. The magnifying power of the glass, therefore, is eight-fold. By moving the paper away from us, we see that the single square seen through the glass covers always an increasing, while if toward us a decreasing, number of squares.

We have seen that with the emmetropic eye the enlargement is $14\frac{1}{3}$ times, and it remains to be seen how this is influenced by a condition of ametropia.

* I might say here that a very convenient representation of the emmetropic eye can be had ready-made, in what is known in the shops as a cotton or linen counter. This consists of a small upright bit of brass, in which is set an inch lens of about half an inch in diameter. This upright is connected with a second upright by a short horizontal bottom-piece which is just the focal length of the glass. To the second upright can be attached a bit of card with the picture of the fundus of the eye drawn upon it.

Let $H \frac{1}{8}$, or 12 D , be present, due to the shortening of the antero-posterior axis. A convex $\frac{1}{8}$ (12 D), placed close against the cornea—the distance between the nodal points being neglected—will, for all practical purposes, reduce the eye to a condition of emmetropia, as rays leaving it would be parallel; yet the lenticular power, at the focal distance of which is the retina in each case, is very different from that of the naturally emmetropic eye, for, whereas in the latter it is equal to 6.7 lines, in the reduced hypermetropic eye it is greater by the lens which we have added, and equals $\frac{1}{6.7} + \frac{1}{8}$, or, reducing this last to lines, $\frac{1}{6.7} + \frac{1}{3.8} = \frac{1}{3.8}$. We have, consequently, as the enlargement, 8", or 96"', divided by 5.6". $\frac{96}{5.6} = 17.1$ times.

It would have been the same had H been latent and corrected by the accommodation.

Suppose $M \frac{1}{8}$, or 12 D , is present, caused by lengthening of the axis. It would require $-\frac{1}{8}$ (12 D) close to the cornea to make the rays leave the eye as parallel. The lenticular system, at the focal distance of which the retina is, would then be equal to $\frac{1}{6.7} - \frac{1}{3.8} = \frac{1}{8.4}$. $\frac{96}{8.4} = 11.4$.

If in any case it could possibly happen that with a normal length of axis there was a faulty condition of refractive power—an increase on the one hand producing M , and on the other a decrease causing H —then the lens which restored the balance would simply reduce the eye to an emmetropic eye, and we should have the same enlargement as in the normal eye.

Now, although all this is exceedingly simple in theory, it is by no means so when we come to apply it in a practical manner and to the wants of the ophthalmoscope; for the correcting-glass can not be applied directly against the cornea, neither can the distance between the nodal points be neglected. Nor can we assume, as we have done, that the anatomical conditions are the same in all eyes to such a degree that the component parts of the fundus—as, for example, the optic disk and vessels—are invariably the same size. Indeed, we are certain that here, as elsewhere in the body, they vary to a considerable amount. This would be naturally expected, and would be in accordance with the fact that considerable variations occur in the size of the image in eyes which are known to be emmetropic.

Mauthner is inclined to believe that this difference in size of the image in a normal eye may be due to a difference in the length of the antero-posterior axis, which is counterbalanced by a corresponding increase or decrease in the refracting apparatus of the eye, by which the rays still issue as parallel. Thus, we might have a longer axis with a weaker, or a shorter axis with a stronger lenticular power. The

eye would in each case be emmetropic, but the enlargement would be greater in the latter than in the former case, and in proportion to the degree of shortening.

Mauthner has calculated that while the enlargement in $H = \frac{1}{3}$ (12 D) is $17\frac{1}{2}$ times, the glass being considered an integral part of the eye, it is in the same degree of H corrected by $+3\frac{1}{2}$, half an inch from the nodal point, but $15\frac{1}{2}$ times; and again, if corrected by $+\frac{1}{4}$ one inch in front of the nodal point it is only $13\frac{1}{2}$ times.

From a series of mathematical deductions, the same author arrives at the following general conclusions: When an anomaly in refraction is corrected by the proper glass one inch from the nodal point, we obtain with M always a greater, and with H always a less, enlargement than with emmetropia, while with the inverted image the enlargement is less with M and greater with H than with E .

The examination of a myopic eye with a concave glass, which is necessarily stronger than the degree of the myopia, since the glass can not be placed at the nodal point, is on the principle of the Galilean telescope, in which the lenticular system of the eye is the object-glass, and the lens behind the mirror the eye-piece. In such a combination the stronger the eye-piece the greater the magnifying power, but the farther the eye-piece must be from the eye.

If, for example, we have a myopia of $\frac{1}{6}$, the fundus can be seen, A being relaxed—either through $-\frac{1}{6}$ at one inch, or $-\frac{1}{4}$ at two, or $-\frac{1}{2}$ at four inches from the nodal point of the observed eye. In each case the fundus will be seen under an increasing enlargement, but at the same time with a rapidly decreasing field of view.

Stammeshaus, taking advantage of this principle, proposed to reduce such eyes as were not naturally myopic to that condition by convex glasses, and then to view the fundus through concave glasses of different strengths and increasing distances in front of the eye, according to the amount of enlargement desired. This method, which had already been tried in this country several years before the suggestion of Stammeshaus appeared in print, possesses theoretical rather than any practical merits, in which indeed it is signally wanting, not only on account of the great reduction of the field, but also from distortion of the image and from annoying reflections which arise from both surfaces of the interposed convex glass. When, however, the myopia is natural, and the pupil fully dilated with atropine, the method may be occasionally used with advantage, though even here it is better to go at once to the inverted image, using a weak object-lens in the manner suggested by Liebreich, and already described in the chapter on the use of the inverted image.

CHAPTER VI.

EXAMINATION OF THE MEDIA OF THE EYE.

THERE are two principal methods of examination of the media:
(1.) Oblique illumination. (2.) The ophthalmoscope.

The former should never be omitted as a preliminary step to the latter, even where there is apparently no reason to suspect that there is any trouble in the media, for I have been so often the subject of mortification myself, and seen it so many times in others, that I can not refrain from again warning those who would use the ophthalmoscope successfully never to neglect this important factor in the detection of disease, especially before speaking of "diffuse opacity or œdema of the retina," or "want of definition in the outlines of the optic disk."

OBLIQUE ILLUMINATION.

THE CORNEA.—The normal cornea, as a rule, even in adult life, has the appearance in ordinary diffused light, whether natural or artificial, of being a perfectly clear and transparent membrane. When, however, condensed light is thrown upon it at an angle, as, for example, by oblique illumination, a delicate, smoke-like haze can be detected, which, though always present, even in infancy, becomes more and more pronounced as life progresses, until, in extreme old age or premature decay, this haziness is sometimes so dense as to lead to the suspicion that it is due to a pathological and not a physiological condition.

This opalescent appearance, whether in old or young eyes, is due to the laminated structure of the cornea and the mesh-like manner in which its component parts are arranged; for, although the substance proper of the cornea can not be said in any very strict sense to be arranged in regular layers, still its tissue, together with the corneal epithelium, Bowman's membrane, the membrane of Descemet, and the endothelium, is sufficiently stratified to present a number of surfaces at different levels, from which, taken as a whole, enough light is reflected to produce the slight want of transparency expressed in the delicate haze just alluded to; and especially is this true when the angle of incidence and reflection is of a considerable degree.

The amount of this haze varies very much with different individuals even of the same age. Thus, in children, or even in young adults, especially in those who seem to have some scrofulous taint, I have often noticed an unnatural pellucidness of the cornea, which gave an unwonted brilliancy and glassy expression to the eye; while, in others of the same age, the cornea, when subjected to oblique light, showed all that want of transparency corresponding to a much later time of life.

By throwing the light obliquely from the side into the eye, we illuminate the surface of the iris and the anterior capsule, which reflect the light thrown upon them back to our own eye. Thus, we detect the shape and position of even the minutest speck in the otherwise clear substance of the cornea, by the contrast produced between it and the surrounding tissue, by transmitted light, while at the same time, from that portion of the light which is reflected from their anterior surfaces, we see the opacities themselves in their true color and form, or what very nearly approaches it. Even when the pupil is thoroughly dilated by atropine, sufficient light is reflected from the anterior capsule and body of the lens and deeper portions of the eye to get the effect of contrast between the opacities and surrounding clear tissue quite as well, and, I have sometimes thought, better marked than with an undilated pupil; and especially is this true with the minutest spots in keratitis punctata and slight disturbances in or upon the membrane of Descemet. The entire surface of the cornea must, of course, be gone over with the eye in its various positions.

Very different from the delicate, smoke-like haze seen in the healthy eye, and which seems to lie beneath the polished surface of the cornea, is the coarse, dull reflex of a diffuse character which is seen by oblique illumination in some forms of superficial corneal disease, and which is due to a lack of transparency and roughness of the epithelial layer. In such cases a part, usually the lower half, or even the whole surface of the cornea, has a dead, lack-lustre look, which is often noticeable even in ordinary daylight, but which under concentrated light becomes strongly, sometimes intensely, marked, so that the surface of the cornea, either in part or whole, has the appearance of ground glass. This may vary in its color from a pure gray to a yellowish-brown, or even a rosy tint, especially near the corneal margin, as if this latter appearance was borrowed from the presence of some vessels too minute to be seen as such. In rare instances, I have also seen what had the appearance of interstitial hæmorrhage, so deep and close was the injection. In one case the entire cornea was a blood-red mass, as if the bleeding had occurred into the very substance of the membrane, the epithelial layer retaining its polish.

So, too, the proper substance of the cornea may be the seat of a diffuse opacity, or want of translucency, which, though of pathological origin, may be so slight as to be distinguished with difficulty from a physiological condition, and which requires oblique illumination for its detection. When, however, the opacity is sufficient to produce any marked effect upon vision, and lies in the outer portions of the membrane, it is usually to be recognized in ordinary daylight, and then presents no difficulty of diagnosis to the naked eye.

This, however, is not the case when the trouble lies in the inner layers of the cornea, or in the membrane of Descemet. Here oblique illumination plays a most important *rôle* and renders a most useful service. With it the minute spots due to inflammation of the membrane of Descemet (Descemitis), or serous iritis, or choroiditis, come out boldly into view, when under examination by diffused light nothing abnormal could be detected. So, too, slight abrasions of the surface, minute specks, or deposits from foreign bodies, or the foreign bodies themselves, are brought distinctly into view.

It is sometimes a little difficult even for a trained observer to tell the precise level which opacities in the cornea occupy, though experience in a little while usually enables him to form a pretty accurate estimate of their position, so much so that I think it hardly necessary to go into an elaborate explanation of the method of examining the cornea for this purpose under water, especially as I have never done it myself or ever seen it done. Still, it is well enough to know that it can be done, and that the instrument by which it is accomplished is called an orthoscope, of which there are various patterns, such as those of Czermak, Coccius, and Arlt.*

THE AQUEOUS HUMOR.

The entire cornea having been thoroughly examined, the observer should pass next to a consideration of the anterior chamber and its contents. The aqueous humor, which in a state of health is a perfectly transparent fluid, is often disturbed to a greater or less degree by the presence of minute particles, which are for the time held in suspension in it, and which make themselves manifest, under oblique illumination, by a more or less diffuse cloudiness of the anterior chamber. These diffused disturbances in the aqueous, whether of a purulent or sanguineous nature, offer but little trouble in their detection and need but little comment, except to call attention to the fact that it sometimes requires a little care to determine whether the opacity in

* "Zander," Carter's Translation, p. 62.

question is really in the anterior chamber itself or in the inner layers of the cornea.

Still less need be said of the aggregate masses of pus, or blood, or other detritus so often found at the lower borders of the anterior chamber, and which can be plainly seen with the naked eye, but which can be rendered a little more conspicuous by means of condensed light, and seen to much better advantage with it than with the ophthalmoscope.

As a great rarity, fine filamentous bands have been seen to stretch across from the apex of a pyramidal cataract which projects from the anterior surface of the lens to the inner surface of the cornea opposite; moreover, very minute, thread-like synechiæ, suggestive of a former and long-past perforation of the cornea, or at least of contact of the iris with its inner surface, are sometimes brought to light in this manner. Precisely the same thing may occur after small perforated wounds, or even after the performance of an iridectomy, where the cut edge of the pupillary border of the iris has laid for a shorter or longer time against the inner surface of the cornea.

While on the subject of the aqueous humor, it may be well to remind the reader that occasionally it is the abode of that species of entozoa known as filaria. These animals have been seen by several observers, among them Macnamara, who says there is no possibility of mistaking the appearance of entozoa of this kind in the anterior chamber, as the creature may be distinctly seen moving about in the aqueous. From Dr. Barkan's case in "Knapp's Archiv," the detection would seem not such an easy matter, as it was not until a portion of the animal was examined under the microscope that a diagnosis was confirmed.

THE IRIS.

By means of light thrown obliquely into the eye, the anterior surface of the iris can be thoroughly illuminated, and can then be seen under considerable enlargement if a second lens is used in the manner already pointed out (page 6). By this method the grosser appearances of the membrane can be studied both in health and disease. With oblique illumination, also, the presence of small cysts, tumors, and other irregularities of its surface, such as condylomata, can be seen and watched in their course of growth and decline. The embossed, roughened, and, at the same time, velvety appearance of the entire surface of the iris due to iritis, and more yet to irido-choroiditis, comes out strongly marked under the influence of condensed light, and even increased vascularity of the membrane with a little care can generally be ascertained. In rare cases the iris may be the seat of

minute crystals of cholesterine, which then glitter like points of diamond dust under oblique illumination. I have seen a case in which the entire iris was studded with minute particles, giving to the membrane the appearance as if made of gold sealing-wax.

The minute, as well as the larger, adhesions of the pupillary borders of the iris to the capsule of the lens, their extent, form, and color, can be observed to the fullest advantage by this method of illumination. So, too, exudations upon the surface of the lens, the remains of capsule after an operation for cataract, or the membranes which so often stretch themselves across from the pillars of an iridectomy, or the thread-like remains of the pupillary membrane. Very delicate membranes, even where no operation has been performed, sometimes form over the pupil, and I have known these web-like formations to be so delicate as not to interfere in some cases, in any appreciable degree, with the clearness of the picture of the fundus as seen with the direct light from the ophthalmoscope, while in others the interference is so slight as to express itself only by a delicate want of definition of the entire fundus, the exact cause of which it is exceedingly puzzling, if not impossible, to ascertain without the aid of oblique illumination.

As a modification of the method of examining the iris by oblique illumination, Liebreich* proposed that the cone of condensed light should be thrown not directly upon the surface of the iris, but obliquely through the pupil and behind the membrane, so that this latter should be seen by transmitted light, or that reflected for the more posterior portions of the fundus. It is, however, only in albinotic eyes, or where the iris itself is destitute of pigment, or very atrophic, that the method yields any satisfactory results.

The same objection is applicable to Becker's method of throwing a cone of light upon the eye from a common ophthalmoscopic mirror in such a way that only one half of the cornea is illuminated, while the remainder of the light falls upon the sclera. In this way one half of the cornea and the deeper parts of the eye are in the shade, and only slightly illuminated by direct light in comparison with that which is reflected from the back of the eye, that is, by transmitted light.†

THE LENS.

Although the lens is apparently a perfectly transparent body when viewed by diffuse light, nevertheless, like the cornea, when subjected to condensed light thrown upon it from an angle, it betrays its want

* Graefe's "Archiv," Vol. I., Ab. i., p. 353.

† "Wiener medicinische Jahrbücher," 1863, p. 162.

of transparency by a delicate network of fine striæ, which cross the anterior portions of the lens and form radiating lines which constitute, as Mr. Tweedy * has expressed it, a visible stellation of the normal lens. These lines are exceedingly fine and difficult to perceive except under the most favorable circumstances.

A much more tangible appearance, and one which can always be obtained, is the delicate and smoke-like cloudiness following the passage of the rays into the substance of the lens. This is due partly to the fact that the anterior capsule has a greater index of refraction than the aqueous humor, but more particularly to the anatomical arrangement of the fibres of the lens itself. From the multiplicity of these fibres, and from the fact that they are laid, as they are, one over the other, sufficient light is reflected to produce the delicate haze in question.

This mist-like opacity exists as a physiological condition, to a greater or less degree, in all lenses. Barely perceptible in early youth, it grows more and more pronounced with progressing years, till oftentimes in old age it becomes, through some chemical or physical change in the fibres, so dense as to suggest unmistakable evidence of the presence of cataract, or, if of a greenish or yellowish hue, the existence of glaucoma. Fortunately this apparent want of transparency in the majority of cases vanishes under the ophthalmoscope, and with it the doubt in the observer's mind whether the turbidity is due to a pathological or physiological condition; for, as a rule, when the reflex in the field of the pupil is perfectly clear and free from interruptions, and the details of the fundus come out sharply, little fear need be entertained as to trouble in the lens. Care, therefore, should be taken not to pronounce too positively as to the presence of disease, from any peculiarity in the color of the reflex from the eye, either under daylight or from oblique illumination, as a physiological reflex may, from age or other circumstances, vary in its density and color from a delicate steel-like gray to a yellowish or reddish-brown. Still, there are cases, especially in young and middle-aged people, or those who have grown prematurely old, in which the utmost care is necessary to make a differential diagnosis, or to say whether a somewhat too pronounced haziness seen under oblique illumination is or is not an abnormal condition of the media. These are the cases which test most thoroughly the skill and acumen of even a practised observer, and the inexperienced must be doubly on their guard.

Luckily, diffuse opacity of the lens, without one or more well-defined imperfections, be they never so small, is very rare. The state

* "Royal London Ophth. Hosp. Reports," vol. viii, Pt. 1, p. 24.

of vision often helps us to a diagnosis, for this is very seldom reduced in itself, or the cause of complaint on the part of the patient, when the want of transparency is due to physiological conditions, perhaps from the fact that it comes, especially in elderly people, so slowly as not to have excited comment. When the diffuse haziness is the result of a pathological process, vision is usually reduced, and the loss, as a rule, easily detected by the patient; even when it happens in one eye, though the reverse may take place, and the trouble escape notice for a long time, and then only by accident be brought to light.

Before the invention of the ophthalmoscope, and the more extended use of oblique illumination, great reliance was placed on what is known in the older works as the catoptric test. In later times this has gradually fallen into disuse, until among the more modern observers it is rarely, if ever, employed. This is regretted, as it should be, by some writers, especially by Mauthner, who loudly and not unpoetically sings its praises. But I must confess that, with the exception of determining, in the most beautiful and, at the same time, most irrefutable manner, the presence or non-presence of the lens itself, this method has not given in my own hands as satisfactory results, either as to the existence or position of lenticular opacity, as have the other more simple methods now in common use, that is, by oblique illumination and the ophthalmoscope. Still, I have introduced a description of this test here, as it is claimed that it lends its most important service in the very conditions now under consideration, that is, diffuse opacity of the lens. The principles which govern this test and its application are briefly stated as follows:

The anterior surface of the lens curves outward, so as to present a convex surface to exterior objects. As the surface is highly polished, and the index of refraction higher than that of the aqueous humor, it has all the properties of a convex mirror, and will produce a reflection of an object placed in front of it. The image of such object will be upright and reduced. It is a little difficult to see this image, as it lies directly behind that from the surface of the cornea; it suffers, moreover, in contrast with the latter, being much less brilliant, since the difference between the index of refraction of the cornea and the air is much greater than that between the lens and the aqueous humor.

The posterior capsule of the lens, on the other hand, backed by the vitreous, presents a concave surface to objects placed in front of it, and, as these latter must always be at a greater distance from the reflecting surface than the length of its radius of curvature, the images of the objects will be reversed as well as reduced. In this way the

reflection from the posterior can readily be told from that of the anterior surface of the lens. It can also be easily distinguished from that of the cornea, since it is not only reversed and paler, but also is at a distance from it. Moreover, the two images move, when the object is moved, in opposite directions to each other.

The best method of viewing these images is to place the object used at one side of the eye examined, and for the observer to stand upon the other. The best object for this test, and the one which gives on the whole the most conspicuous images, is the classical one of a lighted candle.

This should be held as close to the eye as possible, though, as before said, to one side, while the observer stands upon the opposite side. In this way we get the largest possible image and the brightest illumination, since the angle of incidence and reflection are as large as circumstances will allow.

If the candle now be held below the eye (the patient being seated, while the observer stands), the corneal image, which is upright, is formed near the lower border of the membrane, while that from the posterior capsule is reversed and stands considerably above the former, since the line of direction, passing from the candle through the corneal image, will impinge, if continued, at the upper part of the posterior capsule. If the candle is now carried upward, the corneal image rises, while that from the posterior capsule sinks. If the former passes to the right, the latter goes to the left, and so on. In this manner the image may be made to cover, by slight successive movements, the entire surface of the capsule.

If, now, there is a disturbance in the body of the lens anterior to its posterior surface, that part of the image which would be formed by the posterior surface, were the rays not cut off by the opacity lying in front, is wanting. The image of the candle-flame is then either obscured or entirely interrupted, according to the density of the opacity. If, on the other hand, the opacity lies behind the reflecting surface, that is, the posterior capsule, it has no effect either on the continuity or brilliancy of the image. The opacity must lie, therefore, in the vitreous body.

Now as to the diffuse opacity of the lens. "When the sun," says Mauthner, with a pardonable enthusiasm in comparing greater with lesser things, "sets or rises in a murky atmosphere, his at other times golden face has a rosy and occasionally even lurid tinge, from the fact that the red rays survive the quenching effect of a troubled medium better than the others, and therefore pass through it in greater quantities. For precisely the same reason the image of the posterior cap-

sule, in case of a diffuse disturbance in the lens, has a rosy or even blood-red appearance, while that of the anterior capsule is not affected." *

So, too, in cases of mild hyalitis, where there was a delicate, yellowish-gray reflex from the fundus, the writer has been able to exclude all participation of the lens by the perfect brilliancy offered in the reflexes of the anterior and posterior capsules, as shown by the catoptric test.

OPACITIES OF THE LENS.

Passing from the examination of the diffuse disturbances of the lens to those of a defined character, we enter the field where oblique illumination has its happiest exemplification, for in no other way do these lenticular imperfections come out so strongly in their true form, color, and position, as by this method when properly applied.

All lenticular opacities—whether of the capsule, anterior or posterior, or of the substance of the lens, cortical or nuclear—show themselves under oblique illumination as interruptions, of greater or less extent and density, in what under normal conditions is a uniformly clear field of pupil. When the opacity is in the capsule it is called an anterior or posterior capsular cataract, according as it is in the anterior or posterior portion of the investing membrane. If the disturbance is in the outer layers of the lenticular substance it is called a cortical, if in the inner a nuclear, cataract. All these varieties may exist alone or be combined with each other. In the latter case the cataract is said to be mixed.

It is certainly not worth while to weary my readers with a detailed description of all the multitudinous shapes which the opacities included under the name of cataract, either stationary or progressive, may assume. Still, there are several varieties which possess such uniform and characteristic features as to have a distinctive name, and as such merit a short description.

Anterior Capsular Cataract.—This usually appears under lateral illumination as a sharply defined spot in the centre of the capsule; it may, however, be more or less irregular in shape, and vary considerably in size as well as position. So, too, with the posterior capsular cataract.

Pyramidal Cataract.—This consists of a whitish mass in the pupillary space, the apex of which projects, to a greater or less degree, from the centre of the anterior capsule into the anterior chamber, while its base extends backward into the substance of the lens.

* "Lehrbuch der Ophth.," Mauthner, p. 149.

Mauthner* mentions having seen in several cases a modification of this form of cataract, which consisted of a double pyramid with a common base at the anterior capsule. The apex of one extended into the anterior chamber, that of the other backward toward the centre of the lens. In one case he saw two pyramidal cataracts in the same lens. The same author mentions the fact that sometimes, by oblique illumination, the anterior capsule may be seen to lie in radiating folds in the neighborhood of the pyramid.

Zonular Cataract.—This is a disturbance of the lens, in which the outer layers of cortical substance remain clear, as does the centre or nucleus of the lens, while the intermediate portion is affected. Thus, the nucleus is inclosed by a more or less dense and cloudy envelope or zone, which is usually of a uniform thickness, and through which with the ophthalmoscope we get more or less distinctly a reflex from the fundus.

Zonular cataract, instead of consisting of a single zone, may be composed of two (Graefe, Sichel), or even three concentric layers, which are opaque, and which are separated from each other by intermediate layers of clear substance.

The zonular, like other forms of cataract, may be either simple or mixed; when the latter it is usually progressive. In this respect it may be well to mention that Graefe observes that the cataractous process remains stationary so long as the cortical substance preserves its transparency; but, if this becomes the seat of diffuse or punctate opacities, it may be looked upon as a sure sign that the process is progressing.

Spindle-shaped Cataract.—Under this title a curious and very rare form of lenticular disturbance is described by several authors (von Ammon, Pilz, Müller, Becker).

From the centre of the anterior capsule in Becker's case, a bluish-white opacity extended, gradually increasing in size, toward the centre of the lens. Here it inclosed the nucleus in a globular-like envelope, and then gradually decreased in size till its apex was inserted into the posterior capsule. Though not always so regular in its outlines, its general characteristics are to extend along the central axis of the lens and to assume as it progresses a fusiform shape.

Posterior Polar Cataract.—This is one which has its seat in the deepest layers of the lens, near the posterior pole, or which may, according to some, take its rise in the vitreous body. It may exist as a circumscribed and defined mass, but usually has one or more oftentimes spike-like projections leaving it in different directions, and

* "Lehrbuch der Ophth.," p. 140.

which usually take the curve and plane of the posterior capsule. These projections are sometimes so regularly arranged as to resemble the spokes of a wheel. The same effect may take place on the anterior capsule and its neighboring corticalis, or both capsules may be affected at the same time, while the intervening substance of the lens remains clear.

Secondary Cataracts.—These, whether the result of injury or of operative interference, show themselves in the shape of membranes in the pupillary space. Sometimes these membranes are so delicate as to be almost transparent in their entire extent, or again here and there minute opacities or pigment-spots may be scattered over them. On the other hand, these membranes may be so densely opaque as to be impervious to light, either from lateral illumination or the ophthalmoscope, and in this case they sometimes suggest the idea that a cataractous lens is still present.

These membranes may also assume band-like forms, which then appear to run across from one border of the iris to the other, but which in reality have their attachments, as attempts to remove them show, in the neighborhood of the ciliary body.

The size and position of foreign bodies in the lens, such as bits of steel or stone, can often be ascertained by oblique illumination, even when the surrounding substance has become so much disturbed that the imbedded fragments can not be detected with the ophthalmoscope. For this reason lateral illumination should never be neglected after such accidents. Sometimes, however, the lenticular substance surrounding the body remains perfectly clear, even for long periods after the accident, and then, if the fragment is a chip of steel or other polished substance, the characteristic metallic reflex is obtained. So, too, we are often enabled to follow the track of a perforating body by condensed light, and to trace its passage through the cornea and lens, either by the disturbances in transparency at the point of entrance, or sometimes through the entire thickness of the wound. We can thus become convinced that the foreign body, though no longer in sight, has entered the eye.

When a cataract has become fully formed, oblique illumination is by far the best means of studying its peculiarities. This is especially the case after inflammatory processes, such as iritis and choroiditis, through which the lenticular substance has undergone degeneration. In these cases we can often detect with its aid what appears under ordinary illumination as a homogeneous whitish-gray substance, that is concrete masses of chalky degeneration, or a multitude of minute and glittering specks of cholesterine, which give a sparkling appear-

ance, or a satin-like sheen, to the surface of the lens. The lens may, moreover, even when no such degeneration has taken place, have a marbled or segmented appearance, such as the section of a piece of talc or isinglass shows when polished.

The position of the lens, and whether in a given case it lies in its proper place or is dislocated, can often be determined by means of lateral illumination. Especially is this true when a perfectly transparent lens is dislocated into the anterior chamber, either partially or entirely. Through total reflection we then get a beautiful silver ring, which plays round the extreme edge of the lens. As a rule, however, this method, in ordinary dislocations, is not so satisfactory as that with the ophthalmoscope, and for this reason this subject will be more fully treated under that heading.

Opacities in the vitreous are, as a rule, better studied with the ophthalmoscope than with lateral illumination. Still there are occasions where this latter yields the best results, such as profuse hæmorrhages from vessels lying in the anterior parts of the eye, and where we consequently find it impossible to get a reflex from the fundus with the ophthalmoscope. So, too, with tumors or gummata situated in the ciliary region, or in diffuse hyalitis, from which we get a dull, and occasionally a rather bright, yellowish reflex, but never so bright as that which comes from glioma, or from metastatic choroiditis, which is the sequela of cerebro-spinal meningitis. More, however, will be said on this subject in its appropriate place.

EXAMINATION OF THE MEDIA BY THE OPHTHALMOSCOPE.

When light is thrown into the eye from the mirror alone, at the ordinary distance for the inverted image, the pupil is seen to glow with a uniform brilliancy, which varies somewhat in color and intensity, according to the pigmentation of the fundus and the portion of it which is opposite, for the time being, the pupillary space. Should anything be present which interferes with the passage of the light, and therefore with the transparency of the media, this manifests itself either by a general reduction in the intensity of the reflex in the pupil, or by isolated interruptions in the illumination, according as the opacities in the media are of a diffuse or concrete nature; and it may be well to mention here that very delicate disturbances, especially of a diffuse character, are better seen with the weak-light mirror, since with the strong they are, from their delicacy, sometimes overcome by the excess of illumination. On the contrary, these opacities, although diffuse, may be so dense, from their consistency or numbers, as to require all the illumination possible in order to get a reflex from the

fundus. When this is so, either a plane or concave silvered mirror is demanded. With a little care in subduing the light, when occasion requires it, the common concave mirror may be made to answer every purpose. When, however, the eye is very sensitive to light, that is, when the pupil contracts unduly, I prefer, without there are very strong indications against it, to use a mild instillation of atropine than to employ a weak-light mirror, as is recommended abroad, for the purpose of avoiding too great a contraction of the iris; and especially in the case of patients of middle or advanced age, where there is reason to apprehend that there may be trouble in the periphery of the lens.

All interruptions of whatever size in the field of the pupil, no matter where they are situated, appear with the ophthalmoscope, as a rule, black. This is due to contrast, for the rays thrown by the ophthalmoscope directly upon these opacities are not reflected from these surfaces in sufficient quantities, as is the case with oblique illumination, to give them much, if any, individual tinge; while, on the other hand, the light reflected from the fundus is not strong enough, except in the case of thin membranes, to pass through them and thus give them a transparency. In rare instances, opacities in the media may be of such a nature as to reflect light in sufficient quantities to produce a lustre of their own by direct reflection, as is the case sometimes with bits of metal or particles of cholesterine.

Thin membranes, from their delicacy, often appear of a grayish hue in the midst of the otherwise reddish-yellow field. There are other cases in which, in spite of all our efforts at illumination, the entire pupillary space maintains a jetty blackness. This shows that there is some insurmountable obstacle to the penetration of light into the eye.

Sometimes an otherwise uniform and bright reflex is suddenly interrupted by the appearance here and there of black specks, of a greater or less size, due to particles or shreds of mucus which have adhered for the moment to the surface of the cornea. Long, black, string-like formations may come suddenly into the field, due to the eye-lashes, and caused by the drooping of the upper lid. The first requires a little care not to mistake them for deeper-seated and permanent disturbances. They can be removed by rubbing the upper lid gently over the surface of the cornea. The true character of the latter is at once detected when once they have been seen.

Besides the method of viewing the opacities of the anterior parts of the eye with the mirror alone and from a distance, we have two others by which they can be seen under an increased enlargement,

and many may be thus brought to view which would otherwise escape detection.

This first method consists in placing a strong convex glass, $+10$ D or $+12$ D, behind the mirror, and then approaching carefully toward the eye till different levels—cornea, aqueous, humor, anterior capsule, substance of the lens, and even anterior parts of the vitreous—are brought successively into focus.

In this way minute opacities in the cornea, and especially in the membrane of Descemet, are brought into view which would otherwise remain invisible. To reap the full advantages of this method of examination, a brilliant illumination and a dilated pupil are requisite, though a great deal may be done without the last condition being fulfilled.

By slight to-and-fro movements of the head, we can bring different planes of the media of the anterior parts of the eye successively into focus, and thus gain some idea as to the antero-posterior position of the opacities, since the nearer we can approach the eye—the accommodation being as fully relaxed as possible—the deeper seated must the disturbance be.

The second method by which we get increased enlargement and more brilliant illumination consists of using the mirror at a short distance from the eye examined, say six or eight inches, and then interposing a convex lens between the mirror and the observed eye in such a way that the object viewed, the surface of the iris, for instance, shall be just within the principal focal length of the lens. The object-lens being held in front of the ophthalmoscope, acts in the double capacity of magnifier and condenser, and thus increases the amount of the illumination. By slight movements of the lens back and forth, we can bring successively into focus the different planes of the anterior media, and see them under a considerable enlargement. This manner of using the instrument is precisely the same as with the ordinary inverted image; but the head of the observer is at six or eight instead of sixteen inches from the observer's eye, and the image obtained, instead of being inverted, is upright and magnified. This last method is not so comprehensive or satisfactory as the preceding, but is well adapted for studying the surface of the iris, small perforations of the membrane, and minute posterior synechiæ.

A general or diffuse opacity of any of the anterior media of the eye only expresses itself as such under the ophthalmoscope by the disturbing influence which it has upon the fundus oculi, the brilliancy of which when slight it reduces, and the details of which when dense it obscures or veils.

The Cornea.—From the reasons already stated in regard to illumination, and from the fact that with the ophthalmoscope it is somewhat difficult to judge accurately of distances, examination, not only of the cornea, but of all the anterior media, is, as a rule, more satisfactorily performed by oblique illumination than with the ophthalmoscope, still there are some cases where the former yields to the latter; and this is manifestly the case wherever there are slight inequalities in the surfaces by which the media are bounded, and particularly is this true in the condition known as "fascettes" of the cornea, where, from the inequalities of the surface, the light reflected from the fundus is irregularly refracted, so that it produces, under slight movements of the instrument, the characteristic play of light and shadow. Sometimes, too, very minute specks or opacities in the otherwise perfectly transparent substance of the cornea or lens are seen by transmitted light when they would have escaped attention under oblique illumination. Especially is this the case where very small opacities lie deeply in the cornea, in the membrane of Descemet, or in the lens; and examinations with the mirror should never be omitted when the patient complains of a sensation as if something was in the eye, which oblique illumination has failed to detect.

The ease with which these small objects can be seen can be increased, especially when the pupil is enlarged and the light strong, by placing a convex (+ 10 D) glass behind the ophthalmoscope and approaching close to the eye after the manner just described. I have, moreover, in this way often convinced myself that the membrane of Descemet, even when not the seat of actual deposits, has sometimes the appearance of being thrown into delicate folds or undulations, so delicate, indeed, as to escape notice except under the enlargement of the magnifier and the movements of the ophthalmoscope, combined, also, with the movements of the eye in different directions on the part of the patient. When this is done, the pupillary space, which with the mirror alone, and at a distance, had a perfectly uniform reflex, acquires a sheen-like appearance, as if light was reflected from delicate inequality in the surface of a substance, the transparency of which was not, however, affected as a usual thing to any perceptible degree. Sometimes, however, slight but annoying disturbances in vision are an accompaniment of the trouble, and it is important not to overlook them, especially after blows or other contusions of the eye or head. Whether, after all, this appearance is due to some change in the innermost layers of the cornea, or is in the membrane of Descemet itself, may be a question. I am, however, inclined toward the latter view. Of its existence, which is often palpable enough, there can be no doubt.

Aqueous Humor.—The ophthalmoscope is of very little use in the study of the aqueous humor or the accumulations which take place in the anterior chamber. Minute particles can, however, when a magnifying-glass is used behind the instrument, sometimes be seen as they rise above or sink below the borders of the iris, and thus show that they are in a plane anterior to that of the iris.

THE IRIS.

The surface of the iris, like that of the cornea, is generally better studied by means of oblique illumination than with the ophthalmoscope. Still, there are occasions where the instrument performs useful service even here, and when it is used it is better to place a high magnifier (+ 10 D) behind the mirror, and then to employ as strong an illumination as possible while the observer approaches the eye until the plane of the iris is in focus; or, even better still, instead of placing the magnifier behind the mirror, the two-inch object-glass can be held just in front of the eye to be examined, while the observer throws the light from the mirror through it. In this way the glass acts both as a condenser and magnifier. When used in this manner, the observer must approach close to the glass, which by slight to-and-fro movements can be made to focus the plane of the iris or anterior capsule of the lens. In this way minute bodies or apertures may be detected, condylomata studied, or even an increased vascularity of the membrane be seen under a greater enlargement. In this manner also the writer has been able to detect adhesions to the lens, especially in old people, where the pupil is very narrow and very sluggish to light.

Light does not, under ordinary conditions, pass through the iris, at least in sufficient quantities to give any reflex of the fundus beyond. When, however, the membrane is destitute of pigment, as in albinos, or has undergone extensive degeneration through atrophy, sufficient light is returned to the observer to enable him to obtain a more or less feeble reflex through the membrane, or even in pronounced cases to discern the outlines of the ciliary bodies, which then appear as dark projections of various heights. In one case of extensive atrophy which I examined, the membrane presented alternate spaces of light and shade, radiating from the pupil like the fan-shaped sectors of a common ventilator.

Perforations of the iris and separations from its peripheric attachments and the remains of the pupillary membrane, provided the media behind have preserved their transparency sufficiently, betray themselves by the red glow from the fundus, which then occupies the vacancy. The space may, however, especially after injuries, be the

seat of a small hæmorrhage or exudation, or masses of cortical substance, so that no reflex can be obtained through them. The true nature of the obstacles can then usually be easily determined by oblique illumination. On the other hand, what sometimes seems under oblique illumination to be an interruption in the surface of the membrane covered with black pigment or with the remains of a layer of blood, proves with the ophthalmoscope to be a vacant space or cleft in the iris, through which we not only get a perfectly clear reflex, but can even discern some of the details of the fundus. For this reason the ophthalmoscope is most advantageously employed in determining the condition of the pupillary space and its fitness for the passage of light, as, for example, after an attack of iritis, the performance of iridectomy, and especially that of cataract, where by its means we can judge at once whether the field of pupil is limited in extent, or whether adhesions have taken place from the borders of the iris, or whether the pupil is the seat of exudations, the remains of capsule, or cortical substance; in fact, everything which relates to its clearness, size, shape, and permeability to light.

THE LENS.

Alterations in the curvature of the lens can not, as a rule, be told with the ophthalmoscope. One or two cases have been known, however, even in the writer's experience, where a marked inequality in the surface could be detected.

As with the other anterior media, diffuse opacity of the lens betrays itself by a reduction in the brilliancy of the ophthalmoscopic picture, over which it casts a delicate haze. It is, as a rule, better examined with oblique illumination than with the ophthalmoscope; but in either case it requires the closest attention and care on the part of the observer not to overlook this delicate cloudiness, and whenever this is suspected both methods should be employed.

Precisely the same appearances as those which have already been described in the case of the membrane of Descemet, and which suggest a delicate folding or ruffling of the surface, are often seen on the anterior capsule of the lens, or in the cortical substance lying just beneath it. There can be little doubt that oftentimes this is a physiological condition and due to some peculiarity in the capsule, suggesting a continuation of the fold-like arrangement of the zonula on to the surface of the lens; but, on the other hand, it is just as certain that these striæ, or delicate ruffings, in the surface of the capsule are of pathological origin, as if due to some mild form of capsulitis of an idiopathic form. I have also seen them as the result of injury to the eye,

and have now under observation a case of injury from a blow followed by a mild iritis, in which these stripes or folds developed. They ran horizontally across the upper half of the anterior capsule of the lens, the lower part being clear, as was the entire substance of the lens.

Sometimes, moreover, delicate irregularities are seen in the substance of the lens, especially toward the periphery. These have usually a twig-like course, and produce the impression as if they were inequalities in an otherwise transparent and homogeneous substance, having just enough difference in their construction and index of refraction to render them visible under the play of light from the ophthalmoscope. Dust-like aggregations and minute spots are often seen in the peripheral portions of an otherwise perfectly clear lens. There can be no doubt that these appearances are often purely physiological. That they are not always so is proved from the fact that examinations repeated after successive intervals show that they do increase till the lens finally becomes cataractous. I would not wish to mislead the reader, or give the idea that any opacity in the lens is not a matter of serious consideration, which I freely admit it is, but I merely wish to point out the fact that opacities may exist for years without change in size or shape, while the rest of the lens remains perfectly clear; and this is particularly true when the opacity is an isolated one with a clearly defined contour, as, for example, the small, round spots on the posterior surface of the lens, which are often attributed, whether rightly or not, to the remains of the central hyaloid artery. These spots may, however, exist in any part of the lens, not only on the posterior but also on the anterior surface, and not only near the centre, but also at the periphery; and, moreover, they may be of any shape, either circular or cleft-like. This fact ought to make our prognosis a little more guarded than it usually is, and cause us to refrain from unduly alarming a patient about a threatening loss of vision, combined with a serious operation, when no occasion for either may ever occur. Especially is this true in patients who have for years been very myopic, and whose eyes show an extensive posterior staphyloma, with other changes in the choroid.

Defined opacities in the lens appear as black interruptions in a reddish-yellow field, since they lie, as already pointed out, between the observer's eye and the source of illumination, which in this case is the reflection from the fundus. As they reflect from their surfaces but little light when the angle of incidence and reflection is small, they do not appear as they do under oblique illumination in their true color, but, on the other hand, their position, extent, and outline are more clearly defined as they are seen against a brilliant background.

It is certainly not worth while to exhaust the reader's mind with a long and detailed description of the multitudinous variations, either as to place, form, or extent, that these opacities may assume or the changes they may undergo. A single glance with the ophthalmoscope at nature, or even a glance at the accompanying drawings taken from Jaeger's "Atlas," will give a better idea as to their true appearances than the longest and most minute verbal description. The pupillary space is supposed to be illuminated with the mirror, and the dark spots are seen by contrast against the lighter field.

Fig. 56 represents an eye, affected with iritis, under the influence of atropine. The black points extending into the clear field of the pupil mark the points of adhesion between the iris and the anterior capsule of the lens. The festooned appearance of the membrane is due to the fact that the intermediate portions of the iris are still free from the capsule and are capable of dilatation.

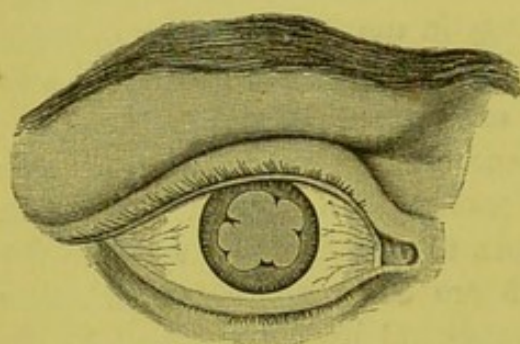


FIG. 56.

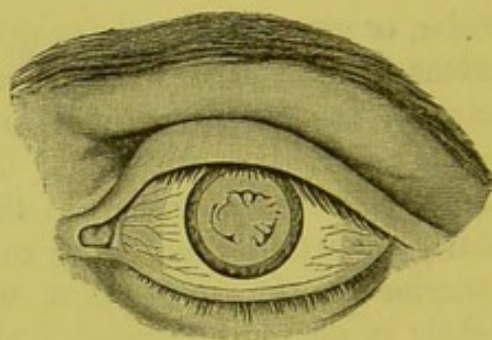


FIG. 57.

Fig. 57 shows the left eye of the same subject, in which the effect of the atropine has been sufficient to sever the attachments from the lens, the remains of which are seen on the anterior capsule. Care should be taken not to confound the remains of such attachments with cataractous opacities. In both eyes oblique illumination, even when the pupil was undilated, showed that besides the synechiæ, which came clearly into view, there was a very delicate membranous opacity which extended over the central portions of the capsule. This was barely visible with the direct light from the ophthalmoscope.

Fig. 58. This represents one of the many forms of cortical cataract. The disturbance is situated in the anterior portions of the lens, and in the centre of the field of pupil. For this reason the opacity does not appear to change its position from the centre of the field, and there are no parallaxic displacements in its relation to the borders of the iris, whatever may be the position or movements of the eye of either patient or observer.

Fig. 59. This also represents another form of anterior cortical cataract. The disturbances here consist of four stripes of opaque cortical substance running from the different quarters of the equator of the lens toward its centre, where they are united by a fifth. There is, moreover, an isolated stripe running from below upward toward

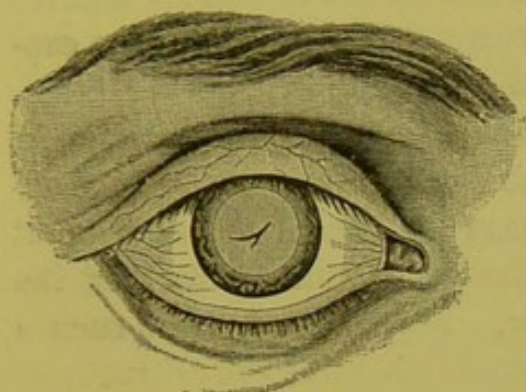


FIG. 58.

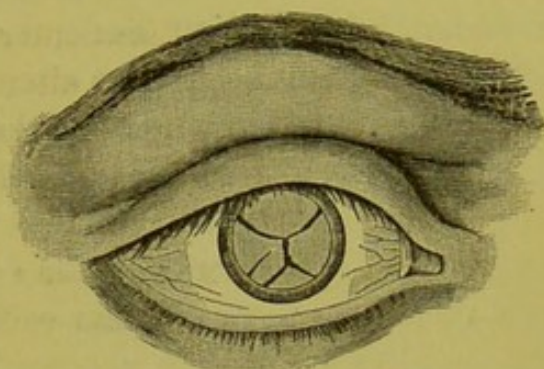


FIG. 59.

the centre. In looking at the central portion of these disturbances they would maintain their respective positions on movements of the head. Inasmuch as they are in the plane of the iris and centre of the field of pupil, their outer extremities would, however, have a slight parallax displacement in relation to the borders of the iris, and the stripes would appear to become longer or shorter, according to the direction in which the eye was turned. Suppose, for example, that the isolated stripe is in the lower and outer quadrant of the lens, and the eye is looking directly forward. If, now, the eye is moved outward, the stripe will appear to move in the same direction and to become a little shorter. If the eye is turned inward, then the opacity moves inward, and at the same time lengthens.

When the same or similar disturbances are found in the posterior layers of the lens, they form a posterior instead of an anterior cortical cataract, and present in the main the same ophthalmoscopic picture. As the opacities in this case lie at a considerable distance behind the plane of the iris, they can not be in focus at the same time with this membrane, as is the case in the anterior cortical or capsular cataract. These deep-seated disturbances seem to lie within and beyond the pupil and in its central portions, provided the eye looks straight toward the observer. On movement of the eye, however, the opacities make a greater or less excursion, according to the distance that they lie behind the plane of the iris. They always move, too, in respect to the iris, in a direction opposite to that in which the eye of the patient is moved, while it will be remembered that the disturbances in the anterior layers move in the same direction; moreover, the

opacities, as a whole, present a surface which is concave toward the observer.

The image produced by the catoptric test is interrupted when it comes over the cataractous portions of the lens lying in front of the posterior capsule. Of course, the image from the anterior capsule will never in any case be interfered with, as the reflecting surface must lie in front of all lenticular disturbances, unless indeed the capsule itself should become so altered by disease as to give no reflection.

There are still other cases where the anterior and posterior cortical layers are affected at the same time, and here we get the ophthalmoscopic appearances which have just been described, united so that upon lateral movements of the eye of the patient the opacities of the two surfaces appear to pass each other. Fig. 60 represents such a cataract, the deeper black opacities representing the disturbances on the plane of the iris are seen to be in focus, while the most posterior,

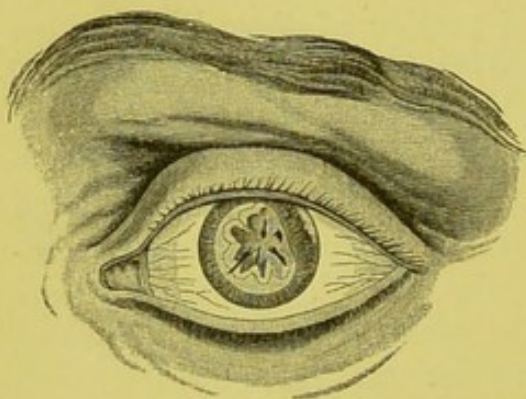


FIG. 60.

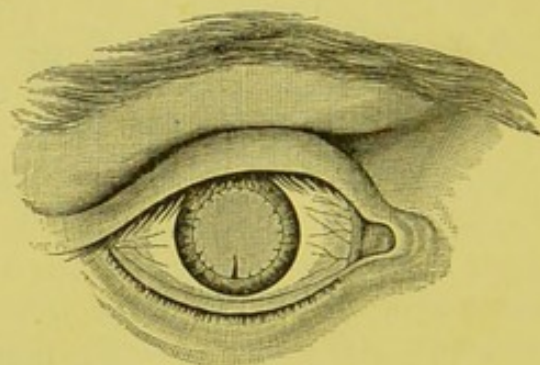


FIG. 61.

from being out of focus, appear of a lighter hue and of a less defined shape. The drawing also shows where the iris has been torn from its attachments by a blow, allowing the light from the fundus to pass through the rent.

Fig. 61. This illustrates peripheral disturbances in the cortical substance, and shows how important it is to make a thorough examination of the periphery of the lens when disturbances of vision, however slight, are complained of. In this case the eye was myopic 9 D, and vision had been gradually decreasing for some years. In ordinary daylight and an undilated pupil, no abnormal appearances whatever were visible. The opacities lay in both the anterior and posterior cortical layers of the lens, and the ophthalmoscopic appearances were such as are represented in the drawing. These changes were supposed to be due to a long-continued form of choroiditis. The most interesting point in the case is the fact that, after a long-

continued treatment, examinations with the ophthalmoscope showed a gradual decrease in the disturbances, till finally at the end of five years they entirely disappeared, "no trace," according to Jaeger, "being left." I have myself often seen these peripheric opacities, especially in near-sighted eyes, remain *in statu quo* for years, and have occasionally convinced myself that they had gradually become reduced in size. I have, moreover, seen a case where, as Jaeger* asserts, opacities in the lens have entirely disappeared.

Fig. 62 is of the same character as Fig. 61, only more pronounced.

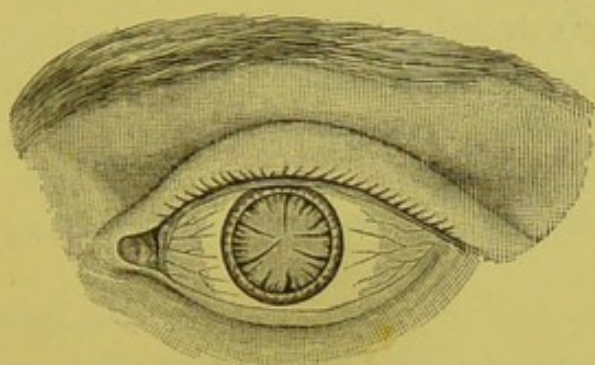


FIG. 62.

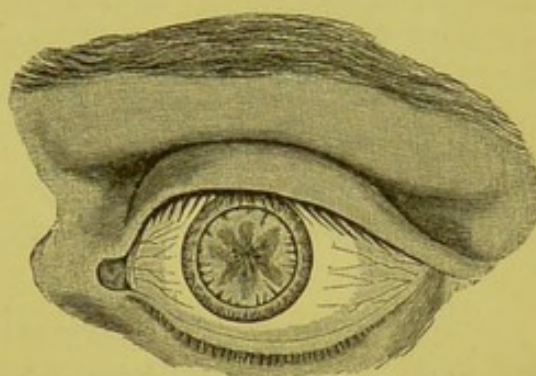


FIG. 63.

The reader must bear in mind that these cortical disturbances are not always clearly defined with sharp pointed processes, but, on the contrary, these may be obtuse or the whole disturbance a more or less ill-defined mass, as in Fig. 63, which represents an anterior and posterior cortical cataract.

Fig. 64 is an example of a zonular cataract, which, as will be remembered, consists of an opaque layer of lenticular fibres lying between the nucleus of the lens on the one hand and the outer layers of the cortical substance on the other, both of these latter having preserved their transparency. Usually, as

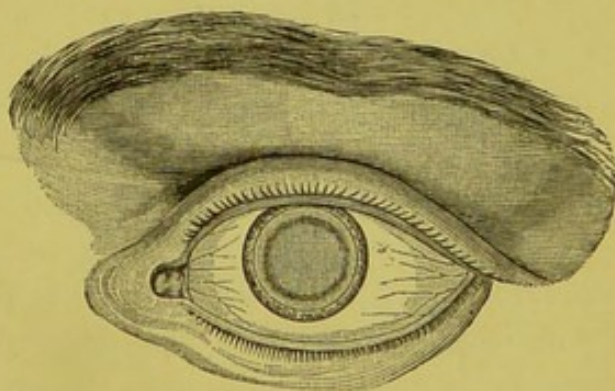


FIG. 64.

in the present case, the opacity is so delicate as to allow the light from the fundus to pass through it. Thus the central portions of the envelope present but little contrast with the rest of the yellowish-red field of pupil; and the portion between the fine dark circle in the drawing and the borders of the iris is seen to be transparent.

* "Wiener Zeitschrift für praktische Heilkunde," 1861, Nos. 31, 32, E. Jaeger. "Ophth. Hand Atlas," p. 9, Taf. II., Fig. 9, E. Jaeger. "Annales d'Oculistique," B. i., iii., p. 201, Galezowski.

From the angle at which the return rays strike the edges of the zonular envelope, these from total reflection appear of a much darker hue, and thus we get the appearance given in the drawing of a dark circle surrounding a central portion of a delicate reddish tinge. The size of the circle will, of course, vary, according as the opacity is nearer the circumference or centre of the lens. So, too, will the contrast between it and the included space vary in proportion to the density of the disturbance. Zonular cataract may be accompanied with changes in the cortical substance, and then it forms a mixed cataract.

The ordinary senile, or nuclear cataract, when it is most marked in the central portions of the lens, gives very much the same ophthalmoscopic picture as that just described. As the opacity increases, however, it loses the characteristic bright centre with a circular border, and becomes a more or less dense and dark mass with radiating spokes.

Dislocation of the Lens.—Under ordinary physiological conditions the borders of the lens are not rendered visible with the ophthalmoscope. This, however, may be the case, as, for example, when the iris is wanting either congenitally, or when it has been removed either in part or whole by surgical interference or accident, or when it has been separated from its attachments, or, under some conditions, when it has been dilated to its fullest extent with atropine, or is so wanting in pigment as to allow large quantities of light from the fundus to pass through it, as with albinos; and, finally, when the lens itself has from any cause become dislocated. Under these conditions the borders of the lens reveal themselves in two distinct ways, according as we view them with reflected or transmitted light.

Suppose any of the above conditions suitable for the observation, such as a dilatation of the pupil to its maximum or a perfectly clean iridectomy, exists. When light is thrown into such a field of pupil by oblique illumination, the great mass of rays will, of course, pass directly through the lens into the vitreous beyond; but the small portion of those which strike upon the very borders of the lens will, after passing through the intervening portions, meet the *posterior* capsule at such an angle that they will be totally reflected, and thus come back to the observer's eye; consequently the very outermost limits of the lens will appear brilliantly illuminated. We see, therefore, the borders of the lens under oblique illumination as a finely drawn and glittering circle. This is very beautifully marked when the lens is entirely dislocated into the anterior chamber, preserving, as it sometimes does, its perfect transparency. On the other hand, when we

use the ophthalmoscope, the rays which return from the fundus and strike upon the borders of the lens after passing through the posterior portions, meet the *anterior* capsule at such an angle that they are totally reflected and pass back again into the eye. The observer does not receive these rays, and consequently the border of the lens appears to him dark, and he sees the lens surrounded by a narrow dark rim. When, however, the lens is entirely dislocated into the anterior chamber, so as to expose the borders of the lens for its entire circuit, we can get, for the reasons stated above, the glittering ring even with the ophthalmoscope, by rotation and displacement of the mirror, combined with the movements of the eye on the part of the patient. The illuminated space between the dark border of the lens and the ciliary processes marks the position of the zonula of Zinn. Usually this membrane is so transparent as to be invisible; but it has been asserted that under favorable conditions the folding of the zonula can be followed in the form of grayish stripes from the ciliary processes to the borders of the lens. I have myself seen something which suggests the above appearance on the marginal portions of the lens, but never any such appearances in the intervening space between its borders and ciliary processes.

The appearances just mentioned as to the borders of the lens will be more marked when the lens is dislocated, so that a part of its border passes through the field of the pupil, as will be seen from Fig. 65. In such a condition the refraction would be very different in the two sections, and there would be, when the eye of the observer was placed so as to receive rays from each section, a doubling of the details of the fundus. The displacement of the lens is usually downward, but may be in any direction. The iris is usually forced somewhat from its plane, and there is generally more or less trembling of the membrane.

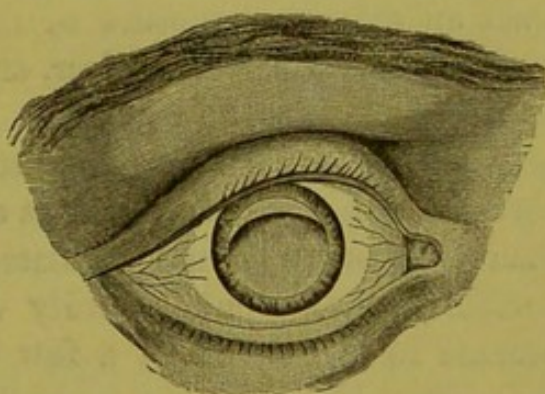


FIG. 65.

Instead of a partial dislocation this may be total, either into the anterior chamber or into the vitreous humor, where it sinks to the bottom of the eye, and presents the appearance, according to the amount of transparency which it has maintained, of either a pellucid or dark lenticular mass.

Fracture of the Capsule of the Lens.—Some ten years ago Dr.

Dyer published a paper* in which he described the fracture of the capsule and substance of the lens from violent hanging. The first subject examined was Probst, the famous murderer. The examination immediately before death showed nothing at all abnormal; that immediately after gave with the mirror the following results in brief:

"In the right eye there was a line running transversely across the lens and about a line below the centre. From this at various angles ran short and long, but very fine lines. These ran close together, but in no regular arrangement. The transverse line had the appearance of a crack in a clear piece of ice. It was evidently a fracture, involving the anterior capsule and extending in a horizontal plane backward into the substance of the lens."

"The left eye showed a line difficult to distinguish but to be made out with certainty, corresponding in position with that of the right eye. It was undoubtedly a fracture of the anterior capsule. Experiments were afterward made on dogs with similar results."

I mention these examinations of Dr. Dyer because I have several times seen very similar appearances from similar causes, that is, from violent concussions, of which the following may serve as an example:

A gentleman while driving was thrown violently from his carriage, striking, when he fell, directly upon his head. He consulted me a little later for a loss of vision in the left eye, which he knew to be the result of the accident. Examination showed that there had been an extensive rupture of the choroid. The media of the eye were, however, perfectly clear, and no disturbance in the lens could be detected. In the right eye, however, there was a delicate split-like opacity in the anterior capsule, which extended from the lower periphery of the lens toward its centre, so as to reach a little higher than the border of the undilated pupil. The rest of the lens was perfectly transparent. Hardly visible at first, this delicate opacity became in the course of a few weeks much more pronounced, and with the ophthalmoscope gave all the appearances that would a single and very delicate spiculum of an ordinary cortical cataract. Whether this disturbance was seated in the capsule or just below it could not be determined with exactness, though from the fact that it never increased in size it was inferred that it must be in the membrane, and that the continuity of this had not been broken, otherwise the lens would have become cataractous, which was not the case at least for the three years that the patient was under observation. During this time the opacity neither increased in size nor shape, or was the perfect transparency of the rest of the lens interfered with in the least. When

* "Trans. Amer. Ophth. Soc.," 1866, p. 13.

seen again, six years after the accident, all signs of any fracture had disappeared.

I have seen several such cases, the results of injury.

An attempt has been made by many writers to divide cataracts into two great classes, the stationary and progressive. This classification should not, however, be taken too literally, as all cataracts have a tendency to increase, whatever may be their kind or situation. All that can be said is that certain forms, as a rule, show this tendency less than others, especially the zonular and polar varieties, which often remain unchanged for years, or even forever. Still, too much stress in the way of a favorable prognosis should not be laid, either from the situation or nature of the disturbance.

The process in the formation of cataract in elderly people usually begins at the nucleus, which separates, as it were, from the cortical substance, and becomes denser and more opaque. This is followed in time by a cloudiness of the more superficial layers, till the whole lens becomes cataractous. When a nuclear cataract appears with a cortical one, it is called a mixed cataract. In young people, on the other hand, the disturbance usually begins in the cortical substance, and thence extends through the lens, forming what is called a soft cataract.

VITREOUS HUMOR.

The vitreous humor in a state of health is, under the ophthalmoscope, a perfectly transparent body. It can, however, from the effect of morbid processes, become the seat of opacities which may vary in size and shape from the merest particle or filament to coarse, broad bands, and from the thinnest possible web, which hardly interferes in the slightest degree with the illumination of the fundus, to the densest membrane which may exclude all light from entering the deeper parts of the eye.

As in the lens and aqueous humor these opacities may be of a general or diffuse nature, or circumscribed masses or membranes suspended or floating about in an otherwise transparent medium. From this fact they are usually classed as fixed and movable, conditions which are often important in a diagnostic point of view as to the true character of the vitreous, and whether in a given case it be of normal consistency or in a "fluid" condition.

Whatever may be the nature of these bodies in the vitreous, and whether they spring from the formation of bands and membranes of the nature of connective tissue, or be the results of morbid exudations or hæmorrhage, they appear, as a rule, black with the ophthalmoscope, because they are seen by transmitted light in contrast with the

surrounding medium, which is transparent, or, in other words, they are interruptions in an otherwise illuminated field. It is only occasionally that a membrane, when of considerable size or density and movable, so turns on itself as to reflect the light which strikes upon it. When this takes place, that part of the membrane from which the light is reflected changes from a black to a darkish gray, or even a grayish-white tinge. The same is true of bits of metal suspended in the vitreous, which frequently preserve their metallic glitter whenever the angle of incidence and reflection is of such a degree as to carry the reflected ray to the observer's eye. When this is not the case, and especially when encapsulated, they appear of a very dark hue or even black.

Another remarkable exception to the rule that opacities in the vitreous appear black with the ophthalmoscope, is the effect due to minute particles of cholesterine which, under the movements of the eye, flash into view like minute motes of light, and then disappear to be replaced by others in the same or in a little different position. I have seen an eye so full of these minute particles as to resemble, more closely than anything I can think of, one of those globular paper weights which represent a mimic landscape in a snow-storm, and which upon being reversed are filled with a myriad of small and feathery particles. These particles of cholesterine may exist with an otherwise perfectly clear vitreous and normal condition of the other parts of the eye, and with perfect or nearly perfect vision.

Such being the general aspect of all kinds of opacities in the vitreous, it remains to study a little more in detail the three classes into which they are commonly divided.

Diffuse Opacities.—That such a condition may and does occur there can be no question, but that it occurs as frequently as is alleged I am inclined to doubt, and from my own experience and frequent mistakes I would strenuously recommend the observer to exhaust every method and detail of examination as to the condition of the anterior media, the cornea, aqueous humor, and lens, and then the vitreous itself, for delicate stationary membranes before adopting such a diagnosis. To this end I would remind the reader that any existing error of refraction in his own eye should be corrected, and that an accurate adjustment of the accommodation, aided if necessary by the proper glasses, should be obtained for different levels or antero-posterior planes in the vitreous. The observer will often be surprised to see, after a careful examination of the anterior media, that what he had taken for a delicate diffused opacity in the vitreous resolves itself into a gauze-like but stationary membrane, which is only to be recog-

nized when the plane in which it lies is accurately in focus. When this takes place the delicate membrane then betrays itself, much in the same manner and with much the same appearance as does the film on an unclean slide under the microscope; that is, with here and there a minute dark speck, and here and there a fine, hair-like line or lines running transversely across the field.

Diffuse opacity of the vitreous, when it is really present, shows itself rather by the effect which it has upon the distinctness of the fundus beyond, than by any marked peculiarity of its own, just as a delicate mist makes itself more apparent from the effect on surrounding objects than it does from its own constituent elements. Here, again, under favorable circumstances, such as a good light and considerable enlargement produced by a somewhat strong convex glass behind the ophthalmoscope, this diffuse opacity may be made to resolve itself into small definite particles or shreds of membranes, or both.

The want of clearness of the fundus from diffused opacity of the vitreous may vary from a scarcely perceptible want of definition of the details of the background of the eye to their almost total obscuration, in which the optic nerve is barely discernible as an indefinite white spot or disk surrounded by a dulled and blurred background, with no vessels apparent, or, if apparent, only to be detected upon the disk itself. When, however, the obscurity is as great as this, care is required on the observer's part not to confound a general haziness of the cornea, especially in glaucomatous affections, with that in the vitreous. It must be borne in mind, too, that any want of transparency in the vitreous shows itself more readily with the upright image. Indeed, with the bright glare of the inverted image, these delicate and diffuse opacities often escape detection.

As regards the etiology of these diffuse troubles, they may be said to be due, as a rule, to some form of choroiditis, especially that of a low type such as the serous variety. Mauthner says that they may also occur in glaucoma.

Unfortunately for the beginner, no picture gives any adequate representation of these delicate and subtle changes in the vitreous, the most difficult to diagnose of all its troubles, and this, too, not only in regard to the media lying in front of the vitreous body, but also in regard to some morbid conditions of the membranes beyond, especially those of the retina. It is often extremely difficult, sometimes impossible, to differentiate between a want of sharp definition in the fundus coming from a slight disturbance in the transparency of the deeper portions of the vitreous and that arising from a

delicate and almost imperceptible haziness of the retina, that is, from some slight œdema, such as I feel convinced occurs in amblyopia p[ot]atorum, and other low types of retinal inflammation. Of some value, then, as a diagnostic mark is the diminution or entire want of the light-streak on the centre of the retinal vessels. Disturbances lying in front of the retina will, it is true, obscure to a certain degree the brilliancy of the image beyond, and thus proportionately reduce the brightness of the light-streak. This will, however, remain comparatively well marked, even when the general obscuration is of a considerable degree; while, on the other hand, should the want of transparency be in the retina itself, the slightest œdema will cause the light-streak to be diminished in size and brilliancy, or to disappear entirely. More will be found in regard to this matter under the head of "The Light-Streak as a Diagnostic Mark," Part II.

Movable Opacities.—These may be of any size or shape, varying from small, circumscribed black masses, with or without processes of different size and length, to long, snake-like membranes, which move with an undulatory motion through the vitreous on the slightest movement of the observed eye. Yet, notwithstanding this freedom of movement and extent of the excursion, which would lead one to believe that these membranes are entirely free, they are often, if not as a rule, attached by filamentary bands to some peripheric portion of the fundus. When of moderate size, and present in considerable numbers, these movable opacities often produce the effect, as well to the observed as observing eye, of what is usually known as the mother in vinegar.

Fig. 66 is taken from a chromo-lithograph by Jaeger, "Hand Atlas," Taf. III., Fig. 21. It represents a myopic eye affected with

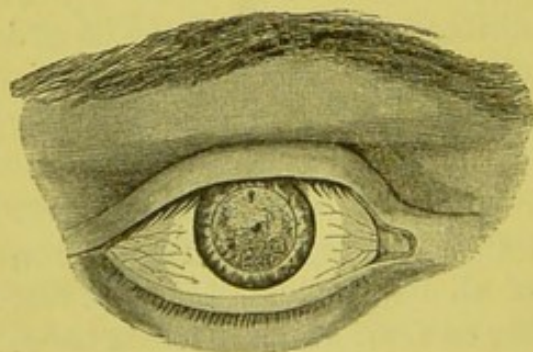


FIG. 66.

inflammation of the choroid with opacities in the vitreous. The lenticular system was perfectly clear, but the vitreous was, for the most part, in a fluid condition. When the eye remained quiet there seemed to be, with the ophthalmoscope, a uniform haze over the entire field. If the eye was moved, however, even to a slight degree, a great number

of very minute as well as some larger opacities of a black or dark-brown color came into view, which rose and fell in a cloud-like manner, especially in the anterior and middle portions of the eye. When

the eye became quiet again, the opacities gradually sank, the larger more quickly than the smaller ones. The back of the eye appeared less clear than usual, but still all the details of the fundus could be plainly seen somewhat veiled to be sure, but still sufficiently distinct and in their normal color.

Fig. 67 (Jaeger, "Hand Atlas," Taf. III., Fig. 22) represents an eye in which there was inflammation of the retina and choroid with opacities in the vitreous. The examination with the ophthalmoscope showed that the lens was perfectly clear, as was, indeed, the vitreous body itself when the eye was motionless. The details of the fundus under this condition of rest preserved their usual clearness and definition. On movement of the eye, however, the opacities in the fluid

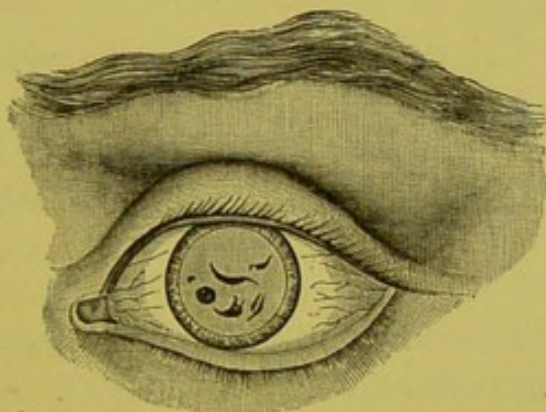


FIG. 67.

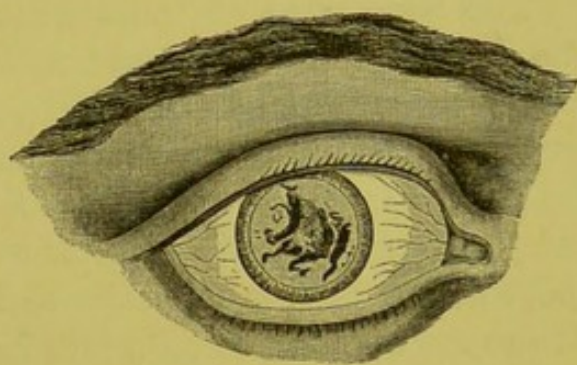


FIG. 68.

vitreous floated up at once into the field of the pupil as compact and untransparent masses of a nearly black hue, and of various sizes and shapes. On the eye becoming quiet again these masses gravitated to the bottom of the eye in the equatorial region, and passed completely out of view behind the iris.

Fig. 68 (Jaeger, Taf. III., Fig. 23) is of the same character, only the opacities are larger and more pronounced. In this case the bottom of the eye was obscured, and the details of the fundus were veiled by the thick masses which only permitted the light to penetrate in reduced quantities to the back of the eye.

Under the head of movable opacities may also be classed clots of blood, the result of hæmorrhage, either from disease or injury, which may assume the shape and form of circumscribed masses or membranes, such as are formed from other causes, and it is exceedingly difficult sometimes to say whether the disturbances in the vitreous are due to hæmorrhage or arise from other formations. Mauthner observes that, when due to bleeding, the edges of *the opacities have a reddish tinge*.* This I have never noticed, these masses always ap-

* "Lehrbuch der Ophthalmoscopie," p. 151.

pearing black, as they necessarily must, unless, indeed, they turn at such an angle that the light returning from the fundus should so strike them as to be reflected again to the observer's eye, which, so far as my experience goes, never happens. There is nothing which so excludes the light from entering the eye as an extensive hæmorrhage into the vitreous and in the immediate neighborhood of the lens. Not the faintest glimmer of the fundus can then be had; the pupillary space preserving a jetty blackness even when condensed light is thrown into it by the oblique method. Sometimes, however, we do succeed by this last method in getting a reddish hue, when the pupil is dilated to its utmost, and the condensing lens is so held as to get the greatest angle of incidence and reflection, and especially is this true when the clot is of recent origin.

The same want of transparency that exists with hæmorrhage is also found in purulent exudations into the vitreous, arising either from injuries or disease, especially that from metastatic choroiditis, as seen in cerebro-spinal and puerperal troubles. Whenever, therefore, the pupil appears with the ophthalmoscope of a uniform blackness, and participation of the anterior media have been excluded by differential diagnosis, it is necessary to have recourse to oblique illumination to resolve the obscurity into its true color and shape. Even with this aid it is sometimes impossible to get a reflection from these abnormal formations unless they happen to be in the most anterior parts of the vitreous, that is, in close proximity to the posterior parts of the lens.

Fixed Opacities.—These present very much the same appearances as the movable ones would if deprived of motion, for like them they may be either circumscribed black points or bodies of various size and shape with or without numerous processes, which may be so arranged as to form with each other the appearance of bands stretched across the vitreous, either in the same or in different planes; or, again, they may be so interwoven with each other as to give the appearance of a more or less regular network or cobweb, which may be either coarse or dense or of extreme tenuity. A favorite place for the formation of these bands is just behind the teleform fossa; especially are they found after an operation for cataract. They then appear to start from the neighborhood of the anterior parts of the ciliary body, and run backward in converging lines toward the centre of the eye. That they are due to some low morbid process which had also affected the nutrition of the lens, and were present before the operation and not the result of the healing process, would seem probable, at least in many cases. On the other hand, they often form after the operation

has been performed, sometimes even after a considerable interval has elapsed, either as the result of a mild inflammatory action following the operation, or sometimes without any apparent cause. At any rate, they are the despair of the surgeon as well as of the patient, as they often resist any and every effort at removal, closing at once over the passage made by the needle. These stationary opacities in the vitreous, if of any density, require but little skill or care in determining their true position and nature. But, as already pointed out under diffuse opacities, it is very different with these delicate stationary membranes, which offer so little resistance to the light as to appear perfectly transparent, except under peculiar conditions, and whose only expression of existence, on a cursory examination, is the vague and indescribable want of definition that they produce on the brilliancy of the general fundus.

Sometimes membranes of considerable density, either extended superficially or in the form of broad bands interwoven together so as to make a coarse network, are seen to protrude from different parts of the fundus into the otherwise clear vitreous. These give a grayish or greenish reflex, according to the angle under which they are seen, and are due evidently to some hypertrophy of the connective tissue, which would seem to be the product of some inflammatory action in the retina. They may become vascularized, and then, especially when movable, present a very beautiful appearance as they sway to and fro with every movement of the eye. These membranes, though common enough to be mentioned by all authors, are nevertheless comparatively rare. I have myself seen some dozen cases, and in two of these the point of origin could be traced directly to the retina. In the first case a delicate gauze-like membrane stretched across the triangle made by the first bifurcation of one of the ascending veins after it had left the nerve. It was of delicate structure, so that the red reflex from the fundus was but slightly dimmed. It lay in a plane close to the retina, and its surface was covered by a delicate and sprig-like ramification of vessels which seemed to be entirely of venous origin. In the second case observed by me, the membrane was of larger extent, and apparently arose from along the course of one of the lower veins at a considerable distance from the nerve. Like the first, it was of gauze-like texture, and was covered with small vessels which had the appearance and ramification of minute veins. The membrane moved freely under every motion of the eye, and bore a close resemblance, as a whole, to one of the more delicate sea-weeds, both in the gracefulness of its motion and the delicate tracings formed by the vessels upon its surface.

Dr. Strawbridge* gives a description and drawing (Fig. 69) of an extensive membrane arising from the deeper-seated portions of the eye, and protruding into the vitreous to such a degree that its anterior limits could be viewed by oblique illumination. The membrane, which was traversed by numerous vessels, was dense and white in

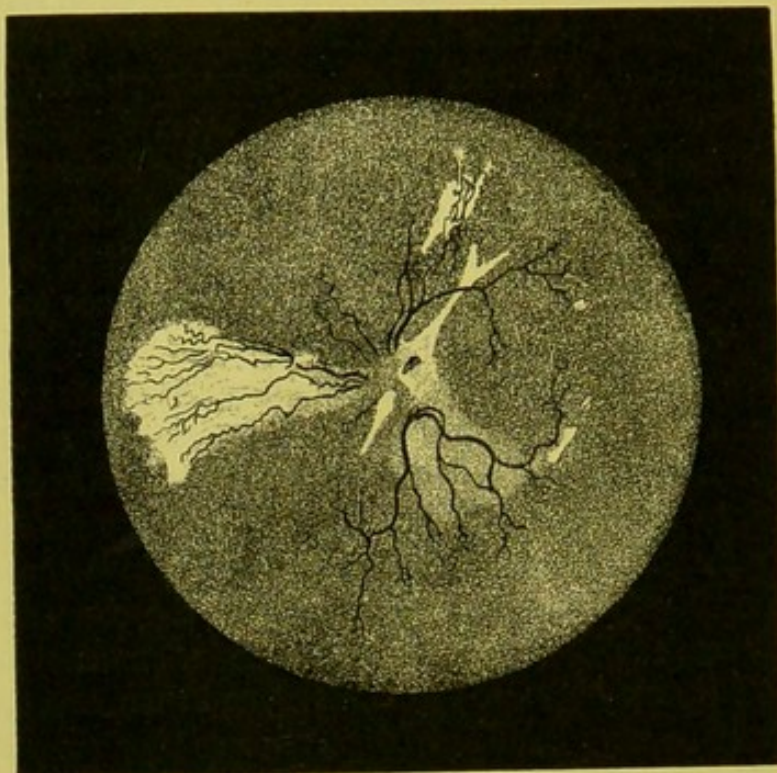


FIG. 69.

some places and attenuated and feathery in others, and through these latter the fundus could be seen beyond, of a normal color and appearance. The retinal veins were, however, tortuous and overfilled.

Jaeger† gives a drawing of an extensive membranous formation which surrounds the optic nerve like the frame to a picture, and then spreads out especially in a downward direction over the course of the principal vessels. The new growth is dense and opaque in some places, and attenuated and transparent in others, allowing the fundus to be seen in its normal condition. The web seems to be combined of layers and bands of connective tissue, so as to form superficial extensions and bands in different places, producing a play of light and shade which gives to it a reticulated or honeycombed appearance. The optic nerve seen through the central aperture of the membrane is much reddened, though the membrane itself does not seem to be the seat of any vessels of new formation.

* "Trans. Amer. Ophth. Soc.," 1875, p. 304.

† "Ophthal. Hand-Atlas," 1869, Tab. XVIII., Fig. 84.

Jaeger describes this membrane as others have under the head of troubles in the vitreous; but it is evident in all these cases, as well from the ophthalmoscopic picture as from the descriptions, that these membranes are rather due to some form of retinitis, such as proliferation of the adventitia or the connective-tissue elements of the limitans interna, than to a morbid process which affects in a primary manner the vitreous humor.

These growths or membranes are evidently of the same nature, only exaggerated in form, as the hypertrophy of the radial fibres and connective-tissue elements of the limitans, which project from the inner surface of the retina into the vitreous, and which have been described by Iwanoff.*

In this connection I might mention a case which at first sight I took for a membrane in the vitreous, but which, upon an exhaustive examination, I was inclined to look upon as a fold of the retina itself. This fold extended from just beyond the macula lutea in a median line half-way toward the ora serrata. When the fold lifted itself up and down under movements of the eye, the transition from the normal part of the retina to the fold could be plainly seen. The vessels, too, could be observed to run over from the adjacent retina uninterrupted in their course, and were evidently the ordinary vessels of the retina and not those of new formation. This deformity was evidently congenital. Both eyes were highly myopic, and vision very much reduced. The patient was a young boy of eight years of age, and did not come of myopic parents.

Neoplasms, strictly speaking, do not develop themselves in the vitreous proper; still, Becker† mentions a remarkable case of a diaphanous substance forming in the vitreous, and provided with vessels which seemed to have a connection with the retinal veins.

The same writer also mentions two cases in which masses projected into the vitreous, one of which was an abscess upon which vessels could be plainly observed, while upon the second, which lay close behind the lens, the vessels could be plainly seen with the naked eye running from the periphery toward the centre of the abscess. In this case, from the first appearance of a general pinkish hue to the detection of individual vessels, there was but the space of four days, while the vessels had entirely disappeared after the thirteenth day.

The writer once saw a very peculiar formation in the vitreous of a gelatinous nature, which resembled in consistency what is seen in the anterior chamber in spongy iritis. It gave the impression that certain parts of the vitreous had solidified into a spongy mass while other

* "Archiv für Ophth," Bd. xi., Abth. i., p. 134.

† "Bericht ueber der Wiener Augenlinik," p. 106.

parts retained their normal clearness. It did not resemble the exudation found in metastatic choroiditis, but rather that of coagulated white of egg. Through the clear places the fundus could be seen in certain districts as if through loop-holes, while it was completely concealed in others by the opaque substance.

There were no vessels at all in the mass, nor did it suggest a tumor in any way, unless it might be one of those very rare cases of glioma, starting from the *limitans interna*.

The vision was reduced to perception of light, and, as there was marked ciliary injection and some photophobia in the well eye, enucleation was proposed but refused, so that the true nature of the formation could not be determined.

Abscesses of the Vitreous.—These are described by Von Graefe and others as giving with the ophthalmoscope, when the vitreous still preserves sufficiently its transparency, the appearance of globular, half-transparent or more or less opaque, and jelly-like bodies, which are attached to the inner membranes of the eye, and sometimes provided with a neck-like projection. The formation and retrogression of these bodies, when the condition of the media will permit, may, according to these authors, be watched from day to day with the instrument. I myself have never seen such an appearance with the ophthalmoscope, though I did observe, on one occasion, a more or less general yellow reflex with the oblique illumination. This seemed to come from the deeper portions of the eye, and proved on section at the time of enucleation to be due to an abscess the size of a small pea in the very centre of the vitreous.

A diffuse purulent infiltration of the vitreous can only be surmised by the instrument by a total loss of reflex from the fundus. With the ophthalmoscope, where the angle of incident and reflected light is very small, we miss the yellowish-greenish reflex obtained under diffuse daylight and by oblique illumination, especially when the trouble is situated in the anterior parts of the vitreous.

Foreign Bodies in the Vitreous.—These follow the general rule of all foreign elements of an opaque nature in the media, and appear black with the ophthalmoscope, unless they happen to be of a metallic nature. Even then, bits of highly polished metal may look black, unless it so happens that they are either themselves fixed in such a position as to produce the right angle of reflection or this latter is brought about under the varying movements of the eye. Often light scales of metal seem to be suspended in the vitreous as if imbedded in a gelatinous substance of sufficient consistency to support them. As a rule, however, a careful examination brings to light one or more delicate

thread-like attachments, which can be often traced far toward the periphery, and sometimes even to the inner membranes. And especially is this the case when the foreign body lies in the anterior half of the globe, and near the posterior surface of the lens. Sometimes these bodies are thus suspended at only one end, and then swing about in the fluid vitreous, occasionally sending out a metallic lustre as they present the proper angle of reflection, and then becoming again perfectly black. These foreign bodies may become either partially or entirely encapsulated, the membrane surrounding them being either opaque, as is the rule, and thus concealing entirely the true nature of the substance, or remaining transparent enough, which is very rare, to allow the body to be seen through it. According to Graefe, even the track made by the passage of these bodies through the vitreous can sometimes be traced a few hours after the injury by a delicate want of transparency, which may subsequently become a defined membranous extension or canal.

The process by which these bodies become enveloped by membranes may extend either from the periphery toward the foreign body, thus gradually concentrating around it, as described by Jaeger and Berlin, or the membrane may form directly round the particle without the slightest participation of the inner membranes so far as can be detected either by the ophthalmoscope or on section—a fact which must be looked upon as strongly corroborative of the view that the vitreous body is capable of independent morbid processes of an inflammatory nature.

One thing is certainly peculiar, and that is that bodies of considerable size, and whose specific gravity is greater than the vitreous, should be suspended in it, even when it is admitted that they are held in the position which they occupy by investing membranes and supporting bands. Since time is required for the formation of these bands, it would naturally appear that long before they could have been formed such objects as shot, bits of iron or glass, would have sunk from their own weight to the floor of the globe, allowing even for the jelly-like consistency of the vitreous. It would seem, therefore, more rational to suppose that they had been invested by membranes of new formation, and had been gradually lifted into their suspended position by the subsequent contraction of the bands, perhaps along the very course by which they had advanced into the eye.

A very curious case occurred in my own practice which, I think, can only be explained in some such manner, although even this explanation seems far-fetched, even if not impossible.

A gentleman of middle age was shooting in the company of a

friend, who, mistaking his position, discharged his gun in such a direction that a single shot, probably a glancing one, struck the right eye. The patient fell to the ground, probably from sudden faintness. On getting up he felt the pain of the blow in and around the eye, but found that he could still see with it, almost if not quite as clearly as with the uninjured one. On the following day he came to town, and a careful examination revealed the following conditions: At the outer and upper angle of the globe, and just over the ciliary region, was a small elevation of tissue, with a few enlarged vessels running over it. This was no doubt the spot of entrance. The wound was, however, closed completely. The iris responded freely to light, and, except the trifling wound alluded to above, there was absolutely no external manifestation that the eye had been injured. Vision was perfect, $V = \frac{2}{3} \frac{0}{0}$. There was no limitation of the field, and not a trace of any injury to the internal parts of the eye could be detected with the most thorough ophthalmoscopic examination. The examination was repeated on the following day, under atropine, for the purpose of definitely answering the question whether the missile had actually penetrated the globe. Nothing could be seen of it. Two alternatives presented themselves—either the shot had entered the eye, and imbedded itself in the ciliary region without penetrating deeply into the tissue, or, as it certainly seemed more probable from the total absence of symptoms, the shot had struck the eye and glanced from it without penetrating the globe. This encouraging view was held by the patient, and I must say shared in by me. He was cautioned against all work and exposure, and told to report in a few days. Three or four days after this he again returned. He had been, he thought, a little imprudent, both as to the use of his eyes and exposure to weather, and had taken cold in the eye. The ball of the eye was inflamed, the wound more prominent, and there was the greenish-yellow reflex in the pupillary space so typical of hyalitis. The lens at this time seemed to be perfectly clear. As the patient was unwilling to have the eye removed, unless he could be assured that the shot was really in it, and as there was not the slightest trace of any sympathetic trouble in the other eye, enucleation was not performed. Two years after this, however, the eye was removed for a recurrent attack of inflammation, and the shot was found in the centre of the lens. How it got there is a mystery, unless it is supposed to have migrated there from its original position, in the same way as we see the migration of foreign substances in other parts of the body.

Sometimes these foreign bodies strike the eye with such velocity as to traverse the entire vitreous and penetrate the opposite wall,

where they can be seen with the ophthalmoscope to remain, sometimes for years, without causing the least disturbance to the surrounding tissue. At other times inflammation ensues, either at the moment of the injury or at some later period. This is followed by atrophy of the tissue of the retina and choroid or altered new-formed tissue, leaving the foreign body as a dark speck in a white patch of atrophy, represented by the sclera, the healthy portions of the choroid being separated from the atrophic by segments, or, indeed, by an entire circle of pigment. Sometimes an injury to the retina and choroid may be seen, either with the mirror or on section, at the back of the eye, while the foreign body itself occupies another position on the floor of the globe, usually at, or oftener still a little in front of, the equator.

When this takes place, Berlin is of the opinion that the body has entered the eye with sufficient force to have traversed the vitreous, struck the opposite wall, and to have rebounded from this to fall finally by gravitation to the floor of the eye. Whether this be the true explanation of the occurrence or not remains to be proved. But that an injury to the inner membranes may be detected in one place and the foreign body seen in another is an established fact; and for this reason when, after an injury has been discovered at the back of the eye, the observer should never neglect to make a diligent search at the periphery of the lower field for the body itself, as his line of action in regard to the removal of the eye may depend on the fact that the presence of a foreign body within the globe is recognized.

It is alleged that separation of the retina is sometimes caused by cicatricial contraction of the wounded parts. This occurs, I can not help thinking, more frequently from some alteration in the vitreous. Separation of this latter, which is described by Iwanoff as not an uncommon occurrence after penetration of the globe by foreign bodies, can not, so far as I know, be recognized with the ophthalmoscope, though, of late, attempts have been made to lay down some rules for that purpose.

Air-bubbles in the Vitreous.—I was indebted to Dr. Mittendorf for the opportunity of viewing the following very rare case, which was unique in my own experience and that of my colleagues. Dr. Mittendorf has, however, curiously enough, seen one other. The case, as reported by him, is as follows:

C. K.—, aged twenty years, strong and healthy, a blacksmith by trade, presented himself at the New York Eye and Ear Infirmary November 6, 1883. There was a large irregular wound at the temporal side of the sclera 3 mm. from the sclero-corneal margin. The patient had been struck in the eye by a splinter of iron three or four

hours before coming to the infirmary. No view of the fundus could be obtained, owing to intra-ocular hæmorrhage, but there was hardly any doubt about the presence of a foreign body in the vitreous. The wound was irregular and slightly gaping, with the vitreous presenting.

In the afternoon of the same day a partial view of the interior of the eye could be had with the ophthalmoscope. This disclosed a large clot of blood at the lower portion of the vitreous, and three round and highly refracting bodies with dark borders at the upper part.

These resembled in every way air-bubbles or oil-globules under the microscope. They were undoubted air-bubbles, and situated immediately behind the upper portion of the lens, which remained perfectly clear. The larger one appeared to be the size of a hemp-seed. The two smaller ones are hardly as large as rape-seed. The next morning the bubbles had coalesced and formed a flat vesicle at the posterior pole of the lens. After the patient had remained in the erect position for some time, the bubble gradually arose to the upper portion of the fundus and assumed a slightly elongated shape, and had the appearance of a small oil-globule rising in water. After a lapse of thirty-six hours the air became completely absorbed, and no trace could be seen of the bubbles on the third day. The eye remained free from inflammation for some time, and the patient left the infirmary doing tolerably well. No attempt was made to extract the foreign body, as the patient objected to all interference with the eye.

In order to establish the diagnosis, Dr. Mittendorf injected a small quantity of air into the vitreous of a rabbit, and the appearances of the bubble which formed were with the ophthalmoscope precisely those which have been described in the case related above, in which air had been either forced into the eye or liberated in some way from the piece of iron within it.

DIFFERENTIAL DIAGNOSIS OF TROUBLES IN THE MEDIA.

Most of the rules and expedients laid down for the proper examination of the anterior media, the cornea, aqueous humor, and lens, are also applicable to that of the vitreous, and need not now be repeated, nor need the method of exactly determining their antero-posterior position be further dwelt upon, as it has already been fully described in the chapter on determining the errors of refraction. Still, there are certain characteristic effects which are produced by opacities in the different media which may serve sometimes to make a differential diagnosis more accurate, or at least more expeditious.

Should, in a given case, the opacities float into view with now a rising and then a falling motion, it would be safe to conclude that

these were in the vitreous and not in any of the other media, and, moreover, a discrimination could be at once made as to their being "movable" and not "fixed opacities." Should, however, the disturbance move only in concert with the eye, and not have any motion of its own, then it is a fixed body, and may, so far as its appearance with the ophthalmoscope is concerned, give rise to a doubt whether it is in the vitreous humor, in the lens, aqueous humor, or even in the cornea. This, it is true, should not have been the case if the observer has fulfilled his duty by carefully examining the anterior media by means of oblique illumination. Still, the observer may, while the instrument is still at his eye, remedy his want of care by attentively observing the behavior of the opacity in regard to the movements of the observed eye and its centre of motion, and the relation which it bears to the pupillary space and the borders of the iris.

The centre of motion lies in the vitreous humor, somewhat behind the middle point of the visual line. Objects lying in front of this centre will, when the eye moves, move in the same direction. If situated *at* the centre they will have no apparent motion. If situated *behind* the centre they will move in the reverse direction from that in which the eye moves, and the farther the opacities are from the centre of motion the greater will be their excursions.

Thus, in a given case, if an opacity is seen to make a considerable excursion toward the right when the observed eye is moved toward the right, and passes rapidly out of the pupillary space in the same direction that the eye moves, the observer knows that it must be in the cornea. Should the amount of displacement be restricted, but yet still toward the right, then in all probability the opacity is on the anterior capsule. If the motion of the disturbance should be still more restricted, but yet in the same direction, then the opacity must be in the neighborhood of the posterior capsule. Should the opacity have no lateral motion whatever, then it must lie at the centre of motion, that is, the centre of the eye. Should, on the contrary, the motion of the disturbance be toward the left when the eye moves toward the right, then the observer knows that it must lie in the vitreous behind the centre of the eye, and the greater its displacement toward the left the deeper its position.

Suppose *A* (Fig. 70) to be a transparent sphere with various

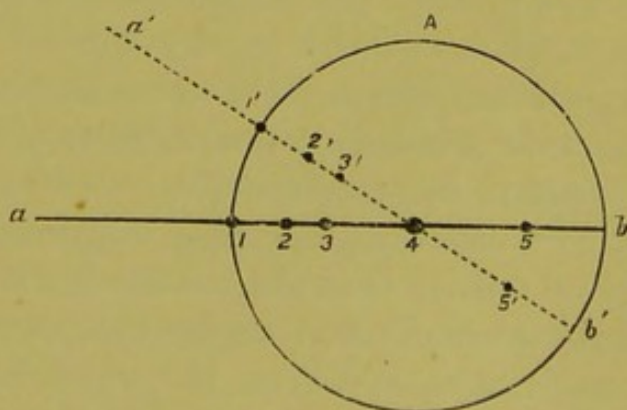


FIG. 70.

opacities situated along its central axis. Suppose it rotates toward the right, so that its axis *a b* occupies the position of the dotted line *a' b'*. No. 1 will make a large excursion and appear to move toward the right; Nos. 2 and 3 will make a less excursion in the same direction. No. 4 will remain stationary, while No. 5 will move in the opposite direction, that is, toward the left.

This is certainly very simple in theory, and, provided the pupil is sufficiently large, or, better still, dilated with atropine, is often very advantageous in practice. But with a narrow pupil the inexperienced observer is apt to be misled, at least in regard to the opacities in the posterior portions of the lens, because the iris being in advance of these makes a proportionately wider excursion, and for this reason the opacity, though still in front of the centre of motion, appears to approach the pupillary margin of the opposite side, and thus to move in a direction opposite to that in which the eye moves, which leads to the idea that the opacity is behind instead of in front of the centre of the eye, or, in other words, in the vitreous instead of in the lens. For this reason it is always well to mark attentively the relations which the opacity bears to the pupillary space and the borders of the iris under movements of the observed eye. If the opacity makes a wide excursion and passes rapidly out of the field of the pupil in the direction in which the eye is moving, it must be in the anterior parts of the eye and probably in the cornea. Oblique illumination will then settle this at once. If, on the contrary, the opacity makes a wide excursion across the pupillary space in a direction opposite to that in which the eye moves, and passes rapidly behind the borders of the iris, then it is in the posterior parts of the eye, and the greater the excursion the farther back it is. If, however, the excursion is limited, and the opacity appears to change its position but slightly in reference to the borders of the iris, and this in the direction in which the eye moves, then the opacity is in the lens, and most probably on the anterior surface, and nearly in a plane with that of the iris. On the contrary, when the displacement is greater in reference to the pupillary space, and the opacity appears to pass across it rapidly in the opposite direction from which the eye is moving and disappears behind the iris, it is in the posterior part of the lens, and the greater the excursion the deeper it lies.

To make a differential diagnosis with certainty as to whether a given opacity is in the anterior parts of the vitreous or the most posterior parts of the lens, say the posterior capsule, we must turn to a nicer and more delicate test which has been described very accurately and clearly by Mauthner in his text-book of "Ophthalmoscopie." This

consists in observing the behavior of the corneal reflex in relation to the opacities on movement of the eye.

When the observed eye looks directly at the hole in the observer's mirror, the visual axis of the observed eye coincides with that of the observer; and as the path of the illuminating rays is also in the same line, the corneal reflex will be seen in the centre of the pupillary space, and will lie at the apex of the cornea; consequently the visual line of the observer will pass through the centre of the reflex and also through the centre of motion of the observed eye. These two points will, therefore, act as fixed points, and always lie in the visual line of the observer—the reflex, because it lies in the path of the rays, which can not change unless the position of the mirror changes and the centre of motion because it is the point round which the eye rotates. For this reason an object situated in front of the centre of motion will appear in reference to the corneal reflex to move in the same direction as the eye moves; if situated behind, it will move in an opposite direction. If the reflex covers the opacity, notwithstanding the various movements of the eye, then the opacity must lie at the very centre of the eye; and Mauthner declares that in this way he has been able to convince himself that the small opacities which are sometimes seen on the axial line in retinitis pigmentosa were really situated in the vitreous, and not, as is commonly supposed, in the posterior capsule of the lens. My own observation would lead me to suspect that, for the same reason, the minute opacity seen so often in very high grades of myopia in the axis of the eye is not, as so commonly supposed, a posterior polar cataract, is not in fact in the lens, but is in reality a minute collection of pigment in the vitreous. The delicacy of this test in regard to the lens depends on the fact that the centre of motion is not really in the centre of the visual axis, but, according to Donders, 1.77 mm. behind it. The fact that the position of the centre of motion varies in myopic and hypermetropic eyes has no appreciable effect on the apparent movement of these opacities.

ENTOZOA.

The presence and detection of entozoa in the eye have always been a very interesting study with ophthalmologists, and the number of recorded cases from the earliest days of ophthalmoscopy has gradually increased until the literature of the present day is exceedingly rich in them.

The varieties hitherto met with are the *cysticercus cellulosæ* and the *filaria*.

The *cysticercus* has been found in every part of the eye and its

appendages—that is to say, under the skin of the lid, in the orbit, under the conjunctiva, in the cornea, iris, lens, in the vitreous, and between the choroid and retina.

A very remarkable fact in the history of this disease is the great frequency in which this parasite has been found within the eye in certain countries, or even in certain districts of the same country, and its rarity or even total absence in others. Thus Von Graefe, in some eighty thousand cases of eye-disease, observed the worm eighty times, or one case in every thousand. Hirschberg, out of twenty-one hundred new patients examined in the short space of six months, saw a cysticercus five times, or one in four hundred and twenty cases of eye-disease; while Mauthner, in Vienna, among thirty thousand cases of general eye-disease of which he had cognizance, had never seen a single case of a cysticercus. Until very recently I had never seen even a doubtful case, nor did I know of a single well-authenticated case ever having been seen in the interior of the eye by any of my colleagues in this or the neighboring cities, or, indeed, in the entire country. Through the kindness of Dr. Minor, I have been permitted within the past few weeks to examine a case in which, from the ophthalmoscopic appearances, there was reason to believe that it was a true case of cysticercus, although it was not absolutely proved to be so.

As, therefore, I have little or no personal knowledge of this subject, I must avail myself of the observations of others, and I therefore reproduce here an abstract of the description furnished by Becker for Mauthner's work on the ophthalmoscope. These observations of Becker are prefaced by Mauthner by a short general description of the animal, as follows:

The worm is provided at its posterior end with a round, cyst-like formation which acts as the *receptaculum scolicis*, into which the animal can withdraw, presenting when in this position the appearance of a round, whitish body. A small fold marks the mouth of this receptacle. When the animal protrudes its head and neck out of the receptacle its body appears to be sprinkled here and there with calcareous deposits, and presents sometimes a smooth and sometimes a wrinkled surface. The body decreases in size toward the neck, to which is attached the head, with its four flattened-down but angular projections. A round-shaped snout can be projected by the animal from the centre of its head, and this latter is provided at its base with a double row of hook-like tentacles, which are capable of retraction. Each of the angular projections of the head is, moreover, provided with a rounded sucking apparatus. The most common seat for the

development of the animal is between the choroid and retina, and it occurs twice as often here, according to Graefe, as in the vitreous. As a rule, the worm is not inclosed in any sac, but on three occasions it was observed to have a peculiar envelope of its own, and on all of these occasions the animal was in the vitreous. The length of time in which the parasite can exist in the eye has not been determined, but Graefe has observed it for the space of two years. Its presence in the eye leads sooner or later (from three to fifteen months) to disturbances of vision, and to the production of irido-choroiditis, which can pass into true panophthalmitis, but the trouble usually runs a more chronic and insidious course, to a gradual atrophy of the bulb. In two cases only, in which the worm in the vitreous was encapsulated, were the form of the eye and a portion of the visual power retained. The case reported by Teal would appear to be unique, in which a free cysticercus was observed for two years without the eye suffering from the entozoön, and without the vision having decreased to any considerable amount. Moreover, as the sight of the eye had been bad from childhood, there were fair grounds for supposing that the animal had maintained itself in the eye from that period.

The ophthalmoscopic appearances in the cases seen by Becker were briefly as follows:

The retina was for a considerable portion of its surface disturbed and of a grayish-white color, instead of a bluish tinge. It was apparently raised but little above its ordinary level, and slightly folded, or perhaps irregularly thickened, so that its surface was not smooth and even, but apparently hollowed out in many places. The vessels were tortuous and bent, following the irregularities of the surface. They still conveyed their contents, and appeared red, but were here and there enveloped by extravasated blood. There was also the appearance of dark gray flecks or spots in the grayish-white retina. That portion of the retina which showed this kind of degeneration was in the posterior portion of the bulb, and included the macula lutea. The fact should here be emphasized that no other disease of the retina produces a similar picture. In the neighborhood of that part of the fundus which had undergone the changes mentioned above there occurred an actual separation of the retina which then projected into the vitreous. The circulation in the vessels of the cyst-like elevation of the retina was not interfered with, as could be told from its red appearance. On two occasions, in which the retina remained, comparatively speaking, transparent, a cyst-like swelling of a bluish color could be observed. The walls of the bladder-like projection could be seen to bend backward with a convex surface, and to be distinctly separated from that of the

retina. A critical examination led to the conclusion that the retina at this point was lifted up from the choroid by an independent bluish but depressed body with rounded contours, the walls of which contained no vessels. This lack of vessels speaks against the diagnosis of a new growth, and in favor of that of an entozoön.

If the bladder perforated the retina, then the appearances were different, and a bluish cyst-like body, which varied in size from two to four diameters of the optic disk, appeared to project into the vitreous. The surface appeared finely granular and, under strong illumination, produced a lively iridescence. The play of all the colors, in which a brilliant red predominated, was particularly noticeable toward the borders, and at some particular point there appeared a glittering white spot.

The cyst-like body was in such cases attached by a neck-like process to a point of the retina which was then degenerated in the manner already pointed out.

The appearances described above would in themselves suffice to mark the diagnosis, but a more convincing proof is obtained by the detection of the movements of the animal. If the observer riveted his attention upon some particular point of the projection, especially toward the borders, or, better still, upon the white spots just alluded to, he would be able to notice, after some moments of delay, and while the observed eye remained motionless, that suddenly an unmistakable change in form took place along the walls of the projection, or of the light-spot so often mentioned. This latter is then seen to be displaced in a certain direction—to become greater or smaller in size, returning, after a short time, to its original condition; or it might even assume a somewhat different shape and position. If the attention was fixed upon the border of the cyst, two kinds of movements might be observed. The contour itself might change its form, now bulging out, and then becoming concave, or a wave-like motion run along the surface, and at the same time a change of color occur, the blue places becoming white, and the white gray. Or the play of color might stop entirely, giving place to a dull shimmer on the surface. The movements upon the surface of the cyst and clear spots in its interior always happened at the same time. The clear spot then corresponded in position to that occupied by the head and neck in the *receptaculum*. Any movement, no matter how slight, in the position of these two made the cyst, which was full of liquid, tremble. The glittering effect which has been spoken of was caused by the minute calcareous deposits in the walls of the cyst. Much as these movements resembled each other, whether the cysticercus was in the vitreous or under

the retina, still certain peculiarities manifested themselves, due to the difference in position. For, if the free cyst extended into the vitreous, all the details described above could be more clearly perceived; while, on the other hand, if the entire process was only seen through the retina, the changes in color were correspondingly dull, although, at the same time, the movements themselves were more conspicuous, since the observer could then estimate directly the amount of motion by comparing the excursion of the walls of the cyst with the retinal vessels, which do not share in the movements. In some cases, however, the movements of the animal were so energetic that the overlying retina was also implicated.

It may be said that all doubt about the diagnosis is removed in these cases when the observer happens to hit, by chance, the time when both the head and neck of the animal are extended from the receptaculum. In such a case the head and neck may be seen to point, for a considerable time, fixed and immovable, toward one direction. The head, from its position, with its suckers somewhat retracted and its snout outstretched, then allows the circle of tenaculi to be divined, rather than clearly perceived, as fine, dark lines. In another moment, however, the neck may be seen to undergo, with comparative rapidity, all sorts of delicate undulations and changes in position. The neck becomes thicker and shorter, or extends itself to its full length, and then twists itself into every position, or even doubles upon itself; while the head, by means of alternate projections and retractions of its sensitive suckers, and of the shorter but thicker snout, assumes the most wonderful and singular shapes. The sucking apparatus resembles precisely the tentacles of the snail, and constantly performs, like them, a ceaseless change in form and movement.

It must be accounted as an exceptionally lucky occurrence when both the head and neck of the animal can be observed outside of the sac. In the short space of twenty or thirty minutes such a cyst-like formation has been observed to shove itself along under the retina for a space of several lines. In what way or by what mechanism these movements are performed has not yet been determined.

The vitreous humor is interspersed with punctate disturbances, which are aggregated together in small collections. Membranous disturbances are only present after repeated operations have been performed without any successful result.

Liebreich gives in his atlas two chromo-lithographs of the ophthalmoscopic appearances of the cysticercus. Fig. 5, Tab. VII., from which the drawing is made (Fig. 71), represents the animal after he had perforated the retina and was in the vitreous, in which it occupied

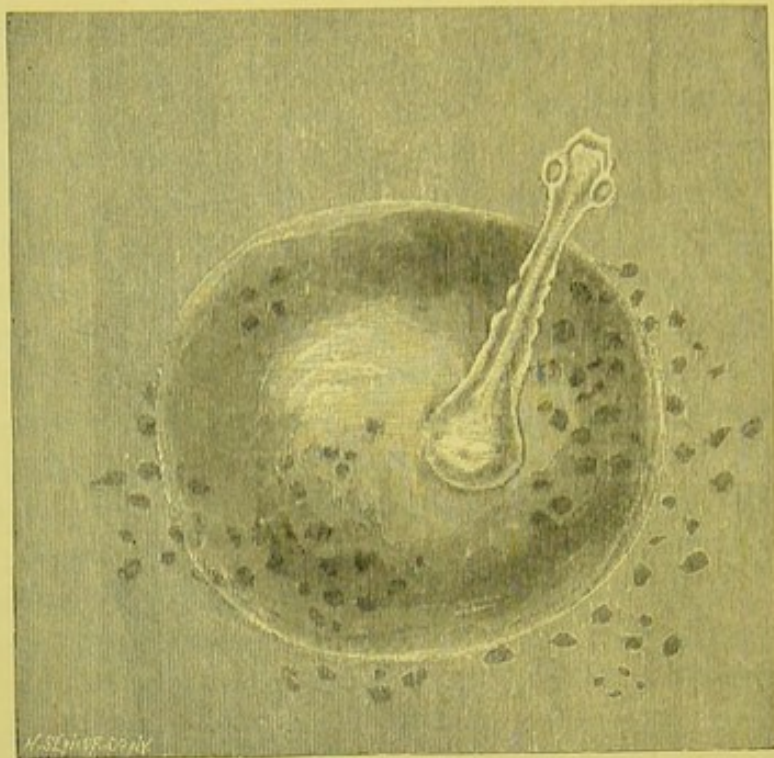


FIG. 71.

such a position that its movements and the contractions of the cyst could be plainly seen. Fig. 6 shows the cysticercus still beneath the

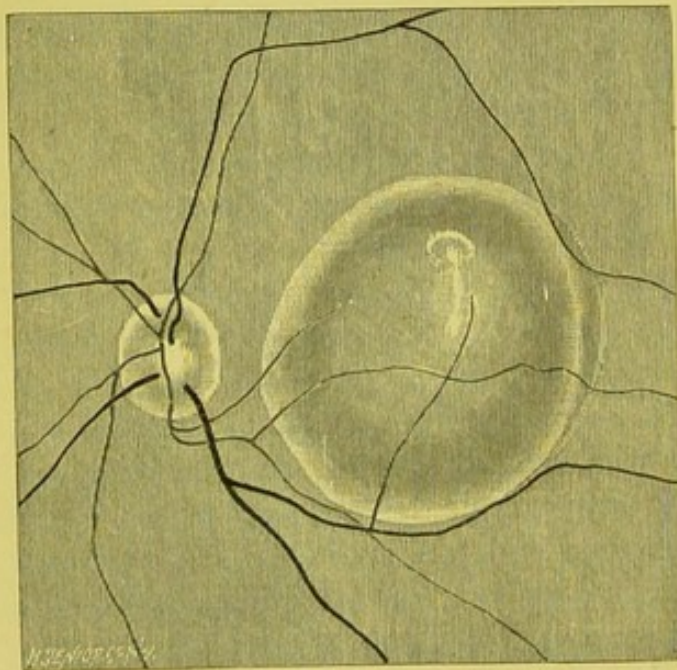


FIG. 72.

retina, as is demonstrated by the retinal vessels which run over it. The head and neck are within the bladder, and only appear very indistinctly through it (Fig. 72).

Jaeger also gives a drawing of a cysticercus in his "Hand-Atlas," Taf. XVIII., Fig. 83, as does Hirschberg, Graefe's "Archives," vol. xxii., Plates V. and VI.

The case alluded to, as reported by Dr. Minor as occurring in New

York, and described by him, is as follows:*

"During the past summer a patient consulted me at the New York

* "The Medical Record," December 27, 1884, p. 703.

Eye and Ear Infirmary for impaired vision, and I made the diagnosis of cysticercus in the vitreous. The extreme rarity of such cases—not a single authentic case, so far as I am aware, having been observed in America—caused at first much doubt in my mind; but the patient has been frequently and carefully observed since he was first seen, and I am now confident that the diagnosis was correct. And I am strengthened in my conclusion by the opinions of some of my *confrères* of the New York Ophthalmological Society—where the patient was shown—who have seen cases of cysticercus in the vitreous in the European clinics. The patient has repulsed all overtures pointing toward an operation for the removal of the entozoön, and I simply desire to place the case on record, with the hope that I may, at some future time, add the result of the operation thereto.

“J. M——, aged sixty, male; seen in July, 1884, when the following notes were made: Ten days ago suffered great reduction in vision in the right eye, which has remained almost unchanged since. Vision in right eye = $\frac{3}{200}$, with excentric fixation, vision being possessed only in the temporal half of the visual field. The ophthalmoscope shows detachment of the retina throughout the temporal half of the fundus. Far forward in the supero-temporal quadrant, just behind the ciliary body, is a cyst, nearly transparent, of ovoid form, which contains (?) a cylindrical mass, apparently about one half of an inch long and one eighth of an inch thick, that terminates in a free somewhat pointed extremity. Just behind the tip on either side is a small black dot—hooklets—and behind these a slight constriction—the neck—above which, after gradual enlargement, the tongue-like process reaches a point so far forward that it can not be seen. Two parallel bands of delicate whitish tissue can be traced from the neck up to the point at which the whole object is lost to view. The upper part of the cyst is lost to view at the same point. The retina, as it approaches the cyst, assumes a wavy and wrinkled outline, and presents a mottled appearance, being interspersed with a number of small grayish spots (see figure). The obliquity of the eye necessary for a proper view is such as to make it difficult to distinguish between movements of the globe as a whole and individual movements of objects in its interior. Yet I have satisfied myself, as others have done, that the tongue-like process does possess individual movements. I have observed slight lengthening

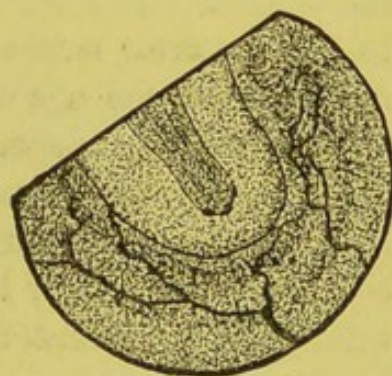


FIG. 73.—As seen by the direct method of examination.

and shortening, a little lateral movement and tremulousness of the process. The position of the entozoön is such as to make it impossible to establish the exact relation of parts. The junction of the neck with the cyst-body can not be seen, and the cyst is so transparent that it can not be positively said whether the head and neck are contained therein, or whether they lie free in the vitreous, just in front of the cyst. I am inclined to think that the latter is the case, for with the inverted image a marked parallax can be obtained, which not only shows considerable depth to the cyst-cavity, but that the head and neck lie well forward in the anterior part of the cyst, or entirely in front of the cyst-wall."

In regard to the second class of entozoa—the filaria—it can only be said that doubtful cases have been reported by Fano, Quadri, and Mauthner; and the latter remarks that he saw in the perfectly clear vitreous of a man of forty years an object that was freely movable, but which had no independent motion of its own, but which he unhesitatingly believed to be a filaria, though perhaps a dead one. I have myself seen a case which was presented at the New York Ophthalmological Society, with the suspicion that it might be a case of filaria in the vitreous. The object in question presented the appearance of a long filiform body, which projected through the vitreous in the median axis from the optic disk to about two thirds the distance to the posterior surface of the lens. It had a graceful, undulatory motion when the eye of the patient was moved, but, like the case of Mauthner's, no independent motion of its own. It resembled, more than anything else, a very much attenuated and minute eel with a delicate, tapering neck, surmounted by a somewhat bulbous head. It was certainly wonderfully like a worm in shape and character; but it was totally untransparent, and the general opinion of the society was that it was not a living organization of any kind, but either a delicate and filamentous band in the vitreous or the remains of the hyaloid artery. This opinion was strengthened by the fact that there was also a small black spot situated on the posterior capsule of the lens close to the posterior pole, and which forcibly suggested the idea that it was once the place of attachment of the anterior portion of the body, whatever it was.

A P P E N D I X .

THE following remarks are intended only for those who are unacquainted with the elements of optics. They illustrate, in a brief and, it is hoped, a simple way, the principles upon which the ophthalmoscope depends, and only include such as are essential for the student to understand.

A luminous body is made up of an infinite number of luminous points, from which lines of light radiate in all directions like the spokes of a wheel, the only difference being that the luminous point is the centre of a sphere, while the hub is only the centre of a circle. It is in the direction of these lines, or, as they are called, rays, that light is propagated in wave-like propulsion. Thus, in the diagram (Fig. 1), the straight lines radiating from the centre, or luminous point, may be looked upon as the ray which shows the direction in which the light travels; while the sinuous lines show the *manner* in which it travels, or its undulatory motion. It is evident that the height of the wave has nothing to do with the direction in which the wave moves.

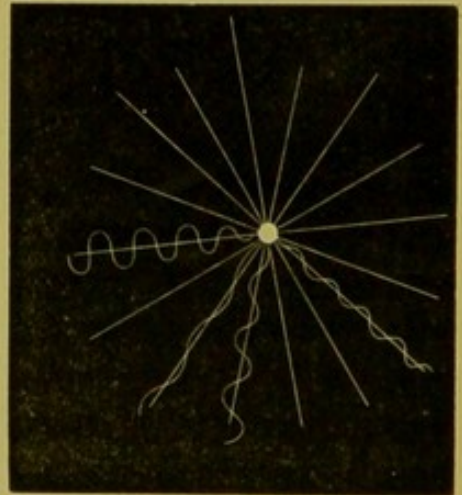


FIG. 1.

Strictly speaking, the term *ray* is a relic of the old emission theory. The ray has no real existence, but is an imaginary straight line drawn from the luminous point, from which the light-wave starts, to the point against which it impinges. Still, as the height of the wave is to the human mind an inappreciable quantity, it is exceedingly convenient in optics to represent, not only the direction in which light travels, but also its wave-like motion, by straight lines instead of undulatory ones.

A collection of luminous rays is called a luminous pencil.

As luminous rays in nature always travel in straight lines, and

always diverge from each other as soon as they leave the luminous point, it follows that, strictly speaking, there can be, from natural sources, but one kind of rays—that is, divergent rays. Thus, the rays from the sun and other heavenly bodies are, in fact, divergent; but, inasmuch as these bodies are at an infinite distance, and inasmuch as the pupil of the eye is only from one to two lines broad, it follows that only those rays which travel nearly parallel to each other can find their way into the eye. Thus, if, in the diagram (Fig. 2), we suppose




FIG. 2.

the sun to be at an infinite distance, it at once becomes apparent that only those rays can enter the pupil which run parallel to each other. The slightest conceivable divergence would prevent this, and these rays would be excluded from the eye. Hence, when we see objects which are at an infinite distance, we do so by means of rays which are practically parallel. Such rays play a very important part in ophthalmoscopy as well as in physiological optics, as they form the standard by which we measure the power, not only of lenses, but also of the eye itself. Moreover, experience teaches us that it is not necessary to go to infinity for parallel rays. Rays coming from any distance greater than twenty feet are assumed, in physiological optics, to be parallel.

When light coming from a luminous body strikes against the surface of a non-luminous one, part of it is absorbed by the body and part of it is reflected by it. There are two kinds of reflection: (1) that which takes place from a polished surface, and is called regular or specular reflection; (2) that which is called irregular, because it produces no image, but only serves to render the object visible. Strictly speaking, perhaps all, certainly most objects, produce both kinds of reflection, but usually one so predominates over the other as to render the distinction a just one.

Let a polished plane mirror be taken, and held about one foot from the eye, so as to catch the reflection of some luminous body, say the lighted chandelier, which we will assume to be at a distance of ten feet. It requires but a little abstraction of the mind to make one lose perception of the surface of the mirror, but what is seen is the fac-simile of the source of light in all its detail of form and color. Now, let a bit of paper, say an inch square, with some very fine printing on it, be pasted upon the centre of the mirror. Repeat the ex-

periment under precisely the same conditions as before. Directing the attention to the image of the chandelier, this will be seen in all its detail, exactly as in the former case, excepting that the small portion of the image corresponding to the bit of paper is wanting. One is indeed conscious of this latter, even while looking intently at the image in the glass; but it appears to the eye only as a blurred piece of white paper, on which not a letter of the type can be deciphered. Now, fix the attention on the paper, so as to read it distinctly. One at once becomes aware of an effort on the part of the eye, and notices that the image of the chandelier has become blurred. Repeat this indefinitely, and it will be found that one never sees both the print and the image distinctly at the same time, although the bit of paper is at precisely the same distance from the eye as the surface of the mirror, and the chandelier, which is the source of light, is at precisely the same distance from each. That there is some difference in the condition of the rays which come from the surface of the mirror, and which go to form the image of the gas-flame, and those which come from the paper, is evident from the consciousness of tension and relaxation taking place in the eye when looking at the objects, and from the alternating distinctness and indistinctness of the objects themselves. The difference is precisely this:

The rays coming from the source of light strike both the paper and the surface of the glass with precisely the same degree of divergence from each other; but the polished surface of the mirror, after receiving the rays, gives them back exactly as it received them in every respect. It simply alters the direction in which the rays were travelling, but does not change their relation to each other. They leave the surface of the mirror with precisely the same degree of divergence that they had when they touched it, consequently the object appears just as it did before the reflection took place, only in a different position. But the slightly roughened surface of the bit of paper, although it received its rays from the same source and under precisely the same degree of divergence as the mirror, does not, like the latter, reflect them just as it receives them, but it absorbs the light, as it were, into itself, and then throws out such rays as it does not consume, just as if it had produced them itself, instead of borrowing them from another source. Thus, the rays coming from the paper enter the eye, in the above experiment, as if they diverged from the surface of the paper itself, which is at a distance of only one foot, while those which form the image enter as if they came from ten feet.

Let *A* in Fig. 3 be the lamp, ten feet from the mirror *m*. Rays

from this will strike the mirror, and be reflected from it with the same degree of divergence among themselves with which they struck it. Entering the eye, they will be projected backward till they intersect at A' , where an image of the lamp will apparently be formed, just as far behind the mirror as the real lamp is in front of it, namely, ten feet. On the other hand, the rays striking upon the paper p will be absorbed practically into it, and then given off as if they came directly from it, and thus enter the eye as if they originally diverged from a distance of one foot. From this it will be at once apparent that the position of the source of light, from which the non-luminous body borrowed its light to become visible, has no effect on the direction of the rays which are practically re-emitted, rather than reflected, from such a body. Thus, if we put the book which we read at twelve inches from the eye, and place the light at any distance we please—be it one foot or twenty—the rays will always enter the eye as if they came from a distance of twelve inches. And, further, we can change in various ways the direction of the incident rays so as to make them divergent, parallel, or convergent; and still, as long as the book is held at a given distance, the rays will always enter the eye as if they diverged from the surface of the page.

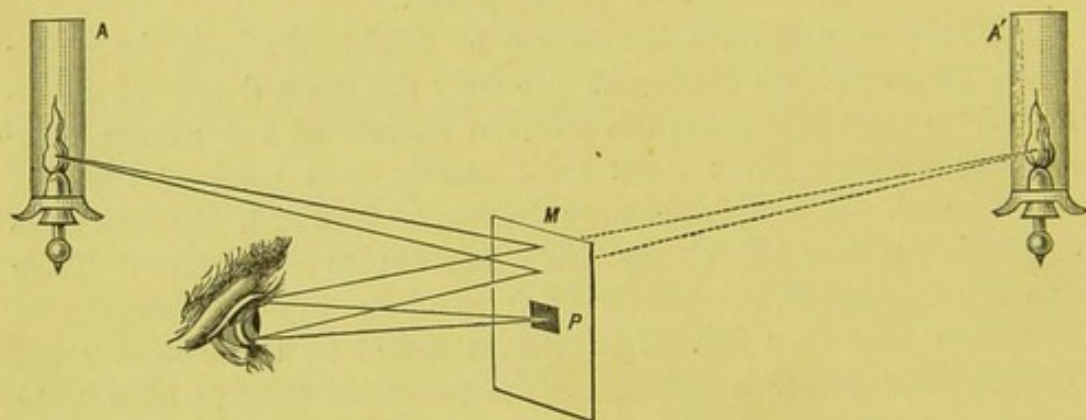


FIG. 3.

This is "irregular reflection," and it is through this that we see the details of the bottom of the eye, in their due form and color, just as we see all other objects. It is for this reason that I have dwelt so particularly on this point; for, by keeping it in mind, the student will be aided essentially in understanding not only the theory of the ophthalmoscope, but also its practical application.

Although there are in nature only divergent, or, at the most, parallel rays, we have, as has just been stated, certain agents at our command by which we can alter the direction of the rays so as to make them at will either divergent, parallel, or convergent. This is done

by lenses and mirrors, and, as these are the two essential elements of all ophthalmoscopes, a thorough acquaintance with their fundamental properties, however elementary, is absolutely necessary.

Convex Lenses.—The simplest form of a lens, and one with which the reader's microscopical studies will have rendered him familiar as a condensing lens, is a piece of glass having a flat or plane surface on one side, and a spherical or convex surface on the other, hence called a plano-convex lens. Such a lens is represented in section in Fig. 4. The amount of curvature of the spherical surface depends on the radius of the sphere on which the glass is ground. Thus, in Fig. 4, RH would be the radius of the sphere on which the lens is ground, or, in the language of optics, the radius of the curvature of the lens. RN and RM would be likewise radii, as in fact would any line drawn from the centre of the sphere to any point on the surface of the glass. The extent of the plane surface would, of course,

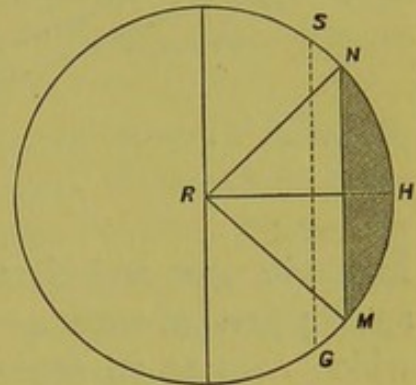


FIG. 4.

depend on the size of the segment of the sphere taken. This might be only the size of the shaded portion in the figure, or what is included between the dotted line SG and the circumference; or, in fact, the whole half-sphere. Yet, the curvature, and of course the radius, would remain the same. Consequently, the strength of the lens does not depend upon its thickness, though it is slightly influenced thereby.

Suppose such a lens to be exposed to the waves of light coming from an infinite distance, and that consequently parallel rays strike upon its convex surface (Fig. 5).

The width of a wave of light can not be estimated, of course, by the human eye. Nevertheless, the wave must have an appreciable breadth as compared with the point where it strikes the surface of the lens. We will suppose, for the sake of illustration, that the rays of light are enlarged to the extent shown in the diagram (Fig. 5), and are advancing, through the air, toward the lens in the direction of, and parallel to a straight line drawn through the centre of the lens, the radius of whose curvature is RH . For the sake of convenience, we will represent the light-waves by straight instead of curved lines.

Take the upper beam in Fig. 5. One end of the beam (a), advancing through the air, will come in contact with the glass at the point h before the end b does. As the glass is a denser medium than the air, the end a will be retarded somewhat in its progress, while b travels with its original velocity. This difference in speed will make

b swing round a , describing a large arc, while a describes a small one, and this disproportionate rate of progress will continue until both ends of the beam, having entered the glass, are subject to the same retard-

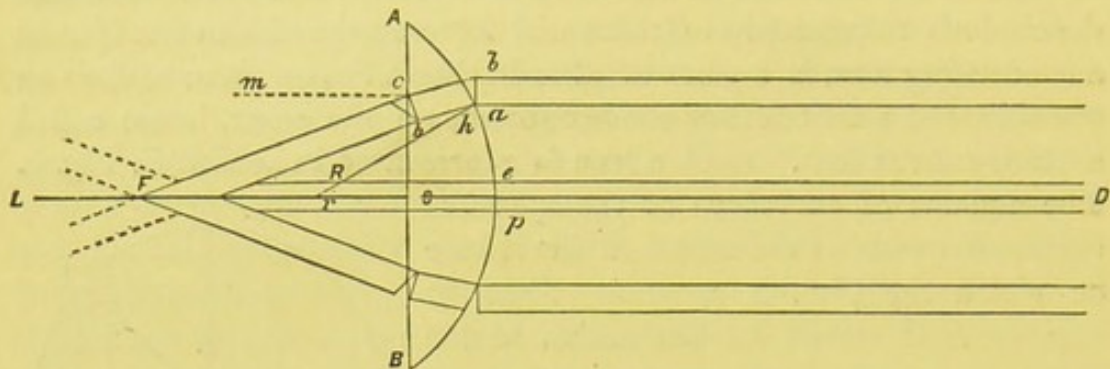


FIG. 5.

ing influences, and then they will both advance at an equal rate of speed; just as, with a column of soldiers in marching into a street which runs at an angle with the one they are already in, the whole front of the column keeps moving, but the outer end of it moves with a greater rapidity than the inner till the line comes fairly into the street, and then both ends advance with the same rapidity.

By contact with the glass the direction of the ray is changed at a , but, once the ray has fairly entered the glass, its direction will be maintained so long as it remains within it. But a glance at the diagram will show that, from the new direction in which the ray is moving, the end b will emerge from the glass sooner than the end a ; and as b will, as soon as it emerges into the air, travel faster than a , it will make the same movement round a that it did before, and this will continue until a emerges from the glass, and thus a new direction will be established. Thus the ray has been bent at two points: first, on entering, and, secondly, on leaving the lens. And it will be seen, by looking at the diagram, that the ray, at its first refraction at a , where it passes from a lighter to a denser medium, is bent *toward* the line Rh , which geometry teaches is the perpendicular to the surface at the point of incidence a , since the perpendicular to any point on the surface of a sphere is the radius of the sphere at that point. But, when the ray emerges from the denser medium of the glass into the air at the point c , it is seen to be bent *away* from the line cm , which is perpendicular to the surface AB at the point c .

Passing now to the central ray, we see that both ends of the ray e and p would impinge upon the glass at the same time. Consequently, as each end of the ray would be retarded at the same moment, and in the same degree, there could then be no change in the *direction* of

the ray, though there would be in its velocity. The ray, in fact, would then pass through the glass without swerving from its course.* It will be seen from the diagram that this ray is not only parallel to the line LOD , but is coincident with it; and, further, that the line LD is but an extension of the line LO , which is a radius, and consequently perpendicular to the point O . It follows from this that, when a ray strikes a spherical surface coincident with the perpendicular to the point of incidence, it passes through the lens without being refracted. This, of course, holds good for all the radii, and not only for the one which passes through the centre of the lens, as represented in the diagram.

Observing the lowest ray, we see that it goes through precisely the same changes as the upper, and we notice that all three rays from the direction which they have acquired must meet behind the lens in the point F , which is therefore called the focus of the lens. If continued beyond this point, the rays would cross each other, and what was the upper ray originally would become the lower one.

The reader will understand that the diagram is not supposed to show exactly how the beam of light is bent in nature; but is simply, as necessarily must be the case, a very rough way of illustrating the principle of retardation of one part of the wave, and its consequent change in direction.

From the explanation given of the cause of refraction, it would follow logically, even if it had not been proved by actual experiment, that certain conditions must affect the amount that a ray is bent by a lens. A glance at the diagram (Fig. 6), which represents two plano-

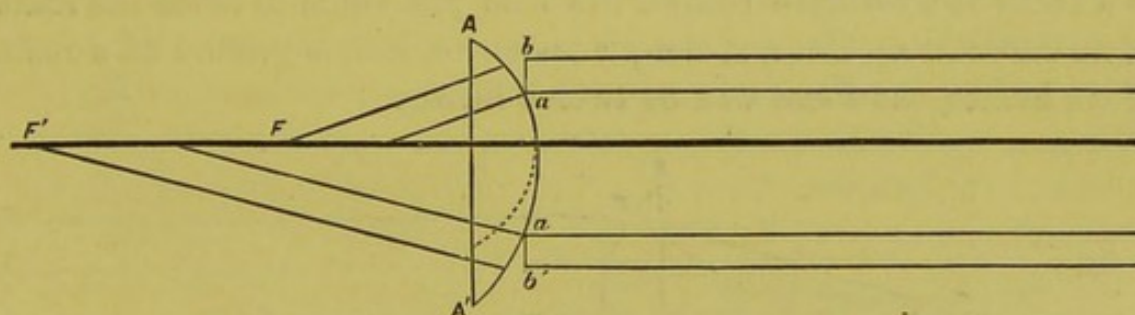


FIG. 6.

convex lenses of different curvature, A and A' , will show that in the lens of greatest curvature, A , the end of the ray marked b will be at a proportionately greater distance from the surface of the glass than in the lens of lesser curvature (A'); consequently, b will have a larger

* This would hold good even in the case pictured in the diagram, where the disproportion between the breadth of the ray and the size of the lens would be utterly absurd were it not for the purposes of illustration.

interval of time and space to travel in the air with its original rate of speed, while a is impeded by the denser medium of the glass; b will therefore rotate round a to a greater degree than when the curvature is less, as in A' , and will therefore come to a focus sooner (F').

Again, the substance of the lens must affect the amount which the ray is bent. If the lens is made of a substance which has comparatively little density or retarding power, that end of the ray which enters it first will be comparatively little impeded, and the direction of the ray consequently but little changed; while, on the other hand, if the lens, having the same curvature, be made of a dense or highly refracting substance, such as the diamond, the opposition to one end of the ray will be increased, and the direction of the whole just so much the more altered. Thus we have two principal factors in a lens, by which the direction of the rays, which pass through it, is governed, and from these we get the law, that the greater the curvature of the lens, or, in other words, the shorter the radius and the greater the density of the substance of which it is made, the greater the amount of refraction. The ratio which the refractive power of one substance bears to another, taken as a standard, is called its index of refraction.

If, now, we have lenses always made of the same substance, and always subject them to the same standard of measurement, it is evident that we can not only express the power of an individual lens, but can also make a comparison of the relative force of different lenses. Lenses in common use are made of glass, and in ophthalmology at least are measured by the effect they have on parallel rays of light; and it so happens that, in the case of glass, parallel rays are brought to a focus at a distance behind the lens just equal to twice the radius of its curvature. Thus, if the plano-convex lens is ground on a radius of six inches, the focus will be twelve inches.

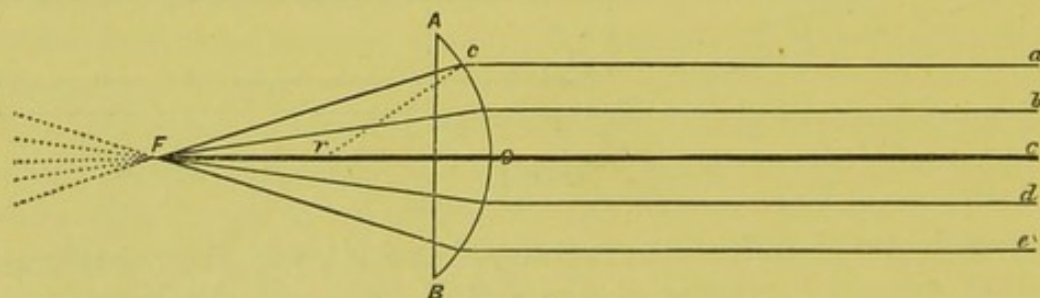


FIG. 7.

Let the lines a, b, c, d, e , in the diagram, be parallel rays, and $A B$ a plano-convex lens, whose radius of curvature $r O$ or $r c$ is six inches, then the point at which the rays meet, or its focus, will be at F , twelve inches behind the lens (Fig. 7).

Plano-convex lenses are the simplest, but, from their thickness, are unwieldy and inconvenient. To avoid this, lenses are usually ground on both sides, and, when the two surfaces are equal, as is commonly the case, the power of the lens is doubled. If, for example, we take the same lens and grind another spherical surface on it, as is

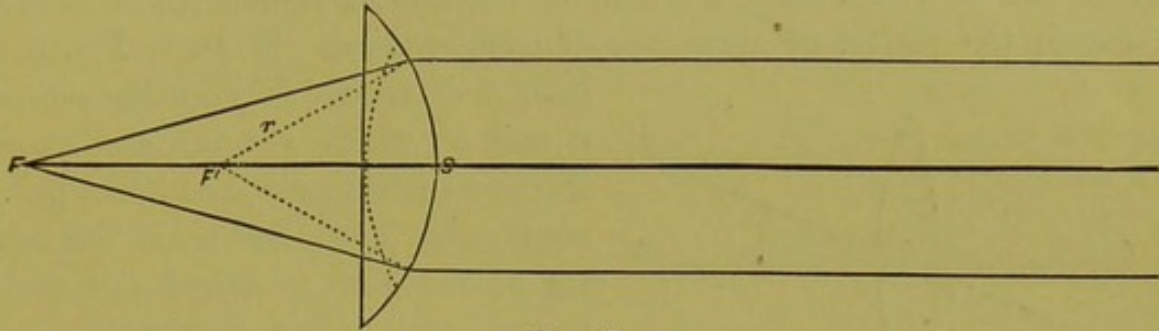


FIG. 8.

shown by the dotted line in Fig. 8, then each surface refracts the ray in an equal degree. The first brings the ray to twelve inches (F'), the second to six inches (F'').

But, as the length of the radius on which each surface is ground is six inches, it follows that the focal length of the glass and the radius are equal to each other; from which we get the general rule that the focal length of a biconvex glass is equal to the radius of its curvature. The power of a lens can therefore be expressed by its focal length, and we speak of a glass of three inches focal length, or of three inches radius, or, shorter still, a three-inch glass. It must follow, from the above, that the strength of a glass is inversely as its focal length, for the longer this is the weaker must be the glass. From this fact, it often becomes a matter of great convenience to express the force of a lens in the form of a fraction which shall show what relation it bears to a common standard, and consequently to other lenses. If we take, as such, a one-inch lens, then parallel rays will meet behind it at a distance of one inch. A two-inch lens will bring such rays to a focus at two inches, and is, therefore, only one half as strong as the first; and a ten-inch lens will only bring the rays to a focus at ten inches, and is consequently but one tenth as strong as the one-inch lens, and so on.

By using this fractional form we are able to express on paper the increase or decrease of refractive power when a combination of lenses takes place; for example, the addition of a four-inch lens and a twelve-inch lens does not make a sixteen-inch lens, but merely shows that we have added together a lens which is equal in focal power to one fourth of the unit or standard to another which is one twelfth of such unit. Thus, $\frac{1}{4} + \frac{1}{12} = \frac{1}{3}$. So, too, if a twelve-inch lens is subtracted from a four-inch one, we express it $\frac{1}{4} - \frac{1}{12} = \frac{1}{6}$.

These fractional expressions are of daily occurrence in optical literature, and this simple explanation may serve to fix their significance in the mind.

There are one or two other technical terms frequently employed in describing the properties of lenses, which it is well to bear in mind. Thus, the principal axis of a lens having two surfaces is a line drawn through the centre of curvature of each surface. Thus, in Fig. 9, a

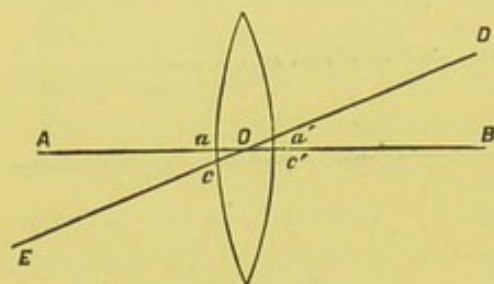


FIG. 9.

line, AB , drawn through the points a and a' , which are the centres of the two surfaces c and c' , is the principal axis. The point O , in the centre of the lens, is called the optic centre, and a line drawn through the optic centre, not coincident with the principal axis, is called a secondary axis. Thus the line $EO D$ is a

secondary axis. And it is evident that, although there can be but one principal axis, there may be any number of secondary axes. For the purposes of ophthalmoscopy, the *nodal points* of a lens may be considered equivalent to its optic centre.

We have seen that a convex lens has the power of collecting the rays coming from a point of light so as to reproduce this at its focus. Thus, if we darken a window on which the sun is shining so that only a pin-hole is left through which the rays could pass, we should get practically only the rays coming from a single point of light. If we now take a lens, and, holding it in the course of the rays, allow these, after passing through the glass, to fall upon a piece of paper or other screen held at the focal distance of the glass, we shall then get the point of light reproduced on the paper. But, what is true of a single point is true of a collection of points; and, if we expose the lens to the full force of the sun, we then get on the paper the reproduction of all the points in the sun, and the round and brilliantly illuminated spot on the paper, vaguely called the "focus," is not a mere collection of rays of light, but is a miniature fac-simile of the shape of the sun itself. So, too, with all luminous bodies.

But, as it has been shown that all bodies which are visible may be considered to have a light of their own, it follows that we ought to be able to get an image of these with a lens just as we do of those which are really luminous—and to show that this is true, we have merely, standing at the far end of a room, to let the light coming from the window pass through the lens and be collected, as before, on the paper. If we do this, we then get, not only the image of the

window, but also the objects of the landscape beyond. And here, as elsewhere, since all the points in the image are proportionally at the same distance from each other as those of the object, the one is a perfect fac-simile of the other, the only difference being that the image is smaller and inverted. The reason of this is as follows:

Let A , in Fig. 10, be a distant point of light, from which the ray Aa emerges. This ray, as soon as it touches the lens, is refracted at a , and then proceeds in the direction aA' . A second ray, Aa' , from

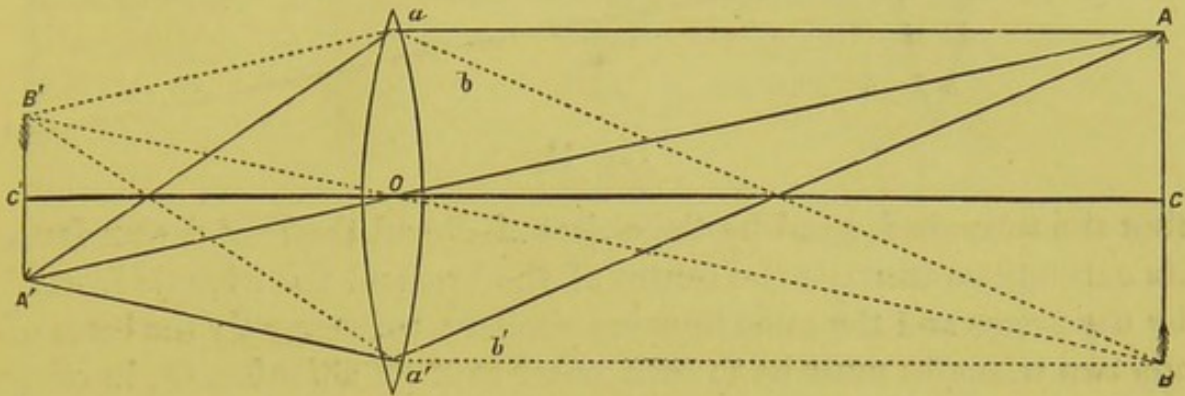


FIG. 10.

the same point, strikes the opposite end of the lens at a' , where it undergoes refraction, and will proceed as $a'A'$. It will be seen that the refracted rays will intersect each other at the point A' , where the image of the point A will be formed. For the sake of simplicity we have taken only the outside rays of the cone $Aa a'$; all the included rays will undergo precisely the same changes, and finally meet at A' . So, too, those coming from B will meet at B' , and all the intermediate points on the straight line between A and B will have their image on the line between A' and B' , and thus an image of the entire object will be produced, inverted and smaller.

If, now, after having found by construction where the image of any point lies behind the lens, we draw a straight line from the point to its image, we find that it passes through the optical centre of the lens. Consequently, in order to find the direction in which the image of any given point will be after being refracted by a lens, we have only to draw a line from such point through the centre of the lens, and we know that the image must lie somewhere on that line.

Thus, the image of the point A (Fig. 10) in the head of the arrow, which we will assume to be at such a distance that the rays coming from it are parallel, will lie somewhere on the line $A O A'$, and that of B on the line $B O B'$; and, since the rays before refraction are parallel, their point of intersection on this line will be at a distance behind the lens equal to its focal length.

Let in Fig. 11 AB be an arrow three feet long placed twenty feet in front of L , a twelve-inch lens, and let ab be the image of AB at the focal distance of the lens, namely, one foot. It will be seen

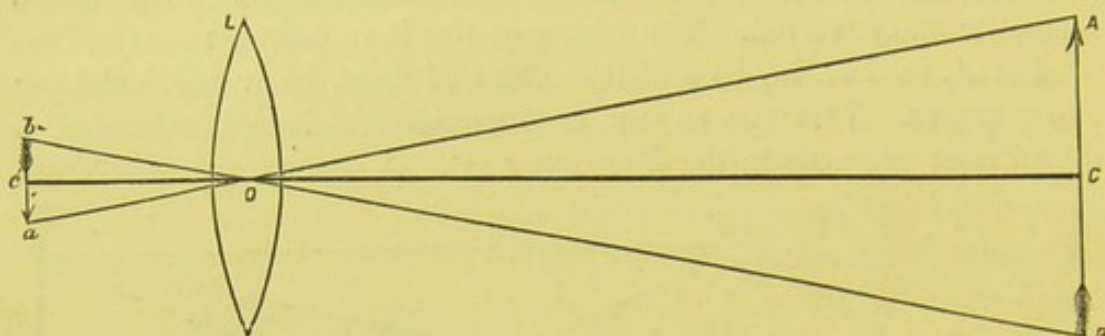


FIG. 11.

that the triangle formed by the object AB and the lines drawn from its extremities through the centre of the lens and the triangle formed by the image and the same lines are similar; consequently the bases of the two triangles must be to each other as their altitudes, or, in other words, the size of the image is to the size of the object as the distance of the image behind the lens is to the distance of the object in front of it; or, more tersely expressed, the image is to the object as their respective distances from the lens. Thus, in Fig. 10 as the object AB is twice as far from the lens as the image, this latter is just half as large as the object. In the shape of a formula (Fig. 11) it is as follows: $ab : AB = c'o : Co$. As we have taken $c'o$ as equal to one foot, and Co equal to twenty feet, we get $ab : AB = 1 : 20$; ab the image is consequently $\frac{1}{20}$ of the object AB .

We have hitherto been occupied in considering the action of a convex lens on rays of light coming from a distant object, the position of which was stationary. A word must be said on rays which are not parallel and objects which change their positions.

If we walk toward a mirror the image also approaches the glass, and if we retire the image recedes; or, in other words, the image and the object have a conjugate relation to each other. It is the same with lenses, only as the object approaches the lens the image retires, and, *vice versa*, as the object recedes from it the image approaches it. This will be made clearer by a diagram, which, as it may be of essential service in explaining the various relations of conjugate foci, merits a short description. This diagram (Fig. 12) is supposed to represent a convex lens (L), painted in this case on a piece of board. We will suppose the lens to be of six inches focal length. The line $C'O C$ is the principal axis of the lens as it passes through the centres of both curvatures. We will further suppose that the line Da is a ray of light

from some distant source, and that its direction before it strikes the lens is parallel to the line $C' O C$. The ray $D a$ would therefore after refraction cut the line $C' O C$ at the focal distance of the lens, that is to say, at F , six inches behind the glass. A slit is made in the diagram along the line $C' O C$, so that the ray after crossing the line disappears, its continuation being shown by the dotted line. The ray itself is made of a piece of sheet-iron cut at such an angle that, while its unrefracted part shall be parallel to the axis, the refracted part shall be so bent as to cut the axis six inches from the lens. The ray is fastened to the lens at a by means of a pivot, round which it can rotate, but by which it is held firmly enough to maintain a given position. As the ray stands in Fig. 12 it is parallel to the axis of the lens, and has the direction as if it came from an infinite distance. If now we change the position of the luminous object, and bring it toward the lens till it reaches the point E (Fig. 12), which we will suppose to be twenty-four inches in front of the glass, then rays will proceed from this point toward the lens, and such rays will no longer be parallel to the axis of the lens, but divergent; and, in order to make our ray $D a$ represent a ray coming from E and striking the

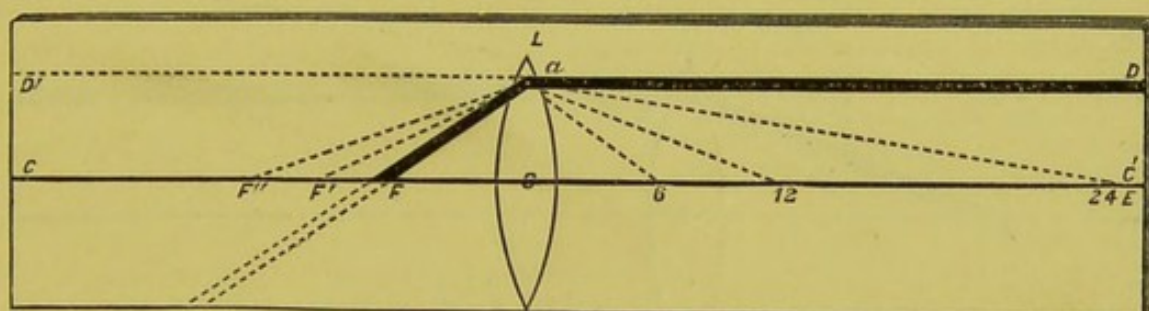


FIG. 12.

lens at a , we must depress the end at D till the ray coincides with the dotted line $E a$. But as soon as we do this the other end of the ray $a F$ rises in precisely the same degree as the first sinks, and the refracted part of the ray will consequently cut the axis at a greater distance behind the lens. Thus, if we bring the point D to E , the image at F recedes to F' , and the line no longer passes at F through the principal focus of the glass, but at a point behind it, F' , which is therefore a secondary focus. Rays leaving F' would, on the other hand, return over the same course and have their focus at E , a fact which it is well to bear in mind, as it plays an important part in the theory of the ophthalmoscope.

If now we advance the object still closer to the lens, say to twelve inches, precisely the same thing occurs, and F' recedes to F'' . If we make a still further advance, that is to six inches, F'' rises to D' , and

we have now come to the exact opposite of the conditions with which we started; for whereas, in the first instance, the unrefracted portion of the ray was parallel to the axis, and the refracted part passed through the principal focus six inches behind the lens, now the unrefracted part is in the principal focus six inches in front of the lens, and the refracted part leaves the lens parallel to its axis. And yet it is evident that in all these changes of the object and its image the amount that the ray itself has been bent has *always* remained the same. This is precisely what takes place with an actual lens, for the reason that the refractive power of the lens is always the same for any given point on its surface. Thus we can alter the position of the object, and so change the angle at which the ray strikes a given point, which in its turn would alter the position of the image; but the angle between that part which is refracted and that which is not is always the same.*

But suppose that, instead of, as in the first instance, depressing the end of the ray at D , we raise it (Fig. 13), then the bent portion, aF , would sink in a corresponding degree and cut the axis nearer to the

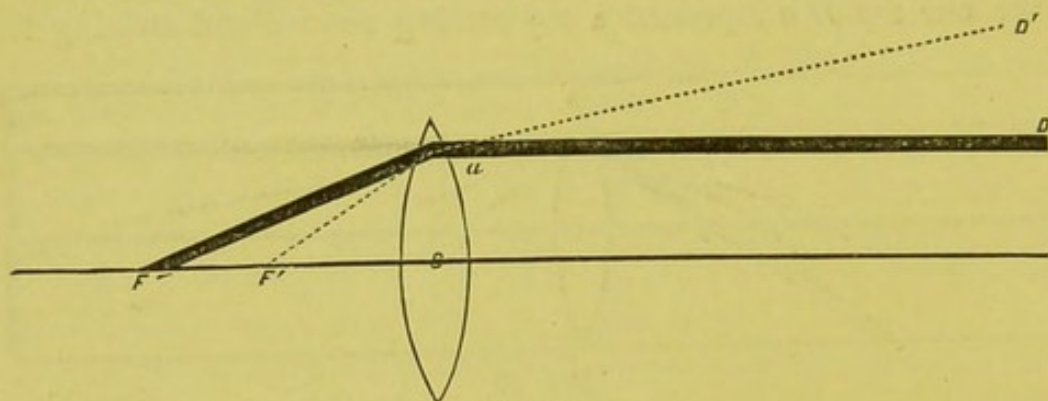


FIG. 13.

lens, and F would then advance to F' ; Da would no longer be parallel to the principal axis of the lens, but convergent to it. When convergent rays, therefore, fall on a convex lens, they must have their focus inside of the principal focus. And here, too, if we reverse the thing and suppose the ray to proceed from F' , it will return over the same path and will leave the lens in the direction aD' , divergent to the principal axis. Consequently, whenever an object is inside of the principal focus, rays leaving it will emerge from the lens as divergent, and no image will be formed.

Having now become familiar with the conjugate connection in a

* This is not absolutely the case, as the most peripheric rays are more refracted than the central rays, causing what is known as "spherical aberration," but for all practical purposes it is correct.

general way between an object and its image, it is often very convenient, and indeed very important, to know the amount of displacement of the image corresponding to a given displacement of the object. The simplest way of illustrating this point seems to me that suggested by Mr. Lawrence.

Let us take a six-inch lens. If the object were at a distance, then the rays, being parallel, would come to a point at the principal focus of the lens and the image would be six inches behind the lens. If now we move the object up to twenty-four inches, the image would retreat, and the question is, how much? As the object is twenty-four inches in front of the lens, it would require a lens of twenty-four inches focal length to render rays coming from it parallel; or, expressed in the form of a fraction, $+\frac{1}{24}$. Consequently, of the six-inch lens what would be equal to $+\frac{1}{24}$ would be expended in making the rays parallel, while the remainder would be left to exercise its power in bringing the rays to a focus. This remainder would of course be equal to $\frac{1}{6} - \frac{1}{24} = \frac{1}{8}$; and, instead of a lens of six inches focal length acting on rays diverging from twenty-four inches, we should have what is equivalent to precisely the same thing, only differently expressed, viz., an eight-inch lens acting on parallel rays, and the image would then lie at eight inches.

Let L , in Fig. 14, be a six-inch lens and A the object at twenty-four inches. It will take a lens equal to $\frac{1}{24}$ to render the rays parallel,

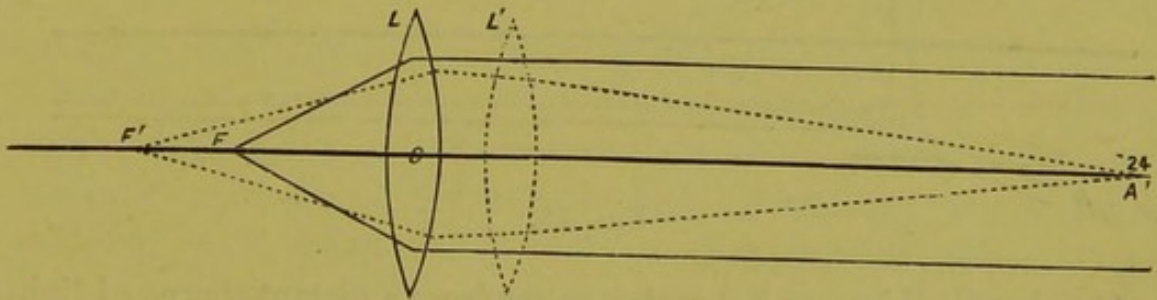


FIG. 14.

and this may be represented by an imaginary lens in front of the actual lens. This second lens, L' , has been borrowed from the first, and consequently the six-inch lens has been reduced by just so much, $\frac{1}{6} - \frac{1}{24} = \frac{1}{8}$, where the image will be formed, at F' .

If we move the object still nearer, say to twelve inches from the lens, then it would take so much more of the original lens to make the rays parallel and the lens, instead of being $\frac{1}{6}$, would be practically $\frac{1}{6} - \frac{1}{12} = \frac{1}{12}$. The image would then lie at twelve inches behind the glass, and so on. Thus, knowing the strength of the lens and the distance of the object, we can always tell just where the image will

lie, for this would be simply the focal length of the lens minus the distance of the object in front of the lens; or, better expressed, minus the strength of the imaginary lens which it takes to render the rays coming from the object parallel. We can express this mathematically as follows: If we take a as the place of the image sought, a the distance of the object from the centre of the lens, and f the focal distance of the glass, we then have $\frac{1}{a} = \frac{1}{f} - \frac{1}{a}$. In our example we took f as six inches and the distance of the object as twenty-four. Consequently we get $\frac{1}{a} = \frac{1}{6} - \frac{1}{24} = \frac{1}{8}$. Therefore, $a = 8$ inches.*

All this can be practically worked out on the diagram (Fig. 12). For if we depress D to C' , twenty-four inches from the lens, then F , which was at six inches, goes out to F' , which is at eight inches, provided the diagram has been made correctly.

Concave Lenses.—A concave lens is simply the reverse of a convex, and its effect on light is to render the rays which pass through it more divergent than they previously were.

Let Fig. 15 represent a common biconcave lens whose surfaces are ground, we will say, on a radius of six inches.

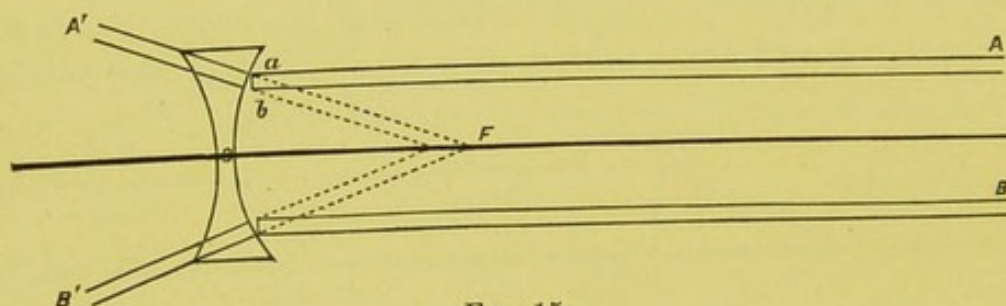


FIG. 15.

Let A and B be parallel rays coming from a distant source of light. The end of the ray, marked a , will strike the glass first and will be impeded by it, while b is still left to travel in the air. This will alter the direction of the ray A , and the same thing will take place with the ray B ; the two will, after passing through the lens, diverge from each other, $A' B'$. Consequently, the rays can never meet, and there can be no such thing as a focus behind the lens in the case of parallel rays. But, if we imagine these rays to be continued backward in the direction $A' F$ and $B' F$, the rays will meet at F in front of the lens. As this focus has no real existence, but only an optical one, it is called a virtual focus, but for all practical purposes it has the same signifi-

* "Lehrbuch der Ophth.," Mauthner, Ab. 1, p. 54.

cance as the focus of a convex lens. And we may remark here, once for all, that all the laws which relate to the one relate to the other, and just as we call a convex lens a positive lens, and affix to it the sign plus, so we call a concave lens a negative lens, and give it the sign minus.

We can calculate the place of the image in the case of a concave lens just as we did that found by a convex lens. Suppose we have a concave lens of six inches focal length, or $-\frac{1}{6}$. If the object were at twenty feet or more, the rays from it would be practically parallel, and, after passing through the lens, would be rendered divergent to such a degree that, if continued backward, they would meet six inches in front of the lens (see Fig. 15), and here the virtual image would lie. If, now, we move the object to a distance of twelve inches, the rays would diverge as if they came from this distance, and, from the new position of the object, the amount of divergence would be the same as if parallel rays passed through $-\frac{1}{12}$. To rays already diverging to this degree we interpose a lens $-\frac{1}{6}$, and, practically speaking, we get the combined force of two lenses, one of which would be equal to $-\frac{1}{12}$, the other to $-\frac{1}{6}$. $-\frac{1}{12} + (-\frac{1}{6}) = -\frac{1}{4}$. Consequently, an object at twelve inches in front of a six-inch lens would have its focus at four inches in front of it.

We can use the same formula as for convex lenses, only substituting for f a negative focal distance, thus: $\frac{1}{a} = -\frac{1}{f} - \frac{1}{a} = -\left(\frac{1}{f} + \frac{1}{a}\right)$. This formula will suffice for infinity, or for any distance less than infinity.

But, if convergent rays fall upon a concave glass, the matter becomes a little more complicated, though still simple enough to be readily understood. If, for example, rays of light have been rendered previously so convergent that they would meet six inches behind a given point, the amount of convergence is the same as if parallel rays had passed through a convex six-inch lens, or, expressed in the form of a fraction, $+\frac{1}{6}$. If now we interpose a $-\frac{1}{12}$ to rays which would meet six inches behind the glass, we reduce the convergence by this amount, and the image recedes in a proportionate degree, $\frac{1}{6} - \frac{1}{12} = \frac{1}{12}$. The image, therefore, will lie twelve inches behind the glass. If, however, we had placed the same glass not at six but at four inches in front of the point where the rays would have met, then the amount of convergence of the rays when they strike the glass would be equal to what $+\frac{1}{4}$ would have produced on parallel rays, and we should have $\frac{1}{4} - \frac{1}{12} = \frac{1}{6}$, and the image would then lie six inches behind the lens. To find the place where the image would fall, we have simply to subtract the strength of the glass from the distance at which the

rays would have met. The formula becomes, therefore, $\frac{1}{a} = \frac{1}{a} - \frac{1}{f}$. Taking, as we did in the above example, $a =$ six inches, and the glass $-\frac{1}{12}$, we get, $\frac{1}{a} = \frac{1}{6} - \frac{1}{12} = \frac{1}{12}$. The image lies, therefore, twelve inches behind the glass.

In the above cases the concave lens used was only sufficient to reduce the degree of convergence; but it may well happen that this shall be strong enough, not only to neutralize the convergence, but after doing this to produce a divergence. Suppose that $-\frac{1}{4}$ is placed in the track of rays which, if uninterrupted, would have met six inches behind where the glass is held, we have then what would be equivalent to a negative glass of $\frac{1}{4}$ meeting a positive one of $\frac{1}{6}$. Of the negative glass, what would be equivalent to $\frac{1}{6}$ is expended in rendering the rays, which were convergent before meeting the lens, parallel. The remainder of the glass would then exert its diverging influence. This would be equal to $\frac{1}{4} - \frac{1}{6} = \frac{1}{12}$. The rays, therefore, though convergent on striking the glass, would diverge after passing through it, to such a degree that if prolonged backward they would meet twelve inches in front of the lens.

Substituting the above values in the same formula, we get, $\frac{1}{a} = \frac{1}{6} - \frac{1}{4} = -\frac{1}{12}$. $a = -12''$. The virtual image lies, therefore, twelve inches in front of the glass.

Cylindric Lenses.—There is still another kind of lens called cylindric, because it is a segment of a cylinder instead of a sphere. Cylindric glasses, like spherical, may be either concave or convex, or sometimes even a combination of both.

The action of a convex cylindric glass may be illustrated by the following figure :

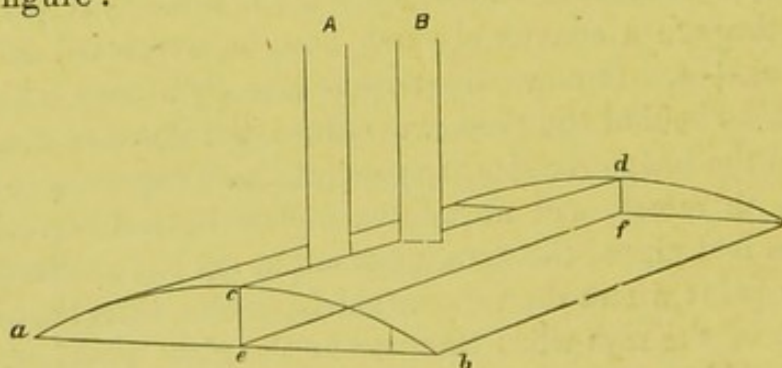


FIG. 16.

Let Fig. 16 represent a convex cylindric glass. If we divide the glass by a plane passing through the centre of curvature and the axis

of the cylinder, it is seen at once that the upper and lower sides of the parallelogram thus formed are parallel to each other.

It will be readily understood that an indefinite number of secondary planes might lie, side by side, parallel to each other, and that the upper and lower boundary-lines of each plane would be also parallel to each other, though the height of the planes would grow less and less as we approached the border of the glass, as shown by the dotted line, toward *b*.

A ray of light passing through one of these planes, and perpendicular to the axis of the cylinder, such as *A*, would not be bent from its course, since both ends of the ray would be retarded in an equal degree; and, even if the ray were not perpendicular to the line *cd*, which represents the first surface struck, it would not have its direction materially changed on leaving the glass, as the line *ef*, representing the second surface, is parallel to the first; consequently, any deviation which took place at the first surface would be rectified by the second, just as happens with the parallel surfaces of window-panes. But, on the other hand, if the ray passes through a plane at right angles to the axis of the cylinder, as, for example, the ray *B*, then one end of the ray will strike the glass before the other, and the same result will follow that has already been so fully described. The ray will be bent from its original direction in proportion to the curvature of the lens. But, if the ray should not pass through the plane *c, d, e, f*, as *A* does, or some plane parallel to it, nor yet, again, just at right angles to it, as *B* does, but somewhere between the two, then the ray would be refracted in an intermediate degree, and in proportion to the angle which it makes with the axis of the cylinder.

We can grind a spherical surface on the under side of the glass, and then we should have the combination of a spherical and a cylindrical lens. These are called sphero-cylindric glasses. They have two principal meridians, one parallel to the axis of the cylinder, the other at right angles with it. These two meridians would of course have different foci; thus, if we had the combination of a spherical surface equal to one sixth, and a cylindric to one twelfth, we should have the focus of one meridian at six inches, because only the spherical surface would affect the rays; while, for the meridian at right angles with it, we should get the force of both lenses, and the focus would be at four inches.

Instead of a spherical surface, we might put on the under surface of the glass another cylindric one at right angles with the first. Such a lens is called bicylindric, but is rarely used.

As rays of light are invisible, we can not trace their passage

through the air, and consequently we can not see the effect that lenses have in altering their direction. But the actual path of the rays can be seen, and all the various effects of lenses and their combinations be beautifully studied, if we allow the rays to pass through smoke instead of air. This can be readily done by arranging a box with a glass cover or side, and by cutting a hole through one end, just large enough to be covered by a given lens, such, for example, as come in the test cases. The smoke is prevented from escaping through the hole by a piece of plane glass. The box is then filled with a light cloud of tobacco-smoke, which must be allowed a few minutes to distribute itself evenly throughout the box. If we now darken the room, and place a strongly-burning light at a suitable distance from the box, so that the rays from the lamp shall pass through the hole, we then get their illuminated track through the smoke, in such a way that all the various changes effected by different glasses and their combinations can be distinctly followed and studied.

Mirrors.—The mirrors now commonly used in ophthalmoscopy are either plane or concave. Let MN (Fig. 17) be a common plane mirror; A a point of light from which the ray AB strikes the surface of the mirror at B . This ray will be reflected in the direction BO , making the angle ABD equal to the angle DBO , D being perpendicular to the point of incidence—or, in other words, the angle of reflection is equal to the angle of incidence. An eye placed at O would receive

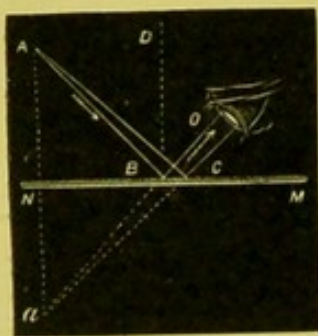


FIG. 17. (From Ganot.)

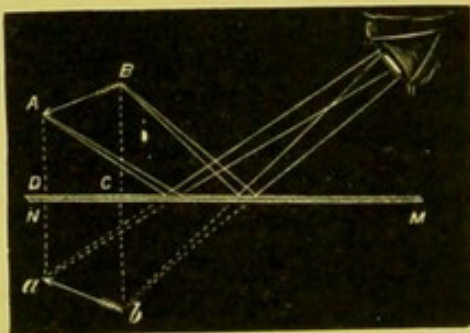


FIG. 18. (From Ganot.)

the ray as if it came from the direction BO , and not AB ; so, too, the ray AC would enter the eye as if it came from aC and not from AC . Consequently, the image would appear to lie in the direction of these rays; and, as the amount of divergence between the rays themselves has not been changed, the distance of the image in this new direction would be found by simply extending the rays backward till they intersected; and this is what the mind in reality does. The image, therefore, for a plane mirror must lie as far behind it as the

object lies in front of it, and the image of A would appear at a . What is true of one point is true of all, as in Fig. 18.

The law that the angle of reflection is equal to that of incidence holds good for all mirrors, spherical as well as plane. Let Fig. 19




FIG. 19.

be a concave mirror, and aR the radius of curvature in which it is ground. Let a be a point on its surface. The perpendicular to this point, as in all other spherical surfaces, would be a line drawn from the point to the centre of the sphere. aR would then be the perpendicular to a . Let Ca be a ray from some distant point which strikes the surface of the mirror at a . This would be reflected from the mirror in the direction aF , so that the angles RaF and Rac would be equal, the ray cutting the principal axis of the mirror at F . Precisely the same thing will take place with the ray Bd , which will also cut the axis at F , which is consequently the focus of the mirror. The focal length of spherical mirrors is determined as in lenses by parallel rays, and is equal to half the radius of curvature on which it is ground.

It will be seen, then, that a concave mirror, by means of reflection, does just what a convex lens does by refraction. It causes rays of light to converge, brings them to a focus, and makes an image. All the laws which are applicable to the one are equally so to the other; the only difference being that the effects of the mirror are produced in front of it, while those of the lens are produced behind it; and

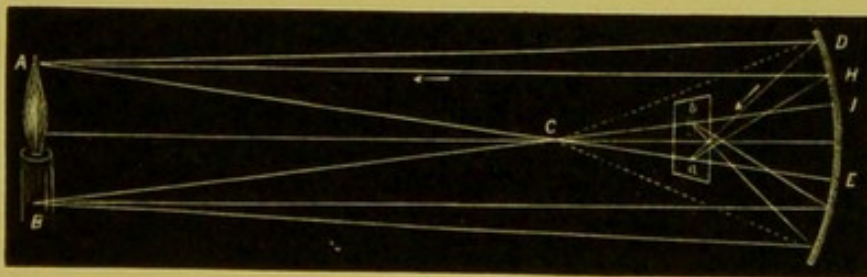


FIG. 20.

that the converging power of a mirror is twice as great, in respect to a given curvature, as that of a biconvex lens. The action of a concave mirror in the formation of an image will be seen in Fig. 20.

As with a lens, so with a mirror, a line drawn from any given

point on its surface through the centre of its curvature forms the axial line for that point, and on which the image of that point is formed; thus the image of A (Fig. 20) lies on the line $A C E$, at a , the focal distance of the mirror, and the image of B on the line $B C D$ at b —the image, like that of a convex lens, being smaller and inverted.

The relation of change in position between object and image, or, in other words, the relation of conjugate foci, can readily be seen from a diagram similar to that used in the case of the convex lens. As the diagram stands, in Fig. 21, the incident ray ca is parallel to

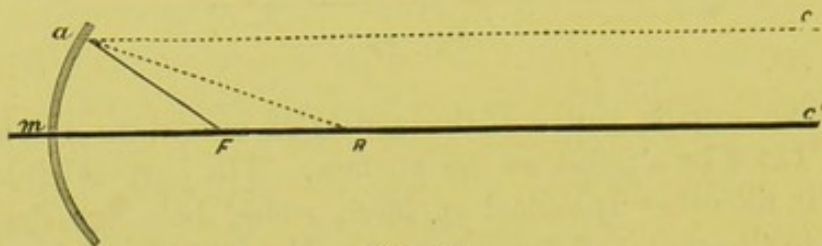


FIG. 21.

the principal axis of the mirror, and the reflected ray $a F$ cuts this at the principal focal length F , $a R$ being the perpendicular to the point a .

By a simple arrangement of strings, at the back of the diagram which is made of board, a movable ray is made to rotate round the point a . By this contrivance the reflected ray moves concurrently with the incident ray, so that the angles which they form with the perpendicular always remain equal. Thus, if we depress the ray $C a$ at C (Fig. 22), so that it cuts the axis at c' , thus approaching the perpendic-

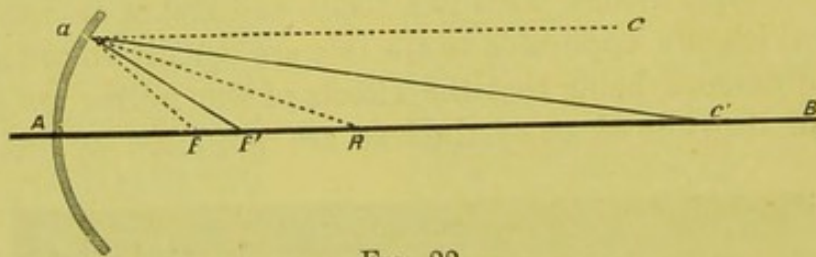


FIG. 22.

ular, and making a smaller angle with it, $R a c'$, instead of, as at first, $R a c$, then $a F$ approaches the perpendicular to the same degree, and cuts the axis at F' , instead of at F , the angles which each part of the ray makes with the perpendicular being still equal. If we carry $a c'$ to R , so that it becomes coincident with the perpendicular, F' advances at the same time, and likewise becomes coincident with it. There is now no angle of incidence, and there can be, therefore, no angle of reflection. The ray would return straight back over the same course. If we depress c' still further, till it reaches F' , the reflected portion

of the ray will rise and pass by the incident portion, and take the position $a c'$. If we carry the incident ray still further, say to F , then the reflected ray rises to $a c$, and becomes parallel to the axis $A B$. If we should persist in carrying the incident ray still nearer the mirror, then the reflected portion would rise still more, and pursue its course divergent to the principal axis $A B$.

The same law of reversion holds good here as with lenses. Thus, parallel rays, passing over the curve, Ca , would have their focus at F , and rays leaving F would return in the direction $a c$; c' would likewise have its image at F' , and F' at c' , and so on.

A convex mirror is the opposite of a concave, and rays reflected from its surface are rendered more divergent. But, as these mirrors are now seldom used in the construction of ophthalmoscopes, a knowledge of their principles is not a matter of necessity, and it is to such alone that these few introductory remarks are confined.

PHYSIOLOGICAL OPTICS.

Practically speaking, the eye may be looked upon as a simple biconvex lens, the focal length of which is about equal to eighteen twentieths of an inch (22.231 mm.), the retina being the screen on which the image formed by the lens is received. It is true, if we look at the diagrammatic section of the eye (Fig. 23), we see at once that the refractive system is not

a simple but a compound one, consisting of various surfaces of different degrees of curvature, and of interlying media of different densities. The principal refracting surface is, of course, the cornea. Behind this comes the aqueous hu-

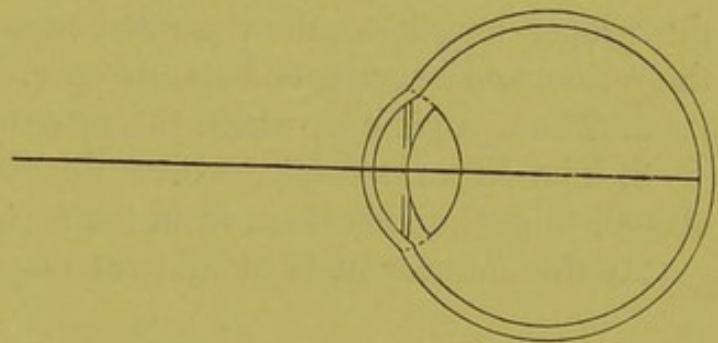


FIG. 23.

mor; then the anterior surface of the lens; then the different strata of the lens itself, with their different densities; and, finally, its posterior surface. All these various elements have, it is true, a determining influence on the direction of the rays. The resolving of all these different factors, however, into one simple biconvex lens may, for the simplicity of illustration, and for practical purposes, be considered justifiable.

This can easily be accomplished—to the eye, at least—by continuing the curve of the posterior surface of the lens till it cuts the cornea above and below, as seen by the dotted line in Fig. 23. This gives a

fair representation of a biconvex lens, the anterior surface of which is formed by the anterior surface of the cornea, and the posterior by the posterior surface of the lens, while all the included media may be looked upon as so many strata of the same lens having different indices of refraction, similar to a Dollond lens, and thus constructed for the same purpose. The beautiful device of putting a movable diaphragm, the iris, between the layers of this composite lens, for the sake of protection, has, of course, simply the effect of cutting off the peripheric rays, and regulating the supply of light. The result of this compound lens is that, in a normal eye, parallel rays just come to a focus on the retina.

Optically speaking, there are three kinds of eyes, their classification depending on the anatomical construction. It is assumed that the anterior parts of the eye, or those portions which refract the light, and which we will assume to extend to the posterior surface of the lens, are the same in all eyes, and that the only difference in their refractive power is occasioned by variations in the length of the antero-posterior axis. This is of course only an assumption, as it is admitted that there are considerable individual differences in different eyes; still, the variations are not so great as to preclude a practical acceptance of the assertion, at least for ophthalmoscopic purposes. The three varieties of eyes are:

1. The normal eye, the antero-posterior axis of which is just of the proper length to allow parallel rays to be brought to a focus on the retina, and hence called *emmetropic*.

2. The myopic eye, where the antero-posterior axis is too long.

3. The hypermetropic, where this is too short. The last two classes, to distinguish them from the first, are called *ametropic*.

As the anterior parts of all eyes may be assumed to be the same,




FIG. 24.

we have simply to alter the length of the antero-posterior axis of the normal eye to get a representation of the two variations from the standard, as in Fig. 24. Here the first fine line shows a shortening,

and the dotted line a lengthening, of the axis; the first representing a hypermetropic, the second a myopic eye.

If, now, we subject this triple representative of the eye to parallel rays of light, we should have the result represented in Fig. 24, which is merely an elaboration of the previous diagram (Fig. 12), with which you are now so familiar, the chief difference being that we have here two rays, ca and $c'a'$, which move round a fixed point on the surface of the lens a and a' , instead of one, as in the former case. For the sake of simplicity, the refraction which takes place at the surface of the cornea is not represented, that only at the lens being shown, as it is from the centre of the lens (o) that the variations in the length of the antero-posterior axis are estimated so far as the practical workings of the ophthalmoscope are concerned.

Looking at the diagram, we see that the rays ca and $c'a'$ just meet on the retina of the normal eye, that they cut the retina of the hypermetropic eye before they come to a focus, while they do not reach the retina of the myopic eye till after they have crossed each other. The optical significance of this is, as will be seen from the figure, not that the refractive power of ametropic or abnormal eyes is faulty, but that the retina, or screen, is no longer in the right position to receive the image; or, in other words, this is no longer at the focal length of the lenticular system, the retina of the hypermetropic eye being in front of this, that of the myopic behind it. The simplest remedy for this would be a displacement of the retina either backward or forward, to suit the circumstances. This can not, of course, be done. We can not alter at will the anatomical construction of the eye, but we can change the direction of the rays so as to make them come to a focus on the retina no matter where this may be. Thus, by depressing the end of the ray c toward the axis (Fig. 25), the other part of the ray,

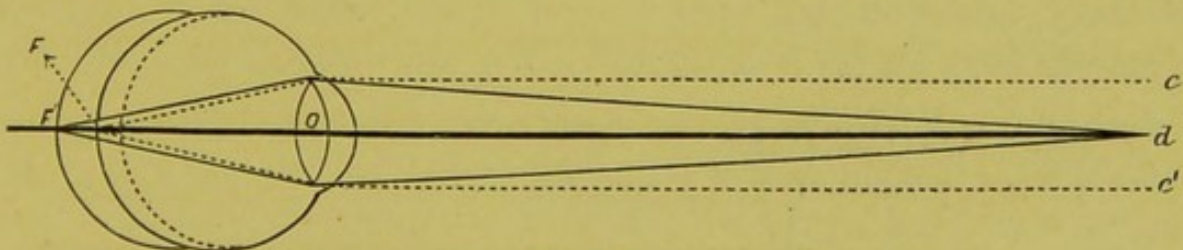


FIG. 25.

or that within the eye, will rise and cut the axis farther back, and in proportion to the amount of depression, which we will assume to be in the present case represented by the point d . If we elevate c' to d , a like recession of the intraocular end takes place with the lower ray, and the crossing of the two is no longer at F , on the retina

of the normal eye, but at F' , on that of the myopic eye. In order to get the rays to cross on the retina of the myopic eye, we have had to force them to leave their previous parallel condition, as shown in Fig. 24, and represented by the dotted line in Fig. 25, and assume, when they strike the cornea, a certain degree of divergence. From this it follows directly that the only rays which can be brought to a focus on the retina of a myopic eye are divergent rays, and the amount of divergence necessary depends on the degree of abnormal lengthening of the axis. Under the conditions taken in the diagram, d would have its image at F' ; and, *vice versa*, rays returning from F' would have their image at d ; consequently, *only convergent rays can leave the fundus of a myopic eye*.

If, on the other hand, we wished to make the rays c and c' , which are parallel in the case of the normal eye, meet on the retina of the hypermetropic eye (Fig. 26), we should have to *separate* the outer

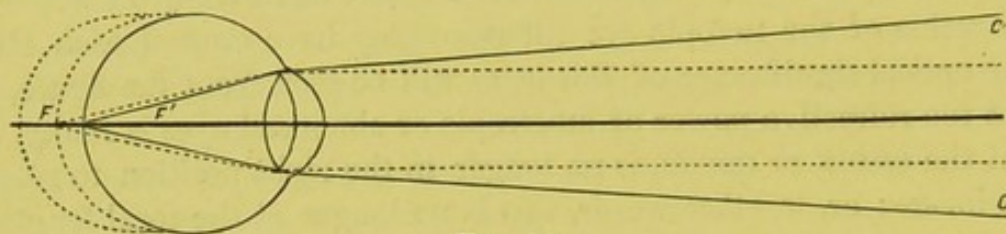


FIG. 26.

ends of the rays from each other, so as to bring their intraocular ends to meet on the anterior line. As we separate the ends of the rays c and c' , F approaches to F' , and when this is reached we see that the rays c and c' no longer run parallel to each other, but are convergent, as in Fig. 26.

Thus we see that the only rays which can meet on the retina of a hypermetropic eye when at rest are convergent rays, while, on the contrary, rays diverging from a point on the retina, say F' , *must of necessity leave the eye as divergent*. We can not, it is true, alter the

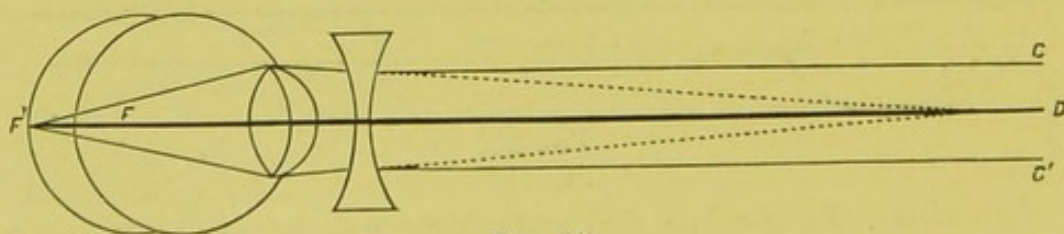


FIG. 27.

direction of the rays in case of the actual eye by the hand, as we have in the diagram, but we can by means of suitable glasses. Thus, with concave glasses, we can make rays which were originally parallel

diverge from each other to any required degree. Take the same diagram, Fig. 27. Instead of compressing c and c' to d , we can use a concave glass, which would make the rays, after they had passed through it, diverge from each other to such a degree that they would strike upon the cornea as if they came from the direction of d , and of course, as we have altered the direction of one end of the ray, we also have that of the other, and F passes to F' .

There are two ways, therefore, by which a near-sighted eye can see objects. Either the objects themselves must be brought toward the eye till the rays from it assume such a divergence that they come to a focus on the retina, or the object remains at a stated distance and the rays from it are rendered sufficiently divergent by means of glasses. Thus, if a person is compelled to bring an object to a distance of twelve inches from the eye before he can see it plainly, his farthest point of distinct vision, or, as is technically said, his "far-point," lies at twelve inches. To produce this effect, that is to say, to render rays coming from a distant object as divergent as if they came from twelve inches, it would require a twelve-inch concave glass, or $-\frac{1}{12}$. The myopia is, therefore, said to be equal to $\frac{1}{12}$ ($M = \frac{1}{12}$). We neglect here, for the sake of simplicity, the distance between the eye and the glass. The myopia in a given case, then, is expressed by the *weakest* glass which renders vision distinct for distant objects.

So, too, with the hypermetropic eye (Fig. 28). The parallel rays $c a c' a'$ would not be brought to a focus on the retina, but would pass

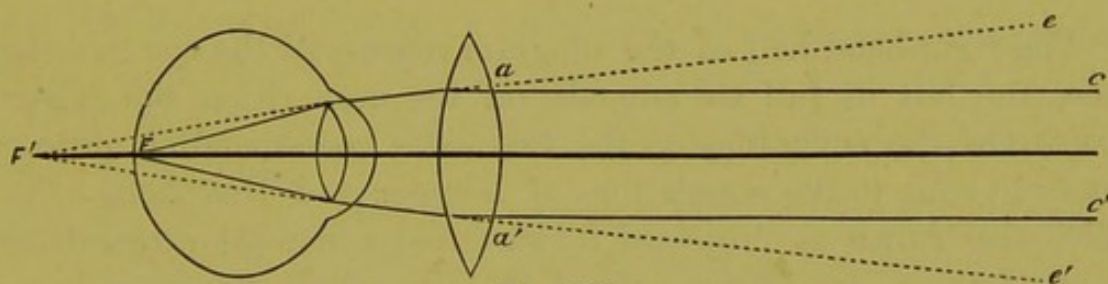


FIG. 28.

behind it before crossing. By means of convex glasses we can make the rays which were originally parallel converge to any required degree. By the proper glass we could make the rays $c a c' a'$, after passing through the lens, bend toward each other and strike the eye as if they really came from the direction of the dotted lines e and e' . F' then would advance to F , and we should have the focus of the rays on the retina and not behind it. That convex glass, therefore, which just renders the rays so convergent that they will meet on the retina, expresses the degree of hypermetropia present. If this glass is $+\frac{1}{12}$, then we call the eye hypermetropic $\frac{1}{12}$, and so on, neglecting for the

sake of simplicity the distance between the glass and the nodal point of the eye.

Mention has been made several times of the eye being at rest, and this leads me naturally to say a few words in regard to another factor which plays an important part in the production of an image upon the retina, namely, the accommodation. This is the ability which we have of increasing the existing refraction of the eye, whatever this may be. This is brought about by the ciliary muscle, which increases the power of the lens, and in precisely the same way in the case of the lens of the eye as with other lenses, that is, by increasing the degree of its curvature. The manner in which this is done is shown in the drawing, "Recent Advances of Ophthalmic Science," p. 109.

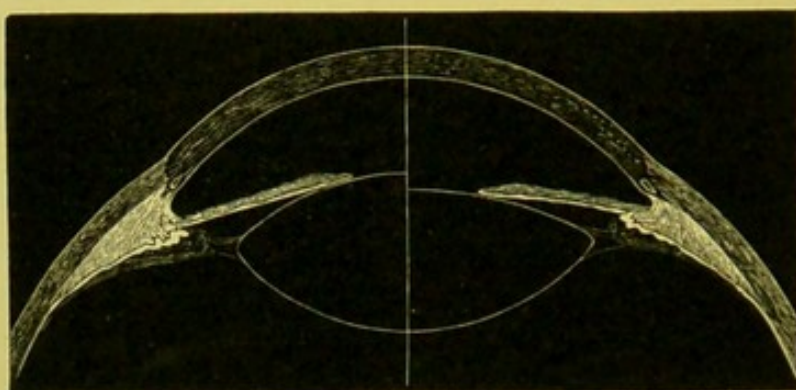


FIG. 29.—Diagram showing the relative condition of the eye when at rest and in strong accommodation (after Kramer and Helmholtz, the anatomy after Arlt).

"The right-hand half of the diagram represents the eye in a state of rest, the left in full accommodation for near vision, the relative curvature of the crystalline on the two sides corresponding quite accurately in scale to the calculations of Kramer and Helmholtz. The pupil is also shown as projected forward and somewhat contracted in accommodation. It will be noticed that the ciliary processes do not, in either case, touch the margin of the lens, an observation due to Von Graefe, and confirmed by other investigators."

The exact manner in which the action of the ciliary muscle is propagated to the lens still remains unsolved, though the commonly accepted theory is that it draws forward the suspensory ligament of the lens, which then through its own elasticity assumes a greater curvature. This, as is seen from the drawing, is represented as taking place entirely at the anterior surface of the lens. By many physiologists a slight, and by some a considerable, change is supposed to take place also in the posterior surface.

An emmetropic eye, therefore, when in a state of rest and looking

at a distant object, is already adjusted for parallel rays which then just come to a focus on the retina at F , as shown by the dotted line $c a F$ (Fig. 30). But if the object is moved to twelve inches, that is, to d , then F goes out to F' , and we should either have to move the retina

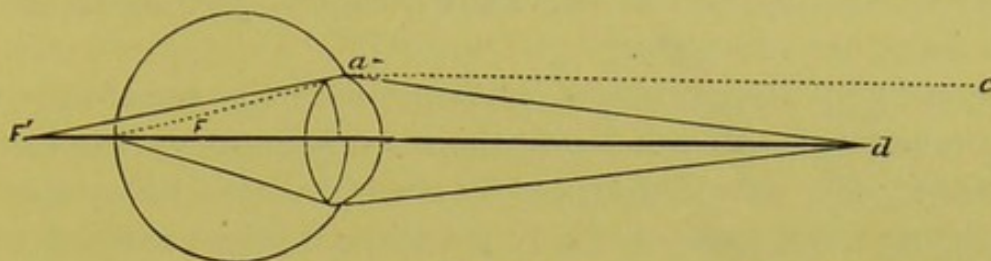


FIG. 30.

backward, as in the case of the myopic eye to reach F' , or we must increase the refractive power of the anterior part of the eye. As we have just seen, Nature prefers to do the latter, and does it by putting on an extra curve to the lens, as shown in the lower half of the diagram (Fig. 30); and the nearer the object to the eye the greater the curve required, or, in other words, the greater the accommodation. By this means F' is brought back to F . Now, an eye which is adjusted for rays that diverge from an object at a distance of twelve inches is a myopic eye; and, practically speaking, the normal eye has become equivalent to a myopic eye, the only difference being that in one case the object is obtained by having a longer antero-posterior axis, and in the other by means of a stronger lenticular power. We might just as well have got this extra refractive force outside of the eye by the help of a lens as by increasing the strength of that within the eye; and when the ciliary muscle is weak, or the lens loses its power by becoming inelastic and flatter through old age, this is precisely what is done.

So, too, with a hypermetropic eye. If this was looking at a distant object from which parallel rays proceeded, these would meet behind




FIG. 31.

the retina, as the antero-posterior axis of this eye is too short, as, for example, at F' (Fig. 31). Here, too, one of two things must happen: either we must move the retina back to F' , or by increasing the refractive power bring F' to F , which, of course, is what really does

take place, as represented in the lower half of the diagram (Fig. 31). We might have done the same thing by means of a glass outside of the eye, as in Fig. 28; and, when for any reason the deformity is so great or the ciliary muscle so weak that the effort to produce or maintain the requisite increase in curvature occasions pain or fatigue, we do then make use of a glass.

Practically speaking, then, a hypermetropic eye transforms itself into an emmetropic or normal eye when it sees an object distinctly in the distance, the only difference between the two being that one brings the rays to a focus on the retina without effort, while the other is obliged to increase the refractive power by increasing the curvature of the lens, or, in other words, by accommodating.

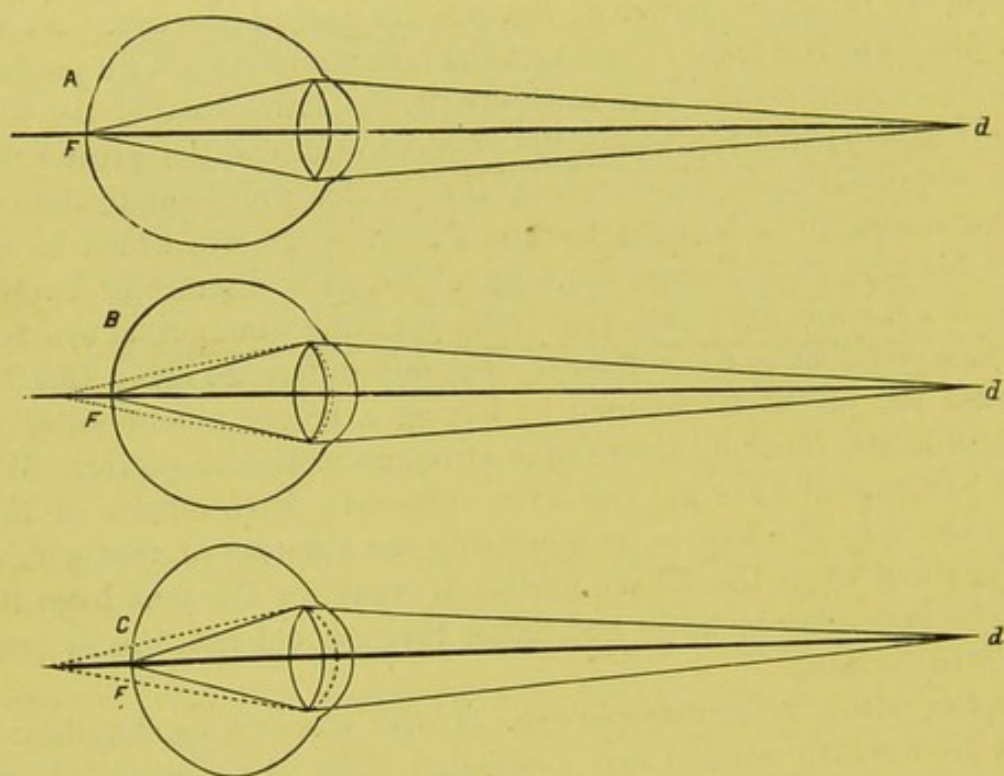


FIG. 32.

If now we bring these three conditions of the eye into comparison with each other, we may get a clearer idea of what accommodation is. In Fig. 32 let *A* be a myopic, *B* an emmetropic, and *C* a hypermetropic eye, and suppose that they are all looking at an object twelve inches from the eye, *d*.

The practical result is the same in each case, since all the eyes bring the rays to a focus on the retina; but the myopic eye, having its far-point in twelve inches, is not compelled to increase its refraction at all. It thus sees the object without any effort. But the emmetropic eye, having its retina inside of the focus for rays coming from

twelve inches, has to use, in making itself equal to the myopic eye, a certain amount of tension of the ciliary muscle. The hypermetropic eye (*C*) must exert still more. If, however, we moved the object to six inches, then the myopic eye would in its turn have to make itself more myopic by calling forth its accommodation, and thus increasing the curve of the lens. Therefore, I repeat that accommodation is simply the means which we possess of increasing the refractive power of the eye, whatever may be its original condition. Thus, a normal eye may be changed for the moment into a myopic eye of a greater or less degree, and then, relaxing its accommodation, return to its primitive condition. So, too, a myopic eye may become more myopic, and a hypermetropic may assume a state of refraction corresponding to an emmetropic or myopic eye to suit existing demands, and then, by relaxing the tension of the ciliary muscle, return to its former condition.

Unfortunately, the converse of the proposition does not hold good. We can not decrease the original condition of refraction by flattening the lens; thus, we can not lessen the refraction of an emmetropic eye so as to make it hypermetropic; neither can we make a myopic eye less myopic nor a hypermetropic eye more hypermetropic. Thus, in Fig. 32, if we should carry the object at *d* away from the eye to twenty-four inches, then both the emmetropic and hypermetropic eyes, in order to see the object, would simply have to relax a little of the tension of the ciliary muscle, and so adjust the eye for twenty-four inches. But the myopic eye, as it used no tension for an object at twelve inches, has none to relax for one at twenty-four inches; and all objects beyond a distance of twelve inches must be seen indistinctly unless a glass is used. When this is done, and the myopic eye is reduced to a normal eye, then the accommodation takes place within certain limits, precisely as if the eye were originally a normal eye.

THE THEORY OF THE OPHTHALMOSCOPE.

We have seen in the earlier part of these remarks that, in order to see an object which is not self-luminous, rays of light coming from some other source must first strike upon the object and then be reflected from it in such a direction as to enter the eye of the observer.

It had been, of course, known for an indefinite period that rays of light must enter the eye; but up to a comparatively recent time it was believed that these did not leave it again, but were absorbed within the eye by virtue of the choroidal and retinal pigmentary layers, which

were supposed to be a special provision for that purpose. But Helmholtz pointed out, if others had not done it before him, that, even if this were true in the main, there were certain parts of the eye not covered by the choroidal pigment—notably the optic nerve—from which rays of light must be reflected, and which ought, at least, to give an indication of the fact of reflection from the back of the eye through the pupil, even if the quantity of light was not enough to permit us to see the fundus oculi in detail. Yet, notwithstanding the fact that light must be reflected back from the eye, the pupil preserves a jetty blackness in the broadest daylight. The solution of this problem, so far as the eye was concerned, was the creation of the ophthalmoscope, which, while it was the work of a single mind, may yet be said to be the embodiment of the labors and aspirations of some of the greatest physiologists for several centuries past.

Helmholtz showed that the blackness of the pupil depended on the optical law, that the rays leaving the eye must return in the same direction in which they enter it, that is, in the direction of the source of illumination.

This may be illustrated in a simple way as follows :

Let *A* be a candle and *B* any small object (Fig. 33). Rays coming from the candle would strike the object *B* and be reflected from

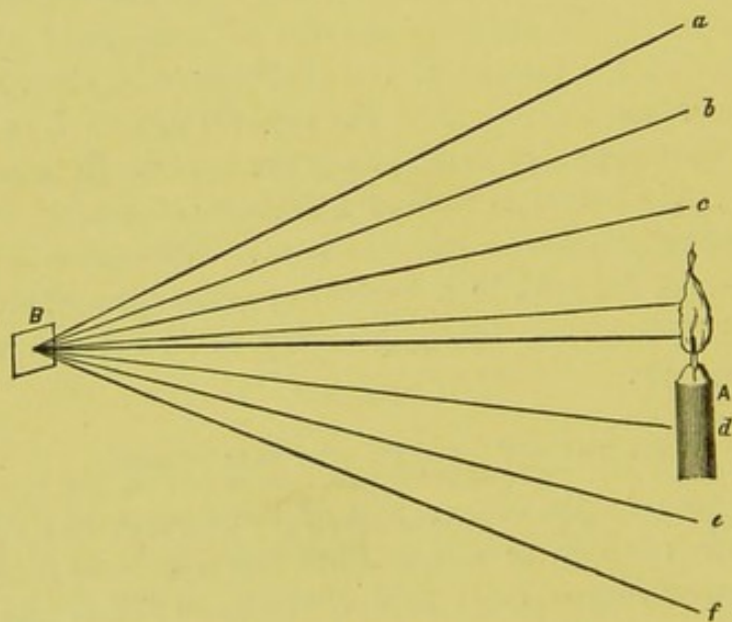


FIG. 33.

it by irregular reflection in all directions, and the object would be visible by means of these reflected rays to observers stationed at different places, as, for example, at *a*, *b*, *c*, *d*, *e*, *f*, the lines running to which may be supposed to represent the rays diverging from a single point

of the object B , the incident rays not being shown. Now, suppose we surround the object by a spherical screen (Fig. 34) in such a way that, starting from the point h , we pass round behind the object, and so on till we stop just short of completing the circle at h' . We see at

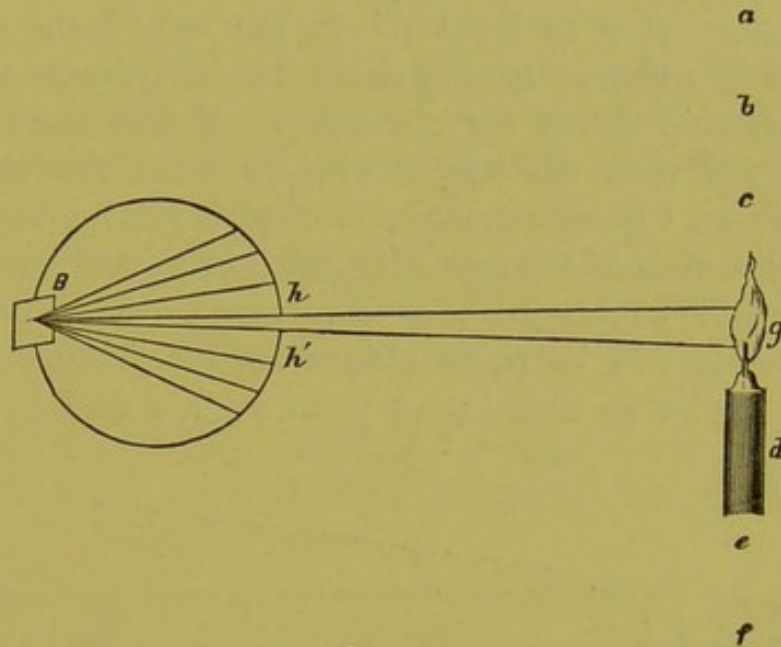


FIG. 34.

once that by doing this we cut off all the rays, both incident and reflected, except those which enter and escape through the narrow opening between h and h' in the direction of the source of light. Consequently, as the eyes stationed at the points a, b, c, d, e, f , do not receive any of these return rays, the object will not be seen, and the aperture through which the rays returned will necessarily appear black. In order, then, to get a view of the object, or even a sensation of light, we must put our eye in the course of the returning rays, and here we at once find ourselves in a dilemma: for, if we place our eye at g , that is, behind the candle, this latter cuts off the returning rays, as the flame is not transparent; and if we place our eye in front of the candle, then our head immediately cuts off the rays emerging from the candle, consequently none can enter the supposed sphere (Fig. 34), and none therefore return.

Now, the above, although a rough, is a sufficiently exact representation of the conditions of the eye to warrant us in asserting that what takes place in one case will in the other. Indeed, we have only to add a dioptric system to make the conditions practically the same. The dioptric system of the eye has no effect upon the general direction in which the rays leave the eye. These must leave it in the direction opposite to that in which they entered it, or, in other words, *toward* the source of the illumination, no matter what the optical condition of the

eye may be. The student, moreover, must bear in mind that toward does not mean *to* the source of illumination, as is often stated and figured in works on the ophthalmoscope, where it is asserted that the surface of the fundus of the eye and the source of illumination are conjugate foci. This, it is true, may possibly be the case; but it never, or almost never, does so happen. It can only happen when the observed eye is adjusted *exactly* either by its refraction or by the use of its accommodation for the lamp. If this were not so, we could never tell with the ophthalmoscope what the refraction of an eye really was. Now, although the dioptric system does not affect the general direction of the rays of light, it of course does affect the amount of their convergence or divergence. This effect of the refracting media will be made clearer by the following diagram: Let *A* (Fig. 35) be an illuminated point on the fundus of the nor-

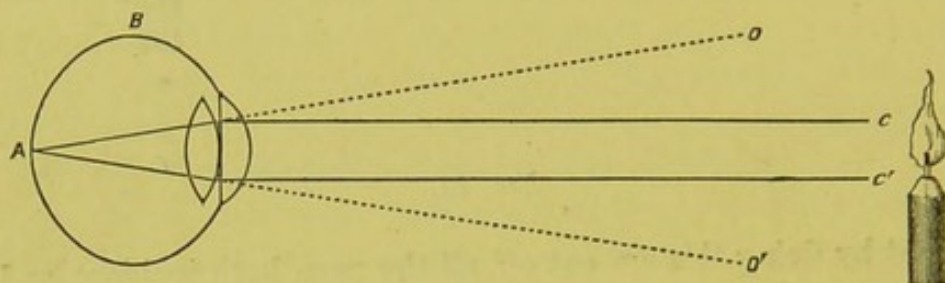


FIG. 35.

mal eye, *B*. Rays diverging from this point will issue from the pupil. If it were not for the lenticular system the external rays of the cone would proceed in the direction *A o* and *A o'*, and an observer's eye at either of these places would receive such rays. Meeting, however, the refracting media, these rays are rendered more convergent and bent in toward the visual axis, and they would then proceed in the direction *c* and *c'*. The observer would have to move his head to these points to get the reflex, and the more he moved his head toward the median line the more apt he would be to cut off the entering rays, without which there could, of course, be no reflected ones, and the more difficult it would be to get a reflex.

To illustrate the preceding principle, we can take a French model of the eye, such as is used for the purposes of teaching the use of the ophthalmoscope. If a candle is placed before this, the pupillary space appears black, no matter how near or how far off the lamp is, for the reasons just stated. But if now, returning to Fig. 34, we could bore a hole in the flame at *g*, so as to make a vacant space through which the rays might pass, we should then, if we placed our eye at *g*, be in the track of the rays returning in the direction *h*, *h'*, *g*, and we ought

then to get either a view of the object itself or at least a sensation of light through reflection. A very simple experiment shows this to be the case.

Let Fig. 36 represent the candle and the model of the eye a foot or two in front of it. A short piece of metal tube is passed through the centre of the flame, and is held in its position by a wire twisted round the candle. We have by this means a perforation through the centre of the flame, and the rays of light returning to the flame and striking within the aperture ought to pass through the tube and make themselves manifest to the eye placed in their path. This is indeed the case, for the pupil of the eye which was formerly black is seen to be illuminated; and if some other simple conditions be fulfilled, which are to be dwelt on a little later, a faint image of the back of the eye is obtained.

As shown in the drawing (Fig. 36), it is better to have a slight shield or screen thrown round the far end of the tube to protect the

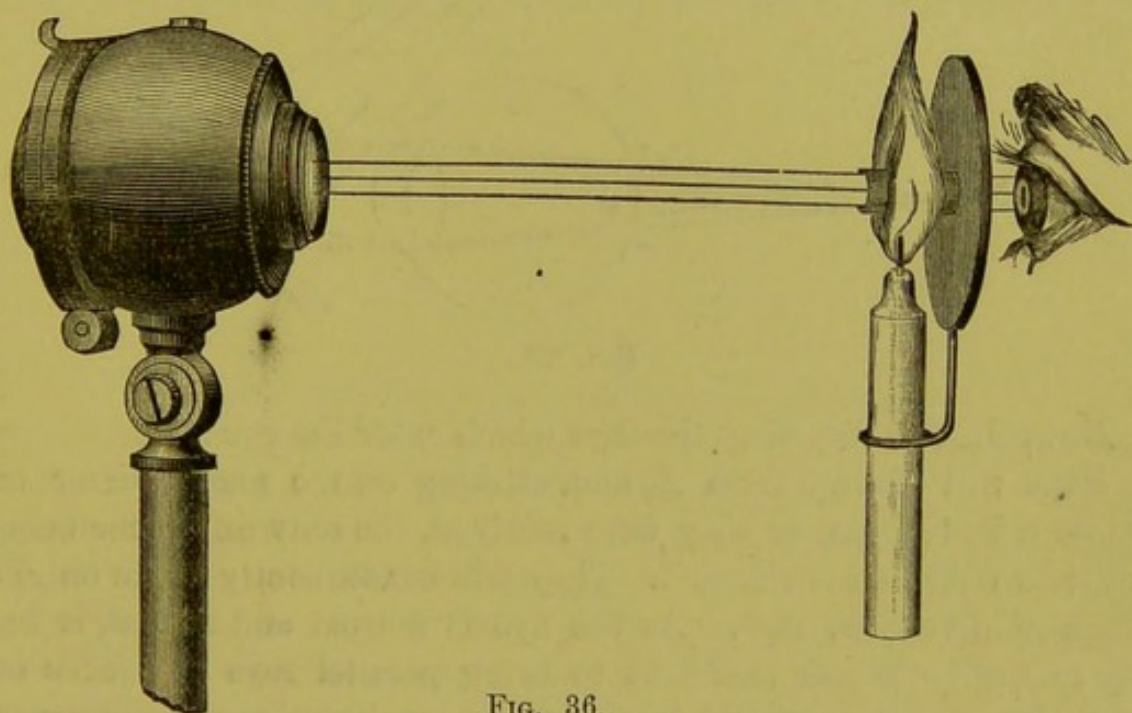


FIG. 36.

eye. This is not, however, necessary, nor indeed is it to have even the tube, for, by carefully approaching the eye to the very edge of the flame, the outside rays of the returning pencil of light will enter the eye of the observer, and the same effect in a less degree will be produced. A screen, if preferred, may be used to protect the eye. This is precisely what Brücke did several years before the ophthalmoscope was invented, thus coming within an ace of being himself the discoverer, and thus adding one more to the long list of those classical failures which are almost as brilliant and almost as immortal as the success itself.

From this to the complete development of the ophthalmoscope was but a single step, which accident might have stumbled upon at any moment, if genius, with its unerring instincts and irrefutable methods, had not anticipated it, and completely solved the whole problem. The deductions of Helmholtz may be illustrated in the following simple way, which is merely the representation of an ordinary ophthalmoscopic examination :

Let L (Fig. 37) be the lamp, which is the source of illumination, at about one foot from B , the observed eye, and m the mirror, consisting of three plates of plane glass, placed at the proper inclination.

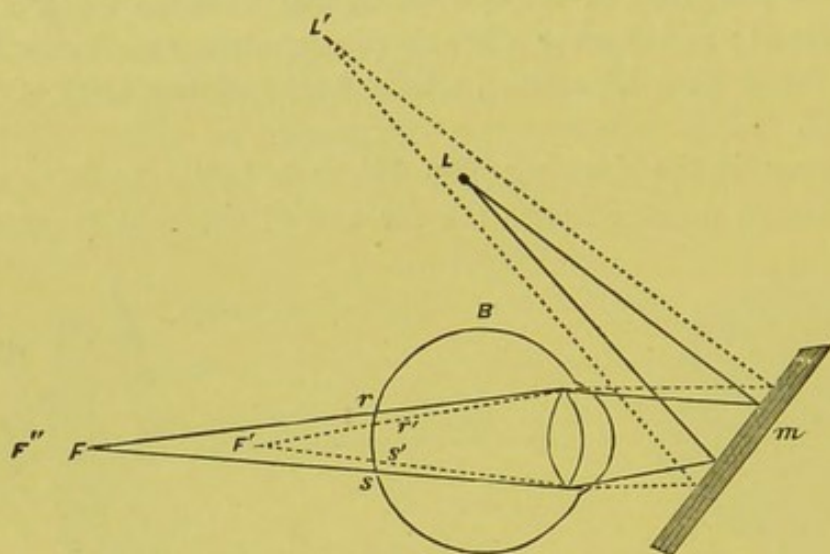


FIG. 37.

Now, first, in regard to the rays which enter the eye :

Rays will diverge from L , and, striking on the plane mirror m , will be reflected just as they were received, the only difference being that their direction is changed. They will consequently strike on B 's cornea as divergent rays. As the eye is normal and at rest, it has only refractive power sufficient to bring parallel rays to a focus on the retina ; these rays, cast into the eye by the mirror as divergent, must, therefore, if continued, meet behind the retina at F , where the image of the point at L would have been formed if B 's retina had not interfered. But B 's retina does interfere, and cuts the cone of light this side of its apex, and thus a circular illuminated spot is formed on its surface between r and s .

It is evident that the size of this illuminated circle must vary with the distance of the lamp from the mirror, and the kind of mirror used, and its distance from the eye to be observed. Thus, if we should move the lamp farther off, say to L' (Fig. 37), the rays striking on the mirror would be less divergent ; and, leaving it less divergent, they

would be brought to a focus nearer to *B*'s retina, say at *F'*. *B*'s retina would then cut the cone of light nearer to its apex, and the circle *r' s'* would be smaller, but brighter, as the rays would be more condensed. On the other hand, if the lamp were brought nearer to the mirror, then the rays reflected against *B*'s cornea would be more divergent, and their focus at a greater distance behind the retina. Consequently, the illuminated circle would be larger, but less brilliant, as the rays would be less condensed.

Of course, this gain in brilliancy, in both of the above cases, has its limits, and can only hold good so long as the condensation of the light by the mirror outweighs the loss of rays consequent on the removal of the lamp.

Experience as well as theory shows us that, for the average practical working of the ophthalmoscope, a concave mirror is better for illuminating purposes than a plane one.

Let the light *L* (Fig. 38) be at twelve inches from the mirror, and all the conditions the same as in the preceding case, with the ex-

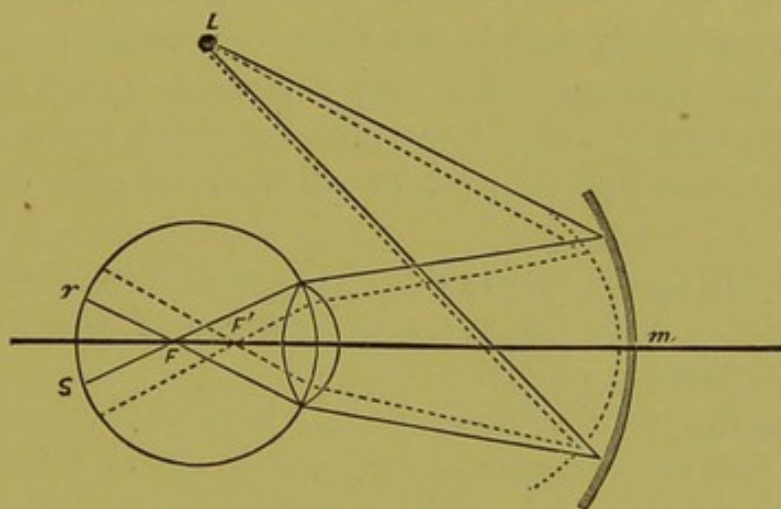


FIG. 38.

ception that, for a plane mirror, we substitute a concave one (*m*), say of six inches focal length. If the lamp was at such a distance that the rays coming from it were parallel, they would, after reflection, meet at six inches in front of the mirror. But, as they come from a distance of only twelve inches, the focus will no longer be at six, but at twelve inches, in front of the mirror ($\frac{1}{6} - \frac{1}{12} = \frac{1}{12}$). Consequently, the rays will leave the mirror as a converging cone of light, and, if unintercepted, would meet at a distance of twelve inches in front of the mirror. *B*'s eye, however, intercepts this already converging cone, which is thus rendered still more converging; and, as *B*'s eye is adapted for parallel rays, these converging rays must come to a focus in front of *B*'s retina, say at *F*, and, crossing here, will form, by the

time they arrive at the retina, the illuminated circle rs (Fig. 38). And if we increased the curvature of the mirror, as is shown by the dotted line, this would simply render the rays leaving it more convergent, by which they would cross each other sooner, at F' , and the circle of illumination on the retina would be larger, but, as a rule, less brilliant; for, although a larger number of rays would be thrown into the eye, they would be diffused, by their early crossing in the vitreous, over a disproportionately large surface of the retina.

It is evident that here also the position of the lamp must have its influence, as must also the refraction of the eye, in this as in all other cases. For, if the eye is myopic, the retina will cut the cone at a greater distance from the apex, and the circle of illumination will be larger, but less brilliant, than in a normal eye; while, with a hypermetropic eye, the reverse will hold good. The size of the pupil must also have an effect on the circle of illumination; the more dilated the former, the larger the latter will be.

Plane and concave mirrors are now the only ones which are commonly used in the construction of ophthalmoscopes. Still, convex mirrors are occasionally seen in the older instruments; and, for a description of the laws on which they depend, I would refer to any good hand-book on optics. A concave mirror of seven inches focal length is the one best adapted to all work, if only one is to be used.

We come now to the second step in the problem, that which relates to the rays which leave the eye, and by means of which the various objects therein become visible.

As soon as the entering rays reach the bottom of the eye, they are received by the various membranes, and by them reflected in two ways: First, by regular reflection, as there are some polished surfaces present. Secondly, by irregular reflection. The first has nothing to do with our ability to see the fundus of the eye. For, if we depended on this regular reflection, we should see only the details of the source of the illumination. We see the objects at the bottom of the eye, just as we see all others, through the irregular reflection. The light thrown into the eye by the ophthalmoscope is received by the different membranes, and then thrown out again by them, just as if they had produced them, and were themselves self-luminous bodies.

Thus the mirror, the position of the lamp, and the direction of the rays, as they enter the eye, only affect the extent and brilliancy of the illumination, and exert no influence whatever on the direction of the rays which leave the eye. These must always *diverge* from the membranes themselves, as a starting-point, although it may well hap-

pen that the incident rays which produce the illumination, when they strike the retina and other membranes, are convergent.

Let the same conditions be repeated, and let us suppose that the entering rays (Fig. 39) have crossed each other in the vitreous, and

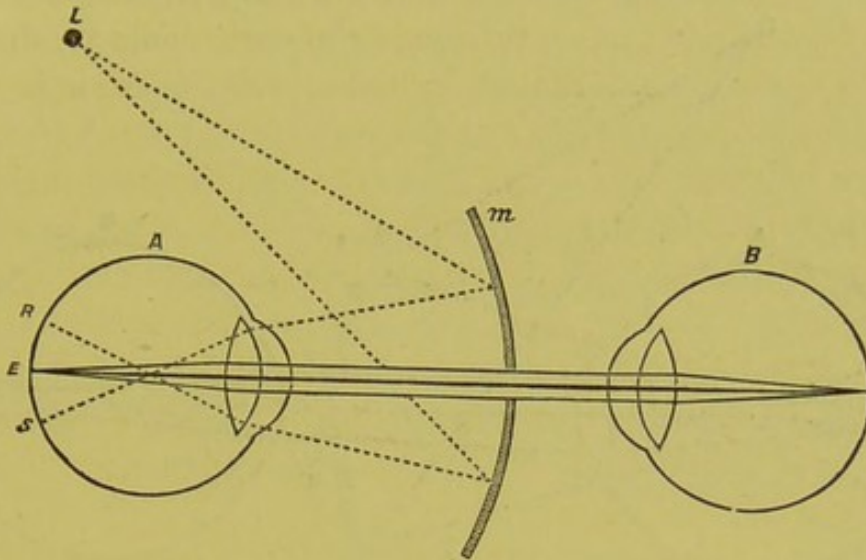


FIG. 39.

that there is a circle of illumination formed on the retina, comprised between the letters *R* and *S*. Rays will be reflected from every point in the circle, just as if they had been generated there; for example, they will diverge from the point *E*, in every direction. Some will strike the sides of the eye, and be again partially reflected and partially absorbed, and this will go on till they are consumed. But such as do find their way out of the pupil must leave the eye parallel to each other, as the surfaces from which they started are practically in the principal focus of the lenticular system of the eye, this being normal. Some of these rays would pass through the hole in the mirror (*m*), and the eye of an observer, supposing this to be adapted for parallel rays, and placed against this hole, would then be in the track of the rays coming from the point *E*, and would thus see this point just as it would any other object.

Rays, therefore, leaving an emmetropic or normal eye at rest must always be parallel, and, if, for illustration, we return to the diagram (Fig. 24), we shall see that we can not arrange the intraocular ends of the rays so that they shall diverge from any point of the circle which represents the retina of the normal eye without having the external parts of the ray run parallel to each other.

Suppose precisely the same conditions to be represented as in the former case, except that we substitute for the observed eye a myopic in the place of a normal eye (Fig. 40). Rays will leave the mirror and strike upon the cornea with precisely the same degree of con-

vergence as before. They will cross at the same distance behind the lens as formerly, but, as the retina of a myopic eye is farther from the place of crossing, the circle of illumination will be larger, but at the same time fainter. Rays will leave this illuminated cir-

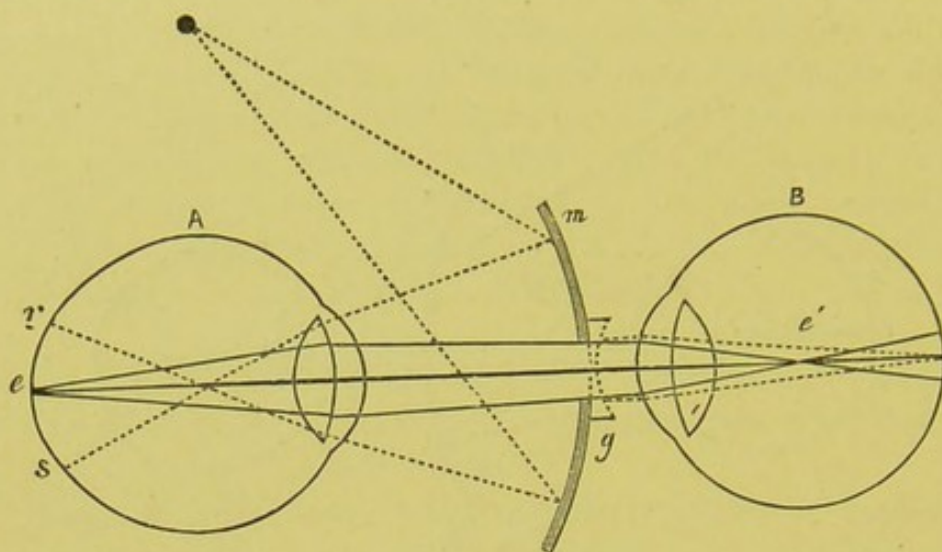


FIG. 40.

cle rs from every point, and those leaving e , for example, will therefore diverge through the vitreous till they strike upon the lenticular system. After passing through this they will leave the eye as convergent, because e is beyond the principal focus of the eye, which is simply in accordance with the law already made manifest. For, if we turn back to Fig. 26, we shall see that we can not make the intraocular end of the rays diverge from any point in the circle representing the retina of a myopic eye without the external portion of the rays converging toward each other. Of course, the amount of this convergence depends on the amount of displacement backward of the retina, or, in other words, on the degree of the myopia present. If there were a myopia of one third, then the rays would meet three inches in front of the eye. Now, if a normal eye were placed behind the hole in the mirror, convergent rays would enter it, and of course come to a focus in front of the retina at e' , and the observer would not have a clear image of e . These rays, leaving the observed eye, must be reduced in their convergence till they become parallel, as B , the observing eye, is accommodated for such rays. This is done by the suitable concave glass (g).

Again, let the same conditions be applied to a hypermetropic eye (Fig. 41). Rays of precisely the same degree of convergence will strike upon the cornea of the observed eye, and cross at the same place in the vitreous; but, as the retina of the hypermetropic eye is

nearer to the apex of the cone, the circle of illumination will be smaller than in either the normal or myopic eye, but, at the same time, more brilliant. Rays diverging from the point e (Fig. 41), as this is inside of the principal focus of the eye, will leave it divergent, and, if we turn again to the diagram (Fig. 26), we shall see that we can not make the intraocular ends of the rays meet on any part of the circle which marks the retina of a hypermetropic eye without the external portions diverging from each other, as is shown in the figure (41). If, now, a normal eye were placed behind the hole in the mirror, divergent rays would enter it, and as such would not come to a focus until they had passed the retina, since the eye is adjusted for parallel rays. The rays must, therefore, be made parallel before they can be brought to e on B 's retina. This is done by rendering the rays leaving A less divergent, that is, parallel, by the proper convex glass (g) behind the ophthalmoscope. But B might, instead of using a

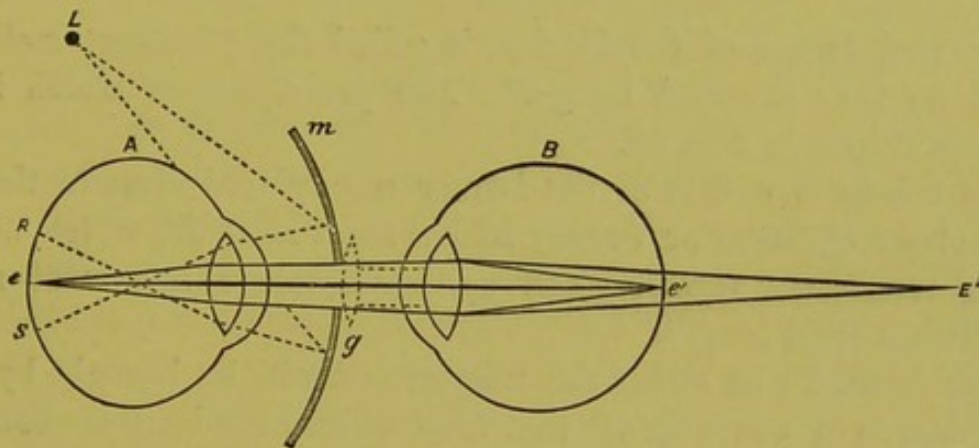


FIG. 41.

glass, obtain the additional focalizing power by increasing the curvature of his own lens, or, in other words, by using the necessary amount of accommodation.

We have, in our examples, for the sake of simplicity, taken only a single point (e) in the illuminated circle, but what is true of one point is true of all. Thus, the image of the bottom of the observed eye is formed on the retina of the observer's eye, just as it is with other objects. The observer sees this image "upright," that is, not inverted. It is magnified also, for, after all, looking into another eye is simply looking through a pretty strong magnifying-glass, formed by its lenticular system, at the various objects beyond, such as the retinal vessels, optic nerve, and choroid.

From the fact that we do look directly into the eye, the above is called the "direct method"; or, since the image is not reversed, that by the "upright image"; and, although this is by far the most beau-

tiful and satisfactory way of seeing the bottom of the eye, there is another which has advantages peculiar to itself, which render it an indispensable adjunct to the one just described. This method, from the fact that we do not look directly into the eye, but see an aërial

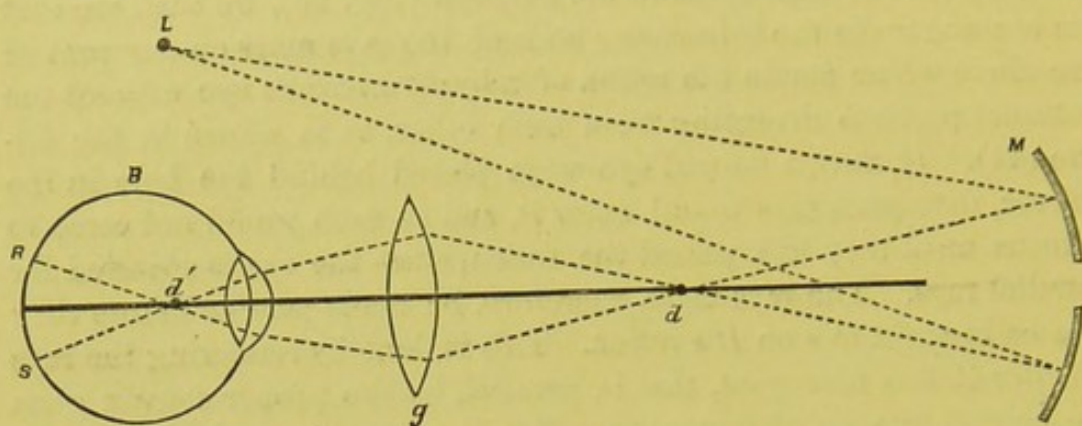


FIG. 42.

and inverted image of the fundus, is called the "indirect method," or that by the "inverted image." The principles on which it depends are shown in Fig. 42.

The mirror is not, as in the former case, placed close to the eye, but at about eighteen or twenty inches from it, as *M*, which we will suppose represents the common ophthalmoscopic mirror of six or seven inches focal length.

Rays from *L* will strike the mirror, and will be brought by it to such a degree of convergence that they will, as the lamp is about two feet away, be brought to a focus, and cross each other at about eight to ten inches in front of the mirror, say at *d*. The rays will then continue their course as divergent rays, and, as such, would enter the observed eye *B* if it were not that a lens (*g*) (which we will assume to be an ordinary two-inch one) is interposed in front of *B*. Passing through this lens, the rays are again changed from divergent to convergent, and as such enter *B*'s eye, by which they are rendered still more convergent, so that they again cross each other in the vitreous, say at *d'*, and thence continue as a diverging cone till they are intercepted by the retina, on which they form the illuminated circle *R* and *s*. This portion of the fundus once illuminated, just as in the former case, sends out rays in every direction, as if they had been generated from it; and, bearing this fact in mind, we can discard the comparatively complicated manner in which the illumination was produced, and turn our attention solely to the emitted rays, which must diverge from every point in the illuminated circle. Take first the point *R* (Fig. 43). Rays would diverge from this in all directions, and, pass-

ing through the lens and pupil, since A is normal, would leave the eye parallel to each other, and parallel to the axial ray, which, as you will remember, is a straight line drawn from the point of emission through the centre of the lens. Rays leaving s would do precisely the same thing. Now, as all these rays, after leaving the eye, are parallel, it is evident that they can never meet, and consequently no image would be formed by them if left to themselves. But here, again, the lens (g) comes into play; for, by this, the rays are changed from parallel to convergent, and of course to such a degree that they will meet, since the rays were parallel before entering the lens, at or about the principal focus of the glass, whatever this may be, where an inverted image will be formed in the air ($R' s'$). As there is no screen or other object to stop the passage of the rays, they will, after crossing and forming the image of all the points in Rs , continue on their course. This crossing of the rays, and their continuance through the air, after forming the image at $R' s'$, is precisely equivalent to rays diverging from an actual object situated at that spot, and we can, therefore, so far as our vision is concerned, look upon this aerial image as an actual object, which throws out rays of its own in the direction of our eye, that is to say, in the direction which they would pursue after crossing. $R' s'$ is then the fac-simile of RS , the bottom of the eye. And, while most of these rays would, if continued, strike against the mirror, and thus be lost to the observer, such as passed through the hole in the mirror would enter his eye as if they came from the points between $R' s'$, and he would thus have the image of these formed on his retina $R'' S''$, and so obtain a view of the fundus. What is really seen, however, as will be plain by looking at Fig. 43, is not the back of the eye itself, but its inverted image.

It will be observed, by looking at Fig. 42, that, if we change the condition of the various factors taken, we must essentially change the

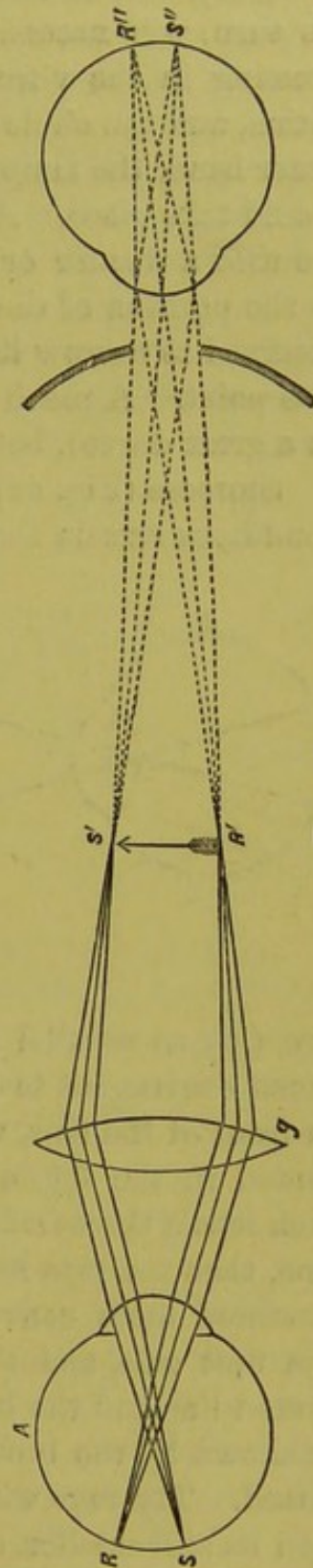


FIG. 43.

results. If, for example, we alter the position of the lamp so as to bring it nearer to the mirror, then the first crossing of the rays, d (Fig. 42), will be farther from the surface of the mirror; and this, in its turn, will necessitate a corresponding displacement of the second crossing in the vitreous humor, which will then take place nearer the retina, and the circle of illumination will then be smaller. If, on the other hand, the lamp were moved farther from the mirror, the reverse would take place. A precisely similar influence would be exerted if we used a weaker or stronger mirror. As, however, the variations as to the position of the lamp and the curve of the mirror are usually confined to narrow limits, it is not worth while to dwell further on this point. A much more essential factor is the lens, as this influences, in a great degree, both the brilliancy and the size of the image.

Suppose (Fig. 44) that, in the first instance, while all the other conditions remain the same, we use a four-inch lens. Rays leaving the

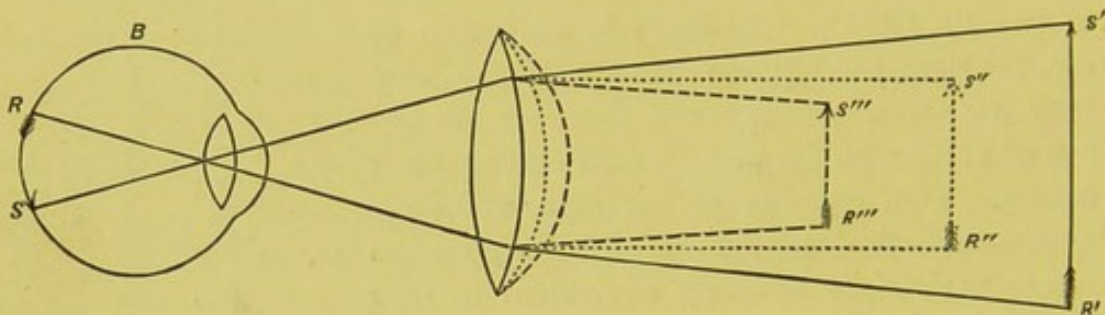


FIG. 44.

eye (B) as parallel would, after passing through the lens, be rendered convergent to such a degree that they would meet four inches in front of the lens, where we should have the aerial image as represented in the figure by $R'S'$. If we now substitute for the four-inch lens a three-inch one, represented in the figure by the first dotted line, then the rays leaving B will, after passing through the glass, be rendered more convergent, and will come to a focus sooner than in the first case, and the image will be smaller, as represented by the dotted line and the letters $R''S''$. If, again, we take a two-inch lens, as shown by the broken lines, precisely the same effect will be produced. The rays will be rendered more convergent, and the image will be still smaller, as shown by the second dotted line and the letters $R'''S'''$. So that, by varying the strength of the glass, we can vary the size of the image. The weaker the glass, the larger the image; but, at the same time, the smaller the field of vision, which fact needs a little explanation. For the sake of simplicity we represented the lens in the last figure as always in one position; and this was per-

fectly allowable so far as its effect on the rays which leave the bottom of *B*'s eye is concerned. But, in point of fact, the position of the lens varies with its strength; the weaker the lens the farther we hold it from the eye to be observed, for two reasons: first, to get a sufficient number of rays into the eye; secondly, in order to sink the image of the eye itself, that is, of the sclera, cornea, and iris. The rule is to hold the glass at about its focal length from the eye, though in practice, however, we find it necessary to place it a little farther than this. Thus, a two inch-lens we hold at about two and a half inches; a three-inch at four; a four-inch at five, and so on.

Fig. 45 shows how, as we use a weaker lens and hold it farther from the eye, the extent of what is seen of *B*'s retina becomes smaller. We will suppose, in the first instance, the outside limitation of the field to be represented by the axial rays *R* and *S*.

These rays will be intercepted by the first glass (*g*), which we will suppose is a two-inch lens at two inches from the eye. But if we use a four-inch lens (*g'*) at four inches from the eye, then these

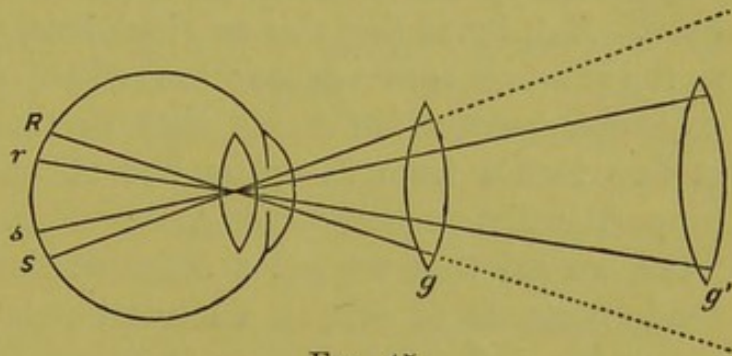


FIG. 45.

external rays will not be intercepted by the glass, and no image of them will be formed. The most external rays which in the last case can be intercepted by the glass are those coming from the points *r*, *s*. Consequently, the extent of *B*'s retina seen will be much reduced, as in the first case it was represented by the space included between *R* and *S*, and in the second by that only included between *r*, *s*. Of course, the size of the pupil affects the field of view; but the comparative effect of the glasses remains virtually the same.

The refraction of the eye must also exert a considerable influence on the size of the image; for, if the observed eye, instead of being normal, is hypermetropic, the rays leaving it will be more or less divergent, and a certain portion of the power of the lens will be consumed in rendering these rays parallel, leaving the remainder only to bring the rays to a focus.

Suppose the observed eye to be hypermetropic $\frac{1}{4}$, and that we use a two-inch lens. The rays leaving *B*'s eye would not be parallel, but would diverge as if they came from a spot four inches behind the nodal point of the eye.

If the lens is two inches in front of the eye, it will be six inches in

front of the point from which the rays would practically come. It would take from the focal power of the lens what would be equivalent to a convex glass of $\frac{1}{6}$ to render these rays parallel, and we should then have remaining $\frac{1}{2} - \frac{1}{6} = \frac{1}{3}$. That is, we should really have a lens of only three inches focal length, although we were actually using a two-inch glass. The image would not lie, as with a normal eye, two inches in front of the lens, but at three, and would be proportionally larger.

If, instead of a hypermetropic, we take a myopic eye of $\frac{1}{4}$, the reverse will hold good. Rays would leave such an eye as convergent, and would meet at four inches in front of the eye, where an inverted image would be formed in the air. If, now, we place our glass two inches in front of the eye, we intercept rays already so convergent that they would meet two inches in front of the proposed position of the glass. But, by adding this two-inch lens, we have added just so much to the previous convergence; that is, $\frac{1}{2} + \frac{1}{2} = 1$. And the rays will no longer meet, as is the case with parallel rays leaving a normal eye, at two inches from the glass, but at one; and the image will be proportionally smaller. Using, therefore, the same glass at the same place, we see that we get a different sized image in each case; and the importance of this, in a clinical point of view, at least to young observers, renders it necessary to bear the fact constantly in mind.

It will have been noticed by the attentive observer that, whereas, with the mirror alone, and at a distance, we usually get only a diffuse illumination of the pupil, we do get in some cases a defined image of a portion of the fundus; for example, a small section of a retinal vessel or a small segment of the optic nerve. This is usually due to some error in refraction, and is most apparent in myopic eyes of the higher degrees.

If the myopia, for example, is $\frac{1}{6}$, rays leaving the fundus of the eye will meet six inches in front of it, where an aerial image will be formed which will be inverted and enlarged. Of this image the observer will see but a small portion, since a comparatively small portion of the rays, that is to say, only the central ones, will, after crossing in the air, have such a direction that they can pass through the hole in the mirror and thus enter the observer's eye. The details which comprise this portion will, however, be much enlarged. The size of the pupil of the observed eye will, of course, make a difference, for, the larger this is, the greater the field seen—but, even at the best, this must be restricted for the reasons given.

With a hypermetropic eye, on the other hand, the return rays leave the eye as divergent instead of convergent, consequently there

is no aërial image formed. This is, on the contrary, virtual, erect, and situated behind the eye instead of in front of it. What we see of this image is seen through the pupil, and the field of view must necessarily be very much restricted, as we are looking through a narrow opening which is at a comparatively great distance from our eye. The larger the pupil the larger our field of view; but, even when fully dilated, the magnifying power of the anterior parts of the eye is so great that even a small portion of the fundus is made to fill the entire pupillary space.

The reason why the observer in emmetropia ordinarily gets only a diffuse illumination in the pupillary space is, in my opinion, simply because his own eye is not adjusted for the rays leaving the fundus of the observed eye. In illuminating the eye with the mirror alone, we instinctively accommodate for the plane of the iris and the edges of the pupillary space, just as in looking at a hole in a shutter we accommodate for the edges of the hole and not for the diffuse light beyond. In accommodating for the plane of the iris our eye is adjusted for divergent rays, while the rays leaving the fundus are parallel. Such rays will not unite on the observer's retina, and consequently he does not get a defined image of even a small portion of the observed fundus as in the other two cases, but only the sensation of a diffuse brilliancy. That this is the correct explanation would appear from the fact that, if we relax our accommodation entirely so as to adjust the eye for parallel rays, then the details of the iris become indistinct, while what was a diffuse illumination of the pupillary space becomes a defined image of a small part of the fundus beyond, a segment of the nerve, or of one of the vessels.

THE METRIC SYSTEM.

In the foregoing remarks the old system has been preserved for the purposes of illustration, as those not acquainted with even the elements of optics are, as a rule, much more familiar with the national than with the metric standard. As, however, the metric system has been adopted as the standard for modern ophthalmoscopes, it is essential to understand how to reduce the old system to the new. Fortunately, this is very simple.

In the new or metric system, the French metre instead of the French inch is used. The metre is taken as the unit, and each metre is called a dioptric, or, as it is usually written, 1 D. As the French metre is equal to thirty-seven inches, $1\text{ D} = \frac{1}{37}$ expressed in the old style; $2\text{ D} = \frac{2}{37}$, or $\frac{1}{18.5}\text{ D}$. As, however, thirty-seven is a difficult number to divide, we may for practical purposes use $\frac{1}{36}$ instead of $\frac{1}{37}$:

thus, $3 D = \frac{3}{\frac{1}{36}} = \frac{1}{12}$, and so on. This is sufficiently exact, except for the few higher numbers of glasses, and the division can readily be performed in the head. Each dioptric, or 1 D, may be therefore looked upon as equal to $\frac{1}{36}$ old style; and, to find the glass in the old system which corresponds to a certain number of dioptries, we have

simply to take as many thirty-sixths as there are dioptries, $4 D = \frac{4}{\frac{1}{36}} = \frac{1}{9}$ old style.

On the other hand, to find what number of dioptries correspond to a given glass in the old style, we have simply to reverse the process. To find, for example, how many dioptries correspond to $\frac{1}{9}$. As each dioptric is equal to $\frac{1}{36}$, there will be as many dioptries as $\frac{1}{36}$ is contained in $\frac{1}{9}$; or here, as before, for the sake of simplicity, $\frac{1}{9}$ divided by $\frac{1}{36}$. $\frac{1}{9}$ divided by $\frac{1}{36}$ is the same as $\frac{36}{9} = 4 D$; $\frac{1}{24} = \frac{36}{24} D = 1.5 D$; $\frac{1}{72} = \frac{36}{72} D = 0.5 D$; and so on.

OPHTHALMOSCOPES.

Such being the principles upon which the ophthalmoscope depends, it remains to consider some of the forms under which in modern times the instrument usually appears. As has been said, of the making of ophthalmoscopes there is no end, and there are a thousand varieties by as many inventors now in use. To describe all these would be impossible; but below will be found some of the forms which have been suggested by the experience of the writer, and which are adapted to various uses dependent on the nature of the work to be performed.

Beginning with the simpler forms, Fig. 46 is an instrument with a single disk with eight perforations. With this instrument the fundus of almost every eye can be seen; but from the nature of things it is not adapted




FIG. 46.

for the nicer shades of ophthalmoscopy. Other instruments similar to this in form, but containing a larger number of glasses—12, 18, and 24—can be had of the various makers, either with or without a cover, the best being that which contains twenty-four lenses with the

ring cover, which, while it protects the glasses, allows the numbers to be plainly visible for the whole extent of the disk.

Fig. 47 represents a combination-instrument consisting of a single disk and a segment of a disk, as shown in the drawing. In the present case a quadrant of a circle is used. This might, however, be made larger or smaller if required.

The single disk contains sixteen glasses on the metric system, the plus being numbered in *white* and the minus in *red*. The first row of numbers, or that just beneath the glass, shows the *real* value of the glass; the second, or inner row, shows the result of the combinations

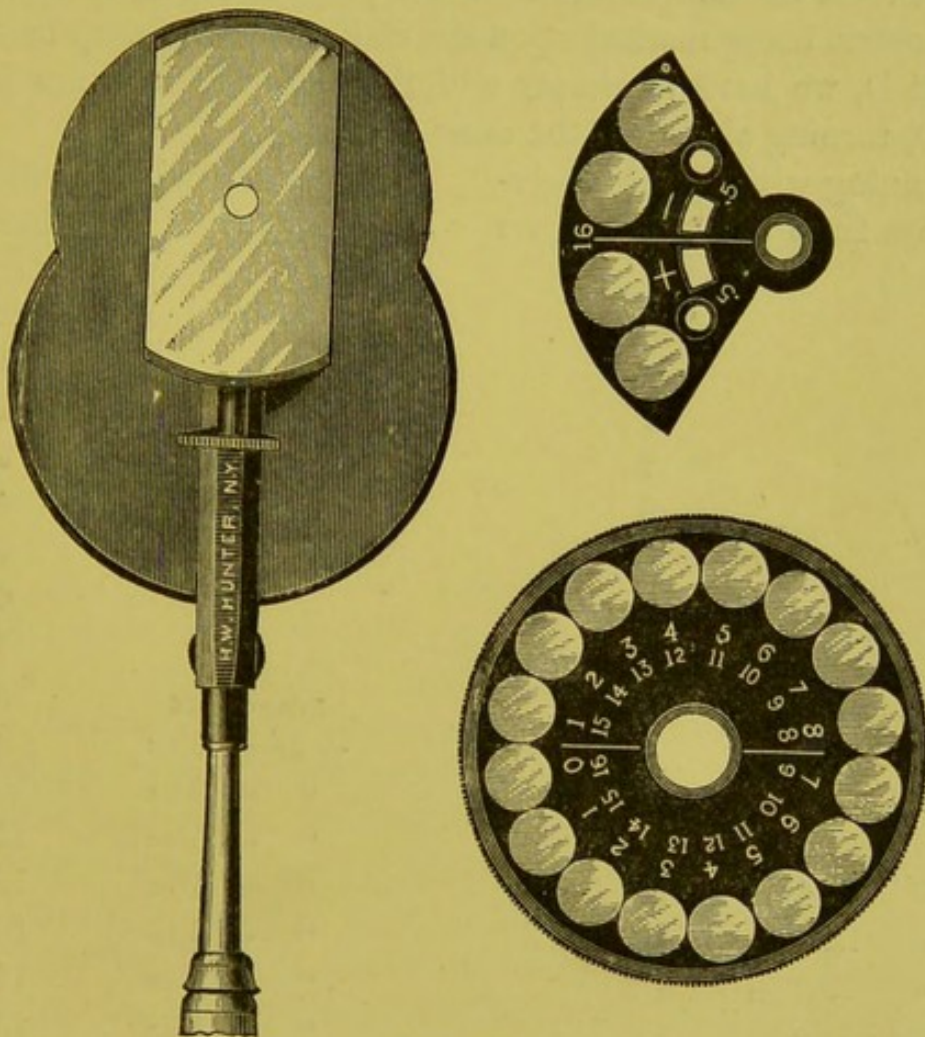


FIG. 47.

when the quadrant is in position. The quadrant rotates immediately over the disk and around the same centre, and contains four glasses — .5 — 16. and + .5 + 16.

When not in use the quadrant is beneath its cover. The instrument then represents a simple ophthalmoscope with sixteen perforations, the series running with an interval of 1. D, and extending from 1 to 7. plus, and from 1. to 8 minus.

This is ample for all ordinary work, as the interval of 1. D is as

close as even an expert usually desires, and can with a little experience be used for even very minute discrepancies; for if in a given case the fundus is seen distinctly with 1. D and a little to spare, while 2. D blurs the picture, we know at once that the refraction must be between the two, or 1.5 D. If, however, for any reason we wish to prove this conclusion, we can bring up 0.5 D. From this glass we get successive half-dioptrics from 1 to 8. plus, and from 1 to 9. minus. In this way we have, so to speak, a fine and coarse adjustment, as in the microscope.

If the higher numbers are desired, these are obtained by combination with those of the quadrant. These progress regularly up to 16 D, every dioptic being marked upon the disk; above this, up to + 23 D and - 24 D, we have to simply add the glass which comes beneath the 16 D, turning always in the same direction.

Beginning with 0, and revolving always from *left* to *right*, we obtain :

Beginning with 0, and revolving always from *right* to *left*, we obtain :

PLUS		MINUS	
	0		1
	1		2
	2		3
	3		4
	4		5
	5		6
	6		7
	7		8
Bring up + 16		Bring up - 16	
+ 16 - 8 =	8	- 16 + 7 =	9
" - 7 =	9	" + 6 =	10
" - 6 =	10	" + 5 =	11
" - 5 =	11	" + 4 =	12
" - 4 =	12	" + 3 =	13
" - 3 =	13	" + 2 =	14
" - 2 =	14	" + 1 =	15
" - 1 =	15	" + 0 =	16
" 0 =	16	" - 1 =	17
" + 1 =	17	" - 2 =	18
" + 2 =	18	" - 3 =	19
" + 3 =	19	" - 4 =	20
" + 4 =	20	" - 5 =	21
" + 5 =	21	" - 6 =	22
" + 6 =	22	" - 7 =	23
" + 7 =	23	" - 8 =	24

Thus, with the superposition of a *single* glass (+ 16 or - 16), and with an uninterrupted rotation, a series is obtained of successive dioptries from 1 to 23 plus, and from 1 to 24 minus.

With the use of the 0.5 we can obtain in addition the following series with an interval of half a dioptric :

+ 0.	- 0.5
+ 0.5	- 1.
+ 1.	- 1.5
+ 1.5	- 2.
+ 2.	- 2.5
+ 2.5	- 3.
+ 3.	- 3.5
+ 3.5	- 4.
+ 4.	- 4.5
+ 4.5	- 5.
+ 5.	- 5.5
+ 5.5	- 6.
+ 6.	- 6.5
+ 6.5	- 7.
+ 7.	- 7.5
+ 7.5	- 8.
+ 8.	- 8.5
	- 9.

Making a total series of eighty glasses. Should the combination at any moment not be wanted, a trifling displacement of the quadrant to either side of the mirror-hole at once dissolves it, and the instrument becomes a single-disk ophthalmoscope.

In this manner an enormous number of glasses can be placed at our service, in case of need, without our being compelled to use them on all occasions, or to turn through them in our search for a particular glass. The fear that by a combination of two glasses the quantity of the light would be diminished has not been realized, and I have frequently got a good view of the fundus with - 24 D ($\frac{1}{1.5}$ old style), which is the severest test which can be applied. Indeed, I have never used an instrument in which I obtained so much light for the upright image. This may be due in part to the extreme thinness of the glasses, the strongest being less than half a millimetre thick.

There is another form of the same instrument with a different method of notation, consisting of two concentric rows of figures, the outer row being the plus and the inner the minus.

This is certainly the more elegant form of the two, the only pos-

sible objection to it being that the *real* value of the glass is not always immediately below the glass itself, its place being sometimes occupied by the equivalent of the combination. No confusion can, however, occur, as the plus and minus numbers have distinctive colors, and pro-

gress in different directions—the red from right to left, and the white left to right.

The instrument is made either with or without a cover, as shown in Fig. 48, for the posterior surface of the glasses. As a matter of fact, the glasses can be kept cleaner when the posterior surface is not covered than when it is, provided that, as in the present case, they are protected by a rim.

Dr. McMahon has made a trifling but very ingenious modification in the arrangement of the glasses in the supplementary quadrant of the writer's ophthalmoscope. This consists of inserting a vacant space, or zero-hole, between the plus and minus glasses in the quadrant. By this arrangement the fine adjustment mentioned in the text is obtained without taking the instrument from the eye. The objection to this is that it brings about precisely what the writer was at a good deal of pains to obviate. It makes the supple-




FIG. 48.

mentary quadrant an integral part of the instrument, and one which is always in position, so that one can not unlock any combination by a sweep of the hand, and thus restore the instrument to a simple ophthalmoscope. Moreover, the enumeration of so many glasses in so contracted a space as this arrangement necessitates is very confusing, while the four thicknesses of brass convert what should be a shallow hole into a long canal, from the edges of which annoying reflections arise. Still, the idea is ingenious, and might be acceptable to those who look upon the ophthalmoscope not as an instrument for the detection of morbid conditions, but solely as a means of determining minute discrepancies in refraction, and who are able, or who think they are able, to do it. A better way of arriving at the same result would be (as it seems to me), to keep, as I had formerly done on

another instrument, the quadrant at the lower part of the disk, and to put the second zero-hole opposite to it above.

A much more useful improvement, at least for the beginner, is the addition by Mr. Meyrowitz of another row of figures upon the back of the disk, so that *all* the combinations can be read at a glance.

Fig. 49 shows a smaller form of the same instrument. The number of combinations in the highest numbers, and those rarely if ever used, is

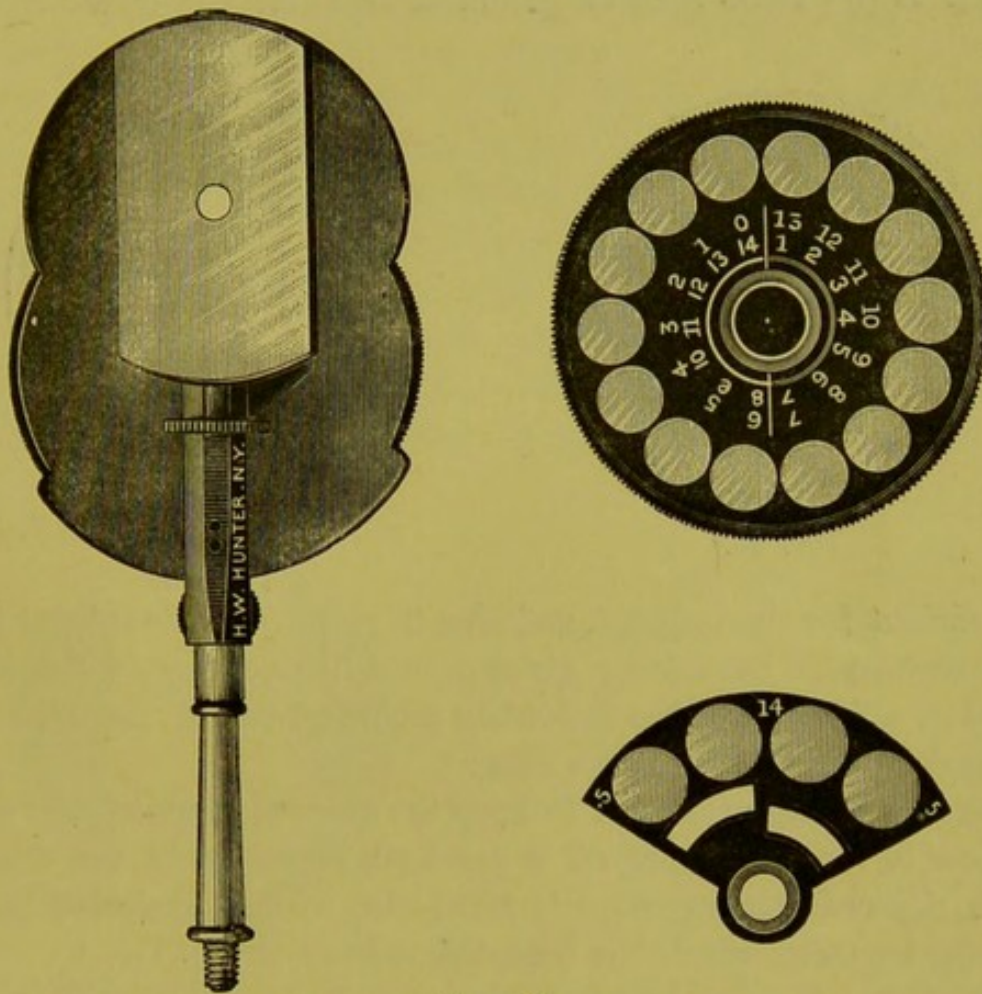


FIG. 49.

a little less than with the larger instrument, but this is more than counterbalanced by the reduced size of the instrument, and the consequent ease and comfort in its manipulation. It is the form which the writer uses, and is, in his estimation, more satisfactory than the other forms.

MODIFICATIONS OF THE OPHTHALMOSCOPIC MIRROR.

Dr. O. F. Wadsworth, of Boston, in 1876, made an ingenious and useful addition to my ophthalmoscope. This consists of an additional mirror, designed particularly for the use of the upright image and the determination of the errors of refraction. The mirror is circular in shape, and of the same focus as that now ordinarily used (Fig. 50).

The peculiarity of the mirror is that it is only fifteen millimetres

in diameter. The small diameter of the mirror permits it to be set at an angle of twenty degrees, and yet allows the hole in the mirror to be brought close to the glass in the disk. The mirror rotates from right to left, so that either eye can be examined. The disadvantages of this mirror are, that it is so small that sufficient light is not obtained to make an examination by the inverted method, thus necessitating an alternate substitution of two mirrors. To avoid this necessity, and at the same time to get more light for the direct method,

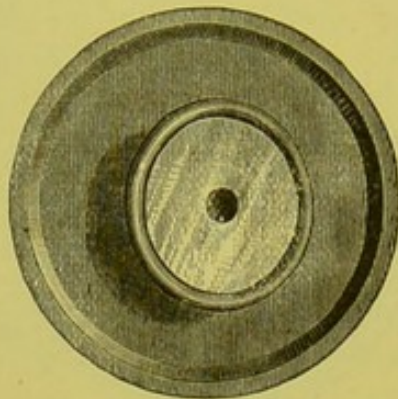


FIG. 50.

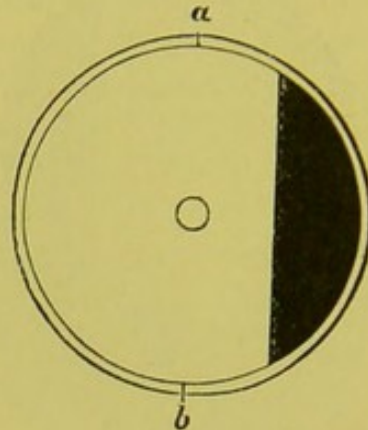


FIG. 51.

and sufficient for the indirect, and also to obtain the advantages which the inclination of the mirror gives in the distinctness of the image, I adopted, a little later, the following modifications of the old mirror, suggested by Dr. Wadsworth's idea :

The first modification was to keep the general shape of the mirror as it now is, merely cutting off a segment, as shown in the drawing. In this the reflecting portion is left plain, while the shaded portion shows the segment which has been taken away (Fig. 51).

The mirror is swung on two pins, *a* and *b*, or made with a hinge at the point of juncture of the mirror and the mirror-case, that is, the part which is shaded in the drawings. This latter arrangement permits the mirror to lie close against the correcting glass when an inclination is not desired. When an inclination is needed, the mirror is raised till it arrives at an angle of 20° , and is here checked by the

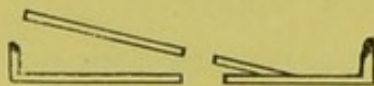


FIG. 52.

hinge. Fig. 52 represents the mirror as seen in section. When used for the inverted image the mirror can be folded back into its case, when it assumes precisely the same appearance as the mirror now in use,

with the exception of the segment, which has been taken away. This, like Jaeger's and Dr. Wadsworth's mirror, rotates from right to left. With it we get abundant light for either method.

The second modification is still simpler, and consists of cutting off both sides of the mirror, thus converting it into a parallelogram, as seen in Fig. 53.

This is swung on two pivots, the inclination being 20° , or, if wanted, 25° . This mirror tilts both ways, and does not have to be rotated, and can be used perfectly well for both upright and inverted image.

This mirror is usually known as the "tilting mirror." It is thirty-three millimetres long by nineteen broad.

In regard to the advantage of a mirror set at an angle for the use of the upright image, there can be no possible doubt in the mind of any one who has once seen the difference, in the ease of the illumination and the clearness and brilliancy of the picture. By its use, a large quantity of light is saved, since the correcting glass, instead of being at a considerable angle with the axis of vision, and therefore in a position favorable to a largely increased loss of light through reflection from the surface of the glass, is nearly at right angles to it, by

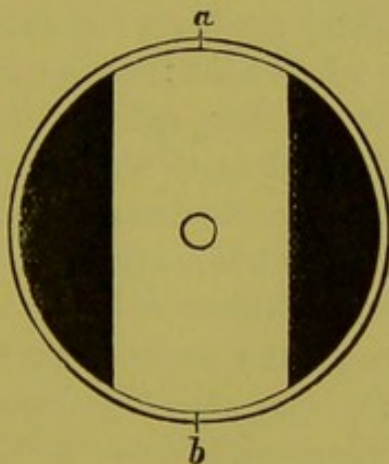


FIG. 53.

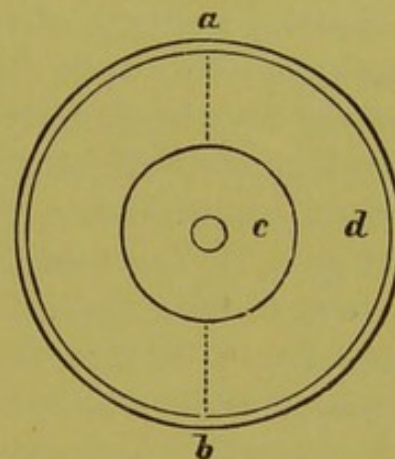


FIG. 54.

which all the light possible is saved. This mirror gives also ample light for the inverted image, and I now use it entirely for all methods of examination.

If, however, more light is needed, this can be obtained by making the shaded portions in the above drawings of mirror glass. A still more elegant though more costly way of obtaining the same result is to have a small mirror, circular in shape, and swung on pinions, *a* and *b*, Fig. 54, and this surrounded by a concentric mirror, *d*, so that the two together form a mirror both in size and shape like that now used in ordinary ophthalmoscopes. The external portion would, of course, be set stationary, the central portion tilting to the right and left as occasion required.

Fixed Ophthalmoscopes.—These instruments, though numerous in kind, seem to have passed out of date, and they are very rarely seen at the present time, and still more rarely used. Among the earlier of these instruments, and one which was most frequently used, was Liebreich's. This consisted of the application of the inverted image through a tube similar to that of a microscope. This was fastened to a stand which allowed the instrument to be raised and lowered as occasion required. It was also fitted with a rest for the patient's chin. At one end of the tube a mirror was fixed, similar to that of Jaeger's ophthalmoscope, while at the other was the object-glass. The image was formed within the tube, between the object-glass and the mirror, precisely as it is with the inverted image. The picture was brilliant and clearly defined. For a further description, the reader is referred to Graefe's "Archives," vol. i, part ii, p. 348.

Dr. Burke, in 1871, proposed a very ingenious fixed ophthalmoscope, which had the rather unexpected merit, at this late day, of being founded, in part at least, on a new principle. This instrument consists of concave mirrors, mounted on stands, with sliding tubes, so as to permit of a change of elevation. The light from the source of illumination, striking upon the first of the mirrors (which is perforated with a focal length of thirty-three centimetres), is reflected against the second mirror. This latter is unperforated, is of nineteen centimetres focal length, and is placed at just its focal distance from the observed eye. By this mirror, the light received from the first is cast into the eye to be examined. The fundus of the eye, being illuminated, reflects, in its turn, the light through the pupil back to the second mirror again, which, being concave, brings the rays to a focus at the focal length, where a very brilliant, reversed, and much enlarged image is formed. The head of the patient is supported by a chin-rest. Unfortunately, the practical handling of the instrument is not as easy as the theory is simple, and the result beautiful, when all things combine favorably. It often exhausts the patience of both the observed and observer before an image is obtained, and, even then, this is apt to be veiled, in spite of every care, by annoying reflections.

Carter's Ophthalmoscope.—Shortly after the appearance of Burke's instrument, Mr. Carter ("Report of Fourth International Ophthalmoscopic Congress," London, 1872, p. 69), while keeping the general form of the stands, substituted for the second mirror a large convex object-glass. This simply reduced the instrument to a much enlarged but ordinary Liebreich's ophthalmoscope. The shape of the instrument and the principles on which it depends are precisely the same, the only difference being that one is fixed and the other portable.

The apparatus requires the use of a table, which should be four feet long, and which need not be more than eighteen inches wide; or it may be arranged across one end of an ordinary dining-table. This is, in many respects, the best demonstrating ophthalmoscope yet proposed, and the only objections to it would appear to lie in the largeness of its dimensions, and the amount of separation, when in use, of its component parts.

Binocular Ophthalmoscopes.—After some previous attempts, for the purposes of getting perspective effect, Giraud Teulon produced ("Physiologie de Vision Binoculaire," Paris, 1861) his binocular ophthalmoscope, which was an exceedingly ingenious and beautiful application of the principles of total reflection by the means of prisms. Before the solution of this problem we were restricted, in our investigations of the fundus oculi, to the use of one eye, and no more forcible argument as to the advantages of seeing with two, and the absolute necessity of an instrument for this purpose, could possibly be brought forward, than the curious mistake universally made as to the true shape and conditions of the optic nerve in glaucoma—now one of the best known of diseases, with one of the most striking ophthalmoscopic pictures. That a deep excavation of the entire optic nerve, with its concavity toward the observer, should have been mistaken, for several years, by observers then and forever famous, for a protruding convexity due to swelling of the entire nerve, seems now to be incredible. A single glance with the binocular instrument would have corrected this impression; and, had it been invented in time to do this, Teulon's beautiful invention would have acquired for itself even a greater renown and a more extensive use than it now possesses. But, curiously enough, the instrument is very rarely used, even in detecting the differences in level in the fundus, since we possess, with the ordinary ophthalmoscope, a means, not only of ascertaining the existence of such variations, but also of measuring their exact extent. Still, the binocular instrument has virtues and beauties of its own, which will always command the respect and excite the interest of every careful student of ophthalmoscopy. The essential parts of the instrument and the manner in which the image is formed are shown in the beautiful drawing (Fig. 55) by Dr. John Green.*

Since the discovery of the principles on which the ophthalmoscope depends, innumerable instruments have been invented with all possible kinds of reflecting surfaces, plane and curved, with their combinations of lenses and prisms—ophthalmoscopes to be used with artificial light, daylight, and even sunlight, autophthalmoscopes, and ophthalmoscopes

* "Recent Advances in Ophthalmic Science," Williams, p. 20.

for one, two, or three observers. All of these, with the exception of those based on the plane mirror proposed by Helmholtz, and on the concave mirror introduced by Ruete, have yielded to the practical and

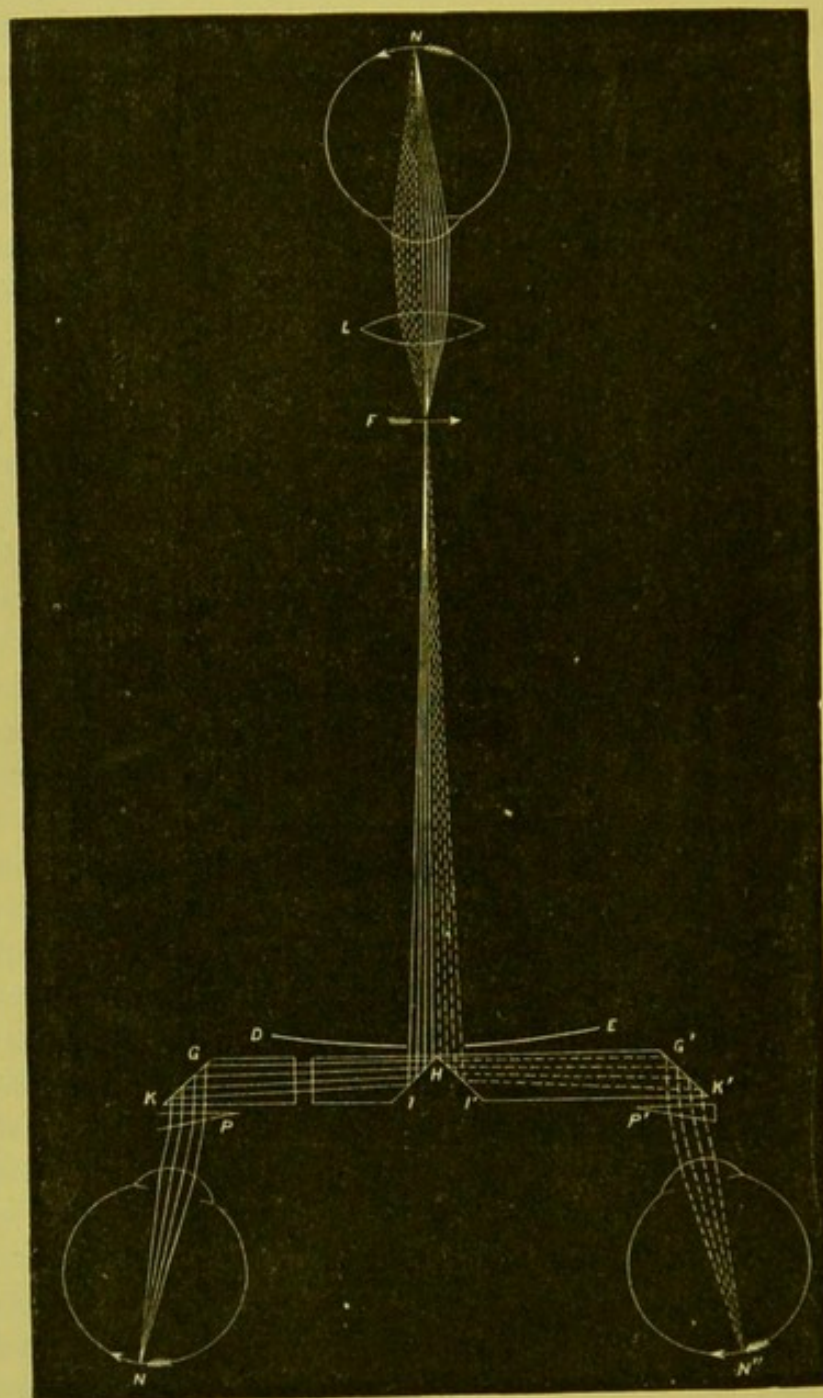


FIG. 55.

realistic tendencies of the day and passed into disuse. Not one in ten thousand of the examinations hourly taking place in all parts of the world is made with any other than the simple concave mirror of Ruete, and it has always struck me that but scanty justice had been

done to one whose beautiful and comprehensive invention is the almost universally used implement of our art—especially when it is taken into consideration that he also rendered practicable, even if he did not invent, a method of examination which forms an indispensable adjunct to that originally proposed by Helmholtz, and which has been used by the great majority of observers, even to the entire exclusion of the former.

These more complex forms of the instrument are rather the solutions of interesting optical problems than the embodiment of any clinical or even physiological purpose, and the reader must be referred to more technical works for their description.

ADJUNCTS TO THE OPHTHALMOSCOPE.

The most important adjunct to the ophthalmoscope, and one, indeed, which forms an essential part of it so far as the inverted image is concerned, is the object-glass. This glass varies in strength from a one to a four or even a five inch lens, according to the amount of enlargement and extent of field which we wish to obtain. These latter stand in inverse proportion to each other: the larger the field of view, the smaller do the details comprising it appear; the weaker the glass, the smaller the field, but the larger its detail.

The best glass for average work is a biconvex lens of two and a half inches focal length. It should have a diameter of one and a half inch, and should be ground as thin as this dimension will permit. It should be made of the best glass, and as highly polished as possible. The comfort of working with a glass of this diameter, and the increased illumination, and the sharpness of the image which it gives, more than repay the little extra trouble and expense in procuring it. This glass serves also as a condensing lens for examining the media of the eye by oblique illumination.

The writer, for the purposes of illuminating the anterior portion of the eye, has made use of the device shown in the drawing (Fig. 56). It is a modification of an idea suggested by Mr. J. E. Adams, of London, and consists of an arm, broken at the various points by ball-and-socket joints, so as to give a perfectly free adjustment to the lens in any direction, and at any distance up to the extreme length of the arm. This leaves both hands of the surgeon unencumbered, permits the use of fixation forceps if necessary, and does away with the necessity of an assistant to hold the lens.

The arm is attached to an elastic head-band precisely like the head-band of an aural or laryngoscopical mirror. When in use, the band is slipped over the head of the patient in such a way that the

hard-rubber support comes at the temporal region and on the side of the eye to be illuminated, the lens being then swung into the position desired. By having the plate at the temporal region, and the lamp well at the side instead of directly in front, we get rid of annoying




FIG. 56.

reflections, and avoid the irritating effects of the light from a strong condensing lens thrown directly through the pupil upon the patient's retina. If the lens is so arranged as to be a little within or a little without its focal length from the eye, the section of the cone of light is large enough to keep the cornea covered, even if the eye makes considerable excursions, while, as the lens is attached to the patient's head, this latter can be moved to a considerable degree without displacing the illumination from the eye. I have found it of great service in operating upon delicate membranes in the pupillary space, as it gives a much steadier illumination, and one which is more easily controlled than when an assistant holds the lens.

By removing the lens from the clip and supplying a mirror, the instrument, from the character of its joints and the mutability of its position, can then be used as a fixed ophthalmoscope for the upright image, and can thus be used in demonstrating the fundus to a class, or in making a sketch of it without the observer being compelled to take up and lay aside the instrument at every look; or the upper half of the ordinary ophthalmoscope can be inserted instead of a simple mirror, and then any optical combination that the refraction of the observed eye may require can be obtained.

I have had a band made which carries two lenses, one on a shorter arm, which is then used as a magnifying-lens, but the single one answers every purpose, and for ordinary occasions is the most convenient.

The instrument is also very useful for the removal of foreign bodies or magnifying small hairs, thus rendering their detection and removal much easier, or in performing any operation at night or whenever the light is poor. When, however, the light is sufficient, and only an increased enlargement is desired, the surgeon, by wearing the band on his own forehead and extending the arm to its utmost, can obtain a large amount of magnifying power, while by slight movements of the head he can successively inspect and keep in front any portion of the anterior surface of the eye or lid.

Ophthalmo-Microscopes.—For the purpose of examining the cornea, iris, and anterior portions of the vitreous, under an increased magnifying power, Liebreich replaced the tube of his large ophthalmoscope with that of a microscope.* With this, in spite of the difficulty in keeping the patient's head immovable, he was enabled to see the cornea, iris, and disturbances in the lens and anterior part of the vitreous under an enlargement of ninety diameters. As the simple to-and-fro movements of the tubes were not sufficient to give a complete control over the instrument, it was subsequently† mounted on two rings, similar to those of a ship's compass, by which motions in all necessary directions were obtained.

Wecker also constructed a small microscope, which, by means of a tripod, was made to rest firmly against the cheek and brow of the patient, lateral illumination being obtained by a condensing lens. This instrument gives an enlargement of eighty diameters.‡

A binocular ophthalmo-microscope has also been constructed.

These instruments, though they deserve a mention here, are of very little practical value, and are rarely used clinically, a sufficient enlargement and illumination being obtained from a simple lens, or, sometimes, by a combination of two lenses.

Artificial Eyes.—It is often convenient, as well as instructive, for the student to have some mechanical contrivance which shall represent the dioptric system of the eye. By its means he is often able to get at a glance a tangible idea as to the different errors of refraction and the manner in which images are formed, which would be impossible from any written description. One of the simplest of such artificial eyes is what is known in the shops as "a cotton-counter," from the fact that dealers use it to magnify and thus count the number of threads in a given area of the fabric. It consists of a one-inch lens set in a short upright of brass, while another upright is placed just at its

* Graefe's "Archives," Band 1, Ab. 2, p. 352.

† "Monatsblätter f. Augenheilkunde," 1863, p. 486.

‡ "Études Ophthalmologique," 1864, vol. i., p. 272.

focal length. A piece of card can be fastened to this second upright, which can then be looked upon as the retinal surface on which images may be formed or a picture of the fundus be painted. A little more extensive apparatus on the same principle is shown in Fig. 57. Here the upright screen which represents the plane of the retina is made movable by a screw, so that the space between the two uprights can be altered at will. The anterior upright is so made that lenses of dif-

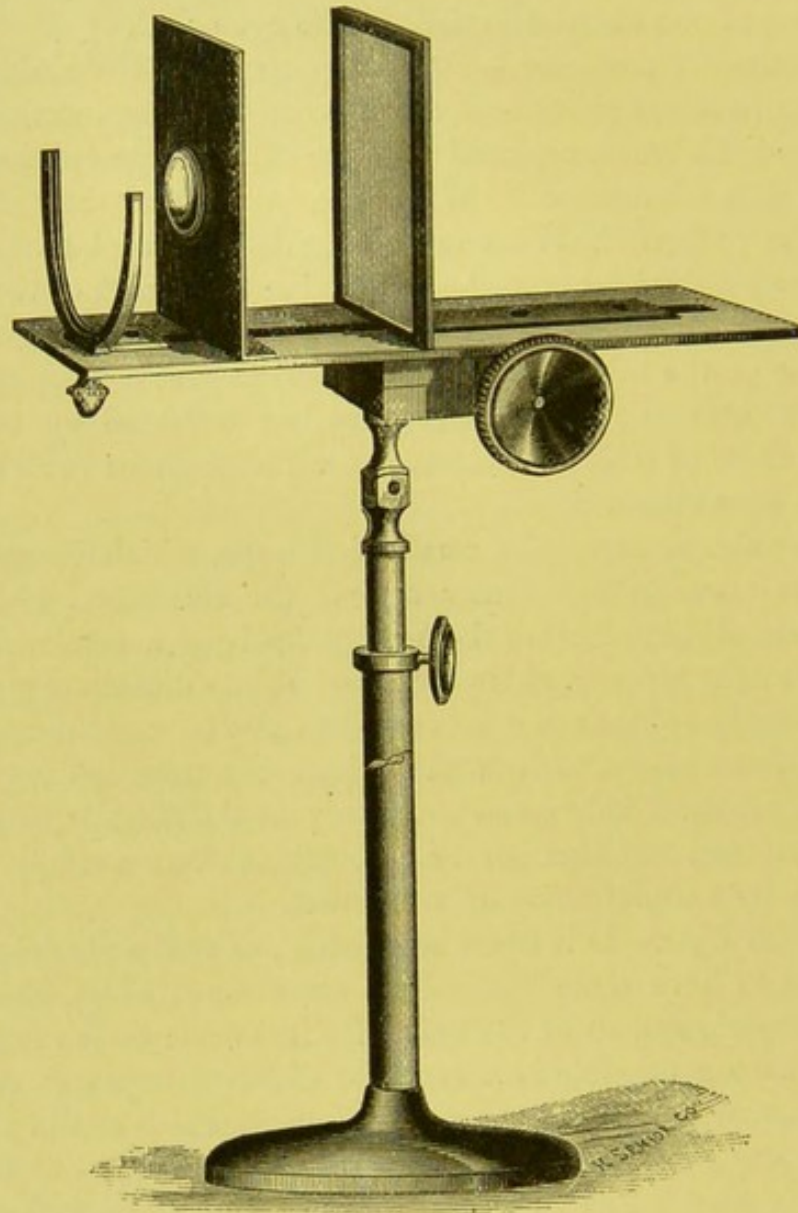


FIG. 57.

ferent power can be inserted. Among these is one, the focal length of which is 6.7 Paris lines. This gives precisely the same enlargement as would be obtained with the ophthalmoscope in examining an emmetropic eye. This is a refinement, however, which is not essen-

tial, as the ordinary one-inch lens answers every purpose. All the varying degrees of myopia and hypermetropia can be obtained by altering the length of the antero-posterior axis, and these can be connected by placing the corresponding glass in the clip in front.

A more elaborate apparatus still is the artificial eye of Perrin, which has been in use for many years. It has the globular form of the eye itself, and is provided with different eye-pieces to represent myopia, hypermetropia, and astigmatism; it is also furnished with a series of pictures of the normal and diseased eyes. It is, however, better adapted for the purposes of teaching the ophthalmoscopic appearances to a class than for the study of optical errors. Other artificial eyes have been invented by Badal, Parent, and Remy.

In 1872 the writer showed to the New York Ophthalmological Society, and in the following summer to the American Ophthalmological Society, the artificial eye shown in Fig. 58. It is the mechanical embodiment of Donders's reduced eye with a cornea ground on a radius of five millimetres with parallel surfaces, the media being represented by water. Every degree of refraction can be expressed upon it, the increase and decrease of the antero-posterior axis being noted in the metric system. It is also fitted with a compound dioptric system of lens and cornea, as well as with a cornea representing the aphakial eye. The instrument has been found very useful both by myself and others in the study and demonstration of every possible phase of dioptries. It is made by W. H. Hunter, 1145 Broadway, New York. Later Landolt* introduced an eye on precisely the same principles, which, if not quite so comprehensive in its scope, is certainly more elegant in its shape and appearance. It can be obtained in this country of Meyrowitz Brothers, 297 Fourth Avenue, New York.

It is often very important to be able to control the result of an ophthalmoscopic examination for refraction by comparing it with that obtained by glasses; but, besides this, it is often of the greatest aid to the student, in arriving at a diagnosis, to know the amount and character of vision, for it often happens that what was at first sight taken for the well-marked signs of a morbid process, has under a careful examination resolved itself into some peculiarity either of a physiological or optical nature, while, on the other hand, the state and character of the vision have called the observer's attention to some incipient and grave disorder in which there were few or no ophthalmoscopic signs. For this reason every ophthalmoscopic examination should be combined with a careful determination of the amount of vision, and the extent of the visual field and the condition of the refraction.

* "Klin. Monatsblätter," July and August, 1876, p. 243.

To do this in a manner at all satisfactory, a set of test-glasses and test-types are necessary. As a rule, these are more elaborate and more expensive than is absolutely essential. By the aid of the metric system, simple combinations can now be made without any knowledge of mathematics whatever. A test-case has been designed by the writer to meet the wants of students and general practitioners.




FIG. 58.

The set contains seven pairs each of concave and convex spherical lenses, and five pairs each of concave and convex cylindrical lenses, and with these almost every combination possible in the most complete sets can be successfully effected; moreover, as all the numbers are in pairs, both eyes can be examined simultaneously with glasses of equal strength.

The case further contains a set of test-types and a triple-grooved, graduated trial-frame, into which one, two, or three lenses may be readily slipped to obtain the desired number.

As mentioned before, the lenses are marked in the metric system.

The simple numbers contained in the trial-case are as follows :

Spherical, concave, and convex : .25, .5, 1., 2., 3., 4., 8.

Cylindrical, concave, and convex : .25, .5, 1., 2., 3.


The combinations made therewith are :

Spherical : .25, .5, 1., 1.25, 1.5, 1.75, 2., 2.25, 2.5, 2.75, 3., 3.25, 3.5, 3.75, 4., 4.25, 4.5, 4.75, 5., 5.25, 5.5, 6., 6.25, 6.5, 7., 7.25, 7.5, 8., 8.25, 8.5, 8.75, 9., 9.25, 9.5, 10., 10.25, 10.5, 11., 11.25, 11.5, 12., 12.25, 12.5, 13., 14., 15.

Cylindrical : .25, .5, .75, 1, 1.25, 1.5, 1.75, 2., 2.25, 2.5, 2.75, 3., 3.25, 3.5, 3.75, 4., 4.25, 4.5, 5., 5.25, 5.5, 6.*

Dr. John Green and Dr. Roosa have also introduced excellent test-cases for students and practitioners.

* This case can be had of Meyrowitz Brothers for the moderate sum of fourteen dollars.



EXPLANATION OF PLATES.

PLATE I.

Fig. 1* represents the fundus of a normal eye in young adult life, of a type that was neither blonde nor brunette. The color of the background is of a uniform hue, and only shows an increase in shade at the macula lutea, the centre of which is marked by the fovea, which, in this case, has the appearance of a small circular spot with the merest perceptible dot in its centre. The increase in hue which marks the central portions of the yellow spot is due both to an increase in the amount of pigment in the epithelial layer and to an increased density in the network of small vessels and capillaries of the choroid lying directly below this region, which is the finest of any in the entire body (p. 45).

The uniformity in color and pigmentation is such that none of the choroidal vessels are individually visible.

The retinal vessels leave the centre of the disk in a perfectly normal manner. The veins are differentiated from the arteries by a somewhat marked difference in color, while the light streak, though present on both arteries and veins, is more marked and more brilliant upon the former than upon the latter. The retinal vessels, after the usual subdivisions, radiate toward the region of the yellow spot, and, having entered this, arrive within a short distance of the fovea centralis—so that the *region* of the macula lutea contains quite a number of minute branches of the retinal vessels (p. 34). It is only the fovea itself which is devoid of any vascular twigs.

* In looking at all ophthalmoscopic drawings, it should be remembered that they are made under artificial light, and that they should be examined by such to get an adequate idea of the shade of color. It should also be borne in mind that all ophthalmoscopic drawings are necessarily diagrammatic in so far that a much larger portion of the field is represented than can be seen at once. The extent of surface seen varies with the kind of mirror, the distance of the lamp, the size of the pupil, and the distance of the observer's eye from it. The extent of surface under view at one time, in the ordinary methods of making the examination by the upright image, is from $1\frac{3}{4}$ to $2\frac{1}{2}$ or 3 millimetres.

The nerve shows the usual concentric markings, with a slightly developed choroidal ring. In this particular case the connective-tissue string is carried well forward along the vessels, and the nerve-fibres are so closely arranged that there is little or no physiological excavation. There is likewise no venous pulsation, which usually shows itself by an increased color of the vessel, just as it bends to enter the nerve-stem.

The vascular portion of the nerve is perhaps somewhat more pronounced than it is usually, though not more so than is often found compatible with a perfectly normal development.

Fig. 2 (Plate I.). This beautiful drawing is from Liebreich (Atlas d'Ophthalmoscopie, Taf. II., Fig. 2). It represents the fundus of an individual of a light blonde type, with a blue iris. From the clearness of the stroma and the weak development of the pigment epithelium, the choroidal vessels can be traced to their finest branches. (Liebreich.) Portions of the branches from the different *venæ vorticæ* are exposed to view. In the lower left-hand corner they are visible nearly to their trunks, but less so in the right upper corner.

PLATE II.

Fig. 1 (Plate II.). In this figure (Liebreich, "Atlas d'Ophthalmoscopie," Taf. II., Fig. 3) the pigmentation of the stroma is more marked, while, according to Liebreich, that of the epithelial layer is very feeble. This is the reason, in his opinion, why the choroidal vessels here appear to be separated by pigmented intervascular spaces. It is only in the right-hand lower corner, near the posterior pole of the eye, that these vessels are concealed by a dark and richly pigmented epithelium. If this explanation is correct, as already remarked (p. 44), it must be assumed that there are different degrees of pigmentation of a very marked character in different portions of the same fundus. A more natural explanation would appear to be, that in this part of the fundus there is a closer arrangement of all the vessels, large and small, and accordingly a denser and more uniform color to the fundus. It is this peculiar striped marking which is called the *choroid tigré*.

Fig. 2 (Plate II.). This picture is diagrammatic, inasmuch as the peculiar concentric markings of the disk have been purposely exaggerated somewhat in color and tone for the sake of defining in a better manner the positions of the different rings. The external ring is the "pigment" or "choroidal ring." The second or white circle is the "scleral ring." The third or colored ring is the "vascular portion" of the disk; and the fourth is the "non-vascular portion" or "clear spot." (See text, p. 58.)

Fig. 3 (Plate II.). This figure (Liebreich, "Atlas d'Ophthalmoscopie") is taken from a perfectly normal eye, although, from the size

of the disk and from the extent and depth of the excavation, the appearances would seem to be due to a pathological condition. This apparent increase in size of the disk is due partly to a distended condition of the head of the nerve and partly to the fact that the choroidal opening is larger than usual, and drawn somewhat to one side. The nerve-fibres are here distended outward, allowing the lamina cribrosa to manifest itself at the bottom of the large and rather deep excavation. The true outer border of the nerve-entrance is shown by the grayish semi-lunar line, while the scleral ring, very much exaggerated in size, extends to the outside of this. The inner edge of the excavation, or that to the left of the central vessel, is sharply defined and pierced by both veins and arteries as they leave the disk. This sharp edge to the excavation occurring within the surface of the disk itself is strongly corroborative of the fact that the excavation is physiological, or at least congenital, and not due to pressure. (See text, p. 55.)

Fig. 4 (Plate II.). This shows a precisely opposite condition—that is to say, a reduction in the size of the choroidal foramen. This is occasioned by a continuation of the choroidal membrane over the borders of the disk. Some of the larger choroidal vessels are visible, and one of these is so arranged that there can be no doubt as to the true nature of the anomaly. The picture is from an eye in which there was a high degree of compound myopic astigmatism. Another member of the same family had similar appearances in both eyes, although to a less degree. (See text, p. 98.)

Fig. 5 (Plate II.). This represents an anomalous collection of pigment in the choroid. There was no defect in the visual field corresponding to the pigmented plaque, and vision was perfect. Its discovery was purely accidental in a person who made no complaint in regard to the eyes, and who, rather singularly, was a pronounced blonde. (See text, p. 89.)

Fig. 6 (Plate II.). This figure (Liebreich, "Atlas d'Ophthalmoscopie," Taf. XII., Fig. 2) represents the anomaly known as "opaque nerve-fibres," due to the continuation of the medullary sheath of the optic nerve-fibres as they pass over into the retina. This is the common form under which the anomaly usually appears. The peripheric border ends in flame-like processes, which seem to shoot out over the retina, sometimes covering a vessel so as to completely hide it, and sometimes passing beneath it. The interior border, or that near the nerve, is sometimes separated from the papilla by a greater or less distance, or sometimes encroaches upon the surface of the disk, the borders of which it then entirely conceals. The plaque, instead of having the radiating tongue-like form, may have the shape of a white crescent with sharply defined contours, which then increases its resemblance to

a pathological condition, and renders the diagnosis much more difficult. (Liebreich.) (See text, p. 98.)

PLATE III.

Fig. 1 (Plate III.). This figure (Jaeger, "Hand Atlas," Taf. IV., Fig. 28) represents the fundus of an albinotic person of the most marked type. The general fundus, instead of being of a uniform red, is of a yellowish-white color, and reflects a large amount of light. The central vessels of the retina are perfectly normal, although the veins are a little more tortuous than is ordinarily the case.

The granular, or shagreen, effect of the general fundus is entirely wanting here, and it is only in the region of the macula lutea that there is any trace of any uniformity in color due to an increased degree of pigment in the epithelial layer and to a closer arrangement of the vessels. The external vascular layer of the choroid is sharply designed over the entire fundus, except in the neighborhood of the yellow spot, where it is somewhat veiled by the overlying layers and by an increased development of pigment, perhaps, in the epithelial layer.

In certain places the choroidal vessels of the middle layer show themselves as band-like formations of more or less orange-color. These bifurcate and anastomose with each other in such a way that a somewhat irregular network is formed, which usually is of a yellowish-white color, and at times of considerable brilliancy of color—so much so, indeed, that one is convinced that this brilliancy is due to a reflection from the sclera. (Jaeger.)

Fig. 2 (Plate III.). This figure (Liebreich, "Atlas d'Ophthalmoscopie," Taf. XII., Fig. 3) shows an opposite condition, or one in which there is an abnormal excess of pigment. These cases are exceedingly rare, and are known under the title of cyanosis of the bulb. The individual in this case had auburn hair and light eyebrows and eyelashes. The iris of the left eye was of a light brown; that of the right was of so deep a color that the pupil could only be distinguished with great difficulty. The cornea at some little distance from its border is marked by a collection of spots of a grayish color, which in some places pass into a violet shade. With the ophthalmoscope there was only a slight reflex from the fundus, and even this, when the patient looked directly in front of him, vanished almost entirely. With the inverted image the bottom of the eye appeared of a dark reddish tinge. It was only in isolated places that there were any traces of the choroidal vessels. The retinal vessels appeared darker than usual, and the light-streak on their anterior surface less brilliant. On the contrary, the substance of the retina revealed itself much more clearly than usual by a delicate grayish haze and by a curious play of light, which was produced, espe-

cially around the region of the yellow spot, with the various movements of the mirror. The macula lutea appeared almost black, the centre of which was surrounded by a deep-brown ring. The general surface of the disk was of a reddish hue, and the borders were sharply defined. The retinal vessels at their point of emergence were enveloped by masses of pigment, which cover about one third of the surface of the nerve, and make what is usually the "clear spot" in a normal eye appear here black. At the periphery also there was a narrow ring of pigment. The eye was myopic. The vision was good, and the organ appeared to be in an excellent condition.

Fig. 3 (Plate III.). This figure (Jaeger, "Hand Atlas," Taf. XIX., Fig. 87) represents the eye of a young girl, who was affected with coloboma of the choroid and iris on both sides. A description of the appearances of the right eye has already been given in the text (p. 93). There was in this, the left eye, a coloboma of the iris which extended as far as the ciliary body. There was, however, no coloboma or other malformation of the ciliary body, so far as could be seen. The media were perfectly clear, and the fundus above and to the outer and inner side was perfectly normal, both as to color and general appearance. Below, on the contrary, corresponding to the coloboma, the effect produced by the mirror was that of a surface of large extent, of a yellowish-white, or a bluish-white, or at places even of a glittering-white color. The nerve was of an oval form, and normal in all its diameters. In the nerve-substance itself there was a deep excavation of a triangular shape, having its base below, with its angle pointing upward and extending as far as the centre of the nerve. From the fact that it extends to the lower borders of the nerve, and that at this place one of the branches of the lower vein makes a sudden bend over the steep edges of the excavation, this latter bears a strong resemblance to one of those glaucomatous excavations of congenital origin. The coloboma taken as a whole has a pear-shaped form, and measures in its greatest breadth about five and a half diameters of the nerve. The upper border lies about one half of the diameter of the disk below the edge of the nerve. The anterior border of the coloboma can not be perceived, as it lies too far forward to be reached by the instrument, but this must be, from the direction in which the lateral borders run to each other, on the other side of the ora serrata and immediately in front of the ciliary processes. The bottom of the coloboma is uneven and lies deeper than the plane of the choroid, and in some places even deeper than the inner surface of the sclera. The coloboma consists of three separate shallow excavations, which adjoin, and in a certain sense, pass into one another. The upper excavation is egg-shaped, and is of a whitish color when taken as a whole, while in its deepest portion it has a weak but decidedly bluish tinge. The middle and smaller excavation has rather a band-like form,

and in its central third is a clear, yellowish white. The peripheral portions are of the same color, though of a somewhat lighter shade.

The third excavation has by far the greatest extent, though it is the shallowest. It is in some portions of a light, and in others of a darker, grayish color. Over its surface—especially toward the nose—white stripes occasionally run. In some parts of the periphery of the coloboma, toward the normal colored portions of the fundus, the choroidal tissue still manifests itself by light yellowish stripes.

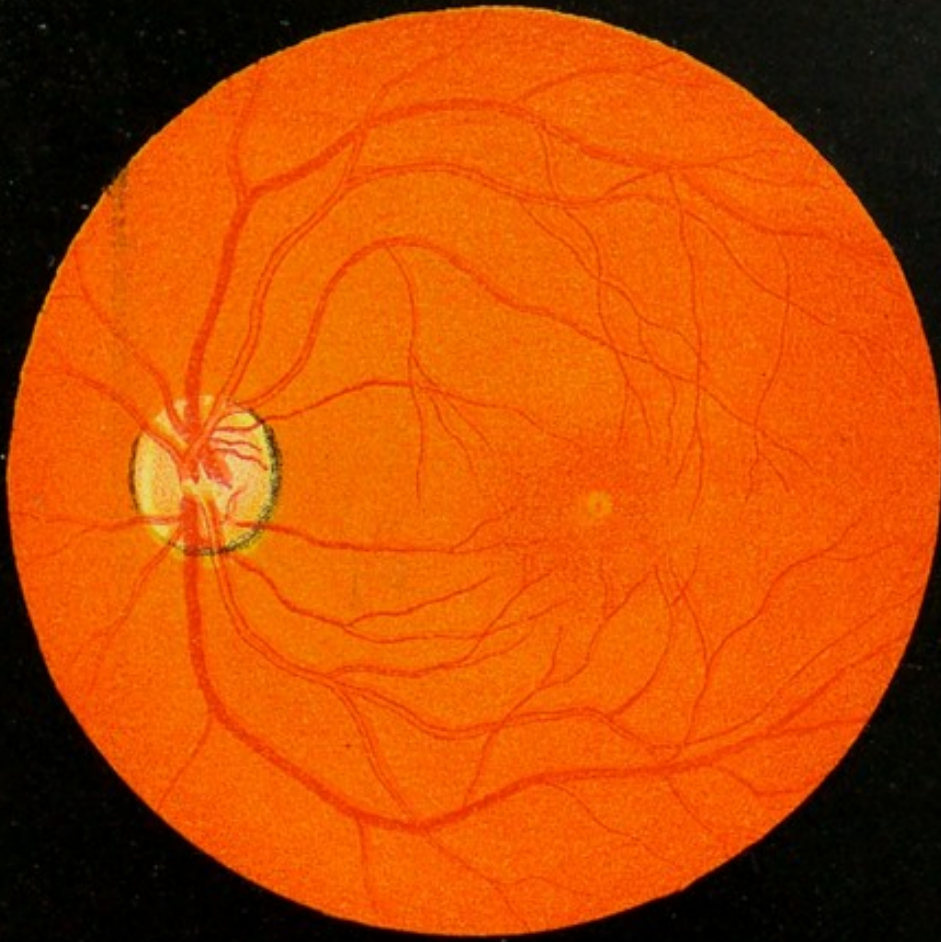The epithelial layer is, however, wanting, and this allows (Jaeger) portions of the network of the larger vessels to become visible as light reddish stripes of a band-like character. Remnants of pigment are also seen in different places at the lateral borders of the coloboma and at the boundary-lines of the different excavations. An extremely delicate and transparent membrane is stretched over the coloboma for its entire surface, all the inequalities of which it follows. The distribution of the central vessels is normal. They run in the usual manner over that part of the fundus in which the choroid has its normal appearance, but only small and delicate branches are continued over the region of the coloboma. In this district, and below the plane of the retinal vessels, broader vessels appear, which have a uniform color across their entire surface. These divide into numerous branches, and run in an irregular and tortuous manner. These vessels spring in part from the region of the coloboma itself, and in part from beneath that portion of the fundus which has a normal color and appearance. They anastomose in certain places near the border of the coloboma with the choroidal vessels which are there visible. From this fact, and from their peculiar band-like character and light color, these vessels show themselves to be really sclero-choroidal vessels. It will be noticed that in this case the coloboma does not include the optic nerve, but that there is immediately below the nerve a narrow strip of normal-looking tissue. That this strip still preserved its normal function was proved by the fact that Mariotte's blind-spot was separated from the defect in the field caused by the coloboma by a narrow band of visual field which still maintained its perceptive power. (See text, p. 92.)

Fig. 4 (Plate III.). This figure represents a coloboma of the macula lutea, with a secondary defect between it and the nerve. These cases are very rare, and are apt to be confounded with an old exudation and subsequent atrophy of the tissue, especially as the rest of the fundus has a normal appearance. (See text, p. 94.)

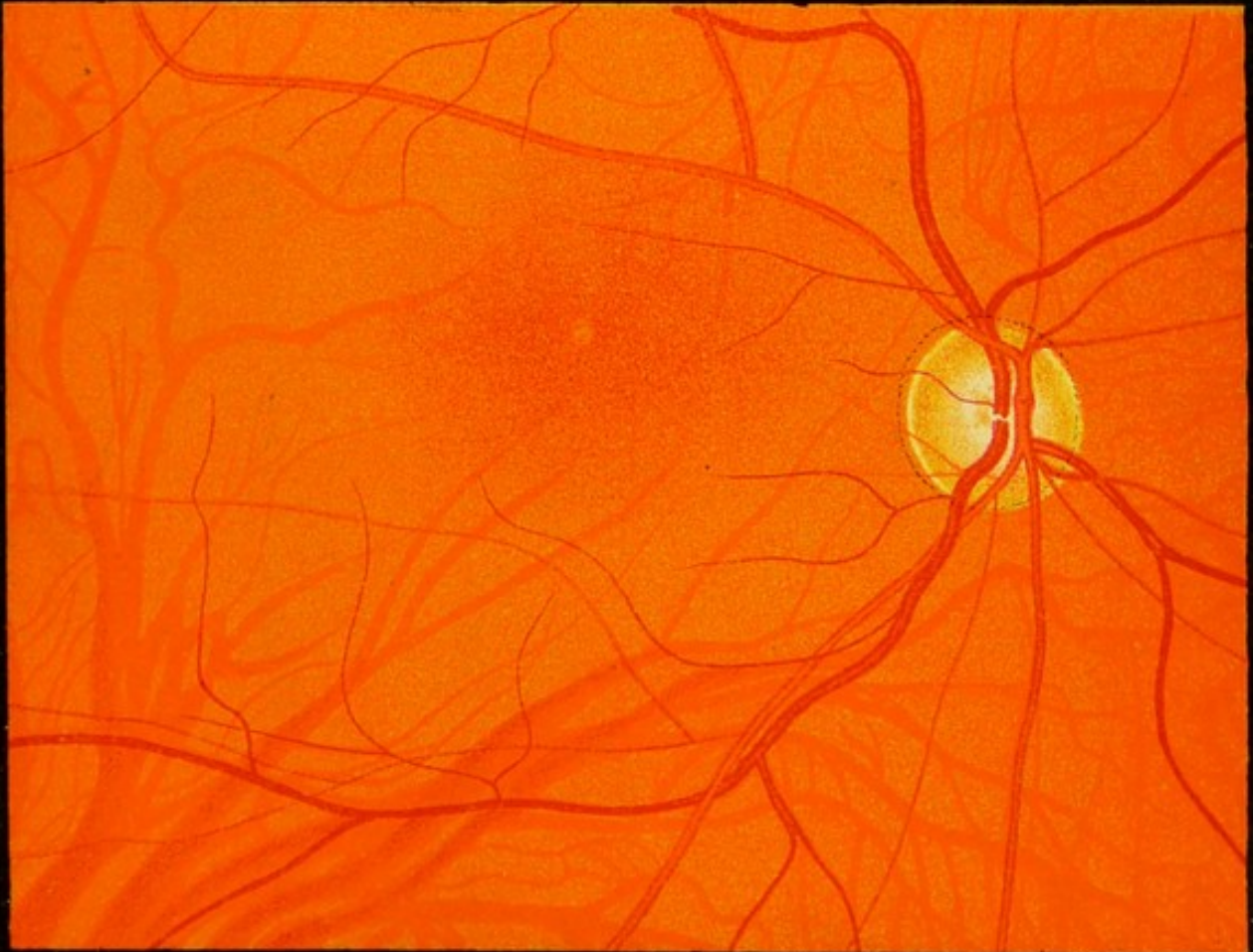Fig. 5 (Plate III.). This picture was taken from a highly astigmatic eye, in which the myopia was equal to 6 D in the vertical meridian, while the horizontal was emmetropic. The fundus, taken as a whole, presented a striated appearance, which, though very delicate, was still perfectly perceptible. This was due, of course, to the optical error,

and was not present when this was properly corrected. It will be seen that the upper and lower borders of the optic nerve are obliterated, while the lateral ones are sharply defined. It is the same with the vessels. Those which run horizontally are very much blurred, or else entirely obliterated, which is the case with the fine horizontal vessels which leave the nerve and run out toward the macula, when the ordinary spherical glass is used which corrects the vertical meridian. These horizontal vessels then come sharply into view, and the vertical vessels are correspondingly indistinct. In order to see both the horizontal and vertical vessels distinctly at the same time, a cylindric glass of 6 D must be used. It is this condition which is so liable to be taken for a case of neuritis by those who are unfamiliar with it. (See "Determination of Astigmatism," p. 116, *et al.*)

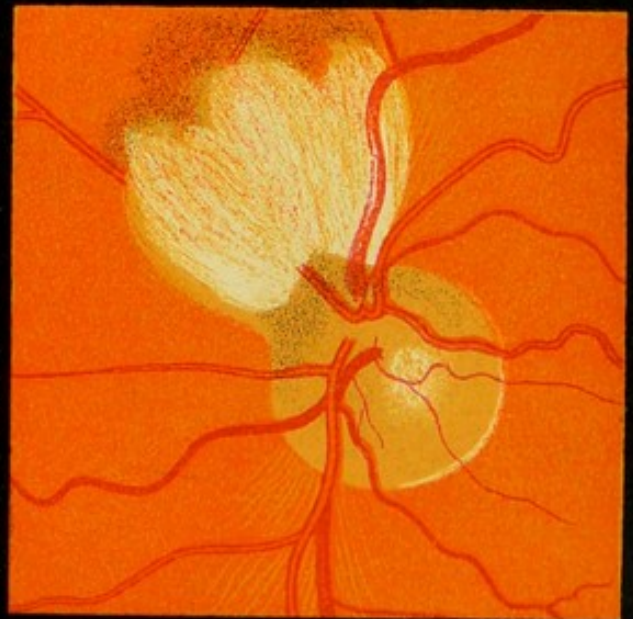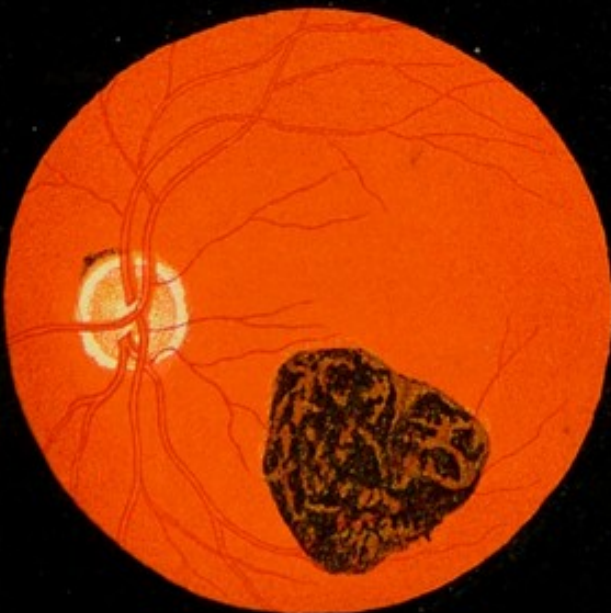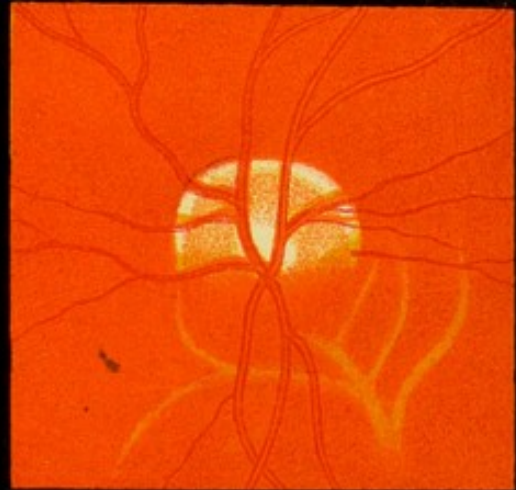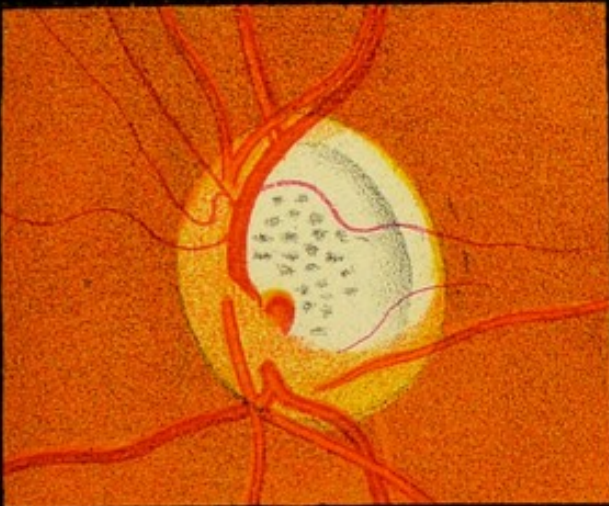
1



2







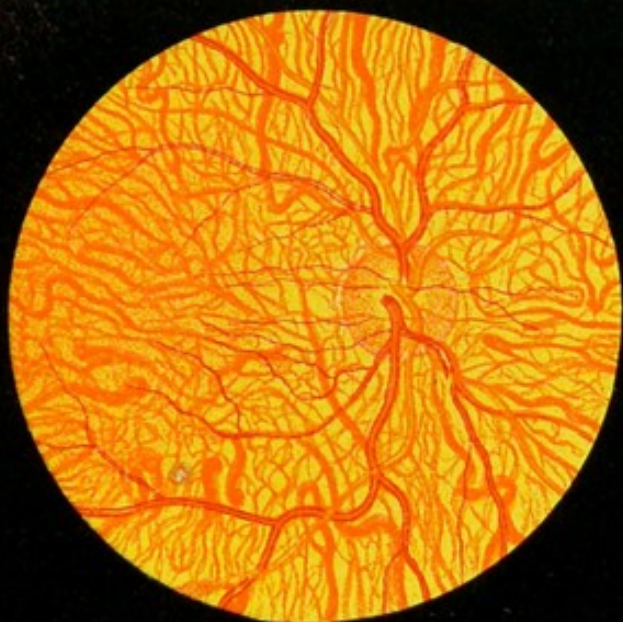2

4

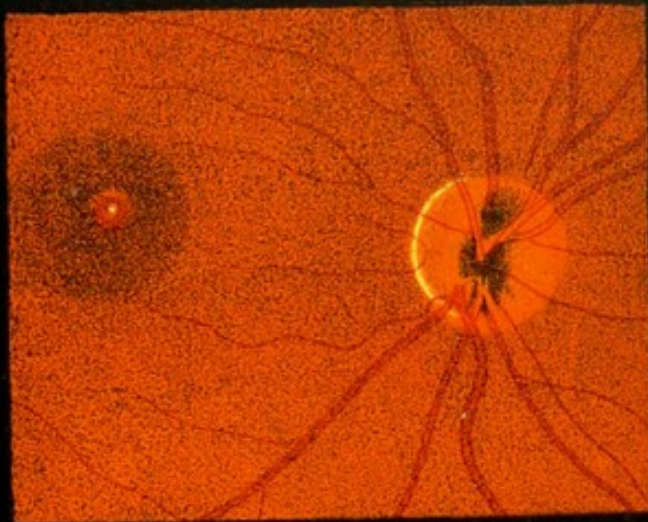
6



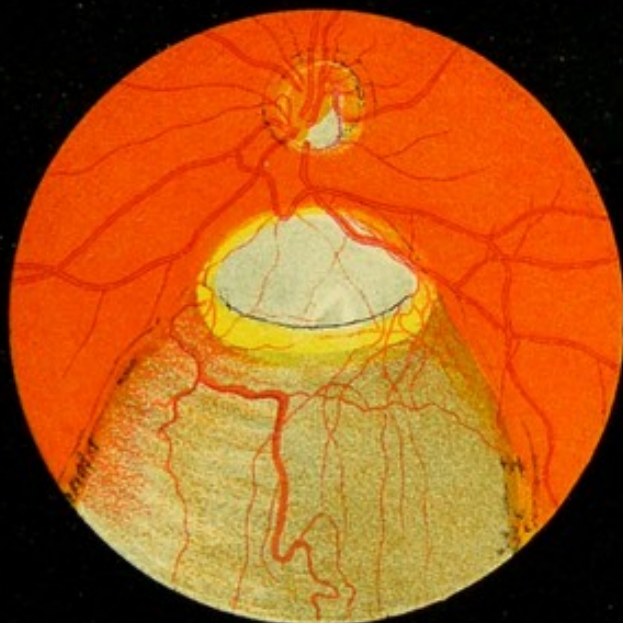1



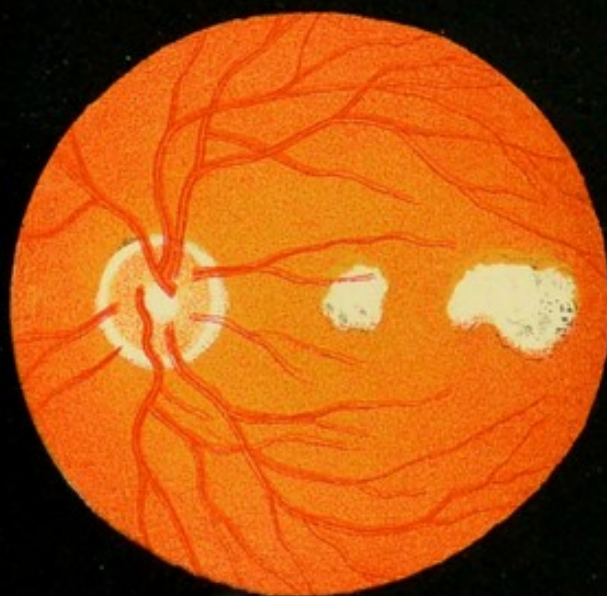2



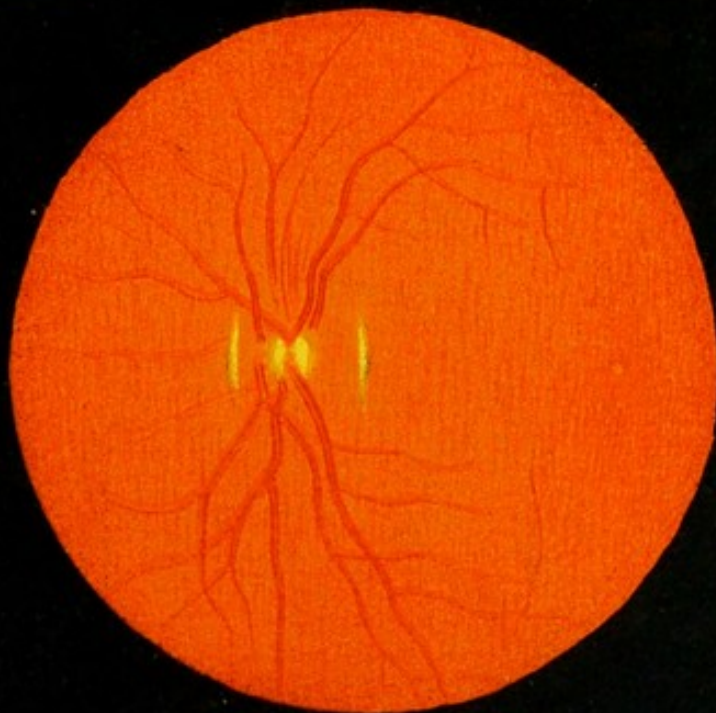
3



4



5





INDEX.

- Abscess, in vitreous, 180.
- Accommodation, 222.
 equivalent to increased refraction, 225.
 in hypermetropic eye, 223.
 in myopic eye, 223.
 in normal eye, 222.
 non-relaxation of, in moderate hypermetropia, 111.
 relaxation of, 107.
 rules for relaxation of, 107, 108.
- Adjuncts to ophthalmoscope, 253.
- Age, effect on fundus, 84.
- Air-bubbles in vitreous, 183.
- Amblyopia, 113.
- Ametropia, 218.
- Ametropic observer, rules for, 127, 129.
 a hypermetrope, 131.
 a myope, 129.
- Anastomosis, arterio-venous, 105.
 between retinal and ciliary system, 29, 30.
 between vessels of sheaths of nerve, 28.
 of retino-choroidal vessels, 104.
- Anatomy, fundus of normal eye, 21.
 inner and outer sheath optic nerve, 21.
 of choroid, 38.
 of retina, 31.
 of the normal eye, 21.
- Anomalies, 86.*
 abnormal transparency of nerve fibres, 100.
 arterio-venous anastomosis, 105.
 bifurcation of optic fibres, 101.
 choroidal opening, 97, 98.
 cilio-retinal blood-vessels, 104.
 coloboma of iris, 90.
 coloboma of sheath of optic nerve, 96.
 coloboma of the choroid, 92.
 coloboma of the lens, 92.
 coloboma of the macula, 94.
 congenital absence of iris, 90.
 discoloration of optic nerve, 101.
 of disk, 97.
 of the lens, 87.
 of the media, 86.
 of pigmentation of choroid, 88.
 of pigmentation of optic nerve, 89.
 of vessel wall, 102.
 opaque nerve-fibres, 98.
 persistent hyaloid artery, 103.
 pink spots at macula, 94.
 pupil, eccentric position of, 92.
 pupillary membrane, 91.
 vascular system, 101.
- Anomaly, anastomosis of retino-choroidal vessels, 104.
- Anterior-chamber, examination (oblique light), 148.
- Aqueous humor, 161.
 diffuse opacities of, 148.
 examination of, 148.
 examination with mirror, 161.
 filaria in, 149.
 pus in, 148.
 synechiæ in, 149.
- Arachnoidal sheath (anatomy), 21.
 space (anatomy), 22.
- Arteria centralis retinae, 29.
- Arterial pulse, 74.
 "apparent" pulsation of, 75.
 character of, 74.
 diagnostic value of, 75.
 produced artificially, 75.
- Arteries, long ciliary, 39.
 persistent hyaloid, 103.
 ophthalmic, 28.
 short ciliary, 29, 41.
 variation in number, 102.
 inferior, of retina, 65, 66.
 subdivisions of, 66.
 superior, of retina, 66.
- Artery, hyaloid, 103.
- Atropine, disks for dilatation of pupil, 9.
- Artificial eye, 143, 255.
- Astigmatism, determination of, 116.
 determination by mirror alone, 136.
 determined by inverted image, 139.
 effect on fundus, 86.
 elongation of disk in, 117.
 hypermetropic, 119.
 irregular, 121.
 irregular, to be detected by mirror alone, 121.
 method of determining, 118.
 mixed, 119.
 myopic, 119.
 test for, 117, 118.
- Atropine, strength of, for purposes of examination, 10.
- Axis, antero-posterior, 218.
 formulæ for length of, 128.
 of eye, 217.
- Becker, method of illuminating cornea, 150.
- Blood-column, composition of, 70.
 bounded by bands, 103.

- Blood, difference in color between arterial and venous, 71.
- Bowman, membrane of, 146.
- Box, for studying passage of rays, 214.
- Brücke, experiment of, 229.
- Canal, central, 29, 65.
displacement of, 65.
- Capillaries, choroidal, 45.
- Capsule, fracture of, 169.
reflex from anterior, 152.
reflex from posterior, 152.
- Cataract, anterior capsular, 154.
as seen with ophthalmoscope, 164.
cortical, 164, 165, 166.
oblique illumination in, 156.
oblique illumination, periphric, 166.
posterior polar, 155.
pyramidal, 154.
secondary, 156.
spindle-shaped, 155.
zonular, 155, 167.
- Catoptric test, 152.
- Centre of motion, 185.
- Cholesterin in iris, 150.
in lens, 156.
- Choroid, anomalies of pigmentation, 88.
attachment to sclera, 38, 39.
capillary net-work of, 45.
coloboma of, 92.
foramen of, 39.
pigmented crescent of, 50.
the (anatomy), 38.
thickness of, 38.
tigré, 48.
veins of, 42.
vessels of, 39.
anastomosis with retinal, 39.
- Choroidal opening, 97.
- Ciliary, long arteries, 39.
short arteries, 41.
vessels, 28.
- Circle, illuminated, 230.
of dispersion, 230.
of dispersion, size of, 231.
of dispersion, varies with different mirrors, 231.
of dispersion, varies with distance of lamp, 230.
of illumination, 230, 231.
scleral, 30.
- Coloboma of iris, 90.
of lens, 92.
of macula, 94.
of the vitreous, 88.
- Color of normal fundus, 46.
- Condensing lens, use of, in oblique illumination, 5 (Fig. 1, p. 6).
- Congenital excavations, 60, 61.
- Connective-tissue ring, 57.
variation in size, shape, and color, 57.
- Connective-tissue string, 29.
effect on appearance of vessels, 66.
- Conus, 97.
- Cornea, 160.
abrasions of, 148.
examination of, 146.
examination of, with mirror, 160.
foreign bodies in, 148.
illuminated by Becker's method, 150.
oblique illumination of, 146.
reflex from, 152.
reflex of, as diagnostic mark, 187.
want of transparency of, 147.
- Crescent, pigmented, 50.
- Cylindric lens, 212.
- Cysticercus, description of, 188, 189.
differential diagnosis of, 190.
drawings of, 192, 193.
ophthalmoscopic appearances of, 189.
sac of, 188, 189.
- Cysts of iris, 149.
- Descemet, membrane of, 146.
- Descemitis, 148.
- Dioptric, definition of, 241.
- Dioptries, conversion into inches, 242.
- Disk, anomalies of, 97.
causes of elevation of surface, 62.
change in form of, 138.
change in, in astigmatism, 139.
change in, in movements of lens, 140.
clear spot of, 55.
concentric markings of, 58.
crescent round, 57.
differences in size, 53.
elevations of surface, 61.
elongation of, in astigmatism, 117.
excavation of, 58, 59.
honeycombed appearance of, 55.
plane of, 53.
shape of, 51.
variations in color, 55.
variations in elevation, 58.
variations in surface of, 54.
vascular portion of, 56.
vessels of, 29.
- Dislocation of the lens, 87.
- Dispersion, circle of, 230.
- Dural sheath (anatomy), 22.
- Ectopia lentis, 87.
- Emmetropia, determination of, 109, 123.
- Enlargement, influenced by ametropia, 143.
hypermetropia, 144.
myopia, 145.
Liebreich's method of, 16.
produced by upright image, 142.
- Entozoa, 187.
- Examination by daylight, advantages of, 4.
by inverted image, 12.
by upright image, 18.
of eye by artificial light, 5.
of media of eye, 146.
aqueous humor, 148.
cornea, 146.
lens, 150.
iris, 149.
vitreous, 157.

- Examination with ophthalmoscope**, 8, 9.
 necessity for use of atropine, 7, 9.
 obstacles in the way of, 9.
 use of atropine in, 9.
- Excavation, "apparent,"** 60.
 congenital, 60, 61.
 measurement of, in glaucoma, 115.
 of disk, 58.
 physiological, 59.
 physiological characteristics of, 59, 60.
- Exudations upon lens**, 150.
- Eye, ametropic**, 218.
 artificial, 143.
 Donders's reduced, 257.
 of author, 257.
 of Landolt, 257.
 emmetropic (definition of), 218.
 equivalent to biconvex lens, 217.
 hypermetropic (definition of), 218.
 myopic (definition of), 218.
- Eyes, artificial**, 255.
- Far-point**, 221.
- Field, influenced by object lens**, 239.
 of view, influenced by strength of object-glass, 14.
- Filaria, description of**, 194.
 existence of, 187.
 in aqueous humor, 149.
- Focal length of eye**, 217.
 of lenticular system, 142.
- Foci, conjugate, of mirrors**, 216.
- Focus, alterations in, by change of object**, 208
 conjugate, 209.
 equal to radius in biconvex glass, 203.
 equal to twice the radius in plano-convex,
 202.
 virtual, 210.
- Foreign bodies in cornea**, 148.
 enveloped in membranes, 180.
 in vitreous, 180.
 rebound of, from back of eye, 183.
 suspension of, in vitreous, 180.
- Formula, to determine length of axis**, 128.
- Fovea, appearance of**, 79.
 distance from edge of nerve, 79.
 shape and appearance of, reflex of, 81.
 centralis (anatomy), 33, 34.
 increased pigmentation of surrounding
 tissue, 34.
 position of, 34.
- Fundus, differences in regard to age**, 84.
 effect on, by optical conditions, 85.
 illumination of, 231.
 illumination of, by ophthalmoscope, 230.
 seen by irregular reflection, 232.
 variations in, owing to optical conditions,
 85.
 visible by irregular reflection, 232.
 oculi, not a conjugate focus with source
 of light, 228.
 variation in texture of, 50.
- Glaucoma, measurement of excavation**, 115.
- Glass, magnifying power of**, 142.
- Halo, absence of, with upright image**, 80.
 cause of, 82.
 surrounding macula, 78.
 the, not seen in all eyes, 79.
 why absent with upright image, 81.
- Helmholtz's weak-light mirror**, 4.
- Hyalitis**, 154.
- Hyaloid artery**, 103.
- Hypermetropia, ability to determine "total,"**
 with the mirror, 110, 111.
 as revealed by upright image, 110.
 determination of, 110, 125.
 determination of "latent," 110.
 non-relaxation of A, in, 111.
- Hypopion, in anterior chamber**, 148.
- Illuminated circle**, 230, 231.
- Illumination, oblique, importance of**, 5.
 kinds of, 3.
 of the fundus, manner of obtaining, 10.
- Image, aerial, of myopic eye**, 11.
 change in position of, by change of ob-
 ject, 207.
 enlargement produced by "upright," 142.
 formation of, by lens, 205.
 from concave mirror, 215.
 "indirect," principles of, 237.
 influence on life of, by refraction, 239.
 of fundus, production of, 11.
 place of reflected, 214.
 projection of, 143.
 reflected, 214.
 size of, as to object, 206.
 to determine whether erect or inverted,
 11.
 virtual, in hypermetropic eye, 11.
- Incidence, angle of**, 214.
- Increased enlargement, by inverted image**, 16
- Inequalities, in fundus, how to detect**, 14.
 measurement of, 113.
- Inner sheath, vessels of**, 28.
- Intervaginal space (anatomy)**, 21.
 (anatomy), 23.
 in myopic eyes, 23.
- Inverted image, examination by**, 12 (Fig. 2).
 increased enlargement in, 16.
- Irido-choroiditis**, 149.
- Iris**, 161.
 absence of, 90.
 adhesion to lens, 150.
 cholesterine in, 150.
 coloboma of, 90.
 condylomata of, 149.
 cysts of, 149.
 examination of, 149.
 examination of, with mirror, 161.
 Liebreich's method of examination, 150.
 oblique illumination of, 147, 149.
- Iritis**, 149.
 as seen with the mirror (Fig. 56), 164.
- Keratotomy**, 137.
- Lamina cribrosa (anatomy)**, 25, 26.
 vessels of, 28.

- Lamina vitrea, 38.
- Lamp, effect on circle of dispersion, 4.
 influence of position, 232.
 influence on circle of illumination, 232.
 position of, 3.
 source of illumination, 230-232.
 varieties of, 3.
- Length, focal, of eye, 217.
- Lens, adhesions to, 150.
 anomalies of, 87.
 coloboma of, 92.
 diffuse opacity of, 151.
 dislocation of, 87.
 dislocation of (as seen in the mirror), 168.
 dislocation of (oblique illumination), 157.
 dislocation of (as seen with mirror), 168.
 examination, 150.
 examination of (oblique light), 150.
 examination of, with ophthalmoscope, 161.
 exudations upon, 150.
 fracture of the capsule of, 169.
 opacities of (circumscribed), 154.
 physiological opacities of, 163.
 physiological reflex from, 151.
 stationary opacities in, 163.
 want of transparency in normal eye, 151.
- Lenses, action of, on light, 199.
 axes of, 204.
 biconvex, 203.
 bicylindric, 214.
 concave, 210.
 condensing, use of, 5.
 convex, 199.
 cylindric, 212.
 effect of changing curvature, 201.
 focus of, 201.
 image of, in case of concave lens, 211.
 image formed by, 204, 205.
 influence on size of image, 238.
 optic centre of, 204.
 plano-convex action of, 200.
 position of, 157.
 radius of, 199.
 sphero-cylindric, 213.
 strength of, 199.
 strength of, expressed in a fraction, 203.
- Light, laws of, 195.
 pencil of, 195.
 quantity of, from different mirrors, 4.
 rays of, 195.
- Light streak, the, 75.
 increase and decrease of, 102.
 test for astigmatism, 118.
 theory of, 76.
 undulatory motion of, 195.
- Lymphatic spaces, 27, 35, 37.
- Luminous bodies, 195.
- Macula, spots at, 94.
 lutea, cause of color, 32.
 coloboma of, 94.
 distance from centre of disk, 32.
 how to examine, with upright image, 79.
 with indirect image, 77.
 increased pigmentation in region of, 49.
- Macula, increased pigmentation of region of, 80.
 not devoid of vessels, 67, 80.
 not synonymous with the fovea centralis, 77.
 reflex round, with indirect image, 77.
 reflexions from, 77.
 region of, 31, 77.
 region of, with upright image, 79.
 situation of, 32.
 size of, 32, 33.
 vessels of, 35, 36.
- Magnifying-glass, power of, 142, 143.
- Media, anomalies of, 86.
 differential diagnosis in troubles of, 184.
 examination of, with mirror, 157.
 examination with ophthalmoscope, 157.
- Medullary sheath (anatomy), loss of, in nerve-stem, 24.
- Membrane, Bowman's, 146.
 determination of position of, in vitreous, 116.
 in vitreous, 177.
 of Descemet, 146.
 vascular in vitreous, 177, 178.
- Method, "indirect," principles of, 236.
- Metre, 241.
- Metric system, 241.
 conversion of, into inches, 242.
- Microscope, ophthalmic, 255.
- Mirror, concave, best adapted for general work, 4.
 concave, best for illumination, 231.
 conjugate foci of, 215.
 of Helmholtz, 230.
 modifications of, 247.
 plane, 214.
 proper focal length of, 4.
 tilting, 249.
 Wadsworth's, 248.
 weak-light, advantages of, in examination of media, 157.
 weak-light of Helmholtz, advantages of, 4.
- Mirrors, 214.
 concave, 215.
- Motion, center of, in eye, 185.
- Myopia, determination of, 110, 124.
- Neoplasms, in vitreous, 179.
- Nerve, discoloration of, 101.
 protrusion of, 115.
- Nerve fibres (anatomy), 26.
 abnormal transparency of, 100.
 bifurcation of, 101.
 opaque, 98.
- Nerve-stem, form of, 25.
 anatomy, 24.
 cross section (anatomy), 25.
 optic (anatomy), 24.
 transparent and non-transparent portion, 24.
- Neuritis, measurement of protrusion of, 115.
- Nodal point, 204.
- Normal eye, cause of color of fundus, 43.
 fundus of, 43.
 variation in shade and color, 46.

- Object-glass, 253.
 (jointed), 253.
 advantages of strong and of weak, in myopia, 15.
- Oblique illumination, condition of the media, 5.
 of iris, 147, 149.
 method of, 7.
 of cornea, 146.
 position of lens, 157.
- Opacities, determination of position, 159.
 in vitreous, 157, 171.
 in vitreous diffuse, 172.
 in vitreous fixed, 176.
 in vitreous movable, 174, 176.
 membranes in, 177.
 of lens (circumscribed), 154.
 (diffuse), 154.
 (physiological), 163.
- Opacity, determination of position in vitreous, 185.
- Ophthalmo-microscopes, 255.
- Ophthalmoscope artists, 254.
 Carter's, 250.
 construction of, 3.
 examination, elements of, 2.
 measurement of differences of level, 113.
 method of examination with, 10.
 remarks on, 11.
 theory of, 225.
 where superior to test by atropia and glasses, 112.
- Ophthalmoscopes, 242.
 binocular, 251.
 fixed, 250.
- Optic axis, dimensions of tables of, 113, 114.
- Optic centre (of lens), 204.
- Optic disk, objective point for examination, 12.
- Optic nerve, anomalous pigmentation of, 89.
 circulation of, 27.
 stem of, 24.
 cross section of, 25.
 diameter of, 52.
 diversity in shape and size, 52, 62.
 enlargement, as seen with ophthalmoscope, 52.
 entrance, 51.
 entrance, designations of, 51.
 entrance, form of, 25, 51.
 longitudinal section of, 23.
- Optics, physiological, 217.
- Optic nerve, coloboma of sheath, 96.
- Orthoscope, 148.
- Papilla, 51.
- Parallax, how to obtain, 13, 14 (Fig. 3).
- Pencil, of light, 195.
- Phantom, 256.
- Physiological optics, 217.
- Pial sheath (anatomy), 21.
 vessels of, 27.
- Pigment ring, 58.
- Plasmic current, 70.
- Position of observer's seat, 10.
 of patient's seat, 10.
- Pulse, absence of, in retinal vessels, 71.
 arterial, 74.
 venous, 72.
- Pupil, blackness of, 226.
 eccentric position of, 92.
- Pupillary membrane, 91.
- Pupiloscopy, 137.
- Purple, visual, 65.
- Radius, of lens, 199.
- Rays, convergent, 200.
 divergent, 210.
 divergent, in nature, 196.
 parallel (description of), 196.
- Reflection, angle of, 214.
 from plane mirror, 214.
 irregular, 196, 198.
 regular, 196.
 regular and irregular, 232.
 image formed by, 214.
 specular, 196.
 two kinds of, 196.
- Reflex, around macula, indirect image, 77.
 around macula lutea, shape of, 78.
 cause of, from yellow spot, 82.
 from lens, 151.
 from yellow spot, 77.
 of fundus, 10.
- Refraction, by cylindric lens, 213.
 cause of, 199, 201.
 conditions affecting, 201.
 determination according to inch standard, 122.
 emmetropia, 123.
 myopia, 124.
 hypermetropia, 125.
 determination of, 106.
 determination of, by mirror alone, 134.
 determination of, by inverted image, 137.
 diagrammatic representation of, 219.
 different degrees of, in various parts of the eye, 108.
 effect on appearance of fundus, 85.
 how to ascertain in a general way, 109.
 index of, 202.
 influence on circle of dispersion, 232.
 influence on size of image, 239.
 object-point for determination, 108.
 ophthalmoscope for, 106.
 smoke-box for study of, 214.
- Region of macula, 31.
- Retina, arteria centralis, 29.
 anatomy of, 31.
 diagrammatic section of, 33.
 differences in level of, 31.
 fold in, 178.
 layers of, 34.
 lymph-spaces of, 36, 37.
 parallactic displacement of vessels of, 63.
 pigment layer of, 36.
 principal branches of vessels of, 65.
 principal vein, anomalous exit of, 65.
 striation of, 64.

- Retina, thickest part of, 31.
 thickness of, as estimated with ophthalmoscope, 63.
 transparency of, 62.
 vessels of, 33, 34.
 vessels of, as seen with mirror, 63.
 vessels, principal branches of, 65.
- Retinal vessels, division of, 66.
- Retinoscopy, 137.
- Reversion, law of, 207, 217.
- Ring, connective-tissue, 57.
 pigment, 58.
 scleral, 57.
 simulating conus, 58.
- Scleral circle, 30, 31.
 Scleral opening, 49, 58.
 Scleral ring, 57.
 more pronounced in glaucoma, 57.
 simulating conus, 58.
- Sheath, arachnoidal, 21.
 dural, 22.
 external vessels of, 28.
- Sheath, medullary, 24.
 outer, inner, 21.
 pial, 21.
- Space, arachnoidal, 22.
 intervaginal, 21, 23.
 lymphatic, 27.
 subarachnoidal, 22.
 subdural, 22.
 subvaginal, 21.
- Strabismus, 112.
- Subarachnoidal space (anatomy), 22.
- Subdural space (anatomy), 22.
- Subvaginal space (anatomy), 21.
- Synechiæ in anterior chamber, 149.
- System, inch, conversion into metric, 242.
 metric, 241.
 old style, 241.
- Table (III), decrease and increase of axis, 127.
- Table (IV), dimensions of axis, old style, 128.
- Table (II), showing increase of optic axis, 114.
- Table (I), showing shortening of optic axis, 113.
- Test, catoptric, 152.
- Theory of the ophthalmoscope, illustration of, 229.
- Tortuosity of vessels, 102.
- Tumors, 149.
- Tumors of iris, 149.
- Tumors, measurement of, 115.
- Upright image, position of observer and patient, 18.
 method of performing, 18, 19, 20.
- Vein, diagrammatic section of, 35.
 principal, of retina, 65.
 inferior, of retina, 65, 66.
- Vein, subdivision of, 66.
 of choroid, 42.
 superior, of retina, 65, 66.
 subdivisions of, 66.
 variation in number, 102.
- Vena centralis, 29.
- Venæ vorticosæ, 42.
 ophthalmoscopic appearances of, 47.
- Venous pulse, 72.
 artificial production, 74.
 diagnostic mark of increased tension, 74.
 position of, 72.
 theory of, 72.
- Vessels, absence of, in macula, with inverted image, 79.
 anastomosis of retino-choroidal, 104.
 ciliary, 28.
 cilio-retinal, 104.
 crossing of retinal, 67.
 diameter of retinal, 69.
 different size of, 69.
 division of retinal, 66.
 no anastomosis of retinal, 67.
 of choroid, 39.
 of disk, 29.
 of retina (with mirror), 63.
 plan of retinal, 66.
 temporal, as seen by inverted image, 67.
 by upright image, 67.
 temporal branches of retina, 67.
 the central, 29.
 tortuosity of, 102.
 tortuosity of retinal, 67.
 transparency of walls, 70.
 walls of, in retina, 70.
- Vessel-wall, anomalies of, 102.
- Visual purple, not visible with the ophthalmoscope, 65.
- Vitreous, abscess in, 180.
 air-bubbles in, 183.
 coloboma of, 88.
 examination of, 157.
 foreign bodies in, 180.
 neoplasms in, 179.
 opacities in, 157.
 position of membranes in, 116.
- Vitreous humor, 180.
 abscess in, 180.
 opacities (as seen by mirror), 171.
- Wall, vessel, decrease in transparency, 102.
- Yellow spot, absence of vessels with inverted image, 79.
 color of, 78.
 how to find, with inverted image, 17.
 color of, 32.
 distance from nerve, 32.
 region of, 31, 77.
 situation of, 32.
 size of, 32.
 vessels of, 35, 36.

THE POPULAR SCIENCE MONTHLY.

CONDUCTED BY E. L. AND W. J. YOUMANS.

THE POPULAR SCIENCE MONTHLY for 1885 will continue, as heretofore, to supply its readers with the results of the latest investigation and the most valuable thought in the various departments of scientific inquiry.

Leaving the dry and technical details of science, which are of chief concern to specialists, to the journals devoted to them, the MONTHLY deals with those more general and practical subjects which are of the greatest interest and importance to the public at large. In this work it has achieved a foremost position, and is now the acknowledged organ of progressive scientific ideas in this country.

The wide range of its discussions includes, among other topics :

The bearing of science upon education ;

Questions relating to the prevention of disease and the improvement of sanitary conditions ;

Subjects of domestic and social economy, including the introduction of better ways of living, and improved applications in the arts of every kind ;

The phenomena and laws of the larger social organizations, with the new standard of ethics, based on scientific principles ;

The subjects of personal and household hygiene, medicine, and architecture, as exemplified in the adaptation of public buildings and private houses to the wants of those who use them ;

Agriculture and the improvement of food-products ;

The study of man, with what appears from time to time in the departments of anthropology and archæology that may throw light upon the development of the race from its primitive conditions.

Whatever of real advance is made in chemistry, geography, astronomy, physiology, psychology, botany, zoölogy, paleontology, geology, or such other department as may have been the field of research, is recorded monthly.

Special attention is also called to the biographies, with portraits, of representative scientific men, in which are recorded their most marked achievements in science, and the general bearing of their work indicated and its value estimated.

Terms: \$5.00 per annum, in advance.

The New York Medical Journal and The Popular Science Monthly to the same address, \$9.00 per annum (full price, \$10.00).

D. APPLETON & CO., 1, 3, & 5 Bond Street, New York.

A
DICTIONARY OF MEDICINE,

INCLUDING

GENERAL PATHOLOGY, GENERAL THERAPEUTICS, HYGIENE, AND THE
DISEASES PECULIAR TO WOMEN AND CHILDREN.

BY VARIOUS WRITERS.

EDITED BY

RICHARD QUAIN, M. D., F. R. S.,

FELLOW OF THE ROYAL COLLEGE OF PHYSICIANS, AND PHYSICIAN TO THE HOSPITAL FOR
DISEASES OF THE CHEST, AT BROMPTON, ETC.

In one large 8vo volume of 1,834 pages, with 138 Illustrations. Half morocco,
price, \$8.00. Sold only by Subscription.

This work is primarily a Dictionary of Medicine, in which the several diseases are fully discussed in alphabetical order. The description of each includes an account of its etiology and anatomical characters; its symptoms, course, duration, and termination; its diagnosis, prognosis, and, lastly, its treatment. General Pathology comprehends articles on the origin, characters, and nature of disease.

General Therapeutics includes articles on the several classes of remedies, their modes of action, and on the methods of their use. The articles devoted to the subject of Hygiene treat of the causes and prevention of disease, of the agencies and laws affecting public health, of the means of preserving the health of the individual, of the construction and management of hospitals, and of the nursing of the sick.

Lastly, the diseases peculiar to women and children are discussed under their respective headings, both in aggregate and in detail.

"A goodly volume of an extremely interesting and important character. Dr. Quain has succeeded in bringing together and conducting a work numbering a body of contributors of whose co-operation any editor might feel proud, and whose combined work could not fail to produce a book of the highest authority and practical value. It is noticeable that the most recent questions are dealt with, and are all treated according to the most recent researches and knowledge."—*British Medical Journal*.

"This new Medical Dictionary contains an immense mass of information, the aggregate value of which it is difficult to estimate, but which may fairly be expected to satisfy the most industrious student of medical science. A very wide and liberal meaning has been given to the word Medicine. To the general practitioners we can most heartily recommend the work; and it will find many readers outside the pale of the medical profession. It should have a place in at least every public, if not in every good private, library."—*Saturday Review*.

"The articles we have read have struck us as models of clear and fluent scientific English. The volume contains many articles on matters of general interest to the public at large, though not less important on that account to the practitioner."—*London Spectator*.

New York: D. APPLETON & CO., 1, 3, & 5 Bond Street.

December, 1885.

MEDICAL

AND

HYGIENIC WORKS

PUBLISHED BY

D. APPLETON & CO., 1, 3, & 5 Bond Street, New York.

- BARKER (FORDYCE). On Sea-Sickness. A Popular Treatise for Travelers and the General Reader. Small 12mo. Cloth, 75 cents.
- BARKER (FORDYCE). On Puerperal Disease. Clinical Lectures delivered at Bellevue Hospital. A Course of Lectures valuable alike to the Student and the Practitioner. Third edition. 8vo. Cloth, \$5.00; sheep, \$6.00.
- BARTHOLOW (ROBERTS). A Treatise on Materia Medica and Therapeutics. **Fifth edition.** Revised, enlarged, and adapted to "The New Pharmacopœia." 8vo. Cloth, \$5.00; sheep, \$6.00.
- BARTHOLOW (ROBERTS). A Treatise on the Practice of Medicine, for the Use of Students and Practitioners. **Fifth edition,** revised and enlarged. 8vo. Cloth, \$5.00; sheep, \$6.00.
- BARTHOLOW (ROBERTS). On the Antagonism between Medicines and between Remedies and Diseases. Being the Cartwright Lectures for the Year 1880. 8vo. Cloth, \$1.25.
- BASTIAN (H. CHARLTON). On Paralysis from Brain-Disease in its Common Forms. 12mo. Cloth, \$1.75.
- BASTIAN (H. CHARLTON). The Brain as an Organ of the Mind. 12mo. Cloth, \$2.50.
- BELLEVUE AND CHARITY HOSPITAL REPORTS. Edited by W. A. Hammond, M. D. 8vo. Cloth, \$4.00.
- BENNET (J. H.). Winter and Spring on the Shores of the Mediterranean; or, The Riviera, Mentone, Italy, Corsica, Sicily, Algeria, Spain, and Biarritz, as Winter Climates. With numerous Illustrations. New revised edition. 12mo. Cloth, \$3.50.
- BENNET (J. H.). On the Treatment of Pulmonary Consumption, by Hygiene, Climate, and Medicine. Thin 8vo. Cloth, \$1.50.
- BILLINGS (F. S.). The Relation of Animal Diseases to the Public Health, and their Prevention. 8vo. Cloth, \$4.00.
- BILLROTH (THEODOR). General Surgical Pathology and Therapeutics. A Text-Book for Students and Physicians. Translated from the tenth German edition, by special permission of the author, by Charles E. Hackley, D. M. **Fifth American edition, revised and enlarged.** 8vo. Cloth, \$5.00; sheep, \$6.00.

- BRAMWELL (BYROM). Diseases of the Heart and Thoracic Aorta. Illustrated with Lithographs, Chromo-Lithographs, and numerous Wood-Engravings. 8vo. Cloth, \$8.00; sheep, \$9.00.
- BUCK (GURDON). Contributions to Reparative Surgery, showing its Application to the Treatment of Deformities produced by Destructive Disease or Injury; Congenital Defects from Arrest or Excess of Development; and Cicatricial Contractions following Burns. Illustrated by Thirty Cases and fine Engravings. 8vo. Cloth, \$3.00.
- CARPENTER (W. B.). Principles of Mental Physiology, with their Application to the Training and Discipline of the Mind, and the Study of its Morbid Conditions. 12mo. Cloth, \$3.00.
- CARTER (ALFRED H.). Elements of Practical Medicine. **Third edition**, revised and enlarged. 12mo. Cloth, \$3.00.
- CHAUVEAU (A.). The Comparative Anatomy of the Domesticated Animals. Translated and edited by George Fleming. Illustrated. 8vo. Cloth, \$6.00.
- COMBE (ANDREW). The Management of Infancy, Physiological and Moral. Revised and edited by Sir James Clark. 12mo. Cloth, \$1.50.
- COOLEY. Cyclopædia of Practical Receipts, and Collateral Information in the Arts, Manufactures, Professions, and Trades, including Medicine, Pharmacy, and Domestic Economy. Designed as a Comprehensive Supplement to the Pharmacopœia, and General Book of Reference for the Manufacturer, Tradesman, Amateur, and Heads of Families. **Sixth edition**, revised and partly rewritten by Richard V. Tuson. With Illustrations. 2 vols., 8vo. Cloth, \$9.00.
- CORNING (J. L.). Brain Exhaustion, with some Preliminary Considerations on Cerebral Dynamics. Crown 8vo. Cloth, \$2.00.
- CORNING (J. L.). Local Anæsthesia in General Medicine and Surgery. Being the Practical Application of the Author's Recent Discoveries in Local Anæsthesia. Small 8vo. volume of about 50 pages, with several Illustrations. (*Nearly ready.*)
- DAVIS (HENRY G.). Conservative Surgery. With Illustrations. 8vo. Cloth, \$3.00.
- ELLIOT (GEORGE T.). Obstetric Clinic: A Practical Contribution to the Study of Obstetrics and the Diseases of Women and Children. 8vo. Cloth, \$4.50.
- EVETZKY (ETIENNE). The Physiological and Therapeutical Action of Ergot. Being the Joseph Mather Smith Prize Essay for 1881. 8vo. Limp cloth, \$1.00.
- FLINT (AUSTIN). Medical Ethics and Etiquette. Commentaries on the National Code of Ethics. 12mo. Cloth, 60 cents.
- FLINT (AUSTIN, JR.). Text-Book of Human Physiology; designed for the Use of Practitioners and Students of Medicine. Illustrated by three Lithographic Plates, and three hundred and thirteen Woodcuts. **Third edition, revised.** Imperial 8vo. Cloth, \$6.00; sheep, \$7.00.
- FLINT (AUSTIN JR.). The Physiological Effects of Severe and Protracted Muscular Exercise; with Special Reference to its Influence upon the Excretion of Nitrogen. 12mo. Cloth, \$1.00.

FLINT (AUSTIN, JR.). Physiology of Man. Designed to represent the Existing State of Physiological Science as applied to the Functions of the Human Body. Complete in 5 vols.

Vol. I. Introduction; The Blood; Circulation; Respiration. 8vo.

Vol. II. Alimentation; Digestion; Absorption; Lymph; and Chyle. 8vo.

Vol. III. Secretion; Excretion; Ductless Glands; Nutrition; Animal Heat; Movements; Voice and Speech. 8vo.

Vol. IV. The Nervous System. 8vo.

Vol. V. (With a General Index to the five volumes.) Special Senses; Generation. Per vol., cloth, \$4.50; sheep, \$5.50.

* * Vols. I and II can be had in cloth and sheep binding; Vol. III in sheep only. Vol. IV is at present out of print.

FLINT (AUSTIN, JR.). The Source of Muscular Power. Arguments and Conclusions drawn from Observation upon the Human Subject under Conditions of Rest and of Muscular Exercise. 12mo. Cloth, \$1.00.

FLINT (AUSTIN, JR.). Manual of Chemical Examinations of the Urine in Disease; with Brief Directions for the Examination of the most Common Varieties of Urinary Calculi. Revised edition. 12mo. Cloth, \$1.00.

FOTHERGILL (J. MILNER). Diseases of Sedentary Life and Old Age. 8vo. Cloth, \$2.00.

FOURNIER (ALFRED). Syphilis and Marriage. Translated by P. Albert Morrow, M. D. 8vo. Cloth, \$2.00; sheep, \$3.00.

FREY (HEINRICH). The Histology and Histochemistry of Man. A Treatise on the Elements of Composition and Structure of the Human Body. Translated from the fourth German edition by Arthur E. J. Barker, M. D., and revised by the author. With 608 Engravings on Wood. 8vo. Cloth, \$5.00; sheep, \$6.00.

FRIEDLANDER (CARL). The Use of the Microscope in Clinical and Pathological Examinations. Second edition, enlarged and improved, with a Chromo-lithograph Plate. Translated, with the permission of the author, by Henry C. Coe, M. D. 8vo. Cloth, \$1.00.

GAMGEE (JOHN). Yellow Fever a Nautical Disease. Its Origin and Prevention. 8vo. Cloth, \$1.50.

GROSS (SAMUEL W.). A Practical Treatise on Tumors of the Mammary Gland. Illustrated. 8vo. Cloth, \$2.50.

GUTMANN (EDWARD). The Watering-Places and Mineral Springs of Germany, Austria, and Switzerland. Illustrated. 12mo. Cloth, \$2.50.

GYNÆCOLOGICAL TRANSACTIONS, VOL. VIII. Being the Proceedings of the Eighth Annual Meeting of the American Gynæcological Society, held in Philadelphia, September 18, 19, and 20, 1883. 8vo. Cloth, \$5.00.

GYNÆCOLOGICAL TRANSACTIONS, VOL. IX. Being the Proceedings of the Ninth Annual Meeting of the American Gynæcological Society, held in Chicago, September 30, and October 1 and 2, 1884. 8vo. Cloth, \$5.00.

HAMILTON (ALLAN McL.). Clinical Electro-Therapeutics, Medical and Surgical. A Hand-Book for Physicians in the Treatment of Nervous and other Diseases. 8vo. Cloth, \$2.00.

HAMMOND (W. A.). A Treatise on Diseases of the Nervous System. **Seventh edition**, rewritten, enlarged, and improved. 8vo. Cloth, \$5.00; sheep, \$6.00.

HAMMOND (W. A.). A Treatise on Insanity, in its Medical Relations. 8vo. Cloth, \$5.00; sheep, \$6.00.

HAMMOND (W. A.). Clinical Lectures on Diseases of the Nervous System. Delivered at Bellevue Hospital Medical College. Edited by T. M. B. Cross, M. D. 8vo. Cloth, \$3.50.

HART (D. BERRY). Atlas of Female Pelvic Anatomy. With Preface by Alexander J. C. Skene, M. D. 37 Plates with 150 Figures, and 89 pages descriptive text. Large 4to. Cloth, \$15.00. (*Sold only by subscription.*)

HARVEY (A.). First Lines of Therapeutics. 12mo. Cloth, \$1.50.

HEALTH PRIMERS. Edited by J. Langdon Down, Henry Power, J. Mortimer-Granville, and John Tweedy. In square 16mo volumes. Cloth, 40 cents each.

- | | |
|--|---|
| I. Exercise and Training. | V. Personal Appearance in Health and Disease. |
| II. Alcohol: Its Use and Abuse. | VI. Baths and Bathing. |
| III. Premature Death: Its Promotion or Prevention. | VII. The Skin and its Troubles. |
| IV. The House and its Surroundings. | VIII. The Heart and its Functions. |
| | IX. The Nervous System. |

HOFFMANN-ULTZMANN. Introduction to an Investigation of Urine, with Special Reference to Diseases of the Urinary Apparatus. By M. B. Hoffmann, Professor in the University of Gratz; and R. Ultzmann, Tutor in the University of Vienna. Second enlarged and improved edition. 8vo. Cloth, \$2.00.

HOWE (JOSEPH W.). Emergencies, and how to treat them. Fourth edition, revised. 8vo. Cloth, \$2.50.

HOWE (JOSEPH W.). The Breath, and the Diseases which give it a Fetid Odor. With Directions for Treatment. **Second edition**, revised and corrected. 12mo. Cloth, \$1.00.

HUEPPE (FERDINAND). The Methods of Bacteriological Investigation. Written at the request of Dr. Robert Koch. Translated by Hermann M. Biggs, M. D. (*Nearly ready.*)

HUXLEY (T. H.). The Anatomy of Vertebrated Animals. Illustrated. 12mo. Cloth, \$2.50.

HUXLEY (THOMAS HENRY). The Anatomy of Invertebrated Animals Illustrated. 12mo. Cloth, \$2.50.

JACCOUD (S.). The Curability and Treatment of Pulmonary Phthisis. Translated and edited by Montagu Lubbock, M. D. 8vo. Cloth, \$4.00.

JOHNSON (JAMES F. W.). The Chemistry of Common Life. A new edition, revised and brought down to the Present Time. By Arthur Herbert Church. Illustrated with Maps and numerous Engravings on Wood. 12mo. Cloth, \$2.00.

JONES (H. MACNAUGHTON). Practical Manual of Diseases of Women and Uterine Therapeutics. For Students and Practitioners. 188 Illustrations. 12mo. Cloth, \$3.00.

- KEYES (E. L.). The Tonic Treatment of Syphilis, including Local Treatment of Lesions. 8vo. Cloth, \$1.00.
- KINGSLEY (N. W.). A Treatise on Oral Deformities as a Branch of Mechanical Surgery. With over 350 Illustrations. 8vo. Cloth, \$5.00; sheep, \$6.00.
- LEGG (J. WICKHAM). On the Bile, Jaundice, and Bilious Diseases. With Illustrations in Chromo-Lithography. 8vo. Cloth, \$6.00; sheep, \$7.00.
- LETTERMANN (JONATHAN). Medical Recollections of the Army of the Potomac. 8vo. Cloth, \$1.00.
- LITTLE (W. J.). Medical and Surgical Aspects of In-Knee (Genu-Valgum): its Relation to Rickets, its Prevention, and its Treatment, with and without Surgical Operation. Illustrated by upward of Fifty Figures and Diagrams. 8vo. Cloth, \$2.00.
- LORING (EDWARD G.). A Text-Book of Ophthalmoscopy. Part I. The Normal Eye, Determination of Refraction, and Diseases of the Media. 8vo. With 131 Illustrations, and 4 Chromo-Lithographs.
- LUSK (WILLIAM T.). The Science and Art of Midwifery. With 246 Illustrations. **Second edition, revised and enlarged.** 8vo. Cloth, \$5.00; sheep, \$6.00.
- LUYS (J.). The Brain and its Functions. With Illustrations. 12mo. Cloth, \$1.50.
- McSHERRY (RICHARD). Health, and how to promote it. 12mo. Cloth, \$1.25.
- MARKOE (T. M.). A Treatise on Diseases of the Bones. With Illustrations. 8vo. Cloth, \$4.50.
- MAUDSLEY (HENRY). Body and Mind: an Inquiry into their Connection and Mutual Influence, specially in reference to Mental Disorders. An enlarged and revised edition, to which are added Psychological Essays. 12mo. Cloth, \$1.50.
- MAUDSLEY (HENRY). Physiology of the Mind. Being the first part of a third edition, revised, enlarged, and in great part rewritten, of "The Physiology and Pathology of the Mind." 12mo. Cloth, \$2.00.
- MAUDSLEY (HENRY). Pathology of the Mind. Third edition. 12mo. Cloth, \$2.00.
- MAUDSLEY (HENRY). Responsibility in Mental Disease. 12mo. Cloth, \$1.50.
- NEFTEL (WM. B.). Galvano-Therapeutics. The Physiological and Therapeutical Action of the Galvanic Current upon the Acoustic, Optic, Sympathetic, and Pneumogastric Nerves. 12mo. Cloth, \$1.50.
- NEUMANN (ISIDOR). Hand-Book of Skin Diseases. Translated by Lucius D. Bulkley, M. D. Illustrated by 66 Wood-Engravings. 8vo. Cloth, \$4.00; sheep, \$5.00.
- THE NEW YORK MEDICAL JOURNAL (weekly). Edited by Frank P. Foster, M. D. Terms per annum, \$5.00.
- GENERAL INDEX, from April, 1865, to June, 1876 (23 vols.) 8vo. Cloth, 75 cents.

- NIEMEYER (FELIX VON). A Text-Book of Practical Medicine, with particular reference to Physiology and Pathological Anatomy. Containing all the author's Additions and Revisions in the eighth and last German edition. Translated from the German edition, by George H. Humphreys, M. D., and Charles E. Hackley, M. D. 2 vols., 8vo. Cloth, \$9.00; sheep, \$11.00.
- NIGHTINGALE'S (FLORENCE). Notes on Nursing. 12mo. Cloth, 75 cents.
- OSWALD (F. L.). Physical Education; or, The Health Laws of Nature. 12mo. Cloth, \$1.00.
- PEASLEE (E. R.). A Treatise on Ovarian Tumors: their Pathology, Diagnosis, and Treatment, with reference especially to Ovariectomy. With Illustrations. 8vo. Cloth, \$5.00; sheep, \$6.00.
- PEREIRA'S (Dr.) Elements of Materia Medica and Therapeutics. Abridged and adapted for the Use of Medical and Pharmaceutical Practitioners and Students, and comprising all the Medicines of the British Pharmacopœia, with such others as are frequently ordered in Prescriptions, or required by the Physician. Edited by Robert Bentley and Theophilus Redwood. Royal 8vo. Cloth, \$7.00; sheep, \$8.00.
- PEYER (ALEXANDER). An Atlas of Clinical Microscopy. Translated and edited by Alfred C. Girard, M. D., Assistant Surgeon United States Army. First American, from the manuscript of the second German edition, with Additions. Ninety Plates, with 105 Illustrations, Chromo-Lithographs. Square 8vo. Cloth, \$6.00.
- POMEROY (OREN D.). The Diagnosis and Treatment of Diseases of the Ear. With One Hundred Illustrations. New edition, revised and enlarged. 8vo. Cloth. (*Nearly ready.*)
- POORE (C. T.). Osteotomy and Osteoclasis, for the Correction of Deformities of the Lower Limbs. 50 Illustrations. 8vo. Cloth, \$2.50.
- QUAIN (RICHARD). A Dictionary of Medicine, including General Pathology, General Therapeutics, Hygiene, and the Diseases peculiar to Women and Children. By Various Writers. Edited by Richard Quain, M. D., In one large 8vo volume, with complete Index, and 138 Illustrations. (*Sold only by subscription.*) Half morocco, \$8.00.
- RANNEY (AMBROSE L.). Applied Anatomy of the Nervous System, being a Study of this Portion of the Human Body from a Standpoint of its General Interest and Practical Utility, designed for Use as a Text-Book and as a Work of Reference. Profusely illustrated. 8vo. Cloth, \$4.00; sheep, \$5.00.
- RANNEY (AMBROSE L.). Lectures on Electricity in Medicine, delivered at the Medical Department of the University of Vermont, Burlington. 12mo. With numerous Illustrations. Cloth, \$1.00.
- RIBOT (TH.). Diseases of Memory: an Essay in the Positive Psychology. Translated from the French by William Huntington. 12mo. Cloth, \$1.50.
- RICHARDSON (B. W.). Diseases of Modern Life. 12mo. Cloth, \$2.00.
- RICHARDSON (B. W.). A Ministry of Health and other Addresses. 12mo. Cloth, \$1.50.
- ROBINSON (A. R.). A Manual of Dermatology. Revised and corrected. 8vo. Cloth, \$5.00.

ROSENTHAL (I.). General Physiology of Muscles and Nerves. With 75 Woodcuts. 12mo. Cloth, \$1.50.

ROSCOE-SCHORLEMMER. Treatise on Chemistry.

Vol. 1. Non-Metallic Elements. 8vo. Cloth, \$5.00.

Vol. 2. Part I. Metals. 8vo. Cloth, \$3.00.

Vol. 2. Part II. Metals. 8vo. Cloth, \$3.00.

Vol. 3. Part I. The Chemistry of the Hydrocarbons and their Derivatives. 8vo. Cloth, \$5.00.

Vol. 3. Part II. The Chemistry of the Hydrocarbons and their Derivatives. 8vo. Cloth, \$5.00.

SAYRE (LEWIS A.). Practical Manual of the Treatment of Club-Foot. **Fourth edition, enlarged and corrected.** 12mo. Cloth, \$1.25.

SAYRE (LEWIS A.). Lectures on Orthopedic Surgery and Diseases of the Joints, delivered at Bellevue Hospital Medical College. **New edition,** illustrated with 324 Engravings on Wood. 8vo. Cloth, \$5.00; sheep, \$6.00.

SCHROEDER (KARL). A Manual of Midwifery, including the Pathology of Pregnancy and the Puerperal State. Translated into English from the third German edition, by Charles H. Carter, M. D. With 26 Engravings on Wood. 8vo. Cloth, \$3.50; Sheep, \$4.50.

SIMPSON (JAMES Y.). Selected Works: Anaesthesia, Diseases of Women. 3 vols., 8vo. Per volume. Cloth, \$3.00; sheep, \$4.00.

SMITH (EDWARD). Foods. 12mo. Cloth, \$1.75.

SMITH (EDWARD). Health: A Hand-Book for Households and Schools. Illustrated. 12mo. Cloth, \$1.00.

STEINER (JOHANNES). Compendium of Children's Diseases: a Hand-Book for Practitioners and Students. Translated from the second German edition, by Lawson Tait. 8vo. Cloth, \$3.50; sheep, \$4.50.

STONE (R. FRENCH). Elements of Modern Medicine, including Principles of Pathology and of Therapeutics, with many Useful Memoranda and Valuable Tables of Reference. Accompanied by Pocket Fever Charts. Designed for the Use of Students and Practitioners of Medicine. In wallet-book form, with pockets on each cover for Memoranda, Temperature Charts, etc. Roan, tuck, \$2.50.

STRECKER (ADOLPH). Short Text-Book of Organic Chemistry. By Dr. Johannes Wislicenus. Translated and edited, with Extensive Additions, by W. H. Hodgkinson and A. J. Greenaway. 8vo. Cloth, \$5.00.

SWANZY (HENRY R.). A Hand-Book of the Diseases of the Eye, and their Treatment. With 122 Illustrations, and Holmgren's Tests for Color-Blindness. Crown 8vo. Cloth, \$3.00.

TRACY (ROGER S.). The Essentials of Anatomy, Physiology, and Hygiene. 12mo. Cloth, \$1.25.

TRACY (ROGER S.). Hand-Book of Sanitary Information for Householders. Containing Facts and Suggestions about Ventilation, Drainage, Care of Contagious Diseases, Disinfection, Food, and Water. With Appendices on Disinfectants and Plumbers' Materials. 16mo. Cloth, 50 cents.

TRANSACTIONS OF THE NEW YORK STATE MEDICAL ASSOCIATION, VOL. I. Being the Proceedings of the First Annual Meeting of the New York State Medical Association, held in New York, November 18, 19, and 20, 1884. Small 8vo. Cloth, \$5.00.

TYNDALL (JOHN). Essays on the Floating Matter of the Air, in Relation to Putrefaction and Infection. 12mo. Cloth, \$1.50.

ULTZMANN (ROBERT). Pyuria, or Pus in the Urine, and its Treatment. Translated by permission, by Dr. Walter B. Platt. 12mo. Cloth, \$1.00.

VAN BUREN (W. H.). Lectures upon Diseases of the Rectum, and the Surgery of the Lower Bowel, delivered at Bellevue Hospital Medical College. **Second edition, revised and enlarged.** 8vo. Cloth, \$3.00; sheep, \$4.00.

VAN BUREN (W. H.). Lectures on the Principles and Practice of Surgery. Delivered at Bellevue Hospital Medical College. Edited by Lewis A. Stimson, M. D. 8vo. Cloth, \$4.00; sheep, \$5.00.

VAN BUREN AND KEYES. A Practical Treatise on the Surgical Diseases of the Genito-Urinary Organs, including Syphilis. Designed as a Manual for Students and Practitioners. With Engravings and Cases. By W. H. Van Buren, M. D., and Edward L. Keyes, M. D. 8vo. Cloth, \$5.00; sheep, \$6.00.

VOGEL (A.). A Practical Treatise on the Diseases of Children. Translated and edited by H. Raphael, M. D. **Third American from the eighth German edition, revised and enlarged.** Illustrated by six Lithographic Plates. 8vo. Cloth, \$4.50; sheep, \$5.50.

WAGNER (RUDOLF). Hand-Book of Chemical Technology. Translated and edited from the eighth German edition, with extensive Additions, by William Crookes. With 336 Illustrations. 8vo. Cloth, \$5.00.

WALTON (GEORGE E.). Mineral Springs of the United States and Canadas. Containing the latest Analyses, with full Description of Localities, Routes, etc. **Second edition, revised and enlarged.** 12mo. Cloth, \$2.00.

WEBBER (S. G.). A Treatise on Nervous Diseases: Their Symptoms and Treatment. A Text-Book for Students and Practitioners. 8vo. Cloth, \$3.00.

WEEKS (CLARA S.). A Text-Book of Nursing. For the Use of Training-Schools, Families, and Private Students. 12mo. With 13 Illustrations, Questions for Review and Examination, and Vocabulary of Medical Terms. 12mo. Cloth, \$1.75.

WELLS (T. SPENCER). Diseases of the Ovaries. 8vo. Cloth, \$4.50.

WYLIE (WILLIAM G.). Hospitals: Their History, Organization, and Construction. 8vo. Cloth, \$2.50.







