

## **The ophthalmoscope and lues / by Ole B. Bull.**

### **Contributors**

Bull, O. B. 1842-1916.  
University College, London. Library Services

### **Publication/Creation**

Christiana : published at P. T. Mallings's Boghandel, 1884.

### **Persistent URL**

<https://wellcomecollection.org/works/vbx3f6zm>

### **Provider**

University College London

### **License and attribution**

This material has been provided by This material has been provided by UCL Library Services. The original may be consulted at UCL (University College London) where the originals may be consulted.

This work has been identified as being free of known restrictions under copyright law, including all related and neighbouring rights and is being made available under the Creative Commons, Public Domain Mark.

You can copy, modify, distribute and perform the work, even for commercial purposes, without asking permission.



Wellcome Collection  
183 Euston Road  
London NW1 2BE UK  
T +44 (0)20 7611 8722  
E [library@wellcomecollection.org](mailto:library@wellcomecollection.org)  
<https://wellcomecollection.org>



III.  
K. 3.



No. 128 / H

III  
K 3.

J.62


360



THE INSTITUTE  
OF  
OPHTHALMOLOGY  
LONDON

EX LIBRIS








B/c 281101425x

B/c 281101425x



B.1.  $\frac{4}{16}$





Digitized by the Internet Archive  
in 2014

<https://archive.org/details/b2128538x>





# THE OPHTHALMOSCOPE AND LUES.

BY

OLE B. BULL M. D.



CHRISTIANIA.

PUBLISHED AT P. T. MALLING'S BOGHANDEL

(G. KR. JOHS. PARMANN).

1884.

# THE OPHTHALMOSCOPE

AND LENSES.

BY

OLE B. BULL, M. D.



CHRISTIANIA.

PRINTED AT MALLINGSKE BOGTRYKKERI.

PUBLISHED BY P. J. MALLING'S BOGHANDEL.

(G. KR. JOHN. TARMAN.)

1854.

4/8/79



To

Sir Henry W. Acland K. C. B., M. D.,

Regius Professor of Medicine in the University of Oxford etc.,

these pages are gratefully and respectfully dedicated by

the Author.

To

Sir Henry W. Acland K. C. B., M. D.,

Regius Professor of Medicine in the University of Oxford etc.

these pages are gratefully and respectfully dedicated by

the Author.



## Introduction.

---

About 15 years ago I became aware that very conspicuous ophthalmological changes are often to be observed in patients suffering from recent syphilis, and that those changes, usually, are not accompanied by any functional disorder. With a view to draw attention to this interesting fact, I published, in Nordisk Medicinsk Archiv Vol III No. 4 1871, a short paper entitled: — «Nogle foreløbige Meddelelser om Retinalaffectioner ved Syphilis.»

I regret, that in this preliminary memoir, I made the mistake of regarding as pathological some physiological abnormalities. Among a comparatively small number of syphilitici, I found several with opaque nerve-fibres, who happened to have a rather low power of vision. By including these cases among the pathological changes too high a number was obtained for the retinal affections. Although undoubtedly with syphilitic retinitis exudations may occur, which, neither by their appearance, nor by their position, close to the optic disc, can be distinguished from congenital nerve-fibres, I was, after a time satisfied that the spots, in the cases referred to, ought not to be considered as such exudations, since they remained for years unaltered. In some critical remarks in Dansks Hospitalstidende 1871 No. 46, *Dr. Hansen Grut*, of Copenhagen, advanced reasons to prove my views on this point erroneous; indicating at the same time, all the opinions expressed in my memoir in Nordisk Medicinsk Archiv, as strange, and unquestionably wrong. This criticism of *Dr. Hansen* caused me to point out more explicitly what I had wished to make known in the memoir; viz. — *that striking pathological changes of the retina and of the optic disc, in cases of recent*



*syphilis, do occur far oftener than is usually supposed and that these changes need not be accompanied by functional disturbances.* (Vide Dansk Hospitalstidende, 1872, No. 6).

It seems however as if, in wider circles, the criticism only of *Dr. Hansen*, and not my response, has been published. This may account for the fact that my views have been, up to the latest date discredited, or even ridiculed. As an example, I shall only quote what Prof. *Mauthner* writes, in Zeils' manual of syphilis, 1875, p. 286. «Der Curiosität wegen, will ich hier die Resultate zu denen *Ole B. Bull*, (vide Centralblatt für die medic. Wissenschaften, 22de Juli, 1871) durch die Untersuchung von 200 an erworbener Syphilis leidende gelangt, zu sein behauptet. Er sah ausser wallenförmigen Schwellung um die Papille, die auch schon *Classen* erwähnt, sehr häufig weisse Flecken in der nächsten Nähe der Papille, jedoch ohne Apoplexien; Schmerz und functionelle Störungen nicht vorhanden, oder nur sehr wenig ausgesprochen. Von 200 zeigte über die Hälfte die Netzhauterkrankung, während Iritis, nur zweimal vorkam. Die Retinitis würde mehrere Malen als erstes Leichen der Syphilis wahrgenommen. Atrophie der Schnerven und der Netzhaut ist ein sehr seltener Ausgang; die Prognose günstiger als angenommen wird. Die Behandlung soll mehr abwartend sein, während energische Anwendung von Mercur eher Nachtheil als Vorthail bringt. (!) *Hansen* hat diese Angabe *Bull's* bereits einer ziemlich vernichtende Kritik unterzogen.» If *Pr. Mauthner* had known my reply to *Dr. Hansen*, and not his criticism only, he would, perhaps, have investigated this matter himself, before giving his decision. That he has now probably changed his opinion on this point is not unlikely, since *Prf. Schnabel* having, at the request of *Prf. Lang*, ophthalmoscopically examined a number of syphilitic patients, has found alterations clearly analogous to those which I first described in the above named periodical.

Prof. *Lang* has explained these changes as being a result of pathological processes within the central nervous system. (Vide Vierteljahrsschrift für Dermalogie und Syphilis, Wien 1881 p. 469, Ueber Meningealirritation bei beginnender Syphilis). To the same conclusion I had come myself many years ago, and I have also in a brief publication, in »Transactions of the Minnesota State Medical Society 1875, entitled:



»The affections of the nervous system, and more especially of the Optic Nerve in Syphilis», set forth my views on this point. It seems however that this publication, as well as a treatise entitled: »De på Syphilis beroende pathologiske Forandringer af Øienbunden,« which I published in 1880, and of which the present treatise is, in some parts, a translation, has passed unnoticed by the profession at large.

In addition to an explicit description of the aforesaid affections comprised in the first part of this book, various other forms of syphilitic eye-affections are described, which have all for a long time been more or less well known; but, as my further observations of such affections have given me an opinion different from that generally accepted, I would not withhold my views concerning them; and that so much the more, as there has not yet appeared any complete description of all the syphilitic affections of the fundus oculi.

I would here take the opportunity to thank the Head Surgeon for the Department of Skin-Diseases at the State Hospital, Dr. *Bidenkap*, who always with the greatest liberality, has placed the patients in his wards at my disposal. Also to Drs. *Scheel* and *Boeck* I here express my gratitude for their assistance during the term of their service at the State-Hospital. Above all I feel grateful to my late teacher, Prof. Dr. *W. Boeck*, for the untiring interest he displayed when I commenced my investigations of syphilitic eye-diseases.

---



## Historical notes.

---

When we have to deal with questions relating to the more special branches of medicine, the results of historical investigations will always be found more or less uncertain; not because the observations of the ancients were less accurate than ours, or their descriptions of the diseases less precise; but because their explanations of the symptoms were different, and their means of making a more detailed diagnosis imperfect as compared with ours. Their nosological system, too, was quite different from that of our days; being in some respects certainly, more minutely subdivided, in other, on the contrary, so imperfectly elaborated, that groups of diseases essentially different in kind may be found classified together. No wonder therefore that, as a rule, it is difficult, or even sometimes impossible, from their records, to recognise diseases, which to the modern physician, are obvious as typical forms. Perhaps of no other branch of medicine does this remark hold so good as of ophthalmology.

Concerning the venereal diseases of the eye, we can, from the writings of the ancients, safely infer that these were not unknown to them. To determine which were the affections of the eye, that we find recorded, is, however, not always possible. The fact that syphilis and gonorrhœa, sometimes even leprosy and several affections of the skin and mucous membranes, were classified together, renders every decision in this respect still more doubtful. So we find in one of the oldest known medical works, in which, certainly, venereal diseases are recorded, viz. — in the system of Hindu medicine, *Ayur-Veda*, — an affection of the eye mentioned; but, although this affection is named among symptoms indicating constitutional



syphilitic affections, its description is more applicable to purulent ophthalmia. (Vide Dr. *Hermann Friedberg*, *Die Lehre von den venerischen Krankheiten in dem Alterthume und Mittelalter*. Berlin, 1865, p. 33).

This quotation from *Ayur-Veda* is the only one yet found that unquestionably shows venereal eye-diseases to have been known in bygone ages. We have however from that time but scanty records to show that syphilis was known; and, consequently, it is not to be expected that more special accounts of this disease should be found.

It was not before the end of the 15th and the beginning of the 16th century that writers on syphilis became numerous. At that time this plague seemed suddenly to have gained a footing formerly unknown; and had, perhaps, also assumed a graver character than it had before exhibited. No wonder therefore that a general interest was at once excited, and that we, in the rich literature of that age, find the foundation laid of our present knowledge of this disease.

The affections of the eye are seen to be frequently mentioned by authors from that period; but, these affections, as several others of *Morbus Gallicus*, were not always recognised as results arising from the disease itself, but are ascribed to other causes, occasionally complicating the disease. No more could be expected so long as physicians had not gained an exact acquaintance with the real nature of syphilis, but saw, in the stars and in the atmospheric conditions, a predominant etiological influence. Thus *Nicolaus Leoniceus*, one of the earliest writers of that time, names diseases of the eye among various other affections, following the epidemy of *Morbus Gallicus*, prevalent during his time, as something well known: »*quandoque etiam oculos infestantia pertulere, non expedit commemorare, quando hæc insigniora fuerunt quam ut egeant enarratione.*« Collating these affections with those *Hippocrates* mentions in his *tertia particula aphorismorum*, he thinks that they are to be attributed to an excess of moisture and heat in the atmosphere (» . . . *nimiam aëris in calore, atque humiditate præsertim intemperiem.*« *N. Leoniceus*, liber de epidemiâ quam Itali Morbum Gallicum vocant 1467. *Aloysius Luicinus*, *Aphrodisiacus*, sive de Lue venerêa. 1728 p. 33). *Angelus Bolognius*, also one of the earliest writers of that



period, thought that drastics were capable of producing *debilitatio visûs* (A. B. de Ulcerum exteriorum medelâ opusculum, perquam utile. 1507; in the collection of Gruner, Aphrodisiacus sive de Lue ven. 1788 p. 122).

Such an erroneous apprehension of the relation between this disease and its symptoms, if at any time general, soon passed away as a more correct idea of the true character of syphilis began to gain ground. As early as the commencement of the 16th century, we find that authors begin to regard eye-affections, originated during the course of the disease, as its direct consequence. So *Hieronimus Emser*, about 1511, states «*puella tredecim annorum Margarita, Joannis balneatorum Rubensis filia, morbo gallico ita graviter laborat, ut oculum alterum penitus amitteret . . .*» (Vide *Fuchs* die ältesten Schriftsteller über die Lustseuche in Deutschland, Göttingen 1843 p. 33). *Johanes de Vigo* says expressly, in his »Tractatus de Morbo Gallico 1514, «*diversos etiam oculorum morbos ab isto morbo genitos multoties curavimus.*» (*Aloys. Luic. p. 450*).

As previously mentioned, it may not always be possible, from single quotations, to determine of what kind were the eye-affections alluded to therein. And, for this reason, that as the ideas of the physiological processes of the visual act and the apprehension of the nature of eye-diseases in general, were then so widely different from ours, we might expect to learn more concerning this question from the reports of *isolated cases*, than from a general description of such eye-affections. Reports of single cases are however rare and, sometimes, very imperfect. Beyond the aforecited case, reported by *Hieronimus Emser*, and which does not give any information touching the cause of the eye-disease, I have found only two others. The first of these is reported by *Nicolaus Massa*, De Morbo Gallico, 1532 as follows: — »*Casus talis fuit. Clarissimus, nobilis, ætatis consistentiæ, complexionis sanguineæ, a juventute enim coepit labi in auditûs, visûs, et odoratûs defectum . . .*» (*Aloys. Luic. p. 75*). As in this case not only the sight, but also the hearing and smell were affected, it is probable that a pathological process of the base of the skull, involving the respective nerves, was the anatomical cause of the patient's sufferings. The other is the



famous case of *Leonardus Botallus*, which *Meilhac* and after him, several other authors have erroneously confounded with a choroiditis syphilitica. Such as *Botallus* reports it, it must be considered a neuritis optica. It is reported that the patient »*jam menses aliquot insomnes peregerat, ex gravi capitis dolore circa sinciput ac tempora, ob Venereum morbum.* *Botallus* proposed the application of caustic to those parts of the skull where the pains had their seat, but this the patient refused, and went to seek relief else where. After the lapse of one month he again called on *Botallus* who then found him » . . . *penitus lumine orbatum . . . oculi tamen nil extranei videbantur pati: primitus dicebat per multos dies antequam integrè oculorum lumine interdiceretur, apparuisse culices semper ante oculos circumvolantes, et telas araneas lumine objectas, mox sensim visum perdidisse.*» *Botallus* tried to persuade him to submit himself to a trepanning, but in vain. Forty days afterwards the patient »*ad superos migravit.*» Of the necropsy, which was performed by *Lucius Montanus*, *Botallus* being present, we read: «. . . *ubi cranium in conterminis coronalis, ac sagittalis commissuræ, os spaciolum putidumque invenimus coronati regii latitudine, statimque cranio serrâ aperto, abundans ichor putrelaginosus, instar aquæ, fuligine fumarii et croceo aspersæ, profluxit, tum per ossis aperturam, tum per aures et nares, membranæque putidæ rectè ad os affectum, verum adhuc integræ erant, quæ solo tactu facile rumpebantur, corruptum et cerebrum, et nervi optici . . .*» *L. B. Luis, Venereæ curandæ ratio. Aloys. Luic. p. 884.* It is consequently apparent, from both the historia morbi and from the post mortem examination, that this case was an optic neuritis, secondary to an affection of the bones — consequently a tertiary syphilitic affection. Hence it is not likely that there should have been even a complication of retino-choroiditis, as this belongs to the secondary stage. The only symptom which could indicate such a complication, is the patient's complaining of myiodesopsia, and his seeing of spider-webs; but as the symptoms of a neuritis are exceedingly variable, no weight can be attached to this.

In the *general* descriptions of syphilis from that time, we find, that the authors often merely state that the sight was affected, or, if they give a more explicit explanation, this is usually



short and full of the obscure doctrines of that age. By comparing, however, the rather numerous statements of the different authors, it will be apparent, that not only was it a well known fact, that the syphilitic virus could produce different eye-affections, but also, that these affections might have their seat both in the globe itself, and in the parts behind the globe, viz. — in the optic nerves, and in the brain.

As might be expected from the relative frequency of the different kinds of affections leading to disturbances of the sight, the diseases of the globe, or of its membranes are those first and most commonly spoken of. Thus I have found, that most of the authors, from the very beginning of the 16th century, who name the affections of the eyes, speak of symptoms indicating diseases of the globe itself. This is the case with *Petrus Pincto*, *Tractatus de morbo foedo et occulto his temporibus affligente*, 1500; — who speaks of the application of cauteria »*ad evacuandum et divertendum fluxus inveteratos oculorum*» (*Gruner Aphrodis.* p. 114); *Johannis Almenar.* *De Morbo Gallico libellus*, 1502; who, among signa sanguinis, names »*rubedo in toto corpore et maxime in venis oculorum*»; (*Luisin.* p. 369), and *Petrus Maynardus*, *De Morbo Gallico Tractatus duo*, 1506. »*Et alteretur color faciei et albedo oculorum*,« (*Luis.* p. 393). The affections of the membranes of the globe are also most frequently spoken of by the authors from the middle of the century. Thus, *Nicolaus Macchellus*, *De Morbo Gallico Tractatus*, 1555 speaks treats rather extensively of them. The membranes, he thinks, are not thickened by a deposit of foreign matter; but, on the contrary, attenuated by an increase of temperature. By this debilitatio or even sublatio visûs is occasioned, so that »*spiritus ipsi visui insertivientes*«, (which, according to the theory of *Galen*, were thought to be diffused from the crystalline through the surrounding air and, by causing vibration in a substance analogous to itself, produced the visual impressions), were too easily allowed to escape from the eye. Therefore adstringentia ought to be used in order to give density to the membrane. (*Luisin.* p. 731 and 755). *Benedictus Rinus*, *De Morbo Gallico tractatus*, 1546; most probably speaks of the same affections; since he, under the head *membra oculi*, names *fluxiones frigidae oculorum*. (*Luisin.* p. 983). Further, *Johannes Sylvius* *De*



Morbo Gallico tractatus, 1557; who mentions that, when the blood is affected *pustulæ* may then appear »*quæ, subtumidæ et rubentes erunt, quemadmodum et oculi ipsi.*« (Luisc p. 1109). Prosper Borgarutius seems to have described a corneal affection, (pannus), when he speaks of that form of diseases »*in qua oculorum visus depravatus est, vel cæcitas tandem consequitur: non enim quamprimum ipsos oculos amittit ægrotus, sed potius pedetentim, affectio quædam ophthalmicæ consequi videtur, rubentesque eos oculos prospexeris, ac venulas eorum tumentes.* (P. B. de Morbo Gallico methodus, 1566. Luisin p. 1121). That also an obscuration of the refracting media has been thought of as a cause of the disturbances of the sight in Morbus Gallicus, is apparent from a place in De Morbo Gallico tractatus 1555 by G. Fallopius, (Luisin p. 780), where this author speaks of »*vapor quidam, qui incipit elevare ab hepate*» owing to which among other disturbances »*immutatur color et spiritus oculorum.*« (Venomous vapors ascending from the abdomen were at that time supposed to be the cause of obscurations of the pellucid parts in the eye).

Much less frequent are the statements indicating that authors of that time regarded affections of the optic nerves as causes of the deterioration of the sight. I have found only one author, who, in the general description of Morbus Gallicus, expressly mentions this cause; *Johannis Pascalis*, De Morbo quodam composito, qui vulgo apud nos Gallicus appellatur liber, 1534. Without naming anatomical investigations as bases of his assumption, the said author states, that *nervi optici, qui sunt viæ virtutis visivæ,*« may be obstructed by a »*humor phlegmaticus grossus et viscosus.*« (Luisin p. 220 and 220 and 225). It appears to me doubtful, whether *Bernardinus Tomitanus* had in mind an affection of the optic nerves, or of the brain, when speaking of the head being the principal seat of the disease; (»*cujus vitio oculi caligant.*« De Morbo Gallico libri duo, cir. 1560, Luis p. 1032). Most probably however *Laurentius Phricius* had in mind an affection of the brain, when he, among »*signa prognostica præaugurantur hanc ægritudinem futuram,*« he mentions tumor pupillarum. (According to the doctrine of *Galen*, the opening in the iris was namely filled up with pneuma, which, through pori nervorum opticorum, passed down from the brain).



Special notice, when treating of the history of syphilitic eye-affections, ought to be granted to *Alexander Trajanus*. No author from that time seems to have paid so much attention to those affections as he. In his work *De morbo Gallico* 1565 he mentions eye-diseases in many places and, in Liber VII, he devotes a separate chapter to such and to diseases of the ear. The various eye-affections are mentioned in several places, but generally only; e. g. in Liber I Cap. I (Luis. p. 1168), and in Liber II Cap. XXII. (Ibid. p. 1222) and Cap. XXVII. (Ibid. p. 1227). In the last places he says, that any patient who, previous to the infection, has had any *locum minoris resistentiæ* will, after being infected, be liable to suffer in that place, «*Hinc nonnulli fieri cæcos, nonnulli surdos*»); — an observation whose general validity, everyone who has treated many syphilitic patients certainly will corroborate. Of what kind of disease of the eyes he is speaking when he says; (Luis. p. 1221 and 1227) that, black eyes under certain circumstances may be converted into blue, and blue into white, remains doubtful. Perhaps an affection of the muscles of the eye is intimated in the following passage; — (Luis. p. 1227): «*Quibus oculi intro cerebrum sentiuntur, et collum dolet, neque facile verti potest, his articulares dolores instare.*» In the Chapter VIII Lib. VII. De aurium atque oculorum læsione, he cautions urgently against the use of lignum Guaiaci when the eyes have become affected; as thereby the detrimental humours are supposed to be driven to the exterior parts of the body. He further speaks of both affections of external parts of the eye, — *rubor, tumor et lippitudo*; — and of affections whereby nothing remains visible; «*quam visûs obscuritas, quæ solum ab ægrotante sentitur.*» He remarks too that external and internal affections may sometimes be combined. Of great interest is the following passage, which shows that micropsia, this rather common symptom of a luetic retino-choroiditis, was already known at that time. «*Ubi ergo integer oculus cernitur, neque aliud in eo vitium apparet, quam quod æger se præter naturam diminutim videre refert, alioqui si taceret, nec idiota, nec medicus id animadverteret . . .*» As *Trajanus* here expressly points out, that neither lay nor learned in such cases can detect anything wrong, paralysis of the ciliary muscle cannot be supposed to have been the cause



of the micropsia. Paralysis of the ciliary muscle is, namely, almost invariably accompanied by paralysis of the sphincter iridis, viz. a dilated pupil. Consequently we must conclude that the patients, here spoken of, have been suffering from a retino-choroiditis, which included the region of the yellow spot.

From what has been mentioned above it is manifest, that syphilitic eye-diseases made their appearance in the 15th and 16th centuries in much the same manner as now, affecting both membranes of the globe and the percipient organs of the eye. As affections of the membranes are named by some authors, (*G. Fallopius, N. Machellus, J. Sylvius*) together with the secondary symptoms, we must further infer, that those affections, as is the case now, appeared in the secondary stage of syphilis.

From the quotations by *Hieronimus Emser, Nicolaus Leonicens, Petrus Pincto, Johannes Almenar, Petrus Maynardus, Angelicus Bolognicus, Johannes de Vigo* and *Johannes Monardus*, we have seen that eye-diseases caused by syphilis were commonly known from the end of the 15th and the beginning of the 16th centuries. It becomes therefore rather unintelligible how *Musa Brassavolus* could ascertain, that they did not make their appearance before about 1530 (*Vide De Morbo Gallico curatione, Lugdoni 1554 p. 457: «At à viginti annis citra, aliæ quædam species ortum habuere . . . . quartus modus . . . in quo homines oculos amittunt . . .»* This work was published in several editions about 1550). That such had not been the fact is proved, not only by the authors cited above, (and among whom is *N. Leonicens* the teacher of *Brassavolus*), but also by the subsequent writers on syphilis from the time between 1495 and 1521; *Alexander Benedictus* cir 1495. (*«Nam oculos, manus, nares et pedes, aliasque corporis partes ablatas videmus in contumaciâ vitæ,» Gruner, Aphrodis. p. 40*), *Francisco Lopez de Villalobos* 1498, (*Vide Hæser, Geschichte der Medicin Vol. III p. 262*) and *Johannes Monardus*, 1521, (*Comitantur interim hunc morbum aliæ quædam malæ affectiones . . . ut ophthalmia,» Luis. p. 603*) The only place I have found which could give an apparent authority to the statement of *Brassavolus*, (quoted by so many later writers on syphilis), is one of *Symphorianus Camperius*: *De licheni seu mentagra sive pudendagra, quam nostri Neapo-*



litanum morbum vocant, Itali vero Gallicum, 1517. He says, «*Est enim morbi genus gravissimum. Occupat plerumque totos vultus, oculis duntaxat exceptis, et in colla, pectusque ac manus foedo vitis furfure descendit,*» (Granner p. 128). No weight can however be attached to this quotation, and so much the more so, as only a syphilitic affection of the skin seems to be treated of here.

Diseases of the eye are frequently mentioned by writers on syphilis in the 17th century. Little however is found during this time to indicate, that the knowledge of these affections was essentially greater than in the 15th and 16th centuries. This is but what could be expected, as anatomical learning of that period, at least so far as the globe of the eye was concerned remained at the same stage as in the preceding century; and the great progress in the physiology of the visual act, of which the foundation had been already laid by *Kepler*, *Scheiner* and *Descartes*, was not taken advantage of by the profession before the 18th century.

The great advance made in this century in the anatomy of the eye, the latter accompanied by a knowledge no less advanced of its physiology, wrought essential changes in the apprehension of its pathological processes. This is also clearly apparent where syphilitic affections of the eye are treated of. The description, given by *Astruc* in his famous work »*De Morbis Venereis*, Paris 1736, evinces a material progress in the study of these diseases. (V. — Editio altera Tom. I p. 426). Truly we still find from *Astruc*, some marks left of the doctrine of humorism, predominant up to that time; but in all essentials, the account of the different anatomical causes given by him, is correct. This may be especially applied to that part which treats of the affections of the optic nerves. Generally speaking *Astruc*, like several other writers of the 18th century, as *Boerhave*, *Petit* and *Bell*, had as correct an apprehension of the nature of the syphilitic eye-diseases, as possibly could be obtained by the diagnostic resources of that age. We also find, the hereditary syphilitic affections of the eye named, by writers of the same century, thus; — by *Antoine Nunes Rebeiro Sanches*; Observations sur les Maladies



vénériennes 1777; (p. 166) and by M. Carrère; *Recherches sur les Maladies vénériennes chroniques sans signes évidents*, 1788. It is interesting to observe that the latter author assigns the hereditary eye-affections to a later period of life; *l'âge de puberté et dans l'adulte*, (pag. 112). Belonging to the first part of this century, there are also found two inaugural dissertations that treat of syphilitic diseases of the eye. Both are only known to me from the work of *Astruc*. The first, that of *Ericus Joachimus Anus*, de ophthalmiâ in genere, ejusque specie venereâ dictâ, 1725, is merely mentioned. By the quotations given from the other, that of *Julius Fredericus Breyer*, Dissert. Inaug. Med. Chirurg. sistens Ophthalmiam venereum etc., it is apparent, the author contends, that of the old writers on syphilis in the collection by *Luisinus*, *Brassavolus*, *Tomitanus*, *Borgarutius*, *A. Petronius* and *Johanne a Stephano* alone, mention these affections. This indicates him to have erroneously believed, that venereal eye-diseases were unknown before 1530, as *Brassavolus* states.

As before-mentioned, the knowledge of these diseases was, in the 18th century, as correct as it possibly could become without an ophthalmoscope. It is, consequently, not to be expected, that the literature of the first part of our century would show any essential progress towards clearer understanding of the nature of the syphilitic eye-affections. Nor is this, in fact, the case. It seems, on the contrary, that the knowledge, of that time was at least so far as the more deeply seated affections are concerned, less than previously. Iritis is the only eye-disease mentioned by many writers on syphilis of that time. The other affections are either not named, or their existence is doubted. Thus already *Hunter*, (V. d. *Traité des maladies vénériennes* 1786, traduit par *M. Audibert*, 1781 p. 343), expresses doubts as to the syphilitic origin of inflammation of the eye in infected patients. *C. M. Gilbert*, *Manuel Pratique des maladies vénériennes*, Paris, 1837, who does not believe much in syphilitic «neuroses» generally, states; — «de toutes les neuroses attribuées au vice syphilitique, l'amaurose serait celle que nous avons le plus de disposition à admettre». (p. 432).

The introduction of the ophthalmoscope brought a clearer light to bear on these affections generally, and especially on



that hitherto obscure chapter, the diseases of the membranes of the eye. Most of the cases, formerly explained as sufferings of the optic nerves, or even of the brain, were, by means of the ophthalmoscope, recognised as affections of the fundus oculi. A comparatively long time passed however, before the syphilitic affections of the fundus became commonly known. Considering how great a part syphilis plays in the etiology of the choroiditis and retinitis, this must be considered rather strange. The only author, within my knowledge, who, not more than 2 years after the invention of *Helmholtz* was introduced, records syphilis as a cause of retinitis, is *Arlt*. In his book, *Die Krankheiten des Auges*, edited in Prague, 1853, he reports, Vol III p. 128, a case of retinitis in which he made an ophthalmoscopical examination; and of this case he says, that. »wahrscheinlich Lues den Anstoss zum Exudationsprocesse in der Netzhaut gegeben hatte.« In the same work Vol II p. 211, he recognises Choroiditis syphilitica, and mentions a case, relatively to which he, however, does not speak of any ophthalmoscopical examination. How far they were, even in 1857, from a correct apprehension of the intimate connexion existing between those affections and syphilis, may be seen from a treatise of *Dupré* entitled »Des affections syphilitiques du globe oculaire.« In this memoir we find, p. 36, the following question put: — »Le venin morbide, — est il susceptible de créer des desordres dans la substance de la retine, comme il en crée de si remarquable du sein de l'iris?« On the page following, the author mentions, that *de Græfe*, among 30 syphilitic amauroses had seen something abnormal on the retina; »quelque chose d'insolite, dont il n'a pas pu encore préciser la nature«.

The first I have found, who has more explicitly described the syphilitic intra-ocular affections, is *C. Bader*. In the years between 1856 and 1859, (*Ophthalmic Hosp. Rep.* Edited by *Streatfield* Vol. 1. p. 245—251), this author published several carefully observed cases by *Wordsworth*, *Dixon*, *Poland* and *Streatfield*. That hereditary syphilis at that time was, to the London ophthalmologists, a well known cause of these affections, appears by a quotation from *Wordsworth* in the same publication. *Wordsworth* says, that, since 1856, he has had occasion to examine no fewer than 10 cases, in which he had



found, in the fundus oculi, circumscribed patches of pigment and atrophy, together with signs of hereditary lues.

Besides the authors just named, I have seen, in medical literature, but few communications of that period. A note by *Donders* in the *Archiv of Græfe* (Vol. III. P. 1. p. 149) in which he mentions having seen this affection combined with lues, is interesting as regards the causal connexion existing between syphilis and retinitis, pigmentosa.

A general description of the affections of the fundus oculi is given by *Græfe*, at the beginning of 1858. (*Allgemeine medicinische Central-Zeitung* XXVII Jahrgang p. 132). As the most common form of disseminated syphilitic choroiditis, v. *Græfe*, curiously enough, here designates that in which white spots bordered with red rims, appear in greatest number around the posterior pole. These spots were considered by v. *Græfe* to result from exudations; and not from isolated atrophies of the choroid. He leaves it doubtful whether retinitis can be directly produced by syphilis.

Still for awhile, syphilis remained but little noticed as a cause of retinitis. This appears from most manuals of ophthalmology of that time, in which syphilis is either not at all, or but cursorily mentioned. Only by *Desmarres*, in his *Traité des maladies des yeux*, Paris 1858, do we find a retinal affection referred to more explicitly. This, he says, he has »assez souvent« seen in persons suffering from syphilis. The affection he regards as œdema of the retina. In the very complete *Lehrbuch der Augenheilkunde*, (Prag 1859), by *Pilz*, Lustseuche is named as a predisposing cause of choroiditis, but is not mentioned when the etiology of retinitis is spoken of, although Morbus Brighti, Diabetes, Glycosuria and Hippuria are enumerated.

Dr. *Jacobsen* is one of the first, who has given a description, more in detail, of syphilitic retinitis. In *Königsberger medicinische Jahrbücher*, Vol. 1 P. 3. 1859, he has published a series of such cases. In the same year *Deval*, in *l'Union médicale*, for 7th August, drew attention to the frequent occurrence of a retinal affection, rendered characteristic by exudation of greyish-white lymph-patches, in syphilitic amaurosis. In the same paper *Deval* states, that in other cases



he has found a more or less pronounced hyperæmia without any exudations. These last cases he explains as choroiditis.

From that time intraocular syphilitic affections became more commonly known. Dr. *Metaxas* gives, in his treatise *De l'exploration de la retine*, Paris 1861, a description of both the retinitis and the choroiditis; indicating the latter as much more frequent than the former. In the work of *Zambago*, *des affections nerveuses syphilitiques*, Paris 1862, these affections are mentioned in several places, and not a few cases are minutely described. A very complete description is given by *Meilhac* in his treatise, *Recherches sur l'amaurose syphilitique*, Paris 1863.

Besides the authors mentioned above, several others have contributed much to a better understanding of these affections. Thus *Galezowsky* in France, has written many essays on this subject; among which I quote only his *Etudes sur les amblyopies et les amauroses syphilitiques*. (Memoir lu a l'academie de medicine de Paris, le 23 fevrier 1859). In England *Bader*, *Hutchinson* and *Nettleship* have been the principal writers on these affections. The hereditary affections are more particularly made an object of description by *Hutchinson*, in his fundamental work; *Diseases of the Eye and Ear consequent on inherited Syphilis*; London 1863. The most complete microscopical investigations have been made by *Nettleship*. In Germany *Foerster* has published, in the *Archiv of Græfe*, Vol. XX P. 1, a treatise entitled: *Zur klinische Kenntniss der choroiditis syphilitica*; — which must be considered the most correct work hitherto issued on these affections.

---



## Hyperæmia of the Optic Nerve.

---

Syphilitic affections of the fundus oculi have hitherto been considered rare, as compared with affections of the iris. This however, in fact, is not the case.

If we would know the parts most frequently affected by syphilis whether the fundus oculi or those parts of the eye freely exposed to view, we must, in a not too limited number of patients, make a frequent examination of the fundus. Failing to do this, we shall certainly be unable so judge of the frequency of those intraocular affections which are not connected with functional disturbances; just as we should remain unacquainted with the frequency of roseola, and other affections of the skin, not associated with such disturbances, if the skin were not exposed to our view.

Anyone, who will take the trouble of a repeated ophthalmoscopical examination of a number of patients, suffering from recent syphilis, will soon be aware that, among all eyeaffections, *hyperæmia* of the optic disc is the most frequent manifestation of the dyscrasy.

This hyperæmia may be more or less pronounced.

In many cases it is but slight. We find the optic disc of a deeper than usual pink color, the retinal veins somewhat enlarged, the parts of the retina adjacent to the disc a little smoke-colored. As well known, all this needs not indicate a morbid state. The color of the optic disc is very variable in different individuals, and, even in the same individual, it may vary within certain limits, strong exertion of the eyes, or other causes, producing a dilatation of the capillary vessels. Enlargement of the veins may also arise from the same cause, indicating only a greater consumption of material, within the



tissues, from which they emerge. The smoky discoloration of the surrounding parts of the retina, is not always easily to be distinguished from the grey appearance, often met with in highly pigmented individuals, although, to my eye, the retina, in such cases, seems to have a more glossy or polished surface.

The probability that a morbid state exists is increased, if we find that the parts of the retina bordering on the optic disc, are swollen, forming a wall around the upper, inner and lower parts of its circumference. The retinal vessels appear, in such cases, darker where they ascend, or descend over the wall; and lighter, where they pass over its summit. However, a slight swelling around the inner periphery of the disc may be found as a physiological peculiarity, although, as a rule, the nerve-fibres, having emerged through the openings in the lamina cribrosa, spread themselves on a level with the fundus.

Cases in which we may be doubtful whether a pathological condition is present or not, are, therefore, not at all rare. In Fig. 1. Plate 1. I have portrayed the fundus of a young man, who, in 1872 (from January 10<sup>th</sup> to April 3<sup>rd</sup>), was treated for constitutional syphilis, at the State Hospital in Christiania. V. was in this case normal. R.  $\frac{1}{2}$ . In my opinion, here fundus cannot be considered normal, especially, because there is a swelling of the retina around the inner part of the disc. Yet the alterations present are hardly considerable enough to justify an absolutely decisive opinion of their pathological nature. Among several distinguished ophthalmologists, to whom I have shown this drawing, there existed different opinions on this point. The reasons why I include this and analogous cases among pathological affections are:

1. That I have very often been unable to discover any cause — such as hypermetropia, overtaxing of the eyes etc. — which could explain why such conditions of the fundus are so frequently found in patients suffering from recent syphilis.
2. That, — in such patients, I have seen the above described state developed from a quite normal appearance, and after a shorter or longer period, again return to a normal state.



3. That, in many cases I have seen this state, by degrees pass over into an undoubted hyperæmia.

Such more pronounced cases of hyperæmia are rather frequent. In those cases the optic disc becomes decidedly rosy, its borders on the nasal side become less visible, giving the impression of an enlargement of the diameter of the disc. The tumor, often existing in an earlier stage around the disc, now encroaches upon it, converting the adjacent parts of the retina and the disc into a smooth prominence. The sheaths of the larger vessels, where these pass over the disc, can often be seen as bright bluish stripes, contrasting with the rosy ground. The veins are enlarged; the arteries on the contrary, sometimes smaller than normally. As a paradigm of such an hyperæmia, Fig. 2, Plate I will serve. (The figure is taken from a young girl, who was treated, at the State-Hospital, for constitutional syphilis, from January 21th to April 7th 1873).

If the hyperæmia increases still more, the well known features of what commonly is termed, »Choked Disc«, may appear. The optic disc is then much enlarged, especially in its perpendicular diameter, as the bordering of its outer part, forming an arc, gives to the whole disc an oval shape. The swelling of the disc itself, and the adjacent parts of the retina too, are most remarkable in the inner half, and can, here, exceed 1 mm. With the swelling, the curvature of the retinal vessels, in their course across the disc, must consequently increase. The veins appear here, — especially in everted image, on account of their dioptric situation — much dilated. The arteries appear decidedly constricted. At the exitus from the optic nerve, the retinal vessels are seen indistinctly, blurred as it were by a bluish white veil. On reaching the borders of the optic disc, they are again seen indistinctly, as if immersed in a medium not fully transparent. The eye ground around the optic disc is, over a surface corresponding to that in which the vessels are seen indistinctly, of a deep red colour. The explanation of this deep colour and of the obscuration of the vessels, I cannot give; but the like is seen in all cases where we find a prominence of the optic disc. In the most marked cases of hyperæmia, a red striped appearance of the fundus oculi, over and under the disc, is sometimes seen. (Vide



Fig. 3 Plate I. portrayed from a girl, treated for constitutional syphilis at the State-Hospital, from February 5<sup>th</sup> to May 9<sup>th</sup>, 1871). Other changes than those above described, are but exceptionally to be observed. Only in three instances have I seen extravasation of blood, and in all these the extravasations took place on, or in the vicinity of the disc. As two of these cases in other respects offered unusual symptoms, they will, further on be more particularly described.

Any formations of new vessels cannot be ascertained by the ophthalmoscopical examination. In the periphery of the eye-ground I have, in fresh cases, — saving the enlargement and the tortuosity of the veins, — never found any changes.

When the hyperæmia has lasted for a shorter or longer period, — from a couple of weeks to several months, — it dwindles away gradually. In cases where swelling of the optic disc has occurred, this gradually diminishes, and thereby the vessels again are straightened, and the dilatation of the veins disappears. The disc assumes a more bluish-cold tint. Instead of the red stripes over and under the disc, white stripes may appear. After some months the ophthalmoscopical appearance, even in cases of choked disc, may be so like that of a normal eye, as to give the impression that there had never been any disturbance. (Vide Fig. 4 Plate II, taken from the patient last mentioned, two months later.) The only symptom that not infrequently continues is, an impaired diaphaneity of those parts of the retina adjacent to the optic disc, and this symptom, to the experienced eye, is somewhat characteristic. This impaired diaphaneity seems, however, not to be more marked in cases of a high, than of a low degree of hyperæmia. Other alterations remaining as indications of a formerly existing hyperæmia are, as far as my experience goes, very rare. Only in two cases, have I seen changes of the pigment-layer the cause of which could have been nothing but a very high degree of preceding hyperæmia. A short account of one of these cases is given below.

1. M. L. G., girl, 25 years old, was treated for constitutional syphilis, at the State-Hospital from June 26<sup>th</sup> to November 15<sup>th</sup> 1877. Her eyes were, during that time, repeatedly examined, and a decisively marked hyperæmia, with



swelling of the disc, was found to remain in both eyes for several weeks. Otherwise nothing abnormal. No functional disturbances. V  $\frac{1}{2}$ . Two years later, the patient was again treated for some excoriations on the genitalia. Since the time of her departure from the hospital, she has had no trouble whatever with her eyes. The ophthalmoscopical examination showed alteration of the pigment-layer of the equatorial part of the fundus, on both eyes. This alteration consisted in an innumerable mass of small pigment-spots with bright yellowish red spots interspersed. (Vide Fig 5 Pl. III.) The alterations were most marked towards the equator where the pigment-spots, in some places collected in larger clusters, here and there encircled the bright spots.

V, L and C normal. The visual field was very carefully examined, but nothing abnormal was found, either, when using as a test object a white 1 cm. large spot on a black ground, or, when a corresponding large grey spot was substituted for the white<sup>1</sup>).

I had, several months later, an opportunity to examine the same patient. The condition of her eyes had during that interval, not undergone any alteration.

In the other case an analogous, but less extensive affection, was seen in one eye only. I must mention, that I have, several times found similar alterations as a sequel of retino-choroiditis; but in such instances, an examination into *historia morbi* has always established functional disturbances.

In the majority of cases, as already stated, patients suffering from non-complicated hyperæmia of the optic disc, do not complain of any functional disturbances. This holds good especially for slight degrees of hyperæmia, though even when it is present in the highest degree, viz. in cases of choked disc, functional disturbances may be wholly absent. In the latter cases, however, we shall not seldom find a moderate lowering of the power of vision, a slight diminution of the light-perception, a lessened functional endurance, and very exceptional phosphenes and photophobia.

---

<sup>1</sup>) The shade of the white in relation to the black, photometrically found to be 192 : 1. The shade of the grey corresponds to that produced on the disc of Maxwell, by a sector of 28° of the same white to 332° of the black.



Concerning V, it is, in the concrete case, not always possible to say whether a lowering, due to an existing hyperæmia, has taken place or not. As well known, we have in the conventional expression  $V \frac{1}{2}$ , no guarantee that this really is not lowered; and, on the other hand, if we find V but a little under this standard, it may be impossible to decide whether or not the present hyperæmia has any influence in the case. The only way to determine whether or not, hyperæmia weakens the power of vision, is to make an exact determination of this in a number of cases, where hyperæmia does not exist, but may be expected. This I have done, by examining several syphilitic patients at an early period of the disease; and, thereby, have been able to compare the state of V before the hyperæmia had set in, and afterwards. From such investigations I can prove, that hyperæmia of the optic nerve does not, necessarily, cause any lowering of V. As I furthermore, in many cases of hyperæmia, — even of the highest degree — where there has not been opportunity to institute such a comparison, have found a normal V, I am convinced, that hyperæmia of the optic disc does not generally interfere with the powers of vision. In cases where a lessening of V has been found, it has not been material, usually not more than to  $\frac{2}{3}$ , but exceptionally, so low as to  $\frac{1}{2}$  of the normal. Light-perception so far as that of the roomy-light-differences in light-room is concerned has been found normal. In a dark room however, I have found sometimes a slight lowering of this perception. As proof-object I have in such examination used a round disc, of which one half white, the other black. The disc has been placed at the distance of one metre from the patient, who has been requested to tell in which direction the white part is turned.

Examinations of the color-sense have not shown any thing abnormal.

In the cases in which the visual field has been examined, I have, as a rule, found this to be of normal extension. In two patients with extreme hyperæmia I found the field of vision concentrically restricted and the spot of *Mariotte* enlarged.

The functional endurance seems to be impaired more frequently than either V or the light-perception L. Complaints of asthenopic symptoms, from prolonged eye-work,



are rather common. A very high degree of hyperæmia may, nevertheless, be present without occasioning any such inconvenience. The patient, from whom Figure 3 was taken, had at the time her eyeground was being figured been occupied with needle-work the greater part of the day, and yet did not feel any annoyance therefrom.

The period of the disease at which hyperæmia most frequently occurs, is the later secondary. I have never found it, unless complicated with cerebral disease, later than 2 years after the infection. As a rule, it appears at that period when roseola, tubercula mucosa and the affections of the mucous membrane of the throat and mouth begin to disappear. In some individual cases, I have found incipient hyperæmia to be the first symptom of the constitutional disease. Its appearance just at that period when the patient usually is discharged, may probably account for the frequency of this fact having hitherto eluded notice and this reason may especially apply in countries where, in the treatment of syphilis mercury is considered indispensable, — such being the case in most countries except Norway, — and where, consequently, the secondary symptoms will be of a shorter duration.

As hyperæmia sometimes appears at an early period, it can be significant as a means of diagnosis. In cases f. ex. where we find an indurated sore, with indolent tumor of the inguinal glands, but where affections of the skin and the mucous membranes are not present, the appearance of incipient hyperæmia nervi optici would prove, that the patient had contracted a constitutional affection.

Inasmuch as the frequency of hyperæmia in syphilis can vary in so very different a degree, that imperceptible transitions from an almost normal state to choked disc may occur, its average frequency is not easily determinable. Here, as everywhere else, it is impossible to draw a definite line between health and disease; such a decision therefore will depend largely on individual judgment. In order to obtain a tolerably accurate estimate in this matter, I have held a register of the syphilitic patients examined by myself with the ophthalmoscope, and distributed their cases into 3 classes.



1. Those in which no hyperæmia was visible.
2. « which were doubtful.
3. « in which hyperæmia was undoubtedly present.

Since many of the entire number of syphilitic patients examined, — amounting to more than 1000, — had been under observation only a short time, some of them, in fact, having been ophthalmoscoped but once, I will not state the result of my investigations in all instances; but select 400 patients, whose cases were most accurately noted. Of these, 200 were observed in the interval between October 1870 and March 1872; the residual 200, from the middle of November 1878 to the beginning of February 1880.

Among the former 200, I found indisputable hyperæmia in 29 cases = 14,5 per cent., and doubtful in 20 = 10 per cent.

Among the latter, 45 cases of indisputable hyperæmia = 22,5 per cent., and 23 doubtful = 11,5 per cent.

Making thus for the whole of the 400 cases in average 18,5 per cent of indisputable, and 10,75 of doubtful hyperæmia.

Excluding the latter, there, will, therefore, remain, of 400 patients, 74 in whom hyperæmia of the optic disc was found. I believe however that greater weight should be attached to the result of the latter, than to that of the former 200 cases of this subdivision. At the time these were observed I was specifically attached to the medical staff of the Department for skin-diseases in the State Hospital; which afforded me greater facilities for a rigorous scrutiny of those cases. As a result I would say, that hyperæmia of the optic disc occurs in more than 20 per cent or, if the doubtful cases be included in more than 30 per cent<sup>1)</sup> of syphilitic patients.

Should anyone feel inclined to test my investigations, I would point out, that it is necessary to have the patients under observation for a pretty considerable time. Were we to rely on a solitary observation of each patient, and thence to draw our conclusions, we might, assuredly, find among a certain number of patients, a lower percentage; — but our conclusions would as certainly be wrong. What would be said

<sup>1)</sup> Of the same total number, I have, for each of the 200, found iritis, or marks of that affection, in exactly 9,5 per cent.



if we proceeded in this way, when seeking to determine the average frequency of syphilitic roseola?

I have designated the pathological changes of the fundus oculi described in the foregoing pages, as a hyperæmia nervorum opticorum, and as simple hyperæmia, I believe they ought to be considered. Such, however, was not my initial belief. In my first communication, — in *Nordisk Medicinsk Archiv*, — I named them, retinal affections, believing that the retina was the organ principally affected. I soon however became doubtful touching the correctness of this opinion; and that mainly, because I did not find any other changes in the retina, than enlargement of its veins, swelling of the parts surrounding the disc, and, exceptionally, in very high degrees of hyperæmia, some blood-extravasations. All these symptoms do not necessarily indicate any affection of the retina itself, but are readily explicable as being symptomatic consequents of hyperæmia of the optic nerves. I willingly admit that a retinal affection, and even a real retinitis, may exceptionally occur in a very early stage of syphilis; and that such affection may not necessarily be accompanied by any, or, by but very slight, functional disorder. Possibly, a real retinitis has preceded in such cases as are described p. 25. In any event, the investigations of Prof. *Schnabel* have convinced me, that such an affection can occur in this stage of syphilis. Prof. *Schnabel* who, at the request of Prof. *Lang*, examined 40 syphilitici, found, in more than 50 per cent, changes which, in the great majority of cases, were strictly analogous to those above described. The absence of functional disorders made him, too, at the first, believe that no inflammation, but only an irritation (*Reizung*), was the cause of the changes ophthalmoscopically visible. In the further course of his investigations, he, however, found no fewer than 7 cases in which there were undoubted signs of inflammation of the choroid, and the retina. As, moreover, in all these cases, none, or but slight functional disturbances could be detected, he thinks the absence of such disorders, to be insufficient as proof of the non-existence of inflammatory process. Considering the great number of patients whom I have examined, without finding any changes that cannot be



explained as symptoms, or sequels of simple hyperæmia, I must take it as a mere accident, that Prof. *Schnabel* among a comparatively small number, found so many cases in which present, or previous retino-choroiditis was indicated.

Judging from my own observations, I must take it for granted, that the retina as a rule is not primarily or principally affected by the affections here spoken of. But ought not those cases, in which the swelling of the disc and the hyperæmia are distinctly marked, to be designated *Neuritis*? In my opinion, certainly not. The absence of almost any functional disturbance speaks strongly against such a diagnosis. Besides this, we miss several objective signs, generally pertaining to true neuritis. For the pathological process of this, as a rule, propagates itself to the adjoining parts of the retina, and appears as neuro-retinitis, which in such affections I have never seen. Further, — from a real inflammation we shall, generally, find the pathological process more and less advanced on different parts of the optic disc, one segment thereof being more tumified and injected than another, which is never the case in simple hyperæmia. So, too, formation of new vessels, exudation of lymph in circumscribed patches, not seldom found, in real neuritis, I have never observed in these cases. Lastly a neuritis very rarely passes off without leaving traces ascertainable either by the ophthalmoscope, or by functional examination. In the many cases of hyperæmia, — some of them with very marked swelling of the disc — which I have seen pass away, I have not, (saving in the 2 cases already cited), found an aftertrace of any changes, beyond a slight haze around the optic disc, and this haze has usually been so little pronounced, as to leave doubtful whether or not it ought to be considered a pathological symptom. The moderate decrease of V, sometimes found in high degrees of hyperæmia, and which, after my opinion, must be considered merely as the symptom of an impaired transmission, always disappears with the hyperæmia. For the extreme degrees of hyperæmia, other terms, such as Choked Disc, Peripapillar œdema, Tschæmia Papillæ etc. might be used; but since those terms differ in meaning, I have preferred the word hyperæmia, as being the word, at one and the same time, most simple and comprehensive. For the less pronounced cases, the word irritation



(Reizung) of the optic discs, perhaps, might be applicable. At all events we have to admit, that the syphilitic infection, in many cases is *causa sufficiens* of this, as other causes such as hypermetropia, or overworking of the eye, have not, as a rule, been present. In the more pronounced cases, the swelling of the disc decidedly indicates, that the stadium of »Reizung« had been surpassed. That a real inflammation may be the consequence in cases of strongly pronounced hyperæmia of long standing, I, of course, shall not deny. A simple hyperæmia may, in some cases, be an introductory to inflammation. Perhaps this stadium in the following cases, had been passed.

2. E. A. H. æt. 26, laborer's wife, was, in the State Hospital, treated for syphilis, from April 17th to September 18th 1879. She was, for the first time, ophthalmoscopically examined April 23th. Only a little haze, about the optic disc, could then be discerned. At the end of May the left disc began to be hyperæmic. On the 11th of June, I noticed a very marked hyperæmia of both optic discs. At the beginning of the same month she suffered from headache, pains in her back, and in some joints. She complained of giddiness when in an erect position. 22 of June some swelling of the conjunctiva and injection of the episcleral vessels were noticed<sup>1)</sup>. Some days later there was seen an oblong extravasation of blood with serrated borders, close to the optic disc. V at that time normal. The urine, which in this, as in all cases where extravasations of blood in the fundus oculi have been noticed, was examined, did not contain anything abnormal. The patient now began to have fits of trembling of the whole body. These fits were usually occasioned by motion, although they, sometimes, would come on even when the patient was quiet in her bed. When she arose, the whole visual field was, for some seconds, darkened. The hyperæmia and other symptoms due to the nervous system, were unaltered during 6—8 weeks. Then they began to disappear gradually. In the beginning of September the hyperæmia was considerably less; the pain in the back and the trembling had left her. Her general condition had greatly improved, although she was still rather weak.

V at that time  $\frac{5}{6}$  for both eyes. L and C almost normal. During the whole term of her illness, the fever was moderate, temperature never rising above 38,5 C.

<sup>1)</sup> These symptoms I have repeatedly seen in patients with strongly marked hyperæmia.



On eyear afterwards, 5th of August 1880, the patient called on me, having at that time, a large ulcer on her left leg. With that exception she then felt quite well, and had been apparently healthy since she left the Hospital.

V.  $\frac{5}{4}$  for both eyes. L and C normal; normal too, the field of vision. Ophthalmoscopically, the fundus, beyond a little haze around the disc, appeared as when she first was examined, normal.

3. C. A., girl, æt. 28; treated, for constitutional syphilis, in the State Hospital, from June 1st to 26th of August 1879. Her eyes were, for the first time, examined 12th of June, and were then found healthy. A re-examination, July 2, showed doubtful hyperæmia of the right eye. Some days afterwards she was seized with violent headache. The 23 of July I noticed a high degree of hyperæmia on both sides, though most marked on the right. The headache continued for the last two days, associated with stiffness and pains in the back. In the middle of August several extravasations of blood, on, and in the vicinity of the right optic disc, were visible. The extravasations consisted of stripes, lying parallel with the nerve-fibres, and of an oblong spot, with serrated borders.

V. r. eye  $\frac{1}{2}$  left.  $\frac{5}{8}$ . (The patient stated that the sight of her left eye had not been good for several years.) L and C normal. The visual field a little concentrically constricted, but the explanation of this may be sought in the deep situation of its globes in their orbits.

She complained at that time of temporary darkening before her eyes, which set in when she suddenly changed her position; e. g. — when she got out of her bed etc.<sup>1)</sup> When this patient left the Hospital, there was still a considerable hyperæmia of both discs, and some slight extravasations of blood; but the headache, the pains in her back, and the temporary obscurations of the field of vision had ceased. The 2 of August next year, I had again an opportunity to see this patient. There was then, saving a little haze of those parts of the retina adjoining the optic disc, nothing abnormal in her eyes.

V. r. eye  $\frac{4}{5}$  (even some letters of Snellen, No. 3, were seen with this eye at 5 metres), l. eye  $\frac{5}{8}$ . The field of vision, as when first examined.

In these two, almost in every respect, analogous cases, there were several symptoms to indicate that a real inflam-

<sup>1)</sup> Exclusively of these 2 cases, I have heard complaints of temporary darkening of the field of vision by movements of the body, in one other case of hyperæmia.



mation had set in, and I have no doubt that most ophthalmologists, who might have seen the patients at the time hyperæmia, with the swelling of the discs, was most marked, and hæmorrhage present, would have given the diagnosis, »Neuritis optica«. In my opinion both ought to be regarded as cases of hyperæmia only, and the *restitutio ad integrum* tells strongly in favour of this opinion.

Concerning the primary cause of hyperæmia, I dare not decide what, precisely, it may be; and will only say, — that the limitation of this affection to the optic nerves and the surrounding parts of the retina, points to the presence of some intercranial cause.

Since the introduction of the ophthalmoscope, it has been a fact well known, that visible alterations of the optic disc are often seen in patients suffering from diseases of the brain. (Vide *Coccius*, Ueber die Anwendung des Augenspiegel, Leipzig 1853, p. 124.) The connexion between affections of the optic nerve and cerebral diseases was, of v. *Græfe*, sought in a hindrance of the venous circulation; the free outlet of the retinal veins, into sinus cavernosus, which was from some cause or other compressed, being impeded. This theory of v. *Græfe* was, for a long time, generally adopted, and is still adhered to by some authors. *Sesemann's* anatomical investigations of the anastomoses between the orbital and facial veins have, for a great part, made the adaptability of this theory to all such cases less probable. The numerous researches into the communication between the lymphatic spaces of the brain, and their connexion with the perineural space of the optic nerve, by *His*, *Schwalbe*, *Schmidt*, *Key* and *Retzius* have given rise to a new theory. According to this theory, the explanation of the hyperæmia of the optic disc is to be sought in the accumulation of liquor cerebro-spinalis in the perineural spaces, and between the delicate sheaths around the fibres of the lamina cribrosa. The veins are thus apt to become strangulated, and hence the swelling of the optic disc and the peripapillar œdema. Numerous sections have shown distention of the sheaths of the optic nerves by this fluid, in cases where there has been a pathological surplus thereof within the cranial



cavity. The distention is, generally, most marked at the ocular end of the nerve, which end assumes a pyriform shape. Here, too, in a single case, a metastatic deposit of cancerous matter has been found; (*Krohn*, Finska Läkaresällskapets Handlingar, Vol. 13th No. 2.) Prof. *Manz*, who has given to this theory the name »Transport theory«, has, by experiments on animals, sought to prove its correctness; and the validity of his experiments has been lately corroborated by the experiments of several other authors, among whom I will name only *Schultén* (*Experimentela och kliniska undersökningar beträffande hjärnskador och deras inflytande på ögats cirkulations förhållanden*. Helsingfors 1882).

There can be no doubt that the transport theory holds good for many cases, as the distention of the perineural spaces by fluids (serum or blood), often is the only ascertainable cause of the hyperæmia found ante mortem; but, on the other hand, this cause is scarcely more than one link of that chain which connects cerebral affections with those of the optic nerve. It would take me beyond due scope to enter more at large into the different theories on this subject. I shall, accordingly, speak only of one; by which it is alleged, that the most general cause of ophthalmoscopical changes through cerebral diseases, is to be sought in the more or less direct influence of the vasomotoric nerves. To this cause already Dr. *Schneller*, (*Archiv of Græfe* Vol. III Abt. 1) for more than twenty years, has called attention; and more recently it has been taken into account, as the principal cause of circulative disturbances of the optic nerves, by *Benedikt* and *Loring*.

Now, in the early period of syphilis there is certainly no lack of symptoms indicating an affection of the central nervous system. This fact, which was well known to the ancients, seems in a later age to have been overlooked; and it has generally been assumed, that affections of the nervous system belonged to the tertiary stage. Some 20 years ago, Dr. *Gjør*, (*Norsk Magazin for Lægevidenskaben*, 1857 p. 774), published some cases which proved that such affections might come on early in the secondary stage. Later Dr. *Ljunggren* in Stockholm, Dr. *Keyes* of New York, and others have maintained, that the central system, as a rule, suffers during this period. A violent headache, which cannot be explained by the, usually



very slight, eruptive fever, is among the most common symptoms. So called rheumatic pains in different parts of the body, and even a more or less complete paralysis of the cerebral nerves (mostly of facialis), are by no means rare. All these symptoms can be easily explained by supposing that the syphilitic virus has produced within the centres of the nervous system hyperæmia, analogous to the hyperæmia of the skin and of the mucous membranes. This affection likewise would certainly in most cases pass unnoticed by the patient and by the physician, if the organ in which they have their seat were not freely exposed. As with cutaneous exanthems, the hyperæmia of the nervous system seldom leads to coarser destruction of the tissues, and consequently we cannot, in those rare cases in which the patients happen to die in the secondary period, expect to discover anything abnormal by necropsy; a simple hyperæmia not leaving any traces. That such is the case with hyperæmia of the optic disc, even when most marked, I have had an opportunity of seeing on two separate occasions. The one case was that of a girl, 20 years old, suffering from secondary syphilis. She was admitted into the Hospital January 2d 1877, and died there a couple of months later. I examined her eyes the 26th of February, and found a high degree of hyperæmia, with swelling of the disc on the right eye; moderate hyperæmia on the left. She had at that time hemiplegia sinistra; pupils dilated; the eyes constantly turned to the right. She died soporose. The section showed affection of the cerebral arteries (Dr. C. Boeck). The right eye was taken out and divided; macroscopically the fundus looked quite normal. The retina was microscopically examined, after being hardened in *Müllers* solution, but nothing abnormal was found. The other case, which shall be more fully described later, was that of a child, suffering from hereditary syphilis. The ophthalmoscopic examination showed a well-marked hyperæmia on both sides, several weeks before death, and yet the optic discs were found quite normal. Therefore, although it is more than probable that the hypothesis of *Keyes* and *Ljunggren*, according to which a cerebral hyperæmia is the real cause of many of the nervous symptoms in recent syphilis, is correct, yet it will, most likely, never be proved by anatomical investigation. Strangely enough nobody has, up to the most recent date,



sought for any objective proofs of the supposed hyperæmia of the meninges and of the brain in that place, where only we could expect to find them, viz. in the fundus oculi; where a nerve, the vessels of which are standing in the closest connexion with those of the brain, is exposed to direct view under the most favorable optical conditions. This is so much the more strange as we know, that intracranial diseases are so often reflected in the fundus oculi, that an ophthalmoscopic examination, ought always to be made, where the symptoms indicate any nervous affection, whether there are, or are not any functional disturbances of the organ of vision. It is, as *Huglings Jackson* again and again has asserted, not at all rare to find well marked ophthalmoscopic changes in patients who do not complain of their sight.

Now the changes found in syphilitic patients, do not in any respect vary from those occasioned by different intracranial diseases. In cases where the hyperæmia of the disc is but faintly pronounced, the dilatation of the veins moderate, and where the parts of the retina adjoining to the disc are but slightly tumified and hazy; the ophthalmoscopic appearance is quite analogous to that almost constantly found in cases of tubercular meningitis. In more pronounced cases of hyperæmia, where the swelling of the disc is well-marked, the fundus does not differ from that so often found in different intracranial diseases, though most commonly in the instance of tumours within the skull.

As said before, (p. 31) I dare not pronounce any definite opinion on the primary cause of hyperæmia of the optic nerves; but, among the symptoms mentioned already, there is one which, in my opinion, tends to show that the real cause must be sought in a hypersecretion of the liquor cerebro-spinalis, and that is identical with the injection of the episcleral vessels, and the swelling of the conjunctiva, seen in some cases of extreme hyperæmia of the optics. The same symptom has been repeatedly observed in meningitis. (Vide *Berthold*, *Græfe Archiv*, Vol. XXIX P. I. p. 178, *Leyden*, *Virchows Archiv* Vol. XXIX p. 199, *Mauthner*, *Vorträge aus dem Gesamtgebiete der Augenheilkunde* p. 573) and has been supposed to depend on intrusion of fluid from the subarachnoidal into the suprachoroid space. There is another fact which may give



this explanation some support. In the secondary stage of syphilis we not seldom find, that the patients get a swelling of different joints. This swelling is not accompanied with any, or with but slight pain. In nearly all such cases, I have found a high degree of hyperæmia of the discs. It is reasonable to explain the coincidence of an accumulation of fluid in the joints with the hyperæmia of the optic, by supposing a hypersecretion from the meninges, analogous to that of the serous membranes of the joints<sup>1)</sup>.

Now, if hyperæmia of the optic nerves is to be considered as a consequence of a pathological condition of the brain, or of its membranes, we should expect to find, in patients in whom it exists, other symptoms indicating a suffering of the nervous system. It seems, too, that such is the case. By looking through the notices of a great number of patients, I have found, that, in cases in which hyperæmia has been present, headache, giddiness, and, so called, rheumatic pains have been more frequently complained of, than in cases in which the hyperæmia has been absent. Taking the 400 cases spoken of p. 26, I find that complaints of headache and the other above-mentioned symptoms have been noticed in 140, or 35 per cent. In 74 of the 400 I have found a decided hyperæmia; and of these 36, or 48 per cent, have complained of headache etc. In 43 in which I have found doubtful hyperæmia, 20 have complained of the same symptoms, or 46,5 per cent. In the 283 cases in which no hyperæmia has been observed, 84 have complained of such symptoms, or only 29,6 per cent. If I take but the last 200, which were followed more closely, I find headache etc. mentioned in relatively, a still higher number of patients, the proportion being for the whole number  $62 = 31\%$ . For the 45, in which undoubted hyperæmia, in  $23 = 51\%$ . For the 23, in which hyperæmia dubious, in  $8 = 34,8\%$ . For the 132, in which the fundus oculi has been found normal, in  $31 =$  only  $23,5\%$ .

Although these figures are too small to allow of a definite conclusion, they tend to show that there exists a connexion

<sup>1)</sup> By the transport-theory, I would also explain the hyperæmia which I have always seen in children suffering from a syphilitic chronic hydrocephalus. In one case I found on the section, the sheaths at the ocular end of the optic nerves, dilated, like the bud of a flower.



between the hyperæmia of the optic nerve and other symptoms, indicating an affection of the nervous system; and thus give, to a certain degree, the right to look upon the hyperæmia as a sign of such an affection. From this point of view, the hyperæmia of the optic nerves acquires an interest, not only for the syphilidologue, but also for the neuropathologue. An ophthalmoscopical appearance, which would, in ordinary circumstances, excite the most serious fears, not only for the sight of the patient, but also for his life, will, so far, in case he suffers from a recent syphilis, be of no significance. Advocates of an indifferent treatment, may, without fear for the appearance of a choked disc, safely let the disease run its course; the hyperæmia will, like the roseola of the skin and the other relatively innocuous affections, after some weeks disappear, leaving the sight as good as before. So too advocates of mercurial treatment would lull themselves into a therapeutical illusion, by believing that the drug in such cases, had saved both sight and life.



## Affections of the Optic Nerve in the later stages of Syphilis.

---

The term, *Neuritis optica*, is still used by different authors with a different meaning. While some have accepted the classification of v. *Græfe* more than 20 years ago, according to which they distinguish between a *Choked Disc*, or a *Passive Hyperæmia*, and a *Neuritis optica*, or *Neuritis descendens*; others contend against the possibility of maintaining this distinction, since the ophthalmoscopic changes may be alike in both.

No doubt the opinion maintained by the latter holds good in some cases; as it may be impossible sometimes, by means of the ophthalmoscope alone, to distinguish between a real inflammation and a passive hyperæmia<sup>1)</sup>. Still I should not think it advisable to dispense with the term *Choked Disc* (*Stauungspapille*), as signifying an ophthalmoscopic appearance, different from that usually observed in a true neuritis. Consequently I shall use both terms; indicating by *Choked Disc*, a state of passive hyperæmia, in which the pathological changes are seen to be confined to the optic disc, and its adjacent parts. The disc itself is found to present an even prominence,

---

<sup>1)</sup> In Lond. Ophth. Rep. Vol. VI p. 100 Dr. *Hulke* reports a case illustrating the correctness of this. The ophthalmoscope showed the appearance typical for a passive hyperæmia; but the post mortem examination revealed a post ocular neuritis, the nerves being considerably tumified in their course within the orbit and the cranium.



and its borders are every where, except in the outer part, much blurred. By *Neuritis Optica*, or *Neuritis Descendens*, on the contrary, the changes are, as a rule, not confined to the optic disc and its surrounding parts, but extend into the more peripheral parts of the retina; hence such cases are those of *Neuro-Retinitis*. The swelling of the disc in *Neuritis* is often seen to be but partial, being confined to a segment, the other parts being relatively normal, or in a state of atrophy.

The distinction between a mere hyperæmia and a choked disc is but conventional; the degree of the swelling being the main point. If this does not exceed half a millimetre, we do not speak of a choked disc, but of a simple hyperæmia.

To be strictly logical, passive hyperæmia should have been mentioned in the same chapter, in which the hyperæmia of the optic nerve was spoken of. In medicine, however, it may sometimes be advisable to sacrifice the merely logical, for the, practically, more important pathogenetic classification; and, taken from this point of view, the choked disc to be treated of here, must be mentioned separately. For the cause here is not, as in the hyperæmia of the early secondary stage, a suffering of the nervous system of an ephemeral nature; but an intracranial disease of a graver kind, generally a tumor cerebri. Therefore, too, this affection is to be considered as totally distinct from the other, in a prognostic respect. It almost always terminates in atrophy of the optic nerve, if indeed, the life of the patient be not before hand brought to an end.

In the two cases in which, in inveterate syphilis, I have found choked disc, the color of the nerve was more bluish than in those of the secondary stage. Touching the subjective symptoms, they were in both cases alike. V moderately lowered, visual field concentrically constricted, and the blind spots enlarged. Both patients had, for a long time, been complaining of different symptoms indicating an intra-cranial disease: — viz. — severe headache, giddiness, mental dulness, and an impaired memory.

As to the *Neuritis Optica*, we shall find in the literature under this term, many cases registered, the description of which, as to their ophthalmoscopical changes, in nowise differs from that of those found in simple hyperæmia of the



optic disc; as is shown by *Hulke*<sup>1)</sup>, *Leon Drouin*<sup>2)</sup>, *Noyes*<sup>3)</sup> and others. That several authors make a too free use of the word Neuritis, is also apparent from the fact, that in several cases mentioned, functional disturbances are said to have been absent. No doubt therefore, many, if not most of the cases recorded as neuritis syphilitica, ought to be considered cases of hyperæmia of the optic disc only; and, if these cases were sifted, the number reported would be comparatively small. That optic neuritis arising from syphilis, in reality is rare, I do not mean to say. That, relatively, but few cases of this kind are mentioned, is I think explained by the fact, that the optic neuritis belongs to a late period of the disease, when generally all signs of the infection have disappeared<sup>4)</sup>. The affection of the visual organ is then, consequently, not recognised as a more or less direct result of the infection, which too often, is denied by the patient. This notwithstanding some authors; — as *Oglesby*<sup>5)</sup>, *Allbutt*<sup>6)</sup> and *Hutchinson*<sup>7)</sup> state that syphilitic optic neuritis is frequent; *Allbutt* even says — that it is very common.

I have myself treated several cases in which, most probably, syphilis was, the real cause of the neuritis. Infection had been proved with certainty in the three cases following.

4. L. F., woman, 34 years old, treated at the Hospital for Chronic Diseases in 1870. (Lb.-No. 34). She had been

---

<sup>1)</sup> Lond. Ophth. Hosp. Rep. Vol. VII P. 11, p. 105 Cases of neuritis optica etc.

<sup>2)</sup> Lesions syphilitiques des membranes de l'oeil, 1875 p. 15.

<sup>3)</sup> Syphilis of the eye, (Chapter III of a practical treatise on the surgical diseases of the genito-urinary organs, including syphilis; by *W. H. van Buren* and *E. L. Keyes*) p. 19.

<sup>4)</sup> That neuritis should appear within the first two years after the infection, must be considered rare. *Forster*, (*Græfe und Sæmisch Augentheilkunde* Bd. VII P. 1, p. 149) records such a case. Another is mentioned by Dr. *R. Bergh*; (*Beretning fra almindelig Hospitals 2den Afdeling for 1879* pag. 30), this case resulted, within few days, in complete amaurosis.

<sup>5)</sup> Edinburgh Med. Journ. January 1870 p. 624.

<sup>6)</sup> The Ophthalmoscope p. 109 and 250.

<sup>7)</sup> Lond. Ophth. Hosp. Rep. Vol. IX, p. 115, where no fewer than 21 cases are recorded, in which syphilis was either positively proved, or most probably, was present.



under care for constitutional syphilis 22 years previously. She suffered from headache, giddiness and fits of trembling. Examined April 1870. This giddiness then so troublesome, that the patient was obliged to keep her bed. Optic discs prominent; their margins blotted out; arteries small, and veins enlarged and tortuous. On the discs several bluish-white shining spots, which seemed to be imbedded in the layers of nervefibres. In the macula some macerations of the pigment-layer. V about  $\frac{1}{8}$ .

5. M. P. K., aged 32. Treated, at the State Hospital, for syphilis, from January 3<sup>rd</sup> to May 16<sup>th</sup> 1866. Nine years later he began to suffer from headache, buzzing in his ears, and pain in his chest, from which symptoms he was repeatedly relieved by the use of potassii iodidum. When examined, October 1878, he had become worse. Headache very severe; giddiness coming on at intervals. Optics swollen, with diffuse margins; on the left eye signs of commencing atrophy. V r. eye  $\frac{1}{2}$ , left  $\frac{1}{6}$ . L  $\frac{2}{3}$  and  $\frac{2}{1\frac{1}{2}}$ . C appeared normal for large objects. The visual field concentrically restricted, especially on the left side.

6. J. P. puella publica, 24 years old. Treated at the State Hospital, for ulcus syphiliticum, in 1875.  $1\frac{1}{2}$  years later she began to suffer from double vision, headache, giddiness and vomiting. I April 1878 she was sent to me by Dr. Boeck. Optic discs on both sides very prominent, their margins invisible. On the discs numerous vessels, and some extravasations of blood, especially on the right eye. V on both sides  $\frac{1}{2}$ , C imperfect for green hues. Paresis of musc. abduc. dexter. After having used some iodide of potassium, she called again in May the same year. The ophthalmoscopical signs of neuritis then less prominent. V  $\frac{5}{6}$  on both eyes. No alteration of C could then be detected.

Atrophy of the optic nerve may be of a primary, or a secondary kind. The latter may be subdivided into two classes; — one being the result of retino-choroiditis, the other of inflammatory changes in the optics, or of passive hyperæmia. The first of these will be mentioned under the affections of the retina and choroid. In the other, the ophthalmoscopical changes may be like those of primary or genuine atrophy; this is more especially the case, when the atrophy is the result of a passive hyperæmia; and hence, unless the patient has been under observation from the beginning of his disease, we may be unable to tell whether it is of a genuine kind or not.

Judging from the recorded cases, genuine atrophy on a syphilitic base is not frequent. In my opinion however, this



is not consistent with fact. When the frequency of this affection is to be determined, the same causes, tending to conceal the real state, must be taken into consideration, as when that of optic neuritis is to be decided. Considering the great part which syphilis plays in the etiology of the degenerative processes of the neuraxis, of which genuine atrophy of the optic is a common result; considering further, that syphilitic affections of the meninges, leading to deposits of lymph on the base, and, secondarily, to strangulation of the nerves in their course within the cranium, are common, I should think that primary atrophy must be, a relatively frequent affection.

Like neuritis, atrophy belongs to a later stage of syphilis. It may therefore be impossible to decide whether this affection is the result of the infection, or not. Although a strong presumption may, in such cases, exist for the syphilitic origin of the affection, it would be too much to assert, that all atrophies in infected patients, are the result of the infection. It is only when, in fresh cases, antisyphilitic treatment is of evident use, that we are entitled to conclude the atrophy to be specific; if otherwise, we must remain uncertain as to the pathogenesis of the affection. *Galezowsky*<sup>1)</sup> reports such a case, in which the patient, on account of her failing sight, was not able to walk alone; but after a mercurial treatment, regained sight sufficiently to resume her mercantile pursuits. As the improvement of sight progressed, the vascularity of the optic discs, (which at one time had been quite white,) reappeared. Another case, mentioned by *Rankin*<sup>2)</sup>, V being in one eye reduced to a mere qualitative perception of light, in the other to  $\frac{16}{200}$ , was, after an antisyphilitic treatment, brought up to the norm (in both eyes?). In the case of *Rankin*, no ophthalmoscopical changes followed recovery of the function, but the discs remained bluish-discolored.

In the 4 cases in which, in infected patients, I have seen ophthalmoscopical signs of genuine atrophy, I can, in only one assert, that no inflammatory changes had preceded. In the

<sup>1)</sup> Annales d'Oculistiques T. 48 p. 270.

<sup>2)</sup> Med. Record. March 13 1875. Ref. in *Nagel's* Jahrsbericht. 6 Jahrgang p. 347.



other three cases, I had no opportunity to see the development of the eye-affection. A brief account of these cases is here given.

6. X., 41 years old; infected 20 years since; about 13 years after infection, his sight began to fail. When examined V  $\frac{10}{800}$  l. eye; right too low to be measured; homonymous hemianopia sinistra.

7. T. A., woman, aged 38; two years after the infection she began to suffer from headache; nausea, and, sometimes, fainting. After a year, her sight began to suffer. V  $\frac{1}{30}$  left eye; the visual field constricted; on right eye mere perception of light. The retinal vessels, especially the arteries thin. C perception of blue and yellow hues only.

8. Mr. J., 30 years old, suffering from debilitatio mentis and polyuria. V left eye  $\frac{4}{12}$  C  $\frac{1}{3}$  for all hues but blue, for which  $\frac{1}{4}$ ; r. eye, fingers at a meter; visual field concentrically constricted, especially on right side. The patient denied most emphatically having ever been infected, but, from his family physician, I learned that he had been treated for syphilis some years previously.

(In this case the atrophy most probably has been of genuine kind, as the sight had begun to fail only half a year previously to examination.)

9. In this case I had the opportunity of seeing the development of the atrophy from the beginning. The patient was, during 3 years, under my observation, being, from April 1878 to May 81, an inpatient of the State Hospital, where she died. During this period she was frequently ophthalmoscopically examined; and, excepting some enlargement of the retinal veins, her eyes were found quite normal. At the end of December 1880 she began to complain of double vision, the cause of which was found to be paralysis of musculus rect. sup. dext. In the course of 2 weeks a complete paralysis of both nervi oculomotorii, a paresis of n. facialis dext. and a paralysis of the right arm and leg had developed. The patient had difficulty in speaking, and was sometimes delirious. She had, however, so far as could be ascertained, a good sight until the end of January. In the middle of February she began to complain of bad sight, and an examination shewed amaurosis of the right, and hemianopia of the left eye, sight being present only in the outer half of the visual field. Of colors she had lost all perception. Ophthalmoscopically some diminution of the arteries. Later, signs of atrophy were visible. At the end of April, she had still perception of light in the left eye. The post mortem examination showed atrophy of corpus striatum, nucleus len-



tiformis and the anterior part of thalamus up to fossa Sylvii on the left side<sup>1</sup>).

Both atrophy and inflammatory changes of the optic nerves occurring in the later stage of syphilis, cannot be considered to stand in such close connexion to the syphilitic infection, as, in the earlier stage, hyperæmias and inflammations of the retina and choroid. As, however, the former, — like all affections on a syphilitic base, without regard to how long a time has elapsed since the infection —, may be influenced by an antisiphilitic treatment, it is of the greatest importance that the true cause of the affection be elicited.

---

<sup>1</sup>) As this case is of interest touching the question of the decussation of the optic fibres within the cerebrum, a full report of it will be given in another place.



## Affections of the Retina and the Choroid.

---

In medical literature we find the syphilitic affections of the fundus oculi classified into different kinds. Generally *Retinitis* and *Choroiditis* are set forth as two nosologically distinct diseases. The choroiditis is further subdivided into different forms, and has different names given. This makes it difficult to form a correct idea of these affections. As they are in fact polymorphous, it is difficult too, to gain from clinical investigations, a correct apprehension of them. This can only be done by following up the cases from the beginning, through their various stages of development. For anyone who has had occasion to do this, it will soon be apparent that most, if not all of these affections, must be, in fact, considered dependent on one and the same pathological process. The cases designated retinitis, he will find to represent but an earlier, those designated choroiditis, a later stage of the same disease.

*Förster* is the first who has drawn attention to this point, and thereby, undoubtedly, done much towards enabling a better apprehension of these affections. As may be seen from the title of his treatise, an affection of the choroid should be deemed the real cause of the disease; the retina itself also may, in an earlier or later period, be affected, but, as the primary seat of the affection is in the choroid, it ought, taken from a genetic view, to be named »choroiditis«.

In this point I cannot agree with Prof. *Förster*. Careful investigation of a number of cases has confirmed me in the opinion that not the choroid, but the retina is the membrane first affected. But, as the external layers of this membrane are the seat of the primary affection, the process will,



as a rule, after a shorter or longer period, be transferred to the choroid, and consequently the name *Retino-choroiditis* may, advisably, be chosen as that most expressive.

That the retina is the primary seat of the affection I think may be inferred from both the functional and the ophthalmoscopical examination, when the latter is prosecuted, for years, through the different stages of the disease. However, when we want to know in which anatomical part the affection originates, most weight must be attached to the result given by the functional examination of fresh cases. In any pathologic process, disturbance in the action of an organ will, especially, as a general rule, precede visible anatomical changes of the organ itself. That functional disorders in the affections here spoken of, may long precede any signs of diseases demonstrable by the ophthalmoscope, has been repeatedly observed<sup>1)</sup>. The latter, even if present, are as a rule at first very slight and but little characteristic. Consequently, in describing these diseases, we, most naturally, begin with the functional disorders.

Among functional disorders none are more worthy of our attention than the appearance of scotomata. It was a careful study of the form and situation of these which first suggested to me the idea, that the original seat of the affection should be sought in the retina. Therefore I will first describe them, although they may not always be either the first, or the most constant sign of an approaching disease.

If we examine the visual field carefully, we shall find scotomata in the most recent cases. In this respect I should think that the syphilitic form of retino-choroiditis is distinguished from its, so called, idiopathic form; scotomata, so far as my experience extends, not being common in the latter.

At the beginning of the disease, the scotomata mostly appear as two fan-shaped obfuscations of the field of vision, continuous, at their narrower end, with *Mariotte's* spot. From

---

<sup>1)</sup> In a case observed by *Hirschberg*, *Beitrage zur praktische Augenheilkunde* Berlin 1876; functional disturbances preceded, by two years, any demonstrable objective symptoms.



this they radiate, either separately or combined in one stem, a little outwards; they then proceed upwards and downwards, at the same time increasing in breadth. Arrived at  $20^{\circ}$  or  $30^{\circ}$  lat. from the blind spot, they bend towards the medial line, where they, usually become broadest, occupying the space between the  $15^{\circ}$  and  $35^{\circ}$  lat. Here, they are either cut off, or give forth a prolongation, often filiform, from their middle part into the inner half of the visual field. The density of the scotomata is, as a rule, greatest in the central parts, diminishing towards their, consequently, not well-defined limits. As in fresh cases they are generally but slight, they may, with a white object, be difficult to detect. If, however, we use a grey object, we shall have much less difficulty both in discovering them, and in fixing, approximately, their boundaries. A grey, reflecting so little light that, it gives to the healthy eye, in broad day-light, normal extension of the visual field, is well adapted for such investigations<sup>1</sup>). Although the density of a scotoma sometimes may be pretty considerable, I have nevertheless in recent cases, never found real defects<sup>2</sup>).

The form and situation of the scotomata can, for days, and even for months, remain unaltered. After a time, however, a change will take place. Should the disease change for the better, the scotomata will diminish, and gradually disappear. First, their continuity with the blind spot will be disrupted. Instead of a fan-shaped figure, we shall then find a more or less irregular triangle, the position of which is generally near the middle of the visual field, in that place where the breadth of the scotoma has been greatest. In graver cases, where the scotomata on the contrary increase, the course is generally as follows: — From the broadest part of the upper and lower scotoma, slender prolongations issue, that gradually increase in length and breadth, until they become united at a point more or less distant from the centre of the visual field. In this way circular, or ringformed scotomata more frequently are produced, than by a clearing up of the central parts of a

<sup>1</sup>) For some years past I have always used that shade of grey given in my chromotoptrical Tables, published *Christiania*. 1882.

<sup>2</sup>) *Förster Archiv of Græfe* Vol. XX P. 1 p. 62 records a case in which 5 days after the beginning of the eye-affection, an extensive defect appeared.



compact scotoma<sup>1)</sup>. Frequently, the blind spot may still be enclosed within the ring forming a part of it, but as frequently, this is not the case. Usually, it is only in recent cases that the scotomata may be recognised as symptomatic of a retinal affection. In elder cases, they may be found to vary much, both in their position, and in their form. So rather large circular scotomata may be discerned outwards in the periphery, between  $40^{\circ}$  and  $50^{\circ}$  lat.; and nearer to the centre, between  $20^{\circ}$  and  $30^{\circ}$ . Sometimes the ring is regular and, approximatively, of equal breadth throughout, sometimes irregular, with sectorlike prolongations. Scotomata, shaped as irregular, spots or stripes, may be found in one or more places; sometimes together with a ring-scotoma. If insular scotomata are situated so near the point of fixation that their form can be determined with tolerable accuracy, this, is in several cases, found to be somewhat typical. They are seen to have a spiriform appearance, defined by curved lines converging to a point. Their density is found to be greatest at the narrow end and in the middle, where, even a white object may be almost invisible.

In inveterate cases we often find an irregular, or a concentric restriction of the visual field<sup>2)</sup>.

Examples of different kinds of scotomata, and defects in the visual field, may be found in the following cases.

<sup>1)</sup> *Leber, Graefe und Sæmisch Augenheilkunde, Vol. V P. 2 p. 625.*

<sup>2)</sup> Concentric contraction is mentioned by *Meilhac* in his »Recherches sur l'amaurose syphilitique« Paris 1863. *Clifford Allbutt*, »The ophthalmoscope, London and New York 1871; thinks, that this symptom is often found during the early stages of the disease. Certainly we, in recent cases, frequently find a restricted field, especially of the upper part; but this must be considered as a symptom of diminished functional activity, by which the perception of light — L — is reduced over the whole retina. Even in the healthy eye L is, in the periphery, at least by day-light, considerably less, than at the centre. Therefore an apparent contraction of the visual field may be found when L, by pathological processes, is diminished over the whole retina. So much the more will this be the case when, as in syphilitic retino-choroiditis, the functional endurance is reduced. Of these causes we may, with a small object, (or with a grey spot,) and by a prolonged examination, find a considerable contraction of the visual field; although this, by use of a large and white spot, and when we have given the patient some rest, may be found of normal extent.

That a real contraction is more common in old, than in recent cases, has been noticed by several authors, as *Galezowski, Leber*.



10. Mrs. E. I., æt. 38, infected, by her husband, about a year ago. For 2 months she had noticed bright, usually, red-colored rings before her eyes; as also apparent vibrations of the objects looked at, as though they were seen through a current of hot air. In the bright day-light, myiodesopsy. Pains in the left eye. She was examined first time 17<sup>th</sup> of August 1877.

V r. eye  $\frac{5}{9}$ , l. e.  $\frac{6}{36}$ . Field of vision, as foll.: —

Fig. 1.

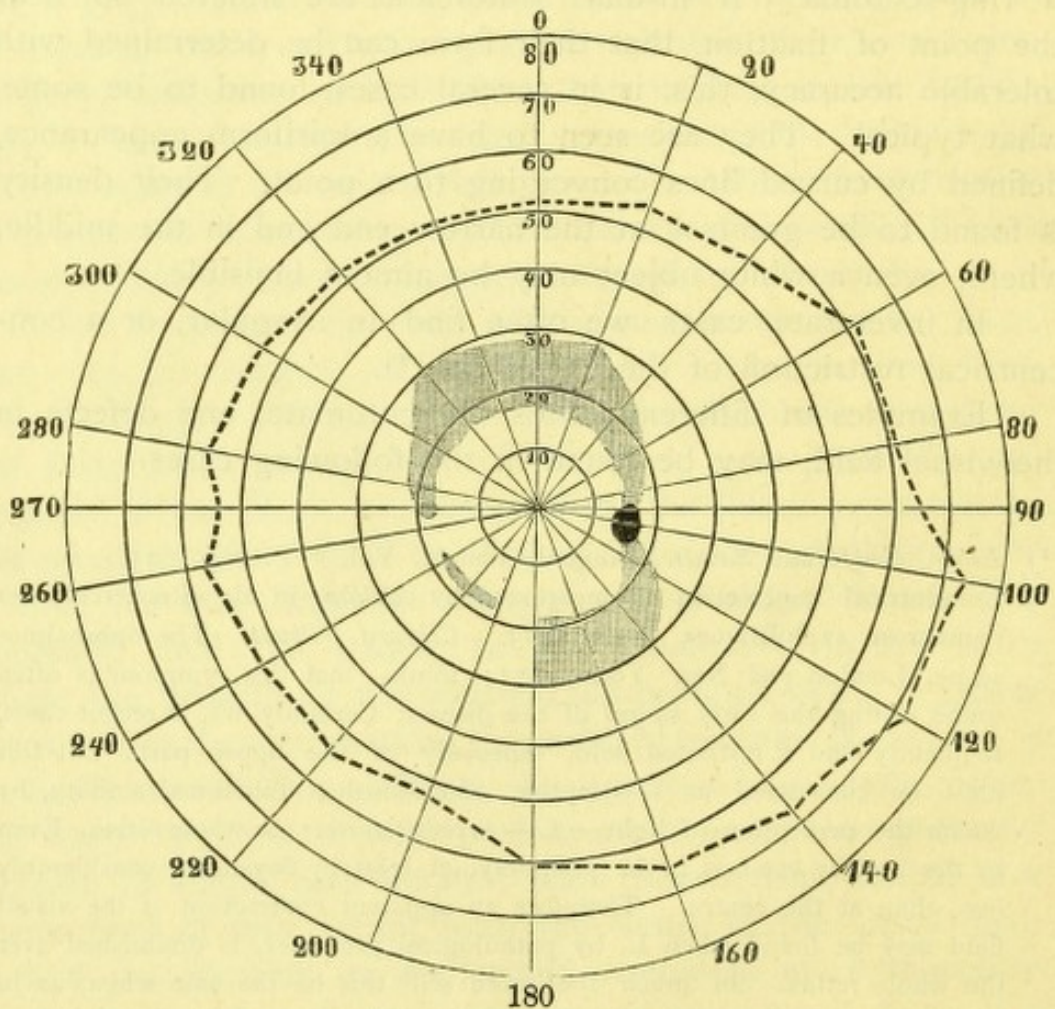
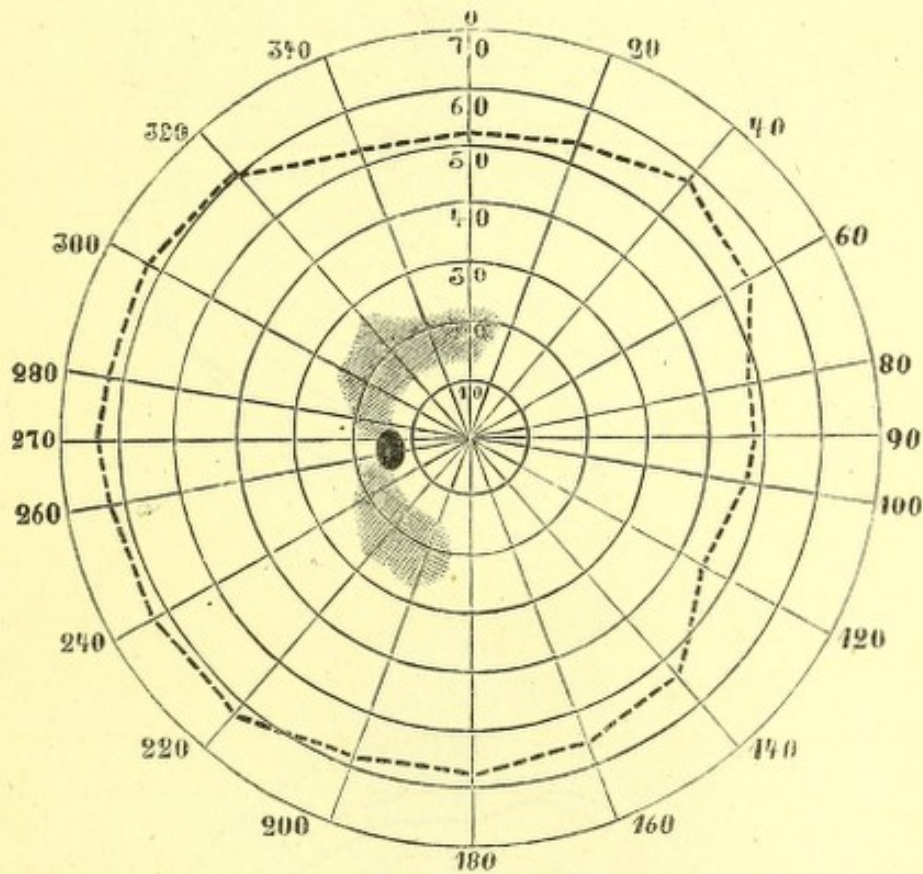




Fig. 2.



Ophthalmoscop. Fundus hazy; in the vitreous, obfuscations formed in stripes.

V in the following weeks, rapidly improving; although no alteration whatever could be detected by the ophthalmoscope, saving the appearance of some small extravasations of blood in the peripheral parts of the fundus.

The 12<sup>th</sup> of September, the visual fields was again mapped, with the result shown below.



Fig. 3.

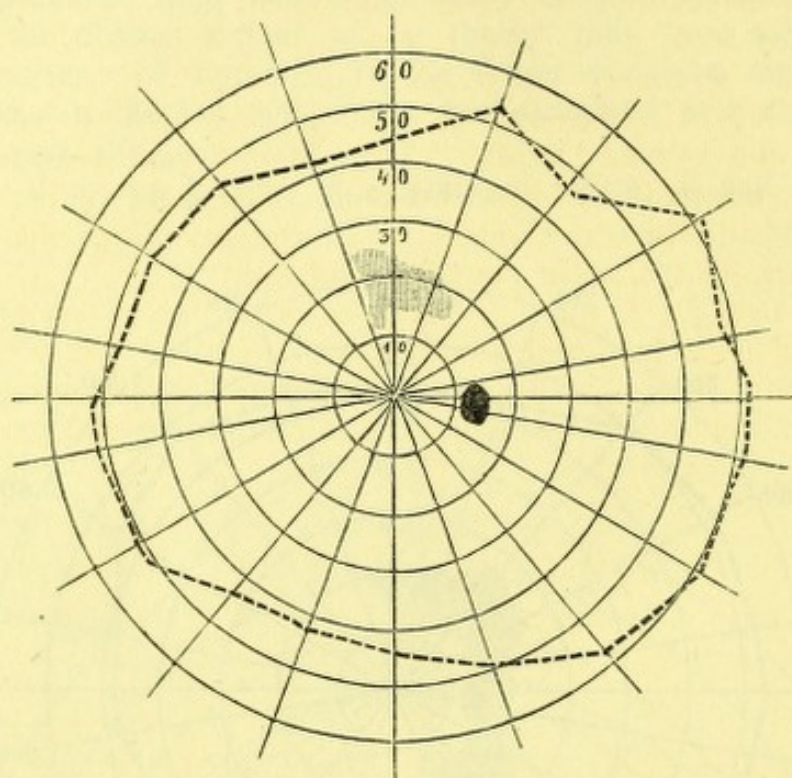
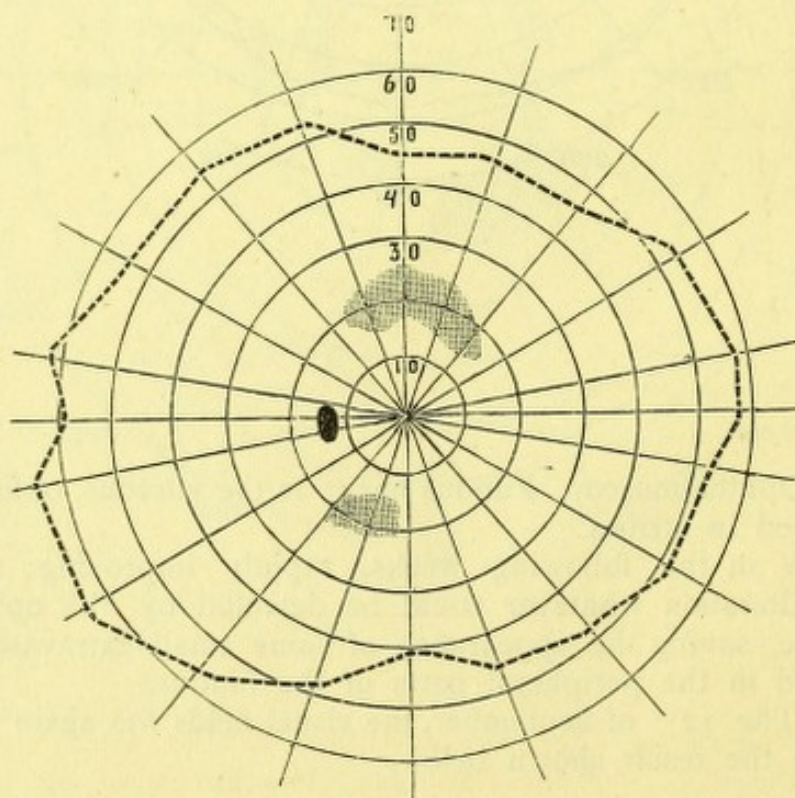


Fig. 4.





Six months later V had increased to  $\frac{1}{2}$  in both eyes.

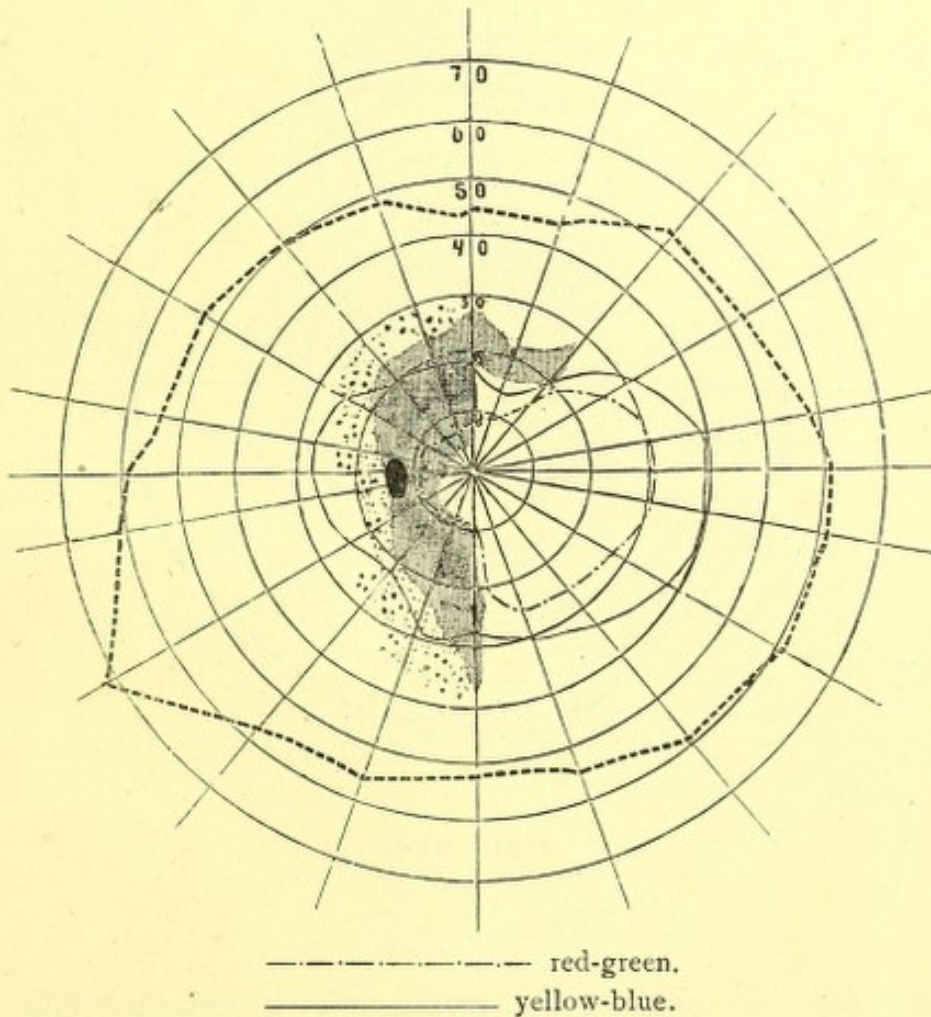
12<sup>th</sup> af March V r. eye  $\frac{6}{12}$ , left eye  $\frac{6}{18}$ . The field of vision of normal extent, and free from scotomata.

18<sup>th</sup> af May 1878 V  $\frac{5}{9}$  r. eye and  $\frac{5}{6}$  l. e. L.  $\frac{1}{6}$ . Ophthalmoscopical appearance unaltered.

11. Mrs. R., laborer's wife, age 50, was sent to me, by Dr. *Vedeler*, the 17<sup>th</sup> of October 1881. Half a year previously, she had been infected by her husband. The sight of her left eye had been bad for three weeks. In the right eye she has, for many years, had a mere perception of light.

V l. eye  $\frac{4}{18}$ , L.  $\frac{1}{20}$ . C confuses from No. 8 on my tables green with blue, and red with yellow. Field of vision examined by grey and by colors, as seen underneath. Perception for red and green, wanting in the scotoma. Micropsia in the parts punctuated.

Fig. 5.



Ophthalmoscop. dense obfuscation of the vitreous; hyperæmia of the disc. On the right eye, detachment of the retina.

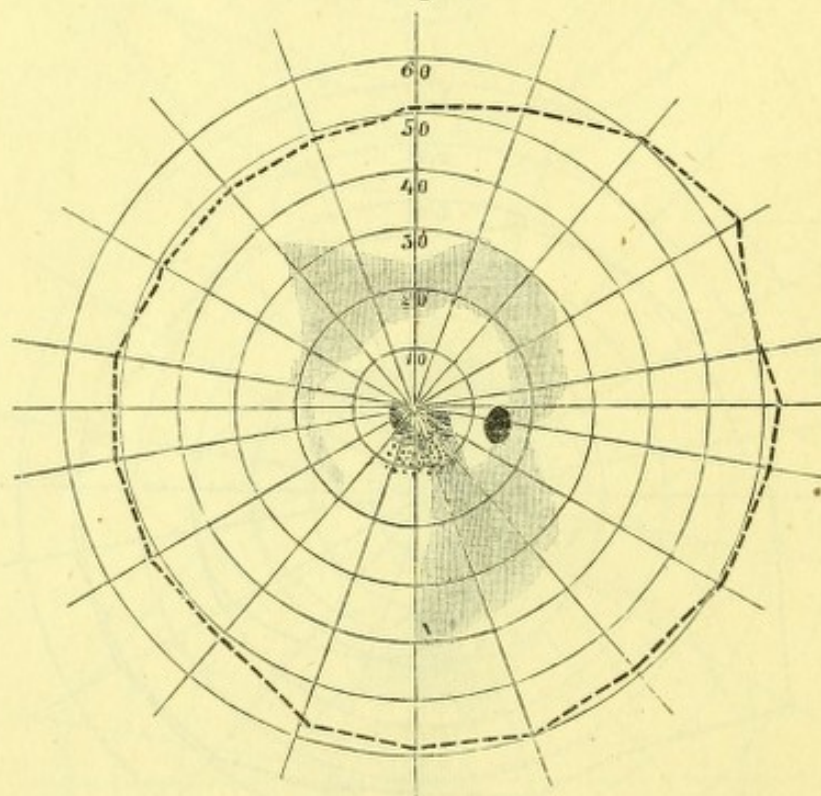
I saw this patient but three times. Subsequently I was told



by Dr. *Vedeler*, that a short time afterwards she had epileptiform fits. Ultimately she became hemiplegic on the left side.

12. Mr. J. B., 44 years old, sent to me by Dr. *Marstrander*. Infected in November 1876. In April of the following year he suffered from pains in his eyes, with impaired V. For a short period he was almost blind. Phosphenes always present. He was examined first time 20<sup>th</sup> of July 1877. V right eye  $\frac{6}{18}$ , left eye normal. He complained of hemeralopia. Scotomata on both sides as seen in the drawings. Micropsia in the place punctuated.

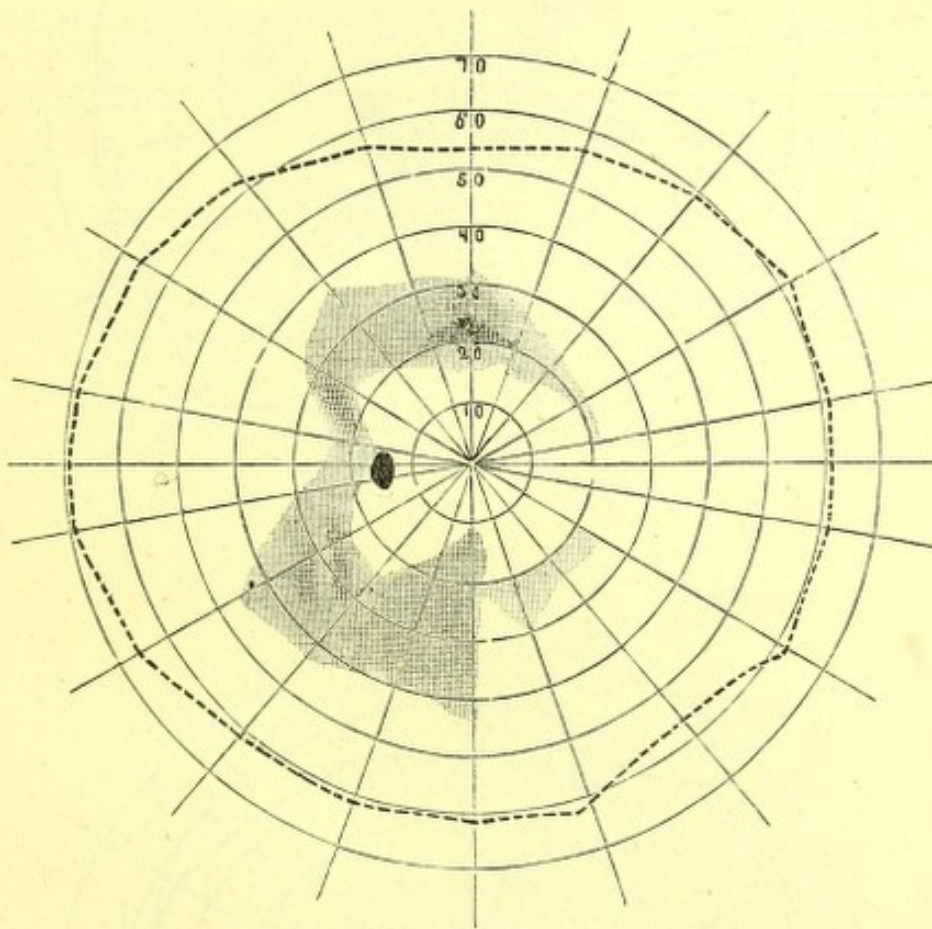
Fig 6.



right eye.



Fig. 7.



left eye.

Ophthalmoscop. Punctiform obfuscation of the vitreous. Fundus highly obscured; in the periphery some light red-colored spots.

V in the following weeks, varying from time to time. The scotomata 3 weeks later, as represented below.



Fig. 8.

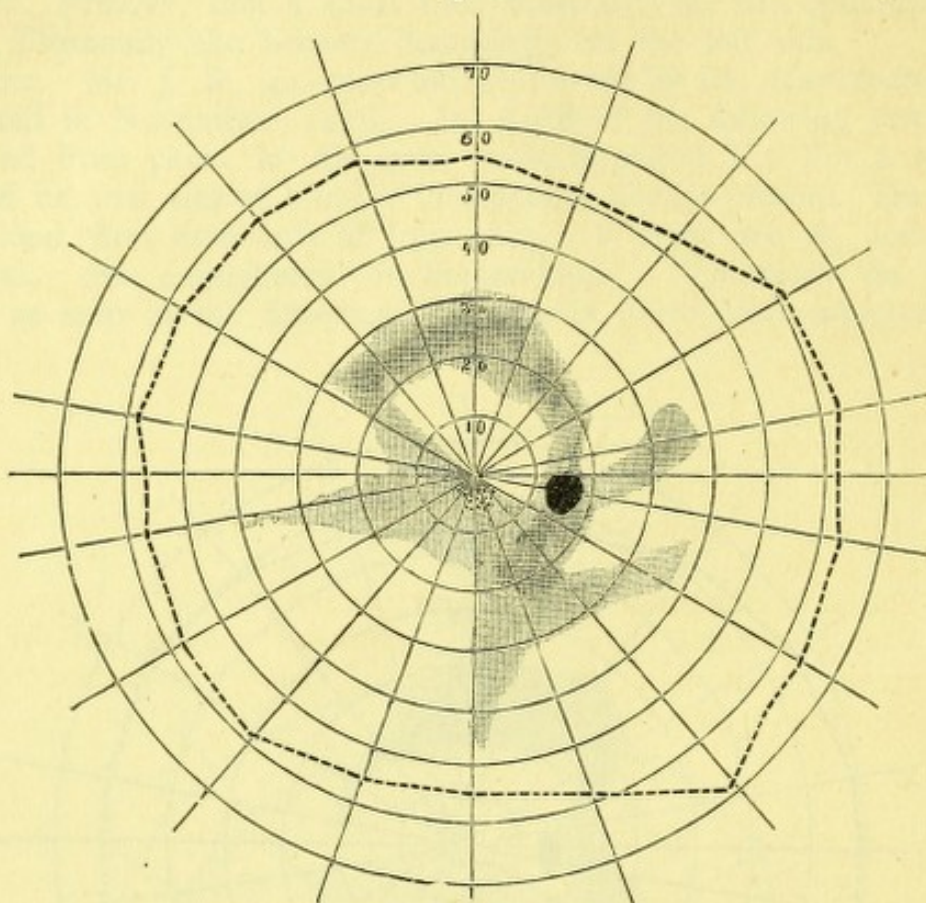
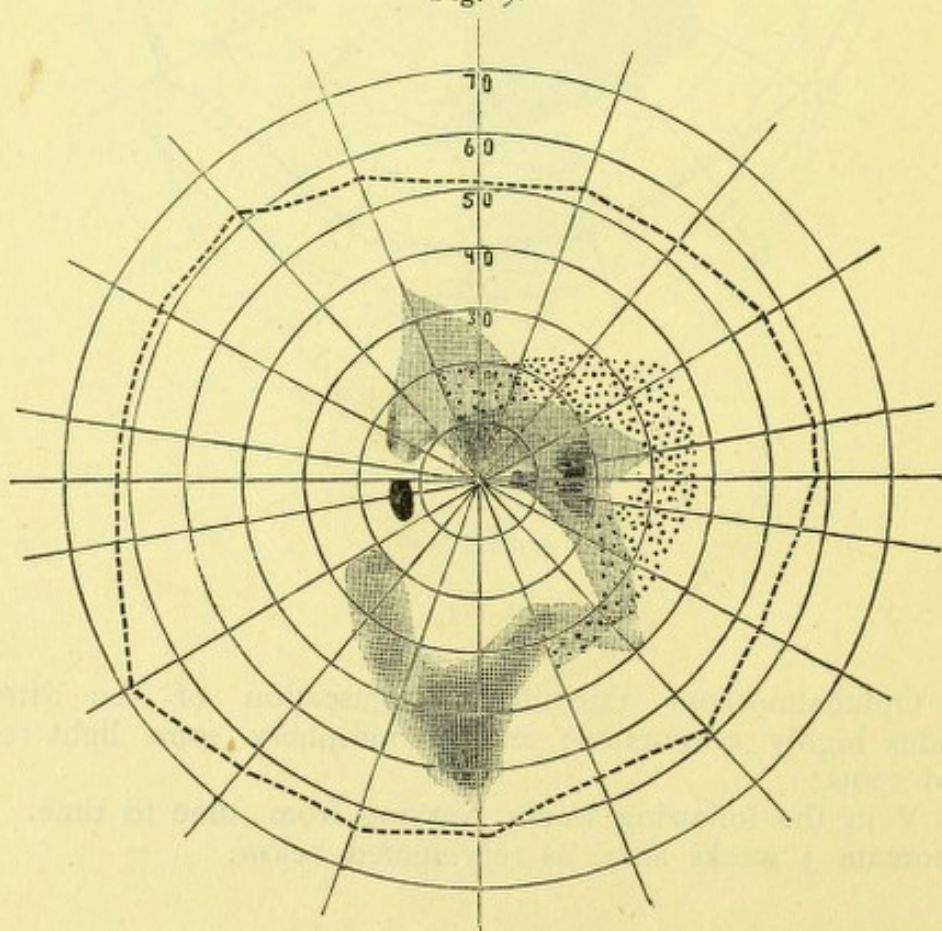


Fig. 9.





The fundus oculi at that time, as seen in figure 7, Pl. IV.

Half a year afterwards the condition of his eyes was growing worse, and V was only  $\frac{1}{4}$  on both sides. He was then confined in a dark room for a period of 4 weeks, during which mercury was prescribed. After that time, his sight improved.

The ophthalmoscopical appearance had remained unaltered up to the time when I last saw this patient, one year later. V then  $\frac{5}{8}$  in both eyes. L right eye  $\frac{2}{5}$ , left  $\frac{2}{3}$ . Visual field of normal extent; only on the outer half of the right eye, some small scotomata could be detected.

13. Mrs. S., 27 years old; treated for constitutional syphilis, in the fall of 1876. Her eyes began to be affected in January of the following year. Myiodesopsia, phosphenes and an apparent vibration of the objects looked at, since that time, have troubled her. Once her sight was so bad that she could hardly venture to walk alone.

She was examined for the first time August 3<sup>rd</sup>, 1877.

V r. e. normal, l. e.  $\frac{1}{80}$ . C confuses weaker tints of blue and green. Scotomata in the field of vision, as represented in the following drawings.

Fig. 10.

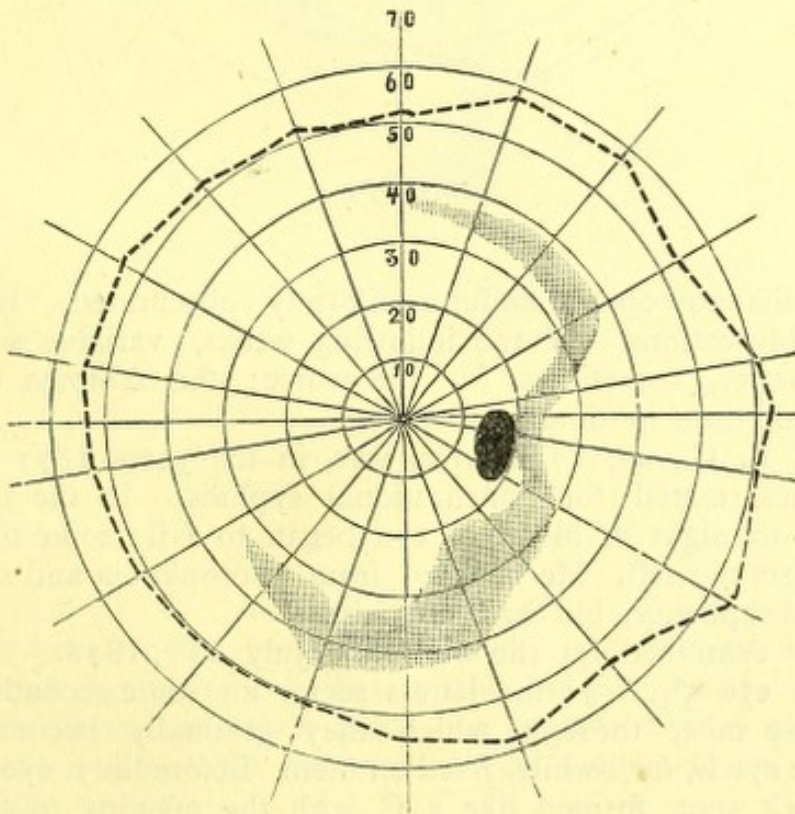
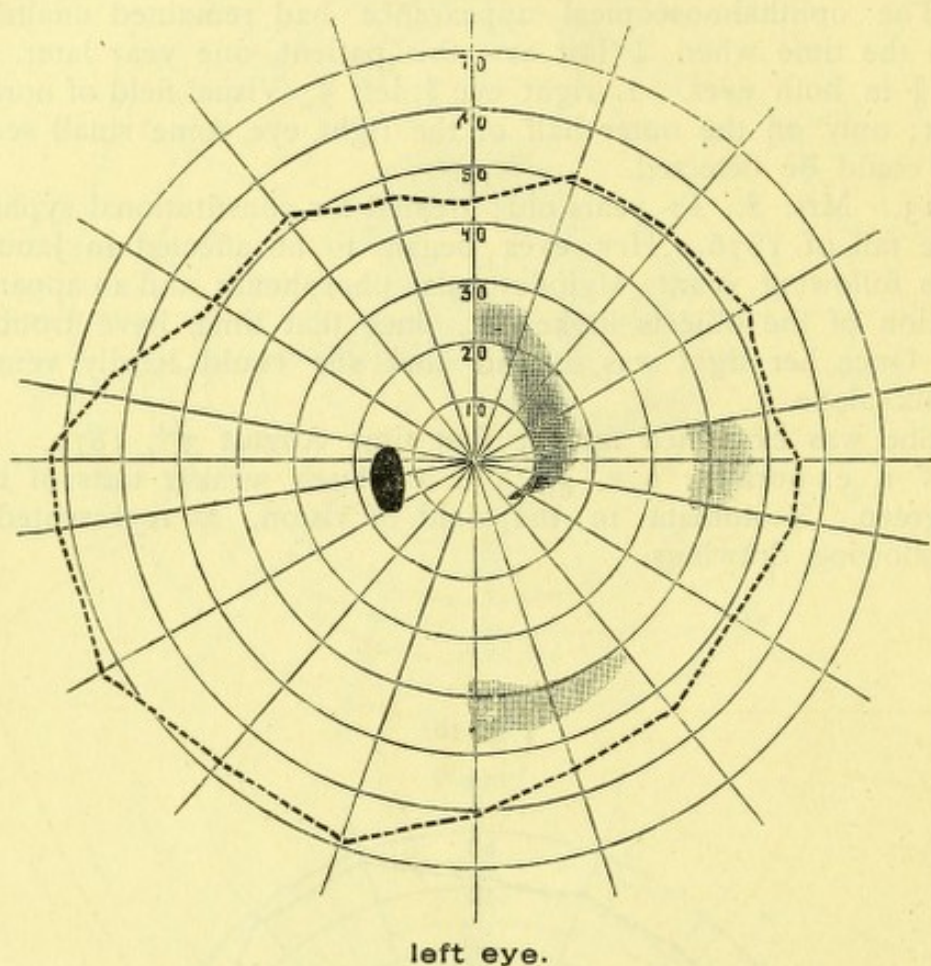




Fig. 11.



Ophthalmoscopic. Fundus uniformly obscured. In the vitreous, obfuscations. V the following weeks, variable sometimes for the better, sometimes for the worse; the scotoma changing place from time to time.

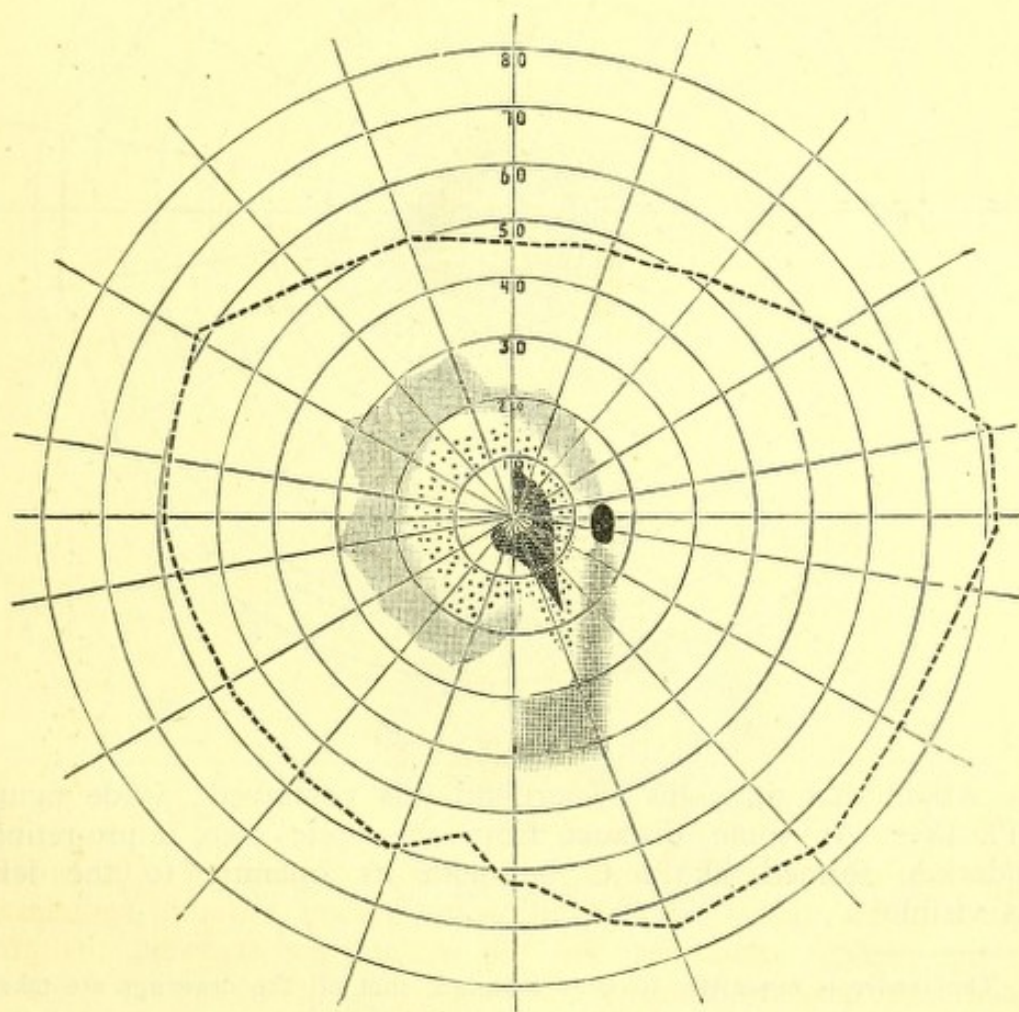
14. E. C., æt. 27 laborer, was, in the years 1877 and '78, three times treated for constitutional syphilis. In the beginning of 1878, the sight of his right eye began to fail; some time afterwards, also the left. He suffered from photophobia and somewhat intense phosphenes, but had no pain.

Eyes examined for the first time, July 26<sup>th</sup>, 1878.

V r. eye  $\frac{5}{24}$ , l.  $\frac{5}{9}$ ; the letters seem, for some seconds, hidden in a dense mist, through which they gradually become visible when the eye is, for awhile, fixed on them. Before the r. eye he sees a large black spot, formed like a C with the opening to the right. L r. eye  $\frac{2}{16}$ , l.  $\frac{2}{3}$ . In both eyes scotomata within the field of vision. The form of those on the r. side as in the following drawing.



Fig. 12.

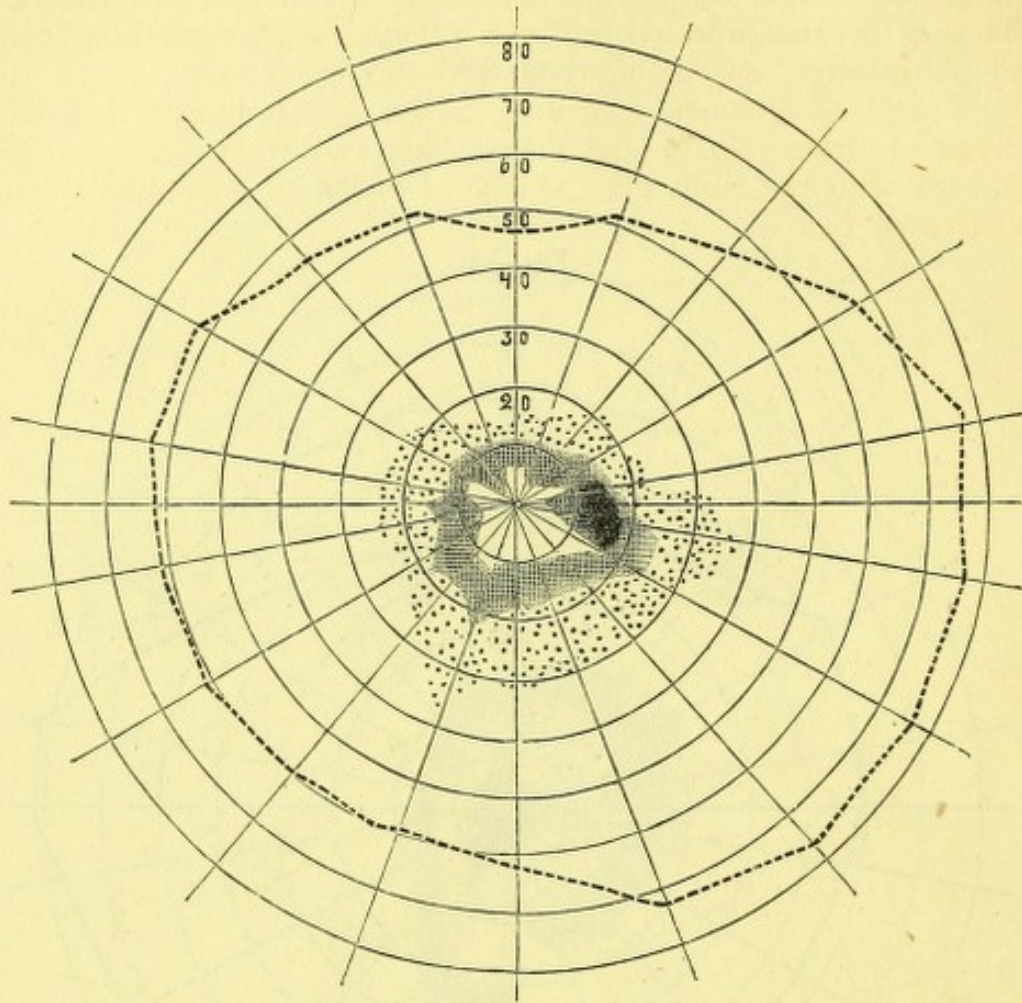


Micropsia in the parts punctuated. In some parts adjacent to the outer periphery of that portion of the visual field within which micropsia had taken place, the patient, without having been questioned, states, that the white object seems *larger* than anywhere else.

Nine days later the scotomata had altered form, as seen underneath.



Fig. 13.



About that time, his eye-ground was portrayed; (vide figure 8 Pl. IV.) At some distance from the optic disc, a pro-retinal exudation, formed like a C but with its opening to the left, was visible<sup>1</sup>).

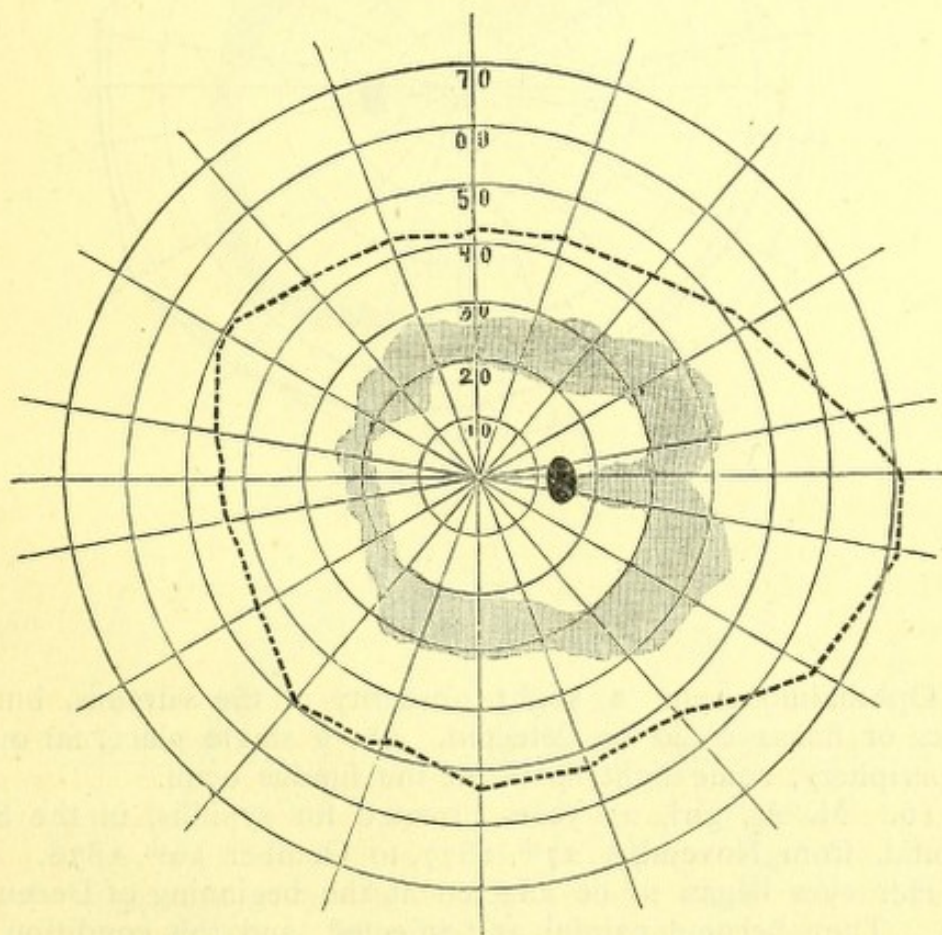
<sup>1</sup>) The reader is requested to bear in mind, that all the drawings are taken in everted image; but the description refers to the erect. Further that scotomata must appear to the patient, in relation to upper and lower in the same position as in the everted image, but not thus relatively to right and left. An obfuscation like that in the drawing is seen by the patient from its inner or posterior surface, by the observer on the contrary through his ophthalmoscope, its anterior surface meets the eye. Consequently, the opening of the C in the figure must to the patient appear on the right, but to the observer, on the left of the spectrum. The same must, of course, hold good of the marks, often left in the eyeground in the same places where scotomata have been detected by perimetrical examination. They must, in everted image, be sought to the right of the optic disc, when found in the visual field to the left of *Mariottes* spot, and vice versâ.



15. M. O., girl, 33 years old, treated for constitutional syphilis in the State Hospital from the 27<sup>th</sup> of August, to the 2<sup>d</sup> of March, 1882. Her sight began to fail in the middle of Octbr., 81. The eyes became injected, and she suffered from periorbital pains and phosphenes, especially when dusk set in.

V 15<sup>th</sup> of October, r. eye,  $\frac{1}{4}$ , l. eye  $\frac{1}{4}$ . L r. eye,  $\frac{1}{8}$ , l. e.  $\frac{1}{4}$ . C confuses from No. 6 green with blue and from No. 5 yellow with red with the right eye. Field of vision of the right side, as represented below.

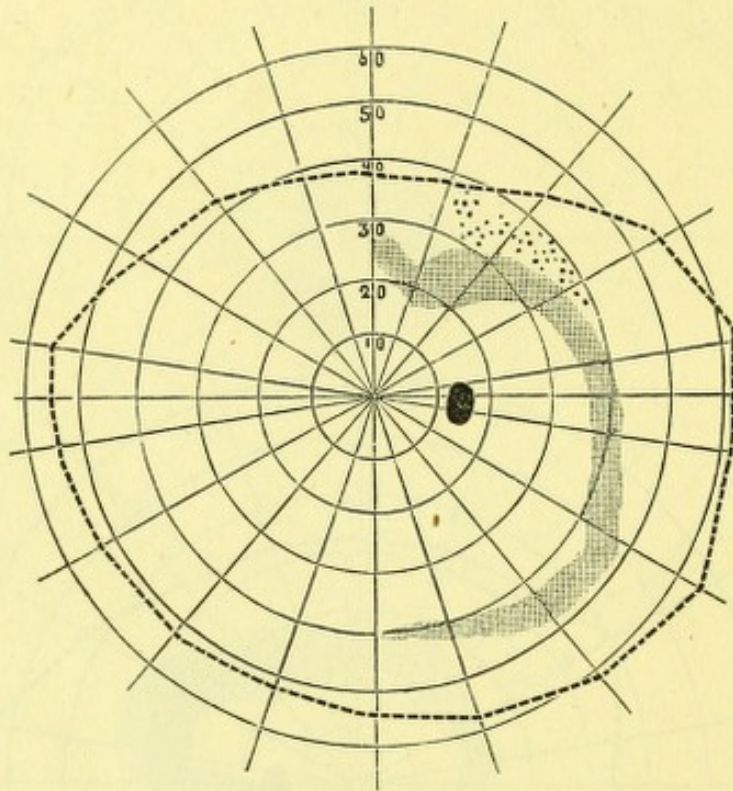
Fig. 14.





Six days later the scotoma had altered its form, as seen in the following drawing.

Fig. 15.



Ophthalmoscopic. a slight obscurity of the vitreous, but no specks or flakes could be detected. On a single place, far out in the periphery, some light spots on the fundus oculi.

16. M. A., girl, 21 years, treated for syphilis, in the State Hospital, from November 27<sup>th</sup>, 1877, to October 26<sup>th</sup>, 1878.

Her eyes began to be affected at the beginning of December 1877. They became painful and injected, and this condition was maintained, with numerous exacerbations and remissions, for more than half a year.

Her eyes were, for the first time, examined October 27<sup>th</sup> '78.

V r. eye,  $\frac{5}{16}$  l. eye,  $\frac{5}{9}$ . L. alike for both,  $\frac{2}{5}$ . Phosphenes and micropsia present. She perceives objects in a state of apparently vibratory movement. Visual fields, as depicted underneath.



Fig. 16.

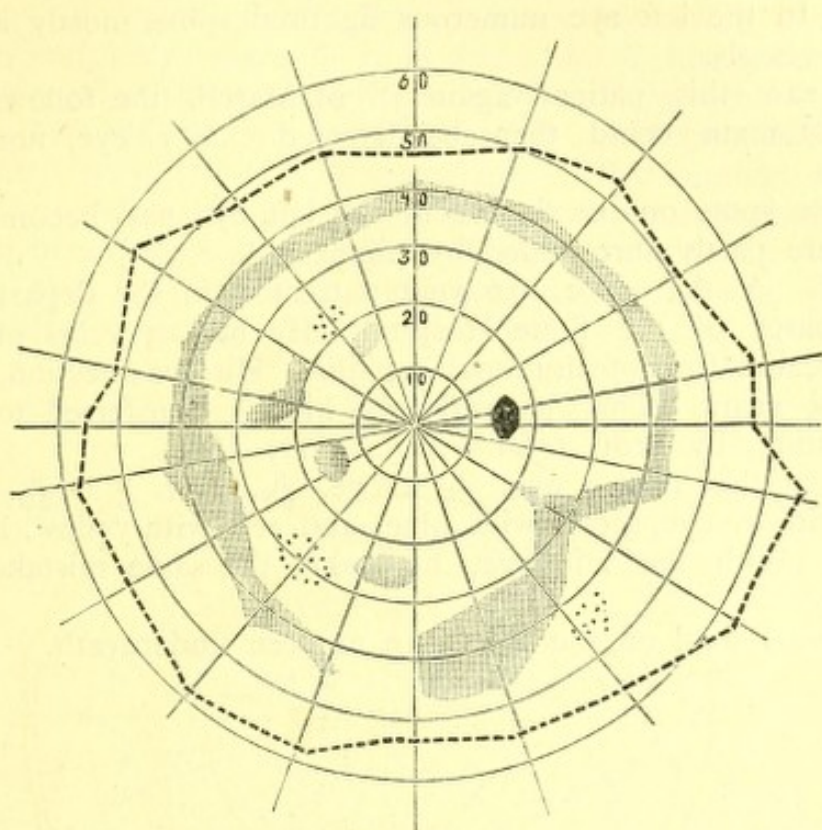
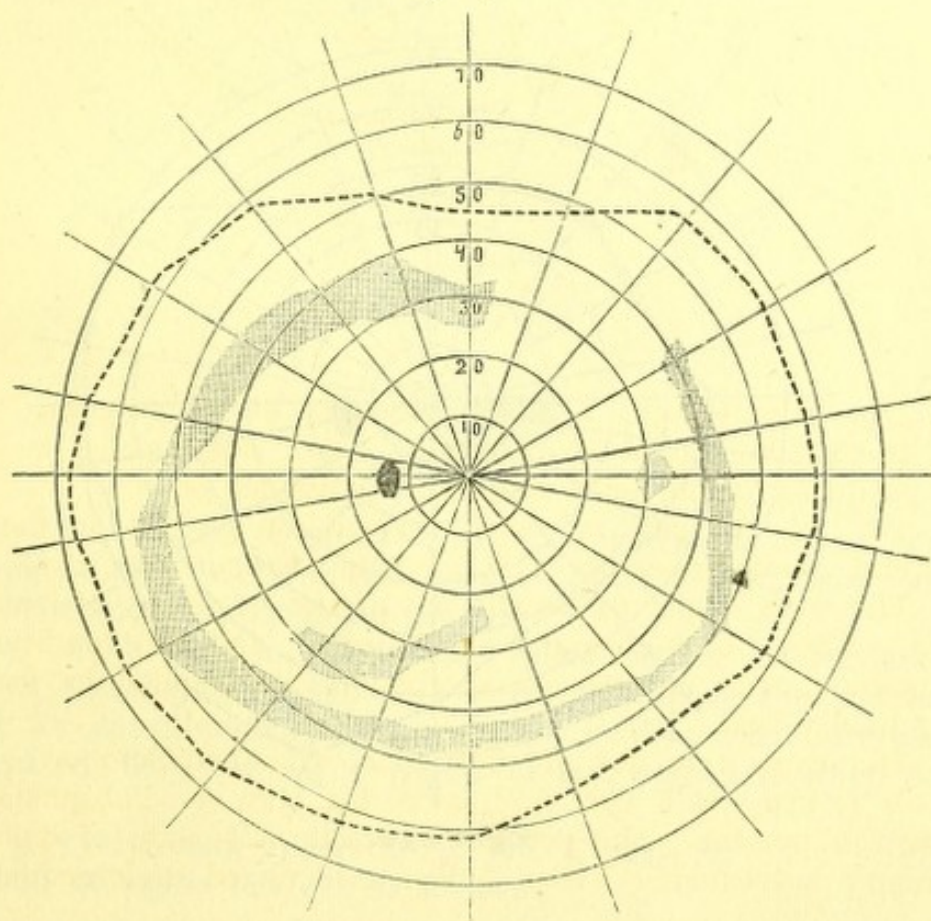


Fig. 17.





Ophthalmoscop. Haze over the optic disc and its surrounding parts. In the left eye numerous light-red spots, mostly along the retinal vessels.

I saw this patient again 4<sup>th</sup> of March, the following year. No scotomata could then be detected. V r. eye, normal; left eye,  $\frac{5}{9}$ .

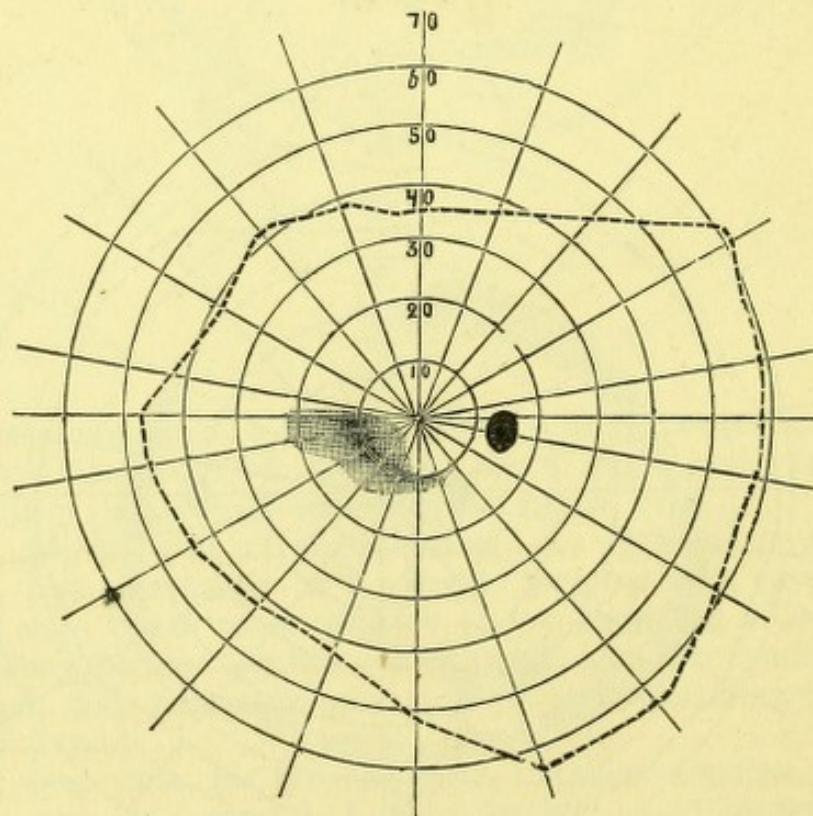
The spots on the fundus of the left eye had become lighter, and were partly surrounded by pigment.

17. A. A., sailor, 36 years; treated in the department for eye-diseases of the State Hospital. He had, 3 years previously, been treated for constitutional syphilis. His eye-affection, he dates back 1½ years. This patient was kindly transferred to me for observation, by Prof. *Hjort*, in January, 1880.

V at that time, r. eye,  $\frac{5}{18}$  l. eye,  $\frac{5}{60}$ . L r.  $\frac{2}{5}$  l.  $\frac{2}{20}$ . C confuses with r. eye, green with blue, and red with yellow, both from No. 4. With the left eye, he makes the same mistakes, up to No. 11.

Visual field on the right eye as seen underneath.

Fig. 18.



right eye.

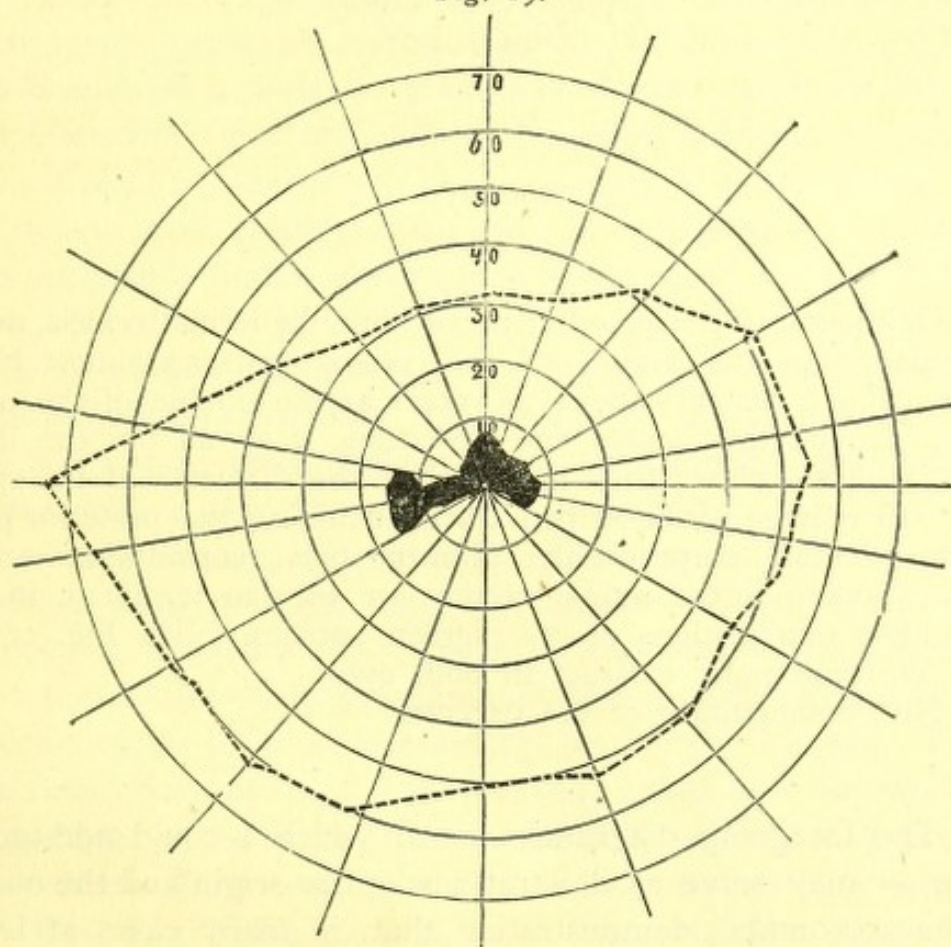


Ophthalmoscop. Haze over and around the optic disc. On the fundus, numerous light-yellowish spots, increasing in size towards the periphery, where they, in some places, become confluent, forming irregular patches, partly covered with pigment.

18. Mrs. M. O., 32 years; married 10 years; infected by her husband some time after marriage. Some months after the infection her sight began to fail, and she suffered from photophobia and phosphenes, especially in the left eye.

V r. eye,  $\frac{4}{5}$ ; l. eye, counts fingers at half a metre. On this eye, a central defect as shown underneath.

Fig. 19.



left eye.

Ophthalmoscop. Destruction of the pigment in a part corresponding to the defect in the field of vision. Peripheral, some small light spots and pigment-patches.

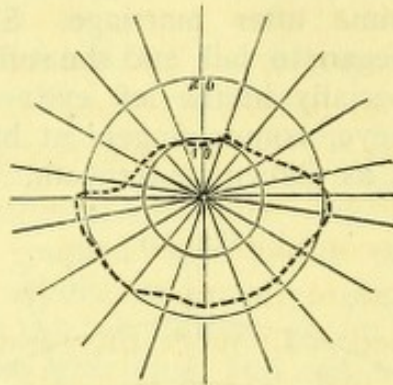
19. C. L. æt. 40, seamstress; called on me on account of her eyes, October 7<sup>th</sup>, 1879. 12 years previously she had been treated for constitutional syphilis. Three or four years afterwards she noticed that her sight began to fail, especially when dusk set in.

V r. eye, counts fingers at 30 cm. l. eye,  $\frac{2}{30}$ .

Field of vision left eye as follows.



Fig. 20.



left eye.

Ophthalmosc. The optic nerve with the retinal vessels, much atrophied. In the region of the yellow spot, an almost black patch, of an extent about as great as the double of the optic disc. Around this patch and enclosing it on all but the inner sides, a bluish. white stripe as broad as the diameter of the optic disc. In a large girdle-shaped tract, encircling the posterior pole, numerous bone corpuscle-like pigment-spots, constituting a network. Some of the retinal vessels are seen to terminate in the thread-like ramifications of the pigment-patches. (Vide Fig. 10 Pl. V.) Posterior polar cataract in both eyes.

No consanguinity of the parents.

The foregoing diagrams, — to which I could add many more — may serve as illustrations of the origin and the course of the scotomata; demonstrating that, in many cases at least, these develop according to the explanation given pp. 45, 6, 7 and following.

In the figures Nos. 1, 2, 5, 6 and 7, we see how they branch out from the blind spot, whence they expand upwards and downwards, in the outer half of the visual field, steadily increasing in breadth until the medial line is reached. Here they are either cut straight off, or considerably diminished in breadth; so that only a slender prolongation, tending downwards in a curve, passes over into the inner half of the visual field. In figures 3 and 4 we see how they may, gradually,



disappear, their connection with the blind spot being first loosened. Figures 8 and 9 show us how they, in graver cases, can become altered, forming irregular figures, whose development, however, from fan-shaped scotomata, starting from the spot of *Mariotte*, is in these cases, clearly seen by comparing them with figures 6 and 7. The development of a ring-scotoma, intimated in figures 1, 6 and 7, is seen distinctly in figures 13, 14, 16 and 17. More irregular ring-scotomata are represented in figures 8 and 12. In all cases of recent date, the density of the scotomata has been, — as indicated in the drawings, — greatest in the middle. Its limits have, usually, not been well defined. In more inveterate cases, on the contrary, we may find real defects brokenly outlined, as in figure 19. In such instances we may, too, find a more or less regular constriction of the visual field, as in figures 18, 19 and 20; the peripheral limits, however, not being so well defined but that a considerable difference may be found, when we use objects of different brightness, — e.g. white or grey spots, as proof-objects. But it is not only the continuity of the scotomata with the blind spot, their fanlike outspreading thence upwards and downwards in the direction of the nerve-fibres, and their sudden disappearance, or diminishing, at the median line, which in fresh cases indicate, that the original seat of the affection is not in the choroid. There is another fact, which shows that these diseases are originated in the nervous system, and which points to a cause acting behind the globes. This is the restriction of that half of the visual field in which the scotomata lie, — viz., of its external half, — frequently found in such cases. Even if white or grey objects be used for mapping out the visual field, we may find this restriction of the outer half. This is intimated in figures 1, 2, 6, 7 and 10; in which the limits of the outer half, in a normal state far exceeding those of the inner, extend outwards but a few degrees further than they. This restriction of the external half may be rendered clearly visible, if, as is done in the case represented figure 5, we use colors in the perimetrical examination. In cases where this restriction is found on both sides, and the scotomata too, on both sides are symmetrically placed an imperfect *hemianopia heteronyma lateralis*, must be said to



be present<sup>1)</sup>. The theoretical explanation of this kind of hemianopia may be different, as we adopt the doctrine of *Müller*, or that of *Charcot*, concerning the course of the optic nerve-fibres within the cerebrum. According to the first, we must seek the cause in chiasma; according to the latter, it may be there, or in one of the hemispheres.

Now, how do the form and the situation of the scotomata, such, as a general rule, we find them in fresh cases, harmonise with the doctrine held by most authors; according to which, the real seat of the affection is to be sought in the choroid? A proof of the trustworthiness of this doctrine is, by some authors, — e. g. *Schön*<sup>2)</sup>, — found even in the form, and the situation of the scotomata. *Schön* especially, has observed that, generally, these do not stand in any relation to the retinal vessels. He therefore seeks the cause in a affection of the choroidal vessels; hence the frequency of central scotomata, and of ring-scotomata between 30° and 35° l., places that correspond to those where most of the choroidal vessels permeate the sclera.

This explanation of *Schön* is not consistent with the facts related above. First-touching the central scotomata; we find that their form and extension may vary much; and no doubt they, sometimes, may be limited to those parts, corresponding to the macula, and its surroundings. As a rule, this however is not so in recent cases; on the contrary, they extend far beyond this part, often enclosing the blind spot, or sending forth prolongations, in different directions. In some cases where I have found isolated scotomata close to the centre, their form has been such, that I had to seek an explanation rather in a retinal, than in a choroidal affection; since they have been either continuous with the blind spot, or have formed spiral-shaped figures, such as those seen in fig. 18. For scotomata of the latter kind, the explanation lies close at

<sup>1)</sup> The case represented in No. 1 may be considered as an imperfect homonymous hemianopia. I dare not however, lay much stress on this case, as it is the only one I ever met, in which a homonymous hemianopia has been intimated; and it is very possible, that accidental causes of some kind or other, played a part in the configuration of the visual field. The disease was, also tolerably far advanced.

<sup>2)</sup> Die Lehre von Gesichtsfelde p. 96, 140 etc.



hand, if it be sought in an affection of the *retinal* vessels. Assume that the nutritive process, by some cause or other, has been disturbed in a part corresponding to that fed by 2 smaller retinal arteries, — e. g. — the circulation hindered from that point where the vessels ramify from their common stem, — then, we can explain both the spiral-like form of the scotoma, and the fact, that its density is greatest in the middle. The top of the scotoma lies in the bifurcate space of the two vessels, these forming its curvilinear limits, the density must therefore be greatest where the nutritive action is most deteriorated, viz. in the middle, as the place furthest from the healthy vessels adjacent. Relatively to the ring-scotomata, so commonly found in those affections<sup>1)</sup>, it may be difficult to trace their origin to a retinal affection; but on the other hand, neither can they be better explained by the hypothesis of a choroidal affection. They are by no means confined to that part of the visual field, which lies between the 30° and 35° lat. A glance at the foregoing figures will show that they can be found both further from, even between 40° and 50°, (vide fig. 15 and 17), and nearer to the centre, — between 5° and 20°, (vide fig. 13). That the ring-scotomata, so far as I have been able to ascertain, do not appear as a primary form, but are developed from scotomata issuing from the blind spot, proves, that they are in nowise connected with a choroidal affection. How an affection starting from the retina, can, in a more advanced stage, spread itself, to all appearance quite independently of the anatomical structure of the organ affected, is another question. We must, however, bear in mind, that the disease shows a tendency to locate itself in the external layers of the retina, where the process once begun, is susceptible of a less direct influence from the nervous system. Something like this we find in the cutaneous affections; these too have, as *Hutchinson* has pointed out, in cases of fresh syphilis, a tendency to spread symmetrically; but at a later stage of the affection, that tendency becomes gradually less.

<sup>1)</sup> *Förster*, l. c. p. 340. *Leber*, in *Grafe and Sämisch*, Vol. V P. 2 p. 612. *Mooren*, Ophthalmiatische Beobacht. p. 290. *Alexander*, Berliner klinische Wochenschrift 30th Jahrg. p. 523. *Imre*, Zehenders klinische Monatblätt. 1876 p. 267.



Before leaving this subject I would remark, that I never, in any case of retino-choroiditis of non-syphilitic origin, have found scotomata of such forms as those which they exhibit in syphilitic cases.

Several other symptoms stand in close relation to the scotomata.

Among such are the *phosphènes*, which seldom fail to appear in an early stage. They may even, for a long period, be the only symptom of the eye-affection, as in the case of *Hirchsberg*, related p. 45. For this reason, they are well worthy of attention. The phosphenes are, in regard to their number and intensity, most variable. Generally they appear as sparks, or shining globules, without any positive color, running across the the visual field with greater or less rapidity. But they can also be stationary; and then, their intensity is generally less pronounced, and may even be so small, that the patient may be at a loss to find an idiomatic simile by means of which his impression can be conveyed<sup>1)</sup>. Sometimes it might seem as if he had rather the sense of a diffused glittering vibration, than of severally luminous objects. The observation of *Förster*<sup>2)</sup>, according to which scotomata can always be shown on the places in the visual field, corresponding with those where stationary phosphenes appear, I have several times had occasion to verify. Nevertheless the contrary, does not hold good; for several times, also, I have found large sized scotomata, in cases where the patient has not complained of any phosphènes.

Every cause by which the heart's action is stimulated, as muscular exertion, or excitement from any cause whatsoever, tends to increase the phosphènes. Hence *Förster* thinks, that they ought to be referred to the bloodcirculation in the choroid, or in the retina, and not to any cause exciting the nervous elements<sup>3)</sup>. It may, however, be not impossible that the same

<sup>1)</sup> *Förster* states, that the phosphènes are always but faint. »Funken oder helleuchtende Flammen werden nie angegeben« l. c. p. 52.

<sup>2)</sup> l. c. 53.

<sup>3)</sup> Hiernach kann man das Symptom der Photopsie wohl nur auf circulatorische Verhältnisse in der Choroidea, oder in der Netzhaut beziehen; nicht auf Reizung der nervösen Elemente durch Exudate, oder dergleichen.



cause which excites the action of the heart, is *causa proxima* of the increase of the phosphènes. As *Förster* himself says, there are other causes that are apt to promote a reappearance of the phosphènes, or an increase of their intensity; among such, intense light, and sudden changes in the degree of illumination are to be numbered. I have found repeated closing and opening of the eyes produce the same effect. All these forces we know, conduce to the rendering of after-images to our perception, and that doubtless, by acting in some way on the nervous elements. At all events we can hardly suppose that causes such as those named above can have any influence of the bloodcirculation within the globe, and, consequently, cannot refer the phænomena of the phosphènes to circulatory movements only.

The phosphenes are in the beginning of the affection but faint, but they increase generally with the development of the affection itself, and can be very troublesome to the patient<sup>1</sup>). The phosphènes, in inveterate cases, are generally of greater expanse, and more fixed in regard to their form and situation. They may remain for years. One of my patients was, for more than six years, troubled with such a phosphène, which appeared before one eye as a silver-glittering wavy line bent at an angle around the point of fixation<sup>2</sup>).

A symptom which is very often combined with phosphènes and scotoms, is an apparent *vibration* of the objects regarded. This is, to the patient, comparable with the impression received when looking through a stream of hot air<sup>3</sup>). Like the phosphènes, the vibration may be a very obstinate symptom; and, being increased by the same causes as those producing the phosphenes, it probably depends on a pathological process of the same kind.

<sup>1</sup>) Phosphènes are named by *Jacobsen*, Königsberger medicinische Jahrb. Bd. XI Hf. 3. p. 284, as a very troublesome symptom, and *Galezowsky*, Diagnostic des maladies des yeux, p. 187, says — they may be the most annoying symptom.

<sup>2</sup>) In another case mentioned by *Förster*, l. c. p. 54, the phosphènes continued for several years.

<sup>3</sup>) Vide *Meilhac*, Recherches sur l'amaurose syphilitique, p. 32. *Galezowsky*, Général de Médecine, 1871, p. 143. *Förster*, l. c. p. 52.



The symptom which, more than any other, can have influence on the whole well-being of the patient, and on his success in life, is the *deterioration of V*. This may be the first symptom noticed. As a rule, we find that V, during the inflammatory stage, is lowered<sup>1)</sup>; but the lowering is, — as stated by several authors, — moderate only. In exceptional cases we may even find V normal; that, however, does not exclude the possibility of some deterioration having taken place. It must further be considered as a rule, that the patient usually does not regain full power of vision, even in cases where the inflammation has been moderate. In severe cases, a more or less grave amblyopia will remain for life. This especially may occur, when several relapses of the inflammation have taken place. Fortunately, a complete amaurosis is rare. I have myself seen but one case. In this, the amaurosis was monocular; and it may be further noted, that iridectomy had been performed on the same eye, some years previously.

That V, during the progress of the disease, usually does not diminish gradually, but suddenly, and with intermissions, is well known<sup>2)</sup>. Some authors have explained this rapid sinking of V, which, — with equal rapidity, may be restored to its former state, — by corresponding changes in the obfuscations<sup>3)</sup>; and this may, in some cases, hold good. Usually however, we cannot, as *Förster* says, by means of the ophthalmoscope, see any alteration which could account for the diminution of sight; and the haze of the vitreous is, even if present, mostly not of such a density, as to sufficiently

<sup>1)</sup> *Wecker*, in *Græfe und Sämisch* Bd. 4 Abt. 2 says, that a more or less pronounced dimness of sight is an invariable symptom.

<sup>2)</sup> *Galezowsky*, *Diagnostic des maladies des yeux par la Chromatoscopie retienne*, p. 196, do. *Archiv generales de medicine*, 1871, p. 141. *Leon Drouin*, *Les lésions syphilitiques des membranes profondes de l'oeil*, p. 26. *Förster*, l. c. p. 62.

<sup>3)</sup> *Nettleship*, *St. Thomas Hosp. Rep.* 1878. *Wecker*, *Græfe und Sämisch*, Bd. 4 Abth. 2 p. 625; on another page, p. 628, *Wecker* admits, that the degree of V does not always stand in direct relation to the greater or less density of the haze in the vitreous.



explain the great diminution sometimes present. Moreover V is, not seldom, tolerably good, in spite of an obfuscation of the vitreous so dense, that the optic disc can be but faintly seen. The cause of the great lowering of V, *Förster* thinks, is a defect in the central part of the visual field. »Diese defecte« he says p. 40 — »pflegen die Eigenthümlichkeit zu haben, dass, gerade am Fixationspunkt, noch eine mehr oder weniger scharfe Perception geblieben ist, die bei heller Beleuchtung steigt, bei Minderung des Lichtes hingegen sehr erheblich sinkt.« From these reasons *Förster* concludes, that the variations of V should be but cautiously referred to corresponding alterations of the function; (p. 63) as the illumination in these diseases plays a greater part than in any other. Judging from my own investigations, I must agree with Prof. *Förster* in the supposition that, in fresh cases, a central scotom is the principal cause of the great sinking of V; and further, that the variations of the illumination [have a considerable effect, but at the same time I must believe, that *Förster* attributes too much influence to the latter cause. The enormous sinking of V which may take place from one day to another, cannot possibly be explained by accidental changes in the illumination. The principal cause must be sought in an alteration of the function, and, according to my experience, it is rather due to the migration of a scotom from the periphery to the central parts. Therefore, so soon as the scotom passes from the centre, V may suddenly regain its former standard. — The correctness of this observation I have several times had occasion to ascertain; — e. g. — in the case related No. 12 in which I followed the movements of the scotom during a considerable period. In cases where there does not exist any scotom in the vicinity of the centre, we do not find those striking changes of V, and this too, in recent cases, is generally not much lowered.

A diminution of the *perception of light*, and a perversion of the *colour-perception*, are always found, at least during the time the process remains in the inflammatory stage.

The diminution of L becomes most apparent to the patient, when the illumination is but faint; and, for this cause,



*hemeralopia* is a well known symptom of these affections<sup>1)</sup>. Exact investigations of the degree in which L may be lowered, we find in the often-cited treatise by Prof. *Förster*. In accordance with this author, I have found that the degree of diminution of L is not always correspondent with that of V; but I have not found so great a difference as *Förster* has, between L and V. My investigations in this point however, cannot be compared with those of *Förster*; having been carried on by a method quite different from his. I have determined L by photoptometrical tables, constructed on the principle described in the Archiv of Græfe, Bd. XXVII Abt. I. According to this, L is determined in a light room. The visual angle, is also, on my tables, taken considerably less than that used by *Förster* in his »Lichtsinnenmesser«. No wonder therefore, that our results in this point differ. The difference is however, not so great in reality, as it appears to be. There are reasons, apart from those above named, which explain why *Förster* has found L so low, relatively to V. Among these the first is —, the incorrect manner according to which *Förster* calculates the results found. For L he takes, as a standard, the least amount of light necessary to render perceptible the white objects on the black ground; for V he takes the diameter of the objects. By doing so he gets an expression relatively far too high for V; as the intensity of the light stands in direct proportion to the superficies of the — retinal — image, and not to its diameter.

Secondly, when examination of L is performed in a dark room, we must bear in mind, that the light, proper to the retina itself, is increased by many pathological conditions; not the least of which is the specific retino-choroiditis. If, with *Helmholtz*, we put this for the healthy retina as  $H_0$ , and the least amount of objective light, perceptible by the normal eye, as  $h$ ; then the augment of the latter cannot be neglected, but must be increased as  $H_0$  increases. Consequently we cannot confer the results of our examination of V and L, when that

<sup>1)</sup> Thus hemeralopia is named by *Deval*, l'union medical 1859 p. 307. *Quaglini* Annales d'oculistique T. XLVIII p. 278. *Meilhac* l. c. p. 34; nearly all authors of later date mention this symptom. The term *hemeralopia* although proved by Drs. *Twedy* and *Greenhill* to be incorrect, is here used to indicate sight only by day in conformity with the classic canon: — *Usus—arbitrium est, et jus, et norma loquendi.*



of the first is made in broad day-light, and of the other, by an illumination so faint as to allow the increase of  $H_0$  to become noticeable.

Another reason, which may be influential, is, that *Foerster*, for the examination of  $V$  — so far as can be seen from his treatise, — has used day-light; but for his examination of  $L$ , artificial, viz. candle-light. As, for the normal eye, the amount of yellow light, necessary to obtain an impression of light, is much larger than that of the uncolored, we cannot, in cases of pathological alterations, make a trustworthy comparison of the results obtained under these different kinds of illumination.

The reasons here named are of force to change considerably the result of our examination. More however than all these, the adaptation of the retina must influence the result, when the examination is made in a dark room<sup>1)</sup>. An eye affected by these diseases needs, as compared with a healthy eye, a much longer time to become adapted to a low illumination. Taking into account the paramount influence of the adaptation, we must conclude that the results of examination in dark room, are to be regarded as an expression of a diminution of this faculty of the retina, rather than of an absolute decrease of  $L$ . And this so much the more, when, as by *Foerster*, only 5 minutes are allowed, for the adaptation. It would also have been surprising that  $L$  could decrease so far in relation to  $V$  as shown by the fractions noted by *Foerster*<sup>2)</sup>, when we bear in mind, that the former is the fundamental condition of all kinds of visual impressions, the latter only an expression for the isolated conduct, having  $L$  for its suppositive major. The contrary, — a low  $V$  and a relatively high  $L$  would be much more readily brought into accordance.

When we use a photoptrical table constructed on a principle like that applied in mine, the examination can be performed under the same circumstances as that of  $V$ . Consequently, the adaptation may be left out of consideration. The result obtained is, however, to be regarded as an expres-

<sup>1)</sup> *Foerster* himself was aware of this.

<sup>2)</sup> l. c. p. 44.



sion of the perception of local light-differences in light room. As an expression for L generally, it can only be taken so far as we, from the former, can draw conclusions concerning the condition of the latter, in the concrete case<sup>1)</sup>. Further when, as in my tables, the object letters are seen at a visual angle as small as about half a degree, (*Snellen* No. 6, at one metre's distance) the result has reference to that part of the retina only which lies close to the centre. In cases of central scotomata, we should, consequently a priori, expect to find a greater diminution of L, when the examination is conducted with such tables, than when made with very large objects in a dark room; provided — that the eye is adapted to the low illumination, — and vice versa, in cases of concentric restriction of the visual field. Comparative examinations made in a number of cases, during the last year, have proved to me that this actually holds good. In the following table therefore the expression given for L is to be regarded as an expression of the degree of this faculty in the central parts of the retina, so far as it can be derived from the patient's perception of local light-differences in a light room.

Date of examination	V calculated according to the usual manner.	V when the superficies of the image is taken as the basis of calculation.	L calculated after the darkest number readable.	Remarks.
1. $\frac{3}{6}$ '78	r. e. $\frac{2}{3}$ , l. e. $\frac{1}{2}$	r. $\frac{4}{9}$ , l. $\frac{1}{4}$	r. $\frac{1}{5}$ , l. $\frac{1}{8}$	The affection commenced 3 years previously.
2. $\frac{22}{2}$ '79	r. e. $\frac{5}{8}$ , l. e. $\frac{1}{1}$	r. $\frac{2}{5}$ , l. $\frac{1}{1}$	r. $\frac{2}{3}$ , l. $\frac{1}{1}$	Vide case No. 12.
3. $\frac{13}{5}$ '79 $\frac{18}{5}$ '79	binocular $\frac{1}{2}$ do. $\frac{5}{6}$	binoc. $\frac{1}{4}$ do. $\frac{2}{3}$ $\frac{5}{6}$	binoc. $\frac{1}{5}$ do. $\frac{1}{3}$	
4. $\frac{14}{5}$ '79 $\frac{4}{7}$ '79	r. e. $\frac{1}{3}$ , l. e. $\frac{5}{18}$ r. e. $\frac{1}{1}$ , l. e. $\frac{1}{2}$	r. $\frac{1}{9}$ , l. $\frac{1}{12}$ r. $\frac{1}{1}$ , l. $\frac{1}{4}$	r. $\frac{2}{3}$ , l. $\frac{1}{5}$ r. $\frac{1}{1}$ , l. $\frac{2}{3}$	Continuance of the affection. 6 weeks.
5. $\frac{26}{7}$ '79 $\frac{5}{8}$ '79	r. e. $\frac{5}{24}$ , l. e. $\frac{5}{6}$ r. e. $\frac{1}{4}$ , l. e. $\frac{1}{2}$	r. $\frac{1}{21}$ , l. $\frac{2}{36}$ r. $\frac{1}{16}$ , l. $\frac{1}{4}$	r. $\frac{1}{5}$ , l. $\frac{2}{3}$ r. $\frac{2}{5}$ , l. $\frac{1}{1}$	

<sup>1)</sup> Vide my treatise in Græfe's Arch. Bd. XXVII, Abt. 1, pag. 66.



Date of examination	V calculated according to the usual manner.	V when the superficies of the image is taken as the basis of calculation.	L calculated after the darkest number readable.	Remarks.
6. $\frac{4}{2}$ '79	r. e. $\frac{5}{8}$ , l. e. $\frac{1}{3}$	r. $\frac{1}{2}$ , l. $\frac{1}{9}$	r. $\frac{2}{5}$ , l. $\frac{1}{10}$	The left eye was the first attacked. Here iritis.
7. $\frac{6}{3}$ '79	r. e. $\frac{1}{1}$ , l. e. $\frac{1}{1}$	r. $\frac{1}{1}$ , l. $\frac{1}{1}$	r. $\frac{2}{3}$ , l. $\frac{1}{5}$	
$\frac{1}{4}$ '79	r. e. $\frac{1}{2}$ , l. e. $\frac{5}{36}$	r. $\frac{1}{4}$ , l. $\frac{1}{52}$	r. $\frac{2}{3}$ , l. $\frac{1}{10}$	
$\frac{22}{4}$ '80	r. e. $\frac{5}{36}$ , l. e. $\frac{5}{36}$	r. $\frac{1}{52}$ , l. $\frac{1}{52}$	r. $\frac{1}{3}$ , l. $\frac{1}{3}$	
$\frac{8}{5}$ '80	do.	do.	do.	
8. $\frac{18}{6}$ '79	binocular $\frac{1}{3}$	binoc. $\frac{1}{9}$	binoc. $\frac{1}{9}$	The inflammatory stage had passed.
$\frac{10}{4}$ '80	do.	do.	do.	
9. $\frac{12}{4}$ '79	r. e. $\frac{5}{9}$ , l. e. $\frac{1}{1}$	r. $\frac{1}{3}$ , l. $\frac{1}{1}$	r. $\frac{2}{3}$ , l. $\frac{1}{1}$	
10. $\frac{13}{1}$ '80	r. e. $\frac{5}{18}$ , l. e. $\frac{5}{60}$	r. $\frac{1}{12}$ , l. $\frac{1}{144}$	r. $\frac{1}{3}$ , l. $\frac{1}{14}$	
11. $\frac{2}{3}$ '80	r. e. $\frac{5}{12}$ , l. e. $\frac{5}{12}$	r. $\frac{1}{6}$ , l. $\frac{1}{6}$	r. $\frac{1}{3}$ , l. $\frac{1}{3}$	
12. $\frac{30}{4}$ '80	r. e. $\frac{5}{6}$ , l. e. $\frac{1}{1}$	r. $\frac{25}{36}$ , l. $\frac{1}{1}$	r. $\frac{1}{3}$ , l. $\frac{1}{1}$	
13. $\frac{18}{9}$ '80	r. e. $\frac{5}{12}$ , l. e. $\frac{1}{1}$	r. $\frac{1}{6}$ , l. $\frac{1}{1}$	r. $\frac{1}{3}$ , l. $\frac{1}{1}$	
14. $\frac{21}{1}$ '81	r. e. $\frac{5}{12}$ , l. e. $\frac{5}{12}$	r. $\frac{1}{6}$ , l. $\frac{1}{6}$	r. $\frac{1}{3}$ , l. $\frac{1}{5}$	
15. $\frac{17}{3}$ '81	r. e. $\frac{4}{5}$ , l. e. $\frac{4}{6}$	r. $\frac{16}{20}$ , l. $\frac{24}{36}$	r. $\frac{1}{1}$ , l. $\frac{2}{3}$	
16. $\frac{24}{4}$ '81	r. e. $\frac{1}{1}$ , l. e. $\frac{4}{18}$	r. $\frac{1}{1}$ , l. $\frac{1}{20}$	r. $\frac{1}{1}$ , l. $\frac{1}{30}$	
$\frac{2}{5}$ '81	do.	do.	do.	
17. $\frac{23}{6}$ '81	r. e. $\frac{5}{6}$ , l. e. $\frac{4}{18}$	r. $\frac{25}{36}$ , l. $\frac{1}{20}$	r. $\frac{2}{5}$ , l. $\frac{2}{7}$	
18. $\frac{15}{10}$ '81	r. e. $\frac{1}{4}$ , l. e. $\frac{1}{1}$	r. $\frac{1}{16}$ , l. $\frac{1}{1}$	r. $\frac{1}{16}$ , l. $\frac{1}{1}$	
$\frac{21}{10}$ '81	r. e. $\frac{1}{7}$ , l. e. $\frac{1}{1}$	r. $\frac{1}{49}$ , l. $\frac{1}{1}$	r. $\frac{1}{30}$ , l. $\frac{1}{1}$	
19. $\frac{17}{12}$ '81	r. e. $\frac{4}{18}$	r. $\frac{1}{20}$	r. $\frac{1}{20}$	On the left eye, amotio retinae of old standing. Vide case No. 11.
$\frac{19}{12}$ '81	do.	do.	do.	
20. $\frac{5}{1}$ '82	r. e. $\frac{4}{18}$ , l. e. $\frac{4}{36}$	r. $\frac{1}{20}$ , l. $\frac{1}{80}$	r. $\frac{1}{14}$ , l. ?	
$\frac{6}{2}$ '82	r. e. $\frac{4}{18}$ , l. e. $\frac{4}{18}$	r. $\frac{1}{20}$ , l. $\frac{1}{20}$	r. $\frac{1}{8}$ , l. $\frac{1}{8}$	
$\frac{10}{5}$ '82	r. e. $\frac{4}{12}$ , l. e. $\frac{4}{6}$	r. $\frac{1}{9}$ , l. $\frac{1}{2}$	r. $\frac{2}{5}$ , l. $\frac{2}{5}$	
21. $\frac{26}{1}$ '82	r. e. $\frac{1}{6}$ , l. e. $\frac{1}{9}$	r. $\frac{1}{36}$ , l. $\frac{1}{81}$	r. $\frac{1}{16}$ , l. $\frac{1}{30}$	
22. $\frac{30}{3}$ '83	r. e. $\frac{1}{1}$ , l. e. $\frac{4}{9}$	r. $\frac{1}{1}$ , l. $\frac{1}{9}$	r. $\frac{2}{3}$ , l. $\frac{1}{14}$ vix.	



A glance at this table shows that, in most cases, (12). V is found lower than L; in others, (5) L and V correspond; and again in others, (4) L is found the lower.

If, however, we take the diameter of the retinal image as the basis for the calculation of V, this will, in most cases, be found higher than L.

In determining L, I have assumed it to be normal, when the patient has been able to read the darkest letters at a distance of one metre; the illumination being that of ordinary day-light. If not, I have supposed L to be diminished, and expressed the degree of diminution by a fraction, in which the darkest number, corresponding to  $2^{\circ}$  white and  $358^{\circ}$  black on the rotating disc, is numerator, and the lowest readable number, denominator. Consequently the light-difference between the letters, expressed by the number indicating the degrees of the white sector, has been taken as the basis of calculation. The amount of light reflected from the black ground, has been left out of consideration.

When we examine how L of the normal eye decreases with the lessening illumination, we are certainly right in doing so; as we can safely assume the quantity of light reflected from the black ground to be so small, that it needs not be taken into account. I am, however, quite aware that it is more than doubtful, whether the amount of light reflected from the black ground can be omitted from consideration, when the examination is conducted in a light room. If the light reflected from the black ground be taken into consideration, the relative value of L in proportion to V will still be considerably higher. For instance in No. I, L is put at  $\frac{2}{16}$  r. eye, and  $\frac{2}{16}$  l. e. If we take the white reflected from the black ground into account, the notation would be but  $\frac{1}{3}$  r. e. and  $\frac{1}{3}$  l. e. The light-difference between the black and white, is found photometrically, to be as 0,0052 : 1; consequently the light-difference between the darkest letters and the ground, corresponding to  $2^{\circ}$  white, and  $358^{\circ}$  black on the rotating disc, — 
$$= \frac{2^{\circ} + (358^{\circ} \text{ black} \times 0,0052)}{360^{\circ}} = 0,0107.$$
 According to this L should be, if  $10^{\circ}$  and  $16^{\circ}$  are the lowest read-



able numbers =  $\frac{0,0107}{0,033} = \text{ca. } \frac{1}{3}$  and  $\frac{0,0107}{0,0494} = \text{ca. } \frac{1}{5}$  <sup>1)</sup>.

Before closing my remarks on this point I would say, — that I have, for the *luetie* retino-choroiditis, made but few comparisons between the result of L as examined by my tables, and in dark room. In these cases where a marked constriction of the visual field is found, we shall probably, as in retinitis pigmentosa, find L under very low illumination and, with large test-objects, diminished comparatively to V, in a greater ratio. And this even when a long time is allowed for adaptation.

Concerning the *colour-sense*, different statements are made by different authors. *Galezowsky* states that a partial colour-blindness is a very constant symptom <sup>2)</sup>. When scotomata have not been present, *Leber* has found this function but exceptionally altered <sup>3)</sup>; and *L. Drouin* states, that he has never found C affected <sup>4)</sup>. Most authors do not say anything on the point.

Alteration of C is, according to my experience, a constant symptom. That it has been overlooked hitherto is only explicable, by the methods used in testing C not having been fitted to demonstrate that kind of alteration, when present in these affections.

The colour-perception suffers in the same manner as from retinitis externa in general. The mistakes of the patients, are analogous to those made by the normal eye, when examined by a low illumination; viz. — more or less intense tints of yellow are confused with those of red; those of green with blue; and of all hues, violet and grass-green will be those that first appear colourless <sup>5)</sup>. If the degree of this perverse perception be ex-

<sup>1)</sup> In my brochure «De på lues beroende pathologiske forandringer af øienbunden» 1880 p. 60 this question is treated in a manner, now admitted to be unintelligible.

<sup>2)</sup> Diagnostic des maladies des yeux, p. 188. Archiv general, 1871, p. 145. Traité iconograf. d'ophth. p. 158.

<sup>3)</sup> Græfe und Sämisch, Bd. V, Abth. 2, p. 613.

<sup>4)</sup> l. c. p. 29.

<sup>5)</sup> Vide my treatises in the Archiv of Græfe, Bd. XXVI, Abt. I, and Bd. XXIX, Aot. III.

Although in medical literature, where the colour-sense under these affections is mentioned, we do not find it stated that C is perverted in the above named manner; we can, by comparing the records of several cases,



pressed numerically, we shall find that it is not always proportional to the decrease of L. The table given below will illustrate this. N. B. The values of C for the normal eye, examined by an illumination so low that only the same number on my photoptrical table would be readable, as that which in the concrete case the patient could read, are, for the first 7 cases, added in parenthesis.

Num- bers same as pp. 74, 75	Date of ex- amination.	L	C
7.	22/4 '79	r. e. $\frac{1}{8}$ l. e. $\frac{1}{8}$	green $\frac{1}{8}$ ( $\frac{1}{5}$ ); yellow $\frac{1}{8}$ ( $\frac{1}{5}$ ); violet appears as grey; confuses weak tints of green with grey, and yellow with red.
8.	10/4 '80	binoc. $\frac{1}{5}$	green appears as blue, ( $\frac{1}{7}$ ); yellow $\frac{1}{6}$ ( $\frac{1}{7}$ ); red and blue $\frac{1}{3}$ , ( $\frac{1}{4}$ ).
10.	13/1 '80	r. e. $\frac{1}{8}$ l. e. $\frac{1}{14}$	green $\frac{1}{4}$ , ( $\frac{1}{5}$ ); yellow $\frac{1}{3}$ , ( $\frac{1}{5}$ ); red ( $\frac{1}{2}$ ) and blue $\frac{1}{2}$ , ( $\frac{1}{3}$ ). l. e. confuses, in all numbers, green and blue.
11.	31/3 '80	both eyes $\frac{1}{3}$	both eyes green $\frac{1}{3}$ , ( $\frac{1}{5}$ ); yellow ( $\frac{1}{5}$ ) and blue ( $\frac{1}{3}$ ) $\frac{1}{2}$ , red $\frac{1}{1}$ , ( $\frac{1}{2}$ ).
12.	30/4 '80	r. e. $\frac{1}{3}$ l. e. $\frac{1}{4}$	r. e. in all numbers, green appears as blue and yellow as red; violet as grey, (green and yellow $\frac{1}{5}$ , blue $\frac{1}{3}$ , red $\frac{1}{2}$ ).
13.	18/9 '80	r. e. $\frac{1}{3}$ l. e. $\frac{1}{4}$	r. e. yellow $\frac{1}{3}$ , ( $\frac{1}{3}$ ), blue $\frac{1}{2}$ , ( $\frac{1}{3}$ ), red $\frac{1}{1}$ , ( $\frac{1}{2}$ ). l. e. $\frac{1}{4}$ .

infer that such has actually been the case. So *Galezowsky*, of one patient, notes that rose colour was seen as greyish-violet; and green, as bluish-green or grey. (*Diagnostic des maladies des yeux*, p. 190.) Of another patient, *Fano* states, that every thing appeared to him of a yellowish hue; and that yellow, rose and violet, appeared as grey. *Alexander* mentions, that one of his patients, who suffered from a central scotoma, within its area, saw red as black, and green as grey. That green and violet appear colourless, is common to all these cases.



Num- bers same as pp. 74, 75	Date of ex- amination.	L	C
14.	20/9 '80	r. e. $\frac{1}{3}$ l. e. $\frac{1}{3}$	r. e. green, violet and yellow $\frac{1}{2}$ , ( $\frac{1}{3}$ ), red ( $\frac{1}{2}$ ) and blue ( $\frac{1}{3}$ ) $\frac{1}{4}$ . l. e. green, violet and yellow $\frac{1}{3}$ , ( $\frac{1}{4}$ ), red ( $\frac{1}{4}$ ) $\frac{1}{4}$ , blue $\frac{1}{2}$ , ( $\frac{1}{4}$ ).
15.	17/3 '81	r. e. $\frac{1}{4}$ l. e. $\frac{2}{3}$	r. e. $\frac{1}{4}$ . l. e. confuses red and yellow; blue and green, up to number 4.
16.	26/4 '81	r. e. $\frac{1}{4}$ l. e. $\frac{1}{30}$	r. e. $\frac{1}{4}$ . l. e. red and yellow $\frac{1}{4}$ , blue and green $\frac{1}{6}$ .
17.	23/6 '81	r. e. $\frac{2}{3}$ l. e. $\frac{2}{7}$	r. e. confuses red with yellow, and blue with green, up to number 4. l. e. the same mistakes, up to num- ber 6.
18.	15/10 '81	r. e. $\frac{1}{16}$ l. e. $\frac{1}{4}$	r. e. confuses blue and green, up to number 4, red and yellow, to number 2. l. e. $\frac{1}{4}$ .
19.	17/2 '81	r. e. $\frac{1}{20}$	r. e. confuses red with yellow, and blue with green, up to number 6.
20.	6/2 '82	both eyes $\frac{1}{8}$	confuses red with yellow, and blue with green, up to number 2.
21.	26/1 '82	r. e. $\frac{1}{16}$ l. e. $\frac{1}{30}$	r. e. confuses red with yellow, and blue with green, up to number 9. l. e. same mistakes, up to number 18.
22.	30/3 '83	r. e. $\frac{2}{3}$ l. e. $\frac{1}{14}$	r. e. $\frac{1}{4}$ . l. e. confuses red with yellow, up to number 18, blue with green, up to number 14.

From this table we see, — that tints of violet and grass-green, more frequently than any other hue, appear grey; and that, if we use the 4 principal colours, which in a physiological



sense must be considered pure<sup>1)</sup>, tints of green are confused with blue, of yellow with red. Further, that the perversity of the colour-sense increases, including tints of greater intensity, in proportion to the decrease of L.

All this undoubtedly shows, that a diminution of L stands in close relation to the alienation of C. Further investigations will decide, whether the decrease of L alone, can explain the abnormalities of C; or if other factors, hitherto unknown, are here cooperative.

*Chromatopsia*, and this always *Xantopsia*, is a phænomenon occasionally found. In the cases I have noticed, *Xantopsia* has been confined to some parts of the visual field, and such parts have been adjacent to those in which scotomata have been found. It seems as though *Xantopsia* remains for a while, as a symptom of an altered condition of the retina, in those places where the scotoms are about to disappear.

*Myiodopsia* is a very frequent symptom. It may appear at a very early stage; is however, according to my experience, more frequent in elder cases, and may become permanent. As the cause of myiodopsia is the presence of specks floating in the vitreous, it will, for reasons easily understood, be rendered most conspicuous by movements of the eyes, and will disappear when the eyes are shut. In some cases the dark spots, seen in the visual field, are caused by exudations of lymph adhering to the inner retinal surface, and thence protruding into the vitreous. If so, it is sometimes possible, by ophthalmoscopical examination, to recognise the formation of the spots seen by the patient. It was so in the case reported under No. 14. The spots may also, in such cases, be seen by the patient with more or less accuracy, as the shade of exudation is, by movements of the eye, cast on places not overshadowed when the eye is at rest; but are always seen at a definite place within the field of vision. *Myiodopsia* is not seldom complicated with the seeing of lines, or stripes, formed like spider-web, or a coarse threaded net; such appearing very plainly under certain optical conditions.

A decrease of the functional endurance, is a symptom

<sup>1)</sup> Vide Transactions of the Internat. Congress, London, 1881, Vol. III p. 49 and text to Chromatoptrical Tables, Christiania, 1882.



which may be very troublesome to the patient. In spite of a relatively high V, it may sometimes be impossible to him, without fatigue, to decipher more than a few lines. This lack of endurance is, as mentioned before, easily made apparent when the peripheral colour-sense is tested. A difference of more than  $20^\circ$  for one and the same colour may be found, accordingly as the patient is examined when the eye is, or is not exhausted. A decrease of the range of accommodation, demonstrated by some authors<sup>1)</sup>, may, in some degree, account for the decrease of functional endurance; but, as the latter takes place also when accommodation is not required, this cannot be the principal cause. In cases where specks, whirling in the vitreous by movement of the eye, prevent the patient from seeing small objects clearly at the first glance, the lack of endurance is felt to be the more troublesome.

Among symptoms occasionally observed are *Micropsia* and *Megalopsia*<sup>2)</sup>. The former is, according to my experience, found more frequently in the periphery than in the centre. When peripheral, I have always found it, together with scotomata, occupying those parts of the visual field adjacent to these, but not in the parts actually obscured, where I have not ever, at least with certainty, found that the objects have appeared diminished. Whether micropsia precedes the scotomata, or is left as a result of the same pathological process which produced them, I cannot tell. Judging from a couple

<sup>1)</sup> *Foerster* l. c. p. 57. *Leon Drouin* l. c. p. 40. As stated by *Wecker*, *Græfe und Sämisch*, Bd. 4, Abt. 2 p. 629; the range of accommodation is difficult to be measured when V is lowered.

<sup>2)</sup> *Micropsia* was already known by the ancients; — v. historical notes p. 12. By some later authors it is said to be rarely found: thus, — *Leber*, *Græfe und Sämisch* Bd. V, Abth. 2, p. 614: by others, to be sometimes found thus; — *Grafe Arch. f. Ophth.* Bd. XII, Abt. 2 p. 215, *Foerster* l. c. p. 54; and yet again by others it is named as frequent: — thus; *Mooren Ophthalmiat. Beobacht.*, Berlin 1867, p. 291. *Solberg Wells* — A treatise on the diseases of the eye, 1859 p. 345. That it may be found in the peripheral parts of the field of vision, I have not seen stated by any author. It seems however, that *Leber* was aware that it can occur beyond the centre; for he, l. c. says »Die Verkleinerung erstreckt sich dem entspreckend auch nur auf einen Theil der Netzhaut, gewöhnlich genau das Centrum.«

*Megalopsia* I do not remember to have ever seen, mentioned in medical literature, as a symptom of these affections.



of cases, in which I have found micropsia in places corresponding to those where scotomata, some days previously, had been detected, I should think that it is subsequently developed. As a material cause of micropsia, scarcely any other can be supposed than that already propounded by *Foerster*, and generally accepted by later writers; — viz. a swelling of the retinal elements. There is however one circumstance which renders this explanation less acceptable; and it is, that Megalopsia is not always found in the area adjacent to that within which Micropsia occurs. It would seem probable that, when the retinal elements in one part are tumified<sup>1)</sup>, the adjacent parts must be compressed. In the latter parts the image must consequently cover, as compared with the norm, a greater number of percipient elements, whence megalopsia must result. Especially when the micropsia is central, we should expect to find megalopsia in the adjoining parts of the visual field; the perfect appreciation of the forms in this part rendering comparison most trustworthy. In one case of marked central micropsia, in a man of scholarly education, and fully competent to give account of his visual impressions, no megalopsia could be proved. In this case, the micropsia continued for several years. In cases of peripheral micropsia it has sometimes happened to me, that the patients, without being questioned, have declared that the test-object, before its arrival at the place where it appeared less, has appeared larger than natural. (Vide case reported under No. 14.)

An *irregular Metamorphopsia* is, according to my experience, far more rare than Micropsia and Megalopsia. Only in one case of central retino-choroiditis (mentioned p. 14) have I met this.

Reviewing the subjective symptoms, we do not find a single one, — the peculiar form of the scotomata perhaps excepted, — that can be said to be pathognomonical for the syphilitic retino-choroiditis. Even if we take the whole as-

<sup>1)</sup> It must be remarked, that only an even swelling of the elements constituting the percipient layer of the retina, — not a expulsion of these by deposition of lymph, or their dispersion by shriveling of masses of connective tissue, can explain the apparently uniform diminution of the object.



semblage of symptoms, it will hardly be found so characteristic, that the disease thereby can be diagnosed from the, so-called, idiopathic retino-choroiditis. The same may be said of the objective symptoms, which are identical with those of retino-choroiditis of any kind. How far, up to the present time, all endeavours have been from success in delineating a picture typical of the *syphilitic* retino-choroiditis, is demonstrated by the fact, that syphilis, in several manuals, is stated as a cause of the so-called idiopathic retino-choroiditis; and still the syphilitic form is described as peculiar. Such an illogical statement can only be the result of our imperfect knowledge; since, in many cases, we cannot discriminate the inflammation to which syphilis gives rise, from that of which the cause still remains unknown. So far as our knowledge now goes, we can, with only approximative certainty, make the diagnosis for the most typical forms. In other instances, this must be derived from the presence of other signs of constitutional syphilis; or, when such are wanting, on the *historia morbi*, which, however, is often but reluctantly given, or even held back altogether.

If we wish to gain a clearer apprehension of luetic retino-choroiditis, I think we ought to exclude all cases in which we do not, with certainty, know that the eye-affection has originated after the patient was infected. Accordingly, I have derived my description of the subjective symptoms given in the foregoing pages, as well as the account of the ophthalmoscopical changes in the sequel, exclusively from such patients.

The *objective* symptoms are, as nearly all authors state, but slight at the beginning. A moderate hyperæmia of the optic disc, and some enlargement of the veins, are all that can in the beginning be seen under the ophthalmoscopical examination.

Soon however, this is followed by a greyish obfuscation, veiling both the disc itself, and its surrounding parts. This greyish obfuscation has been likened to that which may be seen in dark pigmented individuals. It seems to me however, that the latter differs from the pathological obfuscation, in



that the surface of the fundus has a more glossy appearance; and further, that the disc itself, with its vessels and its borders, is distinctly visible. By the pathological obfuscation, it appears as though the retina itself were clouded; and, if we examine in erect image, it seems as if dust had been kneaded into its substance<sup>1</sup>). The obfuscation differs from the greyish discoloration in a simple hyperæmia, inasmuch as it extends further out towards the periphery. When the patient is young, his eyeground seems less clear. This is especially apparent when one eye only is affected. That eye, as compared with the other, looks as though it belonged to a much elder individual.

These are the only symptoms visible at the beginning of the disease; and as they hardly suffice to constitute the diagnosis of an inflammation, functional disturbances being absent, we must usually at an early stage, base our diagnosis on the latter.

After a shorter or longer time the greyish obscuration, in many cases, will increase; a consequence of the refracting media, and more especially the uttermost parts of the vitreous, having become obscured. It seems then, as if a rather dense veil hid all details of the fundus. The obscuration will, by sufficient enlargement, often be resolved into very small granules, in some places grouped in flakes, or stripes, which are set in motion by movements of the eye; retaining, however, the same relative position. The granules are usually so small that they, when the pupil is not dilated, become invisible. Sometimes too, the obfuscation appears quite amorphous, being evenly distributed in the vitreous, or being in some places, more dense; causing the eye-ground to become more or less plainly visible, as these parts change their position, relatively to the observer, by movement of the eye of the patient.

It may remain without other than the above-named changes: the rule is, however, that other changes, after a lapse of some time, do supervene. Such changes consist in altera-

---

<sup>1</sup>) Vide *Nettleship* in Berkely Hill and Cooper p. 277. •The diffused haze may often be resolved by •direct• examination into a somewhat stippled, or granular appearance.



tion of the pigment-layer, in consequence of which, spots will appear on the hitherto uniform eye-ground. It is worthy of notice that these spots, at the beginning, are not well defined, and do not exhibit any tint of blue or yellow. Nor are they elevated above the surrounding eye-ground; at least I have never, in spite of the most minute observation, been able to detect any difference in the *niveau* of the surface of the spots, and that of the adjacent normal parts. They appear as rather indistinct, evenly-colored light stains, through which no traces of the coarser choroidal vessels can be seen. It would seem as if they came forth gradually, by absorption of the pigment-layer of the retina. After having been visible for a time, they become more distinct and may, within a shorter or longer period, be partly covered, or encircled by accumulations of pigment.

In elder cases we do not generally find any hyperæmia of the optic disc, or enlargement of the veins; but a, more or less dense, greyish discoloration remains around the optic disc. Whether this discoloration is caused by an obfuscation of the uttermost parts of the hyaloid, cannot be ascertained by means of the ophthalmoscope. The spots appear in such cases of a brighter, sometimes even of a bluish-white colour; their borders are sharply defined, and pigment-patches are seen partially covering, and surrounding them. Pigment-patches, sometimes in very small dots, sometimes in large masses, are also commonly seen to be scattered over those parts of the fundus, which are found apparently normal. The diffuse obfuscation of the vitreous has, by this time, generally disappeared; and instead, black specks are seen, which by movements of the eye, whirl around, indicating that the vitreous has lost its jelly-like consistence.

Such, generally taken, have been the objective signs in most of the cases that I have observed.

From all these I think we may infer, that the retina, rather than the choroid, is the membrane first affected; but since the choroid becomes, in the more advanced stage, almost invariably engaged in the affection, it may be most appropriately designated *retino-choroiditis*.

That the retina, not the choroid is the membrane first affected is, as mentioned before, not the current belief at pre-



sent. Almost all authors describe retinitis and choroiditis as distinct diseases; although they admit that retinitis is often complicated with choroiditis, and that the latter constantly, in its course, affects the retina. Retinitis is, besides, believed to be a disease far more rare than choroiditis; and it has even been doubted, whether syphilis could originate a simple retinitis.

The reason why choroiditis, as compared with retinitis, is considered to be a frequent disease, is no doubt this, that not many patients have come under observation until the first stage of the affection had been passed, and thus, the pathological process had already become complicated with an affection of the choroid. The light spots seen on the eye-ground are, then, the most conspicuous symptom; and signs indicating an affection of the retina may, at that time be very slight,

Nevertheless, fresh cases also are described by many authors in a manner which might indicate that the disease, from its very beginning, should be considered a choroiditis. Greyish, or yellowish-white exudations *under* the retina, are mentioned as the first cause of the light spots, subsequently considered as isolated atrophies supervening the absorption of the lymph-patches<sup>1</sup>).

Far from denying that atrophies may be the indirect result of an absorption of lymph, I would only remark, that if the presence of lymph-patches be a proof of the disease having originated in choroid, it must first be determined that the exudations have issued from this membrane. And this has not, by any means, been proved. Exceptionally only do we find something noticed, which might speak in favour of this opinion. From what we find mentioned concerning the spots, we cannot, however, even infer that any lymph-patches have existed. The colour of the spots seen, is only mentioned as light; but whether of a yellow- or bluish-white surface colour, — peculiar to the fibrogenous exudations, — or of a red-yellow transparent tint, is not mentioned. Nor do we find stated,

<sup>1</sup>) So far as I know, v. *Grafe* was the first who propounded this explanation in *Allgemein. Medicinische Centralzeit.*, 1878, p. 133, and it has been adopted by most later writers.



that the spots have been prominent, such as they necessarily would have been, had plastic exudations formed their substance<sup>1)</sup>.

Judging from my own experience, exudations of lymph-patches very rarely precede isolated atrophies. I have followed, in several cases, the disease from its very beginning, throughout its different phases, and seen how the spots have gradually appeared, on the quite uniformly coloured eye-ground, as scarcely visible nebulæ; subsequently taking a more distinct form, until, at last, they have appeared as well marked spots, such as those usually seen in choroiditis disseminata; — and in one case only, have I seen anything which bore the slightest resemblance to a subretinal exudation. Hence I should think that, as a rule, the spots are the result of an atrophy caused by a pathological process, not visible by means of the ophthalmoscope<sup>2)</sup>. That the result of my experience in this respect is not to be explained as accidental only, is shown by the investigations of *Foerster*<sup>3)</sup>. This author, who, like myself, followed several cases for years, states that the pathological changes, ophthalmoscopically seen in the beginning of the disease, in the great majority of cases are very slight, (*sehr unscheinbar*) and to be detected only by the most rigorous examination<sup>4)</sup>.

<sup>1)</sup> The difference in the appearance of plastic exudations and isolated atrophies, is clearly pointed out by *Fetzer*: *Beiträge zur Lehre von der Choroiditis disseminata*. Tübingen, 1870.

<sup>2)</sup> Among earlier writers *Meilhac* is the only one I have found who believes that atrophy is the primary cause, vide l. c. p. 16: «Se faudrait peut-être ajouter une troisième classe, qui comprendrait les cas où un travail, plutôt atrophique qu'exudatif, fait disparaître la couche pigmentaire, la disperse; puis, atrophiant les vaisseaux choroïdiens, laisse à leur place, dans la continuité de la choroïde des traces ineffaçables de son passage.»

<sup>3)</sup> l. c. p. 38.

<sup>4)</sup> That by many authors the objective symptoms of *retinitis syphilitica* in recent cases, are said to be very slight, tends to show that the presumption of an exudation, as a precursory step of the isolated atrophies in *choroiditis* is merely theoretical, and not ascertained by direct observation. The division of these pathological processes into retinitis and choroiditis, is specifically, according to *Foerster's* and my own experience, quite artificial. There is only one process; whether this be a primary choroiditis, such as *Foerster* thinks, or a retinitis, is, so far as the present question is concerned, wholly indifferent.



I will nevertheless readily admit, that although nothing can be detected by ophthalmoscopic examination which could point to a choroidal exudation, I cannot from this derive the inference, that the disease originated in the retina. A pathological process, invisible from the beginning by direct examination, may just as likely have its seat in either membrane. A functional, much rather than an ophthalmoscopic examination is, as mentioned before, fitted to decide this question. But if we compare the result of both, then I think, we must admit that all tends to show that the retina is the membrane primarily affected. As first pointed as by *Foerster*<sup>1)</sup>, the spots appear in places corresponding to those in which scotomata, or defects in the visual field, have been previously detected. The correctness of this observation I can fully corroborate. In several cases, I have seen the gradual outcoming of spots in places corresponding to those, in which the scotomata have been found of greatest density and duration. From a drawing taken of the eye-ground after the inflammation had passed away, it has, in some cases, been possible to me to form a tolerably correct idea of the configuration of the formerly existing scotoma; — e. g. — in the cases reported under Nos. 5, 12 and 14. (Figures 7 and 8, plate IV). In none of these cases however, was the situation of the spots such, as to give the impression that they had been caused by a retinal affection. Therefore such an affection would scarcely have been assumed, had not the previous perimetrical investigation proved that a scotoma, issuing from the blind spot, had occupied just those parts in the visual field, which corresponded to the places in the fundus oculi, where the spots appeared afterwards. In the great majority of cases, we find the spots scattered, apparently indiscriminately, over the fundus and therefore we shall, as a rule, not be able to trace the correlation of the spots with a preexisting scotoma, provided that the patient has not come under observation before the scotoma itself had disappeared.

Sometimes however, the spots stand in such a close relation to the retinal vessels, that their origin from an affec-

<sup>1)</sup> l. c. p. 38.



tion of this membrane is obvious<sup>1</sup>). Such a connexion I have several times seen, but mostly it has not been so conspicuous as to be evident at the first glance. It was clearly visible in the case portrayed in Fig. 9, Plate V; — taken from a woman who, in May 1869, was treated for constitutional syphilis at the Hospital for Chronic Diseases (L.-No. 161); and during her stay at the hospital suffered from a severe eye-inflammation. (The drawing was taken two years later).

The origin of the disease from a retinal affection may also be apparent in cases, where isolated atrophies of the pigment are confined to a single part of the fundus; or, where the pigment is destroyed over a single large area. In such cases, we may occasionally find that the place to which the spots are confined, has a sectorlike form, having its apex turned towards, or touching the optic disc, and its base towards the periphery. Such may also be the form of the area over which the pigment is destroyed. *Hutchinson* records such a case, in which the disease was of hereditary origin<sup>2</sup>); and *Nettleship* mentions a similar case<sup>3</sup>). The sectorlike arrangement of the spots was clearly visible in the case reported below.

20. Mr. C. L. S. infected in the spring, 68. In September of the same year he suddenly found that his sight had failed in the left eye, and some time afterwards, black dots appeared before the right eye. A physician performed an iridectomy on the left eye, subsequently to which the sight became still more deteriorated. Examined May 12<sup>th</sup>, '77. Right eye V  $\frac{1}{1}$ , left, complete amaurosis. Ophthalmoscop. r. eye, two sectorlike tracts visible in the lower part of the fundus; towards the equator the limits of the tracts could not be seen; towards the optic disc, one of the tracts extends its apex up to the disc, the other goes not so far towards the centre. Vena

<sup>1</sup>) The same has, in respect of non-syphilitic choroiditis, long ago been demonstrated by *Foerster* and *Nagel*. Beyond *Foerster*, *Fetzer* l. c. p. 19 and *Kortüm*: Archiv für Augen- und Ohrenheilkunde, Bd. III, Abt. 1, p. 55 have in the syphilitic choroiditis, seen spots developed in places corresponding to those in which scotomata in the visual field have been found. In the case observed by *Kortüm*, a real exudation of lymph-patches, (schneeweisse Heerde), was first observed in the places in which, later, isolated atrophies appeared.

<sup>2</sup>) Vide Ophthalmic. Hosp. Rep. Vol. VII, p. 494, drawing.

<sup>3</sup>) Cases in Ophthalmia. Practice with notes and Observations. St. Thomas Hosp. Rep. 1878.



retinalis inferior runs along the former; v. ret. nasalis inf. along the latter. The choroid is in the tracts almost entirely destroyed, showing the bluish-white sclera partly covered with pigment-rings. The top of the sector, extending furthest towards the optic disc, consists of isolated yellowish-red spots in cluster. Left eye — the whole choroid atrophied; showing only in some places isolated red stripes. In the lower part bonecorpuscle-like pigment-dots. Visual field on right eye restricted in the upper half; but no defect in sectorform can be detected.

The reasons which in the foregoing pages are offered as arguments tending to show that the disease, as a rule, originates from the retina are in short as fol.: —

1. The form and the seat of the scotomata in recent cases.
2. The fact, that the retina in fresh cases is found more altered than the choroid.
3. The fact, that the spots which from the beginning appear as slight, not well defined isolated atrophies of the pigment-layer, (belonging to the retina) may be observed in places corresponding to those in which scotomata have been previously found in the visual field.
4. The close relation which sometimes exists between the spots and the retinal vessels.

On the other hand it must be remembered, that some facts tend to show that choroid is, in certain cases at least, the membrane early and chiefly affected. These facts are:—

1. The result of microscopical examination, which might give the opinion that the choroid is primarily and essentially affected.
2. The dense obfuscation of the vitreous, seen in some cases at an early period.
3. The rather frequent complication with iritis, this being sometimes the initial symptom.

Presumptively, we might expect that the patho-anatomical investigation would settle the question of the nature of the disease, better than the clinical. It would, therefore, seem to be rather in disfavour of my view, that most of the microscopical examinations, hitherto published, seem in favour of a choroïditiis. So *Nettleship*, who has paid the most attention to this side of the question, says: — »The disease is essentially a plastic inflammation of the innermost (»capillary«) layer of



the choroid: in this part collections of small round cells are found. These are either in separate little patches which slightly raise the inner surface, and constitute the »miliary gummata« of *Hutchinson*; or similar cells occur in wide-spread tracts of inflammation, occupying the same layer of choroid<sup>1)</sup>. From the chorio-capillaris, he thinks, the cells pass inwards, producing disturbance of the outer layer of the retina, and causing adhesions of this membrane and the choroid. In the retina, *Nettleship* found changes in its bloodvessels, which also have been found by *Edmunds* and *Braily*<sup>2)</sup>, altered in the same manner as observed by *Heubner* in the intima of the cerebral vessels.

The two cases which *Nettleship* has examined microscopically are, so far as I know, the case of *Barlow*, — in which the disease was inherited; and a case in which the eye was excised during the progressive stage of the disease. In the first case, there<sup>3)</sup> was, during life, seen »very small flecks of exudation of brownish colour, apparently situated in the choroid«. The microscopical alterations consisted in the above named changes, designated as »precisely similar« to such as had been found in the other case of choroiditis, in acquired syphilis. In none of these cases do we find it stated, that any microscopical examination of the retina<sup>4)</sup> had been made. The following case, in which the retina was found to be the seat of accumulations of cells, may therefore be of interest, as a supplement to the investigations of *Nettleship*:

21. A. S., born in the State Hospital, December 18<sup>th</sup> '77, from a syphilitic mother, but apparently healthy. 4 weeks after the birth there appeared a bulla on the top of the nose. Later tubercula mucosa about anus, rash on different places, laryngitis, chronic hydrocephalus and nystagmus gradually came on. His eyes were examined for the first time. October 28<sup>th</sup> '78. The refracting media clear; optic disc prominent, of a bluish red colour; its diameter considerably enlarged, and its limits much blurred. The retinal veins enlarged, and tortuous. In different places, most numerous around the yellow spot, small round light coloured

1) Syphilis and Local Contagious Disorders, 2<sup>d</sup> Edition. By *Berkely Hill* and *A. Cooper*, 1881, pag. 274.

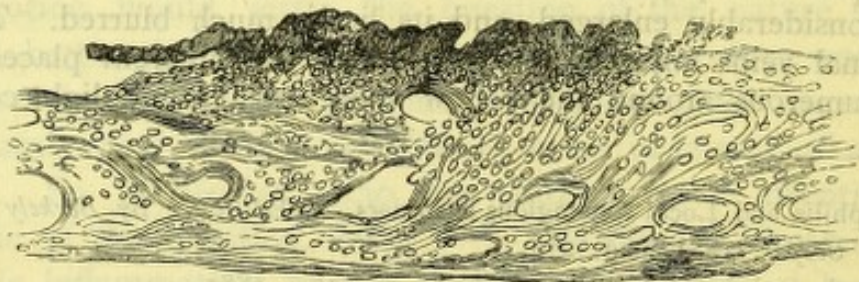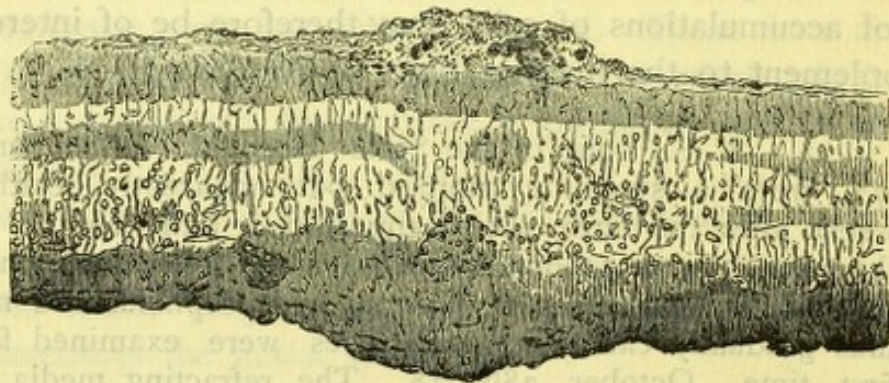
2) Lond. Ophth. Hosp. Rep. Vol. X, p. 137. 1882.



spots of which two or three encircled with a threadlike pigment stripe. The child died December 11<sup>th</sup> same year.

By section, the sheaths of the optic disc were found dilated from an accumulation of fluid. The dilatation was most marked at the ocular end; but close to the globe there was a sharp contraction, giving to the optics a bud-like appearance. After being enucleated, the globes were divided by an equatorial cut. Macroscopically the veins were seen to be a little dilated, and a couple of punctiform spots could be seen. Beyond this the fundus appeared normal.

After being hardened in Müller's solution, the specimen was microscopically examined. As the retina had become loosened from the choroid, and the bacillar layer lost, it was impossible to get vertical cuts of both membranes in situ. The retina was in most places found to be normal. In some places, however, it was thickened by infiltrations of small round cells. In corresponding places, the layers appeared less distinct. In one place, in which the increase amounted to  $\frac{1}{6}$  of its natural thickness, the cells appeared most numerous in the innermost layers, where, they in a couple of places, were seen collected in clusters. In the exterior layers some pigment-cells were found. For the sake of comparison I here set side-by-side, a drawing representing the vertical cut of the retina in this place together with a copy of the drawing of the choroid given by *Nettleship* in the case of *Barlow*.





The passive hyperæmia of the disc, seen, while the child was alive, to complicate the retino-choroiditis, may here safely be left out of consideration. The ophthalmoscopical appearance of the latter had, up to four weeks before death, the character of an inflammation in its progressive stage; the spots being of a vivid red colour, and the pathological accumulation of pigment scanty. The changes in the retina, seen by microscope, indicated also an active process as the proliferation of cells was great. The alteration of the pigment-layer, seen by the first ophthalmoscopical examination, indicates however, that the process already, two months before death, had overpassed its initial stage. Therefore we must be cautious in drawing inferences from the microscopical examination. That the infiltration of cells was found to be greatest in the innermost layer, (the inner granular layer is seen to have disappeared to an extent corresponding with that in which the retina was found thickened; the outer layer however is partly visible,) seems to me to indicate that the pathological process had not passed from the choroid inwards.

Beyond the cases above named, I have not found in medical literature any publication of microscopical examination by others, except in old cases. I shall omit mentioning these, as they must be considered of no value in deciding the question here discussed. But even in the above reported cases the disease had become so far inveterate, before the patient's death, that we, from a post mortem examination, are not entitled to draw any conclusion as to the anatomical part first affected. Nobody can doubt that the choroid is involved, when the disease is so far advanced that the alterations of the pigment-layer are visible by means of the ophthalmoscope. Consequently the microscope does not in such cases teach us anything new. Even should we then find the choroid to be the membrane most affected, we cannot thence conclude, that the affection had been primarily choroidal. To name an example from another disease. In keratitis punctata, an affection not rare in syphilitic patients, the deposits in the cornea become very soon the most conspicuous symptom, and they would, no doubt, be found so by a microscopical



examination<sup>1)</sup>. Still we cannot doubt that, in the great majority of cases, the corneal affection is but secondary to an affection of a membrane, to which cornea does not even stand in direct contact; — viz. to iris.

Be it far from me to deny that a microscopical examination, in more advanced cases, may be of great value in teaching us the particular kind of the pathological process in syphilitic posterior ophthalmia; but when the result of such an examination is adverse to that taught by a clinical investigation, made at the very beginning of the disease, in a number of cases; we must rather rely on the latter. Therefore, although I willingly admit that the microscopical investigations may, in the end, decide this question, I cannot find, in the facts hitherto collected, any evidence of the choroidal origin of these diseases.

Concerning those cases in which we find a dense obfuscation of the vitreous, I must, nevertheless, confess myself dubious. Such cases are usually combined with serous iritis, and punctated keratitis. The exitus is often a general atrophy of the whole choroid and retina. It may be that, in such instances, a serous choroiditis is the primary affection. Two typical cases of this kind of syphilitic ophthalmia I report below: —

22. Mr. T. aged 57, infected at the beginning of 1869. About three months later, while playing at cards, he suddenly noticed that he was not able to see over but a very limited space at one time; e. g. — he mistook a three for an ace. The eyes became injected and painful. Examined first time in February '72. Marks of iritis on both eyes. Ophthalmosc. obfuscation of the vitreous, especially around the posterior pole. The obfuscation in some places so dense as completely to obscure the fundus; in other places, the latter appeared relatively distinct, and here vasa vorticosa were visible; also here and there some light spots and accumulations of pigment. The retinal vessels seemed to be partially atrophied. (Vide Fig 11, Plate VI.) The patient was able to see single letters, but could not read.

In June '72, the obfuscation considerably less. Large

<sup>1)</sup> By some authors, so *Mauthner*, the deposits in keratitis punctata are considered gummata. As a punctated keratitis may be seen in non-syphilitic patients, and not rarely in leprosy, the supposition of a specific character of the deposits, no doubt, must be designated erroneous.



peripheral parts of the fundus now clearly visible; numerous light spots of different size, in some places grouped. The retinal vessels much atrophied; only the four main branches could be followed a short distance from the discs, as hair-like threads bordered on each side by white contours. V right eye  $\frac{1}{30}$ , left  $\frac{1}{10}$ . A large central scotoma on the right side; a considerable contraction of the visual field on the left.

When seen again in March '73 there was no alteration of the ophthalmoscopical appearance. He had then for a while had double vision, the cause of which proved to be a paresis of the right musculus rectus internus.

I saw the patient last time in April '77. He was then in a very emaciated state, suffering from tremor totius corporis. Posterior polar cataract. Ophthalmosc. atrophy of the choroid; the atrophy had especially invaded the innermost vessels, which appeared as a layer of lighter colored, tortuous bands, superimposing another layer of red bands that covered a dark ground. Retinal vessels very much atrophied. (Vide Fig. 12, Plate VI). In the peripheral parts, numerous white spots and pigmentpatches, the latter in some places forming rings.

The patient died in June of the same year, but his death did not come under my notice so early, that I could obtain the eyes for microscopical examination.

23. K. J., 56 years old, infected in August '68. His sight began to suffer two or three months later. Phosphenes were for a while present. As the patient one evening in January of the following year was occupied in reading, he noticed that the letters suddenly became indistinct. Afterwards his sight became so much worse, that for a while, he could scarcely walk without assistance. When I saw him in May '70 there was a very dense obfuscation of the vitreous. The obfuscation was not, however, in all places of like density. It was most remarkable around the posterior pole. The retinal vessels normal. V,  $\frac{1}{2}$ , the letters became gradually visible when the patient had gazed on them awhile.

In June '72 there was still a dense obfuscation of the vitreous, but the fundus appeared then in some places more distinct. V  $\frac{1}{3}$ . Hemeralopia.

May '73, the hitherto diffused obfuscation had partly resolved itself into black spots, stripes, and flakes floating around, as the eye was moved. In some places however the vitreous was yet seen to be of a diffuse grey colour. V  $\frac{1}{5}$ , both eyes.



I did not see the patient before May '78. There was not then any diffused obfuscation of the vitreous, but numerous, specks and punctated flakes. The pigment-layer seemed every where destroyed; vasa vorticosa, plainly visible. Around the optic disc the choroidal stroma appeared so atrophied, that the bluish-white sclera was visible through it. More peripheral spots of yellowish-white, or bluish-white colour, mostly surrounded by a pigment-ring. Towards the equatorial region, these spots increased in number and size. The retinal vessels in an atrophic state. The smaller of them terminated in pellucid stripes. Arteria retinalis inferior is seen, in one place, corresponding in length to the diameter of the optic disc, to be thickened; (fusiform aneurism). V about  $\frac{5}{18}$  both eyes. Concentric constriction of the visual field, with enlargement of the Mariotte's spot.

When seen last May '80 the ophthalmoscopical appearance unaltered. V about  $\frac{1}{2}$ ; L  $\frac{1}{8}$ , C confused up to No. 6, red with yellow, and blue with green. From No. 3 all squares perceived as grey.

Cases of this kind are recorded by *Hutchinson* under the name »Progressive choroiditis«. According to the same author they should be held peculiar to syphilis.

It may be impossible to form any opinion as to the character of single cases, when we, as in the two above recorded, had no opportunity to follow them from the very beginning of the disease. Judging from cases in which the disease commenced in the same manner as a typical retino-choroiditis, but in which, at a later period, a dense obfuscation of the vitreous took place, I cannot, in such obfuscations, see any proof of a primary choroiditis. I should therefore feel inclined to register these and analogous cases among those of common retino-choroiditis, in which the disease had assumed an unusually grave character.

Lastly—Concerning the rather common occurrence of iritis together with retino-choroiditis syphilitica; I admit that this fact favours the theory of a choroidal origin of the disease, at least when iritis was its original symptom. We must, however, remember that we sometimes find iritis uncomplicated with a deep oph-



thalmia<sup>1</sup>). The inflammation of the iris may therefore be only a complication. I would here recal the well-known fact, that in syphilitic eye-affections there is a tendency to complications. At any rate, the occurrence of iritis cannot weaken the positive evidence of a primary retinal affection, found, by careful functional examination, at the beginning of the disease.

While, in the foregoing, I have sought to demonstrate that the affection, as a rule, originates in the retina, I will not, nevertheless, deny that exceptionally the choroid may be the membrane first and principally affected. That at least choroidal exudations can take place during the course of the disease, I do not doubt; and so much the more so, as I believe myself to have seen an example of this. The case was that of a man 32 years old, whom I, in the summer '78, treated for syphilitic ear- and eye-disease. When the eye-affection had lasted for about three weeks, there appeared injection, with œdematous swelling of the outer lower part of the sclera, on both eyes. Some time afterwards a prominent yellowish-white exudate, far out in the periphery, became visible by means of the ophthalmoscope. As the swelling and the injection of the sclera appeared several days before any exudation of lymph could be detected in the fundus, I think it probable that the choroid, and not the retina was the membrane that produced it.

The reader will perhaps find my treatment of the question, »Retinitis or Choroiditis«, prolix. Whether the retina or the choroid is primarily affected, would seem to be irrelevant; as we know that the pathological process soon passes from one membrane to the other; and, as *Foerster* says<sup>2</sup>), when the scheme of the disease is worked out, it would be unimportant whether it was named retinitis, or choroiditis. I will go so far as to admit, that, in the present stage of medical science, even the meaning conveyed by these words would have no influence

<sup>1</sup>) I will here remark that, in most of the cases in which I have found, in *syphilitic* patients, marks of iritis, I have also found alteration of the fundus; consisting, usually, in isolated pigment-atrophies towards the equatorial region. In leprous patients, among whom iritis is a very common disease, I have on the contrary never seen such alterations.

<sup>2</sup>) l. c. p. 62.



on our treatment. As a scientific question, however, it cannot be considered uninteresting. Is the disease of retinal origin; then, this proves to us, that the nervous system is often severely affected in an early period of syphilis; and the occasional complication of mental diseases with the retino-choroiditis<sup>1)</sup>, would then be much better apprehended.

Forms like those described, p. 89 and following, as the final result of grave retino-choroiditis in acquired syphilis, are frequently found in *inherited* syphilis, when the patient, before examination, is already some years old. So the parts of the choroid adjoining the optic disc, are often seen to have been destroyed by the hereditary affections<sup>2)</sup>; the retinal vessels found to be in an atrophic state, and the fundus of a pale orange colour, due to atrophy of the pigment layer, and of the choroidal vessels. A complication of posterior polar cataract, renders still more complete the analogy with old cases of acquired syphilis. In other cases, and more especially in infants, I have found isolated spots, more or less numerous, scattered over the eye-ground; the latter being apparently normal. In all essentials, the retino-choroiditis in hereditary, does not differ from that in acquired syphilis. A separate description of the ophtalmoscopically visible alterations is, consequently, superfluous<sup>3)</sup>. In no cases, whether of infants or those of individuals more advanced in age, have I however seen any obfuscation of the vitreous. In this respect, and perhaps too in a greater abundance of pigment-patches, the hereditary form is distinguished from that of acquired syphilis<sup>4)</sup>. I once saw, in the eye-ground of a middle aged lady,

<sup>1)</sup> *Wecker*, Græfe und Sämisch, Bd. IV, P. 2, p. 630 »often beobachtet man nach längeren Bestehen der Chorio-Retinitis spec. Geistesstörungen. P. Schubert: Ueber syphilitische Augenkrankheiten, Berlin 1881, mentions two such cases, and three have occurred in my own practice.

<sup>2)</sup> Vide *Wordsworth*, Opht. Hosp. Rep. Vol. I; do. *Bader*, Plates illustrating the natural and morbid changes of the human eye, Pl. VI, Fig. 11.

<sup>3)</sup> »There are no material differences between the choroiditis of acquired, and those of inherited syphilis«. *Nettleship*, in Berkely Hill and Arthur Cooper, p. 273.

<sup>4)</sup> Vide *Nettleship*, l. c. p. 273 and 277.



together with marks of interstitial keratitis, and *Hutchinson's* teeth, innumerable round pigment patches, which, towards the equatorial region were so close together, as to give to this part an appearance almost uniformly black.

The general description, given p. 83 and in the following pages, will, I believe, be deemed correct by most authors who have seen many cases of the syphilitic deep ophthalmia; inasmuch as it will be found to answer to the alterations most commonly seen. The ophthalmoscopic appearance may, of course, in the concrete case vary more or less, as one or other of the single symptoms is found to be more conspicuous. Thus the hyperæmia may be present in very different degrees. The greyish discoloration may be more or less dense, and be found to extend more or less towards the equator; it may be distinctly or indistinctly outlined. Sometimes, a greyish discoloration of the retina itself may be seen along its vessels etc. Wishing to render my description as much typical as possible, I could not, at the place referred to, give a detailed description; nor do I consider it to be of any essential use, in a disease so polymorphous as the syphilitic retino-choroiditis. If the various authors had not been too scrupulous in describing the many variations, I think we should not so often find exactly that which one author designates pathognomonic for the luetic, by another taken for pathognomonic for the non-luetic retino-choroiditis. Of this some examples have been already given. In further proof, I would adduce the contradictory statements made by various authors, concerning one of the most constant symptoms, viz. the spots, caused by isolated atrophies of the stratum pigmenti and of the choroidal stroma. According to *Graefe*<sup>1)</sup>, *Wecker*<sup>2)</sup>, *Drouin*<sup>3)</sup>, *Power*<sup>4)</sup> and *Foerster*<sup>5)</sup> the situation of these spots in the vicinity of the posterior pole, is characteristic of the luetic form; according to *Mooren*<sup>6)</sup> the spots are not found more numerous there, than in the equatorial region; and according.

<sup>1)</sup> Allgemeine medicin. Central-Zeitung, 1858, p. 134.

<sup>2)</sup> Etudes ophthalmologiques, T. I, p. 489.

<sup>3)</sup> l. c. p. 21.

<sup>4)</sup> Illustrations of some of the principal diseases of the eye, p. 487.

<sup>5)</sup> l. c. p. 38.

<sup>6)</sup> Ophthalmiatische Beobachtungen, p. 159.



to *Leber*<sup>1)</sup> and *Mauthner*<sup>2)</sup>, they are most numerous in the latter region.

Besides the symptoms named in the general description, there are however, some which occur so often that they should be mentioned in the symptomatology of this disease. Among these, are extravasations of blood<sup>3)</sup>, which may occur at any stage of the disease. I have often seen them the acme of the inflammatory process, when not prevented by photophobia from making a careful examination. They mostly appeared as small round spots, towards the equatorial region. In one case of an elderly woman, treated at the State Hospital from August 31<sup>th</sup> '78 to March 15<sup>th</sup> '79, they were very numerous. Sometimes they may be so profuse as to break into the vitreous, and thus a temporary blindness would be caused. In one patient, to whom a very profuse bleeding in the vitreous of the left eye occurred twice, the accidental cause of the first attack was probably a passive congestion of the head; for the patient noticed a sudden obscuration of the sight, in the respective eye, immediately after having stooped for a

<sup>1)</sup> Græfe und Sämisch, Bd. V, Abt. 2, p. 611.

<sup>2)</sup> Lehrbuch der Ophthalmoscopie, p. 439.

<sup>3)</sup> The occurrence of blood-extravasations is likewise a symptom in respect of which we find quite contradictory statements. Thus, — they are considered to be common, by *Wharton Jones*, Ophthalmic medicine and Surgery, London 1865, p. 340, *Power*, Illustrations of some of the principal diseases of the eye, p. 488, and *Galezowsky*, Archives generales, 1871, p. 124, and Diagnostic des malad. des yeux, 1868, (in this last place they are said to be occasioned by rupture of the retinal veins). *Pagenstecher*, Klinische Beobachtungen, Hf. 3, p. 81, saw them in four cases out of nine; and *Georg Corwell*, St. Georgs Hosp. Rep. Vol. IV, in four out of sixteen.

By others they are considered as not common; viz. by *Macnamara*, Diseases of the eye, London 1868, p. 380; *Mauthner*, Lehrbuch der Ophthalmoscopie, 1868, p. 369; *Leber*, Græfe und Sämisch, Bd. V, Abt. 2, p. 611; *Schweigger*, Augenheilk., 1880, p. 489; again, by others they are considered rare; — as by *Schelske*, Lehrbuch der Augenheilk., 1870, p. 180; *Zehender*, Lehrbuch der Augenheilk. 1870, p. 367; *Schreiber*, Ueber Veränderungen des Augenhintergrundes bei internen Erkrankungen 1878, p. 85; *Nettleship* in Berkely Hill and Cooper, 1878, p. 277; and *P. Schubert*, Ueber syphilit. Augenkrankheiten, Berlin 1881, p. 69.



moment, to gather some strawberries<sup>1)</sup>. The final result in this case was good.

The cases, mentioned by *Leber*<sup>2)</sup> and *Galezowsky*<sup>3)</sup>, are of great interest, as showing a causal connexion of such diseases with nutritive disturbances in some parts of the retina, due to alterations in the respective vessels. The extravasations of blood were here found to be restricted to a sector-like area, corresponding to the extent of some retinal vessels.

Hæmorrhages between the choroid and the retina are, according to *Schön*<sup>4)</sup>, not rare in cases where the inflammation is violent.

A case is mentioned by Dr. *Schillinger*<sup>5)</sup>, in which the hæmorrhages coincided with thromboses. I have seen three cases, in which one of the retinal veins was found thickened to a considerable extent, and of a black colour. In one of these cases, the thickening remained unaltered for three weeks.

Another symptom, rather frequently found, is exudations. These may take place on the inner surface of the retina, — preretinal exudations, — or in its substance, — parenchymatous exudations.

The preretinal exudations are not rare. When newly deposited, they are of a shining bluish-white colour, but, later become of a greyish, or even black tint. In two cases, I had opportunity to see this transmutation gradually going on. In both instances the exudations appeared during the course of a very severe retino-choroiditis, and were situated far out in the periphery, being most numerous in the lower part of the fundus. When first seen, they seemed to be rather prominent. After a couple of weeks, there appeared, attached to their top, dark flakes which, by movement of the

<sup>1)</sup> An example of bleeding in the vitreous is mentioned, as early as 1864, by *Classen*, Archiv f. Ophth., Bd. X, Abt. 2, p. 156. According to *Wharton Jones*, l. c. p. 240, a sudden blindness may be occasioned, at any time in the course of the disease, by retinal hæmorrhage, and infiltration in the vitreous body; and the hæmorrhage is liable to recur after absorption.

<sup>2)</sup> Græfe und Sämitch, Bd. V, Abt. 2, p. 621.

<sup>3)</sup> Traité iconographique d'Ophthalmoscopie, Pl. VI, Fig. 1.

<sup>4)</sup> Die Lehre von Gesichtsfelde, p. 112.

<sup>5)</sup> Reported by *Hirschberg*, Berliner Klin. Wochenschrift, 1870, No. 45.



eye, were set in floating motion. The bluish-white colour gradually disappeared, but still, after the lapse of 6 to 8 weeks, the exudations had a bluish hue. When already considerably diminished, one of the spots became encircled by a dark red halo; and in the place of another, a light red spot was seen, like that produced by atrophy of the pigment layer. In the case reported under No. 14; — the C like figure, still partly of a bluish hue, must be considered an analogous exudation, about to be detached<sup>1</sup>). Obfuscations, protruding from the inner retinal surface into the vitreous, like black rags, I have several times seen, e. g. — in the case portrayed Fig. 6 Pl. III. This figure may, in respect to the ophthalmoscopic appearance in general, serve as the prototype of a syphilitic retino-choroiditis.

The exudations, appertaining to the retina itself, are of a more or less pronounced yellowish-, or bluish-white colour. When bluish-white, they usually seem to be spread in a thin layer over a greater surface. Their situation is, ordinarily close to the optic disc, which may be partly covered<sup>2</sup>), or along the large retinal vessels. They may however be found in any part of the fundus. The number and the configuration of the lymph-patches may vary indefinitely. Sometimes, we may find but a single irregularly formed spot; sometimes, many small spots scattered over the whole fundus, or grouped. Thus, in a case observed by *Körtum*<sup>3</sup>), the small white patches were situated close to the retinal vessels, »wie Trauben an ihren Stielchen haftend«. Once during the course of a severe and protracted case of retino-choroiditis, I saw several well

<sup>1</sup>) Already *Fano*, *Annales d'Oculistique*, 1861, p. 80, had mentioned exudations attached to the inner surface of the retina, and with their inner part floating into the vitreous; by *Meilhac*; l. c. p. 27, such exudations are designated as intermediate between retinal exudations and obfuscations in the vitreous body.

I do not remember to have seen them mentioned by other authors.

<sup>2</sup>) That retinal exudations in syphilis, may have an aspect so similar to that produced by congenital nerve-fibres, that diagnostic mistakes may be made even by the most expert, is shown in a case observed by *Chibret* and *Galezowsky*; (*Traité iconographique*, p. 103). The real nature of the spots was, in that case, first apparent, from their absolute disappearance having following mercurial treatment.

<sup>3</sup>) Mentioned p. 98, note.

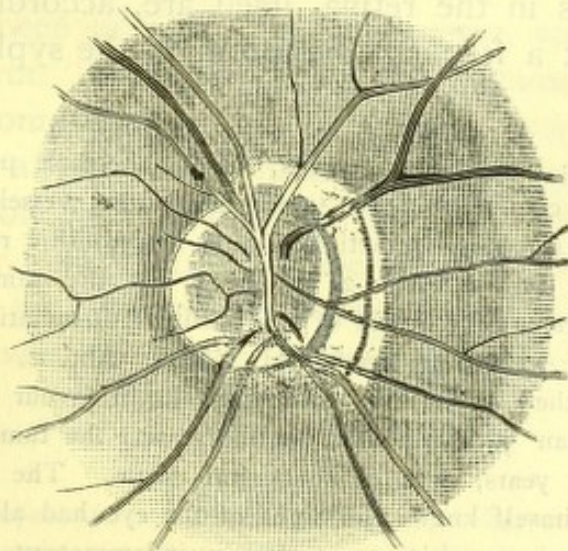


defined, bluish-white spots ranged along vena retinalis inferior, like pearls on a string. They partly covered the vessels, to an extent of twice the diameter of the optic disc.

The retinal exudations are usually absorbed. The absorption may be so complete as not to leave any trace. Sometimes, however, an atrophy of the pigment-layer will remain. Whether the retina itself is at the same time atrophied, cannot be ascertained by means of the ophthalmoscope. It may be impossible to determine this by the functional examination, when the exudations have had peripheral position; as it is very difficult to ascertain by perimetrical examination, the existence of small peripheral defects.

Another result may be, that the exudations become organised into connective tissue<sup>1)</sup>. I have several times seen, in syphilitic individuals, bluish-white deposits on the optic disc, partly hiding the disc and the retinal vessels. They have, as seen in the following drawings, either had the appearance of slender plates, lying in one or two well defined layers; or, have had an oblong shape, forming more or less broad strings along the larger retinal vessels.

Fig. 1.



<sup>1)</sup> According to *Mooren*, Ophth. Beobacht. p. 292, organisation of connective tissue, is more common in syphilitic retinitis, than in any other. *Macnamara*, l. c. p. 380 mentions the tendency of the neoplastic formation to become organised.



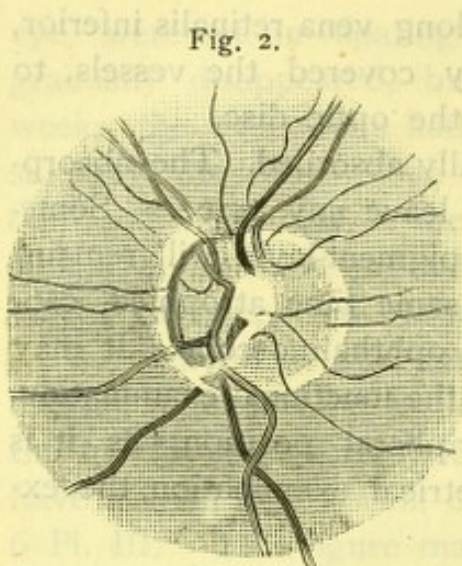


Fig. 2.

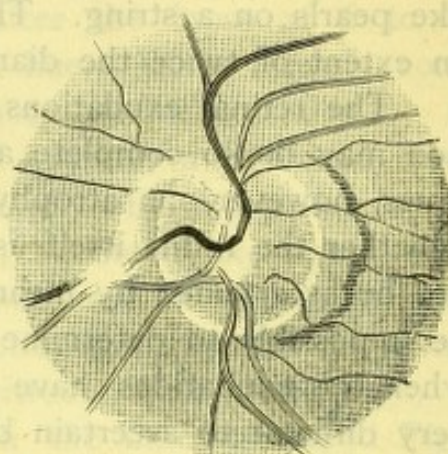


Fig. 3.

As such patches are mentioned by several authors<sup>1)</sup>, they probably are not rare. Patches of a like appearance I have, however, several times found in individuals with healthy eyes; consequently we cannot, with certainty, affirm such patches to be pathological products, when we have not by ophthalmoscopic examination ascertained, that the fundus was normal before the individual became affected. In the case portrayed in Fig. 1 above, this had been done.

Exudations in the retina itself are, according to my own experience, not a frequent symptom in the syphilitic retinitis<sup>2)</sup>.

<sup>1)</sup> *Jacobsen*, l. c., mentions 3 cases, in which such patches were found. Formation of connective tissue along the retinal vessels is also named by *Leber*, as a symptom sometimes found in syphilitic retinitis, vide *Græfe und Sämisch*, Bd. V, Abt. 2, p. 666. In the same place I see that *Leber* considers, as the result of a syphilitic inflammation, a case published by me in the *Archive of Græfe*, Bd. XVIII, Abt. 2. According to my own opinion there is nothing which speaks in favour of this assumption. It is more than probable that in this case, the tumor, which remained unaltered for years, was of congenital origin. The fact that, so far as the patient himself knew, the sight of the eye had always been weaker, and that no signs whatsoever of any inflammatory eye-disease had, at any time, been present, supports this opinion. Moreover, in this case alterations occurred on the posterior capsule of the lens, similar to those usually found in cases of persistent arteria hyaloidea.

<sup>2)</sup> Authors are of different opinions in regard to this question. Some, as *Liebreich*, *Atlas* Berlin 1863, *Mauthner*, *Lehrbuch der Ophthalmoskope* p. 369; *Foerster*, l. c. 39; *Leber*, *Græfe und Sämisch*, Bd. V, p. 511; *Zehender Lehrbuch der Augenheilkunde*, 1879; *Nettleship* in *Berkely Hill*



From what has been said above it appears, that the retinal exudations, in respect of neither color, form nor situation, have, in relation to syphilis any pathognomonical significance. This holds good, at least in most cases. Exceptionally however, the lymph may be deposited in a manner, which has hitherto only been seen in syphilis. Such seems to be the case in that rare form of syphilitic retinitis, which, by *v. Gräfe* is named »Centrale recidiverende Retinitis«<sup>1)</sup>. In this form, the exudations are always situated in the region of the yellow spot; either as a diffuse grey, sometimes faintly greenish obfuscation, or as small separate spots. The exudations may disappear and reappear many, ranging from 10 to 80 times. At length a permanent obfuscation remains. In one case, spots of pigment have been seen. The colour of the pigment has, however, not been like that commonly found in retino-choroiditis, but rather, of a bluish grey. The spots, too, have not been well defined. The functional disturbances are, moreover, characteristic for this form. These appear suddenly; and consist in the forthcoming of a central scotoma, and a considerable lowering of V. At intervals the function is in the beginning quite normal; but when several relapses have occurred, a deterioration of V will remain. In some cases micropsia has been present. I have never seen any typical case of this form. Only in the case of metamorphopsia, mentioned p. 82, some analogy to this form may be traced, so far, — that the affection was confined to the yellow spot, and that relapses, followed by intervals of normal sight, occurred during a longer period. In this case a little light yellow spot, bordered with some pigment, and situated in the centre of macula lutea, was the only alteration to be detected in the fundus oculi.

and Arthur Cooper, p. 278 all are of opinion that exudations of lymph are rare: — others, as *Deval*, *Traité des maladies des yeux*, p. 703; *Galezowsky*, *Diagnostic des maladies des yeux*, p. 188; *Schweigger*, *Handbuch*, p. 451, think them frequent.

<sup>1)</sup> *Archiv für Ophthalmologie*, Bd. XII, Abt. 2, p. 211. It appears as if *Liebreich* had known this form before it was described by *Gräfe*. Vide *Atlas*, 1863. Besides these authors, it is observed by *Schweigger*, *Handbuch* p. 451: and *Alexander*, *Berliner Klinische Wochenschrift*, 1876 Nos. 35 and 36.



According to v. *Græfe*; a deposit of lymph is the real cause of another form of syphilitic retino-choroiditis; that which results in well defined oval spots with red borders, situated around the posterior pole. By *Zehender*<sup>1)</sup>, this form is designated as one for syphilis »ganz besonders verdächtig.« I have myself seen but one such case. It was shown me by Dr. *Buller*, at the London Royal Ophth. Hospital; and in that, the inflammatory stage had passed.

*Serous infiltration* of the retina is, by several authors<sup>2)</sup>, named as a pathological condition commonly found. The hazy look of the parts adjacent to the optic disc is assumed to be occasioned thereby. When no tumor of the parts is demonstrable, it is not probable that any serous infiltration is present. Now we seldom find, in fully developed cases, any appreciable swelling around the optic disc; nor is this mentioned by most authors who speak of serous infiltration as the cause of the hazy look. In earlier stages of the disease I have, exceptionally, found a slight swelling of the parts bordering the disc<sup>3)</sup>, and in such cases, some peripapillar œdema may be present. In elder cases, in which the hazy look has been most plainly visible, I have never found any swelling.

A real *œdema* of the retina, I have seen but once<sup>4)</sup>. It occurred in a patient, treated in the department for eye-diseases of the State Hospital, 1870—71. When I first saw that patient, the obfuscation of the vitreous was too dense to admit a view of the fundus. As the obfuscation gradually diminished, large parts of the light greyish retina could be seen to pro-

<sup>1)</sup> *Augenheilkunde*, p. 429.

<sup>2)</sup> *Desmarres*, *maladies des yeux*, p. 505. *Gerineau*, *Diagnostic des maladies des yeux*, p. 45. *H. Power*, *Illustrations of some of the principal diseases of the eye*, p. 487. *Soelberg, Wells*, *A treatise on the diseases of the eye*, p. 344.

<sup>3)</sup> Such swelling is mentioned also by *Schweigger*, *Augenheilk.* p. 451; *Classen*, *Arch. f. Ophth.*, Bd. X, Abt. 2; and *Meilhac*, l. c. p. 18. The last author assumes, as a cause of the swelling, an accumulation of fluid between the choroid and the retina. Peripapillar œdema is lastly named by *Ogilsby*, *Edinburgh, Med. Journ.* 1870, p. 624. I should think, in some cases only, a hyperæmia such as that described in the first chapter of this book was present.

<sup>4)</sup> *Leon Gros et Lauceraux*, *Des affections syphilitiq.* p. 290, mention a case of amaurosis of short duration occasioned by retinal œdema.



trude far into the vitreous. No undulation of the membrane was visible anywhere. The retinal veins were enormously dilated; in several places extravasations of blood were seen; in one place, a bloodspot was bordered by a white lustrous lymph-coagulum. Of functional disturbances I only noticed V, which varied from  $\frac{1}{20}$  to  $\frac{1}{80}$ <sup>1)</sup>.

Among the affections rarely occasioned by syphilis, are named *detachment of the retina*, and *Glaucoma*<sup>2)</sup>. No doubt these affections may occur as secondary results of syphilitic ophthalmias. There does not perhaps exist any ocular affection of which syphilis may not indirectly be a cause. As an occasional cause, I should doubt whether syphilis is capable of producing detachment of the retina or glaucoma.

As before said, the ophthalmoscopical appearance in old cases of retino-choroiditis in acquired syphilis differs in nothing essential from that in inherited. In both, we may also find forms, more or less like those in *retinitis pigmentosa*. That such is the case in acquired syphilis, was noticed by *Donders* 25 years ago. This author having repeatedly found inluetici, retinitis pigmentosa together with obfuscations of the vitreous, and marks of iritis, concluded therefrom, that an exudative process probably stood in a causal relation to the deposit of pigment, a theory subsequently fully corroborated. It soon appeared that the presence of pigment-patches was not patho-

<sup>1)</sup> It has happened to me, as no doubt to most who are trying to gain an exact knowledge of a subject, that as my fund of knowledge gradually increased, I have myself found my records of earlier date less complete than was desirable. This especially applies to that part of my records which concerns functional disturbances. Photometrical and perimetrical examinations were, when I commenced these researches, almost unknown. From this cause many of my notices at that time, are now less useful.

<sup>2)</sup> Detachment of the retina has been observed by *Galezowsky*, Arch. General. p. 128, and *Traité iconographique*, p. 131. *Leber*, in *Græfe und Sämisch*, Vol. 5, Abt. 2, p. 201, thinks that detachment of the retina occasioned by syphilis is extremely rare; as causal in this affection he assumes a choroiditis or an extravasation of blood. *Loring*, *Bumstead*, Pathology and Treatment of Venereal Dis. p. 675, is also of opinion, that an exudation from the choroidal vessels may occasion ablatio retinae.

\*Glaucomatous condition\* is denoted by *Loring*, *ibid* p. 672, as an affection to which the syphilitic serous choroiditis is prone.



gnomonic in this disease; since these might be more or less abundant, and even in some cases, in which the disease, in every other respect, was quite typical, be wholly absent; — hence, the absurd denomination, *retinitis pigmentosa sine pigmento*. The typical pigment degeneration, as during later years, this disease has been more correctly named, is found to be a result of those affections, in which we, anatomically, find an abundance of connective tissue, associated with destruction of the normal elements of the retina, its pigment layer inclusive.

Now, in syphilitic retino-choroiditis, a diffuse atrophy of the pigment layer, with a more or less abundant formation of pigment-patches, is a result commonly seen. The form of the pigment-patches, however, generally differs from that mostly seen in retinitis pigmentosa. Ring-shaped, or irregularly formed patches, are found indiscriminately dispersed, and not bone-corpuscle-like patches, holding relation to the retinal vessels. However, as stated by *Macnamara*<sup>1)</sup>, *Mannhardt*, and *Kugel*<sup>2)</sup> by *Stephan*<sup>3)</sup> and by *Galezowski*<sup>4)</sup>; in cases of inherited syphilis, a retinitis pigmentosa, in nowise differing from the idiopathic, may sometimes be found. In the case reported under No. 19, the pigment-patches, in regard to both configuration and connexion with the retinal vessels, were quite analogous to those seen in typical cases; and for which frequently, no other cause can be detected than the consanguinity of the parents<sup>5)</sup>. (Vide Fig. 10 Pl. V). Only the destruction of the pigment, in the region of the yellow spot, indicated that the inflammation, in this instance, had once been more acute. In another case of acquired syphilis; I saw only in one eye, in the upper part of the fundus, the characteristical bone-corpuscle-like patches, mingled with light spots scattered

<sup>1)</sup> Diseases of the eye, p. 401.

<sup>2)</sup> Arch. f. Ophthalm., Bd. XIV, Abt. 3, p. 48.

<sup>3)</sup> Jahrsbericht über die Verwaltung des Medicinalwesens etc. der Stadt Frankfurt a. M., 1873—74, p. 182.

<sup>4)</sup> Congress d'ophthalm. Comptes rendus 1868, p. 162.

<sup>5)</sup> *Mannhardt*, l. c. states that he has never been able to trace consanguinity of the parents in any patient suffering from retinitis pigmentosa. This shows how great a share chance may have in the experience of a single observer.



over the peripheral parts. There was in this patient a concentric restriction of the visual field, most marked however in its upper part. The oculomotorius, paralysed<sup>1)</sup>.

In inherited syphilis, I have never seen any case, in which the configuration of the pigment-patches has been like that in typical pigment-degeneration.

Retino-choroiditis is a disease commonly found in syphilitic patients. According to my own experience, the iris and the choroid are affected with like frequency<sup>2)</sup>; and if we say, that between 8 and 10 per cent of all the individuals affected with lues, have to undergo a retino-choroiditis, I think, we shall not be far from the truth. If we would determine the absolute frequency of retino-choroiditis in syphilis, a careful examination must be made, especially of those parts of the fundus where marks therefrom are most frequently left; — viz. of the peripheral parts. Syphilis is, no doubt, the cause of many, if not most of the cases designated as choroiditis disseminata; but this it will always be difficult to elicit, since so many patients are unwilling to admit infection. In cases of hereditary syphilis, the kind of the disease may, even frequently, be unknown to the patient himself. It would seem as though the doctrine, that syphilis is the most frequent cause of retino-choroiditis is now accepted by the majority of authors<sup>3)</sup>.

The retino-choroiditis occurs in the secondary stage of the disease. It rarely appears later than two years after the infection. Among 45 patients, who were able to specify the

<sup>1)</sup> A monocular affection from retinitis pigmentosa should, according to *Leber*, *Græfe und Sämisch*, Bd. 5, Abt. 2, p. 656, indicate a syphilitic origin. Vide also the case of *Steffan*, l. c. p. 182.

<sup>2)</sup> According to *Noyes*, *Syphilis of the eye*, p. 9; — corpus ciliare and the choroid, are even more frequently affected than the iris.

<sup>3)</sup> *Wecker*, *Etudes ophthalm.*, Tom. 1, 4. 488; *Macnamara*, *Diseases of the eye*, p. 335; *Loring* in *Bumstead*, p. 674; *Leber*, *Græfe und Sämisch*, Bd. V, Abt. 2, p. 609; *Nettleship*, in *Berkely Hill and Cooper*, p. 278; — *Zehender*, *Augenheilkunde*, p. 397, gives  $\frac{2}{3}$  to  $\frac{3}{4}$  of all choroidal affections as syphilitic.



time of the infection, the retino-choroiditis occurred in 39, within the first 10 months. In two cases only it supervened later than two years from the date of infection<sup>1</sup>).

In the hereditary form, the disease is often innate. Whether in hereditary syphilis retino-choroiditis may not supervene several years after birth I cannot say; but judging from the late appearance of the interstitial keratitis I should think it probable.

The course of retino-choroiditis may be elicited from the foregoing description. Here I will only remark, that so far as can be judged from the presence of subjective disturbances — phosphenes, photophobia and a diminished functional endurance — abortive forms are not rare. When once fully developed the disease usually takes a subacute course. That there should in this disease be a proneness to relapses, as many authors believe<sup>2</sup>), I have not found<sup>3</sup>).

The prognosis may be said to be good. A restitutio ad

<sup>1</sup>) In both these cases mercury had been administered as soon as the secondary symptoms appeared. When so, it seems as if the eye-affection like tubercula mucosa, and the other symptoms belonging to the secondary stage, may appear several years after the infection. That the mercurial treatment in most countries, except Norway, is that most in use, will perhaps explain, why several authors place retino-choroiditis in a transitional period, between the secondary and tertiary stage. So *Deval*, l. Union médicale, 1859, p. 307; *L. Drouin*, l. c. p. 7; *Wecker*, *Græfe und Sämisch*, Vol. IV, P. 2, p. 630; *Leber*, *ibid.* Bd. V, P. 2, p. 610; *Schreiber*, l. c. p. 91.

*Zehender*, l. c. p. 397, places retino-choroiditis among the tertiary symptoms. Of *Græfe*, *Arch. f. Ophth.*, Vol. XII, P. 2, p. 214; *Hutchinson*, A clinical memoir on certain diseases of the eye and ear, p. 253; *Galezowsky*, *Congres d'Ophthalmol.* 1868; *Nettleship*, *St. Thomas Hosp. Rep.* 1878; and in *Berkely Hill and Cooper*, p. 273, two years is said to be the time within which this eye-affection mostly appears. The opinion most prevalent among earlier authors was, that this affection belonged to the secondary stage. Vide *Roosbroeck*, *Cours d'Ophthalm.* 1853. T. 2, p. 490; *Desmarres*, *Traité des maladies des yeux*, p. 505; *Geurineau*, *Du Diagnostic des maladies des yeux*, p. 377.

<sup>1</sup>) *Jacobsen*, l. c. p. 307; *Deval*, l. c. p. 705; *Foerster*, l. c. 62; *Hirschberg*, *Beiträge zur prakt. Augenheilk.* p. 38; *Noyes*, l. c. 19; *Nettleship*, *St. Thomas Hosp. Rep.* 1878.

<sup>2</sup>) Herein *Alexander* agrees with me.



integrum is not infrequent. As a rule, there will, however, remain some deterioration of the sight; nevertheless, ordinarily, not in any respect so great as to interfere with the patient's practical pursuits. Even in chronic cases, in which V has been very much lowered, and vast destructions of the pigment-layer have taken place, a tolerably good sight may, sometimes unexpectedly, be eventually restored. When a more advanced degree of retinal atrophy has set in, we cannot of course, expect any change for the better. A complete amaurosis is however, as before mentioned, quite exceptional.

In conclusion I would briefly mention, the diagnostic value of the retino-choroiditis in relation to syphilis. As before pointed out, hardly any symptom of syphilitic retino-choroiditis so characteristic exists, that it may be said to be pathognomonic; but, just as syphilitic dermatides may occur in so typical a form, that from this alone the diagnosis of syphilis can, almost with certainty, be made; so too, with the retino-choroiditis. As *Nettleship*<sup>1)</sup> says; this may especially be applied in »all cases of symmetrical disseminated choroiditis, in which the patches, or areas are scattered about in various parts of the fundus...« Obfuscations of the vitreous, especially when this, in erect image, is found to be punctiform (staubenformig)<sup>2)</sup>, render still more probable the syphilitic origin. But, as, no doubt, cases of retino-choroiditis may sometimes be found which in no symptom, differ from the luetic, but wherefrom syphilis, with almost certainty, may be excluded, we can hardly, from the eye-affection alone, establish a peremptory diagnosis. This must therefore, in most cases, be based on the presence of other symptoms of the skin and mucous membranes, with which retino-choroiditis usually is synchronous<sup>3)</sup>. Further, I would state that, in many

<sup>1)</sup> Berkely Hill and Cooper, p. 278.

<sup>2)</sup> *Foerster*, l. c. p. 34; *L. Drouin*, l. c. p. 23; *Wecker*, Græfe und Sämisch, Vol. IV, P. 2, p. 624; *Leber*, ibid. Vol. V, P. 2, p. 611.

<sup>3)</sup> That retino-choroiditis rarely, if ever occurs together with any other signs of lues, as *Mooren*, Ophthalm. Beobacht. p. 287; *Schelske*, Lehrbuch, Vol. I, p. 179; *Wecker*, Græfe und Sämisch, Vol. IV, P. 2, p. 630; and *Schreiber*, l. c. p. 85; all say, — is, so far as my experience goes, not



cases, I have been led on the right track, by the character of the then present eye-affection. The latter has in one point the preference over the exanthems, and the affections of the mucous membranes, inasmuch as it leaves marks which never disappear. This is, especially applicable to the spots left by destructions of the pigment-layer. Another symptom, which also may be found permanent through years, is the greyish obfuscation of the retina, adjacent to the disc<sup>1</sup>). To the complication of iritis no significance in diagnostic respect can be attributed. Non-syphilitic, is as often as syphilitic retino-choroiditis, complicated therewith. Of far more importance in regard to the diagnosis, is the presence of symptoms showing a suffering of the nervous symptoms; such as paralysis of the ocular muscles, the acoustic nerve, etc. which, by no means seldom are found complicating old, or even recent cases of specific retino-choroiditis<sup>2</sup>).

consistent with fact. On the other side, *Power* is not right, when he says that the eye-affection is always associated with other syphilitic symptoms.

<sup>1</sup>) This obfuscation is by *Galezowsky* held to be highly characteristic of syphilis.

<sup>2</sup>) *Meilhac*, l. c. p. 38; *Leon Gros et Lanceran*, des affections syphilitiq. *Galezowsky*, Traité iconograp. p. 178; *Hirschberg*, Klin. Beob. p. 65.



## Literature.

(The papers marked \* I only know through reports.)

- Adams*, Two cases of intra-vitreous hæmorrhage. British medical Journal. December 23. 1876.
- Alexander*, Zehender's klinische Monatsblätter. Bd. V.
- Ueber syphilitischen Augenkrankheiten, Correspondenzbl. der artz. Verein in Rheinland, Westph. & Lothringen. 1874. No. 13\*.
- Zur Casuistik der centralen recidivirenden Retinitis, Berliner Klinische Wochenschrift. 1876. No. 35 og 36.
- Allbutt*, Clifford, The Ophthalmoscope. London & New-York. 1871.
- Arcoleo*, M., Congrès périodique international d'Ophthalmologie. 1867.
- Arlt*, Die Krankheiten des Auges. Prag 1853.
- Bader*, Ophthalmic Hosp. Reports. Vol 1.
- The human eye, its natural and morbid changes, London 1868.
- Plates, illustrating the natural and morbid changes of the human eye. London 1868.
- Guy's Hosp. Reports 1871\*.
- Barbar*, I., Ueber einige seltener syphilitische Erkrankungen des Auges. Zürich 1873.
- Barlow*, Thomas M. D., Meningitis, arteritis and choroiditis in a child, the subject of congenital syphilis.
- Berg*, R., Beretning fra almindelig Hospitals 2den Afdeling. 1879.
- Bousseau*, Sur les retinites secondaires Paris 1869\*.
- Broadbent*, Lancet. March 1874.
- Bull*, C., Two cases of interesting syphilitic lesion of the eye. Transactions of the Americ. Ophthal. Soc. 1874.
- Observations on some Syphilitic Lesions of the eye etc. Americ. Jour. of medical science. April 1875.
- A contribution to the study of inherited syphilis. Americ. Jour. of Medical science. April 1877.
- Bull*, O., Nogle foreløbige Meddelelser om Retinalaffectioner ved Syphilis. Nordisk Medicinsk Archiv. Bd. III. No. 4.
- De på Lues beroende Pathologiske Forandringer af Øienbunden. Christiania 1880.
- The affections of the nervous systems, and more especially of the optic nerve in syphilis. Transactions of the Minnesota State Med. Society 1875.
- Bumstead*, J. F., Pathology and treatment of venereal diseases. New-York 1870.
- Chibret*, Rétinite exudative syphilitique, simulant une plaque fibreuse de la rétine. Recueil d'Ophth. 1875.
- Classen*, Ueber Metamorphose, Archiv für Ophtalmologie. Bd. X. Abt. 2.



- Cooper, Arthur and B. Hill*, Syphilis & Local Contagious Disorders. 2d. Edition 1881.
- Cowel, G.*, Case of Syphilitic Neuroretinitis, Ophthalmic Hosp. Rep. Vol. VI. 1869.
- St. George Hosp. Rep. Vol. VI. 1869\*.
- Delafield, Francis*, General Syphilitic Inflammation of the eye, Transactions of the Americ. Ophthalmolog. Society. 1871.
- Desmarres*, Traité des maladies des yeux, 2me édition. Paris 1858.
- Deval*, Amaurose syphilitique, Utilité de l'ophthalmoscope au point de vue de son traitement, l'Union médicale 1859.
- Traité des maladies des yeux. Paris 1862.
- Dixon*, Ophthalm. Hosp. Rep. Vol. I. 1857.
- Donders*, Beiträge zur pathologische Anatomie des Auges. Archiv für Ophthalmolog. Bd. III. Abt. I.
- Drognat-Landré*, De la choroidite exudative & atrophique. Annales d'Oculistique. T. LXXIII.
- Drouin, Leon*, Lésions syphilitiques des membranes profondes d'oeil. Paris 1857.
- Dupré, A.*, Des affections syphilitiques du globe oculaire. Paris 1857.
- Edmunds and Braily*, Changes in the Blood-vessels of the eye, considered in their relation to general pathology. Ophth. Hosp. Rep. 1882. Vol. X.
- Engelhardt*, Vorträge aus der v. Gräfe'schen Klinik, Zehender klinische Monatsbl. 1865.
- Fano*, De la rétinite syphilitique l'Union méd. 1861, og Annales d'Oculistiq. T. XLVI.
- Traité pratique des maladies des yeux. Paris 1866.
- Fetzer*, Beitrag zur Lehre von der chorioiditis disseminata, Tübingen 1870.
- Follin*, Leçons sur l'ophthalmoscope. Paris 1862.
- Fournier*, Des ophthalmies profondes de la syphilis dans la période secondaire. Journal d'Ophthalmolog. Vol. I\*.
- Fuckel*, Erblindung bei congenitaler Syphilis, Zehender Klinisch. Monatsb. 1867.
- Forster, R.*, Ophthalmologische Beiträge. Berlin 1862.
- Zur klinischen Kenntniss des Chorioiditis syphilitica, Archiv für Ophthalmologi. Bd. XX. Abt. I.
- Gräfe & Sämisch, Augenheilkunde. Bd. VII. I.
- Galeaowsky*, Choroidite syphilitique. Gazette des Hôpitaux 1862\*.
- Amaurose syphilitique. Annales d'Oculistique. T. XLVIII.
- Du Diagnostic des maladies des yeux. Paris 1868.
- Sur la choroidite syphilitique et les rapports qui existent entre cette affection et la rétinite pigmentaire congénitale, Congrès d'Ophthalmologie 1868.
- Amauroses syphilitiques. Gaz. des Hôpit. 1869.
- Etude sur les amblyopies et les amauroses syphilitiques. Archives générales de médecine 1871.
- Quelques considérations sur la cécité par cause pathologique pour les couleurs. Annales d'Oculistique. T. LVX.
- Aperçu général sur les chorioidites, Recueil d'Ophthalm. 1874.
- Traité iconographique d'Ophthalmoscopie. Paris 1876.
- Gascoven*, Medical Times, No. 1104. 1871\*.
- Gräfe*, Ueber syphilitische Augenkrankheiten, Allgemeine medicinische Centralzeitung. 1858.
- Ueber centrale recidiverende Retinitis, Archiv für Ophtalm. Bd. XII. Abt. II.



- Gros Léon & Lanceraux*, Des affections nerveuses syphilitiques. Paris 1861.
- Grossmann*, Berliner Klinische Wochenschrift 1873.
- Guérinan*, Du diagnostic des maladies des yeux a l'aide de ophthalmoscope. Paris 1860.
- Hansen, E.*, Dansk Hospitalstidende 1871 og 1872.
- Hill, Berkely and Cooper, Arthur*, Syphilis and Local Contagious Disorders. 2d Edition. 1881.
- Hirschberg*, Fall von Retinitis specifica, Berliner Klinische Wochenschrift. 1870.
- Græfe's Klinische Vorträge. Berlin 1871.
- Klinische Beobachtungen aus der Augenheilanstalt. Wien 1874.
- Beiträge zur praktischen Augenheilkunde. Berlin 1876.
- Hock, I.*, Die syphilitische Augenkrankheiten. Wiener Klinik II. Hf. 3. 4. 1876\*.
- Horner*, Fall von Neuritis optica. Correspondenzbl. für Schweiz. Aertze. 1871\*.
- Hulke*, Cases of neuritis etc. Ophthalm. Hosp. Rep. Vol. VI.
- Hutchinson*, Ophthalm. Hosp. Rep. Vol. I.
- Medical Times and Gazette 1861\*.
- Syphilitic Diseases of the eye and ear. London 1863.
- Ophthalmic. Hosp. Rep. Vol. V.
- Inherited Syphilis with choroiditis, Ophthalm. Hosp. Rep. Vol. VI.
- Syphilitic choroiditis, symmetrical. Ophthalm. Hosp. Rep. Vol. VI.
- Cases illustrating the Ophthalmoscopic appearances of syphilitic choroiditis. Ophthalm. Hosp. Rep. Vol. VII.
- A clinical lecture on progressive choroiditis in connexion with acquired syphilis. Med. Tim. and Gazette. Nov. 1877. No. 17.
- Hutchinson*, Choroido-Retinitis, as the result of hereditary Syphilis. Ophthalm. Hosp. Vol. VIII.
- Amaurosis from optic neuritis in the tertiary stage of Syphilis. Ophthalm. Hosp. Rep. Vol. IX.
- Jackson, Huglings*, Cases of diseases of the nervous system etc. London 1868
- Syphilitic Amaurosis. Ophthalm. Hosp. Rep. Vol. VIII.
- Jacobsen*, Retinitis syphilitica, Königsberger medicinske Jahrbücher 1859.
- Jäger*, Ophthalmoscop. Handatlas. 1869.
- Imre, I.*, Ein Fall von Ringscotom bei Chorio-retinitis specifica. Zehender Klinische Monatsbl. 1876.
- Jones, Wharton*, Ophthalmic medicine and surgery. London 1865.
- Kaempfer*, Hæmorrhagia retinæ und corp. vit., Oestrich. Zeitschrift für praktisch. Heilkunde 1867\*.
- Knapp*, Ein Fall von neuro-retinitis. Archiv für Augen- und Ohrenheilkunde. Bd. IV. Abth. 2.
- Kortöm*, Choroiditis specifica. Archiv für Augen- und Ohrenheilk. Bd. 3. Abt. 1.
- Lang, Edu., Prof.*, Ueber Meningealirritation bei beginnender Syphilis. Vierteljahresschrift f. Dermatologie und Syphilis. VIII. Jahrg. 1881. 2. og 3. Hf. p. 469.
- Leber*, Archiv für Ophthalmolog. Bd. XV. Abt. 3.
- Ueber anomale Formen der Retinitis pigmentosa. Archiv f. Ophthalm. Bd. XVII. Abt. 1.
- Græfe & Sämisch, Augenheilkunde. Bd. 5. Abt. 2.
- Liebreich*, Atlas. Berlin 1863.
- Loring*, vide Bumstead.
- Mackenzie*, Traduit par Warlomout & Testelin. Paris 1865.
- Macnamara*, Diseases of the eye. London 1868.
- Mandelstamm*, Retinitis parenchymatosa syphilitica; Pagenstecher's klinische Beobachtungen. Wiesbaden 1866.



- Mannhardt*, Retinitis pigmentosa. Archiv f. Ophthalmologie. Bd. XIV. Abt. 3.
- Mauthner*, Lehrbuch der Ophthalmoscopie. Wien 1868.
- Manz*, Nagel's Jahrsbericht über die Leistungen im Gebiete der Ophthalmologie. 1874.
- Meilhac*, Recherches sur l'amaurose syphilitique. Paris 1863.
- Métaxas*, De l'exploration de la rétine. Paris 1861.
- Mooren*, Ophthalmiatriche Beobachtungen. Berlin 1867.
- Nagel*, Ueber Chorioiditis areolaris etc. Zehender Klinische Monatsbl. 1868.
- Nettleship*, E., 1875 vide Barlow.
- 1878. "Cases in ophthalmic practice with notes and observations." St. Thomas Hosp. Reports.
- The eye and its Appendages being the IX Capt. of Syphilis and Local contagious Disorders 2d Edit. by Berkely Hill and Arthur Cooper. 1881.
- Noyes*, Syphilis of the Eye. Cap. VIII of a practical treatise on the surgical diseases of the Genito-urinary organs including Syphilis, by W. van Buren and E. L. Keyes.
- Oglesby*, R. P., On the condition of the Optic Disc and Retina in Acute Iritis. Edinburgh Med. Journal 1870.
- Philipsen*, Oiets sygdomme. Kjøbenhavn 1880.
- Poland*, Ophthalm. Hosp. Rep. Vol I.
- Pooley*, Case of circumscribed exudation in the choroid. American Journal of Syphidologie and Dermatalogie 1872.
- Pope*, B. A., A case of retinitis pigmentosa. Ophthalmic Hosp. Rep. Vol IV. P. I.
- Power*, Henry, Illustration of some of the principal diseases of the eye. London 1868.
- Quaglino*, Sur les conditions pathologiques de l'Héméralopie, ou Amblyopie nocturne, Annales d'Oculistique. T. 47.
- Des conditions pathologiques de l'Héméralopie. Annales d'Oculistique. T. 55.
- Rankin*, A case of atrophy of both optic nerves, Medical Record 1875\*.
- Roosbroeck*, Cours d'Ophthalmologie. Gand 1853.
- Schelske*, Lehrbuch. Berlin 1870.
- Schillinger*, Wiengr medicinische Rundschau 1870\*.
- Schnabel*, Prf., vide Lang.
- Schoen*, Die Lehre vom Gesichtsfelde. Berlin 1874.
- Schott*, Veränderungen des Schnervens bei Syphilis, Arch. für Augen- und Ohrenheilkunde. Bd. V.
- Schreiber*, A., Ueber Veränderungen des Augenhintergrundes bei internen Erkrankungen. Leipzig 1878.
- Schubert*, Paul, Ueber syphilitische Augenkrankheiten. Berlin 1881.
- Schultze*, Sur la choroidite syphilitique. Paris 1859.
- Schweigger*, Handbuch der speciellen Augenheilkunde. Berlin 1871.
- Steffan*, Jahrsbericht über die Verwaltung des Medicinalwesens, die Krankenanstalten etc. der Stadt Frankfurt a. M. 1873—74.
- Sichel père & Deval*, sur l'amaurose syphilitique de l'oeil. Paris 1859\*.
- Stellwag*, Lehrbuch der praktischen Augenheilkunde. Wien 1867.
- Square*, W., Optic Neuritis in connexion with Tertiary syphilis. Ophthalm. Hosp. Rep. Vol. VI.
- Streatfield*, Ophthalmic. Hosp. Rep. Vol I.
- Sturgis*, Fred. R., Clinical Rec. of Syphilitic Affections of the Eye. Archiv of Dermatalogie, Octbr. 1874.
- Swanzy*, Rosborough, A peculiar Form of Retinitis Pigmentosa in connexion with inherited Syphilis. The Dublin Quarterly Journal of Med. Science 1871.




- Thiry*, Des rétinites spécifiques. Presse médicale belge. 1875\*.
- Turnbull, L.*, Clinical observations with cases of diseases of the retina etc. Philadelphia med. and surgical Reporter 1874\*.
- Walker, W. B.*, Case of cerebral syphilis, choroid-retinitis etc. Med. Times and Gaz. 1877. No. 24.
- Watson, S.*, Optic neuritis in connexion with constitutional Syphilis, Ophthalm. Hosp. Rep. Vol. VI.
- Webster, D.*, The etiology of retinitis pigmentosa, Transaction of the American Ophthalm. Society. 1878\*.
- Wecker*, Etudes ophthalmologiques. Paris 1863 & 66.
- Wecker*, Græfe und Sämisch Augenheilkunde. Bd. 4. Abt. 2.
- Wells, Soelberg*, A treatise on the diseases of the eye. London 1869.
- Wiesener*, Norsk Magazin for Lægevidenskaben. Række 3. Bd. 1.
- Wordsworth*, Ophthalmic Hosp. Rep. Vol 1.
- British med. Journal 1862\*.
- Wurst*, Beiträge zur Stauungs-Papille Przegląd lekarski. No. 32 & 33. 1877.\*
- Zambago*, Des affections nerveuse syphilitiques. Paris 1862.
- Zehender*, Lehrbuch der Augenheilkunde. Stuttgart 1879.





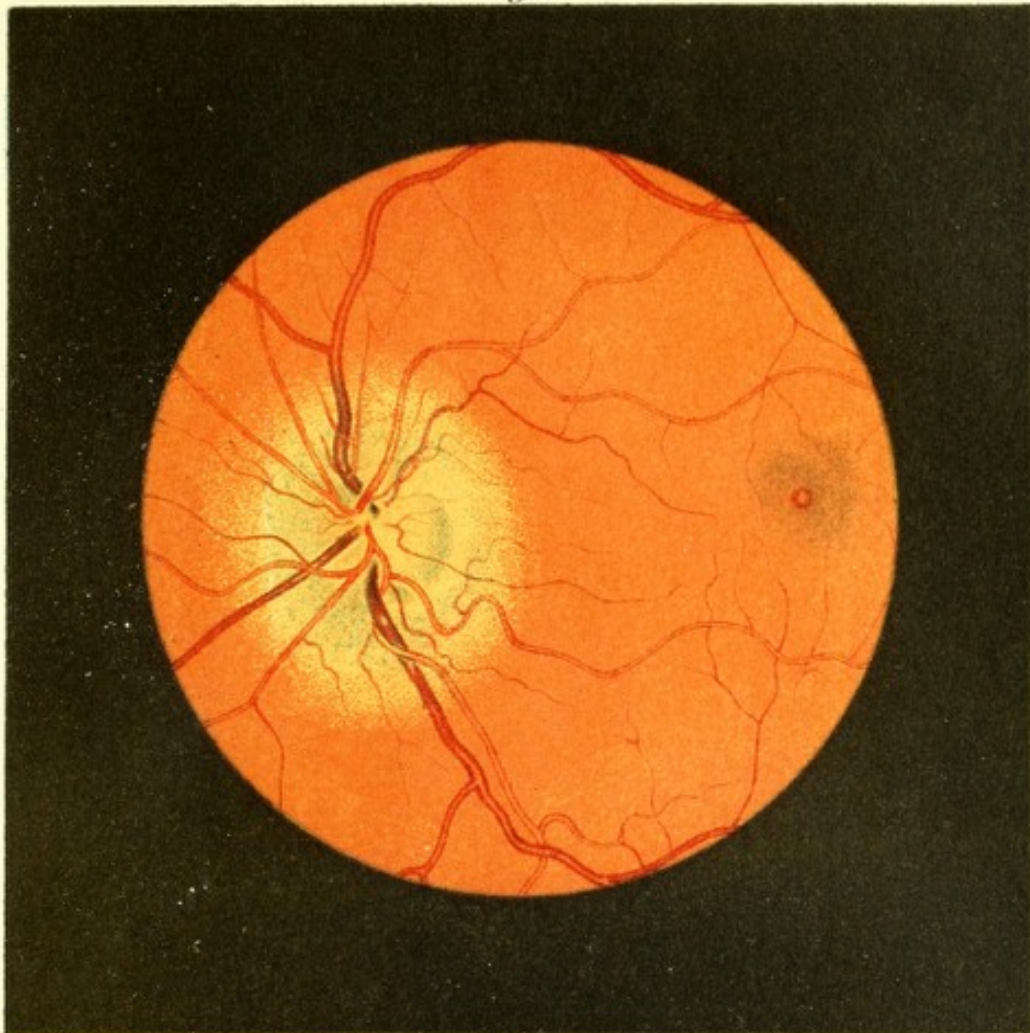




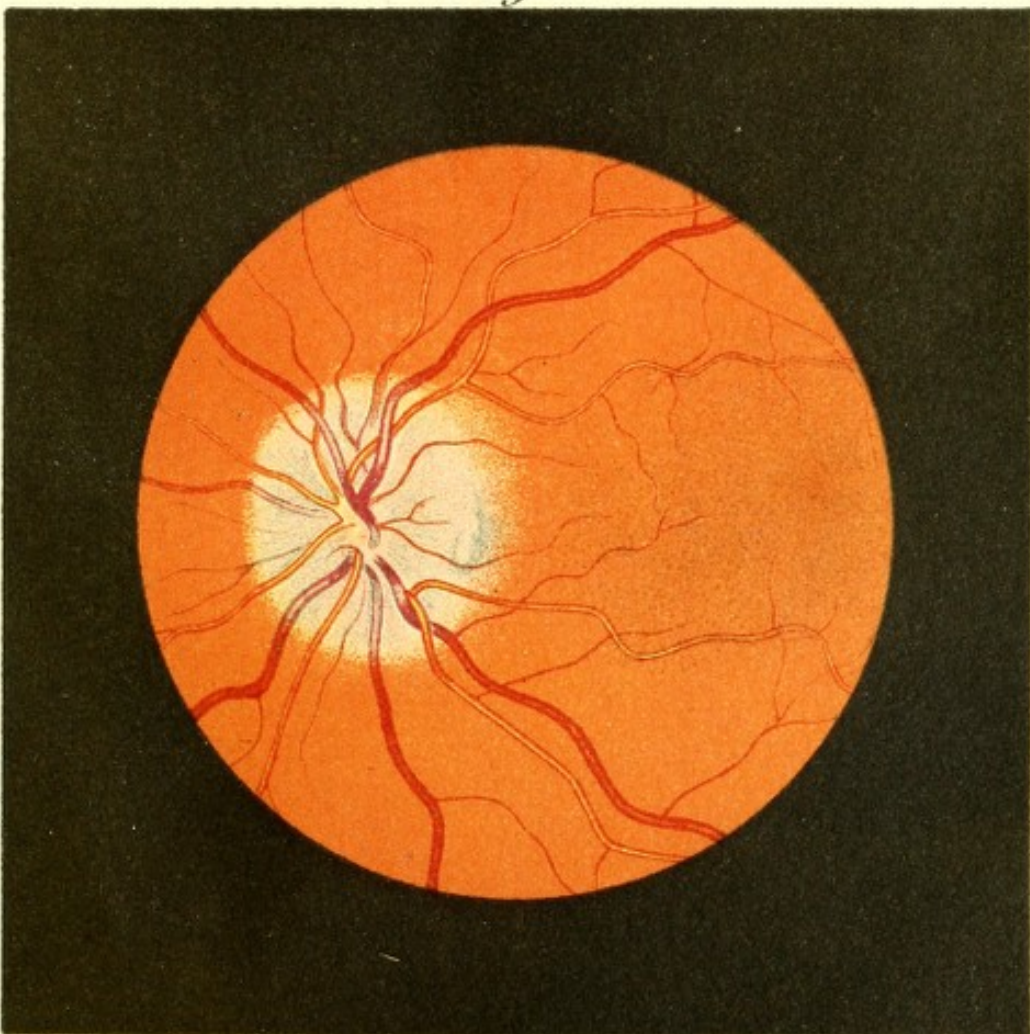








*Fig. 2.*

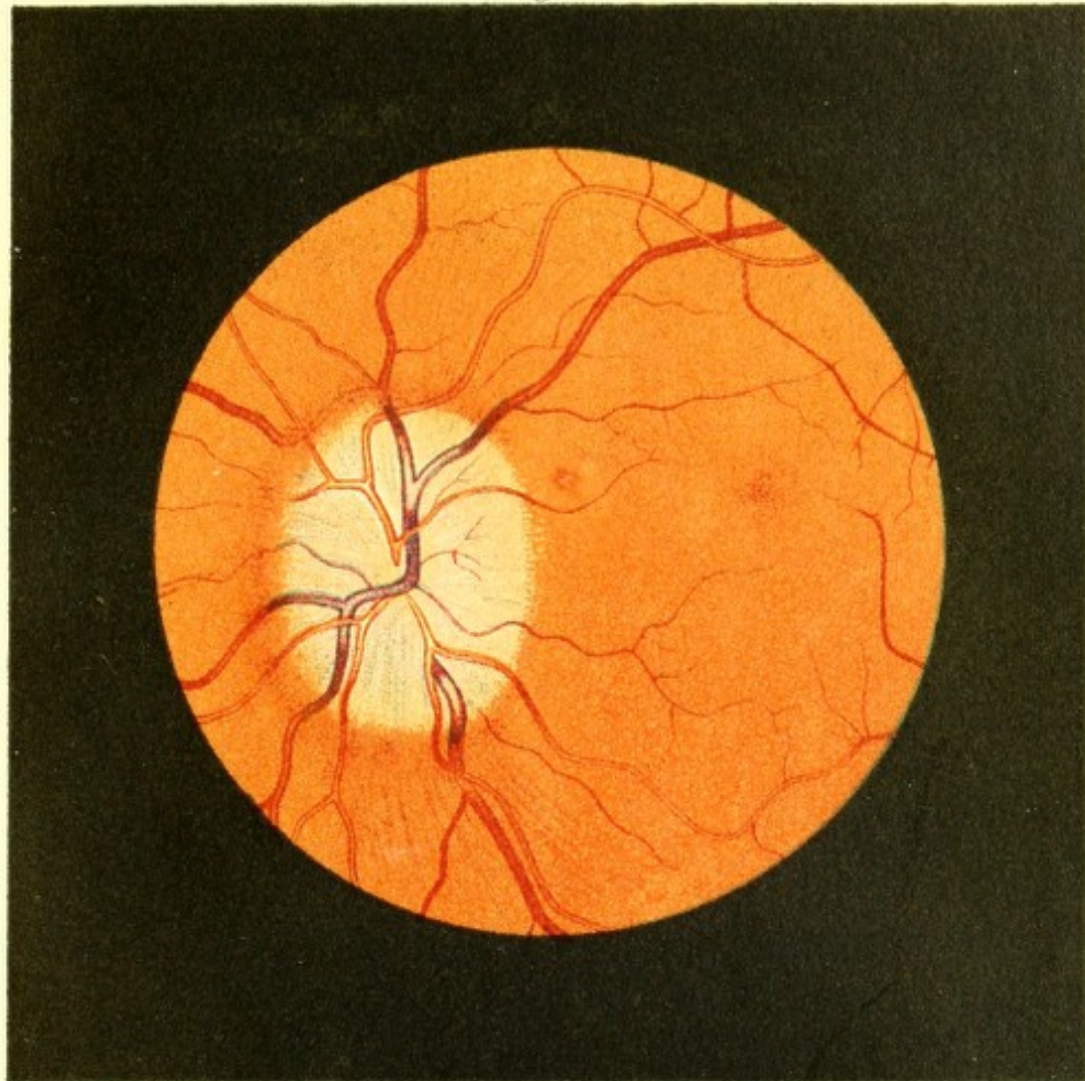




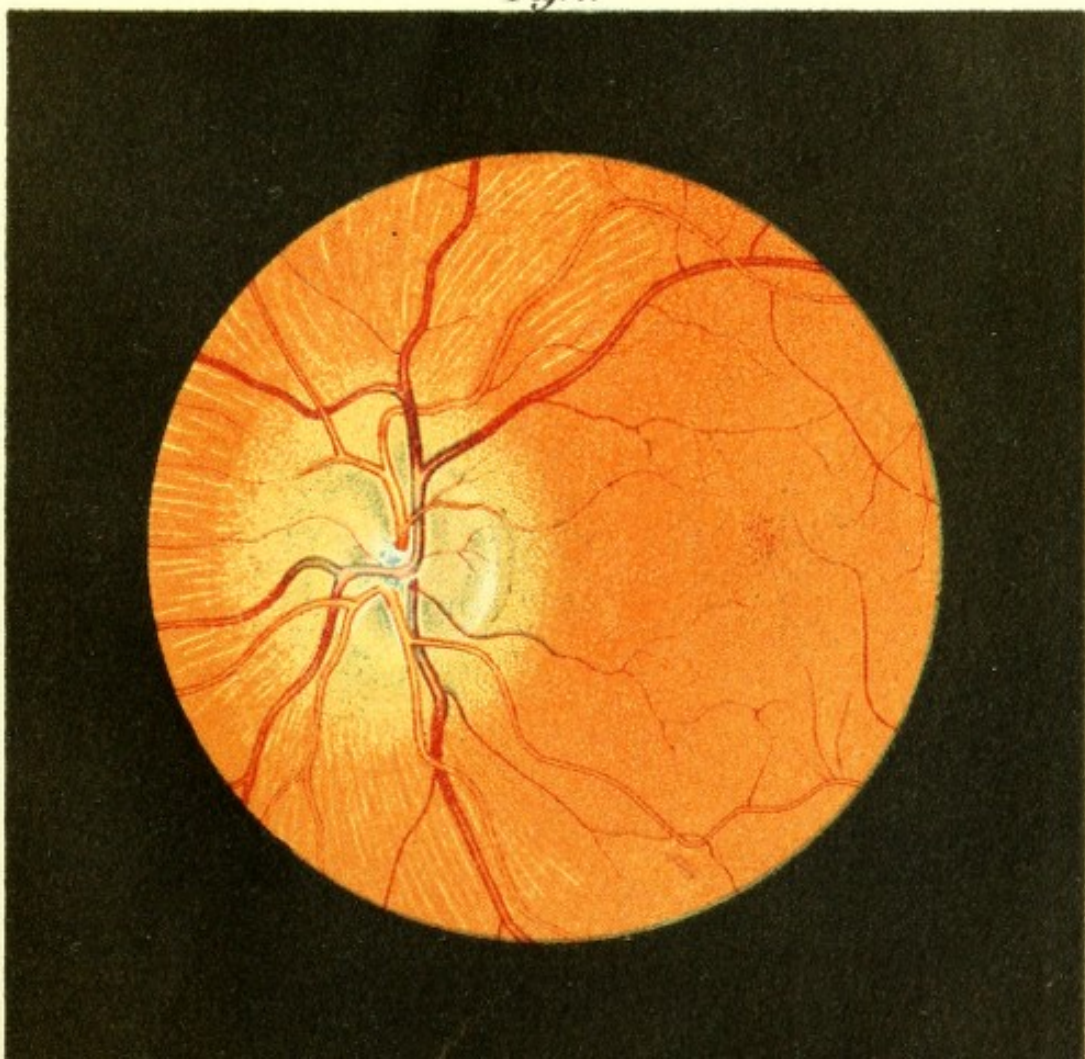




*Fig. 3.*

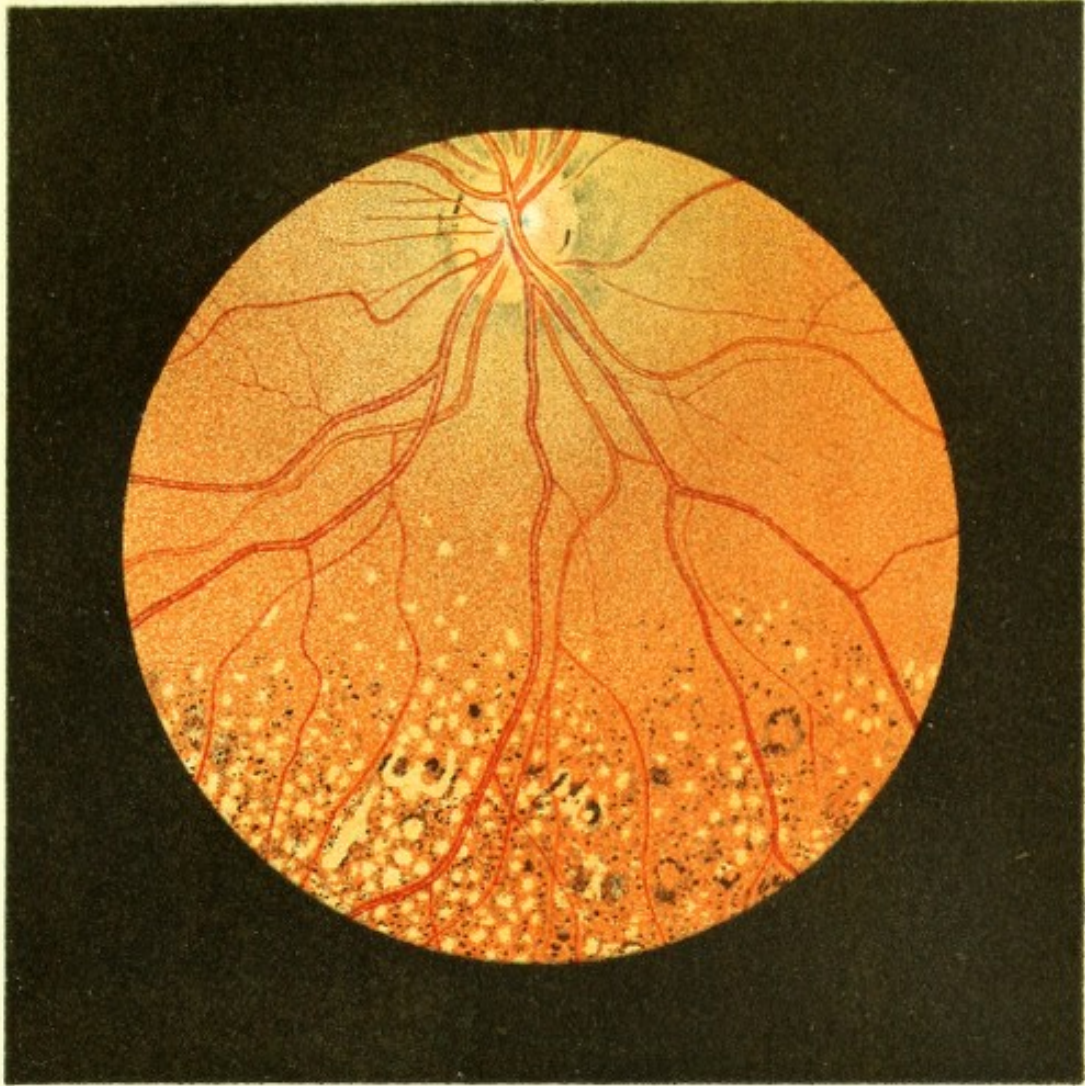


*Fig. 4.*

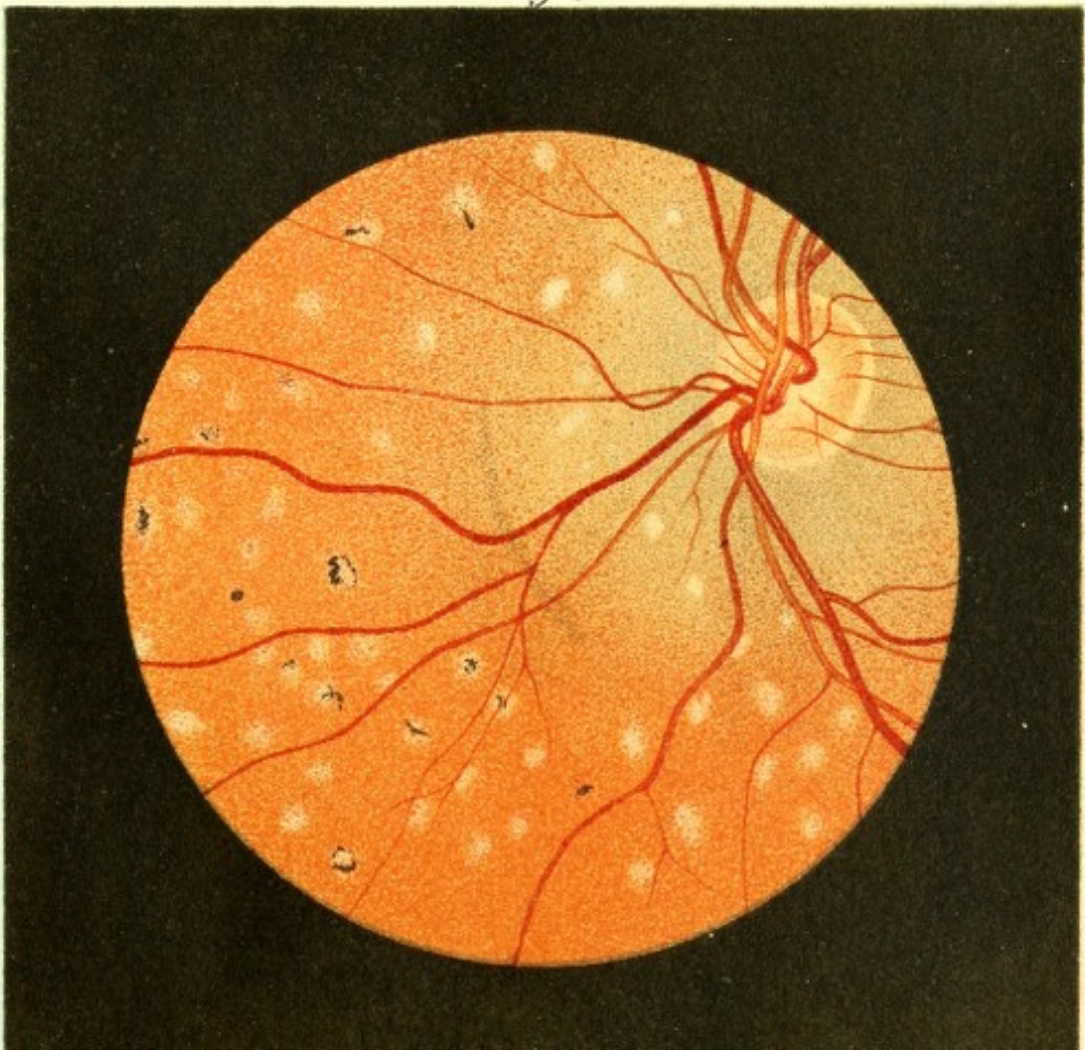




*Fig. 5.*



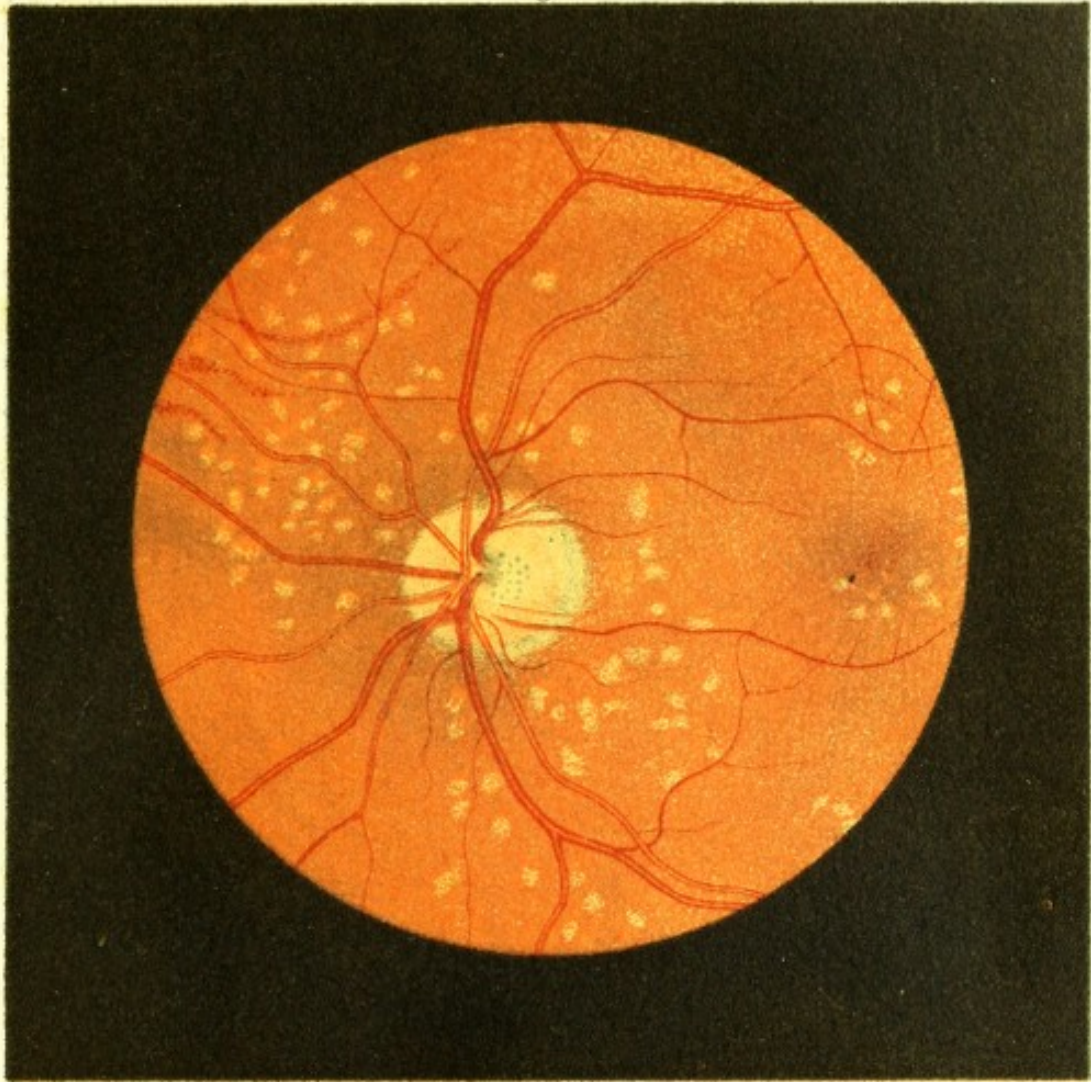
*Fig. 6.*



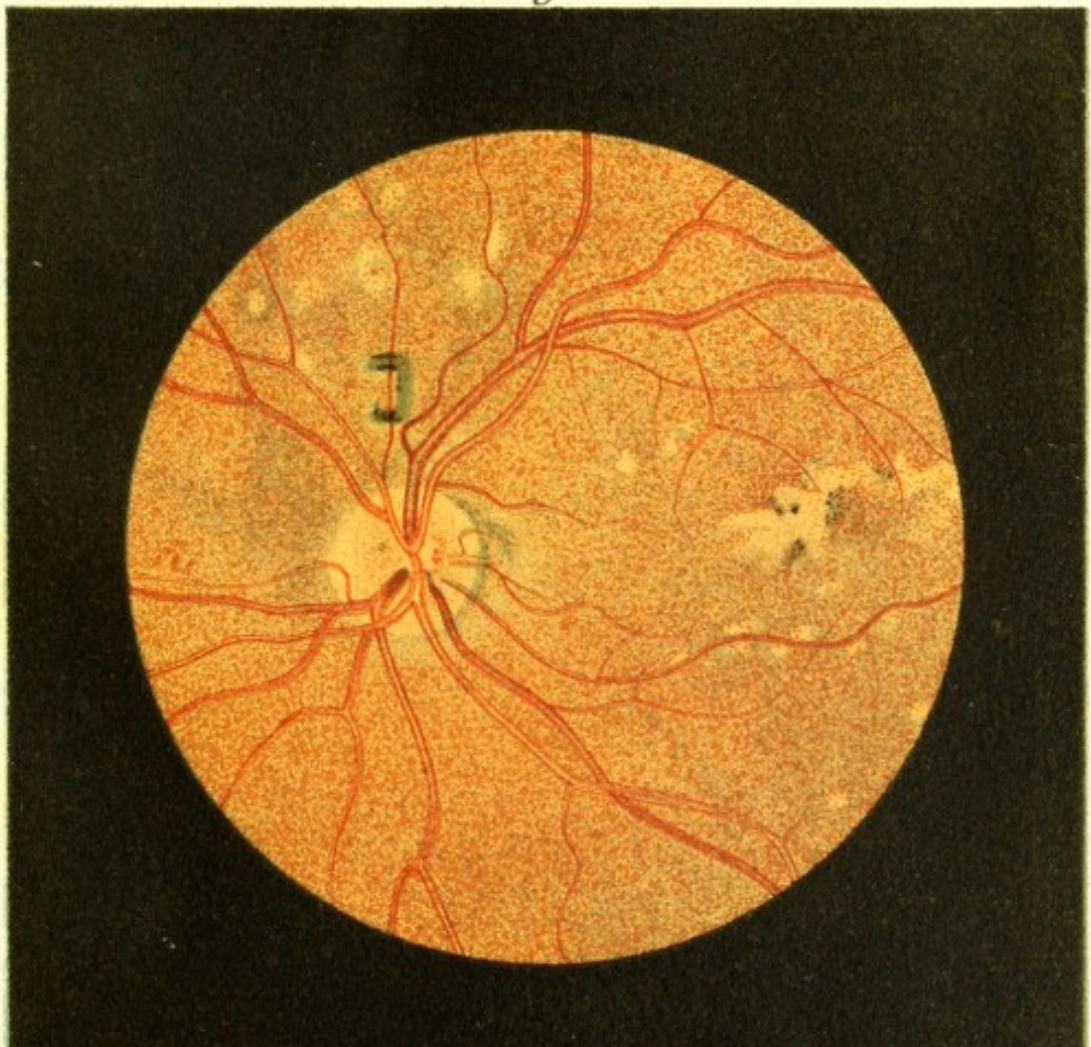




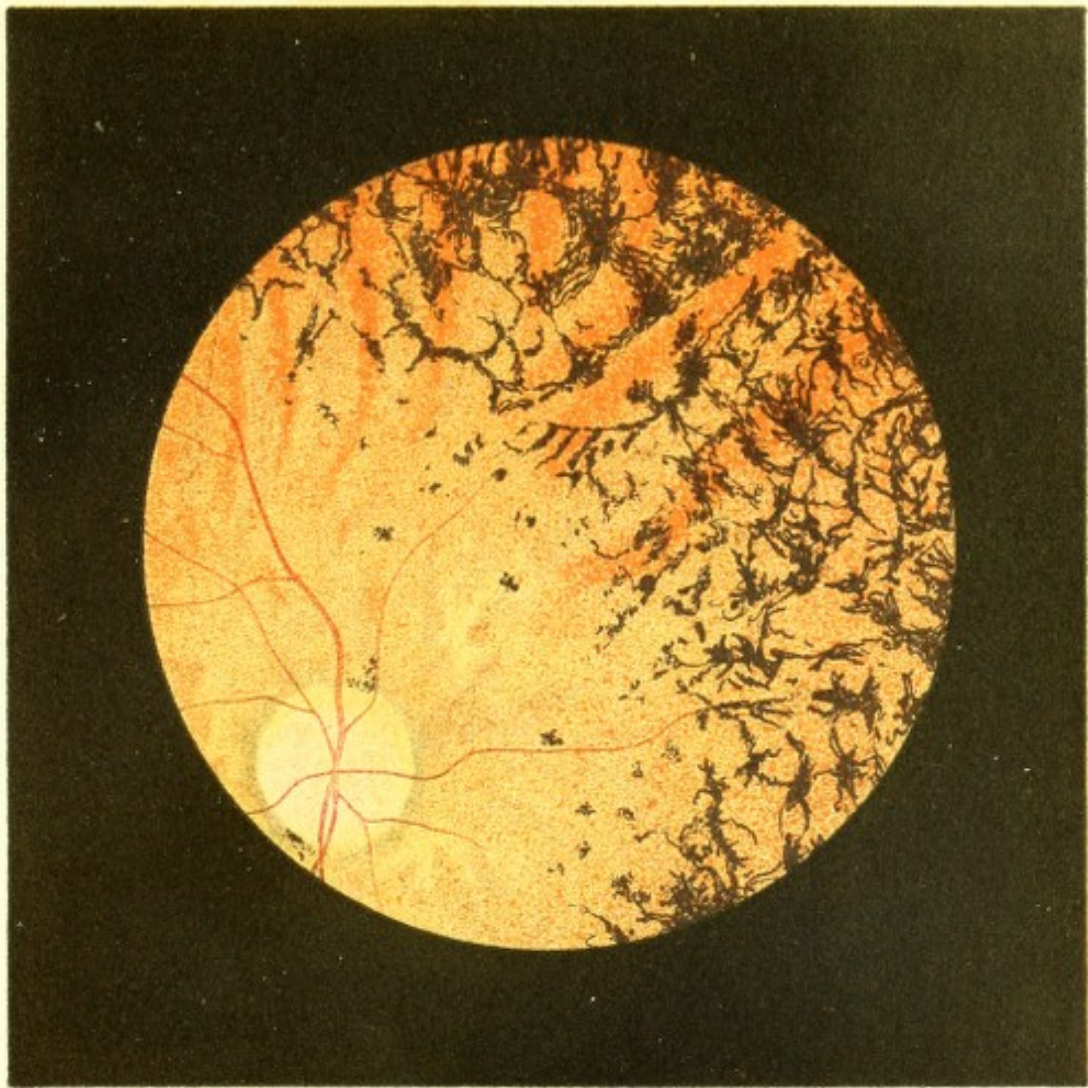




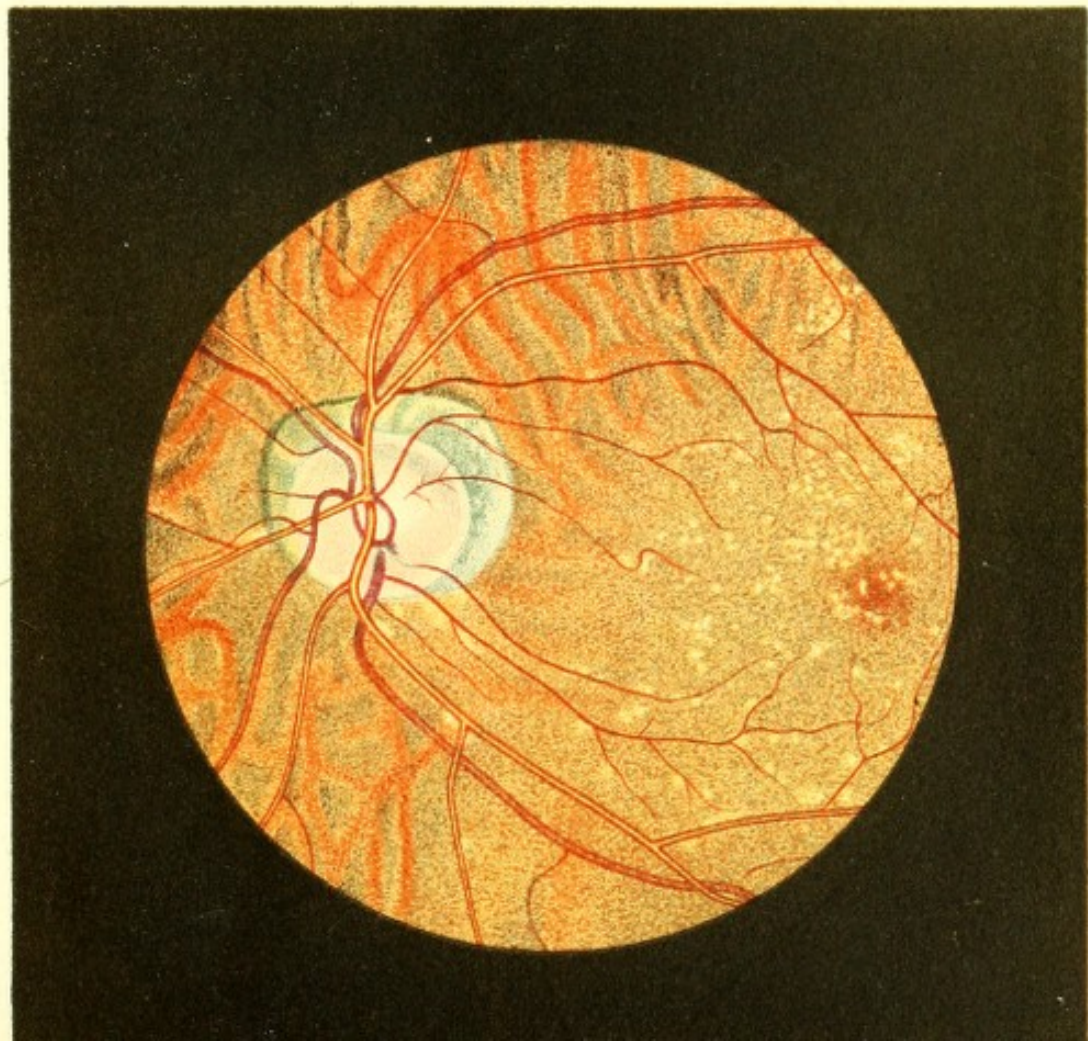
*Fig. 8.*



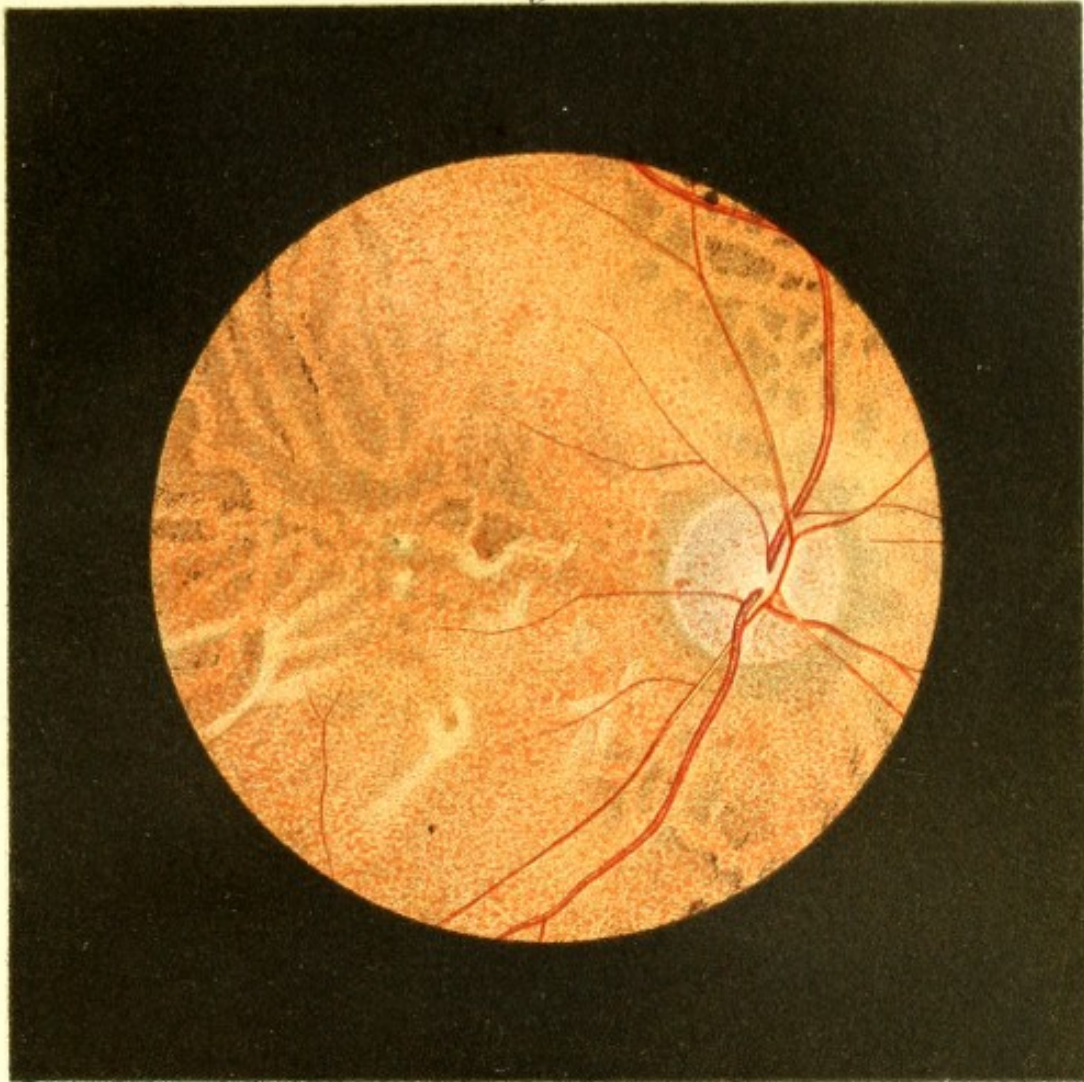




*Fig. 9.*







*Fig. 12.*

